


24 A 404

THE BOSTON
9-28-12
Medical and Surgical
JOURNAL.

Sept. 30, 12



Digitized by the Internet Archive
in 2011 with funding from
Open Knowledge Commons and Harvard Medical School

PATHOLOGY AND TREATMENT
OF
DISEASES OF WOMEN

PATHOLOGY AND TREATMENT
OF
DISEASES OF WOMEN

FOURTH EDITION, REWRITTEN BY

A. MARTIN *e* AND PH. JUNG

PROFESSOR UND DIREKTOR

PROFESSOR UND OBERARZT

DER UNIVERSITÄTS-FRAUENKLINIK IN GREIFSWALD

ONLY AUTHORIZED ENGLISH TRANSLATION, WRITTEN AND EDITED BY

HENRY SCHMITZ, M.D.

PROFESSOR OF GYNECOLOGY, CHICAGO COLLEGE OF MEDICINE AND SURGERY; MEDICAL
DEPARTMENT, VALPARAISO UNIVERSITY; ATTENDING SURGEON, ST. MARY'S OF
NAZARETH HOSPITAL; ATTENDING GYNECOLOGIST, FRANCES E.
WILLARD NATIONAL TEMPERANCE HOSPITAL, CHICAGO

*WITH ONE HUNDRED AND EIGHTY-SEVEN ILLUSTRATIONS
TWENTY-FIVE OF WHICH ARE IN COLORS*




NEW YORK
REBMAN COMPANY
1123 BROADWAY

1572

COPYRIGHT, 1912, BY
REBMAN COMPANY
NEW YORK

—
All Rights reserved



PRINTED IN AMERICA

Translator's Preface

MARTIN AND JUNG'S "Pathologie und Therapie der Frauenkrankheiten" has a number of advantages over similar works which make an English adaptation desirable. These are, first: The conciseness of the book, it only has about 500 pages; second: the classification of the different subjects, which make it invaluable to teacher and student, and third: the indications for general medical and surgical treatment, which render it valuable to the general practitioner and gynecologist alike.

The book originally was the result of lectures given in a vacation post-graduate course at the University of Berlin.

I must thank Dr. J. H. Salisbury for the revision and correction of my translation, and the publishers, the Rebman Company, for the willingness with which they have met every one of my wishes.

May this translation meet with the same warm appreciation that has been accorded to the original.

HENRY SCHMITZ.

1 WEST MADISON STREET, CHICAGO.

Publisher's Announcement

NOTWITHSTANDING the numerous additions to the literature in Gynecology in the last decade, an insistent and constantly increasing demand by gynecologists and the medical profession in Europe for *Pathologie und Therapie der Frauenkrankheiten* has completely exhausted the first three editions, and this latest German edition, rewritten and revised by the authors, is now making an auspicious advent abroad.

The analysis of the universal commendation earned at the hands of reviewers reveals an unswervable consistency of aim on the part of the co-authors, throughout all the editions. Their purpose has been to combine completeness and breadth in the delineation of contemporary opinion and therapeutic procedure with clearness, terseness, and the elimination of mere theories, controversial discussion or needless repetition.

The result achieved is readily discernible in the table of contents which reveals the first manifestation of the clarity, comprehensiveness, and logical sequence in the treatment of the subject matter. To augment its practical value to the general practitioner and student, is an exhaustive and discriminately selected series of illustrations in half tone and colors, scientifically accurate in the portrayal of each anatomical, pathological, and therapeutic phase as described. Thus, various steps in every important gynecological operation are graphically presented. Pathologic histology of each of the pelvic viscera is thoroughly reviewed and profusely illustrated from original slides containing sections of typical lesions.

The character and extent of the bibliographic references are indicative of the wide scope chosen by the authors in the consideration of every topic under discussion.

It is, therefore, not for the mere purpose of making another addition to the gynecologic literature of America, but with a view of meeting the wishes and desires of all those interested in the subject of Gynecology that the publishers offer this treatise to the profession.

TABLE OF CONTENTS

	PAGE
TRANSLATOR'S PREFACE.....	v
PUBLISHER'S ANNOUNCEMENT.....	vi
TABLE OF CONTENTS.....	vii
LIST OF ILLUSTRATIONS.....	xii
I. Anatomy and Topography of the Female Pelvic Organs.....	1
II. Development of the Female Genitalia.....	13
Menstruation and Ovulation.....	14
III. Gynecologic Examinations.....	19
Sounding.....	26
Dilatation of the Cervical Canal. Palpation of the Uterine Cavity.....	28
Curettagc of the Uterus.....	29
Bacteriologic Examination.....	33
Examination of the Uropoetic System.....	37
Anesthesia.....	38
IV. Asepsis. Disinfection.....	40
Disinfection of the Instruments, Dressings and Suture Material.....	41
Disinfection of the Field of Operation.....	42
Disinfection of the Hands.....	43
V. General Operative Technic.....	45
Menstruation and Its Disturbances.....	51
I. Physiologic Behavior.....	51
II. The Disturbances of Menstruation.....	52
A. Amenorrhœa.....	52
B. Menorrhagia. Menstruatio Precox.....	55
C. Dysmenorrhœa.....	56
D. Conception.....	58
E. Sterility.....	58
Pathology of the Vagina and Uterus.....	60
A. Anomalies of Development, Changes of Form and Position.....	60
1. Malformation of the Vagina and Uterus.....	60
I.—Aplasia of the Female Genital Organs.....	60
(a) Absence of Parts and Rudimentary Development.....	61

Pathology of the Vagina and Uterus—Continued.

(b) <i>Incomplete Unilateral Development with the Possibility of Sexual Functions</i>	63
(c) <i>Incomplete Coalescence of Müller's Ducts</i>	67
(d) <i>Incomplete Development with Incomplete Communication of the Genital Canal with the External Surface of the Body</i>	68
II.—Atrophia Uteri.....	75
2. Changes of Position and Form of Uterus and Vagina.....	82
I.—Versions and Flexions of the Uterus.....	83
Retroversions and Retroflexions.....	83
(1) <i>Congenital or Extraperperally Acquired Retroflexion</i>	83
(2) <i>Retroflexio Uteri Gravidæ</i>	87
(3) <i>Puerperal Retroflexion</i>	90
II.—Descensus et Prolapsus Uteri et Vaginæ.....	106
III.—Laceration of the Perineum—Perineorrhaphy.....	135
Operation for Incomplete Perineal Laceration.....	139
Operations for the Complete Laceration of the Perineum.....	140
IV.—Inversio Uteri.....	144
B. Inflammations of the Vulva, Vagina, and Uterus.....	149
1. Inflammation of the Vulva.....	150
Symptoms of Vulvitis.....	152
Pruritis Vulvæ.....	152
Vaginismus.....	157
2. Inflammation of the Vagina (Vaginitis).....	160
3. Inflammations of the Uterus.....	165
a. Inflammations of the Mucosa.....	165
I. <i>Endometritis Corporis</i>	165
Endometritis Post Abortum.....	166
II. <i>Endometritis Cervicis</i>	173
Symptomatology.....	175
A. Acute Cervicitis.....	175
B. Symptoms of Corporeal Endometritis.....	176
III. Diagnosis.....	178
IV. Prognosis.....	180
V. Treatment.....	181
Gonorrhœa in the Female.....	183
Tuberculosis of the Female Genitalia.....	190
The Individual Organs.....	193
1. <i>The Tubes</i>	193
2. <i>The Uterus</i>	195

	PAGE
Pathology of the Vagina and Uterus—Continued.	
3. <i>Vagina and Vulva</i>	197
4. <i>Ovary</i>	198
5. <i>Peritoneum</i>	198
Diagnosis.....	199
Treatment.....	201
<i>b. Metritis</i>	203
I <i>Metritis Acuta</i>	203
II. <i>Chronic Metritis</i>	206
C. <i>Tumors of the Vulva and the Uterus</i>	219
1. <i>Tumors of the Vulva</i>	219
A. <i>Benign Tumors</i>	219
B. <i>Malignant Tumors</i>	222
2. <i>Tumors of the Vagina</i>	224
Benign Tumors.....	225
Vaginal Carcinoma and Sarcoma.....	226
3. <i>New-Formations of the Uterus</i>	228
I. <i>Fibromyomata (Myomata, Fibromata)</i>	228
A. <i>Myomata of the Corpus Uteri</i>	229
1. <i>Subserous</i>	229
2. <i>Submucous</i>	229
3. <i>Intramural</i>	230
4. <i>Intraligamentous</i>	230
B. <i>Myomata of the Cervix Uteri</i>	230
1. <i>Myomata of the Supravaginal Part</i>	230
2. <i>Myomata of the Intravaginal Part</i>	231
3. <i>Submucous Pedunculated Fibrous Polypi</i>	231
<i>Clinical Behavior</i>	237
<i>Operative Treatment</i>	250
1. <i>Vaginal Myoma Operation</i>	256
2. <i>Abdominal Myoma Operations</i>	260
<i>After-Treatment</i>	267
II. <i>Adenoma of the Uterus</i>	269
III. <i>Carcinoma of the Uterus</i>	270
<i>Clinical Behavior</i>	282
<i>Radical Abdominal Total Extirpation of a</i> <i>Carcinomatous Uterus</i>	289
<i>Vaginal Total Extirpation of the Carcino-</i> <i>matous Uterus</i>	293
IV. <i>Malignant Chorion Epithelioma (Marchand)</i>	300
V. <i>Sarcoma of the Uterus</i>	302
1. <i>Mucous Membrane Sarcoma</i>	302
2. <i>Wall Sarcoma</i>	305

	PAGE
Operations for Urogenital Fistulae	307
1. Vesico-Vaginal Fistulae.....	307
<i>Resection of the Orificium Urethrae Externum</i>	315
2. Uretero-Vaginal Fistulae.....	316
3. Intestino-Vaginal Fistulae.....	318
Appendix.....	320
Prolapsus Recti. Hemorrhoidal Nodules. Ulcerative Strictures of the Rectum. Newgrowths of the Rectum.....	320
Operations on the Uterus	322
1. Discisio Orificii Uteri Externi.....	322
2. The Conical Excision.....	322
3. Operation for Laceration of the Cervix (Trachelorrhaphy).....	323
4. Amputation of the Cervix.....	326
Diseases of the Uterine Tubes	330
<i>Tumors of the Tubes</i>	341
<i>Clinical Signs</i>	344
<i>Vaginal Operation for Salpingitis and Sactosalpinx</i>	352
<i>Abdominal Operation for same</i>	353
Tubal Pregnancy.....	353
<i>Clinical Conduct</i>	362
The Diseases of the Ovaries	370
I. Malformations, Hypertrophy, and Atrophy.....	370
II. Changes in Position.....	371
Ovarian Hernia.....	372
III. Circulatory Disturbances.....	373
IV. Inflammations.....	374
A. Acute Oophoritis.....	375
B. Chronic Oophoritis.....	376
V. Tumors of the Ovaries.....	381
I. Epithelial Ovarian Tumors.....	382
The Different Forms of Epithelial Newgrowths.....	382
<i>Cystadenoma Glandulare Multiloculare Pseudomucinosum</i>	382
<i>Cystadenoma Serosum Papillare</i>	386
<i>Carcinoma of the Ovary</i>	387
II. Desmoid or Connective Tissue Ovarian Tumors.....	392
The Different Forms of Connective Tissue Ovarian Tumors....	392
III. The Ovigenuous Tumors of the Ovary.....	394
<i>The Cystic Embryomata</i>	395
The Pedicle Formation of Ovarian Tumors.....	397
Parovarian Cysts.....	400
<i>Clinical Behavior</i>	401
Clinical Conduct of Parovarian Cysts.....	414

TABLE OF CONTENTS

xi

	PAGE
The Diseases of the Pelvic Connective Tissue	415
I. Hematoma Extraperitoneale Periuterinum.....	415
II. Parametritis.....	419
<i>Clinical Behavior</i>	421
1. <i>Acute Parametritis</i>	421
A. <i>Acute Septic Puerperal Parametritis</i>	421
B. <i>Acute Septic Traumatic Parametritis</i>	426
C. <i>Acute Parametritis as a Result of an Infection from Diseased Foci External to the Mucosa (Descending) Form of Parametritis</i>	430
2. <i>Chronic Parametritis</i>	432
 Diseases of the Pelvic Peritoneum	 435
I. Hematocele.....	435
II. Peritonitis, Pelvipерitonitis, Perimetritis.....	439
<i>Clinical Behavior</i>	443
I. <i>Non-Infectious Peritonitis</i>	443
II. <i>Infectious Peritonitis</i>	446
1. <i>Septic Peritonitis</i>	446
2. <i>Sapremic Peritonitis</i>	447
3. <i>Gonorrhеal Peritonitis</i>	447
4. <i>Tuberculous Peritonitis</i>	448
 Supplement	 454
Neoplasms of the Pelvic Connective Tissue.....	454
 REFERENCES	 457
INDEX	467

LIST OF ILLUSTRATIONS

FIGURE	PAGE
1. Schematic Transverse Section through the Vagina.....	2
2. View into the Female Pelvis from Above.....	3
3. Sectio Frontalis Pelvis Feminae. (Colored.)	5
4. Partes Pelvis Virginis XVI annorum. (Colored.).....	7
5. Normal Vaginal Mucous Membrane.....	9
6. Normal Cervical Mucous Membrane	10
6a. Epithelium of the Cervix Uteri	10
7. Normal Uterine Mucous Membrane. (Colored.).....	11
8. Transverse Section through a Normal Tube at the Interstitial Portion	11
8a. Transverse Section of a Tube at the Ostium Abdominale.....	12
9. Menstruating Uterine Mucous Membrane. Subepithelial Hematomata. (Colored.).....	14
10. Surface and Cortical Layer of a Normal Ovary.....	15
11. Folliculus Primarius.....	16
12. Folliculus Vesiculosus. (Graafian Follicle.)	16
13. Corpus Luteum.....	17
14. Corpus Albicans	18
15. Examination Table, after <i>A. Martin</i>	20
16. Bimanual Examination in the Dorsal Position	21
17. Bullet-Forceps with Swivel-Lock for Taking it Apart	23
18. Tubular Speculum.....	24
19. Vaginal Retractors.....	24
20. <i>Nott's</i> Self-Retaining Speculum	25
21. Metal Uterine Sound	26
22. Metal Uterine Dilator, after <i>Hegar</i>	28
23. Curette, after <i>Roux</i> and <i>A. Martin</i>	30
24. Intrauterine Syringe, after <i>Braun</i>	32
25. <i>Playfair's</i> Sound.....	32
26. Gonococcus, <i>Neisser</i>	35
27. Ureter Cystoscope, after <i>Nitze</i>	37
28. Sterilizer for Instruments and Dressing Material, after <i>Lautenschläger</i>	41
29. Needle-Holder and Needles, after <i>A. Martin</i>	46
30. <i>Muzeux's</i> Forceps.....	47
31. <i>Collin's</i> Forceps.....	47
32. <i>Orthmann's</i> Sound Forceps	47
33. Patient in the Dorso-gluteal Position Ready for a Vaginal Operation.....	47
34. Patient upon a <i>Stille</i> Operating Table in a Dorso-gluteal Position for a Vaginal Operation.....	48


FIGURE	PAGE
35. Patient upon a <i>Stille</i> Operating Table in Elevated Pelvic (<i>Trendelenburg's</i>) Position for Laparotomy.....	49
36, 37, 38, 39, 40. Malformations of the Vagina and Uterus.....	60, 61
41, 42, 43. Uterus Unicornis cum Rudimento Cornu Alterius.....	64, 65
44. Hematocolpos and Hematometra Unilateralis Congenita.....	66
45. Hematocolpos Congenita.....	71
46. Hematometra and Hematocolpos Congenita.....	71
47. Hematometra.....	72
48. Hematometra Acquisita.....	74
49. Atrophia Uteri.....	76
50. Uterus Infantilis.....	76
51. Intrauterine Stem Pessary of Ivory.....	79
52. Retroflexio Uteri Congenita, after <i>C. Ruge</i>	84
53. Retroflexio Uteri Gravidii.....	90
54. Retroflexio Uteri Puerperalis.....	91
55. Retroflexio Uteri.....	92
56. <i>Hodge's</i> Pessary.....	95
57. <i>Thomas'</i> Pessary.....	95
58, 59, 60, 61. Anterior Colpotomy. (<i>Colored.</i>).....	102, 103, 104
62. Prolapsus Uteri with Metritis and Endometritis Colli Chronica.....	108
63. Prolapsus Vaginæ Anterioris cum Cystocele.....	109
64. Prolapse of the Anterior Vaginal Wall through Tumor Formation in the Same.....	109
65. Prolapsus Vaginæ Anterioris Superioris et Enterocele Vaginalis Anterior. (<i>Schematic.</i>).....	112
66. Prolapsus Vaginæ Posterioris cum Rectocele. (<i>Schematic.</i>).....	112
67. Prolapsus Vaginæ et Colli Uteri, Cystocele, Rectocele. Elongatio Colli Uteri. (<i>Schematic.</i>).....	113
68. Prolapsus Vaginæ et Uteri. Ectropion of Cervical Lips. (<i>Schematic.</i>).....	114
69. Prolapsus et Inversio Vaginæ, Retroflexio et Prolapsus Uteri, Cystocele et Rectocele.....	115
70. Puerperal Binder of Strong Fustian Material.....	118
71. Stem Pessary, after <i>Valleix</i> and <i>E. Martin</i>	119
72. Incision in Colporrhaphia Anterior. (<i>Colored.</i>).....	122
73. Suturing in Colporrhaphia Anterior. (<i>Colored.</i>).....	123
74. Colporrhaphia Posterior, after <i>Hegar</i> . (<i>Colored.</i>).....	124
75. Colporrhaphia Posterior, after <i>Hegar</i> . Suturing with a Continuous Catgut Stitch in Rows. (<i>Colored.</i>).....	125
76. Colporrhaphia Posterior (<i>A. Martin</i>). Incision of the Left Lateral Fold of the Vagina. (<i>Colored.</i>).....	126
77. Colporrhaphia Posterior (<i>A. Martin</i>). Incision of the Right Lateral Fold after Suturing the Left One. (<i>Colored.</i>).....	127
78. Closing of the Colporrhaphia Posterior, after <i>A. Martin</i> . (<i>Colored.</i>).....	128
79. Preparation of Prolapsed Uterus, which was Extirpated with the Vagina and the Adnexal Organs.....	134

FIGURE	PAGE
80. Flap Splitting Method, after <i>L. Tait</i>	138
81. Suture after the Flap Splitting.....	138
82. Suture of the Complete Perineal Laceration. (<i>Colored.</i>).....	141
83. Suture of the Rectum. (<i>Colored.</i>).....	142
84. Suture of the Perineum after Finishing the Rectal Suture. (<i>Colored.</i>)....	143
85. Inversio Uteri Incompleta.....	145
86. Inversio Uteri Completa. (<i>Schematic.</i>).....	145
87. Inversio Uteri Completa cum Prolapsu. (<i>Schematic.</i>).....	145
88. Kraurosis Vulvæ.....	154
89. Condylomata Acuminata.....	155
90. Epidermification of the Vaginal Mucous Membrane in Prolapsus.....	160
91. Colpitis Granulosa.....	161
92. Colpitis Emphysematosa.....	162
93. Endometritis Decidualis Post Abortum.....	166
94. Endometritis Interstitialis.....	167
95. Interstitial Endometritis. Transverse Section.....	168
96. Endometritis Hyperplastica.....	169
97, 98. Endometritis Glandularis Hypertrophica.....	170, 171
99. Endometritis Exfoliativa.....	172
100. Papillary Erosion of the Portio Vaginalis.....	173
101. Follicular Erosions of the Portio Vaginalis.....	175
102. Tuberculosis Endometrii, Tubarum, et Peritonei.....	192
103. Salpingitis Tuberculosa Miliaris.....	193
104. Salpingitis Tuberculosa Caseosa.....	194
105. Endometritis Tuberculosa Miliaris.....	196
106. Endometritis Tuberculosa Caseosa.....	197
107. Primary Tuberculosis of the Vulva.....	198
108. Tuberculosis Peritonei.....	199
109. Metritis Acuta.....	204
110. Wall of a Cyst of the Glandula Vestibularis Major.....	220
111. Cornified Squamous Epithelial Cell Carcinoma of the Vulva. (<i>Colored.</i>)....	221
112. Cylindrical-celled Carcinoma of the Vulva Arising from the Glandula Ves- tibularis Major.....	222
113. Primary Carcinoma of the Vagina.....	225
114. Primary Round Cell Sarcoma of the Vagina.....	226
115. Submucous Fibromyoma.....	229
116. Multiple Intramural, Submucous and Subserous Myomata of the Uterus....	231
117. Adenomyomata Uteri.....	233
118. Myoma Lymphangiectodes.....	235
119. Myxomatously Degenerated Pedunculated Uterine Myoma.....	236
120. The Exposed Uterus is Split. (<i>Colored.</i>).....	261
121. Suturing of the Bed of the Tumor after Enucleation. (<i>Colored.</i>).....	262
122. The Uterus Wound is Sutured.....	263
123. Superficial Cancerous Ulcer of the Portio Vaginalis.....	271
124. Cauliflowerlike Carcinoma of the Portio Vaginalis.....	271

LIST OF ILLUSTRATIONS

FIGURE	PAGE
125. Carcinoma Cervicis Uteri	272.
126. Cervical Gland with Beginning Carcinomatous Degeneration.....	273.
127. Carcinoma Cervicis Uteri	274.
128. Cervix Carcinoma.....	275.
129. Carcinoma Adenomatousum Corporis Uteri	276.
130. Polypous Carcinoma of the Corpus Uteri	277.
131. The same Preparation as in Fig. 130.....	278.
132. Surface Carcinoma of the Corpus Uteri. (<i>Colored.</i>).....	279.
133. Carcinomatous Uterus, Abdominally Extirpated.....	291.
134. Chorion Epithelioma Malignum.....	300.
135. Mucous Membrane Sarcoma of the Uterus.....	302.
136. Sarcomatously Degenerated Uterine Myoma.....	303.
137. Sarcomatously Degenerated, Intraligamentary Developed Uterine Myoma..	304.
138. Vesico-Vaginal Fistula	308.
139. Deep Vesico-Vaginal Fistula	308.
140. Vesico-Uterine Fistula	309.
141. Vesico-Cervical Fistula.....	309.
142. Urethro-Vaginal Fistula. (<i>Schematic.</i>).....	310.
143. Twisting Apparatus, according to <i>E. Martin</i>	313.
144. Retention Catheter (horse-foot-shaped of <i>Skene</i>).....	313.
145. Excision of the Posterior Lip. (<i>Colored.</i>).....	327.
146. Excision of the Anterior Lip. (<i>Colored.</i>)	328.
147. Tube with Two Accessory Tubes and Follicular Cyst of the Ovary.....	331.
148. Sactosalpinx Purulenta.....	334.
149. Salpingitis Purulenta	335.
150. Salpingitis Pseudofollicularis.....	336.
151. Sactosalpinx Serosa.....	337.
152. Tubal Mucous Folds upon the Highly Thinned Tubal Wall in Sactosalpinx Serosa.....	338.
153. Sactosalpinx Purulenta cum Abscessu Ovarii	339.
154. The same preparation as Fig. 153 in Transverse Section	340.
155. Primary Tubal Carcinoma.....	342.
156. Microscopic Section of the Preparation Represented in Fig. 155	343.
157. Round Celled Sarcoma of the Tubal Mucosa in a Primary Ovarian Sarcoma.	343.
158. Transverse Section Through a Pregnant Tube	354.
159. Tubal Ovisac with Hematomata Mole Formation of the Wall	355.
160. Tubal Pregnancy, Exterior View.....	356.
161. Tubal Mole in Tubal Abortion.....	357.
162. Unimpaired Tubal Pregnancy of the Third Month.....	358.
163. Transverse Section of Fig. 162	359.
164. Decidua Formation in a Pregnant Tube.....	361.
165. Acute Septic Oophoritis and Perioophoritis.....	375.
166. Multiple Ovarian Abscesses	376.
167. Small Cystic Degeneration of the Ovary.....	378.
168, 169. Cystadenoma Multiloculare Pseudomucinosum Ovarii.....	383, 384.

FIGURE	PAGE
170, 171. Cystadenoma Serosum Papillare Ovarii.....	386, 387
172. Carcinoma Alveolare Ovarii.....	388
173. Carcinoma Glandulare Ovarii.....	389
174. Cystadenoma Multiloculare Pseudomucinosum Partim Carcinomatosum Ovarii.....	390
175. Fibroma Papillare Ovarii.....	391
176. Fibrosarcoma Ovarii.....	392
177. Fibromyoma Ovarii.....	393
178. Sarcoma Rotundocellulare Ovarii.....	394
179. Embryoma Cysticum Ovarii.....	396
180. Torsion of Pedicle of an Ovarian Tumor.....	399
181. Parovarian Cyst.....	401
182. Abdominal Ovariectomy.....	411
183. Abdominal Ovariectomy. (<i>Colored.</i>).....	413
184. Pelvic Peritonitis.....	440
185. Perimetritis. (<i>Colored.</i>).....	441



I. Anatomy and Topography of the Female Pelvic Organs

Although we may suppose that the anatomy and topography of the pelvic organs are entirely known to the physician, it seems to be well to present the most important aspects of the anatomy of this subject at the beginning of a treatise on the special pathology and treatment of the female pelvic organs, in view of the fact that it is quite difficult to obtain a conception of these relations in perspective.

One must refer to the text- and handbooks on human anatomy for the minute details. The most comprehensive and latest is *W. Waldeyer*, "Das Becken" (the pelvis), Bonn, 1899, to which we call particular attention.¹

The uterus in the pubescent woman is about the size and form of a middle-sized pear. It is 5 to 8 cm long in the nulliparous, and about 6 to 9 cm in the multiparous (*Waldeyer*). The uterus is divided into three parts: The cervix, projecting into the vaginal vault, from 2.5 to 3 cm long; the corpus, limited by the wedge-shaped and upward spreading cornu of the uterus; and the fundus, that part lying between the upper corners of the cornua. The corpus is 4 to 4.5 cm long. The anterior wall of the corpus is almost flat, while the posterior wall is convex backward. The thickness of the walls of the uterus is about 1 cm in the cervical portion and 1 to 1.5 cm in the corpus and fundus. They consist of irregular bundles of smooth musculature interwoven with each other, enclosing connective tissue, vessels and nerves. The entire organ is bent at an obtuse angle over the anterior surface. The vertex of the angle is at about the junction of the cervix with the corpus: ***The normal anteflexio uteri.***

The cavity of the uterus has nearly a cylindrical form in the cervical canal, with a widening in the middle, a triangular form with the base directed upward in the corpus.

The cervical lips are continued into the anterior and posterior vaginal vaults which pass over to the anterior and posterior vaginal walls. The vagina is a canal surrounded by a muscular wall, and lined with mucous membrane with richly developed folds in the anterior and posterior walls, the ***columnae rugarum anterior et posterior***. The walls lie directly one upon the other, so that an H-form arises (Fig. 1).

A lumen proper, therefore, does not exist. The vagina is separated from the vestibule and the vulva by the hymen or its remains, the ***carunculae myrtiformes***. The latter are surrounded by the labia minora. At

the anterior junction of these labia lies the *clitoris*, and about 2 cm beneath it is found the *os externum urethrae*. Externally to the *labia minora* are the *labia majora*, which unite posteriorly in the *frenulum labiorum pudendi*, or fourchette, and are continuous anteriorly with the *mons veneris*. At the junction of the posterior and middle thirds of the labia majora are the orifices of the ducts of the *glandulae vestibulares majores* (*Bartholin's glands*), whose dot-formed mouths are plainly recognizable. Surrounding the *os externum urethrae*, especially at the posterior border, are the *ductus para-urethrales* (*Skene's ducts*).

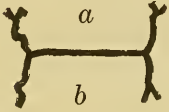


FIG. 1.—Schematic Transverse Section through the Vagina. *a*, Anterior; *b*, Posterior vaginal wall.

Somewhat anteriorly and laterally to the cornua of the fundus uteri are seen the *ligamenta rotunda* which run in a somewhat concave way to the internal abdominal rings. Just above and posteriorly to these are seen the *tubae uterinae* running externally and laterally and then posteriorly in the upper folds of the mesometrium (*ligamentum latum*). Posterior to these and somewhat lower are the *ligamenta ovariorum propria*, attached to the uterine cornua and terminating in the uterine pole of the corresponding ovary.

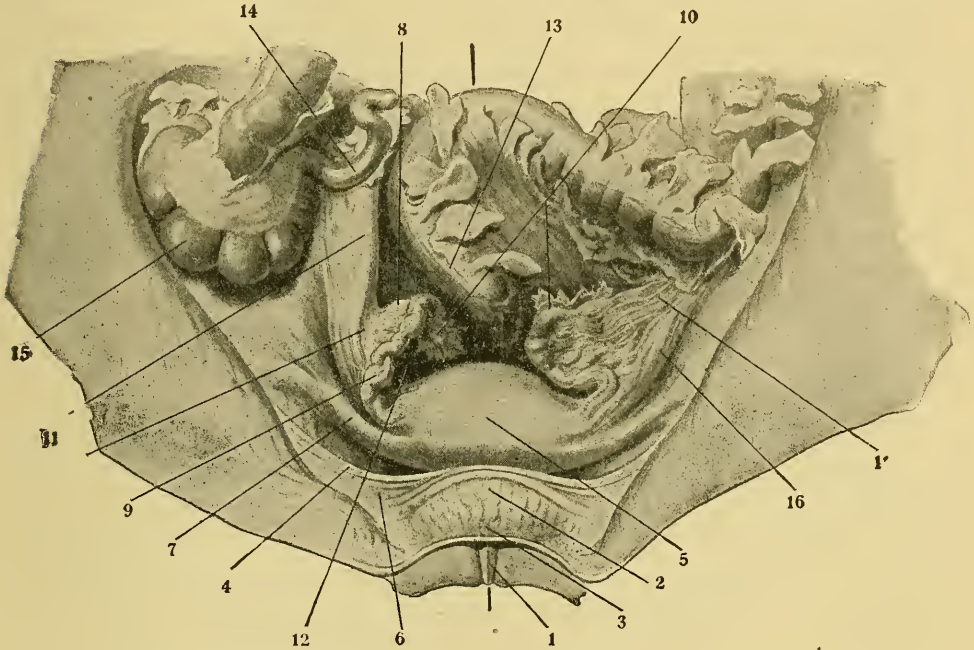
All these parts are covered with peritoneum, with the exception of the ovary. If one looks into the pelvic cavity from above, the bladder and rectum being empty (see Fig. 2), there is seen in the anterior portion and immediately behind the symphysis pubis, the collapsed bladder on which rests the uterus with its anterior wall, so that the fundus is directed forward pointing about to the upper edge of the symphysis pubis. The posterior surface of the uterus points with its corporeal portion directly upward, and its lower cervical portion posteriorly and upward, about in the direction of the promontorium sacri. The *portio vaginalis* is directed downward and backward into the hollow of the sacrum.

Behind the uterus, and usually filled with loops of intestine, is the *excavatio recto-uterina* (*cavum Douglasii*), which is limited posteriorly in its central portion by the rectum.

The *Fallopian tube* is divided into three parts: The *pars interstitialis*, contained within the uterine wall, the *pars isthmica*, reaching from its junction with the uterus to a point marking two-thirds of its entire length, and the *pars ampullaris*, which contains the funnel-shaped abdominal opening surrounded with fimbriæ, the *os abdominale*. The wall of the uterine tube consists of a mucous lining, a muscular layer containing internal circular and external longitudinal muscle fibres, and the peritoneal or serous coat. The tubes, after leaving the uterine wall, run in a nearly straight line laterally and horizontally to a point about midway between the uterine cornu and the side of the bony pelvis, where they turn at an almost right angle backward and downward. The fimbriated extremity is directed downward into the *excavatio recto-uterina* and covers and surrounds its corresponding ovary. The upper portion of the

ligamentum latum, which covers the uterine tube, is termed the *mesosalpinx* (see Figs. 2, 3 and 4).

The *ovary*, a flat almond-shaped body, is connected to the uterus with its uterine pole by the ligamentum ovarii proprium, and hangs down at its hilus or mesovarium from the posterior wall of the ligamentum latum. Its upper or tubal pole is directly connected to the bony pelvis, just external to the articulatio sacro-iliaca, by the ligamentum suspensorium



- | | |
|--------------------------------|-------------------------------|
| 1. Symphysis pubis. | 9. Tube. |
| 2. Vesica urinaria. | 10. Infundibulum tubae. |
| 3. Vertex vesicae. | 11. Lig. suspensorium ovarii. |
| 4. Plica vesicalis transversa. | 12. Fossa parauterina. |
| 5. Fundus uteri. | 13. Rectum. |
| 6. Fossa paravesicalis. | 14. Processus vermiformis. |
| 7. Lig. rotundum. | 15. Coecum. |
| 8. Lig. infundibulo-ovaricum. | 16. Ligamentum latum. |

FIG. 2.—View into the Female Pelvis from Above. After A. Martin "Festschrift" for C. Ruge. Plate 1, Berlin, S. Karger, 1896.

ovarii. The ovary lies in the bursa ovarica, a flat depression in the lateral bony wall of the pelvis. The fimbriated extremity of the tube and the tubal pole of the ovary are further united by the ligamentum infundibulo-ovaricum, and upon its border runs the *fimbria ovarica* from the tube to the ovary. The ovary is *not* covered by peritoneum, but by a single layer of flat or cuboidal cells, the *germinal epithelium*. Beneath this is a thin layer of connective tissue, the *tunica albuginea ovarii*,

which is intimately connected with the underlying stroma. The latter is made up of connective tissue, having small spindle-shaped cells embedded in which are the essential ovarian elements, the *ovarian* or *Graafian follicles*. The stroma is poorly developed in its cortical portion, but is more abundant in the vascular or medullary portion. In the cortical portion the stroma forms a network for the ovarian follicles, while in the medullary or vascular portion it forms a supporting structure for the freely branching bloodvessels and nerves (see Figs. 10, 11 and 12).

The medullary or vascular portion is continued directly with its vessels and nerves into the *hilus ovarii*, which latter is continuous with the posterior wall of the ligamentum latum. Within the hilus ovarii is contained the *parovarium* or *epoophoron*, the rudiments of the sexual portion of the *corpus Wolfii*. The epoophoron is formed almost like a comb, a number of canals or tubules terminating in one large collecting canal or tube, the latter running parallel to the Fallopian tube. These tubes are lined with a single layer of ciliated cylindrical epithelium. Not infrequently the transverse tubules extend into the medullary portion of the ovary.

All the pelvic organs are covered with *peritoneum*, with the exception, of the ovaries.

The peritoneum is continued from the inner side of the anterior abdominal wall over the bladder, descends from the fundus of this organ down into the excavatio vesico-uterina (covered in Fig. 2 by the uterus) and reaches the uterus at a point about midway of its anterior wall. Here it connects intimately with the uterus, ascends and covers the fundus uteri and descends posteriorly into the excavatio recto-uterina (cavum Douglasii) where it reaches its *deepest point* just above the posterior vaginal vault. Then the peritoneum is reflected upward over the anterior wall of the rectum. The space between the peritoneum and vaginal wall is very broad anteriorly, between the two being contained a portion of the bladder, while posteriorly the space is very narrow: at this point it is easy to enter the peritoneal cavity through the vagina. (Important for the surgeon.) In the lateral parts of the pelvis the peritoneum descends into the *fossae paravesicales* (see Figs. 2 and 4), ascends to the height of the ligamentum latum, descends into the fossæ pararectales and ascends on either side of the rectum in front of the sacrum and the ilium.

The cavity above the peritoneal covering is the *cavum serosum pelvis*, and beneath it is the *cavum subserosum pelvis*, which is filled with *pelvic connective tissue* and reaches down to the muscular floor of the pelvis (the *diaphragma pelvis rectale et urogenitale*), on both sides.

The cavum subserosum pelvis is divided into three parts, anteriorly the *subserosium paravesicale*, in the middle the *subserosium parauterinum* and posteriorly the *subserosium pararectale*.

The uterus, vagina, and tubes are completely enclosed with pelvic con-

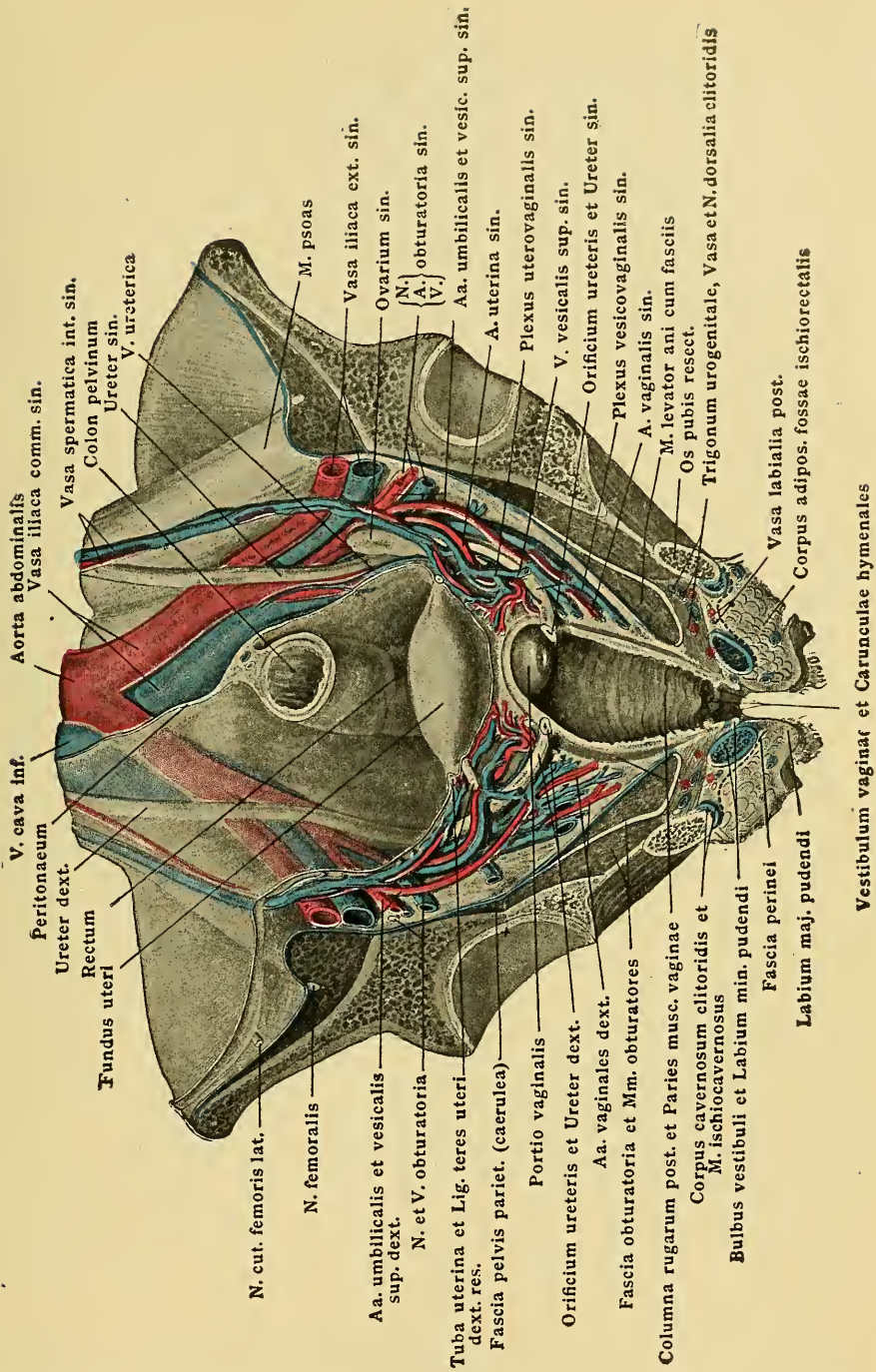


FIG. 3.—Sectio Frontalis Pelvis Feminae. Situs organorum genitalium, ureteris, vasorum. Fasciae pelvis et perinei. Trigonum urogenitale. 1/2 natural size. (Waldeyer, page 727, Fig. 153.)

nective tissue, while the ovaries are only enclosed at the hilus, hanging otherwise free in the peritoneal cavity.

Dense connective-tissue bands, *ligaments*, can be demonstrated in this quite loose connective tissue of the subserous cavity which contribute materially to maintain the pelvic organs in their relative position. These bands consist of dense connective tissue, to a great part also of smooth musculature and elastic fibres and are to a certain degree capable of contracting. The most important ones are the following:

1. *Ligamenta lata*, or broad ligaments, reaching from the cornua uteri to the lateral bony pelvic walls. They are strongest and toughest in the lower portion lateral to the cervix uteri. This portion is known as the *pars cardinalis ligamenta lati*. They support the uterus laterally and from beneath, so that the uterus rides on them as a rope-dancer on a tight rope.

2. *Ligamenta rotunda* (vide supra, Fig. 1). These hold the uterus in normal anteversion. A retrodeviated uterus is returned to its normal position by operative shortening of these ligaments (*Alexander Adams' operation*).

3. *Ligamenta sacro-uterina*. These are attached to the cervix at about the region of the internal os and to the posterior pelvic wall laterally to the rectum, surrounding the latter like a two-pronged fork; they pull the cervix backward.

4. *Ligamenta ovariorum propria* and *suspensoria ovarii*. (Vide supra, Fig. 2.)

The pelvic connective tissue also contains the entire blood and lymph apparatus of the genitalia, with the regional lymph-glands as well as the genital nerves and ganglia. It is directly continuous with the connective tissue of the rest of the body in many places; for instance through the foramina ischiadica et obturatoria and the inguinal canals. A direct continuation exists with the connective tissue of the abdominal walls anteriorly, posteriorly, and laterally. (This is of importance for the spreading of pathologic exudates, pus, etc.)

The cavum subserosum pelvis terminates below at the *fascia pelvis interna* which overlies the muscular floor of the pelvis. The muscular diaphragm consists laterally of the musculus obturator internus and pyriiformis, and in the middle of the anococcygeus and levator ani, known as the *diaphragma pelvis rectale*. The latter is penetrated at its lowest portion by the rectum. The muscular floor of the pelvis is strengthened anteriorly by the *diaphragma pelvis urogenitale* (mm transversus perinei profundus and bulbo cavernosus) which are traversed by the vagina and urethra.

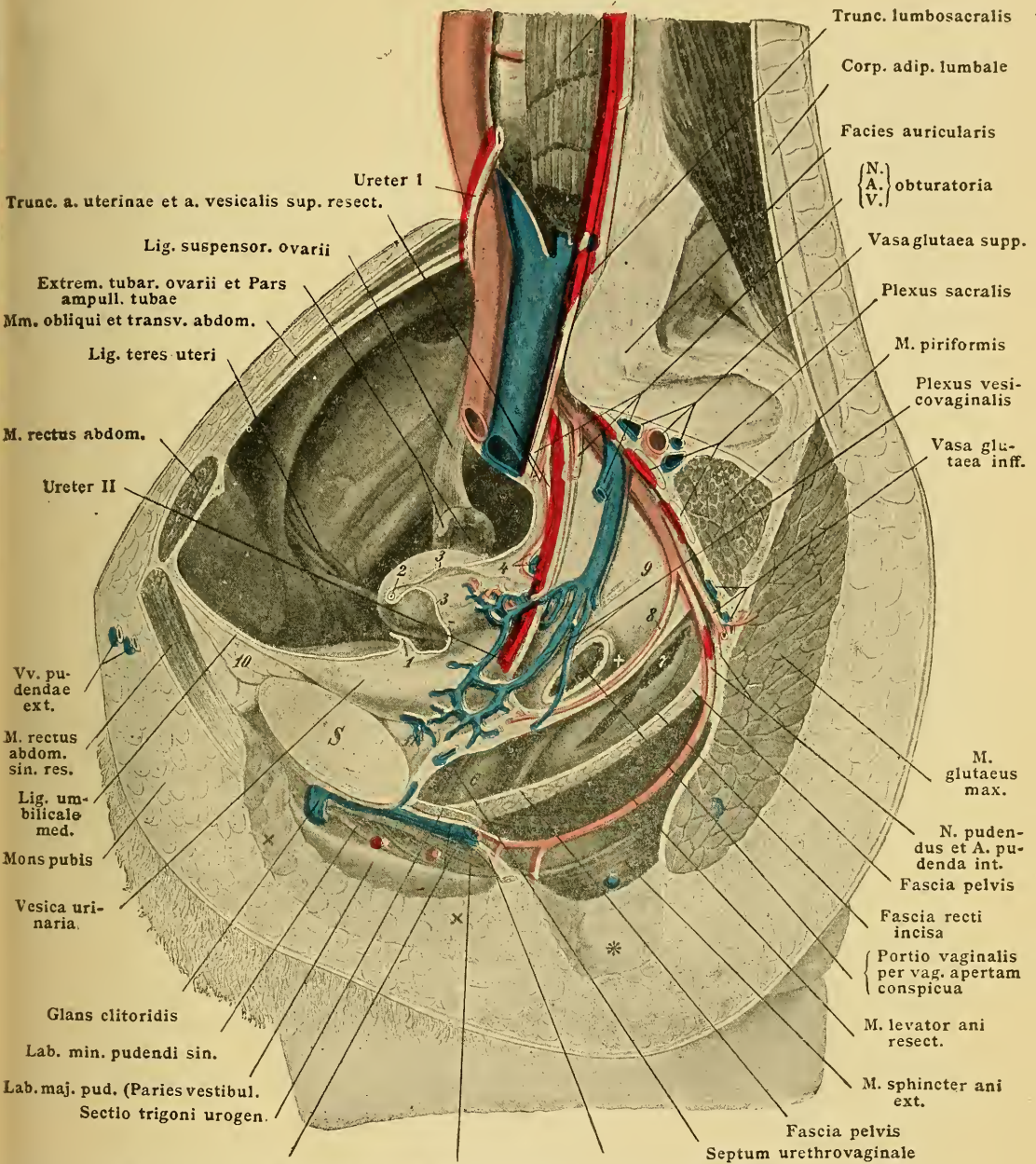
The *bloodvessel supply* of the female generative organs is very abundant, in conformity with the function of nourishing the developing fetus to full term.

The chief arteries are:

1. *Arteria uterina* (see Figs. 3 and 4). A branch of the arteria hypo-

Fig. 4.

M. psoas



Partes pelvis virginis XVI annorum a sinistro latere praeparatae.
Mus. anat. Berlin.

S = Symphysis oss. pub. 1. Plica vesicalis transv. 2. Sectio tubae sin. 3. 3. Sectio perit. 4. A. et V. uterin. 5. Urethra. 6. Vagina. 7. Rectum (apertum). 8. Ram. vesicalis. 9. Lig. rectouterinum. 10. Corp. adip. praeves. sup. 11. Corp. adip. praeves. inf. + = Fundus excavat. rectouterin. * x x Lacunae ablatione telae adiposae exortae. Punctum coeruleum = Locus ani. Punctum rubrum = Locus orific. vagin. Punctum flavum = Locus orif. ext. urethrae. (Waldeyer, a. a. O. S. 757, Fig. 158c.)

gastrica. This traverses the parametrium to the cervix uteri, at about the internal os, sending branches to the anterior and posterior vaginal vault and running along the edge of the uterus laterally up to the fundus, where it anastomoses with branches from the

2. *Arteria spermatica* or *ovarica*, direct branches of the abdominal aorta, arising below the renal arteries. They run through the lig. suspensorium ovarii and the mesosalpinx to the uterus, supplying the tube and ovary.

In this way the blood-supply of the uterus and adnexa is always two-fold, and even if the large vessels of one side are tied off the nourishment of the organs is always sufficient.

The *veins* run parallel to the arteries and form many *plexuses*. (The veins of the ovary form at the hilus the *plexus ovaricus*, the ovarian or pampiniform plexus. This empties in part into the uterine vein and in part into the ovarian vein. The right ovarian vein empties into the inferior vena cava, and the left into the left renal vein. The uterine vein empties into the hypogastric vein.)

The *ureter* (see Figs. 3 and 4), in consequence of its course in the small pelvis, is in close relation to the genital organs. It enters the pelvis laterally to the promontorium and anteriorly to the arteria iliaca communis, crosses the arteria hypogastrica and runs in a concave way through the base of the ligamentum latum close above the lateral vaginal wall, into the bladder.

The arteria uterina, after its exit from the hypogastric artery, runs at first almost parallel to the ureter, but bends at an almost right angle and crosses the ureter about 1 to 1.5 cm laterally to the cervix. (Important for the ligation of the arteria uterina.)

The *lymphatic vessels* of the female generative apparatus generally follow the bloodvessels and lead to a number of lymph-gland groups, which form the primary filters for the physiologic and pathologic lymph excretion from the genitalia.

1. *Lymphoglandulae inguinales externae et internae* receive the lymph from the external genitals and the lowest portion of the vagina.

2. *Lymphoglandulae hypogastricae*, in the triangle between the arteria iliaca externa and hypogastrica, receive the lymph from the upper portion of the vagina, the cervix, and the lower portion of the corpus uteri.

3. *Lymphoglandulae sacrales laterales*, between the arteria hypogastrica and rectum, receive the lymph from the rectum, and the posterior portion of the cervix uteri, through the ligamenta sacro-uterina.

4. *Lymphoglandulae iliacaе externae*, externally to the external iliac artery, receive lymph from the cervix and corpus uteri.

5. *Lymphoglandulae lumbales inferiores et superiores*, along the arteria iliaca communis and aorta, receive the lymph from the tubes and the ovaries.

The *nervous system* of the female generative organs is derived for

the greater part from the sympathetic system, to a lesser part from the spinal system.

The sympathetic fibres run from the ganglion cœliacum down the aorta into the broad plexus uterinus magnus. This divides at the height of the promontorium into the two plexus hypogastrici, which surround the rectum and form laterally at the place where the ureter and the arteria uterina cross, the great *ganglion cervicale* (*Frankenhäuser*). *Spinal branches* of the II (?), III, and IV sacral nerves also enter this ganglion.

Nerve trunks branch off from this ganglion cervicale to all sides, especially to the uterus and along the vagina, surrounding these organs in a dense network and penetrating their parenchyma down to the mucosa. This ganglion even distributes branches to the tubes and ovaries, uniting with branches derived from the spermatic ganglion. Large and small ganglia are everywhere embedded among these nerves.

In this way the entire genital apparatus is richly supplied with nerves.

The entire female genital canal, from the vulva to the abdominal end of the tubes, is lined with *mucous membrane*, which differs histologically in the different parts.

The labia majora are covered with a hairy epidermis containing sudoriferous and sebaceous glands. At the junction of the lower and middle third one sees the duct of the glandula vestibularis major (*Bartholini*). This gland is of an acinous structure, and lined with a single layer of cylindrical epithelium. Its mucous secretion is voided sub cohabitatione.

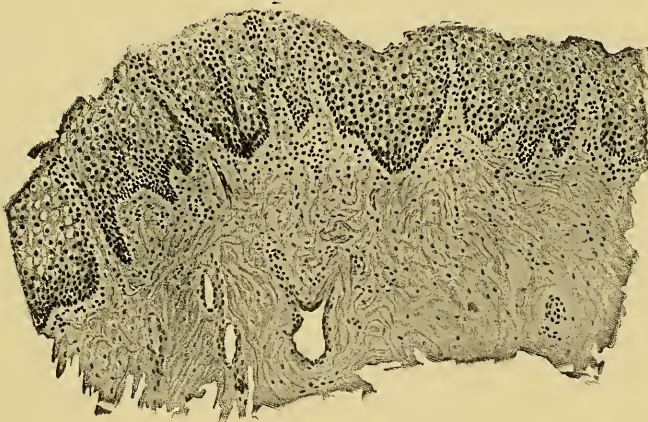


FIG. 5.—Normal Vaginal Mucous Membrane. (Author's preparation
Zeiss, Obj. AA, Oc. 4.)

and makes the introitus vaginæ slippery. This gland has a pathologic significance as the seat of abscesses, cysts, malignant tumors, etc.

The small labia, on the other hand, are covered with a mucous membrane, such as that which lines the entire *vagina* and the external sur-

face of the portio vaginalis. This mucous membrane consists of layers of squamous epithelium resting on a base of cylindrical epithelium, but *without* stratum corneum and without glands (Fig. 5). Beneath the layers of squamous epithelium is found the papillary body, and beneath this a narrow connective-tissue submucosa which terminates in a moderately strong layer of smooth musculature. The papillary body and the

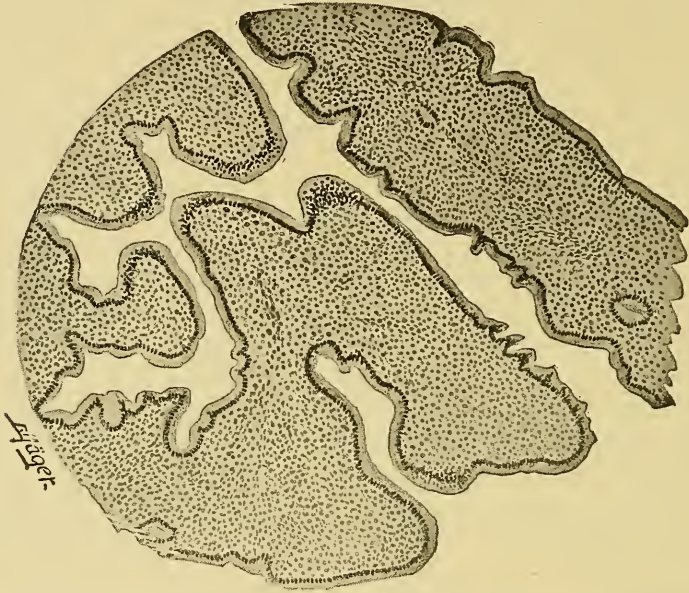

FIG. 6.—Normal Cervical Mucous Membrane. (Author's preparation. Zeiss, Obj. AA, Oc. 2.)

submucosa are rich in elastic fibres (Fig. 5). Glands proper are not found in the vagina.

The so-called secretion of the vagina consists merely of old desquamated epithelium of the upper layer, mixed with the secretions of the upper genital tract, especially the cervix, and exhibits a white, granular substance, which is normally of an *acid* reaction.




FIG. 6a.—Epithelium of the Cervix Uteri. (Zeiss, Obj. DD, Oc. 2.)

The squamous epithelium of the vagina is separated from the cylindrical epithelium of the cervical mucous membrane by a distinct sharp line.

The mucous membrane of the *cervical canal* is distinctly folded (*plicae palmatae*) and provided with many glands of an acinous construction. The surface layer of the mucous membrane, as well as the glandular tubes, is formed of a single layer of very deep cylindrical epithelium with a nucleus at the base, but *without* cilia. This epithelium throws off an abundant mucous secretion of an *alkaline* reaction, which under

normal conditions fills the cervical canal in the form of a glossy, mucous plug, thus closing it off from the vagina. The stratum of the cervical

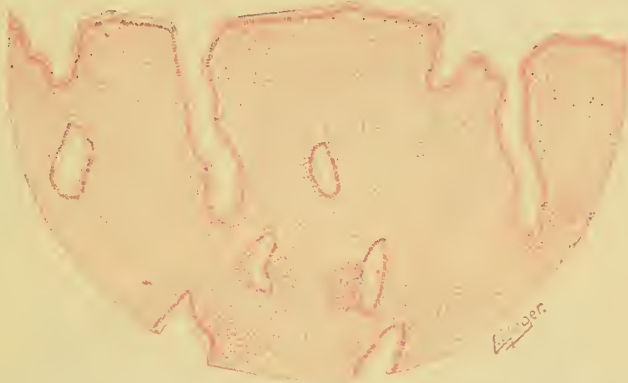

FIG. 7.—Normal Uterine Mucous Membrane. (Author's preparation. Zeiss, Obj. AA, Oc. 4.)

mucous membrane consists of a loose fibrous connective tissue, which is continued into the extensive and dense connective tissue of the cervical

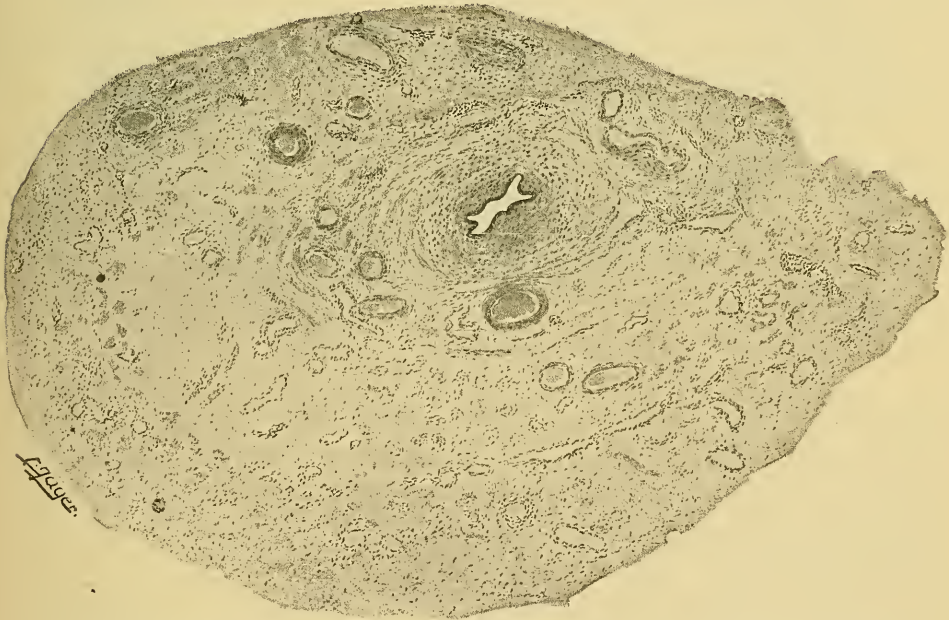

FIG. 8.—Transverse Section through a Normal Tube at the Interstitial Portion. (Author's preparation. Hartnack, Obj. 2, Oc. 3.)

wall. The latter contains a much more scanty smooth musculature than the corpus uteri (see Figs. 6 and 6a).

The cervical mucous membrane is sharply separated from the mucosa corporis at the internal os uteri.

The *corporeal* mucosa is perfectly smooth on the surface in contradistinction to the richly folded cervical mucous membrane, and is composed of a very soft stroma consisting of round and stellate cells mixed with a few spindle-shaped cells and is known as a cytogenetic or lymphoid tissue. The submucosa is entirely wanting (see Fig. 7).

It is permeated by numerous *tubular* glands reaching from the surface down to the muscularis. The tubular glands and the mucous membrane are covered with ciliated cylindrical epithelium with a central

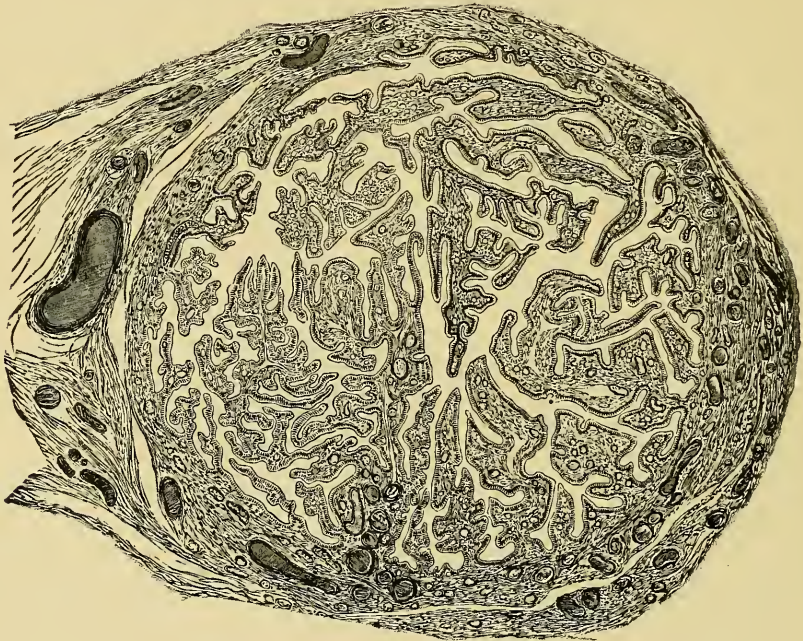

FIG. 8a.—Transverse Section of a Tube at the Ostium Abdominale.
(Hartnack, Obj. 2, Oc. 2 [Orthmann].)

nucleus and distinct basal membrane, its cilia move in the direction from the fundus to the cervix. The secretion of the uterine mucous membrane is thin, serous, and aqueous, in contradistinction to the thick mucous secretion of the cervix. The thickness of the uterine mucous membrane is normally from 1 to 2 mm.

At the orificium tubæ the uterine mucous membrane connects with the *tubal mucous membrane*. The latter is rich in folds which increase gradually in size and number from the uterine to the abdominal end (Figs. 8 and 8a), attaining a labyrinth-like form at the fimbriated extremity. These folds, consisting of fine fibrillar connective tissue, rest immediately upon the inner circular muscle layer. A stroma proper of the mucous membrane does not exist, nor is a submucosa present. The con-

nective-tissue folds are directly covered with ciliated cylindrical epithelium, of the same form as found in the corpus uteri. The motion of the cilia is directed from the abdominal to the uterine end. The fimbriæ of the abdominal end are also covered with this ciliated epithelium, which terminates here directly at the peritoneal endothelium.

The mucosa of the cervix, corpus uteri, and tubes is rich in blood and lymph vessels, with whose dilatation or contraction they correspondingly increase or decrease, as in the process of menstruation. (For the more minute structure of the ovarium see the chapter: Development, Menstruation, and Ovulation.)

II. Development of the Female Genitalia

The text-books² of embryology must be consulted about the *intra-uterine* development of the female genitalia.

The *genitalia of the new-born baby girl* differ not only in size, but also in form, from those of the pubescent woman.

The labia majora lie close together and cover completely the labia minora and the clitoris. The mons veneris, as well as the vulva are still devoid of hair and of the more abundant adipose tissue. The mammæ are completely undeveloped.

The corpus uteri is very small in proportion to the cervix, the mucous membrane thin, the fundus narrow. The tubes are strongly convoluted, the ovaries proportionately longer and cylindrical, with a smooth surface. In their stroma the primordial follicles are much more numerous than later. The connective tissue between them is delicate and sparingly developed. The ovaries at this time lie high, at or above the linea innominata; their longitudinal axis, as well as that of the ligamentum suspensorium ovarii, runs almost vertically from above downward.

Only trifling changes occur in this condition until the entrance of puberty; the growth of the genitalia remains behind the development of the rest of the body.

The genitalia attain their complete development only with the occurrence of puberty, that is, about the thirteenth to fifteenth year of life in our latitude.

The mons veneris and the labia majora grow larger and richer in fat and become covered with curled hair. The mammæ develop also with an abundant deposit of fat. The vagina grows longer and wider, the corpus uteri grows and gains predominance over the cervix, and the fundus becomes broader. The mucous membrane increases in thickness. The tubes straighten out, the ovaries lose their cylindrical form and become more oval and almond-shaped, their stroma becomes more abundant, the primary follicles relatively more scanty. The ovaries descend into the small pelvis with a lengthening of the ligamenta suspensoria which run

at the same time more obliquely from externally above to internally downward.

The genitalia remain so until the time of the decline of puberty, that is to the forty-fifth to the fiftieth year of life. The so-called "change of life," the *climacteric*, begins then.

A general atrophy occurs in this period. The external genitalia and the mammæ become poorer in fat and more flabby. The rugæ of the vaginal mucous membrane fade away and it becomes smooth. The portio vaginalis shrinks up to a complete level with the vaginal vault, which forms a funnel tapering upward, and the external os uteri lies at its upper end. The uterus itself diminishes in size, its walls become thin and flabby, and even the pelvic connective tissue takes part in this general atrophy. (Inclination toward the occurrence of prolapsus during this time.)

The tubes likewise become thin and atrophic. The still existing follicles in the ovaries undergo atresia and connective-tissue transformation until finally only a connective-tissue body the size of the kernel of an almond remains.

Menstruation and Ovulation

Together with the entrance of the female into puberty commences the appearance of *menstruation*³—that is, a bloody flow from the genitalia, recurring in regular periods.

This process, which occurs in the healthy about every twenty-seven to twenty-eight days, and lasts at an average about three to four days, is the expression of a periodically recurring, wavelike ascending and descending change in the entire physiologic functions of a woman (*Goodman*). The intensity of this function reaches its highest point shortly

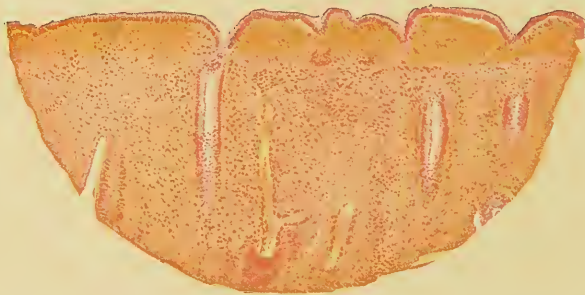

FIG. 9.—Menstruating Uterine Mucous Membrane. Subepithelial hematoma.
(Author's preparation. Zeiss, Obj. A, Oc. 2.)

before the beginning of each menstruation, sinks in a steep curve during the flow, reaching soon afterward its lowest point and gradually ascending again to its height. A gradually increasing hyperemia of the entire genital organs, the *premenstrual congestion*, develops during the latter part of the ascent. The mucous membrane of the uterus swells, the ves-

sels become filled to bursting, and an interstitial edema occurs. The single cell of the stroma also increases in size (formation of a *pseudo-decidua*). A voluminous extravasation of red blood-corpuscles, partly by diapedesis, partly by rhexis, takes place at the height of this hyperemia; these red blood-cells collect especially underneath the cortical epithelium as small extravasations of blood (subepithelial hematoma) (see Fig. 9).

The epithelial layer thus detached ruptures in isolated places, and transmits the blood to the surface drop by drop. Here it is mixed with the uterine secretion which forms abundantly during the congestion, and

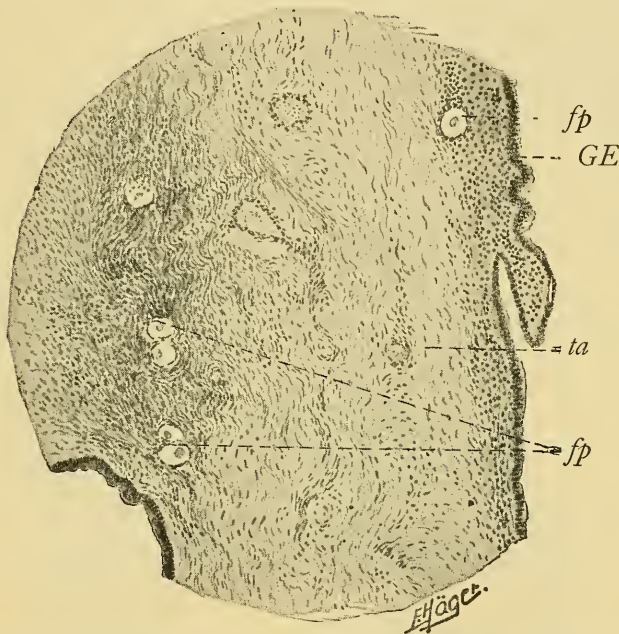


FIG. 10.—Surface and Cortical Layer of a Normal Ovary. *Ge*, germinal epithelium; *ta*, tunica albuginea; *fp*, folliculi primarii. (Author's preparation. Zeiss, Obj. A, Oc. 4.)

also with the secretion from the cervix and vagina during its passage through the cervical and vaginal canals, and reaches the exterior. As a result of this admixture with the mucous secretion the menstrual blood does not clot. It forms light red stains with a yellowish border on the clothing. The epithelial layer which becomes detached during the extravasation of the drops of blood does not perish, but reattaches itself to a very great extent, and the few shed cells are quickly replaced. A rapid decrease in size of the mucous membrane occurs during the flow. After a short intermission a slow growth sets in again until the occurrence of the next premenstrual congestion.

This process of menstruation, however, is not a self-dependent one.

It is dependent on the much more important occurrence of **ovulation** which takes place in the ovaries.

We understand by ovulation the development of a primary follicle to a mature follicle and the expulsion of the ripe ovum from the ovary (Fig. 11).

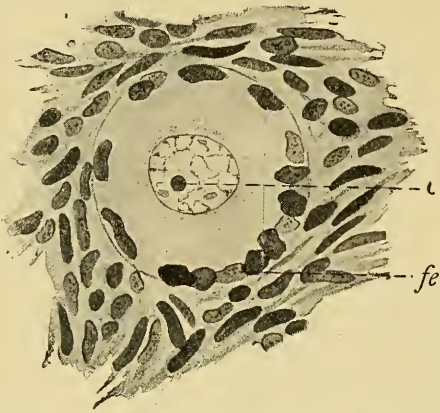

FIG. 11.—Folliculus Primarius. *fe*, follicular epithelium; *o*, ovum. (Author's preparation. Zeiss, Homog. immers. Oc. 4.)

In the transformation of a primary follicle (Fig. 11) to a mature follicle the follicular epithelium becomes many-layered and forms on the side opposite the surface of the ovary the **cumulus oophorus**, which surrounds the ovum, while the rest of the open space becomes filled with the **liquor folliculi** (Fig. 12) and bulges out from the surface of the ovary. One can at times palpate in persons with thin, relaxed abdominal walls the follicle ready to burst as a hump on the ovary.

Finally the follicle ruptures, the

ovum, with the surrounding cells of the cumulus oophorus, is expelled

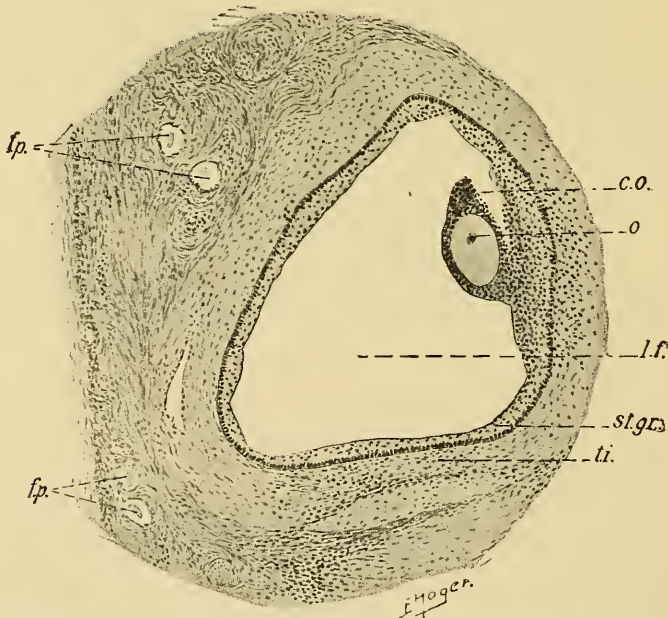


FIG. 12.—Folliculus Vesiculosus (Graafian Follicle). *ti*, tunica interna; *st gr*, stratum granulosum; *lf*, liquor folliculi; *co*, cumulus oophorus; *o*, ovulum; *fp*, folliculi primarii. (Author's preparation. Zeiss, Obj. AA, Oc. 4.)

and gets into the tube. Here it is either impregnated or it perishes unfecundated.

A hematoma is next formed in the ruptured follicle, surrounded by a macroscopically visible, undulated, yellow cellular membrane, the *lutein* membrane (transformed follicular epithelium, *Sobotta*), *corpus luteum* (Fig. 13). The entire formation becomes organized through the connective tissue of the ovary and changes finally into a firm scar tissue, *corpus albicans* (Fig. 14).

The process of menstruation is absolutely dependent on this process of ovulation, for the former becomes forever extinct, if, as in the cli-

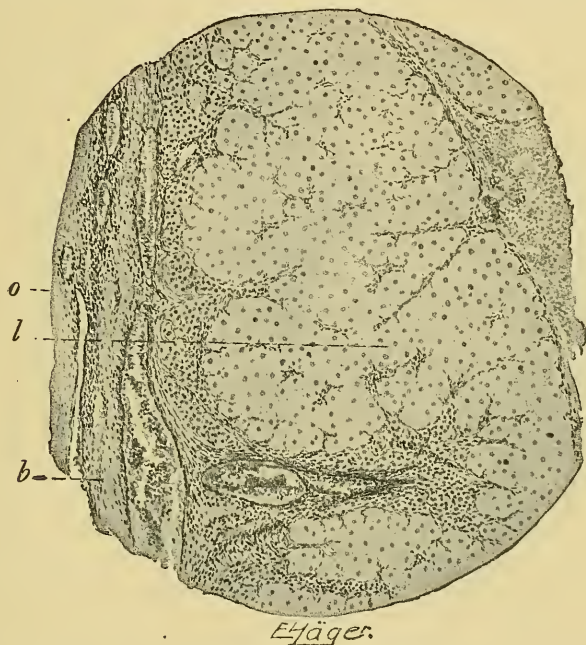


FIG. 13.—Corpus Luteum. *o*, surface of ovary; *l*, lutein layer; *b*, connective tissue with bloodvessels proliferating into the lutein layer. (Author's preparation. Zeiss, Obj. AA, Oc. 2.)

macteric, ovulation ceases. In the same manner it becomes extinct, if both ovaries are removed by an operation. On the other hand, ovulation is entirely independent of menstruation, for the former can very well continue to exist—while the latter ceases. This occurs, for instance, during the puerperal state, during lactation, in the course of many constitutional diseases and so forth. Pregnancy may readily occur during this time of amenorrhea.

No doubt exists any more about these points; however, the *way* in which the process of ovulation influences menstruation has remained unexplained up to this time.

Of all the theories adduced *Pflüger's* was considered for a long time

the most probable one. According to this the slowly growing follicle is supposed to exert a gradually increasing pressure on the ovarian nerves and thus, by the transmission of impulses through the sympathetic to the vaso-motor system, a hyperemia of the pelvic organs is brought about, until finally the irritation ceases with the rupture of the follicle. The mucous membrane of the uterus decreases after the extravasation of blood.

The maturing of a new follicle recommences and with it a new summation of the irritations of the sympathetic nerves. *Knauer*⁴ instituted more recent experimental investigations. He transplanted the ovaries

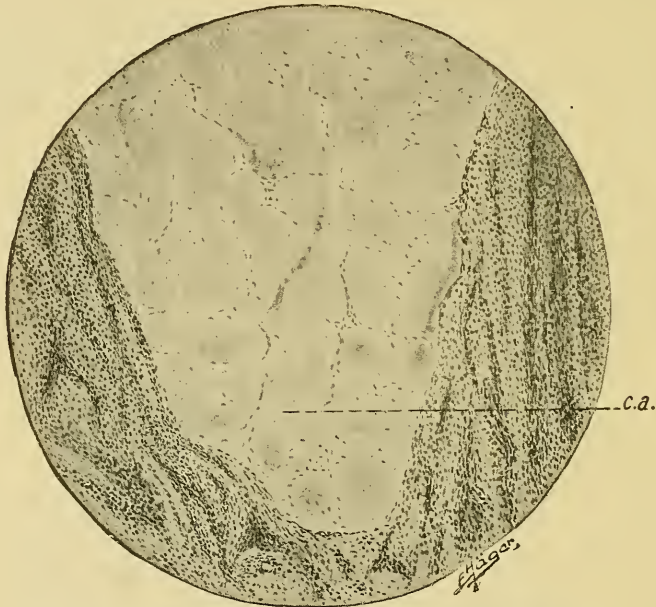


FIG. 14.—Corpus Albicans (*ca*). (Author's preparation.
Zeiss, Obj. AA, Oc. 2.)

of animals, for instance, into a laparotomy incision. The ovaries healed in this place, and menstruation remained preserved. *Pflüger's* theory has suffered a severe jolt through this experiment. Of late an **internal secretion** of the ovaries has been accepted without strong proofs (*Born*, *L. Fränkel*) rendered.

The former supposition that ovulation and menstruation **occur at the same time**, was also dropped, since it had been proven untenable by a number of objective findings, especially during operations.

It is now taken for granted that ovulation precedes menstruation for a number of days, although no facts can be assigned to prove this to any extent, at least for the **human race**.

III. Gynecologic Examinations

From the above-described topography of the uterus it is seen that this organ in the woman, **standing erect** with bladder and rectum empty, is in an almost horizontal position (see Figs. 2, 3 and 4). The fundus lies forward upon the bladder, the axis of the corpus points backward to the apex of the sacrum. In the region of the internal os, the uterus bends downward posteriorly, and is directed somewhat backward and downward, while the axis of the vagina passes nearly perpendicular to it from below upward and backward. From this it is clear that the cervix stands perpendicular to the posterior vaginal wall.

In the **recumbent position**, the position in which we usually examine women, these relations are changed so that the vagina is directed somewhat downward and backward, the cervix somewhat upward and backward, while the axis of the corpus uteri passes directly upward. The uterus is maintained in this position by its ligaments, which, in their turn find their support on the muscular floor of the pelvis (vide supra, page 6).

The uterus, however, is not rigidly fixed in this physiologic position, but possesses to a high degree the capability of adapting itself to the changed conditions of its surroundings, especially the neighboring viscera, the bladder and the rectum. As these changes of position are physiologic, one must know them in order to be able to distinguish them from pathologic positions.

The fundus of the uterus, on the one hand, may be lifted up by an overdistended bladder, so that it does not point directly upward, the woman being in the recumbent position, but is directed upward and backward: **Retro-versio uteri**, besides, it is lifted up into the large pelvis: **Elevatio uteri**. A similar displacement upward is also caused by an overfilled ampulla recti. If the bladder and rectum are overdistended at the same time, then the entire uterus is markedly elevated. This position, also, belongs to the physiologic ones.

As soon as the bladder and rectum are emptied the uterus reassumes its normal position, as described above, in consequence of the action of its ligaments.

It is to be inferred from the above that the **bladder** and if possible also the **rectum must be thoroughly emptied** before a gynecologic examination. It is absolutely necessary to empty the bladder, as this organ in its filled condition is situated directly beneath the abdominal walls, overlies the uterus, and increases the difficulties of the outer palpating hand in reaching deep down into the pelvis. Besides, pressure upon a filled bladder is painful to the patient.

The gynecologic examination can be only a **combined bimanual** one, that is, a palpation of the internal genital organs by one or more fingers introduced into the vagina, with a simultaneous counterpressure on the

organs through the abdominal wall by the other hand. In this way, only, is it possible to form a clear judgment as to the relative *position* of the organs to each other, their *size, form, and consistency*. To *perform the method of combined examination* we should from the beginning accustom ourselves *to place the patient always in the same definite posture*.

A great number of examining tables and chairs have been recommended for this purpose whose various advantages cannot be disputed. The essential requirement of an *examining table* is that the woman can be placed, with relaxed abdominal walls that is in a dorsal position with elevated legs, at such a height that the examiner can easily execute the

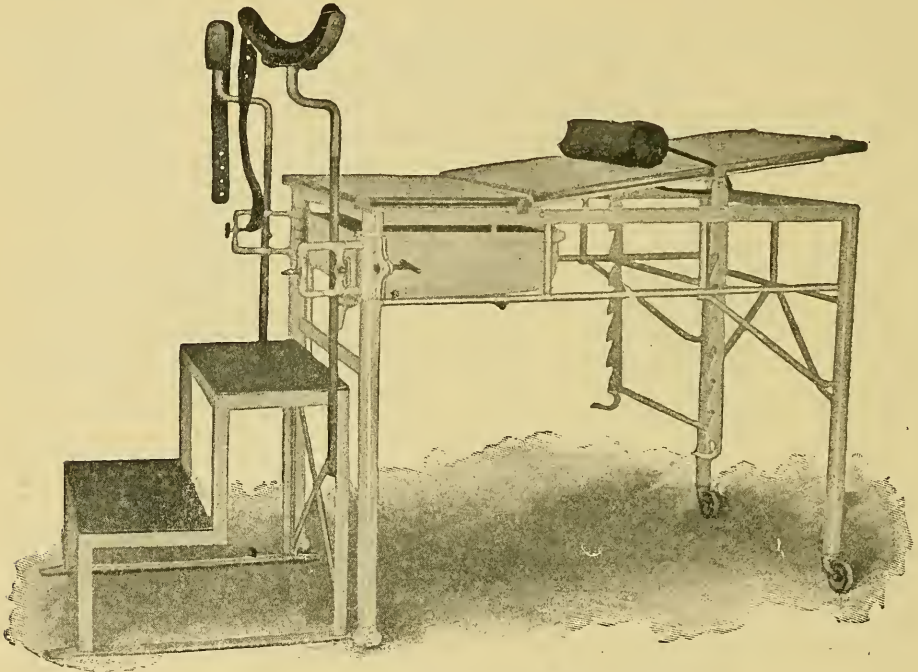


FIG. 15.—Examination Table, after A. Martin.

external palpation as well as the combined bimanual method. We use a plain table of the height of a common kitchen table, the top of which is cut off transversely at one end. The cut off larger end can be folded up to any desirable height. The table is covered with a blanket, a bolster for the head and a roll for the small of the back. The feet are placed upon a high footstool. We usually make all our examinations on a table arranged in this manner. It can be easily imitated in practice.

For clinical purposes these tables have been made of iron and glass, to insure and facilitate thorough cleanliness. They have been furnished with stirrups and legholders, and a pan arranged like a drawer for the reception of irrigation fluids, used tampons and sponges, etc. (Fig. 15).

If such an examining table is not at hand then a couch, sofa, or bed

may suffice for this purpose. It is only necessary to elevate the buttocks sufficiently by the use of a hard pillow or bolster to render the vulva easily accessible for the examining hand. It is, however, almost impossible to execute on a lounge or bed all the finer manipulations that may be eventually necessary for ordinary examination purposes. For these it is required to place the patient transversely across the bed or upon an ordinary table. The examination is always conducted with the patient in the *dorsal recumbent posture* or, better, *dorso-sacral posture* (the so-called *lithotomy posture*).

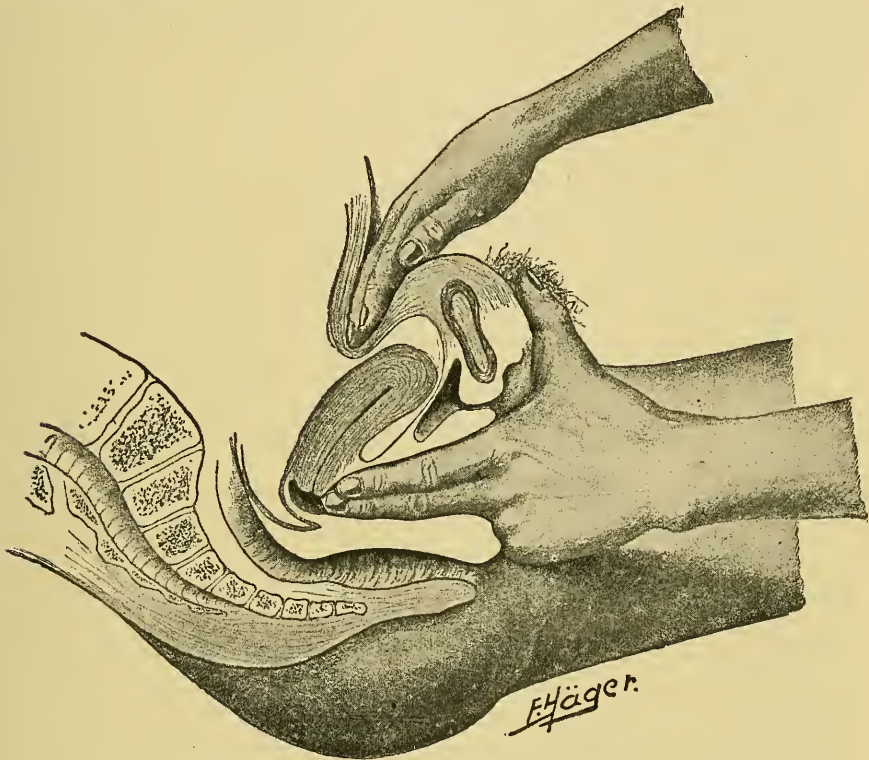


FIG. 16.—Bimanual Examination in the Dorsal Position.

The examining table described will also fully answer all purposes for those rare cases in which another position, for instance lateral or knee-chest position, may become necessary.

After the patient has been placed in the desired position the *examination* is begun by carefully palpating the abdomen with the palmar surface of the flat hands. For the internal examination one inserts carefully the index finger, or if the size of the vagina permits, also the middle finger into the same, after they have been previously anointed, while at the same time one places the other hand externally on the abdominal wall almost directly above the symphysis pubis, and invaginates it corresponding to the progress of the inserted fingers (Fig. 16).

First *the uterus* is located. After the condition of the cervix has been determined one places the inserted fingers underneath it, or the middle finger into the posterior and the index finger into the anterior vaginal vault, lifts the uterus with great care slightly upward, as far as its connection with its surroundings permits, and attempts to palpate the fundus of the uterus, or that part of the corpus presenting itself anteriorly, with the externally placed hand. As a rule one succeeds easily in bringing the uterus between both hands and in determining the *position, size, and consistency*. Then the inserted fingers and the external hand are moved simultaneously to one side of the uterus, and finally, passing behind it, to the other side. All force during the progress of palpation must be avoided.

The gentler one palpates the parts the sooner one succeeds, the less force one uses, the more distinctly the parts are felt, without mentioning that with an overexcess of pressure the inevitable tension of the abdominal walls interposes an extraordinary impediment.

If the position, form, and consistency of the uterus have been determined, the chief point is now to acquire evidence of the condition of the *adnexa*. The examination is incomplete without this, and its neglect may lead to serious diagnostic and therapeutic errors.

Palpation of the adnexa is decidedly more difficult than that of the uterus. It is best to proceed in the following manner: One or two fingers are inserted into the lateral vaginal fornix close along the border of the uterus, and then the external hand presses the region of the tubal angle against the inserted fingers. Through this manoeuvre one succeeds, as a rule, in palpating the tube from its departure from the uterus as a cord about the thickness of a lead pencil and in following it outward. This cord can often be rolled to and fro between the inner and outer hand. After the tube has been followed up in its course outward and backward from the uterus, the ovary is located. This ordinarily lies behind and to the side of the uterus in front of the articulatio sacro-iliaca. It is distinguished under entirely normal conditions by getting between the palpating fingers as an almond-shaped body and by easily slipping away from them. While light pressure on the tubes and uterus is normally not painful, the ovary is often very sensitive to pressure without being diseased.

In the manner described a good knowledge of the condition of the internal female organs can be obtained. However, there are many circumstances which render palpation difficult, and even impossible.

Thickness and tenseness of the abdominal walls play an important rôle. Emaciated multiparæ with diastasis of the recti abdominis offer the easiest, nulliparæ with rigid muscular abdominal walls, the most difficult conditions. Many patients for fear of pain behave awkwardly and resist all deep palpation by straining. In such cases a stronger flexion of the thighs upon the abdomen, which causes a better relaxation, with the request to breathe deeply and quietly, is of great assistance.

Finally it may be helpful to direct the patient to invaginate deeply the lower abdominal region with her own hand and then to allow the palpating hand of the examiner to do the same. Or one penetrates carefully deeper and deeper with each expiration and thus reaches the desired result. *Practice*, at all events, is the principal point. Often cases become clear to a practiced, calm, and, above all, patient examiner, in which the beginner seems to be helpless. *The lighter one palpates and the less power one uses, the sooner one attains his purpose.*

In spite of this a number of cases will always remain in which the greatest skill proves ineffectual. Minute details cannot be determined through adipose tissue which is 10 cm thick. Many a patient cannot be persuaded by any means to relax the boardlike, tense abdominal muscles even for a moment only. Examination under *anesthesia* is here the last resort. The anesthesia must be very complete or profound for a brief period of time, until all reflexes have been abolished. Everything may then be elicited, which must be determined by a combined examination (see chapter: *Narcosis*).

One should never neglect to verify the results of the vagino-abdominal examination by an exploration through the *rectum*. The extent of many diseased conditions of the adnexa and above all of the pelvic connective tissue (tumor formation, exudates) can only be recognized with sufficient clearness through the *rectum*. One must confine himself to a rectal examination in cases in which the vagina is inaccessible on account of pathologic processes (malformations, atresias, stenosis), or if it is by all means desirable to preserve the hymen intact.

(See the chapter: *Asepsis* in regard to asepsis and antisepsis in gynecologic examinations.)

In many cases bimanual palpation alone is not sufficient for the diagnosis of diseased conditions. If, for example, the question arises from which side of the uterus a tumor emanates, or whether it is at all attached to the genitalia, or if we wish to determine whether the uterus is movable or fixed, then it is to be recommended to draw down the uterus with a *bullet-forceps* attached to the cervix (vide Fig. 17) (*Hegar, Küstner*)⁵ or to have an assistant push the tumor upward (*Schultze*). In this way the connection of tumors by a pedicle to the uterus, the position of this organ, its fixation, etc., can be made out very clearly. This manipulation, executed very cautiously, is by no means always painful, as the portio vaginalis appears to be almost entirely insensitive. For that reason anesthesia is not always necessary. If marked sensitiveness



FIG. 17.—Bullet-Forceps with Swivel-Lock for Taking it Apart.

should be caused by other complications, especially peritoneal adhesions, which are so very sensitive, anesthesia must be resorted to.

For the completion of the combined examination, exposure of the vagina and cervix with a *speculum* is necessary.

This purpose is served by the *tubular specula* (see Fig. 18) manufactured from white glass or vulcanized rubber, of which a set of different




FIG. 18.—Tubular Speculum.

widths should be kept at hand. They are made oblique at the lower end to facilitate insertion, they are easily cleansed, inexpensive, and suffice fully to expose to view the cervix and vaginal vault.

The selection of the speculum depends on the width of the vagina; with a little experience the proper size can be easily determined.

Too large specula cause pain on insertion, while too narrow ones allow too small a view, especially with relaxed, loose, vaginal walls.

In *inserting* the tubular speculum, one must see that it is well lubricated with oil or glycerin, and must hold apart the labia with one hand, while the other hand presses the posterior commissure of the vagina far down with the lower border of the speculum until the upper border of the speculum appears beneath the urethral eminence. Then the speculum is pushed forward in the direction in which the cervix has been located by a previous digital examination.

Should folds form in the vagina, which obstruct the view of the cervix, or should the cervix not appear in the mouth of the speculum,

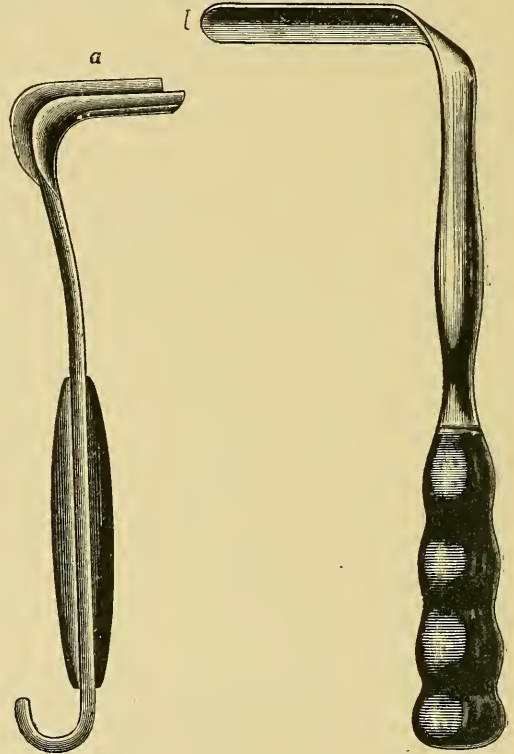


FIG. 19.—Vaginal Retractors. (a) for the posterior wall; (b) for the anterior wall.

the difficulty is easily overcome by rotating the tube on its longitudinal axis.

Since with these tubular specula only such parts naturally can be observed clearly as appear through the mouth of the speculum, such as the portio or a part of the vaginal wall, and since it is at times desirable to view the vaginal walls and vault to a greater extent, we keep for this purpose a second variety of vaginal speculum, *the vaginal retractor* (Fig. 19). We use a large and a small blade of metal. We employ these so that the larger blade is inserted diagonally in the vulva without changing the dorsal position of the patient. With this blade inserted in the vaginal vault, the posterior vaginal wall and the perineum are retracted strongly backward. The small blade is passed along the larger blade for the elevation of the anterior vaginal wall. With some practice it is easy

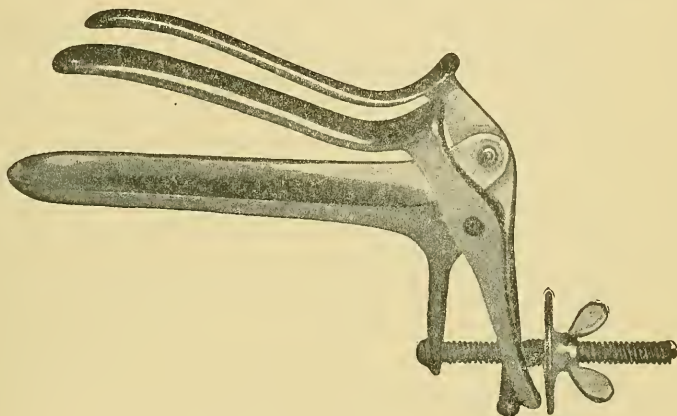


FIG. 20.—*Nott's Self-Retaining Speculum.*

to inspect the lateral vaginal walls and by a corresponding shifting of the retractors also the anterior and posterior vaginal walls and to expose the cervix and vaginal fornices. Both retractors can be drawn apart at the will of the examiner, either at the front in the vulva or in the depth of the vagina, and allow a very complete view. In the absence of an assistant, the *self-retaining* specula can be used to great advantage (*Cusco, Nott*: see Fig. 20).

Secretions, mucus, blood, etc., accumulated in the depth of the vaginal cavity, which prevent a clear view, must be thoroughly removed with pledgets of cotton attached to dressing forceps, before it is possible to obtain a clear picture.

One can in exceedingly rare cases, attempt to examine the woman in the *Trendelenburg* position (elevation of pelvis), or in a warm bath, if the desired end cannot be reached in any other way, or if contraindications exist to an examination under anesthesia.

Sounding

The examination of the cavum uteri with the sound has been relegated to a subordinate position in comparison with former times. The combined examination gives us sufficient information about the position, form, and consistency of the uterus. The use of the sound, however, is necessary for determining the length of the cervix and the corpus uteri,

the width of the uterine cavity, and for elucidating the position of the organ, if it cannot be palpated on account of its surroundings (exudates, tumors). Finally, by means of the sound, one can convince himself about the condition of the uterine mucous membranes, and establish the existence of irregularities, small tumors, etc., in the same.

We use the *inflexible* instrument, with a scale marked in centimetres, designed by *E. Martin* (see Fig. 21).

The sound is absolutely *contraindicated*:

1. *With the Slightest Suspicion of Pregnancy.*—

One cannot be too cautious in practice in this respect. We can protect ourselves from mistakes only by taking into account *before using the sound* the *relation of the last menstruation* and the *findings of a combined examination*. To be sure, not every sounding during pregnancy leads to an interruption of the same. The latter, however, forms the rule. If doubt exists one must desist from the use of the sound.

2. One should not use the sound, if *peri- and parametritic inflammations* exist in an acute state, or in a more or less subacute condition. The posterior vaginal vault must be examined with particular care before sounding, as we find, especially in the ligamenta sacro-uterina or upon the floor of the excavatio recto-uterina, remnants of inflammatory processes, while apparently

the rest of the surroundings appears to be normal.

Overlooking such inflammatory residues exposes us to the danger that we may excite exacerbations on account of the not entirely avoidable irritation during sounding, as has often been observed from the use of the sound.

3. The sound should not be used in acute *inflammatory processes of the uterus*, and *in women who are menstruating*, because it may lead to a more than ordinary hemorrhage, as is wont to occur in sounding narrow canals lined with mucous membrane.

4. Especial warning must be given against sounding the uterus *if an infective process exists in the internal parts of the genital canal*,



FIG. 21.—Metal Uterine Sound.

especially in the vagina or cervix. The infection is carried in such cases only too easily by the sound from the internal uterine os into the cavum uteri. Gonorrhoea must be taken especially into consideration. That the sound must be used only under aseptic conditions is self-evident.

The *introduction* is best done with the patient in the lithotomy position. The portio vaginalis is exposed by a speculum, and made sterile by repeated spongings with tampons saturated with 1:1,000 sublimate solution. The anterior cervical lip is steadied with a tenaculum forceps and the sound is introduced *directly into the cervical canal without touching the vaginal mucous membrane.* This procedure is usually not painful. Great tenderness of the endometrium indicates an acute or subacute inflammatory process. One must desist in such cases from further sounding according to the given contraindications. If an examination of the patient under *anesthesia* is necessary for other reasons, the sounding may be carried out at the same time.

The sound must be lowered as soon as it strikes the internal os, after which it enters the cavum uteri without any difficulty.

The sound, not rarely, meets with resistance at the internal os. It would be absolutely a mistake to overcome this resistance with force, as this might lead rather to a perforation of the uterus. The resistance is mostly produced by the point of the sound becoming caught in a fold of the mucous membrane. One must carefully and with *an easy hand* move the handle to and fro and thus finally *overcome* the hindrance.

The course and form of the uterine cavity are recognized from the direction in which the sound advances. If the hand then fixes the instrument by its handle and thus the uterus, the examining finger of the other hand, after removal of the speculum, can be used to establish the thickness of the uterine walls and the boundary lines of the uterus from the neighboring structures through the vaginal vault or from the outside through the abdominal walls. If the sound is carefully moved to and fro in the uterine body the form and contents of the uterine cavity can be tested approximately. Finally, the index finger introduced along the sound can determine the length of the uterus. In order to determine the length of the cervical canal one must fix the instrument the moment when its head glides through the internal os, which, as a rule, is easily recognizable as a narrow passage.

If the uterus lies in retroflexion then *the sound* can also be *introduced into the retroflexed body, without causing a dislocation of the same.* In retroflexion the sound is advanced in the usual manner up to the region of the internal os. Then the concavity of the instrument is turned backward by a turning of the handle before the genitalia in a wide arc, during which, as a rule, the point glides into the uterine body, while the lower portion of the sound is pressed against the symphysis pubis. The entrance of the uterine sound into the uterine cavity succeeds the more easily the more positively one is assured of the position of the uterus through the preceding bimanual examination. Formerly the sound was

frequently used to elevate the retroflexed uterus. But we must warn generally against this procedure by one with an imperfect experience and practice. Danger of perforation of the uterine walls exists on the one hand, on the other one can replace the non-adherent uterus just as safely with the bimanual method, and further palpate the bands which hold it fixed. It therefore does not necessitate a reposition with the sound, which is not always free from danger.

Dilatation of the Cervical Canal. Palpation of the Uterine Cavity

If a combined examination does not allow of positive diagnosis, especially when definite symptoms point to a diseased condition of the inner surface of the uterus, a digital exploration of the uterine cavity is held indispensable. Some gynecologists go even so far as to demand a dilatation and palpation of the uterus prior to intrauterine interference.

We cannot follow such far-reaching indications for this procedure. *Notwithstanding* this we deem it necessary in a number of cases, for instance for the removal of remnants of an abortion, for the diagnosis of some uterine tumors, etc.

A preceding dilatation of the cervical canal is mostly indispensable in order to execute the digital examination.

For this purpose in former times, *dilating material, compressed sponges, tupelo, laminaria digitata* were used, which when introduced into the cervix would swell by absorbing the tissue secretion and so cause a sufficient dilatation after several hours. However, these dilating materials, which could not be sterilized free of any objections according to the most up-to-date procedures, had the disadvantage, that a special operation was necessary for their introduction, so that the patients had to be subjected to two distinct operations. For that reason metal dilators are now used for dilatation after *Hegar's* method. One must have on hand a set from 1 mm to 2-3 cm thickness, always increasing about 1 mm (see Fig. 22). The patient must be carefully shaved and disinfected for this procedure. After exposure of the cervix by means of a speculum the anterior and posterior cervical lips are seized with tenaculum forceps. The dilators are immersed in a lysol solution or in sterile oil, and introduced into the cervical canal, one after the other, until this permits the passage of the finger. The uterus is then carefully explored under control of




FIG. 22.—Metal Uterine Dilator, after *Hegar*.

the outer hand. Anesthesia is, as a rule, necessary for this painful procedure.

[I wish to call attention to *Sims'* or *Goodell's* dilators almost generally used in the United States for rapid and easy dilatation of the cervical canal. It is composed of two or three blades which are forced apart after introduction into the cervical canal by compressing the handles of the instrument. The latter are provided with a self-adjusting, graduated transverse bar provided with a set-screw and a thumb-screw. In using the instrument the set-screw always should be placed at the point of dilatation desired and the dilatation should be performed by using the thumb-screw only. Thus injuries to the cervix will be avoided. If the dilator will not enter the cervical canal a few small *Hegar* sounds must be first passed.—ED.]

At times small tears occur during the dilatation, especially with a very rigid cervix. They, however, do not cause any further inconvenience. It is seldom that larger ruptures result; they are usually the result of faulty technique, and necessitate the introduction of one or more sutures. This procedure of dilatation has two distinct advantages. First, it can be executed in *one* sitting and can be followed immediately by further diagnostic or therapeutic operations which may become necessary as a result of the exploration.

With strict aseptic precautions, infections can occur only if the existing cause of the infection is already present in the uterus, as may be the case, for example, from the presence of decomposed remnants of an abortion, malignant tumors, or pyometra.

Otherwise the procedure is *contraindicated* in cases of acute and subacute inflammation of the uterus and its *surroundings*. During dilatation one cannot prevent a tearing and pulling of the adnexa and the peritoneum and thus latent germs of infection, which may be present, may easily become mobilized through the forcible manipulations. Thus they may give rise to grave exacerbations of existing inflammatory processes.

Dilatation, according to our opinion, ought to become materially limited on account of these unavoidable disadvantages. Its purpose, an exact knowledge of the condition of the endometrium and cavity of the uterus, may be accomplished by a much simpler procedure, *the curettage of the uterus (abrasio mucosae uteri)*.

Curettage of the Uterus

By curettage of the uterus is meant the scraping off of its mucous membrane by means of a spoonlike instrument, the curette (see Fig. 23).

This operation is executed on account of manifold indications which can be divided into two large groups, *the therapeutic and the diagnostic*.

The diagnostic indications and the technique concern us here only;

the different therapeutic indications will be considered minutely in the chapter on Diseases of the Endometrium.

Whether anesthesia is necessary for the curettage, depends on the conditions of the individual case. One may often get along without anesthesia, but it is advisable to anesthetize sensitive patients, and where the case presents any kind of difficulty, especially in diagnosis, an anesthetic should be used.

The necessary instruments are vaginal retractors, two tenaculum forceps, a sound and a curette. After placing the patient in the lithotomy position on the operating table (examining table, crossbed), and after the exact position of the uterus has been determined again by a bimanual examination, the parts are shaved and carefully disinfected. The cervix is exposed by means of a vaginal retractor. The anterior cervical lip is caught with a bullet or tenaculum forceps, and the uterus drawn down. The length and direction of the cavum uteri are determined with the sound, and the curette carefully introduced with its concavity either directed anteriorly in anteflexion or posteriorly in retroflexion up to the measured length of the cavum uteri. It must then strike the fundus uteri. The introduction should not cause any difficulty even in nulliparæ. The place where one may meet at times with resistance is the internal os uteri. The curette may be caught either in a fold of mucous membrane or the musculature may contract in a spastic manner.

[To overcome the danger of perforating the uterus and to obviate unnecessary examinations of the curette I had my curettes provided with a centimetre division, just like the graduated uterine sound.—ED.]

FIG. 23.—Curette,
after Roux and
A. Martin.

The one rule here strictly to be observed is, **never to advance with force**. Easily executed movements of the instrument in different directions finally enable one to overcome the obstructing fold. The spasm of the musculature of the orificium internum subsides within a few moments. If, in rare cases, an actual stenosis of the internal uterine os should exist it suffices to introduce some of the smallest numbers of *Hegar's* dilators, in order to enable one to pass the curette. As soon as it reaches the fundus uteri, which is plainly indicated by a slight resistance, the walls of the uterus all around are scraped with a flat turning motion of the curette, then the sides are scraped under control by the finger placed against the uterine wall through the vaginal vault, and finally both tubal corners, so that no portion of the endometrium is overlooked.

One recognizes by a hard grating sound of the curette on the musculature that the mucosa has been removed thoroughly.

The construction of the instrument does not leave any doubt of the direction of the spoon at any time.

The scraped off material from the mucous membrane is carefully collected and should be examined microscopically in all cases of diagnostic curettage. It is never possible, even for the most experienced, to make a positive diagnosis macroscopically from the scrapings of the mucous membrane. It is recommended to cleanse the particles superficially from blood and then to immerse them immediately in alcohol (ordinary alcohol is sufficient) and to send them to the laboratory.

The cavum uteri is irrigated after the curettement (see chapter, **Asepsis and Technic**) to remove coagulated blood and loose remaining particles of the endometrium.

[I never use intrauterine irrigation, but firmly pack the uterine cavity with loose gauze. Applying a forceps to the latter I turn the gauze within the uterus with a corkscrewlike motion and thus succeed in detaching all the loose particles eventually yet remaining adherent to the uterine walls. This procedure is repeated until the gauze is returned free from any débris. Cauterization of the mucosa then follows.—ED.]

It is useful in many cases, especially where one has to deal with a chronic hypertrophic endometritis, to follow the curettement with **cauterization** of the uterine wound surface.

The idea is to scorch the remaining parts of the mucous membrane and thus to cause their expulsion later on, and further to secure more complete hemostasis. The number of remedies recommended for this purpose is extraordinarily large, so that their selection can be left more or less to the individual operator, as one can obtain the same result in an equally perfect manner with any of these substances. For a long time we have used undiluted **liquor ferri perchloridi**.

Other, equally recommended remedies are: pure tincture of iodine, pure carbolic acid, 50 per cent. solution of zinc chlorid, formalin pure, or in 50 per cent. or 30 per cent. solution (*Menge*) and many others. Many modifications exist also in the manner and mode of application. For a long time we have employed the following method: We inject 1 ccm liquor ferri perchloridi with a *Braun* syringe (see Fig. 24) into the cavum uteri, in such a way that the syringe is slowly withdrawn while the plunger is pushed on **quite gradually**; thus the contents come forth drop by drop and moisten the walls of the uterus. Very strong pressure must be avoided in this procedure, as otherwise the escharotic enters the tubes, and immediately cauterizes the mucous membrane. It is undisputed, that the escharotic is distributed best in the uterine cavity with the *Braun* syringe (*Menge*⁶). We have no occasion, after our large experience, to dispense with the **careful** use of *Braun's* syringe. However, the possibility of the caustic entering the tube leads many gynecologists to reject the use of it. These prefer to soak a sound-shaped applicator, wrapped with cotton at one end, in the escharotic and to wipe out

the cavum with it (*Sänger's* silver sound, *Menge's* hard rubber applicator, *Playfair's* sound), (see Fig. 25).

The entrance of the caustic solution into the uterine tubes is surely prevented by this instrument. The cauterization, however, is not so thorough as with *Braun's* syringe.

The surplus of the caustic solution is removed by irrigation with a sterile normal saline solution. The tenaculum forceps are removed, the uterus replaced, and a compress of iodoform gauze is inserted in the vagina. The vagina need not be tamponed.

The after-treatment consists of absolute rest in bed for three or four days. The gauze should be removed from the vagina at the latest on the third day.

The **regeneration** of the mucosa results from the fundus of the glands which remain behind in the deeper parts in every case, even with the most careful scraping and cauterization (*Düvelius, Werth*). After the casting off of the eschar the cylindrical epithelium proliferates and overspreads the granulating surface. The reformation of the glands results likewise from the remaining glandular fundi. The entire process is terminated after about three weeks. The menses usually appear again after about six weeks, often even earlier.

Complications.—We must urgently warn against considering curettage a harmless procedure, as is done so often. It does **not** belong in the office, but demands a strict placing of the indications, a thorough preparation, and, above all, the **strictest asepsis**. The procedure is admittedly harmless with these presuppositions.

The only complication to be dreaded is **perforation** of the uterus. This may occur under two conditions:

1. The uterine wall may be so soft and friable (decayed) (for instance in its puerperal condition or in malignant newgrowths), that the curette passes through the tissue without any resistance. The most experienced operator may not escape this complication.

2. The curette finds a resistance at the stenosed internal os uteri. The inexperienced and unpracticed operator attempts to overcome this




FIG. 24.—Intra-uterine Syringe, after *Braun*.

FIG. 25.—*Playfair's* Sound.

with crude force, and the curette suddenly passes through the uterine wall into the abdominal cavity.

This perforation has been represented as a very grave accident, after which fatal peritonitis would be almost inevitable. One must admit that many observations justify this pessimistic view, particularly if the contents of the cavum uteri were strongly infectious. On the other hand it should be stated that with **correct treatment** the perforation passes usually without any grave consequences. It is only necessary to act accordingly.

The curette must be removed immediately, and any further manipulation in and around the uterus must be suspended. One should **not curette** any further, nor use any irrigation, nor any tampon. The patient is put to bed in the dorsal position, an ice-bag is applied over the abdomen, the diet must be liquid. If no alarming symptoms appear within forty-eight hours, the danger may be considered passed, because within this time the peritoneum has become adherent over the small opening at the point of perforation; the patient may leave the bed on the fifth day, the same as after a curettage.

An excision of a piece of tissue from the portio vaginalis for diagnostic purposes is necessary in erosions which look suspiciously malignant. At times it suffices instead to scrape off a few particles with a sharp spoon and to render a diagnosis from a microscopic examination of the same. A firm packing of the vagina with iodoform gauze will stop safely the hemorrhage which at times is considerable. Anesthesia is not necessary for this interference.

If this simple procedure is not sufficient it is advisable to do a complete wedge-shaped excision of one or both cervical lips (see Operations on the uterus).

Bacteriologic Examination

LITERATURE.—See *Menge* and *Kroenig*, Bakteriologie des weiblichen Genitalkanals, Leipsic, 1897; further, *v. Rosthorn* in Handb. d. Geburtsh, von *F. v. Winckel*, Vol. I, page 574, *Frommel's Jahresber. über Geb. u. Gyn.*, 1898–1906.

The lower portion of the female genital tract—vulva and vagina—is, even under normal conditions, the seat of numerous micro-organisms.

These are partly harmless saprophytes, especially bacilli (*Doederlein*), partly also strepto- and staphylococci. It is of no importance for practical purposes, whether the latter are identical or not with the forms known as the exciters of septic infection. It suffices that they **may** be pathogenic, and we must consider them at all times as pathogenic germs (*Menge* and *Kroenig*). Even if we are allowed to attribute to the acid secretion of the vagina a bactericidal power, this is, however, not sufficient for the complete destruction of the infectious germs. For this reason a painstaking strict disinfection must be done before each vaginal operation.

The internal uterine os forms an unsurmountable obstacle to these habitual inhabitants of the vagina. ***The cavity of the uterus is normally to be considered free from germs and sterile.*** This germ-free cavity of the uterus can only become infected if the germs, including those of certain ***specific*** infections, yet to be considered, are artificially introduced from without, from the vagina and the cervix. The best opportunity for this is offered during labor and the puerperium, which does not concern us here any further. Such an artificial infection of the uterine cavity can occur only in cases in which the germs are carried into the cavum uteri during the introduction of instruments (sounds, curette, dilators, etc.).

It is necessary for this reason to observe the strictest asepsis during intrauterine manœuvres. But it is in this that many sin. It does not suffice, for instance, to sterilize merely the sound before its use, but the portio and cervix must also be cleansed as much as possible prior to the introduction of the instrument into the uterus. This is done best by repeated thorough wipings with sponges saturated in a 1:1,000 sublimate solution. It should be self-evident that a painstaking, careful disinfection of the vulva and vagina must precede all surgical interferences, as curettage, excision, etc. Unfortunately this is only too often neglected. The expression, "small, insignificant operations" is a prevalent one, but this lax conception has certainly resulted in many an acute and chronic infection, otherwise avoidable.

An examination of the vaginal and cervical secretion will not be necessary in each and every gynecologic case, according to this statement. The examination of the ***cavum uteri*** for ***septic*** germs need be considered only for cases in which, as after ***labor or abortion***, a possibility or probability exists that such germs have penetrated above the internal os uteri.

Two ***specific infections***, besides the septic ones, must yet be mentioned, whose germs, according to our experience, are in a position to traverse the internal os uteri ***spontaneously*** and to infect the cavity: ***gonorrhœa and tuberculosis***. The last is observed relatively seldom in comparison to the first; its bacteriologic proof is, for that reason, not of such eminent importance as that of ***gonorrhœa***.

It is so important for the diagnosis of a number of diseased conditions of the female genitalia to demonstrate the existence of gonorrhœa, that every physician ought to be familiar with its technic.

Its causative factor, the ***gonococcus***, *Neisser* (see Fig. 26), occurs in all parts of the genital tract, from the vulva as far as the ovaries. Its presence as far up as the cervix can be proven by a bacteriologic examination. The upper parts can only be examined in the non-puerperal condition after extirpation.

One prepares for the bacteriologic examination an alcohol lamp, a platinum wire, and a number of well-cleansed glass slides. The patient is placed upon the examining table, and the different parts of the genital tract are exposed one after the other.

1. **Urethra.**—Thorough cleansing of the external opening and its surroundings from the adherent vaginal secretion with moist and then with dry sponges. Introduction of the index finger of the left hand into the vagina, milking the urethra from the neck of the bladder downward and outward. The secretion appearing at the *orificium externum* is caught with the sterile platinum wire and smeared *thinly* on a glass slide.

2. **Glandulae vestibulares majores (Bartholini).**—The external opening of the gland at the junction of the posterior and middle thirds of the vaginal opening is frequently distinguished from its surroundings by an intense reddening (**Macula gonorrhoeica, Sänger**). After careful cleansing of the opening and its surroundings, the gland is pressed between two fingers, and the drop appearing is received in the platinum wire loop.

3. **Vagina.**—The vaginal secretion is of little value for the examination in any but quite acute cases, because positive results can be obtained only with the quite complicated procedure of culture on account of the great number of all possible bacteria present. A drop of the secretion collected in the vaginal vault is removed on a slide with the platinum wire after exposure of the vaginal walls by a sterile *Cusco* or *Nott* speculum (see Fig. 20).

4. **Cervix.**—The examination of the **cervix uteri** is by far the most important.

This is finally the only place in chronic cases of gonorrhoea where the gonococci are still found, after they have long disappeared from the urethra and the vagina. The cervix for this reason must be examined carefully.

The secretion is carefully removed with sponges from the vaginal vault, after placing the portio vaginalis in a sterile *Nott* speculum. Then the portio itself, as well as the part of the inner cervical canal within reach, are wiped off with sponges saturated in diluted alcohol and finally with dry sponges. Then one enters the cervical canal with the platinum wire bent like a sound, *without touching the portio* and obtains the secretion if possible from the uppermost portion of the cervical canal. Several preparations must always be made from the important cervical secretion.

5. **Uterus.**—We cannot take secretion from the uterine cavity in an **unobjectionable** manner, unless the cervical canal is very wide, as one

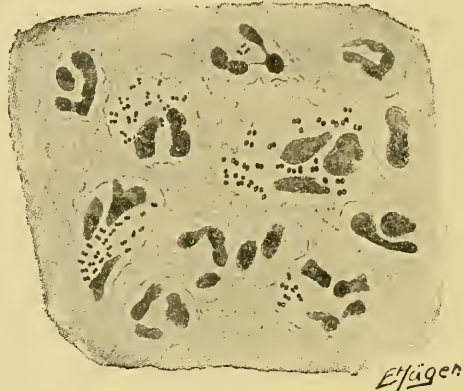

FIG. 26.—Gonococcus, *Neisser*. (Smear preparation from the cervix uteri. Zeiss, Oc. 4, homogeneous immersion.)

always will get some of the cervical secretion on the platinum loop. The removal of secretion from the cavum uteri is therefore of very little value for diagnosis. If the cervical canal is very wide, for example in puerperæ, one uses for the removal of the secretion a sterile glass tube bent like a sound (*Doederlein*).

The preparations obtained are dried, drawn three times through the flame and stained with *carbol-fuchsin* or *Loeffler's methylene blue*.

The staining has to be done according to *Gram's* method for the differential diagnosis; in this the gonococcus is *decolorized*.

One finds on examination mostly mucus and epithelium. The proportion of leucocytes varies greatly, according as a recent or old inflammatory process exists. The secretion consists almost entirely of pus corpuscles in very acute cases.

The gonococcus is a *diplococcus* of which both parts have the form of a roll and lie with their straight, long sides opposite each other, occurring in bunches (see Fig. 26). Their multiplication occurs by fission, so that the longitudinal axis of the young individuals is placed perpendicularly to the longitudinal axis of the parent pair.

The characteristic points by which to recognize the gonococcus are its *arrangement in masses*, its *intracellular position*, and its *Gram-negativity*.

Single pairs of diplococci, situated without the cells, must never be considered as gonococci.

The diagnosis of the gonococcus is not as easy as it frequently appears to be. It requires long experience and practice in order to avoid errors. Such errors, for obvious reasons, may become quite detrimental, especially in an infection of *this* character.

Tuberculosis.—The tubercle bacillus also, although more rarely than the gonococcus, wanders from without even into the internal genitalia. (See chapter: *Tuberculosis*.) Its diagnosis is essentially still more difficult than that of the gonococcus.

Smegma bacilli also occur in the female genital secretion, which exactly simulate the tubercle bacilli in their staining characteristics. It is therefore purposeless to stain the secretion in the usual way for the tubercle bacilli. It is to be recommended under these circumstances, if in any way feasible, rather to make a *histologic* diagnosis. Suspicious ulceration of the external genitalia, the vagina and the portio are excised or scraped off with a sharp spoon. The mucous membrane is obtained from the cavum uteri with a careful stroke of the curette. Imbedding, cutting, and staining of the tissue lead to a positive diagnosis, which if necessary can be done by a pathologic institute or a gynecologic clinic. One may also dilute the secretion from the cervix or uterus, obtained under *sterile* precautions, with a 0.9% normal saline solution and inject this into the abdominal cavity of a guinea-pig. The diagnosis is then certain within three or four weeks.

However, this procedure presents marked technical difficulties for the

practitioner, just as the quite difficult demonstration of gonococci and tubercle bacilli by the process of culture. It is therefore advisable in doubtful cases to seek the advice of a specialist.

Examination of the Uropoetic System

LITERATURE.—*Nitze*, Handbuch der Zystoskopie.—*Stoekel*, Zystoskopie beim Weibe.

The diseases of the uropoetic system of woman are in such close relations with those of the genitalia, that a brief description of methods of examination of these organs appears to be indispensable, even within the limits of a textbook.

We presuppose that the reader is familiar with all methods of examination of the urine voided from the bladder, as to chemical properties, sediments, admixture of bacteria, blood, pus, etc.

While these examinations are quite sufficient in many cases to obtain an idea of the condition of the uropoetic system in *general*, the diseases of the different parts demand special procedures, which have developed into cystoscopy with ureteral catheterization.

It is easy with the *cystoscope* invented by *Nitze* (see Fig. 27) and since manifoldly improved, to make the interior of the bladder easily accessible to vision. With it we can easily recognize inflammatory conditions, new-growths, stones, fistulæ, foreign bodies. We can control the function of the ureters by the condition of their vesical terminations and urine escaping from these can be examined for its condition (clear, purulent, bloody). It is finally possible to introduce the ureteral catheter from the bladder into the ureter and even into the pelvis of the kidney, and thus the course of the former can be determined as to flexions, stones, etc. The urine of each kidney can be collected and examined *separately*.

It is only through the development of this procedure that we have been placed in a position to raise *kidney diagnosis* to its present perfection. Only the separate examination of the urine can enable us to form a positive indication justifying the extirpation of *one* kidney.

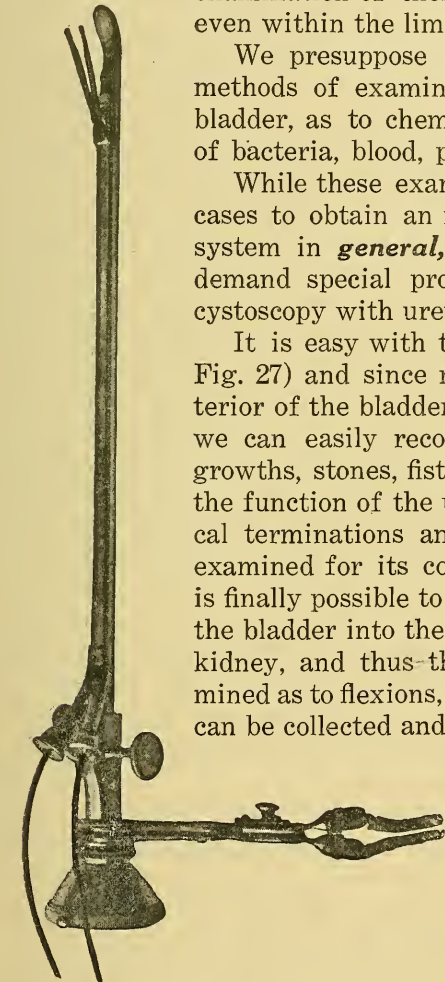


FIG. 27.—Ureter Cystoscope, after *Nitze*.

These procedures unfortunately are so complicated that they have not become the common property of all physicians. However, every practitioner ought to understand at least

their value in diagnosis and treatment, in order to secure their application by practiced specialists if necessary.

Anesthesia

LITERATURE.—*Doederlein-Kroenig*, Operative Gynäkologie. Leipsic, Thieme, 1905.—*v. Mikulicz*, Deutsche Klinik, Vol. VIII.—*Koblanck*, Chloroform und Aethernarkose. Wiesbaden, Bergmann, 1902.—*Frommel's Jahresber. über Geb. u. Gyn.*, 1900–1906.

The same principles, established in surgery, prevail for anesthesia in gynecologic cases. The different and peculiar diseases, however, demand special consideration.

We cannot deny that generally a female patient, usually in the prime of life, offers a priori more favorable conditions for anesthesia than the male material prevalent in the surgical clinics.

The reason for this lies chiefly in the rarer occurrence of alcoholism in women, which renders anesthesia in the male often so very difficult.

Whoever commands a large amount of material for his own observation, cannot be in doubt about the disproportionately easier production of anesthesia of women. Opposed to this are certainly a few isolated aggravating factors. We mention as such before all others chronic anemia, the result of exhausting hemorrhages, with its damaging influence on the heart, then heart complications in myomas, and, finally, the cachexia in malignant tumors of the ovary, uterine cancer, etc.

Quite a number of the minor gynecologic operations according to experience are so slightly painful that strong-willed women can endure them quite well without anesthesia. Special operative measures of a diagnostic nature on the portio and endometrium are almost painless and are borne easily, while the external genitalia and the peritoneum are extremely sensitive.

The urgent desire of many women to be anesthetized, even in minor procedures, arises in many cases not from fear of pain, but from an exaggerated sense of modesty. One frequently cannot help making an allowance for this request if no strict contraindications (heart lesions, etc.) exist. If difficult cases of diagnosis are in question one will prefer to make use of anesthesia, to clear these cases.

One can manage to get along quite well with local anesthesia (*Bier*, *Schleich*) in minor operations, especially on the external parts and even in vaginal cœliotomy. On the other hand we think it imperative to use general anesthesia in all major operations, particularly in laparotomies, even for humane reasons. We use for general anesthetics chiefly chloroform, ether, ether-chloroform-oxygen narcosis according to *Roth-Dräger* and *Billroth's* chloroform ether and alcohol mixture.

Chloroform-ether mixture seems to enjoy special preference at the present time.

The complicated apparatus such as that of *Roth-Dräger*, so often rec-

ommended, are suited only for hospital use and require a very experienced anesthetist. Simple masks and the drop method form the only advisable mode of anesthesia for the general practitioner.

To which method we finally may give preference is a matter of personal experience based partly on the peculiarities of the individual case.

We have used pure chloroform from chloral for a number of years with the best results. We use pure ether only when chloroform is contraindicated as in cardiac disease, nephritis, severe anemia and cachexia, while we in turn avoid ether in diseases of the respiratory organs.

Our results have been good throughout, asphyxias hardly ever occur with an intelligent or judicious administration, and we also have seldom observed the so-called "Spättodesfälle" (cases of late death) in general practice. Ether has the advantage of less danger for the patient, and, on the other hand, the disadvantage of slow action and greater danger in artificially lighted rooms.

Operating in the so-called *ether rausch*, or intoxication, need not be considered for gynecologic purposes, as the operations mostly last too long, and presuppose the extinction of all reflexes.

Different *local anesthetics* are of the greatest importance as they render unnecessary a personal supervision over the patient, and give the physician complete freedom for the necessary operation.

Local tissue-infiltration methods, especially after *Schleich*, have been recommended for minor and plastic operations on the vulva and vagina. However, they are not quite practical because one must continuously infiltrate during the operation, and besides cannot work so smoothly in the edematous tissue. Of late a mixture of *cocain-adrenalin* has been recommended for infiltration anesthesia, which induces painlessness and at the same time bloodlessness of the tissue.

The best local anesthesia for gynecologic purposes, according to our experience, is *Bier's* lumbar anesthesia with *stovain*.

This method of local anesthesia is especially well adapted for a large number of gynecologic procedures, because its action extends chiefly over the lower and middle portions of the body. It commences, as a rule, at the perineum and then extends downward over the lower extremities and upward over the trunk at different heights. But it reaches high enough under all circumstances, so that all operations can be executed painlessly on the lower portion of the abdominal cavity and the external genitalia.

Lumbar anesthesia is, therefore, well adapted for all operations on the perineum, rectum, vulva, vagina, portio vaginalis, bladder and inguinal canal. All kinds of plastic operations and diagnostic procedures, etc., can be executed painlessly. We have made frequent and successful use of it under such circumstances.

The peritoneum, also, becomes sufficiently anesthetized with *stovain-lumbar* anesthesia, according to the more recent modifications, so that we can conveniently perform with it *vaginal caeliotomies*. On the

other hand general anesthesia is used mostly in abdominal cœliotomies, if special contraindications against it do not exist.

Technic.—A long cannula, armed with a sharp mandrin and fitted with a cock, is introduced between the processus spinosi of the first and second lumbar vertebræ after a careful disinfection of the skin, and after the patient, lying on the side, has bent herself as far forward as possible. As soon as the cannula enters the spinal canal, the stylet is removed and a few drops of the liquor cerebrospinalis flow out. The cock is closed immediately, and opened again for attachment of the syringe containing the anesthetizing solution. The latter is injected slowly. The instrument is removed, the puncture-wound closed with cotton and collodion.

Stovain has been approved particularly for making an anesthetizing solution:

Stovain: 0.6—0.8 ccm of a 10 per cent. solution.

This solution is made in a 0.9 per cent. sodium chlorid solution and must be carefully sterilized as well as the instrument.

We have experienced bad effects with this kind of lumbar anesthesia only in a few patients, but success was lacking in a few rare cases, as was also reported by *Bier*. One can then use inhalation anesthesia without any hesitation.

The duration of such a lumbar anesthesia is from three-quarters to one hour. One can therefore execute under it extensive operations.

The scopolamin-morphin-anesthesia (*Schneiderlin-Korff*) which has been tested and recommended in later years, has not been tried sufficiently and does not seem to be without danger. Therefore it cannot be recommended as yet for general practice, notwithstanding its great convenience.

IV. Asepsis. Disinfection

LITERATURE.—*Löhlein, Veit's Handbuch der Gynäkologie*, Vol. I. Wiesbaden, Bergmann, 1897.—*Doederlein-Kroenig, Operative Gynäkologie*. Leipsic, Thieme, 1905.—*M. Hofmeier, Gynäkologische Operationen*, IV. Ed. Leipsic, Deuticke, 1905.

It is self-evident that the rules of general surgery and the principles of prevention of wound infection, as well as the treatment of an already existing wound infection, hold good for the gynecologist.

If in any way possible only such instruments, dressing material and hands should be used in operative procedure as have been made *germ free*, i. e., sterile, either through chemical, thermal, or mechanical means: *aseptic* operating. But as in practice, especially in gynecology, an entirely aseptic procedure is not always possible even with the greatest care, we must attempt to replace asepsis with *antiseptics* in many instances (*Bumm*). A simple cleansing of the hands with soap and water and following immersion in a lysol, or a sublimate solution, is sufficient for an ordinary gynecologic examination if pregnancy is not present.

Disinfection of the Instruments, Dressings and Suture Material

The disinfection of instruments is accomplished throughout by boiling in water for fifteen minutes, best with an addition of 1 per cent. soda. This boiling must be repeated before *each* use of the instruments. It can be done not only in clinics, but in private houses, as a kettle or basin are entirely sufficient. The presupposition is that the instruments are made entirely of metal, and perfectly smooth and without deep furrows and cracks, as in such the pathogenic germs may easily escape the action of heat. *Hand brushes*, for instance, must be boiled for half an hour.

Only a few instruments, for instance cystoscopes and other *electrical* apparatus, further hard rubber instruments cannot be boiled, but they can be safely sterilized, if they are kept in closed glass receptacles, on the bottom of which stands a layer of pure formalin. The ascending formalin vapors suffice completely for the sterilization of these instruments (*Menge, Stoeckel*).

The sterilization of the *dressing material* is done best by live steam to which the material is exposed for one hour. The apparatus of *Lauten-*

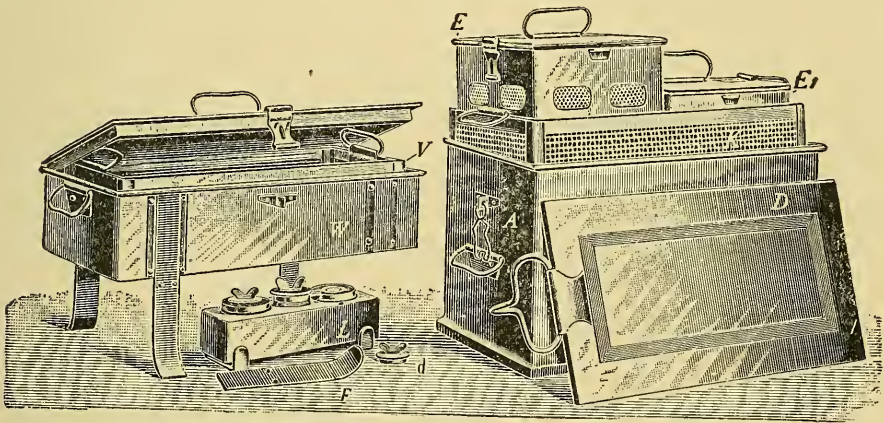


FIG. 28.—Sterilizer for Instruments and Dressing Material, after *Lautenschlager*.

schlager, Berlin, seems to be the most advantageous of the numerous apparatuses found in the shops. Instruments can be boiled, and dressing material sterilized at the same time (see Fig. 28). Small glass tubes containing a metallic alloy melting at about 105° C. (221° F.) serve for the control of the really resulting heat of 100° C. (212° F.) (*Sticher*).

They are placed between the dressing material, and when examined after the sterilization should be found melted if the heat has been sufficient.

Various methods are used for sterilizing *suture material*; silk, silk-

wormgut, linen thread, silver and bronze wire are boiled with the instruments before being used.

Many methods have been recommended for the sterilization of **catgut**. Unless they kill anthrax-spores, they are useless.

The **cumol catgut** after *Kroenig*, which is distributed by the firm of *Dronke*, Cologne, is to be recommended as quite excellent, safely sterile, of great tensile strength and also on account of the handy form in which it is sold. We have used it exclusively for years with the best results. **Iodin catgut** is also spoken of very highly of late.

The selection of suture material is for a great part a matter of personal inclination and experience.

We have employed catgut for some time for all suturing in the abdominal cavity, with the exception of intestinal suturing, which is done with silk. It is also used in all **plastic** operations on the vagina, and for all **buried** sutures.

We use the cheap and durable **aluminum-bronze wire** for suturing the **fascia**, as well as the external skin of the abdomen and the genitalia (vulva, perineum), and for operations on fistulæ.

[For many years I have used the plain and chromic cumol catgut as prepared by Van Horn & Sawtell, New York. It is prepared in different sizes. For **peritoneal** suturing I use No. 0 20-day chromic catgut; for the **fascia**, a No. 1 20-day chromic catgut; for the **muscle**, a No. 1 plain catgut; for the **cervix**, vagina, perineum, and rectum, a 40-day No. 1 or 2 chromic catgut; for the mucous membrane of the rectum and for coaptation of the muscles of the perineal body, a No. 0 or No. 1 40-day chromic catgut. Catgut sutures are always used double. The tissues will absorb two fine strands more readily than a single heavy one. For intestinal work I use silk sutures; for skin, horsehair. Silkwormgut retention sutures are used in the closure of all abdominal incisions and perineorrhaphies.—ED.]

The water used in solutions for cleansing the hands, making infusions, etc., should be boiled for a quarter of an hour. It is thereby rendered germ free.

With sufficient patience and care there should be no longer, at the present day, any difficulty in carrying out these measures of asepsis.

Disinfection of the Field of Operation

The following fact must be placed at the beginning of this section as the leading proposition:

It is impossible with the present means to render the human skin absolutely sterile. However, by careful preparation, an elimination of germs sufficient for practical purposes can be obtained.

A different preparation must be made for the various regions of the skin.

We must consider for gynecologic purposes: 1. The skin of the abdomen. 2. The skin of the external genitalia and the mucous membrane of the vagina.

The abdominal skin is relatively smooth in the upper part and therefore cleansed quite easily, but in the region of the hairy mons veneris, and in the inguinal folds it offers a great obstacle to disinfection.

The skin of the vulva and the mucous membrane of the vagina are still more inconvenient for disinfection. Both are rich in folds and are always covered with all possible species of micro-organisms, often also of a pathogenic nature on account of the nearness of the anus.

The cleansing of these regions requires, therefore, especial care.

The bowels are emptied regularly two days before operation with castor-oil. The rectum is again thoroughly flushed on the morning of the operation.

Several full baths with soaping of the body provide for the preparation of the abdominal skin, which is covered with a compress saturated in a 1:2,000 sublimate solution during the night before the operation.

Immediately before the operation the abdomen, and especially the umbilicus, after careful shaving of the pubic hair, are thoroughly cleansed with water, soap, and brush, dried with a sterile towel and then rubbed energetically with sterile gauze sponges and *tincture of soap* (*Mikulicz*) for five minutes.

The bowels are also thoroughly emptied before *vaginal* operations. The field of operation is prepared with soap sitz-baths for several days. The night before the operation a compress, saturated in a 1:2,000 sublimate solution, is placed over the vulva. The pubic hair is shaved previous to the operation and the vulva and vagina are energetically cleansed with soap and water and finally irrigated with a sublimate solution. *Bumm* recommends to rub the entire vagina and vulva with *alcohol* immediately before the operation.

Extremely dangerous and impossible to render sterile are the foci of infection when present in the genitalia. As such must be considered ichorous tumors (polyps, carcinoma), ulcers of the portio and so forth; they must be cleansed thoroughly with a sharp spoon, or if necessary cauterized on the day preceding the operation. *Mackenrodt* recommends tamponing with 10 per cent. formalin gauze. Such foci, however, remain extremely dangerous and threaten success of the operation in spite of all precautions.

Disinfection of the Hands

The cleansing of the *hands* of the operator is still more important than that of the field of operation. While *highly virulent* organisms of infection are only rarely present on the skin of the patient, and that under pathologic conditions, the hand of the physician comes daily in contact with infectious material, pus, lochia, etc.

It is a fact corroborated by repeated tests, that such hands always remain dangerous even after the strictest and most prudent disinfection.

The disinfection of the hands usually consists in bathing with hot water, soap, and a sterile brush, changed at least once, for at least ten minutes. The space underneath the nails and the nail grooves are thoroughly scraped during this time. Finally the hands are scrubbed with a sterile brush in tincture of soap for five minutes, and then dried with a sterile towel.

This method has given generally good results.

There are still other means to remove the danger lying in the constant contact with infectious material.

1. To prevent altogether the contact with septic material.
2. Not to bring the soiled fingers in direct contact with the wound.

We obtain both through the extensive use of **rubber gloves**.

Whoever may have to conduct labors, and execute operations frequently, should accustom himself never to touch infectious material with unprotected hands.

The hand should be protected with rubber gloves during every examination of bleeding women (carcinoma, polypi, abortions, puerperal infections), during every rectal examination, and likewise every operation should be executed only with rubber gloves.

Two kinds of gloves are placed at our disposal: the thin condomlike of *Friedrich*, and the somewhat heavier ones of *Doederlein*. We prefer the former, especially on account of the cheaper price, otherwise both kinds are of the same value.

The gloves can be easily sterilized between layers of gauze or in a thin bag in live steam. They must be powdered on the interior with talcum **before** sterilization.

To boil and to put on the gloves moist is not to be recommended because the so-called glove-juice in moist gloves collects especially in the finger-points. Quite a number of bacteria are found in this which may enter the wound area on accidental injury of the glove.

The initial uncertainty of touch and the difficulty of handling instruments with smooth gloves are lost very soon, after some practice.

The hands must be disinfected as carefully before putting on the gloves as if we were going to operate with bare hands.

We hold the rubber gloves to be the best means at our disposal to prevent the infection of the wound through direct contact.

Cotton gloves are used by many operators. We can recommend them only for simple operations, for instance ovariectomy. They cannot be recommended for all operations which are associated with long-continued work, especially in the pelvic connective tissue or in the vagina; because if once saturated they allow the micro-organisms of the skin surface to pass easily into the region of the wound. Many operators recommend for this reason pulling linen gloves over the rubber gloves. A sterile

linen coat which covers the entire body and whose sleeves reach down to the wrist and are covered with the gloves must be put on before the operation to complete the asepsis of the operator.

A gauze cap which encloses the entire head, with the exception of the eyes, is put on for protection against falling hair, from the face or beard, and over the mouth, thus preventing infection by droplets expelled during speaking.

The field of operation should be exposed to the smallest possible extent. Its immediate neighborhood is covered with sterile sheets. Also the part of the wound, which is not immediately being operated on, should always be covered with sterile compresses.

It is safe to say that most infections originate through *direct* contact with the wound. Opposed to this is infection through germs contained in the air. These germs are thrown to the floor, especially in operating-rooms, where the air is mostly damp. In order to render these germs the least harmless, *Bumm* recommends, for instance, to immerse the sterile sheets surrounding the field of operation in a 1: 1,000 sublimate solution, so that the germs are destroyed that fall upon these. Just so, it is to be recommended to rinse the gloved hands in a 1:1,000 sublimate solution during the operation.

The simple sterile solutions, for instance *Tavel's*, recommended for this purpose are already strongly permeated with micro-organisms after standing uncovered for a short time in the operating-room. One can convince himself of this fact by making cultures. Such solutions are therefore not to be recommended. The supplementing of asepsis by antiseptics proposed by *Bumm* is to be preferred, particularly where one is forced to operate in localities not entirely free from objections, for instance in private houses.

V. General Operative Technic

It is not within the scope of this text-book to discuss this chapter exhaustively. The rules of general surgery prevail here mainly, especially for abdominal procedures.

We will only mention a few points conditioned by the peculiarities of the regions of gynecologic operations, particularly the vagina.

The instrumentarium of the gynecologist must be distinguished by the greatest possible simplicity. All instruments that are complicated and difficult to cleanse must be excluded.

Free latitude must naturally be allowed to the choice and wants of different operators.

We will only describe what has proven useful in our long practice, and what possibly differs from the usage of other operators. Many details will be specially treated in the different chapters.

A. *Martin's* needle-holder is always used for *suturing*, employing strongly curved sharp needles (Fig. 29). The needle-holder is constructed

according to the principles of a wire forceps without any mechanism. The inner surface of the claws are mounted with copper plates, in which the angular needles are buried by closing the holder and are thus held firmly. It is possible with this needle-holder to give the needles at any time any possible position. Although it is necessary to become accustomed to the great mobility of the needle, yet its simplicity and handi-

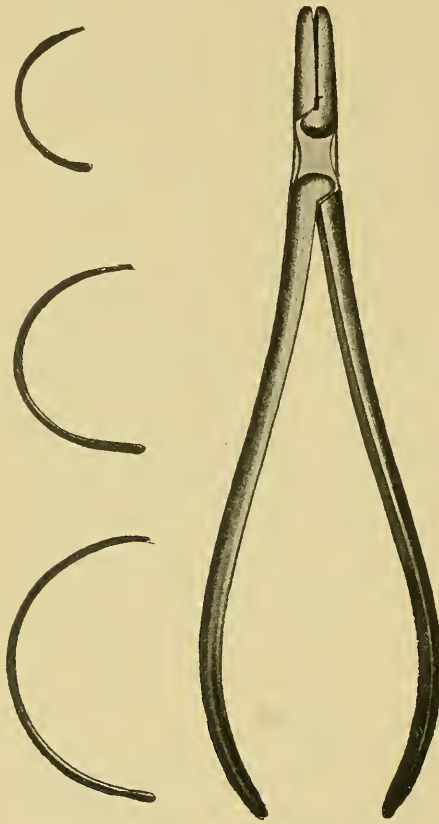


FIG. 29.—Needle-holder and Needles, after
A. Martin.

ness offer great advantages. The strongly curved, sharp needles are especially well adapted for suturing in the depths of the vagina and the abdominal cavity.

For the ligation of parts richly supplied with bloodvessels, therefore, especially in the depths of the pelvis, *Deschamp's* dull ligature carrier is employed in place of sharp needles.

See the chapter "*Asepsis*" for suture material.

We make extensive use of the **continuous catgut suture** in **suturing**. It is employed with the best results in all plastic operations on the vagina, perineum, uterus and coaptation of the peritoneum. **Non-absorbable** material is preferable for the fascia, fistulæ of bladder and rectum, as well as all skin sutures. For this purpose we always use interrupted sutures of aluminum bronze wire. This can be tied just as easily as catgut or silk and does not drain into the deeper tissues. We have discarded silk entirely. This is only used for intestinal sutures.

Leaving the suture instruments out of the question, the forceps for **grasping** are of the greatest importance. We use with preference the simple bullet-forceps (Fig. 17), the double-toothed forceps of *Muzeux* (see Fig. 30), and the vulsellum forceps of *Collin* (Fig. 31). We think it of great importance that all instruments should be made powerful and solid, so that they do not bend when applied to hard tissue. For hemostasis the well-known clamp forceps of *Péan* or *Kocher* are suitable, but they must be chosen quite long for the purpose of ligating in the deeper structures.

The retractors necessary for unfolding the vagina and retracting the

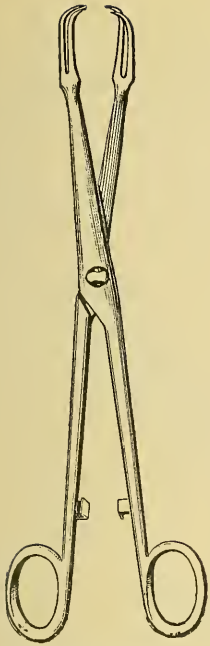


FIG. 30.—*Muzeux's*
Forceps.

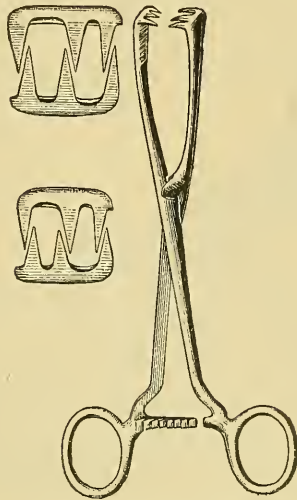


FIG. 31.—*Collin's* Forceps.

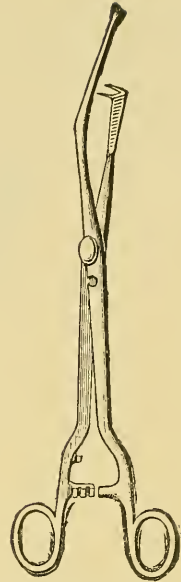


FIG. 32.—*Orthmann's*
Sound Forceps.

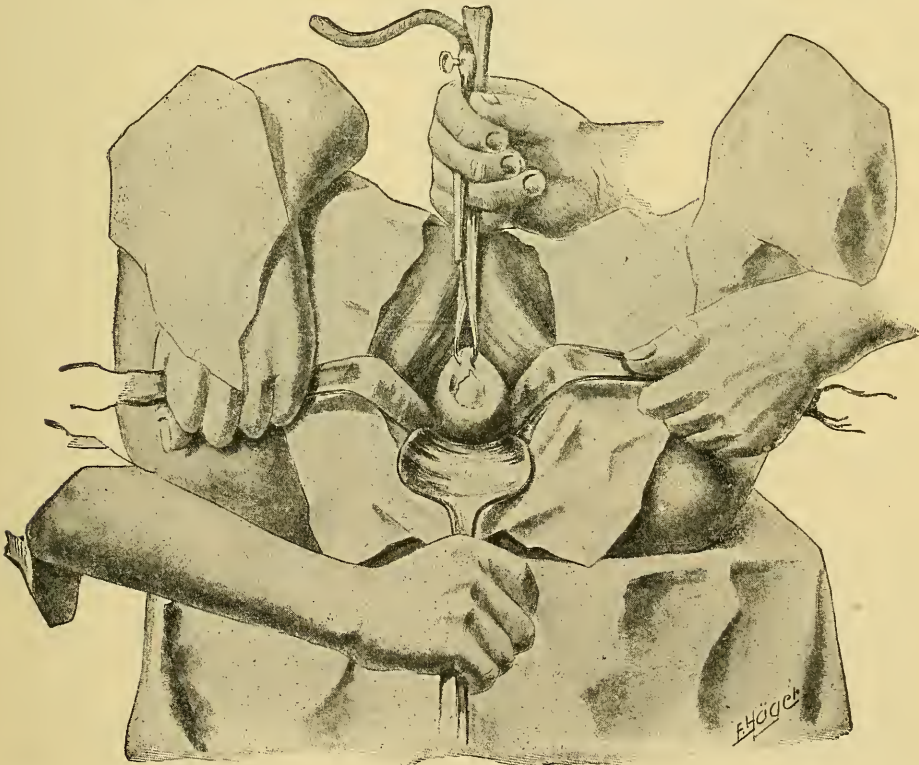


FIG. 33.—Patient in the Dorso-gluteal Position Ready for a Vaginal Operation. The vagina exposed by specula, the anterior cervical lip hooked with tenaculum forceps, besides which the assistant holds the tube for permanent irrigation.

peritoneum are represented in Fig. 19. These instruments must also be built strong and be provided with long blades to allow a good view of the deeper structures. *Von Ott* has, of late, proposed such specula of

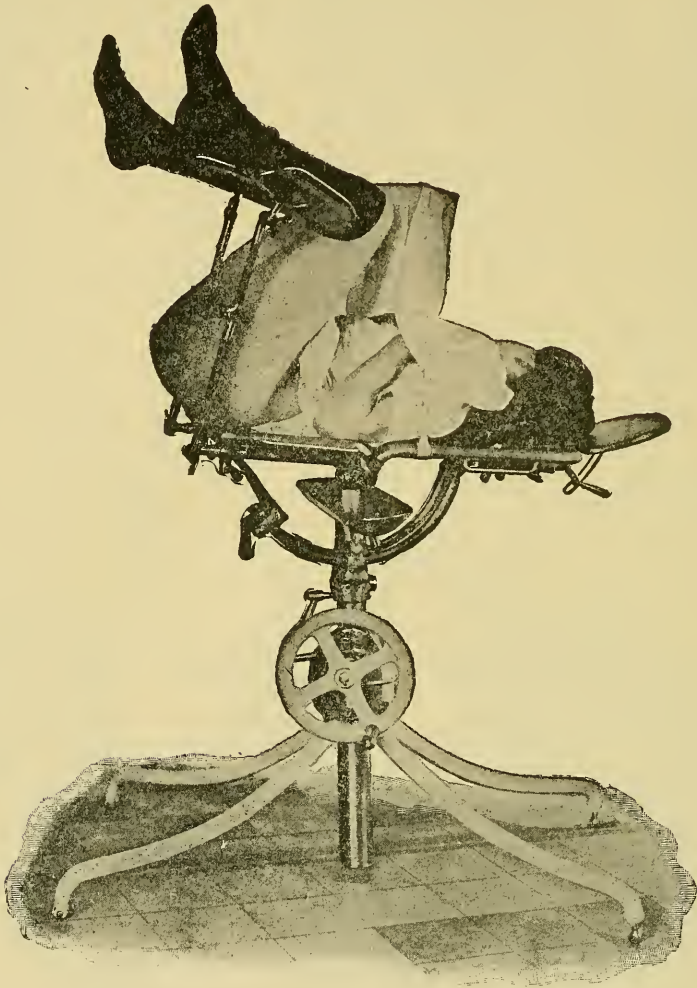


FIG. 34.—Patient Upon a *Stille* Operating Table in a Dorso-gluteal Position for a Vaginal Operation.

extreme length provided with electric lights. They have, however, not been tested for practical purposes.

The large abdominal specula of *Fritsch* or *Stoekel* are used for holding apart the abdominal walls in laparotomies.

We see a special advantage in the use of **continuous irrigation** of the field of operation with a 0.9% sterile table-salt solution in all **vaginal** operations.

This solution is heated to 37° C. (98.6° F.) and placed in a large sterile glass irrigator situated on a firm stand by the side of the operating table. A rubber tube sterilized by boiling conducts the solution to the operation field. At its end is fastened a long, thin metal tube provided with a cock, which permits a very fine stream upon the desired part or the area of operation. The blood is thus immediately washed away, as well as

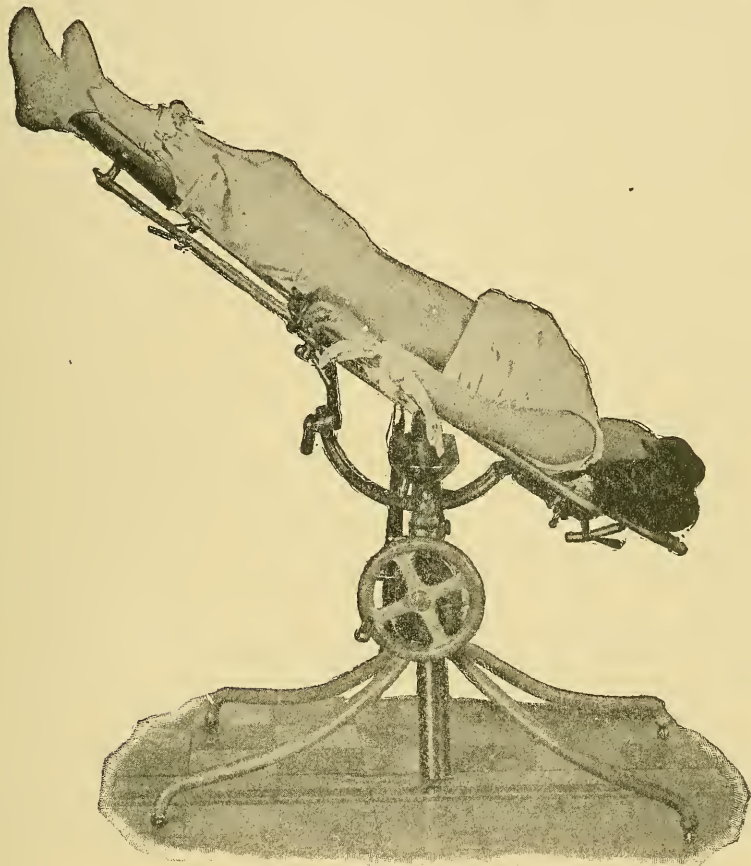


FIG. 35.—Patient Upon a *Stille* Operating Table in Elevated Pelvic (*Trendelenburg's*) Position for Laparotomy.

infectious fluids, pus, etc. We obtain in this way a clear view at all times and spare the time lost in sponging. We have not observed with it any damage to the tissues or healing of the wound.

We make extensive use of the *sound forceps* of *Orthmann* (Fig. 32) in order to stretch better the anterior vaginal walls in vaginal coeliotomy (Colpotomia anterior). It puts the uterus in a decided anteversion and thus brings the anterior vaginal wall with the bladder outward. The vagina can easily and conveniently be dissected off and the bladder

pushed back. The instrument must be removed before the uterus is brought down after opening of the peritoneum.

Fig. 33 gives a picture of a patient prepared for a vaginal operation, the portio vaginalis has been caught and brought down, the vagina is exposed with a speculum. The surroundings of the field of operation are covered with a sterile apron, and one can see the metal tube for permanent irrigation, above and next to the bullet-forceps, which are hooked into the anterior cervical lip.

We use the operation table of *Stille*, of Stockholm (Fig. 35), modified according to our specifications for vaginal as well as abdominal operations. It is comparatively easily handled, allows many different positions, and permits a relatively simple change from a vaginal to an abdominal operation (see Figs. 34 and 35).



Menstruation and Its Disturbances

LITERATURE.—See *Gebhard* in *Veit's Handb. d. Gyn.*, Vol. III, 1. *Bergmann*, Wiesbaden, 1898. *Frommel's Jahresber. über Geb. u. Gyn.*, 1898-1906.

I. Physiologic Behavior

The time shortly before and during menstruation is connected in many women with certain complaints, which, without making them directly ill, diminish their capacity for bodily and mental exertion.

The women are “unwell”—indisposed. The condition manifests itself quite variously; slight dragging pains in the small of the back and in the abdomen, headache, nausea, a disposition to vomit, general fatigue, and nervous irritability occur in many women. On the other hand a considerable number of women remain free from any disagreeable sensation during the period. Indeed there exists even, as it appears, a small number of women, in whom there occurs an *increase* of spirit and capacity for work, especially mental or intellectual. The sexual impulse tends mostly to be increased at this time, probably in connection with the hyperemia of the genital organs.

The duration of menstruation as well as the intensity of the flow fluctuate within wide limits, from one to eight days, without it being possible to call the condition pathologic. Consequently it is very difficult to estimate even approximately the amount of the expelled menstrual fluid.

Küstner states the average amount as 160 ccm.

Hygiene of Menstruation.—Though menstruation is a physiologic condition, still the growing girl should be trained to a proper behavior during this time.

The first cardinal principle is painstaking cleanliness. The external genitalia and the pubic hair should be cleansed at least three times daily of the adherent blood, as the same easily decomposes, especially in the summer, and causes a repugnant odor. The old superstition that a cleansing during menstruation is dangerous, should at least be overcome. The escaping blood should be received in special napkins fastened to a belt around the abdomen to avoid soiling the thighs and the underwear. Such napkins are suitably made from gauze with a layer of woodwool or cotton, and should be burned after use. A thorough cleansing full-bath should be taken after menstruation ceases.

Even if special difficulties do not exist, severe bodily exertion should be avoided during menstruation, as bicycling, horseback riding, playing

tennis, dancing, running a sewing-machine, travelling on foot, etc., and naturally also cohabitation.

Extensive mental exertion also should rather be postponed to another time, at least in young girls. This is an important and frequently neglected point in school hygiene.

However, one cannot draw up rules generally binding, for many a woman can bear even during menstruation, things without injury, which would be decidedly harmful to others.

A condition similar to menstruation occurs in some women in the middle of the interval between the two menstruations. The women have the same disagreeable sensations without the loss of blood as exist at the time of the menses. Often, however, in a lesser degree. One cannot, as a rule, attribute any importance to this occurrence. It has been termed a "*Mittelschmerz*" (small or false period).

II. The Disturbances of Menstruation

In disorders of menstruation we do not generally include those disturbances of which sensitive women frequently complain, so long as they occur within limits which are to be considered physiologic for this process. In this category belong general indisposition, and occasionally transient feeling of pain, a slight fluctuation in the amount of menstrual blood lost, the fluctuation of the duration of menstruation for one or two days, and the mucous discharge in connection with menstruation, lasting usually for some days (see above under *physiology*). By *anomalies of menstruation* we essentially understand **a considerable increase or decrease** in the amount of the menstrual flow, an **irregularity** in the time of the beginning and **intense pains and difficulties**. The forms of menstrual disorders, clinically most important, are **amenorrhea, menorrhagia** and **dysmenorrhea**.

A. Amenorrhea

A very scanty bloody flow or a complete absence of the same is observed in very different forms. A **physiologic amenorrhea** exists during childhood up to puberty, further during pregnancy, and, as a rule, during lactation, finally in advancing age beyond the climacteric. Amenorrhea is **artificially** induced, if both ovaries are removed *in toto* (castration) and also if the uterus is extirpated.

The **pathologic amenorrhea** is differentiated according as it depends on a **defective development** of the genitalia or the entire body or on **general systemic diseases** or on **diseases of the genital apparatus**.

Under **general defective development** we must consider the great variations in the time of development which influence decidedly the maturity of the young girl. By no means is a retarded occurrence of puberty always associated with a correspondingly incomplete bodily development, and it is beyond any doubt that ovulation may have existed for a long time, before menstruation began to appear. In this respect I

refer to the authenticated cases of conception without any preceding menstruation. In such cases of amenorrhea it is a relatively frequent occurrence for menstruation to appear very irregularly in the beginning, so that in the lapse of years one *such* bleeding may have occurred which could be designated as a menstrual flow. *Chlorotic* girls and women are involved in most cases, in whom menstruation began to be regular as soon as this condition subsided. Moreover one meets at times persons in whom the menstrual period never occurred at all, notwithstanding the fact that the genitalia were developed in an apparently normal manner, and even conception had resulted.

Concerning the cases of amenorrhea in *incomplete development of the genital organs* see chapter on *Anomalies of Development*.

The second category of amenorrhea in which *wasting constitutional diseases prevail* or *organic diseases* which disturb the economy of the entire body, hardly demands a gynecologic treatment. The amenorrhea in these cases is only a symptom of another disease. Its treatment coincides with that directed against the latter.

As such diseases are chiefly to be considered:

1. *Tuberculosis*.—A gradual decrease of the menstrual flow, which finally ceases entirely, takes place in this disease before its process has taken a grave form. Women, not rarely, consult the physician on account of this amenorrhea, and the disease which lies at the bottom is discovered after a comprehensive examination of the entire body.

2. *Diabetes Mellitus*.—The first sign of ill-being in this disease, even more so than in tuberculosis, is a cessation of menstruation even before characteristic symptoms have appeared. A careful examination of the urine, which should not be omitted in any case of amenorrhea, leaves no doubt as to the diagnosis.

3. A peculiar form of amenorrhea is observed with marked *general development of fat* which causes the menstrual flow to diminish gradually, often to a complete suppressio mensium.

4. Cases have been reported in which *psychic* influences have led to a suppression of the menses. Those cases observed by us concerned girls and women with a beginning *psychosis*. Gynecologists are frequently consulted by a class of patients in whom the development of symptoms of the psychosis has not advanced far enough to prevent the symptoms referable to the genitalia from still occupying the foreground in the eyes of the laity.

5. Amenorrhea owing to *genital diseases* must at times be considered as a symptom of some special form of such disease.

In *ovarian diseases* amenorrhea may appear if the entire parenchyma which performs the function of ovulation has been destroyed, for example by newgrowths. However, it is deserving of notice that this occurs only occasionally, and then mostly in malignant tumors. In benign tumors, even if they have apparently penetrated the entire organ, small remnants of parenchyma, capable of the function of ovulation, usually remain.

These suffice perfectly for the maintenance of the menses. Lastly amenorrhea may occur if the *entire uterine mucosa* has been destroyed through inflammatory changes. This condition occurs very rarely. It has been observed after severe puerperal septic infections, in which the entire endometrium as far as the musculature has been thrown off in a necrotic condition. Further in the infiltrating cheesy form of *uterine tuberculosis* in which also the endometrium may be destroyed entirely. Finally amenorrhea may appear after *long-continued exhausting diseases*, for instance after typhoid fever, long-continued wound diseases, especially suppuration.

Amenorrhea usually does not develop suddenly, excepting the cases of primary deficiency of any secretion. The discharge of blood becomes first of all scanty, returns at always longer intervals and is of a very short duration. Menstruation may be absent one or more times and appear at a later period at about the usual time of its occurrence or may recur regularly after intervals of five, six, seven or more weeks. Signs of intense congestion may appear at the time of the expected menstruation, especially in cases in which the flow intermits at the regular period, as headache, backache, dyspnea, gastric disorders, drawing in the breasts; occasionally bleeding from the bowels, from the nose, or from the lungs are added to such regularly recurring symptoms. These vicarious bleedings appear particularly in chlorotic individuals. In general one must be very critical in judging them. The secretion of the uterine mucous membrane is increased, especially at the time of the expected menstruation. In the beginning of the affection there may be still an increased succulence, swelling and sensitiveness of the organ, while after a longer duration of this condition all these manifestations may become completely lost. I have often seen, under quite analogous symptoms, the development of a premature climacteric and could observe the involution of the genitalia with symptoms corresponding to the above description and occurring shortly after or even before the thirtieth year of life.

The *treatment* of amenorrhea, which appears as a symptom of systemic or organic disease, may consist only in the treatment of the primary disease. With its removal or decided improvement menstruation frequently reappears. After exhaustive acute diseases menstruation usually recurs during general convalescence.

The *treatment* of amenorrhea as a symptom of chlorosis or of delayed general development consists in a general energetic care of the body, and a restraint from physical and mental work. Sojourn at the seashore, in the mountains, or in the country, supplemented by the use of ferruginous mineral waters or remedies influences this condition in a curative manner. *Marriage* sometimes removes the amenorrhea immediately and permanently.

A strong inducement is offered to treat amenorrhea as such in cases in which agonizing congestive symptoms in other organs co-exist. Only when such disturbances were present have we decided on

local treatment, otherwise we are accustomed to secure the strengthening of the body by a nutritious diet and a corresponding mode of living. A stay in the country, sea baths, energetic walking tours in mountain and forest are especially to be recommended for such patients.

Amenorrhœa as the result of *obesity* is treated with the best results by saline aperients, especially in Marienbad, Kissingen, Bertrich, and similar watering-places. We prescribe the *emmenagogues*, formerly so celebrated, very seldom. We expect much better results from local irritants which excite the uterine mucosa and parenchyma according to experience if no special contraindications exist on account of other genital diseases. We give *scarification* the first place as an irritant, which we make use of extensively in amenorrhœa, especially at the time of the expected menstruation. Sitz-baths, often repeated, sounding of the uterus, also intrauterine stem pessaries cannot be dispensed with in stubborn cases.

B. Menorrhagia. Menstruatio Precox

We understand by menorrhagia menstrual hemorrhages, which influence the health either through their profuseness or through their long duration. It is often quite difficult to estimate an increase in the amount of menstrual flow because we do not know of any means to measure the quantity of the blood passed and thus to fix the relative quantity of a normal menstruation. A control is only possible by the collection of the used cloths, pads, napkins, cotton compresses, etc., and proves often that an excessive loss of blood does not exist in reality.

A really continuous hemorrhage from the genitalia takes place very seldom in this type of menstruation; the blood is expelled mostly intermittently, also with an admixture of coagula, by which women are frightened very much, as a rule.

Most cases of menorrhagia are to be traced to other genital diseases, not only of the uterus, but also the adnexa and the pelvic cellular tissue. Chronic inflammations of the most different varieties, particularly, lead very frequently to menorrhagia.

Menorrhagia is found very seldom *without distinct disease* of the genitalia. One sees occasionally frail, poorly nourished, and irrationally living women, who have quite extraordinary hemorrhages at the time of the menses, without our being able to demonstrate an etiologic factor in the genitalia. At times phthisical patients have such menorrhagias. We have seen these in heart, liver, and kidney diseases as symptoms of congestion of the pelvic organs. Also corpulent persons have at times menorrhagia in contradistinction to the more frequent amenorrhœa. The constitutional disease in all these menorrhagias demands the full attention of the physician, and the menorrhagias improve with the improvement of the primary disease, or in any case lose their importance.

Menstruatio Precox.—We understand by this anomaly a *regularly* recurring bleeding appearing in small children often already during the

first year of life which corresponds quite exactly to the menstrual type.

It must be looked on as a sign of precocity, inasmuch as the genitalia, especially the ovaries, are found usually in full development, and also the genital development of the body is far advanced in proportion to the age. Not infrequently anomalies of other organs, as hydrocephalus, tumors, etc., are associated with the condition. (*Gebhard, Veit's Handbuch.*)

Those hemorrhages which appear sometimes post partum in new-born girls and then again disappear do *not* belong to menstruatio precox.

Regular bleedings may also persist during the climacterium beyond the usual time. They can be called menstrual only if a careful examination of the uterine mucous membrane excludes another cause (tumors, etc.).

In the *treatment* of the hemorrhagias a *causal genital disease must naturally be attacked*. In case of obscure etiology bloodletting shortly before the beginning of the menses plays a peculiarly important rôle. One can restrict the menorrhagia at times by considerable scarification shortly before the beginning of menstruation. In other cases a decrease of the hemorrhage can be obtained at times by the use of ergotin (R. ergotin Denzel, secal. cornut. pulv., aa. 5.0, ft. pilul No. 100. Sig. Three times daily three pills) and *extractum hydrastis canad. fld.* (four times daily up to 25 drops), stypticin (cotarnin hydrochlorid) 0.05 four times daily, or by absolute rest in bed and by avoidance of all exertion at the time of the menorrhagia, also by ice-bags to the abdomen. As a means of controlling the hemorrhage we recommend especially vaginal irrigation with hot sterile normal saline solution at 50° C. (122° F.). We have seen better results from this than from the use of cold in the form of ice-cold irrigations.

Menorrhagias without definite anatomic causes resist only very rarely, and singly, an energetically continued local treatment of this kind, but such cases come under observation once in a great while. Only slight changes in the mucosa with an important increase in the size of the uterus then exist. As a last resort vaginal extirpation of the uterus has been rightly recommended for such desperate cases. But this never should be done before trying to overcome the hemorrhage by thorough and often-repeated abrasio mucosæ uteri (curettage) and subsequent cauterization (see page 31).

C. Dysmenorrhœa

We have no reason to designate as dysmenorrhœa those disturbances which most women experience at the time of menstruation, the pains in the back, the discomfort, the feeling of heaviness in the abdomen, gaping, a continuous desire to urinate, and so forth. These are attendant symptoms of menstruation which are borne by most women prudently as associated with this process. Only when the disturbances render the

woman unfit for anything do they deserve a thorough consideration as a symptom of diseases of the genitalia, especially endometritis, metritis, perimetritis, adnexal diseases and tumor formation in the uterus.

The proper dysmenorrhic symptoms are *colicky pains*, which begin already before the appearance of the flow quite in the manner of labor pains, and disappear with the occurrence of the flow, or in other cases last during the entire time of menstruation. The uterine colics recur on the occasion of abundant secretion also outside the menses. The pains arise, as it appears, through an obstruction to the evacuation of the secreted blood and mucous secretion, partly by a kinking of the genital canal, partly by the obstruction of the same by swelling of the mucous membrane, by stenoses, or by tumor formation. It must be accepted that the blocked secretion as a foreign body excites the uterus to more or less energetic contractions, until the obstacle is overcome. The objection raised by English authors (*M. Duncan, Playfair*), that one does not find such a retention of the contents of the uterus post mortem, seems rather inappropriate, for on the one hand I have already repeatedly seen such retained masses during post-mortem examinations of the uterus. On the other hand it is a fact often to be observed that foreign bodies can be expelled from the uterus during the death-agony or through post-mortem contractions. Why should we not accept the occurrence of such an expulsion also in these cases which are so seldom seen at an autopsy?

The peculiar form of dysmenorrhea in which an expulsion of the superficial layer of the mucous membrane occurs with violent colicky pains, *dysmenorrhea membranacea s. exfoliativa*, represents only a special form of endometritis and will be discussed in the chapter on *Endometritis*.

The *treatment* of dysmenorrhea *in general* coincides with that of the underlying disease.

Apart from the forms of dysmenorrhea just now discussed, in which we finally always find an anatomic cause, there are indisputable cases for which we cannot give such an explanation. These forms have been designated as reflex neuroses. They are not rarely combined with other nervous symptoms, especially of an *hysterical* nature, and offer a very checkered picture in their symptomatology. Not to mention the pains in the pelvis itself, pains occur in all possible regions of the body: headache and bachache, vomiting, paresthesias, etc., occur. One does not go amiss in accepting the view that the nervous excitability, normally already increased at the time of menstruation, develops to a pathologic significance.

It is a noteworthy and indisputable fact that many dysmenorrhœas are permanently cured by sexual intercourse, but above all by conception and labor. It is probable that unsatisfied sexual desires play a rôle in the production of this kind of dysmenorrhœa. The disease disappears with the disappearance of the cause.

D. Conception

The different hypotheses about the occurrence of *conception* cannot be discussed here in detail. I will only refer to the fact that for establishing a conception the presence of a virile sperma is indispensable, and that we must be guarded in attributing the fault in cases of sterility to the woman alone without due reason. Almost one-third of sterile marriages are caused by an impotency of the husband. Before we impute sterility to the wife, and attack even diseased conditions of her genitalia for the removal of sterility, it appears to be prudent to procure positive proofs of the potency of the husband. This can only be established, free of any objection, by an examination of the spermatic fluid for living spermatoocytes. We are fully aware of the great difficulties which this meets in practice and are sorry not to know of any means to establish the procreating power of the male without the cumbersome examination of the semen.

One proceeds best by directing the husband to carry out cohabitation with a condom and to forward it to the physician in a clean and well-stoppered bottle as soon as possible. A cover-glass preparation, best in a hanging-drop, permits us soon to recognize the actively moving spermatoocytes under the microscope. If the semen have been exposed for a long time to the influences of low temperature, then the spermatozoa not rarely have lost their motility, and a picture of *azoosperma* is simulated. A stay of the semen for some time in the incubator at about 37° C. (98.6° F.), or in a warm-water bath, brings the spermatozoa soon back to life and obviates invidious deceptions.

The semen enters the upper genitalia very rapidly, and remains capable of fecundation for a number of days in the genital organs, favored in its viability by the nature of the vaginal and uterine secretion. So one does not need to accept the idea that conception follows cohabitation immediately.

The occurrence of conception is not rarely immediately characterized by a peculiar change in the feelings of the woman. Conception at times appears to follow voluptuous sensations which occur in women moreover relatively seldom and only after long-continued stimulation, and are analogous of the sensation in ejaculatio seminis. Psychic phenomena are observed in other cases immediately in connection with conception. Again other women claim that they experience a peculiar sensation of warmth at this time. Finally women not seldom show the characteristic disturbances of the beginning stages of pregnancy, especially nausea, drawing in the breasts, etc., from the moment of the onset of conception.

E. Sterility

The conditions under which sterility is developed are by no means simple and clear in their final analysis. If we leave out of question the total absence of the germinal organs or a complete closure of the genital

canal leading to them, also impotency of the male, we hardly can prognosticate an absolute sterility of the female even with an extreme development of pathologic processes in the genitalia, for how often have not the conditions most frequently supposed to produce sterility, permitted, nevertheless, perhaps accidentally, a conception. I mention in this relation the cases of hymen imperforatus, the instances of the severest stenoses of the orificium uteri externum, as we have observed them repeatedly, the cases of continued diseases and advanced degeneration of the tubes and ovaries, in which, nevertheless, pregnancy did occur. It would be, therefore, quite imprudent for one to render an absolutely unfavorable prognosis quoad conceptionem in the face of such abnormalities. We have become very careful, especially in regard to the stenoses of the orificium uteri externum, since we have seen conception occur in women, with an opening in the orifice scarcely larger than the point of a pin, in defiance of all known principles. Yet one will be generally permitted to designate as insignificant the probability of a conception in such cases, especially in diseases of the uterus and ovaries. The changes in the female genital apparatus most detrimental to conception make their appearance in connection with infections mostly of gonorrhoeal or puerpero-septic origin in the tubes, the perimetrium and perhaps as a result therefrom, in and around the ovary. We have seen these cases of chronic oophoritis, perioophoritis, perimetritis, salpingitis, and simultaneous chronic uterine catarrh followed only too frequently by permanent sterility. The possibility of a cure of such conditions should be despaired of only after long-continued treatment, and a corresponding reserve in regard to the prognosis should be maintained.

Pathology of the Vagina and Uterus

In the following chapter we will group together the pathology of the vagina and uterus so far as regards developmental defects, changes in form and position, and the description of inflammatory conditions, with the view of discussing together conditions that are closely related in their etiology, pathology, and therapy. The etiology and treatment of these conditions is frequently the same in different portions of the genital tract; our observations are made easier and repetitions avoided by this arrangement.

A. Anomalies of Development, Changes of Form and Position

1. Malformation of the Vagina and Uterus

The development of the genital organs can easily be perceived from the accompanying schematic drawings which have been taken from



FIG. 36.—*all*, Allantois, Later Urinary Bladder. *r*, rectum; *m*, Müller's duct, later vagina. *a*, external invagination of the skin, which is to be the anal opening.



FIG. 37.—The external invagination of the skin is completed and forms the cloaca (*cl*).

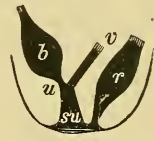

FIG. 38.—The perineum has been formed, so that the anus and sinus urogenitalis (*su*) are separated from each other. *u*, urethra; *v*, vagina; *b*, bladder.

Schroeder's Lehrbuch, Ed. VII, 1884, page 519.

Schroeder's text-book. The study of these lightens the understanding of the following:⁷

I. Aplasia of the Female Genital Organs

Malformations resulting from disturbances of development are mostly combined with other important anomalies of the body, so that the foetus is not capable of extrauterine life and succumbs, even if one succeeds in relieving, for instance, atresia of the rectum or the bladder (Figs. 39,

40) in the new born. This is not the place to enter into a discussion of the manifold possibilities of arrest of development.⁸

(a.) *Absence of Parts and Rudimentary Development*

It is very rarely the case that there is **no indication** of Müller's ducts. In the external depression (Fig. 37, *cl.*) from which the opening to the internal genital organs (Fig. 38, *su*) develops, only the urethra is formed, while the external genitalia are plainly but incompletely developed. The

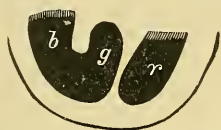


FIG. 39.—Complete Atresia, Allantois Separated from the Rectum. *b*, bladder, and *g*, genital canal distended by urine.




FIG. 40.—Complete Atresia. *b*, bladder; *g*, genital canal; *r*, rectum.

Schroeder's Lehrbuch, Ed. VII, page 530.

ovaries cannot be detected at times. One finds in the hollow of the pelvis, extra median, and near the pelvic wall, a small nodule, which could be called an ovary. This finding has clinically the same importance as that in which Müller's ducts are developed as bandlike unperforated formations instead of a complete absence.

If the ovaries are entirely absent, one finds only a moderate development of the feminine type, these persons being absolutely sexless; they show only scant external indications of the development of puberty and have occasionally molimina, so-called vicarious menstruation, as epistaxis, melena, hemorrhoidal bleeding and the like.

Somewhat more frequently than the foregoing, persons are found in whom the **internal genital organs can be palpated as bands and nodules running transversely across the pelvis, which appears otherwise empty**, with or without connection with the vagina. One may feel especially a fold which runs transversely across the pelvis. These persons have at times an infantile developed vagina, which terminates in a blind sac without it being possible to feel a continuation above it. Attempts at intercourse lead at times to a dilatation of the urethra, in others the fold of skin between the nymphæ is stretched and widened into a short cul-de-sac (blind sac).

The majority of my patients thus constituted were very decrepit women with positive phthisical habitus, children from marriages between blood relatives, very juvenile and neurasthenic persons. The sixteen-year-old wife of a physician had a perfectly beautiful feminine body, but she developed a severe nymphomania, which led her to the insane asylum. Only in one family did I find these persons develop the character of viragos. This family confirmed the isolated observations in

the literature regarding the hereditary character of such arrested developments. In this family belonging to the old nobility I found in two generations of several sisters, only one in each generation with normally developed genitalia, while two in the first generation and one in the second were completely without sex. I had occasion to examine the two sexless ones of the first generation under anesthesia. I did not examine the sexless one of the second generation under anesthesia, yet so that I was able to determine that she belonged to this group. The sexless women of this family have a feminine habit throughout, but an unusual stoutness. The sexually developed women are predisposed to newgrowths. One male descendant of each generation perished from malignant tumor formation.

Even with a feminine type of the body, it is not always the case that the voice and disposition, especially the sexual feelings, are feminine.

If generative glands exist they may give rise to violent disturbances through their physiologic activity, even if they are of a scanty size. These disturbances appear as acute pains at unusually long intervals, with plainly demonstrable increasing and decreasing swelling of the ovaries. The displacement of these generative glands to the floor of the pelvic cavity, in the inguinal canal or in the labia majora, gives rise to various complaints. The increase of these disturbances may compel one to remove the offending gland. There are found in these glands, at times, numerous and apparently normal *Graafian* follicles and traces of ruptured ones. These women, especially, show so-called vicarious menstruation; one of my patients had quite regular and abundant hemorrhoidal bleedings.

It is indispensable for the *diagnosis* of these malformations to submit the genitalia to a very exact inspection and palpation through the rectum. I have not obtained equally satisfactory results from a simultaneous palpation of bladder and rectum, because both hands rather hinder instead of assisting each other. The *most important landmark* for detecting aplasia of the internal organs is *the point of emergence of the ligamenta rotunda*. This point must be looked for after opening the abdomen, eventually post mortem, as it is considered important for the interpretation of existing traces of the internal genitalia, before one can form an opinion about the nature of any palpable bands.

It is clear that one cannot help these women essentially. The attempt to construct a vagina, which occasionally might be deemed necessary on account of the demand of the husband, is not quite hopeless if one can utilize for the lining of the cleft, established between the bladder and rectum, the rectal mucous membrane according to the proposition of *Küstner*⁹ and *Gersuny*,¹⁰ flaps of the external skin according to *Heppner*,¹¹ peritoneum according to *D. V. Ott*,¹² or skin from the prolapse operations according to *Mackenrodt*.¹³

A number of malformations have gained an increased scientific, others also far-reaching, importance through many observations.

As such we mention the termination of the rectum into the sinus urogenitalis, also wrongly termed atresia ani vaginalis. There is, as a rule, no anastomosis with the vagina. Rarely the mouth of the rectum is just below the hymen,¹⁴ anus præternaturalis vestibularis, but more frequently is farther down. At times a second opening, besides the normal opening, may exist in the vestibulum vaginæ.¹⁵

A junction of the vagina and the bladder in the vestibulum vaginæ without urethra is termed a **hypospadias**. *Reichel*¹⁶ has described this as an arrest of development. Epispadias is found in extrophy of the bladder. *Kehrer* (*Berlin. klin. Wochenschrift*, 1904, No. 33) has discussed the attempts for the correction of these deformities.

The cases of **hermaphroditism** have been critically examined of late in a monograph by *Fr. von Neugebauer*.¹⁷ Those known so far are cases of **pseudohermaphroditism**, hypertrophy of the clitoris, scrotumlike formation and growth of the labia with a very narrow opening of the sinus urogenitalis beneath the penislike clitoris, in which terminates the urethra and the vagina. The internal genitalia are rudimentary or normal. The breasts are at times perfect, at others imperfect. Habitus, voice and disposition are sometimes feminine, sometimes masculine. My experience proves how careful one must be in cases of displacement of the ovaries, for instance in inguinal hernias, in which one may palpate the testicle instead of the ovary. I extirpated a testicle instead of the diagnosticated ovary. Existing molimina must be treated symptomatically; there is no objection to the removal of isolated germinal glands as soon as they cause continued suffering or degenerate.

(b) *Incomplete Unilateral Development with the Possibility of Sexual Functions*

More frequently than the forms of aplasia just described there is found one in which the **development and coalescence of Müller's ducts had not led to a complete development of a uniformly healthy genital apparatus**. One cornu may be completely absent, then the adnexa of one side may be entirely absent or are only scantily developed.¹⁸ At times the one horn may be developed, while the other remains rudimentary, either as a solid cordlike muscular band (see Figs. 41, 42, 43), or as a hollow organ, while fusion takes place in an incomplete manner. The half which possesses an external opening undergoes almost complete development; it indeed may even functionate in a regular way by menstruation and eventually undergo development to accommodate the fetus. The accessory cornu appears to be most markedly developed at the point of its transition into the lig. teres, and this itself is unusually long.

The importance of the rudimentary half depends on whether it is perforated completely or partially. If the imperforated portion is developed so that it can menstruate, blood cysts or sacs develop, and they fill up to a point of rupture; rupture may become fatal through hemorrhage or

suppuration. The number of cases known in the literature of retention cysts in such incompletely developed *Müller's* ducts is continually growing. Their importance depends materially on their location and the varying condition of their contents. The farther the affected end lies from the external genitalia, the more difficult is the diagnosis, and the

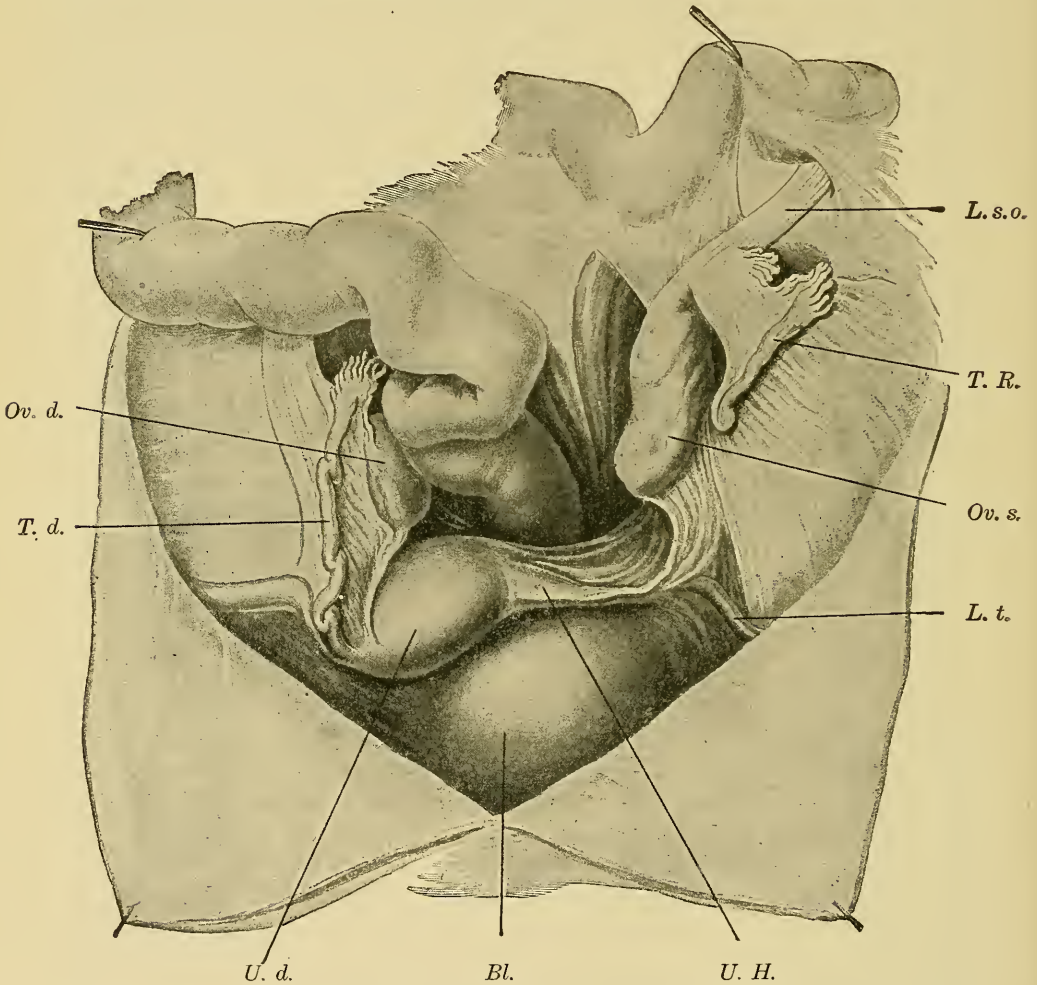


FIG. 41.—Uterus Unicornis Cum Rudimento Cornu Alterius. After *Natanson*, *Monatschr. f. Geb. u. Gyn.*, XX, p. 1104. *Ov. d.*, ovarium dextrum; *T. d.*, tuba dextra; *U. d.*, uterus dexter; *Bl.*, bladder; *U. H.*, rudimentary uterine cornu; *L. t.*, lig. teres, *Ov. s.*, ovarium sinistrum; *I. R.*, rudimentary tube; *L. s. o.*, lig. suspensorium ovarii.

more danger exists that the retention cyst may rupture in the absence of necessary assistance and cause the death of the patient.

One of my patients, a Mrs. B., nineteen years old, well developed, and menstruating since her fifteenth year, felt for about a year pains at each

menstrual period increasing in severity, and noticed the growth of a mass in the abdomen, which she at first thought to be a pregnant uterus. As these pains kept on increasing, and the continuation of menstruation

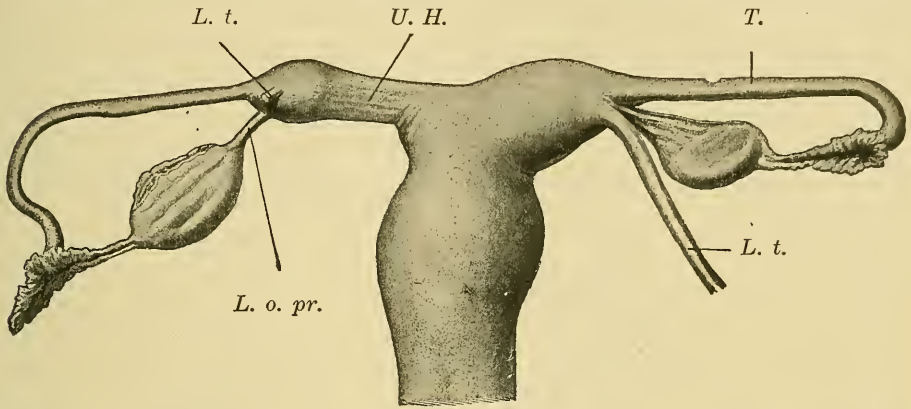


FIG. 42.—*L. t.*, lig. teres; *U. H.*, rudimentary uterine cornu; *T.*, tube; *L. t.*, lig. teres; *L. o. pr.*, lig. ovarii proprium. (See Fig. 41.)

caused her husband to doubt the existence of pregnancy, he brought her for an examination. I found a tumor reaching above the umbilicus, but most prominent in the right lower pelvic region, where it extended into

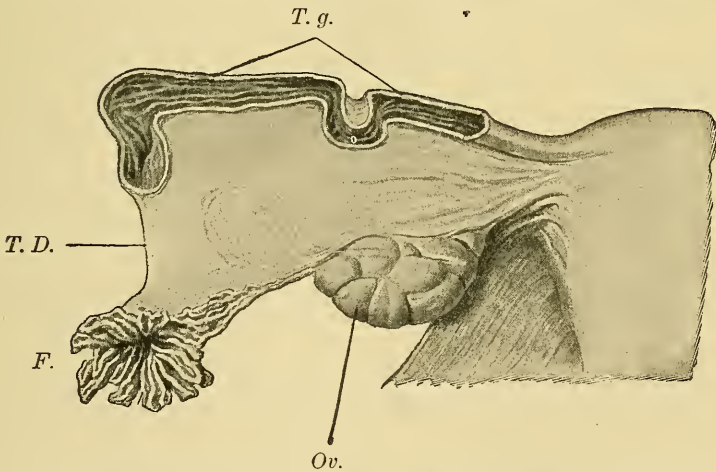


FIG. 43.—*T. g.*, opened tube; *T. D.*, tubal defect; *F.*, fimbria ovarica; *Ov.*, ovarium. (See Fig. 41.)

the small pelvis close to the introitus vaginæ, the vagina being displaced markedly by this mass. The examining finger passed with difficulty to the left of the mass up to the inlet of the small pelvis, where a small portio was located. Under chloroform anesthesia it was possible to prove that the cervix was continued into a sparingly developed cornu

uteri, which was intimately united with the tumor (Fig. 44); one could palpate at the upper and right portion a round band, which had to be considered as the lig. teres. Farther down and posterior was a formation which resembled an ovary in form and consistency. In palpating this finding I could not fail to recognize the similarity with the different pictures of unilateral hematometra and hematocolpos found in the literature.¹⁹ A wide incision was made in the portion of the mass penetrating into the vagina just above introitus vaginæ, and a blackish-brown fluid escaped under the strong pressure of the contracting walls of the cavity. It was impossible to estimate the quantity, because the incision

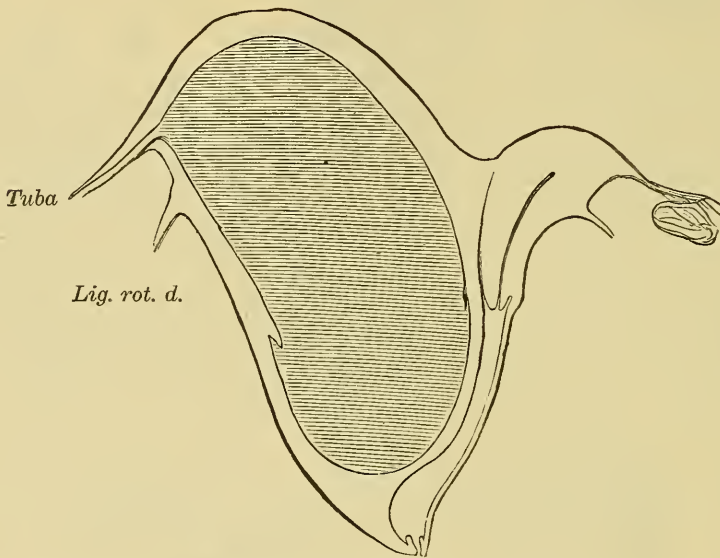


FIG. 44.—Hematocolpos and Hematometra Unilateralis Congenita. After a personal observation.

had been made under permanent irrigation. The cavity collapsed, and a swelling developed in this cavity just above the lower portion, which finally came to lie at the level of the portio of the other side. I could palpate a cavity above this swelling which closed all around could be considered as the cavum colli et corporis of the right cornu uteri, which had been completely closed until now. This corpus shrunk considerably in the course of time; it showed in this case a characteristic torsion around the left uterine cornu. The opening of this cavity had to be repeated several times, because it contracted very readily. Finally I dissected out the entire septum between the two vaginæ and split also the septum of both uterine cornua. The right uterine horn became displaced in spite of this, from time to time, and caused great inconvenience on account of a retention of a purulent and rapidly decomposing secretion. The patient became pregnant after about five years, had a normal labor, and is now

perfectly well. I regret that I did not find another opportunity for an examination under anesthesia.

Cases of unilateral hematometra and sactosalpinx hemorrhagica in such malformations are described by *Hofmeier*²⁰ and *Löhlein*.²¹ If the blood-filled cavity is situated in the upper portions between the separated cornua, while the lower portion remains imperforate, tumors might be simulated, that are connected by a more or less thick pedicle to the apparently poorly developed but healthy uterus, by the side of which we may palpate the tubes, ovary and lig. rotundum. The *diagnosis* in these cases is connected with great difficulties. One must observe an *increase in the volume* of the mass occurring *periodically* at the time of menstruation, *the increase in the severity of pain with the growth of the tumor mass*, and the occurrence of *contractions* in the muscular walls of the tumor on palpation. A peculiar displacement of both halves of the genital tube, to which *W. Freund*²² first called attention, and which has been observed in great regularity in all the later observations, is of diagnostic importance. One-half turns around the other like a corkscrew and mostly the left around the right, which latter, by the way, is more frequently the seat of rudimentary development than the left one.²³

The treatment consists in opening the imperforate sac, which is described on page 73.

(c) *Incomplete Coalescence of Müller's Ducts*

Disturbances of development which concern both halves of the genital organs are not a very rare occurrence. These arrests of development have a more theoretical than practical interest. In these defects the coalescence of *Müller* ducts does not occur at all, and as a result two genital canals exist which open externally. Both halves may functionate quite regularly, each one independently of the other. Both menstruate, at times not simultaneously, both may serve their purpose of cohabitation and can become pregnant. Besides these we may find cases in which only the one-half is widened and may serve the different sexual functions, while the other does not menstruate, does not expand, and cannot become pregnant.

I observed a maiden lady, besides other cases of this kind, in whom inside a well-developed introitus a firm vertical membrane was seen. The equally penetrable lumina of the separate halves of the vagina were found on both sides of the membrane. She menstruated regularly, apparently from both halves and at the same time. The finding had been accidentally discovered by a physician some years previously. The lady worried greatly about the influence of this condition on her future life, as she intended to marry soon. She was a woman thirty-five years old, exceptionally tall, of a feminine body habit, but masculine features. She was one of triplets and stated that her sister and brother showed also unusual forms of body. I dissected out the septum from the introi-

tus up to both cervixes and sutured the cut surface with catgut. Union was good. The patient married, but so far has remained sterile.

It is clear that such cases may run through all the physiologic phases of development without any pathologic disturbances, while on the other hand irregularity in the development of one side or a pregnancy in both halves may result in various difficulties.

In coalescence of both *cervixes, uterus bicornis unicollis*, both corpora diverge in a remarkable way, so that the more they separate from each other the more obtuse becomes the angle between them. In some cases a fold of peritoneum is found running from the rectum to the bladder. I found such a fold strikingly developed in a case of formation of an intramural myoma, the size of an orange, in the left uterine cornu.

A uterus otherwise normally developed externally, may be divided completely by a septum extending from the fundus, either down to the orificium internum or through a small portion of the cavity, a *uterus septus or subseptus*. The vagina may also be divided in a similar way or remain single.²⁴

(d) *Incomplete Development with Incomplete Communication of the Genital Canal with the External Surface of the Body*

Cases in which Müller's ducts during their development coalesce with each other, but do not reach in a normal way a communication with the sinus urogenitalis are of a much greater importance than the foregoing conditions. These cases of atresia must be differentiated according as they are situated at the hymen, *atresia hymenalis*, or higher up in the vagina, *atresia vaginalis*, or in the uterus, *atresia uteri*. The atresia uteri is again differentiated into an atresia of the external os, the cervical canal or the internal os.

To these cases must be added those in which the lumen of the uterine horn is imperforate or not, cases of so-called *congenital atresia of the uterine tubes*, Müller's ducts having otherwise well coalesced.

These cases of congenital atresia resemble in their effect the cases of *acquired atresia*, which may also be situated at the entrance of the genital canal or in its course.

The origin of these atresias is doubtful; even "congenital" atresia may develop through inflammatory processes in intrauterine as well as in early life.²⁵

Congenital atresia does not make itself felt before the development of puberty. As soon as puberty sets in a retention of the menstrual fluid and other secretions takes place, if the genitalia are fit for the development of menstruation. Another consequence is the prevention of conception corresponding to the location of the atresia. Occasionally several atresias occur in the same genital apparatus. In this case several retention cavities may develop during menstruation, which may lie above one another, and need not communicate with each other.

The *symptoms* of atresia appear with the occurrence of menstruation. An external excretion does not take place, but peculiar drawing pains develop in the abdomen which at first are accompanied with only slight discomfort and disappear entirely in the interval; they, however, become more intense with each periodical recurrence, until finally the feeling of discomfort and drawing extends beyond the time of an ordinary menstrual period. The effect on the general condition is increased by the irritation of the peritoneum (localized pain, nausea, vomiting) by anemic symptoms, by interference with the bladder and bowels. This symptom ceases entirely in a small number of cases after a few such incomplete menstruations, while other women menstruate at long intervals and then cease entirely, before further consequences occur. The secretion of the mucous membrane naturally may be retained besides the retention of blood; it seems, however, that such retentions of secretion without menstrual admixture are comparatively rare. The secretion of the mucous membrane occurring before puberty may be penned up, a case of which *Godefroy*²⁶ reports in a child two months old; *Breisky*²⁷ two in early childhood; *Gervis*²⁸ a similar one.

At times *the sacs rupture from increased distention with retained menstrual blood*. The rupture may lead to an escape of the contents through the vulva, which is, naturally, the most favorable result, or into the bowel or the bladder, or the contents may empty at first into the surrounding tissues and then find an escape through the places enumerated, or as has been described in one case through the buttocks.²⁹

The cases are more unfavorable in which rupture takes place through the peritoneum, the blood escaping into the abdominal cavity. An atretic tube (sactosalpinx hemorrhagica) empties its contents very frequently in this way. The peritoneum may absorb such accumulations of blood (retrouterine hematocele) and thus a cure occurs. The rupture is preceded by the formation of adhesions between the surface of the retention cyst and neighboring organs, so that the extravasation becomes immediately encapsulated. In former years timely interference very often was prevented by the uncertainty of the diagnosis, by the condition of collapse, in which the patients were found, and the unfavorable nature of the external circumstances. To-day no gynecologist will hesitate to open the abdomen, remove the blood and carry out any further procedures that may be necessary.

Retention cysts seldom undergo purulent liquefaction and decomposition of the entire contents. Micro-organisms may enter the fluids contained in the cysts from the intestines, or through the infectious diseases which in the beginning caused the atresia (*Veit, Nagel*). Further dangers are added through the decay or decomposition of the contents. In other cases the contents change in a benign manner, through the absorption of the solid portions, so that in place of a hematometra, a hydrometra is developed.

The *diagnosis of congenital atresia* should not offer any difficulties

with a corresponding anamnesis in a patient with otherwise normally developed genitalia. The absence of menstruation generally in young women, the periodically appearing pains, the finding of a mostly globular mass, which one can palpate through the rectum or bladder, and if the atresia is located high up through a vagino-abdominal examination, is hardly ever caused by any other disease, especially if normally developed genitalia cannot be demonstrated.

In ***hymenial atresia*** a bluish transparent and tense membrane bulges out between the labia (Fig. 45). The vagina, at times, is expanded very evidently to one side. As malformation of the genitalia may occur at the same time in several portions, the possibility of a uterus bicornis should not be overlooked.

If the ***atresia was acquired in later life*** then the anamnesis leads to a correct interpretation, as it informs us about preceding difficult labors, or gynecologic diseases or operations.

Atresia hymenalis congenita with hematocolpos is not a rare occurrence. Such an example is illustrated in Fig. 45. The fifteen-year-old well-developed girl had had menstrual molimina four times during the last half year without escape of blood. Another example occurred in a poorly developed girl nineteen years old. She claimed to have suffered for almost a year. Another was sixteen years old, and had difficulties for about five months. A fourth one was fifteen and a half years old, and complained for about three months. Another one was a well-developed seventeen-year-old girl, who had her first difficulties when fifteen years of age, then after one and a half years had attacks repeated every three weeks, which finally terminated in continuous pains. The rest report similar disturbances. All had a large mass in the small pelvis which extended upward into the large pelvis, and one could palpate high up an appendage, which resembled a virgin uterus. This mass at times rounded out the introitus, exposing a septum hymenale of a dark bluish-red color, in others a stronger septum was found between the blood mass and external surface.

The amount of retained blood was from 250 to 1300 cc. The chocolate-colored mass had an alkaline reaction and contained detritus from the blood. The vaginal wall was covered with flattened epithelium, with bloody imbibition. The orificium uteri externum is mostly closed, in a few cases only dilated.

Collection of blood in the tubes, occurring at the same time, may be found in isolated cases, as in the case of *Mackenrodt* reported by *Koch-emburger*.

The ***acquired atresias*** develop mostly from a stenosis of the canal.

Atresia occurs rather seldom in comparison to the frequency of an extreme stenosis. The most competent observations in pregnant and parturient women have been made from the discharge or trickling of the amniotic fluid, while an opening could not be detected on inspection. Such stenoses and atresias developing from them have been observed

after typhoid fever, scarlatina, cholera, diphtheria, gonorrhoea, syphilis, and newgrowths. Simple catarrhal inflammations only very rarely cause atresia. Atresias are more frequently the consequence of injuries during labor, in which the cervix and vaginal vault were destroyed. Finally atresia may form in connection with operative procedures, especially where wound-surfaces were not or could not be covered with mucous membrane, and after cauterizations with zinc chlorid, or atmocausis (treatment by direct application of superheated steam). Acquired atresia is located most frequently in the upper portion of the vagina, the

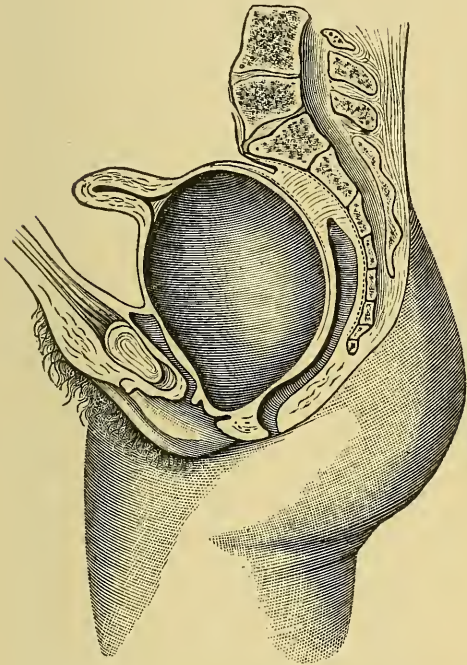


FIG. 45.—Hematocolpos Congenita.

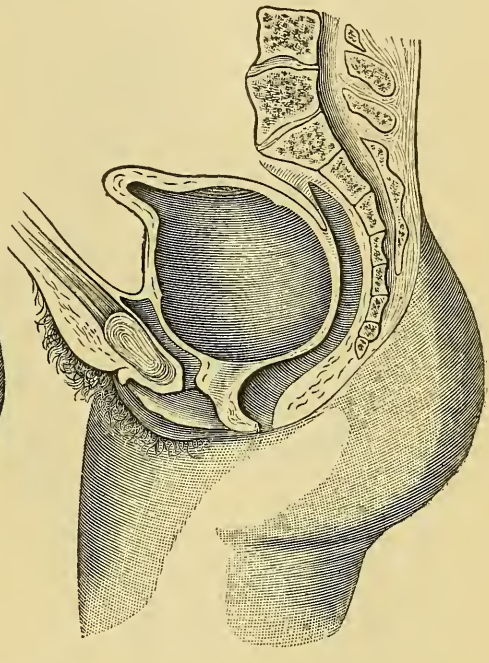


FIG. 46.—Hematometra and Hematocolpos Congenita.

vaginal vault or cervix, corresponding with the etiology. It is very seldom developed in the cervical canal or internal os. **With absence or closure of the lower end of the vagina** (Fig. 46), the uterus seldom dilates and only in the later stages through the pressure of the retained blood. It appears as a hard and strikingly easily movable mass or appendage on the surface of the tumor mass. The latter rises out of the small pelvis into the peritoneal cavity with a broad base, lying close to the anterior abdominal wall in the median line like a tumor of the uterus, feels smooth, tense and elastic.

If retention of the blood takes place in a uterus with atresia uteri, hematometra, the uterus expands first with the shape of a fiddle, and finally becomes globular (Fig. 47). The portio vaginalis becomes obliterated

ated as during labor or during the expulsion of large myomata of the neck.

I have seen such cases of atresia uteri only as *acquired* ones. In one case the collum uteri became gangrenous and was expelled during a grave course of typhoid fever. In another one the atresia developed after an excision colli in which the stump was not covered with mucous membrane. Above the cicatricial cervix could be felt the normal corpus, the size of an apple.

In the case of a twenty-one-year-old young woman (Fr. K.) menstruation occurred regularly but not profusely, corresponding to the poor development of musculature and flabby constitution. During the first year of marriage menstruation became more and more scanty, finally it ceased entirely, so that pregnancy was suspected. The patient finally sought the advice of a physician on account of the intense pains. It was observed that a mass with a round lower border filled the pelvis and displaced the vagina just back of the introitus. The tumor extended upward to the umbilicus and here carried a cap, which resembled a thickening of the tumor-wall (Fig. 46). It terminated in a broad mass below, which filled entirely the pelvic inlet. The bladder and rectum were compressed and pushed upward or backward by the tumor. No opening could be demonstrated in the mass which was

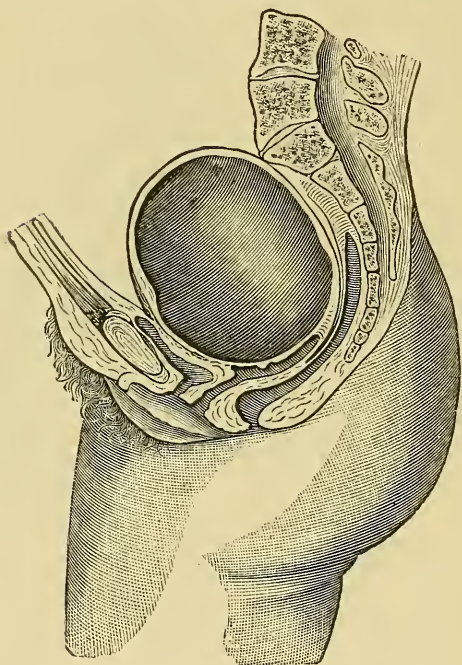


FIG. 47.—Hematometra.

visible per vaginam. I made an incision through the vaginal vault and evacuated a very large quantity of a tarry liquid of a typical color. On palpating the interior of the cavity one soon could feel a contraction. The lower segment of the uterus and the cervix appeared as a wrinkled, flabby sac. The suture of the cervical with the vaginal mucous membrane healed rapidly. The corpus uteri reformed itself within six weeks, the cervix appeared to be quite thick, but especially the orificium externum and the portio reformed completely. The profuse secretion from the cervical mucous membrane disappeared after repeated applications of iodine.

If the *effusion of blood* takes place *in the tubes* then peculiar twisted sacs form as one finds them in similar enlargement of the tubes by other contents. (See Diseases of the tubes.)

Naturally we do not always obtain such a clinical history. Occasionally the palpation of the blood tumor is made difficult by pathologic conditions of adjoining structures, and we find the retention cyst ruptured so that palpation of a distinct tumor is made very difficult. Another obstacle, however, is associated with these forms of atresia: if danger of a rupture exists, one must guard against hastening the rupture by a too extensive and energetic palpation. The diagnosis appears to be especially difficult, if the atresia is located at the internal os uteri and pregnancy or tumors may be simulated by the retention cysts. In the former case one must take into account the conditions and consistency of the growth and the signs of a living child, while in the latter the absence of any excretion of blood during the attacks of pain at the time of the menstrual period differentiates a retention cyst from a tumor.

The **prognosis** depends entirely on a timely discovery and a removal of the atresia in the proper manner and under strict **asepsis**. According to *Fuld*, of sixty-five cases of hematometra, forty-eight terminated fatally in pre-aseptic or antiseptic times.

The **therapeutic indication is a removal of the atresia** as soon as it leads to retention of secretion. Great hesitation was formerly felt in incising the atresia because the patient frequently perished immediately after a division, or in the future course of the illness. The cause for this unfortunate termination was sought partly in the entrance of air into the cavity and the open bloodvessels after evacuation, partly in lacerations or ruptures, which took place in the adherent adjoining structures during the emptying of the blood-sac. Cases are on record in which during an evacuation of an atresic retention cyst, which consisted of the vagina and uterus, lacerations occurred in a hematosalpinx which was not in direct connection with the other cyst. Death ensued through hemorrhages into the peritoneum; it is certain that formerly in many such cases septic infections played the fatal rôle, as under the bane of such apprehension the incision was not made freely and the evacuation was done incompletely.

My own observation of incision of such cavities has not caused me to recognize such a danger. I have executed the same with a complete evacuation of the retained blood under continuous irrigation with a normal salt solution. On the other hand one has to guard against too great pressure from above.

Opening of an atresia hymenalis is best executed by an incision between the labia, and it is practically unimportant whether the incision is made transversely, longitudinally, or H-shaped.³⁰ Without exerting any pressure on the mass the cavity is completely evacuated by irrigation.

If the sac is deeply situated without being easily accessible from the vagina, the bladder, or the rectum, different authors have recommended either one of these routes for the opening.

The **opening through the bowels** by means of a trocar, as well as

the opening through the bladder,³¹ after a dilatation of the urethra, must be considered only as an emergency makeshift. The indicated route is *through the vagina*,³² *respectively through the introitus vaginae*, particularly if the corpus and cervix lie approximately in a straight line. It is certainly not always easy to find this route, because the septum

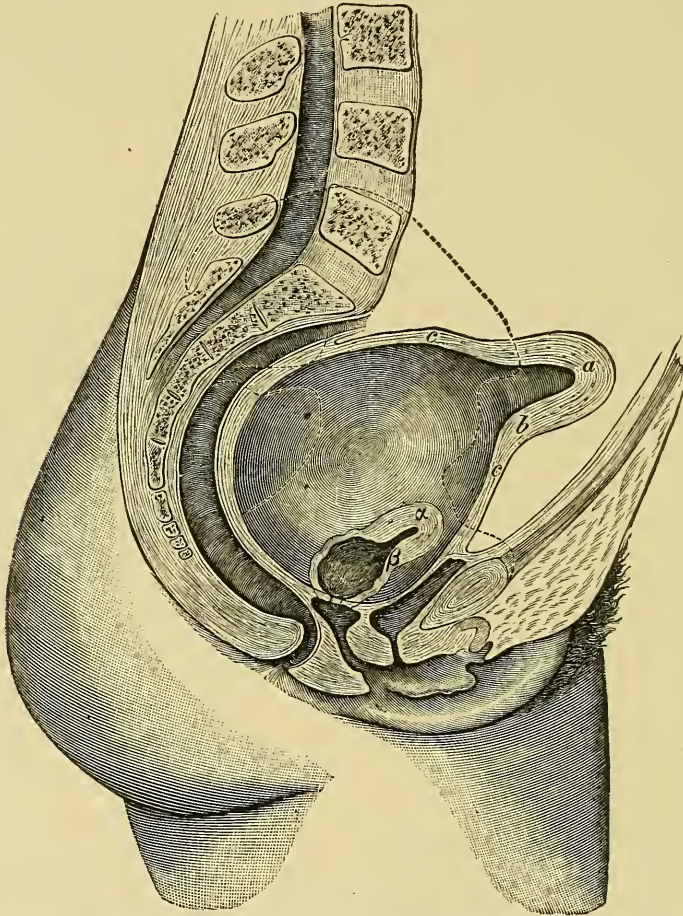


FIG. 48.—Hematometra Acquisita. *a*, before operation; *b*, contraction; *c*, os internum; *a*, after operation; *β*, os internum.

might attain an extraordinary thickness, as I have witnessed. In a case of atresia after typhoid fever, the septum was 7 cm thick.³³ I incised the septum transversely, to prevent an entrance into the rectum or bladder, which might have resulted from a longitudinal dissection. The introduction of a sound into the bladder has always proved unsatisfactory to me. I prefer to fill the bladder ad extremum before the operation. This lifts it out of reach of the incision and renders it palpable as a tense mass. I avoid overdilatation of the rectum because it would en-

croach the more on the already narrow space. The hemorrhage from the cut surfaces, the narrowness and depth of the opened canal make the further dissection the more difficult as pressing down the mass from above is prohibited on account of the danger of a rupture. It is advisable in such cases to proceed with the further widening of the septum by blunt dissection with tissue forceps, the handle of a scalpel or the finger. I have perforated the remaining portion of the septum partly with a trocar, partly with a scalpel, and partly with a sound, and then dilated the opening gradually to the necessary width.

The formation of scar-tissue must be carefully controlled, as its contraction may easily lead to a new atresia. Therefore I immediately coaptate (1880) the mucous membrane of the atretic cavity with the cut surface of the external skin, or with the edges of the neighboring mucous membrane by interrupted or continued sutures, and in this way I prevent the possibility of a new atresia.

In deeper situated atresias I introduce a drainage-tube, and only after convalescence of the patient I suture the mucous membrane of the atretic cavity with that of the vagina, after excising the entire scar.

In the case following typhoid fever a cicatricial contraction made itself felt for all that. The scar remained wide open for a long time on account of repeated soundings and dilatations. As pregnancy ensued and on its account such dilatation was forbidden, the scar contracted to an extreme stenosis, so that it had to be split freely to allow the delivery of a mature child.

I sutured immediately the last cited case of hematometra acquisita and observed healing without any reaction. Continued disinfection, eventually with the use of hot irrigations for the purpose of an involution of the cavity are to be highly recommended after such operations for atresia.

In order to avoid the danger of a late cicatricial contraction, *Heppner** proposed to suture the flaps of the H-incision. *B. Credé*† executed a transplantation of an external skin flap. *Breisky*‡ is certainly right in emphasizing the fact that a periodical dilatation will surely prevent stenosis; and finally the suggestions of *Gersuny* and *Mackenrodt* (vide supra) may be considered. *Küstner*³⁴ and *Wertheim*³⁵ dissected out the atretic cervix from its surroundings and split it high up, opening the cavity and suturing the uterine to the vaginal mucosa.

II. Atrophia Uteri

*W. A. Freund*³⁶ recently has awakened our interest in the arrests of development in general and particularly those of the genitalia. Besides the infantile uterus and the incompletely developed ovaries (small, slim

* Loc. cit.

† Archiv f. Gyn., 1884, xxii, p. 229.

‡ *Billroth-Lücke*, Diseases of the Vagina, 1876, 60, p. 49.

ovaries inclining to small cystic degeneration), an infantile depth of the excavatio recto-uterina appears as the characteristic of *infantilismus genitalium*, together with the inhibition in the circulatory system (chlorosis, *Virchow*) and stenosis of the upper chest aperture (*W. A. Freund*, 1905, at *S. Karger*).

An *atrophy* of the uterus alone is also found at times with an otherwise sufficient development of the rest of the genital organs. The development of the uterus as a whole is imperfect, though its shape is a typically normal one, or during the period of sexual maturity the organ undergoes atrophy with or without disease.

A. In so-called *congenital atrophy* the uterus shows either in form or size the development typical of childhood (Figs. 49 and 50, long collum

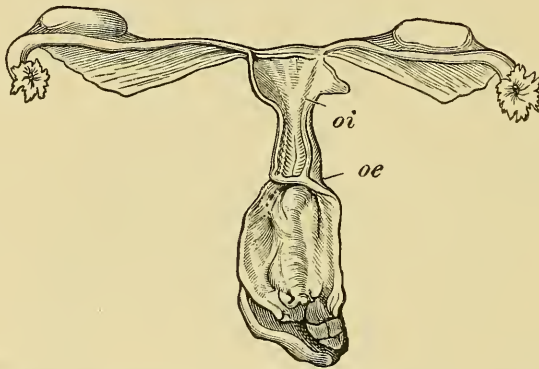


FIG. 49.—Atrophia Uteri, after *Virchow*. *oi*, ostium internum; *oe*, ostium externum.

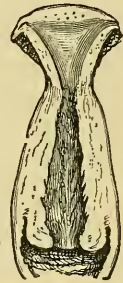

FIG. 50.—Uterus Infantilis.

and small corpus), or we find it in the form of the adult organ, but decreased in size.

The congenital atrophy is *symptomless* until approaching puberty. Even then many bearers of such an infantile uterus—and their number, by the way, is not so small as we are wont to think—experience no difficulty. They have in their outer appearance sometimes a very decided feminine type and feminine way of feeling. I have repeatedly seen such women from thirty to thirty-five years old, who enjoyed perfect health, were happily married, and had no complaint except absence or irregularity of menstruation and sterility.

They are frequently inclined to take on large amounts of fat, while others preserve a virgin—even a childish—exterior till the mature years of life. Chlorosis, scrofulosis, tuberculosis and neurasthenia are often found with atrophica uteri.

The functional symptom of development, i.e., *menstruation*, often presents peculiarities in such a uterus. So-called *molimina menstrualia* make their appearance at long intervals, sometimes dependent on the condition of the weather, in other cases on external conditions of life. The molimina last for several days, disappearing either without a flow or

with quite an insignificant bloody secretion. They consist of colicky pains in the pelvis, particularly in both sides, in an increase of a slimy secretion so as to become troublesome, in a sensation of pressure in the bowel and bladder, in drawing in the breast, in extreme nervousness, and frequently also in an increased sexual excitability. Instead of these molimina which are chiefly localized in the pelvis, other difficulties at times appear, especially on part of the stomach, but also in the form of violent backaches, headaches, stupor, migraine, rheumatoid disturbances, and attacks of psychical depression. Occasionally there appears severe epistaxis, hemorrhoidal bleeding, and also hematemesis, and severe varicose swellings in the lower extremities. Others complain of severe agitation and perspiration and similar symptoms at this time.

Women thus afflicted with atrophy of the genitalia may spend many years in this way, without their sufferings increasing excessively, but disappearing quite gradually when a premature senility develops, especially the hair of the scalp turning gray, and a beard growing. In others irregular hemorrhages intervene, sometimes at intervals of several years, sometimes once in the spring, once in the fall, while in still other cases I have observed more frequent, and then also quite abundant bleedings. These hemorrhages were considered as abortions. Such irregular bleeding now and then induces these poor women to seek medical advice.

The *objective signs* of the atrophic uterus are often elicited with great difficulty, either because of the hindrance to examining the women caused by their great sensitiveness and shyness, or because of very fat abdominal walls, and a very narrow and extraordinarily short or excessively long vagina. These women also suffer from obstinate constipation, so that *the fulness of the rectum* renders an exact examination difficult. One finds in such cases, at the end of the vagina, which is difficult of access on account of the rigidity of the hymen and the firmness of the pelvic floor, the cervix as a small wartlike prominence with a small orifice, and feels above it a small mass, which is with difficulty brought between both hands for palpation, because it lies deep in the hollow of the sacrum. Then one finds either quite a small corpus about 1 cm long above a thin cervix about 3 cm long, the corpus being strongly flexed either forward or backward from the cervix, or in other cases an object corresponding to the shape of an adult uterus above a correspondingly small cervix, which lies occasionally to one side or retroverted.

The examination with the sound appears to be very essential in just such cases to determine the longitudinal measure of cervix and corpus. Sounding does not, as a rule, offer any difficulty in this form of uterus, if one informs himself beforehand about the direction in which the sound must be inserted. The walls of the uterus, not rarely, are flabby and soft, but at times they are peculiarly firm and hard.

In contrast to the striking rigidity of all the tissues in the pelvis, in

the majority of cases, is found a marked flabbiness and want of fat in others. The ovaries are small and situated mostly far to the side, so that they are hard to palpate. We have already referred to the infantile general development; this forms a distinct indication of the possibility of an infantile arrest of development of the genitalia.

The *diagnosis* of atrophy of the uterus rests entirely on palpation. If the patients are otherwise well developed, still, as mentioned above, their sensitiveness, the adipose deposits in the abdominal walls, the narrowness and shortness of the vagina present considerable obstacles to palpating the uterus. On the other hand such women visit the physician under the impression made by preceding hemorrhages or violent acute attacks and *preoccupy* the mind of the examiner with the supposition of a preceding abortion or severe inflammation with formation of extensive exudates. I have examined and treated several women at times, in whom the remarkably divergent opinions of the attending physicians had been caused by suggestions of this sort.

The *prognosis* of defective development of the uterus is held out in text-books as quite bad. I find that it depends materially on whether the disease is treated at a comparatively early age, whether the patients have the necessary persistence to undergo a sometimes tiresome and not quite convenient treatment, and whether also external circumstances allow such a long period of general care and medical attention.

If these conditions occur together in a favorable manner in comparatively young women with proper external circumstances I have not only seen substantial improvement in symptoms in a not inconsiderable percentage, but also have observed a development of the uterus, and in four cases the treatment was followed by pregnancy continuing to full term.

The general care of the body is an indispensable presupposition to the local treatment in these cases. Energetic outdoor exercise, inside gymnastics, a sojourn in the mountains, sea-bathing, swimming, horseback riding, and skating are more important than chalybeate baths, though iron preparations and hemoglobin should not be omitted, with a corresponding attention to digestion. Just as important are meat, milk diet, eggs, small amounts of good beer and not too heavy wine.

If excessive deposits of fat accompany such anomalies of development the reduction of fat is the first step in the treatment. Not rarely a course of treatment in Marienbad; Kissingen, Tarasp, Bertrich and similar places, will influence the menstruation quite favorably, as will also a strictly individualized dietetic antifat treatment.

The local treatment should be postponed as long as possible in young persons, especially in girls, but should be instituted at once in older, especially married women.

The *local treatment* must at first attempt to influence the blood-supply and the development of the muscularis and mucous membrane of the uterus. This purpose is very frequently obtained by *scarification of*

the portio, which is done, to begin with, on three to four consecutive days, then at longer intervals. One scratches the mucosa of the cervical lips from the os in different directions. The bleeding in the beginning is not a considerable one. If so the attempt is made to increase it by directing the patient not to lie down quietly immediately after the scarifications but to move about for a quarter to a half hour. Gradually abundant bleedings are obtained even with superficial scarifications. The patients should remain quiet with more profuse bleedings for one or two hours after the scarification, and if necessary apply douches with a ten per cent. solution of acetic acid. As soon as the bleedings become somewhat copious the scarifications are to be repeated only every two or three days, and finally once a week. In order to irritate the uterine mucous membrane up to the corpus I introduce the sound quite frequently. At the same time sitz-baths (32° C., 90° F.) with an addition of bran, green soap, 0.5 litre brine, duration ten minutes, are prescribed evenings. An intrauterine stem pessary (Fig. 51) is introduced about six to eight weeks after the beginning of the treatment, which, as a foreign body, exercises an intense irritation upon the uterine wall. The pessary must be 1 cm shorter than the longitudinal measurement of the uterus which the sound yields. The uterus swells perceptibly. The swelling not infrequently continues after the removal of the stem pessary and induces a vigorous development of the uterine musculature and mucosa.



FIG. 51.
Intrauterine Stem
Pessary of Ivory.

The favorable opinions of many colleagues and the reports of their own observations justify in my opinion the following statements:

Introduction of the Stem Pessary.—The sound is always introduced under the presupposition that the uterus and its surroundings are or have been made indifferent to the introduction of the sound by scarifications, sitz-baths, and vaginal douches. The entire uterus is lifted by means of the sound as far as possible toward the introitus, and it is fixed here with the right hand which holds the handle of the sound. Then the stem pessary, which is held with the thumb of the left hand upon the left index finger, is advanced along the sound to the external uterine os. With its point in the external uterine os the pessary is pushed up the vagina while the sound is slowly withdrawn, until the button of the pessary has passed the introitus. The sound is withdrawn and the pessary is advanced into the canal by pressure of the left index finger. One often gains the impression that the pessary is aspirated by the uterine canal, so quickly does the instrument slip into the cavity of the uterus. One succeeds in other cases in pushing the pessary up to the internal os uteri while it cannot be introduced into the corpus. The obstacle is caused either by the narrowness of the internal os or the flexion of the corpus upon the cervix. In the first instance a thinner stem is used. In the latter condition the corpus must be straightened first, until the

corpus and the cervix lie approximately in a straight line, when the insertion of the stem succeeds easily. With a little practice the stem pessary can be introduced without injuring the mucosa, and without bleeding. Besides, this is of no significance if the secretions are not decomposed or dirty pessaries are not used. If necessary one can insert the stem pessary under narcosis.

The pessary usually remains *in situ* without any further support. The posterior vaginal wall supports the button, so that it remains *in situ* closely pressed against the cervical lips. Otherwise the uterus may be secured in its normal position by a Hodge pessary.

The patient must remain quiet for a few days after the insertion. Absolute rest in bed is not necessary. As soon as I am convinced that the uterus and its surroundings are not tender I allow the patients to resume their house-work. I also permit them to travel with these pessaries and to continue the above-described rules of treatment and conduct. I have seen each and every time the appearance of periodical bloody discharges after the insertion of stem pessaries, indeed in more than one-half of these cases the periods became very abundant and the general condition of the women was much improved. The pessary is removed after having been worn for from three to five months. The uterus developed very satisfactorily in about one-fourth of my cases, and pregnancy with labor at full term took place several times. In other patients the uterus was, to begin with, in a good condition, the slight reddening which skirted the cervical lips after the removal of the pessary disappeared, the periods occurred regularly for some time, again becoming irregular after half a year or later. In such cases I repeated the pessary treatment, and then obtained permanent improvement, in some cases at least relief for a long time, while the uterus remained moderately developed. The results were less complete in other cases. This occurred especially in such women as came for treatment in later life, that is older than thirty-five years. I obtained, however, an improvement, as long as the pessaries were worn. The uterus developed more vigorously and lastingly under the influence of this treatment, but I did not succeed in these cases in restoring menstruation, and with this a complete cure. The patients, nevertheless, felt very contented with the general régime and with the local treatment repeated from time to time.

Catarrh of the vagina and uterus, especially perimetritis, not seldom complicates atrophy of the uterus and renders local treatment more difficult. The removal of this inflammation must be undertaken first of all, before local treatment is instituted. I have found among other complications, especially severe gastric disorders, headaches and backaches with an inability to walk. If these disorders cannot be removed otherwise and the condition of the patient is made unbearable, I have indeed attempted to bring about insensibility of the uterus through the introduction of bougies (intrauterine suppositories of zinc sulphate and mor-

phin with the simultaneous use of narcotic rectal suppositories. The uterus becomes less sensitive after the inflammation is removed, and one can then proceed with the use of intrauterine stem pessaries.

B. **Atrophia uteri** during the **puerperium**³⁷ starts from an excessive puerperal involution and leads in two peculiar forms to changes very worthy of notice. **An intense atony and flabbiness of the uterine musculature** is developed in the one form. The uterus can be palpated only with difficulty through the abdominal wall. The musculature undergoes fatty degeneration, the uterus loses its normal tonus entirely. The softness reminds one of the second or third month of pregnancy. These are the cases in which perforation of the uterus by the sound results without any use of force. Rarely it is softened only partially, either in the cervix or the corpus. The cervix is at times remarkably thin, apparently reduced to the circumference of a lead pencil, while the body above it appears like a soft plum. Such an atrophy is found especially in very decrepit women, run down through disease of other organs, particularly if the body becomes weakened through continued nursing with defective nutrition. The lactation must be interrupted very soon and the nourishment of the women stimulated according to the indications, which are afforded by the changes in other organs. With it sitz-baths and lukewarm douches must be ordered. A renewed pregnancy, very frequently not preventable, is especially detrimental.

The other form of puerperal atrophy leads to a **shrinking of the uterus**, which reminds one of the conditions of the climacteric. The uterus appears reduced to almost one-third of its volume. The intense atrophy of the portio is particularly surprising, this part appearing in the lumen of the vagina like a wartlike growth of tough consistency. This atrophy is found especially during the puerperium in such women as have nursed long, did not yet menstruate, and have refrained from sexual intercourse: it is the highest degree of the normal puerperal involution. The atrophy disappears with the cessation of lactation, the recurrence of menstruation, and the resumption of sexual intercourse. The uterus develops within a short period to its normal size, form, and consistency. If the normal course should fail to come, then the treatment mentioned above, page 78, must be instituted.

C. **A shrinking of the entire genital apparatus resembling puerperal atrophy** has been observed in women who have resided for a long time in the tropics. They are during this time sterile, become debilitated, nervous and amenorrhic. Decreased secretion of mucus and marked pallor of the genital mucous membrane are conspicuous phenomena. The genital apparatus, as a rule, also changes in the temperate zone with proper care and simultaneous recovery of the general health. Increased swelling of the mucous membrane, abundant secretion and menorrhagias have appeared at this time in the cases observed by me, which necessitated a local treatment. Following this a sojourn in an Alpine climate and a long absence from the tropics brought about the

desired recovery, which also continued with renewed residence in warm climates. Pregnancy also ensued.

D. Another form of *atrophy* develops as the result of diseases during the puerperium or independently, which bring on disturbances of nutrition in the pelvis through cicatricial formations in the parametrium (see the chapter on Parametritis for further details about this *atrophying parametritis* according to *W. A. Freund*).

An especially successful action in the treatment of atrophy has been attributed to electrotherapy. I am in a position to confirm this, however, with the addition that this procedure must be employed with great care, as nervous excitement frequently appears as a very critical complication.

2. Changes of Position and Form of Uterus and Vagina

The opinion, advocated already in the earlier editions of this work that the great influence cannot appertain to the versions and flexions of the uterus, which our gynecologic predecessors awarded them, is shared to-day almost generally. Especially the opinion advocated by us already in 1883, has more and more marked a new epoch, that inflammatory processes, especially of the peritoneum and the adnexa, must be given first place even in cases in which they complicate versions and flexions of the uterus and procidentia of the genital organs, just as the tumor formations, which influence position and form of the uterus. We will also adhere in this edition of the book to the arrangement that all such cases shall be discarded from observation at this place and referred to the chapters, Perimetritis and Parametritis, or that on Tumor formation. Quite an important group of uterine deviations remain undoubtedly, which is the cause of severe suffering and must be designated as an important and grateful ground for treatment.

We will adhere to and emphasize the fact that a number of symptoms depend on the complication of changes in position and form by inflammatory processes, especially of the uterine mucosa. It is almost generally recognized to-day that a very great number of uterine deviations exist without symptoms.

The differentiation between versions and flexions was considered for a long time as very important. It is not to be denied in the least, that it makes a difference, whether the longitudinal axis of the uterus is bent at an acute angle, or in contrast with its normal, gentle version, runs rigid and straight. I consider the difference between a version and a flexion a gradual one, which appears especially when a uterus, hitherto normally bent, becomes rigidly stretched or flexed through an uninterrupted continuous action of pernicious agents upon it, through chronic inflammation, and thereby the results of impeded circulation in the uterus or neighboring organs are produced.

We will discuss here those forms of uterine deviations in which

appear the disturbances solely caused by the anomalies of position and form.

It does not lie in the province of this book to describe in detail the process of development of the views regarding changes of position. The added literary references will lead to the sources in this respect.³³

We will consider here as belonging together *versions and flexions of the uterus, prolapse of the vagina and uterus, and inversion of the uterus.*

The diminution or destruction of the healthy, normal condition of the uterine musculature and the pelvic connective tissue belongs to them jointly, at all events for the great majority of cases. The musculature and pelvic connective tissue may be developed imperfectly. They are damaged, predominantly, by the disturbances of nutrition and the trauma of the process of labor, the infections, carried to them at the same time or on other occasions, and finally senile metaplasias make themselves felt detrimentally.

I. Versions and Flexions of the Uterus

We consider them, according as they are met with: 1, as *congenital, at all events extra puerperal*; 2, *during pregnancy*; 3, *in early or late puerperium.*

The anteverted, i. e., normally placed uterus causes disturbances only when it loses the capability to adapt itself to the ever-changing distention of the bladder and rectum if it has become rigid and inflexible through infiltration of the myometrium, through chronic metritis, and overlies the bladder and presses its cervix into the rectum behind. The rigidity develops seldom in corpus and cervix at the same time; we meet with it much more frequently in connection with cervical catarrhs. The healthy corpus hangs forward over the collum, which becomes lengthened or stretched, especially in its pars supravaginalis.

The clinical significance, the diagnosis and the treatment of these cervical diseases are discussed in the chapter on Metritis.

Retroversions and Retroflexions

(1) *Congenital or Extrapuerperally Acquired Retroflexion*

It has been sufficiently proved through post-mortem examinations of the new-born, by *C. Ruge*³⁹ and others⁴⁰ that a retroflexion may occur congenitally (Fig. 52). Retroflexions are not rare conditions in grown-up girls and nulliparous young women. It is generally accepted that the corpus uteri, in the course of development, can bend backward over its posterior surface, and can fall into retro-versio-flexio.

Defective development of the musculature is the presupposition for the retroflexion. The overdistention of the bladder, also from conventional causes, is often cited as a cause for it. The filled bladder lifts the entire uterus backward and up, but how it should flex thereby the corpus

over the collum, without the cooperation of another factor, must appear unexplained. Constipation exists as a rule, the fecal matter is stored in the ampulla recti. The uterus is lifted *in toto* out of the small pelvis. It seems more reasonable to bring the process into connection with the deficient nutrition of the musculature and the pelvic connective tissue, without attributing a special rôle to the often-emphasized insufficiency of the ligamenta lata and their pars cardinalis (*Kocks*). The uterus, later on, descends into the lower parts, resting on the diaphragma pelvis with an emaciation of the pelvis or delayed development with improper nutrition, in such cases as chlorosis, tuberculosis, infantilismus, but also in atony due to masturbation. The uterus glides into the longitudinal

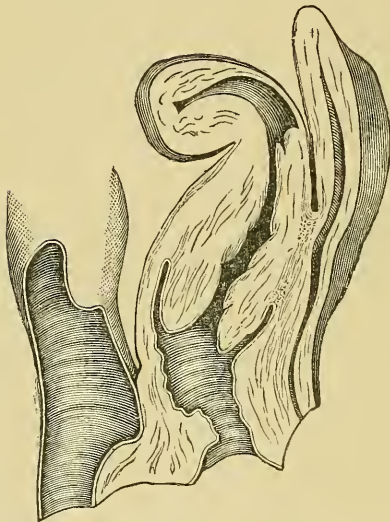


FIG. 52.—Retroflexio Uteri Congenita,
after *C. Ruge*.

axis of the vagina, which crosses the axis of the uterus at an acute angle in a normal development. The anterior surface of the uterine corpus is thereby exposed to the pressure of the abdominal viscera. If a swelling of the corpus now takes place, for instance during menstruation, it sinks down into the depth of the excavatio rectouterine, and the cervix is advanced toward the symphysis. Uninterrupted burdening of the corpus, for instance through a downward pressure of hard scybala, leads to flexion, if, for instance, the bladder, hindered in its evacuation, prevents the cervix from moving any farther downward, the bladder in the region of the trigonum being often in broad and intimate relation with this portion of the uterus.

A striking shortness and rigidity of the anterior vaginal wall is not rarely found in these retroflexions. *Sänger* saw with this so often a short median ledge of mucous membrane in the anterior vaginal wall, that he deemed it an important diagnostic sign for this form of retroflexion.⁴¹

The uterus is only seldom still flabby in this form of retrodeviation which is either congenital or originates during the course of puberty. The disease is recognized only after long years of suffering, especially also after repeated intercurrent inflammatory irritations. An improvement in the tonus of the musculature and connective-tissue structures takes place under the influence of the care and general treatment indicated by the presence of chlorosis or other disturbance of nutrition. The uterus is then found with a delicate long cervix and small corpus, in the longitudinal proportion of the infantile organ. More frequently the corpus, rendered massy and hard through inflammatory processes, stands out in distinct contrast to the firm, long hard cervix which terminates in

a pointed portio vaginalis. The uterus lies seldom retroverted. A flexion with an acute angle exists usually, seldom a post-hornlike curvature. The place of flexion is thin, but it can also be thick and firm, particularly in its posterior wall, as in the case shown above (Fig. 52), and in the cases described by *F. v. Winckel*. The fundus fills the floor of the excavatio rectouterina, and often brings down the posterior vaginal vault. The cervix lies close to the corpus or touches apparently the posterior surface of the symphysis. The uterus is as a whole movable, it can be straightened and raised up, but it usually falls back again into retroflexion.

The form of the portio is, as a rule, unaltered in these cases, the cervical os is a little dimple, the anterior lip is at times remarkably small, it appears distorted beneath the place of attachment to the anterior vaginal vault.

Symptoms.—Many girls and women have no disturbances whatsoever from their retroverted, flexed uterus, they menstruate without any disturbances and in normal limits of time they conceive and give birth to a child without any difficulty.⁴² As a first symptom appears at times a troublesome *strangury*. **Constipation** exists almost constantly, a symptom which girls and women underestimate so frequently, until they cannot master the difficulty any more with their domestic remedies. A great part of gastric disturbances of which patients with retroflexion complain is surely to be referred to it. In other cases **menstruation** begins with tormenting backache, is accompanied by colicky pains, is abundant and leaves behind a feeling of soreness and discomfort for a long time. This **dysmenorrhœa** torments such persons for a short time, to others it becomes a companion for many years, until the climacteric. Another symptom is **sterility**. If one sees in a large practice often such women with this retroflexion conceive soon after marriage, one meets on the other hand also many whose sterility seems to depend solely on the retroflexion, any fault on the part of the husband and the influence of inflammation being excluded. A proof of this is afforded by the cases in which conception follows immediately a reposition of the uterus.

Certain young women with this form of retroflexion conceive and carry a child to full term, the uterus resuming its retroflexed position during the puerperium. The retroflexion constitutes for these cases the normal form and position and does not disturb the well-being of these women in any respect.

Nervous disturbances form the last group of symptoms of these non-puerperal retroflexions. Nervous affections, backache, headache, gastric disturbances, eructations, nausea, globus hystericus, are not rarely observed in these cases. It remains a question in what relation they stand to the retroflexion. Cure by reposition undoubtedly very frequently owes its effect to suggestion. On the other hand the pressure of the uterus on the nerve-trunks of the anterior surface of the sacrum cannot be excluded as a cause of paralysis. The most varied neuroses disappear with reposition.

tion.⁴³ *Schroeder*⁴⁴ cured a chorea, *Chrobak*⁴⁵ a marked respiratory neurosis.

The patient with retroflexion presents an entirely different picture as soon as **inflammatory processes in the endometrium are added**. Even the retroflexion, which before caused no symptoms, now produces severe manifestations as well in the beginning stages, as also in the chronic course, which ensues almost without exception as long as the uterus remains in a retroflexed position. Menorrhagias are added to the disagreeable signs of a chronic endometritis (increased secretion of mucus). The enlarged uterus causes venous stasis in the region of the hemorrhoidal vessels, a sensation of fulness and heaviness in the pelvis, with pressure downward, backaches, and constant pains. The same holds good for cases complicated with **perimetritis**.

Diagnosis.—It is at times not so easy to make a diagnosis by palpation, because the virgin's tense abdominal walls render difficult an energetic invagination of the abdomen and a thorough combined examination. The examination per rectum, the advance of the finger through the lateral vaginal vault along the edges of the uterus, eventually under anesthesia should clear up the condition. The portio is situated mostly lower down than normal, near the introitus vaginæ, also raised behind the symphysis, or in retroversion even turned toward it. One must always establish the continuity of the cervix and corpus. In this way we guard against mistaking the uterus for newgrowths (myoma), exudates, and extravasations in the excavatio rectouterina. The sound is an indispensable aid in difficult cases. It is inserted with its concavity backward, beginning at the internal os. We pay attention to any disproportion in the longitudinal development of the cervix and corpus.

A **prognosis** can only come in question in so far as the retroflexion-version causes disturbances. In such a case it is possible to place the uterus in normal anteflexion and to secure this position permanently. The prognosis accordingly is not unfavorable. The patient often remains well subjectively without permanent change of position and form of the uterus after inflammatory complications are removed. The prognosis in these cases is therefore not unfavorable.

Treatment is accordingly instituted only if the retroversio-flexio causes disturbances. The symptoms of the complications must be separated from those of the flexion. If the flexion causes difficulties, then reposition and fixation of the replaced uterus are indicated, measures which are thoroughly discussed on page 94. Forced feeding and general tonic measures should be added to the local treatment when indicated by lack of tone of the musculature of the uterus and the condition of the pelvic cellular tissue. The regulation of emptying the bladder and function of the bowels plays an important rôle in the treatment.

Menorrhagias and hypersecretions must be treated according to the principles given in the discussion of endometritis.

Reposition is an important factor in endometritis. The correction of

position offers an opportunity for a harmful increase in diseased processes of the tubes, but especially the peritoneum and pelvic cellular tissue.

(2) *Retroflexio Uteri Gravidæ*

If it appears more correct to refer the discussion of this complication of pregnancy to the text-book on obstetrics, it shall not be neglected in this treatise entirely, because the patients only too frequently deny or overlook the fact that they are pregnant, and because we meet occasionally with a kind of retroflexio uteri gravidæ as an unsuspected secondary phenomenon resulting from gynecologic interference.

While retroflexio uteri gravidæ, according to the respective reports in literature, appeared formerly as an exceedingly dangerous complication,⁴⁶ we are justified at present in adopting an opinion essentially more favorable. The improved manner of examinations by physicians and midwives, and the increasing understanding of this disturbance of pregnancy enables a diagnosis to be made much earlier than formerly. Today only especially unhappy circumstances allow the evil to grow so far as one observed it formerly. The patients above all come earlier for treatment.

The following statistical account, which I gave in the third edition of this book, is included in the fourth edition, because it still possesses actual interest, and because it also tallies with the material of the clinic at Greifswald.

I have seen, up to 1889, one hundred and twenty-one cases of retroflexio uteri gravidæ among about 24,000 gynecological cases of my own practice. Not a single case offered a serious danger. Twenty-seven women conceived with congenital retroflexion. Ninety-four women came under observation with a retroflexio uteri gravidæ. Conception occurred only in isolated cases, while a pessary was worn, but diseased conditions of the uterine mucosa or other diseases of the uterus and its adnexa had to be removed beforehand in many cases.⁴⁷

The retroflexio uteri gravidæ is most probably brought about by impregnation taking place in a retroflexed uterus. ***The great majority of these cases do not come to the knowledge of the physician because the uterus escapes from its narrow limits into the large pelvis without producing any notable symptoms.***

The pregnant women feel hardly any more molested in such cases than from the development of pregnancy in a normally placed uterus. They experience the relief startlingly, which occurs at the moment in which the pregnant organ passes from the small pelvis up into the large one. Before, they could not clearly comprehend the condition present.

Of the 121 patients cited above 97 went to term, 24 were not kept under supervision or aborted, 8 of the 97 women had fully developed perimetritic adhesions, which at first apparently prevented reposition. The raising by reposition manœuvres succeeded after long-continued

abdominal posture with proper control of the bladder. Pregnancy proceeded normally afterward.

In the minority we get the well-known *symptoms of incarceration*. The obstacle for the spontaneous development upward lies partly in the configuration of the pelvis, partly in the perimetritic adhesions, partly in uterine or abdominal tumors.

Symptoms.—Besides the general feeling of fulness in the pelvis the displacement of the bladder and rectum stand out particularly among the symptoms. The increase in the difficulty of urination terminating in ischuria to ischuria paradoxa makes itself so overwhelmingly conspicuous that the coprostasis is hardly mentioned by the patients. The retention of feces surely and materially contributes to the result that the uterus does not rise from the small pelvis.⁴⁸

If replacement of the uterus does not take place spontaneously, then the *urinary disturbances* call for medical assistance. The increasing size of the uterus rarely causes tormenting troubles of defecation and peritonitic pains with abdominal tympanitis, nausea, and vomiting. It leads often to premature contractions of the uterus and abortion respectively, spontaneous expulsion, very seldom to gangrene of the uterus or bladder, or peritonitis and its consequences. The perineum becomes edematous, especially in the region of the anus, leading to an infiltration which threatens to become gangrenous.⁴⁹

Increasing difficulties of urination should draw the attention of the physician at all times to the possibility of this malposition in cases of cessation or irregularity of menstruation.

Diagnosis.—A tumor is felt externally which lies remarkably near to the abdominal walls. The lower end of this presumed tumor appears to reach down into the depths of the pelvis, so that errors are easily possible in given cases, indeed in the most severe cases, which the literature records, diagnostic errors became the source of further complications. The pelvis is filled completely with a hard, firm mass, the portio displaced entirely forward and upward, and flexed at the symphysis, or lying on or even above it. The mass is perceptible externally and appears to be intimately connected with the internally palpable one. The bladder must be emptied with a catheter as for any other bimanual palpation, especially if with a continued vesical tenesmus the urine is expelled in drops (*ischuria paradoxa*). I always use a male metal catheter, since the bladder being pushed up very high on account of the fulness of the pelvis, the urethra becomes lengthened and perhaps also laterally displaced, so that the female instruments prove ineffectual. At present soft instruments are used frequently. The combined examination gives us, as a rule, a completely clear picture of the contents of the pelvis after emptying the bladder, even when it is possible only with difficulty to palpate the continuity of cervix with corpus.

The women, as a rule, to-day, come much earlier for an examination. One succeeds without difficulty in recognizing the bladder, not yet filled

ad extremum, as such, above the uterus, which fills the pelvis completely. An emptying of the bladder, now undertaken, permits the exclusion of every doubt from the findings.

The **prognosis** depends on whether the uterus is movable and can be pushed up into the large pelvis in spite of the obstacles to its spontaneous elevation.

Treatment.—If *the uterus is still* movable, **abdominal or lateral position** with a marked elevation of the pelvis are often sufficient after complete emptying of the bladder and rectum. The uterine body then often moves upward, without any other operation on the uterus being necessary. If the uterus is sufficiently large so that one need not fear its sinking down again into the small pelvis from the strain of the abdominal pressure, or in a simple dorsal position, it does not demand any further support. Otherwise the normal position must be secured by a vaginal pessary.

Even if the possibility of elevation appears at first doubtful, I desire to recommend, to the less experienced, to make use at first of the abdominal or lateral position, the knee-chest position, or elevated pelvis position, especially in sensitive women, after emptying the bladder and if possible the rectum. The patients feel often already so relieved that a reposition is not urgent. I have seen a **spontaneous reposition** occur under these conditions even in apparently totally fixed uteri.

If spontaneous reposition does not result, then the **reposition** must be executed **manually**, as in all such cases, in which urgent indications exist for an immediate elevation of the uterus.

The corpus uteri is pushed upward by means of two fingers through the posterior vaginal vault, the patient being in lateral position, in knee-chest position or in elevated pelvis position. The body of the uterus is not moved upward in the median line, because the protuberant promontorium easily renders such reposition difficult. The corpus is pushed upward along one or the other sacro-iliac synchondrosis. One may also take hold of the portio with a tenaculum or *Muzeux* forceps and pull it down while the corpus is replaced through the posterior vaginal fornix.

Forced reposition manœuvres have always many objections. It is better to repeat the attempt at reposition in different sittings with gradually increasing force, eventually under anesthesia, and in the meantime see to it that regular evacuation of bladder and bowels takes place.

The cause for the **failure of the reposition** lies not so often in the size of the uterus, as in the **intimate connection** of the posterior surface of the corpus with the floor of the excavatio rectouterina by perimetritic indurations. Such **perimetritic adhesions** not seldom loosen up under the influence of pregnancy so that the uterus withdraws from the adhesions by its increasing growth and escapes upward.

The formation of a diverticulum⁵⁰ of the upward directed anterior wall of the corpus may occur with continued fixation of the uterus within the pelvis. This may develop as a womb in spite of the continuous retro-

flexion and fixation of the posterior wall. It is even capable of sheltering the full-grown fetus (Fig. 53). Labor may occur at full term and be completed with a corresponding spontaneous or artificial dilatation of the cervix, as is shown by the still meagre reports of such cases.

If one does not succeed even in several sittings in replacing the uterus it is not justifiable to interrupt pregnancy without hesitation by puncturing of the ovum through the cervical canal or through the wall of the uterus. One can wait with uninterrupted control of the evacuation

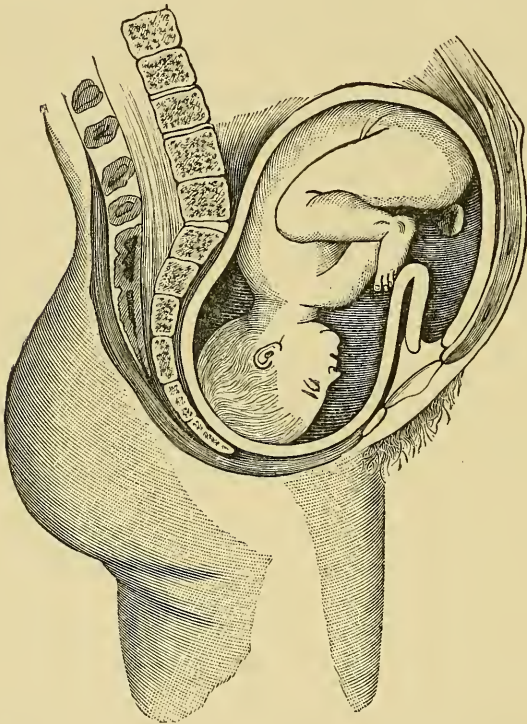


FIG. 53.—Retroflexio Uteri Gravidi with a Diverticulum Formation of the Anterior Wall (G. Veit, Volkmannsche Sammlung, No. 170).

of bladder and bowel until further threatening symptoms arise, severe continued pains, edema of the genitalia, bloody secretion and decomposition of the ovum. We yet recommend to introduce a colpeurynter into the vagina and await its action.

The **delivery in incarceration of the retroflexed non-replaceable uterus**, whose evacuation results spontaneously but incompletely is, as a rule, not easy. *P. Müller* has mentioned a special instrument of his own for bringing down the lower angle of the uterus.⁵¹

The anterior or posterior utero-vaginal incision takes nowadays the place of puncturing practised formerly in such cases. The cavity of the uterus must be emptied by all means very carefully, to avoid a retention and a

decomposition of portions of the ovum or lochia. *Ohlshausen*⁵² has extirpated the uterus through the vagina in a case of non-replaceable **retroflexio uteri gravidi incarcerata** complicated with osteomalacia.

(3) Puerperal Retroflexion

The majority of retroflexions develop in **connection with the puerperium**, or at all events show symptoms first after a puerperium following labor at full term or an abortion.

The **etiology of puerperal retroflexion** cannot be explained exclusively by the fact that the site of attachment of the placenta (Fig. 54), at the anterior wall of the uterus, regenerates incompletely. This may act

as a favorable factor, just as newgrowths situated externally to the uterus, extreme flabbiness of the puerperal uterus, excessive stretching and relaxation of the pelvic floor, undue retention of urine, long-continued filling of the bowel with long-retained dorsal position cause the development of retroflexion.

A. The *retroversion and flexion* may already take place early in the puerperium. The *symptoms* of this peculiar incident are quite extraordinarily stormy ones, violent rectal tenesmus, uneasiness on the part of the bladder, abundant hemorrhages. The distress for the moment was so severe in such cases observed by me, there existed such severe hemorrhage and difficulties (tenesmus of the bladder and bowel) and back-ache, that the physician was called immediately.

The *diagnosis*, which in all cases is already suggested by the anamnesis (five to seven days post partum), cannot go amiss; not to mention that the large uterus can be felt neither in the large pelvis nor in the depth of its normal situation, one finds the thick mass in the posterior vaginal vault. The finger penetrates without difficulty through the incompletely reformed cervix, which lies close to the symphysis, and through the

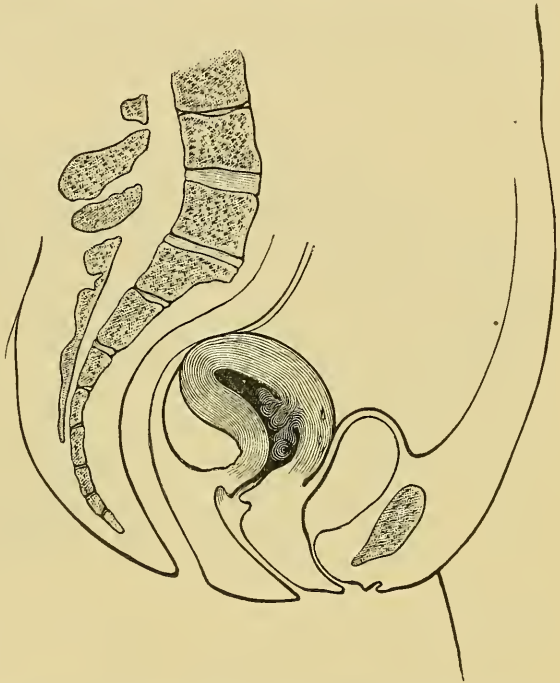


FIG. 54.—Retroflexio Uteri Puerperalis with Incomplete Expulsion of the Placenta, Attached to the Anterior Wall.

internal os to the site of attachment of the placenta at the anterior wall which is directed upward. In the majority of the cases appertaining thereto, which I have seen, the question is about the incomplete detachment of the placenta situated at the anterior wall. I have seen the retroflexion without such retention only three times, with a remarkable flabbiness of the uterus in otherwise healthy puerperæ. These three had remarkably rapid labors, were primiparæ, at the end of the first week of the puerperium and nursed their children. They had felt suddenly the symptoms of pressure in the pelvis after violent turning around or on attempting to lift the crying child, lying next to them, without assistance.

In incomplete expulsion of the placenta the *treatment* consists in a

thorough scraping of the placental site. This offers, as a rule, no difficulty for the inserted finger. Curette or placenta forceps are superfluous. The uterus contracts powerfully after this, with bimanual massage, hot irrigation (50° C. = 122° F.) repeated subcutaneous injections of ergotin (0.1) or secale cornutum (1.0) per os. The uterus remains, as a rule, in the replaced position. I have introduced a pessary during the first week in two cases of retrodeviation of the uterus and allowed it to remain for four weeks.

B. If the cases which *follow the puerperium do not come under treatment so soon*, that is during the second to the sixth week, so that one cannot advance with the finger without effort to the placental site

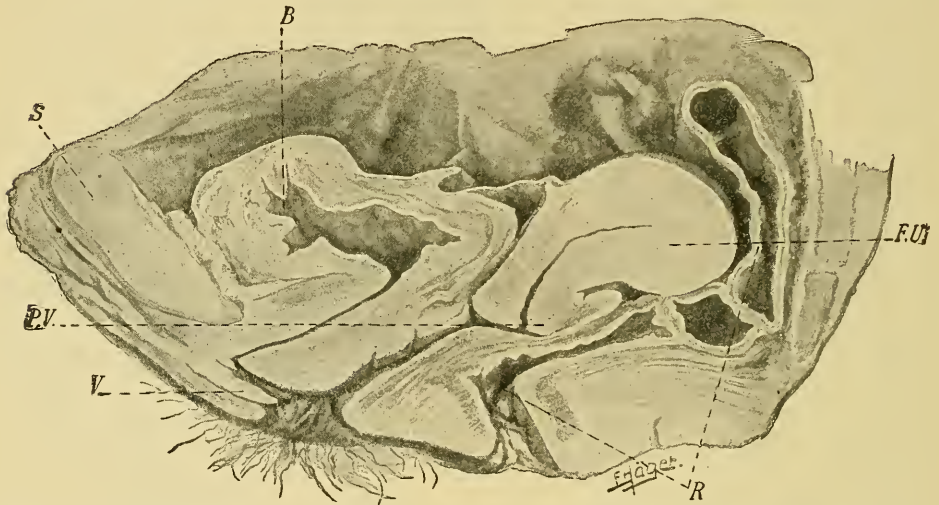


FIG. 55.—Retroflexio Uteri. (Preparation of the women's clinic of Greifswald.) *F.* U., fundus uteri; *P. V.*, portio vaginalis; *V.*, vagina; *R.*, rectum; *S.*, symphysis pubis; *B.*, bladder. The *plica peritonei transversa* shows plainly on the bladder wall. The separation of the peritoneum posterior to the plica as far as the corpus is an artefact.

through the internal os, then one must determine whether a retention of parts of the ovum exists. Ill-smelling secretions, expulsion of shreds of decidua, bloody flow, which stops for a time, then returns abundantly, and excessive size and softness of the uterus point to it.

Retained products of gestation must be removed immediately. The finger can always be inserted with slight force, without anesthesia, otherwise with it.

The hemorrhages stop as soon as the uterine wall is scraped off completely. The uterus contracts strongly and can be fixed in the normal position with a pessary, if it falls again into reflexion without it.

C. Most of the puerperal retroflexions come for treatment *months and years after confinement*. They form by far the majority of the patients with retroflexions of the uterus (Fig. 55).

The women weather the puerperium with severe hemorrhages, backaches, and bowel disturbances remain which the patients at first bear patiently as a matter of course; when the symptoms increase so as to be unbearable the patients become nervous, lose strength and humor and become emaciated, and the condition of their pelvis becomes the object of medical consultation.

Symptoms.—These puerperal retroflexions quite often also cause only very slight disturbances. Some patients complain severely about the above-mentioned symptoms.

Dysmenorrhea, ushered in with colic, accidental expulsion of coagula, excessive duration of the profuse menstrual discharge, and long-continued leucorrhœa prevail in puerperal retroflexions.

Besides the cases in which symptoms of a retroflexion of the uterus are decidedly pronounced, there exists a not small number in which residues of a septic puerperal infection remain behind in the mucosa, in the myometrium, but particularly in the peritoneum, tubes and ovaries, or other infectious processes, particularly gonorrhœa or tuberculosis, are added. Then the women appear to suffer severely, the retroflexion forming only a link in the chain of diseased processes.

The **diagnosis** does not offer any difficulties to one with some practice in combined examinations: the portio is placed forward, the cervix is sometimes flexed upon the corpus, sometimes directed with its uterine orifice toward the symphysis. The corpus cannot be felt above the anterior vaginal fornix, but deep in the pelvis in the hollow of the sacrum through the posterior vaginal vault. One succeeds in palpating deep down in the depth of the pelvis, with not quite excessively fat abdominal walls, if the patient is placed in a correspondingly comfortable position, head lowered, legs somewhat elevated, the buttocks advanced to the edge of the examining table and elevated. If one now invaginates the abdomen lightly, the body of the uterus is felt, as a rule, in the posterior vaginal vault. **One must palpate the corpus itself above the posterior vaginal vault for diagnosis.** If this fundus cannot be felt through the vagina with sufficient distinctness one may be able to reach it at times more easily through the rectum, however not without the external hand controlling what the inserted hand palpates. One can demonstrate for the sake of clearness, the point of flexion of the uterine body through the lateral vaginal vault along the lateral border of the uterus.

If the portio is pulled downward with a tenaculum forceps attached to it then the straightened uterus can be palpated more easily. One must only remember thereby that one can tear peritoneal adhesions easily, causing tubes filled with pus to break.

The sound enables a welcome control of the palpating fingers, but the experienced can dispense with it. The inexperienced examiner often has much trouble inserting the instrument correctly. We only use inflexible instruments, and have not had any difficulty with them so far. (Vide supra, pages 27 and 72.)

Extensive swellings of the uterine body and the cervix, particularly the lips, often complicate the state of affairs. The mucosa then projects out from the orificium externum uteri in the form of an ectropion. Rarely the entire pelvic floor may be edematous under the influence of the retroflexed uterus even in a non-pregnant condition. The pelvic floor is then found to be markedly softened and the vaginal mucosa bluish.

Treatment.—One must interfere as soon as disturbances are caused by the retroflexed uterus, but as long as the retro-versio-flexio is an accidental finding and neither subjective disturbances nor anatomic changes are connected with it, it does not demand local treatment. One must provide energetically for uterine involution.

Disturbances of menstruation, of the blood-supply of the mucosa and the myometrium, require consequent treatment, and the same is true where there is *interference with the neighboring organs*. Finally, the retroflexion should be removed in *sterility*. The treatment must have for its object *reposition of the uterus and maintenance of the typical normal position*.

Endometritis and metritis appear as the most frequent complications of retroflexion. Their removal succeeds only after a reposition of the uterus. From this appears a definite indication for an orthopedic treatment. If the cure of endometritis and metritis is secured it appears to be superfluous in many cases to still further enforce reposition. If *retroflexion exists as a complication of perimetritis*, then it passes also for a secondary condition as in diseases of the *adnexal organs*. If one succeeds in healing these processes without the removal of the retroflexion, an orthopedic treatment becomes superfluous. In severe pathologic changes of the adnexa operative interference becomes necessary. In that case the retroflexion must be removed surgically. A pessary treatment is not advisable in these conditions, indeed it is immediately dangerous and must be omitted.

The orthopedic treatment consists:

1. *In replacement of the uterus.*
2. *In the maintenance of the uterus in its normal position.*

1. The *replacement* is always to be executed bimanually, with the patient in the dorsal, lateral, abdominal or knee-chest position. The corpus uteri is forced upward with one or two fingers through the posterior vaginal vault or the rectum; it is caught from above by the external hand and pushed forward, while the fingers, lying in the vagina, push the cervix backward. If the replacement of the cervix with the fingers does not succeed, it can be pushed backward by a tenaculum forceps.⁵³ Only if one can feel through the anterior vaginal vault that the corpus lies upon the anterior vaginal wall and that the portio is placed entirely backward, can it be considered that the reposition is completed.

If the bimanual reposition cannot be executed easily, then I make use of the ordinary inflexible sound for this purpose. I insert the same with

quite particular care in the usual manner up to the internal os uteri, then turn the handle in a wide half circle, so that the concavity of the sound is directed backward, and then allow the sound to *glide* into the retroflexed uterus. Now the sound is turned around, by moving the handle again in a wide half circle before the genitalia, until the concavity is directed upward. The corpus is lifted up either simply by the weight of the handle of the sound itself, or by a very slight pressure on the handle, while one of the fingers held beneath the sound at the external os uteri serves as a fulcrum, until the handle presses entirely backward, the head therefore standing forward. I ascertain by bimanual examination, that the uterus lies in a normal position. It is practically of no consequence that occasionally a drop of blood is lost with this procedure of reposition. One must prepare the patient for it.

We have presumed until now that the uterus is freely movable. If the adhesions hampering this movability, such as remains of long passed

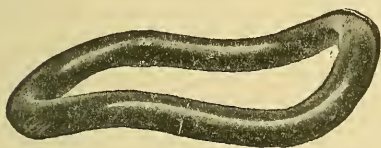

FIG. 56.—Hodge's Pessary.

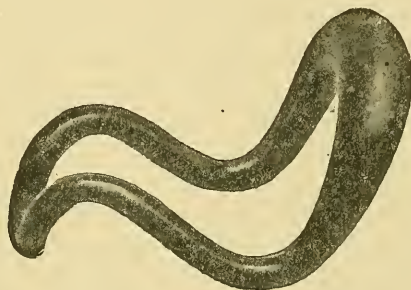


FIG. 57.—Thomas' Pessary.

perimetritides, can be recognized already by their sensitiveness, without numerous attempts at reposition, then reposition first of all should be omitted.

If these remnants are, however, very limited and allow a certain mobility of the uterus, they become often noticeable only, when the uterus is pressed upward.

2. *The replaced uterus must be secured in its normal position.*

It is not my intention to give a description of the polymorphean apparatuses which have been recommended for the maintenance of the uterus in its normal position. I use the hard rubber pessary according to Hodge (Fig. 56) or Thomas (Fig. 57), which must be kept in readiness in different sizes from 6 to 12 cm. These pessaries are cleanly, conveniently inserted and removed; they must be selected according to the width of the vagina. The larger transverse bar must be put uppermost into the posterior vaginal vault. The pessary acts by stretching the vaginal walls and vault. Thereby the cervix uteri is prevented from sinking forward. The point of attack is not in the uterus. The pessary is held by stretching the vagina, but is not permitted to press against the symphysis.

Introduction of the Pessary.—After the uterus is replaced the anointed pessary is held so that the lateral bars lie between the thumb and middle finger, the index finger covers the inner space of the pessary and touches with its point the transverse bar. The pessary is held before the introitus so that the transverse bar lies vertically in the rima. Then the instrument is pressed against the opening, at the same time it pushes the yielding and little sensitive *commisura labiorum posterior* down so far, that the instrument with the transverse bar ahead enters the vagina. In the latter the pessary is turned transversely, so that the transverse bar comes to lie horizontally in the posterior vaginal vault back of the portio. The latter falls into the cavity of the pessary, while the anterior bar of the instrument touches the anterior vaginal wall at about the upper end of the lower third. It is not permissible to leave the pessary or to discharge the patient until one has again convinced himself of the correct position of the uterus in the pessary by a bimanual examination or by insertion of the sound. Likewise one must assure himself that the pessary does not cause any pain, either in walking, sitting, or stooping.

The pessary may remain in position during menstruation, and it hinders neither cohabitation nor conception. The vagina is irrigated for the purpose of cleanliness daily with lukewarm water, with normal saline solution, and in case of abundant or decomposed secretion with a disinfectant or deodorizing solution. The pessary is permitted to remain three to six months. I make a control examination the next day after the insertion, then after each menstruation, provided the patients do not come sooner for an examination on account of discomfort or pain.

All kinds of pessaries, if of improper size, may cause decubital ulcers in the vaginal wall and even perforation. It may occur then that they enter the surrounding cavities, especially the monstrous forms occasionally used.⁵⁴

The *Hodge* or *Thomas* forms suffice me: I have found them perfectly satisfactory, with only a few exceptions.

The disturbances of the retroflexed movable uterus are relieved as if by magic.⁵⁵ Catarrhs and parenchymatous diseases of the cervix, which did not heal during the continuance of deviation, disappear surprisingly soon after reposition and pessary treatment.

The question, however, whether the uterus remains in a normal position, that is a permanent cure of the retroflexion, is to be answered in the negative for the majority of the cases.⁵⁶ The retroflexed uterus remains in the anterior position only in a moderate percentage after removal of the pessary. The latter is removed in most women, because the uterus is in good position and the disturbances have ceased, or they remove it themselves. Many lose it and do not find it necessary to be treated any further, because they feel relieved. Only a comparatively limited number of such cases, especially in clinic practice, allow continued control during the wearing of the pessary and for a long time beyond it. Complete cure can then be ascertained in hardly more

than 25 per cent. An explanation of this peculiar circumstance lies in the fact that the flexion as such does not always cause the disturbances, that more frequently intercurrent disturbances cause the symptoms,⁵⁷ but the latter cannot be cured until the retroflexion is removed at least temporarily. If the catarrh is cured, if the enlargement of the uterus, caused by interference in the blood-supply, has ceased, then the uterus can functionate normally in spite of the retroflexed position, until perhaps renewed disease necessitates the reinsertion of the pessary for some time.

If pregnancy occurs, the danger for a recurrence of the flexion ceases after the fifth month and the pessary must be removed. If conception fails, then no objection can be raised against wearing the pessary, that is, if no bad results arise.

According to my opinion one should at first examine very carefully the surroundings of the uterus in retroflexion. Diseases of the adnexa, perimetritis, salpingitis, especially in their overlooked remnants form absolute contraindications for all immediate orthopedic manoeuvres. These diseases must be treated first, afterward the retroflexion can be treated orthopedically. Disturbances in a movable uterus, dependent on changes in position and form, are indications for reposition and maintenance with a pessary. If the disturbances disappear and consistency, size, and function of the uterus become normal, the pessary treatment should not be continued indefinitely, but the patients should be left to themselves from time to time, that is without the pessary, whether the flexion is cured or not. If the disturbances do not recur, any further orthopedic treatment may be omitted, but if they recur the pessary is again resorted to. Only if the retroflexion forms an obstacle to conception, even without any other disturbances, the pessary is introduced, it must be admitted almost *experimenti causa*. At times the *Thomas* pessary does help, when the *Hodge* proves ineffectual.

Movable retroflexions, which cause difficulties, become symptomless with the pessary. If disturbances continue in spite of the correct insertion of a proper pessary, then the suspicion is well founded that complications, especially in the pelvic peritoneum and the adnexa, have not been recognized. This is only too often overlooked during the orthopedic treatment. In these the treatment of the retroflexion is not at all indicated, but that of the perimetritis and the other diseases (compare the respective chapters).

Vaginal pessaries do not suffice in the rare cases of retroflexion with a shortening of the anterior vaginal wall, either congenital, infantile, or acquired through ulceration or operation, and finally where the uterus is so severely and permanently flexed by inflammatory cicatrization in its walls, that its position is not changed by traction on the posterior surface of the cervix.

In such extreme cases the attempt was formerly made to straighten the uterus by a stem pessary and then to support it by a *Hodge* pessary.

These attempts have been generally discarded nowadays, as well as straightening by the excision of a portion of the uterine wall.

The success of the pessary treatment depends on the careful and complete reposition of the uterus and the suitable selection of the instrument. One often errs in the first regard. The pessary lies beneath or to the side of the uterus which remains retroflexed, having assumed the retrodeviated position in consequence of its flabbiness before the pessary was able to fix it, if it was replaced at all. With respect to the latter too large or too small pessaries are to be blamed for the failure. But also the small virginal vagina, the extreme emaciation of the pelvis, and the defects of the pelvic floor are to be mentioned in this connection. Pessaries are often removed, and their removal is demanded by the women or their husbands, because they interfere with cohabitation, or are lost during the expulsion of hard fecal masses. In such cases, which, however, are not numerous, surgical replacement is indicated, even with a movable retroflexion, according to my opinion.

In entering here on the wide field of operations for retroflexion, we encroach on the presentation of the treatment of prolapse of the genitalia and the inflammatory diseases. We find the uterus very often retroflexed in both these exceedingly frequent groups of diseases, perhaps in the proportion of 10 to 1 with free mobility. The active and general interest, especially also of the practising physician, who considers the treatment of deviations as his proper domain, makes it seem justifiable to describe the operations for the correction of position. At this time we wish to point especially to the fact, that, in my opinion, retroflexions, without the given complications, only rarely are indications for operation, a fact which is of decisive importance in the selection of the operative procedure.

The first proposals for a retroflexion operation were made by *Alexander*.⁵⁸ After many initial doubts the warm recommendation of *Werth*⁵⁹ and the exact anatomic description of the topographic anatomic relations by *Sellheim*⁶⁰ and finally *Küstner's*⁶¹ recommendation, have gained for the *Alexander-Adams* operation with its many variations to-day a wide recognition.

Operation according to *Alexander-Adams*. The uterus is replaced and fixed in a pessary. Incision is made parallel to and 2 cm. distant from the *lig. inguinale* from the *tuberculum pubicum* upward 5 to 6 cm. long, down to the fascia of the *muscularis obliquus externus*. Free exposure of the external inguinal ring, until *Imlach's* fat-plug becomes visible. Incision of the upper wall of the inguinal canal in the direction toward the *vasa epigastrica* about 4 cm. long, whereby the *nervus ileo-inguinalis*, if possible also the *vasa epigastrica externa* are saved, and if necessary the latter ligated. The reddened ligamentum teres lies in the open inguinal canal. It is isolated and pulled out about 8 to 10 cm. If the *processus vaginalis peritonei* comes into view, it is pushed back by blunt dissection, and eventually sutured, if it has been accidentally

opened. Then the other ligamentum teres is exposed in the same manner. *Kocher* advises to lift up the ligament in a direction outward and up, toward the **spina anterior superior** and to fasten it with three silk sutures to the ligamentum inguinale (*Poupart's*). 2. Suturing of the inguinal canal according to *Bassini's* principle of hernia operation. Suturing of the **musculus obliquus internus** with the ligamentum teres (which should only be punctured and not be included *in toto*) to the upper ledge of the ligamentum inguinale and above this separate closure of the fascia. The projecting part of the ligamentum teres is removed. Coaptation of the skin incision. Many changes and details have been recommended from the typical operation. The propositions to make only one large curved incision for the simultaneous exposure of both inguinal rings (*Rumpf, Archiv f. Gyn., XLIV, Casati*) to make only one opening above the inner abdominal ring (*V. Muir, Hegar's Beiträge, Vol. IV*), to extract the ligamentum teres without splitting of the fascia (*Reifferscheidt, Archiv f. Gyn., LXXIII*), are merely mentioned. *Goldspohn's* (*Amer. Jour. of Obstetrics, 1900, No. 5*) proposition, to open the peritoneum with the inguinal ring, in order to free adhesions in the latter, and to deliver the adnexa, has hardly any prospects of imitation, in spite of the warm recommendation of *R. Kossmann* (*Berlin. klin. Wochensch., 1904, No. 25*), as it is then technically preferable to do a typical coeliotomy. Strict after-treatment for several weeks, leaving the uterus in the perysary, are necessary.

Besides the brilliant permanent results, there are also unfavorable experiences. I have even seen recurrent retroflexion and hernia formation in the abdominal scar in the cases of *Pernice* (Greifswald Klinik up to 1899, *Wieland, Inaug. Diss., 1902*). Other variations of reposition of the uterus through shortening of the ligamenta teretia proceed through a median abdominal incision. *Wertheim* (*Centralbl. f. Gyn., 1896*), *Bode* (*Centralbl. f. Gyn., 1889, No. 3*) and *Gill Wylie* (*Amer. Jour. of Obstetrics, Vol. XXII*), form a fold in the ligament. *Kiefer* (*Zeitschr. f. Geb. u. Gyn., 1897*) and *Menge* (*Centralbl. f. Gyn., 1904, No. 21*) suture the ligamenta teretia upon the anterior surface of the uterus, the former through an opening in the anterior vaginal vault, the latter through an abdominal incision (compare also *Bucura, Zeitschrift f. Geb. u. Gyn., XLVI*, and *Halban, Monatsschr. f. Geb. u. Gyn., Vol. XI*). Another point of attack for securing the uterus was found by *W. A. Freund*⁶² by fixing the cervix on the sacrum by shortening of the ligamentum **sacro-uterina** after opening the abdomen. *Frommel*⁶³ followed him in this way. *Sänger* endeavored to obtain the same results by deep suture around *Douglas'* folds through the posterior vaginal vaults. *Stratz*⁶⁴ obliterated the **excavatio recto uterina** by a **colporrhaphia posterior**, executed high up in sixteen cases with good permanent results, also after later occurring pregnancies.

[*J. C. Webster* (*Journal of Am. Med. Assoc., May 10, 1901*) advises the following procedure: Place an ordinary long forceps against the posterior

surface of the broad ligament close to the uterus and immediately under the lig. ovarii prop., perforate the broad ligament from behind and emerge just above the round ligament. The latter is grasped and pulled back in a loop, and then attached to the posterior surface of the uterus by catgut sutures.—ED.]

Another group of *retroflexion operations* attempts to arrive at the object of *securing the uterus in anteversion, by fixing the fundus uteri to the abdominal wall.*

The first suggestion of *Olshausen*⁶⁵ (suturing of the ligamenta teretia at their insertion in the uterus to the abdominal wall) gave this plan a lasting stimulus. *Sänger*⁶⁶ sutured according to *Olshausen's*⁶⁷ suggestion. *Czerny*⁶⁸ and *Leopold*⁶⁹ proposed to bring the sutures through the fundus uteri.

I have, like many others (*Köberle, Schroeder, Hennig, Staude, P. Müller*) sutured the uterus in the abdominal incision in performing laparotomies for other indications, particularly enucleation of myomata and, according to the proposition of *E. Martin*, during *sectio caesarea.*

Spaeth (*Centralbl. f. Gyn.*, 1904, No. 47) opens the abdominal cavity by a suprapubic fascial transverse incision up to the region of the internal inguinal ring, pushes the ligaments on both sides with bullet-forceps through the inguinal canal until they are underneath the fascia, splits these, resects the ligament as far as necessary, and secures it externally. *Bardescu* (*Centralbl. f. Gyn.*, 1904, No. 3) brings the ligaments together from both sides and sutures them to each other.

The number of modifications for ventro-fixation is very large. The one class of operators change the point of attack: *Kelly*, posterior surface of the ligamenta lata; *Kaltenbach, Czempin*,⁷⁰ sutured through the unopened peritoneum; *Werth*⁷¹ attaches the anterior surface of the uterus to the peritoneum of the anterior pelvic wall, respectively the bladder. *Fritsch* and *Engström*⁷² cover a portion of the anterior surface of the fundus with peritoneum, so that a preperitoneal fixation is formed. Others prefer a different suture material: silk, metal, catgut, Fil de Florence.

Execution of *ventro-fixation*: Cœliotomia abdominalis in elevated pelvic position. Small incision, eventually suprapubic fascial transverse incision, bringing up the uterus, freeing it of adhesions. Introduction of the needle through the body of the uterus in the region of the origin of the ligamenta teretia, the needles being then brought through the fascia abdominalis. In fixation of the middle of the corpus two or three sutures are introduced in a similar manner about 1 cm apart.

*Gebhard*⁷³ described a combination of abdominal and vaginal operation. He brings the uterus through the colpotomia anterior and inserts in each ligamentum teres at its uterine origin a catgut suture and conducts this with a long ligature carrier from below at a previously marked place under guidance of the finger from within out through the abdominal walls. By tying these sutures externally over gauze pads upon the

abdominal wall the uterus is brought close to the abdominal wall. Closure of the abdominal incision in a typical way.

I have met only seldom with a motive for a ventro-fixation for the relief of movable retroflexions, corresponding to my opinion against the importance of retroflexion in general.⁷⁴ I have operated only four times for freely movable retroflexions, the uterus free from perimetritic adhesions thirty-one times, after enucleation for myomata eight times. The remote results are not brilliant. The connection of the uterus with the abdominal wall becomes stretched after one to four years so strongly, that the uterus is freely movable. It was brought again into reflexion by the perimetritis existing before as well as afterward in seven of my cases. It lay in anteflexion in the other women. Nevertheless a majority of the patients remained permanently free from disturbances.

A third group of **operative propositions** transfers the field of operation to the vagina.

*Schücking*⁷⁵ fastens the fundus uteri to the anterior vaginal vault by a suture, which is introduced from the cavum uteri through the fundus and anterior vaginal vault. *Zweifel*⁷⁶ and *Klotz*⁷⁷ detach beforehand the bladder from the cervix through the anterior vaginal incision.

The number of reported accidental injuries proves at all events the erroneousness of *Schücking's* procedure. *Klotz* had 70 per cent. of bladder injuries with the method.⁷⁸

*Dührssen*⁷⁹ opened first the anterior vaginal vault transversely, pushed the bladder back by blunt dissection and then sutured the corpus to the vagina, in the beginning without opening the peritoneum.

*Mackenrodt*⁸⁰ executed the anterior vaginal incision at the same time as *Dührssen*. He incised the anterior vaginal vault from about 1 to 1½ cm beneath the urethral opening on the urethral eminence to the portio, dissected the vaginal wall from the bladder, pushed it up along the cervix, and secured it with several catgut sutures, which drew together the detached base of the bladder. Then *Mackenrodt* placed a few sutures (silver, Fil de Florence, or silk) through the vaginal wall and transversely through the anterior wall of the uterine corpus, or the cervix, by which the uterus became fixed to the anterior vaginal wall. Superficial catgut stitches close the rest of the vaginal incision. The bladder, pushed upward and forward, is not irritated by the uterus. The uterus lies firmly fixed in anteflexion.

Mackenrodt modified this method by fixing the peritoneum of the bladder to the uterus (vesico-fixation). Later he freed, besides this, the basis of the ligamenta lata bilaterally to the uterus and united them anterior to the cervix by a suture with the formation of folds.

Mackenrodt, after detachment of the anterior wall of the uterus, excised a wedge from the apparently inflexible uterus, and closed it by sutures before the vagino-fixation, in order to bend the uterus forward.

*Doederlein*⁸¹ made a deep longitudinal incision in the anterior uterine wall for the same purpose, and closed it in a transverse direction.

Uncomplicated retroflexions only rarely induce me to make a vaginal operation. In the proportion of 1 to 10, I operate in cases of perimetritis adhesiva and adnexal diseases, during which I free the uterus from the deviation and place it in a normal position. For this purpose I prefer the *vagino-fixation* since 1894⁸² (Figs. 58, 59, 60, 61).

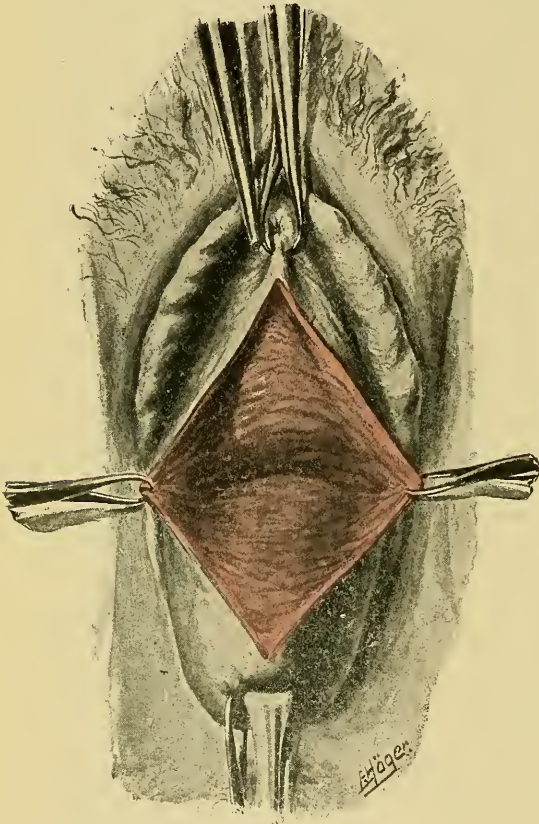


FIG. 58.¹—Colpotomia Anterior. The anterior vaginal wall has been detached from the bladder, which is plainly contrasted from the cervix as a thick protrusion.

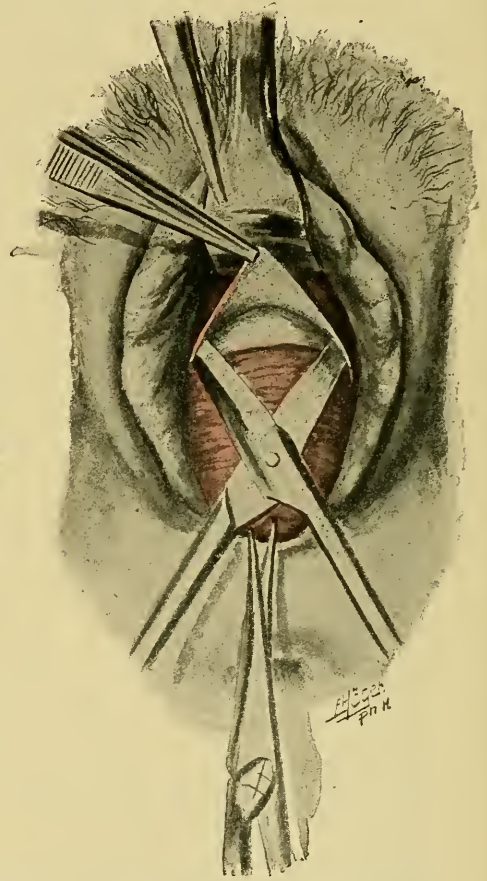


FIG. 59.—Colpotomia Anterior. Opening the plica vesico-uterina.

Execution of Vagino-Fixation.—Position of the patient, see Figs. 33 and 34 (pages 47 and 48). With a narrow vagina *Schuchardt's* paravaginal accessory incision. ***Abrasio mucosae corporis*** and cauterization of cavum with liq. ferri perchlor. Continuous irrigation with sterile water at 32° C. = 89.6° F. Stretching of the anterior vaginal wall by pulling down the portio vaginalis with *Orthmann's* sound forceps and

¹ These figures are drawn after preparations on the operation phantom, shaving the vulva was consequently overlooked.

attaching a tenaculum forceps to the anterior wall about 2 to 3 cm beneath the orificium urethrae externum. Incision of the vagina by a longitudinal cut, which is somewhat transverse at the anterior fornix. Dissection of the vagina from the bladder, dissection of the bladder from the cervix with knife or scissors as far as dense connective tissue reaches,

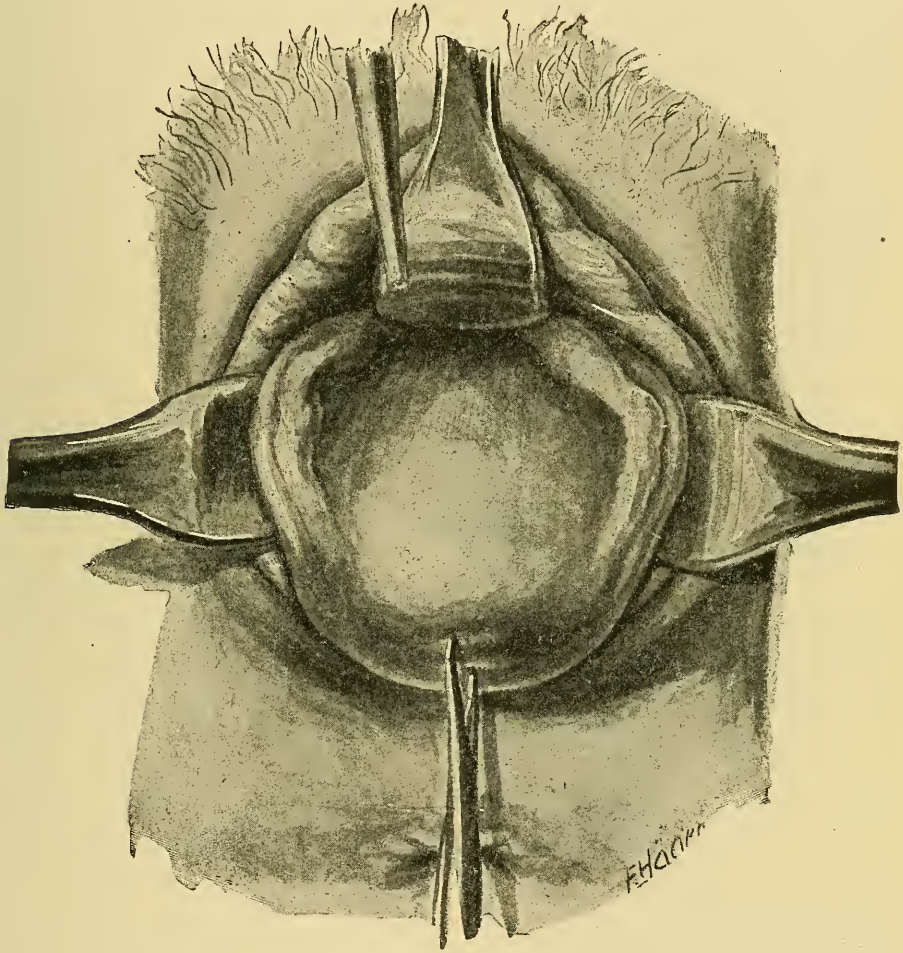


FIG. 60.—Colpotomia Anterior.

then blunt exposure of the plica vesico-uterina (Fig. 58). If the connection of the bladder and the uterus is broader than usual, I attach a tenaculum forceps to the upper part of the cervix, and after removal of the *Orthmann* forceps I bend down the uterus, so as better to stretch this part and facilitate the blunt dissection. Opening of the plica which is detached on both sides to the lateral uterine edges (Fig. 59). The corpus is brought into the vaginal opening by attaching the tenaculum forceps higher and higher, corresponding to its mobility. The fundus

glides before the vulva, after a vaginal retractor has been pushed beneath the bladder into the excavatio vesico-uterina (Fig. 60). Examination of the pelvic cavity by palpation and inspection. The tubes and ovaries are brought into view, in case they do not follow the corpus uteri, by tissue or tenaculum forceps and the use of gauze pads. Breaking up of

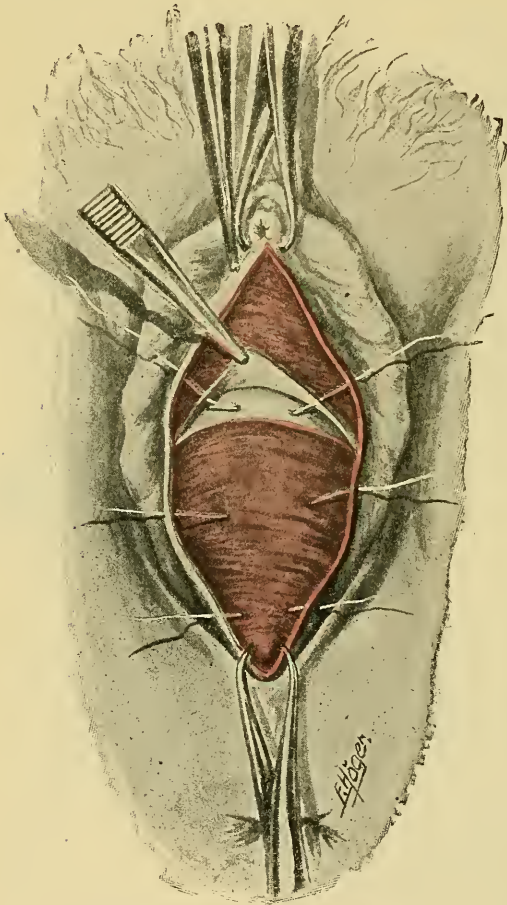


FIG. 61.—Colpotomia Anterior. Vagino-fixation. Sutures are inserted: the upper one includes vagina, peritoneum, uterus, peritoneum, vagina and thus closes the abdominal cavity.

adhesions, attending to the pathologic conditions of the ovary (punctio-folliculo, excision), suturing of the tubes (cleaning of the lumen, resection of atretic sactosalpinx, excision of purulently diseased organs, separation of peritoneal adhesions). Cleansing of the abdominal cavity, which eventually must be protected by lap pads from being soiled with tubal and ovarian cyst contents. The anterior surface of the uterus is caught with bullet-forceps at the height of the old place of folding of the plicæ. Closure of the lacerations caused by forceps in the corpus uteri with continuous catgut stitch. Reposition of the corpus uteri. Vagino-fixation with catgut (Fig. 61). The first suture is introduced at about the middle of the anterior vaginal wall to the left of the cut in the bladder wall at about the peritoneal plicæ, sufficiently deep through the peritoneum and uterine wall close to the forceps holding the uterus, emerging to the right, through the corresponding parts of the perito-

neal plicæ beneath the bladder wall and then the vaginal wall. Tying of the sutures, which closes the plicæ and thereby the cavum peritonei. Second suture through vagina and cervix, tying after removal of the tenaculum forceps. Third suture close to the lower edge of the vaginal incision. Closure of the vaginal incision with a continuous catgut suture from below upward. Closure of the paravaginal incision. Evacuation of the bladder, which was not catheterized before. Rest for ten days.

Accidental injuries arise in this as in all operations not only through the awkwardness of the operator, but also through abnormal development, cicatricial distortions and abnormal softness of the tissues. This applies especially to the bladder and ureters. These injuries should not be overlooked and must be rendered harmless immediately by proper suturing.

Critique of Retroflexion Operations.—The justification of an operative treatment of retroflexion cannot be disputed any more at present. An estimation of the importance of abdominal positions and form of the uterus will cause them to seem indicated more frequently or more rarely according to the individual perception of the physician. Movable retroflexions require in our opinion only very rarely a correction of position. In by far the greater majority of cases, complications, particularly prolapsus and inflammatory disturbances of the generative organs, necessitate an operation, as they exclude orthopedic treatment and indeed even contraindicate massage. The operation is not indicated on account of the retroflexion alone, but it is permitted on account of other processes that cannot be cured in any other way.

The three methods, which must be considered for this operation, are the *Alexander-Adams*, the ventro-fixation, and the vagino-fixation.

The **primary** results are equally good for all three if aseptically performed. Ventro-fixation requires the least technical skill, the *Alexander* operation somewhat more, and vagino-fixation the greatest. The permanent results by all these methods are not such that a return of uterine displacement is excluded.

Reifferscheidt has found 12.42 per cent. recurrences in 840 operations in the literature, with variations between 0 to 44 per cent. in the individual operators. All statistics of this kind are liable to excite many doubts because of the great difference in the mastery of the technic by the operators, the difference in the selection of cases, the dissimilarity in the later condition of the patients are not presented with sufficient clearness in such statistical computations. No method, however, is sure from recurrence—according to their prepossessions the operators see a smaller or larger number of recurrences in the different methods.

It is certain for the greater number of the surgical patients, that **they are permanently relieved from their disturbances**; our experience in this respect is especially in favor of vagino-fixation. The danger of ventral hernia in ventro-fixation and the *Alexander* operation is diminished by the improved operative technic, even if not entirely excluded. The same must be said of the danger of post-operative adhesive chronic peritonitis, which threatens all abdominal operations, less so the vaginal. **Pregnancy** is not excluded by any of these methods, as is shown by a large number of happily terminated **labors**, so that also in this direction no hesitation should be felt about operating. Especially in regard to **vagino-fixation** we must call attention to the fact that with a **deep fixation**, i. e., at the lower end of the corpus, the **disturbances of labor**

observed at first with *high fixation of the corpus* have been entirely lacking. To lay stress on this seems to be imperative, as even at present this objection, which in our opinion is no longer justified, is still made by many authors against the vagino-fixation, the operation being regarded by them as admissible only in persons in the climacteric age. We only practise the vagino-fixation, because it allows us in a safe, and, in our opinion, simple manner to treat the diseased adnexa from the one opening in the abdominal cavity and to remedy especially also descensus respectively prolapsus, from which the great majority of our patients on whom we operate for retroflexion are permanent sufferers.

Another method of curing retroflexions is used by masseurs. They claim to secure permanently a *normal position of the uterus by massaging the posterior vaginal vault and the ligamenta sacro-uterina*.⁸³ Massage in gynecologic diseases in general has almost fallen into disuse at present after an enthusiastic approval in the beginning. Results in the hands of eminent masseurs, *Metzger, Kleen, Kumpf*, are unquestionable. On the other hand, one must state that a great number of patients, generally nervous and excitable, are subjected to hazardous emotional excitement by massaging the pelvis through the vagina. I have given up massage for special gynecologic ailments, while I make a very good use of it for general purposes.

II. Descensus et Prolapsus Uteri et Vaginae

Prolapsus of the genitalia is not to be regarded solely as a local disease, it is, as a rule, the result of a general disturbance of nutrition. The trauma which these organs sustain during one or a number of parturitions becomes detrimental to a great number of these women. This becomes the more detrimental the deeper during the act of delivery the solution of continuity reaches below the surface into the deeper structures and involves the connective-tissue supports and the musculature. Although the puerperium itself leads very frequently to permanent disturbance of nutrition in the pelvis, yet septic and infectious processes and losses of blood may increase the same to an almost irreparable extent, especially if an improper burden should be added through premature work, renewed pregnancy, and infections.

Another physiologic phase in the life of a woman, the climacteric, produces a similar detrimental effect by means of senile atrophic tissue changes. However, all physiologic processes which lead to a general disturbance of nutrition, usher in a displacement of the genitalia. It holds good especially for diseased processes of the pelvic organs and primarily for those of the uterus.

The disappearance of the natural closure of the vagina forms the beginning for the great majority of cases. The loosening of the vaginal walls, which arises from the same causes, discloses the puffy vaginal walls in the gaping introitus. The loosening or progressing destruction

of the tonus of the pelvic connective tissue exerts itself with overwhelming frequency in the region of the bladder. The changing conditions of fullness, the efforts at evacuation, press down the anterior vaginal wall with the puffy urethral eminence. The typical initial stage of the descensus of the lower half of the anterior vaginal wall with a diverticulum of the bladder begins. Descensus of the posterior wall with a diverticulum of the anterior rectal wall follows in the greater percentage of cases. The loosening of the deeper fascial parts, the overstretching of the muscles during the act of delivery—the levator ani, the transversi perinei, the sphincteres, the constrictor cunni—with the relaxation of the muscle fibres and the atrophy of the tense adipose tissue prepare for and finally terminate in a lasting relaxation. If the sphincter ani continues to functionate, and if it is strengthened by scar-tissue formation in the perineum, a coprostasis takes place in the ampulla recti, and just as the bladder presses the anterior vaginal wall down into the lumen of the vagina, so the rectum presses down the posterior vaginal wall into the introitus, at one time immediately above the perineal skin through weakening or destruction of the sphincteres and transversi perinei, at another time above these, so that the proper pronas vaginae and the lower eighth of the posterior vaginal wall remain attached *in situ* and the pouchlike puffy vagina into which projects the diverticulum of the anterior rectal wall passes forward above these. A descensus vaginae posterior, as a rule, combined with a rectocele, is rarely found alone, much more frequently the *descensus vaginae anterioris* and *posterioris*, with the diverticula of their adjacent hollow organs, occur together. Another and detrimental step in the development of prolapsus of the genitalia follows the disturbances of nutrition in the condensation zone of the connective tissue of the parametrium, in the pars cardinalis ligamenti lati. The insufficiency of the latter adds to the changes in the vagina the displacement of the uterus. At times this detrimental complication occurs without the uterus changing in size, weight, or form. These are rare cases. Their importance lies in the fact that the cause for the displacement of the uterus is to be sought solely in the supporting structures of this organ. The pelvic connective tissue holds the uterus, however it may be changed otherwise. The displacement, i. e., either descensus or prolapsus begins with the pathologic changes in the pelvic connective tissue, whether the uterus be normal or abnormal. Naturally the results of the insufficiency of the pelvic connective tissue appear the sooner and are the more lasting if the uterus becomes retroverted and the broad anterior wall of the corpus is subjected to the weight of the intestines and the *intraabdominal pressure* from above and a retroflexion of the uterus results. The consequences of the defects in the pelvic connective tissues appear surely if the uterus either subinvolved or the cervix hypertrophied through chronic inflammatory processes with its edematous and puffy cervical lips descends into the vagina and appears at the introitus vaginae (Fig. 62).

The insufficiency of the ligamenta lata appears at times alone, without any other destruction or degeneration of tissue in the pelvis; it is rare, however, to find a descensus uteri without descensus vaginæ. The rule is that the described forms of descensus vaginæ occur first, followed only too soon by descensus uteri, and nothing will stop the prolapse in

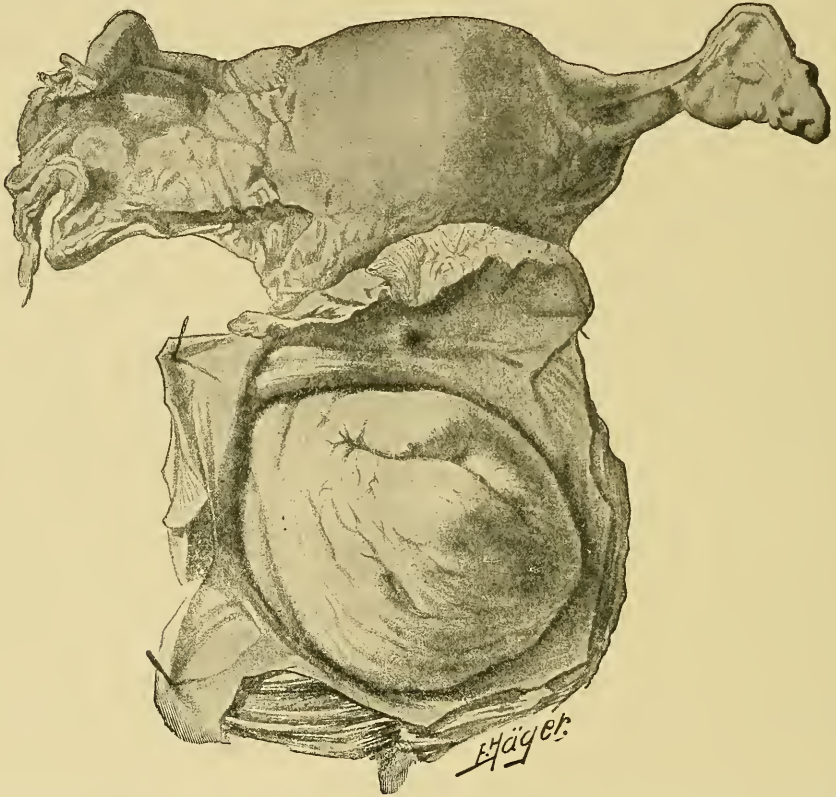


FIG. 62.—Prolapsus Uteri with Metritis and Endometritis Colli Chronica. (Exstirp. uteri et partis superioris vaginæ.)

whose multiform types it is impossible to recognize the initial stage (Fig. 63).

We meet with a rare form of descensus in poorly nourished persons, mostly in the third decade of life, but also earlier or later, also in children. Irrespective of the consequences of rapidly growing restriction of space in the pelvic cavity through tumors, ascites, extravasation of blood, or pus formation, we find at times a defective development which we have learned to designate with *W. A. Freund* as **infantilismus**: a short vagina with a defective connective-tissue supporting structure, excavatio recto-uterina reaching deep down between the vagina and the rectum, a short perineal body, a pelvic floor devoid of adipose tissue. In other, according to my experience, more frequent cases, the condition of

development, in itself non-pathologic, is complicated by a grave disturbance of the general nutrition, which we find in scrofulosis, tuberculosis, in long wasting and febrile diseases, and disturbances of the function of the stomach and bowels, in nephritis chronica, in psychosis, in diabetes, also in improper and faulty nutrition on account of failing means of subsistence, in cachexia from alcoholism, carcinoma, and in conditions termed neurasthenic. If we mention enteroptosis in this connection we recognize in the displacement of the organs, especially of the kidneys, the

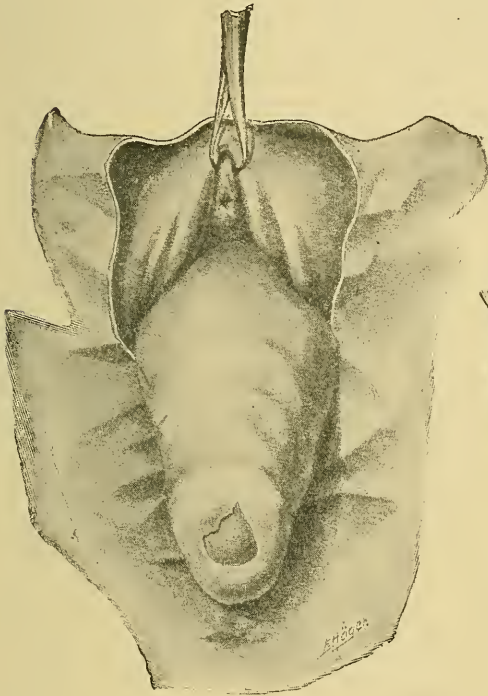


FIG. 63.—Prolapsus Vaginæ Anterioris Cum Cystocele. Prolapsus colli uteri elongati. Ulcus decubitale (result of action of pessary) labii anterioris.

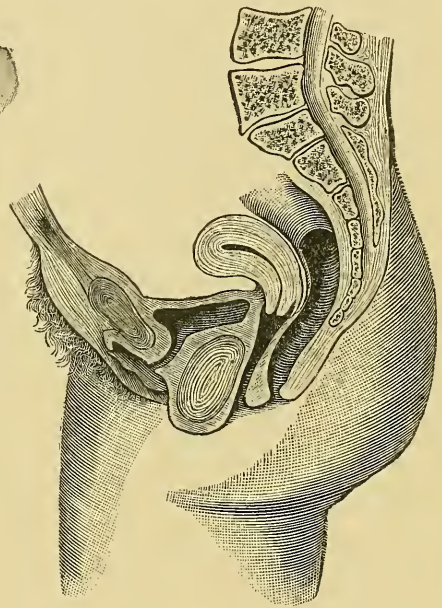


FIG. 64.—Prolapse of the Anterior Vaginal Wall through Tumor Formation in the Same.

effect of the same factors which lead to an insufficiency of the pelvic connective tissue.

Our conception of the participation of the uterus in the displacement debars a discussion of the question whether the so frequent stretching and elongation of the cervix uteri could be a result of the dragging of the anterior vaginal wall or the bladder. Such a dragging could only be considered if the corpus has become fixed by perimetritic induration. This perimetritis, as a rule, appears after the occurrence of the prolapse. Perimetritis is considered justly as a sort of safeguard against descensus and prolapsus. The insufficiency of the pelvic connective-tissue structures

and the following prolapsus appear after a cure of the perimetritis. The action of the same infection, which caused the perimetritis, is shown in the uterus: it remains thick and the cervix edematous. The flabbiness of the walls of the body does not prevent a retroversion. The corpus, just the same, may enter into a normal anteflexion.

A rare variety of prolapse is found in the cases of tumor development in the walls of the vagina. These rarely can be considered as neoplasms. They are mostly retention cysts, some of which can be considered as persistent rudiments of *Gärtner's* duct.

A marked example of tumor formation of the anterior vaginal wall is represented in the above sketch (Fig. 64). The patient withdrew from any further treatment and the consequent classification of the nature of the tumor. The tumor could be plainly outlined on palpation between the vagina and the bladder, and its consistency could be determined. It was situated more on the right side of the anterior vaginal wall without any communication with the structures above it. The uterus and bladder lay in a normal relation to each other.

These are followed by such prolapses in which *neoplasms of the pelvic connective tissue* push forward beneath the vaginal wall toward the surface. I have observed a number of examples among all varieties of tumors of the pelvic connective tissue and the ovaries. The cases found in the literature have been exhaustively collected by *J. A. Amann* (*A. Martin*, "Handbook of the Disease of the Adnexa," Vol. III. "Diseases of the Pelvic Connective Tissue, Neoplasms of the Same").

The development of descensus and prolapsus is decidedly a chronic process. This is contrary to the frequent statements of the patients, that the prolapse began acutely. The physician is unusually frequently put in the position where he must give an opinion on this matter, as many women of the working class attribute the development of the disease to an accident due to their occupation which may allow the possibility of a claim for insurance. Acutely developing prolapses are extremely rare.

I have seen two cases of an acute development of a complete prolapse. One was in a puerpera who claimed to have been perfectly well and who fell suddenly in a faint on the seventh day *post partum* during a painful evacuation of the bowels, the result of an intense intestinal inflammation. Being called in the case I found the uterus prolapsed up to the middle of the corpus, with an *inversio vaginæ* and above this an intraligamentous and extraperitoneal hemorrhage. Intense collapse of the patient. I replaced the uterus and left the woman in the recumbent position, and could follow up the absorption of the hematoma. As soon as the patient got up, a complete prolapse came down. Cases of incomplete processes are not so rare any more in recent times. I had treated the other woman gynecologically before. She recovered completely after the removal of the remnants of abortion. About half a year later and after carrying a heavy load she received, with violent pains, a complete prolapse of the uterus with an inversion of the vagina. About four days later I could

also demonstrate the presence of an intraligamentous hematoma. It became absorbed, while the prolapse continued. I treated the same by a corresponding colporrhaphy. The patient succumbed within one year to a rapidly proliferating carcinoma. Similar examples are reported by *Fritsch* (l. c.).

Normally placed genitalia, with a normal condition of the pelvic supporting structures, may become prolapsed only by the action of a decided force. The displacement leads us to expect always the occurrence of an extensive laceration of the bloodvessels, though they adapt themselves easily to the ever and at times suddenly changing condition of pregnancy and labor. Certainly it is not to be denied that a marked increase of an existing old descensus sometimes occurs through the influence of trauma without an extensive laceration. However, one must weigh this far-reaching disposition, which existed already, in rendering a professional opinion on the accident. In giving expert opinions we have often been impressed with the fact that the accidental origin of the condition in this sense has in very many cases not been satisfactorily determined by the arbitrators. Very often women become conscious of the necessity of assistance only after the lapse of many days. Not a trace of an acute tear exists in the obviously old prolapse. Yet the so-called accident proves to be entirely unqualified to cause an acute displacement of the genital parts. Not infrequently in the course of a slowly developing prolapse there has been observed an acute aggravation of the symptoms and of the displacement after severe exertions or intercurrent diseases. Especially during the menopause the danger increases perceptibly after an extraordinary physical exertion, so that the women perhaps now come to realize their condition, although the cornification of the epithelium of the protruding parts shows beyond a doubt their long-continued projection from the internal structures.

The Findings.—A puffy mass protrudes from the gaping rima above the relaxed perineum shortened through cicatrices. It consists of the deformed thickened anterior vaginal wall, above which lies the urethral eminence with the thick protuberances of the lateral parts of this mass. The posterior vaginal wall crops out above the carunculæ myrtiformes which frequently have become enlarged to long skin flaps. As soon as the patient bears down, both puffs roll out. The deformed cervix emerges between these. In many cases the cervix is preserved as a small plug, in others with lateral laceration of the cervix it bears the turned up everted cervix-lips and the everted, chronically inflamed, hypertrophic mucous membrane of the cervix. At times one does not succeed even with long-continued pressure in deeply inverting the vagina. Not rarely the whole mass of the hypertrophied cervix with the vaginal walls still preserved as a sulcus, emerges gradually and slowly. Behind this anterior vaginal wall lies the bladder which in its empty state is situated in its entire extent external to the rima, so that the sound can be introduced in a normal direction only as far as the urethra is connected with the

ligamentum arcuatum. Then the point must be conducted downward along the cervix uteri. On introducing the finger into the anus it passes just above the more or less strongly closed sphincters into the roomy diverticulum of the anterior rectal wall and enters without effort above the posterior commissure of the introitus into the pouch of the posterior vaginal wall. The body of the uterus lies above these in a retroflexed position. The cervix shows a considerable elongation of its supravaginal portion. The sound can enter only in a posterior and downward direc-

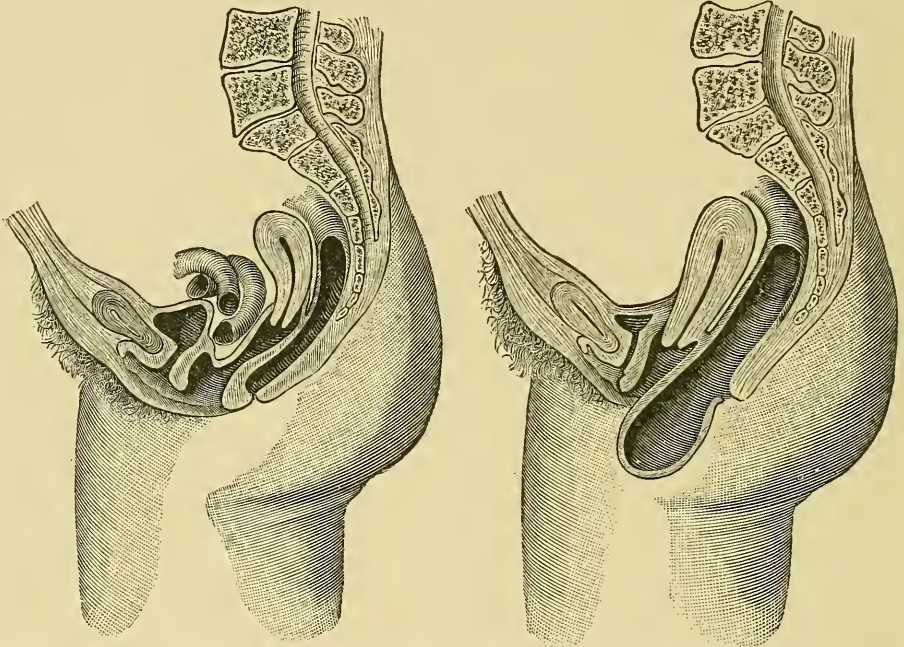


FIG. 65. — Prolapsus Vaginae Anterioris Superioris et Enterocele Vaginalis Anterior. (Schematic.)

FIG. 66. — Prolapsus Vaginae Posterioris cum Rectocele. (Schematic.)

tion. The cervix measures 6 to 11 cm, the body 4 to 8 cm. Its walls are mostly thickened. However, they may be highly atrophied in older persons, so that the thickened corpus seems to hang on a slender stem. The different forms of prolapsus develop from this initial stage.

1. *A descent of the lower half of the anterior vaginal wall* into the lumen of the vagina is the most frequent. (*Prolapsus vaginae anterioris.*)

2. *The upper third of the anterior vaginal wall* (Fig. 65) alone is rarely pressed down by intestinal loops between the uterus and the vagina. Such a *prolapsus vaginae anterioris superioris with enterocele vaginalis anterior*, I have seen in a Policlinic patient similar to the one proven by post-mortem examination by *E. Martin*.⁸⁴ The possibility must be admitted a priori, as the connection between the cervix uteri and

the bladder is so loose and dilatable that such a protrusion of the upper third of the vagina can readily take place.

3. Somewhat more frequent is *prolapsus vaginae posterioris with enterocele vaginalis posterior*. The posterior vaginal vault is pressed down into the lumen of the vagina by intestinal loops, which fill out the excavatio recto-uterina without the uterus or the lower half of the vagina being markedly displaced. With only a trifling displacement of the uterus I found emerging from the rima a swelling the size of half a fist, which pressed down only the upper half of the posterior vaginal wall.

4. We see undoubtedly much more frequently than 2 and 3 rare forms of prolapse of the *lower half or of the lower two-thirds of the posterior vaginal wall*. An initial swelling the size of a plum, of the posterior vaginal wall, projects above a tolerably tight scar of the deeply lacerated perineum. A diverticulum of the anterior rectal wall of corresponding size enters this vaginal prolapse (Fig. 66). The posterior vaginal wall may form swellings the size of the fist which lie in front of the rima. The diverticulum which fills the sac shelters fecal masses and flatus. (*Prolapsus vaginae posterioris with rectocele*.)

The different forms of the prolapsus of the vagina are, as a rule, found combined together, and in all the anterior and poste-

rior vaginal walls participate in an almost always predominating manner (Fig. 67). *The lateral vaginal walls* are also disposed in an almost similar manner to the formation of these swellings, but they are not driven forward by the neighboring organs contained in them with the same natural necessity. If cysts or other newgrowths occur in them, then they also form quite similar swellings as the anterior and posterior vaginal walls. The entire vagina may descend out of the rima like an extroverted leather bag; this is nevertheless rare, and occurs usually in old women, or at all events in those with advanced senile transformations of the genitalia. The uterus lies in this bag sometimes anteverted, and sometimes retroverted (Figs. 68 and 69), sometimes small and atrophic, at others bulky and deformed. In other cases the fundus is still fixed in the pelvis by peritonic adhesions, so that the cervix lies in the dilated

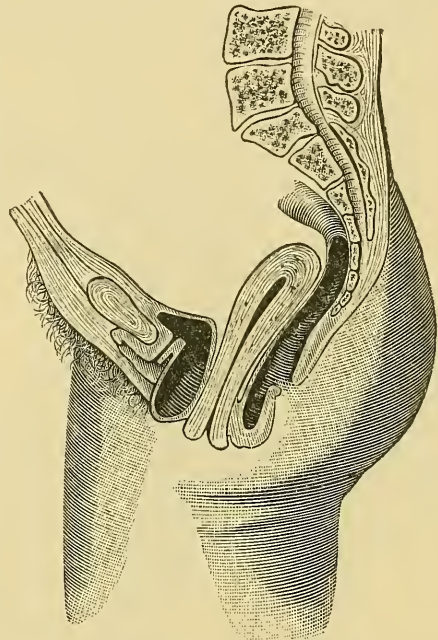


FIG. 67.—Prolapsus Vaginæ et Colli Uteri, Cystocele, Rectocele. Elongatio Colli Uteri. (Schematic.)

vaginal pouch in an elongated condition like a small filler the thickness of a finger. Ovaries, Fallopian tubes, and intestinal loops fill the bag, if it is not claimed by the filled bladder or the rectal diverticulum filled with feces and flatus. The participation of the uterus in the descensus and prolapsus of the genitalia has been considered above.

The peritoneum follows the different varieties of prolapsus to a very different extent. The bottom of the excavatio recto-uterina moves down beneath the posterior edge of the cervix into the prolapse. It may, how-

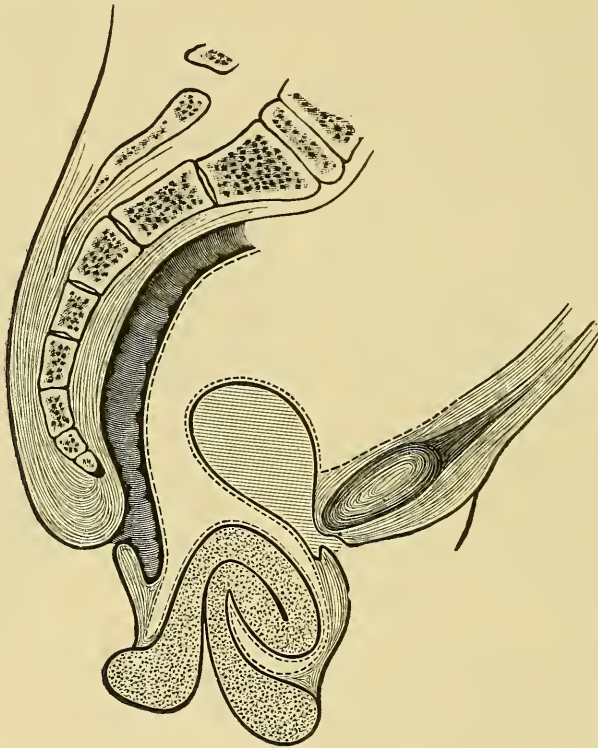


FIG. 68.—Prolapsus Vaginae et Uteri. Ectropion of Cervical Lips. (Schematic.)

ever, lie far above the posterior vaginal vault if the septum is strikingly thickened. The ligamenta sacro-uterina may be noticed either as long stretched folds, or they may atrophy so that they can be neither palpated nor observed. I have been able to verify this latter fact repeatedly in extirpation of prolapsed uteri. The bladder also is at times connected with the cervix to a great extent, at others it is completely separated so that it hardly comes in contact with the uterus (compare *Fritsch*, l. c., p. 206).

Fritsch lays stress on the fact, and my observations coincide with his, that the distortions of the peritoneum, as a rule, terminate at the linea innominata. This must be emphasized, as some authors have tried to

make the procidentia responsible for the distortions of the peritoneum as far up as the kidneys. Against this view that prolapse must be blamed for a movable kidney, speaks the occurrence of both *conditions* separately, finally also the observation that in cases where both are present, the movable kidney existed long before procidentia of the genitalia occurred.

The mucous membrane of the prolapsed part naturally suffers first of all. Its covering with squamous epithelium and the want of glandular elements favors the drying and the cornification of the protruding vaginal mucous membrane even in young persons, so that the surface of the prolapsus assumes a completely epidermoid character. The cervical mucous membrane which is visible in the cervical canal also dries up by contact with the air. The cylindrical epithelium changes into squamous epithelium through metaplasia as far as the gaping orificium exposes the cervical mucous membrane. Such a metaplasia of the exposed surface is seen only in very clean women. The contact with the air and wearing apparel, the frequent soiling with feces, urine, dust and perspiration macerates the mucous membrane and gives rise to *decubital ulcers*. Badly placed and decomposed pessaries favor this form of decubitus. *Küstner* ("Referat f. den Kongr. d. Deutsch. Ges. f. Gynäk.," Würzburg, 1903, p. 10) emphasizes the fact that lacerated and fissured ulcers arise through the rupture of the edematous and less resisting, hardened and brittle cervical or vaginal mucous membrane due to eversion and erosion with glandular infiltration and consequent edema and hypertrophy. Such fissures spread freely over the vaginal wall, at times in different places which do not connect with each other. The *ulcers* become infected and an intense inflammation arises. Deep-seated loss of tissue substance follows the acute inflammatory stage. They have sharply defined edges, which rise steeply above the ulcer, and surround smaller and larger islands of ulcerating areas in a jagged and irregular form. They bleed easily at the lightest touch and secrete a sticky serous fluid which causes the ulcer to adhere to the underwear or the skin with which it comes accidentally in contact. The ulcerations mostly have weak granulations

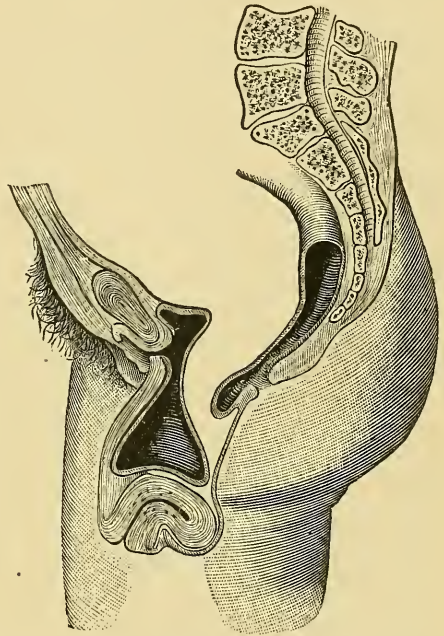


FIG. 69.—Prolapsus et Inversio Vaginæ, Retroflexio et Prolapsus Uteri, Cystocele et Rectocele.

and are surrounded and undermined by an extensive edema. They are covered with fetid-smelling crusts in unclean women. They may heal after prolonged care and treatment, even spontaneously, when they disfigure the prolapsed mass with peculiar scar formations.

However persistent the ulcerations may be and however early they simulate the clinical picture of a *malignant degeneration* through their putrefaction and hemorrhages, the latter rarely occurs in the prolapsed genitalia. The immunity to cancer which was accepted formerly for prolapsus does not by any means exist, for others⁸⁵ as well as myself have observed cancer of the prolapsed parts.

Pregnancy may occur not only in prolapsus of a moderate extent but also in complete inversion of the vagina. The pregnant body of the uterus which lies in the small pelvis develops almost regularly upward into the large pelvis. It pulls the prolapsed vagina and cervix along so that the patients never felt better and easier at any period in their life than in the second half of pregnancy. Their hope of permanent relief is, as a rule, illusory, for the vagina with the uterus are sooner or later again pressed forward out of the rima. Only when adhesions exist in the pelvis, or the entire uterus is situated before the external genitalia may an incarceration of the pregnant uterus occur, as in the analogous cases of retroflexio uteri gravidi. If pregnancy does not terminate prematurely, as through an abortion, signs of a grave and severe congestion with the danger of threatening necrosis of the entire pelvic organs and ensuing peritonitis may develop. It is only very rarely that the entire uterus is situated outside of the genitalia, so that it lies in the enormously relaxed and inverted vagina between the woman's legs. The expulsion of the ovum in these latter cases is naturally left entirely to the uterine musculature, so that artificial aid may become necessary.

The *scars* of the prolapsus do not, as a rule, form an obstacle to delivery. They loosen up completely if in the course of the pregnancy the uterus recedes, but if the cervix remains external, then a peculiar difficulty might arise during labor. The cicatrized, contracted and cornified surface may offer a serious resistance to its dilatation, which can only be overcome at the expense of the continuity of the rigid and unyielding walls. Proper assistance, however, may ward off serious danger, as I myself have observed several times.

The *symptoms* of prolapsus consist of a feeling of gaping of the genitalia, and a sensation as if the abdominal viscera wanted to fall out, and a fear of a prolapsus resulting from this while standing or walking. The functions of the bladder and the rectum are at the same time aggravated to a high degree. The necessity of replacing manually the prolapsus for an evacuation of the urine and feces has a powerfully depressing effect. The difficulties disappear almost entirely in the recumbent and sometimes in the sitting position. The further the prolapse develops the more tormenting becomes the impediment. The patients lose appetite, they emaciate. To this are added the feeling of debility and the knowledge that

they are becoming sexually invalid which reacts detrimentally on the mind. At times the suffering is tolerated and the earning capacity is not disturbed. I have only seen quite isolated and indolent persons who did not seek any relief; resolute women, who work for a living, help themselves in a peculiar manner by bandages and supports, which only the ingenuity of these persons discovers. Most of them, especially the poor, become disabled; they cannot move about properly, they lose their capability to digest regularly and decline physically and mentally, so that they are a burden to themselves and to their relatives.

The *diagnosis* of the prolapsus does not offer any difficulties. The relations of the different parts to each other in the descensus and prolapsus are easily determined. One lets the patients which are in the dorso-sacral position bear down strongly to develop the prolapsus completely, and assists through traction with a bullet-forceps on the cervix or eventually through pressure on the abdomen. After the position and length of the uterus have been established and the participation of the bladder in the prolapse is established with a sound or a catheter one must determine the part the rectum plays in the procidentia. Finally the entire mass is replaced in the pelvis, and the physician examines again the uterus in this replaced position, also the adnexa and the condition of the perineum, vaginal vaults, and the lateral vaginal walls.

The *prognosis* cannot be a favorable one, after all that has been said, as long as the evil is left to itself. ***But we are in a position to call the prognosis favorable as soon as the patients find enough courage to submit to a proper treatment.***

The *prophylaxis* of prolapsus is still too much neglected by obstetricians, and especially midwives. We have to induce much more energetically the promotion of strength of the puerpera by a more nourishing diet, by avoiding premature exertion and by increasing the involution of the genitalia by an early use of astringent vaginal douches and sitz-baths. Long-continued rest in bed is serviceable only under proper conditions. Too early rising acts, by all means detrimentally. Rest in bed is necessary as long as the lochia are tinged with blood. Afterward exercise without overexertion only acts to increase the appetite and digestion.

As soon as signs of a descensus vaginæ et uteri are noticeable, bodily exertions are to be avoided absolutely as well as all marital relations. We must lay stress on an energetic nursing of the body, especially a more nourishing diet, and attention to securing easy defecation. Hot vaginal douches at a temperature of 50° C. (122° F.) eventually in sitz-bath [sitz-bath of 32.5° C. (90.5° F.) with a decoction of oak-bark] have a permanent beneficial and curative action. (Two handfuls of oak-bark are boiled in two or three litres of water, and enough water is added to fill the tub for the sitz-bath.) A quarter of such a decoction can be added to three-quarters of a litre of water for the vaginal douche. Tampons of sterile cotton (with glycerin and tannic acid 5 to 10 per cent.) are worn at night or during the day for ten to twelve hours. They

may be left in even longer without any hesitation. One can substitute for the tampons suppositories of gelatin or cocoa butter with an addition of tannin. A cool sitz-bath may also act favorably, cold water is poured into the lukewarm water while bathing. As soon as the temperature has been reduced to 18° C. (64° F.) and then to 12° C. (54° F.) the patient, after five to ten minutes, goes to bed for one hour in order to get warm again.

The introduction of pessaries in descensus is to be avoided by all means.

One not infrequently succeeds in removing the feeling of descensus by a timely and diligent use of the means described and obtains a notice-

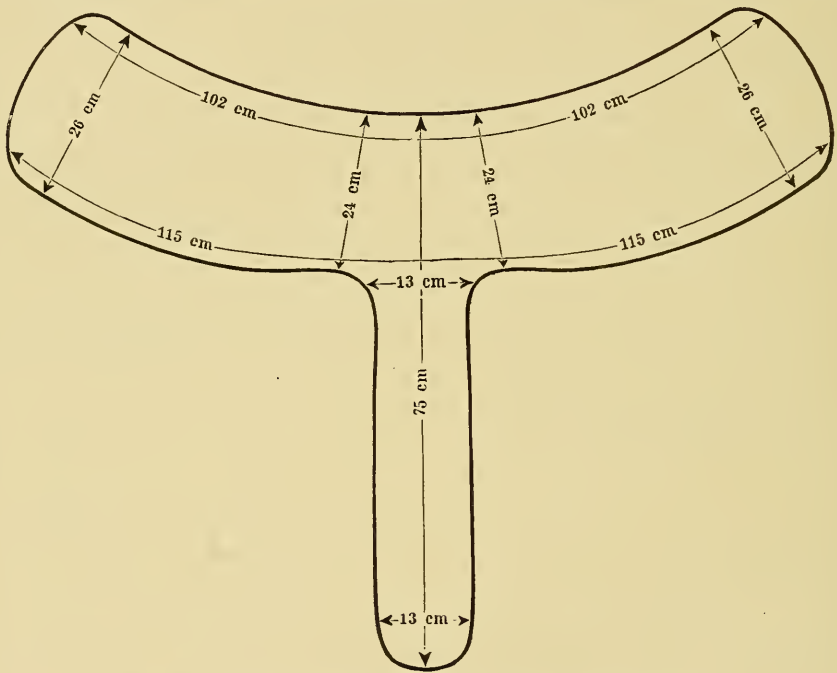


FIG. 70.—Puerperal Binder of Strong Fustian Material.

able increase in the tonicity of the tissues, later also an increasing fat formation, in other words a complete cure, if deep lacerations have not destroyed the vaginal opening.

If the prolapsus develops incessantly, or if the woman comes with a completely developed prolapse for treatment, then only local treatment remains.

This can be only a ***surgical one*** and we may expect a permanent success for the great majority if subsequent care of the entire body is employed in connection with surgical treatment.

I advise to insist on an operative treatment if the general condition or grave diseases do not exclude any operation.

I omit intentionally the description of those supports which have been designed for the retention of prolapsus. Decrepit persons are made to wear broad bandages, after the shape of puerperal binders (Fig. 70).

The same are made according to the accompanying pattern from a strong washable material. They are secured by safety-pins, after applying the bandage in the reclining posture. A layer of cotton (absorbent, if necessary medicated), can be inclosed in the perineal strap.

I seldom insert stem pessaries (Fig. 71). These are selected in the proper sizes, inverted and held before the rima, so that the stem lies horizontally and transversely to the rima, naturally after the prolapse has been replaced and also the uterus brought into a normal position. The pessary is pressed into the rima and as soon as it has passed the lower third of the vagina it is placed transversely, so that the stem is directed downward. The pessary fills the upper half of the vagina and is prevented by the stem, which hangs downward and outward, and by the pressure of the anterior and posterior vaginal walls, from turning on its edge, or falling out. The pessaries must be kept clean by regular daily vaginal douches with a disinfecting solution. I usually take three tablespoonfuls of acetic acid to one litre of water. It is necessary to remove and examine them at least every three months (but not during each menstruation) and to replace them by another one if necessary. One may have to use a somewhat larger size, seldom smaller ones. If decubitus is formed in the vagina it must be healed first before a new ring is introduced. At times a chronic peri- or parametritis may be brought about through the pressure of the pessary, which may lead to a cure and removal of the prolapse.

How widespread even to-day is the psychologically explainable wish of the patient, to remedy the evil without an operative interference, is shown by the enthusiasm which greeted the massage of *Thure Brandt*, especially for the treatment of prolapse. The final results of massage did not speak in favor of this procedure. The same holds good for the experiments with injection of petrolatum (*Halban*), and of paraffin (*Pankow-Krönig*), or of quinin (*Parsons*) to secure a permanent retention of the prolapse. The same prognosis can be made to the proposition of *Slatow* and *Iwancow*, based on anatomic conditions, who by increasing the tonus of the muscles by a three-phase current, claim thus to strengthen the ligaments of the uterus, and hope thereby to cure the disease. One hardly would subject young and strong persons to such treatment which is always uncertain and doubtful in its anatomic principles. If one fears inhalation or spinal narcosis for the operation, local anesthesia, which we do not like and do not generally employ, is sufficient to save the women the excitement which is always connected with the operation and also insure complete immobility of the patient. All decrepit women, whom

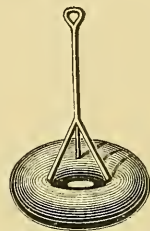

FIG. 71. — Stem Pessary, after *Valleix* and *E. Martin*.

one wishes to spare from a long rest in bed, have such poorly nourished tissues that gangrene easily results from vaselin or paraffin injections, as we also have observed, or every condition favorable to success with treatment by electricity is lacking.

I have described the history of the *operative treatment of prolapsus* in my report for the "Kongress der Deutschen Gesellschaft für Gynäkologie, in Würzburg, 1903." I refrain from mentioning here those methods which to-day are only of historical interest. A great number of these methods discussed prior to the last fifteen years, and illustrated partly with my own experience, are described in the third edition of this book.

It is generally recognized that neither a plastic operation on the introitus vaginæ nor a narrowing of the vagina suffice for a typical genital prolapse. In every case one must make allowance for the position and condition of the uterus, bladder, rectum, and the entire pelvic connective tissue.

The plan of operation must comprise according to the condition of the parts *the reposition and fixation of the uterus*, the strengthening or *reinforcement of the pelvic connective tissue as a support for the bladder and rectum*, *the removal of the superfluous vaginal tissue*, and *the rebuilding of the perineal body*.

The extent of a single surgical interference varies within the limits of this programme.

The *treatment of the hypertrophic cervix uteri* is still a matter of dispute. As soon as the uterus is retained within the vagina in a normal position, the edema of the cervix disappears in many cases. I deem it very important to relieve the scar formations from the beginning from the pressure by this mass. I excise, like a great number of gynecologists, the hypertrophic cervix, just as I remove the chronically inflamed uterine mucosa by curettement, in order to remove the pathologic secretion from the same.

Another point of dispute is the *manner of the procedure*. I prefer, if possible, to proceed from *one* incision, as long as this offers the possibility of disposing of the different problems from this point and in one sitting. This last rule to-day is recognized as generally obligatory.

The preliminary removal of the dirty covered ulceration of the decubital and other sores both on the structures situated outside the introitus and in the sinuses of the vagina must precede the operation.

Rest in bed, packs with aluminum acetate clay ($\frac{1}{2}$ per cent.), sitz-bath with green soap, two tablespoonfuls to each bath, also addition of mercuric chlorid (1.0 to each bath), cauterization with silver nitrate, iodin, ichthyol tampons (10 per cent.), packing with iodoform gauze: these are the means through which, as a rule, I succeed in obtaining healthy granulations within ten to fourteen days or earlier. The kind of anesthesia used is less important: I prefer stovain-lumbar anesthesia or chloroform or ether by inhalation. The high price of the former forms an objection

for clinical operations and the known difficulties in the corpulent is another.

1. If *uterine catarrh* exists, curettement is done. The operation for *elongatio cervicis*, *hypertrophia cervicis*, *eversio lacorium with erosions* and *laceration of the cervix* form the introductory measures. If the uterus lies in *retroflexion*, it must be brought into a *normal position and form*.

The *Alexander-Adams* operation, ventro-fixation and vagino-fixation are at our disposal for this purpose, the execution of which has been discussed on page 98 and farther.

I favor the vagino-fixation. It can be joined immediately to the above-mentioned procedures. It permits the proper attention to the frequent complications of perimetritis, oöphoritis, and salpingitis. It immediately leads over to the treatment of the bladder and vagina. Vagino-fixation, as it is practised to-day, i. e., deep fixation of the corpus at its lowest portion, does not involve any danger in case of pregnancy, and, therefore, may be executed in women of every age without sterilization by an operation on the ovaries or uterine tubes.

2. The deep diverticulation of the *bladder* into the anterior vaginal wall demands special attention by a *suture* of the *bladder wall*. The bladder wall must be freed to a great extent by dissection from the anterior vaginal wall. This may be done without trouble through the longitudinal incision in the anterior vaginal wall which was made for the vagino-fixation. The end of this incision is enlarged by transverse incisions on both sides of the cervical lips. The vaginal wall can be freed by simple pressure with the fingers, beginning at this point, while the anterior cervical lip is held tightly pulled down with bullet-forceps or *Muzeux'* forceps or *Orthmann's* sound-forceps. The bladder wall is drawn together by a purse-string suture. With a diverticulum of larger extent several rows of sutures are introduced one after the other.

3. *Treatment of the Prolapse of the Anterior Vaginal Wall*.—If the prolapse operation began with vagino-fixation no other incision is required.

For a *colporrhaphia anterior without vagino-fixation* the anterior vaginal wall (Fig. 72) is put on the stretch by four bullet-forceps; the upper one lies close to the urethral eminence, one on each side at the transition of the anterior into the lateral vaginal walls, the fourth one close to the portio. The entire operation field can be stretched out quite well between these four instruments. An ovoid figure is cut all around, which has its apex close underneath the orificium urethræ and occupies in its extent almost the entire anterior vaginal wall. The eminence which we frequently notice near the external urethral opening must be included in the ovoid. The vaginal mucous membrane of the area thus outlined is dissected out by advancing from each side toward the centre. One can make an additional median longitudinal incision in this area and then loosen each half beginning from the median incision toward the edges (vide Fig. 72). This step is essentially facilitated by constant irri-

gation with a normal saline solution, which saves cleansing by mopping. The wound-surface does not bleed profusely if it is correspondingly stretched. For years I have not ligated spurting arteries in the colporrhaphy wound.

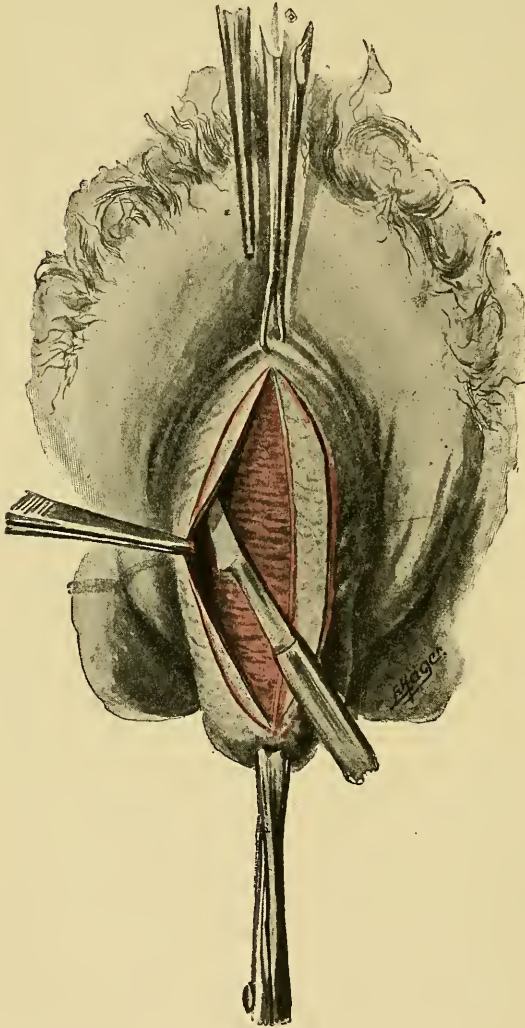


FIG. 72.—Incision in Colporrhaphia Anterior. If it is desirable to excise a still larger portion, three bullet-forceps must be used laterally, as described in the text.

connective tissue of the pelvis. *Hegar*⁸⁷ does not intend to create a pedestal on which the uterus rests (*Simon*), but to restore the tonus of the connective tissue of the pelvic floor by **drawing it together in the median line so as to form such a firm scar that the uterus is to a certain degree suspended from it** and prevented from descending.

If it comes to the worst it is sufficient for the assistant to press a finger or a compress on it, while the operation is continued. Remaining edges and unevennesses are removed with scissors.

*Fehling*⁸⁶ proposed to divide the large median dissection into two lateral sections parallel to the median line.

The entire wound surface is closed with a continuous catgut suture (Fig. 73). As soon as the margins of the wound become tense interrupted sutures may be used.

4. The task of removing the hyperplasia and pouch formation of the **posterior vaginal wall** includes the removal of the **rectal diverticulum** and the formation of a **vaginal outlet** fitted for its functions. The operation to be executed is the **colporrhaphia posterior** in its different variations. The septum recto-vaginale, as a rule, is taken up in such a manner that a special operation on the rectal wall does not appear necessary.

A. After the principles propounded by *Hegar* one endeavors to tighten the

The execution of the incision according to *Hegar* has been retained even at present by many operators. The denudation is carried up into the posterior vaginal vault, eventually up to the cervix. An acute angled triangle is dissected out of the *posterior vaginal wall* (Fig. 74) which reaches up to about the middle of the same, from here it passes over to the lateral wall and along these outward. It strikes the region of the hymenial ring beneath the opening of the glandulæ vestibulares majores. The incision is then continued through the vestibulum vaginæ close to and parallel with the hymenial ring, which thus connects the two lateral incisions. The tissue between these incisions is removed and the wound-surface is united by closely introduced interrupted sutures or a continuous stitch, and forms, when union takes place, a very firm scar, which permanently strengthens the pelvic floor and thus prevents the uterus from descending (Fig. 75).

B. The plan for the *colporrhaphia posterior* described by me in 1879 ("Naturforscherversammlung," Baden-Baden), is based

on the physiologic condition of the vagina. It arose from the observation of *Freund's* drawing of the plastic of the perineum ("Naturforscherversammlung," Wiesbaden, 1873). *Freund* pointed out that we must look for the firm eminence in the anterior and posterior vaginal walls according to the

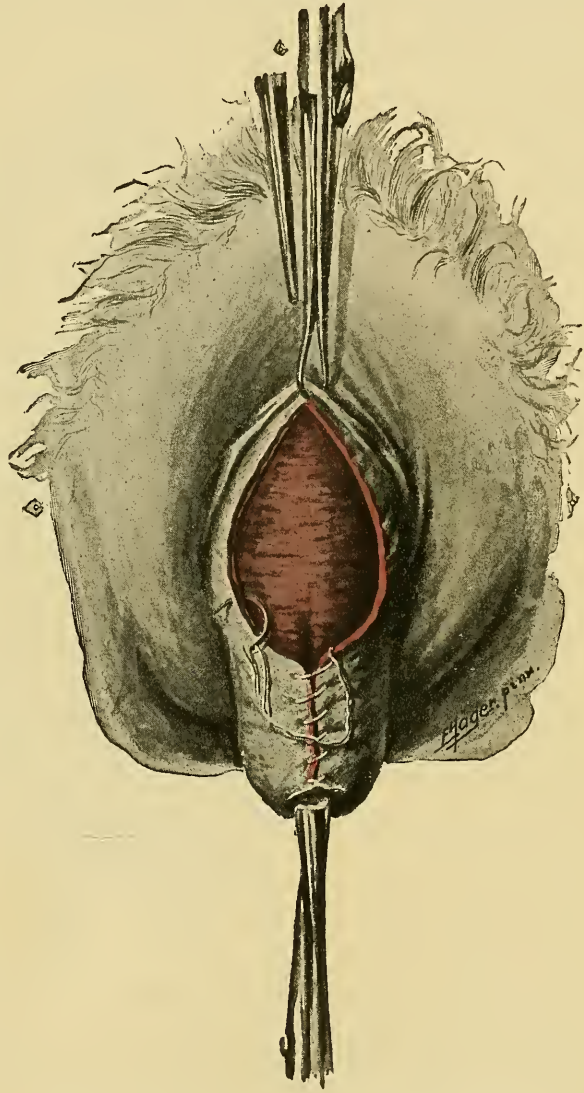


FIG. 73.—Suturing in Colporrhaphia Anterior.

H-formed lumen of the vagina (Fig. 1, p. 2). The lateral walls remain as remnants of *Müller's* ducts. The coalescence of the same in the median line produces anteriorly and posteriorly those tissue masses, reinforced with abundant fibrous strands which we can plainly see and palpate in the *columna rugarum anterior* (whose lower end forms the urethral eminence) and the *columna rugarum posterior* of extrauterine life before their

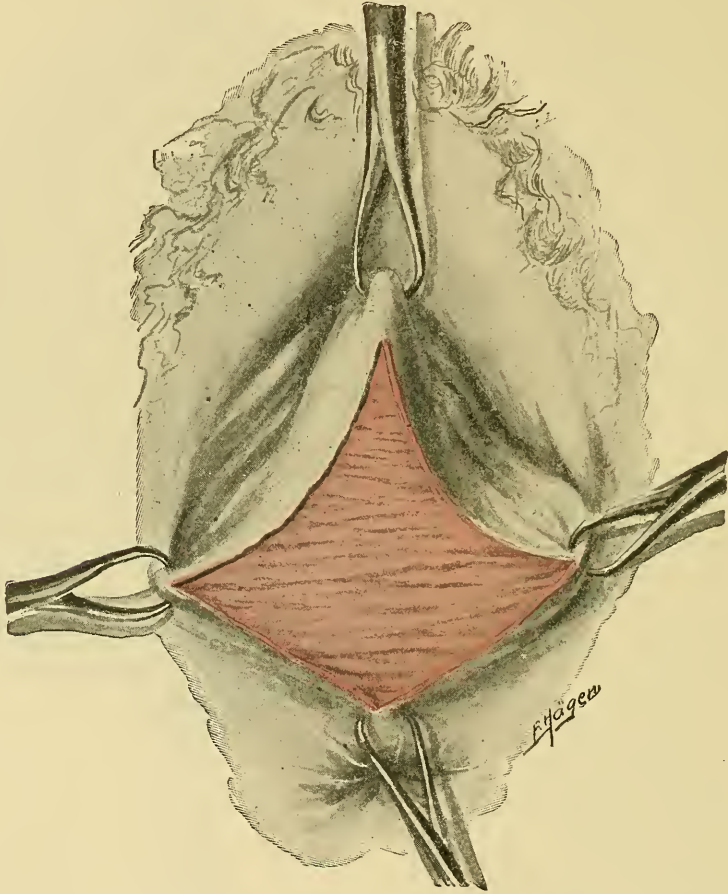


FIG. 74.—Colporrhaphia Posterior after *Hegar*.

folks have become obliterated by frequent cohabitation and many labors. But even if these folds of the vaginal mucous membrane have been smoothed out we can point out the fasciculi of the fibrous strands. I make use of these ***tough tissue masses for the support of the posterior vaginal wall, to be newly formed, cut into the sides of the same, and loosen the mucous membrane from this incision laterally and upward to about the middle of the lateral vaginal walls.*** Two wound-surfaces are thus created in the posterior vaginal wall above the introitus vaginæ,

which about correspond to the lower portion of the remnants of *Müller's* ducts. The margin of the *columna rugarum* comes to lie at about half the height of the lateral vaginal walls by the suturing. The *columna rugarum* posterior with its tough tissue masses is thus advanced toward the anterior vaginal wall. As soon as the vagina has been narrowed in this manner, and a firm contraction of the tissues of the pelvic floor toward the median line has been reached through these laterally situated

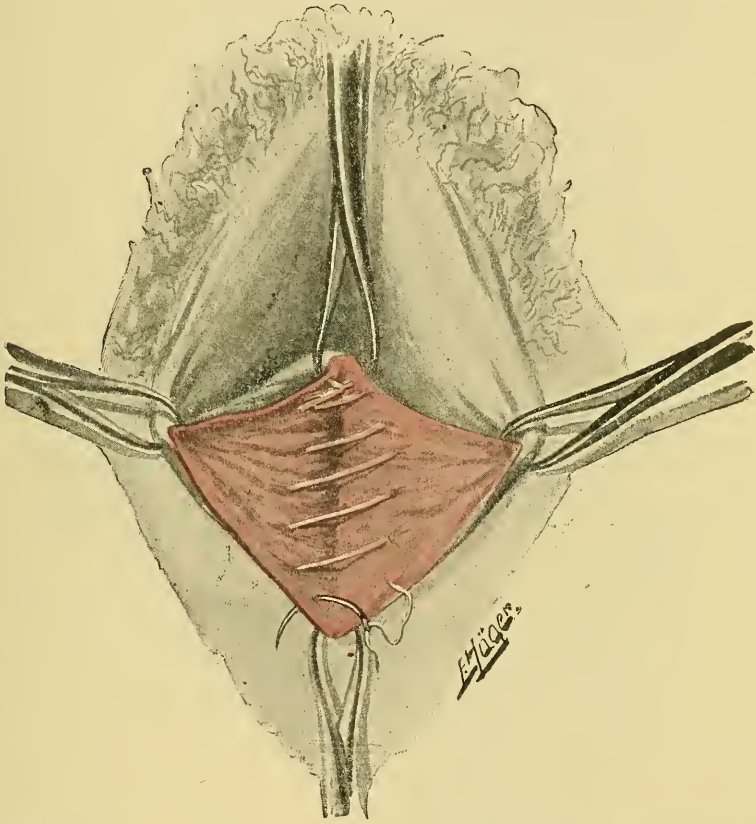


FIG. 75.—Colporrhaphia Posterior after *Hegar*. Suturing with a continuous catgut stitch in rows.

wound-surfaces—a contraction which because it is distributed over two areas prevents healing much less than if it took place only in a single line—the operation is terminated by a corresponding strengthening and enlarging of the perineum.

My method of *colporrhaphia posterior* is therefore composed of two operations, an *elythrorrhaphia duplex lateralis* and a *perineauxesis*.

Elythrorrhaphia Duplex Lateralis.—The posterior vaginal wall is drawn downward with a bullet-forceps attached to the lower end of the *columna rugarum* posterior (Fig. 76). The latter is palpable even in

very old prolapses, if not superficially any more, then deeply. I fix the upper end of the columna with two bullet-forceps, also both lateral ends of the denuded area in the lateral vaginal walls, close to the hymenial

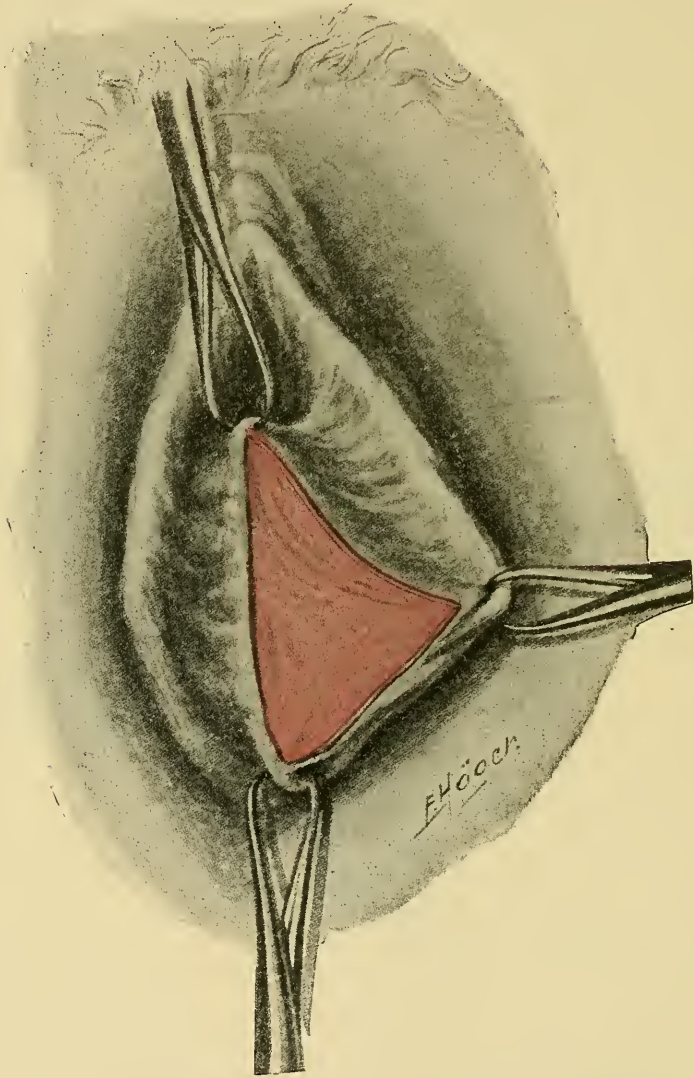


FIG. 76.—Colporrhaphia Posterior (*A. Martin*). Incision of the left lateral fold of the vagina.

ring. After this I make an incision on one side along the edge of the columna down to the lower end, and then from the upper end of this cut to the outer one through the folds of the lateral vaginal walls down to the corresponding bullet-forceps. The lateral circumcised flap of vaginal

mucous membrane is dissected out. The wound-surface is immediately firmly brought together by a continuous catgut stitch (Fig. 77). The same procedure is repeated on the other side. The bullet-forceps are removed, the elythrorrhaphy is finished.

One must, in suturing, see to it that the column is shortened in its longitudinal diameter at the same time that it is fixed to the lateral

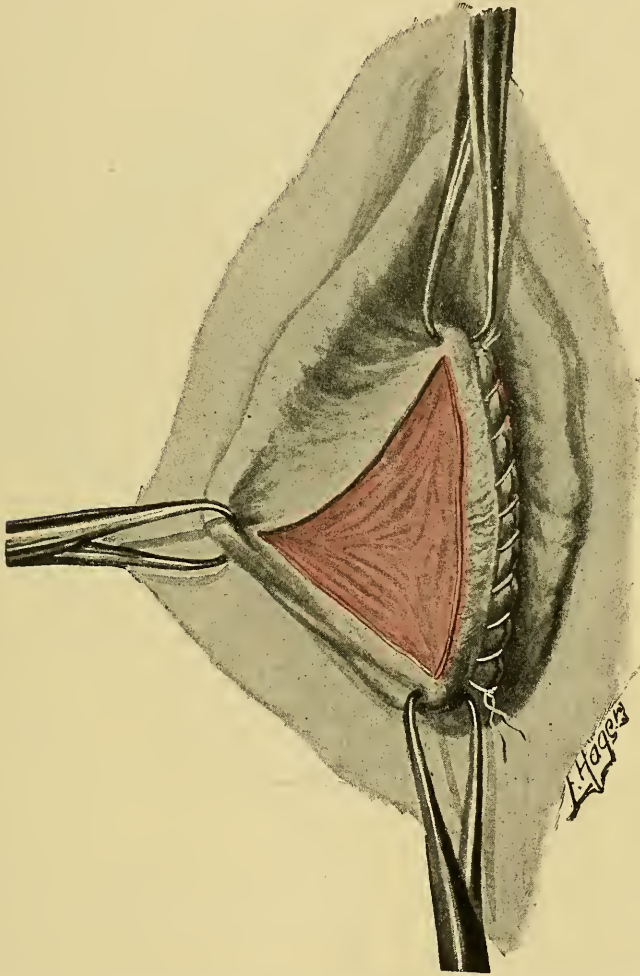


FIG. 77.—Colporrhaphia Posterior (*A. Martin*). Incision of the right lateral fold after suturing the left one.

vaginal walls. One attains this by having the stitches closer together in the lateral wound margin than in the columna.

The *perineauxesis* is then begun by incising transversely the columna rugarum posterior from the lower ends of the elythrorrhaphy incision. The incision is carried laterally to about the lower edges of the nymphæ.

into the vulva (Fig. 78). Finally, the introitus is incised at the termination of the pronaus, so that this incision reaches the other at the termination of the nymphæ. The tissues thus circumscribed are freshened, smoothed, and sutured.

The *stitches* unite first the incisions in the lateral vaginal walls with each other. Correspondingly strong sutures are introduced in the lateral

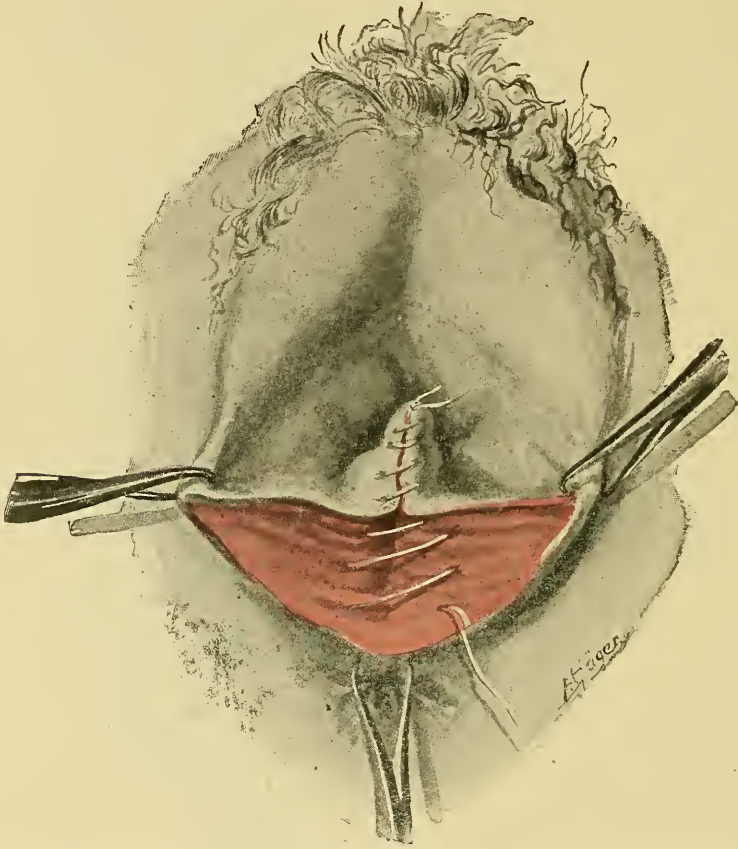


FIG. 78.—Closing of the Colporrhaphia Posterior after A. Martin. Perineauxesis after Hegar. Closure with a continuous suture.

wall, where the circumcission forms an angle between the vaginal denudation and the one in the introitus. The first suture incloses all the tissues, emerges at the lower termination of the columna at about the median line, is introduced close to it, incloses all the tissues of the other half and emerges at the corresponding point on the other side between the vaginal denudation and the lateral denudation of the introitus. The suture is tied, the lower end of the columna rugarum posterior is completely covered from below by this suture, or by an additional suture close to this one. The margins of the denuded surface of the introitus are

thereby approximated so that the coaptation of the wound-surfaces succeeds without difficulty with a continuous suture in two rows. The defect in the external skin is then easily closed. A loose iodoform gauze strip is introduced into the vagina, which hangs down over the external wound. The vulva is protected by sterile cotton.

The patient is put to bed with the *legs bound, but not too tightly*.

Rest in bed for eleven days, then lateral position on the twelfth day, sitting up in bed on the thirteenth day, getting up on the fourteenth, patient is discharged on the seventeenth or eighteenth day. Catheterization is indicated if the patient experiences difficulty in spontaneous evacuation. To promote the passage of flatus, strychnin sulf., 0.01 in three doses (twice 0.003 and once 0.004) is given subcutaneously within three hours on the second day.

The suture material has experienced an essentially technical perfection in late years. The sterilization is executed with different raw materials. I use at present exclusively *Krönig's* cumol catgut. I use braided silk for intestinal sutures, bronze-aluminum sutures for the surface and for suturing the fascia in the abdominal walls, and silver wire, once in a while, for fistulæ.

The metal sutures are removed on the fifteenth or sixteenth day. An aseptic course and *prima intentio* healing form the rule.

If primary failure results due to an infection of the wound during or following operation, *secondary suture*,⁸⁸ after the expiration of the first reaction and the development of healthy granulations (eight to twelve days after operation) offers not unfavorable prospects.

Energetic scraping of the wound-surface, trimming of the wound-edges. Exact approximation of the wound-surfaces. I like to introduce three to five metal sutures (retention sutures) then a continuous catgut in rows one after the other, and finally coaptation of the mucous membrane and skin surfaces, thus insuring correct coaptation.

Recurrence through yielding of the supporting tissues requires a new operation after general treatment and care corresponding to their anatomic conditions. At this new operation I extirpate the uterus in desperate cases, especially in old women.

Sexual intercourse is deferred three months, as well as hard labor. After their discharge (seventeenth or eighteenth day), the patients are directed to use vaginal douches with acetic acid (1 to 3 tablespoonfuls to 1 litre of water) or a solution of iodine (tinct. iodi, 25.0; kali iodi, 5.0; aquæ, 170.0, 1 tablespoonful to 1 litre of lukewarm water) or any other disinfectant or astringent. Sitz-baths are ordered after another week, when they prove agreeable to the patient.

While it seemed justifiable in 1893 to introduce at this place a report on the frequency of primary union in operations for prolapse, at present an examination of the *permanent results* possesses greater importance.

The permanent results of operations for prolapse depend on the one hand on primary union and the recovery of good general nutrition; on

the other hand on the absence of the harmful influences above mentioned, to which younger women are naturally subjected through the possibility of a pregnancy, older ones through senile changes. To prevent the former is the task of the physician, the second cannot be prevented, in spite of energetic care and mode of living. The radical proposition to combine with the prolapse operation in young women a sterilization, in view of the dangers of pregnancy, can only be justified under very restrictive conditions. I have not found this indication as expressed in 1 per cent. of my prolapse operations (nearly 3,000 cases).

We must reckon with the danger of a renewed procidentia. The material of a private practice shows how far we can succeed with careful asepsis and after-care. I have obtained an objectively good permanent result in 93.1 per cent. and a subjectively good result in 90.8 per cent. during an observation period of more than four years.

The material in the literature has been compiled in my report for the Würzburger Kongress, 1903 ("Verhandlung der Deutschen Gesellschaft für Gynäkologie," Bd. X), from the communications of a great number of operators. A simple statistical conclusion could not have been drawn, because the material at this time had been controlled too unevenly. A period of more than four years of personal observation and control of the patients by the operator is essential for the collection of subsequent reliable statistics for which also groups of cases subjected to nearly equivalent methods should be put together. The results it is confidently expected will improve. The old cases of the time of defective asepsis must be excluded. The cases of early operation with simple plastic procedures on the uterus, vagina, and perineum should be grouped together and, on the other hand, the cases with extensive old prolapse with severe complications which could only be dealt with by extensive operations.

While, as a rule, a sufficient support for an extensive rectocele in the prolapse of the posterior vaginal wall can be created by all the methods of colpoperineorrhaphy through the utilization of the pelvic connective tissue, the median coaptation of the stumps of the ligamenta lata, the tightening of the levator ani and the building up of the septum rectovaginale, an elytrorrhaphia anterior often proves comparatively ineffectual. Besides the older methods mentioned the attempt has been made to strengthen the basis vesicæ by a more careful reefing, for instance also by purse-string sutures. *Pasteau* forms a longitudinal fold in the lower bladder wall by suturing the anterior vaginal wall; the vesical mucous membrane stands out above this in a similar manner. *Marsi* makes, by a sort of bilateral flap splitting, two flaps like the two folds of a folding door in the anterior vaginal wall, which has been incised longitudinally in the median line; he overlaps these to form a strong columna, a procedure which resembles the one which I practised successfully for more than ten years in conjunction with the colpotomia anterior.

Winter,⁸⁹ *A. v. Arx*, *Gersuny*, also *Sänger*, made use of the cervix uteri for the support of the denuded basis of the bladder. *Hadra* oper-

ated similarly in vaginal operations; *Dührssen* supported it by the body of the uterus tilted forward and downward. *Hanks, Loroyenne, Reynier, Kreuzmann, Stone*, go still further in separating the bladder from the cervix through an abdominal coeliotomy incision, then suturing the bladder upon the corpus and fundus, and fixing the uterus to the abdominal wall; the first two named supplemented already in 1899 this operation by an extensive plastic of the perineal body, the others also followed them.

The method which *W. A. Freund* published in 1897 apparently obtained its results from the lasting action on the bladder, though the support of the bladder by the uterus is thereby not put in the foreground but that of the anterior vaginal wall. In old non-menstruating women the corpus uteri is tilted downward into the posterior vaginal vault after a colpotomia posterior, its posterior denuded surface is fixed to the denuded anterior vaginal wall, and the anterior denuded wall to the posterior vaginal wall. A new os uteri is made in the downward directed fundus. *Wertheim* found the fixation of the anteriorly tilted uterus with its posterior surface to the anterior vaginal wall to be sufficient, and saw a distinct advantage in the possibility of preserving the function of the uterus, and through this the capability of cohabitation in comparison with *Freund's* procedure.

Schauta placed the uterus not in the vagina but in the anterior vaginal wall, fixed the bladder, respectively the peritoneal coat upon the posterior surface of the uterus, and sutured the vagina to the anterior wall of the uterus, a procedure which is also practised by *Pfannenstiel*. I had very unsatisfactory results with this method. I found the uterus retroflexed again after three months in a well-to-do, well-nourished farmer's wife, who performed no hard labor.

Late control examinations prove that the doubts which were entertained concerning this procedure are justified. The flabby and unfirm uterus descends lower and lower even after *torsion* of its ligamenta cardinalia; the fundus appears at the introitus as an extremely troublesome foreign body and causes constant discomfort.

Further attempts to use the uterus as a support for the prolapse operations by way of the vagina were made by *Péan*, who thought he could retain the uterus in the lateral fornix by a heavy scar, which he formed with two rows of vaginal sutures, which remained until they cut through. After this a colpoperineorrhaphy would be sufficient for a retention. *P. Müller*, in consequence of the unsatisfactory final results of ventro-fixation which he at first made use of, used this plastic in such a way that he scarified the vaginal fornix and the upper half of the uterus; he then dissected the uterus from the vagina, and sutured the uterus by displacing it downward in the funnel thus made from the vaginal vaults and walls; finally, he amputated the cervix if necessary. The external os uteri came to lie close to or even in the introitus vaginæ. Entirely satisfactory and lasting results were obtained by this method, according to the reports by *Varnier, Chiarleoni* and *Prunas Tola*; also *Stocker* and

Spinelli (Prinzivalle) have operated in a similar manner (*Spinelli* even demands a castration in the young, to prevent the dangers of conception). They formed triangular denudations of the vagina, the apex pointing downward, in which the stump of the partially excised cervix was fixed.

The method of retrofixation of the cervix uteri, as proposed by *Sänger* in 1891 at first for the treatment of retroflexion finally points the way to a plastic use of the uterus for the support of the prolapsed genitalia. Already *F. Frank* and *Stratz* penetrated upward through the cul-de-sac of *Douglas*, doing the flap splitting for the purpose of a colpoperineorrhaphy and resected eventually also the peritoneal cavum *Douglasii*. *Ruggi* (1894) appears to have been the first to advance in this direction. He incised the anterior and the posterior vaginal vaults, detached the peritoneum from the excavatio-vesico and recto-uterina, resected the superfluous portion of the peritoneum and then sutured the edges of the peritoneal coats of the rectum and bladder to the corresponding edges of the anterior and posterior serosa uteri after the suggestion of *Fabris*; *Spérling* took the same course. *Pagenstecher* concluded with a colpoperineoplastic. *Byford*, in very severe cases, in which the peritoneal duplications as well as the entire apparatus of ligaments, are relaxed, shortens the ligaments and sews up the stump after a cœliotomy. The round ligaments are stitched to the inner abdominal wall above and toward the median line from the inner abdominal ring, the ovaricopelvic ligaments to the abdominal wall externally to the inner abdominal ring. The broad ligaments are fixed above the bladder, the sacro-uterine ligaments at the sides of or to the cervix. He declines to use the round ligaments in this plastic. However, he attempts to narrow the lumen of the vagina by cicatricial contraction caused by longitudinal cauterization of the entire vagina.

Such heroic operations naturally always concern an extensively developed procidentia with extensive relaxation of the pelvic connective tissue and peritoneum, with a destruction of the vaginal outlet and a dissolution of the support and the relations of the pelvic organs with each other. The organs themselves are very rarely unchanged pathologically, their physiologic functions are many times destroyed or extinguished through senility. The displacement of the vagina and the cervix uteri externally from the pelvis offers chances for deep-seated decubital ulcer formations and chronic conditions of irritation. The prolapsed portions not rarely are interspersed with newgrowths, and chronic inflammatory processes in the adnexa and the peritoneum frequently complicate the affair, and extensive adhesions frustrate all attempt at reposition and retention. These are the cases which have been held to require a removal of the uterus. *Kaltenbach* (1880), myself and *Fritsch* have operated according to this indication. It has apparently found a rapidly increasing recognition during the last ten years, especially with our French confrères. *Bumm* and *Pozzi* on the one side

were content to remove the uterus as the hindrance to a reposition and retention and then followed with a colpoperineoplastic after one of the known methods, while others have proposed, especially in later years, to fuse the stumps of the ligaments and the peritoneum with a corresponding resection of the superfluous tissues, so that a support for the vagina is created thereby. It suffices then only to narrow the vaginal outlet by a perineoplastic.

To this class of operations belong the trachelopexie intraligamentaire of *Jacobs* and the procedure of *Quénu*, who attaches great importance to the removal of the diseased adnexa and the suturing of the stump.

In Germany *Fritsch* was the first to enter lastingly upon this course, by resecting, after a vaginal extirpation of the uterus, an extensive part of the vagina from the vaginal fornices down. That we are able to detach the vagina *in toto* in a comparatively simple manner, is shown by the many-sided experiences in the extirpation of the carcinomatous vagina.

The question was now whether a useful result could be obtained in cases of advanced procidentia on account of the extreme flabbiness of the pelvic connective tissue. Experience in total extirpations of the uterus with resection of the vaginal vault is not in favor of such procedure. My tests have been undertaken in senile persons, widows or old virgins (in 1891). Such cases are involved in which it may be said that the pelvic organs as a whole have lost citizenship in the pelvis. In the bag of the vagina, larger than two fists, and hanging before the external genitalia, was contained the bladder, the uterus almost completely, or so that only a small and at all events not normally formed portion was still in the pelvis; a larger diverticulum of the rectum and besides this the adnexa of both sides. These structures were united with each other through peritonitic adhesions. It was impossible to replace the mass, there was no chance of retaining or of rebuilding the pelvic closure apparatus, while the hope of retaining these organs in the pelvis by shortening or resection of the relaxed ligaments and the peritoneum was excluded.

Extirpatio Uteri et Vaginae.—After forcible traction upon the entire prolapse, which lies *in toto* before the vulva, with a *Muzeux* tenaculum forceps attached to the portio vaginalis, a circular incision is made in the traces of the hymenial ring, especially also about 2 cm beneath the urethral opening. Division of the posterior vaginal vault through a vertical incision beginning at the attachment of the fornix to the cervix. Opening the excavatio recto-uterina and division of the peritoneum down to about 1 cm from the rectum. The posterior vaginal wall is divided down to the circular incision around the hymen, suturing the wound thus made with a sweeping stitch, extending from the peritoneum, beneath the wound-surface through the skin border in the vulva, with a catgut buttonhole stitch. Detachment of the vagina on the left and the right to about half of the height of the vulva, that is about the height of the

openings of the ducts of the glandulæ vestibulares majores, dissecting of the peritoneum *pari passu*, always suturing the wound-surface before cutting, to prevent loss of blood. Division of the anterior vaginal wall, which is stretched by forcible pulling of the cervix uteri downward, up close to the anterior vaginal vault, detachment of the anterior vaginal wall from the anterior periphery of the circular incision upward to about one-half. After loosening (peeling) of the anterior vaginal fornix from the cervix to the neighborhood of the bladder, the fundus of the uterus is retroflexed and delivered through the cleft in the posterior vaginal vault. The index finger of the left hand is brought forward into the

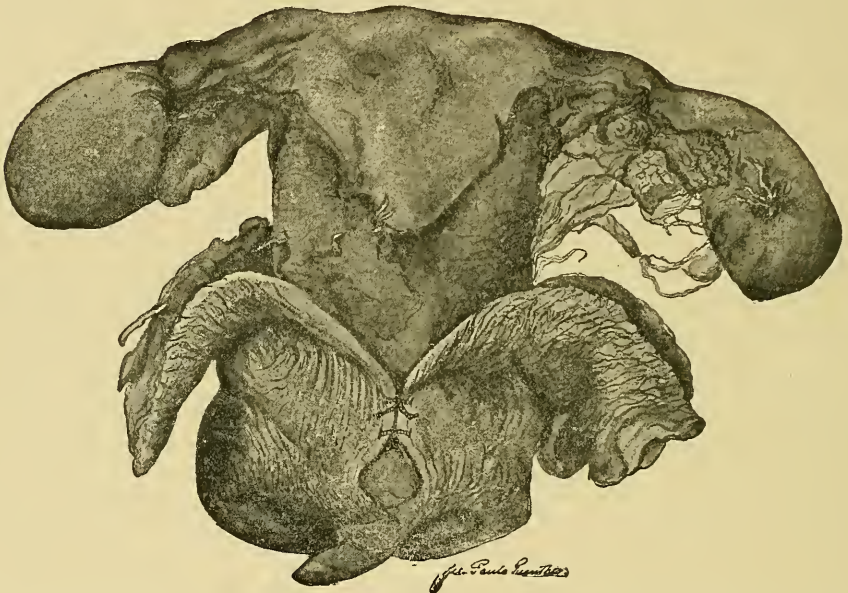


FIG. 79.—Preparation of Prolapsed Uterus, which was Extirpated with the Vagina and the Adnexal Organs.

excavatio vesico-uterina and the union of the bladder and the cervix is thus marked. Opening of the plica peritonei, whose cut edge is immediately united with the corresponding portion in the circular incision beneath the external opening of the urethra. The suture is introduced underneath the entire wound-surface of the anterior vaginal wall, respectively the bladder. Going to the right and left of this marked suture, the anterior vaginal wall is freed from the bladder and the peritoneum is incised, followed with an immediate suturing of the peritoneum to the corresponding portion of the circular incision in the vulva partially before and partially after the severing of the tissue structures. The uterus with its adnexa is suspended from the ligamenta lata. Detachment of the vagina up to the pars cardinalis of the ligamenta lata. Ligation of the ligamenta suspensoria ovarica. Detachment of the ovaries and

the tubes. Tying off of the pars cardinalis in several sections running through in such a manner, that small stumps of the ligament remain behind, but so that these stumps from both sides can be united with each other in the median line. Cutting off of the stumps under exact hemostasis. The bladder is pushed up immediately after opening of the plica with a retractor and forced upward behind the symphysis pubis. The bladder is not evacuated before this operation, it moves far out of the operating field in its half-filled condition. In none of my operations did the bladder or ureters cause any difficulty.

A funnel remains after the removal of the entire prolapsus (Fig. 79) which falls in rapidly. The intestines are held back by tampons, if they do not disappear from the field of view by an inclination of the upper part of the trunk (tilting of the operating table). The wound-cavity is closed by a transverse union of the stumps of the ligaments by means of deep catgut stitches and sewing up the peritoneal edges drawn down into the vulva to each other. Finally, the posterior portion of the vulva starting from the perineum is freshened and closed up after the manner of the perineauxesis. The bladder is then emptied and a retention catheter introduced. After-treatment the same as after all prolapse operations.

The results of the operation are absolutely favorable. The operation causes an insignificant loss of blood. The primary results are satisfactory, also the remote results, because finally a very tense scar is formed so that the subjective state of health has been absolutely satisfactory in all cases reexamined by me, even when after several years a scar as large as a quarter piece became visible between the labia underneath the urethra.

The joy of life and the ability to work were restored as far as one could expect in such old women.

The number of women operated on in this manner is at present still small, the duration of observation is not yet extended so that the last word can be said about the operation as the *ultima ratio*. Eighteen of twenty-two belong to the hard working class, all are naturally senile, corresponding to their years of life.

III. Laceration of the Perineum—Perineorrhaphy

Injuries of the perineum arise with predominant frequency during labor, only rarely in consequence of injuries sustained otherwise, as a fall, a blow, during forced sexual intercourse,⁹⁰ or during the removal of newgrowths.⁹¹

The coaptation of the wound-surfaces should always be done immediately after the occurrence of the laceration of the perineum. The opposing view of *K. Hegar*⁹² has not found any adherents. Occasionally unsurmountable obstacles to an immediate operation are met with in practice on account of the immediate exigencies of the injured person.

In other cases the prospect for a union of the forcibly separated tissue masses is obscured through gangrene or through puerperal diseases. This explains the reason why lacerations of the perineum come comparatively late for observation and operation and long after cicatrization has taken place. Older physicians also saw in nursing a contraindication for a plastic operation. The first attempt at repair, at times, proves a failure, and the second one is postponed indefinitely. I have seen the most disfiguring scars after dissection of the perineum according to *Dührsen's* method. A not rare cause for postponing the operation finally is the inattention of the attending nurse and the indolence of the patient. The patients seek relief when further symptoms are later associated with the defects of the pelvic floor.

The perineal lacerations are *incomplete or complete*.

1. ***Incomplete Lacerations of the Perineum.***—The perineal body, as a rule, tears in the raphé perinei from the commissura posterior as far as close in front of the anus. In the vagina the tear runs inward mostly in the median line up to the lower end of the columna rugarum posterior, and surrounds this on one or both sides. The tear runs farther upward, with remarkable frequency along the side on which the occiput is delivered. It only rarely breaks through the columna rugarum and tears a part of it. The tear may circumscribe the columna on both sides in isolated cases, reaching higher on one side than the other. A dense scar tissue, conspicuous by its whiteness, takes the place of the commissure in the scar formation, whose radiant branches deform the surrounding parts in an irregular manner. Thick puffs (rolls) of skin project from the branches of scar tissue. The scar may limit the capability of expansion of the anterior tissues of the rectum even when the intestine is uninjured and thus hinder, to a certain degree, the evacuation of the bowel. The introitus gapes, the lateral and anterior and posterior vaginal walls puff out, and a procidentia of the lower vaginal wall with the formation of a rectocele takes place.

2. ***Complete Laceration of the Perineum.***—The bowel is split in the middle of its anterior periphery. Higher up the tear follows the course which the injury takes in the vagina. The retraction of the scar tissues leads to an extensive gaping of the rectum. The stumps of the sphincters retract decidedly, the ectropic mucous membrane is highly reddened, and an extensive prolapse of the mucous membrane may occur. The bowel is rarely torn more than 5 cm. More frequently only a portion of the sphincter is lacerated, so that the bowel is opened to the extent of only 2 to 3 cm. Prolapse of the uterus occurs remarkably seldom in extensive lacerations of the perineum, and marked destruction, as the uterus and with it the entire pelvic floor is held firmly by exudates in the pelvis as a consequence of difficult deliveries.

In isolated cases the laceration does not involve the bowel in the median line, but runs around it on the sides, so that the lumen of the bowel is opened laterally. Still more rarely does the injury leave the

gut intact and extend laterally and backward to near the os coccygeus, thus lacerating the posterior portion of the perineum.

Symptoms of Laceration of the Perineal Body.—Laceration of the perineum seldom leads to immediate and severe hemorrhages.⁹³ The non-puerperal perineal injuries strangely heal more firmly than the puerperal ones. One sees women with extensive injuries of the perineum tide over all difficulties of cicatrization without any medical assistance. They gain gradually a certain control over the rectum and do not complain. On the contrary others complain even with quite insignificant injuries of the perineum, before a chronic condition of irritation in the lower portion of the vagina or even a real prolapse has taken place in consequence of the open condition of the introitus. They have intolerable difficulties, which prevent them from walking or even standing, incapacitating them for any work and making their condition tolerable only in a quiet, dorsal position. Further symptoms of laceration of the perineum depend essentially on the disturbances of the coherence of the pelvic floor. If the pelvic floor cannot any more support the uterus, the bladder, and the intestines; if the vaginal walls turn down into the lumen of the vagina, then the extremely painful sensation develops of a state of openness of the vagina and the fear that the abdominal organs will slip out. The signs of descensus and prolapse of the vagina and the uterus also occur with an incomplete laceration of the perineum. If signs of irritation of the lower portion of the vagina in consequence of a defective closure of the introitus vaginae are added by moistening with urine and feces, and by the entrance of dust, then even incomplete perineal lacerations may cause quite considerable difficulties. The difficulties increase until they become intolerable, if with a **complete perineal laceration** control of the rectum is lost, if not only fecal masses but above all flatus, pass involuntarily even if only from time to time. These women are then subjected to an intolerable condition and sink into a melancholic state of mind.

Prognosis.—An improvement without a restoration of a normal relation of the parts to each other cannot be expected, though incomplete lacerations may at times heal spontaneously during the puerperium. A cure can only be expected from a plastic operation.

Different directions hold good for the operation for laceration of the perineum depending on whether the laceration is treated immediately after its occurrence or a long time afterward.⁹⁴

1. **The recent perineal laceration** is undoubtedly best treated by an immediate union of the freshly separated parts in their former relation. If possible the patient is to be anesthetized (lumbar anesthesia or inhalation narcosis). Women just after labor are so exhausted that they do not experience any pain from the operation, or they patiently stand the few stitches. Anesthesia has the advantage, that one can place the patient in any desirable position. After cleansing and smoothing the wound-surface, the parts belonging together are coaptated and united by

deep stitches not too close to each other, so that no cavities remain between the wound-surfaces. Corresponding to the course of the laceration the sutures enclose the columna rugarum from the side, if it runs laterally to the latter, and close the raphé perinei and the posterior commissure through subcutaneous catgut stitches.⁹⁵

Suturing with a *continuous catgut stitch* is essentially simpler. It is important to shorten the operation on the exhausted woman, bathed in

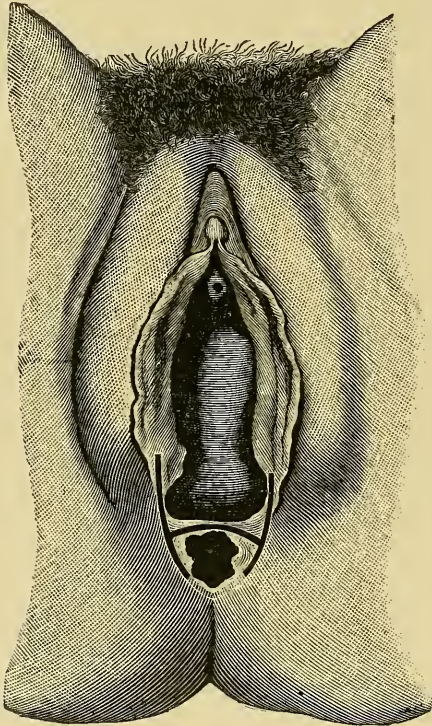


FIG. 80.—Flap Splitting Method, after
L. Tait.

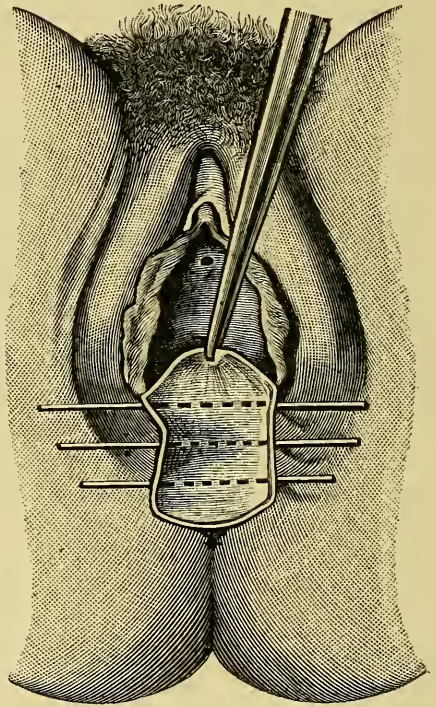


FIG. 81.—Suture After the Flap
Splitting.

perspiration, and secure safety from irritation by the lochial secretion. The method of introduction of the suture depends on the extent of the laceration; the wound is united from the bottom up with one or several rows, before the external wound is closed.⁹⁶

These recent puerperal wound-lines are best irrigated only externally during the progress of healing. The lying-in woman must remain in the dorsal position up to the fourteenth day, the external stitches are removed on the tenth or twelfth day if non-absorbable material has been used.

2. The same directions hold good for many of the operations for *cicatrized incomplete perineal lacerations* as have been described for the operation of colporrhaphia posterior.

The *method of flap splitting*, as it was introduced in 1880 by *Lawson Tait*,⁹⁷ has been accepted by many operators. The procedure, which was pointed out first by *v. Langenbeck*,⁹⁸ then in another form by *Wilms*,⁹⁹ *Staude*,¹⁰⁰ and others, has been developed by *Sänger*,¹⁰¹ who rendered meritorious services in the most productive manner for the history, rationale, and execution of this procedure, and in England by *Alex. R. Simpson*,¹⁰² in France by *Doléris*.¹⁰³ *Fritsch* also enters actively into it in his text-book. Figs. 80 and 81 show the method of *Tait* and *Simpson*.

I have described my experience with the flap-splitting method in the *Berlin. klin. Wochenschr.*, 1889, No. 6. I gave up the method entirely because I observed that the patients experienced troublesome and not unimportant difficulties on part of the rectum. A pocket formed in the anterior rectal wall, in which fecal matter accumulated which could only be evacuated with a great deal of exertion. A recto-perineal fecal fistula was formed in two cases by the forcible attempt at expression. I had to dissect out the scar in both cases and replace it by an ordinary rectoplastic operation.

I operated on complete perineal lacerations at first by the method of *Hegar*.¹⁰⁴ Afterward under the impression made by the exposition of *W. A. Freund*,¹⁰⁵ I always endeavored in these perineal operations to unite the parts belonging together anatomically, thus preserving the proper support of the posterior vaginal wall, that is the *columna rugarum*.

Operation for Incomplete Perineal Laceration

General or lumbar anesthesia, dorso-gluteal position, continuous irrigation with a 1 per cent. table salt solution. The upper limit of the perineal injury is caught with a bullet-forceps and drawn up and into the introitus as far as possible. If the old scar is situated laterally to the *columna rugarum*, then the bullet-forceps are attached to the corresponding lateral sulcus, if it is situated in the median line the forceps are attached to this. The vagina is stretched with two tenaculum-forceps, where the laceration runs out into the median line at the lower end of the *columna rugarum* posterior, one forceps attaches to the end of the column, the other to the opposite lateral vaginal wall. The scar is outlined between the bullet-forceps and dissected out. The smoothed wound-surface is closed by sutures.

The linear scar thus made, terminates at the lower end in the middle of the *columna rugarum*. The tenacula are removed and the vaginal walls that have been drawn downward are replaced in their usual position.

If the *columna* is surrounded on both sides by scar formations, then one dissection follows the other, just as in prolapse operations.

A skin flap is dissected off for the formation of the perineum proper, which reaches above to the *columna rugarum*, below to the lower limit of the scar tissue, just in front of the anus. The lateral limits extend along the end of the *labia majora*. The denudation terminates upward

at the lower end of the nymphæ. If the scar is irregular then the denudation outline follows this irregularity.

The bullet-forceps are attached to the lower end of the columna, to the lower limit of the scar in front of the anus, to the lower end of the nymphæ, and between these the operation area is stretched. The same is circumcised along the limits pointed out by the forceps, and the circumcised flaps are dissected out *in toto*. The wound-surfaces are trimmed, in which the continuous irrigation assists naturally by pointing out plainly unevenness in the wound-surface.

The suturing commences at the upper wound-angle in the columna. Two to four interrupted sutures are sufficient to unite the wound-edges down to the place where the wound is too broad to be drawn together without difficulty. Then the continuous suturing begins. The first stitch of the continuous suture is tied, it also includes the wound-edges in the vagina. Now the first row of sutures are introduced uniting the deeper parts in the median line. This is followed by a second row, in case the external wound-edges cannot yet be coaptated without pulling.

I use only cumol catgut for the continuous suture and usually use one stitch for the vagina and one for the perineum. The external skin incision in the perineum is closed with 5 to 6 aluminum bronze sutures in extensive plastic operations. These are covered with iodoform gauze strips, which are fastened with collodion after cleansing of the suture-wound with ether.

Operations for the Complete Laceration of the Perineum

In the operation for complete laceration of the perineum one must aim first *to restore the bowel and vagina* and then *to build up the perineum*. The denudation may be extremely difficult if cicatrix formation is very extensive, the defect large and the rectal mucous membrane considerably distorted. Moreover it bleeds very easily.

A careful preparation of the patient is indispensable, so that the contents of the bowel do not press forward during the operation.

General or stovain lumbar anesthesia. Lithotomy position. The denudation in the vagina must reach 2 to 3 cm above the apex of the laceration in the rectal wall. Scanty depth of the septum at this place renders the suturing very difficult and endangers the results, as experience shows, by the formation of a recto-vaginal fistula. Then I circumcise the *remainder of the scar tissue*. The edges are stretched by tenaculum-forceps, which are attached to the apex of the columna, to the lower end of the nymphæ, and finally where the edge of the anus is recognized by the scar (Fig. 82). All cicatricial tissue is carefully removed within this outline.

The beginning of the continuous suture is tied in the vagina at the columna rugarum. The first loop of the sutures is to lie in the septum. The assistant draws on the suture and thus expands the septum broadly.

The bowel is closed by suturing, so the needle does not touch the mucous membrane but penetrates close to it. I usually come out with the needle close to the right edge in the rectum, then I stitch into the left close to the mucous membrane, enclose a healthy mass of tissue and come out on the left side about half a centimetre from the edge of the rectal mucous

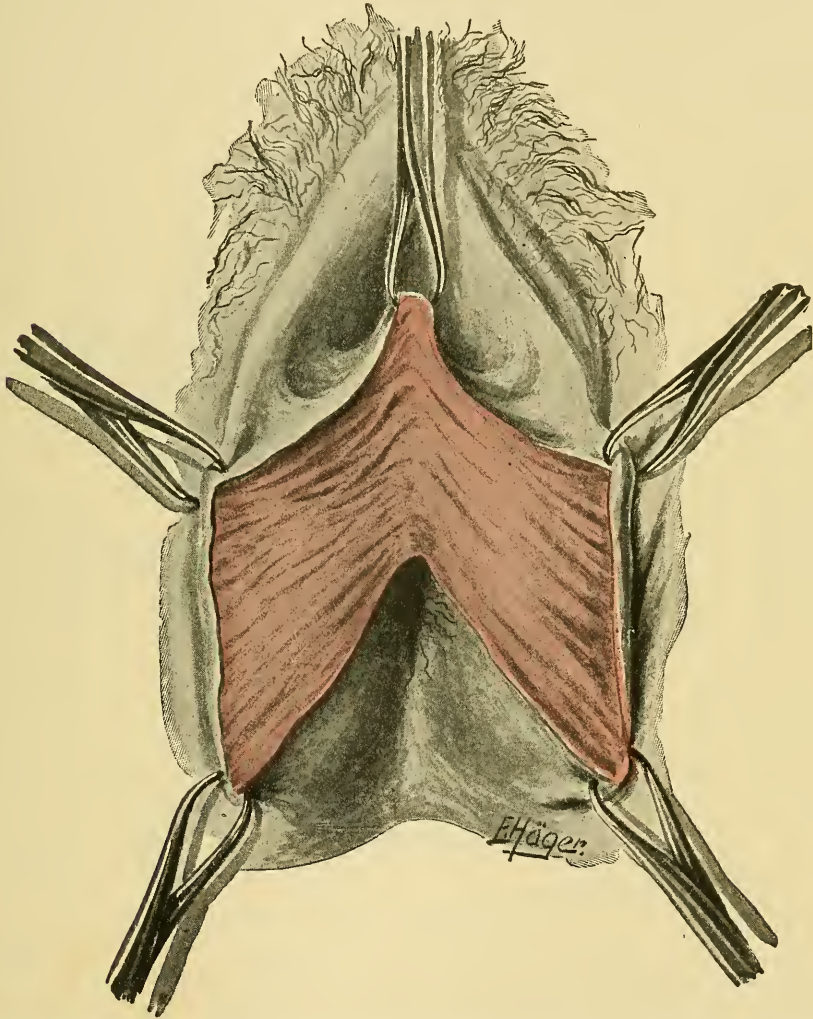


FIG. 82.—Suture of the Complete Perineal Laceration. Stretching of the wound edges and denudation.

membrane. The needle is reintroduced close to this stitch on the left side, runs beneath the wound-surface to the right and is brought out again. It reenters close to this point, that is, on the right side, to come out at the edge of the wound in the mucous membrane (continuous mattress suture, Fig. 83) in its entire extent.

As soon as the rectum is closed down to the anus, the first row of stitches is made by the same suture running backward, that is from the perineum on upward into the recto-vaginal septum to the upper wound-angle. If this row of sutures is sufficient for the coaptation of the wound-surfaces then the edges of the vaginal mucous membrane are coaptated and finally the skin incision in the perineum is closed (Fig. 84). If the wound-surfaces are too extensive, then a second row of

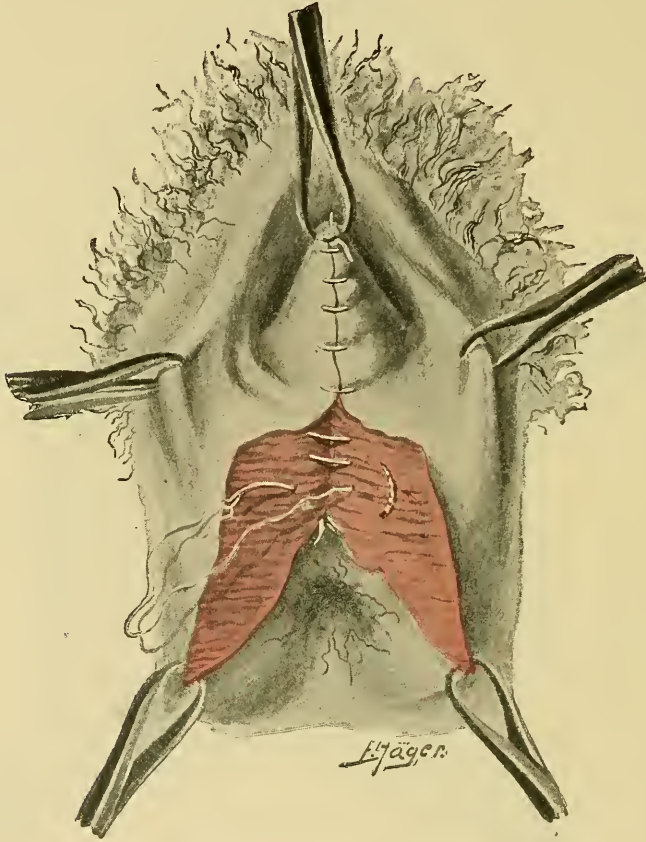


FIG. 83.—Suture of the Rectum.

sutures is formed, before the vaginal mucous membrane and skin are closed, which latter can be done then, as a rule, very easily.

If *interrupted sutures* are used then two or three stitches are introduced through the rectum and they are tied on the rectal mucous membrane, then the rectum and the vagina are stitched up one after the other. If the sutures from the rectum and vagina are introduced so that they interlock with each other at their deepest places, and the rectum is finally closed, then only the lower portion of the introitus remains to be stitched in order to close the vagina completely. The wound-edges which have to be united to form the raphe perinei, lie close together at

this stage of the operation and can be closed easily with superficial sutures through the external skin. One must pay attention so as not to leave any cavities in the depth of the wound.

If the *columna rugarum* is surrounded by the scar, or if the lower end has become detached, then the denudation must make allowance for this condition.

Many different variations in the direction of the incision and stitches have been proposed. The attempt was made to avoid tying of the sutures

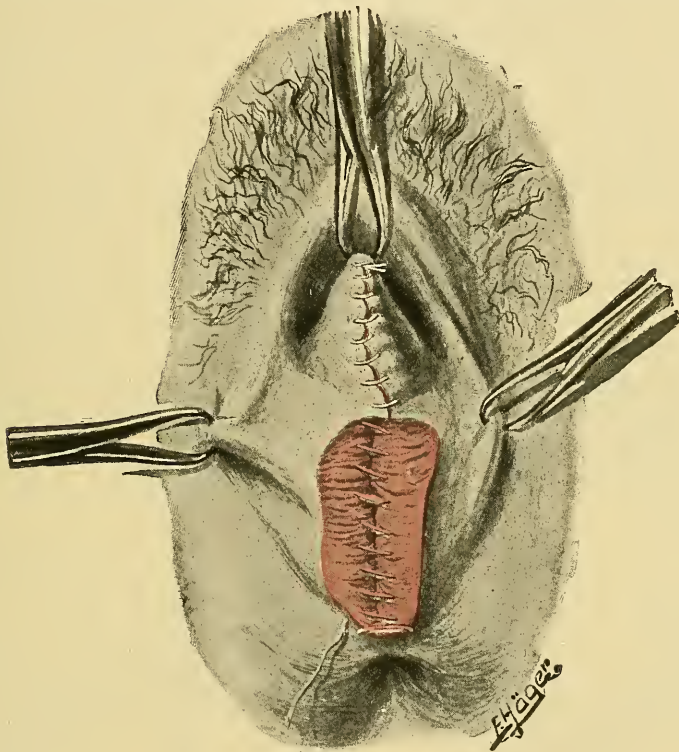


FIG. 84.—Suture of the Perineum after Finishing the Rectal Suture.

on the rectal mucous membrane, and therefore a figure-of-eight stitch was used, which is tied in the vagina itself. *Heppner*¹⁰⁶ has wound metal sutures to a figure-of-eight which were tied in the rectum and vagina. Then it was attempted to introduce the sutures only superficially in the rectum and begin below the uppermost vaginal suture to introduce in the rectum from the perineum, so that thereby the perineum and vagina would be closed. The methods of *Hildebrandt*¹⁰⁷ and *J. Veit*¹⁰⁸ specified for the operation of recent perineal laceration resembles this procedure, the suture being introduced from the perineum. The oblique tying of the wound-surfaces to be coaptated cannot be favorable to a union.

If the interrupted sutures are tied from the vagina, rectum, and perineum, then the septum becomes very narrow. The continuous catgut stitch avoids this disadvantage entirely by the different rows of sutures.

A thin rubber tube is introduced into the rectum after the termination of the operation to facilitate the passage of flatus. Strychnia, 0.01 in 3 doses, is given hypodermatically on the second day to facilitate the passage of the gas, oleum ricini is given on the seventh day. As soon as it begins to act an oil enema is given through the retention rubber tube to soften the fecal masses. The rubber tube is expelled along with the stool. The patient is made to move the bowels every other day thereafter.

The patient must remain quiet for twelve days before the healing is sufficiently advanced to allow sitting up. External douches are given only after urination and defecation.

If union does not result completely *per primam* then the granulations are scraped off with a sharp spoon, according to the suggestion of *J. Veit* (l. c.), and a **secondary stitch** is introduced. The patient must again remain in the recumbent position thereafter for at least another twelve days. I have not yet observed a failure after such a secondary suture.

Vaginal douches, with tr. iodi, are ordered for four weeks as after-treatment, then douches with acetic acid for another eight weeks. Besides very persistent care for regular bowel movements, I recommend sitz-baths with oak-bark decoction for six weeks after the operation and seek to prevent intercourse possibly for six months.

IV. Inversio Uteri

Inversio uteri originates through an act of pulling on the inner surface of the uterus. The pulling is most frequently executed by drawing by means of the cord on the adherent placenta. This may occur exceptionally on account of an abnormal shortening of the funis (*Dyhrenfurth*). The greatest number of inversions occur through traction on the umbilical cord for the purpose of delivering the placenta. The strict prohibition of this method for midwives has made puerperal inversion a rare occurrence. Mistakes are naturally not yet avoidable.

*Lepage*¹⁰⁹ reports a very unusual example of recurring inversion during the same puerperium. The first inversion, the result of delivering the placenta, was easily replaced. The uterus inverted again after four weeks without any demonstrable cause. Difficult reposition, cure with tamponing of the uterus.

Inversion is only rarely the result of an awkward execution of *Credé's* method. It occurs still rarer in the absence of either condition through irregular contraction of the walls of the uterus or other influences upon the same. Inversio uteri arises beyond the puerperium as a result of an expulsion of intrauterine tumors. Fibromyomas are mostly concerned in these cases, which as polypi excite uterine contractions and are finally delivered spontaneously, drawing down the fundus with their pedicle.

The uterine walls under these conditions are very frequently atrophied or fatty degenerated, especially in the region of the attachment of the polypoid growths.

The beginning stage of inversion of the uterus is rarely observed, on account of the fundus or the respective portion of the uterine wall being strongly drawn and reaching with its inner surface to about the neighborhood of the internal uterine os, the *invagination of the uterus*. The inversion extends either only to the

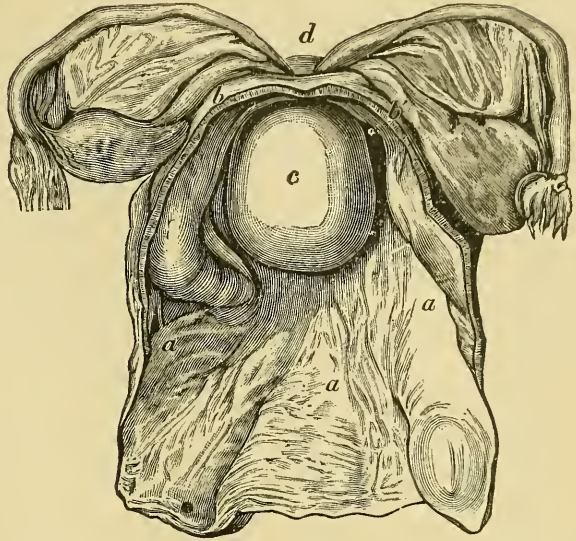


FIG. 85.—*Inversio Uteri Incompleta*. *a*, vagina; *b*, cervix; *c*, corpus; *d* funnel of the inversion.

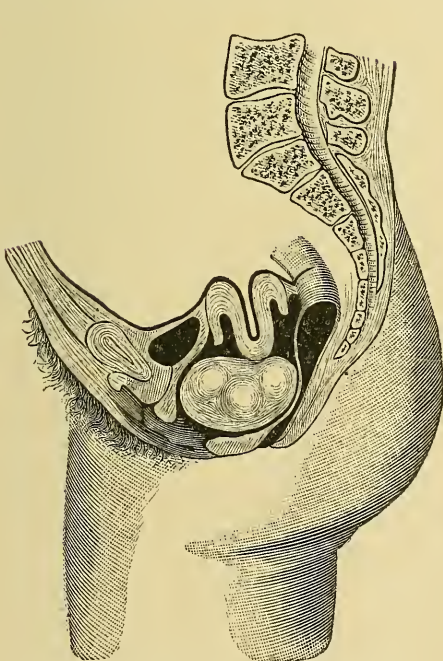


FIG. 86.—*Inversio Uteri Completa*. (Schematic.)

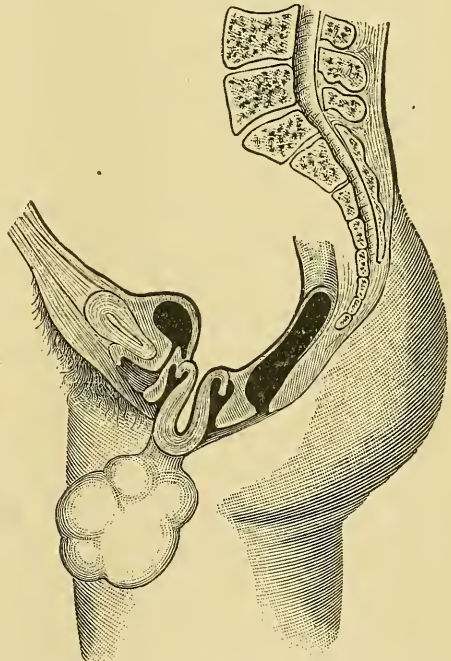


FIG. 87.—*Inversio Uteri Completa Cum Prolapsu*. (Schematic.)

corpus uteri, which appears with its fundus through the cervix at the external os: *Inversio uteri incompleta* (Fig. 85), or corpus and cervix are

inverted—*inversio uteri completa* (Fig. 86)—and lie in the vagina. The completely inverted uterus sinks down before the genitalia in extreme cases—*inversio uteri completa cum prolapsu* (Fig. 87). The prolapsed portion mostly becomes gangrenous and disintegrates rapidly.

The inversion arises always suddenly during the puerperium, and it is always accompanied by extremely *threatening symptoms*. The inversion is often effected gradually in non-puerperal cases, the expelling forces of the uterus are developed very gradually up to the intensity which is necessary to deliver the foreign body and thereby allow an inversion to take place. However, as in the process in *puerperio*, the inversion may occur very suddenly in these instances, and then resemble in its phenomena the puerperal conditions.

Profuse hemorrhages are the *first symptoms* observed, so that many patients perish immediately from anemia. Others succumb to shock.

I found a woman with a complete inversion dead, when I reached her not quite a quarter of an hour after the delivery of the after-birth (by a midwife by means of traction on the umbilical cord). The quantity of blood lost could not alone explain death, which resulted after the patient had fainted immediately following the *inversio uteri*.

However, not all puerperal cases take such a stormy course. The patient may react without the uterus being replaced. The first threatening symptoms disappear, but the profuse menstruation which recurs frequently and with great irregularity, the profuse discharges from the inverted mucous membrane, the pressure and pain in the sacrum, and the disturbance of the bladder and rectum finally necessitate treatment.

Rarely a state of relative well-being occurs, while the inverted organ undergoes a puerperal involution. The patients require the utmost attention and care. The uterus shrinks to a minimum of its circumference and is fatty degenerated, as I was able to prove in a patient post mortem.

Gangrene and disintegration of tumor and uterus had occurred on account of the constriction of the tough cervix in a case of inversion through a tumor which I saw in the gynecologic department of *E. Martin* in 1873.

The *diagnosis* of inversion is quite often easy, if one succeeds with a corresponding anamnesis in recognizing by combined examination that the body of the uterus does not lie *above the pear-shaped mass projecting into the vagina, while during the combined examination the inversion funnel can be palpated by the external hand*.

These positive signs cannot always be established with the same distinctness. Adipose abdominal walls, marked sensitiveness of the patient, or the presence of other newgrowths may mask both observations. Whoever adheres to the rule that he must demonstrate the body of the uterus during each gynecologic examination, is led with certainty to the diagnosis, as soon as he feels a pear-shaped, mostly smooth mass projecting into the lumen of the vagina, above which he cannot demonstrate the body of the uterus. The surface of this mass, projecting downward,

is of a velvety softness, and in puerperal cases the placenta is often still attached to it. Higher up, the finger reaches the still preserved portion of the cervix uteri, which surrounds the pedicle of the mass like a firm collar.

The finger rarely and the sound easily penetrates up along the pedicle to the place of overturning. One can palpate the border of the uterine orifice embracing the neck or body of uterus in an incomplete inversion, while one cannot find an *orificium uteri* in a complete *inversio uteri*. The external hand may remain in doubt about the inversion funnel, especially if intestinal loops are adherent to it. One finally may palpate the inversion funnel through the rectum, after a downward displacement of the uterus.

The **prognosis** of inversion is always grave. If the uterus occasionally recedes spontaneously in recently observed cases, or can be pushed back with comparative ease, sooner or later by suitable manipulations, one must recognize—apart from the danger of infection through attempts at arrest of hemorrhage and immediate assistance—that reposition manœuvres cannot be executed without endangering the continuity of the walls of the uterus, and that many cases perish from peritonitis.

I saw a case of inversion which had existed for six and a half years, in which a very cautiously executed attempt at reposition caused the completely fatty uterine wall to yield like wax to pressure of the finger, resulting in a great tear, which led into the abdominal cavity. The patient did not lose any blood as a result of the injury, but succumbed in a few days.

We should not despair too early of the possibility of a reposition. The reposition may yet succeed after a duration of several years and the uterus functionate again normally, so that pregnancy occurs. Two of my patients conceived some time after the reposition of the uterus from a puerperal inversion. Just so a patient of *Emmet*.¹¹⁰

Treatment.—The great severity of an inversion warns urgently to use caution during delivery of the placenta, as well as during the detachment of a polypoid tumor.

An attempt must always be made to replace the inversion immediately after its formation. This is the easier, the sooner the defect is discovered and its removal attempted. If the placenta is still attached to its place of insertion in puerperal cases one must decide in each instance whether the placenta can be left *in situ* until after the completion of the reposition, or whether it should be removed before the reposition. One need not fear in the first case, that air might enter into the dilated lumen of the placental vessels during reposition. In the other case the compression of the corpus succeeds only after the delivery of the placenta.

In one of my own observed cases of inversion the uterus was lying before the genitalia covered with the placenta at its site of insertion, as it inverted during the attempts of a midwife to terminate the delivery of the placenta by traction on the umbilical cord. The placenta was

loosened during the attempt at reposition which the colleagues that had first been called in the case had made. It fell off during my examination, before I succeeded in pushing the uterus back into the vagina. The patient was pulseless, was in a deep collapse with cold extremities, and woke up with violent motions and mutterings at each attempt to touch her. The patient was put under anesthesia and the reposition of the strongly contracted uterus was executed with comparative ease. The pulse returned immediately after reposition, and the patient not only recovered, but was also delivered spontaneously three years later.

One must attempt to push back the uterus first of all with the placenta; if one does not succeed, the placenta must be removed and replacement made afterward.

Reposition of an incomplete inversion results at times, as soon as the placenta has been removed or traction on the funis or corporeal wall has ceased.

The longer the time that has elapsed since the occurrence of the inversion, the more difficult proves the reposition, because the ring of the os uteri or the cervix contracts and is difficult to dilate. The very peculiar observation of *Spiegelberg* (l. c.), who observed a spontaneous reduction after two weeks in a reclining position during severe diarrheal attacks, has remained unique according to my knowledge.

Reposition.—One takes hold of the corpus uteri and compresses it between the fingers, pushes it upward while the spread fingers of the external hand fix the cuplike depression through the abdominal walls. The last inverted part is pushed back first with the point of the fingers, either from all sides at the same time or first on one side then on the other (tubal portion, *Noegerath*). This manœuvre must be repeated in *Trendelenburg's* position (raising of the pelvis and lowering of the chest). The reposition has often succeeded after repeated sittings for hours at a time, even many years after the occurrence of the inversion. One can replace the counterpressure of the external hand by spreading the fingers introduced from above the funnel or cup (*Emmet*) or by vulsellum forceps, which are attached to the external lip of the os uteri during the reposition (*Schroeder*). It is very useful at times to cause a decrease of the inverted corpus, by long-continued rest in bed, iodine and glycerin tampons, and massage, while the vagina is expanded through colpeurynters for days at a time. The uterus often slips back during this treatment.

*Lawson Tait*¹¹¹ put a correspondingly cup-shaped wooden disc in place of the replacing hand which is fastened with strong rubber tubes to a waist-belt. The disc takes up the uterus. The rubber tubes exert a pressure which can be arbitrarily modified according to the degree of tightening of the same. The compression is continued for days and is said to have led to the desired result in many cases. I made use of a ball-shaped instrument with a long and firm handle in operating on an inversion caused by a polypoid myoma of the fundus. I placed the handle upon my abdomen, directed the ball with my left hand against the in-

verted fundus and made counterpressure upon the inversion funnel with my right hand. The replacement occurred quite readily.¹¹² It has been recommended for severe and apparently incurable cases to incise the uterus partially, and to treat it provisionally by suturing the cervix which has been drawn over the uterus (*Emmet*), (*Amer. Jour. of the Med. Sci.*, Jan., 1868; *W. A. Freund*, "Zur Path. und Ther. der Veralt. Invers. Uteri Puerp.," 1870). *Barnes*¹¹³ recommended to incise the ring of the uterine os, in order to push up the nearest portion of the uterine wall.

A real progress in the technic of reposition is shown by the incision of one wall of the uterus through which *Küstner*¹¹⁴ taught us to enforce replacement. He opens the excavatio recto-uterina through the posterior vaginal fornix, enters with one finger the funnel of the inversion, in order to split the posterior uterine wall at that point. He replaces the uterus, thereafter draws the retroflexed organ into the vagina through the opening in the posterior vaginal wall, closes the longitudinal incision in the uterus which he replaces in the abdominal cavity. Closing of the vaginal incision.—*Polk*, *Borelius*, and *Kehrer* recommend to incise the anterior wall. *Borelius* and *Westermarck* lengthened the longitudinal incision through the cervix into the transverse incision in the posterior vaginal vault.

B. Inflammations of the Vulva, Vagina, and Uterus

LITERATURE: See *J. Veit* in *Veit's Handbuch der Gynäkologie*, Bergmann, Wiesbaden, 1897-1898, Vols. I and III. *Frommel's Jahresberichte über Geb. u. Gyn.*, 1897-1906.

Although the inflammatory diseases of the different regions of the female genital tract should be discussed separately for reasons of a better understanding, a few general aspects must be considered beforehand.

It is no longer feasible according to our present views to conceive the inflammations of the separate parts of the genitalia as diseased conditions peculiar to each region. On the contrary we know that manifestations of disease of one portion result in the majority of the infectious inflammatory processes often with certainty in a participation of the adjacent part or parts.

A frequent peculiarity exists in the infections of the female genitalia caused by schizomycetes. These infections can *travel* as well *downward* from the peritoneum and the ovary toward the vulva, as *upward* from the vulva toward the ovary and the peritoneum.

The former movement, the *descending* one, is promoted by the action of the ciliated epithelium waving in a direction from the ostium tubæ uterinum to the ostium uteri externum, and in the vagina by the course of the secretions.

The *ascending* movement of the bacteria, causing the infection, which are altogether incapable of motion of their own, is difficult

to explain, because it must overcome the conditions which favor descent.

Whether it takes place through the lymph stream, or is transported by the leucocytes or seminal fluid (gonorrhoea, tuberculosis) or through continued growth or through a sort of antiperistaltic motion cannot be determined at present. The last modes could not be rejected as improbable according to experiments made on animals.

It is a fact that most of the infectious agents can invade every portion of the genital tract as well as several portions, all at the same time or at different times, so that the most varied end results can arise from a combination of these possibilities.

The inflammations caused by bacteria are indisputably the most frequent ones. Besides these are quite a number of other conditions affecting especially the uterus, but also other parts, which run the course of a chronic inflammation as a hypertrophy or hyperplasia, for which we cannot accept the possibility of a bacterial origin, but which we are compelled to attribute etiologically in the most cases to abnormalities of the blood-supply, passive (venous) as well as active (arterial) hyperemia.

The specific infections of the genitalia: gonorrhoea and tuberculosis, will be treated collectively for the entire system in a special chapter.

For the other non-specific processes it is commendable to consider the different regions separately for practical reasons.

1. Inflammation of the Vulva

The vulva is exposed to frequent soiling on account of its position between the urethral and anal openings, as well as to a constant infection with the different forms of micro-organisms, and chemical irritants through contact with the secretions from the upper genital tract.

The thick horny epidermis of its external surface indirectly offers quite a good protection against these injurious influences. However, this protection is already absent on the inner surface of the small labia. Moreover the constant moistening and desquamation of the epithelial covering easily opens the way for an entrance of the infective agent.

The vulva may become the seat of inflammatory affections during infancy from birth to puberty. Without mentioning the quite frequent ***gonorrhoea*** and the rare ***tuberculosis*** (see the respective chapters) the acute infectious diseases, diphtheria, typhoid fever, smallpox, measles, scarlet fever, are localized in this region. The participation of the vulva in these infections is certainly not so very rare. They remain mostly unobserved on account of the preponderance of other local and general symptoms, because their eventually resulting consequences tend to appear much later at the time of puberty.

These acute infectious diseases appear on the vulva mostly as a more or less extensive ulceration with a purulent coating in which specific

organisms (diphtheria and typhoid) can be demonstrated in many cases. The remote result tends to be an extensive cicatrization, often with adhesions of the labia majora and total or partial closure of the introitus vaginæ.

The same infections with the same end results or stenosis, eventually atresia may also appear in the vagina, and indeed this occurs still oftener than in the vulva (see this chapter).

It is certain that a great number of so-called congenital stenoses and atresias of the vulva and vagina must be traced to such infectious diseases in early childhood (*Veit-Nagel*).

Naturally also later in the pubescent age the genitalia may participate in systemic infections. This has been proven without any doubt in quite a number of observations during typhoid, diphtheria, and smallpox.

These infections tend to decrease in frequency of occurrence during the years of sexual activity in contradistinction to the **septic and gonorrhæal** infections, which tend to increase in frequency.

Septic vulvitis arises almost exclusively in connection with febrile puerperia. One finds the small lesions in the introitus which are always present post partum covered with lardaceous matter and the surrounding parts, especially the large labia and the perineum infiltrated, as hard as a board, and edematous. Streptococci are always found in the coating of the recesses. A genuine **erysipelas** may result from them, which also may invade the thighs and the abdomen.

Besides these acute severe infections there are a large number of more chronic inflammations of the vulva, which may originate from the most varied causes.

An extensive **intertrigo of the vulva**, the inguinal and gluteal folds and of the internal surface of the thighs not rarely appears in very fat persons during the hot season who lack cleanliness. If this condition continues to exist for some time an extensive **acne of the vulva** results through an infection of the sebaceous glands. A few isolated or even numerous **furuncles** may form in severe cases. The ducts of the glandula vestibularis major (*Bartholini*) may become infected by the staphylococci producing these skin infections, and this gland is transformed into an **abscess**.

A frequent etiologic factor for a vulvitis is formed by the continuous contamination with infectious and irritating secretions from the upper genital organs. Putrefying tumors of the uterus and the vagina (carcinoma, sarcoma, polyps, myomata, foreign bodies, pessaries), purulent endometritis, especially post partum and abortum, also gonorrhæal, may occasion an intense, mostly **eczematous inflammation** which may also invade the thighs. Single or multiple furuncles also may appear upon this portion of the inflamed epidermis.

A similar action is caused by the continuous or very frequent wetting of the vulva with **urine**. Such a moistening is found in vesical or uretero-vaginal fistulæ, further in diabetes, in which the frequent moist-

ening with *sugar-laden* urine exercises a continuous irritation. Finally the continuous soiling with *feces* in perineal tears of the third degree as well as in recto-vaginal fistulæ may provoke chronic vulvitis.

The continuous moistening of the skin in all these conditions plays undoubtedly the greatest rôle for the formation of the vulvitis, because through it the way is opened for the entrance of the infectious agent into the deeper structures. Besides this the chemical composition of the urine, for example in diabetes, must be considered, as in this disease the glucose favors extraordinarily the growth of bacteria. Eczema of the vulva and its surroundings arises in all these continued soilings.

Finally, vulvitis may be caused by the chemical influence of remedies: *Iodoform eczema* and so forth. Too hot vaginal irrigations may lead to extensive *burns* of the vulva.

Masturbation also must be considered as a cause for many a vulvitis, which, however, appears not to be so intense and anatomically less characteristic. A condition of irritation, especially of the clitoris and the urinary meatus, but also the larger and the smaller labia seem to characterize this form of vulvitis.

A vulvo-vaginitis occurs not very rarely in infants during the first years of life. It is produced mostly by gonorrhœa (see this chapter), more rarely through intestinal parasites (*oxyurus vermicularis*).

Symptoms of Vulvitis

The evidences of vulvitis tend to vary according to the degree of the inflammatory process. At first an intense burning is usually complained of, especially during sitting and walking, and also urinating. A sensation of tickling and itching not seldom appears to be more pronounced. Intense burning and sensitiveness appear in an extensive eczema, especially when moving about. Severe pains are directly present in acne and furunculosis.

The sensation of burning, but still more the itching, may become very severe and unbearable under the influence of the warmth of the bed. The result of this is an unsurmountable desire to rub and scratch, so that effects of scratching must always be considered in judging of the etiology of the vulvitis, otherwise cause and effect of the cases presented may be easily interchanged one with the other.

Cases which are accompanied by this paroxysmal itching have been described as a distinctly separate disease, *pruritus vulvæ*.

Pruritus Vulvæ

The itching of the vulva and its surroundings form a strange complaint which attacks apparently healthy women and the unmarried in every period of life, being especially frequent in later years. Now it consists in burning, now in itching; it occurs mostly as soon as the parts become warm, be it through rubbing of the clothes or be it in bed. It is difficult,

indeed impossible, to resist the desire to rub and scratch. Often the unfortunate patients produce deep injuries by scratching; often relief only ensues when voluptuous sexual sensations ensue.

The irritation of the vulva by soiling with urine, feces, dust, by gonorrhœa, drying of the menstrual blood, by discharges of all kinds of diseases of the genital mucous membrane, also by tumor formation (carcinoma) need no further discussion here, for they belong to the symptomatology of these diseases. Pruritus has an exceptional diagnostic significance in diabetes mellitus; the vulva is covered with great patches or spots of micro-organisms, especially the *oidium albicans*. The vulva looks as if covered with flour dust. Every patient with pruritus must be examined for diabetes first.

Not infrequently none of the complications described can be demonstrated. One finds the skin of the vulva, especially on the inner surface of the greater and smaller labia covered as by spawn of frogs. Sometimes this appearance is produced by distended sebaceous glands, sometimes the condition in question is a hyperplasia of the stratum papillare, which produces a peculiar picture. Even these changes in the tissues may be absent. In such cases one speaks of an essential pruritus (*Ohlshausen*) or of a vulvitis pruriginosa (*Sänger*).

In consequence of the chronic inflammatory processes in the epidermis and in the corium a **cicatricial contraction** may ensue in the entire region of the external genitalia, including the anus.

The scar contraction has been described first by *Breisky* as **Kraurosis vulvæ**.

In this the epidermis of the vulva is found strongly contracted, so that the small labia and the clitoris are almost or completely destroyed. The skin looks thinned, white, shining like asbestos, covered with excoriated epidermic scales, often fissured, intermixed with rhagades, so that the introitus vaginæ appears to be strongly contracted.

Pathologically one finds, in the beginning cases, hyperplasia of the papillary bodies and of the rete Malpighii with round-cell infiltration, in the advanced stages, a cicatricial contraction of the corium and the papillæ which may become completely obliterated, so that the squamous epithelium covers almost in a straight line the non-nucleated corium (see Fig. 88). Atrophy of the glands and **complete destruction of the elastic fibres** belong to the characteristic signs of this condition.

Many different hypotheses have been advanced concerning the etiology of this disease, which formerly was considered as an independent disease. We regard it, as we have said above, as the end stage of a chronic inflammatory process. No matter what causation was originally at the bottom of it, any inflammation of the vulva can finally lead to a kraurosis.

The **symptoms** are in the beginning cases those of vulvitis in general, burning, itching, etc. In the more advanced stages, in which the elas-

ticity of the skin has been completely lost, a sensation of tension of the vulva, especially during walking, but also during cohabitation, partus and during vaginal examination enters into the foreground.

By forcible stretching or dilatation, for instance during labor, deep lacerations of the skin may occur.

It is remarkable that a carcinoma not seldom develops on the basis of a kraurosis (see chapter on Tumors).

Another secondary phenomenon of vulvitis is the formation of so-called *acuminated condylomata* (verruca acuminata), especially of gonorrheal origin, but also when due to other causes.

By these we understand proliferations covered with epidermis of the papillary bodies, of the vulvar skin, and mucous membrane, which grow

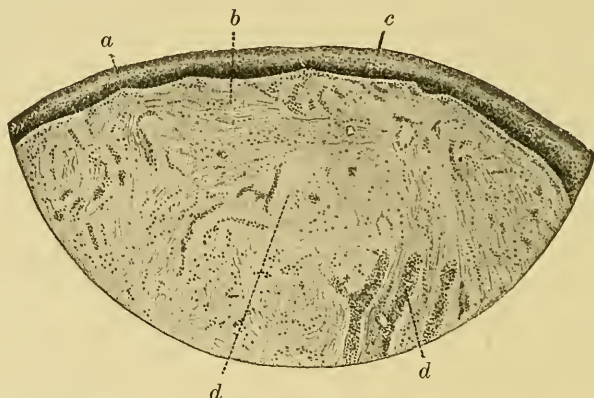


FIG. 88.—Kraurosis Vulvæ. The papillæ are obliterated, the corium infiltrated with small cells, the glands have completely disappeared. *a*, thinned epidermis, almost drawn like a straight line over the corium; *b*, infiltrated with round cells; *c*, thinned horny layer; *d*, subcutaneous connective tissue edematous and infiltrated with round cells.

from the smallest excrescences, the size of a pinhead, to cauliflower-like tumors, almost the size of the fist. They may also form in the vagina, and their growth is often a very rapid one, especially during pregnancy (see Fig. 89). The condylomata acuminata, as rapidly developing papillomata of the skin, properly belong to the newgrowths; however, they are better considered here because originating on an inflammatory basis.

As the acuminate condylomas secrete mostly very abundantly, they very soon provoke an eczema of the surrounding regions. The secretion can be materially limited with pulvis sabinæ and alum equal parts.

Treatment of Vulvitis.—In acute vulvitis during septicemia, diphtheria, typhoid, erysipelas, etc., the general treatment is paramount. A cure results with a retrogression of the general infection. Large deforming scars often remain behind on the vulva.

Locally one must care for the removal of the decomposed and stagnated

secretion by frequent irrigations with weak antiseptic solutions (lysol, 1 per cent. ; thymol, $\frac{1}{10}$ per cent. ; sublimate, $\frac{1}{20}$ per cent.).

See the chapter on *Gonorrhœa* for its treatment.

Two basic principles can be put forward for all other forms of vulvitis.

1. Treatment of the primary disease.
2. Strict cleanliness.

It is clear that local treatment must remain unsuccessful without fulfilment of the first principle on account of the irritation continuously

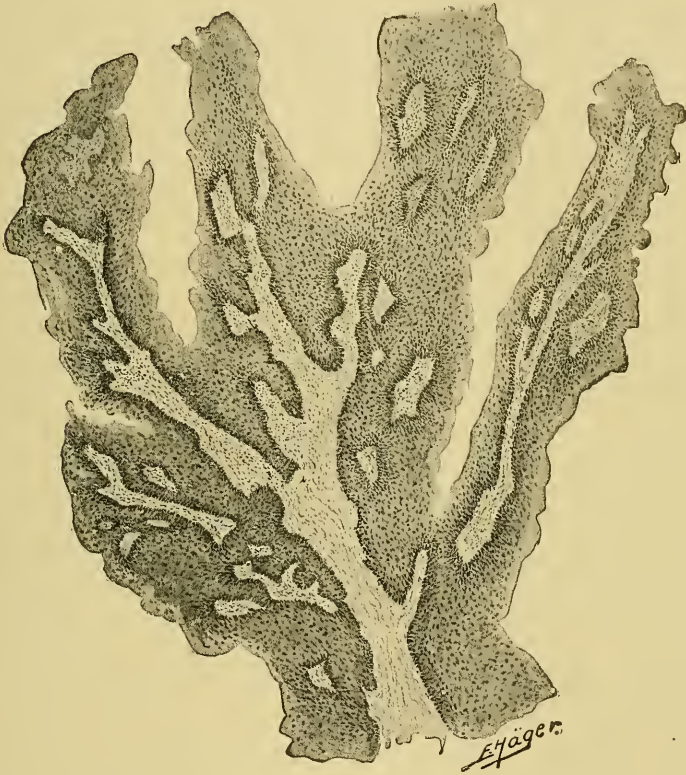

FIG. 89.—Condylomata Acuminata.

acting anew. Ichorous tumors of the vagina and uterus must be removed, fistulæ closed, catarrhs of the uterus done away with, the diabetes must be improved. General rules cannot be formulated for this, but every case must be considered separately.

If the primary disease is removed the vulvitis can then be easily cured in many cases.

We recommend for it especially *soapsuds sitz baths* of a duration of fifteen minutes. The vulva is thoroughly cleansed with green soap and lukewarm water before the first sitz bath. If necessary the pubic hair

must be shaved off (*P. Ruge*). All irritations, especially antiseptics, must be kept away. A dusting with talcum powder or zinc oxide and starch in equal parts is to be recommended after the bath and thorough drying. The latter preparations are especially valuable in intertrigo.

If acne pustules or furuncles are present they must first be lanced and the remaining infiltrations must eventually be treated with applications of 2 per cent. aluminum acetate. The sitz baths are in the meantime continued. As soon as the basic cause of the vulvitis is removed, it heals most rapidly with this treatment.

The cure of the primary disease is not always easy and often requires a long time, especially in old uterine inflammations.

The vulvitis, also, in such cases, will not disappear all at once. New foci of inflammation are always formed, especially in the form complicated with pruritus, on account of the scratching. The general well-being, especially the nervous system, is often strongly interfered with through disturbance of sleep.

The treatment in such cases must have for its purpose also a removal of the pruritus with cleanliness of the vulva.

In extensive eczemas it is recommendable to apply thickly *Lassar's* paste (acid. salicyl., 2.0; zinc. oxid., amyli, āā 24.0; vaselin and lanolin, āā 50.0) and to wipe it off again dry the next day before the sitz bath.

Cocain salve (5 to 10 per cent.) always renders excellent service in tormenting pruritus (℞ cocain mur., 5.0; lanolin, 40.0; olei oliv., 10.0. M. ft. ungt.), also menthol ointment has been recommended (menthol, 2.5; olei oliv., 7.5, lanolin ad. 50.0).

One sees often even obstinate pruritus cured within a short time by the use of this cocain ointment; however, recurrences are frequent.

The **treatment of kraurosis** is in pronounced cases rather ineffectual. A treatment with **ointments** is naturally unable to cause a retrogression of the extensive anatomic changes. *Heller*¹¹⁵ reports, to be sure, a cure with treatment by official solution of formaldehyde in the form of cauterization repeated weekly, hot water applications, 50 per cent. ichthyol applications, and indifferent ointments.

Excision of the entire vulva, which was performed first by *A. Martin* for kraurosis, leads most surely to our aim. Most favorable permanent results have been recorded from this procedure.

The **treatment of the condylomata** can only consist in the removal of the tumors.

Quite small tumors can be removed by cauterization with a silver nitrate stick. Large ones are cut off with scissors, if necessary, under local anesthesia. The cut surface, which bleeds usually quite profusely, is cauterized with a silver nitrate stick or fuming nitric acid, or with a *Paquelin* cautery. One cannot do without spinal or general anesthesia in large tumors. They must be excised freely together with the surrounding skin. The hemorrhage, which is always free, is stopped by ligation and the wound is exactly coaptated with stitches. Healing ensues

then mostly *per primam intentionem*. Large tumors also may be removed with the cutting *Paquelin*, thus securing at the same time an arrest of the hemorrhage. Large vessels must be ligated, however, even with this procedure.

Recurrences are not rare when the primary disease persists (catarrhal conditions of the mucosa).

By ***elephantiasis vulva*** is designated a very marked increase in the size mostly of the labia majora, which is accompanied by edema and sclerosis of the connective tissue and a lymph stasis, eventually leading to a lymphorrhea.

This condition may be caused by an interruption of the secretory lymphvessels, for instance of the inguinal glands. Its etiology remains entirely obscure in many cases.

The treatment can only be an excision of the tumors and suturing of the wound. Recurrences not rarely take place.

The enlargements and indurations of the labia majora in initial luetic sclerosis, which resemble the above described conditions at times, require no further consideration at this place.

An ulcer formation named ***ulcus rodens vulvae*** (Esthiomène of the French) appears especially at the fossa navicularis and the posterior periphery of the vulva. It combines a great tendency to spread gradually into the deeper structures and form a rectal fistula with a torpid character and slight inclination to heal.

The ***etiology*** of the ulcers is still unexplainable. A condition similar to tuberculosis is found in many cases. In others it is completely wanting.

The ***treatment*** is of no avail. It can consist only of a radical excision of the entire ulcer, together with its basis, with suturing of recto-vaginal fistulæ which may perhaps exist.

The entire periphery of the vulva must be removed as a rule in this disease.

When the above described procedure of *P. Ruge*, shaving and soaping, then a mild caustic, as carbol-vaselin with following anointing or dusting proves ineffectual, I have excised more or less extensive particles of skin with uniform success. The defect is covered by drawing healthy strips of skin over it with continuous catgut sutures.

*Vaginismus*¹¹⁶

By ***vaginismus*** is meant an abnormal sensitiveness of the external genitalia, which occasionally may develop to a spasmodic contraction of the constrictor cunni, the levator ani, and the muscles of the entire pelvic floor.¹¹⁷ The ailment attacks mostly virgins, and appears as a rule on the wedding night, seldom later, apparently without any special cause. There exists, as a rule, an unusual narrowness of the introitus, often a rigid condition of the hymen, but vaginismus may also occur with a comparatively easily dilatable vaginal orifice. Nervous, sexually overexcitable persons seem to be predisposed, but especially women in whom the

vulva extends far forward, so that the urethral and hymenial orifices lie upon the symphysis or the ligamentum arcuatum.¹¹⁸

Any considerable *anatomic* changes are not demonstrable, either in the external skin or in the nerve terminations lying in it. The vaginismus appears with the first attempt at cohabitation, because copulation is difficult from the extreme sensitiveness of the highly excited young bride or from the abnormal size of the penis, or from awkward attempts at approach under the influence of alcoholic intoxication and excessive excitability. Often also an incomplete erection is involved in neurasthenics. So far as I have observed, immissio penis did not succeed in all these persons suffering from this evil, and as a result the hymen was not completely torn. Spasms of the constrictor cunni occur also after successful immission, as is shown by the accounts of penis captivus.¹¹⁹

Renewed brutal attempts lead to injuries and to inflammatory lesions in these. Often with the anteposition of the external organs of generation there occur injuries of the urethra which exceptionally may become dilated, so that the immission into it may succeed. The state of irritation assumes a very serious aspect with continuously unsatisfied attempts, and with timidity about confessing the condition to a physician. The parts become inflamed, particularly if the husband enters the marriage with gonorrhœa, and vulvitis, Bartholinitis, urethritis, also colpitis and endometritis result. The most usual consequence is an ill-humor of husband and wife, of whom the latter particularly suffers from dread of the approach of the male and from the feeling of her own feminine imperfection. The susceptibility of the irritation may increase to such an extent, that every touch of the external genitalia causes severe pains. Finally, the disturbances appear also without contact in some from fear of the approach of the husband, in others from exertions, for instance during defecation and urination.

Such women, as may easily be conceived, are mostly sterile, even if cohabitation in spite of the pain is enforced. However, conception may take place by the sperma being dashed against the external genitalia and thus pregnancy results notwithstanding the continued vaginismus. *Hofmeier* in one case saw always a considerable aggravation of the entire condition during the following pregnancy; *Benicke*¹²⁰ observed vaginismus as an obstacle to delivery. Such spasms of the muscles of the pelvic floor, especially the levator ani, may appear also through the influence of colds, just as rheumatic contractions may occur in other muscular structures. It is questionable whether masturbation or other perverted sexual pleasures do not play a rôle in the etiology.

The *diagnosis* of vaginismus as a rule is established by touching the external genitalia ever so lightly with the finger, with the point of a sound, or even a firm cotton brush. Violent contractions of the musculature of the pelvic floor occur, the vagina appears closed, even the vulva becomes inaccessible. By an extension of the contractions to the nates and thighs the extreme sensitiveness of the patients may exclude every

kind of approach. The spastic contractions are, as a rule, of short duration. Only in isolated cases have I seen them last more than ten minutes.

The hymenial ring is sometimes rigid; I have seen it as hard as cartilage in newly married women of advanced age. The external genitalia show injuries which have resulted from forcible attempts to overcome the difficulty. At times a swelling of the stratum papillare of the nymphæ is found as the only anatomic substratum. Many localize their pains in the hymenial ring or its remains, the carunculæ myrtiformes, without these parts showing any particular changes in their structure. The examination proves not so rarely that the alleged vaginismus is only a symptom of a colpitis, endometritis, or perimetritis, that it is not touching the introitus that causes the pains, but these develop only after reaching the vaginal vaults and the uterus.

Treatment.—Forcible stretching of the hymen and the involved muscles is only exceptionally unavoidable. A dulling of the sensitiveness and gradual accustoming the parts to a corresponding dilatation are sufficient. The utmost possible rest of the parts, avoiding all kinds of irritation and removal of the sensation of pain, felt in them, are the first indications for treatment. Soothing vaginal irrigations (aq. plumbi, one or two tablespoonfuls in one litre of water; zinc. sulph., copper sulph., or copper aluminate, 4.0 gm. to 1 litre of water), narcotics in the form of morphin suppositories (morphin hydrochlor., 0.01; olei theobromatis, 2.0. M. f. suppos. No. V, S., to be used externally, and in the vagina and rectum), belladonna (0.01) and similar remedies, painting with cocain in 1 to 10 per cent. solution, lukewarm sitz baths with decoctions of wheat bran, lukewarm douches with infusion of hemlock (infusi conii) (25.0), 175.0; aq. laurocerasi, 25.0. M. S. Externally one or two tablespoonfuls in one litre of lukewarm water, with linseed-tea and other mucilaginous decoctions seldom fail in their effect. It is self-evident that every attempt at cohabitation in recently married people must be prohibited, that a free evacuation of the bowels and a non-irritating diet should be provided for, and alcoholic beverages must be avoided by all means. After the irritation in the external genitalia is removed, the fissures and wounds healed, and the sensitiveness without direct irritation has been lessened, treatment by gradual dilatation by means of the well-known bath specula commences. The smallest sized one is anointed and introduced by the patient herself while in a sitz bath. Patients, as a rule, acquire the necessary manipulation in a short time, even with a certain awkwardness in the beginning, and they can proceed to the next larger size after using the first for four or five consecutive times. As soon as a speculum the size of a penis can be introduced painlessly, the approach of the male should be allowed. This may have already been successfully accomplished.

It is only seldom that such a simple treatment does not suffice. If it does not the introitus should be split. A rigid hymenial ring, sensitive caruncles, scars and condylomata at the vaginal orifice, should be removed

by excision. It may suffice at the time forcibly to dilate the hymen under anesthesia. The wound edges made by excision of the hymen are closed with a continued catgut stitch, which unites the edges of the labia with that of the vaginal mucous membrane and arrests the hemorrhage. Bath specula have to be used in a sitz bath for some time after suturing.

2. Inflammation of the Vagina (Vaginitis)

Inflammations of the vagina coincide in many points with those of the vulva as regards their etiology. Everything said about puerperal sepsis, about secretions from ichorous tumors, inflammations of the endometrium, etc., holds good also for the vagina.

Inflammations of the vagina have a general tendency to heal spontaneously, as the covering of squamous epithelium is with difficulty penetrated by micro-organisms. The vagina besides lies in a protected situation. Finally, and this is the most important point, the normal *acid*

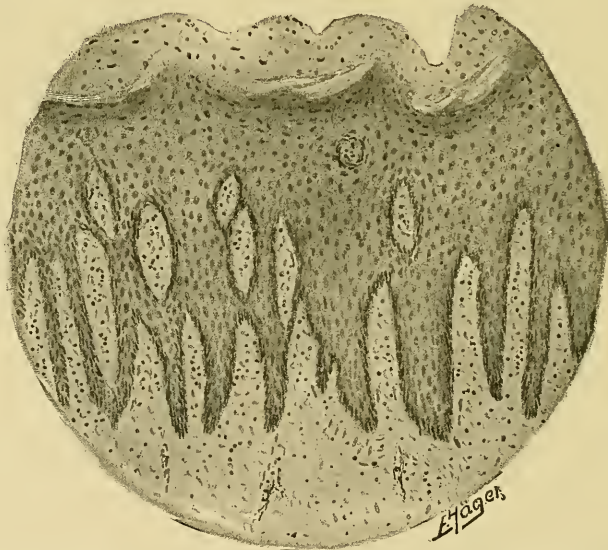


FIG. 90.—Epidermification of the Vaginal Mucous Membrane in Prolapsus. (Author's preparation. Zeiss, Obj. AA, Oc. 4.)

vaginal secretion offers a natural protection which also destroys pathogenic micro-organisms in a short time (*Doederlein, Menge, and Krönig*).

Acute puerpero-septic vaginitis develops, as a rule, in the parts of the vaginal mucous membrane which are injured in labor. The exciting cause, mostly streptococci, finds here its port of entry. Ulcers, covered with a lardaceous substance, are formed with a boardlike infiltration of a considerable extent of the surrounding mucosa, which finally leads to a necrosis and sloughing of the tissues, *vaginitis dissecans*. If healing

ensues extensive scars are formed, causing an extreme stenosis of the vagina.

Similar processes follow infections of the vagina by diphtheria, typhoid, smallpox, scarlet fever, etc., which occur even in little girls but also in adults. They may lead to stenosis and even complete atresia of the vagina. (*Veit and Nagel's* theory. See chapter *Vulvitis* and *Malformations*.)

In the remaining acute forms of vaginitis not based on such serious infections, the mucosa is deeply reddened and swollen and feels velvety, secretes freely and abundantly and is very sensitive to the touch.

As the vagina does not possess any glands the secretion consists of an inflammatory transudate from the overfilled blood and lymph vessels of the submucous connective tissue.

If the inflammation is not a general one, the vaginal mucous membrane presents the picture of reddened spots with paler parts lying between them.

The vaginal mucous membrane becomes dry in most instances and the superficial squamous epithelium undergoes *cornification*, so that it assumes an epidermislike character in prolapse of the vagina where the mucous membrane is exposed for a long time to the action of the air: *Epi-dermification* of the

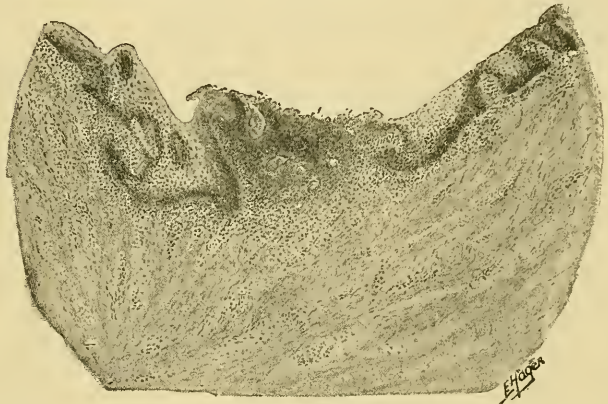

FIG. 91.—Colpitis Granulosa. Atrophy of the squamous epithelial layer and small-celled infiltration of the exposed papilla. (Author's preparation. Zeiss, Obj. AA, Oc. 2.)

vaginal mucous membrane (see Fig. 90). A special form of vaginitis is the so-called *colpitis granulosa*. In this an acute inflammatory hyperemia and leucocytic infiltration with a swelling of the capillary bodies and shedding of the epithelium takes place, so that the points of the papillæ are exposed to the air (see Fig. 91). Through this the mucosa feels granular like a grater. Through the speculum the swollen papillæ are seen as disseminated dark granules on the freely secreting mucosa. If the inflammatory irritation persists, a formation of *acuminated condylomata* may take place in the vagina, especially during pregnancy (see chapter *Vulvitis*).

Chronic inflammations of the vagina frequently follow inflammatory conditions of the uterus, as in the vulva (see previous chapter).

Some varieties, however, demand a special description.

We understand by *colpitis senilis* an inflammation of the vagina which

appears usually during the climacteric. There is found with it at this time a physiologic progressive and gradual atrophy of the vaginal mucous membrane. The rugæ are smoothed out by contraction of the submucous connective tissue and the papillary bodies (Fig. 91). The epithelial covering grows thinner, the upper layers are thrown off, and the entire mucous membrane looks smooth and shiny. The points of the papillæ are freely exposed through the atrophy of the epithelium, so that the picture of a colpitis granulosa may be formed at this time. Now if portions of the connective tissue of the opposing walls freed from epithelium lie in apposition they may completely grow together. This may occur especially at the portio vaginalis, whose external surface is in continued contact with the vaginal vault. Both adhere and finally coalesce

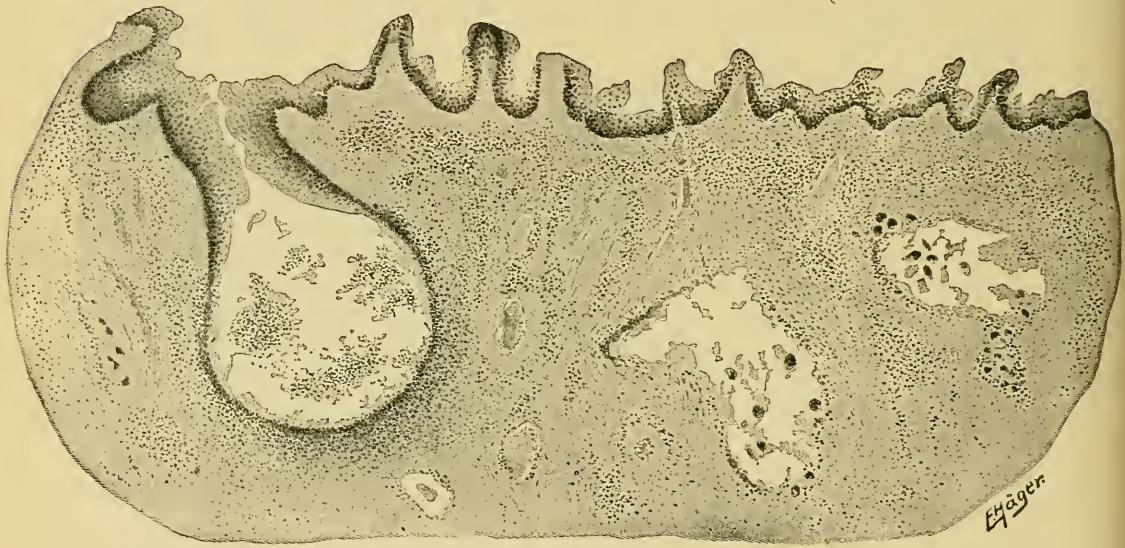


FIG. 92.—Colpitis Emphysematosa. Gaseous cysts in the vaginal walls produced by gas-forming bacteria. (Author's preparation. Zeiss, Obj. AA, Oc. 2.)

completely, so that a pointed funnel-shaped tube forms in place of the vaginal vault and the portio, at the apex of which is situated the external uterine orifice. Colpitis senilis is accompanied by an abundant serous transudation which appears as a discharge.

Foreign bodies also, which remain in the vagina for a long time, may cause long-continued severe inflammations of the vagina. **Pessaries** are chiefly concerned in this regard which have remained for a long time without control and without the necessary cleansing. Such pessaries tend to produce, first of all, a profuse, at times purulent secretion, and finally decubital ulcers. The edges of these ulcers are commonly raised like a wall. A proliferation of the connective tissue may ensue, finally enclosing the upper bar of the pessary and thus holding it firmly. Indeed,

even *carcinoma* has been seen to arise from the basis of these vaginal ulcers caused by pessaries. Pessaries by no means always cause such manifestations. I removed a pessary from a vagina in which it had been lying for sixteen years without being changed. There was no trace of inflammatory infiltration in the vagina of this patient, who, however, paid painstaking attention to cleanliness.

In addition to pessaries other foreign bodies also, such as spoons, pencils, etc., mostly introduced for purposes of masturbation, must be considered. I removed with difficulty the *inferior epiphysis of the femur of a pig* from the vagina of an elderly woman in which it was firmly grown. A peculiar form of inflammation has been described under the name of *colpitis emphysematosa* (see Fig. 92). The disease consists in the appearance of numerous small bubbles in and beneath the epithelium of the vaginal mucosa on account of which it gives the sensation of a peculiar granular condition. The formation of the vesicles is the result of the presence of gas forming, probably anaerobic, bacteria of a character not yet differentiated (*Lindenthal*). The disease is not frequent, most of the observed cases occurred during pregnancy. The usual signs of inflammation appear in the vicinity of the bubbles, as small-celled infiltration, hyperemia, etc.

The *vulvo-vaginitis infantum*, which appears not rarely in little girls, is caused in the greater number of cases by *gonorrhoea* (see this chapter) only very rarely by intestinal parasites (oxyuris vermicularis).

Symptoms of Vaginitis.—The symptoms of *acute* vaginitis consist chiefly in *reddening* and *swelling of the mucosa*, partly diffuse and partly isolated, leaving out of the question deep infiltrations and necroses from puerperal processes, etc. (see above, p. 160), further in an increased secretion and finally an increased sensitiveness on handling (palpation, cohabitation), also in burning from contact with urine, or also spontaneously. In this respect the symptoms are the same as those of acute vulvitis.

Symptoms may be almost entirely wanting in *chronic* vaginitis; at least they may be overlooked by insensitive persons. This concerns especially the increased discharge which is hardly ever absent in chronic colpitis. While some women experience a disagreeable sensation on a slight increase in the secretion, others remain entirely indifferent to a pronounced fluor. Some other symptom like pain first brings them to the physician, to whom on questioning they admit the fact that an increased secretion exists.

The character of the discharge varies markedly. A purulent secretion predominates in acute infectious processes, a more aqueous one in the chronic, especially the senile form. Many times an admixture of *blood* is present in the vaginal discharge, especially with the presence of granulations (pessaries, foreign bodies, acuminated condylomata, adhesions, in colpitis senilis, carcinoma). If the secretion has not a sufficient means

of escape, it soon becomes decomposed by the saprophytes of the vagina and takes on a repugnant foul odor, which makes itself noticeable at a marked distance and excludes the patients from society. Really severe *spontaneous* pains do not occur in chronic inflammation of the vagina; at most they may be felt during traumas (examination, cohabitation).

Treatment of Vaginitis.—The treatment of acute puerperal vaginitis can only be symptomatic, consisting in the removal of the decomposed secretion by irrigation with a mild antiseptic (lysol, 1 per cent.; thymol, 1 to 1,000; potassium permanganate in a pink solution). If the patient survives the infection, the vaginitis finally heals, often, however, with considerable cicatrization (see above).

In all other acute and especially in chronic inflammation, the task is first to eliminate an eventual causal factor. Ichorous tumors of the uterus must be extirpated, pessaries and foreign bodies must be removed, endometritis must be cured.

The chief attention must be given to a *minute cleanliness* of the vagina in all those cases in which a primary cause cannot be found (see Vulvitis). Irrigations repeated twice daily with lukewarm water, eventually with the addition of a mild antiseptic (lysol, 1 per cent.; thymol, 0.1 per cent.; potassium permanganate in weak solution; zinc sulphate, 1 per cent.; boric acid, 3 per cent.; lead acetate, 0.5 per cent.) or an astringent (*Lugol's* solution, 1 tablespoonful to 1 litre of water, purified wood vinegar, 1 to 2 tablespoonfuls to 1 litre of water).

Acetic acid is especially to be recommended in colpitis senilis for which it may be considered a specific. It may be used either diluted as irrigations or in the concentrated form by pouring it into a tubular speculum which has been inserted in the vagina. The latter is slowly withdrawn and thus each mucous fold is brought in contact with the agent. Besides the use of liquid solutions the introduction of tampons which are saturated with astringent remedies, is especially to be recommended in case of profuse secretion.

Tannin-glycerin (tannic acid 10 parts, glycerin to 100).

Ichthyol 10 parts glycerin to 100.

The tampons are wreathed with a tape that hangs out from the vulva. They are introduced by the physician, remain in position for twenty-four hours, and are then removed by the patient who takes immediately an abundant cleansing vaginal douche.

One succeeds in this way in the majority of cases in healing the primary vaginitis. If the latter resists all therapeutic efforts the suspicion naturally arises that after all another causal factor is present which has been overlooked hitherto and the prognosis then depends on its removal (see the respective chapters on *Gonorrhœa* and *Tuberculosis*).

3. Inflammations of the Uterus

LITERATURE: See *Doederlein*. Entzündungen der Gebärmutter. *Veit's Handb. d. Gyn.* *Bergmann*, Wiesbaden, 1897, Vol. II. *Fronmel's Jahresber. über Geb. u. Gyn.*, 1898-1906.

A. Inflammations of the Mucosa

I. *Endometritis Corporis*

The inflammatory diseases of the uterus may be divided into two large groups:

1. Those depending on infection.
2. Those depending on non-infectious chronic causes.

Both forms usually invade the entire organ, the corpus as well as the cervix, the endometrium as well as the myometrium, often also the perimetrium.

Infectious inflammations appear chiefly in four varieties: 1, septic; 2, saprophytic; 3, gonorrhœal; 4, tuberculous infections.

Rarer forms, as typhoid, diphtheritic, and variolous are practically without importance, because they form mostly only accidental phenomena of a grave general infection. See the respective chapters on **Gonorrhœa** and **Tuberculosis** for these specific infections.

The most frequent infectious diseases of the uterus are the septic and the saprophytic. Their origin is almost exclusively associated with the processes of pregnancy, labor, and the puerperium. Other occasions for infection like trauma, examinations without aseptic precautions, intra-uterine operations, are seldom at fault.

Septic infections always gain entrance through the endometrium, which forms at all stages of gestation an easily accessible portal of entry for micro-organisms.

The infection may either remain limited to the mucous membrane or it may penetrate to any depth into the myometrium and even reach the perimetrium. This depends on the severity of the infection, which may be different in each case.

The **saprophytic** processes also infect the mucous membrane, but they never penetrate deeper into the walls of the uterus. Their micro-organisms maintain their existence only on necrotic tissue débris in the uterus, and they are rapidly annihilated after the removal of the débris on account of the reactive power of the organism.

The septic as well as the saprophytic agents of infection form pathologically in **recent** cases always the picture of a grave **interstitial** endometritis. Severe hyperemia of the mucosa (or of the still present decidua), extensive round-celled infiltration either diffuse or focally arranged and gradually decreasing from the surface to the deep structures. There are often found wholly on the surface extensive total necroses of the mucosa, which are later thrown off.

In **septic** infections this small-celled infiltration tends to penetrate

especially along the bloodvessels more or less deep into the muscularis uteri, eventually reaching the perimetrium. The lymph and blood vessels are often completely clogged by the cocci.

In *saprophytic* processes the dam of small-celled infiltration is always confined to the mucosa and, in extreme cases, to the most superficial layers of the muscularis. Deep penetrating lesions, as a rule, do not occur in them. In mixed infection the picture of the *septic* infection tends to preponderate.

Endometritis Post Abortum

If during labor or abortion remnants of the amniotic membrane and decidua remain behind in the uterus, a diagnosis of the disease that has

preceded may be made from them a long time afterward. Islands of decidua shreds with pronounced round-celled infiltration may be found; the decidua is in a state of degeneration. And perhaps also degenerated chorionic villi with more or less well-preserved fetal ectoblasts may be seen (see Fig. 93). If these positive remnants of the ovum are missing, one may draw many times the conclusion that pregnancy has preceded, from the form of the hypoblastic glands. The latter show frequently a serrated form, and the

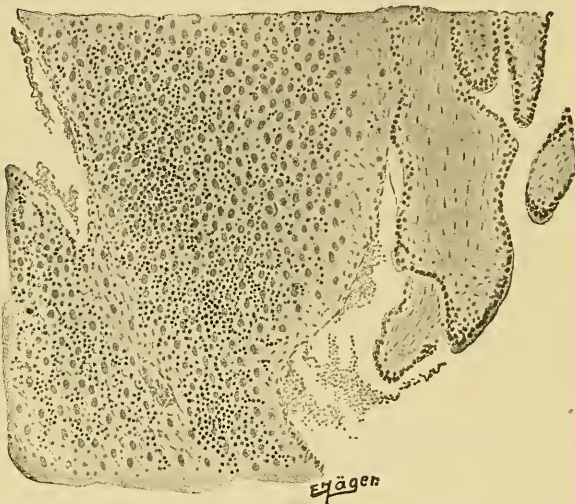


FIG. 93.—Endometritis Decidualis Post Abortum. To the right chorionic villi, to the left decidua in a state of degeneration with a marked round cell infiltration. (Author's preparation, Zeiss, Obj. AA, Oc. 4.)

epithelium projects like a cluster into the lumen (*Opitz*).

The saprophytic acute endometritis in its further course tends to heal completely, because its exciting agents are always overpowered in the course of time by the protective powers of the organism.

It is different with *septic* endometritis. In this the acute endometritis is gradually merged into a chronic form, provided the organism does not succumb to the severe general infection.

Small cell infiltration areas are found scattered about in the hypertrophic mucosa with edema in the connective tissue and *in places dilated blood and lymph vessels* (see Fig. 94). The glandular structures may also partake in the pathologic changes by hypertrophy and hyperplasia of the glands (*endometritis diffusa*). The demonstration of the primary

causative agent no longer succeeds, as a rule. This chronic stage may gradually lead to a complete cure, so that even pregnancy, labor, and the puerperium may run a physiologic course.

In other cases, however, the chronic interstitial process advances slowly but continually. A proliferation of the connective tissue of the mucosa takes place, whose round and stellate cells are gradually replaced by fibrous connective tissue. The glands are slowly surrounded by this proliferation and compressed, so that an atrophy of the glandular bodies and finally a general atrophy of the connective tissue of the entire mucosa results, which cannot be distinguished from the atrophy occurring during the climacteric (see Figs. 94 and 95).

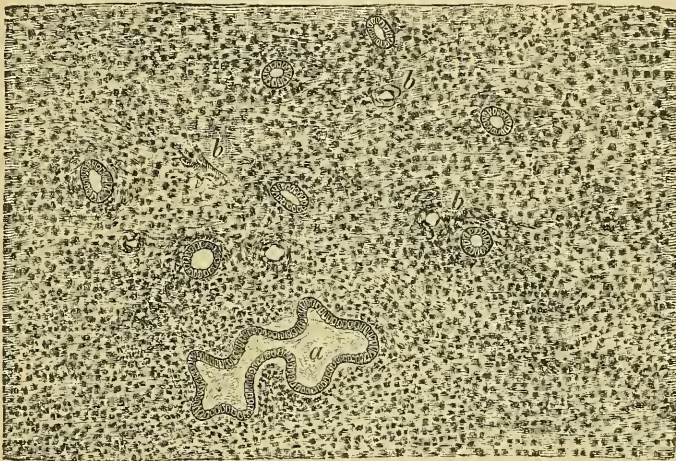


FIG. 94.—Endometritis Interstitialis (Hartnack, Obj. 4, Oc. 2). *a*, glands; *b*, vessels (Orthmann).

This chronic process runs mostly a slow course for many years and finally passes imperceptibly into the climacteric. In other cases the connective-tissue proliferation advances rapidly, and then a premature complete atrophy of the entire uterus may result, as has often been observed after very grave puerperal infection. Exceptionally the cavum uteri becomes completely obliterated in cases in which the entire decidua materna sloughs with the upper layers of the myometrium.

If through any cause an atresia of the internal uterine os occurs and if the uterine cavity has been previously infected, a retention of the purulent secretion, a *pyometra*, results.

This, perhaps, is most frequently found in puerperæ in the form of lochiometra. Otherwise pyometra occurs chiefly in old women, in whom a complete or partial atresia of the internal uterine os is not rare during the climacteric. If micro-organisms enter the uterine cavity from the vagina through any cause a pyometra also not infrequently is produced.

The rare infections caused by typhoid, diphtheria, smallpox, scarla-

tina, etc., run the same course as septic endometritis. Anticipation of the climax may, therefore, also occur in them.

Chronic disease of the myometrium, depending on a septic infection belongs to chronic endometritis, both anatomically and clinically. It will, however, be discussed in a special chapter (see chapter *Metritis*).

Endometritis depending on sepsis, however, does not always pursue the course above described, which ends sooner or later in atrophy.

As noted above, there exists in the subacute stage of septic endometritis a general hypertrophy of the mucous membrane, especially char-

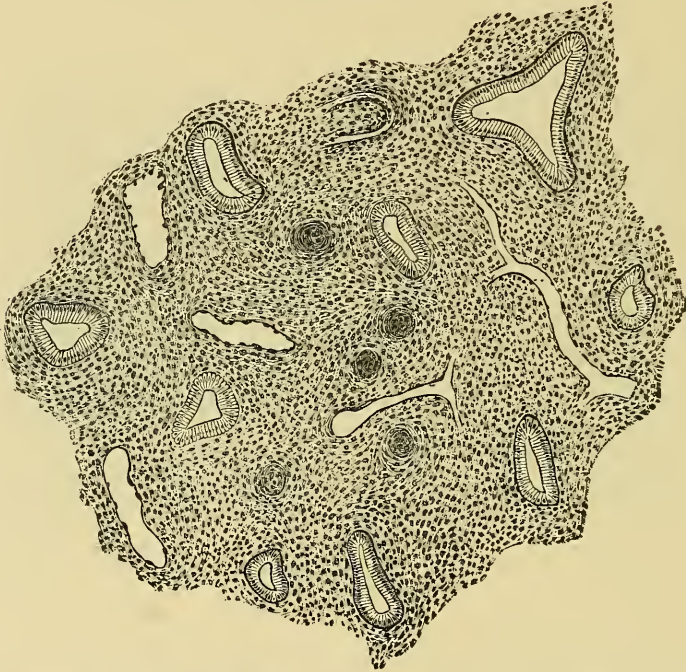


FIG. 95.—Interstitial Endometritis. Transverse section. (Enlarged 250 times.)
Orthmann.

acterized by hypertrophy and hyperplasia of the glands. If now, as not infrequently happens, the interstitial process heals at this stage, a permanent hypertrophy of the entire mucous membrane of the uterus remains as a vestige of a previous septic infection, without it being possible after a long time for one to distinguish a trace of the latter in the anatomic picture, just as in the myometrium such a hypertrophy may develop (see chapter on *Metritis*).

Accordingly septic infection may lead to two entirely opposite final results: Atrophy on the one hand, hypertrophy on the other. We have not as yet any basis on which to determine the future course of a septic process.

The anatomic pictures as we find them in endometritides, terminating

in a general hypertrophy of the mucosa, are met with in the second large group of inflammatory uterine diseases, those diseases of the endo- and myometrium which do not rest on an infectious basis, but on other chronic irritations.

It is to the identity of the clinical pictures produced by the two processes, so essentially different in their etiology, that we must ascribe the fact that the names chronic endometritis and metritis have been

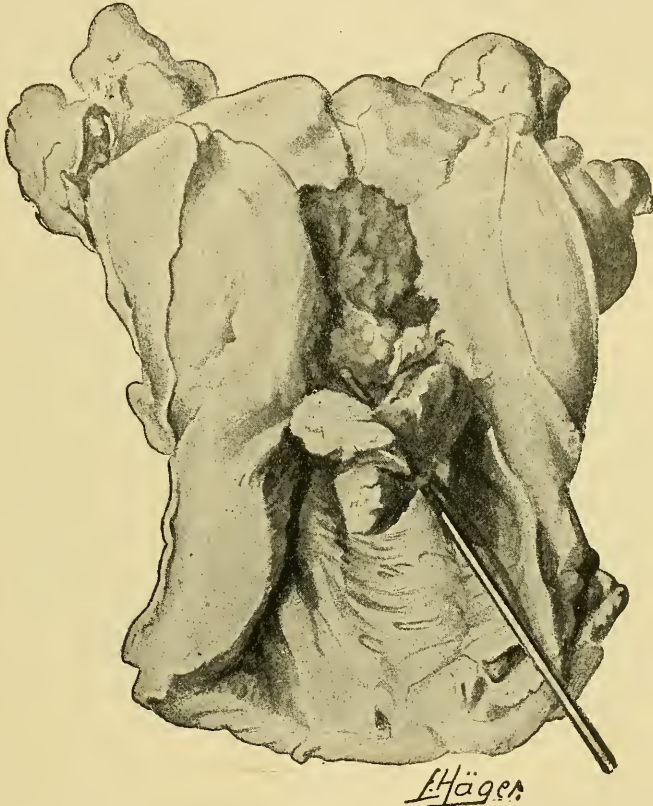


FIG. 96.—Endometritis Hyperplastica. Two mucous polypi, emanating from both sides, have grown together to form a bridge. (Author's preparation.)

given to changes in the endometrium and myometrium which do not depend on infection.

It is by no means easy to establish with certainty whether in a given case a process in the uterus depends on an infection or other chronic condition of irritation. In all cases in which a partus or abortion precedes, or where tumors with ulcerating surfaces (carcinoma) are found in the uterus, the possibility of a mild infection which caused no symptoms can never be entirely denied.

We, therefore, do well to speak of an endometritis without infection, only in cases in which we can exclude such possibilities. This is, above

all, the case in virgins and nulliparæ in whom other infections are not demonstrable (see chapters on *Gonorrhœa* and *Tuberculosis*).

We find in such women often enormously hypertrophic conditions of the uterine mucosa and also of the myometrium which may affect the glandular structures as well as the stroma or both.

The causes for these hypertrophies may be different, although it is not possible for us to elicit them with absolute certainty in every instance. First to be taken into consideration are those conditions which produce a chronic stasis and venous hyperemia in the uterus. Accordingly retroflexio uteri is one of the most frequent causes; in addition myomata, tumors of the ovaries and tubes, further chronic constipation, cardiac defects, etc., also such conditions as cause chronic *active* (arterial) hyperemia. We are generally only slightly informed about these causes. Masturbation, excesses in venery, coitus interruptus, defective hygiene during menstruation, etc., are inculcated.

It is very difficult to state where the diseased process begins and where the physiologic ceases in this condition of the uterus, for one finds

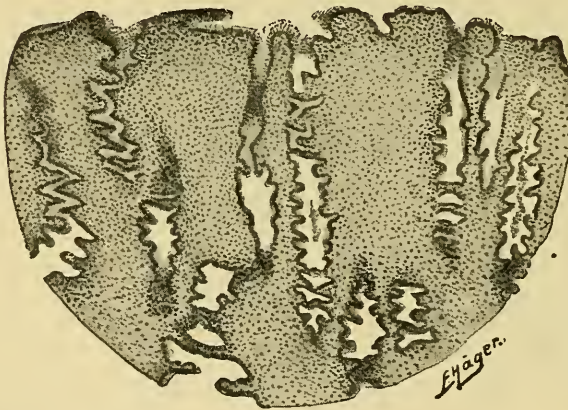


FIG. 97.—Endometritis Glandularis Hypertrophica. Serrated form of glands. (Author's preparation. Zeiss, Obj. AA, Oc. 2.)

the endometrium only very rarely entirely normal when curettement is made in connection with other operations. A hypertrophy exists very often, even if the patient has never had symptoms on the part of the endometrium.

Pathology.—The quite considerable thickening of the uterine mucosa is noticed first of all. It may reach a thickness of 1 cm and, indeed, the

formation of *mucous polypi*, single or multiple, may occur during the course of the chronic irritation, and these may project into the lumen and may even coalesce with each other (see Fig. 96).

Microscopically one finds as the most predominant changes those of the glandular apparatus. Mostly an increase in number, *hyperplasia*, as well as an enlargement, *hypertrophy* of the individual glands takes place. The hyperplasia causes in the microscopic picture quite peculiar figures as a result of the marked surface proliferation of the glandular epithelium. The tubular glands may divide in their depth into several finger-shaped processes, so that a pseudo-acinous arrangement arises. Or the gland-ducts yield laterally with the increasing hypertrophy whereby manifold

spiral forms (corkscrew or serrated forms) of the glands arise (see Fig. 97).

Very often an *invagination* of the ducts occurs on account of their vigorous growth in length, so that in a section several circular epithelial crowns packed into each other appear. The hypertrophy and hyperplasia of the glands of the mucosa may become so extreme that the stroma is almost entirely crushed and a narrow strip only remains between the glands. Such cases have been spoken of as *benign adenomata*. As, however, the epithelial cells never penetrate the basal membrane of the gland we cannot admit the term *adenoma*, which signifies a *new growth*.

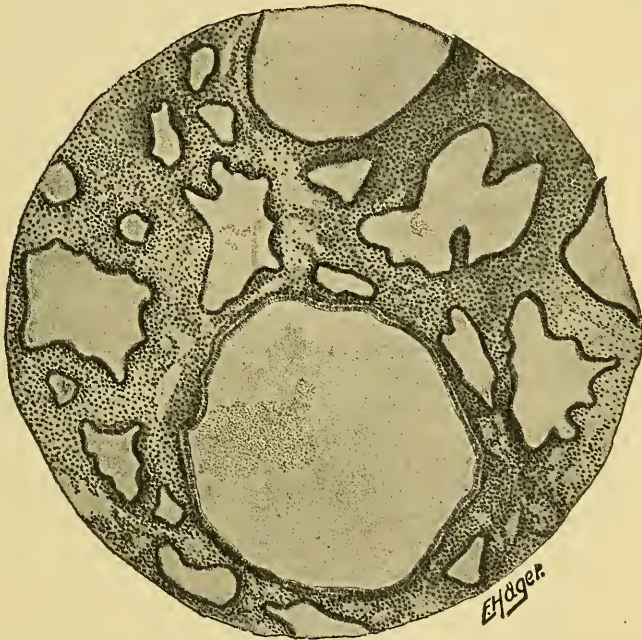


FIG. 98.—Endometritis Glandularis Hypertrophica. Cystic enlargement of the lumen of the gland. (Author's preparation. Zeiss, Obj. AA, Oc. 2.)

The matter in question is only a chronic hypertrophic condition which is capable of a spontaneous resolution. All these processes appear with a pronounced increase of the glandular secretion which empties as *fluor albus* (leucorrhœa) from the uterus into the vagina. A closure of the duct may arise from the pressure of glands lying close together. Then the secretion is blocked within the glands, the lumen expands, the epithelium is flattened by the increased internal pressure, and a *cystic* enlargement of the glands arises (retention cysts, see Fig. 98), *endometritis glandularis cystica, s. ectatica*. In this the epithelium always preserves its *single-layered* character. The increase always takes place *on the surface*, a penetration into the deeper layers never ensues, and the basement membrane of the glands always remains preserved, so tha the

process retains an entirely benign character in spite of the great capability for proliferation of the epithelium.

The *stroma* also takes part in the general hypertrophy; it becomes richer in blood and tissue fluids, an *interstitial edema* appears in places, the stroma cells proliferate, and they are large with round and readily staining nuclei. A round cell infiltration is, however, found only very rarely in these forms, and particularly at the time of the premenstrual congestion.

A spontaneous resolution of such hypertrophies may ensue, with the removal of the cause if the condition has not yet become chronic.

While a shedding of the superficial epithelium of the mucosa, as is well known, does not take place during the menses, or only in a very mod-

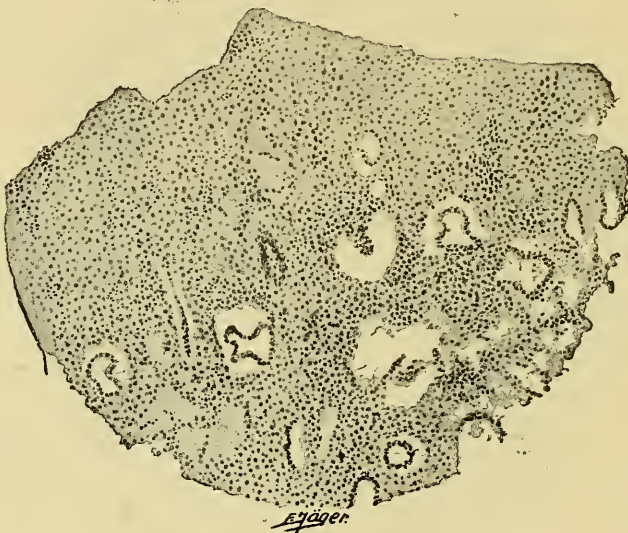

FIG. 99.—Endometritis Exfoliativa. Mucous membrane of the corpus uteri expelled during menstruation. (Author's preparation. Zeiss, Obj. AA, Oc. 2.)

erate degree (see p. 15), there are rare cases in which a thick layer of mucosa is expelled as a coherent membrane, always with menstruation, or is expelled also in several shreds with the menstrual blood often with laborlike pains (*decidua menstruationis*). This occurrence, the etiology of which is entirely inexplicable, has been designated *dysmenorrhea membranacea* on account of the disturbances connected with it.

Anatomically the surface epithelium of the expelled membrane is almost always found destroyed. The stroma cells are swollen and stain with difficulty, like the decidual cells. With it there exists an abundant round cell infiltration and a permeation of the entire mucosa with serum. The glandular epithelium is often exfoliated, but at other times still well preserved (see Fig. 99).

This expulsion of the superficial layers of the uterine mucosa may be

repeated with each menstruation. This form of disease, entirely independent of pregnancy, and therefore also occurring in virgins, must be strictly differentiated from *endometritis post partum* or *abortum* (see p. 166).

II. Endometritis Cervicis

It has already been stated that inflammatory diseases affect the entire uterus, mucosa and wall, corpus and cervix, in the same manner, but

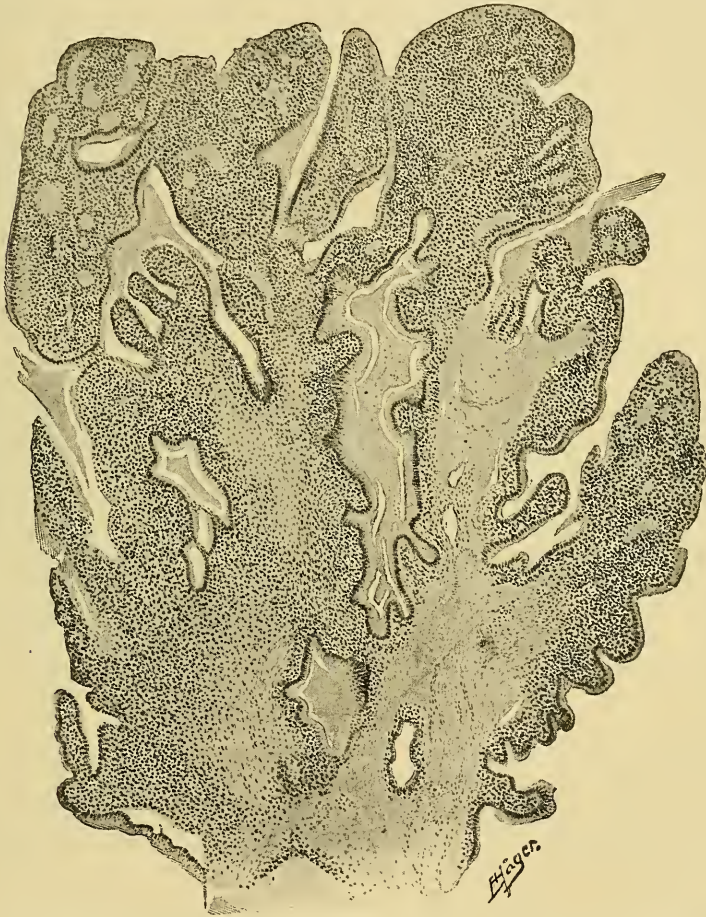

FIG. 100.—Papillary Erosion of the Portio Vaginalis. (Author's preparation. Zeiss, Obj. AA, Oc. 2.)

that some parts may become diseased independently. The latter statement concerns particularly the cervix uteri, which not at all infrequently may be the only seat of inflammation. The latter probably always depends on the continuous contact of the cervix with the vagina, which always contains bacteria, while the corpus is protected more or less by

the internal uterine os, which under normal conditions forms a barrier against the immigration of bacteria.

Inflammations of the cervix, like those of the corpus, have their place of origin mostly in the mucous membrane. Here also occurs a continuation into the wall of the cervix and portio. In the cervix also inflammations caused by infection are distinguished from those attributable to chronic hyperemia.

Inflammation of the cervix, depending on infection, almost always follows the occurrence of labor and the puerperium. During labor there always occur superficial and in most cases also deep wounds and tears, which form an excellent place of entrance for the bacteria of the vagina. Therefore, they do not heal by primary intention, but continue to exist as cervical lacerations. If they extend into the vaginal vault they are termed *cervico-laquear lacerations*.

A gaping of the external uterine os and of the lower portions of the cervical canal originates from these tears, and thereby the cervical mucous membrane is everted to a greater or less extent into the vagina: *Eversion of the mucosa, ectropium of the cervical lips*. The bacteria exercise an influence on the layer of cylindrical epithelium entirely different from that on the squamous epithelium and an acute inflammation results very soon.

The mucosa becomes hyperemic, permeated with serum, and a profuse round cell infiltration arises. A proliferation of the cervical glands as well as of the connective tissue ensues from the chronic irritation, so that soon the surface of the mucosa assumes a knobby, uneven character. The color is intensely red, the frail papillary elevations tend to bleed on the slightest manipulation (*papillary erosions*, see Fig. 100).

In this condition also an enormous increase of the secretion (fluor albus, leucorrhœa) results, a blocking of the secretion by agglutination of the glandular ducts, or the formation of large or small retention cysts may also take place (*follicular erosions*, so-called *ovula Nabothi*, see Fig. 101).

Both forms, papillary and follicular erosions, may exist at the same time, as they are only different stages of the same diseased condition. A formation of large mucous polypi may result from a prolonged duration of the chronic irritation, which have all the above described anatomic characteristics.

The two varieties of epithelium which verge on each other at the portio show a peculiar behavior in the erosion. While otherwise a distinct line of demarcation exists at the boundary between the squamous epithelium of the portio and the cylindrical epithelium of the cervix both encroach on each other in the erosions. The cylindrical epithelium of the cervix proliferates often far over the surface of the portio, while the squamous epithelium may penetrate deeply into the canals of the cervical glands. Retention cysts (ovula Nabothi, see above) may arise through overproliferation of the duct of the gland by squamous epithelium.

Symptomatology

A. *Acute cervicitis* expresses itself less in acute sensations (pain) than in changed secretion. The scanty normal secretion of which the woman is insensible, becomes more abundant, mostly a thin and serous liquid, also somewhat bloody, but at times also creamy and purulent. It is, as a rule, caustic for the surface of the vulva. Fissures and lacerations in this region burn intensely. This stage may subside rapidly. However, as a rule, it passes into a chronic condition in consequence of defective care. Virgins and sensitive persons become easily irritated

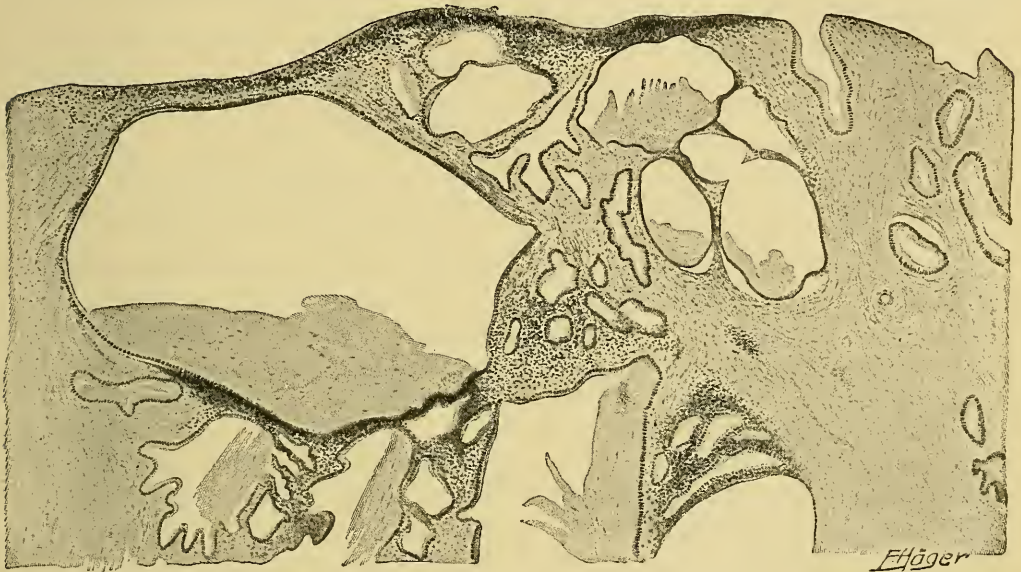


FIG. 101.—Follicular Erosions of the Portio Vaginalis. So-called **Ovula Nabothi**. (Author's preparation. Zeiss, Obj. AA, Oc. 2.)

by these secretions. Fever occurs only in infections with highly virulent germs of inflammation.

Chronic cervicitis is characterized by the continued increase of secretion and by a gradually developing sensation of dull pain in the womb. The secretion is usually abundant, dirty, also whitish (**fluor albus, leucorrhœa**). The patients are often not at all disturbed by it as to their general health. A bad odor develops rapidly with uncleanness. The secretion in other cases acts like a caustic, even when it is produced only in small quantities. If erosions develop on the cervical lips a bloody secretion is produced, and abundant atypical hemorrhages occur even with the slightest manipulation of the diseased mucous surface.

The conception of the mutual action of uterine inflammations and solution of continuity of the cervix, the so-called **cervical lacerations**

that so often occur in connection with labor, as advocated in the well-known writings of *Emmet*, particularly in American literature, receives at present a materially calmer estimate. One often has opportunity to observe such tears unaccompanied by catarrh.¹²¹ Cervical lacerations merely furnish an opportunity for the entrance of the different germs of disease. With the existence of such tears the hypertrophied mucosa swells out either within its old limits on the surface of the portio with pronounced changes in its substratum and forces apart the cervical lips, deprived of their support in the closed uterine orifice—*Eversio labiorum*—or the process creeps through the place of laceration on to the external surface of the portio and spreads over the surrounding tissues, the vaginal vault.¹²²

If a complete occlusion of the gland-ducts occurs on account of the hypertrophy of the glands, *retention follicles* arise (see supra, p. 174), which through pressure irritate the surrounding parts. A feeling of pressure and burning ensues which gives the patients no rest.

Another peculiar result of cervicitis is the development of *stenosis of the external os uteri*. Such cicatricial contractions occur at the border of the mucosa during the process of healing, so that often an opening only the size of a pinhead remains. The secretion becomes blocked back of this narrow opening and the cervical canal is dilated to the form of an ampulla; below, the space is closed by the stenosed external os, above by the rigid tissues surrounding the internal os. The cervix thereby becomes elongated to form the *elongatio colli supravaginalis*. If in the further course of the disease the catarrh recedes and the secretion decreases on account of atrophy of the mucosa, a *supravaginal elongation* of the cervix and a *stenosis* of the external os remain. It is comparatively rare that one has the opportunity to observe this etiologic connection immediately in virgins, for girls shun treatment for a long time on account of modesty. A diagnosis of stenosis and elongation is not made until after marriage or some other circumstance brings them to the physician. The now scanty secretion flows out painlessly from the external os. In rare instances only is the stenosis so rigid that only a fine sound can be inserted. In most cases one succeeds in inserting not only the thickened head of the sound, but also the curette. *Elongatio supravaginalis* is much the most important result of the disease of the mucous membrane.

B. *Symptoms of Corporeal Endometritis.*

Acute inflammation of the mucous membrane of the corpus may begin with chills and fever, but these symptoms are seldom severe or lasting, although one must always regard this inflammation as infectious. Pain usually accompanies this disease and a sensation of pressure and troublesome weight in the pelvis is not lacking. If the inflammation begins at the time of menstruation a sudden cessation of the bloody discharge is frequently observed as a result, but not as a cause of the uterine inflammation. The *suppressio mensium* is followed, sometimes after a

few hours, sometimes after days, by a much more profuse bleeding, and with this the pains decrease. The entire pelvic organs, especially the bladder and rectum, become sensitive. The secretion increases, an admixture of pus takes place, as well as one of blood, which results from the disintegration of the ciliated epithelium and of the superficial layers of the mucous membrane.

All varieties of *chronic disease of the mucosa corporis*, which have been described as *diffuse hyperplastic fungous endometritis* and as *glandular endometritis*, have as the most pronounced symptoms *increased secretion* and *bloody discharges*. The leucorrhœa is watery or creamy, serous or purulent; at times it appears to become periodically decreased or increased. As *W. V. Franqué*¹²³ has shown, it is not possible to establish, from the secretion or the bleeding, anything characteristic of the various anatomic forms.

The *bloody discharge* commences usually in connection with the typical menstrual flow, occurring, however, in its further development, quite often between the periods.

Pains do not manifest themselves constantly as a symptom of catarrh of the mucosa corporis. They are often dull and intermittent, appearing shortly before and during the menses, while in other cases they occur as continuous sensations localized in the depths of the pelvis. There is nothing characteristic in these pains as accompaniments of menstruation. Dysmenorrhœa may be either present or absent.

It is remarkable that the pains usually precede the bloody flow proper and cease with the establishment of the menstrual discharge. In other cases they occur, but only for a few hours, with the beginning of the flow or during its continuance. They are at times the more violent the less blood is secreted. The pain shows such variation that one does not seem justified in selecting a special form of *endometritis dolerosa*.¹²⁴ Likewise I see no possibility of bringing the cases of *Mittelschmerz*, the disturbances which take place with some sort of regularity between two periods, in connection with a definite variety of disease of the mucous membrane. I have observed for many years women with intermenstrual pains, to be sure, of no great severity who otherwise felt quite well, did not show any demonstrable anatomic changes in the genitalia, and enjoyed life thoroughly without any treatment.

However, it appears to me that precisely the peculiar changes in the cervix, the *elongatio colli supravaginalis*, which I consider a result of the catarrh, are with overwhelming frequency to be held responsible for the *sterility*. Observations, repeated several times, speak, in my opinion, for this connection. When the stenosis or the endometritis were at first alone made the point of attack, the results were unsuccessful, but when the *elongatio supravaginalis* was removed, conception followed. The viability of the spermatozoa can without doubt be affected by the nature of the secretion and it is quite evident that the ovum cannot imbed itself in the mucosa when deprived of its normal epithelium and in the secre-

tion covering it, and that the power of the mucosa to develop the decidua ceases after chronic inflammation, even after a partial regeneration of the internal surface of the uterus. We have become more careful in judging of the causes of sterility since we have learned what value to put on the participation of the husband. The changes in the cervix certainly deserve full consideration, but the causes for sterility lie too often not in the uterus at all, but in the tubes, ovaries, and especially in the peritoneum (see chapter *Perimetritis*).

Endometritis chronica catarrhalis is regarded as a source of disorders of the stomach, dyspepsia in all its forms, headaches, and complex, severe nervous symptoms. The changes in the secretion and the bloody flow certainly conduce to disturbance of the general well-being of the patients and tend to lessen their enjoyment of life, rendering them permanent invalids. Frequently other diseases, not only of the genitalia, but disturbances of the general nutrition, and an education ill adapted to an energetic and rational mode of living and vocation, cooperate with it.

In the *exfoliative form of endometritis* the symptoms occur frequently in connection with menstruation usually before, often during, and seldom afterward. Menstruation is often absent for six to twelve weeks, so that pregnancy is suspected. If blood is lost the suspicion lies near that an abortion may have occurred.

The expulsion of membranes is almost always accompanied by extremely violent, colicky pains. Frequently an intense feeling of fulness and malaise is experienced occasionally for a week before this period, until, with laborlike pains, an abundant flow of blood occurs, during the course of which the membrane is expelled. Menstruation remains absent for days and weeks in other cases, so that the patient thinks herself pregnant, until the pains and loss of blood occur again, at times apparently as the result of some unimportant injury. The expulsion of membranes takes place rarely without pains. *Winter* has inferred from this that the exudation preceding the detachment of the membrane and not the contraction of the uterus causes the pain.

Women with dysmenorrhea membranacea are, as a rule, sterile; pregnancy, at all events, is seldom carried to full term, as long as such mucous shreds are expelled. The idea, however, formerly generally accepted, that membranous dysmenorrhea is an absolute cause of sterility, has been disproven by many observers. (*Löhlein*, 6 in 27, *Hofmeier*, and also in five of my cases.)

III. Diagnosis

The *diagnosis* of *acute* endometritis is effected by the demonstration of the specific germs of sepsis, gonorrhoea, or tuberculosis, and in the catarrhal form by pain, fever, tenderness, and increase in the discharge.

The *diagnosis of chronic catarrh of the uterus* may be very difficult, especially if the diseased mucosa, situated in the depth of the cavum, is

inaccessible to palpation. The tedious development of the symptoms, the menorrhagia, characterized by a gradually increasing severity, and the change in the discharge are regularly elicited facts of the clinical history which also shows that the symptoms apparently appeared without premonition and unexpectedly, although in other cases they are almost entirely lacking. Most frequently, however, the affected part, the cervical mucous membrane, is so accessible that it bulges out of the os uteri in its hypertrophic condition, whether the os is torn or is still tightly closed.

The erosions extending over the borders of the uterine orifice, and eventually the disintegration of the tissue projecting over the surface of the portio, are positive diagnostic points which seldom admit of doubt. Doubts as to whether we are dealing with a simple catarrh or with a beginning newgrowth, are removed by the same method as we adopt to establish a diagnosis of special diseased conditions of the deeper-situated parts. For this purpose the leucorrhœa and the changes in menstruation afford signs which are to a certain degree characteristic. **Palpation** with the **sound** gives information as to the sensitiveness of the diseased region, a symptom of diagnostic importance, but, as it appears to me, overestimated. Whoever has used the sound much himself and has observed its use by others is likely to be very critical in his estimate of the value of determinations of sensitiveness by the sound.

A complete diagnosis is assured only by the microscope. For the use of the curette to obtain the material necessary for this examination see above, p. 29.

The examination of the secretion obtained on a test tampon (*B. S. Schultze*¹²⁵) allows no conclusion as to the location of the source of the secretion. The examination of the secretion should not be omitted in doubtful cases, but it accords better with our present views to take samples for inoculation and cultivation with a sterile platinum loop.

The **differential diagnosis of** endometritis exfoliativa is determined by the absence of chorionic villi in a preparation of the mucous membrane when examined by the microscope; this sign is at all events more important than the distinction between larger and smaller so-called decidual cells. Similar decidual formations are expelled in ectopic gestation. The demonstration of the extrauterine fetal sac is necessary to determine whether the membrane cast off is to be considered as due to the stimulation of such a pregnancy or to a disease of the mucous membrane.

The **differential diagnosis**, it must be emphasized again, is not determined by any kind of clinical symptoms. The microscopic examination of the secretion, or if necessary of the mucous membrane, must decide. In regard to tuberculous endometritis we wish to lay stress once more on the fact that it hardly ever runs an acute course. A positive diagnosis by demonstration of the histologic changes is, however, often very difficult.

IV. Prognosis

The prognosis of diseases of the corporeal uterine mucosa is not unfavorable in *acute* catarrhal attacks. The *chronic changes* also, which appear after a neglected puerperium or as complications of general diseases like chlorosis, scrofulosis, etc., often heal with surprising rapidity when given the necessary attention. *The prognosis is less favorable with chronic interstitial or glandular proliferation*, and in cases in which erosions develop with extension of the hypertrophied mucous membrane beyond the boundaries of the external os uteri.

It is one of the characteristics of chronic diseases of the mucous membrane that they fluctuate in their intensity, apparent periods of quiescence alternating with more or less stormy exacerbations. On the other hand, chronic metritis and perimetritis must not be looked on as unimportant complications with respect to prognosis. The general health is permanently disturbed, the patients become anemic, miserable, disgusted with life, sterile, and a burden to themselves and others.

The prognosis is further influenced by the *tendency of the catarrhal process to recurrence*. Relapses from insignificant causes protract convalescence in spite of every kind of treatment, least perhaps after curettement followed by cauterization. Diseased gland-ducts are left behind which extend down into the musculature and become the starting-point of recurrences. On the other hand, the old injurious influences such as marital relations, perverse sexual excitability, or infection only too often reexert their influence in a short time and render uncertain the result obtained with such care.

The diseases of the endometrium have a particular significance as regards the *capability for conception*. Numerous women conceive, if not in the acute stage, at least when affected with chronic catarrh of the uterus. Pregnancy proceeds undisturbed with the exception of somewhat increased secretion and occasionally bloody discharges. The child is born healthy and in normal labor. The puerperium also passes normally. In contrast to this some women with an apparently insignificant catarrh either do not conceive at all or abort habitually in the early months and with profuse hemorrhages. In others the child is born prematurely and is poorly nourished. The mothers become sick during the puerperium, after an irregular expulsion of the fetal membranes. The cause of these disturbances is certainly to be sought for in the continued action of the exciting cause of the disease. It remains a question in many cases whether or not operative interference may have introduced new germs or caused the migration of those contained in old lesions to the upper portion of the genital canal. With reference to the reproductive functions, therefore, the prognosis of uterine catarrh must be a guarded one.

Pregnancy has many times been acclaimed as a panacea for diseases of the uterine mucosa. The changes in the uterus connected with it may

certainly have a favorable action. If, however, one takes into consideration all the disturbances which too readily accompany this physiologic condition, it is not surprising that this cure so often proves a failure; abortion occurs and consequently the prognosis is not improved.

When we consider that diseases of the mucosa with a certain degree of intensity always lead to proliferations either of the glands or of the interstitial tissues, it cannot be denied that in this tendency to new-growths there lies at least a favorable soil for the development of malignant neoplasms.

V. Treatment

We will not discuss the treatment of septic endometritis which is usually puerperal. For the treatment of gonorrhœa, see p. 183.

An appropriate general treatment is the first step to be taken in the treatment of uterine catarrh, whether in the cervix or the corpus. So-called constitutional diseases deserve the fullest consideration; the state of nutrition should be improved by proper diet, muscular exercise, living in the open air—as far as possible in the woods and mountains, or, with moderate losses of blood, at the seashore, with the aid, if necessary, of iron and arsenic, forced feeding, and the like. These measures must be supplemented by the utmost rest of the genital organs (intermission of sexual intercourse) and especially by the omission of all forms of local treatment. The last provision especially is of decisive importance while the patients are taking a course of treatment at a watering-place for the improvement of their general health. The salutary effect of such balneo-therapeutic measures is only too frequently compromised in a serious manner by local treatment.

Unfortunately the directions above described are only too often imperfectly carried out, and lack of judgment or want of pecuniary means or negligence thwart the beneficial action of such advice.

On the other hand, it cannot be denied that uterine catarrhs are not permanently influenced by these remedies. Deep-seated disease of the glands, injuries after labor, accompanying disease of the myometrium are found as the reason for such failures, especially when the process has remained unobserved for a long time. Moreover, the injuries produced by a therapeutic maltreatment, the so-called local treatment,* cauterization, dilatation with tents and the like, retard healing, not to mention new infections, and their spread by frequent and very thorough examinations, the use of the sound, etc.

For the cure of *cervical catarrh* we make extensive scarifications of the diseased mucous membrane, which include the erosions down to their base. The scarifier (any scalpel, particularly a bistoury, is suitable) is inserted into the cervical canal in hypertrophy of the mucous membrane and brought out with a long cut through the mucous membrane. After the bleeding ceases a tampon of sterile gauze is inserted which is removed

* See also *Pfannenstiel*, Monatschr. f. Geb. u. Gyn., Vol. XXIII, p. 601.

after six hours, during which time the patient remains quiet, strict rest in bed not being required. With it vaginal irrigations of 0.9 per cent. saline solutions must be used once daily. The scarification is twice repeated at intervals of two or three days, then after four or five days once or twice according to its curative action. Then tannin glycerin tampons are used five or six times (acid. tannic., 10.0; glycerin, 100.0) or ichthyol tampons (ichthyol, 10.0; glycerin ad, 100.0). If a cure does not occur with this treatment in four to six weeks an excision of the erosion should be made which removes, in deep-seated infiltrations, a proportionately large part of the cervix.

As soon as the *corporeal mucous* membrane does not heal after regulation of the general health, suitable cleanliness, and consideration of the genital organs, with vaginal irrigations and sitz baths, and in such cases as do not afford favorable opportunity for such treatment I remove the *diseased mucous membrane with the curette*. The diseased parts are thus removed at one sitting, without the necessity of a preceding dilatation of the cervix and at the same time a sure foundation is obtained for the diagnosis of the special variety of the disease and for future treatment if necessary. No other local treatment of the corporeal mucous membrane has given such uniform good results as *curettage followed by cauterization*. All other measures, even the dilatation with *Hegar's* sounds and irrigation of the uterine mucosa are essentially more troublesome. So far as I have been able to follow it they have not been as frequently and proportionately efficacious as curettement from which, on the other hand, I have not seen any bad results of any severity.

Abrasion of the mucous membrane must be immediately employed if the chief symptom of a disease of the mucous membrane is a profuse meno- or metrorrhagia, which cannot be permanently influenced by the well-known styptic remedies (ergotin, stypticin, hydrastin, and the like).

The use of the *sharp curette* admits the possibility of particles of the mucosa remaining, which are perhaps the ones characteristically diseased. The *dull curette* removes with certainty by proper manipulation the entire internal surface of the uterus. That pathologic processes may invade again the reformed mucous membrane from the glandular ducts situated in its deepest layers, so that a recurrence of the catarrh takes place, not to mention the action of other irritants which may reach it, cannot be denied. There is at present no procedure which can exclude recurrences of disease of mucous membranes unless it completely and permanently removes the mucosa.

The necessity of cauterization after curettage is perhaps generally recognized;¹²⁶ the question is only whether one should employ it immediately after curettement. I consider this the simplest plan and cannot understand why one should cauterize a new-formed mucosa days and weeks after the operation. Local treatment is virtually disposed of with the one operation, the general treatment takes its rightful place, and the

patients follow instructions more obediently in view of the seriousness of the treatment.

The **remote results** are influenced not only by baneful external agents, but a special danger is offered by **complicating adnexal disease**. At present no gynecologist hesitates to attack these conditions. **They form the barrier for every local treatment of the uterus in case one does not perform both tasks at the same time.**

Electrotherapy of endometritis has not given satisfactory results.

Vaporization (atmocausis) of the uterine cavity, recommended by *Sneguireff*,¹²⁷ in 1897, has found an eloquent advocate in *Pinkus*.¹²⁸ Even with very careful technic the procedure does not seem to be free from danger, as one cannot control the amount administered. Even cases of death have been reported from the treatment. The objection that with energetic application a fatal destruction of the mucosa even down to the muscularis, with complete obliteration occurs, is of more importance. It seems to me that the method has no decided advantage over curettement. I welcome with satisfaction the communication of *Pfannenstiel*¹²⁹ who takes the same ground.

Exfoliative endometritis is one of the most obstinate forms of disease. Repetition of curettement with thorough cauterization (with iodine, liquor ferri perchloridi, chlorid of zinc in concentrated solutions, and the like) finally brings about a transformation of the mucous membrane. At first the result does not last longer than from one-half to one year. I was able to follow a number of such patients who remained well for years; in others the successful result was only complete after years. But I have also seen dysmenorrhea membranacea return after years, in spite of the fact that immediately after the excision of the hypertrophic cervix, the uterus became very markedly reduced in size and from the clinical findings it could be rightly assumed that it had undergone a transformation. Only bodily rest and the use of narcotics are left at our command in such cases when the pain occurs. Recovery naturally ensues with the climacteric.

Total extirpation of the uterus is justifiable for the relief of the severe pain caused by uterine catarrh, if the above-described treatment after repeated trials is unsuccessful.

Gonorrhoea in the Female

Gonorrhoeal disease of the female has attained such importance through the biologic, anatomic, and clinical research of the last decades that it seems imperative to discuss it here in all its relations and in its entire extent. The first suggestion of its importance by *Noeggerath*¹³⁰ met at first with skeptical rejection. The work of *Neisser*¹³¹ gave the necessary foundation for diagnosis. This was supplemented to an important degree by *Bumm*¹³² and especially by *Wertheim*.¹³³

The method of bacteriologic examination will be found on pp. 33-37.

Transmission occurs in adults, as a rule, through sexual intercourse. *Noeggerath* assumed that 90 per cent. of those infected with gonorrhœa remained capable of conveying infection even when they had no objective or subjective signs of gonorrhœa. He designated this condition as "**latent gonorrhœa.**" At present we assume that this percentage is too high. On the other hand, it must be recognized that a large proportion of men who have had gonorrhœa still remain capable of conveying the infection. The well-known signs of chronic gonorrhœa in men, the gluing together of the urethral opening, the *goutte militaire*, threads in the urine, have a certain significance, but the demonstration of gonococci is the decisive criterion. That this requires great practice, that the matured form of the bacterium must be discriminated with great care, has been presented above. For the mode of the starting-point of the infectious processes it must be observed, as *Doederlein* rightly remarks, that in virgins the narrow introitus vaginæ seems to be more easily, and the urethra very much more, endangered than in those who have been deflorated, in whom the deeper parts of the vagina and the cervix are more likely to come in contact with the infectious material. Probably fresh gonorrhœal pus excites more stormily commencing symptoms, and an infection more likely to spread upward than old, latent gonorrhœa. Nevertheless, **infection** with an old gonorrhœa occasionally runs a very acute course in the **infected** individual. Infection shortly before the onset of the menses is mostly very detrimental. An acute propagation of the cocci occurs at times during childbed, which causes very stormy symptoms.

A sort of immunity occurs in marriage, but intercourse with a third party may prove dangerous to the latter (*Wertheim*). Still not every coitus is detrimental, for the genital secretions may be free from gonococci at times in chronic gonorrhœa. Severe irritation of the genitals by frequent cohabitation, approaching menstruation or pregnancy, favor the propagation of the virus in woman, so that she may become dangerous for her own husband, even though he is the victim of a chronic gonorrhœa. The same applies to the male whose latent gonorrhœa may break out afresh, from intense irritation (recent wedlock, even after an interval of many [20] years). Apparently puzzling occurrences in practice find in this fact a natural explanation. It is not necessary in such cases to assume a recent infection by illegitimate intercourse.

That the transmission of the cocci may take place in other ways admits no question. Rape in children is rarer than the laity suppose; the infection is more frequently due to touching with fingers soiled with gonorrhœal pus, by the father, mother, or perverts, or by the accidental contamination with gonorrhœa-soiled sponges, wash linen, bath-tubs (*Skutsch*).

The localization of the infectious material occurs naturally first of all in the **vulva** and the adjacent parts of the **vagina: Vulvo-vaginitis gonorrhœica.** Intense reddening and swelling, severe pains, abundant

secretion, which stagnates in the folds and sinuses. The sometimes shallower and sometimes deeper recesses at the sides of the urethral opening (*Skene's* ducts, glandulæ vestibulares minores) and *Bartholin's* glands (glandulæ vestibulares majores) are places of predilection. The ducts of these glands appear surrounded by a red area, a sign which *Sänger*,¹³⁵ according to my observations with a certain justification, emphasized as **macula gonorrhoeica**. Closure of the opening by edema leads to the retention of secretion. Whether the discharge finally occurs only in mixed infection, as *Doederlein* claims, may be left unsettled. Rupture of these abscesses to the exterior, into the deeper tissues, the rectum, or the periphery of the anus, are not quite rare accompanying phenomena. *Pölehen*¹³⁶ traced a great number of periproctal abscesses back to Bartholinitis.

The **vulva**, and especially the **vagina**, of a child seems to suffer more extensively and longer from a gonorrhoeal infection. Doubts for the disease of the vagina of adults are also excluded through observations in my cases.

The **urethra** takes part in the process, but with a less marked intensity than in the male.

As a matter of fact women rarely complain about the burning in the urethra; the moistening by urine of the inflamed vulva or of fissures in the latter resulting perhaps from defloration, cause much more frequent and intense pains. However, the strongly increasing strangury is very troublesome and leads to much complaint. Shortness and width of the urethra, and the absence of glands in women explains the subsidence, frequently so rapid, of the inflammatory process. Chronic changes, thickening and discharge may last for a long time without any sensation of pain. *Wertheim* has proven that a cystitis gonorrhoeica may arise. It is seldom that an ascending ureteritis or pyelonephritis occurs.

The gonorrhoeal diseases of the vulva and the adjacent vaginal portion present at times the picture of **a colpitis granulosa**, the epithelial layers are macerated, the inflamed, infiltrated papillæ appear like red little knobs. A **proliferation of the stratum papillare in the external genitalia and vagina** may result from a chronic action of the gonococci. The papillary hypertrophy extends over the entire genitalia in the form of acuminate condylomata, which often are found coalesced into small groups in the fossa navicularis, or appear in groups in the external parts as far as the nates. As is well known the acuminate condylomata can develop to a large size. I have extirpated masses of condylomata in a fifteen-year-old girl, which covered the labia until far beyond the anal groove, with tumors the thickness of four fingers.

Scratch marks and abrasions of the epithelial covering are converted into small, then large **ulcers** in gonorrhoea, just as in other diseases. The edges appear at times strongly infiltrated, the granulations weak and with a dirty coating. These ulcers are not limited to the posterior commissure as the syphilitic ones or on the edges of the labia, but they are

located also in the anterior periphery of the vulva and all over the lower vaginal portion.

Inguinal buboes in women contain, besides the gonorrhoeal coccus, a mixture of germs. I have not found in them pure cultures of gonococci.

The *dissemination of gonorrhoea* above the locus infectionis comes under observation partly in the form of a swelling of the inguinal lymph-glands, partly in an extension into the deeper lying parts of the genital mucous membrane.

The *endometritis gonorrhoeica* belongs to-day to the relatively not rare findings. The cervical mucous membrane offers first of all the most favorable nutrient medium, the alkaline mucous plugs, the mucosa lined with cylindrical epithelium, with their numerous glands admit directly the cocci introduced with the spermatic fluid, which penetrate the uninjured epithelial covering,¹³⁷ and still easier the mucosa injured during labor or operations or macerated by the fluid of other diseased processes.

Reddening and swelling, abundant muco-purulent secretion and erosions are signs of this disease; sensations of pain are less pronounced. The entire changes may at first be insignificant, and remain so for a long time, to become aggravated from occasional injuries as, for instance, during menstruation, but particularly the puerperium so as to cause surprising stormy manifestations.

My experience permits me to agree with *Bumm*¹³⁸ that the ascent above the ostium uterinum internum is a relatively rare occurrence. A purulent discharge, at first slight, then in a few days increasing in amount, appears with fever and severe pains. An abundant round cell infiltration of the endometrium corporis may be demonstrated. The stormy beginning is soon followed by a striking subsidence of all symptoms, so that chronic corporeal gonorrhoea is at all events a rare occurrence, in remarkable contradistinction to the cervical gonorrhoea with its non-healing erosions of the cervical lips and the exhaustless secretions.

The encroachment of the cocci on the *tubes*, from there on the *ovaries* and *pelvic peritoneum* is carried into effect mostly with extremely stormy initial symptoms. Fever and pains, which at first appear to be exclusively confined to the flanks soon adopt the character of a pelveoperitonitis and extend over the entire lower abdomen, begin suddenly apparently without cause. One may frequently establish, with an exact inquiry into the anamnesis, that the disease followed sexual excess, the beginning of menstruation, gynecologic examinations, or efforts at treatment (sounding, attempts at reposition, treatment of cervical catarrh by pencilling). The symptoms—hyperpyrexia, meteorism, excessive pains, threatening collapse—may become so severe that the possibility of saving the life of the patient is only seen in an immediate operation, which then usually consists in extirpation of the adnexa and, if necessary, also the uterus. I have since learned to look at these cases more calmly. Only in mixed infections do I regard the danger so imminent that at the present time I consider a radical interference as justifiable.

The gonorrhœa is completely obscured in *mixed infections*. The gonococcus becomes overwhelmed with the luxurious growth of other cocci, for instance, septic.

The acute stage of pure salpingitis gonorrhœica runs a smooth course in the majority of cases, contrary to *Doederlein* (in the passage quoted). Even complete restoration of the capability of function to the tube results. With the exception of a minority of severe changes, the majority recover, even if the tubal gonorrhœa of one side, with the following invasion of the ovary and peritoneum within eight to sixteen days, is followed in weeks or months by the same infection on the other side. It certainly may progress with an absorption of part of the exudates to a chronic pelveo-peritonitis and perimetritis with all the characteristic peculiarities, i.e., their injurious influences on position and mobility of the pelvic viscera, on the general nutrition of the individual, and on her capability for locomotion and work with frequent exacerbations from the slightest injury, particularly at each menstruation. A severe cachexia appears very often, even if the peritonic complications disappear in the course of a long-continued treatment and involution takes place; such women remain very much hampered in their activity, as the adhesions developing from these acute conditions lead to painful and continued disturbances of the normal mobility of the uterus, to an interference principally with the evacuation of the bowels and similar symptoms.

I have observed in nine cases that a complete recovery may occur with consequent care and treatment. The young women recovered so far as to conceive normally and bear a child, and to enjoy complete well-being. These were youthful persons, who had not gone through labor and puerperium, and had not had gynecologic operations. It has not yet been decided whether the most unfavorable cases were caused by an ascending gonorrhœa, or whether other infectious influences were present in which cultivation of various old germs took place during trauma and during the action of menstruation and labor. I lean to the opinion that considering the great frequency of gonorrhœa in men (80 per cent.) and the certainly very frequent infection of women, the local process in these disappears quickly with overwhelming frequency and without any treatment in the initial stages. Further invasion by excursions comes to a stop at the os internum in the majority of cases. Ascending diseases of the corpus, tubes, ovaries and pelvic peritoneum may run a benign course in spite of stormy initial symptoms; on the other hand it may take a severe course, indeed, with destructive changes.

The occurrence of a gonorrhœal parametritis must be recognized. Often it is the result of a mixed infection (see under *Parametritis*, farther down) in which the septic character appears in the foreground.

The *diagnosis* is not difficult for the observer who has seen the development of the entire process. The finding of gonococci makes it positive, but the absence of the diplococcus of *Neisser* in one or two

preparations should not be held to negative the gonorrhoeal nature of the infection.

The other cocci in the secretions of the urethra and cervix increase with the decrease of the gonococci, so that the secretion becomes more turbid and dirtier (*Doederlein*).

The diagnosis becomes, however, very doubtful if the initial lesions have disappeared. We may then obtain a differentiation only by examination of the cocci, a test which often succeeds in endometritis cervicis, but is already difficult in endometritis corporis, and is only possible after operative treatment in salpingitis and peritonitis. Preceding urethritis and vulvitis suggest the etiology which before was a matter of conjecture. The gonorrhoea certainly predominates in the material of a big city in opposition to the material in small towns and the open country. By the mobility of our population, however, this difference seems to become obliterated more and more.

Typhlitis in women is very frequently mistaken for salpingitis gonorrhoeica.

The *differential diagnosis* of gonorrhoeal disease of the mucous membrane in a woman is in some circumstances one of the most difficult and delicate tasks. However easy the demonstration of gonococci may be in certain cases, such a task is equally difficult in other cases, particularly in chronic affections. It is not sufficient to make a large number of examinations, but they must be repeated at long intervals. The demonstration of residual phenomena may be of great importance. The task is a difficult one for reasons sufficiently well understood, both on the part of the woman and on that of the man. As a last resort the occurrence of joint affections or of conjunctivitis in children may assist in deciding.

The *prognosis* of *gonorrhoea*, in view of its great tendency to extension, must be looked on always as doubtful. Urethritis and vulvitis are quickly and completely overcome by those infected in the majority of cases, and the patients recover completely. The minority, in whom a further extension results, on the other hand, are seriously menaced. We have, in depicting the course of the disease, summed up our own experience. Here the prognosis of the disease with reference to the reproductive capacity of the patient will be sketched.

A large number of formerly healthy women encounter a long and severe illness as the result of a gonorrhoea acquired at the beginning of married life. The marriage, apparently favored by external circumstances, is not only childless, but is disturbed by the continued suffering of the wife and especially by her speedily appearing sexual incapacity. It is at present generally acknowledged that the man is chiefly to blame for this condition. The one-child-marriage is, according to my experience, very frequently referable to this. Another group of women infected early in wedlock suffer from the destructive action of septic infection in the puerperium; *Sänger* first drew attention to this, and he has

been supported by *Kaltenbach* and many others. Along with many analogous cases, I have seen frequent exceptions.

Women may **conceive** normally, **carry to full term** and **bring forth** a child and pass through a normal puerperium in spite of old or recent gonorrhœa. Others are **sterile**, or **abort**, or **have fever during the puerperium**. The late fever occurring in the first puerperium is not always to be traced only to gonorrhœa. How far a gonorrhœa which comes to notice in the puerperium is the cause of later illness is not easy to determine, as frequently later injuries and other infections are contributing factors.

The **prophylaxis** of gonorrhœa has not found a satisfactory solution. Segregation of prostitutes and their careful examination offers only a very imperfect protection. All such laws are powerless against "free love." Control by penal enactments is illusory. Only a very small portion of those injured will initiate a prosecution on account of *dolus eventualis* or of bodily injury resulting from gonorrhœal infection. Very few women avail themselves of the fact that gonorrhœa has been communicated to them in wedlock by their husband, even if they are able to obtain evidence of this, as a cause for a separate maintenance and a basis for a claim for indemnity before the court.

The **treatment** has undergone a remarkable change. **The attempt to combat the acute disease with caustics is falling more and more into disrepute**. All operative measures are of doubtful curative value, and they are open to the serious objection that they are likely to occasion the dissemination of the gonococci. If at all possible the infected woman must be subjected to absolute rest in bed; every sexual approach and also all handling of the parts, like masturbation, must be strictly forbidden. Beyond this precaution I confess to be completely a nihilist.

The specifics tried by me and used patiently and according to directions have failed me uniformly in the long run. I do not like any more to try internal remedies, I fear their influence on the digestion—preventing proper nourishment. I look on this as an indispensable supplement to rest and nursing. Local measures serve the purpose of cleanliness, the removal of secretions and the relief of pain. Easily digestible, strong food, abundant taking of mineral water, abstinence from alcohol and stimulating spices. In **vulvar** and **vaginal** diseases I order sitz baths of 32° C. (89.6° F.) water (ten minutes duration, next to the bed in a warm room, drying off in bed). External irrigations, vaginal irrigations with 0.9 per cent. table salt solution, or the addition of plumbi acetat. (2 per cent.), alum crud. (4 per cent.), thymol (0.01 per cent.) to 1 litre of warm water. Cocain solution or ointment, 1 to 10 per cent. In severe inflammations of the vulva an ice-bag, with strong irritation of the vagina, suppositories or capsules (2.0 cocoa butter with morph., 0.01; cocain, 0.05; menthol, 0.05) are well borne.

I insert at times zymin bougies in **urethritis chronica**. I make irrigations with sol. zinc sulpho-carbolatis (5 per cent.) in chronic discharges.

Endometritis cervicalis gonorrhoeica is treated with vaginal irrigations and rest in bed. Erosions of the cervical lips are touched with iodine, liquor ferri perchlor., zinc chlor., 10 per cent.; vaginal tampons with zinc oxid, 20.0; vaselin, 20.5; menthol, 1.5, are thought of agreeably. **Endometritis corporis gonorrhoeica**, as well as **salpingitis**, **oophoritis** and **pelveoperitonitis** are treated corresponding to their appearance antiphlogistically (ice-coil) during the acute stage. **All kinds of operations** are avoided as long as possible during the acute stage. The treatment during the chronic stage is at first directed toward resorption: hyperemia in all its modes of use, iodine, mud, etc. For further treatment see below under **Salpingitis**, **Oophoritis** and **Pelveoperitonitis**.

Tuberculosis of the Female Genitalia

LITERATURE: See *Kleinhaus*, Die Erkrankungen der Tuben in *Veit's Handbuch der Gynäkologie*, Vol. III. Wiesbaden, Bergmann, 1899. *Frommel's Jahresber. über Geb. u. Gyn.*, 1899-1906.

Genital tuberculosis of the female must be considered as a general disease of the entire system which may attack the whole as well as the separate parts. While formerly regarded only as a part of the symptomatology of general tuberculosis it has been restored by *A. Hegar* to the place which belongs to it among gynecologic affections. According to recent experience the opinion that tuberculosis of the female genitals is **rare**—about 1 per cent. was found in post-mortem examinations (*von Winkel* and others), is no longer tenable. It appears, however, that its frequency varies in different parts of the country. For instance in Greifswald among the cases of **purulent** disease of the adnexa we must attribute 24 per cent. to tuberculosis, an exorbitant percentage as compared with Berlin. Also *Menge* found in Leipsic only 7.4 per cent. of tuberculosis among the patients of the gynecologic clinic. The belief in the rarity of the disease may partly depend on the fact that the diagnosis was not made. This is often impossible to determine with certainty even by the **macroscopic** examination of the extirpated preparation, as will be shown later.* Unless a microscopic examination is made the true nature of the disease may remain unexplained.

The **mode of infection** in female genital tuberculosis is an old point of dispute. *A. Hegar* laid down two modes besides hematogenous infection, one a descending or secondary, and the other the ascending or primary infection, the former occurring by the extension of tuberculosis from the peritoneum to the genitalia, the latter by an ascent of the infectious agent from the vulva to the upper genital tract. *Hegar* perhaps attributed to the last two modes of infection too great an importance in comparison with the hematogenous. For we must designate the **hema-**

* The frequent occurrence of genital tuberculosis in men has also been demonstrated from the material of the Greifswald surgical clinic.

togenous infection as by far the most probable in all cases in which in addition to the genital tuberculosis another tuberculous focus, especially in the lung, can be demonstrated.

As, however, such foci often cannot be demonstrated in the living, a number of authors (*Amann*) will only allow an exclusion of the secondary hematogenous infection in case the absence of tuberculous foci can be proved by a *sectio cadaveris*. Under these conditions only an extremely small number of cases remain in which a hematogenous infection can be excluded.

However, important objections may be raised against this view. The female genital canal stands in uninterrupted direct communication with the outer world. The **ubiquitous** tubercle bacilli may be introduced into the genital canal at least into the vagina under the most various circumstances (coitus, masturbation, labor and puerperium, gynecologic examinations).

If we are dealing with a **predisposed** individual the tubercle bacilli may infect the genital mucosa quite as readily as the mucous membrane of the respiratory tract. Animal experimentation regarding these conditions has shown varying results. *Baumgarten* has shown that an upward wandering of the tubercle bacilli introduced into the vagina of a hare never occurred. His attempt to produce a descending tuberculosis in a rabbit by injection into the peritoneal cavity was equally unsuccessful. On the other hand, in infections of the tube he always obtained a descending tuberculosis of the uterus and vagina. He denies, therefore, the ascending mode of infection. My own experiments (*Ph. Jung*) undertaken with *Bennecke* led to the result that both a descending and an ascending (about 10 per cent. of cases) infection take place. This is confirmed by our very abundant **clinical** experience.

It is an undisputed fact that in case of primary tuberculous infection of the tube the parts of the genital tract lower down (the uterus, vagina, and vulva) become also very frequently diseased in human beings. In an ascending infection the vagina may be passed over on account of its greater capability of resistance, due to the squamous epithelium and its acid secretion, and the uterus and tube may become immediately infected.

According to the preceding statements we define our views concerning the spread of infection in tuberculosis of the female genitals as follows:

1. Where another recent tuberculous focus can be demonstrated in the body in addition to the genital infection, a **secondary hematogenous infection** must be taken for granted. (This group comprises the great majority of cases.)

2. Where tuberculosis of another organ cannot be proved, an ascending **primary** infection is to be accepted as probable. (This group is less numerous.)

It has been proven by animal experiment that the non-motile tubercle bacillus can spread upward against the force of the secretion.

The **form** in which tuberculosis appears in the female genitalia.

varies. We distinguish two chief types in the closed hollow organs, the tubes and uterus.

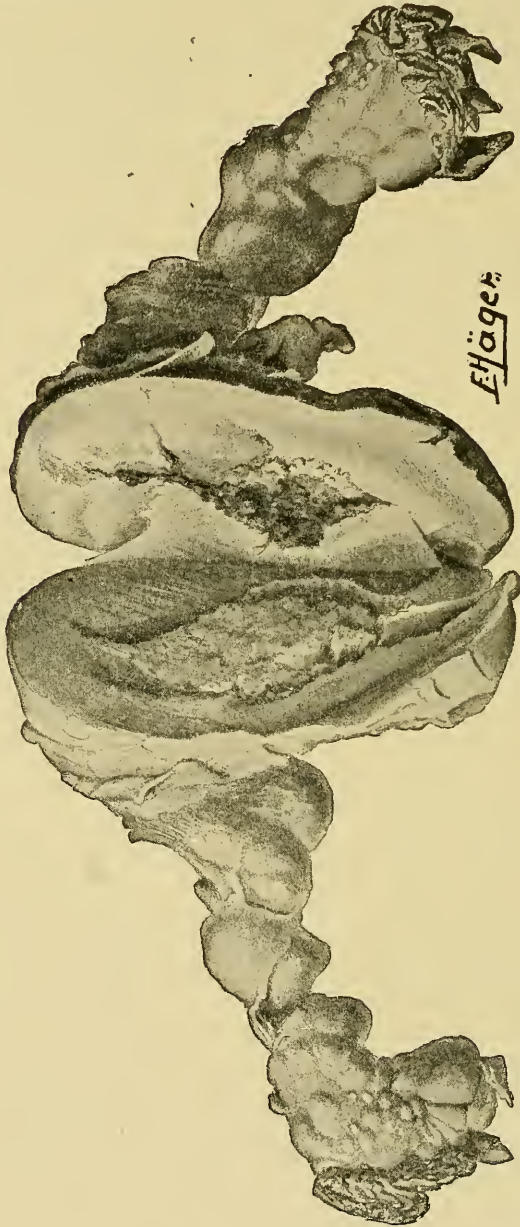


FIG. 102.—Tuberculosis Endometrii, Tubarum, et Peritonei. (Author's preparation.)
(See page 198.)

1. The *miliary form*, with well-developed epithelioid tubercles and giant cells.
2. The *cheesy infiltrating form*, without typical tubercles and with scanty giant cells.

The demonstration of the tubercle bacillus according to many authorities (for instance, *Sellheim*) is very difficult and oftentimes altogether impossible. This does not coincide with my very large experience. I succeed almost always in demonstrating tubercle bacilli in the tissues themselves with good fixation of the preparation (formalin-alcohol) and thin sections and adequate staining (I employ the method of *Ziehl-Neelsen*). The negative findings are probably in many cases to be referred to defects in technic. Demonstration of bacilli in the *secretion* is very uncertain and difficult without a culture process. (See chapter on *Bacteriology*.)

Of the different parts of the genital apparatus the *tubes* are by far most frequently attacked by tuberculosis, next the corpus uteri, more rarely the cervix and ovaries, and quite seldom the vagina and vulva.

The Individual Organs

1. The Tubes

The tube is jointly diseased in most cases of genital tuberculosis. The view that this organ with its secluded position could become dis-

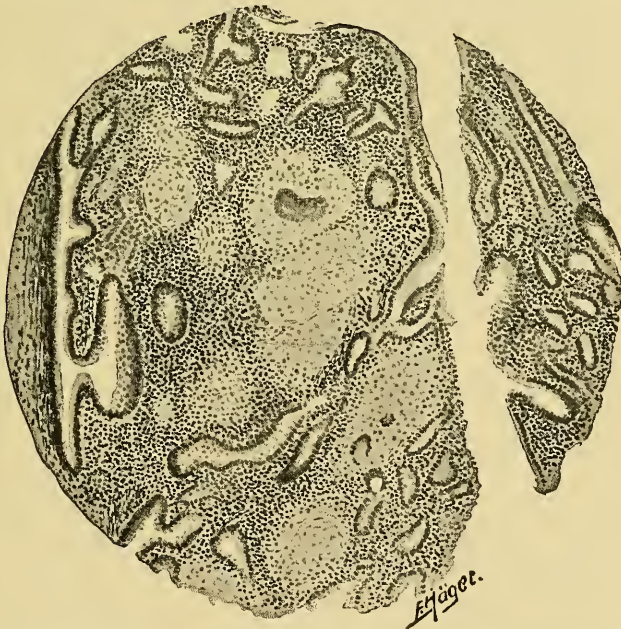


FIG. 103.—Salpingitis Tuberculosa Miliaris. (Author's preparation. Zeiss, Obj. AA, Oc. 4.)

eased only secondarily cannot be sustained in view of the fact that a number of indisputable observations from the post-mortem table exist in which not a trace of tuberculosis could be found on very exact and

close examination of the body, except in the tube. We suppose that in this *primary* tuberculosis the bacilli pass through the vagina and uterus without leaving a trace and settle first in the tube. In some cases a uterine tuberculosis may have been overlooked which experience shows may not rarely happen. We also differentiate in the tube the two forms mentioned above.

1. *The Miliary form.* The mucosa is attacked first; it offers in general the picture of a catarrhal inflammation. Typical epithelioid tubercles with giant cells and positive but scanty proof of bacilli are found isolated or in small groups in the folds of the mucosa. (See Fig. 103.)

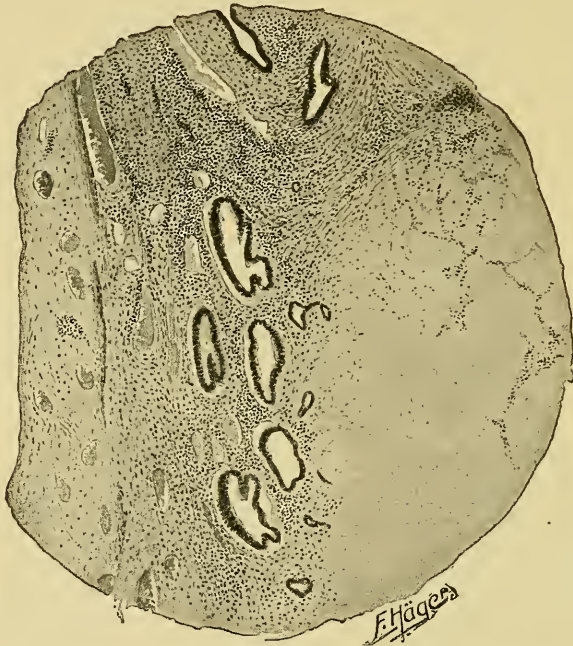


FIG. 104.—Salpingitis Tuberculosa Caseosa. Round cell infiltration of the tubal mucosa undergoing rapid cheesy degeneration, with many bacilli. (Author's preparation, Zeiss, Obj. AA, Oc. 2.)

As the tube is only moderately thickened in these cases and the muscular and serous coats are entirely free from tuberculosis, the signs of a catarrhal salpingitis only exist and the nature of the disease is easily overlooked if a microscopic examination is omitted.

In advanced cases a destruction of the tubal folds and a filling up of the lumen with cheesy masses, formed by confluence and cheesy degeneration of the tubercles, occurs while peripherally in the musculature and on the peritoneum well-developed tubercles are found. The wall thus becomes thickened, a spiral twisting of the tube occurs with adhesion of the different coils, but the fimbriated extremity usually remains open even in far-advanced cases. (See Fig. 102.)

The process does not always advance so far; it may heal and in place of the tubercles, fibrous nodules are found, especially underneath the peritoneum, while the mucosa as a rule undergoes atrophy.

2. The **cheesy form** is characterized by a change of the entire tube into a sac, sometimes of the size of a child's head, filled with cheesy masses. The wall is for the most part destroyed and in advanced cases the mucosa is, as a rule, recognizable only in traces even with the microscope. The fimbriated extremity is closed, the tube is adherent throughout with surrounding structures, in which, after penetration of the tubal walls, tuberculous foci may form. (See Fig. 104.)

A rupture frequently results in such cases, with especial frequency into the intestine, more rarely into the bladder, from which other infectious agents than tubercle bacilli, especially streptococci and bacterium coli, pass over into the contents of the tubal sac and thus cause putrefaction of the latter. In this way the danger of operative interference is very much increased. Tubercle bacilli are found in the cheesy masses in great abundance, and in case of communication with neighboring organs often also streptococci and bacteria coli.

The opinion that this cheesy form always originates as a secondary infection, mostly hematogenous, rarely by extension from the peritoneum, cannot be sustained. A rapid cheesy degeneration may also occur when the infection is of the ascending variety.

2. Uterus

Uterine tuberculosis is much more frequent than is commonly admitted. It is somewhat frequently found in vaginal operations in the course of which curettement is made on account of catarrhal symptoms on the part of the uterus, but, to be sure, usually combined with tubal tuberculosis. Primary tuberculosis of the uterine body, however, may be observed when the tubes are entirely normal.

Mrs. B., from K., No. 49 (1903). I-para, **no hereditary tendency**, often treated on account of vague symptoms and **fluor albus** with pessaries and irrigations. Strong woman, **without a trace of infection of the lungs**, etc. Uterus retroflexed, movable. May 6, 1903: Abrasio, colpotomia, vagini-fixation, plastic perineorrhaphy. The adnexa, on inspection, proved to be perfectly normal, no thickening, no adhesions. The endometrial scrapings were **rather scanty**.

Well-developed epithelioid tubercles with giant cells and positive bacillary findings were found on microscopic examination. Recovery without complications. Reappeared for examination in June, 1905. **Perfectly well, no fluor, regular menstruation, without difficulty, excellent state of general health, complete ability to work.**

Unfortunately it was impossible to obtain material for histologic examination of the uterine mucous membrane at the second examination in June, 1905.

From the dearth of any symptoms and the regularity of the menses,

one may be permitted to assume, however, a healing of the tuberculous process. In this case it may be accepted as quite probable that the tuberculosis was *primary* in the uterus. Inspection convinced us that the tubes were healthy. Also the symptoms of catarrhal salpingitis were completely absent.

In the uterus also we distinguish between the *miliary* and the *cheesy* form. In the former we find, besides the signs of an interstitial inflammation, hyperemia and round cell infiltration, scattered epithelioid tubercles with giant cells and scanty bacilli. (See Fig. 105.)

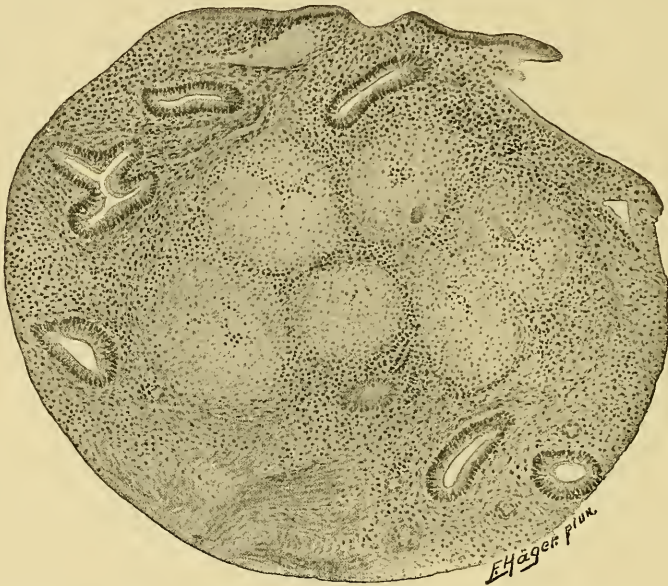


FIG. 105.—Endometritis Tuberculosa Miliaris. A group of epithelial tubercles in the uterine mucosa. (Author's preparation. Zeiss, Obj. AA, Oc. 4.)

The mucous membrane is rapidly destroyed in cheesy endometritis, the process penetrating deep into the musculature. (See Fig. 106.)

The entire uterine cavity becomes filled with cheesy masses and the organ is enlarged *in toto*. (See Fig. 102.) This enlargement, with the absence of the menses, may cause the condition to be mistaken for beginning pregnancy.

As a rule, uterine tuberculosis attacks only the corpus, while the cervix remains exempt. Yet enough cases are known in which the cervix was affected in addition to the body, or still rarer where the cervix alone was diseased. Here, usually, the cheesy infiltrating form was concerned. (See Fig. 106.)

Tuberculous ulcers with their base covered with a dirty coating occur on the portio vaginalis, which may be mistaken for the primary affection of lues. Another very rare form is a cauliflowerlike tumor with a dis-

integrating, easily bleeding surface, which at first sight impresses one as a carcinoma. The microscope only can furnish an elucidation.

3. *Vagina and Vulva*

Tuberculosis of the vagina and vulva is very rare as the heavy layer of squamous epithelium gives due protection. **Primary** infection is still rarer; we are concerned mostly with a process descending from the uterus and tubes. The lower genitals are easily passed by in ascending disease.

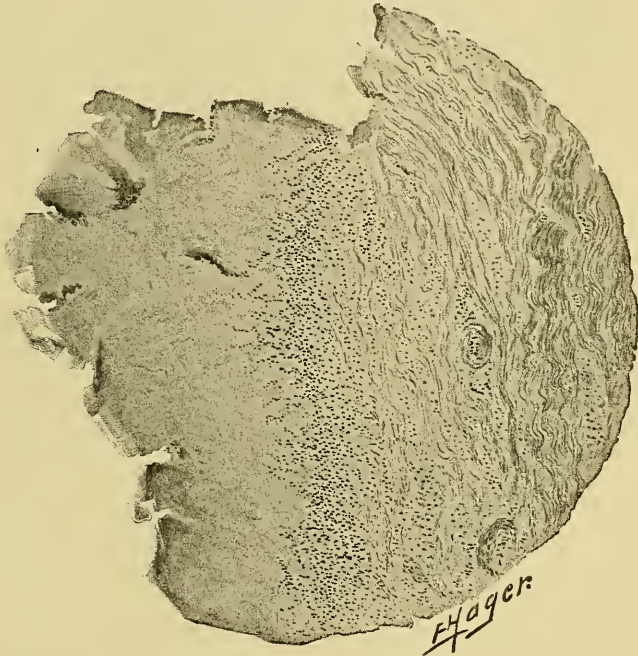

FIG. 106.—Endometritis Tuberculosa Caseosa. Complete destruction of the uterine mucosa, many bacilli. (Author's preparation. Zeiss, Obj. AA, Oc. 2.)

The **form** in the **vagina** is mostly a flat ulcer with indurated edges and a tendency to a slow process of extension (differential diagnosis against lues).

Extensive ulcers may form in the **vulva** with a tendency to the formation of a fistula and a further proliferation upward into the vagina. (Cases of *Rieck*¹³⁹ and *Viatte*.¹⁴⁰) These ulcers have mostly undermined edges and at the same time a tendency to connective-tissue newgrowth and elephantoid thickening of the labia exists (*Rieck*). Real tubercles are, as a rule, not formed, and the appearance is not in any way characteristic. Lues, elephantiasis, and *ulcus rodens* may create similar pictures, so that the diagnosis must be made with the microscope. These ulcerative tuberculous processes of the vulva are extremely rare. (See Fig. 107.)

4. Ovary

The ovary becomes diseased relatively rarely in comparison to the tubes and uterus. However, numerous cases are also overlooked here, since, as a rule, only the *miliary* form is present in the cortical layer and is with difficulty diagnosed macroscopically. The relatively rarer

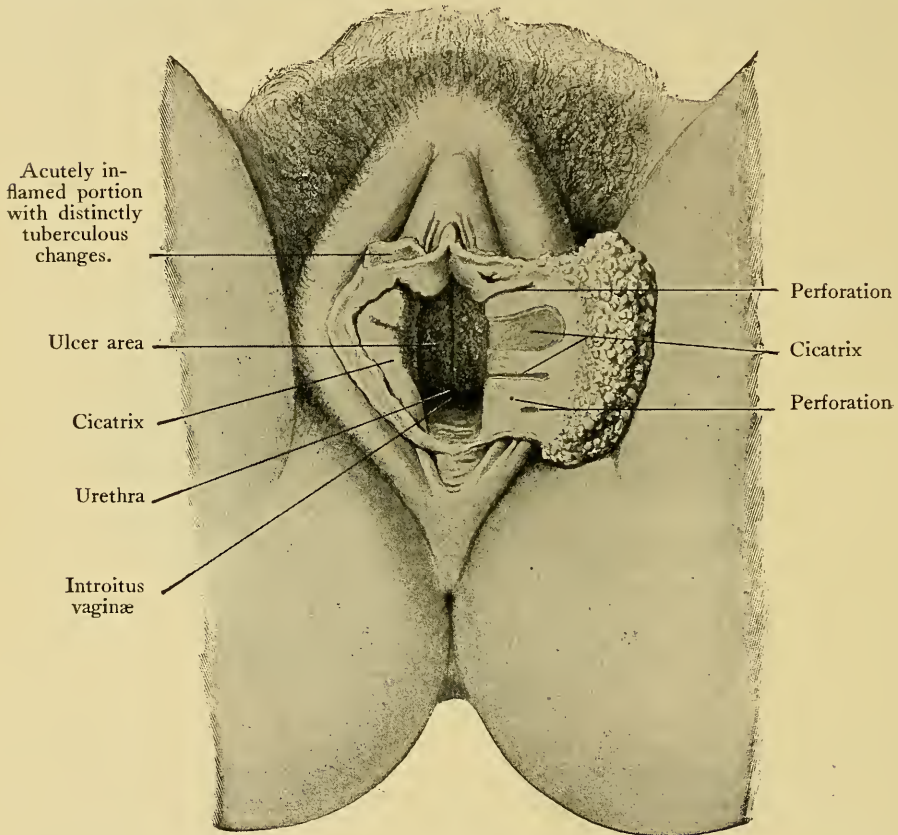


FIG. 107.—Primary Tuberculosis of the Vulva. (From *Rieck*, *Monatschrift f. Geb. u. Gyn.*, Vol. IX, p. 842.)

cases of cheesy infiltration, however, cannot very well be overlooked and are easily interpreted.

Primary ovarian tuberculosis so far has not been positively observed (*Orthmann*).

In rare cases, ovarian tumors (cystoma) may also become infected with tuberculosis.

5. Peritoneum

Peritoneal tuberculosis is very frequent, and attacks, as a rule, young individuals.

It has always a secondary origin in one of three different ways.

(1) by hematogenous infection.

(2) directly by immigration of bacilli from the intestines or the retro-peritoneal lymph-nodes.

(3) by immigration of bacilli from the lungs and pleuræ through the stomata of the diaphragm.

The rarest form of infection is from the female genitalia, corresponding to the relatively rare primary infection of this tract.

Peritoneal tuberculosis has two principal forms:

(1) The diffuse miliary form mostly accompanied by a profuse ascites. (See Fig. 108.)

(2) The so-called "dry form" with multiple adhesions of the abdominal organs with each other and with the peritoneum, often with abun-

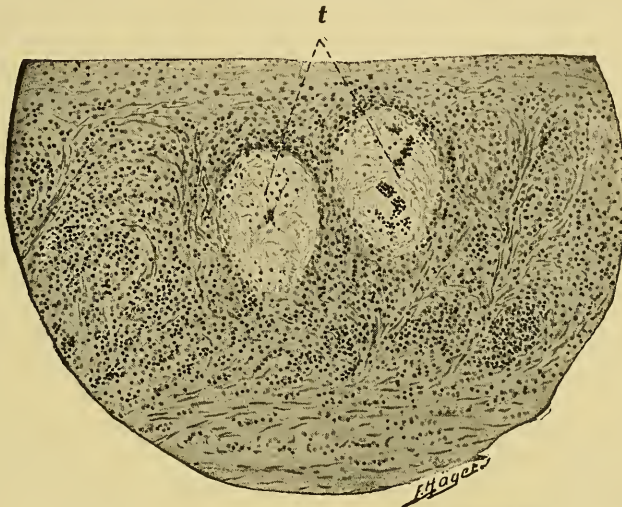


FIG. 108.—Tuberculosis Peritonei. *t*, tubercle, the tissues surrounding it are strongly infiltrated. (Author's preparation. Zeiss, Obj. AA, Oc. 2.)

dant ascites or cheesy formations in the sacculated hollow spaces. *v. Rosthorn* would consider the latter as a special third form, but both are so intermingled that we consider them as different varieties of the same form.

In this way encapsulated abscesses may arise which in their turn again may rupture into the hollow organs (intestines, bladder).

Diagnosis

The diagnosis of genital tuberculosis must be considered as a very difficult one. Only when pronounced general symptoms of tuberculosis (lungs, bones, joints) are present can it be considered with a tolerable certainty that a genital disease existing at the same time is also tuberculous. The diagnosis in such cases is easy and positive. We have already referred, in considering the individual organs, to the fact that

tuberculosis occurs with extreme rarity in the portions of the genital tract that are accessible to inspection, and in these cases there are so few characteristic signs that the microscope is necessary to a decision. Tuberculous infection of the *endometrium* also does not show any characteristic symptoms; it presents only the signs of chronic endometritis. Many a curettement is certainly made in practice on account of this illness instead of a uterine tuberculosis, without the diagnosis being made for want of a microscopic examination. (See case cited on p. 195.)

In tubal tuberculosis which is relatively the most frequent, the physician tries to get along at first with bimanual palpation. Here also not a single characteristic symptom may exist.

Hegar and his school (*Sellheim, Altermum*) brought forward as characteristics the feeling of miliary tubercles in the excavatio recto-uterina and also the so-called rosary form of the tube (salpingitis isthmica nodosa). But neither one nor the other of these signs can be looked on as decisive, though they may even occur together at times. The fixation of tuberculous adnexa with their surroundings may be such that a differentiation of details of such adnexal tumors is out of the question, even for the most practiced and most experienced examiner.

In the presence of these difficulties we must employ other diagnostic means than bimanual examination. We have tried many times to attain the object in doubtful cases by the diagnostic injection of tuberculin *Koch*, not without success. However, this method can be employed only when no elevation of temperature is present at the beginning. If elevated temperature has been excluded by exact measurements, one injects at first 0.003 cc subcutaneously. If the temperature rises after this above 38° C. (100.4° F.) tuberculosis may be diagnosticated; if the reaction does not occur, then, after two days, .005 cc are injected and finally, after another two days, 0.01 cc. If a reaction results, tuberculosis is probable. However, it may be located in an internal focus not accessible to examination (lymphatic gland). Therefore absolute certainty cannot be obtained even here.

After many experiments we can recommend the following procedure, although cumbersome, in diseases of the uterus and adnexa suspected to be tuberculous. After taking a very careful history and making a thorough physical examination, especially of the lungs, and observing the temperature before and after a tuberculin injection, a few scrapings with a curette are made in the cavum uteri under *anesthesia*, using *great care*. The material is examined with the microscope. If an adnexal tumor exists at the same time, a long paracentesis needle is introduced and the contents are aspirated. If pus is found a smear preparation is made and the rest is injected under aseptic precautions into the peritoneal cavity of a guinea-pig. The diagnosis can be made with some positiveness in this manner, although one must wait at least three weeks before killing the guinea-pig. The smear preparation frequently contains no bacilli even when tuberculosis is present, the process of culture

is difficult and troublesome, and even the vaccination of the guinea-pig requires a special apparatus, so that the practicing physician cannot make use of these accessory methods without difficulty.

Many times also other micro-organisms (streptococci, bacterium coli, are present in the smear preparations (mixed infections, see p. 195), so that by this the diagnosis is also obscured. A very interesting case of this sort has been reported by *Hager*, from the gynecologic clinic at Greifswald (*Monatsschr. f. Geb. u. Gyn.*, Vol. XIII, p. 595). We must designate the diagnosis of genital tuberculosis as one of the most delicate tasks of gynecologic practice, in view of all these difficulties. The diagnosis of peritoneal tuberculosis is essentially easier than that of genital tuberculosis. Often both occur together.

If ascites occurs at the same time as adnexal tumors, possibly with still other symptoms (fever, loss of weight, and pulmonary signs) the interpretation of all these signs due to tuberculosis is quite rational. Still more difficult is the diagnosis of sacculated peritoneal foci with the dry form of tuberculous peritonitis, as, in this case, confusion with tumors, especially adherent ovarian cystomas, is likely. An exact examination of the heart and kidneys will guard against mistaking ascites from other sources (heart and kidney diseases). Not infrequently the diagnosis of genital as well as peritoneal tuberculosis is based on the autopsy *in viva*, made after an operative opening of the abdominal cavity. Whenever the interpretation of the findings is not quite clear one should always think of tuberculosis and attempt to exclude it first of all.

Treatment

If the genital disease is only a symptom of a marked general tuberculosis it is recommended to desist from all local treatment and to institute only a general treatment. The tendency of genital tuberculosis to heal spontaneously with a favorable general provision for care and nourishment is apparently quite great. It is doubtless quite nonsensical to treat genital tuberculosis by operation while still other recent localizations are present. For, according to experience, an already existing tuberculosis, for instance of the lungs, easily undergoes a considerable aggravation through operative interference. The indication in such cases is clear.

It is much more difficult in cases in which no other manifest tuberculous foci can be determined besides the genitalia. Then it will depend on whether the symptoms are very pronounced or, as is happily often the case, are only somewhat inconvenient. Quite especially it will depend on the social and pecuniary position of the patient.

If she has the ability to take care of herself and if the local disturbances are bearable and if the general state of health is not very much disturbed (fever), then a *conservative* procedure is urgently advisable with the usual general tonic treatment of tuberculosis. This principle, unfortunately, cannot be carried out in the large mass of patients of lower social and pecuniary standing, especially as the tuberculosis sana-

toria inconsistently do not admit genital tuberculosis. In many cases an operation will be decided on in these women who need to regain quickly their working ability, who might have been treated conservatively under other circumstances.

Finally, there are still a number of cases in which operative interference is necessary on account of the general health, for instance in febrile cases of mixed infection with pus-forming agents. This will need consideration, especially in the case of large tuberculous pus-tubes. Often the treatment of these cases may be undertaken at the same time as an aspiration for diagnostic purposes. After the aspiration of the pus the sac is opened widely and the pus or cheesy matter is removed and drained. Such cases may heal in consequence of the evacuation or may at least be brought to a standstill. It is seldom that it is necessary to undertake a deliberate removal of the diseased parts at the outset, and indeed only when a long-continued conservative treatment proves unsuccessful and the symptoms, the general health, and the social position urgently demand relief.

If such a measure is determined on, it should be made as radical as possible; and along with the diseased adnexa the uterus also should always be removed as it is usually also diseased, or will become so later on if left. This principle is not affected by the fact that a few cures of tuberculous endometritis have followed simple curettement, as we also have seen. (See p. 195.)

Such operations are less dangerous *if a pure tuberculous infection* is present, as even an escape of the cheesy masses into the abdominal cavity usually produces no bad results. The prognosis, on the contrary, is more unfavorable if communication with the intestines exists. The pus in these cases is highly virulent and, besides, the intestinal wall becomes brittle, so that perforation and septic peritonitis not rarely are the immediate results.

An excision of the entire diseased parts in tuberculosis of the external genitalia and the portio vaginalis will be the only correct course at the beginning. Eventually a *Finsen* treatment might be beneficial. It has been said above that local therapy is best not undertaken in the conservative treatment of adnexal tuberculosis. The experience which we have had with the usual absorption method of treatment fully justifies this warning. Either these measures do no good (for instance hot irrigations, sitz baths, ichthyol tampons, etc.) or they may be directly harmful. The latter holds good especially for the *hot-air treatment* which acts so favorably in adnexal diseases of another nature, but which we have repeatedly seen followed by an aggravation of the condition in tuberculosis and against which we therefore urgently advise.

The principles of treatment of purely genital tuberculosis do not hold good for that of *peritoneal tuberculosis*. Laparotomy, with the removal of the ascitic fluid without any further manipulation, has proved entirely sufficient for a permanent cure of the miliary form accompanied by free

ascites, so that we can only advise this course. As in such cases with the absence of other destructive lesions in the body only the peritoneal covering of the genitalia is diseased, it is self-evident that we should desist from interfering with these organs. But if we find thick tuberculous pus-tubes and cheesy degenerations on the pelvic floor, indicating that the infection of the peritoneum originated from this region, we should not hesitate, since the peritoneal cavity is already opened, to remove the entire internal genitalia.

In the so-called dry form of tuberculous peritonitis all operative interference of any sort is contraindicated. If, however, one has made a laparotomy on account of a mistaken diagnosis, for instance in sacculated cheesy or ascitic foci, then it is to be recommended to dispose of the fluid, if necessary, and to drain the cavity with iodoform gauze. However, the prognosis in such cases is a very doubtful one, as the tendency to permanent fistulæ of the abdominal walls or of the intestine is great, and in that case the patients usually perish in a short time from exhaustion.

B. Metritis

I. *Metritis Acuta*

Acute inflammation of the muscular uterine wall follows almost exclusively a primary acute inflammation of the uterine mucous membrane and, beginning at this point, may invade the entire thickness of the wall and the perimetrium, and may even attack from the latter a part or even the entire abdominal cavity. From our present viewpoint we can recognize no other origin than a bacterial one for such acute inflammations. Consequently acute metritis almost always follows the two most frequent acute infections of the endometrium, the septic and the gonorrhæal. The former occurs almost exclusively during labor and the puerperium while the latter arises also outside of this period, because the gonococcus can ascend into the cavum uteri without any direct external cause (see above under *Gonorrhæa*). That a septic infection may take place aside from labor and the puerperium is possible, but certainly extremely rare, and can be induced only by direct trauma, uncleanly surgical operations, particularly the introduction of the sound and curettement without aseptic conditions, masturbation, etc.

An acute septic infection of the endometrium may very well remain confined to the endometrium. Very often, however, it encroaches more or less extensively on the myometrium and produces here characteristic pathologic lesions. The spread of infectious agents (strepto- and staphylococci) proceeds by way of the lymphatics. One finds the lymph capillaries in the connective tissue between the muscle fibres crammed with cocci which also migrate into the surrounding tissues, the latter showing throughout a perivascular round cell infiltration. The smaller bloodvessels behave themselves much in the same way, a thrombophlebitic form,

especially near the site of the attachment of the placenta, is seen (see Fig. 109). The invading agents of infection may penetrate the entire uterine wall, the cocci may wander to the perimetrium and thus reach the abdominal cavity. Here they cause either a general peritonitis which leads to a rapidly fatal termination, or a more localized inflammation of the pelvic peritoneum occurs, resulting later in extensive adhesions of the uterus.

More or less extensive purulent breaking down of the uterine walls occurs, and abscesses also frequently form in such severe cases. The abscesses, however, rupture, as a rule, into the uterine cavity and there evacuate their contents. Abscesses in the wall, which casually arise at

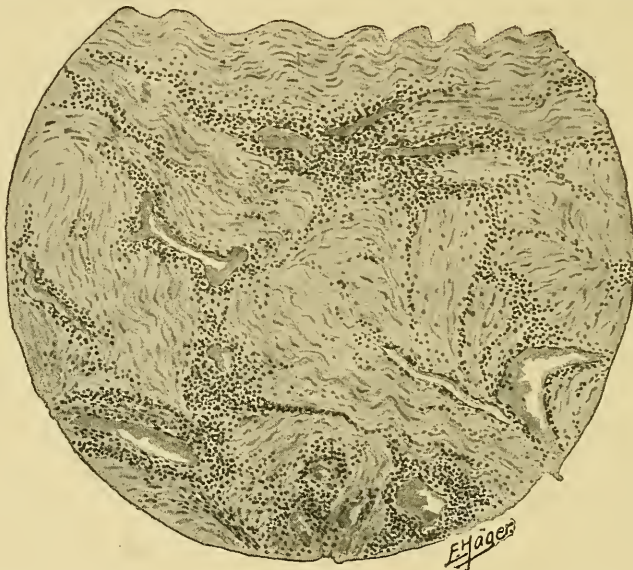

FIG. 109.—Metritis Acuta. Pronounced round cell infiltration of the uterine wall extending beneath the peritoneum, especially in the neighborhood of the vessels. (Author's preparation. Zeiss, Obj. AA, Oc. 4.)

the point of junction with the parametrium, may encroach on the latter and lead to extensive exudates.

If the patient does not succumb to the infection a *restitutio ad integrum* may occur. The cocci are subdued by the organism, the round cell infiltration foci are absorbed, the abscess pus thickens, is absorbed, and in place of the abscess scar tissue forms. In what percentage of cases such a cure takes place cannot be determined even approximately. It is, however, certain that in a great number of cases complete recovery does **not** occur. The acute signs, indeed, retrocede. The cocci are destroyed gradually, but the absorption of the inflammatory exudate is not complete and a chronic condition of irritation remains which, little by little, leads to the formation of scars and the proliferation of the intermuscular con-

nective tissue in the uterine wall. The *acute* metritis has passed into a *chronic* metritis.

The conditions are not quite the same in the gonorrheal form as in the septic.

The gonococcus is, all in all, a mucous membrane parasite which spreads by predilection along the canal of the internal genitalia thus lined and, therefore, remains confined to the *uterine mucous membrane* in most cases. (See chapter *Bacteriology*.)

However, this course is not the one exclusively observed. It has been moreover proved that the gonococcus may enter the blood-stream and cause metastases throughout the body. It also may enter the connective tissue and musculature in many cases, and indeed even produce abscesses therein (*Wertheim*). While, however, this as stated is not the rule, still the softening of the uterine wall during pregnancy offers the germs an easy opportunity during the puerperium to abandon their character as pure mucous membrane parasites and to infect the myometrium. The pathologic picture is not as well marked as in septic metritis. The cocci especially are not demonstrable in the tissues in such numbers. However, observations on this matter are still sparse, as such organs are seldom subjected to an anatomic examination. These gonorrheal infections never become as grave as the septic ones. They also can and do certainly very frequently terminate in complete recovery, but they may pass on into the subacute and finally the chronic stage, and thus lead to a *chronic metritis*.

The symptoms of acute metritis, which begin with rigors and an elevation of temperature, consist of violent pains in the abdomen and in the sacrum, and of painful disturbances of the bladder and rectum. We consider acute metritis as a complication of the puerperium developing as a result of all varieties of infection following premature or full term expulsion of the ovum. Corresponding to this the symptoms of endometritis appear predominant, i. e., discharge of foul-smelling lochia, eventually with the passage of broken-down remnants of the ovum. Profuse loss of blood has also been observed. Additional symptoms depend on the disease of the perimetrium and of the entire peritoneum, or on the progress of the infection into the pelvic connective tissue. These symptoms and still more the general septicemia may cause one to overlook the acute metritis completely.

The *diagnosis* of acute metritis is based on the intense swelling and sensitiveness of the uterus which occur, as a rule, at the same time in the cervix and the corpus. The size of the uterus is especially increased in its transverse and anterior-posterior diameters.

The *prognosis* of acute metritis is always grave. It depends on the kind and virulence of the infective agents. Rapid resolution and recovery may follow the acute stage of the inflammation, for instance in gonorrheal infection. The possibility of the diseased process spreading makes the prognosis always doubtful until the cause and extent of the disease

are definitely known. Formation of abscess is rare, but a disposition to recurrence remains because on a change of soil (a new gestation or another endometritis) a portentous growth of the germ occurs in the residual infectious foci. Thus is explained the not unusual observation that women, even after a complete recovery from a septic puerperium (for instance after abortion), again develop fever and become very ill in spite of the most extreme care in the aseptic attendance during another labor.

The local *treatment* remains an outspoken antiphlogistic one, involving the utmost possible rest, the application of ice, and continuous confinement to bed. As soon as puerperal sepsis is discernible from the history or findings the removal of the retained products of gestation becomes unavoidable. In addition we must refer here to the modern ideas of the treatment of so-called puerperal fevers. Gonorrhoeal acute metritis is also in our opinion an indication for operation at present only in case of very grave complication, which naturally leads to a mutilation. With signs of an ascending infection it becomes essential to evacuate the pus promptly and if necessary to extirpate the uterus.

If the acute symptoms of the first few days have passed and if the fever which is rarely absent in the beginning of the disease subsides, we adopt the treatment which I will mention more in detail in the discussion of chronic metritis. The invasion of the surrounding region by the infection can be prevented in no other way than by energetic antiphlogistic treatment.

II. *Chronic Metritis*

Chronic metritis is certainly in the great majority of cases a result and terminal stage of acute metritis depending on a bacterial infection. (See p. 203.)

This connection, however, cannot always be anamnesticly proven with certainty. If we consider, however, that a great number of puerperal infections, especially after abortion, run such a light course that they are hardly noticed and disappear from the recollection of the patient, and that, further, also, a long-passed gonorrhoeal infection is sometimes forgotten or is intentionally concealed, we must be very careful in excluding bacterial infection from the etiology of chronic metritis.

The bacterial causation must be accepted as at any rate probable in all cases which are preceded by labor, and above all by abortion; and, further, in those in which residues of inflammatory disease of the genitalia, especially of the adnexa and of the abdominal cavity can be demonstrated. To construct another etiology in such cases would appear artificial.

While the greatest number of recent authors view the etiology of chronic metritis chiefly as an infection emanating from the mucous membrane, *Teilhaver*¹⁴¹ advocates another opinion. He believes that a *primary* disease of the myometrium takes place in most cases consisting of a hyperplasia of the connective tissue and as a result therefrom an

atrophy of the musculature. Out of this arise the so frequent chronic hemorrhages of metritis, because the weakened musculature is not capable of contracting to drive the venous blood from the uterus. While we are also inclined to follow this latter idea of *Teilhaver* at least for some cases, and while we also believe that a hyperplasia of the connective tissue leads to a partial atrophy of the musculature, we must still decline the first view for the majority of cases, while we adhere in the main to the infectious etiology. This is not the place to demonstrate this fact exhaustively.

Nevertheless it cannot be denied that a number of chronic metritides exist in which with *Teilhaver* we cannot very well accept a bacterial cause at present.

There are cases in which none of the above-mentioned conditions are found. They comprise above all virgines intactæ and a great number of nulliparæ in which no residue of a former acute infection can be elicited. Of course the possibility of a past gonorrhæal infection always remains in nulliparæ, but this will be found to be rare.

Different views are held as to the manner in which metritis is produced in these cases which do not depend on an infectious origin. It is probable that all conditions which lead to a chronic congestion of the pelvic organs are to be considered also as causes of chronic metritis. A chronic connective-tissue induration of the uterus results as in other passive hyperemias, i.e., metritis chronica. As such etiologic conditions we may especially incriminate changes of position of the uterus, like prolapse and retroflexion, chronic obstipation, as well as ungratified sexual desires, coitus interruptus, impotency of the husband, masturbation, cardiac disturbances, and, finally, an improper sedentary life and want of bodily exercise. We agree in this more or less with *Teilhaver*.

Whether also exposure to cold, or improper conduct at the time of menstruation, should be reckoned as exciting causes, as is many times still taken for granted, is at least very doubtful. It cannot be decided with certainty which one of the given causes is to blame in a given case, but we must bear in mind the different possibilities and attempt to remove the etiologic factor before instituting the treatment proper. One should not forget in this connection that the question of etiology is concerned only with more or less well-founded theories. While we do not yet know the etiology of chronic metritis in many instances, the **patho-logicico-anatomic relations** are tolerably clear. It is remarkable that in this respect no difference seems to exist between cases depending on actual infection and the non-infectious cases.

We find always a more or less marked enlargement of the uterus, either in its entirety or only in some of its different parts (**metritis corporis, colli**). The consistency is hard and firm in contradistinction to the normal organ. The tissue grates under the knife, which meets marked resistance in cutting through it. This tissue has a shining white appearance on account of the hypertrophic connective tissue fas-

ciculi, between which the muscle-bundles stand out decidedly diminished in proportion to the normal. Especially striking in pronounced cases are the numerous lumina of the sclerotic vessels, protruding above the cut surface, which are found particularly in strikingly large numbers in multiparæ.

Microscopically one sees, especially after staining according to *Van Gieson's* method, the hypertrophic intermuscular connective tissue stand out a flaming red, and between these the muscular tissue decreased from the normal. The vessel-walls have often undergone hyaline degeneration and sometimes also calcareous plates are seen embedded in them. Round cell infiltration is for the most part only scanty in the interstitial tissue, especially in that surrounding the vessel. Micro-organisms are never found in such chronic cases. In the forms of chronic metritis originally depending on infection of the endometrium almost always also one finds corresponding to them chronic endometritis in different forms; but the endometrium is also as a rule in a condition of chronic hyperplasia in cases not depending on an infection, a proof that disease of the myometrium cannot very well be separated from that of the endometrium. It is not possible to draw any conclusions from the findings in the uterine mucosa as to the original cause of the metro-endometritis. (See chapter *Endometritis*.)

The *entire* organ is usually affected in chronic metritis, but it may sometimes involve only the corpus or the collum.

Whether in one case only the corpus, in another the cervix, in others again the entire uterus is attacked by chronic metritis, depends many times on the location of the original infection. This condition is especially striking in the chronic metritis colli in which ectropion of the cervical mucous membrane, an endometritis and finally a metritis cervicis develop in connection with cervical lacerations during labor which may lead to an enormous hypertrophy of the entire cervix without the corpus taking the slightest part in this process. Similar extensive hypertrophies of the cervix uteri develop not infrequently in cases of vaginal prolapse as the result of the continuous traction on the cervix, particularly in uteri firmly fixed in the pelvis.

A metritis cervicis is not rarely found also in virgines intactæ. The small corpus sits on this cervix in sharp anteflexion, the so-called "post-horn form" of the uterus.

The etiology of metritis colli is not clear in these cases; as stated above it is not easy to understand especially why the cervix alone hypertrophies so frequently. For the chronic irritations which are held responsible for metritis in virgins affect certainly the entire organ and not the cervix alone.

The unaffected portion seldom remains in the long run intact with isolated or at any rate preponderating *localization* of the disease, either in the corpus or in the cervix. When the corpus is enormously enlarged the cervix appears virginal. The same changes are seen in the long run,

although developed only to a slight degree in the part which was unaffected in the beginning.

The corpus participates at first so slightly in the process in diseases of the cervix that it appears as a small pendant to the enormously enlarged cervix. On the other hand, the picture of the form of hypertrophy of the cervix which I sketch below as *elongatio colli supravaginalis* is frequently characterized by the corpus hanging down usually on the anterior surface, but sometimes behind or to the side of the greatly elongated cervix, and then it is not markedly smaller than the cervix. The two parts have the same relative size as in an infantile uterus in which the corpus constitutes one-third and the cervix two-thirds of the entire organ.

A further peculiar transformation occurs in *metritis colli chronica* when it is connected with a laceration of the uterine os. The cervical lips may appear as if turned inside out in unilateral cervical laceration; in bilateral ruptura cervicis, the lips spread apart from each other so that they appear rolled up and resemble a fungoid growth. The unimportant remnant of the cervix looks like a pedicle on which the almost vanishing corpus is placed (see below, the chapter on *Lacerations of the Cervix*). (See Fig. 62.) The transverse diameter as well as the length of the uterus and especially of the cervix are changed in this condition. There appears in a subacute stage a penislike formation which projects deeply into the lumen of the vagina and may be extruded from it. Such extremes are very rare.

Two striking observations are here chosen for examples: I saw the one in a hysterical girl who apparently was ill solely on account of masturbation, the other in a delicate peasant woman with a suspicion of tuberculosis. In both a dark bluish-red mass, resembling the glans penis appeared in the rima and protruded from it for several centimetres; a profuse, thin fluid secretion poured forth from the gaping opening in the centre of the mass. The surface showed fissures and bled easily on the slightest touch. A fold could be seen in the head about 3 cm in length, which corresponded to the enormously dilated os uteri and the greatly enlarged but otherwise unchanged external covering of the portio lay above this. In the other case this fold was torn on one side and the entire surface of this side appeared actively inflamed. The insertion of the vaginal wall at the anterior periphery lay in the one case 5 cm, in the other 6 cm above the penislike formation. The insertion of the posterior fornices was felt only slightly above it. The entire uterus was markedly hypertrophied with the corpus anterior and deep in the pelvis. The cervix was in the one case about 7 cm, in the other about 8.5 cm long.

Cases of *elongatio colli*, in which the *infra-* and *supravaginal portions* are uniformly diseased, come under observation, as a rule, in a very chronic stage.

Thus a relative of the woman just mentioned had a considerable

hypertrophy of the portio with a marked stenosis of the entire cervical canal, but well-preserved external configuration of the portio which was pushed downward to the rima and measured more than 4 cm on the anterior wall up to the insertion of the vagina. The inflammatory signs had disappeared a long time before the bashful patient submitted herself to an examination.

The infravaginal part of the portio is of a conical shape, usually on account of the pressure of the vagina and the resistance of the mucosa covering it.

Elongatio Colli Supravaginalis.—The supravaginal portion becomes a long-drawn out rigid mass which is mostly longer, rarely considerably thicker, than the corpus which is unaffected by the inflammation. The proportion between the corpus and the cervix appears infantile. This very circumstance leads authors to consider such changes in the shape of the uterus as congenital. I have, however, often followed up by clinical observation the development in adults of elongatio colli supravaginalis and the anteflexion of the small remaining corpus depending on it.¹⁴² The uterus in this case lies sunken deeply in the hollow of the sacrum. The long cervix reaches far forward and downward, the portio media of the infravaginal portion is apparently much enlarged and the finger may follow through the posterior vaginal vault the neck of the uterus to a great extent, so that with an attentive examination a retroversion is always diagnosed. The corpus uteri lies flexed like a small appendix wholly upon the anterior surface of the elongated cervix and is here perceived by a bimanual examination or by sliding the finger along the sides of the cervix. The isthmus between the cervix and the corpus is reached deep in the vaginal vault.

Prognosis.—The hyperplasia of the connective tissue may continue to exist in various forms more or less unchanged for a long time, while occasional exacerbation of the inflammation may appear sometimes in the entire organ and sometimes in different portions.

The symptoms of chronic metritis in their initial stage frequently elude a distinct definition. As metritis chronica only rarely occurs as the manifest result of an ***acute*** process, therefore the symptoms develop, as a rule, gradually and only with the further considerable development of the local changes reach the severity which finally compels the patients to submit to an examination of the pelvic cavity.

If chronic metritis is the result of an interrupted puerperal involution, the patients do not recuperate from their confinement. Instead of gaining strength the puerperæ feel continuously a profound exhaustion and with it lose in weight, while the breast milk dries up with pain radiating toward the scapula. ***Pains*** occur in the small of the back and the pelvis with any exertion. The uterine ***secretion*** continues, rather increases; the ***feeling of a sure closure of the external genitalia disappears***; and the patients complain of the sensation of openness of the vulva. Frequently vesical tenesmus and obstinate constipation occur.

The **menstruation** appears early, is profuse, occurs at short intervals, and occasionally a bloody discoloration of the leucorrhœal discharge takes place in the interval. These pains may continue with fluctuating intensity, the symptoms grow worse from apparently slight causes and then continue for weeks, sometimes for months in a minor degree, and always prevent the feeling of convalescence.

Although women with this form of the malady resist for a variable length of time the feeling of malaise following the puerperium and often only after another pregnancy and continued ill-health admit what the persons around them perhaps have most confidently conjectured for some time, the symptoms of **the non-puerperal form of chronic endometritis develop still more slowly**. Girls, especially those thrown on their own resources, who become ill as a result of disease of the mucosa (gonorrhœal infection), bear the trouble often for many years before the source of the disease becomes known and is subjected to treatment. The symptoms of chlorosis then appear, the enjoyment of work and life vanishes, an insurmountable fatigue develops, accompanied by an excessive emaciation, which gradually render the girl who entered puberty in a blooming condition, a creature disgusted both with work and youthful pleasures. These girls must remain in bed during the time of menstruation or pass it with painful suffering and a diminished capacity for work. The symptoms complained of often are not referred to the pelvis; sometimes it is migraine, sometimes dyspeptic disturbances which are most prominent and only rarely does the patient admit that above all the change in the lower abdomen, the sensation of heaviness, backache, colicky pains before and during the menses, and the discharges, add more to the feeling of discomfort than the loss of appetite and the pains. Every cold, every excess causes exacerbation of the symptoms, and at times also a febrile movement.

The objective symptoms of chronic metritis show a material increase in the volume of the uterus, especially in the transverse diameter. With it the uterus may be almost insensitive, while in other cases it may be found intensely sensitive, especially during the introduction of the sound. The parametria are also tender on pressure to the same degree. A plainly increased sensitiveness is always present in the acute exacerbations. With it the uterus swells and shows a decreased firmness, indeed almost a doughy consistency, reminding one of pregnancy. Only when the process has subsided can a proportionately hard consistency of the diseased parts be observed. With the hardening the size also occasionally diminishes and the uterus becomes small and hard as cartilage. The sensitiveness may cease entirely or may be diminished in comparison with the more rarely occurring acute exacerbations.

The objective findings of the **diseased corpus** in reference to the healthy or less changed cervix are complicated usually by a coexistent disease of the endometrium at the height of the diseased process. With the increased sensitiveness there exists pronounced fluor and a striking

sensitiveness of the mucosa. The disease of the *perimetrium* is less marked, but symptoms of disease of the pelvic peritoneum are rarely absent. The floor of the excavatio recto-uterina and the region of the ligamenta sacro-uterina are excessively sensitive. The sensitiveness recedes somewhat during the period of quiescence of the disease, so that only direct palpation, the attempt to replace the uterus, or the displacement by hard fecal matter, or by cohabitation, give warning of the coexisting perimetritis.

The diseased cervix is thick, solidly edematous, later hard, like cartilage. The abundant secretion, often of tenacious mucus, gushes forth on palpation. Enlarged follicles give the mucosa a knobby surface. The portio vaginalis is sometimes knoblike, sometimes peculiarly pointed, with the configuration of the os uteri retained, in the beginning of a softness characteristic of pregnancy, later hard.

Among the *symptoms disturbances of menstruation and conception* are particularly predominant. Menstruation is always very abundant in the *post-puerperal* form of chronic metritis, especially in the early stage when dark blood mixed with clots is discharged in large amounts at very short intervals. The menses last longer than the usual time and not infrequently only incompletely disappear. An improvement may gradually occur, so that the amount and color of the discharged blood equals that which was formerly usual, and only the abundant secretion during the interval indicates the continuation of the malady. Menstruation occurs in many different ways in the *non-puerperal* forms of chronic metritis. It remains for a long time of the three or four weeks' type, but its course is marked by violent colicky pains which sometimes cease with the appearance of the blood, sometimes continue during the entire flow. The menstruation becomes continually more abundant so that at the height of the disease large amounts of blood, even in clots, are discharged. In other cases, however, the flow of blood becomes less. Menstruation occurs at increasing intervals, and smaller amounts of the bright red blood are discharged within only a few hours. The patients, who have been troubled with sensations of fulness in the abdomen and with severe congestions in the regions of the heart and the head, feel relieved and improved in the entire state of health, but only for a short time, however. A premature cessation of the menstruation occurs very often. Amenorrhœa appears long before the physiologic time from which the patients often suffer in an extraordinary manner. An adjustment also in this respect may finally occur at the time of the normal menopause, and with it a spontaneous recovery.

The influence of chronic metritis on conception depends apparently less on the development of changes in the uterine parenchyma than on the complicating diseases of the mucosa and the adnexa. Thus may be explained the fact that many women, particularly in the puerperal form of the disease, always conceive again, almost at the first cohabitation, post partum or abortum, while others remain sterile. It is not the me-

tritis, and, to a much less degree than commonly supposed, the endometritis which prevent conception, but rather the chronic catarrhal salpingitis, perimetritis, and perioophoritis.

The *influence of pregnancy* on chronic metritis is not always so beneficial as is supposed, although without doubt such an effect must be recognized quite often in isolated cases. Women affected with chronic metritis often abort, either because the mucosa is incapable of forming a normal decidua, or because the uterine parenchyma remains unsuitable as a place for the development of the fetus. A pregnancy with normal course results, in my experience, especially in cases in which the complicating adnexal disease has been successfully removed. If then the lying-in period is rationally conducted, the hyperplasia of the connective tissue may indeed be cured, so that for these cases one may be *justified* in terming *pregnancy a means of cure for chronic metritis*.

In the *differential diagnosis* of chronic metritis the differentiation from the early stages of *pregnancy* come first into consideration. Increase in size, softness, and increased secretion are common to both. The fact, which later becomes a characteristic sign that in pregnancy the corpus increases continually in size while the cervix is only softened, is of no assistance in the first months. Perceptible contractions of the uterus must naturally be taken into consideration. Women with endometritis bleed frequently quite copiously at the first menstrual period of pregnancy, while in others a premature expulsion of the ovum is thereby ushered in. The softness of the vagina, the strong pulsations of the vessels in the ligamenta lata, and later *Hegar's*¹⁴³ sign of pregnancy, together with the morning sickness, pressure on the bladder, and often drawing pains in the breast are links which, considered together, have a definite value in constructing a diagnosis of pregnancy.

The conspicuous softness of the lower uterine segment may easily lead to mistakes in another direction. In elongatio colli supravaginalis, the thickened corpus passes down into the vaginal vault by the side of the cervix, like a flabby ovarian cyst, a condition which I have observed especially often in the early stages of pregnancy.¹⁴⁴ The elongatio colli gives the impression of a moderately enlarged uterus, by the side of which lies the tumor. The markedly softened uterine segment which forms the yielding connection between the two becomes recognizable only by a very careful examination.

The *growth of myomata* rarely occasions a symmetrical thickening of the entire uterus or even the whole of the corpus. The hard lumps are, as a rule, easily distinguished from their softer surroundings in the mass of the uterus, above whose surface, moreover, they project.

The *prognosis* of chronic metritis is not as bad as *Scanzoni* considered it in his time.¹⁴⁵ The form resulting from septic infection is more amenable to recovery than that which develops from other causes. But even in the latter cases, with some patience on the part of the affected woman and somewhat favorable external circumstances, resolution of the altered

uterus may be obtained, resulting in a satisfactory if not also a complete recovery, providing the diagnosis of the disease has been made in due time. The prognosis is influenced by the complicating diseases of the genital apparatus: endometritis, diseases of the adnexa and the peritoneum may seriously retard complete recovery; indeed, they offer a never-failing source of painful acute exacerbations.

It seems natural also that the uterus should be especially liable to become cancerous in chronic metritis, a fact to which many observations point.

With the climacteric an opportunity for recovery from chronic metritis is afforded, but the patients are then only too often reduced in their sensibilities and vitality to such an extent that a final cure admits of only a limited enjoyment of life.

Treatment.—The prophylaxis of this peculiar and in its consequence grave disease must begin with a rational treatment of labor and the puerperium. Asepsis and complete removal of the ovum and its débris form the essential conditions for escaping infection of the uterus. Nourishing diet with corresponding care of digestion and a due proportion of rest and exercise assist each other in promoting the general strength and also the involution of the genitalia. Frequently repeated doses of ergotin, etc., hot douches (50° C., 122° F.) and tonic sitz baths are not to be underrated as prophylactic measures.

On the other hand, the strengthening of the bodies of girls during the years of development should receive due attention. Weak, chlorotic, hereditarily neurasthenic girls should be withdrawn from compulsory school attendance, especially if menstruation begins irregularly.

Appropriate and timely care to avoid the common sluggishness of the bowels and the frequent retention of the urine on account of social conditions belong to the same category. Girls and women should continue in their usual mode of life at the time of menstruation, however, avoiding everything which may cause extraordinary concussion of the abdomen or lead to taking cold or other disturbance at this period. As prophylactic measures, young married women should be cautioned against excess in sexual intercourse and too great activity in housework, and we would strongly recommend intelligent care of the body.

The treatment of puerperal sepsis cannot be discussed here in detail. Complete removal of retained and decomposing parts of the ovum is essential, but we must warn against too readily repeated operations. Profuse hemorrhage must be treated by thorough curettement of the endometrium and cauterization with liquor ferri perchloridi in the official form, or with solution of zinc chlorid (10 per cent.).

In chronic cases the indication is to secure a transformation of the uterus by a lasting influence on nutrition.

Local bloodletting is an empirically successful remedy. The mucosa of the portio vaginalis is slit open through a tubular speculum with a long-handled scapula, or deep cuts are made in the cervical lips. When

aseptically executed this acts more surely and promptly than bloodletting with leeches. Repetition of [the scarification must be regulated by the general strength of the patient and the plethora of the uterus. The amount of blood discharged must always be determined in the beginning. If the bleeding from such a scarification is too profuse it may easily be rendered harmless, as a rule, by touching the bleeding parts with acetum pyrolignosum or, if necessary, with liquor ferri perchloridi and tamponing the vagina. Only in cases of extreme urgency with profuse hemorrhage need the wound be closed by suture. If a very vascular uterus is scarified a few days before menstruation, the amount of menstrual blood is often markedly diminished. If the bleeding in connection with the scarification is severe, the patient should lie down for one or two hours. If, on the contrary, the bleeding is only slight, as during the stage of cicatrization in chronic metritis, I prefer to have the patients walk about immediately after the scarification. It is seldom that the bleeding does not stop almost immediately after the operation, so that only a slight amount of blood is expelled after the withdrawal of the speculum.

Sitz baths give great relief in chronic metritis. I use them with plain water, or with the addition of salt, wheat bran, or a decoction of oak-bark, beginning with a temperature of 32° C. (90° F.). The bathtub is placed beside the bed, the patient sits in it for from six to ten minutes, being covered with a woollen blanket, and then puts a towel around the hips and lies down in a warm sheet, in which she dries herself underneath the cover. Many women bear cooler sitz baths badly, while others experience a marked relief on reduction of the temperature. One may, while the patient is seated in the bath, cool down the water to 20° C. (68° F.) or still less, and may allow her to remain in this cool liquid for a few minutes.

It is not necessary to use narcotics exclusively for the relief of *pain*. Cutaneous irritation near the pelvis, especially vesicants and sinapisms, *Priessnitz* compresses, inunction with narcotic or irritating ointments often suffice.

A careful examination for diseases of the mucosa, and especially of the condition of the adnexa and the peritoneum, must precede every treatment by scarification.

Overlooking pus foci, localized in these parts, and other conditions of irritation, leads only too often to the fatal complications which so often discredit gynecologic treatment by the sound, by scarification, or to a greater extent by orthopedic operations. As soon as such complications exist, chronic metritis falls into the background; the uterus heals, if recovery from these much more important diseases is secured. For the therapeutic measures suitable to these complications consult the appropriate chapters.

Non-complicated chronic metritis, which at present is diagnosticated less often than a few decades ago, when the diseases of the adnexa were not well known, is favorably influenced by a number of other methods of

treatment. If scarification with local treatment by cleansing and disinfecting irrigations and sitz baths, and general care and moderation in sexual indulgence (coitus, masturbation) have been continued for some weeks and the curative action is manifest in a diminution of the amount of menstrual flow, of the leucorrhœa and tenderness, the use of iodine, tannin, ichthyol, and similar remedies for promoting absorption may be begun. I have made extensive use of iodine since 1876.¹⁴⁶ Tincture of iodine is applied to the portio vaginalis, in full strength or mixed with an equal amount of glycerin. I consider intrauterine application of iodine relatively the best of all similar methods. At the same time vaginal douches, with one tablespoonful of tincture of iodine (25.0 in 175.0 of water) in a litre of lukewarm water, are taken once daily. I make only a cautious use of *iodoform* in the vagina, dusted on cotton and placed against the portio, as I have frequently observed intoxication after small doses. Malaise, headache, and even loss of strength, yellow vision and the like occur, so that I think it advisable to be very cautious in the application of iodoform to the mucosa. I avoid severe cauterization, especially with *silver nitrate*, solution of zinc chlorid, or the hot iron on account of very serious scars that may follow it.

The softness of the uterus not infrequently disappears by the use of glycerin-tannin tampons and capsules, or ichthyol tampons and suppositories, the use of which I have described in the discussion of endometritis. (Acidi tannici, 10.0; glycerin, 100.0; or ichthyol, 10.0; glycerin, 90.0. D. S. externally.) Both mixtures are applied on cotton pledgets wrung out of cold water. Suppositories of ichthyol, 0.1, or tannic acid, 0.25, in cocoa butter act similarly.

Sluggishness of the bowels plays an important rôle among the complications of chronic metritis. It contributes often more to the *impairment* of the general nutrition than uterine hemorrhage and pain. As a rule there is a chronic catarrh of the colon.¹⁴⁷ There has occurred a very beneficial reaction against the misuse of cathartics which was for a long time so prevalent, especially in the treatment of diseases of women, a reaction in favor of the more rational treatment by diet, massage, gymnastic exercises (sport), and, when needed, galvano-faradic applications.

The regular use of fruit, salads, water, milk, fruit juices, a more vegetable diet, the lessened use of alcohol, especially in concentrated mixtures, combined with frequent walks in the open air, adjusted to the patient's strength, tennis playing, rowing, bicycling, indoor gymnastics during winter, and exercises in a medico-mechanic institute, lead with patient use to the subduing of very obstinate constipation. *P. Ruge*¹⁴⁸ recommends a reversal of the ordinary menu, beginning with fruit instead of soup, then sauce, vegetables, meat and soup, from which he obtains good results. Massage with massage apparatus,¹⁴⁹ if necessary in a suspended position, is justly celebrated. The use of galvanic currents with the insertion of the anode into the rectum has been found of especial benefit by *Hühnerfaut* (*Deutsche med. Wehnschr.*, 1898, Ther-

ap. addition, p. 93). Without doubt the use of laxatives or enemata cannot be dispensed with at the beginning. Terrain cures (*Oertel's* treatment) with bitter waters are very successful during the stage of cicatricial contractions with otherwise perfect conditions of health. Among the household preparations we especially recommend senna preparations, electuaries, the many rhubarb preparations, cascara sagrada, and tamarinds. Besides cold or warm solutions of table salt (one tablespoonful of salt in 125.0 of water), glycerin, 10.0, and soapsuds and sweet-oil from 200 to 500 cc are used for enemas.

℞ Infus. sennæ 80.0
 Sod. tartrat..... 7.5
 Aq. 12.5
 M.S. Shake well and use one tablespoonful in
 morning on empty stomach.

Also ℞ Fol. sennæ,
 Cort. frangulæ,
 Herb. achilleæ millefol..... āā 10.0
 M. f. species.
 S. Take one teaspoonful in one cup of hot water.

Massage also has been applied as a curative agent for chronic metritis. In addition to the various reports of Swedish lay masseurs, *Bunge*¹⁵⁰ and *Prochownik*¹⁵¹ have reported favorable results. In cases which are not complicated by perimetritis or fresh exacerbations in the endometrium, the so-called pulling and pressing massage (*Zugdruck* massage) and kneading of the uterus between the fingers inserted in the vagina and the hand lying externally, has a not unfavorable action. It necessitates always a very patient and careful employment of the method, fatiguing alike to the physician and patient, so that the results which can hardly be expected until after five or six weeks, appear to be purchased at a high enough cost. I massage only married women and discontinue the treatment in these as soon as I perceive any signs of erotic excitement.

Balneologic treatment must be considered as a very successful aid in absorbing chronic infarcts of the uterus as well as in improving the general well-being and thereby the resistance. According to our experience it is necessary to carry local measures in treatment of the genitalia to such an extent at the patient's home or in the hospital that the trip to the spa is to be considered more as a supplement and a recreation from such gynecologic treatment. The sojourn at the watering-place with its abundance of new impressions, and the influence of special means of treatment, the change of air and conditions of nutrition form a burden from which especially weakened persons suffer more than convalescents; these must often recuperate at home from the effects of their recreation trip.

Overnourished women with metritis chronica bear Kissingen, Tarasp, and Marienbad waters well, while older persons with chronic digestive

disturbances should go to such spas as Homburg, Carlsbad, and Soden, and also to the saline springs of Elster and Franzenbad. Chlorotic persons bear well the iron springs with their varied mineral constituents, as a rule.

I allow very weak women to visit sea-baths or also iron-containing springs. I send with preference to the first bathing-places women with poor appetite and decreased menstrual secretion, while I send those suffering from diffuse menorrhagias to the iron-containing springs, providing their stomachs will bear it. If the patients have lost much strength on account of the illness, I prefer a sojourn in a salubrious mountain climate and forest air, and I allow them to make use of mineral waters and baths only in accordance with definite individual indications. I have seen very good results from the use of saline springs, especially in chronic metritis during the development of puberty.

In spite of the best care and the regular employment of the means of treatment just described, a stillstand or retrogression of the disease fails to occur not infrequently, an observation which naturally is not rare in polyclinic practice. But even with favorable external circumstances, the repetition of internal injuries, especially repeated pregnancies, rapidly following each other with premature expulsion of the ovum, exercise a detrimental influence, particularly if septic infections accompany them (*abortus provocatus*). The patients then suffer from abundant losses of blood, which are not remedied by often-repeated curettements and local treatment. The patients become so anemic and cachectic that the fear of malignancy seems well grounded.

I advised in the third edition of this work (1893), *high excision* of the cervix for such cases. I could rest my claim for this procedure on hundreds of observations made since I established and recommended it in 1878.¹⁵²

This procedure has been adopted by many.¹⁵³ Since that time our knowledge of the frequency of complication by adnexal diseases in these cases, as well as our technic have so developed that to-day we consider far-reaching operations as legitimate and indicated for these obstinate cases of chronic metritis with hemorrhages endangering life. The complicating adnexal diseases require operation on their own account. If these diseased organs must be removed a cure of chronic metritis often follows. I do not classify the extirpation of diseased ovaries as *castration*, as by this I understand extirpation of healthy ovaries. (See under *Castration*.)

If the changes in the uterus are far advanced, extirpation of this organ is also considered at the present time as justifiable. For extreme cases also the propriety of this operation *in the absence of* complicating adnexal diseases is no longer disapproved. I consider it as indisputable in women during the climacteric. Referring to the remarks which I made during the discussion of myoma operations to justify my conservative ground on this question, I report that I have executed another procedure in such cases for the last three years. If the adnexal organs are

healthy or at all events not so much diseased as to demand their removal, I have not excised the thickened cervix, but often performed colpotomia anterior and have cut out of the anterior wall of the body of the uterus, which has thus been delivered into the vagina, more or less melonlike cuts reaching into the cavum with its mucosa, as one does in enucleation of myomata. These incisions are sutured in different rows with a continuous catgut stitch. A part of the wound is covered by the vaginal fixation. Healing results with aseptic operations without difficulty. During the period of cicatrization the uterus shrinks to normal, while in other respects it performs its normal functions.

The number of my observations is still small (7) and extends over a few years. At all events they encourage us in continuing this procedure, which does not lead to mutilation. A similar method is recommended by *Pfannenstiel* (l. c., p. 720).

C. Tumors of the Vulva and the Uterus

1. Tumors of the Vulva

LITERATURE.—See *J. Veit*, *Erkrankungen der Vulva*, *Handb. der Gyn.*, Vol. II. Wiesbaden, Bergmann, 1897.—*Gebhard*, *Pathologische Anatomie der weiblichen Sexualorgane*. Leipzig, Hirzel, 1899.—*Frommel's Jahresber. über Geb. u. Gyn.*, 1900–1905.

Tumors of the vulvâ are in general rare; those which occur are more frequently malignant than benign. This fact—as well as the seat of tumors which, even when of small size, mostly leads to considerable discomfort in walking, urinating, cohabitation, etc.—gives those tumors a considerable *practical* importance.

A. Of benign tumors of the vulva are to be mentioned *fibromata*, *lipomata*, *cystomata* and *polypi*.

Fibromata or *fibromyomata* are generally rare, but occur in all parts of the vulva. Particularly predisposed for their location are the labia majora. Fibroid tumors which appear here, originate mostly from the radiating fibres of the *ligamentum rotundum* in the upper part of the labia majora, which also explains their often more abundant supply of smooth muscle fibres. They may grow to an enormous size proportionally and show very often a pedunculated process into the inguinal region. Indeed, they may even undergo sarcomatous degeneration (*Küstner*). The fibromata must not be mistaken for *elephantiasis* (vide supra, p. 157), which quite often resembles the former in the labia majora.

Sometimes fibromata are pedunculated also, *fibroma pendulum*.

By a decided stretching of the peduncle, fibromata as well as lipomata may become necrotic and then sometimes fall off on their own account.

The *lipomata*, as a rule, originate also from the labia majora, eventually also from the mons veneris; they, too, are quite frequently pedunculated and may attain considerable size.

Relatively common are the **cysts** of the vulva. They mostly take their origin from the glandula vestibularis major (*Bartholini*), and are therefore localized in the lower part of the labium majus. They are mostly unilateral, seldom bilateral. They are looked upon as retention cysts; developed by an obstruction of the excretory duct of the gland. Their contents consist of mucous glandular secretion. Their walls are smooth, covered by stratified cylindrical epithelium, and not rarely still intact glandular ducts are found in them. (See Fig. 110.)

The vulva becomes displaced in its lower portion to the opposite side by the unilaterally developed cysts. The cysts may attain a considerable size.

The papillomata appearing at the vulva in the form of the so-called **acuminate condylomata** have been discussed already under the inflammatory conditions (see p. 154). At the **urethral opening**, particularly in old women, smaller or larger **polypoid proliferations**, usually of a high red color and intense development of bloodvessels, are not uncommon. Anatomically they are characterized as **angiomata**. With longer

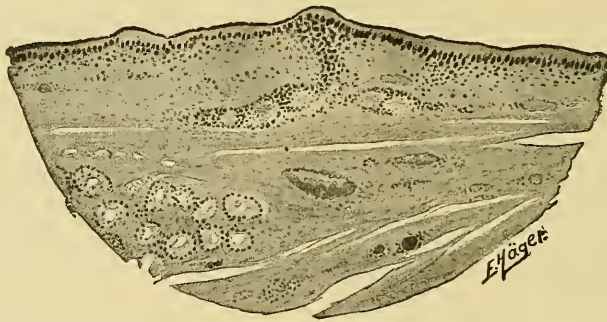


FIG. 110.—Wall of a Cyst of the Glandula Vestibularis Major. Stratified cylindrical epithelium lines the cyst-wall. Deeper down unchanged glandular ducts. (Author's preparation. Zeiss, Obj. AA, Oc. 4.)

existence the surface of the mucous membrane may become partly necrotic, in consequence of the settling on them of urine and micro-organisms. They are then covered with a greasy, grayish-yellow pseudomembrane.

The **symptoms** of benign tumors are less marked as long as they are still small. Only when of large size, especially if they are pedunculated, do they give rise to the sensation of interference during walking, cohabitation, and urination. The small polypi of the urethra may lead especially to painful ischuria, which can be relieved only by catheterization, as well as to chronic cystitis.

There can be no doubt as to the **diagnosis**. The tumors can be recognized without any difficulty by inspection; whether in a given case a soft fibroma or lipoma is in question may be easily decided by the eventually existing lobulated formation. Fibromata of the ligamentum rotundum are distinguished by their peduncle connection with the in-

guinal canal. Here caution is always advisable in regard to the differential diagnosis from *hernia*.

The cysts of the *glandula vestibularis major* might in some cases be mistaken for abscesses of the glands; however, the complete absence of any inflammatory irritation, especially at the excretory duct of the gland (*macula gonorrhoeica*) excludes an abscess in most cases.

The *treatment* of these benign tumors consists in their removal, which is usually very simple. Pedunculated fibromata and lipomata are simply removed after ligating the peduncle. If the tumors are deeply located the skin is incised over them, if possible always on the outer wall of the labium majus, and the tumor peeled out by blunt dissection; eventually the continuation into the inguinal canal is ligated and

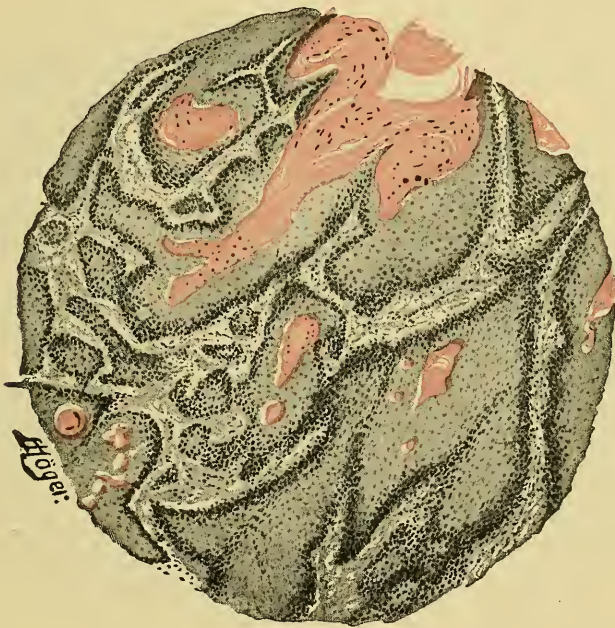


FIG. 111.—Cornified Squamous Epithelial Cell Carcinoma of the Vulva.
(Author's preparation. Zeiss, Obj. AA, Oc. 4.)

severed. One proceeds in the same way with cysts of the vestibular gland, which can be peeled out after very careful dissection of the capsule, usually without rupturing it. The vessels of the vulva, which are often very numerous, are caught separately and ligated. The bed of the tumor, or cysts, is closed with deep-continued catgut sutures, the skin with interrupted bronze wire sutures.

Polypi of the urethral external orifice are removed with a fine pair of scissors, and then the urethral mucosa is united with the vulvar mucosa by means of interrupted fine catgut sutures; besides this, a soft retention catheter is inserted into the bladder for the first five or six days post

operationem. A cystitis, if it exists, should be removed before operation, if possible.

The healing of all benign vulvar tumors ensues mostly *per primam* after the operation. Recurrences usually do not occur, so that the prognosis may be considered as quite favorable.

B. *The malignant tumors of the vulva* occur mostly as *squamous epithelial cell cancers*, often with a pronounced tendency to cornification (Fig. 111). Their seat of origin is, with a certain predilection, the clitoris, further the urethral orifice, more rarely the other parts. The very rare carcinomas of the vestibular gland are, on the contrary, cylindrical epithelial cancers (see Fig. 112). All these forms show a pronounced tendency to rapid disintegration, favored by the richness in

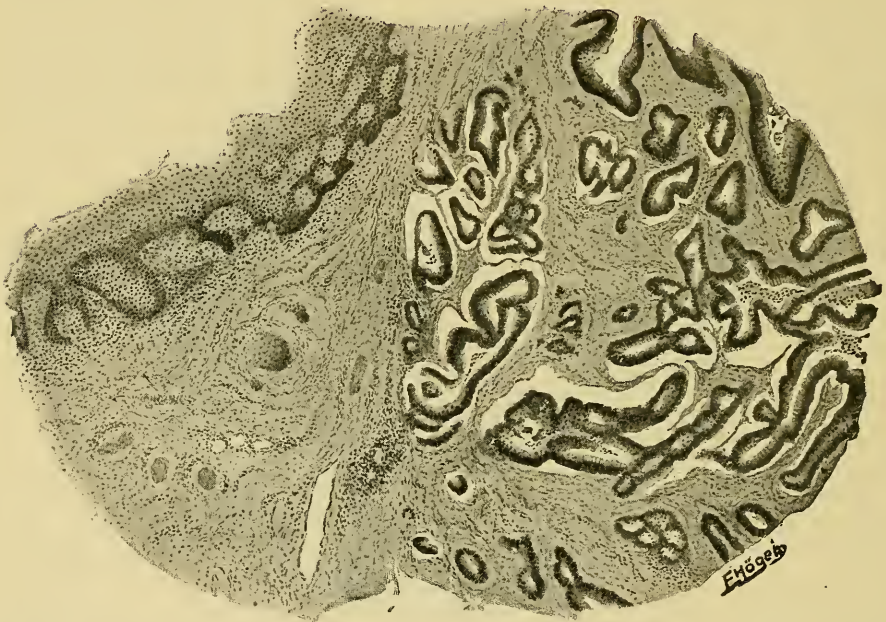

FIG. 112.—Cylindrical-celled Carcinoma of the Vulva Arising from the Glandula Vestibularis Major. (Author's preparation. Zeiss, Obj. AA, Oc. 2.)

bacteria of the vulva and the moistening with urine. As the vulvar carcinomata grow very rapidly the patients often go to the physician when the exact recognition of the original point of beginning is no longer possible, as the larger part of the vulva is already destroyed by the newgrowth. This may invade the vagina and rectum as well as the urethra and the bladder, whereby in the further course extensive fistula formation of the organs may occur. Vulvar cancers have been observed relatively frequently on the bases of chronic vulvitides, especially the *Kraurosis vulvae*. (See above, p. 153.)

Sarcomata are found much more rarely in the vulva, mostly in the

form of the exceedingly malignant *melano-sarcomata*. They also have a great tendency to disintegration and act in advanced stages anatomic-ally, quite like the carcinomata, so that the differential diagnosis often can be made only by the microscope.

The *symptoms* of these malignant vulvar tumors consist in their interference with walking, further in burning pains during urination and cohabitation, regardless of those produced by sloughing, and eventually by hemorrhages.

The *diagnosis* of malignant tumors is very easily made by inspection and palpation. Only in the initial stage of newgrowths confusion with ulcers of other etiology may occur, especially luetic primary affections.

A patient was brought into the gynecologic clinic at Greifswald with the diagnosis of *ulcus durum*. On the inside of the right labium majus was found an ulceration the size of a dime with an indurated base. As the treatment by inunction was without any result, the ulcer was excised and microscopically the diagnosis of *squamous epithelial cell carcinoma* was made.

These cases are rare, and the illness usually already possesses the characteristics of a malignant newgrowth, easy to diagnose. The special diagnosis can be reserved for microscopic examination later on, as it is immaterial for *treatment*.

This must always consist in *the excision of the entire vulva with removal of the inguinal glands of both sides, perhaps with partial resection of the urethra*, if a radical removal of the tumor is at all possible. Every operation without removal of the inguinal glands, even if these are not palpably enlarged, must be regarded as incomplete.

The operation is performed so that first the entire vulva is circumcised far outward from the newgrowth, then internally the same way even as far as posterior to the vaginal introitus. If the urethra does not take any part in the tumor formation it is cut close around its external orifice; if it is involved, which chiefly occurs in clitoris cancers, it must be partially resected.

The *subcutaneous adipose connective tissue* of the vulva and of the mons veneris must be peeled out as deep as possible. The numerous and large vessels, especially in the region of the clitoris, are caught best separately, and ligated. The entire large wound surface is sutured with a deep continuous catgut stitch and the skin with bronze wire interrupted sutures. Special care must be given thereby to the fixation of the external urethral orifice in the anterior margin of the wound.

Then a long incision is made at both sides of the upper angle of the wound, beginning at the mons veneris, parallel to the ligamentum inguinale, as far as the spina anterior superior ossis ilei. The entire adipose tissue of the inguinal region, together with the lymph-glands, are cleaned out. The deep inguinal glands also must often be removed. Hereby urgent caution is always to be advised on account of the nearness of the large crural vessels. The lymph-glands with the surround-

ing adipose tissue lying on the anterior surface of the thigh are not seldom affected and must be extirpated also. The coaptation of the wound edges is done best with interrupted bronze wire sutures.

The **prognosis** of vulvar carcinomata is extremely grave, in spite of this radical operation. Most of the cases recur in the course of a short time. Permanent cures have been recorded only in a few cases. **Inoperable** cases may be treated by thorough scraping with a sharp spoon and cauterization with a *Paquelin*. However, the improvement in most cases is only of short duration. One must guard against too far-reaching interferences, lest the condition of the patient becomes still more intolerable through the formation of fistulas in the bladder and the rectum.

2. Tumors of the Vagina

LITERATURE.—See *J. Veit* in *Veit's Handb. der Gyn.*, Bd. I. Wiesbaden, Bergmann, 1897.—*Gebhard*, *Pathologische Anatomie der weiblichen Sexualorgane*. Leipsic, Hirzel, 1899.—*Frommel's Jahresber. über Geb. u. Gyn.*, 1900-1905.

The tumors of the vagina also belong to the rarer tumors. They resemble in many respects those occurring in the vulva on account of the homogeneity of the epithelial covering and of its substratum of fibromuscular tissue.

Of the benign tumors we will mention the **fibromata**, **fibromyomata**, and further the **cystomata**.

Fibromata and **fibromyomata** take their origin from the wall of the vaginal canal at the most different places, preferring perhaps somewhat the anterior wall. They cause a bulging of the vaginal mucosa, whereby pressure atrophy and decubital ulcers may take place at the extreme top of the tumor. The fibromata are of different consistency, sometimes extremely hard, at others softened through the lymph-stasis, so that they may resemble a cyst. However, the absence of fluctuation almost always makes the differential diagnosis positive from cysts.

The **cysts** of the vagina may be of different origin. One class originates from adherent folds of the mucous membrane, or the **glands** which rarely occur in the vagina. They develop by retention of the vaginal secretion and may attain the size of a hen's egg or larger. Their inner lining membrane is mostly not uniform, but consists in places of stratified cylindrical epithelium and in others of many layered squamous epithelium. The contents are mostly a clear, somewhat tenacious fluid rich in albumin. Some cysts of the vagina are referable to enlargements of the ductus epoophori longitudinales (*Gärtneri*). As it has been proven that this duct runs also in the human being next to the anterior lateral vaginal wall down to the hymenial ring, the possibility is very pronounced that it can become cystically dilated in its different parts and therefore become the matrix of cysts also in its vaginal portion. These are lined

by stratified cylindrical epithelium and have clear, serous contents like the parovarian cysts (see under *Ovarium*). These cysts will therefore always have their seat at the anterior or anterior lateral wall of the vagina, while those which are developed from the vaginal wall by adhesions and retention may be located all over. It might be very difficult in a given case to decide with certainty from what point this or that vaginal cyst originated.

The **symptoms** of the vaginal fibromata and cysts appear only when the tumors have attained a certain size. If they are only small they may exist without symptoms for a long time, especially in the vaginal vault and are then accidentally discovered during an examination for other reasons.

If they grow they mostly cause the sensation of a prolapse, especially in the anterior vaginal wall, and may give us that impression on inspection and superficial examination. An exact palpation of the bladder with a catheter or of the rectum with the finger will, however, prove at once that the supposed cysto- or rectocele is not present, therefore a new-growth in the vaginal wall itself must be under discussion. If fibromata or cysts are located in one of the lateral walls of the vagina, they may narrow the lumen laterally and particularly cause much discomfort during cohabitation.

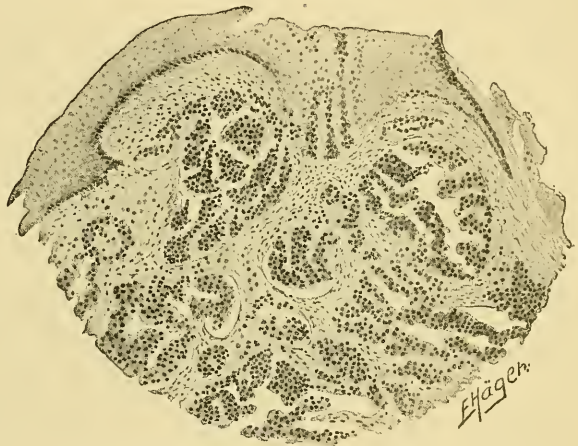

FIG. 113.—Primary Carcinoma of the Vagina.
(Author's preparation. Zeiss, Obj. AA, Oc. 4.)

The **treatment** of benign vaginal tumors can only consist in **excision**, which is mostly very simple. After splitting the mucosa these tumors are peeled out from the para-vaginal connective tissue, if possible *in toto* without opening the cysts. The bed is closed with continuous catgut sutures, and the vaginal mucous membrane united over this. If the tumor or the cyst extends deep into the pelvic connective tissue, which happens especially in cysts of the ductus epoophori longitudinalis (*Gärtneri*), it will not uncommonly become necessary to ligate the larger branches of the arteria uterina. Tumors of the posterior vaginal wall may approach the rectum and those of the anterior wall the bladder; however, on account of the non-infiltrating growth of the benign tumors, one will succeed in delivering them by dull dissection without opening the hollow organs mentioned.

Vaginal Carcinoma and Sarcoma

The **malignant tumors** of the vagina are in most cases **carcinomata**, seldom **sarcomata**. We will here waive the consideration of all implantation tumors of the vagina, which secondarily arise from malignant tumors of the uterus. We will discuss only the **primary** vaginal tumors.

The **primary carcinomata** of the vagina are squamous epithelial cell cancers, frequently with a great tendency to cornification. Two forms can be distinguished:

1. Circumscribed carcinomatous ulcers with wall-like thickened margins.

2. Diffuse carcinomata infiltrating the wall which, surrounding the whole periphery, change the vagina into a rigid narrow tube. The vag-

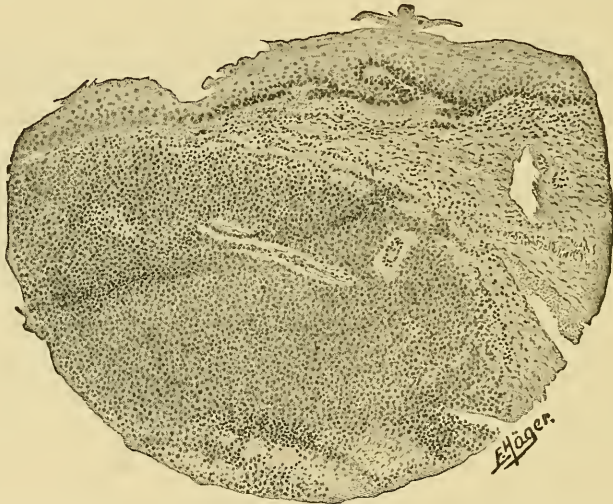


FIG. 114.—Primary Round Cell Sarcoma of the Vagina. Epithelial surface layer still preserved. To the right the normal vaginal wall, to the left sarcoma. (Author's preparation. Zeiss, Obj. AA, Oc. 4.)

inal carcinomata incline much to superficial disintegration while, on the other hand, they spread rapidly deep down into the rectum or the bladder, as well as upward into the pelvic connective tissue. The lymph-glands of the pelvis, particularly the deep inguinal and the iliac, also become affected quite early.

Primary **sarcomata** of the vagina belong to the rarest of new-formations of the female genital canal. They have been described in a small number of cases in small children as well as in adults, and then as round- or spindle-cell sarcomata. Their point of origin is the connective tissue of the mucosa, but they always penetrate very early into the lumen of the vagina (Fig. 114). They occur either in the form of circumscribed

ulcers of the vaginal wall, as in carcinoma, or in the form of tumors developed far into the pelvic connective tissue, their summit extending into the vagina in which it ulcerates mostly superficially.

The decision, whether in a given case a sarcoma or carcinoma is present, can only be made with the aid of the microscope on account of the similarity of their gross appearance. This is, moreover, irrelevant for their clinical behavior.

The *symptoms* of the malignant vaginal tumors are only slightly pronounced in the beginning; they are often altogether absent. Later they are analogous to those of uterine carcinoma: irregular hemorrhages, especially after coitus and discharges like meat washings of a repulsive odor are the most marked symptoms. (See *Tumors of the Uterus*.)

Many cases come first for examination in the advanced stages on account of the insignificance of the symptoms in the beginning of the disease.

The *diagnosis* is very easily made by digital exploration of the vagina; in addition one needs to make certain that the uterus is free from malignant disease.

The *treatment* of malignant vaginal tumors can only consist in an early and most radical extirpation of the *entire* vagina and uterus, even if the latter does not yet participate in the disease.

Olshausen advocated a method of operation in which, after transverse splitting of the perineum, the vagina is dissected bluntly from the rectum and then successively from its remaining connections in the pelvic connective tissue as well as the bladder, and is finally removed with the uterus in one piece. The primary results with this method, of course, were very favorable, the remote results, however, very unfavorable. We have also made use of it in about twelve cases. According to our present knowledge of the spread of uterine carcinomata into the pelvic connective tissue and along the lymphatic system we will not hesitate in a given case to attack also *abdominally* the primary malignant new-formations of the vagina and to extirpate them with a most extensive removal of the pelvic connective tissue and the probably infected lymph-glands, together with the uterus. The details of this method will be found in the chapter, *Carcinoma Uteri*. The final step of the operation after extirpation of the vaginal tube from above would consist in circumcising the introitus from below and loosening the vagina from its remaining connections.

In tumors inoperable from the onset one may scrape the tumor masses with a sharp spoon and cauterize the field with the *Paquelin*. Hemorrhage and ichorous suppuration are thereby brought to a standstill, at least for a short time. One must be cautious herein not to perforate the rectum and bladder, as fistulæ of these organs naturally considerably aggravate the condition of the patient. However, such complications not seldom appear spontaneously during the last stages. The indications at this time are to produce always a subjective euphoria by large doses

of morphin and, if necessary, also alcohol. Hemorrhage must be controlled by repeated cauterization with liquor ferri perchloridi or with the cautory-iron (*Paquelin*).

3. New-Formations of the Uterus

The uterus is the organ in the female body most frequently attacked by new-formations. The most frequent of these are:

I. Fibromyomata (Myomata, Fibromata)

LITERATURE.—On the *Anatomy of the Myomata*: C. Gebhard, Pathologische Anatomie der weiblichen Sexualorgane, Leipsic, Hirzel, 1899. C. Gebhard in *Veit's Handb. d. Gyn.*, Bd. II. Wiesbaden, 1897.—*Frommel's Jahresber. über Geb. u. Gyn.*—G. Winter, *Zeitschr. f. Gyn.*, Bd. 55.

As to the *etiology* of these tumors we know just as little as about the etiology of tumors in general. All hypotheses advanced about it so far lack tenable proof; to pay any attention to them is therefore useless.

The fibromyomata of the uterus are tumors which are composed of elements of the uterine wall, connective tissue, and smooth musculature. In an individual case one or the other constituent part predominates, so that the tumors consist either almost entirely of connective tissue with few muscle fasciculi or almost completely of such with less connective tissue. In the first case the tumors are rigid, hard, crunching on section, and of tendonlike, white, shining color; in the latter case softer, more vascular, more juicy, and of a red color. Between these two extremes are found all degrees of consistency. The imbedding of the tumors within the uterine wall is often of such a kind that the myomatous tissue is distinctly differentiated from the uterine wall tissue and may easily be peeled out from it by dull dissection, a characteristic very important for the operative treatment of these tumors. The layer of the uterine tissue which adjoins directly the myoma is called the *capsule* of the myoma. Only in rare cases is this differentiation absent, so that the myoma passes *diffusely* into the uterine tissue; especially a particular form of myoma, the *adenomyoma*, is characterized by its deficiency of differentiation from the surrounding tissue (see below).

A single fibromyoma nodule seldom develops alone in the uterus. The uterus is usually permeated by a great number of such tumors, which may reach the number of fifty or more.

The size of the single tumors varies extraordinarily in one and the same uterus; besides nodules of the size of the head of a pin, tumors may be present weighing twenty kg, with all intermediate grades.

The *location* of the different tumors is of quite special importance also in a clinico-therapeutic respect. *They develop mostly in the corpus, much more rarely in the cervix.*

A. Myomata of the Corpus Uteri

We distinguish four large groups:

1. **Subserous.**
2. **Submucous.**
3. **Intramural.**
4. **Intraligamentous** development.

1. **Subserous** include such myomata as have grown on the outer surface of the uterus toward the open abdominal cavity and project as more or less large nodules above the surface of the uterus. This development can go so far that as a connection of the tumor with the uterus only a more or less thickened peduncle remains, **pedunculated subserous myomata** (see Fig. 119). Finally, by torsion of the peduncle and atrophy of its vessels necrosis can occur and thereby a complete separation of the tumor from the uterus may result, after which the tumor remains lying in the abdominal cavity as a **free foreign body**.

2. **Submucous** include those myomata which are located beneath the mucosa of the uterus and protrude into the uterine cavity. They also grow gradually out of the uterine wall, so that they are connected only by a thin band of tissue with the uterine wall, just as the subserous pedunculated myomata, **pedunculated submucous myomata**, also called **fibrous polypi**. (See Fig. 115.)

Just as the subserous pedunculated tumors may become separated from the uterus, the same may happen with the submucous. By exercising irritation as a foreign body on the musculature

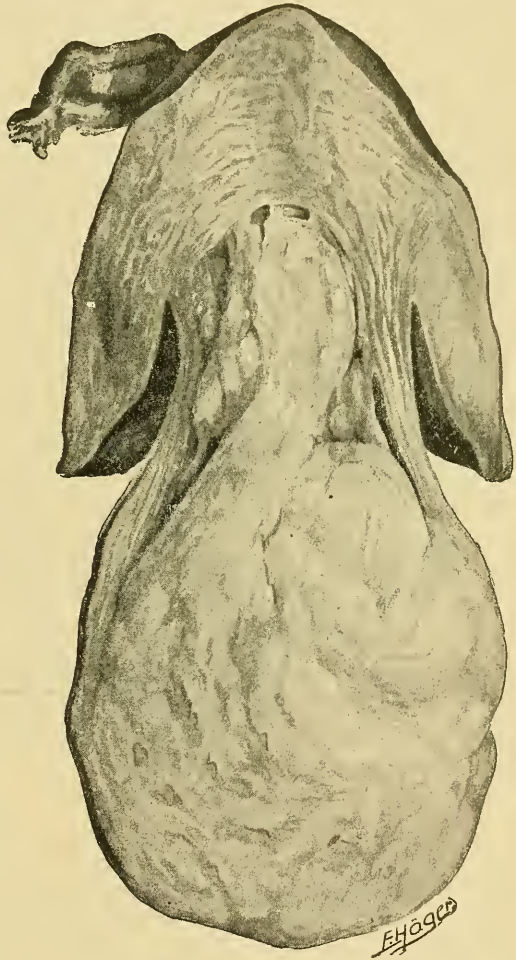


FIG. 115.—Submucous Fibromyoma Originating in the Fundus Uteri and Delivered into the Vagina. (Author's preparation.)

of the uterus, like the growing or mature ovum, they stimulate the musculature to contraction, so that they may be extruded from the uterus into the vagina with laborlike pains. Here, also, through atrophy of the peduncle, a complete separation of the tumor from the uterus may occur, and with it an expulsion from the genitals altogether may take place.

If the peduncle is too strong to atrophy and separate, the traction of the tumor may cause a partial or complete *inversion of the uterus*.

3. As *intramural* are designated such myomata as develop within the uterine wall itself. However, these tumors during their further development seldom remain intramural. According as their original location was more toward the serosa or toward the mucosa, they may develop in the course of time to either subserous or submucous tumors, so that thus one form may gradually pass over into the other (see Fig. 116). Especially with submucous tumors one may witness that in the course of years one tumor after the other gradually advances from the intramural bed toward the cavum uteri, and that in the course of time the expulsion of several tumors occurs.

4. *Intraligamentous* tumors are such myomata as develop in the lateral walls of the uterus toward the broad ligament, at the point where the peritoneal folds of the ligamentum latum pass into the serosa of the uterus. In another place such tumors would be called subserous, but here they must extend their growth into the ligamentum latum, that is, intraligamentous. (See Fig. 137.)

Here, also, as many authors admit, a separation of the tumor from the uterus may take place, so that the myoma lies isolated within the ligamentum latum.

It appears more probable to us that such tumors may have developed primarily within the ligamentum latum. (See chapter, *New-Formations of the Pelvic Connective Tissue*.)

The intraligamentous myomata not rarely exercise pressure on the neighboring organs on account of their location and the impossibility of developing freely. The bladder and rectum especially, as also the ureters, may be made fellow-sufferers in this manner.

B. Myomata of the Cervix Uteri

Of these we can differentiate three different groups:

1. *Myomata of the supravaginal part.*
2. *Myomata of the intravaginal part.*
3. *Pedunculated submucous fibrous polypi of the cervix uteri.*

1. *Supravaginal tumors* are relatively rare. They always develop in the cavum subserosum pelvis, either laterally or anteriorly or posteriorly. The lateral developed ones constitute transitional forms with the intraligamentary myomata of the corpus. Those extending anteriorly may lift the bladder from off the uterus and displace it considerably, occasionally also flex the uterus. By a posterior extension they may compress

the rectum considerably or push it to the side. Like the intraligamentous myomata of the corpus, they may, on account of their location, give the greatest opportunity to complications.

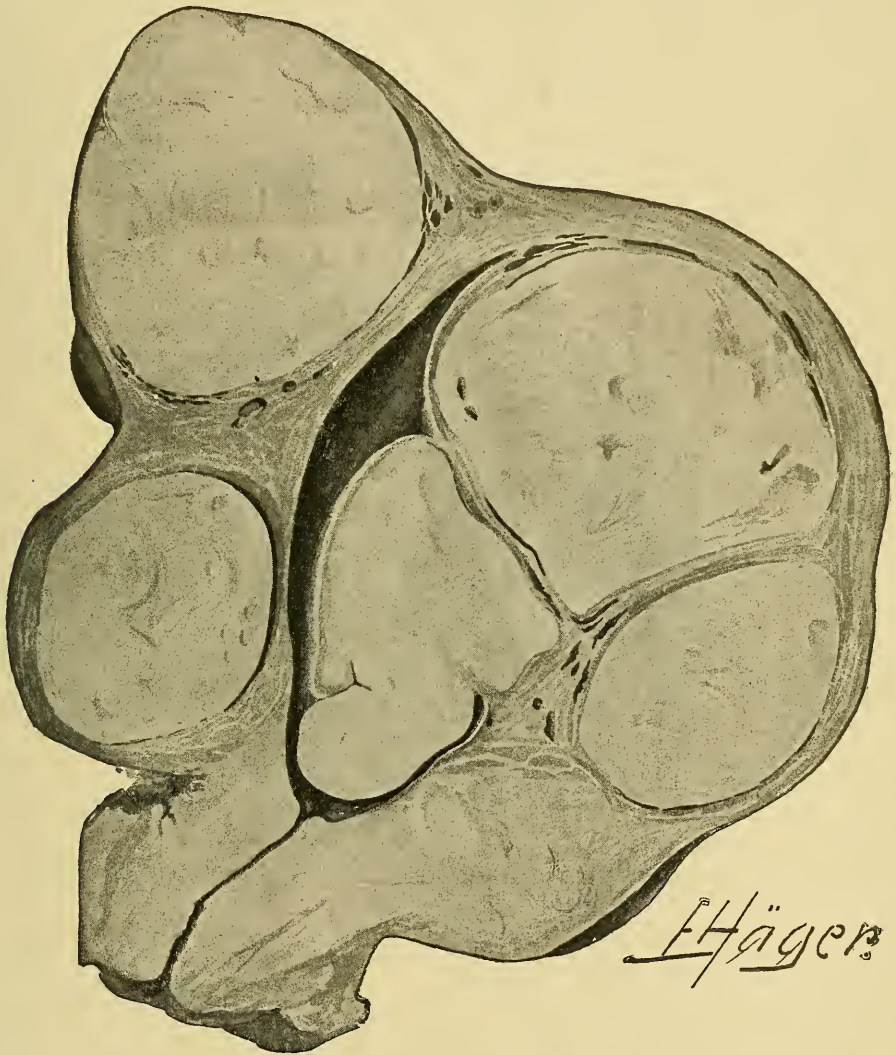


FIG. 116.—Multiple Intramural, Submucous and Subserous Myomata of the Uterus.
(Author's preparation.)

2. Myomata of the *intravaginal* portion of the cervix develop from the tissues of the portio vaginalis. They represent generally the rarest location of myomata, and do not usually attain an important size (they have been observed up to 1,700 gr.).

3. The *submucous pedunculated fibrous polypi* of the cervix are relatively common. They may originate from all parts of the cervical

canal, and are mostly very soon delivered through the external orifice of the uterus into the vagina. They are not seldom cast off spontaneously by overextension and necrosis of the peduncle.

All the described forms of myomata of the corpus as well as of the cervix may exist side by side in the same uterus and give this organ the most varied and most fantastic forms (see Fig. 116).

The **occurrence of myomata** is generally connected with the period of sexual activity (child-bearing period). Only in extremely rare and exceptional cases are they observed during childhood. They are also yet **relatively** rare until the thirtieth year of life. The majority of cases (about 70 per cent.) are noticed between the thirtieth and fiftieth years of life; in old age they again are rare.

It has been claimed many times that myomata occur relatively frequently in virgins and nulliparæ. However, this supposition cannot be considered as proven on critical examination of the existing statistics, just as little as sexual irritations, accused by different authors as etiologic, may be maintained as causative factors. An impenetrable darkness hovers, now as ever, over all these etiologic questions.

The **growth** of myomata is mostly slow, in case there are no complications. Year after year may pass without it being possible that anything but a quite gradual enlargement of the tumors can be established by regular observation. But in this respect also the cases behave differently; some remain almost stationary, others, however, grow continually, so that a distinct increase can be proven during examinations repeated from time to time, which often also may be noticeable by the carriers. Myomata may attain in gradual growth a considerable circumference in the course of time. Some have been described up to forty pounds and more.

A peculiar characteristic, which distinguishes the myomata of the uterus from all other tumors, is the not rare **spontaneous** decrease during the **climacterium**. Tumors, which before were engaged in a slow growth, become stationary with the beginning of the menopause, to decrease then slowly in size, and indeed it may even happen that they undergo absorption and entirely disappear. A treatment has been based on this characteristic of the tumors by holding the patients by palliative measures as far as the climax, and then hoping for the spontaneous retrogression of the tumors and the cessation of the complaints. But this is a very doubtful measure. For not all myomata decrease in size during the climacteric or become symptomless; a very large proportion continue to grow further, and thus finally force a radical treatment.

Apart from the more frequent true fibromyomata we have recently learned to recognize a variety of myomata, especially through the investigation of *v. Recklinghausen*, which contain besides connective tissue and smooth muscle fibres, also **glandular** structures in greater or lesser extent; **adenomyomata** (see Fig. 117). The glands have partly the type of uterine glands and are to be regarded as mucous islands scattered from

the uterine mucosa into the myoma, *mucous adenomyomata*, or the glands have more or less the type of parovarian tubules and are, as is accepted, to be considered as dispersed embryonic epoophoral cells (*v. Recklinghausen*), *epoophoral adenomyomata*. For the latter the dorsal side of the fundus uteri and the cornua of the tubes should be a characteristic location (*W. A. Freund*). How far these tumors really belong to the epoophoron, or, as we would rather believe, are still of a mucous origin in the great majority of cases, still needs to be settled. However, for clinical and therapeutic purposes it is important to know that adenomyomata are, as a rule, not easily peeled out of the capsule,

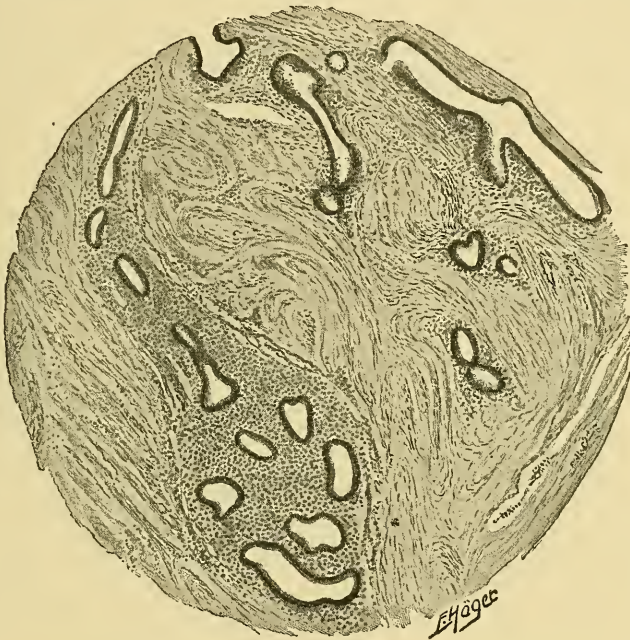

FIG. 117.—*Adenomyomata Uteri*. (Author's preparation. Zeiss, Obj. AA, Oc. 2.)

but the periphery not being well defined, pass more diffusely into the adjacent uterine structures. Adenomyomata are generally small, but may, however, attain in rare instances also a considerable size. The anatomic diagnosis will be easily established microscopically from the presence of glands in the fibromyomatous tissue. Macroscopically at times small cavities lined with mucous membrane, often with hemorrhagic contents, are found. Confusion with blood and lymph vessels is, however, possible on observation with the naked eye.

The influence of the development of the myoma on the uterus is mostly very intensive. The external form of the organ is changed manifoldly according to the number, location, and size of the tumors; the lumen is narrowed and displaced in various directions, so that numerous angles and cavities may develop within it (see Fig. 116).

While **subserous** myomata do not usually exercise an important influence on the uterine wall, the **intramural** tumors mostly cause a hypertrophy of the entire organ, perhaps due to the effort to expel these foreign bodies by muscular contraction. The action of the **submucous** myomata on the uterus is very marked. Here, also, the uterine wall undergoes hypertrophy; besides the mucous membrane also reacts, as a rule, very strongly to the tumors.

The chronic irritation of the tumors protruding into the cavum often causes a marked hypertrophy of the entire mucosa, in which the glands and the interstitium participate equally, so that the thickness amounts to more than 1 cm. A severe **hypercæmia** usually accompanies it, which often may lead to considerable hemorrhages. (See under **Symptoms.**) **Atrophy** often takes place over the tumor, caused by the vast dilatation of the mucosa by the growing tumor. Indeed, this extensive atrophy may become so severe that the entire mucosa disappears and the tumor lies exposed naked within the uterus. (See also chapter, **Endometritis.**)

If, also, the myomata, on account of their anatomic structure and their slow, never-infiltrating or metastatic growth, must be designated histologically as absolutely benign, clinically this is true only in a very conditional sense, on account of the frequency of the most diversified **degenerative processes** to which the myomata are exposed at any time of their existence.

In about 4 per cent. of all observed cases they are subjected to a really malignant **sarcomatous** degeneration (see chapter, **Sarcoma of the Uterus**), **very rarely** to a carcinomatous degeneration, when the glandular part of an adenomyoma degenerates to an adenocarcinoma.

A very rapid growth of the tumors always takes place with these malignant degenerations, with which an extensive metastasis soon occurs. The not rare **combination** of myomata with cancer of the cervix or corpus uteri **do not** belong to the **degenerations**. The malignant newgrowth may well grow into the myoma, but a **degeneration** proper, i. e., a metaplasia of the myoma into a carcinoma does not take place.

But irrespective of this, other processes not rarely occur in the fibromyomata, which directly endanger the life of the patient without being malignant in an oncologic sense. All myomata which are located within or near the cavum uteri, are exposed in a high degree to an invasion by bacteria. Particularly such tumors as project into the cervix and vagina, and which have suffered in their blood-supply by compression, torsion, or distortion of their peduncle, easily fall victims to necrosis and gangrene, but also tumors lying themselves within or reaching into the cavity, may become infected spontaneously or by external influences, especially improper interferences (sounding, abrasio). By an accumulation of the ichorous secretion within the folds and recesses of the cavum uteri, **pyometra** and grave septic disease may occur. The **subserous** myomata are less menaced by this danger of sloughing. If their blood-supply is too much affected by circulatory disturbances in their peduncle, they also

suffer nutritive disturbances and may degenerate in different ways. But they are only seldom subjected to gangrene on account of their position, being protected from the invasion of bacteria. Bacteria from the bowel may also invade those subserous tumors which form extensive adhesions with the intestines.

Not seldom extensive stases in the bloodvessels take place on account of the influence of circulatory disturbances in the pedicle or capsule of myomata, which are mostly accompanied with a considerable dilatation of the lumen of the vessels: *Myoma teleangiectodes* or *lymphangiectodes* (see Fig. 118). Large hemorrhages sometimes occur in them which lead to extensive destruction of tissue. All these circulatory disturbances

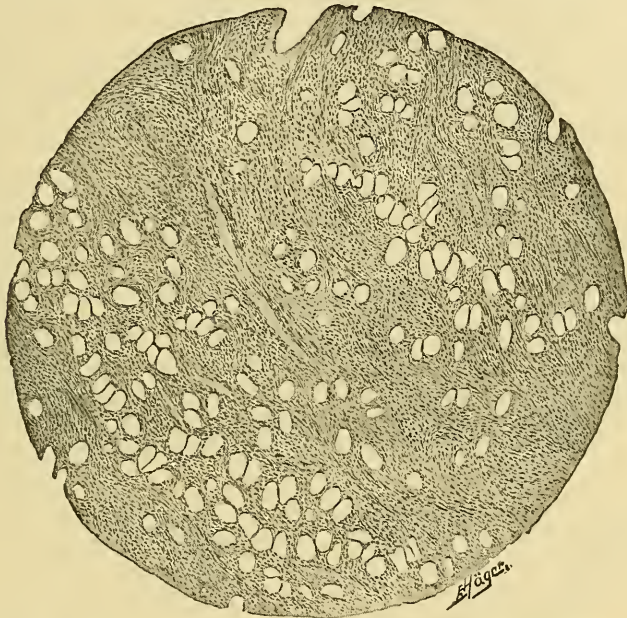

FIG. 118.—Myoma Lymphangiectodes. (Author's preparation.
Zeiss, Obj. AA, Oc. 4.)

are accompanied by an intense and rapid increase in the size of the tumors.

As already mentioned, many myomata experience a spontaneous retrogressive metamorphosis, which may lead to an almost complete atrophy, eventually also to a **calcification** of the entire tumor (so-called **uterine stones**), which then acquires a consistency of stony hardness. The atrophy and calcification of the myomata are to be considered as favorable for the carrier, and in a certain sense, as a spontaneous cure, in contradistinction to other degenerative processes. Calcified myomata not rarely are carried for many decades without any difficulties.

Fatty degeneration also has been observed comparatively frequently; it likewise must be considered as a sign of retrogressive metamorphosis

particularly in myomata, which have passed through a pregnancy. Not rarely fatty degeneration takes place during the puerperium. It, as a rule, commences in the centre of the tumor and progresses outwardly.

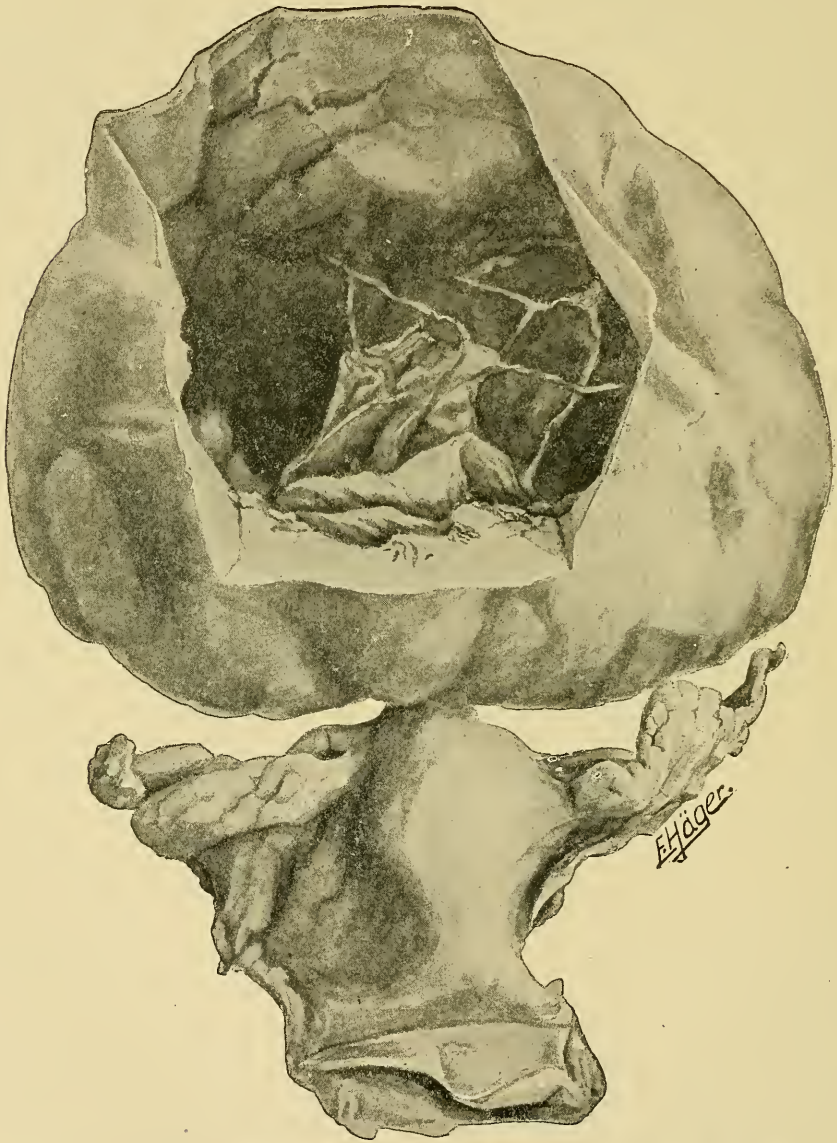


FIG. 119.—Myxomatously Degenerated Pedunculated Uterine Myoma.
(Author's preparation.)

The fatty degenerated parts are characterized on cross-section by their homogeneous, yellowish coloration. The *myxomatous* degeneration of myoma also belongs to the not uncommon forms of degeneration. Usually

with a considerable increase in the size of the tumor, its interior liquefies gradually, so that finally a large thick-walled cyst with thick, fluid, mostly hemorrhagic contents, arises, in whose interior still are preserved connective tissue cords and plaques as remnants of the tumor structure (see Fig. 119).

The anatomically well-characterized forms of degeneration mentioned are not always found, even with pronounced circulatory disturbances. A myoma, disconnected from the circulation, may become *necrobiotic*, if only micro-organisms are prevented from gaining entrance.

Such tumors are then found somewhat softer than usual and thoroughly saturated with serum. On cross section the color is brownish-red on account of diffused blood-pigments; the structure otherwise, however, is maintained. Sometimes the signs of beginning myxomatous degeneration are already noticeable in such necrobiotic myomata.

Amyloid degeneration (with general amyloid degeneration) as well as the just as uncommon mixed tumors, *chondromyomata* and *osteomyomata*, are of no practical importance on account of their rarity.

The *pathologic anatomy* of the myomata is like their form, exceedingly variable, so that hardly ever one case resembles the other. *As, however, the processes of degeneration mentioned, irrespective of the sarcomatous, but especially the fatty and myxomatous, as well as suppuration and sloughing, form a constant danger for the bearer, we must classify the myomata in this sense, as only conditionally benign tumors.*

Clinical Behavior

Myomata, doubtless, belong to the most frequent new formations of the uterus. *Hofmeier*, with large material, has recorded 4.3 per cent.; *Essen-Möller*, 4.7 per cent. Myoma uteri has been found in post-mortem examinations in women above fifty years of age in 40 per cent.

Colored and mulatto women suffer essentially more frequently from myomata than the white race. Private patients—that is, in general, women of more comfortable conditions of life—more frequently give us opportunity to diagnose myomata than those of the physically harder working classes. Unmarried women have symptoms of myomata comparatively more frequently than married: I find noted in my private material a relatively high number of teachers. The statistics approximately agree in these relations. However, they are entitled only to a limited value. For we must bear in mind that a very large number of myomatous processes attain only an insignificant size and that a still much larger number do not cause the bearers any difficulty. The statistics of the pathologic institutes report only a small fraction of the entire post-mortem examinations. The medical death certificates are not of any value without an autopsy. But also clinical reports may appear as of full value only to a limited extent, as only too frequently especially small myomatous roots escape diagnosis by palpation. Myomata of a consider-

able circumference very often are found accidentally during examinations for other reasons, which cause no symptoms or only unimportant ones. This happens especially in persons during the climacteric who are found in the "change" of menstruation. On the contrary, we find myomata of very small size in every kind of localization and in every period of adult life, causing very severe disturbances. These complaints are not always of the same degree of severity, and their fluctuation does not always depend on demonstrable changes in the structure of the new-growth. However, rapid growth and suppuration are important exceptions. Myomata complicated by conception and labor attain a special importance (see p. 244).

Assuredly the lack of importance of the myomata continues as long as the uterus does not become affected by other diseased processes. This danger naturally threatens in the first place from the mucosa, then from the adnexal organs. The intense proliferation of the endometrium which is favored by the bulging form of the cavum, is not only of importance on account of the hyperplastic condition, but also on account of the increase of the discharge and hemorrhage which is connected with it. The irritation from the proliferation of the new formations is manifested by a considerable hyperplasia of the ovaries. The germinal organ is unusually frequently met as quite enormously developed in uterine myomata. Retention cysts, as well as follicle-hematomata, belong to the regular complications of uterine tumors. Among the rest of the secondary phenomena those of the heart have only lately found complete estimation. From this point of view *E. Rose*,¹⁵⁴ as the first, requested an early operation of the myomata. Since then many observations¹⁵⁵ have enabled us to recognize that fatty and brownish degeneration of the heart muscle not rarely occur in such patients (*myomatous heart*), as well as embolism of the large vessels of such tumors.

Among the typical symptoms *hemorrhages* stand first. *Pains* are found much less constantly in myomatous uteri. Certainly not a small number of myomatous patients suffer from *profuse leucorrhea*. These three kinds of subjective symptoms, which of course do not belong to the myomata exclusively, deserve discussion before we occupy ourselves with the question in how far different myomatous varieties and their localization are concerned in them.

The *hemorrhages* occur at first and almost constantly as increased menses, by a slow increase of the quantity of blood excreted, by their appearance at shorter intervals, and by the evacuation of clots. Abundant losses of blood take place, which may cause a severe, life-endangering acute anemia. More frequently a more chronic condition develops with the degenerative changes of the heart (fatty heart, brown atrophy). Sudden death by hemorrhage is rare, I have seen only one such case. The cause of the hemorrhage is the chronic hyperplasia of the uterine mucosa and the immense extension of its surface. But neither the intensity of the inflammation nor this surface-extension is equally decisive.

The location of the myomata, their growth, and the development connected with them from the original bed obviously exercise great influence. The climacteric, taking place at the normal time, rarely favors it with a decrease of the hemorrhage. Much more frequently menstruation is prolonged far beyond the fifth decade of life, ceasing gradually, seldom suddenly. The chronic anemia leaves the pulse feeble and frequent. The blood-pressure falls, the percentage of hæmoglobin drops to 30 or even considerably less—we have seen it drop to 16 per cent.

Pains appear as dysmenorrhea or as the result of impaction, due to limitation of space. The pain during the time of *menstruation* is sometimes the first symptom of a growing myomatous root. This becomes palpable only after years; until then only an endometritis chronica may be recognized. While in many women the menses appear and pass off without any difficulties, symptoms of pain announce in others the approaching menstruation, they increase to great intensity and become laborlike. Exercise, exertion, cohabitation, defecation increase them; at times they decrease if profuse hemorrhages take place. It is accepted that the menstrual swelling of the myoma and of the uterus causes these pains. If expulsion of myomata that have become submucous takes place typical symptoms of labor develop. Soft myomata, rich in muscle tissue and permeated with large bloodvessels, swell up during the time of menstruation to almost flabby tumors.

Complaints of pain especially due to *limitation of space* causing impaction of the tumor in the pelvis or the abdominal cavity occur already in less voluminous myomata; they, however, may be completely absent in very large heavy myomata. Not seldom they become noticeable, particularly during the time of menstruation. The pressure, the troublesome sensation of fulness disappears—if the tumor which has hitherto occupied the small pelvis moves up into the large pelvis. Symptoms referred to the bladder as incessant pressure, feeling of the last drop, even complete displacement of the urethra make themselves most felt, also those of the ureters with *uremic symptoms* and hydronephrosis become observable. But also displacement of the bowel may become exceedingly troublesome. The fixation of the myomata in perimetritis or in subserous, intraligamentary development may become quite detrimental. The compression of the nerve-trunks leads to lancinating pains along the extremities. Edema of the legs and thrombosis of the veins with embolic complications occur, which may result fatally.* The limitation of space leads to permanent disturbances in the ingestion of food. To this are added the results of loss of blood, and the disturbances of the kidneys. Interfer-

* A patient, thirty-seven years old, a nullipara, suffered for years from an obstruction of the vessels in the chest, especially of the lungs, caused by an obstruction of the vessels in the pelvis as far down as the legs. In 1895 I extirpated abdominally a myomatous uterus the size of a man's head. Recovery without complications. The patient recovered completely, except for a permanent although slight edema of the legs. The last examination was made in 1906.

ence with each movement, edema of the legs and dyspnea may lead with the severe anemia to a profound loss of vitality, so that the patients die of otherwise unimportant intercurrent catarrhs or similar disturbances. Others may endure extensive limitations of space even for a long time; slowly growing processes may induce a sort of habituation on the part of the neighboring organs.

The climacteric frequently leads to an involution of the myomata corresponding to that of the generative organs; slowly, and later than the physiologic time, the myomata finally undergo involution and shrink to hard, fibrous nodules in which a deposit of lime salts takes place which leads to complete calcification. Through it the limitation of space disappears and the pressure pains become less. It is not by any means a rare observation that myomata either remain completely uninfluenced by the climax, or start to grow again after a pause, more or less long continued. Sometimes fatty degeneration takes place during the puerperium; it may also lead to absorption and shrinking, even in tumors the size of an ostrich egg, as observed in a puerpera, who was dying with the symptoms of psychosis of about three months. These *processes of degeneration*, as described above, edematization and fatty degeneration are rare in later life—more frequently *teleangiectases* and *sarcomatous degeneration* occur. The hemorrhages which have already ceased, not only reappear apparently in the type of a not quite regular menstruation but a fatal anemia rapidly develops. The tumors become the seat of severe pains, they grow rapidly and lead to a limitation of space in their surroundings—interference with the bladder, bowels, or stomach. Symptoms of congestion with edema of the legs develop. The compression of the ureters leads to development of coma. *Suppuration* leads rapidly to signs of septic absorption. Gangrene of the myomatous polypi protruding into the vagina ushers in a sapremic fever with a profuse, grayish-brown secretion and large *voluminous* hemorrhages with a cadaverous odor of the excreted masses. The decaying myomata may completely break down into pus, a kind of healing process which, however, runs its course with very *serious* general symptoms. Occasionally gangrene also takes place in the vagina. *Swiecicki*¹⁵⁶ saw a breaking down thereby of the rectal wall also.

Another opportunity for circulatory disturbances and disintegration develops in subserous myomata from the *torsion* or *complete twisting* of the *pedicle*. If the tumor develops within the pelvic connective tissue the myomata become subserous, intraligamentary or retroperitoneal. Also with this kind of development, complete separation of the tumor from the uterus may take place, so that they appear as primary myomata of the pelvic connective tissue. Subserous myomata are exposed to adhesions with other organs of the abdominal cavity, particularly with the intestines and omentum. A new source of blood-supply develops from these organs if a separation of the connection with the uterus occurs, which assists the tumors to increased and more rapid development. On

the other hand, these tumors help to elongate the cervix and they even may completely separate the corpus from it.¹⁵⁷ The torsion of the pedicle affects also the uterus, the latter rotates to the extent of closing its cavity, in which the secretion of blood is stowed up (hydrometra, hematometra), giving rise to bladder disturbances and peritonitis. A formation of cysts even takes place in the tumors (*B. S. Schultze*¹⁵⁸).

The *decursus morbi* has been reported above in discussing the stage of the development of the myomata. We cannot doubt that many roots undergo only an unimportant development; they may remain of a small size and finally shrink. This also is seen in tumors of a larger size. But when a certain proliferation-energy has developed we must assume from a large material for observation that spontaneous atrophy and thereby a complete recovery is rarer than it has previously been generally considered to be. *Hofmeister*¹⁵⁹ also points out that particularly soft myomata very frequently deviate from this course, assuredly when they degenerate into sarcomata.

The importance of the *puerperium* for the atrophy has already been pointed out. Expulsion also was mentioned. Both processes belong to the very rare occurrences and do not tend at all, especially if accompanied by symptoms of infection, to warrant a favorable prognosis (see older literature in *Gusserow, Handbuch von Billroth-Lücke*).

The theory adhered to since olden times, that a relation exists between the formation of myomata and *sterility* has been opposed by *Hofmeister* and later by *Kleinwächter*, on account of numerous contradictory facts. The presumption of *Hofmeister* that, contrary to the opinion formerly generally maintained myomatous roots are stimulated to growth under the influence of pregnancy and the hyperæmia connected with it, has been confirmed by frequent experiences.

This does not contradict the fact that also in the unmarried and sterile myomatous roots undergo development from other causes. *Hofmeister* admits appropriately that many a myomatous root, developed under the influence of pregnancy, may atrophy or disappear during the puerperal involution. At all events the fact remains that myomatous patients have gone through 3.6 pregnancies in opposition to 4.5 for women not suffering from the disease.

According to the location and size of the myomata *pregnancy, labor, and puerperium may run a normal course*, or may be fatally disturbed at every stage of the process. Generally abortion is not as frequent as one might expect, according to the size and number of the tumors. Irregular hemorrhages not rarely occur in the beginning. Subserous *tumors* disturb the development of the uterus by *their size*, and the *myomata* in the lower uterine segment and in the cervix interfere with labor already in the first stage. They may completely prevent the passage of the child. During the puerperium they frequently cause retention of the lochia and symptoms of absorption. The difficulty of a spontaneous progress necessitates operations, which in a serious manner

promote infection and accessory injuries. We have referred before to the possibility of a fatty degeneration of the myomata during the puerperium and the absorption and cure produced thereby.

The **diagnosis of fibromyomata** is not at all easy, as it is occasionally represented, unless we feel the projection of the tumors above the body of the uterus, or can palpate the surface of the same through the cervical canal, or also unless the entire mass of the uterus is permeated and embossed by larger or smaller myomatous roots which can be felt by bimanual examination through thin abdominal walls.

The diagnosis is facilitated by displacing the cervix downward by means of a bullet- or *Muzeux* forceps during bimanual palpation. Of course one must see to it in this connection that sactosalpinges, ovarian abscesses, extravasations or exudations are not overlooked, which may be torn thereby. Rectal palpation often gives us a clear understanding of complicated conditions.

Interstitial and submucous myomata are occasionally detected with difficulty, especially if of small size which, however, makes them, notwithstanding, a source of very severe disturbances. Obstinate hemorrhages with apparently not a considerable size of the uterus, which resist the usual treatment and even curettement, always strengthen the suspicion of a myoma. This suspicion is considerably fortified by the existence of endometritis hypertrophica. Dilatation of the cervix is then often recommended for the digital palpation of the uterine walls. As a rule I have made use of the sound for this purpose with uniform success. The thickening in parts of the uterus is felt by sounding as a circumscribed hardness in the otherwise soft uterine wall. If several newgrowths are present, the uterus attains an irregular form; the question arises then, whether the tumor is lying outside of the uterus, intimately adherent to it, or within the walls of the uterus. The course of the uterine canal, as it is established with the sound, tends to be of quite diagnostic importance in just such cases. The uterus is almost always lengthened by the myoma, the uterine cavity is displaced laterally with a moderate extension of the interstitially located myoma. If the sound is then inserted with some difficulty, one can diagnosticate the position and form of the newgrowth by bimanual examination between the point of the sound and the external hand. The shifting of the uterine canal is, according to my opinion, of great diagnostic importance. On the other hand, sounding and necessary feeling about in the uterine cavity often cause hemorrhage and severe pains, not to speak of the danger of infection.

While these remarks concern the **diagnosis of the interstitial spheroidal myomata**, *W. A. Freund*¹⁶⁰ and *A. v. Rosthorn*¹⁶¹ have emphasized the fact that we are able to make clinically a differentiation of these from **adenomyomata** with a certain degree of probability.

Freund was able to prove that the carriers of adenomyomata are mostly weakly, not rarely tuberculous, hereditarily predisposed persons. They

suffer from chlorosis with menostasis and cymenorrhœa. They are mostly sterile. Pelveoperitonitic symptoms almost regularly predominate. Serious disturbances of vesical and rectal functions are quite pronounced. The local pains are characterized by a pronounced intensity. The general wellbeing is considerably disturbed and leads to incapacity to work. Tædium coitus exists very frequently. Conservative treatment is entirely unsuccessful. During examination there are found besides a general hypoplasia and infantilismus, a short vagina, an anteflexed uterus arcuatus, a flat, diffuse, chiefly subserous, tumorlike prominence upon the posterior surface of the uterine cornua, residues of old terminated pelveoperitonitides in the form of adhesions, which often reach deep down into the *Douglas*, fixation of all pelvic organs, peculiar direction of growth of the new formations during the occasion of long-continued observation, especially downward as far as the cervix and the retractores. Not rarely there is a combination with ordinary myomata. *Rosthorn* confirms these conditions from his own observations, without establishing thereby more than a probable diagnosis. It is to be hoped that further observations will furnish distinctness. At present we must adhere to the view that the location of the not large tumor in the posterior wall toward the tubal angle is characteristic for this kind of tumor. The deficient differentiation from its surroundings is hardly felt with a proximate distinctness before the tumors are freely exposed upon the operating table.

The *submucous* myomata, like the interstitial, give the appearance that the uterus is enlarged *in toto*, as long as they do not attain a circumference besides which the uterine mass itself retrocedes. They often press toward the cervical canal, even if they sit on a broad base, so they may be recognized through the open uterine os. These myomata occasionally cause the uterine wall to appear stretched, so that one must think of a hematometra, but then the sound easily clears up the condition. The dilatation of the cervical canal is particularly marked at the time of menstruation, so that one may be compelled to examine also during this period.

Cervical myomata present themselves through the uterine os or the vagina to the examining finger, although it may be very difficult to reach the uterus around and above these tumors and to establish the relation of the tumor to the cervix.

The fact of the existence of a *pregnancy* is often detected only with difficulty, specially if an old primipara is concerned; softening, discoloration of the cervix, deposits of pigment, increase of the breasts, are cardinal facts not to be underestimated before the fetus is recognized by the heart-sounds and movements. The observation of the further development clears up these cases, if complications do not force an earlier decision. The location and size of the myomata permit with difficulty to distinguish which part of the voluminous mass is tumor and which uterus. The portion containing the ovum is not always the softer one. Occasionally the contractions occurring during palpation lead to a diagnosis. Very

unpleasant surprises are met with in spite of all carefulness in very extensive tumors.

The *differential diagnosis from masses lying within the peritoneal cavity*, the *tubal* and *ovarian tumors, old exudates* and *hematoceles* may become extraordinarily difficult under certain circumstances, if a preceding inflammation has developed extensive adhesions. Palpation along the isthmus tubæ in tubal enlargements and the location of the ligamentum ovarii proprium in ovarian enlargements usually lead to a clearing up. Old exudates and hematomata are indeed also tough; their form, however, is less uniform; they lie immovably fixed in the pelvis. The anamnesis, as a rule, facilitates the diagnosis. Ovarian cysts have an elastic consistency, peritonitic adhesions, however, may give them the firmness of the myomata, while, on the other hand, these latter may also appear to be soft. Palpation under anesthesia and sounding, as a rule, lead to the desired end. The uterus is mostly enlarged and is in intimate connection with the myoma. The conditions, however, may be so complicated that the elucidation may even cause difficulties during section; this must occasionally console us for having made a diagnostic mistake *intra vitam*. Paracentesis is urgently advised against. Finally, certainty is only obtained by an exploratory opening, which must always be undertaken abdominally in such inextricable cases.

The diagnosis of *intraligamentary development* of the myomata often offers unusual difficulties. The tumor, as a rule, lies almost immovable in the pelvic connective tissue, on all sides displaces the vagina, the rectum, and the bladder with the ureters and the urethra, removing the adnexal organs from the small pelvis backward and upward, also at times quite typically forward. The mass mostly has a bonelike hardness, with a sharply defined, often nodular surface.

All *parametritic* exudates are similar to these; a preceding puerperium, disturbed by fever, a feverish course of convalescence after a vaginal operation point to such an origin of the nodular tumor. But at times similar complications are met with in myoma patients; the latter abort in the early months, expel the ovum completely, and, preceding and during the removal infection occurs. This then also offers an opportunity for disease of the adnexal organs, sactosalpinx, oophoritis septica and peritonitis, whose remnants of exudation behave similarly to intraligamentary myomata. *Pelvic hematomata* also give occasion to conditions which may lead to diagnostic difficulties.

The behavior of the uterus—not considering the anamnesis—assists first in the differentiation. In intraligamentary myomata the intimate relation of the tumor to its matrix, the uterine wall, does not completely disappear. Irrespective of the very rare cases of complete detachment the myoma partly remains in its place, the uterus itself is therefore intimately connected to a great extent with the myoma. The remaining part of the uterus can be demonstrated by palpation as being connected with the tubal extremity and the beginning of the ligamenta teretia

—eventually with the assistance of the sound. The uterus is elongated in its longitudinal axis above the margin of the tumor, as if mounted upon the intraligamentary tumor, with a long cervix and large sinuous cavum corporis. The consistency of the unaffected part is softer than that of the myoma; in pregnancy contractions can always be elicited in such a uterus with the extensive palpation which is unavoidable in these cases. I have also felt pulsations in the large vessels of the pregnant corpus laterally to the intraligamentary myomata. The latter is almost immovably fixed in the pelvis. It causes at times a severe stasis in the hemorrhoidal venous plexus, prolapsus recti, loosening as far as the vulva.

Parametritic exudates hardly ever have the same sharp limitations as the myomata. They spread when they have already occupied the entire parametrium, broadly on the pelvic wall, and become palpable above *Poupart's* ligament (ligamentum inguinale). The uterus is thereby completely surrounded and walled in by the exudate. Often, however, I could move it up and down along such old exudates, if only to a slight degree, or I could advance along the lateral border of the uterus through the vaginal vault, as well as from above downward. Through the rectum the myoma remains palpable as a mass without any difference in the surface and consistency, the rectum is pushed to one side and displaced. Parametritis, also, pushes the rectum to one side when its localization is entirely unilateral; however, the exudate mostly also penetrates into the other portions of the parauterine space behind the cervix, into the other side as far as posterior to the rectum, and closes its lumen in a more semicircular or circular manner, instead of simply compressing it transversely.

The exudate is absorbed during further observations, becomes hard like bone, of uneven surface, and shrinks to a remnant along the uterine border or pelvic wall—only cords running here and there, the adnexa, the sactosalpinx and the oophoritis chronica become recognizable. The exudate finally disappears completely. The myomata appears unchanged until its growth is plainly discernible. The uterus shrinks in parametritis—it undergoes involution after puerperal infection—it rather appears to grow in myoma, even if no other myoma roots increase in it; it becomes even elongated by intraligamentary myoma.

Pelvic hematmata tend to shrink rapidly. If puriform softening takes place in them with spontaneous or artificial evacuation, the diagnosis is made in the same way as from parametritis.

Sactosalpinx and **oophoritis** remain well characterized by palpating their relation to the uterine body (isthmus tubæ, ligamentum suspensorium ovarii), by their form (puffy formations with knoblike end, which sink deeply posteriorly and fill the excavatio recto-uterina). Generally they lie close to the corpus—intraligamentary myomata reach down as far as the collum, they lie more to the side, inflammatory masses more posteriorly. Adnexal enlargements spread the ligamenta sacro-uterina apart. The myoma pushes the corresponding ligamentum sacro-uterinum

of its side toward the other. The inflammatory adnexal tumors displace the rectum from before and eventually from the side, myomata essentially more from the respective side.

In intraligamentary development of ovarian newgrowths the relation to the uterus (ligamentum ovarii proprium) often remains recognizable. In such cases I could always palpate the uterus completely from within; the fingers press against each other from above and below with light pressure along the *side* of the corpus.

Peritonitic foci lie well pronounced behind the uterus, which they push forward and displace mostly upward, more rarely downward. The reason why all subserous myomata should not take a similar course of development certainly is not conceivable. According to experience, however, if it occurs it is extremely rare. Here also the anamnesis and the observation of the further progress must help out. If necessary we must incise here the posterior vaginal vault, which appears always to be accessible; from this the diagnosis follows, if it was still doubtful.

Polypi often are recognized with great difficulty, as long as they are small and located within the uterine cavity. One often suspects polypi and only finds hypertrophic mucous membrane masses, while in cases in which one has cause to think merely of an endometritis from other signs, occasionally also polypoid proliferations are found. In such cases the only resort is curettage of the uterus. If the polypus is felt with the fingers, if its pedicle can be circumscribed by the sound, then doubt cannot exist about the diagnosis, especially as soon as it can be caught with a tenaculum forceps and turned around on its longitudinal axis. The *polypi* are gradually forced down into the vagina. Especially at the time of menstruation they lie in such a way in the uterine os that they hardly can escape an exact and thorough examination. It only remains doubtful whether the polypus consists of mucous membrane proliferation, or whether a more or less developed fibrous or myomatous matrix is found.

If the *polypi* disintegrate at their apex, and the parts constricted by the uterine os become gangrenous, then the possibility of confusion with malignant degeneration is present, which can only be avoided by the microscope.

In the larger polypi one must attempt to prove with especial care how far they invert the wall of the uterine body, especially the fundus, and draw it down with them. If not otherwise possible one must outline the uterine body under anesthesia and eventually endeavor to palpate the inversion-funnel through the abdominal wall or through the rectum.

The *prognosis of myomata* undoubtedly is an absolutely favorable one in a large number of cases; they not only do not cause any difficulties, they spontaneously disappear without any external interference, leaving no trace. But it is not justified thereby, simply to designate the myomata *clinically as benign newgrowths*, for the myomata may be located wherever they desire, their size may be still so different: yet

in not a small number of cases they give rise to very severe symptoms and may even very severely endanger the life of their carriers.

Already the above-described processes of transformation and degeneration characterize the grave prognosis of not a small number of myomata. I have reported, in 1893, in the third edition of this book, that among my material the myoma had suppurated in twenty-one cases, cystically degenerated in twelve, teleangiectatically in twelve, and sarcomatously in nine cases; that, therefore, in 408 myoma cases the myoma was found changed in a menacing manner in fifty-five cases. The uterus was diseased with the myoma in twenty-three cases; pregnant once with myoma and cancer. It was pregnant in nine cases and became thereby dangerous to life, and the myomatous uterus was carcinomatous in fourteen cases.

Forty-four times complications were found in the adnexa besides the uterine myoma, eleven times sactosalpinx purulenta (three of these patients had been before treated electrically), once sactosalpinx serosa, four times tubo-ovarian tumors, twice carcinoma ovarii, once abscessus ovarii, six times bilateral, thirteen times unilateral ovarian tumors, three times embryoma, three times large hematoma of ovarian follicles.

The statistics of an observation period of seven years at the Greifswald clinic confirm these statements.

*Doederlein*¹⁶² recently determined, in two hundred cases, complications of a more or less serious nature, partly within the myoma, partly external to it in 102 cases; that is, in more than half of the patients. While this statistical statement already is sufficient to contradict the so-called benignity of these tumors, the prognosis in a great number of cases appears to be bad on account of the hemorrhages connected with the disease.

Occasionally only do we see patients directly succumb to hemorrhages. I have made two such observations. Much more frequently than by the incessant hemorrhages and the anemia caused thereby, these women perish from a cessation of their power of resistance against the pernicious influences of daily life.

Enjoyment of life and working efficiency are interfered with to the extreme. The chronic ill-health becomes detrimental, especially if external circumstances render difficult or exclude appropriate care. The earlier the myomata cause disturbance, the more doubtful is the prognosis, but also in advanced periods of life the women are not exempt from directly annihilating disturbances. The relative cure, cessation of growth, involution, and calcification—indeed is relatively very rare, as also the expulsion of the tumor.

Treatment.—Myomata which do not cause any disturbances do not require any treatment. The women often are not conscious of any symptoms caused by the myoma. They only slowly and gradually admit not inconsiderable changes in their state of health, which could only be caused by the myoma. As occasionally the surprise of learning of the

presence of a myoma by a woman in a difficult period in life makes the condition only the harder, I prefer to explain the facts to my patients with the assurance that treatment is not necessary at present and also will not become necessary in the future should the climacteric run a normal course. If severe disturbances of the state of health should occur then the patients should immediately procure competent assistance.

Slight ailing, increased menstrual bleeding, occasional interferences of the function of the bladder and rectum, also increased discharges in subserous and interstitial myomata of moderate size, as long as thereby capability to work and activity of life do not suffer, permit the tentative use of therapeutic methods to which we were formerly essentially confined. The **ergotin treatment**, the use of **iodin** and **salt water baths** belong to these methods.

The **ergotin treatment**, which was first recommended by *Hildebrandt*¹⁶³ in 1872, at present consists in the use of *extractum secalis cornuti*. A very great number of injections and thereby a duration of treatment of many months are however needed if success is to be attained. The occurrence of ergotism (tingling in the hands)¹⁶⁴ must receive due attention. Even with a long continuation (up to two hundred injections, *F. v. Winckel*) an influence on the myoma may not be obtained.

The use of **iodin** and **bromin** containing mineral springs (*Kreuznach*,¹⁶⁵ *Tölz*, *Hall*, in Austria), as well as the **iron-mudbaths** and strong **saline baths**, undoubtedly serve to permanently strengthen the women suffering from myomata. The myoma does not grow, it shrinks with the occurrence of the climacteric. I have occasionally observed such results in my patients. The patients entered the climacteric permanently strengthened. A further treatment was not necessary.

The **electrolytic treatment** of *Apostoli*,¹⁶⁶ recommended with so much emphasis, has lost its credit. Its results, finally, were negative, if one overlooks a few quite isolated favorable effects. The women grew highly nervous on account of the treatment, and not a few accidents occurred thereby. A **symptomatic treatment** can only be directed against the **hemorrhages** and **increased secretions**. The former are evidently favorably influenced in the beginning and not quite isolated by fluid *extractum hydrastis canadensis* (twenty drops four times daily), by **stypticin** tablets (five to six daily) or

℞ Stypticini..... 1.5
 Succus glycyrrhizæ q.s.
 M. et f. pil. No. XXX.
 S. One pill four to five times daily.

See *Heffner, Monatschrift f. Geb. u. Gyn.*, Vol. I, p. 131.

Extensive mucous membrane proliferations with uninterrupted profuse menstrual flows are at times checked by a **curettement** if the subserous tumors are little extended. As, however, the *cavum uteri* often

shows many depressions, especially also in interstitial tumors, it is not always easy to remove the mucosa entirely, so that the success is already weakened by it. In these cases the action of the abrasio is also supplemented by an injection of chlorid of iron immediately following the curettage.

While I thus acknowledge a certain field for the methods of treatment mentioned for cases of slight disturbances in subserous and interstitial myomata, I will immediately state that I dispute their value for the submucous myomata of the corpus and the cervical myomata. These ***latter forms indicate operative removal as soon as they make their appearance.***

Considering the evidently great difficulties and uncertain results of operation in the first developmental period of myoma operations, it appeared as an important advance to produce prematurely and artificially the climacteric by an apparently less radical operation, i. e., removal of the ovaries by castration. *Hegar*¹⁶⁷ deserves thanks for the theoretic examinations, intelligent demonstrations of proof and extensive practical experience concerning this operation. Nevertheless it was proved that the operation is a very serious one in a not inconsiderable percentage of cases. The number of these in which the hemorrhages were not permanently influenced ought not to be too lightly regarded. Finally, the removal of the ovaries failed to prevent further growth and degeneration of the myomata in a remarkably large number of cases. At all events the great majority of operators have at present abandoned castration. We have learned to attack the tumors themselves.

If myomata seriously disturb the well-being of the patient, if enjoyment of life and earning capacity are injured, and if by the above-mentioned symptomatic method of treatment this reactive effect is not removed, then the removal of the myoma, myomotomy, is indicated.

Submucous myomata, as a rule, necessitate very early and immediate removal, as undoubtedly is also the case with cervical and polypoid tumors.

Such disturbances are least seen in ***subserous*** and ***interstitial*** myomata.

However, these also urgently require operation by their ***growing, pressure symptoms, degeneration,*** and the ***far-reaching disturbances,*** especially in the ***heart,*** not to mention hemorrhages and pains.

Myomata take a peculiar position in the indication for treatment ***in women who still hope for offspring, and in those who become pregnant with their myoma.*** ***Sterility*** justifies the eventual removal of this barrier to a healthy condition of the genital organs in a woman whose husband is found capable of procreation.

In ***pregnant*** women an operation is only justifiable if the myoma prevents the development of the uterus by its location and size, and excludes the normal escape of the fetus.

Signs of changes in the myomata, degeneration, disintegration, suppuration, but also simultaneous invasion of the uterus by cancer, always justify the immediate removal of the **tumor and if necessary the uterus**.

Calculations of the *frequency* with which the different gynecologists find the indication for operation in their cases under observation are naturally subject to wide fluctuations. The practising physician often enough sees cases in which the myomata do not at all indicate treatment. The specialist only gets referred to him those cases in which the operation appears indicated to the family physician. A not small number of myomata form accidental findings which we obtain in other genital diseases; prolapse, retrodeviations, diseases of the adnexal organs, especially the pelvic peritoneum, form besides the mucous membrane diseases the large contingent of these cases which bring the patient to the physician. **If these diseased processes indicate an operative treatment, then it seems certainly justifiable to include the myoma in order to remove at one operation all diseased structures from the patient. A large number of my myoma operations were caused by such complications.**

Formerly—until the last decade of the nineteenth century—the *prognosis of the operation* for myomata was very grave and it seemed fully justified to postpone the operation as long as possible and to make a persevering attempt by the above-mentioned measures to avoid an operation, with the hope that the *physiologic involution* also of the tumor would take place with the beginning of the *climacteric*. This manner of treatment *to-day* appears **less justified**. Undoubtedly the myoma operations are incomparably much safer to life as long as the tumor is so small that it is possible to make a comparatively trivial operation. To this must be added that in these cases the power of resistance of the patients is very much higher, so that we may depend on a rapid and complete restoration of strength after the operation. As long as the above-mentioned complications of uterine myomata are absent the prognosis of the operation is much more favorable.

These discussions must be given due weight in the cases in which the myomata cause symptoms. The same holds good for the social status of the patients. Working women and those without means for treatment will themselves demand that, if necessary, the operation shall be performed at an earlier period than in the patient who is enabled to employ time and money and every attention for her cure. Finally, the complications mentioned are to be considered which induce us to remove a myoma even if it does not yet cause severe disturbances.

The Operative Treatment of Myomata

After the primary result of the operation attained approximately by the development of asepsis the same safety which operations for ovarian tumors already possessed for decades, the consideration of the **remote**

condition of the persons operated on for a myoma attained decided prominence which it still retains. If with the myoma the uterus is removed, not to mention the mutilation caused thereby, the symptom-group of the **signs of amenorrhea** naturally develops in women who have not yet entered the menopause. These difficulties, as congestion of the head and heart, paroxysmally recurring dizziness, flushes of heat and a sense of impending danger permanently cloud the well-feeling of the convalescent. But also those radically operated on after the climacteric are often long and intensively exposed to such complaints to a surprising extent. The attempts to meet these symptoms of amenorrhea by a conservation of ovarian tissue have not yet so far matured as to give entirely satisfactory results.

The decision to remove the uterus with the myoma in youthful persons is finally rendered difficult by the fact that such young persons severely suffer mentally by the knowledge of being mutilated. Especially married people are still more hurt by the unavoidable sterility. The examination of a large number of myomatous uteri shows that it is quite possible to peel out the myomata from their bed, not only in simple but also in multiple spherical myomata. A sufficient portion of uterine tissue capable of functioning still remains behind thereby, especially uterine corpus mucosa capable of functioning, and of thus preserving to these women not only the capability of menstruating, but also of ovum-imbedding.

The efforts to proceed **conservatively** in this manner have been lowered in their value by a critical investigation of *Winter*.¹⁶⁸ Also others, as *Bumm*,¹⁶⁹ have had so few favorable experiences with it that they, as a rule, execute the **radical operation** in cases where myomata compel an operation. Only with the expressed desire of the patient to preserve the capability of menstruation and conception should one operate conservatively according to their opinion.

I cannot recognize the justification of the objections against the conservative operation.¹⁷⁰ It is assumed that both methods, the radical and the conservative, approximately give equally good primary results. The objection is urged to the conservative procedure that it does not protect the women from a new **development of myomata roots**, that the **conservation of menstrual and reproductive capacity** are **questionable resulting conditions**, that those **conservatively** treated show a **less satisfactory remote well-being** than the patients operated on **radically**.

We must acknowledge that myomata roots can be overlooked in the reconstructed uterus by the operator even with the most careful palpation after enucleation of myomata, and may sooner or later go through a more or less rapid development to even extensive tumors. I myself, analogous to *Winter* from his material, have observed this kind of recurrent formation in my material in four per cent. of the cases in which the tumor was enucleated. But only one-third of my patients were so far annoyed thereby that another operation became necessary. The parties concerned

thankfully acknowledge that the feeling not to have been mutilated by the operation had been preserved them so long.

Menstruation after enucleation at times does not occur immediately in the beginning without symptoms and in small amount. If, however, the corporeal mucous membrane is always also thoroughly removed by curettement during the enucleation operation, as I practise it, the normal menstrual type appears after a few periods.

That women may become pregnant after enucleation has been proved by a sufficient number of observations. The course of labor also may be favorable, although it also must be admitted, a priori, that the scar in the uterus may rupture on account of the stretching caused by the growing ovum; this dangerous eventuality in fact has been observed by *Doederlein*.¹⁷¹ According to my opinion it would be wrong to draw the conclusion therefrom that the enucleation should be rejected. The uterus, emptied by the classical *Cæsarean* section, also occasionally ruptures if it again becomes distended by a growing ovum. I only draw from *Doederlein's* reports the lesson to direct, even more emphatically than I did so far, the patients after enucleation, that they must always put themselves under expert supervision with a beginning pregnancy, and under all circumstances immediately on the commencement of labor.

The protest that enucleated patients comparatively seldom become pregnant appears to me unimportant. Undoubtedly a great number of unmarried and widowed persons are found among the myoma patients. A large number of these patients are of the age in which pregnancy altogether occurs only comparatively seldom. And how many husbands among the ones concerned are themselves impotent; how many have accustomed themselves to refrain from intercourse during the long years of sickness of their wives.

This, however, does not authorize us to mutilate the patients without a compelling necessity. Apart from the psychic moment it means to interfere almost arbitrarily with the fate of such persons. Who can predict what opportunities are offered to the convalescent as long as she may be considered as still capable of reproduction.

If *Winter* refers to the occurrence of abnormal discharges in the enucleated, I only can oppose to it the observations in my patients that these do not suffer from such discharges. I trace this difference to the fact that I remove the uterine mucosa by a curettement under all circumstances during the enucleation. My enucleated patients, especially those of the better classes, have soon obtained gratifying health after many years in 97 per cent. of cases.

However, I must refer to still another point of view, which cannot be left unnoticed, for the critical examination of the remote health of patients operated on for myoma. The patients in whom the myoma symptoms were the only occasion for operation, present a real surprise in the rapidity of their complete convalescence. Those in whom the myomata were removed along with inflammatory or other complications,

take a longer time for their complete recovery. The tenderness and neurasthenia, developed during the course of an illness of many years, often extraordinarily increase in the well-to-do the critical estimation. In poor people the possibility of an invalid pension at present throws a shadow on the tendency of these women to self-criticism in an unsuspected manner. If one succeeds in forming an opinion about the condition of these patients in a purely professional manner, then it follows from a consideration of many years of a classification of many observations, that both groups, the radical and the conservatively operated, finally reach a perfect state of health. Only those patients become permanent invalids in whom the operation scars interfere with the function of the pelvic organs after they have otherwise recovered from their long-standing original illness.

The conservative operation has a natural limitation in the assumption emphasized above, that a sufficient amount of uterine tissue capable of functioning must remain. A further restriction results from the age of the women, and finally from the condition of the adnexal organs. If the latter indicates their removal, then the conservation of the uterus is absurd. From this the conclusion is to be drawn at the outset that the enucleation operation can only be used to a limited extent. Among my myoma patients operated on in Greifswald (1899-1905), of 181 clinical patients 89 were operated on radically and 88 conservatively; of the private patients, 65 radically and 59 conservatively.

According to my observations the *choice of operative method, whether abdominal or vaginal*, has a decided influence on the future condition of health. Although we formerly saw in the remote behavior of the abdominal wall-incision a critical complication, this objection is at present permanently removed on account of the coaptation in layers, and perhaps also on account of the suprasymphysial fascial transverse incision. The fact, however, remains that, in spite of the utmost care of the peritoneum, intestines, omentum, and the edges of the peritoneal incision adhere to each other in a detrimental manner. However, such adhesions and the widening of the abdominal scar, formerly often observed, also may render patients operated on abdominally invalids for the remainder of life.

Scar neuroses and adhesions of the scar with intestinal loops in the pelvis are certainly not impossible after vaginal operations. They are, however, by all means rarer than after abdominal operations.

While, therefore, the preference must be accorded to the vaginal operation, we should not overlook the fact that it is less the size of the tumor than adhesions with the surroundings which render it difficult to get a clear view that form a limit to the vaginal procedure. The technic of the vaginal methods can be developed quite *extraordinarily*. *The paravaginal accessory incision of Schuchardt* has proved a *far-reaching aid; the vaginal vault becomes thereby accessible almost without limit*. This possibility of *decreasing the tumor under safe control of*

the eye and finger, allows us easily to overcome the obstacle created by the size of the tumor. Nevertheless, individuality and technic of the operator are of decided importance in view of the above-mentioned limitations.

For my decision—at first whether to operate or not—great importance is attached to whether, according to location and kind of tumor and the symptoms, a symptomatic treatment, as long as such has not been instituted by the family physician, will result in a marked improvement of the general state of health and an amelioration of symptoms; this means a steady employment for from six to eight weeks. Permanent disturbances in the function of the heart and in the condition of the blood, pressure symptoms in the pelvis, above all, however, profuse *hemorrhages* induce me to operate early. The sooner the operation is undertaken, the fewer extensive *interferences* become necessary. If in operations for other reasons the myomatous uterus has also been exposed, then I always remove the myomata, even if they have not yet caused serious symptoms, so as to become a prominent part of the diseased picture.

Less voluminous tumors, where extensive adhesions are not demonstrable, are operated vaginally, even such as are as high up as the navel, if their relation to the surroundings can be clearly seen. *Indistinct* findings, extensive adhesions, especially in the upper periphery, and colossal tumors indicate an *abdominal* operation. All myoma operations in women up to the forty-fifth year of life, are undertaken with the object of being conservatively executed, if possible. Hereto, however, not only the conservation of a uterus capable of functioning is a determining factor, but also the condition of the adnexal organs.

It cannot be our task here to present minutely the progress of myoma operations in all their changes; the text-book of *Hegar* and *Kaltenbach* on gynecologic operations (fourth edition, 1903), *Hofmeier* (third edition, 1905), *Doederlein* and *Kroenig* (1905), contain the numerous methods with an explanation of the different episodes, which preceded the perfection attained to date. I, as one of the coworkers since 1874, may be permitted to point out in a few sentences the milestones which especially have impressed me in the observation of the joint labors of the gynecologic meetings.

Köberle,¹⁷² *Péan*,¹⁷³ and *Thomas Keith*¹⁷⁴ appeared as the first principal myoma operators, if we do not consider the fact that myomata, which were accessible through the uterine os, have been removed by all operators with of course often very doubtful success. The attempts to attack myomata in the uterine cavity presented remarkable difficulties, and they lost interest, especially when *Péan* had successfully developed his procedure of the extraperitoneal *care of the pedicle*. He was followed by *Hegar*,¹⁷⁵ who recommended the removal of the ovaries, castration for an anticipation of the climacteric, in consideration of the high percentage of mortality in myomotomies. *Schroeder*¹⁷⁶ gave a new aspect to the entire operation when he requested, in 1878, the *amputatio supravaginalis*

with **peritoneal covering of the stump and intraperitoneal closure** also of the myoma operation similar to that of the ovarian tumors. While *Péan* made allowance for the hemorrhages prevailingly feared at that time and controlled with difficulty by the constriction of the different segments of the tumor with wire (*Kleeberg-Odessa* introduced rubber bands instead of wire with the long needles of *Péan*). **The constriction of the collum uteri**, with a rubber tube recommended by *A. Martin*,¹⁷⁷ made it possible to detach the tumor almost without loss of blood and to suture the pedicle and cover it with peritoneum before it is buried. The transition from antisepsis to asepsis led to a generalization of the operation, especially the abdominal, which shortly almost completely replaced the vaginal. From the number of propositions for the care of the stump two have been retained up to the present time, **the ligature en masse of Zweifel**¹⁷⁸ and the **sub- and retroperitoneal care of the pedicle** according to *Hofmeister*¹⁷⁹ and *Chrobak*.¹⁸⁰

The finding of large parts of uterine tissue capable of functioning next to the myomata and the ease of enucleation of the myomata, which present themselves with a dilated uterine os, induced *A. Martin*¹⁸¹ to peel out single spherical myomata also abdominally, to suture the bed, and to conserve the uterus with the adnexa. The symptoms to which the remaining stump of the cervix gave rise (leucorrhœa, hemorrhage, eventually also cervical carcinoma¹⁸²), led *A. Martin*¹⁸³ to systematize the **abdominal total extirpation of the myomatous uterus**, which *Bardenhauer*, 1881, also recommended for similar reasons. This radical procedure has become the typical one, especially in the United States,¹⁸⁴ in France¹⁸⁵ and Italy. The propositions of *Amussat*,¹⁸⁶ which *Péan* (loc. cit.), *P. Müller*, *Doederlein*, and *Kroenig* have further developed, are not to be underestimated in their value for the perfection of the myoma operation, to make the tumors more accessible for delivery by circular longitudinal incisions (allongement opératoire), or to facilitate the care of the tumor-bed by splitting the entire mass of the uterus and removing it piecemeal (*morcellement*).

After the primary results of the operation were brought up to an equality with those of analogous abdominal operations (5 to 7 per cent.), one could approach the observation of the **remote results after myoma operations**.¹⁸⁷ It was generally acknowledged that the signs of artificial amenorrhœa appear more pronounced than in bilateral ovariectomies. The enucleation, which preserves menstruation to the women, can be executed only in a limited number of cases. *Chrobak*,¹⁸⁸ with his pupils (*Knauer*), were the first to attempt to prevent these disturbances by the conservation of one ovary or only part of one. The results met the expectations only to a limited extent, even after *Werth*¹⁸⁹ pointed to the further possibility of preventing the atrophy of these remaining germinal organs. The attempts to implant ovaries have matured in animal experiments completely satisfactory results. Ovarian substance,¹⁹⁰ administered per os, has not found full approval. In this difficulty the propositions of

*Zweifel*¹⁹¹ to preserve if possible a part of the menstruating corporeal mucosa in amputatio uteri myomatosi, and of *Mackenrodt*,¹⁹² to peel out the myomata after excision of the cervix and the lower portion of the corpus, and to suture the rest of the fundus to the vagina, are to be further investigated.

A further and highly important phase of development of the myoma operations has been instituted by the reintroduction of the vaginal methods of operation. *Mackenrodt*¹⁹³ and *Dührssen*¹⁹⁴ have also in this matter produced permanent and suggestive results by their advocacy of this method for the treatment of retroflexion. ***Celiotomia vaginalis*** (compare also *A. Martin, Centralbl. f. Gyn.*, 1902, No. 14) has reached its highly developmental stage only through the perfection of the paravaginal accessory incision of *K. Schuchardt*.¹⁹⁵

1. Vaginal Myoma Operation

The vaginal introitus and the vagina as far as the vaginal vault must be accessible to the operator with the utmost convenience; if these pre-suppositions are not entirely fulfilled by preceding labors or senile relaxation, the ***paravaginal accessory incision*** of *Schuchardt* must be executed. Under a permanent irrigation with a sterile lukewarm salt solution, an incision is made at the junction of the middle and lower thirds of the left side of the introitus. The incision is carried externally 5 cm through the external skin, and inwardly through the vaginal wall, fascia, and musculatures as far up as the vaginal vault, avoiding the rectum. The hemorrhage stops, as a rule, if a vaginal retractor is now inserted posteriorly and pressed downward and also one laterally; only exceptionally is ligation of spurting vessels necessary.

The now freely exposed portio vaginalis is seized with a bullet-forceps and pulled downward. The uterine sound is inserted to establish the course of the uterine cavity, and eventually the location of the tumor. ***Abrasio mucosæ corporis*** is performed. The cavity is irrigated with a normal saline solution, eventually with a sublimate or lysol solution. The further proceeding depends on the seat of the tumor.

Cervical Myomata.—The tissues covering the tumor are incised at the most conveniently accessible place. The myoma, visible after separation of the overlying tissues, is seized with a bullet- or *Muzeux* forceps and stretched. The index finger of the other hand detaches the tumor from its surrounding tissues. As a rule, one hardly needs the assistance of the scissors or knife. The tumor-bed seldom bleeds; its walls are trimmed with scissors and surplus tissue is cut away. The tumor-bed is sutured in stages.

Polypoid tumors are seized with the bullet- or *Muzeux* forceps at the largest portion attainable and pulled down. The insertion of the pedicle if possible must be established with the finger, otherwise with the sound under control of the hand externally placed. One should notice the configuration of the body of the uterus and be careful not to overlook an in-

version. With a thin pedicle, however, a few torsions of the tumor around its longitudinal axis with a forcible jerk are sufficient to twist off the pedicle. As a rule, the pedicle does not bleed. Thick pedicles are pierced with a double suture as near their origin as possible, ligated on both sides and cut off. If the pedicle reaches up to the uterine cavity, and if it is inserted with a broad base, care must be taken especially to observe how far the uterine wall inverts with traction on the tumor. Often it is sufficient with a broad-based, polypous myoma energetically to circumscribe the base with the tip of the index finger, while the tumor is pulled down. Mucosa and capsule wall break, the finger reaches beneath the myoma and peels it out. If this is not possible, insert the finger into the uterine cavity beside the tumor or its pedicle. Then split the neck of the uterus. If necessary the anterior wall is also incised and even the posterior wall.

In operating for *interstitial corpus myomata*, I generally prefer colpotomy anterior. The anterior wall of the vagina is incised transversely through the portio vaginalis. The vaginal vault may also be incised by a vertical incision, continued on each side along and close to the cervix if necessary. The sound-forceps of *Orthmann*, which seize the anterior lips and hold the cervix, eventually also the corpus stretched by pulling strongly downward, facilitate extraordinarily the separation of the bladder. The pressure of the index finger or a gauze sponge suffices with rare exception. The insertions of the ligamenta utero-vesicalia has to be bisected quite frequently. A spurting artery, as a rule, contracts immediately, so that ligation is also unnecessary. *Pfannenstiel* ligates the same as a matter of precaution. If the separation of the bladder and of the plica peritonei is sufficient to expose a sufficiently large part of the anterior wall of the body of the uterus it is not necessary to open the peritoneum. The detached bladder and the plica are pushed upward behind the symphysis by a vaginal retractor. The cervix and corpus are now ready for incision. Often an incision into the lowest part of the body of the uterus, free from peritoneum, is sufficient to freely expose the tumor in the uterine cavity without splitting the cervix. Otherwise the anterior wall of the cervix is incised. The margins of the incision are fixed by bullet-forceps. Under some circumstances a vaginal retractor is placed between the tumor and its bed.

If the myoma appears so voluminous that it cannot be brought through a not too extensive opening, the tumor may be decreased without any hesitation. The myoma knife of *Segond* is very suitable for this purpose. After the tumor, decreased or not decreased, has been brought forward, so that the peduncle or the basis is accessible, the enucleation is completed. Here also bleeding of the myoma bed is rare.

If the posterior vaginal vault is incised corresponding to the seat of the tumor, then, as a rule, one advances as far as the peritoneum and through the same into the posterior wall of the cervix or the corpus, in order to proceed otherwise as above described after a corresponding ex-

posure of the margins of the incision by means of a bullet-forceps. If after opening the peritoneum a myoma does not present, but the uterine wall, which eventually conceals the myoma lying in the posterior wall, then the uterus is incised if necessary down into the uterine cavity, until the myoma or myomata are located. The myoma is then enucleated in the manner described above, if necessary, after it has been divided in melon slices. As soon as the uterus has been decreased in this manner, its surface becomes accessible to a correspondingly wider extent to control by palpation. The condition of the adnexal organs also must be determined to gain a positive view as to which of the organs are perhaps adherent to the uterus.

Loops of the intestine which press downward are pushed back by large tampons of sterile gauze or by lowering the head of the table. The illumination apparatus of *D. v. Ott* can be used to its full extent during this stage. Adhesions may be loosened with the finger, scissors, or the knife. As soon as the danger of trauma by forcible tearing is excluded, the uterus and remnants of the tumor mostly with the adnexal organs are easily brought out through the vagina. As a rule, adherent organs are easily separated with a tampon and without any danger. Otherwise they can be separated by an electrocautery under the guidance of *Ott's* speculum, which is provided with miniature *Edison* lights.

The uterus now can be freed completely of its myomata and it may be decided whether a sufficient quantity of functioning uterine tissue remains to allow a reconstruction of the organ. If it should prove that the conditions for later sexual function on the part of the patient are still present, eventually after removal or resection of diseased adnexal organs, **the uterus is preserved: conservative operation.** If the uterine cavity has not been opened, then the closure of the one or the different beds of myomata follows with continued catgut sutures in several layers, after the walls of the myoma bed have been carefully freed from any excessive and lacerated tissue. The surface of the uterus particularly must be sutured exactly—if the uterine cavity has been opened the cavum is minutely inspected, and the mucosa scraped off again. If it is seen that the unopened uterine mucosa is strongly hypertrophic, I incise the cavity in order to resect excessive parts of the uterine mucosa. In suturing, the catgut suture should not enclose the upper layers of the mucosa.

Before **finishing the operation** the abdominal cavity must be cleansed, its serosa examined for injuries, the uterus replaced after the traces of the bullet-forceps on its surface also have been taken care of by continued catgut sutures. Finally the plica peritonei is sutured, providing for the bladder and the vagina as in the vaginifixation (see above, p. 102). Cleansing of the vagina, control of the bladder by catheterization, closing of the *Schuchardt* incision by a continued catgut suture, which, inserted into the vaginal vault, unites the entire vaginal wound as far as the hymen. The same catgut suture closes the depth of the external incision. The skin is closed by five or six aluminum bronze sutures. These are

covered with a thin piece of gauze, which is fixed by collodion. A loose iodoform gauze strip is placed in the vagina.

As a rule, *subserous, more or less pedunculated tumors* become easily accessible after extroversion of the uterus through colpotomy anterior. They are brought forward, undecreased or decreased, according to their size, and their peduncle is excised from the uterine wall. The wound is best closed in stages. With broader formation of the pedicle the myoma frequently lies with a segment in the uterine wall. After the serosa has been incised all around it is easily peeled out. Thereafter suturing succeeds without any difficulty. If other myoma roots lie intraparietal near the pedunculated myoma, they are incised in order to enucleate them—supposing that the multiplicity of the nodules does not make it advisable to extirpate the entire uterus. In the enucleation of the various roots, I try to reach the next lying myoma from the already exposed myoma bed in order to escape a multiplicity of incisions in the serosa.

If it be discovered that on account of too extensive destruction of the uterus or on account of disease of the adnexal organs a reconstruction of the uterus is not advisable, *extirpatio uteri* follows, i. e., the *radical operation*. If possible I preserve an ovary even in elderly women. In order to leave the ovary undisturbed in its future function, the removal of the uterus is begun close to its lateral margin. As a rule, I ligate the mesosalpinx and the pars cardinalis, in several small parts in order to amputate the uterus correspondingly. The hemorrhage from the ligaments is sometimes surprisingly profuse, therefore careful ligation is advised. The peritoneum must be carefully enclosed in the ligatures. If ligation and amputation on one side have been executed until close to the vaginal vault, then amputation follows on the other side. Accordingly even if the ovarium and tube are also to be removed, ligation is carried over the ligamentum teres ovarii, then continuing as far as into the pars cardinalis.

One can naturally take care of these vessels later on also, if the ligaments have been clamped by forceps before the bisection.

After the uterus is liberated on all sides till close above the vaginal vault, the entire mass—or, after the removal of the body of the uterus, which otherwise hinders the further operation—the rest of the cervix is pulled up in front of the symphysis. Thereby the posterior vaginal vault becomes stretched. Here, also, I seize the parts in several ligatures and then completely loosen the cervix almost without shedding blood. Sterile tampons inserted into the abdominal cavity, prevent, until this stage, the intestines from pressing forward. The vaginal retractor placed anteriorly has forced the bladder upward behind the symphysis. Next the covering of the wound margins by the peritoneum and the stopping of the hemorrhage are inspected all around. The margin of the incision of the plica peritonei vesicæ is sutured with the margin of the anterior vaginal wound, also toward both sides as far as the ligatures lying in the liga-

ment stumps. Cleansing of the abdominal cavity. As a rule the opening of the vaginal vault falls together considerably, so that the ligatures lying in the anterior and posterior vaginal vault may be tied together in pairs without any trouble. Otherwise the anterior wound margin is pulled to the posterior one by strong ligatures and united with interrupted stitches. Closure of *Schuchardt's* incision as above. Evacuation of the bladder in order to control its intactness.

If the examination under anesthesia before commencement of the operation showed that conservation of the uterus is excluded from the beginning, especially in old women, then the operation of the **vaginal total extirpation** is commenced in the typical manner, as this was formerly executed in carcinoma.

The procedure which has been recommended by *Doederlein* is an essential improvement, if it is practicable.

The portio vaginalis is pulled upward after exposure of the vaginal vault (paravaginal accessory incision if necessary) in front of the symphysis. The posterior vaginal vault is opened by a longitudinal incision through the posterior cervical lip. The posterior lip is split thereby. When the peritoneum of the excavatio recto-uterina is reached, one stitches it first to the margins of the incision of the posterior vaginal wall. During the detachment of the vagina from the cervix, I insert two or three ligatures in order to draw together the peritoneum above the entire surface of the wound underneath which the rectum lies. The posterior wall of the uterus is pulled downward from both sides close beside the vaginal incision with bullet-forceps attached to the side of the uterus, and split between them. If masses of the myomata are in the way, then they are separately seized by bullet-forceps, enucleated or decreased by melon incisions until the rest of the tumor corresponding in size to the opening present, can be removed. The uterus is split until over the fundus. The bladder remains far backward, so that finally only a small bridge remains between the anterior vaginal vault and the fundus of the plica. Incision of the anterior wall of the cervix uteri as far as the antecervical connective tissue, suturing of the anterior vaginal vault with the plica, detachment of the two halves of the uterus as far as their lateral connection. These can be severed after strong clamps have been applied to the ligament stumps. Then the incised lumina of the vessels in the ligaments are attended to and after removal of the clamp forceps the stump is covered by peritoneum. I prefer to ligate the ligamentum suspensorium ovarii and the pars cardinalis, in several small parts before cutting them.

The surface of the incision is examined for hemorrhage, and then covered by peritoneum. Closure as above.

2. Abdominal Myoma Operations

For abdominal myoma operations different methods, conservative as well as radical, may be chosen.

Here also the choice can be made only after exposure of the uterus,

indeed often only after enucleation of the myoma. Accordingly we proceed so that we incise the abdominal wall in the median line or by a transverse incision after *Pfannenstiel*. The latter leads close above the

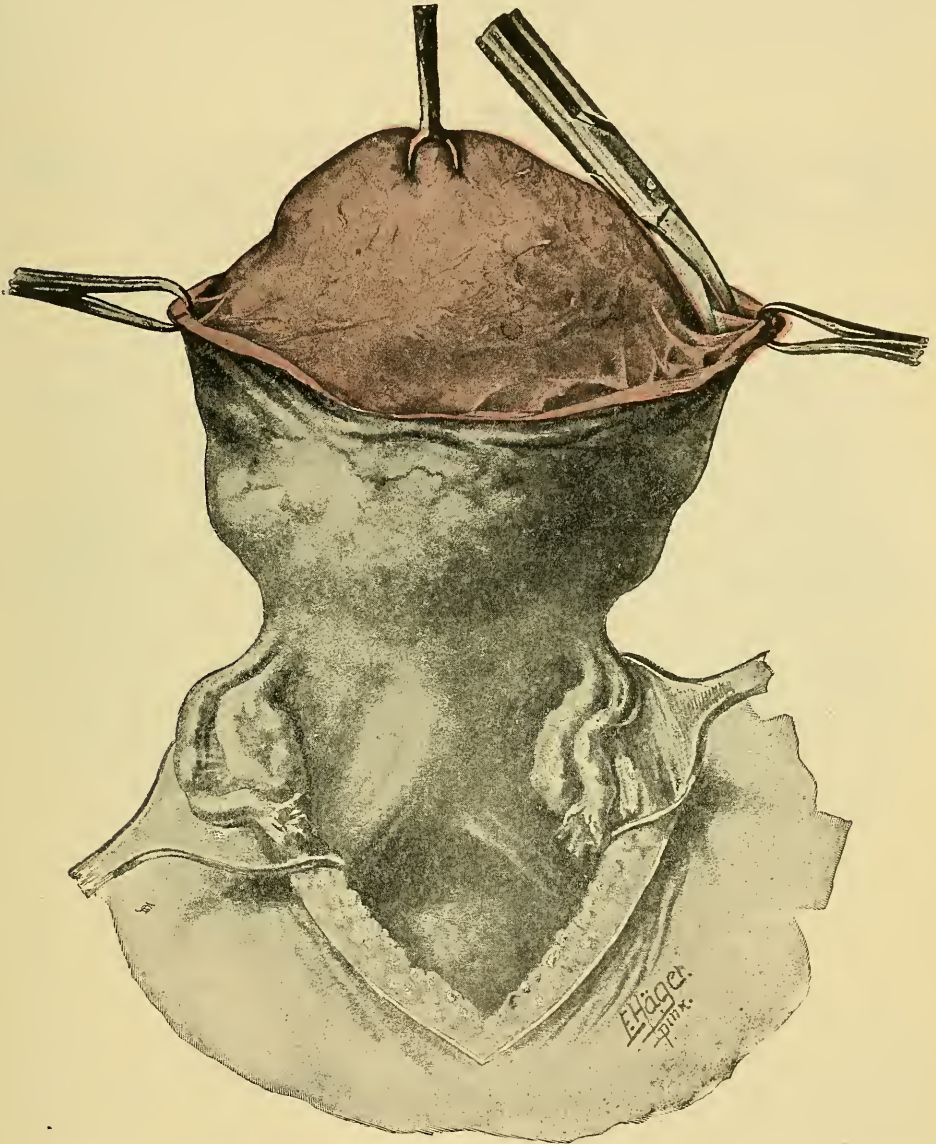

FIG. 120.—The exposed uterus is split. The myoma pulled taut by a *Muzex* forceps. Firm connections with the bed of the tumor are separated with the scissors.

pubic folds deep down to the fascia of the musculus recti respectively obliqui. Incision and detachment of the fascia from the musculature, careful arrest of hemorrhage, incision of the linea alba as far as the

abdominal cavity. The myomatous uterus is brought out of the abdominal wound. Lowering of the head part of the operating-table, protection of the abdominal cavity by sterile gauze dressings. Exact inspection now shows how much of the functioning tissue of the uterus remains, also whether the ovaries and tubes are healthy.

(a) With sufficient functionable uterine tissue in solitary round myo-

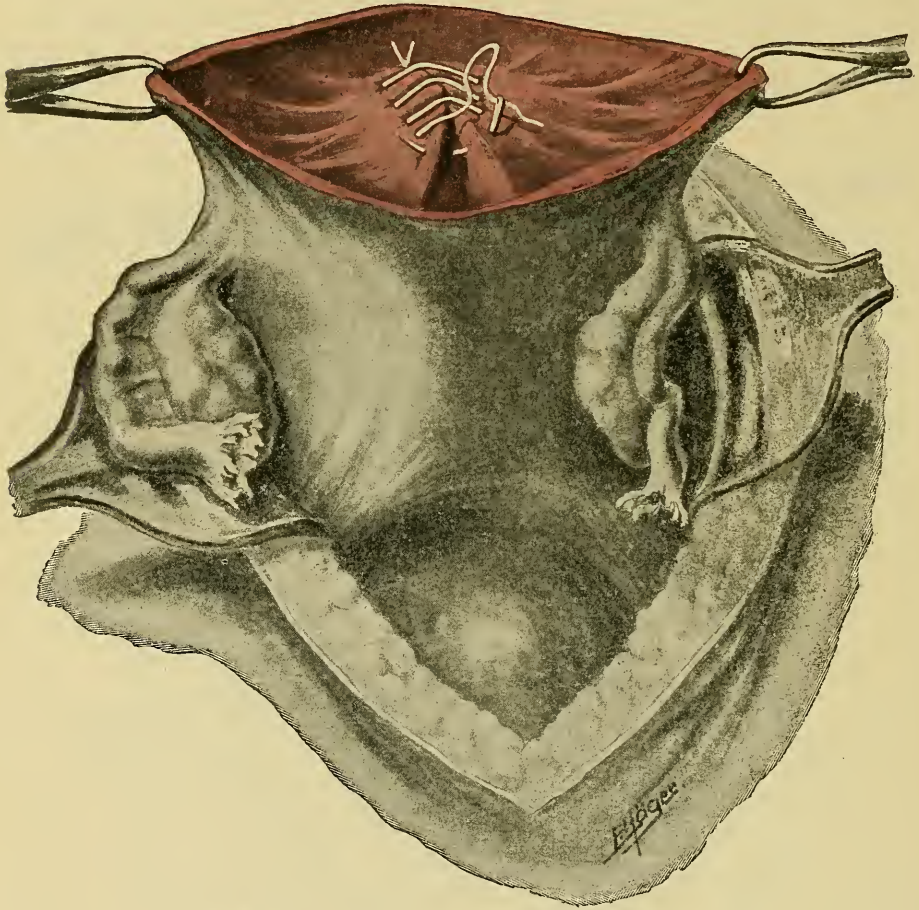


FIG. 121.—Suturing of the Bed of the Tumor after Enucleation. (Abdominal operation.)

mata, **enucleation** is executed by opening the peritoneum and the capsule at the apex of the tumor (Fig. 120).

If several myomata have formed independently of each other, then from the bed of the first enucleated tumor the second myoma is incised. If the tumors are too far apart from each other separate incisions are made at such points on the surface as appear suitable. I seize the tumors with bullet- or *Muzeux* forceps; the introduction of drill instruments only retards the process of the operation. The tumor, now, is

pulled upward and peeled out with the fingers. Stronger bands, connecting the growth with the capsule of the tumor are cut with knife or scissors. The bed of the tumor mostly does not bleed. The hemorrhage stops, at all events, if the assistant presses the cervix with both hands from the sides. Otherwise use artery clamps. The bed of the tumor is smoothed as much as possible, thereby the capsule is removed in most

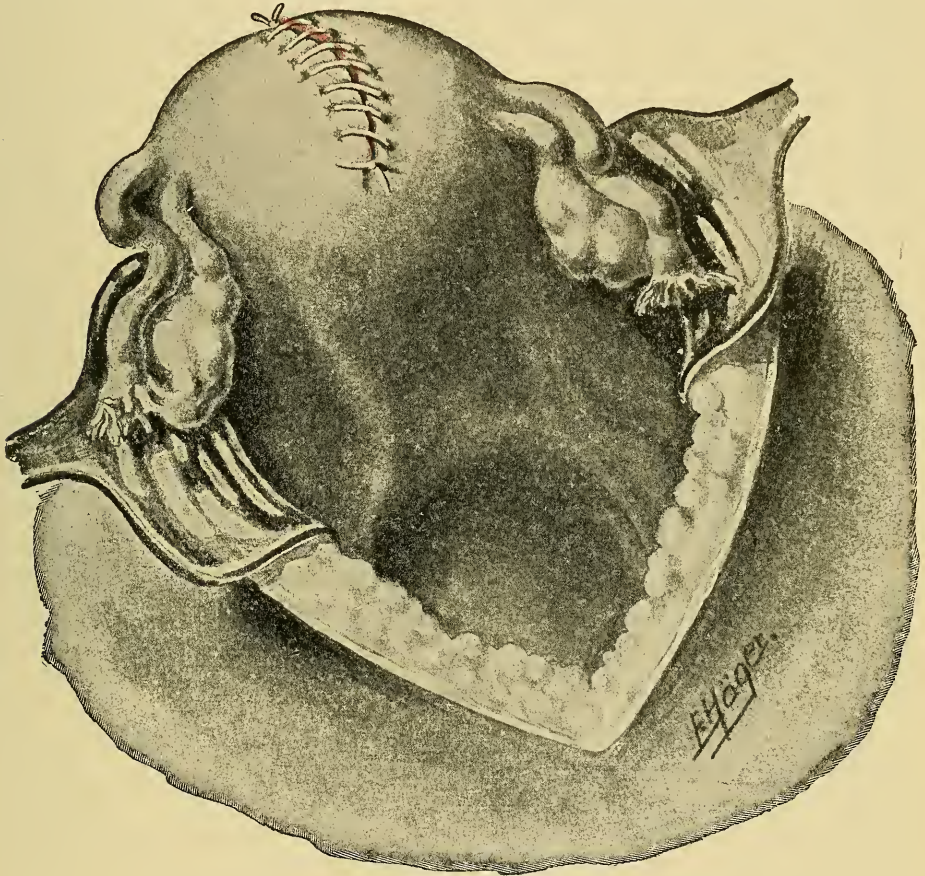


FIG. 122.—The uterus wound is sutured.

cases. *Henkel*¹⁹⁶ has recommended the systematic excision of the capsule. The uterine mucosa is examined thoroughly after opening of the uterine cavity. Abrasio mucosæ through the existing opening, and eventually resection of the superfluous parts of the mucosa. Closure of the uterine cavity by a continued submucous catgut stitch (Fig. 121). Suturing of the bed of the myoma with continued sutures in rows. Coaptation of the wound margins by a continuous catgut stitch (Fig. 122). The entire body of the uterus is palpated for myoma-nuclei. Diseased ovaries and tubes are removed or resected. Examination of the peritoneal

cavity for changes previously unnoticed. Replacing of the uterus, cleansing of the abdominal cavity, suturing of the peritoneum with continued suture after placing a sterile cloth on the intestines which tend to press forward, which is removed, before the last stitch through the upper end of the peritoneal wound is inserted.

Continuous suture of the posterior fascia with catgut. Suture of the anterior fascia with buried aluminum bronze sutures. The same suture material is used for the abdominal skin, whose knots lie externally on it. Iodoform gauze strips cover the incision, which are secured with strips of zinc oxid adhesive plaster.

(b) ***Pedunculated subserous myomata*** are excised with their peduncle from the wall of the uterus. In order to cover the loss of the substance, a corresponding flap of the peritoneum is excised at the peduncle. If the defect is deep it is closed with continued catgut sutures in rows.

(c) If it is not advisable to preserve the corpus of the uterus, then ***supravaginal amputation of the myomatous uterus*** is performed. The method of *Hofmeier* and *Chrobak* for ***retroperitoneal care of the pedicle*** enjoys a large preference in German gynecologic circles. The tissues are either clamped or ligated in three or four stages on each side between the ligamentum suspensorium ovarii and lateral margins of the uterus; if clamped, ligatures are applied afterward. The stumps of the arteria uterinæ are ligated on the uterus itself, then the cervix is amputated, accordingly either high or low. Instead of any further suturing the stump is covered with a flap of peritoneum, without any further treatment of the serosa of the cervix or extensive cauterization of the latter. The flap has been dissected out according to conditions present, either from the anterior or posterior surface of the body of the uterus. Suturing of these flaps with the corresponding margin of the peritoneal wound edges of the opposite surface.

Zweifel preserves a piece of uterine mucosa in the stump of a size varying with the local conditions. This stump has to be formed, therefore, partly out of the lower part of the uterus. Through the conservation of this piece of the uterine mucosa which is suitable for menstruation, menstrual hemorrhages and excretions are made possible according to *Zweifel's* experiences, and especially then if an ovary or functioning ovarian tissue can be retained, the patients are saved from the symptoms of the climacteric.

In order to preserve one or both ovaries, the ligamenta lata are separated from the cornu of the uterus according to *Chrobak's* proposition. Not seldom a premature atrophy of these ovaries is observed, *Werth* recommends, therefore, to execute the ligation of the vessels, nourishing the ovaries, in an especially careful manner and to cover the ovaries themselves with peritoneum.

(d) If an examination of the tumor brought out of the pelvis shows that not sufficient functioning tissue in the uterus can be preserved,

eventually after enucleation of the myomatous masses, then the **abdominal total extirpation of the myomatous uterus** is performed. The operation is begun with the release of the uterus from the ligamenta lata on both sides, by ligating these in three or four partitions beginning from the ligamenta suspensorii ovarii or approximately in front of the ovary. One may naturally also seize the corresponding tissues with three or four clamps and amputate first, in order to later grasp the vessels upon the surface of the incision. Inasmuch as the connection of the bladder with the anterior wall of the uterus is subject to great variations in breadth the plica vesica uterina is incised first. The tumor follows the traction above the symphysis. The posterior vaginal vault stretches itself, the cervix and the portio vaginalis become well recognizable. The vaginal vault is incised by a longitudinal or transverse incision. If it is not found immediately it may be brought forward by means of a dressing forceps which is inserted into the vagina in order to cut down upon it from above or to perforate it from below, after which it is freely and fully opened. It is recommendable to unite the margins of the peritoneum and the vagina by interrupted stitches. If the conditions are simple one separates first the one, then the other lateral vaginal vault and takes care of them by ligatures, in which operation one must watch with special care for the circular branches of the bloodvessels in order to ligate them preventively if possible. In other cases the amputation of the cervix is facilitated by seizing the portio vaginalis—that is, both uterine lips—with a *Muzeux* forceps and pulling them out of the vaginal introitus. At the same time the os uteri is thereby closed and the soiling of the field of operation by uterine secretion is prevented. The pars cardinalis is stretched on both sides conveniently for amputation and suturing. The anterior vaginal vault is free, so that the incision can be made close to the portio. The loosening of the bladder results easily by continued traction upon the portio vaginalis and blunt dissection of the loose cellular tissue. Closure of the vaginal and peritoneal margins is obtained by sutures which pass through the entire surface of the wound of the bladder. Covering of the entire wound of the stumps of the ligaments by union of the peritoneal margins from before backward. Symperitoneal suture over the vaginal vault, also between peritoneum of the excavatio recto-uterina and vesico-uterina vel. vesicæ.

Among the numerous variations of the direction of growth of the myomata, those of the **intraligamentous development** offer particular difficulties. The myomata may not only expand the folds of the ligaments, they also grow retroperitoneal along the colon reaching beneath the colon or the typhlon. The enucleation of the same may cause severe difficulties on account of the displacement of the vessels, ureters, bowel and nerve ganglia. The operation is rendered difficult there by the fact that these tumors at first seem immovable. If the uterus, on account of its permeation with myomata or its complete displacement from its old relations, must be removed, then the operation is materially simplified. On the

other hand one must always endeavor to preserve the uterus. With a multiple formation of myomatous lobules, space is gained by the peeling out a few single lobules. Otherwise a possible extensive decrease by removal in pieces is recommended, so that the last part may be loosened under full view of the eye. In this way large vessels become visible with comparative ease, so that they may be ligated at the proper time. The bladder and ureters offer greater difficulties. The fulness of the bladder eventually during the operation is disagreeable and the ureters may be freely exposed from above downward. Special attention must be given the rectum as soon as its serosa comes in contact with the field of operation. After injuries of the serosa the transverse arrangement of the musculature is easily distinguished, so that, as a rule, at least the opening of the lumen of the rectum may be avoided.

If the myomata are softened or suppurating then the tumor and contents must be protected with special care from the abdominal cavity. It has been proposed to remove such septic and suspicious myomatous masses supravaginally and to fix the peduncle extraperitoneally.

Such *extraperitoneal provision of the peduncle* does not prevent abdominal wall infection, and always includes the danger of the formation of hernia of the abdominal wall. It depends on circumstances and on the opinion of the operator, whether or not he would also prefer a radical operation in such cases. If *extensive wound surfaces* in the peritoneum have occurred, which cannot be covered by drawing together the peritoneal margins, sometimes a covering of the wound can be obtained by making use of the uterus for this purpose, otherwise it suffices to stop a probably continuing parenchymatous hemorrhage by mattress sutures or to pack sterile gauze upon it. If possible I bring such dressings out through the vagina, only in extreme cases through the lower angle of the abdominal wound.

Cervix myomata and submucous myomata of the corpus in the act of being expelled may give rise to peculiar difficulties, inasmuch as it is difficult or impossible to outline them from the vagina prior to morcellation on account of their size. Formerly I occasionally pulled such tumors upward through the opened abdominal cavity after incision of the corpus. At present I would prefer to make room from below by an extensive excision of pieces of the tumor until a clear view is presented.

A peculiar complication arises from the necessity of attacking the *pregnant myomatous uterus*. Rapid growth of the myomata hinders the development of the uterus. A hemorrhage which indicates a threatened premature expulsion, as well as the displacement of the lower uterine segment and the cervix by the myoma may already compel premature interference during pregnancy, or at the normal termination. The removal of a subserous myoma from the pregnant uterus is occasionally borne without an interruption of the pregnancy. Often after five or six days of completely quiet convalescence, uterine contractions suddenly appear and the expulsion of the ovum cannot be prevented. It may take

place without any disturbance, it may, however, be accompanied by profuse hemorrhage and result in collapse. I have repeatedly lost such patients. The necropsy did not yield the slightest evidence of sepsis.

With displacement of the cervix uteri, removal of the myoma from the vagina during pregnancy only remains to be done or the delivery of the women through a *Cæsarian* section in connection with extirpation of the uterus may become indicated. The individual conditions determine the choice of operation.

After-Treatment

Generally patients operated on for myomata do not need any special after-care. Rest in bed for ten to twelve days is deemed advisable on account of the healing of the wound. Abdominal incisions as well as vaginal incisions within this time attain a sufficient firmness of scar-formation. Aseptic wounds, even if of large size, require only a corresponding consideration.

With the use of catgut I order after vaginal operations irrigations with a solution of thymol (1 to 2,000-3,000) with the occurrence of an abundant wound-secretion, after the loose iodoform gauze strips have been removed on the third or fourth day. Metallic sutures, which perhaps have been placed in the external end of the paravaginal accessory incision, are removed after the patients have left the bed (fourteen to sixteen days).

Abdominal wounds are left completely untouched until the seventh day. If then the first dressing is removed only dry iodoform gauze or iodoform powder is applied. A puerperal binder is fastened around the abdomen. Between the tenth and fourteenth day the sutures are removed from the skin. For protection of the scar, four or five adhesive plasters are placed over the iodoform gauze, then applied.

Generally the patients lie quietly on their backs, for eleven days. On the twelfth day they are placed on their sides, on the thirteenth day they sit up, and on the fourteenth day get up.

With abscess formation I carry out a simple open-wound treatment. Special attention must be given to urination. If the patient cannot empty the bladder after eight or ten hours without any trouble, she must be catheterized. The prophylactic rules, which are intended to exclude post-operative cystitis, have not given us any convincing results. On the occurrence of cystitis the bladder is irrigated with boric acid solution or silver nitrate (1-1,000 to 1-2,000).

Out of regard for the so very important motus peristalticus, the use of morphin is excluded as far as practicable. The patients do not get anything to drink until the next morning. Then water, coffee, cognac, wine, or champagne is given in very small quantities. If the motus peristalticus should not start the first day, small quantities of cognac or tinctura valerianæ, 10 to 20 drops, may promote the passage of the flatus. If the bowels remain continuously quiet, strychnia is given subcutaneously

(twice in one-hour intervals, 0.003; the third time, 0.004). Eventually, on the evening or the next morning, a glycerin enema, about 20 grm., is given. After passage of the flatus liquids are given oftener, according to the desire and the condition of strength, also bouillon and the like. On the fifth day a movement of the bowels is produced by oleum ricini (1 to 1½ tablespoonsful, or in tablets), aperient water (one glass) or an infusion of senna.

℞ Infusi sennæ.....	80.0
Sodii tartratis.....	12.5
Syrupi glycyrrhizæ.....	7.5

M.

S. Shake well. One tablespoonful on empty stomach in early morning.

[I have during the last ten years faithfully carried out the following post-operative treatment, which is the generally accepted one in St. Mary's of Nazareth Hospital, Chicago, where it was introduced by A. J. Ochsner. I have never had any occasion to change the treatment in any essential point.

The head of the patient's bed is raised from six to eight inches to prevent nausea and hypostatic congestion. Obstinate vomiting, after nausea from the anesthesia should have subsided, is treated by gastric lavage. If the patient is in severe pain, morph. sulph., 0.016 is given hypodermically, and repeated once or twice if absolutely necessary. If the shock is very marked, or the patient is extremely weak, continuous proctoclysis with normal saline solution is indicated. As soon as nausea subsides, sips of hot water are allowed. On the morning of the third day a simple soap-sud enema is given. If this is successful, and if signs of peritoneal irritation do not exist, weak tea, beef-tea, broth and buttermilk are allowed. On the fourth day, general liquid diet is ordered, the sixth light diet, and the eighth general diet. On the latter day, also, a cathartic is given per mouth, preferably oleum ricini, 3.00, in beer-foam or orange-juice.

The patients are allowed a backrest on the eighth day, may be up in a chair on the tenth, and are allowed to walk about on the twelfth. The wound is inspected and the stitches removed on the twelfth day. The patient is allowed to go home on the fifteenth day. Abdominal bandages or supporters are never used. The post-operative dressings are dispensed with from the 21st to the 28th day following the operation.—ED.]

To promote healing of the vaginal wound, douches, with the addition of iodine (tinct. iod., 25.0; pot. iodati, 5.0; aq. 170.0, a tablespoonful), are given once or twice daily, then sitz baths, with decoctions of tan, green soap, or the addition of tannin.

As soon as the patients feel strong enough they are taken into the open air. Often repeated walks, at first short then longer, alternate with rest in bed. After six weeks any further local treatment is discontinued,

housework may be undertaken gradually. Cohabitation is prohibited for at least three months. Those patients operated on conservatively are requested to lie down in bed for the first three menstrual periods. Patients entitled to sick benefit are completely disabled up to the end of the third month, 50 per cent., during the fourth and fifth, are completely capable to work after six months with a corresponding condition of health.

Those patients operated on radically must accustom themselves to energetic physical exercises, are not allowed to partake of alcohol, or hot liquids. A careful dietetic regulation of their digestion, fruit, drinking of water, and so forth, is recommended.

The removal of the *polypous growth* (mucous polypi, pedunculated myomata) does not offer any serious difficulty. Much more serious is the fact that behind the polypi, which occasionally obstruct the cervical canal like corks, decomposed secretions frequently stagnate. The occasional protrusion of the polypi into the vagina and retreating into the uterine cavity apparently causes an absorption of the vaginal contents into the uterine cavity.

Perhaps this accounts for the fact that with polypi the endometrium is so frequently found in a condition of severe irritation. A very critical consequence of septic or a sapremic endometritis is the feverish reaction after an apparently simple removal of a pedunculated polypus by twisting or cutting. On this account I confine myself of late to the removal of the polypi, to curettement of the endometrium and to cauterization with liquor ferri. More extensive operations, which are indicated by prolapse, erosions, displacements, multiple myoma formations or diseased adnexal organs, are performed during a second operation, as soon as the polypus operation has been recovered from without reaction.

II. Adenoma of the Uterus

Already, during the discussion of the hyperplastic diseases of the uterine mucosa, it has been mentioned that these processes may lead to pictures, which remind one of the character of an epithelial tumor of glandular structure and therefore have been designated by many authors as *benign adenomata*. This name has an especial importance for the *polypoid* forms of the disease in which especially in the cervix uteri the picture of a tumor is produced by the pedunculation and the circumscribed appearance. But as these formations have originally an inflammatory origin, and as every tendency to dissemination and proliferation into the deeper layers as well as to formation of metastases is absent, we deem it more correct to include them among inflammatory conditions and not among tumors.

Therefore we have entirely abandoned the idea of an adenoma benignum uteri and count all forms of diseases formerly classed under this head as hypertrophied and hyperplastic diseases of the endometrium corporis et cervicis (see chapter Endometritis).

III. Carcinoma of the Uterus

For literature on CARCINOMA UTERI see *Winter: Anatomie des Carcinoma Uteri in Veit's Handb. d. Gyn., Vol. III, Wiesbaden, Bergmann, 1899. Frommel's Jahresber. über Geb. u. Gyn., 1899-1906.*

Of all the organs of the female body, the uterus becomes most frequently affected with carcinoma. Of the tumors which attack the uterus, carcinoma stands next in frequency to myoma.

These two statements express the reason for the grave importance of the study of uterine carcinomata. Since 1900 our knowledge of the pathologic anatomy as well as of the therapy of carcinomata of the uterus has been extraordinarily enriched by the efforts of *Ries, Rumpf, Küstner, W. A. Freund, Wertheim, v. Rosthorn, Bumm, Mackenrodt, Kroemer*, and many others. While the period of great changes in this field is by no means closed at the present time, our **anatomic** knowledge and views are strengthened to such an extent, that from the **morphologic** standpoint further additions to our knowledge are hardly to be expected.

Further progress is to be expected only from a study of the biology of malignant tumors, looking chiefly to an eventual discovery of their **etiology**.

As we know nothing of the etiology and biology it is not necessary to enter into further details within the limits of a text-book which should give facts only.

No part of the uterus is exempt from cancerous degeneration, but carcinomata of the **collum** exceed in number many times those of the **corpus**.

We differentiate:

1. **Carcinomata of the collum**, including:

(a) **Carcinomata of the portio vaginalis** (starting from the **squamous** epithelial covering or from **erosions** of the portio vaginalis).

(b) **Carcinomata of the cervix** (starting from the **mucosa** of the cervical canal).

2. **Carcinomata of the corpus** (starting from the **mucosa** of the corpus uteri).

1. Carcinomata of (a) the **portio vaginalis** occur in different forms according as they arise from the squamous epithelial covering or from erosions.

The first type presents itself chiefly in the anatomic form of epithelioma, i.e., solid cell cones proliferate from the squamous epithelium into the connective tissue of the portio and form very frequently so-called cancrioid or epithelial pearls, the old squamous epithelial cells found in the centre of the cell-cone undergoing cornification (see Fig. 111, p. 221).

A different picture is presented by those carcinomata which originate in erosions. The erosion, in fact, represents a proliferation of elements

of the cervical mucosa extending from the cervical canal through the os externum to the portio, and they with all their numerous glands are covered with cylindrical epithelium of the structure of cervical epithelium. This cylindrical cell epithelium may undergo a metaplasia into squamous epithelium and then also sends cell plugs into the deeper layers. (See Fig. 125.) Cornification, however, is much rarer in these erosion carcinomata than in the purely squamous carcinomata. Both forms, however, have the type of *alveolar* carcinomata. Concerning *glandular* carcinomata of the portio vaginalis, see below under *Carcinoma* of the Cervix.

Carcinomata of the portio also present different clinical forms.

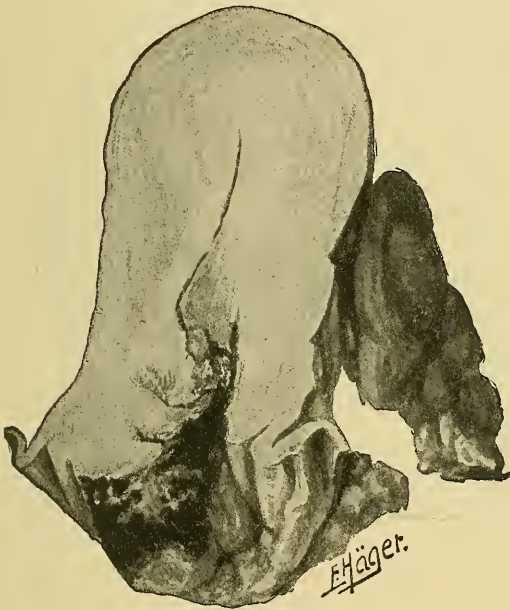

FIG. 123.—Superficial Cancerous Ulcer of the Portio Vaginalis. (Author's preparation.)

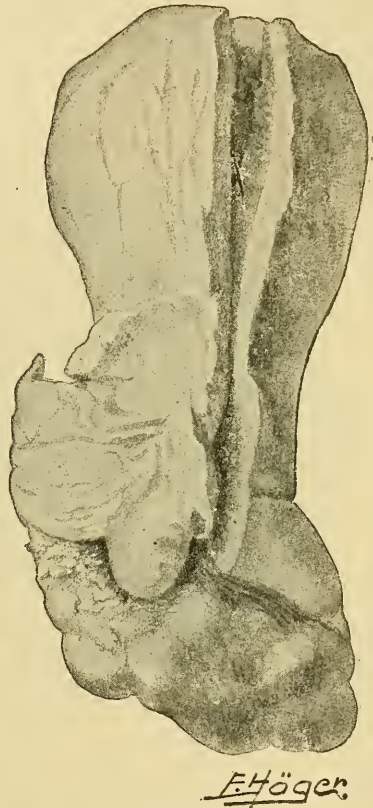


FIG. 124.—Cauliflowerlike Carcinoma of the Portio Vaginalis. (Preparation from the Pathologic Institute of Greifswald.)

Either they are *ulcers* with wall-like margins, and often with lardaceous base like *ulcus rodens*, and with hard infiltrated surroundings (see Fig. 123). These may in the beginning give rise to confusion with *leucitic* primary affections. These ulcers may occur on one or both cervical lips or, wreathlike, enclose the external os uteri.

Or the carcinomata proliferate only into the deeper structures, leaving the surface relatively intact and form round nodules within the tissue

of the portio. If the surface is, after all, finally destroyed by the further growth and disintegration of the tumor, then deep cavities, filled with necrotic tumor-masses, arise in the portio.

Another relatively frequent form of the portio carcinoma is of a more marked proliferating character. Starting usually from one of the labia of the uterus, a rapidly growing tumor developing toward the lumen of the vagina arises which may attain a considerable size (as large as a fist or larger), but always sits with a relatively small base on the portio: **Cauliflower tumor of the portio** (see Fig. 124).

These cauliflower growths are mostly of an uneven, nodulated, disintegrating surface; on palpation the tissue breaks down easily.

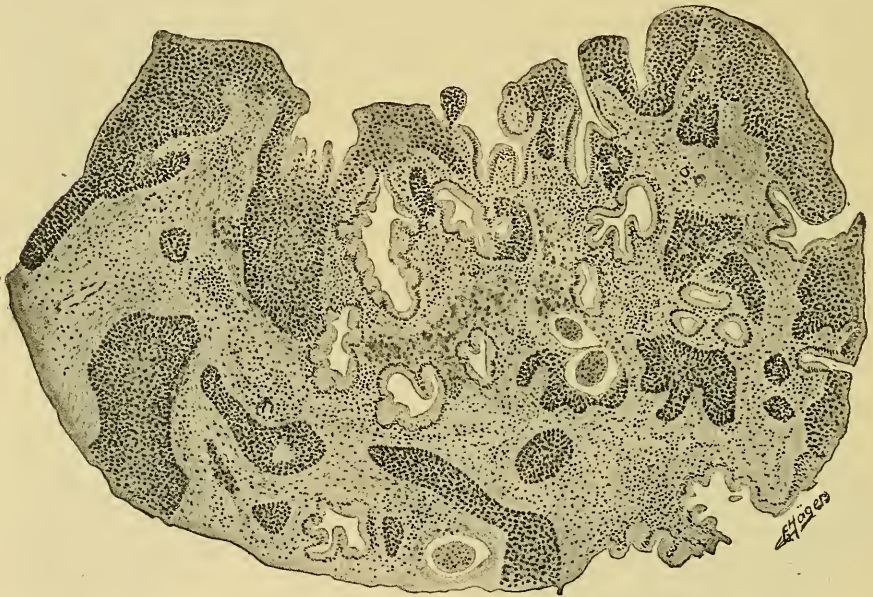

FIG. 125.—Carcinoma Cervicis Uteri. Carcinoma cones proliferating from the surface into and between the cervical glands, lined with normal lamellar cylindrical epithelium. (Author's preparation. Zeiss, Obj. AA, Oc. 2.)

(b) The carcinomata of the **cervix** take their origin from the mucosa of the cervical canal. They appear pathologically the same as the erosion carcinomata of the portio, i.e., after the cylindrical surface epithelium has changed into squamous epithelium, solid cell-cones proliferate into the depth of the cervical wall (see Fig. 125).

The **glands** of the cervix are more rarely the matrix of the cancer. The cylindrical epithelia then proliferate as well toward the lumen as also into the tissue after breaking through the basal membrane of the gland and displacing connective tissue, which only remains behind in small tracts between the different glandular ducts. Just such pictures

may also exist in erosion carcinomata of the portio, as numerous glands having the structure of the cervical glands are also present in the erosion (see Fig. 126).

We designate this variety of carcinomata as *carcinoma adenomatosum* to differentiate it from the much more frequent alveolar carcinomata. (*For the so-called malignant adenoma see under Corpus-carcinoma.*)

Clinically the cervix carcinomata frequently present themselves as *polypous* tumors; they originate then usually on the base of a benign mucous polypus; in other cases the wall of the cervical canal is found to be infiltrated all over by the newgrowth, which toward the lumen is already in a state of disintegration, so that in place of the cervical canal

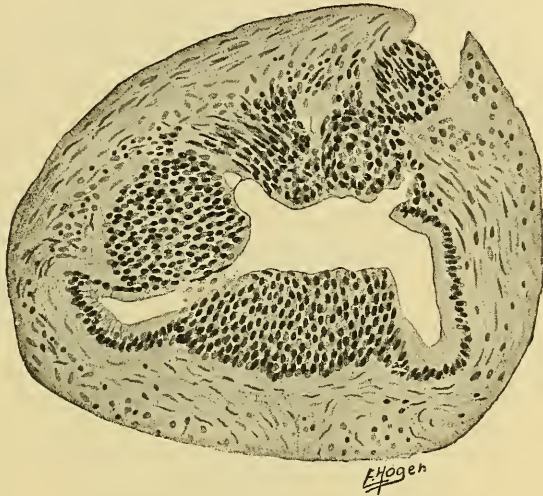

FIG. 126.—Cervical Gland with Beginning Carcinomatous Degeneration.
(Author's preparation. Zeiss, Obj. DD, Oc. 2.)

a cavity arises lined with necrotic tumor débris. (See Fig. 127.) Also the polypous cervical carcinomata show on their surface already more or less advanced disintegration.

Finally, a destruction of the portio vaginalis may result from the cervix carcinoma, so that a broad crater lined with disintegrated tumor-masses develops, whose widest portion is continuous with the vagina, not a trace of the uterine lips remaining.

The form of malignant neoplasm of the cervix described under the name of *endotheliolymphoma* seldom occurs. Some of the reported cases surely are true cervix carcinomata, whose cells have filled the lymph-spaces in every direction and thus have produced the impression of a primary disease of these vessels. But such cases also have been observed with certainty in which the new-formation consists in a primary proliferation of the endothelium in the cervical lymph-canals. These

exceedingly malignant tumors do not differ clinically from the cervix carcinomata (see Fig. 128).

2. *Corpus carcinomata* originate in *the mucosa of the corpus uteri*. Only seldom is the surface of the epithelium the matrix of the tumor.

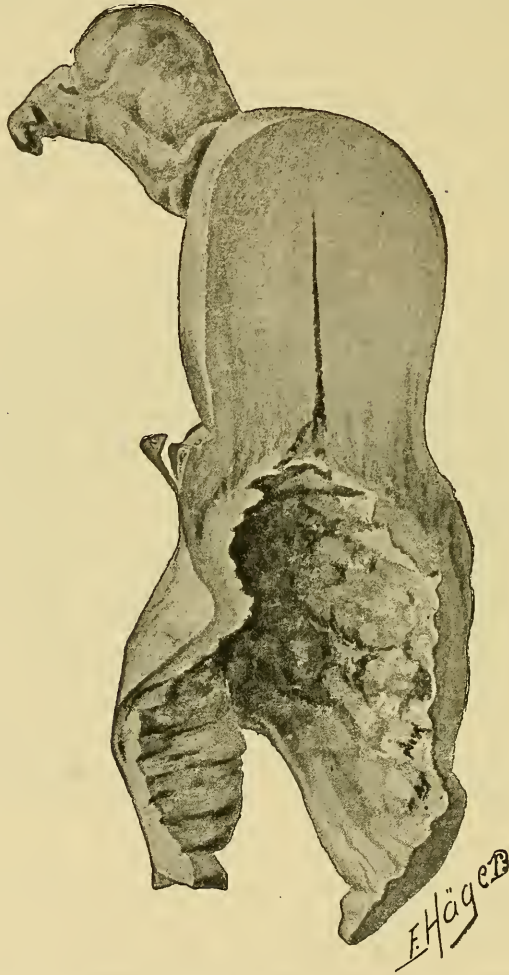


FIG. 127.—Carcinoma Cervicis Uteri. The cervix is destroyed; in its place is a crater filled with disintegrated tumor-masses. (Author's preparation.)

Then the cylindrical surface epithelium changes also into squamous epithelium, solid plugs proliferate into the depth and, indeed, a cornification of the central portions of such plugs may occur and thereby a true canceroid or epithelioma of the corpus uteri arises.

Very much more frequently, however, the carcinoma of the corpus starts from the *glands*. These experience a marked increase, proliferate into the depth of the uterine wall as far as the peritoneal covering, and,

finally, also perforate this, and thus reach the open abdominal cavity. On the other hand, just as in the cervix so in the corpus, the carcinoma may develop on the basis of a mucous polypus, at first permeating this and later on proliferating into the uterine wall. The structure of the glands in such cases may remain apparently normal in the beginning, so that only stratified epithelium and a preserved basal membrane is seen. If one, however, examines more carefully, he finds in each one of such cases also polymorphous epithelia, perforation of the basal membrane and solid cell-plugs growing into the depths, so that the new-formation proves to be a true carcinoma (see Fig. 129).

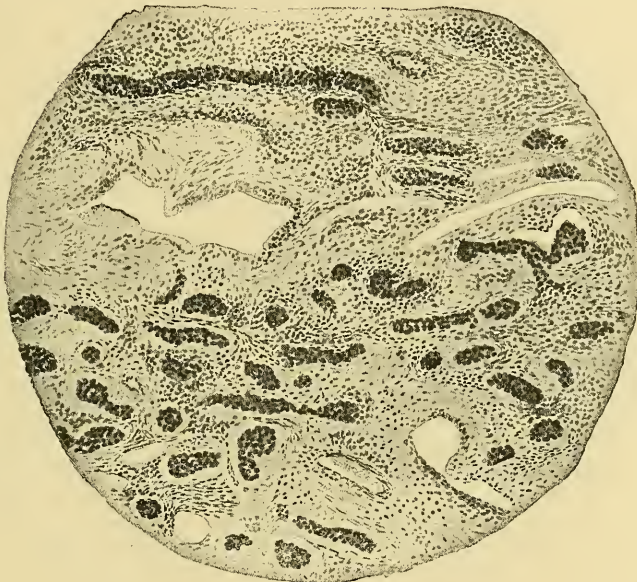

FIG. 128.—Cervix Carcinoma Extending Farther into the Lymph-Spaces, and Thereby Suggesting an Endotheliolymphoma. (Author's preparation. Zeiss, Obj. AA, Oc. 2.)

The characteristic of carcinoma adenomatosum of the corpus uteri, in common with the similar, much rarer tumors of the cervix and portio, that in the beginning apparently a true adenomatous character is retained, has led authors to name these new-formations *adenoma malignum* (corporis, cervicis, portionis vaginalis). We hold this designation incorrect, just as *Winter*. We also regard these glandlike epithelial new-formations always as genuine carcinomata, because the characteristic features, such as metaplastic epithelial proliferation, infiltrating growth, formation of metastases, can be proven in *all cases* by a thorough examination.

According to our view-point the conception of adenoma malignum must be dropped.

Corpus carcinomata may appear in the beginning as circumscribed (especially those which develop on a basis of mucous polypi—see Figs.

130 and 131), or as diffuse in a large area of the mucosa of the corpus (see Fig. 132). In these also a superficial disintegration takes place, although, for reasons still to be discussed, it occurs later than in the case of carcinomata of the cervix.

The behavior toward the supporting tissue of the mucosa, respectively the fibromuscular tissue of the uterine wall, is common to all the described forms of uterine carcinoma. As in most of the carcinomata the supporting tissue is gradually rarefied and finally entirely displaced by the advancing tumor. Especially the adenomatous carcinomata are character-

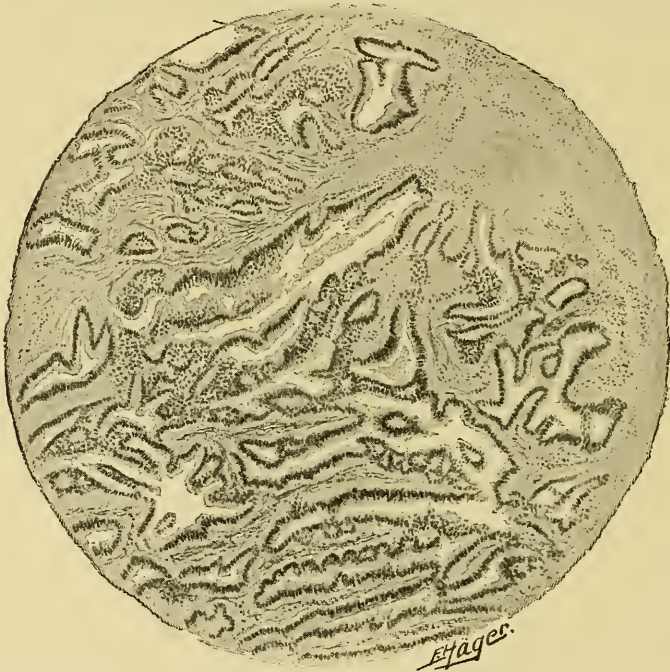

FIG. 129.—Carcinoma Adenomatosum Corporis Uteri. (Author's preparation. Zeiss, Obj. AA, Oc. 4.)

ized by their exceedingly delicate, intraglandular connective-tissue tracts, often consisting only of a single cell layer, while in the cauliflower growth and in many carcinomata occurring in the *scirrhus* form (so-called *wormy* carcinomata, *C. Ruge*) the connective tissue takes a larger part in the tumor formation. All around the margin of the malignant tumor the supporting tissue is found in a condition of an exceedingly dense *round cell infiltration*, which, according to our present conception, is probably to be looked on as an expression of a hopeless fight of the organism against the advancing enemy.

We have already referred to the peculiar tendency of uterine carcinomata to *superficial disintegration*. The result of this peculiarity is that the necrotic tumor-masses offer an excellent culture medium for the

numerous micro-organisms which are always present in the portio as well as the cervix. However, corpus carcinomata are also penetrated by cocci, which find a good culture medium in the secretion and blood flowing toward the cervix, and thus probably proliferate in continuo into the cavum uteri. This infection appears *later* in the corpus carcinoma than in the carcinoma of the portio and cervix, because the internal os uteri forms in the beginning at least a certain barrier against the micro-organism. If the secretion is dammed up by displacement of the cervix, then

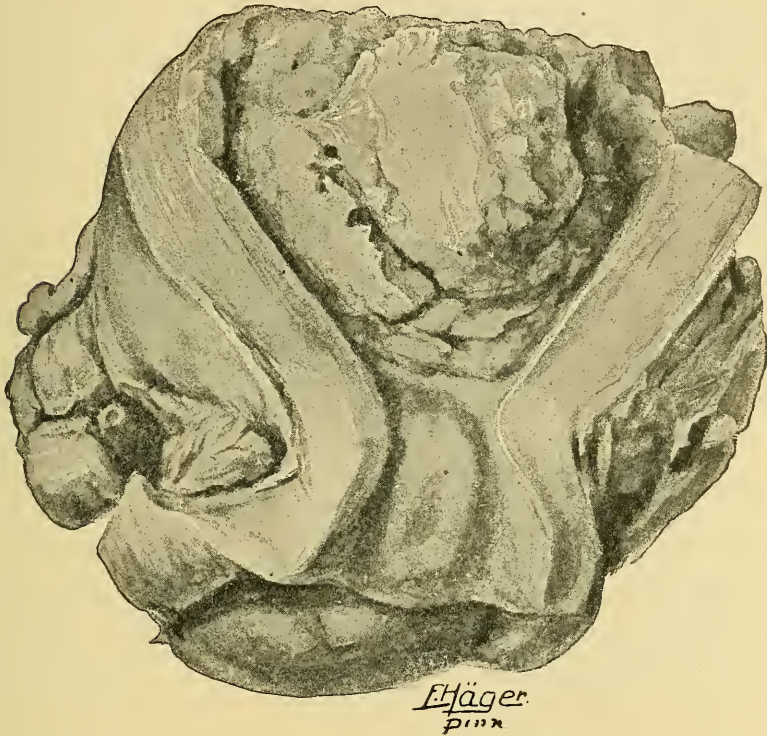


FIG. 130.—Polypous Carcinoma of the Corpus Uteri. (Author's preparation)

a pyometra may result from it which is not rare in the corpus and in carcinomata proliferating in the upper part of the cervix. *The carcinomata, therefore, must be looked on as a real place of incubation not only of harmless saprophytes, but also of highly pathogenic micro-organisms, especially of streptococci.*

This characteristic is exceedingly important for practical purposes. Apart from the grave danger of infection, to which physicians and midwives who examine carcinomas with hands, unprotected by gloves, expose patients and parturient women whom they examine or treat later on, a radical or palliative operation for carcinoma can never be aseptically performed, as the removal of germs from such tumors is always impos-

sible. The fever which appears not rarely quite spontaneously, as also the frequently occurring grave infections in spite of painstaking aseptic precautions after palliative and radical operations find their unconstrained explanation in the large number of pathogenic micro-organisms present.

The hemorrhages, also, which are so characteristic of carcinomata, at least in advanced stages, have their origin in the anatomic conditions. As soon as the tumor disintegrates superficially, the very numerous vessels also become eroded and bleed often profusely with the least.

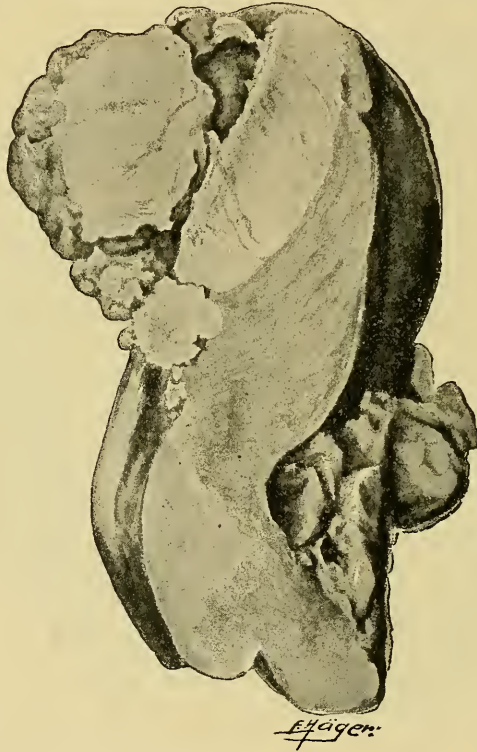
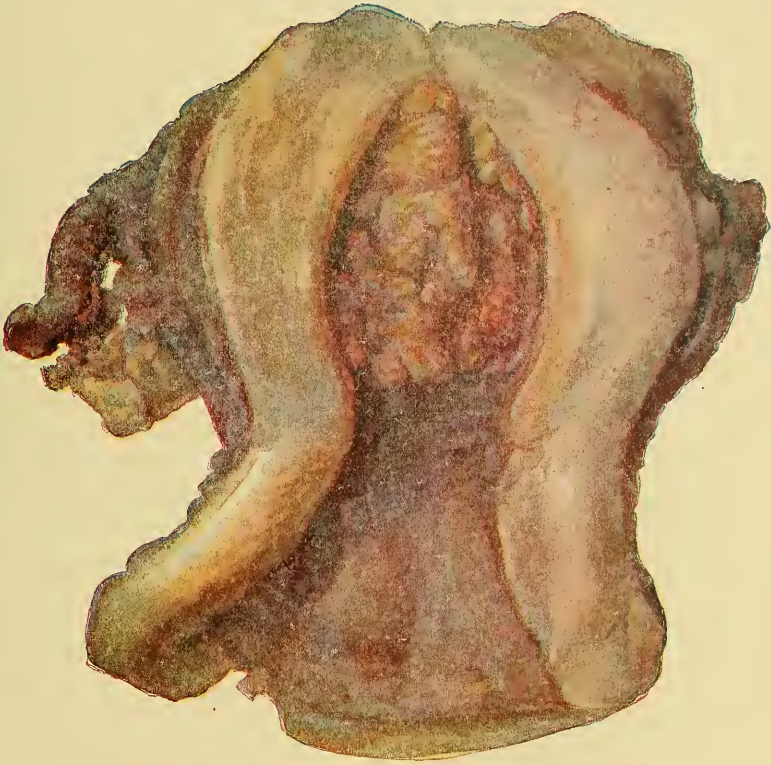

FIG. 131.—The same preparation as in Fig. 130. The transverse section shows the extensive penetration of the uterine wall by the carcinoma.

traumatism affecting the tumor. The hemorrhages in portio and cervix carcinomata during cohabitation often are the first signs which call attention to the disease. During internal examinations severe hemorrhages also occur very often.

The different varieties of uterine carcinomata can be anatomically positively differentiated only in the beginning of the disease in the manner mentioned above. In the advanced stages, on the contrary, the different forms soon merge into each other. After destruction of the portio proper the portio carcinoma may proliferate far upward into the cervix,

the cervix carcinoma may pass downward and destroy the portio and grow upward into the corpus uteri, the corpus carcinoma may extend downward as far as the cervix. This extension into the different parts of the uterus need not always result in continuo. For instance, cervix carcinomata may form metastases in the corpus uteri which are entirely separated from the mother tumor, and the same is true of carcinomata in the cervix and at the portio.



L. Häger

FIG. 132.—Surface Carcinoma of the Corpus Uteri. (Author's preparation, preserved in *Kaiserling's* fluid.)

In their further progress, the carcinomata do not remain limited merely to the uterus, but also extend into the adjacent structures. Frequently there occur the so-called implantation metastases in the vagina, which arise from implantation and further growth of a cancer particle, carried downward by the flow of the secretion to the vaginal mucosa or through retrograde lymph transportation and which occur in all forms of carcinomata.

Furthermore, carcinomata very soon proliferate by continuity through the uterine wall. This occurs the earliest in cervix carcinomata, but also

the portio cancers, if they have finally reached up into the cervix, soon tend to follow the same route. They then break through the thin cervical wall and reach the parametric connective tissue in which they very rapidly extend to the pelvic wall. The ureters are then surrounded and gradually compressed to a complete occlusion, so that finally death results from uremia, or the carcinoma (portio as well as cervix) penetrates anteriorly into the bladder wall, so that extensive vesico-vaginal fistulæ are formed. Cervix carcinomata may also invade the excavatio recto-uterina, and thus a general dissemination on the peritoneum may result.

The corpus carcinomata usually rapidly perforate the uterine wall and cause general peritoneal carcinosis; sometimes they spread also *in continuo* to the mucosa of the tubes and in this way reach the peritoneum.

In the last stage of all the uterine carcinomata in which death did not take place before, the small pelvis becomes completely filled with a single rigid mass, out of which details of the imbedded organs cannot be clinically differentiated any more. Intense compression of the rectum and the ureters, formation of fistulæ and so forth are the inevitable accompanying signs of these end-stages.

Uterine carcinomata form distant metastases, already much earlier than through direct proliferation into the surrounding tissues, and dissemination almost exclusively takes place through the lymph-channels. Infection of the lymph-glands of the pelvis from uterine carcinoma may already occur in the earliest phases of the development of the primary tumor. An estimation of the possibility of an already resultant or not yet resultant infection of the lymph according to the condition of the primary tumor is entirely excluded as a result of more recent investigations. Even in primary tumors found in their first beginning, far-reaching infection of the pelvic lymph-glands may already have taken place, while on the other hand in primary tumors relatively far proliferated, infection also may be absent. As a rule, definite groups of pelvic lymph-glands may become invaded by the different forms of carcinoma in the beginning, while these differentiations mostly cease in advanced stages, the different groups of lymph-glands being found infected at the same time.

If we consider only incipient cases of the different forms of uterine carcinoma, the infection of the lymph-canals would take place somewhat according to the following plan:

1. *Carcinoma Portionis Vaginalis*.—The *lymphoglandulæ hypogastricæ* are mainly attacked at first. These lie in the bifurcation between arteria iliaca externa and hypogastrica. Upon this route the lymph-canals pass a few small lymph-glands in the ligamentum latum, directly at the crossing of the arteria uterina with the ureter which often first become diseased with carcinoma. The *lymphoglandulæ inguinales internæ* are also early invaded.

2. *Carcinoma Cervicis*.—Besides the lymphoglandulæ hypogastricæ

and inguinales internæ the *lymphoglandulae sacrales laterales* between the arteria hypogastrica and rectum, as well as the *lymphoglandulae iliacaе externae*, located externally to the arteria iliaca externa, also come into consideration here.

In somewhat advanced stages a difference between carcinoma portionis and colli cannot be sustained; both forms of lymph-gland groups are infected.

3. *Carcinoma Corporis*.—Besides the lymphoglandulae iliacaе externæ, already mentioned, the *lymphoglandulae lumbales inferiores*, at and upon the arteria iliaca communis, as well as the *lymphoglandulae lumbales superiores*, on both sides of the lowest part of the aorta, become especially infected in this variety.

In all far advanced uterine carcinomata it does not matter where the primary tumor is located, all of the mentioned lymph-glands, and still others as far up as underneath the diaphragm, may be found affected with carcinoma.

Furthermore, metastases naturally may develop from these first halting places in all possible organs of the body, without it being possible to formulate any definite rules therefor.

Practically the knowledge of the secondary infection of the lymph-glands through the carcinoma is of importance in so far that it must be our therapeutic endeavor to remove these secondary foci if possible at the same time with the primary tumor.

Thorough examination of the lymph-apparatus in carcinomata now has shown that enlargement of the lymph-glands is not always to be traced to carcinomatous infiltration. The intumescence of the glands may be really an *inflammatory one*, as we see it in all other regions of the body, produced by micro-organisms which are present in large number in the carcinomata (see above, page 277). Entire groups of glands not seldom are found markedly enlarged and even suppurating, and numerous streptococci can be detected in them, but no carcinoma. The infiltrations of the parametrium, which are palpable in direct connection with the primary tumor, may show the same behavior. These also may be of a purely inflammatory nature and may be entirely identical with other parametritides, while the carcinoma as yet is entirely confined to the uterus.

It is necessary always to keep in mind this possibility that enlargement of the lymph-glands and parametric infiltration also may be of a true inflammatory and not carcinomatous nature, because on their correct interpretation may depend quite frequently the highly important decision whether a carcinomatous uterus can still be removed radically or not.

In regard to the malignancy of the uterine cancers *carcinomata of the cervix* stand in first rank, because they proliferate with extraordinary rapidity outside of the uterus and tend to infect the lymph-tracts. Almost equal to them are the *portio carcinomata*, but they are somewhat longer limited to the uterus. Relatively the least malignant are the *corpus car-*

cinomata. Especially the infection of the lymph-tracts may remain absent in these for quite a long time.

The Clinical Behavior of Carcinoma

The really initial stage of carcinoma comes extraordinarily seldom under clinical observation. We have met with only one case in the more than two hundred cases of carcinoma uteri in the Greifswald gynecologic clinic, 1899-1906. *Zweifel* has reported that he never has seen a case of carcinoma in any of the patients formerly treated by him gynecologically. *Lomer* describes an observation¹⁹⁷ in which he could follow beginning and end in a woman whom he had treated before. I have seen two such cases.

The first one came under my care in 1874, in a woman thirty years of age. She had borne a child nine years previously, and became sick with irregular hemorrhages from a corpus polypus when twenty-nine. It was a case of "benign adenoma," as *Carl Ruge* confirmed. This woman after complete recovery became pregnant. I delivered her. She had a rachitic flat pelvis, so that it was difficult to engage the very large head of the boy with the forceps. As a result I naturally made repeated examinations. This child died from an injury of the mandibular mucosa, which the midwife caused while washing out the mouth. The puerperium ran a normal course at first. Then, after nine days, the already light-colored lochia showed a very marked admixture of blood. I found, during an examination, a small nodule, hardly the size of a pea, at the anterior cervical lip. As this nodule grew rapidly, I performed the high excision of the cervix fourteen days after the examination, in 1876, that is, before the report of *Freund* on total extirpation. The carcinomatous character of the nodule was confirmed microscopically. The woman died in the seventh week after delivery, with the formation of diffuse carcinomatous metastases over the entire body.

The other patient was a woman forty-two years old, who suffered from very intensely developed portio erosions. I excised these; they were not carcinomatous. Almost a year later the patient came to me with a pronounced cauliflower tumor. I performed total extirpation. After seven months the patient relapsed, and died four months later.

With regard to the possibility that certain toxins are of influence for the development of uterine carcinoma, *Lomer* (p. 337) cites *Williams*, who maintains that carcinoma occurs after or at the same time with the cure of tuberculosis of the lungs. As a matter of fact connecting links do not exist for the original connection of these two grave diseases. An accidental coincidence could more or less be only in question. In this manner I view two observations which I made in 1878 and 1879.

I performed a high excision on account of cervix carcinoma in a woman thirty-seven years old, and in another twenty-six years old. The one was treated five times with the actual cautery and other remedies, then a standstill in the proliferating activity took place in the rest of the

uterus and the pelvic connective tissue. Hemorrhages and discharges stopped as well as the pains. Instead of this, pronounced laryngeal tuberculosis developed from whose painful manifestations the patient succumbed five years after the first operation. The other one died with the symptoms of tuberculosis of the lungs, after the process in the genitals had ceased so far as concerned the subjective state of health, three and a half years after the first operation. The diagnostic demonstration of tubercle bacilli was not yet known at that time.

Lomer emphasizes furthermore the statement of *Williams* (loc. cit., p. 352) that luetics seldom become diseased by carcinoma. I have made a large number of observations in which exactly the contrary occurred.

In the Greifswald clinic, carcinoma uteri is observed in 6 per cent. of all gynecologic cases. On the average the disease seems to have existed six and a half months before the first request for medical assistance.

The majority of carcinoma patients have had labors. *Hofmeier*¹⁹⁸ found only 4.8 per cent. among 812 patients who had not borne children. Each patient averaged 8.02 labors.

Uterine carcinoma appears somewhat more frequently in the less wealthy people, while the well-to-do suffer more frequently from myomata of the uterus. *Bücker's* statistics¹⁹⁹ on the influence of endometritis entirely corresponds with our experience. Heredity plays an important rôle in the opinion of the laity, without any positive facts regarding it having been established so far.

The symptoms of cervix carcinoma are in the initial stages by no means distinctly characterized. Women only seldom complain from the beginning, and before the malignant disease can be diagnosed, of **abundant menses** and **profuse discharges**. Almost pathognomonic is the statement of older women that the menstruation which had already disappeared has reoccurred. Others are forced to go to the physician because the menses do not cease, or, instead of decreasing, increase.

Some claim to remain free of any symptoms in already far-advanced infiltration: the observation is then a casual one. Hemorrhages during cohabitation have been often complained of as the first symptom.

The discharge of blood keeps in the beginning within the type of menstruation; the latter becomes abundant. After a time the women also bleed outside the period at each irritation which affects the genitalia, as cohabitation, difficult stool, exertion. More abundant discharges of blood may also occur immediately in the beginning, more frequently, however, only a bloody admixture of the profuse excretion occurs; the discolored discharge awakens the attention of the unhappy woman. The **bad odor** and the dirty brownish color are designated as the most characteristic sign of the excretion. Both, however, may be absent in already far-advanced malignant degeneration, and may occur also in non-malignant degeneration. The excretions occurring with **surface disintegration** are mostly contaminated with admixtures of blood and tissue débris and acquire a peculiar odor with the dirty dark-brownish discoloration.

The *pain* varies extraordinarily: often it is completely absent until the final catastrophe, often it is prominent from the beginning. The pains in cervix carcinoma seldom are designated as colic. Some patients complain of pain in the small of the back. In others again they appear in the form of peritonitic symptoms (tenderness of the abdomen, distention, nausea) as slight, intermittent or continuous, gnawing or drawing pains. Sooner or later are added, according to the progress of the disease, the other consecutive signs, the general cachexia, emaciation, and prostration. *Schroeder* has pointed out a peculiar tenseness of the abdominal musculature. I have noticed in carcinomatous patients in addition changes in the abdominal walls characteristic, of course, of the later stages; always a peculiar dryness and brittleness of the skin of the entire trunk and extremities.*

If the bladder has been reached by the infiltration, strangury, difficulty in evacuation, the feeling of the last drop appear.

If the infiltration approaches and invades the rectum, rectal tenesmus, obstruction to the evacuation of solid masses of fæces, *hemorrhoidal* bloody discharges, the appearance of nodules, and burning and intense pain in the rectum occur.

The patients suffer comparatively frequently from an undefinable *restlessness* and *insomnia*, often before a localized disease can be distinctly established. Indeed not infrequently patients boast of their improved condition when increased hemorrhages bring on sleep due to severe exhaustion or somnolence and coma in consequence of the beginning uremic intoxication.

Carcinoma patients suffer with overwhelming frequency from an absolute *loss of appetite*, not only as a result of the malodorous excretion or of the medicines intended for relief of pain, but also before these two factors make themselves felt. The nutrition is considerably disturbed by nausea and vomiting. As a peculiar feature the *sexual desire* in carcinoma patients not seldom is rather increased than decreased.

The diagnosis of carcinoma of the cervix is not difficult with extensive disintegration and plainly appearing disease-symptoms: age, progress, physical findings speak so clearly that mistakes are excluded.

The diagnosis of the early stages is the source of very great difficulty. All clinical symptoms which are found in malignant diseases may fail, but digital examination aids in attaining necessary positiveness which we can *only gain by the microscopic examination* (see above, p. 29). Even comparatively small fragments cut out or scraped from the mucosa or from the nodules, may assure the diagnosis with proper hardening and preparation. Especially with regard to the similarity of the clinical find-

* *Stratz (Zeitschrift f. Geb. u. Gyn., XIII, H. 1)* mentions as especially important signs, that the diseased part sharply contrasts with the healthy surroundings, shows a difference in the level of the surface, always has a slight yellowish coloration and mostly presents a small granular, yellowish-white shining elevation.

ings in advanced stages of chronic metritis with extensive infiltration and deep-seated changes of the mucosa of the cervix (erosions) and vagina, and in ulcerations, decubital ulcers after pessary treatment, cauterization and deep-seated destruction (zinc chlorid, atmocausis and so forth) it must be urgently advised not to make a diagnosis of cancer merely from the clinical course alone and based merely on a digital examination. A serious opportunity for mistakes is furnished by cases of neglected abortion with long-continued hemorrhages and malodorous discharge.

Regarding the infiltration of the pelvic connective tissue our perception is impaired through old or even fresh inflammatory products. The cancerous lymph-tracts often are covered up by traces of inflammation, which result from the disintegration of a newgrowth and the septic parametritis induced thereby. Such a parametritis seldom occurs first and then afterward a carcinomatous infiltration.

Winter and *Zangemeister* have made use of the result of **cystoscopy** to decide the question of the infiltration of the antecervical tissue. The swelling of the trigonum, formations of thick prominences of the mucosa on the floor of the bladder, irregularity in the appearance of the sphincter, injections of the bloodvessels and hemorrhages in the mucosa, bullous edema, changes in the termination of the ureters, flat protuberances, papillary excrescences are said to be almost identical with the sequelæ of paracervical inflammations, and they see in them the results of circulatory disturbances. Just as the after-investigation at the clinic of Breslau (*W. Hirt*), so also those of the Greifswald clinic have also proven that these so clearly resemble the inflammatory changes of the vesical mucosa that we were not in a position to make use of them in the above-mentioned etiologic connection.

As a fact *G. Winter* deserves credit that he aroused an earlier recognition of carcinoma by public instruction of the laity through an emphatic influence of physicians and midwives. In Germany we all follow this example. In the province of Pommerania the medical society distributes to the physicians the letter of warning of the Pommeranian Society for Obstetrics and Gynecology. The Vaterländische Frauenverein distributes a memorandum with a corresponding reference in its circles, the county chairman to the midwives, the registrar of vital statistics to all those entering marriage. Like *Winter* in his province, so we also in Pommerania see this action gaining ground, especially in professional circles.

The **corpus carcinoma** is observed in about 9 to 11 per cent. of uterine cancers, predominatingly frequent during and after the menopause, often, however, much later. Chronic endometritis with long-continued profuse menstruation is usually revealed by the history; nulliparæ are relatively more frequent among patients with corpus carcinoma than among those suffering from cervical carcinoma.²⁰⁰ Corpus carcinoma is characterized by its slow development. *Löhlein*, *Schülein*, *Odebrecht* could demonstrate that the carcinoma was still confined to the body of the uterus even

after more than four and three-quarter years. With this fact coincides the favorable permanence of cure after extirpation.

Among the *symptoms* of the *corpus carcinoma* the long duration and the profuse course of the menses also predominate. The *reappearance* of the menses after a shorter or longer cessation, especially also plays an important rôle. In addition we have the *profuse discharge*, at first watery, like meat washings, then more like pus of a bad odor. The discharge is slight in other cases, also without any bloody admixture. If disintegration of the carcinomatous nodules occurs, the discharge becomes very penetrating; this is often evacuated with laborlike pains.

The third symptom, *the pains*, shows similar alternations between an aching feeling and early occurring intense pains in the abdomen, small of the back and legs. If these pains occur like colic at certain times during the day, until offensive smelling, bloody lumps with detritus masses are evacuated, it is regarded as pathognomonic, according to *Sir James Simpson*. I can confirm this from my own observations, the patients being perhaps accidentally also nulliparæ. *Hofmeier* (*Handbuch*, 1901, p. 426) correctly refers to the fact that the observation of such characteristic pains is nowadays more rarely recorded, which finds its natural explanation in the much earlier treatment of such patients. Moreover one finds relatively early perimetritic pains and all signs of perimetritic irritation, as these correspond to the spread of the carcinoma until it has appeared beneath the serosa.

The *diagnosis* of corpus carcinoma can only be secured by examination of fragments of the wall of the cavum. The uterus is often considerably enlarged evenly or nodular. The cervical canal as a rule is not entirely occluded, in nulliparæ also a certain rigidity is remarkably distinguishable. Especially if an evacuation of the detritus masses already has taken place, the cervical cavity appears to be enlarged like an ampulla by such débris forced into it with the above-mentioned colicky pains. The anamnesis with the reappearance of menstruation and the pains and the flow offer the possibility of correctly interpreting the hardness, size, and nodular consistency: carcinoma of the corpus and not myoma. Only the microscope enables us to dispel all doubts; the diagnosis, therefore, presupposes a curettement as unavoidable. The opportunity to make a diagnosis by palpation is not seldom offered in advanced cases.

The *prognosis* of all forms of carcinoma is absolutely bad. This is not contraindicated by observation of the disease lingering for many years in very old women, especially as in many of them the exact diagnosis of the new formation is deemed unnecessary.

Among thousands of cancer cases which I have seen, I can refer to only one diagnosed with scientific exactness in which the patient lived for many years.

In 1872, as representative of my father, a forty-year-old patient was brought to me, in whom the entire vaginal vault and the cervix were changed into one crater. It was a case of scirrhus, as was diagnosed

microscopically. The patient refused an operation. The house physician gave her condurango preparations which were so frequently recommended at that time. The patient only had mild symptoms and she could take good care of herself. The attending physician reported after twenty-two years that the woman was still living and did not require any medical attention. The physician has since died and I have never again seen the lady.

If we adhere to the view that these patients will all die from their uterine cancer, there is still a kind of exception, as a few, especially very old persons, are only very slightly disturbed by the new-formation and clinically die from the symptoms of a senile exhaustion, years after the carcinoma has been diagnosed. Of this group I observed three examples.

One was the mother-in-law of a gynecologist, the other was brought to me by her grandchild, who was a physician. The third also stood in relationship with a physician. All three were over seventy years of age. They were very active women, in good circumstances. The insignificant bloody, also purulent, discharge, irregularly recurring for years, determined their relatives to overcome the objection of the headstrong old ladies. In all three cases there was clinically no doubt of the diagnosis of a carcinoma of the cervix with infiltrations of the parametrium. All three refused any kind of treatment. I received reports of all three that they succumbed after more than a year (one after three years) following my examinations from the symptoms of senility, without even complaining, or having suffered at all from any abundant hemorrhages, profuse discharges or intense pains.

The prognosis is so much more uncertain, as the great majority of the patients come to the operation in a condition in which the infection has extended far beyond the primary disease-focus. The most malignant form of cancer is, from this point of view, the *cervix carcinoma*. But also *carcinoma* of the *portio vaginalis*, the cauliflower tumor, leads with a hardly foreseen rapidity to infection of the lymphatic vessels, apparently somewhat later the *corpus carcinoma*.

A permanent cure, if at all, can only be expected from the removal of all diseased foci. For the prognosis therefore the diagnosis of the extent of the disease must be considered as decisive. The conception, still extensively existing at present among physicians, that the infiltrations of the inguinal gland group is of importance in this respect, is disproved by the observation of the anatomic relations. (See above, p. 280.)

The **prognosis** of the operation on corpus carcinoma is essentially more favorable than that of the cervical cancer. *Winter* found permanent cures in 53.3 per cent.; the primary success also is essentially more favorable. If the radical operation is excluded one succeeds through repeated local treatments (excochleation, cauterization) in keeping the patients in a tolerable condition for a relatively long time.

The treatment at present in cases in which a radical extirpation also of the parametrium and of the infiltrated glands seems practicable, con-

sists in the total extirpation of the uterus, adnexal organs (ovaries, tubes and pelvic connective tissue) and the recognizable diseased retroperitoneal lymph-nodules.

The treatment of other cases is a symptomatic one. Here, also, the destruction of the carcinoma, by a suitable operation, forms the indicated procedure for the great majority.

I. *Operation in Cases Operable in the Sense Referred To.*—

The conception of the percentage of patients suitable for operation has naturally experienced a complete revolution on the one hand with the growing understanding of the anatomic conditions, on the other hand with the development of the technic of the removal not only of the diseased uterus, but also of pelvic connective tissue of suspicious appearance or already diseased.

The priority in *extirpating the carcinomatous uterus* belongs to *J. N. Sauter*,²⁰¹ physician in Konstanz. *Blundel*²⁰² operated in 1828. But neither their example nor that of *C. Hennig*,²⁰³ 1876 established the validity of the operation. This was reserved for *W. A. Freund*.²⁰⁴ His method has given a few good results. The first patient successfully operated on he demonstrated in 1904 in excellent health to the gynecologic section of the Association of Science. Vaginal extirpation was first taught by *Czerny*.²⁰⁵ *Billroth*,²⁰⁶ *Schroeder*,²⁰⁶ *Schede*,²⁰⁷ *A. Martin*,²⁰⁸ and *Fritsch*,²⁰⁹ followed him. In place of ligatures often quite difficult to apply, *Richelot*²¹⁰ used the clamp for the prevention and permanent arrest of hemorrhage, which had already been proposed by *Sir Thomas Spencer Wells*.²¹¹ *Péan*²¹² improved the proposition to diminish the uterus *in situ*, by means of morcelllement. For the simplification of hemostasis, *Doyen* introduced the angiotribe in 1897. The abundance of principally less important variations finds an exhaustive criticism in text-books of gynecologic operations. The procedure of *Mackenrodt*²¹³ seems to be of great importance for avoiding inoculation-recurrences by the preponderant or exclusive enucleation of the uterus by the electrocautery.

Great credit is due to *Rumpf*²¹³ for originally suggesting the marked extension of the radical operation. He was soon followed by *Ries*²¹⁴ and *Küstner*.²¹⁵ *Wertheim*,²¹⁶ *A. v. Rosthorn*,²¹⁷ *Mackenrodt*,²¹⁸ *Amann*,²¹⁹ and especially *Bumm*, have perfected by the total removal of the pelvic connective tissue and glands the ***extensive abdominal extirpation of the uterus which at present is considered the radical operation.***

The ***vaginal total extirpation*** gave on the average a primary mortality of between 5 to 10 per cent. The permanent results were placed at 30 per cent.²²⁰

It cannot be disputed that against these numbers the primary results of the improved abdominal operation, with its 20 per cent. operative mortality and permanent results of about 11 to 20 per cent., appears essentially of less value. To this must be added, that the infection of the glands cannot be estimated macroscopically with certainty in regard to their pathologic importance. The infinitely laborious examination in

serial sections has been consequently carried out at first by *Kundrat* of *Wertheim's* clinic,²²² and by *Schauta*.²²¹ The technic of the operative method has obviously gained considerably in safety. The frequency of accidental injuries decreases. With the introduction of the stovain-lumbar anesthesia the danger of the long-continued inhalation anesthesia is diminished.

Our hopes for better permanent results are considerably raised by the introduction of the removal of recurrent carcinomas (*A. v. Rosthorn*, *G. Klein*, *Doederlein*). The results of collective investigation on this subject give us reason to hope for even better results in the future. Further shining examples of universal co-labor upon this ground so important for our patients leave us hope for even more satisfactory results.

While ten years ago about 10 per cent. (*Bäcker*), 35 per cent. (*Thorn*) of the cancer cases were considered as operable, many operators at present have reached an average operability percentage of more than 50 per cent. (*Olshausen*), *Wertheim* and *Mackenrodt*, also *Bumm* as high as 90 per cent. Our own experience impels us to designate as unimportant such a percentual figuring at present. If the agitation which followed *Winter's* example from all sides remains a permanent one, as it appears at present, and thus brings earlier forms of the disease for operation, it is to be expected that everywhere with an increasing confidence in the technic a general increase also in the direction of operability will take place.

The Radical Abdominal Total Extirpation of a Carcinomatous Uterus

For LITERATURE and history of the operation see *Hofmeier*, *Doederlein* and *Kroenig*, *Operative Gynäkologie*, 1905.

In addition to ordinary preparatory measures (shaving of the vulva, profuse evacuatio alvi) at the present time, the attempt is made to produce immunity by the injection of an *attenuated* (*Bumm*) or *dead* culture (*Polano*) of streptococci.

As a preliminary operation the neutralization of the cancer ulceration, if possible, must be vaginally performed the preceding day under stovain-lumbar anesthesia or ether-intoxication, or with a wide vagina and slight sensitiveness also without an anesthesia. After thorough cleaning (shaving) and disinfection of the vagina an excochleation, identical with the later-described excochleation of the so-called inoperable cervix carcinoma, is begun with the sharp curette. Particles of tissue protruding over the surface are removed with the scissors or with the knife, and the hot iron is applied to the infiltrated area (*Paquelin* or electrocautery). The cauterization must be thorough and extensive. The cavity is tamponed with iodoform gauze. *Mackenrodt* has recommended, instead of the intense heat, a 10 per cent. formalin tamponade. [Just as *A. Ochsner* (see *Ochsner's* "Clinical Surgery," p. 400, 1902), I also have used the

ordinary soldering-iron, heated in a coal fire or in the flame of a gas-stove with satisfactory results during the last ten years.—THE EDITOR.]

This preliminary operation is not performed by the operator who is to perform the extirpation. It is executed with special instruments and by other assistants. After the ordinary preparation the extirpation follows the next day (with formalin preparatory treatment after twelve hours) by opening of the abdominal walls (lumbar- or chloroform anesthesia), by an incision in the median line or the suprasymphysial transverse fascial incision or horse-shoe shaped or tongue-shaped incision of *Mackenrodt*.

Although *Mackenrodt* in the beginning temporarily fastened this tongue-like flap to the posterior wall of the pelvic inlet in order to completely shut off the upper part of the abdominal cavity from the further course of the operation, not very many surgeons have carried out this plan, because much valuable time is always lost in doing it. It suffices to protect the upper abdomen with the intestines by sterile gauze laparotomy-pads. The lumbar retro-peritoneal glands are then examined. If these are infiltrated, the operation seems to be hopeless, and it is better discontinued right here. Furthermore it next becomes necessary to safeguard the ureters. For this purpose one can immediately advance toward them through the peritoneum.

We again prefer, of late, to commence the operation proper by ligating the ligamentum suspensorium ovarii. The ligamentum rotundum is ligated, then we advance by blunt dissection between the folds of the ligamentum latum and first expose the ureters and the vessel triangle. The arteria uterina is now ligated at its exit from the arteria hypogastrica. The ureter is then isolated as far as its entrance into the bladder.

After this first step has been performed on both sides, the separation of the bladder from the uterus and the vagina—as far as the vagina must be extirpated—is performed. After cutting the ligamenta sacro-uterina the peritoneum is separated from the cervix uteri down to the upper surface of the posterior vaginal vault, eventually the vagina must be removed from the rectum as far as its posterior surface. To separate the bladder, the peritoneum is transversely incised above the plica at the corpus uteri, the finger bluntly advances into the depth and pushes the bladder from the cervix and from the anterior vaginal vault. The uterus now is free, it is pulled upon strongly and thereby also the vagina is drawn tight. The posterior and anterior wall of the latter are next incised. From the vagina, incised through its lumen, the finger advances laterally beneath the pelvic connective tissue, and this at all events is completely cleared out. It remains laterally in connection with the cervix, and if necessary the entire vagina, the pelvic connective tissue, and the adnexal organs are removed in one piece (Fig. 133). The hemorrhage must be arrested during the entire course of the operation. The margin of the cut off vagina is sutured anteriorly and posteriorly, if possible, in such a way that the peritoneal and vaginal margins come in contact with each other.

Herewith the first part of the operation is completed. It is now necessary to examine the retroperitoneal glands along the arteria iliaca and spermatica as far up as the lumbar region. All infiltrated glands must be removed. Their enucleation mostly succeeds by blunt dissection. The attached fat must be removed with them. Seldom only are glands intimately adherent to the bloodvessels, even if they should extend beneath and behind them. I have so far only once resected the vena iliaca communis with its intimately adherent glandular masses to the

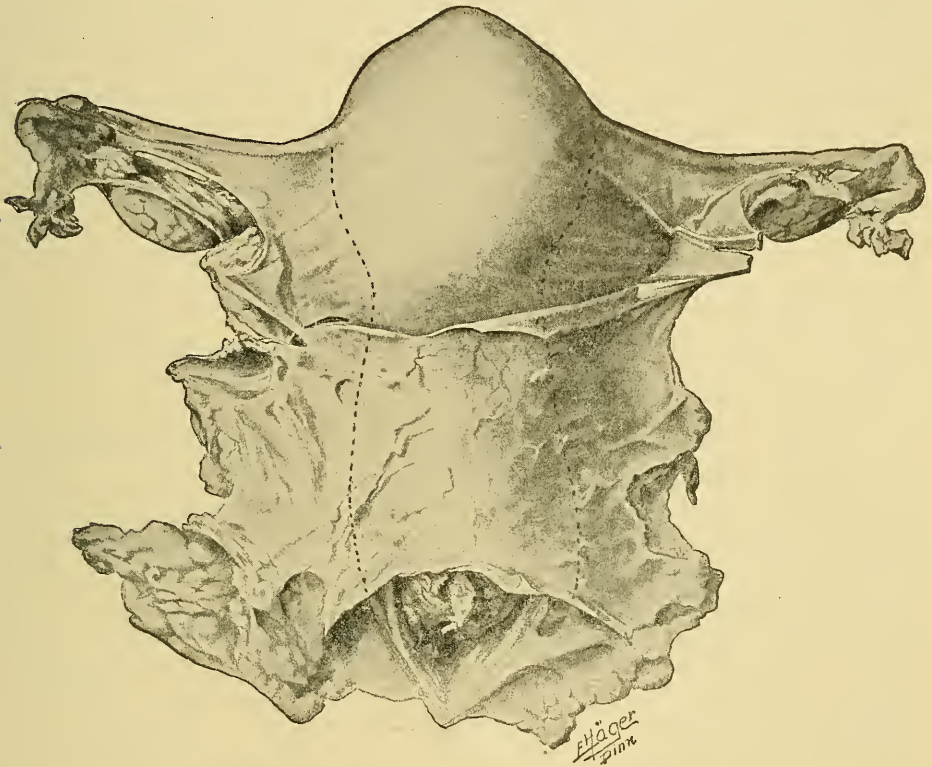


FIG. 133.—Carcinomatous Uterus, Abdominally Extirpated together with the largest part of the Pelvic Connective Tissue. The dotted lines designate the contour of the uterus. (Author's preparation.)

extent of 3 *cm.* After all suspicious tissue-masses have been removed and the bleeding has been safely arrested the peritoneum is closed above the pelvic floor. With complete removal I prefer to insert loosely sterile gauze, which is brought out through the vagina. *Amann* has proposed to drain the empty cavities directly outward through the cavum ischio-rectale by rubber tube drains. Suturing the peritoneal margins within the ligamenta lata offers no difficulties. If the middle portions of the anterior and posterior vaginal walls were already closed by stitching of the peritoneum the overlying zone of peritoneal covering of the bladder

and rectum is united without any difficulties. Closure of the abdominal incision.

Among the *complications of the total extirpation, injuries of the ureters and of the bladder* stand in the first place with respect to frequency and importance.

The exposure of the ureters secures against traumatism of these structures. Sometimes the ureters are so strongly contracted that it is not easy to recognize them; especially the relaxation of the contraction which one awaits, facilitates the exact determination of location. If the ureter runs through infiltrated tissue, it can, generally, be easily peeled out, because its infection with carcinoma apparently occurs late, as a rule. However, that it does not remain excluded, has been proved free of any objection. In that case resection of the diseased portion becomes necessary. Under these circumstances, and with unintentional trauma, different ways remain open: *The ureter-uretero anastomosis, implantation of the ureter at a suitable point in the bladder, establishment of a uretero-intestinal fistula, extirpation of the kidney.*

Ureter-uretero-anastomosis succeeds at first without particular difficulty with sufficient mobility of the ends of the ureter. One splits the lower end, inserts the upper end and fastens it by interrupted sutures, to suture in a corresponding way the end of the slit externally above it.

The implantation into the bladder, which may also be performed at an upper portion of the same, is instituted by suturing the internal surface of the ureter, which has been drawn out of the divided ureter, with the mucosa of the bladder; the sutures must not be placed within the bladder. The fixation of the ureter wall with the bladder is performed with interrupted sutures, which are placed in several layers through the unfolded or obliquely divided muscular wall of the bladder and the ureter. All sutures are inserted outside the ureter and bladder mucosa; for these I use the thinnest silk. For suturing the serosa vesicæ to the ureter I use catgut.

Injuries of the bladder wall occur easily on account of the peculiar atrophy of the same which is often met with in carcinomatous-cachectic persons. Even with the most careful separation of the bladder from the cervix uteri and the anterior vaginal vault, the edematous thin wall lacerates, in other cases an infiltration of the bladder wall already exists if disintegration has not already taken place. This complication must be previously determined cystoscopically. Then resection of the diseased part only remains to be considered. The mucosa is united from without with interrupted sutures, and above it a layer of muscularis; the suture of the serosa forms the final step. To secure healing a retention catheter is inserted.

In a case of excision of multiple cancer-nodules of the bladder wall in 1890 I had to split the wall over the vertex as far as into the trigonum. The bladder, which was sutured in this manner, spontaneously evacuated

a bloodless urine after six hours without any difficulty. The retention catheter had slipped out.

Injuries of the *intestines* (rectum) during the total extirpation are caused partly by adhesions with the uterus which occasionally can hardly be diagnosed beforehand, partly by removal of the pelvic connective tissue as deep down as the subserosium pararectale. While under ordinary circumstances these injuries can easily be overlooked even with a good view of the field of operation, the nearness of the rectum may be veiled by cicatricial callosities, by remnants of parametric foci and by carcinomatous nodules. Injury of the intestinal muscularis is noticeable by the oblique arrangement of the muscle fibres, injury of the mucosa by its characteristic formation of folds, if not by escaping intestinal contents. Sometimes the injured portions of the intestinal wall in all its parts bleed from ectatic vessels or from numerous capillaries. Only the careful suturing of the different tissue layers remains to be done. The mucosa is closed from without. I have never had any occasion to insert a *Murphy* button.

Vaginal Total Extirpation of the Carcinomatous Uterus.

In cases of quite primary carcinoma development of the portio vaginalis and in the beginning stages of corpus carcinoma, the vaginal total extirpation is to-day still recognized by some operators as the radical procedure.

A preliminary operation is performed as stated above.

It is necessary for the operation, if the vagina is not accessible in a sufficient manner, to expose the vaginal vault through the paravaginal accessory incision (*Schuchardt*). The operation has been described above, p. 260. Suspicious masses of tissue, which are met with in the pelvic connective tissue, may also be removed in this operation to a considerable extent.

The measures for the *after-treatment*, which are the same as after all serious abdominal operations, justly demand particular care following this operation. Through injection of camphor (2 to 3 gm. every hour or every two hours), and through normal salt infusions repeated in intervals of several hours, the influence of the operation in regard to the general condition is, as a rule, soon overcome. The patient who is placed in a well-warmed bed, upon a rubber mattress filled with warm water, is kept by proper heating arrangements permanently in comfortable warm surroundings. Even if a stovain lumbar anesthesia has been induced, it seems correct to be careful with the nourishment per os. After inhalation narcosis one must wait until the next morning. Then mineral waters, milk, eventually cognac, coffee, and wine are given to begin with in teaspoonful doses every half hour, and, if vomiting does not take place, much oftener.

The discharge of *flatus*, which is preceded by peristaltic pains, forms a certain turning point in the condition of the operated patients. As

mentioned above, we give strychnin subcutaneously, where cognac and valerian do not suffice. Even in anemic patients whose heart energy is continuously supported by camphorated oil (linimentum camphoratum), a disagreeable disturbance from the simultaneous injection of strychnin is not to be feared. In intensely anemic patients we commence dieting, after passing of *flatus*, usually on the fourth or fifth day, after spontaneous *stool* has occurred or has been induced by castor-oil in bouillon, coffee, milk, or by a small dose of bitter water or by a glycerin enema (15 to 20 gm). If *nutrition per os* seems to be difficult, we make extensive use of grape-sugar enemata or subcutaneous infusion of the same. The same attention must be devoted to the *evacuation of the urine*. If it does not take place easily and spontaneously, the catheter must be used. As mentioned above, the attempts to overcome the insufficiency of the detrusor urinæ by injections into the bladder, and so forth, did not give satisfactory results. If the bladder was strongly displaced and if it became necessary to expose it to a greater extent, I prefer to insert a retention catheter at the conclusion of the operation. The sterile gauze, which fills the space freed from the pelvic connective tissue and brought out through the vagina, is removed at the latest on the second day. Abundant discharges from the vagina are combated by douches of normal salt solution.

The first dressing is changed on the seventh day. Iodoform powder is thickly applied to the dry wound. The stitches in the skin are removed between the eleventh and twelfth day; on the twelfth day the patients are placed on their side, on the thirteenth day they are allowed to sit up, and on the fourteenth day they may get up. As a support for their abdominal scar I order a simple puerperal binder. At the discharge each patient receives a *Beely* binder, which is fitted according to the direction and size of the abdominal incision.

For the promotion of further convalescence absolute abstinence from bodily exercise is recommended for two months. Sick benefit patients are able to perform 50 per cent. of work during the third and fourth months, and 75 for the fifth and sixth. After that the determination of the capability of work depends on another examination.

Disturbances of the convalescence develop in the first place through *septic infection*. This is considered in the chapter on the septic post-operative para- and perimetritis in its entire extent. Post-operative hemorrhages occur only seldom in carefully operated patients. These require an exposure of the operative wound and an immediate arrest of bleeding.

Narcotic medicaments are, as a rule, not necessary, although by no means excluded in proper dosage according to the condition of the heart energy. The troublesome tendency to vomit is better treated by lavage of the stomach, than by any other means.

II. *If the treatment must dispense with a radical removal of the carcinoma, then every treatment is omitted in cases which run their*

course without symptoms. Cleanliness, proper diet, the greatest possible comfort are to be promoted according to conditions. If disturbances appear, the point in question can only be to improve the *general condition* and to combat the *three local symptoms* of the disease, *hemorrhage, secretion, and pain.*

The remedies for improving the general condition are the same as applied in all so-called wasting and incurable diseases. Although alcohol for some time has been thought an essential remedy, most gynecologists have receded more or less from this panacea. It must always be acknowledged that alcohol is indispensable as a stimulant and as a comforter, but carcinomatous patients especially frequently feel their pains so much more when the stimulating and intoxicating effects of the alcohol have subsided. The aversion to substantial nourishment, notwithstanding, renders alcohol in many cases indispensable.

In *local treatment* the well-known drugs at present have rapidly lost their credit. *Acetate of potassium, chian turpentine, extractum herbarum chelidonii majoris* may be designated as entirely unreliable, whether used in any form internally or locally on the cancerous granulations, or even after removal of the same on the infiltration area. The *condurango* preparations in my experience have proven of no effect for uterine cancer.

With great emphasis *electrolytic* treatment, so far as I have been able to determine, was first applied and recommended by *Semeleder*, of Mexico. I have tested the procedure with an exact adaptation of *Semeleder's* directions in twelve cases.²²³ It was very painful in some cases, in others, of course, completely without sensation for the patients. We saw after it at times very serious hemorrhages; in no cases was there any other effect than the disintegration of the granulations mechanically destroyed by the electrode, no shrinking and not a trace of healing.

I have tried in one or two cases the parenchymatous injections of silver nitrate (*Thiersch*), of *sublimate, sodium chlorid* (*Schramm*), of alcohol (*Schultz, Vulliet*), without any encouraging result. Instead such intense pains occurred, especially with alcohol injections, that I regretted having used the remedy. I have not tried *pyoktanin* and *methylene blue*.

The *removal* of the *granulation masses* with sharp scoops or curettes always seemed necessary to me. The margins of the removed crater are smoothed with scissors. Not frequently the hemorrhage is a profuse one, but one sees occasionally also large spurting arteries. The treatment of the anterior and posterior crater wall is difficult on account of the danger of perforation of the bladder, peritoneum, and rectum. However, the danger can always be controlled to some extent. I cover the thin vaginal wall with a vaginal retractor or with the finger of the other hand while I scrape off the granulations. The protruding borders are removed with scissors.

No doubt *excochleation*, as a rule, will not suffice. Formerly I carried

out a kind of suturing, with which sometimes remarkable primary results of healing could be obtained.²²⁴ These were cases in which the stumps of the corpus, after excochleation of the cervix still could be distorted to some extent and the walls of the crater offered the possibility of turning in: that is, in fact, cases in which to-day one probably would attempt a radical abdominal operation. Healing took place with an agglutination, even if not complete, of the coapted wound-surfaces, the wound-funnel was covered with portio or with vaginal surface. The secretion, as a rule, was very slight, temporary healing often seemed to justify hopes which, sooner or later, were destroyed by recurrences.

In cases of immobility of the margins of the crater I formerly placed at times a chain ligature through the rest of the ligamenta lata, as well as through the anterior and posterior vaginal vaults. The hemorrhage stopped promptly. The wall of the crater was then cauterized. The ligatures finally dropped off with the necrosed margins. A healthy contraction, which often resisted for a long time the recurring proliferation took place. A radical cure could not be expected.

Of late I have not seen cases suitable for such ligaturing. These are also at present probably subjected to a trial of the radical operation.

Ferrum candens was formerly, until about forty years ago, used for the cauterization. The hemorrhages did not always stop promptly, so that pieces of cotton were pressed on the wound-surface already at that time. In place of the hot iron came the *Paquelin*, which came in use in 1868. Now the **electrocautery** has taken its place. Although *Gessner* objects to these two latter methods because the effect was impaired by the blood adhering to the hot iron, I cannot recognize this inconvenience to such a degree as to make me adverse to these otherwise convenient instruments. The preparation of the hot iron is so difficult that I see therein a much more inconvenient complication. I touch, as a rule, the crater wall intensively only at those places at which it bleeds. I put more stress on the radiating heat of the hot iron which penetrates the tissue to a short distance. Then the so-called difficulty of the slow burning of the adherent clots and tissue débris almost ceases.

I learned to know the cauterization with ***acidum nitricum fumans*** when assistant of the Berliner Frauen Klinik under my father. Even the warm recommendation by *Chrobak* could not reconcile me again to it.

In 1890 I used zinc chlorid liberally, as recommended by *Labbé* in the form of pâte de Canquoin (one part zinc chlorid to eight parts of amyllum). This forms thick caustic crusts, whose action in the depths of the tissue, however, is very uncertain.

*Ely Vandewarker*²²⁵ (New York) later on advocated it warmly, and in Germany *Ehlers*,²²⁶ following the suggestion of *Löhlein*. I have repeatedly seen severe cauterization of the unaffected parts of the vagina. The bladder, rectum, and peritoneum were opened; at the end and in the second week very considerable hemorrhages occurred. As favorable as

the granulation formation at times appears to be under the caustic eschar, and strongly as the scars then developed, the effects which I have mentioned were such that I dispensed with it.

I have confined myself for years to inserting a few cotton plugs, saturated with *liquor ferri perchloridi* into the crater cavity. The vagina below it is tamponed with sterile gauze, so that a considerable pressure effect is obtained. This tampon is removed after four to six days. As a rule the liquor ferri crusts fall off slowly after another four or five days, the wound granulates healthily, and can be brought to a firm healing within three or four weeks by irrigations with dilute tincture of iodine.

Especially in private practice I have controlled such cases constantly and for a long time. Sometimes carcinoma nodules soon appeared in the still granulating wound. Those were the most unfavorable cases. The crater closes completely, as a rule. The secretion stops, the menstrual hemorrhage is less, and often completely disappears for some time and pains are not felt. The patients begin to improve. After months and years, however, recurrences take place.

On the further fate of the excochleated patients, many reports have been published of late years by different authors. The end results, in regard to the duration of life of the patients, fluctuate within slight limits.

*Eyring*²²⁷ found 224 days as the duration of life of those operated on in the Erlangen clinic after the operation, *Gebaur*, Halle,²²⁸ 229 days; *Blau*, Vienna,²²⁹ clinic of *Chrobak*, 252 days; *Liek*, Greifswald²³⁰ (my own material), 259 days; *Berton*, Munich,²³¹ 281 days.

Of 60 such patients in the Greifswald Clinic (1889-1904), one died after the operation. She suffered from advanced tuberculous peritonitis and the immediate cause of death was purulent peritonitis. Of the excochleated patients, 70 per cent. died in the first year after the operation performed by us, 20.6 per cent. during the second year, one after twenty-three and a half months, one after four and a half years.

According to my conception, the therapeutic indications in inoperable carcinoma require that where only slight disturbances are present, the patients should be left to themselves. If the symptoms are more marked, then the arrest of the hemorrhage, removal of the stinking discharge and the relief of pains are not the only indications; for such unhappy persons the psychic effect of an operative assistance is of an extraordinary value. If even the attempt at an operation is refused them, they consider themselves as hopelessly lost. If, however, the disturbances then decrease only for a short time, they gain courage, even if the final catastrophe is not prevented. But if we only succeed in stopping the hemorrhage, the stinking discharge, and the pains, the general well feeling improves, the taking of nourishment is favorably influenced, especially if through lessening of the pains the necessity of taking narcotics is no longer constant and the patient begins to improve in a surprising manner.

If recurrent symptoms appear, I am in the habit of repeating the ex-

cochleation and cauterization, as long as it is possible to avoid injury to the bladder, the rectum, and the peritoneum. If this danger is without doubt a threatening one, then I again resort to the use of tampons with liquor ferri on account of the hemorrhages. A 1 to 1,000 solution of thymol, besides other well-known antiseptics (lysol, sublimate, potassium permanganate), has served me well in combating the penetrating odor, also hydrogen peroxid solution, as it is brought into commerce (16 per cent.). The pains necessitate an extensive use of narcotic remedies, while alcohol helps to deceive the unhappy patients as to their condition, until they succumb to anemic or uremic delirium.

Carcinoma and pregnancy indicate an extremely serious complication. In these cases we have almost always to do with carcinoma of the cervix whose growth is extraordinarily favored by the hyperemia of pregnancy according to concurring observations.

As long as a radical operation seems to be possible, every consideration to the child ceases; the chief indication is to perform as radical an operation as possible. *Olshausen*, among 25 cases of vaginal operations, secured primary healing of all the patients, in four a permanent cure up to seven and a half years. In the vaginal operation the uterus is previously emptied by a colpohysterotomia anterior. In the abdominal operation the evacuation through the fundus offers no difficulty.

More frequently the carcinoma in pregnant women is found in the pelvic connective tissue in such an extensive dissemination that a radical operation is out of the question. Then hemorrhage, putrefaction, and pains may make the condition of the pregnant woman unbearable. In this case the treatment should be instituted which has been given for inoperable carcinoma. With it the continuance of the pregnancy is very much endangered, because with the exception of a few cases of complete indifference of the uterus to such interference, as a rule, expulsion of the ovum follows the operation upon the cervix.²³²

If the child is capable of extrauterine existence it is delivered by Cæsarian section, eventually with the excision of the corpus (*Porro* operation). The delivery per vias naturales makes the destruction of the carcinomatous ulcer and the dissemination of the septic germs developing in the carcinoma so threatening that it must be avoided. After the evacuation of the corpus, excochleation and cauterization must be performed.

I have seen seven cases of pregnancy with inoperable carcinoma. I performed excochleation twice in the sixth and seventh month to combat the profuse hemorrhages. Premature labor rapidly took place in one case. The child was expelled in a few hours. The placenta had to be delivered manually. The puerperium passed without any disturbances. I did not see this woman again.

In the other case the pregnancy went to full term. The woman had a spontaneous labor at the normal time. About her further fate I could not get any information.

I was called in two other cases, when the pregnancy terminated in the third and fourth month by expulsion of the ovum with profuse hemorrhages. I cleared away the carcinoma granulations with the finger, then removed the remnants of the ovum and pressed liquor ferri sponges on the infiltration area. The puerperia ran a normal course. I did not hear again from the patients.

I have seen three women with inoperable carcinoma during labor. The one had a far advanced carcinoma of the vagina. She suffered from severe hemorrhages. The midwife sent to the gynecologic clinic, because she alleged to have found the placenta in the vagina, while the child was still in the uterus and lived. I found in the twenty six year old person a carcinoma of the posterior vaginal wall larger than the size of the palm of the hand. Along the anterior vaginal wall the finger entered the upper vaginal vault, where I found, through the almost completely dilated os uteri, the presenting head behind the erect bladder. I advanced by blunt dissection along the lower periphery of the carcinoma into the paravaginal tissue, reached underneath the new-formation, peeled it out, and removed finally the mucous island in the vaginal vault with the scissors. Then I delivered the woman through the open vagina with forceps, covering the not inconsiderable bleeding defect in the vagina with a liquor ferri sponge. The patient passed through an undisturbed puerperium. Not quite a year later she was delivered again in the Policlinic with a recurrence. Further reports are missing.

I was called to a woman with an inoperable cervix carcinoma, when the birth would not terminate spontaneously. I found the cervical margin behind and on the left side occupied by a carcinomatous infiltration, which bled very freely. The remaining periphery of the cervix was only very little dilated. The woman was exhausted to a high degree by the profuse hemorrhages. I delivered her with forceps, but the infiltrated mass as well as the apparently unaffected portion of the cervical wall was lacerated in the process. The hemorrhage ceased by the energetic use of hot irrigations and ergotin. The puerperium went by without any disturbance. I have lost sight of the patient.

I saw the third patient as an assistant at the Woman's Clinic. She suffered from a complete carcinomatous infiltration of the cervix and of the pelvic floor. She was at the end of pregnancy and was troubled less by hemorrhages than by extreme pains. I performed Cæsarean section in view of the apparent impossibility of advancing by way of the vaginal vault. The incised wound was sutured with catgut. The incomplete technic at that time (1876) made me tie the threads with a simple knot. They loosened on the third day and the patient bled to death.

It certainly is one of our most difficult tasks to assist such patients. As a rule, however, they are thankful and are finally relieved to a certain extent by the described treatment.

IV. Malignant Chorion Epithelioma (Marchand)

Synonyms: Deciduoma Malignum (*Sänger*), Syncytioma Malignum.

LITERATURE: *Veit*, Handbuch der Gynäkologie, Vol. III. Wiesbaden, Bergmann, 1899. *Frommel's* Jahresber. über Geb. u. Gyn., 1899-1906.

Malignant chorion epithelioma is a variety of tumor first characterized in the ninth decade of the nineteenth century chiefly by *Sänger*. The further study and the oncologic classification we owe chiefly to *Marchand* and his pupils.

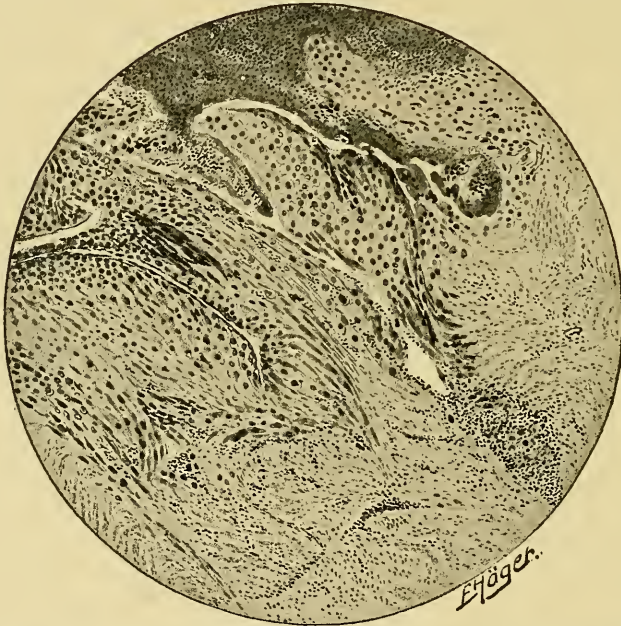


FIG. 134.—Chorion Epithelioma Malignum. (Author's preparation. .
Zeiss, Obj. AA, Oc. 2.)

The chorion epithelioma is a tumor starting from the epithelium of the chorionic villi and accordingly always connected with a preceding normal or pathologic pregnancy.

The epithelium of the chorionic villi consists of two layers; the outer one is the syncytium and the inner is known as *Langhan's* layer. Both layers proliferate in the chorion epithelioma, so that these tumors are composed partly of large columns of cells of *Langhan's* devoid of distinct borders partly of large multiple nucleated masses of protoplasm without cell boundaries (syncytial part, see Fig. 134). The extent of participation of both components in the tumor formation varies considerably in each case, so that the tumor is composed now almost entirely of one, now of the other cell variety with all possible transitional changes.

The chorion epitheliomata are exceedingly malignant. They are

characterized by a great tendency for disintegration; they are very vascular, but poor in supporting tissue.

Their location is always the corpus uteri, where they represent villous, soft tumors filling the largest part of the endometrium, usually of a reddish blue color.

With comparative rarity the preceding pregnancy was normal; the disease mostly appears after abortion, and most frequently after a *hydatid mole*. In this the villi always proliferate deep into the musculature of the uterus, even if no malignant degeneration follows and remains partly after the expulsion of the chief masses of the mole. When the epithelium of these villi undergoes proliferation for causes unknown to us, they rapidly invade the thin uterine wall as far as the perimetrium.

The formation of distinct metastases occurs very early in chorion epithelioma, and not as in carcinoma by the way of the lymph-tracts, but by way of the bloodvessels, as the chorionic villi already normally invade the maternal blood sinus. Mostly a very rapidly extending metastases formation *takes place* in the *lungs*, but also in other organs, which soon leads to death.

Very peculiar is the fact, corroborated by a number of observations, free of any objection, that the malignant chorion epithelioma in the cavum uteri may disappear entirely, while in other places the epithelial villi, carried into the blood-stream, undergo proliferation. This has been many times observed, particularly in the *vagina*. The secondary tumors thus developed are anatomically and clinically of the same character* as the above-described primary tumors.

The *symptoms* of malignant chorion epithelioma are the same as those of corpus carcinoma. If anything indicates that we are dealing with this neoplasm, which is malignant to such a pronounced extent, it is the rapid course and the early appearing cachexia, more pronounced and earlier than in carcinomata. Hemorrhages, malodorous discharge, and pains bring the patients to a physician. The rapidly developed exhaustion at all events in cases in which a hydatid mole pregnancy has preceded, compel him to determine the histologic character of the inner surface of the uterus.

The *diagnosis* can be made only from the microscopic examination of the tissue débris, which are suspended in the excreted secretion or must be obtained with the curette. The uterus is often considerably enlarged.

The *prognosis* is very gloomy, unless interference is made in the very early stages. Metastases appear early, and the parametrium and the peritoneum become rapidly involved in the process of the disease.

The treatment consists in the extirpation of the uterus, but too often metastases and peritonitic adhesions occlude every prospect of permanent success. Prophylactically, careful observation of the patients after hydatid mole is imperative.

The technic is the same as in the radical treatment of uterine carcinoma or nonnucleable myoma.

V. Sarcoma of the Uterus

LITERATURE: Compare *Gessner* in *Veit's Handbuch der Gynäkologie*, Vol. III. Wiesbaden, Bergmann, 1899. *Frommel's Jahresber. über Geb. u. Gyn.*, 1899-1906.

Sarcoma of the uterus is proportionately rare in comparison to carcinoma. *Gessner* figures the ratio of sarcomata to carcinomata as about one to forty. This is based on a large number of cases.

Sarcoma occurs in the uterus in two forms.

1. **Mucous membrane sarcoma.**

2. **Wall sarcoma.**

The first one is perhaps more frequent than the last.

Each of the two forms may start from the **corpus** or from the **cervix** uteri.

The **mucous membrane sarcomata** of the **corpus** occur mostly as round, much more rarely as spindle-cell sarcoma, developing partly in

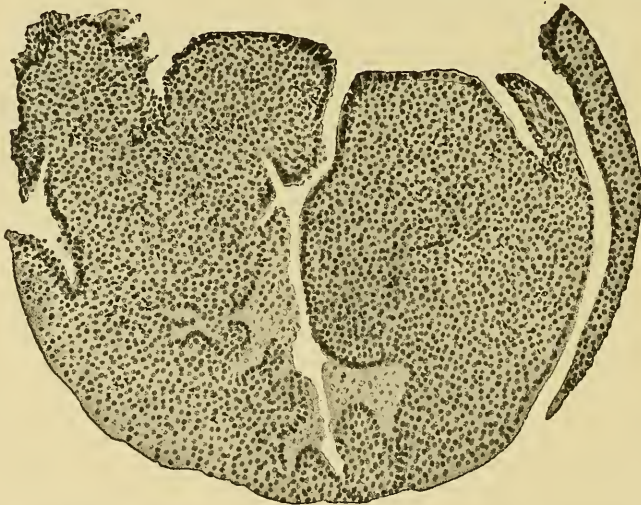


FIG. 135.—Mucous Membrane Sarcoma of the Uterus. Above the stroma, which is changed into a large, round celled sarcoma, is seen in many places the still intact, partly also squamous epithelium. (Author's preparation. *Zeiss*, Obj. AA, Oc. 4.)

a circumscribed region, mostly in the fundus, partly diffused over large tracts of the endometrium. In somewhat advanced stages, the cavum uteri is filled by an irregular polypoid tumor, often with a disintegrating surface and numerous hemorrhagic extravasations, which, according to the length of its existence may invade also more or less deeply the uterine wall. The latter of course tends to offer to the mucoid sarcoma a relatively long resistance.

The surface epithelium also and the glands remain for a long time preserved in the mucous membrane sarcoma, only the glands become pressed together and the epithelium is flattened to a cuboidal or even a flat form

(see Fig. 135); later they undergo complete destruction on account of the growth of the tumor. If the cases are left to themselves, the entire corpus is finally replaced by the new-formation, which also invades the cervix and the pelvic connective tissue, and clinically the same picture results as in carcinoma.

The mucous membrane sarcomata of the *cervix* are exceedingly rare, but they differ in essential points from those of the corpus.

The tendency to polypoid proliferation, already present in the latter, increases to such an extent, that it comes to the formation of multiple

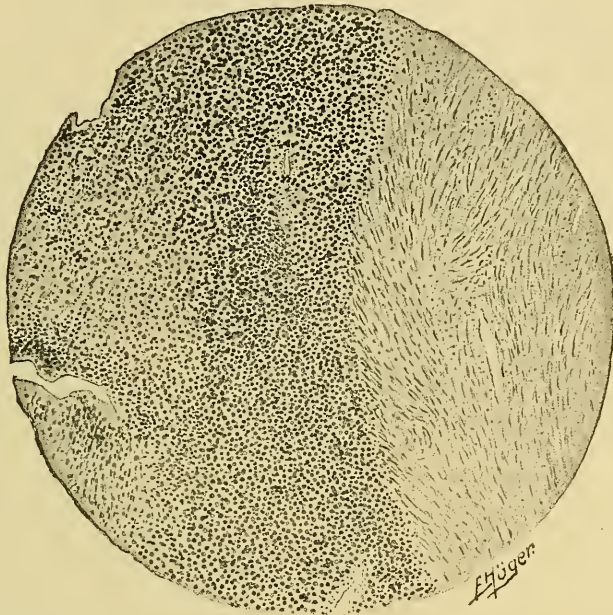


FIG. 136.—Sarcomatously Degenerated Uterine Myoma. (Author's preparation. Zeiss, Obj. AA, Oc. 2.)

pedunculated grapelike tumors emanating from the mucosa of the cervix which soon proliferate through the external os uteri into the vagina and finally almost fill the latter. They are almost always spindle cell sarcomata, sometimes of a complicated structure, because transversely striped musculature and cartilage are found.

The *wall sarcomata* of the uterus develop, as a rule, through sarcomatous degeneration of *myoma* already present, only in rarer cases a primary wall sarcoma *without* myoma formation takes place.

A great number of statistics of different authors have shown that 3 to 4 per cent. of all myomata undergo sarcomatous degeneration. The malignant formation always starts from the *connective tissue* of the tumors (see Fig. 136). The sarcomatous degeneration is usually associated with a considerable and rapid increase in the size of the tumors

and in the further course all possible forms of regressive metamorphosis, necrosis, and hemorrhagic infiltration occur. If submucous or polypous myomata undergo sarcomatous degeneration, they may entirely putrefy by the action of pathogenic micro-organisms.

A fundamental difference between wall sarcomata of the cervix and of the corpus does not exist; they behave like myomata of these parts.

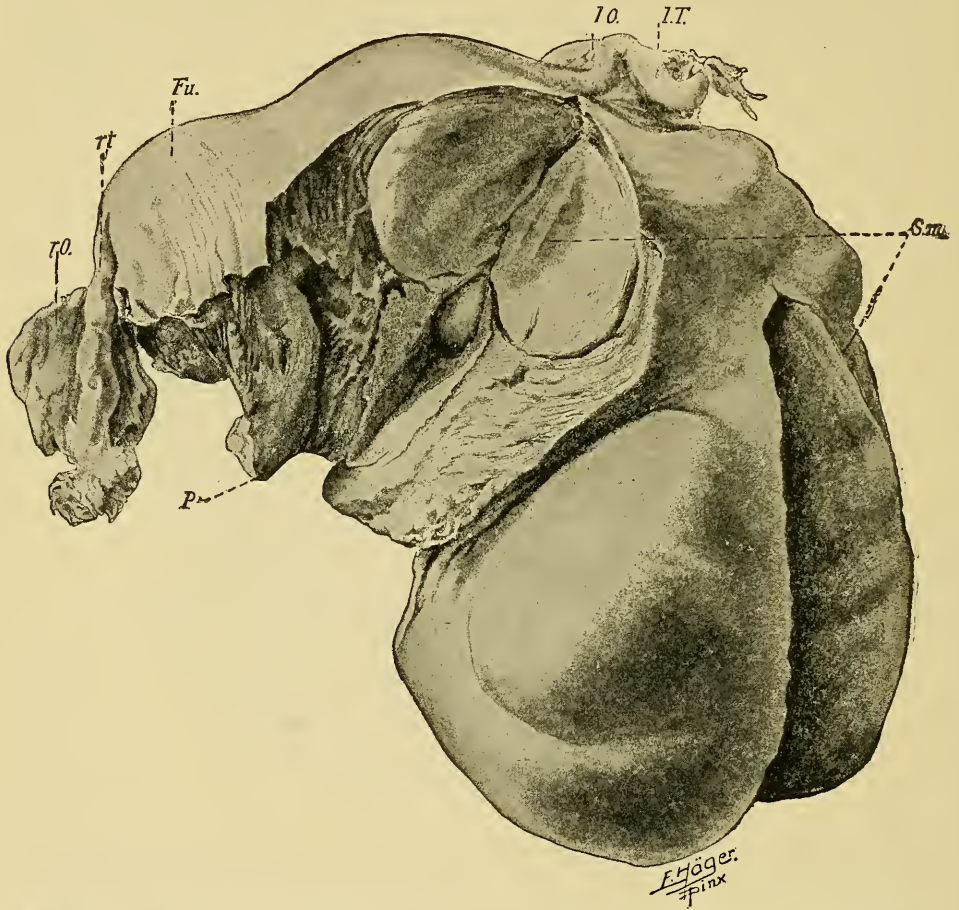


FIG. 137.—Sarcomatously Degenerated, Intraligamentary Developed Uterine Myoma. P, portio vaginalis; F.u., fundus uteri; r.T., right tube; l.T., left tube; r.o., right ovary; l.o., left ovary; S. M., sarcomatously degenerated myoma nodules which had developed deeply into the ligamentum latum. (Author's preparation.)

The *metastasis* of all uterine sarcomata takes place usually by way of the bloodvessels. It often occurs early and leads in a short time to the death of the patient, as a number of different organs are invaded at the same time.

The *occurrence* of sarcoma of the uterus falls chiefly in the fifth and sixth decades of life (*Gessner*), but it is by no means confined to them as

cases are known in which uterine sarcoma has developed in children long before the age of puberty.

Symptoms: 1. Of the mucous membrane sarcomata.—The first symptoms are *hemorrhages* and *serous bloody colored discharges*. The abundant secretion looks like meat washings, has at first a stale and later a cadaverous odor. These profuse discharges form a striking contrast to those of carcinoma, in which the discharge of blood is more prominent in the beginning. Pains are comparatively rare and are observed later when the polypous newgrowth is expelled with laborlike pains.

The uterus is enlarged, the cervix is closed in the beginning. Later the os uteri opens, and the protruding masses are accessible to the finger. In the further course a process similar to labor is observed by which the new-formation is pushed forward through the open os uteri into the vagina. *L. Pernice*²³³ even has observed an inversion of the uterus. The patients lose strength and become pronouncedly cachectic.

Diagnosis.—This is always based on a microscopic examination. One must observe, that also beginning forms of endometritis, especially decidua remnants and carcinomata, may give rise to confusion. In regard to the latter it deserves to be pointed out, that carcinoma and sarcoma may occur in the same uterus at the same time. Like *C. Ruge*,²³⁴ we emphasize the view that the diagnosis must be made only on the basis of a thorough knowledge of the pathology of the uterine mucosa and under full realization of the anatomic findings. *Amann* has referred to the gradual transitional change from the normal muscular and connective tissue into pronounced sarcomatous tissue.

The grapelike tumors of the cervix mucosa are macroscopically positively recognized as such.

Prognosis.—The outlook is absolutely unfavorable, if help is not procured early.

Treatment.—The radical operation only remains for which the methods described under the chapter on Carcinoma must be considered. *Gessner* designates the result of the operation as similar to that of the corpus carcinoma. An essential difference exists apparently in the fact that if after one year a recurrence has not occurred, a permanent cure may be accepted as probable. The grapelike sarcomata of the cervix are uncommonly malignant. For those who cannot any more be operated on radically, the treatment described for inoperable carcinoma holds good.

Symptoms: 2. Of the wall sarcoma.—The wall sarcoma of the uterus causes the symptoms of interstitial myofibromata. The *hemorrhages* occur as meno- and metrorrhagia. A discharge, like meat washings, exists. This acquires a putrefactive malodorous character, if disintegration of the tumor occurs, and also if the mucosa disintegrates above the tumor.

Pains are at first not connected with the wall sarcoma. Also in this

variety they occur only when the new-formation undergoes polypoid proliferation and becomes expelled.

The uterus is enlarged in size and nodular. If the tumor develops in the cavum it is expelled like a polypus. Its broad base can be felt in the uterine wall. Usually wall sarcomata for a long time present the picture of uterine myomata.

Diagnosis.—Very frequently one succeeds only by a careful microscopic examination of the removed preparation in differentiating the wall sarcoma from a fibromyoma. Rapid growth of fibromyomatous tumors during the climacteric must be looked upon with suspicion. I have seen in six cases after long-continued ergot treatment that the myomata underwent sarcomatous degeneration. *Doederlein*²³⁵ reports that he has observed among forty-five myoma patients castrated by *Säxinger* three with subsequent sarcomatous degeneration. This degeneration occurs with renewed hemorrhages and watery discharge. The tumor grows very rapidly, polypi recur quickly, and show a soft consistency. However, a careful microscopic examination is necessary in order to obtain a correct diagnosis.

Prognosis.—The prediction is especially bad, as this kind of neoplasm is recognized very late. Better results will be attained here also, if the myomata are not left to grow indefinitely. Then, also, the almost symptomless sarcomata will be removed in proper time.

Treatment can only consist in a radical operation. The same also holds good for those cases in which a polypoid tumor is concealed. The character of the development of the neoplasm determines the way to be chosen. This holds good particularly for the cases undergoing putrefaction.

Operations for Urogenital Fistulae

1. Vesico-Vaginal Fistulae

Defects in the septum between the bladder and genital canal mostly result from injuries during labor. Very seldom are perforations of the vaginal wall caused directly by instrumental delivery, but, as a rule, a pressure necrosis takes place as a result of the process of labor which after several days leads to sloughing of the necrosed tissue and the establishment of a fistula: it is **the result of a spontaneous process of labor**. Correspondingly they are most frequent in country districts which have an inadequate settlement of physicians.

Undoubtedly contusions of a short duration lead comparatively seldom to such a deeply extending necrosis that from them a communication with the bladder develops.

The bladder during labor is drawn so far upward from the small pelvis that its lower edge, or the neck of the bladder, usually comes to lie behind the symphysis, that is at a point where the advancing head may produce a contusion. In very rare cases the bladder remains with the greater portion of its posterior wall within the area of this pressure; on the other hand, the urethra may be involved to a larger extent than merely its orificium internum. The corpus uteri hardly ever comes into consideration. Indeed, considering the connection between the bladder and the neck of the uterus one must admit that a communication between the bladder and the corpus can take place only in abnormal relations of these two structures. The cervix also is subjected to the danger of being contused only very seldom farther than the region of its lips. The contusion attacks most frequently the vaginal vault and the anterior vaginal wall in their entire extent. The ureter more frequently comes into the sphere of the contused structures, so that it takes part in the formation of necrosis and fistula after labors.

The wearing of **pessaries**, especially of the *Zwank* pessary, by which I have seen fistulae caused thirteen times, belongs among the other causes of fistula formation. A fistula observed by me owed its formation to a spool, which had been pushed into the vagina for the purpose of masturbation. **Diseases of the Bladder**, the result of stone formation, among others also tuberculous ulcers of the vesical mucous membrane as well as **ulcerative destructions** of the genital canal lead to the formation of fistulae; a not at all rare occasion finally is given by the breaking down of the vaginal wall as a result of a carcinoma uteri, vaginæ, vel vesicæ.

The number of *artificial fistulae* has grown considerably with the increasing frequency of gynecologic operations.

Fistulae occur also by wandering of ligatures after laparotomies; these particularly distinguish themselves by the tendency to spontaneous closure.

The *fistulae lie*, in consequence of the irregular distortion during the progress of labor, sometimes median at other times laterally, their course is mostly a very short one, the edges are distorted by cicatrices, the size of the opening may vary between one as fine as a hair up to the extent of the entire anterior vaginal wall. The cicatricial contraction causes quite remarkably different and irregular forms of fistulae. As

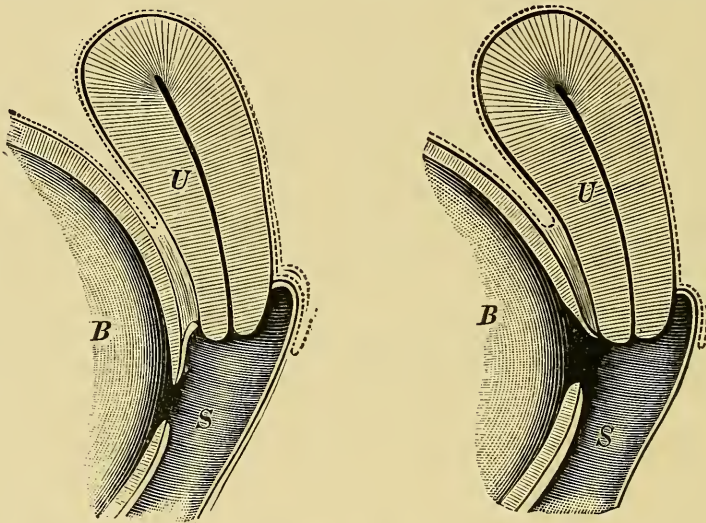


FIG. 138.—Vesico-Vaginal Fistula. FIG. 139.—Deep Vesico-Vaginal Fistula.
After Schroeder, Handbuch der weiblichen Geschlechtsorgane.
B, bladder; S, vagina; U, uterus.

soon as it is any way extensive, the bladder falls into the fistulae and appears as a bright red, velvetlike mass in the lumen of the vagina. In some cases the urine retains continuously its normal character, in which case the vaginal mucous membrane and the vulva may remain approximately healthy in spite of the continued moistening. Intense irritation of the moistened parts occurs in case of decomposition of the urine, which may lead to extensive ulcerations and the formation of large defects, in which uric acid salts deposit and form very extensive incrustations.

The most frequent form, the *vesico-vaginal fistula* (Fig. 138), is mostly round or oval, or also distorted like a cleft by cicatricial contraction. The vesical mucosa prolapses into the vagina in large fistulae. Fistulous canals are, as a rule, only short, the edges stretched to fine lines. The fistula runs obliquely through the septum vesico-vaginale. In other

cases it is located in the vault close in front of the cervix uteri, *deep vesico-vaginal fistulae* (Fig. 139). The fistulae become much more irregular in their course as soon as the *uterus* is involved. In such *vesico-uterine fistulae* (Fig. 140) a part of the anterior cervical lip may be torn off, or the fistula may terminate in the cervical canal, and the shape of the external uterine orifice is unchanged (Fig. 141). These *vesico-cervical fistulae* occur probably not so rarely, as one might deduce from reports in literature,²³⁶ as they are seldom diagnosed. After a not small number of difficult labors with a narrow pelvis we hear the puerpera complain on the third to the fifth day of incontinence of the bladder and escape of urine from the vagina. Thereby it is difficult to determine

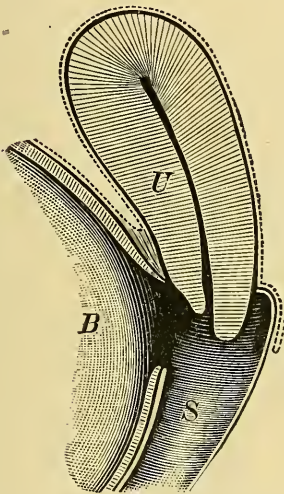


Fig. 140.—Vesico-Uterine Fistula.

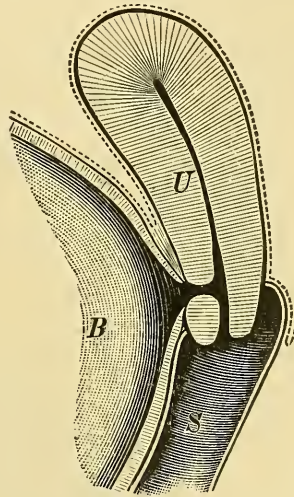


FIG. 141.—Vesico-Cervical Fistula.

After Schroeder (l. c.). (Schematic.) B, bladder; S, vagina, U, uterus.

whether the lochial secretion is contaminated with urine escaping involuntarily from the incompletely closed urethra or from a fistula. The slow recovery from the difficult labor makes it inopportune to take the patient immediately out of bed, in order to establish the facts of the case. After a further four to six days their complaint disappears completely and, moreover, the patients have evacuated a certain amount of urine through the urethra. When later the patients finally leave the bed, the urine is evacuated completely per urethram. In these cases the dripping of urine is to be traced mostly to vesico-cervical injuries. These are especially and peculiarly disposed to heal spontaneously as the fistulous canal is stretched and displaced by the transformation of the cervix and the hardening of its wall, increasing with the puerperal involution and by the changes in the position of the uterine body. Spontaneous recovery is thereby induced.

Injuries of the *urethra* are, as a rule, only part phenomenon of injuries

of the vesico-vaginal septum. However, the urethra may also be destroyed to a large extent. The lower part of the same may then form a blind pouch (Fig. 142). Similar deformities and distortions also occur, both in the vagina and even in the bladder, so that the parts are distorted in an entirely irregular manner. Adhesions with neighboring organs and extensive cicatricial stenoses form, which displace the edges extensively, e.g., to the posterior wall of the symphysis and the ossa pubis.

Post-operative fistulæ develop from bladder injuries, which were overlooked during the operation; they then make themselves immediately perceptible. Although the perforation of the bladder was noticed immediately and sutured correspondingly, primary healing sometimes does

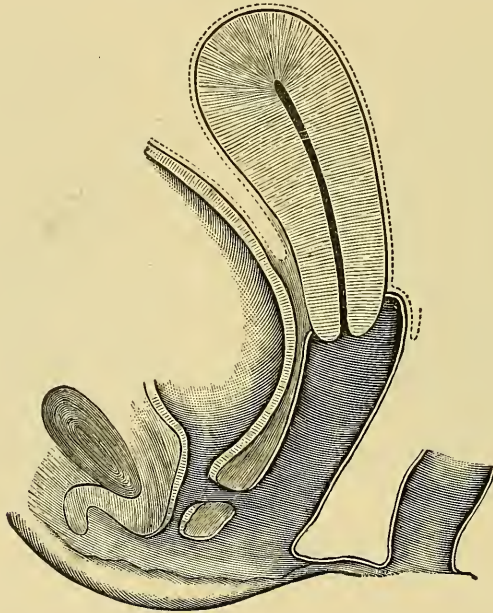


FIG. 142.—Urethro-Vaginal Fistula. (Schematic.)

not result. After a few days the patient lies wet. In other cases the septic disintegration of the operative wound destroys the adjacent vesical wall, for instance, in stitch abscess and suture canal infection. The escape of urine announces itself with the breaking down of the wound.

The *symptom of vesico-vaginal fistula* is the involuntary passage of urine. This occurs only very rarely immediately after labor; it develops much more frequently between the third to the fifth days. It may happen in small and oblique fistulas that the urine escapes by way of the vagina only during a certain position of the body, otherwise, however, in a normal way through the urethra. At times the involuntary escape of urine occurs only for a day, while the urine on other days escapes through the urethra with the exception of small traces. In larger fistulæ the entire amount always passes per vaginam. In urethral fistula the

discharge takes place on emptying the bladder. Chronic cystitis exists very frequently. The urine is often decomposed in the vagina and surrounds these unhappy women with a pungent odor, so that a diagnosis already can be made from a distance. Incrustations of uric acid salts develop around the sutures left behind. Such fistulæ have not by any means a disadvantageous action on the capability for procreation; women become pregnant with them and bear children corresponding to the conditions of the pelvis and the distortions of the soft parts, without this focus of pathogenic germs leading inevitably to an infection or intoxication of the puerpera.

The *diagnosis of vesico-vaginal fistulae* is, as a rule, made directly; it may be very difficult in smaller fistulæ and with extensive cicatricial contraction.

The vagina is exposed with retractors or retaining specula and the fistula is made perceptible to the eye by the sound or catheter or injections of colored fluids through the bladder. *Vesico-vaginal fistulae* may cause peculiar difficulties.

The bladder must be subjected to an examination with the cystoscope in every instance, if a severe cystitis does not contraindicate it. Eventually the ureters must also be sounded, in order to determine exactly their relations to the fistula and the cicatricial contractions in the neighborhood.

The *prognosis* is not bad. Probably we get an opportunity to see and to treat only that part of the fistulæ which did not heal spontaneously. Spontaneous recovery follows at times, also, after long existence by scar formation, distortion, and displacement of the edges of the fistula.

Treatment.—Immediately after the injury, that is in recent cases, an attempt is made to assist the spontaneous healing of the fistula by a retention catheter, particularly since the operative closure can be undertaken only after termination of the first granulation of the edges of the defect. Until then one cauterizes partly the fistulous canal, partly a zone about 1 cm. wide of the vaginal margin of the fistula at intervals of several days with silver nitrate, tincture of iodine, Vienna caustic paste or the thermal cautery.

The cystitis is treated at the same time with an irrigation of 0.5 to 1 per cent. silver nitrate solution with a corresponding attention to a profuse diuresis. In a few instances recent fistulæ heal in this way in one or two weeks. Only after such an attempt—in any case after the formation of well-granulating wound edges—should one resort to the knife. As a rule, six to eight weeks should pass after labor.

The presupposition for healing of *vesico-vaginal fistula* is a *complete and abundantly wide exposure of the opening by way of the vagina*. *Schuchardt's* paravaginal accessory incision forms a material aid.

A preliminary treatment must precede the operation in case of cica-

tricial contractions and irregular firm adhesions of the edges of the fistula. The irritation of the vaginal mucosa, the vagina and the external genitalia and the contraction of the bladder are to be removed, the scars in the vesico-vaginal septum are to be stretched so far, that the edges of the fistula become movable and their coaptation succeeds without forcible traction.

Sitz baths, rest in bed, application of zinc salve and similar non-irritating remedies to the vaginal wound lead to this. In order to increase the continence of the bladder, the fistula is plugged from the vagina and the bladder filled gradually. The scars are stretched by the above mentioned *Bozeman* bougies or by tamponing, are little by little loosened deeper, until the edges of the fistula become accessible. Scars, which extend to the posterior wall of the symphysis and the ossa pubis, are separated according to the procedure of *Schauta*.

The merit of having materially advanced operations for fistula belongs to *Marion Sims*,²³⁷ his assistant *Bozeman*,²³⁸ and in a special degree to *Gustav Simon*,²³⁹ and *Hegar*.²⁴⁰ A considerable advance was made by the method of **flap splitting** after *Fritsch* and *Walcher*;²⁴¹ the cicatricial edge of the fistula is not cut away to a large extent, but it is freshened by splitting and thus prepared for the suture. In this way *Walcher*, *Fritsch*, and *Sänger*, and others have taught us to operate successfully. The problem of preparing particularly immovable fixed edges of the fistula for the suturing, so as to cover large defects, has matured a number of ingenious methods, of which the most noteworthy are to be described during the discussion of operation for complicated cases.

The **operation** is executed in ordinary cases of vesico-vaginal fistula in the lithotomy position. Vaginal retractors expose the field of operation, tenaculum forceps stretch it, a sound or catheter, passed into the bladder, serves for orientation. Permanent irrigation saves sponging of the cut surface. Formerly the edges of the fistula were dissected in a complete circle and all the cicatricial tissue was removed. Correspondingly the refreshing of the surfaces is extended farther in the vagina than in the bladder. The vesical mucosa was dissected out only in case a formation of cicatrices was here also noticed. Accordingly the incision was straight or more slanting, also the amount of the excised tissue varied. The suturing of the fistula was performed in that direction in which the edges of the fistula could be brought together the easiest without tension. I make use of this procedure at present only in small fistulæ, where sufficient material is present for the closure or when the edges are strongly infiltrated and consist of tough cicatricial tissue.

Division of the cicatrix and flap formation are to be preferred in more extensive defects. After a correspondingly free exposure of the fistulous tract all around one cuts between the bladder and the vagina, so that from both large flaps hang down. These are made of such a size that they can be brought together over the fistulous opening without any force. The vesical wall is then sutured and beneath it the vaginal wall.

The question of the suture material played for a long time a great rôle in the discussion of the operation for vesico-vaginal fistula. The successes of *Sims* were attributed by himself and many others materially to the use of **silver wire**. I still like even at present to make use of this or bronze aluminum wire after the excision of the scars.

The needle is introduced from the vagina underneath the freshened surface through the boundary between the wound surface and vesical mucosa, and brought out on the other side in an exactly corresponding manner. All the necessary sutures are placed next to each other, before they are tied.

It is less important to suture close, than to obtain an exact coaptation of the wound edges with a few well-placed sutures. The metal sutures may be tied or closed with the twisting apparatus of *E. Martin* (Fig. 143).

The ends of the wire are bent upon themselves. The intimate coaptation of the wound-edges in the vagina is secured by a row of superficial catgut stitches.

In the **flap-splitting** operation the bladder is sutured with catgut so that the stitches do not touch the mucosa. The knots lie externally on the bladder wall. Above it I insert silver wire or bronze aluminum wires into the vagina, which

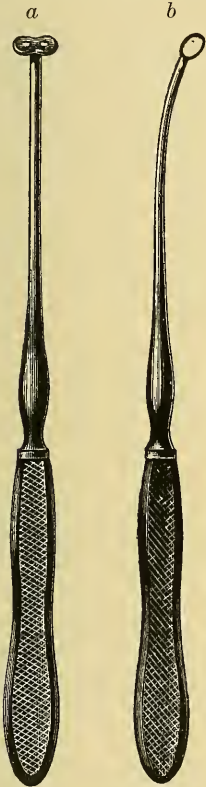


FIG. 143.—Twisting Apparatus, According to *E. Martin*.

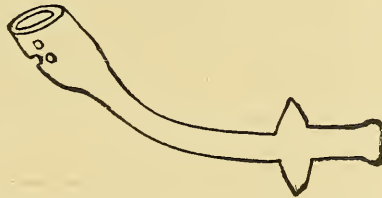

FIG. 144.—Retention Catheter (horsefoot-shaped of *Skene*).

include a superficial layer of the bladder, and thus exclude the formation of a dead space between the bladder and the vagina.

Gersuny closed the vesicular opening by a circular suture.

After termination of the operation I fill the bladder with warm water, in order to test the continency.

The **after-treatment** has been conducted in very different ways.

While some inserted a retention catheter, others evacuated the urine during the first three to five days by means of a catheter, others again favor a spontaneous evacuation of urine from the beginning.

I always insert a retention catheter until the fifth to the eighth day.

Different forms of retention catheters have been specified, for instance the horsefoot shaped catheter of *Skene* (Fig. 144). I attach an ordinary *Nélaton* catheter with a catgut stitch to the external skin; when the first one must be changed, the second one is secured with adhesive plaster.

It is not necessary, indeed often even undesirable, to keep the patients long in the recumbent position; they are soon allowed to turn carefully on their side. They may get up after ten to twelve days. The metal sutures are removed on the tenth to the twelfth day.

In case of failure and repeated non-success of primary union, it has been attempted to stop the continued discharges of urine by **closure of the vagina**. The **transverse obliteration of the vagina** in incurability of the fistula gives unsatisfactory results. The vagina bears badly the continued wetting with urine; the stagnation of urine, blood, and uterine secretion in the created receptacle causes unbearable conditions.²⁴²

As a last, very desperate attempt to help in such cases, *Rose*²⁴³ made a **recto-vaginal fistula** and caused the evacuation through this after obliteration of the vagina. The results also of this procedure are absolutely unsatisfactory.²⁴⁴

The women finally content themselves with rubber receptacles, which furnish, with thorough cleanliness, a bearable condition. Two such receptacles must be obtained, so that one always may be left in water for twenty-four hours.

Complications of the operation arise to a minor degree through the irregular form of the fistula. The distortion of the normal edges is oftener detrimental. One must avoid making the defect still larger by the operation, and adapt himself to the configuration of the fistula, instead of dissecting out the fistula according to a fixed scheme. More difficult is the covering of excessive defects and the cicatricial fixation of one of the margins at a distance. If the urethra is closed or displaced, then the reopening of the same and a complete securing of its functional capacity must precede the operation.

The preparatory treatment of *Bozeman* proves ineffectual. *Trendelenburg* (*Archiv für klin. Chirurgie*, XXXI) has transplanted a flap of the posterior vaginal wall forward. First it is sutured into the posterior half of the periphery, then, after corresponding healing is completed, it is separated and inserted into the anterior half.

I have detached the lateral vaginal walls on both sides at the attachment to the posterior vaginal wall in a case of complete defect of the entire upper anterior vaginal wall and sutured them in the median line with the wound edges, so that the vaginal mucosa was directed toward the bladder. The wound surface in the vagina was covered with the movable mucosa of the posterior vaginal wall (*Gesellsch. f. Geb. u. Gyn.*, Berlin, July, 1890). Healing resulted, with the exception of two hairlike fistulous tracts.

Mackenrodt, and particularly *Sellheim*,²⁴⁴ have been able to cover not

only the defects in the bladder and urethra by a methodical transplantation of suitable neighboring tissues, but also secured the functional capability of the urinary apparatus thus reconstructed.

Trendelenburg was the first to attempt the operation through the bladder from above, which he exposed and opened extraperitoneally above the symphysis pubis.

In vesico-cervical fistula (Figs. 140 and 141), the cervix is used partly as a support, according to the methods of *Wölfler*,²⁴⁶ *Follet*, and *Champneys*, *Küstner* and *W. A. Freund*. Partly by a complete separation of the bladder from the uterus the former may be so extensively mobilized that it can be easily closed by sutures, and then the cervix is again attached beneath it to an approximately normal extent. According to *Freund* the corpus uteri also may be used as a support.

We have also succeeded in closing vesical fistulæ several times by this method. The attempts to strengthen the defectively acting vesical sphincter by injections of paraffin by the method of *Gersuny* resulted in failures: in an old tuberculous woman an extensive disintegration of the entire tissue portion occurred three weeks after this injection, which made the evil worse than ever.

Among the post-operative complications are to be mentioned primarily **vesical hemorrhages**. These are not in every instance a direct sign of failure and can be combated by careful cold irrigation of the urinary bladder, by the use of ice-bag or ice-coil, eventually irrigations of the bladder with dilute liquor ferri. Profuse hemorrhages, however, always thwart a complete success of the treatment, as the extravasation of large amounts of blood and the formation of coagula in the bladder lead to continual contractions and thereby healing of the wound edges is disturbed.

Another very troublesome complication is the **insufficiency** of the completely closed bladder, which causes painful symptoms. I have obtained relief of course with a treatment lasting several weeks, consisting in the use of retention catheters and of dilatation of the bladder methodically carried out by filling it with sterile water and the cautious use of narcotics. In others, with contractions of the bladder after necrotic expulsion of the mucosa as a consequence of stone-formation, after retroflexio uteri gravidi, after septic infections, after operations for fistula and dilatation, of which I have seen several examples in consultation, the wearing of retention catheters and rubber urinals was the only resource.

The **persistence of small fistulae**, as they may develop from suture channels, as a rule, retards the complete healing only for a short time. They can be made to close easily subsequently by cauterization, eventually by a slight circumcision.

Resection of the Orificium Urethræ Externam

In order to remove the **incontinence of the urethra**, which at times remains behind after a dilatation, and the gaping of the orificium after

ulcerative destruction, *Franke*²⁴⁷ and *F. v. Winckel*²⁴⁸ have devised an operation which aims at the narrowing of the lumen of the urethra. A wedge is excised out of the posterior wall of the urethra, whose base is to be placed at the orificium, and the apex arbitrarily high up at the urethral eminence. This wedge contains the urethral eminence and the corresponding portion of the mucosa of the urethra. The cleft is closed by transversely inserted sutures, which do not include the urethral mucosa.

Healing, according to my experience, is not as uniform as otherwise in wounds of the vagina, on account, I suppose, of the moistening with urine. But also when primary healing results, the retraction of the scar proves very troublesome, so that the continence, satisfactory in the beginning, disappears more and more on account of the dilatation of the cicatrix.

I have learned to regard hydrastis as a very effective remedy to increase continence.

I hit upon it, when patients who were taking extractum hydrastis for hemorrhages, complained to me that voiding urine became difficult and a feeling of contraction, particularly low in the pelvis appeared which often could be only overcome with difficulty during urination. Since then I have administered it to a great number of women with troublesome incontinence during the first few days after a urethral dilatation and all noticed soon a material increase in the continence.

Another method of narrowing the urethra has been given by *Pawlik*.²⁴⁹ I have often operated in a similar manner in prolapsus mucosæ urethræ²⁵⁰ and teleangiectatic proliferations of the urethra²⁵¹—the papillary vascular angiomas (*F. v. Winckel*, in loc. cit.).

*Schroeder*²⁵² recommended to dissect wedge-shaped pieces laterally out of the entire wall of the urethra, sparing the mucosa as much as possible. Location and extent determine the direction and depth of the excision.

I cut off the prolapsed mucosa of the urethra in prolapsus mucosæ and suture the upper wound edge in the urethra to the edge of the vaginal mucosa. In polypi I make an elliptical excision and suture the wound in the longitudinal direction of the urethra.

In incontinence without injury one may dissect out the urethra about the length of 2 cm. from its surroundings according to *Gersuny*. As much tissue as possible is taken in order to assure its viability. The freed urethra is turned one-half or once around its longitudinal axis and then sutured again into its position.

2. Uretero-Vaginal Fistulae

The rapid development of gynecologic operations has created a very unfortunate complication in injuries of the ureters in not at all rare instances. Only a minor number of the cases subjected to treatment at present originated in complicated spontaneous labors or difficult or instrumental deliveries.

As a rule, in the last named cases very extensive cicatricial masses surround the opening of the ureter in the vagina or cervix. In the former a more simple scar is met with, although here also such extensive distortions of the vaginal vault and the pelvic connective tissue arise, that it is very difficult, if not impossible, to isolate the ureter in this scar tissue or to find traces of it at all.

Permanent soiling of the patients with urine with regular evacuation of a sometimes abundant amount of urine through the urethra are characteristic symptoms. At times the sphincter of the vagina functionates so powerfully that the patients become wet only during exertion (getting up, coughing, sneezing, bowel and urine evacuation). Nevertheless, incontinentia urinæ exists. The results, such as excoriations, uratic incrustations, sickening odor and such, are not lacking.

The *diagnosis* may be very difficult, not at all with reference to the existence of a ureteral fistula, but as to the location of the fistulous opening itself. Extensive exposure of the vaginal vault, cystoscopic confirmation of the inactivity of one of the ureters, the existence of whose obliteration must be established with the ureteral catheter, insure the diagnosis. One often succeeds in catheterizing through the fistula itself; in other cases I could not make a diagnosis by this means.

Treatment.—We are indebted to *L. Landau*²⁵³ for an important **systematic proposal** for a cure for ureteral fistulæ. The ureter is armed with a catheter, and the lower end and a correspondingly placed opening in the bladder above are united by sutures (see the history of these fistula operations in *Viertel, Handbuch d. Gyn. Veit*).

*Mackenrodt*²⁵⁴ placed a vesico-vaginal opening next to the ureteral fistula. From the edge of the vesical fistula the edges of the ureteral fistula were cut all around and the circumscribed portion formed into a flap which was sutured into the vesico-vaginal fistula.

The unsatisfactory results of these extremely laborious operations made us greet the treatment through the abdominal cavity as an exceedingly favorable substitute. *Veit*,²⁵⁵ as one of the first, implanted the end severed during an abdominal operation into the bladder. In the literature numerous reports of experience with this procedure are found.²⁵⁶ The details must be looked for there.

According to our experience the complete extraperitoneal exposure may be rendered extremely difficult by the presence of much scar tissue. Then it is certainly technically more simple to cut through the peritoneum twice and then to cover the fenestrum in the bladder through which the ureter is implanted, extraperitoneally, by clothing it to a great distance with bladder peritoneum.

The **ureteral fistulae** are united by suture either over an inserted catheter, or after cutting out a corresponding opening in the bladder by suturing of the uretero-vesical-vaginal opening thus created. In cases of cicatricial contraction the danger exists on the one side of injury to the peritoneum and on the other of distortion of the ureter higher

up. The former complication would be the less important one, for unless intestinal loops are brought into the suture, and if one operates aseptically, the peritoneum does not react to such an injury. Much worse is the acute bending of the ureter, the estimation of which is the more difficult, as a sufficient amount of urine may reach the bladder by way of the other healthy ureter and a plentiful amount may be voided.

The **implantation of the ureter into the bladder** may cause considerably more serious difficulties. The suture must secure the flowing in of the urine into the bladder, without stricture, which may occur already as a result of the healing process of the wound. According to the procedure of *Lichtenauer*²⁵⁷ an I-shaped incision is cut into the bladder, whose flaps are raised up. The ureter is slit up 8 mm. in two flaps, each of which is armed with a catgut stitch, both ends of each suture are supplied with needles. The ureteral flaps are inserted into the bladder, after these needles have been passed through the flaps of the I from the side of the vesical mucous membrane. If the ureter is then pushed into the bladder by a dressing forceps, and the sutures are tied externally upon the vesical mucosa, the ureteral flaps lie close to the latter. The muscularis vesicæ, eventually also the serosa, may then be sutured to the ureter. Lastly the peritoneum and abdominal wall are closed above it. A retention catheter is inserted into the bladder.

For an end to end anastomosis of the **separated ureter** one slits the lower end, inserts the upper one about 5 to 10 mm. deep into this, and secures it with two rows of sutures, which pierce through the wall of the receiving end, and only catch the external layer of the wall of the inserted end.

A *Boari* button, which is copied after the *Murphy* button, was used by *Calderini*; it must be removed after two months from the ureter, necessitating another incision.

Berard (*Prager Vierteljahrsschr.*, 1846, Vol. IV) gave the first reports of **uretero-uterine fistulae**, and then *W. A. Freund* (*Klin. Beiträge zur Gyn.*, parts 1 and 2; lastly *Berlin. Klin. Wochenschr.*, 1869, p. 504).

If implantation of the ureter proves a failure, then extirpation of the respective kidney remains.²⁵⁸ Normal functioning of the other kidney is the indispensable prerequisite.

3. Intestino-Vaginal Fistulae

The communication between the vagina and the intestines, the **vagino-intestinal fistula**, is partly also a result of processes of labor, of injuries during delivery or septic diseased processes (para-perimetritic abscesses). **Intestinal ulcers** (tuberculous, carcinomatous), **breaking down tumors**, and **also operative interference** are occasional causes, especially if extensive adhesions are found. **Pessaries** or syringe nozzles or sharp objects on which persons fall or strike, occasionally perforate the vaginal

wall. A not rare occasion for such injuries is afforded by attempts to induce abortion and masturbation.

The opening is situated mostly between the *vagina* and *rectum*, rarely in the *region of the small intestines*. The *fistulous canal* is of very different length and width, from the size of a urinary fistula to a wide communication of both lumina. The walls of the communication show just as different a condition as those of the urinary fistula, at times they are distorted by cicatrices, provided with a recessus, at others smooth and little changed. Occasionally several lie close together.

The *symptoms* of vesico-intestinal fistula are due to the escape of intestinal contents into the vagina. This contents corresponds in fistulæ of the small intestines to the chyme, according to the location of the opening; it escapes accordingly in regular intervals after the meals. In rectal fistulæ the fæces evacuate in a paplike form, rarely in more consistent scybala. The escape of flatus produces the worst inconvenience, as it is incontrollable, while fecal masses with a proper diet escape, as a rule, at longer intervals and intermittently, at least from the introitus vaginæ. It is manifest that the vaginal mucosa passes, as a rule, into a condition of tormenting irritation by the escape of the intestinal contents.

The *diagnosis*, as a rule, follows easily from inspection. Fistulæ are rarely so narrow that they require injections into the rectum, in order to confirm them.

The *treatment* of intestino-vaginal fistulæ may cause extraordinary difficulty, especially fistulæ of the small intestines,²⁵⁹ which often defy all attempts at closure. With chronic suppurations the openings become displaced not infrequently with the extinction of the secretion and the organization of granulations. Irrigation of the pus cavity with solutions of iodine (see above), or 2 per cent. solution of silver nitrate, with good general care favors this healing process. Failures of this treatment necessitate an enterorrhaphy, whose technic permits a positive success to be expected. In recto-vaginal fistulæ one attempts first to pass a rectal tube beyond the fistula. Its edges are then cauterized with *argentum nitricum*, or tincture of iodine. Oftentimes spontaneous healing results within two or three weeks. The otherwise unavoidable suturing is executed just as the suturing of the vesical wall after flap splitting, resection of the edges of the intestinal opening, union by suturing submucously with interrupted catgut sutures. Closing of the vagina with bronze aluminum wire, which includes the mucosa recti, down to but not inclosing it.

If the recto-vaginal fistulæ are located deep down, close behind the perineum, then this, as a rule, must be incised. Then the operation for closing recto-vagino-perineal defect [complete laceration of the perineum.—ED.] is executed (supra, p. 141).

APPENDIX

Prolapsus Recti. Hemorrhoidal Nodules. Ulcerative Strictures of the Rectum. Newgrowths of the Rectum

Not rarely women come to the gynecologist with complaints, which they localize in the genitalia, while the examination proves that pathologic changes in the rectum are concerned, with a more or less normal condition of the sexual organs.

I meet most frequently among these:

1. Prolapsus of the rectal mucosa.
2. Extensive hemorrhoidal nodules.
3. Ulcers and ulcerous strictures of the rectum, suppurating hemorrhoidal nodules, luetic ulcers.
4. Periproctal abscesses and fistulæ (suppurating gonorrhœal Bartholinitis *Poelchen*).
5. Newgrowths of the rectum.

It is alien to the purpose of this book to discuss the etiology, symptomatology, diagnosis and prognosis of rectal conditions.

I introduce these usually very painful conditions into the sphere of discussion here only in order to point to the fact that not quite rarely mistakes of the indicated kind, especially with perimetritis, slip in. One should never omit examination of the rectum, if during the taking of the anamnesis complaints are made of disturbances in the lower and external parts of the pelvis, whose localization in the genitalia cannot clearly be proved.

I have employed a mode of procedure²⁶⁰ for the treatment of such cases in which operative relief is unavoidable and the rectum must be excised partially or to a great extent, which deserves to be mentioned at this place.

In lithotomy position the surroundings of the anus are ligated by provisional sutures, by causing anteriorly and posteriorly and on both sides a large semilunar needle to enter about 2 to 3 cm. externally to the anus. This needle encloses subcutaneously a mass of tissue as large as possible, passing it with a strong curve and is again brought out at the point of insertion. The heavy catgut stitch is drawn tight and tied. Thereby a **deep reaching prophylactic hemostasis** is induced. Then the anus is dilated and the rectum brought down by tenaculum forceps until healthy mucosa is visible. This limit is variable according to the indication of the operation. The bowel can be drawn down over the so-called sphincter tertius in prolapsus recti, past the ectatic veins in hemorrhoids. Ulcerations and strictures must first be divided before healthy mucosa is visible. In newgrowths and periproctic abscesses I go likewise above the sphincter tertius. A cotton tampon with a string prevents the fæces from coming down.

The healthy mucosa is held by tenaculum forceps. A fourth of the periphery of the healthy skin is cut around externally in front of the ligatures, and also—corresponding to this—the healthy mucosa at the boundary of the diseased region, with long strokes of the knife the diseased portion is more or less flatly removed between these two boundary lines. The sphincter is most freely exposed; at times a part of it must be removed.

The hemorrhage is very scanty as a result of the provisional ligatures, so that the healthy mucous membrane can be united with the external skin by interrupted catgut stitches almost without loss of blood. Deep sutures alternate with superficial ones, until an exact coaptation of the wound-edges is obtained. The entire wound-surface is firmly covered by mucosa.

In the same manner the remaining quadrants are excised and closed by sutures. The provisional ligatures are then removed. If isolated vessels bleed, the hemorrhage is checked by additional sutures.

The new-formed anus gapes, as a rule, after the operation is finished; the sutures are cut short and the tampons are removed.

The after-treatment is confined to irrigation of the external wound, in case it is soiled by urine or intestinal contents. As a rule, flatus escapes soon, a bowel movement results spontaneously with liquid-soft diet after six to seven days, otherwise the same is to be furthered in the usual manner.

In about twelve to fourteen days epidermization and contraction have so far proceeded that patients can leave the bed.

As soon as patients have recovered somewhat they receive sitz baths and, if necessary, irrigation with weak iodine solution in the lower portion of the rectum. The cicatrization is thereby carried into effect very rapidly. An uncomfortable scar retraction is obviated by ample stimulation of the motus peristalticus and by a long-continued use of rectal bougies.

Operations on the Uterus

1. Discisio Orificii Uteri Externi

Among the operations on the uterus the *discision of the uterine os* was considered for a long time the proper "gynecologic operation." First practiced by *Sir James Y. Simpson* in 1843, in Edinburgh,²⁶¹ and independently of him first in Germany by *E. Martin*,²⁶² in 1849, this operation was introduced into gynecologic practice particularly by *M. Sims*.²⁶³ In the beginning used only in stenoses of the *orificium uteri externum*, it was later performed in all forms of displacement of the cervical canal, and lastly, with certain modifications, it was executed also in stenosis of the *orificium uteri internum*. Also cases of dysmenorrhea in which the lumen of the cervical canal did not show the full width of the normal have often been subjected to discision.

The discision was recommended by *Sims* warmly and convincingly as a not dangerous and very successful operation, but, used in a most extensive measure and with not convincingly given indications, it has failed to give the results which were expected from it. Primary failures also were not wanting; septic infection became only too frequently the source of detrimental complications, also hemorrhages which were neglected for a long time or according to the status of technic at that time treated with improper means have caused many deaths. While at present asepsis and the generally practiced technic protect us against such mistakes, our knowledge of the pathologic-anatomic causes of dysmenorrhea and sterility lead us to consider the stenosis of the cervical canal differently. This operation, which was the typical gynecologic procedure in the beginning stage of modern gynecology,²⁶⁴ belongs almost to history. The original technic justly received the objection of the surgeons.²⁶⁵ The simple splitting of the cervix did not insure against renewed formation of stenoses.

In very rare cases of stenosis, in which this alone must be considered as the obstacle to conception, I split the cervical lips bilaterally with an ordinary scalpel or scissors. After an abrasio mucosæ corporis et colli, I unite with sutures the ends of the former cervical lips with an infolding of the same. The rest of the lateral incisions are closed by two or three vertically introduced interrupted interrupted catgut stitches.

2. The Conical Excision

Among the propositions which have been mentioned as a substitute for the discision for the formation of a wide gaping uterine os, the *con-*

ical-shaped excision proposed by *Simon* (loc. cit.) occupies the first place as a surgically correct operation. The stenosis is radically removed by the same, and also in a simple manner free from danger the hypertrophy of the cervix is diminished (*E. Küster*, loc. cit.). The mucosa of the cervical canal remains intact, presuming that it is healthy. Such cases are, however, comparatively rare; the diseased processes of the mucosa are mostly already far advanced in stenosis and require, with the elongatio or hypertrophia colli, a more extensive operative treatment. For this reason I deem the operation of conical-shaped excision indicated only in a comparatively limited number of cases.

Conical Excision.—The cervical lips are first incised bilaterally until close to the insertion of the vagina with a narrow scalpel. The posterior lip is then incised to a corresponding distance from the cervical mucosa. This cut is deepened to one, two, or more centimetres, according to the extent to which the cervix should be removed, and reaches from the commissure of one side to the other around the cervical os. Then a second cut is made externally at about the boundary of the lower and posterior surfaces of the portio vaginalis, likewise from one commissure to the other, which is directed obliquely upward on the first cut and intersects with this at a suitable depth.

The part removed in this manner is as a fact conical. The sutures should bring about the union of the wound-surfaces, so that the cervical mucosa remains intact. The excision of the anterior lip is performed in the same manner. The lateral commissures are finally closed by sutures.

3. Operation for Laceration of the Cervix (Trachelorrhaphy)

In known opposition to the opinion which designated and treated the narrowness of the cervix as a source of very extensive disturbances, *Emmet*, in 1874,²⁶⁶ attributed an exaggerated importance to the gaping width of the cervical os and demanded its removal by **trachelorrhaphy**.

The gaping of the cervix, of which *Roser*,²⁶⁷ thirteen years prior, furnished a very appropriate description, was believed to be the cause of chronic endometritis and metritis, dysmenorrhœa, sterility, intense sensitiveness, habitual abortion, even malignant diseases of the cervix uteri. We acknowledge with the majority of the German gynecologists also that cervical lacerations are not unimportant injuries. Numerous observations prove, however, that a deep separation of the lips may exist without any interference in the function of the uterus. In accidental inflammations of the mucosa the cervical lacerations facilitate the transformation of the portio to a shapeless mass, the everted cervical mucous membrane is exposed to a great extent to irritations from the vagina. The scars become the seat of severe scar neuroses. **Cervical lacerations favor a rapid spreading of the infection in the everted mucosa. By cicatricial contractions they become an inexhaustible source of irri-**

tation in the entire pelvic connective tissue. They may prevent the development of the uterus as a bearer of the fertilized ovum. Not rarely cancers are met on the everted edges of the cervical tears. I consider cervical lacerations as unimportant in otherwise healthy conditions of the genitalia and do not see in them any indications for interference. If such chronic processes of disease develop in the mucosa and its surroundings then their removal is imperative.*

Cervical lacerations are always found in the sides of the cervix. Exceptions to this are very rare. The portio vaginalis mostly gapes, at times unilaterally, at others bilaterally. An extensive, rigid, and sensitive scar traverses the entire vaginal vault and the pelvic connective tissue. The scars of the cervix tend to project over those of the vaginal vault. Tense, radiating scar-tissue develops mostly in the vault, which traverses the vaginal vault and pelvic floor for a great distance, drawing and fixing the uterus rigidly to one or the other side—**the cervico-laquear laceration.** In bilateral lacerations both cervical lips frequently roll out in such a manner that they fill the vaginal vault with a cauliflowerlike new-formation, while above it the small ante- or retroflexed uterine body is to be palpated only with difficulty, the rupture reaching up to the lower end of the corpus.

The **symptoms** are caused, as a rule, by the diseases complicating the **cervical lacerations.**

The signs are quite peculiar in **cervico-laquear tears.** The scars in the vault or, better expressed, in the pelvic floor, fix the uterus to the pelvic wall, distort it in quite an irregular manner and cause a severe disturbance in the pelvic connective tissue and uterus, whose vascular apparatus and innervation suffer thereby (see farther down, Atrophying Parametritis). With extensive cicatricial contractions in the cervix the unfortunate women may become completely exhausted and present the picture of the deepest cachexia by the continuous pains and difficulties which appear with each physical exertion, bowel movement, or urination. The diseased mucosa springs forth from the wide gaping crater of the cervix, and erosions extend over the cervical scars. Its extremely increased secretion, its great tendency to bleed, its hard consistency remind one very vividly of malignant disease. The microscopic examination only will show that merely an intense endometritis is concerned in these changes.

Conception is prevented more by the complicating endometritis than by the gaping of the cervical canal. On the other hand the scar in the cervix is often so tense and unyielding that it prevents the development of the uterus in gestation and induces thereby a premature termination of the pregnancy.

* My first cases were reported by *Arning*, Wiener med. Wochensch., 1881, Nos. 32 and 33, and *Czempin*, Zeitschr. f. Geb. u. Gyn., Vol. XII. I explained my opinion minutely in a communication to the Gyn. Soc. of Boston, 1885.

The *diagnosis* of the cervical lacerations is made from the findings of palpation and inspection. The relation of the cervix to the corpus must be carefully determined. It is easy to measure the depth of the cervical laceration with the finger and sound, and to determine how far up in the cervix the rupture extends, especially also behind the scar in the vaginal vault.

The *treatment* of cervical lacerations depends on whether one *recognizes it intrapartum or after primary cicatrization*. Extensive new cervical lacerations, extending over the insertion of the vagina, cause mostly profuse hemorrhages in connection with delivery, and if the hemorrhage does not stop instantly with the puerperal contractions of the uterus, an immediate coaptation of the wound-surfaces is required, which is to be performed in the manner soon to be described. If the cervical tear is found already cicatrized, then the cleft as such does not demand an operative treatment, if complications like endometritis, metritis, and parametritis are absent. *If the cervical laceration favors and supports a chronic endometritis or metritis or parametritis, then I deem it an urgent necessity to remove the tears.* The same is true in *scar neuroses*.

One cannot depend on a healing of the freshened cervical lips by suturing while there is an extensive infiltration of the tissues. An excision of the portio is then to be preferred.

Trachelorrhaphy.—After typical exposure of the vaginal vault and curettement, the anterior and posterior lips are caught with tenaculum forceps where the margin of the cervical os is to be reestablished and the third tenaculum forceps which serves for the stretching of the wound-edges is placed in the vaginal vault above the scar to be excised. The wound incisions are made so that the surface to be freshened is detached in continuo. Occasionally the hard scar formation in the upper angle of the tear causes difficulties. The complete freshening is secured by excising the flap in continuo. The hemorrhage is mostly not profuse. The wound-surface is smoothed and united, so that the uppermost suture is introduced from the vaginal vault to the margin of the freshened area at the cervical canal, and then brought out again through the opposite flap, in a similar manner into the vaginal vault. Each suture is immediately tied.

Four to five deep interrupted catgut sutures, as a rule, suffice. Between these are inserted superficial sutures for an exact coaptation of the wound margins in the vaginal mucous membrane. After completion of the suturing the cervical canal must be examined for its width.

In bilateral lacerations a suture is inserted in the upper angle after freshening of one side, to stop the hemorrhage. Then the laceration of the other side is freshened and the sutures are inserted alternately in the one or the other side, until the commissure of the cervical lip is restored. Extreme narrowing of the cervical os is to be carefully avoided.

In cervico-laquear lacerations and parametric scars the fixation of

the uterus must be removed with the cicatricial tissue. The uterus is pulled toward the side opposite to its fixation, as far as the retraction of the scar permits. The scar is excised by an incision from the external surface of the cervix uteri, which encircles it in a crescent. As a rule, I push in a double-edged, pointed knife externally along the cervix and cut with it around the uterus as deep as necessary until I no longer feel the tension produced by the scars. The wound gapes very considerably, the uterus sinks decidedly into the middle of the pelvis. The entire scar is peeled out of the vaginal vault. It is very seldom necessary to ligate an isolated vessel.

For suturing, the uterus is pulled strongly toward the opposite side. The wound-edges of the semilunar incision fall together and form a straight line running transversely through the vaginal vault, so that the shortening of the vaginal vault appears to have been removed. The operation for cervical laceration is executed as above described.

The scars form throughout smoothly and allow the uterus free mobility. The pains which were formerly so tormenting, disappear instantly. The uterus remains movable and involutes in a normal way.

4. Amputation of the Cervix

The amputation of the portio vaginalis was one of the first operations which came into fashion during the time of development of modern gynecology. With the perfection of antisepsis and asepsis, the technic of handling the knife and the suture in the depth of the vagina, the special instruments used formerly have fallen into oblivion, the *écraseur* of *Chassaignac*, the guillotine, and the thermocautery, as well as the circular incision, which *Sims*²⁶⁸ described and *Emmet*²⁶⁹ still recommended twenty years ago.

We are indebted to *Hegar*²⁷⁰ for the proper establishment of amputatio colli, who by his procedure enabled the individualization in the most complete manner and thereby gave the mode of the scar formation and the assurance against secondary hemorrhages into the hand of the operator. *Schroeder*²⁷¹ improved the operation by extending it to an excision of the diseased mucosa of the cervical canal. The configuration of the scar takes such a shape that the stump of the cervix is covered with the mucosa of the vaginal vault drawn over it. The lower border of the cervical mucosa is transferred quite a distance upward in the constructed funnel, removed as far as possible from irritations from the vagina.

Amputation of the cervical lips is indicated in all chronic inflammatory processes of the cervix, especially of the cervical lips. It is oftentimes executed for obtaining material for examinations in suspicious proliferations. By extending the operation higher up over the cervix, where the removal of a large portion of the hypertrophic cervix is required, it becomes a *high excision*, which was considered by some individuals as

sufficient for the early stages of carcinomatous disease of the portio until the last decade of the nineteenth century.

As a rule, the mucosa of the cavum uteri also is not healthy; its microscopic examination is, however, certainly indicated. Accordingly I commence each excision of the cervix with a curettement of the entire uterus (vide supra, p. 30).

If the uterus is movable, it is easy to draw it down to the introitus with tenaculum forceps. Otherwise the vaginal vault is exposed by the paravaginal accessory incision according to *Schuchardt*.

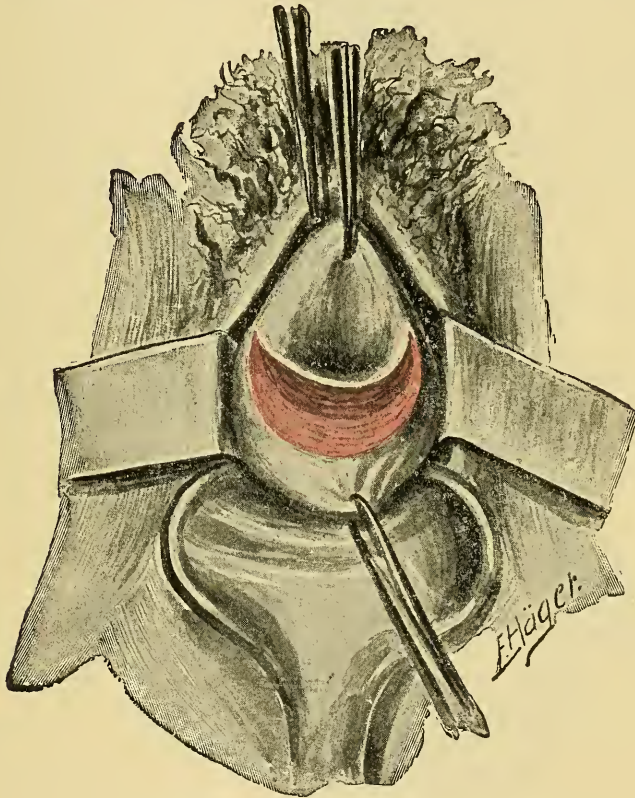


FIG. 145.—Excision of the Posterior Lip.

The anterior cervical lip is caught with a tenaculum forceps, just so the posterior one. Either the lateral commissures of the cervical lips are incised with the knife close to the vaginal vault, or the excision is confined to the lips, as in Figs. 145 and 146. The posterior lip is first proceeded with: An incision is made as long and as far as each case demands. Closure by three or four sutures introduced in the cervical mucosa, penetrating underneath the entire wound-surface and coming out on the vaginal surface of the portio. They are immediately tied. Between these deep sutures superficial ones are placed, until the wound-edges are exactly

coaptated. Then the anterior lip⁷³ is excised; the cervix is first caught externally to the border of the excision. Suturing is done as in the posterior lip. Finally, the lateral commissures, in case these were split, are closed by deep stitches: between these, superficial ones are to be introduced. If the bleeding stops, the cervix is pushed upward. Loose iodoform gauze strips are inserted, followed by rest in bed for eight days. Cleansing vaginal douches are ordered only if profuse secretion is pres-

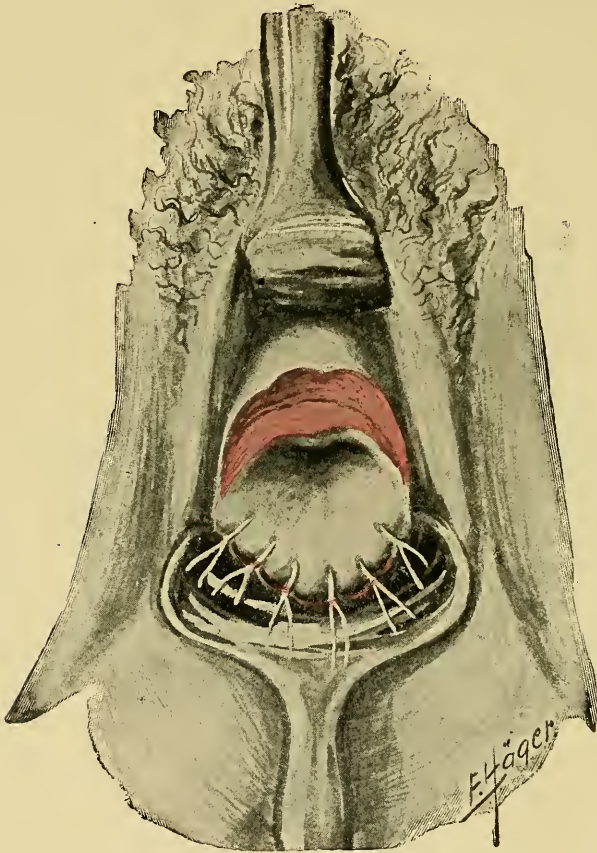


FIG. 146.—Excision of the Anterior Lip.

ent. The temporary ligating of the ligamenta lata²⁷² is at present rarely employed. The rubber tube constriction devised by me (*Berlin. klin. Wochenschr.*, 1876, No. 4) is used at present just as little as the uterine tourniquet contrived by *Emmet* ("Gynecology," Ed. III, p. 466).

Secondary hemorrhages are hardly ever observed, thanks to the generally practiced technic of suturing. Should a patient have a secondary hemorrhage as a result of an unlucky accident or premature absorption of poor material, no time should be lost with tamponing and irrigations,

but the patient should be put on the operating table, the wound exposed, and the bleeding place closed by a new suture.

The remote results are uniformly good. Primary healing fails only with infection of the wound.

*Schroeder*²⁷³ perfected the operation by extending it to an excision of the diseased mucosa of the cervical canal. **After bilateral incision** the cervical lips are separated, and at the macroscopically observable boundary between healthy and diseased cervical mucosa an incision is made vertically to the wall of the cervix. From the external side of the lip one cuts it at the end of the first incision, at the point at which the disease requires it in each instance. Accordingly a superficial or large piece of the tissue is removed. The coaptation is performed by sutures running underneath the wound-surface, the remnants of the corresponding lip being turned up or down. After the lateral commissures are closed finally, the configuration of the scar is such that the stump of the cervix is covered with the mucosa of the vaginal vault displaced upward into the cervical canal, while the lower end of the cervical mucosa is placed tolerably far up into the constructed funnel, and removed as much as possible beyond the influence of the vagina.

Both these operations, *Hegar's* and *Schroeder's*, I am in the habit of combining with the excision of the cervix and proceed in the manner which the indication for the operation on the cervix renders necessary in the individual case.

Diseases of the Uterine Tubes

LITERATURE: *Veit* and *Kleinhaus* in *Veit's Handbuch der Gyn.*, Wiesbaden, Bergmann, 1899. *Frommel's Jahresber. über Geb. u. Gyn.*, 1899-1905. *A. Martin*, *Krankheiten der Eileiter*. Leipzig, Georgi, 1895.

The **tube** may be primarily **deformed**.

As the uppermost part of *Müller's* ducts, which coalesce in their lower parts to uterus and vagina, the tube not rarely takes part in their malformations.

Thus with rudimentary development of one of the cornua of the uterus (rudimentary cornu, atresic accessory cornu) the tube of the same side may have only a stunted development or may be entirely absent.

An absence of both tubes is, as a rule, accompanied by an absence of the uterus and vagina also.

All these malformations have, however, no practical interest, inasmuch as such atrophied organs hardly ever give rise to diseases, with the exception of pregnancy in the atresic accessory cornu of the uterus.

In direct opposition to the absence or deformity of development of the tube, **hyperplastic** processes in the same, however, may also take place. Thus we have cases with two complete tubes on the same side running independently of each other. Or they pursue only partially a separated course, and the surplus tube inosculates with the completely developed one as a longer or shorter accessory branch.

One or more accessory ostia are found relatively frequently in otherwise healthy tubes which mostly branch off near the abdominal end from the main tube, and each one may carry a well-developed fimbriated extremity (see Fig. 147). The lumen of these accessory tubes terminates either freely in the lumen of the main tube, or it is closed in the form of a cul-de-sac. In this case the opening of the cul-de-sac may be situated either inwardly, toward the tube, or outwardly, toward the fimbriated extremity. Such accessory tubes may become of practical importance, inasmuch as they may replace functionally the main ostium in closure of the latter, that is, the migration of the ovum and sperma may take place through them.

More important than these forms of congenital malformations are those which secondarily follow malformations of other parts of the genital canal.

We already referred in the chapter "Anomalies of Development of the Uterus and Vagina" (compare p. 60 and following) to the fact that in atresia of the vagina, either congenital or acquired during infectious

diseases in childhood, a collection of menstrual blood above the place of obliteration occurs, and consequently a hematocolpos or hematometra may result at the time of puberty. If the pressure of blood is very great, then it may also be stowed back into the tubes.

It does not matter now whether the pent-up mass shelters infectious germs which originated from the infectious diseases causing the closure (scarlatina, diphtheria, etc., *Veit-Nagel*) or not, a plastic inflammation and thus a closure of the fimbria will always be caused by the blood escaping from the abdominal ostium of the tube. Then an atresia is always

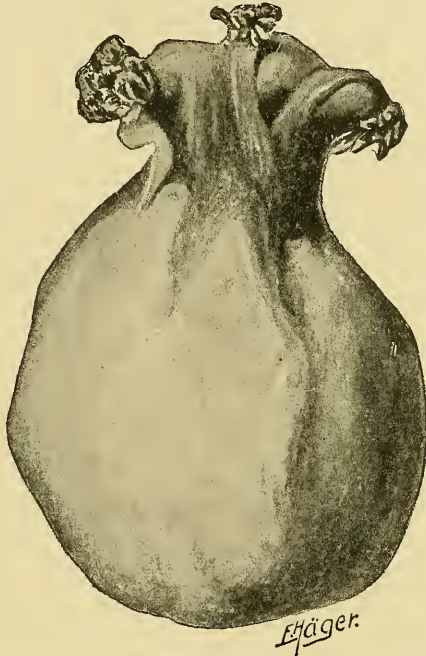


FIG. 147.—Tube with two Accessory Tubes and Follicular Cyst of the Ovary.
(Author's preparation.)

formed here, the menstrual blood is also stowed in the tubes, and a *sac-tosalpinx hemorrhagica* occurs, whose walls always grow gradually thinner and thinner by the increased internal pressure during every menstruation, so that finally a spontaneous rupture and escape of blood into the abdominal cavity may take place. If, prior to this, the closure of the vagina or cervix is opened, this occurrence may be avoided; however, the changes in the tubes are mostly so severe that a spontaneous reformation, especially a reopening of the fimbriated extremity, is excluded and permanent sterility is the result.

If rupture of the tubal sac occurs and if this contains still viable micro-organisms, as is not rarely the case, then a septic peritonitis results which may rapidly terminate fatally.

In spite of their position apparently so protected in the depths of the pelvis, the tubes belong to the most frequently diseased parts of the genital apparatus, and the diseases are of an infectious nature in the greatest majority of cases. Other varieties of tubal disease come relatively less into consideration in comparison with the infections.

A purely *catarrhal* inflammation, taking place without bacterial infection which even at present we still must accept for certain conditions of the uterus, cannot any longer be maintained for the tube.

Such tumefactions and hyperemias of the tube, which generally may perhaps simulate the picture of a catarrhal inflammation, occur with congestion in the pelvis or in isolated parts of the same. Severe displacement, for instance retroversion and prolapsus of the uterus, congestion from cardiac disease, severe constipation, torsion or strangulation in ovarian tumors, in hernias, etc., must be blamed etiologically for this. In these cases the organ may be excessively thickened, hyperemic, of a dark bluish-red color, with enormously dilated vessels and serous infiltration of the musculature and the mucosa. Proper inflammatory manifestations are always absent with the absence of bacterial infection.

All the causes, otherwise blamed for the so-called catarrhal inflammations, as colds, trauma, and so forth, cannot be any longer recognized at the present data.

The *inflammations* of the tubes may depend on many different micro-organisms; however, three groups are practically to be considered on account of their predominating frequency. *The septic and saprophytic bacteria, strepto- and staphylococci*, intestinal bacteria, especially *the bacterium coli commune, the gonococcus and the tubercle bacillus*. Besides, in rarer cases, there have been observed the *pneumococcus, Fränkel*, the *typhoid bacillus* and *actinomyces*; however, all these are exceptional.

The mode of infection may be threefold.

1. *Direct immigration along the mucosa ascending from the corpus uteri.*

2. *Direct immigration from the peritoneum, that is, descending, or from adherent intestinal loops whose diseased walls are penetrated by the bacteria.*

3. *Hematogenous infection.*

1. *Exclusively* to immigration along the mucosa from the cavum uteri is attributable the infection of the tube by *gonorrhoea* (see this chapter), to an overwhelming degree by the *streptococcic* and *saprophytic* infection, rarely by tuberculosis (see *Tuberculosis* chapter).

The explanation of this mode of infection is not so simple. On the one hand none of the bacteria mentioned possesses a mobility of its own; on the other hand a continuous ciliated motion from the abdominal tubal ostium toward the internal uterine os exists, which therefore directly opposes the upward transportation of the micro-organisms and must be overcome. One may imagine that the transportation results by wander-

ing leucocytes, in rare cases perhaps also by the serum or by *antiperistaltic* movement of the tubes; however, these are hypotheses, so far not exactly proved. (This modus is rather probable according to the analogy of observations in animals.) Only when a *blocking* of the bacteria-containing secretion takes place in some way, for instance with lochio-, pyo-, or hematometra, may the fission fungi be directly forced into the tubes.

Notwithstanding that we do not know the mode of the ascending tubal infection, we cannot doubt its very frequent occurrence.

2. An infection of the tube *descending* from the peritoneal cavity is comparatively rare, because the presence of *free* micro-organisms in the abdominal cavity is unusual. This mode of invasion of the tube has been relatively frequently accepted only in tuberculosis, although the experiments of *Baumgarten* speak against it (see chapter *Tuberculosis*).

An infection of the tube from diseased parts of the intestines takes place oftener. Thus the tube not rarely participates in appendiceal inflammations. At first it becomes adherent by peritoneal exudations to the diseased intestine, and then the micro-organisms migrate through the intestinal wall into the tube. Also if the latter is primarily diseased and later becomes adherent to the intestinal wall, the bacteria of the latter may spread to the diseased tube and thus add to the original infection a secondary one of a different kind: *mixed infection*. For instance this occurs not rarely in tuberculosis, where one finds in the tubes besides the tubercle bacilli, also intestinal bacteria, streptococci, bacterium coli, etc. (See chapter *Tuberculosis*.) *Actinomyces* also immigrate into the tube directly from the bowel.

3. In a *hematogenous* way *tuberculosis* of the tube arises, at least in the great majority of cases and a few other rarer forms, as the infection with bacilli typhosi, in so far as they do not directly migrate from the adherent intestine, pneumococci, and others. This mode of infection is the rarest one for the tubes. (For further details about tubal tuberculosis see chapter *Tuberculosis*.)

As the infection of the tubes with gonorrhœa and septic bacteria are the most frequent and mostly take place along the mucous canal, the first stage of the tubal inflammation is in the overwhelming majority of cases an *acute endosalpingitis*, at first of serous, then seropurulent, and finally of a purely purulent nature. On account of the accompanying circumstances we seldom see the first stage, and then mostly on the post-mortem table, if the bearer perished from a general infection, for instance during the puerperium. Surgical operations, on the contrary, permit us to view the tubes only in the stage of chronic disease.

In *acute endosalpingitis* the mucosa is deep red on account of the hyperemia and much swollen, and the fimbriæ particularly are extremely turgescient. The mucosa discharges a serous and sero-purulent secretion, which consists of a transudation from the blood- and lymphvessels with numerous leucocytes, and in which the germs of the particular disease are demonstrable in large masses. The secretion partially runs into the

uterus; in its greater portion, however, it passes through the open extremity into the free peritoneal cavity.

Microscopically there is found, besides an excessive fulness of the vessels, an extensive round cell infiltration of the mucous folds, the epithelium partially destroyed, also permeated with leucocytes which together with the epithelial cells also fill the lumen. The deep layers of the walls, particularly the musculature, are usually found still free during this beginning stage. In a beginning **tuberculosis** such violent signs of inflammation are not found, but only moderate round cell infiltration and scanty tubercle bacilli in the lumen between the leucocytes.

Without a doubt a complete recovery, a *restitutio ad integrum*, may occur in all varieties of infections during this stage. After overpower-

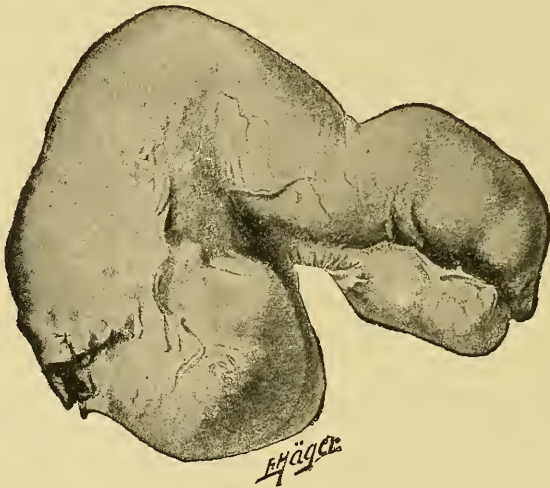


FIG. 148.—Sactosalpinx Purulenta. (Author's preparation.)

ing the invading bacteria the mucosa decreases in size, the secretion is absorbed, the shed epithelium rapidly regenerated.

If, however, this spontaneous healing does **not** occur, then other anatomic changes soon follow.

The infectious agents advance from the mucosa through the lymph-vessels farther into the tubal wall, into the musculature and down upon the peritoneum. Through this the entire organ becomes much thickened. At times an abscess formation in the wall takes place, in any case a severe inflammatory edema.

Very important changes are produced at the fimbriated extremity. The different folds agglutinate with each other by the spreading of the inflammation on the fimbriæ and their peritoneal covering, and roll inwardly, and thus there soon arises a complete closure of the abdominal tubal ostium. In other cases the fimbriæ do not become agglutinated and adherent to each other, but to the neighboring parietal perito-

neum of the excavatio recto-uterina, the intestinal loops, especially the sigmoid flexure, through which also a closure of the tubal ostium results.

The end results, the closure of the abdominal tubal extremity, is the same in both of the processes just described. The result of it is an accumulation of the always continuously produced purulent secretion and a distention of the tubal walls, which finally leads to a formation of a **tubal sac filled with pus, sactosalpinx purulenta, pyosalpinx** (see Fig. 148). In this stage the process has already passed from the acute to the chronic stage. In place of the round cell infiltration there occurs a chronic connective tissue proliferation, which thickens the tubal walls

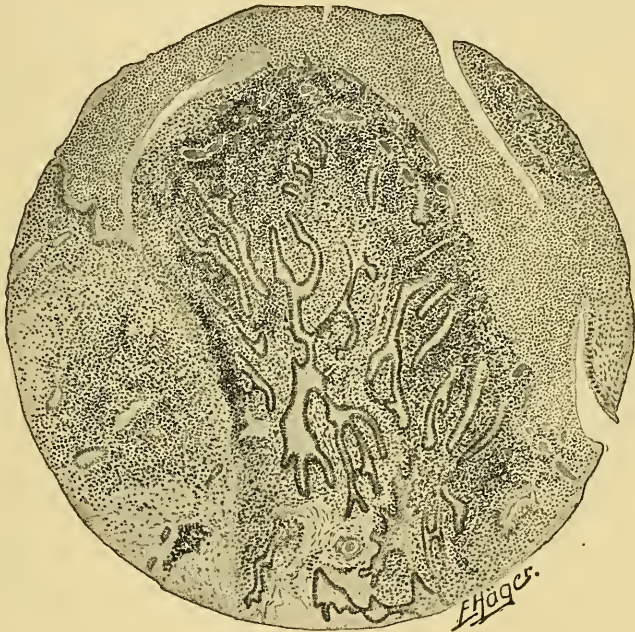

FIG. 149.—Salpingitis Purulenta. (Author's preparation. Zeiss, Obj. AA, Oc. 2.)

to many times their normal condition. The entire organ becomes serpentine, the folds coalesce with each other, so that the most fantastic forms may result as larger and smaller, richly sinuated sacs, also more sausage-shaped, thick-walled formations, as also rosarylike forms, if the connective tissue proliferation has acted more intensively in some places. The latter are termed **salpingitis isthmica nodosa**. The **acute endosalpingitis** has become a chronic **pansalpingitis**.

Microscopically the mucous epithelium is found mostly destroyed, the naked tubal folds are covered with granulation tissue and project into the pus-filled lumen. The folds are, however, no longer so fine but coarser, lower, and torn asunder by the internal pressure; with it exist foci of round cell infiltration in the entire wall, especially around the vessels (see Fig. 149).

The *infectious agents* of purulent salpingitis, mostly gonococci or strepto-staphylococci, bacterium coli, etc., can be demonstrated always in the secretion in *recent* cases, as long as the tube is still open. If, however, the abdominal end is closed and a closed sac has formed, then the behavior is different. If the closure has not yet existed long, the demonstration of the infectious agent will mostly yet succeed. If it has existed, however, for a longer time, the *gonococci*, perhaps in the course of a year, perish, as usually believed, by their own toxins. *Streptococci*, on the contrary, are more capable of resistance; we have found them still completely virulent after nineteen years in a sactosalpinx originating

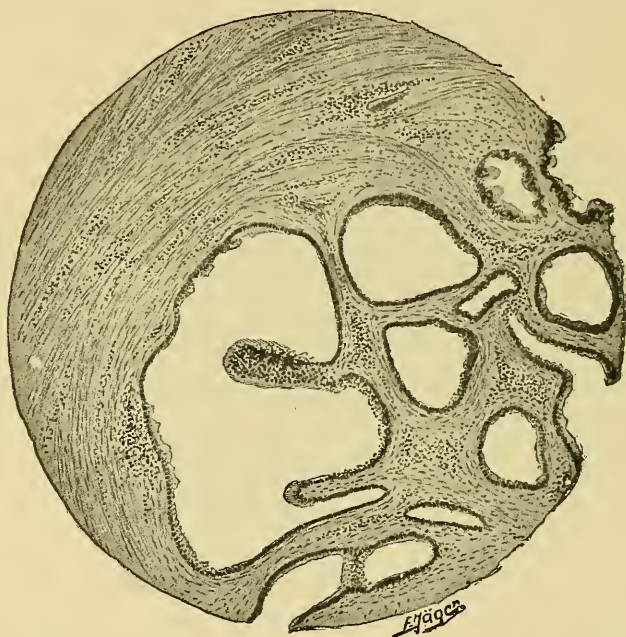


FIG. 150.—Salpingitis Pseudofollicularis. (Author's preparation. Zeiss, Obj. AA, Oc. 2.)

from a puerperal infection. However, they may perish also earlier. The *tubal pus* is found to be *sterile* in these cases. If communications or very intimate adhesions with the intestines exist, a rich flora in the tubal pus is preserved by migration from the latter (bacteria coli).

For the behavior of the tubercle bacilli see chapter *Tuberculosis*.

The inflammatory processes, however, do not always attain such a degree that the extreme changes just described result from it. The infection may also reach its termination during earlier stages; in the latter instance it leaves behind, it is true, also its traces, but the destructions are not of such a severe nature. An agglutination of a few or a group of tubal folds may take place with a preservation of the epithelium, so that saclike, apparently cystic spaces arise in the tubal walls: *Salpingitis pseudofollicularis* (see Fig. 150). The tubal wall in this condition

is also thickened by connective tissue, infiltrated by round cells, and *serous* contents are often found in the tubal lumen without the fimbriated end being of necessity always closed.

In other cases with a *closure* of the fimbriated end, larger or smaller tubal sacs with *serous* contents develop, *sactosalpinx serosa*, *hydrosalpinx* (see Fig. 151). It is not quite clear how these serous contents are formed. The closure of the fimbriated extremity has certainly originated upon an *infectious* basis, and we must therefore assume that the tubal mucous membrane was also infected.

Many authors suppose that originally a *sactosalpinx purulenta* did exist, but that the pus, however, changed gradually to a serous exudate

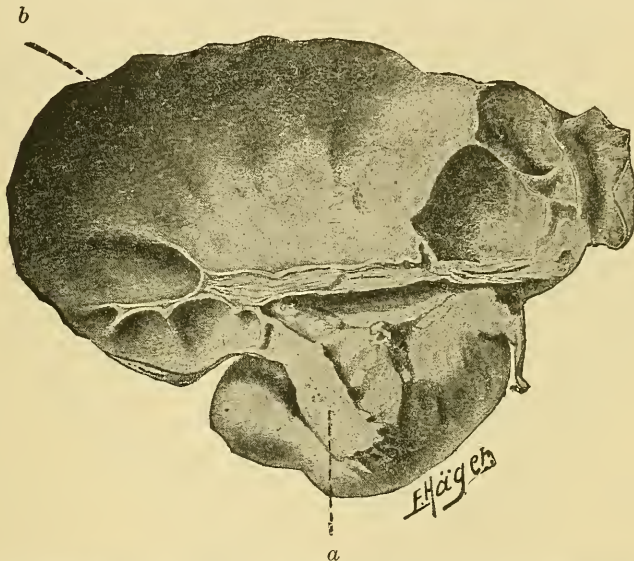


FIG. 151.—Sactosalpinx Serosa. *a*, uterine end of tube; *b*, saclike distention of the closed tube. (Author's preparation.)

after the death of the bacteria. Yet the genesis of this transformation cannot be explained so that it would be free of any objections.

The supposition of a simple retention of a physiologic secretion cannot be accepted, as such can occur only to a limited extent in the tube. It seems to me that the hypothesis that has the best claim for probability is, that during the original primary infection the closure of the fimbriated end developed rapidly, and that then before a pus formation appeared the bacteria perished in the closed sac, and then the purely serous contents, increased by transudation from the vessels, remained behind. At all events we have never succeeded in many experimental cultures in demonstrating micro-organisms in the serous tubal secretion.

The walls of the serous sactosalpinx are mostly not thickened in contradistinction to the purulent form, but are very much thinned by passive distention to a transparent membrane, thin, like paper, whose smooth

musculature is almost entirely atrophied and only demonstrable in traces. As a result the tubal folds are smoothed out to a large degree, although a few folds may still be recognized as scanty, small ledges upon the inner wall of the sac (see Fig. 152).

If for any reason an *escape of blood* takes place into a sactosalpinx serosa or purulenta, then the sac receives *hemorrhagic* contents—*sactosalpinx hemorrhagica, hematosalpinx*. In most cases this is traceable to a *tubal pregnancy* (see this chapter); in some cases, however, such a pregnancy cannot be demonstrated. Then the escape of blood is attributable to a stasis; for instance, by torsion of the tube or by pressure of tumors (myomata, ovarian tumors) or by erosion of vessels by inflammatory processes. In contrast to the sactosalpinx hemorrhagica arising during tubal pregnancy, whose contents are mostly clotted, they tend to be mostly a thin fluid in the inflammatory form. See above for

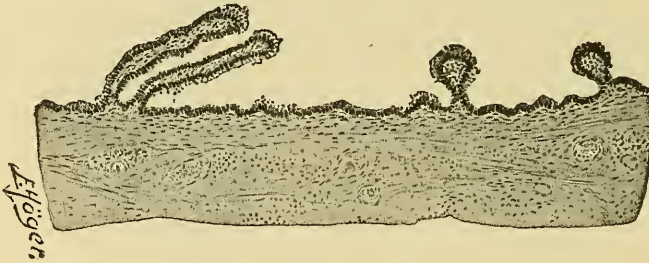


FIG. 152.—Tubal Mucous Folds upon the Highly Thinned Tubal Wall in Sactosalpinx Serosa. (Author's preparation. Zeiss, Obj. AA, Oc. 4.)

the sactosalpinx hemorrhagica developing during the *malformations* of the lower parts of the genitalia.

In a relatively small number of cases it is true it has been observed that such serous sactosalpinges forced their contents toward the uterine end into the cavity of the uterus by the pressure of their walls distended to the maximum, whereby a sudden profuse outpouring per vaginam was occasioned with a disappearance at the same time of the tubal sac for the palpating hand, *salpingitis profluens*. Little by little the sac fills again; with a maximum distention the evacuation results in the manner described, and thus the process may often repeat itself. The alternation between filling and evacuation also appears then distinctively in the symptoms (see below under *Symptoms*).

It must, after all, be admitted in these cases that a considerable secretion, occasioned by inflammatory irritation, takes place within the tubal sac.

The *ovary* becomes involved in the majority of cases of inflammatory processes of the tube. Both organs are mostly fixed to each other by very intimate adhesions; the so-called *tumor tubo-ovarialis* arises. The stroma of the ovary also undergoes inflammatory changes. With purulent processes in the tubes abscesses occur and with serous salpingitis

the changes comprised under the name *chronic oophoritis* (see chapter *Ovaries*).

If the tube has been transformed into a sactosalpinx serosa or purulenta a direct communication may take place between the tubal sac and the cavities of the ovary, which have also an inflammatory origin. Thus suppurating or cystically degenerating *follicles* or corpus luteum cysts arise.

Under these circumstances the so-called *tubo-ovarian tumor* is produced (see Figs. 153 and 154).

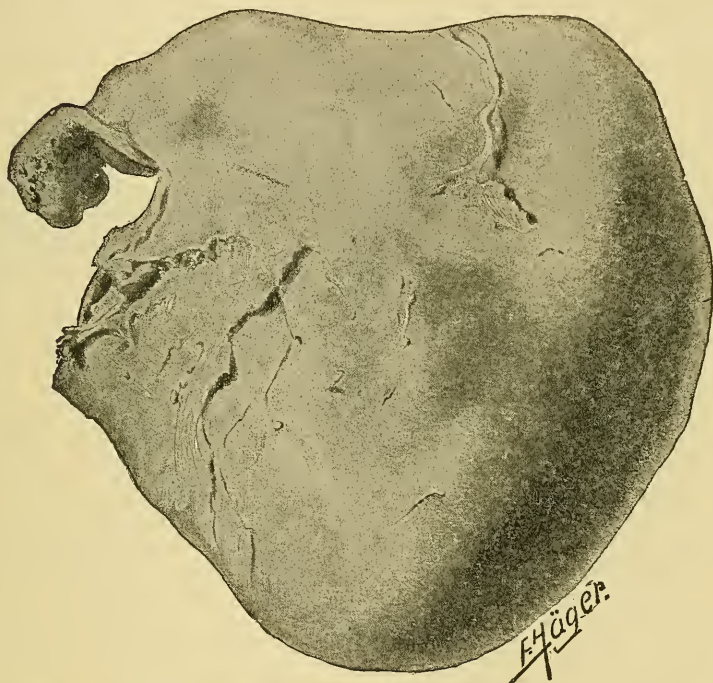


FIG. 153.—Sactosalpinx Purulenta Cum Abscessu Ovarii. (Author's preparation.)

The process is to be explained by supposing that first the tubal sac, filled with serous or purulent contents, whose fimbriated extremity was also primarily closed by inflammation, becomes adherent to the ovary.

By internal pressure in both cavities the separating wall becomes thinned more and more, until it finally ruptures and the communication is formed. The *still open* fimbriated extremity may, however, become adherent to the cystic degenerated ovary and here grow together with it so that a cystic cavity of the ovary may rupture into the tube.

In both cases a tubo-ovarian tumor is formed of typical *retort-like form*, on whose outer surface the transition can be recognized mostly with difficulty or not at all (see Figs. 153 and 154).

On *section* the boundary, however, is mostly very distinctly marked in the preparation, because the place of the former fimbriated crown is

brought into contrast by a sharp ridge on the inner wall of the cavity (see Fig. 154). Microscopically an immediate transition from the tubal epithelium to the lining of the ovarian cyst is found, if the epithelium has not become destroyed altogether by the *purulent contents*.

It is a peculiarity common to all tubes changed by inflammatory infection that they become adherent very rapidly and very intimately with the neighborhood. The parietal peritoneum of the excavatio recto-uterina as well as the visceral peritoneum of the intestines, particularly of

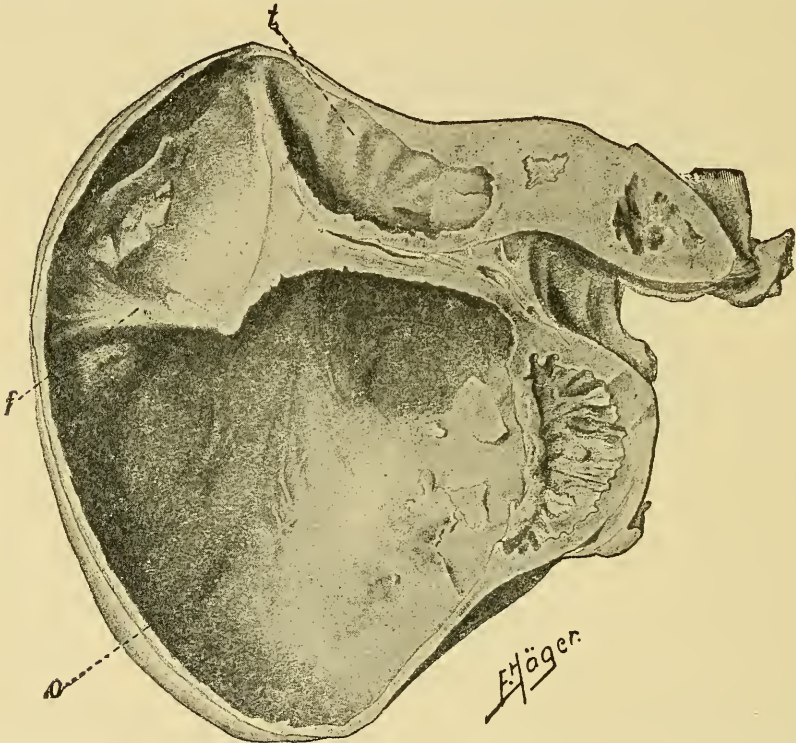


FIG. 154.—The same preparation as Fig. 153 in Transverse Section. Distinct *retort-like form* of the entire tubo-ovarian tumor. *t*, tube; *f*, remnants of the fimbriæ; *o*, ovarian abscess.

the sigmoid flexure, the cecum, the uterus, and the bladder, are drawn into these adhesions, which may become very firm by long-continued existence, so that a separation of the tube or the organs adherent to it is impossible. This may lead to detrimental complications above all in the intestines or the bladder, especially during operative procedures.

During the course of *purulent* tubal diseases a direct rupture of the tubal sac into the bowel or bladder may take place whereby a putrefaction of the contents of the tube usually occurs. But also without direct communication, the adhesions with the *intestines* may lead to an invasion of bacteria into the tubal sac, even if its pus was previously sterile.

For the *diseased* intestinal wall is permeable to the bacteria of the intestinal contents, as numerous experiments have proven.

In this manner, for instance, a sactosalpinx purulenta gonorrhoeica, in which the gonococci have already perished, may become inhabited again by bacteria from the intestines and a tuberculous diseased tube may secondarily become infected with septic bacteria. It is naturally very important for therapeutic purposes to keep this possibility always in mind.

The final *termination* of the sactosalpinx serosa and purulenta, whose course is not interrupted by therapeutic interference, tends to coincide with the natural climax. With abolition of the sexual functions and their periodic hyperemia, the contents of the tubal sacs become absorbed, the entire tube contracts, even if its walls were strongly thickened, and is finally left with its more or less intimate adhesions on the pelvic floor together with the equally atrophied uterus. A necessary condition for this termination by atrophy is that the pyogenic organisms have died and that a new infection is not constantly maintained, perhaps from the intestines. Such cases, however, tend to demand sooner or later almost always an active interference, and can seldom be left to their natural termination until after the menopause.

Tumors of the Tubes

LITERATURE: See *M. Sanger, Die Neubildungen der Eileiter* in *A. Martin Handb. d. Adnexorgane*. Leipzig, Georgi, 1895. *Frommel's Jahresber. uber Geb. u. Gyn.*, 1896-1905.

Primary newgrowths of the uterine tube belong to the greatest rarities and have therefore only a minor practical interest in comparison to the other diseases of the oviduct.

The great majority of all known primary tubal tumors belong to the *mucosa*, only a few concern the wall.

Of the benign tumors of the mucosa, *polypi* occur in rare cases which, however, only attain a practical importance if other pathologic conditions are induced by them (see *Tubal Pregnancy*).

Quite as rarely *benign papillomata of the tubal mucosa* have been observed which distend the lumen of the tube as villous, waving tumors. They originate just as the polypi, always upon the basis of chronic inflammations of the mucous membrane.

Relatively the most frequent newgrowth, yet until now seen only in about fifty to sixty cases, has been observed in *primary tubal carcinoma*, which has been first described by *Orthmann*. This also is always of a *papillary construction*, and originates mostly on the basis of a chronic salpingitis (see Figs. 155 and 156).

The preparation represented in Fig. 155 was obtained from a fifty-six-year-old woman, *Fr. Sch. J.*, No. 366, 1904-1905; 3-para, with increase in size of the abdomen for the last three months, and occasional pains.

Large tumor, reaching a hand's breadth above the navel, localized especially in the right half of the abdomen, with a partially cystic and partially solid feeling. Uterus markedly elevated and deviated to the left. Laparotomy: Sausage-shaped tumor of the right tube, which continues into a cystic tumor of the right ovary. Separation of quite extensive adhesions with the omentum, small intestines, and serosa of the pelvis. The ovarian tumor burst and evacuated putrefactive, ill-smelling contents into the abdominal cavity. Drainage upward and downward. Exitus by septic peritonitis.

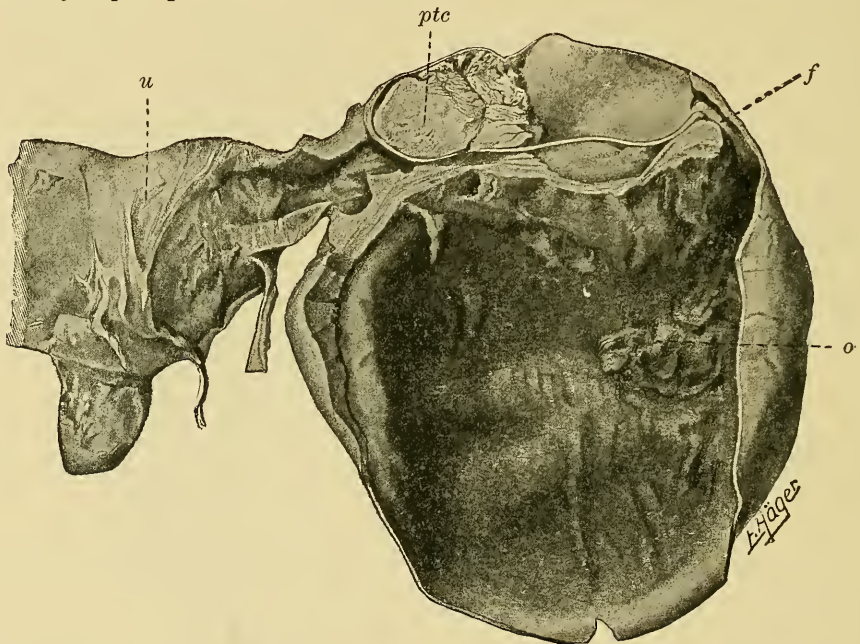


FIG. 155.—Primary Tubal Carcinoma. *u*, uterus; *ptc*, primary tubal carcinoma; *f*, fimbriated extremity which forms a communication with the ovarian cyst, *o*. (Author's preparation.)

So-called *adeno-myomata* of the tube like those of the uterus have been described recently (*v. Recklinghausen*). (See *Tumors of the Uterus*.) They are located mostly close to the uterus on the tubal angle, but may appear also at the isthmus tubæ. They are traced by many authors, particularly by *v. Recklinghausen*, mostly to a proliferation of epophoral, scattered embryonic cells. My own observations have brought me and many others to the conviction that these newgrowths are quite often of an inflammatory origin, and thus conform to the so-called salpingitis isthmica nodosa.

They seldom attain a considerable size, mostly only about the circumference of a walnut, and consist of smooth musculature with connective tissue and numerous interspersed epithelial ducts, whose connection with the tubal mucosa is at times still demonstrable.

Finally, it must be mentioned that in quite rare cases also *embryomata* (dermoid tumors) have been observed in the tube (*Orthmann*).

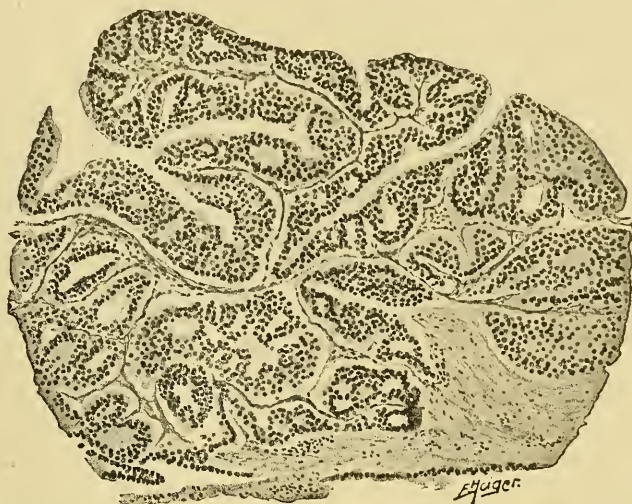

FIG. 156.—Microscopic Section of the Preparation Represented in Fig. 155.
(Zeiss, Obj. AA, Oc. 4.)

They do not differ materially in their anatomic and clinical demeanor from the *ovarian embryomata* (see *New-Formations of the Ovary*).

Malignant tumors of neighboring organs may *secondarily* invade

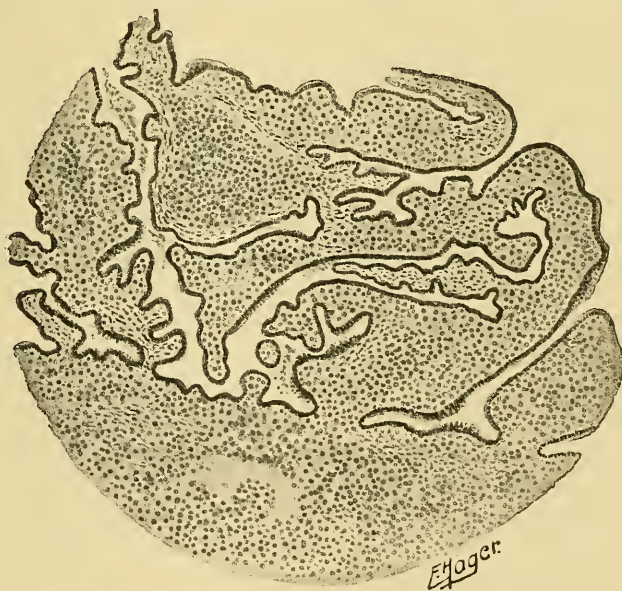

FIG. 157.—Round Celled Sarcoma of the Tubal Mucosa in a Primary Ovarian Sarcoma.
The mostly still intact epithelium overlies the sarcomatously degenerated tubal folds. (Author's preparation. Zeiss, Obj. AA, Oc. 4.)

the tube *in continuo*. This occurs very early in malignant ovarian tumors (see Fig. 157). Carcinoma corporis uteri also frequently encroaches on the tube *in continuo*.

Clinical Signs

The disturbances of nutrition of the oviducts, *salpingitis*, have no pathognomonic *symptoms* in their different stages of development. They are not primary diseases, they develop under the influence of very different agents capable of exciting inflammation. The disease only rarely becomes exclusively localized in the oviducts. With predominant frequency inflammatory processes of the vagina and uterus have preceded those of the tubes. Often the process soon encroaches on the pelvic peritoneum and ovaries, if it has not spread from these organs downward to the tubes.

As a rule the *symptoms* also of *salpingitis* are part phenomena of an endometritis or of a pelvic peritonitis. While in the beginning the endometritis, as a rule, precedes with its chronic symptoms, the pelvic peritonitis develops almost at the same time as the salpingitis and causes in its turn such stormy symptoms and afterward such intense disturbances in all pelvic organs that the salpingitis recedes in comparison almost completely and the former entirely dominates the picture of the disease. We certainly see cases with intense pains, in which we find only the tube inflamed, as shown by palpation and a subsequent laparotomy. We encounter, however, also extensive sactosalpinges whose occurrence has not made any lasting impression on the state of health of the patients, as also in diseases of the pelvic peritoneum.

This holds especially good for the salpingitis, which was formerly termed *catarrhal*, for which we are not in a position to demonstrate at present the bacterial cause of the inflammation. It holds good, however, also for the cases whose infective bacterial agents are known, the most significant being salpingitis *tuberculosa*, and in isolated cases also *gonorrhoeica*, even also septica. All these forms have the common feature that the disease may appear like a catastrophe after an apparently quite insignificant trauma, not seldom after an awkward examination and after a menstruation apparently otherwise not disturbed.

Acute salpingitis, however, may also cause *intense pains*. We become acquainted with the type of such an acute painful stage in a gonorrhoeal salpingitis. Peritonitic irritability in the form of intense sensitiveness to pressure, nausea, and distention of the abdomen are seldom absent. These pains have frequently been designated "tubal pains," "colica scortorum," on account of their coliclike appearance. It is very questionable whether the tubal muscularis contracts, for it is strongly infiltrated in these cases and the muscles are, as a rule, hardly able to functionate.

The acute disease passes by at times with a *febrile reaction*. However, as in these cases the tube alone is very seldom diseased, it remains

a question in how far the tubal process can be blamed for the elevation of temperature. That fever occurs particularly with the puriform softening is unquestionable.

Under the name of *hydrops* or *sactosalpinx profluens* cases have been described with an intermittent or continuous evacuation of the tubal contents through the uterus outward. These cases play a certain rôle in the literature without being able to claim an equal importance in practice. As I could demonstrate in my handbook, in 1895,²⁷⁴ I had at that time under approximately 1,700 observations of salpingitis only eight cases in which I observed this peculiar symptom.

The symptoms of uterine catarrh have mostly preceded it for a long time. After a less important disturbance of the state of health (for instance catching cold, influenza, bodily exertion), the discomfort until now perceived as a dull pain in the one or the other side increases to a violent drawing pain. In spite of every kind of treatment symptoms of peritonitis appear, also disturbances of the bladder, the uterus, and the bowel. A sudden relief ensues after this prelude has lasted for some hours to several days.

The evacuation through the uterus significantly ensued only twice during my observations, immediately after the abatement of the pains, which then ceased as if cut off. In other cases only an increase in the secretion was noticeable. It appeared to be watery, blood-stained, of a stale odor. The pain decreased gradually in a marked manner, interrupted by insignificant exacerbations; relapses, however, only very mild, resulted for several years at each menstruation. Such pains developed only every four or five months to a severe degree. One of my patients was approaching the climacteric, the other was twenty-seven years old when the ailment began. In other cases the symptoms appeared suddenly after a relatively painless progress of several menstruations, to recur for years with moderate intensity and then gradually to disappear.

In all my observations sactosalpinges serosæ were concerned. In gonorrhoeicæ, exacerbations of the difficulties occur not rarely at the time of the menses, and increased secretions appear without it being possible to speak of a typical sactosalpinx profluens.

Among the symptoms of salpingitis chronica, sensations of pain and interference with the function of the neighboring organs are especially prominent. With these are most intimately and essentially combined also those changes of the peritoneum and ovary which develop at the same time as the sactosalpinx. The *gonorrhœal* forms of salpingitis and sactosalpingitis are distinguished by the more or less acute development, the relatively frequent decrease in the intensity of the process after only a short duration, and the renewed exacerbations with the slightest injury, especially at the time of menstruation and during medical interference.

The *septic form* exhibits less marked symptoms in its acute stage than the parametritis, eventually peritonitis appearing at the same time.

While, however, the parametritis heals comparatively in the great majority of cases sooner or later, the tubal disease continues to exist in a chronic stage. After months and years, when the function of the lymph- and bloodvessels proceeds apparently normally in the parametrium, the tubal sacs and the chronic inflammation of the ovary with their adhesions cause at times a slight sensation of pain, at others occasionally stormy symptoms (fever, pain, perimetritic symptoms).

Tuberculous salpingitis shows, as a rule, an exquisitely chronic course with symptoms often completely latent for years, then to cause acute phenomena (especially with purulent softening) in connection with another localization of tuberculosis.

The tubal diseases caused by other pathogenic germs (*bacterium coli*, pneumococcus and the like) develop, as a rule, also more or less brusquely and lead to softening and abscess formation or yield with a slow extinction to a sort of cure according to the virulence of the germs and their quantity.

Inflammatory processes occur with a considerable frequency **bilaterally**, usually first on one side and then on the other, so that the process is almost healed in the one tube when the extension of the infection to the other tube begins.

Among the **symptoms** of salpingitis chronica, **disturbances of menstruation** play a very serious rôle. We should, however, not forget that thereby the uterus primarily, then also diseases of the peritoneum and ovary extending from the tube, must be made prominently responsible for the **dysmenorrhea**, the former also for the abundant hemorrhages during and between the menses. Obviously disturbances of the uterine function occur also in the tubal processes diseased in a descending manner, to which *Czempin* called attention in 1896. It is left undecided how far this descending process encroaches thereby upon the endometrium.

The disease of the tube is considered in quite a special manner a cause for **sterility**. Particularly gonorrhœa is made responsible for those frequent cases in which pregnancy, happening shortly after marriage, terminates by an abortion, as well as the cases of so-called **one child sterility**. My conception of these cases does not quite coincide with the general view, at least in so far as I consider as responsible for it above all the preceding endometritis. Further, however, I desire to judge the disease of the tube alone as altogether milder in this sense, especially in reference to gonorrhœa. I have observed, especially in private practice, too many cases of salpingitis, clinically unquestionable and almost positively diagnosed by the demonstration of the gonococcus, at any rate in the uterine secretion, in which women later on conceived repeatedly and had normal labors.

The often cited observations of *Krönig* of continuous indisposition of gonorrhœically infected puerperæ, I am inclined to attribute to a renewed disease. At least similar patients under our observation²⁷⁵ recovered

after long care and nursing, and even passed undisturbed also through succeeding pregnancies.

Diagnosis.—The diagnosis of the disease of the tube can be accomplished only by palpation on account of the absence of a characteristic symptom-complex. This palpation, indeed, presupposes an extensive practice and experience in bimanual examination. Whoever makes it his business to locate the adnexal organs in each and every case after exact palpation of the uterus, will succeed with some aptness in palpating also the isthmus tubæ in the great majority of his patients. One may succeed, then, if particularly fat or sensitive abdominal walls or an abnormal hindrance through the unyielding introitus or filled rectum do not exist, in palpating the tube to its abdominal termination, if it is only thickened to a slight extent. One gains then also with increasing practice the capability of detecting an abnormal sensitiveness of this organ. Inflammatory processes of the uterus, peritoneum, and ovary aggravate naturally the palpation not only through the resistance of the patient, but also from the consideration of the possibility of doing harm.

If one succeeds in palpating the thickened tube, then it appears, in the condition of **chronic inflammation**, as a cord of a size varying from the thickness of the little finger to that of the thumb. The mobility suffers through the infiltration of the mesosalpinx as well as the peritonitic adhesions; still more when at the time of the acute disease massive exudations and extravasations formed in the peritoneum, whose residues occupy the pelvis.

At times hard knots are felt at the commencement of the oviduct, one or several beside each other, one in the interstitial part of the tube, others are to be felt like a string of pearls, **salpingitis isthmica nodosa**. As it was elucidated above, this form of change in the tube is to be considered as characteristic neither for the gonorrhœa nor tuberculosis.

Sactosalpinges swell up the ampulla, as a rule, like a club. They are united to the uterine cornu as with a thin stem. This latter is hard and strongly thickened. However, the circumference of the closed tube always increases toward the distal end. The thick, clublike tubal end sinks down posterior to the side of the uterus into the depth of the excavatio recto-uterina. Here it may occupy the entire space. Sactosalpinges, particularly with serous contents, may also reach the peritoneal cavity just as ovarian tumors. Even torsions of the peduncle have occasionally been observed in such cases.

In the formation of these voluminous sactosalpinges the **ovary**, as a rule, participates with the development of retention follicles with serous, bloody, or purulent contents. Ovary and sactosalpinx agglutinate with each other and with their surroundings by perimetritic adhesions. The tubo-ovarian tumor then fills the pelvis, where it becomes frequently fixed by peritonitic adhesions to the posterior wall of the ligamentum latum (**pseudo-intraligamentary development**).

The tumor may appear to be located farther forward and adherent in

this place, while occasionally it comes to lie on the fundus uteri. It may move upward into the large peritoneal cavity and here represent one single large tumor on account of the intestinal loops being firmly adherent to it. Such extensive masses I have seen not quite rarely in my Berlin material, they have been noticed quite isolatedly in Greifswald. They are mostly of the size of a child's head up to two fists, and diminish toward the uterine cornu. The rounded end found in this mass of adhesions, which are not any more soft and already organized, is easily detected by the finger, advancing through the vagina or rectum. It is frequently possible during the course of resolution to palpate, in this convoluted or serpentine mass, a body, characterized by its consistency and roundish form—the ovary. In oophoritis chronica, the single distended follicles may at times be palpated.

Blood-filled cavities are mostly somewhat softer than those with serous contents. After puriform softening the doughy character of these may be felt. The abscess is at times markedly sensitive on palpation. Not seldom in the large mass the proximal part of the ovary at the ligamentum ovarii proprium may be palpated. The palpation must be further continued with the greatest care, as soon as only a suspicion of a sactosalpingitis is suggested by the anamnesis as well as in cases of oophoritis and perimetritis. Rupture of the sac with diffusion of contents besides hemorrhage are to be expected. We know of cases in which these dangerous results appeared after palpation in clinical courses but passed over without severe results. We also had to combat such cases with immediate laparotomy and direct the arrest of the hemorrhage respectively by removal and drainage. In view of this, *Hegar's* manœuvre (pulling down of the uterus at the portio and palpation above the uterus through the vagina and rectum and abdominal walls) also must appear as a procedure not without danger.

The *diagnosis* of salpingitis follows in very many cases from palpation as soon as the corresponding anamnesis is known. It is then of the greatest importance to establish in how far virulent germs are still capable of development. Although gonococci from cultures even many years old can still be propagated, experience teaches that this danger exists only exceptionally. Septic germs remain still very dangerous after years. Especially through the invasion of the bacterium coli such old sactosalpinges become complicated in the most serious manner. In tuberculosis the danger exists in that other foci become mobile in a detrimental manner.

In the difficulty of determining the actual degree of virulence of the contents of the tube the observation of *leucocytosis* in the patients' blood has aided us materially for years in sactosalpinx as well as in other conditions. Observation of the condition of the leucocytes for several days, each and every time performed at the same hour of the day, has only rarely failed us. We supplement it by careful and frequent measurements of the body temperature, by which slight and short-lived rises

in temperature can be established after repeated and thorough explorations.

In the *differential diagnosis extrauterine pregnancy* comes first in question. We shall have to enter later into the diagnostic signs of the beginning stages. Here we will especially refer to the fact that the irregularity of menstruation must be carefully observed with the other changes of pregnancy. The swelling of the uterus, its livid discoloration, eventually the proof of a uterine decidua gain quite certainly a deciding importance. In sactosalpinx hemorrhagica at times a sudden disturbance of the state of health (anemia) is observed which is not possible in sactosalpinx purulenta. Extrauterine pregnancy appears with a pronounced enlargement of the uterus, softening of the same, and strong pulsations of the vessels in the pelvis, as long as the ovum is intact. This is seen in salpingitis only during the stage of very recent inflammation. With this there always exists an active pyrexia. This accompanies on the other hand, however, also the puriform softening of sactosalpinx hemorrhagica. These points allow in very many cases a differentiation between sactosalpinx serosa or purulenta and the tubal implantation of the ovum.

We confess, however, unreservedly that we have not been spared from wrong diagnoses, even at present, and that we therefore examine every single case with quite especial care.

Sactosalpinges are often not easily distinguished from *tumors of the ovary*. In reference especially to the diagnosis of the early stages of ovarian tumors we emphasize the fact that the participation of the tube in the ovarian newgrowths only very seldom consists in the development of a sactosalpinx. The tubes in ovarian tumors are mostly considerably lengthened, but only seldom thickened and hard in their consistency. This change belongs to salpingitis and its final stage, sactosalpinx, as pathognomonic.

Tumors of the uterus, therefore, chiefly *myomata*, may be mistaken for sactosalpinges. The latter are occasionally so grown together with the fundus or the upper portion of the corpus, that they appear to originate from it. Their consistency may resemble perfectly the one of the subserous myoma. The enlargement of the uterus, as it can be demonstrated especially by the sound, and the hemorrhages characteristic of the development of myomata, also the slower course of development of myomata must assist here. In the history of the sactosalpinges thus adherent, the occurrence of a feverish puerperium, or of a previous infection will be hardly ever denied.

To differentiate *perimetritic* exudates and also intraperitoneal hemothecoele from sactosalpinx offers in the beginning often extraordinary difficulties. The tube participates intensively in the progress of the illness. The perimetritis originated from the salpingitis, the hemothecoele from the tubal pregnancy. Perimetritides arise only rarely without salpingitis. In referring to the special diagnosis of perimetritis and

hematocele, I lay stress on the fact that the deformed tube and ovary during the stage of resolution, as a rule, become palpable anteriorly and laterally to the mass which fills the excavatio recto-uterina.

Prognosis.—Contrary to former opinions I incline to-day to consider the prognosis of salpingitis as serious indeed in the large majority of cases, but not as absolutely unfavorable. Let us consider the frequency with which cases, designated as catarrhal, whose source of infection we do not know as yet, are overcome without lasting damage.

How many women fall ill with septic puerperal processes in which surely the tube participates without suffering permanent damage! How often is gonorrhœa, the commonest human plague next to tuberculosis, accompanied by a serious and stormy development beyond the place of original infection, and how many such patients overcome the process without permanent damage! Tuberculous salpingitis appears to me at present as the most serious. This finds its explanation in the fact that the localization in the tube, as a rule, is only a part symptom of the illness. If a formation of sactosalpinx has occurred, then the capability of function of the oviduct is of course interrupted. Healing without artificial opening can well take place during the course of resolution, so that further disturbances are not caused by it. The sactosalpinx, however, always remains exposed to the danger that the micro-organisms not yet completely perished may develop anew on account of hyperemia or other disturbances of nutrition. In this sense these processes retain a serious importance, not only as a source of sterility, but also as a dangerous locus minoris resistentiæ.

Puriform softening in tubal disease is unquestionably a serious danger. If, however, the pus escapes or is evacuated, such women may still recover and even conceive, as the experience of the clinic of *Chrobak* and the Greifswald clinic shows.

Treatment.—If we are permitted to speak of a prophylaxis in infectious processes, it also applies in salpingitis. The danger of an ascending of all inflammatory processes of the external genitalia, the vagina and cervix must be an earnest warning to treat them promptly. If the diagnosis has been made one should always abstain during the acute stage and far beyond it from the local treatment with sounds, specula, introduction of cauterizing agents, atmocausis which seems to be too popular. Undoubtedly treating the uterus with the curette, or orthopedic attempts, pessary treatment are better dispensed with completely. Finally, one correct, aseptically performed operation by all means is preferable to often-repeated local treatment (office treatment).

A serious opportunity for the further dissemination of pathogenic germs is marital intercourse. The prophylaxis of salpingitis and perimetritis following it, justifies an absolute interdict for the husband. This holds good the more, if the male is still ill with gonorrhœa or suffers from tuberculosis of the testicle. Masturbation also acts seriously in this sense, so that one is almost obliged to refer to this danger when

definite signs point to a suspicion of it (hypertrophic clitoris, flabby labia, erethistic attacks).

The **treatment** of tubal inflammations in the acute stage is begun with absolute rest in bed, ice-bag or coil to the abdomen, prohibition of coitus. Every kind of local treatment on the part of the physician is omitted. I attach great importance to the administration of mild laxatives. With profuse and burning discharges I order, very carefully given, vaginal douches with lukewarm table-salt solution or 1:2000 solution of thymol.

A powerful curative factor, far in advance of all formerly used measures, is the **hyperemia** after *Bier*. Its use is appropriate, as soon as the patients have been free from fever for several weeks. Then ten to fifteen sèances, at intervals of one or two days, secure very frequently a surprising progress in the organization of sactosalpinges. Quite especial care is demanded in tuberculosis. Such a treatment is further augmented by sitz baths in decoctions of oak-bark (32° C. or 89.6° F.), hot irrigations (50° C. or 122° F.), Priessnitz compresses, by a strengthening diet, rational alternation of rest in bed and comfortable exercise in the open. The above-mentioned therapy (p. 214 and following) for the stimulation of absorption and organization leads to the desired end in many cases, especially with complete rest of the genitalia. Mud and brine baths, sojourn at the seashore and in the mountains stimulate metabolism and promote nutrition, and thereby exercise a beneficial influence also on these chronic conditions. Treatment by massage, particularly uterine, for instance for bringing about an evacuation of the tubal contents has been at present quite generally abandoned. Massage in sactosalpinx must always be considered as an uncertain undertaking. As the diagnosis of the contents gives rise to many doubts, and the danger of expelling the infectious material cannot be foretold, it is imperative to desist from such a treatment, as long as these structures are still sensitive.

Continued fever and pains, the symptoms of a serious absorption (increasing pulse-rate, loss of strength) threatening rupture of the sactosalpinges into the vagina, bowel, the abdominal walls, the bladder, or even the peritoneum indicate an **operation**.

In the **operation on the diseased tube** it may be considered whether it is absolutely necessary, in a given case, to remove it completely. One or both ovaries, that is the entirety of the bilateral adnexal organs, are then also usually removed. Considering the results which threaten to follow such radical procedures in the form of an artificial climax we cannot sufficiently urgently refer to the fact that this operation must be limited to the most extreme cases of necessity. Certainly it cannot be denied that the women must be saved under circumstances from a continued invalidism caused from chronic salpingitis and the oophoritis and peritonitis which, as a rule, accompany it. Our experiences, however, impel us always more and more to have recourse to an operation only

when the acute disturbances cause an immediate danger to life, and in the chronic stage only when the above-mentioned directions for the promotion of absorption have been made use of in a patient manner, but without any result.

Vaginal Operation for Salpingitis and Sactosalpinx

We prefer this method to the abdominal operation, as long as palpation assures one a clear perception, especially as regards adhesions with the bowel. As long as clinical observation and the control of the condition of leucocytosis justify the supposition that the contents are no longer virulent the operation is undertaken through the anterior vaginal incision. In view of the almost regular complication with endometritis the operation is begun with a thorough curettement of the endometrium. Anterior vaginal incision, as described on p. 102. The uterus is brought forward and with it, under complete control of the eyes, the tubes and ovaries, after they have been freed from adhesions if necessary. For protection against the escape of tubal contents lap-pads are placed behind the tubes. Finally one succeeds, as a rule, with the use of gauze sponges in bringing forward the adnexa. If the contents of the tube are not suspiciously virulent (salpingitis chronica catarrhalis, sactosalpinx serosa), I clean out the tube with an irrigation of a normal saline solution. I construct a new ostium after an incision in the sactosalpinx by suturing the tubal mucosa outwardly to the peritoneal tubal coat.

This manner of opening and new-formation of the ostium offers, according to experience, the possibility of a perfect restitution. Moreover it does not exclude the occurrence of a normal pregnancy.

The request is out of place that one should inform himself before such a salpingo-stomato-plastic about the potency of the male. A not small number of our patients, in whom we performed this operation, were unmarried at the time. For married people such a restitution of the sexual functional capacity has certainly a high value. Think only of the possibility that these women as widows may enter a new marriage.

With suspicious contents the excision of the tube follows, after the adnexal organs of the other side have been examined. If the ovary is healthy, then only the tube is removed after the mesosalpinx has been ligated in not too large sections. If after section of the uterine tube the uterine end appears diseased, then this is eventually entirely excised out of the uterine cornu. The cut surface is covered with peritoneum by a continuous suture.

The termination of the operation follows after careful arrest of hemorrhage eventually, also from the severed peritonitic adhesions.

Even with bilateral tubal inflammation the simultaneous removal of the uterus appears to me only justified, if the latter is diseased.

Abdominal Operation for Salpingitis and Sactosalpinx

If the vaginal operation is contraindicated on account of the extent of the sactosalpinx or the indistinctness of the findings, the operation through the opened abdominal wall is the indicated procedure. See the details under the directions for abdominal ovariectomy.

If **pus tubes** necessitate operation, while slight elevation of temperature and high leucocyte count justify the assertion, that the contents are still capable of infection, we have desisted from the extirpation of the adnexal organs and only drain them.²⁷⁶

The widely existing supposition that the **incision and drainage** of such purulent foci through the vagina does not suffice for a complete cure of the same is disproved fully also by our experience. The often observed cure encourages at all events to continue upon this path. At any rate these results absolutely speak against the radical procedure, in which eventually even with unilateral sactosalpinx also the uterus and the not at all hopelessly diseased adnexal organs of the other side are removed.

The incision is carried out at the accessible place in the vaginal vault, step by step, down to the diseased area. After the bleeding vessels have been looked after, the pus cavity is opened, irrigated with normal saline solution, the abscess membranes are removed with a sponge, a rubber T-drain inserted, and next to it sterile gauze. The gauze is removed on the second or third day, the drain according to the progress of the contraction. Occasionally absorption may be promoted by irrigations of tincture of iodine and potassium iodide solution, beginning after the second week. After the fever has completely disappeared (ten to fourteen days) hyperemia in a sweat-box, with good general care, leads mostly uniformly to a recovery.

Tubal Pregnancy

LITERATURE: *Werth in v. Winckel's Handbuch der Geburtshilfe*, 1905.

Tubal pregnancy, although in a strict sense belonging to obstetrics, is in such a pronounced manner a gynecologic ailment, that its discussion appears to come unavoidably within the limits of a gynecologic text-book.

We understand by tubal pregnancy the implantation of an impregnated ovum in the tube instead of the uterus.

This imbedding may take place in different parts of the organ. We distinguish according to the placement of the ovum three forms which, arranged in the order of frequency, are the following:

1. **Graviditas tubaria ampullaris**, implantation of the ovum in the ampulla tubæ.

2. **Graviditas tubaria isthmica**, implantation of the ovum in the isthmic portion of the tube.

3. *Graviditas tubaria interstitialis*, implantation of the ovum into the interstitial portion of the tube, i. e., within the uterine wall.

As the fecundation of the ovum takes place in all probability in the ampullary portion of the tube, as has been demonstrated in many mammalia, or "each pregnancy begins extrauterine" (*Strassman*), the possibility of a tubal pregnancy is present at all times.

We are well informed about the modus of the imbedding of the ovum within the tube by the experiments of *Werth* and *Füth* among others. The ovum, after penetration of the epithelium, buries itself in the tube into the mucosa, just as it does in the uterus into the decidua.

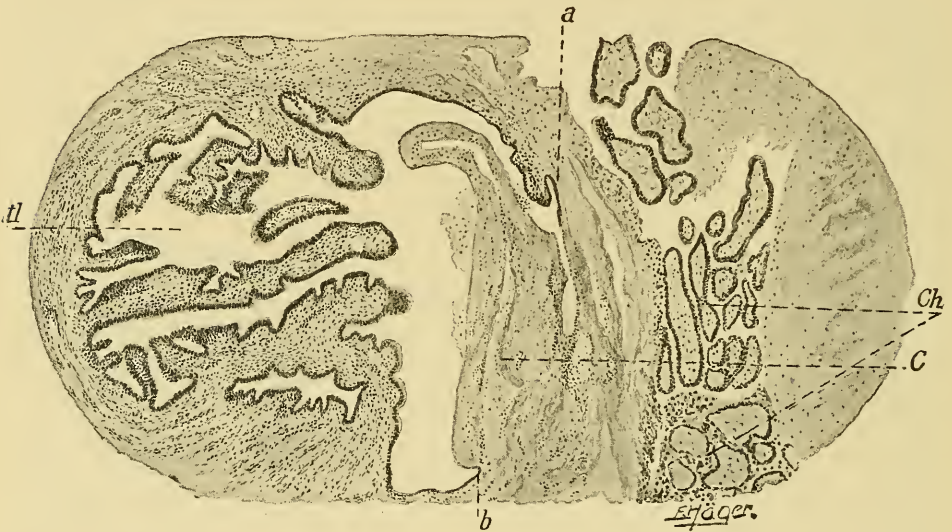

FIG. 158.—Transverse Section Through a Pregnant Tube. *tl*, tubal lumen; *C*, coagulum; *ch*, chorionic villi; *ab*, area of the original insertion of the ovum. (Author's preparation. *Zeiss*, Obj. AA, Oc. 2.)

This process may occur either in the space between two folds, *intercolumnar*, or on the apex of a fold, *columnar imbedding*. As the ovum does not find in the tube a decidua as in the uterus, in which it may continue to develop, it proliferates immediately into the connective tissue and musculature of the tube. The chorionic villi with the cellular columns of *Langhans* at their apex grow into the mother-tissues, just as in the intrauterine pregnancy. Consequently the ovum, very soon after the imbedding, is situated *externally* to the lumen of the tube. The lumen is preserved in the beginning stages in the greatest portion of its circumference, its mucous membrane is destroyed only laterally to the insertion of the ovum by the growth of the same (see Fig. 158).

In its further progress the opposite wall of the tubal canal is either also destroyed by the growing ovum, or the latter continues to proliferate within the tubal wall, by pushing aside the tubal lumen and growing

around it in a half circle (*dissezierendes Wachstum des Eies, Früh—dissecting growth of the ovum*). On transverse section of a tubal ovum *in situ*, therefore, no tubal lumen at all is found any more, and uterine and abdominal end empty unhindered into the oval sac, or the tubal canal runs laterally along the ovum, both communicating with each other only in one place, the original place of insertion.

In the further course the tube only very rarely develops in size, corresponding to the growth of the ovum, so that it could serve uninjured as ovum carrier until the later months. The oviduct, in the majority of

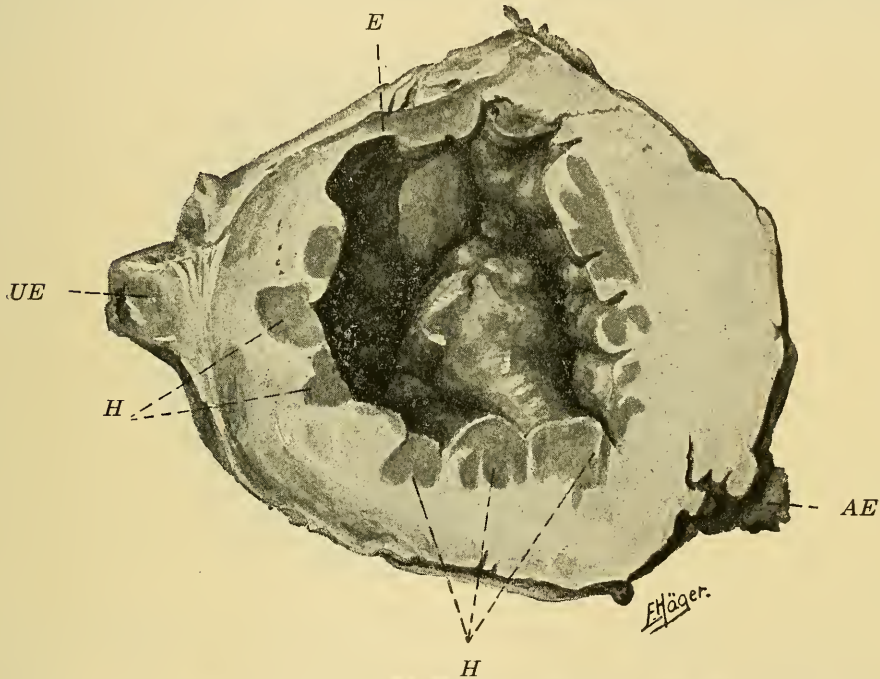


FIG. 159.—Tubal Ovisac with Hematoma Mole Formation of the Wall. *UE*, uterine; *AE*, abdominal end of the tube; *E*, cavity of the ovum; *H*, hematoma. (Author's preparation.)

cases, is not capable of following the growth of the ovum. The chorionic villi of the periphery of the ovum proliferate with their columns of *Langhan's* cells through the musculature into the serosa. During this process the maternal vessels never remain entirely intact, their walls become eroded and hemorrhages occur into the ovum, whose growth thereby is frequently interrupted and the escaped blood appears in the form of a hematoma mole within its investing membranes (see Fig. 159). If the tubal wall at the periphery of the ovum is completely eroded, the sac finally **ruptures**. This may happen in two different ways: either the rupture results toward the interior into the lumen of the tube, **internal rupture of the fetal sac** (*Werth*), **tubal abortion**, or the rupture takes

place at the outer wall of the tube, at the peritoneal covering, **external rupture of the fetal sac** (*Werth*), **tubal rupture**. The former accident is essentially much more frequent than the latter.

With the occurrence of the rupture of the fetal membranes the growth of the ovum is, as a rule, definitively interrupted; only rarely does the development of the placenta and the fetus still continue afterward.

The rupture of the fetal membrane is always wont to be accompanied by larger or smaller **hemorrhages**, which not rarely are so profuse, that death by bleeding occurs, if prompt assistance is not immediately at hand. Especially in **rupture** of the pregnant tube hemorrhage from even

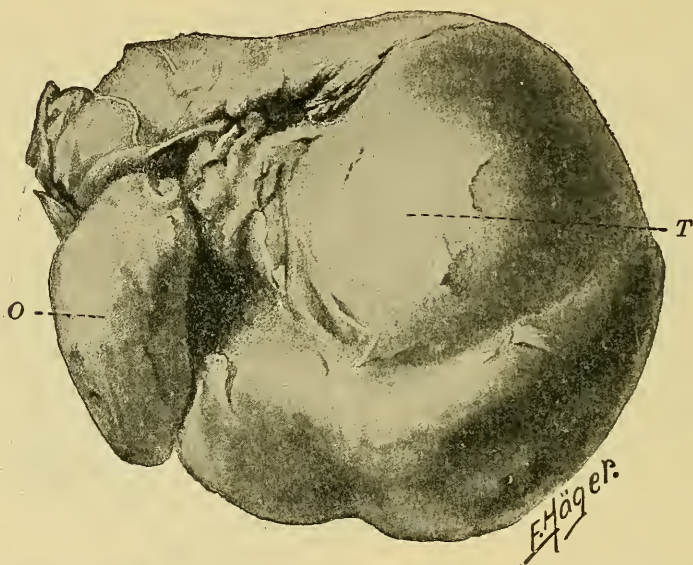


FIG. 160.—Tubal Pregnancy, Exterior View of a Preparation of an Internal Tubal Abortion with the Formation of a Mole. *T*, enlarged tube; *O*, ovary. (Author's preparation.)

quite small ruptures is often extremely profuse, but it may also attain a threatening intensity in tubal abortion.

If the hemorrhage stops, then the escaped blood collects, according to the law of gravity, at the deepest point of the abdominal cavity, the excavatio recto-uterina and a so-called **retro-uterine hematocoele** forms, into which the tube containing the ovum dips.

If the amount of the effused blood is not very large, as is especially often the case in **tubal abortion**, then it may deposit itself around the ampullary end of the tube like the tunicated coats of an onion bulb, and form a large tumor, whose nucleus is formed by the fimbriated extremity of the tube with the ovum—**peritubal hematocoele**.

The formation of hematocoeles need not of necessity take place all at once, but one or **several subsequent hemorrhages** may occur, if the

chorionic villi continue to proliferate and to erode other bloodvessels. After an apparent subsidence of the first hemorrhage, a renewed secondary attack may subsequently occur.

The blood effused in the peritoneal cavity in tubal pregnancy is, as a rule, *not immediately* absorbed, as is evident from the preceding, although we cannot give a reason free of any objections for this fact as blood, brought experimentally into the abdominal cavity of animals, disappears rapidly.

Smaller hematoceles are almost always gradually absorbed, without any traces remaining. Larger retro-uterine and peritubal hemorrhages deteriorate by a slow transformation if the patient did not succumb from

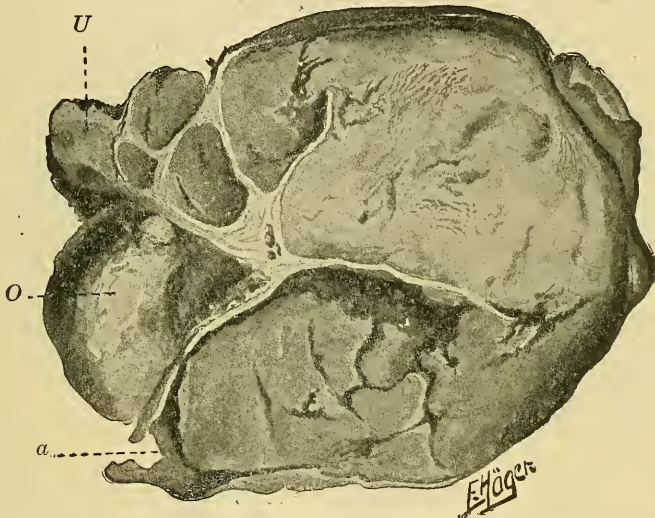


FIG. 161.—Tubal Mole in Tubal Abortion (section through the preparation represented in Fig. 160). *U*, uterine; *a*, abdominal end of tube; *O*, ovary.

the hemorrhage. At first the omentum, intestinal loops and uterus settle themselves upon the periphery of the hematocele and thus form a *roof (capsule)* by which the effusion of blood is separated from the free peritoneal cavity. A connective tissue proliferation gradually occurs through the inflammation of the peritoneum, the result of a reaction, which traverses the mass of blood with single strands and thus divides it into several parts. After a long time the blood within these partitions is quite gradually absorbed, so that these connective tissue bands form adhesions between the organs partaking in the capsule formation—*Pelveoperitonitis chronica adhesiva* (see chapter: *Diseases of the Pelvic Peritoneum*). If the connective tissue proliferation spreads also beneath the hematocele, that is, underneath its deepest point in the pelvis, then it may become completely detached from the peritoneum and a ball-like blood-tumor, encapsulated all over, forms—*solitary hematocele* (*Sänger*).

This process, dragging along over years in larger hematoceles, may be

disturbed, from the fact that an *infection* and with it *suppuration* and *putrefaction* of the blood-tumor occurs. The micro-organisms causing this do not penetrate as frequently from the pregnant tube, perhaps previously inflamed, as from the adherent intestinal loops, which permit passage to the pus-agents through the walls, changed by chronic inflammation.

Hematoceles thus putrefied may, on their part, rupture into the bowel, the bladder, vagina, or through the abdominal wall externally, an occurrence especially frequently observed in former times.

Not rarely the ovum remaining in the tube in internal rupture of the

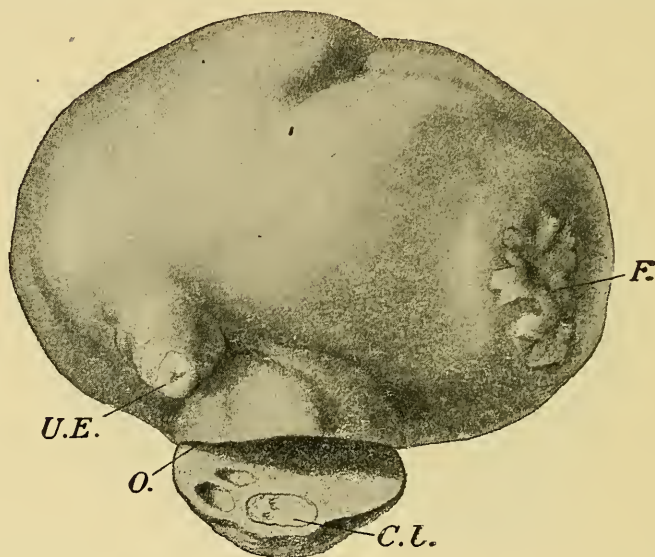


FIG. 162.--Unimpaired Tubal Pregnancy of the Third Month. *UE*, uterine tubal end; *F*, fimbriated extremity; *O*, ovary; *Cl*, Corpus luteum. After *A. Martin*, "Diseases of the Oviducts."

fetal sac is transformed to a *mole*, which bears all characteristic signs of a blood-mole (*Breus*) (see Figs. 159 and 161).

The termination of tubal pregnancy is, however, in many cases quite different. Certainly hemorrhage, and with it death of the ovum, very frequently takes place at such an early stage, that the process does not make itself known clinically by any symptoms whatsoever. This is evident from observations in which were found small bleedings in the tube after opening of the peritoneal cavity undertaken for different reasons. These hemorrhages could be removed without difficulty and they proved to be remnants of terminated tubal pregnancy by the unmistakable microscopic demonstration of chorionic villi. Such cases are certainly extremely frequent, but are, however, in no manner clinically recognizable.

As opposed to the overwhelming frequency with which the ovum in

the tube perishes prematurely, the tubal pregnancy in rare instances reaches the age of several months (see Figs. 162 and 163), or is even carried to full term. The ovum carrier may thereby develop, so that it also surrounds the ovum unimpaired at the termination of pregnancy. In the overwhelming majority of cases the rupture of the fetal membranes (mostly the external, more seldom the internal) occurs, however, much earlier, and the fetus wanders within the fetal membranes or, also naked, within the abdominal cavity, still remaining, however, united with the placenta by the umbilical cord. The placenta grows out laterally over the original maternal basis in the tube and takes root on the peritoneum,

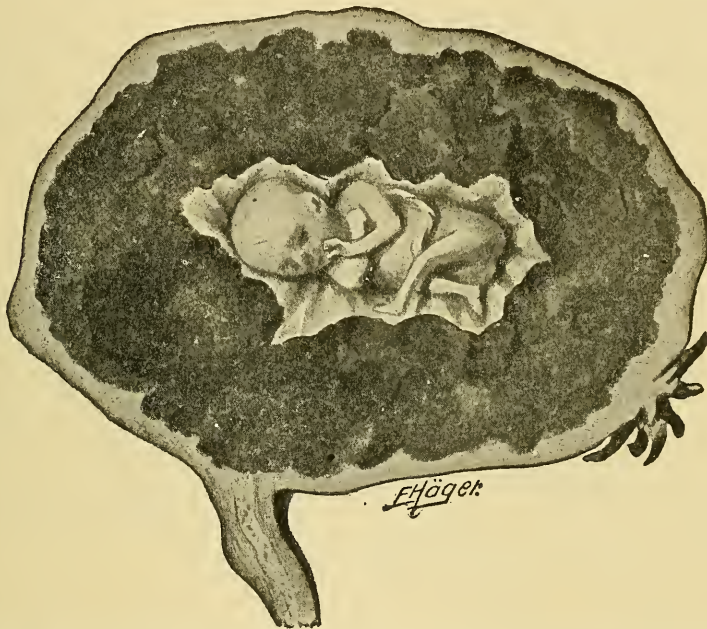


FIG. 163.—Transverse Section Through the Preparation Represented in Fig. 162.

so that its blood-supply remains permanently secured. Thus the fetus may be found living free in the abdominal cavity during a laparotomy eventually performed. If it dies before, it may become encapsulated by connective tissue, the result of a reactive inflammation, just as the hemocele.

The *fate of the fetus*, in cases of premature interruption of tubal pregnancy in its early stages, is always complete absorption, so that it cannot be found any more.

If its development had already advanced to the formation of bone then its fate may be a varied one. After absorption of the soft parts a complete skeletonization takes place, or the fetus becomes encapsulated by connective tissue, as described above, and *dries up—mummification*. Later, an impregnation of the encapsulating connective tissue cover

with lime salts takes place, which encloses the mummified fetus like a hard shell—*lithokelyphos*; if the impregnation with lime salts affects also the superficial layers of the fetus itself, then a *lithokelyphopædion* (the most frequent form) is found; if the entire fetus calcifies, then a *genuine lithopedion* arises. Such encapsulated extrauterine fetuses may be harbored by the bearers often for decades without special disturbances.

If through immigration of bacteria an infection takes place in the fetal sac (see above) the soft parts of the fetus also are destroyed by the suppuration. If the fetal sac ruptures in this case into a neighboring hollow organ or toward the exterior (see above) the bones of the fetus may escape separately into the external world.

Twin pregnancies in the tube, also, have been observed in a number of cases, just so simultaneous pregnancy in *both* tubes, but of different age. Finally a combination of *tubal* with *intrauterine* pregnancy is found not very seldom.

The *uterus* participates in the first months in the extrauterine pregnancy by enlargement, softening, engorgement, and at least in the majority of cases by the formation of a *decidua*. If the pregnancy reaches the later months the uterus does not develop to the same extent, but soon lags behind, while the decidua is expelled with hemorrhages and laborlike pains, whereupon a regeneration of the mucosa takes place. Often, therefore, a decidua is not found in older tubal pregnancies.

The *tube* in most cases does *not* produce a decidua externally to the insertion of the ovum. Only in isolated cases has the formation of such a one been observed (see Fig. 164).

Contrary to this the mucosa presents mostly the picture of a chronic inflammation, which is perhaps the result, perhaps the cause of tubal pregnancy (compare below under *Etiology*).

The majority of ectopic pregnancies have their seat in the tube itself. However, there are a few rare observations, in which the implantation and development of the ovum in the *ovary* has been proven (*Van Tussembroek*). Such cases practically do not come into consideration on account of their rarity.

The supposition that the fecundated ovum may be inserted also entirely externally to the tube and ovary in the *peritoneum* (primary abdominal pregnancy) has been most generally abandoned. In such cases the insertion resulted originally mostly upon the fimbria ovarica tubæ and further development of the placenta took place secondarily on the peritoneum—*Graviditas tubo-abdominalis*. In this the placenta may be found in quite peculiar places. It has been observed several times that it has taken its new seat at the inferior surface of the *liver*.

These rare cases are not differentiated in their progress and anatomic behavior from those, in which, after rupture of the fetal membranes, the further growth of the placenta proceeded on the peritoneum neighboring the tube (see above).

It may happen, that the external rupture of the fetal sac does not take place toward the side of the free peritoneum, but downward, between the folds of the ligamentum latum—*intra*ligamentary development of tubal pregnancy. Thereby, with profuse hemorrhages, extensive *hematomata* may form in the pelvic connective tissue.

Many hypotheses have been advanced for the *etiology* of tubal pregnancy, of which the great majority do not hold good for *most* of the cases, but may be considered at the best for isolated observations.

To these belong the anomalies of the layer of follicular epithelium surrounding the ovum (*Kossmann*), infantilismus in the form of numerous

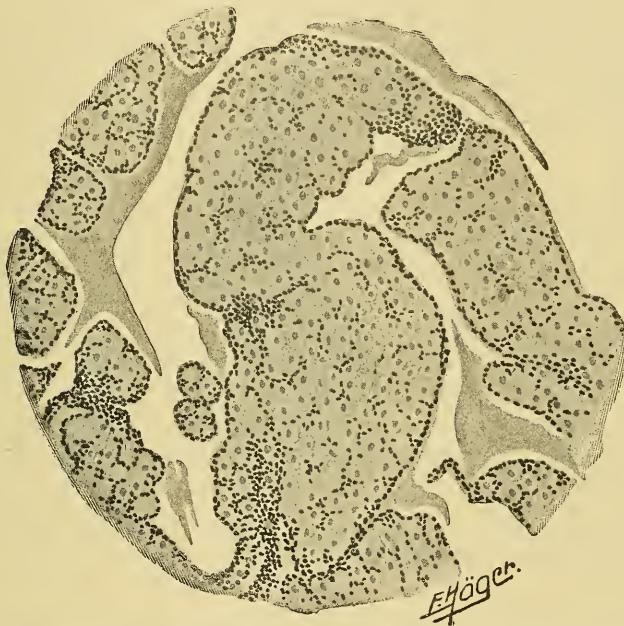

FIG. 164.—Decidua Formation in a Pregnant Tube. (Author's preparation. Zeiss, Obj. AA, Oc. 4.)

convolutions of the tube, as it is found in the new-born girl and up to the time of puberty (*W. A. Freund*), interruption of the ciliary motion of the tube, polypi, and other antiperistaltic motions of the oviduct.

All these conditions may come into consideration in isolated cases perhaps for the causation of tubal pregnancy, but cannot lay claim to a general applicability.

The most probable theory is that laid down a long time ago and confirmed again recently in an exhaustive anatomic way by *Opitz* and *Werth*, that *inflammatory* processes in the tube render a hindrance to the wandering of the ovum.

These changes do not need to be so severe that they are immediately evident macroscopically in the tube. Slight residues, for instance, ag-

glutination of a few mucous folds (compare Salpingitis pseudo-follicularis) suffice to create sinuses and cavities for the migrating ovum, which prevent its advance.

With it the condition of the mucosa is not at all changed so extremely pathologically that it would form an improper parent-tissue for the insertion of the ovum.

If in a number of cases the observation has been positively secured, that the pregnant *tube* did *not* show microscopically any traces of an inflammation externally to the insertion of the ovum, this proves only that also the inflammatory hypothesis is not capable of explaining etiologically *all* cases of tubal pregnancy. *We adhere to this view, however, for the great majority of observations, that obstacles for the migration of the ovum through the tube have arisen as a result of previous inflammatory processes, which have caused the implantation of the ovum at this pathologic place.*

Clinical Conduct

The *symptomatology* of ectopic gestation cannot be a simple one on account of the different forms of its development. As an almost regular accompanying symptom we find perimetritis and chronic inflammatory processes in the uterine mucosa. While the importance of these as regards the etiology gives occasion for much doubt, the same must at all events be well considered in describing the symptoms.

The patients not rarely express the suspicion that they are pregnant. They undoubtedly experience the well-known feeling of warmth in the pelvis, the sensation of fulness, drawing in the breasts, certain disturbances in the function of the stomach—as if the implantation of the ovum had occurred in the uterus. If pregnancy takes an undisturbed course, then the disturbances of the state of health stand out markedly as more or less prominent. Some experience perhaps undefinable pains, until the fetal movements make themselves felt more intensely. At the physiologic termination colicky pains appear, as a rule. Blood escapes, and with it the uterine decidua, if the latter has not already passed before. We will not at this place describe more in detail how the child dies with rigors, if as yet no assistance is rendered. Suppuration of the ovum, as it occurs thereafter, generally gives the picture of an internal abscess formation, a formation of lithopedion takes place mostly with severe disturbances of the general state of health, less so mummification. The women, however, may feel very well with it, they may again become pregnant intrauterine. If then other disturbances do not appear, the lithopedion is confirmed as an accidental finding during a post-mortem examination.

Such instances are remarkably rare. The ovum perishes with overwhelming frequency in the first days or weeks as a result of hemorrhage, although we can give no statistical data. If we register these cases under the heading of rupture of the fetal sac, this occurrence is posi-

tively very frequent and subsides without influencing the general state of health. We find casually in operations upon the genitalia on account of other diseases, a swelling of the tube the size of a cherry-stone, or a plum or also an egg. Its contents are translucent with a bluish lustre. If we incise these knots in the tube we may remove blood-clots from it which contain infallible traces of the ovum in the earliest stages of development. The place of implantation of the ovum does not bleed any more. We may simply close the incised wound of the tubal wall. The involution results without disturbance, with preservation of the complete functional capacity of the tube.

In the most striking opposition to this course cases are observed in which the ovum, permeated with blood, is emptied from the tube into the abdominal cavity: ***Internal rupture of the fetal sac-tubal abortion—or external rupture of the fetal sac-tubal rupture.***

In the ***internal rupture of the fetal sac*** the symptoms are essentially different, according as the hemorrhage leads to a destruction of the ovum or to the formation of a ***sactosalpinx hemorrhagica***. A closure of the tube by means of adhesions is not necessary for this. If the women experience any subjective symptoms at all then they report a drawing pain in the depth of the pelvis, somewhat toward the side. A light collapse may occur, which may repeat itself under circumstances when it becomes always more pronounced. Also here therapeutic efforts probably aggravate the evil at times. Puriform softening, changing the oval sac into an abscess, correspondingly causes fever from absorption with signs of peritoneal irritation (marked pain, distention of the abdomen, irritability of bladder and rectum). By rupture of the abscess wall outwardly very illsmelling masses are expelled (parts of the ovum, blood). Healing may result with abatement of the fever and pains. Chronic abscesses and fistulæ may be formed which finally bring about extensive infiltration and breaking down of the pelvic organs, if they do not lead to chronic sepsis.

The ***internal rupture of the fetal sac*** with escape of blood from the ostium tubæ abdominale into the abdominal cavity with or without ovum or parts of the ovum, may take place with only very slight disturbances of the general state of health. More frequently quite considerable amounts of blood escape therewith into the abdominal cavity and form blood-tumors to be described in the chapter on ***Hematocele***, without the occurrence of intense pains, severe collapse, and such a disturbance of the general state of health that the incident passes by as a real catastrophe. Especially in patients from the rural districts we often see such women, whose blood-tumors are confidently of three or four months standing, without the women being compelled to seek so much as continued rest in bed. They were, indeed, ailing, but performed their domestic labors and looked for medical aid only when they did not improve at all.

Contrary to these, other cases of internal rupture of the fetal sac

occur with *one violent, laborlike pain*. Collapse takes place and death may occur immediately. In other cases the patients overcome slowly the first attack, to succumb after hours, days, or weeks to a second or third attack, or to recover slowly. Not rarely the expulsion of the decidua uterina, with moderate or abundant hemorrhage and renewed laborlike pains, intervenes as a grave complication. This also is mostly well overcome. These cases certainly may recover with a severe anemia. On the other hand suppuration also may occur with the formation of a perimetritic abscess.

The course of the internal rupture of the fetal sac (*tubal abortion*) undoubtedly is, as a rule, essentially milder than that of the external rupture of the fetal sac (*tubal rupture*). We may, however, prognosticate the end from the initial symptoms and the beginning events only with great reserve. A further difficulty exists therein that the diagnosis of extrauterine pregnancy gives rise to mistakes with quite an objectionable frequency.

The *external rupture of the fecal sac (tubal rupture)* may also pass by almost painlessly and without symptoms at all periods of pregnancy. For this we can adduce in proof striking observations free from any objections. As a rule, this form of interruption of pregnancy occurs with violent attacks of pain and threatening collapse. The rupture takes place, after drawing pains had been felt on and off for a shorter or longer time. Without any external interference, with quite insignificant exertion, but also after more extensive violent motions agonizing pains appear with attacks of syncope and profound collapse, during which the women die. At times the occurrence passes by with remissions. The women seem to recover, only to succumb to a renewed attack. But very severe attacks are finally also borne well and overcome. This is seen as well in rupture of the tube with complete expulsion of the ovum, as also in partial escape, particularly in cases in which the ovum remains still connected with its parent tissue and develops further, until new disturbances occur and with it the belated final catastrophe. The fetus in a few cases may develop to its physiologic maturity. However, a formation of a lithopedion or mummification may take place. Such cases gradually pass with severe suffering to a convalescence, especially if suppuration does not occur.

Diagnosis.—Corresponding to the inconsistency of the symptoms the diagnosis of ectopic pregnancy offers at times only unessential difficulties. In other cases we do not succeed with the present means of diagnosis in determining the existence of this peculiar complication before the exposure of the seat of the ovum, indeed not until the careful microscopic examination of the preparation.

If menstruation has failed to appear, if the woman feels pregnant, if we can feel next to the somewhat enlarged, softened, lividly discolored uterus a mass, which lies laterally and somewhat posterior to the uterus, of an approximately circular form, of moderately soft consistency, insen-

sitive, and surrounded by pulsating vessels, then we must decidedly think, especially if changes of pregnancy exist in the breasts, that an extrauterine pregnancy is present. If, with further development of pregnancy, the fetal heart beat and fetal extremities can be noticed and it can be demonstrated that either a decidua uterina has passed or that the uterus does not contain a fetus, then the diagnosis offers at all events no difficulties.

Difficulties in diagnosis begin in all stages in which the ovum is not any more intact. The cases disposed of in the first weeks as a result of hemorrhages (internal rupture of the fetal sac without escape of blood from the ostium abdominale) in which the question is only about an entirely circumscribed blood mass, situated intratubal, are only unexpected secondary findings. In internal rupture of the fetal sac with extravasation of blood into the abdominal cavity the plainly palpable isthmus tubæ is felt to pass over into an indistinctly palpable mass of at first soft, later much harder consistency. The ovary is palpable beneath it in favorable cases. Such findings can be interpreted with an approximate certainty when accompanied by an anamnesis of irregularity in the menstruation (premature or delayed occurrence, more or less abundant escape of blood from the vagina) and of mostly acutely appearing pains, which surely enough may also stand in connection with the pre-existing endometritis and perimetritis.

The pregnancy of the *interstitial portion of the tube* offers especially peculiar difficulties. The uterine wall takes part in an extensive manner in the development of the pregnancy. The seat of the ovum bulges forth like an intramural myoma. The uterine cavity appears to be laterally bent and widened during sounding. Next to the uterine horn, which is therefore enlarged like a projection from the uterine wall, the tubal departure and that of the ligamentum rotundum, also the ovary are perceptible. In my own observed cases it was not possible to make use of the ligamentum teres for diagnosis. The majority of these cases terminated in the catastrophe of external rupture of the fetal sac.

The diagnosis of *the external rupture* of the fetal sac joins, as a rule, closely the typical picture as formerly outlined for extrauterine pregnancy: violent pains, laborlike, perfectly unexpected, increasing immediately to an extreme intensity, sometimes with short remissions, profound collapse. With it vomiting, signs of extreme anemia, distention of the abdomen are found. The abdomen becomes sensitive. As far as the blood, which has escaped into the free abdominal cavity, reaches there is absolute flatness, which changes in the border zone, corresponding to the blood-layer lying therein between the intestines gradually to the tympanitic intestinal note. In the internal examination the uterus appears generally somewhat enlarged. Laterally, posteriorly, inferiorly, or superiorly to it lies a mass not clearly palpable—the blood in the first stages of coagulation. Soon the consistency becomes harder. One feels in it at times, occasionally in the beginning more frequently somewhat

later, a thicker deposit, the ovum or the embryo, without it being always possible to differentiate any further in consideration of the necessary caution. Death does not always result even with a profuse hemorrhage. It may, however, occur with comparatively limited bleeding. The blood-tumor shrinks during further metamorphosis. Quite hard deposits are to be felt in it so plainly, that the tube may be recognized in them.

Corresponding to this presentation an exact diagnosis is sufficiently insured under circumstances from the history and signs, from an expulsion of the decidua with demonstrable parts of an ovum, to be submitted to an examination, from the course of the catastrophe and also from an uncertain result of palpation.

It is more frequently the case, especially in the early stages, that we make a diagnosis only with a conditional certainty. The different forms of sactosalpinx in particular give rise to errors. The proof of a previous gonorrhoeal or septic infection is here of importance. Sactosalpinges and salpingitis frequently are bilateral. Of course one sees also on one side a sactosalpinx, on the other a salpingitis chronica, and one of the two may very well be an ectopic gestation. As long as acute incidents, anemia, peritonitis, puriform breaking down with symptoms of septic absorption do not necessitate an operation, it is possible, by clinical observation with careful determination of the temperature and pulse and careful observation of leucocytes, to differentiate approximately between extrauterine pregnancy and salpingitis chronica, peritonitis, or oophoritis. Contrary to many assertions made in discussions during congresses we emphasize here without reserve that even at present we cannot escape the danger of a mistake in diagnosis.

Prognosis.—The great variation in the course of extrauterine pregnancy permits us to adhere to the view by all means, that the prognosis of the perverse implantation of the ovum must be called under all circumstances a grave one. The possibility of a spontaneous involution (retrogressive metamorphosis) cannot be denied, but even in the course of such a termination so many complications occur, that it appears foolhardy to poise one's self in security. Every variety of the implantation of the ovum can be disturbed suddenly and in a manner threatening to life. On the other side it follows that since the general recognition of the necessity of operative treatment with timely recognition, the prognosis has become essentially favorable. It is certain that very many cases recover without an operation, particularly with early detachment of the ovum. It appears just as positive to us that among the reported cases of a cure without operation many a case of mistaken diagnosis slipped in. We recognize that the prognosis of cases not treated surgically is not unfavorable with continued hospital control. We adhere to the view that in general practice the prognosis is only favorable when the product of pregnancy is removed, as soon as it causes such signs that the woman seeks the advice of the physician.

Treatment.—*When the diagnosis of tubal pregnancy in an undisturbed condition has been made, according to general conceptions the indication exists to remove the same.* The proposition to puncture the oval sac or to bring about death by injections of morphin have not acquired a lasting acceptance. Cases adapted for this treatment come altogether seldom to diagnosis. Nursing and control for many weeks is necessary for this in order to secure recovery. Suppuration is not excluded thereby, one must wait then until the pus escapes externally, either spontaneously or is removed operatively. According to experience death of the ovum does not secure against secondary hemorrhages, and with these such catastrophes as we witness in spontaneous rupture of the fetal sac. Under these circumstances the immediate removal of the pregnancy and its products is generally preferred.

At the **height of the catastrophe** the danger that the hemorrhage cannot be controlled safely **compels** us, according to our opinion, to undertake **surgical removal**. The proposition to wait in internal rupture of the fetal sac until the formation of a hemocele has taken place, and to operate only if disturbances occur in the process of absorption, has given us so few good results, that we only wait in those cases in which the arrest of hemorrhage and the inspissation are evident in a pronounced degree from the condition of the patient (evident improvement in the general state of health, the pulse, hardening of the escaped blood) and with the presupposition of the possibility of interfering immediately, if the progress of convalescence is interrupted. In these conditions we make use of the ice-coil to the abdomen, *Priessnitz* compresses, absolute rest in bed, and consequent use of analeptic remedies. In the majority of the cases we deem the **immediate removal of the product of gestation and direct arrest of the hemorrhage** as the indicated life-saving procedure.

In like manner we deem **justifiable the removal of the escaped blood and the products of pregnancy, if the absorption is retarded with continued ill-feeling of the patient or if suppuration takes place.**

The operation can be performed through the **vagina** or through the opened **abdominal wall**.

Vaginal Operation.—We prefer in less extensive formations (ovum, blood-tumor) to operate through the vagina. If it is necessary to remove the product of conception which has not yet escaped from the tube, it may be done, as a rule, easily through the anterior vaginal vault. After the uterus has been brought out through the colpotomia anterior the tube becomes visible and palpable. One can loosen it with the corresponding ovary from eventual adhesions and can bring it forward to the level of the vulva by underlaid sponges. If the tube is still intact, we incise the tubal wall over the contents, clear out the ovum and close the incision, so that the lumen of the tube is again restored. If the tube cannot be preserved, then it is removed by ligating the mesosalpinx in small

portions. The uterine end of the tube is left open if the mucosa, visible after section, appears healthy. The tube is then split in this place, and the cut edge of the mucosa is sutured to the serosa (*tubal stomatoplastic*).

If an escape of blood has taken place in the excavatio recto-uterina, the blood is removed, the vaginal incision and eventually the vaginal accessory incision is closed by sutures.

In extensive blood-tumors of the excavatio recto-uterina it appears more convenient to incise the posterior vaginal vault along the collum uteri. The blood, which glistens through bluish black, as soon as the peritoneum is reached, empties itself immediately after the incision as a pitchlike mass. One can promote this evacuation by irrigation with physiologic salt solution. If the hematocele is encapsulated above by pseudo-membranes, the perforation of the same is generally to be avoided. It appears, however, important to bring the tube out at all events, in order to examine it. If the tube cannot be preserved, it is removed. The arrest of hemorrhage must be safely and completely secured in the depth of the pelvis.

Then arises the question, whether the emptied space can be completely left to itself. If the peritoneum is permeated with blood, if it bleeds parenchymatously, then the space is filled with gauze and a rubber tube is inserted.

The edges of the incision in the vaginal vault must be examined for bleeding vessels, so the same may be ligated. The gauze is removed with beginning contraction of the cavity (three to six days).

Abdominal Operation.—The abdominal operation seems to be technically the simpler one. It is unavoidable with extensive products of conception and obscure conditions (adhesions). Also in this operation a safe arrest of hemorrhage must follow the removal of the ovum and tube, if it can otherwise not be secured.

As the ovum lies in the overwhelming majority of cases in the tube and only rarely in the ovary the removal of the contents of the ovum must theoretically always be possible. Many times in the operation for still *living ovum*, the manner of dealing with *the site of attachment of the placenta* has caused difficulties. The tube (or also the ovary) is separated from the adhesions and removed. At times, however, the agglutination of the tube and ovary with the surroundings is such an intimate one that this peeling out without cutting injuries of the neighboring organs (bowel) appears difficult and inexecutable. In some cases the development of the intervillous blood-spaces at the site of attachment of the placenta has advanced to spongelike, gaping hollow spaces, so that the surgeon desists from the completion of the operation. The women bleed to death. According to our experience one must always succeed with consequent procedure in enucleating and ligating the tube. In some cases an arrest was attained by large clamps.

Still greater difficulties may be caused by the membranes of the ovum

infiltrated with blood and forming leatherlike indurations which have grown indissolubly to the bowel and other organs. In such cases the cavity may be drained through the vagina or the abdominal wall, just as in surface bleedings. If possible I have stitched together the remnants of such pseudo-membranes after removal of the ovum upward, after I had drained the cavity toward the vagina (compare International Congress, London, 1881).

The Diseases of the Ovaries

I. Malformations, Hypertrophy, and Atrophy

LITERATURE: *Nagel* in *Bardleben*, Anatomie des Menschen. *Pfannenstiel*, Handbuch der Adnexorganeerkrankungen von *A. Martin*, Vol II, 1899.

Congenital malformations occur also in the ovaries just as in the rest of the genital organs. However, they are not of frequent occurrence. Complete absence of both ovaries is always observed with a total aplasia of the tubes and uterus. Every sexual function is naturally excluded in such cases. **Unilateral** absence of the ovaries is associated with aplasia of the corresponding portion of *Müller's duct* (tube and uterus).

Hypoplasia of the ovary has likewise been described. The tube and often also the uterine horn of the corresponding side tend therein to be defectively developed. However, follicles may very well develop in such hypoplastic ovaries.

A pseudo-hermaphroditic malformation, on the other hand, may also be found therewith in the external genitalia.

In some cases one has, to be sure, not observed a hypoplasia, but a persistence of the ovarium in its **infantile** condition. The ovary, then, has retained the long, sausage-shaped form of the intrauterine life; it lies high, above the *linea innominata*, close underneath the kidney, and its axis runs almost parallel to the spinal column. This form of infantilismus is, however, without any import for the function.

Three ovaries have been found in a few rare cases: besides the two normally situated ones, a third one is found fixed at any point of the *ligamentum latum*. These observations are to be separated from those, in which a normally developed ovary later becomes divided by an inflammatory pseudo-membrane or a torsion, and thus separated into two completely distinct parts. **Tumor formations** have been observed in such third ovaries, formed in one of the described manners; however, all such reports must be received very critically.

These cases gain a certain importance from the fact that they must be taken into consideration in the explanation of the otherwise puzzling occurrence of pregnancy after operative removal of two ovaries.

Hypertrophy and **atrophy** of the otherwise normal organ may appear without known cause, yet it must always be remembered that the size of the ovary fluctuates altogether within very wide limits.

We have referred above (p. 65 and farther) to the manner in which

persons thus affected demean themselves in regard to their sexual life, if their generative organs are developed imperfectly. These cases elude, as a rule, a diagnosis without an autopsy on the operating or post-mortem table. It may not rarely be possible (as given loc. cit.) approximately to diagnose such malformations by a thorough examination. Nevertheless we must reckon with the circumstance that these rudimentary formations lie out of reach, atypically scattered about and thereby either do not come at all under observation or do not admit of an exact interpretation. With occurring degeneration, but also already with a disturbed progress of the maturing of a follicle in these formations—no physician at present hesitates to establish a diagnosis operatively and to proceed according to the state of affairs.²⁷⁸

The ***fold and furrow formations*** on the surface of the ovary do ***not*** belong to the malformations, though the organ may acquire thereby quite remarkable forms. These arise very probably from the circumstance that the physiologic cicatricially contracted remnants of the ***corpora albicantia***, draw the surface with them down into the ovary. In this way quite odd pictures, similar to the cerebral gyri, develop. They do not deserve any pathologic importance, however, they may represent a certain preliminary step for tumor formations on account of the proliferation of the germinal epithelium present in them.

Physiologic atrophy of the ovary takes place during the climacteric. This may also occur earlier, already in the third decade, in individuals especially weakened by severe diseases: ***Climax precox***.

II. Changes in Position

The ovaries naturally always participate in a certain degree in the displacement of the uterus. Particularly in retro-flexio uteri they lie always posteriorly with the corpus, either at the posterior wall of the pelvis or upon the floor of the excavatio recto-uterina.

However, also without the participation of the uterus the ovaries may sink down along the posterior surface of the ligamenta lata upon the floor of the excavatio recto-uterina as a result of an excessive relaxation of the pelvic connective tissue, so that they then lie close above the posterior vaginal vault. During an examination they are easily palpated here; besides, they are exposed to all the trauma befalling the posterior vaginal vault (during cohabitation, defecation of hard constipated stools) and become not rarely extremely sensitive.

At times it seems that even the maturing of a follicle may cause troublesome symptoms, such as sensations of pressure in the bowel. Occasionally patients complain of very frequent and continued pains.

The ***diagnosis*** follows from the examination. The ovary in its characteristic form is, as a rule, very sensitive to the touch of the examining finger advancing toward the posterior vaginal vault. The sensitiveness

is regularly a very intense one if the ovarium takes part in the process of hyperemia and inflammation of the peritoneum.

Occasionally the ovary appears to be almost the size of an egg, and can then be outlined only imperfectly in its entire extent by palpation, made difficult by fat abdominal walls. It is recommendable, in such cases at all events, to remember that the displaced kidney as well as the spleen may cause similar findings. In this case the palpation of these organs in their normal place decides the question.

Treatment.—Rest, fomentations, ice-bags, narcotic vaginal irrigations,* liquefaction of the intestinal contents by neutral salines allow the sensitiveness to abate. Then the ovary may be pushed upward. A vaginal pessary, which holds the cervix uteri strongly backward, will mostly remedy the trouble in minor cases.

*Sänger*²⁷⁹ succeeded in fixing the ovary by shortening the ligamentum suspensorium ovarii. In extreme cases the vaginal or abdominal removal of the displaced ovary must be considered.

Ovarian Hernia

The ovary is not seldom found in congenital hernial sacs, most frequently in inguinal hernias, rarer in femoral or hernias of other orifices.

Ovarian inguinal hernias are mostly congenital and bilateral. The acquired inguinal hernias of women are observed relatively frequently first during the puerperium, in a previously existing hernial sac.

The uterus in these cases is displaced toward the corresponding side, it reaches, with its horn, to the internal abdominal ring, while the tube runs through the inguinal canal to the ovary. This is frequently fixed by adhesions in the hernial sac. It swells with each premenstrual congestion and may cause extraordinary pains at this time on account of limited space in the surroundings. In pseudo-hermaphroditism one must pay attention to the danger of mistaking it for a non-descending testicle remaining in the external inguinal canal.

The ovary is exposed to frequent injuries like those of the male germinal organs displaced in ruptures. Hemorrhages and inflammations may occur. Newgrowths also have been observed from the constant irritation.

The ovary alone tends to fill the hernial sac in congenital ruptures, it is irreducible. It forms a mass the size of a plum to a chicken egg, hydrops and hemorrhagic follicles may increase its circumference. The ovary is always sensitive. With intercurrent diseases the sensitiveness increases perceptibly. It resembles an enlarged gland, especially when it is diseased.

* Infus. herb. conii macul. (25.0) 170.0, aqua laurocerasi, 25.0. D. S. Externally two to three tablespoonfuls in two quarts of lukewarm water. Or morphin suppos. (0.01) 20 oleum theobromatis.

In the *diagnosis* all the signs characteristic of inguinal hernias hold good. The changing sensitiveness with ovulation must be considered as a characteristic sign, as well as the inclination of the uterus with its corresponding horn toward the side of the rupture, the distortion of tube and ligamentum ovarii proprium toward this direction, particularly if one pushes the uterus toward the other side.

Femoral hernias resemble the inguinal ones; the state of freedom of the inguinal canal supports this diagnosis.

The rare cases of hernia ischiadica, abdominalis, and obturatoria must be diagnosticated by the proof of the presence of the ovary itself in these respective places.

Treatment.—As reposition in congenital hernias is impracticable, one may allow the same to remain protected by a truss pad as long as the displaced ovary does not cause any disturbances. If difficulties appear extirpation is to be recommended.

III. Circulatory Disturbances

The ovary naturally takes part in the physiologic premenstrual congestion of the pelvic organs. But also irrespective of this its blood circulation is not rarely subjected to severe disturbances.

By virtue of its easy mobility on thin ligaments it may suffer torsions, which are often connected with displacements of the uterus, myomata, and such like. As a result of such torsion severe stases may occur in the ovary, as also in general disturbances of the blood circulation (cardiac, hepatic, and renal diseases).

In all these cases, ruptures of vessels and consequent hemorrhages and destruction in the tissues may arise, *apoplectic foci*.

Sometimes such hemorrhages take place also in the preformed places, the *follicles*, then a *follicular hematoma* is formed. At times bodily exertions, especially during the time of menstruation, excesses in venery, severe awkward examinations, and such like, must be made responsible for the formation of such blood-cysts. Such hemorrhages are favored by degenerations of the vessel walls appearing so often in the ovary. If a follicle is ruptured, and if the corpus luteum arising from it has undergone involution, the until now overdistended, corkscrewlike vessels lying in dense coils in the neighboring tissues undergo obliteration and hyalin degeneration. Under the microscope complete islands of such hyalin and finally fibrous degenerated vessels are frequently seen (see also *Oophoritis*).

Even if a considerable escape of blood should occur with the maturing of a follicle, absorption tends to take place sooner or later. Nevertheless this, however, does not always exclude the voluminous follicle-hematoma from leading to quite considerable difficulties, especially in the majority of such hemorrhages. Absorption fails to appear. The large

ovary causes pressure symptoms. Such follicles filled with blood, however, appear quite especially worthy of notice, as they may suppurate. An attack of pelveo-peritonitis is thereby never absent, whose symptoms combine with the formation of the blood-cysts.

Interstitial hemorrhages into the fibrous network of the ovary are rare, except in septic diseases. Small hemorrhages are frequent in the new-born.

Symptoms are seldom caused in the acute stage by the escape of blood. Especially if of large size they may cause the symptoms of new-formations of the ovary of a corresponding size. The follicular hematomata become more disagreeable if absorption is retarded for a long time. Rupture, for instance, connected with an enforced examination, causes the signs of peritonitic irritation, collapse and hemothecle.

The special **diagnosis** can be made with a certain probability by the suddenness of its occurrence, and eventually the rapid absorption if the condition of the genitalia was previously known.

The **treatment** consists, if the diagnosis can be made with some positiveness, only in absolute rest, and an ice-coil, later, in the promotion of involution and stimulation of absorption. The operative exposure is absolutely justified in doubtful cases with the appearance of serious disturbances (anemia). This is followed by the excision of the blood-cysts in an otherwise healthy ovary and by a removal of the ovary in extensive and multiple blood-cyst formation.

IV. Inflammations

The **inflammations** of the ovary are most intimately connected with those of its excretory canal, the uterine tube. In the greater majority of the cases the ovarium is first attacked by contact with the inflammatory agents coming from the tubes.

These agents may, however, reach the ovary besides from the tube, also from the abdominal cavity and from the blood and lymph channels.

We must also distinguish **acute** and **chronic inflammations** of the ovary, although the latter one in most cases results from the first one. The **etiology** is almost always bacterial, although conditions exist at times in the ovary just as in the uterus, which present the pictures of a chronic inflammation, not caused by an infection, but by chronic disturbances of nutrition.

The exciting agents of oophoritis chiefly to be considered are:

1. Strepto- and staphylococci.
2. Gonococci.
3. Tubercle bacilli.

Besides these chief forms the rarer infections with bacterium coli commune, pneumococci, and typhoid bacilli among others are taken less into consideration.

A. Acute Oophoritis

Acute oophoritis is a very frequent accompanying phenomenon of puerperal septic infection, which may reach the ovary in two different ways.

Either it ascends through the tube and infects the ovary directly from the surface, or the infective agents are carried by the lymph-channels through the ligamentum latum, or by thrombosed veins of this area into the hilus ovarii and after penetrating the entire structure arrive finally also upon the surface. Such ovaries are seldom seen except on the dissecting table. The surface is then covered by a thick, fibrinous, purulent exudate which is often only a part phenomenon of a general peritonitis.

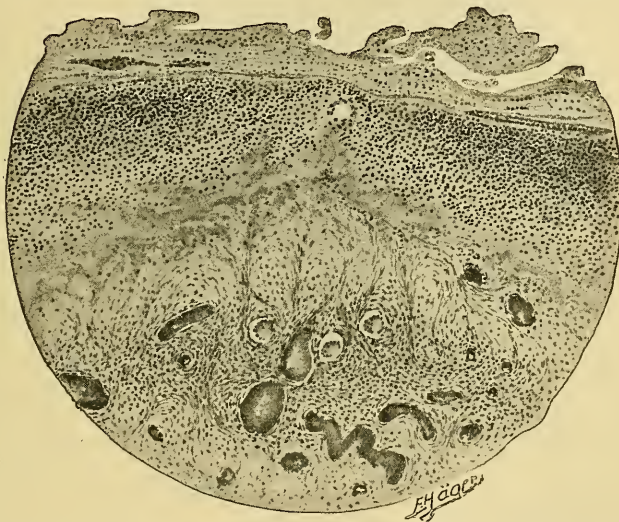

FIG. 165.—Acute Septic Oophoritis and Perioophoritis. Fibrinous purulent exudate upon the ovarian surface, round cell infiltration of the tissues, septic thrombi in the vessels. (Author's preparation. Zeiss, Obj. AA, Oc. 2.)

Upon section a marked hyperemia, and mostly a gelatinous edema, in some cases also multiple small abscesses are seen. *Microscopically* an enormous round cell infiltration of the entire structure is found (see Fig. 165); in places purulent softening exists and the follicles are destroyed in the greatest part. Streptococci in large quantities can usually be demonstrated in the blood and lymph vessels. If in such puerperal oophoritis a corpus luteum is still found in the ovarium, the exciting agents settle with predilection upon this favorable nutrient basis and a *corpus luteum abscess* arises (see Fig. 166). However, this is not a frequent occurrence in acute septic oophoritis, because a recent corpus luteum is mostly no longer found.

Acute *gonorrhoeal* infection reaches the ovary, always ascending from

the tube, and is anatomically and clinically hardly separable from gonorrhoeal salpingitis. The gonococcus, whose capability of permeating the firmer connective tissue layers is not very great, occasions in the beginning frequently only an acute *perioophoritis*, while the firm albuginea prevents it from penetrating into the interior of the organ. If, however, then a defect in the albuginea arises on account of the rupture of a follicle, the gonococcus enters here very easily, finds a good nutrient medium in the blood-clot of the corpus luteum and forms here also a *corpus luteum abscess*. The gonococcus also may cause several abscesses in the ovary, which become confluent with each other by rupturing of their

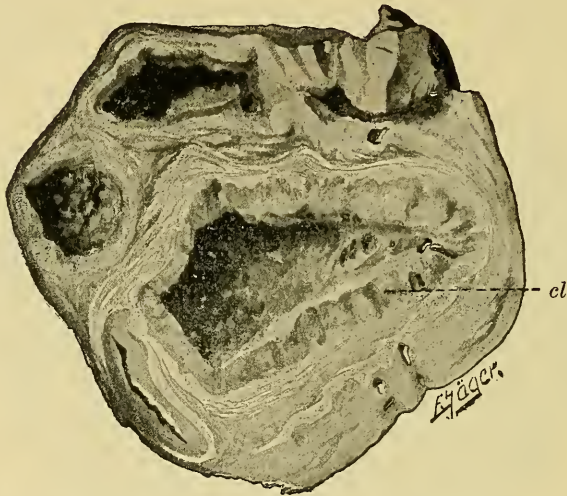


FIG. 166.—Multiple Ovarian Abscesses. *cl*, corpus luteum abscess.

walls and may change the ovary into a polysinuated hollow organ (see also chapter on *Gonorrhoea*).

See chapter, *Tuberculosis of the female genitalia for Tuberculosis of the ovary* (vide p. 190 and farther).

B. Chronic Oophoritis

Acute oophoritis, just like the acute endosalpingitis, may heal completely, which certainly not infrequently occurs particularly in gonorrhoea, but also in the septic form. The bacteria are then overpowered by the organism, the edema is absorbed, the small abscesses, which may have formed inspissate and undergo connective tissue degeneration, the superficial fibrinous purulent deposits also become organized and form adhesions with the organs surrounding the ovary.

Recovery, however, is frequently incomplete. The acute symptoms, to be sure, recede, but the abscesses remain. The ovary and the tube, also inflamed, are held together in a tumor tubo-ovarialis by the connec-

tive tissue pseudo-membranes continually growing firmer. The different abscess cavities of the ovary may coalesce with the purulent tubes to a common tubo-ovarian abscess (see Fig. 154). An irreparable chronic salpingo-oophoritis has developed. The micro-organisms conduct themselves in the ovarian abscesses just as in the pus-tubes, that is, they may perish, or retain their virulence for a long time (see p. 338). A secondary new implantation, respectively a mixed infection, may also arise from an emigration of bacteria from the adherent and diseased intestinal wall (see chapter *Tuberculosis*).

The processus vermiformis, above all others, plays an important rôle in this respect. Infectious agents are transmitted not rarely from it to the right ovary, most usually the *bacterium coli* and *actinomyces*.

If the ovarian abscesses are not influenced by any external interferences whatsoever, they tend to undergo complete contraction during the climacteric. Not rarely *deposits of lime* take place in the old abscesses, also if the suppuration was not of a tuberculous nature.

The original infection need not always lead to pus- and abscess-formation in the ovary. Just as suppuration does not always occur in the tubes, but only a serous discharge takes place in the tubal sac, so the inflammatory process in the ovary may also pass over to the chronic stage without any preceding suppuration. Here then develop the characteristic changes of a *chronic interstitial oophoritis*. These consist chiefly in a *chronic connective tissue proliferation* produced by the original infectious process. The ovarian stroma becomes gradually harder and poorer in nuclei. The vessels, often having undergone hyalin degeneration in larger groups, are also subjected to a connective tissue metaplasia; the primary follicles also become diminished gradually in number; indeed they may even disappear entirely, so that finally a premature senile atrophy of the entire ovary to a small connective tissue body takes place.

The albuginea also participates in the connective tissue proliferation, so that it becomes much harder and denser than under normal conditions. This has a special effect on the process of ovulation. The maturing follicles are not able, as otherwise, to rupture the surface of the ovary at the proper time, but are hindered in this by the thickened albuginea. As a result a continually stronger transudation results within the follicle under the influence of the menstrual congestion and the chronic condition of inflammation, so that finally the ovum perishes and is subjected to a disintegration with the greater part of the follicular epithelium. This process has been designated *follicular atresia*. From it a cyst results which may attain the size of a child's head, lined internally by a single- or many-layered, cubical epithelium—*follicular cysts*.

During this transformation the maturing of follicles progresses without restraint, and as the contents cannot be evacuated at the proper time, they become atretic. Thus it happens, that such chronically inflamed ovaries are finally interspersed by quite a number of larger and smaller follicular cysts causing an irregularity of the surface of the ovary, leav-

ing only thin septa between each other; in fact, finally, they may burst and become confluent through the continuously increasing internal pressure and through the influence of external traumata (for instance, bimanual examination)—*small cystic degeneration of the ovary* (see Fig. 167).

Not rarely among the many cysts of such a chronically inflamed ovary some cysts are found that permit the positive clear recognition on the inner surface of a somewhat broader, undulatory layer as remnants of the former *lutein membrane—corpus luteum cysts* (see Fig. 166). Its contents are like that of the follicular cysts, a thin, serous liquid, not

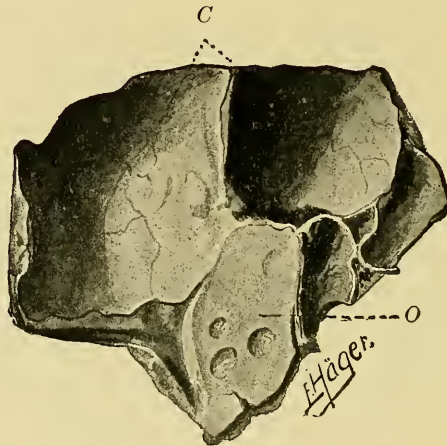


FIG. 167.—Small Cystic Degeneration of the Ovary. O, solid portion of the ovary; C, cystically degenerated follicle. (Author's preparation.)

rarely hemorrhagic. The *corpus luteum cysts* must be sharply separated from the *corpus luteum hematomata* caused by stasis.

Traces of an old perioophoritis, in the form of pseudo-membranes, exist also with the cysts. The ovary is fixed by these to the surrounding structures, especially the tube. Here, also, a communication may form between a hydrosalpinx and a follicular cyst (compare above, p. 338).

Larger examples, which may grow to the size of a child's head, have been designated by *Pfannenstiel* as a special form of newgrowths—*cystoma serosum simplex*. However, as every kind of proliferating growth is missing in these cysts, we prefer to class them among the follicular cysts, as they originate on a chronic inflammatory basis.

Although the last described chronic changes of the ovary, just like the abscess formations, are almost exclusively traced back to *infectious* processes, there are, however, rare cases in which an infection must remain highly improbable in spite of the most critical examination. Virgines intactæ are mostly concerned, in whom one finds, besides other changes in the genital tract, also the characteristic representation of chronic oophoritis.

Cases of chronic hyperemia are here especially to be considered, as they occur in myomata, cardiac diseases, nephritis, displacement, etc. Also excesses in venery, especially masturbation, have been accused of originating these chronic hyperemias. One will do well, however, to accept an oophoritis chronica as *not* caused by infection, only when the possibility of a previous infection can be excluded really with good reason.

Pathognomonic *symptoms* are not caused by acute oophoritis. The inflammatory processes in the ovary are masked by those of the surrounding tissues, particularly by those of the peritoneum. If an abscess formation occurs, grave general symptoms arise, as in abscesses of encapsulated cavities. As a rule, sactosalpinx and peritoneal abscesses are associated. It is always to be observed that in the healing of inflammatory processes of all these organs the ovary comparatively frequently lags behind the peritoneum and perimetrium, as well as the tube in the organization of the inflammatory products. The inflammatory processes remaining here unchanged for a long time are liable to acute intercurrent attacks.

Diagnosis.—*Acute* oophoritis is established as a part phenomenon of a general disease by demonstrating an enlargement of the ovary, as soon as the same can be isolated in the simultaneously developed inflammatory products of the rest of the pelvic organs. Ovarian abscesses form sensitive swellings in the uterine adnexa which, however, cannot, as a rule, be differentiated with complete certainty from sactosalpinx.

The *treatment* coincides with that of perimetritis and salpingitis. Extirpation (vaginal or abdominal) must appear always as a hazardous undertaking in the acute stage. It coincides with that of salpingitis purulenta and sactosalpinx purulenta.

Symptoms of Chronic Oophoritis.—Among the symptoms which *chronic* oophoritis occasions, the continued *pains* in the pelvis are paramount. As the disease not rarely occurs unilaterally, the point in question is very often a pain centre deeply situated in one flank. The pains appear frequently with every exertion and motion. In other cases they do not disappear, even in a quiet position. Agonizing constipation exists often, and the pressure of the fecal masses increases these pains, while gastric disturbances, anorexia, and imperfect sleep render the patient irritable and make her nervous to a high degree. *Menstruation* is very frequently irregular, very painful, always abundant. Profuse hemorrhages do not always bring relief.

The *diagnosis* is ordinarily established by the observation of increased sensitiveness of the enlarged organ. The ovary is mostly unevenly enlarged, often also immovable. The uterus, tubes, and intestines are adherent to it on account of the coexisting peritonitis. The sensitiveness usually renders an exact differentiation from the surrounding tissues difficult. The observation of the further course sometimes eliminates newgrowths of the ovary. These are, as a rule, not sensitive; they may, however, cause a confusion by a transient cessation of growth. In new-

growths we also meet the complication of peritonitis. The possibility of a differentiation results very frequently from the behavior at the time of menstruation. In newgrowths without peritonitis pains during ovulation are certainly much rarer than in chronic oophoritis. Extensive chronic oophoritis leads, as a rule, to *sterility*.

The ovarialgia of *Charcot* is not a symptom of ovarian disease; an ovarian neuralgia does not exist. Ovarialgia is a neurosis which is to be remanded to the department of hysteria.

Treatment.—The treatment of oophoritis chronica is urgently indicated in very many cases by the continued difficulties and the detrimental reaction on the general health. As long as the inflammatory processes are subacute they must be treated according to the rule of all inflammatory diseases by rest in bed, sexual continence, and regular evacuation of the bowels. An ice-bag must be applied with severe sensitiveness, eventually *Priessnitz* compresses. Only after the subsidence of the violent pains do the above-mentioned means for the promotion of absorption come in question. Local treatment is to be recommended with the same reserve as in all other inflammatory processes. Orthopedic treatment especially has appeared to us always as a source of serious complications. All the measures which markedly stimulate metabolism have an exceptionally favorable action also in chronic oophoritis. To them belong *Bier's* hyperemic method, the use of saline and mud baths, the employment of aperient mineral waters, sojourn in the mountains, in forests, and at the sea. A rationally used sport serves for the completion of the cure.

Operative treatment is indicated in cases of permanent serious disturbances of the general health, and a continued lessening of ability to work. We have seen, especially in chronic oophoritis, permanent and satisfactory results from a resection of the ovary in contrast to the radical operation. It is very frequently seen that one portion of the ovary is more diseased than another. Particularly the small cystic follicular degeneration affects the entire ovary only in extreme cases. Macroscopically healthy portions remain with especial frequency at the base. If only multilocular follicular cysts are concerned, then the evacuation of the same frequently leads to a considerable decrease in the volume of the organ and to a cure. Undoubtedly essential relief of the more or less acute pain is brought about thereby in many cases. We empty the follicles simply with the scalpel. *P. Müller* and *Pozzi* execute this puncture with the thermocautery. I do not recognize an essential difference for the further behavior after these different procedures. In any case a complete well feeling occurs not seldom after such an evacuation of follicles, even pregnancy has been observed frequently, but of course relapses also occur.

The **resection**, which was first done by *Schroeder*, was undertaken in the beginning for new-formations which presented nothing histologically suspicious and for simple cysts (hydrops folliculi), for hematomata folliculi, and oophoritis chronica. The resection is at present recognized as

justifiable in newgrowths only under quite peculiar circumstances—for instance, urgent demand for the preservation of the capability of conception, since the histologic character of ovarian newgrowths appears more and more questionable, even with an apparently benign character and the benignity cannot be determined macroscopically.

Considering the technical safety of excision of follicular hematomata and small cystically degenerated follicles we deem resection even at present still justified; the arrest of hemorrhage by suture is demanded, as well as when such follicles filled with blood and serum rupture during the exposure and examination of the ovaries.

The resection is also indicated, if we are enabled by preserving only part of the ovary, for instance, in total extirpation of the myomatous uterus, if not to exclude, yet decidedly to ameliorate the symptoms of an artificial change of life. As mentioned above, the ovaries are very frequently hypertrophic and filled with cysts or follicular hematomata, especially in myomata.

For the purpose of *resection* we bring or pull the ovary out of the abdomen, either through the vagina or an abdominal incision depending on a vaginal or an abdominal operation. An inserted laparotomy pad protects the surroundings from being soiled with the contents of the hematomata or the follicular cysts. The diseased part is then detached from the ovary in a wedge-shaped piece as one cuts a melon. The cleft is easily closed with a continuous catgut stitch. The only difficulty exists in the softness of the ovarian tissue. The sutures should not be drawn too tight, so that it enables the surgeon to suture the wound exactly, thereby arresting hemorrhage and reconstructing the ovary.

A preventive hemostasis, by clamping the pedicle, has been proposed by *Pozzi*. He sutures the resected ovary into the infundibulum tubæ, if possible.

V. Tumors of the Ovaries

Of all the parts of the female genitalia the ovaries, next to the uterus, are most frequently affected by newgrowths. Ovarian tumors are the most frequent of all intra-abdominal newgrowths in the female.

The etiology of ovarian tumors, like that of all other newgrowths, is, with one exception, completely unknown (compare under Embryomyomata), and therefore a discussion of them is superfluous. On the other hand the histogenesis of ovarian tumors has been cleared up in a sufficient manner.

The following varieties are distinguished according to the matrix of the newgrowths coming under consideration:

1. Epithelial.
2. Desmoid or connective tissue.
3. Ovigenuous (fetal) tumors.

I. Epithelial Ovarian Tumors

We wish to make a preliminary statement, that, according to our opinion, a form of epithelium-carrying cyst, the *cystoma serosum simplex*, classed by many authors (*Pfannenstiel* among others) as an epithelial newgrowth, does not belong to the tumors proper, but to the chronic inflammatory changes of the ovary. These cysts, reaching the size of a child's head, whose usually thin connective tissue is lined with a single layer of cubical epithelium, do not show any trace of proliferation and are, according to our judgment, to be regarded as *follicular cysts* and develop therefore upon the basis of a *chronic oophoritis* (compare above, p. 377).

We must look on the *germinal epithelium* (surface epithelium) as the matrix of all epithelial ovarian tumors considered as proliferating newgrowths in an oncologic sense.

The opinion held, to be sure only by a few, is at present still advocated, that the *follicular epithelium* is able to produce proliferating tumors in many cases; however, this opinion is hardly sufficiently supported by objective findings. At all events we cannot sustain it from information derived from numerous personal examinations.

On the other hand we find in the ovary at all times (as already mentioned above, p. 371) deep depressions and segmentations of the germinal epithelium in the depth of the organ, so that the interpretation of all epithelial newgrowths as arising from the proliferation of these cells, removed from their original parent tissue, is a natural one. As a further step *Pfannenstiel* proved that the germinal epithelium may undergo transformation into *ciliated epithelium*, especially under the influence of inflammatory changes; hence the *forms of epithelial newgrowths* with ciliated epithelium described below must be referred without hesitation to such germinal epithelium with modified function.

At any rate the cylindrical epithelium of ovarian tumors is met with in two entirely different forms, one a so-called pseudomucinous, i.e., a *non-ciliated* epithelium secreting a stringy fluid containing pseudomucin, the other a *ciliated* cylindrical epithelium with a thin-fluid serous secretion. All knowledge of the *etiology* is wanting as mentioned above.

The Different Forms of Epithelial Newgrowths

LITERATURE: See *Pfannenstiel* in *Veit's Handbuch der Gynäkologie*, Vol. III. Wiesbaden, Bergmann, 1899. *A. Martin*, *Handbuch der Adnexorgane*, Vol. II. Leipzig, Georgi, 1898. *Frommel*, *Jahresber. über Geb. u. Gyn.*, 1899-1906.

The Cystadenoma Glandulare Multiloculare Pseudomucinosum

When the germinal epithelium commences to proliferate, for reasons entirely unknown to us, it sends first *glandlike* canals into the depth of the ovarian stroma, which penetrate the latter to a great distance.

When, later, the neck of this glandular tube becomes constricted by a reactive proliferation of the connective tissue, a cyst forms from it. Its epithelium continues to proliferate incessantly and again to form multi-

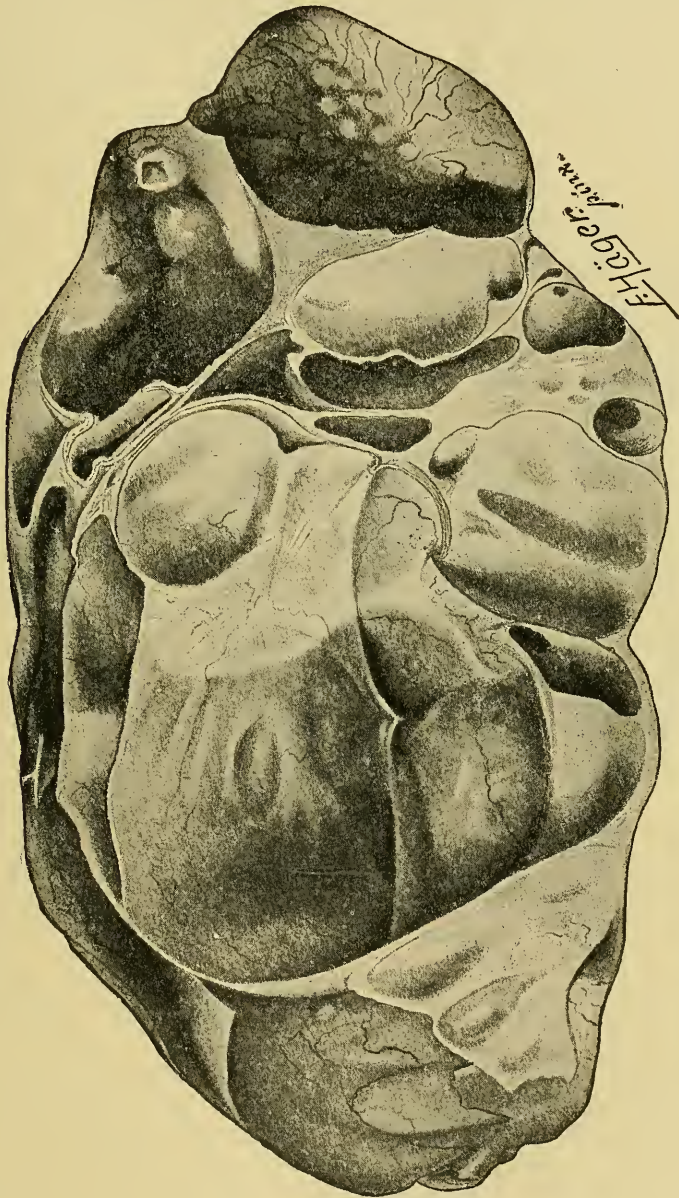


FIG. 168.—Cystadenoma Multiloculare Pseudomucinosum Ovarii. (Author's preparation.)

ple secondary or *daughter cysts*. This process of proliferation pursues an uninterrupted progress, the separated chambers enlarging further and further by profuse secretion and epithelial proliferation. Thus is

formed a conglomeration of larger and smaller cysts, a cystoma multiloculare glandulare (see Fig. 169).

The connective tissue, as mentioned, participates secondarily in the proliferation, because it represents the **supporting structure** of the new-growth, which, however, recedes much in the numerous large cysts. It is not always able to keep pace with the epithelial proliferation. Between a few large cysts an **atrophy** of the wall may occur on account of strong internal pressure, which finally leads to a rupture and thereby a

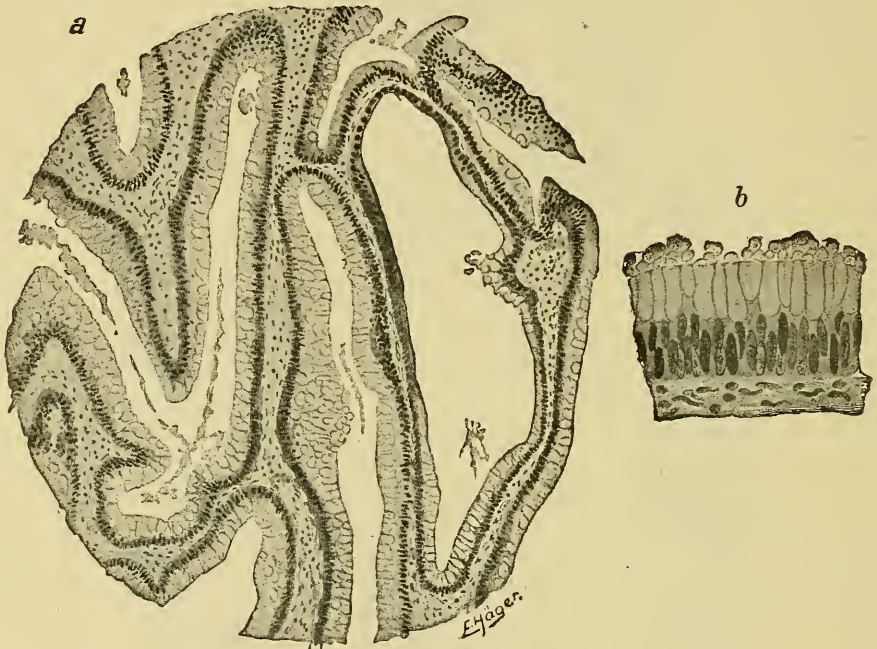


FIG. 169.—Cystadenoma multiloculare Pseudomucinosum Ovarii. *a*, microscopic transverse section, Zeiss, Obj. AA, Oc. 1; *b*, single-layered very high cylindrical epithelium with oval nuclei in the bottom of the cells and high protoplasmic body. (Zeiss, Obj. DD, Oc. 4.)

coalescence of two or more cysts, so that cavities of quite an enormous extent may arise.

Connective tissue bands, projecting into the lumen of these large conglomerate cysts, remain as remnants of the original partition walls and prove its development from multiple cysts, even if finally only a single large cavity is present. In addition one finds in such tumors, besides the large cavities, often apparently **solid** parts, which are shown by the microscope to be composed of innumerable smaller cysts. This mode of development holds good for all, even the **serous cystadenomata** described below.

In the **pseudomucinous** form all these cyst cavities are lined with a

single-layered, high, non-ciliated cylindrical epithelium with the nucleus *at the bottom of the cells*, and high glossy protoplasmic body. The epithelium reminds one of the *cervical* and *intestinal* epithelium. Pronounced *goblet cells* are found in this layer (see Fig. 169, *a* and *b*). Only in cysts in which a high internal pressure exists, is it sometimes flattened to a cubical form.

However, in these anatomically absolutely benign tumors an atypical proliferation of the epithelium or a polymorphism or multiple layers or anything else which suggests malignancy is never seen. They form papillary elevations only rarely in the interior of the cyst cavities, which then consist of a weak connective tissue basis with a covering of the described typical epithelium.

The *contents* of the pseudomucinous cyst is a white, glossy, sticky, stringy fluid, rich in albumin, which contains *pseudomucin* as the characteristic chemical body. Many times the *color* of the contents is found to be changed; it may be chocolate brown, red, yellow, and even green. These discolorations are due to the *blood coloring matter* frequently mixed with the cyst contents, which then suffer the before-mentioned changes in color with its decomposition. The hemorrhage originates from eroded partition walls of the cyst; they are especially profuse, with torsions of pedunculated tumors (compare below).

The pseudomucinous cystadenomata may attain quite enormous dimensions and fill out the entire abdomen, even pushing the diaphragm far up. This may form a direct danger to life, and indeed death by suffocation may occur.

The *external form* of the tumors is sometimes similar to that of the normal ovary; often, however, they form an irregularly formed mass, in which the different cysts can be recognized already plainly from the exterior as distinct protuberances. The *surface* of the tumor is smooth and glistening, covered with germinal epithelium, if pathologic changes have not occurred. For the *formation of peduncles* see farther down.

If the internal pressure increases too much, a cyst may burst spontaneously and its contents escape into the abdominal cavity, as frequently happens during the operative removal of these tumors. The escaped cyst contents are then usually absorbed; in rare cases, however, still viable epithelia escape also, and may implant themselves on the peritoneum and continue to proliferate, and then produce also here their typical secretion. These areas, which occur mostly multiple in the abdominal cavity, become encapsulated by a reactive peritonitis. Thus arises the so-called *pseudomyxoma peritonei*, which, without being anatomically malignant, may lead to dangerous disturbances by interference with the blood circulation, especially that of the portal vein.

Pseudomucinous cystomata are usually unilateral, more rarely bilateral. If one of the ovaries has once degenerated to this form and been removed operatively, quite a similar tumor formation not rarely occurs sooner or later, often even after many years, in the other ovary. For

malignant degeneration of pseudomucinous cystoma see under *Carcinoma*.

Cystadenoma Serosum Papillare

If the germinal epithelium has been transformed into *ciliated epithelium* (see above, p. 382) and undergoes proliferation, then a *cystadenoma serosum* is formed. This variety of tumor also appears as a *multilocular* cyst and its formation results just as described before for the pseudomucinous cysts. Its behavior regarding the epithelial membrane, etc., is also entirely the same. However, the serous cystadenomata have a few characteristics, which distinguish them sharply from the pseudomucinous cysts.

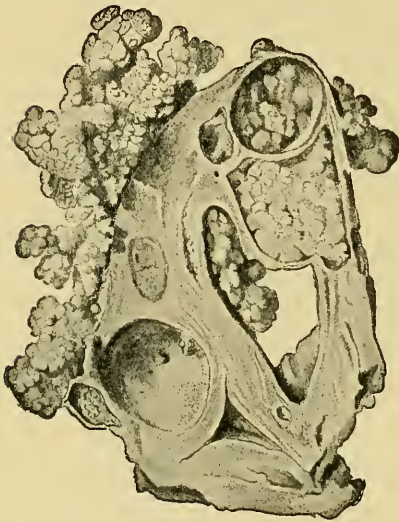


FIG. 170.—Cystadenoma Serosum Papillare Ovarii. (Author's preparation.)

The *epithelium* is throughout different from that of the pseudomucinous. It is a moderately high ciliated cylindrical epithelium, with large, oblong, *centrally located* nucleus, filling out the greatest part of the cell (see Fig. 171). The *secretion* is a thin, not stringy, serous fluid, very rich in albumin, which, normally of a yellow color, may suffer different changes in color on account of hemorrhages.

The property most characteristic for the serous cystadenomas is, however, their pronounced inclination to the *formation of papillæ*. In many cases on section of such tumors smaller or larger fine, papillary-like excrescences are found on the inner surfaces of the different cavities which

are in the most varied stages of development in the different portions of the tumor (see Figs. 170 and 171). They have a great energy for proliferation, and soon fill out the cyst cavities. Then they *perforate the wall and reach the surface of the tumors*, which is soon covered completely with these papillary excrescences. In other cases the formation of papillæ may begin *primarily* upon the surface of the ovary—*Surface papilloma*.

This formation of papillæ on the *surface* is very important for the further progress, as the serous epithelia which become detached in great numbers from the tumor are distributed by the peristalsis of the intestines through the entire abdominal cavity. They implant themselves at many places on the parietal and visceral serosa and thus cause multiple regionary metastatic formations in the form of very small papillary excrescences, *without, however, being anatomically malignant*. In

the further course these multiple papillomata excrete their serous secretion in large amounts, so that the *formation* of a copious *ascites* occurs. The ascites belongs to the typical picture of the serous papillary cystadenoma; it has, not very seldom, an outspoken hemorrhagic character. If the serous papillary cystadenomata are, according to what has been said, *anatomically* benign tumors, they can be designated *clinically only as conditionally benign* in consequence of their inclination toward dissemination upon the peritoneum and of excessive proliferation. They

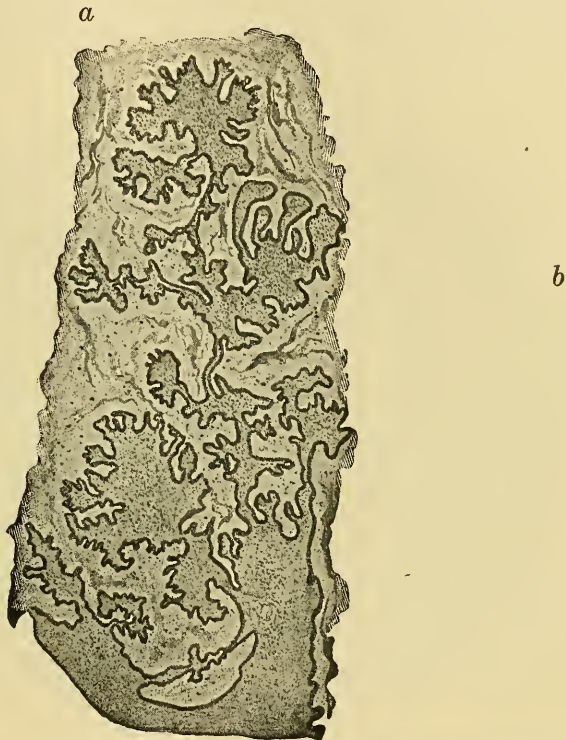


FIG. 171.—Cystadenoma Serosum Papillare Ovarii. *a*, microscopic transverse section. Zeiss, Obj. AA, Oc. 1; *b*, single-layered cylindric epithelium with long, centrally located nucleus. The cilia have been lost during the preparation. (Author's preparation. Zeiss, Obj. DD, Oc. 4.)

also possess a pronounced inclination to a *bilateral* occurrence. At first one ovary becomes diseased and shortly afterward the other, so that one meets with two different stages of the disease.

Carcinoma of the Ovary

The anatomically and clinically *malignant* epithelial ovarian tumors, the *carcinomata*, are relatively frequent. They occur in three different forms.

1. As primary, genuine carcinomata.

2. As carcinomatously degenerated, serous or pseudomucinous cystadenomata or embryomata (vide infra).

3. As metastases of other primary carcinomas, especially of the digestive tract.

The *primary, genuine ovarian carcinoma* develops from the germinal epithelium by unlimited proliferation of the same into the deeper parts with more or less pronounced proliferation, also of the connective tissue stroma. The tumors thus formed have usually still retained the approximate form of the ovary or they are nodular, the surface being mostly smooth. On section they are firm, but with exact observation a

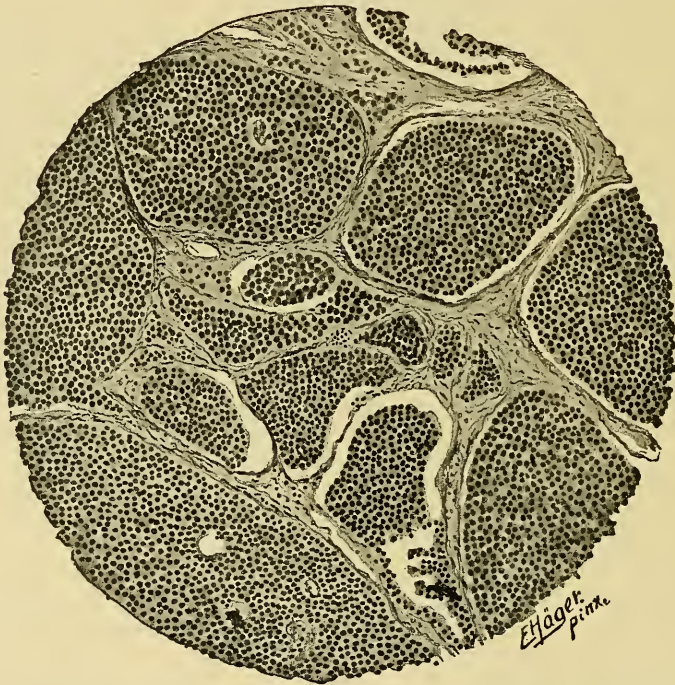

FIG. 172.—Carcinoma Alveolare Ovarii. (Author's preparation. Zeiss, Obj. AA, Oc. 4.)

connective tissue structure may be recognized in whose meshes the medullary tumor-masses lie. Accordingly, whether the interstitial or the carcinomatous tissue preponderates, either hard scirrhus or soft medullary carcinomas can be distinguished, between which occur all transitions.

Not rarely cysts are found in the interior, due to softening of the tissue and apoplectic foci occasioned by necrosis or hemorrhagic destruction of the tumor substance. It also happens not rarely that the carcinomatous masses penetrate the external connective tissue capsule of the tumor, reach the surface, and then rapidly cause a general peritoneal cancer usually with extensive formation of a hemorrhagic ascites. A general metastatic formation also in other organs, especially the retro-

peritoneal lymph-glands, tends early to take place by way of the blood and lymph vessels. The disease soon terminates fatally with profound cachexia from rapid growth of the primary tumor as well as of the metastases.

The carcinomata of the ovaries have *microscopically* either an alveolar structure, when single strands or nests of cancer cells lie between the smaller connective tissue bands, containing the bloodvessels: *carcinoma alveolare* (Fig. 172), or the structure is a glandular one, when the carcinoma permeates the stroma in the form of glandular tubes with a lining of stratified, polymorphous epithelia: *carcinoma glandulare* (see Fig. 173). All ovarian cancers have a pronounced inclination to a *bilateral*

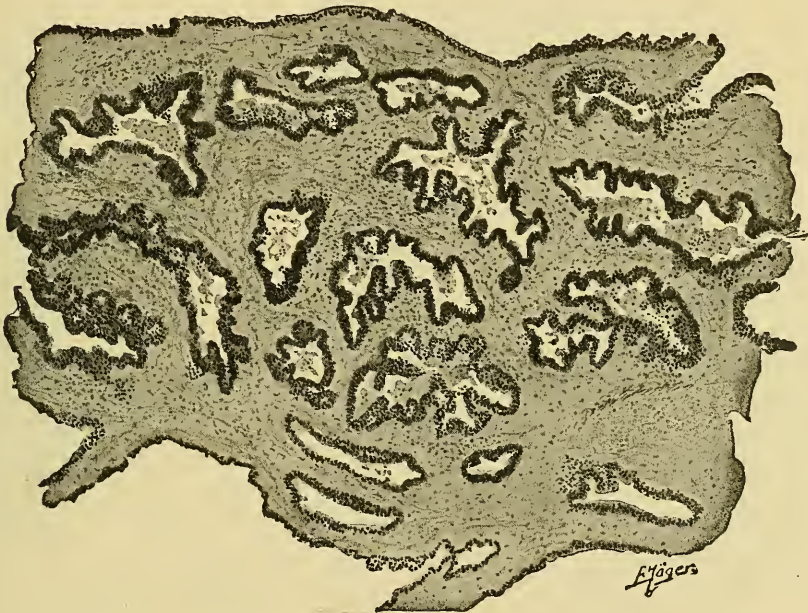

FIG. 173.—Carcinoma Glandulare Ovarii. (Author's preparation. Zeiss, Obj. AA, Oc. 4.)

occurrence. The disease of the second ovary can be often traced back to a metastatic formation from the first one.

The *carcinomatous degeneration* of *ovarian cystadenomata* ensues more rarely in the pseudomucinous, more frequently in the serous form. In the former portions of medullary consistency and grayish white color, which show the picture of an adenocarcinoma are found in the conglomeration of cysts, while otherwise the tumor retains the structure of the pseudomucinous cystoma (see Fig. 174). Gradually always larger parts of the tumor are seized with the carcinomatous transformation. The further progress and termination is then the same as in the genuine carcinoma.

The *serous*, especially the *papillary*, cystomata relatively frequently undergo carcinomatous degeneration. The papillæ resemble externally entirely the ordinary benign ones. On transverse section, however, one sees often that medullary masses penetrate the connective tissue structure and thus indicate the malignant character of the tumor. *Microscopically* the papillæ are not found coated all over by a lamella of ciliated cylindric cells, but by many layered, polymorphous epithelium which

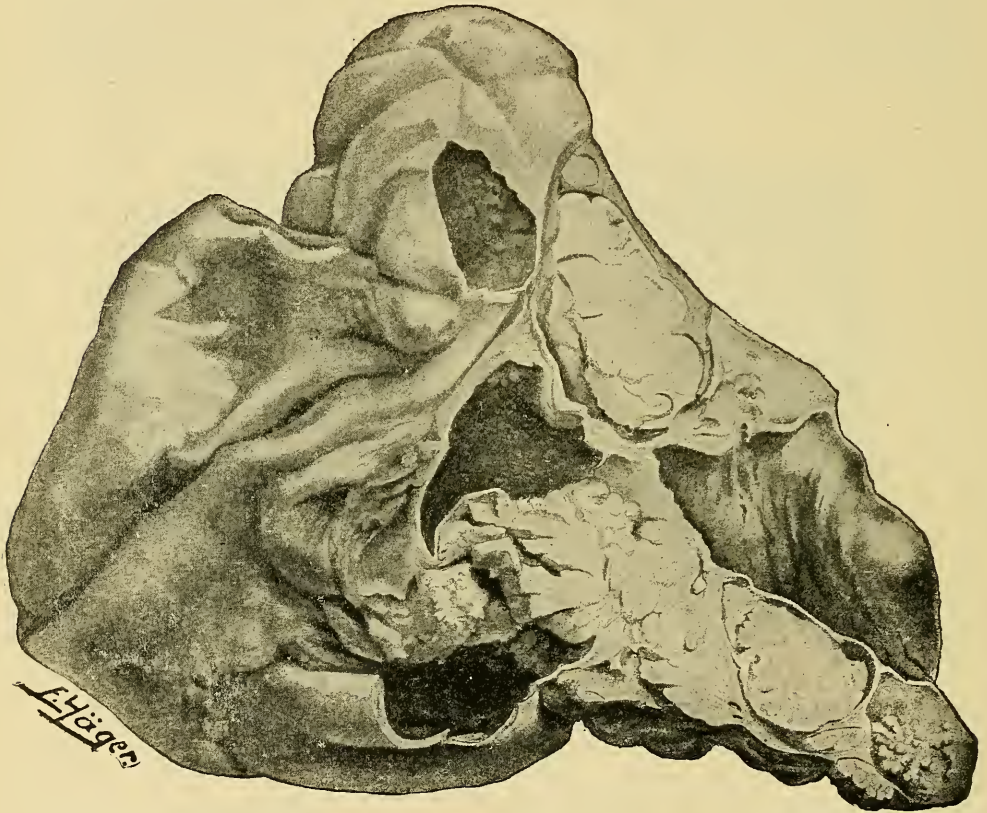


FIG. 174.—Cystadenoma Multiloculare Pseudomucinosum Partim Carcinomatosum Ovarii. (Author's preparation.)

penetrates also into the deeper portions of the stroma in the form of solid conical processes and glandular ductlike formations. Here, also, rapid growth, dissemination on the peritoneum, with formation of ascites, formation of metastases also in distant organs and rapid fatal termination is the rule.

It finally happens in rare instances that the epidermal part of the *cystic embryoma* (vide infra) is subjected to cancerous degeneration. A squamous epithelium carcinoma is then formed whose further progress does not differ from that of the other ovarian cancers.

Finally, the ovaries are very frequently the seat of *metastases with primary carcinoma of other organs*.

This fact has become more exactly known only in recent times and many cases of alleged primary ovarian cancer of former times must certainly be added to this group.

The primary tumors are located in most of the cases in the gastrointestinal tract, more rarely in the uterus, the mammæ, etc. Thereby the first symptoms appear often from the metastases, which become so

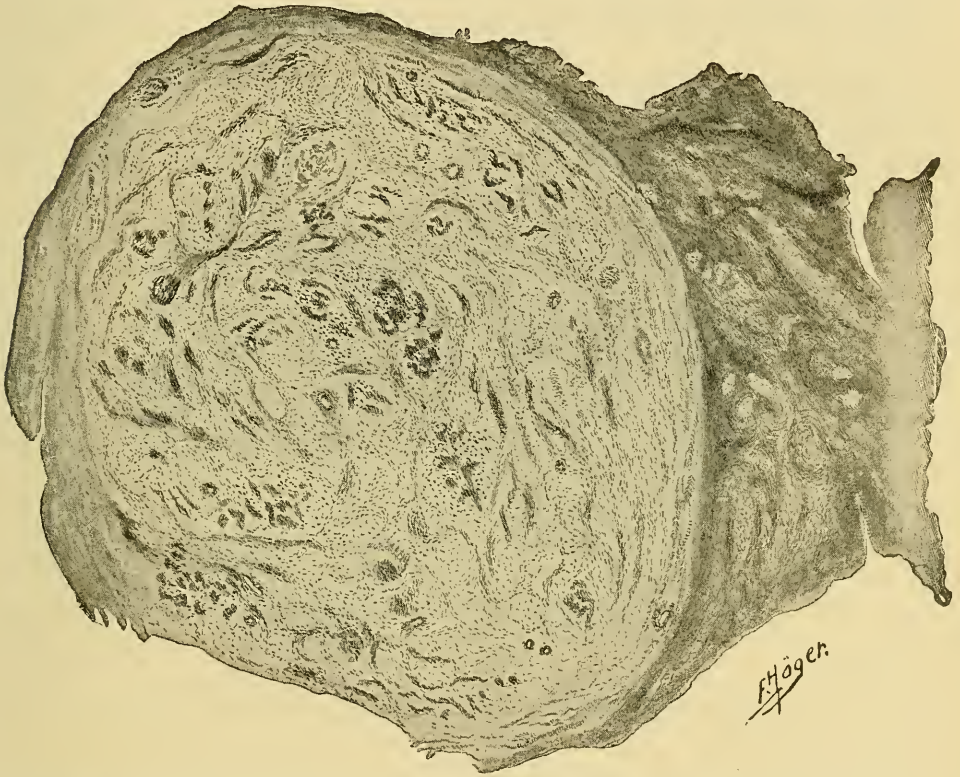


FIG. 175.—Fibroma Papillare Ovarii. (Author's preparation. Zeiss, Obj. AA, Oc. 2.)

prominent by the enlargement of the abdomen and formation of ascites, that the hidden primary tumor is entirely overlooked. Indeed, even *in cadavere*, its location may cause difficulties. Sometimes it is only a very small cancerous ulcer of the bowel or a symptomless mammary nodule, which is found after a long search as the origin of the disease. This fact of the frequency of *secondary* ovarian cancers has in the main a clinical interest, particularly in reference to rendering a diagnosis and to the remaining course of the disease (*vide infra*). The ovarian metastases form naturally the same *anatomic* picture as the primary tumors. They occur mostly bilaterally.

II. Desmoid or Connective Tissue Ovarian Tumors

As the ovary consists of connective tissue and contains also not inconsiderable amounts of smooth musculature in the walls of the numerous vessels, various forms of connective tissue tumors may originate here. However, they are *in toto* much less frequent than the epithelial ovarian tumors.

The Different Forms of Connective Tissue Ovarian Tumors

Fibromata of the ovary are relatively frequent. On the surface of the organ small fibrous knots, up to the size of a cherry or hazel nut, and attached to the surface with a narrow base, are not rarely found as an

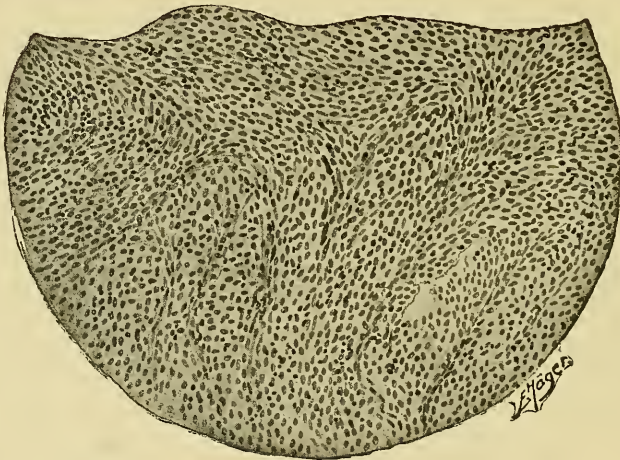


FIG. 176.—Fibrosarcoma Ovarii. (Author's preparation.
Zeiss, Obj. AA, Oc. 4.)

accidental finding, *fibroma papillare* (see Fig. 175). Hardly any importance can be attributed to them. They originate mostly from a cicatricial contraction of the surrounding ovarian stroma as a result of contraction of the corpora lutea (see above, p. 371), have almost no tendency to grow, and often never occasion any clinical symptoms.

When from any cause the connective tissue of the ovary undergoes actual proliferation, ovarian fibromata proper originate. These may grow to a considerable size, twice or thrice the size of the human head, of solid, either harder or softer consistency, according to the degree of tenseness of the connective tissue and have a smooth surface. *Microscopically* they consist of tangled bundles of spindle-shaped elements and more or less abundant, imbedded, fibrillary tissue (see Fig. 176).

If the tumors are very rich in cellular elements, then they have also been noted as *fibrosarcomata*, a designation which is, however, calculated to mislead, as these tumors are *benign* clinically, and therefore would be better designated as *richly cellular fibromata*. Edematous infiltrations of tissue, apoplectic foci and necrotic cysts caused by disturbances of the circulation are also not seldom formed in these tumors, similar to those described under *Uterine Fibromyomata*.

Fibromyomata, with more or less considerable portions of smooth musculature, occur in the ovary. They are, however, relatively rare, and otherwise to be separated from the fibromata only by means of the

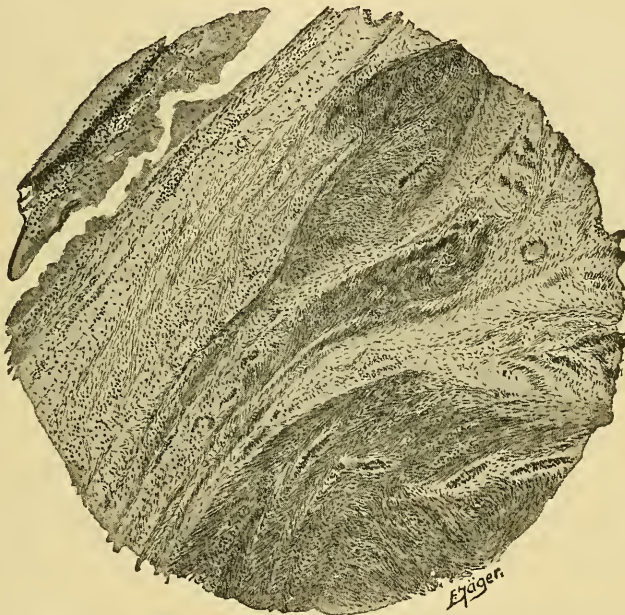


FIG. 177.—Fibromyoma Ovarii. (Author's preparation.
Zeiss, Obj. AA, Oc. 2.)

microscope. Their matrix must be looked for in the vessel walls. All fibrous tumors of the ovary are usually only *unilateral* (see Fig. 177).

The *sarcomata proper* of the ovary are relatively rare, they occur as spindle- or round-cell sarcomata. They have a rapid growth, attain a considerable size and are extremely malignant, as they lead very early to death by implantation on the peritoneum or by general metastasis by way of the blood-stream. The ovarian sarcomas mostly attack girls and young women (see Fig. 178). They develop mostly *bilaterally*.

Some connective tissue ovarian tumors described as extreme varieties, for instance, enchondromata, chondrosarcomata, osteosarcomata, and the so-called endo- and peri-theliomata, are here only mentioned. They are all characterized by great malignancy.

III. The Ovigenuous Tumors of the Ovary

These tumors, formerly generally included under the name of *dermoids* respectively *teratomata*, represent an especial and peculiar type. They prove, on close examination, to be composed of a motley mixture of the most different tissues, which collectively represent offsprings of all the germinal layers, the ectoderm, mesoderm, and endoderm. The ectodermal portion predominates almost always, and that is the reason why these formations were formerly named *dermoids*. The examinations of *Wilms* who proved the construction from the derivatives of all these

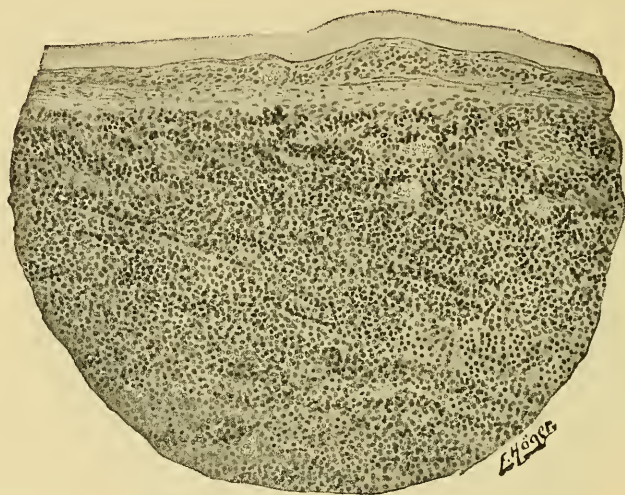


FIG. 178.—Sarcoma Rotundocellulare Ovarii. (Author's preparation. Zeiss, Obj. AA, Oc. 4.)

germinal layers, first brought clearness in regard to the peculiar nature of these tumors.

We distinguish *cystic* and *solid embryomata*, the former identical with the dermoids, the latter with the teratomata.

The origin of these newgrowths has given rise to many hypotheses. *Pfannenstiel* and *Krömer*, at first also *Wilms*, believed they should be explained by a proliferation of the primary follicles, that is in a certain degree as parthenogenetic formations. As parthenogenesis, however, does not exist in mammalia, *Marchand* and *Bonnet* set up each another scientifically well-based theory of the genesis of these tumors.

Marchand believed that they originate from fecundated *polar globules*, *Bonnet* from impregnated *blastomeres* in the earliest stage of fetal life. The possibility of both processes has been proven for lower animals. Both theories, therefore, are not without a scientific support. According to *Bonnet's* conception the detached, fecundated blastomere would be taken up by the *Wolffian* body of the fetus, that is, by the

mesoderm. The earlier the detachment and fecundation results, the less, therefore, the differentiation of the cells has advanced so much more various elementary tissue-forms would later arise from them; the later this process occurred and the farther the differentiation had progressed, the fewer varieties of tissues can be later produced. The predominance of the embryomata in the ovary, although they also occur in other parts of the body, *Bonnet* explains by the fact that in the earliest fetal stage the mesonephros, out of which the ovary forms, reaches almost through the entire length of the fetal structure, so that here the best opportunity is offered for the inclusion.

In any case the embryoma does not differ principally from other fetal inclusions, no matter which one of these two theories may be accepted.

In the fetal rudiment parts of the *head* mostly predominate, which normally already takes place in the earliest beginning. Relatively the least developed is the *endodermal* part of the rudiment.

According to this theory of development all embryomata would be congenital. To this corresponds the fact that they have been found accidentally in small girls and that small tumors about the size of a cherry not rarely are occasional findings in ovaries during post-mortem examinations and operations.

With the influence of the regular recurring hyperemias of the pelvic organs during menstruation occurs the slow growth of the tumors, whose bearers relatively are of a youthful age, until finally the symptoms of tumor formation begin to show.

The Cystic Embryomata

The cystic embryomata are by far the most frequently occurring representatives of their species. They appear in the form of round, movable tumors with smooth surface, and attain only rarely the size of a man's head. They are mostly considerably smaller, about the size of a fist or child's head.

They consist, as a rule, of one solitary cyst, in whose walls are embedded the embryologic structures. At times they form also several cysts mostly of a *pseudomucinous* nature. The embryologic structures, also, may be present manifoldly; however, it must be admitted rarely. It consists of a larger or smaller mass projecting into the lumen of the cyst, which is covered by *epidermis*, while the lining membrane of the wall of the cyst is formed mostly of a single layered cylindrical (eventually pseudomucinous) epithelium.

Tufts of long, mostly blond, hair always grow on the epidermis, which lie like coils in the cyst cavity. The latter is otherwise filled with sebaceous matter secreted by the epidermis, which represents an oily liquid at the temperature of the body and hardens to a grayish white fatty mass during the cooling after removal from the body. Not rarely one or more *teeth* of different kinds sit on the fetal structures (see Fig. 179).

Islands of cartilage and bone are frequently encountered on section

through the fetal part. Tolerably far developed portions of the skeleton, especially maxilla and also flat skull-bones, may have formed. The development of the entire portion has advanced differently from quite rudimentary fragments up to almost completely developed organs with all varieties of intermediate transitional stages. The ectoblast is chiefly represented by the epidermis, teeth and central nervous system; especially is the latter present very abundantly corresponding to the predomi-

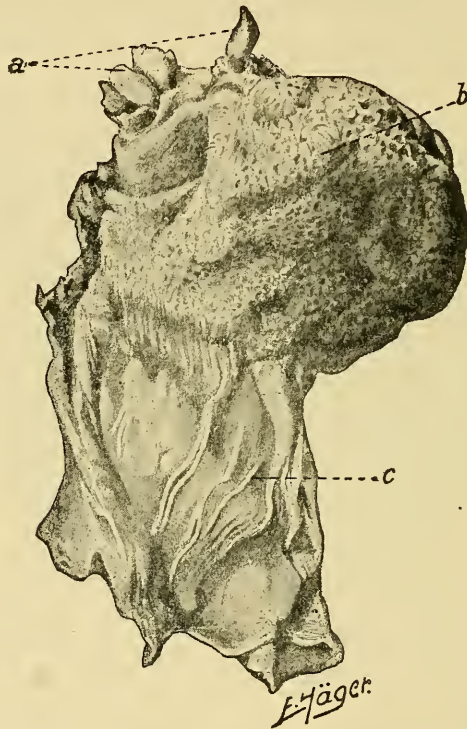


FIG. 179.—Embryoma Cysticum Ovarii. *a*, teeth; *b*, epidermis with hair; *c*, cyst wall. (Author's preparation.)

nance of the cranial portion. The mesoblast is represented by connective tissue of various kinds, adipose tissue, musculature, cartilage and bone, the endoblast by tubes (intestinal portion) lined with high cylindrical epithelium and often provided with circular smooth musculature.

The tissues always preserve a certain regularity in the cystic embryomata; an unlimited irregular proliferation is never observed.

The growth of the cystic embryomata is very slow, they may be carried without difficulty to adult age, although congenital. They are mostly unilateral, only rarely bilateral. They are absolutely benign as must be supposed as a matter of course according to their character as fetal inclusions. It has already been mentioned (see *Carcinoma of the Ovary*),

that in a few rare cases the epidermis of the fetal rudiment may degenerate to a squamous epithelium carcinoma.

The **solid embryomata (teratomata)** are much rarer than the cystic.

These tumors genetically conform to the cystic embryomata, they differ from them, however, morphologically in many points. As the name indicates, they are solid tumors, which grow most rapidly and may attain a considerable size. (A solid embryoma removed by me weighed thirty-two pounds.) In further contradistinction to the cystic embryomas is the fact that the peculiar regularity in the fetal construction of the latter is entirely absent in the solid ones, so that there is not the question any more of a uniform construction, but the whole forms an irregular conglomeration of the most varied derivatives of all the three germinal layers, among which, however, the ecto- and mesoblast play again the most prominent part in contrast to the scantily represented endoblast. The bony tissue mostly is especially largely developed.

The solid embryomata have a smooth surface with many eminences; on section they show an epidermal structure with hair, pigmentary spots, bones, cartilage, and so forth. Degenerations are frequent, as a result of hemorrhages. **Microscopically** the central nervous system, besides the epidermis, is above all others largely represented.

The solid embryomata have been compared to the cystic ones as having a relation similar to that of the carcinomas to the adenomas (*Pfanzenstiel*), and they have been designated as absolutely malignant.

We cannot admit this for reasons of our own experience, as here, in the Greifswald clinic, patients subjected to the removal of only **one** ovary remained perfectly well; in three cases already for five years.

In the cases which came later with a general metastatic formation *ad exitum*, the matter in question was not a metastasis of **embryonal** tissue.

In these cases the primary solid embryoma was first **sarcomatously** degenerated in its mesodermal part, and the sarcoma rapidly resulted, as usually in a general sarcomatosis by way of the blood. It is important for clinical and therapeutic purposes to remember a characteristic of the solid embryomata, that they are only conditionally malignant.

The Pedicle Formation of Ovarian Tumors

The pedicle of the ovarian tumors, if they freely develop in the abdominal cavity, is formed from the natural ligamentous apparatus of the ovary that is toward the pelvic wall by the ligamentum suspensorium ovarii, toward the uterus by the ligamentum ovarii proprium, toward the ligamentum latum by the hilus ovarii. The tube may show a various behavior. Either it runs entirely without participation beside or underneath the tumor, or it has partly developed into the mesosalpinx, when the tube must accommodate itself to the growth of the tumor, and running in its surface becomes stretched to a very considerable length.

The pedicle is usually ligamentous according to the statement made, short, about 5 to 6 **cm.** broad, and only seldom considerably lengthened by

stretching and decreased to the thickness of a finger. The arteries to be ligated are the arteria spermatica toward the pelvis, the anastomosis between the arteria spermatica, and uterina toward the uterus. At the hilus usually only a few small branches bleed. It is a rule, holding good for all ovarian tumors with the exception of the advanced malignant newgrowths, that remnants of ovarian tissue still capable of functioning are usually found near the pedicle, through which ovulation and menstruation may be maintained. Pregnancies in connection with bilateral ovarian tumors are also explained by this fact.

It may, however, occur that the development of the ovarian tumors does not take place into the free abdominal cavity, but in the direction of the hilus between the folds of the meso-ovarium—***intraligamentous development***. This modification is especially frequently found in the ***serous*** cystadenomata. It may lead to considerable changes in position of the other pelvic organs and to a displacement of the uterus and bladder out of the small pelvis, and also to a serious compression of vagina, rectum, and ureter. These are very disagreeable complications for the surgeon.

Under normal conditions ovarian tumors always develop first in one side of the pelvis into the excavatio recto-uterina. If they have attained such a size that they fill out the space at their disposition in the small pelvis, they ascend just as the pregnant uterus for the same reasons into the large pelvis. Here they place themselves, just as the pregnant uterus, always in the middle and close to the anterior abdominal wall, so that the ***intestines lie posterior to them***. In the course of its further continued development the tumor gradually fills always large portions of the abdominal cavity, presses on the stomach and liver and elevates the diaphragm, so that compression of the lungs and displacement of the heart may occur. In the further course of development the presence of such an enormous foreign body remains only seldom without influence on the peritoneum. At the places where the tumor presses firmly on the serosa, the epithelium of the tumor and the peritoneum perish, an exudation forms, from which agglutination and finally connective tissue adhesions result. The intestines, omentum, and parietal serosa are not rarely found adherent to the tumor. That such adhesions may also take place during the progress of an infection of the tubes or from the bowel, is self-evident. Sometimes the entire parietal peritoneum as well as the surface of the tumor suffers a marked increase in thickness up to 4 or 5 mm by the chronic irritation of the pressure, which is especially met with in colossal tumors and lowers considerably the resistance of the peritoneum against the dangers of an operation.

As long as the tumors have not yet grown too large, a certain degree of mobility in the abdominal cavity is guaranteed them with a good pedicle. This mobility makes it possible that the tumors turn around their axis during the change of position of the bearer or one extreme exertion and so forth, whereby naturally the ***pedicle*** must suffer a ***torsion***.

This event, which is not rare, is of extraordinary importance for the further fate of the tumor and its bearer. A compression of the bloodvessels quite naturally results from the torsion of the pedicle; at first of the venous system, while the arterial conveyance is still maintained. The result of this is a rapidly increasing stasis in the tumor, which may enlarge its circumference rapidly to twice its size or more. Finally, the arterial blood-current is also interrupted by a continuation of the torsion, and thus the tumor is entirely cut off from the circulation. The result

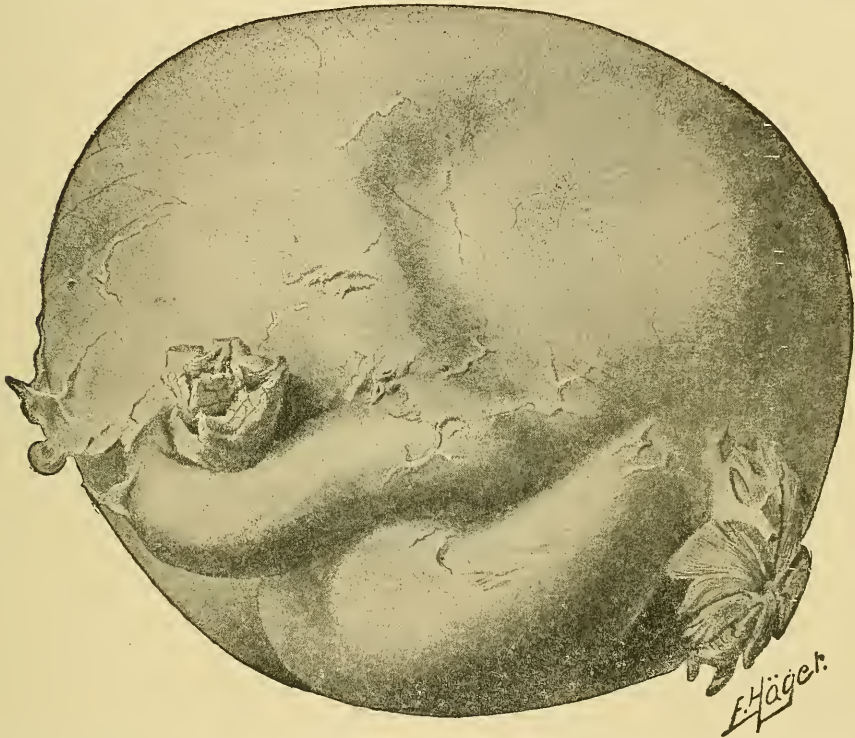


FIG. 180.—Torsion of Pedicle of an Ovarian Tumor. Marked thickening of the ligamentum ovarii proprium and the tube. (Author's preparation.)

of this is a *necrobiosis*, provided micro-organisms are absent; its interior softens and breaks down, and thus, for instance, large cysts, formed by softening of the tissues, occur in solid tumors. Such a cyst with a torsion pedicle is dark-bluish as a result of the enormous stasis, the ligamentum ovarii proprium may swell up to the thickness of a thumb (see Fig. 180), as likewise also the tube drawn into the torsion. The surface of such ovarian tumors with twisted pedicle loses rapidly its glittering brightness, as the superficial epithelium perishes. The tumor acts on the peritoneum as a very irritating foreign body, which causes soon a circumscribed, fibrinous peritonitis, and becomes gradually enclosed from all sides by adhesions. If they are very firm and extensive new vessels

may penetrate into the tumor through these adhesions which takes place especially from the omentum, and thus circulation by the bloodvessels in place of the excluded vessels of the pedicle is established. The pedicle may finally be twisted off entirely; the tumor may loosen completely from its pedicle and becomes then soon encapsulated on all sides by peritonitic adhesions and remains lying in the abdominal cavity as a dead foreign body, where it may finally undergo shrinking and calcareous degeneration if its proliferation energy has become extinct.

During the course of torsion of the pedicle as well as of the various disturbances of circulation, especially in malignant ovarian tumors, degenerative processes often take place in the tumor tissues. Edema, hemorrhages, fatty and myomatous degeneration, necrosis, calcareous degeneration are very frequently occurring changes in larger ovarian tumors, of which different varieties may be present at the same time in the same tumor.

Calcareous degeneration especially appears in many ovarian tumors, especially the papillary cystomata and carcinomata, often in the form of multiple small deposits of lime in the tissues which have been designated **psammo-bodies** (*psammo-cystoma*, *psammo-carcinoma*).

Ovarian tumors also may become invaded by infectious agents and thereby undergo a complete **suppuration** and **putrefaction**.

The opportunities for an immigration of micro-organisms are many. Thus a feverish puerperium may cause it, but other infectious processes external to the genitalia may lead to metastases in ovarian tumors. Infections with **pneumococci** in pneumonia, with **typhoid bacilli** and **tubercle bacilli** are indeed not frequent, but have been observed positively.

If extensive adhesions with the **bowels** exist and if their walls are thereby injured, intestinal bacteria may also immigrate into the ovarian tumors and cause them to putrefy. In connection with this a rupture of the tumor into the bowel may arise and a permanent open communication of both cavities may form, keeping up the putrefaction. Rupture of ovarian tumors into the bladder, uterus, and also into the vagina and through the external abdominal walls have been observed in rare instances.

Parovarian Cysts

The **parovarium**, lying as a rudimentary organ between the tube and ovary, may become the seat of cystic tumor formation. For its normal structure, see p. 4. An increased secretion of the parovarian ducts may occur for reasons unknown to us, and lead gradually to a distention of the different glandular canals, and finally to the formation of an always **unilocular cyst**. It is to be regarded purely as a **retention cyst** according to its mode of formation and **not** as a newgrowth in the sense of the pathology of tumors, and has therefore absolutely a **benign** character.

These cysts always develop extraperitoneally, corresponding to the

position of the parovarium, at first in the connective tissue of the meso-ovarium, then the mesosalpinx, so that with some size of cyst the tube passes over this in a long-drawn-out manner (see Fig. 181).

The cyst sac consists of peritoneum which can easily be peeled off, and then of a connective tissue layer with numerous *smooth muscle-fibres*. The parovarian cysts are lined internally with a single layered cylindrical epithelium, which in small examples still shows ciliated margins, while in large cysts it is flattened out mostly by the internal pressure and has lost its ciliated border. Papillary excrescences are isolatedly found at

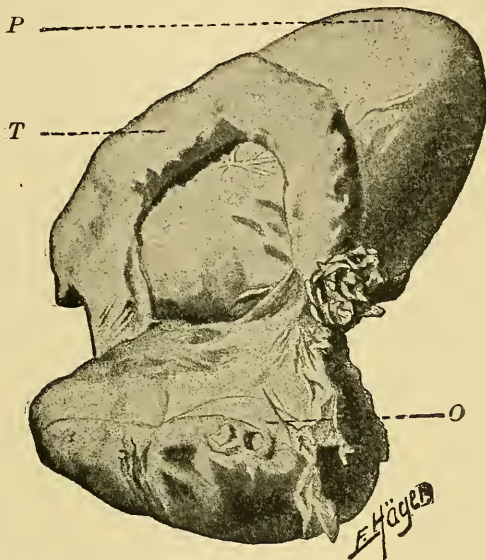


FIG. 181.—Parovarian Cyst. *T*, tube; *P*, parovarian cyst; *O*, ovary.
(Author's preparation.)

the internal wall, which, however, are not to be considered in the sense of a tumor actively proliferating but as remnants of the original fold of the parovarium.

Parovarian cysts are mostly not large in circumference, but may, however, attain the size of a man's head. Their connection with the uterus and the ligamentum latum is mostly very slight in spite of their intraligamentous development, so that they may become pedunculated with all its resulting conditions.

Clinical Behavior

Ovarian tumors develop during the prime of life of a woman, but also childhood is not exempt from it. Ovarian tumors may develop to a very large size without causing difficulties. The sensation of *restriction of space* in the pelvis and in the abdominal cavity makes itself very early noticeable in other cases. A feeling of fulness, pressure in the abdomen, bowel difficulties, and strangury set in. If the tumors grow out of

the small pelvis, then the increase in the size of the abdomen may even startle the patient. Many a woman succeeds in palpating the developing mass within the abdomen; with further growth a *tenseness of the abdominal walls* becomes observable with an increase in the symptoms, especially on the part of the bladder, but also of the intestines. At times edema of the vulva, of the dependent portion of the walls, and finally also the legs develops. Just as during pregnancy, the umbilicus becomes obliterated or is forced out as a hernia. The breasts rarely enlarge and allow a few drops of colostrum to evacuate. With loss of appetite, discomfort, and pain, inability to lie comfortably, a picture of cachexia, especially in the very suffering expression of the countenance, which has been designated as *facies ovarica* by *Spencer Wells*, develops even in the benign tumors with unlimited increase of the abdomen. The musculature atrophies with complete decline of strength, the skin becomes dry and harsh, and the patients succumb with dyspnea and increasing cardiac weakness.

As a rule *menstruation* remains undisturbed, at times it becomes increased. Only with bilateral degeneration amenorrhœa is a result and symptom of the complete exhaustion.

The *course of the disease* in ovarian newgrowths is mostly slow but continuous. The tumors grow rapidly in a few isolated cases. Malignant degeneration frequently brings about a more rapid development of the final catastrophe. Since we know to-day that ovarian carcinomata develop with remarkable frequency as metastases of gastric, intestinal, or mammary carcinoma, we must also well understand why in some women the manifestations of ovarian degeneration are recognized so late and the patients then succumb with astonishing rapidity. Ovarian tumors do not exclude pregnancy. We will later enter more in detail into the signs of these complications.

Diagnosis of Ovarian Tumors.—The diagnosis of these newgrowths in general succeeds at present easily. We should, however, not overlook the fact that a vast profusion of complications may obscure it.

(1) *Diagnosis of Ovarian Tumors as long as these lie in the small Pelvis.*—Through the vagina is felt the portio vaginalis displaced from the median line. A more or less round, sharply limited, tense swelling presses above, lateral, anterior, and posterior to the portio between the hands. If the uterus lies to the side of the mass, then it is pushed to the opposite side. The tumor lies, as a rule, behind it. The uterus may be pushed somewhat upward in the pelvis, just as well also downward. In the first case the portio lies high, close behind the symphysis, the fundus projects laterally to the growth upward above the pelvic inlet. In the latter case the uterus is found behind the symphysis or the os pubis, overlapped by the tumor. The first condition is found not merely with an intraligamentous position of the mass, but also in case of adhesions between it and the uterus. At times the uterus lies retroverted beneath the mass, and also displaced laterally. The tumors

seldom lie anteriorly and laterally from the uterus. According to *Küstner* and *Ahlfeld* such positions frequently correspond to dermoid cyst formations. Such tumors, the size of a fist or a child's head, are not always tense and hard. Fluctuation can be seldom felt in them. Tumors with weak walls are rare, a soft consistency is found more frequently in retention cysts. At times denser parts are felt in the tumors. The other ovary may be, if also not regularly, palpated in newgrowths which do not entirely take up the pelvis. Examination through the rectum often shows a displacement of the healthy ovary.

Ovarian tumors of this size are more difficultly and exactly outlined when they completely fill the pelvis. An edema of the vagina and the pelvic floor, as far as the external parts, occurs often in such cases. The vagina is completely compressed, as well as the bowel. Both lie at the periphery of the tumor mass. It is then quite often difficult to palpate the uterus.

One succeeds only rarely in feeling a more increased stretching of the ligamentum ovarii proprium, with this size of tumors. Such an observation is important for the diagnosis.

Subserous intraligamentously developed ovarian tumors lie as tense elastic masses immovable on the pelvic floor. They push the uterus high up from the side or from behind, or lengthen it apparently if it lies with one border intimately adherent to them. At times the tumors push the uterus entirely upward out of the pelvis and force down the vaginal vault, and one succeeds with difficulty only in palpating freely the other side of the uterus, or in feeling the adnexa.

Similar conditions arise with **perimetritic adhesions of the tumors** in the small pelvis. A differentiation is made possible only when the anamnesis refers to inflammatory disturbances, which are absent in the intraligamentary development, but cannot be excluded as complications.

Finally, it must not be denied that many cases of ovarian newgrowths of such size by their adhesions cause such unsurmountable difficulties in the differentiation that a positive diagnosis is impossible before the operation.

Differential Diagnosis.—**Inflammatory ovarian diseases**, especially in connection with the inflammatory enlargement of the tube and tubal pregnancy may result in quite similar findings. However, peritonitic signs and symptoms of a preceding disease of the mucosa of the uterus are hardly ever absent which even now are still demonstrable. Inflammatory adnexal diseases are more frequently, though not always bilateral. Contrary to the course of development of adnexal disease the newgrowths develop mostly without symptoms as long as they are of the same size. The diseased tube is felt beginning at the uterine cornu in its characteristic increase in size and formation of convolutions. Such adnexal enlargements are almost always broadly adherent to the uterus. Their mobility is limited as a result of their peritonitic adhesions. The mass

itself is of an indistinct contour. Ovarian cystic tumors are usually uniform, firm, and tense and of a distinct outline.

Extrauterine pregnancy is anamnestically usually well distinguished by the characteristic symptoms, irregularity of menstruation, and also pains. The consistency of the fetal sac is soft, as long as the ovum remains undisturbed; the vessels in the neighborhood pulsate powerfully. If the ovum is permeated by blood, then the mass becomes in the beginning doughy, later hard. Acute catastrophes make a deep impression on the general state of health. If a hemocele is formed, the blood lies in the lower part of the excavatio recto-uterina. The consistency of the hemocele is only very seldom comparable to that of a cyst. The blood turns hard, although not uniformly, and disappears. The blood mass is hard to outline superiorly. Recent cases are so characterized by the reaction on the general condition, that mistaking it for ovarian tumors seems excluded in general.

The **enlarged uterus** may very well be mistaken for an ovarian new-growth. **Retroflexio uteri gravidi** has often impressed me as such. Quite especially difficult are the cases of **elongatio colli uteri gravidi**. The behavior of menstruation and the changes peculiar to menstruation assist in putting one on the right track. One can feel in these cases by careful examination the transition of the elongated and markedly softened uterine cervix into the pregnant corpus uteri, push the same up out of the small pelvis with proper precautions and now determine the connection of the cervix with the body.

In **hematometra** and **hematocolpos unilateralis** similar conditions arise; the development of the mass and the intermittent filling of the new cavity, together with the palpatory findings, elucidate the diagnosis.

Myomata with a subserous development may be mistaken for small ovarian tumors. They have usually a still harder consistency. Their pedunculation to the uterus is short, firm, and broad. Ovarian tumors have a thin pedicle, palpable often only with difficulty, in which one hardly perceives the tube, somewhat more plainly the ligamentum ovarii proprium. Besides the myoma both ovaries are palpable. One very frequently also palpates even smaller or larger myomatous knots in the uterine body. The uterus is thereby enlarged, as a rule. The patients complain usually of menorrhagias.

A preceding opportunity for infection (labor, injury, operation) can be always established in **parametritic exudates**. The formation was accompanied by fever. The parametritic exudates extend within the pelvic connective tissue, the ovarian tumor, as a rule, lies above it.

In quite similar conditions of **hematoma extraperitoneale ligamenti lati** the anamnesis and the course decide.

(2) **In the more voluminous tumors** the diagnosis of the **middle-sized** from the so-called **colossal tumors** must again be discriminated.

(a) **The middle-sized tumors**, which fill the abdomen up to the umbilicus and scarcely above it, stretch the hypogastrium to a semi-spherical

shape. They lie immediately adjacent to the abdominal walls and seem movable behind them. With both hands one may feel above along the tumors into the pelvis and perceive here an extension into the pelvis or even palpate beneath it. The apex of the tumor on percussion gives dulness, bilaterally and above the tumor a tympanitic sound. The lower segment of the tumor is felt per vaginam; on pressure from above a larger portion is palpable. The uterus lies down and forward or backward, also displaced laterally, mostly, however, displaced upwardly. The pedicle connection, the *ligamentum ovarii proprium*, is at times palpable with remarkable clearness, at others not at all. At times the pedicle can be stretched by the weight of the tumor gliding into the upper abdomen during an examination in the elevated pelvis position as well as by traction downward upon the portio according to *Schultze* and *Hegar*. It becomes then perceptible between the fingers introduced into the vagina and rectum. In this way the ovary of the other side is usually also found. *Fluctuation* is felt, as a rule, between both hands lying laterally on the abdomen or between the hand lying externally and the other introduced into the vagina. The *surface of the tumor* is mostly smooth and can be sharply outlined from the surrounding intestines. The consistency is usually hard and tense.

Other ovarian diseases, retention cysts, parovarian tumors, have very seldom such a circumference, though they may also attain the size of a cocoanut.

Differential diagnostic difficulties are at times offered by the *uterus during the sixth or seventh month of pregnancy*. The perception of the fetal heart-sounds and fetal movements with the anamnesis, amenorrhoea and symptoms of pregnancy, also the changes in the breasts leave one in the lurch in some isolated cases (death of the fetus, hydramnion, hydatid mole). The cases of *elongatio colli uteri gravidi supravaginalis* already above mentioned quite particularly dispose to disappointment until one succeeds in establishing the connection of the cervix with the uterus. The pregnant uterus contracts on the pressure of the examining hand; this is a valuable sign. The perception of one ovary, the non-perception of the other, may also be turned to good account.

Myomata of a corresponding size may especially lead to mistakes with cystic degeneration. Multiple tumors are mostly concerned with myomata of this circumference. The uterus can be demonstrated in the mass by the sound. At times the ligamenta rotunda become plainly palpable. In correspondingly large ovarian tumors the uterus can, as a rule, be well differentiated.

Tumors of *other abdominal organs* properly ought not to be mistaken for ovarian tumors by gynecologists. One succeeds, as a rule, in palpating the pelvic organs as such or in proving, at all events, that the tumors are not in connection with them. Renal tumors seem the most difficult, which may attain a considerable size on account of the overdistention of the pelvis of the kidney and have a cystic character. What leads to the

mistake is the fact that the kidney at times completely moves out of its bed and protrudes down into the pelvis. The examination of urine by cystoscopy and ureteral catheterization are carefully to be used. Full of importance is the determination whether a kidney lies at the typical place or not. The relations of renal tumors to the colon are often quite important, if they are not yet considerably displaced.

Tumors of the *mesenterium* may be confused with middle-sized ovarian cysts on account of their consistency and mobility. The question here is to find out especially the part of the pelvic organs in the tumor formation, just as in the other voluminous tumors of the hypogastrium.

(b) *The large (colossal) tumors of the ovarium* fill the abdomen more than a well-advanced pregnant uterus. They reach up to the pit. of the stomach, force outward the lower border of the ribs, and fill the abdomen down to the pelvis. The abdominal walls can often be pushed to and fro over their surface, in other cases isolated parts of the abdominal wall do not follow the shifting (peritonitic adhesions). According as the tumor in question is uni- or multi-locular, the fluctuation wave is differently formed. The percussion-sound is absolutely flat at the height of the tumor. Entirely above and beneath the ensiform process, and entirely laterally in the flanks, one may still perceive intestinal sound. The abdominal walls may be stretched *ad extremum*. In a quiet dorsal position, after removal of the clothing, the abdomen does not flatten out or, only a little, in contradistinction to cases of extensive ascites, which also extraordinarily stretch the abdomen, but admit of a visible flattening of the abdomen in the dorsal position.

In ascites, change of position is accompanied by a shifting of the sound phenomena, provided that extensive adhesions in the peritoneum do not partially encapsulate it.

Large tumors frequently prevent a combined palpation of the pelvic organs. One must, therefore, confine one's self to establishing the condition, if necessary, by one hand per rectum.

Such colossal tumors only rarely develop from other organs than the ovaries. However, the combination of different uterine and ovarian tumors with newgrowth or swellings due to passive congestion of other organs may essentially veil the condition. It remains of importance that tumors of almost equal size as these may be derived from the stomach, but still more frequently from the pancreas and liver. They are characterized on the one hand by their place of origin; on the other hand by the fact that they leave the pelvic organs free. To this must be added that their shape for a long time reminds one of that of the original organ and that their vascular supply remains accessible to palpation to a certain extent. Hepatic tumors participate in the respiratory movements of the diaphragm, and their accompanying symptoms leave hardly any doubt. Such large masses, if malignant degeneration is not present, arise especially in cases of leukemia and malaria, which are to be diagnosed by the characteristic blood changes. Retroperitoneal tumors, as a rule, displace

the bowel from behind, so that it is noticed by the tympanitic sound at the border of the tumor, its consistency on pressure, and the palpable peristalsis.

The diagnosis of the special variety of the tumor is no longer considered of such importance, inasmuch as every ovarian tumor is considered as an urgent indication for operation. The above-mentioned symptoms comply in their majority with the *pseudomucinous cystadenomata*.

The *serous cystadenoma*, upon whose surface we feel sometimes roughnesses, frequently causes ascites very early. These serous tumors are at times less tense and permit recognition of the harder masses by the side of softer ones. The tumors many times are bilateral.

It is not especially characteristic, that they may be also intraligamentary and appear then less movable.

From the *embryomata* slow growth and the occurrence during still youthful age is considered as characteristic to a certain degree. The phenomenon of *Küstner-Ahlfeld*, i.e., the position anterior to the uterus, has not been regularly perceived during my examinations. With a long pedicle they may be very movable, others with a very short peduncle are almost immovable. Hour-glass form is only at times distinctly palpable. The consistency is mostly hard. At times harder constituents, as bones and teeth, are felt.

Carcinomatous degeneration of cystadenomata may be suspected with suddenly accelerated growth of the tumor and the occurrence of pains, which otherwise appear only very seldom, especially if ascites and edema of the abdominal walls and lower extremities develop with great rapidity. As a rule, both ovaries degenerate at the same time. More frequently secondary cancer formation in the ovary is to be thought of. It is therefore always necessary to look for the primary tumor (stomach, intestines, liver, mamma). Less extensive cancerous tumors are hard and knotty. They not seldom appear to soon unite with their surroundings. The ascites appearing in such cases permits a kind of fluctuation in the excavatio recto-uterina beside and beneath the tumor to be perceived if a blow is struck on the hypogastrium. Metastases in the peritoneum appear early, their nodules or the hard infiltration are perceptible through the vagina or rectum. Occasionally the sensation of crunching of snowballs is experienced thereby. Metastases in the upper portion of the abdomen appear as nodular formations. It is remarkable that the cachexia appears in a very different intensity and temporarily not uniformly. Some patients are highly cachectic from the beginning, a sign which, however, may be at times observed in other than malignant ovarian growths. In some patients the cachexia is observed only in far-advanced stages, and then is surprisingly sudden in its appearance. Carcinomatous degeneration is overwhelmingly found in adult life. Nevertheless one must always observe that the rapid loss of weight and the severe suffering expression occur in ovarian tumor-formations also

without malignant changes. *Fibromata* and *sarcomata* startle one already during palpation by their kidneylike shape and by their hard consistency. In the latter, ascites develops surprisingly early.

A peculiar difficulty is offered by the so-called *phantom tumors* of the abdomen, the *pseudo-tumors*. Conditions of extreme overfilling of the bowels with gas and feces, large deposits of fat in the omentum and the bowel, spastic contractions of different parts of the abdominal muscles reveal their true nature under chloroform anesthesia after a thorough evacuation of the bowels.

While free ascites is recognizable by the flattening of the abdomen in a relaxed dorsal position, if necessary in narcosis, and gives a dull percussion-note in the dependent portions of the abdomen with clear intestinal note at the height of the abdomen, and changes of the sound phenomenon in different positions, mistakes, difficult to avoid, occur in sacculated ascites (tuberculosis, carcinoma). With a clearly pronounced anamnesis one must remember that particularly the sensitiveness is often increased in this condition, while ovarian tumors become sensitive only as a result of complicating peritonitis and degeneration. Encapsulated exudates have less sharply defined outlines than cysts. At times one may elicit thereby intestinal notes by deep percussion. Here, also, the condition of the genitalia must be observed.

The complication of the *small ovarian tumors with pelvic peritonitis* of the larger tumors with inflammation of the portion of the peritoneum of the upper half of the abdomen coming in contact with them, is of special frequency. The acute stage of the inflammatory process is not always brought into the history. Small tumors, especially, may agglutinate so intimately with the posterior layer of the ligamentum latum and the intestines, that they appear to be either developed beneath the peritoneum (*pseudo-intraligamentary development*) or that they resemble peritonic exudates or inflammatory adnexal enlargements.

Purulent contents cause fever during the acute stage, and hyperleucocytosis far beyond it, as long as they are infectious. Exact control of temperature and pulse aids the diagnosis. The advice to test the contents by puncture and aspiration of the contents seems to be only without danger in case it is immediately followed by a thorough evacuation eventually with drainage.

The development of *circumscribed adhesive peritonitis* in large tumors at those parts of the surface directed upward mostly passes with very slight general disturbances. These adhesions cause, in the course of time, pains with each movement and concussion of the abdomen, during digestion and especially during bowel movements. These adhesions become observable during palpation by pushing the tumor to and fro beneath the abdominal walls. The patients themselves point to the seat of the pain. If the adhesions are on the anterior surface, then the corresponding parts of skin move with the tumor and the skin is thrown into folds.

Pedicle torsions play an especial rôle among the complications. The mobility of the middle-sized tumors, which have ascended into the abdominal cavity, produces a detrimental disposition. Unmistakably farmer women are especially predisposed to axis torsion. The symptoms often set in in a very stormy manner: severe pains in the abdomen, meteoristic distention, chills and fever, vomiting and collapse. In other cases the signs develop less markedly. We see, comparatively often, persons in Greifswald, who evidently have carried a tumor with a twisted pedicle six to eight weeks. A deep depression of the general state of health is regularly observable in them. Moderate elevation of temperature (38.5° C.; rectal, 101.3° F.), frequent pulse, moderate leucocyte count are the characteristic symptoms. The sensitiveness of the abdomen has abated, as well as the meteorism. Nausea persists, together with vomiting and constipation. If the tumor suppurates, then, as a rule, high fever and acute threatening phenomena appear.

Suppuration and putrefaction occur not only after torsion of the pedicle but each peritonitis, even each septic disease may hematogenously infect the cystoma. This is of special importance if adhesions with the bowels have formed after a slow development of a circumscribed inflammation, running a chronic course, and the disease originates secondarily from that place, as is particularly observed in infections during the puerperium.

Puriform softening appears in embryomata the most frequently of all ovarian tumors. The wall breaks down. The contents escape into the abdomen. A local peritonitis takes place, which easily may develop to a general one. If rupture occurs into the bowel, the bladder, or the vagina, then hair and solid particles (bone, teeth) are discharged. Recovery, however, is frequently protracted beyond all bounds because of permanent fistula formation and painful symptoms on account of a temporary diversion of the fistulous tract. The formation of extensive peritonitic adhesions, as a rule, protects the patients from rupture of the contents of the suppuration-focus into the abdominal cavity.

Certainly a not rare complication exists in the **rupture of cystic ovarian tumors**. If the contents are indifferent, they are rapidly absorbed by the peritoneum and mostly eliminated by the kidneys. The place of rupture closes and the cyst refills. This alternate play may go on for years at longer or shorter intervals. Trauma (especially during an awkward examination) is an occasional causative factor. Intra-cystic or intra-abdominal hemorrhages occur only in isolated instances during the rupture by laceration of small bloodvessels. At times the patients bear such internal losses of blood for a long time; death, however, also may take place immediately.

A remarkable complication of **ovarian tumors** is found in **pregnancy**. As the entire ovarian stroma is rarely consumed by the new formations (for instance carcinoma) the possibility of conception cannot be excluded. The tumor, as a rule, grows at an accelerated rate during pregnancy. If

the tumor lies in the small pelvis the pregnancy may proceed undisturbed—the obstacle becomes first noticeable during parturition. If the tumor and the uterus rise into the large abdominal cavity both at the same time, then, at times, a suspicion of twins may be aroused. At times premature contractions appear on account of the pressure on the uterus, and abortion or premature labor takes place. In one such case I have preserved pregnancy by an ovariectomy immediately executed, though the advancing part of the ovum could already be felt in the cervical canal.

Another danger arises from the fact that the ovarian tumors burst from the pressure of the growing uterus. Undoubtedly torsions of the pedicle occasionally occur in this condition. Quite perilous is the interference with the work of the uterus and the abdominal pressure by large as well as by small but tensely rigid ovarian tumors. Surgical aid often becomes necessary; tumors lying in advance of the head and filling the pelvis must be removed (reposition, ovariectomy in partu). In other cases one must interfere on account of an abnormal engagement of the head or a transverse position. The state of affairs is only too frequently recognized too late. In the meantime the patient has become infected. The formerly not infrequent suppuration of the tumor, which had been an obstacle to delivery, must certainly be traced to this fact.

Prognosis.—The different varieties of the ovarian tumors were up to the present time sharply separated prognostically. The pseudomucinous tumors were considered as absolutely benign, as long as no degenerations had occurred in them. The serous, as well as the solid embryomata were considered as of bad prognosis. All others, with the exception of the fibromata, were considered malignant. The admirable collective investigation by *Hofmeier* and *Pfannenstiel* (Congress der Deutschen Gesellschaft für Gynäkologie, Kiel, 1905) has shown, that doubts also cannot be declined as regards the pseudomucinous tumors.

Treatment.—Under these circumstances ovarian tumors of a pronounced pseudomucinous character are to be operated just as radically as all others. In young people, the other ovary may be left behind if it possesses an appearance free from all suspicion. Just so in embryomata. The prognosis as to the life of the patient seems to be favorable only with the removal of both ovaries, if the other looks at all suspicious. Pronounced carcinomatous or sarcomatous tumors necessitate an immediate extirpation also of the uterus.

The majority of gynecologists, at present, condemn the attempt at an exploratory puncture if a radical operation does not immediately follow it. Even then it appears admissible only after an exposure by an abdominal incision, because not only the escape of fluid into the abdominal cavity through the puncture wound must be feared, but still more the displacement of tissue, which may lead to a metastasis.

Ovariectomy is at present universally executed by ligating *the pedicle and after removal of the tumor the cut surface of the pedicle is*

covered with peritoneum over the ligature. The delivery of the tumor until the pedicle is accessible may be undertaken through the incised abdominal wall (abdominal) or through the vagina (vaginal).

The *vaginal* route is reserved for the less voluminous tumors, especially if they are movable, and therefore adhesions presumably do not

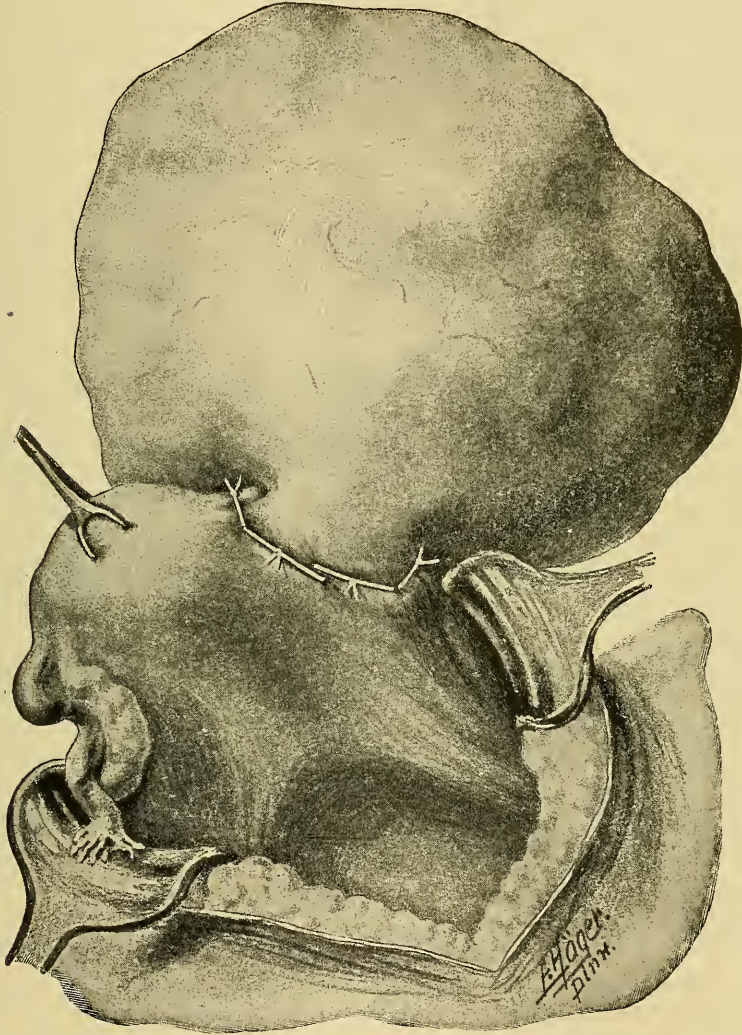


FIG. 182.—Abdominal Ovariectomy. The uterus has emerged with the cystoma out of the abdominal incision. Ligature of the pedicle in four parts.

exist. Finally, somewhat more voluminous cystomata, even if they have already ascended out of the pelvis, may very well be removed per vaginam.

Abdominal Ovariectomy.—Large tumors and those in which adhesions cannot safely be excluded are preferably attacked through an inci-

sion of the abdominal wall. It rests with the operator to make a median line or a transverse incision. Moderately sized tumors are delivered always undiminished in size, by inserting the hand underneath them and at the same time examining the condition of the pedicle. In very large tumors one has the choice either of enlarging the abdominal incision until the entire tumor can pass through, or of diminishing the latter. I am always influenced by the conditions present. The surroundings are carefully protected by lap sponges before the delivery or diminution.

The cardinal question is, whether *adhesions* exist. The agglutination with the anterior abdominal wall, caused by peritonitis parietalis may be easily separated by the flat hand. With firmer adhesions the adherent portion of the tumor surface is circumcised and separated with an excision of the peritoneum. The defect, caused thereby, must be carefully closed up by a continuous catgut suture so that only a narrow scar remains behind. Adhesions after visceral peritonitis are carefully removed step by step, where they are easily separable, either with the finger or gauze sponges, or otherwise with scalpel or scissors. The wound in the serosa intestini is closed with a fine catgut stitch. In histologically doubtful tumors the respective parts of the bowel must be resected. The tumor is placed over the abdominal wall, so that its pedicle is in complete view. I ligate it with a number of ligatures corresponding to its breadth, in which only so much tissue is included, that the tying may be done without great force (Fig. 183). The pedicle is severed about 1 to 1.5 cm above the ligatures with scissors. If vessels are still bleeding on the cut surface, then they are separately ligated. Just so, attention must be paid to see that the peritoneum lies firmly all around within the ligatures. The cut edge of it is sutured together with continued catgut stitches over the wound surface (Fig. 184). Long jawed forceps may also be applied to the pedicle, the tumor cut off, the severed bloodvessels separately ligated on the cut-surface and the latter finally covered with peritoneum. Cauterization of the pedicle is at present no longer practiced.

The safe arrest of hemorrhage is once more ascertained in all directions, the other ovary is examined, removed if necessary, the abdominal cavity is carefully cleaned, and the abdominal incision closed. (For the latter see above, p. 265, consult the same place, also, for after-treatment.)

Vaginal Operation.—If the tumor fills the excavatio recto-uterina this is incised after the portio vaginalis uteri has been drawn strongly forward with the patient in the dorsal-gluteal position. If the vagina is narrow and the perineum rigid a paravaginal accessory incision is made. Whether the incision is executed transversely or vertically depends on the custom of the operator. If the tumor does not immediately press forward during the vaginal operation, it may be carefully pressed downward from above, or it may be seized at the pedicle with a bullet-forceps, in order to deliver it with its lower surface. Finally, the tumor may be grasped with a tenaculum forceps, after protecting the surroundings with gauze sponges. If it tears in this process the escaping con-

tents must be completely kept away from the peritoneum by gauze sponges.

The cases of *intraligamentous development of the tumor* offer a peculiar difficulty. At times the portion projecting into the abdominal cavity is surrounded by peritoneum, as with a neck frill. After abdominal exposure this portion projecting into the abdominal cavity is incised beneath this frill and the peritoneum is split, the finger is pushed between the tumor and its bed, and the former enucleated. If possible the

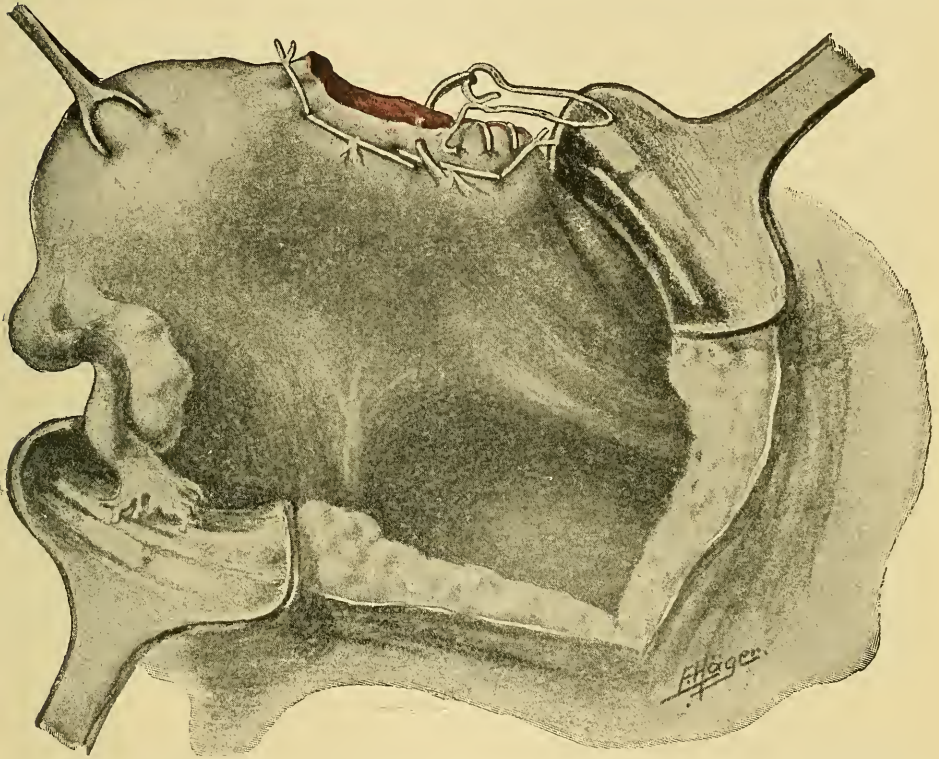


FIG. 183.—Abdominal Ovariectomy. The cut surface of the pedicle stump is covered with peritoneum by a continued catgut suture through the cut edges.

vessels are ligated before their separation. The hemorrhage must be completely controlled in every instance. Attention must be paid to the ureters. The emptied cavity usually collapses; it suffices to suture the wound in the peritoneum with a continuous stitch. If a cavity is large, the suturing is done in rows. If blood oozes continuously from the torn edges of the cavity, as sometimes occurs, then the cavity is drained with gauze through the posterior vaginal vault, and the cavity packed with gauze so that the hemorrhage is arrested. The peritoneum is closed above by a suture.

In pseudo-ligamentary development, that is, when a part of the surface

of the tumor is adherent by peritonitis adhesiva to the posterior surface of the ligamentum latum and other parts of the excavatio recto- or vesico-uterina, a cavity with torn walls remains behind after an abdominally executed enucleation. Exact arrest of hemorrhage is often difficult in such cases. If one does not succeed in securing complete hemostasis, or if tumors are concerned with imperfectly aseptic contents, then tamponading and drainage with gauze strips through the posterior vaginal vault is advisable. I prefer this procedure to the drainage through the inferior angle of the abdominal incision, on account of the threatened disposition to the formation of hernia in abdominal drainage.

The separation of the adhesions with the bowel and other organs may be executed also with the red hot iron. The eschar is aseptic. Adhesions are said not to occur thereafter. At all events the neighboring organs must be very carefully protected.

General experience forces us to the view that an ovariectomy *during pregnancy* must be performed as early as possible in every kind of an ovarian newgrowth.

Ovariectomy During Pregnancy.—The closer to the physiologic termination the more one must contend with the dilated large bloodvessels behind whose ligatures large thrombi may immediately develop. Considering the disadvantage one should not hesitate to perform ovariectomy as early as possible in the pregnant. Small tumors which still lie in the pelvis beneath the uterus can be attacked through a colpotomia posterior, larger ones through an abdominal incision. Contusion and irritation of the pregnant uterus must be avoided. This at times necessitates making the incision larger than would otherwise be necessary. Here also special care must be directed toward the covering of the pedicle.

In partu ovarian tumors, which fill the pelvis may be operated on per vaginam. I close the wound in the posterior vaginal vault before I allow labor to occur spontaneously or to be terminated artificially.

Clinical Conduct of Parovarian Cysts

In general parovarian cysts cause the same symptoms as ovarian cysts. At times they are in a pronounced manner developed intraligamentary; they appear broadly adherent to the uterus at whose side they lie. The contents of the parovarian cysts is a thin fluid of low specific gravity. The cysts are unilocular, thin walled. Especially the last observation may be very well made use of in the diagnosis. At times a healthy ovary can still be demonstrated by the side of the tumor.

Although the prognosis of these newgrowths is always favorable, their removal is always imperative. The extirpation is at times rendered very difficult, on account of its intraligamentary development.

The Diseases of the Pelvic Connective Tissue

I. Hematoma Extraperitoneale Periuterinum

LITERATURE: A. Martin, Handbuch der Adnexerkrankungen, III, 1906. A. v. Rosthorn, Veit's Handbuch, 1899. Frommel, Jahresberichte.

There cannot be any dispute any more at present, that **extravasations of blood** take place in the pelvic connective tissue. Their frequency of occurrence, it is true, is established with difficulty. They are not rarely observed after labor. Injuries during the latter are mostly concerned. Hematomata of non-puerperal origin are found about once in a thousand gynecologic cases. As predisposing influences appear the natural hyperemia at the time of the menses, the enormous varicose dilatation of the vessels in connection with spontaneous and artificial labors, in cardiac diseases, in scar-formations in the pelvic connective tissue and the organs lying adjacent to it. Concussions of the abdomen, blows, severe bodily exertions, sudden increase in the abdominal pressure may lead to an apoplectic-like rupture of the vessels under these favorable circumstances. Perverted and violent coitus and masturbation act in the same manner. In extrauterine pregnancy intraligamentary hemorrhage occurs only when the fetal sac ruptures incidentally between the folds of the broad ligament; then the blood soon perforates one or the other layer of the peritoneum, and an extraperitoneal extravasation of blood soon develops from it.

Gynecologic operations form a particular occasional cause.

The blood spreads according to the location of the torn vessel. It extends under the diaphragm of the pelvis and forms a paravaginal hematoma, reaching down underneath the vulva. If a vessel bleeds between the diaphragm and the condensation zones of the pelvic connective tissue, extravasations of blood form, which lie adjacent to the upper portion of the cervix and the corpus.

The most important group is that of the so-called **ligament-hematomata**, the extravasations of blood in the upper portions of the ligamenta lata. Arising on the one or the other side they spread out corresponding to the ready capability of the peritoneal layer to unfold. They undermine the peritoneum upward above the linea innominata, infiltrate the mesosigmoideum on the left side and terminate in the fatty capsule of the kidney. On the right side the blood mass likewise follows the ureter and the spermatic vessels. The hematoma, however, may also spread

beneath the serosa toward the ligamentum inguinale and push forward toward the median line.

At times the hematoma is bilateral. The blood advances anterior or posterior to the cervix under the peritoneum of the excavatio vesico- or recto-uterina toward the other side and there separates the peritoneum: thus are formed dumb-bell shaped hematomata, whose place of connection lies anterior or posterior to the cervix.

Singularly a hematoma has been observed in the ligamentum teres. The blood lies here mostly in the abdominal portion of the ligament; it owes its origin, as a rule, to a blow. In the majority of cases an absorption of the extravasated blood takes place. However, a puriform softening may occur, the suppurating focus ruptures into the different hollow organs of the pelvis and discharges outward.

Symptoms.—We will omit the symptoms of the hematoma originating intra partum. As a rule, they make themselves noticeable by the sensation of pressure and by the displacement of the genital organs.

The non-puerperal ligament-hematomata often develop at the time of menstrual congestion, with which the trauma incidentally occurs. The menses sometimes occur prematurely, sometimes are delayed, at times much increased, at others diminished. Intraligamentous hematomata cause *sensations of pain* of varying intensity. Complaints of the feeling of heaviness and sinking, but also of severe pains are heard. At times the sensation of interference with the bladder and rectum only develops. Besides a moderate disturbance of the general state of health, there occurs in others a pronounced anemia and even vomiting. At times, especially with preceding sexual trauma, escape of blood from the vagina takes place.

Post-operative hematomas usually make themselves felt by a sensation of pain in the field of operation. Here, also, the hindrance of bladder and rectum is marked; rarely a tumefaction extends as far as the external parts.

Objective Findings.—The blood-tumor is hardly sensitive. Its size varies between the size of a pigeon's egg and a man's head. It lies in a pronounced manner *laterally* in the pelvis or the abdomen. The left side seems to be more frequently involved than the right. The tumor rarely reaches to the height of the umbilicus. The uterus accordingly is displaced laterally and forward, also backward. It lies rarely beneath the tumor. The fundus mostly overtops the vertex of the same; however, it may also be felt at the side or deeper than the hematoma, filling out the lateral half of the pelvis. With patient and very careful palpation a certain mobility of the uterus along the tumor may be observed. According to the extension of the latter it fills out one-half of the pelvis, reaches as far as the pelvic wall, spreads around the uterus mostly posteriorly, rarely anteriorly. In isolated cases the blood advances as far as the other side. With bilateral hemorrhage the uterus appears to be walled in, and a further differentiation of each structure is impossible.

The outlines of the tumor are not sharply defined. In unilateral hemorrhage, even when extensive, the adnexal organs of the other side can be palpated with distinctiveness, but those of the diseased side only accidentally. The rectum is displaced, the excavatio recto-uterina free. Beneath it a strong pulsation of the uterus is felt.

The blood tumor is in the beginning moderately soft, also doughy.

Course.—The symptoms, as a rule, soon decrease in intensity and gradually *disappear*. The sensation of weakness, inclination to syncope, and the pale look are soon lost; the weak pulse improves and the temperature is not any more elevated though a feeling of cold, a sign of anemia, is complained of. Evacuation of the bowels and emptying the bladder are rendered difficult. In isolated cases farther reaching pressure-symptoms (pain in the small of the back, i.e., sacralgia, weakness, resembling paralysis in the lower extremities) are mentioned. The next menstruation may be entirely absent, or scanty. It may set in more copiously with drawing pains in the diseased side. At times the impression of a relapse immediately arises thereby.

It is exceptional that severe life-threatening symptoms of collapse or grave chronic malaise occur. As a rule, with the described abatement of the symptoms, organization and absorption take place. The tumor gradually diminishes in size and finally disappears after it has remained apparently unchanged for a long time. In some cases, in a small remaining portion, occasionally additional outbreaks will cause a repetition of the initial picture of pains and anemia. With puriform softening hyperpyrexia, beginning with rigor, appears with peritoneal symptoms. Rupture follows sooner or later, as a rule, into the vagina, bowel, or bladder. The ill-smelling, brownish discolored contents of the abscess, mixed with old blood-clots, are discharged.

Diagnosis.—Small blood extravasations are certainly frequently entirely overlooked. Larger ones, appearing with severe disturbances, cause symptoms which are well characterized by their development in connection with a trauma. The finding of a mass, which has formed in a very short space of time with a course free from fever, arouses suspicion of hematoma. The further undisturbed absorption of the mass makes the diagnosis very probable. The diagnosis is more difficult when the first attack has passed off with less pronounced symptoms and the observation is first made in an advanced stage of involution. One must aim first to find out whether the tumor has an extraperitoneal or intraperitoneal situation. *Hematocels* lie approximately in the centre, posterior to the uterus and fill out the excavatio recto-uterina, and only rarely and incompletely force down the lateral vaginal fornices. They are not sharply limited above. As a rule, an anamnesis, characteristic of extra-uterine pregnancy, is noted in hematocel.

The consistency of the hematomata is not hard, but firm, in isolated places perhaps softer. Hematocels are in the beginning also not hard, one has the sensation of a vague fluctuation, they render at times the

sensation of crunching of a snowball, which is never observed in hematomata according to my experience. The hematoma is only indifferently sensitive, in hemocele a certain sensitiveness of the pelvic peritoneum exists, as a rule. In hemoceles, if the hemorrhage does not stop, collapse increases rapidly and threateningly; in hematoma the danger does not exist, unless the wall ruptures and the hemorrhage continues into the free peritoneal cavity, that is, the hematoma is transformed into a hemocele, or if the blood spreads retroperitoneally to a very great extent.

Both are liable in the same degree to a puriform softening. Then the fever seriously imperils the anemic patient.

Parametritis develops as a result of an infection during the puerperium or an accidental genital disease or an operation. The clinical picture of a progressing sepsis is in itself sufficiently characteristic. Hematomata do not cause an elevation of temperature, except when they soften and are converted into abscesses in the pelvic connective tissue. Parametritides without elevation of temperature are very rare.

Intraligamentous myomata are sharply limited, mostly nodular. They need many years for their development. Their relation to the uterus, their tough consistency, their sharp contour are important characteristic signs. **Ovarian tumors**, which are intimately agglutinated to the posterior layer of the ligamentum latum by perimetritic adhesions, take a long time for their development. The perimetritis, as a rule, shows a slow insidious development, but not without the experience of pain.

If positive data have been obtained by the history and the objective findings, further observation, as a rule, renders the evidence complete.

Hematomata shrink and become absorbed; ovarian tumors grow. It is characteristic of tumors, lying in the peritoneal cavity as well as for intraperitoneal exudations and extravasations, that they distend the excavatio recto-uterina, force apart the ligamenta sacro-uterina, while intraligamentary hematomata lie to one side, leave intact the ligamentum sacro-uterinum of its corresponding side and displace it toward the median line and over far beyond it. In comparison to tumors of the uterus, and also to uterus didelphys, or a collection of blood in an atretic cornu one must pay attention to the importance of the **ligamentum teres uteri**. The location of this ligament must be determined in all changes of the uterine body, and, as a rule, clears up the state of affairs. Hematoma, as mentioned above, may be mistaken for **extrauterine pregnancy** or, better expressed, originate with it. The ligament in that case is ruptured early. The extraperitoneal hemorrhage becomes an intraperitoneal one, the hematoma changes to a hemocele. When in doubt it is certainly more correct to think of the much more frequent extrauterine pregnancy than of the so much rarer hematoma and to proceed accordingly.

Prognosis.—While the great majority of hematomata, as a rule, recover completely, experience requires a guarded prognosis of this ailment

to be rendered. The possibility of an increase in size until rupture occurs and of puriform softening makes the prospects grave.

Absorption tends to terminate in typical cases within six to eight weeks. In severe anemia, threatened rupture, or suppuration, early surgical interference offers a chance for a favorable termination.

Treatment.—With absolute rest, ice-bags, eventually narcotics, improvement of the symptoms soon takes place. The hemorrhage stops. With the use of the above-mentioned remedies, beginning after the third or fourth week (iodin, ichthyol, mud-baths, brine-baths, hot-air treatment according to *Bier*) absorption is promoted. Uninterrupted growth of the tumor and increasing anemia necessitate the supposition that arrest of hemorrhage has not yet occurred, and in that case the opening of the blood-sac is imperative. Location and accessibility of the tumor decide the route of operation. Low-seated tumors are attacked mostly per vaginam, high seated ones abdominally. The possibility that bleeding vessels may still be found in the walls of the blood cavity, indicates the abdominal route as the most suitable in case the hemorrhage still continues.

II. Parametritis

LITERATURE: See *A. Martin* and *O. Busse* in *A. Martin's Handbuch der Krankheiten der weiblichen Adnexorgane*, Vol. III, 1906.

Our knowledge of the inflammations of the pelvic connective tissue has been only lately developed. *Virchow* gave these diseased processes the name **parametritis**. *Matthews Duncan*, *W. A. Freund*, and *A. v. Rosthorn* rendered especially meritorious services to our science.

Parametritis is always the result of an infectious process. As a rule, the infectious germ advances toward the parametrium from the surface of the genitalia. The infection, however, may ensue from all sides, especially also from the intestines and bladder.

Parametritis is overwhelmingly frequently observed in connection with the puerperium. A thrombophlebitic and a lymphangitic form are distinguished. An exudate forms, which according to *A. v. Rosthorn* most frequently extends horizontally in the basal portions of the ligamentum latum, with an inclination to advance toward the posterior lateral pelvic portions in the retrocervical pelvic connective tissue. These exudates are always in intimate connection with the cervix uteri, which is thus joined to the pelvic wall with a rigid, inflexible infiltration mass.

A rarer localization is shown by the higher situated exudates which develop in the upper parts of the ligamenta lata. They originate immediately from the corpus and have an outspoken tendency to spread on the iliac fossa while they do not penetrate the condensation zones of the ligament. The exudate extends upward into the ligamenta sacro-uterina; downward into the septum recto-vaginale. Rarer localizations are met with in the precervical or paravesical connective tissue. They form

phlegmons of the cavum preperitoneale Retzii and spread along the subserosium of the anterior abdominal wall (ascending abscesses according to *Sänger*).

We distinguish the **acute septic puerperal parametritis** from the **acute septic, non-puerperal** which latter results from infections from diseased foci externally to the genital mucosa or from those in the genitalia—for instance, carcinomata.

To these pelvic infections we add those following **infections during operations**—the **acute septic post-operative parametritis**. They accordingly vary in location and extent. Frequently they appear as stitch canal abscesses. They may be localized as such and remain without further reaction, but on the other hand may become the source of a severe infection.

Among the causative agents the chief rôle is played by the **streptococcus pyogenes**, and, in addition, **staphylococci** and the **bacterium coli**. A mixture of bacteria is often found in which the bacterium coli appears with overwhelming frequency compared with others. The **gonococcus** of *Neisser* may undoubtedly cause parametritis, but it takes part as the sole exciter of the inflammation only in a minority of cases. **Actinomycosis** does not seem to be as rare as was formerly supposed. On the other hand, it is astonishing that **tuberculous inflammatory foci** have been only quite rarely observed in the parametrium.

In the literature, in addition to the **chronic** parametritis following an **acute** attack, another form of chronic inflammation of the parametrium is recognized, which cannot be considered as a residue of an acute infection. According to our view they are all of an infectious origin, even if the acute stage had not been observed.

Busse justly emphasizes the fact that also in the **old** condensations and scars there are found not infrequently remnants of pus foci in the form of small, soft deposits and cavities, fistulous canals and fine canaliculi, which still contain virulent bacteria, capable of development even after an existence of many years.

The merit of having called attention to a second peculiar group of chronic processes belongs to *W. A. Freund*. He included these under the name **parametritis chronica atrophicans**. A specially frequent symptom in these cases is a marked atrophy of the adipose tissue: **An emaciation of the pelvis**. To this group certainly belongs many a case of parametritis posterior observed by *E. Martin* and *B. S. Schultze*. In the light of our present knowledge these cases must be designated as a disease of unexplained origin. Probably infections from the bowel, to which *W. A. Freund* first referred, play a prominent part.

These parametritides especially are in very numerous cases complicated by **perimetritis**. The question remains, as *Küstner* remarks, how far the process primarily belongs to the parametrium or perimetrium. *H. W. Freund* has demonstrated conditions of contraction, pigmentation, atrophy and loss of nuclei of the ganglion cells as a result of the increase

and condensation of the connective tissue, an anatomic confirmation of the results of severe reflex neuroses, which accompany parametritis atrophicans.

Busse points out that the arteries and veins of the parametrium suffer also lasting changes as a consequence of parametritis (arterio-sclerosis, formation of aneurisms, varicose dilatation, phleboliths).

Clinical Behavior

We consider in the following:

1. Acute parametritis.
2. Chronic parametritis.

We distinguish in the first group:

- A. Acute septic puerperal parametritis.
- B. Acute septic traumatic parametritis, with which we classify the gonorrhoeal.

C. Acute parametritis originating from infections from diseased foci external to the genital mucosa.

1. *Acute Parametritis*

A. *Acute Septic Puerperal Parametritis*

There is no reason why we should here dispense with a discussion of puerperal parametritis. It is not only the most frequent and in a certain sense most important form of the diseases of the pelvic connective tissue, it so often engages the attention of the physician apparently apart from labor and puerperium, and it is such a frequent cause of "gynecologic" disturbances that we must enter on a discussion of its development also in gynecologic text-books.

Elevation of temperature and **acceleration of pulse** take place in a parallel curve in acute septic puerperal parametritis. A gradual decrease in temperature follows not rarely after four to seven days, after the patients have already been feverish for a more or less long time as a result of the preceding endometritis and metritis. Parametritis begins with attacks of rigor or chills and a circumscribed pain in the pelvis or in the sides or deeper. Repeated acute elevations of temperature three or four or more days after the defervescence are not rare. They are not always a symptom of suppuration, absorption also occasionally runs its course with such relapses of fever. The temperature and the pulse-curve ascend at all events during softening, dropping abruptly on the escape of the pus.

The **sensation of pain** precedes at times every other symptom. The subjective state of health, as a rule, grows gloomy. The symptoms very frequently make themselves especially felt in the bladder and bowel, but also in the peritoneum.

What here interests us most is the fact that the majority of these puerperal parametritides proceed within a short time to a complete reso-

lution also, after apparently very stormy symptoms. The possibility of a complete *restitutio ad integrum* is thereby given. On the other hand a puriform softening may occur after a few days or weeks, and even after months. A not unusual observation is offered by puerperæ, in whom the early lying-in period has apparently passed undisturbed. Not before they get up and after the uterus has apparently reached a good degree of involution do symptoms of a parametritis develop (pain and fever). If pus-formation takes place, the abscess, as a rule, empties through the vagina or rectum, more rarely and then mostly in abscesses of the upper portions of the ligamentum latum, does the pus reach the external skin above the centre of the ligamentum inguinale, after the infiltration could already for a long time be felt above the iliac fossa. Evacuation above the pubic symphysis or through the umbilicus, like ascending abscesses generally, is rare. The rupture into the free peritoneal cavity is unusual. In such cases, however, small foci suffice to produce a rapidly progressing fatal peritonitis.

Parametric exudates must be considered as the cause of thrombosis of the femoral veins of the puerperæ. At times the ureters become displaced by the exudates, so that obstruction of the kidney, with all its serious consequences, arises.

The *diagnosis* can only be made by the palpatory findings. An intense sensitiveness often precedes the formation of the exudate. A hard edema is felt which extends mostly to the height of the portio supravaginalis cervicis, rarely laterally to the corpus, and spreads toward the pelvic wall. Later on the exudate completely fills the pelvis. Unilateral parametritides push the uterus to the other side, either anteriorly or posteriorly.

The exudation seldom lies in the anterior half of the pelvis. The hypogastrium is sensitive. The palpation of the uterus is rendered difficult, the vaginal vault of the respective side becomes plainly edematous. The uterus is later on, as it were, walled in. The exudation gains rapidly in firmness and becomes hard as a board.

The surface of the mass is not sharply outlined. The rectum is displaced laterally with a unilateral exudate, the bowel is completely compressed in bilateral exudates filling the entire pelvis. The mucosa recti feels as if swollen. The narrow passage at the upper end of the ampulla recti is several centimetres broad. The rectal mucosa discharges a glairy mucus. Similar conditions seem to take place in the bladder. A cystoscopic examination is executed with difficulty in this condition.

The edema of the vaginal vault disappears after the beginning of absorption. The infiltration appears less firm at the periphery. The portion adjacent to the uterus remains hard for a longer time. In favorable cases the absorption of the exudate in the ligament is already observable after eight to ten days. The adnexal organs, which previously could not be closely distinguished, appear in its place. They were involved by the same infectious process, but until now they were enclosed

in the exudate, forming one single broad mass. Now they become plainly distinguishable by their outline. The infundibulum tubæ, swollen like a knob, the sactosalpinx, fills the excavatio recto-uterina and covers the thick ovary. The displaced rectum extends plainly around this mass. This condition may be maintained for weeks, months, even years, after the pelvic connective tissue itself has become completely clear.

Suppuration, as a rule, attracts notice by pain, temperature, and pulse-changes and also by a *hyperleucocytosis*. The number of leucocytes increases by several thousand within twenty-four hours, and rises high above ten thousand. The examinations must be repeated daily at the same hour.

These symptoms at the time do not immediately rise to their full meaning. The softening seems to stop. At times an uncomplicated resolution yet follows a first rise of temperature and pain. In other cases a rather sudden softening occurs at longer or shorter intervals, for instance at the occasion of menstruation.

For purposes of *differential diagnosis* parametritic exudates are characterized by the fact that their development, as a rule, is connected with the process of labor.

Non-puerperal parametritis is easily distinguished usually immediately by the etiology. Trauma and operations are only exceptionally concealed, as well as preceding abortions and labors. Genital gonorrhœa can be proven, excepting the neglected cases. Parametritis, in connection with intestinal and genital diseases and burrowing abscesses, finds its respective explanation in the anamnesis. Newgrowths in the pelvic connective tissue, as a rule, do not develop during a puerperium. If such a newgrowth, which in itself does not exclude pregnancy, becomes an obstacle to delivery, then the same is recognizable before a parametritic infiltration has taken place. Concerning the differentiation of parametritic exudates from *inflammatory processes* of the *tube* and *ovary* we refer to the description of the diagnosis of the same given above. The ligamenta sacro-uterina have a great importance for the palpatory findings. Everything that lies within the peritoneum forces them apart, while everything that lies within the pelvic connective tissues, pushes them together.

The decisive characteristics in regard to *hematocele* and *extrauterine pregnancy* have been given above. *Newgrowths* of the *uterus* and the *ovaries* seldom develop with fever and pain. Infectious processes may well be added in the course of their development, even parametritis and perimetritis may develop. In these cases the observation of the course must discriminate. Parametritic and peritonitic exudates, as a rule, are absorbed, newgrowths never. If exudates break down, newgrowths also may participate in this process. Then the examination of a portion of tissue removed eventually for a test must finally decide.

For the *interpretation* of the findings of parametritis it must be observed, that their initial symptoms often are only insignificant

and that the formation of the exudate may take an unusually chronic course.

The first named form, the *subacute septic puerperal parametritis*, is often met with in appalling frequency, particularly in the indolent country people. At times such a parametritis is detected after months and years in women, who, when confined in the clinic, have had mild increases in temperature for one or several days during the puerperium. At that time streptococci were found in the lochial secretion. At the discharge the disease had apparently completely subsided, the uterus was well involuted, the parametrium clear. Many months or even years later we see the patients with pronounced chronic parametritic exudates.

The disturbances during the puerperium only too often elude observation in out-patients, on account of deficient attention and temperature measurements without sufficient control. The women sooner or later come to the physician sickly and incapacitated for work; they complain of pain in the small of the back, weakness in the legs, and leucorrhœa. Menstruation often is abundant and painful. They also complain of *Mittelschmerz* (interval pains).

The palpatory findings show remarkable relaxation of the pelvic organs. The uterus is thickened, displaced, fixed by adhesions, which traverse the pelvic connective tissue, surround the collum, and radiate toward the periphery. Cervical lacerations are frequently found. The ligamenta sacro-uterina are often thickened and painful. Perimetritis regularly exists with it.

Chronic course of the acute septic puerperal parametritis.

Without visible cause exudates of acute pelvic phlegmons resist absorption. The indurated, small-sized exudation apparently remains unchanged for years. In these cases the obstruction of the bladder at times is the foremost complaint, as the evacuation causes continued difficulties (the feeling of the last drop). Catheter infection and ascending ureteritis have occurred. The evacuation of the bowels too, is hindered. Dysmenorrhœa exists. The patients are sterile. If, however, conception occurs, then the remnants of the old exudate become a source of severe disturbances (abortions, infectious fever). The above-mentioned findings of *Busse* of old foci with virulent bacteria in such indurations enables one to understand these cases. Many times important disturbances in the circulation occur (metritis chronica, thrombosis of the femoral vein, chronic edema of the lower extremities). Finally the scars also cause conditions of contraction as far as the ilio-psoas muscle group.

Prognosis.—The prognosis of *acute septic puerperal parametritis* is grave, but not an absolutely unfavorable one. The course does not entirely depend on the degree of virulence and the number of the introduced germs, but especially also on the condition of the infected tissue and the power of resistance of the patient. In cases in which the para-

metritis is only a part phenomenon of a severe septic infection, the prognosis naturally becomes very grave. The rapid extension of the infection to the peritoneum is a very serious symptom.

As a rule, complete absorption results if suppuration and rupture of the abscess have taken place. The sterility observed after parametritides is dependent more on the synchronous disease of the ovary and the oviduct. The renewed propagation of old remnants of bacteria, encapsulated in the indurations, forms a grave danger in future childbeds.

The **prognosis** of septic puerperal parametritides terminating in the **subacute or chronic form** is obviously a very grave one as regards the capability of complete function of the involved tissues. It is the more serious, the more incomplete or improper the treatment that has been employed. Protracted illness with premature climax of the genital organs is threatened.

Treatment.—The entire rational hygiene of labor and puerperium also belongs to the prophylaxis of parametritis. While so far all our efforts have not been completely successful in excluding disease from the lying-in bed and thereby also puerperal parametritis, we cannot deny that to-day, nevertheless, the severe acute forms which formerly were so frequent in the lying-in institutions have become essentially rarer.

The first indications of parametritis require absolute rest and anti-phlogistic measures (ice-bag, fomentations). Other measures, as a rule, are indicated by the preceding endometritis. High temperatures are combated by packs, baths, and, if necessary, antipyrin (*Curschmann*). Gastric lavage is indicated in nausea and vomiting. Narcotics are only used with very severe pains. Powerful nourishment is urgently demanded, including, if necessary, the introduction of food per rectum or subcutaneously (glucose solution). The decline of the pains and the fever indicates the beginning of resolution. For its promotion, iodine and hot irrigations, 50° C. (122° F.), are useful. After the absence of fever for at least eight days, the patients may leave the bed. Then full baths and sitz baths tend materially to promote absorption, later with the addition of bog and brine. After four to six weeks the sweatbox treatment, according to *Bier*, is a powerful agent for this purpose. Massage should be omitted entirely as long as a remote suspicion of a retention of septic germs still exists.

The scars of old parametritides, which distort the cervix and cause considerable difficulties, may be surgically attacked with the coexisting cervical laceration (vide supra "**The cervico-laquear laceration,**" p. 324).

As soon as the parametritic exudate suppurates, evacuation is indicated. The vaginal vault is incised down to the deeply situated abscesses; a paracentesis, if necessary, immediately precedes it. Abscesses situated higher up are opened by an incision parallel to the ligamentum inguinale.

B. Acute Septic Traumatic Parametritis

This form, to be distinguished from the puerperal, suggests the fact that the multiplication and spread of the septic germs is not effected in an analogous way by the penetration of the tissues and the vessels and lymph-channels. The inoculation, as a rule, results from an operation more or less deeply extending beneath the body surface. A trauma proper, as a blow with instruments, during coitus, or masturbation only rarely is concerned. To-day gynecologic examinations and operations take front rank in this respect. The inflammatory processes in the mucosa or newgrowths, which were the object of the operation, have prepared the nutrient medium for the infectious germs.

In not a small number of cases the infection ensues during examinations and treatment with dirty hands, instruments, pessaries, sounds, and attempts at dilatation with compressed sponges and similar apparatus. Plastic and other vaginal and abdominal operations are a frequent cause. The radical operations for cancer, in which a part of the entire pelvic connective tissue with the vessels contained in it has been removed, are the most detrimental among these. The acute traumatic parametritides not rarely develop from extraperitoneal blood extravasations, which were the immediate result of the trauma.

The infiltration naturally, at first, extends into the surroundings of the operation wound, a tissue necrosis and disintegration of the retained blood-clot develop in it. The freshly formed scar breaks down and the pus empties through the same or the stitch-canals of the sutures. Suppurating newgrowths of the uterus and vagina also furnish the infectious material for the pelvic connective tissue. An especially detrimental rôle is played in such cases by the uterine cancers and polypi.

Symptoms and Course.—The infections of the pelvic connective tissue develop at times rapidly, at other times more slowly. Sometimes already within a few hours after the operation rigors and pain in the parametrium appear. The disease, as a rule, runs a much slower course. After several days, in the second week, also after recovery has apparently resulted without reaction, the pain sets in with a sensation of chills, pulse and temperature go up, to drop again after a few days. In other cases the temperature runs through several days or weeks with typical morning remissions and evening exacerbations. At times slight evening rises are first noticed. The pulse, as a rule, early becomes frequent and weak—especially in anemic persons. Soon more or less intense pains appear at the diseased place. The increase of the same, with nausea and vomiting, points to a further spread of the disease, particularly, however to the perimetrium. Then develop meteorism, painful constipation, not seldom the picture of pseudo-ileus. If the exudate lies near the bladder, troublesome tenesmus occurs, the patients are not able to empty the bladder completely. This is the more surprising as often enough after the initial symptoms the emptying already had become corrected to the

great relief of patients. Not rarely the uncomfortable catheter cystitis developed from the beginning, as well as a troublesome gastric catarrh, a result of the continually required cathartics, or tenesmus after the frequent clysmata.

Also in post-operative parametritis the exudates do not always break down, they may proceed to absorption after longer or shorter existence. This is also observed when they are of considerable size.

The induration is comparatively frequent in the stump exudates in the pelvic connective tissue beneath the ligatures *en masse* of inflammatory swellings (sactosalpinx, oophoritis), extrauterine pregnancy and tumors (ovarian tumors, uterine myomata). Congestive hematmata are at first concerned, which undergo puriform softening. Not infrequently we meet with such residues also after plastic operations.

The sign of **post-operative septic parametritis** is at first that of a very sensitive swelling in the adjacent portions of the wound, respectively the operation-scar. The latter is hard, and edema spreads to all sides as far as the pelvic brim and advances to the iliac fossa. The remaining pelvic organs are enclosed by the edema and are displaced at times backward, at others to one side. The mass may be noticed also from above by bimanual palpation, also its extent to the iliac fossa as far as the ligamentum inguinale. Severe sensitiveness renders often difficult the exact differentiation toward the uterus and adnexal organs. The rectum is compressed, the bladder, with increasing distention, rapidly ascends above the symphysis. Either increased induration as a precursor of absorption or softening occurs after a few days. Abatement of the sensitiveness and fever are, as a rule, accompanying phenomena of the former, increase of fever and pains, especially, however, the sensitiveness, signs of the latter. At times, however, a circumscribed softening, which subsequently breaks down the entire exudation mass occurs during the process of induration; renewed chills, violent pains, sensitiveness, and interference with the neighboring organs appear anew, and indicate in such cases a disturbance in the absorptive process which is confirmed by the increase of the leucocytes in the blood.

Stump exudations, after total extirpation of the uterus as well as those occurring after enucleation of intraligamentary tumors, are usually hermetically closed. Small blood extravasations are certainly very frequent after vaginal plastic operations; they are usually absorbed without reaction. Phlegmons originating therefrom, as far as I have observed, very rapidly advance to suppuration in a majority of cases.

This certainly holds good for the phlegmons after injuries, in which the trauma has penetrated as far as the pelvic connective tissue.

Traumatic post-operative parametritides lastly may form completely painless scars, with their organization no disturbances of any kind in the function of the pelvic connective tissue remains behind, they disappear completely and are not observable either by palpation nor by inspection. Opposed to this possibility is the observation, that such scars organize

very slowly, often only after years. They may cause a continued feeling of pain also without palpation, which becomes exacerbated on slight concussions of the body (loud talking and sneezing). The scars remain sensitive to pressure during examination, the activity of the abdominal pressure, evacuation of the bowel and bladder, and cohabitation.

The exudates lying higher in the pelvis are, as a rule, complicated by analogous changes in the peritoneum. Adhesions with intestinal loops, the omentum, uterus, and so forth, whereby the symptom picture is permanently influenced.

The scars of the post-operative parametritis very frequently cause disturbances during *menstruation*. After extensive prodromata (agitation, palpitation of the heart and the like) pains appear days and weeks before. Even if the uterus and ovaries are no longer the seat of marked sensitiveness, pains continue to exist in the remnants of the exudates mostly beyond the menstrual period. The exudation itself becomes sensitive, at times I could feel a recurring swelling of the same. In isolated cases thereby evening elevations of temperature may be observed in this condition without it being possible to establish any other cause for it. Only after many months, indeed in a few cases after years, these menstrual disturbances subside very gradually.

The cicatricial indurations may not only displace the uterus but cause permanent disturbances of the function of the entire genital apparatus by compression of the bloodvessels.

The *prognosis* of acute septic traumatic parametritis accordingly must be designated as quite grave. Under favorable conditions recovery by absorption or a scar-formation finally results. The women often, however, are permanently injured, the more so, if the pelvic peritoneum and adnexal organs have been diseased at the same time. The disturbances of the function of the uterus, the tubes and ovaries, lead to a premature cessation of menstruation and ovulation. The patients become sickly and aged long before the physiologic time.

Treatment.—If a post-operative parametritis develops, the directions for antiphlogistic treatment hold good, which were given for the puerperal form. The necessity of preventing a retention of secretion in plastic operations by opening the wound is, as a rule, obviated by the circumstance that, especially in these cases, running an acute course, suppuration takes place very rapidly, which empties through the stitch canals or bursting wound edges. If this process is retarded, then it is necessary to open the wound. If healing results per secundam a flat and broad scar forms, which only too frequently is predisposed to relaxation. A not small number of failures in plastic operations may be explained in this manner. The treatment of the residues conforms to the one mentioned above for puerperal parametritis.

Parametritis Gonorrhoeica.—As previously mentioned (p. 187), there cannot be any doubt that the gonococcus may also penetrate into the pelvic connective tissue. That, however, a purely gonorrhoeal parametritis

occurs very seldom, must be adhered to after a critical examination of the reported cases. This is not the place to discuss the possibilities of a mixed infection. We ourselves have seen a case of puerperal gonorrhœal exudate of the cavum Retzii with rupture through the umbilicus. Further observations must be awaited to clear the matter. Only cases verified by autopsies upon the operating or post-mortem table may be considered free of any objections. I incline to the conception of *Bumm* that a mixed infection, as a rule, forms the basis for the ascending parametritis of cervical gonorrhœa. Besides, all cases hitherto observed (*Kroenig, Jung, Schumacher-Fehling*) took place in connection with a puerperium.

Symptoms.—Gonorrhœal parametritis is characterized by the slow course of the disease, as far as it could be observed until the present. An abatement soon follows the somewhat stormy beginning (high fever, violent pains), then moderate sporadic elevations of temperature, and continued, though not severe symptoms. Discomfort and malaise continue for a long time. Suppuration causes an exacerbation of fever and pain. Both disappear at the moment of perforation or evacuation. The symptoms of gonorrhœal disease of the urinary tract and the genital mucosa appear as the most prominent, as could also be observed in our cases.

Diagnosis.—The palpatory findings in the pelvic connective tissue resemble those of the puerperal septic disease. The demonstration of the gonococci in the mucosa of the genital canal or urethra suggest the possibility that gonorrhœa was a factor in the development of the process in the parametrium. The diagnosis *presupposes the demonstration of gonococci in the contents of the abscess*. The slow, lingering course, however, and the slight general reaction with a preceding gonorrhœal disease of the cervical mucosa point to the possibility of a participation of gonococci also in the pelvic connective tissue inflammation. Simultaneous articular disease or conjunctivitis gonorrhœica of a child, born of the patient shortly before are points not to be underestimated in the diagnosis. In view of the frequency of genital gonorrhœa the certainly extraordinary rarity of gonorrhœal abscesses in the parametrium at all events remains very remarkable.

Prognosis.—In all the cases belonging to this class, suppuration took place. Therefore parametritis gonorrhœica does not incline to a simple resolution. Observation, on the other hand, indicates that an absorption of the induration is possible after complete evacuation.

Treatment.—If puriform softening takes place, recovery can be obtained only by an evacuation of the abscess. In other respects the entire method outlined above for the promotion of absorption must be applied. The excellent prospects for success demand a very careful deliberation, whether one should undertake a radical operation in such pelvic abscesses.

C. Acute Parametritis as a Result of an Infection from Diseased Foci External to the Mucosa (Descending) Form of Parametritis

The intimate relation of the pelvic connective tissue to the peritoneum covering the pelvis, and to the organs and tissues surrounding and passing through the same (bladder, bowels in their different parts, adnexal organs, bones), permits one to consider an encroachment of the inflammation of these organs on the parametrium as occasionally very obvious. The very profuse net of blood- and lymph-vessels which runs through the pelvic connective tissue, the connective tissue bands, which pass around the vessels, are given natural highways for the infectious germs.

As a matter of fact the pelvic connective tissue takes part in the inflammatory processes, especially of the bladder and rectum, not simply at its margin; it becomes penetrated by them from all sides at an early stage, and at times very quickly.

Especial importance attaches to the parametritides which originate by extension of inflammation to the parametrium from distantly situated diseased foci. Typhlitis, perityphlitis and appendicitis are especially frequently mentioned in this relation (*Rotter, Sonnenburg*). In reality, however, perimetritic abscesses are overwhelmingly more frequently concerned in this. The retroperitoneal disease around the typhlon spreads with great consistency either in an upward direction on the musculus iliopsoas toward the bed of the kidney, or downward toward the ligamentum inguinale. It cannot be denied, however, that the pus finally pushes subperitoneally also into the pelvic connective tissue during the softening of such abscesses. Suppurations of the kidneys and their surroundings take the same route, as well as subphrenic abscesses and those of the gall-ducts. Diseases of the bones of the pelvis (osteomyelitis, periostitis, coxitis) and the lumbar region of the spine comparatively seldom infect the pelvic connective tissue, more frequently those of the pelvic articulation and bone injuries (for instance after symphysiotomy and pubiotomy). The primary diseases appear foremost in all these forms of disease; the parametritis only forms a link in the diseased process.

A particular interest is claimed by *actinomycosis* and *tuberculosis* which may develop, although only very rarely, in the parametrium apparently as isolated foci separated from their primary localization, so that their connection with these only too easily escapes our observation.

The number of observations of actinomycosis of the female genitalia has increased of late years. *Henriot* has collected ten cases of this disease of the internal genitalia. To them must be added the case of *Whipple* and *Webber*.

Amann observed a case of actinomycosis, in which a hard, knotty infiltration of the hypogastric region reached downward into the small pelvis; at the umbilicus a fistula existed from which granular pus escaped, in which the ray-fungus could be distinctly demonstrated. He incised several times the multiple abscesses of the abdominal wall and curetted

the same. A cure gradually resulted after a course of three years with the free use of iodine (*Deutler*, Diss. inaug., Munich, 1903).

There can be no doubt that the disease, as a rule, spreads from the bowel. The general participation of the pelvic organs renders difficult the demonstration of the primary seat of the disease, even upon the post-mortem table.

It is remarkable, that we, as also *Sauter* and *Fehmers*, at first could demonstrate only streptococci in the pelvic connective tissue abscess some time before the evacuation of the pus containing the actinomyces. In a second abscess, distantly situated, we also could not find any actinomyces after months. The demonstration of the ray-fungi succeeded in a third abscess only after another further two months.

The clinical picture is at first dominated by the disturbance in the bowels with occasional fever, pain, and incessantly increasing cachexia.

The **diagnosis** follows from the demonstration of the fungus. The possibility of actinomycosis must be considered in hard infiltrations of the pelvic connective tissue, if puerperium and gonorrhoea are excluded. The examination of the pus, the success of long-continued treatment with potassium iodid, confirm the diagnosis. Consequent **local treatment** leads to recovery, if medical assistance has not been invoked too late.

Tuberculosis foci in the pelvic connective tissue are met with remarkably seldom. The destructive influences of genital tuberculosis naturally also extend to the pelvic connective tissue. They, however, form only a stepping-stone in the fatal progress of the disease, without causing characteristic symptoms.

The **diagnosis** is secured by the demonstration of the bacilli. As a rule, the nature of the disease has already previously been established in the primary foci.

The treatment **can be only a symptomatic one.**

Purulent embryomata and **echinococci** give rise to a peculiar form of abscess formation in the pelvic connective tissue. They often occur without the bearer having any suspicion of the existence of such a new-growth. The echinococci become apparent by their growth, the embryomata as soon as they suppurate, at times during a pregnancy or in connection therewith.

Embryomata seem to be immovably fixed in the pelvic connective tissue. Their surface, as a rule, is round and sharply contoured. At times one succeeds in recognizing characteristic constituent parts in the tumor, which is besides not insensitive.

Echinococci are characterized by their occasionally rapid growth, their sharp contour and firm consistency, at times by hydatid thrills. Severe absorption fever arises at the moment of suppuration. The mass grows, becomes sensitive, and peritonitic symptoms appear. The number of leucocytes is increased with high fever and frequent pulse. The connection with a puerperium or a trauma may render the discrimination very difficult. The examination of the pus only, secures the diagnosis.

We have mentioned above, that the pelvic connective tissue to a great extent takes part in the **inflammatory processes of the tubes and ovaries**. The parametritis then becomes perceptible by the edematous swelling in the surrounding of the tumor. If the edema breaks down or the sactosalpinx purulenta ruptures into the pelvic connective tissue, the above-mentioned symptoms of abscess formation appear. The pus escapes as in suppurating newgrowths through the vagina and rectum, bladder and uterus, rarely pararectally. These are the typical cases of so-called pelvic suppuration, for whose cure extirpation of the uterus was proposed. It is gratifying to know that with this designation, which only corresponded to an ignorance in the diagnosis, the proposed treatment, the excision also of the uterus, no matter whether it is irreparably diseased or not, has been given up.

2. Chronic Parametritis

By this name are designated less the scars after acute septic puerperal or post-operative metritis, than senile atrophic processes, which apparently arise without any connection with the puerperium or trauma, at times during the climacteric, at others before this time. According to our present views we must consider these cases as the result of a pelvic connective tissue inflammation, whose cause we do not know. In a number of cases the process develops without any doubt with acute substages, permanently retains the chronic character and compels the patients to suffer pains of different intensity and symptoms of all varieties and lesser or greater disturbance and changes of the general condition of health (*A. v. Rosthorn*).

W. A. Freund taught us to designate this peculiar form as **diffuse atrophic parametritis**. General disturbances of nutrition (chlorosis, tuberculosis, infantile bodily development), exhaustion of the body by pregnancies rapidly following one another, and difficult labors, which are accompanied by abundant losses of blood, long-continued excessive exertions of the body with mostly improper nourishment, finally also long-continued sexual overirritation favor its development.

W. A. Freund and his pupils, especially *H. Freund*, have proven that a deep-seated disturbance of the ganglia and nerves in the pelvic connective tissue develops with it. The palpatory finding of this atrophic disease surprises one by contraction, the want of elasticity, the atrophy of fat in the adjacent parts of the vagina, and the **emaciation of the entire pelvis**. The vagina is dry, the vaginal vault, as it were, retracted. The portio vaginalis uteri is changed to a wartlike formation, above which the small corpus can be palpated only with difficulty. The contraction of the uterus at times appears on palpation more distinctly on one side than the other. With this condition there develops the general picture of premature senile involution and climax precox, loss and graying of the hair, falling out of the teeth, shrinking of the skin of the entire body, muscular atrophy and so forth.

The disease of the pelvic connective tissue forms in many cases only a part phenomenon of the changes in the connective tissue in general. In this process cases of enteroptosis play an important rôle.

The disturbance becomes also noticed in a detrimental manner in extensive regions of the nervous system. While gynecologists formerly were only too often inclined to bring such nervous disturbances in connection with the chronic genital diseases, another view has become general on account of the not rare observation, that similar neuroses also develop with normal conditions of the genital organs. The importance of the genital disease was essentially lowered and the emphasis was shifted to the local changes of the nervous system. *W. A. Freund's* researches have cleared the relation of the above-mentioned changes in the pelvic connective tissue with the grave disturbances of the nerve apparatus of the genitalia. At present we no longer deny the influence of these anatomic disturbances upon a body, predisposed to it from hereditary taint. In neuropathic constitutions, neurasthenia and infantilismus we see the basis for at least a part of the disease concept of *hysteria*.

Freund distinguished a sympathetic, spinal, and cerebral *hysteria*. (The interest of the gynecologist in this neurosis justifies the insertion of the following remarks at this place.) In the first group the collective conception of neuralgia cœliaca predominates. In the second group are distinguished the symptoms of spinal irritation, disturbances in the region of the sciatic and brachial nerves and arthropathies, disturbances in the mammary gland, and of sensibility and motility. In the third group belong the trigeminal neuralgias, headache, disturbances of vision, copiozia hysterica and the vasomotor disturbances, abnormal irritation of the skin, and hysterical hemorrhage.

The *prognosis* is a very doubtful one, even if the process becomes latent. It depends on how far the balance in the general function of the body and in the nutrition must be restored. The most favorable cases are those in which diseased adnexal organs form the never-exhausting source of irritation. If these are removed, recovery may take place. The prognosis of pronounced hysteria is to some extent only favorable in the localized forms.

The *treatment* is to be conducted under simultaneous regulation of the mode of living and mental dietetics. A local treatment is only to be introduced with the greatest precaution; especially a frequent invasion of the genitalia, on the part of the physician or the nurse, must be avoided as much as possible. In like manner narcotics must be excluded, if possible. Disturbances, which obviously delay recovery by their weakened influence (hemorrhages, profuse leucorrhœa) are better combated by one operation than by continued local treatment. Massage can only be recommended in the hands of an experienced operator, all necessary circumstances being taken into consideration. The use of weak faradic currents often brings a palliation of the symptoms. A

hydrotherapeutic treatment in proper institutions, a course of treatment in the mountains, or at the seashore, often act successfully without local treatment.

An *operative treatment* of the cicatricial bands (incision of the same, or excision) does not promise any results. Castration has given such doubtful results, that gynecologists have given it up completely.

Diseases of the Pelvic Peritoneum

I. Hematocele

LITERATURE: A. *Martin*, Handbuch der Krankheiten der weiblichen Adnexorgane, Vol. III, *Werth*, Handbuch der Geburtshilfe von *F. v. Winckel*.

The effusion of blood, encapsulated between the uterus and rectum in the *excavatio recto-uterina*, was first appropriately described by *Nélaton* in 1851.

Such blood effusions undoubtedly are found in severe disturbances of nutrition, for instance during the course of typhus, cholera, poisoning (phosphorus), burns, morbus maculosus, purpura, and morbus Brightii. Pelvic peritonitis plays a prominent rôle in its causation, but venous stasis is a more prominent agent.

The typical hematocele is a disease of the prime of life in women. It may arise from ruptured ovarian follicles, but the possibility, that the blood comes from the tubes by a backward flow, cannot be excluded. Also injuries of the genitalia, as well as gynecologic operations, must be recognized as exciting causes. Compared with all these, hematocele during extrauterine pregnancy predominates quite overwhelmingly in frequency and importance. It develops during the internal as well as the external rupture of the fetal sac (see above, p. 355).

Pathologic Anatomy.—The blood effusion, with overwhelming frequency, lies in the *excavatio recto-uterina*. If this is occupied by the retroflexed uterus, or obstructed by peritonitic adhesions, the blood-clots may form in the parauterine or anteuterine pocket. *Busse* has proven that a formation of a hematocele only takes place when the power of absorption of the peritoneum is impaired (*C. Schroeder*) in consequence of chronic irritation and inflammation, otherwise the blood is changed by the admixture, for instance, of parts of the ovum (*Veit*). There is seldom formed a diffuse mass in which the blood lies in the network of threadlike or membranous adhesions or represents one solitary blood-tumor (*Sänger*). As long as the blood is liquid, its absorption may rapidly ensue. If coagulation has occurred, the much more difficult process of organization follows. The formation of the same has been exhaustively described by *Busse* (*A. Martin's Handbuch der Erkrankungen der Adnexorgane*, Vol. III, p. 193).

Under some circumstances the external zones of the tumor are often found organized. The adjacent layers consist of hard, stiff fibrin, which

shows in a fresh condition a peculiar light gloss under the microscope, while the central portions usually soften afterward and liquefy. With infection a dirty puslike mass (puriform softening) forms in it. Then the processes of organization completely recede behind the destructive processes. The blood-clots break down to a more or less stinking, pitchlike to greenish ichor. A toxic general disease may rapidly take place. The contents of the abscess, however, may also empty outwardly with a softening of the adjacent tissue. Rupture into the open peritoneal cavity occurs remarkably seldom, as it is protected by the preceding, reactive inflammation of the intestines.

Symptomatology.—The blood effusion from passive hyperemia causes, as a rule, as such only a very few marked symptoms. The difficulties of the primary disease at times appear even relieved by the extravasation of blood as by a physiologic bloodletting. If the patients overcome the shocklike initial effect, absorption rapidly takes place, if the absorptive power of the peritoneum and the vital energy of the patient in general have not been lowered or completely broken. Puriform softening causes characteristic disturbances and symptoms of irritation. Traumatic hemocele passes by with the signs of anemia, sensation of pain, and interference of neighboring organs, only simultaneous infection leads to increase in temperature.

Post-operative hemocele itself causes only inconsiderable pains. Here the sensation of pain in the region of the place of operation is paramount. Rise in temperature appears only with suppuration. Absorption and complete recovery occur surprisingly early, even when large amounts of blood have escaped. Preceding peritonitides and other genital diseases are not unimportant complications.

Diagnosis.—As long as the blood is liquid, it cannot be palpated. The displacement of the uterus, the broadening of the excavatio recto-uterina indeed are surprising. A marked sensitiveness of the hypogastrium is a constant sign. The percussion-note is dulled, without a sharply defined mass being observed.

Coagulated blood fills the excavatio recto-uterina. The posterior vaginal vault and the anterior rectal wall are firmly pushed down. The coagula are felt as a thick fluid mass, besides which the adnexal organs, especially if they are not normal, are occasionally just noticeable, considering the care in palpation demanded by the condition. If the coagulation advances, the whole becomes harder, less bulky. It is felt as a hard, firm body in close contact with the posterior surface of the uterus and the floor of the excavatio as well as the other organs. The intestines agglutinated with it form a soft layer, in which rumbling and shifting of the intestinal contents become observable. The uterus, as a rule, is pressed forward and pushed up at the symphysis. The lumen of the intestines is displaced by the blood-tumor. With further thickening and organization of the blood the uterus moves away from the symphysis into the depth of the pelvis. The blood-clot may simulate a subserous myoma

of the posterior wall. After further absorption the indurations resemble the residues following peritonitic exudation.

The blood-tumor, in the beginning, is plainly, but not acutely sensitive. The sensitiveness slowly disappears with increasing organization, to reappear anew with puriform softening. Then various places feel softer. With threatening rupture, corresponding signs of irritation appear in the neighboring organs (vesical tenesmus, intestinal irritation, with evacuation of glassy mucus) and in the abdominal wall (reddening and formation of edema).

Hematoceles after gynecologic operations often suppurate very rapidly. The blood-tumor becomes very sensitive with high absorption fever (leucocytosis). The pus rapidly burrows toward the vagina, bowel, or bladder, if a general septic peritonitis does not immediately follow. The development of hematocele after rupture of the fetal sac in extrauterine pregnancy has been described above. As a rule, coagulation results in the formation of a single blood-clot. If absorption goes on unhindered, after recovery from the initial collapse with acute thirst and profuse perspiration, restoration of the general strength promptly follows. The pressure symptoms abate, the functions of the bladder and bowel return to the normal. With delay of further organization serious protracted invalidism occurs. Abundant secretions and hemorrhages from the uterine mucosa, especially at the time of the menses, occur in this condition. The strength is permanently broken. Puriform softening causes the symptoms which have already been cited several times.

It is, above all, of importance for the *diagnosis* of hematocele whether extrauterine pregnancy can be recognized at all (vide supra, p. 364). The condition of the hematocele after extrauterine pregnancy resembles that described in the different phases of organization. Elevation of temperature indicates suppuration.

Differential Diagnosis.—The hematocele offers findings which resemble those of perimetritic exudates. Here, also, as a rule, an encapsulation toward the abdominal cavity exists. The exudation of *pelvioperitonitis* is usually not very extensive. In general peritonitis masses of exudate are felt in the excavatio recto-uterina, if pseudo-membranous encapsulation exists in this locality. The organization of the effused blood is comparatively slowly carried into effect, purulent softening essentially more rapidly. Pelvic peritonitis usually follows a puerperium or infectious disease, it follows gonorrhœa, infection during masturbation, and therapeutic remedial efforts. Peritonitis always develops with more or less violent pains and fever, pressure sensitiveness, nausea up to vomiting, intestinal sluggishness even amounting to intestinal paralysis. Peritonitis after typhlitis and other intestinal diseases forms a part phenomenon in the decursus morbi. The same holds good for the tuberculous and carcinomatous disease. If a hematocele suppurates, then the findings of hematocele and peritonitis resemble each other.

The blood-tumor in hematocele may be mistaken for a *retroflexio*

uteri gravidi, especially if indolent women have not paid attention to the development of the incarceration. An exact palpation of the uterus must guard us against this mistake.

Subserous myomata of the posterior uterine wall at times indeed resemble an organized hematocele. As a rule, however, the relation of the myomata to the uterus is essentially more intimate. The adnexal organs are felt laterally to it. Myomata have a smooth surface, occasionally they appear bossed. The surface of the hematocele is rough, but at the same time uniform. Otherwise the anamnesis shows mostly long-existing irregularities in the menstrual flow. With further observation the progressing absorption of the blood-effusion must lead to a decrease in the volume, while myomata remain stationary, if they do not grow. The occasional difficulties of a differentiation of a hematocele from a hematometra, especially in a double uterus and in pregnancy in the accessory cornu is cleared up by palpation of the ligamenta teretia. Palpation per rectum is especially important for these cases.

The same holds good for the tubal diseases and the changes in the ovaries, to whose characteristic peculiarities we referred above.

Besides the new-formations of the genitalia other *tumor masses* in the pelvis offer a possibility for mistakes. I have observed high-seated rectal carcinomata, metastases in primary gastric, hepatic, and gall-bladder carcinomas, but also cancers of the wall of the flexura sigmoidea, which gave the palpatory signs of an old hematocele on account of the peculiar filling of the excavatio recto-uterina. The clinical picture of profound cachexia, whose development, as a rule, follows positive incidents and injuries, increases the difficulty. The uterus not rarely has grown together with such masses, in a similar manner as in hematoceles. The age of the patient does not speak against the possibility of a blood-effusion. The differentiation is finally successfully made by rectal palpation with an exhaustive consideration of the anamnesis.

Displaced *abdominal organs*, kidney and spleen, may occasion similar findings if they are fixed by peritonitic adhesions in the excavatio. As a rule, the acute development is not present in these cases, which we do not miss in the hematoceles. Nevertheless here, also, a trauma may first cause acute symptoms. As a rule, the shape of the displaced organ and the proof that it is absent from its normal place, together with the symptoms, which began with the interference of the function, make a differentiation possible.

Prognosis.—The prognosis of hematocele in the course of grave disturbances of compensation, signs of congestion and trauma depends not so much on the amount of the effused blood, but more upon the cause itself, farther on, whether the patient may endure the internal loss of blood and whether the conditions for absorption are present. In extra-uterine pregnancy less copious hemorrhages are not absolutely dangerous. However, so much blood may be emptied into the abdominal cavity at one time that death immediately takes place.

Encapsulation, as a rule, leads to absorption. Subsequent hemorrhages appear to be very perilous. If the patients overcome the shock the formation of indurations and bands may be very critical in connection with the genital disease, already previously existing. In spite of suppuration healing may occur by organization after rupture outwardly.

Women may bear normally after they have weathered an extrauterine pregnancy, an observation which gives an important suggestion for the treatment.

Treatment.—Hematocele, the result of a congestion or trauma, only rarely causes in the beginning such disturbances that the arrest of hemorrhage must be immediately undertaken. For the cases in which operation is required laparotomy is the indicated procedure. If coagulation has occurred the patients must be kept under continued observation. Rest in bed, general care, ice-compresses, eventually also artificial feeding are indicated. Continued interference with the function of the pelvic organs, as disturbances of menstruation, especially profuse hemorrhages, may necessitate surgical interference. The duration of recovery is thereby materially shortened according to our experience.

In hematocele after rupture of the fetal sac operation is indicated under the following conditions: 1. If the hemorrhage does not stop positively. 2. If organization and resolution, notwithstanding proper treatment, do not follow and lasting difficulties are induced thereby, especially disturbances in the function of bowel and bladder, and, 3, as soon as puriform softening takes place.

Evacuation through the vagina with drainage appears as the indicated procedure. Extensive blood tumors with obscure palpatory findings absolutely justify laparotomy. The hematocele must be emptied under all conditions, and perfect arrest of hemorrhage must also be secured.

II. Peritonitis, Pelvipерitonitis, Perimetritis

LITERATURE: A. *Martin*, Handbuch der Adnexerkrankungen, Vol. III, A. *Martin* and O. *Busse*.

The peritoneum takes up disease germs from all directions and in all manners. Those peritonitides are chiefly considered in this chapter whose starting-point is in the genital organs. That form of peritoneal disease especially interests us here, which we designate as **pelvic peritonitis** and **perimetritis**, the general peritonitis only as a result of a spread of these. Pelvic peritonitis is the most frequent disease of the female sexual organs. The serosa of the uterus is most frequently affected. Extensive exudates are seldom found, much more soft or hard deposits, pseudo-membranes and bands, which bridge the Douglas from the posterior wall of the uterus (Fig. 184). Tubes and ovaries, intestinal loops and omentum, are involved in the process.

The excavatio recto-uterina, with overwhelming frequency, partici-

pates according to the advance of the infectious germs from the tubes or bowels. Perimetritic processes already develop during intrauterine life (vide supra, p. 68). Ovulation and sexual life during the prime of life of women are in themselves sources of hyperemia, which prepare the nutrient ground for the infectious agents. A momentous cause is formed by ectopic gestation, and the same holds good of newgrowths of the genitalia. Infections during pregnancy, labor, and puerperium, during operations and therapeutic manœuvres, soundings, dilatations, etc., with overwhelming frequency form the beginning also for perimetritis. Finally,

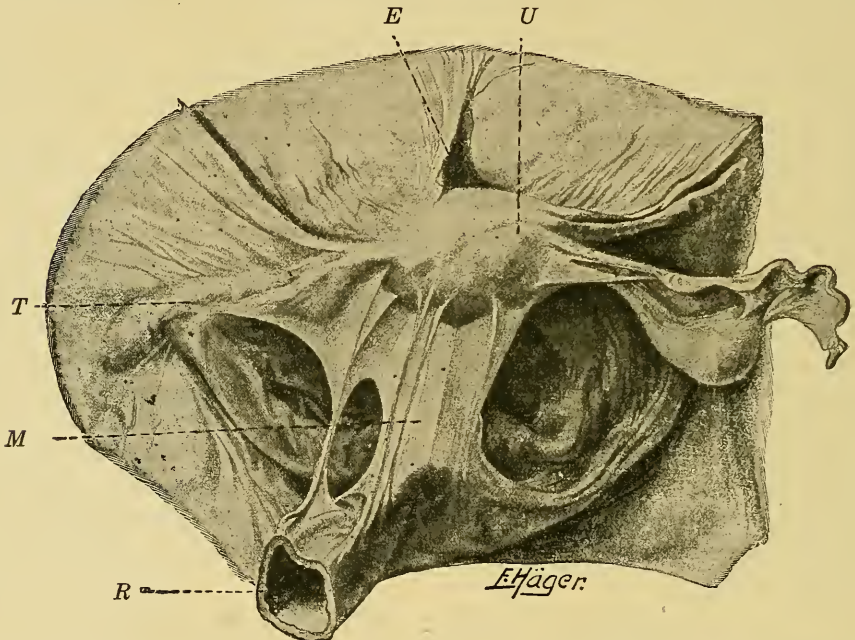


FIG. 184.—Pelvic Peritonitis. *R*, rectum; *M*, pseudo-membranes, which bridge over the excavatio recto-uterina; *T*, tuba sinistra; *U*, uterus; *E*, excavatio vesico-uterina. (Author's preparation.)

we must mention diseases of the bladder and bowel as not the least productive sources, as well as the organs of the upper abdomen, especially the kidney and gall-bladder.

Pathologic Anatomy.—Acute inflammations of the peritoneum are accompanied by the formation and secretion of an exudate, which considerably varies in amount and quality. Depending on the intensity of the inflammatory irritation (virulence of germs) and the power of reaction of the patient, serous, fibrinous, hemorrhagic, purulent or ichorous inflammations appear. Only the last is due to the presence of saprophytic bacteria. Acute peritonitis often terminates after a few days in death. In the great majority of cases, however, healing ensues with the formation of connective tissue condensation bands, induration, and adhe-

sions. Encapsulated intraperitoneal foci with serous (Fig. 185) and purulent contents remain behind. Organization takes place in the most favorable cases, in whose further course only a superficial scar and tissue thickening results; in others, however, also very thick membranes are left, while the inflammatory process spreads into the tissue layers, lying beneath the peritoneum as far down as the mucosa. Mechanic insults and

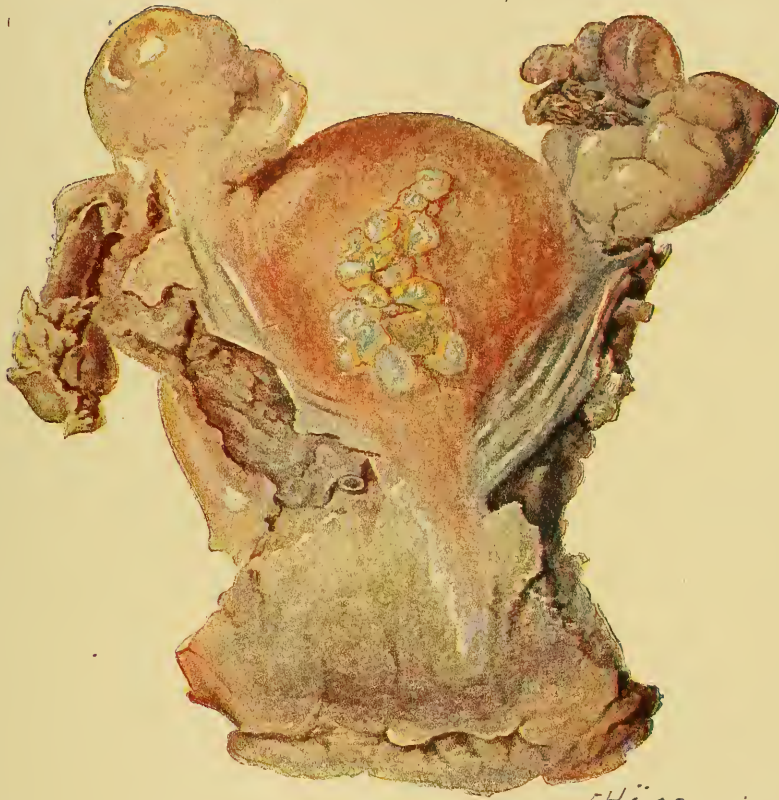


FIG. 185.—Perimetritis. Vesicles filled with serous exudate stand in one group on the posterior surface of the uterus. (Author's preparation.)

chemic irritations may occasion extensive, even fatal, inflammatory recurrences.

All disease and pus-causing bacteria are therein demonstrated. That the gonococcus *Neisser* may cause peritonitis, cannot be denied. The bacterium coli undoubtedly causes it oftener than the latter.

A peculiar form of chronic inflammation is caused by the tubercle bacillus. The immigration may certainly result also from the tubes by an ascending process (*Jung*), much more frequently by the hematogenous route. As primary foci must be apparently considered in first place the

intestines and lymph-nodes; they may, however, be carried into the abdominal cavity from the lungs or any other place. In a number of cases peritonitis tuberculosa is of the so-called dry form, without the occurrence of an abundant secretion and collection of inflammatory fluid in the abdominal cavity. The surface of the organs agglutinate and become adherent. Tuberculous nodules the size of a millet-seed up to large cheesy foci develop. These tubercles spread without limit, destroy the entire thickness of the intestinal wall and finally form fecal fistulæ. At times the abdominal cavity is found almost obliterated. This dry form is particularly observed in children. Exudation and collection of large or smaller amounts of inflammatory fluid in the abdominal cavity are more frequently found in adults. This exudate is many times serous, not rarely bloody, also purulent. Adhesions tend to be less extensive.

Tuberculous peritonitis may heal by replacing of the nodules by cicatricial formation. These fibrous tubercles also undergo involution to a hardly visible remnant (compare above, p. 190, the chapter on **Genital Tuberculosis**).

Chronic pelviperitonitis is essentially a stage in the process of cure, the result and the residuum of the inflammatory processes which ran an acute course a long time previously. Germs capable of development are often preserved in it, which lose their virulence only after a long time. These old abscesses sometimes communicate with the bowel by capillary fistulæ (*Busse*). In other cases a formation of thick indurations occurs which distort the entire pelvic organs. The uterus becomes displaced, the oviduct flexed, as well as the intestines and ureters. The residues are seen with quite especial frequency in the surroundings of the tubes, from which the infection of the peritoneum resulted. At times the peritoneum of the pelvis is in a condition of a more or less pronounced vascularity, permeated by small echymoses, here and there covered with fibrin. The adjacent surfaces of the organs are adherent to each other. An encystment of clear or turbid exudate takes place in sacs thus formed. In the further course these agglutinations develop to thin membranes and bands which unite the organs of the pelvis with each other, and completely envelop them as with a veil. A quite especially detrimental influence is exerted by such adhesions on the intestines. The intestinal mucous membrane is drawn outward so as to form a funnel, and there is danger that the distorted mucous points may be injured by the operative loosening of these adhesions. Adhesions of the processus vermiformis exert a similar influence. It appears self-evident with the intimate relation of the peritoneum to the parametrium, that also in the pelvic cellular tissue traces of the chronic inflammation are maintained for a long time. We have already referred to the combination with parametritis. Also in the surroundings of hernial protrusions such indurations occur. It seems of importance for the gynecologist, that the retroflexed uterus and more frequently the tumor formation of the pelvic organs, especially ovarian cystomata, most intimately agglutinate with more or less extensive por-

tions of the pelvis by extensive pseudo-membranes. These indurations form a natural hindrance to the absorption of transudates and extravasations. Another form of peritonitis develops with the myomatous ovarian new-formations (*pseudomyxoma peritonei*). In opposition to the view that this process forms by the entrance of the gelatinous contents of the cyst, which are with difficulty absorbed and mixed with elements capable of proliferation, *Wendeler* supposes that on account of the irritation of the same a special kind of peritonitis originates, in which the new-formed portions undergo a mucous degeneration.

Peritonitis carcinomatosa forms a peculiar variety of the disease. It passes more as a picture of an inflammation than a tumor-formation; usually a hemorrhagic exudate develops. Many times a hard infiltration of extensive portions of the parietal and visceral peritoneum takes place. The omentum takes part in this in quite a particular manner. It grows to a mass the thickness of several fingers, which is more or less broadly adherent with the abdominal wall or the intestines. Before this occurs, carcinomatous nodules are frequently seen which particularly cover the pelvic peritoneum, either as isolated nodules or in groups of nodules.

The peculiar development of large cells (decidua cells) rich in protoplasm, which form in the peritoneum during ectopic pregnancy, has been first described by *Orthmann*, *Schmorl*, *Füth*, and *Heinsius* among others. They are decidual formations. We must accept the view that they arise from an enormous development of the scanty connective tissue bodies of the normal peritoneum, as a result of powerful hyperemia and infiltration of the tissue caused by the implantation of the ovum (*Busse*).

Clinical Behavior

I. Non-Infectious Peritonitis

Although at present we continue to separate a non-infectious peritonitis from an infectious one, we find the motive for it in the fact that for a number of the inflammatory processes we only know mechanic and chemic irritants for which we cannot succeed by the method of examination at present known, in demonstrating parasitic or toxic excitors. We include here the cases of unknown etiology.

In addition blood and the products of pregnancy suspended in it, chyle, the contact with myoma masses, ovarian cysts, and their contents are considered as intensive irritants for the peritoneum (*Doederlein*).

A form of peritonitis, belonging hereto, is observed in young women and girls between the ages of fifteen to twenty-five. Peritonitic indurations, adhesions, especially also at the tube, develop without any clinical symptoms. Cases in which vulvovaginitis preceded in early childhood I do not reckon under this chapter, nor those originating from masturbation. Foreign bodies must not be added to these, as one cannot tell to what extent pathogenic germs have also been introduced with these foreign bodies (also hematodes).

Symptoms.—It is almost characteristic for this form of peritonitis, that typical symptoms of peritonitis are absent during its development. Very extensive adhesions with intimate agglutination of the abdominal organs with each other do not cause any subjective symptoms and difficulties, as long as the organs do not become immobilized. Sluggish bowels and sterility are constantly present. These peritonitides in other cases cause very troublesome difficulties, continued pains for which no cause can be felt, as pains during defecation, urination, cohabitation, with each exercise. Digestion is poor, the patients emaciate, suffer from headaches, are incapable of bodily and mental exertion. It is remarkable that ileus does not occur in this connection. Intercurrent acute disease seems rare. It apparently forms after insignificant causes, colds, over-exertion during an amusement. Dysmenorrhea exists in some cases. The course is, as a rule, free from any fever, but rare exceptions may occur. Of course a high degree of intelligence is necessary for such patients to control the entire atypical indisposition by timely, consequent, usable measurements of temperature.

This non-infectious peritonitis, as a rule, is a **localized diseased process**. The peritoneum is seldom found to be diseased to a great extent, nor above the pelvis, unless the action of uterine or ovarian tumor formations is concerned. The peritoneum, then, may appear discolored and pronouncedly hyperemic up to a dark blue, as in incarcerated hernias, with thick fibrinous deposits on all organs, which in such cases are intimately agglutinated to one mass. At times tuberclelike nodules are seen, in which the characteristic histologic changes are found. The process is limited most frequently to the pelvic peritoneum. In contradistinction to infectious peritonitis we see the localization of the non-infectious less constantly bound to the ampulla tubæ, the rectum, the region of the flexura sigmoidea and the typhlon. Hyperemia, adhesions and indurations extend over the external surface of the fundus uteri, the anterior surface of the corpus, posteriorly in the surroundings of the ovaries, over the tube downward into the depth of the fossæ pararectales, parauterinæ, and also the paravesicales. Now in larger areas, now in smaller shreds they appear like stratifications of the peritoneum, like veils, thin bands, and threads, but also like thick masses, firm adhesions, whose loosening causes a loss of substance in the surface of the organs and not rarely very considerable bleeding.

A further peculiarity of the non-infectious peritonitis consists in the insignificance of the exudation. The exudate is a yellowish serous fluid rich in albumin, in which no organized bodies except free endothelial cells and no bacteria have been demonstrated in cultures made upon nutrient media. This exudate lies in vesicles (**seroceles**) (see Fig. 185), on the uterus, ovary, and peritoneum viscerale and parietale. The vesicles, the size of peas or cherries up to hen's eggs, even as large as a fist, are found especially on the omentum and between the abdominal organs. Such cysts may fill the peritoneal pockets, and be located beside

or above the adnexal organs. They often cannot be palpated on account of the flabbiness of the pseudo-membranes surrounding them.

The *palpatory findings* offer the most varied pictures corresponding to the inconstancy of the symptoms. We meet with apparently normally situated organs showing signs of a chronic catarrh at the cervix uteri, the relations of the different structures to each other are only indistinctly shifted, a thickening of the peritoneum in the region of the excavatio recto-uterina and vesico-uterina and above the adnexal organs is observed only by a very expert palpation. Occasionally these adnexa appear at first considerably enlarged. In long-continued palpation one feels the gurgling of the escaping contents of the intestines, the intestinal loops adherent to the pelvic organs collapse and at the same time allow the examiner to gain an idea of the various structures. The whole is little or not at all sensitive.

In other cases the organs are distorted, distinctly agglutinated to thick masses, so that it is hardly possible to differentiate the various structures. Intense sensitiveness prevents the external examination, more so the combined. The thickening of the uterus and adnexa causes them to appear as considerably diseased and new-formations of all kinds are simulated. The diagnosis may be rendered continuously difficult by the simultaneous disease of different organs, which is rarely absent, especially if intercurrent acute exacerbations occur.

The exudation is rarely bloody. It becomes purulent if complicated with intercurrent infectious processes. Then the symptoms connected with the infection become paramount.

The findings in *diffuse non-infectious peritonitis* offer equal difficulties in a similar manner; it confronts us, almost surprisingly so, in the form of extensive agglutinations and formation of indurations. Also larger conglomerations, arising thereby, elude palpation by the delicacy and softness of the adhesions. Harder infiltrations simulate newgrowths whereby the similarity with findings of the tuberculous form causes great diagnostic difficulty. Completely free, bulky exudations are seldom met with, but extensive seroceles, which might be mistaken for cysts of all abdominal organs. Thin abdominal walls, the possibility of excluding malignant growths, the proof of the above described changes in the pelvis, and the negative findings, particularly of tuberculosis, lead to a probable diagnosis. Development without fever, absence of any marked infectious process speaks for non-infectious peritonitis. The insignificance of the symptoms particularly must be considered in these cases. Symptoms of ileus are always absent in the diffuse non-infectious peritonitis as far as known to me.

Diagnosis.—One must attempt to establish the diagnosis, in view of these findings, by a prolonged observation of the condition of the general health and careful consideration of the anamnesis and the symptoms. The absence of fever, and the usually not very considerable influence on the state of health allow an expectant attitude.

If the peritonitis is caused by newgrowths or by changes in position, then it may considerably aggravate the interpretation of the findings; it especially obscures the indications as to the operability of the same. On the other hand it advances with the growth of the tumors and increases their influence upon the state of health in a serious manner.

The *prognosis* must always appear as a grave one. These adhesions are not to be considered as unimportant under any circumstances.

The *treatment* is directed toward the absorption of the products of peritonitis. Further disturbance necessitates an immediate separation of the adhesions, which is described farther down.

II. Infectious Peritonitis

We distinguish the septic, sapremic, gonorrhoeic, and tuberculous peritonitis.

1. Septic Peritonitis

This complication of the puerperium and gynecologic operations and interferences (sounding, dilatation, and so forth) is characterized by its usually stormy course. It begins with fever and pains. Meteorism and vomiting of bile, even ileus, occur very soon. The pulse curve advances analogous to the temperature curve. Cardiac weakness makes itself early noticeable, it occurs at times shortly before the end, which latter is, as a rule, always sudden and unexpected. Pains may be absent, especially if the sensorium becomes early dulled. Meteorism often develops extraordinarily rapidly. Nausea, vomiting, dryness of the tongue and lips appear. The evacuation of the bowels ceases either from paralysis of peristalsis or the occurrence of mechanical obstruction (strangulation) or kinking of the bowel. The formation of exudate fluctuates within wide limits. To-day we seldom see such large masses of pus, as formerly formed the rule in septic puerperæ. Especially with previously existing encapsulation abscess cavities of different sizes form. These may become confluent, and a diffuse general disease may take place.

The *course* of puerperal, septic peritonitis is, as a rule, fatal during the first week, in the post-operative within three to four days, especially if it begins in a stormy manner and soon invades other portions of the peritoneum. With a favorable course the virulence of the bacteria may decline or an outlet for the exudate may be created. The temperature then, as a rule, drops, the pulse becomes slower, its quality improves. The re-establishment of peristalsis is a favorable symptom.

The exudations may become organized and disappear in weeks and months. The healing process frequently does not pass by without intermitting fever. Even the last remnants may become the actual cause for renewed violent attacks of the disease. The interference with the organs does not always correspond to the extent of the indurations or abscesses. If suppuration continues or a renewed maturation of the germs takes place acute symptoms mostly reappear. The patients succumb if the pus

is not spontaneously or artificially evacuated by the known routes through the vagina or rectum. Obstruction of the perforation opening retards healing. The evacuation through the bladder also may rapidly lead to recovery, however, also with the danger of an ascending kidney disease or painful fistula formations. The same danger exists with evacuation through the abdominal wall. Occasionally fecal fistulæ develop here, from which a general peritonitis with a fatal ending may unexpectedly arise.

2. *Sapremic Peritonitis*

The action of the sapremic disease on the patient makes the impression of an intoxication. The temperature in the beginning usually rises to a considerable height; as a rule, however, remissions soon follow down to 38° C. (100.4° F.) or even beneath 37° C. (98.6° F.). The prompt action of antifebrilia, to which *Doederlein* refers, I have not seen appear in the same manner. Elevation of temperature, however, may also be completely absent, as I, as well as *Menge*, have observed. In contradistinction to the irregularity of the fever the pulse regularly becomes frequent and small. Just the incongruence of both curves is the characteristic symptom of the sapremic peritonitis. In these cases I have constantly observed the early occurrence of distress and hunger for air; the curve of the frequency of respiration also contrasts strongly with that of the temperature. As a further symptom of the severe intoxication, the disturbance of the sensorium must be noted. Compared with the few cases of unimpaired clearness those complicated by coma and delirium predominate.

The behavior of the intestines fluctuates between a paralysis meteorism—absolute absence of any peristalsis—and exhausting diarrheas, with evacuation of extremely foul-smelling gases and masses intermixed with blood. A nasty, stale *fetor ex ore* makes itself conspicuous, to which *Menge* also refers.

The amount of exudation fluctuates, as in the septic forms. We not infrequently meet with encapsulated abscesses with putrid contents in the small pelvis, but a further extension does not ensue. The sapremic intoxication often develops with a severe exacerbation of a previously existing disease—to leave behind with a slow decrease of the symptoms an exudation mass which is with difficulty completely absorbed. The chronic illness thus contracted may be cured by proper treatment. On the other hand intercurrent incidents cause an abrupt outbreak of the disease, which then runs an acutely unfavorable course. A detrimental catastrophe follows perforation which occurs sooner or later; the old abscesses are evacuated, as a rule, only incompletely, and the patients succumb to a chronic sepsis.

3. *Gonorrhœal Peritonitis*

The symptoms of this form of peritonitis fluctuate within wide limits. Besides extremely violent initial symptoms, which furnish the picture of

the acutest peritonitis, the course is an absolutely slow one, which, however, is characterized by an inclination to recurrences. I have generally drawn the conclusion from my observation that the stormy commencement soon passes over into a quieter stage with some patience and otherwise not unfavorable circumstances, and then heals in an unexpectedly complete manner. In this I find also an explanation for the fact that we not infrequently elicit the history of previous attacks, which were not brought to the knowledge of the physician for one cause or another. The symptoms of chronic genital gonorrhoea persist for a long time. Pains in the pelvis, painful constipation, which alternates with an exhausting diarrhea, increasing loss of strength, and dyspareunia become associated with it. Occasionally acute attacks may follow the latter, also after a menstruation, as well as during attempts at medical treatment (pessaries, sounding, dilatation).

Extensive exudates seldom occur; they become organized, and the above described signs of adhesions remain behind. Otherwise it is a remarkable fact that the more serious forms of peritonitis gonorrhoeica are comparatively rare in contrast to the extreme frequency of gonorrhoea. There is no doubt, that even when gonococci are continuously found in the genitalia, pregnancy may take place, as I have had occasion to prove in my clinical material. That pregnancy may develop then to a normal termination—although at times an abortion occurs—that labor and puerperium may run an entirely normal course, of this we have observed examples free from any objections. In a number of these cases, which we could not exactly determine, fever appears in the early puerperium. Although the conclusion has been drawn from some observation of *Kroenig* and *Schauta* that these cases of chronic gonorrhoeal peritonitis generally have a bad prognosis on account of the indisposition of the patient during the late puerperium, my experience permits me to designate this conclusion as generally not well founded. My observations compel me to state that in these cases the influence of new injuries, especially renewed infections, has not been excluded with sufficient care.

4. *Tuberculous Peritonitis*

Tuberculosis almost exclusively develops slowly in the most marked contrast to the other described forms of peritonitis. It has been described on pp. 198 and 441.

Diagnosis.—The possibility of a differentiation of the various forms of peritonitis results from the mentioned symptoms and the course. The actual cause, as a rule, is evident. The chronic peritonitides, with their adhesions and exudates, may cause very serious diagnostic difficulties.

Adhesions become predominantly observable through the functional disturbances of the organs. At times the cords and bands within the pelvis, as well as the adhesions of the different organs, are palpable. The agglutinations of intestinal loops with the pelvic organs are observable under favorable conditions. Occasionally the artificial filling of the

bowel with a liquid aids in diagnosing adhesions. The attempt to make a diagnosis by displacement of the uterus with forceps attached to the cervix can only be recommended if done with extreme caution.

Perimetritic exudations are chiefly found in the excavatio recto-uterina, rarely do they fill only the parauterina or paracervicalis or vesico-uterina. They are usually sensitive, in the beginning more acutely than during the process of organization; old exudation residues may even become entirely insensitive. Exudations are immovable or almost indisplaceable, like an effusion of hollow cavities which the fluid may occupy. The retro-uterine exudates form tumor-masses of unequal form and hard consistency, as soon as their encapsulation has taken place. They mostly appear to be the size of a fist, however the mass varies between the size of a hen's egg and that of a voluminous ovarian tumor, which reaches above the level of the umbilicus. They then displace, as a rule, all other structures forward, at times to one side at others to the opposite side. As they become organized, they push down still further the posterior vaginal vault like the round end of an egg. Lateral or anteuterine position of the exudate is frequently observed after conditions of chronic irritation (so-called non-infectious peritonitis) have here created adhesions and encapsulations. If they, also, press downward, a resemblance to parametritic exudates appears. As a rule, the inflammatory process emanating from the tubes and ovaries has involved also the subserosium, so that edema and exudation in the parametrium are added to the tubo-ovarian tumors. The bladder then may become completely displaced out of the pelvis and the rectum displaced laterally.

With progressing organization of the exudate the inflammatory masses at times cause the impression of new-formations, either firmly fixed within the pelvis or developed intraligamentary. These, however, only rarely fill the pelvis as uniformly as those thickened, liquid exudates of the excavatio recto-uterina. The exudates lie intimately in contact with a large part of the uterus; the ovaries and tubes are, in a few instances, palpable as well-outlined structures, recognized by the isthmus tubæ and the ligamentum ovarii proprium. Palpation through the rectum offers an important means for differentiation. Perimetritic exudates surround the bowel mostly on all sides, although more extensively on one side than on the other. Newgrowths displace the rectum, which is felt as a slit at their border, instead of a rigidly walled-in canal, as in perimetritic abscesses. Neoplasms, which fill the excavatio recto-uterina, may reach down just as deep and push down the posterior vault like the round end of an egg. The ligamenta sacro-uterina lie then like tensely stretched gut strings at the periphery of these masses, while in perimetritic exudates they are included within these and cannot be recognized as such. In contradistinction to exudation residues, which lie unchanged in the pelvis often for years, newgrowths are to be distinguished by their anamnesis and their development, also by their form. Old exudations may become as hard as bones and show an irregular form. They are also

somewhat movable with their surroundings and have a rough, uneven surface. Besides them the generative organs later become palpable; eventually changes may be positively differentiated in the same.

Abscesses, with still liquid contents, do not always appear tensely stretched, especially if the softening develops toward the vagina, the rectum, or eventually also toward the abdominal wall soft, doughy portions are felt in them. Purulent softening of hematoceles resemble them also in this respect.

If the abscess reaches deep down in the pelvis, its nature is easily determined. But encapsulated pus foci, localized higher up by a wall of adhesions and indurations, are often reached with difficulty, especially if the excavatio recto-uterina is obliterated by old adhesions or the abscess lies above the lateral recessus. Then the mass reaches upward over the pelvic inlet and appears completely indistinct in its relations to the pelvic organs as a result of the extensive adhesions, which are never absent in such cases. Remitting fever and sensitiveness are not always referable to the still persisting virulence of the germs, while the sickly appearance, the frequent pulse, and the pains call urgently for relief. Fluctuation often cannot be observed with certainty through the wall, the thickness of a centimetre. Occasionally percussion indicates gaseous contents; however **gas abscesses**, on account of their mostly thick wall formation and the intestinal loops extensively adherent with them, are to be diagnosed with probability only in cases in which they lie in their greater extent close to the abdominal wall.

Repeated determinations of leucocytosis and the differential leucocyte count are of value, especially for the demonstration of pus in such diseases, although we must also admit exceptions. Exploratory paracentesis, advocated by many, does not always give the desired results. Bad accidents may be caused thereby unless it is immediately followed by a complete evacuation and drainage.

Gonorrheal perimetritis is characterized by its stormy beginning and the surprisingly rapid decline of the alarming symptoms. If proof of gonococci in the vagina or uterus is obtained, if residual changes (Bartholinitis, urethritis among others) are admitted by the husband, then a judgment as to the apparently so threatening condition of the disease is essentially facilitated. The proof of a simultaneously existing sactosalpinx purulenta, which, it is true, is not obtained in the first beginning on account of the extreme sensitiveness of the abdomen and the vagina, must naturally corroborate the diagnosis of the gonorrheal character of the perimetritis. Just so the salpingitis isthmica nodosa is characteristic.

The diagnosis of **tuberculous** peritonitis may easily and unobjectionably follow from the slow course of its development with otherwise tuberculous disease of the patient, especially with intestinal tuberculosis. Amenorrhœa has been designated as a symptom of an already far progressed cachexia.

Also those cases in which, especially in young people, exist fever,

loss of strength, loss of fat, also emaciation of the pelvis, a slowly increasing ascites and cystlike, soft tumor-masses, situated atypically in the peritoneal cavity, are easily recognized and correctly interpreted in regard to their connection. Knobby tumors of atypical form and localization, which are not in marked connection with one of the pelvic organs, are very suspicious. The finding of disseminated tubercles, which can be especially palpated in the pelvic peritoneum through the bowel (*Heger*) is, however, not an infallible proof, with otherwise suspicious symptoms, but nevertheless of importance. *Fehling* especially attaches importance to a more round enlargement of the spleen, which he never found absent. This test did not succeed with me in the last seven cases, which I examined. *Löhlein* saw the accumulation of ascites more frequently upon the left than the right side, in consequence of a retraction of the mesenterium. *Hofmeier* confirms this sign. I could not detect such a preference for the left side in the seven cases mentioned. The mass of bloody colored ascites, in which the uterine body can be moved as if swimming about, is the more surprising when neither hectic fever nor otherwise severe disturbances of health exist in connection with it, as I demonstrated in a number of cases, also in patients under careful medical observation.

Although the diagnosis of tuberculous peritonitis and perimetritis is certainly essentially facilitated by such observations and signs, we must admit that the findings of peritoneal tuberculosis often enough surprise us completely, not only in the initial stages of the process, but also in advanced forms. When opening the abdominal cavity, one meets unexpectedly with almost fearful destruction, general adhesions, cheesy degeneration of large foci. Boardlike infiltrations of the omentum are surprisingly often overlooked during a careful examination. The test with tuberculin injections, whose value has often been attacked, I have made in many cases with satisfactory results without disagreeable complications.

Prognosis.—The prognosis of acute septic and sapremic peritonitis is always an extremely grave one. Experience shows, that the patients may, however, recover after the occurrence of the most dangerous symptoms, with extensive exudates and adhesions, as they are often met with long after the infection. We do not possess any sign which offers an indication for the prognosis during the stormy initial symptoms.

Localized septic perimetritides are sometimes made surprisingly harmless by early evacuation of the exudation. How many women, however, are found after months and years with residues of such processes, which have weathered the acute stage without medical assistance! How many are passive enough to bear the invalidism connected with them through long years! The prognosis of the adhesions is in the beginning less threatening; their consequences, however, are very often of importance. The functional disturbances of the pelvic organs make the women ill and invalid. Pregnancy, if it occurs at all, is by no means always a beneficial process; the interference with the uterus leads to a premature

expulsion of the ovum whereby an opportunity for a new infection is given. But also without it there is danger of renewed propagation of the not yet extinct germs from the old foci. This process, however, must appear quite especially suspicious as the given actual cause of ectopic embedding. The patients not rarely remain invalid beyond the climacteric.

The prognosis of gonorrhœal perimetritis is certainly a serious one. Experience, however, teaches, that not a few patients recover with complete good health, conceive and go through a normal puerperium. It becomes always more questionable whether in the unfavorable cases, complications (mixed infections) are not concerned.

The prognosis of tuberculous peritonitis essentially depends on the presence and the extent of other localizations of the tuberculosis.

Treatment.—It is superfluous here to discuss prophylaxis. We will not neglect, however, to refer to the danger of the so-called minor gynecology. In *acute peritonitis* free exudates are to be attacked according to recognized surgical procedures (one must not overlook the fact that the results of surgeons have been mostly obtained from non-puerperal peritonitides) and, following the example of *F. v. Winckel* and *Bumm*, by extensive incisions and counterincisions, insertion of drainage-tubes and thorough irrigations with sodium chlorid solution. Abscesses and encapsulated foci must be looked for according to their location, evacuated, drained, and left to heal by granulation. These measures find an important supplement in artificial feeding. Besides rectal feeding the subcutaneous introduction of glucose solution according to the proposal of *Friedrich* deserves special consideration. (Sodium chlorid, 5.9, and chemically pure glucose, 38.8, are dissolved in 1,000 cc of water. The solution is boiled for ten minutes and 2,000 cc of it transfused best in three to four doses.)

In gonorrhœal peritonitis I would advise to operate only in immediate danger to life. I have seen very threatening cases finally recover also without operation.

Surprising results have been obtained in tuberculous peritonitis with a simple opening of the abdominal cavity. Care is always necessary and a continued rational phthiseo-therapy must be introduced. Observations extending over years justify in speaking of recovery.

The extirpation of the uterus, recommended by *Péan* as the last expedient in extensive abscesses, has lost credit.

In *chronic peritonitis* the above-mentioned methods for local treatment with modern general care come under consideration. We must make patient and abundant use of the hyperemic treatment of *Bier*. Massage can be considered as a harmless expedient only in very experienced hands; the same holds good for the mechanical compression or weight-treatment.

If such measures are ineffectual, if the adhesions cause continued difficulties, if the patients are not in a position to carry out such a tedious

and costly course of treatment, then the *operative separation of the adhesions and indurations comes in question*. *Hofmeier* refers properly to the fact, that in these cases not rarely other diseased organs (tubes, ovaries) have remained which already justify an operative interference. This was the train of thought which induced me to separate the adhesions found present in connection with the removal of the diseased tubes and other organs, and to seek a therapeutic interference also on these by the extensive separation of the same.²⁸⁰

Hofmeier considers such a procedure rational and safer than the rough tearing of the adhesions without exposure through a laparotomy. While I formerly proposed the latter procedure I have gradually changed to colpotomia anterior during the last ten years, as long as adhesions within the area of the pelvis are concerned. The remote results are entirely satisfactory. We have repeatedly observed pregnancy after it. The control of the results on the occasion of a second colpotomy, performed years after for other diseases, has in nine cases shown that, although all adhesions have not disappeared completely, additional adhesions had formed only in isolated instances. *Küstner* proposes a separation of the adhesions by the Paquelin as eschars should secure against renewed adhesions (*Franz*). The attempts to render harmless the separated adhesion surfaces by daubing them with sterilized oil I have given up for a number of years on account of uncertain results. An early stimulation of intestinal peristalsis apparently appears to prevent the development of adhesions of intestinal loops and omentum. Therefore I order strychnin up to 0.01 in three doses subcutaneously already on the second day in all vaginal and abdominal cœliotomies. Physostigmin salicylate (0.0001 in three doses) recommended by others (compare *Vogel*) has seemed to me to be not uniformly reliable in its action. Perfect asepsis and consequent avoidance of all traumatic injuries and interferences with the peritoneum during operation remain at all events the best prophylactic.

SUPPLEMENT

Neoplasms of the Pelvic Connective Tissue

LITERATURE: *Amann*, in *A. Martin's Handbuch der Adnexerkrankungen*, Vol. III, Berlin, S. Karger, 1905.

The pelvic connective tissue may also become the seat of newgrowths, whose matrix tends to be either the fibro-muscular tissue itself or the still present remnants of embryonic organs.

Fibromyomata and **fibromata** are here most frequent, which in many cases can be distinguished from intraligamentary tumors of the same kind connected with the uterus. At times these tumors lie completely at a distance from the uterus in the parametral tissue, so that one must accept their origin from this tissue. Not rarely **glandular** tissues are found in them, so that then **adenomyomata** arise, which must be considered as inclusions of elements of the *Wolffian* ducts in the myoma formations (*v. Recklinghausen*). A **carcinomatous** degeneration of such adenomyomata has been observed in quite rare cases (*Heinsius*), while otherwise cancers do not primarily occur in pelvic connective tissue.

The different **ligaments** of the uterus are not rarely recognized as the place of origin of fibromyomata, especially the ligamentum rotundum is frequently the matrix of such tumors. These are situated then either in the space between the uterine cornu and abdominal wall, or, however, externally in front of the external inguinal ring in the labium majus. They may also appear in the form of the **adenomyomata**.

A **sarcomatous** degeneration of these parametral myomata has been observed in many cases.

Cysts in the pelvic connective tissue in case the ovary can be excluded as matrix are to be referred to dilatations of parts of *Gärtner's* ducts by blocked secretion. They may appear multiple, lying in a row beneath each other and often are not to be distinguished from **vaginal** cysts.

Also **mesonephric rudiments** have been observed in the ligamentum latum and may exceptionally grow to large tumors; likewise **dermoids** have been found in a number of cases in the pelvic connective tissue, which must be referred to an inclusion of ectodermal structures in the earliest fetal life.

Finally it may be mentioned that the **echinococcus** also not rarely develops in the region of the pelvic connective tissue.

All tumors and cysts of the region have the common property, that they displace or compress the other organs of the small pelvis, uterus,

bladder, rectum, ureters and therefore that they may easily secondarily give rise to severe disturbances. If they proliferate very deeply into the pelvic connective tissue, they may appear at the pelvic outlet next to the vagina or rectum. Cysts and dermoids frequently rupture into the bowel and bladder, as also malignant tumors after they have involved the wall of these hollow organs.

The **diagnosis** of tumors of the pelvic connective tissue essentially coincides with that of intraligamentary developed ovarian tumors (see above, p. 403). It is only relatively rarely possible, to exclude with certainty a participation of the ovaries and uterus in the tumor formation, if one can palpate the organs mentioned laterally and separated from the tumors. Only those tumors of the ligamentum rotundum which have developed externally to the inguinal canal form an exception to this rule. In these the differential diagnosis from hernia, displaced ovaries or testicles must always be taken into consideration.

The **prognosis** depends on the anatomic character of the neoplasm, whereby it may be observed, that **malignant** tumors give a very bad prognosis, as their enucleation from the meshes of the pelvic connective tissue into healthy tissue can hardly be completely carried out.

The **treatment** can only consist in extirpation, as the indications are the same as in ovarian tumors for want of positive clinical differential signs. Whether in a given case one must proceed abdominally or vaginally can only be determined by a bimanual examination. Whichever route may thereby be taken, careful attention at all events must be paid to the large vessels, the ureter, bladder, and rectum, as otherwise these organs may easily be injured. On account of the impossibility of closing completely by suturing the extensive tumor-beds in the pelvic connective tissue it is often necessary to drain through the abdominal walls, the vagina, or the cavum ischio-rectale.

References

1. A. v. Rosthorn, Die Erkrankungen des Beckenbindegewebes. *Veit's Handb. d. Gyn.*, Bd. III. H. Sellheim, Atlas zur pathologischen Anatomie des Beckenbindegewebes. Freiburg, 1899. Ph. Jung, Die Anatomie und Physiologie des Beckenbindegewebes in A. Martin, Handbuch der Adnexerkrankungen, Bd. III, 1906. Berlin, S. Karger.
2. Literature about the development of the female genitalia: See Nagel, Entwicklungsfehler der weiblichen Genitalien. *Veit's Handb. d. Gyn.*, Vol. I. Wiesbaden, Bergmann, 1897. Frommel's Jahresber. Über Geb. u. Gyn., 1898-1906.
3. Literature: See Gebhard, Die Menstruation. *Veit's Handb. d. Gyn.*, Vol. III. Wiesbaden, Bergmann, 1898. Frommel's Jahresber. über Geb. u. Gyn., 1899-1906.
4. Die Ovarientransplantation. *Arch. f. Gyn.*, Vol. 60.
5. Centralblatt für Gyn., 1882, No. 28.
6. Die Therapie der chronischen Endometritis in der allgemeinen Praxis. *Arch. f. Gyn.*, Vol. 63.
7. See also Nagel, A. f. mikrosk. Anat., XXXIV, 1889. Entwicklung und Anatomie der weiblichen Genitalien.
8. A number of my older observations has been published in the reports of my students. Kiderlen, *Zeitschr. f. Geb. u. Gyn.*, XV. Kochenburger, loc. cit., XXV.
9. *Zeitschr. f. Geb. u. Gyn.*, Vol. 18.
10. Centralblatt f. Gyn., 1904, No. 15, and 1905, No. 1.
11. St. Petersburger med. Wochenschr., 1872.
12. Sitsinsky, M. f. Geb. u. Gyn., Vol. XII.
13. *Zeitschr. f. Geb. u. Gyn.*, Vol. 34, p. 530.
14. See Himmelfarb, *Arch. f. Gyn.*, Vol. 42.
15. See Reichel, *Zeitschr. f. Geb. u. Gyn.*, Vol. 14; Transactions of the "Würzburger Physic. med. Gesellsch.," N. F., Vol. 27. Pincus. Kl. Vortr., N. F., No. 31, and Schauta, *Lehrb. d. ges. Gyn.* Ed. 2, 1906.
16. Malformations of the Bladder and Urethra. *Langenbeck's Archiv*, Vol. 46.
17. *Monatsschr. f. Geb. und Gyn.*, 1898, also *Centralblatt f. Gyn.*, 1889, No. 5. See Kochenburger, *Zeitschr. f. Geb. u. Gyn.*, Vol. 25.
18. E. Kehrler, Das Nebenhorn des doppelten Uterus. Heidelberg, 1900.
19. See the literature of Nagel, *Handb. der Gyn. (J. Veit)*, Vol. I.
20. *Handb. d. Frauenkrankh.* (XIII. Ed. of Schroeder's *Handb.*), 1901, p. 162.
21. *Centralbl. f. Gyn.*, 1894, No. 41. See also A. Martin, *Handbuch der Erkrankungen der Adnexorgane*, Vol. I. *Erkrankungen der Tuben*.
22. *Berl. Beitr. z. Geburtsh. u. Gyn.*, 1873, Vol. II.
23. Pfannenstiel, *Festschr. d. Deutschen Gesellsch. zum 50 jähr. Stiftungsfest der Berl. Gesellsch. Wien*, 1894.
24. See Hofmeier, *Handb. d. Frauenkrankheiten*, 1901, p. 158 and ff.
25. Ballantyne, *Manual of Antenatal Pathology and Hygiene of Fetus*. Edinburgh, 1902. Nagel, *Handbuch (J. Veit)*, Vol. I, and J. Veit, *Die Krankheiten der Scheide*, loc. cit.
26. *Gaz. des hop.*, 1856, 142.
27. *Archiv. f. Gyn.*, II, p. 92.
28. *London Obstetr. Transactions*, V, p. 284.

29. *Graf*, *Virchow's Archiv*, XIX, p. 548.
30. *Heppner*, *Petersburger med. Wochenschr.*, 1872, H. 6, p. 552.
31. *Simon*, *Berliner klin. Wochenschr.*, 1875, No. 20.
32. *Amussat*, *Observ. sur une opération de vagin artificiel*. Paris, 1835.
33. *v. Rabenau*, *Zentralbl. f. Gyn.*, 1881.
34. *Zentralbl. f. Gyn.*, 1895, No. 30.
35. *Loc. cit.*, No. 40.
36. *Hegar's Beiträge*, Vol. IX, 1899, p. 223. Zur Anatomie, Physiologie und Pathologie der Douglastasche.
37. *Frommel*, *Zeitschr. f. Geburtsh. u. Gyn.*, VII, and *Thorn*, same, XVII. *P. Müller*, *Festschrift f. Kölliker*. Leipzig, 1887. *Thorn*, *Zeitschr. f. Geburtsh. u. Gyn.*, XVI. *Gottschalk*, *Samml. klin. Vorträge, N. F.*, 43. *Engström*, *Festschrift d. Berliner geb. Gesellsch.*, 1894. *Fränkel*, *Archiv f. Gyn.*, LXII.
38. See *E. Martin*, *Die Neigungen und Beugungen des Uterus nach vorn und hinten*. Berlin, II Ed., 1870. *B. S. Schultze*, *Naturforschervers.* Leipzig, 1872. *Volkmann*, *Samml.*, 50, 176. *Archiv f. Gyn.*, IV, VIII, IX, und Lageveränderungen des Uterus, 1880. *F. v. Winckel*, *Die Behandlung der Flexionen des Uterus*. Berlin, 1872. *Fritsch*, *Lageveränderungen*. Stuttgart, 1886. See also the extensive literary data in *O. Küstner*, *Lage- und Bewegungsanomalien des Uterus*. *Handbuch d. Gynäkologie von J. Veit*, Vol. I. *O. Küstner* and *A. Martin*, *Referate für den Kongress d. Deutschen Gesellsch. f. Gyn.* Würzburg, 1903.
39. *Zeitschr. f. Geb. u. Gyn.*, Vol. I.
40. *F. v. Winckel*, *Lehrbuch*, Ed. II, p. 337.
41. *Festschrift d. Deutschen Ges. f. Gynäk. für die Berliner Ges. f. Geb. u. Gynäk.* Wien, 1894.
42. To this comprehension, advocated by *Matthews-Duncan* and also already for a long time by *A. Martin*, see also *Transactions of the VI Congress (Vienna)*, and VII Congress of the "Deutschen Gesellsch. f. Geb. u. Gyn.," Leipzig, 1897. Recently also *G. Klein* joined the standpoint taken and especially warmly defended by *Theilhaber*. *Monatsschrift f. Geb. u. Gyn.*, 1906, XXIII, p. 155.
43. *Krantz*, *Diagnose und Therapie der Nervösen Frauenkrankheiten infolge gestörter Mechanik der Sexualorgane*. Wiesbaden, Bergmann, 1899. See also *Meyer*. *Monatsschr. f. Geb. u. Gyn.*, 1906, XXIII, p. 1.
44. *Berliner klin. Wochenschr.*, 1899, No. 1.
45. *Wiener med. Presse*, 1869, No. 2.
46. *E. Martin* has collected such exclusively severe cases in his monograph, "Über die Neigungen und Beugungen des Uterus," Ed. II, 1870, and *Zeitschrift f. Geb. u. Frauenkrankheiten*, 1874.
47. See also *Deutsche med. Wochenschrift*, 1889, No. 39, and *Transact. American Gyn. Soc.*, Boston, 1889.
48. Also *Stoeckel* refers to this relationship in his thesis: *Wann und wie soll der praktische Arzt die Retroflexio uteri behandeln?* *Berliner klin. Wochenschr.*, 1905, Nos. 48 and 49.
49. See the older literature: *E. Martin*, II Ed., 1870; *B. S. Schultze*, *Lageveränderungen*, 1882; *Küstner*, *Veit's Handbuch*; *Frommel's Jahresberichte*.
50. *G. Veit*, *Volkmann's Samml.*, No. 170. *Dührssen*, *Arch. f. Gynäk.*, Vol. 57. *F. Frank*, *Monatsschr. f. Geb. u. Gynäk.*, 1906, XXIII, p. 129.
51. *Berliner Beitr. z. Geb. u. Gyn.*, Vol. III, p. 67.
52. *Zeitschr. f. Geb. u. Gyn.*, XVIII.
53. See also *Küstner*, *Centralbl. f. Gyn.*, 1882, No. 28.
54. *Kasuistik der durch Pessare verursachten Schäden*. See *F. v. Neugebauer*. *Arch. f. Gyn.*, Vol. 43.
55. Pregnant examples can be reported confidently by every busy gynecologist. See also *Olshausen*, *Verhandl. d. Deutschen Gesellsch. f. Gyn.*, *Kongress. Leipzig*, 1897. *Kroenig* und *Feuchtwanger*, *Archiv. f. Gyn.*, Vol. 63.

56. *P. Mundé* (Amer. Journ. of Obstetr., October, 1881) and *Löhlein* have collected their respective observations. See the discussion of *Löhlein's* paper in the reports of the Gesellsch. f. Geb. u. Gyn. Berlin, 1882. Zeitschrift f. Geb. u. Gyn., VIII, p. 102. Lastly, *E. Fränkel*, Naturforscherversamml. Berlin, 1886.
57. Verhandl. d. Deutschen Gesellsch. f. Gyn., Leipzig, 1897. *Theilhaber*, *Winter*, *Heinricius*, Arch. f. Gyn., Vol. 63 (literature).
58. The Treatment of Backward Displacements of the Uterus and of Prolapsus Uteri by the New Method of Shortening the Round Ligaments. London, 1884. See also *Doléris*, Traitement opérative, etc. Nouvelles arch. d'obstétrique et de gynécol., 1886, and I, 1889 and 1890.
59. Verh. d. III Kongr. d. Deutschen Gesellsch. f. Gyn., 1889.
60. *Hegar*, Beitr., Vol. IV, *Eisler*, Münchener med. Wochenschr., 1898, No. 16, and *Beutner*, Monatsschr. f. Geb. u. Gyn., 1897, Vol. V.
61. Lage-und Bewegungsanomalien: *Veit*, Handb. d. Gyn., Vol. I, *Rubeska*, Monatsschr. f. Geb. u. Gyn., Vol. II, *Kleinwächter*, Uterusverlagerungen und operative Uterusfixationen. Wien, Urban & Schwarzenberg, 1899.
62. Verh. d. Deutschen Ges. f. Gyn., Halle, 1889.
63. Centralbl. f. Gyn., 1880 and 1897.
64. Zeitschr. f. Geb. u. Gyn., XXI.
65. Centralbl. f. Gyn., 1886, No. 46, and Zeitschr. f. Geb. u. Gyn., XXXII.
66. Centralbl. f. Gyn., 1888, Nos. 2 and 3; 1891, No. 46.
67. Beitr. f. Klin. Chirurgie, IV.
68. *Volkman*, Samml., 333, and Centralbl. f. Gyn., 1891, No. 16.
69. See *Kleinwächter*, Zeitschr. f. Geb. u. Gyn., 21. *Kelly*, Johns Hopkins Hosp. Reports, 1891-1892. *Küstner*, Kl. Vortr., N. F., No. 171. *Koblanck*, Zeitschrift f. Geb. u. Gyn., XLVII.
70. Verh. d. Deutsch. Gyn. Ges. Wien, 1897.
71. *Westfalen*, Monatsschr. f. Geb. u. Gyn., Vol. II, 1895.
72. *Boje*, *Engström's* Mitteilungen, Vol. II.
73. Zeitschr. f. Geb. u. Gyn., XXV. Verh. d. Deutsch. Ges. f. Gyn., X Kongr., 1903.
74. See Ber. d. Gesellsch. f. Geb. u. Gyn., Berlin. Zeitschr. f. Geb. u. Gyn., XIX.
75. Centralbl. f. Gyn., 1888, No. 12; 1890, No. 13. See also *Frommel*, Jahresberichte.
76. *Zweifel*, Centralbl. f. Gyn., 1890, No. 39.
77. *Klotz*, Centralbl. f. Gyn., 1891, No. 4.
78. See *Glaeser*, Centralbl. f. Gyn., 1892, No. 21.
79. Zeitschr. f. Geb. u. Gyn., XXIV.
80. Zeitschr. f. Geb. u. Gyn., XXIV, p. 315, and XXXIII. Deutsche med. Wochenschrift, 1892, No. 2. Berliner klin. Wochenschr., 1896, No. 50. Arbeiten aus *Mackenrodt's* Klinik, Heft III, Berlin, Karger, 1898.
81. Centralbl. f. Gyn., 1896, p. 73. See also *Strassmann*, Arch. f. Gyn., Vol. L. *Graefe*, Monatsschr. f. Geb. u. Gyn., 1896, No. 2. *Pape*, Zeitschr. f. Geb. u. Gyn., 1901, No. 16.
82. Transactions of the Deutschen Gesellsch. f. Gyn. Wien, 1898. A comprehensive report about my operations in Greifswald has been made by *Rieck*, Monatsschr. f. Geb. u. Gyn., 1902, Vol. XIV. See also *Guttwein*, Diss. Inaug., Greifswald.
83. *Thure Brandt*, Nouvelle méthode gymnast. et magnét. pour le traitement des maladies des organes du bassin et principalement utérines. Stockholm, 1886. *O. Bunge*, Berliner klin. Wochenschr., 1882, No. 25. *Arndt*, same, 1891, Nos. 27 and 28. Finally *Kumpf*, Monatsschr. f. Geb. u. Gyn., XXIII, 1905.
84. *E. Martin*, Monatsschr. f. Geb., 1866, 28, p. 168. Also *Breisky*, Krankheiten der Vagina, 1886, p. 69. *Küstner*, *Veit's* Handbuch. *Frommel*, Jahresberichte.
85. See *Fritsch*, loc. cit., p. 212.
86. Naturforschervers. Heidelberg, 1889. Archiv f. Gyn., XXXVI.

87. *Hegar and Kaltenbach*, Operative Gynäkologie, Ed. IV, 1903.
88. *J. Veit*, Deutsche med. Wochenschr., 1881, p. 280.
89. Festschr. f. *Karl Ruge*. 1895. S. Karger, Berlin.
90. *Schroeder* had to perform a perineorrhaphy on a six-year-old child, which its own father had lacerated in stuprum. See *Hofmeier*, Handb. d. Frauenkrankheiten, 1901.
91. See *Schülein*, Zeitschr. f. Geb. u. Gyn., XXI.
92. Münchener klin. Wochenschr., 1904.
93. For such exceptional cases see *Dützmann*, Monatsschr. f. Geb. u. Gyn., XVII, und *Sitzenfrey*, Zeitschr. f. Geb. u. Gyn., LVI.
94. See "Geschichte der Dammoperationen" in den gynäkologischen Operationslehren von *Hegar-Kaltenbach*, Ed. IV; *Hofmeier*, Ed. IV, 1905, and *Doederlein-Kroenig*, 1905.
95. *Werth*, Centralbl. f. Gyn., 1879, No. 29. *Hofmeier*, Berliner klin. Wochenschrift, 1884, No. 1.
96. *Bröse*, Centralbl. f. Gyn., 1883, p. 777.
97. Obst. Soc. of London, XXI, 1879-1880.
98. *Biefel*, Monatsschr. f. Geburtsh., XV, 1860, p. 401.
99. *Güterbock*, Archiv f. klin. Chirurgie, XXIV, 1879.
100. Zeitschr. f. Geb. u. Gyn., V, 1880.
101. *Volkmann's* klin. Vorträge, No. 301.
102. Manual of Gynecol., 1886, III, 15.
103. Nouv. arch. d'obst., 1891, No. 6.
104. Operative Gyn., Ed. III, p. 802.
105. Archiv f. Gyn., 1873, VI, p. 317. Naturforschervers., V. Wiesbaden, 1877.
106. *Langenbeck's* Archiv, Vols. X and XV.
107. Die neue gynäkologische Klinik in Königsberg, 1876, p. 45.
108. Deutsche med. Wochenschr., 1881, p. 280.
109. Pariser Ges. f. Geb. u. Gyn. u. Pädiatrie, 9 Okt., 1905. See Monatsschr. f. Geb. u. Gyn., Vol. XIII, p. 296.
110. Amer. Journ. of the Med. Sci., Jan., 1866, and Amer. Journ. of Obst., II, p. 213.
111. Obst. Soc. of London, 1870, XI, and Obst. Journ. of Gr. Brit. and Irel., 1873, LXIX, p. 585.
112. *Hagemann*, D. i., Berlin, 1891.
113. Obst. Journ. of Gr. Brit. and Irel., April, 1873.
114. Kurzes Lehrbuch der Gynäkologie, 1904, Ed. II, p. 148.
115. Zeitschr. f. Gyn., Vol. 43, p. 120.
116. *J. Veit*, Handbuch d. Gyn., 1898, Vol. III. See also *Gräfe*, Samml. zwangl. Abh., Vol. II, H. 5, 1897.
117. *Sir James Simpson*, Edinb. Med. Journ., December, 1861, p. 594. *Sims*, London Obstetr. Transactions, 1862, Vol. III. *Debout and Michon*, Bull. de thérapeutique, 1861, Nos. 3, 4, 7. *Budin*, Progrès méd., 1881, No. 2. *Olshausen*, Zeitschr. f. Geb. u. Gyn., XXII, and *Lorner*, Centralbl. f. Gyn., 1889, No. 50; also *Frommel*, Jahresberichte.
118. *Schroeder*, Handbuch, VII, p. 525.
119. *Hildebrandt*, Archiv f. Gyn., III, p. 221.
120. Zeitschr. f. Geb. u. Gyn., II, p. 262.
121. Transactions of the Boston Gynecolo. Soc., Dec., 1885. Communication of *A. Martin* to the society.
122. See *Freund*, Die gynäkol. Klinik in Strassburg, 1885. *Czempin*, Zeitschr. f. Geb. u. Gyn., 1886, Vol. XII, p. 287.
123. Zeitschr. f. Geb. u. Gyn., Vols. XXVII and XXXVII.
124. *Sneguireff*, Intern. Kongress, Moskau, 1897, and Arch. f. Gyn., LIX and LXII.
125. Centralbl. f. Gyn., 1880, No. 17, and 1889, No. 19.

126. *A. Martin*, Naturforschervers. Danzig, 1880. *Zeitschr. f. Geb. u. Gyn.*, VII. *Düvelius*, *Zeitschr. f. Geb. u. Gyn.*, X, 175, and *Schwartz*, *Arch. f. Gyn.*, XX, p. 245. *Menge*, *Arch. f. Gyn.*
127. *Hofmeier*, *Handbuch d. Frauenkrankh.*, 1901, p. 238.
128. *Centralbl. f. Gyn.*, 1895, p. 74.
129. *Monatsschr.*, 1906, Vol. XXIII, p. 718.
130. *Die latente Gonorrhoe*. Bonn, 1873.
131. Über eine der Gonorrhoe eigentümliche Mikrokokkenform. *Centralbl. f. med. Wissensch.*, 1879, No. 28.
132. Der Mikroorganismus der gonorrhöischen Schleimhautrekrankungen. Wiesbaden, 1887. *Centralbl. f. Gyn.*, p. 444. See *Veit's Handbuch*, Vol. I, 1898; here also the comprehensive literature.
133. Deutsche Gesellsch. f. Gyn. u. Geb. Bonn, 1891. See also *Archiv f. Gyn.* and *Gebhardt*, *Berliner klin. Wochenschr.*, 1892. See *Witte*, *Zeitschr. f. Geb. u. Gyn.*, XXV.
134. *Kurzes Lehrbuch d. Gyn.*, Ed. II, 1904, p. 389. We follow this representation in the following, as it coincides in many points with our experiences. Also see *Bumm*, in *Veit's Handbuch*, Vol. I.
135. *Arch. f. Gyn.*, XXV, and *Naturforschervers.* Magdeburg, 1884.
136. *Virchow's Archiv*, 1892, Vol. CXXXVII.
137. *Menge*, *Bakteriologie des Genitalkanals der nichtschwangeren und nichtpuerperalen Frau*. Leipzig, 1898.
138. *Deutsche Klinik am Eingang des XX. Jahrhunderts*, Vol. IX, p. 412. Amongst 119 patients of private practice 27 per cent. got uterine gonorrhoea and 13 per cent. tubal gonorrhoea.
139. *Monatsschr. f. Geb. u. Gyn.*, Vol. IX.
140. *Inaug. Diss.* Basel, 1891. *Arch. f. Gyn.*, Vol. XL.
141. *Arch. f. Gyn.*, Vol. LXX.
142. See my cases up to 1882. v. *Rabenau*, *Berliner klin. Wochenschr.*, 1882.
143. *Reinl*, *Berliner klin. Wochenschr.*, 1885, No. 13.
144. *Zeitschr. f. Geb. u. Gyn.*, 1880, VI. See *Howitz*, 1884, VIII. *Intern. med. Kongr. Selman*, D, i. Berlin, 1891.
145. *Die chronische Metritis*, 1861.
146. Also *Breisky*, *Centralbl. f. Gyn.*, 1878, p. 301. *Johannowsky*, *Prager Vierteljahrsschr.*, 1879, p. 88. See also *Mackenrodt*, loc. cit.
147. *Pincus*, *Constipatio chr.* *Arch. f. Gyn.*, Vol. 53.
148. *Zeitschr. f. Geb. u. Gyn.*, Vol. 34; also v. *Wild*, *Naturforscherversammlung*. Frankfurt, 1896.
149. *Pincus*, *Monatsschr. f. Geb. u. Gyn.*, XX, 1904.
150. *Berliner klin. Wochenschr.*, 1882, No. 25.
151. *Naturforscherversammlung in Magdeburg*, 1884, *Centralbl. f. Gyn.*, 1884, 42. See also *Hegar* and *Kaltenbach*, Ed. II, p. 176; also *Arendt*, *Berliner klin. Wochenschr.*, 1891, Nos. 27 and 28; finally, *Kumpf*, *Monatsschr. f. Geb. u. Gyn.*, XX, 1905.
152. *Naturforschervers.* in Kassel, 1878; see *Archiv f. Gyn.* and *Centralbl. f. Gyn.*, also *Berliner klin. Wochenschr.*, 1878.
153. See also *Pfannenstiel*, *Vortrag auf dem internat. med. Kongr.* Lissabon, 1906. *Monatsschr. f. Geb. u. Gyn.*, XXIII, p. 720.
154. *Deutsche Zeitschr. f. Chirurgie*, XIX, H. I.
155. *Hofmeier*, *Zeitschr. f. Geb. u. Gyn.*, XI; loc. cit., *Dohrn.-Landau*, *Centralbl. f. Gyn.*, No. II, 1889. *Strassmann* and *Lehmann*, *Arch. f. Gyn.*, 56. See also *H. J. Boldt*, *New York Med. Journ.*, October 28, 1905.
156. *Arch. f. Gyn.*, 63.
157. *Hofmeier*, *Zeitschr. f. Geb. u. Gyn.*, Vol. 5.
158. *Lenander*, *Centralbl. f. Gyn.*, 1898, No. 6; *Zeitschr. f. Geb. u. Gyn.*, 28.
159. *Handb. d. Frauenkrankh.*, 1901, p. 332.

160. Die Adenomyome des Uterus, v. *Recklinghausen*, *W. A. Freund*. Berlin, 1896. Hirschwald.
161. Med. Klinik, 1905, No. 9, p. 201.
162. Kurzes Handb. d. Gyn., Ed. II, 1904, p. 195.
163. Berliner klin. Wochenschr., 1872, No. 25.
164. See discussion to *A. Martin's* Vortr., Naturforscherversammlung, Magdeburg, 1884.
165. *Engelmann*, Deutsche med. Wochenschr., 1891, No. 20.
166. Comptes rendus de l'Acad. des scienc. Paris, 1884, XCIX, 177. See literature bei *O. Schäffer*, in *Veit's* Handb. d. Gynäk., Vol. II.
167. *Hegar*, Centralbl. f. Gyn., 1877, 17, and 1878, No. 2, Sammlung klin. Vorträge, 136-138. See also *Batthey*, Transact. Amer. Gyn. Soc., 1877; *Trenholme*, Amer. Journ. of Obstetr., Vol. IX; *Hegar* and *Kaltenbach*, Operative Gyn., Ed. IV, 1903, and the text-books of Gynecologic Operations of *Hofmeier*, and *Doederlein* and *Kroenig*.
168. Zeitschr. f. Geb. u. Gyn., Vol. 51.
169. Disk. d. Berliner Ges. f. Geb. u. Gyn., Vol. 50.
170. See *A. Martin*, Naturforscherversammlung, Meran, 1905, and Festschr. f. *D. v. Ott*, St. Petersburg, 1906, Monatsschr. f. Geb. u. Gyn., XX, XXII, XXIII.
171. Operative Gynäk., 1905, p. 435.
172. Gaz. méd. de Strasbourg, 1864.
173. *Péan* et *Urdy*, Hystérotomie. Paris, 1873.
174. British Med. Journ., December 10, 1887.
175. Operative Gyn., Ed. II, 1886.
176. Naturforschervers., Cassel, 1878, and Zeitschr. f. Geb. u. Gyn., VIII and X.
177. Naturforschervers. Cassel, 1878.
178. Die Stielbehandlung bei der Myomektomie, Stuttgart, 1888, and Centralbl. f. Gyn., 1894, and *Blum*, Zeitschr. f. Geb. u. Gyn., XXXV.
179. Kongress d. Deutschen Ges. f. Gyn. Halle, 1888.
180. Centralbl. f. Gyn., 1891, No. 35, and Wiener med. Wochenschr., 1894, No. 52. See also *v. Rosthorn* and *Schick*, Klin. Vortr., N. F., 158.
181. See *Burkhardt*, Deutsche med. Wochenschr., 1880, No. 27; *Czempin*, Ges. f. Geb. u. Gyn. Berlin, October, 1886. *A. Martin*, V. Kongr. d. Deutschen Ges. f. Gyn. Breslau, 1893. Monatsschr. f. Geb. u. Gyn., XVIII and XX. *Engström*, Monatsschr. f. Geb. u. Gyn., V. *Olshausen* and *Henkel*, Zeitschr. f. Geb. u. Gyn., LII, have first participated in the perfection of the operations for enucleation.
182. *Richelot*, Ann. d. Gyn., 1895. Same, Vol. LII, XIII Kongr. d. franz. Ges. f. Chirurgie. See *Botzons*, Diss. Inaug. Berlin, 1902. *Möller-Essen*, Monatsschr. f. Geb. u. Gyn., XXI. *Lumpe*, Centralbl. f. Gyn., 1905, No. 44.
183. Internat. Med. Congress, Berlin, 1890. Berliner med. Wochenschr., 1895, No. 29. *Mackenrodt*, Zeitschr. f. Geb. u. Gyn., XXI, 224. See also *Bardenhauer*, Zur Frage der Drainierung der Bauchhöhle. Stuttgart, 1881. *Trendelenburg*, *M. Dixon Jones*, *Chrobak*, Centralbl. f. Gyn., 1891, Nos. 8 and 35.
184. *J. F. W. Ross*, Amer. Journ. of Obst., 1891, XXIV. *Fl. Krug*, New York Journ. of Gyn. and Obst., January, 1892.
185. *Pozzi*, Traité de Gyn., Ed. IV, 1905. See also *Luigi Acconci*, Rendiconi clinici. Padova, 1892. *Howard Kelly*, Oper. Gynecology.
186. Revue méd., Aout, 1840, and Mémoire, 1842.
187. *Glaevecke*, Arch. f. Gyn., XXXV. *Abel*, loc. cit., LVII. *Burkhardt*, Zeitschr. f. Geb. u. Gyn., XLIII. *Mandl* and *Burger*, Die biologische Bedeutung der Eierstöcke. Wien, 1904. *Deuticke*. *Keitler*, Monatsschr. f. Geb. u. Gyn., XX. *Winter*, Zeitschr. f. Geb. u. Gyn., Vol. LI and ff.
188. Centralbl. f. Gyn., 1896, No. 20.
189. Zeitschr. f. Geb. u. Gyn., 1901, XLII.
190. *Mond*, Münchener med. Wochenschr., 1896, No. 15. *Mainzer*, Deutsche med. Wochenschr., 1896, No. 25.

191. VIII Kongres. d. Deutschen Ges. f. Gyn.
192. Radikale zentrale Enukleation mit Morcellement. Zeitschr. f. Geb. u. Gyn., L.
193. Deutsche med. Wochenschr., No. 22.
194. Zeitschr. f. Geb. u. Gyn., XXIV.
195. Centralbl. f. Chirurgie, 1893, No. 51. Monatsschr. f. Geb. u. Gyn., XIII.
- Verh. d. IX Kongr. d. Deutschen Ges. f. Gyn. Giesen, 1901. See also *Staudé*, Monatsschr. f. Geb. u. Gyn., XV.
196. Zeitschr. f. Geb. u. Gyn., LII, p. 403.
197. Zur Frage der Heilbarkeit des Carcinom., Zeitschr. f. Geb. u. Gyn., L., 1903.
198. Zeitschr. f. Geburtsh. u. Gyn., X and XIII. See also *Frommel* and *Winter*, in *Veit's* Handb. d. Gyn., Vol. III.
199. *Bäcker*, A. f. Gyn., 53.
200. *Frommel* and *Winter*, Handb. d. Gyn. (*Veit*), Vol. III. *Hofmeier*, Zeitschr. f. Geb. u. Gyn., 32. *Löhlein*, Gyn. Tagesfragen., H. III, 1895. *Wisselink*, Zeitschrift f. Geb. u. Gyn., 37. *Schüle*, Zeitschr. f. Geb. u. Gyn., 16. *Odebrecht*, loc. cit., 41.
201. Die gänzliche Extirpation der carcinomatösen Gebärmutter. Konstanz, 1822.
202. Med. Gaz., 1828, p. 840.
203. Naturforschervers. Hamburg, 1876.
204. Centralblatt f. Gyn., 1878, No. 12, and *Volkmann's* Sammlung, No. 133, and Berliner klin. Wochenschr., 1878, No. 27.
205. Wiener med. Wochenschr., 1879, Nos. 45-49.
206. See also *Wölfler*, Kongress der Deutschen Ges. f. Chirurgie, 1880.
207. Naturforschervers. Danzig, 1880. IV Chirurgen Kongress.
208. Naturforschervers. Danzig, 1880, and Berliner klin. Wochenschr., 1881, No. 19.
209. Centralbl. f. Gyn., 1883, No. 57.
210. Union médicale, 1886, Nos. 95 and 96.
211. Ovarian and Uterine Tumors, London, 1882, p. 526. *Ch. E. Jennings* operated according to this suggestion. *Richelot* made extensive use of it in 1886. *Péan* generalized this procedure. (Gonot, Thèse de Paris, 1886. De l'hystérectomie vaginale de France.) See also *Péan*, X Internat. Congr., Berlin, 1890.
212. X Kongr. d. Deutschen Gyn. Ges. Zeitschr. f. Geb. u. Gyn., XXIX and XXXII, also *Gellhorn*, Resultate der Radikalbehandlung. Berlin, Karger, 1898.
213. Zeitschr. f. Geb. u. Gyn., 33 and Arch. f. Gyn., 55.
214. Zeitschr. f. Geb. u. Gyn., 32 and 37.
215. Samml. klin. Vortr., N. F., No. 204.
216. Archiv f. Gyn., 61.
217. See *Kermauner* and *Laméris*. *Hegar's* Beiträge, V.
218. *M. Brunet*, Zeitschr. f. Geb. u. Gyn., LVI, 51.
219. Centralbl. f. Gyn., 1901, No. 25.
220. *Winter* gained a deserved credit for the statistics of cancer operations. Zeitschr. f. Geb. u. Gyn., 22. Later, Kongress d. Deutschen Ges. f. Gyn. Giessen, 1901.
221. Monatsschr. f. Geb. u. Gyn., XIX, p. 475. See also *Mackenrodt*, *ibid*.
222. See Kongress d. Deutschen Ges. f. Gyn. Kiel, 1905. Also *Opitz*, Der Stand der Bekämpfung des Gebärmutterkrebses. Monatsschr. f. Geb. u. Gyn., XXIII, p. 62.
223. See *v. Rabenau*, Berliner klin. Wochenschr., 1883, No. 13.
224. See *A. Martin*, Pathologie und Therapie der Frauenkrankheiten, Vol. III, 1894.
225. A New Method of Partial Extirpation of the Cancerous Uterus. Amer. Journ. of Obstetrics, XVII.
226. Zeitschr. f. Geb. u. Gyn., Vol. XVI, p. 151.
227. Diss. Inaug. Erlangen, 1900.
228. Diss. Inaug. Halle, 1896.
229. Festschrift für *Chrobak*, 1903.
230. Monatsschr. f. Geb. u. Gyn., July, 1904.
231. Diss. Inaug. München, 1896.

232. *Benicke*, Zeitschr. f. Geb. u. Gyn., 1877, Vol. I. See also *Frommel*, Zeitschr. f. Geb. u. Gyn., V, 158, and *Stratz*, Zeitschr., XII, H. 2, and Sitzungsber. d. Gesellsch. f. Geb. u. Gyn., 1886.
233. *Virchow's Archiv*, Vol. 113.
234. Gynäk. Diagnostik von *Winter*, Vol. 243.
235. Kurzgefasstes Lehrbuch (*Küstner*), Vol. II, 1904, p. 212.
236. *A. Martin*, Zeitschr. f. Geb. u. Gyn., IV, p. 320.
237. American Journ. of the Med. Sciences, January, 1852.
238. Remarks on Vesico-Vag. Fist., 1856; finally Annal. de Gyn., Paris, 1876, VI, pp. 108-116. See also *Bandl*, Zur Operation der Blasenscheidenfisteln. Wien, 1878, and *Pawlik*, Zeitschr. f. Geb. u. Gyn., VIII.
239. Über die Heilung der Blasencheidenfistel. Giessen, 1875, and Rostock, 1862.
240. See Operative Gynäk. *Fritsch*, Centralbl. f. Gyn., 1888, No. 49, Krankheiten d. Weibl. Blase. Handbuch d. Gyn. (*Veit*), Vol. II.
241. See *Walcher*, Centralbl. f. Gyn., 1889, No. 1. *F. v. Winckel*, Münchener med. Wochenschr., 1891.
242. See *Winckel*, Lehrb., Ed. III, 1890.
243. Deutsche Zeitschr. f. Geb. u. Gyn., X, p. 126.
244. *Broese*, Zeitschr. f. Geb. u. Gyn., 1904.
245. *Hegar's* Beiträge, IX, Heft 2.
246. See also *Wölfler*, Deutsche Ges. f. Chir., XVI. *Von Herff*, Zeitschr. f. Geb. u. Gyn., XXII, and *Benkieser*, *Follet*, Bullet. Soc. d. Chir., 1886, p. 445; Obstetr. Soc. Lond. *Champney's* Transaction, XXX, p. 348; ad loc. cit., XXV.
247. Centralbl. f. Gyn., 1884.
248. Archiv f. Gyn., XXIII, H. 2.
249. Zeitschr. f. Geb. u. Gyn., VII, p. 22.
250. *Benicke*, Zeitschr. f. Geb. u. Gyn., XIX, also *A. Martin*, Diskussion, ibid., 306.
251. *Stechow*, Zeitschr. f. Geb. u. Gyn., X.
252. *Möricke*, Zeitschr. f. Geb. u. Gyn., V, p. 324.
253. Archiv f. Gyn., Vol. I.
254. *Schede (Drucker)*, Arch. f. Gyn, 43, also *Geyl*, Samml. klin. Vortr., N. F., 37; also *Bastionelli*, Sammelreferat, Monatsschr. f. Geb. u. Gyn., Vol. IV.
255. Zeitschr. f. Geb. u. Gyn., XXXI.
256. *Franz*, Zeitschr. f. Geb. u. Gyn., *L. Witzel*, Centralbl. f. Gyn., 1896; *Sänger*, Monatsschr. f. Geb. u. Gyn., IX. *Martin*, ibid., X. *Stöckel*, Arch. f. Gyn., LXVII; Zeitschr., LI, Ureterfistel und Ureterverletzungen, Leipzig, Breitkopf & Härtel, 1900, *Kroenig*, Archiv, LXXII, *Lichtenauer*, Monatsschr. f. Geb. u. Gyn., *H. Kelly*, Amer. Journ. of Obst., 1896.
257. Monatsschr. f. Geb. u. Gyn., 1904.
258. *Zweifel*, 1878, Archiv f. Gyn., XV. *B. Credé*, ibid., XVII. *Fritsch*, Centralbl. f. Gyn., 1886, No. 1. *Bardenheuer*, Berl. klin. Wochenschr., 1886.
259. *Bidder*, Verh. d. Deutschen Ges. f. Chirurgie, 1885, XIV, p. 52.
260. See Monatsschrift f. Geb. u. Gyn., VII, p. 489, 1898.
261. Med. Times and Gaz., February and March, 1859.
262. Reported first in 1875 in Zeitschr. f. Geb. u. Frauenkh.
263. Lancet, 1865, and Gebärmutterchirurgie, 1866.
264. See *Jaquet*, Zeitschr. f. Geb. u. Gyn., Vol. 47, and Diskussion in der Berliner Ges. f. Geb. u. Gyn.
265. *Simon (Marckwald)*, Archiv f. Gyn., VIII, p. 48). *E. Küster*, Zeitschr. f. Geb. u. Gyn., IV, p. 298. See *Schroeder*, Charité-Annalen, 1880, p. 343.
266. Amer. Journ. of Obstetr., November, 1874; Amer. Practitioner, January, 1877.
267. Archiv f. Heilk., II, 7.
268. Uterine Surgery, 1866.
269. Gyn., 1885, Ed. III.

270. Naturforschervers. Innsbruck, 1871, No. 7, p. 183. *Odebrecht*, Berl. Beitr. zur Geb. u. Gyn., III, p. 220.
271. Charité-Annalen, 1878. Zeitschr. f. Geb. u. Gyn., III, p. 419, and *Möricke*, *ibid.*, III, p. 328.
272. *Schroeder*, Zeitschr. f. Geb. u. Gyn., III, p. 419, and VI, p. 213.
273. Charité-Annalen, 1878. Zeitschr. f. Geb. u. Gyn., III, p. 419, and *Möricke*, *ibid.*, III, p. 328.
274. Handbuch der Krankheiten der Adnexorgane, Vol. I, Die Krankheiten der Eileiter, 1895, p. 158.
275. Berl. klin. Wochenschr., 1904, No. 13.
276. See *Ph. Jung*, Naturforscherversammlung. Karlsbad, 1903. Münchener medizinische Wochenschr., 1905. *A. Martin*, Festschrift für *Chrobak*. Wien, 1904.
277. Also here we must refer to the comprehensive and masterful representation of *Werth*, Handbuch der Geburtshilfe von *F. v. Winckel*, 1905.
278. *Seitz*, Klinische Vorträge, N. F., No. 286.
279. Zentralblatt für Gynäkologie, 1896, No. 9.
280. Zeitschr. f. Geb. u. Gyn., Vol. XXX, 1895; Monatsschr. f. Geb. u. Gyn., Vol. VI.

INDEX

- Abdominal ovariectomy, 411
 Abrasio mucosæ uteri (curettage), 29
 Acne, vulvar, 151
 Acuminated condylomata, 154, 161, 220
 Adenomata of the uterus, 269
 Adenomyomata, 233
 epoophoral, 233
 mucus, 233
 Adnexa, uterine, 2-3
 examination of, 22
 After-treatment of curettage, 32
 cervical amputation, 328
 colporrhaphy, 129
 myomectomy, 267
 ovariectomy, 414
 perineorrhaphy, 144
 vaginal extirpation of uterus, 293
Alexander-Adams operation, 98
 Aluminum-bronze wire for fascial sutures, 42
 Amenorrhœa, 52-55
 after suppurative diseases, 54
 after typhoid fever, 54
 after wound diseases, 54
 artificially induced, 52
 chlorosis as a factor in, 53
 diseases of genitalia in, 52-54
 due to anomalies in development, 53
 in systemic diseases, 52-53
 pathologic, 52
 physiologic, 52
 treatment of, 55
 Amputation of the cervix, 323
 in operation for uterine prolapse, 120
 Anatomy of, 1-3
 fallopian tubes, 2
 female pelvic organs, 1
 ovary, 3
 uterine ligaments, 2
 uterus, 1
 vagina, 1
 Anesthesia, 38-40
 chloroform, 38, 39
 cocain-adrenalin, 39
 ether, 39
 ether chloroform-oxygen, 38
 in vaginal cœliotomy, 39
 local (*Bier*), 38
 (*Schleich*), 38-39
 lumbar (technic), 39-40
 scopolomine-morphine, 40
 stovain, 39-40
 tissue infiltration, 39
 Angiomata, 220
 Anomalies of development of vagina and uterus, 60
 Anteflexio uteri, 1, 83
 Anterior colporrhaphy, 121
 Anteversion of uterus, 83
 Aplasia of female genitalia, 60
 Arteria ovaria vel spermatica, 8
 Arteria uterina, 6
 Ascending inflammation of female genitalia, 149
 Asepsis, 40
 of suture material, 41, 42, 45
 Atmocaustis, 183
 Atresia hymenalis, 68
 acquired, 70
 congenital, 70
 treatment, 73
 Atresia, uterine, 68
 acquired, 70
 congenital, 68
 diagnosis of, 69
 prognosis in, 73
 retention of blood in, 71
 symptoms, 69
 therapeutic indications, 73
 Atresia, vaginal, 68
 diagnosis of, 69
 symptoms of, 69
 treatment of, 73-74
 Atresia, vulvar, in acute infectious diseases, 151
 Atresia of the tubes, 68
 acquired, 68
 congenital, 68
 Atrophic parametritis, acute, 432
 Atrophy, uterine, 75
 Atrophy, uterine, congenital, 75
 diagnosis of, 78
 during puerperium, 81
 examination in, 77-78
 local treatment of, 78-79
 objective signs in, 77
 prognosis, 78
 pseudo-puerperal, 81
 stem pessaries in, 79, 80
 treatment of, 78, 79, 81
 Azoosperma, 58
 Bacteriological examination of female genital tract, 33
 cervix uteri, 35
Doederlein's method, 36
 of *Bartholin's* glands, 35
 urethra, 35
 uterus, 35-36
 vagina, 35
Bartholin's glands, 2
 abscess of, 185
 bacteriologic examination of, 35
 gonorrhœal infection of, 184, 185
 Benign tumors of ovaries, 392
 pelvic connective tissue, 454
 tubes, 341
 uterus, 228
 vagina, 225
 vulva, 219
 Bimanual examination, 19
 Bladder, 4
 evacuation of, after colporrhaphy, 135
 Bladder, injuries of, 310
 after-treatment, 316
 diagnosis, 311
 operation for, 312-316
 pathologic anatomy, 307-310
 prognosis, 311
 symptomatology, 310
 treatment, 311-316
 vesico-vaginal fistulæ, 307-316
 Bloodletting (local) in chronic metritis, 214
 Blood-supply of female genitalia, 6

- Braun's* syringe, 31
 Bullet-forceps in gynecological examination, 23
- Cancroid of portio vaginalis, 270
- Carcinoma-adenomatosum, 273
- Carcinoma, alveolar, 271 (adenoma malignum), 275
- Carcinoma cervicis, 280
 mode of infection of, 280
 symptoms of, 283
- Carcinoma corporis, 281
 diagnosis of, 284 (endotheliolymphoma), 273
- Carcinoma glandular, 271
 incubation of bacteria in, 277
- Carcinoma of portio vaginalis, 270, 280 (cancroid of, 270) (cauliflower growth of, 272)
 mode of invasion in, 280
- Carcinoma of uterus, 270, 281
 diagnosis of, 286
 localization of, 270
 prognosis of, 286
 symptoms of, 286
- Carcinoma of vagina, 226, 270
 diagnosis of, 227
 symptoms of, 227
 treatment of, 227
- Carcinoma of vulva, 222, 270
- Carcinoma, pregnancy complicating, 298
 treatment of, 287-295
 treatment of operative, 288
 treatment of, non-operative, 294
 treatment of, local, 295
- Carunculæ myrtiformes, 1
- Catgut sutures, 42
 choice of, 42
 sterilization of, 42
- Cauterization, after curettage, 31
- Cavum Douglasii (pouch of Douglas), 2
- Cavum serosum pelvis, 4-6
 Cavum subserosum pelvis, 4
- Cervicitis (*see* Endometritis Cervici)
- Cervico-laquear laceration, 324, 425
- Cervix uteri, amputation of, 326
 anatomy of, 1
 bacteriological examination of, 35
 conical excision of, 322
 cystomata of, 220
- Cervix uteri, dilatation of, 28
 dilatation methods of, 28-29
 discision of uterine os in, 322
 follicular erosions of, 174
 gangrene of, 72
 high excision of, 327
 lacerations of, 175, 323
 " diagnosis of, 325
 " endometritis due to, 323
 " metritis due to, 323
 " operations for, 323-326
 " trachelorrhaphy in, 325
 " treatment of, 325
- Clitoris, anatomy of, 2
- Colpitis emphysematosa, 163
- Colpitis granulosa, 161, 185
- Colpitis senilis, 161
- Colporrhaphy, anterior, 121
 posterior, 122
 according to *Hegar*, 122
 according to *A. Martin*, 123
 after-treatment of, 129
 recurrence of prolapse after, 129
- Columnæ rugarum, 1
- Conception, 58
 relative to psychic phenomena, 58
- Condylomata, acuminated, 154
- Congenital uterine atrophy, 25
- Congestion, premenstrual, 14
- Continuous catgut sutures, 46
- Corpus albicans, 17
- Corpus luteum, 17
 abscess of, 375
- Corpus, Wolffii, 4
- Cumulus oophorus, 16
- Curettage, 29
 after-treatment in, 32
 anesthesia in, 30
 as diagnostic measure, 29
 as therapeutic measure, 30
 asepsis in, 30
 complications, 32
 indications for, 30
- Curette, 30
- Cyst, Bartholinian, 224
 vaginal, 224
 vulvar, 219
- Cystocele, 117
- Cystomata, ovarian, 382
 uterine, 220
- Cystoscope of *Nitze*, 37
- Cystoscopy, 37
- Deciduamenstruationis, 172
- Deciduoma Malignum (*Sänger*) (*See* Malignant Chorion Epithelica, 300)
- Decubital ulcers 115
- Dermoids, ovarian, 394
- Descending inflammation of female genitalia, 149-150
- Descensus uteri, with elongated neck, 113
- Descensus vaginae anteriores et posteriores, 109
 diagnosis, 117
 pathology, 107-111
 pregnancy in, 116
 prognosis, 117
 prophylaxis, 119
 symptoms, 116
 treatment, 118-135
 types of, 111-115
 ulcers in, 115
- Diabetes mellitus, 53
- Diabetes vulvitis in, 151
- Diagnosis of genital malformations, 62
 round ligament in, 62
- Diaphragma pelvis, rectale, 2
- Diaphragma pelvis rectale et urogenitale, 4
- Dilatation of cervix, 28
 contraindications to, 29
 materials for, 28
- Dilators, cervical, 28
Goodell's, 29
Hegar's, 28
Sims', 29
- Diphtheritic vaginitis, 161
- Discisio colli, 322
- Discisio orificii uteri externi, 322
- Disinfection of, 40
 dressings, 41
 hands, 43-44
 instruments, 41
 operative field, 42-43
 suture material, 41-42
- Displacements, of the uterus and vagina, 8, 144
 of the ovaries, 371-372
 of the tubes, 331
- Dissecting growth of ovum, 315
- Disturbances of menstruation, 52
- Ductus paraurethrales (*Skene's*), 2
- Dysmenorrhœa, 56
 action of uterus, during, 57

- Dysmenorrhœa, hysterical, 57
 in post-puerperal retroflexion, 93
 in retroflexio uteri, 85
 membranacea s. exfoliativa (*see* Endometritis)
 symptoms of, 75
 treatment of, 57
- Dyspareunia, 157-158. (*See* also Vaginismus)
- Echinococci, 431
- Ectropium of cervical lips, 174
- Eczema, iodoform, of vulva, 152
- Ecematous vulvitis, 151
- Elephantiasis vulvæ, 157
- Elongatio colli supravaginalis, 176, 209
- Elythorrhaphia duplex lateralis, in *A. Martin's* posterior colporrhaphy, 125
- Embryomata, ovarian, 394
 tubal, 343
- Emmet* operation for cervical laceration, 323
- Endometritis cervicis, 173
 acute, 175
 chronic, 175-176
 ectropium of cervical lips in, 174
 eversion of mucosa in, 174
 ovula *Nabothi* (follicular erosions), 174-175
 papillary erosions in, 174
 symptomatology of, 175
- Endometritis corporis, 165
 acute, 176
 acute infections in, 167
 chronic, 177
 complicated by chronic metritis, 168
 diagnosis, 178
 differential diagnosis, 179
 diffuse, 166
 diffuse hyperplastic fungous, 177
 dolorosa, 177
 exfoliative, 178
 glandular, 177
 glandularis cystica s. ectatica, 171
 gonorrhœal, 186
 interstitial, 167-168
 pathology of, 170
 post-abortum, 166
 post-partum, 166
 prognosis of, 180
 recurrence of, 180
 saprophytic, 165
 septic, 165
- Endometritis corporis, symptomatology of, 177-178
 treatment of, 181
 tuberculous, 186
 types of, 165
 uterine sound in, 179
 varieties of, 177-178
- Endosalpingitis acuta, 133
- Epithelium, uterine, during menstruation, 15
- Epoophoral adenomyomata, 233
- Epoophoron, 4
- Erosions, cervical, 173-175
 follicular, 174-175
 papillary, 174
 vulvar, 153
- Erysipelas in vulvar inflammation, 151
- Examination, gynecologic, 19
 asepsis in, 23
 bimanual, 19
 by palpation, 22
 cystoscopic, 37
 internal method of, 21
 of adnexa, 22
 of bladder, 37
 of curetted mucous membrane, 31
 of uropoietic system, 37
 of uterus, 22
 per rectum, 23
 table for, 20
 under anesthesia, 23
 ureteral, 37
 with uterine sound, 26-28
 with vaginal speculum, 24
- Excavatio recto-uterina, 2
- External genitalia, anatomy of, 2
- Extirpation of uterus and vagina, 133-135
- Fallopian tubes, anatomy of, 1
 diseases of, 320. (*See* also Uterine tubes)
- Fascia pelvis uterina, 6
- Female generative organs; absence of parts in, 60
 anatomy of, 1-6
 aplasia of, 60
 bacteriologic examination of, 33
 blood-supply of, 6
 development of, 13
 gonorrhœal infection of, 34
 inflammation of (ascending), 149-150
 inflammation, of (descending), 149
 lymphatic supply of, 8
 nerve supply of, 8-9
- Fibromata of the ovary, 381, 391
 tubes, 341
 uterus, 228
 vagina, 224
 vulva, 219
- Fimbria ovarica, 3
- Fistulæ, intestinovaginal, 318-319
 ureterovaginal, 316-318
 urogenital, 307
 vesicovaginal, 307-316
- Follicles, *Graafian* or *ovarian*, 4
 malnutrition of, 16
 migration of, 17
 rupture of, 16
- Forceps, double-toothed (*Muzeux*), 46
 hemostatic clamp (*Kocher*), 46
 simple bullet, 46
 sound (*Orthmann*), 47-49
 tenaculum, 47
- Fornices, vaginal, 1
- Fossæ paravesicales, 4
- Fourchette (frenulum labiorum pudendi) 2
- Ganglion, cervical (*Frankenhauser*), 9
- General operative technique, 45
- Genitalia, female, 1
 absence of parts in, 61
 aplasia of, 60
 examination of, 19
 rudimentary development of, 61
- Genitalia of the newborn, 13
- Glandulæ vestibulæ majores (*Bartholin's*), 2
- Gonococcus, 34-36
 staining for, 36
- Gonorrhœa, 34, 183
 bacteriologic examination, 33-37
 course of infection, 184
 diagnosis of, 187
 differential diagnosis of, 188
 endometritic, 186
 latent, 184
 of the ovaries, 186
 of the pelvic peritoneum, 186
 of the urethra, 185
 of the uterus, 186
 of the vagina, 184-185
 of the vulva, 184
 parametritis due to, 187
 prognosis of, 188
 prophylaxis of, 189
 treatment of, 189
- Graafian* follicle, 4, 16
- Graviditas tubaria ampullaris, 353

- Graviditas tubaria interstitialis, 354
 Graviditas tubaria isthmica, 353
 Gynecological examination, 19
 Gynecological operations, postures for, 50
 Hands, disinfection of, 43-44
Hegar's dilators, 28
 Hematocele, 435. (*See also* Tubal Pregnancy, 356)
 anatomy, pathologic, 435
 diagnosis of, 436
 differential diagnosis, 437
 in tubal pregnancy, 356
 prognosis of, 438
 retrouterine, 69
 symptomatology, 436
 treatment of, 439
 Hematocolpos, 66
 Hematoma, extraperitoneal, 469
 anatomy, pathologic, 469
 course, 417
 diagnosis, 417
 etiology, 469
 objective findings, 416
 prognosis, 418
 symptoms of, 416
 treatment, 419
 Hematometra, 66
 congenital, 66
 diagnosis, 67
 treatment, 67
 Hematosalpinx, 331, 338. (*See also* Sactosalpinx)
 Hemorrhage, due to carcinoma, 283
 due to myomata, 238
 intosactosalpinx, 338
 Hemorrhoidal nodules, 320
 Hermaphroditism, 63
 Hilus ovarii, 4
Hodge's pessary, 95
 Hydrops profluens, 345
 Hydrosalpinx, 345. (*See also* Sactosalpinx)
 Hypertrophic cervix uteri, 120-121
 Hypospadias, 63
 Incomplete unilateral genital development, 63
 Infantile genitalia, 76
 Inflammations of the uterus, 165
 vagina, 160
 vulva, 150
 Instruments in gynecologic operation, 45
 Internal gynecologic examination, 21
 Intertrigo of the vulva, 151
 Intestino-vaginal fistulae, 318-319
 diagnosis, 319
 etiology, 318
 symptoms, 319
 treatment, 319
 Introitus in congenital malformation, 67
 Invagination of the uterus, 145
 Inversion of the uterus, 144
 complete, 146
 diagnosis, 146
 etiology, 144-145
 incomplete, 145
 prognosis, 147
 reposition of, 148-149
 symptomatology, 146
 treatment, 147-148
 Irrigation, uterine, after curettage, 31
 vaginal, during operations, 48
 vaginal, continuous, (technique), 49
 Kidney, tumors, in differential diagnosis, 405
 Kraurosis vulvæ, 153
 treatment of, 156
 Labia majora, 2
 Labia minora, 2
 Laceration of the cervix, 175, 324
 operations for, 323
 Laceration of the perineum, 135-140
 Laminaria digitata, 28
 Laparotomy for myomectomy, 260
Lautenschläger instrument sterilizer, 41
 Ligamenta lata, 6
 Ligamenta ovariorum propria, 2-6
 Ligamenta rotunda, 2-6
 Ligamenta sacro uterina, 6
 Ligature-carrier (*Deschamps*), 46
 Lipomata, 219
 Liquor ferri chloridi, use of, after curettage, 31
 Liquor folliculi, 16
 Lithokelyphoedion, 360
 Lithokelyphos, 360
 Lithopedion (true), 360
 Local anesthesia, 38-39
 Lochiometra, 167
 Lumbar anesthesia, 39-40
 stovain in, 39-40
 technique of, 40
 Lupus of vulva (*see* Tuberculosis)
 Lutein membrane, 17
 Lymphatics of the female genitalia, 8
 Lymphoglandulæ hypogastricæ, 8
 Lymphoglandulæ iliacæ externæ, 8
 Lymphoglandulæ inguinales interna and externa, 8
 Lymphoglandulæ lumbales superiores et inferiores, 8
 Lymphoglandulæ sacrales laterales, 8
 Macula gonorrhoeica, 35, 105
 Malformations of the ovaries, 370
 uterus, 60
 vagina, 60
 Malignant chorion epithelioma (deciduoma malignum, *Sänger*, syntioma malignum) 30
 diagnosis, 301
 etiology, 300
 metastases of, 301
 pathology, 300
 prognosis, 301
 symptoms, 301
 treatment, 301
Martin, A., methods of operation in:
 colporrhaphy posterior, 125-130
 elythorrhaphia duplex lateralis, 125
 perineauxesis, 127
 Menorrhagia, 55
 accompanying obesity, 55
 constitutional diseases in, 55
 due to diseases of genitalia, 55
 in tuberculosis, 55
 in visceral diseases, 55
 treatment of, 56
 Menstruatio precox (menorrhagia), 55
 Menstruation, anomalies of, 52
 at puberty, 14
 congestion preceding, 14
 disturbances of, 51
 duration of, 51
 epithelium uteri, during, 15
 hygiene of, 51
 in congenital uterine atrophy, 76
 in retroflexion of the uterus, 85
 onset of, 51
 physiologic behavior of, 51
 relation to ovulation of, 16-17

- Mesosalpinx, 3
- Metritis, acute, 203-206
 bacteriology of, 35, 36, 205
 cervical disease in, 212
 cervical hypertrophy in, 209
 cervical laceration with, 209
 diagnosis of, 205
 prognosis, 205
 symptoms of, 205
 treatment, 206
- Metritis, chronic, 206
 differential diagnosis, 213
 due to interrupted puerperal involution, 210
 elongatio colli supravaginalis in, 209-210
 influence on conception in, 212
 influence on pregnancy in, 213
 localization of, 208
 non-puerperal form of, 211
 objective symptoms of, 211
 pathology of, 207
 pregnancy as a cure of, 213
 prognosis, 210-213
 symptoms of, 210
 treatment of, 210-219
- Molemina-menstrualia, 76
- Mucous adenomyomata, 235
- Mucous membrane, of cervical canal (plicæ palmetæ), 10
 corpus uteri, 12
 Fallopian tubes, 12
 labia, 9
 vagina, 9-10
- Müller's ducts, coalescence of, 63
 incomplete coalescence of, 60
 in embryonic malformations, 60
 in unilateral genital development, 63
 retention cysts in incomplete development of, 63
- Myomata, amyloid degeneration of, 236
 after-treatment of, 267
 calcification of, 235
 clinical behavior of, 237-242
 diagnosis of, 242
 differential diagnosis of, 244
 fatty degeneration of, 235
 growth of, 232
 lymphangiectodia, 235
- Myomata, myxomatous degeneration of, 236
 occurrence of, 232
 of cervix, 230
 of cervix of infravaginal portion, 231
 of cervix of supravaginal portion, 230
 of uterus (*see* Tumors of Uterus)
 pathologic anatomy of, 237
 pedunculated submucous polypi, 231
 prognosis of, 246
 treatment of, 247
 treatment of, operative, 250-256
 treatment of, operative, abdominal, 260-267
 treatment of, operative, vaginal, 256-260
- Needle-holder, *A. Martin's*, 45
- Nerve-supply of female genitalia, 8-9
- Newgrowths (*see* Tumors) of the rectum, 320
- Nott's* self-retaining speculum, 25
- Nymphæ, 2. (*See* also Labia Majora)
- Oophoritis, acute, 375
 chronic, 339-376
- Orthmann's* sound forceps, 47-49
- Os externum urethræ, 2
- Ovarian ligaments, 2
- Ovaries, anatomy of, 3
 atrophy of, 370
 changes in position of, 371
 circulatory disturbances of, 373
 corpus luteum, abscess of, 375
 corpus luteum, cysts of, 370
 corpus luteum, hematomata of, 378
 cystoma serosum simplex of, 378
 diseases of, 370
 follicular atresia of, 377
 follicular cysts in, 377
 follicular hematomata in, 373
 gonorrheal infection of, 186, 375. (*See* also Gonorrhea)
 hernia of, 372
 hypertrophy of, 370
 inflammations of, 374. (*See* also Oophoritis)
 internal secretion of, 18
 malformations of, 370
- Ovaries, small cystic degeneration of, 378
 tubercular infection of, 376
- Ovaries, tumors of, 381. (*See* also Tumors)
 (a) epithelial, 382-392
 (b) desmoid, 392-394
 (c) ovigenous, 394
 diagnosis of, 401
 differential diagnosis of, 402
 menstruation in, 401
 parovarian cysts of, 400
 parovarian cysts of, clinical behavior of, 414
 pedicle formation of, 397
 pedicle formation, clinical behavior of, 401
 pedicle formation, course of, 401
 prognosis, 410
 treatment, 410
 treatment, abdominal ovariectomy, 411
 treatment, vaginal ovariectomy, 412
- Ovula-Nabothi (follicular erosions), 174-175
- Ovulation, 16
Knauer's investigations of, 18
Pfäuger's theory of, 17
 relation to menstruation of, 17-18
- Palpation of uterus, 28
- Pansalpingitis, 335
- Papillomata of vulva (acuminate condylomata), 154, 220
- Parametritis, 419
 treatment of, 425
- Parametritis, acute septic puerperal, 421-424
 actinomycoses in, 430
 diagnosis, 430
 etiology, 430
 from external diseased foci (descending form), 430
 symptoms, 431
 treatment of, 431
 tuberculosis in, 430-431
- Parametritis acute septic traumatic, 426
 post-operative 427
 prognosis of, 428
 symptoms of, 426
 treatment of, 428
- Parametritis, cervico laquear laceration in, 425
 chronic, 432-434
 chronic septic puerperal, 424-425

- Parametritis, clinical behavior of, 421
etiology of, 419
- Parametritis gonorrhoea, 428
diagnosis of, 429
prognosis of, 429
symptoms of, 429
treatment of, 429
- Parovarium, 4
- Pars cardinalis ligamentum lata, 6
- Pathology of uterus, 60
- Pathology of vagina, 60
- Pelvic connective tissue, 415
(hematoma extraperitoneale periuterinum, 415)
ligament hematmata of, 415
neoplasms of, 454-455
- Pelvic peritoneum, diseases of, 435-439
- Pelvic peritonitis, 439
- Perimetritis, 439
in retroflexio uteri, 86
- Perineal body, laceration of, 136
prognosis of, 137
symptoms of, 137
- Perineal lacerations, complete, 136
incomplete, 136
of recent occurrence, 137
prognosis of, 137
symptoms of, 137
treatment of, 139-140
- Perineauxesis (*see* *Martin's* posterior colporrhaphy, 127)
- Perineorrhaphy, 135
- Peritonitis, 439
carcinomatosa, 443
chronic, 452
clinical behavior, 439
diagnosis, 445
gonorrhoeal, 447
infectious, 446
non-infectious, 443
prognosis, 446
saprophytic, 447
septic, 446
treatment of, 446
- Pessary, *Hodge's*, 95
in treatment of retroflexion, 94-96
Thomas's, 95
- Physiologic behavior of menstruation, 51
Playfair's sound, 32
- Plexus ovaricus, 8
- Polypi of vulva, 220
- Posterior colporrhaphy, *Hegar's*, 122
A. Martin's, 123-125
- Posture during operations, 48
- Posture during operations, dorsogluteal, 48
Trendelenburg, 49
- Posture, gynecologic, in examination, 19-21
dorsocumbent (lithotomy), 21
dorsosacral, 21
erect, 19
- Premenstrual congestion, 14
- Prolapse of rectum, 320
- Prolapse of uterus, 106
Alexander-Adams operation in, 121
binder in, 118
decubital ulcers in, 115
diagnosis, 117
etiology of, 107-110
local treatment in, 120
Martin's posterior colporrhaphy for, 123
operative treatment in, 120
pregnancy in, 116
prognosis, 117
recurrence of, 129-139
stem pessary in, 119
symptoms of, 116
- Prolapse of the vagina, anterior, 112
enterocele vaginalis in, 112
pregnancy in, 116
treatment of, 121
- Pruritis vulvæ, 152
etiology of, 153
symptoms of, 153
treatment of, 154
- Pseudo-decidua, 15
- Pseudo-hermaphroditism, 63
- Pseudo-myxomata peritonei, 443
- Puerperal retroflexion (*see* Retroflexion)
- Purulent embryomata, 431
- Pyometra, 167
- Pyosalpinx, 335
- Rectum, hemorrhoidal nodules of, 320
newgrowths of, 320
prolapse of, 320
ulcerative strictures of, 320
- Reposition of inverted uterus, 148-149
- Retractors, vaginal, 24
- Retroflexio utero-gravidi, 87
delivery in, 90
diagnosis, 88
failure in reposition in, 89
prognosis of, 89
symptoms of, 88
treatment of, 89
- Retroflexion operations, review of, 105
- Retroflexion, puerperal, 91
diagnosis, 91
symptoms, 91
treatment, 91-92
- Retroflexion, post-puerperal, 92
Alexander-Adams operation for, 98
diagnosis in, 93
dysmenorrhea in, 93
general treatment of, 94
Olshausen operation for, 100
operations for, 89
orthopedic treatment in, 94
pessaries in, 95
Spaeth operation for, 100
symptomatology, 93
vaginal operations for, 101-104
Webster operation for, 99
- Retroflexion, uterine, 83
acquired, 83-85
congenital, 83
etiology, 84
menstruation in, 85
perimetritis in, 86
prognosis of, 86
symptoms of, 85
treatment of, 86
- Retroversion of uterus, 83
- Round ligament, 2-6
- Rupture of tube, in tubal pregnancy, 355, 363
- Sactosalpinx, 331-335
hemorrhagica, 67, 331
purulenta, 335
serosa, 331
- Salpingitis, 332-353
diagnosis of, 348
differential diagnosis of, 349
infectious agents of, 336
isthmica nodosa, 335, 347
profuens, 338
prognosis of, 350
purulent, 335, 340
streptococcic, 332, 336
symptoms, acute, 344
symptoms, chronic, 345
treatment of, 353
treatment of, abdominal operations in, 352-353
treatment of, vaginal operations in, 352-353
- Sarcoma, ovarian, 393
parametric myomatous, 454

- Sarcoma, uterine, 302
 mucous membrane, 302
 diagnosis, 305
 metastases, 304
 occurrence, 304
 prognosis, 305
 symptoms, 305
 treatment, 305
 wall, 303
 diagnosis, 306
 prognosis, 306
 symptoms, 305-306
 treatment, 306
- Sarcoma, vaginal, 226
 vulvar, 222-223
- Scopolomin-morphin anesthesia, 40
- Septic vulvar inflammation, 151
- Sims'* position in gynecologic examination, 21
- Sitz baths in chronic metritis, 215
 in vulvitis, 154
- Skene's* ducts, 2
- Smegma bacilli, 36
- Sound, uterine, examination with, 26-28, 179
 contraindications to use of, 26-27
 uterine, *Playfair's*, 32
Sänger's, 32
- Specific infection of uterus, 34
- Speculum, abdominal (*Fritsch*), 48
- Speculum, abdominal (*Stoekel*), 48
- Speculum, electric illuminated (*Von Ott*), 48
 vaginal, 24
 vaginal varieties of, 24
- Sterility, 58-59
 azoosperma in, 58
 causes of, 58
 determination of, 58.
 (See also Conception)
 stenosis of uterine os in, 59
 treatment, 59
- Stille* operating table, 48-50
- Strangury with retroflexed uterus, 85
- Subserosum pararectale, 4
- Subserosum paravesicale, 4
- Subserosum parauterinum, 4
- Suspensoria ovarii, 6
- Sutures, bronze wire, 46
 catgut, 42
 continuous, 46
 interrupted, 48
 interrupted in perineorrhaphy, 142
 silk, 46
 sterilization of, 41-42.
 (See also Asepsis)
- Synctioma malignum (see Malignant chorion epithelioma)
- Syringe, *Braun's*, 31
- Table for gynecologic examination (after *A. Martin*), 20
- Technique, general operative, 45
 of continuous irrigation, 49
 of lumbar anesthesia, 40
 of operative field disinfection, 42-43
- Teratomata, 394
- Trachelorrhaphy, 325
- Trendelenburg* position, 49
- Tubal abortion, 355
- Tubal pregnancy, 353
 decidual formation in, 360
 diagnosis of, 363-366
 fate of foetus in, 359
 (Graviditas tubaria ampullaris, 353)
 (Graviditas tubaria interstitiales, 354)
 (Graviditas tubaria isthmica, 353)
 hemorrhage in, 356
 infection of hematocele in, 358
 lithokelyphopædion in, 360
 lithokelyphos in, 360
 lithopedion (true) in, 360
 mole formation in, 358
 pelveo-peritonitis (chronic adhesive) in, 375
 peritubal hematocele, 356
 prognosis of, 366
 putrefaction of hematocele in, 358
 retrouterine hematocele in, 356
 rupture in, 355, 363-364
 solitary hematocele in, 357
 suppuration of hematocele in, 358
 treatment of, 367
 treatment of, abdominal operative, 367
 treatment of, vaginal operative, 368
 twin pregnancy, 360
- Tubal tuberculosis, 193. (See also Tuberculosis)
- Tuberculosis of female genitalia, 34, 190
 caseous form, 195
 diagnosis, 199
 examination for, 36
 forms of, 191-194
- Tuberculosis of female genitalia, miliary form, 193-194
 mode of infection, 190
 of ovary, 198
 peritoneum, 198-199
 tubes, 193
 uterus, 195
 vagina, 197
 vulva, 197
 primary infection, 191
 secondary hematogenous infection, 191
 treatment, 201
- Tubes, Fallopian (see Uterine tubes)
- Tubo-ovarian tumor, 339
- Tumors of the ovary, 381-414
 (a) epithelial, 382-392
 carcinoma, 387-392
 cystadenoma glandulare multiloculare pseudomucinosum, 382-385
 cystadenomata serosa, 384
 cystadenomata serosum papillare, 386
 pseudomyxoma peritonei, 385
 (b) desmoid or connective tissue, 392-393
 fibromata, 392
 fibromyomata, 393
 fibrosarcomata, 393
 sarcomata, 393
 (c) ovigenous, 394-395
 cystic embryomata, 394, 395
 dermoids, 394
 solid embryomata (teratomata), 394, 397
 clinical behavior of, 401
 course of, 401
 diagnosis of, 401
 differential diagnosis of, 402
 menstruation in, 401
 necrobiosis of, 399
 (parovarian cysts), 400
 parovarian cysts, clinical course of, 401
 prognosis, 410
 treatment, 410-412
 treatment of, abdominal operations in, 411
 treatment of, vaginal operations in, 412
- Tumors of the pelvic peritoneum, 454-455
- Tumors of the tubes, 341
- Tumors of the uterus, 228-308
 adenomata, 269
 carcinomata, 290
 fibromata, 228
 fibromyomata, 228

- Tumors of the uterus, malignant chorion epitheliomata, 300
 myomata cervicis, 230
 clinical behavior, 237
 infravaginalis, 231
 submucous pedunculated fibrous polypi, 231
 supravaginalis, 230
 treatment:
 operations, abdominal, 260
 operations, vaginal, 256
 after-treatment for, 267
 myomata corporis, 229
 intraligamentous, 230
 intramural, 230
 submucous, 229
 subserous, 229
 sarcomata, 302
 mucous membrane, 302
 wall, 305
- Tumors of the vagina, 224
 benign:
 cystomata, 224
 fibromata, 224
 fibromyomata, 224
 symptoms of, 225
 treatment of, 225
 malignant:
 carcinomata, 226
 diagnosis, 220-221
 sarcomata, 226
 symptoms, 220
 treatment, 221
- Tumors of the vulva, 219
 benign, 219-220
 malignant, 222
 diagnosis, 220-221
 symptoms, 220
 treatment, 221
- Tunica albuginea ovarii, 3
- Ulcerative strictures of the rectum, 320
- Ulcers, decubital, 115
 with prolapsus vaginae, 115
- Ureter, anatomy of, 8
 examination of, 37
 catheterization of, 37
- Uretero-vaginal fistulæ, 316-318
- Urethra, bacterial examination of, 35
 gonorrhœa of, 185
- Urogenital fistulæ, 307-319
- Uropoietic system, examination of, 37
- Uterine cavity, palpation of, 28
- Uterine ligaments, anatomy of, 2
- Uterine sounds, 26
- Uterine tubes, 330-353
 acute endosalpingitis, 333
 adenomyomata of, 342
 anatomy of, 2
 benign papillomata of, 341
 course of infections in, 332
 diseases of, 330
 embryomata of, 343
 gonorrhœal infection of, 332, 336. (*See also* Gonorrhœa)
 malformations of, 330
 pregnancy in, 353
 primary carcinoma of, 341
 (pyosalpinx), 335
 (sactosalpinx), 331
 streptococcal infection of, 332, 336
 tuberculosis of, 332, 335. (*See also* Tuberculosis)
 tumors of, 341
 vaginal operations of, 352
- Uterine tube inflammation (salpingitis), clinical signs of, 344
 diagnosis of, 348
 differential diagnosis of, 349
 prognosis, 350
 treatment of, 350-353
 treatment operative, 352
- Uterus, adenoma of (*see* Tumors, Uterine)
 anatomy of, 1
 antelexion of, 1, 83
 anteversion of, 83
 atresia of, 68-75
 atrophy of, 75
 after septic endometritis, 168
 congenital, 76
 diagnosis of, 78
 during puerperium, 81
 examination in, 77-78
 local treatment in, 78-79
 menstruation in, 76
 objective signs in, 77
 prognosis of, 78
 stem pessary in, 79-80
 bicornis unicollis, 67-68
 carcinoma of (*see* Tumors, Uterine)
 changes of form of, 82
 changes of position of, 82
 gonorrhœal infection of, 18, 34
 hypertrophy after septic endometritis, 168
- Uterus bicornis unicollis, incomplete communication with external surface of body, 67
 inflammations of, 149, 165
 inflammations of mucosa (*see* Endometritis)
 invagination of, 144
 inversion of, 145
 diagnosis of, 146
 prognosis of, 147
 reposition of, 148-149
 symptoms of, 146
 treatment of, 147-148
 malformations of, 60
 myomata of (*see* Tumors and Myomata)
 pathology of, 60
 prolapse of, 106
 prolapse with pregnancy, 116
 retroflexion of, 83
 acquired, 83-85
 congenital, 83
 menstruation in, 85
 perimetritis in, 86
 prognosis in, 86
 symptoms of, 85
 treatment, 86
 retroflexion (gravid), diagnosis, 88
 etiologic factors in, 87
 failure of reposition in, 89
 obstetric delivery in, 90
 prognosis, 89
 symptoms, 88
 treatment, 89
 retroflexion, puerperal, 90
 etiology, 90
 diagnosis, 91
 symptoms, 91
 treatment, 91
 sarcoma of (*see* Tumors)
 septus, 68
 specific infection of, 34
 subseptus, 68
 treatment, operative of, 322
 cervical amputation, 326
 discisio orificio uteri externi, 322
 operations for lacerated cervix, 323
 the conical incision, 322-323
 trachelorrhaphy, 323-326
 tuberculosis of, 34
 tumors of (*see* Tumors)

- Vagina, anatomy of, 1
 atresia of, 68
 change in form of, 82
 inflammations of (vagin-
 itis), 149
 acuminated condy-
 lomata in, 161
 acute, 160
 chronic, 161
 colpitis emphyse-
 matosa, 163
 colpitis granulosa,
 161
 colpitis senilis,
 161
 etiology of, 160
 foreign bodies as
 etiologic factors,
 162
 gonorrhœal, 185
 symptoms of, 163
 treatment of, 164
 vaginitis dissecans,
 160
 varieties of, 161
 malformations of, 60
 mucous membrane cor-
 nification, 161
 mucous membrane epi-
 dermification, 161
 outlet of, absence of,
 71
 closure of, 71
 pathology of, 60
 prolapse of, 106
- Vagina, tumors of, 224.
 (See also Tumors of
 vagina)
- Vaginal pessaries, 94-98
- Vaginal retractors, 24
- Vaginismus, 157
 diagnosis of, 158-159
 gonorrhœa, complica-
 ting, 158
 pregnancy in cases of,
 158
 sterility in, 158
 treatment of, 159
- Vaginitis (see Vagina, in-
 flammations of, 149)
- Veins of the female geni-
 talia, 8
- Ventrofixation, 100
- Ventrosuspension, 101
- Vesico-vaginal fistulæ, 307-
 316
- Vulva, abscess of, 151
 acne of, 151
 acuminated condylo-
 mata of, 154-220
 acute infections in in-
 flammations of, 150
 burns of, 152
 condylomata of, 153,
 154
 treatment of, 156
 eczema of, 151
 elephantiasis of, 157
 erysipelas of, 151
 excision of, 156
- Vulva, fecal inflammation
 of, 152
 furuncles of, 151
 gonorrhœa of, 185
 infections of, 151
 inflammation of, 149-157
 acute infectious
 diseases in, 150
 etiology of, 150
 septic, 150
 specific (see Gonor-
 rhea)
 symptoms of, 152
 treatment of, 154
 intertrigo of, 151
 iodoform eczema of, 152
 kraurosis of, 153
 treatment of, 156
 pruritis of, 152
 tumors of, benign, 219-
 222
 malignant, 222.
 (See also Tumors
 of vulva)
 etiology, 157
 treatment, 157
 ulcer rodens of, 157
- Vulvitis (see Vulva, inflam-
 mation of)
- Wall sarcoma, 302-304
- Wolffian body, 4
- Zymin bougies in gonor-
 rheal urethritis, 189

