

Kelly (H. A.)

ON HYSTERORRHAPHY.

By HOWARD A. KELLY, A. M., M. D.,

*Gynaecologist to the Johns Hopkins Hospital and Associate Professor of Gynaecology  
and Obstetrics in the Johns Hopkins University.*

401.



## ON HYSTERORRHAPHY.

By HOWARD A. KELLY, A. M., M. D.,  
*Gynaecologist to the Johns Hopkins Hospital and Associate Professor of Gynaecology  
and Obstetrics in the Johns Hopkins University.*

### OUTLINE OF PAPER.

[*Consideration of natural supports which hold the uterus in its normal position. These for convenience of study considered as acting at three points: (1) PELVIC DIAPHRAGM BELOW, (2) UTERO-SACRAL LIGAMENTS BEHIND, (3) BROAD LIGAMENTS IN FRONT (v. Fig. 1).*

(1) *Pelvic diaphragm catches the blows of succussion and intra-abdominal pressure. Is in no way weakened by the clefts of rectum, vagina and urethra, as these are either placed eccentrically, or cleave it in an oblique direction.*

*Weakening of the pelvic diaphragm throws the weight of the uterus on (2) and (3), which finally yield, resulting in a displacement of the uterus.*

*Repair of this injury by closure of the enlarged vaginal outlet.*

(2) *Relaxation of the utero-sacral ligaments involves a displacement of the cervix downwards in the vagina, and a consequent backward displacement of the fundus uteri.*

*Repair of this injury not to be attained by operation; substituted by packing, pessary, etc.*

(3) *Relaxation of the broad ligaments results in backward displacement of the fundus uteri—retroposition or retroflexion.*

*Repaired often by simple packing or pessary in vagina, keeping cervix well back in the pelvis.*

*Sometimes all attempts per vaginam and rectum fail. In these cases hysterorrhaphy will succeed.*

### *Conclusions.*

*All the uterine supports must be examined in every case of displacement.*

*Where several factors conjoin to produce displacement, p. d. and s. u. (Fig. 1), must in all cases be repaired first, then if further infra-pubic treatment fails to remedy the remaining defect in l. l., supra-pubic Hysterorrhaphy is called for.*

*Hysterorrhaphy—defect of previous method (by Olshausen, Sanger, Kelly) is that the attachment of the uterus to the abdominal wall by its anterior face feathered it backwards, thus putting it at a mechanical disadvantage.*

*New method here described is the attachment by the ovarian ligaments thus throwing uterus into marked antelexion. Three cases reported.]*

HYSTERORRHAPHY is the operation for the correction of mal-positions of the uterus, by suturing it to the abdominal or pelvic walls. It is a surgical procedure involving first an abdominal section, low down in the median line, next the elevation of the corpus uteri out of the sacral hollow, with the separation of any adhesions binding it down, and finally its fixation by a series of sutures passing through the body of the uterus or close to its sides, and into or through the abdominal walls. These fixation sutures

can be cut short and dropped within the peritoneum, or fastened outside on the skin and removed after the persistence of the uterus in its new posture has been assured.

A brief preliminary consideration of the mechanical factors concerned in the support of the uterus *in its normal position*, will greatly assist the appreciation of these rarer conditions, when it is necessary to resort to this more serious and radical method of treatment of its deviations.

For convenience of representation the uterine supports which preserve its *equipoise* in health may be considered as acting at three points. The body of the uterus is held in its position of mobile anteflexion by the broad ligaments in front (*l. l.*) at its fundus, and by the utero-sacral ligaments behind (*s. u.*) acting at the cervical end.

The weight of the uterus does not fall upon either of these stays in health.

Every movement of the body is communicated to the uterus. The succussions of coughing, sneezing, walking and running, and above all, the force of intra-abdominal pressure, increased by all exertion, especially by one-handed lifting and the straining necessary to overcome constipation, act in the direction of the arrows *p. i.*, driving the uterus down towards the pelvic diaphragm *p. d.*, which is resilient, and immediately sends it up again to its former position.

There are three breaks in the pelvic floor, the two outlets the rectum and the urethra, and the out- and inlet, the vagina (Fig. 2), but these are either placed excentrically forwards or cleave its layers in an oblique direction and thus in no way weaken its resisting power.

If, however, the pelvic diaphragm is broken down, or the outlet of the vagina becomes relaxed (commonly called rupture of the perineum), the mechanical factor *p. d.* disappears, that is there is no longer anything below to catch the blows of *p. i.* (v. Fig. 1) and the uterus unsupported at this point, now rests with its full weight, increased by such impacts as fall upon it, upon the slender stays *s. u.* and *l. l.* If it takes a force of say fifteen units to support the uterus distributed as follows: two at the broad ligaments to hold it forwards, three at the cervical end to hold it back, and ten below holding it and all the pelvic viscera up, if eight of these units are taken out of the pelvic floor by a relaxation, *l. l.* and *s. u.* must at once do more work making up the deficiency of the eight units needed for its support, or the inevitable result will be that *s. u.* and *l. l.* will in time yield, and the uterus be driven down towards the weak spot by *p. i.* above (v. Fig. 3). The mechanism is as follows: the fundus cannot descend through the anterior vaginal wall to escape from the lax outlet, on account of the interposed bladder, a water-cushion upon which it now rests.

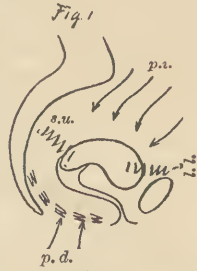


FIG. 1.

Showing the points at which the normal uterine supports act to preserve its equipoise; *l. l.* broad ligaments; *s. u.* utero-sacral ligaments; *p. d.* represents the resiliency of the pelvic diaphragm; *p. i.* is intra-abdominal pressure tending to displace a uterus in which any of these supports are broken down.

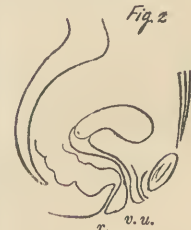


FIG. 2.

Shows the directions of the rectal, vaginal and urethral outlets piercing the pelvic floor obliquely and placed forwards.




FIG. 3.

The arrows at *p. i.* represent units of intra-abdominal pressure; the arrows *p. d.* the resisting power of the pelvic diaphragm; *s. u.* and *l. l.* the forces which keep the poles of the uterus in position.




FIG. 4.

The long wavy line *s. u.* represents the relaxed utero-sacral ligament, allowing the downward displacement of the cervix.

The force of the blows *p. i.* falls therefore upon *s. u.*, which yields gradually, and the cervix begins to slide down the vaginal canal (*v.* Fig. 4). At this juncture the fundus uteri comes more directly between the lines of downward pressure and the vaginal outlet, and is as a consequence finally retroverted and driven back into the sacral hollow.

If now on the other hand from any causes the *l. l.* becomes relaxed, or has to bear the undue strain of an enlarged uterus, it rapidly yields to the strain, and a simple flexion or retroposition backwards is the immediate result (*v.* Fig. 5).

From this brief consideration of the three factors concerned in producing displacements, we are prepared for a rational consideration of the treatment of displacements. It is at once manifest that it is not worth while to try to do much with the two weaker superior supports (*s. u.* and *l. l.*) as long as the strong pelvic diaphragm is deficient, for no treatment or operation we can perform will enable these slender supports to substitute the stronger, and bear the brunt of all the attacks of the abdominal viscera bearing down upon a corpus uteri devoid of support below.




FIG. 5.

The wavy line shows *l. l.* (ligamenta lata) relaxed, no longer able to hold the fundus forward.

Thus the pelvic diaphragm (*p. d.*) must in all cases be restored first, and no device for retaining the uterus *in situ* is rational, which does not first



FIG. 6.

Shows substitution of a wedge, after the old method, by which the relaxed outlet is corked up, as it were.



FIG. 7.

Shows by the loops the restoration of the relaxed vaginal outlet, giving the levator ani a new hold on the tissues torn away and dropped back out of its grasp.

assure the integrity of this, its inferior support. This can be accomplished, when the pelvic diaphragm is broken down, by a closure of the outlet, either by the old-fashioned denudation methods on the posterior wall, narrowing the outlet by the substitution of a wedge, apex upwards (*v.* Fig. 6), or by

Emmet's or Martin's operations, which closely imitate nature in the restoration of the pelvic diaphragm (v. Fig. 7).

We have unfortunately no good surgical procedure for restoring the utero-sacral ligaments, but we can form a substitute by packing the vagina, or inserting a pessary, which keeps the cervix back in the sacral hollow by means of its posterior bar.

With *s. u.* and *p. d.* thus rendered functionally active, we still have the problem of restoring *l. l.* to a state of efficiency. *Sometimes but little more is necessary than a simple elevation of the fundus, after which it remains in situ naturali, or is easily retained by a pessary.*

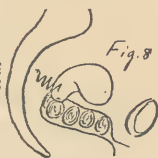

FIG. 8.  
Keeping the cervix up by cotton when *s. u.* is weak.

In other cases it is simply impossible to keep the fundus forward by any treatment through the vagina; and where strong adhesions exist binding it down in retroflexion, it is manifestly impossible to accomplish anything by treatment through the inferior strait of the pelvis. If there be no relaxation at the vaginal outlet, and the cervix be held well back in the pelvis, it is clear that *when we bring the uterus into such a position, that the blows of the intra-abdominal pressure fall upon its posterior surface, the degree of its ante flexion will be constantly increased, and the gentlest force applied at its anterior pole will be sufficient to detain it in its new position.*

In this way in simple retroflexion the operation of shortening the round ligaments by cutting down over the inguinal canals, and pulling them out to such a degree as to draw the uterus well forwards, and cutting off the excess and stitching the stumps into the wound, has proved very successful in some hands.

On the other hand there are a number of operators who prefer the more direct plan of making a small abdominal incision, which allows at the same time a thorough examination of all the pelvic organs, and enables the operator to deal directly with the displaced uterus, elevating it, and even breaking up any bands of adhesions binding it down to the pelvic floor.

One of these direct intra-pelvic plans is *hysterorrhaphy*—the attachment by suture of the displaced uterus by corpus or broad ligaments close to its body, to anterior abdominal or pelvic wall.

As originally devised and practiced by Olshausen, Sanger, Werth, Brennecke and myself, the procedure consists in catching the broad ligaments on their anterior face (through the round ligament, Olshausen) elevation and attachment by suture to the lower part of the anterior abdominal wall. (Fig. 10.)




FIG. 9.

Showing the suspension of the uterus to the anterior abdominal wall by suture about the round ligament.

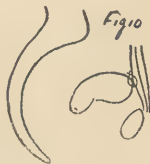


FIG. 10.

Showing the suspension by ligature through the fundus.

Boldt and Leopold have *hung the uterus directly by sutures passed through the fundus.* (Fig. 10.)



This is not unlike the original device of Prof. Koeberle who was the first to open the abdomen for the simple purpose of correcting a retroflexion. He removed the left ovary, and by means of its stump and the left tube clamped into the lower angle of the wound, thus fixed the uterus in anteposition, where it was found six years later.\*

The advantages of Hysterorrhaphy are that it has unquestionably both cured many cases of misplacement, and relieved the distress of a large number of patients upon whom it has been performed.

The disadvantage has been a percentage of failures in which the uterus has slipped back into its old position. I attribute these disadvantages to a fault in the mechanism of the operation as hitherto performed, for by the method catching the uterus by the broad ligament on its anterior face and suturing it to the abdominal wall it is necessarily left in such a position that *it must hang upon the sutures*, and such adhesions as are formed at this point, and at the central incision. This hanging is a disadvantage, and is by no means a satisfactory substitute for the natural condition of mobile equipoise. It is also coupled with another mechanical disadvantage in that *it is by this means feathered backwards*.

I have succeeded in remedying this difficulty *by the simple plan of reaching over the tops of the broad ligaments, and lifting the uterus by the ovarian ligaments* (v. Fig. 11), thus necessarily throwing it into anteflexion just as the body of a man would be bent forwards if he were caught by the shoulder-blades, and drawn up against the ceiling. Three of these cases have been operated upon in this Hospital. The results attained have thus far surpassed my expectations, and seem about to realize the ideal method of hysterorrhaphy after which I have been striving since my first original work in this line.†

Ten days after thus raising the uterus by the ovarian ligaments I have in each case found the cervix well back in the vagina and the body of the uterus lying upon the anterior vaginal wall, no longer hugging the abdominal wall, from which it is separated by a distinct interval. Its posture is thus one of marked anteflexion, from which all moderate efforts fail to dislodge it. Any efforts to displace it backwards simply results in carrying the corpus uteri up against the abdominal wall.

The technique of the improved operation is as follows: Careful preparation of the patient for laparotomy. As thorough an aseptic regime on the part of the operator, assistants, instruments and field of operation as for the greatest abdominal operation. As soon as the patient is placed upon the table all genital hairs must be shaved off and the urine drawn. The incision is made  $1\frac{1}{2}$  inches in length, nearer to the symphysis pubis than in case of abdominal section for diseased tubes.

The next step is the insertion of six sutures into the abdominal *parietal peritoneum*, three on either side of the lower angle of the wound (v. Fig. 12). These are brought out on either side and grasped by two pairs of forceps.



FIG. 11.

OV. is the right ovary; between this and the abdominal wall lies the ovarian ligament which is sutured to the abdominal wall by s.

\*Gastrotomie dans un cas de Retroversion uterine. Gastrotomie avec ovariectomie, dans le but de fixer l'uterus d'une maniere permanente a la paroi abdominale. E. Koeberle, Strassbourg, 1877.

†Amer. Jour. Obs., Jan., 1887, and Amer. Jour. Obs., May, 1888.

The index and middle fingers then go down into the pelvis to seek and raise the uterus from its retroflexion. Before the fingers are withdrawn, the ovary and tube of one side are caught and drawn out through the incision. In this way the ovarian ligament is brought into plain view and within easy reach, and the three ligatures on the same side, already passed through

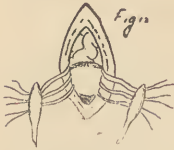

FIG. 12.

Showing the six ligatures passed through the parietal peritoneum and temporarily grasped by forceps on either side.

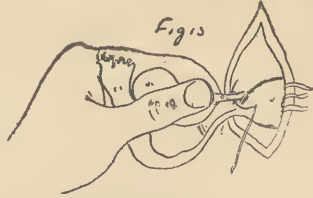


FIG. 13.

Showing the fallopian tube and ovary grasped in the right hand while the needle with a leader is passed under the ovarian ligament, ready to carry through one of the parietal sutures already in place (Fig. 12).

the parietal peritoneum, are conducted by means of a carrier (Fig. 13), in the order in which they lie from within outward, around the ovarian ligament, midway between corpus uteri and ovary.

These are not to be pulled up and tied at once. The ovary and tube are dropped back into the peritoneal cavity and the ligatures left untied in the grasp of the forceps until the three ligatures of the opposite side are in the same way passed around the other ovarian ligament. Both ovarian ligaments are thus caught by ligatures connecting them to the abdominal wall. Before tying these ligatures it is necessary to slip the index finger around the uterus on both sides, making sure that neither intestines nor mesentery have become entangled in any of the ligatures, or in front of the uterus. If all is clear the ligatures may then be

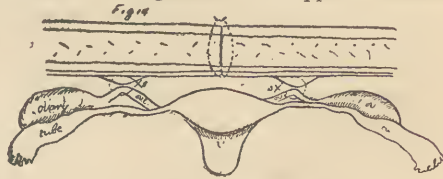


FIG. 14.

The sutures embrace the ovarian ligaments, peritoneum and some of the muscle in the abdominal wall. The uterus hangs anteflexed in the middle and ovaries and tubes at the sides.

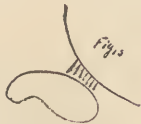

FIG. 15.

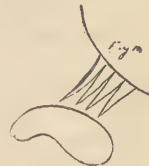

FIG. 16.

drawn up one by one, tied firmly, cut short, dropped, and the abdominal wound closed. The result is seen in Fig. 14.

Adhesions form at once (Fig. 15), but these soon stretch by the simple weight of the uterus (Fig. 16), so that within two weeks the corpus uteri sinks on to the level of the anterior vaginal wall, to the position it now occupies in all my cases.



These delicate filaments of drawn out adhesions serve effectually to prevent any backward rotation of the uterus. If the cervix tends to descend in the vagina a pessary must be worn.

The three cases which follow were operated upon in this Hospital, and present results similar to those obtained in each of the cases in which this method has been employed, I present them therefore as typical.

CASE I.—Mrs. W., age 28, mar., 3-Par, youngest four years old, had puerperal fever after her last confinement, and has ever since been a constant sufferer with distress in head and back, making her at times so nervous that she “fears she will become crazy.” When she first came into my office she was in a wild, excited condition. She had for a long time been almost constantly confined to bed. I found a large relaxed vaginal outlet associated with a sharp retroflexion of a large infiltrated fundus uteri. In the spring of this year the outlet was repaired, and at the same sitting I raised the fundus up against the abdominal wall, and passed a suture through the abdominal parietes and corpus uteri, by means of a large curved needle, *without opening the abdomen*. The perineum healed rapidly, and gave strong support at the outlet, but the single stitch, which was removed in the second week, had been insufficient to cure the displacement permanently, as the uterus soon rolled back into the sacral hollow.

On Oct. 16, 1889, I made an abdominal incision close to the pubes  $1\frac{1}{2}$  in. long, raised the uterus into anteflexion and attached it by its ovarian ligaments to the anterior abdominal wall. Two silk sutures were used on each side. Drainage tube used. She rose from bed in three weeks, and left the hospital after four weeks. The outlet was tight, the cervix well back, and the anterior face of the uterus lay upon the anterior vaginal wall in easy anteflexion, quite mobile and not touching the scar in the abdomen, but I could not throw it back beyond the abdominal scar.

CASE II.—Mrs. H., age 21, 3-Par. Extensive relaxation of the vaginal outlet with a sharp retroflexion of the body of the uterus which lay with fundus lower than cervix in Douglass' pouch.

I restored the pelvic floor in April, at the same time catching up the uterus by a suture passed through the body, and through the abdominal walls. The vaginal operation healed perfectly, but the uterus soon dropped back, in spite of a repetition of the suspensary operation without anaesthesia, and no local treatment or pessary served to keep it even for a short time in place.

Oct. 17, 1889, I performed hysterorrhaphy by the new method described, tying at the same time the enormous varicose ovarian veins on each side. (Fig. 17).

No drainage tube was used.

She made a rapid and perfect recovery, leaving the hospital Nov. 15.

She was examined by Dr. Neal of this city, and several others interested

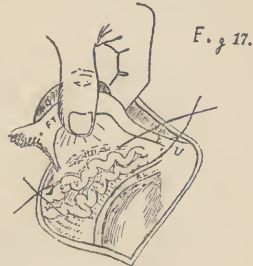


FIG. 17.

Figure showing method of ligating ovarian veins in the angle between the ovarian hilum and the round ligament.

in the new operation, who verified the apparently perfectly natural position of the uterus.

Case III. Mrs. S., a patient of Dr. Radcliffe Cheston, of Philadelphia, is 41, and has had eight children, the last 5½ years ago.

Last spring I repaired a large open vaginal outlet and at the same time lifted the uterus and fixed it to the abdominal wall without incision as in the other cases.

This soon dropped back and I performed hysterorrhaphy Oct. 29th, 1889. The uterus was easily raised and two sutures passed under the ovarian ligaments of each side raising it to the abdominal wall. No drain.

She has made a rapid recovery, and the uterus is in a position of ante-flexion, the body lying on the vaginal wall and the cervix well back in the pelvis, a position from which no ordinary moderate efforts can dislodge it. She has since returned home.

In conclusion I wish to state that my effort thus far has been to discover an operative method which will cure certain obstinate retroflexions. Whether the cure of the retroflexion will, in all cases, relieve the patients of their sufferings is yet to be determined, and is of course the more important question.

[*Note*, January 26, 1890. I have seen these three patients within a few days, and their condition remains as reported.]



