

ifornia
nal
ty



Digitized by the Internet Archive
in 2007 with funding from
Microsoft Corporation







X 75. A. A. obj. Zeiss. In three sections. Micro-photograph reduced one-half size.

SECTION OF LOWER JAW OF TWELVE-YEAR-OLD DOG WITH CUSPID TOOTH IN SITU.

Nearly every phase of disease of tooth and jaw is here illustrated. The last stages of interstitial gingivitis with resultant pyorrhoea alveolaris appear, showing tooth attached by fibrous union for only a short distance upon one side near apex of root. Thickening of the cementum (cementosis), due to irritation and inflammation of the periodontal membrane, is present. Cementoclasts (indistinctly seen) are producing absorption of the end of the root. Marked inflammation has occurred at gingival margin with pus pockets at the labial and lingual borders. Absorption of the lingual border appears directly upon the end. Absorption of the outer plate has occurred in a lateral direction for the entire length, from the root of the tooth outward, with obliteration of the pulp cavity.

INTERSTITIAL GINGIVITIS

OR

SO-CALLED PYORRHŒA ALVEOLARIS

BY

EUGENE S. TALBOT, M. D., D. D. S.

PROFESSOR OF DENTAL AND ORAL SURGERY, NORTHWESTERN UNIVERSITY, WOMAN'S MEDICAL SCHOOL
HONORARY PRESIDENT OF THE DENTAL SECTION OF THE TENTH INTERNATIONAL MEDICAL CONGRESS,
BERLIN, 1890; HONORARY PRESIDENT OF THE DENTAL SECTION OF THE TWELFTH INTERNATIONAL
MEDICAL CONGRESS, MOSCOW, 1897; HONORARY SECRETARY OF THE PAN-AMERICAN MEDICAL
CONGRESS, WASHINGTON, 1893; MEMBER OF THE AMERICAN MEDICAL ASSOCIATION; FELLOW
OF THE CHICAGO ACADEMY OF MEDICINE; MEMBER OF THE CHICAGO MEDICAL SOCIETY;
SECRETARY OF THE SECTION ON STOMATOLOGY OF THE AMERICAN MEDICAL ASSO-
CIATION; MEMBER OF THE CHICAGO ACADEMY OF SCIENCES; HONORARY MEMBER
OF THE ODONTOLOGISCHEN GESELLSCHAFT, BERLIN, GERMANY; MEMBRE
HONORAIRE DE L'ASSOCIATION GENERALE DES DENTISTES DE FRANCE;
HONORARY MEMBER SOCIEDAD ODONTOLOGIA ESPANOLA; AUTHOR OF
"THE IRREGULARITIES OF THE TEETH AND THEIR TREATMENT"
AUTHOR OF "CHART OF TYPICAL FORMS OF CONSTITUTIONAL
IRREGULARITIES OF THE TEETH"; AUTHOR OF "THE ETI-
OLOGY OF OSSEOUS DEFORMITIES OF THE HEAD, FACE,
JAWS AND TEETH"; AUTHOR OF "DEGENERACY, ITS
CAUSES, SIGNS AND RESULTS"; ETC., ETC.

WITH SEVENTY-THREE ILLUSTRATIONS.

PHILADELPHIA :

THE S. S. WHITE DENTAL MANUFACTURING CO.

1899.

Entered According to Act of Congress, in the Year 1899, by
EUGENE S. TALBOT,
in the Office of the Librarian of Congress at Washington, D. C.

Biomed


WLI

240

T142i

1899

TO
ALL CO-WORKERS IN DENTAL SCIENCE,
This Work,
As a Slight Token of Appreciation of Their Contributions to Science,
is Respectfully Dedicated.



D 64
T

1472585

PREFACE.

The great law of medical science, that to know the cause is half the treatment, is as applicable to dentistry as to any other specialty of medicine, and is as applicable to dental problems as to those of biology generally. Treatment of any disease without knowledge of its pathology is practically a failure.

While much has been written upon the pyorrhœic stage of interstitial gingivitis and its treatment, during the past two decades, no new principle has been advanced whereby the parts can be restored to a healthy condition, or whereby the disease can be prevented. The disease is admittedly on the increase. This seems at first sight to indicate that dental prophylaxis and treatment, so far as this disease is concerned, is a failure.

Other specialists restore patients to health. Nearly every patient with this disease applies to dentists. Most dentists, however, hardly know the disease exists and much less are capable of offering suggestions as to treatment. It seems strange that in America so little original work has been done upon a disease more to be dreaded than tooth decay. Treatment has been wholly at random, and hence, as a rule, only to limited extent successful. Destruction of the alveolar process and loss of the teeth is so rapidly sure that the necessity for dental scientists to solve the etiology of this very common disease seems imperative.


Nearly two decades ago I felt and expressed the necessity for more extended study (*Dental Cosmos*, 1886, page 689) of the clinical aspects and etiology of this disease. Even during apparently diverse and separated studies, such as those related to dental and maxillary irregularities and degeneracy, the necessity for this has forced itself still further upon me. In the present study, the disease has, of necessity, been considered from the broad standpoint of general pathology. In all instances where possible personal elements of error are present, these have been eliminated by having researches made by more than one observer.

The attempt has been made to summarize all researches on the subject. So much have opinions been intermingled that it is possible that proper credit for priority has unintentionally not been given.

The author is under obligation to the following scientists for their kind assistance: Dr. Ludwig Hektoen, Pathologist, Rush Medical College; Dr. Jerome H. Salisbury, Chemist, Rush Medical College; Dr. W. A. Evans, Pathologist, Columbus Medical Laboratory, Professor of Pathology, Chicago College of Physicians and Surgeons and Milwaukee Medical College; Dr. J. A. Wesener, Chemist, Columbus Medical Laboratory, Professor of Chemistry, Chicago College of Physicians and Surgeons; Dr. Vida A. Latham, Pathologist, Northwestern University, Woman's Medical School; Dr. Maximilian Herzog, Pathologist, Chicago Polyclinic Hospital; Professor Theo. A. Edwin Klebs and Dr. Robert F. Zeit, Pathologists, and Dr. W. L. Baum, Professor of Diseases of the Skin, Post-Graduate Medical School, Chicago; Dr. G. V. I. Brown, Professor of Oral Surgery, Dental Department, Milwaukee Medical College; Dr. Frederick Noyes, Histologist, Dental Department, Northwestern University; Dr. J. G. Kiernan, and to Blomgren Bros. & Co. for electrotypes, etc.


THE AUTHOR.

103 STATE STREET, CHICAGO.



CONTENTS.

CHAPTER.	PAGE.
I. HISTORY	1
II. INTRODUCTION	10
III. TRANSITORY STRUCTURES —	
THE JAWS	20
THE ALVEOLAR PROCESS	21
PERIOSTEUM AND PERIDENTAL MEMBRANE	33
THE GUMS AND MUCOUS MEMBRANE	42
DO GLANDS EXIST IN EPITHELIAL AND PERIDENTAL MEM- BRANE?	47
BONE BUILDING AND ABSORPTION	59
IV. THEORIES OF INTERSTITIAL GINGIVITIS	65
V. URIC ACID AND INTERSTITIAL GINGIVITIS	68
VI. INORGANIC SALTS AND INTERSTITIAL GINGIVITIS	73
VII. HEREDITY AND ENVIRONMENT	83
VIII. DEGENERACY AND DEGENERATE TISSUES	86
IX. NEUROTIC, DIATHETIC AND DEGENERATE CHILDREN	89
X. INTERSTITIAL GINGIVITIS IN DOGS	98
XI. MERCURIAL INTERSTITIAL GINGIVITIS IN DOGS	117
XII. BACTERIOLOGY OF INTERSTITIAL GINGIVITIS	122
XIII. SCORBUTIC INTERSTITIAL GINGIVITIS IN MAN	127
XIV. INTERSTITIAL GINGIVITIS IN MAN FROM METALLIC AND OTHER DRUG ACTION	142
XV. CONCLUSIONS	146
PATHOGENESIS OF INTERSTITIAL GINGIVITIS	151
ENDARTERITIS OBLITERANS	154
ABSORPTION OF THE ALVEOLAR PROCESS	157
PYORRHEA ALVEOLARIS FROM INTERSTITIAL GINGIVITIS	162
CONSTITUTIONAL EFFECTS OF PYORRHEA ALVEOLARIS	167
CALCIC DEPOSITS	168
XVI. TREATMENT	172



INTERSTITIAL GINGIVITIS.

CHAPTER I.

HISTORY.

Inflammation of the peridental membrane is probably coeval with man. Some of the skulls found earliest in the cave-dwelling period exhibit evidences of its presence. In some of these, careful observation has shown deposits encroaching upon the roots of the teeth and resultant absorption of the alveolar process.

In the Swiss lake-dwellings and in the earlier Irish cran-noges of like construction and situation, skulls are found, which exhibit deposits of tartar, inflammation of the peridental membrane and absorption of the alveolar process. These skulls were those of primitive races in whom disease of the jaws and teeth is supposed to be absent or infrequent. In the skulls of the peoples exhibiting the highest civilization at the earliest period—those of the Accadians and Egyptians—similar inflammatory conditions are to be found. This, however, was to have been expected, to judge from the dental directions left among the medical records of these peoples. The Greeks, Syrians, Arabians, Dravidians and Aryans of India and the early Burmese all suffered from this disorder. In the museum at Constantinople are the skulls of soldiers who fought at a battle 328 B. C. One of these skulls has the anterior alveolar process entirely absorbed away. The roots of the right central, the right lateral and the left central incisors are exposed.

Inflammation of the peridental membranes, it will be evident, is, therefore, not a modern disease; not a disease confined either to civilized or primitive races, but one which attacked man early

in his evolution. Like most diseases it has been chiefly discussed and analyzed during the past two centuries.

In 1740 H. A. Fauchard¹ (while recognizing the disease in all its essential features and describing its principal symptoms) advanced no theory as to its origin.

In 1778 M. Jourdain² advanced the opinion that the disease was of scorbutic origin.

In 1821 L. Kaecker³ discussed the disorder in an essay on the devastations of the gums and alveolar processes.

In 1822 M. Joirac⁴ (in a discussion of the disease), while advancing no theory as to its origin, called it "pyorrhœa inter-alveolo-dentaire."

In 1860 Marshall de Calve⁵ advanced the opinion that the disorder was of hereditary origin.

In 1867 Magitot, discussing the disorder, advanced the opinion that the gum, being in all cases only attacked subsequently, is not the original seat of the lesion. In his opinion systemic disorders like gout, rheumatism, albuminuria, diabetes and anæmia had an influence.

Bonwill⁶ during the same year expressed the opinion that the disorder was due to thinness of the alveolar process between the teeth, thus depriving the peridental membrane and gum tissue of proper support. The want of proper articulation of the teeth also exerted an influence.

In 1870 Brown ascribed the disorder to serumal calculus.

In 1875 John T. Riggs, after whom the disorder is frequently called, entitled it (in a paper read before the American Academy of Dental Surgery) suppurative inflammation of the gums and absorption of the gums and alveolar process.

During the same year Scheff⁷ of Vienna entitled the disorder periostitis dentalis. He was of the opinion that it originated from external irritation through mechanical, thermic and chemic changes. The real origin of the disorder was, in his opinion,

¹ Independent Dental Journal, 1875.

² Philadelphia Journal of Medical and Physical Science, 1821.

³ International Dental Journal, Vol. XIII.

⁴ Journal of the American Medical Association.

⁵ Journal of the American Medical Association.

⁶ Dental Cosmos, Vol. XXIV.

⁷ Wiener Med. Presse, Vol. XVI.

very often obscure. He doubted, however, the influence of rheumatism.

In 1876 Sirletti¹ (in a discussion of the pathology of the disorder, which he called alveolo-dental periostitis) regarded it as due to constitutional conditions, like rheumatism, scrofula, syphilis, etc., with local causes as exciting factors.

In 1877 Rehwinkle,² in a paper on pyorrhœa alveolaris, after citing from Albright (of Berlin) the claim that the disorder was due to uncleanness, mercury and the suppression of habitual secretions, expressed the opinion that acquired and inherited constitutional defect often played an important part as etiologic factors. He was also of opinion that mercury exerted an influence in its causation. Salivary deposits were, in his opinion, without influence. Clowes³ was of opinion in 1879 that the general cause was lack of nutrition in the parts. The use of wedges often excited the disorder.

C. J. Essig,⁴ in 1880, expressed the opinion that its predisposing causes were unknown, that it occurred as a rule in healthy persons, and that irregular and crowded teeth acted as an exciting cause.

In another paper during the same year G. A. Mills⁵ expressed the opinion that the disorder was of systemic origin. Various mental and physical influences aided its progress, such as nervous exhaustion and bodily and mental overwork. In his opinion it frequently occurred in children and adolescents from eruptive fevers. The deposit was only a local manifestation of the disorder.

In 1881 N. S. Niles⁶ expressed the opinion that constitutional conditions were, as a rule, without influence, and that local irritating deposits were the cause in twenty-five per cent of the cases coming under his observation. He was of opinion also that the amount of lime salts taken into the system in drinking water exerted an influence. A calcic and phosphatic diathesis had an influence in the production of the disorder.

¹ Gazzetta Medica di Roma, 1876.

² Dental Cosmos, Vol. XIX.

³ Ibid., Vol. XXI.

⁴ Dental Cosmos, Vol. XXI.

⁵ Ibid., Vol. XXIII.

⁶ Ibid., Vol. XXIV.

In 1881 (when there seemed to have been many contributions to the literature of the subject) Atkinson¹ expressed the opinion that nervous debility or original defect in innervation exerted an influence in the production of the disorder. The deposits of tartar were a secondary consequence. In the course of his paper he cited the opinion of Hamilton Cartwright that Riggs's disease commenced in an unhealthy condition of the gums with a secondary deposit of tartar.

In a paper read before the Dental Section of the International Medical Congress, Walker² claimed that the starting point of the disease was subacute inflammation passing into the depths of the alveolar process adjacent to the inflamed gum. In the discussion of this paper, Archovy and Joseph Izklai, of Buda Pesth, ascribed the disorder to minute organisms. Oakley Coles thought that systemic states were the predisposing factors, while minute organisms exerted an exciting influence.

In 1882, L. C. Ingersol³ regarded sanguinary calculus as a manifestation of the disorder, and distinguished it from salivary deposits.

Malasses and Gallippe,⁴ in 1884, expressed the opinion that the disorder was of microbic origin.

In 1885, A. O. Rawls⁵ expressed the opinion that the causes were environment with morbid factors, such as malaria, excessive sodium, etc., chloride and mercury.

In 1886, Reese⁶ expressed the opinion that the disorder had its source in the uric acid diathesis resultant on abuse of alcohol.

During the same year, J. D. Patterson⁷ expressed the opinion that the disorder was of catarrhal origin. Later, in 1886, J. N. Farrar⁸ regarded the disorder as a combined result of systemic tendencies and local irritants. There was a peculiar condition of the system associated with hypersecretion laden with increased earthy deposits.

¹ Dental Cosmos, Vol. XXIV.

² Transactions of the International Medical Congress, 1881.

³ Dental Cosmos, Vol. XXV.

⁴ Ibid., Vol. XXVI.

⁵ Ibid., Vol. XXVII.

⁶ Independent Practitioner, Vol. VI.

⁷ Dental Cosmos, Vol. XXI.

⁸ Independent Practitioner, Vol. VII.

A. R. Starr later also expressed the same opinion. He, however, was unable to determine the local irritation factor, but regarded it as the same as that which causes exostosis of the cementum. He had found most cases in the upper jaws.

Black¹ designated the disorder phagadenic pericementitis. It was a specific infection of an inflammatory character, having its origin in the gingiva, and was accompanied with destruction of the periodontal membrane and alveolar walls.

E. S. Talbot² during the same year regarded the disorder as a local one, due to both local and constitutional causes. The disorder began with simple inflammation of the gums, which afterward became chronic.

Of the status of this disease at the close of the year 1887, the following analytic picture was drawn by W. X. Sudduth³: Pyorrhœa alveolaris is a term applied to the secondary stages of a disease that has its inception in a catarrhal stomatitis. Being confined, as a rule, to the margin of the gums surrounding the teeth, it might be called a "gingivitis," were it not for the general catarrhal tendency shown by the entire mucous membrane of the mouth and nasal passages. The intimate relation between a general catarrhal idiosyncrasy and pyorrhœa alveolaris is more than mere coincidence. Its common occurrence in persons who have irregular teeth has also been often noted by Dr. Sudduth, who considers that this fact has, besides the matter of uncleanness, a direct bearing upon its pathogeny. It is well known that the irregularities of the teeth present an indication of a degenerative taint, and that persons in whom irregularities occur are very prone to catarrhal affections of the respiratory organs, including the nasal passage. Their skin is usually very susceptible to inflammatory affections. Another feature is offensive odor of the saliva of individuals who show this particular tendency to catarrhal affections even in persons who take most scrupulous care of the teeth. In the majority of cases, pyorrhœa is a stomatitis in which the local and constitutional factors in the production of the disease are largely dependent upon hereditary catarrhal dyscrasia for their ability to engraft themselves upon

¹ American System of Dentistry.

² Dental Cosmos, Vol. XXVIII.

³ Sajous' Annual, 1888, Vol. III, page 365.

the tissues. This position is borne out by the clinical experience of Patterson, of Kansas City, Missouri, who reports thirty-eight cases of well marked pyorrhœa observed by him, thirty-three of which presented undoubted evidence of nasal catarrhal conditions; two were the result of direct irritation of misfitting partial plates, and the remaining three were apparently caused by calcific deposits. Patterson remarks that a close examination of the history of the above quoted cases confirms the opinion that the disease is, as a rule, an "oral catarrh."

From the foregoing W. X. Sudduth feels justified in classing the disease as a localized catarrhal stomatitis which may be either acute or chronic. Acute catarrhal inflammation of the gums begins in circumscribed points which present a bright or rose-red color, and which are generally located on the margin or the rugæ of the palate. There is but little swelling because of the dense nature of the sub-epithelial connective tissues. The gums present the same stages as are found in inflammation of other mucous surfaces—first dryness, followed by an increased secretion of mucus. The parts are very sensitive to pressure; the patient complains of an annoying, burning sensation. The appearance of the gums is noticeably smooth and glistening. They bleed easily when the brush is used or even during a meal. This stage does not last very long, but soon heals by resolution or passes into a chronic catarrhal stomatitis in which condition the gums become markedly swollen and turgid. They present a condition of tumefaction that sometimes rapidly passes into hypertrophy; at other times there is an indurated appearance that may last for some time. Granulation tissue may be produced as the result of overstimulation. The gums become detached from the necks of the teeth; and pockets are formed from which a fetid discharge may be pressed, giving a peculiarly disagreeable odor. Bullæ are apt to form, which, by rupturing in the process of mastication, give rise to intense smarting. The tongue constantly seeks the surface if it be on the inner side.

The pathologic changes which take place are, according to Newland Pedley, of England, "hypertrophy of the muco-periosteal fold around the teeth, accompanied by dilatation of capillary loops, enlargement of the papillæ and rapid proliferation of epithelial cells. Later the gums become firm and contracted and

display increase of fibrous tissue. The changes which go on in the socket have not been as yet satisfactorily worked out. The examination of the jaws of carnivora, apparently affected with pyorrhœa alveolaris, leads to the supposition that osteitis of the alveolar process spreading toward the apex of the socket is present. Later the alveolar walls become absorbed and are at times more or less denuded, while the fangs of the teeth become coated with a layer of thin, hard, green-brown tartar. Ultimately the disease progressing, the teeth, one after another, drop out."

From what has been said it will be seen that the pathology of pyorrhœa alveolaris may be explained in several ways. The general causes are local or symptomatic, or both combined. The most common cause of catarrhal gingivitis is found in local irritation, combined with some hereditary disposition to catarrhal affections. The next greatest etiologic factor is symptomatic—the local manifestation of a constitutional vice. The most common manifestation is that of syphilis and of its antidotes, mercury and potassium iodide, both of which sometimes find expression in a localized inflammation which may be the starting point for pyorrhœa alveolaris. As a complication of the disease in its secondary stages there can be no doubt of the action of micro-organisms, but Sudduth does not feel justified in conceding to them a position of specificity.

His position above quoted is sustained by Pedley, who finds that in most instances it is due to some constitutional condition. The fact that it is often symmetrical and frequently hereditary gives support as to this view. It occurs in mouths of patients whose health has been undermined by debilitating influences and injudicious habits of living. It is a common sequel of malarial fever. Young persons recovering from eruptive fevers are sometimes subjects of pyorrhœa alveolaris. Frequent pregnancies are a fruitful source of the disorder. Attention has been lately drawn to the shedding of the teeth in tabes dorsalis, but it does not, however, seem to be a constant symptom. Pedley's view, although tending entirely toward the constitutional character of the disease, does not militate against its catarrhal nature.

Bland Sutton has found shedding of teeth frequent in rheumatoid arthritis in animals. He has also met with it in mollities ossium and other wasting diseases. Magitot (who views the

alveolar dental periosteum as a ligament and not of the same nature as osseous periosteum) calls the disease symptomatic alveolar-arthritis, and mentions especially as causes, chronic Bright's disease and glycosuria, in which latter condition the phenomenon is absolutely constant.

Patterson holds that "mouth-breathing has, in his experience, been a very common accompanying condition which he cannot help connecting with the production of the disease. By it the gums are kept dry, their functions destroyed and the way paved for catarrhal inflammation. The majority of the patients he has been called upon to treat have been otherwise healthy, robust persons. From this fact he does not favor the idea of the disease being dependent upon constitutional derangement. It is, however, a well-known fact that these are the very class of people who when irritation is once set up in their system, present the most aggravated cases, by reason of their superfluous vitality. He says he has occasionally met with cases where the local condition was evidently aggravated by constitutional derangement and cure was thereby retarded. The great majority of cases, however, have shown no indication of constitutional predisposition, but have pointed unerringly to local irritation by means of which the function of the mucous membrane had been destroyed."

Syphilis and other affections may engraft themselves upon the gums without a predisposition of the parts toward an inflammatory condition, and having disturbed the normal status of the gingival margins they pave the way for subsequent disease in the alveolus. Certain drugs, such as mercury, phosphorus, lead, etc., have a known deleterious action upon the ligamentous attachment of the teeth.

In 1890 Miller¹ expressed the opinion that the disorder was of a parasitic nature.

In 1892 C. N. Pierce² charged the disorder chiefly to systemic predisposition and enthusiastically advocated the theory of Reese as to the influence of the uric acid diathesis. In 1894 W. X. Sudduth³ strongly urged the influence of lactic acid as a local factor in the disorder.

¹ *Micro-Organisms of the Human Mouth.*

² *International Dental Journal*, Vol. XIII.

³ *Ibid.*, Vol. XIV.

John Fitzgerald,¹ in 1899, claimed that "The production of pyorrhœa depends upon two factors, a predisposing cause and a local irritation. The predisposing cause may be tubercle, syphilis, scurvy, the exhaustion of acute infectious diseases or any other source of malnutrition. The exciting cause may be, and most usually is, a gingivitis produced in one of the ways to be presently described. There is also a pyorrhœa of gouty origin, in which the local necrosis of the peridental membrane is caused by gouty disease of one of the blood vessels in its substance."

The views on etiology of this condition have varied, it will be observed, from purely constitutional causes to purely local causes, inclusive of microbic affections. In the main it will be obvious, however, that both constitutional causes, whether inherited or acquired, have been regarded as of influence by the majority of those who have written on the subject. There has, however, been very little exact study of either the predisposing or the exciting causes of the condition. Even the impetus given the study of etiology by bacteriology and embryology has as yet failed to make itself felt to any considerable degree in this department of dental pathology.

¹ Clinical Journal, March 1, 1899.

CHAPTER II.

INTRODUCTION.

The attempt has been made in the present work to reduce to order the chaotic notions as to etiology, pathology and treatment which, during the present century, have gathered around the morbid condition erroneously entitled *Pyorrhœa Alveolaris*. While even erroneous titles may have their meaning so fixed by usage that any danger from the error involved in the title may be practically nil, still this is not the case with the title just cited. It suggests erroneous etiology, since *pyorrhœa* implies that there must always be a flow of pus, and hence that the disease must always result from infection with pus microbes. It implies erroneous pathology and erroneous treatment for the same reason. This being the case, such a title is so dangerously misleading as to compel in the present stage of dental science its complete disuse. With a view of clearing up this question at the outset by the use of a proper title, I have adopted as a designation for the condition hitherto known as *pyorrhœa alveolaris*, the term "Interstitial Gingivitis." To this designation (as to all other attempts to express within a small space an extended pathology, etiology, prognosis, and clinical aspects) there are some objections. The term *interstitial* is used by some pathologists in a limited obscure sense. By the mass of dental pathologists, surgeons, physicians, and by medical lexicographers; the term is employed in precisely the sense in which it is used in the present work. The English surgeon and lexicographer Quain defines *interstitial* as follows: "Interstitial (inter, between; and sto, I stand); relating to the interstices of an organ. The term is applied in physiology to the tissue which exists between the proper elements of any structure, namely, some form of connective tissue. In pathology the word is used in connection with absorption when a part is gradually removed without any obvious

breaking off, and also to indicate the implication of the interstitial tissues in morbid processes or their infiltration with morbid products, as interstitial pneumonia, interstitial hepatitis.”

The Encyclopædic Medical Dictionary of the American Foster, states that interstitial has three significations: First, it is applied to a condition disseminated through the substance of an organ or part, and to an inflammation affecting the connective tissue of an organ; second, it is also applied to that form of growth which consists in the interposition of new elements between old ones, instead of in addition to the surfaces; third, it is applied to pathologic processés occupying the space between the essential parts of an organ which constitute its proper tissue, and is then employed in a sense opposed to that of parenchymatous.

A glance at the illustrations demonstrates the validity of the application of the term interstitial (in the sense of Quain, Foster, and the other lexicographers) to the condition erroneously called pyorrhœa alveolaris.

I have adopted the term gingivitis for reasons which will be obvious at the first glance. The philologic objection may be made that in it Greek and Latin are yoked together. Practically this is no objection, since German, French, as well as English, medical authorities employ such terms of mixed origin. Indeed the French (Mailhol¹ for example) apply the term gingivitis to the very condition to which I have applied it. In addition, they add to it the specific term “expulsive,” to designate “a form of recession of the gums, accompanied by alveolar osteoperiostitis, and the gradual expulsion of the tooth from its socket.” Foster² suggests the substitution of the term ulitis as more philologically correct. The term gingivitis, however, has crept into such wide use, that it would be futile to attempt to displace it for merely philologic reasons. The two terms I have employed convey a fairly correct idea of the pathologic process involved, and do not imply erroneous views as to etiology, pathology, prognosis and treatment.

The pathologic conception adopted in the present work anent interstitial gingivitis is that the disorder is a local inflammatory

¹ Odontalgie.

² Foster, op. cit.

condition of the gums, tending to accelerate their normal tendency to disappearance at certain periods of stress, or involution, of which involution the changes produced by old age are a type. In this early senility of the gums, for such it may be termed, two great types of causes play a part; the exciting and the predisposing causes. The exciting causes may be purely local, or may be local expressions of constitutional states. Thus it will be shown that the influence of uric acid when present is exerted as a local irritant, and not as a constitutional factor—the theory urged so strongly by Pierce, whose views have been of late so advocated by Kirk.¹ The uric acid hypothesis, once very dominant in medicine, is now losing its force. The trend of medical opinion is to consider it one of the danger signals of auto-intoxication which assumes prominence because of its tendency to excite local irritation. It is but one of a number of local expressions of constitutional defect. This view of the influence of uric acid in etiology the present work will try to demonstrate. Prominent among etiologic factors which have to be reckoned with, are pathogenic germs. In the present work it will be shown by all laws of bacteriology (under which investigations must be conducted) that there is no specific germ which is capable of producing the disease itself, and furthermore, that the pyorrhœa stage of the disease is merely a complication due to pyogenic germ infection of the already diseased gums. The views of Galippe as to a specific organism will be shown to have failed of support by numerous control experiments described in the present work. As these have been conducted by different experimenters they are free from the personal elements of error which vitiate the researches of Galippe, who violated that canon of the laws of Koch which compels production of the disease by the alleged specific germ. One predisposing factor will be shown in the present work to be the nature of the structures affected. This in pathology is called local predisposition. The gums, etc., will be shown to be transitory structures in themselves predestined (as already stated) to certain changes at certain ages. By the influence of the disease, about to be discussed, these changes occur prematurely. The influence of the toxic agents (mercury, potassium iodide, etc.) will be shown to have

¹ International Dental Journal, May, 1899.

been exerted constitutionally through the central nervous system, their local effects being a secondary consequence of this. The same will be shown to be the case with conditions like scurvy (where the constitutional factor is most prominent), and with the great neuroses (paretic dementia, locomotor ataxia, etc.). Here, as in the toxic conditions, one great element considered is the influence of the constitutional conditions upon the nerves governing local blood supply and tissue waste and repair. These influences are significantly illustrated in the various processes described later which tear down and build up.

The influence of morbid heredity as a direct factor will be shown not to be great. The influence, however, of degeneracy expressing itself along the lines of least resistance will appear as an ominously important factor. Heredity here, as elsewhere, is a warning rather than a destiny.

The influence of the nervous system on the processes of growth and repair, which is called its trophic function, has been shown to play a part in both the etiology of the disease and in its progress. This function has received but little attention from dentists, albeit its influence has been recognized in dental pathology in connection with great neuroses like parietic dementia and locomotor ataxia, in which gum disorders occur, followed by loosening of the teeth. The pathology of the disease has been discussed in the light of established facts of general pathology which have been accepted by the leading dental investigators, and not merely from a hypothetic standpoint. The disease has been regarded as a local exaggeration of certain physiologic processes, accompanied by diminution of the intensity of others. In the study of this phase of the question, the latest researches of dental pathologists as well as original observation and experiment have been employed.

Among the many questions which the present treatise is believed to settle (so far as experimentation can) is the following: The question of the influence and nature of its etiology. It is shown that here, as elsewhere in biology, the etiology of morbid conditions has many phases; that in it exciting and predisposing causes have alike to be considered; that while causes may be constitutional in origin they very often exert their action locally; that the disease is not a product of civilization nor a product of

any one etiologic factor; that there is no ground yet adduced for believing the disease to be specifically infectious and due to a germ of a specific nature; that in it the germ infection occurs as a consequence of existing disease, and is not the cause of the morbid condition, but one of its stages: Pyorrhœa. The experiments made, as well as the pathologic and clinical data, have been obtained from many observers, so that as many control observations should be had as were necessary to eliminate personal elements of error inevitable upon original observation and research. In the pathology no statement is made which is not demonstrated by corroboratory data, including a photograph of the condition. The treatment has been based upon the pathology and etiology. Its central idea is that the human being must be regarded as something more than his mouth and teeth; hence the duty of the dental scientist is, like that of all medical scientists, best shown in a prophylactic direction.

The pathologic material for the study of interstitial gingivitis in man is obtained with such difficulty in the recent state as to necessitate research upon animals. This disease was noticeably present among the carnivora, casually inspected in American and European zoölogic gardens. Cats and dogs were also known to be liable to the disease. As the first step in investigation, two practitioners of comparative medicine, with an extensive hospital practice (Dr. Charles E. Sayre and Dr. Alsop E. Flower), were consulted as to the frequency of this disease in animals. All animals under their care suffered from it more or less, but eighty per cent of dogs over eight years of age had the disease. Nearly every dog in the hospital under their care was so affected. These dogs comprised all breeds, from spaniels and terriers to the Newfoundland, St. Bernard and great Dane. On examination, every phase of interstitial gingivitis was found in the mouths of these dogs, from its inception to the loss of the teeth. The number of dogs observed was twenty-seven. The roots of the teeth of some were covered with deposits and so exposed that the teeth could be removed with the fingers. Such diseased mouths are rarely, if ever, present in human beings. The outer plate of bone was absorbed, the roots entirely exposed, pus was oozing from around them and the mucous membrane was badly inflamed.

It should be remembered that the jaw of the dog, like the jaw

of man, is undergoing considerable variation. Like man, the dog, having put himself under new social conditions (so to speak), is varying greatly both as to brain, skull and jaw from his wolf-like ancestor. As he is under the protection of man, the struggle for existence as to food is less intense than in the



FIG. 1.

wild state and consequently there is less occasion, even for fighting purposes, of his jaws and teeth.

Independently of conditions of this type, many of the dogs suffered from constitutional disorders. Eight had skin diseases which in the dog are more likely to produce obvious constitutional defects than in man. Some were old and blind. Some had been injured and were under treatment for wounds. Some

were suffering from rachitis, nervous diseases, and were overbred. Others were constipated or had germ types of diarrhoea. One had kidney inflammation and bronchitis with high fever. In short, these dogs, being house dogs, presented most of the constitutional diseases to which man is liable.

The mouth of a Scotch terrier is shown in Fig. 1. The

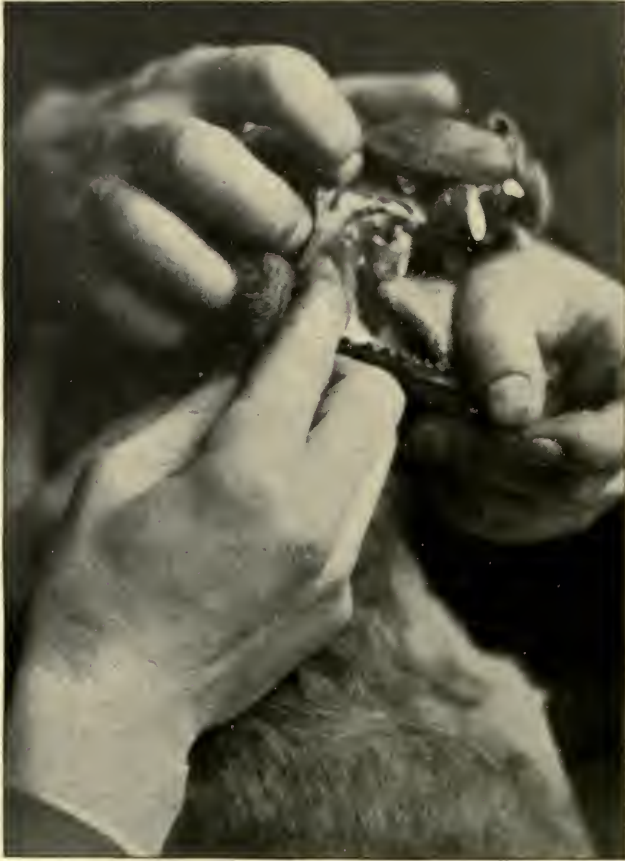

FIG. 2:

molar and premolar had been removed with the fingers. The cuspids and incisors are quite loose. There are large deposits of tartar. The gum and alveolar process have been absorbed nearly one-half the length of the roots of the teeth. In Fig. 2 is seen the mouth of a Boston terrier with the incisors and premolars removed. There is extensive pyorrhœa. There are

calcic deposits upon the cuspids and molars. There is recession of the gums and alveolar process. In Fig. 3 is shown the mouth of another Boston terrier. In it one premolar in the upper and one on the lower jaw have been extracted. There is extensive inflammation of the gum about the molar, cuspid and incisor with large calcic deposits about the teeth. In Fig. 4 are shown

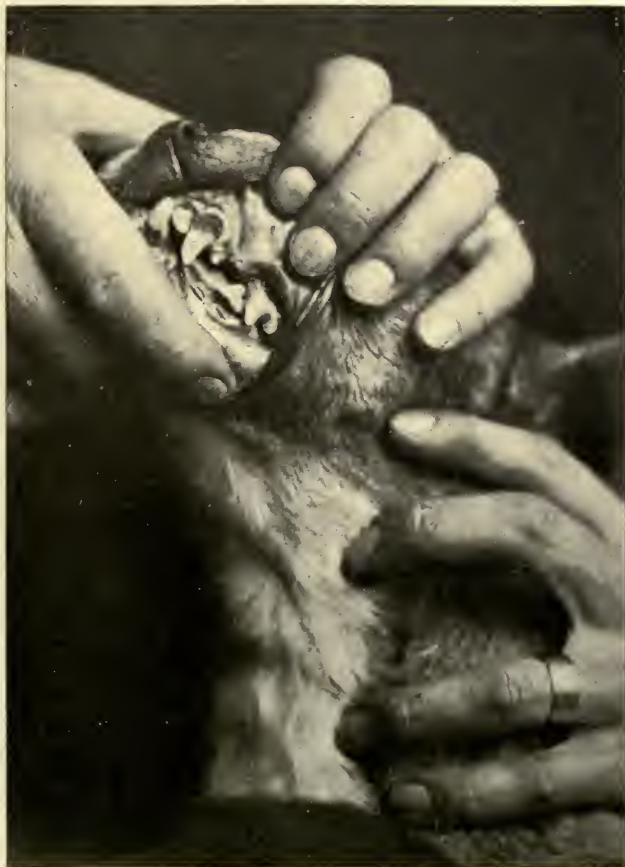

FIG. 3.

teeth covered with calcic deposit the entire length of the root. These teeth were removed by the fingers from the mouths of two dogs, one of whom was later obtained for scientific study. This was all the material to be obtained from the hospital, since the dogs were pets who had been placed under treatment by their owners.

Through the courtesy of Poundmaster Hugh Curran, the necessary material was obtained from the Chicago Dog Pound. Here from four hundred to a thousand dogs are killed per week during June, July and August each year. Ninety-five per cent are mongrel curs leading a street life, hence neither luxurious diet nor luxurious care can be charged with any disease in them. They have, at least, plenty of outdoor exercise and fresh air. Many, despite this reversion to the life of their wolf-like ancestors, have skin diseases and are deaf and blind from old age. The bodies were secured after death, at which time examinations of the mouths were made. Five per cent of the dogs entering the pound are of good breeds. These, if not called for by the owners, are sold for a moderate price.

The dogs selected for the death penalty are collected in a large box pen, leading out of which is a door through which they



FIG. 4.

pass into an air-tight box. Communicating with this box is a stove in which sulphur is burned with charcoal. The fumes pass into the box and death is almost instantaneous and painless. After they remain fifteen minutes, a door leading to the air is opened and the bodies are carted away. It was at this time that access was had to them. The mouths were then examined. Such cases as were of interest were placed on one side and the jaws removed from the bodies. Inside of one-half hour the specimens were in a solution to be kept until desired for use. Jaws (with interstitial gingivitis in all stages of progress, from simple inflammation of the gums to the most extreme cases of exfoliation of the teeth) were obtained in an abundance for future studies. It is not an easy matter to ascertain the ages of these animals. In a general way, it was found that inflammation of the gums, especially about the canine teeth, was almost always present in dogs over one year. About twenty-five per cent of

these dogs at four years of age had the disease, eighty per cent at from eight to ten years, ninety-five per cent over twelve years of age. Since I commenced my investigation (four years ago), I have examined quite a large number of dogs about homes, but have never found a dog over four years without this disease to a greater or less extent. Many house dogs at one year had inflammation of the gums. Dogs for infection and those used for mercurialization were picked up in the streets.

Most of the dogs exhibited at the last three animal dog shows held in Chicago were young, ranging from one to four years of age. About twenty-five per cent would range four years to eight. Three years ago, on a casual examination of their mouths, interstitial gingivitis was found to be common. Occasionally recession of the gums and pyorrhœa alveolaris occurred. During the last two years, on more careful examination, twenty-five per cent of dogs between the ages of one and four were found to have interstitial gingivitis and seventy-five per cent of dogs from four to eight years were found to have interstitial gingivitis with recession of the gums and pyorrhœa alveolaris. In the study of this disease, therefore, dogs are excellent substitutes, since for pathologic research they can be obtained at any stage of the disease.

CHAPTER III.

TRANSITORY STRUCTURES.

THE JAWS.

Because of man's advance in evolution and because of the local degeneracies thereon resultant, through the law of economy of growth whereby one structure is sacrificed for the benefit of the organism as a whole, the face, jaws, teeth, gums, alveolar process and peridental membrane, being variable structures, are predisposed to disease in their very order of evolution.

The jaws are growing smaller because large ones are not required. The structures are changing their shapes to adapt themselves to the new environment. Thus—instead of broad large jaws with low vaults; short, broad alveolar processes with plenty of blood supply and vitality to resist mastication; teeth short, with large bell crowns to give plenty of room between the roots for considerable thickness of the alveolar process for the nourishment of the peridental membrane and support and protection of the gum tissue—small narrow jaws occur with apparently high vaults; long, slender and thin alveolar processes, which are not used in mastication with sufficient force to carry the blood for the nourishment of the tissues. The teeth are changing their shape, causing the roots to come closer together, and thus lessening the area of the alveolar process.

That the jaws of man are growing smaller is easily demonstrated by the following procedure: Drop a perpendicular line from the supraorbital ridge, whereupon it will be found that the jaws of the primitive races protrude beyond the line, as is the case with many peoples of Europe and Asia today.

Mummery, on examination of the skulls of two hundred Britons and Roman soldiers in Hythe Church, Kent, England, found the narrowest width 2.12 inches, the highest 2.62, with an average of 2.50. The width of jaws of 402 British soldiers today is: narrowest 1.88; widest 2.63, average 2.28.

The highest width was very rare, only eight measured 2.50. The jaws of the mound-builders compared with the existing cliff-dwellers show similar results, the average width is about 2.50 inches. Measurements of normal jaws of 855 Italians of Central Italy were: narrowest 1.88, widest 2.63, average 2.17. Measurements of normal jaws of 4,935 Americans gave the following results: narrowest 1.75, widest (only one case) 2.56, average 2.13. While in the highest type of primitive man, the width of the upper jaw from the outer surfaces of the first permanent molars near the margin of the gum was 2.50 inches in diameter, the jaws of people now living in the same locality are from 0.25 to 0.33 of an inch smaller. The antero-posterior diameter has also shortened from one-half to five-eighths of an inch.

Standing on the corner of Picadilly Circus and Regent street, London, in the fall of 1897, I examined the faces of 10,000 passers-by and found that eighty-three per cent possessed jaws inside of the perpendicular line. Of 3,000 English school children under ten years of age ninety-three per cent possessed jaws inside of the perpendicular line, thus showing a difference of ten per cent in one generation.

The negroes were formerly, in the opinion of anthropologists, in the main a long-headed dolichocephalic race with protruding jaws. Of the Northern negroes, who in the main have white blood, very few have long heads. The same is true of the relations of the jaws. The protrusion of the jaws has largely disappeared.

That the jaw is becoming smaller is further shown by the disappearance of the third molar, or the irregularities resultant on its eruption because of want of room, or its eruption with pain for like reason. In the primitive races it is large and well developed.

THE ALVEOLAR PROCESS.

The alveolar processes are situated upon the superior border of the inferior maxilla and upon the inferior border of the superior maxilla. These bones, considered a part of the maxillary bones often so described by anatomists, should, however, be considered as practically distinct bones — their structure, functions.

and embryology differ so completely from the structure and functions of the maxillary bones. The superior and inferior maxillæ are (unlike the alveolar processes) composed of hard, compact bone structure. The large, powerful muscles attached to them indicate that powerful work is to be accomplished. When fully developed they retain their full size through life. The alveolar processes are composed of soft, spongy bone of a cancelloid structure. As early as the eleventh week of intra-uterine life, calcification of the deciduous teeth commences, and by the twentieth week calcific material is abundantly deposited. Ossification is also rapidly progressing about the dental follicles. At birth, the sacs are nearly or quite inclosed in their soft, bony crypts, and the crowns of the teeth upon their outer surface are composed of enamel, which is dense and hard. The embryologic phases of the dental shelf elsewhere cited indicate this development.

The alveolar process, being soft and spongy, molds itself about the sacs containing the crowns of the teeth and about their roots after their eruption, regardless of their position in the jaw. While the alveolar processes have grown rapidly, they have up to this time developed only sufficiently to cover and protect the follicles while calcification proceeds. When the crowns have become calcified and the roots have begun to take in their calcific material, absorption of the borders of the processes takes place in the order of the eruption of the teeth. When the teeth have erupted, the alveolar process develops downward and upward with the teeth until they attain the depth of the roots of the teeth, which extend in most instances into the maxillary bones in the anterior part of the mouth at least, and the upper and lower teeth rest at a point in harmony with the rami. The depth at which they penetrate the bone differs in different mouths. This depends upon the length of the roots and the alveolar process. This in turn depends upon the length of the rami. The incisive fossa, the canine eminence and the canine fossa give evidence of this externally. These sockets are lined with extensions of the process, thus making its upper border irregular. The crypts of the permanent teeth are located at the apices of the roots of the temporary teeth. The permanent teeth have large crowns which touch each other, forming a line to the posterior part of the jaw.

These teeth, as they erupt, entirely absorb the alveolar process which surrounded the temporary teeth, and as the new set comes into place a new process is built up around them for their support. The permanent teeth require a deeper alveolar process to support their roots, which are much longer than those of the temporary teeth. Hence the difference in the depth of the vault of the first and second sets of teeth.

The alveolar process of each superior maxilla includes the tuberosity, and extends as far forward as the median line of the bone, where it articulates with the process upon the opposite side. It is narrow in front, and gradually enlarges until it reaches the tuberosity, where it becomes rounded.

The process is composed of two plates of bones, an outer and an inner, which are united at intervals by septa of cancellous tissue. These form the alveoli for the reception of the roots of the teeth. In some cases the buccal and labial surfaces of the roots of healthy teeth extend nearly or quite through the outer bony plate and are covered by the peridental and mucous membranes only.

This plate is continuous with the facial and zygomatic surfaces of the maxillary bone. The inner plate is thicker and stronger than the outer, and is fortified by the palate bones. The external plate is irregular upon the outer surface, prominent over the roots of the teeth, and depressed between the roots or interspaces.

With the change in the size of jaws there is also change in the shape of the vault and alveolar processes. When the dental arches are large, measuring from 2.25 to 2.50 inches, the vaults are low and the alveolar processes are short and thick, not only giving stability to the teeth, but also plenty of nourishment. Now that the dental arches are growing smaller, with an average of from 1.90 to 2.00 inches, the vaults are higher in proportion, the alveolar processes long and thin. This renders the teeth and jaws more susceptible to trophic changes and hence to disease. The alveolar process in the anterior part of the mouth, in which the incisors and cuspids are situated, is much thinner than in the posterior parts.

The sockets for the incisors and cuspids are conical and much larger than any of the other single sockets. The alveolar process is longer and thinner than at any of the other teeth. The

sockets for the bicuspid are flattened upon their anterior and posterior surfaces; and near the apices they are frequently bifurcated. The sockets of the molars are large at the openings. About the middle of their length, however, they are divided into three smaller sockets for the reception of the roots. In the case of the third molar the number of sockets ranges from one large cavity to three or four of smaller size. When disease attacks the tissues, destruction is, therefore, more rapid in its progress in the anterior parts of the mouth than in the posterior, where the processes are thicker and more nourishment is required.

The septa are very thin at the margin and gradually increase in width to the middle of the jaw, where they become thicker, and are finally lost in the substance of the jaw. Some septa are thicker than others, and where two teeth are widely separated, the width of the septa naturally corresponds to the space between the teeth.

What is true in regard to a change in the size of the jaws is also true in respect to the shape of the crowns of the teeth. While they are not growing smaller in proportion to the size of the jaws, they are changing shapes. Once they were quite well-shaped, giving considerable space between the roots for a thick alveolar process, thus rendering support to the peridental and mucous membranes, now the shape has changed. The proximal surfaces are almost straight, lessening the width and thus allowing only for a thin septum, with barely sufficient surface to support the tissues.

The sockets are lined with a thin plate of compact, bony substance, extending from the outer and inner plates of the alveolar process to the apex, where there are small openings for the entrance of the nerve and blood vessels for the nourishment of the teeth.

The bony plate has upon its inner surface the elastic peridental membrane, which acts as a cushion for the teeth, while it is surrounded by a spongy bone.

The teeth are held firmly in their alveolar sockets by the peridental membrane. Teeth with one conical root, and those with two or more perpendicular roots, are retained in position by an exact adaptation of the tissues. Teeth having more than one

root and those bent or irregular, receive support from all sides by reason of their irregularity. Fig. 5 (a section of the jaw of a cat) illustrates the relative position of the teeth, peridental membrane and alveolar process to each other.

After the removal of the permanent teeth the alveolar process is entirely absorbed. Fig. 6 shows how the absorption takes place. The teeth have all been removed from the superior maxilla and the alveolar process has been entirely absorbed. The

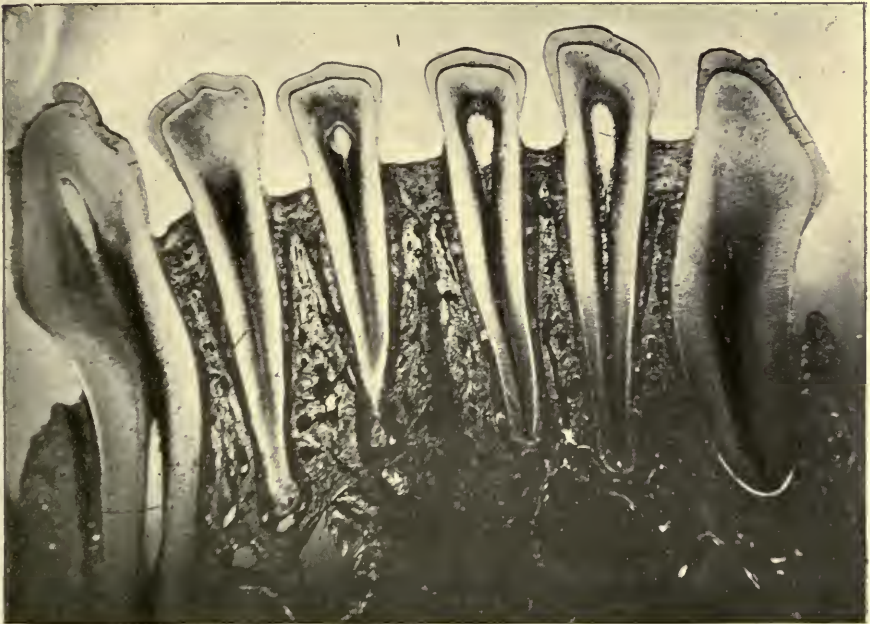

FIG. 5.—GROUND SECTION OF JAW AND TEETH OF CAT. (ANDREWS.)

molars on the lower jaw having been extracted, absorption of the alveolar process has resulted in marked contrast with the anterior alveolar process, which remains intact and holds the teeth firmly in place. It is, hence, evident from the changes which occur, from the first development of the teeth to their final extraction, that the alveolar process exists solely to protect the teeth in their crypts during development and after eruption. After the temporary teeth are in place the alveolar process remains unchanged (except by gradual enlargement in harmony with the growth of the maxillary bones) until about the sixth year, when the second set appears. The crowns of the perma-

nent teeth require more space than those of the temporary set; and the alveolar process must necessarily enlarge to accommodate them. This enlargement of the alveolar process is caused chiefly by formation of the crowns of the permanent teeth before eruption, and to a limited extent only by growth of

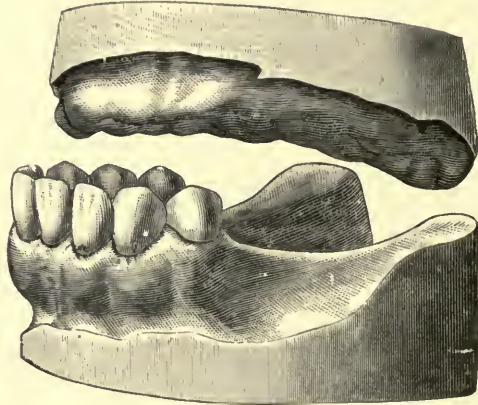


FIG. 6.

the maxillary bones. These may cease development at any period of the life of the individual, or continue as late as the thirty-sixth year. As diameter of the crowns of the permanent teeth form a larger circle than that of the maxillary bones, the

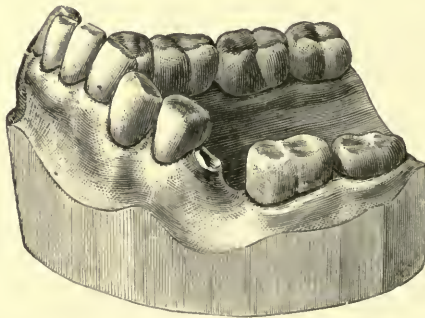


FIG. 7.

alveolar process must necessarily increase its diameter and present large spaces between the roots of the teeth for the development of the alveolar process.

The process is solely for retaining the teeth, and if for any reason the dental follicles should not be present, and the tooth

should not erupt, or if it should be extracted early, the process would not be developed at that point. In my collection of models are cases of arrested development of the alveolar process, caused by the lack of bicuspid and lateral incisor germs, and by extraction of deciduous and permanent teeth.

If one or more teeth were not to antagonize, the alveolar process would extend beyond the natural border, carrying the teeth with it. A marked illustration of this is seen where the molars are decayed to the gum and the roots remain. The vascularity of the process may be such that hypertrophy results. Excessive development of the alveolar process is frequently observed by every practitioner in connection with the anterior inferior teeth. When the articulation is normal, occlusion of these teeth never takes place. Frequently (especially in patients from six to twelve years of age) these teeth extend to and occlude with the mucous membrane of the hard palate. Such a case is illustrated in Fig. 7. This model is taken from the jaw of a person thirty-seven years of age, but this excessive development took place between the ages of six and twelve years, since at that period the vascularity of the tissues is more vigorous, and the development of the process more formative than at any period subsequent to the development of the first permanent teeth.

In one case under observation the incisors and cuspids, together with their alveolar process, are situated upon the external surface, while the bicuspid, molars and their alveolar process are located upon the inner border of the jaw. In another case, the alveolar process failed to cover the roots of the bicuspid and molars upon the outer surface, the teeth having forced themselves into a larger circle through the alveolar process by the contact of the crowns. The roots in this case can easily be outlined by the finger through the mucous membrane, the outer plate of the alveolar process barely, if at all, covering them. Tomes¹ illustrates a case of faulty development of the outer plate of the alveolar process, exposing the crown of the temporary teeth. This occurred in a hydrocephalic. I have a number of models showing the anterior alveolar process projecting beyond the normal position through the forward movement

¹ Dental Surgery, page 44.

of the molars. This may be due to a natural movement of the molars forward, or the process may be forced forward by the improper occlusion of the jaws. The teeth are moved from one position to another simply by the force consequent upon absorption and deposition of bone. This is noticeable in the spaces between the centrals, when the alveolar process develops to a larger circle than is necessary to accommodate the teeth. The alveolar processes are influenced in one direction or the other by the pressure of articulation. This results from inharmonious development of the jaws. The teeth may come together in such a manner as to throw the alveolar processes either to the right or the left, thus producing a full, round arch upon one side of the jaws, and a perfectly flat or straight arch upon the other. Occasionally both upper and lower alveolar processes are carried forward in the same manner. The alveolar process upon the lower jaw is more liable to be found upon the inner border of the jaw than is the upper alveolar process, as the inferior maxilla is larger and more dense than the superior, and when the teeth are once in position upon the lower jaw they are not so liable to subsequent change. Owing to this the teeth of the superior maxilla do not form so great a circle. This causes the teeth upon the sides of the jaw to conflict, and the lower teeth and alveolar processes to be carried in, while the anterior teeth of the lower jaw are held inside of the superior anterior teeth, thus carrying the alveolar processes inward.

The teeth are continually changing their positions in the mouth. This is as often beneficial as it is detrimental. That the teeth may perform their full function, they should not only remain firmly in the alveolar process, but they should also antagonize properly. The teeth may be compared to the bricks in an arch. Remove a brick and the arch falls to pieces. It is frequently found that the teeth do not articulate properly; by a slight movement, or by cutting away the grinding surfaces, a better articulation may be secured. When this operation is performed, the teeth move in their sockets by absorption and deposition of bone, demonstrating the fact that the process changes in shape and substance. Ziegler¹ says absence of functional use is a frequent cause of premature lacunar absorption of the bone.

¹ A Text-Book of Special Pathological Anatomy, page 145.

This form of atrophy from disuse occurs not only when a limb or a part of a limb is deprived of its normal activity, but also when portions of a single bone cease to perform their function of support, and finally, like all the bones of the body, as age advances, normal or physiologic absorption takes place, while the teeth are still in the jaws. Unlike other bones of the body, however, the absorption of the alveolus progresses to a greater extent because of the unstable condition of the structures.

From what has already been said of the vascularity of the alveolar process, it is evident that hypertrophy of the tissue may

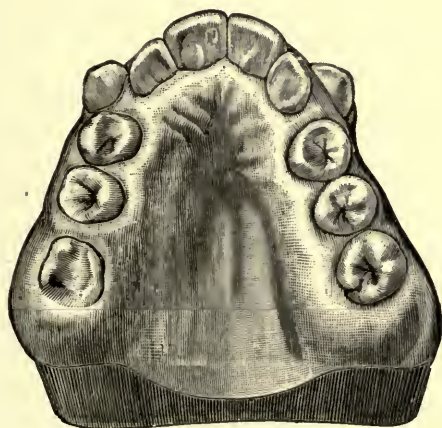


FIG. 8.

ensue from an unbalanced nervous system and from simple irritation of varying degree. The irritation consequent upon the eruption of the teeth, together with the excessive blood supply, are both primal causes of overbuilding of tissue, i. e., hyperplasia.

The ragged roots of the temporary teeth, produced by absorption of the gases from the putrescent pulps, and the pressure of the permanent crowns against the tissues, produce sufficient stimulation to excite physiological action. Tissue-building generally is seen in connection with all the teeth, and the process becomes unnaturally thick, the teeth frequently are carried in one direction and another; cementosis of the roots of the teeth and hypertrophy of the process result.

In cases of hypertrophy of the alveolar process, enlargement is associated with the inner plate of the alveolar process. In cases coming under my observation the inner plate in most is the

part of the alveolar process affected (Fig. 8 case). The outer plate, although quite irregular from the arrangement of the teeth, is usually normal in thickness. This disparity in the two plates of the alveolar process is due to the fact that the inner plate of the alveolar process possesses a large blood supply, the posterior or descending palatine arteries furnishing the ossific material. I have observed but few cases where hypertrophy has extended to and included the outer plate. When the outer plate becomes involved the alveolar process assumes a very thick condition. Occasionally hypertrophy will affect one side only or one distinct

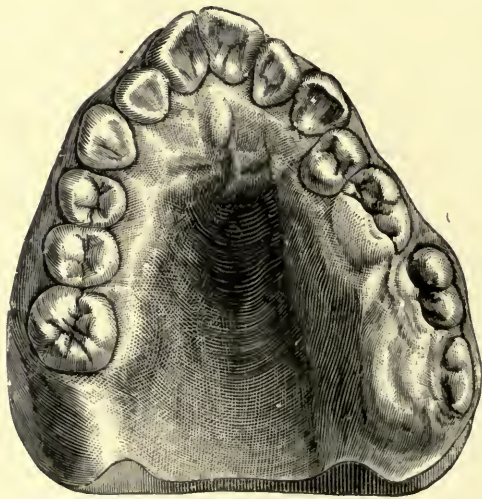


FIG. 9.

locality (Fig. 9). In this case the enlargement is upon the left side and extends from the first bicuspid posterior to and including the maxillary tuberosity. Instead of the force being directed inward, as is generally the case, the process is forced outward and backward. This enlargement occurred previously to the development of the second and third molars. The alveolar process extends downward and occludes with the teeth upon the lower jaw, thus preventing the molars from erupting.

Under the microscope, two systems of Haversian canals are seen in the alveolar process. Kolliker¹ describes these as follows:

“The Haversian canals are of two kinds. One with the regular lamellæ system surrounding it, and the other, the so-called

¹ Handbuch der Gewebelehre, page 272.

Volkman's canals, containing the perforating vessels from Von Ebner, which have no surrounding lamellæ, but simply penetrate through the layers of bone. Volkman's canals are present in all tubular bones in old and young. While especially present in the outer basal lamellæ, they occur also in the interstitial leaflets and in the inner chief lamellæ as well as in the periosteal layers of the skull bone. Here their number is very variable (Fig. 10). They run partly transversely or obliquely, and also partly longitudinally, through the lamellæ. Many of these canals open in

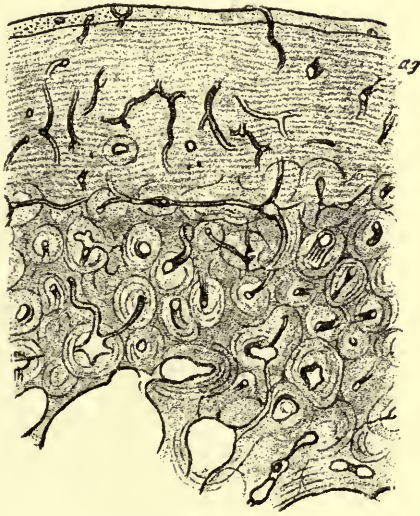


FIG. 10.—SECTION OF BONE SHOWING BLOOD VESSELS OF VON EBNER.

the outer or inner surfaces of the substantia (compact substance), and also here and there in the Haversian canals, and form altogether usually a wide-meshed irregular network. In their structure they are sometimes smooth and sometimes furnished with dilatations and angles projecting in and out in profile. The widest has a diameter of 100 micrometers or more, and the narrowest not more than 10 or 20 micrometers, and there are still narrower ones which are altogether obliterated, appearing like rings or circular-formed structures without any lumen, or like those far from rare obliterated true Haversian canals first described by Tomes and de Morgan. The contents of the Volkman canals are the same as the Haversian canals."

Fig. 10 is a cross section of the medulla of a calcified human

humerus slightly enlarged. The outer lamellæ contains a large number of Volkmann's canals running longitudinally and transversely and extending through the outer plate of bone into the periosteum. Fig. 11, the cross section of the section seen in Fig. 10, shows these canals more highly magnified. The Haversian canals are large round spaces (Fig. 12), containing a single artery and vein. The fine hair-like spaces running from these large spaces are the canaliculi. The dark spots circulating each Haversian canal are the lacunæ. The canaliculi run from one lacunæ to another or into a Haversian canal or they anastomose with each other. The rings of bone about each Haversian canal are called lamellæ. The lacunæ seem to be about uniformly

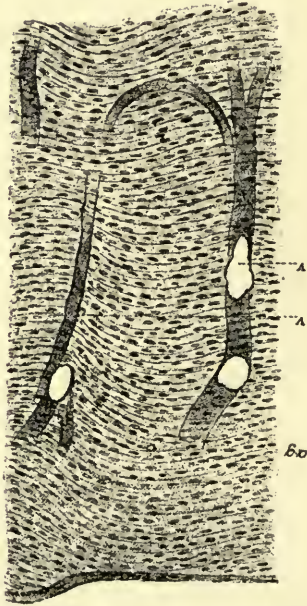


FIG. 11.—SECTION OF BONE (HIGHER MAGNIFICATION) SHOWING BLOOD VESSELS OF VON EBNER.

distributed throughout the bone. The spaces between the lacunæ and canaliculi are filled with lime salts.

A longitudinal section of bone (Fig. 13) is similar in appearance to the cross section. Instead of the lacunæ being arranged in rows around the Haversian canals they are parallel. It will be noticed that the Haversian canals run in different directions and communicate with each other at certain intervals. The

foregoing description, with illustrations from Kolliker, is essentially that of the minute anatomy of the alveolar process.

THE PERIOSTEUM AND PERIDENTAL MEMBRANE.

The periosteum is a fibrous tissue covering the outer surface of the alveolus. The peridental membrane is composed of similar structures covering the roots of the teeth and lining

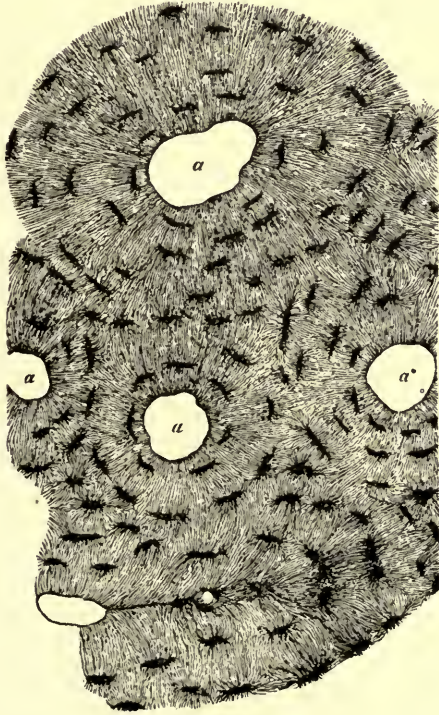


FIG. 12.—TRANSVERSE SECTION OF THE DIAPHYSIS OF THE HUMERUS MAGNIFIED 350 TIMES.

a, Haversian Canal. Dark spaces, Lacunar. Hair-like spaces, Canaliculi.

the inner wall of the alveolus. They are both derived from the mesoblastic layer. For this reason there can be very little difference in the character of the structure of each, except so far as function is concerned. The periosteum is made up of four different kinds of fibers. An outer layer of coarse, white fibrous tissue, an inner layer of fine, white fibrous tissue, elastic fibers, and penetrating fibers (fibers of Sharpey).

The fibers of the periosteum are coarser than those of the peridental membrane. The coarser fibers run parallel with the

alveolar process (J) over the border and extend as far as the union of the epithelial layer (E) and the periosteum (H), Fig. 14. ("The dental ligament," Black.¹) The finer fibers run in all directions and enter the alveolar process at every point. If a section of the alveolar process treated with acids or a section affected by haliteresis or osteomalacia be placed under the microscope, the fibers are seen to retain the original shape of the bone.

The fibers of the periosteum, therefore, are continued throughout the process from the periosteum on the one side

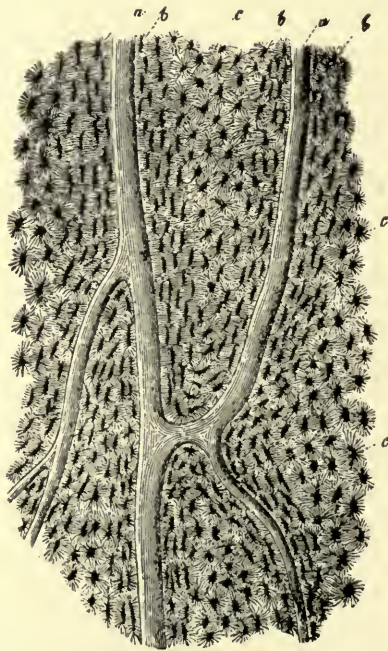


FIG. 13.—LONGITUDINAL SECTION OF BONE MAGNIFIED 100 TIMES.

a, Haversian Canals. *b*, Lacunæ seen from the side. *c*, Canaliculi.

to the periodental membrane on the other. This is also illustrated in the mouths of persons, where (after wearing artificial dentures for a short time) heat produces absorption of the lime salts, leaving the fibrous tissues intact.

The periosteum is abundantly supplied with blood vessels which anastomose with each other and enter the alveolar process at the Haversian canals. The plexus of blood vessels is much

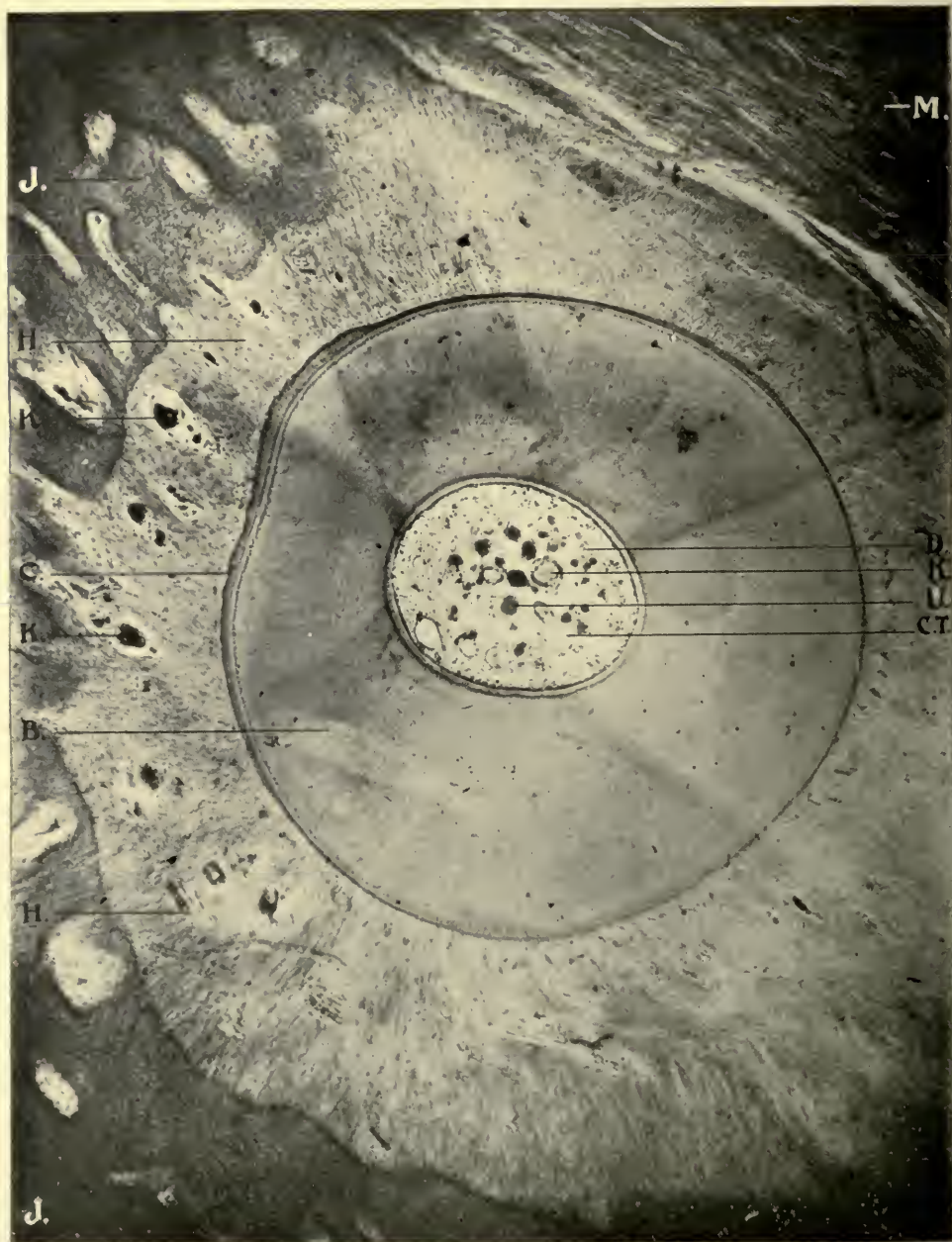
¹ American System of Dentistry, page 663.



X 75. A. A. obj. Zeiss. Micro-photographs, reduced one-third.

FIG. 14.—LONGITUDINAL SECTION OF TOOTH, ALVEOLAR PROCESS, PERIDONTAL MEMBRANE AND PERIOSTEUM. NORMAL TISSUE. SHEEP.

B, Dentine. C, Cementum. E, Epithelial Tissue. G, Submucous Membrane. H, Periosteum. J, Alveolar Process. K, Capillaries. L, Haversian Canals. M, Fibrous Tissue. AA, Point of union of epithelial tissue and periodontal membrane.



X 75. A. A. obj. Zeiss. Micro-photographs, reduced one-third.

FIG. 15.—CROSS SECTION OF TOOTH, ALVEOLAR PROCESS, PERIDONTAL MEMBRANE AND PERIOSTEUM. NORMAL TISSUE. DOG.

B, Dentine. C, Cementum. D, Pulp. H, Periosteum. J, Alveolar Process.
K, Capillaries. M, Fibrous Tissue. U, Nerve Tissue. CT, Connective Tissue.

larger proportionately in connection with the alveolar process than with other bones of the body, owing to its transitory nature.

The periodontal membrane commences at the margin of the epithelium at the neck of the tooth AA, Fig. 14, and is attached directly to the cementum. This membrane has various functions: First, it fills the space between these two structures, forming a cushion for the teeth to rest upon; second, like the alveolar process, it is present only when the teeth are present, and therefore develops with the alveolar process when the first teeth erupt, it is entirely lost when the temporary teeth are shed, is restored with the eruption of the second set, and when the permanent teeth are extracted it disappears with the alveolar process completely; third, it furnishes the nourishment for the teeth while they are in position in the jaw, and holds them in their sockets.

The fibrous tissue, in its earliest stages comprises nearly all or quite all of that portion of the jaw which eventually becomes the alveolar process. Calcification begins at the center of the jaws and gradually closes in upon the fibrous membrane until it becomes the thickness of a sheet of paper. In young persons the membrane is much thicker than in old age, since, as age advances, the osteoblasts on the one hand and the cementoblasts on the other send out new material and each wall closes in upon the membrane, which becomes very thin in old age and almost lost.

The fibers which compose this membrane extend in all directions; some crosswise penetrating the cementum, on the one hand, and the alveolar process on the other. In a general way, since the fibers extend through the alveolar wall, they are more closely adherent to the bone than to the cementum, and usually cling to the latter when the tooth is removed. It will be observed that these fibers do not enter the alveolar process uniformly as claimed by Gray¹ and Pierce², like tacks or nails driven regularly into a board (the "fibers of Sharpey" Fig. 14), but vary as to quantity in different localities. In some localities they penetrate in large quantities and almost surround a piece of alveolar process, while a few fibers penetrate but a short distance. In some

¹ Anatomy.

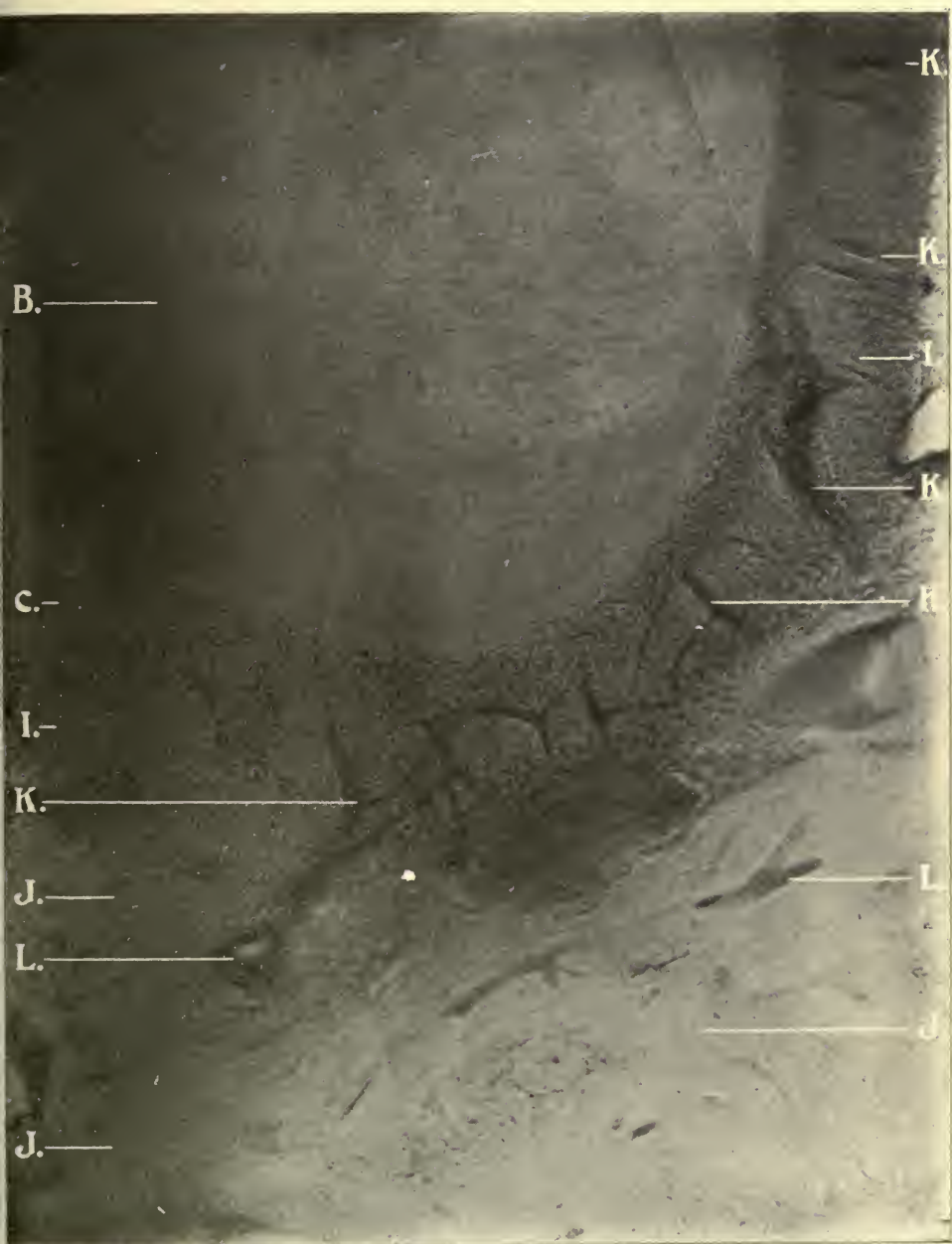
² American System of Dentistry, page 668.

places, they can be traced almost through the alveolar process. These fibers are much finer in man (Fig. 15) than in the lower animals (Fig. 14, dog). In connection with the fibers which pass into the alveolar process are numerous blood vessels. Others run diagonally, and still others lengthwise, all making up a tissue which holds the tooth in position in the jaw. The fibers enter the peridental membrane at all points of the process, from its margin to the apex of the roots. The elasticity of this membrane is so great that in correcting irregularities a tooth may be turned from one-fourth to one-half around without breaking the fibers. The elasticity is greatest in youth. As age advances, the membrane grows thinner and thinner until, late in life, there is almost a bony union between the tooth and the alveolar process, thus preventing stretching of the fibers. At the upper border, under the gum tissue, these fibers extend over the edge of the alveolar border and unite with the fibers of the periosteum on the outer border of the process, forming the interstitial tissue.

If absorption of the inorganic substance of the alveolar process occurs, the fibrous tissue retains the shape of the process. The same results when inflammation of the peridental membrane takes place at the gum margin or at the apex of the root of the tooth. What was once alveolar process is now peridental membrane or fibrous tissue.

Two kinds of structures are present in the alveolar process—a dense, compact, hard structure (composed of lime salts), and a fibrous tissue; either alone will retain the shape of the tissue.

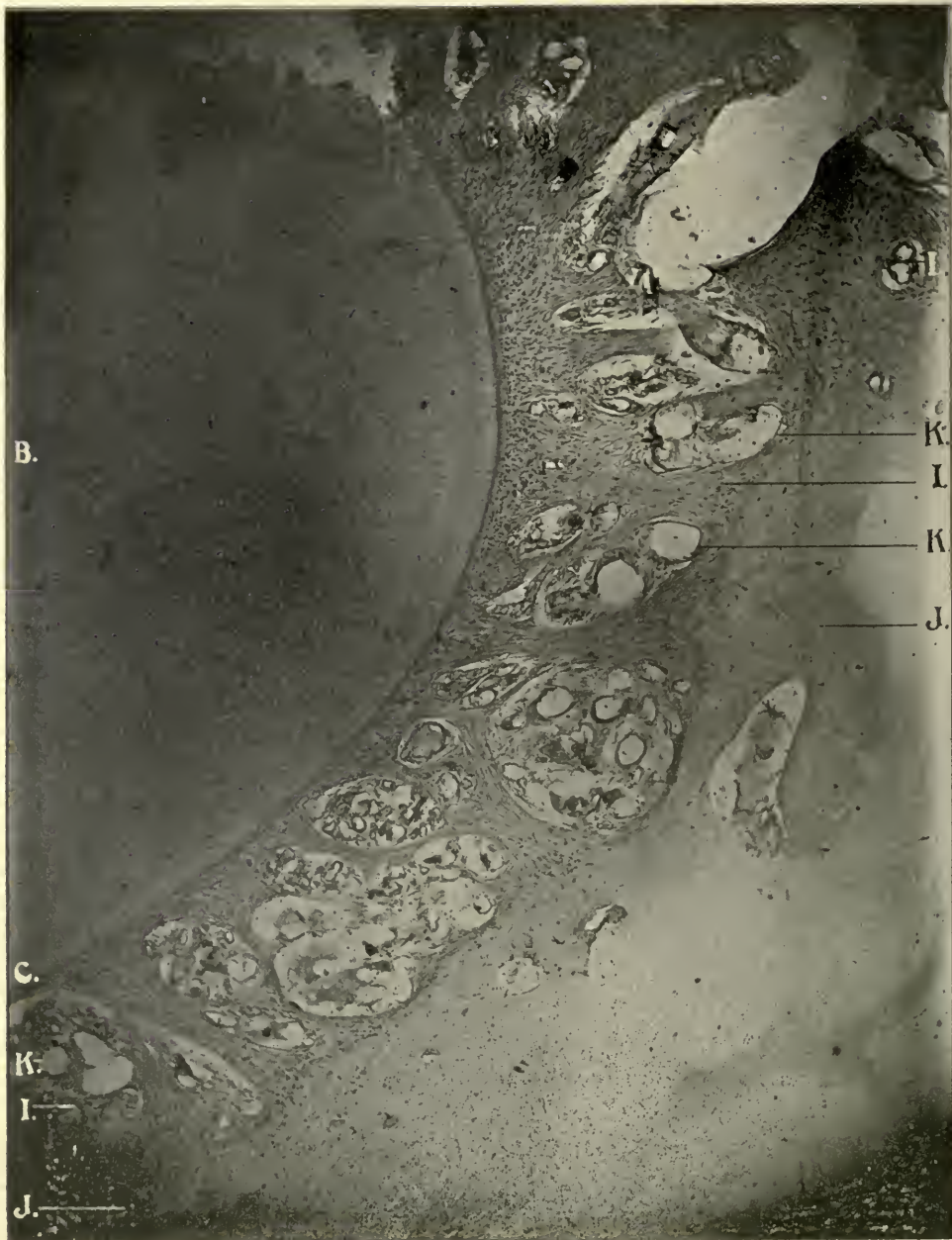Blood vessels permeate this membrane throughout from the gum tissue at the neck of the tooth, through the alveolar walls to the end of the roots. They are most abundant in youth. Capillary blood vessels enter the Haversian canals through the process and into the cementum. Many of these blood vessels extend the entire length from the gum margin to the apex in straight lines and vice versa. In many of the illustrations, the blood vessels will be seen to follow the line of the alveolar process (Fig. 14). A great supply of blood vessels penetrate the membrane through the alveolar walls. These vessels unite and anastomose with the arteries which traverse lengthwise, forming a complicated plexus (Fig. 16). According to some writers the vascular supply of the peridental membrane is situated in the



x 75. A. A. obj. Zeiss. Micro-photographs, reduced one-third.

FIG. 16.—CROSS SECTION OF TOOTH, ALVEOLAR PROCESS AND PERIDONTAL MEMBRANE.
INJECTED BLOOD VESSELS. NORMAL DOG.

B, Dentine. C, Cementum. I, Peridental Membrane. J, Alveolar Process. K, Capillaries.
L, Haversian Canals.



X 75. A. A. obj. Zeiss. Micro-photographs, reduced one-third.

FIG. 17.—CROSS SECTION OF TOOTH, ALVEOLAR PROCESS AND PERIDENTAL MEMBRANE.
INJECTED BLOOD VESSELS. NORMAL. DOG.

B, Dentine. C, Cementum. I, Peridental Membrane. J, Alveolar Process. K, Capillaries.
L, Haversian Canals.

center of the structure. This has not been my experience. All of my slides, as well as those here presented, show the blood vessels to be situated nearest the alveolar process. It is quite natural that this should be so, since very little blood is required for the nourishment of the cementum, while the largest amount is required to supply the alveolar process. The system of blood vessels situated in the peridental membrane and showing their relation to the surrounding tissue is well shown in the injected specimen from healthy dogs (Figs. 16 and 17). Pus pockets and abscesses are hence more liable to form near and in the alveolar process than near the tooth structure. When infection takes place, the products of inflammation are carried through the blood vessels and the foci of round cell inflammation are located near or in the alveolar process where abscesses form. The vessels seen in the membrane anastomose very freely with those at the gum margin, showing the membrane to be well nourished in all its parts. Should one part become involved by disease the other parts are overnourished in consequence.

These blood vessels enter the alveolar walls with the fibrous tissue through the Haversian canals and these in turn permeate the entire bone. As age advances, however, the bone becomes more dense, and the Haversian canals become smaller and (under certain conditions) cease to exist. When disease takes place, either at the gingivus or at the apex of the root, the supply of blood being thus cut off, the tissues receive sufficient nourishment through the alveolar wall. Since the structures are in a transitory state, being destroyed and repaired so frequently, it is evident why the blood supply is so rich.

CALCOSPHERITES.

Small, hard bodies are frequently found in the peridental membrane. These are sometimes in the form of concentric rings of lime salts and are called calcospherites. They are not always round, but may be of any shape and vary as well in size. They bear the same relation to the peridental membrane that pulp stones do to the dental pulp. Black¹ says: "I have seen more of them about the roots of the molars than elsewhere, but have found them along the sides of the roots of the bicuspid."

¹ Periosteum and Peridental Membrane, Page 94.

When irritation and inflammation take place in the peridental membrane, the cementoblasts build up cement substance, just as the osteoblasts do in the alveolar process and the odontoblasts do in the pulp chamber. Sometimes they are attached to the root of the tooth, which produces what is called exostosis or cementosis. They may remain unattached, floating in the fibrous tissue. These are very common in connection with interstitial gingivitis.

GUMS AND MUCOUS MEMBRANE.

The tooth, according to Minot,¹ is a papilla which projects into the epidermis, and ossifying in a particular way, changes into ivory around the soft core or pulp. To the papilla the epidermis adds a layer of enamel. The tooth proper unites with a small plate of dermal bone at its base. By a modification on the jaw, the epidermis first grows into the dermis, and then the dermal tooth papilla is developed. The teeth were primitively organs of the skin and widely developed over the surfaces of the body. As the mucous membrane is practically a continuation of the skin, it, in accordance with the law of individuation, became specialized and lost some of the functions of the skin while developing the others to greater perfection.

The mucous membrane lines the cavity of the mouth, the nose, and extends through the larynx into the lungs and through the œsophagus into the stomach. It covers the tongue, jaws, alveolar process, dipping down between the necks of the teeth and the alveolar process as far as the peridental membrane, leaving a free space between the membrane and the teeth through its entire length.

It consists of two layers (Fig. 18), the epithelium (A) and corium (B), separated by the basement membrane (C). The epithelium is composed of the epithelial cells: First, one row of columnar cells (B) situated upon the basement membrane (C); second, two rows of six-sided prickly shells (E); third, two rows of six-sided cells (F); fourth, two or three rows of squamous cells (G); and fifth, four or five rows of flattened dead cells (H), which were originally the columnar cells upon the basement membrane. The young new cells are the columnar cells which pass from one stage to another, changing their shapes until they

¹ Embryology, page 481.

eventually become dead cells and are exfoliated from the surface of the tissue. The basement membrane (C) is made up of fibers running longitudinally, from papillæ, which allow the tunica propria containing blood vessels and nerves to pass up into the epithelium structure.

The corium (B) (which lies below the basement membrane) is composed of alveolar connective tissue, white yellow fibrous connective tissue, muscular fibers, nerves, blood vessels and lymphatics. It is made up of the tunica propria and the submucosa.

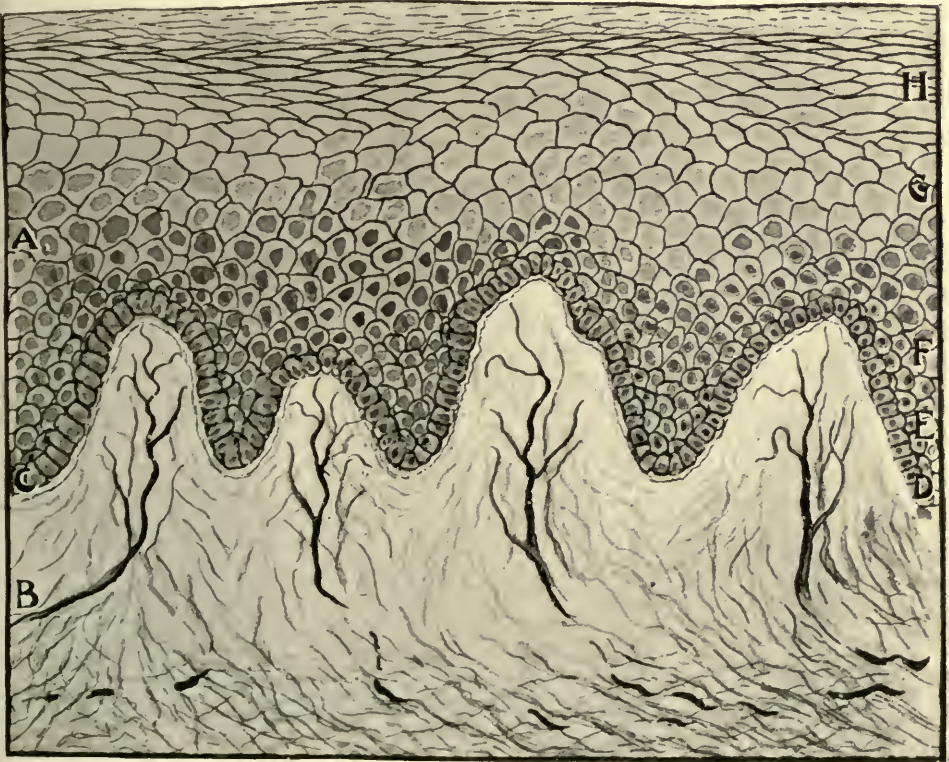


FIG. 18.—DIAGRAMMATIC ILLUSTRATION OF THE EPITHELIUM AND SUBMUCOUS LAYERS OF THE MUCOUS MEMBRANE.

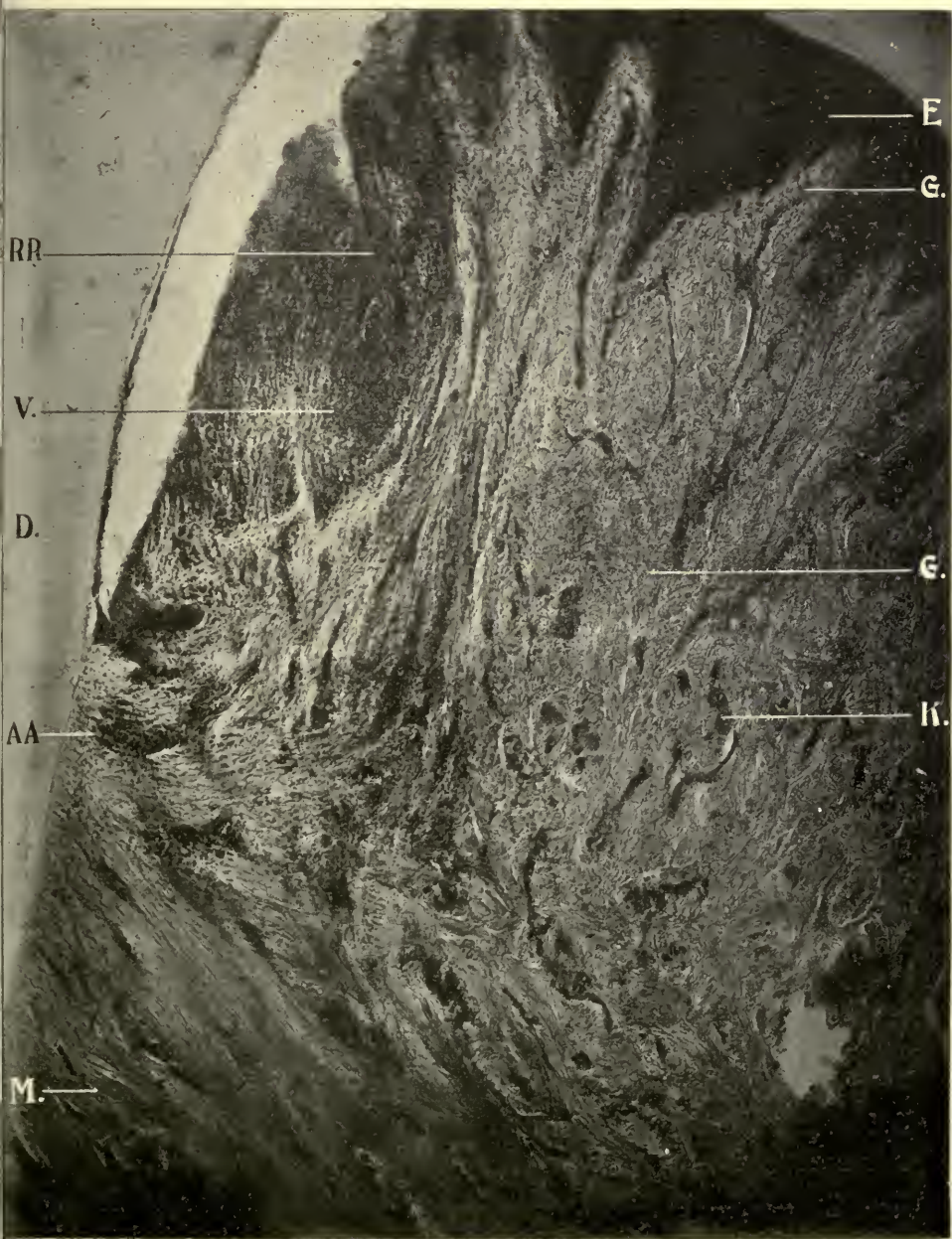
A, Epithelium. B, Corium. C, Basement Membrane. D, Columna Cells. E, Prickle Cells. F, Six-sided Cells. G, Squamous Cells. H, Flattened Dead Cells.

The tunica propria (beautifully shown in Fig. 19) consists of interlacing connecting fibers interspersed with much elastic fibrous tissue. This tissue penetrates the epithelial layer in the

form of cone-shaped papillæ, varying in length with the thickness of the epithelium. This layer being the thickest at the gum margin (E), these papillæ are the longest and largest at this locality. The fibers of the tunica propria pass gradually into the submucous membrane (G), and from there into the periosteum and peridental membrane (M), so that it is difficult to determine the mucous capacity line of demarcation separating the different structures. The submucosa is composed of fibrous connective tissue of a much less compact variety. This structure is attached to the bones through the periosteum and peridental membrane. In this structure the glands, blood vessels, nerves, fat cells, etc., occur.

The larger blood vessels (K) are found in this structure. From these large blood vessels small capillaries extend to the tunica propria. It is here that inflammation commences in interstitial gingivitis. Numerous veins accompany each artery, and lymphatics form a network around them. Small nerve filaments are also in this structure, which pass through the tunica propria and into each papilla in connection with the capillaries. The terminal nerve fibers come in contact with the muscular fibers, so that there is direct communication by blood vessel and nerve throughout the mucous membrane from the nose, stomach and lungs. The gum tissue is very thick and made up of fibrous tissue running in three or four directions, rendering it dense, tough and hard. The membrane thus differs from the same structure in other parts of the body. On account of these numerous fibers, this structure is bound tightly to the alveolar process. The gum tissue acts as a cushion and protection from irritation which may arise from hard substances being taken into the mouth. As this membrane passes and coalesces with the membrane of the lips and cheeks, it becomes much thinner and less dense. In the center of the tooth, the parallel fibers in the tunica propria are composed of flattened fasciculi of connective tissue. There are three sets of fibers — those which run vertically, those which radiate and are fan-shaped, and those which are horizontal.

The mucous membrane, like the alveolar process and peridental membrane, is composed of very unstable tissue. It changes its structure, blood vessels and nerve system as often



X 75. A. A. obj. Zeiss. Micro-photographs, reduced one-third.

FIG. 19.—LONGITUDINAL SECTION OF TOOTH AND GUM TISSUE. DOG.

D, Dentine. E, Epithelial Tissue. G, Submucous Membrane. K, Capillaries. M, Fibrous Tissue. V, Violent Inflammation. AA, Point of Union of Epithelial Tissue and Peridental Membrane. RR, Space Pocket from Want of Union of the Epithelial Fold.

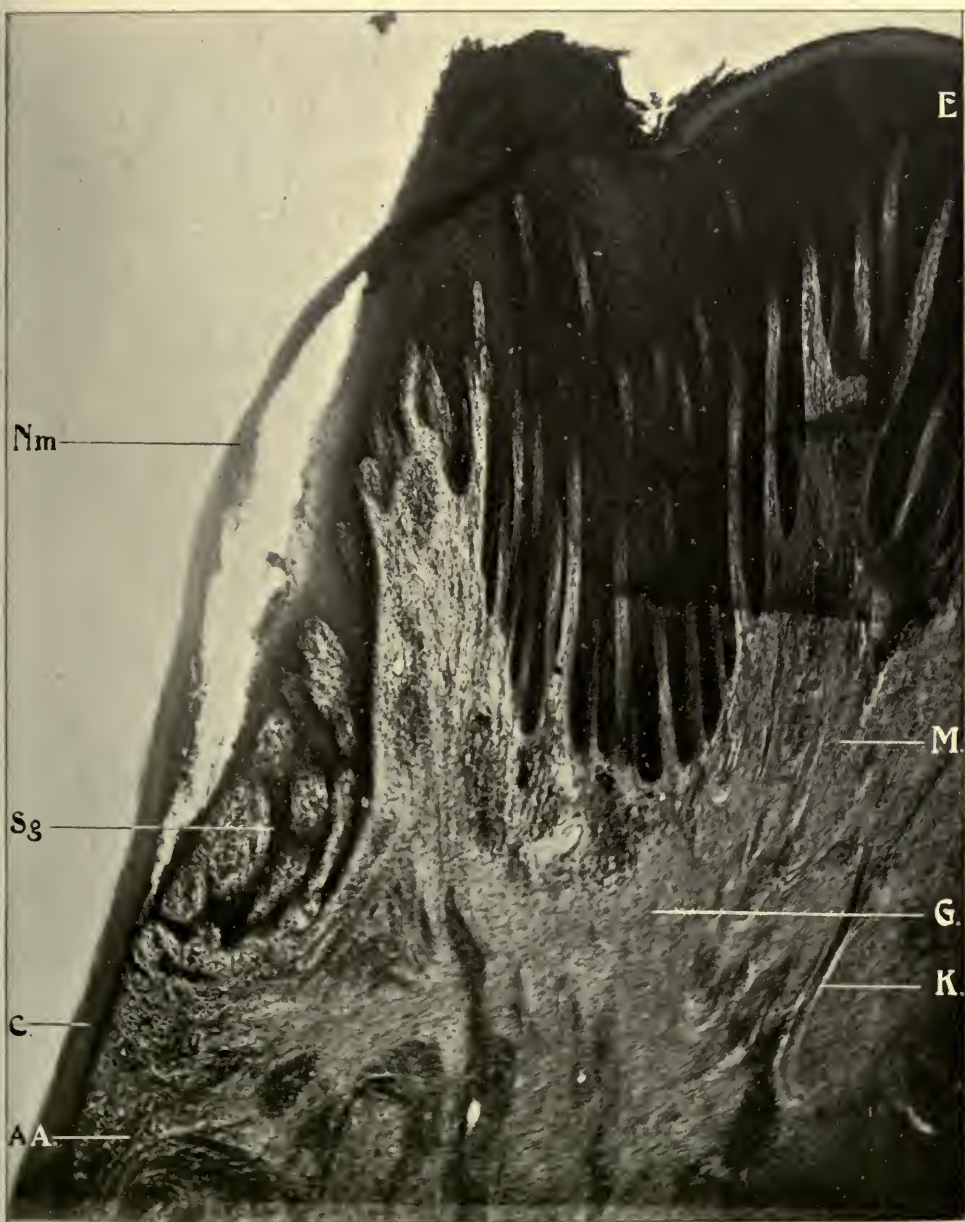
as the other structures. Its blood vessels and nerve system are continually renewing connective tissue, periosteum and peridental membrane.

A difference is noticed in the structure of the papillary layer in man and the lower animals, such as the dog, the sheep and the calf. In man the gum tissue is not so thick, therefore the papillæ are broader and shorter, while in the lower animals the papillæ are narrow, long and more closely set together. Blood vessels and nerves are not so numerous and close together in man as in animals.

DO GLANDS EXIST IN THE MUCOUS AND PERIDENTAL MEMBRANES?

A somewhat widespread opinion locates special glands in the gingival tissues and the peridental membrane. This seems, to a certain extent, to be in part due to the lack of definite knowledge as to the etiology of interstitial gingivitis, and in part to the fact that certain constitutional conditions, such as mercurial and potassium iodide poisoning and scurvy, manifest themselves in the gum tissue in a way similarly to their action in the glandular structures of the body. Black¹ claims, for example: "That part of the gingival margin that lies in against the neck of the tooth is of a different structure from its other parts. Here it is clothed with a very soft, round or polygonal gland-like epithelium that suggests the formation of a gland, but fails to assume the glandular structure, though it seems to have been regarded as such by Serres. This — which I shall call the gingival organ — emits a profusion of small rounded cells which are always found in the saliva (Salter) and are usually called mucous-corpuseles. It is well known that certain glands have the power of the selection and excretion of certain poisons, and in this way of eliminating them from the system, and that if the substance be in large amount, hyperæmia, or even inflammation, may result. It is also known that mercury and potassium iodide will produce inflammation of the free margins of the gums, and Salter has found that these cells are in greater abundance under these circumstances; also that the cells taken from the gingival border

¹ American System of Dentistry, pages 955-956.



X 75. A. A. obj. Zeiss. Micro-photographs, reduced one-third.

FIG. 20.—LONGITUDINAL SECTION OF GUM. NORMAL TISSUE. SHEEP.

C, Cementum. E, Epithelial Tissue. G, Submucous Membrane. K, Capillaries. M, Fibrous Tissue. AA, Point of Union of Epithelial Tissue and Peridental Membrane. Nm, Naysmith's Membrane. Sg, So-called Glands of Serres.

and submitted to chemical tests after the person has taken potassium iodide, are found to yield, and are tinged with, iodin."

Longitudinal sections of the tooth, alveolus and surrounding tissues, under the microscope, exhibit a very peculiar formation of the mucous membrane at its line of union with the peridental membrane at the neck of the tooth. Black¹ (in an article beautifully illustrated by Frederick Noyes) seems to identify these with the so-called glands of Serres, or gingival glands (Fig. 20). He speaks of them as glands in various places throughout the article; for example, "But little can now be said of the function of the network of glands of the peridental membrane, beyond what is indicated by their form, location and histological characters. With the knowledge of their position and general character, clinical observation leads to the conclusion that they are readily disturbed by certain drugs, notably by mercury and iodine; and that they are often disturbed by substances poisonous to them floating in the blood streams. This is evidenced by the appearance of marginal gingivitis, with soreness of the peridental membrane. Such disturbances would not be likely to occur without the presence of some specialized or secretory tissue. . . . It seems to me very certain that the disease which I have described as phagedenic pericementitis has its seat in these glands." Black, however, does not seem quite certain of the validity of his position, since he further remarks, "Though definitely lobulated, this body does not seem to possess the characters of a gland, and I should not suppose from an examination of its tissues that it had a glandular function. It encircles but a portion of the neck of the tooth, usually only the approximal portion, thinning away toward the buccal and lingual, so that in many of the lengthwise sections it may be very small, or does not appear at all."

In many slides of sections from canine jaws and human,² the same peculiar arrangement of structure was observed, although not in so marked a degree. In the immature herbivora (calf and

¹ Dental Cosmos, February, 1899.

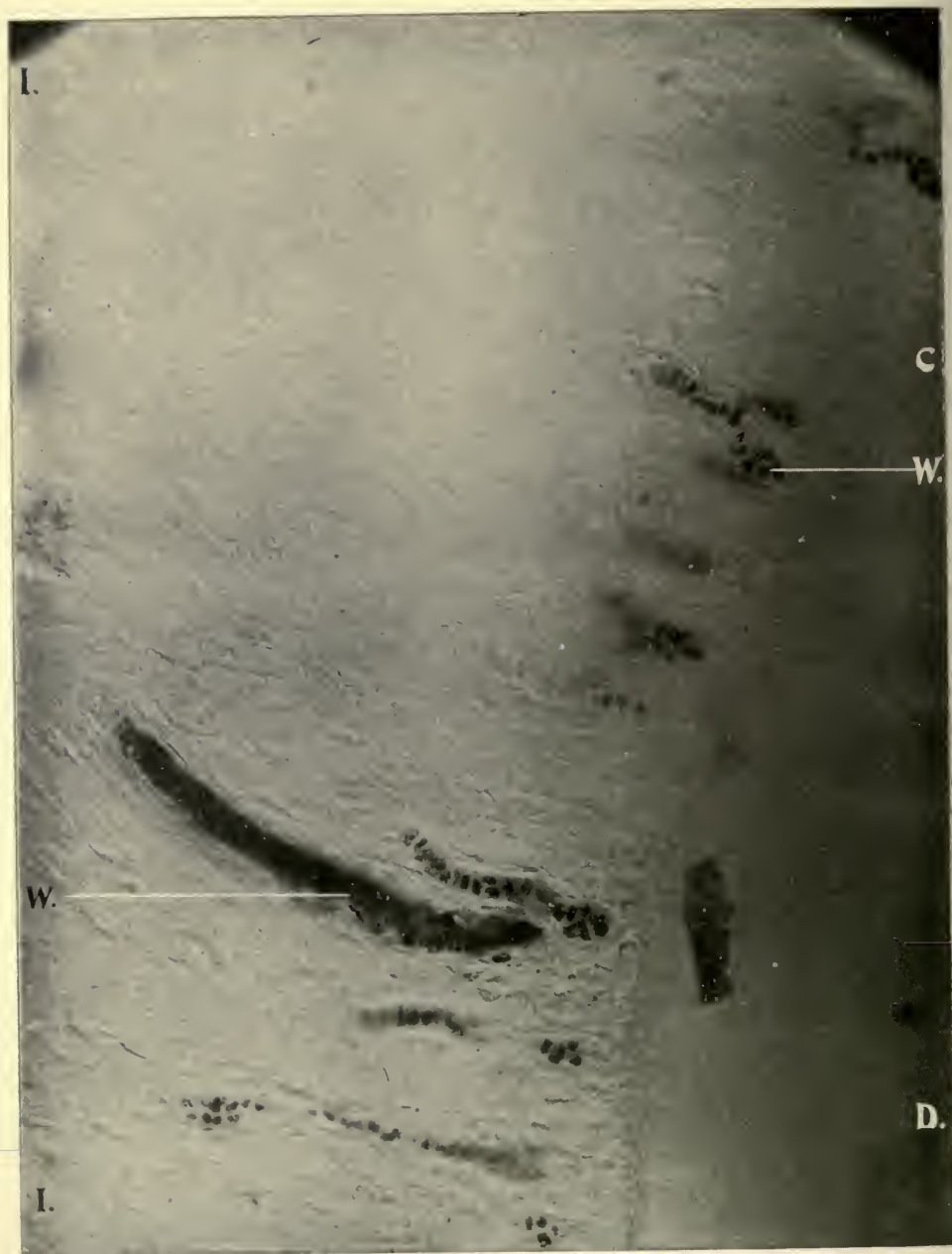² The material obtained for making slides from man, other than the scurvy cases, was obtained through the kindness of surgeons from jaws removed from hospital patients, as a result of disease; the surgeons placing them into alcohol or Müller's solution as soon as removed.

20
N. Y. CITY
COLLEGE OF DENTISTRY



X 75. A. A. obj. Zeiss. Micro-photographs, reduced one-third.

FIG. 21.—CROSS SECTION OF TOOTH AND PERIDENTAL MEMBRANE. NORMAL TISSUE. SHEEP.
C, Cementum. D, Dentine. I, Peridental Membrane. W, Epithelial Débris.



x 300. No. 2 projection ocular. D. D. obj. Zeiss. Micro-photographs, reduced one-third.

FIG. 22.—CROSS SECTION OF TOOTH AND PERIDENTAL MEMERANE. NORMAL TISSUE. SHEEP.

C, Cementum. D, Dentine. I, Peridental Membrane. W, Epithelial Débris.

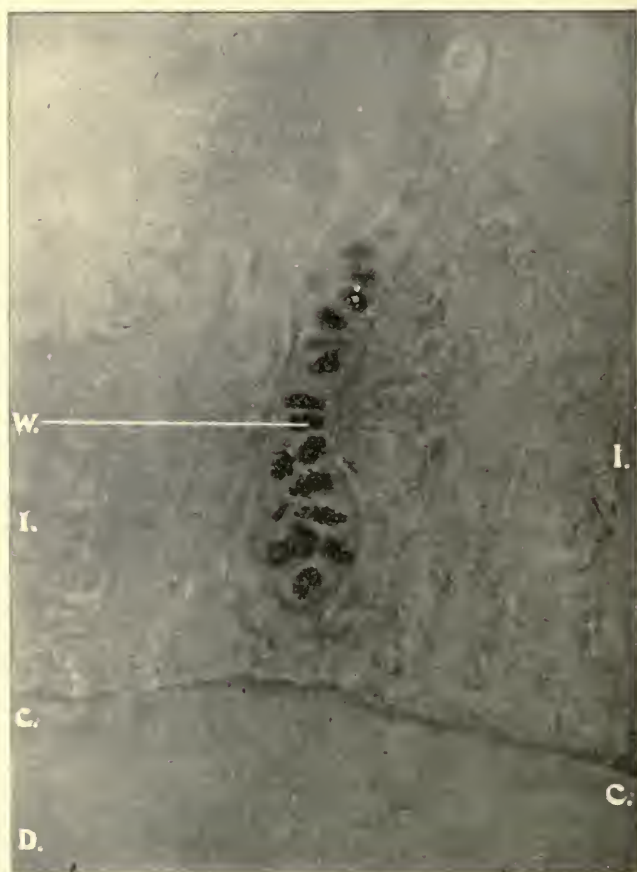
lamb) these peculiar formations of structure are well marked, albeit less so in the carnivora, and still less in man.

Were glands present in this locality it is logical to infer that they would become involved in mercurialism, plumbism and scurvy, and exhibit marked inflammation with broken-down structures in a given locality, as at the union of the gum tissue with the peridental membrane. Such a case is unknown.

The mucous membrane under the microscope appears at a point between the teeth (and faintly so at the inner and outer border as shown by Black) to double upon itself. When the tooth erupts, absorption of the gums occurs at the highest point. The gum tissue passing down to the neck of the tooth folds or crowds upon itself between the teeth with a peculiar curve downward, inward and then outward and upward. At the upper border, about midway from the gingival margin to the neck of the tooth, may be seen a space or pocket (never twice alike in appearance) where the edge of the gum tissue comes in contact with the original epithelium. Sometimes the space or pocket is closed up (Figs. 43, 44, 51). Again it remains open (Figs. 19, 32, 50, 53). Frequently this peculiar type of structure is absent, showing that the fold of gum tissue either has been absorbed in the eruption of the tooth or did not form. This peculiar form encircles only a portion of the neck of the tooth (according to Black's examination of the structure in sheep). This in itself seems to offset the glandular theory, since gingivitis almost invariably starts on the lingual or palatine and labial surfaces where this structure does not appear. In the slides of the scurvy case there does not appear the slightest evidence of anything resembling glandular structure. Hence it would seem safe to conclude that the glandular structure does not occur in this locality. It is by no means impossible that in the peculiar epithelium in this locality, epithelial cells undergo changes which to some observers simulate glandular structure, but on histologic analysis are distinguishable from it, resembling in this the crypts of the head of the penis.

In cross sections of the peridental membrane, with a low power may be seen dark bodies arranged along the margin of the cementum in the peridental membrane (Fig. 21). They are more numerous, however, near the gingival border than at the

root extremity. These bodies are more numerous and better defined in the sheep than in the calf, and more apparent in the canine jaw than in the human. Under higher power (Fig. 22) they may be distinctly demarcated as epithelial cells arranged



x 560. No. 2 projector ocular. One-twelfth obj. Zeiss.

FIG. 23.—CROSS SECTION OF TOOTH AND PERIDENTAL MEMBRANE. NORMAL TISSUE. SHEEP.

C, Cementum. D, Dentine. I, Peridental Membrane. W, Epithelial Débris.

in single rows of loops, again in double rows, again in rows of three and sometimes in round or oblong groups, with clusters of cells without shape or form. With a still higher magnifying power (Fig. 23) it will be seen that these masses of cells are polygonous, never prismatic. They hence are similar in shape

to the epithelial cells situated above the columnar cells. They also resemble the cells which are situated inside of the epithelial lamina. In the larger amplification the nucleus can be readily observed.

Black¹ has attempted to demonstrate that glands exist in the structure and that the cells last mentioned are glands. Black lays down as a *sine qua non* of a gland that there should be an opening to the surface. He has made an attempt (Fig. 15) to demonstrate such an outlet, but this figure does not show clearly that the glands empty into the duct or have an exit at the surface. These bodies, however, not only fail (like the ductless glands) in this particular, but in more important characteristics of glands. They do not have (as Robin and Magitot remark) a columnar or prismatic cell wall. It is not difficult to understand how epithelial cells are scattered in different shapes and sizes throughout the peridental membrane. Epithelial cells have the property of multiplying and developing in structures wherever located.²

If epithelial cells should migrate within the submucous membrane and fibrous tissue, proliferation will occur under certain circumstances. The tooth, according to Minot,³ is a papilla which projects into the epidermis and, ossifying (calcifying) in a particular way, changes into ivory around the soft core or pulp; to the papilla the epidermis adds a layer of enamel. The tooth proper unites with a small plate of dermal bones at its base. By a modification in the jaws the epidermis first grows into the dermis and then the dermal tooth papilla is developed. The first indication of the development of tooth germs in mammals is a thickening of the epithelium covering the jaw. This thickening, which appears as a ridge during the sixth week of embryonic life, forms on the under side of the epithelium. This curving ridge expands into an outer portion (the outline of the groove between the lip and the gum) and an inner portion, the dental shelf which grows obliquely inward. The papillæ for the milk teeth are formed on the under side of the shelf, and it is thus possible for the shelf to continue growing toward the lingual

¹ Dental Cosmos, February, 1899, pages 112-118.

² Dental Follicle, page 116.

³ Embryology, pages 581-90.

side, so that the second set of germs is developed for the permanent teeth. The end of the shelf, toward the articulation of the jaws, is prolonged without retaining the direct connection with the epithelium and from this prolongation arise the enamel organs for the three permanent molars. Wherever a tooth-germ arises the dental shelf is locally enlarged, and the local enlargement constitutes an enamel organ which projects from the under side of the shelf. The portions of the shelf between the enamel organs gradually break up, forming first an irregular network, and later separate fragments¹ which may persist throughout life and lead to various pathological structures. While the permanent germs are forming, the shelf is solid between them, although it has assumed the reticulate structure between the germs of the milk teeth. In consequence of the reticular formation, the fully developed enamel organs have several bands or threads by which they are connected with the dental shelf proper.

After the shelf has developed somewhat, its line of connection with the epithelium of the gum becomes marked by a superficial groove, as may be seen in the human embryo of eight to ten weeks. This groove was formerly supposed to be the first trace of the dental shelf, but Rose's observations correct the supposition.

The second step in mammals is the formation of outgrowths (in man ten in each jaw) from the under side of the dental shelf; each outgrowth is the outline of an enamel organ for a milk tooth. The outgrowth is covered toward the mesoderm by a layer of the epidermis, while the core is filled with polygonal cells which resemble those of the middle part of the Malpighian layer of the skin. The outgrowths, after penetrating a short distance, expand at the lower ends, but remain each connected by a narrow neck with the overlying epidermis. The expanded end is the enamel germ proper; it very soon assumes a triangular outline, as seen in sections, owing to the flattening of its under side, and at the same time it moves somewhat toward the lips. Meanwhile the shelf continues growing on the lingual side of each ingrowth to produce the enamel organs destined for the second or permanent teeth.

At this stage it is noticed that the mesenchyma under the flattened end of the enamel organ has become more dense, to

¹ Including the epithelial débris of Robin and Magitot.

form the outline of the dental papilla, and is beginning to develop fibrillæ around both the enamel germ and the papillary outline. The fibrillar envelope is the future dental follicle.

The third step is a final differentiation of the enamel organ and the accompanying shaping of the papilla. The enamel organ continues growing and becomes concave on its under side so that the mesoderm underneath acquires the shape of the papilla. It is now that the form of the tooth is determined by the form assumed by the papilla, which in its turn is probably determined by the growth of the enamel organ.

The follicle is merely an envelope of connective tissue in which can be distinguished an outer dense and inner looser layer; in the latter the cells are more distinct and the fibrillæ are less numerous than in the former. A rich network of capillary vessels is developed in the follicle and appears in part as a series of villous-like growth into the enamel organ. The follicle develops first over the lower part of the papilla, then over the enamel organ, the neck of which aborts and the follicle closes over, completely separating the enamel organ from its parent epidermis. The enamel organ changes greatly in appearance. The layer of cylinder cells is well preserved over the concave surface, but only where the epithelium is in contact with the dental papilla. In the neck the cells become irregular in form. Over the convex surface the cells become lower and cuboidal. They ultimately atrophy and flatten out. The cells in the center of the enamel organs undergo a peculiar metamorphosis. They remain united together by a few thread-like processes.

It is obvious from these changes in the embryo how what Robin calls the epithelial débris is derived from the epithelial cord, the follicular wall and the round bodies of lamina epithelium débris. According to Ch. Robin and Magitot,¹ who were the first to describe these bodies, "The phenomena of budding commences, namely, when the epithelial cord has finished its course, having conducted the primary enamel organ to that point whence its subsequent evolution will be effected and soon after the formation of the secondary follicle, immediately after the rupture of the cord of the primitive follicle." Robin leans to

¹ See their Memoir on the Genesis and Development of the Dental Follicle in Jour. de Physiologie de Brown-Sequard, 1860.

the opinion that these bodies disappear soon after they are formed, "The time of their disappearance varies, they remark, in different species of animals. In the human embryo the remains of the cord of the primitive follicles may be found, even after the formation of the follicles of the permanent teeth, and it is probably during the process of eruption that these bud-dings become atrophied; in the canine embryo the facts are nearly the same; in the bovine and ovine embryos (calf and lamb) it has seemed to us that these proliferations disappear at a

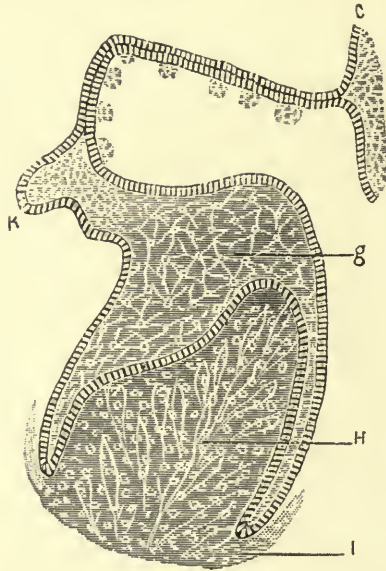


FIG. 24.—SECTION THROUGH THE INCISIVE PORTION OF THE LOWER JAW OF AN OVINE EMBRYO, MEASURING 82 MILLIM ($3\frac{1}{2}$ INCHES) IN LENGTH. MAGNIFIED 260 DIAM., AFTER DRs. CH. LEGROS AND E. MAGITOT.

D, Oral Epithelium. C, Lowest Layer of Cells in the Stratum Malpighii. F, Epithelial Cord. K, Bourgeon of the Secondary Cord. I, Follicular Wall. H, Dental Bulb.

correspondingly earlier stage; and we think it safe to say that, as a general rule, the complete absorption occurs toward the period of eruption."

The embryology of the dental shelf, which has been summarized by Minot from Waldeyer, Kolliker, Von Ebner¹ and O. Hertwig, indicates the source of the structures which have been mistaken by Black for the limiting walls of glands.

¹ Handbuch der Zahnheilkunde, 1890, pages 209-262.

After the epithelial cords of the temporary and permanent sets of teeth have been demarcated from their follicles, the process of cell building proceeds like the process of cord building. These buds, according to Charles Robin and Magitot,¹ are given off at the upper border of the follicle and below the epithelium of the gum. "In fact, as soon as the epithelial lamina loses its connection with the follicle, by the rupture of the cord, the epithelial cells composing it become greatly increased in number at the severed point. The multiplication of cell-elements results

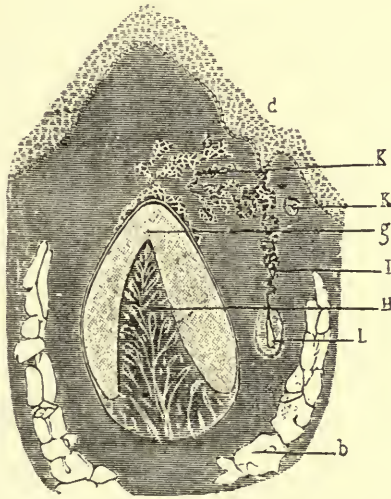


FIG. 25.—VERTICAL TRANSVERSE SECTION THROUGH THE INCISIVE REGION OF THE LOWER JAW OF HUMAN FETUS MEASURING 38 CENTIMETRES (15½ INCHES), MAGNIFIED 80 DIAM., AFTER DRS. CH. LEGROS AND E. MAGITOT.

b, Bony Formation. d, Oral Epithelium. g, Enamel Organs. H, Dental Bulb. I, Cord of the Permanent Follicle. K, Débris on the Follicular Wall of the Primitive Follicle and from its Cord. K, Epithelial Globule. L, Enamel Organ of the Permanent Tooth.

in the formation of irregular buddings, which wander in different directions into the deeper portions of the embryonal tissue. These buddings vary greatly in form; sometimes they are simple cylinders, retaining their connection with the primitive lamina by pedicles of various lengths, and sometimes this slight connective is absorbed, thus isolating an epithelial mass."

This budding occurs at different points along the cord (Fig. 24) at the end and upon the outer surface of the follicular wall (Figs. 25 and 26) at the point where the cord is severed from the

¹Loc. cit., 1860.

enamel organ. These gradually diminish as they descend upon its sides. Doubtless the epithelial cord remains in the periosteal and submucous tissue throughout life. Fig. 27 represents evident sections of epithelial cord in a man sixty-eight years of age, and Fig. 28 in a dog eight years. In the photographs of the scurvy cases and of dogs will be seen evidences of the persistence of epithelial débris late in life. The position already cited from

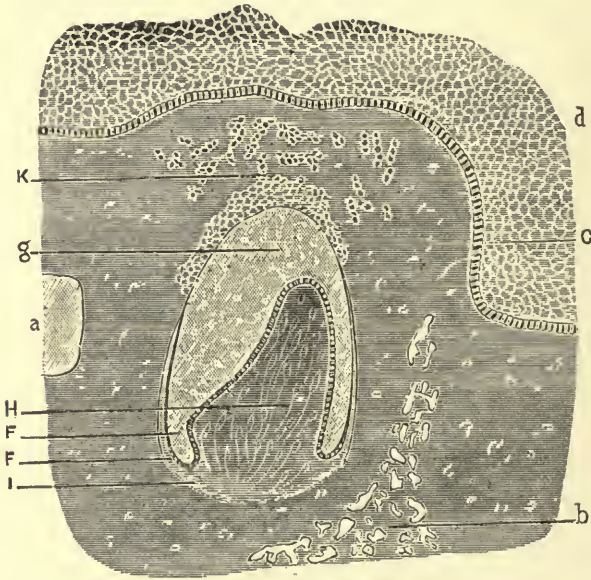


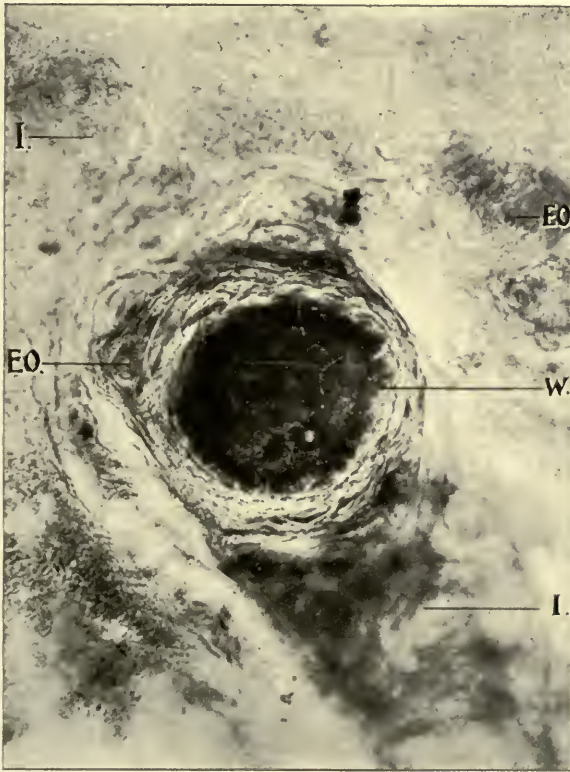
FIG. 26.—FROM THE LOWER JAW OF AN OVINE EMBRYO, MAGNIFIED 80 DIAMETERS, SHOWING THE COMPLETED DENTAL FOLLICLE AND THE SURROUNDING TISSUES, AFTER DRs. CH. LEGROS AND E. MAGITOT.

a, Meckel's Cartilage. b, Traces of Ossification. c, Lowest Layer of Epithelial Cells. d, Oral Epithelium. F, Ameloblastic Layer. F, (Lower) External Layer of the Enamel Organ—a continuation of the Layer of Ameloblasts. g, Stellate reticulum of the Enamel Organ. H, Bulb. I, Follicular Wall. K, Buddings from the Cord.

Robin and Magitot as to its early disappearance would hence appear to be too strongly taken.

Robin and Magitot claim that this budding process occurs at or about the time of the rupture of the cord. Up to this period ossification has not taken place, but then deposits of bone appear in the fibrous tissue of the middle and outer surfaces. The bone deposit gradually takes the form of the jaw, filling in and encroaching upon the fibrous tissue, forming a bony wall on the

one hand, and the crown and root of the tooth on the other. When the tooth is ready to erupt, the crown pushes the soft tissue laterally, while the root develops, forms a defined wall with the peridental membrane between them. The epithelial débris (to use their term) which before was scattered over the entire surface of the dental follicle, is now crowded into the very narrow space



X 50. One-half-in. obj. No. Oc.

FIG. 27.—CROSS SECTION OF EPITHELIAL CORD. MAN.

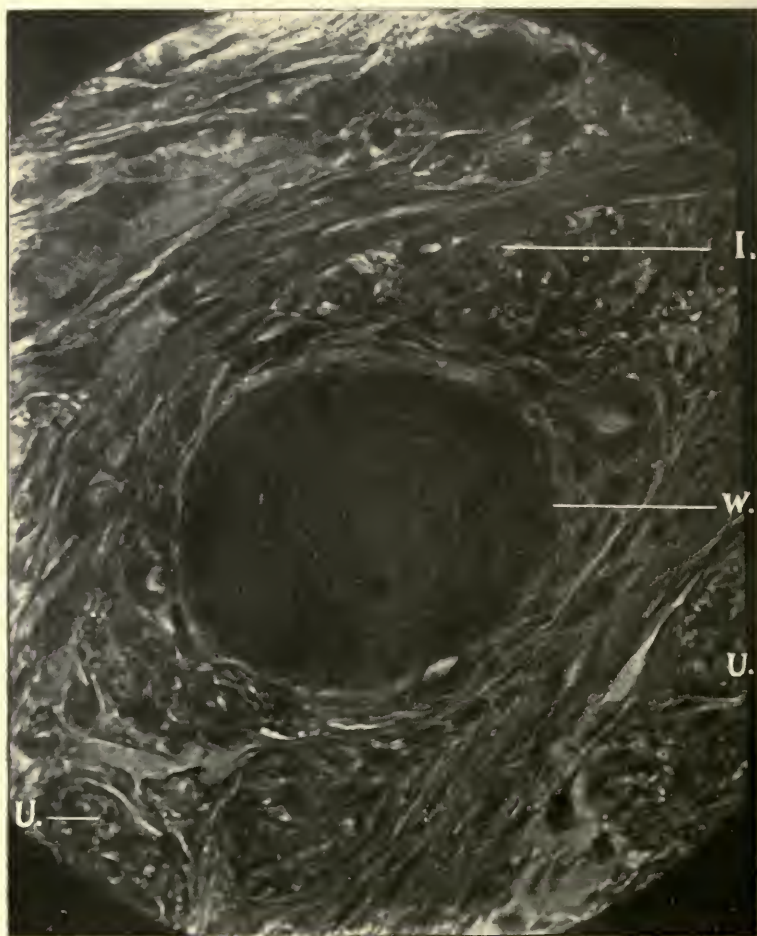
I, Peridental Membrane. W, Epithelial Débris or Cord. EO, Endarteritis Obliterans.

of the peridental membrane, and owing to the position of the débris at the upper part of the follicle, it would be natural to find most of it at the peridental membrane.

BONE BUILDING AND ABSORPTION.

Development of the alveolar process is relegated to a series of cells situated in the fibers of the peridental membrane or fibrous tissue, and close to the margin of the bone tissue, and

throughout the Haversian canals. These cells are called the osteoblasts. They perform the function of building up the bone tissue. Even after the alveolar process has developed its normal shape, so unstable is the nervous system which presides over these cells at this locality, that at the slightest provocation, either



X 500. No. 2 projection ocular. One-twelfth obj. Zeiss.

FIG. 28.—CROSS SECTION EPITHELIAL CORD. DOG.

I, Peridental Membrane. W, Epithelial Débris or Cord. U, Nerve Tissue.

local or constitutional, they will continue their process of construction. Hence, the frequency of hypertrophy of the process, and in disease the calcification of the peridental membrane.

On the other side of the membrane, next the root surfaces,

may be seen other cells which build up and destroy the cementum; these are called cementoblasts and cementoclasts. These are of little importance in this connection with the study of this disease, although they are frequently present and at work when inflammation of the membrane occurs.

There is, however, another class of cells found in the peridental membrane of the utmost importance in this connection, the osteoclasts, located in the fibers, and in close proximity to the alveolar wall, and around the inner border of the Haversian canals. The function of these cells is to tear down irregular bone and tooth structure due to unstable nervous tissue, and from the slightest irritation.

The gums, mucous membrane, alveolar process and peridental membrane, owing to their transient nature, are influenced by the slightest irritation. This influence is the result of both constitutional and local causes. It consists of an irritation in the peripheral nerves which sets the osteoblasts and osteoclasts at work to build up or tear down the alveolar process. This influence may be only sufficient to stimulate these cells to action without inflammation. This is noticed in the advance toward old age, in long, lingering debility, in the development of bone, especially the tearing down and the building up of the inferior maxillary backward. It may be noted in mild or intense inflammation of the peridental membrane, due to more acute forms of disease, to scurvy, mercurial, lead and iodide poisoning, or to local irritation. So sensitive are these structures that in neurotics and degenerates the slightest irritation produced in the physiologic development of the permanent teeth is sufficient to start the osteoblasts to building up bone structure, thus producing that pathologic condition called hypertrophy of the alveolar process; one of the most marked evidences of an unstable nervous system.

The breaking down of the tissues by the osteoclasts may be induced by as slight a cause. The alveolar process being so thin about the teeth, destruction of the entire walls is accomplished without difficulty, and in a very short time, thus loosening the teeth, which eventually drop out.

According to Kaufmann¹ the following processes take part in

¹ Pathologische Anatomie.

the absorption of bone: (a) Lacunar Absorption, (b) Formation of Perforating Canals, (c) Disappearance after Prior Absorption of Lime (Halisteresis) (Bony Waste) and Osteomalacia.

“By far the commonest form of bone destruction is by lacunar absorption. This process occurs not only under physiologic conditions, but is extraordinarily frequent in pathologic states, e. g., in the various types of atrophy. They form on the smooth, superficial surfaces of the bone deep grooves (so-called Howship’s lacunæ) in which lie smaller or greater polynuclear cells (osteoclasts, Kolliker) which evidently blend together (Fig. 29). There are no alterations of the bone substance that would

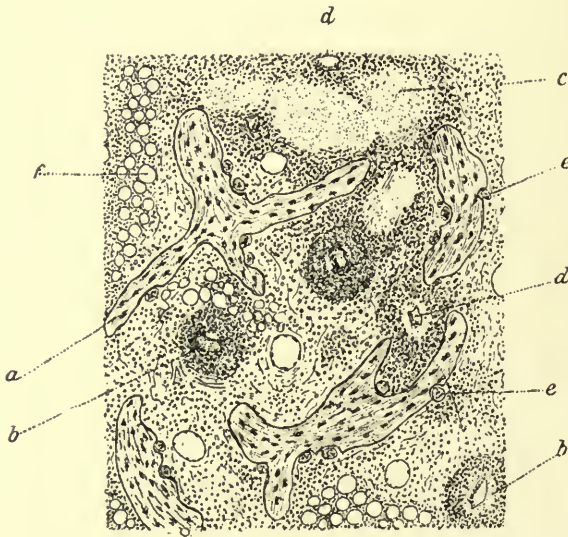


FIG. 29.

a, Bone Trabeculae. *b*, Tubercle with Granulation Tissue. *c*, Broken-down Tissue. *d*, Blood Vessel. *e*, Osteoclasts. *f*, Fat Cells.

indicate a primary line of absorption (Plummer). The confluence of these lacunæ form larger cavities.

“The second form of bone absorption, which is occasionally met under physiologic conditions, is by means of perforating canals (so-called Volkmann canals). Under physiologic conditions canals occur in varying numbers in the lamellæ (general lamellæ) which contain vessels (perforating vessels). These are often associated with the Haversian canals and gradually pass

into them, but unlike them, are surrounded with circular lamellæ. Under pathologic conditions the conception of these perforating canals is somewhat widened. On the one hand Volkmann's canals are spoken of when reference is made to the

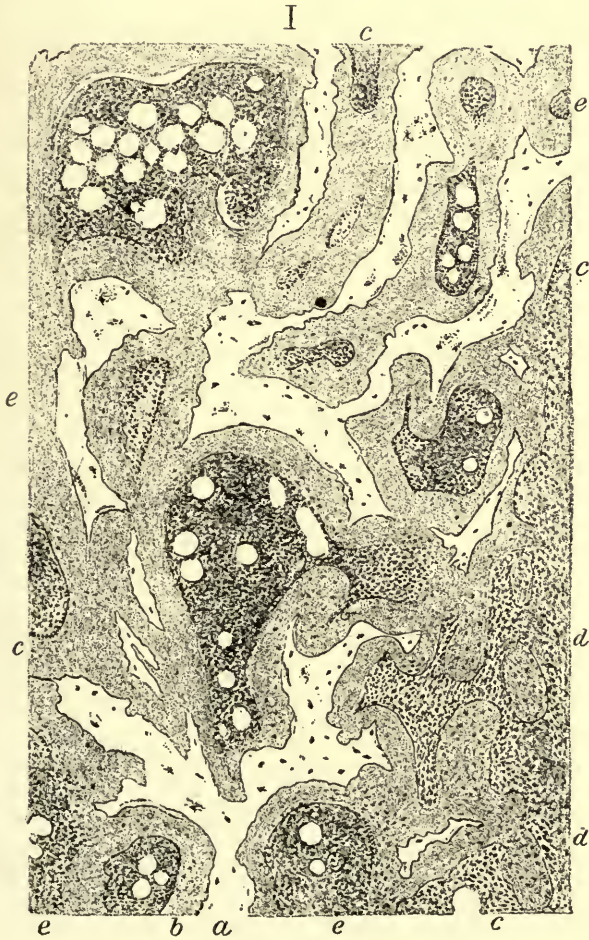

FIG. 30.

a, Large Spaces Resulting from Absorption of the Trabeculae. *b*, Decalcified Bone.
c and *d*, Decalcified Bone and Atrophied Trabeculae. *e*, Haversian Canals.

vessels or vascular connective tissue penetrating from one medullary space in the spongy substance, or from one Haversian canal in the compact substance, to another, in such a way that a passage is made from one part of the bone to the other; Volkmann's canals also include irregular ampula-formed dilations or cavities

(Fig. 30). By confluence of these are produced cavities or irregularly outlined canals penetrating the bone substance. These, if they empty into the medullary space, become filled with cells.

“Under much rarer conditions, especially in senile marasmic osteomalacia and also in that occurring in pregnancy, bone absorption takes place after a prior abstraction of lime (halisteresis) and the remaining substance (bone cartilage) is then further dissolved, passing through a temporary fibroid stage. This destruction of the decalcified and interfibrillæ decomposed bone is produced as a rule without osteoclasts. The decalcified border zones of the trabeculæ appear with simple carmine (coloring) or by double stains.”

CHAPTER IV.

THEORIES OF INTERSTITIAL GINGIVITIS.

The etiology of interstitial gingivitis, according to the views summarized previously, is divisible into local and constitutional. While one school leans largely to the local etiology, another advocates as strongly the constitutional theory. In a general way, etiology may be divided into exciting and predisposing. Etiology may also depend upon an element dependent on the exciting cause, an element dependent on the constitution of the individual attacked, and finally an element dependent on his condition when attacked, both as regards his general system or any one of his organs. The chief constitutional causes to which the disease has been ascribed are general conditions of the health, heredity, constitutional disorders, excessive lime salt secretion, meat-eating, nervous exhaustion, scorbutus and uric acid states, as well as environment. The local causes assigned are acute inflammation of the mucous membranes, catarrhal states, germs or fungi, irregular teeth, lactic acid, pocket disease, hæmorrhagic deposits, serumal calculi and uncleanness. That all these factors exercise an influence is undeniable, but the enormous etiologic rôle which has been assigned to some of them is the result of generalization from too few cases. Many of the assigned causes could be compressed into fewer etiologic influences. Thus meat-eating and the uric acid states are too intimately connected to be regarded as different causes, from a constitutional standpoint. As has been already pointed out, uric acid acts, when it acts at all, like lactic and other acids, as a local irritant rather than as the constitutional condition (as many suppose) which underlies its production and of which it serves as an index.

Scorbutus is an expression of a nutritional disorder due very frequently in the adult to an excess of meat or a monotony of diet. It is a constitutional disorder, peculiarly apt to have its local expression in the gums long ere the general constitutional

symptoms are manifest. The germs and fungi etiologists, on the other hand, tend to ignore the constitutional state behind the local culture medium, which must be furnished before growth of the germ or fungus can occur. In order, therefore, to determine whether an alleged cause be exciting or predisposing and what is the influence of the etiologic moment, as the union at one time of the two constitutional factors already cited is called, analysis is required of all the varied factors charged with producing the disease. The influence of heredity is generally left out of consideration unless it be direct, which it rarely is, since heredity, as has been well remarked, is usually a prophecy rather than a destiny. It hence constitutes, as a rule, a predisposition.

The chief tissues concerned in the elimination of waste products are the skin, the lungs and air passages, including the mouth and nose, the kidneys, liver and intestines. Interference with the eliminatory powers of the kidneys, liver and intestines is especially apt to throw extra work on the skin, lungs and air passages. Of this a sour-winey odor of the breath in diabetes is an excellent illustration. What is true of such a marked form of suboxidation, resulting in auto-intoxication, is true of less pronounced forms. The peculiarly foul odor of the breath and skin in fecal intoxication indicates that the mucous membranes of the nose, throat, mouth and gums are doing the work of elimination which should have been done by the intestines. The failure of the kidney to perform its share of eliminatory work is most apt, however, to find expression in the skin, lungs, nose, mouth and gums.

The influence of the nervous system on the growth and repair of any tissue is admitted by every physiologist. This influence is entitled the trophic function of nerves. It is not, however, exactly settled whether it be exerted through the nerves themselves or secondarily through their control of the vaso-motor (blood vessel) system. Many trophic disturbances, as J. Collins¹ remarks, are probably due to vaso-motor changes, and it is not possible to separate by any sharply defined line the vaso-motor from the tropho-neuroses. At the same time, it should be distinctly remembered that there exist tropho-neuroses in which there are no appreciable vaso-motor change as in many

¹ Nervous Diseases, by Dr. F. X. Dereum.

cases of acromegaly and hypertrophies. On the other hand, there are any amount of vaso-motor disturbance which are by no means trophic in character. Trophic disturbance, which may play a very important part at the onset of interstitial gingivitis, is neurotic œdema due to nerve irritation. While this is most frequent on the face, lips, tongue, pharynx, forehead and genital organs, it also appears on the gums. The œdema reaches its full development from one-half to two hours. There is a feeling of stiffness and unyieldingness, but no sensation of inflammatory swelling. This type of trophic disorder often initiates changes in the mucous membrane which may readily form the basis of interstitial gingivitis. This condition may not be only due to ordinary nervous causes, but may arise from constitutional conditions, gout, etc., and toxic influences.

CHAPTER V.

URIC ACID AND INTERSTITIAL GINGIVITIS.

What John Fitzgerald¹ calls the gingival organs, possess, as he remarks, in common with some other tissues of the body, the power of selecting and excreting poisonous substances from the blood. Some of these cause hyperæmia, or even inflammation, in their passage. Uric acid has been found to play a part in so many excretions that it has naturally attracted attention here. The trend of medical opinion has set strongly in this direction, but of late this trend is changing.

During the past two decades uric acid has assumed again the prominence in pathogeny which it once had when called suppressed gout. It is not surprising, therefore, to find that Reeves, Pierce, Kirk, Rhein and others claim a uric acid etiology for interstitial gingivitis. In support of this claim are advanced the results of three experiments which Pierce has had made on tooth deposits. These deposits were examined chemically by Ernst Congdon, of the Drexel Institute.² The first specimen contained a number of needle crystals of calcium urate, a few crystals of free uric acid and crystals of calcium phosphate. Destructive distillation gave a strong ammoniac reaction. The murexid test for uric acid and its compounds gave faint results, although its characteristic color was evident in several places. The second specimen presented the same crystals. The reaction to the murexid test was strong and resulted in a number of purplish-red spots. Similar results were obtained from the third specimen. A. B. Brubaker examined six or eight specimens in Pierce's presence, with like results to those obtained in the previous examination. In three an abundance of sodium urate crystals was present.

The great deficiency in the experiments thus described is the small number of cases examined and the lack of proper control

¹ The Clinical Journal, March 1, 1899.

² International Dental Journal, Vol. XV, pages 1, 217, 501.

experiments. These elements have so frequently led to errors in dental pathology that I determined upon a series of investigations in two different laboratories, whose results were reported some years ago.¹ The Columbus Medical Laboratory was selected for one series of experiments in special cases. The laboratory of the Northwestern University Woman's Medical School was selected for the other series of experiments, to which teeth were sent as soon as they were obtained. One hundred and fifteen teeth were sent to the laboratory last named from three institutions in Chicago which make a specialty of extraction. These teeth had no history other than the fact that the cases were well-marked instances of interstitial gingivitis with plenty of calcic deposits, and that the teeth were loose in the sockets when extracted. Of the one hundred examinations made in the Columbus Medical Laboratory, fifty were upon specimens of calcic deposits from my patients and fifty were upon specimens obtained from the institutions just mentioned, and were therefore without history. The tests employed were the hydrochloric acid, the dry distillation, and the murexid, these being the tests recommended by Pierce. The examinations in the Columbus Medical Laboratory were made by J. A. Wesener, and those in the laboratory of the Northwestern University Women's Medical School by J. H. Salisbury.

Of the one hundred and fifteen examinations made at the Northwestern University Woman's Medical School by the first test, in only two cases was found the needle-shaped crystals, and one in which there was a slight resemblance of uric-acid crystals. By the dry distillation test, thirteen gave no reaction from ammonia, and in seven the reaction was slight. The remaining eighty gave a decided reaction. By the murexid test, four gave a slight murexid color, but remainder gave no reaction. Special examination was made of twelve of these teeth by the addition of strong hydrochloric acid, warming, decanting the acid, and washing with water. These gave no reaction by the dry distillation tests for ammonia. Two gave a slight reaction by the murexid test. In examination of the teeth of three uric-acid diathetic women, over forty years of age, uric acid was not

¹ Dental Cosmos, April, 1896, page 310. Journal of the American Medical Association, January 16, 1897.

detectible either by the murexid test or microscopically. The examinations made in the Columbus Medical Laboratory were still more interesting, since among them were specimens from patients whose history could be obtained. Of the fifty obtained outside, eight gave positive results from all three tests. The other forty-two were positive by dry distillation, and negative by the murexid and microscopical tests. Of the fifty patients, thirty-eight females and twelve males, thirty-two were over forty years of age, twelve over thirty years, and six over fifteen years.

Twenty-six have uric acid to a greater or less extent, nine suffer with indigestion, seven of which are subject to sick headache, thirty-four have rheumatism. Six are English, and four of these have the true gout; the other two have rheumatism.

All are positive with the dry distillation test. All are negative with the murexid test. Forty-nine are negative with the microscopical test. One shows needle-shaped crystals, but not uric acid. It is a singular fact that in both laboratories, the cases in which there was uric acid and gouty histories gave negative results. By the dry distillation test, out of two hundred and fifteen cases, all but twelve cases (which have been treated to remove nitrogenous material) responded. The twelve cases so treated did not respond, since nitrogenous compounds in and about teeth (even the saliva) burned to an ash will produce ammonia. By the murexid test only twelve out of the two hundred and fifteen gave a positive reaction. By the microscopic examination but ten showed crystals. One of the chemists who made the examination is positive that they were uric acid crystals. The other is not, since lime-phosphate crystals resemble uric acid crystals too minutely to be distinguished positively.

For three years Wesener made further examinations as to the relative value of the three tests employed. According to his experiments the murexid test is the most valuable, the crystal test second, and the dry distillation third. The murexid test is the most reliable in testing tartar for uric acid, since its red color is easily distinguished from other colors and the test is simple in application. The test for crystallized uric acid is very unsatisfactory, since here must be dealt with a complex mass which not only contains crystals of calcium phosphate (very similar to those of uric acid) but a great mass of detritus obscuring the crystals

of uric acid. If crystals be present they by no means settle the existence of uric acid. When the faintest quantity possible of uric acid is mixed with tartar from teeth and subjected to crystallization, the results are always negative. If subjected to the murexid test, the results are always positive. The dry distillation test is so inaccurate as to be unworthy consideration.

Since these results were published, seven hundred and thirty-five cases have been examined. These examinations were conducted by Jerome H. Salisbury, now of Rush Medical College. The teeth procured from institutions which make a specialty of extracting contained the dark calcic deposit above the pus line. By the murexid test, six out of the three hundred gave a distinct reaction; eighteen showed crystals under the microscope. The murexid test was performed as follows: The deposit was selected as carefully as possible, removed from the tooth, and placed in a small porcelain crucible. A drop of pure nitric acid was added and the mixture evaporated on the water bath. When dry, the evaporation was repeated with another drop of nitric acid, and the crucible allowed to cool. When cool, the color produced by the nitric acid was observed, and then a glass rod, wet with ammonia water, was brought near the deposit, and any color produced was noted. If no color was observed, the ammonia was allowed to flow over the residue. A yellow color was produced in many cases by the nitric acid, which was deepened by the addition of ammonia. The microscopic examination was made by scraping off the deposit and evaporating it with a drop of hydrochloric acid. The residue was moistened with water, and the insoluble material placed on a slide and covered with a cover-glass. It was examined with a No. 7 objective. Uric acid, therefore, occurred in a certain very small proportion of cases of calcic deposit on the teeth.

Four hundred and thirty-five cases were later examined, making in all nine hundred and fifty. Out of these four hundred and thirty-five cases only four per cent showed uric acid by the murexid test and eight per cent by the crystal test. Since the crystal test is not so accurate as the murexid test, it is safe to say that six per cent was the actual per cent of uric acid. As a result of the different experiments, in the first two hundred and fifteen cases five per cent uric acid was found. In the second

three hundred cases, four per cent, and in the third four hundred and thirty-five cases, six per cent was found. In an examination of nine hundred and fifty cases by different chemists at different periods, five to six per cent give positive results as to uric acid by the chemic and microscopic examination. These results demonstrate conclusively that interstitial gingivitis is not due solely to uric acid; that uric acid when found is merely an expression of the uric acid diathesis and a coincidence, since it is not always present in the gums and tartar of patients attacked either by gout or the uric acid diathesis. In the six per cent of cases there was nothing to show that uric acid was the cause of interstitial gingivitis, since the deposits were examined after the teeth had been removed. Any other irritation may have been the exciting cause. Uric acid acts, when at all, solely as a local irritant.

CHAPTER VI.

INORGANIC SALTS AND INTERSTITIAL GINGIVITIS.

The foods which enable the body to repair its waste, to build up new tissue and to supply the energy, are divisible into four classes: the inorganic substances, the fats or hydrocarbons, and the starches and sugars, or carbohydrates, and the proteid compounds. These divisions are, however, relative, since the proteids may contain both hydrocarbons and carbohydrates. The inorganic substances, such as water, phosphates, chlorides, carbonates, sulphates, etc., enter the body, as a rule, under their own form, either alone or in combination with other classes. They are not oxidized or split up within the system to enter into the chemical formations of other compounds, but are united mechanically with the proteid group. These bodies act, as a rule, in a purely mechanical manner. After having served their purpose, they pass out of the system with the excretions, comparatively unchanged in their composition. They are the only member of the group of foods which are of a special interest in the present research. The inorganic salts have, however, not received the attention from physiologic chemists that their importance demands. They are, as a rule, found in greater or lesser quantity in all foods that are taken into the body. They do not serve as a source of energy, but as the other foods are needed for the development of the tissues, so the inorganic salts are needed for the building of bone tissue and the repair of waste. This is accomplished by the soluble salts in the blood. Human blood has the following composition :

ANALYSIS OF HUMAN BLOOD (C. SCHMIDT). HOWELL'S PHYSIOLOGY.

	MAN.		WOMAN.
	25 Years.		30 Years.
Water	788.71	824.55
Solids	211.29	175.45
Proteids and Extractives.....	191.78	157.93
Fibrin	3.93	1.91
Hæmatin (and iron)	7.70	6.99
Salts.....	7.88	8.62

INORGANIC SALTS OF HUMAN BLOOD, 1,000 PARTS
(C. SCHMIDT).

BLOOD CORPUSCLES.		BLOOD PLASMA.	
Cl	1.75	Cl	3.536
K ₂₀	3.091	K ₂₀	0.314
NA ₂₀	0.470	NA ₂₀	3.410
SO ₃	0.061	SO ₃	0.129
P ₂₀₅	1.355	P ₂₀₅	0.145
CaO		CaO	
M ₉₀		M ₉₀	

These acids and bases exist, of course, in the plasma and the corpuscles as salts. It is not possible to determine exactly how they are combined as salts, but Schmidt suggests the following combination :

PROBABLE SALTS IN THE CORPUSCLE.

Potassium Sulphate	0.132
Potassium Chloride.....	3.679
Potassium Phosphate.....	2.343
Sodium Phosphate.....	0.633
Sodium Carbonate.....	0.341
Calcium Phosphate.....	0.094
Magnesium Phosphate.....	0.060

PROBABLE SALTS IN THE PLASMA.

Potassium Sulphate	0.281
Potassium Chloride.....	0.359
Sodium Chloride.....	5.546
Sodium Phosphate.....	0.271
Sodium Carbonate.....	1.532
Calcium Phosphate	0.298
Magnesium Phosphate	0.218

It will be seen that the corpuscle contains an excess of potassium salts, and the plasma contains an excess of sodium salts. All parts of the blood contain salts, however.

Throughout the entire body, there is a rich supply of blood vessels penetrating every tissue. The plasma of the blood passing by exosmosis through the walls of the capillaries is thus brought in immediate contact with the tissues to which it brings nourishment and oxygen of the blood, and from which it removes the waste products of metabolism. Other usable products or lymph are collected in small capillary spaces, which in turn open into definite lymphatic vessels. These vessels unite

into larger and larger ones, which eventually pour this usable waste product into the great thoracic or left lymphatic ducts, and a second smaller right lymphatic duct. These in turn empty into blood vessels, each upon its own side. The lymph contains essentially the same constituents as the blood plasma, and the salts are found in the same proportion as in it. They are then eliminated through the sweat glands, tonsils, mucous glands, kidneys, large intestines and salivary glands.

The composition of the deposits in the various parts of the body vary according to the locality and the character of the excreta eliminated in connection with them.

The chemical composition of the human bile, according to Jacobson,¹ is as follows:

Water	977.40
Sodium Glycocholate	9.94
Cholesterin	0.54
Free fat	0.10
Sodium palmitate and sterrate.	1.26
Lecitine	0.04
Other organic matter	2.26
Sodium chloride	5.45
Potassium chloride.	0.28
Sodium phosphate	1.33
Lime phosphate	0.37
Sodium carbonate.	0.93

Of this analysis the solid ingredients constitute 22.5 parts per thousand, of which two-thirds are organic and one-third inorganic. The inorganic salts of the bile are in most cases returned to the blood, where they are redistributed to the tissues. Occasionally, however, gall stones occur, which are composed of (analysis H. D. Geddings²):

Moisture	3.32
Biliary matter	32.182
Cholesterin	54.952
Matter soluble in ether.	7.77
Iron	traces
Phosphoric acid	traces
Lime	traces
Magnesium	traces

¹American System of Dentistry.

²Transactions South Carolina Medical Association, 1880.

Secretions of the pancreatic juice (dog) by C. Schmidt are as follows :

Water	900.76
Solids	99.24
Organic substances	90.44
Ash	8.80
Sodium carbonate.....	0.58
Sodium chloride	7.35
Calcium magnesium and sodium phosphate.....	0.53

The composition of the normal human pancreatic juice has not been determined completely owing to the difficulty of obtaining the secretion. According to Zawadsky the composition of the secretion of a young woman was as follows :

Water.....in 1,000 parts.....	864.05
Organic substance.....in 1,000 parts.....	132.51
Proteids.....in 1,000 parts.....	92.05
Salts.....in 1,000 parts.....	3.44

INORGANIC SALTS IN THE SWEAT.

“Of the inorganic salts, NaCl is by far the most abundant ; it occurs in quantities varying from 2 to 3.5 parts per thousand. The elements of the sweat which are of importance from an excretory standpoint are water, inorganic salts and urea or related nitrogenous compounds.”

Inorganic salts from the fæces are made up of the salts of sodium, potassium, calcium, magnesium and iron. According to Enderlin¹ the following represent the composition of the material matter in the fæces :

SALTS SOLUBLE IN WATER.

Sodium chloride and sulphate.....	1.37
Sodium phosphate.....	2.63

SALTS INSOLUBLE IN WATER.

Earth phosphate.....	80.37
Ferric phosphate	2.09
Calcium sulphate.....	4.53
Silicic acid.....	7.94

Like other constituents of the lymph, the salts vary considerably in proportion, according as the fluid is more or less rich in

¹ Gamgee, Physiological Chemistry of the Animal Body.

water. The salts are much more abundant than the organic solids.

Inorganic salts in the urine consist, according to Howell,¹ chiefly of chlorides, phosphates and sulphates of the alkalies and the alkaline earths. As a rule they arise partly from the salts ingested with the food, which salts are eliminated from the blood by the kidney in the water secretion, and in part they are formed in the destructive metabolism which takes place in the body, particularly that involving the proteids. Sodium chloride occurs in the largest quantities (about 15 grams per day), of which the greater part is derived directly from the salt taken in the food. The phosphates occur in combination with Ca and Mg, but chiefly as acid phosphates, of Na or K. The acid reaction of the urine is caused by these latter. The phosphates are produced in part from destruction of phosphorus-containing tissues in the body, but chiefly proceed from phosphates in the food. Following are the average quantities in grams of the chief substances normally excreted in the urine in six hours :²

Water	1440	—	1500
Solids	57	—	68
Organic :			
Urea	28	—	68
Uric acid	7		
Hippuric acid	3	—	2
Kreatinin	1.7	—	2.1
Inorganic :			
Sodium chloride	15	—	20
Phosphoric acid	2.5	—	3
Sulphuric acid	2	—	2.5
Sodium	5	—	7
Magnesium04		
Potassium	3	—	4
Calcium03		

Urinary calculi (classified according to their principal ingredients), are divided into :

1. Uric stone, composed of uric acid and acid urates.
2. Oxalic stone, composed of lime oxalate.
3. Phosphoric stone, which are composed of magnesium phosphate and carbonate with urate of ammonia.

¹ American Text-Book of Physiology.

² Landolt, Physiology.

Each one of these compounds is nearly in a pure state. A stone may be composed entirely of one salt or it may be composed of two, three or four, each compound forming separate consecutive layers through the stone. One examination made by Howship Dickinson¹ showed eighty-nine per cent lime carbonate and the rest lime oxalate and phosphate of lime.

The deposits upon the teeth are derived partly from the salts ingested with foods, which salts are eliminated from the blood in water secretion, and in part they are found in the waste of tissue which takes place in the body.

The saliva, according to Schmidt, is made up of the following :

Water	991.45
Organic material.....	2.89
Inorganic :	
Calcic chloride.....	4.50
Sodium chloride.....
Calcic phosphate.....	1.16
Magnesium.....
	1,000.00

This material floating in the saliva, together with the epithelial scales and other extraneous matters, contribute to form what is known as tartar. This material collects upon the teeth, and according to examinations by Stevenson consists of :

	Soft tartar on molars.	Hard tartar on lower incisors.
Water and organic matter	21.48	17.51
Magnesium phosphate	1.31	1.31
Calcium phosphate with a little car- bonate and trace of fluorine....	77.21	81.18
	100.00	100.00

Another analysis made by Scheheoetskey resulted thus :

Water and organic matter	22.07
Magnesium phosphate.....	1.07
Calcium phosphate.....	67.18
Calcium carbonate	8.13
Calcium fluoride	1.55
	100.00

¹ Renal and Urinary Affections.

Malenfant found that salivary calculi (located in Wharton's duct) was composed of:

Lime phosphate.....	27
Magnesium phosphate.....	1
Basic lime phosphate.....	60
Alcohol and muriatic acid.....	4
Ptyalin.....	2
Loss.....	6

100

The following are results of analysis of salivary calculi by various observers:

100 Parts.	Weight.			Bivra.	Lecanu.	Besson.	Golding Bird.
	1	2	3				
Calcium carbonate...	81.2	79.4	80.7	13.9	30	15	2
Calcium phosphate...	4.1	5.0	4.2	38.2	75	55	75
Magnesium phosphate	5.1	1	..
Soluble solids.....	6.2	4.8	5.1	38.1	5	25	23
Organic matter.....	7.1	8.5	8.3				
Water and loss.....	1.3	2.3	1.7	6.3

Deposits in the tissues in gout are made up of soda and lime urates. In order to compare the calcic deposits in other parts of the body with the serumal deposits upon the teeth affected with interstitial gingivitis, thousands of teeth were obtained from three dental offices which make a practice of extracting teeth. From these one thousand were selected at two different times, making two thousand teeth containing deposits direct from the tissues. These were submitted to a chemical analysis by J. H. Salisbury, at Rush Medical College, who reports as follows:

“The method which I employed in analysis of calcic deposits was as follows: The material was so selected as to be free as possible from salivary tartar and a weighed portion was dried at 100° C. This was then carefully incinerated and again weighed, and the difference calculated as organic matter. The residue after incineration was divided into two portions, A and B.

“A was used for the estimation of phosphates as follows: The ash was dissolved in nitric acid and the solution precipitated with ammonium molybdate. The precipitate was washed, dissolved in ammonia precipitated by magnesia mixture and the

precipitate of ammonia magnesium phosphate, washed, dried, ignited and weighed.

“In B, calcium and magnesium were estimated as follows: The ash was dissolved in hydrochloric acid and the acid just neutralized with ammonia water and sodium acetate added. It was then made slightly acid with a drop of hydrochloric acid and precipitated with ammonium oxalate. The precipitate of calcium oxalate was filtered off, washed, converted into calcium oxide and weighed. The filtrate was made alkaline, sodium phosphate added, and the precipitate of magnesium-ammonium phosphate collected, washed, dried, ignited and weighed. In case the phosphoric acid determined in A did not saturate the calcium and magnesium obtained in B, the excess of base was calculated as carbonate.

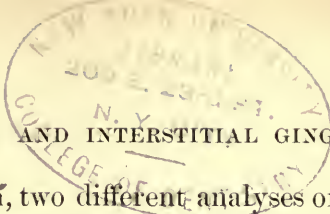
“The following is the composition of the serumal tartar according to analysis of April 18, 1898:

Water and organic matter	32.24
Magnesium phosphate.....	.98
Calcium phosphate.....	63.08
Calcium carbonate	3.70
	100.00

“Analysis of the serumal tartar, October 24, 1898, shows it to have the following composition:

Water.....	4.48
Organic matter.....	27.00
Calcium phosphate.....	72.73
Magnesium phosphate.....	4.91
	99.12

While nearly every kind of food taken into the stomach contains inorganic salts, every excretory organ of the body throws out a certain amount of these salts. Some of these organs excrete the salts in a pure state, while in others the salts are combined with acids or fluids peculiar to that organ. These salts differ in composition and quantity on different days, at different hours of the same day; differ at different ages of the same person and differ in persons of like age, on the same diet. No matter how careful the chemist may be in analysis, no two results will be exactly alike. For this reason, in tartar and calcic deposit



upon the roots of teeth, two different analyses of the same deposits are cited. It is evident that while slight differences occur in the table, these are due chiefly to the character of the secretions. The kidneys and salivary glands clearly excrete most of the waste inorganic salts.

Since each excretory organ has its part in elimination of waste inorganic salts, it is clear that if one organ becomes tired or diseased, other organs have an extra amount of material to excrete. In any event, the blood becomes surcharged with waste inorganic salts. There is a class of patients with deformed jaws and irregular teeth, tonsil hypertrophy, mucous membrane, nasal bone and post-nasal space disorder, adenoids, arrest of the facial bones. They are neurotics and degenerates. This class comprehends those whose nervous system is unstable and whose physical development is a departure from the race type. This unstable or tired condition may affect but one excretory organ. In most cases it affects all organs as well as the entire body. In these patients, especially in youth, does hypertrophy of the alveolar process take place and large deposits are observed upon the teeth. In this class may be placed rachitic children.

Inorganic salts taken in food are generally utilized until the osseous system has attained its growth. This usually occurs at about the twenty-sixth year, but full growth may not be attained until the thirty-sixth year. When this period has been reached, although the body still has the same supply of inorganic salts, the system can assimilate only what it needs. The remainder becomes waste. Under such conditions the blood is overcharged with these salts.

A condition of the system, which has received too little attention, occurs in a class of children ranging from six to eight years, who excrete larger quantities of inorganic salts through the kidneys and salivary glands. In such cases the teeth become coated with tartar. The gums become inflamed from irritation. Interstitial gingivitis is developed in youth. These children may be rachitic, or border upon the disease. They are neurotic, degenerate, suffer from rachitis, rapid decay of the teeth and irregularities. They occur in American and European schools of idiocy and for dependent and defective children. From seventy-five to ninety per cent of these children have

interstitial gingivitis, ranging from simple inflammation of the gums to absorption of the gums and alveolar process with pus exudate. Miller noticed in an examination of twenty-six cases of rachitic children under twelve years of age that seven manifested pronounced symptoms of interstitial gingivitis. This was no doubt due to accumulation of calcic salts upon the teeth, producing irritation and absorption of the alveolar process and contraction of the gums.

In cases where large collections of tartar are deposited upon the teeth of children there is also an excess of excreta through the kidneys. Examination of urine in such cases will reveal always from four to eight times more deposit than the normal for the age of the patient. Defective nutrition is the result, the bones are small, and the jaws and teeth are irregular. The teeth decay early in life and it is with difficulty that the decay can be arrested. What is true of children is also true of people at advanced age.

After the skeleton had attained its growth (even in those cases where no deposits were before observed) the blood became overcharged with lime salts and the teeth became a nidus for the deposit from the salivary glands. It is, therefore, clear why deposits and inflammation of the gums are so common after the twenty-sixth year, and more common later in life. Defective children and people who have obtained their growth are more susceptible to trophic disorders of nutrition and the tissues take on disease more readily than healthy individuals earlier in life. When inflammation takes place in connective tissue in all parts of the body (especially if the blood be surcharged with inorganic salts) deposits take place in that tissue through the capillary system. On the other hand, when inflammation of the connective tissue takes place, if inorganic salts be scarce in the blood, deposits do not take place. As is elsewhere shown,¹ calcic deposits on the roots of teeth are a result of inflammation and pus infection and not the cause.

¹ International Dental Journal, April, 1896.

CHAPTER VII.

HEREDITY AND ENVIRONMENT.

The influence of heredity in interstitial gingivitis, as in other morbid conditions, is still a mooted question. Morbid heredity, as I have elsewhere shown,¹ is practically divisible into direct and indirect. In the first type the morbid condition is directly inherited; in the second, a deficiency is due to the morbid condition which may or may not express itself in a tendency to the morbid condition of which it is the offshoot. Heredity further should be separated from congenital states which result from the operation of germs or toxins during a particular pregnancy wherein these pass through the placenta to the fœtus. A child may be born of a tuberculous mother with a tendency to tuberculosis, but the tubercle bacilli may also directly infect it through the placenta so that it is born with tuberculosis. The first is the inheritance of the weakened organism of the mother. The second is a condition of intra-uterine infection.

The reported cases of direct heredity of the pyorrhœic stage of interstitial gingivitis may afford instances of one or the other of these categories. As has elsewhere been shown, transitory organs are peculiarly apt to be weakened by heredity both in their structure and in their resistance to morbid germs and agencies. These weaknesses are especially apt to be shown during the period of systemic stress connected with the first and second dentition. Such weaknesses may be the outcome of general nerve exhaustion on the part of the parents (the mother especially), and constitutes transformed heredity, which is far more frequent than direct. This transformed heredity may be more intense than the constitutional deficiency of the immediate ancestry. On the other hand, the conservative influence of several generations may so offset the evil results of the defects in the parents that the inheritance of defect is slight, if at all existent.

¹ Talbot: Degeneracy; Its Signs, Causes and Effects.

This last type of heredity is called atavism (or "throw-back," by the breeders). It is more likely to work for good than evil, albeit the evil effects are more generally looked for. Because of this atavism a serious nervous defect in a parent might express itself only in an increased tendency to disease on the part of transitory structures. The periods of stress are times in the life of man when certain great life functions are developing or undergoing retrogression. These periods of development or evolution are marked by the two dentitions and the development of the sexual organs, which might more aptly be called the third dentition, since ere its close the wisdom tooth appears, if at all. The periods of retrogression are when the great sexual functions are undergoing involution or when the whole body is undergoing senile change. These periods often constitute an etiologic moment for the production of disease even when potent hereditary defect is absent, albeit at these periods such defect is apt to appear.

Another possibility to be considered in this connection as complicating the diagnosis of heredity in disease is environment, understanding by this term all the external conditions that can favor the development of a disorder. Family habits and surroundings are apt to be alike for every member. If anything in the environment especially favors the breaking out of a disease in one member, the cause is equally apt to be effective with another, provided the individual idiosyncrasy is similar. This may give rise to a suspicion of heredity, since conditions of life, family habits and intimate household surroundings favor the occurrence of a disorder in several members or generations of the same family. Habits are often transmitted by imitation from parents to offspring. These may be direct exciting or predisposing causes of an affection, especially if it be more or less favored by their existence.

That constitutional conditions of hereditary origin favor the occurrence of interstitial gingivitis is undeniable, but this does not prove that gingivitis itself is hereditary. They favor its occurrence as they favor other morbid conditions, by lessening resistance, or by preparing the way. The gingivitis is only one of the many accidents that are thus facilitated. So far as salivary concretions are to be regarded as an exciting cause, heredity

may be disregarded, since these (though varying widely in different individuals in the amount of the deposit, and consequently the irritation produced) are dependent upon more remote constitutional or local conditions without direct connection with the heredity.

The varieties (charged to lithæmia or arthritic conditions notoriously hereditary) are of accidental origin rather than essentially connected with constitutional conditions that happen to furnish the irritant.

Local uric acid poisoning¹ is, as I have elsewhere shown, occasionally associated with gingivitis. The coëxistence illustrates the lowered vitality of the system, rather than the etiology.

The same is true of all the other neurotic, rachitic and degenerative conditions, hereditary or otherwise, that are met with, associated with gingival inflammation. They all favor the occurrence of the disease by causing a weakened power of resistance predisposing to the attack of any irritation. The mouth, resistant as it ordinarily is, is at all times open to irritation. When resistance is impaired it gives way at its most vulnerable point, and the gingival margin is one. Interstitial gingivitis is favored or hindered, like other disorders of its kind, by constitutional conditions which may or may not be inherited, and which bear toward it the relations only of predisposing and accessory causes.

¹ Dental Cosmos, 1896, page 312.

CHAPTER VIII.

DEGENERACY AND DEGENERATE TISSUES.

One of the most important factors of predisposition is that of degeneracy, either local or general. Three possibilities of life await, as has been elsewhere pointed out,¹ each living being: either it remains primitive and unchanged, or it progresses toward a higher type, or it backslides and retrogresses. The factors underlying the stable state force the animal to remain as it is; these underlying the progressive tendency make it more elaborate, while the factors of degeneration tend to simplify its structure. Degeneracy is, therefore, a gradual change of structure by which the organism becomes adapted to less varied and less complex conditions of life. It is a reverse of development which proceeds from the indefinite and homogeneous to the definite and heterogeneous with a loss of explosive force due to the acquirement of inhibitions or checks. In proportion to the depth of degeneracy does it affect the earlier simpler, or later complicated, acquisitions. The opposite process of progression is a gradual change of structures by which the organism becomes adapted to more varied and more complex conditions of life. In progression there is a new expression of form corresponding to new perfection of work in the animal machine. In degeneracy there is suppression of form corresponding to the cessation of work. Elaboration of some one organ may be the necessary accompaniment of degeneracy in all the others. On the other hand, degeneracy in one organ may be the necessary accompaniment to the elaboration in all the other organs. During the period of stress defects due to degeneracy are apt to appear and affect the line of least resistance, determined by the depth of degeneracy, as well as the variability of the structures concerned. As the teeth and jaws are among the most variable structures in the body, they are peculiarly apt to be affected by either general degeneracy, which affects the body as a whole, and has local

¹ Talbot : Degeneracy ; Its Causes, Signs, and Results.

expressions or local degeneracy by which the body benefits. The factors producing degeneracy act by causing nervous exhaustion in the first generation. This implies a practical degeneration in function, since tone is lost.

Every nerve cell has two functions; one connected with sensation or motion, and the other with growth. If the cell be tired by excessive work along the line of sensation or motion, the function as regards growth later becomes impaired. The cell then not only ceases to continue in strength, but becomes self-poisoned. Each of the organs (heart, liver, kidneys, etc.) has its own system of nerves (the sympathetic ganglia) which, while under control by the spinal cord and brain, act independently. If these nerve centers become tired, the organ fails to perform its functions, the general system becomes both poisoned and ill-fed, and nervous exhaustion results. In most cases, however, the brain and spinal cord are first exhausted. The nerves of the organs are thus allowed too free play, and exhaust themselves later. This systemic exhaustion has local expression in the testicle in the male, in the womb and ovaries in the female. Through this the body is imperfectly supplied with natural tonics (antitoxins) formed by these structures, and the general nervous exhaustion becomes still more complete. All the organs of the body are weakened in their function. Practically the neurasthenic in regard to his organs has taken on a degenerative function, albeit not degenerating in structure, since the restlessness of the organs is a return to the undue expenditure of force which occurs in the lower animals in proportion as it is unchecked by a central nervous system. Through the influence of various exhaustion agencies the spinal cord and the brain lose the gains of evolution and the neurasthenic is no longer adjusted to environment. Since the reproductive organs suffer particularly, children, born after the acquirement of nervous exhaustion, are more or less checked in development as the influence of atavism is healthy or not—have degenerations in the structure of their organs which in the parent were represented by neurasthenic disorder in function. As the ovaries of the neurasthenic woman generally exhibit prominently the effects of the nervous exhaustion, the offspring of these do not retain enough vigor to pass through the normal process of development.

The action of degeneracy, considered as a local factor of constitutional origin, may be exerted to preserve embryonic conditions in adult life. Such preservation may result in the breakdown of tissues which would otherwise withstand germs or other causes of disease external to the tissues. Given this condition of local degeneracy, a local predisposing factor is added to both the exciting causes and the constitutional predisposing factors. So long as the teeth and transitory structures remain in the comparatively stable condition of primitive races, this factor is to a great extent in abeyance. When, however, the jaw begins to evolve, the degenerate types find this factor adding dangers to their evolution. In the degenerate the struggle for existence between the organs is not properly balanced, whence the dangers from these local states of degeneracy that in the higher types are expressions of advance undergone without danger. This is excellently illustrated in the embryology of the mucous membrane. This in degenerate children often fails so to develop that the bactericidal function of mucus does not appear. This hereditary feebleness of the mucous membrane is peculiarly apt to occur in the nose, throat and gums, but other mucous membranes are not exempt.

CHAPTER IX.

NEUROTIC, DIATHETIC AND DEGENERATE CHILDREN.

Miller, as elsewhere stated, found a little over thirty-three and one-third per cent on examination of twenty-six rachitic children under twelve years who manifested interstitial gingivitis. Considering that most of these manifested symptoms of inherited congenital or acquired constitutional defect, such a small proportion is rather remarkable. The fact suggests one of two explanations — either the children in the institute visited by Doctor Miller took better care of their teeth and gums than is usual with this class, or the cases in which pus existed only were classed as pyorrhœa. I have examined the mouths of deaf-mutes, blind, idiotic, feeble-minded and rachitic children in the institutions in America and Europe. Interstitial gingivitis was found in all its stages, from simple inflammation of the gums to loosening of the teeth, in from twenty-five to seventy-five per cent. In these cases not only are there constitutional factors, but also uncleanliness of the mouth and gum tissues. The degenerate children encountered in office practice usually have jaw deformities and teeth irregularities. Patterson has had under observation thirty-eight cases of well-marked pyorrhœa, thirty-three of which coexisted with nasal catarrh. These cases were, no doubt, those of degenerate patients. The nasal catarrh was a coincidence dependent on the general deficiency of the mucous membrane.

Luxury and modern degeneracy are generally charged with the production of diseases later found to have attacked man in prehistoric periods. This has been the case with interstitial gingivitis.

R. R. Andrews expresses the following opinion as to modes of life: "I have been led to believe from my own experience that this trouble exists largely in the mouths of people accustomed to luxury — good livers, people about middle age who over-eat and under-work."

No method of living can be regarded as a cause of this disease, except so far as it affects the general system, thus producing trophic changes. There is probably a slight difference in liability to interstitial gingivitis between people of sedentary habits and active outdoor workers, as well as between animals domesticated or in captivity and those which run at large.

It is, however, obvious, from the data of the chapter upon "History," that all races and stations, regardless of time, climate, or mode of life, have suffered with the disease. Examinations of animals in the American and European zoölogical gardens show that it is not confined to any class of animals. Dogs and cats, whether housed or running at large, suffer with it.

The question how far this region is affected by toxic agents introduced into the system is an open one; still it seems probable that they exert some influence. In chronic phosphorus poisoning the jaw is particularly and seriously involved. This has been attributed chiefly to the entrance of phosphorus into the deeper tissues through carious teeth or through solutions of continuity of tissue due to tartar. In the case of other poisons this local factor is not so evident. Mercury has among its first effects a soreness of the teeth with loosening of them in their sockets. Here it appears that the alveolus was one of the first special points of attack independent of any traumatism or abrasion of the soft tissues. In a similar way the toxins of scurvÿ directly attack the alveolus. Its fleshy covering is later involved in the progress of the disease. This sometimes extends to complete loosening and falling out of the teeth. Here an irritation of a toxin from within the organism has a point of election, a structure that from its constitution or other reason is particularly vulnerable to attack. Another constitutional disorder in which the alveolus is early affected is diabetes. The exact pathology of this is uncertain, but in many cases at least it is largely dependent on disordered action of the central nerve system. Renal disease is another common condition which tests the vulnerability of the alveoli. An ideally normal kidney is probably rare, but only when its abnormalities pass beyond a certain point can it be called diseased. In the less advanced conditions that have passed the line of morbidity, alveolar implication is often very marked. This may be one cause of the

unusual frequency in the insane, who are especially liable (as Bondurant¹ and others have shown) to suffer from renal disease. They are very liable likewise to auto-intoxications and trophic disorders as² well, since the balance of the nervous system has been disordered. Some (the parietic and organic dements) exhibit especial tendencies to trophoneurotic disturbances affecting the teeth. In states of depression and stupor, circulatory disturbances predispose to these.

The constitutional results of acute and chronic infections are apt to produce auto-intoxication in addition to the action of the toxins of their germs. The eruptive fevers, especially scarlatina or measles, have been long known to be followed by wasting or necrosis of the alveoli.³ Here the condition is notably symmetrical and unaccompanied by exfoliation or necrosis of the osseous system elsewhere. Tuberculosis does not spare the alveolar process. The well-developed disorder known as Riggs's disease has been charged by Robin and Magitot to the direct influence of the arthritic (gouty and rheumatic) process, and declared a special form of arthritic manifestation.

The alveolus is clearly vulnerable to the toxins of many infectious diseases. It is also quickly affected by some of the autotoxic influences of disordered metabolism. Its vital resistance to these agencies is less than that of other tissues. It is the earliest sacrifice when these toxins or all toxins disturb the harmony of the organism.

Another cause for implication of these parts than the action of toxins exists. Whenever tissue waste, whether local or general, exceeds repair there is trophic change. This latter depends directly upon disordered local or general nervous functions. Trophic alterations from the first cause appear in growth disorders of the nails and loss of hair (alopecia) after fevers—the most familiar obvious examples of this pathologic process. Of the other type are localized neurotic atrophies where the direct intervention of toxins can be excluded. The alveolus is liable to the first form of trophic deterioration. The influence of acute diseases upon the alveolus is probably thus exerted in many cases

¹ American Journal of Insanity, 1892.

² Kiernan, Journal of Nervous and Mental Diseases, 1878.

³ Salter: Transactions of Pathological Society, London, 1859-60, Vol. XI, page 309. Lucas, Lancet, 1887, page 692.

rather than by direct infection. Where no cause has been ascertained, examination directed to this factor would probably reveal it. The general failure of the trophic centers after the prime of life (in senile states), which is attended with loss of teeth and wasting of the alveoli, is perhaps the most prominent instance of this type of trophic failure affecting the part. Even simple anæmia may thus rise to alveolar wasting.

The second form of trophic failure in the alveolus is less prominent since it generally coexists with overshadowing disturbance elsewhere which masks it to a certain extent. C. Cruveillier¹ noticed its occurrence associated with paraplegia and invokes a nervous influence in its causation. In facial hemiatrophy local wasting of the alveolus has appeared before the disorder had involved generally the jaws. This may sometimes be due to a local cause, but its occurrence and association with other neurotrophic symptoms is suggestive.

The causes which, acting locally, produce direct interstitial gingivitis, are the toxic effects of mercury, lead, brass, uric and other acids, potass. iodide, and other agencies acting in a similar manner, and scurvy. It is not the intention to enter into an elaborate discussion of the toxic action of these drugs, but in a general way to show the similarity in action and results upon the tissues. Scurvy, a disturbance of metabolism, produces the same train of symptoms as the metals.

It is a widespread opinion among dentists that in toxic cases the gums are the first tissues involved. The fact is, however, that when the salts of mercury are taken into the system, as noted elsewhere, they act directly upon the central nervous system; later occur nausea and vomiting, tremor in the arms and hands. Besides local nerve inflammation (neurites), mercurial and brass poisoning produces paralysis agitans, and lead poisoning, drop wrist, etc.

Excessive secretions of the glands of the body, especially the salivary glands, later occur with rise in temperature, gingivitis with periosteal and peridental membrane swelling, thickening of the gums and loss of the teeth. The central nerve system disturbance affects all other structures. Inflammation of the mucous membrane of the mouth, as well as of the gums, and of

¹ *Bak. Soc. de Chir. Paris, 1870, pages 30 and 31.*

the alimentary canal, frequently occurs with sloughing of tissue. The kidneys become involved, and are unable to carry off the effete matter.

The cachexia, which resembles that of scurvy, is characterized by great debility, anæmia, emaciation, alopecia, atrophy and coarseness of the nails, with pain in the muscles and joints.

Mercury is eliminated by all excretory organs for which it has a great affinity. The soluble salts pass out by the bowels. So long as the excretory organs of the body eliminate mercury, the tissues are not effected. Small doses are eliminated, but continuation of dosage soon involves the nervous system, and afterwards the tissues of the body, especially the jaws. The first effect of mercury upon dogs is to produce vivacity and animation. This lasts for two or three days, when the limbs begin to tremble. The kidneys and bowels act at first freely. At the end of seven or eight days paralysis agitans occurs. There is constant trembling, whether when awake or asleep; loss of appetite, with slight rise of temperature. At the end of two weeks, the gums become inflamed at the margins. If the drug be continued, death occurs in about three weeks. The loss of flesh is remarkable. Miners working in mercury mines, and looking-glass makers, are all affected to a greater or less extent. The nervous system is always involved. The kidneys become diseased. The hair drops out. The miners think it a happy issue from their trouble when they have lost all their teeth, or even the molars. They are henceforth exempt from suffering so far as the teeth are concerned. Many are toothless at thirty-five.

Mercury taken by the mouth is found in the urine in two hours, and in the saliva in four hours. It appears in the urine fourteen hours after it has been applied to the skin.¹ Although it is believed to have passed entirely out of the system, it has been found in the brain, liver, kidneys and muscles. It is claimed that, like lead, it forms combinations with albuminoids in the tissues, for a time remaining inert, to be subsequently oxidized and returned to the circulation as an active poison. While a single dose of mercury may be rapidly eliminated from the system, repeated small doses distributed over a long period are not so eliminated on account of the thickness and occlusion

¹ Twentieth Century Practice of Medicine, Vol. III, page 935.

of the walls of the capillaries, producing endarteritis obliterans, hence more or less of it is deposited in the tissue.

Lead enters the system through the alimentary canal, skin and respiratory tract. A longer time is required to produce plumbism (lead poisoning) than mercurial poisoning. Lead is stored up in the system in minutest quantities for an indefinite length of time. Its effects are not manifest until the central and peripheral nervous systems have become involved, as evinced by the effect of plumbism upon the wrists. Occasionally, the chief seat of deposit is the liver or muscles. It is chiefly eliminated through the kidneys, and very slightly through the liver and salivary glands. Not until a considerable length of time has elapsed is lead traceable upon the gums. This usually occurs about the lower incisors and cuspids. This deposit (lead sulphite) is always in the tissue outside of the blood vessels. Plumbism causes trembling, nausea and vomiting. The patient loses flesh, becomes anæmic, and has great resultant debility.

The lead circulating in the capillaries accumulates, owing to impeded circulation resultant on a thickening of the coats of the vessel, producing occlusion. A bluish line upon the gums indicates that the system is completely saturated. Like mercury, lead collects in the mucous membrane upon the inside of the mouth, producing blue patches from a line to one-half an inch in length. Lead not only produces local irritation, but affects the peripheral nerves as well, producing trophic changes; upon the capillaries a thickening of the inner coat results in endarteritis obliterans. Brass produces, as Hogben¹ has shown, similar effects to mercury and lead; the green gum is an early symptom.

Potassium iodide exerts a like toxic influence to lead and mercury, as its pathology is similar thereto, but it is of infrequent occurrence.

Scurvy is due to poor food and hygiene. Insufficient alternation of food, impure air, want of bodily exercise, ennui and uncleanness combine the causes of this disease. Previous to the introduction of canned goods, sailors on long voyages, prisoners and others under confinement were subject to scurvy. Lunatics, idiots or people who have had a long sickness, are now

¹ Birmingham Medical Review, 1887.

most prone to it. Anæmic convalescents from protracted fevers suffer from it.

In the British Arctic Expedition of 1875-76 over forty-eight per cent of the men suffered from scurvy. When the potato crop failed in Ireland, in 1846, scurvy became prevalent. In the Crimean war 23,000 cases occurred among the French troops alone. Scurvy contributed over fifteen per cent to the death rate in the late civil war. It occurs among the Klondyke miners.

In public institutions for degenerate children it is very prevalent. I have observed it in both American and European institutions.

Thomas Barlow¹ found scurvy associated with rachitis. Sunderland² found that rachitic diathesis was a very strong factor. Jacobi reports forty cases of scurvy and rachitis. Babies in good families brought up solely on the proprietary infant foods are prone to scurvy. They lose their appetites, become pallid, perspire freely, have diarrhœa, the mouth becomes sore with inflamed mucous membrane and gums. Purpura and hæmorrhages of mucous membrane are common with pain and swelling of the joints.

In adults, excess of sodium chloride in the blood from consumption of salt meats and fish has been noted with scurvy. For this reason Rawls, of Cincinnati, Ohio, believed that an excess of salt in the system produced gingivitis. Languor, depression, anæmia, with a rise of temperature, and enlarged joints with soreness are the first symptoms.

The effects of this disease upon the system are almost identical with those of mercury and lead. Bruise-like (purpuric) eruptions occur upon the skin and mucous membrane, on the serous membrane (notably the pleura, pericardium, meninges and synovial linings of the joints), mucous membrane of the mouth, stomach, intestines and bronchi.

Owing to the anæmia, vascular weakness and altered composition of the blood, œdema is common both in the lungs and in the submucous and subcutaneous tissue, especially the feet and legs. The gums begin to swell with redness and fibrous thickening of the deeper layer, which cause protrusion, especially in

¹ Medical Chir. Trans., London, Vol. CXVI, 1883.

² Practitioner, London, February, 1894.

the cases of degenerates. The blood vessels, especially the capillaries, become thickened, in some cases they are occluded, or erosion and ulceration occurs. The patient becomes decidedly pale and markedly debilitated. The skin is dry and blanched. General emaciation is evident.

The mucous membrane and gums become swollen and bleed, stomatitis ulcerans results in greater or lesser degree. The tongue is at first swollen, then it becomes dry and hard. The gums are at first red and swollen. They bleed easily upon the slightest touch. Later they become pale and are irregularly larger, somewhat fungoid and friable, protruding between the teeth. They are quite tender to the touch. Ulcers appear on the buccal surfaces. The stomach becomes irritable, nausea and vomiting are common. Constipation occurs early and diarrhœa later appears.

Factors acting through local trophic disturbances are not only local disorders but also constitutional diseases, especially those which prevent elimination of effete matter (Bright's disease, diabetes, etc.) skin eruptions, lung affections, auto-intoxication (gout, etc.) and conditions like pregnancy, amenorrhœa, dysmenorrhœa, etc. The physiologic processes of nutrition, growth and repair are regulated by local nerves which, as already pointed out, because of this function are called trophic. These are under control of both spinal and brain centers. Disorders of the local nerve or of the higher centers may produce trophic change. Such disorders affect more decidedly provisional structures, since the growth, nutrition and repair of these is normally unstable. The alveolar process is an outgrowth of a permanent portion of the skeletal structure, provoked and maintained by the existence of what are really dermal appendages and not true bones. It is a provisional structure, almost unique of its kind in adult life, which has apparently little independent vitality. This is in part due to mechanical causes, since its slender structure unsupported by the teeth offers little resistance to impacts from without, to which its situation renders it especially liable. There is more than this to be considered in reckoning the special vulnerability of the alveolus. It is protected by a thin layer of fleshy tissue only, which itself is peculiarly liable to injuries, thus exposing the bone to infection. There is, more-

over, no cavity of the body that is more open to germs than the mouth, and some of these that are considered especially virulent are its constant residents. Access of germs and accidental pathogenic factors to the alveolus is constantly afforded by carious teeth, the irritation of tartar deposits, etc. Its liability to disease is thus indefinitely increased. As it is not very resistant to morbid influences, the infections have thus free play, hence suppurative disease is more readily induced.

Great practical importance, as Hirt¹ remarks, must be attributed to the changes in the hair and teeth which are observed in tabetics (locomotor ataxia). The teeth become loosened without pain and fall out without appearance of inflammation; the tooth being seemingly intact. This Hirt ascribes to disturbance in the nutrition of the jaw; an atrophic change connected with a lesion of the nucleus of the trigeminus. The fact that this condition is often connected with laryngeal crisis tends, in Hirt's opinion, to support the view of Buzzard² that the center for bone nutrition lies quite close to the vagus. Similar facts have been observed by C. L. Dana in America.³ The conclusion is obvious that disturbance of the nerve centers governing nutrition, growth and repair exerts the same influence on the alveolus, jaws and teeth as similar disturbances do upon the skin, hair, mucous membranes and bones elsewhere.

These structures, which have previously become affected by disease, although the patient has been restored to health, readily become the seat of interstitial gingivitis. This is illustrated in those persons who have been affected with scurvy, salivation, etc.

¹ Handbuch der Nervenkrankheiten, 1896.

² British Medical Journal, February 19, 1886.

³ Diseases of the Nervous System.

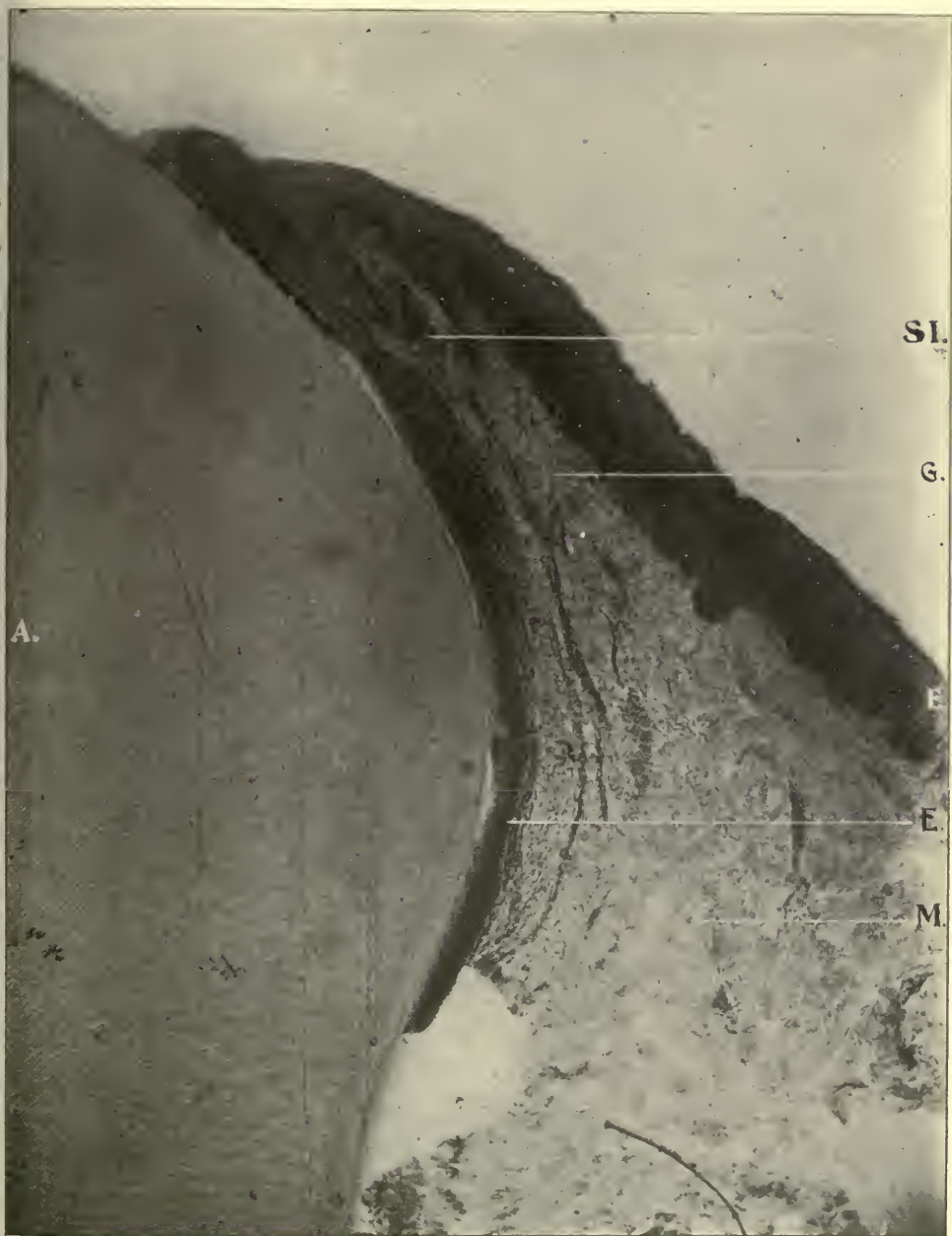
CHAPTER X.

INTERSTITIAL GINGIVITIS IN DOGS.

The technique of the examinations of interstitial gingivitis and pyorrhœa alveolaris in dogs was as follows: After fixing and hardening in two per cent formalin, alcohol, or Müller's fluid, the tissues were decalcified in a five per cent alcoholic solution of nitric acid, imbedded in celluloidin and stained in various ways, the principal ones being hæmatoxylin and eosin. Ten or more slides would be obtained from each tooth. Out of these slides have been selected a series illustrating the progress of the disease from beginning to the loosening of the tooth.

Fig. 31 is a longitudinal section of a cuspid tooth with the alveolar process in situ. A illustrates the enamel of the tooth, (E) the epithelium passes from the outer margin to the lower border, then folds upon itself and extends down the side of the crown of the tooth as far as the neck. Unfortunately, in this specimen, the structure connecting the epithelium and the fibrous tissue of the periosteum has been destroyed. The papillary layer of the sub-epithelial tissue is plainly shown at the outer border. Small round-cell inflammation may be seen extending along the border of this layer. It can also be observed extending down the capillary blood vessels into the submucous tissue (SI and G).

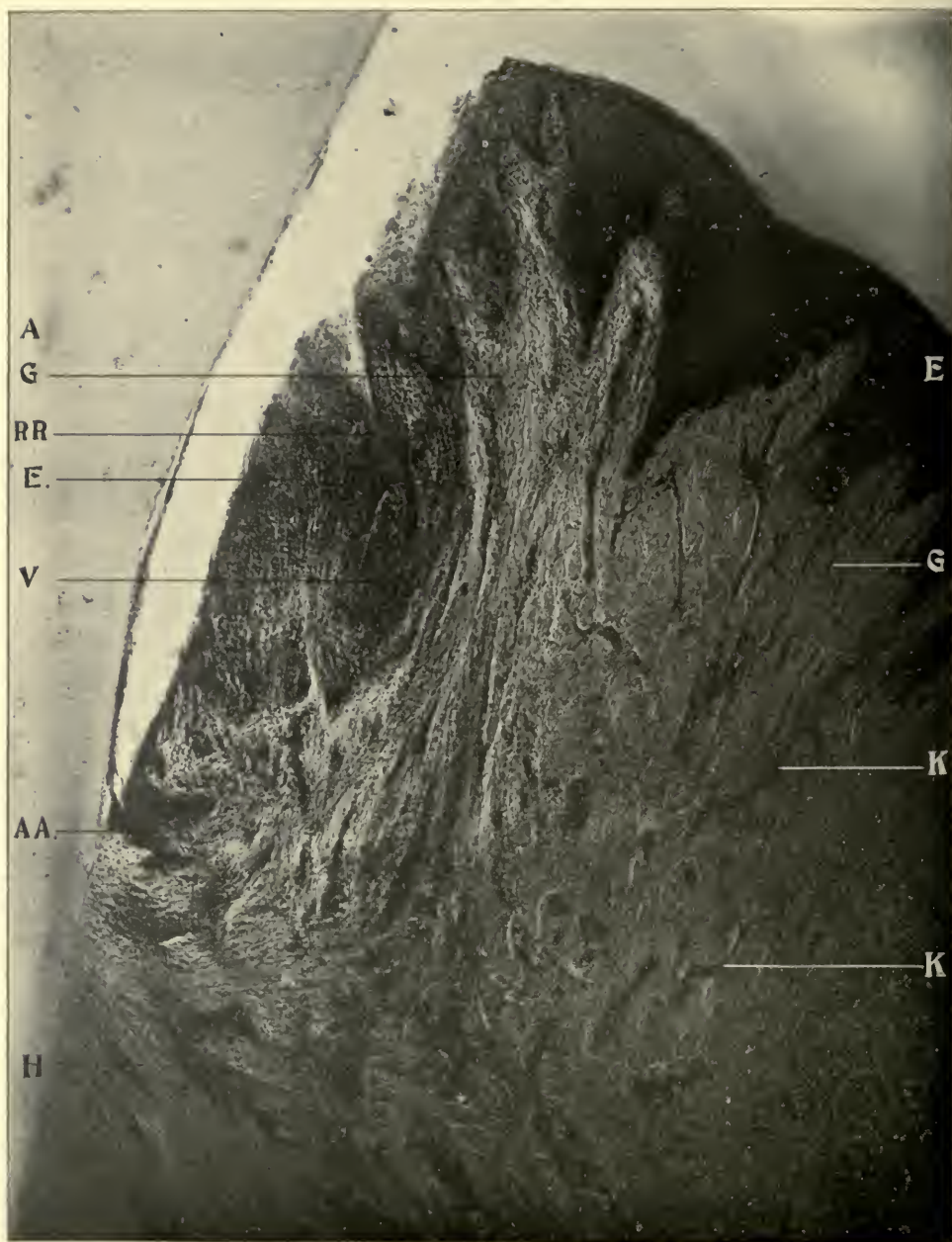
Fig. 32 shows a similar section of another tooth. Here the epithelial structure (E) is pulled away slightly from the edge of enamel (A). In this section the infolding of the epithelium is shown at the neck of the tooth. This structure passes downward, folds outward and upon itself (AA) and returns two-thirds of the distance toward the gingival border, leaving a pocket (RR). The epithelium (E) is very dense and thick. The papillary layer of the submucous tissue (G) is very clearly defined. The capillaries (K) can be distinctly traced from the deeper fibrous tissue through the submucous layer into the papillary layer. The thick and heavy fibrous tissue of the periosteum ("Dental Ligament," Black) may be seen at H, inserted firmly into the



X75. A. A. obj. Zeiss. Micro-photograph, reduced one-third.

FIG. 31.—LONGITUDINAL SECTION OF TOOTH AND GUM TISSUE. SLIGHT GINGIVITIS. DOG.

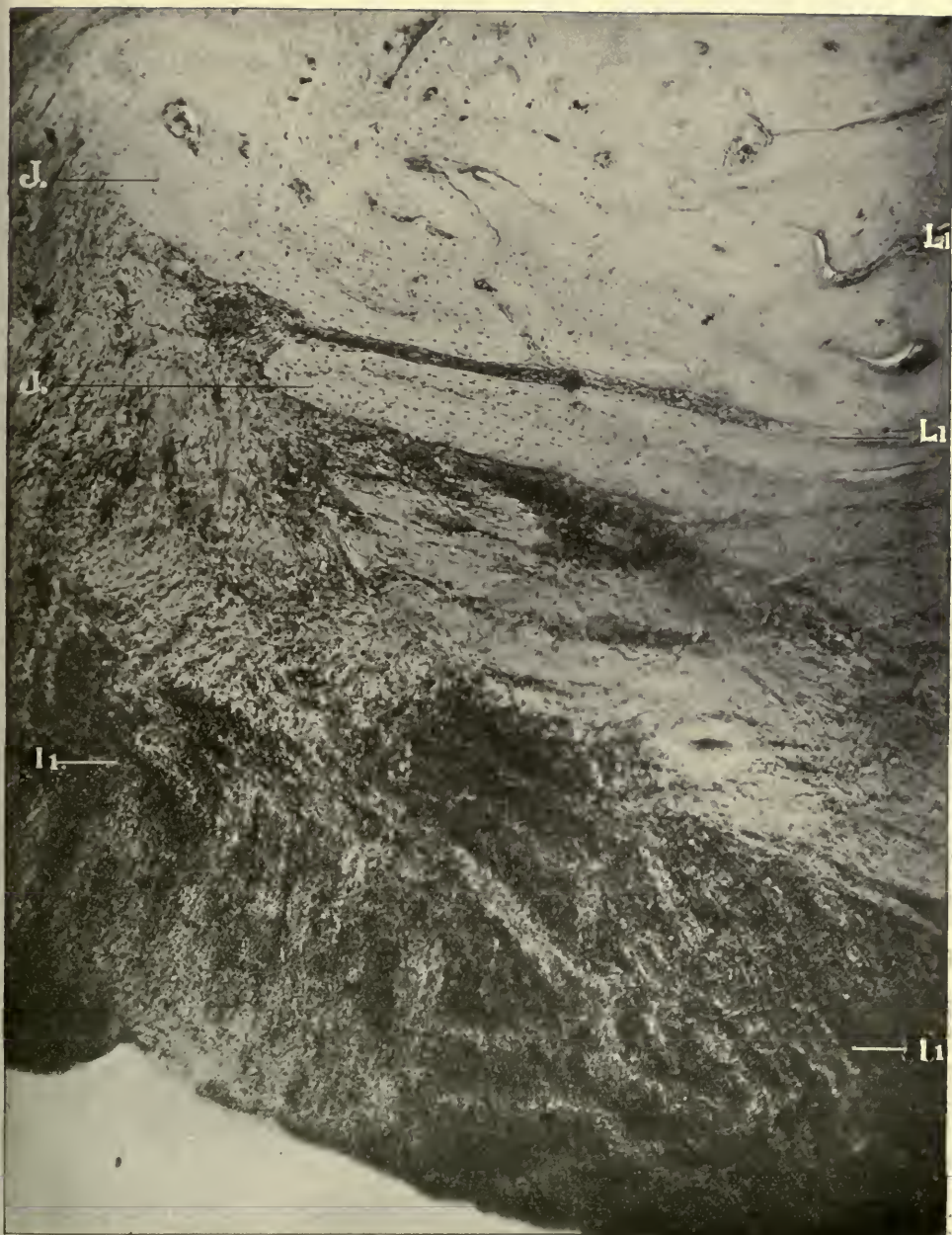
A, Enamel. E, Epithelial Tissue. G, Submucous Membrane. M, Fibrous Tissue.
SI, Slight Inflammation.



X 75. A. A. obj. Zeiss. Micro-photograph, reduced one-third.

FIG. 32.—LONGITUDINAL SECTION OF TOOTH AND GUM TISSUE. CHRONIC INTERSTITIAL GINGIVITIS. DOG.

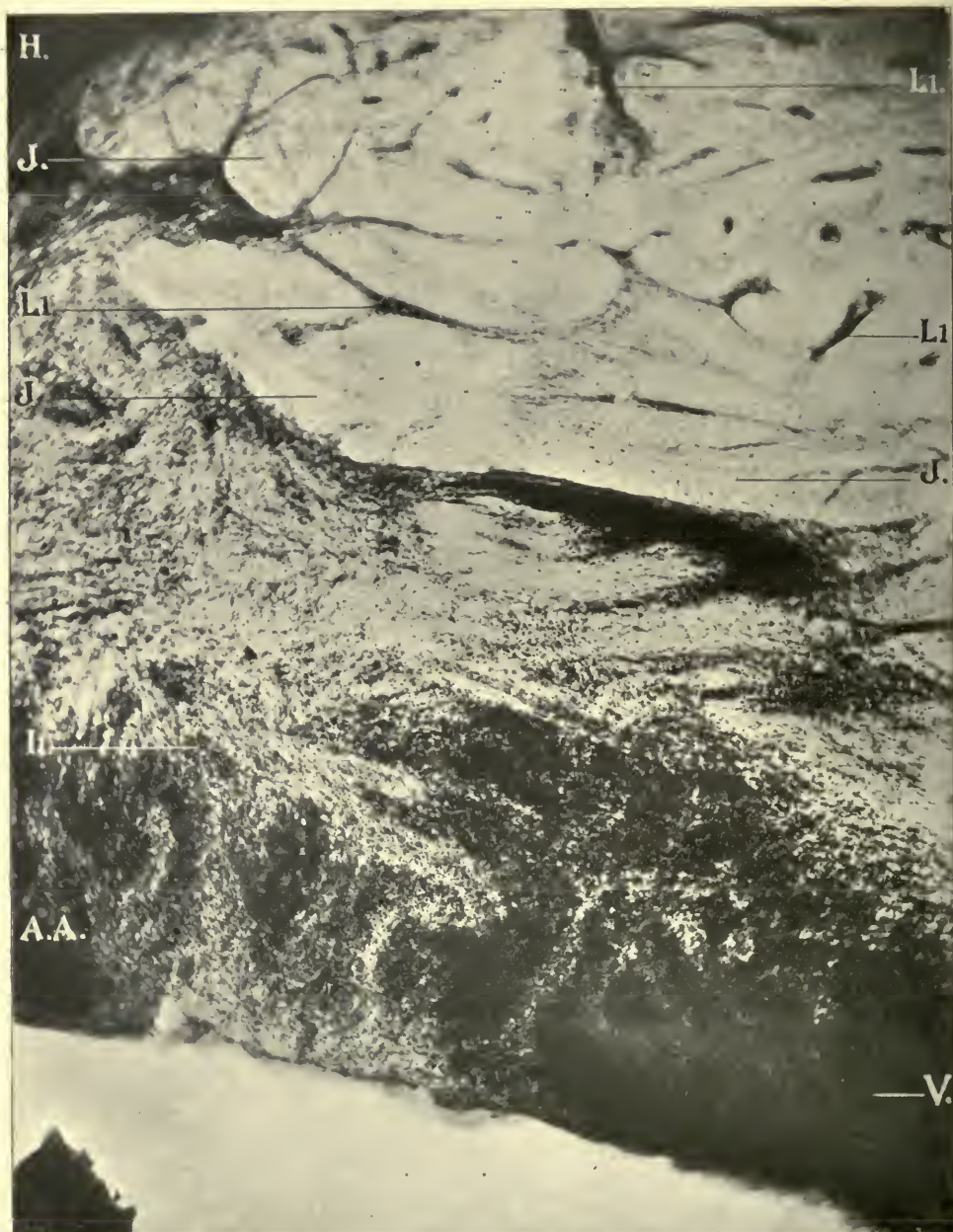A, Enamel. E, Epithelial Tissue. G, Submucous Membrane. H, Periosteum. K, Capillaries. V, Violent Inflammation. AA, Point of Union of Epithelial Tissue and Peridental Membrane. RR, Space Pocket from want of Union of Epithelial Fold.



X 75. A. A. obj. Zeiss. Micro-photograph, reduced one-third.

FIG. 33.—LONGITUDINAL SECTION OF ALVEOLAR PROCESS AND PERIODONTAL MEMBRANE. SLIGHT INTERSTITIAL GINGIVITIS, EXTENDING INTO ALVEOLAR PROCESS. DOG.

J, Alveolar Process. L¹, Inflammation Extending through Enlarged Haversian Canals.
I¹, Inflamed Periodontal Membrane.



x 75. A. A. obj. Zeiss. Micro-photograph, reduced one-third.

FIG. 34.—LONGITUDINAL SECTION OF ALVEOLAR PROCESS AND PERIDENTAL MEMBRANE. CHRONIC INTERSTITIAL GINGIVITIS, EXTENDING INTO ALVEOLAR PROCESS. DOG.

H, Periosteum. J, Alveolar Process. V, Violent Inflammation. AA, Point of Union of Epithelial Tissue and Peridental Membrane. I, Inflamed Peridental Membrane. L¹, Inflammation Extending through Enlarged Haversian Canals.

cementum and extending outward and downward. Just below (AA) may be seen the interlacing of the coarser fibers of the periosteum with the finer fibers of the submucous tissue. Chronic round-cell inflammation may be seen extending from the papillary layer through the capillaries into the interstitial tissue of the submucous layer and the periosteum. Marked inflammation has occurred at V. The openings in the folds of the epithelium are fruitful sources for the accumulation of food, epithelial scales and detritus, in which fermentation and decomposition from micro-organisms result, producing inflammation.

Fig. 33 is a section through the peridental membrane (I) and alveolar process (J) at the lateral incisor. The inflammation has extended down from the papillary layer through the submucous tissue, the fibrous tissue of the periosteum into the peridental membrane and into the alveolar process. Round-cell inflammation may be seen in the blood vessels extending through the Haversian canals (L¹).

Fig. 34 is a similar section from another tooth showing chronic inflammation extending throughout the peridental membrane (I) and alveolar process (J). The Haversian canals (L) are well outlined by the inflammatory progress. Marked inflammation has resulted at V and also at the margin of the alveolar process.

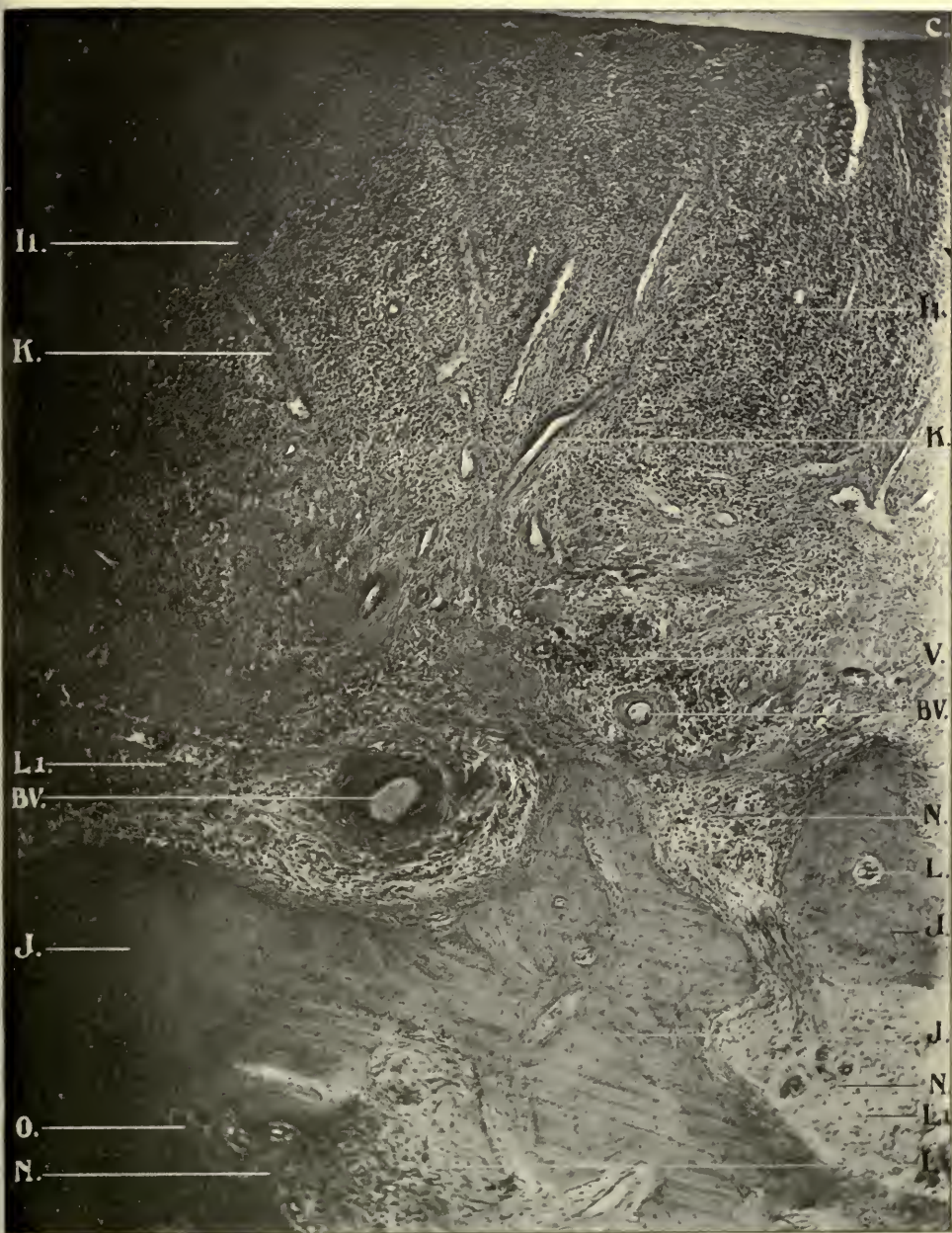
Fig. 35 is a section of the peridental membrane and alveolar process, illustrating the effect of interstitial inflammation upon the blood vessels and alveolar process. Chronic inflammation extends throughout the peridental membrane with very decided inflammatory change (V). The cut ends of the blood vessels which were originally situated in the Haversian canals are seen (BV). They have become involved with the result of a thickening of the walls and endarteritis obliterans. The bone about these vessels has been entirely absorbed. The inflammation has extended beyond, into and through the Haversian canals, producing the type of absorption of the trabeculae known as halisteresis ossium. Lacunar absorption has also occurred (O). Where decided inflammation (V) has taken place, abscesses are more liable to occur (as will be noticed later) from the large number of blood vessels at this locality.

Fig. 36 is a section from another location of the alveolar process with a greater amplification, showing the inflammatory

process extending through the alveolar process. Endarteritis obliterans may be seen in different localities (EO). Three forms of absorption are evident in this figure: Enlarged areas arising from absorption of the trabeculæ (halisteresis ossium) due to the inflammatory process. The vessels of Von Ebner precede perforating canal absorption (BB), distributed over the entire field, also the result of the inflammatory process and lacunar absorption (O) which may result from inflammation. As long as the fibrous tissue remains in these large areas to retain the osteoblasts, new bone tissue may be produced under favorable conditions. On the other hand, when this tissue and the osteoblasts are destroyed, the alveolar process cannot be restored.

Fig. 37 shows a section of the alveolar process from another dog. Here lacunar and other absorption (halisteresis ossium) are well shown. Thirty-seven osteoclasts (O) may be counted in the field while destruction of bone by halisteresis (Q) is rapidly going on. Remains of Haversian canals with the blood vessels may be seen (BV, L). In the discussion of the periodontal membrane extending into the alveolar process (page 37), particular attention was called to the fact that large bundles of fibers extended into the process in such a manner as almost to isolate portions of bone. In the lower left-hand corner (X) may be seen two pieces of the alveolar process entirely separated from each other and the main body of the bone. In interstitial gingivitis, it is not uncommon to find pieces of the alveolar process separated by halisteresis and lacunar absorption. When loose teeth are extracted as a result of this disease, pieces of the alveolar process come away with the periodontal membrane attached to the tooth. Fig. 66 was obtained in this manner. In the upper left-hand corner may be seen eight or ten new osteoclasts (O) in an enlarged Haversian canal, at work isolating one piece of the alveolar process from the other.

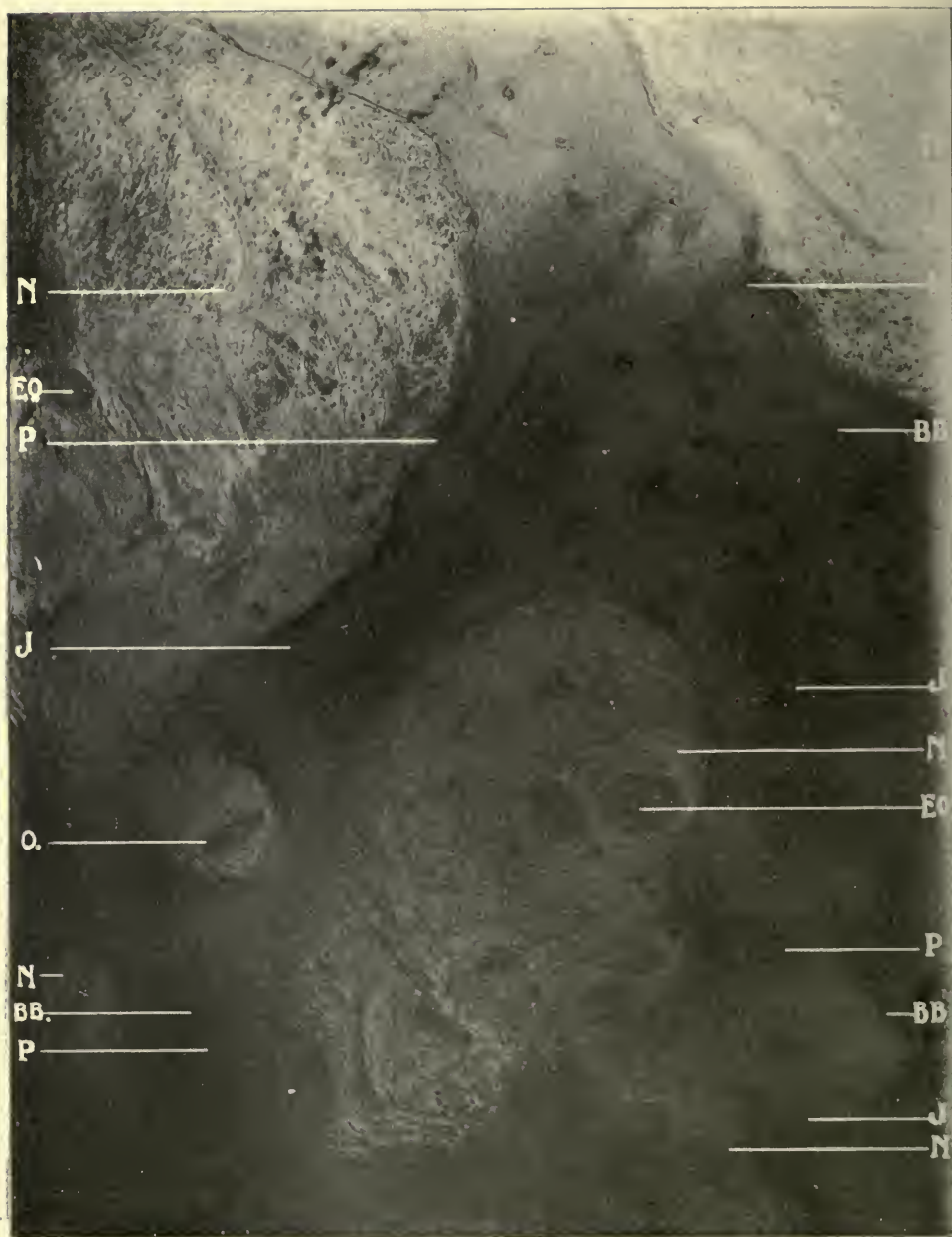
Fig. 38 shows a slide from still another dog. Halisteresis (Q) and perforating canal (P) absorption are here well shown. In the larger space at the lower left-hand corner may be seen two arteries (EO) which were originally the location of Haversian canals and which have thickened walls and a tendency to obliteration. The light color shows decalcification, the dark normal bone. At P may be seen perforating canal absorption. At FG



X 75. A. A. obj. Zeiss. Micro-photograph, reduced one-third.

FIG. 35.—LONGITUDINAL SECTION OF TOOTH, ALVEOLAR PROCESS AND PERIODONTAL MEMBRANE. VIOLENT ROUND-CELL INFLAMMATION OF PERIODONTAL MEMBRANE, EXTENDING THROUGH THE HAVERSIAN CANALS INTO THE ALVEOLAR PROCESS.

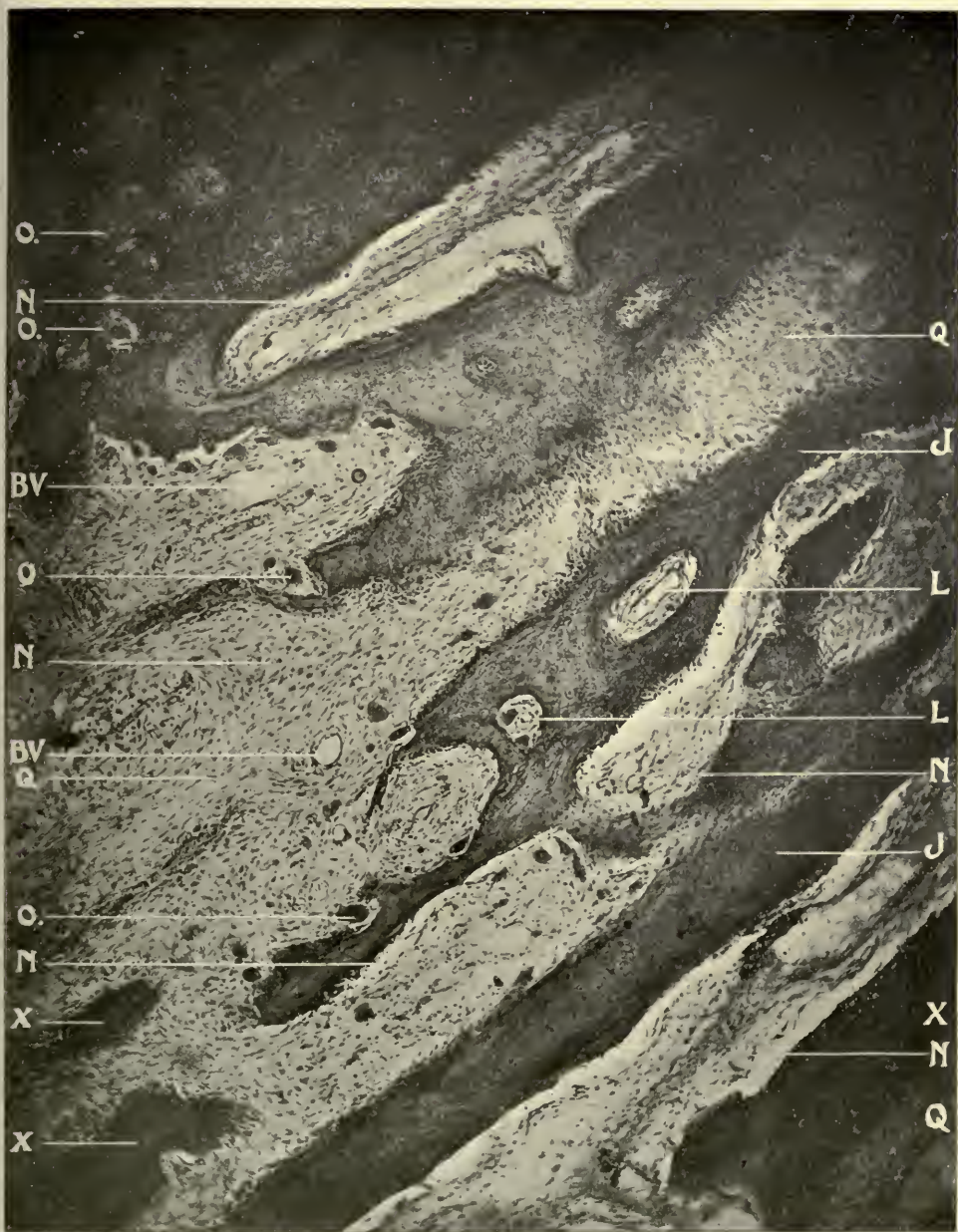
C, Cementum. J, Alveolar Process. K, Capillaries. L, Haversian Canals. N, Large Spaces arising from Absorption of the Trabeculae, starting in the Haversian Canals (Halisteresis). O, Lacunar Absorption. V, Violent Inflammation. BV, Blood Vessels, originally Haversian Canals. I, Inflamed Periodontal Membrane. L¹, Inflammation Extending through Enlarged Haversian Canals.



X 150. D. D. obj. Zeiss. Micro-photograph, reduced one-third.

FIG. 36.—LONGITUDINAL SECTION OF ALVEOLAR PROCESS. CHRONIC INFLAMMATION EXTENDING THROUGHOUT, SHOWING HALISTERESIS, PERFORATING CANAL AND LACUNAR ABSORPTION. DOG.

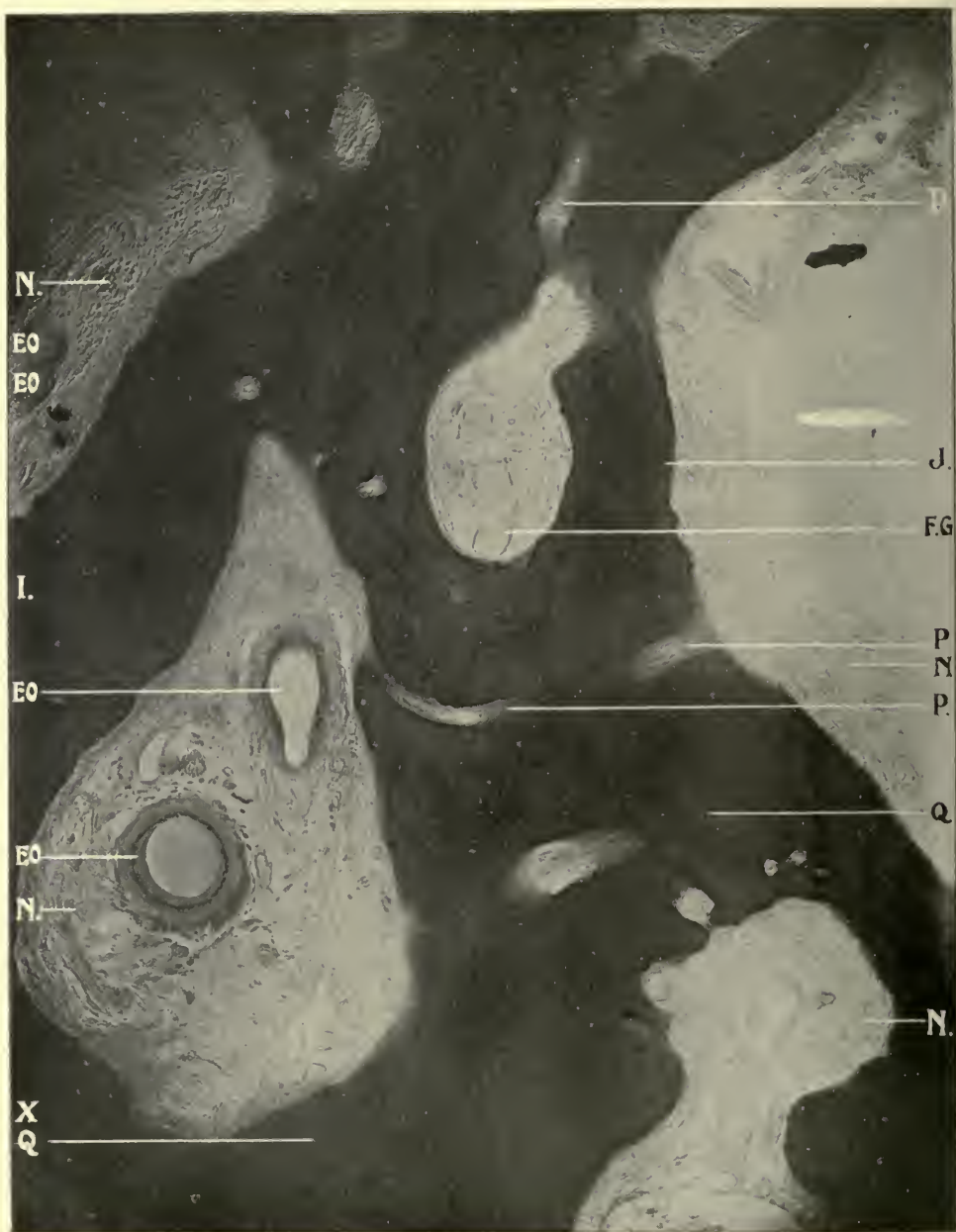J, Alveolar Process. N, Large Spaces arising from Absorption of the Trabeculae, starting in the Haversian Canals (Halisteresis). O, Lacunar Absorption. P, Perforating Canal Absorption. BB, Blood Vessels of V. Ebner preceding Perforating Canals. EO, Endarteritis Obliterans.



X 75. A. A. obj. Zeiss. Micro-photograph, reduced one-third.

FIG. 37.—LONGITUDINAL SECTION OF ALVEOLAR PROCESS. CHRONIC INFLAMMATION EXTENDING THROUGHOUT, SHOWING HALISTERESIS AND LACUNAR ABSORPTION. DOG.

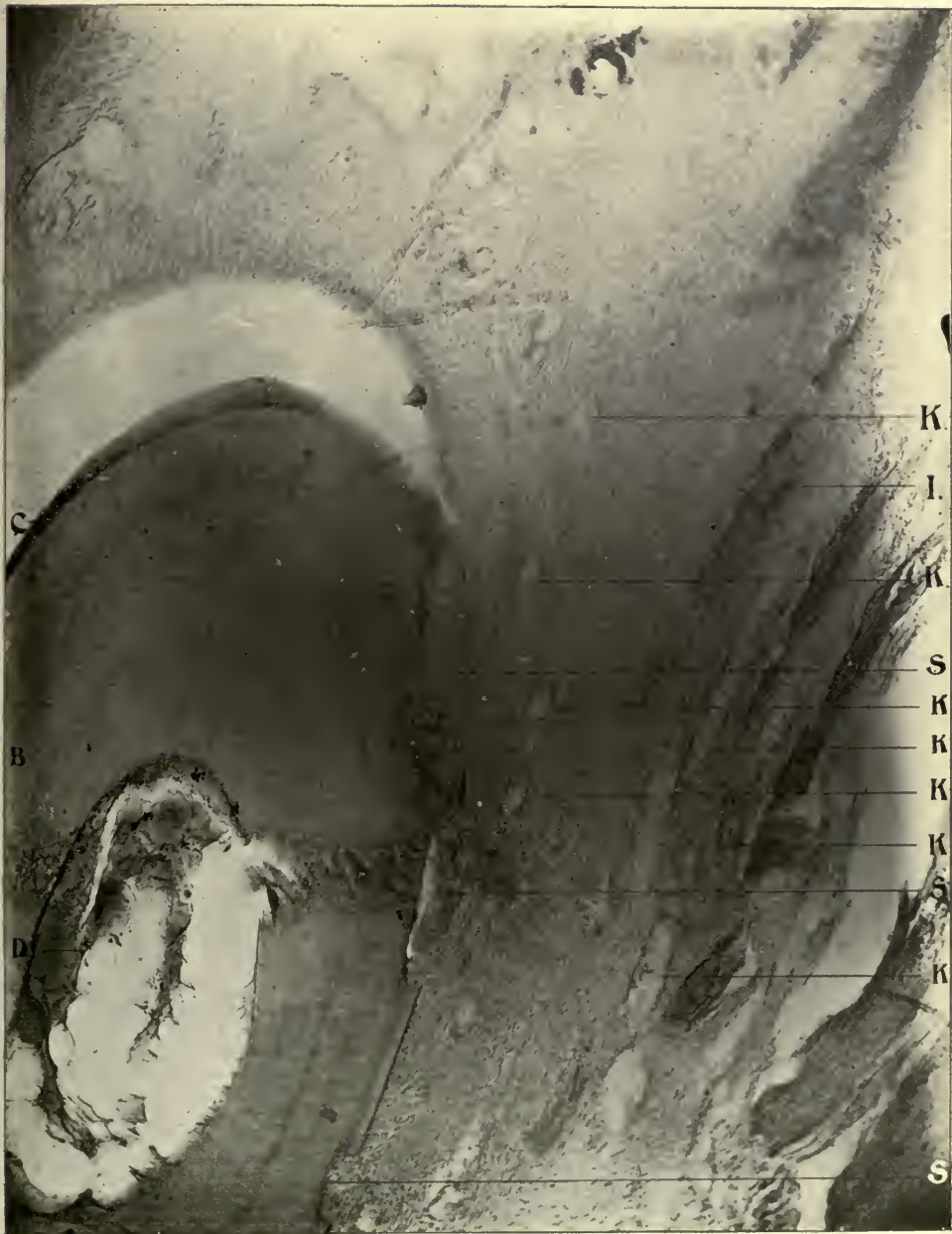
J, Alveolar Process. L, Haversian Canals. N, Large Spaces arising from Absorption of the Trabeculae, starting in the Haversian Canals. O, Lacunar Absorption. Q, Halisteresis Ossium or Decalcified Bone. X, Remains of Calcified Bone. BV, Blood Vessels originally Haversian Canals.



X 75. A. A. obj. Zeiss. Micro-photograph, reduced one-third.

FIG. 38.—TRANSVERSE SECTION, ALVEOLAR PROCESS. CHRONIC INFLAMMATION EXTENDING THROUGHOUT. DOG.

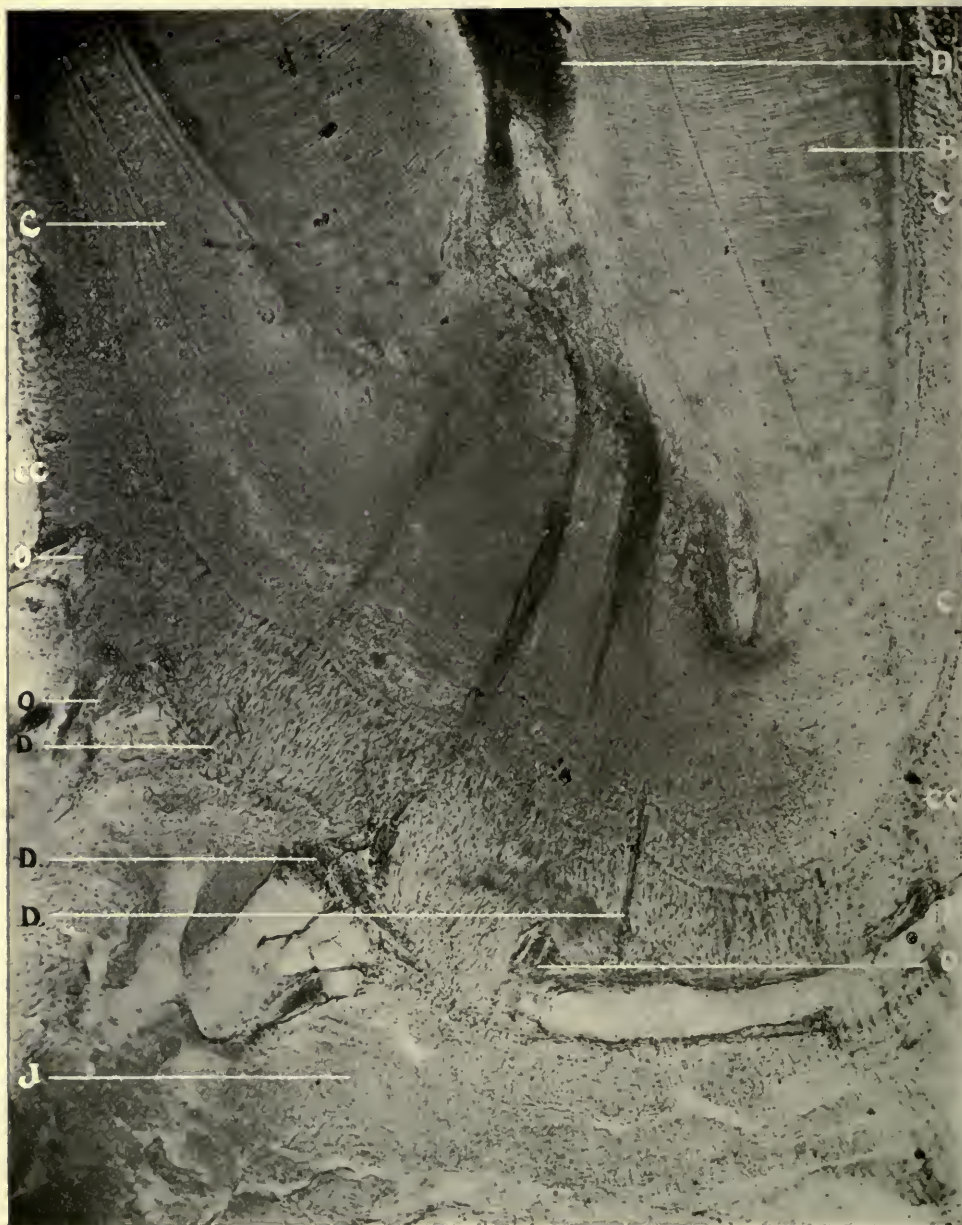J, Alveolar Process. N, Large Spaces arising from Absorption of the Trabeculae, starting in the Haversian Canals. P, Perforating Canal Absorption. Q, Haliteresis Ossium or Decalcified Bone. X, Remains of Calcified Bones. EO, Endarteritis Obliterans. FG, Fat Globules.



X 75. A. A. obj. Zeiss. Micro-photograph, reduced one-third.

FIG. 39.— CROSS SECTION OF TOOTH, ALVEOLAR PROCESS AND PERIDENTAL MEMBRANE. CHRONIC INFLAMMATION OF PERIDENTAL MEMBRANE AND ABSORPTION OF THE ROOT OF TOOTH. DOG.

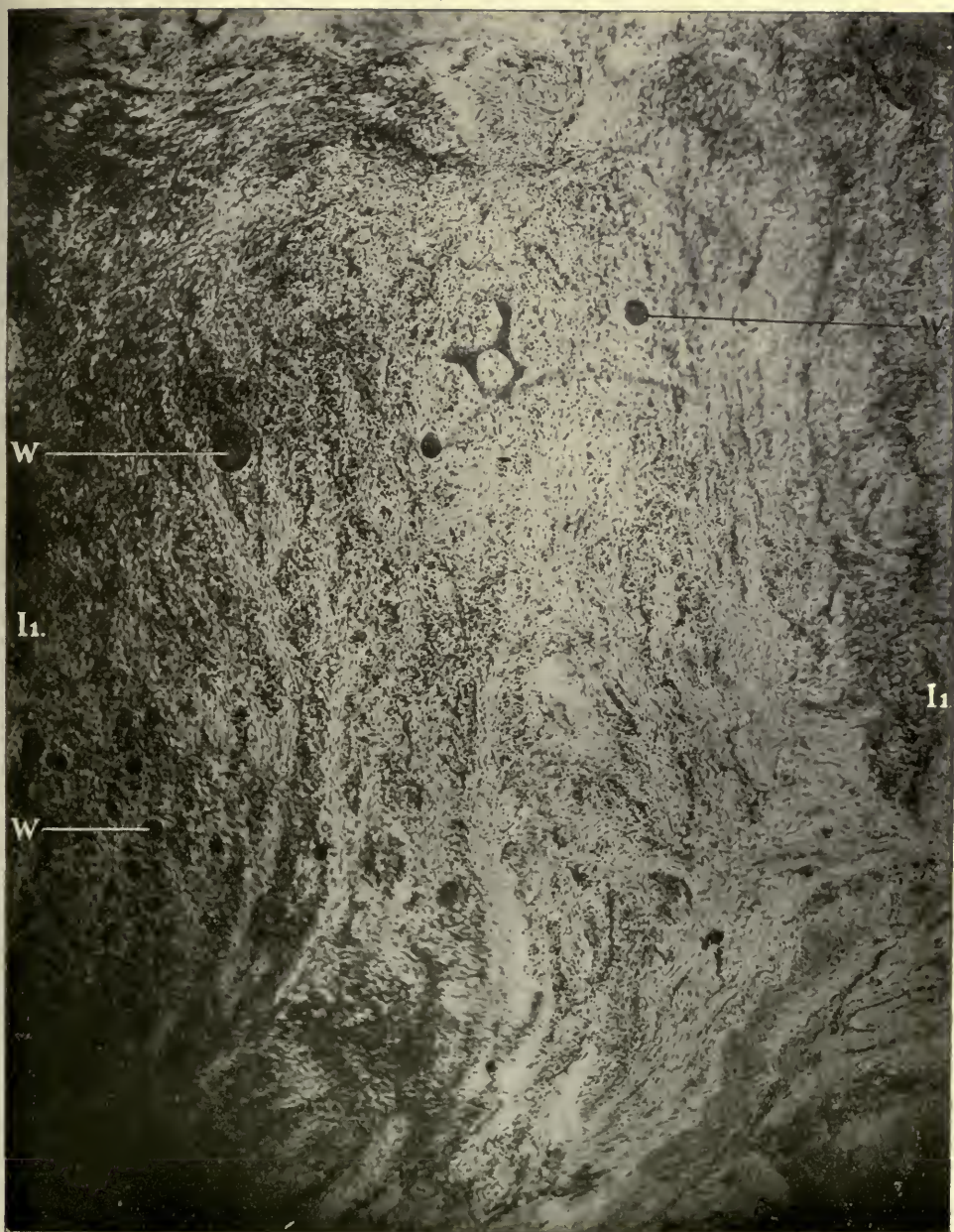
B, Dentine. C, Cementum. D, Pulp. I', Inflamed Peridental Membrane. K, Capillaries. S, Root-absorption.



X 75. A. A. obj. Zeiss. Micro-photograph, reduced one-third.

FIG. 40.—LONGITUDINAL SECTION OF THE END OF THE ROOT OF A TOOTH, ALVEOLAR PROCESS AND PERIODONTAL MEMBRANE, SHOWING CHRONIC INFLAMMATION OF THE PERIODONTAL MEMBRANE. EXOSTOSIS OF THE ROOT OF THE TOOTH AND LACUNAR ABSORPTION. DOG.

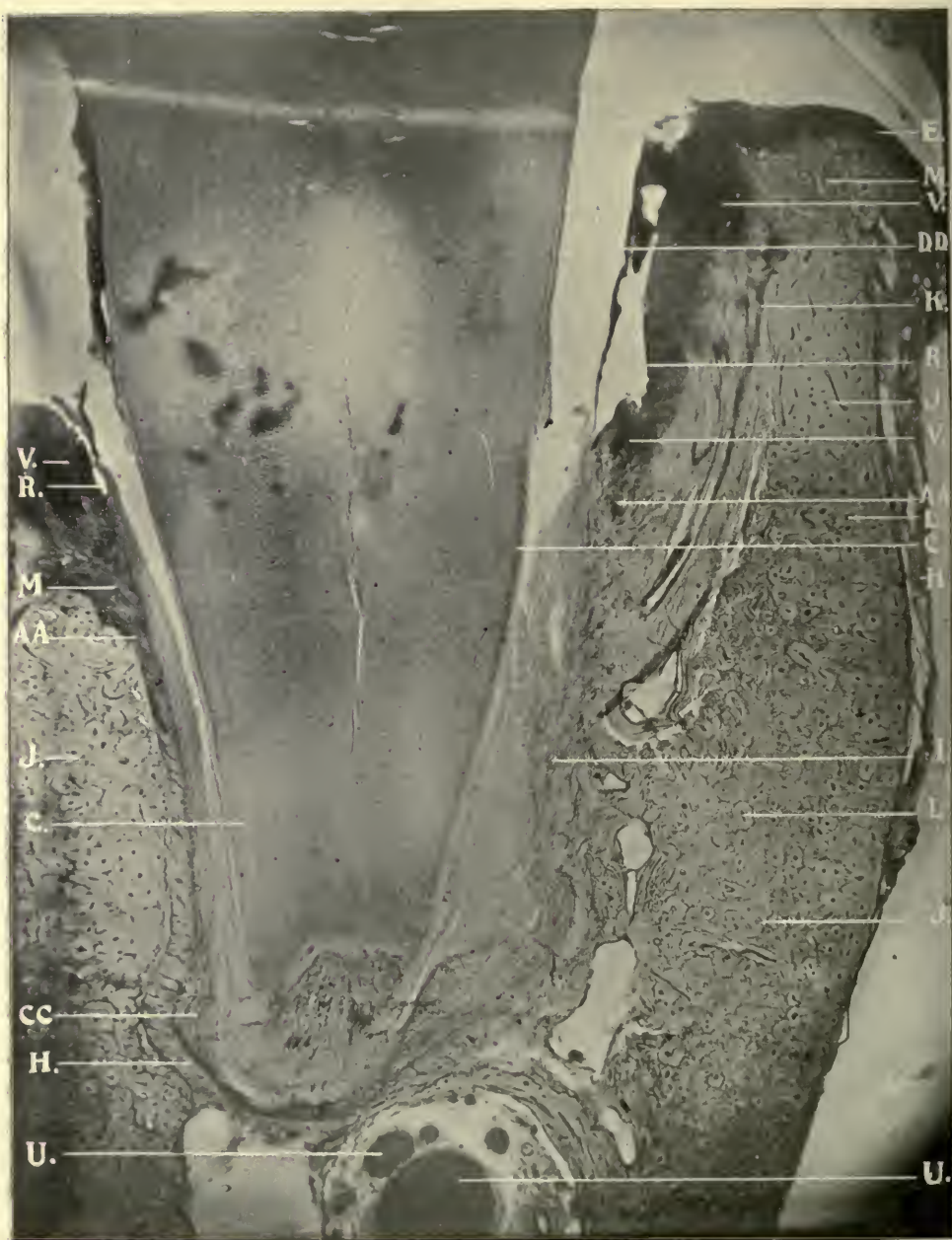
C, Cementum. D, Pulp, with 3 Foramina. J, Alveolar Process. O, Lacunar Absorption. P, Perforating Canal Absorption. CC, Cementosis.



X 75. A. A. obj. Zeiss. Micro-photograph, reduced one-third.

FIG. 41.—CROSS SECTION OF INFLAMED PERIDONTAL MEMBRANE. DOG.

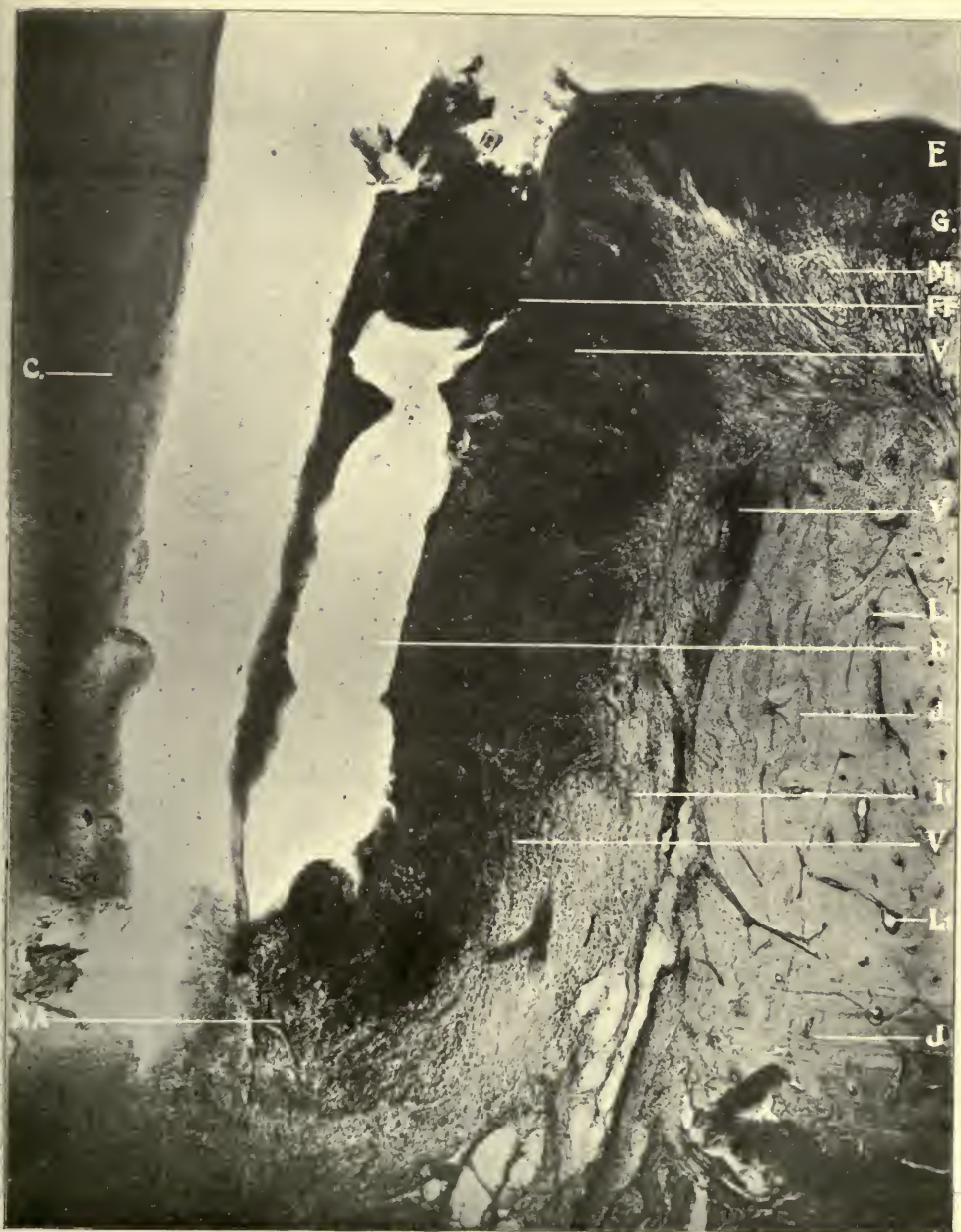I1, Inflamed Peridental Membrane. W, Epithelial Débris.



X 15. 75 M.M. obj. Spencer. Micro-photograph, reduced one-third.

FIG. 42.—LONGITUDINAL SECTION OF TOOTH, ALVEOLAR PROCESS, PERIODONTAL MEMBRANE, SHOWING INTERSTITIAL GINGIVITIS AND PYORRŒA ALVEOLARIS, WITH TOOTH ABOUT TO BE EXFOLIATED. DOG.

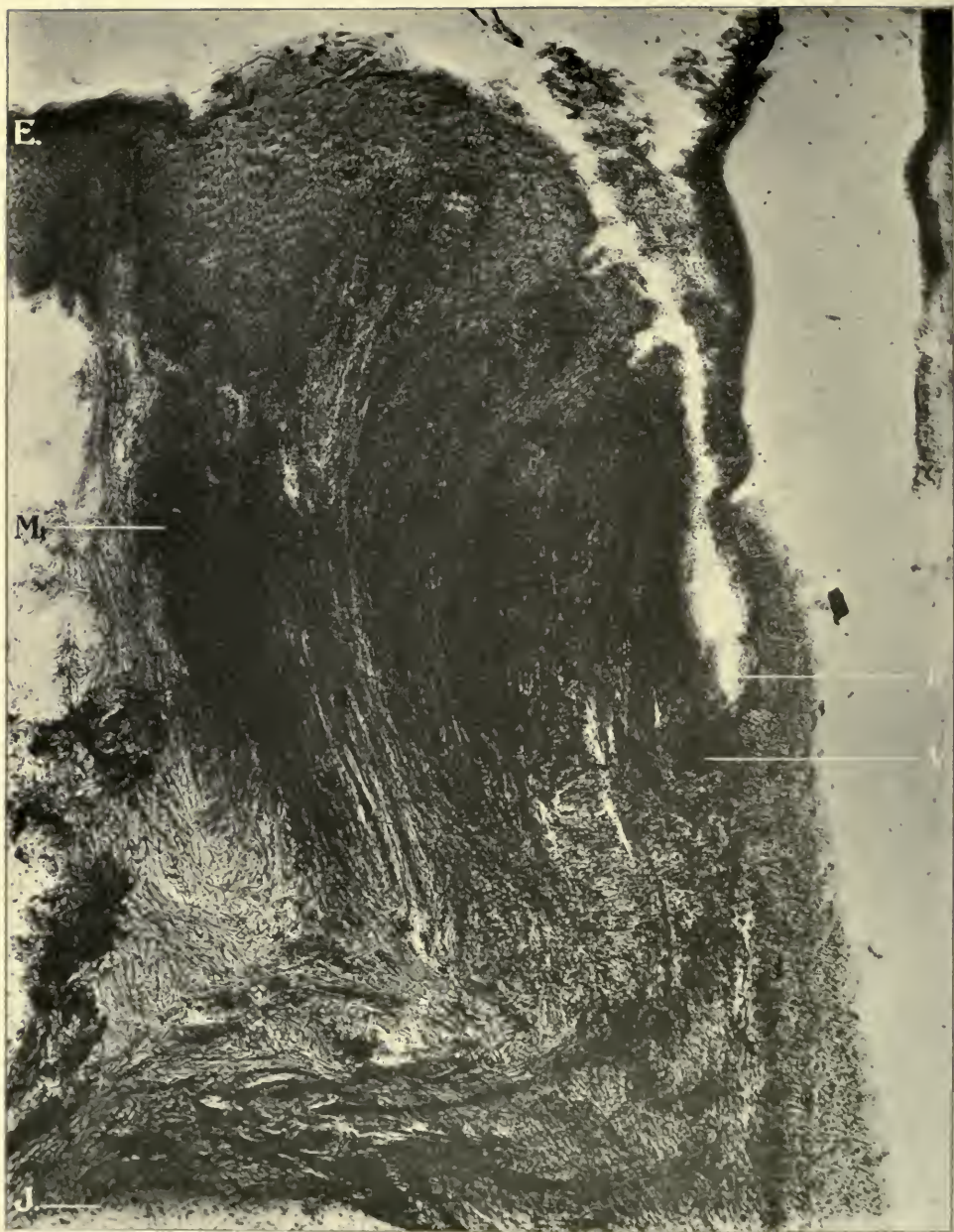
C, Cementum. E, Epithelial Tissue. H, Periosteum. I, Periodontal Membrane. J, Alveolar Process. K, Capillaries. L, Haversian Canals. M, Fibrous Tissue. R, Pus Pockets. U, Nerve Tissue. V, Violent Inflammation. AA, Point of Union of Epithelial Tissue and Periodontal Membrane. CC, Cementosis. DD, Calcific Deposits Destroyed by Acids.



X 40. 35 M.M. obj. Zeiss. Micro-photograph, reduced one-third.

FIG. 43.—LONGITUDINAL SECTION OF TOOTH, ALVEOLAR PROCESS, PERIDENTAL MEMBRANE AND GUM TISSUE, ENLARGED FROM FIG. 42, SHOWING ACTIVE INFLAMMATION, WITH PUS POCKET. Dog.

C, Cementum. E, Epithelial Tissue. G, Submucous Membrane. I', Inflamed Peridental Membrane. J, Alveolar Process. L', Inflammation Extending through Enlarged Haversian Canals. M', Inflamed Fibrous Tissue. R, Pus Pocket. V, Violent Inflammation. AA, Point of Union of Epithelial Tissue and Peridental Membrane. FF, Food Containing Micro-Organisms.



x 75. A. A. obj. Zeiss. Micro-photograph, reduced one-third.

FIG. 44.—LONGITUDINAL SECTION OF TOOTH, ALVEOLAR PROCESS, PERIDENTAL MEMBRANE AND GUM TISSUE, ENLARGED FROM FIG. 42, SHOWING ACTIVE INFLAMMATION WITH PUS POCKET. DOG.

C, Cementum. E, Epithelial Tissue. J, Alveolar Process. M¹, Inflamed Fibrous Tissue. R, Pus Pocket. V, Violent Inflammation.

fat globules may be seen, while in the larger space at the upper right-hand corner is evident entire destruction of the fibrous tissue.

Fig. 39 illustrates a cross section of alveolar process and cuspid root, showing absorption of the root. Inflammation extends throughout the peridental membrane (I). The capillaries (K) are quite numerous. These are cut both crosswise and lengthwise. Absorption (S) of the root may be seen progressing at these localities.

Fig. 40 shows a longitudinal section of the end of the root. Active destruction has been going on both in the pulp chamber (D) and at the external surface of the cementum (C). The irritation and inflammation has caused the odontoblasts to fill up the pulp chamber with secondary dentine, and obliteration of the chamber has taken place. Below the constricted pulp may be seen three divisions of the pulp (D) extending through three separate canals in the cementum (C). Cementosis (CC) may be seen at the end of the root. Lacunar absorption is going on (O). Thus results a building up and tearing down of the same tissue from the same cause, interstitial gingivitis..

Fig. 41 shows inflammation of the peridental membrane (I¹) with epithelial débris (W) scattered throughout the field.

Fig. 42 is a section through the jaw and incisor tooth, showing the relation of the structures to each other in a severe case of interstitial gingivitis and pyorrhœa alveolaris. The tooth is attached at only a very small portion of the apical end of the root. The disease has been of long standing. Absorption of the alveolar process on one side has progressed on fully one-half of the root, while upon the other about one-third the distance. Inflammation commenced at the gingival border and extended through the periosteum (H), peridental membrane (I) and alveolar process (J). Marked inflammation (V) has occurred in the mucous membrane fold. An abscess has formed with a fistula extending to the gingival border. The thin border at the left of the fistulous tract is the epithelium layer next to the tooth. It is evident that the pus burrowed to the surface through the structure instead of between the epithelium and the tooth. A similar abscess and fistulous tract are evident upon the gingival border on the opposite side of the tooth. The irritation produced by

the movement of the tooth has caused the cementoblasts to deposit large quantities of material upon the sides and the end of the root. The main nerve trunks (U) may be seen at and below the end of the root.

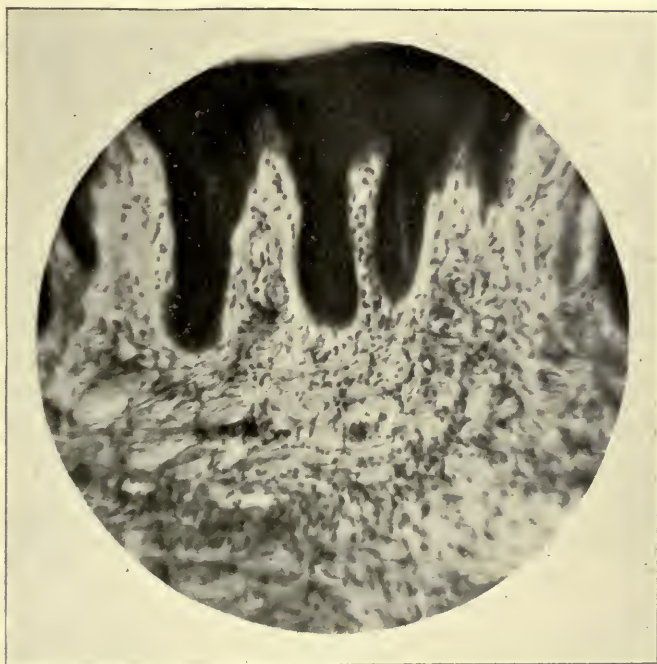
Fig. 43 illustrates the alveolar border on the right side of Fig. 40, greatly amplified. This shows the progress of interstitial gingivitis extending through the alveolar process producing absorption with intense inflammation of the peridental membrane and abscess with fistulous tract.

Fig. 44 shows a similar process amplified from the left side of Fig. 42. It is interesting to note in this illustration that the fibers of the sub-epithelium pass down and become interwoven with the coarser fibers of the periosteum in just the opposite direction from those in the other side of the tooth, and in other illustrations. The fibers from the mucous membrane along the side of the tooth extend down and into the peridental membrane without a break in the structure. The arrangement of the fibers of the submucous layer in producing the fold is well illustrated in the figure. This picture illustrates inflammation starting in the gingival border.

CHAPTER XI.

MERCURIAL INTERSTITIAL GINGIVITIS IN DOGS.

To secure a chain of evidence that interstitial gingivitis (due to the metals, drugs, uric, lactic and other acids) commenced in the papillary layer of the sub-epithelial, mucous membrane, I instituted a series of experiments in mercurialization of dogs.

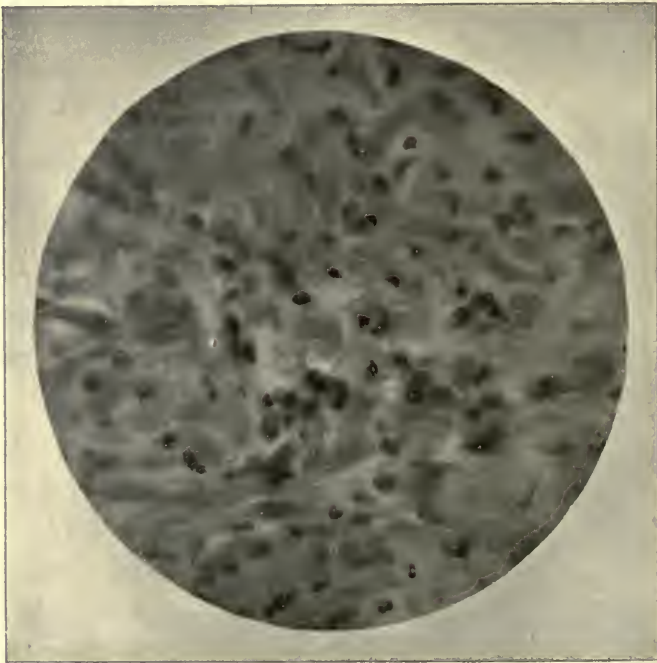


Proj. $\frac{1}{4}$ inch, ocular $1\frac{1}{2}$ inch. Spencer.

FIG. 45.—LONGITUDINAL SECTION OF GINGIVAL BORDER, SHOWING ROUND-CELL INFLAMMATION DUE TO MERCURIAL POISONING.

Dogs for the purpose were picked up in the streets. Some of these were operated upon by myself, but most of them were under treatment at the Post-Graduate Medical School. Care was taken to secure those in health and with healthy gums. Mercury was introduced by the mouth, skin and hypodermic

injection. It was no easy matter to get them under influence of the drug, since the power of the glands to eliminate the poison was enormous. In no case was salivation produced. The first symptom noticed was exhilaration, which would last from three days to a week. Then paralysis agitans would continue until death. In about a week the appetite would commence to fail and it was difficult to get the dogs to take food of any kind. The kidneys and bowels eliminated the poison. There was a



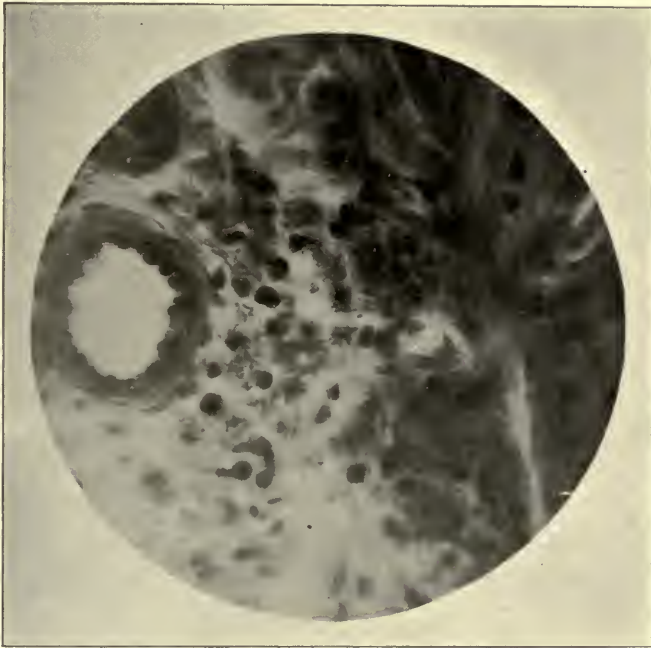
Pantachr. oil imm. $\frac{1}{2}$ inch ocular. No. 3. Leitz.

FIG. 46.—LONGITUDINAL SECTION OF GINGIVAL BORDER. HIGHER MAGNIFICATION, SHOWING CONNECTIVE TISSUE INFILTRATION WITH PLASMA CELLS AND POLYNUCLEAR LEUCOSYTES. DOG.

rise in temperature. Some of the dogs died before gingivitis was observed. This demonstrated that not only does the nervous system become involved, but the organs of the body may be morbidly affected and death ensue before the gums show symptoms of disease. Some dogs were killed after the gums became diseased. The time required to obtain results was from three to eight weeks. The age and physical condition of the dog caused

this variation in time. After death the gum tissue was dissected from different parts of the jaws and placed in either fifty per cent alcohol, Müller's fluid, or two per cent formalin.

Sections of tissue from the gum margin and sides were made on a number of places. Some were imbedded in paraffin, others in celluloidin. The sections were stained according to various methods: Delafield's hæmatoxylin, eosin (Unna's), alkalin methylblue, carmin, Gramm's stain, etc.



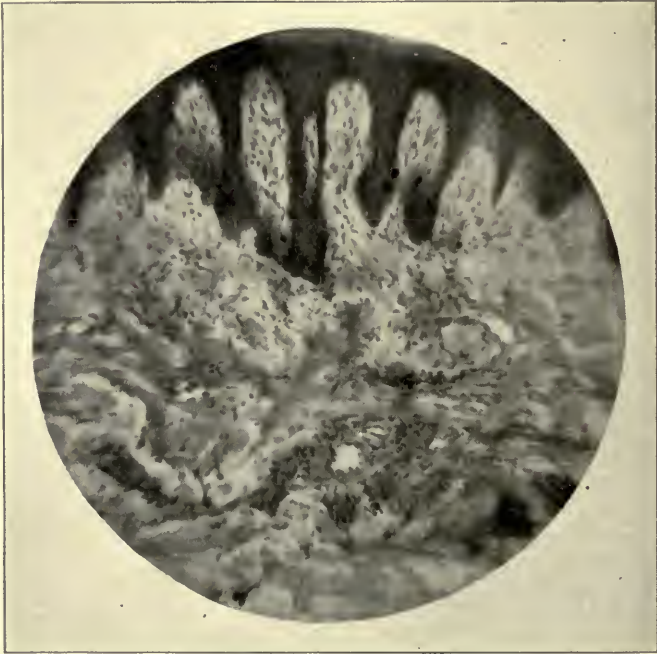
Pantachr. oil imm. $\frac{1}{2}$ inch ocular. No. 3. Leitz.

FIG. 47.—LONGITUDINAL SECTION OF GINGIVAL BORDER. HIGHER MAGNIFICATION, SHOWING ROUND-CELL INFLAMMATION EXTENDING TO THE INNER COAT OF THE BLOOD VESSEL AND ALSO PLASMA-MAST CELLS.

Microscopic examination showed that the epithelial lining of the gums did not present pathologic changes, but appeared normal in every respect. Connective tissue below the gum epithelium (the tissue analogous to the papillary layer of the derma and the derma proper) presented unmistakable evidences of a mild inflammatory process. There occurred in this connective tissue round-cell infiltration, generally moderate but in

some places quite dense. This cellular infiltration extended from below (where it was densest) upward into the papillary layer (Figs. 45 and 46). The densest cellular infiltration usually occurred around the vessels (Fig. 46).

Under high magnification, the cellular infiltration was found to consist of polymorphonuclear leucocytes, plasma cells and



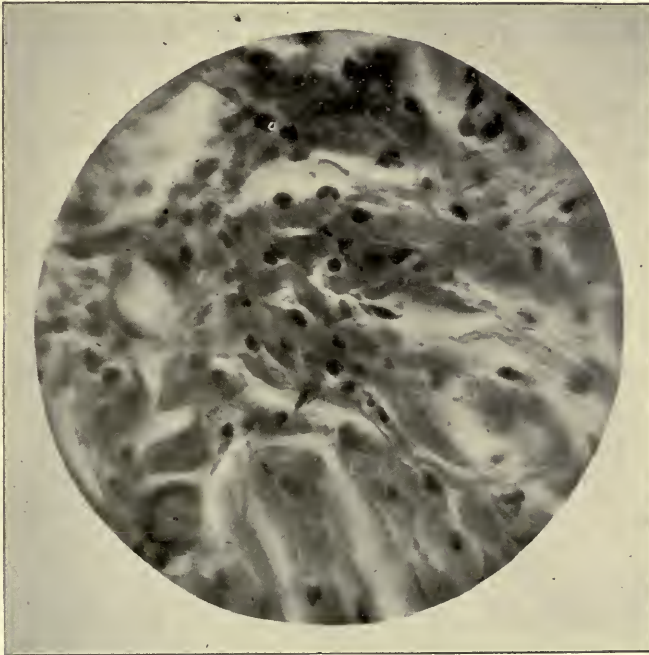
Projection $\frac{1}{4}$ inch, ocular $1\frac{1}{2}$ inch. Spencer.

FIG. 48.—LONGITUDINAL SECTION OF GINGIVAL BORDER, SHOWING ROUND-CELL INFILTRATION IN THE CONNECTIVE TISSUE AND EXTENDING INTO THE PAPILLE. DOG.

plasma-mast cells, the latter with coarse basophilic granulations (Figs. 47 and 48).

In some places were seen between the round cells, short, broad fusiform cells, the protoplasm of which took quite well basic methylblue. These cells resemble very much fibroblasts and appear to be derivations of the plasma cells (Fig. 49). No bacteria were found either in the areas of cellular infiltration (inflammatory areas) or elsewhere. In these cases it is obvious that there had occurred a mild inflammation of the gums (gingi-

vitis). While this could not be seen with the naked eye, microscopic examination demonstrated histologic features of an inflammatory process. The absence of bacteria justified the belief that this inflammation was not of microbial origin, but due to mercury, which by its well-known chemotactic influence produced the histologic changes of an inflammation.



Pantachr. oil imm. $\frac{1}{2}$ inch ocular. No. 3. Leitz.

FIG. 49.—LONGITUDINAL SECTION OF GINGIVAL BORDER, SHOWING ROUND-CELL INFLAMMATION DUE TO MERCURIAL POISONING. HIGHER MAGNIFICATION.

CHAPTER XII.

BACTERIOLOGY OF INTERSTITIAL GINGIVITIS.

The bacteric etiology of interstitial gingivitis has been incidentally discussed by many writers.

Galippe¹ was probably among the first to make analytic experimentation in the bacteriology of this disease. He claims that there is found in the pus of pyorrhœa a parasite, resembling in shape the Greek letter N. Injecting this into the belly of a guinea pig, abscesses resulted, which had a special tendency to affect bone tissue. Injections into the space between the teeth and gums were negative in result. Galippe regards his experiments as suggestions for further research, but not demonstrative. Miller,² after explaining his own methods, made a series of culture experiments on agar-agar at blood temperature. Twelve cases of pyorrhœa in human beings, and six in dogs, were examined. He isolated twenty different bacteria from human beings, and nine from dogs. Among the twenty kinds, staphylococcus pyogenes aureus was found twice. Staphylococcus pyogenes albus once, streptococcus pyogenes once. Of the other sixteen, nine subcutaneously injected produced no particular reaction, four a slight, three a severe suppuration in the subcutaneous connective tissue. . . . Among the nine species found in dogs, staphylococcus pyogenes albus occurred once. Of the other eight, two subcutaneously injected caused no reaction, and five but slight. One caused very profuse suppuration, by which large portions of skin exfoliated. . . . Microscopic examination of stained sections revealed masses of different bacteria, cocci and bacilli. Leptothrix occurred infrequently, and then only on the surface of the cement, and where there were microscopical cavities in it. . . . Miller succeeded consequently in cultivating a large number of bacteria from pyorrhœa alveolaris which possessed pyogenic properties, but was not able to

¹ Die Infectiöse Arthro-Dentäre Gingivitis, 1888.

² Micro-Organisms of the Human Mouth.

determine the constant occurrence of any one which might be regarded as the specific micro-organism of pyorrhœa alveolaris. Miller remarks that it is not evident from Galippe's communication whether he found the N or β bacterium in all cases examined, or but once.

Sudduth, after repeated examinations, arrived at the same conclusion as Miller.

The results obtained in the Columbus Memorial Laboratory of Chicago, by W. A. Evans, were as follows:

In order to determine whether a specific bacterium existed in the pyorrhœic stage of interstitial gingivitis in man (necessary to constitute this stage a special disease), pus from more than fifty cases was examined. In all, the pus was obtained from the gums by a platinum needle under proper methods of sterilization. The pus from some cases was smeared on a slide. This was stained and such determination made as was possible with this procedure. With the pus from fifteen cases, agar was inoculated and placed in Petrie's dishes. The individual colonies were grown on gelatin, agar, bouillon, potato and blood serum. The results were as follows: In fifteen cases in which the organisms were plated out, fifty-five organisms were found. In two there was no growth. Two had but one species of germs, two had six, one had seven, and one had ten. The germs found are divisible into three classes: Those usually pathogenic to man, those exceptionally pathogenic to man, and those never pathogenic to man. The first class was found thirty times, the second twelve, and the third thirteen. Class third is, no doubt, seemingly smaller than it should be, since many members of it probably do not grow on ordinary culture media. Of the germs most frequent and important, staphylococcus pyogenes aureus occurred nine times, staphylococcus pyogenes albus six times, and staphylococcus pyogenes citreus once. A lanceolate diplococcus, growing like pneumococcus, was found six times. Streptococcus pyogenes was found twice. Bacillus coli commune was found twice. A bacillus growing like the diphtheria bacillus occurred twice. This last bacillus had the appearance of the Kleb-Loeffler bacillus. It lay on the slide like it and it stained irregularly. Of the less important organisms, bacillus pyocyaneus was found three times, micrococcus tetragenus seven times, leptothrix seven times,

bacillus mesentericus twice, bacillus subtilis three times. There was also present a peculiar large club-shaped fungus somewhat resembling the degenerative forms of actinomycosis.

Did these examinations stand alone, definite conclusions could not be drawn from them. These, however, are admissible since all observations on this subject tend in the same direction. While, as already stated, Galippe believed that he had isolated two bacteria capable of causing pyorrhœa alveolaris, still he failed with both to produce the disease. This failure, according to the laws of Koch, is fatal to the position taken.

M. Herzog, of the Chicago Polyclinic, on examination of cases of interstitial gingivitis, which had not reached the pyorrhœic stage, had the following results: Pieces from the gum margin which had been fixed and hardened in a formalin solution, were partly imbedded in celloidin, partly in paraffin. The sections were stained according to various methods, including Gramm's, eosin (Unna's) and alkaline methylblue stain. The examination of the tissue shows an unchanged lining of stratified squamous epithelium, and, in the connective tissue below the former, well-marked evidences of an inflammatory process. The round-cell infiltration is best marked in the deeper layers toward the periosteum, while the layers of connective tissue fibers nearer to the lining epithelium show less evidences of inflammation and are partly entirely free from any round-cell infiltration. The infiltrating round cells are of the type of lymphocytes, plasma cells and plasma mast cells. Very large and typical mast cells are frequently found in the neighborhood of small vessels. Many of the vessels seen are quite tortuous, and the vascular supply of the connective tissue appears to be considerably increased beyond the normal. Bacteria could not be demonstrated in the inflamed areas.

M. Herzog's examination of the interstitial gingivitis, produced by mercury in dogs, failed to reveal any bacteria. He was of opinion that the histologic changes of inflammatory type found, were due to the chemotactic influence of mercury and not to microbial action.

In a paper¹ read before the Section on Stomatology of the

¹Some Points on the Etiology, Pathology and Treatment of Persistent Pyorrhœa Alveolaris.

American Medical Association, at Columbus, Ohio, George T. Carpenter mentioned some very interesting experiments in this connection. By infecting a fresh wound in the gums of rabbits with pyorrhœa and other pus he found the parts will remain infected only from two to five days. In other rabbits a rubber band was placed around teeth and pressed under the gums until inflammation resulted, when the parts were infected with pyorrhœa and pus from a chronic ulcer; pus infection resulted.

Like experiments were made in the human mouth on gums which had been neglected as well as on healthy gums, and with similar results. His experiments tend to show that, when animals and man are healthy, the tissues resist infection; but when diseased, infection results. All yield to treatment.

On examination of pus taken from pyorrhœa, pockets proceeding from acute infection, two competent bacteriologists were unable to find a micro-organism not found in pus from other infected tissues.

These results, in Carpenter's opinion, tend to show that a specific germ, to which pyorrhœa alveolaris is attributable, has not yet been found.

The disease being so prevalent among dogs, it occurred to me that they would be of great value for experimental inoculation. The prevalence of the disease in dogs suggests that if it were a specific infection, these must be inoculable. Miller¹ had made a few inoculations of pus as well as of the deposits around the teeth. Slight inflammation, and, in one case, a little suppuration alone resulted. He afterward isolated twenty different bacteria from the human mouth and nine from dogs. Some of the uncommon varieties were infective, but without marked results. Isolated varieties would probably not produce results that could be attained by inoculating animals with the fresh secretion (pus and other deposits) from dogs already affected with the disease. A dog was procured from the Veterinary Hospital whose gums and outer alveolar process were almost entirely absorbed with pus exudate. Street dogs selected for inoculation were forty-six in number, ranging in age from one year to seven. They were of all breeds and conditions. Some were well fed, others very thin. Many had sound, healthy gums; others had slight inflammation

¹ Micro-Organisms of the Human Mouth, page 329

at different localities. No dog was used whose gums and alveolar process had become infected or whose tissues were absorbed. Two dogs were operated upon at a time. The gum was separated from the necks of the teeth down to the alveolar process and peridental membrane—one half at the canine, the other at the second pre-molar, since in a majority of cases the disease began at the canine tooth, probably on account of its prominence and the thinness of the alveolar process. The second pre-molar was selected because it is the least prominent. The secretions about the teeth and gums of the diseased dog were collected upon a platinum wire (previously sterilized) and conveyed to the injured parts. Thirty-nine healed in eight days. In these the gum tissues were healthy. The pus had no effect. The wounds healed as rapidly as any wounds possibly could. In seven the gums were inflamed and infection occurred. Suppuration was slight in four and considerable in three. The pathologic findings in these cases were not unlike inflammation and infection in other tissues. Similar results would, no doubt, have taken place if inoculation had been performed with pus from an abscess. The last three dogs were allowed to depart at the end of four weeks with slight pus infection.

CHAPTER XIII.

SCORBUTIC INTERSTITIAL GINGIVITIS IN MAN.

While hundreds of slides could be adduced in support of this chain of evidence, sufficient have been given to permit of the introduction of evidence from other phases of the subject.

The following autopsy was made by L. Hektoen on an old man, in whose case the pathologic diagnosis was as follows: Senile marasmus (senile emphysema, senile sclerosis of the aorta, atrophy of the parenchymatous organs), scurvy (hæmorrhagic gingivitis); chronic aortic and mitral endocarditis; fibrous myocarditis; chronic nephritis; caseo-calcareous areas in the right apex, spleen and left adrenal; double hydrothorax; bronchitis; fibroma of the stomach; amputation of the left lower extremity at the lower third of the thigh. The findings unrelated to the scope of the present investigation are omitted. The gums were found swollen, and here and there infiltrated with blood. There was purulent matter about the roots of the teeth, many of which were loosened and some of which could be removed with the fingers. The roots of the loosened teeth were covered with a granular grayish material.

Bacteriologic examination of the root of the tooth gave the following results: Tube of bouillon from which agar plates were made, inoculated twenty-four hours before date, July 29, 1898. There were two varieties of colonies: Both grayish white. One kind is round, pin-head size, slightly elevated, with thin, wavy, but sharply defined border. Finely granular. Media inoculated from one of these. *Agar Slant*: White, tallow-like growth along the track of the needle, with thin, more translucent layer covering the rest of the surface. Only moderately elevated. Greenish tinge given to media. *Potato*: Elevated, "clumpy" growth, white on top, confined to needle track. Potato much darkened. *Blood Serum*: Gray, waxy growth, little elevated, sharply defined and thick border. *Gelatin Slab*: Saucer-shaped liquefaction at upper part, more tubular in deeper

portions. Flocculent masses throughout. *Glucose Agar*: Gas produced, white, thick growth on top. *Milk*: Alkaline, soft coagulation. *Bouillon*: Cloudy. *Characteristics*: Rapid growth, a sour, nauseating odor given off from all media. *Morphology*: Large coccus, single, in pairs and in groups. Stains easily by ordinary methods, also by Grams. The smaller colonies on agar plates (pin-point sized in center) with nearly transparent, illly defined peripheral zone. Border indistinct. Central portion in gray. Finely granular throughout. *Agar Slant*: Gray film over entire surface, somewhat thicker along the inoculation streak. At bottom there is a nearly white growth. Very light, greenish tinge to media. *Blood Serum*: Like on agar. *Potato*: Heavy dirty gray growth, wavy and sharply defined border. Looks like bunch of cauliflower. *Gelatin Slab*: Liquefied, saucer-shaped at top, tubular in deeper part. Growth mostly in upper stratum. *Lit. Milk*: Negative. *Bouillon*: Cloudy. *Glucose Agar*: Gas produced. *Characteristics*: Rapid growth, stinking odor from all media. *Morphology*: Small, slender bacilli; actively mobile, spores. Takes ordinary stains readily and is not decolorized by Gram's method.

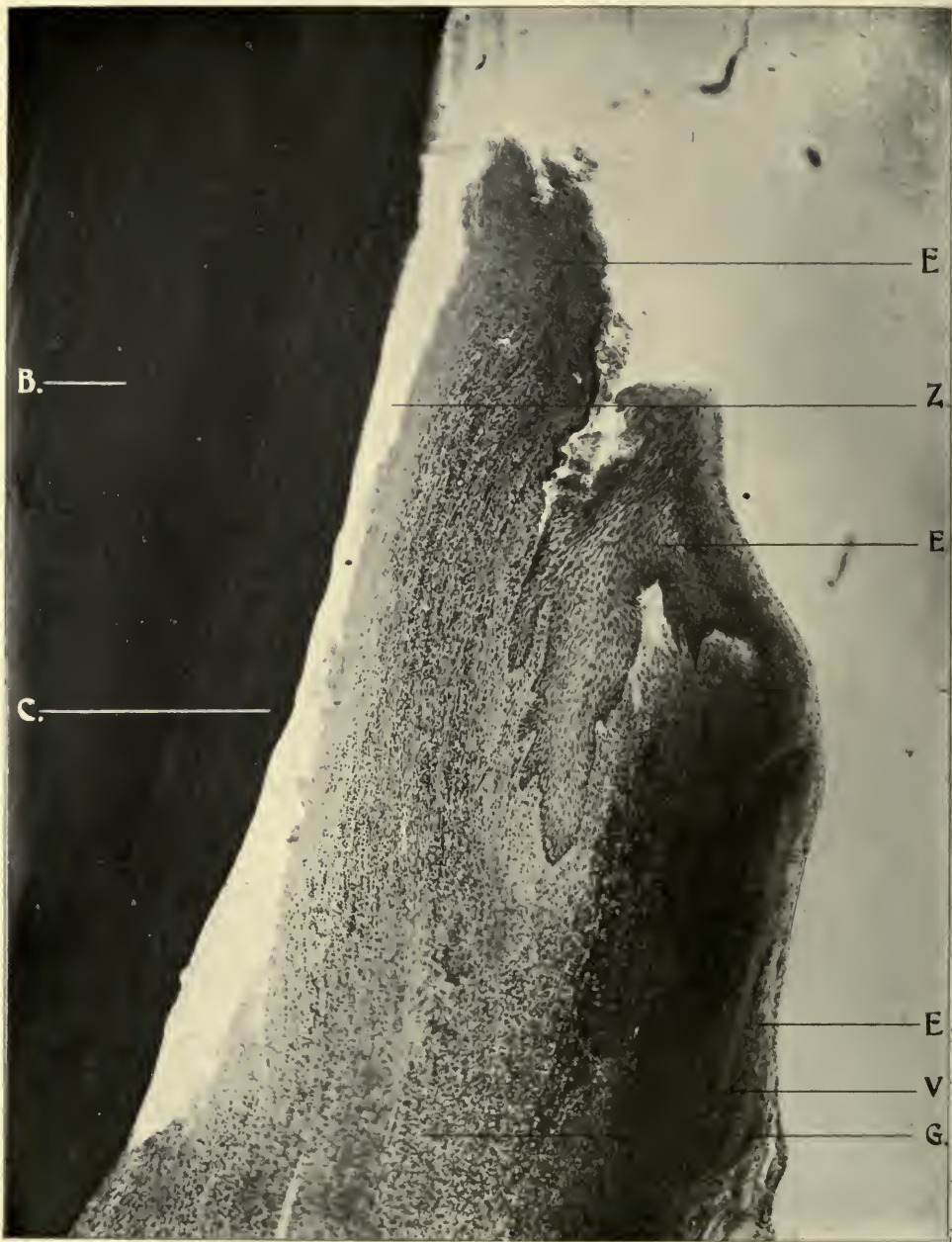Only the lower frontal teeth and corresponding part of the jaw could be examined. The epithelial covering of the gums appeared to be quite intact. In some places it was a little thickened, and its lower layers infiltrated with new cells. The sub-epithelial tissue was much thickened, presenting the general structure of an inflammatory granulation tissue of some standing. Areas occurred in which there were many new cells and but little stroma. In other foci the tissue was more fibrous, the new cells running in bands. Here and there occurred free and intracellular granular, yellow pigment. Typical hyaline bodies of various sizes, and staining a precise bluish violet with Gram's method, were found in rather small numbers. In some places small sub-epithelial abscesses were met with, which (in the instance of a district including a lower incisor) were really subperiosteal. The contents consisted of nuclear detritus and bacteria (mostly cocci) which have accumulated, especially upon and in the walls of the minute cavities extending from such an abscess. There seems to be a complete occlusion of the vessels (capillaries) with typical bacteria masses, staining a peculiar bluish violet color



X 40. 35 M.M. Zeiss. Micro-photograph, reduced one-third

FIG. 50.—LONGITUDINAL SECTION OF TOOTH, ALVEOLAR PROCESS AND GINGIVAL BORDER, SHOWING ACTIVE INFLAMMATION IN SCURVY IN MAN.

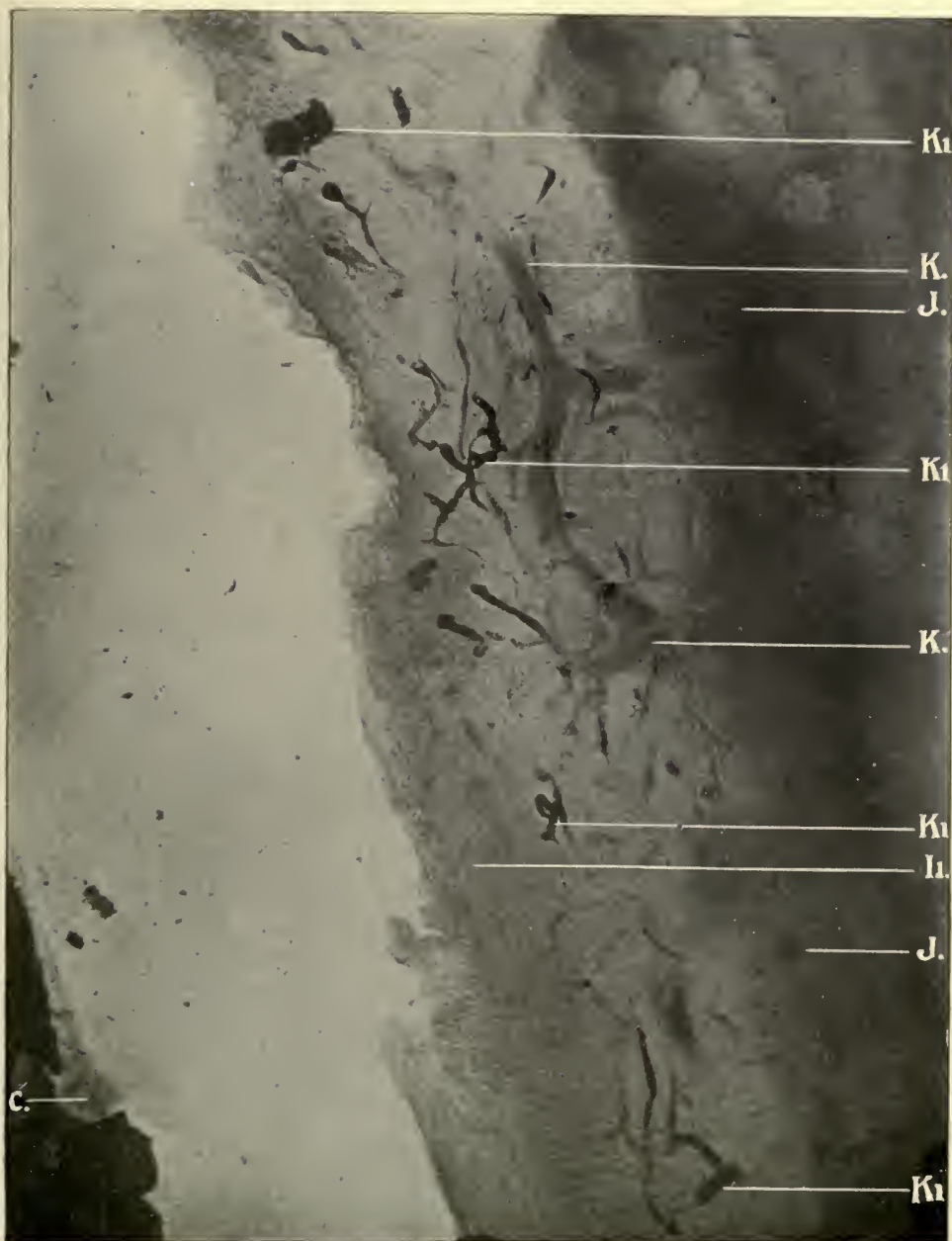
B, Dentine. C, Cementum. E, Epithelial Tissue. G, Submucous Membrane. H, Periosteum. J, Alveolar Process. L, Haversian Canals. M, Fibrous Tissue. V, Violent Inflammation. AA, Point of Union of Epithelial Tissue and Peridental Membrane. RR, Space Pocket from Want of Union of the Epithelial Fold.



X 40. 35 M.M. Zeiss. Micro-photograph, reduced one-third.

FIG. 51.—LONGITUDINAL SECTION OF A TOOTH, ALVEOLAR PROCESS AND GINGIVAL BORDER, SHOWING ACTIVE INFLAMMATION IN SCURVY IN MAN.

B, Dentine. C, Cementum. E, Epithelial Tissue. G, Submucous Membrane. V, Violent Inflammation. Z, Sloughing of the Epithelial Tissue Due to Calcic Deposits. AA, Point of Union of Epithelial Tissue and Peridental Membrane.



X 75. A. A. obj. Zeiss. Micro-photograph, reduced one-third.

FIG. 52.—LONGITUDINAL SECTION OF TOOTH, ALVEOLAR PROCESS AND PERIDENTAL MEMBRANE, SHOWING BLOOD PIGMENT IN BLOOD VESSELS OF PERIDENTAL MEMBRANE IN SCURVY IN MAN.

C, Cementum. J, Alveolar Process. K, Capillaries. I¹, Inflamed Peridental Membrane. K¹, Blood Pigment in Capillaries.



X 75. A. A. obj. Zeiss. Micro-photograph, reduced one-third.

FIG. 53.—LONGITUDINAL SECTION OF TOOTH AND GINGIVAL BORDER, SHOWING ACTIVE INFLAMMATION EXTENDING THROUGH THE MUCOUS AND PERIDONTAL MEMBRANES. SCURVY IN MAN.

B, Dentine. C, Cementum. E, Epithelial Tissue. V, Violent Inflammation. AA, Point of Union of Epithelial Tissue and Peridental Membrane. RR, Space Pocket from Want of Union of Epithelial Fold. M', Inflamed Fibrous Tissue.

with hematoxylin, and blue with Gram's method, so that the vessels presented the appearance of being very successfully filled by an infection mass: the small dilatations, the branches and the larger vessels (judging from structure these seemed to be veins) were sometimes brought out very nicely. The intravascular growth of bacteria extended into the bone below as well as, and more especially into, the peridental membrane.¹ These abscesses (suppurative periostitis) occur almost exclusively upon the inner surface of the alveolar process, being confined (as far as there was occasion to observe) to the external aspect of the process. There was always a thin, sound layer of bone separating the abscess from the peridental membrane. Very generally the spaces in the adjacent bone were filled with a cellular fibrous tissue in which occurred islands of osteoid tissue. The bone trabeculæ were generally covered by a thin layer of osteoid tissue, which (from the greater number of cells it contains, as compared with the other bones) must be newly formed. Rows of osteoblasts were found often upon the trabeculæ. Few Howship's lacunæ were found, and these were filled with small cells. There were no osteoclasts in the areas about the abscesses. The bone outside of the alveolar process is quite unchanged.

The "bacterial thrombosis" not unusually extended into the peridental membrane, which then refused to stain as clearly as normal. The upper part of the peridental membrane was usually the seat of cell proliferation, and of the formation of fibrous tissue, due to the direct extension of the similar process in the sub-epithelial connective tissue of the gingivus. There were no indications that the process began below, at the apex of the tooth, for example, and extended upward. In the peridental membrane, and often connected with the cementum of every tooth examined, were very many so-called calcospherites; calcified, concentrically lamellated, round or oval bodies, not unlike the "corpora amylacea." In many instances, it seemed as if the body had formed in the cement or at its margin—the cement presenting here a nodular condition.

Fig. 50 illustrates a section through the tissues of the jaw

¹The abscesses have a definite outline or wall of ordinary cellular fibrous tissue displaying striking evidences of active inflammation. The tissue about the capillaries filled with bacteria refuse to stain clearly, but there are no signs of inflammation.


and cuspid tooth. The epithelium is not so dense and thick as in a similar section from the dog. Inflammation extends along the papillary layer of the submucous membrane (G) and involves the deeper structures. The mucous membrane layer has doubled upon itself, forming a pocket (R R). Violent inflammation is evident at V. This is of unusual interest, since it demonstrates that inflammatory products may be carried by the blood vessels anywhere throughout the alveolar process, and may result in abscesses. The inflammation extends throughout the periosteum (H), the fibers of which extend from the root of the tooth over the border of the alveolar process (J). There the coarse fibers of the periosteum contrast decidedly with the finer fibers of the sub-epithelium. Absorption and contraction of the alveolar process (fully one-half the length of the root of the tooth) has taken place, as well as lateral absorption. The inflammatory process extends through the Haversian canals (L).

Fig. 51 is a section through the jaw at the lateral incisor. The epithelium (E) is seen upon the outer surface of the alveolar process as far as the root of the tooth. The inner fold next to the tooth has disappeared through encroachment of deposits which have been destroyed by nitric acid. Inflammation extends throughout the entire submucous membrane (G). The most marked inflammation in this case is entirely upon the outer border (V).

Fig. 52 shows a section of the peridental membrane (I) and alveolar process (J). Capillaries (K) interlace through the field, the largest number being distributed along the alveolar wall. Blood pigment containing bacteria are noticeable (K').

Fig. 53 is an amplification of a section depicted in Fig. 50. This gives a clearer idea of the folding of the epithelium (E) and submucous membrane (G) layer upon itself, forming a pocket (RR), in which may be seen an accumulation of food and bacteria. It also shows extensive inflammation throughout the entire field. Marked inflammation is evident at V. The point of union of the sub-epithelial layer and the periosteum is shown (AA).

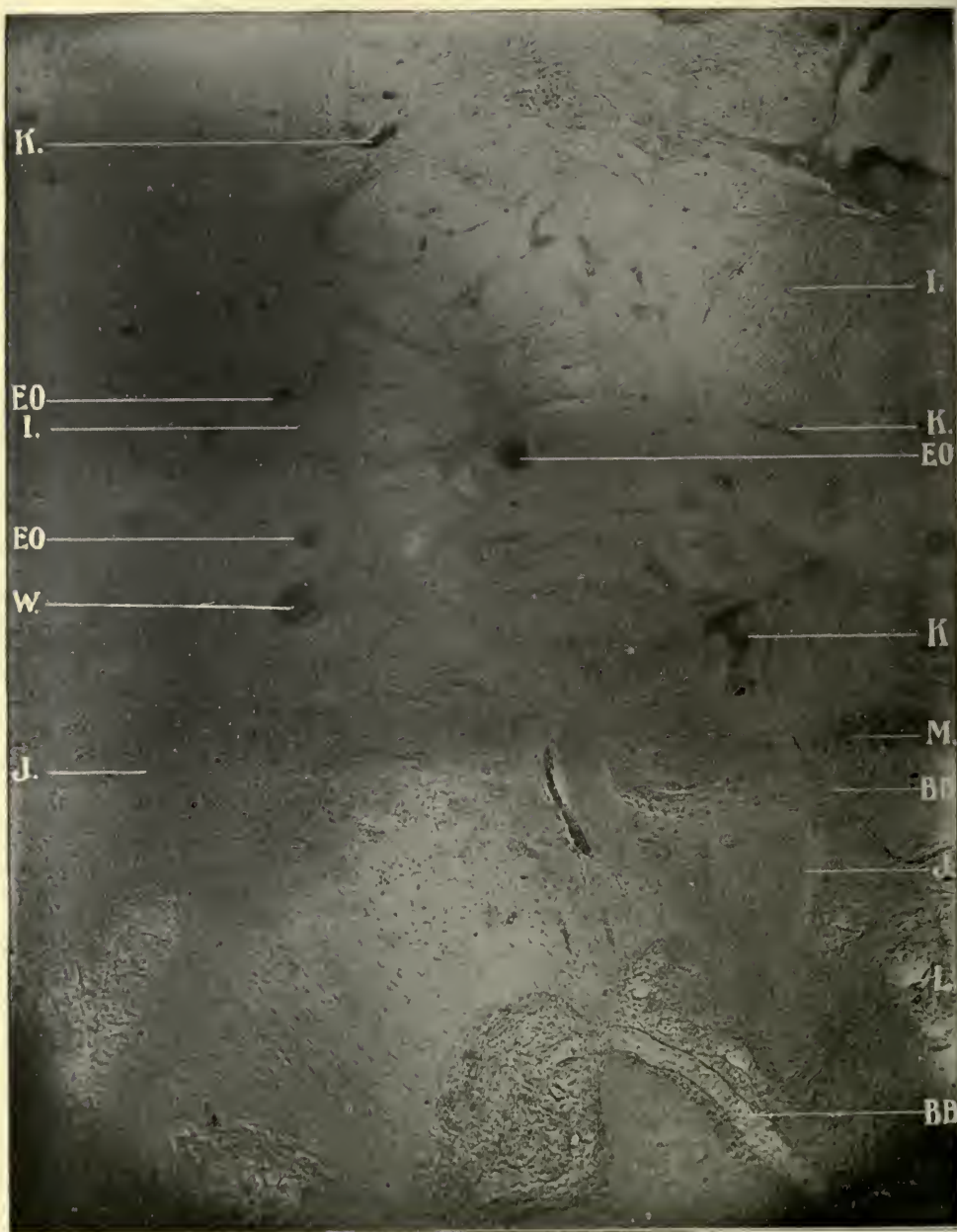
Fig. 54 illustrates inflammation of the peridental membrane with epithelial débris (W) scattered over the field, Enderteritis



X 75. A. A. obj. Zeiss. Micro-photograph, reduced one-third.

FIG. 54.—CROSS SECTION PERIODONTAL MEMBRANE, SHOWING ACTIVE ROUND-CELL INFLAMMATION. SCURVY IN MAN.

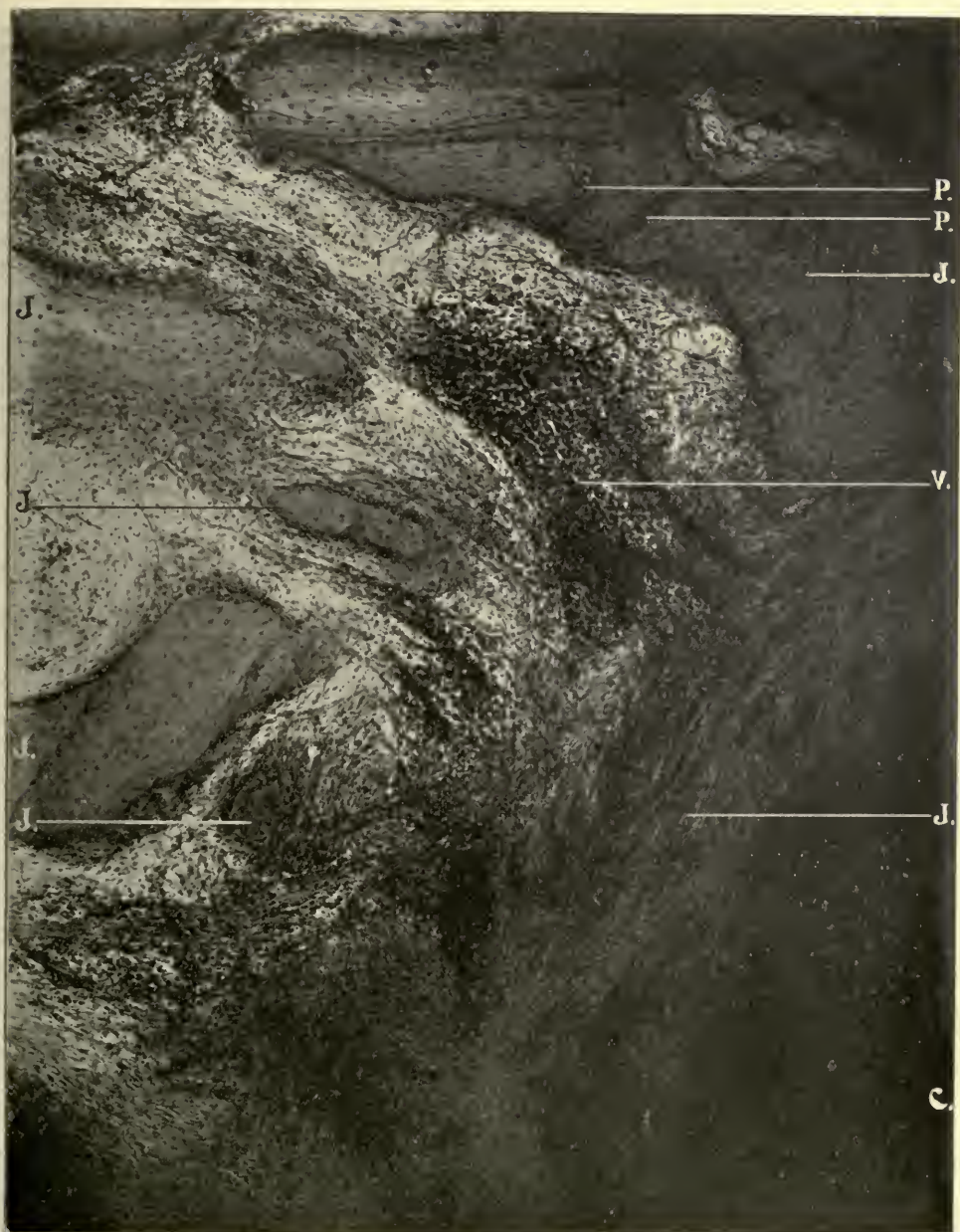C, Cementum. V, Violent Inflammation. W, Epithelial Débris. EO, Endarteritis Obliterans.



X 75. A. A. obj. Zeiss. Micro-photograph, reduced one-third.

FIG. 55.—CROSS SECTION OF INFLAMED PERIODONTAL MEMBRANE. SCURVY IN MAN.

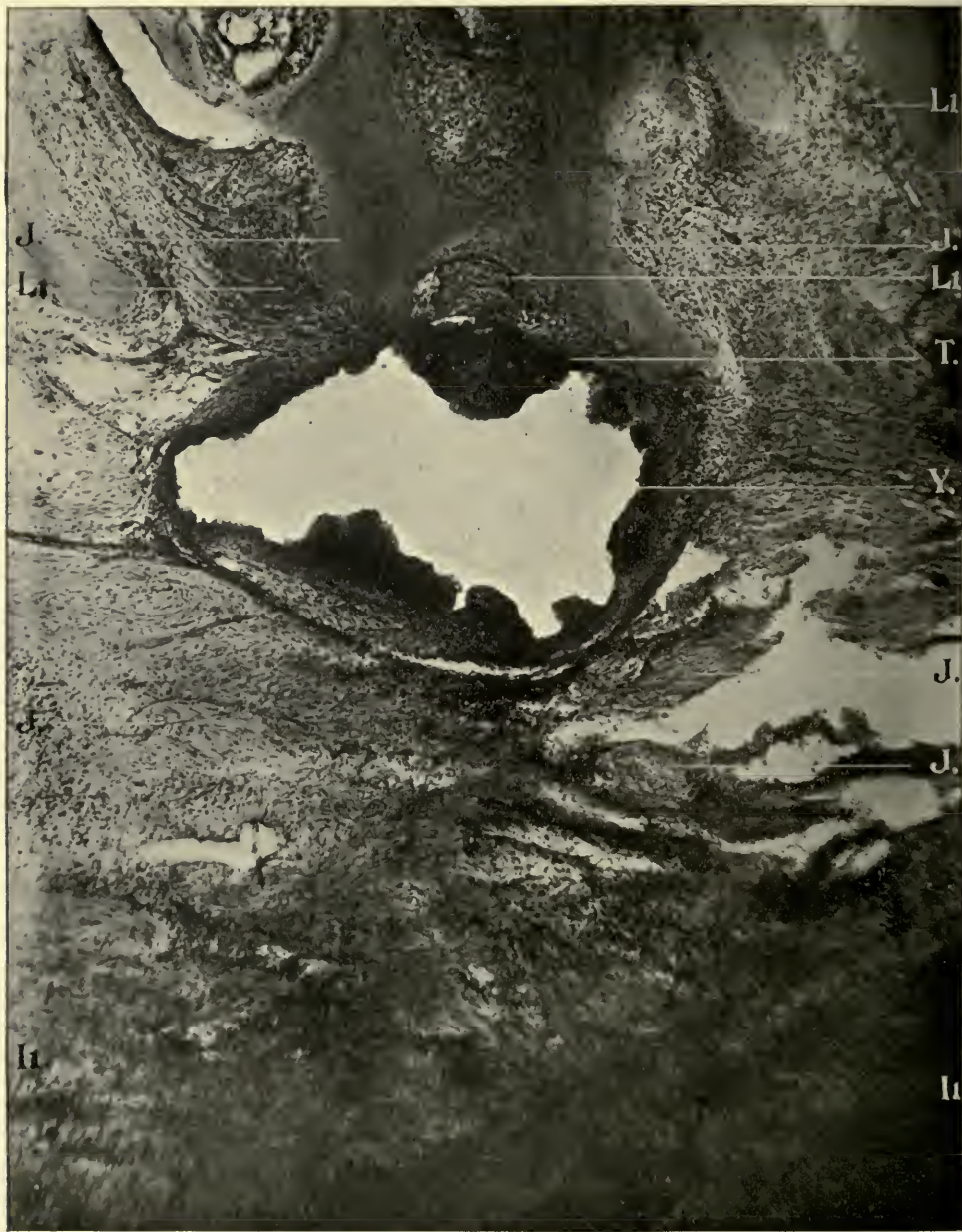I, Periodontal Membrane. J, Alveolar Process. K, Capillaries. L, Haversian Canals. BB, Blood Vessels of Von Ebner Preceding Perforating Canals. EO, Endarteritis Obliterans. W, Epithelial Débris.



X 75. A. A. obj. Zeiss. Micro-photograph, reduced one-third.

FIG. 56.—CROSS SECTION OF TOOTH, ALVEOLAR PROCESS AND PERIDONTAL MEMBRANE, SHOWING ACTIVE INFLAMMATION AND ABSORPTION OF BONE. SCURVY IN MAN.


C, Cementum. I, Peridental Membrane. J, Alveolar Process. P, Perforating Canal Absorption. V, Violent Inflammation.



x 40, 35 M.M. obj. Zeiss. Micro-photograph, reduced one-third.

FIG. 57.—CROSS SECTION OF PERIDONTAL MEMBRANE AND ALVEOLAR PROCESS, SHOWING ACTIVE INFLAMMATION AND ABSCESS. SCURVY IN MAN.

J, Alveolar Process. T, Bacteria. Y, Abscess. I', Inflamed Peridental Membrane. L, Inflammation Extending through Enlarged Haversian Canals.



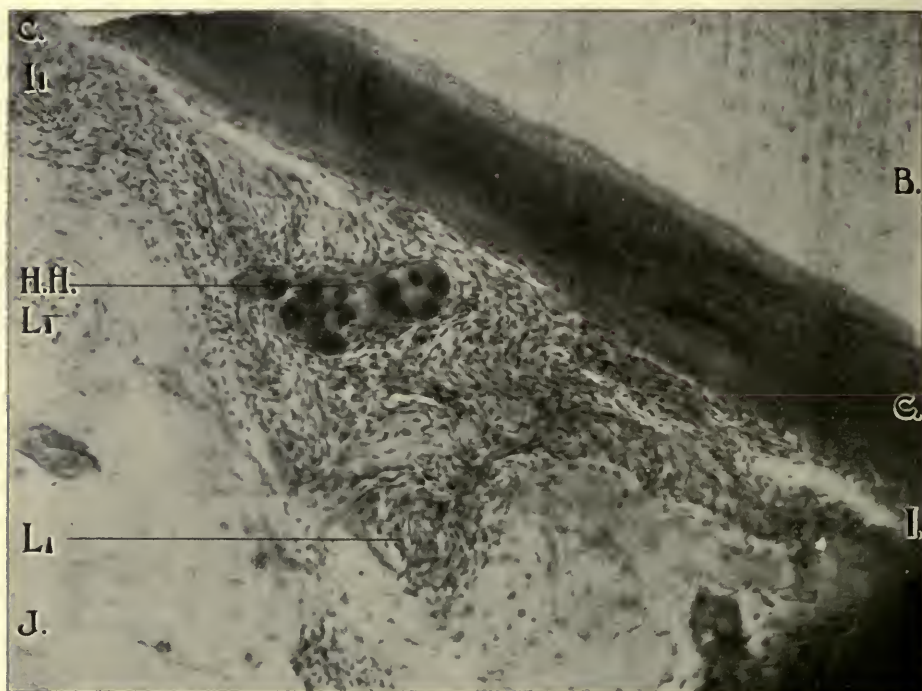
X 75. A. A. obj. Zeiss. Micro-photograph, reduced one-third.

FIG. 58.—CROSS SECTION OF PERIDENTAL MEMBRANE AND ALVEOLAR PROCESS, SHOWING ACTIVE INFLAMMATION AND ANOTHER LARGER ABSCESS. SCURVY IN MAN.

J, Alveolar Process. P, Perforating Canal Absorption. V, Violent Inflammation. Y, Abscess. P¹, Inflamed Peridental Membrane. L¹, Inflammation Extending through Enlarged Haversian Canals.

obliterans (EO) is also noticed at various positions. Marked inflammation may be seen at V.

Fig. 55 illustrates a section of the peridental membrane (I) and alveolar process (J) with inflammation extending throughout. Capillaries (K) are also noticeable in large quantities, nearer the alveolar process than the root of the tooth. Epithelial débris are evident at W. Enderteritis obliterans (EO) may



× 300. No. 2 projection ocular. D. D. obj. Zeiss.

FIG. 59.—CROSS SECTION OF TOOTH, ALVEOLAR PROCESS AND PERIDENTAL MEMBRANE, SHOWING ACTIVE INFLAMMATION WITH CALCOSPHERITE IN MEMBRANE. SCURVY IN MAN.

B, Dentine. C, Cementum. I, Peridental Membrane. J, Alveolar Process. HH, Calcospherite. J¹, Inflamed Peridental Membrane. L¹, Inflammation Extending through Enlarged Haversian Canals.

be seen in different portions of the field. Inflammation has extended into the Haversian canals (L) but absorption has not occurred to any great extent. The blood vessels of Von Ebner (BB) are quite well shown.

Fig. 56 is a section showing the cementum (C), the peridental membrane (I) and the alveolar process (J). Marked

inflammation extends through the peridental membrane, thence through the Haversian canals (which are entirely obliterated). Absorption of the trabeculae (halisteresis) has resulted to the extent that what remains of the alveolar process (J) are islands of bone held in place by the fibrous tissue. Blood vessels of Von Ebner with perforating canals are seen at P.

Fig. 57 shows a section of the peridental membrane and alveolar process with a large abscess originally within the alveolar wall. Inflammation spreading through the peridental membrane has occurred at I', while the decalcified alveolar process is also shown (J). Violent inflammation has taken place within the alveolar wall, and an abscess (Y) has formed. The wall of the abscess is distinctly seen, with masses of bacteria (T) clinging to the inner sides. The process of halisteresis (Q) (bone decalcification) is seen as a result of the violent inflammation. The entire wall next to the peridental membrane and about the abscess has been destroyed, and the different stages in the process by which this has been accomplished are beautifully shown.

Fig. 58 illustrates a larger abscess (Y) from another location. This is also situated within the alveolar wall, showing that the inflammatory products extend through the blood vessels. Marked inflammation is seen upon the side next to the peridental membrane (I'), while rapid absorption — halisteresis (Q) and perforating canal (P) — is proceeding at the borders of the abscess and nearest the alveolar process.

Fig. 59 shows a section of a tooth (B and C), inflamed peridental membrane (I'), with absorption of the alveolar process (J). In the inflamed peridental membrane may be seen a calcospherite, oblong in form.

CHAPTER XIV.

INTERSTITIAL GINGIVITIS IN MAN FROM DRUG ACTION.

A forty-eight-year-old merchant was dyspeptic, debilitated and asthmatic, and for the treatment of these conditions he had been under calomel and tonics for a little less than two weeks. When he came under observation, the mucous membrane and gums

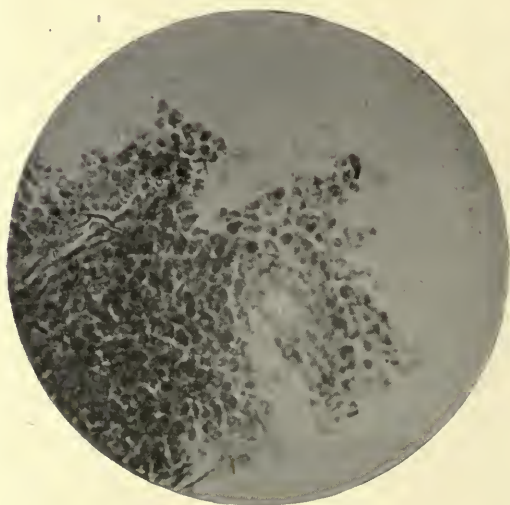


FIG. 60.

were then much inflamed. There was marked sialorrhœa. The teeth were loose. The gums were swollen. Pus oozed from the gums. The breath had a decided metallic odor. At my suggestion, his medical attendant stopped the calomel. He was then ordered six pints of spring water daily. The gums were, on alternate days, saturated with iodine. In a few days the soreness and swelling were so reduced that the deposits could be removed. The patient was discharged cured in a short time other than as to the right inferior second molar, which was so loose as to require removal. This tooth was placed immediately in fifty per cent alcohol for twenty-four hours and then removed to absolute

alcohol for twenty-four hours more. The membranes had receded about two-thirds the length of the root. Sections for microscopic purposes were made from the lower third of the root. Of these sections, Fig. 60 shows a small fragment of inflamed peridental membrane. Fig. 61 exhibits violent round-cell inflammation, degeneration and liquefaction of tissue.

A thirty-five-year-old diabetic painter came under observation for plumbic poisoning. His gums were swollen. There was decided sialorrhœa. The teeth were loose. Pus flowed from the



FIG. 61.

gums. He was placed on ozonate spring water and the gums were saturated with iodine on alternate days. Three loose teeth were removed and placed in alcohol. Sections from the upper third of the left superior second bicuspid gave results on microscopic examination similar to those already described as occurring in mercurial poisoning. Fig. 62 shows round cells of inflammation. Fig. 63 illustrates very marked degeneration of the peridental membrane. In the lower right-hand corner are seen the root of the tooth, dentine and cementum. The whole surface of

the peridental membrane is in an advanced phase of inflammation. Just at the border of the root is evident an area of membrane softening. Just beyond, but joining, is noticeable breaking down of tissue. In the center are seen two areas of softened tissue more advanced in degeneration.

One occupation disease which has been ignored in the etiology of interstitial gingivitis is "brass-workers' ague." In almost all brass-workers, a stain varying from a bright to a brownish green is detectable on the necks of the teeth between the crowns and the gum insertion. This is most obvious in the upper jaw. After a while, as E. Hogben¹ has shown, the teeth become

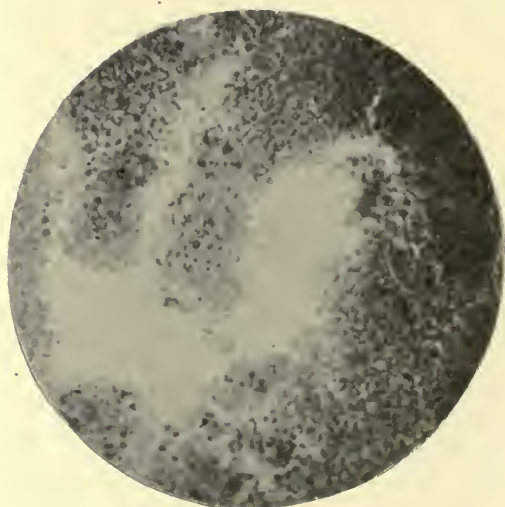


FIG. 62.

loosened and fall out, Before these changes in the gum occur nervous symptoms have developed from the brass poisoning.

Arsenic should be taken into account in the etiology of interstitial gingivitis. This drug has a very decided tendency in certain subjects to cause, even in small doses, marked stomatitis and irritation of the mucous membranes throughout the body.

Tartar emetic and the other preparations of antimony, producing irritation of the mucous membranes of the mouth and elsewhere, may act as predisposing and exciting factors of interstitial gingivitis.²

¹ Birmingham Medical Review, 1887.

² Lewin: Untoward Effects of Drugs.

Among the drugs which should be taken into account in the etiology of interstitial gingivitis is potassium bromide. This produces in certain individuals, or when given to excess, marked increase of the saliva with irritation of the mucous membranes of the mouth, followed later by dryness of the mouth and shrinking of the gums. The bromides have, as H. C. B. Alexander¹ has shown, a tendency to irritate all the mucous membranes of the body as well as the skin. Therefore, in dealing with cases of interstitial gingivitis in which the bromides are being taken, this factor should not be neglected. In these cases the symptoms

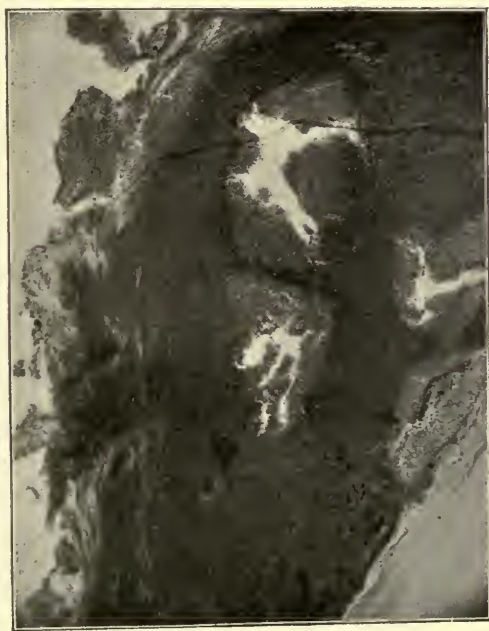

FIG. 63.

due to the bromides are apt to be charged to the nervous state for which the bromides have been given. The irritation of the mucous membrane by the bromides may occur quite early among the untoward effects produced by them. In all probability the bromine rather than the alkali is the source of these untoward effects.

What is true of the bromides is also true to an even greater degree, as has elsewhere been shown, of the iodides.

¹ Alienist and Neurologist, July, 1896.

CHAPTER XV.

CONCLUSIONS.

While, as already shown, the teeth originated in the epidermis, still, even as early as the sharks, the teeth of the mouth departed from this primitive method of development, since they did not arise on the surface, but deep down, as Minot¹ has pointed out. As Hertwig has shown, this occurs because the dentiferous epithelium grows down into the dermis, forming an oblique shelf, which may be regarded as a special tooth-forming organ. On the under side of the shelf the teeth are developed in the same way as over the skin, although they are much larger. The teeth are, however, in various stages of development, and only one is fully exposed; when, as happens in time, it is lost, the next tooth behind replaces it. Since the production of new tooth germs goes on in adult life, replacement of the tooth in the shark's jaw continues indefinitely; hence sharks are termed polyphyodont. Mammals, having two sets of teeth only, are called diphyodont. There is, therefore, even in mammals where the change is limited, a tendency to change. Since the human being and the higher mammals (noticeably the omnivora, like dogs, whose food is as varied as that of man) are born practically toothless, this struggle begins between the teeth at a later time than in the lower vertebrates.

The teeth are temporary structures, intended to be shed at certain times; the temporary set ere the onset of puberty, the permanent with the onset of senile involution at the premonitory period of old age. This last period depends on the individual rather than the number of years lived. At the senile period, which may occur at any time after the eruption of the permanent set, osteomalacia (which is the normal absorption of the alveolar process) may take place. The period at which this commences depends upon the constitution of the patient. Through congenital defect or disease, senility may begin earlier

¹ Human Embryology.

in life. In certain types of degeneracy (precocity, for example), senility with absorption of the alveolar process may begin even at twenty. Absorption of the alveolar process and loss of the permanent teeth, is, therefore, certain at a period dependent upon the constitution of the patient. Between these two periods, birth and senility, two sets of teeth have been furnished man. In the meantime, the alveolar process, the gums, periosteum, periodental membrane, blood vessels, nerves, have come and gone to suit the convenience of these two sets of teeth. Tissues like these are called adventitious or transitory. Adventitious tissues are much more apt to be affected by disease than permanent in type and persistent in function.

As transitory structures, destined to fulfill temporary purposes, the teeth of necessity tend to decrease in number with advance in development for the benefit of the organism as a whole, thereby preventing waste of nutriment on useless structures. The shapes of teeth hence vary in order to adapt themselves to the work and surroundings produced by evolution. The teeth and its setting being of different structures and composition, each proceeds to destruction along lines imposed by the laws of its structure. The tooth is destroyed by decay, the alveolar process by inflammation. Decay of the tooth and interstitial gingivitis are expressions of that natural line of involution which is foreshadowed from the outset in both by laws of their development. The laws governing transitory structures naturally place these at the mercy of both under and over stimulation. From its position, location and functions the mouth is of necessity exposed to invasion of microbes. These tend directly and indirectly, from infection and through their toxins, to aggravate the effects of both under and over stimulation. Not only do the very structure and embryogeny of the teeth and alveolar process expose them to the too early onset of the processes of removal, initiated by under and over stimulation, but these last increase and are increased by the local results of constitutional defects, like idiocy, and diseases, like tabes dorsalis, parietic dementia, and allied disorders, as well as the results of injuries to the jaw.

When more work is required of one tooth (as when the dental arch is broken by the loss of one or more teeth, and the others have moved out of their normal position, or when a seam-

stress bites her thread with one or more teeth, or when plates are attached or come in contact with natural teeth, or when a piece of bridgework is adjusted) and the roots of one or two teeth must support and do the work of a greater number, this character of adventitious structure predisposes to inflammation about the root or roots of the teeth.

When due to irregularities of the teeth, or when antagonizing teeth have been extracted, or in the mouths of idiots, parietic dements, etc., who do not use their teeth, understimulation also predisposes to inflammation.

The mass of evidence previously presented demonstrates that the causes of interstitial gingivitis are divisible into predisposing causes (which may be subdivided into local predisposing and constitutional) and exciting causes. The exciting causes are either constitutional or local, but as a rule are local or have local action.

The predisposing factors of this disease, as already mentioned, are: conditions of jaw evolution, transitory nature of certain structures, degeneracy and conditions of previous irritation and inflammation.

Moreover, in accordance with a general law of pathology whereby tissues (for example the lungs in pneumonia once attacked by toxic agencies or even by the toxins of germs) acquire a local predisposition to future attacks of disease, the gums and alveolar process often become thus susceptible to constitutional and local influences.

It is obvious from the data given in the chapter upon "History" that interstitial gingivitis is as old as man and that it was observed and discussed by the earliest writers on medicine. While it is by no means improbable that constitutional factors assisted in its early progress in man, still the exciting cause of this disease was tartar. Many skulls from prehistoric periods exhibit gingivitis upon the teeth exposed to the influence of tartar. This gingivitis extends along the roots nearly or quite to the apices, resulting in absorption of the alveolar process. Upon the surface of the teeth where tartar is absent, interstitial gingivitis and absorption rarely occur. The same is true of the teeth of wild animals at large and confined in zoölogical gardens. In them gingivitis from local conditions, other than tartar, very seldom occurs. The jaws of the skulls of prehistoric periods are

always broad, measuring 2.25 to 2.50 inches in diameter. Third molars are always present. The vaults are very low, the alveolar process short and thick, and the teeth short. As already shown in the chapter on the "Alveolar Process," the jaws have been growing smaller until they range in different races from 2.50 to 1.75 inches in diameter. Mixed Celto-Teutonic¹ races, like the English-speaking peoples and the Scandinavian peoples, have the smallest jaws with the most marked deformities as a result. These changes in jaw forms occur, as has been elsewhere shown, in harmony² with the law of evolution of the race in face forms. With these changes in jaw diameter there also occurs an alteration in the antero-posterior diameter. A change in tooth forms also occurs. Small crowns and long roots replace large broad crowns and short roots.

These changes necessarily alter the shape and form of the alveolar processes. Instead of being short and broad, they become long and thin. The septum between roots is not as wide, thick or heavy as formerly. The long, thin alveolar process is more subject to the influence of local irritation and trophic change than the short, thick one. A long, thin alveolar process will be more readily absorbed than a short, thick one. This is demonstrable where the roots of the teeth are situated near the outer border of the process. Disease of the periodontal membrane and absorption of the outer plate extends along the roots, exposing them throughout their entire length. Similar conditions are noticeable along the palatine roots of the molar teeth in the upper jaw.

From the length and thinness of the alveolar process resultant on the evolution of the jaws, the periosteum on one side and the periodontal membrane on the other hold the structures together and afford nourishment for the tooth and bone tissues. The blood vessels pass, as elsewhere shown, in a vast plexus from the periosteum to the periodontal membrane through the process. This plexus deposits and removes calcium salts. Potent for good under normal conditions, it is equally potent for evil under states of irritation and disturbed nutrition. Local irritation is greatly

¹ Keane, *Ethnology*.

² *Degeneracy: Its Causes, Signs and Results* (Talbot).

Osseous Deformities of the Head, Face, Jaws and Teeth (Talbot).

assisted by a peculiar structural variation of the gum tissue (R R, see any figure); accumulation of débris and resultant chemical decomposition producing inflammation.

Tartar is an active source of local irritation and inflammation of the gum margin. This in turn extends through the capillaries to the alveolar process. Calcic deposits are a result and not a cause.

A predisposing cause for local inflammation is that of approximal tooth decay or cutting away the approximal surfaces for the purpose of filling this class of cavities. If the teeth be not so contoured (Bonwill) as to retain them in their proper positions, absorption of the alveolar process between the roots will take place, thus bringing the crowns in contact. The result of such absorption will restrict bone surface for the protection and nourishment of the gum tissue. Undernourished tissues are hence more liable to irritation and inflammation.

When death of the pulp occurs, the teeth often become loose without inconvenience to the patient. This results from the formation of gases in the pulp chamber, which suffice to produce inflammation of the peridental membrane with or without pain. This occurs, since slight irritation only is needed to produce absorption of the alveolar process, at the apical end of the root. Chronic inflammation of the peridental membrane and the fibrous tissue of the alveolar process occurs. The teeth finally become loose. Irritation from movements of the tooth increase the inflammation through the Haversian canals and further absorption takes place, until the tooth is exfoliated.

This disease from the onset of gum inflammation may proceed for years without pain. Indeed, not until the formation of abscess, or until absorption has affected the nerve at the end of the root does pain occur. Slight soreness may be felt after the tooth begins to loosen. Absorption of the alveolar process and exfoliation of the tooth may occur without any pain whatever.

In the chapter upon "Transitory Structures," it has been shown that the alveolar processes have their structures arranged to accommodate the teeth. When the teeth are extracted, the alveolar process becomes entirely absorbed. The periosteum, peridental membrane and fibrous tissues are entirely lost. The mucous membrane and gum tissue so contract that none of the

original structure remains. Absorption of the alveolar process is very common in advanced age. Even when the teeth remain in the jaw in old age, whether of man or animal (this is especially noticeable in old dogs), absorption of the alveolar process continues. This is due to the fact that the alveolar process, especially when long and thin, is composed of cancellated bone structure which is easily acted upon by its abundant blood and lymph supply. This produces absorption upon the slightest stimulation or irritation of nerve fibers. Even such slight factors as heat, brain overstrain, and want of proper articulation and occlusion and implantation of the teeth, suffices so to stimulate the nerve fibers as to produce absorption. There are four varieties of absorption; osteoclast or lacunar absorption, penetrating canal absorption, halisteresis, and osteomalaciary absorption. These have already been beautifully shown in the illustrations. It is, therefore, not astonishing that the slightest local irritation or tissue nutrition disturbance from constitutional causes suffices to produce local tissue change. This unstable condition of structures tends to prevent successful implantation of teeth.

The question has arisen whether there exists a specific bacterium, which bears the same relation to the pyorrhœic stage that the streptococcus does to streptococcus diphtheria. This question, raised by Galippe, must, in the light of careful research, be regarded as settled in the negative. No special bacterium has been found which complies with the laws of Koch. Dogs are liable to this disease. Galippe had but to infect their gums with his bacterium to demonstrate its specific pathogenic activity. He has not done this. As the researches (already cited) also failed to find a bacterium which could comply with this test required by the laws of Koch, it must be admitted that there is no bacteriologic evidence of a specific bacterium. Furthermore, the pathologic evidence demonstrates that bacteria play the very subordinate rôle in this disease that they do in ordinary wound infection.

PATHOGENESIS OF INTERSTITIAL GINGIVITIS.

Inflammation of the gums and deeper structures chiefly results from mechanic and chemic (lactic and uric acid, potassium iodide, mercury, etc.) causes, bacterial influence being an

incidental complication. From their action, the blood stream is increased and dilatation of the capillaries is produced. The capillaries become crowded with blood corpuscles. These accumulate along the walls of the blood vessels, to which they apparently adhere. Accumulations of small, round cells occur in the submucous connective tissue, the spaces of which are filled with inflammatory exudate. The papillæ become enlarged. The epithelial layer becomes hyperplastic. As a result, the gum tissues swell and become intensely crimson. They bleed upon the slightest touch.

Inflammation may be confined to a single point upon the side of a tooth. This localization often results from predisposition due to a local injury, originating in a cavity in the tooth with sharp, rough edges, from overlapping fillings or from too frequent and violent use of the toothpick at one point. As a result, granulation tissue forms, which (according to Sudduth) is often due to the irritation of lactic acid.¹ In the production of this, however, the influence of the lactogenic bacteria on particles of food cannot be excluded.

The peculiar formation of the gum tissue on the inner border of the gingivus into a pocket or cul-de-sac (RR in Figures) here described for the first time, is a fertile source of this irritation and consequent inflammation, from its collection of resultant decomposition of foods. This pocket varies, as has been shown, in size as well as locality. Sometimes it is very large and deep, or it may be almost, if not entirely, obliterated. Frequently it is situated near the gum margin, again near the union of the submucous and peridental membranes. The degenerate epithelium cell structure (so-called glands of Serres) is also more liable and more easily irritated than the normal epithelium structure. As in the similar crypts of the penis,² the degeneration and death of the epithelial cells with which this cavity is lined produce³ by their accumulation a source of irritation as well as culture medium for pathogenic bacteria. Therefore, not only is the anatomical arrangement of the structures a fruitful source for the accumulation of irritative substances, but

¹ I have made examinations of pockets about the necks of teeth and can corroborate this statement.

² Medicine, 1898.

the structures themselves are also well adapted for inflammatory action.

The gum tissue about one or more teeth may be injured by a badly fitted gold crown, with rough edges. The gold crown may be too far down on the root. Injury may result from ligatures, rubber dam and bands left about the teeth after operations. Accumulations of tartar or any local irritation may lead to inflammation varying with the extent of the deposit. The extent of the inflammation will depend upon the nature and duration of the irritating influence. If it be local in action and temporary, slight gingivitis results. If it be permanent, gingivitis assumes a chronic type, extends into the fibrous tissue below and becomes interstitial in character. The extent of this interstitial inflammation depends upon the nature of the irritation. If the irritation be located upon the side of one tooth, the inflammation will extend through the fibrous tissue in the direction of the course of the blood vessels. It may be in line with the peridental membrane. It may be in line with the periosteum, or it may be in direct line with the alveolar process. Interstitial inflammation (if one or more teeth be involved) extends not only through the peridental membrane, but to the periosteum and alveolar process as well, since the capillaries in surrounding structures are involved. The inflammation extends into the alveolar process through the Haversian canals and the blood vessels of Von Ebner by way of the periosteum and peridental membrane. Irritation thereon resultant causes absorption of the alveolar process by (a) haliteresis, (b) Volkmann's perforating canals, (c) lacunar absorption (osteoclasts). The interstitial inflammation and the absorption of the alveolar process continues so long as the irritation remains or until the tooth or teeth are exfoliated. Previous irritations often produce osteomalacia and trophic changes, and thus assist greatly the progress of the pathologic phenomena. Loosening of the tooth or teeth adds a very efficient irritation which increases the extent of and intensifies the inflammation. Loosening of the teeth is their death knell, no matter what the original cause for the disease may have been.

The following complications may occur: Endarteritis Obliterans, Absorption of the Alveolar Process, Pyorrhœa Alveolaris, and finally Calcic Deposits.

ENDARTERITIS OBLITERANS.

Endarteritis is an inflammation of the internal coat of an artery or capillary, generally of chronic type. Its pathogeny is as follows: In direct contact with the blood streams is the endothelium (a layer of flattened cells); next is the tunica intima, composed of elastic fibers arranged longitudinally; next comes the middle coat, composed of muscular fibers arranged transversely. The outer coat consists of longitudinal connective tissue, which contains the vasa vasorum. In the capillaries, the intima lies in immediate contact with the surrounding tissues, or accompanied by a rudimentary adventitia. In other words, the walls of the capillaries consist of almost nothing but the intima. The capillaries have certain contractility; they contract or dilate without muscular fibers. The veins probably also have a certain amount of contraction and dilatation from irritability of

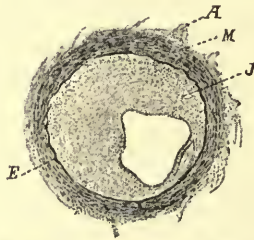


FIG. 64.—ENDARTERITIS OBLITERANS (KAUFMANN).

A, Adventitia. E, Elastic Tissue between Middle Coat and Intima. M, Muscular.
J, Thickened Intima.

the intima. Each coat of the arteries takes on special type of inflammation. The causes of endarteritis are numerous. Inflammation of the intima of the blood vessels may be due to irritation from without or within.

When it occurs from without, any local irritation will set up an inflammation which may extend to the outer coats of the capillaries. This produces a marked increase of blood. The vasa vasorum becomes swollen, the white blood corpuscles crowd into the terminal capillaries and migrate into the extra vascular space. Rapid proliferation of the round-cell elements takes place. The walls of the vessels become thickened. Owing to the projecting intervals of the intima, the caliber of the blood vessels diminishes (Fig. 64).

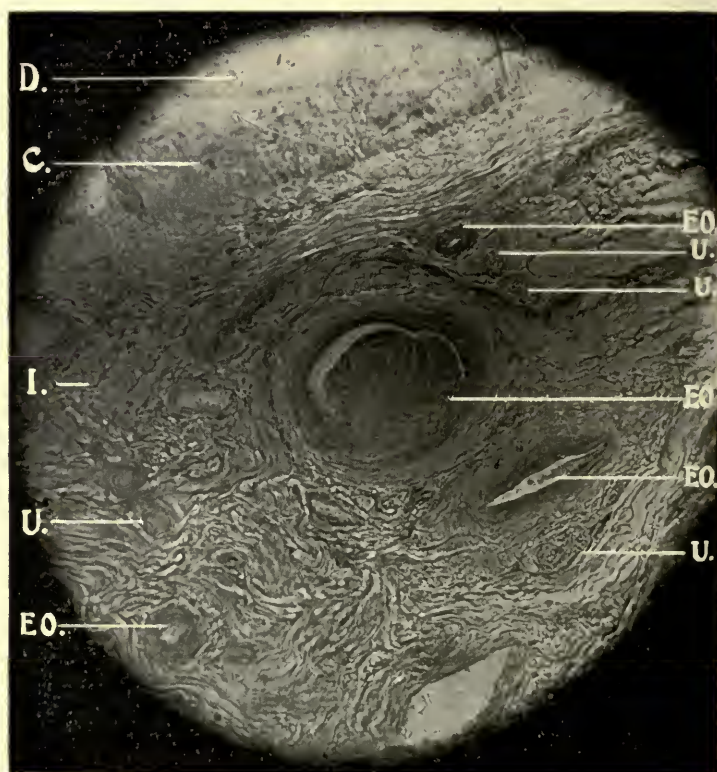
Irritation occurring from within, results either from trophic changes in the system from direct irritation from toxæmias, or from both interdependently. Under these circumstances a germ disease or other toxins may have an affinity for a certain organ, tissue or part, and produce irritation in the capillaries in a distinct part of the body, or the capillaries through the entire body may become involved. Thus, in typhoid fever, the Peyer's gland in the intestine becomes involved; in scarlet fever, the skin or kidney; in malaria, the liver and spleen; in Bright's disease, the kidney; while in mercurial and lead poisoning and scurvy, the mucous membrane, and especially the gums, become diseased. In many of these conditions, however, before the tissue already irritated becomes involved, the nervous system has become affected. The nervous system may already have become affected from other causes. Thus, locomotor ataxia, traumatic injuries to the spine, parietic dementia, cerebral paralysis, neuroticism and degeneracy, and last, but not least, stomach neurasthenia. The poison in the blood, together with the diseased peripheral nerves, produce irritation and inflammation of the inner coat of the capillaries. If this irritation does not disappear soon after its inception, the inflammation tends to affect the other coats of the blood vessels. Under certain conditions, endarteritis may, however, never involve the other coats of the vessels. When irritation of the inner coat of the capillaries takes place, proliferation of the endothelium occurs. This inflammatory growth tends to obstruct the lumen of the vessel. The media may likewise become thickened by an increased connective tissue. The capillaries become obstructed, and finally obliterated. This finally impedes the circulation. Fig. 65 shows such a condition in the scurvy case, elsewhere illustrated.

Irritation may be of less intensity but greater duration, as in case of syphilis, tuberculosis, scurvy, mercurialism, plumbism (lead poisoning), etc., and the results are then slowly effected. Proliferation of sub-endothelial connective tissue gradually increases until it reaches its limit (endarteritis obliterans). This influence of the proliferation is exerted in addition to that of the round-cell infiltration about the structure.

The recent studies of Hektoen¹ on meningeal tuberculosis

¹American System of the Practice of Medicine, page 119.

demonstrate that tubercle bacilli may penetrate the unbroken endothelial layers of the vessel and stimulate marked proliferation of the sub-endothelial connective tissue. An internal irritant, such as may be produced in the course of any infectious disease or from suboxidation, probably acts upon the endothelium of the walls of the smaller blood vessels in such a way as to permit the escape through the walls first of serum, then of leucocytes, the



X 150. D. D. obj. Zeiss.

FIG. 65.—CROSS SECTION OF PERIDENTAL MEMBRANE, SHOWING ENDARTERITIS OBLITERANS. SCURVY IN MAN.

C, Cementum. D, Dentine. I, Peridental Membrane. U, Nerve Tissue. EO, Endarteritis Obliterans.

latter infecting and surrounding the vessels. The effect of the chronic endarteritis is to check the blood supply to the gum tissue. Mercury, lead and other poisons circulating through the blood are forced to remain, hence discoloration of tissue along the gum margin. Interstitial gingivitis, resulting in a slow disturb-

ance of nutrition, produces overgrowth of connective tissue. In all cases of chronic interstitial gingivitis, as shown in the illustration, are the blood vessels thus involved.

Among the predisposing influences which cause this disease are syphilis, tuberculosis, mercurialism, plumbism, brass poisoning, lithæmia, nephritis, gout, rheumatism, alcoholism, scurvy, nervous diseases, pregnancy and old age. Under certain conditions of the system any and all diseases which tend to lower the vitality, producing anæmia, will assist in producing this disease. The direct cause may be resultant overstrain of the blood vessels.

Owing to obliteration of the arteriols in the alveolar process stasis of blood must follow. The detritus from the alveolar process, therefore, must remain in the tissue and collect upon the roots of the teeth.

ABSORPTION OF THE ALVEOLAR PROCESS.

Absorption of the alveolar process is the result of irritation, resultant malnutrition, and subsequent inflammation. The osteoblasts and osteoclasts are ever present to build up and tear down bone structure on the slightest provocation. Hypertrophy (building up of bone tissue) is the result of intermittent pressure, and atrophy, or absorption of bone, is due to constant irritation and pressure. As has been elsewhere shown, from its transitory nature the alveolar process is unusually susceptible to these influences. The causes of absorption are loss of teeth by extraction, undue pressure upon one or more teeth from improper articulation (Bonwill), wedging and irregularity correction, heat under artificial dentures, and interstitial gingivitis of local and constitutional origin.

According to Kaufmann, lacunar absorption is the most common type. This may be true in morbid anatomy of bone tissue generally, but it is not true of absorption of the alveolar process. On an examination of hundreds of slides prepared from canine and human jaws (of which characteristic types are illustrated), by far the most common form of absorption was found to be halisteresis. Perforating canal absorption, which Kaufmann has "occasionally met with," is certainly very common, while lacunar absorption holds third position. This order of absorption is accounted for by the fact that where structures

are transitory, halisteresis, as quickest method, follows by the law of the survival of the fittest. For the same reason perforating canal absorption should stand second. The blood vessels of Von Ebner being most numerous, although considered smaller, they would naturally be the second tissue involved. As in interstitial gingivitis, absorption of the alveolar process is invariably due to inflammation, halisteresis apparently starts at the larger Haversian canals from which this form of absorption invariably originates.

Interstitial gingivitis extends to the alveolar process through the periosteum as well as the peridental membrane (not, as dentists usually believe, by way of the peridental membrane alone). This is demonstrated by the illustrations. The entire alveolar process thus becomes involved. The products of inflammation extend through the Haversian canals (a path obviously evident in pathologic illustrations), setting in action the three forms of absorption as elsewhere illustrated.

Halisteresis Ossium (*ἀβολος* of salt, *στέρησις* deprivation) or decalcification, is that process of absorption wherein solution of the lime salts first takes place, while the cartilage or matrix remains for the time undisturbed.

Solution of the lime salts begins at the periphery of the Haversian canal and advances toward the center of the trabeculæ. This absorption follows, as a rule, the bone layers. Bone centers are, therefore, usually the last to be absorbed. Frequently decalcification becomes complete; nothing remaining but the organic matrix or cartilage. Finally, this is also entirely destroyed. As the osteoblasts occur in the matrix or cartilage, it is not difficult to understand that absorption may extend far, yet restoration of the alveolar process may occur. After destruction of the matrix such a restoration is impossible. New fibrous tissue may be partly restored, but it is doubtful if the alveolar process can be.

Both Ziegler¹ and Kaufmann² divide osteomalacia into senile and juvenile. The latter occurs most frequently during pregnancy. In senile absorption, after a certain period, the entire skeleton is affected. The condition begins most frequently in

¹Special Pathological Anatomy, page 151.

²Pathologische Anatomie.

the "vertebræ and thorax; later extending to the extremities." In pregnancy "the pelvic bones are first involved, the process then extends to the other bones." It is singular that the alveolar process should have been so much neglected by pathologists, since, in both states, the alveolar process becomes involved long before the bones of the body.

This is due to three reasons: first, to trophic changes; second, to the alveolar process being a transitory structure; and third, to improper care of the gums at these periods.

Osteomalacia occurs in the alveolar process much earlier than at the so-called "senile" period. It is found at twenty, or even earlier. At any period beyond that year, it occurs probably from the prematurely senile states of which precocity is a type. The lost tissue is regained often after confinement in the "pregnancy" type, but is never regained in the senile.

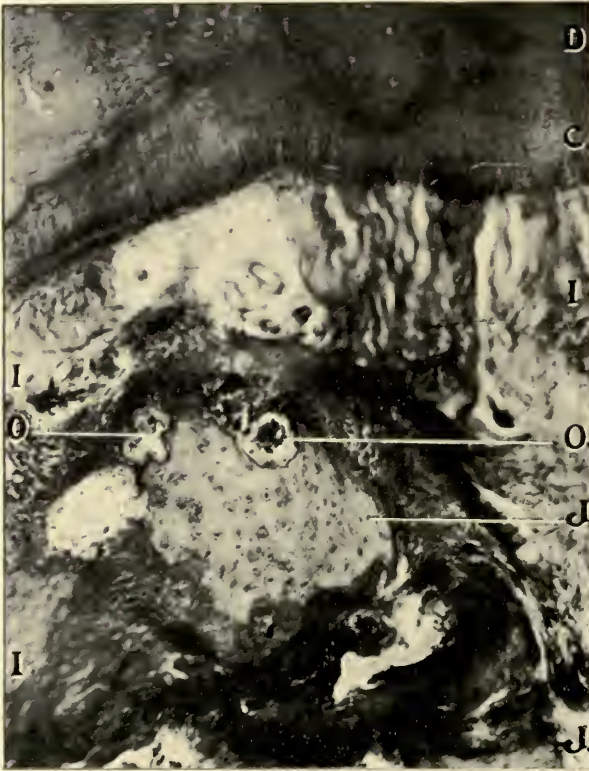
The causes which produce morbid decalcification are not thoroughly determined. Some believe it to be due to lactic acid in the system, others attribute it to an increased amount of carbonic acid in the blood. Eisenhart believes it to be due to a want of alkalinity of the blood, while Von Rechlinghausen charges it to a local irritation of the vascular mechanism of the bones. It would seem, from examinations already cited, that, so far as the alveolar process is concerned, local irritation from biochemic changes in the blood, as suggested by Von Rechlinghausen, is the chief cause. Premature absorption of the alveolar process accompanies the movement of the teeth in their correction or in rapid wedging. Frequently the alveolar process is never fully restored, thus producing a predisposing factor for future disease.

Premature absorption, or osteomalacia of the alveolar process, is easily recognized. A shrinking of the gums and alveolar process exposing the necks of the teeth is very conspicuous. Frequently the gums and mucous membrane covering the alveolar process is quite red (this is very noticeable in dogs), and a thinning of the alveolar process over and between the roots of the teeth. The process of one tooth only may become involved; again the process over two, or the whole jaw, and again both jaws become affected.

When osteomalacia occurs, either of pregnancy or senile type, although the tissues be seemingly restored to health, struc-

tural change has taken place to such an extent that it ever remains a predisposing factor to interstitial gingivitis.

In Fig. 36 may be seen the blood vessels of Von Ebner. These blood vessels are also to be observed in Fig. 55. They are very common in the alveolar process and, according to Volkmann, are the source of the perforating canals which bear his name.



x 50. ½-inch obj. No. Oc.

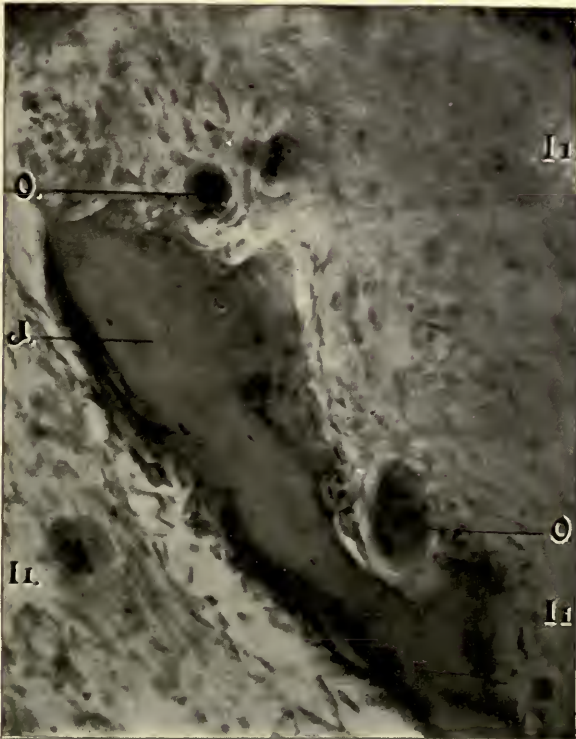
FIG. 66.—CROSS SECTION OF TOOTH, ALVEOLAR PROCESS AND PERIODONTAL MEMBRANE, SHOWING LACUNAR ABSORPTION. MAN.

C, Cementum. D, Dentine. I, Periodontal Membrane. J, Alveolar Process. O, Lacunar Absorption.

These canals run in all directions. After absorption has gone on to form medullary spaces, these canals penetrate through the trabeculae from one space to the other (Fig. 38). The position of this type of absorption in the order of frequency comes from the fact that, in this disease, absorption is almost entirely due to

inflammation; hence the blood vessels are the first to become involved. Those entering the Haversian canals, being the larger, are first affected, and hence halisteresis naturally precedes.

When irritation takes place in a nerve or part of bone which is about to be absorbed, multinuclear cells arise at the border in the periosteum and peridental membrane. They attach themselves to the surface of the bony trabeculæ. According to Sud-duth, "the absorber and the absorbed must be in touch with each



X 300. No. 2, projection ocular. D. D. obj. Zeiss.

FIG. 67.—SECTION OF PERIDENTAL MEMBRANE, SHOWING LACUNAR ABSORPTION IN DOG.
J, Alveolar Process. O, Lacunar Absorption. I, Inflamed Peridental Membrane.

other." Kolliker has named these cells "Osteoclasts," which term has come into general use. Very soon after these cells make their appearance, cavities are seen in the bone tissue. These cavities are called Howship's lacunæ. Lacunar absorption, as elsewhere shown, takes place as a result of irritation and overstimulation. Fig. 66 shows a cross section of the end of one

of the buccal roots of Fig. 68. As will be observed, this tooth was held in place by two buccal roots. As much resistance was required of these two roots as was formerly required of three. Irritation due to excessive force in mastication was causing absorption. Round-cell inflammation is not present in the periodontal membrane. The irritation may be continued until inflammation sets in and until the bone is entirely absorbed, as noticed in Fig. 67. Small round-cell inflammation is quite noticeable in the surrounding tissue.

Sometimes these lacunæ may be seen extending along the entire length of bone. As many as thirty-seven may be counted in some fields (Fig. 37). Lacunar absorption frequently so extends through the Haversian canals as to cut off pieces of the alveolar process. A casual glance at Fig. 66 demonstrates this. This figure could be multiplied many times from other slides. These frequently come away with the periodontal membrane when the tooth is extracted. This is often noticed in removing loose teeth due to interstitial gingivitis. By passing the finger over the surface of the root, the rough pieces of bone may be easily felt.

Aside from the forms of absorption already noted, absorption of the alveolar process is often seen, the result of neuropathic lesions. Paralytic dementia, diseases of the spinal cord, low forms of inflammation, general debility and traumatism, together with unhygienic conditions of the mouth, are fruitful sources of interstitial gingivitis and absorption of the alveolar process. Absorption of the alveolar process takes place also in diathetic diseases in which the nervous system has been involved (syphilis, scurvy, lithæmia, etc.).

PYORRHEA ALVEOLARIS FROM INTERSTITIAL GINGIVITIS.

Recovery from interstitial gingivitis and return to normal conditions without change in structure is called restoration. Should the damage be extensive, and accumulations of cell and liquid exudate so press upon the tissues as to extinguish their vitality, ordinary restoration is impossible. This is also true when the inflammation is more decided and persistent. This inflammation may extend throughout the tissue. Absorption of the alveolar process may take place, and exfoliation of the teeth

result without pus infection. The tissues may be in a favorable condition for infection, yet the mouth and blood vessels be free from pus germs. This is not uncommon. The tissues are often invaded, however, by micro-organisms, resulting in suppuration. Interstitial gingivitis, with pus infection in and about the alveolar process, resembles suppuration elsewhere in the body. It results either in an abscess or ulceration. An abscess is a collection of pus within the tissues. Ulceration is a collection of pus upon the surface of the tissues. Both of these marked conditions, being dependent upon inflammation, are associated with interstitial gingivitis.

Suppuration (due to pyogenic cocci) is the usual termination of infective inflammation. Healthy gum tissue is intolerant of bacteria, and will resist the invasion of micro-organism. When inflammation takes place, the diseased part is unable to resist them. Lowered vitality of tissue is a fruitful source of infection and suppuration. Since, as Miller¹ has shown, pus germs are found in almost every mouth, infection is a very probable outcome of gingivitis.

The organism most frequently producing pus are the staphylococcus pyogenes aureus, and albus. These have a tendency to accumulate in groups. When they collect at a given point in the tissue, suppuration results. The streptococci (occasionally present in the mouth) do not as a rule produce local suppuration, but spread through the tissue by way of the lymphatics and blood vessels, and eventually give rise to abscess. The delicate reticulum of the blood vessels found in the Haversian canals is a convenient lodging place for swarms of bacteria, owing to the slowness of the blood current and the tortuous course of the blood channels. When² the circulation has been impeded or arrested by an extravasation of blood or congestion of a part, the conditions are favorable for intravascular infection if organism happen to be circulating in the blood at the time. As we have seen, micro-organisms may from time to time be found in the circulation, particularly in individuals of feeble constitution. The anatomic nature of the part will therefore determine suppuration in certain localities.

¹ Micro-Organisms of the Human Mouth.

² American Text-Book of Surgery.

In whatever part or tissue the change may occur, the process is the same. The original structures disintegrate. Their place is taken by a closely packed crowd of migrated leucocytes. Should the cause continue to act, the process culminates in the formation of pus. The migrated cells cut off from proper nutrition by pressure are exposed to the injurious action of micro-organism. The central cells of the group degenerate from want of nutrition or die from direct action of the irritation. The intercellular substance softens, and the liquid exudate from the surrounding parts mingles with the broken-down tissue to form an abscess.

As I have shown, foci of infection and intense inflammation, to the point of degeneration and liquefaction, occur in most every locality within the peridental membrane, periosteum and alveolar process. These abscesses are just as likely to point upon the surface of the gum as on the inner surface next to the root of the tooth. When abscesses form in and about the alveolar process, with fistulas opening outside of the inner alveolar wall, the disease cannot be entitled pyorrhœa alveolaris, since, as elsewhere shown, strict definition of this title implies pus flowing from the alveolus.

Abscesses which discharge their contents into the space between the alveolar wall and the root of the tooth, and ulceration of the peridental membrane only, could literally be considered under the head of pyorrhœa alveolaris.

Abscesses in and about the alveolar process (other than those due to dead pulps) are very common. This is due first to the unstable condition of the structures, and second to the ready access of pus germs through the inflamed gums and peridental membrane. Those most susceptible to infection are patients who are anæmic and below par in vitality, and whose gums have become inflamed either from local or constitutional causes. Especially is this the case in those who have osteomalacia where the gums have receded quite a distance from the necks of the teeth. Pus germs collect at the necks of the teeth, infect the raw inflamed surfaces of the epithelial layer, and entering the circulation are carried into the deeper structures. Intense inflammation results. Abscesses form, discharging their contents upon the surface. Pus germs also enter the deeper structures through exposed pulps.

Two cases of interest in this connection occurred recently in practice. An active business man, fifty-five years of age, presented himself with an abscess over the buccal roots of the left superior second molar. There were no dead pulps in any of the teeth upon that side of the jaw. Absorption of the alveolar process and contraction of the gums had occurred around all the teeth. He had been overworked and was nervously exhausted. Five years ago cataracts were removed from both eyes. He is exceedingly sensitive to pain. Examination of blood revealed slight anæmia. On examination of urine, other than a specific gravity of 1028, it was found normal. The abscess was lanced and cavity cleansed. It healed within a week. Subsequently he returned with another abscess over the root of the right superior central incisor. Live pulps were in all the teeth upon this side as far as the second molar. Infection, therefore, must have occurred through the gum and peridental membrane.

The teeth of a lady forty-six years of age were being put in order; after filling a cavity, May 14, 1899, she called attention to a space between the second and third superior right molars, and stated food lodged at that point, causing pain and bleeding. The space was cleansed with an excavator and the cavity syringed with warm water and then explored. Absorption of the gums and alveolar process had extended one-half the length of the buccal root. Applications of iodine were made to reduce the inflammation. The patient was dismissed with an appointment for May 17. She returned at the appointed time with an abscess over the palatine root as large as the thumb. The lady had had acute pain from the time she left the office until her return. The parts had been infected with pus germs through the peridental membrane. The pus was collected in a tin tea spoon, from which cultures were obtained and glass slabs smeared for microscopic examination. The pus was examined by George T. Carpenter for calcic deposits; the usual aseptic precautions having been taken.

Microscopic examination revealed the usual pus germs. Chemical analysis for calcic deposits in the pus was made as follows: The pus was placed in a test tube with hydrochloric acid (diluted with four times its bulk in water). The phosphate is dissolved. It is then diluted with water, boiled, and when

cold excess of solution of ammonia added. The lime salts are then re-precipitated as an amorphous powder.

Many dentists, ignoring the laws of pathology, insist that intense inflammation in remote parts of the alveolar process is not due to invasion by micro-organisms of an inflamed tissue, but is the result of gouty deposits. The utter lack of foundation for this theory must be apparent on the slightest study of pathology.

Ulceration is always located upon the surface of a tissue. When ulceration occurs from contact irritation of the gum margin or by mechanical or chemical means, congestion and œdema result, thickening of the epithelial layer and increased growth of cells. The sub-epithelial tissue becomes inflamed. The process is not unlike that of the formation of an abscess, since the infected tissue resembles part of an abscess wall. In slowness of progress only does ulceration differ from acute inflammation.

Such is the condition of the peridental membrane. When simple gingivitis becomes chronic, the inflammation extends to the surface of the peridental membrane. This is situated at the lower extremity of a cul-de-sac, formed by the gum on the one hand and the tooth on the other. This cavity is filled with foreign material in which decomposition continually occurs. The tissues are thereby constantly irritated. Necrosis occurs at the surface. In the deeper tissues that have become inflamed pus cells also are found. These not only arise from the normal blood vessels in the vicinity, but also from the granulation tissue. The causes of peridental membrane ulceration are disturbances of nutrition, endarteritis obliterans (a disease of the blood vessels due to constitutional diseases, such as syphilis, scurvy, tuberculosis, uric acid and other blood poisons) and starvation of tissue, feeble circulation (as in anæmia) and inflammation. If the ulcerated surface be examined under the microscope, a general thickening of the tissues will be seen. In the papillary layer deposits of blood pigment (Fig. 52) occur. The surface is covered with granulation tissue. The tissue may, in part, resemble the type of healthy granulation. It is composed of round cells closely packed together and supplied with rich capillary network. Coagulation necrosis from breaking down of granulation tissue may be present.

CONSTITUTIONAL EFFECTS OF PYORRHŒA ALVEOLARIS.

The influence of the stage of interstitial gingivitis known as pyorrhœa alveolaris on the system has been discussed by John Fitzgerald.¹ He points out that pyorrhœa alveolaris may act in three different ways in the causation of systemic disease. The pus, with its multitude of putrefactive organisms and decayed food remnants from the pus pockets, may be swallowed and either act locally upon the stomach wall or set up fermentation of the stomach contents. The toxins generated in the mouth may be absorbed by the mucous membrane of the mouth or stomach and thus pass into the general circulation. The local conditions of the mouth may favor the growth of pathogenic organisms, and thus render the patient more liable to certain infectious disorders, noticeably influenza. The power of pyorrhœa alveolaris to produce aggravation of existing gastric trouble reaches its maximum in cases where there is retention of food residues. This happens when the muscular walls of the stomach are in a state of atony and also when there is some pyloric obstruction which prevents the organ emptying itself. In both these conditions stomach dilatation is eventually produced, with the result that the stomach is never completely emptied. The first condition is a very frequent concomitant of neurasthenia and allied states. It is easy to see how pyorrhœa can at once be predisposed to by neurasthenic states and at the same time increase the neurasthenia by causing gastric trouble through its interference with gastro-intestinal digestion under the conditions mentioned.

Herschell² is of opinion that many of the chronic indigestions are due to continual absorption of pus into the system from a pyorrhœa alveolaris. In these cases he remarks there should be other evidences of the absorption of toxins, such as pigment spots, urticaria, etc. Fitzgerald points out that the bacterium coli commune is a constant inhabitant of the oral cavity, and, as a rule, seemingly harmless. Under the influences of a culture medium such as would be furnished by a pyorrhœa or an inflammatory state of the gum, this bacterium might, as elsewhere in the mucous membrane, acquire sufficient virulence to produce serious disturbances of the system, such as colitis, dysentery and cholera nostras.

¹ Clinical Journal, March 6, 1899.

² Indigestion, 1895.

CALCIC DEPOSITS.

There are many instances in which interstitial gingivitis takes place, with absorption of the alveolar process and exfoliation of the teeth, without calcic deposits. In such cases the blood is charged with only sufficient lime salts for the nourishment of the body. The waste products are carried off with the excreta. In absorption of the alveolar process, inflammation does not seem to extend to the capillaries, the result of which is, this waste material is carried into the circulation. In this way, calcic material



FIG. 68.

does not collect in the fluids and upon the teeth. In those cases in which pus is not present (there being a lessened amount of carbonic acid) calcic deposits rarely take place. The percentage of teeth so found, however, is not so large as those with deposits.

Examination, by a magnifying glass, of a recently extracted tooth (whose root is covered with serumal deposits) shows the lime deposited in a manner resembling that of stalactite formation. The deposits often stand out distinctly independent of each other (Fig. 68). This condition is due to deposits from the blood, resultant on biochemic changes in the inflamed tissues. Blood

stasis occurs in the gum tissue, fibrous tissue of the periosteum, peridental membrane and alveolar process, through which last much of the blood circulates. This stasis may be consequent upon conditions varying from simple inflammation to disease of the endothelium, producing endarteritis obliterans.

The blood has become surcharged in all constitutional diseases, but more especially in kidney lesions. Deposits occur in the fluids and upon the roots of the teeth. Frequently the deposit is found only on one side or only at one particular spot on the side of the root; again at the apex, when the pulp is destroyed. It may encircle the root. The inflammatory process may therefore be circumscribed as to area or the whole tissue may be involved. The deposit is circumscribed in the area of inflammation. The calcareous matter absorbed from the alveolar process in the immediate vicinity of the root is not improbably soon deposited upon the root or roots because of the impeded circulation.¹ "Ossification, as has been well remarked, is an active development in which the tissues are abundantly supplied with blood. There is a rapid cell proliferation, and the calcareous matter forms an intimate and permanent union with the tissues. Calcification, on the other hand, is passive, and indicates an impaired vitality. Calcification begins as a rule in the interstitial tissue. In regard to the origin of the calcareous salts, it is generally believed that they come more or less immediately from the blood, although Rokitansky supposes that they were formed by a metamorphosis of the tissues involved."

Calcification is due to two varieties of causes: general and local. The former are dependent upon changes in the blood or its circulation, due, for example, to disease or senile change. In composition the blood may be so altered as to contain an abnormal amount of calcareous matter. This effect is most commonly produced by absorption of lime salts from osseous tissues which are the seat of extensive caries, osseous cancer, osteo-sarcoma or osteomalacia. The calcareous matter thus taken up is conveyed to other and often remote parts and there deposited, constituting the "metastatic calcification" of Virchow. Küttner, of St. Petersburg, has observed a rapid calcification of nearly all of the small arteries as a result of caries involving the dorsal and lumbar

¹ Wood's Handbook of Medical Sciences, Vol. I, page 743.

vertebræ in a nineteen-year-old boy. Virchow has observed a case in which, as a result of bone cancer (affecting nearly all of the larger bones, particularly the borders of the vertebræ and the skull), the calix and pelvis of the kidneys, the lungs, parenchyma, and the stomach mucous membrane were calcified.

Circulation of the blood may be retarded and thus favor precipitation of calcareous matter normally held in solution. To this is chiefly due the frequency of calcareous degeneration from general loss of vitality.

Calcification rarely, if ever, depends upon general causes alone. There is, as a rule, a local influence. Very often this is due to preëxisting chronic inflammation. Old accumulations of pus and exudates are exceedingly prone to calcification. The deposit frequently occurs also in fibrous walls surrounding the accumulation. A mere loss of function predisposes to calcification. Such is the case in and about the tissue of the alveolar process. The decalcified material from the alveolar process collects in the soft tissues as well as upon the roots. In his paper George T. Carpenter¹ asks the question: Can a tissue be absorbed and still remain as débris in the pocket? Such is the condition found, and this can be easily proven. Take the contents of a pocket and dissolve it in hydrochloric acid, add three times its bulk of water, to this add ammonia, which will precipitate the phosphate and the calcium. The same results may be obtained by rinsing a freshly extracted tooth of a pyorrhœa case in cold water. With a stiff brush remove the accumulation and place it in a test tube, add hydrochloric acid and more water if necessary. To this add a solution of ammonia and the lime salts are precipitated.

Roots of teeth that have become entirely denuded of periodontal membrane and bathed in pus accumulate large quantities of calcic deposits direct from the absorption of the alveolar process.

Difference of opinion exists as to the nature of the process immediately involved in precipitation of lime salts. The simplest and seemingly most logical explanation is that the process is similar to that involved in the formation of stalactites. A certain

¹Some Points on the Etiology, Pathology and Treatment of Persistent Pyorrhœa Alveolaris.

amount of calcareous matter is a normal constituent of the blood. Herein it is held in solution by carbonic acid, always present in sufficient quantity for this purpose. When the circulation is impeded the free carbonic acid (because of its great diffusibility) is readily absorbed by the tissues or goes to form new compounds, necessitating a precipitation of the calcareous matter. Calcareous matter may be deposited in either a fibrous or fluid matrix. It shows a preference for newly formed fibrous tissue, particularly when this is associated with old tissue undergoing fatty degeneration and absorption. In a fibrous matrix the infiltration usually begins in the intercellular substance, but may involve the cellular elements at a later period. In a fluid matrix (like pus) the granules are frequently deposited primarily within the cells. The process may advance slowly or rapidly. When local causes exert the chief influence it is more limited in area of invasion than when there is a general factor in its production, as in the metastatic forms.

CHAPTER XVI.

TREATMENT.

The clinical history of interstitial gingivitis is essentially that of any other disease of the mucous membranes. The disorder responds quickly to treatment at its outset. Later, its complications and the extent of structure involved render treatment very ineffacious, and always insure loss of the tooth. As the general surgeon's duty is to save life, if need be, at the expense of limb or organ, but to save these last if possible, so the dental surgeon's duty is to remove the teeth, if need be, for the benefit of the general health, but to save them, when possible, for the same reason. The patient, therefore, should be told frankly at the outset of interstitial gingivitis, that it is a condition requiring time for its treatment, and should not be given that prognosis too frequently made of quick cure. To such a prognosis many a case of constitutional disorder is due. The dentist is a practitioner of a surgical specialty, not a mere tooth-puller. The surgical side of dentistry has received too much attention, however; the medical or prophylactic too little. Patients are beginning to pay more attention to the prophylaxis of the teeth and jaws, and need but little encouragement and instruction to see the absolute necessity of early prophylaxis and treatment of interstitial gingivitis. The trend in general medicine is to prophylaxis, and this has undoubtedly so impressed patients as to open the way for dental prophylactic suggestions. Viewing the question from the narrowest standpoint of remuneration, the dentist could not fail to profit by instructions to his patients on prophylaxis. He certainly fails in his duty as the member of a learned profession by not doing this. Furthermore, with the known necessity for prophylaxis, it is an open question whether the failure to inform the patient of the dangers of the incipient disease could not be successfully pleaded as a basis for a malpractice suit.

From the etiology of this disease, the treatment would appear simple and easy.

Early diagnosis is not difficult, since the simple inflammation of the gums is easily recognized by the patient. Bleeding when the toothbrush or toothpick is used can never be mistaken. The dentist with his accomplished eye can readily detect the slightest change in color or puffiness around the necks of the teeth or of the festoons between the teeth. Redness, puffiness and bleeding are pathognomonic of this disease in its incipency.

Few dentists have, however, given this stage of the disease any thought, albeit they have filled the teeth of their patients from year to year. I have in mind three patients with loose teeth and inflammation extending throughout the peridental membrane and alveolar process, who had been under an old practitioner now retired from practice. The patients had never had the gums treated or even their teeth cleaned. This is not an uncommon occurrence. The excuse usually made by the dentist is that he cannot get paid for his time. Gingivitis is a disease which the dentist is as much bound to treat and cure as any disease of the mouth and teeth. It is a part of his specialty which should not be ignored. It is claimed that the dental profession is overcrowded. Were this disease treated until the gums were placed in a healthy condition, there would be practice enough for as many more dentists as there are today. The busy dentist of today could attend only to one-half the patients whom he now serves.

The treatment, then, should be prophylactic in its nature, preventive rather than corrective. The disease and treatment is not unlike an inverted pyramid: the farther from the apex or beginning, the more difficult and hopeless the task becomes. Since the teeth have nothing directly to do with this disease, they should be ignored. In the early stages, the gums should receive proper attention. These, like other parts and organs of the body, must be exercised to be kept healthy. The gums should be properly massaged, just as the liver, kidneys or skin are when they are not doing proper work. This can be accomplished by properly made brushes. The ordinary toothbrush is not adapted to the work under discussion. It will brush the teeth but not reach the gums. What is needed is a massage brush that will miss the teeth to a certain extent, but will reach

the gums and contract them tight around the teeth, thus preventing the accumulation of foreign substances. The patient should be instructed with this single idea in view, "that the gum margin is to be exercised and stimulated and not the teeth, which must be ignored." A brush, properly made for gum massage (Fig. 69), will do sufficient work upon the teeth with the aid of the floss silk and toothpick. It should have printed upon the handle, in large letters, "gum massage brush." The handle should be bent a little more than the "prophylactic," so that the end containing the bristles can be brought in contact with the gum, posterior to the central incisors, upper and lower, and around the third molar teeth. There should be a tuft of bristles at the point with a space for the teeth. The tuft should be longer than those on the body of the brush. This tuft will



FIG. 69.

reach the gums at all points inside of the mouth and around the molars. The bristles on the body must have spaces between them, so that when the upward and downward movement is given, the bristles will go between the teeth and reach the gum festoons. The bristles must be medium and hard. The quality of bristles must depend, however, upon the condition of the gums. If they be soft and spongy, the medium may be used. If the processes are heavy and thick, the gums swollen and engorged with blood, hard bristles must be used. Soft bristles (although sometimes recommended) should never be used.

The antique theory that vigorous stimulation is injurious is too much accepted. Barrett,¹ for example, says, "massage of the gums with the ball of the finger and by the frequent use of a rather soft brush should be resorted to." Beodecker² remarks that too frequent application of the toothbrush is sufficient to

¹ Dental Cosmos, 1883, page 532.

² Anatomy and Pathology of the Teeth, page 365.

produce papillary hyperplasia. Tomes¹ says, "in my own experience I have found that frequent and vigorous rubbing of the gums with the finger, shampooing them in fact, has often been productive of great advantage, the patient of course being cautioned not to rub the actual edge; but even on this point there is difference of opinion, for in a recent paper on the subject, rest and the avoidance of all friction is advocated." Dr. Meyer L. Rhein² in introducing the "Prophylactic Toothbrush" to the profession, says, in his article on "Oral Hygiene," each brush comes inclosed in an envelope, upon which are printed directions for the intelligent use thereof, and the following caution: "Never pass the brush across the teeth, as this movement destroys the delicate membrane which attaches the gum to the teeth, causing recession of the gum, and ultimate loosening and loss of the teeth." Citations of this could be multiplied, showing the general impression is that the gums should not be stimulated to any great extent; that the finger, a soft cloth, or a very soft toothbrush alone should be employed. The use of the finger is a superstition which is handed down from generation to generation without the slightest critical analysis. If the advocate of this use would try the experiment, he would see how impossible it would be to bring it in contact with all the tissues of the mouth that are involved in this disease; were it possible, the fingers, cloth and soft toothbrush would not accomplish the desired result.

No brush should be used whose bristles are softer than the medium; very often these, used once or twice and dipped into water or mouth washes, become so soft as to be wholly unfit for use. It is always a good plan to have two brushes to be used on alternate days. In this way one can dry while the other is being used. The general opinion has been that friction upon the gums was detrimental on account of the resultant tendency to absorption of the gums. While this may exceptionally be true, it is not true of a majority. Should milk, arsenic, iron, strychnine or quinine be entirely abolished as remedies because occasionally a person presents untoward effects? If the alveolar process be very thin over the roots of the teeth, especially the cuspids, the

¹ Dental Surgery, page, 704.

² New England Journal of Dentistry, October, 1884.

patient must be instructed so to use the brush as not to over-stimulate these particular parts. In such cases the inner alveolar process and gum tissue may be stimulated with impunity and with the hardest brush. Again, if the chronic interstitial gingivitis be of long standing, or even if chronic gingivitis has been present for some time, stimulation of the brush will cause the gums and mucous membrane to recede until hard, sound, healthy structure has been secured. Then absorption will cease. In most cases absorption and contraction of the gum tissue will take place to a more or less marked degree. If absorption of the alveolar process has taken place and the gums are puffy, red and swollen, a disease exists to be cured, regardless of consequences. The alveolar process and gums will never return to their original position, but it is a decided advantage to have a healthy mouth, even if the alveolar process and gums have slightly receded.

I have used medium and stiff brushes in my practice for the last fifteen years and have failed to see any ill results. For the past four years I have made constant experiments, with the view of securing the proper shape and stiffness of the bristles and have obtained uniform results in gum treatment.

Proper employment of the "gum massage brush" requires skill. Every dentist should train his patient in the method of using the brush. The gingival borders should not only be stimulated, but the bristles should be so passed in between the gum margin and the tooth as to remove the débris and exfoliated epithelial scales which have accumulated therein. These are often the cause of the irritation. Unless this be done the gum or epithelial tissue cannot perform its functions or be restored to health. Stimulating astringents and germicidal mouth washes should be employed whenever the gums are massaged. The massage should be done three times a day. The patient should be under the care of the dentist at least twice or thrice a week, so that he may direct the treatment. If the teeth are irregular, care and patience are required to reach the festoons between the teeth. After the gums are in perfect health, the patient should visit his dentist at least four times a year for further instruction. If on inspection the gums be found diseased at any point, the dentist can direct the attention of the patient to the particular locality and the disease

be eradicated. By this method and this alone can the gums be kept in a healthy condition. Each patient must be given specific directions as to the treatment of his or her case.

If the gums have become swollen and engorged with blood a different method must be employed. Here the absolute law of medicine obtains — “remove the cause,” no matter whether of local or constitutional origin. If due to improper articulation this must be corrected. If constitutional, and due to any of the mineral poisons or scurvy, the system should be flooded with large quantities of pure water. There is nothing better to rid the system of poisons and impurities than flushing the blood with from three to five quarts of pure water a day. Cathartics should be employed. A Turkish bath should be used to open the pores of the skin, at which time the masseur should be instructed to stimulate the liver, kidneys, skin and peripheral nerves. If the patient suffer from disease like syphilis, tuberculosis, diabetes, Bright’s disease, colds, including catarrh, nervous prostration, anæmia, etc., special treatment is indicated. Remove all deposits and other irritants from around the teeth.

Two decades ago, I advocated the use of the following set of scalers; nothing better has been produced since. They consist of handles, shanks bent at different angles, and blades three-cornered, so that they can be used in three directions without removing the fingers from the tooth (Fig. 70). These are all delicately made, and tempered very hard. Sharp edges are there retained. They will reach every point where tartar can collect. After the deposits have been fairly well removed, the gums may be syringed with hot water (Cravens) to remove all débris. The gums should be saturated with tincture of iodine (U. S. P.) or iodine and aconite, in the following manner: Have a number of wooden toothpicks (Portuguese preferable) wound with cotton, and kept in a little box. Saturate the cotton and paint the gum as far as it will go. Throw this into the waste basket and take another, and so on until the gums are well saturated. From three to five picks will be required. The assistant can keep these in order between patients. In such cases a different massage brush is to be used. One is here required that will so lacerate and stimulate the gums as to relieve the congestions. This brush, made of coarser and stiffer bristles, should be used like

the other. After two or three days the gums will contract, and healthy circulation follow. Pain will now be experienced in the gums. The massage must still be kept up. An astringent, stimulating and general mouth wash, should be used in connection with the massage. The patient should return every other day for further treatment with the iodine, or iodine and aconite used as before. To reach an inflammation, chronic and deep-seated, extending into the periodontal membrane, periosteum and alveolar process, there is nothing in medicine better than iodine, or iodine and aconite. This, and this alone, will reach the deeper inflammation. After a few treatments and constant use of the massage brush, the gums will contract, and other deposits which

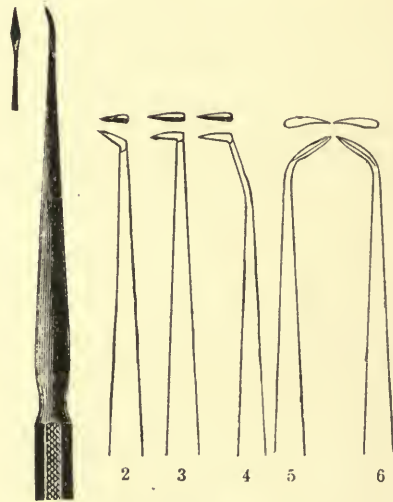


FIG. 70.

were overlooked at the first sitting will now be presented to view. If the gums be very painful at the first sitting, no effort should be made to remove the deposits until the inflammation has, in a measure, subsided. The iodine treatment and massage should be conducted as suggested until the gums have been reduced and the pain ceases. After they have been restored to health, constant massage with the medium brush must be employed two or three times a day. The patient should return to the dentist as often as necessary (every month or two) to have the gums examined, and for further direction.

As has been already shown, chronic interstitial gingivitis may extend only to the peridental membrane, to the periosteum, or it may extend throughout the alveolar process with the absorption of the bone the entire length of the root of the tooth. Pus infection and serumal deposit may or may not take place. In the early stages of this progressive inflammation, the first is probable. If pus and deposits are present they can be treated with signal success according to the symptoms and as hereinafter explained. As already suggested, the gum massage brush must be vigorously used to relieve the engorged tissues of blood. Since absorption of the alveolar process depends upon irritation and inflammation, this must be removed as quickly as possible.

In the treatment of deep-seated interstitial inflammation, iodine or iodine and aconite has always been regarded by physicians and surgeons as the best remedy. The gums should be thoroughly saturated twice or thrice weekly, as already suggested. If the alveolar process be so absorbed that the tooth has become loose, the case is hopeless. In such unstable tissues, especially when inflammation extends through the process and lacunar, perforating canal absorption and haliteresis is going on, reversal of the order so as to set the osteoblasts to tissue-building is hardly to be expected. The tendency is to destroy and not restore the alveolar process. In such cases the tooth must be fastened to the other teeth perfectly tight to prevent motion in any direction. The movement of the tooth in mastication intensifies the irritation, which in time only increases the absorption. Liberal use of iodine or iodine and aconite and the gum massage brush is all that can be done to reduce the inflammation and absorption as much as possible. The exfoliation is only a matter of time. If the tooth or teeth cannot be retained perfectly tight, no matter how healthy the surrounding tissues may be restored, the irritation produced by the loose teeth will soon set up inflammation in the surrounding tissues. The sooner the loose teeth are removed the better. In no case can the bone tissue be restored, if the matrix or cartilage be destroyed, since in this the osteoblasts are located. If the matrix or cartilage be destroyed, a fibrous union (such as occurs in the case of implanted teeth and the imbedding of foreign bodies in the tissues of the body) only is possible.

If inflammation have extended into the periosteum, periodontal membrane and alveolar process, serumal calculi are frequently deposited upon the roots of the teeth. When this has taken place, the calculus must be removed. This should be done with the utmost care, in order that adjacent tissues may not be injured, or inflamed parts infected with pus germs. Since dead bone is not present, the operator should confine his instrumentation entirely to the root or roots of the teeth, with as little injury as possible to the adjacent tissues. The alveolar process must under no consideration be touched. Riggs believed that the edge of the alveolar process was always in a state of disintegration, and that it should be so scraped as to get a fresh surface, on the principle of caries of bone. Many dentists are operating in this manner at the present time. I have elsewhere shown simple absorption and not caries is present. Such treat-

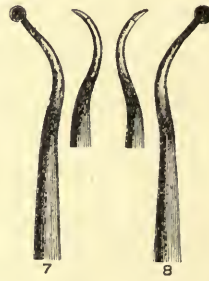

FIG. 71.

ment is wholly unnecessary and contraindicated. The object of the removal is to allow the fibrous tissue of the periodontal membrane (after health is restored) to tighten about the root, which cannot be accomplished when foreign substances are present. Pushing instruments must never be used, but only such instruments as have smooth and round backs, tempered very hard so as to retain sharp edges. These instruments should be small, with small points to reach depressions, and to be as universal as possible. Such an instrument is to be found in the spoon excavator (Fig. 71). The shank can be bent to suit the operator. This is to be carried gently along the length of the root and passed over the deposit with a firm hand, resting the finger upon some other teeth. The drawing motion is invariably to be from the membrane, and toward the crown. The deposits are scaled off

painlessly. The round blade being larger than the shank, and cutting upon three edges, half of the root in both directions can be circled without removing the instrument. A similar instrument bent at the shank in the opposite direction may be used on the other side. After all of the roots of the teeth have been scaled, the spaces are to be syringed out with warm or hot water (Cravens). The gums are to be thoroughly saturated inside and out with iodine. The gum massage brush is to be used thrice daily as before. The patient should return twice or thrice a week for further instructions. The contracting gums will assist greatly in revealing the deposit. If deposits still remain on the roots (the appearance of the gums will indicate its presence) further use of the scalers is indicated. The delicate instruments and the accustomed sense of touch will reveal the hidden calculus.

With the precautions already noted, local anæsthesia is unnecessary. The smooth, round surface of the back of the instrument, if carefully inserted, will not produce pain.

If the gum be painful to the touch, or if the patient be nervous and sensitive, application of tincture iodine may be used, together with massage, for a few days before scaling is resorted to. The sensitiveness will soon disappear, when the instrument may be inserted without difficulty.

A few years hence, the profession will regard a dentist whose patients have pus oozing from the gums as a prehistoric relic and the patient as an individual whose filth provokes the contempt of his fellows. In this day of antiseptics, the dentist is as accountable for pus infection of his patients as the physician or surgeon.

There is no more excuse for the dentist's patient being infected than the surgeon's. If ordinary antiseptic precautions are taken, pus infection will not often occur. Prevent inflammation of the gum margin and pus infection cannot follow, no matter how many germs be in the mouth. This is an absolute law of general pathology. It has been proven by the experiments made by Miller, G. T. Carpenter and myself on dogs, rabbits and man.

The illustrations of the progress of interstitial gingivitis teach that only the mildest treatment is indicated. Harsh treatment on the inflamed bone or fibrous tissue, either with instruments or drugs, must not be employed. Heroic treatment, such as the

indiscriminate application of sulphuric and lactic acid and similar drugs in nearly or quite full strength, is not justified by the surgical principles of today. No surgeon would think of making such an application to inflamed bone in other parts of the body without he wished necrosis with a desired sequestrum. Much less would the intelligent operator use such treatment in a transitory structure which predisposed to destruction. In a number of instances exfoliation of the anterior plate of the alveolar process has resulted from this treatment, to say nothing of the intense pain produced. J. M. Whitney¹ has had four cases in his practice in which serious results followed. The first indication is to remove the cause. Instrumentation should be resorted to only to remove tartar and calcic deposits. This must be done in such a manner as not to infect the deeper inflamed tissue or carry the products of inflammation into healthy tissue. The treatment of infected tissue within and about the alveoli is not unlike treatment of abscesses and ulceration elsewhere. Such drugs as are used in abscesses and ulcers in other tissues are indicated here in the same strength. If strong drugs be used they should not be permitted to remain in the tissue, lest necrosis of the alveolar process occur. They must be diluted or removed altogether after they have accomplished their purpose. Very serious results have occurred from careless use of drugs. When abscesses have formed they should be opened and hydrogen peroxid — or, which has answered my purpose equally well, hot water (Cravens) — is all that is necessary. More difficult is treatment of ulceration of the tissue near the root of the tooth. Ordinary cases will heal after hot water or hydrogen peroxid have been applied. In some cases the pus germs have followed the inflammation along the course of the vessels quite a distance into the interstitial tissue. In such cases they are difficult to reach. A small syringe (George T. Carpenter's) may be employed, or the drug may be carried to the part on the end of a long, thin orange-wood stick. In all cases the drug must be directly applied to the part in order to have beneficial results. Applications of iodine should be used, as already suggested. Iodine carried to the ulcerated surface often suffices to destroy the pus secretion. Ordinarily one or two applications is sufficient. Occasionally calcic deposits are located

¹ International Dental Journal, April, 1899.

in front of the infected surface and the drug does not reach the part. In such cases the deposit must be removed. If the pus do not cease at the first, second or even third application, this is not because the drug is not sufficiently strong, but because it does not reach the infected part. Continued applications of iodine externally and internally, carried well up between the roots of the tooth and the alveolar process will, in time, produce the desired result. When pus ceases to flow, antiseptic treatment must stop. The iodine and massage treatment must then be pushed until the interstitial inflammation has been reduced and the gums contracted tightly about the necks of the teeth.

After the tissues have been placed in a healthy condition, they will require the constant attention of the operator, since, like other tissues of the body when once diseased, favorable conditions will cause a recurrence. The patient must return to the operator frequently so that he can advise as to the use of massage.

I have elsewhere shown that uric acid (like lactic and other acids, mercury, lead and brass poisoning) may produce local irritation in a small number of cases, resulting in interstitial gingivitis. Uric acid is absorbed into the blood and is thus carried to all parts of the body. As mercury, lead, brass and potassium iodide collect in the tissues of the alveolar process, on account of the sluggish blood supply, so does uric acid, setting up inflammation. These cases are easily diagnosed, since, unlike the ninety-four per cent of cases that begin at the gum margin without pain and are of long standing, these set up a spontaneous inflammation in an otherwise healthy alveolar process. This may occur about one tooth, or more may be involved; usually it involves the tooth or teeth standing alone or having improper or no articulation. The inflammation is followed by acute pain. If this be not reduced an abscess may, as elsewhere shown, form at some locality about the alveolar process. Inflammation will extend throughout the alveolar process and rapid absorption result. The tooth will loosen in the socket. If systemic treatment be not at once instituted, exfoliation of the tooth or teeth shortly ensues. The first thing indicated in such cases is an application of iodine to reduce inflammation and pain. The urine for twenty-four hours should be secured for chemical analysis.

The materials and appliances necessary for the purpose of

making an examination of the urine for uric acid are many and the method requires considerable time. The dentist can do the work, but it will be much more satisfactory (if he must know the quantity eliminated each day) to send it to a competent chemist. Should he desire to make the urine analysis, I should recommend the method suggested by Bartley¹ in which he says, "The estimation of uric acid is usually attended with much difficulty and consumption of time. The author has devised the following volumetric method, which is fairly rapid, reasonably accurate and requires little skill. It can therefore claim a place as a clinical method. The process is based upon the well-known fact that uric acid is completely precipitated from its solutions containing an excess of ammonium-magnesium mixture and ammonium hydroxide, by silver nitrate. When the precipitation is complete, the slightest trace of silver in solution is shown by the dark color produced in a drop of the clear solution by a soluble sulphide." The method of procedure is thus explained, should the uric acid excreted in twenty-four hours be less than .8 grams or 10.8 grains it is safe to say that it is retained in the system.

Imperfect tissue metabolism, as V. A. Gudex,² of Milwaukee, has shown, results in the formation of the following acids and substances: uric, hippuric, oxaluric, carbonic, lactic and lactates, caprylic, caproic, valerianic, butyric, propionic, acetic, stearic, oleic, palmitic, formic, cholalic, tuarilic, damaluric, damalic, and succinic acids. Of these, the uric acid seems to act least as an irritant. The urine, therefore, should be examined for general acidity, the general treatment of which will accomplish all that is to be desired. A safe and delicate test can be accomplished by determining the alkalinity of the urine, saliva, perspiration, expectoration and dejection. The dentist is fortunate in this because he has every convenience at hand. Liebreich's methods of the use of plaster of paris plates as elaborated by A. H. Hoy,³ of Chicago, is most admirably adapted for this purpose, since the test can be readily applied. To make the plates, mix a very thin quantity of dental plaster to the con-

¹ Medical Chemistry, page 641; fifth edition.

² Items of Interest, May, 1890.

³ Eating and Drinking.

sistency of cream, care being taken to thoroughly incorporate the plaster. Take two panes of window glass, cut four pieces of wood three-sixteenths of an inch in thickness and place one at each corner of the glass; now pour the plaster into the center, place the other plate of glass above and press it down upon the blocks of wood. By this method a very smooth surface can be obtained. Make a round cutter out of tin, the size of a twenty-five cent piece. Remove the upper piece by sliding it off, cut out round disks just before the plaster hardens. These are prepared in the following manner: A solution of litmus in 12 parts of water is rendered alkaline or bright blue by adding a few drops of aqua ammonia. After the disks have become perfectly hard, the smooth polished surface is to be painted with the solution, using a camel's-hair brush. Two or three applications are to be made, until an even blue stain is obtained. Have a solution of chemically pure sulphuric acid, two parts in five hundred of distilled water, ready in a bottle, and a bottle of distilled water. To prepare the disk for the test, scrape one-half of the dark blue surface of the plate until a slight blue surface is obtained. This requires the removal of only a slight amount, since the blue stain only penetrates a short distance. With a small brush, dipped into the acid, draw it quickly over the surface exposed, giving a red appearance to the field adjoining the blue.¹ A bit of cotton, wound around the end of a toothpick wet with distilled water and applied to the two colors, will produce no change, thus proving everything to be in working order. The fluid to be tested — urine, saliva or perspiration — may now be applied. When possible, the exudate must be applied to the test as soon as it leaves the body, care being taken to apply a fixed amount each time. Apply the fluid to be examined to both the blue and red fields. When saliva is used, the mouth must be rinsed two or three times and the quantity first sucked out of the ducts must not be used. Fresh saliva direct from the glands should only be used. The plates, after they have been used, may be re-stained and used indefinitely. The dentist should make repeated tests of the secretions of healthy individuals under different conditions

¹ It is almost impossible to obtain a satisfactory permanent red litmus. By this method the red and blue fields stand out in bold contrast.

before studying those of diseased conditions. This method is a more delicate test than it is possible to make even with litmus paper. Litmus paper often fails to reveal reaction, which will be most obvious by this method.


The secretions of the body, if found to be acid, must be placed in an amphoteric condition as soon as possible. An amphoteric condition is a reaction of the urine, by which both the blue and the red litmus are affected. If the red becomes blue and the blue red it indicates that there is an amphoteric reaction. The salt giving the alkaline reaction is the trisodic phosphate; that giving the acid reaction is the monosodic phosphate. When a uniform color is produced it shows that the alkaline and acid salts are being properly excreted in proper amounts with no excess of free acid.

The normal urine specific gravity is 1018 to 1025. To determine the specific gravity the morning urine should be used. If about 1018 or lower and acid, it is due to fermentation in small intestines. In such cases avoid yeast bread, acid fruits, wines, vinegar and all acids. If specific gravity is 1025 or more and acid, avoid meats. From five to seven pints of pure water should be taken each day, to flush the blood and kidneys and thus cleanse the system. Certain patients, especially neurasthenics, nervous dyspeptics and many lithæmics, have a repulsion to pure water. The water can be adjusted to these idiosyncrasies by the employment of lithia or other effervescent tablets. The main object is to preserve in such cases the prominent idea of the water being medicated. Local treatment, as elsewhere described, should here be resorted to. Besides the use of water, dietetics in dentistry involve chiefly a conservative question.

Under most conditions of suboxidation and imperfect elimination, as elsewhere shown, the gums are forced to assume an excretory energy to which they are unequal. As a consequence a foundation is laid for interstitial gingivitis, which, in all of its types, may seriously threaten the integrity of the teeth. Nay, more, by furnishing a culture medium for pus microbes it may threaten the general health, not only through systemic infection, but also through its interference with proper gastro-intestinal digestion. Among the restrictions in diet which dental hygiene

demands is, first, a restriction in foods and water containing an excess of lime salts, which produce tartar. As excess of foods containing nitrogen, when aided by an imperfect assimilation of the carbohydrates, tend to produce constitutional conditions like lithæmia, gout, etc., which affect tissue nutrition of the gums, these foods require restriction and adaptation to the particular case. While the constitutional condition underlying lithæmia markedly predisposes to gum irritations and inflammations, its value as an exciting cause is but slight. Lactic acid, as has been elsewhere pointed out, is a more marked local excitant. In the constitutional production of lactic acid, ingestion of the carbohydrates without assimilation plays a part. Scurvy, which may seriously threaten the integrity of the gums, requires the usual dietetic treatment. While there are indications of the untoward effects of infantile scurvy on the gums, the pathology and consequences of it are not as well known as those of scurvy in the adult. The researches on scurvy in the infant tend to show that it results from a monotony of diet rather than the absence of any article of diet. The dietetics of dentistry, therefore, involve precisely the same principles as do the treatment of the constitutional conditions which are the predisposing factors of the gum disorders.

During the entire process of treatment (indeed before the treatment begins) a suitable mouth wash should be used two or three times a day. This should be composed of a germicide, antiseptic disinfectant and deodorant, and should be used at the time of the massage.




INDEX OF AUTHORS.

	PAGE		PAGE
Alexander, H. C. B.	145	Hirt	97
Allbright	3	Hogben	94
Andrews, R. R.	89	Howell	77
Arcovy	4	Hoy, A. H.	184
Barlow, Thomas	95	Ingersol, L. C.	4
Barrett	174	Izklaï, Joseph	4
Bartley	184	Jacobi	95
Black 5, 34, 41, 47, 48, 51, 53, 56,	98	Jacobson	75
Beodecker	174	Joirac	2
Bondurant	91	Jourdain	2
Bonwill	2, 157	Kaecker	2
Brown	2	Kaufmann 61, 154, 157, 158	158
Brubaker, A. B.	68	Kirk	12, 68
Buzzard	97	Koch	12, 151
Calve, Marshall de	2	Kölliker 30, 33, 56, 62, 161	161
Carpenter, G. T. 125, 165, 170,	181, 182	Kuttner	169
Cartright, Hamilton	4	Magitot 2, 7, 53, 55, 57, 58, 91	91
Clowes	3	Mailhol	11
Coles, Oakley	4	Malasses	4
Collins, J.	66	Malenfant	79
Congdon	68	Miller 8, 82, 89, 122, 123, 125, 181	181
Cravens	181, 182	Mills	3
Cruveilier, C.	92	Minot 42, 53, 56, 146	146
Dana, C. L.	97	Morgan, de	31
Dickinson, Howship	78	Niles, N. S.	3
Ebner, Von 56, 153, 158, 160	160	Noyes, Frederick	48
Eisenhart	159	Patterson 4, 6, 8, 89	89
Enderlin	76	Pedley	6, 7
Essig, C. J.	3	Pierce, C. N. 8, 12, 37, 68, 96	96
Evans, W. A.	123	Quain	10, 11
Farrar, F. N.	4	Rawls, A. O.	4, 95
Fitzgerald 9, 68, 167	167	Rechlinghausen, Von	159
Flower, Alsop	14	Reese	4
Foster	11	Reeves	68
Fuchard, H. A.	2	Rehwinkle	3
Galippe 4, 12, 122, 123, 124, 151	151	Rhein	68, 175
Geddings, H. D.	75	Riggs, J. T.	2, 180
Gray	37	Robin 53, 55, 57, 58, 91	91
Gudex, V. A.	184	Rokitansky	169
Hektoen, L.	127, 155	Rose	54
Hertwig, O.	56, 146	Salisbury, J. H. 69, 71, 79	79
Herzog, M.	124	Sayre, Charles E.	14
		Scheff	2

INDEX OF AUTHORS.

	PAGE		PAGE
Scheeotskey	78	Tomes	27, 31, 175
Schmidt, C.	73, 74, 76, 78	Volkman	31, 62, 63, 153, 160
Serres	47	Virchow	169, 170
Sirletti	3	Waldeyer	56
Starr, A. R.	5	Walker	4
Stevenson	78	Wesener, J. A.	69, 70
Sudduth, W. X.	5, 6, 7, 8, 161	Whitney, J. M.	182
Sutton, Bland	7	Zawadsky	76
Talbot, E. S.	5, 47	Ziegler	28, 158



INDEX OF SUBJECTS.

	PAGE		PAGE
Acadians, Teeth of	1	Embryology of the Tooth	46
Alveolar Process	21	Endarteritis Obliterans	154
Absorption of	147	and Tuberculosis	155
Absorption	157	Exanthemata and Catarrhal Gingi-	
Absorption and Trophic		vitis	7
Change	162	Follicle, The Dental	55
Changes	149	Gingivitis	5
Dermal Bones	96	Expulsive	11
Germ Infection	96	Interstitial	9
Hypertrophy of	29	and Pyorrhœa	9
Antimony	144	Glands of Mucous and Peridental	
Arsenic	144	Membranes	47
Bone Absorption	59	Greeks, Teeth of	1
Bone Building	59	Gums	42
Brass	144	Halisteresis	61, 62, 153, 158
Interstitial Gingivitis	94	Haversian Canals	30
Bromides	145	Heredity	13
Calcic Deposits	168	Interstitial Gingivitis	10, 12
Calcospherites	41, 133	Antimony	144
Calculi, Salivary	78	Arsenic	144
Carnivora, Interstitial Gingivitis in	14	Atavism and	83
Catarrhal Idiosyncrasy	5	Auto-Intoxication and	66
Cave Dwellers, Teeth of	1	Bacteriology of	122
Cementoblasts	42	Brass	144
Cementoclasts	61	Bromide	145
Children, Degenerate	89	Carnivora in	14
Diathetic	89	Causes	12
Interstitial Gingivitis in	81	Degeneracy and	86
Neurotic	89	Dogs	98
Pyorrhœa in	89	Environment and	84
Débris, Epithelial	55	Heredity and	83
Dental Operations and Alveolar Pro-		Heredity in	13
cess	150	Inorganic Salts and	73
and Bone Absorption	150	Iodide	145
Dental Shelf	55, 56	Lactic Acid and	152
Degeneracy and Degenerate Tissues	87	Mercuric	142
Dentitions, The Three	84	In Dogs	117
Dogs, Interstitial Gingivitis in	14, 98	Nerve Phases of	13
Mercuric Interstitial Gingi-		Pathogeny of	151
vitis in	117	Plumbic	143
Pyorrhœa Alveolaris in	98	Pyorrhœa Alveolaris and	162
Ebner, Von, Vessels of	31	Scorbutic in Man	127
Egyptians, Teeth of	1	Scurvy and	13, 65, 94

	PAGE		PAGE
Interstitial Gingivitis —		Potassium Iodid and Interstitial	
Tartar and	148	Gingivitis	94
Theories of	65	Pregnancy and Osteomalacia	159
Toxic Causes of	13, 92	Primitive Races, Teeth of	1
Treatment	172	Pyorrhœa Alveolaris, Bacteriology of	162
Tropho-Neuroses and	66, 92	Catarrhal Idiosyncrasy	5
Uric Acid and	68	Causes of	2
Iodides	145	Constitutional Causes	3, 4, 5
Jaw, Evolution of	149	Constitutional Effects of	167
Evolutionary Changes in	20	Degeneracy and	5
Racial Changes in	20	Dogs	98
Lake Dwellers, Teeth of	1	Eruptive Fevers	7
Lactic Acid and Interstitial Gingivitis	152	History	2
Lacunar Absorption	62, 153	Intestinal Disorders from	167
Lead	143	Lactic Acid	8
Interstitial Gingivitis and	94	Nervous Causes	3
Locomotor Ataxia and Gum Disorder	13	Parasites and	8
Mercury	142	Pathology of	6, 7
Interstitial Gingivitis and	93	Syphilis and	8
Mouth Breathing and Catarrhal Gingivitis	7	Systemic Disease and	8
Mucous Membrane, Glands of	47	Uric Acid and	8
Histology of	42	Scurvy	96, 127
Mucus, Bactericidal Function of	88	Sodium Chloride and Interstitial	
Odontoblasts	42	Gingivitis	95
Osteoblasts	42	Stomatitis Catarrhalis	6
Osteoclasts	61	Teeth, Changes in	146
Osteomalacia	62, 146, 159	Changes in Position of	28
Papillary Layer, Comparative Anatomy	47	Decay of	147
Paretic Dementia and Gum Disorder	13	Embryology of	146
Perforating Canal Absorption	62, 153	Irregularities of	148
Pericementitis Phagadenica	5	Periods of Evolution	146
Peridental Membrane	33	Periods of Involution	146
Glands of	47	Trophic Disorders of	96
Inflammation	1	Third Molar	149
Periosteum	33	Disappearance of	21
Periostitis Alveo-Dentalis	2	Tooth Embryology	42, 53
Dentalis	2	Form Changes	149
Pockets and Interstitial Gingivitis	152	Transitory Structures	20, 147
		Tropho-Neuroses	13, 96
		Ulitis	11
		Uric Acid and Pyorrhœa Alveolaris	3, 8
		Volkman's Canals	31

JK

UNIVERSITY OF CALIFORNIA LIBRARY

Los Angeles

This book is DUE on the last date stamped below.

BIOMED LIB. AUG 10 '75

AUG 3 REC'D

OCT 8 1977

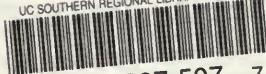BIOMED. OCT 22 '77

BIOMED LIB. NOV 7 1977
NOV 17 REC'D



3 1158 00260 0947

UC SOUTHERN REGIONAL LIBRARY FACILITY



A 000 387 507 7

U