



THE LIBRARY
OF
THE UNIVERSITY
OF CALIFORNIA

PRESENTED BY
PROF. CHARLES A. KOFOID AND
MRS. PRUDENCE W. KOFOID

Memorial Edition

THE WORKS

OF

FRANCIS MAITLAND BALFOUR

VOL. IV.

PLATES.

London :
MACMILLAN AND CO.
1885

THE WORKS
OF
FRANCIS MAITLAND BALFOUR.

VOL. IV.

Memorial Edition.

THE WORKS

Cambridge:

PRINTED BY C. J. CLAY, M.A. AND SON,
AT THE UNIVERSITY PRESS.

VOL. IV.

Historical Grammar

Memorial Edition.

THE WORKS

OF

FRANCIS MAITLAND BALFOUR,

M.A., LL.D., F.R.S.,

FELLOW OF TRINITY COLLEGE,

AND PROFESSOR OF ANIMAL MORPHOLOGY IN THE UNIVERSITY OF
CAMBRIDGE.

EDITED BY

M. FOSTER, F.R.S.,

PROFESSOR OF PHYSIOLOGY IN THE UNIVERSITY OF CAMBRIDGE;

AND

ADAM SEDGWICK, M.A.,

FELLOW AND LECTURER OF TRINITY COLLEGE, CAMBRIDGE.

VOL. IV.

PLATES.

London :

MACMILLAN AND CO.

1885

Memorial Edition.

THE WORKS

OF

FRANCIS MAITLAND BALFOUR,

M.A., LL.D., F.R.S.

FELLOW OF TRINITY COLLEGE,

AND PROFESSOR OF ANIMAL MORPHOLOGY IN THE UNIVERSITY OF
CAMBRIDGE.

EDITED BY

[The Right of Translation is reserved.]

M. FOSTER, F.R.S.

PROFESSOR OF PHYSIOLOGY IN THE UNIVERSITY OF CAMBRIDGE;

AND

ADAM SEDGWICK, M.A.

FELLOW AND TUTOR OF TRINITY COLLEGE, CAMBRIDGE.

VOL. IV.

PLATES

London:

MACMILLAN AND CO.

1882

K-QL955

B18

v. 4

Biology
Library

LIST OF PLATES, ILLUSTRATING THE ORIGINAL
MEMOIRS IN VOL. I.

	PAGE
Plate 1. Development of the layers of the blastoderm . . .	29
" Disappearance of primitive groove	41
" 2. Development of blood-vessels	47
" 3. Preliminary account of development of Elasmobranch	
" 4. Fishes	60
" 5. Comparison of early stages of Vertebrates	112
" 6. Development of Elasmobranch Fishes. ch. II.	222
" 7. " " " " III.	246
" 8. " " " " IV.	286
" 9. " " " " V.	298
" 10. " " " " VI.	315
" 11. " " " " VII.	361
" 12. " " " " VIII.	378
" 13. " " " " IX.	397
" 14. " " " " X.	446
" 15. " " " " XI.	460
" 16. " " " " XII.	479
" 17. " " " " XII.	479
" 18. " " " " XII.	479
" 19. " " " " XII.	479
" 20. " " " " XII.	479
" 21. " " " " XII.	479
" 22. } Development of spinal nerves in Elasmobranchs	168
" 23. }	
" 24. }	
" 25. } Structure and development of Vertebrate ovary	549
" 26. }	
" 27. } Head-kidney in embryo Chick	618
" 28. }	
" 29. Early development of Lacertilia	644
" 30. }	
" 31. } Development of Araneina	668
" 32. }	
B. IV.	b

M345581

	PAGE
Plate 33. Development of paired fins of Elasmobranchii . . .	714
" 34. }	
" 35. }	
" 36. }	
" 37. }	
" 38. } Structure and development of Lepidosteus	738
" 39. }	
" 40. }	
" 41. }	
" 42. }	
" 43. }	
" 44. } Germinal layers of the Chick	854
" 45. }	
" 46. }	
" 47. }	
" 48. }	
" 49. } Anatomy and development of Peripatus Capensis	871
" 50. }	
" 51. }	
" 52. }	
" 53. }	
" 54. }	
" 55. }	
" 56. }	
" 57. }	
" 58. }	
" 59. }	
" 60. }	
" 61. }	
" 62. }	
" 63. }	
" 64. }	
" 65. }	
" 66. }	
" 67. }	
" 68. }	
" 69. }	
" 70. }	
" 71. }	
" 72. }	
" 73. }	
" 74. }	
" 75. }	
" 76. }	
" 77. }	
" 78. }	
" 79. }	
" 80. }	
" 81. }	
" 82. }	
" 83. }	
" 84. }	
" 85. }	
" 86. }	
" 87. }	
" 88. }	
" 89. }	
" 90. }	
" 91. }	
" 92. }	
" 93. }	
" 94. }	
" 95. }	
" 96. }	
" 97. }	
" 98. }	
" 99. }	
" 100. }	

EXPLANATION OF PLATES.

EXPLANATION OF PLATE 1. Figs. 1—5 and 9—12. (II. p. 29.)

Fig. 1. Section through an unincubated blastoderm, shewing the upper layer, composed of a single row of columnar cells, and the lower layer, composed of several rows of rounded cells in which no nucleus is visible. Some of the "formative cells," at the bottom of the segmentation cavity, are seen at (*b*).

Fig. 2. Section through the periphery of an eight hours' blastoderm, shewing the epiblast (*p*), the hypoblast (*h*), and the mesoblast commencing to be formed (*c*), partly by lower-layer cells enclosed between the epiblast and hypoblast, and partly by formative cells. Formative cells at the bottom of the segmentation cavity are seen at *b*. At *s* is one of the side folds parallel to the primitive groove.

Fig. 3. Portion of the hypoblast of a thirteen hours' blastoderm, treated with silver nitrate, shewing the great variation in the size of the cells at this period. An hour-glass shaped nucleus is seen at *a*.

Fig. 4. Periphery of a twenty-three hours' blastoderm, shewing cell for cell the junction between the hypoblast (*h*) and white-yolk spheres (*w*).

Fig. 5. Junction between the white-yolk spheres and the hypoblast cells at the passage from the area pellucida to the area opaca. The specimen was treated with silver nitrate to bring out the shape of the cells. The line of junction between the opaque and pellucid areas passes diagonally.

Fig. 9. Section through the primitive streak of an eight hours' blastoderm. The specimen shews the mesoblast very much thickened in the immediate neighbourhood of the primitive streak, but hardly formed at all on each side of the streak. It also shews the primitive groove just beginning to be formed (*pr*), and the fusion between the epiblast and the mesoblast under the primitive groove. The hypoblast is completely formed in the central part of the blastoderm. At *f* is seen one of the side folds parallel to the primitive groove. Its depth has been increased by the action of the chromic acid.

Fig. 10. Hypoblast cells from the hinder end of a thirty-six hours' embryo, treated with silver nitrate, shewing the regularity and elongated shape of the cells over the embryo and the smaller cells on each side.

Fig. 11. Epiblast cells from an unincubated blastoderm, treated with silver nitrate, shewing the regular hexagonal shape of the cells and the small spherules they contain.

Fig. 12. Portion of the epiblast of a thirty-six hours' embryo, treated with silver nitrate, shewing the small rounded cells frequently found at the meeting-points of several larger cells which are characteristic of the upper layer.

EXPLANATION OF PLATE I. Figs. 6—8 and 13—19. (III. p. 41.)

Figs. 6 and 7 are sections through an embryo rather earlier than the one drawn in fig. 8. Fig. 6 passes through the just commencing medullary groove (*md*), which appears in fresh specimens, as in fig. 8, merely as an opaque streak coming from the end of the primitive groove. The notochord is hardly differentiated, but the complete separation of mesoblast and hypoblast under the primitive groove is clearly shewn. Fig. 7 passes through the anterior end of the primitive groove (*pr*), and shews the fusion between the mesoblast and epiblast, which is always to be found under the primitive groove.

Fig. 8 is a view from above of a twenty hours' blastoderm, seen as a transparent object. Primitive groove (*pr*). Medullary groove (*md*), which passes off from the anterior end of the primitive groove, and is produced by the thickening of the mesoblast. Head-fold (*pf*).

Figs. 13—17 are sections through the blastoderm, drawn in fig. 18 through the lines 1, 2, 3, 4, 5 respectively.

The first section (fig. 13) passes through the true medullary groove (*mc*); the two medullary folds (*A, A*) are seen on each side with the thickened mesoblast, and the mesoblast cells are beginning to form the notochord (*nc*) under the medullary groove. There is no adherence between the mesoblast cells and the epiblast under the medullary groove.

The second (fig. 14) section passes through the medullary groove where it has become wider. Medullary folds, *A, A*; notochord, *ch*.

In the third section (fig. 15) the notochord (*ch*) is broader, and the epiblast is raised in the centre, while the medullary folds are seen far apart at *A*.

In section fig. 16 the medullary folds (*A*) are still to be seen enclosing the anterior end of the primitive groove (*pr*). Where the primitive groove appears there is a fusion of the epiblast and mesoblast, and no appearance of the notochord.

In the last section, fig. 17, no trace is to be seen of the medullary folds.

Figs. 18 and 19 are magnified views of two hardened blastoderms. Fig. 18 is twenty-three hours old; fig. 19 twenty-five hours. They both shew how the medullary canal arises entirely independently of the primitive groove and in front of it, and also how the primitive groove gets pushed backwards by the growth of the medullary groove. *pv*, Proto-vertebræ; other references as above. Fig. 18 is the blastoderm from which sections figs. 13—17 were cut.

EXPLANATION OF PLATE 2. (IV. p. 47.)

Fig. 1 is taken from the anterior part of the pellucid area of a thirty hours' chick, with four proto-vertebræ. At *n* is a nucleus with two nucleoli.

Figs. 2 and 3 are taken from the posterior end of the pellucid area of a chick with eight protò-vertebræ. In fig. 3 the nuclei are seen to have considerably increased in number at the points of starting of the protoplasmic processes. At *n* is seen a nucleus with two nucleoli.

Fig. 4 is taken from the anterior part of the pellucid area of an embryo of thirty-six hours. It shews the narrow processes characteristic of the anterior part of the pellucid area, and the fewer nuclei. Small spaces, which have the appearance of vacuoles, are shewn at *v*.

Fig. 5 is taken from the posterior part of the pellucid area of a thirty-six hours' embryo. It shews the nuclei, with somewhat irregular nucleoli, which have begun to acquire the red colour of blood-corpuscles; the protoplasmic processes containing the nuclei; the nuclei in the protoplasm surrounding the corpuscles, as shewn at *a*, *a'*.

Fig. 6 shews fully formed blood-vessels, in part filled with blood-corpuscles and in part empty. The walls of the capillaries, formed of cells, spindle-shaped in section, are shewn, and also the secondary investment of Klein at *k*, and at *b* is seen a narrow protoplasmic process filled with blood-corpuscles.

Fig. 7 is taken from the anterior part of the pellucid area of a thirty-six hours' embryo. It shews a collection of nuclei which are beginning to become blood-corpuscles.

Figs. 1—5 are drawn with an $\frac{1}{3}$ object-glass. Fig. 6 is on a much smaller scale. Fig. 7 is intermediate.

Fig. 8. A transverse section through the dorsal region of a forty-five hours' embryo; *ao*. aorta with a few blood-corpuscles. *v*. Blood-vessels, all of them being formed in the splanchnopleure, and all of them provided with the secondary investment of Klein; *p*. pellucid area; *op*. opaque area.

Fig. 9. Small portion of a section through the opaque area of a thirty-five hours' embryo, shewing protoplasmic processes, with nuclei passing from the somatopleure to the splanchnopleure.

Fig. 10. Section through the heart of a thirty-four hours' embryo. *a*. Alimentary canal; *hb*. hind brain; *nc*. notochord; *e*. epiblast; *so*. mesoblast of the somatopleure; *sp*. mesoblast of the splanchnopleure; *hy*. hypoblast; *hz*. cavity of the heart.

Fig. 11. Section through the same embryo as fig. 10, and passing through the orifice of the omphalo-meseraic vein. *of*. Omphalo-meseraic vein; other references as above.

These two sections shew that the heart is entirely formed from the mesoblast of the *splanchnopleure*, and that it is formed by the splitting of that part of the mesoblast which has turned to assume its normal direction after being folded in to form the muscular wall of the alimentary canal. In fig. 11 the cavities so formed on each side have not yet united, but in fig. 10 they have united. When the folding becomes more complete the cavities (*of, of*) in fig. 11 will unite, and in this way the origin of the omphalo-meseraic veins will be carried further backwards. In the section immediately behind section 11 the mesoblast had become thickened, but had not split.

EXPLANATION OF PLATES 3 AND 4. (V. p. 65.)

COMPLETE LIST OF REFERENCE LETTERS.

a l. Alimentary canal. *a o.* Dorsal aorta. *au v.* Auditory vesicle. *b d.* Formative cell probably derived from the yolk. *ca v.* Cardinal vein. *ch.* Notochord. *ch'.* Thickening of hypoblast to form the notochord. *eb.* Line indicating the edge of the blastoderm. *ep.* Epiblast. *ep'.* Epidermis. *er.* Embryonic rim. *es.* Embryonic swelling. *gl.* Glosso-pharyngeal nerve. *h.* Head. *ht.* Heart. *hy.* Hypoblast. *ll.* Lower layer cells. *ly.* Line of separation between the blastoderm and the yolk. *m.* Mesoblast. *mc.* Medullary canal. *mg.* Medullary groove. *mp.* Muscle-plate. *mp'.* Early formed mass of muscles. *n.* Peculiar nuclei formed in the yolk. *n'.* Similar nuclei in the cells of the blastoderm. *na.* Cells which help to close in the alimentary canal, and which are derived from the yolk. *ny.* Network of lines present in the food-yolk. *ol.* Olfactory pit. *op.* Eye. *ov.* Oviduct. *pn.* Pineal gland. *pov.* Projection which becomes the ovary. *pp.* Pleuro-peritoneal cavity. *pp'.* Remains of pleuro-peritoneal cavity in the head. *prv.* Protovertebræ. *pwd.* Primary points of involution from the pleuro-peritoneal cavity by the coalescence of which the Wolffian duct is formed. *sg.* Segmentation cavity. *so.* Somatopleure. *so s.* Stalk connecting embryo with yolk-sac. *sp.* Splanchnopleure. *sp n.* Spinal nerve. *sur.* Supra-renal body. *ts.* Caudal lobes. *v.* Blood-vessel. *vg.* Vagus nerve. *v.* Fifth nerve. *vii.* Seventh nerve. *vc, 1, 2, 3, &c.* 1st, 2nd and 3rd &c. visceral clefts. *vp.* Vertebral plates. *w d.* Wolffian duct. *x.* Peculiar body underlying the notochord derived from the hypoblast. *yk.* Yolk spherules.

All the figures were drawn with the Camera Lucida.

PLATE 3.

Fig. 1. Section parallel with the long axis of the embryo through a blastoderm, in which the floor of the segmentation cavity (*sg*) is not yet completely lined by cells. The roof of the segmentation cavity is broken. (Magnified 60 diam.) The section is intended chiefly to illustrate the distribution of nuclei (*n*) in the yolk under the blastoderm. One of the chief points to be noticed in their distribution is the fact that they form almost a complete layer under the floor of the segmentation cavity. This probably indicates that the cells whose nuclei they become take some share in forming the layer of cells which subsequently (vide fig. 4) forms the floor of the cavity.

Fig. 2. Small portion of blastoderm and subjacent yolk of an embryo at the time of the first appearance of the medullary groove. (Magnified 300 diam.)

The specimen is taken from a portion of the blastoderm which will form part of the embryo. It shews two large nuclei of the yolk (*n*) and the network in the yolk between them; this network is seen to be closer around the nuclei than in the intervening space. The specimen further shews that there are no areas representing cells around the nuclei.

Fig. 3. Section parallel with the long axis of the embryo through a blastoderm, in which the floor of the segmentation cavity is not yet covered by a complete layer of cells. (Magnified 60 diam.)

It illustrates (1) the characters of the epiblast, (2) the embryonic swelling (*es*), (3) the segmentation cavity (*sg*). It should have been drawn upon the same scale as fig. 4; the line above it represents its true length upon this scale.

Fig. 4. Longitudinal section through a blastoderm at the time of the first appearance of the embryonic rim, and before the formation of the medullary groove. (Magnified 45 diam.)

It illustrates (1) the embryonic rim, (2) the continuity of epiblast and hypoblast at edge of this, (3) the continual differentiation of the lower layer cells, to form, on the one hand, the hypoblast, which is continuous with the epiblast, and on the other the mesoblast, between this and the epiblast; (4) the segmentation cavity, whose floor of cells is now completed.

N.B. The cells at the embryonic end of the blastoderm have been made rather too large.

Fig. 5. Surface view of the blastoderm shortly after the appearance of the medullary groove. To shew the relation of the embryo to the blastoderm.

Fig. 6 *a* and *b*. Two transverse sections of the same embryo, shortly after the appearance of the medullary groove. (Magnified 96 diam.)

a. In the region of the groove. It shews (1) the two masses of mesoblast on each side, and the deficiency of the mesoblast underneath the medullary groove; (2) the commencement of the closing in of the alimentary canal below, chiefly from cells (*na*) derived from the yolk.

b. Section in the region of the head where the medullary groove is deficient, other points as above.

Fig. 7 *a* and *b*. Two transverse sections of an embryo about the age or rather younger than that represented in fig. 5. (Magnified 96 diam.)

a. Section nearer the tail; it shews the thickening of the hypoblast to form the notochord (*ch'*).

In *b* the thickening has become completely separated from the hypoblast as the notochord. In *a* the epiblast and hypoblast are continuous at the edge of the section, owing to the section passing through the embryonic rim.

Fig. 8. Surface view of a spatula-shaped embryo. The figure shews (1) the flattened head (*h*) where the medullary groove is deficient, (2) the caudal lobes, with a groove between them; it also shews that at this point, the medullary groove has become roofed over and converted into a canal.

Fig. 8 *a*. Transverse section of fig. 8, passing through the line *a*. (Magnified 90 diam.) The section shews (1) the absence of the medullary groove in the head and the medullary folds turning down at this time instead of upwards; (2) the presence of the pleuro-peritoneal cavity in the head (*pp*); (3) the completely closed alimentary canal (*al*).

Fig. 8 *b*. Transverse section of fig. 8, through the line *b*. (Magnified 90 diam.) It shews (1) the neural canal completely formed; (2) the vertebral plates of mesoblast not yet split up into somatopleure and splanchnopleure.

Fig. 9. Side view of an embryo of the Torpedo, seen as a transparent object a little older than the embryo represented in fig. 8. (Magnified 20 diam.) The internal anatomy has hardly altered, with the exception of the medullary folds having closed over above the head and the whole embryo having become more folded off from the germ.

The two caudal lobes, and the very marked groove between them, are seen at *t s*. The front end of the notochord became indistinct, and I could not see its exact termination. The epithelium of the alimentary canal (*a l*) is seen closely underlying the notochord and becoming continuous with the epiblast at the hind end of the notochord.

The first visceral cleft (*i v c*) and eye (*o p*) are just commencing to be formed, and the cranial flexure has just appeared.

Fig. 10. Section through the dorsal region of an embryo somewhat older than the one represented in fig. 9. (Magnified 96 diam.)

It shews (1) the formation by a pinching off from the top of the alimentary canal of a peculiar body which underlies the notochord (*x*); (2) the primitive extension of the pleuro-peritoneal cavity up to the top of the vertebral plates.

PLATE 4.

Fig. 11 *a, b, and c*. Three sections closely following each other from an embryo in which three visceral clefts are present; *a* is the most anterior of the three. (Magnified 96 diam.) In all of these the muscle-plates are shewn at *m p*. They have become separated from the lateral plates in *b* and *c*, but are still continuous with them in *a*. The early formed mass of muscles is also shewn in all the figures (*m p'*).

The figures further shew (1) the formation of the spinal nerves (*sp n*) as small bodies of cells closely applied to the upper and outer edge of the neural canal.

(2) The commencing formation of the cells which form the axial skeleton from the inner (splanchnopleuric) layer of the muscle-plate. Sections *b* and *c* are given more especially to shew the mode of formation of the oviduct (*ov*).

In *b* it is seen as a *solid knob* (*ov*), arising from the point where the somatopleure and splanchnopleure unite, and in *c* (the section behind *b*) as a *solid rod* (*ov*) closely applied to the epiblast, which has grown backwards from the knob seen in *b*.

N.B. In all three sections only one side is completed.

Fig. 12 *a and b*. Two transverse sections of an embryo just before the appearance of the external gills. (Magnified 96 diam.)

In *a* there is seen to be an involution on each side (*p w d*), while *b* is a section from the space between two involutions from the pleuro-peritoneal cavity, so that the Wolffian duct (at first solid) (*w d*) is not connected as in *a* with the pleuro-peritoneal cavity. The further points shewn in the sections are—

- (1) The commencing formation of the spiral valve (*a l*).
- (2) The supra-renal body (*su r*).
- (3) The oviduct (*ov*), which has acquired a lumen.
- (4) The increase in length of the muscle-plates, the spinal nerves, &c.

Fig. 13. Section through the dorsal region of an embryo in which the external gills are of considerable length. (Magnified 40 diam.) The chief points to be noticed:

- (1) The formation of the Wolffian body by outgrowths from the Wolffian duct (*w d*).
- (2) One of the still continuing connections (primitive involutions) between the Wolffian duct and the pleuro-peritoneal cavity (*p w d*).
- (3) The oviduct largely increased in size (*ov*).

N.B. On the left side the oviduct has been accidentally made too small.

(4) The growth downwards of the muscle-plate to form the muscles of the abdomen.

(5) The formation of an outgrowth on each side of the mesentery (*p ov*), which will become the ovary.

(6) The spiral valve (*a l*).

Fig. 14. Transparent view of the head of an embryo shortly before the appearance of the external gills. (Magnified 20 diam.) The chief points to be noticed are—

(1) The relation of the cranial nerves to the visceral clefts and the manner in which the glosso-pharyngeal (*g l*) and vagus (*v g*) are united.

(2) The remnants of the pleuro-peritoneal cavity in the head (*p p*).

(3) The eye (*ep*). The stalk, as well as the bulb of the eye, are supposed to be in focus, so that the whole eye has a somewhat peculiar appearance.

EXPLANATION OF PLATE 5. (VI. p. 112.)

COMPLETE LIST OF REFERENCE LETTERS.

al. Cavity of alimentary canal. *bl.* Blastoderm. *ch.* Notochord. *em.* Embryo. *ep.* Epiblast. *f.* Formative cells. *hy.* Hypoblast. *ll.* Lower layer cells. *m.* Mesoblast. *n.* Nuclei of yolk of Selachian egg. *nc.* Neural canal. *sg.* Segmentation cavity. *x.* Point where epiblast and hypoblast are continuous at the mouth of the alimentary involution. This point is always situated at the tail end of the embryo. *yk.* Yolk.

Epiblast is coloured blue, mesoblast red, and hypoblast yellow. The lower layer cells before their separation into hypoblast and mesoblast are also coloured green.

A I, A II, A III. Diagrammatic sections of Amphioxus in its early stages (founded upon Kowalevsky's observations).

B I, B II, B III. Diagrammatic longitudinal sections of an hypothetical animal, intermediate between Amphioxus and Batrachians, in its early stages.

C I, C II, C III. Diagrammatic longitudinal sections of *Bombinator igneus* in its early stages (founded upon Götte's observations). In C III the neural canal is completed, which was not the case in B III. The epiblast in C III has been diagrammatically represented as a single layer.

D I, D II, D III. Diagrammatic longitudinal sections of an animal, intermediate between Batrachians and Selachians, in its early stages.

E I, E II, E III. Diagrammatic longitudinal sections of a Selachian in its early stages.

E'. Surface view of the yolk of a Selachian's egg to shew the manner in which it is enclosed by the blastoderm. The yolk is represented yellow and the blastoderm blue.

F I, F II, F III. Diagrammatic longitudinal sections of a Bird in its early stages.

B. IV.

c

EXPLANATION OF PLATE 6. (X. p. 222.)

Fig. 1. Section through the germinal disc of a ripe ovarian ovum of the Skate. *gv.* germinal vesicle.

Fig. 2. Surface-view of a germinal disc with two furrows.

Figs. 3, 4, 5. Surface-views of three germinal discs in different stages of segmentation.

Fig. 6. Section through the germinal disc represented in fig 3. *n.* nucleus; *x.* edge of germinal disc. The engraver has not accurately copied my original drawings in respect to the structure of the segmentation furrows.

Figs. 6*a* and 6*b*. Two furrows of the same germinal disc more highly magnified.

Fig. 6*c*. A nucleus from the same germinal disc highly magnified.

Fig. 7. Section through a germinal disc of the same age as that represented in fig. 4. *n.* nucleus; *nx.* modified nucleus; *nx'.* modified nucleus of the yolk; *f.* furrow appearing in the yolk around the germinal disc.

Figs. 7*a*, 7*b*, 7*c*. Three segments with modified nuclei from the same germinal disc.

Fig. 8. Section through a somewhat older germinal disc. *ep.* epiblast; *n'.* nuclei of yolk.

Figs. 8*a*, 8*b*, 8*c*. Modified nuclei from the yolk from the same germinal disc.

Fig. 8*d*. Segment in the act of division from the same germinal disc.

Fig. 9. Section through a germinal disc in which the segmentation is completed. It shows the larger collection of cells at the embryonic end of the germinal disc than at the non-embryonic. *ep.* epiblast.

EXPLANATION OF PLATE 7. (X. p. 246.)

COMPLETE LIST OF REFERENCE LETTERS.

a. Cells formed in the yolk around the nuclei of the yolk. *ep.* Epiblast. *er.* Embryonic ring. *es.* Embryo swelling. *hy.* Hypoblast. *ll.* Lower layer cells. *ly.* Line separating the yolk from the blastoderm. *m.* Mesoblast. *mg.* Medullary groove. *n'.* Nuclei of yolk. *na.* Cells to form ventral wall of alimentary canal which have been derived from the yolk. *nal.* Cells formed around the nuclei of the yolk which have entered the hypoblast. *sc.* Segmentation cavity. *vp.* Combined lateral and vertebral plate of mesoblast.

Fig. 1. Longitudinal section of a blastoderm at the first appearance of the segmentation cavity.

Fig. 2. Longitudinal section through a blastoderm after the layer of cells has disappeared from the floor of the segmentation cavity. *bd.* Large cell resting on the yolk, probably remaining over from the later periods of segmentation. Magnified 60 diameters. (Hardened in chromic acid.)

The section is intended to illustrate the fact that the nuclei form a layer in the yolk under the floor of the segmentation cavity. The roof of the segmentation cavity is broken.

Fig. 2 *a*. Portion of same blastoderm highly magnified, to shew the characters of the nuclei of the yolk *n'* and the nuclei in the cells of the blastoderm.

Fig. 2 *b*. Large knobbed nucleus from the same blastoderm, very highly magnified.

Fig. 2 *c*. Nucleus of yolk from the same blastoderm.

Fig. 3. Longitudinal section of blastoderm of same stage as fig. 2. (Hardened in chromic acid.)

Fig. 4. Longitudinal section of blastoderm slightly older than fig. 2. Magnified 45 diameters. (Hardened in osmic acid.)

It illustrates (1) the characters of the epiblast; (2) the embryonic swelling; (3) the segmentation cavity.

Fig. 5. Longitudinal section through a blastoderm at the time of the first appearance of the embryonic rim, and before the formation of the medullary groove. Magnified 45 diameters.

Fig. 5 *a*. Section through the periphery of the embryonic rim of the blastoderm of which fig. 5 represents a section.

Fig. 6. Section through the embryonic rim of a blastoderm somewhat younger than that represented on Pl. 8, fig. B.

Fig. 7. Section through the most projecting portion of the embryonic rim of a blastoderm of the same age as that represented on Pl. 8, fig. B. The section is drawn on a very considerably smaller scale than that on fig. 5. It is intended to illustrate the growth of the embryonic rim and the disappearance of the segmentation cavity.

Fig. 7 *a*. Section through peripheral portion of the embryonic rim of the same blastoderm, highly magnified. It specially illustrates the formation of a cell (*c*) around a nucleus in the yolk. The nuclei of the blastoderm have been inaccurately rendered by the artist.

Figs. 8 *a*, 8 *b*, 8 *c*. Three sections of the same embryo. Inserted mainly to illustrate the formation of the mesoblast as two independent lateral masses of cells; only half of each section is represented. 8 *a* is the most posterior of the three sections. In it the mesoblast forms a large mass on each side, imperfectly separated from the hypoblast. In 8 *b*, from the anterior part of the embryo, the main mass of mesoblast is far smaller, and only forms a cap to the hypoblast at the highest point of the medullary fold. In 8 *c* a cap of mesoblast is present, similar to that in 8 *b*, though much smaller. The sections of these embryos were somewhat oblique, and it has unfortunately happened that while in 8 *a* one side is represented, in 8 *b* and 8 *c* the other side is figured, had it not been for this the sections 8 *b* and 8 *c* would have been considerably longer than 8 *a*.

Fig. 9. Longitudinal section of an embryo belonging to a slightly later stage than B.

This section passes through one of the medullary folds. It illustrates the continuity of the hypoblast with the remaining lower layer cells of the blastoderm.

Figs. 10 *a*, 10 *b*, 10 *c*. Three sections of the same embryo belonging to a stage slightly later than B, Pl. 8. The space between the mesoblast and the hypoblast has been made considerably too great in the figures of the three sections.

10 *a*. The most posterior of the three sections. It shews the posterior flatness of the medullary groove and the two isolated vertebral plates.

10 *b*. This section is taken from the anterior part of the same embryo and shews the deep medullary groove and the commencing formation of the ventral wall of the alimentary canal from the nuclei of the yolk.

10 *c* shews the disappearance of the medullary groove and the thinning out of the mesoblast plates in the region of the head.

Fig. 11. Small portion of the blastoderm and the subjacent yolk of an embryo at the time of the first appearance of the medullary groove $\times 300$. It shews two large nuclei of the yolk (*n*) and the protoplasmic network in the yolk between them; the network is seen to be closer round the nuclei than in the intervening space. There are no areas representing cells around the nuclei.

Fig. 12. Nucleus of the yolk in connection with the protoplasmic network hardened in osmic acid.

Fig. 13. Portion of posterior end of a blastoderm of stage B, shewing the formation of cells around the nuclei of the yolk.

Fig. 14. Section through part of a young Scyllium egg, about $\frac{1}{16}$ th of an inch in diameter.

n. Protoplasmic network in yolk. *z p*. Zona pellucida. *ch*. Structureless chorion. *f ep*. Follicular epithelium. *x*. Structureless membrane external to this.

EXPLANATION OF PLATES 8 AND 9. (X. p. 286.)

COMPLETE LIST OF REFERENCE LETTERS.

a. Arteries of yolk sac (red). *al*. Alimentary cavity. *al v*. Alimentary vesicle at the posterior end of the alimentary canal. *an*. Point where anus will appear. *au v*. Auditory vesicle. *bl*. Blastoderm. *ch*. Notochord. *es*. Embryo-swelling. *h*. Head. *ht*. Heart. *m*. Mouth. *mg*. Medullary groove. *mp*. Muscle-plate or proto-vertebra. *op*. Eye. *sc*. Segmentation cavity. *so s*. Somatic stalk. *ts*. Tail-swelling. *v*. Veins of yolk sac (blue). *vc*. Visceral cleft. *I. vc*. 1st visceral cleft. *x*. Portion of blastoderm outside the arterial circle in which no blood-vessels are present. *yk*. Yolk.

PLATE 8.

Fig. A. Surface view of blastoderm of *Pristiurus* hardened in chromic acid.

Fig. B. Surface view of fresh blastoderm of *Pristiurus*.

Figs. C, D, E, and F. *Pristiurus* embryos hardened in chromic acid.

Fig. G. Torpedo embryo viewed as a transparent object.

Figs. H, I. *Pristiurus* embryos viewed as transparent objects.

Fig. K. *Pristiurus* embryo hardened in chromic acid.

The remainder of the figures are representations of embryos of *Scyllium canicula* hardened in chromic acid. In every case, with the exception of the figures marked P and Q, two representations of the same embryo are given; one from the side and one from the under surface.

PLATE 9.

Fig. 1. Yolk of a *Pristiurus* egg with blastoderm and embryo. About two-thirds of the yolk have been enveloped by the blastoderm. The embryo is still situated at the edge of the blastoderm, but at the end of a bay in the outline of this. The thickened edge of the blastoderm is indicated by a darker shading. Two arteries have appeared.

Fig. 2. Yolk of an older *Pristiurus* egg. The yolk has become all but enveloped by the blastoderm, and the embryo ceases to lie at the edge of the blastoderm, owing to the coalescence of the two sides of the bay which existed in the earlier stage. The circulation is now largely developed. It consists of an external arterial ring, and an internal venous ring, the latter having been developed in the thickened edge of the blastoderm. Outside the arterial ring no vessels are developed.

Fig. 3. The yolk has now become completely enveloped by the blastoderm. The arterial ring has increased in size. The venous ring has vanished, owing to the complete enclosure of the yolk by the blastoderm. The point where it existed is still indicated (*y*) by the brush-like termination of the main venous trunk in a number of small branches.

Fig. 4. Diagrammatic projection of the vascular system of the yolk sac of a somewhat older embryo.

The arterial ring has grown much larger and the portion of the yolk where no vessels exist is very small (*x*). The brush-like termination of the venous trunk is still to be noticed.

The two main trunks (arterial and venous) in reality are in close contact as in fig. 5, and enter the somatic stalk close together.

The letter *a* which points to the venous (blue) trunk should be *v* and not *a*.

Fig. 5. Circulation of the yolk sac of a still older embryo, in which the arterial circle has ceased to exist, owing to the space outside it having become smaller and smaller and finally vanished.

EXPLANATION OF PLATE 10. (X. p. 298.)

COMPLETE LIST OF REFERENCE LETTERS.

al. Alimentary canal. *ch.* Chorda dorsalis or notochord. *ch'*. Ridge of hypoblast, which will become separated off as the notochord. *ep.* Epiblast. *hy.* Hypoblast. *lp.* Coalesced lateral and vertebral plate of mesoblast. *mg.* Medullary groove. *n.* Nucleus of yolk. *na.* Cells formed around the nuclei of the yolk to enter into the ventral wall of the alimentary canal. *nc.* Neural or medullary canal. *pv.* Proto-vertebra. *so.* Somatopleure. *sp.* Splanchnopleure. *ts.* Mesoblast of tail-swelling. *yk.* Yolk-spherules.

Figs. 1 *a*, 1 *b*, 1 *c*. Three sections from the same embryo belonging to a stage intermediate between B and C, of which fig. 1 *a* is the most anterior. ($\times 96$ diameters.)

The sections illustrate (1) The different characters of the medullary groove in the different regions of the embryo. (2) The structure of the coalesced lateral and vertebral plates. (3) The mode of formation of the notochord as a thickening of the hypoblast (*ch'*), which eventually becomes separated from the hypoblast as an elliptical rod (1 *a*, *ch*).

Fig. 2. Section through the anterior part of an embryo belonging to stage C. The section is mainly intended to illustrate the formation of the ventral wall of the alimentary canal from cells formed around the nuclei of the yolk. It also shews the shallowness of the medullary groove in the anterior part of the body.

Figs. 2 *a*, 2 *b*, 2 *c*. Three sections from the same embryo as fig. 2. Fig. 2 *a* is the most anterior of the three sections and is taken through a point shortly in front of fig. 2. The figures illustrate the general features of an embryo of stage C, more especially the complete closing of the alimentary canal in front and the triangular section which it there presents.

Fig. 3. Section through the posterior part of an embryo belonging to stage D. ($\times 86$ diameters.)

It shews the general features of the layers during the stage, more especially the differentiation of somatic and splanchnic layers of the mesoblast.

Figs. 3 *a*, 3 *b*, 3 *c*, 3 *d*, 3 *e*, 3 *f*. Sections of the same embryo as fig. 3. ($\times 60$ diameters.) Fig. 3 belongs to part of the embryo intermediate between figs. 3 *e* and 3 *f*.

The sections shew the features of various parts of the embryo. Figs. 3 *a*, 3 *b* and 3 *c* belong to the head, and special attention should be paid to the presence of a cavity in the mesoblast in 3 *b* and to the ventral curvature of the medullary folds.

Fig. 3 *d* belongs to the neck, fig. 3 *e* to the back, and fig. 3 *f* to the tail.

Fig. 4. Section through the region of the tail at the commencement of stage F. ($\times 60$ diameters.)

The section shews the character of the tail-swellings and the commencing closure of the medullary groove.

Fig. 5. Transverse section through the anterior part of the head of an embryo belonging to stage F. ($\times 60$ diameters.) It shews (1) the ventral curvature of the medullary folds next the head. (2) The absence of mesoblast in the anterior part of the head. *ly* points to the extreme front end of the alimentary canal.

Fig. 6. Section through the head of an embryo at a stage intermediate between F and G. ($\times 86$ diameters.)

It shews the manner in which the medullary folds of the head unite to form the medullary canal.

Fig. 7. Longitudinal and vertical section through the tail of an embryo belonging to stage G.

It shews the direct communication which exists between the neural and alimentary canals.

The section is not quite parallel to the long axis of the embryo, so that the proto-vertebræ are cut through in its anterior part, and the neural canal passes out of the section anteriorly.

Fig. 8. Network of nuclei from the yolk of an embryo belonging to stage H.

EXPLANATION OF PLATES II AND 12. (X. p. 315.)

COMPLETE LIST OF REFERENCE LETTERS.

al. Alimentary tract. *an.* Point where anus will be formed. *ao.* Dorsal aorta. *ar.* Rudiment of anterior root of spinal nerve. *b.* Anterior fin. *c.* Connective-tissue cells. *ca v.* Cardinal vein. *ch.* Notochord. *df.* Dorsal fin. *ep.* Epiblast. *gc.*

Germinal epithelium. *ht.* Heart. *l.* Liver. *m p.* Muscle-plate. *mp'*. Early formed band of muscles from the splanchnic layer of the muscle-plates. *nc.* Neural canal. *p.* Protoplasm from yolk in the alimentary tract. *p c.* Pericardial cavity. *p o.* Primitive ovum. *pp.* Body cavity. *p r.* Rudiment of posterior root of spinal nerve. *s d.* Segmental duct. *sh.* Cuticular sheath of notochord. *so.* Somatic layer of mesoblast. *sp.* Splanchnic layer of mesoblast. *sp c.* Spinal cord. *sp. v.* Spiral valve. *sr.* Interrenal body. *st.* Segmental tube. *sv.* Sinus venosus. *ua.* Umbilical artery. *um.* Umbilical cord. *uv.* Umbilical vein. *v.* Splanchnic vein. *v.* Blood-vessel. *vc.* Visceral cleft. *V r.* Vertebral rudiment. *W.* White matter of spinal cord. *x.* Subnotochordal rod (except in fig. 14 *a*). *y.* Passage connecting the neural and alimentary canals.

PLATE II.

Fig. 1. Section from the caudal region of a *Pristiurus* embryo belonging to stage H. Zeiss C, ocul. 1. Osmic acid specimen.

It shews (1) the constriction of the subnotochordal rod (*x*) from the summit of the alimentary canal. (2) The formation of the body-cavity in the muscle-plate and the ventral thickening of the parietal plate.

Fig. 1 *a*. Portion of alimentary wall of the same embryo, shewing the formation of the subnotochordal rod (*x*).

Fig. 2. Section through the caudal vesicle of a *Pristiurus* embryo belonging to stage H. Zeiss C, ocul. 1.

It shews the bilobed condition of the alimentary vesicle and the fusion of the mesoblast and hypoblast at the caudal vesicle.

Fig. 3 *a*. Sections from the caudal region of a *Pristiurus* embryo belonging to stage H. Zeiss C, ocul. 1. Picric acid specimen.

It shews the communication which exists posteriorly between the neural and alimentary canals, and also by comparison with 3 *b* it exhibits the dilatation undergone by the alimentary canal in the caudal vesicle.

Fig. 3 *b*. Section from the caudal region of an embryo slightly younger than 3 *a*. Zeiss C, ocul. 1. Osmic acid specimen.

Fig. 4. Section from the cardiac region of a *Pristiurus* embryo belonging to stage H. Zeiss C, ocul. 1. Osmic acid specimen.

It shews the formation of the heart (*ht*) as a cavity between the splanchnopleure and the wall of the throat.

Fig. 5. Section from the posterior dorsal region of a *Scyllium* embryo, belonging to stage H. Zeiss C, ocul. 1. Osmic acid specimen.

It shews the general features of an embryo of stage H, more especially the relations of the body-cavity in the parietal and vertebral portions of the lateral plate, and the early-formed band of muscle (*mp'*) in the splanchnic layer of the vertebral plate.

Fig. 6. Section from the œsophageal region of *Scyllium* embryo belonging to stage I. Zeiss C, ocul. 1. Chromic acid specimen.

It shews the formation of the rudiments of the posterior nerve-roots (*p r*) and of the vertebral rudiments (*V r*).

Fig. 7. Section of a *Torpedo* embryo belonging to stage slightly later than I. Zeiss C, ocul. 1, reduced $\frac{1}{3}$. Osmic acid specimen.

It shews (1) the formation of the anterior and posterior nerve-roots. (2) The solid knob from which the segmental duct (*sd*) originates.

Fig. 8. Section from the dorsal region of a Scyllium embryo belonging to a stage intermediate between I and K. Zeiss C, ocul. 1. Chromic acid specimen.

It illustrates the structure of the primitive ova, segmental tubes, notochord, etc.

Fig. 8*a*. Section from the caudal region of an embryo of the same age as 8. Zeiss A, ocul. 1.

It shews (1) the solid oesophagus. (2) The narrow passage connecting the pericardial (*pc*) and body cavities (*pp*).

Fig. 9. Section of a Pristiurus embryo belonging to stage K. Zeiss A, ocul. 1. Osmic acid specimen.

It shews the formation of the liver (*l*), the structure of the anterior fins (*b*), and the anterior opening of the segmental duct into the body-cavity (*s d*).

Figs. 9*a*, 9*b*, 9*c*, 9*d*. Four sections through the anterior region of the same embryo as 9. Osmic acid specimens.

The sections shew (1) the atrophy of the post-anal section of the alimentary tract (9*b*, 9*c*, 9*d*). (2) The existence of the segmental tubes behind the anus (9*b*, 9*c*, 9*d*). With reference to these it deserves to be noted that the segmental tubes behind the anus are quite disconnected, as is proved by the fact that a tube is absent on one side in 9*c* but reappears in 9*d*. (3) The downward prolongation of the segmental duct to join the posterior or cloacal extremity of the alimentary tract (9*b*).

PLATE 12.

Fig. 10. Longitudinal and horizontal section of a Scyllium embryo of stage H. Zeiss C, ocul. 1. Reduced by $\frac{1}{3}$. Picric acid specimen.

It shews (1) the structure of the notochord; (2) the appearance of the early formed band of muscles (*mp'*) in the splanchnic layer of the protovertebra.

Fig. 11. Longitudinal and horizontal sections of an embryo belonging to stage I. Zeiss C, ocul. 1. Chromic acid specimen. It illustrates the same points as the previous section, but in addition shews the formation of the rudiments of the vertebral bodies (*V'*) which are seen to have the same segmentation as the muscle-plates.

Fig. 12.¹ Longitudinal and horizontal section of an embryo belonging to the stage intermediate between I and K. Zeiss C, ocul. 1. Osmic acid specimen illustrating the same points as the previous section.

Fig. 13. Longitudinal and horizontal section of an embryo belonging to stage K. Zeiss C, ocul. 1, and illustrating same points as previous section.

Figs. 14*a*, 14*b*, 14*c*, 14*d*. Figures taken from preparations of an embryo of an age intermediate between I and K, and illustrating the structure of the primitive ova. Figs. 14*a* and 14*b* are portions of transverse sections. Zeiss C, ocul. 3 reduced $\frac{1}{3}$. Figs. 14*c* and 14*d* are individual ova, shewing the lobate form of nucleus. Zeiss F, ocul. 2.

Fig. 15. Osmic acid preparation of primitive ova belonging to stage K. Zeiss immersion No. 2, ocul. 1. The protoplasm of the ova is seen to be nearly filled with bodies resembling yolk-spherules: and one ovum is apparently undergoing division.

¹ The apparent structure in the sheath of the notochord in this and the succeeding figure is merely the result of an attempt on the part of the engraver to represent the dark colour of the sheath in the original figure.

fore-brain; the mid-brain; the commencing cerebellum in the hind-brain. (2) The relation of the mouth involution to the infundibulum. (3) The termination of the notochord.

9 *b* is a section to one side of the same brain. It shews (1) The divisions of the brain. (2) The point of outgrowth of the optic nerves (*opn*). (3) The sections of the body-cavity in the head and the bifurcation of the optic nerve over the second of these.

Fig. 10. Longitudinal section through the head of a *Pristiurus* embryo somewhat younger than fig. 9. Zeiss a, ocul. 4. It shews the relation of the nerves and the junction of the fifth, seventh, and auditory nerves with the brain.

Fig. 11. Longitudinal section through the fore-brain of a *Pristiurus* embryo of stage K, slightly to one side of the middle line. It shews the deep constriction separating the thalamencephalon from the cerebral hemispheres.

Fig. 12. Longitudinal section through the base of the brain of an embryo of a stage intermediate between I and K.

It shews (1) the condition of the end of the notochord; (2) the relation of the mouth involution to the infundibulum.

Fig. 13 *a*. Longitudinal and horizontal section through part of the head of a *Pristiurus* embryo rather older than K. Zeiss A, ocul. 1.

The figure contains the eye cut through in the plane of the choroid slit. Thus the optic nerve (*opn*) and choroid slit (*chl*) are both exhibited. Through the latter is seen passing mesoblast accompanied by a blood-vessel (*v*). *Op* represents part of the optic vesicle to one side of the choroid slit.

No mesoblast can be seen passing round the outside of the optic cup; and the only mesoblast which enters the optic cup passes through the choroid slit.

Fig. 13 *b*. Transverse section through the last arch but one of the same embryo as 13 *a*. Zeiss A, ocul. 1.

The figure shews (1) The mode of formation of a visceral cleft without any involution of the external skin. (2) The head-cavity in the arch and its situation in relation to the aortic arch.

Fig. 14. Surface view of the nasal pit of an embryo of same age as fig. 13, considerably magnified. The specimen was prepared by removing the nasal pit, flattening it out and mounting in glycerine after treatment with chromic acid. It shews the primitive arrangement of the Schneiderian folds. One side has been injured.

Figs. 15 *a* and 15 *b*. Two longitudinal and vertical sections through the head of a *Pristiurus* embryo belonging to stage K. Zeiss a, ocul. 3.

15 *a* is the most superficial section of the two. It shews the constitution of the seventh and fifth nerves, and of the intestinal branch of the vagus. The anterior branch of the seventh nerve deserves a special notice.

15 *b* mainly illustrates the dorsal commissure of the vagus nerve (*com*) continuous with the dorsal commissures of the posterior root of the spinal nerves.

Fig. 16. Two longitudinal and vertical sections of the head of a *Pristiurus* embryo belonging to the end of stage K. Zeiss a, ocul. 1.

16 *a* passes through the median line of the brain and shews the infundibulum, notochord and pituitary body, etc.

The pituitary body still opens into the mouth, though the septum between the mouth and the throat is broken through.

16*b* is a more superficial section shewing the head-cavities *pp* 1, 2, 3, and the lower vagus commissure.

PLATE 16. (X. p. 397.)

COMPLETE LIST OF REFERENCE LETTERS.

au v. Auditory vesicle. *cb.* Cerebellum. *cer.* Cerebral hemispheres. *ch.* Notochord. *cin.* Internal carotid. *ft.* Fasciculi teretes. *in.* Infundibulum. *lv.* Lateral ventricle. *mb.* Mid-brain, or optic lobes. *md.* Medulla oblongata. *mn.* Mandible. *ol.* Olfactory pit. *oli.* Olfactory lobe. *op.* Eye. *op n.* Optic nerve. *op th.* Optic thalamus. *pc.* Posterior commissure. *pcl.* Posterior clinoid. *pn.* Pineal gland. *pt.* Pituitary body. *rt.* Restiform tracts. *tv.* Tela vasculosa of the roof of the fourth ventricle. *iv. v.* Fourth ventricle. *vii.* Seventh nerve. *x.* Rudiment of septum which will grow backwards and divide the unpaired cerebral rudiment into the two hemispheres.

Figs. 1*a*, 1*b*, 1*c*. Longitudinal sections of the brain of a Scyllium embryo belonging to stage L. Zeiss a, ocul. 1.

1*a* is taken slightly to one side of the middle line, and shews the general features of the brain, and more especially the infundibulum (*in*) and pituitary body (*pt*).

1*b* is through the median line of the pineal gland.

1*c* is through the median line of the base of the brain, and shews the notochord (*ch*) and pituitary body (*pt*); the latter still communicating with the mouth. It also shews the wide opening of the infundibulum in the middle line into the base of the brain.

Fig. 2. Section through the unpaired cerebral rudiment during stage O, to shew the origin of the olfactory lobe and the olfactory nerve. The latter is seen to divide into numerous branches, one of which passes into each Schneiderian fold. At its origin are numerous ganglion cells represented by dots. Zeiss a, ocul. 2.

Fig. 3. Horizontal section through the three lobes of the brain during stage O. Zeiss a, ocul. 2.

The figure shews (1) the very slight indications which have appeared by this stage of an ingrowth to divide the cerebral rudiment into two lobes (*x*): (2) the optic thalami united by a posterior commissure, and on one side joining the base of the mid-brain, and behind them the pineal gland: (3) the thin posterior wall of the cerebral rudiment with folds projecting into the cerebral cavity.

Figs. 4*a*, 4*b*, 4*c*. Views from the side, from above, and from below, of a brain of Scyllium canicula during stage P. In the view from the side the eye (*op*) has not been removed.

The bilobed appearance both of the mid-brain and cerebellum should be noticed.

Fig. 5. Longitudinal section of a brain of Scyllium canicula during stage P. Zeiss a, ocul. 2.

There should be noticed (1) the increase in the flexure of the brain accompanying a rectification of the cranial axis; (2) the elongated pineal gland, and (3) the structure of the optic thalamus.

Figs. 6*a*, 6*b*, 6*c*. Views from the side, from above, and from below, of a brain of *Scyllium stellare* during a slightly later stage than Q.

Figs. 7*a* and 7*b*. Two longitudinal sections through the brain of a *Scyllium* embryo during stage Q. Zeiss a, ocul. 2.

7*a* cuts the hind part of the brain nearly through the middle line; while 7*b* cuts the cerebral hemispheres and pineal gland through the middle.

In 7*a* the infundibulum (1), cerebellum (2), the passage of the restiform tracts (*rt*) into the cerebellum (3), and the rudiments of the tela vasculosa (4) are shewn. In 7*b* the septum between the two lobes of the cerebral hemispheres (1), the pineal gland (2), and the relations of the optic thalami (3) are shewn.

Figs. 8*a*, 8*b*, 8*c*, 8*d*. Four transverse sections of the brain of an embryo slightly older than Q. Zeiss a, ocul. 1.

8*a* passes through the cerebral hemispheres at their junction with the olfactory lobes. On the right side is seen the olfactory nerve coming off from the olfactory lobe. At the dorsal side of the hemispheres is seen the pineal gland (*pn*).

8*b* passes through the mid-brain now slightly bilobed, and the opening into the infundibulum (*in*). At the base of the section are seen the optic nerves and their chiasma.

8*c* passes through the opening from the ventricle of the mid-brain into that of the cerebellum. Below the optic lobes is seen the infundibulum with the rudiments of the sacci vasculosi.

8*d* passes through the front end of the medulla, and shews the roots of the seventh pair of nerves, and the overlapping of the medulla by the cerebellum.

PLATE 17. (X. p. 397.)

COMPLETE LIST OF REFERENCE LETTERS.

vii. *a*. Anterior branch of seventh nerve. *ar*. Anterior root of spinal nerve. *au v*. Auditory vesicle. *cer*. Cerebrum, *ch*. Notochord. *ch*. Epithelial layer of choroid membrane. *gl*. Glossopharyngeal nerve. vii. *hy*. Hyoid branch of seventh nerve. *hym*. Hyaloid membrane. *ll*. Lateral line. v. *mn*. Ramus mandibularis of fifth nerve. vii. *mn*. Mandibular (spiracular) branch of seventh nerve. v. *mx*. Ramus maxillæ superioris of fifth nerve. *nl*. Nervus lateralis. *ol*. Olfactory pit. *op*. Eye. v. *op th*. Ramus ophthalmicus of fifth nerve. *p ch*. Parachordal cartilage. *p fal*. Processus falciformis. *pp*. Head cavity. *pr*. Posterior root of spinal nerve. *rt*. Retina. *sp*. Spiracle. v. Fifth nerve. vii. Seventh nerve. *vc*. Visceral cleft. *vg*. Vagus nerve. *vg br*. Branchial branch of vagus. *vg com*. Commissure uniting the roots of the vagus, and continuous with commissure uniting the posterior roots of the spinal nerves. *vg r*. Roots of vagus nerves in the brain. *vg in*. Intestinal branch of vagus. *vh*. Vitreous humour.

Fig. 1. Diagram of cranial nerves at stage L.

A description of the part of this referring to the vagus and glossopharyngeal

nerves is given at p. 426. It should be noticed that there are only five strands indicated as springing from the spinal cord to form the vagus and glossopharyngeal nerves. It is however probable that there are even from the first a greater number of strands than this.

Fig. 2. Section through the hinder part of the medulla oblongata, stage between K and L. Zeiss A, ocul. 2.

It shews (1) the vagus commissure with branches on one side from the medulla : (2) the intestinal branch of the vagus giving off a nerve to the lateral line.

Fig. 3. Longitudinal and vertical section through the head of a Scyllium embryo of stage L. Zeiss a, ocul. 2.

It shews the course of the anterior branch of the seventh nerve (vii.); especially with relation to the ophthalmic branch of the fifth nerve (v. *oth*).

Figs. 4 *a* and 4 *b*. Two horizontal and longitudinal sections through the head of a Scyllium embryo belonging to stage O. Zeiss a, ocul. 2.

4 *a* is the most dorsal of the two sections, and shews the course of the anterior branch of the seventh nerve above the eye.

4 *b* is a slightly more ventral section, and shews the course of the fifth nerve.

Fig. 5. Longitudinal and horizontal section through the hind-brain at stage O, shewing the roots of the vagus and glossopharyngeal nerves in the brain. Zeiss B, ocul. 2.

There appears to be one root in the brain for the glossopharyngeal, and at least six for the vagus. The fibres from the roots divide in many cases into two bundles before leaving the brain. Swellings of the brain towards the interior of the fourth ventricle are in connection with the first five roots of the vagus, and the glossopharyngeal root; and a swelling is also intercalated between the first vagus root and the glossopharyngeal root.

Fig. 6. Horizontal section through a part of the choroid slit at stage P. Zeiss B, ocul. 2.

The figure shews (1) the rudimentary processus falciformis (*p fal*) giving origin to the vitreous humour; and (2) the hyaloid membrane (*hym*) which is seen to adhere to the retina, and not to the vitreous humour or processus falciformis.

EXPLANATION OF PLATE 18. (X. p. 446.)

COMPLETE LIST OF REFERENCE LETTERS.

Nervous System.

a r. Anterior root of spinal nerve. *n c.* Neural canal. *p r.* Posterior root of spinal nerve. *sp n.* Spinal nerve. *sy g.* Sympathetic ganglion.

Alimentary Canal.

al. Alimentary canal. *al v.* Caudal vesicle of the postanal gut. *cl al.* Cloacal section of alimentary canal. *du.* Duodenum. *h p d.* Ductus choledochus. *pan.* pancreas. *s œ s.* Solid œsophagus. *sp v.* Intestine with rudiment of spiral valve. *um c.* Umbilical canal.

General.

ao. Dorsal aorta. *aur.* Auricle of heart. *ca v.* Cardinal vein. *ch.* Notochord.
ep pp. Epithelial lining of the body-cavity. *ir.* Interrenal body. *me.* Mesentery.
mp. Muscle-plate. *mpl.* Muscle-plate sending a prolongation into the limb. *po.*
 Primitive ovum. *pp.* Body-cavity. *sd.* Segmental duct. *st.* Segmental tube.
ts. Tail swelling. *v cau.* Caudal vein. *x.* Subnotochordal rod.

Fig. 1. Transverse section through the anterior abdominal region of an embryo of a stage between K and L. Zeiss B, ocul. 2. Reduced one-third.

The section illustrates the junction of a sympathetic ganglion with a spinal nerve and the sprouting of the muscle-plates into the limbs (*mpl.*).

Fig. 2. Transverse section through the abdominal region of an embryo belonging to stage L. Zeiss B, ocul. 2. Reduced one-third.

The section illustrates the junction of a sympathetic ganglion with a spinal nerve, and also the commencing formation of a branch from the aorta (still solid) which will pass through the sympathetic ganglion, and forms the first sign of the conversion of part of a sympathetic ganglion into one of the suprarenal bodies.

Fig. 3. Longitudinal and vertical section of an embryo of a stage between L and M, shewing the successive junctions of the spinal nerves and sympathetic ganglia.

Fig. 4. Section through the solid œsophagus during stage L. Zeiss A, ocul. 1. The section is taken through the region of the heart, so that the cavity of the auricle (*aur.*) lies immediately below the œsophagus.

Fig. 5. Optical section of the tail of an embryo between stages I and K, shewing the junction between the neural and alimentary canals.

Fig. 6. Four sections through the caudal region of an embryo belonging to stage K, shewing the condition of the postanal section of the alimentary tract. Zeiss A, ocul. 2. An explanation of these figures is given on p. 449.

Fig. 7. Section through the interrenal body of a Scyllium embryo belonging to stage Q. Zeiss C, ocul. 2.

Fig. 8. Portion of a section of the interrenal body of an adult Scyllium. Zeiss C, ocul. 2.

EXPLANATION OF PLATE 19. (X. p. 460.)

COMPLETE LIST OF REFERENCE LETTERS.

Nervous System.

n. Nerve. *sp n.* Spinal nerve. *sy g.* Sympathetic ganglion.

Alimentary Canal.

cl. Cloaca. *in cl.* Cloacal involution. *œ ep.* Œsophageal epithelium. *pan.* Pancreas. *th.* Thyroid body.

General.

ab p. Abdominal pocket (pore). *aur.* Auricle. *ca v.* Cardinal vein. *cau v.* Caudal vein. *ly.* Lymphoid tissue. *m m.* Muscles. *od.* Oviduct. *pc.* Pericardium.

ap. Body cavity. *sr.* Suprarenal body. *u.* Ureter. *vao.* Ventral aorta (anterior continuation of bulbus arteriosus). *ven.* Ventricle. *wd.* Wolffian duct.

Figs. 1 *a*, 1 *b*, 1 *c*. Three sections through the cloacal region of an embryo belonging to stage O. 1 *a* is the anterior of the three sections. Zeiss A, ocul. 2. Reduced one-third.

1 *a* shews the cloacal involution at its deepest part abutting on the cloacal section of the alimentary tract.

1 *b* is a section through a point somewhat behind this close to the opening of the Wolffian ducts into the cloaca.

1 *c* shews the opening to the exterior in the posterior part of the cloaca, and also the rudiments of the two abdominal pockets (*ab p.*).

Fig. 2. Section through the cloacal region of an embryo belonging to stage P. Zeiss A, ocul. 2.

The figure shews the solid anterior extremity of the cloacal involution.

Fig. 3. Longitudinal vertical section through the thyroid body in a stage between O and P. Zeiss *aa*, ocul. 1.

The figure shews the solid thyroid body (*th*) connected in front with throat, and terminating below the bulbus arteriosus.

Fig. 4. Pancreas (*pan*) and adjoining part of the alimentary tract in longitudinal section, from an embryo between stages L and M. Zeiss A, ocul. 2.

Fig. 5. Portion of liver network of stage L. Zeiss C, ocul. 2. The section is intended to illustrate the fact that the tubules or cylinders of which the liver is composed are hollow and not solid. Between the liver tubules are seen blood spaces with distinct walls, and blood corpuscles in their interior.

Fig. 6. Section through part of one of the suprarenal bodies of an adult Scyllium hardened in chromic acid. Zeiss C, ocul. 2. The section shews the columnar cells forming the cortex and the more polygonal cells of the medulla.

Fig. 7. Transverse section through the anterior suprarenal body of an adult Scyllium. Zeiss B, ocul. 2. Reduced one-third. The tissue of the suprarenal body has not been filled in, but only the sympathetic ganglion cells which are seen to be irregularly scattered through the substance of the body. The entrance of the nerve (*n*) is shewn, and indications are given of the distribution of the nerve-fibres.

Fig. 8. Section through the sympathetic ganglion of a Scyllium embryo between stages M and N, shewing the connecting trunk between the suprarenal body and the spinal nerve (*sp n*), and the appearance of an indication in the ganglion of a portion more directly connected with the nerve. Zeiss D, ocul. 2.

Fig. 9. Section through one of the anterior sympathetic ganglia of an embryo of stage Q, shewing its division into a true ganglionic portion (*sy g*), and a suprarenal body (*sr*). Zeiss C, ocul. 2.

EXPLANATION OF PLATES 20 AND 21. (X. p. 479.)

COMPLETE LIST OF REFERENCE LETTERS.

amg. Accessory Malpighian body. *ca v.* Cardinal vein. *gz.* Germinal epithelium.
k. True kidney. *l.c.* Longitudinal canal of the Wolffian body connected with vasa

efferentia. *mg.* Malpighian body. *nt.* Network and central canal at the base of the testis. *o.* External aperture of urinal cloaca. *od.* Oviduct or Müllerian duct of the female. *od'.* Müllerian duct of the male. *ou.* Openings of ureters in Wolffian duct in the female (fig. 3). *pmg.* Primary Malpighian body. *px.* Growth from vesicle at the end of a segmental tube to join the collecting tube of the preceding segment. *rst.* Rudimentary segmental tube. *ru.* Ureter commencing to be formed. *sb.* Seminal bladder. *sd.* Segmental duct. *st.* Segmental tube. *sto.* Opening of segmental tube into body-cavity. *sur.* Suprarenal body. *t.* Testis. *u.* Ureters. *ve.* Vas efferens. *wb.* Wolffian body. *wd.* Wolffian duct.

PLATE 20.

Fig. 1. Diagrammatic representation of excretory organs on one side of a male *Scyllium canicula*, natural size.

Fig. 2. Diagrammatic representation of the kidney proper on one side of a female *Scyllium canicula*, natural size, shewing the ducts of the kidney and the dilated portion of the Wolffian duct.

Fig. 3. Opening of the ureters into the Wolffian duct of a female *Scyllium canicula*. The figure represents the Wolffian ducts (*wd*) with ventral portion removed so as to expose their inner surface, and shews the junction of the two W. ducts to form the common urinal cloaca, the single external opening of this (*o*), and openings of ureters into one Wolffian duct (*ou*).

Fig. 4. Anterior extremity of Wolffian body of a young male *Scyllium canicula* shewing the vasa efferentia and their connection with the kidneys and the testis. The vasa efferentia and longitudinal canal are coloured to render them distinct. They are intended to be continuous with the uncoloured coils of the Wolffian body, though this connection has not been very successfully rendered by the artist.

Fig. 5. Part of the Wolffian body of a nearly ripe male embryo of *Scyllium canicula* as a transparent object. Zeiss a a, ocul. 3. The figure shews two segmental tubes opening into the body-cavity and connected with a primary Malpighian body, and also, by a fibrous connection, with a secondary Malpighian body of the preceding segment. It also shews one segmental tube (*rst*) imperfectly connected with the accessory Malpighian body of the preceding segment of the kidney. The coils of the kidney are represented somewhat diagrammatically.

Fig. 6. Vasa efferentia of a male embryo of *Scyllium canicula* eight centimetres in length. Zeiss a a, ocul. 2.

There are seen to be at the least six and possibly seven distinct vasa going to as many segments of the Wolffian body and connected with a longitudinal canal in the base of the testis. They were probably also connected with a longitudinal canal in the Wolffian body, but this could not be clearly made out.

Fig. 7. The anterior four vasa efferentia of a nearly ripe embryo. Connected with the foremost one is seen a body which looks like the remnant of a segmental tube and its opening (*rst?*).

Fig. 8. Testis and anterior part of Wolffian body of an embryo of *Squatina vulgaris*.

The figure is intended to illustrate the arrangement of the vasa efferentia. There

are five of these connected with a longitudinal canal in the base of the testis, and with another longitudinal canal in the Wolffian body. From the second longitudinal canal there pass off four ducts to as many Malpighian bodies. Through the Malpighian bodies these ducts are continuous with the several coils of the Wolffian body, and so eventually with the Wolffian duct. Close to the hindermost vas efferens is seen a body which resembles a rudimentary segmental tube (*rst?*).

PLATE 21.

Figs. 1 A, 1 B, 1 C, 1 D. Four sections from a female *Scyllium canicula* of a stage between M and N through the part where the segmental duct becomes split into Wolffian duct and oviduct. Zeiss B, ocul. 2. 1 A is the foremost section.

The sections shew that the oviduct arises as a thickening on the under surface of the segmental duct into which at the utmost a very narrow prolongation of the lumen of the segmental duct is carried. The small size of the lumen of the Wolffian duct in the foremost section is due to the section passing through nearly its anterior blind extremity.

Fig. 2. Section close to the junction of the Wolffian duct and oviduct in a female embryo of *Scyllium canicula* belonging to stage N. Zeiss B, ocul. 2.

The section represented shews that in some instances the formation of the oviduct and Wolffian duct is accompanied by a division of the lumen of the segmental duct into two not very unequal parts.

Figs. 3 A, 3 B, 3 C. Three sections illustrating the formation of a ureter in a female embryo belonging to stage N. Zeiss B, ocul. 2.

3 A is the foremost section.

The figures shew that the lumen of the developing ureter is enclosed in front by an independent wall (fig. 3 A), but that further back the lumen is partly shut in by the subjacent Wolffian duct, while behind no lumen is present, but the ureter ends as a solid knob of cells without an opening into the Wolffian duct.

Fig. 4. Section through the ureters of the same embryo as fig. 3, but nearer the cloaca. Zeiss B, ocul. 2.

The figure shews the appearance of a transverse section through the wall of cells above the Wolffian duct formed by the overlapping ureters, the lumens of which appear as perforations in it. It should be compared with fig. 9 A, which represents a longitudinal section through a similar wall of cells.

Fig. 5. Section through the ureters, the Wolffian duct and the oviduct of a female embryo of *Scy. canicula* belonging to stage P. Zeiss B, ocul. 2.

Fig. 6. Section of part of the Wolffian body of a male embryo of *Scyllium canicula* belonging to stage O. Zeiss B, ocul. 2.

The section illustrates (1) the formation of a Malpighian body (*mg*) from the dilatation at the end of a segmental tube, (2) the appearance of the rudiment of the Müllerian duct in the male (*od'*).

Figs. 7 a, 7 b. Two longitudinal and vertical sections through part of the kidney of an embryo between stages L and M. Zeiss B, ocul. 2.

7 *a* illustrates the parts of a single segment of the Wolffian body at this stage, vide p. 491. The segmental tube and opening are not in the plane of the section, but the dilated vesicle is shewn into which the segmental tube opens.

7 *b* is taken from the region of the kidney proper. To the right is seen the opening of a segmental tube into the body-cavity, and in the segment to the left the commencing formation of a ureter, vide p. 502.

Fig. 8. Longitudinal and vertical section through the posterior part of the kidney proper of an embryo of *Scyllium canicula* at a stage between N and O. Zeiss A, ocul. 2.

The section shews the nearly completed ureters, developing Malpighian bodies, &c.

Fig. 9. Longitudinal and vertical section through the anterior part of the kidney proper of the same embryo as fig. 8. Zeiss A, ocul. 2.

The figure illustrates the mode of growth of the developing ureters.

9 A. More highly magnified portion of the same section as fig. 9.

Compare with transverse section fig. 4.

Fig. 10. Longitudinal and vertical section through part of the Wolffian body of an embryo of *Scyllium canicula* at a stage between O and P.

The section contains two examples of the budding out of the vesicle of a segmental tube to form a Malpighian body in its own segment and to unite with the tubulus of the preceding segment close to its opening into the Wolffian duct.

EXPLANATION OF PLATES 22 AND 23¹. (VIII. p. 168.)

PLATE 22.

Fig. A. Section through the dorsal region of an embryo of *Scyllium stellare*, with the rudiments of two visceral clefts. The section illustrates the general features at a period anterior to the appearance of the posterior nerve-roots.

nc. neural canal. *mp.* muscle-plate. *ch.* notochord. *x.* subnotochordal rod. *ao.* rudiment of dorsal aorta. *so.* somatopleure. *sp.* splanchnopleure. *al.* alimentary tract. All the parts of the section except the spinal cord are drawn somewhat diagrammatically.

Figs. B I, B II, B III. Three sections of a *Pristiurus*-embryo. B I is through the heart, B II through the anterior part of the dorsal region, and B III through a point slightly behind this. Drawn with a camera. (Zeiss CC, ocul. 2.)

In B III there is visible a slight proliferation of cells from the dorsal summit of the neural canal.

In B II this proliferation definitely constitutes two club-shaped masses of cells (*pr*), both attached to the dorsal summit of the neural canal. The masses are the rudiments of the posterior nerve-roots.

¹ The figures on these Plates give a fair general idea of the appearance presented by the developing spinal nerves; but the finer details of the original drawings have in several cases become lost in the process of copying.

The figures which are tinted represent sections of embryos hardened in osmic acid; those without colour sections of embryos hardened in chromic acid.

In B I the rudiments of the posterior roots are of considerable length.

pr. rudiment of posterior roots. *nc.* neural canal. *mp.* muscle-plate. *ch.* notochord. *x.* subnotochordal rod. *ao.* dorsal aorta. *so.* somatopleure. *sp.* splanchnopleure. *al.* alimentary canal. *ht.* heart.

Fig. C. Section from a *Pristiurus*-embryo, slightly older than B. Camera. (Zeiss CC, ocul. 2.) The embryo from which this figure was taken was slightly distorted in the process of removal from the blastoderm.

vr. rudiment of vertebral body. Other reference letters as in previous figures.

Fig. D a. Section through the dorsal region of a *Torpedo*-embryo with three visceral clefts. (Zeiss CC, ocul. 2.) The section shows the formation of the dorsal nerve-rudiments (*pr*) and of a ventral anterior nerve-rudiment (*ar*), which at this early stage is not distinctly cellular.

ar. rudiment of an anterior nerve-root. *y.* cells left behind on the separation of the external skin from the spinal cord. *c.* connective-tissue cells springing from the summit of the muscle-plates. Other reference letters as above.

Fig. D b. Section from dorsal region of a *Torpedo*-embryo somewhat older than D a. Camera. (Zeiss CC, ocul. 2.) The posterior nerve-rudiment is considerably longer than in fig. D a, and its pedicle of attachment to the spinal cord is thinner. The anterior nerve-rudiment, of which only the edge is present in the section, is distinctly cellular.

m. mesoblast growing up from vertebral rudiment. *sd.* segmental duct.

Fig. D c. Section from a still older *Torpedo*-embryo. Camera. (Zeiss CC, ocul. 2.) The connective-tissue cells are omitted. The rudiment of the ganglion (*g*) on the posterior root has appeared. The rudiment of the posterior nerve is much longer than before, and its junction with the spinal cord is difficult to detect. The anterior root is now an elongated cellular structure.

g. ganglion.

Fig. D d. Longitudinal and vertical section through a *Torpedo*-embryo of the same age as D c.

The section shows the commissures (*x*) uniting the posterior roots.

Fig. E a. Section of a *Pristiurus*-embryo belonging to the second stage. Camera. (Zeiss CC, ocul. 2.) The section shows the constriction of the pedicle which attaches the posterior nerve-rudiments to the spinal cord.

pr. rudiment of posterior nerve-root. *nc.* neural canal. *mp.* muscle-plate. *vr.* vertebral rudiment. *sd.* segmental duct. *ch.* notochord. *so.* somatopleure. *sp.* splanchnopleure. *ao.* aorta. *al.* alimentary canal.

Fig. E b. Section of a *Pristiurus*-embryo slightly older than E a. Camera. (Zeiss CC, ocul. 2.) The section shows the formation of the anterior nerve-root (*ar*).
ar. rudiment of the anterior nerve-root.

Fig. F. Section of a *Pristiurus*-embryo with the rudiments of five visceral clefts. Camera. (Zeiss CC, ocul. 2.)

The rudiment of the posterior root is seen surrounded by connective-tissue, from which it cannot easily be distinguished. The artist has not been very successful in rendering this figure.

Figs. G 1, G 2, G 3. Three longitudinal and horizontal sections of an embryo somewhat older than F. The embryo from which these sections were taken was hardened

in osmic acid, but the sections have been represented without tinting. G 1 is most dorsal of the three sections. Camera. (Zeiss CC, ocul. 1.)

nc. neural canal. *sp.c.* spinal cord. *pr.* rudiment of posterior root. *ar.* rudiment of anterior root. *mp.* muscle-plate. *c.* connective-tissue cells. *ch.* notochord.

PLATE 23.

Fig. H 1. Section through the dorsal region of a *Pristiurus*-embryo in which the rudimentary external gills are present as very small knobs. Camera. (Zeiss CC, ocul. 2.)

The section shews the commencing differentiation of the posterior nerve-rudiment into root (*pr*), ganglion (*sp.g.*), and nerve (*n*), and also the attachment of the nerve-root to the spinal cord (*x*). The variations in the size and shape of the cells in the different parts of the nerve-rudiment are completely lost in the figure.

pr. posterior nerve-root. *sp.g.* ganglion of posterior root. *n.* nerve of posterior root. *x.* attachment of posterior root to spinal cord. *w.* white matter of spinal cord. *i.* mesoblastic investment to the spinal cord.

Fig. H 11. Section through the same embryo as H 1. (Zeiss CC, ocul. 1.)

The section contains an anterior root, which takes its origin at a point opposite the interval between two posterior roots.

The white matter has not been very satisfactorily represented by the artist.

Figs. I 1, I 11. Two sections of a *Pristiurus*-embryo somewhat older than H. Camera. (Zeiss CC, ocul. 1.)

The connective-tissue cells are omitted.

Figs. I a, I b, I c. Three isolated cells from the ganglion of one of the posterior roots of the same embryo.

Figs. K 1, K 11. Two horizontal longitudinal sections through an embryo in which the external gills have just appeared. K 1 is the most dorsal of the two sections. Camera. (Zeiss CC, ocul. 1.)

The sections shew the relative positions of the anterior and posterior roots at different levels.

pr. posterior nerve-rudiment. *ar.* anterior nerve-rudiment. *sp.c.* spinal cord. *n.c.* neural canal. *mp.* muscle-plate. *mp'.* first-formed muscles.

Fig. L. Longitudinal and vertical section through the trunk of a *Scyllium*-embryo after the external gills have attained their full development. Camera. (Zeiss CC, ocul. 1.)

The embryo was hardened in a mixture of chromic acid and osmic acid.

The section shews the commissures which dorsally unite the posterior roots, and also the junction of the anterior and posterior roots. The commissures are unfortunately not represented in the figure with great accuracy; their outlines are in nature perfectly regular, and not, as in the figure, notched at the junctions of the cells composing them. Their cells are apparently more or less completely fused, and certainly not nearly so clearly marked as in the figure. The commissures stain very deeply with the mixture of osmic and chromic acid, and form one of the most conspicuous features in successful longitudinal sections of embryos so hardened. In sections hardened with chromic acid only they cannot be seen with the same facility.

sp.c. spinal cord. *gr.* grey matter. *w.* white matter. *ar.* anterior root. *pr.* posterior root. *x.* commissure uniting the posterior roots.

Figs. M I, M II. Two sections through the head of the same embryo as fig. B. M I, the foremost of the two, passes through the anterior part of the thickening of epiblast, which becomes involuted as the auditory vesicle. It contains the rudiment of the seventh nerve, VII. Camera. (Zeiss CC, ocul. 2.)

VII. rudiment of seventh nerve. *au.* thickening of external epiblast, which becomes involuted as the auditory vesicle. *n.c.* neural canal. *ch.* notochord. *pp.* body-cavity in the head. *so.* somatopleure. *sp.* splanchnopleure. *al.* throat exhibiting an outgrowth to form the first visceral cleft.

EXPLANATION OF PLATES 24, 25, 26. (XII. p. 549.)

PLATE 24.

LIST OF REFERENCE LETTERS.

d n. Modified nucleus of primitive ovum. *d o.* Permanent ovum in the act of being formed. *d v.* Developing blood-vessels. *d yk.* Developing yolk. *e p.* Non-ovarian epithelium of ovarian ridge. *f e.* Follicular epithelium. *g v.* Germinal vesicle. *l str.* Lymphatic region of stroma. *n n.* Nests of nuclei of ovarian region. *o.* Permanent ovum. *ov r.* Ovarian portion of ovarian ridge. *p o.* Primitive ovum. *ps e.* Pseudo-epithelium of ovarian ridge. *str.* Stroma ingrowths into ovarian epithelium. *v.* Blood-vessel. *v str.* Vascular region of stroma adjoining ovarian ridge. *vt.* Vitelline membrane. *x.* Modified nucleus. *yk.* Yolk. *z n.* Zona radiata.

Fig. 1. Transverse section of the ovarian ridge of an embryo of *Scy. canicula*, belonging to stage P, shewing the ovarian region with thickened epithelium and numerous primitive ova. Zeiss C, ocul. 2. *Picric acid.*

Fig. 2. Transverse section of the ovarian ridge of an embryo of *Scyllium canicula*, considerably older than stage Q. Zeiss C, ocul. 2. *Picric acid.* Several nests, some with distinct ova, and others with the ova fused together, are present in the section (*n. n.*), and several examples of modified nuclei in still distinct ova are also represented. One of these is marked *x*. The stroma of the ovarian ridge is exceptionally scanty.

Fig. 3. Transverse section through part of the ovarian ridge, including the ovarian region of an almost ripe embryo of *Scyllium canicula*. Zeiss C, ocul. 2. *Picric acid.* Nuclear nests (*n. n.*), developing ova (*d. o.*), and ova (*o.*), with completely formed follicular epithelium, are now present. The ovarian region is still well separated from the subjacent stroma, and does not appear to contain any cells except those of the original germinal epithelium.

Fig. 4. Section through ovarian ridge of the same embryo as fig. 3, to illustrate the relation of the stroma (*str.*) and ovarian region. Zeiss a a, ocul. 2. *Picric acid.*

Fig. 5. Section through the ovarian ridge of an embryo of *Scyllium canicula*, 10 cm. long, in which the ovary was slightly less advanced than in fig. 3. To illus-

trate the relation of the ovarian epithelium to the subjacent vascular stroma. Zeiss A, ocul. 2. *Osmic acid*. *y*. points to a small separated portion of the germinal epithelium.

Fig. 6. Section through the ovarian ridge of an embryo of *Scyllium canicula*, slightly older than fig. 5. To illustrate the relation of the ovarian epithelium to the subjacent vascular stroma. Zeiss A, ocul. 2. *Osmic acid*.

Fig. 7. More highly magnified portion of the same ovary as fig. 6. To illustrate the same points. Zeiss C, ocul. 2. *Osmic acid*.

Fig. 8. Section through the ovarian region (close to one extremity, where it is very small) from a young female of *Scy. canicula*. Zeiss C, ocul. 2. *Picric acid*. It shews the vascular ingrowths amongst the original epithelial cells of the ovarian region.

Fig. 9. Section through the ovarian region of the same embryo as fig. 8, at its point of maximum development. Zeiss A, ocul. 2. *Picric acid*.

Fig. 10. Section through superficial part of the ovary of an embryo, shewing the pseudo-epithelium; the cells of which are provided with tails prolonged into the general tissue of the ovary. At *f. e.* is seen a surface view of the follicular epithelium of an ovum. Zeiss C, ocul. 2. *Picric acid*.

Fig. 11. Section through part of an ovary of *Scyllium canicula* of stage Q, with three primitive ova, the most superficial one containing a modified nucleus.

Fig. 12. Section through part of an ovary of an example of *Scyllium canicula*, 8 cm. long. The section passes through a nest of ova with modified nuclei, in which the outlines of the individual ova are quite distinct. Zeiss E, ocul. 2. *Picric acid*.

Fig. 13. Section through part of ovary of the same embryo as in fig. 5. The section passes through a nest of nuclei, with at the least two developing ova, and also through one already formed permanent ovum. Zeiss E, ocul. 2. *Osmic acid*.

Figs. 14, 15, 16, 17, 18 [Figs. 17 and 18 are on Pl. 25]. Sections through parts of the ovary of the same embryo as fig. 3, with nests of nuclei and a permanent ova in the act of formation. Fig. 14 is drawn with Zeiss DD, ocul. 2. Figs. 15, 16, 17, with Zeiss E, ocul. 2. *Picric acid*.

PLATE 25.

LIST OF REFERENCE LETTERS.

do. Permanent ovum in the act of being formed. *dyk.* Developing yolk. *f. e.* Follicular epithelium. *f. l.* Secondary follicular epithelium. *g. v.* Germinal vesicle. *nn.* Nests of nuclei of ovarian region. *o.* Permanent ovum. *p. se.* Pseudo-epithelium. *str.* Stroma ingrowths into ovarian epithelium. *vt.* Vitelline membrane. *x.* Modified nucleus. *y. k.* Yolk (vitellus). *z. n.* Zona radiata.

[Figs. 17 and 18. Vide description of Plate 24.]

Fig. 19. Two nuclei from a nest which appear to be in the act of division. From ovary of the same embryo as fig. 3.

Fig. 20. Section through part of an ovary of the same embryo as fig. 6, containing a nest of nuclei. Zeiss F, ocul. 2. *Osmic acid*.

Fig. 21. Ovum from the ovary of a half-grown female, containing isolated deeply stained patches of developing yolk granules. Zeiss B, ocul. 2. *Picric acid*.

Fig. 22. Section through a small part of the ovum of an immature female of *Scyllium canicula*, to shew the constitution of the yolk, the follicular epithelium, and the egg membranes. Zeiss E, ocul. 2. *Chromic acid*.

Fig. 23. Section through part of the periphery of a nearly ripe ovum of *Scy. canicula*. Zeiss C, ocul. 2. It shews the remnant of the vitelline membrane (*v. t.*) separating the columnar but delicate cells of the follicular epithelium (*f. e.*) from the yolk (*y. k.*). In the yolk are seen yolk-spherules in a protoplasmic network. The transverse markings in the yolk-spherules have been made oblique by the artist.

Fig. 24. Fully formed ovum containing a second nucleus (*x*), probably about to be employed as pabulum; from the same ovary as fig. 5. The follicular epithelium is much thicker on the side adjoining the stroma than on the upper side of the ovum. Zeiss F, ocul. 2. *Osmic acid*.

Fig. 25. A. Ovum from the same ovary as fig. 21, containing in the yolk three peculiar bodies, similar in appearance to the two small bodies in the germinal vesicle. B. Germinal vesicle of a large ovum from the same ovary, containing a body of a strikingly similar appearance to those in the body of the ovum in A. Zeiss E, ocul. 2. *Picric acid*.

Fig. 26. Section of the ovary of a young female of *Scyllium stellare* 16½ centimetres in length. The ovary is exceptional, on account of the large size of the stroma ingrowths into the epithelium. Zeiss C, ocul. 2. *Osmic acid*.

Fig. 27. Ovum of *Scyllium canicula*, 5 mm. in diameter, treated with osmic acid. The figure illustrates the development of the yolk and a peculiar mode of proliferation of the germinal spots. Zeiss A, ocul. 2.

Fig. 28. Small part of the follicular epithelium and egg membranes of a somewhat larger ovum of *Scyllium canicula* than fig. 22. Zeiss D D, ocul. 2.

Fig. 29. The same parts as in fig. 28, from a still larger ovum. Zeiss D D, ocul. 2.

Fig. 30. Ovum of *Raja* with follicular epithelium. Zeiss C, ocul. 2.

Fig. 31. Small portion of a larger ovum of *Raja* than fig. 30. Zeiss D D, ocul. 2.

Fig. 32. Follicular epithelium, &c., from an ovum of *Raja* still larger than fig. 31. Zeiss D D, ocul. 2.

Fig. 33. Surface view of follicular epithelium from an ovum of *Raja* of about the same age as fig. 32.

Fig. 34. Vertical section through the superficial part of an ovary of an adult *Raja* to shew the relation of the pseudo-epithelium to the subjacent stroma. Zeiss D D, ocul. 2.

PLATE 26.

COMPLETE LIST OF REFERENCE LETTERS.

d. o. Developing ovum. *f. c.* Cells which will form the follicular epithelium. *f. e.* Follicular epithelium. *g. e.* Germinal epithelium. *mg.* Malpighian body. *n.* Nest of cells of the germinal epithelium. *n. d.* Nuclei in the act of dividing. *a.* Permanent

ovum. *ov.* Ovary. *p o.* Primitive ovum. *t.* Tubuliferous tissue, derived from Malpighian bodies.

Fig. 35. Transverse section through the ovary of an embryo rabbit of eighteen days, hardened in osmic acid. The colours employed are intended to render clear the distinction between the germinal epithelium (*g e.*) and the tubuliferous tissue (*t.*), which has grown in from the Wolffian body, and which gives rise in the male to parts of the tubuli seminiferi. Zeiss A, ocul. 2.

Fig. 35 A. Transverse section through a small part of the ovary of an embryo from the same female as fig. 35, hardened in picric acid, shewing the relation of the germinal epithelium to the subjacent tissue. Zeiss D D, ocul. 2.

Fig. 35 B. Longitudinal section through part of the Wolffian body and the anterior end of the ovary of an eighteen days' embryo, to shew the derivation of tubuliferous tissue (*t.*) from the Malpighian bodies, close to the anterior extremity of the ovary. Zeiss A, ocul. 1.

Fig. 36. Transverse section through the ovary of an embryo rabbit of twenty-two days, hardened in osmic acid. It is coloured in the same manner as fig. 35. Zeiss A, ocul. 2.

Fig. 36 A. Transverse section through a small part of the ovary of an embryo, from the same female as fig. 36, hardened in picric acid, shewing the relation of the germinal epithelium to the stroma of the ovary. Zeiss D D, ocul. 2.

Figs. 37 and 37 A. The same parts of an ovary of a twenty-eight days' embryo as figs. 36 and 36 A of a twenty-two days' embryo.

Fig. 38. Ovary of a rabbit five days after birth, coloured in the same manner as figs. 35, 36 and 37, but represented on a somewhat smaller scale. *Picric acid.*

Fig. 38 A. Vertical section through a small part of the surface of the same ovary as fig. 38. Zeiss D D, ocul. 2.

Fig. 38 B. Small portion of the deeper layer of the germinal epithelium of the same ovary as fig. 38. The figure shews the commencing differentiation of the cells of the germinal epithelium into true ova and follicle cells. Zeiss D D, ocul. 2.

Fig. 39 A. Section through a small part of the middle region of the germinal epithelium of a rabbit seven days after birth. Zeiss D D, ocul. 2.

Fig. 39 B. Section through a small part of the innermost layer of the germinal epithelium of a rabbit seven days after birth, shewing the formation of Graafian follicles. Zeiss D D, ocul. 2.

Figs. 40 A and 40 B. Small portions of the middle region of the germinal epithelium of a rabbit four weeks after birth. Zeiss D D, ocul. 2.

Fig. 41. Graafian follicle with two ova, about to divide into two follicles, from a rabbit six weeks after birth. Zeiss D D, ocul. 2.

EXPLANATION OF PLATES 27 AND 28. (XIII. p. 618.)

COMPLETE LIST OF REFERENCE LETTERS.

ao. Aorta. *cv.* Cardinal vein. *gl.* Glomerulus. *gr*₁. First groove of head-kidney. *gr*₂. Second groove of head-kidney. *gr*₃. Third groove of head-kidney.

ge. Germinal epithelium. *mr b.* Malpighian body. *me.* Mesentery. *md.* Müllerian duct. *r₁.* First ridge of head-kidney. *r₂.* Second ridge of head-kidney. *r₃.* Third ridge of head-kidney. *Wd.* Wolffian duct. *x.* Fold in germinal epithelium.

PLATE 27.

SERIES A. Sections through the head-kidney at our second stage. Zeiss 2, ocul. 3 (reduced one-third). The second and third grooves are represented with the ridge connecting them, and the rod of cells running backwards for a short distance.

No. 1. Section through the second groove.

No. 2. Section through the ridge connecting the second and third grooves.

No. 3. Section passing through the same ridge at a point nearer the third groove.

Nos. 4, 5, 6. Sections through the third groove.

No. 7. Section through the point where the third groove passes into the solid rod of cells.

No. 8. Section through the rod when quite separated from the germinal epithelium.

No. 9. Section very near the termination of the rod.

No. 10. Last section in which any trace of the rod is seen.

SERIES B. Sections passing through the head-kidney at our third stage. Zeiss C, ocul. 2. Our figures are representations of the following sections of the series, section 1 being the first which passes through the anterior groove of the head-kidney.

No. 1	SECTION	3.		No. 8	SECTION	13.
„ 2	„	4.		„ 9	„	15.
„ 3	„	5.		„ 10	„	16.
„ 4	„	6.		„ 11	„	17.
„ 5	„	8.		„ 12	„	18.
„ 6	„	10.		„ 13	„	19.
„ 7	„	11.		„ 14	„	20.

The Müllerian duct extends through eleven more sections.

The first groove (*gr₁.*) extends to No. 3.

The second groove (*gr₂.*) extends from No. 4 to No. 7.

The third groove (*gr₃.*) extends from No. 11 to No. 13.

The first ridge (*r₁.*) extends from No. 2 to No. 5.

The second ridge (*r₂.*) extends from No. 8 to No. 11.

The third ridge (*r₃.*) extends from No. 13 backwards through twelve sections, when it terminates by a pointed extremity.

FIG. C. Section through the ridge connecting the second and third grooves of the head-kidney of an embryo slightly younger than that from which Series B was taken. Zeiss C, ocul. 3 (reduced one-third).

The fold of the germinal epithelium, which gives rise to a deep groove (*x.*) external to the head-kidney is well marked.

SERIES G. Sections through the rod of cells constituting the termination of the Müllerian duct at a stage in which the head-kidney is still present. Zeiss C, ocul. 2.

PLATE 28.

SERIES D. Sections chosen at intervals from a complete series traversing the peritoneal opening of the Müllerian duct, the remnant of the head-kidney, and the termination of the Müllerian duct. Zeiss C, ocul. 3 (reduced one-third).

Nos. 1 and 2. Sections through the persistent anterior opening of the head-kidney (abdominal opening of Müllerian duct). The approach of the Wolffian duct to the groove may be seen by a comparison of these two figures. In the sections in front of these (not figured) the two are much more widely separated than in No. 1.

No. 3. Section through the Müllerian duct, just posterior to the persistent opening.

Nos. 4 and 5. Remains of the ridges, which at an earlier stage connected the first and second grooves, are seen passing from the Müllerian duct to the peritoneal epithelium.

No. 6. Rudiment of the second groove (gr_2) of the head-kidney.

Between 6 and 7 is a considerable interval.

No. 7. All traces of this groove (gr_2) have vanished, and the Müllerian duct is quite disconnected from the epithelium.

No. 8. Rudiment of the third groove (gr_3).

No. 9. Müllerian duct quite free in the space between the peritoneal epithelium and the Wolffian duct, in which condition it extends until near its termination.

Between Nos. 9 and 10 is an interval of eight sections.

No. 10. The penultimate section in which the Müllerian duct is seen. A lumen cannot be clearly made out.

No. 11. The last section in which any trace of the Müllerian duct is visible. No line of demarcation can be seen separating the solid end of the Müllerian duct from the ventral wall of the Wolffian duct.

FIGS. E. and F. Sections through the glomerulus of the head-kidney from an embryo prior to the appearance of the head-kidney. Zeiss B, ocul. 2. A comparison of the two figures shews the variation in the thickness of the stalk of the glomerulus. E. Section anterior to the foremost Malpighian body. F. Section through both the glomerulus of the head-kidney and that of a Malpighian body. The two are seen to be connected.

SERIES H. Consecutive sections through the hind end of the Müllerian duct, from an embryo in which the head-kidney was only represented by a rudiment. (The embryo was, perhaps, very slightly older than that from which Series D was taken.) Zeiss C, ocul. 3 (reduced one-third).

No. 1. Müllerian duct is without a lumen, and quite distinct from the Wolffian wall.

No. 2. The solid end of the Müllerian duct is no longer distinct from the internal wall of the Wolffian duct.

No. 3. All trace of the Müllerian duct has vanished.

SERIES I. Sections through the hinder end of the Müllerian duct from an embryo of about the middle of the sixth day. Zeiss C, ocul. 2 (reduced one-third).

No. 1. The Müllerian duct is distinct and small.

No. 2. Is posterior by twelve sections to No. 1. The Müllerian duct is dilated, and its cells are vacuolated.

No. 3. Penultimate section, in which the Müllerian duct is visible; it is separated by three sections from No. 2.

No. 4. Last section in which any trace of the Müllerian duct is visible; the lumen, which was visible in the previous section, is now absent.

No. 5. No trace of Müllerian duct. Nos. 3, 4, and 5 are consecutive sections.

FIG. K. Section through the hind end of the abdominal opening of the Müllerian duct of a chick of 123 hours. Zeiss C, ocul. 2 (reduced one-third). It illustrates the peculiar cord connecting the Müllerian and Wolffian ducts.

EXPLANATION OF PLATE 29. (XIV. p. 644.)

COMPLETE LIST OF REFERENCE LETTERS.

am. Amnion. *ch.* Notochord. *ch'*. Notochordal thickening of hypoblast.
ep. Epiblast. *hy.* Hypoblast. *m.g.* Medullary groove. *me.p.* Mesoblastic plate.
ne. Neurenteric canal (blastopore). *pr.* Primitive streak.

SERIES A. Sections through an embryo shortly after the formation of the medullary groove. $\times 120^1$.

Fig. 1. Section through the trunk of the embryo.

Figs. 2—5. Sections through the neurenteric canal.

Fig. B. Surface view of a somewhat older embryo than that from which Series A is taken. $\times 30$.

SERIES B. Sections through the embryo represented in Fig. B. $\times 120$.

Fig. 1. Section through the trunk of the embryo.

Figs. 2, 3. Sections through the hind end of the medullary groove.

Fig. 4. Section through the neurenteric canal.

Fig. 5. Section through the primitive streak.

Fig. C. Surface view of a somewhat older embryo than that represented in Fig. B. $\times 30$.

EXPLANATION OF PLATES 30, 31, 32. (XVII. p. 668.)

PLATE 30.

COMPLETE LIST OF REFERENCE LETTERS.

ch. Chelicerae. *ch.g.* Ganglion of chelicerae. *c.l.* Caudal lobe. *p.c.* Primitive cumulus. *pd.* Pedipalpi. *pr.l.* Præoral lobe. *pp¹*, *pp²*, etc. Provisional appendages. *sp.* Spinnerets. *st.* Stomodæum.

I—IV. Ambulatory appendages. 1—16. Postoral segments.

Fig. 1. Ovum, with primitive cumulus and streak proceeding from it.

¹ The spaces between the layers in these sections are due to the action of the hardening re-agent.

Fig. 2. Somewhat later stage, in which the primitive cumulus is still visible. Near the opposite end of the blastoderm is a white area, which is probably the rudiment of the procephalic lobe.

Fig. 3*a* and 3*b*. View of an embryo from the ventral surface and from the side when six segments have become established.

Fig. 4. View of an embryo, ideally unrolled, when the first rudiments of the appendages become visible.

Fig. 5. Embryo ideally unrolled at the stage when all the appendages have become established.

Fig. 6. Somewhat older stage, when the limbs begin to be jointed. Viewed from the side.

Fig. 7. Later stage, viewed from the side.

Fig. 7*a*. Same embryo as fig. 7, ideally unrolled.

Figs. 8*a* and 8*b*. View from the ventral surface and from the side of an embryo, after the ventral flexure has considerably advanced.

Fig. 9. Somewhat older embryo, viewed from the ventral surface.

PLATES 31 AND 32.

COMPLETE LIST OF REFERENCE LETTERS.

ao. Aorta. *ab. g.* Abdominal nerve cord. *ch.* Chelicerae. *ch. g.* Ganglion of chelicerae. *ep.* Epiblast. *hs.* Hemispherical lobe of supra-oesophageal ganglion. *ht.* Heart. *ll.* Lower lip. *m.* Muscles. *me.* Mesoblast. *mes.* Mesenteron. *mp. g.* Malpighian tube. *ms.* Mesoblastic somite. *ø.* Oesophagus. *p. c.* Pericardium. *pd.* Pedipalpi. *pd. g.* Ganglion of pedipalpi. *pr.* Proctodæum (rectum). *pr. c.* Primitive cumulus. *s.* Septum in abdomen. *so.* Somatopleure. *sp.* Splanchnopleure. *st.* Stomodæum. *su.* Suctorial apparatus. *su. g.* Supra-oesophageal ganglion. *th. g.* Thoracic ganglion. *v. g.* Ventral nerve cord. *y. c.* Cells derived from yolk. *yk.* Yolk. *n.* Nuclei of yolk cells.

I *g*—IV *g.* Ganglia of ambulatory limbs. 1—16. Postoral segments.

Fig. 10. Section through an ovum, slightly younger than fig. 1. Shewing the primitive cumulus and the columnar character of the cells of one half of the blastoderm.

Fig. 11. Section through an embryo of the same age as fig. 2. Shewing the median thickening of the blastoderm.

Fig. 12. Transverse section through the ventral plate of a somewhat older embryo. Shewing the division of the ventral plate into epiblast and mesoblast.

Fig. 13. Section through the ventral plate of an embryo of the same age as fig. 3, shewing the division of the mesoblast of the ventral plate into two mesoblastic bands.

Fig. 14. Transverse section through an embryo of the same age as fig. 5, passing through an abdominal segment above and a thoracic segment below.

Fig. 15. Longitudinal section slightly to one side of the middle line through an embryo of the same age.

Fig. 16. Transverse section through the ventral plate in the thoracic region of an embryo of the same age as fig. 7.

Fig. 17. Transverse section through the procephalic lobes of an embryo of the same age. *gr.* Section of hemicircular groove in procephalic lobe.

Fig. 18. Transverse section through the thoracic region of an embryo of the same age as fig. 8.

Fig. 19. Section through the procephalic lobes of an embryo of the same age.

Fig. 20 *a, b, c, d, e.* Five sections through an embryo of the same age as fig. 9. *a* and *b* are sections through the procephalic lobes, *c* through the front part of the thorax. *d* cuts transversely the posterior parts of the thorax, and longitudinally and horizontally the ventral surface of the abdomen. *e* cuts the posterior part of the abdomen longitudinally and horizontally, and shews the commencement of the mesenteron.

Fig. 21. Longitudinal and vertical section of an embryo of the same age. The section passes somewhat to one side of the middle line, and shews the structure of the nervous system.

Fig. 22. Transverse section through the dorsal part of the abdomen of an embryo of the same stage as fig. 9.

EXPLANATION OF PLATE 33. (XX. p. 714.)

Fig. 1. Transverse section through the pelvic fin of an embryo of *Scyllium* belonging to stage P¹, magnified 50 diameters. *bp.* basipterygium. *br.* fin ray. *m.* muscle. *hf.* horny fibres supporting the peripheral part of the fin.

Fig. 2. Pelvic fin of a very young female embryo of *Scyllium stellare*, magnified 16 diameters. *bp.* basipterygium. *pu.* pubic process of pelvic girdle (cut across below). *il.* iliac process of pelvic girdle. *fo.* foramen.

Fig. 3. Pelvic fin of a young male embryo of *Scyllium stellare*, magnified 16 diameters. *bp.* basipterygium. *mo.* process of basipterygium continued into clasper. *il.* iliac process of pelvic girdle. *pu.* pubic section of pelvic girdle.

Fig. 4. Transverse section through the ventral part of the trunk of an embryo *Scyllium* of stage P, in the region of the pectoral fins, to shew how the fins are attached to the body, magnified 18 diameters. *br.* cartilaginous fin-ray. *bp.* basipterygium. *m.* muscle of fin. *mp.* muscle-plate.

Fig. 5. Transverse section through the ventral part of the trunk of an embryo *Scyllium* of stage P, in the region of the pelvic fin, on the same scale as fig. 4. *bp.* basipterygium. *br.* cartilaginous fin-rays. *m.* muscle of the fins. *mp.* muscle-plate.

Fig. 6. Pectoral fin of an embryo of *Scyllium canicula*, of a stage between O and P, in longitudinal and horizontal section (the skeleton of the fin was still in the condition of embryonic cartilage), magnified 36 diameters. *bp.* basipterygium (eventual

¹ I employ here the same letters to indicate the stages as in my "Monograph on Elasmobranch Fishes."

metapterygium). *fr.* cartilaginous fin-rays. *pg.* pectoral girdle in transverse section. *fo.* foramen in pectoral girdle. *pe.* epithelium of peritoneal cavity.

Fig. 7. Transverse section through the pectoral fin of a *Scyllium* embryo of stage P, magnified 50 diameters. *bp.* basiptyerygium. *br.* cartilaginous fin-ray. *m.* muscle. *hf.* horny fibres.

Fig. 8. Pectoral fin of an embryo of *Scyllium stellare*, magnified 16 diameters. *mp.* metapterygium (basiptyerygium of earlier stage). *me.p.* rudiment of future pro- and mesopterygium. *sc.* cut surface of a scapular process. *cr.* coracoid process. *fr.* foramen. *hf.* horny fibres.

Fig. 9. Skeleton of the pectoral fin and part of pectoral girdle of a nearly ripe embryo of *Scyllium stellare*, magnified 10 diameters. *mp.* metapterygium. *mes.* mesopterygium. *pp.* proptyerygium. *cr.* coracoid process.

EXPLANATION OF PLATES 34—42. (XXII. p. 738.)

LIST OF REFERENCE LETTERS.

a. Anus. *ab.* Air-bladder. *ab.* Aperture of air-bladder into throat. *ac.* Anterior commissure. *af.* Anal fin. *al.* Alimentary canal. *ao.* Aorta. *ar.* Artery. *au.* Auditory pit. *b.* Brain. *bc.* Body-cavity. *bd.* Bile duct. *bd.* Aperture of bile duct into duodenum. *bl.* Coalesced portion of segmental ducts, forming urino-genital bladder. *bra.* Branchial arches. *brc.* Branchial clefts. *c.* Pyloric cæca. *c.* Apertures of cæca into duodenum. *cb.* Cerebellum. *cdv.* Cardinal vein. *cc.* Cerebrum: in figs. 47 A and B, anterior lobe of cerebrum. *cd.* Posterior lobe of cerebrum. *cf.* Caudal fin. *cn.* Centrum. *ch.* Choroidal fissure. *crv.* Circular vein of vascular membrane of eye. *csk.* Cuticular sheath of notochord. *cv.* Caudal vein. *d.* Duodenum. *dc.* Dorsal cartilage of neural arch. *df.* Dermal fin-rays. *dl.* Dorsal lobe of caudal fin. *dlf.* Dorsal fin. *e.* Eye. *ed.* Epidermis. *ep.* Epiblast. *fb.* Fore-brain. *fe.* Pyriform bodies surrounding the zona radiata of the ovum, probably the remains of epithelial cells. *gb.* Gall-bladder. *gd.* Genital duct. *gl.* Glomerulus. *gr.* Genital ridge. *h.* Heart. *ha.* Hæmal arch. *hb.* Hind-brain. *hc.* Head-cavity. *hp d.* Hepatic duct. *hm.* Hyomandibular cleft. *hop.* Operculum. *hy.* Hypoblast; in fig. 10, hyoid arch. *hyl.* Hyaloid membrane. *ic.* Intercalated cartilaginous elements of the neural arches. *in.* Infundibulum. *ir.* Iris. *is.* Interspinous cartilage or bones. *iv.* Sub-intestinal vein. *ivr.* Intervertebral ring of cartilage. *k.* Kidney. *l.* Lens. *lc.* Longitudinal canal, formed by union of the vasa efferentia. *lin.* Lobi inferiores. *ll.* Ligamentum longitudinale superius. *lr.* Liver. *lt.* Lateral line. *ly.* Lymphatic body in front of kidney. *m.* Mouth. *mb.* Mid-brain. *mc.* Medullary cord. *mel.* Membrana elastica externa. *mes.* Mesorchium. *mn.* Mandible. *md.* and *mo.* Medulla oblongata. *ms.* Mesoblast. *na.* Neural arch. *na.* Dorsal element of neural arch. *nc.* Notochord. *nve.* Network formed by vasa efferentia on inner face of testis. *od.* Oviduct. *od.* Aperture of oviduct into bladder. *ol.* Nasal pit or aperture. *olf.* Olfactory lobe. *op.* Optic vesicle. *opch.* Optic chiasma. *opl.* Optic lobes. *opth.* Optic thalami. *or ep.* Oral epithelium. *ov.* Ovary. *p.* Pancreas. *pc.* Pericardium. *pcf.* Pectoral fin.

pch. Pigmented layer of choroid. *pf.* Peritoneal funnel of segmental tube of mesonephros. *pfp.* Peritoneal funnel leading into pronephric chamber. *pg.* Pectoral girdle. *plf.* Pelvic fin. *pn.* Pineal gland. *po.* Primitive germinal cells. *pr.* Mesoblastic somite. *prc.* Pronephric chamber. *prn.* Pronephros. *prn'*. Opening of pronephros into pronephric chamber. *pt.* Pituitary body. *py.* Pyloric valve. *pz.* Parietal zone of blastoderm. *r.* Rostrum. *rb.* Rib. *rc.* Rectum. *s.* Spleen. *sc.* Seminal vessels passing from the longitudinal canal into the kidney. *sd.* Suctorial disc. *sg.* Segmental or archinephric duct. *sgt.* Segmental tubules. *sh.* Granular outer portion of the sheath of the notochord in the vertebral regions. *smx.* Superior maxillary process. *sn.* Sub-notochordal rod. *so.* Somatic mesoblast. *sp.* Splanchnic mesoblast. *spn.* Spinal nerve. *spv.* Spiral valve. *st.* Stomach. *st.* Seminal tubes of the testis. *sup.* Suctorial papillæ. *t.* Testis. *th.* Thalamencephalon. *thl.* Lobes of the roof of the thalamencephalon. *tr.* Trabeculæ. *ug.* Urinogenital aperture. *v.* Ventricle. *ve.* Vasa efferentia. *vh.* Vitreous humour. *vl.* Ventral lobe of the caudal fin. *vm.* Ventral mesentery. *vn.* Vein. *vs.* Blood-vessel. *vsh.* Vascular sheath between the hyaloid membrane and the vitreous humour. *vth.* Vesicle of the thalamencephalon. *x.* Groove in epiblast, probably formed in process of hardening. *y.* Yolk. *z.* Commissure in front of pineal gland. *zr.* Outer striated portion of investing membrane (zona radiata) of ovum. *zr'*. Inner non-striated portion of investing membrane of ovum. I. Olfactory nerve. II. Optic nerve. III. Oculomotor nerve. V. Trigeminal nerve. VIII. Facial and auditory nerves.

PLATE 34.

Figs. 1—4. Different stages in the segmentation of the ovum.

Fig. 1. Ovum with a single vertical furrow, from above.

Fig. 2. Ovum with two vertical furrows, from above.

Fig. 3. Side view of an ovum with a completely formed blastodermic disc.

Fig. 4. The same ovum as fig. 3, from below, shewing four vertical furrows nearly meeting at the vegetative pole.

Figs. 5—10. External views of embryos up to time of hatching.

Fig. 5. Embryo, 3.5 millims. long, third day after impregnation.

Fig. 6. Embryo on the fifth day after impregnation.

Fig. 7. Posterior part of same embryo as fig. 6, shewing tail swelling.

Fig. 8. Embryo on the sixth day after impregnation.

Fig. 9. Embryo on the seventh day after impregnation.

Fig. 10. Embryo on the eleventh day after impregnation (shortly before hatching).

Fig. 11. Head of embryo about the same age as fig. 10, ventral aspect.

Fig. 12. Side view of a larva about 11 millims. in length, shortly after hatching.

Fig. 13. Head of a larva about the same age as fig. 12, ventral aspect.

Fig. 14. Side view of a larva about 15 millims. long, five days after hatching.

Fig. 15. Head of a larva 23 millims. in length.

Fig. 16. Tail of a larva 11 centims. in length.

Fig. 17. Transverse section through the egg-membranes of a just-laid ovum.

We are indebted to Professor W. K. Parker for figs. 12, 14 and 15.

PLATE 35.

- Figs. 18—22. Transverse sections of embryo on the third day after impregnation.
- Fig. 18. Through head, shewing the medullary keel.
- Fig. 19. Through anterior part of trunk.
- Fig. 20. Through same region as fig. 19, shewing a groove (α) in the epiblast, probably artificially formed in the process of hardening.
- Fig. 21. Through anterior part of tail region, shewing partial fusion of layers.
- Fig. 22. Through posterior part of tail region, shewing more complete fusion of layers than fig. 21.
- Figs. 23—25. Transverse sections of an embryo on the fifth day after impregnation.
- Fig. 23. Through fore-brain and optic vesicles.
- Fig. 24. Through hind-brain and auditory pits.
- Fig. 25. Through anterior part of trunk.
- Figs. 26—27. Transverse sections of the head of an embryo on the sixth day after impregnation.
- Fig. 26. Through fore-brain and optic vesicles.
- Fig. 27. Through hind-brain and auditory pits.

PLATE 36.

- Figs. 28—29. Transverse sections of the trunk of an embryo on the sixth day after impregnation.
- Fig. 28. Through anterior part of trunk (from a slightly older embryo than the other sections of this stage).
- Fig. 29. Slightly posterior to fig. 28, shewing formation of segmental duct as a fold of the somatic mesoblast.
- Fig. 30. Longitudinal horizontal section of embryo on the sixth day after impregnation, passing through the mesoblastic somites, notochord, and medullary canal.
- Figs. 31—34. Transverse sections through an embryo on the seventh day after impregnation.
- Fig. 31. Through anterior part of trunk.
- Fig. 32. Through the trunk somewhat behind fig. 31.
- Fig. 33. Through tail region.
- Fig. 34. Further back than fig. 33, shewing constriction of tail from the yolk.
- Figs. 35—37. Transverse sections through an embryo on the eighth day after impregnation.
- Fig. 35. Through fore-brain and optic vesicles.
- Fig. 36. Through hind-brain, shewing closed auditory pits, &c.
- Fig. 37. Through anterior part of trunk.
- Fig. 38. Section through tail of an embryo on the ninth day after impregnation.

PLATE 37.

Fig. 39. Section through the olfactory involution and part of fore-brain of a larva on the ninth day after impregnation, shewing olfactory nerve.

Fig. 40. Section through the anterior part of the head of the same larva, shewing pituitary involution.

Figs. 41—43. Transverse sections through an embryo on the eleventh day after impregnation.

Fig. 41. Through fore-part of head, shewing the pituitary body still connected with the oral epithelium.

Fig. 42. Slightly further back than fig. 41, shewing the pituitary body constricted off from the oral epithelium.

Fig. 43. Slightly posterior to fig. 42, to shew olfactory involution, eye, and hyomandibular cleft.

Fig. 44. Longitudinal section of the head of an embryo of 15 millims. in length, a few days after hatching, shewing the structure of the brain.

Fig. 45. Longitudinal section of the head of an embryo, about five weeks after hatching, 26 millims. in length, shewing the structure of the brain. In the front part of the brain the section passes slightly to one side of the median line.

Figs. 46 A to 46 G. Transverse sections through the brain of an embryo 25 millims. in length, about a month after hatching.

Fig. 46 A. Through anterior lobes of cerebrum.

Fig. 46 B. Through posterior lobes of cerebrum.

Fig. 46 C. Through thalamencephalon.

Fig. 46 D. Through optic thalami and optic chiasma.

Fig. 46 E. Through optic lobes and infundibulum.

Fig. 46 F. Through optic lobes and cerebellum.

Fig. 46 G. Through optic lobes and cerebellum, slightly in front of fig. 46 F.

PLATE 38.

Figs. 47 A, B, C. Figures of adult brain.

Fig. 47 A. From the side.

Fig. 47 B. From above.

Fig. 47 C. From below.

Fig. 48. Longitudinal vertical section through the eye of an embryo, about a week after hatching, shewing the vascular membrane surrounding the vitreous humour.

Fig. 49. Diagram shewing the arrangement of the vessels in the vascular membrane of the vitreous humour of adult eye.

Fig. 50. Capillaries of the same vascular membrane.

Fig. 51. Transverse section through anterior part of trunk of an embryo on the ninth day after impregnation, shewing the pronephros and pronephric chamber.

Fig. 52. Transverse section through the region of the stomach of an embryo 15 millims. in length, shortly after hatching, to shew the glomerulus and peritoneal funnel of pronephros.

Fig. 53. Transverse section through posterior part of the body of an embryo, about a month after hatching, shewing the structure of the mesonephros, the spiral valve, &c.

PLATE 39.

Figs. 54, 55, 56, and 57 are a series of transverse sections through the genital ridge and mesonephros of one side from a larva of 11 centims.

Fig. 54. Section of the lymphatic organ which lies in front of the mesonephros.

Fig. 55. Section near the anterior end of the mesonephros, where the genital sack is completely formed.

Fig. 56. Section somewhat further back, shewing the mode of formation of the genital sack.

Fig. 57. Section posterior to the above, the formation of the genital sack not having commenced, and the genital ridge with primitive germinal cells projecting freely into the body-cavity.

Fig. 58 A. View of the testis, mesorchium, and duct of the kidney of the left side of an adult male example of *Lepidosteus*, 60 centims. in length, shewing the vasa efferentia and the longitudinal canal at the base of the mesorchium. The kidney ducts have been cut open posteriorly to shew the structure of the interior.

Fig. 58 B. Inner aspect of the posterior lobe of the testis from the same example, to shew the vasa efferentia forming a network on the face of the testis.

Figs. 59 A and B. Two sections shewing the structure and relations of the efferent ducts of the testis in the same example.

Fig. 59 A. Section through the inner aspect of a portion of the testis and mesorchium, to shew the network of the vasa efferentia (*n v e*) becoming continuous with the seminal tubes (*st*). The granular matter nearly filling the vasa efferentia and the seminal tubes represent the spermatozoa.

Fig. 59 B. Section through part of the kidney and its duct and the longitudinal canal (*lc*) at the base of the mesorchium. Canals (*sc*) are seen passing off from the latter, which enter the kidney and join the uriniferous tubuli. Some of the latter (as well as the seminal tubes) are seen to be filled with granular matter, which we believe to be the remains of spermatozoa.

Fig. 60. Diagram of the urinogenital organs of the left side of an adult female example of *Lepidosteus* 100 centims. in length. This figure shews the oviduct (*od*) continuous with the investment of the ovary, opening at *od'* into the dilated part of the kidney duct (segmental duct). It also shews the segmental duct and the junction of the latter with its fellow of the right side to form the so-called bladder, this part being represented as cut open. The kidney (*k*) and lymphatic organ (*ly*) in front of it are also shewn.

PLATE 40.

Fig. 61. Transverse section through the developing pancreas (*p*) of a larva 11 millims. in length.

Fig. 62. Longitudinal section through portions of the stomach, liver, and duodenum of an embryo about a month after hatching, to shew the relations of the pancreas (*p*) to the surrounding parts.

Fig. 63. External view of portions of the liver, stomach, duodenum, &c., of a young Fish, 11 centims. in length, to shew the pancreas (*p*).

Fig. 64. Transverse section through the anterior part of the trunk of an embryo, about a month after hatching, shewing the connection of the air-bladder with the throat (*a b'*).

Fig. 65. Transverse section through the same embryo as fig. 64 further back, shewing the posterior part of the air-bladder (*a b*).

Fig. 66. Viscera of an adult female, 100 centims. in length, shewing the alimentary canal with its appended glands in natural position, and the air-bladder with its aperture into the throat (*a b'*). The proximal part of the duodenum and the terminal part of the intestine are represented as cut open, the former to shew the pyloric valve and the apertures of the pyloric cæca and bile duct, and the latter to shew the spiral valve.

This figure was drawn for us by Professor A. C. Haddon.

PLATE 41.

Fig. 67. Transverse section through the tail of an advanced larva, shewing the neural and hæmal processes, the independently developed interneural and interhæmal elements (*i s*), and the commencing dermal fin-rays (*d f*).

Fig. 68. Side view of the tail of a larva, 21 millims. in length, dissected so as to shew the structure of the skeleton.

Fig. 69. Longitudinal horizontal section through the vertebral column of a larva, 5.5 centims. in length, on the level of the hæmal arches, shewing the intervertebral rings of cartilage continuous with the arches, the vertebral constriction of the notochord, &c.

Figs. 70 and 71. Transverse sections through the vertebral column of a larva of 5.5 centims. The red represents bone, and the blue cartilage.

Fig. 70. Through the vertebral region, shewing the neural and hæmal arches, the notochordal sheath, &c.

Fig. 71. Through the intervertebral region, shewing the intervertebral cartilage.

Figs. 72 and 73. Transverse sections through the trunk of a larva of 5.5 centims. to shew the structure of the ribs and hæmal arches.

Fig. 72. Through the anterior part of the trunk.

Fig. 73. Through the posterior part of the trunk.

PLATE 42.

Figs. 74—76. Transverse sections through the trunk of the same larva as figs. 72 and 73.

Fig. 74. Through the posterior part of the trunk (rather further back than fig. 73).

Fig. 75. Through the anterior part of the tail.

Fig. 76. Rather further back than fig. 75.

Fig. 77. Longitudinal horizontal section through the vertebral column of a larva of 11 centims., passing through the level of the hæmal arches, and shewing the intervertebral constriction of the notochord, the ossification of the cartilage, &c.

Fig. 78. Transverse section through a vertebral region of the vertebral column of a larva 11 centims. in length.

Fig. 79. Transverse section through an intervertebral region of the same larva as fig. 78.

Fig. 80. Side view of two trunk vertebræ of an adult *Lepidosteus*.

Fig. 81. Front view of a trunk vertebra of adult.

In figures 80 and 81 the red does not represent bone as in the other figures, but simply the ligamentum longitudinale superius.

EXPLANATION OF PLATES 43—45. (XXIV. p. 854.)

N.B. The series of sections are in all cases numbered from before backwards.

LIST OF REFERENCE LETTERS.

a. p. Area pellucida. *ep.* Epiblast. *ch.* Notochord. *gr.* Germinal wall. *hy.* Hypoblast. *m.* Mesoblast. *o. p.* Area opaca. *pr. g.* Primitive groove. *pv s.* Primitive streak. *yk.* Yolk of germinal wall.

PLATE 43.

SERIES A, 1 and 2. Sections through the blastoderm before the appearance of primitive streak.

1. Section through anterior part of area pellucida in front of embryonic shield. The hypoblast here forms an imperfect layer. The figure represents about half the section. 2. Section through same blastoderm, in the region of the embryonic shield. Between the epiblast and hypoblast are a number of undifferentiated cells. The figure represents considerably more than half the section.

SERIES B, 1, 2 and 3. Sections through a blastoderm with a very young primitive streak.

1. Section through the anterior part of the area pellucida in front of the primitive streak. 2. Section through about the middle of the primitive streak. 3. Section through the posterior part of the primitive streak.

SERIES C, 1 and 2. Sections through a blastoderm with a young primitive streak.

1. Section through the front end of the primitive streak. 2. Section through the primitive streak, somewhat behind 1. Both figures shew very clearly the difference in character between the cells of the epiblastic mesoblast of the primitive streak, and the more granular cells of the mesoblast derived from the hypoblast.

FIG. D. Longitudinal section through the axial line of the primitive streak, and the part of the blastoderm in front of it, of an embryo duck with a well-developed primitive streak.

PLATE 44.

SERIES E, 1, 2, 3 and 4. Sections through blastoderm with a primitive streak, towards the end of the first stage.

1. Section through the anterior part of the area pellucida. 2. Section a little way behind 1 shewing a forward growth of mesoblast from the primitive streak. 3. Section through primitive streak. 4. Section through posterior part of primitive streak, shewing the great widening of primitive streak behind.

SERIES F, 1 and 2. Sections through a blastoderm with primitive groove.

1. Section shewing a deep pit in front of primitive streak, probably an early indication of the neurenteric canal. 2. Section immediately following 1.

FIG. G. Section through blastoderm with well-developed primitive streak, shewing an exceptionally deep slit-like primitive groove.

SERIES H, 1 and 2. Sections through a blastoderm with a fully-developed primitive streak.

1. Section through the anterior part of area pellucida, shewing the cubical granular hypoblast cells in this region. 2. Section slightly behind 1, shewing the primitive hypoblast cells differentiated into stellate cells, which can hardly be resolved in the middle line into hypoblast and mesoblast.

PLATE 45.

SERIES I, 1, 2, 3, 4 and 5. Sections through blastoderm somewhat older than Series H.

1. Section through area pellucida well in front of primitive streak. 2. Section through area pellucida just in front of primitive streak. 3. Section through the front end of primitive streak. 4. Section slightly behind 3. 5. Section slightly behind 4.

SERIES K, 1, 2, 3, 4 and 5. Sections through a blastoderm in which the first traces of notochord and medullary groove have made their appearance. Rather more than half the section is represented in each figure, but the right half is represented in 1 and 3, and the left in 2 and 4.

1. Section through notochord immediately behind the head-fold. 2. Section shewing medullary groove a little behind 1. 3. Section just in front of the primitive streak. 4 and 5. Sections through the front end of the primitive streak.

FIG. L. Surface view of blastoderm with a very young primitive streak.

EXPLANATION OF PLATES 46—53¹. (XXV. p. 871.)

COMPLETE LIST OF REFERENCE LETTERS.

A. Anus. *a*. Dorso-lateral horn of white matter in brain. *a.g.* Accessory gland of male (modified accessory leg gland). *at*. Antenna. *at.n.* Antennary nerve. *b*. Ventro-lateral horn of white matter of brain. *b.c.* Body-cavity. *bl.* Blastopore. *c*. Cutis. *c.* Postero-dorsal lobe of white matter of brain. *c.g.* Supræesophageal ganglia. *cl.* Claw. *c.m.* Circular layer of muscles. *co.* Commissures between the ventral nerve-cords. *co.2.* Second commissure between the ventral nerve-cords. *co¹.2.* Mass of cells developed on second commissure. *cor.* Cornea. *c.s.d.* Common duct for the two salivary glands. *cu.* Cuticle. *d.* Ventral protuberance of brain. *d.l.m.* Dorsal longitudinal muscle of pharynx. *d.n.* Median dorsal nerve to integument from supræesophageal ganglia. *d.o.* Muscular bands passing from the ventro-lateral wall of the pharynx at the region of its opening into the buccal cavity. E. Eye. *e.* Central lobe of white matter of brain. *e.n.* Nerves passing outwards from the ventral cords. *ep.* Epidermis. *ep.c.* Epidermis cells. F. 1, F. 2, &c. First and second pair of feet, &c. *f.* Small accessory glandular tubes of the male generative apparatus. *F.g.* Ganglionic enlargement on ventral nerve-cord, from which a pair of nerves to foot pass off. *f.gl.* Accessory foot-gland. *F.n.* Nerves to feet. *g.co.* Commissures between the ventral nerve-cords containing ganglion cells. *g.o.* Generative orifice. H. Heart. *h.* Cells in lateral division of body-cavity. *hy.* Hypoblast. *i.j.* Inner jaw. *j.* Jaw. *j.n.* Nerves to jaws. L. Lips. *l.* Lens. *l.b.c.* Lateral compartment of body-cavity. *le.* Jaw lever (cuticular prolongation of inner jaw lying in a backwardly projecting diverticulum of the buccal cavity). *l.m.* Bands of longitudinal muscles. M. Buccal cavity. *m¹.* Median backward diverticulum of mouth or common salivary duct which receives the salivary ducts. *me.* Mesenteron. *mes.* Mesoblastic somite. *m.l.* Muscles of jaw lever. *m.s.* Sheets of muscle passing round the side walls of pharynx to dorsal body wall. *od.* Oviduct. *œ.* Œsophagus. *œ.co.* Œsophageal commissures. *o.f.g.* Orifice of duct of foot-gland. *o.j.* Outer jaw. *op.* Optic ganglion. *op.n.* Optic nerve. *or.g.* Ganglionic enlargements for oral papillæ. *or.n.* Nerves to oral papillæ. *or.p.* Oral papillæ. *o.s.* Orifice of duct of segmental organ. *ov.* Ovary. P. Pads on ventral side of foot. *p.* Common duct into which the vasa deferentia open. *p.c.* Posterior lobe of brain. *p.d.c.* Posterior commissure passing dorsal to rectum. *p.f.* Internal opening of nephridium into body cavity. *ph.* Pharynx. *pi.* Pigment in outer ends of epidermic cells. *pi.r.* Retinal pigment. *p.n.* Nerves to feet. *p.p.* Primary papilla. *pr.* Prostate. R. Rectum. *Re.* Retinal rods. *R.m.* Muscle of claw. *s.* Vesicle of nephridium. *s¹.* Part of 4th or 5th nephridium which corresponds to vesicle of other nephridia. *s.c.1.* Region No. 1 of coiled tube of nephridium. *s.c.2.* Region No. 2 of ditto. *s.c.3.* Region No. 3 of ditto. *s.c.4.* Region No. 4 of ditto. *s.d.* Salivary duct. *s.g.* Salivary gland. *sl.d.* Reservoir of slime gland. *sl.g.* Tubules of slime gland. *s.o.1,2,3, &c.* Nephridia of 1st, 2nd, &c., feet. *s.o.f.* Terminal portion of nephridium. *s.p.* Secondary papilla. *st.* Stomach. *st.e.* Epithelium of stomach. *sy.* Sympathetic nerve running in muscles of tongue and pharynx. *sy¹.* Origin of pharynx-

¹ The explanations of the figures printed within inverted commas are by Professor Balfour, the rest are by the Editors.

geal sympathetic nerves. T. Tongue. t. Teeth on tongue. te. Testis. tr. Tracheæ. tr. c. Cells found along the course of the tracheæ. tr. o. Tracheal stigma. tr. p. Tracheal pit. ut. Uterus. v. c. Ventral nerve cord. v. d. Vas deferens. v. g. Imperfect ganglia of ventral cord.

PLATE 46.

Fig. 1. *Peripatus capensis*, $\times 4$; viewed from the dorsal surface. (From a drawing by Miss Balfour.)

PLATE 47.

Fig. 2. A left leg of *Peripatus capensis*, viewed from the ventral surface; $\times 30$. (From a drawing by Miss Balfour.)

Fig. 3. A right leg of *Peripatus capensis*, viewed from the front side. (From a drawing by Miss Balfour.)

Fig. 4. The last left (17th) leg of a male *Peripatus capensis*, viewed from the ventral side to shew the papilla at the apex of which the accessory gland of the male, or enlarged crural gland, opens to the exterior. (From a drawing by Miss Balfour.) Prof. Balfour left a rough drawing (not reproduced) shewing the papilla, to which is appended the following note. "Figure shewing the accessory genital gland of male, which opens on the last pair of legs by a papilla on the ventral side. The papilla has got a slit-like aperture at its extremity."

Fig. 5. Ventral view of head and oral region of *Peripatus capensis*. (From a drawing by Miss Balfour.)

PLATE 48.

Figs. 6 and 7 are from one drawing.

Fig. 6. *Peripatus capensis* dissected so as to shew the alimentary canal, slime glands, and salivary glands; $\times 3$. (From a drawing by Miss Balfour.)

Fig. 7. The anterior end of Fig. 6 enlarged; $\times 6$. (From a drawing by Miss Balfour.) The dissection is viewed from the ventral side, and the lips, L., have been cut through in the middle line behind and pulled outwards, so as to expose the jaws, j., which have been turned outwards, and the tongue, T., bearing a median row of chitinous teeth, which branches behind into two. The junction of the salivary ducts, s. d., and the opening of the median duct so formed into the buccal cavity is also shewn. The muscular pharynx, extending back into the space between the 1st and 2nd pairs of legs, is followed by a short tubular œsophagus. The latter opens into the large stomach with plicated walls, extending almost to the hind end of the animal. The stomach at its point of junction with the rectum presents an S-shaped ventro-dorsal curve.

A. Anus. at. Antenna. F. 1, F. 2. First and second feet. j. Jaws. L. Lips. œ. œsophagus. or. p. Oral papilla. ph. Pharynx. R. Rectum. s. d. Salivary duct. s. g. Salivary gland. sl. d. Slime reservoir. sl. g. Portion of tubules of slime gland. st. Stomach. T. Tongue in roof of mouth.

Fig. 8. *Peripatus capensis*, $\times 4$; male. (From a drawing by Miss Balfour.) Dissected so as to shew the nervous system, slime glands, ducts of the latter passing

into the oral papilla, accessory glands opening on the last pair of legs (enlarged crural glands), and segmental organs, viewed from dorsal surface. The first three pairs of segmental organs consist only of the vesicle and duct leading to the exterior. The fourth and fifth pairs are larger than the succeeding, and open externally to the crural glands. The ventral nerve-cords unite behind dorsal to the rectum.

A. Anus. *a. g.* Accessory generative gland, or enlarged crural gland of the 17th leg. *at.* Antenna. *c. g.* Supra-oesophageal ganglia with eyes. *co.* Commissures between the ventral nerve-cords. *d. n.* Large median nerve to dorsal integument from hinder part of brain. F. 1, 2, &c. Feet. *g. o.* Generative orifice. *æ.* Oesophagus. *æs. co.* Oesophageal commissures. *or. p.* Oral papilla. *p. d. c.* Posterior dorsal commissure between the ventral nerve-cords. *ph.* Pharynx. *p. n.* Nerves to feet, one pair from each ganglionic enlargement. *sl. d.* Reservoir of slime gland. *sl. g.* Tubules of slime gland. *s. o.* 1, 2, 3, &c. Segmental organs. *v. c.* Ventral nerve-cords. *v. g.* Imperfect ganglia of ventral cords.

Figs. 9 and 10. Left jaw of *Peripatus capensis* (male), shewing reserve jaws. (From a drawing by Miss Balfour.)

Fig. 9. Inner jaw.

Fig. 10. Outer jaw.

PLATE 49.

Figs. 11—16. A series of six transverse sections through the head of *Peripatus capensis*.

Fig. 11. The section is taken immediately behind the junction of the supra-oesophageal ganglia, *c. g.*, and passes through the buccal cavity, *m.*, and jaws, *o. j.* and *i. j.*

Fig. 12. The section is taken through the hinder part of the buccal cavity at the level of the opening of the mouth into the pharynx and behind the jaws. The cuticular rod-like continuation (*lc.*) of the inner jaw lying in a backwardly directed pit of the buccal cavity is shewn; on the right hand side the section passes through the opening of this pit.

Fig. 13. The section passes through the front part of the pharynx, and shews the opening into the latter of the median backward diverticulum of the mouth (M^1), which receives the salivary ducts. It also shews the commencement of the ventral nerve-cords, and the backwardly projecting lobes of the brain.

Fig. 14. The section passes through the anterior part of the pharynx at the level of the second commissure (*co. 2*), between the ventral nerve-trunks, and shews the mass of cells developed on this commissure, which is in contact with the epithelium of the backward continuation of the buccal cavity (M^1).

Fig. 15. Section through the point of junction of the salivary ducts with the median oral diverticulum.

Fig. 16. Section behind the pharynx through the oesophagus.

b. c. Body-cavity. *c.* Cutis. *c. b. c.* Central compartment of body-cavity. *c. g.* Supra-oesophageal ganglia. *c. m.* Layer of circular muscles. *co.* Commissure between ventral nerve-cords. *co. 2.* Second commissure between the ventral nerve-cords. *co¹. 2.* Mass of cells developed on second commissure (probably sensory). *c. s. d.* Common duct for the two salivary glands. *d. l. m.* Dorsal longitudinal muscles of pharynx. *d. o.* Muscles serving to dilate the opening of the pharynx. *Ep.* Epidermis. *e. n.* Nerve passing outwards from ventral nerve-cord. *h.* Heart. *i. j.* Inner jaw. *j. p.* Jaw papillæ. *l.* Lips of buccal cavity. *l. b. c.* Lateral compartment of body-cavity. *le.* Rod-like cuticular continuation of inner jaw, lying in a pit of the buccal cavity. *l. m.* Bands of longitudinal muscles. *m.* Buccal cavity. *m¹.* Median backward continuation of buccal cavity. *m. l.* Muscles of jaw lever. *m. s.* Muscular sheets passing from side walls of pharynx to dorsal body wall. *æ.* Oesophagus. *æ. s. co.* Oesophageal commissures. *o. j.* Outer jaw. *ph.* Pharynx. *s. d.* Salivary duct. *s. g.* Salivary gland. *sl. d.* Reservoir of slime gland. *sy.* Sympathetic nerves running in muscles of tongue or pharynx. *sy¹.* Origin of sympathetic nerves to pharynx. *t.* Tongue. *v. c.* Ventral nerve-cords.

Figs. 17, 18. Two longitudinal horizontal sections through the head of *Peripatus capensis*. Fig. 17 is the most ventral. They are both taken ventral to the cerebral ganglia. In Fig. 17 dorsal tracheal pits are shewn with tracheæ passing off from them. (Zeiss a a, Hartnack's camera.) *c.* Cutis. *c. s. d.* Common salivary duct. *ep.* Epidermis. *i. j.* Inner jaw. *m.* Buccal cavity. *m¹.* Median backward diverticulum of mouth. *o. j.* Outer jaw. *s. d.* Salivary ducts. *t.* Tongue. *t.* Teeth on tongue. *tr.* Tracheæ. *tr. p.* Tracheal pits.

PLATE 50.

Fig. 19. "A, B, C, D, E, F, G. Seven transverse sections illustrating the structure of the supra-oesophageal ganglia. (Zeiss A, Hartnack's camera.) *a.* Dorso-lateral horn of white matter. *b.* Vento-lateral horn of white matter. *c.* Postero-dorsal lobe of white matter. *d.* Ventral protuberance of brain. *e.* Central lobe of white matter. *o. p.* Optic ganglion.

"A. Section through anterior portions of ganglia close to the origin of the antennary nerve. B. Section a little in front of the point where the two ganglia unite. C. Section close to anterior junction of two ganglia. D. Section through origin of optic nerve on the right side. E. Section shewing origin of the optic nerve on the left side. F. Section through the dorso-median lobe of white matter. G. Section near the termination of the dorsal tongue of ganglion cells."

PLATE 51.

Fig. 20. Portion of a transverse section through the hinder part of *Peripatus capensis* (male). The section passes through a leg, and shews the opening of the segmental organ (*o. s.*), and of a crural gland, *o. f. g.*, and the forward continuation of the enlarged crural gland of the 17th leg (*f. gl.*). (Zeiss a a, Hartnack's camera.) *a. g.* accessory gland of male (modified crural gland of last leg). *c.* Cutis. *cl.* Claw.

cu. Cuticle. *ep.* Epidermis. *f.gl.* Crural gland. *h.* Cells in lateral compartment of body cavity. *o.f.g.* Orifice of accessory foot gland. *o.s.* Opening of segmental organ. *p.* Three spinous pads on ventral surface of foot. *pr.* Prostate. *R. M.* Retractor muscle of claw. *s.* Vesicle of nephridium. *s. c. i.* Region No. 1 of coiled part of nephridium. *sl.g.* Tubule of slime gland. *s. o. t.* Terminal portion of nephridium. *st.* Stomach. *st. e.* Epithelium of stomach. *v. c.* Ventral nerve-cord. *v. d.* Vas deferens.

Fig. 21. "Longitudinal vertical section through the supra-oesophageal ganglion and oesophageal commissures of *Peripatus capensis*. (Zeiss a a, Hartnack.)" *at.* Antenna. *ε.* Central lobe of white matter. *j.* Part of jaw. *s.g.* Salivary gland.

Fig. 22: drawn by Miss Balfour. Brain and anterior part of the ventral nerve-cords of *Peripatus capensis* enlarged and viewed from the ventral surface. The paired appendages (*d*) of the ventral surface of the brain are seen, and the pair of sympathetic nerves (*sy*¹) arising from the ventral surface of the hinder part.

From the commencement of the oesophageal commissures (*æs. co.*) pass off on each side a pair of nerves to the jaws (*j. n.*).

The three anterior commissures between the ventral nerve-cords are placed close together; immediately behind them the nerve-cords are swollen, to form the ganglionic enlargements from which pass off to the oral papillæ a pair of large nerves on each side (*or. n.*)

Behind this the cords present a series of enlargements, one pair for each pair of feet, from which a pair of large nerves pass off on each side to the feet (*p. n.*). *at. n.* Antennary nerves. *co.* Commissures between ventral cords. *d.* Ventral appendages of brain. *E.* Eye. *e. n.* Nerves passing outwards from ventral cord. *F. g.* Ganglionic enlargements from which nerves to feet pass off. *j. n.* Nerves to jaws. *or. g.* Ganglionic enlargement from which nerves to oral papillæ pass off. *or. n.* Nerves to oral papillæ. *p. c.* Posterior lobe of brain. *p. n.* Nerves to feet. *s. y.* Sympathetic nerves.

Fig. 23. "Longitudinal horizontal section through the head of *Peripatus capensis*, shewing the structure of the brain, the antennary and optic nerves, &c. (Zeiss a a, Hartnack's camera.)" *at.* Antenna. *at. n.* Antennary nerve. *cor.* Cornea. *e.* Central mass of white matter. *l.* Lens. *op. n.* Optic nerve. *ph.* Pharynx. *p. p.* Primary papilla covered with secondary papillæ and terminating in a long spine. *sy.* Pharyngeal sympathetic nerves.

Fig. 24. "Eye of *Peripatus capensis*, as shewn in a longitudinal horizontal section through the head. The figure is so far diagrammatic that the lens is represented as filling up the whole space between the rods and the cornea. In the actual section there is a considerable space between the parts, but this space is probably artificial, being in part caused by the shrinkage of the lens and in part by the action of the razor. (Zeiss c, Hartnack's camera.)" (It appears that the ganglionic region of the eye is covered by a thin capsule, which is omitted in the figure.)

cor. Cornea. *l.* Lens. *op.* Optic ganglion. *op. n.* Optic nerve. *pi. r.* Pigment. *R. e.* rods. *s. p.* Secondary papillæ.

Fig. 25. Longitudinal horizontal section through the dorsal skin, shewing the peculiar arrangement of the circular muscular fibres. (Zeiss A, Hartnack's camera.)

PLATE 52.

Fig. 26. Portion of ventral cord of *Peripatus capensis* enlarged, shewing two ganglionic enlargements and the origin of the nerves and commissures. (From a drawing by Miss Balfour.)

co. Commissures. *E. n.* Nerves passing out from ventral cords. *F. n.* Nerves to feet. *g. co.* Commissures between the ventral cords containing ganglion cells. *v. g.* Ganglionic enlargements.

Fig. 27. Segmental organ from the 5th pair of legs of *Peripatus capensis*. This nephridium resembles those of the 4th legs, and differs from all the others in its large size and in the absence of any dilatation giving rise to a collecting vesicle on its external portion (enlarged). The terminal portion has the same histological characters as in the case of the hinder segmental organs. (From a drawing by Miss Balfour.)

Fig. 28. Segmental organ or nephridium from the 9th pair of legs of *Peripatus capensis*, shewing the external opening, the vesicle, the coiled portion and the terminal portion with internal opening (enlarged). (From a drawing by Miss Balfour.)

o. s. External opening of segmental organ. *p. f.* Internal opening of nephridium into the body-cavity (lateral compartment). *s.* Vesicle of segmental organ. *s¹.* Portion of segmental organ of 4th and 5th legs, corresponding to vesicle of the other nephridia. *s. c. 1.* First or external portion of coiled tube of nephridium, lined by columnar epithelium with small nuclei; the cells project for very different distances, giving the inner boundary of this region a ragged appearance. *s. c. 2.* Region No. 2 of coiled tube of nephridium, lined by small closely-packed columnar cells. *s. c. 3.* Region No. 3 of coiled tube of segmental organ, lined by large flat cells with large disc-shaped nuclei. *s. c. 4.* Region No. 4 of coiled tube of nephridium; this region is very short and lined by small columnar cells. *s. o. t.* Terminal portion of nephridium.

Fig. 29. "Portion of nephridium of the hindermost leg of *Peripatus capensis*, seen in longitudinal and vertical section. The figure is given to shew the peritoneal funnel of the nephridium. Portions of the collecting sack (*s.*) and other parts are also represented. (Zeiss B, Hartnack's camera.)"

p. f. Peritoneal funnel. *s.* Vesicle. *s. c. 1.*, *s. c. 2.*, *s. c. 3.* Portions of coiled tube.

Fig. 30. "Section through a tracheal pit and diverging bundles of tracheal tubes" taken transversely to the long axis of the body. (Zeiss E, oc. 2.) (From a rough drawing by Prof. Balfour.)

tr. Tracheæ, shewing rudimentary spiral fibre. *tr. c.* Cells resembling those lining the tracheal pits, which occur at intervals along the course of the tracheæ. *tr. s.* Tracheal stigma. *tr. p.* Tracheal pit.

Fig. 31. "Sense organs and nerves attached from antenna of *Peripatus capensis* (Zeiss, immersion 2, oc. 2.)" (From a rough drawing by Prof. Balfour.) The figure shews the arrangement of the epidermis cells round the base of the spine. The spine is seen to be continuous with the inner layer of the cuticle.

Fig. 32. Section through the skin of *Peripatus capensis*; it shews the secondary papillæ covered with minute spinous tubercles and the relation of the epidermis to them. (The cuticle in the process of cutting has been torn away from the subjacent cells.) The cells of the epidermis are provided with large oval nuclei, and there is a deposit of pigment in the outer ends of the cells. The granules in the protoplasm of the inner ends of the cells are arranged in lines, so as to give a streaked appearance. (Zeiss E, oc. 2.) (From a rough drawing by Prof. Balfour.)

c. Dermis. *cu.* Cuticle. *ep. c.* Epidermis cells. *pi.* Deposit of pigment in outer ends of epidermis cells. *s. p.* Secondary papillæ.

Fig. 33. Female generative organs of *Peripatus capensis*, $\times 5$. (From a rough drawing by Prof. Balfour.) The following note was appended to this drawing: "Ovary rather to dorsal side, lying in a central compartment of body-cavity and attached to one of the longitudinal septa, dividing this from the lateral compartment between the penultimate pair of legs and that next in front. The oviducts cross before opening to the exterior, the right oviduct passing under the rectum and the left over it. They meet by opening into a common vestibule, which in its turn opens below the anus. On each side of it are a pair of short papillæ (aborted feet?)"

F. 16, 17. Last two pairs of legs. *od.* Oviduct. *ov.* Ovary. *ut.* Uterus. *v. c.* Nerve cord.

PLATE 53.

Figs. 34—39. Five young embryos of *Peripatus capensis*; ventral view. All, excepting Fig. 37, from drawings by Miss Balfour. In Figures 34 to 38 *a* denotes what is probably the anterior extremity.

Fig. 34, Stage A. Youngest embryo found, with slightly elongated blastopore.

Fig. 35, Stage B. Embryo with three mesoblastic somites and elongated blastopore. The external boundaries of the somites are not distinct.

Fig. 36, Stage C. Embryo with five somites. The blastopore is closing in its middle portion.

Fig. 37, Stage D. The blastopore has completely closed in its middle portion, and given rise to two openings, the future mouth and anus. (From a rough drawing left by Professor Balfour.) (Zeiss A, Camera Oberhaus. on level of stage.)

The following note was appended to this drawing in his handwriting: "Young larva of *Peripatus capensis*. I could not tell for certain which was the anterior end. Length, 1'34 mm."

Fig. 38, Stage E. Embryo with about thirteen mesoblastic somites in which the flexure of the hind part of the body has commenced. The remains of the original blastopore are present as the mouth, placed between the second pair of mesoblastic somites, and the anus placed on the concavity of the commencing flexure of the hind part of the body.

Fig. 39. Side view of same embryo.

Figs. 40—42. Drawings by Professor Balfour of three transverse sections through the embryo from which fig. 36 was taken. (Zeiss c, Camera.) Figs. 40 and 42 pass through the region of the blastopore.

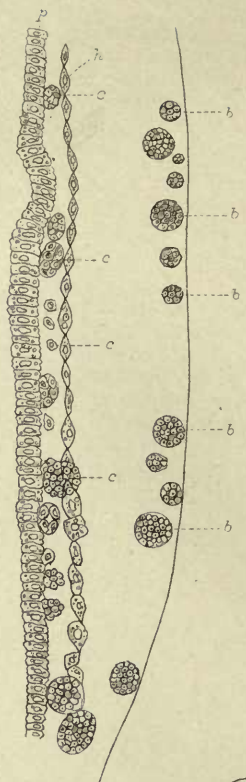
bl. Blastopore. *ep.* Epiblast. *hy.* Hypoblast. *me.* Mesenteron. *mes.* Mesoblastic somite.

Fig. 43. Male generative organs of *Peripatus capensis*, viewed from the dorsal surface. (From a drawing by Miss Balfour.)

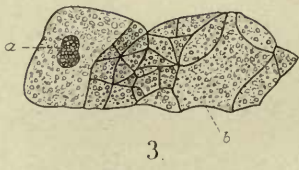
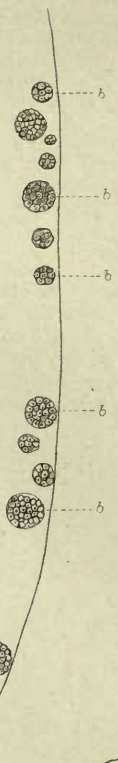
a. g. Enlarged crural glands of last pair of legs. *F. 16, 17.* Last pairs of legs. *f.* Small accessory glandular tubes. *p.* Common duct into which vasa deferentia open. *p. r.* Prostate. *te.* Testes. *v. c.* Nerve-cord. *v. d.* Vas deferens.



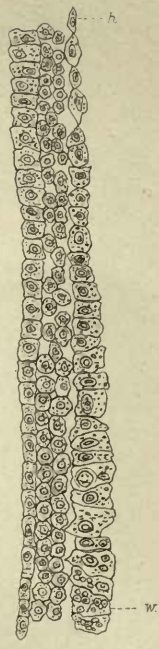1.



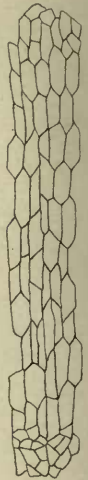2.



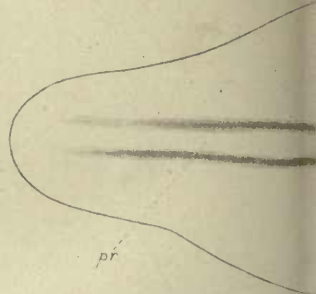
3.



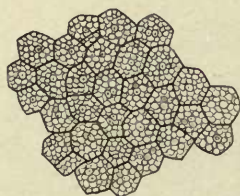
4.



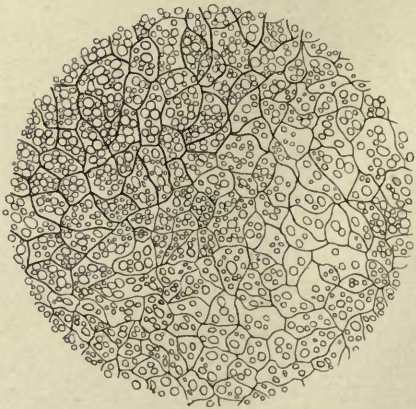
10.



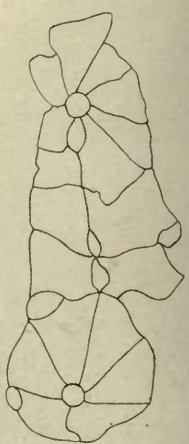
8.



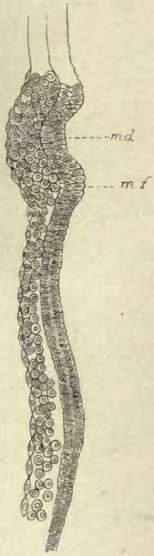11.



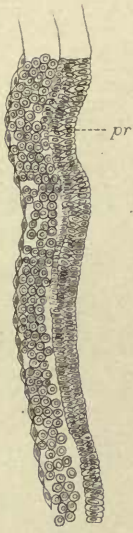5.



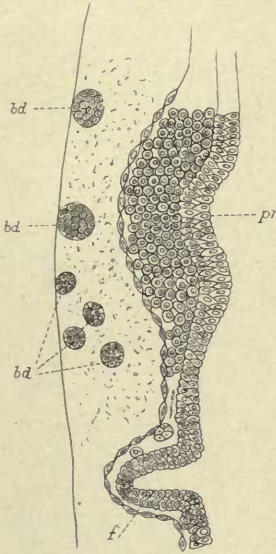
12.



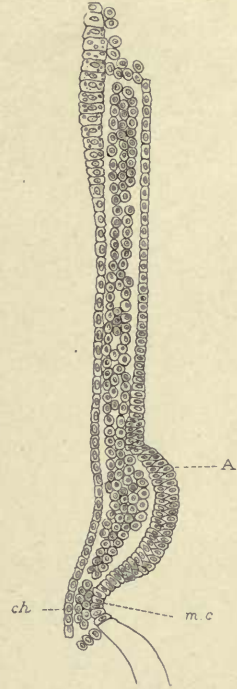
6.



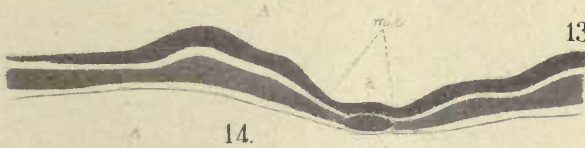
7.



9.



13.



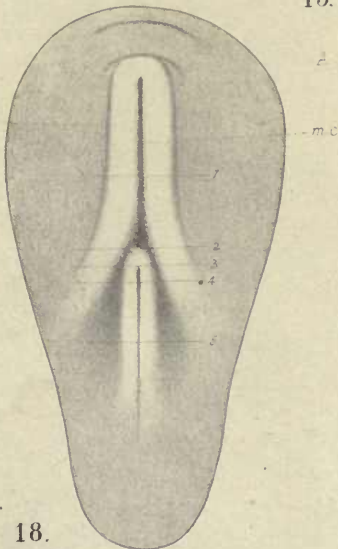
14.



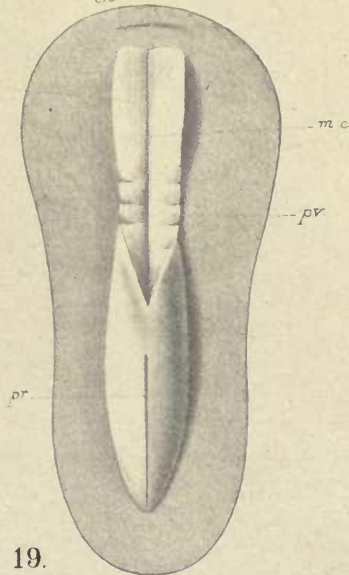
15.



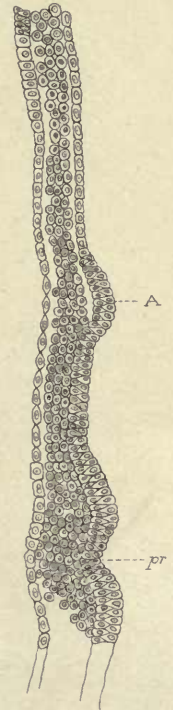
17.




18.




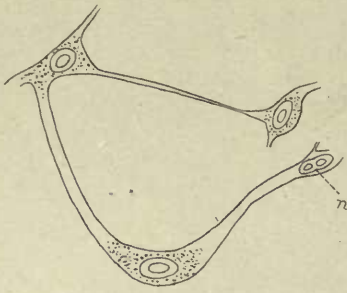
19.



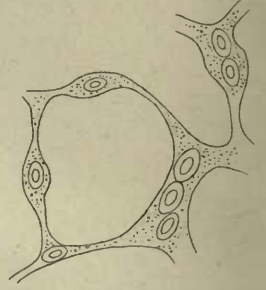
16.



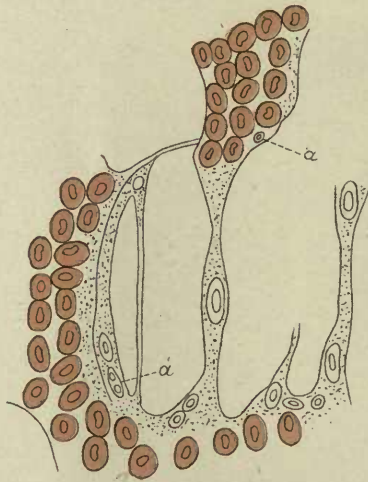




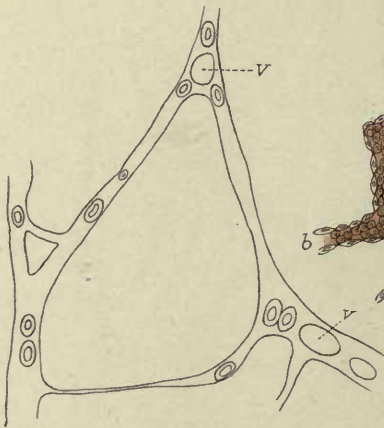
1.



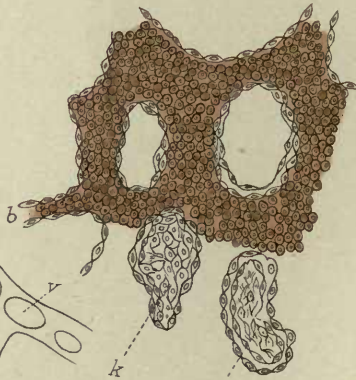
2.



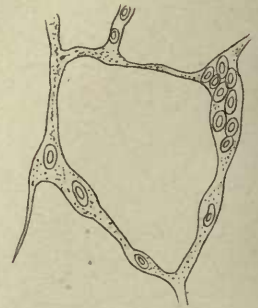
5.



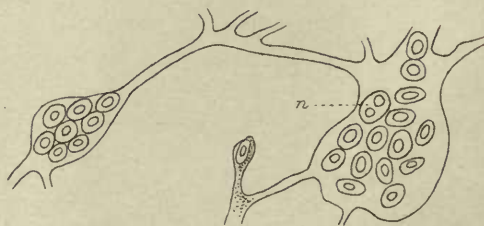
4.



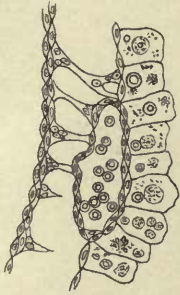
6. k



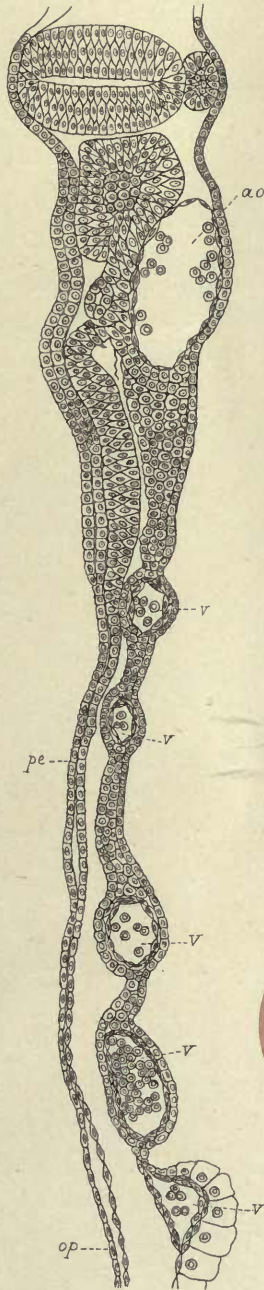
7.



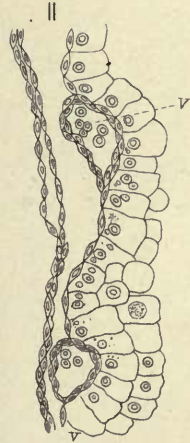
3.



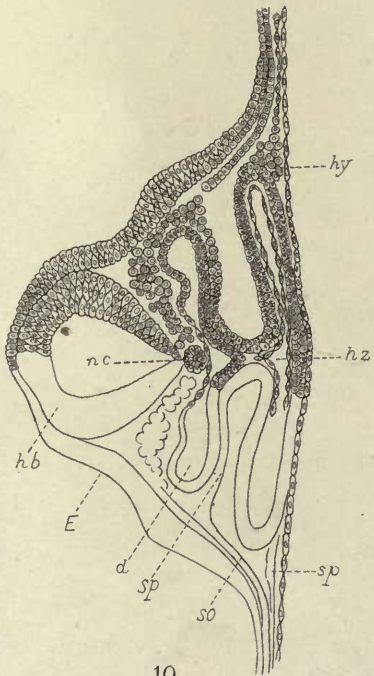
9.



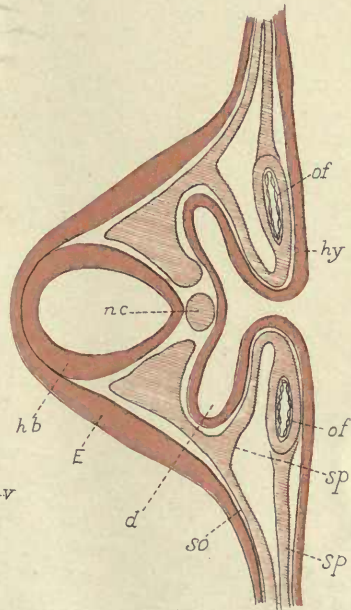
8.

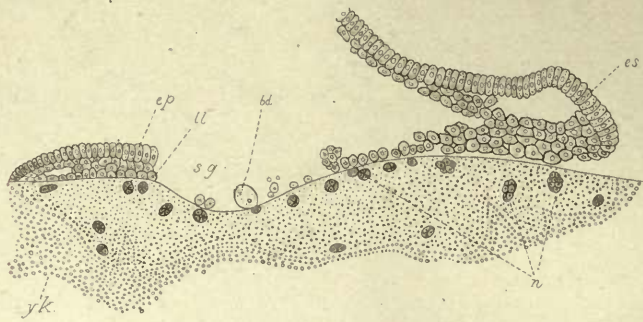


11.

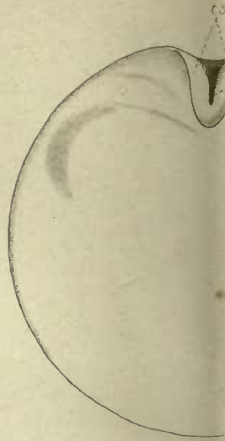

10.

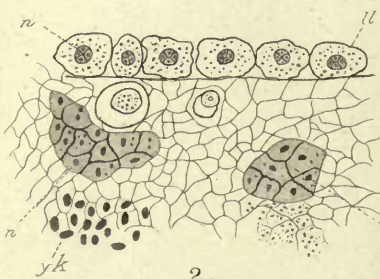



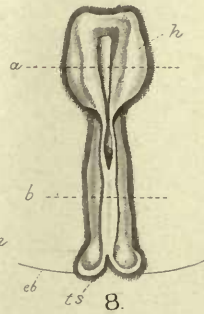
1.



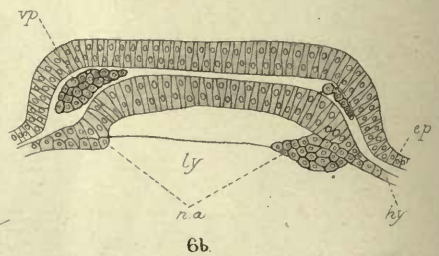
5.



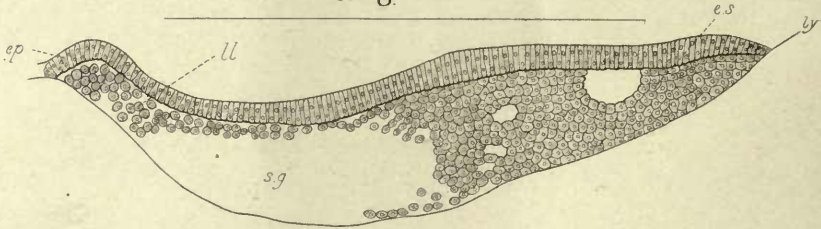
2.



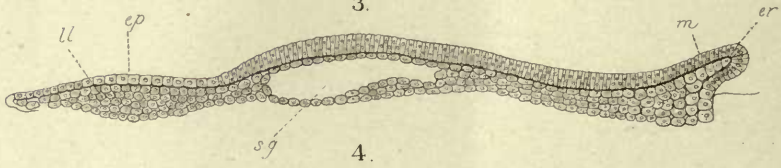
8.



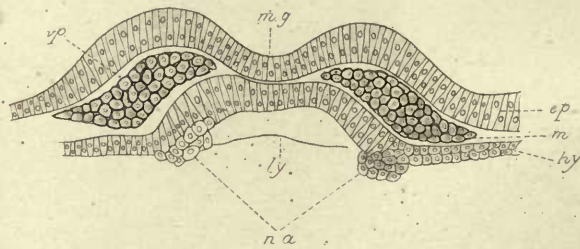
6b.



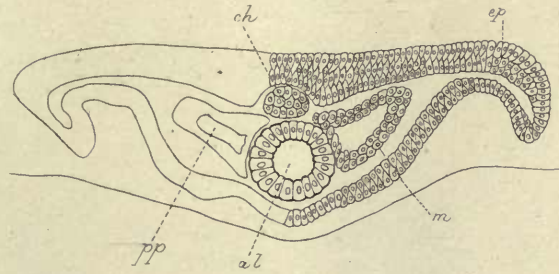

3.



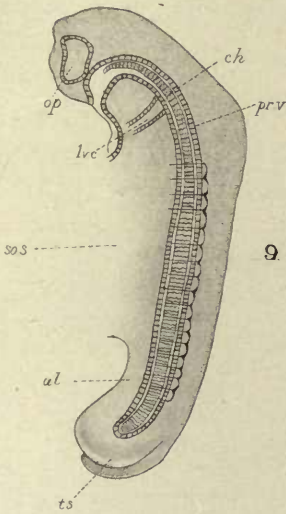
4.



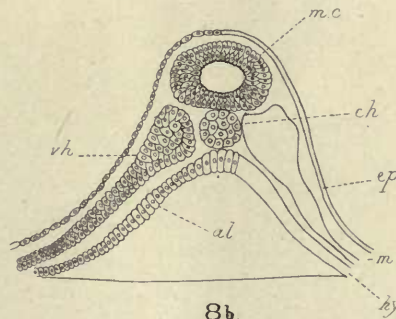
6a.



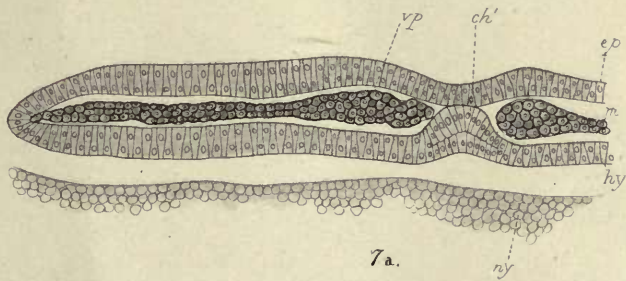
8a.



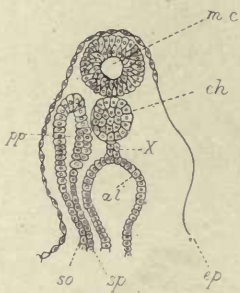
9.



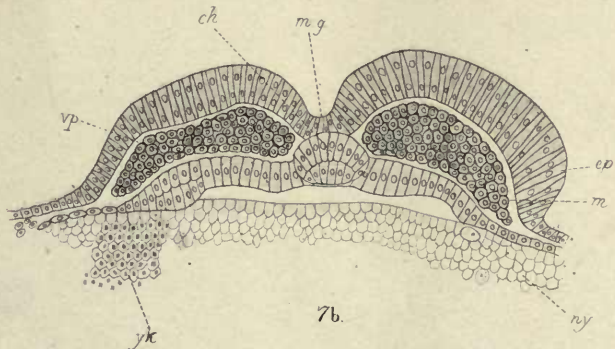
8b.



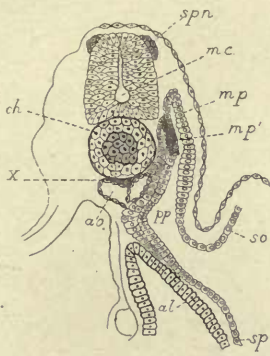
7a.



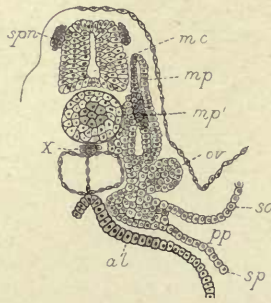
10.



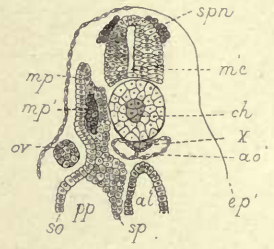
7b.



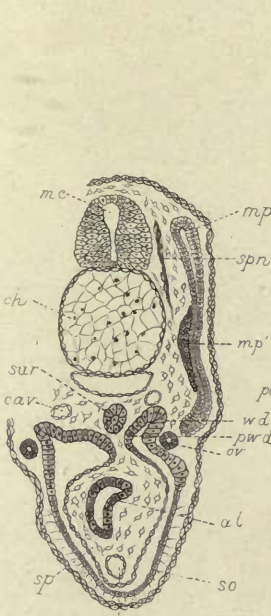
11a.



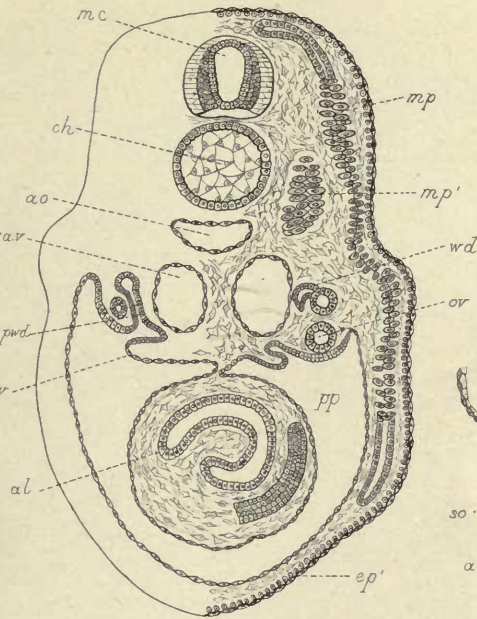
11b.



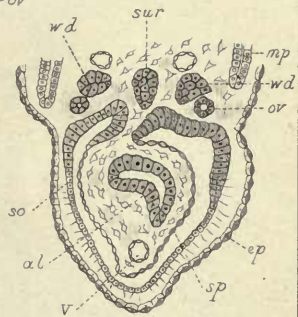
11c.



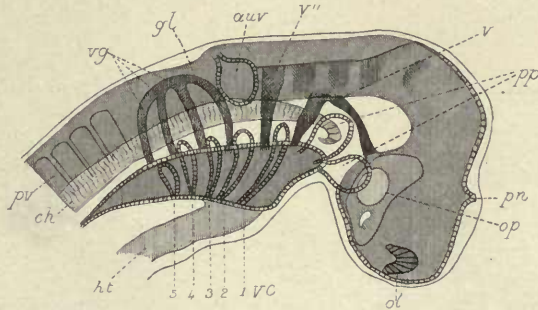
12a



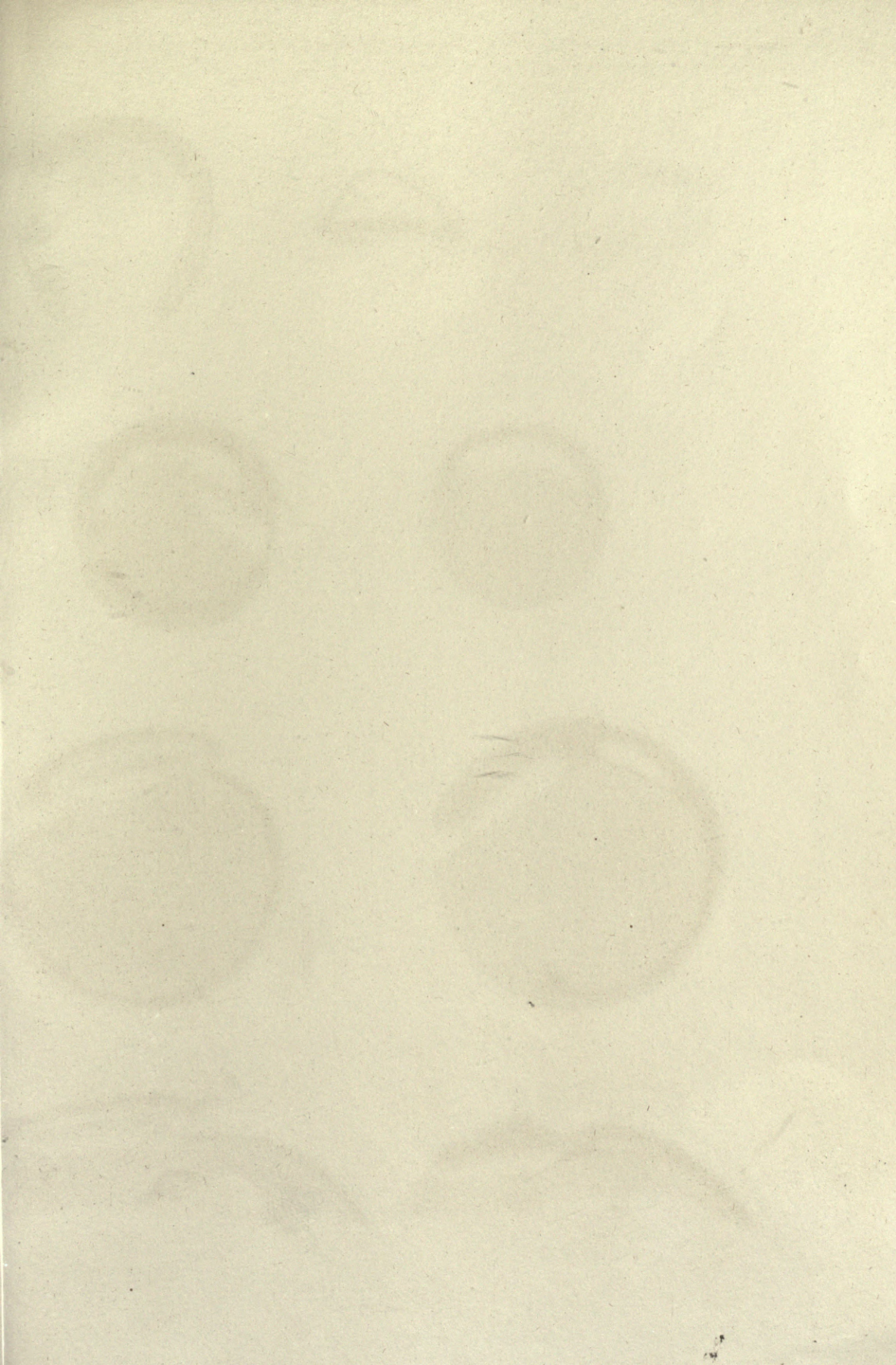13.

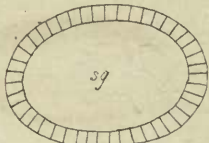


12b.

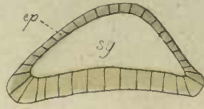

14.

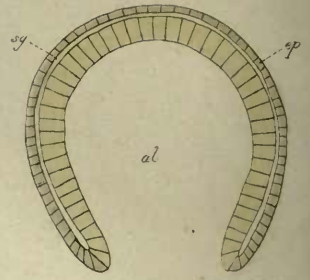




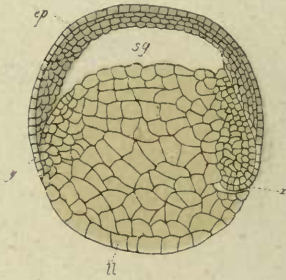
A I.



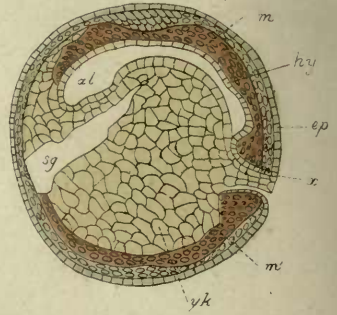
A II.



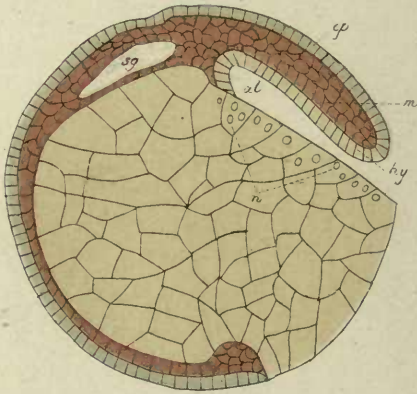
A III.



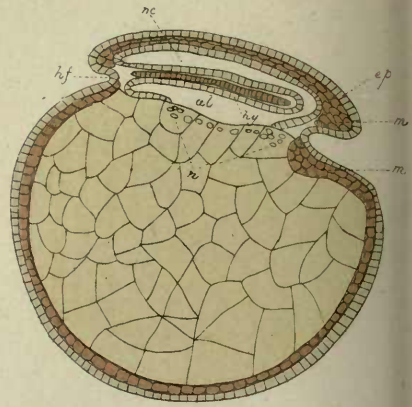
C I.



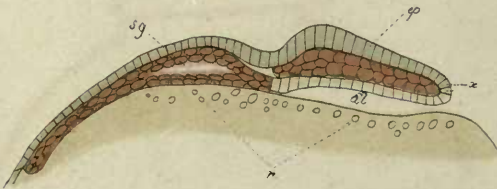
C II.



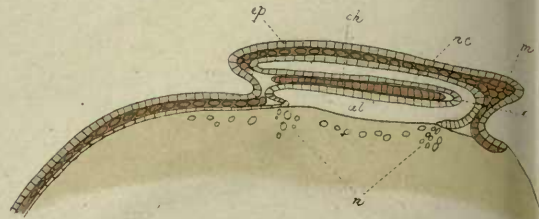
D II.



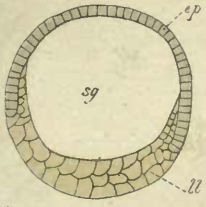
D III.



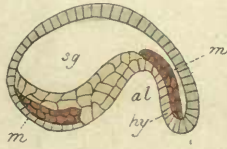
E II.



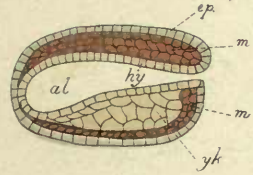
E III.



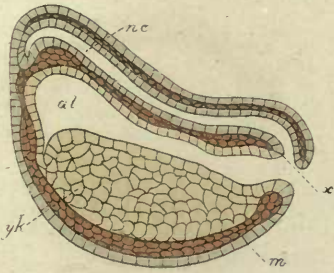
B I.



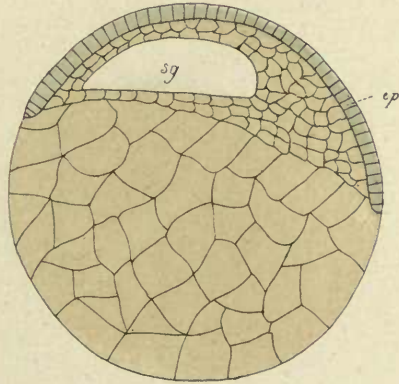
B II.



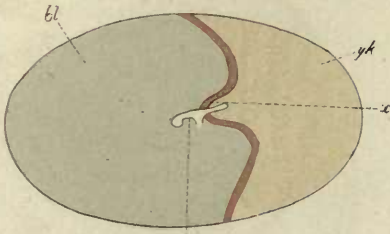
B III.



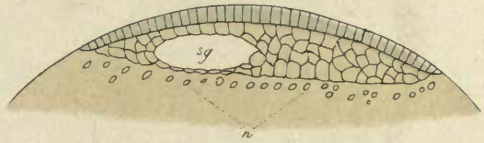
C III.



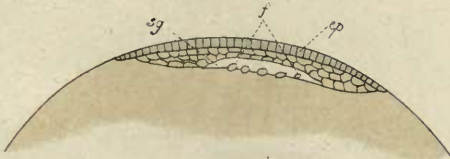
D I.



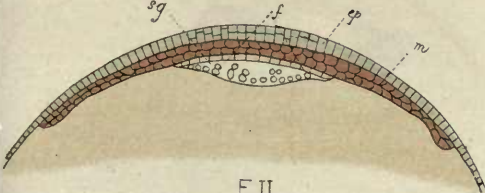
E.



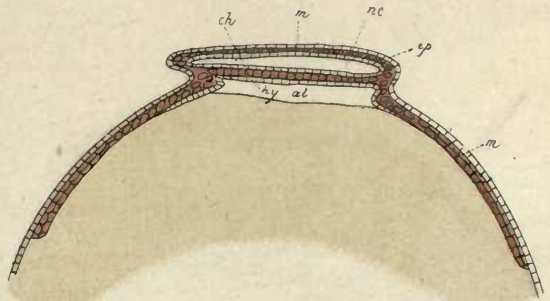
E I.



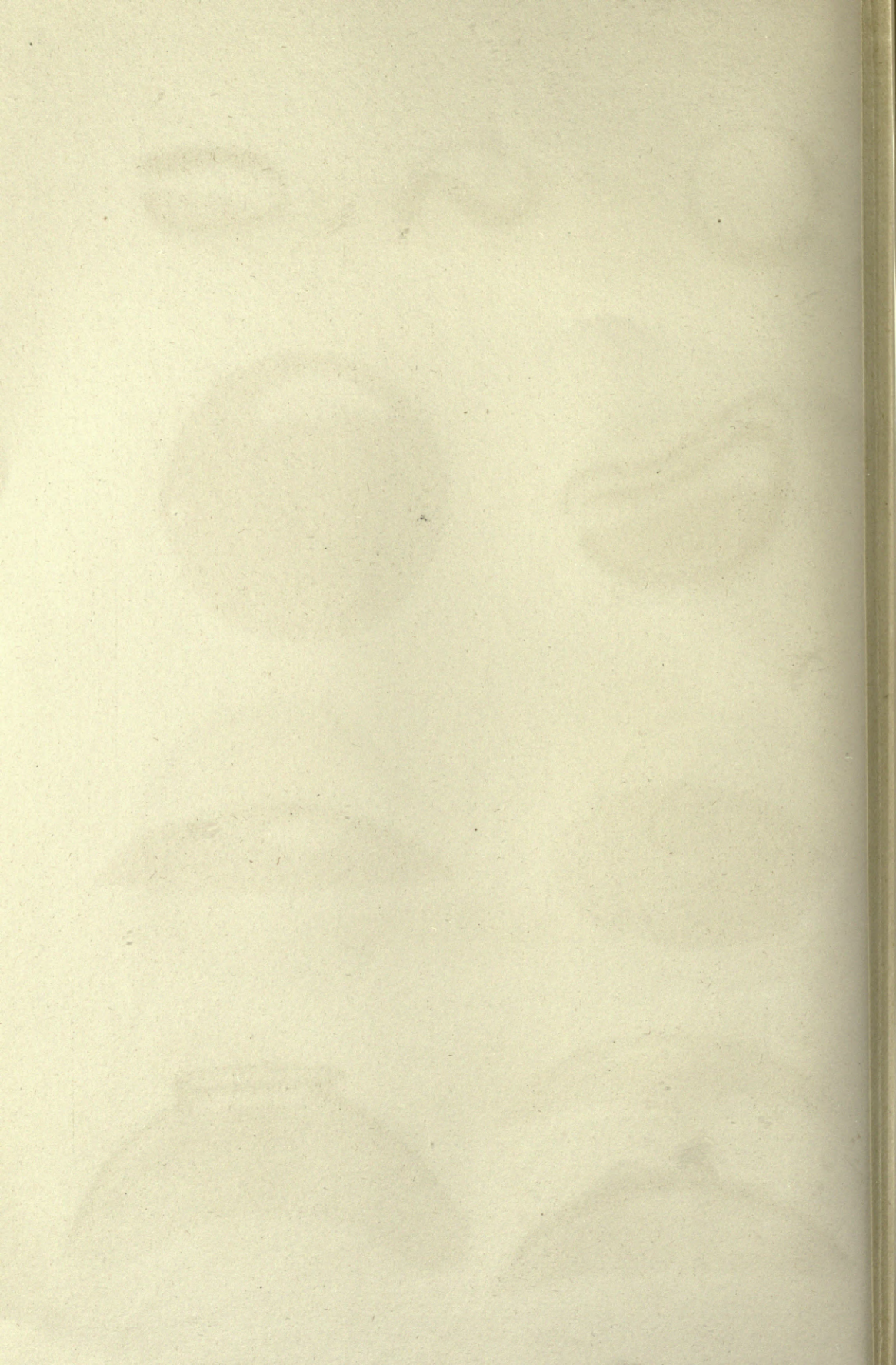
F I.

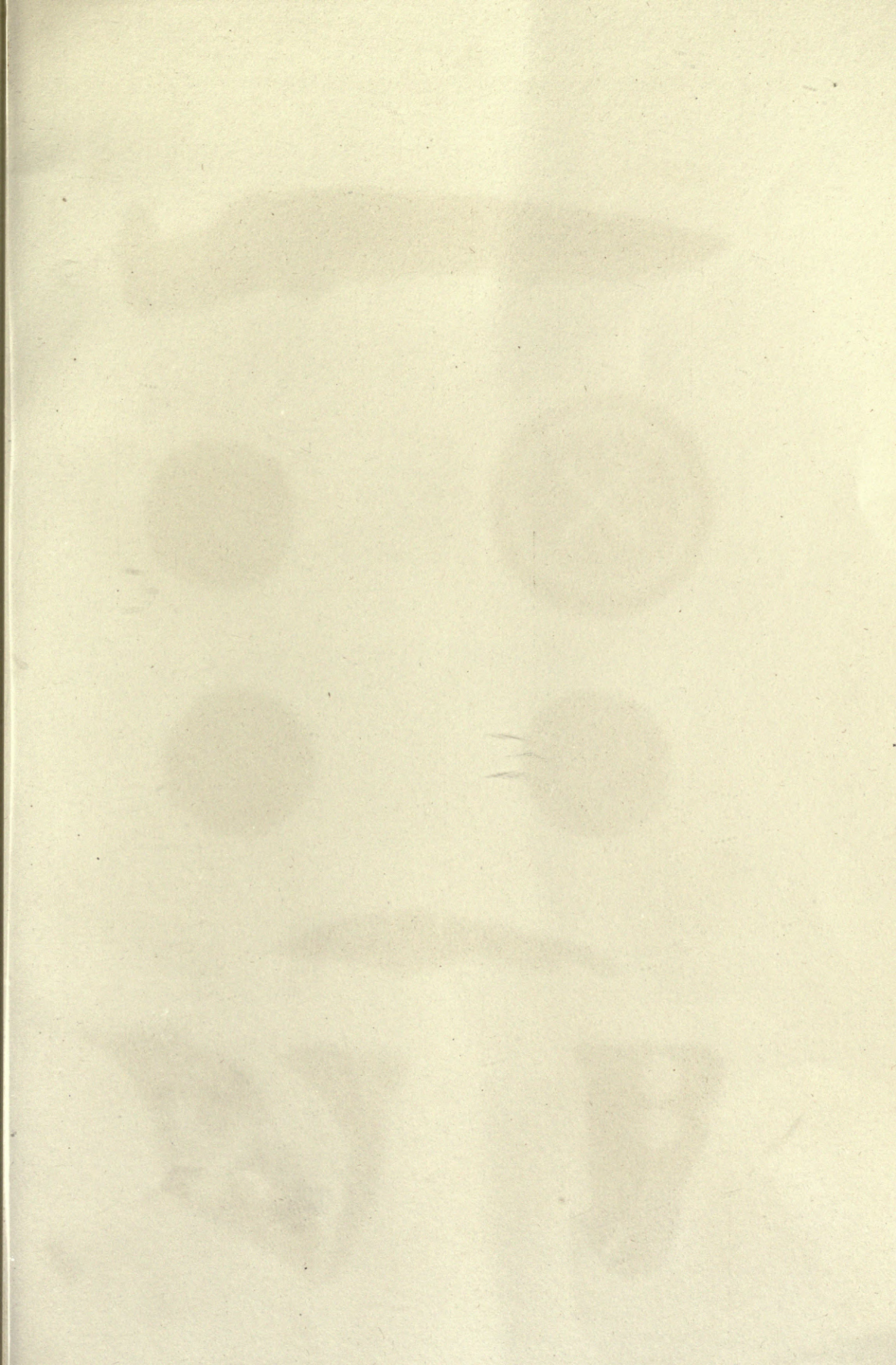


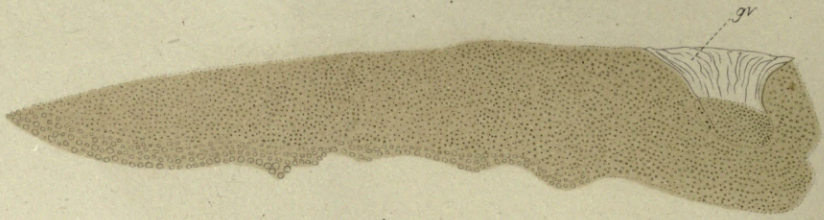F II.



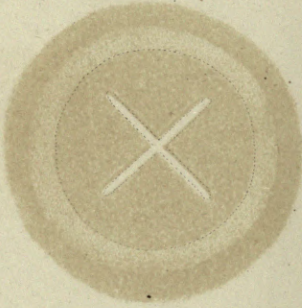
F III.



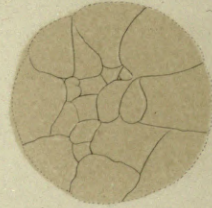





1.



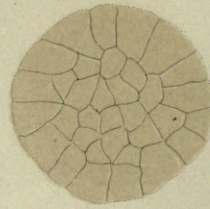
2.



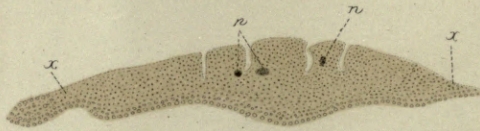
3.



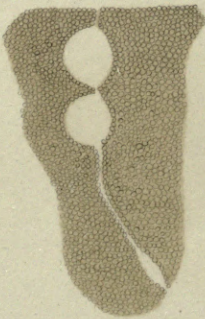
5.



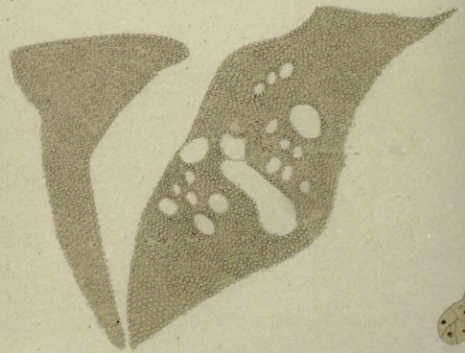4.



6.



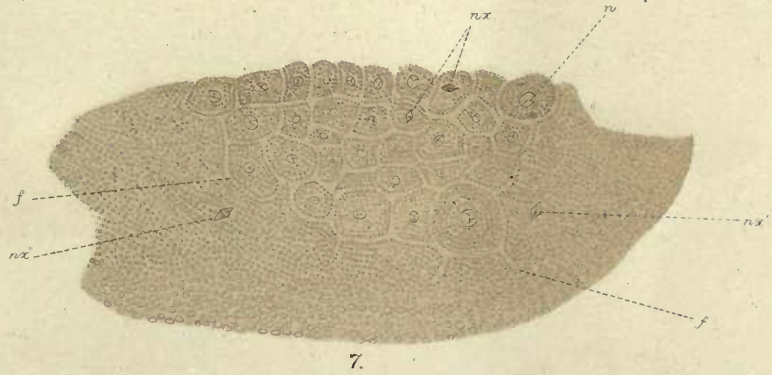
6a.



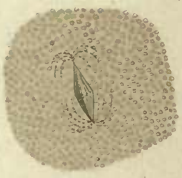6b.



6c.



7.



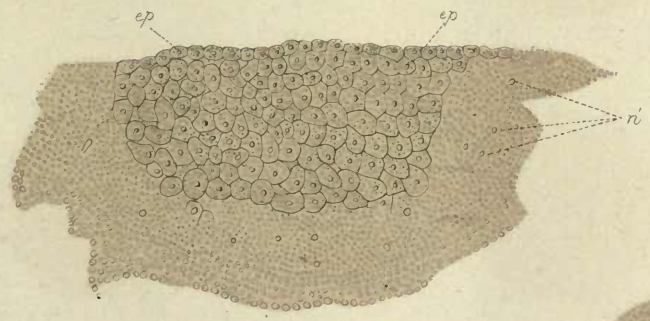
7a.



7b.



7c.



8.



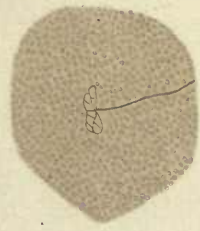
8a.



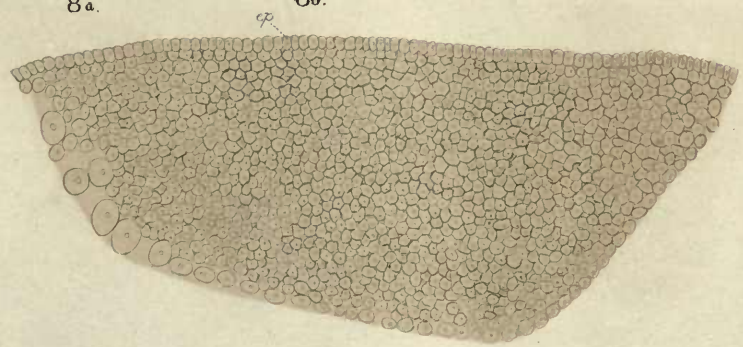
8b.




8c.

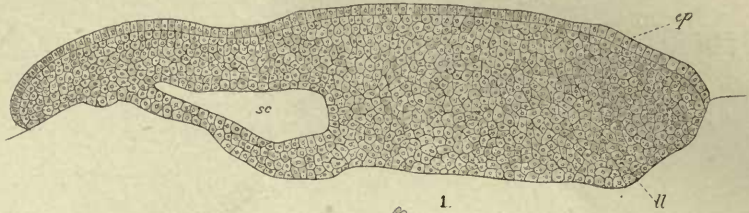


8d.

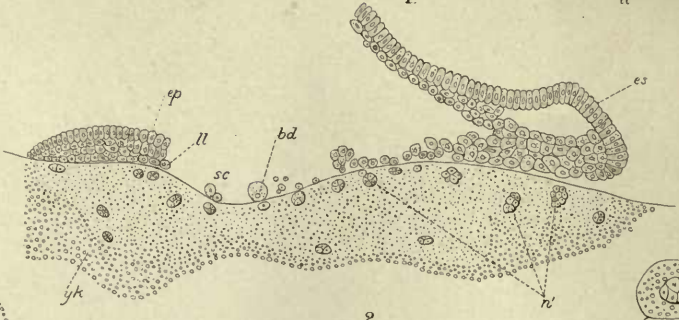


9.

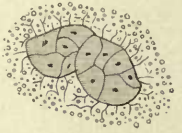




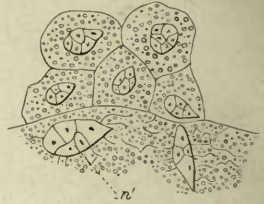
1.



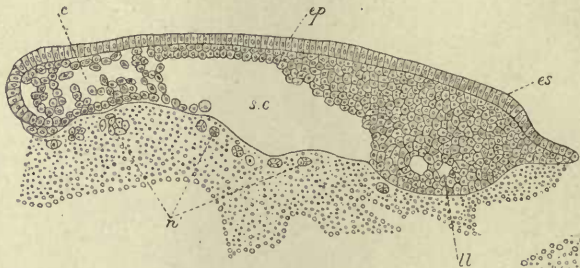
2.



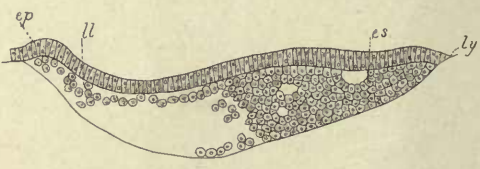2c.



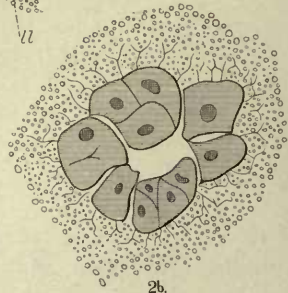
2a.



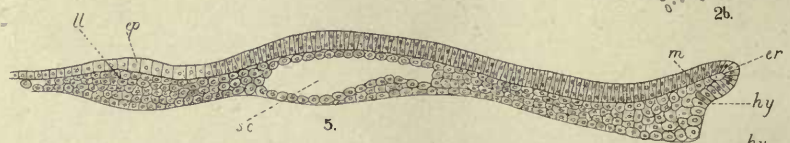
3.



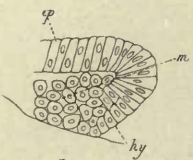
4.



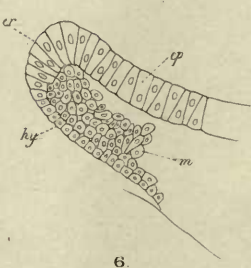
2b.



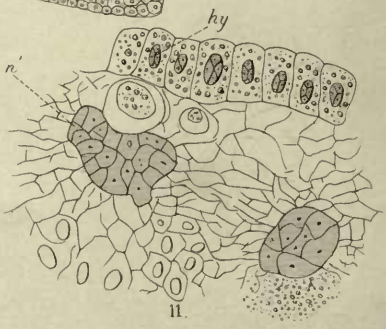
5.



5a.



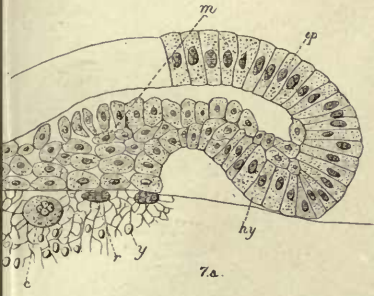
6.



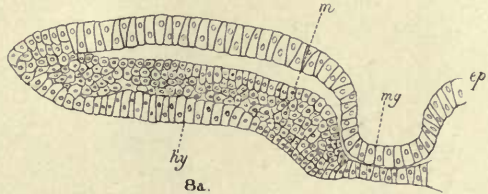
11.



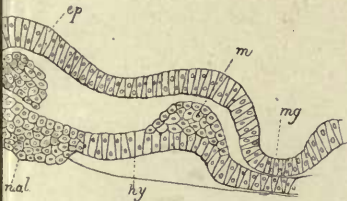
7.



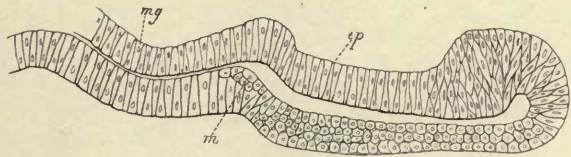
7a.



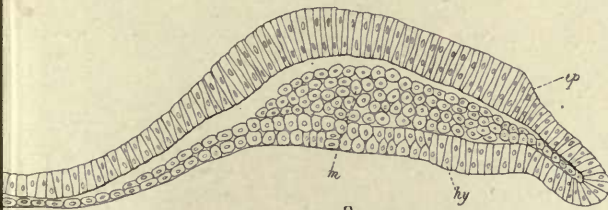
8a.



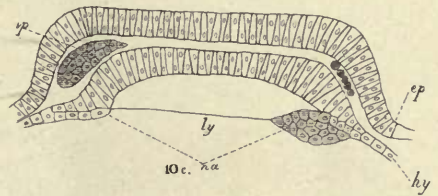
8b.



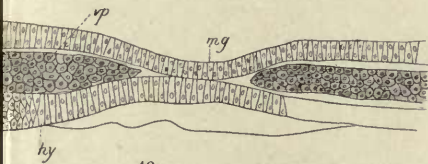
8c.



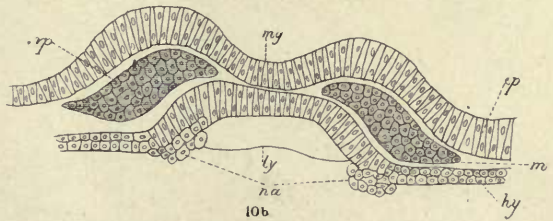
9.



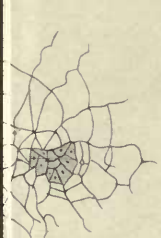10c. na



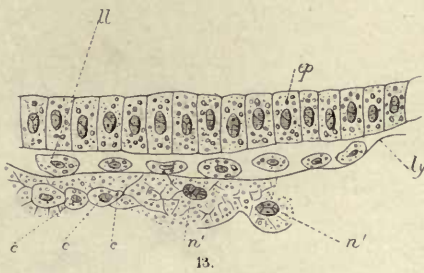
10a.



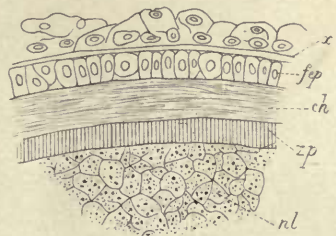
10b.




12.










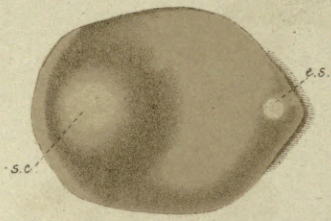
13.



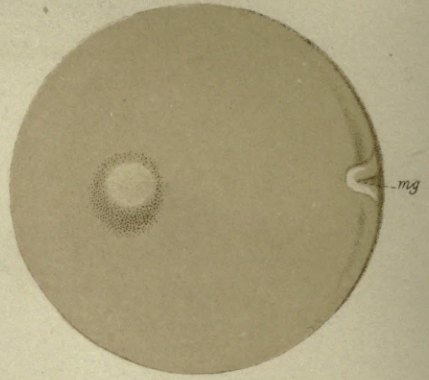
14.



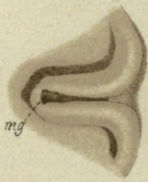




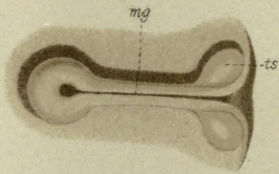
A.



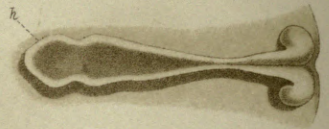
B.



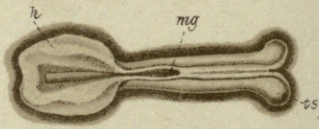
C.



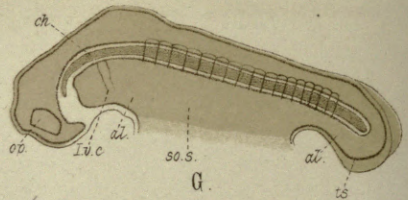
D.



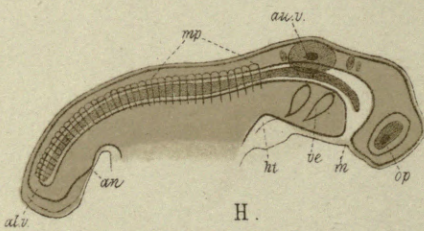
E.



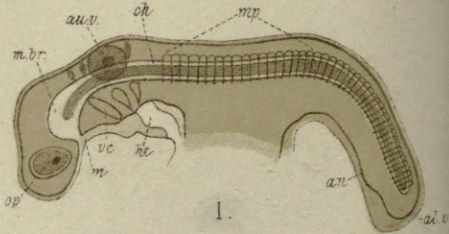
F.



G.




H.



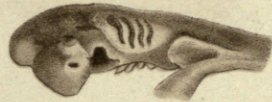I.



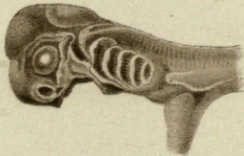
K. x 5 1/2



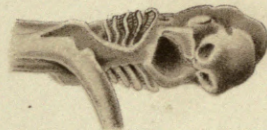x 3. L.



L'. x 5.



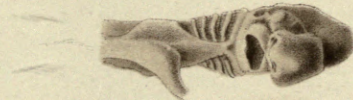x 5. M



M'. x 5



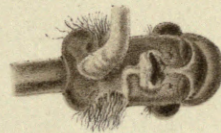
x 3. N.



N'. x 5.



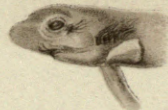x 1 1/2. O.




O' x 3

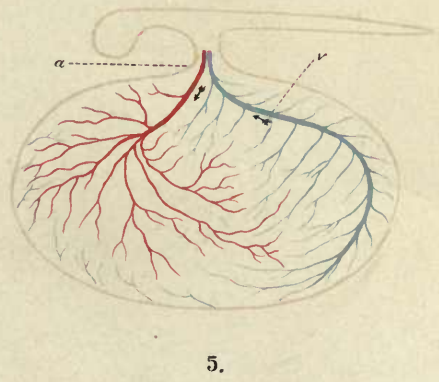
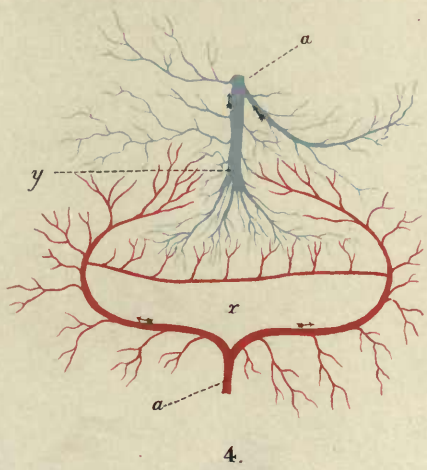
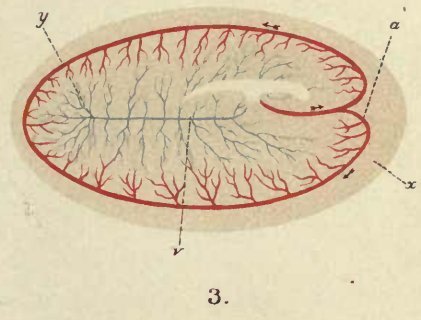
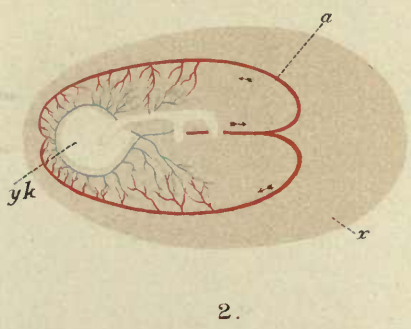
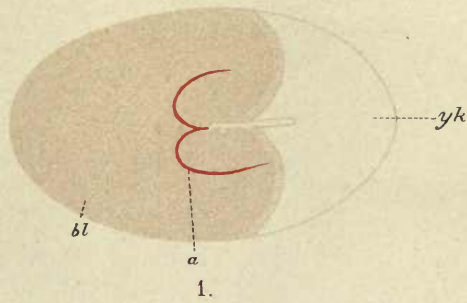



x 1 1/2. P.




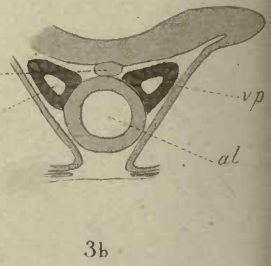
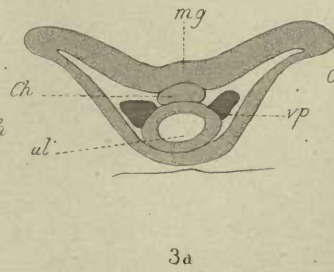
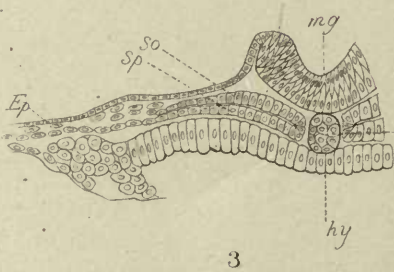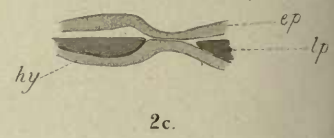
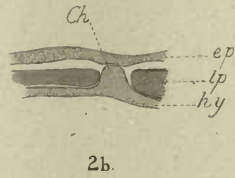
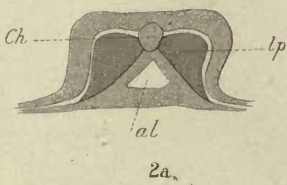
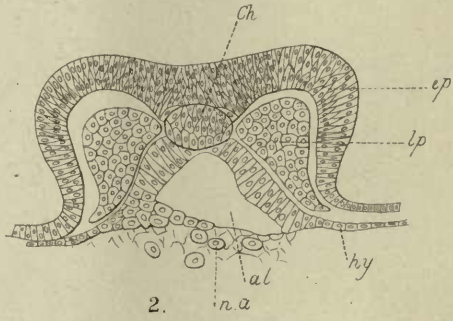
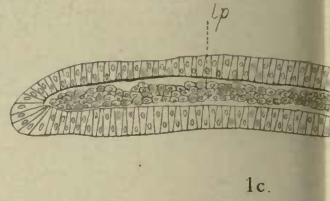
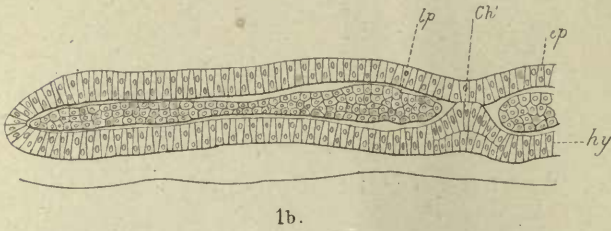
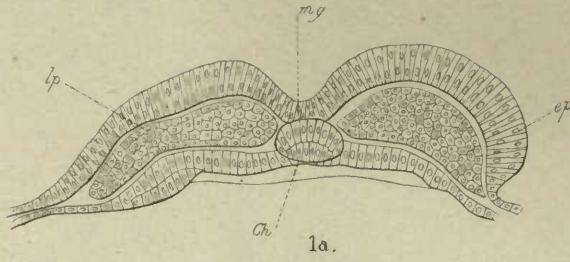
Q. x 1 1/2

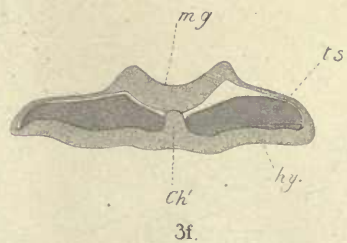
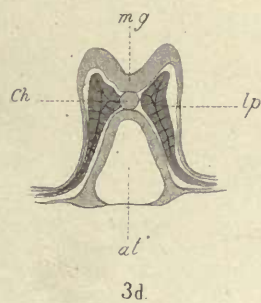
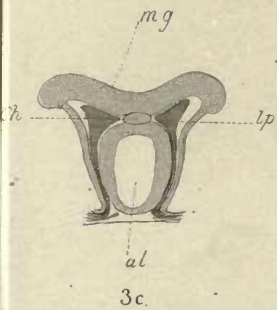
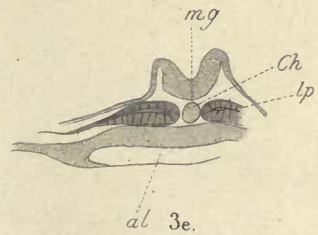
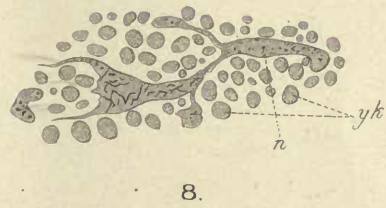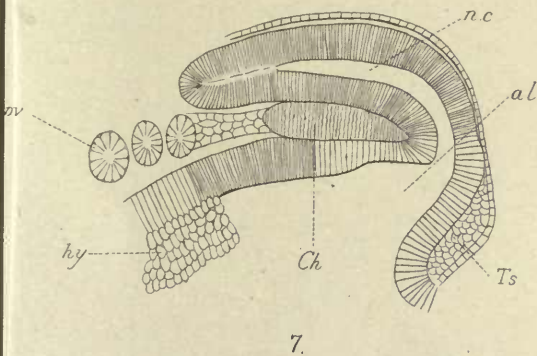
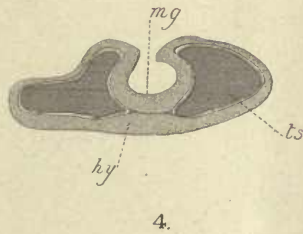
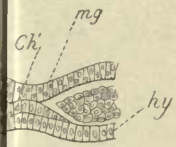
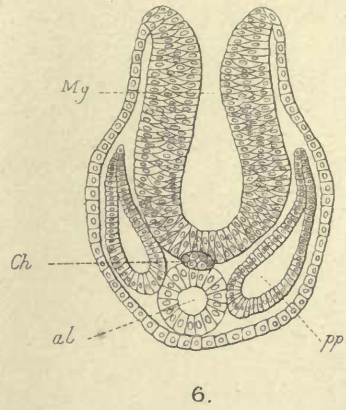
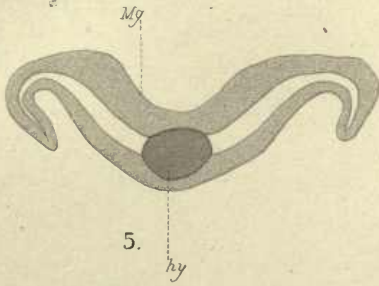








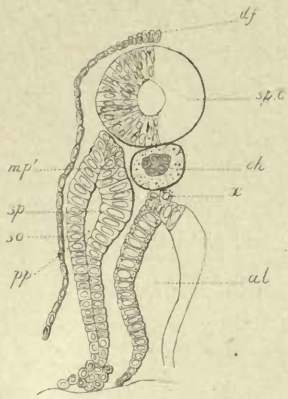




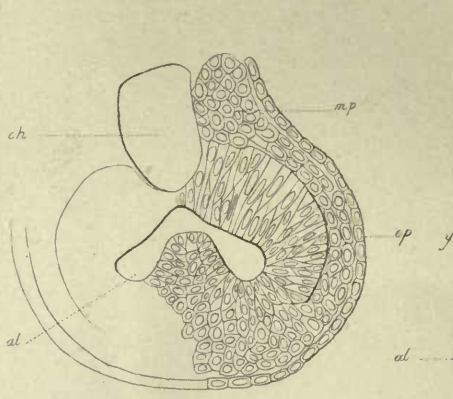




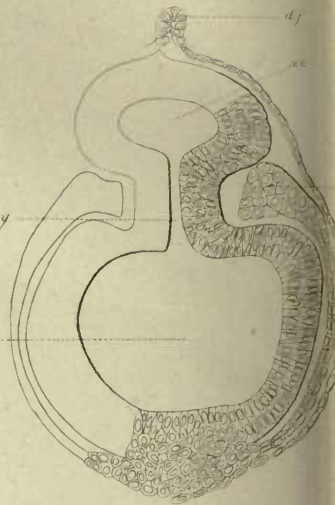



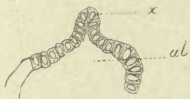
1



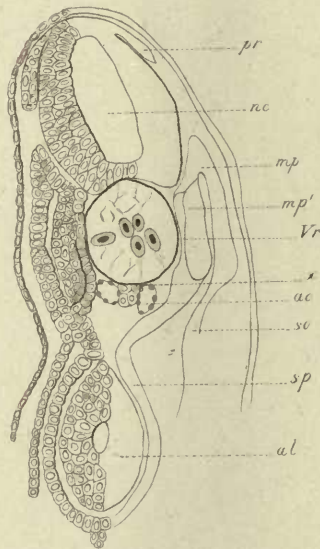
2



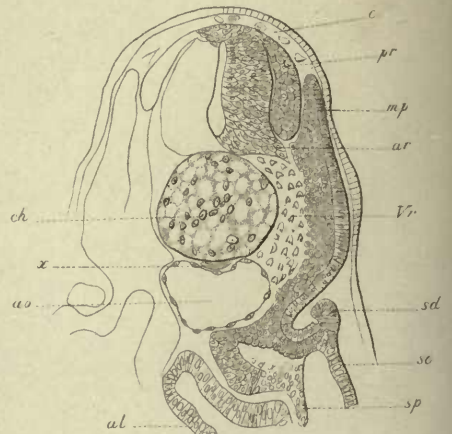
3a



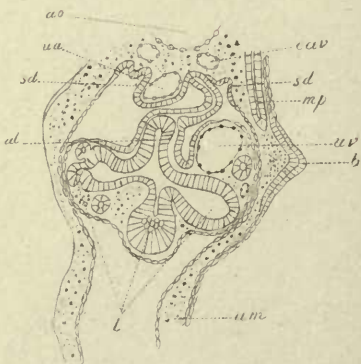
1a



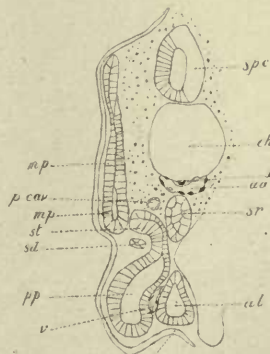
6



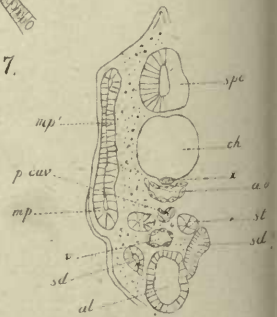
7



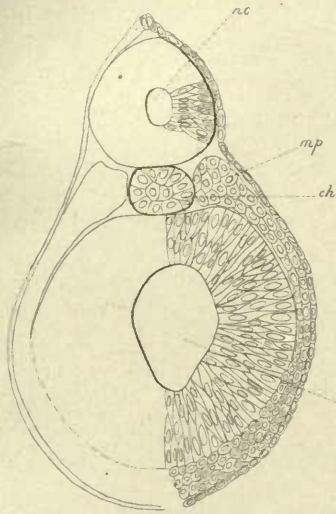
9



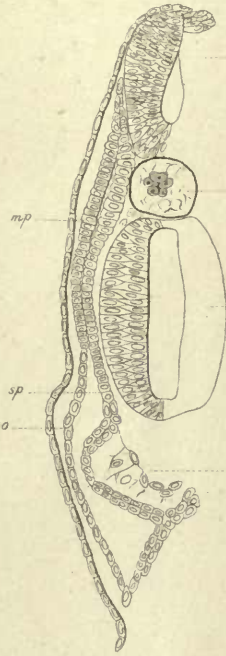
9a



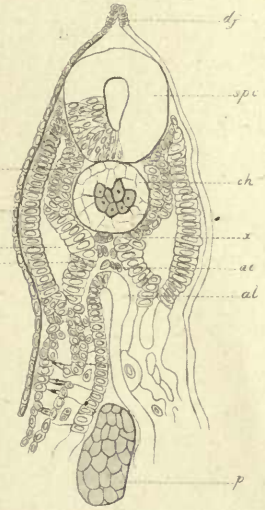
9b



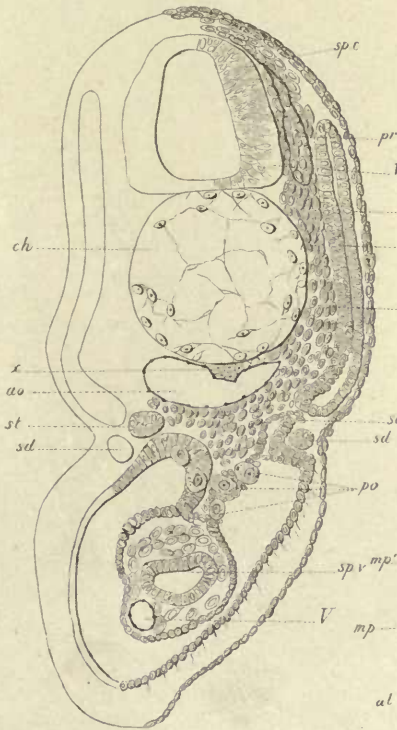
3b.



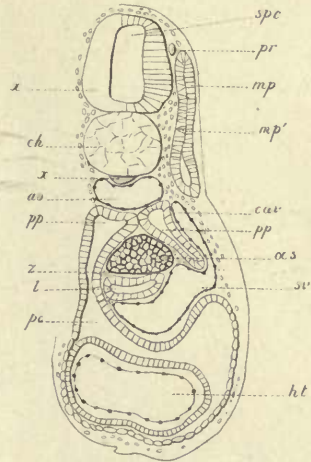
4.



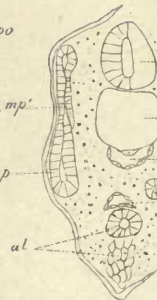5.



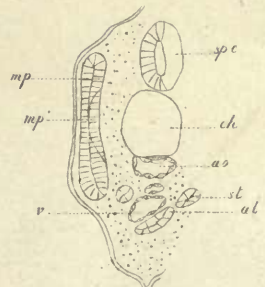
8




8a.

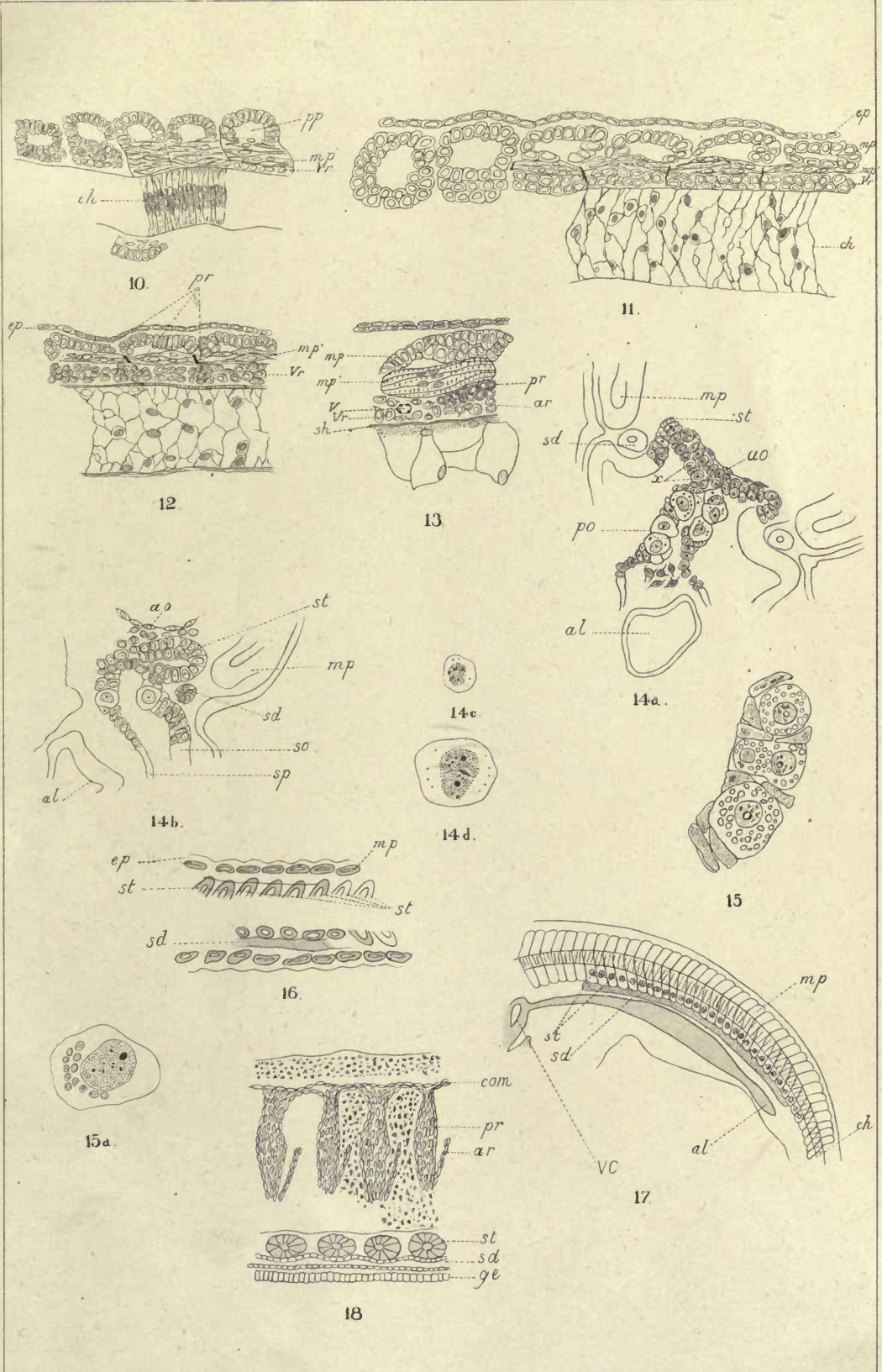



9c.

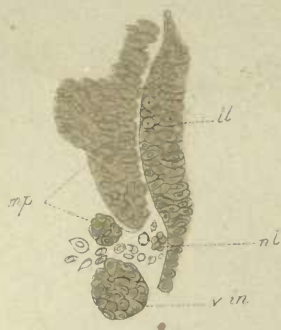


9d

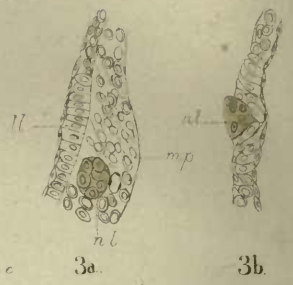






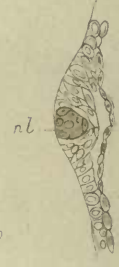

2.




3a.

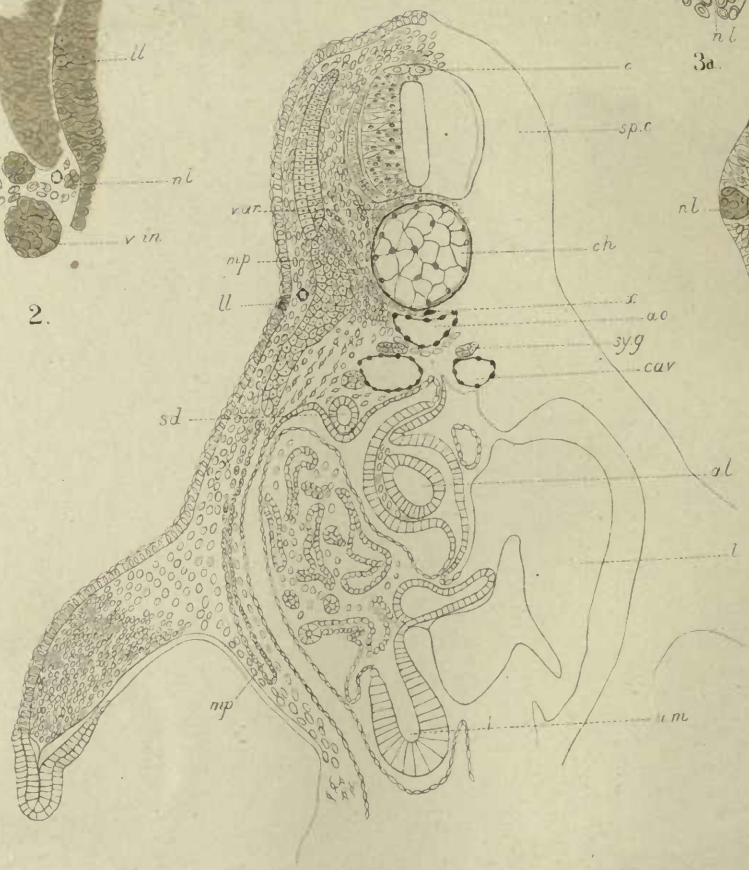
3b.



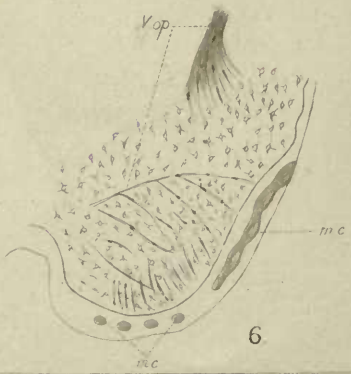
3c.



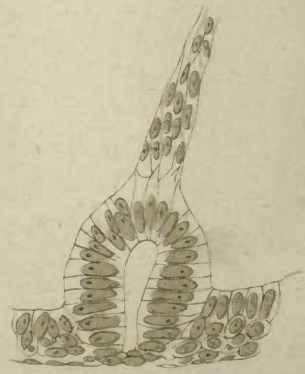
3d.



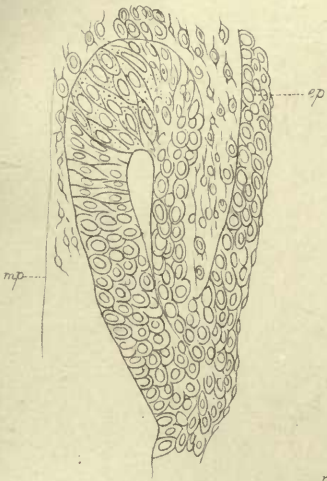1.



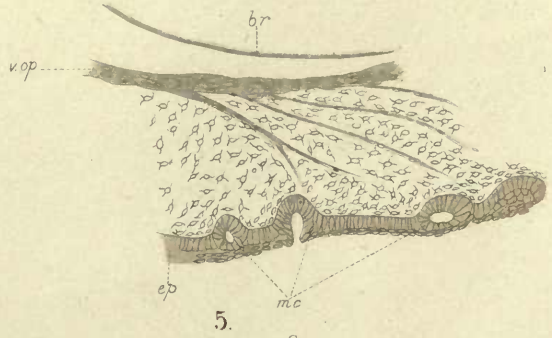
6.



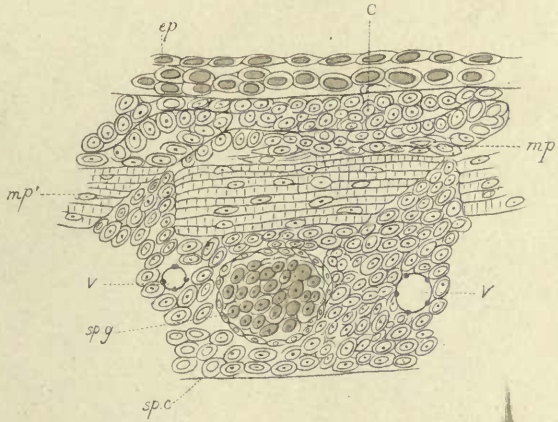
7.



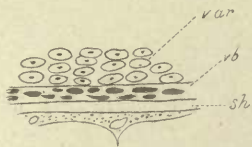
4.



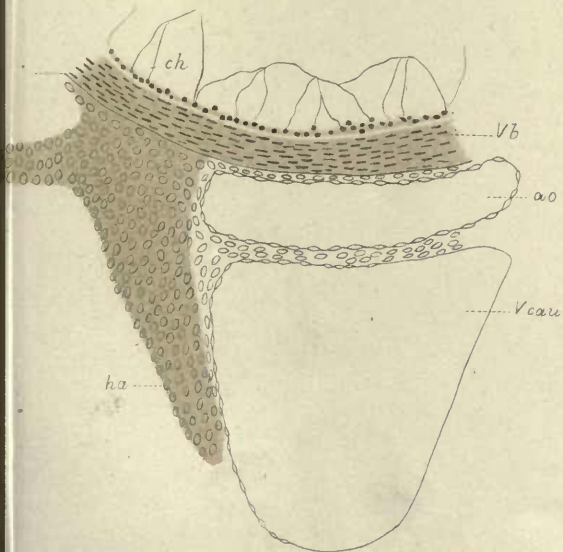
5.



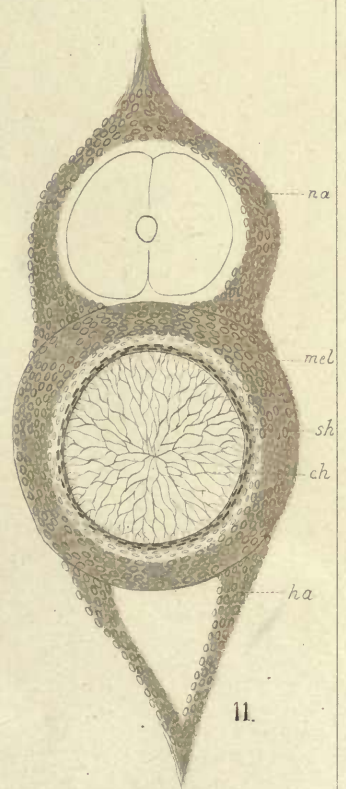
8.




9.

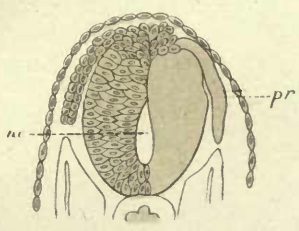


10.

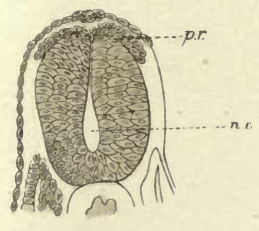


11.

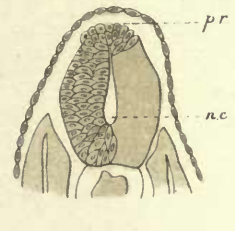




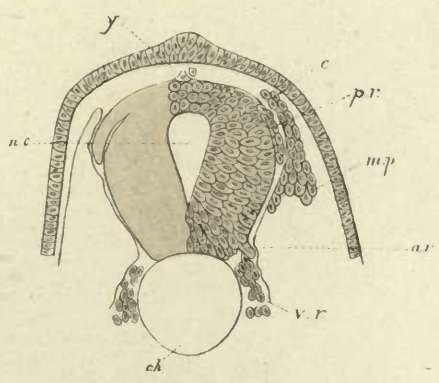
1.



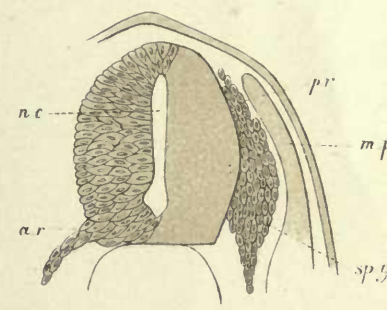
2.



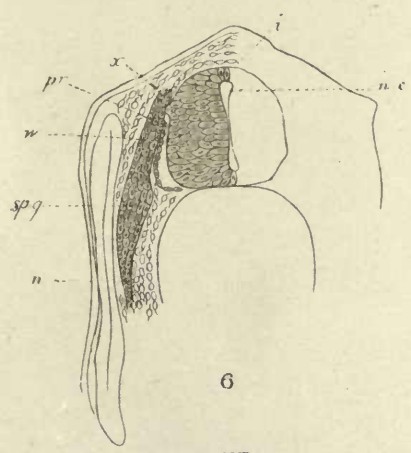
3.



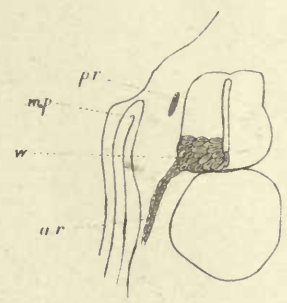
4.



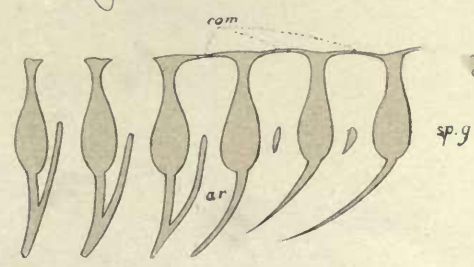
5.



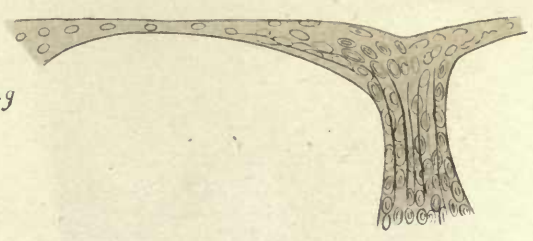6.



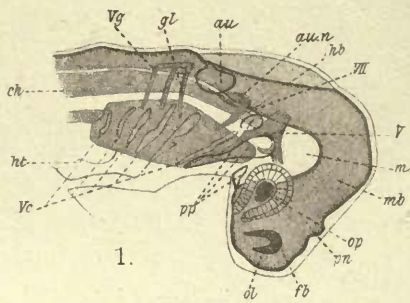
7.



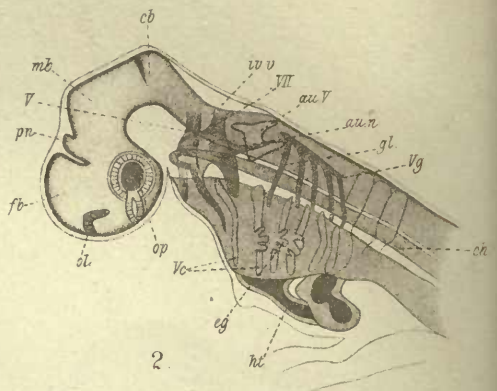
8.



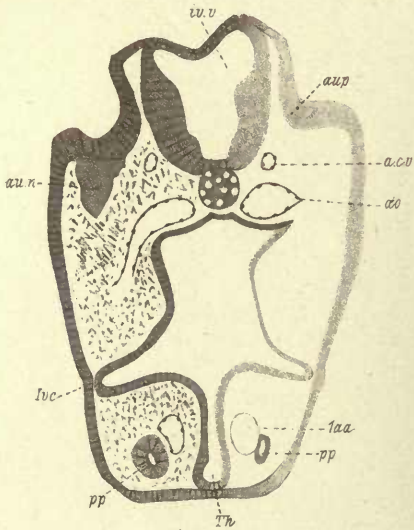
9.



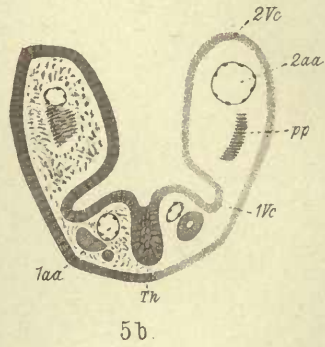
1.



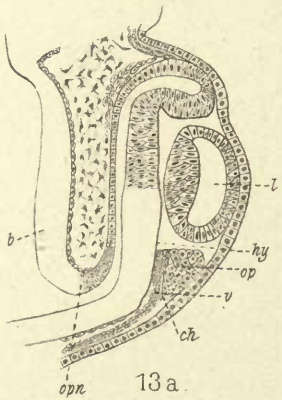
2.



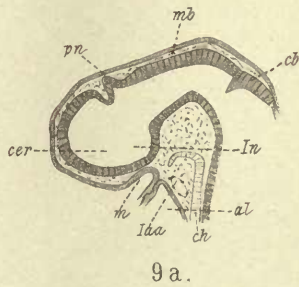
5a.



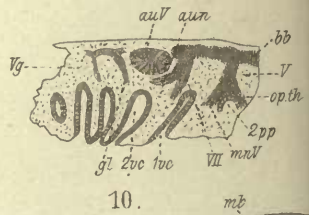
5b.



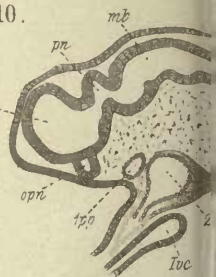13a.



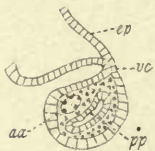
9a.



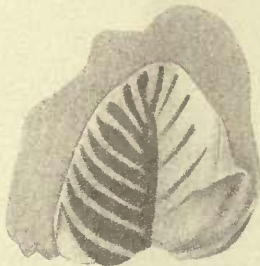
10.



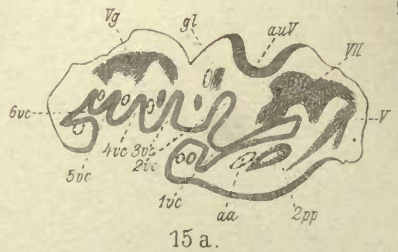9b.



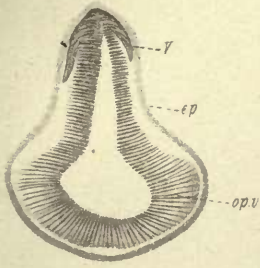
13b.



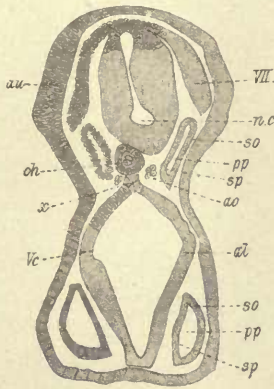
14.



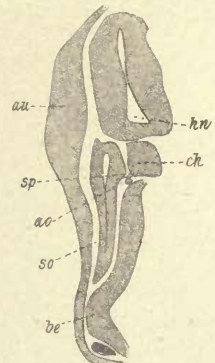
15a.



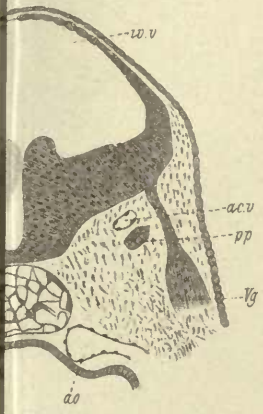
3



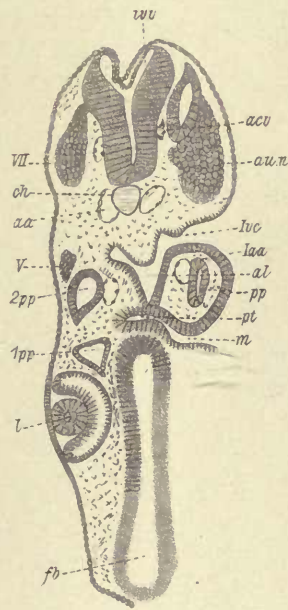
4 a.



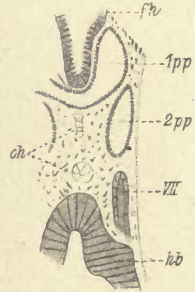
4 b.



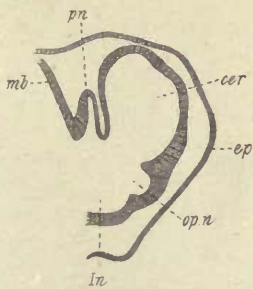
6.



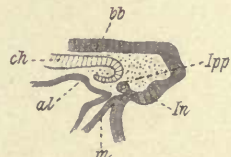
7.



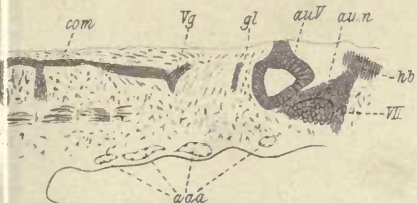
8.



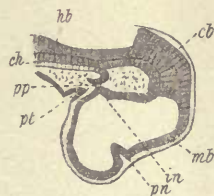
11.



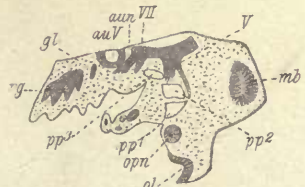
12.



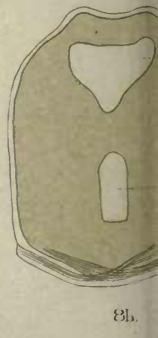
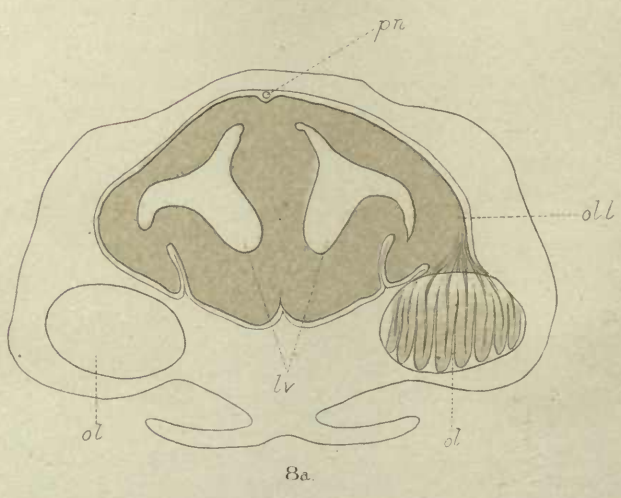
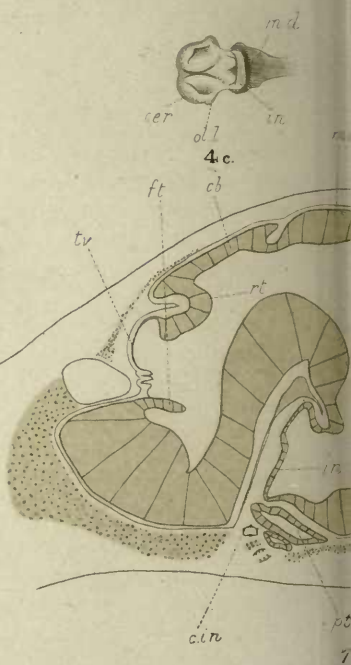
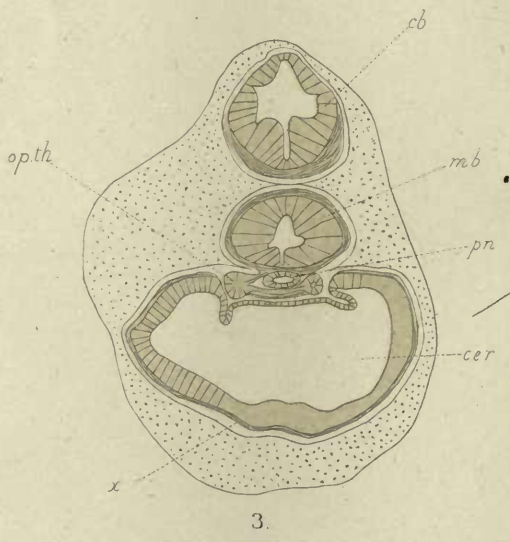
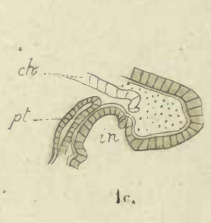
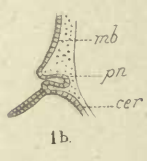
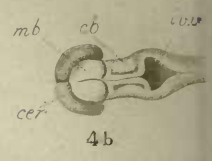
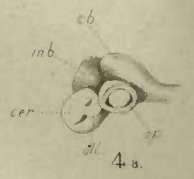
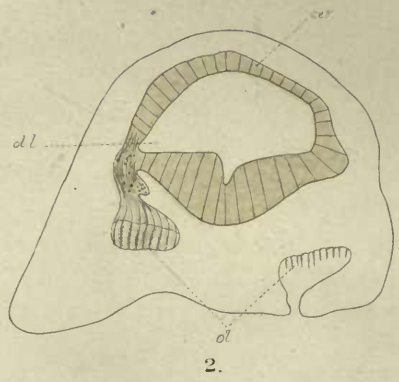
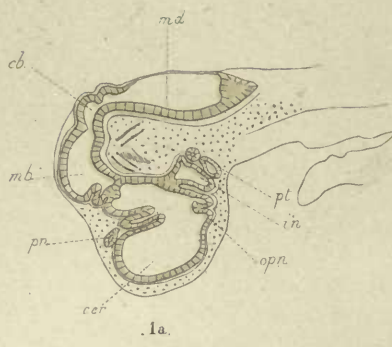
15 b.



16 a.



16 b.



1a.

2.

4a.

4b.

1b.

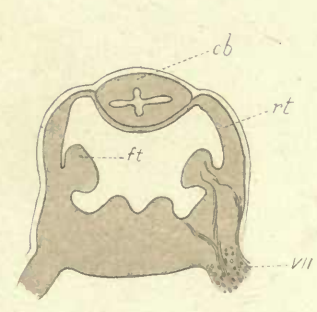

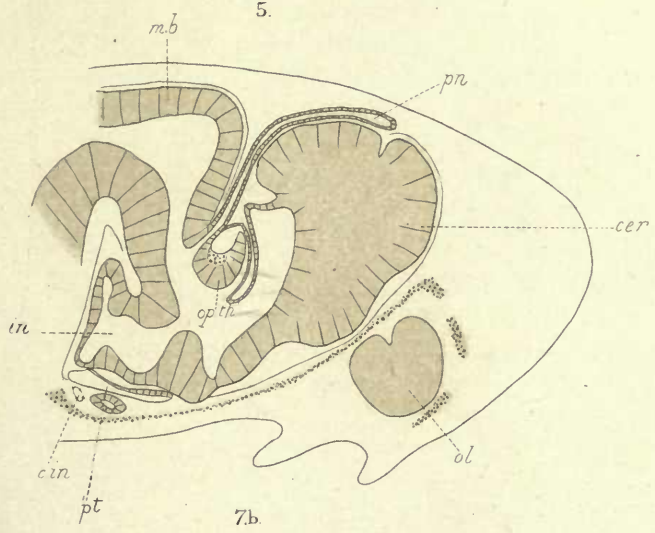
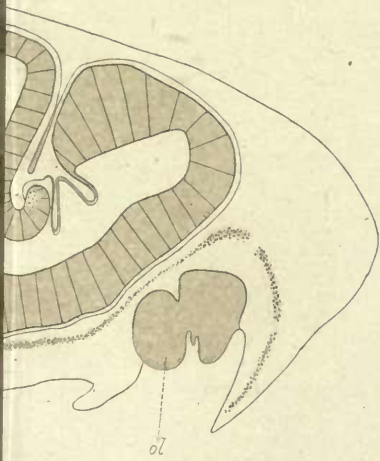
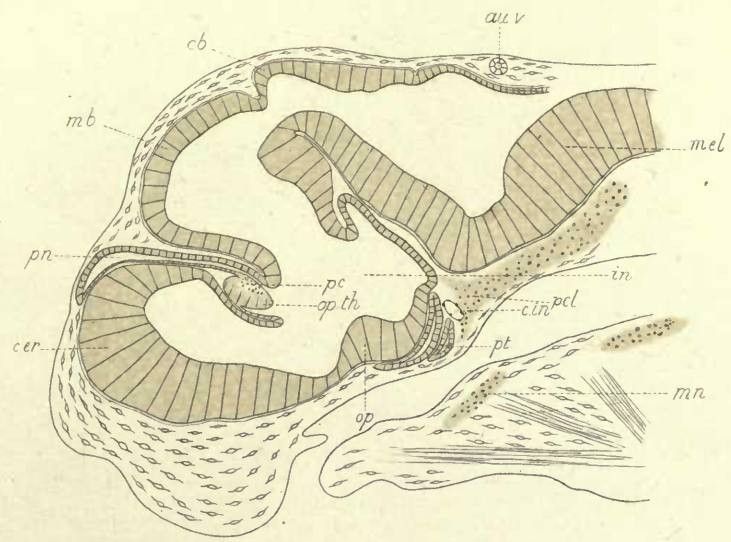
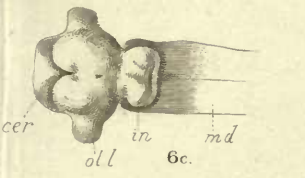
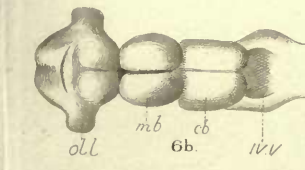
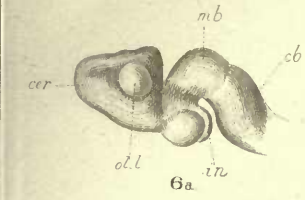
1c.

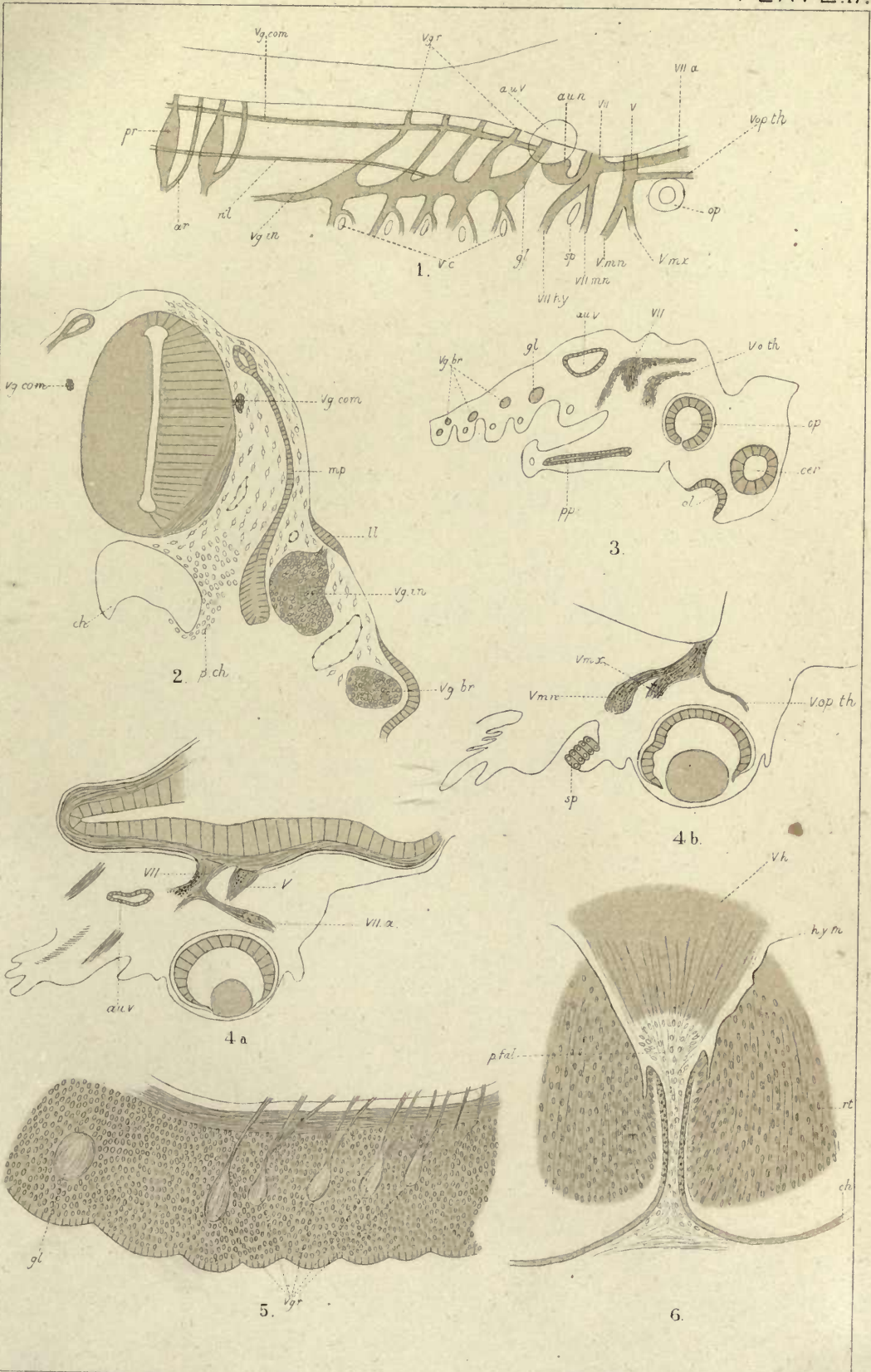
3.

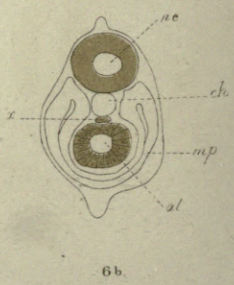
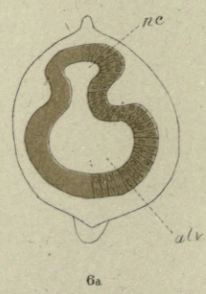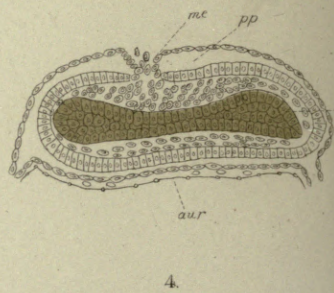
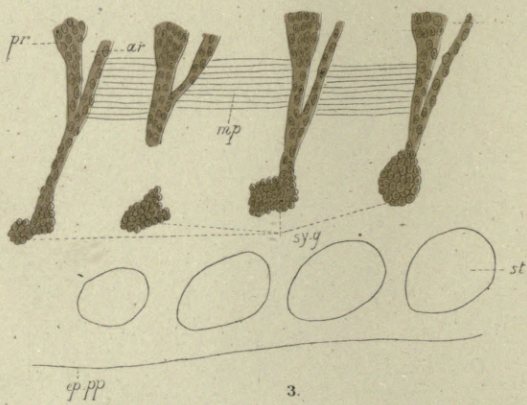
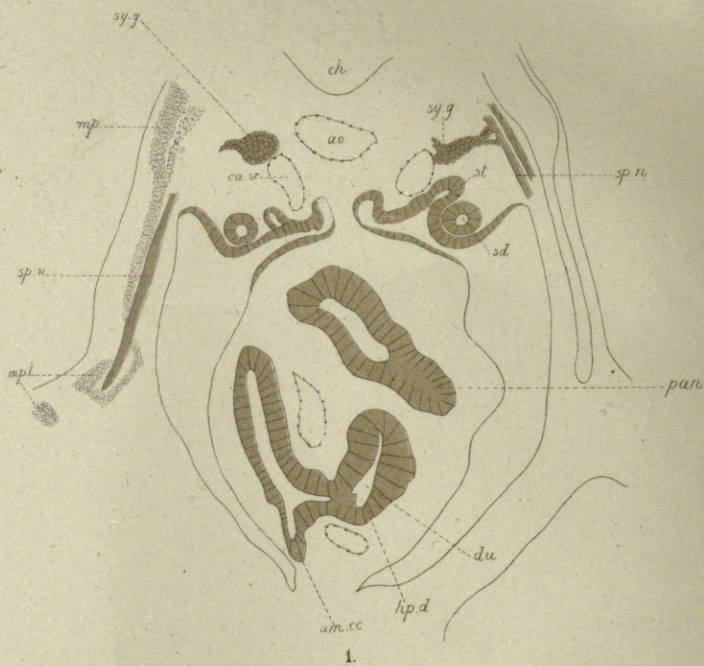
4c.

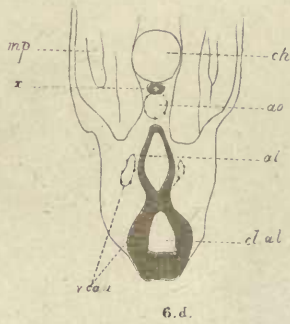
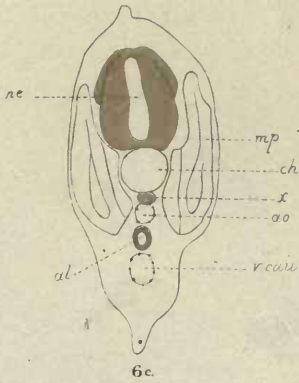
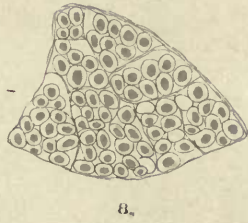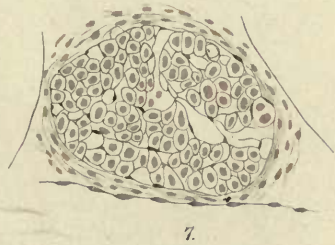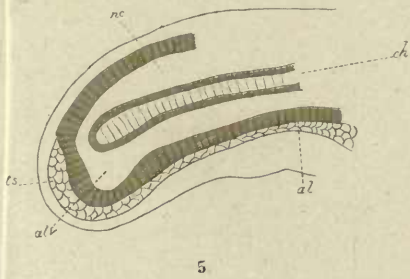
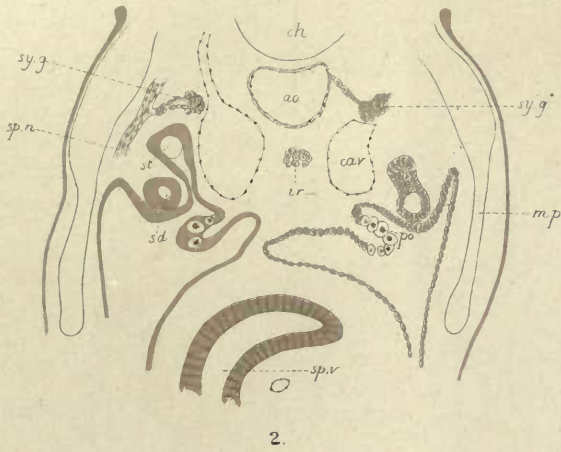
8a.

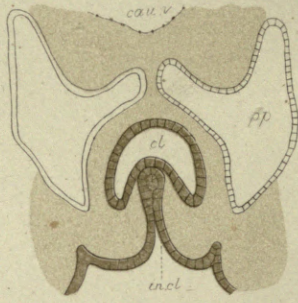
8b.



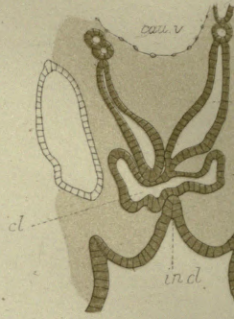




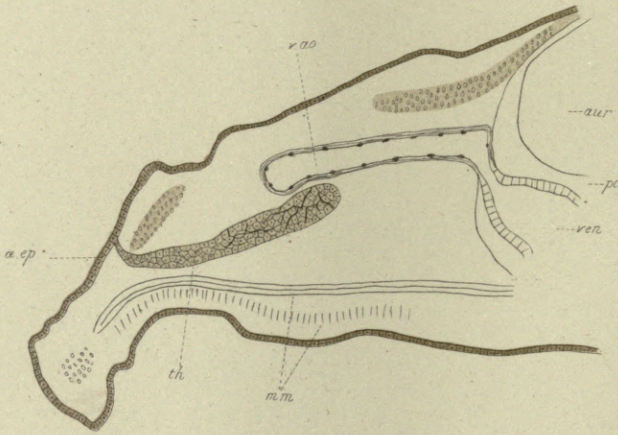




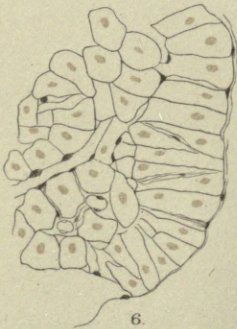
1a.



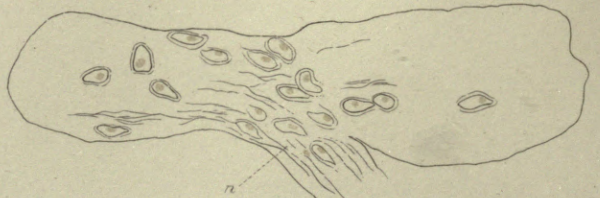1b.



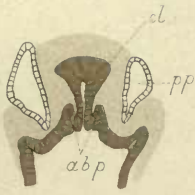
3.



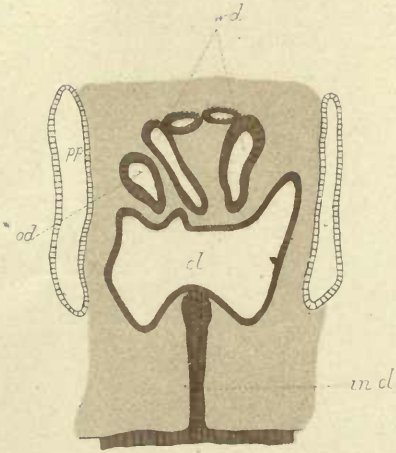
6.



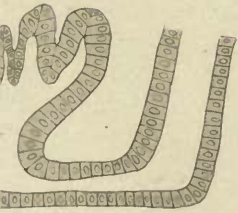
7.



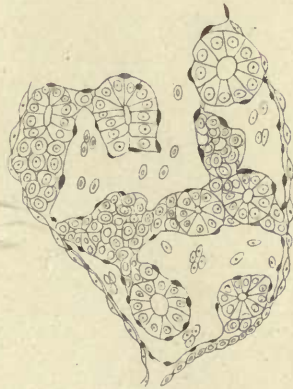
1c.



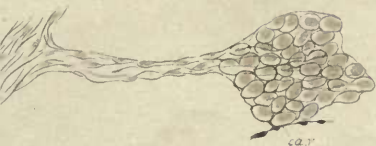2



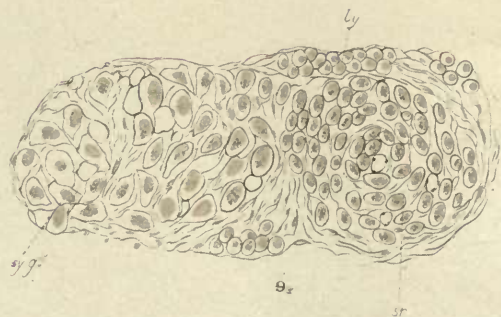
4.



5.

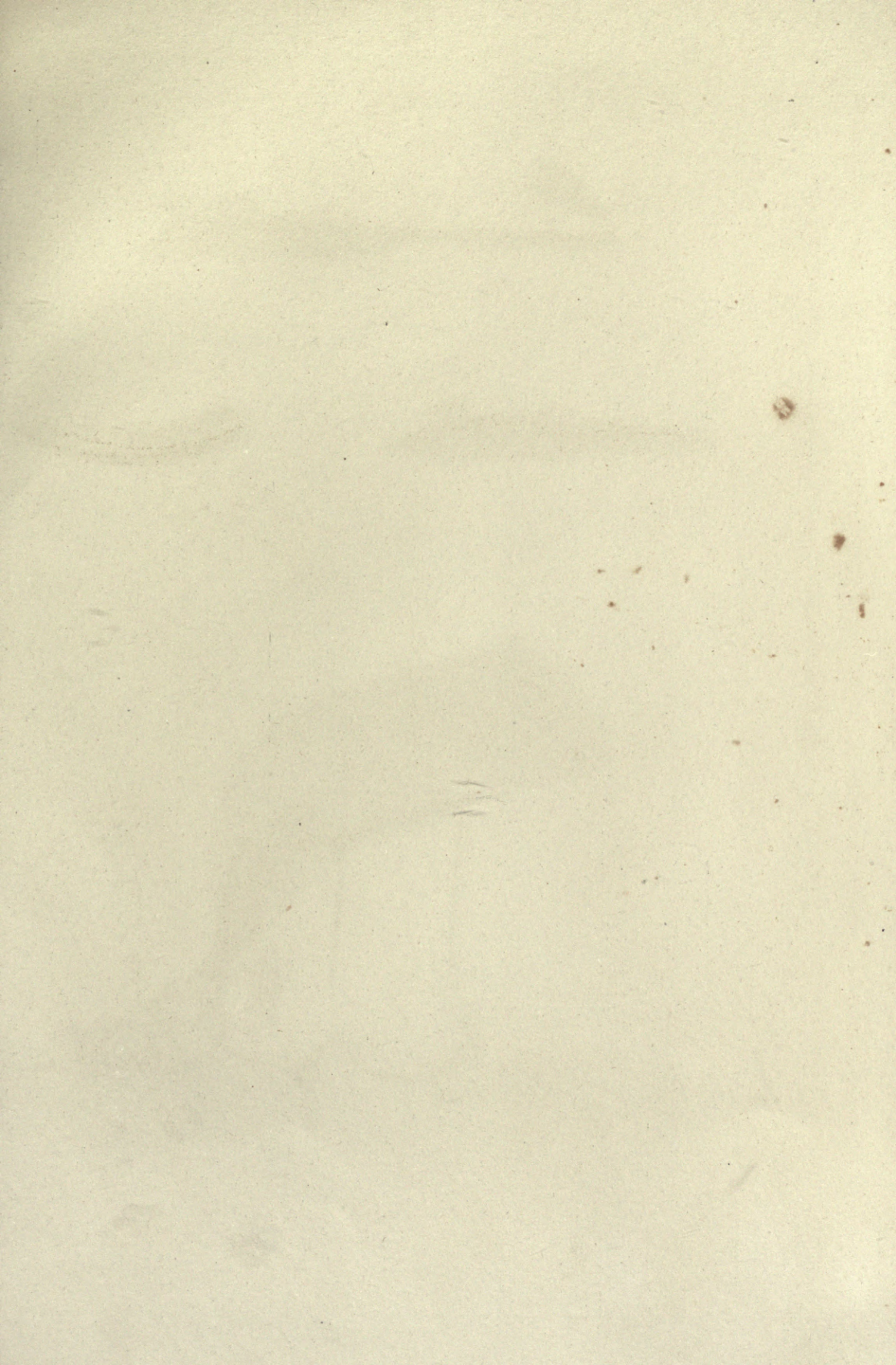

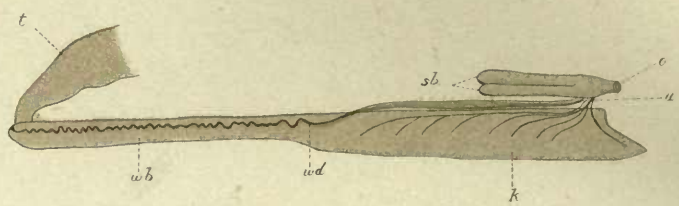
8.



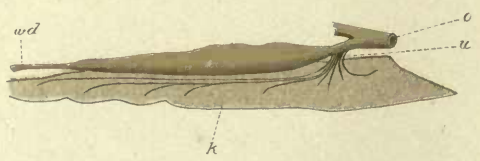
9.



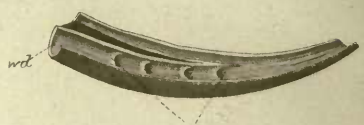




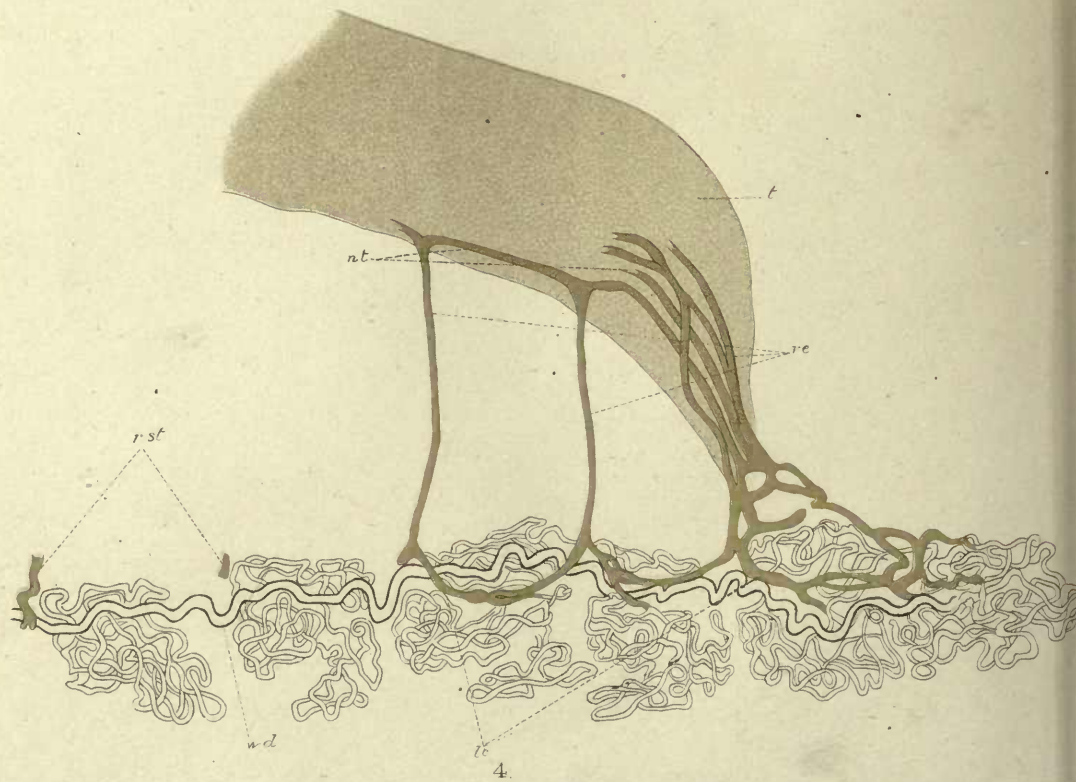
1.



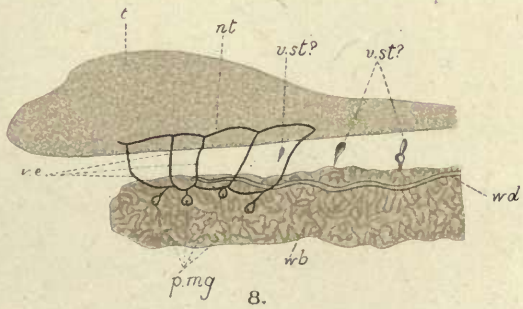
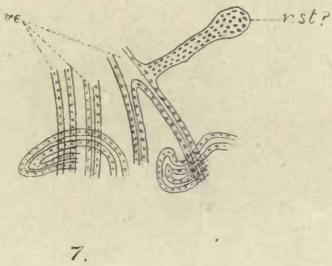
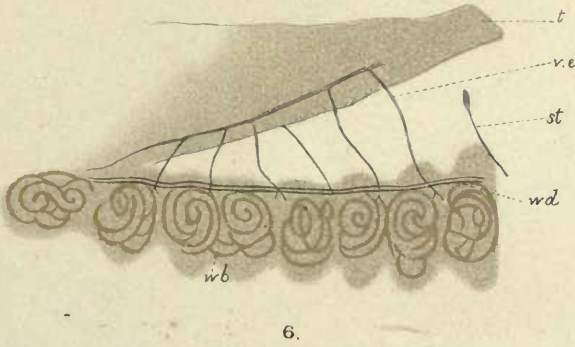
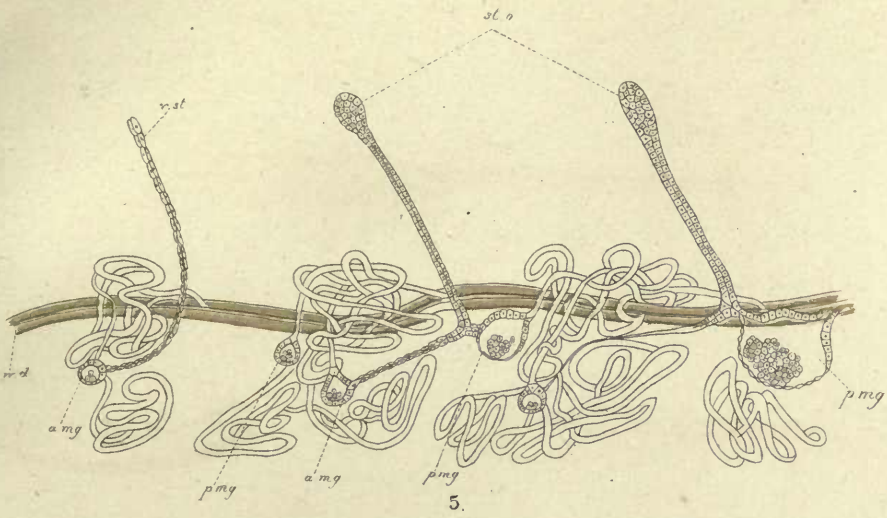
2.



3.



4.






Fig. 15*a*. Picric acid preparation shewing a primitive ovum partially filled with bodies resembling yolk-spherules.

Fig. 16. Horizontal and longitudinal section of *Scyllium* embryo belonging to stage K. Zeiss A, ocul. 1. Picric acid preparation. The connective-tissue cells are omitted.

The section shews that there is one segmental tube to each vertebral segment.

Fig. 17. Portion of a *Scyllium* embryo belonging to stage K, viewed as a transparent object.

It shews the segmental duct and the segmental involutions—two of which are seen to belong to segments behind the end of the alimentary tract.

Fig. 18. Vertical longitudinal section of a *Scyllium* embryo belonging to stage K. Zeiss A, ocul. 1. Hardened in a mixture of osmic and chromic acid. It shews

- (1) the commissures connecting together the posterior roots of the spinal nerves;
- (2) the junction of the anterior and posterior roots;
- (3) the relations of the segmental ducts to the segmental involutions and the alternation of calibre in the segmental tube;
- (4) the germinal epithelium lining the body-cavity.

EXPLANATION OF PLATE 13. (X. p. 361.)

COMPLETE LIST OF REFERENCE LETTERS.

al. Alimentary tract. *ao.* Aorta. *c.* Connective tissue. *ca v.* Cardinal vein. *ch.* Notochord. *ep.* Epiblast. *ha.* Hæmal arch. *l.* Liver. *ll.* Lateral line. *m c.* Mucous canal of the head. *mel.* Membrana elastica externa. *m p.* Muscle-plate. *m p'.* Muscles of muscle-plate. *na.* Neural arch. *nl.* Nervus lateralis. *rp.* Rib process. *s d.* Segmental duct. *sh.* Sheath of notochord. *sp c.* Spinal cord. *sp g.* Spinal ganglion. *sy g.* Sympathetic ganglion. *um.* Ductus choledochus. *v.* Blood-vessel. *var.* Vertebral arch. *vb.* Vertebral body. *v cau.* Caudal vein. *vin.* Intestinal branch of the vagus. *v op.* Ramus ophthalmicus of the fifth nerve. *x.* Sub-notochordal rod.

Fig. 1. Section through the anterior part of an embryo of *Scyllium canicula* during stage L.

c. Peculiar large cells which are found at the dorsal part of the spinal cord. Sympathetic ganglion shewn at *sy g.* Zeiss A, ocul. 1.

Fig. 2. Section through the lateral line at the time of its first formation.

The cells marked *nl* were not sufficiently distinct to make it quite certain that they really formed part of the lateral nerve. Zeiss B, ocul. 2.

Figs. 3*a*, 3*b*, 3*c*, 3*d*. Four sections of the lateral line from an embryo belonging to stage L. 3*a* is the most anterior. In 3*a* the lateral nerve (*nl*) is seen to lie in the mesoblast at some little distance from the lateral line. In 3*b* and 3*c* it lies in immediate contact with and partly enclosed by the modified epiblast cells of the lateral line. In 3*d*, the hindermost section, the lateral line is much larger than in the other sections, but no trace is present of the lateral nerve. The sections were taken from the following slides of my series of the embryo (the series commencing at the tail end) 3*d* (46), 3*c* (64), 3*b* (84), 3*a* (93). The figures all drawn on the same scale, but 3*a* is not from the same side of the body as the other sections.

Fig. 4. Section through lateral line of an embryo of stage P at the point where it is acquiring an opening to the exterior. The peculiar modified cells of its innermost part deserve to be noticed. Zeiss D, ocul. 2.

Fig. 5. Mucous canals of the head with branches of the ramus ophthalmicus growing towards them. Stage O. Zeiss A, ocul. 2.

Fig. 6. Mucous canals of head with branches of the ramus ophthalmicus growing towards them. Stage between O and P. Zeiss aa, ocul. 2.

Fig. 7. Junction of a nerve and mucous canal. Stage P. Zeiss D, ocul. 2.

Fig. 8. Longitudinal and horizontal section through the muscle-plates and adjoining structures at a stage intermediate between L and M. The section is intended to shew the gradual conversion of the cells of the somatic layer of muscle-plates into muscles.

Fig. 9. Longitudinal section through the notochord and adjoining parts to shew the first appearance of the cartilaginous notochordal sheath which forms the vertebral centra. Stage N.

Fig. 10. Transverse section through the tail of an embryo of stage P to shew the coexistence of the rib-process and hæmal arches in the first few sections behind the point where the latter appear. Zeiss C, ocul. 1.

Fig. 11. Transverse section through the centre of a caudal vertebra of an embryo somewhat older than Q. It shews (1) the similarity between the arch-tissue and the hyaline tissue of the outer layer of the vertebral centrum, and (2) the separation of the two by the membrana elastica externa¹ (*mel*). It shews also the differentiation of three layers in the vertebral centrum: vide p. 374.

EXPLANATION OF PLATE 14. (X. p. 378.)

This Plate illustrates the Formation of the Spinal Nerves.

COMPLETE LIST OF REFERENCE LETTERS.

a r. Anterior root of a spinal nerve. *ch.* Notochord. *com.* Commissure connecting the posterior roots of the spinal nerves. *i.* Mesoblastic investment of spinal cord. *m p.* Muscle-plate. *n.* Spinal nerve. *nc.* Neural canal. *pr.* Posterior root of a spinal nerve. *spg.* Ganglion on posterior root of spinal nerve. *vr.* Vertebral rudiment. *w.* White matter of spinal cord. *y.* Point where the spinal cord became segmented off from the superjacent epiblast.

Figs. 1, 2, and 3. Three sections of a *Pristiurus* embryo belonging to stage I. Fig. 1 passes through the heart, fig. 2 through the anterior part of the dorsal region, fig. 3 through a point slightly behind this. (Zeiss CC, ocul. 2.) In fig. 3 there is visible a slight proliferation of cells from the dorsal summit of the neural canal. In fig. 2 this proliferation definitely constitutes two club-shaped masses of cells (*pr*)—the rudiments of the posterior nerve-roots,—both attached to the dorsal summit of the spinal cord. In fig. 1 the rudiments of the posterior roots are of considerable length.

¹ The slight difference observable between these two tissues in the arrangement of their nuclei has been much exaggerated by the engraver.

Fig. 4. Section through the dorsal region of a Torpedo embryo slightly older than stage I, with three visceral clefts. (Zeiss CC, ocul. 2.) The section shews the formation of a pair of dorsal nerve-rudiments (*pr*) and a ventral nerve-rudiment (*ar*). The latter is shewn in its youngest condition, and is not distinctly cellular.

Fig. 5. Section through the dorsal region of a Torpedo embryo slightly younger than stage K. (Zeiss CC, ocul. 2.) The connective-tissue cells are omitted. The rudiment of the ganglion (*spg*) on the posterior root has appeared, and the junction of posterior root with the cord is difficult to detect. The anterior root forms an elongated cellular structure.

Fig. 6. Section through the dorsal region of a Pristiurus embryo of stage K. (Zeiss CC, ocul. 2.) The section especially illustrates the attachment of the posterior root to the spinal cord.

Fig. 7. Section through the same embryo as fig. 6. (Zeiss CC, ocul. 1.) The section contains an anterior root, which takes its origin at a point opposite the interval between two posterior roots.

Fig. 8. A series of posterior roots with their central ends united by a dorsal commissure, from a longitudinal and vertical section of a Scyllium embryo belonging to a stage intermediate between L and M. The embryo was hardened in a mixture of osmic and chromic acids.

Fig. 9. The central end of a posterior nerve-root from the same embryo, with the commissure springing out from it on either side.

EXPLANATION OF PLATES 15, 16, 17. (X. p. 397.)

PLATE 15. (THE HEAD DURING STAGES G—K.)

COMPLETE LIST OF REFERENCE LETTERS.

1 *aa*, 2 *aa*, etc. 1st, 2d, etc. aortic arch. *acv*. Anterior cardinal vein. *al*. Alimentary canal. *ao*. Aorta. *au*. Thickening of epiblast to form the auditory pit. *avn*. Auditory nerve. *aup*. Auditory pit. *auv*. Auditory vesicle. *b*. Wall of brain. *bb*. Base of brain. *cb*. Cerebellum. *cer*. Cerebrum. *Ch*. Choroid slit. *ch*. Notochord. *com*. Commissure connecting roots of vagus nerve. 1, 2, 3 etc. *eg*. External gills. *ep*. External epiblast. *fb*. Fore-brain. *gl*. Glossopharyngeal nerve. *hb*. Hind-brain. *ht*. Heart. *hy*. Hyaloid membrane. *In*. Infundibulum. *l*. Lens. *M*. Mouth involution. *m*. Mesoblast at the base of the brain. *mb*. Mid-brain. *mv*. Mandibular branch of fifth. *ol*. Olfactory pit. *op*. Eye. *opn*. Optic nerve. *opv*. Optic vesicle. *oph* v. Ophthalmic branch of fifth. *p*. Posterior root of spinal nerve. *pn*. Pineal gland. 1, 2 etc. *pp*. First, second, etc. section of body-cavity in the head. *pt*. Pituitary body. *so*. Somatopleure. *sp*. Splanchnopleure. *spc*. Spinal cord. *Th*. Thyroid body. *v*. Blood-vessel. *iv*. v. Fourth ventricle. v. Fifth nerve. *Vc*. Visceral cleft. *Vg*. Vagus. *vii*. Seventh or facial nerve.

Fig. 1. Head of a Pristiurus embryo of stage K viewed as a transparent object.

The points which deserve special attention are: (1) The sections of the body-cavity in the head (*pp*): the first or premandibular section being situated close to the eye, the second in the mandibular arch. Above this one the fifth nerve bifurcates. The third at the summit of the hyoid arch.

The cranial nerves and the general appearance of the brain are well shewn in the figure.

The notochord cannot be traced in the living embryo so far forward as it is represented. It has been inserted according to the position which it is seen to occupy in sections.

Fig. 2. Head of an embryo of *Scyllium canicula* somewhat later than stage K, viewed as a transparent object.

The figure shews the condition of the brain; the branches of the fifth and seventh nerves (v. vii.); the rudiments of the semicircular canals; and the commencing appearance of the external gills as buds on both walls of 2nd, 3rd, and 4th clefts. The external gills have not appeared on the first cleft or spiracle.

Fig. 3. Section through the head of a *Pristiurus* embryo during stage G. It shews (1) the fifth nerve (v.) arising as an outgrowth from the dorsal summit of the brain. (2) The optic vesicles not yet constricted off from the fore-brain.

Figs. 4 *a* and 4 *b*. Two sections through the head of a *Pristiurus* embryo of stage I. They shew (1) the appearance of the seventh nerve. (2) The portion of the body cavity belonging to the first and second visceral arches. (3) The commencing thickening of epiblast to form the auditory involution.

In 4 *b*, the posterior of the two sections, no trace of an auditory nerve is to be seen.

Figs. 5 *a* and 5 *b*. Two sections through the head of a *Torpedo* embryo with 3 visceral clefts. Zeiss A, ocul. 1.

5 *a* shews the formation of the thin roof of the fourth ventricle by a divarication of the two lateral halves of the brain.

Both sections shew the commencing formation of the thyroid body (*th*) at the base of the mandibular arch.

They also illustrate the formation of the visceral clefts by an outgrowth from the alimentary tract without any corresponding ingrowth of the external epiblast.

Fig. 6. Section through the hind-brain of a somewhat older *Torpedo* embryo. Zeiss A, ocul. 1.

The section shews (1) the attachment of a branch of the vagus to the walls of the hind-brain. (2) The peculiar form of the hind-brain.

Fig. 7. Transverse section through the head of a *Pristiurus* embryo belonging to a stage intermediate between I and K, passing through both the fore-brain and the hind-brain. Zeiss A, ocul. 1.

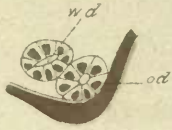
The section illustrates (1) the formation of the pituitary body (*pt*) from the mouth involution (*m*), and proves that, although the wall of the throat (*al*) is in contact with the mouth involution, there is by this stage no communication between the two. (2) The eye. (3) The sections of the body-cavity in the head (1 *pp*, 2 *pp*). (4) The fifth nerve (v.) and the seventh nerve (vii.).

Fig. 8. Transverse section through the brain of a rather older embryo than fig. 7. It shews the ventral junction of the anterior sections of the body-cavity in the head (1 *pp*).

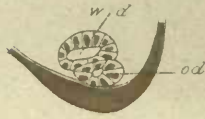Figs. 9 *a* and 9 *b*. Two longitudinal sections through the brain of a *Pristiurus* embryo belonging to a stage intermediate between I and K. Zeiss A, ocul. 1.

9 *a* is taken through the median line, but is reconstructed from two sections. It shews (1) The divisions of the brain—The cerebrum and thalamencephalon in the





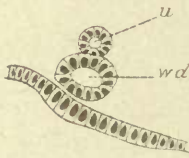
1a.



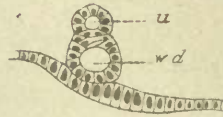
1b.



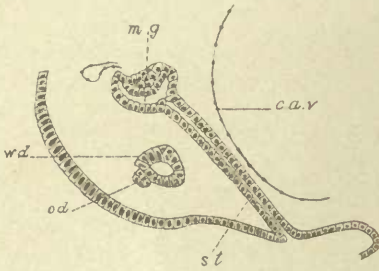
1c.



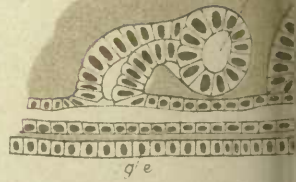
3a.



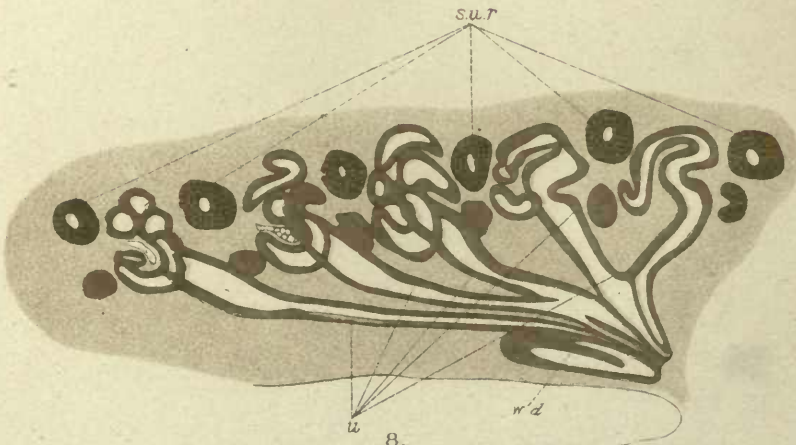
3b.



6.



7a.

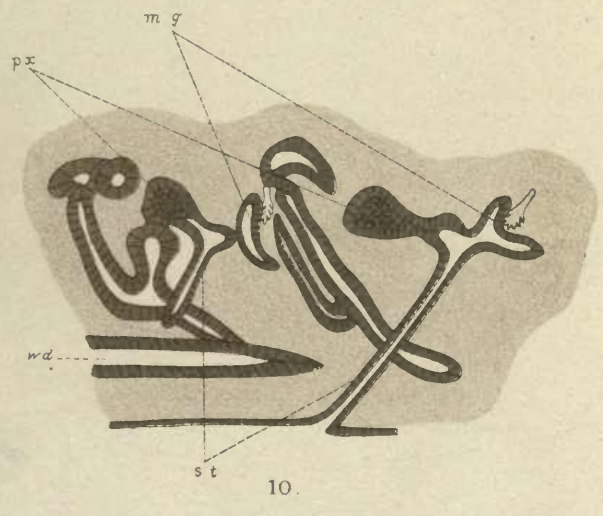
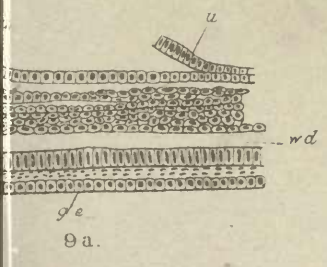
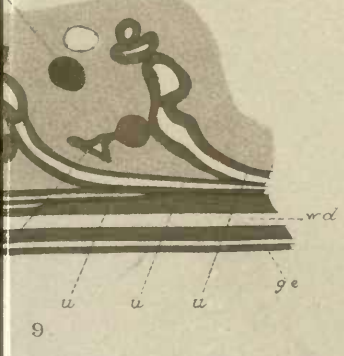
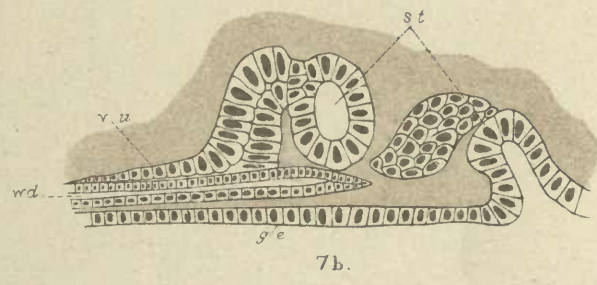
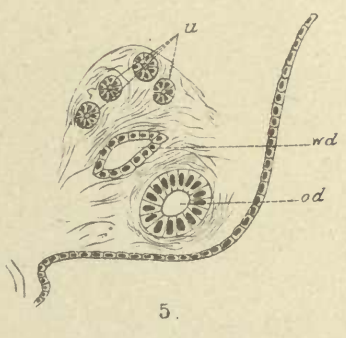
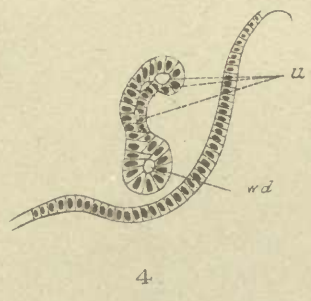
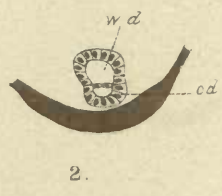



8.

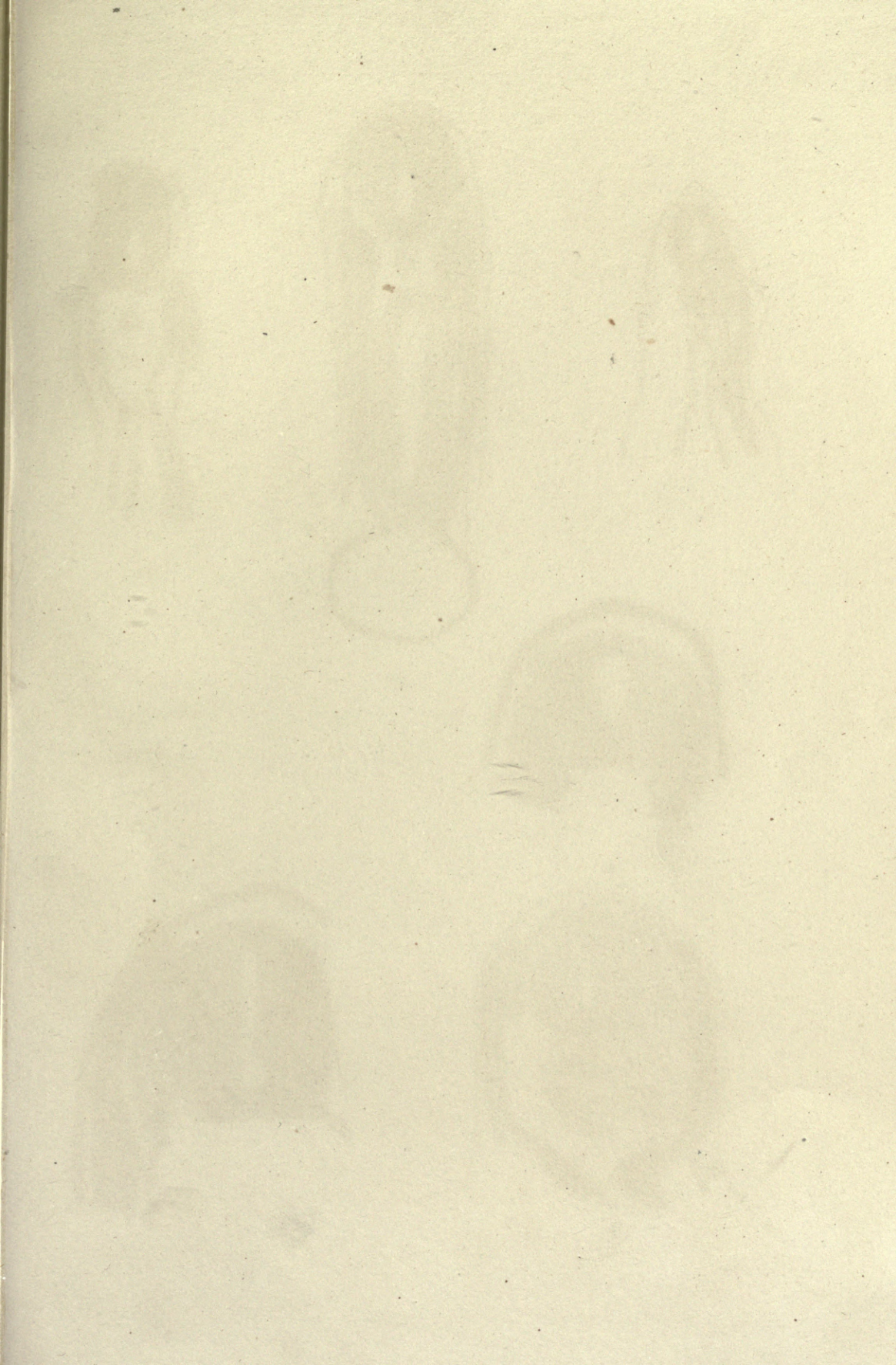


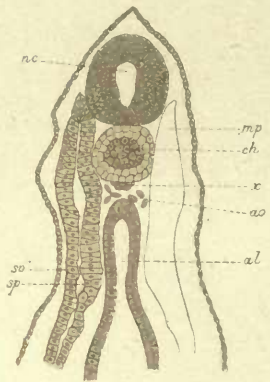
9.



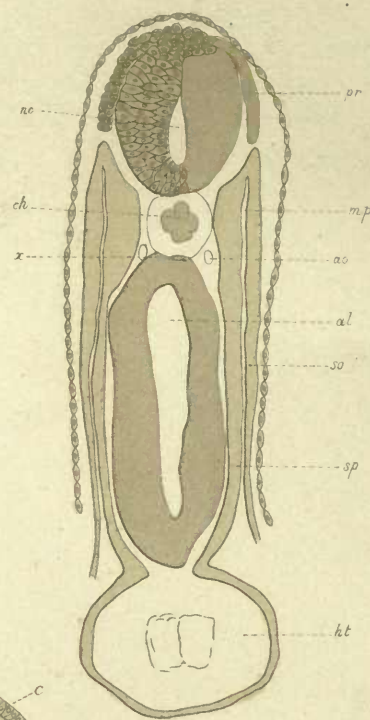




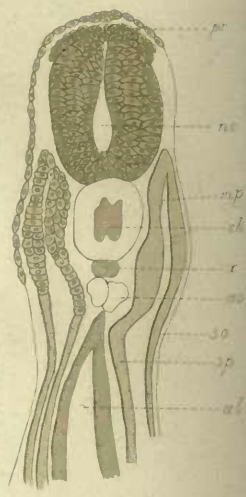



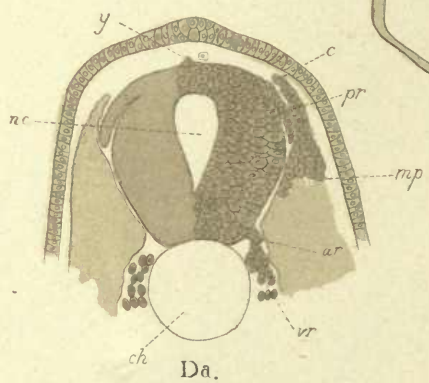
A.



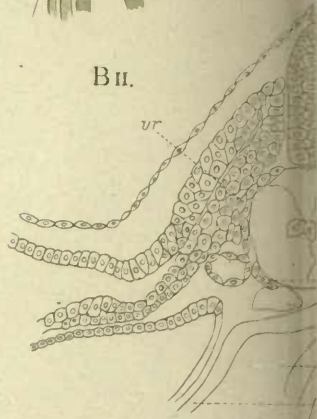
B I.



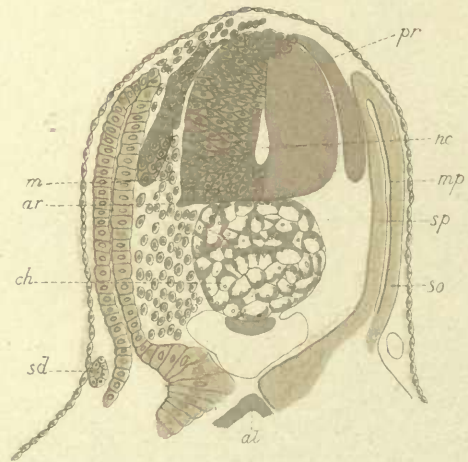
B II.



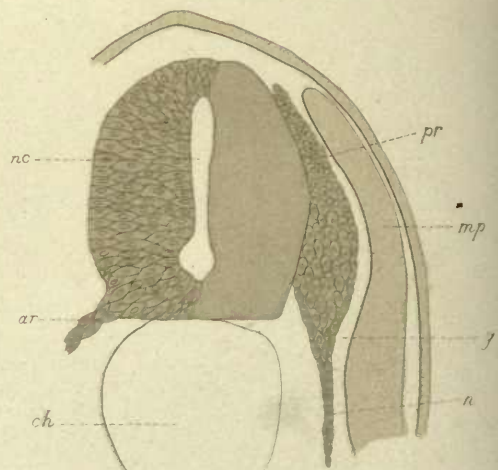
D a.



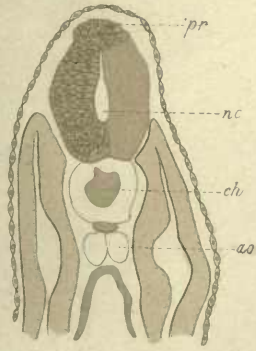
C.



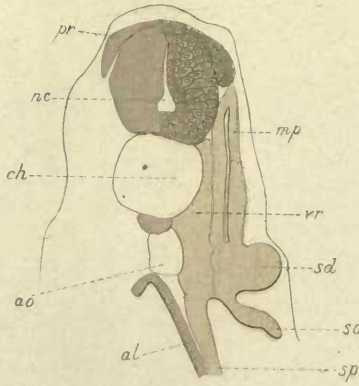
D b.



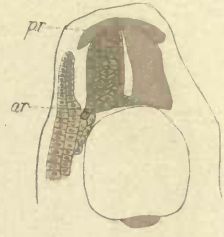
D c.



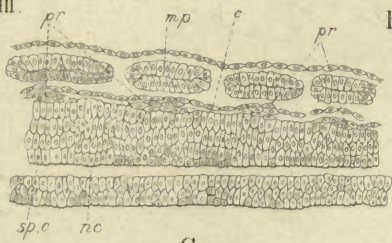
B III



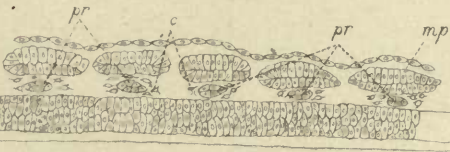

Ea.



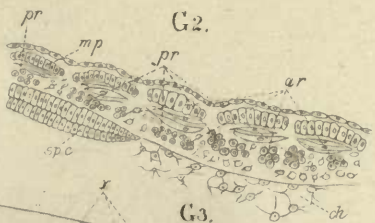Eb



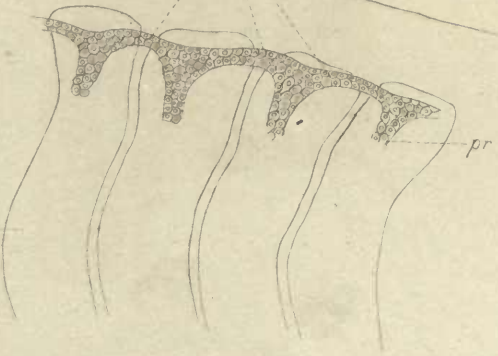G1.



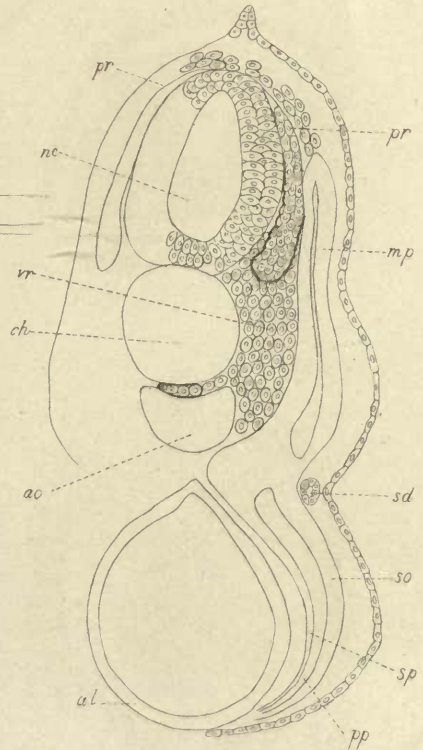
G2.



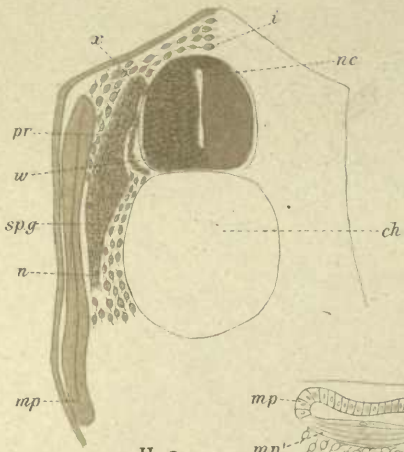
G3.



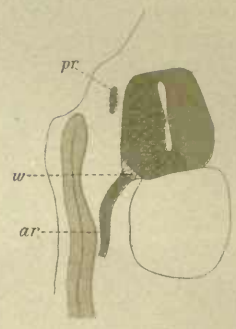
Dd.



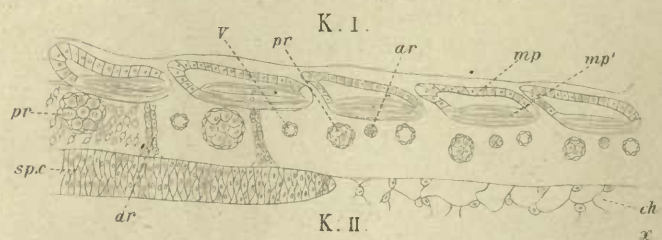
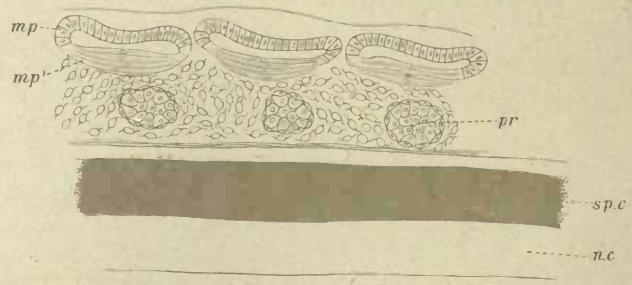
F.




H I.



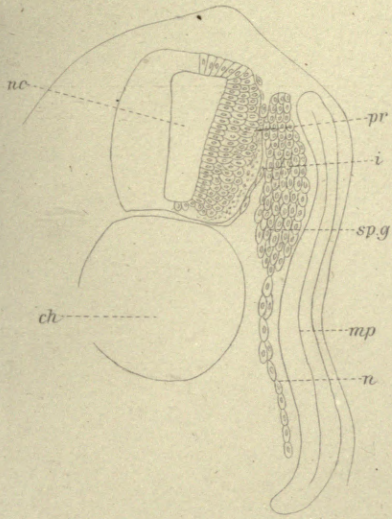
H II.



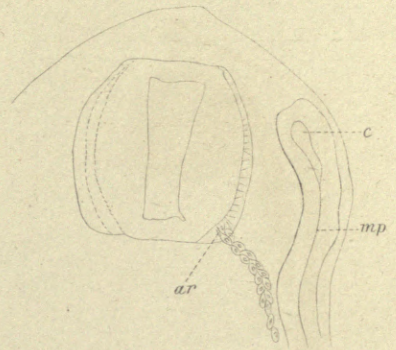
K II.



L.



I. I.



I. II.



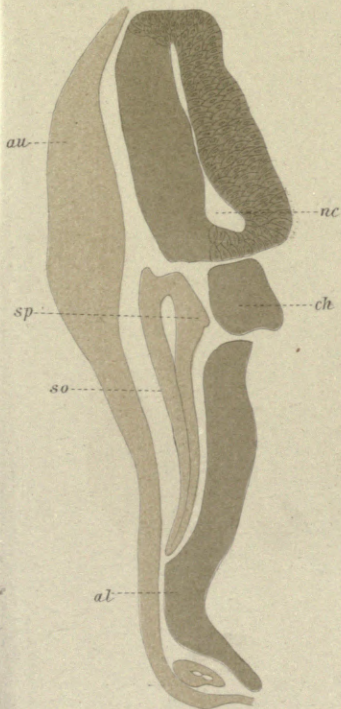
Ia.



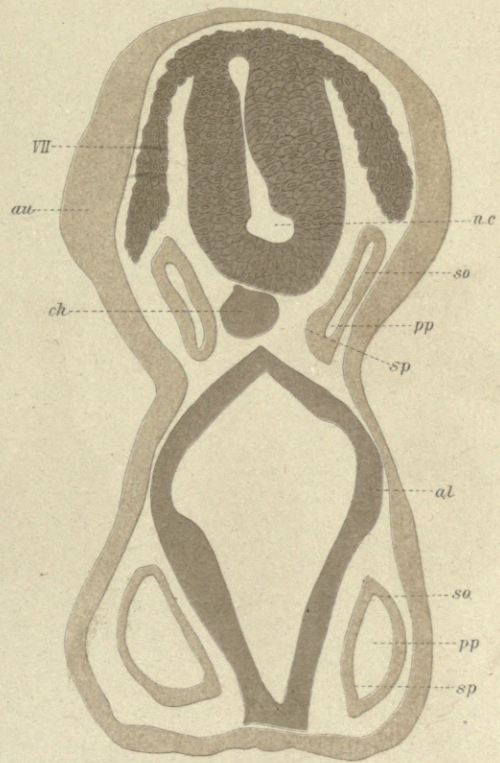
Ib.




Ic.

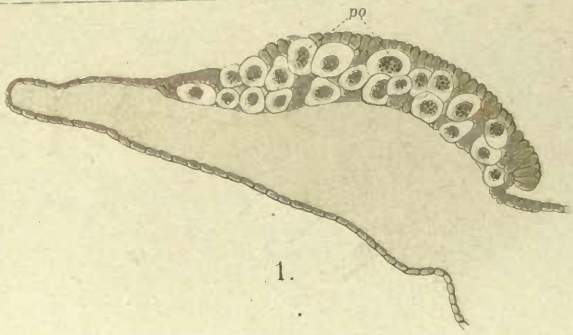


M. II.

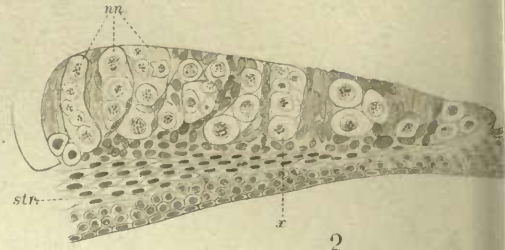


M. I.

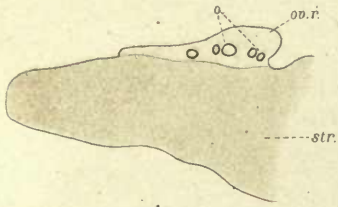



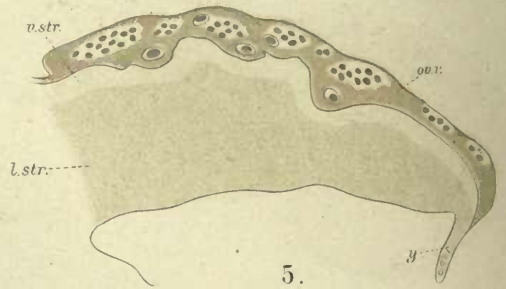
1.



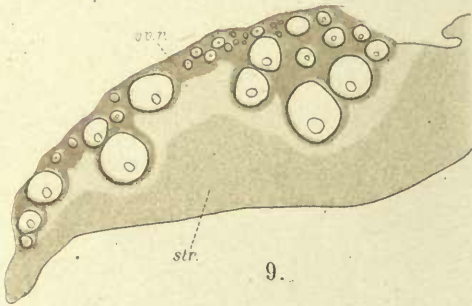
2.



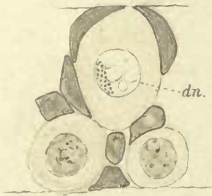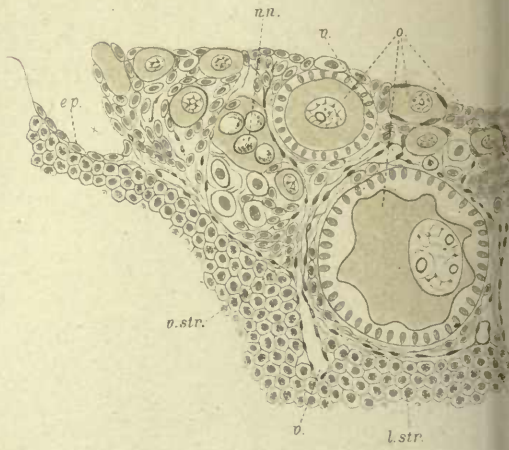
4.



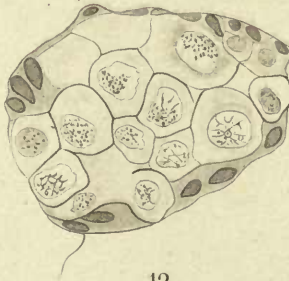5.



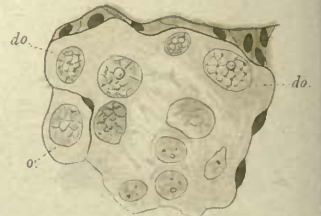
9.



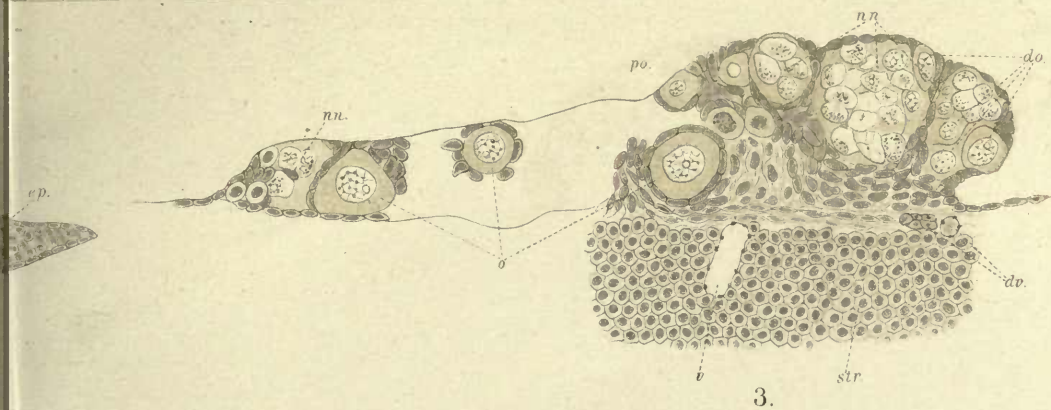
11.



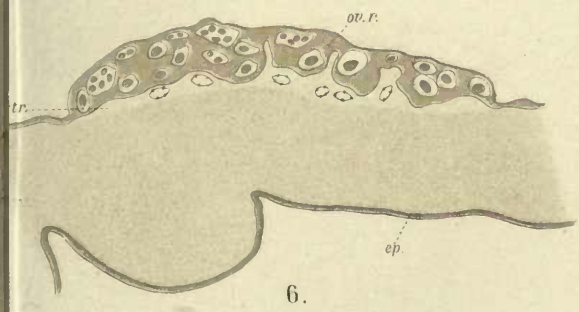
12.



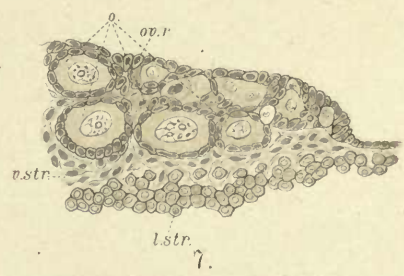13.



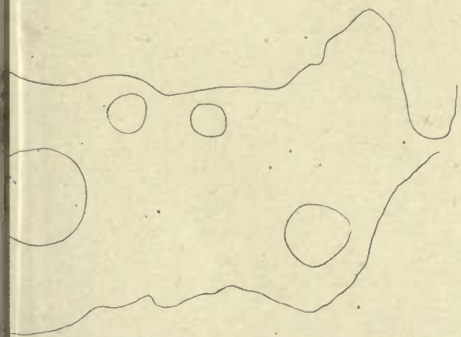
3.



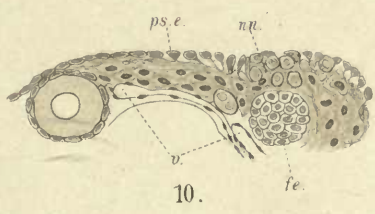
6.



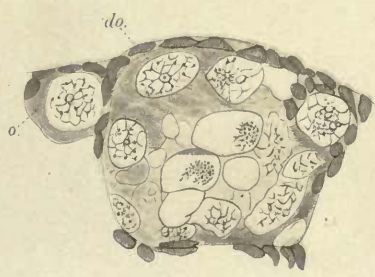
7.



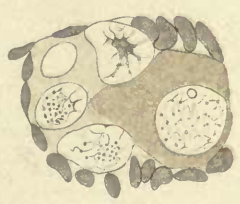
14.



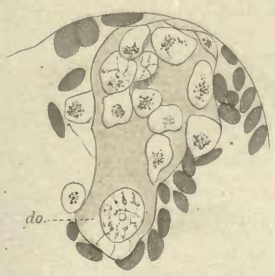10.

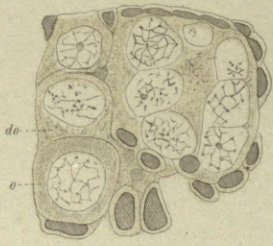


15.

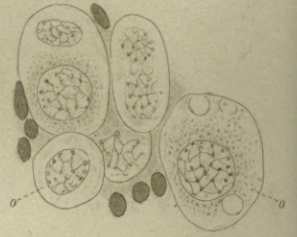


16.

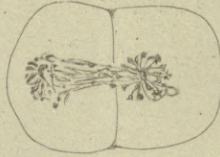




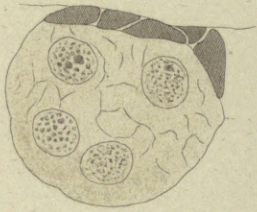
17.



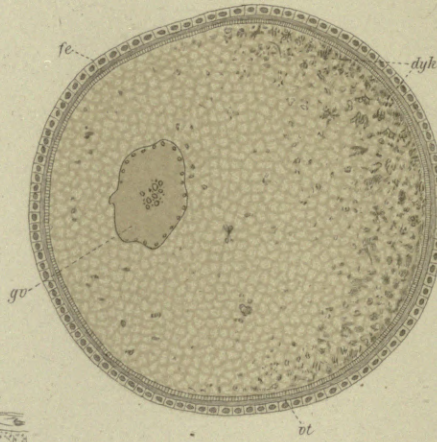18.



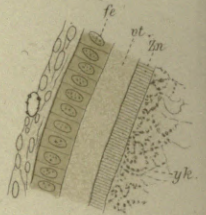
19.



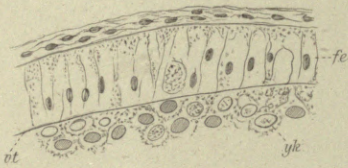20.



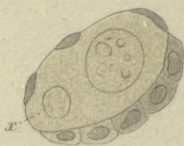
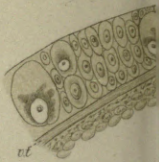
21.



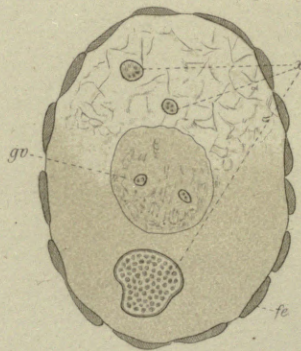
22.



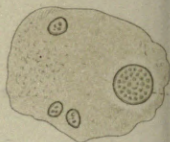23.



24.

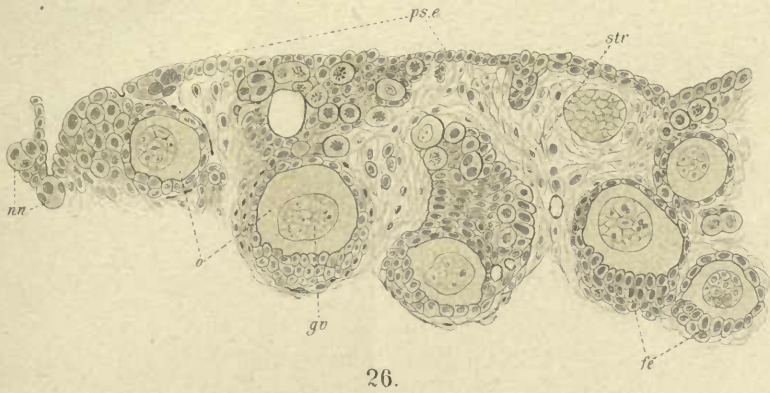


A.

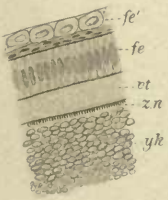


B.

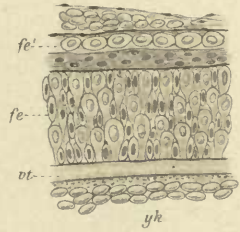
25.



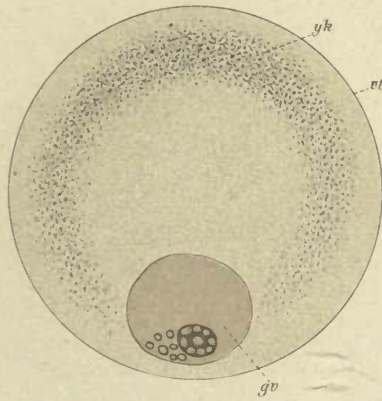
26.



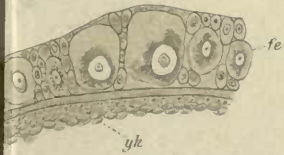28.



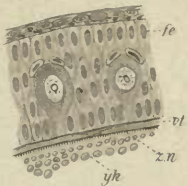
29.



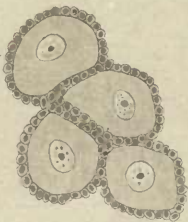
27.



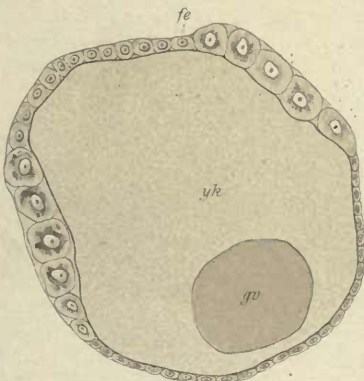
31.



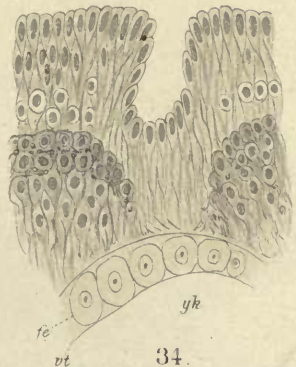
32.




33.




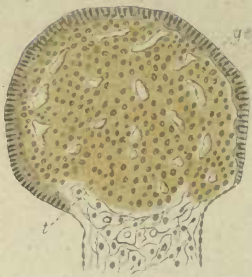
30.



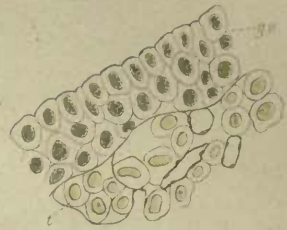
34.



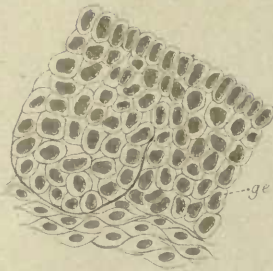




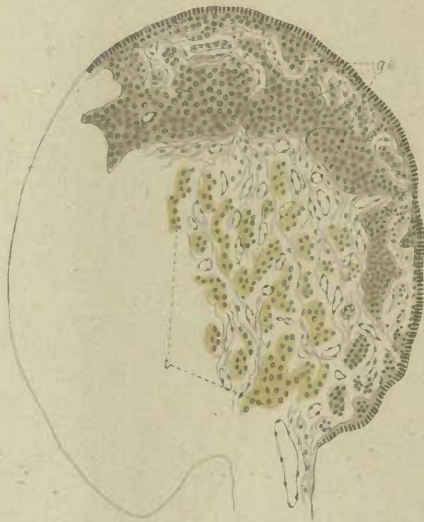35.



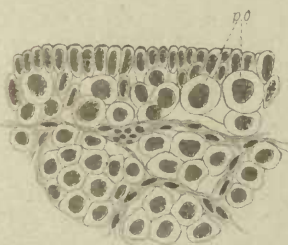
35 A.



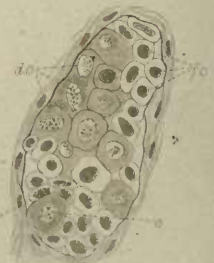36 A.



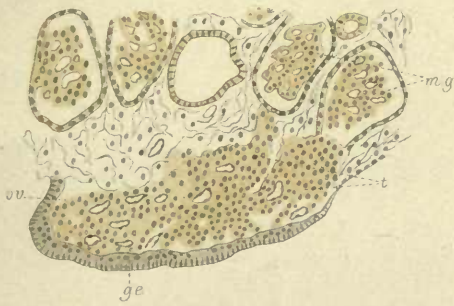37.



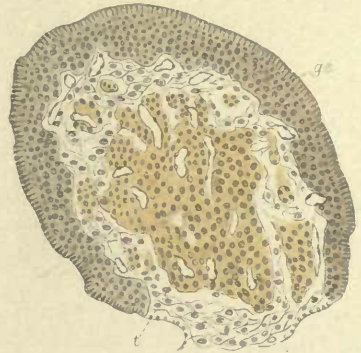
38 A.



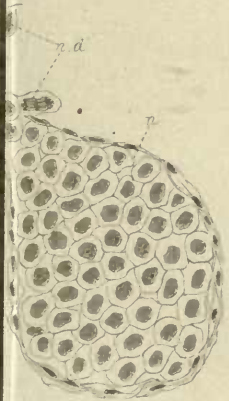38 B.



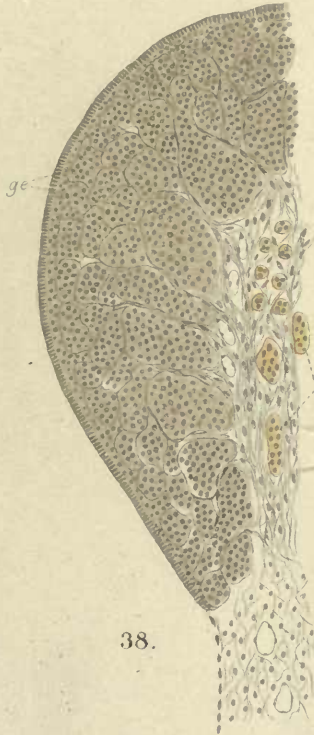35 B.




36.



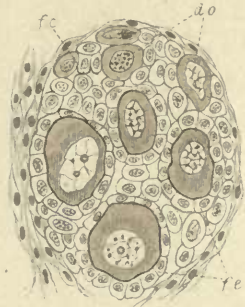
37 A.



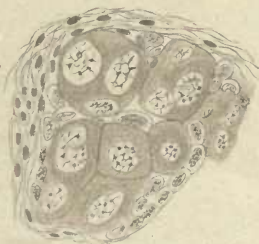38.



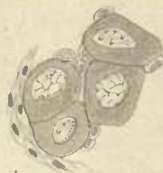39 A.



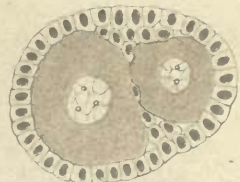
39 B.



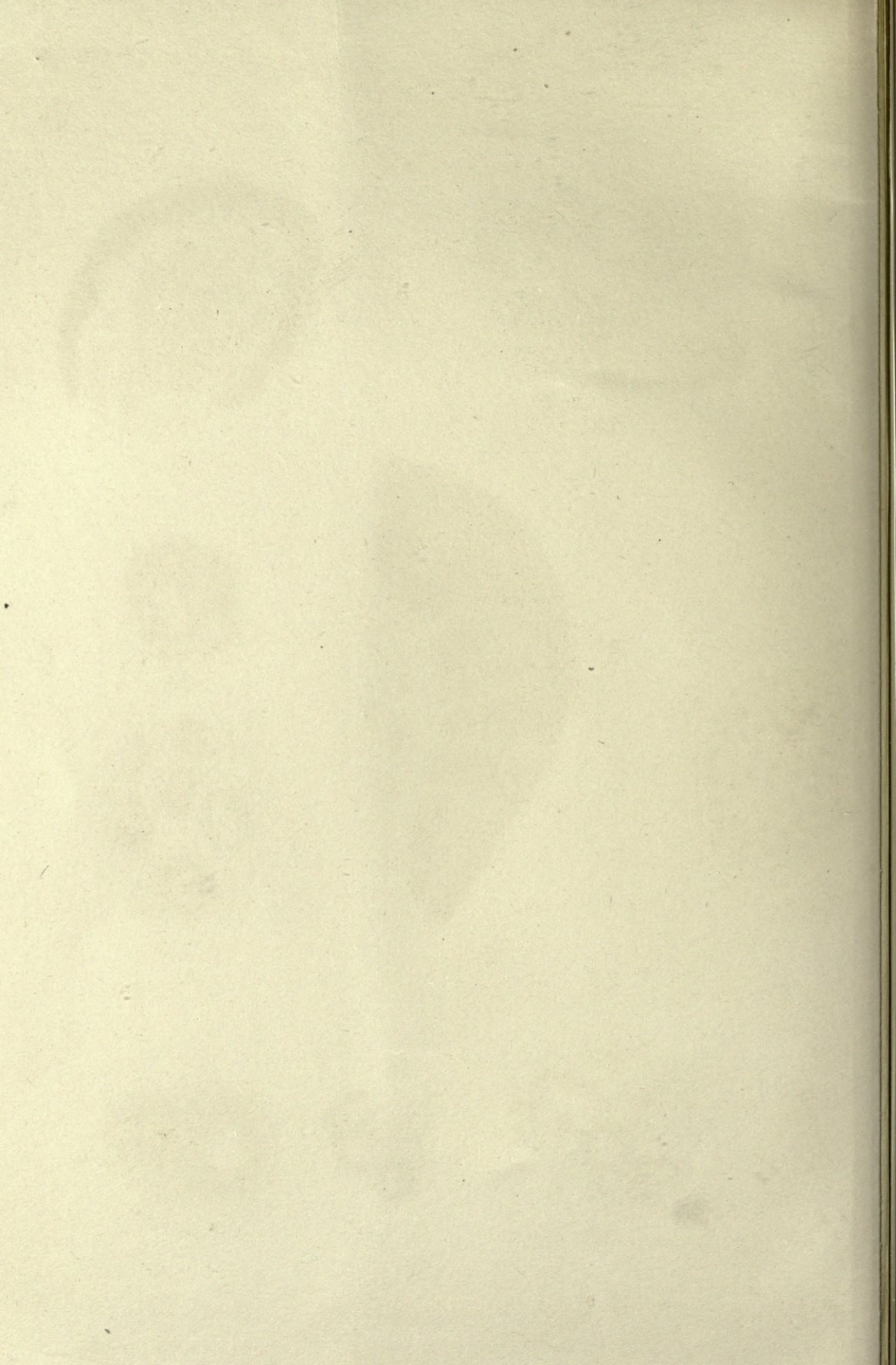
40 A.




40 B.

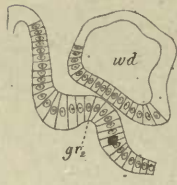


41.

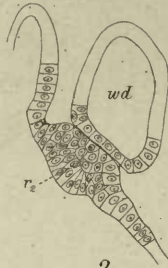




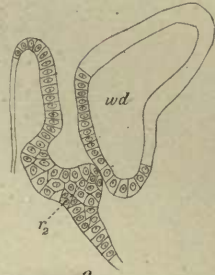
Series A.



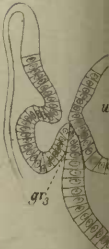
1.



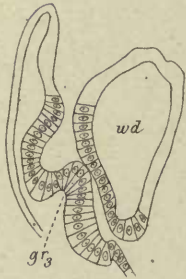
2.



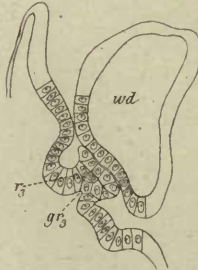
3.



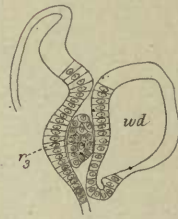
4.




6.



7.

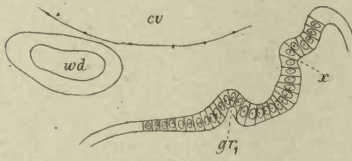


8.

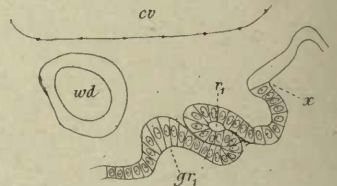


9.

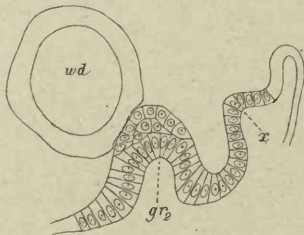
Series B.



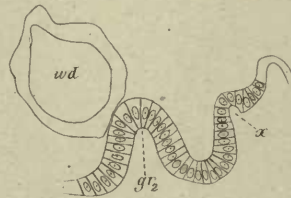
1.



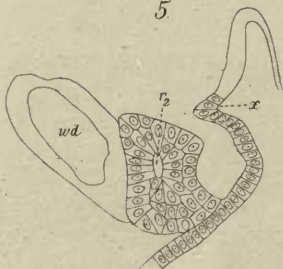
2.



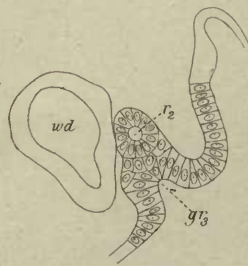
5.




6.



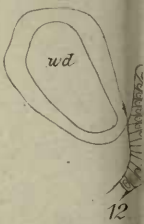
10.



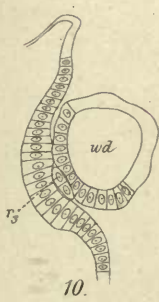
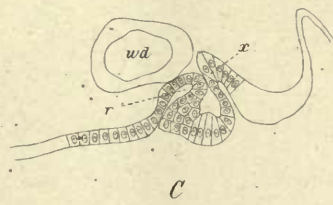
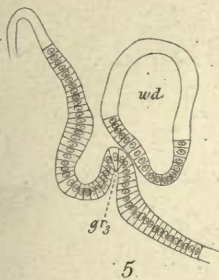
11.



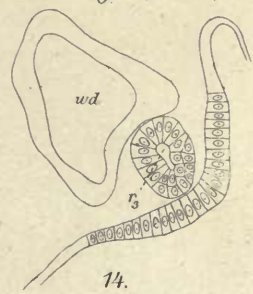
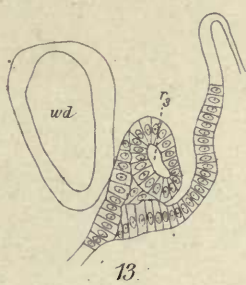
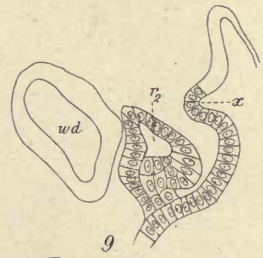
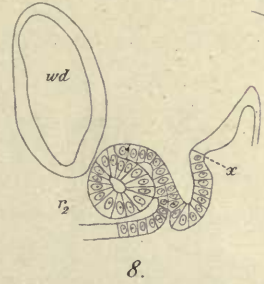
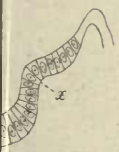
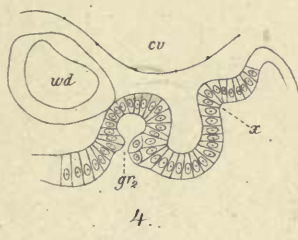
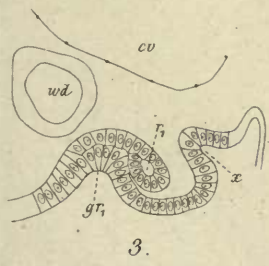
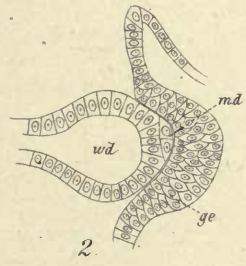
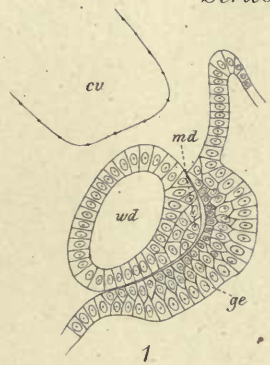
7.




12.

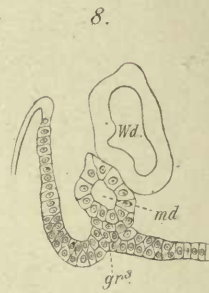
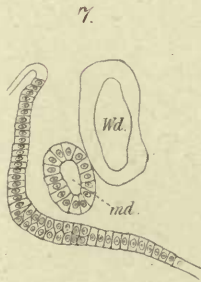
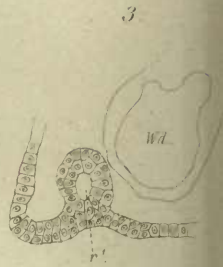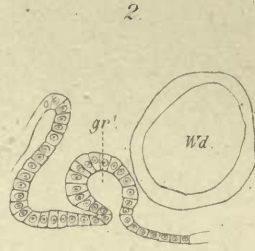
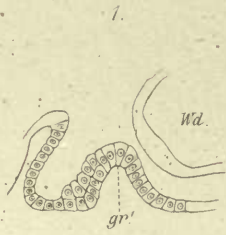


Series G.

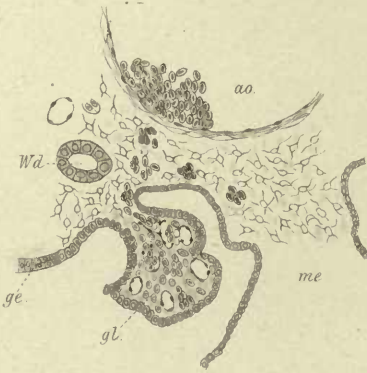



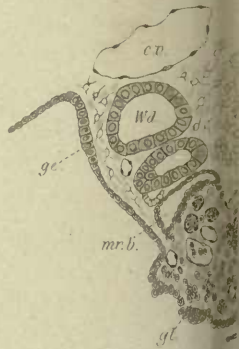Series D.



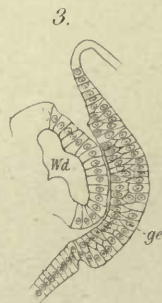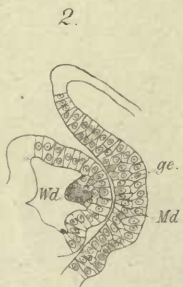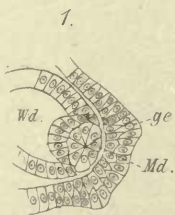
E.



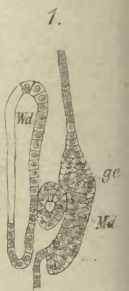F.



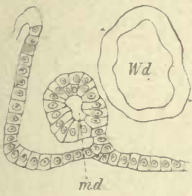
Series H.



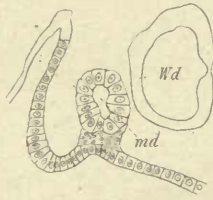
Series I.



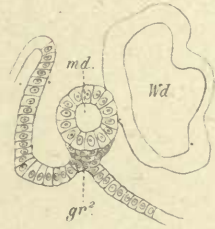
4.



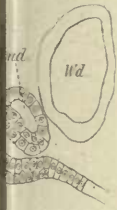
5.



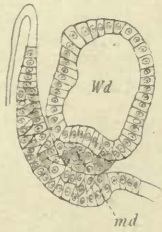
6.



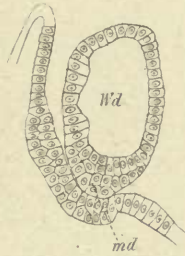
9.



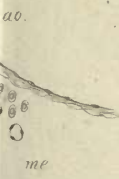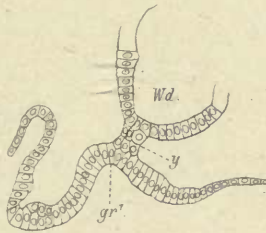
10.



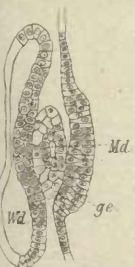11.



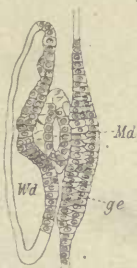K.



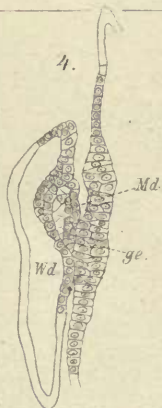2.



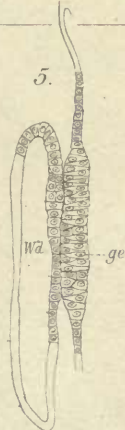3.



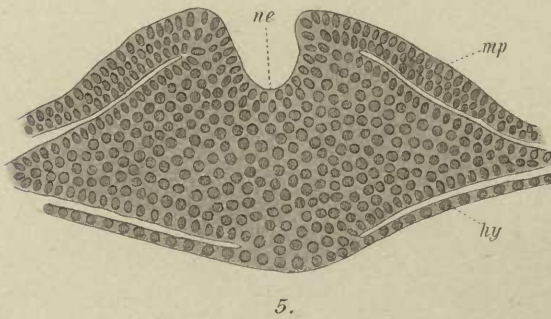
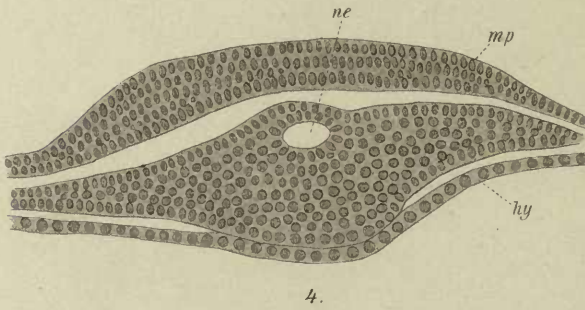
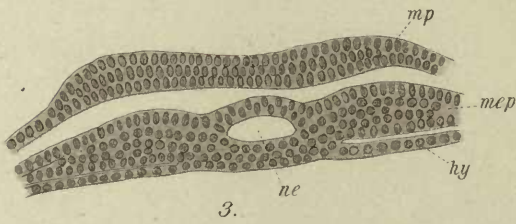
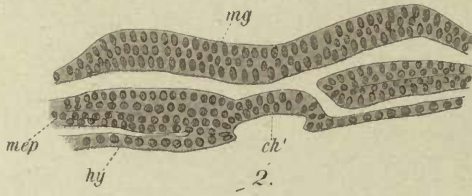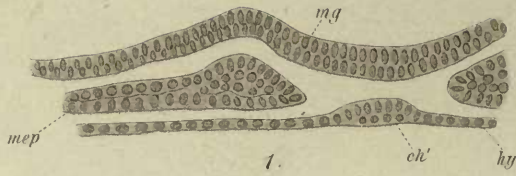
4.



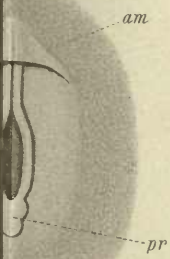
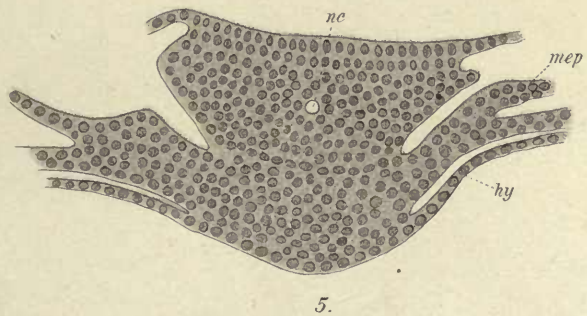
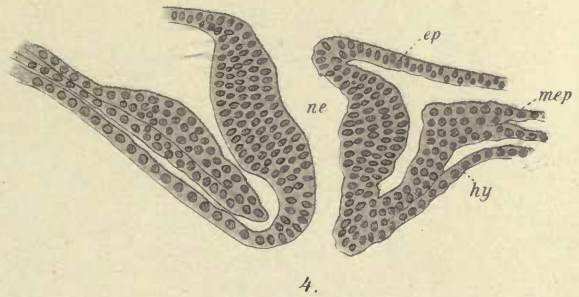
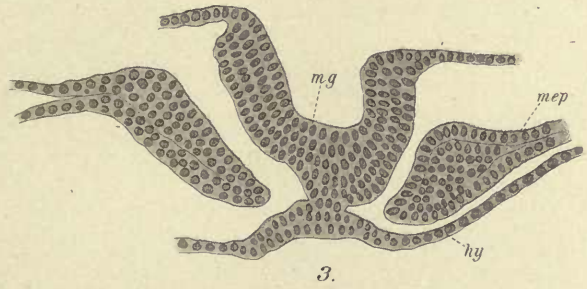
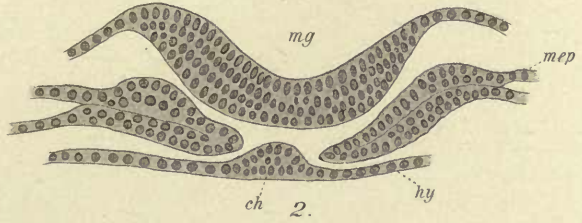
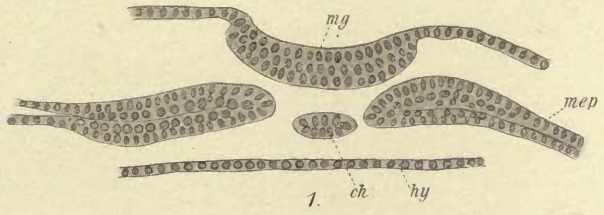
5.




Series A.




Series B.

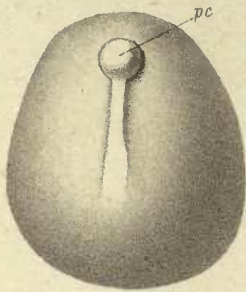


B.




A.

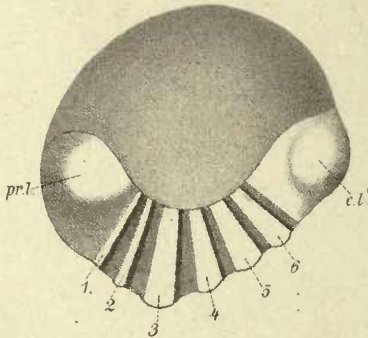




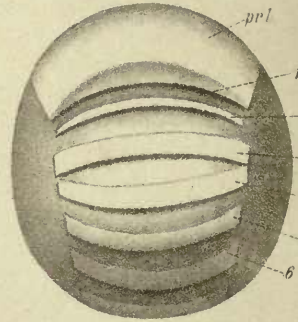
1.



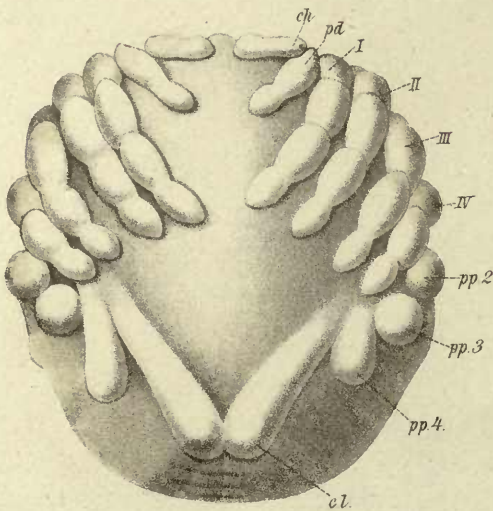
2.



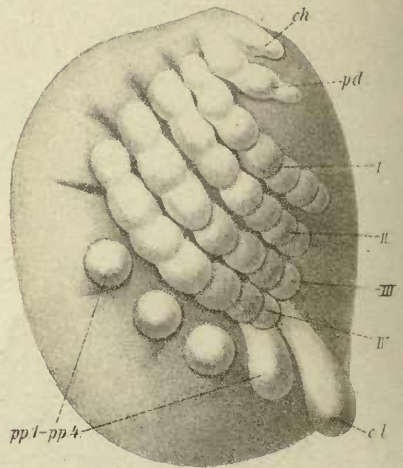
3a.



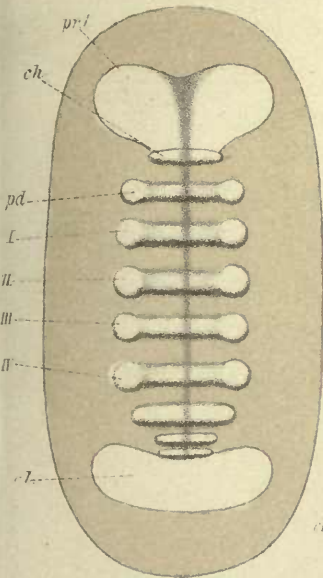
3b



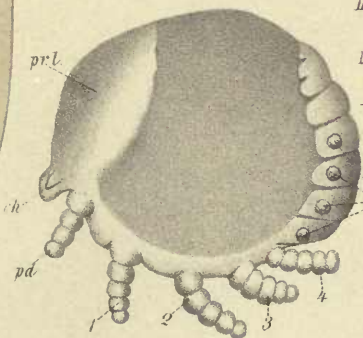
8a.



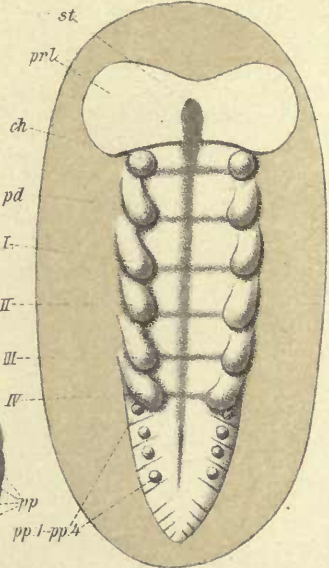
8b.



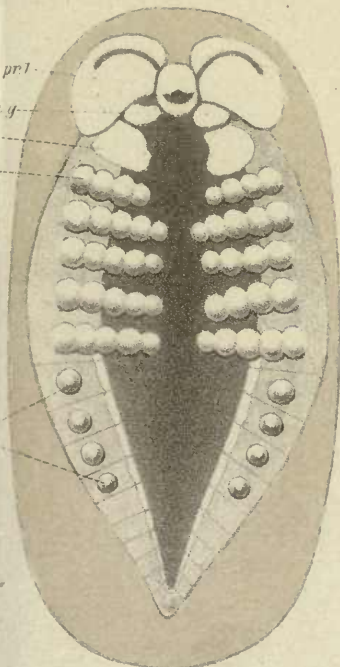4.



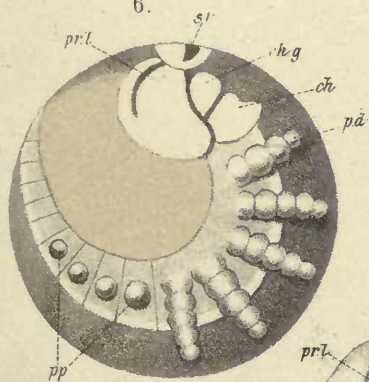
6.



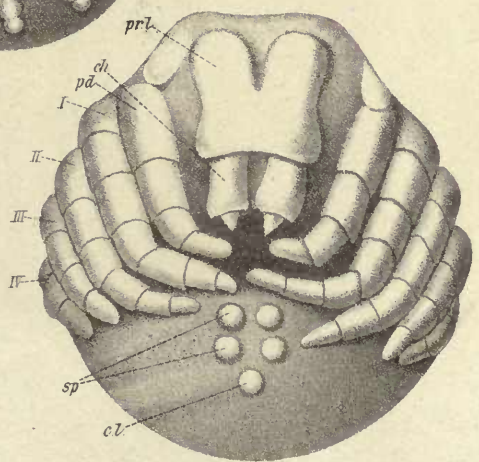
5.




7a.

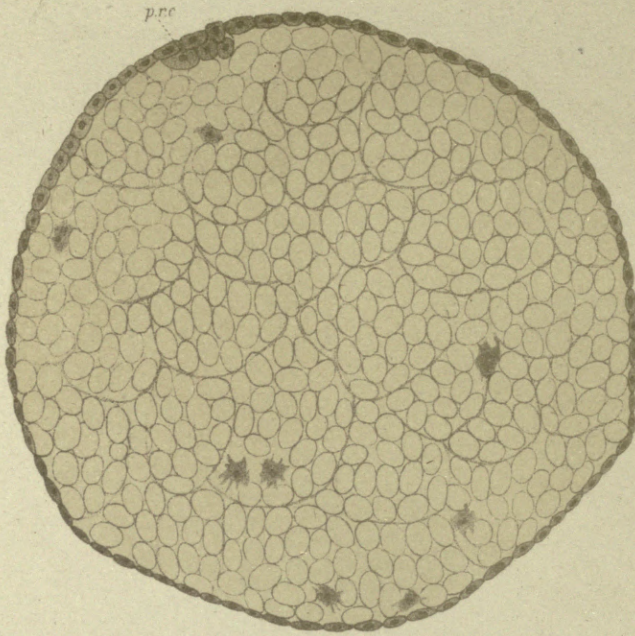


7.

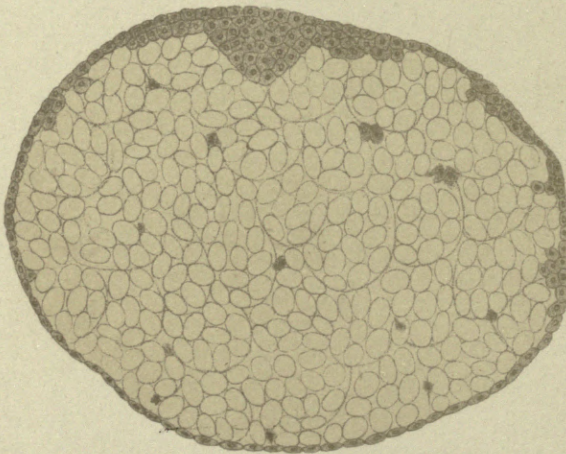


9.

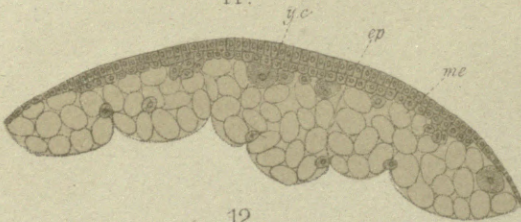




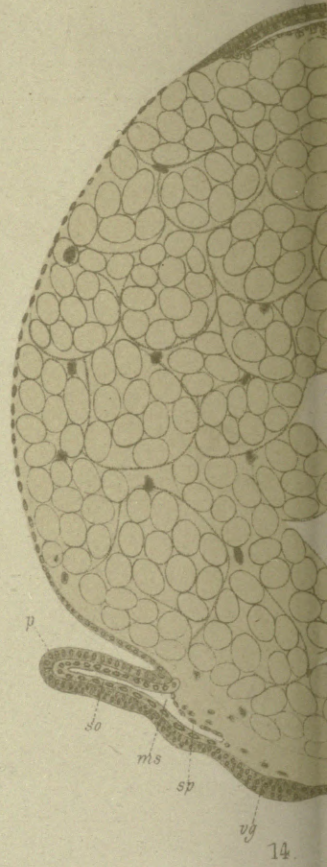
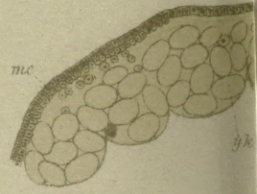
10.



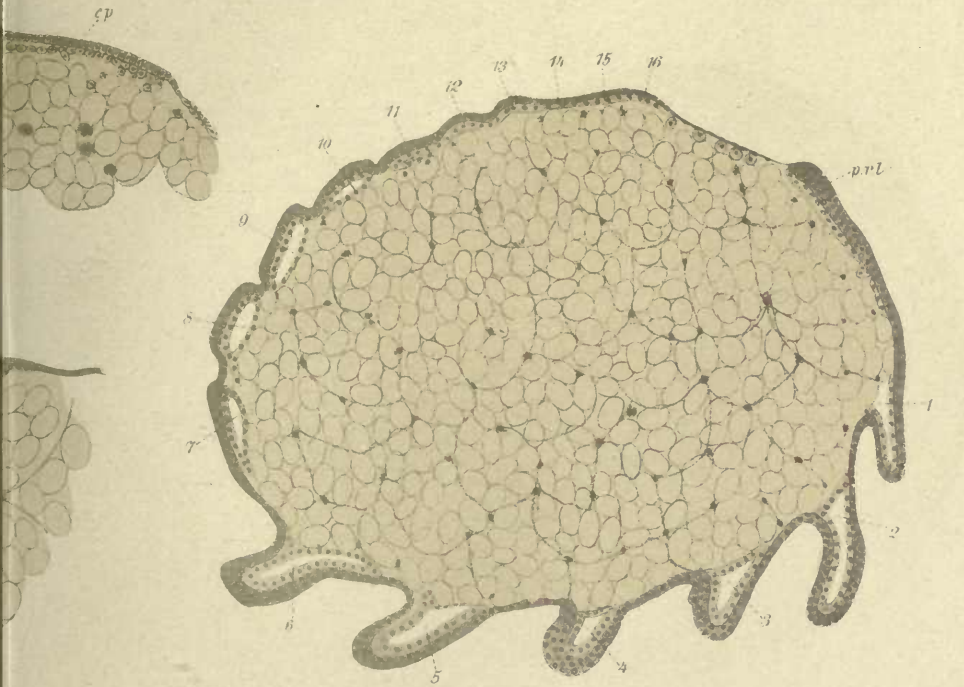
11.



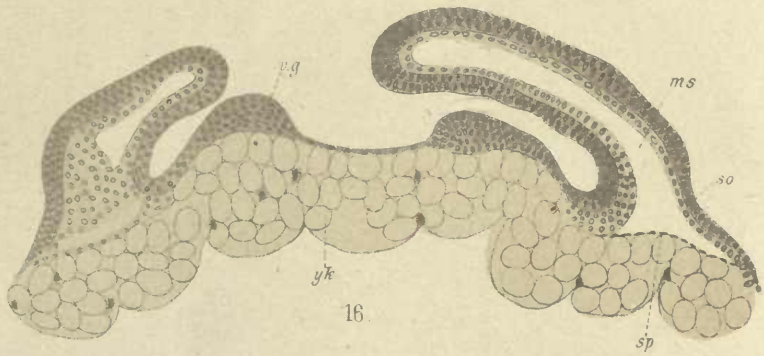
12.



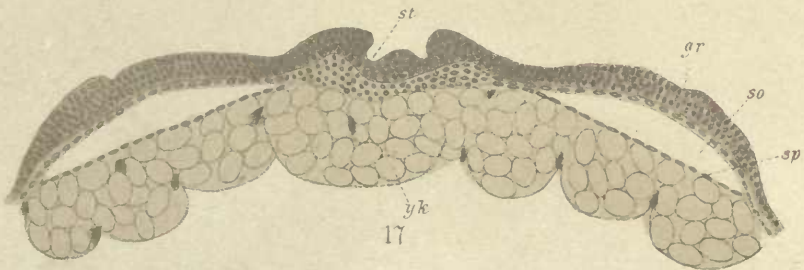
14.




15

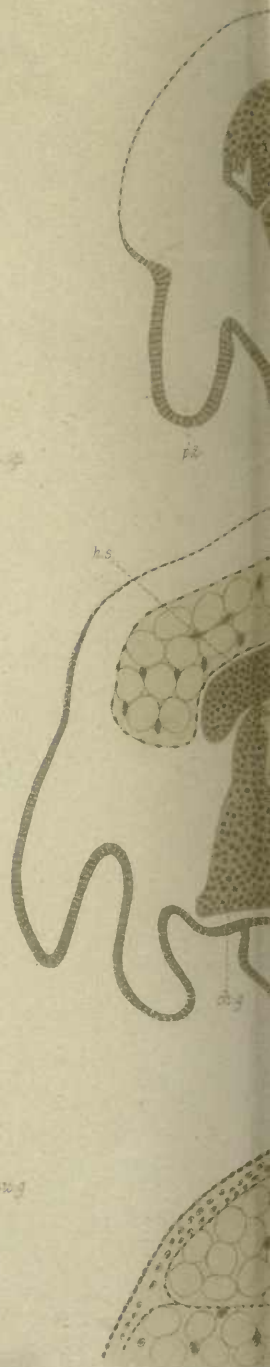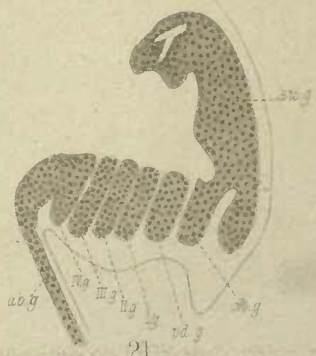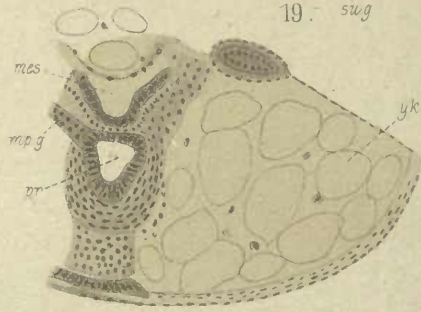
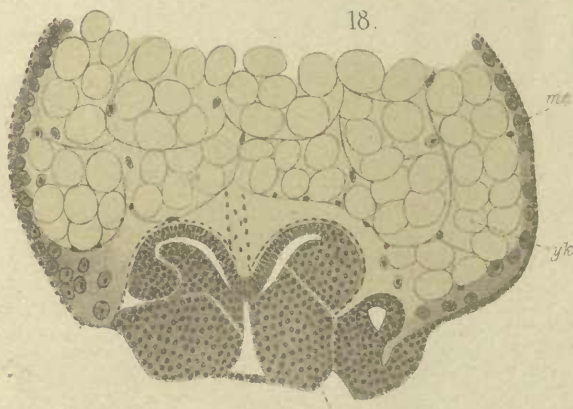
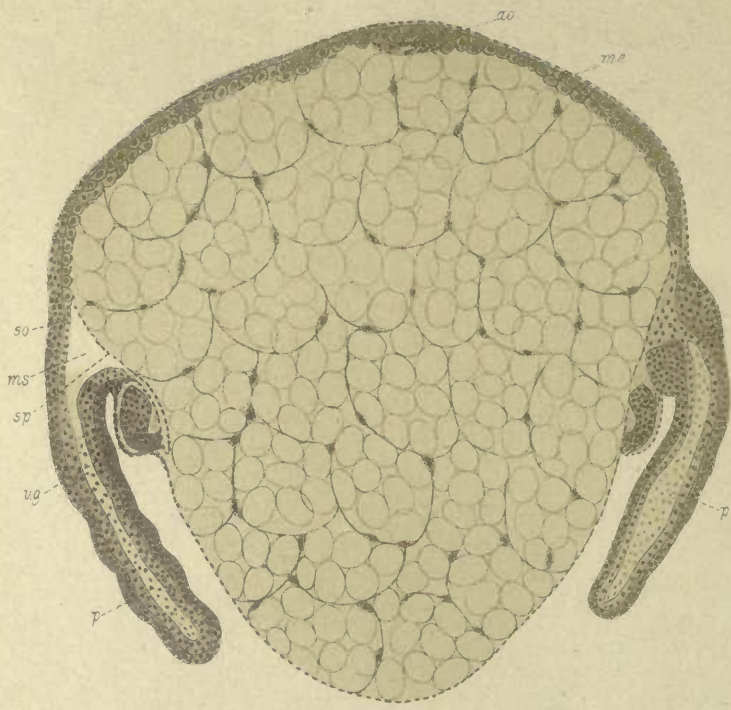


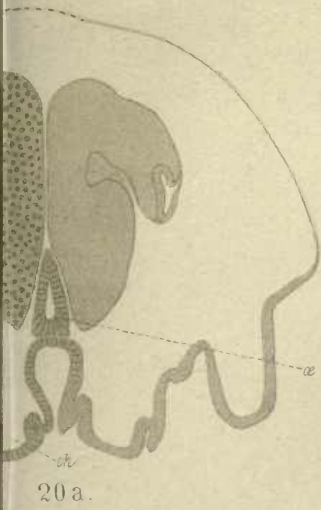
16



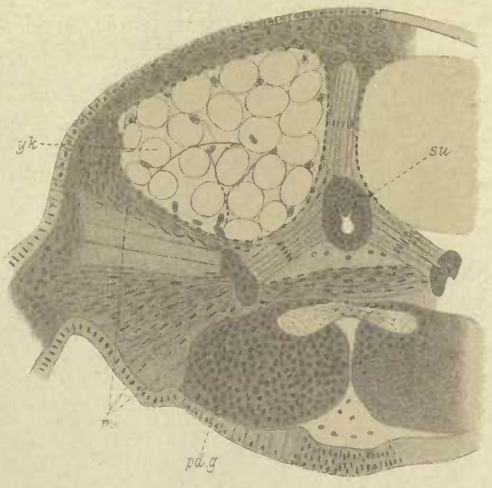
17








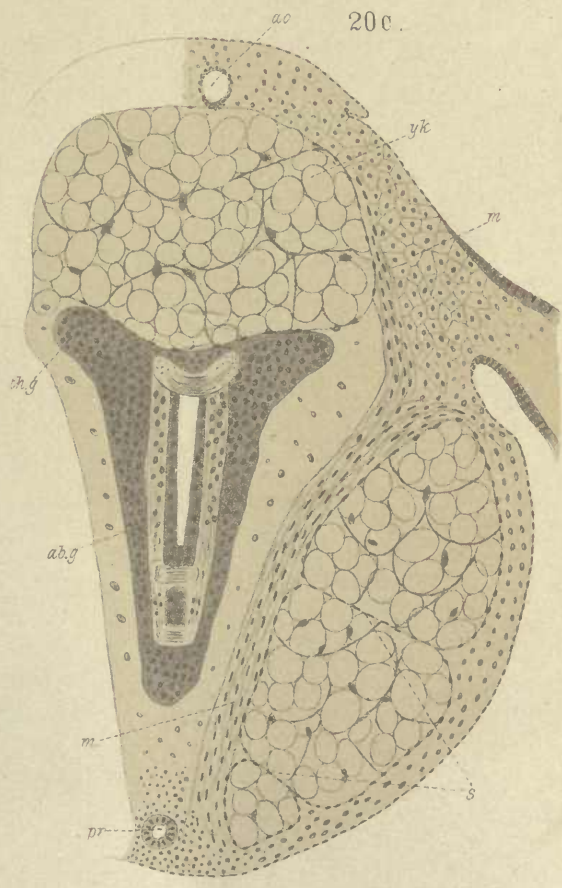
20 a.



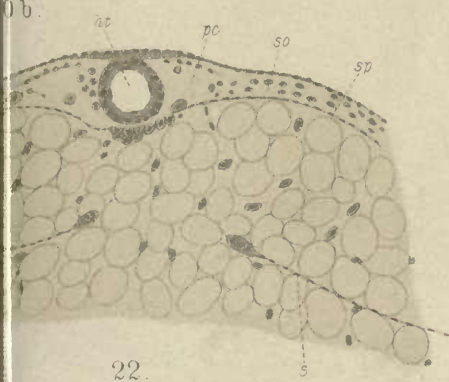
20 c.




20 b.

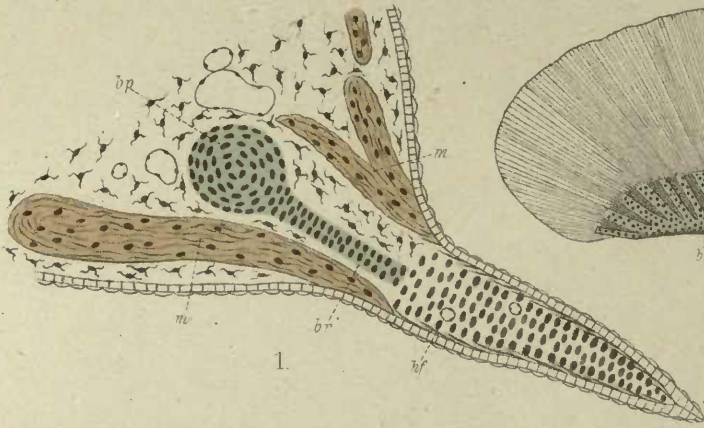


20 d.

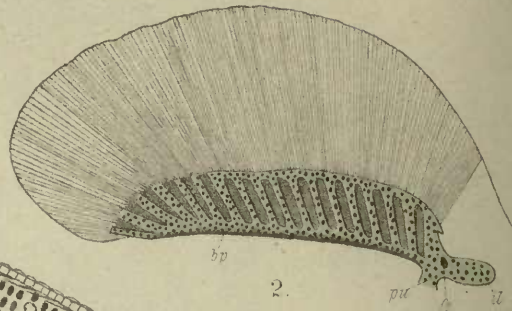


22.





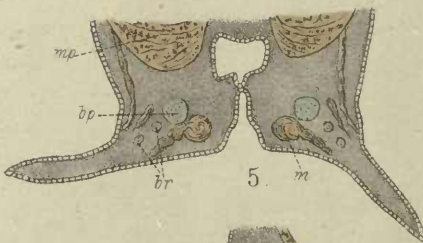
1.




2.



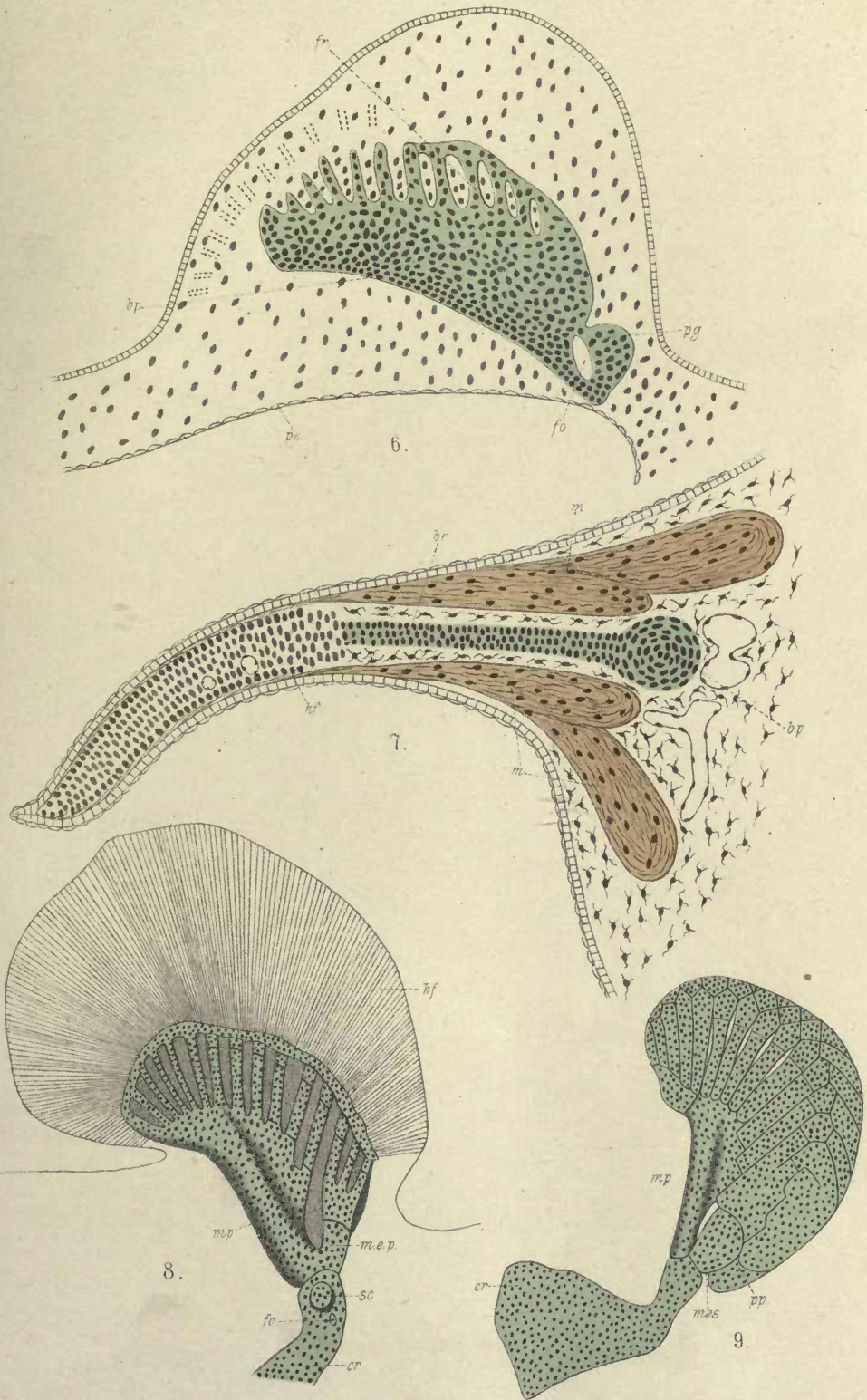
3.




5.




4.

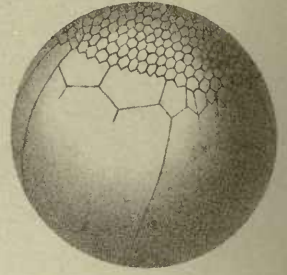




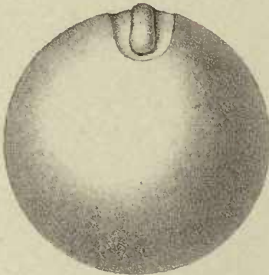
1.



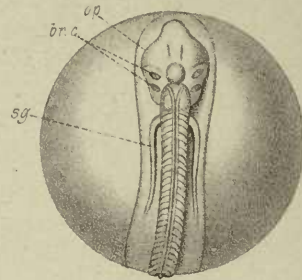
2.



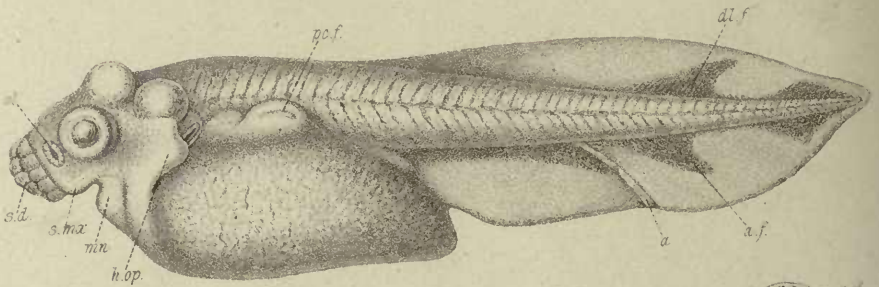
3.



7.



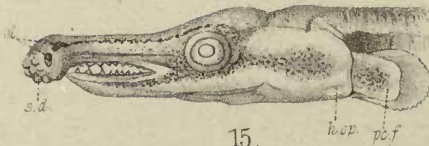8.



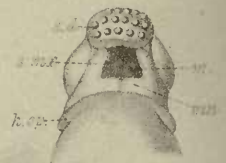12.




11.



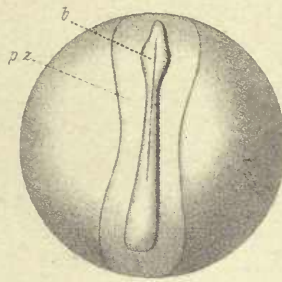
15.



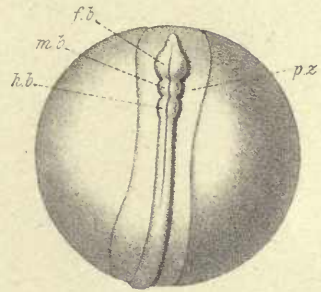
13.



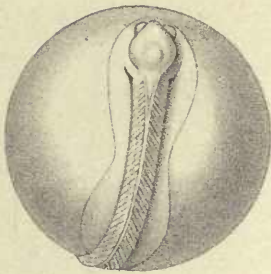
4.



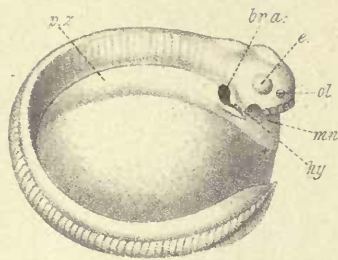
5.



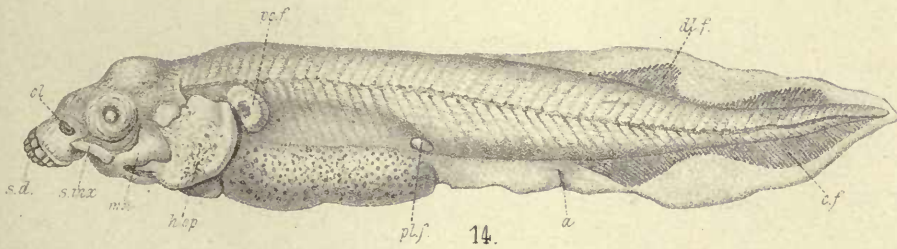
6.



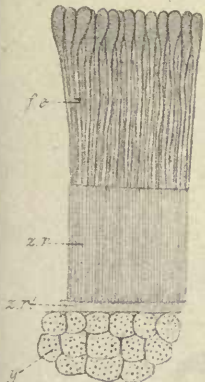
9.



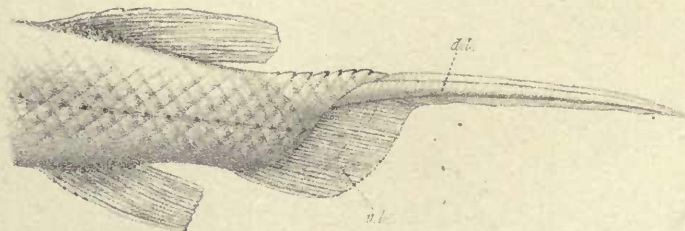
10.




14.




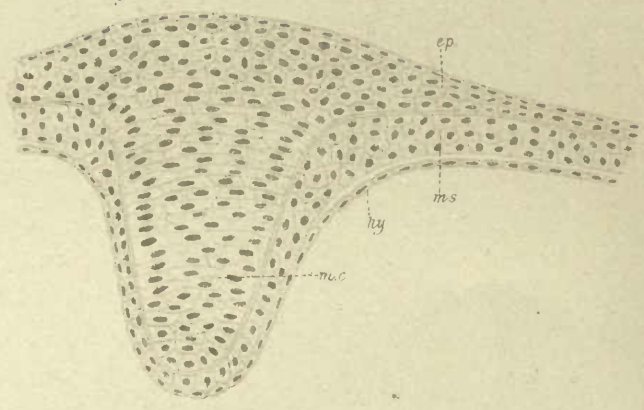
17.



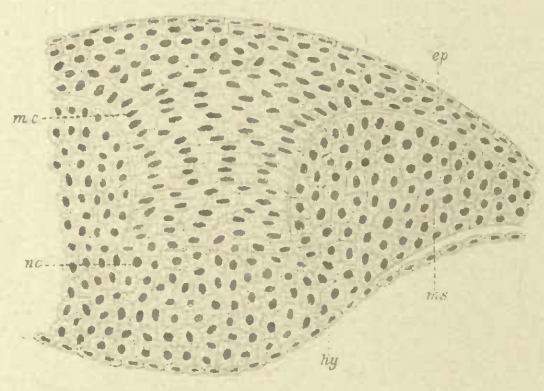
16.



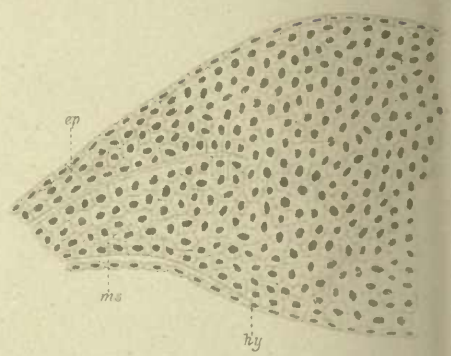




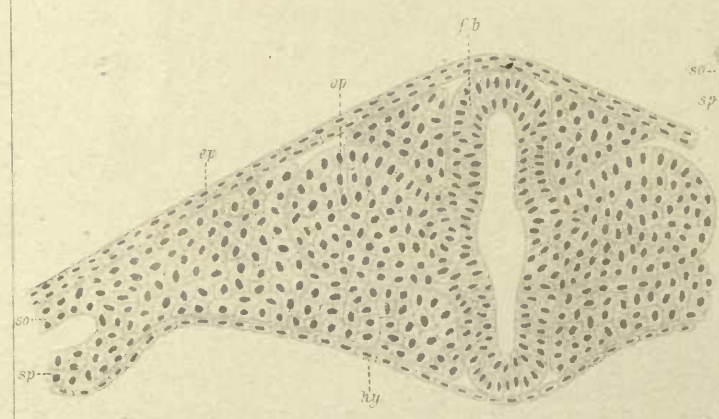
18.



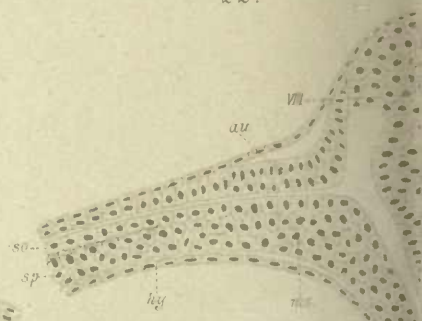
21.

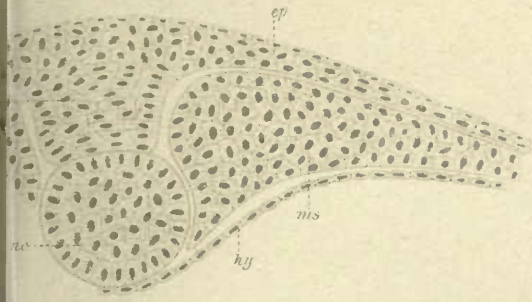


22.

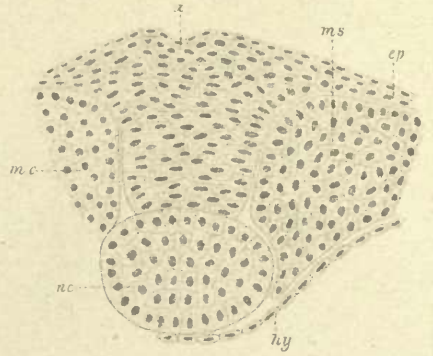


26

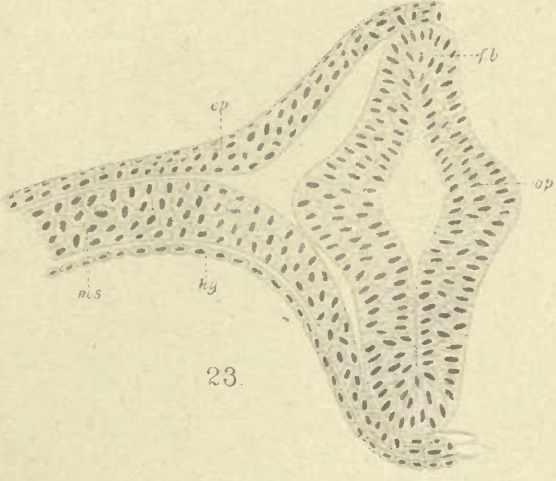




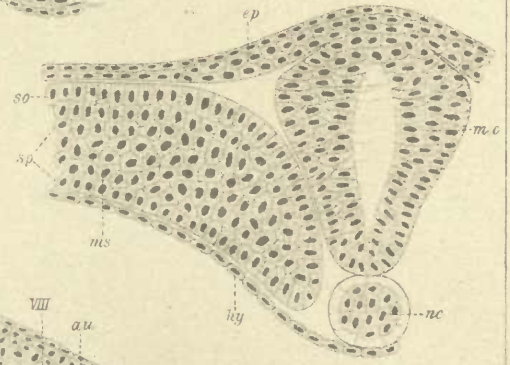
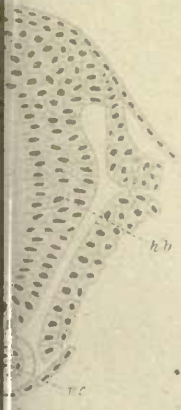19.



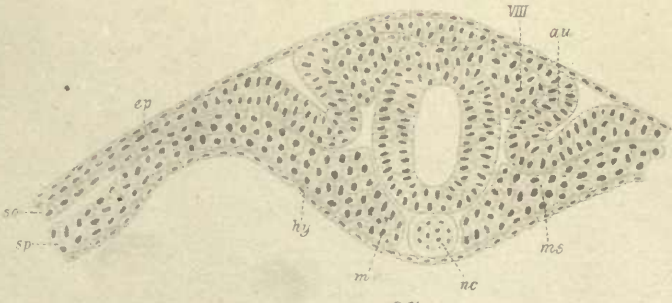
20.




23.

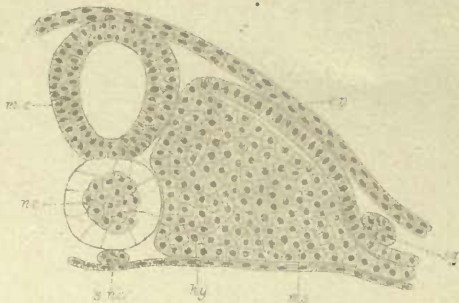


25.

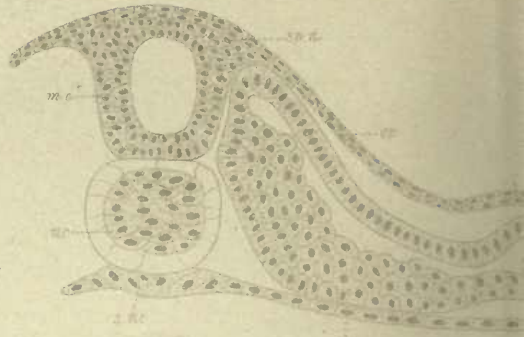


27.

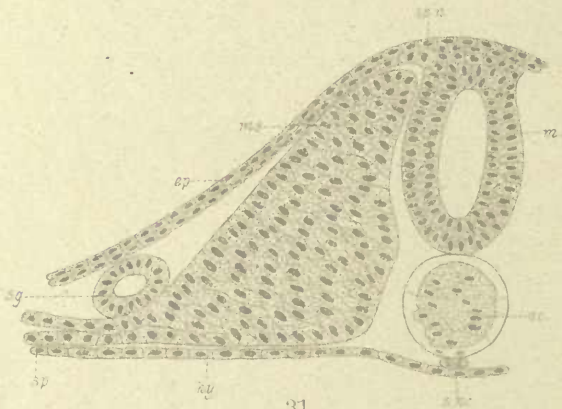




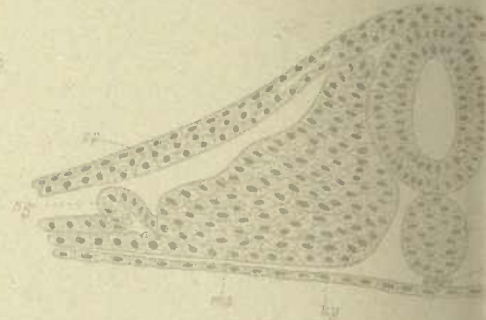
28.



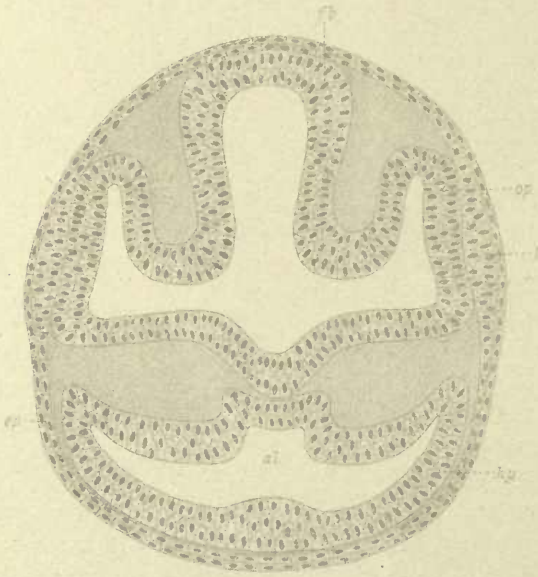
29.



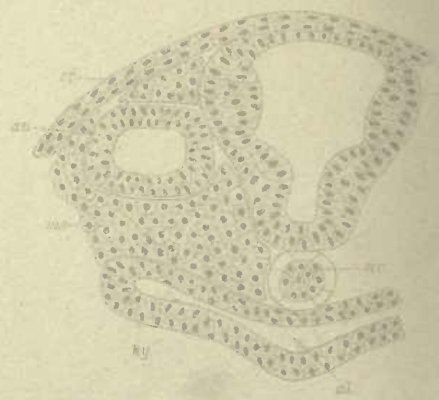
31.



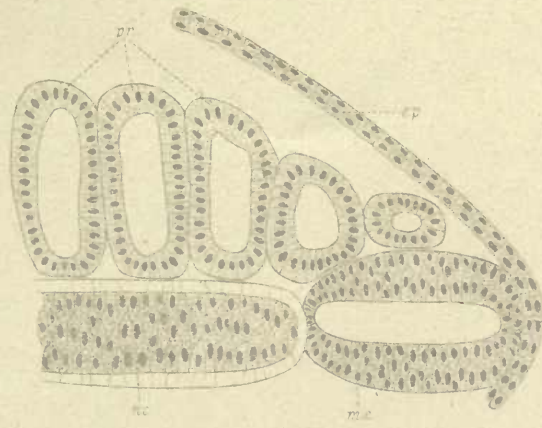
32.



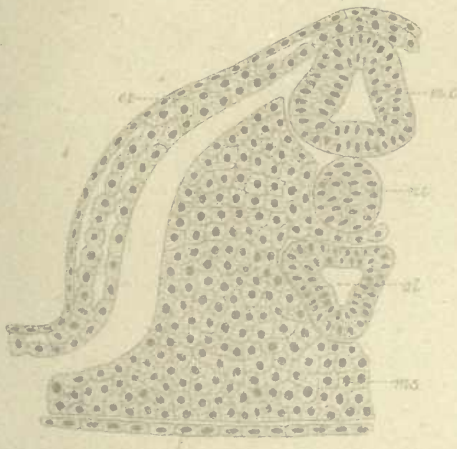
35.



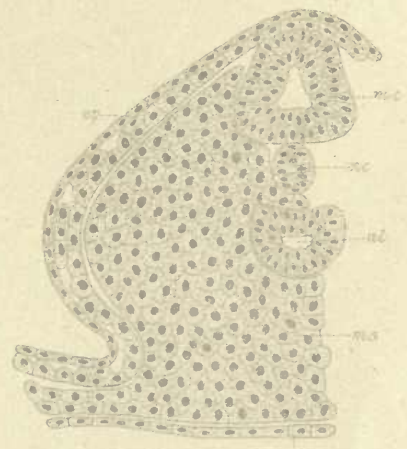36.



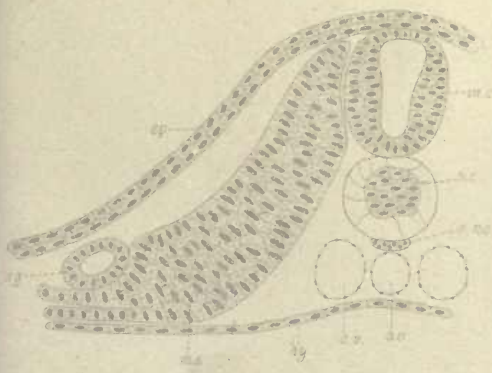
30.



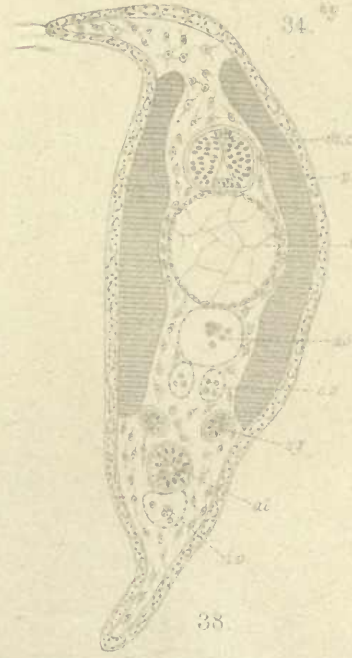
33




34.

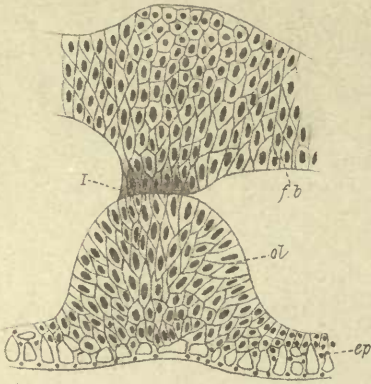


37

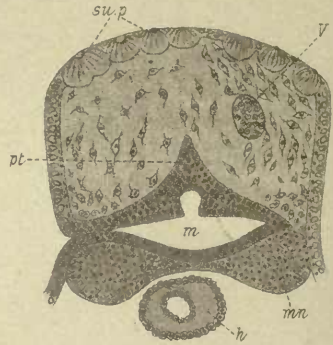


38

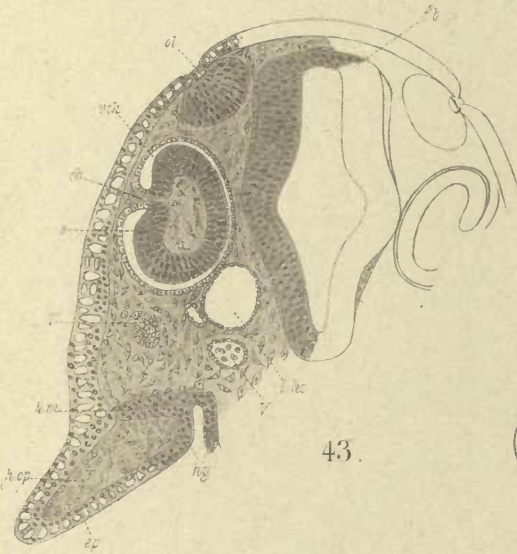




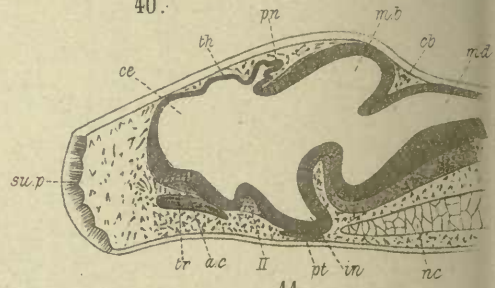
39.




40.



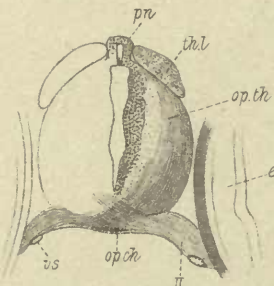
43.



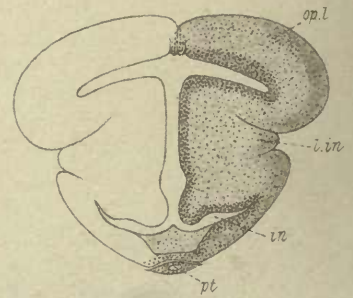
44.



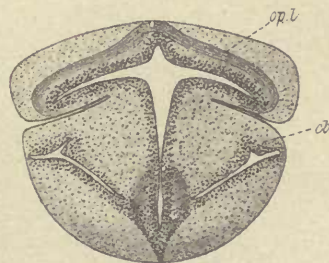
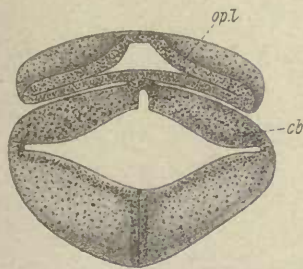
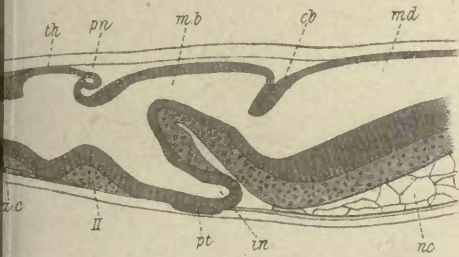
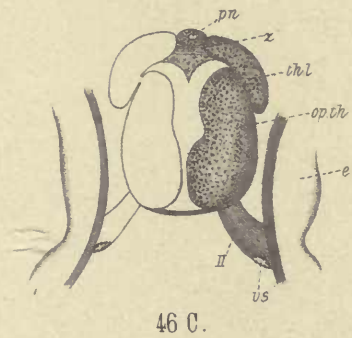
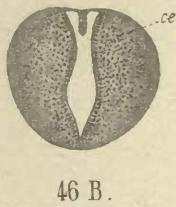
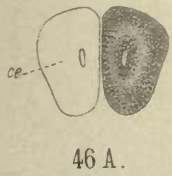
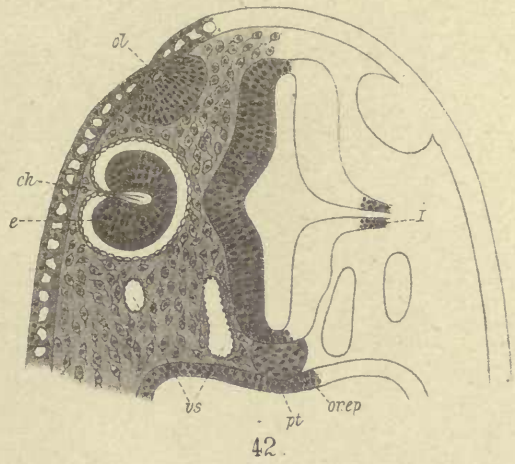
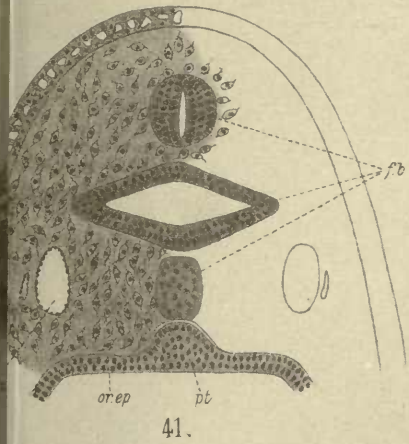
45




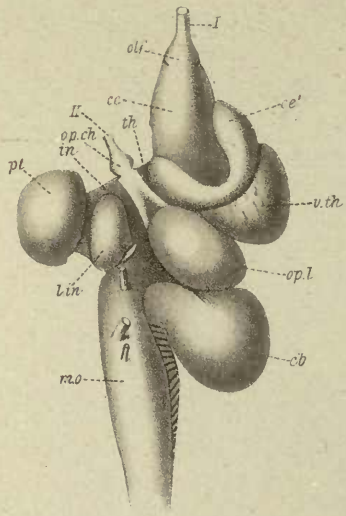
46 D.



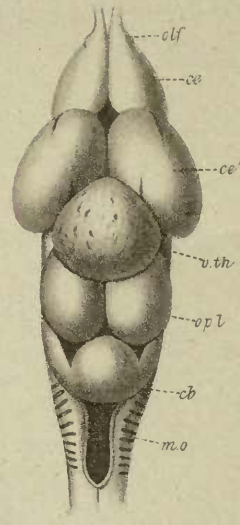
46 E.



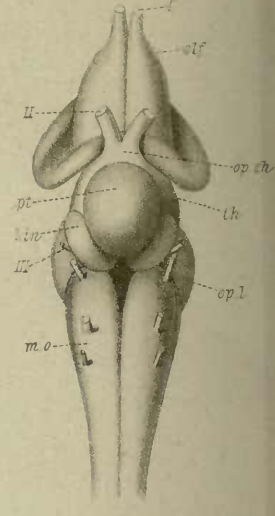




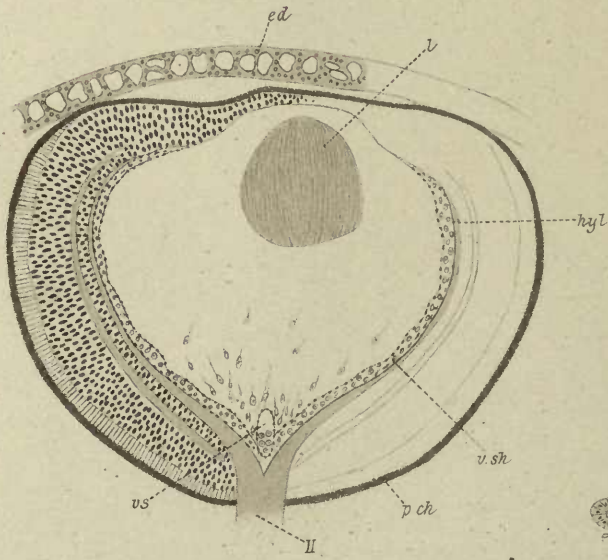
47 A.



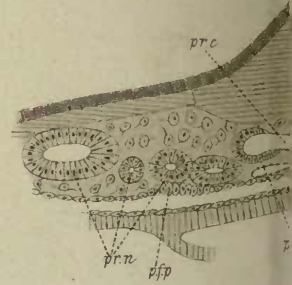
47 B.

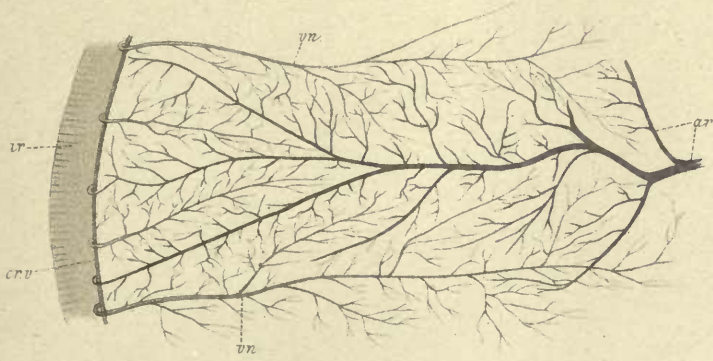


47 C.



48.

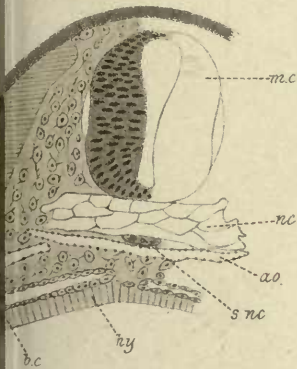




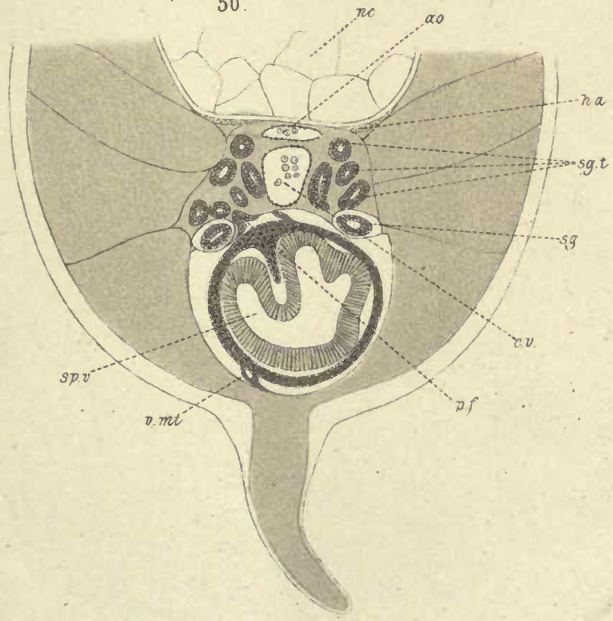
49.



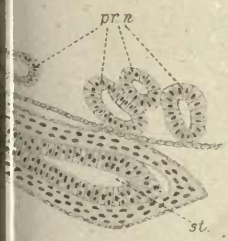
50.





51.

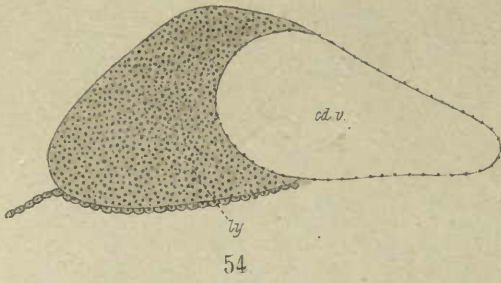


53.

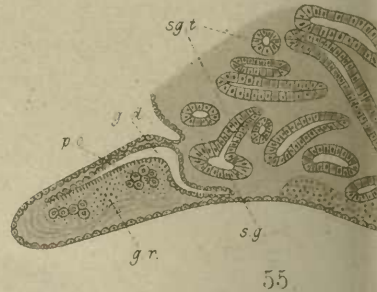




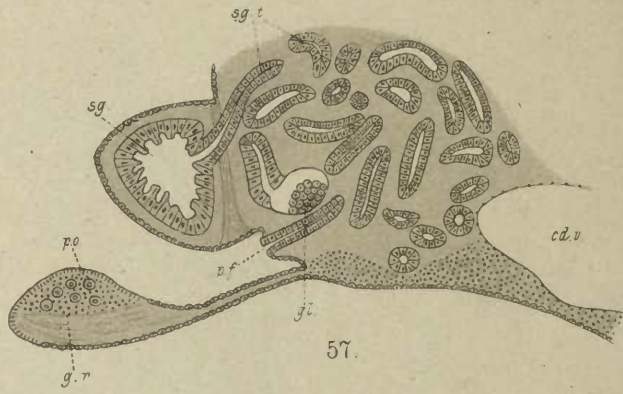




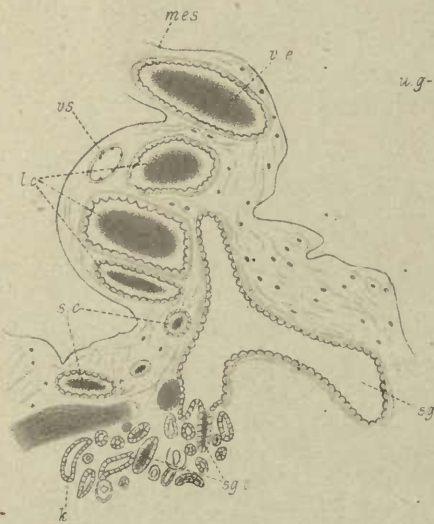54



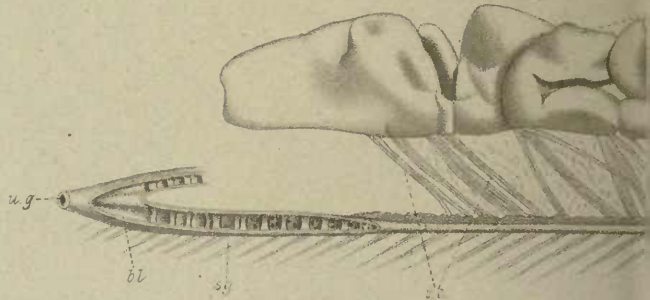
55



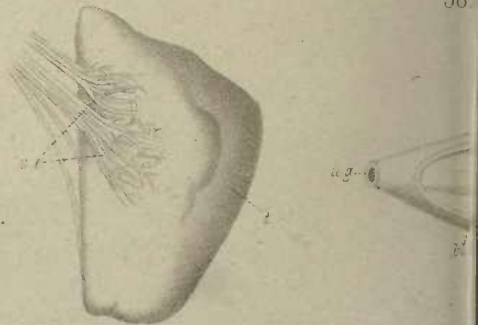
57.



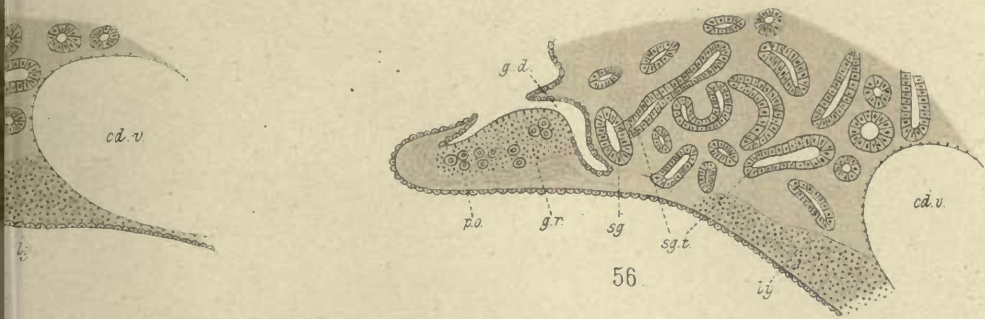
59.B.



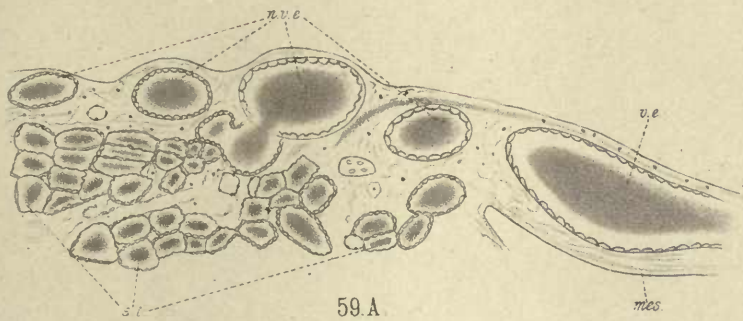
58



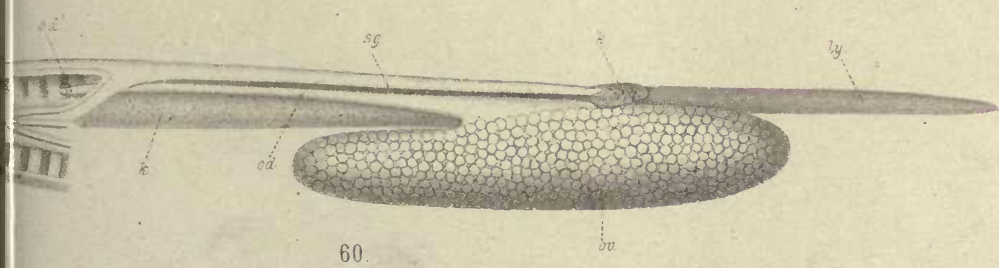
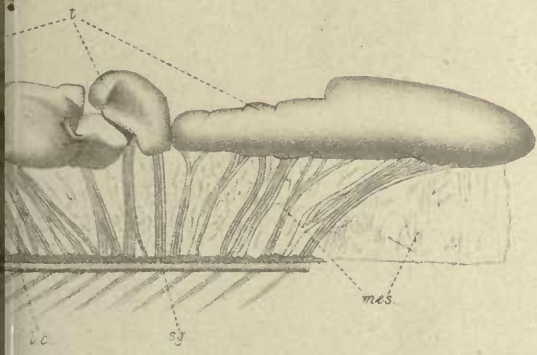
58.B.




56

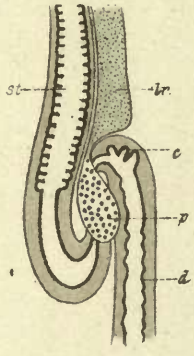


59.A

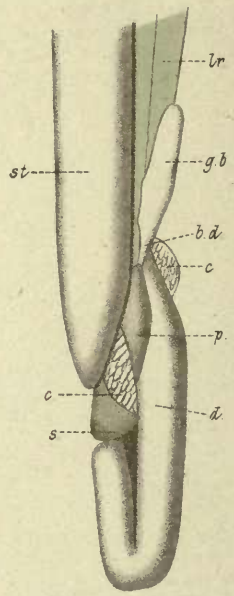


60

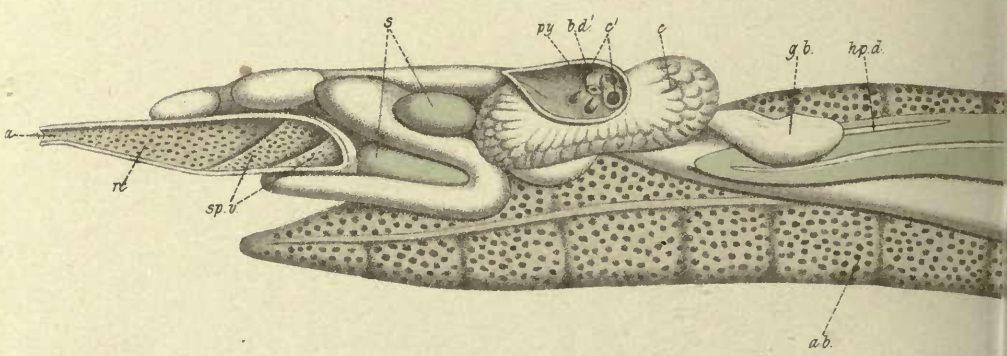




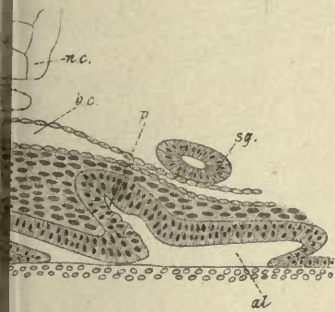
62.



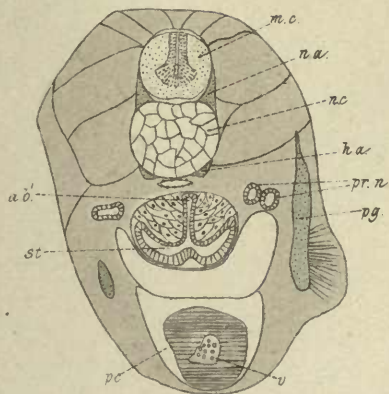
63.



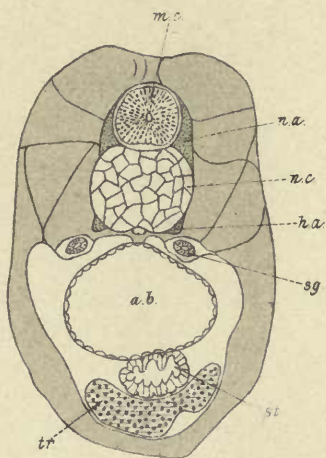
64.



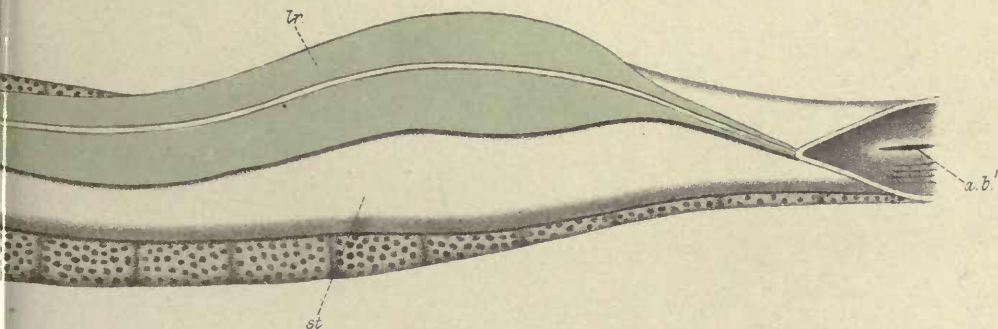
61.




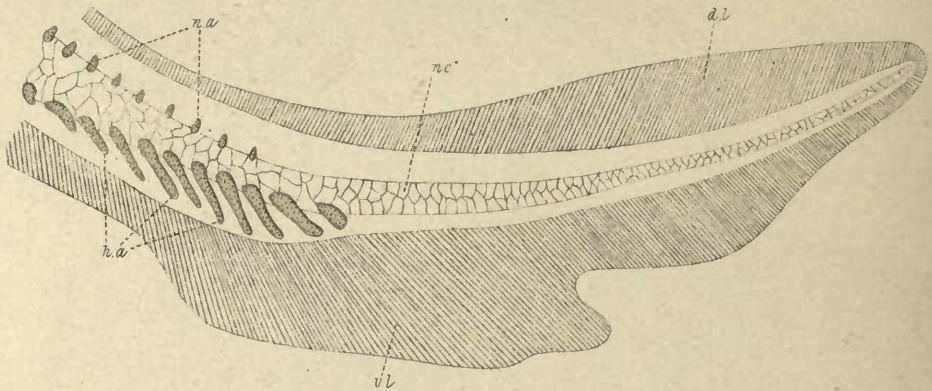
64.



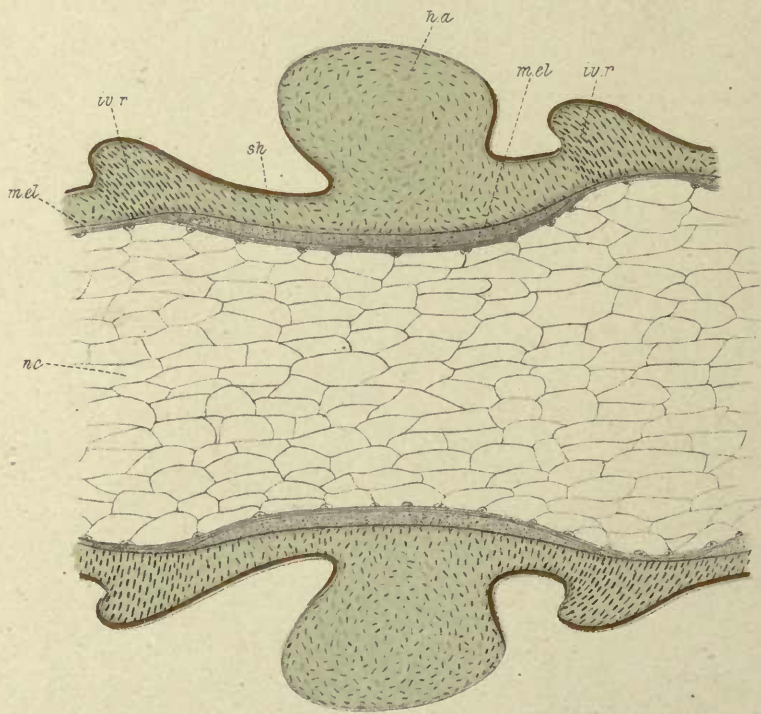
65.



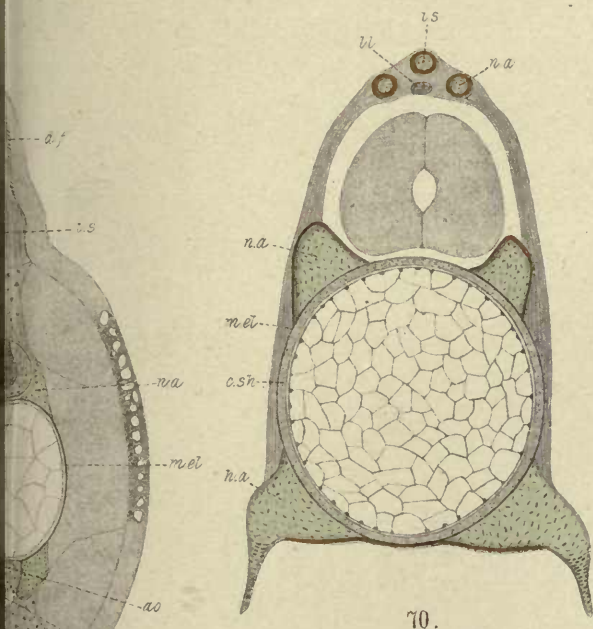




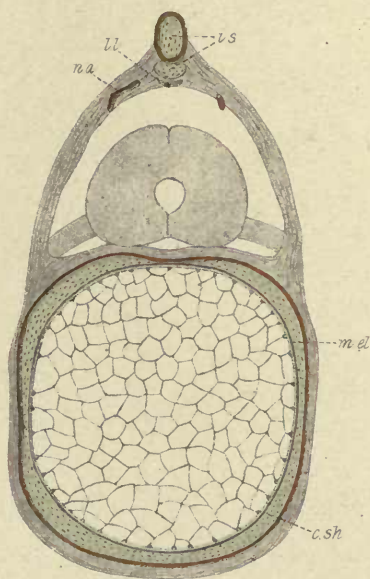
68.



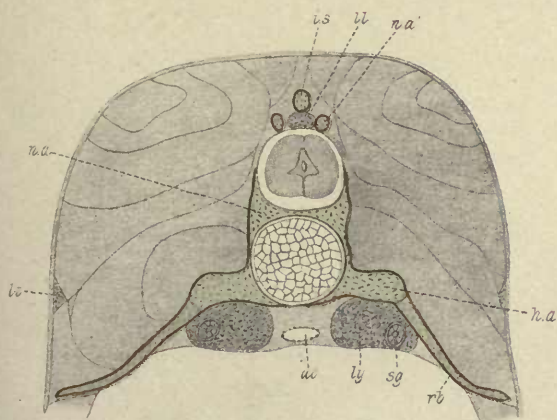
69.



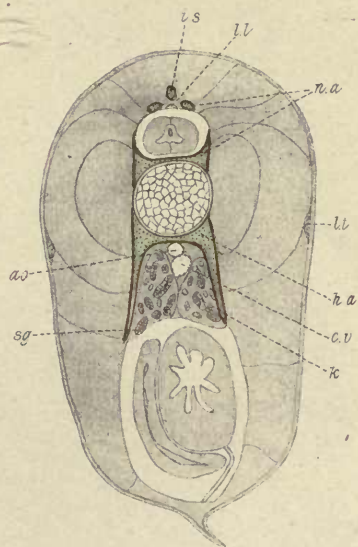
70.




71.




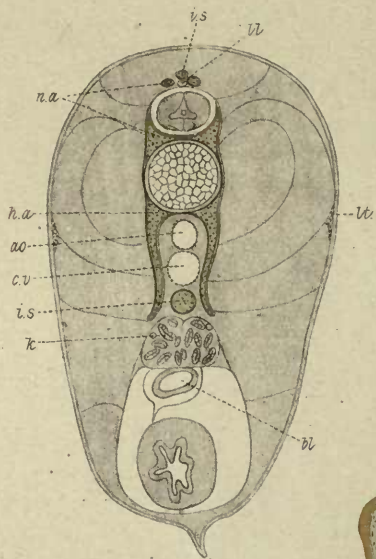
72.



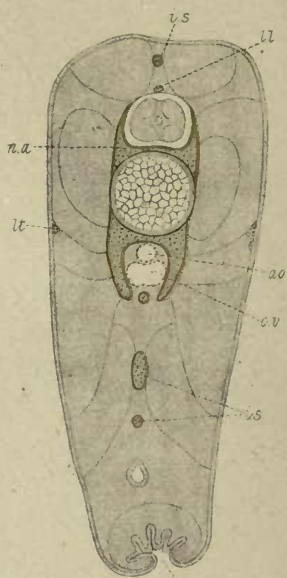
73.



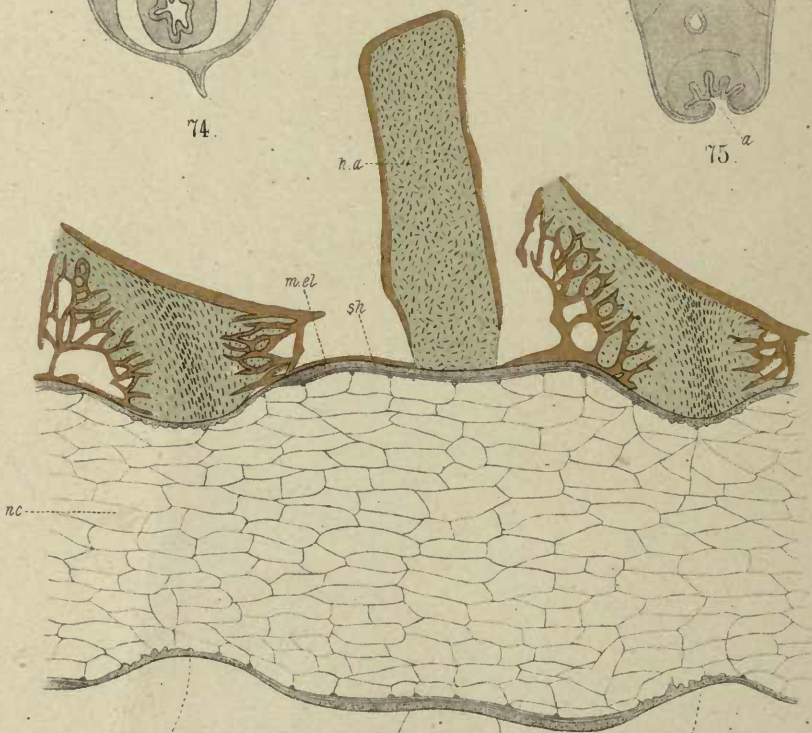




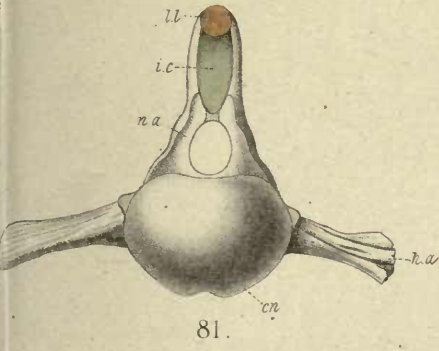
74.



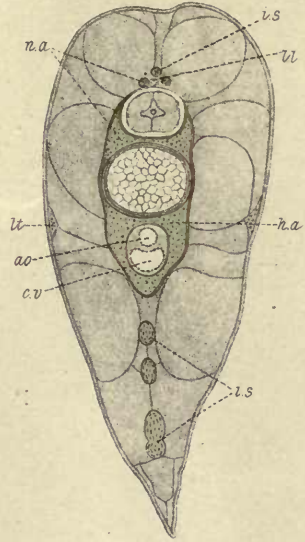
75.^a



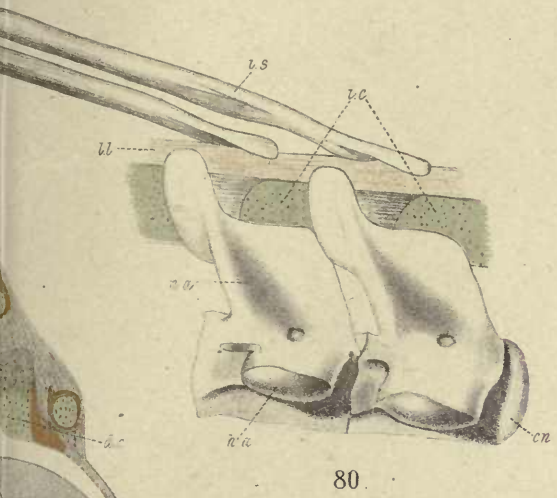
77.



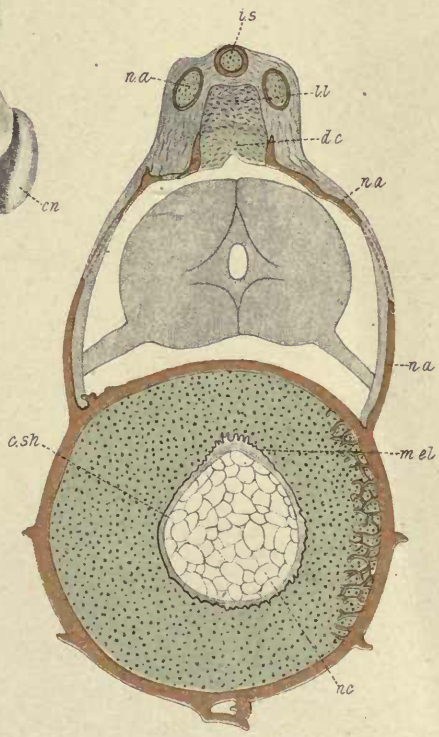
81.



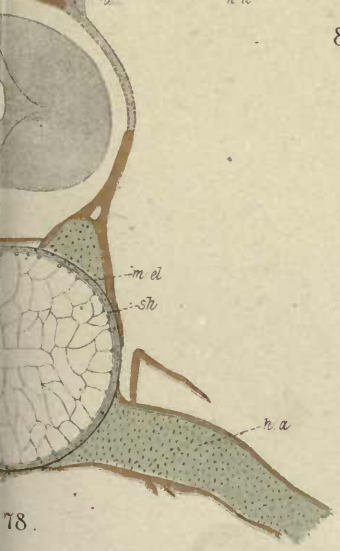
76.




80.



79.



78.



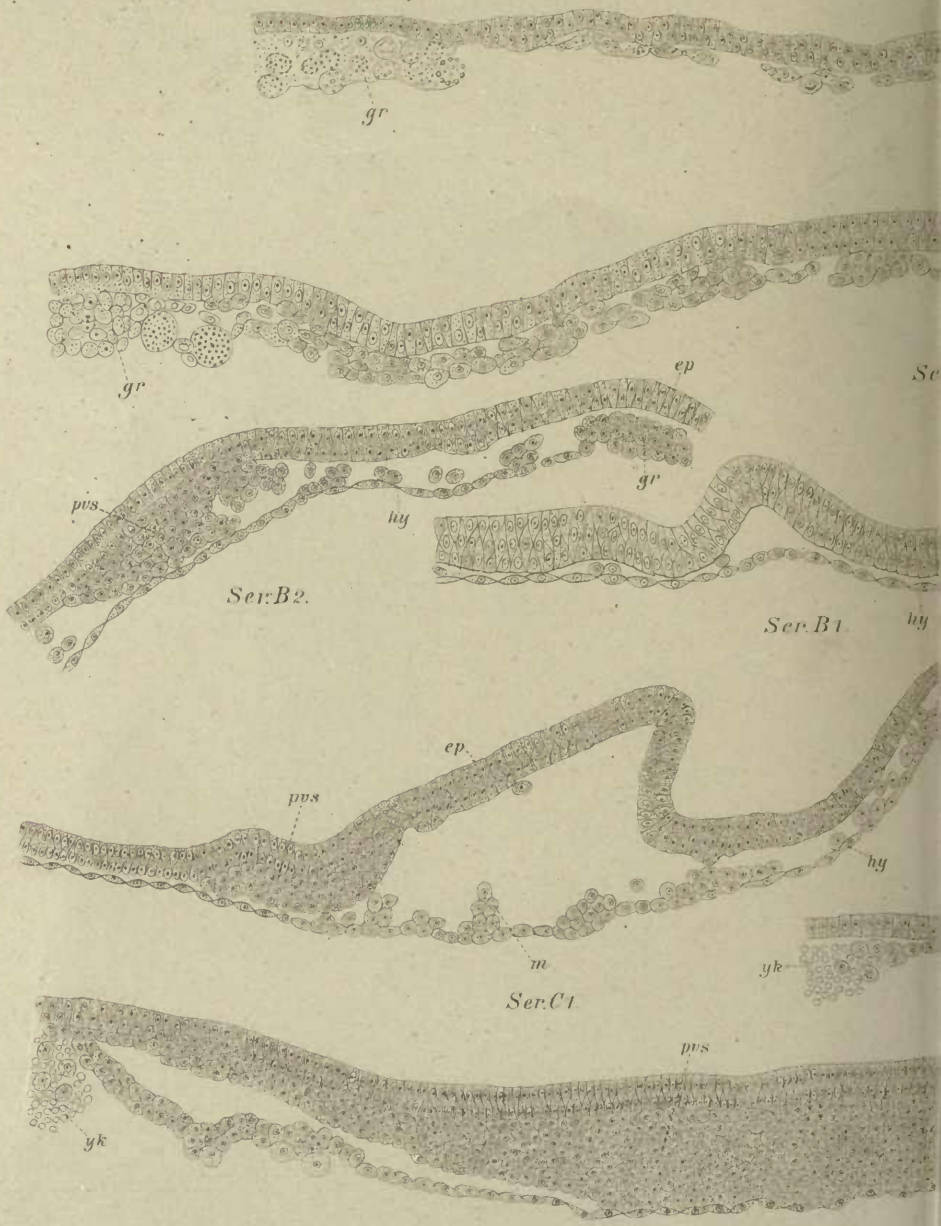
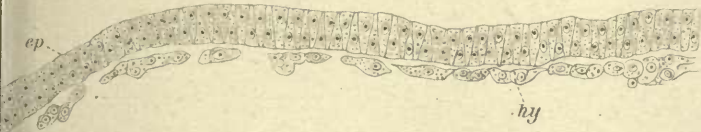
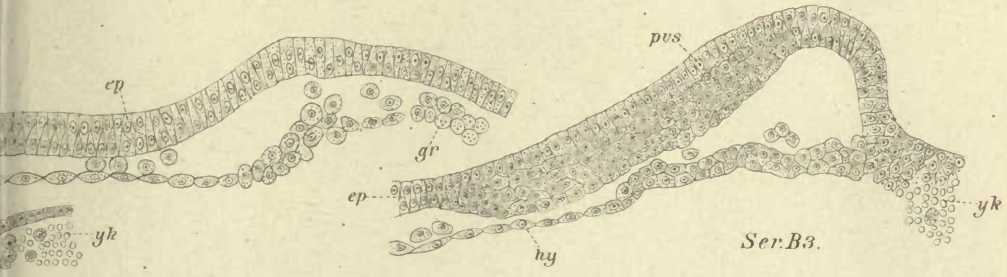
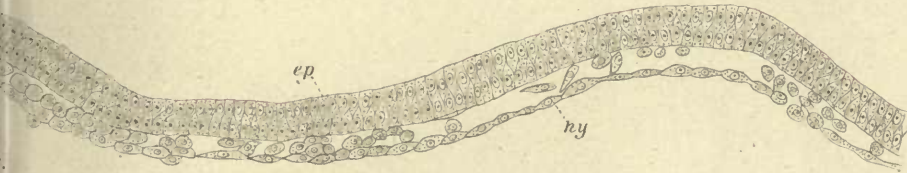

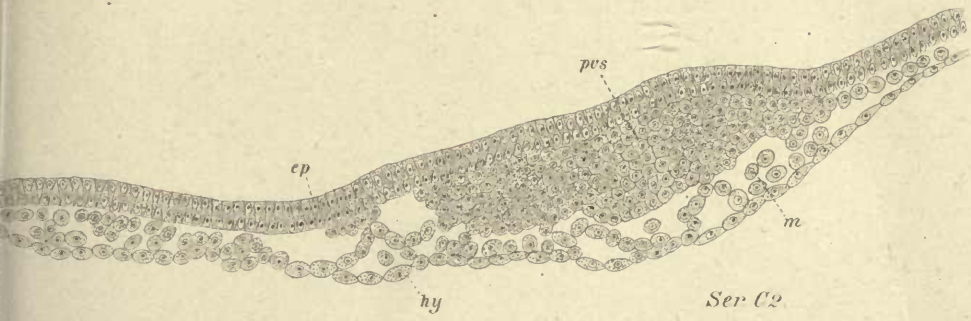
Fig. D



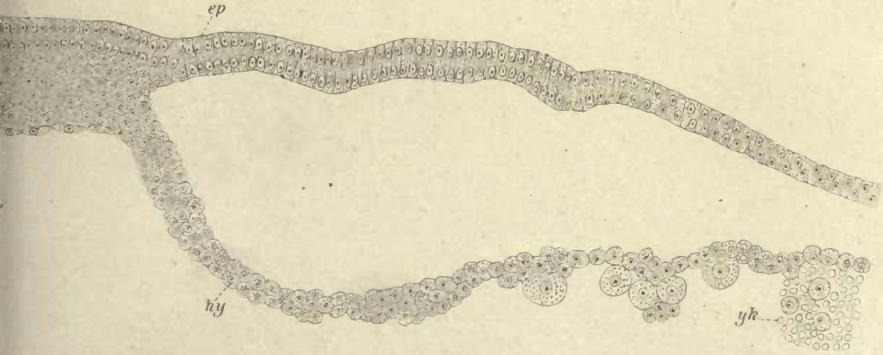
Ser. A1.




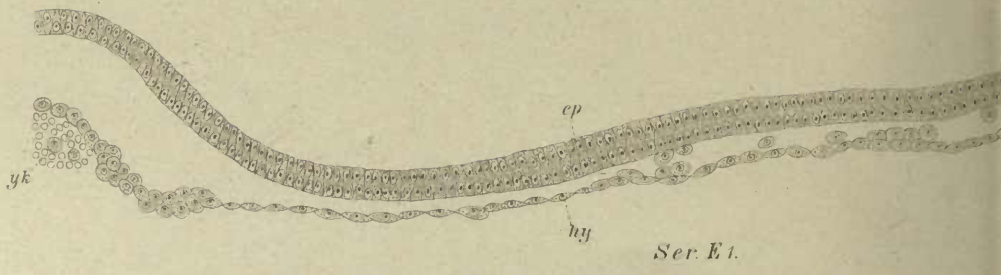
Ser. B3.



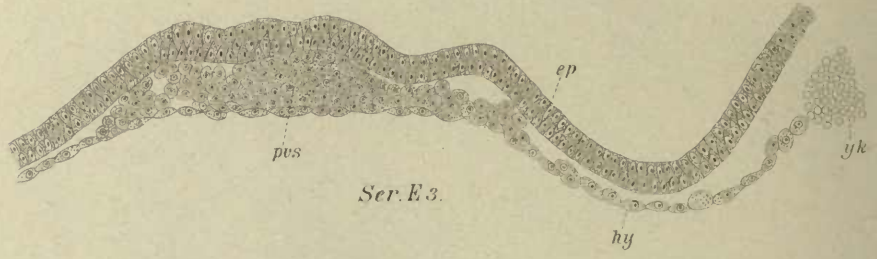
Ser. C2.



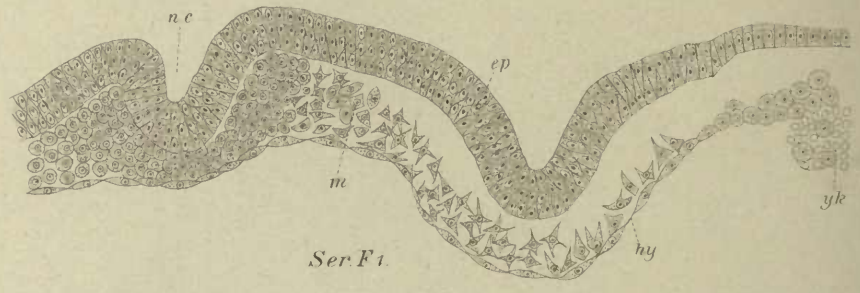




Ser. E1.



Ser. E3.



Ser. F1.

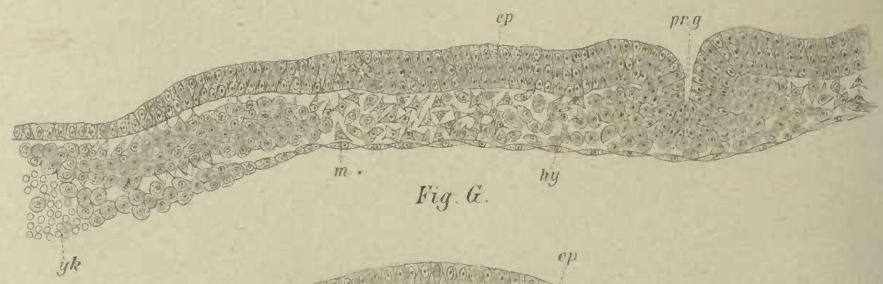
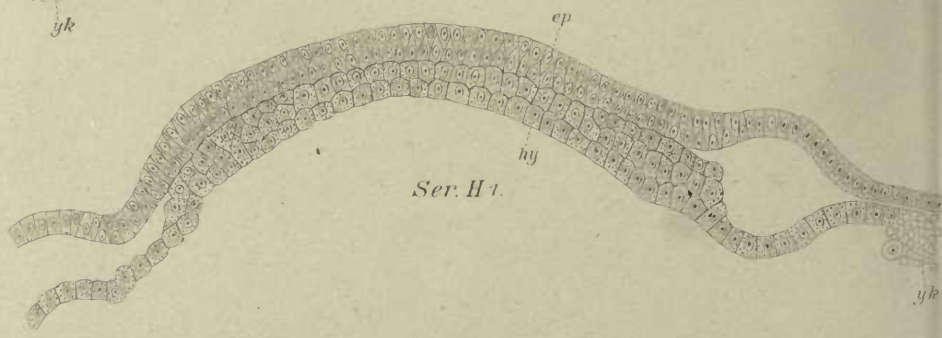
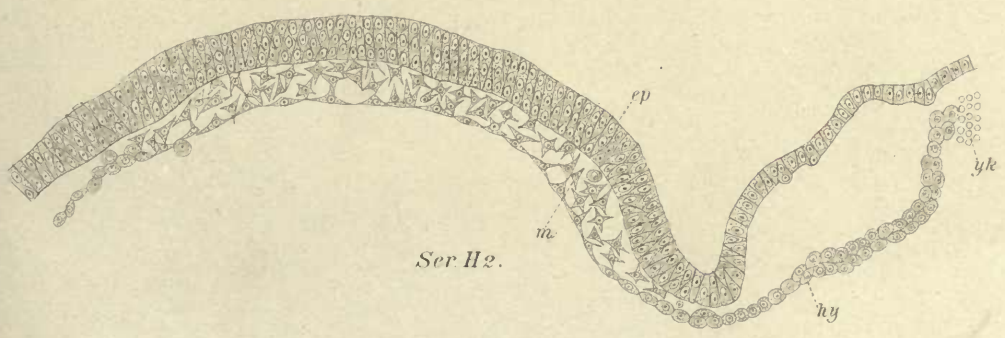
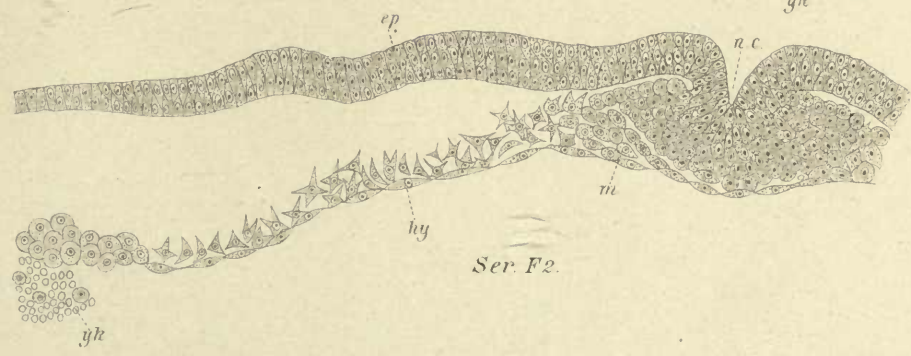
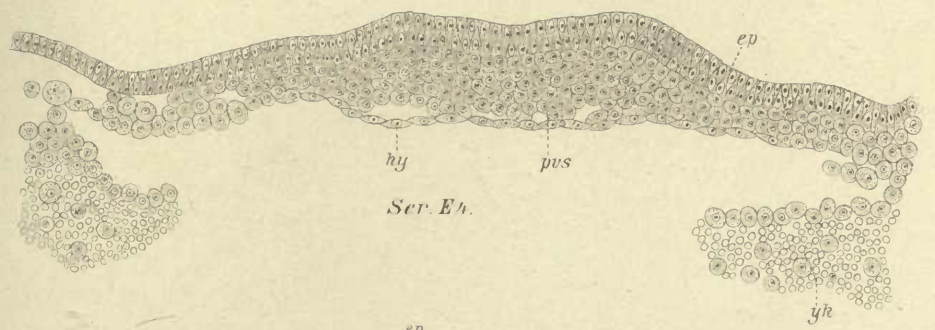
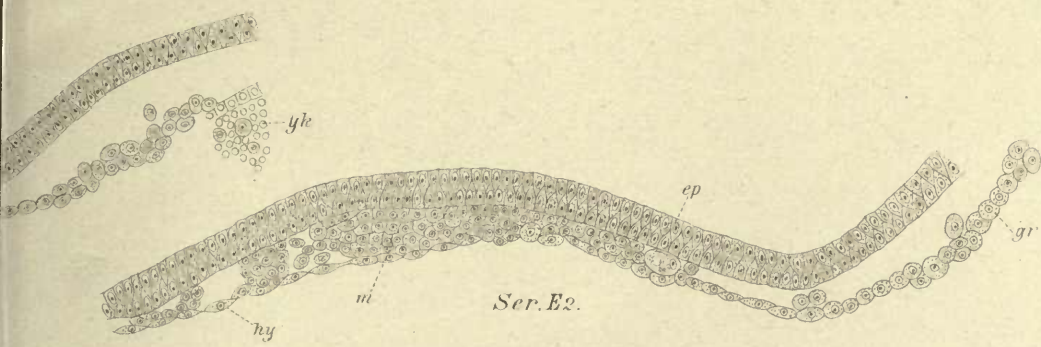



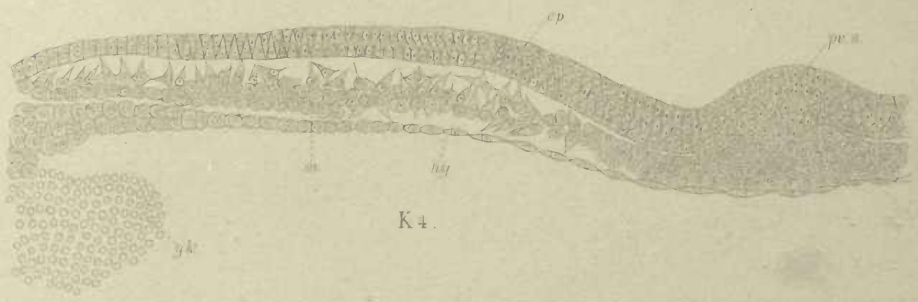
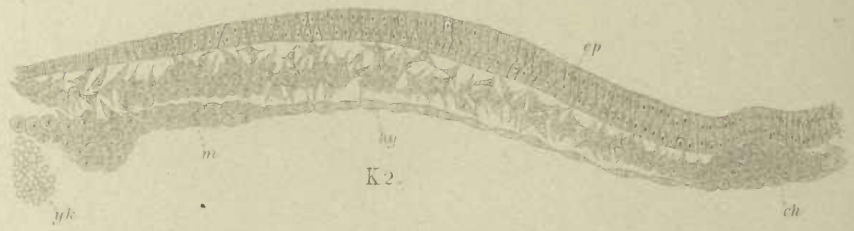
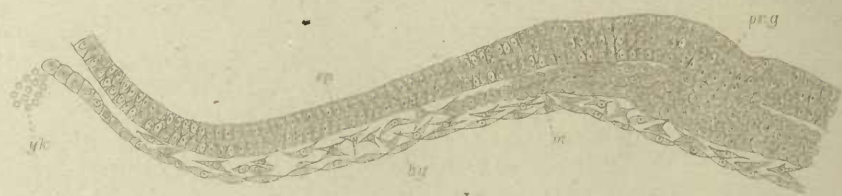
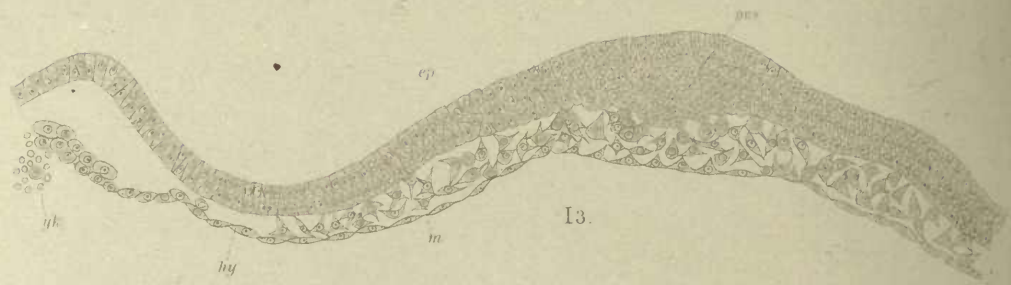
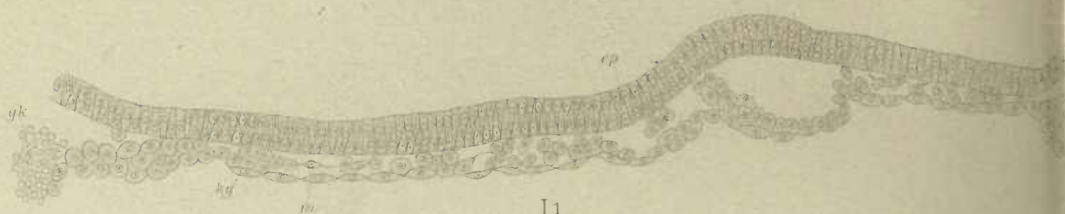
Fig. G.

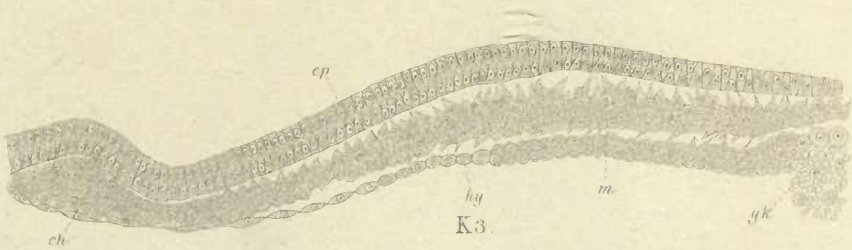
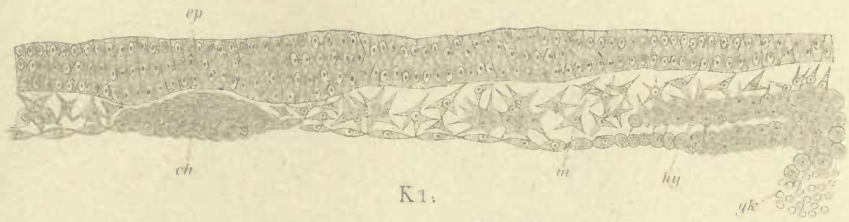
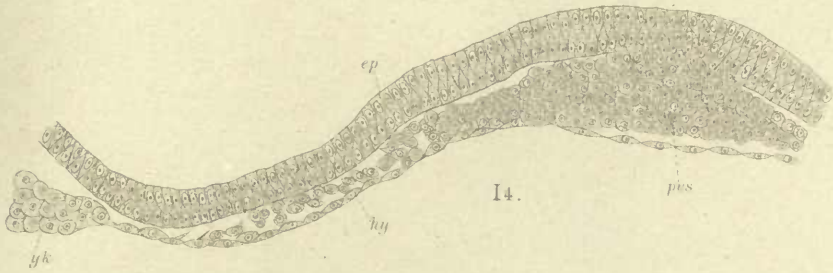
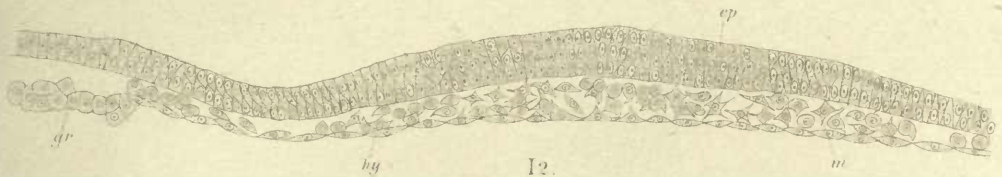


Ser. H1.







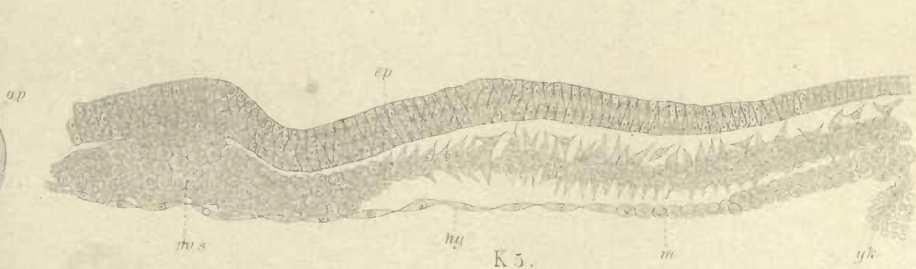






Fig. 1.






Fig. 2.




Fig. 5.

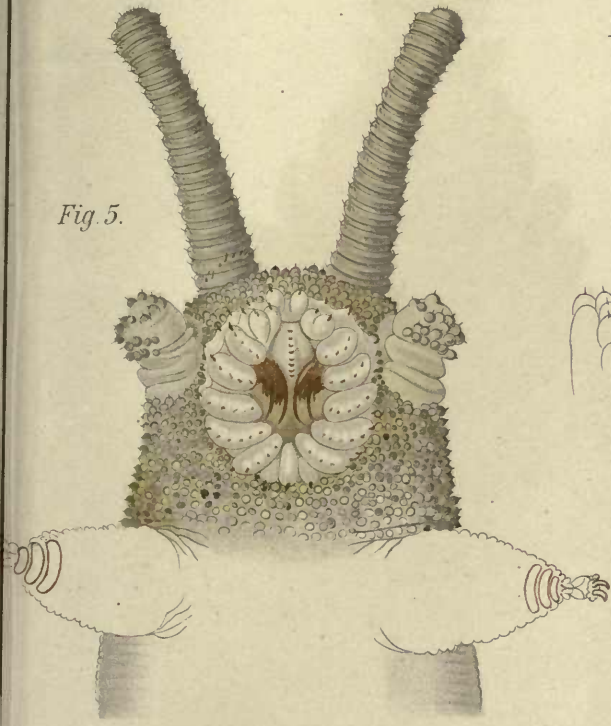


Fig. 4.

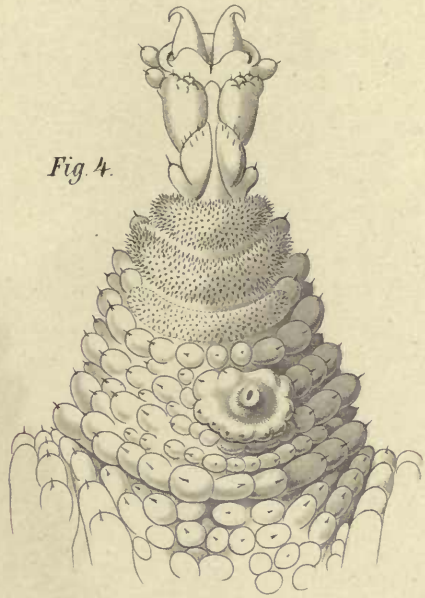
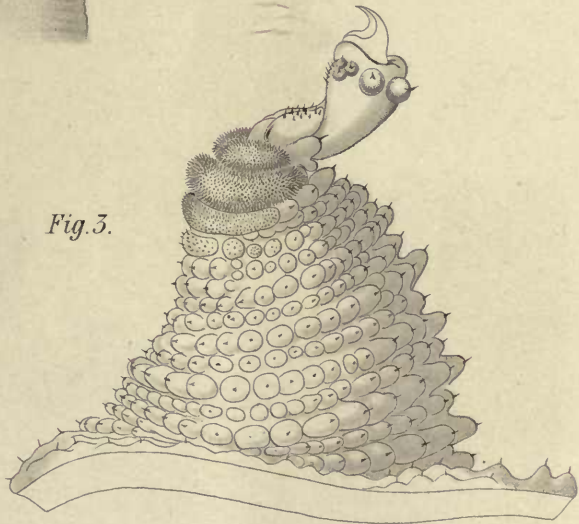


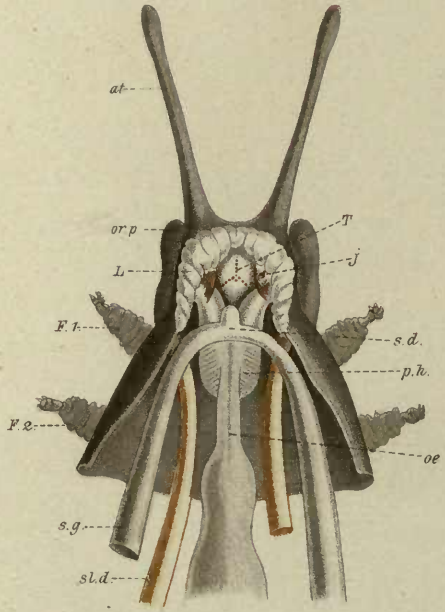
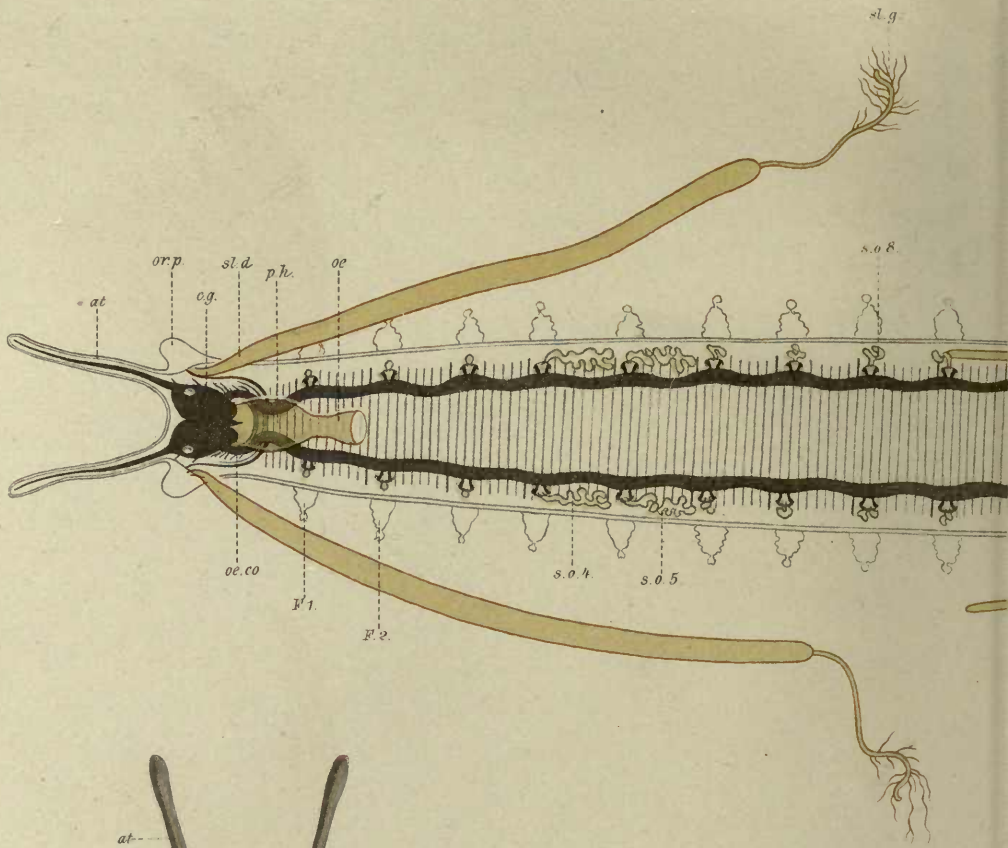


Fig. 3.


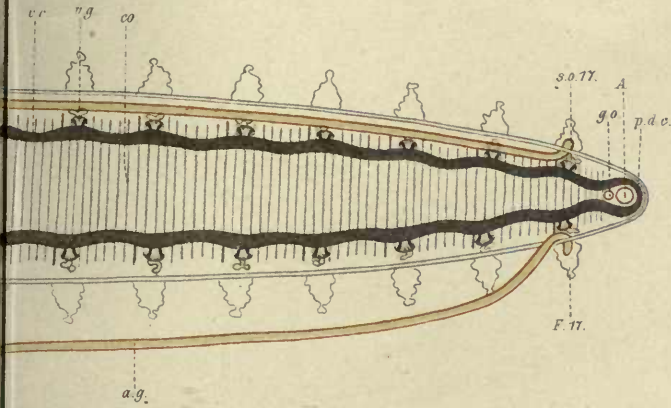




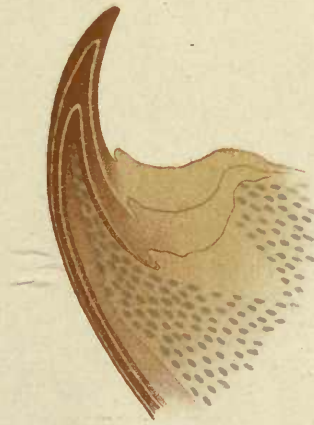


8


7



9.

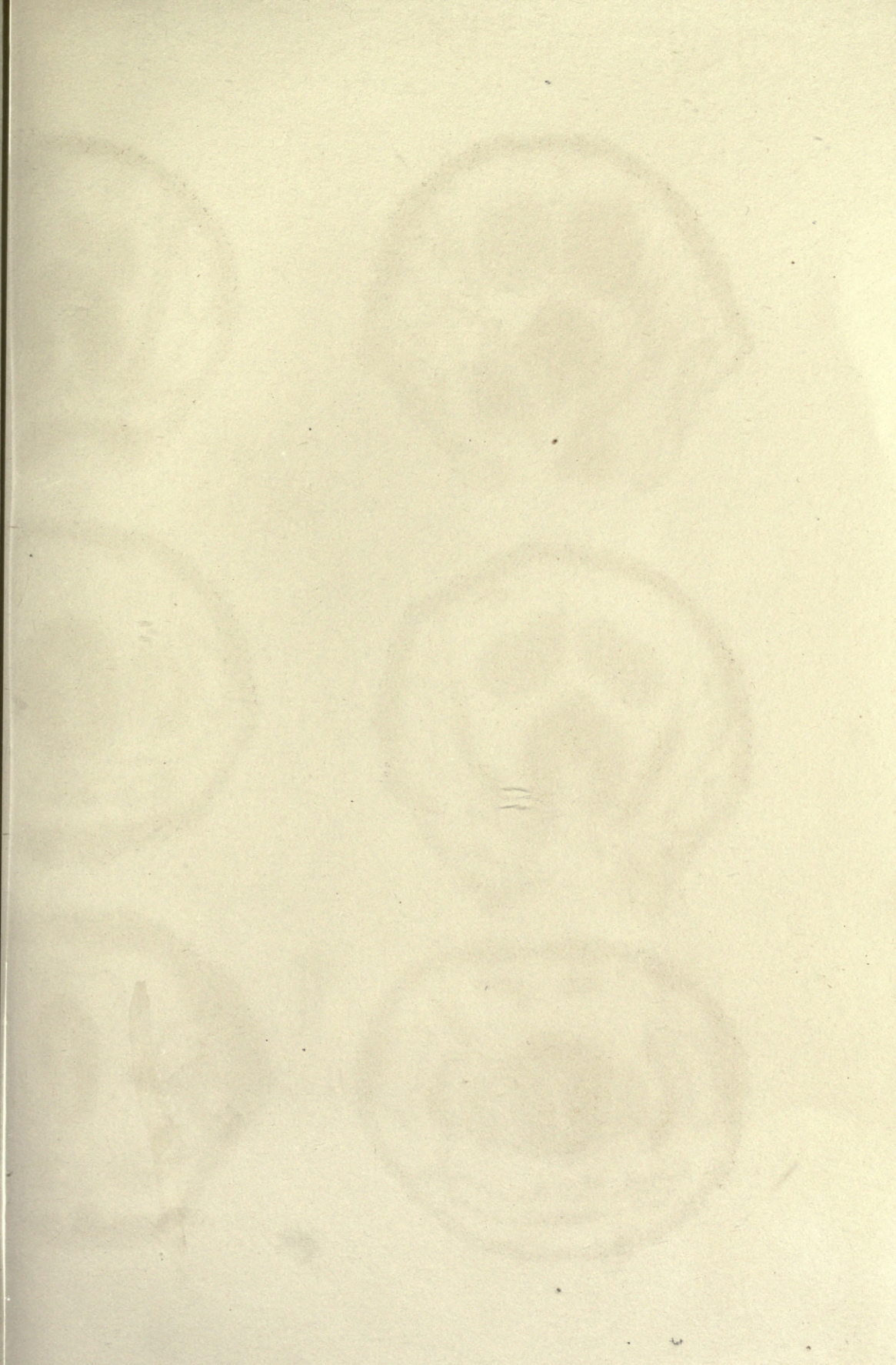


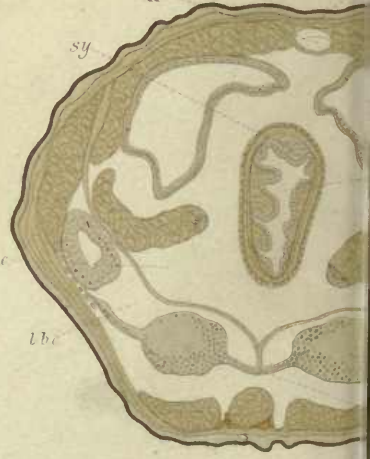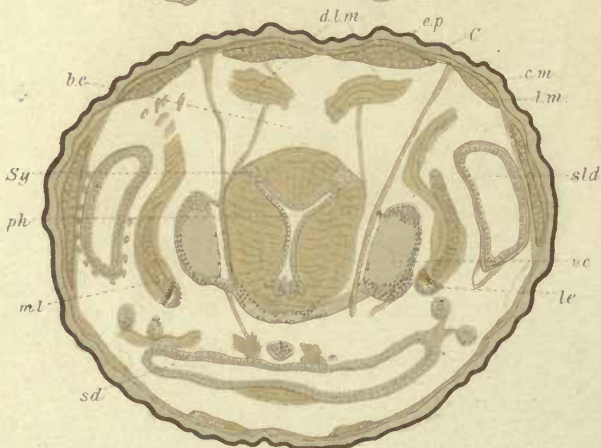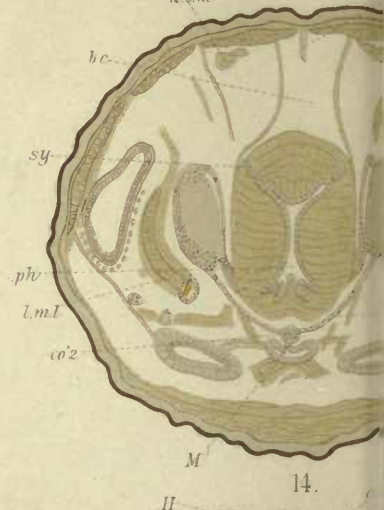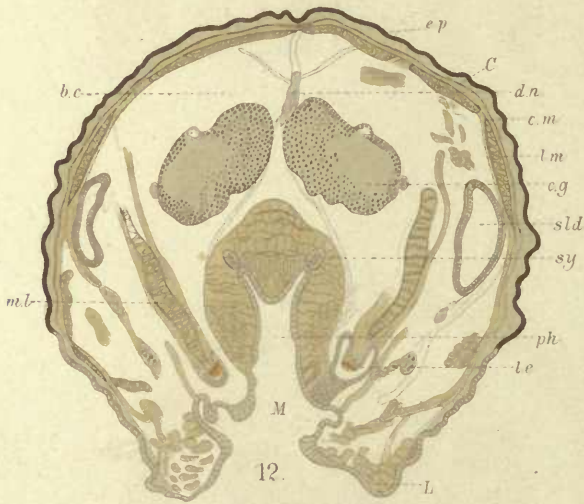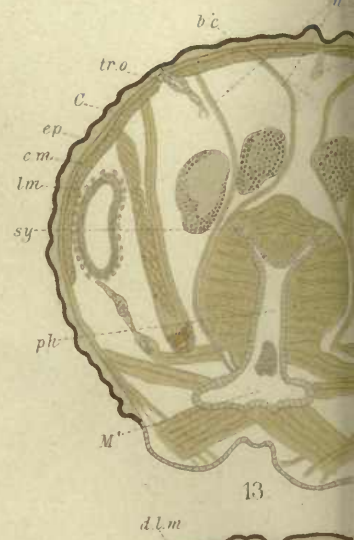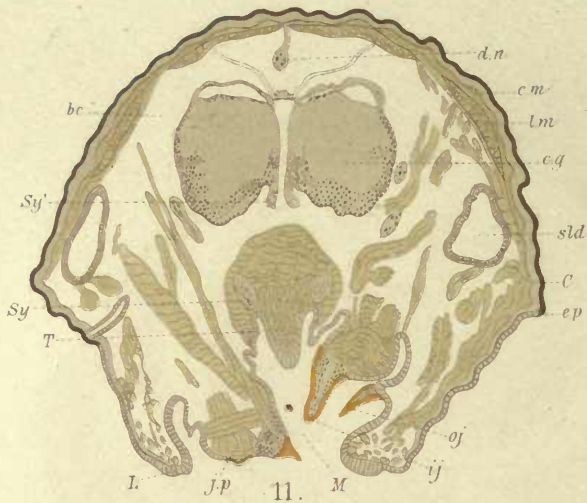
10.

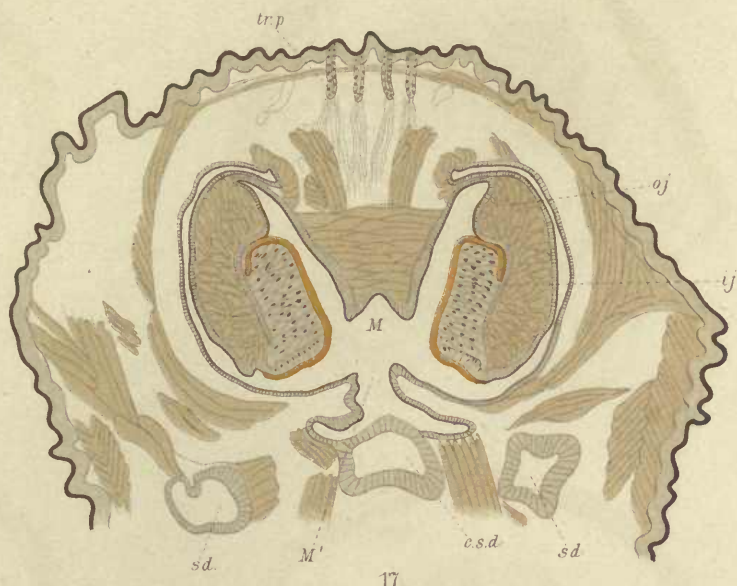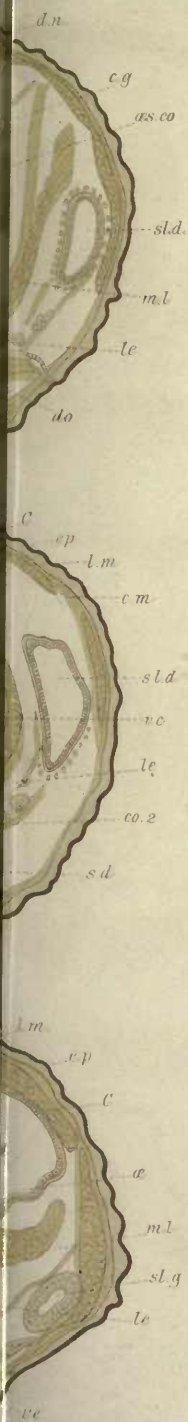


sl.g.

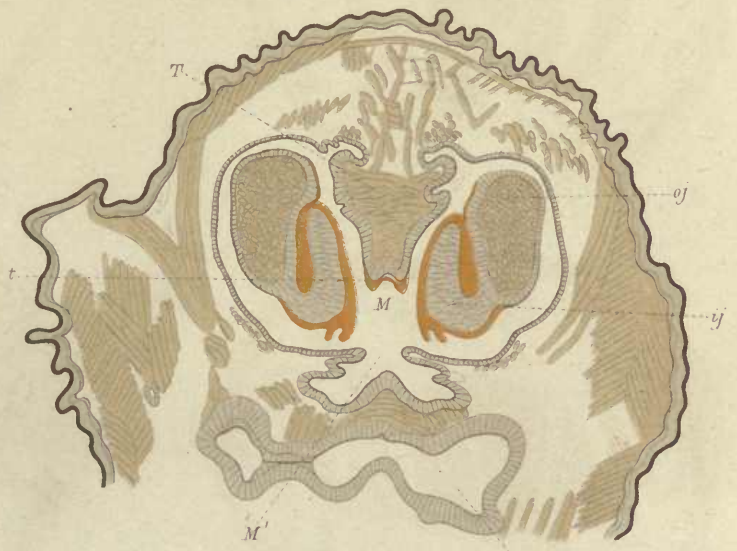6.






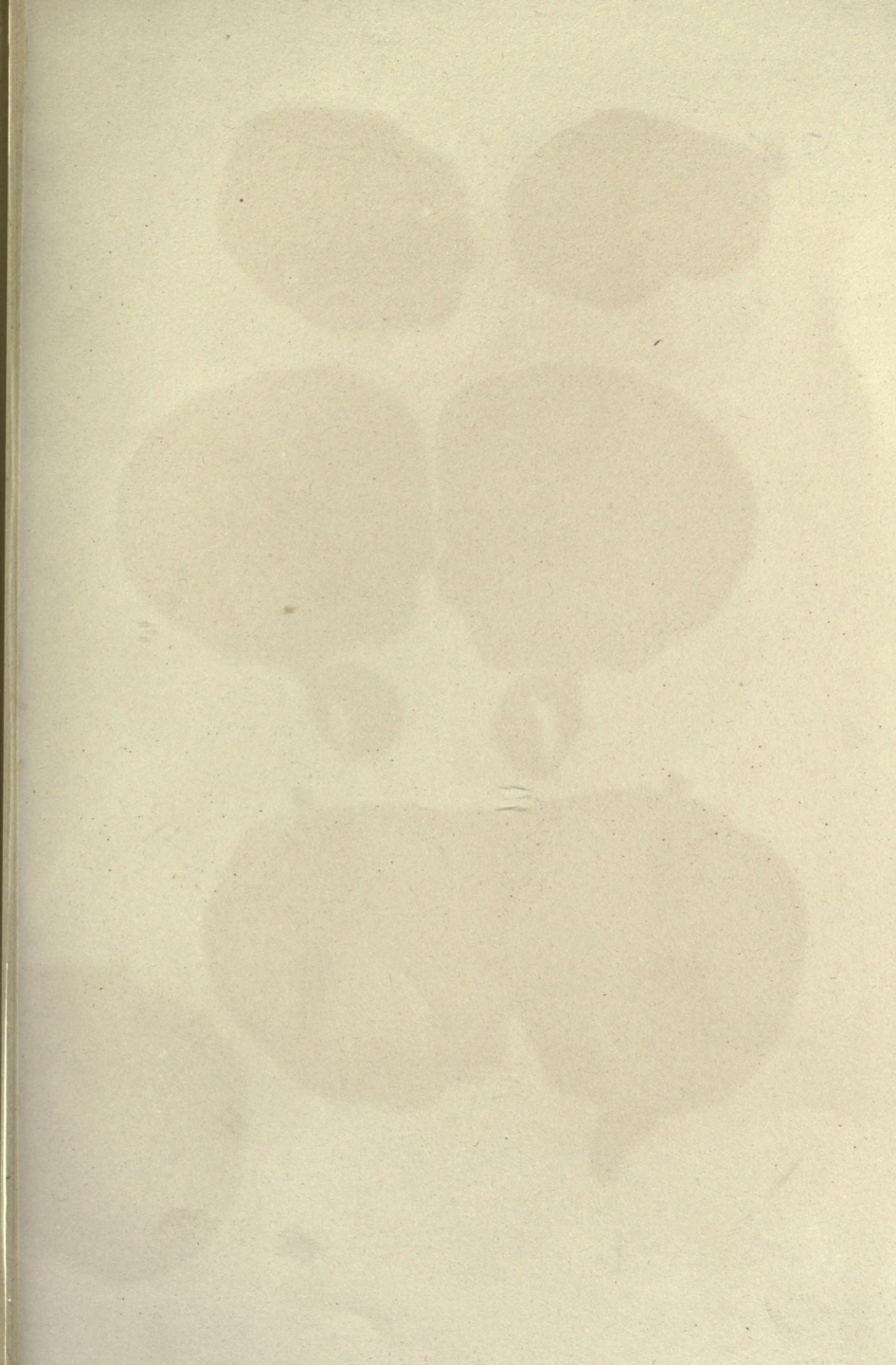


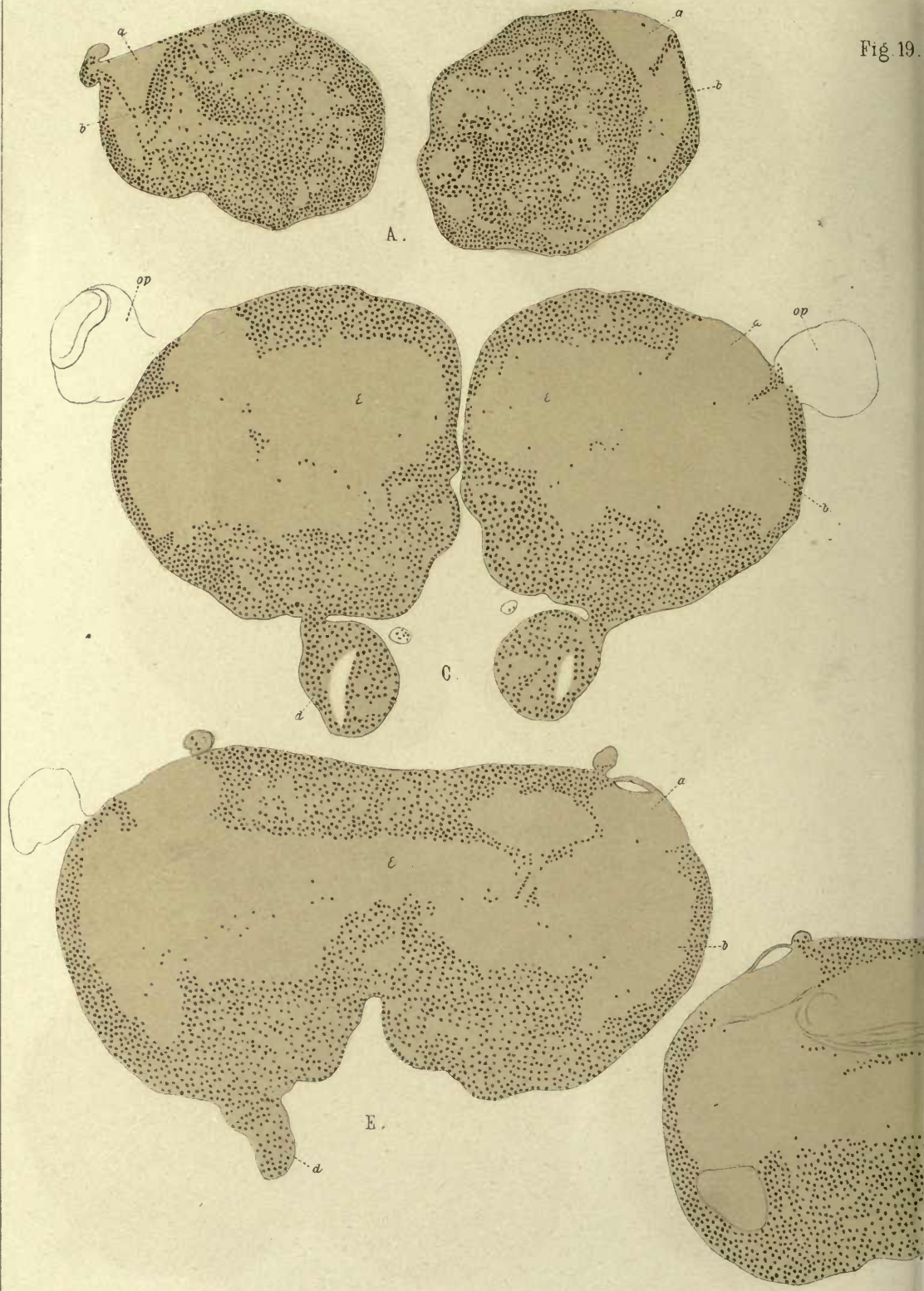
17.




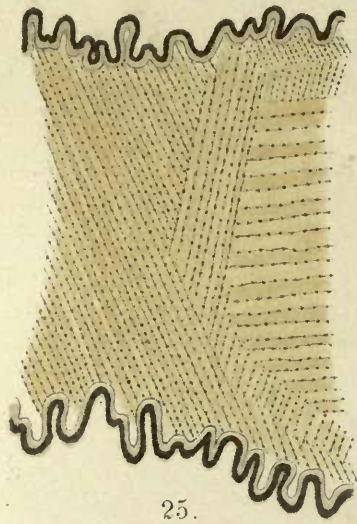
18.



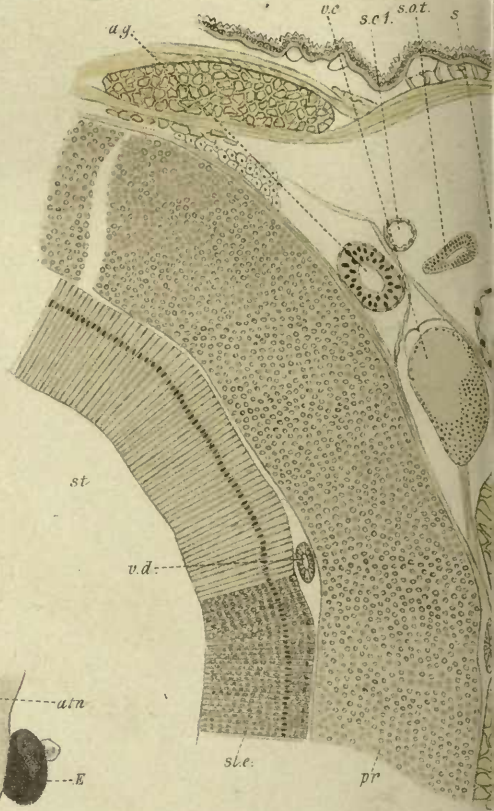








25.



20.

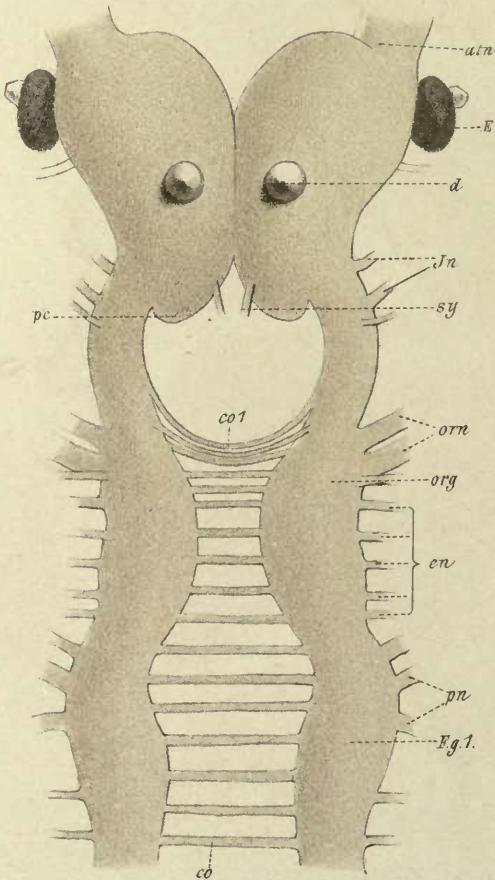
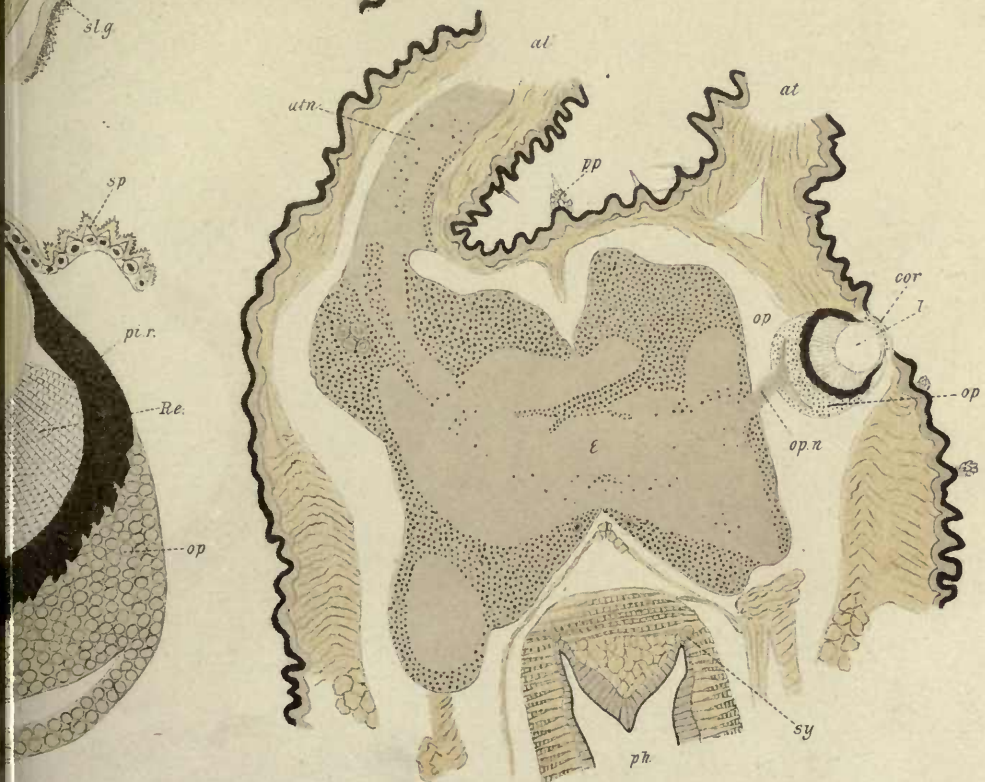
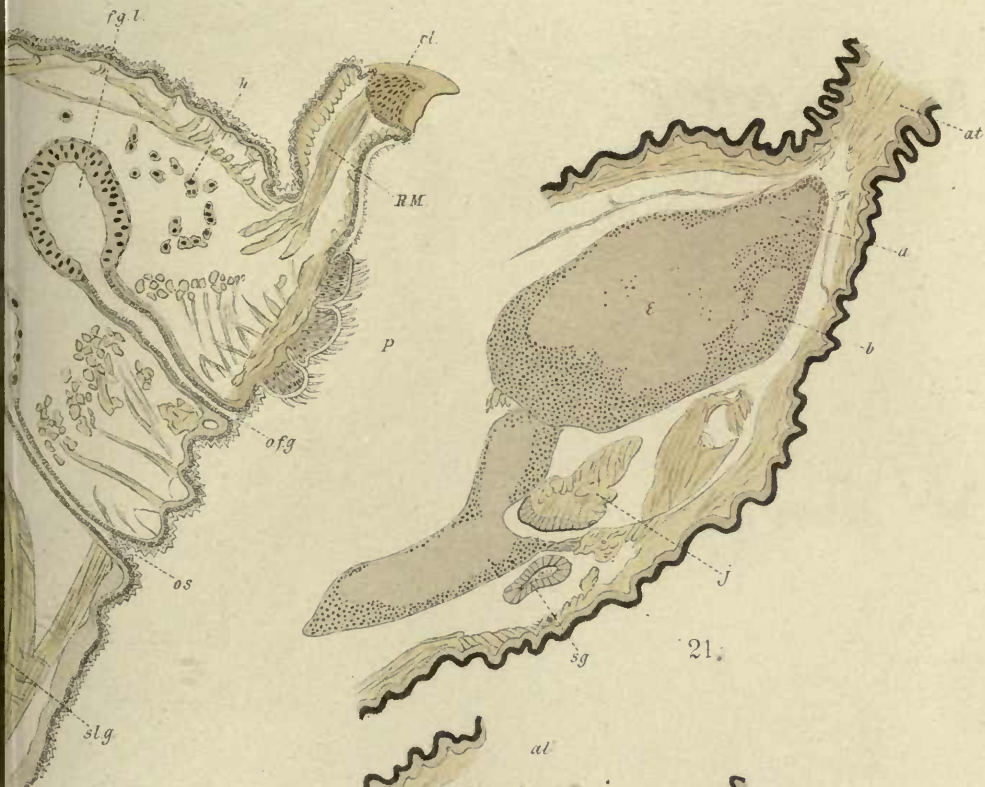


Fig. 1.


22.

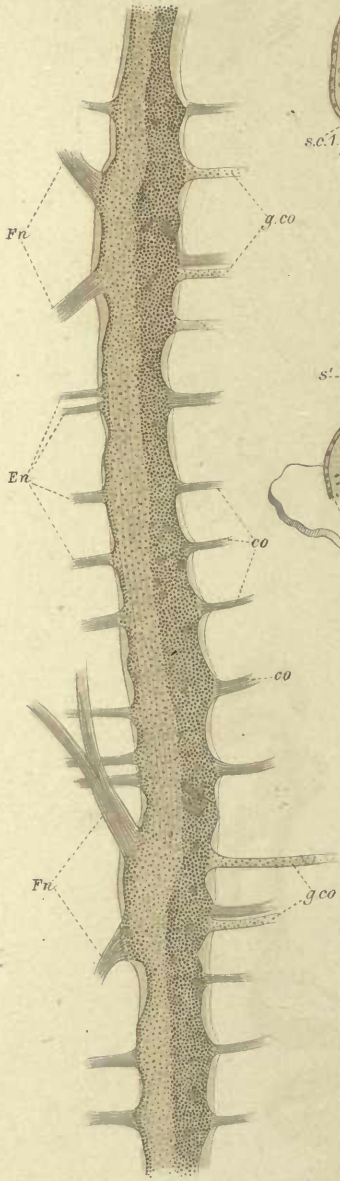


24

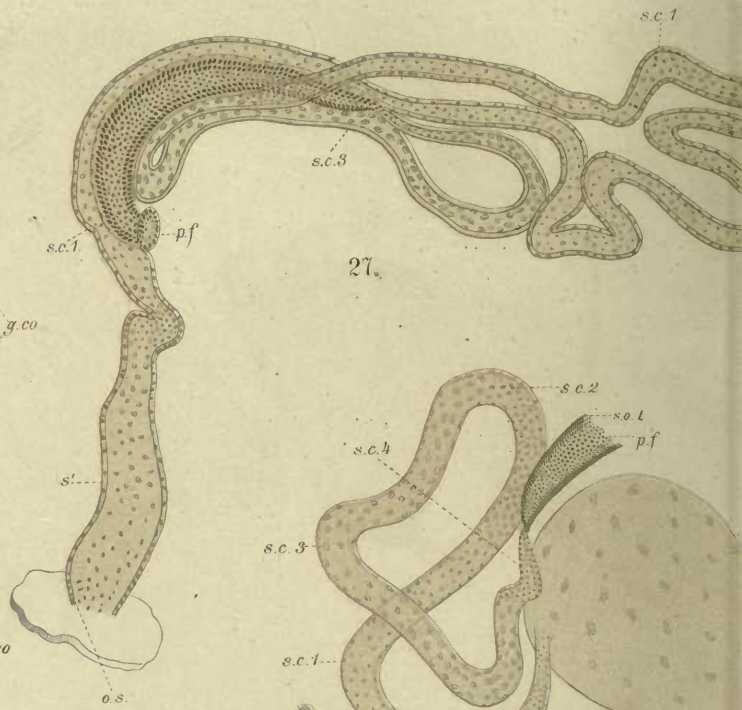




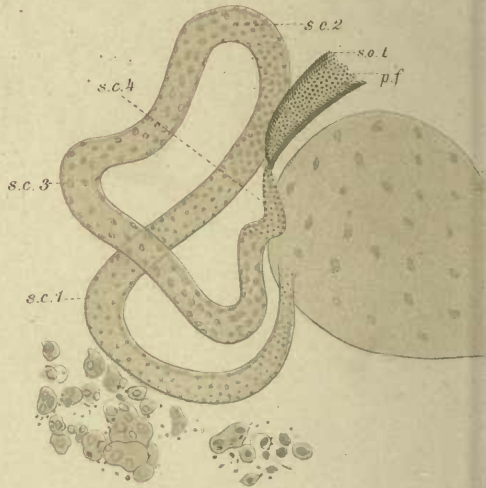




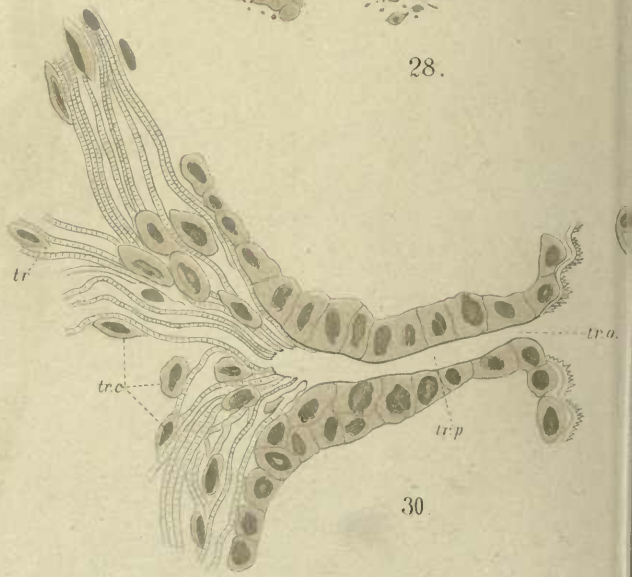26.



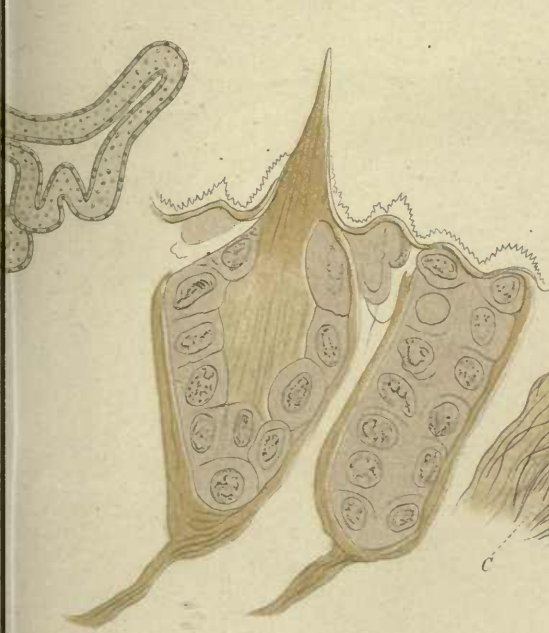27.



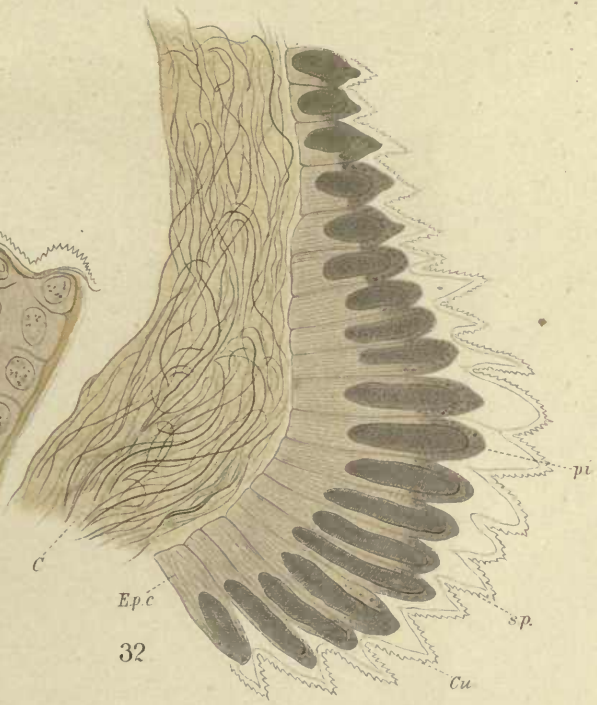
28.



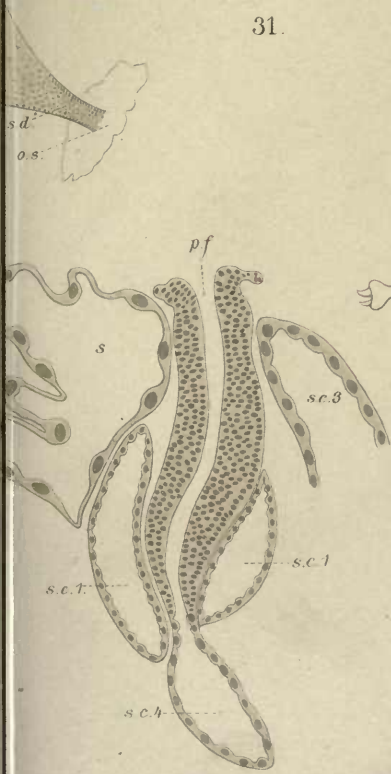
30.



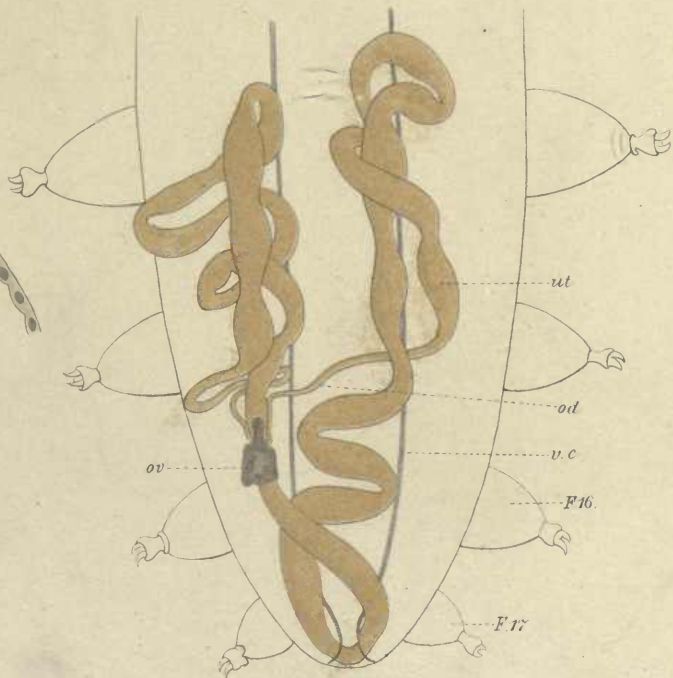
31



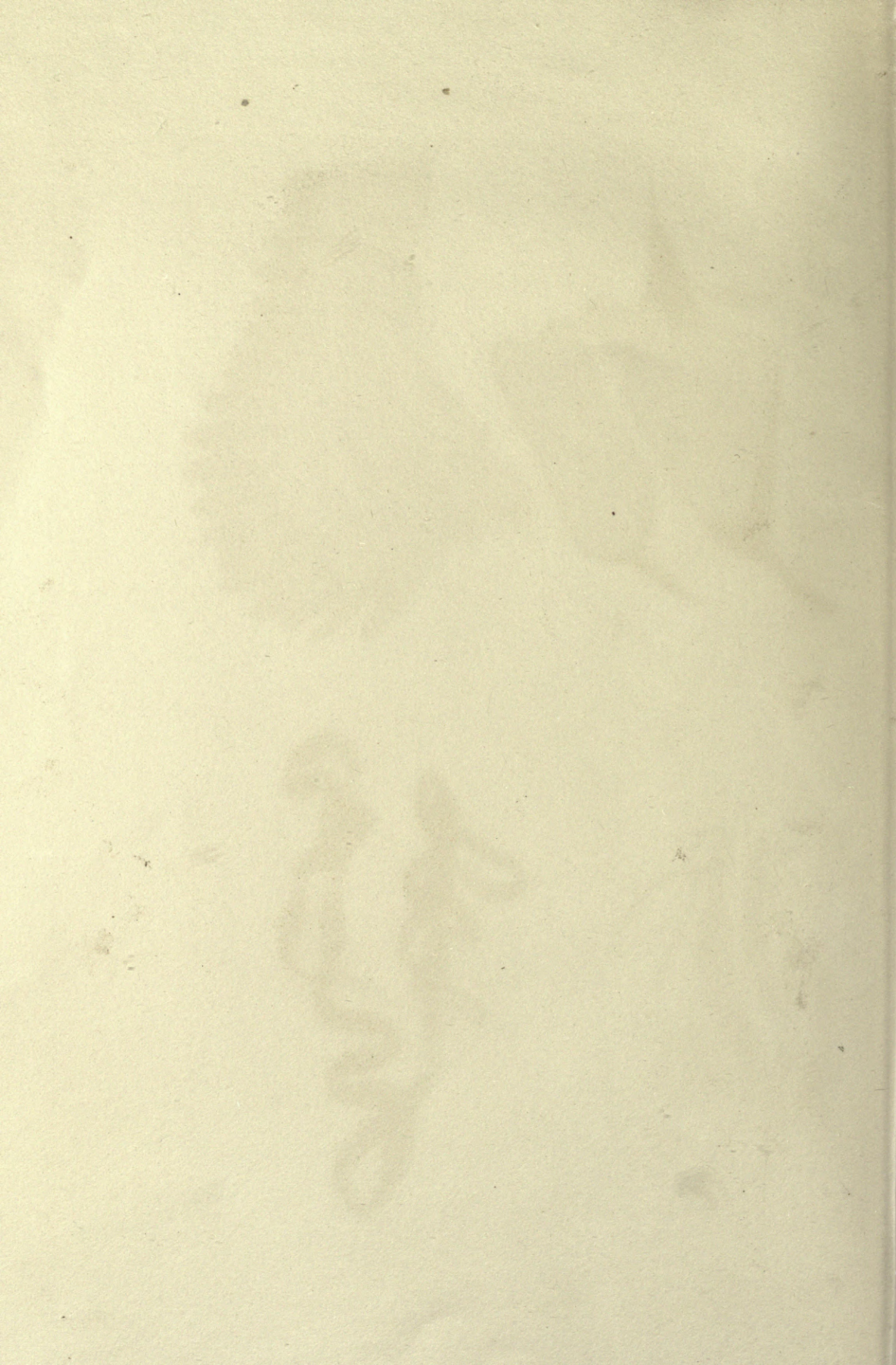
32




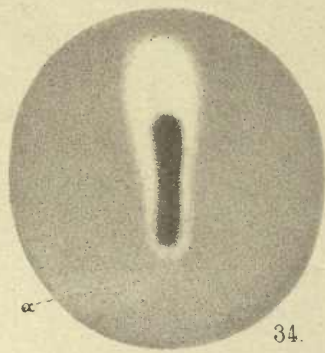
29



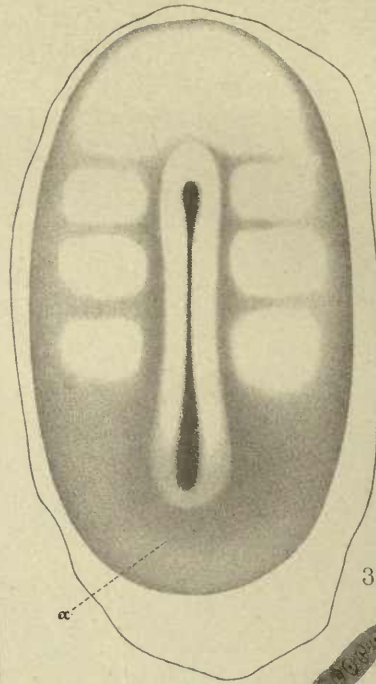
33



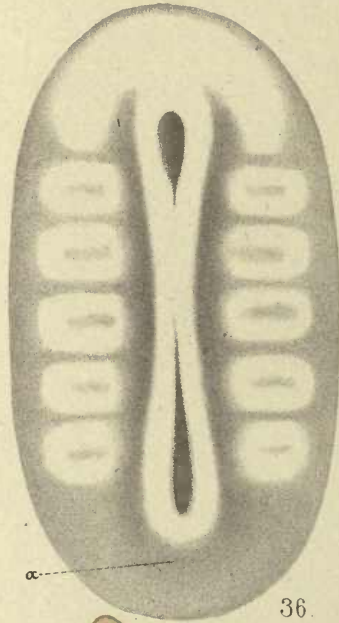




34.



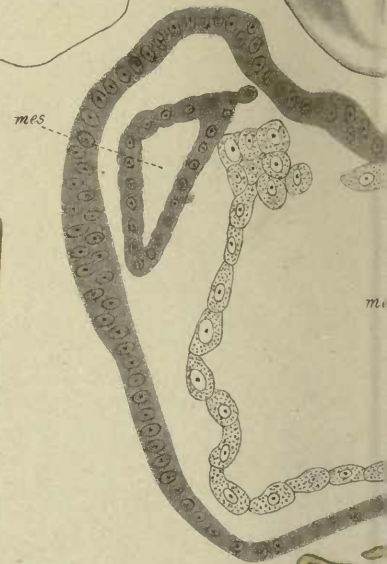
35.



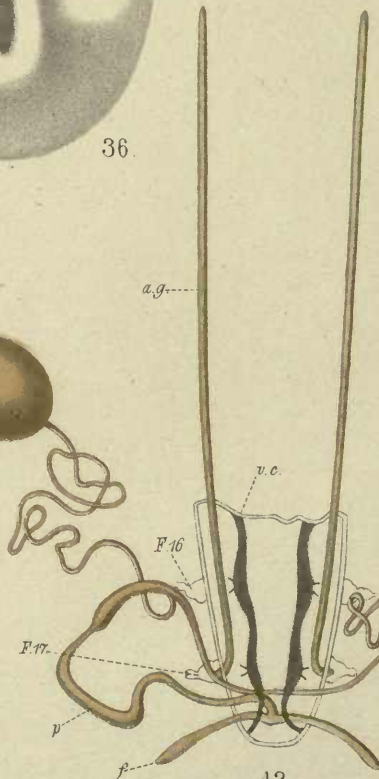
36.



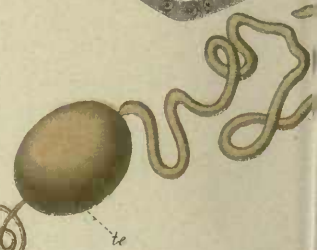
a.g.



mes

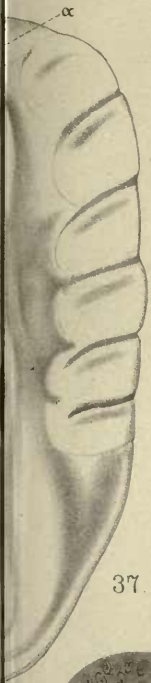


43.

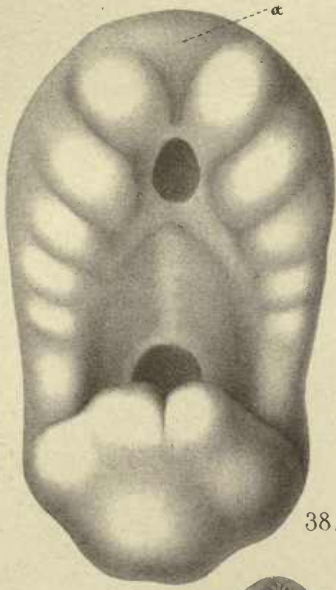


te

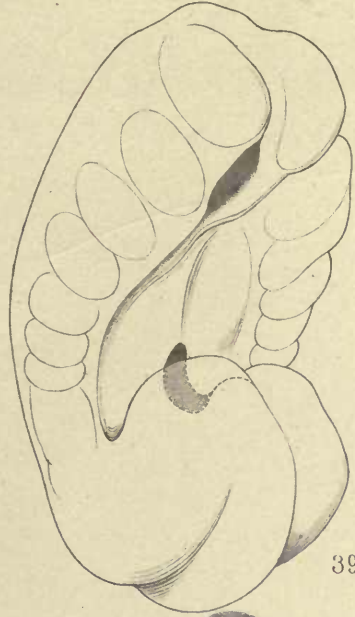
va



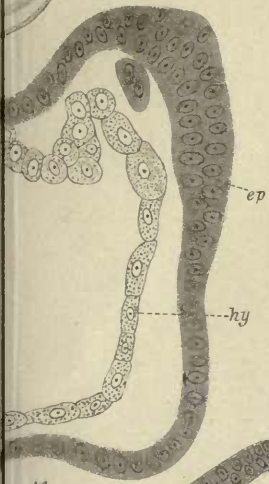
37.



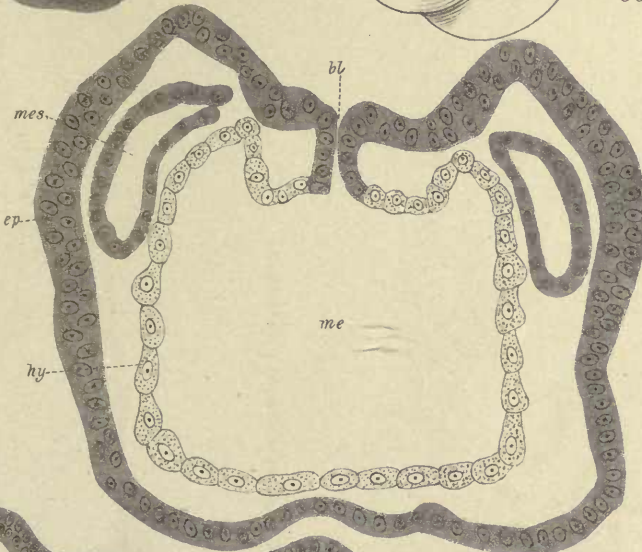
38.



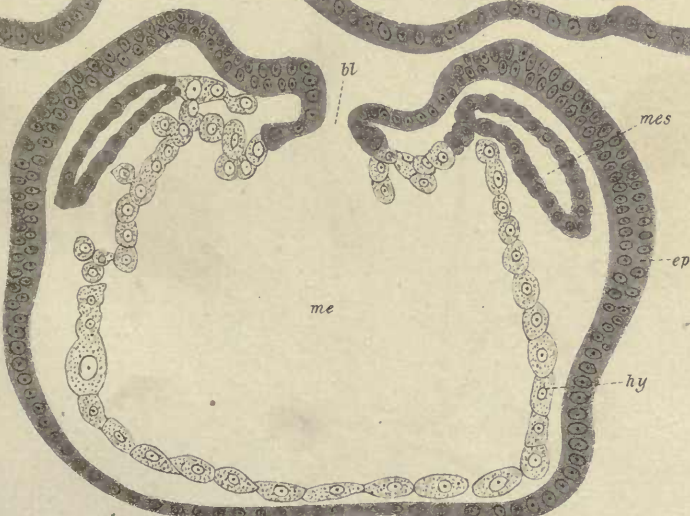
39.




41.





40.

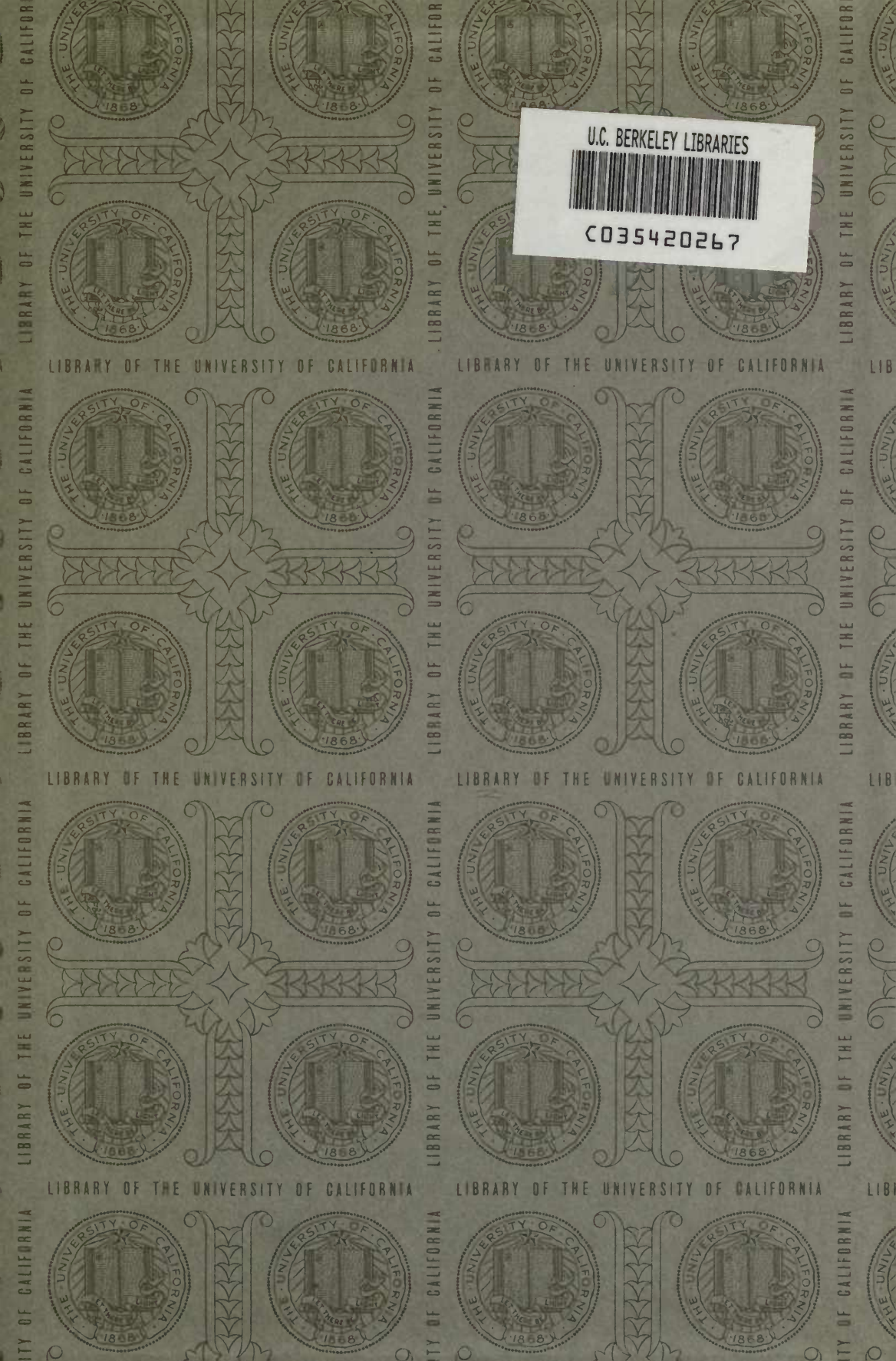


42.










U.C. BERKELEY LIBRARIES



C035420267

