

WILSON'S
HUMAN ANATOMY.



A SYSTEM
OF
HUMAN ANATOMY.
GENERAL AND SPECIAL.


BY
ERASMUS WILSON, F.R.S.,
AUTHOR OF

"THE DISSECTOR'S MANUAL," "A TREATISE ON DISEASES OF THE SKIN," ETC. ETC.

A NEW AND IMPROVED AMERICAN,
FROM AN ENLARGED LONDON EDITION.

EDITED BY
WILLIAM H. GOBRECHT, M.D.,
PROFESSOR OF ANATOMY IN THE MEDICAL DEPARTMENT OF PENNSYLVANIA COLLEGE
FELLOW OF THE COLLEGE OF PHYSICIANS OF PHILADELPHIA, ETC.

WITH THREE HUNDRED AND NINETY-SEVEN
ILLUSTRATIONS ON WOOD



PHILADELPHIA:
BLANCHARD AND LEA.
1859.

QS
W7472
1859

Entered, according to the Act of Congress, in the year 1858, by

BLANCHARD AND LEA,

in the Clerk's Office of the District Court of the United States for the Eastern District of
Pennsylvania.

COLLIN'S, PRINTER.

AMERICAN PUBLISHERS' ADVERTISEMENT.

IN presenting a new edition of "WILSON'S HUMAN ANATOMY," the publishers have only to express the hope that it will be found to merit a continuance of the very distinguished favor with which it has been hitherto received. The extensive additions made by the hand of the author, in successive revisions, are indicated by the fact that it contains fully one-fourth more matter than the previous American edition, rendering a smaller type, and an enlarged page, necessary to keep the volume within a convenient size.

The engagements of the former editor, DR. GODDARD, being such as to prevent his taking charge of the work, it has been placed in the hands of DR. GOBRECHT, who has made such additions as his experience of the wants of students has suggested as desirable, including an Introductory Chapter of a general character, containing such preliminary information as appeared necessary to facilitate the progress of those commencing the study of anatomy. The number of woodcuts has also been largely increased by the addition of about one hundred and thirty illustrations, selected from various authorities, which, it is hoped, may assist the student to an easy comprehension of the text. These, and such notes as are introduced, are distinguished by inclosure in brackets []. The utmost care has been employed throughout to render the text correct, and to verify all the references to the illustrations; and some few errors, which had escaped the attention of the author, or of his assistants, have thus been removed.

Although the English edition is still known by the name of "THE ANATOMIST'S VADE MECUM," the publishers find, in the increased size of the work, an additional motive for retaining the title of "A SYSTEM OF HUMAN ANATOMY," by which it has been so long and so favorably known to the American profession.

AUTHOR'S NOTE TO THE SEVENTH EDITION.

THE present Edition has been carefully revised and corrected; many parts, especially those relating to Histological Anatomy, have been rewritten, and a considerable addition has been made to the number of the Woodcuts. The Author, therefore, feels some confidence and satisfaction in presenting this Edition to his Readers; and trusts that the ANATOMIST'S VADE MECUM may continue to deserve the favor which it has hitherto received at the hands of the Student of Medicine.

17 HENRIETTA STREET, CAVENDISH SQUARE, 1857.

P R E F A C E .

IN presenting for the SIXTH time a new Edition of the ANATOMIST'S VADE MECUM to my brethren of the profession of medicine, it gives me great and heartfelt satisfaction to have the opportunity of announcing, that, in the preparation of the present Edition, I have received the valuable aid of a distinguished Professor of Medicine of northern Europe, Andreas Retzius, M. D., F. R. Acad. S., Master of Surgery, Dean, and Professor of Anatomy in the Royal Caroline Institute of Stockholm — a man justly renowned in the science of our art.

The assistance of Professor Retzius is the more gratifying to me, as being the spontaneous offering of a great and distinguished man of science to a humble but zealous fellow-laborer; and his approbation has served as a stimulus to me to make the present Edition not unworthy of the praise which he has kindly bestowed upon it. "I use your Anatomist's Vade Mecum," he observes, "for my students in the dissecting-room. It has become my favorite manual for young students; for I find that, by it, they get a clearer and quicker insight into the study of Anatomy, than by any other book. These are my reasons for interesting myself in its success, and for contributing my remarks for its emendation."

In pursuance of these observations, Dr. Retzius had conveyed to me an interleaved copy of the work containing many notes for its improvement; and, furthermore, took the trouble of sending to me, from across the seas, a preparation of the ligaments of the foot, showing the ligament to which he has given the name of liga-

mentum fundiforme (page 280). More deeply cherished is the promise conveyed in the following passage: "If the Almighty God will continue to bless me with health and life for some years longer, I will assist you in revising every new Edition, and introducing all those new discoveries in anatomy which may be of use to the Student of Medicine."

While thus acknowledging the assistance given to me by the great Scandinavian Professor, it may not be out of place to put on record an act of liberality, in connexion with this book, from another foreign source, namely, from the well-known medical publishers of Philadelphia, Messrs. Blanchard and Lea. The following extract from a letter addressed to me by them, and bearing date April 4, 1854, will explain the incident to which I refer.

"You may perhaps be acquainted with the name of our house as having published in this country your works on Anatomy and Diseases of the Skin. When English works which we issue are successful, it always affords us pleasure to make the author an acknowledgment more substantial, if not more gratifying, than the transatlantic reputation thus obtained; and we accordingly take pleasure in handing you the annexed draft, which we trust you will do us the favor to accept."

With the above encouraging passages in the annals of the Anatomist's Vade Mecum, I now conclude, trusting that my reader, and those for whom the book was specially written, may find no reason to utter a judgment less favorable than the foreign reputation and wide circulation of the volume would seem to justify.

CONTENTS.

CHAPTER I.

INTRODUCTORY.

	PAGE		PAGE
Classification of natural objects	27	HISTOLOGY	32
Definition of anatomy	27	Simple structural elements	32
Divisions of anatomy	27	The tissues	35
STÆCHIOLOGY	28	Tabular classification	36
Simple chemical elements	28	Properties	38
Immediate principles	28	Groups of organs	39
Tabular classification	29		

CHAPTER II.

OSTEOLOGY.

Definition	41	Lumbar vertebræ	51
Chemical composition of bone	41	General considerations	52
Division of bones into classes	41	Development	53
Structure of bone	42	Attachment of muscles	54
Development of bone	44	Sacrum	55
Periods of ossification	47	Coccyx	57
The skeleton	48	THE SKULL	57
VERTEBRAL COLUMN	48	Bones of the cranium	57
Cervical vertebræ	49	Occipital bone	57
Dorsal vertebræ	51	Parietal bone	60

Frontal bone	61	Os hyoides	98
Temporal bone	63	THORAX AND UPPER EXTREMITY	99
Sphenoid bone	67	Sternum	99
Ethmoid bone	70	Ribs	100
Bones of the face	72	Costal cartilages	102
Nasal	72	Clavicle	102
Superior maxillary	73	Scapula	103
Lachrymal bone	75	Humerus	105
Malar bone	76	Ulna	107
Palate bone	77	Radius	108
Inferior turbinated bone	78	Carpal bones	109
Vomer	79	Metacarpal bones	112
Inferior maxillary	80	Phalanges	113
Table of developments, articulations, &c.	82	PELVIS AND LOWER EXTREMITY	113
Sutures	82	Os innominatum	113
Regions of the skull	83	Ilium	114
Superior region	83	Ischium	115
Lateral regions	83	Os pubis	115
Base of the skull	85	Pelvis as a whole	117
Face	88	Axes	117
Orbits	89	Diameters	117
Nasal fossæ	90	Femur	119
Teeth	91	Patella	121
Structure	92	Tibia	121
Development	94	Fibula	122
Growth	96	Tarsal bones	124
Eruption	98	Metatarsal bones	127
Succession	98	Phalanges	128
		Sesamoid bones	129

CHAPTER III.

THE LIGAMENTS

Forms of articulation	129	Rotation	131
Synarthrosis	129	General anatomy of articular struc- tures	131
Amphi-arthritis	130	Cartilage	132
Diarthritis	130	True cartilage	132
Movements of joints	131	Reticular cartilage	133
Gliding	131	Fibrous cartilage	133
Angular movement	131	Fibrous tissue	134
Circumduction	131		

White fibrous tissue	134	Scapulo-clavicular articulation	151
Ligament	134	Ligaments of the scapula	152
Tendon	134	Shoulder joint	152
Yellow fibrous tissue	135	Elbow joint	153
Adipose tissue	135	Radio-ulnar articulation	154
Synovial membrane	136	Wrist joint	155
LIGAMENTS OF THE TRUNK	137	Articulations of the carpal bones	156
Articulation of vertebral column	137	Carpo-metacarpal articulations	157
of Atlas with occipital bone	139	Metacarpo-phalangeal articulation	158
" Axis with occipital bone	140	Articulation of the phalanges	158
" Atlas with axis	141	LIGAMENTS OF THE LOWER EXTREMITY	158
" Lower jaw	142	Hip joint	159
" Ribs with vertebræ	144	Knee joint	160
" Ribs with sternum, and to- gether	145	Articulation of tibia and fibula	163
" Sternum	147	Ankle joint	164
" Vertebral column with pelvis	147	Articulation of the tarsal bones	165
" Pelvis	147	Tarso-metatarsal articulation	167
LIGAMENTS OF THE UPPER EXTREMITY	150	Metatarso-phalangeal articulation	167
Sterno-clavicular articulation	150	Articulation of the phalanges	167

CHAPTER IV.

THE MUSCLES

General anatomy of muscle	168	Muscles of the tongue	191
Nomenclature	168	Muscles of the pharynx	193
Structure	169	Muscles of the soft palate	195
MUSCLES OF THE HEAD AND NECK	172	Prævertebral muscles	196
Muscles of the head and face	172	Laryngeal group	198
Cranial group	173	MUSCLES OF THE TRUNK	198
Orbital group	174	Muscles of the back	198
Ocular group	176	First layer	199
Nasal group	179	Second layer	201
Superior labial group	181	Third layer	202
Inferior labial group	182	Fourth layer	203
Maxillary group	183	Fifth layer	206
Auricular group	185	Sixth layer	207
Muscles of the neck	186	Table of origins and insertions	210
Superficial group	186	Muscles of the thorax	212
Depressors, os hyoides and larynx	188	Muscles of the abdomen	213
Elevators of the os hyoides	189	Table of actions of muscles	221

Muscles of the perineum	222	Table of actions of muscles	245
Male perineum	222	MUSCLES OF THE LOWER EXTREMITY	247
Female perineum	225	Gluteal region	248
MUSCLES OF THE UPPER EXTREMITY	227	Anterior femoral region	251
Anterior thoracic region	228	Internal femoral region	253
Lateral thoracic region	229	Posterior femoral region	255
Anterior scapular region	230	Anterior tibial region	257
Posterior scapular region	230	Posterior tibial region	258
Acromial region	232	Fibular region	261
Anterior humeral region	232	Foot	262
Posterior humeral region	234	Dorsal region	262
Anterior brachial region	235	Plantar region	262
Posterior brachial region	238	Table of actions of muscles	266
Muscles of the hand	242		

CHAPTER V.

THE FASCIÆ.

General anatomy	268	Direct inguinal hernia	273
FASCIÆ OF THE HEAD AND NECK	269	Fascia iliaca	273
Temporal fascia	269	Fascia pelvica	273
Cervical fasciæ	269	Obturator fascia	275
FASCIÆ OF THE TRUNK	270	Perineal fasciæ	275
Thoracic fascia	270	FASCIÆ OF THE UPPER EXTREMITY	276
Fascia transversalis	271	FASCIÆ OF THE LOWER EXTREMITY	277
Oblique inguinal hernia.	271	Fascia lata	277
Congenital hernia.	272	Femoral hernia	280
Encysted hernia	273	Plantar fascia	281

CHAPTER VI.

THE ARTERIES.

General anatomy of arteries	281	Arteria innominata	289
Inosculations	282	Common carotid arteries	289
Structure	283	External carotid artery	290
Capillaries	285	Table of branches	291
Aorta	286	Superior thyroid artery	292
Table of branches	288	Lingual artery	292
Coronary arteries	288	Facial artery	292

Sterno-mastoid artery	294	Ulnar artery	313
Occipital artery	294	Thoracic aorta; branches	316
Posterior auricular artery	294	Abdominal aorta; branches	317
Ascending pharyngeal artery	294	Phrenic arteries	317
Parotidean arteries	294	Cœliac axis	317
Temporal artery	295	Gastric artery	317
Internal maxillary artery	295	Hepatic artery	317
Internal carotid artery	298	Splenic artery	319
Ophthalmic artery	299	Superior mesenteric artery	320
Anterior cerebral artery	300	Spermatic arteries	321
Middle cerebral artery	301	Inferior mesenteric artery	321
Subclavian artery	301	Renal arteries	323
Table of branches	303	Common iliac arteries	323
Vertebral artery	303	Internal iliac artery	324
Basilar artery	303	Ischiatic	325
Circle of Willis	304	Internal pudic artery	326
Internal mammary artery	305	External iliac artery	328
Inferior thyroid artery	306	Femoral artery	329
Supra-scapular artery	306	Popliteal artery	333
Transversa colli artery	306	Anterior tibial artery	334
Superior intercostal artery	307	Dorsalis pedis artery	335
Axillary artery	307	Posterior tibial artery	337
Table of branches	308	Peroneal artery	337
Brachial artery	310	Plantar arteries	338
Radial artery	311	Pulmonary artery	340

CHAPTER VII.

THE VEINS.

General anatomy	341	VEINS OF THE TRUNK	352
Valves of veins	343	Venæ innominatæ	353
VEINS OF THE HEAD AND NECK	343	Superior vena cava	354
Veins of the exterior of the head	344	Iliac veins	354
Veins of the diploë	345	Inferior vena cava	354
Cerebral and cerebellar veins	346	Azygos veins	355
Sinuses of the dura mater	346	Vertebral and spinal veins	356
Veins of the neck	348	Cardiac veins	356
VEINS OF THE UPPER EXTREMITY	349	Portal vein	357
VEINS OF THE LOWER EXTREMITY	351	Pulmonary veins	358

CHAPTER VIII.

THE LYMPHATICS.

General anatomy	359	Lymphatics of the viscera	365
Lymphatics of head and neck	362	Lacteals	366
Lymphatics of upper extremity	363	Thoracic duct	367
Lymphatics of lower extremity	363	Ductus lymphaticus dexter	368
Lymphatics of the trunk	364		

CHAPTER IX.

THE NERVOUS SYSTEM.

General anatomy	368	CRANIAL NERVES	405
THE BRAIN	383	SPINAL NERVES	425
Membranes of the encephalon	383	Cervical nerves	426
Dura mater	383	Cervical plexus	426
Arachnoid membrane	386	Brachial plexus	429
Pia mater	387	Dorsal nerves	436
Cerebrum	387	Lumbar nerves	438
Lateral ventricles	389	Lumbar plexus	438
Fifth ventricle	392	Sacral nerves	443
Third ventricle	393	Sacral plexus	444
Fourth ventricle	395	SYMPATHETIC SYSTEM	449
Lining membrane of ventricles	396	Cranial ganglia	449
Cerebellum	396	Cervical ganglia	453
Base of the brain	398	Thoracic ganglia	456
Medulla oblongata	401	Lumbar ganglia	457
SPINAL CORD	402	Sacral ganglia	458

CHAPTER X.

ORGANS OF SENSE.

ORGAN OF SMELL	458	ORGAN OF VISION	462
Nose	459	Eyeball	462
Nasal fossæ	460	Sclerotic coat and cornea	462

Choroid coat	464	Internal ear or labyrinth	479
Ciliary ligament; iris	465	Vestibule	479
Retina; zonula ciliaris	466	Semicircular canals	480
Humors	467	Cochlea	481
Physiological observations	469	Membranous labyrinth	483
Appendages of the eye	469	ORGAN OF TASTE	484
Lachrymal apparatus	471	Tongue	484
ORGAN OF HEARING	473	ORGAN OF TOUCH	486
External ear	473	Skin	486
Pinna	473	Appendages of the skin	489
Mentus auditorius	475	Nails	489
Middle ear or tympanum	475	Hair	489
Ossicula auditûs	475	Sebiparous glands	490
Muscles of the tympanum	477	Sudoriparous glands	491

CHAPTER XI.

THE VISCERA.

THORAX	492	Liver	543
Heart	492	Gall-bladder	552
Structure of the heart	500	Pancreas	553
Organs of respiration and voice	503	Spleen	554
Larynx	503	Supra-renal capsules	556
Trachea and bronchi	509	Kidneys	558
Thyroid gland	510	PELVIS	562
Lungs	511	Male pelvis	562
Pleuræ	514	Bladder	562
Mediastinum	514	Prostate gland	565
ABDOMEN	515	Vesiculæ seminales	566
Peritoneum	517	Male organs of generation	567
Alimentary canal	520	Penis	567
Cheeks	521	Urethra	569
Gums	521	Testes	572
Palate	521	Female pelvis	575
Tonsils	522	Bladder	576
Fauces	522	Urethra	576
Mucous glands	522	Internal organs of generation	577
Salivary glands	524	Vagina	577
Pharynx	526	Uterus	578
Stomach	527	Fallopian tubes	580
Small intestine	528	Ovaries	582
Large intestine	529	External organs of generation	584
Structure of the intestinal canal	531	MAMMARY GLANDS	586

CHAPTER XII.

ANATOMY OF THE FÆTUS.

Osseous system	588	Fœtal lungs	594
Ligamentous system	589	Fœtal heart	595
Muscular system	589	Viscera of the abdomen	595
Vascular system	589	Omphalo-mesenteric vessels	595
Fœtal circulation	589	Alimentary canal	595
Nervous system	590	Spleen	595
Organs of sense	591	Liver	596
Eye	591	Kidneys	596
Ear	591	Supra-renal capsules	596
Nose	591	Viscera of the pelvis	596
Thyroid gland	591	Testes	597
Thymus gland	591	Descent	597

LIST OF ILLUSTRATIONS.

FIG.	PAGE	FIG.	PAGE
1. Vegetable nucleated cells	33	27. Axis	50
2. Formation of animal nucleated cells	33	28. Dorsal vertebra	51
3. Cells	33	29. Lumbar vertebra	51
4. Endogenous cell development	34	30. Section of spinal column	52
5. Multiplication of cells by division,	34	31. Development of vertebræ	54
6. Cytoid corpuscles	35	32. Development of vertebral epiphyses	54
7. Development of red blood-corpus- cles	35	33. Sacrum: anterior face	55
8. Development of striated muscular fibre	36	34. Sacrum: posterior face	55
9. Epithelial plates	37	35. Coccyx	57
10. Pigment-cells	37	36. Occipital bone: external face	58
11. Development of cartilage	37	37. Occipital bone: internal face	58
12. Id. advanced stage	37	38. Development of occipital bone	59
13. Id. more advanced stage	37	39. Parietal bone: external face	60
14. Ligneous cells	37	40. Parietal bone: internal face	60
15. Formation of fibres	38	41. Frontal bone: external face	61
16. Haversian canals	42	42. Frontal bone: internal face	62
17. Intimate structure of bone	42	43. Development of frontal bone	63
18. Section of femur	43	44. Temporal bone: external face	63
19. Lacunæ of osseous tissue	44	45. Meatus auditorius	64
20. Periosteum	44	46. Temporal bone: internal face	65
21. Development of bone	45	47. Meatus auditorius internus	65
22. Id. advanced stage	46	48. Tympanic bone	67
23. Id. more advanced stage	46	49. Sphenoid bone: superior face	68
24. Young femur	47	50. Sphenoid bone: anterior face	69
25. Cervical vertebra	49	51. Ethmoid bone	71
26. Atlas	49	52. Nasal bone: internal surface	72
		53. Nasal bone: external surface	72
		54. Superior maxillary bone: exter- nal surface	73

FIG.	PAGE	FIG.	PAGE
55. Superior maxillary bone: internal surface	74	93. Male and female pelves	118
56. Lachrymal bone	76	94. Femur: anterior view	119
57. Malar bone	76	95. Femur: posterior view	120
58. Palate bone: internal surface . .	77	96. Patella: anterior view	121
59. Palate bone: external surface .	78	97. Patella: posterior view	121
60. Inferior turbinated bone: internal view	79	98. Tibia and fibula: anterior view .	122
61. Inferior turbinated bone: external view	79	99. Tibia and fibula: posterior view	123
62. Vomer	80	100. Foot: dorsal surface	124
63. Inferior maxillary bone	81	101. Foot: plantar surface	127
64. Skull: anterior view	84	102. Articular cartilage: its cells near the bone	132
65. Base of the skull: interior . . .	85	103. Articular cartilage: its cells further from the bone	132
66. Base of the skull: exterior . . .	87	104. Articular cartilage: its cells near the free surface	132
67. Section of cranium and face . . .	88	105. Reticular cartilage	133
68. Nasal fossa; turbinated bones .	90	106. Fibrous cartilage	133
69. Permanent teeth	91	107. White fibrous tissue	134
70. Temporary teeth	92	108. Yellow fibrous tissue	135
71. Section of molar tooth	93	109. Fat vesicles	136
72. Development of teeth: at fourteenth week	94	110. Serous epithelium	136
73. Id. the various stages	96	111. Ligaments of vertebræ and ribs	137
74. Id. pulp cavity and enamel sac	96	112. Posterior common ligament . . .	138
75. Id. tooth-sacs of an eight months' fœtus	97	113. Intervertebral substance	138
76. Gubernaculum dentis	98	114. Intervertebral substance	138
77. Os hyoides	99	115. Ligamenta subflava	139
78. Sternum	99	116. Ligaments of atlas, axis, and occipital bone	140
79. Thorax	101	117. Id. posterior view	140
80. Rib	101	118. Id. internal view	141
81. First rib	102	119. Id. internal view	141
82. Clavicle	103	120. Ligaments of the lower jaw . .	142
83. Scapula: anterior face	104	121. Id. internal view	143
84. Scapula: axillary border	104	122. Id. section	143
85. Scapula: posterior face	105	123. Ligaments of vertebræ and ribs .	144
86. Humerus	106	124. Ligaments of vertebral column and ribs	144
87. Ulna and radius	107	125. Middle costo-transverse ligament	145
88. Bones of the carpus, dorsum . .	109	126. Costo-sternal articulations: anterior view	146
89. Hand: anterior view	111	127. Costo-sternal articulations: posterior view	146
90. Os innominatum	114	128. Costo-sternal articulations: in section	146
91. Development of os innominatum	116		
92. Female pelvis: anterior view . .	117		

FIG.	PAGE	FIG.	PAGE
129. Ligaments of pelvis and hip . . .	148	172. Muscles of the male perineum . . .	224
130. Ligaments of pelvis and hip . . .	149	173. Muscles of the female perineum . . .	226
131. Ligaments of clavicle and costal cartilages	150	174. Posterior scapular muscles . . .	231
132. Ligaments of scapula and shoulder joint	151	175. Muscles of the humerus . . .	233
133. Scapulo-clavicular ligaments . . .	152	176. Triceps extensor cubiti . . .	234
134. Ligaments of elbow: internal . . .	153	177. Muscles of the forearm . . .	235
135. Id. external view . . .	153	178. Tendons of the fingers . . .	236
136. Orbicular ligament	154	179. Muscles of forearm: deep layer . . .	237
137. Inferior radio-ulnar articulation . . .	155	180. Muscles of forearm: posterior . . .	238
138. Ligaments of wrist and hand . . .	155	181. Extensor tendons of a finger . . .	239
139. Synovial membranes of wrist . . .	157	182. Muscles of forearm: deep layer . . .	241
140. Knee joint: anterior view . . .	160	183. Muscles of the hand	242
141. Knee joint: posterior view . . .	161	184. Palmar interosseous muscles of the hand	244
142. Knee joint: internal view . . .	162	185. Dorsal interosseous muscles of the hand	244
143. Knee joint: synovial membrane . . .	163	186. Muscles of gluteal region . . .	249
144. Ankle joint: posterior view . . .	164	187. Muscles of anterior and internal femoral region	252
145. Ankle joint: internal view . . .	164	188. Muscles of gluteal and posterior femoral region	255
146. Ankle joint: external view . . .	165	189. Muscles, anterior tibial . . .	257
147. Ligaments, sole of foot . . .	166	190. Id., posterior tibial . . .	258
148. Muscular fibre	169	191. Id., deep layer . . .	260
149. Id., transverse section . . .	169	192. Dorsal interosseous muscles of the foot	262
150. Id., animal fibre . . .	169	193. Muscles of sole of foot . . .	263
151. Id., transverse splitting . . .	170	194. Id. deep	264
152. Id., foetal	170	195. Id. second layer	264
153. Id., ultimate fibril . . .	171	196. Plantar interosseous muscles of the foot	265
154. Id., organic fibre . . .	172	197. Section of neck, showing deep cervical fascia	269
155. Muscles of the face	174	198. Anatomy of the spermatic canal . . .	272
156. Tensor tarsi muscle	175	199. Transverse section of pelvis, show- ing fasciæ	274
157. Muscles of the orbit	177	200. Pelvic fasciæ	274
158. Ocular fascia and muscles . . .	179	201. Perineal fasciæ	276
159. Muscles of the nose	180	202. Saphenous opening in fascia lata . . .	278
160. Pterygoid muscles	184	203. Distribution of fasciæ at the fem- oral arch	279
161. Muscles of the neck	187	204. Smooth muscular fibre cells . . .	283
162. Muscles of the tongue	191	205. Coarse network of elastic tissue . . .	284
163. Muscles of the pharynx	193	206. Fenestrated membrane of elastic tissue	284
164. Muscles of the soft palate . . .	195		
165. Muscles: prævertebral region . . .	197		
166. Muscles of the back	200		
167. Muscles of the back: deep . . .	203		
168. Muscles of the back: deep . . .	204		
169. Muscles of trunk: anterior . . .	215		
170. Muscles of trunk: lateral . . .	217		
171. Diaphragm	219		

FIG.	PAGE	FIG.	PAGE
366. Splenic corpuscles	555	383. Section of virgin uterus	578
367. Splenic corpuscle: structure	555	384. Muscular fibres of uterus: ex-	
368. Section of supra-renal capsule	556	ternal	579
369. Bloodvessels of supra-renal cap-		385. Id. internal	579
sule	557	386. Mucous membrane of the ute-	
370. Section of the kidney	559	rus	580
371. Structure of kidney	560	387. Section of ovary	582
372. Plan of renal circulation	561	388. Graafian follicle	582
373. Viscera of the male pelvis.	563	389. Female external organs of gene-	
374. Bladder and vesiculæ seminales	566	ration	584
375. Erectile tissue of corpus caver-		390. Erectile structures of female or-	
nosum	569	gans	585
376. Anatomy of urethra	570	391. Section of mammary gland	586
377. Anatomy of urethra	571	392. Milk-globules	587
378. Transverse section of testis	573	393. Fœtal circulation	589
379. Anatomy of testis	574	394. Section of thymus gland	592
380. Glandular structure of testis	575	395. Duct of thymus gland	593
381. Viscera of the female pelvis	576	396. Descent of testis in the fœtus	597
382. Uterus, with appendages	578	397. Id. completed	597

A

SYSTEM OF HUMAN ANATOMY.

CHAPTER I.

INTRODUCTORY.

BY THE EDITOR.

ALL natural objects are divided into two great kingdoms, the *organic* and *inorganic*.

A mineral, inorganic or *unorganized* object undergoes no change except through the agency of mechanical or chemical forces; any augmentation of its bulk being caused by the addition of similar particles to its exterior; it therefore increases not by growth but by accretion.

An *organized* body or organism is possessed of such an internal cellular or cellulo-vascular structure as admits of the reception of fluid matters into its interior which it may alter or assimilate and add to itself. The acts by which these results are produced being inexplicable on any known mechanical or chemical principles, are called "vital acts," and during their continuance the object lives, and is a living being. Animals and vegetables are both included in this kingdom, forming its two grand divisions, between which and inorganic bodies there is a wide distinction; the former being composed of dissimilar parts or *organs*, which have a mutual relation to and dependence upon each other, whilst the latter are homogeneous in their structure.

The science which has for its object the structure of living beings is ANATOMY. The word is derived from the Greek, ἀνα, up, τέμνω, I cut, since it is by dissections principally that we are enabled to separate and study the different organs.

In accordance with the division of living beings, therefore, we must have an *animal* and a *vegetable* anatomy; with the latter the botanist is more particularly concerned.

When anatomy considers the entire series of animals, comparing the same organs in the different species, it is called *zoological* or *comparative*.

When anatomy is restricted to the examination of one species only, it is denominated *special*, as the anatomy of man, etc.

Physiological anatomy regards the organs in their healthy state. *Pathological anatomy*, regards them as influenced by disease.

Descriptive anatomy gives us all the knowledge of an organ which may be learned without division of its substance; thus its name, situation, size, color, weight, etc. *Regional, topographical* or *surgical anatomy* is that branch of descriptive anatomy which teaches us the order of superposition and relations of all the parts in a given region, and embraces the practical application of our anatomical knowledge to both medicine and surgery.

General anatomy, anatomy of textures or *histology*, separates the elementary textures of a part or organ, thus determining its particular construction; it is of essential service to the physician and physiologist.

An animal body is composed of *solids* and *fluids*, the former differing in density from being permeated to a greater or less extent by the latter, of which

water is the chief constituent. In the completely developed human body about two-thirds the entire weight is water.

In a minute examination of the human body we shall find that it is composed of *simple chemical elements*, which, uniting in various manners, constitute certain compounds, which are called *immediate principles*, from which are developed the *simple structural elements*, and from these the *tissues*, properly so called, are formed; these latter by their combinations constituting the organs.

The consideration of the simple chemical elements and immediate principles which compose the tissues and fluids of the body is denominated *stæchiology*, from *στοιχείον*, an element, and *λόγος*, a discourse.

The description of the tissues and the simple structural elements from which they are formed, and of those which are found in the fluids, is called *histology*, from *ιστός*, a web, and *λόγος*, a discourse.

STÆCHIOLOGY.

The consideration of the simple chemical elements and immediate principles.

SIMPLE CHEMICAL ELEMENTS.

Fifteen simple chemical elements are recognized as occurring naturally in the human body. These are —

Oxygen, hydrogen, carbon and nitrogen, found in all the tissues and most of the fluids, except fat; the latter is devoid of nitrogen.

Sulphur, in the albuminous group of immediate principles and the tissues which they form, and in the brain, hair, and nails; and as sulphuric acid in the urine.

Phosphorus, in the albuminous group of immediate principles and their tissues; in the brain; as phosphoric acid in the urine, and in the bones, combined with lime and magnesia.

Calcium and magnesium, found only in combination with oxygen as lime and magnesia, and these with acids forming salts; they are found in the bones, milk, and other fluids.

Sodium, with chlorine as a chloride, to form common salt, found in every part of the body; and with oxygen forming soda, which forms salts by its combination with acids, and is found in various tissues and fluids.

Potassium occurs, as a chloride, in the muscular tissue; and as an oxide in combination with acids.

Chlorine forms hydrochloric acid when combined with hydrogen, and is thus found in the gastric juice; it also forms the chlorides of sodium and potassium, as before stated.

Fluorine is found combined with calcium, in the bones.

Silicium is found combined with oxygen, as silica, in the hair and urine.

Iron is found in the blood, hair, muscle, milk, and pigment-cells.

Manganese is found as the oxide in bones, coloring-matter of the hair, and in the bile.

Besides these fifteen elements, others, as arsenic, copper and lead, have been stated to exist in small proportions in the human body as normal constituents, but they are no doubt merely accidental.

IMMEDIATE PRINCIPLES.

The immediate principles of the tissues are "the last bodies constituting the organism to which the tissues can be reduced by mere anatomical analysis; and which admit of no further subdivision without chemical decomposition."

Water, albumen, fat, etc., are immediate principles; the oxygen, hydrogen, carbon, etc., into which these may be decomposed by chemical agencies, are the simple chemical elements. Oxygen, nitrogen, and hydrogen are, however, also under certain conditions immediate principles, that is, when existing in a free state in solution. The exact number of immediate principles in the human body is not determined. The subjoined table of 84, being Robin and Verdeil's modified by Peaslee, presents them in a classified form.¹

Tabular Classification of the Immediate Principles.

Group I.—PRINCIPLES CRYSTALLIZABLE OR VOLATILE, INDEPENDENTLY OF DECOMPOSITION.

FIRST CLASS.—PRINCIPLES OF MINERAL ORIGIN (24).

First Division. GASEOUS AND NOT SALINE (5).

Oxygen,	Carbonic acid,
Hydrogen,	Water.
Nitrogen,	

Second Division. SALTS (19).

Chloride of Sodium,	Sulphate of Soda,
“ Potassium,	“ Lime,
Fluoride of Calcium,	Basic Phosphate of Lime (Bones),
Hydrochlorate of Ammonia,	Acid Phosphate “
Carbonate of Lime,	Phosphate of Magnesia,
“ Magnesia,	Neutral Phosphate of Soda,
“ Potassa,	Acid “ “
“ Soda,	Phosphate of Potassa,
Bicarbonate “	Ammonio-Magnesian Phosphate.
Sulphate of Potassa,	

SECOND CLASS.—PRINCIPLES OF ORGANIC ORIGIN FORMED WITHIN THE BODY BY DIS-ASSIMILATION (42).

First Division. ACID OR SALINE PRINCIPLES (23).

Lactic Acid,	Hippuric Acid,
Lactate of Soda,	Hippurate of Lime,
“ Potassa,	“ Soda,
“ Lime,	“ Potassa,
Oxalate of Lime,	Inosate of Potassa,
Uric Acid,	Pneumatic Acid,
Neutral Urate of Soda,	Pneumate of Soda,
Acid “ “	Taurocholate “
Urate of Potassa,	Hyochoinline “
“ Magnesia,	Glycocholate “
“ Lime,	Lithofellic Acid.
“ Ammonia,	

Second Division. NEUTRAL NITROGENIZED COMPOUNDS (5).

(Nitrogenized *Alkaloids*.)

Creatine,	Urea (and Chloro-sodate of Urea —
Creatinine,	Urea with marine salt),
	Cystine.

¹ For more detailed information concerning these subjects the student is referred to Professor Peaslee's "Human Histology," an excellent compendium of the present state of Histological science, and the only American work of this character with which we are acquainted.

Third Division. NEUTRAL NON-NITROGENIZED COMPOUND. SUGARS (2).

Sugar from the Liver,	Sugar of Milk.
-----------------------	----------------

Fourth Division. FATTY AND SAPONACEOUS COMPOUNDS (13).

Cholesterin,	Caproate of Potass., Soda, &c
Oleic Acid,	Olein,
Margaric Acid,	Margarin,
Stearic “	Stearin,
Oleate of Soda,	Elaterin,
Margarate “	Stearerin.
Stearate “	

Group II.—PRINCIPLES NON-CRYSTALLIZABLE OR NON-VOLATILE, INDEPENDENTLY OF DECOMPOSITION.

THIRD CLASS.—ORGANIC SUBSTANCES, OR COAGULABLE PRINCIPLES (18).

First Division. THOSE NATURALLY LIQUID (7).

Fibrin,	Pancreatin,
Albumen,	Mucosin,
Albuminose,	Ptyalin.
Casein,	

Second Division. THE SOLID AND DEMI-SOLID (7).

Globulin,	Cartilagein,
Crystallin,	Ostèin,
Musculin,	Keratin.
Elasticin,	

Third Division. PIGMENTARY SUBSTANCES (4).

Hæmatin, or Hæmatosin,	Melamin.
Biliverdin,	Urosacin.

Besides these, there are other substances known to exist, but which being doubtful, or not well determined as immediate principles, it is unnecessary here to enumerate.

The organic substances or coagulable immediate principles constituting the third class, compose the greatest part of the body, the principles of the first class being in much smaller proportions; whilst those of the second, except the fatty principles, being formed by dis-assimilation or waste, to be quickly thrown off, must be regarded as merely accessory to, and not as original components of the organism.

The first and third classes (including fat) then are alone assimilable.

OF THE FIRST CLASS. *Oxygen* (O) is an immediate principle when it exists in a free state; it is thus dissolved in the blood, and acts as a vital stimulus — its combination with the tissues and elements producing heat.

Hydrogen (H) exists free in the stomach and large intestine, though none has as yet been found in the blood.

Nitrogen (N) is found dissolved in the blood.

Carbonic Acid (Co₂) resulting from the combination of oxygen with the carbon of the tissues, etc., is found dissolved in all the fluids. It is removed principally by the lungs.

Water (Protoxide of Hydrogen, HO) is one of the most important immediate principles, forming as it does a part of every tissue or fluid in the organism; and is essential to their existence; nearly every tissue is more than half

water. It exists in a solid, demi-solid, liquid, and gaseous state. Thus in muscle it is in such chemical combination with the tissue that it is solid; in other substances not being in sufficient quantity to effect solution, it is rendered demi-solid; in fluids it is fluid; in the halitus of the lungs it is gaseous. It is taken into the body in food and drink, and is also supposed to be formed in the system. Without its presence in the body, chemical and vital acts would be impossible.

The Salts are found in every tissue and fluid, dissolved in their water, and thus serve as solvents for certain other immediate principles; and some of them by combining in the state of solution with certain organic immediate principles compose tissues.

Common Salt (Chloride of Sodium, NaCl) is found in every portion of the body, both solid and fluid, except enamel; and exists in greater quantity than any other immediate principle of inorganic origin. It always freely exists in fluids where cells are developing. Its existence in the blood is necessary to endosmosis of dissolved alimentary substances from the digestive tract. It is necessary for the performance of assimilation and dis-assimilation.

Chloride of Potassium (KCl.) is always dissolved in water, like common salt, and is found in the milk, muscles, liver, blood, etc.

Carbonate of Lime (CaO, CO₂) is found in all cases combined with the phosphates of lime.

Carbonate of Soda (NaO, Co₂) is found in the blood, etc., and is always dissolved in water; it is combined with and dissolves the albumen of the blood.

Sub-phosphate or Basic Phosphate of Lime (8CaO, 3PO₅) is found in the bones, teeth, nails and hair, in a solid state, and in a liquid form in the blood and all the other fluids.

OF THE SECOND CLASS.—*The immediate principles of organic origin formed within the body by dis-assimilation or waste* contain but nine of the simple chemical elements, viz., sodium, potassium, calcium, magnesium, sulphur, carbon, oxygen, hydrogen, and nitrogen, as may be observed by reference to the table. These compounds, although so numerous, constitute by far the smallest part of the body; about two-thirds of them are found in the blood—they are also found in the urine and bile, by which they are for the most part removed from the system.

It is not necessary for our purpose to enter into a detailed description of these immediate principles, or do more than state that it is not so certain that all the fatty principles (which are non-nitrogenized) included in this category are the results of "waste" or dis-assimilation; in a normal condition they all exist in the body in a fluid state, either inclosed in cells forming adipose tissue, in chemical combination with other elements, or as oil-globules, without any envelop. existing in nearly every tissue. Most of these fatty principles are taken into the body already formed in the food, and may also be, to some extent, formed in the body; thus cholesterin is probably a result of "waste" of the liver itself. The uses of the fatty principles are manifold—they serve to nourish the tissues which contain fat, and to be consumed by uniting with oxygen, and thus maintain vital heat. The presence of fat seems to be indispensable to the original development of the tissues, for the nuclei of all primary cells contain fat-granules.

OF THE THIRD CLASS of immediate principles, which constitute the greater part of the body, all are composed of the four elements, carbon, hydrogen, oxygen and nitrogen, and are called *nitrogenized* compounds; they are prone to rapid decomposition. The two first divisions form the *albuminous compounds*, which are found, as is shown in the table, either in a liquid or in a solid or demi-solid condition; water, however, being an essential part of their chemical constitution, since, if they are completely dessicated, their vital properties are completely lost.

Albumen, fibrin and casein have been called protein compounds; since they may be supposed to be formed by the combination of small proportions of either sulphur or phosphorus, or both, with a compound radical, called protein (*πρωτεϊνα*, I am first) by Mulder. Protein, however, does not exist in nature, and is only obtained by the destructive decomposition of the substances which it is supposed to aid in forming. The formula of Mulder for protein is, $C_{36}H_{25}N_4O_{10} + 2HO$, which represents, according to him, perfectly non-sulphurous protein.

Albumen ($Pr_{10} + PS_2$) is found in the serum of the blood, chyle, and lymph; like all other of these organic immediate principles, its chemical composition is not definite. Sulphur and phosphorus are always found aiding to form it. It is the essential *pabulum* of the tissues, for from it they are all developed and nourished. It is itself probably formed from *Albuminose*, which is formed in the alimentary canal by the digestion of albuminous compounds.

Fibrin ($Pr_{10} + PS$) is found in the blood, chyle and lymph. It is probably not a simple substance as has been supposed, but is formed from albumen, fat, and some saline materials. It has the property of spontaneous coagulability or *fibrillation*, which is readily witnessed a few minutes after venesection; and by this property exercised within the body affords a *matrix* for new growth, but is not the only plastic element which is called into requisition. Fibrin may be formed directly from albuminose, or from the albumen in the blood.

Casein ($Pr_{10} + S$) is found in the milk, both as the investing membrane of the milk-globules and in solution; its properties generally resemble albumen.

Pancreatin is found in the pancreatic juice.

Ptyalin is found in the saliva.

Mucosin is found in mucus, and varies according to its source.

Globulin constitutes the principal part of the red corpuscles of the blood, and is no doubt developed from albumen by their cell-membranes.

Crystallin exists in the crystalline lens, and is similar to globulin.

Musculin exists in the striated and non-striated muscular tissue, and is its main constituent; it is probably formed from albumen; that which has been called fibrin in the muscles is musculin.

Ostein exists in bone and white-fibrous tissue; in bone it is chemically combined with phosphate of lime.

Cartilagein is found in cartilage and fibro-cartilage.

Elasticin is found in yellow-fibrous tissue.

Keratin is peculiar to nails, hair, and epidermis.

Hæmatin, *Biliverdin*, *Melanin*, and *Urosacin* are the coloring matters of the blood, bile, pigment-cells and urine.

HISTOLOGY.

This is the description of the simple structural elements, and the tissues which are formed from them.

THE SIMPLE STRUCTURAL ELEMENTS.

The simple structural elements, of which the proper tissues are formed, are --

1. Homogeneous substance,
2. Simple membrane,
3. Simple fibre,
4. Cells.

1. *Homogeneous substance, homogeneous matrix* or *hyaline substance*, is a structureless material, varying in density, found in several tissues, often filling up the spaces between fibres and cells, and sometimes constituting a great part of their bulk; sometimes it is granular. It is developed from albumen, which

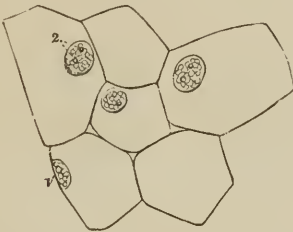
has thereby assumed a higher stage, and with it a low grade of vital properties. It is used to connect other structural elements, and is found in bone and cartilage.

2. *Simple membrane* is a thin structureless layer of coagulated albumen, occasionally being granular; it is not traversed by either vessels or nerves, but receives its nourishment from neighboring capillaries; it forms limitary membrane and the walls of every variety of cell.

3. *Simple fibre* consists of threads of coagulated fibrin, and it is supposed a rete or net thus formed furnishes a matrix for the development of tissues, and the nidus for repair of solutions of continuity, being absorbed after the higher structural elements are developed.

4. *Cells.* The cell is the most important of the simple structural elements; for from cells almost all the tissues proper are formed—the three just described structural elements being inferior in grade, and of course not derived from them. Vegetable tissues are likewise formed from cells.

FIG. 1.



NUCLEATED CELLS FROM A BULBOUS ROOT; magnified 290 diameters. (Schwann.)

FIG. 2.

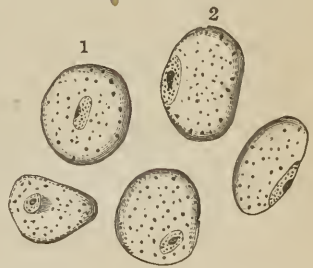


PLAN REPRESENTING THE FORMATION, FROM BLASTEMA, OF A NUCLEUS, and of a cell on the nucleus, according to Schleiden's view.

A cell is a vesicle, which may be from $\frac{1}{120}$ to $\frac{1}{5000}$ of an inch in diameter, formed from a plasma, blastema, or cytoblastema, which is the liquor sanguinis: a granule first appears in the clear plasma, and is called the *nucleus* or *cytoblast* ($\alpha\nu\tau\omicron\varsigma$, cell, $\beta\lambda\alpha\sigma\tau\epsilon\omega$, to produce), this increases in size and becomes vesicular, and there is then perceived in its interior other granules, one of which being larger than the others is called the *nucleolus*; from the nucleus is developed the *cell-wall*, and the space between the nucleus and the cell-wall is filled with a fluid containing granules, which constitute the *cell-contents*.

The *cell-wall* is simple membrane, formed from albumen, and possessing great endosmotic properties. The contained *fluid* varies in composition according to the character of the cell, that is, it differs in epithelial, epidermic, or fat cells, etc.; the granules contained, which are very numerous or may be altogether absent, may be fat-globules devoid of investment, or pigment-granules, etc. The *nucleus* is generally attached to some part of the wall of the cell, and contains a fluid, and, as stated, the *nucleolus*, supposed to be formed of fat with an albuminous envelop, and which may itself become vesicular; sometimes several nucleoli are found in one nucleus.

FIG. 3.



CELLS SHOWING THE CELL-MEMBRANE, THE CONTAINED GRANULES, THE NUCLEUS, AND THE NUCLEOLUS. 1 and 2. The typical spherical form. The rest as changed by pressure.

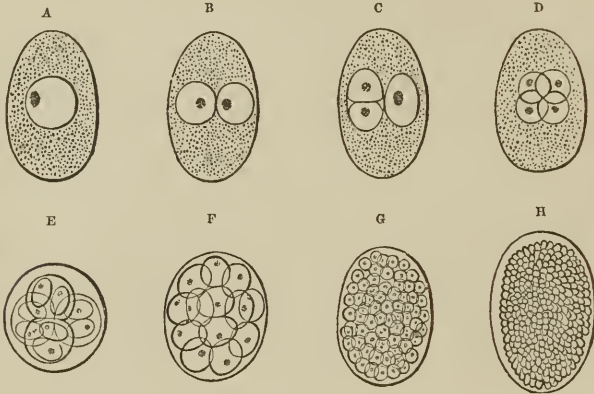
Cells are *developed* in several ways:

1st. Directly from the plasma (by virtue of the vital force communicated by

its contact with living tissues), in the manner already described, which is called *free cell-development*.

2dly. In the interior of other cells, which is the *endogenous* method. By this method the nucleus of the primary cell, after enlarging, and becoming possessed of two nucleoli, becomes constricted in the middle, and finally divides into two distinct portions, each of which becomes the nucleus of a new cell.

FIG. 4.

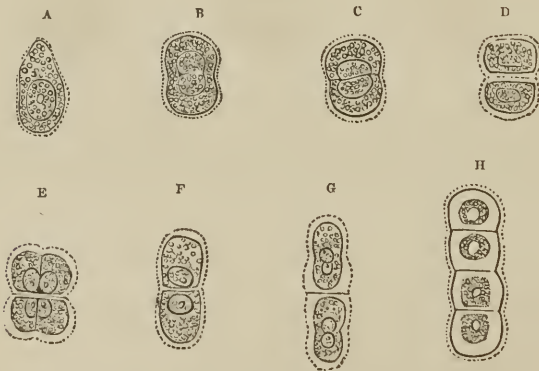

ENDOGENOUS CELL-DEVELOPMENT. A, B, C, D. Early stages of the process, showing duplication of cells (ovum of *Ascaris dentata*). E, F, G, H. More advanced stages (ovum of *Cucullanus elegans*).

The original cell may now burst, and set free the secondary cells, or enlarge until several generations have been formed in the same manner within it; the nucleoli becoming the nuclei of the new cells, and developing new nucleoli within themselves.

3dly. Cells may multiply by *division*. Here the original cell elongates, and

FIG. 5.



MULTIPLICATION OF CARTILAGE-CELLS BY DIVISION: A, original cell; B, the same beginning to divide; C, the same showing complete division of the nucleus; D, the same with the halves of the nucleus separated, and the cavity of the cell subdivided; E, continuation of the same process, with cleavage in *contrary* direction, to form a cluster of four cells; F, G, H, production of a longitudinal series of cells, by continuation of cleavage in the *same* direction.

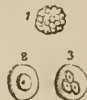the nucleus divides into two. The cell then, after being constricted, divides into two distinct nucleated cells, and this process may be continued.

Different cells have different functions, thus some are *Formative*, producing the solids of the body, by absorbing from the surrounding blastema their pabulum, which they alter by a vital process.

Others are *Secreting*, and may receive their pabulum without altering it, or but slightly, where they are intended simply to separate formed materials from the blood, or they may produce substances in their interior from the pabulum furnished, as in the bile-cells.

A peculiar structural element, called the *Cytoid corpuscle* ($\kappa\upsilon\tau\omicron\varsigma$, $\epsilon\iota\delta\omicron\varsigma$, cell-resembling), is found in some of the fluids of the body, viz., in the lymph, chyle, blood, etc., and has been called the lymph-, chyle-, and colorless blood-corpuscle, etc.; from this element the red blood-corpuscle is formed, probably by being converted into a non-nucleated cell by alteration and solidification of the cell-contents, and change of color, and the assumption of a bi-concave discoid form; the colorless blood-corpuscles originating by free cell-formation in the lymph and chyle, and perhaps in the liquor sanguinis itself. These cytoïd corpuscles also exist in mucus, pus, and exudations. In exudations they form the basis of new tissues, but in mucus and pus never arrive at a higher organization.

FIG. 6.



CYTOÏD CORPUSCLES OF BLOOD. 1. Natural appearance. 2 and 3. Changed by dilute acetic acid.

FIG. 7.



DEVELOPMENT OF THE RED FROM THE COLORLESS CORPUSCLES OF THE BLOOD. A. Cytoïd corpuscle. B. Same, being converted into a red corpuscle. C. Cytoïd corpuscle with its membrane raised by the action of water. D. Same, having lost most of its granules. E. Same, acquiring color; a single granule remaining like a nucleus. F. Perfect red corpuscle.

THE TISSUES.

The tissues are formed from the simple structural or histological elements, and of these the cells are of chief importance. In some tissues the cellular structure is retained as a permanent characteristic, as in the adipose; whilst in others the cells are converted into other forms, as in the striped muscular tissue. The following table, from Todd and Bowman, will present a general view of the various tissues which enter into the construction of the organs of which the body is composed.

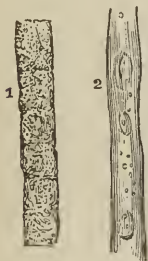Tabular View of the Tissues of the Human Body.

- | | |
|--|---|
| <ol style="list-style-type: none"> 1. Simple membrane, homogeneous, or nearly so, employed alone, or in the formation of compound membranes. 2. Filamentous tissues, the elements of which are real or apparent filaments. 3. Compound membranes, composed of simple membrane, and a layer of cells, of various forms (epithelium or epidermis), or of areolar tissue and epithelium. 4. Tissues which retain the primitive cellular structure as their permanent character. 5. Sclerous or hard tissue. 6. Compound tissues. <ol style="list-style-type: none"> a. Composed of tubes of homogeneous membrane, containing a peculiar substance. b. Composed of white fibrous tissues and cartilage. | <p>Examples.—Posterior layer of the Cornea.—Capsule of the lens.—Sarcolemma of muscle, &c.</p> <p>White and yellow fibrous tissues.—Areolar tissue.</p> <p>Mucous membrane.—Skin.—True or secreting glands.—Serous and synovial membranes.</p> <p>Adipose tissue.—Cartilage.—Gray nervous matter.</p> <p>Bone.—Teeth.</p> <p>Muscle.—Nerve.</p> <p>Fibro-cartilage.</p> |
|--|---|

Simple membrane has been before described, but is here referred to as forming part of the tissues.

The *Filamentous tissues* are employed to connect different parts, and for associating the elements of other tissues: thus, the ligaments which bind together the bones forming joints, and the areolar or proper connective tissue, composed of yellow and white fibrous tissues, which surrounds the fibres of muscles and nerves, etc., are filamentous tissues.

FIG. 8.



FIRST STAGES OF THE DEVELOPMENT OF STRIATED MUSCULAR FIBRE. 1. Arrangement of the primitive cells in a linear series, after Schwann. 2. The cells united; the nuclei separated and some broken up, longitudinal series becoming apparent — from a fetal calf three inches long.

The *Compound membranes* are formed of the simple membrane lying upon vessels, nerves and areolar tissue, and covered by epithelium. The skin and mucous membrane, and glands which open upon their surfaces, are formed in this manner, as are also the serous and synovial membranes.

The tissues which retain their *Primitive cellular form*, are very dissimilar as regards their vital endowments, as also in the relative cohesion of their cells. In adipose tissue the intervals between the cells containing the fat are filled with areolar tissue and capillaries; in the gray nervous matter, capillaries and nerve tubes exist between the cells; and in cartilage there is a firm intercellular substance.

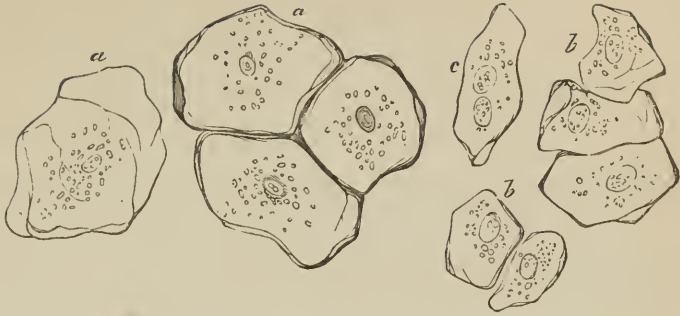
The *Sclerous tissue* (*σκληρος*, hard) owes its hardness to the amount of inorganic matter combined with its animal matter, as in bone and teeth.

The *Compound tissues* are those, the elementary parts of which are made up of two distinct tissues. In the muscular fibre, a tube composed of simple membrane incloses the sarcous element in which the vital properties of the tissue reside. In nerves similar tubes contain the neurine. Fibro-cartilage is also properly a compound tissue, being formed of cartilage and white fibrous tissue.

The transformation of cells into tissues is effected in several ways. At the earliest period of embryonic life textures are as yet unformed, but the embryo consists of primordial cells, from which others are developed by the endogenous method, or from the intercellular granular blastema. In these cells changes take place for the production of the elementary parts of the tissues.

1. Cells may lose their fluid contents; and their walls collapsing until they come in contact and adhere, they form simple, membranous and transparent

FIG. 9.



EPITHELIAL PLATES OF THE ORAL CAVITY. a. Large. b. Middle-sized. c. Same, with two nuclei.—Magnified 350 diameters. (Kölliker.)


dises, as in some kinds of epithelium, epidermis, etc. Some physiologists suppose that simple homogeneous membrane is formed by the flattening of cells and the fusion of their walls.

2. In the tissues which are composed of tubes of homogeneous membrane, containing a peculiar substance, as muscle and nerve, neighboring cells adhere by their ends, and the partitions between them being removed their cavities communicate, and thus a tube or sheath is formed, containing the proper muscular or nervous substance. Capillary bloodvessels are formed in the same manner. Curious forms are produced by modifications of the same method, as in pigment-cells.

3. Solid deposits may be formed within the cell, obliterating its cavity.

4. The intercellular substance may become thickened, and solid deposit, or a new arrangement of particles, occur.

FIG. 10.



PIGMENT-CELLS FROM THE TAIL OF A TADPOLE, magnified about two hundred and twenty-five diameters. (Schwann.)

Cartilage is a good example of the last two methods.

FIG. 11.

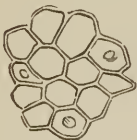

FIG. 12.

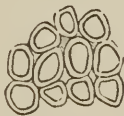

FIG. 13.




FIG. 14.



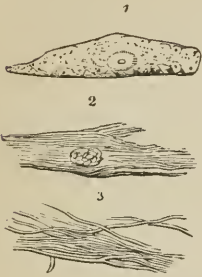
DEVELOPMENT OF CARTILAGE. Cartilage of the branchial ray of a fish (*Cyprinus erythrophthalmus*) in different stages of advancement; magnified 450 diameters. (Schwann.)

CROSS SECTION OF LIGNEOUS CELLS containing stratified deposit.

A similar method is seen in the deposits in the interior of vegetable cells. A curious modification of development occurs in the feathers of birds, where

a nucleated cell elongates, and becomes filled with fibres, the cell-wall is rubbed off, and the fibres are exposed. In fact the nucleated cell is the agent of most of the organic processes, both in animals and vegetables, from their earlier stages to their full development, in the formation of their tissues, and the production of their secretions.

FIG. 15.



CELLS FROM THE CORTEX OF A GROWING FEATHER, showing their division into fibres.

Properties of the Tissues.

The fully-developed tissues are possessed of properties which differ among themselves. These are physical and vital.

Physical properties.—These are the results of the peculiar arrangement of their component particles, and their chemical constitution, and can be perceived both in dead and living textures.

Elasticity is the property by which a tissue returns to its original condition after being stretched or compressed. The ligamenta flava and the middle coat of

arteries exhibit this property in a remarkable degree.

Extensibility. This property allows a tissue to be stretched, but in the healthy state only after a long-continued effort.

Porosity is a property possessed by the various tissues, and seems to play a most important part in the maintenance of the functions of life. It admits of the transudation of the solids by the fluids, and this process was called by Dutrochet, who first described it, *Endosmose* and *Exosmose*. All the tissues contain water, some of them more than four-fifths their weight; to this is due their pliancy and other physical properties, besides which it allows nutritious materials to be conveyed into, and the products of dis-assimilation out of, their substance.

A tissue saturated with water, and placed in contact with another tissue or fluid having a greater affinity for water than it has, will part with its superabundance, and if not supplied from behind will even part with a portion of that which is essential to its natural condition. If, however, it is supplied from the other side, it will continue to supply the imbibing fluid, and receive more from behind. Thus a current will be established from the water on one side of the tissue to the fluid having a high affinity for it on the other (*Endosmose*). But this is not all, for the fluid, in turn, transudes the tissue to mix with the water on the other side, and thus a counter-current (*Exosmose*) is set up in an opposite direction, which is, however, slower than the first, and this will continue until the two liquids are equally saturated by each other.

That this process is purely physical is proved by the fact that it will take place through porous inorganic bodies, as well as through organic membranes. It is supposed to be employed in the processes of secretion and absorption.

Vital properties.—The most prominent vital property possessed by the tissues is the power of *assimilation*, or of appropriating to themselves such of the organizable substances presented to them as may suit their purposes. This power is supposed to be partly due to chemical affinity, and partly to *vital affinity*. It is most probable, however, that future researches will prove that the power of assimilating is subject to the ordinary chemical laws, but under modifying circumstances, which can only exist in a living body or tissue.

To this may be added the power of reproducing, in its appropriate place, a new portion of a tissue, when injured or destroyed.

Another property which is essentially vital is *contractility*—a phenomenon which is made manifest by the visible shrinking or contraction of a living tissue

when irritated, either by mechanical or chemical stimuli. This property is characteristic of muscle, and probably exists in no other animal texture.

A third vital property is *sensibility*, which, however, requires that the tissues shall be united so as to form a continuous line from the part manifesting it to the brain. This property is enjoyed in very different degrees by the different tissues, and constitutes an important distinction between them, depending upon the presence and number of nerve-fibres mixed with the tissue.

The tissues, the manner of whose formation, and properties we have just described, are variously combined to constitute the organs of the body, all of which differ in their structure and use, but are combined for a double purpose, viz.: 1. The preservation of the individual; and 2. The continuance of the species.

To effect these objects the organs are arranged in groups, each of which has a definite purpose or *function* to fulfil. Each group of organs is called an *apparatus*.

The general distribution of organs is shown in the following table:

A. FOR THE PRESERVATION OF THE INDIVIDUAL.

1. *Apparatus of Relation.*

a. Apparatus of Sensation,	{	Organs of Sense, Nerves, Brain and Spinal Cord.	
b. Apparatus of Motion,	{	Muscles . . . Active Organs. Bones, Articulations, } Passive " Aponeuroses, }	

2. *Apparatus of Nutrition.*

a. Apparatus of Digestion,	{	Alimentary canal, {	Mouth, Pharynx, Œsophagus, Stomach,	
			Small intestine, {	Duodenum, Jejunum, Ileum.
			Large intestine, {	Cæcum, Colon, Rectum.
		Annexed organs, {	Salivary Glands, Liver, Spleen, Pancreas, etc.	
b. Apparatus of Circulation,	{	Heart, Arteries, Veins, Lymphatics.		
c. Apparatus of Respiration,	{	Larynx, } Voice. Trachea, } Lungs.		

d. Urinary Apparatus, $\left\{ \begin{array}{l} \text{Kidneys,} \\ \text{Ureters,} \\ \text{Bladder,} \\ \text{Urethra.} \end{array} \right.$

B. FOR THE CONTINUANCE OF THE SPECIES.

Apparatus of Generation.

In the Male,

Testicles -- vasa deferentia,
 Vesiculæ seminales — ejaculatory ducts,
 Prostate gland,
 Penis.

In the Female,

Ovaries,
 Fallopian tubes,
 Uterus,
 Vagina,
 Mammary glands.

The succeeding pages are descriptive of the various organs, an outline of whose classification we have just presented.

CHAPTER II.

OSTEOLOGY.

THE bones are the organs of support of the animal frame; they give firmness and strength to the entire fabric, afford points of connection to the numerous muscles, and bestow individual character on the body. In the limbs they are hollow cylinders, admirably calculated, by their conformation and structure, to resist violence and support weight. In the trunk and head, they are flattened and arched, to protect cavities and provide an extensive surface for attachment. In some situations they present projections of variable length, which serve as levers; and in others are grooved into smooth surfaces, which act as pulleys for the passage of tendons. Moreover, besides supplying strength and solidity, they are equally adapted, by their numerous divisions and mutual apposition, to fulfil every movement which may tend to the preservation of the creature, or be conducive to his welfare.

According to the latest analysis by Berzelius, bone is composed of about one-third of animal substance, which is almost completely reducible to gelatine by boiling, and two-thirds of earthy and alkaline salts. The special constituents of bone are present in the following proportions:—

Cartilage	32·17 parts.
Bloodvessels	1·13
Phosphate of lime	51·04
Carbonate of lime	11·30
Fluate of lime	2·00
Phosphate of magnesia	1·16
Soda, chloride of sodium	1·20
	<hr/>
	100·00

[That bony tissue is composed essentially of two distinct elements, one *organic* and the other *inorganic*, can be readily shown, on the one hand, by calcination, when the whole of the organic matter is destroyed, emitting the odor of burned horn during the process, the residuary inorganic matter, which is light and porous, preserving the shape and size of the original bone, and being exceedingly friable, crumbles on the slightest pressure: whilst, on the other hand, if the bone be treated with dilute hydrochloric acid, the saline components are removed, and the remaining organic mass, which also preserves the original size and form of the bone, is tough and flexible, and much diminished in weight.]

Bones are divisible into three classes:—*Long, flat, and irregular.*

The *Long* bones are found principally in the limbs, and consist of a shaft and two extremities. The shaft is cylindrical or prismoid in form, dense and hard in texture, and hollowed in the interior into a medullary canal. The extremities are broad and expanded, to articulate with adjoining bones; and, in internal structure, are cellular or cancellous. Upon the exterior of the bone are processes and rough surfaces for the attachment of muscles, and foramina for the transmission of vessels and nerves. The character of long bones is, therefore, their general type of structure and their divisibility into a central portion and extremities, and not so much their length; for there are certain long bones, as the second phalanges of the toes, which are less than a quarter of an inch in length, and which, in some instances, exceed in breadth their longitudinal axis. The long bones are, the clavicle, humerus, radius and ulna, femur, tibia and fibula, metacarpal bones, metatarsal, phalanges, and ribs.

Flat bones are composed of two layers of dense bone with an intermediate cellular structure, and are divisible into surfaces, borders, angles, and processes.

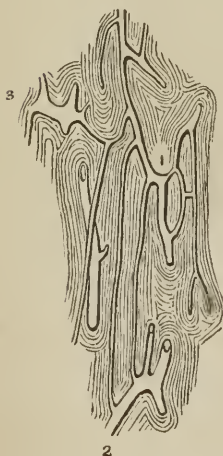They are adapted to inclose cavities; have processes upon their surface for the attachment of muscles; and are perforated by foramina, for the passage of nutrient vessels to their cells, and for the transmission of vessels and nerves. They articulate with long bones by means of smooth surfaces plated with cartilage, and with each other, either by fibro-cartilaginous tissue, as at the symphysis pubis, or by suture, as in the bones of the skull. The two condensed layers of the bones of the skull are named tables; and the intermediate cellular structure, *diplœ*. The flat bones are the occipital, parietal, frontal, nasal, lachrymal, vomer, sternum, scapulæ, and ossa innominata.

The *Irregular* bones include all that remain after the long and the flat bones have been selected. They are essentially irregular in their form, in some parts flat, in others short and thick; and are constructed on the same general principle as other bones: they have an exterior dense, and an interior more or less cellular. The bones of this class are the temporal, sphenoid, ethmoid, superior maxillary, inferior maxillary, palate, inferior turbinated, hyoid, vertebræ, sacrum, coccyx, carpal, tarsal, and sesamoid bones, the latter including the patellæ.

[The symmetry or want of symmetry of bones is also a basis for the determination of their figure. Thus, some bones being divisible into two halves, exactly resembling each other, are called *symmetrical* or *azygos* bones, and as these always occupy the mesial line, they are also denominated *median*; whilst the remainder, which cannot be divided into two similar parts, are called *asymmetrical*, and as they always occur in pairs, and are situated on opposite sides of the mesial line, they are also denominated *corresponding* or *lateral* bones.]


Structure of Bone.—Bone is a dense, compact, and homogeneous substance (basis substance) filled with minute cells [*lacunæ*] (corpuseles of Purkinje),

[FIG. 16.]



HAVERSIAN CANALS, seen on a longitudinal section of the compact tissue of the shaft of one of the long bones. 1. Arterial canal. 2. Venous canal. 3. Dilatation of another venous canal.]

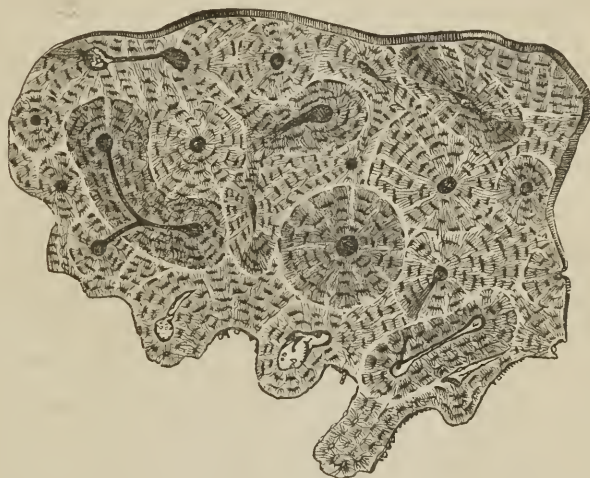FIG. 17.



MINUTE STRUCTURE OF BONE, drawn with the microscope from nature, by Bagg. Magnified 300 diameters. 1. One of the Haversian canals surrounded by its concentric lamellæ. The corpuscles are seen between the lamellæ; but the calcigerous tubuli are omitted. 2. An Haversian canal with its concentric lamellæ, Purkinjean corpuscles, and tubuli. 3. The area of one of the canals. 4, 4. Direction of the lamellæ of the great medullary canal. Between the lamellæ, at the upper part of the figure, several very long corpuscles with their tubuli are seen. In the lower part of the figure, the outlines of two other canals are given, to show their form and mode of arrangement in the entire bone.

which are scattered numerously through its structure. The *basis-substance* of bone is subfibrous and obscurely lamellated, the lamellæ being concentric in long, and parallel in flat bones: it is traversed in all directions, but especially in the longitudinal axis, by branching and inosculating canals (Haversian¹ canals), which give passage to vessels and nerves, and in certain situations the lamellæ separate from each other, and leave between them arcolar spaces (cancelli) of various magnitude. The lamellæ have an average diameter of $\frac{1}{800}$ of an inch, and, besides constituting the general structure of the basis substance, are collected concentrically around the Haversian canals, and form boundaries to those canals of about $\frac{1}{20}$ of an inch in thickness. The number of lamellæ surrounding each Haversian canal is commonly ten or fifteen, and the diameter of the canals has a medium average of $\frac{1}{800}$ of an inch. The cancelli of bone, like its compact substance, have walls which are composed of lamellæ: and, such is the similarity in structure of the parts of a bone, that the entire bone may be compared to an Haversian canal, of which the medullary cavity is the magnified channel; and the Haversian canals may be likened to elongated and ramified cancelli. The Haversian canals are smallest near the surface of a bone, and largest near its centre, where they gradually merge into cancelli; by the frequent communications of their branches they form a coarse network in the basis substance.

[FIG. 18.]



TRANSVERSE SECTION OF A HUMAN FEMUR, about its middle, exhibiting the erratic course of the Haversian canals, and their relations to each other, and at the same time the general laminated condition of a long bone. This laminated condition is well shown by polarized light, which causes the corpuscles to disappear, and the laminae to come out boldly.]

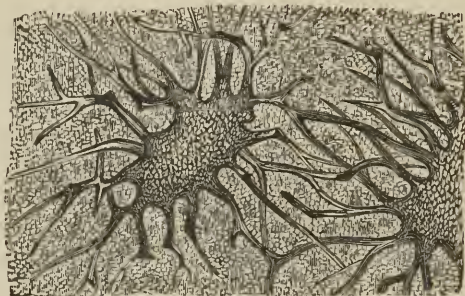
The *corpuscles of Purkinje*, are thickly disseminated through the basis-substance; they are irregular in size and form, give off numerous minute branching tubuli [canaliculi], which radiate from all parts of their circumference, and, in the dried state of the bone, contain merely the remains of membranous cells and some calcareous salts.² In the living bone, the corpuscles and their tubuli are probably filled with a nutritive fluid holding calcareous salts in solution. The form of the cells is oval or round, and more or less flattened; their long diameter

¹ [After their discoverer, Clopton Havers, an English physician and writer of the 17th century.]

² Müller and Henle conceived that the bone cells and tubuli were the principal seat of the calcareous matter. Hence they were called *calcareous cells and tubuli*.

corresponds with the long axis of the bone, and their tubuli cross the direction of the lamellæ, and constitute a delicate network in the basis-substance by communicating with each other and with the tubuli of neighboring cells. The tubuli of the cells nearest the Haversian canals terminate on the internal surface of

[FIG. 19.]



TWO LACUNÆ OF OSSEOUS TISSUE, seen on their surfaces, showing the disposition of their pores. The granular aspect of the tissue, both on their walls and around them, is well represented. Magnified 1200 diameters. Drawn from a preparation of the cancelli of the Femur made by Mr. Tomes.]

those passages. The size of the cells varies in extreme measurement from $\frac{1}{5000}$ to $\frac{1}{600}$ of an inch in long diameter, an ordinary average being $\frac{1}{1000}$; the breadth of the oval cells is about one-half or one-third their length, and their thickness one-half their breadth. They are situated between the lamellæ, to which circumstance they owe their compressed form.

[FIG. 20.]



THE PERIOSTEUM laid open and turned off from a young humerus.]

In the fresh state, bones are invested by a dense fibrous membrane, the *periosteum*, which covers every part of their surface with the exception of the articular extremities, the latter being coated by a thin layer of cartilage. The periosteum of the bones of the skull is termed *pericranium*; and the analogous membrane of external cartilages, *perichondrium*. Lining the interior of the medullary canal of long bones, the Haversian canals, the cancelli, and the cancelli of the flat and irregular bones, is the *medullary membrane*, which acts as an internal periosteum. It is through the medium of the vessels ramifying in these membranes that the changes required by nutrition occur in bones, and the secretion of medulla into their interior is effected. The medullary canal, Haversian canals and cancelli of long bones, and the cancelli of other bones, are filled with a yellowish, oily substance, the *medulla*, which is contained in a loose, cellular tissue formed by the medullary membrane.

Development of Bone.—To explain the development of bone, it is necessary to inform the student that all organized bodies, whether belonging to the vegetable or animal kingdom, are developed primordially from minute vesicles. These vesicles, or, as they are properly termed, *cells*, are composed of a thin membrane, containing a fluid or granular matter, and a small rounded mass, the *nucleus*, around which the cell was originally formed. Moreover, the nucleus generally contains one or more small round granules, the *nucleolus*, or *nucleoli*. From cells having this structure all the tissues of the body are elaborated; the ovum itself originally presented this simple form, and the embryo at an early period is wholly composed of such nucleated cells. In their relation to each other, cells may be


isolated and independent, as is exemplified in the corpuscles of the blood, chyle, and lymph; secondly, they may cohere by their surfaces and borders, as in the epidermis and epithelium; thirdly, they may be connected by an intermediate substance, which is then termed *intercellular*, as in cartilage and bone; and, fourthly, they may unite with each other in rows, and upon the removal, by liquefaction, of their adherent surfaces, be converted into hollow tubuli. In the latter mode capillary vessels are formed, as also are the tubuli of nerves. One of the properties of cells may also be adverted to in this place; it is that of reproducing similar cells in their interior. In this case, the nucleoli become the nuclei of the secondary cells, and, as the latter increase in size, the membrane of the primary or parent cell is lost.

Bone, in its earliest stage, is composed of an assemblage of these minute cells, which are soft and transparent, and are disposed within the embryo in the site of the future skeleton. From the resemblance which the soft bone-tissue bears to jelly, this has been termed the *gelatinous stage* of osteo-genesis. As development advances, the cells, heretofore loosely connected together, become separated by the interposition of a transparent intercellular substance, which, at first fluid, gradually becomes hard and condensed. The *cartilaginous stage* of osteo-genesis is now established, and cartilage is shown to consist of a transparent basis-substance, having minute cells disseminated through it at pretty equal distances. Coincident with the formation of cartilage is the development of vascular canals in its substance, the canals being formed by the union of the cells in rows, and the subsequent liquefaction of their adhering surfaces.

The change which next ensues is the concentration of the vascular canals towards some one point; for example, the centre of the shaft in a long, or the mid-point of a flat bone, and here the *punctum ossificationis*, or centre of ossification, is established. What determines the vascular concentration now alluded to, is a question not easily solved, but that it takes place is certain, and the vascular punctum is the most easily demonstrable of all the phenomena of ossification.

During the formation of the *punctum ossificationis*, changes begin to be apparent in the cartilage cells. Originally they are simple nucleated cells ($\frac{1}{5000}$ to $\frac{1}{2000}$ of an inch in diameter), having a rounded form. As growth proceeds, they become elongated, and it is then perceived that each cell contains two and often three nucleoli, around which smaller cells are in progress of formation. If we examine them nearer the *punctum ossificationis*, we find that the young or secondary cells have each attained the size of the parent cell ($\frac{1}{2000}$ of an inch), the membrane of the parent cell has disappeared, and the young cells are separated to a short distance by freshly effused intercellular substance. Nearer still to the *punctum ossificationis* a more remarkable change has ensued, the energy of cellule reproduction has augmented with proximity to the ossifying point, and each cell, in place of producing two, gives birth to four, five, or six young cells, which rapidly destroy the parent membrane and attain a greater size ($\frac{1}{1500}$ of an inch) than the parent cell, each cell being, as in the previous


FIG. 21.



FIGURES ILLUSTRATIVE OF THE DEVELOPMENT OF BONE; magnified 155 times, and drawn with the camera lucida. A. A portion of cartilage the furthest removed from the seat of ossification, showing simple nucleated cells, having an ordinary size of $\frac{1}{2000}$ of an inch, long diameter. B. The same cartilage, nearer the seat of ossification; each simple cell has produced two, a little larger than the cells in figure A.

ease, separated to a slight extent from its neighbor by intercellular substance. By one other repetition of the same process, each cell producing four, five, or six


FIG. 22.



THE SAME CARTILAGE, STILL NEARER THE SEAT OF OSSIFICATION; each single cell of B has given birth to four, five, or six cells, which form clusters. The clusters become larger towards the right of their figure, and their cells more numerous and larger, $\frac{1}{3 \frac{1}{2} 50}$ of an inch, long diameter.

from neighboring clusters by a broader layer ($\frac{1}{3 \frac{1}{2} 50}$ of an inch) of intercellular substance. Such are the changes which occur in cartilage preparatory to the formation of bone.

FIG. 23.



THE SAME CARTILAGE AT THE SEAT OF OSSIFICATION: the clusters of cells are arranged in columns; the intercellular spaces between the columns being $\frac{1}{3 \frac{1}{2} 50}$ of an inch in breadth. To the right of the figure osseous fibres are seen occupying the intercellular spaces, at first bounding the clusters laterally, then splitting them longitudinally, and encircling each separate cell. The greater opacity of the right-hand border is due to a threefold cause, namely, increase of osseous fibres, opacity of the contents of the cells, and multiplication of oil-globules. In the lower part of the figure some attempt has been made to show the texture of the cells.

Ossification is accomplished by the formation of very fine and delicate fibres within the intercellular substance: this process commences at the punctum ossificationis, and extends from that point through every part of the bone, in a longitudinal direction in long, and in a radiated direction in flat bones. Starting from the punctum ossificationis, the fibres embrace each cluster of cells, and then send branches between the individual cells of each group. In this manner the network, characteristic of bone, is formed, while the cells by their conjunction constitute the permanent areolæ and Haversian canals. With a high magnifying power, the delicate ossific fibres here alluded to are seen themselves to be composed of minute cells having an elliptical form and central nuclei. These cells attract into their interior the calcareous salts of the blood, and their nuclei become developed, as I believe, into the future corpuscles of Purkinje. It is possible also that some of the cartilage cells become corpuscles of Purkinje in the fully developed bone.

During the progress of the phenomena above described, the contents of the cells undergo certain changes. At first, they are transparent, then they become granular, and still later opaque, from the presence of amorphous matter mingled with nuclei, nucleoli, and the remains of secondary cells. In the latter state the cells contain an abundance of minute oil-globules, which increase in size as the ossification advances, and in the newly-formed osseous areolæ, have attained the ordinary size of adipose cells.

Cartilaginification is complete in the human embryo at about the sixth week; and the first point of ossification is observed in the clavicle at about the fifth week. Ossification commences at the centre, and thence proceeds towards the surface; in flat bones the osseous tissue radiates between two membranes from a central point towards the periphery, in short bones from a centre towards the circumference, and in long bones from a central portion, *diaphysis*, towards a secondary centre, *epiphysis*, situated at each extremity. Large processes, as the trochanters, are provided with a distinct centre of development, which is named *apophysis*.

The *growth* of bone in length takes place at the extremity of the diaphysis, and in bulk by fresh deposition on the surface; while the medullary canal is formed and increased by absorption from within.

The *period* of ossification is different in different bones; the order of succession may be thus arranged:—

During the fifth week, ossification commences in the clavicle, lower jaw, and upper jaw.

During the sixth week, in the femur, humerus, tibia, radius, and ulna.

During the seventh and eighth weeks, in the fibula, frontal, occipital, sphenoid, ribs, parietal, temporal, nasal, vomer, palate, vertebræ, first three pieces of sacrum, malar, metacarpus, metatarsus, third phalanges of the hands and feet, and ilium.

During the third month, in the first and second phalanges of the hands and feet, lachrymal bone, and ischium.

During the fifth month, in the mastoid portion of the temporal, ethmoid, inferior turbinated, sternum, os pubis, and last two pieces of sacrum.

During the sixth month, in the body and odontoid process of the axis, and in the os calcis.

During the seventh month, in the astragalus.

During the tenth month, in the cuboid bone and os hyoides.

During the first year, in the coracoid process of the scapula; first piece of the coccyx, inferior turbinated bone, last piece of the sternum, anterior arch of the atlas, os magnum, os unciniforme, and external cuneiform bone.

During the third year, in the cuneiform of the carpus, internal cuneiform of the tarsus, and patella.

During the fourth year, in the middle cuneiform and scaphoid of the tarsus.

During the fifth year, in the trapezium and os semilunare.

During the seventh year, in the second piece of the coccyx.

During the eighth year, in the scaphoid of the carpus.

During the ninth year, in the os trapezoides.


During the twelfth year, in the os pisiforme and third piece of the coccyx.

During the eighteenth year, in the fourth piece of the coccyx.

The ossicula auditûs are the only bones completely ossified at birth; the vertebræ are not completed until the five-and-twentieth year.

The entire osseous framework of the body constitutes the skeleton, which, in

[FIG. 24.]



A YOUNG FEMUR.
1, 5. The epiphyses. 4. The diaphysis. 2, 3. Apophyses.]

the adult man, is composed of two hundred and forty-six distinct bones. They may be thus arranged:—

Head	8
Ossicula auditūs	6
Face	14
Teeth	32
Vertebral column, including sacrum and coccyx	26
Os hyoides, sternum, and ribs	26
Upper extremities	64
Lower extremities	62
Sesamoid bones	8
	246

[When the bones which constitute the skeleton, as presented for study, are connected with each other by their own ligaments, it is called a *natural skeleton*; when, however, they are connected by wires, or other artificial media, it is called an *artificial skeleton*.]

The *skeleton* is divisible into: 1. The vertebral column, or central axis. 2. The head and face, or superior development of the central axis. 3. The hyoid arch. 4. The thoracic arch and upper extremities. 5. The pelvic arch and lower extremities.

VERTEBRAL COLUMN.

The *vertebral column* is the first and only rudiment of internal skeleton in the lower Vertebrata, and constitutes the type of that great division of the animal kingdom. It is also the first developed portion of the skeleton in man, and the centre around which all the other parts are produced. In its earliest formation it is a simple cartilaginous cylinder, surrounding and protecting the primitive trace of the nervous system; but, as it advances in growth and organization, it becomes divided into distinct pieces, which constitute *vertebræ*.

The *vertebræ* admit of a division into *true* and *false*. The true *vertebræ* are twenty-four in number, and are classed, according to the three regions of the trunk which they occupy, into cervical, dorsal, and lumbar. The false *vertebræ* consist of nine pieces united into two bones, the sacrum and coccyx. The arrangement of the *vertebræ* may be better comprehended by means of the accompanying table:—

True <i>vertebræ</i> , 24	$\left\{ \begin{array}{l} 7 \text{ Cervical,} \\ 12 \text{ Dorsal,} \\ 5 \text{ Lumbar.} \end{array} \right.$	False <i>vertebræ</i> , 9	$\left\{ \begin{array}{l} 5 \text{ Sacrum,} \\ 4 \text{ Coccyx.} \end{array} \right.$
---------------------------	---	---------------------------	---

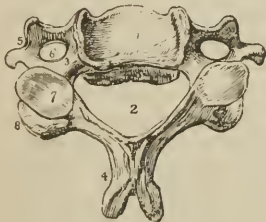
Characters of a Vertebra.—A vertebra consists of a body, two laminæ, a spinous process, two transverse processes, and four articular processes. The *body* is the solid part of the vertebra; and, by its articulation with adjoining *vertebræ*, gives strength and support to the trunk. It is flattened above and below, convex in front, and slightly concave behind. Its anterior surface is constricted around the middle, and pierced by numerous small openings, which give passage to nutritious vessels. On its posterior surface is a single irregular opening, or several, for the exit of the *venæ basis vertebræ*.

The *laminæ* commence upon the sides of the posterior part of the body of the vertebra by two *pedicles*; they then expand; and, arching backwards, inclose a *foramen*, which serves for the protection of the spinal cord. The upper and lower borders of the laminæ are rough for the attachment of the *ligamenta subflava*. The concavities above and below the pedicles are the *intervertebral notches*. The *spinous process* stands backwards from the angle of union of the laminæ. It is the succession of these projecting processes along the middle line of the back, that has given rise to the common designation of the vertebral

column, the *spine*. The use of the spinous process is for the attachment of muscles. The *transverse processes* project, one at each side, from the laminae of the vertebra; they also are intended for the attachment of muscles. The *articular processes*, four in number, stand upwards and downwards from the laminae, to articulate with the vertebra above and below.

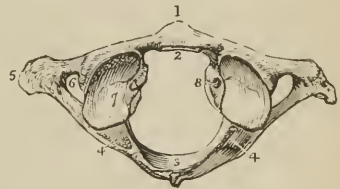
Cervical Vertebræ—In a cervical vertebra the *body* is smaller than in the other regions; it is thicker before than behind, broad from side to side, concave on the upper surface, and convex below; so that, when articulated, the vertebrae lock the one into the other. The *laminae* are narrow and long, and the included *spinal foramen* large and triangular. The *superior intervertebral notches* are slightly deeper than the inferior; the *inferior* being the broadest. The *spinous process* is short and bifid at the extremity, increasing in length from the fourth to the seventh. The *transverse processes* are also short and bifid, and deeply grooved along the upper surface for the cervical nerves. Piercing the base of the transverse process is the vertebral foramen,¹ which gives passage to the vertebral artery and vein, and vertebral plexus of nerves. The transverse processes in this region are formed by two small developments, which proceed, the one from the side of the body, the other from the pedicle of the lamina, and unite near their extremities to inclose the circular area of the vertebral foramen. The anterior of these developments is the rudiment of a cervical rib; the posterior, the analogue of the transverse processes in the dorsal region. The extremities of these developments are the *anterior* and *posterior tubercles* of the transverse process. The *articular processes* are oblique; the superior looking upwards and backwards; the inferior, downwards and forwards.

FIG. 25.



A CENTRAL CERVICAL VERTEBRÆ, SEEN UPON ITS UPPER SURFACE. 1. The body, concave in the middle, and rising on each side into a sharp ridge. 2. The lamina. 3. The pedicle, rendered concave by the superior intervertebral notch. 4. The bifid spinous process. 5. The bifid transverse process. The figure is placed in the concavity between the anterior and posterior tubercle, between the two processes which correspond with the rudimentary rib and the true transverse process. 6. The vertebral foramen. 7. The superior articular process, looking backwards and upwards. 8. The inferior articular process.

FIG. 26.



THE UPPER SURFACE OF THE ATLAS. 1. The anterior tubercle projecting from the anterior arch. 2. The articular surface for the odontoid process on the posterior surface of the anterior arch. 3. The posterior arch, with its rudimentary spinous process. 4. The intervertebral notch. 5. The transverse process. 6. The vertebral foramen. 7. Superior articular surface. 8. Tubercle for the attachment of the transverse ligament. The tubercle referred to is just above the head of the figure; the convexity below it is the margin of the inferior articulating process.

There are three peculiar vertebrae in the cervical region:—The first, or atlas; the second, or axis; and the seventh, or vertebra prominens.

The *Atlas* (named from supporting the head) is a simple ring of bone, without body, and composed of arches and processes. The *anterior arch* has a tubercle on its anterior surface, for the attachment of the longus colli muscle; and on its

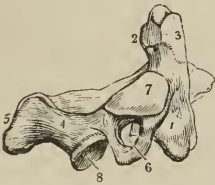
¹ Sometimes, as in a vertebra now before me, a small additional opening exists by the side of the vertebral foramen, in which case it is traversed by a second vein.

posterior aspect is a smooth surface, for articulation with the odontoid process of the axis.

The *posterior arch* is longer and more slender than the anterior, and flattened from above downwards; at its middle is a rudimentary spinous process; and upon its upper surface, near the articular processes, a shallow groove¹ at each side, which represents a superior intervertebral notch, and supports the vertebral artery (just before it perforates the dura mater) and the first cervical nerve. The intervertebral notches are peculiar, from being situated behind the articular processes, instead of before them as in the other vertebræ. The *transverse processes* are remarkably large and long, and pierced by the foramen for the vertebral artery. The *articular processes* are situated on the most bulky and strongest part of the atlas. The superior are oval and concave, and look inwards, so as to form a kind of cup for the condyles of the occipital bone, and are adapted to the nodding movements of the head; the inferior are circular, and nearly horizontal, to permit of the rotatory movements. Upon the inner face of the *lateral mass* which supports the articular processes, is a small tubercle at each side, to which the extremities of the transverse ligament are attached, a ligament which divides the ring of the atlas into two unequal segments; the smaller and anterior, for receiving the odontoid process of the axis; the larger and posterior, to give passage to the spinal cord and its membranes.

The *Axis* (vertebra dentata) is so named from having a process, shaped like a tooth, upon which the head turns as on a pivot. The *body* is of large size, and supports a strong process, the odontoid, which rises perpendicularly from its

FIG. 27.



A LATERAL VIEW OF THE AXIS.

1. The body; the figure is placed on the depression which gives attachment to the longus colli.
2. The odontoid process.
3. The smooth facet on the anterior surface of the odontoid process which articulates with the anterior arch of the atlas; the facet for the transverse ligament is beneath No. 2, where the constriction called the neck of the odontoid process is seen; the bulk of the process between 2, 3, would represent its head.
4. The lamina.
5. The spinous process.
6. The transverse process, pierced obliquely by the vertebral foramen.
7. The superior articular surface.
8. The inferior articular process.

The lower surface of the body is convex, and is received into the concavity upon the upper surface of the third vertebra.

The *Vertebra prominens*, or seventh cervical, approaches in character the upper dorsal vertebræ. It has received its designation from having a very long

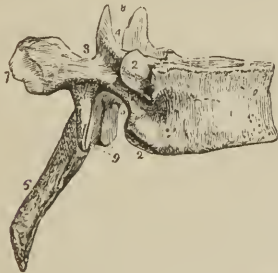¹ This groove is sometimes converted into a foramen.

spinous process, which is single and terminated by a tubercle, and forms a projection on the back part of the neck; to the extremity of this process the ligamentum nuchæ is attached. The transverse processes are but slightly grooved along the upper surface, have each a small foramen for the transmission of the vertebral vein, and present only a rudimentary bifurcation at their extremity. Sometimes the anterior tubercle represents a small but distinct rib.

Dorsal Vertebræ.—The *body* of a dorsal vertebra is as long from before backwards as from side to side, particularly in the middle of the dorsal region; it is thicker behind than before, and marked on each side by two half articulating surfaces for the heads of two ribs. The *pedicles* are strong, and the *laminæ* broad and thick; the *spinal foramen* small and round, and the inferior *intervertebral notch* of large size, the superior can scarcely be said to exist. The *spinous process* is long, prismoid, directed very obliquely downwards, and terminated by a tubercle. The *transverse processes* are large and strong, and directed obliquely backwards. Upon the anterior and superior aspect of their summits is a small facet for the articulation of the tubercle of a rib. The *articular processes* are vertical, the superior facing directly backwards, the inferior directly forwards.

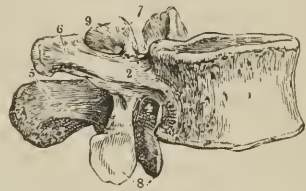
The peculiar vertebræ in the dorsal region are, the first, ninth, tenth, eleventh, and twelfth. The *first* dorsal vertebra approaches very closely in character, the last cervical. The body is broad from side to side, and concave above. The superior articular processes are oblique, and the spinous process horizontal. It has an entire articular surface for the [head of the] first rib, and a half surface for the second. The *ninth* dorsal vertebra has only one half articular surface at each side. The *tenth* has a single entire articular surface at each side. The *eleventh* and *twelfth* have each a single entire articular surface at each side; they approach in character, the lumbar vertebræ: their transverse processes are very short, trifid at their summits, and have no articulation with the corresponding ribs. The transverse processes of the twelfth dorsal vertebra are rudimentary, and its inferior articular processes look outwards.

FIG. 28.



LATERAL VIEW OF A DORSAL VERTEBRA. 1. The body. 2. Articular facets for the heads of ribs. 3. The pedicle. 4. The superior intervertebral notch. 5. The inferior intervertebral notch. 6. The spinous process. 7. The extremity of the transverse process, marked by an articular surface for the tubercle of a rib. 8. The two superior articular processes, looking backwards. 9. The two inferior articular processes, looking forwards.

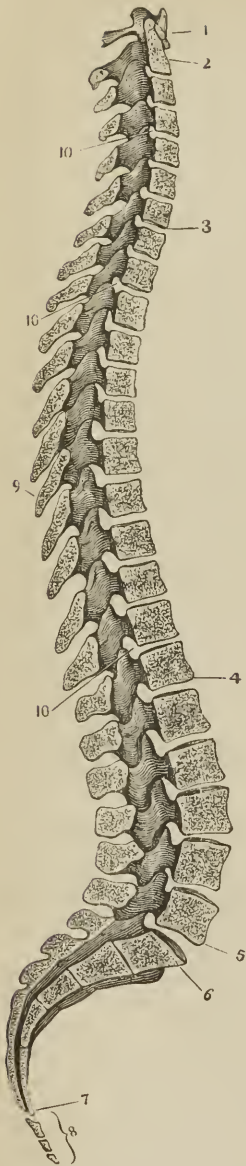
FIG. 29.



LATERAL VIEW OF A LUMBAR VERTEBRA. 1. The body. 2. The pedicle. 3. The superior intervertebral notch. 4. The inferior intervertebral notch. 5. The spinous process. 6. The transverse process. 7. The superior articular processes. 8. The inferior articular processes. 9. The posterior transverse process.

Lumbar Vertebræ.—These are the largest pieces of the vertebral column. The *body* is broad and large, and thicker before than behind. The *pedicles* very strong; the *laminæ* short, thick, and broad; the *inferior intervertebral notches*

[Fig. 30.]



A LATERAL VIEW OF THE SPINAL COLUMN, SHOWING ITS CURVATURES AND INTERNAL STRUCTURE. 1. Atlas. 2. Dentata. 3. Seventh cervical vertebra. 4. Twelfth dorsal vertebra. 5. Fifth lumbar vertebra. 6. First piece of sacrum. 7. Last piece of sacrum. 8. Coccyx. 9. A spinous process. 10, 10, 10. Intervertebral foramina.]

very large, and the spinal *foramen* large and oval. The *spinous process* is thick and broad. The *transverse processes* (costiform processes) are slender, pointed, and directed very slightly backwards. The superior *articular processes* are concave, and look backwards and inwards; the inferior convex, look forwards and outwards. Projecting backwards and upwards from the superior articular process is a short and flattened tubercle or *posterior transverse process*, and in a strongly marked vertebra there is not unfrequently at the base of this a smaller tubercle which has a direction downwards. The *last lumbar vertebra* differs from the rest in having the body very much bevelled posteriorly, so as to be thick in front and thin behind, and the transverse processes thick and large.

General Considerations.—Viewed as a whole, the vertebral column represents two pyramids applied base to base, the superior being formed by all the vertebræ from the second cervical to the last lumbar, the inferior by the sacrum and coccyx. Examined more attentively, it will be seen to be composed of four irregular pyramids, applied to each other by their smaller extremities and by their bases. The smaller extremity of the uppermost pyramid is formed by the axis, or second cervical vertebra; and its base, by the first dorsal. The second pyramid is inverted; having its base at the first dorsal, and the smaller end at the fourth. The third pyramid commences at the fourth dorsal, and gradually enlarges to the fifth lumbar. The fourth pyramid is formed by the sacrum and coccyx.

The *bodies* of the vertebræ are broad in the cervical region; narrowed almost to an angle in the middle of the dorsal, and again broad in the lumbar region. The *arches* are broad and imbricated in the cervical and dorsal regions, the inferior border of each overlapping the superior of the next; in the lumbar region an interval is left between them. A considerable interval exists between the cranium and atlas, and another between the last lumbar vertebra and sacrum.

The *spinous processes* are horizontal in the cervical, and become gradually oblique in the upper part of the dorsal region. In the middle of the dorsal region they are nearly vertical, and imbricated, and towards its lower part assume the direction of the lumbar spines, which are quite horizontal. The *transverse processes* developed in their most rudimentary form in the axis, gradually increase in length to the first dorsal vertebra. In the dorsal region they project obliquely backwards, and diminish suddenly in length in the eleventh and twelfth vertebræ, where they are

very small. In the lumbar region they increase in length to the middle vertebra, and again subside to the last.

The transverse processes consist essentially of two parts, the anterior of which in the dorsal region is the rib, while the posterior retains the name of transverse process. In the cervical region these two elements are quite apparent, both by their different points of attachment to the vertebra, and by the vertebral foramen which divides them at their base. In the lumbar region the so-called transverse processes are in reality lumbar ribs, while the transverse processes will be found behind them in a rudimentary state, developed like the true transverse processes in the cervical region, from the superior articular processes. When the anterior and posterior transverse processes are examined in relation with each other, they will be observed to converge; if they were prolonged they would unite as in the cervical region and inclose a foramen, or they would rest in contact as in the dorsal region, or become consolidated as in the formation of the sacrum. Moreover, the posterior transverse processes are directed upwards, and if they were prolonged, they would come into contact with a small tubercle which is found at the base of the posterior transverse process (in strongly marked vertebræ) in the vertebra above. This junction would form a posterior intervertebral foramen, as actually occurs in the sacrum. In brief, the lumbar vertebræ exhibit those transitional changes which are calculated, by an easy gradation, to convert separate vertebræ into a solid bone. The transverse processes of the eleventh and twelfth dorsal vertebræ are interesting in a transcendental point of view, as exhibiting a tendency, which exists obscurely in all the rest, to trifurcate. Now, supposing these three branches to be lengthened in order to fulfil their purposes, the anterior would constitute the articulation or union with a rib, while the superior and inferior would join similar branches in the vertebra above and below, and form a posterior intervertebral foramen.

The *intervertebral foramina* formed by the juxtaposition of the intervertebral notches are smallest in the cervical region, and gradually increase to the last lumbar. On either side of the spinous processes, and extending the whole length of the column, is the *vertebral groove*, which is shallow and broad in the cervical, and deeper and narrower in the dorsal and lumbar regions. It lodges the principal muscles of the back.

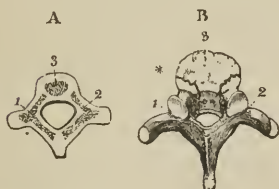
Viewed from the side, the vertebral column presents several curves, the principal of which is situated in the dorsal region, the concavity looking forwards. In the cervical and lumbar regions the column is convex in front; and in the pelvis an anterior concave curve is formed by the sacrum and coccyx. Besides the antero-posterior curves, a slight lateral curve exists in the dorsal region, having its convexity towards the right side.

Development.—The vertebræ are developed by three primary and five secondary centres or epiphyses. The primary centres are, one for each lamella, and one for the body; the epiphyses, one for the apex of the spinous process, one for that of each transverse process, one for the upper and one for the under surface of the body. Exceptions to this mode of development are met with in the atlas, axis, vertebra prominens, and lumbar vertebræ. The *atlas* has four centres: one for each lateral mass, one (sometimes two) for the anterior arch, and one for the centre of the posterior arch. The *axis* has five: one (sometimes two) for the body, two for the odontoid process, appearing side by side in its base, and one for each lamella. The *vertebra prominens* has two additional centres for the anterior or costal segments of the transverse processes, and the *lumbar vertebræ* two for the posterior segments of the transverse processes.

The primary centres of the vertebræ make their appearance during the seventh or eighth week of embryonic existence, the lamella being somewhat in advance of the body. From the lamellæ are produced the spinous, transverse, and articular processes, and the sides of the body; they unite, to complete the arch, one year after birth, and with the body during the fifth year. The epiphyses for the extre-

mities of the spinous and transverse processes make their appearance at fifteen or sixteen, and become united between twenty and twenty-five. The epiphyses of the body are somewhat later in appearance, and are consolidated between the periods of twenty five and thirty years of age.

[FIG. 31.]



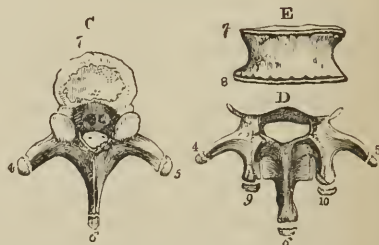
DEVELOPMENT OF VERTEBRÆ.

A. The three principal pieces of the vertebræ are seen to be distinct.

B. The lateral pieces have joined behind. The spinous and transverse processes remain cartilaginous at their ends. The arch is still separable from the middle anterior piece, and the cartilage having been removed from the body, the surface of this is rounded, rough, and fissured.

1, 2. The lateral pieces. 3. The anterior part for the body. * Line of separation between the lateral pieces and the anterior.]

[FIG. 32.]



DEVELOPMENT OF VERTEBRAL EPIPHYSES.

c. Dorsal vertebra. The epiphyses of the processes are drawn slightly away from the rest of the bone.

d. The arch and processes of a lumbar vertebra, with the epiphyses. These are somewhat elongated, but are apparently reduced in the drawing by being viewed from above.

e. A front view of the body of a vertebra, to exhibit the thin epiphyses which belong to its upper and lower surfaces.

4, 5. The ends of the transverse processes. 6. Spinous process. 7, 8. The two epiphyses of the body; the flat surface of one is seen in figure c; the edges of both are marked in figure e. 9, 10. Epiphyses of the articular tubercles of a lumbar vertebra.]

The ossific centres, for the lateral masses, of the *atlas*, appear at the same time as those of the other vertebræ; they unite posteriorly at the end of the second year, by the intervention of the centre for the posterior arch. The one or two centres of the anterior arch appear during the first year, and become consolidated with the lateral pieces during the fifth or sixth year. The *axis* develops its lateral pieces at the same time as the other vertebræ: they join posteriorly soon after birth, and with the body during the fourth or fifth year. The centres for the body and odontoid process appear during the sixth month, and are consolidated during the third year. The body of the *axis* is more largely developed at birth than that of the other vertebræ. The costal segments of the *vertebra prominens* appear during the second month, and become united to the body at the fifth or sixth year; they sometimes remain permanently separate, and constitute cervical ribs. The transverse process of the *first lumbar vertebra* has sometimes a distinct centre, which may remain permanently separate, in that case forming a lumbar rib.

The ossification of the arches of the vertebræ commences from above, and proceeds gradually downwards; hence arrest of development gives rise to *spina bifida*, generally in the loins. Ossification of the bodies, on the contrary, commences at the centre, and proceeds from that point towards the extremities of the column; hence imperfection of the bodies occurs either in the upper or lower vertebræ.

Attachment of Muscles.—To the *atlas* are attached nine pairs of muscles; the *longus colli*, *rectus anticus minor*, *rectus lateralis*, *rectus posticus minor*, *obliquus superior* and *inferior*, *splenius colli*, *levator anguli scapulæ*, and *first intertransversales*.

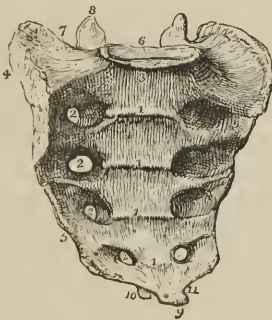To the *axis* are attached eleven pairs, viz. : longus colli, intertransversales, obliquus inferior, rectus posticus major, interspinales, semi-spinalis colli, multifidus spinæ, levator anguli scapulæ, splenius colli, transversalis cervicis, and scalenus medius.

To the remaining *vertebræ* collectively, thirty-one pairs and one single muscle, viz. : *posteriorly*, trapezius, latissimus dorsi, levator anguli scapulæ, rhomboideus minor and major, serratus posticus superior and inferior, splenius, sacro-lumbalis, longissimus dorsi, spinalis dorsi, cervicalis ascendens, transversalis cervicis, trachelo-mastoideus, complexus, semispinalis dorsi and colli, multifidus spinæ, interspinales, intertransversales, levatores costarum : *anteriorly*, rectus anticus major, longus colli, scalenus anticus, medius, and posticus, psoas magnus, psoas parvus, quadratus lumborum, diaphragm, obliquus internus and transversalis.

The SACRUM is a triangular bone, situated at the lower extremity of the vertebral column, and formed by the consolidation of five false vertebræ. It is divisible into an anterior and a posterior surface, two lateral and a superior border, and an inferior extremity.

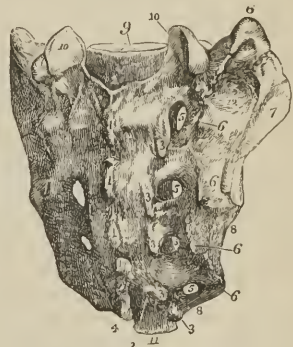The *anterior surface* is concave, and marked by four transverse lines, which indicate its original constitution of five separate pieces. At the extremities of these lines, on each side, are the four anterior sacral foramina, which diminish in size from above downwards, and transmit the anterior sacral nerves. The projection of the superior piece is the sacro-vertebral angle or *promontory*.

FIG. 33.



THE SACRUM SEEN UPON ITS ANTERIOR SURFACE. 1, 1, 1, 1. Transverse lines marking the original constitution of the bone of four pieces. 2, 2, 2, 2. Anterior sacral foramina. 3. Promontory of the sacrum. 4. Ear-shaped surface to articulate with the ilium. 5. The sharp edge to which the sacro-ischiatic ligaments are attached. 6. The vertebral articular surface. 7. The broad triangular surface which supports the psoas muscle and lumbo-sacral nerve. 8. Articular process of the right side. 9. Inferior extremity, or apex of the sacrum. 10. One of the sacral cornua. 11. The notch which is converted into a foramen by the coccyx.

FIG. 34.



POSTERIOR VIEW OF THE SACRUM.— 1, 1, 1, 1. The four rudimentary spinous processes. 2, 2. The sacral canal. 3, 3, 3, 3. Rudimentary articular processes. The lowest of these processes, with the corresponding process of the opposite side, are the sacral cornua. 5, 5, 5, 5. The four posterior sacral foramina. 6, 6, 6, 6. Posterior transverse tubercles. 7. The auricular surface. 8. Sharp edge for the attachment of the sacro-ischiatic ligaments. 9. Surface for articulation with the body of the last lumbar vertebra. 10, 10. Articulating facets of the articular processes. 11. Apex of the sacrum by which it articulates with the coccyx. 12. Rough surface for the attachment of the posterior sacro-iliac ligaments.

The *posterior surface* is narrower than the anterior, and convex. On the middle line is a rough crest formed by the rudiments of four spinous processes, the fifth remaining undeveloped, and exposing the lower termination of the sacral

canal. Immediately external to and parallel with the median crest, is a range of five small tubercles which represent the articular processes of the true vertebræ; beyond these is a shallow groove in which the four posterior sacral foramina open, and further outwards, a range of five tubercles corresponding with the posterior transverse processes of the lumbar vertebræ. The lowest pair of articular tubercles bound on each side the termination of the sacral canal, and send each a process downwards to articulate with the coccyx. The two descending processes are the *sacral cornua*. The posterior sacral foramina are smaller than the anterior, and transmit the posterior sacral nerves. Of the posterior transverse tubercles the *first* corresponds with the angle of the superior border of the bone; the *second* is small, and enters into the formation of the sacro-iliac articulation; the *third* is large, and gives attachment to the oblique sacro-iliac ligament; the *fourth* and *fifth* are smaller, and serve for the attachment of the sacro-ischiatic ligaments.

The *lateral border* of the sacrum presents superiorly a broad and ear-shaped (auricular) surface to articulate with the ilium; and inferiorly a sharp edge, to which the greater and lesser sacro-ischiatic ligaments are attached.

On the *superior border*, in the middle line, is an oval articular surface, corresponding with the under part of the body of the last lumbar vertebra; and on each side a broad triangular surface, which supports the lumbo-sacral nerve and psoas magnus muscle. Immediately behind the vertebral articular surface is the triangular entrance of the sacral canal; and, on each side of this opening, an articular process, which looks backwards and inwards, like the superior articular processes of the lumbar vertebræ. In front of each articular process is an intervertebral notch.

The *inferior extremity* of the bone presents a small oval surface which articulates with the coccyx; and on each side a notch, which, with a corresponding notch in the upper border of the coccyx, forms the foramen for the transmission of the fifth sacral nerve.

The sacrum presents some variety in respect of curvature, and of the number of pieces which enter into its structure. The curve is often very slight, and situated only near the lower part of the bone; while in other subjects it is considerable, and occurs at the middle of the sacrum. The sexual differences in the sacrum relate to its greater breadth, and the greater angle which it forms with the rest of the vertebral column in the female, rather than to any peculiarity in shape. It is sometimes composed of six pieces, more rarely of four, and, occasionally, the first and second pieces remain permanently separate.

Development. — By *twenty-one* points of ossification; five for each of the first three pieces, viz., one for the body, one for each lateral portion, and one for each lamina; and three for each of the last two, namely, one for the body and one for each lateral portion. In the progress of growth, and after puberty, fourteen epiphysal centres are added, namely, two for the surfaces of each body, one for each auricular surface, and one for the thin edge of each lateral border. Ossification begins in the bodies of the sacral pieces somewhat later than in those of the true vertebræ; the first three appearing during the eighth and ninth week, and the last two at about the middle of intra-uterine existence. Ossification of the lamellæ takes place during the interval between the sixth and ninth month. The epiphyses for the upper and under surface of the bodies are developed during the interval between the fifteenth and eighteenth year; and for the auricular and marginal piece, after twenty. The two lower vertebral pieces, although the last to appear, are the first to be completed (between the fourth and fifth year), and unite by their bodies. The union of the bodies takes place from below upwards, and finishes, between the twenty-fifth and thirtieth year, with the first two pieces.

Articulation. — With *four* bones; the last lumbar vertebra, ossa innominata, and coccyx.

Attachment of Muscles.—To seven pairs; *in front*, pyriformis; *on the side*, coeeygeus; and *behind*, glutæus maximus, latissimus dorsi, longissimus dorsi, sacro-lumbalis, and multifidus spinæ.

The COCCYX ($\rho\acute{o}\kappa\kappa\upsilon\varsigma$, cuckoo, resembling a cuckoo's beak) is composed of four small pieces, which form the caudal termination of the vertebral column. The superior piece is broad, and expands laterally into two transverse processes; it is surmounted by an oval articular surface and two cornua, the former to articulate with the apex of the sacrum, the latter with the sacral cornua. The lateral wings sometimes become connected with the sacrum, and convert the notches for the fifth pair of sacral nerves into foramina. The remaining three pieces diminish in size from above downwards.

Development.—By four centres, one for each piece. Ossification commences in the first piece soon after birth; in the second, between five and ten years; in the third, between ten and fifteen; and in the fourth, between fifteen and twenty. The pieces unite at an earlier period than the bodies of the sacrum, the first two pieces first, then the third and fourth, and lastly the second and third. Between forty and sixty years, the coccyx becomes consolidated with the sacrum; this event taking place later in the female than in the male.

Articulations.—With the sacrum.

Attachment of Muscles.—To three pairs, and one single muscle; glutæus maximus, coeeygeus, posterior fibres of the levator ani, and sphincter ani.

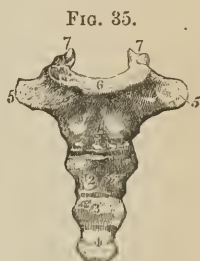


FIG. 35.
FRONT VIEW OF THE COCCYX. 1, 2, 3, 4. The four pieces of the bone. 5, 5. The transverse processes of the first piece. 6. Articular surface for the extremity of the sacrum. 7, 7. The cornua which articulate with the sacral cornua.

OF THE SKULL.

The skull, or superior expansion of the vertebral column, is divisible into two parts, the cranium and the face; the former being adapted, by its form, structure, and strength, to contain and protect the brain; the latter, the chief organs of sense.

The CRANIUM is composed of eight separate bones; viz., the

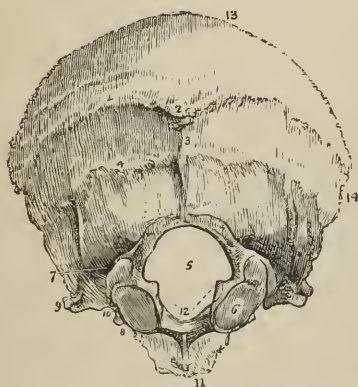Occipital,	Two Temporal,
Two Parietal,	Sphenoid,
Frontal,	Ethmoid.

OCCIPITAL BONE.—This bone is situated at the posterior part and base of the cranium. It is trapezoid in figure, and divisible into two surfaces, four borders, and four angles.

External Surface.—Crossing the middle of the bone transversely, from one lateral angle to the other, is a prominent ridge, the *superior curved line*. In the middle of the ridge is a projection, called the *external occipital protuberance*; and descending from it a small vertical ridge, the *spine*. Above and below the superior curved line the surface is rough, for the attachment of muscles; and on either side of the spine is a convexity, the *receptaculum cerebelli*. About three-quarters of an inch below the superior curved line is another transverse ridge, the *inferior curved line*, and beneath the latter the *foramen magnum*. On each side of the foramen magnum, nearer its anterior than its posterior segment, and encroaching somewhat upon the opening, is an oblong articular surface, the *condyle*, for articulation with the atlas. The condyles approach towards each other anteriorly, their articular surfaces looking downwards and outwards. Directly

behind each condyle is an irregular fossa, and a small opening, the *posterior condyloid foramen*, for the transmission of a vein to the lateral sinus. In front of the condyle is the *anterior condyloid foramen*, for the hypoglossal nerve; on the outer side of each condyle, a projecting ridge, the *transverse process*, excavated in front by a notch which forms part of the jugular foramen; and directly behind the ridge, and forming its posterior boundary, a prominent process, the *jugular tubercle*.¹ In front of the foramen magnum is a thick square mass, the *basilar process*, and in the centre of the basilar process a small tubercle for the attachment of the superior and middle constrictor muscles of the pharynx.

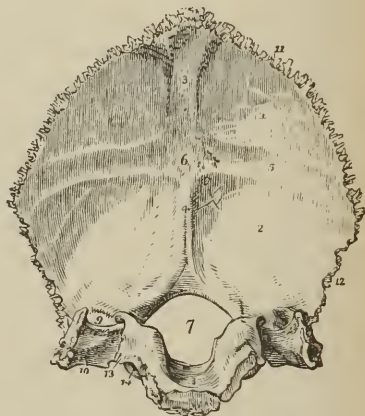
FIG. 36.



EXTERNAL SURFACE OF THE OCCIPITAL BONE. 1. Superior curved line. 2. External occipital protuberance. 3. Spine. 4. Inferior curved line. The convexity of the bone in this situation on either side of the spine is the *receptaculum cerebelli*. 5. Foramen magnum. 6. Condyle of the right side. 7. Posterior condyloid fossa, in which the posterior condyloid foramen is found. 8. Anterior condyloid foramen, concealed by the margin of the condyle. 9. Transverse process; this process on the internal surface of the bone forms the jugular eminence. 10. The notch in front of the jugular eminence, forming part of the jugular foramen. 11. Basilar process. 12. Rough projections into which the odontoid ligaments are inserted. 13. Superior border. 14. Inferior border.

Internal Surface.—On the internal surface is a crucial ridge, which divides the bone into four fossæ; the two superior or cerebral fossæ lodging the posterior lobes of the cerebrum; the two inferior or cerebellar, the lateral lobes of the cerebellum. The superior arm of the crucial ridge is grooved for the superior longitudinal sinus, and gives attachment to the falx cerebri; the inferior arm is sharp and prominent for the attachment of the falx cerebelli, and slightly grooved for the two occipital sinuses. The transverse ridge gives attachment to the tentorium cerebelli, and is deeply grooved for the lateral sinuses. At the point of

FIG. 37.



INTERNAL SURFACE OF THE OCCIPITAL BONE. 1. Left cerebral fossa. 2. Left cerebellar fossa. 3. Groove for the posterior part of the superior longitudinal sinus. 4. Spine for the falx cerebelli, and groove for the occipital sinuses. 5. Groove for the left lateral sinus. 6. Internal occipital protuberance, the groove in which lodges the torcular Herophili. 7. Foramen magnum. 8. Basilar process, grooved for the medulla oblongata. 9. Termination of the groove for the lateral sinus, bounded externally by the jugular eminence. 10. Jugular fossa; this fossa is completed by the petrous portion of the temporal bone. 11. Superior border. 12. Inferior border. 13. Border which articulates with the petrous portion of the temporal bone, grooved by the inferior petrosal sinus. 14. Anterior condyloid foramen.

¹ Retzius remarks that the jugular tubercle is very long in certain mammalia.

meeting of the four arms is a projection, the *internal occipital protuberance*, which corresponds with the similar process situated on the external surface of the bone. The convergence of the four grooves forms a slightly depressed fossa, upon which rests the torcular Herophili. In the centre of the basilar portion of the bone is the foramen magnum, oblong in form, and larger behind than before, transmitting the spinal cord [with its envelops], spinal accessory nerves, and vertebral arteries. Upon the lateral margins of the foramen magnum are two rough eminences, which give attachment to the odontoid ligaments, and immediately above these, the openings of the anterior condyloid foramina. In front of the foramen magnum is the basilar process, grooved on its surface for supporting the medulla oblongata, and along each lateral border for the inferior petrosal sinus. On each side of the foramen magnum is a groove, for the termination of the lateral sinus; a smooth surface, which forms part of the jugular fossa; and a projecting process, which divides the two, and is called the *jugular eminence*. Into the jugular fossa will be seen opening the posterior condyloid foramen.

The *superior borders* are strongly serrated, and assist in forming the lambdoidal suture; the *inferior* are rough, not serrated, and articulate with the mastoid portion of the temporal bone by means of the additamentum suturæ lambdoidalidis. The jugular eminence and side of the basilar process articulate with the petrous portion of the temporal bone, and the intervening space, which is irregularly notched, forms the posterior boundary of the jugular foramen, or foramen lacerum posterius.

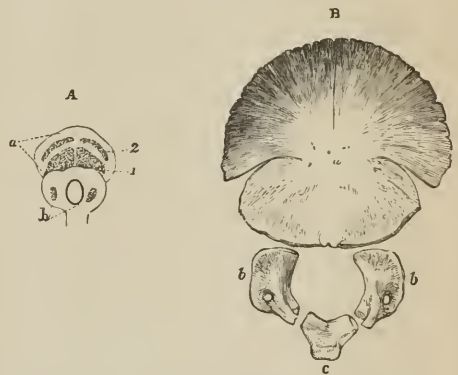
The *angles* of the occipital bone are, the superior, inferior, and two lateral. The *superior angle* is received in the interval formed by the union of the posterior and superior angles of the parietal bones, and corresponds with that portion of the fœtal head which is called the *posterior fontanel*. The *inferior angle* is the articular extremity of the basilar process. The *lateral angles*, at each side, project into the interval formed by the articulation of the posterior and inferior angle of the parietal with the mastoid portion of the temporal bone.

Development. — By seven centres; four for the four parts of the expanded portion divided by the crucial ridge, one for each condyle, and one for the basilar process. Ossification commences in the expanded portion of the bone at a period anterior to the vertebræ; at birth the bone consists of four distinct pieces; which are united at about the fifth or sixth year. After twenty the basilar process unites with the body of the sphenoid.

Articulations. — With six bones; two parietal, two temporal, sphenoid, and atlas.

Attachment of Muscles. — To thirteen pairs; to the rough surface above the superior curved line, the occipito-frontalis; to the superior curved line, the trapezius and sterno-mastoid; to the rough space between the curved lines, complexus, and splenius capitis; to the space between

[FIG. 38.



THE OCCIPITAL BONE AT DIFFERENT PERIODS OF ITS GROWTH.

A. At about the tenth week. *a*, the expanded portion of the bone. 1, 2. Its four nuclei. *b*, the nuclei for the condyloid pieces. The basilar nucleus is not yet apparent.

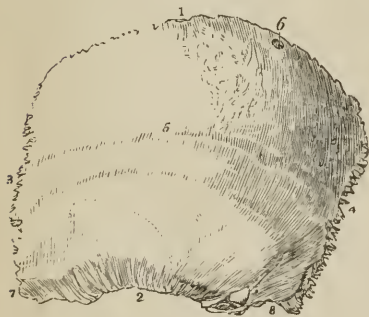B. At the ordinary period of birth, composed of four pieces. *a*, posterior or proper occipital. *b, b*, condyloid pieces. *c*, basilar portion.]

the inferior curved line and the foramen magnum, the rectus posticus major and minor, and obliquus superior; to the transverse process, the rectus lateralis; and to the basilar process, the rectus anticus major and minor, and superior and middle constrictor muscles.

PARIETAL BONE. — The parietal bone is situated at the side and vertex of the skull; it is quadrilateral in form, and divisible into an external and internal surface, four borders and four angles. The superior border is straight, to articulate with its fellow of the opposite side. The inferior border is arched and thin, to articulate with the temporal bone. The anterior border is concave, and the posterior somewhat convex.

External Surface. — Crossing the bone in a longitudinal direction from the anterior to the posterior border, is an arched line, the *temporal ridge*, to which the temporal fascia is attached. In the middle of this line, and nearly in the centre of the bone, is the projection called the *parietal eminence*, which marks the centre of ossification. Above the temporal ridge the surface is rough, and covered by the aponeurosis of the occipito-frontalis; below the ridge the bone is smooth (*planum semicirculare*), for the attachment of the fleshy fibres of the temporal muscle. Near the superior border of the bone, and at about one-third from its posterior extremity, is the *parietal foramen*, which transmits a vein to the superior longitudinal sinus. This foramen is often absent.

FIG. 39.

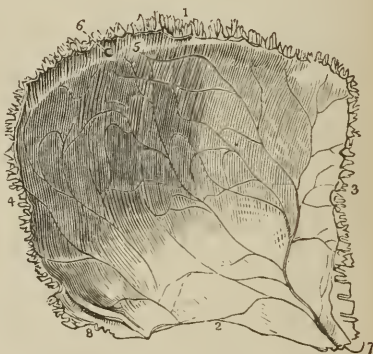

EXTERNAL SURFACE OF THE LEFT PARIETAL BONE. 1. Superior, or sagittal border. 2. Inferior, or squamous border. 3. Anterior or coronal border. 4. Posterior, or lambdoidal border. 5. Temporal ridge; the figure is situated immediately in front of the parietal eminence. 6. The parietal foramen, unusually large in the bone from which this figure was drawn. 7. Anterior inferior angle. 8. Posterior inferior angle.

Internal Surface. — The internal table is smooth; it is marked by numerous furrows, which lodge the ramifications of the arteria meningeæ media, and by digital fossæ which correspond with the convolutions of the brain. Along the upper border is part of a shallow groove, completed by the opposite parietal bone, which serves to contain the superior longitudinal sinus. Some slight pits are also observable near this groove, which lodge the glandulæ Pacchioni.

The *anterior inferior angle* is thin and lengthened, and articulates with the

FIG. 40.



INTERNAL SURFACE OF THE LEFT PARIETAL BONE. 1. Superior, or sagittal border. 2. Inferior, or squamous border. 3. Anterior, or coronal border. 4. Posterior, or lambdoidal border. 5. Part of the groove for the superior longitudinal sinus. 6. Internal termination of the parietal foramen. 7. Anterior inferior angle of the bone, on which is seen the groove for the trunk of the arteria meningeæ media. 8. Posterior inferior angle, on which is seen a portion of the groove for the lateral sinus.

greater wing of the sphenoid bone. Its inner surface is deeply grooved for the trunk of the arteria meningea media; the groove being frequently converted into a closed canal. The *posterior inferior angle* is thick, and presents a broad and shallow groove for the lateral sinus.

Development. — By a single centre. Ossification commences in the parietal eminence at the same time as in the bodies of the vertebrae.

Articulations. — With *five* bones; with the opposite parietal, occipital, frontal, temporal, and sphenoid.

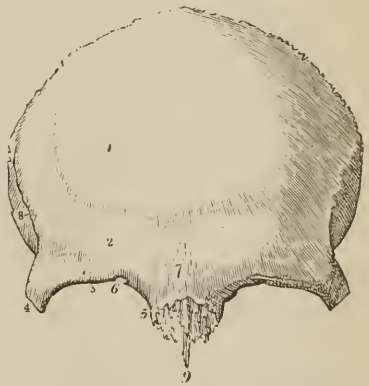
Attachment of Muscles. — To *one* only, the temporal. The aponeurosis of the occipito-frontalis glides over its upper surface.

FRONTAL BONE. — The frontal bone bears some resemblance in form to the under valve of a scallop-shell. It is situated at the anterior part of the cranium, forming the forehead, and assisting in the construction of the roof of the orbits and nose. Hence it is divisible into a superior or frontal portion, and an inferior or orbito-nasal portion. Each of these portions presents for examination an external and internal surface, borders, and processes.

External Surface. — At about the middle of each lateral half of the frontal portion is a projection, the *frontal eminence*. Below these points are the *superciliary ridges*, large towards their inner termination, and becoming gradually smaller as they arch outwards: they support the eyebrows. Beneath the superciliary ridges are the sharp and prominent arches which form the upper margin of the orbits, the *supraorbital ridges*. Externally the supraorbital ridge terminates in the *external angular process*, internally in the *internal angular process*; at the inner third of this ridge is a notch, sometimes converted into a foramen, the *supraorbital notch*, which gives passage to the supraorbital artery, veins, and nerve. Between the two superciliary ridges is a rough projection, the *nasal tuberosity* [glabella]; this portion of the bone denotes by its prominence the situation of the frontal sinuses. Extending upwards and backwards from the external angular process is a sharp ridge, the commencement of the *temporal ridge*, and beneath the ridge a depressed surface, forming part of the *temporal fossa*.

The *orbito-nasal portion* of the bone consists of two thin processes, the *orbital plates*, which form the roof of the orbits, and an intervening notch which lodges the ethmoid bone, and is called the *ethmoidal fissure*. The edges of the ethmoidal fissure are hollowed into cavities, which, by their union with the ethmoid bone, complete the ethmoidal cells; and, crossing these edges transversely, are two small grooves, sometimes canals, which open into the orbit by the anterior and posterior ethmoidal foramina. At the anterior termination of these edges are the irregular openings which lead into the frontal sinuses; and between the

FIG. 41.



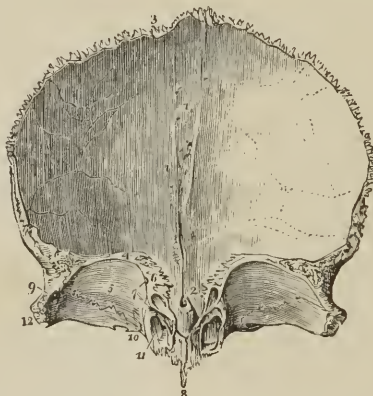
EXTERNAL SURFACE OF THE FRONTAL BONE.
 1. Situation of the frontal eminence of the right side. 2. Superciliary ridge. 3. Supraorbital ridge. 4. External angular process. 5. Internal angular process. 6. Supraorbital notch, for the transmission of the supraorbital nerve and artery; in the figure it is partly converted into a foramen by a spiculum of bone. 7. Nasal tuberosity; the swelling around this point denotes the situation of the frontal sinuses. 8. Temporal ridge, commencing from the external angular process (4). The depression in which the figure 8 is situated is part of the temporal fossa. 9. Nasal spine.

two internal angular processes is a rough excavation which receives the nasal bones, and a projecting process, the *nasal spine*. On each orbital plate, immediately beneath the external angular process, is a shallow depression which lodges the lachrymal gland; and beneath the internal angular process a small pit, sometimes a tubercle, to which the cartilaginous pulley of the superior oblique muscle is attached.

Internal Surface.—Along the middle line of this surface is a *grooved ridge*, the edges of the ridge giving attachment to the falx cerebri, the groove lodging the superior longitudinal sinus. At the commencement of the ridge is an opening, sometimes completed by the ethmoid bone, the *foramen cæcum*. This opening lodges a process of the dura mater, and occasionally gives passage to a small vein which communicates with the nasal veins. On each side of the vertical ridge are some slight depressions which lodge the glandulæ Pacchioni, and on the orbital plates a number of irregular pits called *digital fossæ*, which correspond with the convolutions of the anterior lobes of the cerebrum.

The *superior border* is thick and strongly serrated, bevelled at the expense of the internal table in the middle, where it rests on the junction of the two parietal,

FIG. 42.



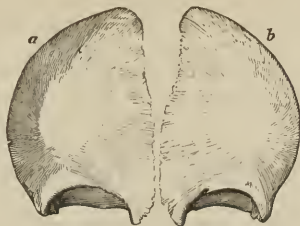INTERNAL SURFACE OF THE FRONTAL BONE; the bone is raised to show the orbito-nasal portion. 1. Grooved ridge for the lodgment of the superior longitudinal sinus and attachment of the falx. 2. Foramen cæcum. 3. Superior, or coronal border of the bone; the figure is situated near that part which is bevelled at the expense of the internal table. 4. Inferior border of the bone. 5. Orbital plate of the left side. 6. Cellular border of the ethmoidal fissure. The foramen cæcum (2) is seen through the ethmoidal fissure. 7. Anterior and posterior ethmoidal foramina; the anterior is seen leading into its canal. 8. Nasal spine. 9. The depression within the external angular process (12) for the lachrymal gland. 10. Depression for the pulley of the superior oblique muscle of the eye; immediately to the left of this number is the supraorbital notch, and to its right the internal angular process. 11. Opening leading into the frontal sinuses; the leading line crosses the internal angular process. 12. External angular process. The corresponding parts are seen on the other side of the figure.

[in young subjects this obtuse angle, which is received into the retiring angle formed by the two parietal bones, is wanting; in its situation the anterior angle of the *anterior fontanel* is found,] and at the expense of the external table on each side where it receives the lateral pressure of those bones. The *inferior border* is thin, irregular, and squamous, and articulates with the sphenoid bone.

Development.—By two centres, one for each lateral half. Ossification begins in the orbital arches, somewhat before the vertebræ. The two pieces are separate at birth, and unite by suture during the first year, the suture sometimes

remaining permanent through life, *frontal suture*. The frontal sinuses make their appearance during the first year, and increase in size until old age.

[FIG. 43.]



FRONTAL BONE OF A FÆTUS born a short time before the usual period. *a*, right lateral portion. *b*, left lateral portion.]

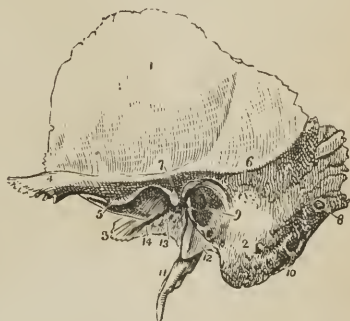Articulations.—With twelve bones; two parietal, sphenoid, ethmoid, two nasal, two superior maxillary, two lachrymal, and two malar.

Attachment of Muscles.—To two pairs; corrugator supercillii, and temporal.

TEMPORAL BONE.—The temporal bone is situated at the side and base of the skull, and is divisible into a squamous, mastoid, and petrous portion.

The *Squamous portion*, forming the anterior part of the bone, is thin, translucent, and contains no diploë. On its *external surface* it is smooth, gives attachment to the fleshy fibres of the temporal muscle, and has projecting from it an arched and lengthened process, the *zygoma*. Near the commencement of the zygoma, upon its lower border, is a projection called the *tubercle*, to which is attached the external lateral ligament of the lower jaw, and continued horizontally inwards from the tubercle, a rounded eminence, the *eminentia articularis*. The process of bone which is continued from the tubercle of the zygoma into the eminentia articularis is the *inferior root* of the zygoma. The *superior root* is continued upwards from the upper border of the zygoma, and forms the posterior part of the temporal ridge, serving by its projection to mark the division of the squamous from the mastoid portion of the bone; and the *middle root* is continued directly backwards, and terminates abruptly at a narrow fissure, the *fissura Glaseri*. The *internal surface* of the squamous portion is marked by several shallow fossæ, which correspond with the convolutions of the cerebrum, and, by a furrow for the posterior branch of the *arteria meningea media*. The *superior or squamous border*, is very thin, and bevelled at the expense of the inner surface, so as to overlap the lower and arched border of the parietal bone.

FIG. 44.



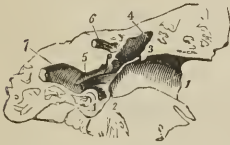EXTERNAL SURFACE OF THE TEMPORAL BONE OF THE LEFT SIDE. 1. Squamous portion. 2. Mastoid portion. 3. Extremity of the petrous portion. 4. The zygoma. 5. Indicates the tubercle of the zygoma, and at the same time its inferior root turning inwards to form the eminentia articularis. 6. Superior root of the zygoma, forming the posterior part of the temporal ridge. 7. Middle root of the zygoma, terminating abruptly at the glenoid fissure. 8. Mastoid foramen. 9. Meatus auditorius externus, surrounded by the processus auditorius. 10. The digastric fossa, situated immediately to the inner side of (2) the mastoid process. 11. Styloid process. 12. Vaginal process of tympanic lamina. 13. Glenoid or Glaserian fissure; the leading line from this number crosses the rough posterior portion of the glenoid fossa. 14. The opening and part of the groove for the Eustachian tube.

The *inferior border* is thick, and dentated to articulate with the spinous process of the sphenoid bone.

The *Mastoid portion* forms the posterior part of the bone; it is thick, and hollowed between its tables into a loose and cellular diploë. On its *external surface* it is rough for the attachment of muscles, and contrasts strongly with the smooth and polished surface of the squamous portion; every part of the surface is pierced by small foramina, which give passage to minute arteries and veins; one of these openings, oblique in direction, of large size, and situated near the posterior border of the bone, the *mastoid foramen*, transmits a vein to the lateral sinus. Not unfrequently this foramen is situated in the occipital bone. The inferior part of the mastoid portion is round and expanded, the *mastoid process*, and excavated in its interior into numerous cells, which form part of the organ of hearing. In front of the mastoid process, and between the superior and middle root of the zygoma, is the large oval opening of the *meatus auditorius externus*, surrounded by a rough lip, the *processus auditorius*. Directly to the inner side of, and partly concealed by, the mastoid process, is a deep groove, the *digastric fossa*; and a little more internally the *occipital groove*, which lodges the occipital artery. On its *internal surface* the mastoid portion presents a broad and shallow groove (*fossa sigmoidea*) for the lateral sinus, and terminating in this groove the internal opening of the mastoid foramen. The *superior border* of the mastoid portion is dentated; and its posterior border, thick and less serrated, articulates with the inferior border of the occipital bone.

The *meatus auditorius externus* is a slightly curved canal, somewhat more than half an inch in length, longer along its lower than its upper wall, and directed obliquely inwards and forwards. The canal is narrower at the middle than at the extremities, is broadest in its horizontal diameter, and terminates at the outer wall of the tympanum by an abrupt oval border. Within the margin of this border is a groove for the insertion of the *membrana tympani*.

FIG. 45.



SECTION OF THE TEMPORAL BONE, RIGHT SIDE, showing the curved direction of the meatus auditorius externus. 1. Edge of the process auditorius. 2. Groove into which the membrana tympani is inserted. The obliquity of the line from 2 to 3 indicates the oblique termination of the meatus, and the consequent oblique direction of the membrana tympani. 4. 4. Cavity of the tympanum. 5. Opening of the Eustachian tube. 6. Part of the aquæductus Fallopii. 7. Part of the carotid canal.

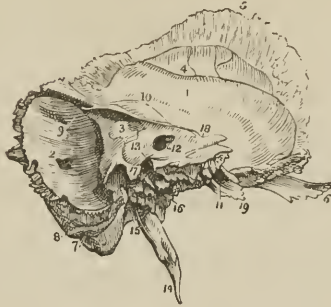The *Petrous portion* of the temporal bone is named from its extreme hardness and density. It is a three-sided pyramid, projecting horizontally forwards into the base of the skull, the base being applied against the internal surface of the squamous and mastoid portions, and the apex being received into the triangular interval between the spinous process of the sphenoid and the basilar process of the occipital bone. For convenience of description it is divisible into three surfaces, anterior, posterior, and basilar; and three borders, superior, anterior, and posterior.

The *anterior surface*, forming the posterior boundary of the middle fossa of the interior of the base of the skull, presents for examination from base to apex, firstly, an *eminence* caused by the projection of the perpendicular semicircular canal; next, a groove leading to an irregular oblique opening, the *hiatus Fallopii*, for the transmission of the petrosal branch of the Vidian nerve; thirdly, another and smaller oblique foramen, immediately beneath the preceding, for the passage of the nervus petrosus superficialis minor, a branch of Jacobson's nerve; and, lastly, a large foramen near the apex of the bone, the termination of the carotid canal.

The *posterior surface* forms the front boundary of the posterior fossa of the base of the skull; near its middle is the oblique entrance of the *meatus auditorius internus*. Above the meatus auditorius internus is a small oblique fissure,

and a minute foramen; the former lodges a process of the dura mater, and the foramen gives passage to a small vein. Further outwards, towards the mastoid

FIG. 46.



LEFT TEMPORAL BONE, SEEN FROM WITHIN. 1. Squamous portion. 2. Mastoid portion. The cipher is placed immediately above the inner opening of the mastoid foramen. 3. Petrous portion. 4. Groove for the posterior branch of the arteria meningea media. 5. Bevelled edge of the squamous border of the bone. 6. Zygoma. 7. Digastric fossa, immediately internal to the mastoid process. 8. Occipital groove. 9. Groove for the lateral sinus. 10. Elevation on the anterior surface of the petrous bone, marking the situation of the perpendicular semicircular canal. 11. Opening of termination of the carotid canal. 12. Meatus auditorius internus. 13. A dotted line leads upwards from this cipher to the narrow fissure which lodges a process of the dura mater. Another line leads downwards to the sharp edge which conceals the opening of the aquæductus cochleæ, while the cipher itself is situated on the bony lamina which overlies the opening of the aquæductus vestibuli. 14. Styloid process. 15. Stylo-mastoid foramen. 16. Carotid foramen. 17. Jugular process. The deep excavation to the left of this process forms part of the jugular fossa, that to the right is the groove for the eighth pair of nerves. 18. Notch for the fifth nerve on the upper border of the petrous bone, near its apex. 19. Extremity of the petrous bone, this part gives origin to the levator palati and tensor tympani muscle.

portion of the bone, is a small slit, almost hidden by a thin plate of bone; this is the *aquæductus vestibuli*, and transmits a small artery and vein of the vestibule and a process of dura mater. Below the meatus, and partly concealed by the margin of the posterior border of the bone, is the *aquæductus cochleæ*, through which passes a vein from the cochlea to the internal jugular vein, and a process of dura mater.

The *meatus auditorius internus* is about one-third of an inch in depth, and pursues a slightly oblique course in relation to the petrous portion of the temporal bone, but a course directly outwards in relation to the cranium. At the bottom of the meatus, and upon its anterior aspect, is a reniform fossa, the concave border of which is directed towards the entrance of the meatus. The reniform fossa is divided into an upper and lower compartment by a sharp ridge, which is prolonged for some distance upon the anterior wall of the meatus, and sometimes as far as its aperture; this ridge marks the situation of the two nerves of the seventh pair, facial and auditory, which are lodged in the meatus. Along the convexity of the reniform fossa, and arranged in a curved line from above downwards, are four or five openings, the two upper ones being the largest, and occupying the superior compartment, the two or three inferior ones, smaller, the inferior com-

FIG. 47.



RENIFORM FOSSA OF THE MEATUS AUDITORIUS INTERNUS; right temporal bone. 1. Ridge dividing the reniform fossa into two compartments. 2. Opening of the aquæductus Fallopii. The openings following that of the aquæductus Fallopii in a curved direction require no reference. 3. Cluster of three or four oblique openings on the posterior wall of the meatus. 4. The spirally-grooved base of the cochlea.

partment. Behind the latter, at the distance of a line and a half, and on the posterior wall of the meatus, is a cluster of three or four oblique openings, two of which are minute. The inferior and larger compartment of the reniform fossa presents a well-marked spiral groove, which commences on the convex border of the fossa, immediately below the line of openings above described, and, sweeping round the convexity of the inferior compartment, and becoming deeper as it proceeds, terminates by a small round aperture in the centre of the spire. The uppermost of the openings of the reniform fossa is the aperture of the aquæductus Fallopii, and gives passage to the facial nerve. The rest are culs-de-sac, pierced at the bottom by numerous minute foramina for the passage of filaments of the vestibular nerve, while the cluster of three openings on the posterior wall of the meatus is intended for single filaments of the same nerve. The spiral groove corresponds with the base of the cochlea, and being pierced by a number of minute foramina for filaments of the cochlear nerve, is named *tractus spiralis foraminulentus*. The opening in the centre of the spiral impression leads into a canal which occupies the central axis of the modiolus, and is thence called *tubulus centralis modioli*.

The *basilar surface* of the petrous portion is rough, irregular, and enters into the formation of the under surface of the base of the skull. Projecting downwards, near its middle, is a long sharp spine, the *styloid process*, occasionally connected with the bone only by cartilage, and lost during maceration, particularly in the young subject.¹ At the base of this process is a rough sheath-like ridge, into which the styloid process appears implanted, the *vaginal process* or tympanic lamina. In front of the vaginal process is a broad triangular depression, the *glenoid fossa*, bounded in front by the eminentia articularis, behind by the vaginal process, and externally by the rough lip of the *processus auditorius*.

The *glenoid fossa* is divided transversely by the *glenoid fissure* (fissura Glaseri), which receives the extremity of the *processus gracilis* of the malleus, and transmits the *laxator tympani* muscle, *chorda tympani* nerve, and anterior tympanic artery. The surface of the fossa in front of the fissure is smooth, to articulate with the condyle of the lower jaw; and that behind the fissure rough, for the reception of part of the parotid gland. At the extremity of the inner angle of the glenoid fossa is the foramen of the *Eustachian tube*; and separated from it by a thin lamella of bone, called *processus cochleariformis*, a small canal for the transmission of the *tensor tympani* muscle.

Directly behind, and at the root of the styloid process, is the *stylo-mastoid foramen*, the opening of exit of the facial nerve, and entrance of the *stylo-mastoid* artery. Nearer the apex of the bone is a large oval opening, the *carotid foramen*, the commencement of the carotid canal, which lodges the internal carotid artery and carotid plexus. And between the stylo-mastoid and carotid foramen, in the posterior border, is an irregular excavation forming part of the jugular fossa for the commencement of the internal jugular vein. The share of the jugular fossa formed by the petrous portion of the temporal bone is different in different bones; but in all, the fossa presents a vertical ridge on its inner side, which cuts off a small portion from the rest. The upper part of this ridge forms a spinous projection, the *jugular process*, the groove to the inner side of ridge lodges the eighth pair of nerves, and the lower part of the ridge is the septum of division between the jugular fossa and carotid foramen. Upon the latter portion of the ridge near the posterior margin of the carotid foramen is a small opening leading into a canal, which transmits the tympanic branch (Jacobson's nerve) of the *glossopharyngeal* nerve. And between the jugular fossa and the

¹ Retzius remarks that the styloid process, which is connected with the lesser cornu of the os hyoides by means of the stylo-hyoidean ligament, belongs in reality to the os hyoides, and completes the hyoid arch; he also notes that the vaginal process or tympanic lamina is a distinct bone in many vertebrata.

stylo-mastoid foramen is another small opening leading into the canal for the passage of the auricular branch of the pneumogastric nerve.

The *superior border* of the petrous portion is sharp, and gives attachment to the tentorium cerebelli. It is grooved for the superior petrosal sinus, and near its extremity is marked by a smooth notch upon which reclines the fifth nerve. The *anterior border* is grooved for the Eustachian tube, and forms the posterior boundary of the foramen lacerum basis cranii; by its sharp extremity it gives attachment to the tensor tympani and levator palati muscle. The *posterior border* is grooved for the inferior petrosal sinus, and excavated for the jugular fossa: it forms the anterior boundary of the foramen lacerum posterius.

Development.—By five centres: one for the squamous portion, one for the mastoid process, one for the petrous portion, one for the auditory process, which in the fœtus is a mere bony ring incomplete superiorly, and serving for the attachment of the membrana tympani, *annulus membranæ tympani*; and one for the styloid process. Ossification occurs in these pieces in the following order; in the squamous portion immediately after the vertebræ, then in the petrous, tympanic, mastoid, and styloid. The tympanic ring is united by its extremities to the squamous portion during the last month of intra-uterine life; the squamous, petrous, and mastoid portions are consolidated during the first year; and the styloid some years after birth. It not unfrequently happens that the latter remains permanently separate, or is prolonged by a series of pieces to the os hyoides, and so completes the hyoid arch. The subsequent changes in the bone are, the increase of size of the glenoid fossa, the growth of the meatus auditorius externus, the levelling of the surfaces of the petrous portion, and the development of mastoid cells. Traces of the union of the petrous with the squamous portion of the bone are usually perceptible in the adult.

Articulations.—With five bones: occipital, parietal, sphenoid, inferior maxillary, and malar.

Attachment of Muscles.—To fourteen: by the squamous portion, to the temporal; by the zygoma, to the masseter; by the mastoid portion, to the occipitofrontalis, splenius capitis, sterno-mastoid, trachelo-mastoid, digastricus, and retrahens aurem; by the styloid process, to the stylo-pharyngeus, stylo-hyoideus, stylo-glossus, and two ligaments, stylo-hyoid and stylo-maxillary; and by the petrous portion, to the levator palati, tensor tympani, and stapedius.

SPHENOID BONE.—The sphenoid ($\sigma\phi\eta\nu$, a wedge) is an irregular bone, situated at the base of the skull, wedged between the other bones of the cranium, and entering into the formation both of the cranium and face. It bears some resemblance, in form, to a bat with its wings extended, and is divisible into body, wings, and processes.

The *body* forms the central mass of the bone, from which the wings and processes are projected. From the upper and anterior part of the body extend, one to each side, two small triangular plates, the lesser wings; from either side and expanding laterally are the greater wings; proceeding backwards from the base of the greater wings, the spinous processes, and downwards, the pterygoid processes. The body presents for examination a superior or cerebral surface, an antero-inferior surface, and a posterior surface.

Superior surface.—At the anterior extremity of this surface is a small projecting plate, the *ethmoidal spine*, and spreading out on either side the lesser wings. Behind the ethmoidal spine in the middle line is a rounded elevation, the *olivary process* [marked by a transverse groove, the optic groove], which supports the commissure of the optic nerves; and on either side of the posterior margin of that process a tubercle, the *middle clinoid process*. Passing outwards

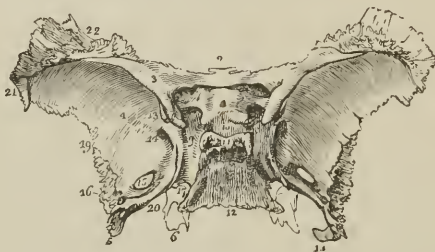FIG. 48.



THE ANNULUS MEMBRANÆ TYMPANI, or tympanic bone of the fœtal skull; right side.

and forwards from the olivary process, are the *optic foramina*, which transmit the optic nerves and ophthalmic arteries. Behind the optic foramina are two sharp tubercles, the *anterior clinoid processes*, which are the inner termination of the lesser wings. Beneath these processes, on the sides of the olivary process, are two depressions¹ for the last turn of the internal carotid arteries. Behind the olivary process is the *sella turcica* (ephippium), the deep fossa which lodges the pituitary gland and circular sinus; behind and somewhat overhanging the sella turcica, is a broad rough plate (dorsum ephippii) bounded at each angle by a tubercle, the *posterior clinoid processes*; and behind this plate an inclined surface (clivus Blumenbachii), which is continuous with the basilar process of the occipital bone. On either side of the sella turcica is a broad groove (*carotid*) which lodges the internal carotid artery, cavernous sinus, and orbital nerves.

FIG. 49.



SUPERIOR OR CEREBRAL SURFACE OF THE SPHENOID BONE. 1. Processus olivaris. 2. Ethmoidal spine. 3. Lesser wing of the left side. 4. Cerebral surface of the greater wing of the same side. 5. Spinous process. 6. Extremity of the pterygoid process of the same side, projecting downwards from the under surface of the body of the bone. 7. Foramen opticum. 8. Anterior clinoid process. 9. Groove by the side of the sella turcica; for lodging the internal carotid artery, cavernous plexus, cavernous sinus, and orbital nerves. 10. Sella turcica; the two tubercles in front of the figure are the middle clinoid processes. 11. Posterior boundary of the sella turcica; its projecting angles are the posterior clinoid processes. 12. Basilar portion of the bone. 13. Part of the sphenoidal fissure. 14. Foramen rotundum. 15. Foramen ovale. 16. Foramen spinosum. 17. The angular interval which receives the apex of the petrous portion of the temporal bone. The posterior extremity of the Vidian canal terminates at this angle. 18. Spine of the spinous process; it affords attachment to the internal lateral ligament of the lower jaw. 19. The border of the greater wing and spinous process, which articulates with the anterior part of the squamous portion of the temporal bone. 20. The internal border of the spinous process, which assists in the formation of the foramen lacerum basis cranii. 21. That portion of the greater ala which articulates with the anterior inferior angle of the parietal bone. 22. The portion of the greater ala which articulates with the orbital process of the frontal bone.

Immediately external to this groove, at the junction of the greater wings with the body, are four foramina: the first is a broad interval, the *sphenoidal fissure*, which separates the greater and lesser wing, and transmits the third, fourth, the three branches of the ophthalmic division of the fifth, and sixth nerve, and the ophthalmic vein. Behind and beneath this fissure is the *foramen rotundum* for the superior maxillary nerve; and still further back, in the base of the spinous process, the *foramen ovale* for the inferior maxillary nerve, arteria meningea parva, and nervus petrosus superficialis minor. Behind the foramen ovale, near the apex of the spinous process, is the *foramen spinosum* for the arteria meningea media.

Upon the *antero-inferior surface* of the body of the sphenoid is a long flattened spine or crest, the superior part of which, *crista sphenoidalis*, articulates

¹ These depressions are occasionally, as in a skull before me, converted into foramina by the extension of a short bony pillar from the middle to the anterior clinoid process.

with the central lamella of the ethmoid, while the inferior part, longer and sharper, the *rostrum sphenoidale*, is intended to be inserted into the sheath formed by the upper border of the vomer. On either side of the crista sphenoidalis is an irregular opening leading into the sphenoidal cells. The sphenoidal cells, absent in the young subject, are divided by a median septum which is continuous with the crista, and are partially closed by two thin plates of bone (frequently broken away), the *sphenoidal spongy bones*. On each side of the sphenoidal cells are the outlets of the optic foramina, sphenoidal fissures, and foramina rotunda; the lesser and greater wings; and, below, the pterygoid processes. At the under surface of the body are two thin plates of bone (*processus vaginales*) proceeding from the base of the pterygoid process at each side, and intended for articulation with the border of the vomer. On each of these plates, close to the root of the pterygoid process, is a groove (sometimes a canal) converted into a canal by the palate bone, the *pterygo-palatine canal* for the pterygo-palatine artery; and traversing the root of the pterygoid process at its union with the body of the bone, is the *pterygoid or Vidian canal*, which gives passage to the Vidian nerve and artery.

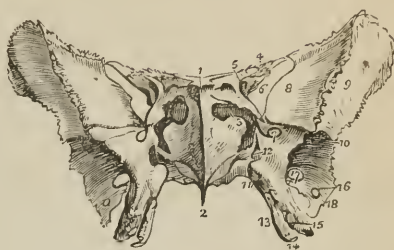
The *posterior surface* of the body is flat and rough, and articulates with the basilar process of the occipital bone. In the adult this union is usually completed by bone; from which circumstance the sphenoid, in conjunction with the occipital, is described by Soëmmering and Meckel as a single bone, under the name of *spheno-occipital*. The posterior surface is continuous at each side with the spinous process, and in the angle of union is the termination of the Vidian canal.

The *lesser wings* (processes of Ingrassias) are thin and triangular, the base being attached to the upper and anterior part of the body of the sphenoid; and the apex, prolonged outwards, terminating in an acute point. The anterior border is irregularly serrated, the posterior being free and rounded, and received into the fissure of Sylvius of the cerebrum. The inner extremity of this border is the anterior clinoid process, which is supported by a short pillar of bone, giving attachment to part of the common tendon of the muscles of the orbit. The lesser wing forms the posterior part of the roof of the orbit, and its base is traversed by the optic foramen.

The *greater wings* present three surfaces; a superior or cerebral, which forms part of the middle fossa of the base of the skull; an anterior surface, which assists in forming the outer wall of the orbit; and an external surface, divided into two parts by the *pterygoid ridge*. The superior part of the external surface enters into the formation of the temporal fossa, the inferior portion forms part of the zygomatic fossa. The pterygoid ridge, dividing the two, gives attachment to the upper origin of the pterygoideus externus muscle.

The *spinous processes* project backwards, one at each side, from the base of the greater wings of the sphenoid, and are received into the angular interval between

FIG. 50.



ANTERO-INFERIOR VIEW OF THE SPHENOID BONE. 1. Ethmoid spine. 2. The rostrum. 3. Sphenoidal spongy bone, partly closing the left opening of the sphenoidal cells. 4. Lesser wing. 5. Foramen opticum, piercing the base of the lesser wing. 6. Sphenoidal fissure. 7. Foramen rotundum. 8. Orbital surface of the greater wing. 9. Its temporal surface. 10. The pterygoid ridge. 11. Pterygo-palatine canal. 12. Foramen of entrance of the Vidian canal. 13. Internal pterygoid plate. 14. Hamular process. 15. External pterygoid plate. 16. Foramen spinosum. 17. Foramen ovale. 18. Extremity of the spinous process of the sphenoid.

the squamous and petrous portion of the temporal bones. Piercing the base of each process is a large oval opening, the *foramen ovale*; nearer its apex a smaller opening, the *foramen spinosum*; and extending downwards from the apex, a short *spine*, which gives attachment to the internal lateral ligament of the lower jaw and to the laxator tympani muscle. The external border of the spinous process is rough, to articulate with the lower border of the squamous portion of the temporal bone; the internal border forms the anterior boundary of the foramen lacerum basis cranii, and is somewhat grooved for the reception of the Eustachian tube.

The *pterygoid processes* descend perpendicularly from the base of the greater wings, and form in the articulated skull the lateral boundary of the posterior nares. Each process consists of an external and internal plate, and an anterior surface. The *external plate* is broad and thin, giving attachment, by its external surface, to the external pterygoid muscle, and by its internal surface to the internal pterygoid. This plate is sometimes pierced by a foramen, which is not unfrequently formed by a process of communication passing between it and the spinous process. The *internal pterygoid plate* is long and narrow, and terminated at its extremity by a curved hook, the *hamular process*, around which plays the tendon of the tensor palati muscle. At the base of the internal pterygoid plate is a small oblong depression, the *scaphoid fossa*, from which arises the circumflexus or tensor palati muscle. The interval between the two pterygoid plates is the *pterygoid fossa*; and the two plates are separated inferiorly by an angular notch (*palatine*) which receives the tuberosity, or *pterygoid process*, of the palate bone. The *anterior surface* of the pterygoid process is broad near its base, and supports Meckel's ganglion. The base of the process is pierced by the Vidian canal.

Development. — By *twelve* centres; four for the body, viz., two for its anterior (spheno-orbital), and two for its posterior part (spheno-temporal); four for the four wings; two for the internal pterygoid plates, and two for the sphenoidal spongy bones. Ossification commences in the various pieces of the sphenoid in the following order: — greater alæ, at about the same time with the other bones of the cranium; lesser alæ and posterior body, at the end of the second month; anterior body at the end of the third; internal pterygoid plate and spongy bones, between the period of birth and the second year. Osseous union occurs first between the centres for the posterior body, and at about the same time between each centre of the anterior body and its corresponding (lesser) ala; the third union takes place between the internal pterygoid plate and the greater ala; the fourth, between the two centres of the anterior body, and at the same time between the anterior and posterior body. This is the state of union at birth, the bone consisting of five centres, one being the body and lesser alæ; one, on each side, the great ala and internal pterygoid plate; and the remaining two, the sphenoidal spongy bones. The greater alæ unite with the body during the first year; the spongy bones after puberty; and the body of the sphenoid with the basilar process of the occipital bone between eighteen and twenty-five.

Articulations. — With *twelve* bones: that is, with all the bones of the head, and five of the face, viz., two malar, two palatæ, and vomer.

Attachment of Muscles. — To *twelve* pairs: temporal, external pterygoid, internal pterygoid, superior constrictor, tensor palati, laxator tympani, levator palpebræ, obliquus superior, superior rectus, internal rectus, inferior rectus, and external rectus.

ETHMOID BONE. — The ethmoid (*ἔθμῶς*, a sieve) is a square-shaped cellular bone, situated between the two orbits, at the root of the nose, and perforated on its upper surface by a number of small openings, from which peculiarity it has received its name. It consists of a perpendicular lamella and two lateral masses.

The *perpendicular lamella* is a thin central plate, which articulates with the vomer and cartilage of the septum, and assists in forming the septum of the nose. It is surmounted superiorly by a thick and strong process, the *crista galli*, which projects into the cavity of the skull, and gives attachment to the falx cerebri. From the base of the anterior border of this process there project forwards two small plates, *alar processes*, which are received into corresponding depressions in the frontal bone, and often complete posteriorly the foramen cæcum. At each side of the *crista galli*, on the upper surface of the bone, is a thin and grooved plate perforated by a number of small openings, the *cribriform lamella*, which supports the bulb of the olfactory nerve, and gives passage to its filaments, and to the nasal branch of the ophthalmic nerve. In the middle of the groove of this lamella the foramina pierce the bone completely, but at either side they are the apertures of canals, which run for some distance in the substance of the central lamella, inner wall of the lateral mass, and spongy bones. The opening for the nasal nerve is a narrow slit in the anterior part of the cribriform lamella, close to the *crista galli*. The cribriform lamella serves to connect the lateral masses with the perpendicular plate.

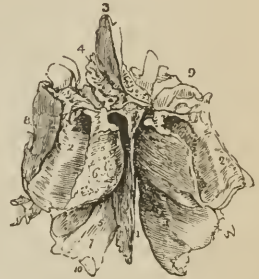
The *lateral masses* (labyrinthi) are divisible into an internal and external surface, and four borders, superior, inferior, anterior, and posterior.

The *internal surface* is rough, slightly convex, and forms the external boundary of the upper part of the nasal fossæ. Towards the posterior border of this surface is a narrow horizontal fissure, the *superior meatus* of the nose; the upper margin of this fissure is thin, and somewhat curled inwards, hence it is named the *superior turbinated bone* (*concha superior*). Below the meatus is the convex surface of another thin plate, which is curled outwards, and forms the lower border of the mass, the *middle turbinated bone* (*concha media*). The *external surface* is quadrilateral and smooth; hence it is named *os planum*, and, from its thinness, *lamina papyracea*; it enters into the formation of the inner wall of the orbit.

The *superior border* is uneven and cellular, the cells being completed by the edges of the ethmoidal fissure of the frontal bone. This border is crossed by two grooves, sometimes complete canals, opening into the orbit by the anterior and posterior ethmoidal foramina. The *inferior border* is formed internally by the lower border of the middle turbinated bone, and externally by a concave irregular fossa, the upper boundary of the middle meatus. The *anterior border* presents a number of incomplete cells, which are closed by the superior maxillary and lachrymal bone; the *posterior border* is irregularly cellular, to articulate with the sphenoid and palate bone.

The lateral masses are composed of cells, divided by a thin partition into anterior and posterior ethmoidal cells. The anterior, the most numerous, communicate with the frontal sinuses, and open by means of an irregular and incomplete tubular canal, the *infundibulum*, into the middle meatus. The posterior cells, fewer in number, open into the superior meatus.

FIG. 51.



ETHMOID BONE, SEEN FROM ABOVE AND BEHIND. 1. Central lamella. 2. Lateral masses; the ciphers are placed on the posterior border of the lateral mass at each side. 3. Crista galli process. 4. Cribriform plate of the left side, pierced by its foramina. 5. The hollow space immediately above and to the left of this number is the superior meatus. 6. Superior turbinated bone. 7. Middle turbinated bone; the numbers 5, 6, 7, are situated on the internal surface of the lateral mass, near its posterior part. 8. External surface of the lateral mass, or *os planum*. 9. Superior or frontal border of the lateral mass, grooved by the anterior and posterior ethmoidal canals. 10. Refers to the concavity of the middle turbinated bone, which is the upper boundary of the middle meatus.

Development. — By *three* centres: one for each lateral mass, and one for the perpendicular lamella. Ossification commences in the lateral masses at about the beginning of the fifth month, appearing first in the os planum, and then in the spongy bones. During the latter half of the first year after birth, the central lamella and lamina cribrosa begin to ossify, and are united to the lateral masses by the beginning of the second year. The cells of the ethmoid are developed in the course of the fourth and fifth year.

Articulations. — With *thirteen* bones: two of the cranium, frontal and sphenoid; and eleven of the face, viz., nasal, superior maxillary, lachrymal, palate, inferior turbinated, and vomer.

No muscles are attached to this bone.

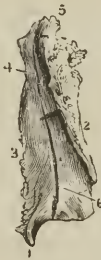BONES OF THE FACE.

The face is composed of fourteen bones; namely,

Two Nasal,	Two Palate,
Two Superior Maxillary,	Two Inferior Turbinated,
Two Lachrymal,	Vomer,
Two Malar,	Inferior Maxillary.

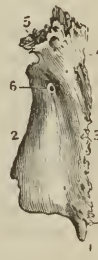NASAL BONES. — The nasal are two small quadrangular bones, forming by their union the bridge and base of the nose. On the upper surface they are convex, and pierced by a foramen for a small artery; on the under surface they are somewhat concave, and marked by a groove, which lodges the nasal branch of the ophthalmic nerve. The superior border is narrow and thick, the inferior broad,

[Fig. 52.



INTERNAL SURFACE OF THE LEFT NASAL BONE. 1. Posterior inferior extremity. 2. Border for its fellow. 3. Border for the nasal process of the superior maxilla. 4. Groove for the nasal nerve. 5. Border for the os frontis. 6. Lower portion of the groove for the nasal nerve.]

Fig. 53.



EXTERNAL SURFACE OF THE LEFT NASAL BONE. 1. Posterior inferior extremity. 2. Border for its fellow. 3. Border for the nasal process of the superior maxillary bone. 4. Points to the groove on the inner surface for the nasal nerve. 5. Border for the os frontis. 6. Nutrient foramen.

thin and irregular. [The internal border is thick above, and bevelled, so that when applied to its fellow, the two present a furrow in which are received the nasal spine of the frontal and the perpendicular lamella of the ethmoid. The external border is rather longer than the internal, and is slightly bevelled at the expense of the outer table, and indented for articulation with the nasal process of the superior maxillary bone, which rests upon it.]

Development. — By a *single* centre for each bone, the first ossific deposition making its appearance at the same time as in the vertebræ.

Articulations.—With four bones: frontal, ethmoid, nasal, and superior maxillary.

Attachment of Muscles.—It has in relation with it the *pyramidalis nasi* and *compressor naris*; but neither is inserted into it.

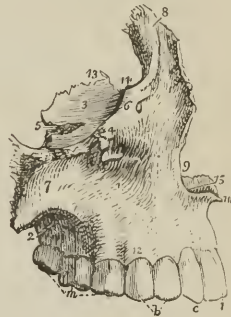SUPERIOR MAXILLARY BONES.—The superior maxillary is the largest bone of the face, with the exception of the lower jaw; they form, by their union, the whole of the upper jaw, and assist in the construction of the nose, orbit, cheek, and palate. Each bone is divisible into a body and four processes.

The *body* is triangular in form, and hollowed in its interior into a large cavity, the *antrum maxillare* (antrum of Highmore). It presents for examination four surfaces, external or facial, internal or nasal, posterior or zygomatic, and superior or orbital.

The *external or facial surface*, forms the anterior part of the bone; it is irregularly concave, and presents a deep depression towards its centre, the *canine fossa*, which gives attachment to two muscles, *compressor nasi* and *levator anguli oris*. Immediately above this fossa is the *infraorbital foramen*, the termination of the infraorbital canal, transmitting the superior maxillary nerve and infraorbital artery; and above the infraorbital foramen in the lower margin of the orbit, continuous externally with the rough articular surface of the malar process, and internally with a thick ascending plate, the nasal process. Towards the middle line of the face the external surface is bounded by the concave border of the opening of the nose, this border is projected forwards at its inferior termination into a sharp process, forming, with a similar process of the opposite bone, the *nasal spine*. Beneath the nasal spine, and above the two superior incisor teeth, is a slight depression, the *incisive, or myrtiform fossa*, which gives origin to the *depressor labii superioris* and *æque nasi* muscle. The myrtiform fossa is divided from the canine fossa by a perpendicular ridge, corresponding with the root of the canine tooth. The inferior boundary of the facial surface is the alveolar process which contains the teeth of the upper jaw; and the facial is separated from the zygomatic surface by a long projecting eminence, the malar process.

The *internal, or nasal surface*, presents a large irregular opening, leading into the *antrum maxillare*; this opening is nearly closed in the articulated skull by the ethmoid, palate, lachrymal, and inferior turbinated bone. The cavity of the antrum is somewhat triangular, corresponding in shape with the form of the body of the bone. On its inner wall are numerous grooves, lodging branches of the superior maxillary nerve, and projecting into its floor several conical processes,

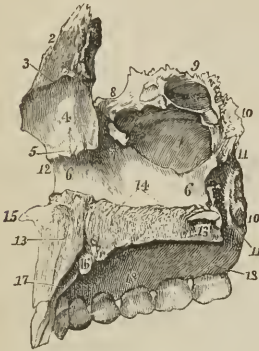
FIG. 54.



SUPERIOR MAXILLARY BONE OF THE RIGHT SIDE, as seen on its lateral aspect. 1. External or facial surface; the depression in which the cipher is placed is the canine fossa. 2. Posterior, or zygomatic surface. 3. Superior or orbital surface. 4. Infraorbital foramen; situated immediately below the cipher. 5. Infraorbital canal, leading to the infraorbital foramen. 6. Inferior border of the orbit. 7. Malar process. 8. Nasal process. 9. Concavity forming the lateral boundary of the anterior nares. 10. Nasal spine. 11. Incisive, or myrtiform fossa. 12. Alveolar process. 13. The internal border of the orbital surface, which articulates with the ethmoid and palate bone. 14. Concavity which articulates with the lachrymal bone, and forms the commencement of the nasal duct. 15. Crista nasalis of the palate process. *i.* Two incisor teeth. *c.* Canine. *b.* Two bicuspidati. *m.* Three molares.

corresponding with the roots of the first and second molar tooth. In front of the opening of the antrum is the strong ascending plate of the nasal process, marked inferiorly by a rough horizontal ridge (*crista turbinalis inferior*), which gives attachment to the inferior turbinated bone. The concave depression immediately

FIG. 55.



RIGHT SUPERIOR MAXILLARY BONE; INTERNAL SURFACE. 1. Antrum. 2. Nasal process. 3. Crista turbinalis superior. 4. Depression corresponding with the middle meatus. 5. Crista turbinalis inferior. 6, 6. Inferior meatus. 7. Sulcus lachrymalis. 8. Notch for articulation with the lachrymal bone. 9. Superior border of the bone, in which are seen three ethmoidal cells. 10, 10. Posterior border; the lower ten, marks the articulating surface for the palate bone. 11, 11. Groove of the posterior palatine canal. 12. Anterior border of the bone. 13, 13. Palate process. 14. Crista nasalis. 15. Nasal spine. 16. Anterior palatine canal. 17. Situation of the incisive foramen. 18, 18. Alveolar process.

The *inferior* boundary is the alveolar process, containing the last two molar teeth.

The *orbital surface* is triangular and thin, and constitutes the floor of the orbit. It is bounded internally by an irregular edge, which articulates with the palate, ethmoid, and lachrymal bone; posteriorly, by the smooth border which enters into the formation of the speno-maxillary fissure; and, anteriorly, by a convex margin, partly smooth and partly rough, the smooth portion forming part of the lower border of the orbit, the rough portion articulating with the malar bone. The middle of this surface is channelled by a deep groove and canal, the infra-orbital, which terminates at the infraorbital foramen; and near the root of the nasal process is a slight depression, marking the origin of the inferior oblique muscle of the eyeball.

The *four processes* of the superior maxillary bone are, the nasal, malar, alveolar, and palate.

The *nasal process* ascends by the side of the nose, to which it forms the lateral boundary, and articulates with the frontal and nasal bone. By its *external surface* it gives attachment to the levator labii superioris alæque nasi, and to the orbicularis palpebrarum muscle. Its *internal surface* contributes to form the

above this ridge corresponds with the middle meatus of the nose, that below the ridge with the inferior meatus. Between the nasal process and the opening of the antrum is a deep vertical groove (*sulcus lachrymalis*), converted into a canal by the lachrymal and inferior turbinated bone, and constituting the nasal duct. The *superior border* of the nasal surface is irregularly cellular, and articulates with the lachrymal and ethmoid bone; the *posterior border* is rough, and articulates with the palate bone; the *anterior border* is sharp, and forms the free margin of the opening of the nose; and, from the *inferior border*, projects inwards a strong horizontal plate, the palate process.

The *posterior surface* may be called *zygomatic*, as forming part of the zygomatic fossa; it is bounded externally by the malar process, and internally by a rough and rounded border, the *tuberosity*, which is pierced by a number of small foramina (*foramina alveolaria posteriora*), giving passage to the posterior dental nerves and branches of the superior dental artery. The lower part of this tuberosity presents a rough oval surface, to articulate with the palate bone, and immediately above and to the inner side of this articular surface a smooth groove, which forms part of the posterior palatine canal. The *superior border* is smooth and rounded, forming the lower boundary of the speno-maxillary fissure, and marked by a notch, the commencement of the infraorbital canal.

outer wall of the nares, and is marked transversely by a horizontal ridge (*crista turbinalis superior*), which divides it into two portions, one above the ridge, irregular and uneven, for giving attachment to and completing the cells of the lateral mass of the ethmoid; the other below, smooth and concave, corresponding with the middle meatus. The *posterior border* is thick and grooved for the nasal duct; while the prominent margin in front of that groove is continuous with the lower border of the orbit; this margin is marked by a small *tubercle*, which serves as a guide to the introduction of the knife in the operation for *fistula lachrymalis*.

The *malar process*, large and irregular, is situated at the angle of separation between the facial and zygomatic surface, and presents a triangular surface for articulation with the malar bone.

The *alveolar process* forms the lower margin of the bone; it is spongy and cellular in texture, and excavated into deep holes for the reception of eight teeth.

The *palate process* is thick and strong, and projects horizontally inwards from the inner surface of the body of the bone. *Superiorly*, it is concave and smooth, and forms the floor of the nares; *inferiorly*, it is also concave, but uneven, and assists in the formation of the roof of the palate. The latter surface is marked by a deep groove, which lodges the anterior palatine nerve and superior palatine artery. Its internal edge is raised into a ridge (*crista nasalis*), which, with a corresponding ridge in the opposite bone, forms a groove for the reception of the vomer. The prolongation of this ridge forwards beyond the level of the facial surface of the bone is the *nasal spine*. At the anterior extremity of its nasal surface is a foramen, which leads into a canal formed conjointly by the two superior maxillary bones, the anterior palatine canal. The termination of this canal is situated immediately behind the incisor teeth, hence it is also named the incisive foramen. Associated with the incisive canal are two smaller canals, the naso-palatine, which transmits the naso-palatine nerves. The naso-palatine canals are situated in the walls of the incisive canal, and terminate inferiorly in that canal, either by separate openings or conjoined.

Development. — By four centres: one for the anterior part of the palate and incisive portion of the alveolar process (the permanence of this piece constitutes the intermaxillary bone of animals); one for that portion of the bone lying internally to the infraorbital canal and foramen; one for that portion lying externally to the infraorbital groove and canal; and one for the palate process. The superior maxillary bone is one of the earliest to show signs of ossification, this action beginning in the alveolar process, and being associated with the early development of teeth. The early development of the alveolar process, and the consequent fusion at this point of the original pieces, explains the difficulties which have been felt by anatomists in determining the precise number of ossifying centres of this bone.

Articulations. — With nine bones; viz., two of the cranium, and all the bones of the face, excepting the inferior maxillary. These are, frontal and ethmoid; nasal, lachrymal, malar, inferior turbinated, palate, vomer, and its fellow of the opposite side.

Attachment of Muscles. — To ten; orbicularis palpebrarum, obliquus inferior oculi, levator labii superioris aequae nasi, levator labii superioris proprius, levator anguli oris, compressor naris, dilatator naris, depressor aë nasi, buccinator, masseter.

LACHRYMAL BONES (*os unguis*, from an imagined resemblance to a finger nail). — The lachrymal is a thin oval-shaped plate of bone, situated in front and at the inner angle of the orbit. It may be divided into an external and internal surface and four borders. The *external surface* is smooth, and marked by a ver-

tical ridge, the lachrymal crest, into two portions, one of which is flat and enters into the formation of the orbit, hence may be called the orbital portion; the other is concave, and lodges the lachrymal sac, hence, the lachrymal portion. The crest is expanded inferiorly into a hook-shaped process (hamulus lachrymalis), which forms part of the outer boundary of the fossa lachrymalis. The *internal surface* is uneven, and completes the anterior ethmoid cells; it assists also in forming the wall of the nasal fossæ and nasal duct. The four borders articulate with adjoining bones.

Development. — By a single centre, appearing in the early part of the third month.

Articulations. — With *four* bones; two of the cranium, frontal and ethmoid; and two of the face, superior maxillary and inferior turbinated bone.

Attachment of Muscles. — To *one* muscle, the tensor tarsi, and to an expansion of the tendo oculi, the former arising from the orbital surface, the other being attached to the lachrymal crest.

FIG. 56.

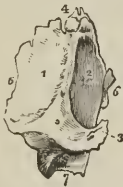
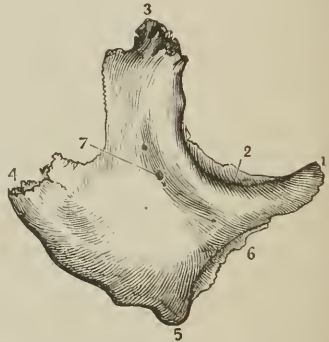
FIG. 57.



LACHRYMAL BONE OF THE RIGHT SIDE, viewed on its external or orbital surface. 1. Orbital portion of the bone. 2. Lachrymal portion; the prominent ridge between these two portions is the crest. 3. Lower termination of the crest, the hamulus lachrymalis. 4. Superior border, which articulates with the frontal bone. 5. Posterior border, which articulates with the ethmoid bone. 6. Anterior border, which articulates with the superior maxillary bone. 7. The border which articulates with the inferior turbinated bone.

MALAR BONE OF THE RIGHT SIDE; EXTERNAL SURFACE. 1. Anterior angle. 2. Orbital process. 3. Frontal process — superior angle. 4. Zygomatic process, — posterior angle. 5. Inferior angle. 6. Maxillary process. 7. Opening for an artery and nerve.

MALAR BONES (*mala*, the cheek). — The malar (os jugale) is the strong quadrangular bone which forms the prominence of the cheek. It is divisible into an external and internal surface, and four processes, frontal, orbital, maxillary, and zygomatic. The *external surface* is smooth and convex, and pierced by several small openings, which give passage to filaments of the temporo-malar nerve and minute arteries. The *internal surface* is concave, partly smooth and partly rough; smooth where it forms part of the temporal fossa, and rough where it articulates with the superior maxillary bone.

The *frontal process* ascends perpendicularly to form the outer border of the orbit, and articulates with the external angular process of the frontal bone. The *orbital process* is a thick plate, which projects inwards from the frontal process, and unites with the great ala of the sphenoid to constitute the outer wall of the orbit. It is pierced by several small foramina for the passage of temporo-malar filaments of the superior maxillary nerve. The *maxillary process* is broad, and articulates with the superior maxillary bone. The *zygomatic process*, narrower than the rest, projects backwards to unite with the zygoma of the temporal bone.

Development. — By a single centre; in rare instances by two or three. In

many animals the malar bone is permanently divided into two portions, orbital and malar. Ossification commences in the malar bone soon after the vertebræ.

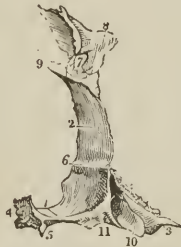Articulations. — With *four* bones; three of the cranium, frontal, temporal, and sphenoid; and one of the face, superior maxillary.

Attachment of Muscles. — To *five*: levator labii superioris proprius, zygomaticus minor and major, masseter, and temporal.

PALATE BONES. — The palate bones are situated at the posterior part of the nares, where they enter into the formation of the palate, side of the nose, and posterior part of the floor of the orbit; hence they might be named the palatono-orbital bones. Each bone resembles in general form the letter L, and is divisible into a horizontal plate, a perpendicular plate, and a pterygoid process or tuberosity.

The *horizontal plate* is quadrilateral; and presents two surfaces, one superior, which enters into the formation of the floor of the nares, the other inferior, forming the posterior part of the hard palate. The *superior surface* is concave, and

FIG. 58.



POSTERIOR VIEW OF THE RIGHT PALATE BONE in its natural position; it is slightly turned on one side, to obtain a sight of the internal surface of the perpendicular plate (2). 1. Horizontal plate of the bone; its upper or nasal surface. 2. Perpendicular plate; its internal or nasal surface. 3, 10, 11. Pterygoid process or tuberosity. 4. Internal border of the horizontal plate, which, articulating with the similar border of the opposite bone, forms the crista nasalis for the reception of the vomer. 5. The pointed process, which, with a similar process of the opposite bone, forms the palate spine. 6. The horizontal ridge which gives attachment to the inferior turbinated bone; the concavity below this ridge enters into the formation of the inferior meatus; the concavity (2) above the ridge, into that of the middle meatus. 7. Spheno-palatine notch. 8. Orbital portion. 9. Crista turbinalis superior for the middle turbinated bone. 10. The middle facet of the tuberosity, which enters into the formation of the pterygoid fossa. The facets 11 and 3 articulate with the two pterygoid plates, 11 with the internal, 3 with the external.

rises towards the middle line, where it unites with its fellow of the opposite side and forms part of a crest (*crista nasalis*), which articulates with the vomer. The *inferior surface* is uneven, and marked by a slight transverse ridge, to which is attached the tendinous expansion of the tensor palati muscle. Near its external border are two openings, one large and one small, the *posterior palatine foramina*; the former transmits the anterior palatine nerve and superior palatine artery, the latter the middle palatine nerve. The posterior border is concave, and presents at its inner extremity a sharp point, which with a corresponding point in the opposite bone constitutes the *palate spine* for the attachment of the *azygos uvulæ* muscle.

The *perpendicular plate* is also quadrilateral; and presents two surfaces, one internal or nasal, forming part of the wall of the nares; the other external, bounding the spheno-maxillary fossa and antrum. The *internal surface* is marked near its middle by a horizontal ridge (*crista turbinalis inferior*), to which is united the inferior turbinated bone; and, about half an inch above this, by

another ridge (*crista turbinalis superior*), for the attachment of the middle turbinated bone. The concave surface below the inferior ridge is the lateral boundary of the inferior meatus of the nose; that between the two ridges corresponds with the middle meatus, and the surface above the superior ridge with the superior meatus. The *external surface*, extremely irregular, is rough on each side for articulation with neighboring bones, and smooth in the middle to constitute the inner boundary of the sphenomaxillary fossa. This smooth surface terminates inferiorly in a deep groove, which, being completed by the tuberosity of the superior maxillary bone and pterygoid process of the sphenoid, forms the *posterior palatine canal*.

Near the upper part of the perpendicular plate is a large oval notch completed by the sphenoid, the *spheno-palatine foramen*, which transmits the superior nasal and naso-palatine nerves and sphenomaxillary artery, and serves to divide the upper extremity of the bone into two portions, an anterior or orbital, and a posterior or sphenoidal portion. The *orbital portion* is hollow within, and presents five surfaces externally, three articular, and two free; the three articular are, anterior, which looks forwards, and articulates with the superior maxillary bone, internal with the ethmoid, and posterior with the sphenoid. The free surfaces are, superior or orbital, which forms the posterior part of the floor of the orbit, and external, which looks into the sphenomaxillary fossa.

FIG. 59.



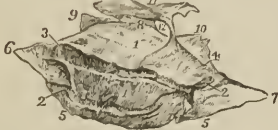PERPENDICULAR PLATE OF THE RIGHT PALATE BONE, seen on its external or sphenomaxillary surface. 1. The rough surface of this plate which articulates with the superior maxillary bone and bounds the antrum. 2. Posterior palatine canal; completed by the tuberosity of the superior maxillary bone and pterygoid process. The rough surface to the left of the canal (2) articulates with the internal pterygoid plate. 3. Spheno-palatine notch 4, 5, 6. Orbital portion of the perpendicular plate. 4. Spheno-maxillary facet of this portion; 5, orbital facet; 6, maxillary facet, to articulate with the superior maxillary bone. 7. Sphenoidal portion of the perpendicular plate. 8. Pterygoid process or tuberosity of the bone.

Attachment of Muscles. — To four; tensor palati, azygos uvulæ, internal and external pterygoid.

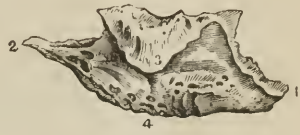INFERIOR TURBINATED BONES. — The inferior turbinated or spongy bone, is

a thin layer of light and porous bone, attached to the crista turbinalis inferior of the outer wall of the nares, and projecting inwards towards the septum narium. It is somewhat triangular in form, one angle being directed upwards and the curved base downwards; and slightly curled upon itself, so as to bear some resemblance to one valve of a bivalve shell, hence its designation, *concha inferior*. The bone presents for examination, two surfaces, internal and external; three borders, anterior, superior, and inferior; and three angles, anterior, posterior, and superior. The *internal* or *convex surface* looks inwards and upwards, and forms the inferior boundary of the middle meatus naris; it is

FIG. 60.



[FIG. 61.]



INFERIOR TURBINATED BONE OF THE RIGHT SIDE. 1, 1. Its internal or convex surface. 2, 2, 3. Canal for the nasalis posterior externa artery, dividing into two deep grooves. The eipher 3 also denotes the anterior border of the bone. 4. Posterior border. 5, 5. Inferior border. 6. Anterior angle. 7. Posterior angle. 8. Superior angle. 9. Processus lachrymalis. 10. Processus ethmoidalis. 11. A large irregular process, appertaining to the ethmoidal process, and articulating with the ethmoid bone. 12. An opening into the antrum.

EXTERNAL VIEW OF THE INFERIOR TURBINATED BONE OF THE RIGHT SIDE. 1. Anterior angle, which rests on the crista turbinalis inferior of the superior maxillary. 2. Posterior angle, which rests on the crista turbinalis inferior of the palate bone. 3. Unciform process, which rests on the lower margin of the opening into the antrum. 4. Inferior border.]

marked by one or two longitudinal grooves or canals for branches of the nasal nerves and spheno-palatine artery. The *external* or *concave surface* looks downwards and outwards, and constitutes the roof of the inferior meatus. The *anterior border* looks upwards and forwards, is thin and somewhat concave, and articulates with the crista turbinalis of the superior maxillary and with the lachrymal bone. The *superior border*, long and uneven, articulates with the crista turbinalis of the palate bone, and with the superior maxillary. The *inferior border* is convex, rounded, and free, and thicker than the rest of the bone. The *anterior angle*, attached to the superior maxillary bone, advances forwards nearly to the anterior margin of the nares. The *posterior angle*, sharp and pointed, is prolonged backwards on the internal pterygoid plate. The *superior angle*, more or less rounded, gives origin to three thin and laminated processes. The most anterior of these processes, *processus lachrymalis*, derived from the upper extremity of the anterior border, articulates with the lachrymal bone, and assists in completing the nasal duct; the posterior process, *processus ethmoidalis*, derived directly from the superior angle or border, often from both, articulates with the ethmoid bone; the middle process, *processus maxillaris* [*unciform process*], proceeding also from the superior border, is reflected downwards, and assists in completing the inner wall of the antrum, articulating with the superior maxillary and palate bone.

Development. — By a single centre, which appears at about the middle of the first year.

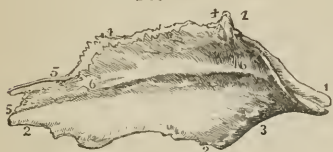It affords no attachment to muscles.

Articulations. — With *four* bones; ethmoid, superior maxillary, lachrymal, and palate.

VOMER. — The vomer is a thin, quadrilateral plate of bone, forming the posterior and inferior part of the septum of the nares.

The *superior border* is broad and expanded, to articulate, in the middle, with the under surface of the body of the sphenoid, and on each side (ala) with the

FIG. 62.



THE VOMER VIEWED ON ITS LEFT ASPECT.
 1, 1. Its superior border, with the two alæ.
 2, 2. Inferior border. 3. Posterior border.
 4, 4. That portion of the anterior border which articulates with the central lamella of the ethmoid. 5, 5. Inferior portion of the anterior border, which unites with the cartilage of the septum. 6, 6. An elevation on the bone marking its point of separation into two layers; the two layers are seen along the whole length of the anterior border from 4 to the lower 5.

processus vaginalis of the pterygoid process. The anterior part of this border is hollowed into a sheath for the reception of the rostrum of the sphenoid. The *inferior border* is thin and uneven, and is received into the grooved summit of the crista nasalis. The *posterior border* is sharp and free, and forms the posterior division of the two nares. The *anterior border* is more or less deeply grooved for the reception of the central lamella of the ethmoid and the cartilage of the septum. This groove is an indication of the early constitution of the bone of two lamellæ, united at the inferior border. The vomer not unfrequently presents a convexity to one or the other side, generally, it is said, to the left.

Development.—By a single centre, which makes its appearance at the same time with those of the vertebræ. Ossification begins from below and proceeds upwards. At birth, the vomer presents the form of a trough, in the concavity of which the cartilage of the septum nasi is placed; it is this disposition which subsequently enables the bone to embrace the rostrum of the sphenoid.

The vomer has no muscles attached to it.

Articulations.—With *six* bones: sphenoid, ethmoid, two superior maxillary, two palate; and the cartilage of the septum.

INFERIOR MAXILLARY BONE.—The *lower jaw* is the arch of bone which contains the inferior teeth: it is divisible into a horizontal portion or body, and a perpendicular portion, the ramus, at each side.

Upon the *external surface* of the *body* of the bone, at the middle line, and extending from between the two first incisor teeth to the chin, is a slight ridge, *crista mentalis*, which indicates the point of conjunction of the lateral halves of the bone in the young subject, the *symphysis*. [The crista mentalis terminates in front and below by a triangular eminence, the *mental process*.] Immediately external to this ridge is a depression which gives origin to the depressor labii inferioris muscle; and, corresponding with the root of the lateral incisor tooth, another depression, the *incisive fossa*, for the levator labii inferioris. Further outwards is an oblique opening, the *mental foramen*, for the exit of the mental nerve and inferior dental artery; and below this foramen, the commencement of an oblique ridge, which runs upwards and outwards to the base of the coronoid process, and gives attachment to the depressor anguli oris, platysma myoides, and buccinator muscle. Near the posterior part of this surface is a rough impression made by the masseter muscle; and, immediately in front of this impression, a groove for the facial artery. The projecting tuberosity at the posterior extremity of the lower jaw, at the point where the body and ramus meet, is the *angle*.

Upon the *internal surface* of the *body* of the bone, at the symphysis, are two small pointed tubercles; immediately beneath these, two other tubercles, less marked; beneath them, a ridge, and beneath the ridge two rough depressions of some size. These four points give attachment, from above downwards, to the genio-hyo-glossi, genio-hyoidei, part of the mylo-hyoidei, and digastric muscles. Running outwards into the body of the bone from the above ridge is a prominent line, the

mylo-hyoidean ridge, which gives attachment to the mylo-hyoideus muscle, and by its extremity to the pterygo-maxillary ligament and superior constrictor muscle. Immediately above the ridge, and by the side of the symphysis, is a smooth concave surface, which corresponds with the sublingual gland; and below the ridge, and more externally, a deeper fossa for the submaxillary gland.

The *superior border* of the body of the bone is the alveolar process, furnished in the adult with alveoli for sixteen teeth. The *inferior border* or base is rounded and smooth; thick and everted in front to form the chin, and thin behind where it merges into the angle of the bone.

The *ramus* is a strong square-shaped process, differing in direction at various periods of life; thus, in the fœtus and infant, it is almost parallel with the body; in youth it is oblique, and gradually approaches the vertical direction until manhood; in old age, after the loss of the teeth, it again declines, and assumes the oblique direction. On its external surface it is rough, for the attachment of the masseter muscle; and at the junction of its posterior border with the body of the bone, it has a rough tuberosity, the *angle* of the lower jaw, which gives attachment by its inner margin to the stylo-maxillary ligament.

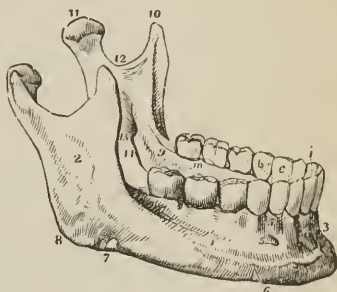
The upper extremity of the ramus presents two processes, separated by a concave sweep, the *sigmoid notch*. The anterior is the *coronoid process*; it is sharp and pointed, and gives attachment by its inner surface to the temporal muscle. The anterior border of the coronoid process is grooved at its lower part for the buccinator muscle. The posterior process is the *condyle*, which is flattened from before backwards, oblique in direction [from without, inwards and backwards], and smooth on its upper surface, to articulate with the glenoid cavity of the temporal bone. The constriction around the base of the condyle is its *neck*, into which is inserted the external pterygoid muscle. The sigmoid notch is crossed by the masseteric artery and nerve.

The *internal surface* of the ramus is marked near its centre by a large oblique foramen, the *inferior dental*, for the entrance of the inferior dental artery and nerve into the dental canal. Bounding this opening is a sharp margin, to which is attached the internal lateral ligament, and passing downwards from the opening a narrow groove which lodges the mylo-hyoidean nerve with a small artery and vein. To the uneven surface above and in front of the inferior dental foramen, is attached the temporal muscle, and to that below it, the internal pterygoid. The internal surface of the neck of the condyle gives attachment to the external pterygoid muscle; and the angle to the stylo-maxillary ligament.

Development.—By two centres; one for each lateral half, the two sides meeting at the symphysis, where they become united. The lower jaw is the earliest of the bones of the skeleton to exhibit ossification with the exception of the clavicle; ossific union of the symphysis takes place during the first year.

Articulations.—With the glenoid fossæ of the two temporal bones, through the medium of a fibro-cartilage.

FIG. 63.



THE LOWER JAW. 1. Body. 2. Ramus. 3. Symphysis. 4. Fossa for the depressor labii inferioris muscle. 5. Mental foramen. 6. External oblique ridge. 7. Groove for the facial artery; the situation of the groove is marked by a notch in the bone a little in front of the cifer. 8. The angle. 9. Extremity of the mylo-hyoidean ridge. 10. Coronoid process. 11. Condyle. 12. Sigmoid notch. 13. Inferior dental foramen. 14. Mylo-hyoidean groove. 15. Alveolar process. *i*. Middle and lateral incisor tooth of one side. *c*. Canine tooth. *b*. Two bicuspides. *m*. Three molars.

Attachment of Muscles.—To fourteen pairs; by the external surface, commencing at the symphysis and proceeding outwards, levator labii inferioris, depressor labii inferioris, depressor anguli oris, platysma myoides, buccinator, and masseter; by the internal surface, also commencing at the symphysis, the genio-hyo-glossus, genio-hyoideus, mylo-hyoideus, digastricus, superior constrictor, temporal, external pterygoid, and internal pterygoid.

Table showing the Points of Development, Articulations, and Attachment of Muscles, of the Bones of the Head.

	Development.	Articulations.	Attachment of Muscles.
Occipital	7	6	13 pairs.
Parietal	1	5	1 muscle.
Frontal	2	12	2 pairs.
Temporal	5	5	14 muscles.
Sphenoid	12	12	12 pairs.
Ethmoid	3	13	none.
Nasal	1	4	none.
Superior Maxillary	4	9	10 muscles.
Lachrymal	1	4	1 muscle.
Malar	1	4	5 muscles.
Palate	1	6	4 "
Inferior Turbinated	1	4	none.
Vomer	1	6	none.
Lower Jaw	2	2	14 pairs.

SUTURES.

The bones of the cranium and face are connected with each other by means of sutures (*sutura*, a seam), of which there are four principal varieties: serrated, squamous, harmonia, and schindylesis.

The *serrated suture* is formed by the union of two borders possessing serrated edges, as in the coronal, sagittal, and lambdoid sutures. In these sutures the serrations are formed almost wholly by the external table, the edges of the internal table lying merely in apposition.

The *squamous suture* (*squama*, a scale) is formed by the overlapping of the bevelled edges of two contiguous bones, as in the articulation between the temporal and lower border of the parietal. In this suture the approximated surfaces are roughened, so as to adhere mechanically with each other.

The *harmonia suture* (*ἀρῆν*, to adapt) is the simple apposition of contiguous surfaces, the surfaces being more or less rough and retentive. This suture is seen in the connexion between the superior maxillary bones, or of the palate processes of the palate bones with each other.

The *schindylesis suture* (*σχινδύλησις*, a fissure) is the reception of one bone into a sheath or fissure of another, as occurs in the articulation of the rostrum of the sphenoid with the vomer, or of the latter with the perpendicular lamella of the ethmoid, and with the crista nasalis of the superior maxillary and palate bones.

The serrated suture is formed by the interlocking of the radiating fibres along the edges of the flat bones of the cranium during growth. When this process is retarded by over-distension of the head, as in hydrocephalus, and sometimes without any such apparent cause, distinct ossific centres are developed in the interval between the edges; and being surrounded by the suture, form independent pieces, which are called *ossa triquetra*, or *ossa Wormiana*. In the lambdoid suture there is generally one or more of these bones; and, in a beautiful hydrocephalic skeleton¹ in the College of Surgeons, there are upwards of one hundred.

¹ This skeleton belonged to Mr. Liston.

The *coronal suture* (fig. 64) extends transversely across the vertex of the skull, from the upper part of the greater wing of the sphenoid of one side to the same point of the opposite side; it connects the frontal with the parietal bones. In the formation of this suture the edges of the articulating bones are bevelled, so that the parietal rest upon the frontal at each side, and in the middle the frontal rests upon the parietal bones; they thus afford to each other mutual support, and increased consolidation to the skull.

The *sagittal suture* extends longitudinally backwards along the vertex of the skull, from the middle of the coronal to the apex of the lambdoid suture. It is much serrated, and serves to unite the two parietal bones. In the young subject, and sometimes in the adult, this suture is continued through the middle of the frontal bone to the root of the nose, under the name of the *frontal suture*. *Ossa triquetra* are sometimes found in the sagittal suture.

The *lambdoid suture* is named from some resemblance to the Greek letter Λ , consisting of two branches, which diverge at an acute angle from the extremity of the sagittal suture. This suture connects the occipital with the parietal bones. At the posterior and inferior angle of the parietal bones, the lambdoid suture is continued onwards in a curved direction to the base of the skull, and serves to unite the occipital bone with the mastoid portion of the temporal, under the name of *additamentum suturæ lambdoidalis*. It is in the lambdoid suture that *ossa triquetra* occur most frequently.

The *squamous suture* (fig. 64) unites the squamous portion of the temporal bone with the greater ala of the sphenoid, and with the parietal, overlapping the lower border of the latter. The portion of the suture which is continued backwards from the squamous portion of the bone to the lambdoid suture, and connects the mastoid portion with the posterior inferior angle of the parietal, is the *additamentum suturæ squamosæ*.

The *additamentum suturæ lambdoidalis*, and *additamentum suturæ squamosæ*, constitute together the *mastoid suture*.

Across the upper part of the face is an irregular suture, the *transverse*, which connects the frontal bone with the nasal, superior maxillary, lachrymal, ethmoid, sphenoid, and malar bones. The remaining sutures are not sufficiently important to deserve particular names or description.

REGIONS OF THE SKULL.

The skull, considered as a whole, is divisible into four regions: a superior region or vertex; a lateral region¹; an inferior region or base; and an anterior region, the face.

The SUPERIOR REGION, or vertex of the skull, is bounded anteriorly by the frontal eminences; on each side by the temporal ridge and parietal eminence; and behind by the superior curved line of the occipital bone and occipital protuberance. It is crossed transversely by the coronal suture, and marked from before backwards by the sagittal, which terminates posteriorly in the lambdoid suture. Near the posterior extremity of the region, and on each side of the sagittal suture, is the parietal foramen.

On the *inner* or *cerebral surface* of this region is a shallow groove, extending along the middle line from before backwards, for the superior longitudinal sinus; at either side of this groove are several small fossæ for the Pacchionian bodies, and further outwards, digital fossæ corresponding with the convexities of the convolutions, and numerous ramified grooves for lodging the branches of the *arteria meningea media*.

The LATERAL REGION of the skull is divisible into three portions; temporal, mastoid, and zygomatic.

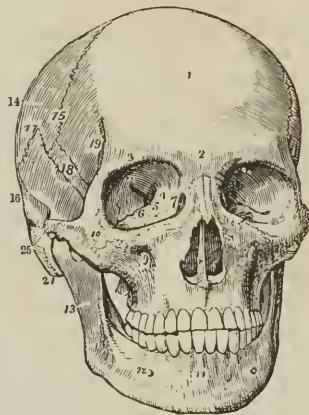
The *temporal portion*, or *temporal fossa*, is bounded above and behind by the temporal ridge, in front by the external angular process of the frontal and by the

¹ [There are, of course, two lateral regions.]

malar bone, and below by the zygoma. It is formed by part of the frontal, great wing of the sphenoid, parietal, squamous portion of the temporal, malar bone, and zygoma, and lodges the temporal muscle with the deep temporal arteries and nerves.

The *mastoid portion* is rough, for the attachment of muscles: On its posterior part is the mastoid foramen; and below, the mastoid process. In front of the mastoid process is the external auditory foramen, surrounded by the external auditory process; and in front of this foramen the glenoid cavity, bounded above by the middle root of the zygoma and in front by its tubercle.

FIG. 64.



FRONT VIEW OF THE SKULL. 1. Frontal portion of the frontal bone. The 2, immediately over the root of the nose, refers to the nasal tuberosity; the 3, over the orbit, to the supra-orbital ridge. 4. Optic foramen. 5. Sphenoidal fissure. 6. Spheno-maxillary fissure. 7. Lachrymal fossa in the lachrymal bone, the commencement of the nasal duct. The figures 4, 5, 6, 7, are within the orbit. 8. Opening of the anterior nares, divided into two parts by the vomer; the cipher is placed upon the latter. 9. Infraorbital foramen. 10. Malar bone. 11. Symphysis of the lower jaw. 12. Mental foramen. 13. Ramus of the lower jaw. 14. Parietal bone. 15. Coronal suture. 16. Temporal bone. 17. Squamous suture. 18. Upper part of the great ala of the sphenoid bone. 19. Commencement of the temporal ridge. 20. Zygoma of the temporal bone, assisting to form the zygomatic arch. 21. Mastoid process.

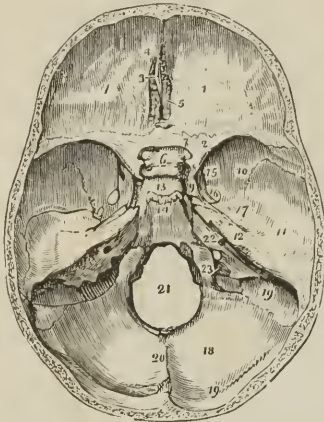
The *zygomatic portion*, or *fossa*, is the irregular cavity below the zygoma, bounded in front by the superior maxillary bone, internally by the external pterygoid plate, above by part of the great wing of the sphenoid, squamous portion of the temporal bone, and temporal fossa; and externally by the zygomatic arch and ramus of the lower jaw. It contains the external pterygoid, part of the temporal, and internal pterygoid muscle, the internal maxillary artery and inferior maxillary nerve, with their branches. At the inner side and upper part of the zygomatic fossa are two fissures, spheno-maxillary and pterygo-maxillary. The *spheno-maxillary fissure*, horizontal in direction, opens into the orbit, and is situated between the great ala of the sphenoid and the superior maxillary bone. It is completed externally by the malar bone. The *pterygo-maxillary fissure* is vertical, and descends at a right angle from the [inner] extremity of the preceding. It is situated between the pterygoid process and the tuberosity of the superior maxillary bone, and transmits the internal maxillary artery. At the angle of junction of these two fissures is a small space, the *spheno-maxillary fossa*, bounded by the sphenoid, palate, and superior maxillary bone. In this space are seen the openings of five foramina; foramen rotundum, spheno-palatine, pterygo-palatine,

posterior palatine, and Vidian. The spheno-maxillary fossa lodges Meckel's ganglion and the termination of the internal maxillary artery.

The BASE OF THE SKULL presents an internal or cerebral, and an external or basilar surface.

The *cerebral surface* is divisible into three parts, which are named, anterior, middle, and posterior fossa of the base of the cranium. The *anterior fossa* is somewhat convex at each side, where it corresponds with the roof of the orbit; and concave in the middle, in the situation of the ethmoid bone and anterior part

FIG. 65.



CEREBRAL SURFACE OF THE BASE OF THE SKULL. 1. One side of the anterior fossa; the cipher is placed on the roof of the orbit, formed by the orbital plate of the frontal bone. 2. Lesser wing of the sphenoid. 3. Crista galli. 4. Foramen cæcum. 5. Cribriform lamella of the ethmoid. 6. Processus olivaris. 7. Foramen opticum. 8. Anterior clinoid process. 9. Carotid groove on the side of the sella turcica, for the internal carotid artery and cavernous sinus. 10, 11, 12. [One side of the] middle fossa of the base of the skull. 10, marks the great ala of the sphenoid. 11. Squamous portion of the temporal bone. 12. Petrous portion of the temporal. 13. Sella turcica. 14. Basilar portion of the sphenoid and occipital bone (clivus Blumenbachii). The uneven ridge between Nos. 13, 14, is the dorsum ephippii, and the prominent angles of this ridge the posterior clinoid processes. 15. Foramen rotundum. 16. Foramen ovale. 17. Foramen spinosum; the small irregular opening between 17 and 12 is the hiatus Fallopii. 18. [One side of the] posterior fossa of the base of the skull; receptaculum cerebelli. 19, 19. Groove for the lateral sinus. 20. Ridge on the occipital bone, which gives attachment to the falx cerebelli. 21. Foramen magnum. 22. Meatus auditorius internus. 23. Jugular foramen.

of the body of the sphenoid. The latter and the lesser wings constitute its posterior boundary. It supports the anterior lobes of the cerebrum. In the middle line of this fossa, at its anterior part, is the *crista galli*; immediately in front of that process, the *foramen cæcum*; and on each side, the *cribriform plate* with its *foramina*, for the transmission of the filaments of the olfactory and nasal branch of the ophthalmic nerve. Further back in the middle line is the *processus olivaris*, and at the sides of this process the *optic foramina*, *anterior* and *middle clinoid processes*, and vertical *grooves* for the internal carotid arteries.

The *middle fossa* of the base, deeper than the preceding, is bounded [on each side] in front by the lesser wing of the sphenoid; behind, by the petrous portion of the temporal bone; and is divided into two lateral parts by the sella turcica. It is formed [on either side] by the posterior part of the body, great ala, and spinous process of the sphenoid, and by the petrous and squamous portion of the temporal bone. In the centre of this fossa is the *sella turcica*, which lodges the pituitary gland,

bounded in front by the *anterior* and *middle*, and behind by the *dorsum ephippii* and *posterior clinoid processes*. On each side of the sella turcica is the *carotid groove* for the internal carotid artery, cavernous plexus of nerves, cavernous sinus, and orbital nerves; and further outwards the following foramina, from before backwards: *sphenoidal fissure* (foramen lacerum anterius) for the transmission of the third, fourth, three branches of the ophthalmic division of the fifth, and the sixth nerve, and ophthalmic vein; *foramen rotundum*, for the superior maxillary nerve; *foramen ovale*, for the inferior maxillary nerve, arteria meningea parva and nervus petrosus superficialis minor; *foramen spinosum*, for the arteria meningea media; *foramen lacerum basis cranii*, which gives passage to the internal carotid artery, carotid plexus, and petrosal branch of the Vidian nerve. On the anterior surface of the petrous portion of the temporal bone is a groove, leading to a fissured opening, the *hiatus Fallopii*, for the petrosal branch of the Vidian nerve; and, immediately beneath this, a smaller foramen, for the nervus petrosus superficialis minor. Towards the apex of the petrous portion is the notch for the fifth nerve, and below it a slight depression for the Gasserian ganglion. Further outwards is the eminence which marks the position of the perpendicular semi-circular canal. Proceeding from the foramen spinosum are two grooves, which indicate the course of the trunks of the arteria meningea media. The whole fossa lodges the middle lobes of the cerebrum.

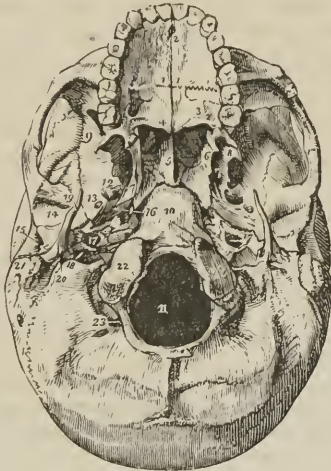
The *posterior fossa*, larger than the other two, is formed by the occipital bone, petrous and mastoid portion of the temporals, and by a small part of the sphenoid and parietals. It is bounded in front by the upper border of the petrous portion and dorsum ephippii, and along its posterior circumference by the groove for the lateral sinuses; it gives support to the pons Varolii, medulla oblongata, and cerebellum. In the centre of this fossa is the *foramen magnum*, bounded at each side by a rough tubercle, which gives attachment to the odontoid ligament, and by the anterior condyloid foramen. In front of the foramen magnum is the concave surface (clivus Blumenbachii) which supports the medulla oblongata and pons Varolii, and, on each side, the following foramina, from before backwards. The *internal auditory foramen*, for the auditory and facial nerve and auditory artery; behind, and externally to this, is a small foramen leading into the *aquæductus vestibuli*; and below it, partly concealed by the edge of the petrous bone, the *aquæductus cochleæ*; next, a long fissure, the *foramen lacerum posterius*, or jugular foramen, giving passage externally to the commencement of the internal jugular vein, and internally to the eighth pair of nerves. Converging towards this foramen from behind is the deep groove of the lateral sinus, and from the front the groove for the inferior petrosal sinus.

Behind the foramen magnum is a longitudinal ridge, which gives attachment to the falx cerebelli, and divides the two inferior fossæ of the occipital bone; and above the ridge is the internal occipital protuberance and the transverse groove lodging the lateral sinus.

The *external surface* of the base of the skull is extremely uneven. From before backwards it is formed by the palate processes of the superior maxillary and palate bones; the vomer; pterygoid, spinous processes, and part of the body of the sphenoid; under surface of the squamous, petrous, and mastoid portion of the temporals; and by the occipital bone. The palate processes of the superior maxillary and palate bones constitute the hard palate, which is raised above the level of the rest of the base, and is surrounded by the alveolar processes containing the teeth of the upper jaw. At the anterior extremity of the hard palate, and directly behind the front incisor teeth, is the *anterior palatine* or *incisive foramen*, the termination of the anterior palatine canal, which transmits the naso-palatine nerves. At the posterior angles of the palate are the *posterior palatine foramina*, for the palatine nerves and arteries. Passing inwards from these foramina are the *transverse ridges*, to which are attached the aponeurotic expansions of the tensor palati muscles; and at the middle line of the posterior border,

the *palate spine*, which gives origin to the *azygos uvulæ*. The hard palate is marked by a crucial suture, which distinguishes the four processes of which it is composed. Behind, and above the hard palate, are the *posterior nares*, separated by the vomer, and bounded on each side by the pterygoid processes. At the

FIG. 66.



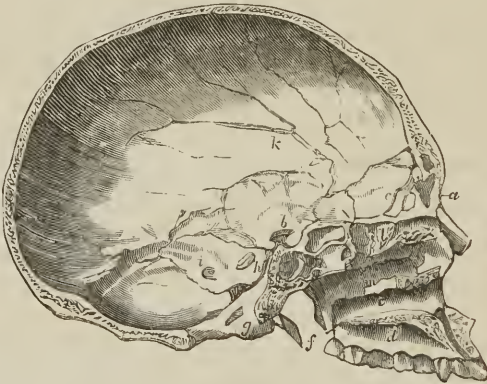EXTERNAL OR BASILAR SURFACE OF THE BASE OF THE SKULL. 1, 1. The hard palate. The figures are placed on the palate processes of the superior maxillary bones. 2. Incisive, or anterior palatine foramen. 3. Palate process of the palate bone. The large opening near the figure is the posterior palatine foramen. 4. Palate spine; the curved line upon which the cipher rests is the transverse ridge. 5. Vomer, dividing the openings of the posterior nares. 6. Internal pterygoid plate. 7. Scaphoid fossa. 8. External pterygoid plate. The interval between 6 and 8 (right side of the figure) is the pterygoid fossa. 9. Zygomatic fossa. 10. Basilar process of the occipital bone. 11. Foramen magnum. 12. Foramen ovale. 13. Foramen spinosum. 14. Glenoid fossa. 15. Meatus auditorius externus. 16, Foramen lacerum anterius basis cranii. 17. The carotid foramen of the left side. 18. Foramen lacerum posterius, or jugular foramen. 19. Styloid process. 20. Stylo-mastoid foramen. The elevation just to the right of the figure is the jugular tubercle; and the groove to its left the digastric fossa. 21. Mastoid process. 22. One of the condyles of the occipital bone. 23. Posterior condyloid fossa.

base of the pterygoid processes are *pterygo-palatine canals*. The internal pterygoid plate is long and narrow, terminated at its apex by the hamular process, and at its base by the scaphoid fossa. The external plate is broad; the space between the two is the pterygoid fossa; it contains part of the internal pterygoid muscle, and the tensor palati. Externally to the external pterygoid plate is the zygomatic fossa. Behind the nasal fossæ, in the middle line, is the under surface of the body of the sphenoid, and the basilar process of the occipital bone, and still further back, the foramen magnum. At the base of the external pterygoid plate, on each side, is the *foramen ovale*, and behind this the *foramen spinosum*, with the prominent spine which gives attachment to the internal lateral ligament of the lower jaw and laxator tympani muscle. Running outwards from the apex of the spinous process of the sphenoid bone, is the fissura Glaseri, which crosses the glenoid fossa transversely, and divides it into an anterior smooth surface, bounded by the eminentia articularis, for the condyle of the lower jaw, and a posterior rough surface for a part of the parotid gland. Behind the foramen ovale and spinosum, is the irregular fissure between the spinous process of the

sphenoid bone and the petrous portion of the temporal, the foramen lacerum anterius basis cranii, which lodges the internal carotid artery and Eustachian tube, and in which the carotid branch of the Vidian nerve joins the carotid plexus. Following the direction of this fissure outwards, we see the foramen for the Eustachian tube, and that for the tensor tympani muscle, separated from each other by the processus cochleariformis. Behind the fissure is the pointed process of the petrous bone which gives origin to the levator palati muscle, and externally to this process, the carotid foramen for the transmission of the internal carotid artery and ascending branch of the superior cervical ganglion of the sympathetic; and behind the carotid foramen, the foramen lacerum posterius basis cranii and jugular fossa. Externally, and somewhat in front of the latter, is the styloid process, and at its base the vaginal process. Behind and at the root of the styloid process is the stylo-mastoid foramen, for the facial nerve and stylo-mastoid artery, and further outwards the mastoid process. At the inner side of the root of the mastoid process is the digastric fossa; and a little further inwards, the occipital groove. On the sides of the foramen magnum, and near its anterior circumference, are the condyles of the occipital bone. In front of each condyle, and piercing its base, is the anterior condyloid foramen for the hypoglossal nerve, and directly behind the condyle the irregular fossa in which the posterior condyloid foramen is situated. Behind the foramen magnum are the two curved lines of the occipital bone, the spine, and the protuberance, with the rough surfaces for the attachment of muscles.

The FACE is somewhat oval in contour, uneven in surface, and excavated for the reception of two principal organs of sense, the eye and the nose. It is formed by part of the frontal bone and by the bones of the face. Superiorly it is bounded

[Fig. 67.]



RESPECTIVE DIMENSIONS OF THE CRANIUM AND FACE. Vertical section of the cranium and upper jaw; left side, seen from within. Besides showing the anatomical details of these extensive and complex osseous surfaces, the section is a valuable one, physiologically: it enables the student to compare the area of the cerebral and cerebellar cavities with the area of the face, or at least of the upper jaw; the relation therefore which the encephalon has to organs of sense. It displays also the position of the brain to the face, pharynx, and vertebral column, although these last are not present in the figure. — *d*. The osseous palate; *e*. Inferior meatus of the nostril. *m*. Middle meatus. *l*. A portion of the perpendicular lamella of the ethmoid, *a*. Points to the frontal sinus. *c*. Crista galli. *k*. Grooves for the branches of the middle meningeal artery. *b*. Posterior clinoid processes. *h*. Foramen ovale. *i*. Groove for the left lateral sinus. *g*. Is placed near the section of the foramen magnum; the anterior condyloid foramen is just above the letter. *f*. Styloid process of the temporal bone.]

by the frontal eminences; beneath these are the superciliary ridges, converging towards the nasal tuberosity; beneath the superciliary ridges are the supraorbital

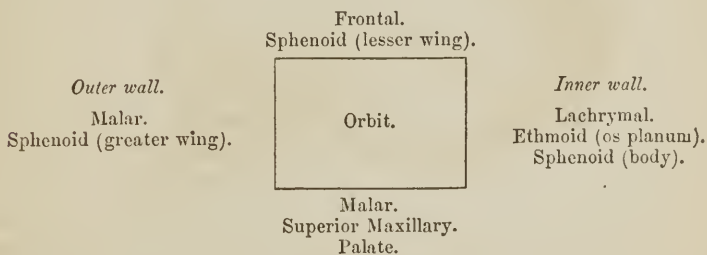
ridges, terminating externally in the external border of the orbit, and internally in the internal border, and presenting towards their inner third the supraorbital notch, for the supraorbital nerve and artery. Beneath the supraorbital ridges are the cavities of the orbits. Between the orbits is the bridge of the nose, over-arching the anterior nares; and on each side of the nares the canine fossa of the superior maxillary bone, the infraorbital foramen, and still further outwards the prominence of the malar bone; at the lower margin of the nares is the nasal spine, and beneath it the superior alveolar arch, containing the teeth of the upper jaw. Forming the lower boundary of the face is the lower jaw, containing in its alveolar process the lower teeth, and projecting inferiorly to constitute the chin; on either side of the chin is the mental foramen. If a perpendicular line be drawn from the inner third of the supraorbital ridge to the inner third of the body of the lower jaw, it will be found to intersect three openings; the supraorbital, infraorbital, and mental, each giving passage to a facial branch of the fifth nerve.

[An antero-posterior vertical section of the cranium presents an oval with the broad end backwards; a similar section of the face is triangular.

In the Caucasian race the area of the cranium equals four times that of the face, without the lower jaw; in the negro the area of the face is increased one-fifth.]

ORBITS.

The *orbits* are two quadrilateral hollow cones, situated in the upper part of the face, and intended for the reception of the eyeballs, with their muscles, vessels, and nerves, and the lachrymal glands. The central axis of each orbit is directed outwards, so that the axes of the two, continued into the skull through the optic foramina, would intersect over the middle of the sella turcica. The *superior boundary* of the orbit is formed by the orbital plate of the frontal bone, and part of the lesser wing of the sphenoid; the *inferior*, by part of the malar bone, superior maxillary, and palate bone; the *internal*, by the lachrymal bone, os planum of the ethmoid, and part of the body of the sphenoid; the *external*, by the orbital process of the malar bone and great ala of the sphenoid. These may be expressed more clearly in a tabular form:—



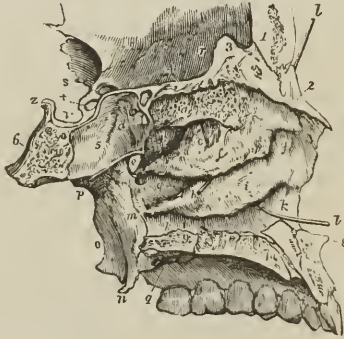
There are *nine* openings communicating with the orbit: the *optic*, for the admission of the optic nerve and ophthalmic artery; the *sphenoidal fissure*, for the transmission of the third, fourth, the three branches of the ophthalmic division of the fifth nerve, the sixth nerve, and the ophthalmic vein; the *sphenomaxillary fissure*, for the passage of the superior maxillary nerve and infraorbital artery to the opening of entrance of the *infraorbital canal*; *temporo-malar foramina*, two or three small openings in the orbital process of the malar bone, for the passage of filaments of the orbital branch of the superior maxillary nerve; *anterior and posterior ethmoidal foramina* in the suture between the os planum and frontal bone, the former transmitting the nasal nerve and anterior ethmoidal artery, the latter the posterior ethmoidal artery and vein; the opening of the

nasal duct; and the *supraorbital notch* or foramen, for the supraorbital nerve and artery.

NASAL FOSSÆ.

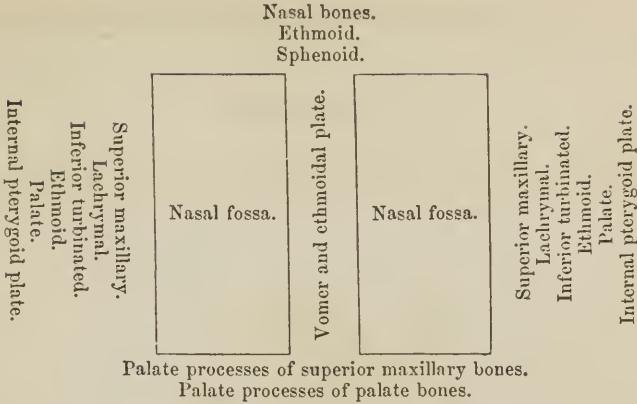
The nasal fossæ are two irregular cavities, situated in the middle of the face, and extending from before backwards. They are bounded *above* by the nasal

FIG. 68.



LONGITUDINAL SECTION OF THE NASAL FOSSÆ made immediately to the right of the middle line, the bony septum removed in order to show the external wall of the left fossa. 1. Frontal bone. 2. Nasal bone. 3. Crista galli process of the ethmoid. The groove between 1 and 3 is the lateral boundary of the foramen cæcum. 4. Cribriform plate of the ethmoid. 5. Part of the sphenoidal cells. 6. Basilar portion of the sphenoid bone. Bones 2, 4, and 5, form the superior boundary of the nasal fossa. 7, 7. Articulating surface of the palatine process of the superior maxillary bone. The groove between 7, 7, is the lateral half of the incisive canal, and the dark aperture in the groove the inferior termination of the left nasopalatine canal. 8. Nasal spine. 9. Palatine process of the palate bone. *a*. Superior turbinated bone, marked by grooves and apertures for filaments of the olfactory nerve. *b*. Superior meatus. *c*. A probe passed into the posterior ethmoidal cells. *d*. Opening of the sphenoidal cells into the superior meatus. *e*. Spheno-palatine foramen. *f*. Middle turbinated bone. *g, g*. Middle meatus. *h*. A probe passed into the infundibular canal, leading from the frontal sinuses and anterior ethmoid cells; the triangular aperture immediately above the letter is the opening of the maxillary sinus. *i*. Inferior turbinated bone. *k, k*. Inferior meatus. *l, l*. A probe passed up the nasal duct, showing the direction of that canal. The anterior letters *g, k*, are placed on the superior maxillary bone, the posterior on the palate bone. *m*. Internal pterygoid plate. *n*. Its hamular process. *o*. External pterygoid plate. *p*. Root of the pterygoid processes. *q*. Posterior palatine foramina. *r*. Roof of the left orbit. *s*. Optic foramen. *t*. Groove for the last turn of the internal carotid artery converted into a foramen by the development of an osseous communication between the anterior and middle clinoid process. *v*. Sella turcica. *z*. Posterior clinoid process.

bones, ethmoid and sphenoid; *below* by the palate processes of the superior maxillary and palate bones; *externally* by the superior maxillary, lachrymal, inferior turbinated, superior and middle turbinated bones of the ethmoid, palate, and internal pterygoid plate of the sphenoid; and the two fossæ are separated by the vomer and perpendicular lamella of the ethmoid. These may be more clearly expressed in a tabular form: —

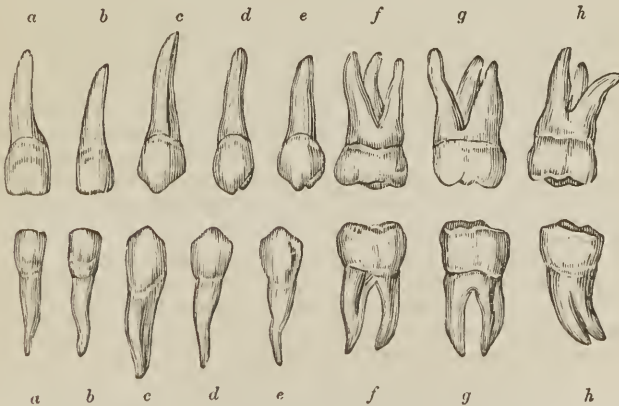


Each nasal fossa is divided into three irregular longitudinal passages, or *meatuses*, by three processes of bone, which project from its outer wall, the superior, middle, and inferior turbinated bones; the superior and middle turbinated bones being processes of the ethmoid; the inferior, a distinct bone of the face. The *superior meatus* occupies the superior and posterior part of each fossa; it is situated between the superior and middle turbinated bones, and has opening into it three foramina, viz., foramen of the posterior ethmoid cells, foramen of the sphenoid cells, and spheno-palatine foramen. The *middle meatus* is the space between the middle and inferior turbinated bones; it also presents three foramina, the opening of the frontal sinus, of the anterior ethmoid cells, and of the antrum. The largest of the three passages is the *inferior meatus*, which is the space between the inferior turbinated bone and the floor of the nasal fossa; in it there are two foramina, the termination of the nasal duct, and one opening of the anterior palatine canal. The nasal fossæ commence upon the face by a large irregular opening, the anterior nares, and terminate posteriorly in the two posterior nares.

TEETH.

Man is provided with two successions of teeth: the first are the teeth of childhood; they are called, temporary, deciduous, or milk teeth; the second continue until old age, and are named permanent.

[Fig. 69.]

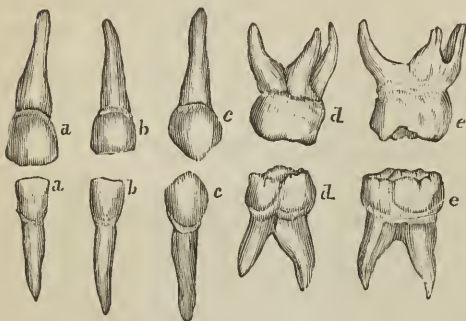


PERMANENT TEETH OF LEFT SIDE. *a.* Central incisor. *b.* Lateral incisor. *c.* Cuspid or canine. *d.* First bicuspid. *e.* Second bicuspid. *f.* First molar. *g.* Second molar. *h.* Third molar or *dens sapientia*.]

The *permanent teeth* are thirty-two in number, sixteen in each jaw; they are divisible into four classes; *incisors*, of which there are four in each jaw, two central, and two lateral; *canine*, two above and two below; *bicuspid*, four above and four below; and *molars*, six above and six below. [Those of the upper jaw form the larger arch, so as to overlap those of the lower jaw in front, and to overhang them somewhat at the sides, when the mouth is closed.]

The *temporary teeth* are twenty in number; eight incisors, four canine, and eight molars. The temporary molars have four tubercles, and are succeeded by the permanent bicuspid, which have only two tubercles.

[FIG. 70.]



TEMPORARY TEETH OF LEFT SIDE. a. Central incisor. b. Lateral incisor. c. Canine. d. First molar. e. Second molar.]

Each tooth is divisible into a *crown*, which is the part apparent above the gum; a constricted portion around the base of the crown, the *neck*; and a *root* or *fang*, which is contained within the alveolus. The root is invested by periosteum, which is a bond of connexion between it and the alveolus.

The *incisor teeth* (cutting teeth) are named from presenting a sharp and cutting edge, formed at the expense of the posterior

surface. The crown is flattened from before backwards, being somewhat convex in front and concave behind; the neck is much constricted, and the root compressed from side to side; at its apex is a small opening for the passage of the nerve and artery of the tooth.

The *canine teeth* (cuspidati) follow the incisors in order from before backwards; two are situated in the upper jaw, one at each side, and two in the lower. The crown is larger than that of the incisors, convex before, concave behind, and tapering to a blunted point. The root is longer than that of all the other teeth, compressed at each side, and marked by a slight groove.

The *bicuspid teeth* (bicuspidati, small molars), two at each side in each jaw, follow the canine, and are intermediate in size between them and the molars. The crown is compressed from before backwards, and surmounted by two tubercles, one internal, the other external; the neck is oval; the root compressed, marked on each side by a deep groove, and bifid near its apex. The teeth of the upper jaw have a greater tendency to the division of their roots than those of the lower, and the posterior than the anterior pair.

The *molar teeth* (multicuspidati, grinders), three at each side in each jaw, are the largest of the permanent set. The crown is quadrilateral, and surmounted by four tubercles; the neck large and round, and the root divided into several fangs. In the upper jaw the first and second molar teeth have three roots, sometimes four, which are more or less widely separated from each other, two of the roots being external, the other internal. In the lower there are but two roots, which are anterior and posterior; they are flattened from behind forwards, and grooved so as to mark a tendency to division. The third molars, or *dentes sapientiae*, are smaller than the other two; they present three tubercles on the surface of the crown: and the root is single and grooved, appearing to be made up of four or five fangs compressed together, or partially divided. In the lower jaw the fangs are frequently separated to some distance from each other, and much curved, so as to offer considerable resistance in the operation of extraction.

Structure. — The base of the crown of each tooth is hollowed in its interior

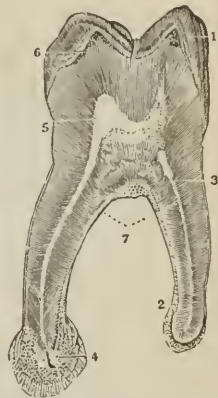
into a small cavity which is continuous with a canal passing through the middle of each fang. The cavity and canal, or canals, constitute the *cavitas pulpæ*, and contain a soft cellulo-vascular organ, the *pulp*, which receives its supply of vessels and nerves through the small opening at the apex of each root. Nasmyth has observed, with regard to the pulp, that it is composed of two different tissues, *vascular* and *reticular*, the former being an intricate web of minute vessels terminating in simple capillary loops; the latter, a network of nucleated cells in which calcareous salts are gradually deposited, and which, by a systematic continuance of that process, are gradually converted into ivory. This process naturally takes place at the surface of the pulp, and as the pulp is thus robbed of its cells, new cells are produced by the capillary plexus to supply their place, and be in their turn similarly transformed.

A tooth is composed of three distinct structures, ivory or tooth-bone [*dentine*], enamel, and a cortical substance or cementum. When viewed with the microscope, the *ivory* appears to consist of very minute, tapering, and branching fibres, imbedded in a dense, homogeneous, interfibrous substance. The fibres commence by their larger ends in the walls of the *cavitas pulpæ*, and pursue a radiating and serpentine course towards the periphery of the tooth, where they terminate in ramifications of extreme minuteness. These fibres, formerly considered as hollow tubuli, were shown by Nasmyth to be rows of minute opaque bodies, arranged in a linear series (baccated fibres), to be, in fact, the nuclei of the ivory cells, the interfibrous substance being the rest of the cell filled with calcareous matter. In the natural state of the tooth all trace of the parietes or mode of connexion of the cells is lost, but, after steeping in weak acid, the cellular network is made evident.

The *enamel* forms a crust over the whole exposed surface of the crown of the tooth to the commencement of its root; it is thickest on the summit of the tooth, and becomes gradually thinner as it approaches the neck. It is composed of minute hexagonal crystalline fibres, resting by one extremity against the surface of the ivory, and constituting by the other the free surface of the crown. The fibres, examined on the face of a longitudinal section, have a waving arrangement, and consist, like those of ivory, of cells connected by their surfaces and ends, and filled with calcareous substance. When the latter is removed by weak acid, the enamel presents a delicate cellular network of animal tissue.

The *cortical substance*, or cementum (*substantia ostoidea*) forms a thin coating over the root of the tooth, from the termination of the enamel to the opening in the apex of the fang. In structure it is analogous to bone, and is characterized by the presence of Purkinjean cells and tubuli. The cementum increases in thickness with the advance of age, and gives rise to those exostosed appearances occasionally seen on the teeth of very old persons, or in those who have taken much mercury. In old age the *cavitas pulpæ* is often found filled up and obliterated by osseous substance analogous to the cementum. Nasmyth has shown

[FIG. 71.]



MICROSCOPIC SECTION OF A MOLAR TOOTH. 1. Enamel, with its columns and laminated structure. 2, 7. Cortical substance, or cementum, on the outside of the fang. 3. Ivory, showing tubuli. 4. Foramen, entering the dental cavity from the end of the fang. This fang has a bulbous enlargement, in consequence of a hypertrophy of the cementum. 5. Dental cavity. 6. A few osseous corpuscles in the ivory, just under the enamel.]

that this, like the other structures composing a tooth, is formed of cells having a reticular arrangement.

Development. — The development of the teeth in the human subject has been successfully investigated by Mr. Goodsir,¹ whose inquiries commenced as early as the sixth week after conception, in an embryo, which measured seven lines and a half in length, and weighed fifteen grains. At this early period each upper jaw presents two semicircular folds around its circumference; the most external is the true lip; the internal, the rudiment of the palate; and between these is a deep groove, lined by the common mucous membrane of the mouth. A little later a ridge is developed from the floor of this groove in a direction from behind forwards; this is the rudiment of the external alveolus; and the arrangement of the appearances from without inwards at this period is the following: Most externally, and forming the boundary of the mouth, is the *lip*; next we find a *deep groove*, which separates the lip from the future jaw; then comes the *external alveolar ridge*; fourthly, another groove, in which the germs of the teeth are developed, the *primitive dental groove*; fifthly, a rudiment of the *internal alveolar ridge*; and sixthly, the rudiment of the *future palate* bounding the whole internally. At the seventh week the germ of the first deciduous molar of the upper jaw has made its appearance, in the form of a "simple, free, granular papilla" of the mucous membrane, projecting from the floor of the primitive dental groove; at the eighth week, the papilla of the canine tooth is developed; at the ninth week, the papillæ of the four incisors (the middle preceding the lateral) appear; and at the tenth week, the papilla of the second molar is seen behind the anterior molar in the primitive dental groove. So that at this early period, the tenth week, the papillæ or germs of the whole ten deciduous teeth of the upper jaw are quite distinct. Those of the lower jaw are a little more tardy; the papilla of the first molar is merely a slight bulging at the seventh week, and the tenth papilla is not apparent until the eleventh week.

[FIG. 72.]

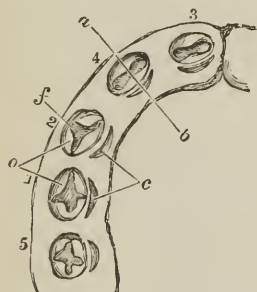


DIAGRAM OF THE LEFT HALF OF THE LOWER JAW, AT ABOUT THE FOURTEENTH WEEK, considerably magnified, to show the follicles of the milk teeth opened out, their opercula, and the position of the lunated recesses behind them, from which the sacs of the five anterior permanent teeth are developed. — 1 to 5. Milk-teeth follicles, numbered in their order of appearance and formation. 1. First molar. 2. Canine. 3. Central incisor. 4. Lateral incisor. 5. Second molar. *a, b.* A dotted line, to indicate the direction in which the cross sections, represented in Fig. 73, are supposed to be made. *f.* The cavity of the follicle, the papilla being hid. *o.* The opercula. *c.* Lunated depressions, which resist the subsequent adhesion of the mucous membrane, and become the cavities of reserve for the permanent teeth.]

From about the eighth week the primitive dental groove becomes contracted before and behind the first deciduous molar, and laminae of the mucous membrane are developed around the other papillæ; the laminae increase in growth, and inclose the papillæ in follicles with open mouths. At the tenth week the follicle of the first molar is completed, then that of the canine; during the eleventh and twelfth weeks the follicles of the incisors succeed, and at the thirteenth week the follicle of the posterior deciduous molar.

During the thirteenth week the papillæ undergo an alteration of form, and assume the shape of the teeth they are intended to represent. And at the same time small membranous processes are developed from the mouths of the follicles; these pro-

¹ "On the Origin and Development of the Pulp and Sacs of the Human Teeth," by John Goodsir, jun., in the Edinburgh Medical and Surgical Journal, January, 1839.

cesses are intended to serve the purposes of opercula to the follicles, and they correspond in shape with the form of the crowns of the appertaining teeth. To the follicles of the incisor teeth there are two opercula; to the canine, three; and to the molars, a number relative to the number of their tubercles, either four or five. During the fourteenth or fifteenth weeks the opercula have completely closed the follicles, so as to convert them into *dental sacs*, and at the same time the papillæ have become *pulps*.

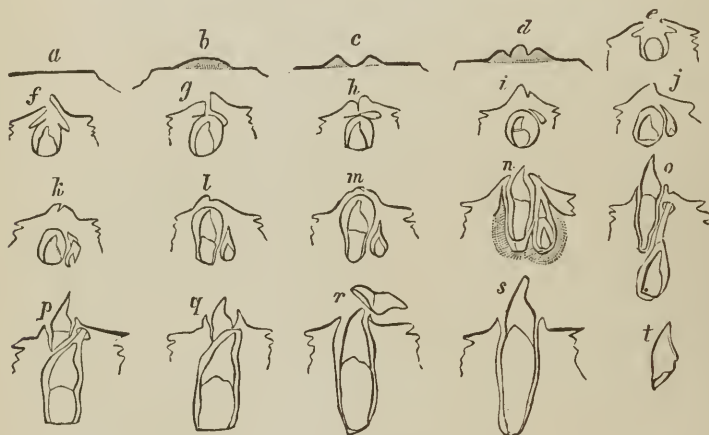
The deep portion of the primitive dental groove, viz., that which contains the dental sacs of the deciduous teeth, being thus closed in, the remaining portion, that which is nearer the surface of the gum, is still left open, and to this Mr. Goodsir has given the title of *secondary dental groove*, as it serves for the development of all the permanent teeth, with the exception of the anterior molars. During the fourteenth and fifteenth weeks, small lunated inflexions of the mucous membrane are formed, immediately to the inner side of the closing opercula of the deciduous dental follicles, commencing behind the incisors and proceeding onwards through the rest; these are the rudiments of the follicles or *cavities of reserve* of the four permanent incisors, two permanent canines, and four bicuspides. As the secondary dental groove gradually closes, these follicular inflexions of the mucous membrane are converted into closed *cavities of reserve*, which recede from the surface of the gum, and lie immediately to the inner side, and in close contact with the dental sacs of the deciduous teeth, being inclosed in their submucous cellular tissue. At about the fifth month the anterior of these cavities of reserve dilate at their distal extremities, and a fold or papilla projects into their fundus, constituting the rudiment of the germ of the permanent tooth; at the same time two small opercular folds are produced at their proximal or small extremities, and convert them into true dental sacs.

During the fifth month the posterior part of the primitive dental groove behind the sac of the last deciduous tooth has remained open, and in it has developed the papilla and follicle of the first permanent molar. Upon the closure of this follicle by its opercula, the secondary dental groove upon the summit of its crown forms a large cavity of reserve, lying in contact with the dental sac on the one side and with the gum on the superficial side. At this period the deciduous teeth, and the sacs of the ten anterior permanent teeth, increase so much in size, without a corresponding lengthening of the jaws, that the first permanent molars are gradually pressed backwards and upwards into the maxillary tuberosity in the upper jaw, and into the base of the coronoid process of the lower jaw; a position which they occupy at the eighth and ninth month of fœtal life. In the infant of seven or eight months, the jaws have grown in length, and the first permanent molar returns to its proper position in the dental range. The cavity of reserve, which has been previously elongated by the upward movement of the first permanent molar, now dilates into the cavity which that tooth has just quitted; a papilla is developed from its fundus, the cavity becomes constricted, and the dental sac of the second molar tooth is formed, still leaving a portion of the great cavity of reserve in connexion with the superficial side of the sac. As the jaws continue to grow in length, the second permanent dental sac descends from its elevated position and advances forwards into the dental range, following the same curve as the first permanent molar. The remainder of the cavity of reserve, already lengthened backwards by the previous position of the second molar, again dilates for the last time, develops a papilla and sac in the same manner as the preceding, and forms the third permanent molar or wisdom tooth, which, at the age of nineteen or twenty, on the increased growth of the jaw, follows the course of the first and second molars into the dental range.

From a consideration of the foregoing phenomena, Mr. Goodsir has divided the process of dentition into three natural stages: follicular, saccular, and eruptive. The first, or *follicular stage*, he makes to include all the changes which take place from the first appearance of the dental groove and papillæ to the clo-

sure of their follicles; occupying a period which extends from the sixth week to the fourth or fifth month of intra-uterine existence. The second, or *succular stage*, comprises the period when the follicles are shut sacs, and the included papillæ, pulps; it commences at the fourth and fifth months of intra-uterine existence, and terminates, for the median incisors, at the seventh or eighth month of infantile life, and for the wisdom teeth, at about the twenty-first year. The third, or *eruptive stage*, includes the completion of the teeth, the eruption and shedding of the temporary set, the eruption of the permanent, and the necessary changes in the alveolar process. It extends from the seventh month to the twenty-first year.

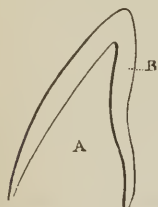
[FIG. 73.]



FORMATION OF A TEMPORARY AND ITS CORRESPONDING PERMANENT TOOTH, in a sac of the mucous membrane. *a* to *d*. Papillary stage¹; *e* to *g*. Follicular stage; *h* to *m*. Saecular stage; *n*, *o*. Eruptive stage; *p* to *t*. Falling out of first set. The relations of the cavity of *reserve* are also shown.]

"The *anterior permanent molar*," says Mr. Goodsir, "is the most remarkable tooth in man, as it forms a transition between the milk and the permanent set." If considered anatomically, that is, in its development from the primitive dental groove, by a papilla and follicle, "it is decidedly a milk tooth;" if physiologically, "as the most efficient grinder in the adult mouth, we must consider it a permanent tooth." "It

[FIG. 74.]



A. The cavity containing the pulp, and the dentine when formed. B. Closed sac in which the enamel is formed.]

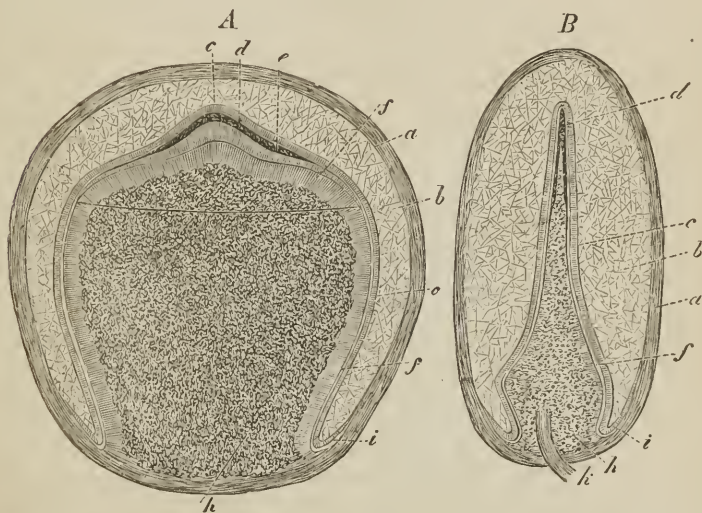
is a curious circumstance, and one which will readily suggest itself to the surgeon, that laying out of view the wisdom teeth, which sometimes decay at an early period from other causes, the anterior molars are the permanent teeth which most frequently give way first, and in the most symmetrical manner, and at the same time, and frequently before the milk set."

Growth of teeth. — Immediately the dental follicles have been closed by their opercula, the pulps become moulded into the form of the future teeth; and the bases of the molars are divided into two or three portions representing the future fangs. The dental sac is composed of two layers, an internal or vascular layer, originally a part of the mucous surface of the mouth; and a cellulo-fibrous layer, analogous to the corium of the mucous membrane.

¹ [This stage is recognized by many physiologists as preceding the true follicular.]

On the formation of this sac by the closure of the follicle, the mucous membrane resembles a serous membrane in being a shut sac, and may be considered as consisting of a tunica propria, which invests the pulp; and a tunica reflexa, which is adherent by its outer surface to the structures composing the jaw, and by the inner surface is free, being separated from the pulp by an intervening space. As soon as the moulding of the pulp has commenced, this space increases and becomes filled with a gelatinous granular substance, the *enamel organ*, which is adherent to the whole internal surface of the tunica reflexa, but

[FIG. 75.]



DEVELOPMENT OF TEETH.—A. Tooth-sac of the second incisor of an eight months' foetus, seen on the broad surface. *a*. Dental sac. *b*. Enamel-pulp. *c*. Enamel-membrane. *d*. Enamel. *e*. Dentine. *f*. Dental cells. *h*. Dental pulp. *i*. Free edge of the enamel-organ.—B. First incisor of the same embryo, seen on the narrow surface; letters as before. *a*. Dental cap in toto. *k*. Nerves and vessels of the pulp.—Magnified 7 diameters.]

not to the tunica propria and pulp. At the same period, viz. during the fourth or fifth month, a thin lamina of ivory is formed in the pulp, and occupies its most prominent point; if the tooth be incisor or canine, the newly-formed layer has the figure of a small hollow cone; if molar, there will be four or five small cones corresponding with the number of tubercles on its crown. These cones are united by the formation of additional layers, the pulp becomes gradually surrounded and diminishes in size, evolving fresh layers during its retreat into the jaw, until the entire tooth with its fangs is completed, and the small *cavitas pulpæ* of the perfect tooth alone remains, communicating through the opening in the apex of each fang with the dental vessels and nerves. The number of roots of a tooth appears to depend on the number of nervous filaments sent to each pulp. When the formation of the ivory has commenced, the enamel organ becomes transformed into a laminated tissue, corresponding with the direction of the fibres of the enamel, and the crystalline substance of the enamel is secreted into its meshes by the vascular lining of the sac.

The *cementum* appears to be formed at a later period of life, either by the production of osseous substance by that portion of the dental sac which continues to inclose the fang, and acts as its periosteum, or by the conversion of that membrane itself into bone; the former supposition is the more probable.

The formation of ivory commences in the first permanent molar previously to birth.

Eruption.—When the crown of the tooth has been formed and coated with enamel, and the fang has grown to the bottom of its socket by the progressive lengthening of the pulp, the formation of ivory, and the adhesion of the ivory to the contiguous portion of the sac, the pressure of the socket causes the reflected portion of the sac and the edge of the tooth to approach, and the latter to pass through the gum. The sac has thereby resumed¹ its original follicular condition, and has become continuous with the mucous membrane of the mouth. The opened sac now begins to shorten more rapidly than the fang lengthens, and the tooth is quickly drawn upwards by the contraction, leaving a space between the extremity of the unfinished root and the bottom of the socket, in which the growth and completion of the fang are effected.

During the changes above described as taking place among the dental sacs contained within the jaws, the septa between the sacs, at first consisting of spongy tissue, gradually became fibrous, and subsequently osseous, the bone being developed from the surface and proceeding by degrees more deeply into the jaws, to constitute the alveoli. The sacs of the ten anterior permanent teeth, at first

[FIG. 76.]



GUBERNACULUM DENTIS.—Temporary tooth with the capsule of its permanent successor attached to it by the gubernaculum dentis.]

inclosed in the submucous cellular tissue of the deciduous dental sacs, and received during growth into crypts situated behind the deciduous teeth, advanced by degrees beneath the fangs of those teeth, and became separated from them by distinct osseous alveoli. The necks of the sacs of the permanent teeth, by which they originally communicated with the mucous lining of the secondary groove, still exist, in the form of cords, separated from the deciduous teeth by their alveolus, but communicating through minute osseous canals with the mucous membrane of the mouth, immediately behind the corresponding deciduous teeth. "These cords and foramina are not obliterated in the child," says Mr. Goodsir, "either because the cords are to become useful as '*gubernacula*' and the canals as '*itineraria dentium*;' or, much more probably, in virtue of a law, which appears to be a general one in the development of animal bodies, viz., *that parts, or organs, which have once acted an important part, however atrophied they may afterwards become, yet never altogether disappear, as long as they do not interfere with other parts or functions.*"

Succession.—The periods of appearance of the teeth are extremely irregular; it is necessary, therefore, to have recourse to an average, which, for the temporary teeth, may be stated as follows, the teeth of the lower jaw preceding those of the upper by a short interval:—

7th month, two middle incisors.	18th month, canine.
9th month, two lateral incisors.	24th month, two last molars.
12th month, first molars.	

The periods for the permanent teeth are:—

6½ year, first molars.	10th year, second bicuspides.
7th year, two middle incisors.	11th to 12th year, canine.
8th year, two lateral incisors.	12th to 13th year, second molars.
9th year, first bicuspides.	17th to 21st year, last molars.

OS HYOIDES.

The *os hyoides* forms the second arch developed from the cranium, gives sup-

¹ Nasmyth is of opinion that it is "by a process of absorption, and not of disruption, that the tooth is emancipated."—*Medico-Chirurgical Transactions*, 1839.

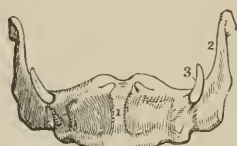port to the tongue, and attachment to numerous muscles in the neck. It is named from its resemblance to the Greek letter ν , and consists of a central portion or body, of two larger cornua, which project backwards from the body; and two lesser cornua, which ascend from the angle of union between the body and the greater cornua.

The body is somewhat quadrilateral, rough and convex on its antero-superior surface, by which it gives attachment to muscles; concave and smooth on the postero-inferior surface, by which it lies in contact with the thyro-hyoidean membrane. The greater cornua are flattened from above downwards, and terminated posteriorly by a tubercle; and the lesser cornua, conical in form, give attachment to the stylo-hyoid ligaments. In early age and in the adult, the cornua are connected with the body by cartilaginous surfaces and ligamentous fibres; in old age they become united by bone.

Development. — By five centres, one for the body, and one for each cornu. Ossification commences in the greater cornua during the last month of foetal life, and in the lesser cornua and body soon after birth.

Attachment of Muscles. — To eleven pairs: sterno-hyoid, thyro-hyoid, omo-hyoid, pulley of the digastricus, stylo-hyoid, mylo-hyoid, genio-hyoid, genio-hyo-glossus, hyo-glossus, lingualis, and middle constrictor of the pharynx. It also gives attachment to the stylo-hyoid, thyro-hyoid, and hyo-epiglottic ligaments, and to the thyro-hyoidean membrane.

FIG. 77.



THE OS HYOIDES SEEN FROM BEFORE. 1. Antero-superior, or convex side of the body. 2. Great cornu of the left side. 3. Lesser cornu of the same side. The cornua were ossified to the body of the bone in the specimen from which this figure was drawn.

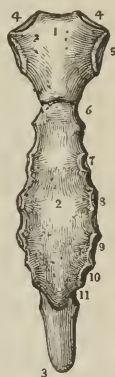THORAX AND UPPER EXTREMITY.

The bones of the thorax are the sternum and ribs [and the dorsal vertebræ, which are common to it and to other parts]; and those of the upper extremity, the clavicle, scapula, humerus, ulna and radius, bones of the carpus, metacarpus, and phalanges.

STERNUM. — The sternum is situated in the middle line of the front of the chest, and is oblique in direction, the superior end lying within a few inches of the vertebral column, the inferior being projected forwards so as to be placed at a considerable distance from the spine. The bone is flat or slightly concave in front, and marked by five transverse lines, which indicate its original subdivision into six pieces. It is convex behind, broad and thick above, flattened and pointed below, and divisible in the adult into three pieces, superior, middle, and inferior.

The *superior piece*, or manubrium, is nearly quadrilateral; it is broad and thick above, where it presents a concave border, incisura semilunaris; and narrow at its junction with the middle piece. At each superior angle is a deep articular depression, incisura clavicularis, for the clavicle; and on either side two notches, for articulation with the cartilage of the first rib, and one half that of the second. The articulation of the manu-

[FIG. 78.



ANTERIOR VIEW OF THE STERNUM. 1. Superior piece, or manubrium. 2. Middle piece, or body. 3. Ensiform cartilage, or inferior piece. 4, 4. Articular depressions for the clavicles. 5. Articular notch for the first rib. 6. Articular notch for the second rib. 7, 8, 9, 10, 11. Articular notches for the last five true ribs.]

brium with the body is often moveable, often anehylosed; when the latter state exists, the line of union is marked by a transverse ridge.

The *middle piece*, or body, considerably longer than the superior, is broad in the middle, and somewhat narrower at each extremity. It presents at either side six articular notches, for the lower half of the second rib, the four next ribs, and the upper half of the seventh. This piece is sometimes perforated by an opening of various magnitude, resulting from arrest of development.

The *inferior piece* (ensiform or xiphoid cartilage) is the smallest of the three, often merely cartilaginous, and very various in appearance, being sometimes pointed, at other times broad and thin, and at other times, again, perforated by a round hole, or bifid. It presents a notch at each side for articulation with the lower half of the cartilage of the seventh rib.

Development.—By a variable number of centres, generally ten, namely, two for the manubrium; one (sometimes two) for the first piece of the body, two for each of the remaining pieces, and one for the ensiform cartilage. Ossification commences towards the end of the fifth month in the manubrium, the two pieces for this part being placed one above the other. At about the same time the centres for the first and second pieces of the body are apparent; the centres for the third piece of the body appear a few months later, and those for the fourth piece soon after birth. The osseous centre for the ensiform cartilage is so variable in its advent, that it may exist at any period between the third and eighteenth year. The double centres for the body of the sternum are disposed side by side in pairs, and it is the irregular union of these pairs in the last three pieces of the body that gives rise to the large aperture occasionally seen in the sternum towards its lower part. Union of the pieces of the sternum commences from below and proceeds upwards; the fourth and the third unite at about puberty, the third and the second between twenty and twenty-five, the second and the first between twenty-five and thirty. The ensiform appendix becomes joined to the body of the sternum at forty or fifty years; and the manubrium to the body only in very old age. Two small pisiform pieces have been described by Beclard and Breschet, as being situated upon and somewhat behind each extremity of the incisura semilunaris of the upper border of the manubrium. These pre-sternal or suprasternal pieces, by no means constant, appear at about the thirty-fifth year. Beclard considers them as the analogue of the fourchette of birds, and Breschet as the sternal ends of a pair of cervical ribs.

Articulations.—With sixteen bones; viz., the clavicles and seven true ribs at each side; the latter by means of the costal cartilages.

Attachment of Muscles.—To nine pairs and one single muscle, viz., pectoralis major, sterno-mastoid, sterno-hyoid, sterno-thyroid, triangularis sterni, aponeurosis of the obliquus externus, internus, and transversalis, rectus, and diaphragm.

RIBS.—The ribs are twelve in number at each side: the first seven are connected with the sternum, and are thence named *sternal* or *true* ribs; the remaining five are the *asternal* or *false* ribs; and the last two, shorter than the rest, and free at their extremities, are the *floating* ribs. The ribs increase in length from the first to the eighth, whence they diminish to the twelfth; in breadth they diminish gradually from the first to the last, and, with the exception of the last two, are broader at the anterior than at the posterior end. The first rib is horizontal in direction; all the rest are oblique, the anterior extremity falling considerably below the posterior. Each rib presents an external and internal surface, a superior and inferior border, and two extremities; it is curved to correspond with the arch of the thorax, and twisted, so that, when laid on a horizontal surface, one end is tilted up.

The *external surface* is convex, and marked by the attachment of muscles; the *internal* is flat, and corresponds with the pleura; the *superior border* is rounded; the *inferior* sharp and grooved on its inner edge, for the attachment

of the intercostal muscles.¹ Near its vertebral extremity, the rib is somewhat bent; and opposite the bend, on the external surface, is a rough oblique ridge, which gives attachment to a tendon of the sacro-lumbalis muscle, and is called the *angle*. The distance between the vertebral extremity, and the angle increases gradually, from the second to the eleventh rib. Beyond the angle is a rough elevation, the *tubercle*; and immediately at the base and under side of the tubercle a smooth surface for articulation with the extremity of the transverse process of the corresponding vertebra. The vertebral end of the rib is somewhat expanded, and termed the *head*, and that portion between the head and the tubercle, the *neck*. On the extremity of the head is an oval smooth surface, divided by a transverse ridge into two facets for articulation with two contiguous vertebræ. The posterior surface of the neck is rough, for the attachment of the middle costo-transverse ligament; and upon its upper border is a crest, which gives attachment to the anterior costo-transverse ligament. The sternal extremity is flattened, and presents an oval depression, for the reception of the costal cartilage.

The ribs that demand especial consideration are the first, tenth, eleventh, and twelfth.

The *first* is the shortest rib; it is broad and flat, and placed horizontally at the upper part of the thorax, the surfaces looking upwards and downwards, in place of forwards and backwards, as in the other ribs. At about the anterior third of the upper surface of the bone,

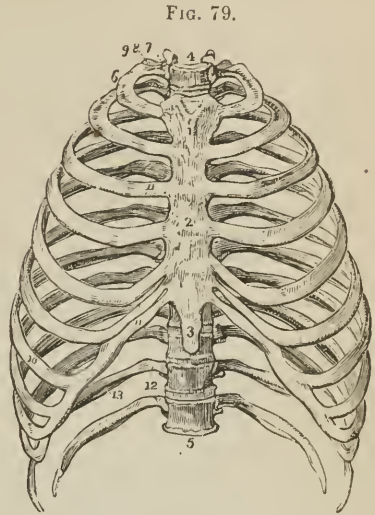
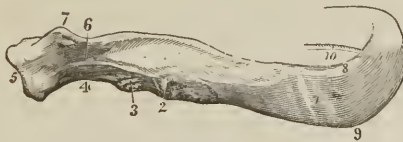

FIG. 79.
ANTERIOR VIEW OF THE THORAX 1. Superior piece of the sternum. 2. Middle piece, or body. 3. Inferior piece, or ensiform cartilage. 4. First dorsal vertebra. 5. Last dorsal vertebra. 6. First rib. 7. Its head. 8. Its neck, resting against the transverse process of the first dorsal vertebra. 9. Its tubercle. 10. Seventh, or last true rib. 11, 11. Costal cartilages of the true ribs. 12. The last two false ribs, or floating ribs. 13. The groove along the lower border of the rib.

FIG. 80.



VERTEBRAL EXTREMITY OF THE SEVENTH RIB OF THE RIGHT SIDE. 1. The angle, marked by a groove for the tendon of the sacro-lumbalis. 2. The tubercle. 3. Articular surface. 4. Neck of the rib. 5. Head, presenting two articular facets. 6. Rough surface for the attachment of the middle costo-transverse ligament. 7. Crest for the anterior costo-transverse ligament. 8. Upper rounded border. 9. Lower sharp border. 10. Groove on the inner edge of the lower border.

and near its internal border, is a tubercle which gives attachment to the scalenus anticus muscle, and immediately before and behind that tubercle, a shallow

¹ This groove is commonly described as supporting the intercostal artery, vein, and nerve; which is not the case.

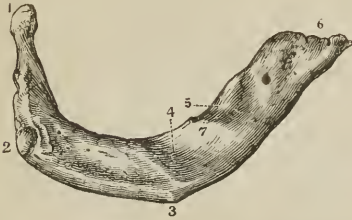
oblique groove, the former for the subclavian vein, the latter for the subclavian artery. Near the posterior extremity of the bone is a thick and prominent

tubercle, with a smooth articular surface for the transverse process of the first dorsal vertebra. There is no angle. Beyond the tubercle is a narrow constricted neck; and at the extremity, a head, presenting a single articular surface. The second rib, in some of its characters, resembles the first.

The *tenth* rib has a single articular surface on its head.

The *eleventh* and *twelfth* have each a single articular surface on the head, no neck or tubercle, and are pointed at the free extremity. The eleventh has a slight ridge, representing the angle, and a shallow groove on the lower border; the twelfth has neither.

[FIG. 81.]



UPPER SURFACE OF THE FIRST RIB OF THE RIGHT SIDE. 1. The head. 2. The tubercle. 3. Outer border. 4. Groove for the subclavian artery. 5. Groove for the subclavian vein. 6. Anterior extremity for the cartilage. 7. Tubercle for the scalenus anticus muscle.]

COSTAL CARTILAGES. — The costal cartilages serve to prolong the ribs forwards to the anterior part of the chest, and contribute mainly to the elasticity of the thorax. They are broad at their attachment with the ribs, and taper slightly towards the sternal end; they diminish gradually in breadth from the first to the last; in length they increase from the first to the seventh, and then decrease to the last. The cartilages of the first two ribs are horizontal in direction, the rest incline more and more upwards. In advanced age the costal cartilages are converted more or less completely into bone, the change taking place earlier in the male than in the female.

The first seven cartilages articulate with the sternum; the three next, with the lower border of the cartilage immediately preceding; the last two lie free between the abdominal muscles. All the cartilages of the false ribs terminate by pointed extremities.

Development. — The ribs are developed by *three* centres; one for the central part, one for the head, and one for the tubercle. The last two have no centre for the tubercle. Ossification commences in the body somewhat before its appearance in the vertebræ; the epiphysal centres for the head and tubercle appear between sixteen and twenty, and are consolidated with the rest of the bone at twenty-five.

Articulations. — Each rib articulates with two vertebræ and one costal cartilage, with the exception of the first, tenth, eleventh, and twelfth, which articulate each with a single vertebra only.

Attachment of Muscles. — To the ribs and their cartilages are attached *twenty-three* pairs, and *one* single muscle. To the *cartilages*, the subclavius, sterno-thyroid, pectoralis major, internal oblique, rectus, transversalis, diaphragm, triangularis sterni, internal and external intercostals. To the *ribs*, intercostal muscles, scalenus anticus, medius, and posticus, pectoralis minor, serratus magnus, obliquus externus, obliquus internus, latissimus dorsi, quadratus lumborum, serratus posticus superior, serratus posticus inferior, sacro-lumbalis, longissimus dorsi, cervicalis ascendens, levatores costarum, transversalis, and diaphragm.

CLAVICLE. — The clavicle is a long bone, shaped like the italic letter *f*, and extended across the upper part of the side of the chest from the upper piece of the sternum to the point of the shoulder, where it articulates with the scapula. In position it is slightly oblique, the sternal end being somewhat lower and more anterior than the scapular, and the curves are so disposed that at the sternal end

the convexity, and at the scapular the concavity, is directed forwards. The sternal half of the bone is rounded or irregularly quadrilateral, and terminates in a broad articular surface. The scapular half is flattened from above downwards, and broad at its extremity, the articular surface occupying only part of its extent. The upper surface is smooth, convex, and partly subcutaneous; the under surface rough and depressed, for the insertion of the subclavius muscle. At the sternal extremity of the under surface is a very rough prominence, which gives attachment to the rhomboid ligament; and at the other extremity a rough tubercle

FIG. 82.



CLAVICLE OF THE RIGHT SIDE; its upper and anterior face. 1. The sternal end. 2. The portion which articulates with the first rib. 3, 3. Ridge of attachment of the pectoralis major. 4. Scapular end. 5. Surface of articulation with the acromion. 6, 6. Ridge for the attachment of the deltoid. 7, 7. Line of origin of the trapezius. 8. Line of origin of the sterno-mastoid.

and ridge, for the coraco-clavicular ligament. The opening for the nutritious vessels is seen at the under surface of the bone.

Development. — By two centres; one for the shaft and one for the sternal extremity; the former appearing before any other bone of the skeleton, the latter between fifteen and eighteen.

Articulations — With the sternum and scapula.

Attachment of Muscles — To six: sterno-cleido-mastoid, trapezius, pectoralis major, deltoid, subclavius, and sterno-oid.

SCAPULA. — The *scapula* is a flat triangular bone, situated on the posterior aspect and side of the thorax, and occupying the space from the second to the seventh rib. It is divisible into an anterior and posterior surface; superior, inferior, and posterior border; anterior, superior, and inferior angle; and processes.

The *anterior surface*, [venter,] or subscapular fossa, is concave and uneven, and marked by several oblique ridges, which have a direction upwards and outwards. The whole concavity is occupied by the subscapularis muscle, with the exception of a small triangular portion near the superior angle. The *posterior surface*, or dorsum, is convex, and unequally divided into two portions by the spine; that portion above the spine is the supra-spinous fossa; and that below, the infra-spinous fossa.

The *superior border* is the shortest of the three; it is thin and concave, terminated at one extremity by the superior angle, and at the other by the coracoid process. At its humeral end, and formed partly by the base of the coracoid process, is the supra-scapular notch, for the transmission of the supra-scapular nerve.

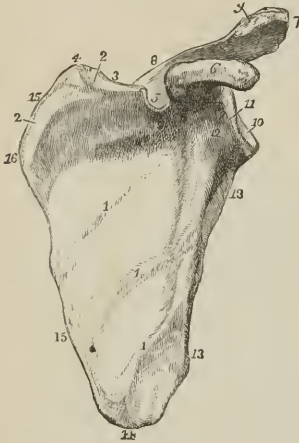
The *inferior* or *axillary border* is thick, and marked by several grooves and depressions; it terminates superiorly at the glenoid cavity, and inferiorly at the inferior angle. Immediately below the glenoid cavity is a rough ridge, which gives origin to the long head of the triceps muscle. On the posterior surface of this border is a depression for the teres minor; and on its anterior surface a deeper groove for the teres major; near the inferior angle is a projecting lip, which increases the surface of origin of the latter muscle.

The *posterior border* or *base*, the longest of the three is turned towards the

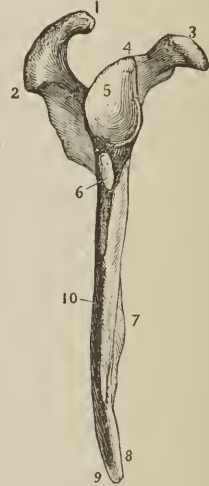
vertebral column. It is intermediate in thickness between the superior and inferior, and convex.

The *anterior angle* is the thickest part of the bone, and forms the *head* of the scapula; it is immediately surrounded by a constricted portion, the *neck*. The

FIG. 83.



[FIG. 84.]



ANTERIOR SURFACE OR VENTER OF THE SCAPULA.

1, 1, 1. Oblique ridges crossing the subscapular fossa. 2, 2. Surface unoccupied by the subscapularis muscle. 3. Superior border. 4. Superior angle. 5. Supra-scapular notch. 6. Coracoid process. 7. Acromion process. 8. Spine of the scapula; the cipher 5, while indicating the supra-scapular notch, is placed on the spine. 9. Articular surface of the acromio-clavicular joint. 10. Glenoid cavity. 11. Head of the scapula. 12. Its neck. 13, 13. Inferior border; the upper 13 is placed against the ridge of the triceps. 14. Inferior angle. 15, 15. Posterior border. 16. Prominence corresponding with the origin of the spine of the scapula.

THE INFERIOR OR AXILARY BORDER OF THE SCAPULA OF THE RIGHT SIDE.

1. Articular surface for the clavicle. 2. Acromion process. 3. Coracoid process. 4. Origin of the long head of the biceps muscle. 5. Glenoid cavity. 6. Origin of the long head of the triceps muscle. 7. Anterior surface or venter. 8. Surface for the teres major. 9. Surface for a slip of the latissimus dorsi. 10. Depression for the teres minor muscle.]

head presents a shallow pyriform articular surface, the *glenoid cavity*, having the pointed extremity upwards; and at its apex is a rough depression, which gives attachment to the long tendon of the biceps. The *superior angle* is thin and pointed. The *inferior angle* is thick, and smooth upon the external surface for the origin of the teres major, and for a large bursa over which the upper border of the latissimus dorsi muscle plays.

The *spine* of the scapula, triangular in form, crosses the upper part of the dorsum of the bone; it commences at the posterior border by a smooth triangular surface, over which the fan-shaped tendon of the trapezius glides, and terminates at the point of the shoulder in the acromion process. At a short distance from its origin, where the triangular surface rises to the level of the spine, is a prominent tubercle, the *tuberculum spinæ scapulæ* (Retzius), which marks the termination of the line of attachment of the tendon of the trapezius. The upper [or posterior] border of the spine is rough and subcutaneous, and gives attachment, by two projecting lips, to the trapezius above and deltoid below; the surfaces of the spine enter into the formation of the supra- and infra-spinous fossa. The nutritious foramina of the scapula are situated in the base of the spine.

The *acromion*, somewhat triangular in form, is flattened from above downwards; it overhangs the glenoid cavity, the upper surface being rough and subcutaneous, the lower smooth and corresponding with the shoulder-joint. Near its extremity, on the anterior border, is an oval articular surface, for the end of the clavicle.

The *coracoid process* is a thick, round, and curved process of bone, arising from the upper part of the neck of the scapula, and overarching the glenoid cavity. It is about two inches in length, very strong, and gives attachment to several ligaments and muscles.

Development. — By six centres: one for the body, one for the coracoid process, two for the acromion, one for the inferior angle, and one for the posterior border. The ossific centre for the body appears in the infra-spinous fossa at about the same time as the ossification of the vertebræ; for the coracoid process during the first year; the acromion process, at puberty; the inferior angle in the fifteenth year; and the posterior border at seventeen or eighteen. Union between the coracoid process and body takes place during the fifteenth year; the bone is not complete till manhood.

Articulations. — With the clavicle and humerus.

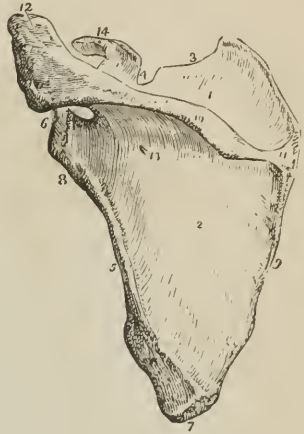Attachment of Muscles. — To sixteen: by its *anterior surface* to the subscapularis; *posterior surface*, supra-spinatus and infra-spinatus; *superior border*, omo-hyoid; *posterior border*, levator anguli scapulæ, rhomboideus minor, rhomboideus major, serratus magnus; *anterior border*, long head of the triceps, teres minor, teres major; upper angle of the glenoid cavity, long tendon of the biceps; spine and acromion, trapezius and deltoid; coracoid process, pectoralis minor, short head of the biceps, and coraco-brachialis. The ligaments attached to the coracoid process are, coracoid, coraco-clavicular, coraco-humeral; and the costo-coracoid membrane.

HUMERUS. — The humerus is a long bone, and is therefore divisible into a shaft and two extremities.

The *superior extremity* presents a rounded *head*; a constriction immediately around the base of the head, the [anatomical] *neck*; a *greater* and a *lesser tuberosity*. The greater tuberosity is situated most externally, and is separated from the lesser by a vertical furrow, the *bicipital groove*, which lodges the long tendon of the biceps. The edges of this groove below the head of the bone are prominent and rough, and called the *anterior* and *posterior bicipital ridge*; the former serves for the insertion of the pectoralis major muscle, the latter for the tendon of the latissimus dorsi and teres major.

The constriction of the bone below the tuberosities is the surgical neck, and is

Fig. 85



POSTERIOR VIEW OF THE SCAPULA. 1. Supra-spinous fossa. 2. Infra-spinous fossa. 3. Superior border. 4. Supra-seapular notch. 5. Anterior or axillary border. 6. Head of the scapula and glenoid cavity. 7. Inferior angle. 8. Neck of the scapula; the ridge opposite the figure gives origin to the long head of the triceps. 9. Posterior border or base of the scapula. 10. The spine. 11. Triangular smooth surface, over which the tendon of the trapezius glides. The prominent process between 10 and 11 is the tuberculum spinæ scapulæ. 12. Acromion process. 13. One of the nutritious foramina. 14. Coracoid process.

so named, in contradistinction to the true neck, from being the seat of the accident called by surgical writers *fracture of the neck of the humerus*.

The *shaft* of the bone is prismoid at its upper part, and flattened from before backwards below. On the outer side, at about its middle, is a rough triangular eminence, which gives insertion to the deltoid; and immediately on each side of this eminence is a smooth depression, corresponding with the two heads of the brachialis anticus. On the inner side of the middle of the shaft is a ridge, for the attachment of the coraco-brachialis muscle; and behind, an oblique and shallow groove, which lodges the musculo-spiral nerve and superior profunda artery. The foramen for the medullary vessels is situated on the inner surface of the shaft of the bone a little below the coraco-brachial ridge; it is directed downwards.

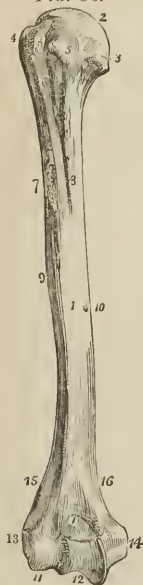The *lower extremity* is flattened from before backwards, and terminated inferiorly by a long articular surface, divided into two parts by an elevated ridge. The external portion of the articular surface is a rounded protuberance, *eminentia capitata*, which articulates with the cup-shaped depression on the head of the radius; the internal portion is a concave and pulley-like surface, *trochlea*, for articulation with the ulna. Projecting beyond the articular surface at each side are the *external* and *internal condyle*, the latter being considerably the longer; and running upwards from the condyles along the borders of the bone are the condyloid ridges, of which the external is the most prominent. Immediately in front of the trochlea is a small depression for receiving the coronoid process of the ulna during flexion of the forearm; and immediately behind it a large and deep fossa, for containing the olecranon process during extension.

Development.—By seven centres: one for the shaft, one for the head, one for the tuberosities, one for the eminentia capitata, one for the trochlea, and one for each condyle, the internal preceding the external. Ossification commences in the diaphysis of the humerus soon after the clavicle; in the head and tuberosities, during the second and third year of infantile life; in the eminentia capitata and trochlea during the third and sixth year; and in the condyles during the twelfth and fifteenth. The entire bone is consolidated at twenty.

Articulations.—With the glenoid cavity of the scapula, the ulna, and radius.

Attachment of Muscles—To *twenty-four*: by the greater tuberosity, supra-spinatus, infra-spinatus, and teres minor; lesser tuberosity, subscapularis; anterior bicipital ridge, pectoralis major; posterior bicipital ridge and groove, teres major and latissimus dorsi; shaft, external and internal head of the triceps, deltoid, coraco-brachialis, and brachialis anticus; external condyloid ridge and condyle (*condylus extensorius*), extensors and supinators of the forearm, viz., supinator longus, extensor carpi radialis longior, extensor carpi radialis brevior, extensor communis digitorum, extensor minimi digiti, extensor carpi ulnaris, anconeus, and supinator brevis; internal condyle (*condylus flexorius*), flexors and one pronator, viz., pronator

FIG. 86.



HUMERUS OF THE RIGHT

SIDE; ITS ANTERIOR SURFACE. 1. Shaft of the bone. 2. Head. 3. Anatomical neck. 4. Greater tuberosity. 5. Lesser tuberosity. 6. Bicipital groove. 7. Anterior bicipital ridge. 8. Posterior bicipital ridge. 9. Rough surface into which the deltoid is inserted. 10. Nutritious foramen. 11. Eminentia capitata. 12. Trochlea. 13. External condyle. 14. Internal condyle. 15. External condyloid ridge. 16. Internal condyloid ridge. 17. Fossa for the coronoid process of the ulna.

radii teres, flexor carpi radialis, palmaris longus, flexor sublimis digitorum, and flexor carpi ulnaris.

ULNA.—The ulna is a long bone, divisible into a shaft and two extremities. The upper extremity is large, and forms principally the articulation of the elbow; the lower extremity is small, and is excluded from the wrist-joint by an interarticular fibro-cartilage.

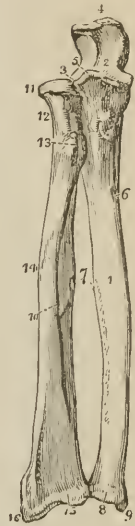
The *superior extremity* presents a semilunar concavity of large size, the *greater sigmoid notch*, for articulation with the humerus; and on the outer side a *lesser sigmoid notch*, for the head of the radius. Bounding the greater sigmoid notch posteriorly is the *olecranon process*; and, overhanging it in front, a pointed eminence with a rough triangular base, the *coronoid process*. Behind the lesser sigmoid notch, and extending downwards on the side of the olecranon, is a triangular uneven surface, for the anconeus muscle; and on the posterior surface of the olecranon a smooth triangular surface, which is subcutaneous.

The *shaft* is prismoid in form, and presents three surfaces, anterior, posterior, and internal; and three borders. The *anterior surface* is occupied by the flexor profundus digitorum for the upper three-fourths of its extent; and below, by a depression for the pronator quadratus muscle. A little above its middle is the nutritious foramen, directed upwards. On the *posterior surface*, at the upper part of the bone, is the triangular uneven depression for the anconeus muscle, bounded inferiorly by an oblique ridge which runs downwards from the posterior extremity of the lesser sigmoid notch. Below the ridge, the surface is marked into several grooves, for the attachment of the extensor ossis metacarpi, extensor secundi internodii, and extensor indicis muscle. The *internal surface* is covered in for the greater part of its extent by the flexor profundus digitorum. The *anterior border* is rounded, and gives origin by its lower fourth to the pronator quadratus. The *posterior* is prominent, and affords attachment to the flexor carpi ulnaris and extensor carpi ulnaris; expanding at its upper extremity into the triangular subcutaneous surface of the olecranon. The *external or radial border* is sharp and prominent, for the attachment of the interosseous membrane.

The *lower extremity* terminates in a small rounded head, *capitulum ulnæ*, from the [posterior and inner] side of which projects the *styloid process*. The latter presents a deep notch at its base for the attachment of the apex of the triangular interarticular cartilage, and by its point gives attachment to the internal lateral ligament. On the posterior surface of the head is a groove, for the tendon of the extensor carpi ulnaris; and on the side opposite the styloid process a smooth surface, for articulation with the side of the radius.

Development.—By three centres; one for the shaft, one for the inferior extremity, and one for the olecranon. Ossification commences in the ulna shortly after the humerus and radius; the ends of the bone are cartilaginous at birth.

FIG. 87.



THE TWO BONES OF THE FOREARM SEEN FROM THE FRONT. 1. Shaft of the ulna. 2. Greater sigmoid notch. 3. Lesser sigmoid notch, with which the head of the radius is articulated. 4. Olecranon process. 5. The coronoid process. 6. Nutritious foramen. 7. The sharp ridges upon the two bones to which the interosseous membrane is attached. 8. Capitulum ulnæ. 9. Styloid process. 10. Shaft of radius. 11. Its head surrounded by the smooth border for articulation with the orbicular ligament. 12. Neck of radius. 13. Its tuberosity. 14. The oblique line. 15. Lower extremity of the bone. 16. Styloid process.

The centre for the lower end appears at about the fifth; that for the olecranon about the seventh year. The bone is completed at about the twentieth year.

Articulations. — With *two* bones; humerus and radius; it is separated from the cuneiform bone of the carpus by the triangular interarticular cartilage.

Attachment of Muscles. — To *twelve*: by the olecranon to the triceps extensor cubiti, one head of the flexor carpi ulnaris, and anconeus; by the coronoid process, brachialis anticus, pronator radii teres, flexor sublimis digitorum, and flexor profundus digitorum; by the shaft, flexor profundus digitorum, flexor carpi ulnaris, pronator quadratus, anconeus, extensor carpi ulnaris, extensor ossis metacarpi pollicis, extensor secundi internodii pollicis, and extensor indicis.

RADIUS. — The radius is the rotatory bone of the forearm; it is divisible into a shaft and two extremities; unlike the ulna, its upper extremity is small, and merely accessory to the formation of the elbow-joint; while the lower extremity is large, and forms almost solely the joint of the wrist.

The *superior extremity* presents a rounded *head*, depressed on its upper surface into a shallow cup. Around the margin of the head is a smooth articular surface, which is broad on the inner side, where it articulates with the lesser sigmoid notch of the ulna, and narrow in the rest of its circumference, to play in the orbicular ligament. Beneath the head is a constricted circular *neck*; and beneath the neck, on its internal aspect, a prominent process, the *tuberosity*. The surface of the tuberosity is partly smooth and partly rough; rough below, where it receives the attachment of the tendon of the biceps; and smooth above, where a bursa is interposed between the tendon and the bone.

The *shaft* of the bone is prismoid, and presents three surfaces. The *anterior surface* is somewhat concave superiorly, where it lodges the flexor longus pollicis; and flat below, where it supports the pronator quadratus. At about the upper third of this surface is the nutritious foramen, which is directed upwards. The *posterior surface* is round above, where it supports the supinator brevis muscle, and marked below by several shallow oblique grooves, which afford attachment to the extensor muscles of the thumb. The *external surface* is round and convex, and marked by an *oblique ridge*, which extends from the tuberosity to the styloid process at the lower extremity of the bone. On the *inner margin* is a sharp and prominent crest, which gives attachment to the interosseous membrane.

The *lower extremity* of the radius is broad and triangular, and provided with two articular surfaces; one at the side of the bone, which is concave to receive the rounded head of the ulna; the other at the extremity, and marked by a slight ridge into two facets, one external and triangular, corresponding with the scaphoid; the other square, with the semilunar bone. At the outer side of the extremity is a strong conical projection, the *styloid process*, which gives attachment by its base to the tendon of the supinator longus, and by its apex to the external lateral ligament of the wrist joint. The inner edge of the articular surface affords attachment to the base of the triangular interarticular fibrocartilage of the ulna.

Immediately in front of the styloid process is a groove, which lodges the tendons of the extensor ossis metacarpi pollicis and extensor primi internodii; and, behind the process, a broader groove, for the tendons of the extensor carpi radialis longior and brevior, and extensor secundi internodii; behind this is a prominent ridge, and a deep and narrow groove, for the tendon of the extensor indicis; and further back, part of a broad groove, completed by the ulna, for the tendons of the extensor communis digitorum.

Development. — By *three* centres; one for the shaft, and one for each extremity. Ossification commences in the shaft soon after the humerus, and before the ulna. The inferior centre appears during the second year, the superior about the seventh. The bone is perfected at twenty.

Articulations. — With four bones; humerus, ulna, scaphoid, and semilunar.

Attachment of Muscles. — To nine: by the tuberosity to the biceps; by the oblique ridge, supinator brevis, pronator radii teres, flexor sublimis digitorum, and pronator quadratus; by the anterior surface, flexor longus pollicis and pronator quadratus; by the posterior surface, extensor ossis metacarpi pollicis and extensor primi internodii; and by the styloid process, supinator longus.

CARPUS. — The bones of the carpus are eight in number; and arranged in two rows. In the first row, commencing from the radial side, are the, os scaphoides, semilunare, cuneiforme, pisiforme; in the second row, in the same order, os trapezium, trapezoides, os magnum, and unciiforme.

The **SCAPHOID** bone is named from bearing some resemblance to the shape of a boat, being broad at one end, and narrowed like a prow at the opposite, concave on one side, and convex on the other. It is, however, more similar in form to a cashew nut flattened and concave on one side. If carefully examined, it will be found to present a *convex* and a *concave surface*, a *convex* and a *concave border*, a *broad end*, and a *narrow and pointed extremity*, the tuberosity.

To ascertain to which hand the bone belongs, let the student hold it horizontally, the convex surface looking backwards (*i. e.*, towards himself), and the convex border upwards: the broad extremity will indicate its appropriate hand; if it be directed to the right, the bone belongs to the right; if to the left, to the left carpus.

Articulations. — With five bones; by its convex surface with the radius; by its concave surface, with the os magnum and semilunare; by the extremity of its upper or dorsal border, with the trapezium and trapezoides.

Attachments. — By its tuberosity to the anterior annular ligament.

The **SEMIUNAR** bone may be known by having a crescentic concavity, and a somewhat crescentic figure. It presents for examination four articular surfaces and two extremities; the *articular surfaces* are, one *concave*, one *convex*, and two *lateral*, one lateral surface being crescentic, the other nearly circular and divided generally into two facets. The *extremities* are, one *dorsal*, which is quadrilateral, flat, and indented, for the attachment of ligaments; the other *palmar*, which is convex, rounded, and of larger size.

To determine to which hand it belongs, let the bone be held perpendicularly, the dorsal or flat extremity looking upwards, and the convex side backwards (towards the holder). The circular lateral surface will point to the side corresponding with the hand to which the bone belongs.

Articulations. — With five bones, but occasionally with only four; by its

FIG. 88.

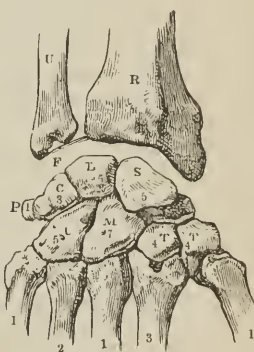


DIAGRAM SHOWING THE DORSAL SURFACE OF THE BONES OF THE CARPUS, WITH THEIR ARTICULATIONS. — RIGHT HAND. R. Lower end of the radius. U. Lower extremity of the ulna. F. Inter-articular fibrocartilage, attached to the styloid process of the ulna, and to the margin of the articular surface of the radius. S. Scaphoid bone: the cipher (5) indicates the number of bones with which it articulates. L. Semilunare articulating with five bones. C. Cuneiforme, articulating with three bones. P. Pisiforme, articulating with the cuneiforme only. T. First bone of the second row, the trapezium, articulating with four bones. T. Second bone, the trapezoides, articulating also with four bones. M. Os magnum, articulating with seven. U. Unciiforme, articulating with five. The figures, 1, 3, 1, 2, 1, on the metacarpal bones, refer to the number of their articulations with the carpal bones.

convex surface, with the radius; by its concave surface, with the os magnum; by its crescentic lateral facet, with the scaphoid; by the circular surface, with the cuneiform bone, and the point of the unciform. This surface is divided into two parts by a ridge, when it articulates with the unciform as well as with the cuneiform bone.

The CUNEIFORM bone, although somewhat wedge-shaped in form, may be best distinguished by a circular and isolated facet, which articulates with the pisiform bone. It presents for examination *three surfaces*, a *base* and an *apex*. One surface is very rough and uneven; the opposite forms a concave articular surface; the third is partly rough and partly smooth, and presents that circular facet which is characteristic of the bone. The base is an articular surface, and the apex rough and pointed.

To distinguish its appropriate hand, let the base be directed backwards, and the pisiform facet upwards; the concave articular surface will point to the hand to which the bone belongs.

Articulations. — With *three* bones, and the triangular fibrocartilage. By the base, with the semilunarc; by the concave surface, with the unciforme; by the circular facet, with the pisiforme; and by the superior angle of the rough surface, with the fibro-cartilage.

The PISIFORM bone may be recognised by its small size, and by the possession of only one articular facet. Examined carefully, it will be observed to present four sides and two extremities; one side is articular, the smooth facet approaching nearer the superior than the inferior extremity. The side opposite to this is rounded; the remaining sides are, one slightly concave, the other slightly convex.

If the bone be held so that the articular facet shall look downwards, and the extremity which overhangs the articular facet forwards, the concave side will point to the hand to which it belongs.

Articulations. — With the cuneiform bone only.

Attachments. — To *two* muscles, flexor carpi ulnaris, and abductor minimi digiti; and to the anterior annular ligament.

The TRAPEZIUM (os multangulum majus) is too irregular in form to be compared to any known object; and may be distinguished by a deep groove, for the tendon of the flexor carpi radialis muscle. It is somewhat compressed, and may be divided into two surfaces which are smooth and articular, and three rough borders. One of the *articular surfaces* is *oval*, concave in one direction, and convex in the other (saddle-seat shaped); the other is marked into *three facets*. One of the *borders* presents the groove for the tendon of the flexor carpi radialis, which is surmounted by a prominent tubercle for the attachment of the anterior annular ligament; the other two borders are rough, and form the outer side of the carpus. The grooved border is narrow at one extremity, and broad at the other, where it presents the groove and tubercle.

If the bone be held so that the grooved border look upwards while the apex of this border be directed forwards, and the base with the tubercle backwards, the concavo-convex surface will point to the hand to which the bone belongs.

Articulations. — With *four* bones; by the concavo-convex surface, with the metacarpal bone of the thumb; and by the three facets of the other articular surface, with the scaphoid, trapezoid, and second metacarpal bone.

Attachments. — To *three* muscles, abductor pollicis, flexor ossis metacarpi, and flexor brevis pollicis; and by the tubercle to the anterior annular ligament.

The TRAPEZOIDES (os multangulum minus) is a small, oblong, and quadrilateral bone, bent near its middle (bean-shaped). It presents four articular surfaces and two extremities. One of the surfaces is *concavo-convex*, *i. e.*, concave in one direction, and convex in the other; another, contiguous to the preceding, is *concave*, so as to be almost angular in the middle, and often marked by a small rough depression, for an interosseous ligament; the two remaining sides are *flat*.

One of the two extremities is broad and of large size, *dorsal*; the other, *palmar*, is small and rough.

If the bone be held perpendicularly, so that the broad extremity be upwards, and the concavo-convex surface forwards, the angular concave surface will point to the hand to which the bone belongs.

Articulations.—With *four* bones: by the concavo-convex surface, with the second metacarpal bone; by the angular concave surface, with the os magnum; and by the other two surfaces, with the trapezium and scaphoid.

Attachments.—To the flexor brevis pollicis muscle.

The OS MAGNUM (capitatum) is the largest bone of the carpus, and divisible into a body and head. The *head* is round for the greater part of its extent, but flattened at one side. The *body* is irregularly quadrilateral, and presents four sides and a smooth extremity. Two of the sides are rough, the one being square and flat, dorsal; the other rounded and prominent, palmar; the two remaining sides are articular, one being concave, the other convex. The extremity is a triangular articular surface, divided into three facets.

If the bone be held perpendicularly, the articular extremity looking upwards, and the broad dorsal surface backwards (towards the holder), the concave articular surface will point to the hand to which the bone belongs.

Articulations.—With *seven* bones: by the rounded head, with the cup formed by the scaphoid and semilunar bone; by the side of the convex surface, with the trapezoides; by the concave surface, with the unciforme; and by the extremity, with the second, third, and fourth metacarpal bone.

Attachments.—To the flexor brevis pollicis muscle.

The UNCIFORME is a triangular-shaped bone, remarkable for a long and curved process, which projects from its palmar aspect. It presents five surfaces; three articular, and two free. One of the articular surfaces is divided by a slight ridge into two facets; the other two converge, and meet at a flattened angle.¹ One of the free surfaces, the dorsal, is rough and triangular; the other, palmar, also triangular, but somewhat smaller, gives origin to the unciform process.

If the bone be held perpendicularly, the articular surface with two facets looking upwards, and the unciform process backwards (towards the holder), the concavity of the unciform process will point to the hand to which the bone belongs.

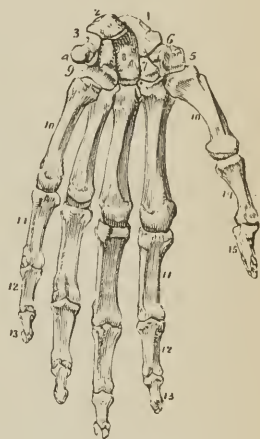
Articulations.—With *five* bones; by the two facets on its base, with the fourth and fifth metacarpal bone; by the two lateral articulating surfaces, with the magnum and cunciforme; and by the flattened angle of its apex, with the semilunare.

Attachments.—To *two* muscles, adductor minimi digiti, and flexor brevis minimi digiti; and by the hook-shaped process to the anterior annular ligament.

Development.—The bones of the carpus are each developed by a single centre; they are cartilaginous at birth. Ossification commences towards the end of the

¹ When the unciforme does not articulate with the semilunare, this angle is sharp.

FIG. 89.



LEFT HAND VIEWED ON ITS ANTERIOR, OR PALMAR ASPECT.

1. Scaphoid bone. 2. Semilunare.
3. Cunciforme. 4. Pisiforme.
5. Trapezium. 6. Groove in the trapezium which lodges the tendon of the flexor carpi radialis.
7. Trapezoides. 8. Os magnum.
9. Unciforme. 10, 10. The five metacarpal bones. 11, 11. First row of phalanges. 12, 12. Second row of phalanges. 13, 13. Third row, or ungual phalanges. 14. First phalanx of the thumb. 15. Second and last phalanx of the thumb.

first year in the os magnum and unciforme; at the end of the third year, in the cuneiforme; during the fifth year, in the trapezium and semilunare; during the eighth, in the scaphoides; ninth, in the trapezoides; and twelfth, in the pisiforme. The latter bone is the last in the skeleton to ossify; it is, in reality, a sesamoid bone of the tendon of the flexor carpi ulnaris.

The number of articulations which each bone of the carpus maintains with surrounding bones may be expressed in figures, which will facilitate the student's recollection; the cipher for the first row is 5531, and for the second 4475.

[The carpus considered as a whole, is oblong and transversely elliptical, and forms about one-sixth of the hand; its palmar aspect is deeply concave (to lodge the flexor tendons), whilst its dorsal surface is convex; its radio-ulnar border is convex, and its metacarpal border presents a sinuous and angular line. It is about an inch in height, and two and a half inches in breadth.

The bones of the first row, the pisiform excepted, form a sort of interrupted condyle by their upper convex surfaces, which are in apposition with the inferior articular extremities of the bones of the forearm. By their lower surfaces they form a strongly marked concavo-convex border, which articulates with the upper border of the second row; the concavity being formed by the cuneiform, semilunar, and scaphoid bones, whilst the convexity is caused by the projection downwards and forwards of the smaller extremity of the scaphoid. The concavity just mentioned, receives a large spheroidal head, which projects upwards into it, composed of the magnum and unciform, whilst the extremity of the scaphoid is received in a shallow depression formed by the trapezium and trapezoid.

The superior surface of the second row would therefore also be concavo-convex, but in a manner precisely the reverse of the first, so that the two rows are reciprocal dove-tailed.

To obtain an adequate idea of this method of articulation, the bones should not only be examined individually, but when combined to form the structure which they collectively constitute.]

METACARPUS. — The bones of the metacarpus are five in number. They are long bones, divisible into a head, shaft, and base.

The *head* is rounded at the extremity, and flattened at each side for the insertion of strong ligaments; the *shaft* is prismoid, and marked deeply on each side, for the attachment of the interossei muscles; the *base* is irregularly quadrilateral, and rough for the insertion of tendons and ligaments. The *base* presents three articular surfaces: one at each side, for adjoining metacarpal bones; and one at the extremity, for the carpus.

The metacarpal bone of the thumb is one-third shorter than the rest, flattened and broad on its dorsal aspect, and convex on its palmar side; the articular surface of the head is not so round as that of the other metacarpal bones; and the base has a single concavo-convex surface, to articulate with the corresponding surface of the trapezium.

The metacarpal bones of the different fingers may be distinguished by certain special characters. The base of the metacarpal bone of the index finger is the largest of the four, and presents four articular surfaces. That of the middle finger may be distinguished by a rounded projecting process at the radial side of its base, and two small circular facets on its ulnar lateral surface. The base of the metacarpal bone of the ring-finger is small and square, and has two small circular facets to correspond with those of the middle metacarpal. The metacarpal bone of the little finger has only one lateral articular surface.

Development. — By two centres; one for the shaft, and one for the digital extremity, with the exception of the metacarpal bone of the thumb, the epiphysis of which, like that of the phalanges, occupies the carpal end of the bone. Ossification of the metacarpal bones commences in the embryo between the tenth and twelfth week, that is, soon after the bones of the forearm. The epiphyses make

their appearance at the end of the second, or early in the third year, and the bones are completed at twenty.

Articulations. — The *first* with the trapezium; *second*, trapezium, trapezoides, os magnum, and middle metacarpal; *third*, or middle, os magnum, and adjoining metacarpal bones; *fourth*, os magnum, unciforme, and adjoining metacarpal bones; *fifth*, unciforme, and metacarpal bone of the ring-finger.

The figures representing the number of articulations which each metacarpal bone possesses, taken from the radial to the ulnar side are 13121.

Attachment of Muscles. — To the metacarpal bone of the thumb, *three*, flexor ossis metacarpi, extensor ossis metacarpi, and first dorsal interosseous; index finger, *five*, extensor carpi radialis longior, flexor carpi radialis, first and second dorsal and first palmar interosseous; middle finger, *four*, extensor carpi radialis brevior, adductor pollicis, second and third dorsal interosseous; ring-finger, *three*, third and fourth dorsal interosseous, and second palmar; little finger, *four*, extensor carpi ulnaris, adductor minimi digiti, fourth dorsal and third palmar interosseous.

PHALANGES. — The phalanges (internodia) are the bones of the fingers; they are named from their arrangement in rows, and are fourteen in number, three to each finger, and two to the thumb. In conformation they are long bones, divisible into a shaft, and two extremities.

The *shaft* is compressed from before backwards, convex on its posterior surface, and flat with raised edges in front. The metacarpal extremity or *base* in the first row, is a simple concave articular surface; that in the other two rows a double concavity, separated by a slight ridge. The digital extremities of the first and second row present a pulley-like surface, concave in the middle, and convex at each side. The unguis extremity of the last phalanx is broad, rough, and expanded into a semilunar crest.

Development. — By *two* centres; one for the shaft, and one for the base. Ossification commences in the third, or unguis phalanges, then in the first, and lastly, in the second. The period of commencement corresponds with that of the metacarpal bones. The epiphyses of the first row appear during the third or fourth year, those of the second row during the fourth or fifth, and of the last during the sixth or seventh. The phalanges are perfected by the twentieth year.

Articulations. — The first row, with the metacarpal bones and second row of phalanges; the second row, with the first and third; the third, with the second row.

Attachment of Muscles. — To the base of the *first phalanx* of the thumb *four* muscles, abductor pollicis, flexor brevis pollicis, adductor pollicis, and extensor primi internodii; to the *second phalanx*, *two*, flexor longus pollicis, and extensor secundi internodii. To the *first phalanx* of the second, third, and fourth fingers, one dorsal and one palmar interosseous; to that of the little finger, abductor minimi digiti, flexor brevis minimi digiti, and one palmar interosseous. To the *second phalanges*, flexor sublimis and extensor communis digitorum; to the *last phalanges*, flexor profundus and extensor communis digitorum.

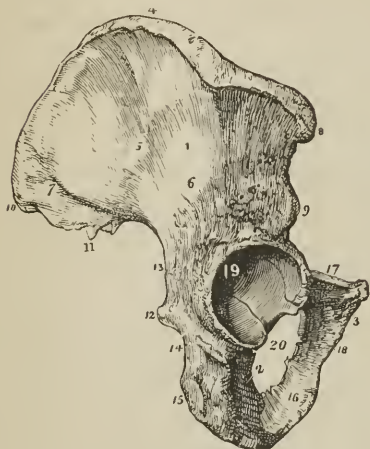
PELVIS AND LOWER EXTREMITY.

The bones of the pelvis are the two ossa innominata, the sacrum, and the coccyx; and those of the lower extremity, the femur, patella, tibia and fibula, tarsus, metatarsus, and phalanges.

OS INNOMINATUM. — The os innominatum (os coxæ) is an irregular, flat bone, consisting in the young subject of three parts, which meet at the acetabulum. Hence it is described in the adult as divisible into three portions, ilium, ischium

and pubes. The *ilium* is the superior, broad, and expanded portion which forms the prominence of the hip, and articulates with the sacrum. The *ischium* is the inferior and strong part of the bone on

FIG. 90.



OS INNOMINATUM OF THE RIGHT SIDE. 1. Ilium; its external surface. 2. Ischium. 3. Os pubis. 4. Crest of the ilium. The prominent tubercle on the outer lip of the crest of the ilium, between 8 and 4, is the *tuberculum cristæ ili*, of Retzius. 5. Superior curved line. 6. Inferior curved line. 7. Surface for the *gluteus maximus*. 8. Anterior superior spinous process. 9. Anterior inferior spinous process. 10. Posterior superior spinous process. 11. Posterior inferior spinous process. 12. Spine of the ischium. 13. Great sacro-ischiatic notch. 14. Lesser sacro-ischiatic notch. 15. Tuberosity of the ischium, showing its three facets. 16. Ramus of the ischium. 17. Body of the os pubis. 18. Ramus of the pubes. 19. Acetabulum. 20. Obturator foramen.

a short distance below this, a rough ridge, the *inferior curved line*. The surface included between the superior curved line and the crest gives origin to the *gluteus medius* muscle; that between the curved lines, to the *gluteus minimus*; and the rough interval between the inferior curved line and the arch of the acetabulum, to one head of the *rectus*. The posterior sixth of the external surface is rough and raised, and gives origin to part of the *gluteus maximus*.

The *crest of the ilium* is arched, and curved in direction like the italic letter *f*, being bent inwards at its anterior termination, and outwards at the posterior. It is broad for the attachment of three planes of muscle, which are connected with its external and internal border or lip, and with the intermediate space. On its outer lip, at about midway between the anterior superior spinous process and the summit of the crest, is a prominent tubercle, *tuberculum cristæ ili* (Retzius), from which a strong ridge runs down to the acetabulum. This is the broadest part of the crest, and the descending ridge serves as a buttress in giving strength to the bone.

The *anterior border* is marked by two prominences, the *anterior superior spinous process*, which is the anterior termination of the crest, and the *anterior infe-*

rior and strong part of the bone on which the body rests in sitting. The *os pubis* is that portion which forms the front of the pelvis, and gives support to the external organs of generation.

The ILIUM may be described as divisible into an internal and external surface, a crest, and an anterior and posterior border.

The *internal surface* is bounded above by the crest, below by a prominent line, the *linea ilio-pectinea*, and before and behind by the anterior and posterior border; it is concave and smooth for the anterior two-thirds of its extent, and lodges the *iliacus* muscle. The posterior third is rough, for articulation with the sacrum, and divided by a deep groove into two parts; an anterior or *auricular portion*, shaped like the pinna, and coated by cartilage in the fresh bone; and a posterior portion, very rough and uneven, for the attachment of interosseous ligaments.

The *external surface* is uneven, partly convex, and partly concave: it is bounded above by the crest; below by a prominent arch, which forms the upper segment of the acetabulum; and, before and behind, by the anterior and posterior border. Crossing this surface in an arched direction, from the anterior extremity of the crest to a notch on the lower part of the posterior border, is a groove, which lodges the *gluteal vessels and nerve*, the *superior curved line*; and

rior spinous process; the two processes being separated by a notch for the attachment of the sartorius muscle. This border terminates inferiorly in the lip of the acetabulum. The *posterior border* also presents two prominences, the *posterior superior* and *posterior inferior spinous process*, separated by a notch. Inferiorly this border is broad and arched, and forms the upper part of the great sacro-schiatic notch.

The ISCHIUM is divisible into a thick and solid portion, the *body*, and a thin and ascending part, the *ramus*; it may be considered also, for convenience of description, as presenting an external and internal surface, and three borders, posterior, inferior, and superior.

The *external surface* is rough and uneven, for the attachment of muscles; and broad and smooth above, where it enters into the formation of the acetabulum. Below the inferior lip of the acetabulum is a notch, which lodges the obturator externus muscle in its passage outwards to the trochanteric fossa of the femur. The *internal surface* is smooth, and somewhat encroached upon at its posterior border by the spine.

The *posterior border* of the ischium presents towards its middle a remarkable projection, the *spine*. Immediately above the spine is a notch of large size, the *great sacro-ischiatic*, and below the spine, the *lesser sacro-ischiatic notch*; the former, being converted into a foramen by the lesser sacro-ischiatic ligament, gives passage to the pyriformis muscle, the gluteal vessels and nerve, pudic vessels and nerve, and ischiatic vessels and nerves; the lesser, completed by the great sacro-ischiatic ligament, to the obturator internus muscle, and internal pudic vessels and nerve. The *inferior border* is thick and broad, and called the *tuberosity*. The surface of the tuberosity is divided into three facets; one anterior, which is rough for the origin of the semi-membranosus; and two posterior, which are smooth, and separated by a slight ridge, for the semi-tendinosus and biceps muscle. The inner margin of the tuberosity is bounded by a sharp ridge, which gives attachment to a prolongation of the great sacro-ischiatic ligament; and the outer margin by a prominent ridge, from which the quadratus femoris muscle arises. The *superior border* of the ischium is thin, and forms the lower circumference of the obturator foramen. The *ramus* of the ischium is continuous with the ramus of the pubes, and is slightly everted.

The OS PUBIS [os pectinis] is divided into a horizontal portion or *body* (horizontal ramus of Albinus), and a descending portion or *ramus*; it presents for examination an external and internal surface, superior and inferior border, and symphysis.

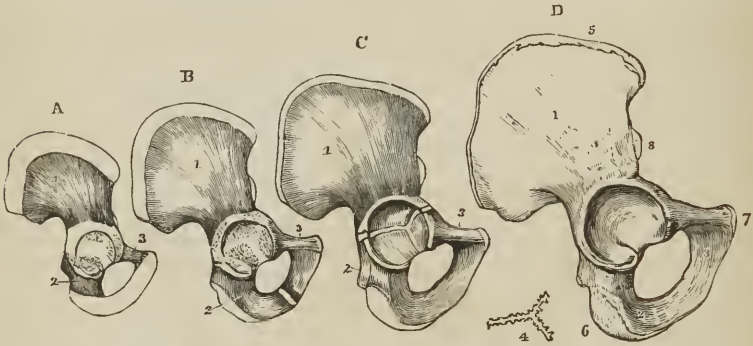
The *external surface* is rough, for the attachment of muscles; and prominent at its outer extremity, where it forms part of the acetabulum. The *internal surface* is smooth, and enters into the formation of the cavity of the pelvis. The *superior border* is marked by a rough ridge, the *crest*; the inner termination of the crest is the *angle*; the outer end, the *spine* or *tubercle*. Running outwards from the spine is a sharp ridge, the *pectineal line*, or *linea ilio-pectinea*, which marks the brim of the true pelvis. In front of the pectineal line is a smooth depression, which supports the femoral artery and vein, and a little more externally an elevated prominence, the *ilio-pectineal eminence*, which divides the surface for the femoral vessels from another depression which overhangs the acetabulum, and lodges the psoas and iliacus muscle. The ilio-pectineal eminence, moreover, marks the junction of the pubes with the ilium. The *inferior border* is broad, deeply grooved for the passage of the obturator vessels and nerve, and sharp on the side of the ramus, to form part of the boundary of the obturator foramen. The *symphysis* is the inner extremity of the body of the bone; it is oval and rough, for the attachment of a ligamentous structure analogous to the intervertebral substance. The *ramus* of the pubes descends obliquely outwards, and is continuous with the ramus of the ischium. The inner border of the ramus forms with the corresponding bone the *arch of the pubes*, and at its inferior part is everted, to give attachment to the crus penis.

The *acetabulum* (*cavitas cotyloidea*) is a deep cup-shaped cavity, situated at the point of union between the ilium, ischium, and pubes; a little less than two-fifths being formed by the ilium, a little more than two-fifths by the ischium, the remaining fifth by the pubes. It is bounded by a deep rim or lip, broad and strong above, where most resistance is required, and marked in front by a deep notch, which is arched over in the fresh subject by a strong ligament, and transmits the nutrient vessels of the joint. At the bottom of the cup, and communicating with the notch, is a deep circular pit (*fundus acetabuli*), which lodges a mass of fat, and gives attachment to the broad extremity of the *ligamentum teres*.

The *obturator* or *thyroid foramen* is a large oval interval between the ischium and pubes, bounded by a narrow rough margin, to which a ligamentous membrane is attached. The upper part of the foramen is increased in depth by the groove in the under surface of the os pubis, which lodges the obturator vessels and nerve.

Development. — By *eight* centres: three principal, one for the ilium, one for the ischium, and one for the pubes; and five secondary, one, the Y-shaped piece

[FIG. 91.]



SOME STAGES OF THE GROWTH OF THE OS INNOMINATUM, showing its development from three primitive and five secondary centres. A. In a full-grown fetus; ossification having extended from the primitive nuclei; a considerable cartilaginous interval separates the pieces in the acetabulum. B. From a child under six years of age. C. The rami of the ischium and pubes are joined; a cartilaginous Y-shaped interspace is apparent in the acetabulum. D. From a person aged about twenty years; union has taken place in the acetabulum, and the epiphyses are fully formed. 1. Ilium. 2. Ischium. 3. Pubes. 4. A plan of the Y-shaped piece. 5. Epiphysis of the crest of the ilium. 6. That for the tuber ischii. 7. For the angle of the pubes. 8. For the antero-inferior spine of the ilium.]

for the interval between the primitive pieces in the bottom of the acetabulum, one for the crest of the ilium, one (not constant) for the anterior and inferior spinous process of the ilium, one for the tuberosity of the ischium, and one (not constant) for the angle of the os pubis. Ossification commences in the primitive pieces, immediately after that in the vertebræ, firstly in the ilium, then in the ischium, and lastly in the pubes; the first ossific deposits being situated near the future acetabulum. At birth, the acetabulum, crest of the ilium, and ramus of the pubes and ischium, are cartilaginous. The secondary centres appear at puberty, the entire bone not being completed until the twenty-fifth year.

Articulations. — With *three* bones; sacrum, opposite innominatum, and femur.

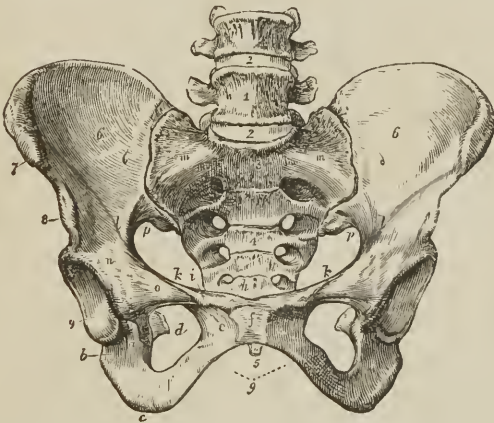
Attachment of Muscles and Ligaments. — To *thirty-three* muscles: to the ilium *thirteen*; by the outer lip of the crest, *obliquus externus* for two-thirds its

length, latissimus dorsi one-third, and tensor vaginae femoris its anterior fourth; by the middle of the crest, internal oblique three-fourths its length, erector spinæ the remaining fourth; by the internal lip, transversalis three-fourths, and quadratus lumborum the posterior part of its middle third. By the external surface, gluteus medius, minimus, maximus, and one head of the rectus; by the internal surface, iliacus; by the anterior border, sartorius, and the other head of the rectus. To the ischium *fourteen*; by its external surface, adductor magnus and obturator externus; by the internal surface, obturator internus and levator ani; by the spine, gemellus superior, levator ani, coccygeus, and lesser sacro-ischiatic ligament; by the tuberosity, biceps, semi-tendinosus, semi-membranosus, gemellus inferior, quadratus femoris, erector penis, and great sacro-ischiatic ligament; by the ramus, gracilis, and transversus perinei. To the os pubis *sixteen*: by its upper border, obliquus externus, obliquus internus, transversalis, rectus, pyramidalis, pectineus, and psoas parvus; by its external surface, adductor longus, adductor brevis, gracilis, and obturator externus; by its internal surface, levator ani and obturator internus; and by the ramus, adductor magnus, erector penis, and accelerator urinæ.

PELVIS.

The pelvis, considered as a whole, is divisible into a *false* and *true* pelvis; the former is the expanded portion, bounded on each side by the ilium, and sepa-

FIG. 92.



FEMALE PELVIS. 1. Last lumbar vertebra. 2, 2. Intervertebral substance connecting the last lumbar vertebra with the fourth and sacrum. 3. Promontory of the sacrum. 4. Anterior surface of the sacrum, on which its transverse lines and foramina are seen. 5. Tip of the coccyx. 6, 6. Iliac fossæ, forming the lateral boundaries of the false pelvis. 7. Anterior superior spinous process of the ilium; right side. 8. Anterior inferior spinous process. 9. Acetabulum. a. Notch of the acetabulum. b. Body of the ischium. c. Its tuberosity. d. Spine of the ischium seen through the obturator foramen. e. Os pubis. f. Symphysis pubis. g. Arch of the pubes. h. Angle of the os pubis. i. Spine of the pubes; the prominent ridge between h and i is the crest of the pubes. k, k. Pectineal line of the pubes. l, l. Ilio-pectineal line; m, m. The prolongation of this line to the promontory of the sacrum. The line represented by h, i, k, k, l, l, and m, m, is the brim of the true pelvis. n. Ilio-pectineal eminence. o. The smooth surface which supports the femoral vessels. p, p. Great sacro-ischiatic notch.

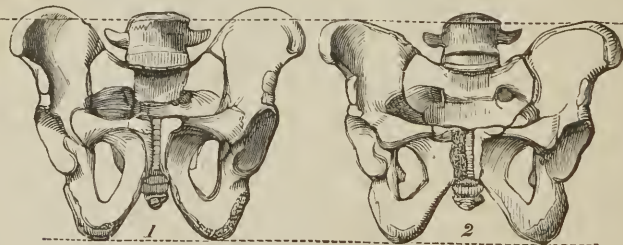rated from the true pelvis by the linea ilio-pectinea. The true pelvis is all that portion which is situated below the linea ilio-pectinea. This line forms the

margin or *brim* of the true pelvis, while the included area is called the *inlet*. The form of the inlet is heart-shaped, obtusely pointed in front at the symphysis pubis, expanded on each side, and encroached upon behind by a projection of the upper part of the sacrum, which is named the promontory. The cavity is somewhat encroached upon at each side by a smooth quadrangular plane of bone, corresponding with the internal surface of the acetabulum, and prolonged posteriorly into the spine of the ischium. In front are two fossæ around the obturator foramina, for lodging the obturator internus muscle at each side. The inferior termination of the pelvis is very irregular, and is termed the *outlet*. It is bounded, in front, by the convergence of the rami of the ischium and pubes, which constitute the arch of the pubes; on each side by the tuberosity of the ischium, and two irregular fissures formed by the greater and lesser sacro-ischiatic notches; and behind by the lateral borders of the sacrum; and the coccyx.

The pelvis is placed obliquely with regard to the trunk of the body, the inner surface of the ossa pubis being directed upwards, and serving to support the weight of the abdominal viscera. The base of the sacrum rises nearly four inches above the level of the upper border of the symphysis pubis, and the apex of the coccyx somewhat more than half an inch above its lower border. If a line were carried through the central axis of the inlet, it would impinge by one extremity against the umbilicus, and by the other against the middle of the coccyx. The *axis of the inlet* is, therefore, directed *downwards and backwards*, while that of the *outlet* points *downwards and forwards*, and corresponds with a line drawn from the upper part of the sacrum, through the centre of the outlet. The axis of the cavity represents a curve, corresponding very nearly with the curve of the sacrum, the extremities being indicated by the central points of the inlet and outlet. A knowledge of the direction of these axes is important to the surgeon, as indicating the line in which instruments should be used in operations upon the viscera of the pelvis, and the direction of force in the removal of calculi from the bladder; and to the accoucheur, as explaining the course taken by the fœtus during parturition.

There are certain characteristic differences between the male and female pelvis. In the male the bones are thicker, stronger, and more solid, the cavity being

[Fig. 93.]



1. Male pelvis. 2. Female pelvis.]

deeper and narrower. In the female the bones are lighter and more delicate, the iliac fossæ large, and the ilia expanded; the inlet, outlet, and cavity are large, and the acetabula further removed from each other: the cavity is shallow, the tuberosities widely separated, the obturator foramina triangular, and the span of the pubic arch greater. The precise diameter of the inlet and outlet, and the depth of the cavity of the female pelvis, are important considerations to the accoucheur.

The diameters of the inlet or brim are three: 1. Antero-posterior, sacro-pubic

or conjugate; 2. transverse; and 3. oblique. The *antero-posterior* extends from the symphysis pubis to the middle of the promontory of the sacrum, and measures four inches. The *transverse* extends from the middle of the brim on one side to the same point on the opposite, and measures five inches. The *oblique* extends from the sacro-iliac symphysis on one side to the margin of the brim corresponding with the acetabulum on the opposite, and also measures five inches.

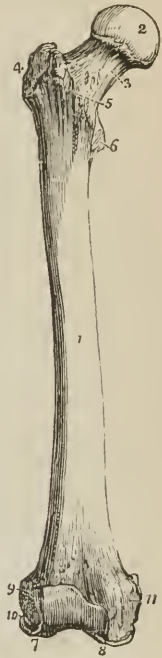The diameters of the outlet are two: 1. Antero-posterior; and 2. transverse. The *antero-posterior* diameter extends from the lower part of the symphysis pubis to the apex of the coccyx; the *transverse*, from the posterior part of one tuberosity to the same point on the opposite side; they both measure four inches. The cavity of the pelvis measures in depth four inches and a half, posteriorly: three inches and a half in the middle; and one and a half at the symphysis pubis.

FEMUR.—The femur, the longest bone of the skeleton, is situated obliquely in the upper part of the lower limb, articulating by means of its head with the acetabulum, and inclining inwards as it descends, until it almost meets its fellow of the opposite side at the knee. In the female this obliquity is greater than in the male, in consequence of the greater breadth of the pelvis. The femur is divisible into a shaft, a superior, and an inferior extremity.

At the *superior extremity* is a round *head* directed upwards and inwards, and marked just below its centre by an oval depression for the ligamentum teres. The head is supported by a *neck*, which varies in length and obliquity with sex and period of life, being long and oblique in the adult male, shorter and more horizontal in the female and in old age. [The vertical diameter of the neck is about double its antero-posterior, which increases its power of supporting the weight of the body, and of resisting force applied in a vertical direction. Its upper edge is about half the length of the lower.] Externally to the neck is a large process, the *trochanter major*, which presents on its anterior surface an oval facet, for the attachment of the tendon of the gluteus minimus muscle; and above, a double facet for the insertion of the gluteus medius. On its posterior side is a vertical ridge, *linea quadrati*, for the attachment of the quadratus femoris muscle. At the inner side of the trochanter major is a deep pit, *trochanteric* or *digital fossa*, in which are inserted the tendons of the pyriformis, gemellus superior and inferior, and obturator externus and internus muscles. Passing downwards from the trochanter major in front of the bone is an oblique ridge, which forms the inferior boundary of the neck, the *anterior intertrochanteric line*; and behind, another oblique ridge, the *posterior intertrochanteric line*, which terminates in a rounded tubercle on the posterior and inner side of the bone, the *trochanter minor*.

The *shaft* of the femur is convex and round in front, and covered with muscles; and somewhat concave and raised into a rough and prominent ridge behind, the *linea aspera*. The *linea aspera* near the upper extremity of the bone divides into three branches. The

FIG. 94.



THE RIGHT FEMUR, SEEN ON ITS ANTERIOR ASPECT.
 1. The shaft. 2. The head.
 3. The neck. 4. Great trochanter. 5. Anterior intertrochanteric line. 6. Lesser trochanter. 7. External condyle. 8. Internal condyle. 9. Tuberosity for the attachment of the external lateral ligament. 10. Fossa for the tendon of origin of the popliteus muscle. 11. Tuberosity for the attachment of the internal lateral ligament.

anterior branch is continued forwards in front of the lesser trochanter, and is continuous with the anterior intertrochanteric line; the middle is continued directly upwards into the linea quadrati; and the posterior, broad and strongly marked, ascends to the base of the trochanter major. Towards the lower extremity of

the bone the linea aspera divides into two ridges, which descend to the two condyles, and inclose a triangular space upon which rests the popliteal artery. The internal condyloid ridge is less marked than the external, and presents a broad and shallow groove, for the passage of the femoral artery. The nutritious foramen is situated in or near the linea aspera, at about one-third from its upper extremity, and is directed obliquely from below upwards.

The lower extremity of the femur is broad and porous, and divided by a smooth depression in front, and by a large fossa (fossa intercondyloidea) behind, into two condyles. [The union of the two condyles in front, forms the femoral trochlea, on which the patella glides.]

The external condyle is the broadest and most prominent, the internal the narrowest and longest; the difference in length depending on the obliquity of the femur, in consequence of the separation of the two bones at their upper extremity by the breadth of the pelvis. The external condyle is marked on its outer side by a prominent tuberosity, which gives attachment to the [long] external lateral ligament; and immediately beneath this is the fossa which lodges the tendon of origin of the popliteus. By the internal surface it gives attachment to the anterior crucial ligament of the knee-joint; and by its upper and posterior part, to the external head of the gastrocnemius, and plantaris. The internal condyle projects on its inner side into a tuberosity, to which is attached the internal lateral ligament; above this tuberosity, at the extremity of the internal condyloid ridge, is a tubercle, for the insertion of the tendon of the adductor magnus; and below the tubercle, on the upper surface of the condyle, a depression from which the internal head of the gastrocnemius arises. The outer side of the internal condyle is rough and concave, for the attachment of the posterior crucial ligament.

Development. — By five centres; one for the shaft, one for each extremity, and one for each trochanter [see Fig. 24.] The femur is the first of the long bones to show signs of ossification. In it, ossific matter is found immediately after the maxillæ and before the termination of the second month of embryonic life. The secondary deposits take place in the following order: in the condyloid extremity¹ during the last month of foetal life; in the head towards the end of the first year; in the greater trochanter between the third and fourth year; in the lesser trochanter between the thirteenth and fourteenth.

The epiphyses and apophyses are joined to the diaphysis in the reverse order of their appearance, the junction commencing after puberty and not being completed for the condyloid epiphysis until after the twentieth year.

¹ Cruveilhier remarks that this centre is so constant in the last fortnight of foetal life, that it may be regarded as an important proof of the foetus having reached its full term.

FIG. 95.

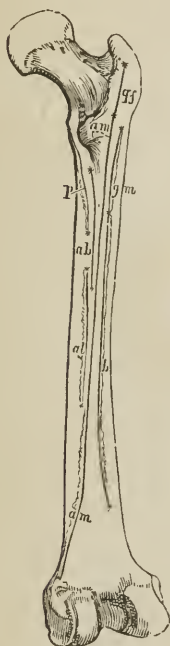


DIAGRAM OF THE POSTERIOR ASPECT OF THE RIGHT FEMUR, SHOWING THE LINES OF ATTACHMENT OF THE MUSCLES. The muscles attached to the inner lip are, *p*. Pectineus. *ab*. Adductor brevis. *al*. Adductor longus. The middle portion is occupied for its whole extent by *a m*, *a m*, adductor magnus; and is continuous superiorly with *g f*, linea quadrati, into which the quadratus femoris is inserted. The outer lip is occupied by *g m*, gluteus maximus; and *b*, short head of biceps.

Articulations. — With *three* bones; os innominatum, tibia, and patella.

Attachment of Muscles. — To *twenty-three*; by the *greater trochanter*, to the gluteus medius and minimus, pyriformis, gemellus superior, obturator internus, gemellus inferior, obturator externus, and quadratus femoris; by the *lesser trochanter*, to the common tendon of the psoas and iliacus. By the *linea aspera*, its outer lip, to the vastus externus, gluteus maximus, and a short head of the biceps; by its inner lip, vastus internus, pectineus, adductor brevis, and adductor longus; by its middle, adductor magnus; by the *anterior part* of the bone, crureus and suberureus; by its *condyles*, gastrocnemius, plantaris, and popliteus.

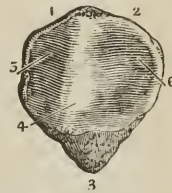
PATELLA. — The patella is a sesamoid bone, developed in the tendon of the quadriceps extensor muscle, and usually described as a bone of the lower extre-

[FIG. 96.



ANTERIOR, OR SUBCUTANEOUS SURFACE OF THE PATELLA. 1, 2. Base, to which the tendon of the quadriceps extensor cruris is attached. 3. Apex, from which the so-called ligamentum patellæ descends.]

FIG. 97.



POSTERIOR, OR FEMORAL SURFACE OF THE RIGHT PATELLA. 1, 2. Base. 3. Apex. 4. Articular ridge, received into the groove of the femoral trochlea. 5. Surface applied to the internal condyle. 6. Surface applied to the external condyle.

mity. It is heart-shaped in figure, the broad end being directed upwards, the apex downwards, the external surface is convex, and the internal divided by a ridge into two smooth surfaces, to articulate with the condyles of the femur. The external articular surface, corresponding with the external condyle, is the larger of the two, and serves to indicate the leg to which the bone belongs.

Development. — By a single centre, at about the middle of the third year.

Articulations. — With the two condyles of the femur.

Attachment of Muscles. — To *four*; rectus, crureus, vastus internus, vastus externus; and to the ligamentum patellæ.

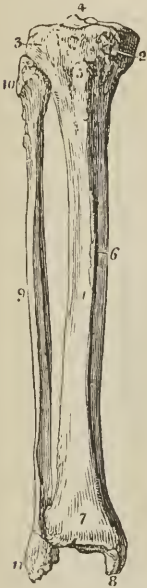TIBIA. — The tibia is the inner and larger bone of the leg; it is prismoid in form, and divisible into a shaft, an upper and lower extremity.

The *upper extremity*, or head, is large, and expanded laterally into two *tuberosities*. On the upper surface the tuberosities are smooth, to articulate with the condyles of the femur; the internal articular surface being oval and oblong, to correspond with the internal condyle; the external, broad and nearly circular. Between the two articular surfaces [*glenoid cavities*] is a *spinous process*; and in front of and behind the spinous process a rough depression, giving attachment to the anterior and posterior crucial ligament. Between the two tuberosities on the front aspect of the bone is a prominent elevation, the *tubercle* [*anterior tuberosity*], for the insertion of the ligamentum patellæ, and immediately above the tubercle a smooth facet, corresponding with a bursa. Upon the [back part of the] outer side of the external tuberosity is an articular surface, for the head of the fibula; and upon the posterior part of the internal tuberosity a depression, for the insertion of the tendon of the semi-membranosus muscle.

The *shaft* of the tibia presents three surfaces; *internal*, which is subcutaneous

and superficial; *external*, concave and marked by a sharp ridge, for the insertion of the interosseous membrane; and *posterior*, grooved, for the attachment of muscles. Near the upper extremity of the posterior surface is an oblique ridge, the *popliteal line*, for the attachment of the fascia of the popliteus muscle; and immediately below the oblique line, the nutritious canal, which is directed downwards. [The anterior edge formed by the junction of the internal and external surfaces, is for the most part subcutaneous; its lower part is blunt, but the upper part, particularly towards the middle, is prominent and sharp, and is called the *crest* of the tibia.]

FIG. 98.



TIBIA AND FIBULA OF THE RIGHT LEG, ARTICULATED AND SEEN FROM THE FRONT. 1. Shaft of the tibia. 2. Inner tuberosity. 3. Outer tuberosity. 4. Spinous process. 5. Tubercle. 6. Internal or subcutaneous surface of the shaft. 7. Lower extremity of the tibia. 8. Internal malleolus. 9. Shaft of the fibula. 10. Its upper extremity. 11. Its lower extremity, the external malleolus. The sharp border between 1 and 6 is the crest of the tibia.

The *inferior extremity* of the bone is somewhat quadrilateral, and prolonged on its inner side into a large process, the *internal malleolus* [the internal surface of which is convex and subcutaneous; whilst its external surface forms a part of the inferior articular cavity of the tibia, and opposes the internal lateral articular facet of the astragalus.] Behind the internal malleolus, is a broad and shallow groove, for lodging the tendons of the tibialis posticus and flexor longus digitorum; and further outwards another groove, for the tendon of the flexor longus pollicis. At the outer side the surface is concave and triangular, rough above for the attachment of the interosseous ligament; and smooth below, to articulate with the fibula. On the extremity of the bone is a triangular smooth surface, for articulation with the astragalus.

Development.—By three centres; one for the shaft, and one for each extremity. Ossification commences in the tibia, immediately after the femur; the centre for the head of the bone appears soon after birth, and that for the lower extremity during the second year; the latter is the first to join the diaphysis. The bone is not complete until nearly the twenty-fifth year. Two occasional centres are sometimes found in the tibia, one for the tubercle, the other for the internal malleolus.

Articulations.—With three bones; femur, fibula, and astragalus.

Attachment of Muscles.—To ten; by the internal tuberosity, to the sartorius, gracilis, semi-tendinosus, and semi-membranosus; by the external tuberosity, tibialis anticus and extensor longus digitorum; by the tubercle, ligamentum patellæ; by the external surface of the shaft, tibialis anticus; and by the posterior surface, popliteus, soleus, flexor longus digitorum, and tibialis posticus.

FIBULA.—The fibula (*περόνη*, a brooch, from its resemblance, in conjunction with the tibia, to the pin of an ancient brooch) is the outer and smaller bone of the leg; it is long and slender in figure, prismoid in shape, and, like other long bones, divisible into a shaft and two extremities.

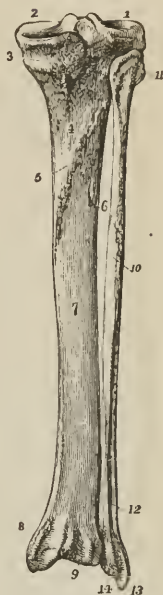
The *superior extremity* or head is thick and large, and depressed at the upper part by a concave surface, which articulates with the external tuberosity of the tibia. Externally to this surface is a thick and rough prominence, for the attachment of the [long] external lateral ligament of the knee-joint, terminated behind by a styloid process, for the insertion of the tendon of the biceps.

The *lower extremity* is flattened from without inwards, and prolonged down-

wards beyond the articular surface of the tibia, forming the *external malleolus*. Its external side presents a rough and triangular surface, which is subcutaneous.

FIG. 99.

TIBIA AND FIBULA OF THE RIGHT LEG ARTICULATED AND SEEN FROM BEHIND. 1. Articular depression for the external condyle of the femur. 2. Articular depression for the internal condyle; the prominence between the two is the spinous process. 3. Fossa and groove for the insertion of the tendon of the semi-membranosus. 4. Popliteal plane, for the support of the popliteus. 5. Popliteal line. 6. Nutritious foramen. 7. Surface of the shaft on which the flexor longus digitorum rests. 8. Broad groove on the back part of the inner malleolus, for the tendons of the flexor longus digitorum and tibialis posticus. 9. Groove for the tendon of the flexor longus pollicis. 10. Shaft of the fibula. The flexor longus pollicis lies on the surface of the bone; its superior limit being marked by the oblique line immediately above the cipher. 11. Styloid process on the head of the fibula for the attachment of the tendon of the biceps. 12. Subcutaneous surface of the lower part of the shaft of the fibula. 13. External malleolus formed by the lower extremity of the fibula. 14. Groove on the posterior part of the external malleolus for the tendons of the peronei muscles.



On the internal surface is a smooth triangular facet, to articulate with the astragalus; and a rough depression, for the insertion of the [inferior] interosseous ligament. The *anterior border* is thin and sharp; the *posterior*, broad and grooved, for the tendons of the peronei muscles.

To place the bone in its proper position, and ascertain to which leg it belongs, let the inferior or flattened extremity be directed downwards, and the narrow border of the malleolus forwards; the triangular subcutaneous surface will then point to the side corresponding with the limb of which the bone should form a part.

The *shaft* of the fibula is prismoid, and presents three surfaces; external, internal, and posterior; and three borders. The *external surface* is the broadest of the three; it commences on the anterior part of the bone above, and curves around it so as to terminate on its posterior side below. This surface is completely occupied by the two peronei muscles. The *internal surface* commences on the side of the superior articular surface, and terminates below, by narrowing to a ridge which is continuous with the anterior border of the malleolus. It is marked along its middle by the *interosseous ridge*, which is lost above and below in the inner border of the bone. The *posterior surface* is twisted like the external, it commences above on the posterior side of the bone, and terminates below on its internal side; at about the middle of this surface is the *nutritious foramen*, which is directed downwards.

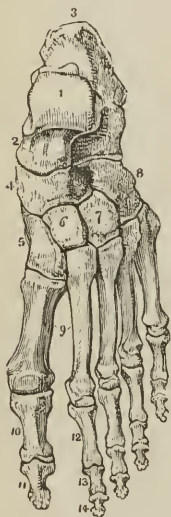
The *internal border* commences superiorly in common with the interosseous ridge, and bifurcates inferiorly into two lines, which bound the triangular subcutaneous surface of the external malleolus. The *external border* begins at the base of the styloid process of the head, and winds around the bone, following the direction of the corresponding surface. The *posterior border*, sharp and prominent, is lost inferiorly in the interosseous ridge.

Development. — By three centres; one for the shaft, and one for each extremity. Ossification commences in the shaft soon after its appearance in the tibia; at birth the extremities are cartilaginous, an osseous deposit taking place in the inferior epiphysis during the second year, and in the superior during the fourth or fifth. The inferior epiphysis is the first to become united with the diaphysis, but the bone is not completed until nearly the twenty-fifth year.

Articulation — With the tibia and astragalus.

Attachment of Muscles. — To ten; by the head, to the tendon of the biceps and soleus; by the shaft, its external surface, peroneus longus and brevis; internal surface, extensor digitorum, extensor proprius pollicis, peroneus tertius, and tibialis posticus; by the posterior surface, popliteus and flexor longus pollicis.

FIG. 100.



DORSAL SURFACE OF THE LEFT FOOT. 1. Astragalus; its superior quadrilateral articular surface. 2. Anterior extremity of the astragalus, which articulates with (4) the scaphoid bone. 3, 3. Os calcis. 4. Scaphoid bone. 5. Internal cuneiform bone. 6. Middle cuneiform bone. 7. External cuneiform bone. 8. Cuboid bone. 9. Metatarsal bones of the first and second toes. 10. First phalanx of the great toe. 11. Second phalanx of the great toe. 12. First phalanx of the second toe. 13. Its second phalanx. 14. Its third phalanx.

TARSUS. — The bones of the tarsus are seven in number: viz., astragalus, os calcis, scaphoid, internal, middle, and external cuneiform, and cuboid.

The ASTRAGALUS (os tali) may be recognized by its rounded head, a broad articular facet on its convex surface, and two articular facets, separated by a deep groove, on its concave surface. [It is the only bone of the tarsus which enters into the formation of the ankle-joint.]

The bone is divisible into a superior and inferior surface, an external and internal border, and an anterior and posterior extremity. The *superior surface* is convex, and presents a large quadrilateral and smooth facet, somewhat broader in front than behind, to articulate with the tibia. The *inferior surface* is concave, and divided by a deep and rough groove (sulcus tali), which lodges a strong interosseous ligament, into two facets, the posterior large and quadrangular, the anterior smaller and elliptic, which articulate with the os calcis. The *internal border*, flat and uneven, is marked by a pyriform articular surface for the inner malleolus. The *external* presents a large triangular articular facet, for the external malleolus, and is rough and concave in front. The *anterior extremity* presents a rounded head, encircled by a constriction somewhat resembling a neck; the *posterior extremity* is narrow, and marked by a deep groove, for the tendon of the flexor longus pollicis.

Hold the astragalus with the broad articular surface upwards, and rounded head forwards; the triangular lateral articular surface will point to the side to which the bone belongs.

Articulations. — With four bones: tibia, fibula, os calcis, and scaphoid.

The OS CALCIS [calcaneum] may be known by its large size and oblong figure, by the massive portion which forms the heel, and by two articular surfaces, separated by a broad groove, upon its upper side.

The os calcis is divisible into four surfaces, superior, inferior, external and internal; and two extremities, anterior and posterior. The *superior surface* is

convex behind and irregularly concave in front, where it presents two and sometimes three articular facets, divided by a broad and shallow groove (sulcus calcanei), for the interosseous ligament. The *inferior surface* is convex and rough, and bounded posteriorly by the two inferior tuberosities, of which the internal is broad and large, the external smaller and prominent. The *external surface* is convex and subcutaneous, and marked towards its anterior third by two grooves, often separated by a tubercle, for the tendons of the peroneus longus and brevis. The *internal surface* is concave and grooved, for the tendons and vessels which pass into the sole of the foot. At the anterior extremity of this surface is a projecting process (sustentaculum tali), which supports the anterior articulating surface of the astragalus, and serves as a pulley for the tendon of the flexor longus digitorum.

At the *anterior extremity* of the bone is a flat articular surface, surmounted by a rough prominence, which affords one of the guides to the surgeon in the performance of Chopart's operation. The *posterior extremity* is prominent and convex, and constitutes the *posterior tuberosity*; it is smooth for the upper half of its extent, where it corresponds with a bursa; and rough below, for the insertion of the tendo Achillis; the lower part of this surface is bounded by the two inferior tuberosities.

Articulations.—With *two* bones: astragalus and cuboid. In their articulated state a large oblique canal is situated between the astragalus and calcaneum, being formed by the apposition of the two grooves, sulcus tali and sulcus calcanei. This groove is called the *sinus tarsi*, and serves to lodge a strong interosseous ligament, which binds the two bones together.

Attachment of Muscles.—To *eight*: by the posterior tuberosity, to the tendo Achillis and plantaris; by the inferior tuberosities and under surface, abductor pollicis, abductor minimi digiti, flexor brevis digitorum, flexor accessorius, and plantar fascia; by the external surface, extensor brevis digitorum.

The SCAPHOID bone [os naviculare] may be distinguished by its boat-like figure, concave on one side, and convex with three facets on the other. It presents for examination an anterior and posterior surface, superior and inferior border, and two extremities, one broad, the other pointed and thick. The *anterior surface* is convex, and divided into three facets, to articulate with the three cuneiform bones; the *posterior* is concave, to articulate with the rounded head of the astragalus. The *superior border* is convex and rough, and the *inferior* somewhat concave and uneven. The *external extremity* is broad and rough; and the *internal* pointed and prominent, so as to form a tuberosity. The external extremity sometimes presents a facet of articulation with the cuboid.

If the bone be held so that the convex surface with three facets look forwards, and the convex border upwards, the broad extremity will point to the side corresponding with the foot to which the bone belongs.

Articulations.—With *four* bones: astragalus and three cuneiform, sometimes also with the cuboid.

Attachment of Muscles.—To the tendon of the tibialis posticus.

The INTERNAL CUNEIFORM may be known by its irregular wedge-shape, and by being larger than the two other bones which bear the same name. It presents for examination a convex and a concave surface, a long and a short articular border, and a small and a large extremity.

Place the bone so that the small extremity may look upwards and the long articular border forwards, the concave surface will point to the side corresponding with the foot to which it belongs.

The *convex surface* is internal and free, and assists in forming the inner border of the foot; the *concave* is external, and in apposition with the middle cuneiform and second metatarsal bone; the *long border* articulates with the metatarsal bone

of the great toe, the *short border* with the scaphoid bone. The small extremity (edge) is sharp [and looks upwards]; the larger extremity (base) rounded into a broad tuberosity.

Articulations.— With *four* bones: scaphoid, middle cuneiform, and first two metatarsal bones.

Attachment of Muscles.— To the tibialis anticus and posticus.

The MIDDLE CUNEIFORM is the smallest of the three; it is wedge-shaped, the broad extremity being placed upwards, the sharp end downwards in the foot. It presents for examination four articular surfaces and two extremities. The *anterior* and *posterior surface* have nothing worthy of remark. One of the *lateral surfaces* has a long articular facet, extending its whole length, for the internal cuneiform; the *other* has only a partial articular facet for the external cuneiform bone.

If the bone be held so that the square extremity look upwards, the broadest edge of the square being towards the holder, the small and partial articular surface will point to the side to which the bone belongs.

Articulations.— With *four* bones: scaphoid, internal and external cuneiform, and second metatarsal bone.

The EXTERNAL CUNEIFORM is intermediate in size between the two preceding, and placed, like the middle, with the broad end upwards, and sharp extremity downwards. It presents for examination five surfaces, and a superior and inferior extremity. The *upper extremity* is flat, of an oblong square form, and bevelled posteriorly, at the expense of the outer surface, into a sharp edge.

If the bone be held so that the square extremity look upwards, and the sharp border backwards, the bevelled surface will point to the side to which the bone belongs.

Articulations.— With *six* bones: scaphoid, middle cuneiform, cuboid, and second, third, and fourth metatarsal bone.

Attachment of Muscles.— To the flexor brevis pollicis.

The CUBOID BONE is irregularly cuboid in shape, and marked on its under surface by a deep groove, for the tendon of the peroneus longus muscle. It presents for examination, six surfaces, three articular, and three non-articular. The *non-articular surfaces* are, *superior*, which is slightly convex, and assists in forming the dorsum of the foot; *inferior*, marked by a prominent ridge, the *tuberosity*, and a deep groove for the tendon of the peroneus longus; and *external*, the smallest of the whole, and deeply notched by the commencement of the peroneal groove. The *articular surfaces* are, *posterior*, of large size, and concavo-convex, to articulate with the os calcis; *anterior*, of smaller size, divided by a slight ridge into two facets, for the fourth and fifth metatarsal bones; and *internal*, a small oval articular facet, upon a large and quadrangular surface, for the external cuneiform bone.

If the bone be held so that the plantar surface, with the peroneal groove, look downwards, and the largest articular surface backwards, the small non-articular surface, marked by the deep notch, will point to the side to which the bone belongs.

Articulations.— With *four* bones: os calcis, external cuneiform, fourth and fifth metatarsal bone, and sometimes the scaphoid.

Attachment of Muscles.— To *two*: flexor brevis pollicis, and adductor pollicis.

Upon a consideration of the articulations of the tarsus it will be observed, that each bone articulates with four adjoining bones, with the exception of the calcaneum, which articulates with two, and the external cuneiform with six.

Development.— By a single centre for each bone, with the exception of the os

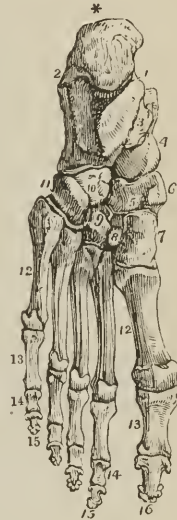calcis, which has an epiphysis for its posterior tuberosity. The centres appear in the following order; calcaean, sixth month; astragalan, seventh month; cuboid, tenth month; external cuneiform, end of the first year; internal cuneiform, during the third year; middle cuneiform and scaphoid during the fourth year. The epiphysis of the calcaneum appears at the ninth year, and is united with the diaphysis at about the fifteenth.

[When we consider the tarsus as a whole, we find that its antero-posterior diameter is about twice as great as its transverse, and that its seven bones are disposed in two rows; the *first* or tibial row, is formed by the os calcis and the astragalus, which are placed not side by side, but one (the astragalus) above and resting upon the other. The *second* or metatarsal row, is composed of the scaphoid, on the inner side, and the three cuneiform bones, which are articulated to its anterior surface; and on the outer side, of the cuboid. These bones collectively form the posterior half of the foot, and constitute an arch, on the summit of which the weight of the leg is received; the plantar aspect of the arch is deeply excavated both antero-posteriorly and transversely, which not only secures to the structure the peculiar advantages of such a mechanism, but protects from pressure, during standing or walking, the vessels and nerves which are here located. The posterior extremity of the tarsus is narrow and non-articular, being formed by the posterior tuberosity of the calcaneum, but it progressively increases in width, forwards, the anterior extremity being formed by the three cuneiform bones and the cuboid, which present a sinuous articular border for the bases of the metatarsal bones. This border has a direction obliquely forwards from the outer to the inner side of the foot—hence the inner edge or border of the tarsus is longer, and extends further forwards than the outer. This point, taken in connection with shortness of the middle cuneiform, admitting of a dove-tailing of the base of the second metatarsal bone into this border is of great importance in reference to Hey's operation of amputation at the tarso-metatarsal articulation.]

The METATARSAL BONES, *five* in number, are long bones, and divisible therefore into a shaft and two extremities. The shaft is prismatic, and compressed from side to side; the posterior extremity, or base, is square-shaped, to articulate with the tarsal bones, and with each other; the anterior extremity presents a rounded head, circumscribed by a neck, to articulate with the first row of the phalanges.

Peculiar Metatarsal Bones.—The *first* is shorter and larger than the rest, and forms part of the inner border of the foot; its posterior extremity presents only one lateral articular surface, and an oval

FIG. 101.



SOLE OF THE LEFT FOOT. 1. Inner tuberosity of the os calcis. 2. Outer tuberosity. * Posterior tuberosity. 3. Groove for the tendon of the flexor longus digitorum; this figure indicates also the sustentaculum tali, upon which it is placed. 4. Rounded head of the astragalus. 5. Scaphoid bone. 6. Its tuberosity. 7. Internal cuneiform bone; its broad extremity. 8. Middle cuneiform bone. 9. External cuneiform bone. 10, 11. Cuboid bone: 11. Groove for the tendon of the peroneus longus; the prominence between this groove and figure 10 is the tuberosity of this bone. 12, 12. Metatarsal bones. 13, 13. First phalanges. 14, 14. Second phalanges of the four lesser toes. 15, 15. Third, or ungual phalanges of the four lesser toes. 16. Last phalanx of the great toe.

rough prominence beneath, for the insertion of the tendon of the peroneus longus. The anterior extremity has, on its plantar surface, two grooved facets, for sesamoid bones.

The *second* is the longest and largest of the remaining metatarsal bones; it presents at its base three articular facets, for the three cuneiform bones; a large oval facet, but often no articular surface, on its inner side, to articulate with the metatarsal bone of the great toe, and two externally, for the third metatarsal bone.

The *third* may be known by two facets on the inner side of its base, corresponding with the second, and may be distinguished by its smaller size.

The *fourth* may be distinguished by its smaller size, and by having a single articular surface on each side of the base.

The *fifth* is recognised by its broad base, and by the large tuberosity at its outer side.

Development. — Each bone by *two* centres; one for the body and one for the digital extremity in the four outer metatarsal bones; and one for the body, the other for the base, in the metatarsal bone of the great toe. Ossification appears in these bones at the same time with the vertebræ; the epiphyses commencing with the great toe and proceeding to the fifth, appear towards the close of the second year, consolidation being effected at eighteen.

Articulations. — With the tarsal bones by one extremity, and first row of phalanges by the other. The number of tarsal bones with which each metatarsal articulates from within outwards, is the same as between the bones of the metacarpus and carpus, one for the first, three for the second, one for the third, two for the fourth, and one for the fifth, forming the cipher 13121.

Attachment of Muscles. — To *fourteen*: to the first, peroneus longus and first dorsal interosseous; to the second, two dorsal interossei and transversus pedis; to the third, two dorsal and one plantar interosseous, adductor pollicis and transversus pedis; to the fourth, two dorsal and one plantar interosseous, adductor pollicis and transversus pedis; to the fifth, one dorsal and one plantar interosseous, peroneus brevis, peroneus tertius, adductor minimi digiti, flexor brevis minimi digiti, and transversus pedis.

PHALANGES. — There are two phalanges in the great toe and three in the other toes, as in the hand. They are long bones, divisible into a central portion and extremities.

The phalanges of the first row are convex above, concave on the under surface, and compressed from side to side. The posterior extremity has a single concave articular surface, for the head of the metatarsal bone; the anterior extremity, a pulley-like surface, for the second phalanx.

The *second phalanges* are short and diminutive, but somewhat broader than those of the first row.

The *third or unequal phalanges*, including the second phalanx of the great toe, are flattened from above downwards, spread out laterally at the base to articulate with the second row, and at the opposite extremity to support the nail and the rounded extremity of the toe.

Development. — By *two* centres; one for the body and one for the metatarsal extremity. Ossification commences in these bones after that in the metatarsus, appearing firstly in the last phalanges, then in the first, and lastly in the middle row. The bones are completed at eighteen.

Articulations. — The first row with the metatarsal bones and second phalanges; the second, of the great toe, with the first phalanx; of the other toes, with the first and third phalanges; the third, with the second row.

Attachment of Muscles. — To *twenty-three*: to the *first phalanges*; great toe, innermost tendon of the extensor brevis digitorum, abductor pollicis, adductor pollicis, flexor brevis pollicis, and transversus pedis; *second toe*, first dorsal and first

plantar interosseous and lumbricalis; *third toe*, second dorsal and second plantar interosseous and lumbricalis; *fourth toe*, third dorsal and third plantar interosseous and lumbricalis; *fifth toe*, fourth dorsal interosseous, abductor minimi digiti, flexor brevis minimi digiti and lumbricalis. *Second phalanges: great toe*, extensor longus pollicis, and flexor longus pollicis; *other toes*, one slip of the common tendon of the extensor longus and extensor brevis digitorum, and flexor brevis digitorum. *Third phalanges*; two slips of the common tendon of the extensor longus and extensor brevis digitorum, and the flexor longus digitorum.

SESAMOID BONES [osteids].—These are small osseous masses, developed in those tendons which exert a certain degree of force upon the surface over which they glide, or where, by continued pressure and friction, the tendon would become a source of irritation to neighbouring parts, as to joints. The best example of a sesamoid bone is the patella, developed in the common tendon of the quadriceps extensor, and resting against the front of the knee-joint. Besides the patella, there are four pairs of sesamoid bones included in the number of pieces which compose the skeleton, two on the metacarpo-phalangeal articulation of each thumb, and existing in the tendons of insertion of the flexor brevis pollicis, and two upon the corresponding joint in the foot, in the tendons of the muscles inserted into the base of first phalanx. In addition to these there is often a sesamoid bone on the metacarpo-phalangeal joint of the little finger; and on the corresponding joint in the foot, in the tendons inserted into the base of the first phalanx; there is one also in the tendon of the peroneus longus muscle, where it glides through the groove in the cuboid bone; sometimes in the tendons, as they wind around the inner and outer malleolus; in the psoas and iliacus, where they glide over the body of the os pubis: and in the external head of the gastrocnemius.

The *bones of the tympanum*, as they belong to the apparatus of hearing, will be described with the anatomy of the ear.

CHAPTER III.

OF THE LIGAMENTS.

THE bones are variously connected with each other in the construction of the skeleton, and the connexion between any two bones constitutes a joint or articulation. If the joint be immovable, the surfaces of the bones are applied in direct contact; but if motion be intended, the opposing surfaces are expanded and coated by an elastic substance named cartilage; a fluid secreted by a membrane closed on all sides lubricates their surface, and they are firmly held together by means of short bands of glistening fibres, which are called ligaments (ligare, to bind). The study of the ligaments is termed syndesmology (σύν, together, δεσμός, bond), which, with the anatomy of the articulations, forms the subject of the present chapter.

The forms of articulation met with in the human frame may be considered under three classes: Synarthrosis, Amphiarthrosis, and Diarthrosis.

SYNARTHROSIS (σύν, ἀρθρωσις, articulation) is expressive of the fixed form of joint in which the bones are immovably connected with each other. The kinds of synarthrosis are four in number. *Sutura*, *Harmonia*, *Schindylesis*, *Gomphosis*. The characters of the three first have been sufficiently explained in the preceding chapter, p. 82. It is here only necessary to state that, in the construction of sutures, the substance of the bones is not in immediate contact, but separated by

a layer of membrane, which is continuous externally with the pericranium and internally with the dura mater. It is the latter connexion which gives rise to the resistance experienced in tearing the calvaria from the dura mater. Cruveilhier describes this interposed membrane as the *sutural cartilage*; I never saw any structure in the sutures which could be regarded as cartilage, and the history of the formation of the cranial bones would suggest a different explanation. The fourth, Gomphosis (γόμφος, a nail), is expressive of the insertion of one bone into another, as a nail is fixed into a board; this is illustrated in the articulation of the teeth with the alveoli of the maxillary bones.

AMPHI-ARTHROSIS (ἀμφί, both, ἄρθρωσις) is a joint intermediate in aptitude for motion between the immovable synarthrosis and the movable diarthrosis. It is constituted by the approximation of surfaces partly coated with cartilage lined by synovial membrane, and partly connected by interosseous ligaments, or by the intervention of an elastic fibro-cartilage which adheres to the ends of both bones. Examples of this mode of articulation are seen in the union between the bodies of the vertebræ, the sacrum with the coccyx, the pieces of the sternum, the sacroiliac and pubic symphyses (σύν φείειν, to grow together), and according to some, the necks of the ribs, with the transverse processes.

DIARTHROSIS (διά, through, ἄρθρωσις) is the movable articulation, which constitutes by far the greater number of the joints of the body. The degree of motion in this class has given rise to a subdivision into three genera, Arthrodia, Ginglymus, and Enarthrosis.

Arthrodia [ἄρθρον, a joint, ἄρω, to adapt] is the movable joint in which the extent of motion is slight and limited, as in the articulations of the clavicle, ribs, articular processes of the vertebræ, axis with the atlas, radius with the ulna, fibula with the tibia, carpal and metacarpal, tarsal and metatarsal bones.

Ginglymus (γίγγλυμός, a hinge), or hinge-joint, is the movement of bones upon each other in two directions only, viz., forwards and backwards; but the degree of motion may be very considerable. Instances of this form of joint are numerous; they comprehend the elbow, wrist, metacarpo-phalangeal, and phalangeal joints in the upper extremity; the knee, ankle, metatarso-phalangeal, and phalangeal joints in the lower extremity. The lower jaw may also be admitted into this category, as partaking more of the character of the hinge-joint than of the less movable arthrodia.

The form of the ginglymoid joint is somewhat quadrilateral, each of its four sides being provided with a ligament, which is named from its position, *anterior*, *posterior*, *internal lateral*, or *external lateral*. The *lateral ligaments* are thick and strong, and the chief bond of union between the bones. The *anterior* and *posterior* are thin and loose, in order to permit the required extent of movement.

Enarthrosis (ἐν, in, ἄρθρωσις) is the most extensive in its range of motion of all the movable joints. From the manner of connexion and form of the bones in this articulation, it is called the ball-and-socket joint. There are two instances in the body, namely, the hip and the shoulder.

I have been in the habit of adding to the preceding the carpo-metacarpal articulation of the thumb, although not strictly a ball-and-socket joint, from the great extent of motion which it enjoys, and from the nature of the ligament connecting the bones. As far as the articular surfaces are concerned, it is rather a double than a single ball-and-socket; and the whole of these considerations remove it from the simple arthrodioid and ginglymoid groups.

The ball-and-socket joint has a circular form; and, in place of the four distinct ligaments of the ginglymus, is inclosed in a bag of ligamentous membrane, called, *capsular ligament*.

The kinds of articulation may be shown in a tabular form, as follows:

Synarthrosis.	{	Sutura	bones of the skull.
		Harmonia	superior maxillary bones.
		Schindylesis	vomer with rostrum.
		Gomphosis	teeth with alveoli.
Amphi-arthritis.		Bodies of the vertebræ.	Symphyses.
Diarthrosis.	{	Arthrodia	carpal and tarsal bones.
		Ginglymus	elbow, wrist, knee, ankle.
		Enarthrosis	hip, shoulder.

The motions of joints may be referred to four heads, viz., Gliding, Angular movement, Circumduction, and Rotation.

1. *Gliding* is the simple movement of one articular surface on another, and exists to a greater or less extent in all the joints. In the least movable joints, as in the carpus and tarsus, this is the only motion which is permitted.

2. *Angular movement* may be performed in four different directions, either forwards and backwards, as in flexion and extension; or, inwards and outwards, constituting adduction and abduction. Flexion and extension are illustrated in the ginglymoid joint, and exist in a large proportion of the joints of the body. Adduction and abduction conjoined with flexion and extension are met with complete only in the most movable joints, as the shoulder, hip, and thumb. In the wrist and ankle, adduction and abduction are only partial.

3. *Circumduction* is most strikingly exhibited in the shoulder and hip joints; it consists in the slight degree of motion which takes place between the head of a bone and its articular cavity, while the extremity of the limb is made to describe a large circle on a plane surface. It is also seen, but in a less degree, in the carpo-metacarpal articulation of the thumb, metacarpo-phalangeal articulation of the fingers and toes, and in the elbow when that joint is flexed and the end of the humerus fixed.

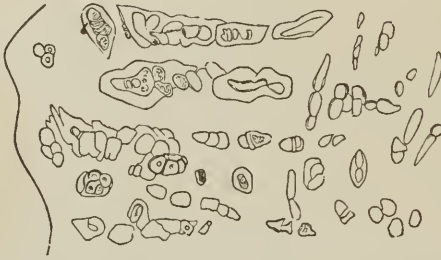4. *Rotation* is the movement of a bone on its own axis, and is illustrated in the hip and shoulder, or better, in the rotation of the cup of the radius against the eminentia capitata of the humerus. Rotation is also observed in the movements of the atlas upon the axis, where the odontoid process serves as a pivot around which the atlas turns.

THE STRUCTURES entering into the composition of a joint are, bone, cartilage, areolar tissue, fibrous tissue, yellow or elastic tissue, adipose tissue, and synovial membrane. Cartilage forms a thin coating to the articular extremities of bones, sometimes presenting a smooth surface which moves on a corresponding smooth surface of the articulating bone; sometimes forming a plate smooth on both surfaces and interposed between the cartilaginous ends of two bones, *interarticular*; and sometimes acting as the connecting medium between bones without any free surface, *interosseous*. White fibrous tissue enters into the construction of joints under the form of ligament, in one situation constituting bands of various breadth and thickness; in another, a layer which extends completely round the joint, and is then called a *capsular ligament*. All the ligaments of joints are composed of that variety of fibrous tissue termed white fibrous tissue; but in some situations ligaments are found which consist of yellow fibrous tissue, for example, the ligamenta subflava of the arches of the vertebral column. Adipose tissue exists in variable quantity in relation with joints, where it performs, among other offices, that of a valve or spring, which occupies any vacant space that may be formed during the movements of the joint, and prevents the occurrence of a vacuum in those cavities. This purpose of adipose tissue is exemplified in the cushion of fat at the bottom of the acetabulum, and in the similar cushion behind the ligamentum patellæ. Synovial membrane constitutes the smooth and polished lining of a joint, and contains the fluid termed synovia, by means of which the adapted surfaces are enabled to move upon each other with ease and freedom.

CARTILAGE. — In the structure of joints, cartilage serves the double purpose of a connecting and separating medium. In the former capacity possessing great strength; in the latter, smoothness and elasticity. In reference to structure it admits of classification into three kinds; true cartilage, reticular cartilage, and fibrous cartilage.

True cartilage is composed of a semi-transparent homogeneous substance (hyaline or vitreous substance, matrix) containing a number of minute cells (cartilage

FIG. 102.



A PORTION OF ARTICULAR (TRUE) CARTILAGE from the head of the fibula. The section is made vertically to the surface, and magnified 155 times. It exhibits the appearance and arrangement of the cells near the bone. The flexuous line to the left is the boundary of the bone.

cells) dispersed at short intervals through its structure. The cells are oval, oblong, or polyhedral in shape, and more or less flattened; their membranous envelop is thick and sometimes laminated, and they contain in their interior a clear fluid, together with nuclei, oil-globules, and more or less granular matter. Cartilage cells have an average measurement of $\frac{1}{1500}$ th of an inch in long diameter; they are sometimes isolated, sometimes grouped in pairs, and sometimes dis-

FIG. 103.



ARRANGEMENT OF THE CELLS IN ARTICULAR CARTILAGE. The drawing is made from the same section as fig. 102, the part selected being midway between the free surface of the cartilage and the bone.

FIG. 104.



ARRANGEMENT OF THE CELLS IN ARTICULAR CARTILAGE near to, and at its free surface. The figure is drawn from the same section as the two preceding. The edge to the right, where the cells are most condensed, represents the free surface. The cells exhibit the fusiform shape.

posed in a linear group of three or four. Near the bone they are larger than at the surface, and in the latter situation are long and slender (fusiform) in form, and arranged in rows having their long axes parallel with the plane of the surface. True cartilage is pearl-white or bluish and opaline in colour, its intercellular sub-


stance being semitransparent, and homogeneous or finely granular. These characters, however, are changed when it exhibits a tendency to ossify; in which case the intercellular substance becomes fibrous and more or less opaque, its colour yellowish, and the cells filled with a greater number of oil-globules than in its natural state. The special chemical proximate principle of the matrix of cartilage is chondrine, its cells yielding gelatine.

The true cartilages are, the articular, costal, ensiform, thyroid, cricoid, arytenoid, tracheal, bronchial, nasal, meatus auris, pulley of the trochlearis muscle, and temporary cartilage, or the cartilage of bone previously to ossification.¹

Reticular cartilage [or yellow cartilage] is composed of cells ($\frac{1}{1500}$ th of an inch in diameter), separated from each other by an opaque, fibrous, intercellular network, the breadth of the cells being considerably greater than that of the intercellular structure. The cells contain nuclei, granular matter, and oil-globules, the latter in greater number than in true cartilage; the fibres are short, imperfect, loose in texture, and yellowish; and chemically there is an absence of chondrine. Instances of reticular cartilage are, the pinna, epiglottis, and Eustachian tube.

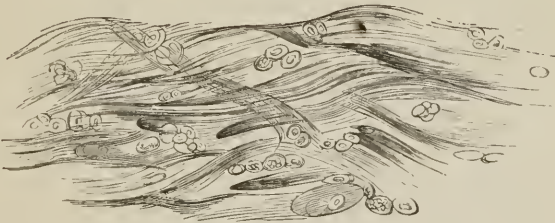Fibrous cartilage is composed of an interlacement of fasciculi of white fibrous tissue, containing in its meshes scattered groups of cartilage cells; and the difference of density of different fibrous cartilage, is referable to the greater or less abundance, and more or less condensed state of the fibrous tissue. In some, as in interarticular car-

FIG. 105.



A PORTION OF RETICULAR CARTILAGE. The section is made from the pinna, and magnified 155 times.

FIG. 106.



A PORTION OF FIBROUS CARTILAGE. The section is made from the symphysis pubis, and magnified 155 times.

tilages, the fibrous element exists in a concentrated form, while in the intervertebral substance it is loose, and contains an abundance of areolar spaces.

Fibrous cartilages admit of arrangement into four groups: interarticular, stratiform, interosseous, and free. Instances of *interarticular fibrous cartilage* (menisci) are those of the lower jaw, sternal and acromial end of the clavicle, wrist, carpus, knee, to which may be added the fibrous cartilages of circumference, glenoid, and cotyloid. The *stratiform fibrous cartilages* are such as form a thin coating to the grooves on bone through which tendons play. The *interosseous fibrous cartilages* are the intervertebral substances and symphysis pubis. The *free fibrous cartilages* are the tarsal cartilages of the eyelids.

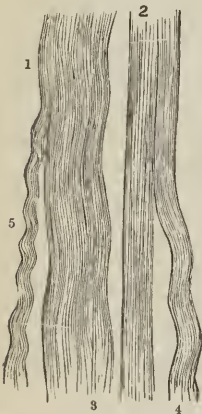The *development* of [permanent] cartilage is the same as that of cartilage of bone [or temporary cartilage], the different forms of cartilage resulting from subsequent changes in the intercellular substance and cells. Thus in articular cartilage the cells undergo the lowest degree of development, are very disproportionate to the

intercellular substance, and the latter remains for the most part homogeneous. In reticular cartilage the cells possess a more active growth, and surpass in bulk the intercellular substance, while the latter assumes a fibrous character. In fibrous cartilage, development is most energetic in the intercellular substance; this is converted into fasciculi of fibrous tissue, while the interspaces are filled with cells and imperfect fibrous tissue in every stage of development.

FIBROUS TISSUE is one of the most generally distributed of all the animal tissues; it is composed of *fibres* of extreme minuteness, and presents itself under two elementary forms; namely, white fibrous tissue, and yellow fibrous or elastic tissue.

In *white fibrous tissue* (connective tissue), the fibres are cylindrical, exceedingly minute (about $\frac{1}{150000}$ th of an inch in diameter), transparent and undulating; they are collected into small fasciculi (from $\frac{1}{30000}$ th to $\frac{1}{10000}$ th of an inch), and these latter form larger fasciculi, which, according to their arrangement, give rise to the production of thin laminae, membranes, ligamentous bands, and tendinous cords. The connecting medium of the fibres in the formation of the primitive fasciculi is a transparent, structureless, interfibrous substance or blastema, to which in most situations are added numerous minute dark filaments of elastic tissue. The elastic filaments are sometimes wound spirally round the fasciculi, or interlace with their separate fibres; at other times they are variously twisted, and run parallel with the fasciculi. The fasciculi are connected and held together in the formation of membranes and cords by loose fibres interwoven between them, or by mutual interlacement. White fibrous tissue is converted by boiling into gelatine.

[FIG. 107.]



WHITE FIBROUS TISSUE:—
1, 3, 4, 5. Various wavy appearances which the tissue exhibits when not stretched.
2. Straight appearance of the tissue when stretched. [Magnified 320 times].

Examples of white fibrous tissue are met with in three principal forms; namely, membrane, ligament, and tendon.

The *membranous form* of white fibrous tissue is seen in the common connecting medium of the body, namely, cellular membrane, fibro-cellular, cellular, areolar, or filamentous tissue, in which the membrane is extremely thin, and disposed in laminae, bands, or threads, leaving interstices of various size between them. It exhibits two principal forms, in one of which it is *lax*, and serves to connect organs or parts of organs, or to establish a medium of separation between them; in the other it constitutes the condensed covering of various organs, as the periosteum, perichondrium, capsulae propriae of glands, membranes of the brain, sclerotic coat of the eyeball, pericardium, fasciae; sheaths of muscles, tendons, vessels, nerves, and ducts; sheaths of the erectile organs, serous membrane, and the corium of the dermal and mucous membrane.

Ligament is the name given to those bands of various breadth and thickness which retain the articular ends of bones in contact in the construction of joints. They are glistening, but slightly elastic, and composed of fasciculi of fibrous tissue ranged in a parallel direction side by side, or in some situations interwoven with each other. The fasciculi are held together by separate fibres, by fine elastic fibres, and by areolar tissue.

Tendon is the collection of parallel fasciculi of fibrous tissue, by means of which muscles are attached to bones. They are constructed on the same principle as ligaments, are usually rounded in their figure, but in some instances are spread

out so as to assume a membranous form. In the latter state they are called *aponeuroses*.

Yellow fibrous tissue, or *elastic tissue*, enters very generally into the structure of tissues and organs in which the property of elasticity is an important quality, and serves the additional purpose of binding structures together. As an elastic and binding element it is present in the common cellular tissue and superficial fascia, in the fascial sheaths of muscles, in the fibrous capsules of different organs, as of the spleen, in the corium of the skin, in serous and mucous membranes, in the coats of bloodvessels and ducts; and, in certain situations is the sole tissue present, as in the ligamenta subflava, chordæ vocales, thyro-epiglottic ligament, crico-thyroidean membrane, the membranous layers connecting the cartilaginous rings of the trachea and bronchial tubes, the ligamentum nuchæ, and ligamentum suspensorium penis. It is also met with around some parts of the alimentary canal, as the œsophagus, cardia, and anus, and around the male and female urethra.

The fibres of elastic tissue are cylindrical or flattened, brittle, colorless when single but yellowish in an aggregated form, elastic, admitting of being stretched to double their length and returning to their original size, and variable in dimensions, ranging from extreme fineness to a considerable breadth. They present themselves, therefore, in the two forms of *fine* and *coarse*, and are distributed among the textures of the body either as single and *isolated filaments* or as a *network*.

Isolated elastic fibres of extreme fineness are met with coiled around or entwined among the fasciculi of areolar tissue, holding them together, and have received the name of *nuclear fibres*, from their supposed origin in the nuclei of the formative cells. There seems, however, to be no reason for the belief of their origin being different from that of other primitive tissues, namely, from cells.

The *elastic network* formed by these fibres may be extremely fine and delicate, as in thin membranes; or it may be coarser, as in the various ligamentous bands composed of this tissue; or it may be spread out like a membrane, the interstices forming but a small part of its extent, as in the *fenestrated membrane* of the arteries. In the construction of yellow elastic ligaments, the fibres communicate with each other by means of short oblique bands, which unite with adjoining fibres at acute or obtuse angles without any enlargement of the fibres with which they are joined. This circumstance has given rise to the idea of the fibres giving off branches, an expression derived from the division of bloodvessels, and another term borrowed from the same source has been applied to their communication with each other, namely, *inosculation*; but both these expressions in their literal meaning are incorrect. When yellow fibrous tissue is cut or torn, the fibres, in consequence of their elasticity, become clubbed and curved at the extremity, a special character of this tissue.

ADIPOSE TISSUE is composed of minute cells, aggregated together in clusters of various size within the areolæ of common cellular [*areolar*] tissue. The cells of adipose tissue are identical in manner of formation with other cells, being developed around nuclei, and increasing in size by the formation of fluid in their interior. In adipose cells, this fluid, instead of being albuminous as in other cells, is oleaginous, the oil at first appearing in separate globules, which subsequently coalesce into a single drop. The size of adipose cells at their full develop-

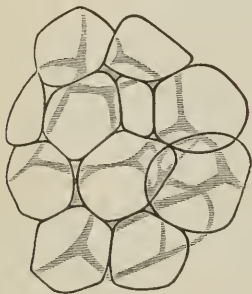
[FIG. 108.]



YELLOW FIBROUS TISSUE, showing the curly and branched disposition of its fibrillæ, their definite outline, and abrupt mode of fracture. At 1, the structure is not disturbed as in the rest of the specimen. Magnified 320 diameters.]

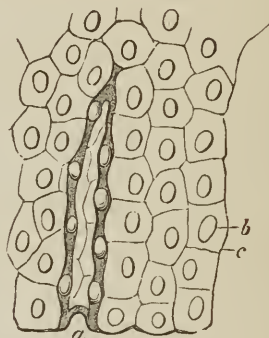
lopment is about $\frac{1}{500}$ th of an inch in diameter; when isolated they are globular in form, but are hexagonal or polyhedral when compressed. They are perfectly transparent, the cell-membrane being structureless, and their nucleus disappearing as they attain their full size. [Each fat-cell is surrounded by a loop or loops of capillary vessels.]

[FIG. 109.]



FAT VESICLES, assuming the polyhedral form from pressure against one another. The capillary vessels are not represented. —From the omentum: magnified about 300 diameters.]

[FIG. 110.]



TESSELATED EPITHELIUM OF SEROUS MEMBRANE. *a.* A fold showing the thickness of the cells at its dark edges. *b.* One of the nuclei. *c.* Line of junction of two cells. Magnified 300 diameters.]

SYNOVIAL MEMBRANE is a thin membranous layer, investing the articular extremities of bones, and the [internal] surface of the ligaments which surround and enter into the composition of a joint. It resembles the serous membranes in being a shut sac (*capsula synovialis*), and secretes a transparent and viscous fluid, which is named *synovia*. *Synovia* is an alkaline secretion, containing albumen and mucus, the albumen being coagulable at a boiling temperature. In some joints the synovial membrane is pressed into the articular cavity by a cushion of fat: this mass was called by Havers the synovial gland, from an idea of its being the source of the *synovia*; it is found in the hip and knee joint. In the knee, moreover, the synovial membrane forms folds, which are improperly named ligaments, as the mucous and alar ligaments, the two latter being an appendage to the cushion of fat. Besides the synovial membranes entering into the composition of joints, there are numerous smaller sacs of a similar kind interposed between surfaces which move upon each other so as to cause friction; they are often associated with the articulations. These are the *bursæ mucosæ*; they are shut sacs, analogous in structure to synovial membranes, and secreting a similar synovial fluid.

The epithelium of synovial membrane is of the kind termed tesselated or *pavement epithelium*; it is developed in the same manner as the epithelium of other free surfaces, but presents only a single stratum of cells.

ARTICULATIONS.

The joints may be arranged, according to a natural division, into those of the trunk, those of the upper extremity, and those of the lower extremity.

LIGAMENTS OF THE TRUNK.

The articulations of the trunk are divisible into ten groups, namely,

1. Of the vertebral column.
2. Of the atlas, with the occipital bone.
3. Of the axis, with the occipital bone.
4. Of the atlas, with the axis.
5. Of the lower jaw.
6. Of the ribs, with the vertebræ.
7. Of the ribs, with the sternum, and with each other.
8. Of the sternum.
9. Of the vertebral column, with the pelvis.
10. Of the pelvis.

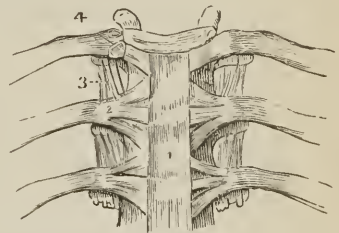
1. *Articulation of the Vertebral column.* The ligaments connecting together the different pieces of the vertebral column, admit of the same arrangement as the vertebræ themselves. Thus the ligaments

Of the <i>bodies</i> , are the	Anterior common ligament, Posterior common ligament, Intervertebral substance
Of the <i>arches</i> ,	Ligamenta subflava.
Of the <i>articular processes</i> ,	Capsular ligaments, Synovial membranes.
Of the <i>spinous processes</i> ,	Interspinous, Supraspinous.
Of the <i>transverse processes</i> ,	Intertransverse.

BODIES. — The *Anterior common ligament* (fascia longitudinalis anterior) is a broad and riband-like band of ligamentous fibres, extending along the front surface of the vertebral column, from the axis to the sacrum. It is intimately connected with the intervertebral substance, and less closely with the bodies of the vertebræ. In the dorsal region it is thicker than in the cervical and lumbar, and consists of a median and two lateral portions, separated from each other by a series of openings for the passage of vessels. The ligament is composed of fibres of various length closely interwoven with each other; the *deeper* and shorter crossing the intervertebral substance from one vertebra to the next; the *superficial* and longer fibres crossing three or four vertebræ.

The anterior common ligament is in relation by its *posterior* or *vertebral surface*, with the intervertebral substance, bodies of the vertebræ, and vessels, principally veins, which separate its central from its lateral portions. By its *anterior* or *visceral surface* it is in relation, in the neck, with the longus colli muscles, pharynx and œsophagus; in the thoracic region, with the aorta, venæ azygos, and thoracic duct; in the lumbar

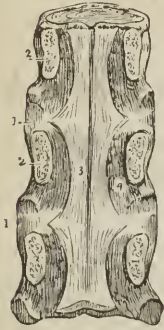
FIG. 111.



ANTERIOR LIGAMENTS OF THE VERTEBRÆ, AND LIGAMENTS OF THE RIBS. 1. Anterior common ligament. 2. Anterior costo-vertebral or stellate ligament. 3. Anterior costo-transverse ligament. 4. Interarticular ligament connecting the head of the rib to the intervertebral substance, and separating the two synovial membranes of this articulation.

region, with the aorta, right renal artery, right lumbar arteries, arteria sacra media, vena cava inferior, left lumbar veins, receptaculum chyli, commencement of the thoracic duct, and tendons of the diaphragm, with the fibres of which the ligamentous fibres interlace.

FIG. 112.



A POSTERIOR VIEW OF THE BODIES OF THREE DORSAL VERTEBRÆ, CONNECTED BY 1, 1, THEIR INTERVERTEBRAL SUBSTANCE. — The laminæ (2, 2) have been sawn through near the bodies of the vertebræ, and the arches and processes removed, in order to show (3) the posterior common ligament. Part of one of the openings in the posterior surface of the vertebra, for the transmission of the vena basis vertebræ, is seen at 4, by the side of the narrow and unattached portion of the ligament.

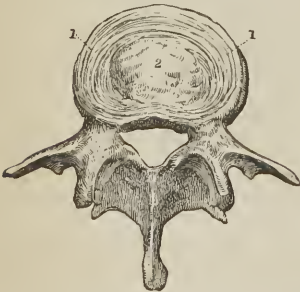The *Posterior common ligament* (fascia longitudinalis posterior) lies on the posterior surface of the bodies of the vertebræ, and extends from the axis to the sacrum [having a regular festooned appearance]. It is broad opposite the intervertebral substance, to which it is closely adherent; narrow and thick over the bodies of the vertebræ, from which it is separated by the veins of the base of each vertebra; and composed, like the anterior ligament of shorter and longer fibres, arranged in a similar manner. It is broader above than below, the reverse of the anterior common ligament.

The posterior common ligament is in relation by its *anterior surface*, with the intervertebral substance, bodies of the vertebræ, and venæ basium vertebrarum; by its *posterior surface*, with the dura mater of the spinal cord, some loose cellular tissue and numerous small veins being interposed.

The *Intervertebral substance* (ligamentum intervertebrale) is a lenticular disk of fibrous cartilage, interposed between the bodies of the vertebræ from the axis to the sacrum, and retaining them firmly in connexion with each other. It varies in thickness in different parts of the column, and at different points of the same disk, being thickest in the lumbar region, deepest in front in the cervical and lumbar region, and behind in the dorsal region; and contributes to the formation of the natural curves of the vertebral column. The aggregate thickness of the intervertebral substance has been estimated at one-fourth that of the entire verte-

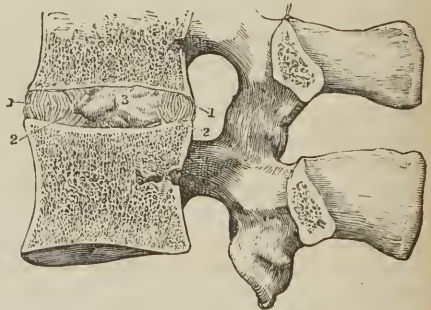
bral column, exclusive of the sacrum and coccyx.

[FIG. 113.]



A LUMBAR VERTEBRA, WITH A HORIZONTAL SECTION OF INTERVERTEBRAL SUBSTANCE ABOVE IT. At the circumference (1, 1) the concentric arrangement of the layers of the latter is shown, and in the middle (2) the pulpy substance is indicated.]

[FIG. 114.]



A VERTICAL SECTION OF TWO VERTEBRÆ, AND THE SUBSTANCE INTERPOSED BETWEEN THEIR BODIES. The direction of the layers of the intervertebral substance is displayed. 1, 1. Layers curved outwards. 2, 2. Those curved inwards. 3. Pulpy substance in the middle.]

When the intervertebral substance is bisected either horizontally or vertically, it is seen to be composed of a series of [concentric] layers of dense fibrous tissue, separated by interstices filled with the softer kind. The central part of each intervertebral disk is wholly made up of this softer fibrous cartilage, which has the appearance of a pulp, and is so elastic as to rise above the level of the section as soon as its division is completed. Examined from the exterior, the layers are found to consist of fibres passing obliquely between the two vertebræ, in one layer passing from left to right, in the next from right to left, alternating in each successive layer.

ARCHES.—The *ligamenta subflava* are two thin planes of yellow fibrous tissue, situated between the arches of the vertebræ, from the axis to the sacrum. From the imbricated position of the laminæ, they are attached to the posterior surface of the [arch of the] vertebra below, and the anterior surface of the arch of the vertebra above, being separated from each other at the middle line by a slight interspace. They counteract, by their elasticity, the efforts of the flexor muscles of the trunk; and, preserving the upright position of the spine, limit the expenditure of muscular force. They are longest in the cervical and thickest in the lumbar region.

The *ligamenta subflava* are in relation by both surfaces with the meningo-rachidian veins, and, internally, are separated from the dura mater of the spinal cord by those veins and some loose cellular and adipose tissue.

ARTICULAR PROCESSES.—The ligaments of the articular processes of the vertebræ (*ligamenta processuum obliquorum*) are thin capsules of ligamentous fibres which surround and inclose the synovial membrane; the latter being looser in the cervical than in the other regions of the spine.

SPINOUS PROCESSES.—The *interspinous ligaments* (*membrana interspinalis*), thin and membranous, are extended between the spinous processes in the dorsal and lumbar region; being thickest in the latter. They are in relation with the multifidus spinæ muscle at each side.

The *Supraspinous ligament* (*ligamenta apicum*, fig. 124) is a strong, fibrous cord, extending from the apex of the spinous process of the last cervical vertebra to the sacrum, and attached to each spinous process in its course. Like the anterior and posterior common ligaments, it is composed of fibres of unequal length, the deeper fibres passing from one vertebra to the next, the superficial fibres extending over several spinous processes. It is thickest in the lumbar region. The continuation of this ligament upwards to the tuberosity of the occipital bone, constitutes the rudimentary *ligamentum nuchæ* of man. The latter is strengthened, as in animals, by a thin slip from the spinous process of each cervical vertebra.

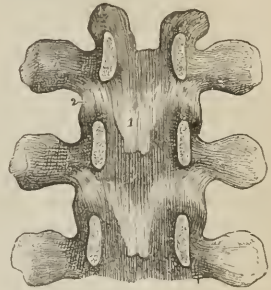
TRANSVERSE PROCESSES.—The *intertransverse ligaments*, thin and membranous, are found, only; between the transverse processes of the lower dorsal vertebræ.

2. *Articulation of the Atlas with the Occipital bone.*—The ligaments of this articulation are seven in number:

Two anterior occipito-atloid,
Posterior occipito-atloid,

[Two] lateral occipito-atloid,
Two capsular.

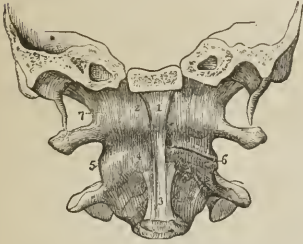
FIG. 115.



INTERNAL VIEW OF THE ARCHES OF THREE VERTEBRÆ. To obtain this view the laminæ have been divided through their pedicles. 1. One of the *ligamenta subflava*. 2. The capsular ligament of one side.

Of the two *anterior ligaments*, one is a *rounded cord*, situated in the middle line, and superficially to the other; it is attached above to the basilar process of

FIG. 116.

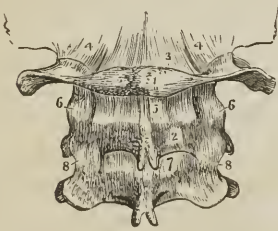


ANTERIOR VIEW OF THE LIGAMENTS CONNECTING THE ATLAS, AXIS AND OCCIPITAL BONE. A transverse section has been carried through the base of the skull, dividing the basilar process of the occipital bone and the petrous portion of the temporal bones. 1. Anterior round occipito-atloid ligament. 2. Anterior broad occipito-atloid ligament. 3. Commencement of the anterior common ligament. 4. Anterior atlo-axoid ligament, continuous inferiorly with the commencement of the anterior common ligament. 5. One of the atlo-axoid capsular ligaments; that on the opposite side has been removed, to show the approximated surfaces of the articular processes (6). 7. One of the occipito-atloid capsular ligaments. The most external of these fibres constitute the lateral occipito-atloid ligament.

the occipital bone; below, to the anterior tubercle of the atlas. The deeper ligament is a *broad membranous layer*, attached above to the margin of the occipital foramen, between the two condyles; and below, to the whole length of the anterior arch of the atlas. It is in relation in front with the recti antici minores, behind with the odontoid ligaments.

The *posterior ligament* is thin and membranous; attached above to the margin of the occipital foramen, between the two condyles; and below, to the posterior arch of the atlas. It is closely adherent to the dura mater, by its inner surface; and forms a ligamentous arch at each side, for the passage of the vertebral artery and first cervical nerve. It is in relation posteriorly with the recti postici minores and obliqui superiores.

FIG. 117.



POSTERIOR LIGAMENTS OF THE OCCIPITO-ATLOID, and ATLO-AXOID ARTICULATIONS. 1. Atlas. 2. Axis. 3. Posterior ligament of the occipito-atloid articulation. 4, 4. Capsular and lateral ligaments of this articulation. 5. Posterior ligament of the atlo-axoid articulation. 6, 6. Its capsular ligaments. 7. The first pair of ligamenta subflava; passing between the axis and third cervical vertebra. 8, 8. Capsular ligaments of those vertebrae.

fibres are most numerous on the anterior and external part of the articulation.

The *movements* taking place between the cranium and atlas, are those of flexion and erection, giving rise to the forward nodding of the head. When this motion is increased to any extent, the whole of the cervical region concurs in its production.

3. *Articulation of the Axis with the Occipital bone.* — The ligaments of this articulation are *three* in number,

Occipito-axoid,

Two odontoid.

The *occipito-axoid ligament* (*apparatus ligamentosus colli*) is a broad and strong band, which covers in the odontoid process and its ligaments. It is attached below to the body of the axis, where it is continuous with the posterior common ligament; superiorly it is inserted by a broad expansion, into the basilar groove of the occipital bone. It is firmly connected opposite the body of the axis, with the dura mater; and is sometimes described as consisting of a central and two lateral portions.

The *odontoid ligaments* (*alaria*) are two short and thick fasciculi, which pass outwards from the apex of the odontoid process, to the sides of the occipital foramen and condyles. A third and smaller fasciculus (*ligamentum dentis suspensorium*) proceeds from the apex of the odontoid process to the anterior margin of the foramen magnum.

These ligaments serve to limit the extent to which rotation of the head can be carried, hence they are termed *check* [or *moderator*] ligaments.

4. *Articulation of the Atlas with the Axis.* — The ligaments of this articulation are five in number, —

- Anterior atlo-axoid,
- Posterior atlo-axoid,
- Two capsular,
- Transverse.

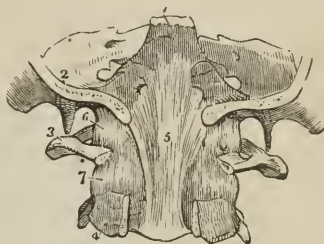The *anterior ligament* consists of ligamentous fibres, which pass from the anterior tubercle and arch of the atlas to the base of the odontoid process and body of the axis, where they are continuous with the commencement of the anterior common ligament.

The *posterior ligament* is a thin, membranous layer, passing between the posterior arch of the atlas and the laminae of the axis.

The *capsular ligaments* surround the articular processes of the atlas and axis; they are loose, to permit of the free movement which subsists between these vertebrae. The ligamentous fibres are most numerous on the outer and anterior part of the articulation; and the synovial membrane usually communicates with the synovial cavity between the transverse ligament and odontoid process.

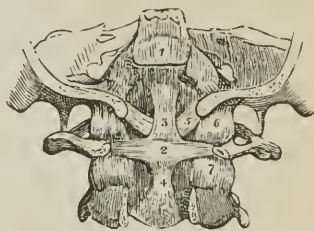
The *transverse ligament* is a strong ligamentous band, which arches across the area of the ring of the atlas from a rough tubercle on the inner surface of one

FIG. 118.



UPPER PART OF THE VERTEBRAL CANAL, OPENED FROM BEHIND IN ORDER TO SHOW THE OCCIPITO-AXOID LIGAMENT. 1. Basilar portion of the sphenoid bone. 2. Section of the occipital bone. 3. Atlas, its posterior arch removed. 4. Axis, posterior arch removed. 5. Occipito-axoid ligament, rendered prominent at its middle by the projection of the odontoid process. 6. Lateral and capsular ligament of the occipito-atloid articulation. 7. Capsular ligament of the articular process of the atlas and axis.

FIG. 119.



POSTERIOR VIEW OF THE LIGAMENTS CONNECTING THE ATLAS, AXIS, AND OCCIPITAL BONE. The posterior part of the occipital bone has been sawn away, and the arches of the atlas and axis removed. 1. Superior part of the occipito-axoid ligament, which has been cut away in order to show the ligaments beneath. 2. Transverse ligament of the atlas. 3, 4. Ascending and descending slips of the transverse ligament, which have obtained for it the title of cruceiform ligament. 5. One of the odontoid ligaments; the fellow ligament is seen on the opposite side. 6. One of the occipito-atloid capsular ligaments. 7. One of the atlo-axoid capsular ligaments.

articular process to a corresponding tubercle on the other; and serves to retain the odontoid process of the axis, in connexion with the anterior arch of the atlas. As it crosses the neck of the odontoid process, some fibres are sent downwards to be attached to the body of the axis, and others pass upwards to be inserted into the basilar process of the occipital bone; hence the ligament has a cross-like appearance, and is termed *cruciform*. A synovial membrane is situated between the transverse ligament and odontoid process; and another between that process and the anterior arch of the atlas.

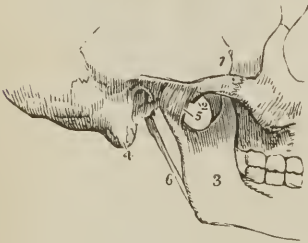
Actions. — It is the peculiar disposition of the transverse ligament in relation to the odontoid process, that enables the atlas, and with it the entire cranium, to rotate upon the axis; the perfect freedom of movement between these bones being insured by the two synovial membranes. The lower part of the ring formed by the transverse ligament with the atlas, is smaller than the upper, while the summit of the odontoid process is larger than its base; hence the process is retained in its place by the transverse ligament, when the other ligaments are cut through. The extent to which rotation of the head upon the axis can be carried, is determined by the odontoid or check ligaments. The odontoid process with its ligaments is covered in by the occipito-axoid ligament.

5. *Articulation of the Lower Jaw.* — [This articulation is formed, at each side, by one of the condyles of the inferior maxillary bone below, and the anterior part of the glenoid cavity, and the inferior or articular root of the zygoma of the corresponding temporal bone above.] The lower jaw has properly but one ligament, the *external lateral*; the ligaments usually described are *three* in number; to which may be added, as appertaining to the mechanism of the joint, an interarticular fibrous cartilage and two synovial membranes, thus: —

External lateral,	Capsular,
Internal lateral,	Interarticular fibrous cartilage.
Two synovial membranes.	

The *external lateral ligament* is a short and thick band of fibres, passing obliquely backwards from the tubercle of the zygoma, to the external surface of the neck of the lower jaw. It is in relation externally, with the integument of the face; internally, with the two synovial membranes of the articulation and the interarticular cartilage. The external lateral ligament acts conjointly with its fellow of the opposite condyle in the movements of the jaw.

FIG. 120.



EXTERNAL VIEW OF THE ARTICULATION OF THE LOWER JAW. 1. Zygomatic arch. 2. Tubercle of the zygoma. 3. Ramus of the lower jaw. 4. Mastoid portion of the temporal bone. 5. External lateral ligament. 6. Stylo-maxillary ligament.

The *internal lateral ligament* (sphenomaxillary) has no connexion with the articulation of the lower jaw, and is, therefore, incorrectly named; it is a thin aponeurotic expansion, extending from the extremity of the spinous process of the sphenoid bone to the margin of the dental foramen; and is pierced at its insertion by the mylo-hyoidean nerve.

Between the internal lateral ligament and neck of the jaw is a triangular space, in which are situated the internal maxillary artery, auriculo-temporal nerve, inferior dental artery and nerve, and part of the external pterygoid muscle; internally the ligament is in relation with the internal pterygoid muscle.

The *capsular ligament* (*membrana maxillæ articularis*) consists of numerous

irregular ligamentous fibres, which pass from the edge of the glenoid cavity to the neck of the lower jaw, and surround the articulation; on the inner side of the joint they form a pretty strong fasciculus.

The *interarticular fibrous cartilage* (*cartilago intermedia*) is a thin oval plate, thicker at the edges than in the centre, placed horizontally between the head of the condyle of the lower jaw and the glenoid cavity. It is connected by its outer border with the external lateral ligament, and receives in front some fibres of insertion of the external pterygoid muscle. It divides the joint into two cavities, one being above, the other below the cartilage; but it is occasionally incomplete in the centre.

The *synovial membranes* are situated, one above, the other below the fibrous cartilage, the former being the larger of the two. When the fibrous cartilage is perforate, the synovial membranes communicate.

Besides the lower jaw, there are several other joints provided with a complete interarticular cartilage, and, consequently, with two synovial membranes; they are, the *sterno-clavicular*, *acromio-clavicular*, and the articulation of the *ulna* with the *cuneiform bone*. The interarticular fibrous cartilages of the *knee-joint* are partial, and there is but one synovial membrane.

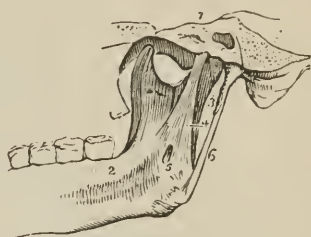
The articulations of the heads of the ribs with the vertebræ have two synovial membranes separated by an interarticular ligament without fibrous cartilage.

Connected with the lower jaw, though not with the joint, is the *stylo-maxillary ligament*, a process of the deep cervical fascia extended between the point of the styloid process and the angle of the jaw. It is attached to the jaw between the insertions of the masseter and internal pterygoid muscle, and separates the parotid from the submaxillary gland.

Actions.—The movements of the lower jaw are *depression*, by which the mouth is opened, *elevation*, by which it is closed; a *forward* and *backward* movement, and a movement from *side to side*.

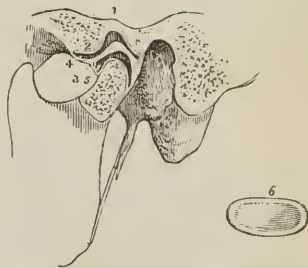
In the movement of *depression* the interarticular cartilage glides forwards on the eminentia articularis, carrying with it the condyle. If this movement be carried too far, the superior synovial membrane is ruptured, and dislocation of the fibro-cartilage with its condyle into the zygomatic fossa occurs. In *elevation* the fibrous cartilage and condyle are returned to their original position. The *forward* and *backward* movement is a gliding of the fibro-cartilage on the glenoid articular

FIG. 121.



INTERNAL VIEW OF THE ARTICULATION OF THE LOWER JAW. 1. Section through the petrous portion of the temporal bone and spinous process of the sphenoid. 2. Internal surface of the ramus, and body of the lower jaw. 3. Capsular ligament. 4. Internal lateral ligament. 5. A small interval at its insertion through which the mylo-hyoidean nerve passes. 6. Stylo-maxillary ligament, a process of the deep cervical fascia.

FIG. 122.



IN THIS SKETCH A SECTION HAS BEEN MADE THROUGH THE JOINT TO SHOW THE POSITION OF THE INTERARTICULAR FIBRO-CARTILAGE, and the manner of its adaptation to the articulating surfaces. 1. Glenoid fossa. 2. Eminentia articularis. 3. Interarticular fibro-cartilage. 4. Superior synovial cavity. 5. Inferior synovial cavity. 6. An interarticular fibro-cartilage, removed from the joint, in order to show its oval and concave form; it is seen from below.

surface, in the antero-posterior direction; and the movement from *side to side*, in the lateral direction.

6. *Articulation of the Ribs with the Vertebrae*.—The ligaments of these articulations are remarkable for their strength, being in fact so strong as to render dislocation impossible; the neck of the rib must break before displacement could occur; they are divisible into two groups:—1. Those connecting the *head of the rib* with the bodies of the *vertebrae*; and, 2. Those connecting the *neck and tubercle of the rib* with the *transverse processes*.

1st Group.

Anterior costo vertebral or stellate,
Capsular,
Interarticular ligament,
Two synovial membranes.

2d Group.

Anterior costo-transverse,
Middle costo-transverse,
Posterior costo-transverse.

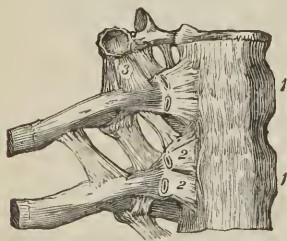
The *anterior costo-vertebral* or *stellate ligament* (lig. capituli costarum, fig. 111) consists of three short bands of ligamentous fibres which radiate from the anterior part of the head of the rib. The *superior band* passes upwards to be attached to the vertebra above; the *middle fasciculus* is attached to the intervertebral substance; the *inferior*, to the vertebra below.

In the *first, eleventh, and twelfth* rib, the three fasciculi are attached to the body of the corresponding vertebra.

The *capsular ligament* is a thin layer of ligamentous fibres surrounding the joint in the interval left by the anterior ligament; it is thickest above and below the articulation, and protects the synovial membranes.

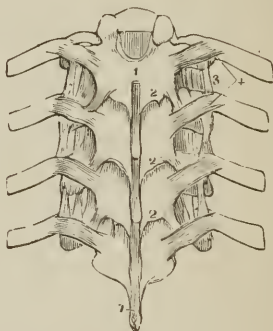
The *interarticular ligament* is a thin band which passes between the sharp crest on the head of the rib and the intervertebral substance. It divides the joint into two cavities, each being furnished with a separate *synovial membrane*.

[FIG. 123.]



THE BODIES OF THREE DORSAL VERTEBRÆ, CONNECTED BY THEIR INTERVERTEBRAL SUBSTANCES, WITH TWO RIBS, IN SITU. 1, 1. The anterior common vertebral ligament; the figures are opposite the intervertebral substances. 2, 2. Anterior costo-vertebral or stellate ligament. 3. Anterior costo-transverse ligament. The position of the two synovial membranes of the head of the rib are indicated, and the articular facet on one transverse process is shown.]

FIG. 124.



POSTERIOR VIEW OF PART OF THE THORACIC PORTION OF THE VERTEBRAL COLUMN, SHOWING THE LIGAMENTS CONNECTING THE VERTEBRÆ WITH EACH OTHER, AND THE RIBS WITH THE VERTEBRÆ. 1, 1. Supraspinous ligament. 2, 2, 2. Ligamenta subflava, connecting the laminae. 3. Anterior costo-transverse ligament. 4. Posterior costo-transverse ligaments.

The *first, eleventh, and twelfth* rib have no interarticular ligament, and consequently but one synovial membrane.

The *anterior costo-transverse ligament* (lig. transversarium internum) is a broad band composed of two fasciuli, which ascend from the crest-like ridge on the neck of the rib, to the transverse process immediately above. This ligament separates the anterior from the dorsal branch of the intercostal nerve.

The *middle costo-transverse ligament* (lig. cervicis externum) is a strong interosseous ligament passing directly between the posterior surface of the neck of the rib, and the transverse process against which it rests. It is absent in the first and two inferior ribs.

The *posterior costo-transverse ligament* (lig. transversarium externum) is a small but strong fasciculus, passing obliquely from the tubercle of the rib to the apex of the transverse process. The articulation between the tubercle of the rib and the transverse process is provided with a small synovial membrane.

There is no anterior costo-transverse ligament to the first or last rib; and only rudimentary posterior costo-transverse ligaments to the eleventh and twelfth rib. Several accessory bands (*ligamenta accessoria*) are found passing between the transverse processes and the ribs; a broad band of this kind connects the last rib with the transverse process of the first or second lumbar vertebra.

Actions. — The movements permitted by the articulations of the ribs are *upwards, downwards,* and slightly *forwards and backwards*; the movement increasing in extent from the head to the extremity of the rib. The forward and backward movement is trifling in the seven superior, but greater in the inferior ribs; the eleventh and twelfth are very movable.

7. *Articulation of the Ribs with the Sternum, and with each other.* — The ligaments of the costo-sternal articulations are —

Anterior costo-sternal,	Superior costo-sternal,
Posterior costo-sternal,	Inferior costo-sternal,
Synovial membranes.	

The *anterior costo-sternal ligament* (lig. costo-sternale radiatum) is a thin band of ligamentous fibres, passing in a radiated direction from the extremity of the costal cartilage to the anterior surface of the sternum, and intermingling its fibres with those of the ligament of the opposite side, and with the tendinous fibres of origin of the pectoralis major muscle.

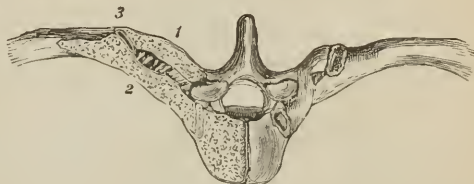The *posterior costo-sternal ligament*, much smaller than the anterior, consists of a thin fasciculus of fibres, situated on the posterior surface of the articulation.

The *superior and inferior costo-sternal ligaments* are narrow fasciuli corresponding with the breadth of the cartilage, and connecting its superior and inferior border with the side of the sternum.

The *synovial membrane* is absent in the articulation of the first rib, its cartilage being usually adherent to the sternum; that of the second rib has an inter-articular ligament, with two synovial membranes; the synovial membranes of the other costal cartilages are single.

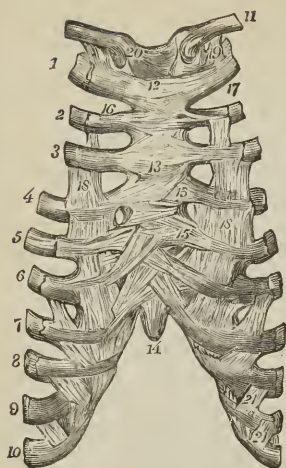
The *sixth and seventh ribs* have several fasciuli of strong ligamentous fibres, passing from the extremity of their cartilages to the anterior surface of the ensi-

[Fig. 125.]



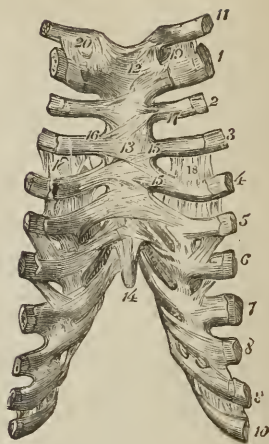
SECTION OF ONE-HALF OF THE BODY, AND ONE TRANSVERSE PROCESS OF A DORSAL VERTEBRA, AND OF PART OF A RIB, IN SITU, to show the interosseous or middle costo-transverse ligament. 1. Transverse process. 2. Neck of the rib. — The middle costo-transverse ligament is seen between them. 3. The synovial membrane between the tubercle of the rib and the articular facet of the transverse process.]

[FIG. 126.]



COSTO-STERNAL ARTICULATIONS, ETC.:
 ANTERIOR VIEW. 1 to 10. The ten superior ribs. 11. Clavicle. 12. Manubrium sterni. 13. Body of sternum. 14. Ensiform cartilage. 15, 15. Anterior costo-sternal ligaments. 16. Superior costo-sternal ligament. 17. Inferior costo-sternal ligament. Fig. 13 rests upon the middle of the anterior sternal ligament. 18, 18. Aponeurotic laminae of the external intercostal muscles. 19. Costo-clavicular or rhomboid ligament. 20. Anterior sterno-clavicular ligament. 21, 21. Ligaments uniting the cartilages of the false ribs.]

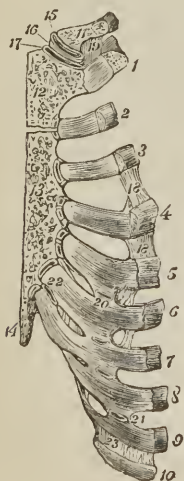[FIG. 127.]



COSTO-STERNAL ARTICULATIONS, ETC.:
 POSTERIOR VIEW. 1 to 10. The ten superior ribs. 11. Clavicle. 12. Manubrium sterni. 13. Body of sternum. 14. Ensiform cartilage. 15, 15. Posterior costo-sternal ligaments. 16. Superior costo-sternal ligament. 17. Inferior costo-sternal ligament. Fig. 13 rests upon the middle of the posterior sternal ligament. 18, 18. Aponeurotic laminae of the exterior intercostal muscles. 19. Costo-clavicular or rhomboid ligament. 20. Posterior sterno-clavicular ligament.]

form cartilage, which latter they are intended to support. They are named the *costo-xyphoid ligaments*.

[FIG. 128.]



SECTION OF STERNUM, CLAVICLE, AND COSTAL CARTILAGES, showing the spongy character of the sternum; the sterno-clavicular articulation; and the articulations of the costal cartilages, with each other, with the sternum, and with the ribs. 1 to 10. The ten superior ribs. 1 to 4 shows the mode of union between the costal cartilages and the ribs. 11. Clavicle. 12. Manubrium sterni. 13. Body of sternum. 14. Ensiform cartilage. 15. Superior synovial membrane of sterno-clavicular joint. 16. Inter-articular cartilage of same. 17. Inferior synovial membrane of same. 18, 18. Aponeurotic laminae of external intercostal muscles. 19. Costo-clavicular or rhomboid ligament. 20 to 21. Articulations of costal cartilages with each other, showing the synovial membranes. 22. A second articulation which sometimes occurs between the sixth and seventh cartilages. 23. Ligamentous fibres connecting the extremities of the ninth and tenth cartilages.]

The *sixth*, *seventh*, and *eighth*, and sometimes the *fifth* and the *ninth* costal cartilages, have articulations with each other, and a synovial membrane at each articulation. They are connected by ligamentous fibres, (*ligamenta corruscantia*), which pass from one cartilage to the other, *external* and *internal ligaments*.

The *ninth* and *tenth* are connected at their extremity by ligamentous fibres, but have no synovial membrane.

Actions.—The movements of the costo-sternal articulations are very trifling, being limited to a slight degree of sliding motion. The first rib is the least, the second the most movable.

[The costal cartilages are immovably united by their outer extremities to the anterior extremities of the ribs, which are excavated to receive them. The only bond of union between them, is periosteum.]

8. *Articulation of the Sternum.*—The pieces of the sternum are connected by means of a thin plate of interosseous cartilage placed between each, and by an anterior and posterior ligament (*membrana ossium sterni*). The fibres of the *anterior sternal ligament* are longitudinal in direction, but so blended with the anterior costo-sternal ligaments and tendinous fibres of origin of the pectoral muscles, as scarcely to be distinguished as a distinct ligament. The *posterior sternal ligament* is a broad smooth plane of longitudinal fibres, placed on the posterior surface of the bone, and extending from the manubrium to the ensiform cartilage. These ligaments contribute very materially to the strength of the sternum and elasticity of the front of the chest; their continuation downwards on the ensiform cartilage constitutes the *sterno-xyphoid ligaments*.

9. *Articulation of the Vertebral Column with the Pelvis.*—The last lumbar vertebra is connected with the sacrum by the same ligaments as those with which the various vertebræ are connected to each other; viz., anterior and posterior common ligament, intervertebral substance, ligamenta subflava, capsular ligaments, interspinous and supraspinous ligament.

There are, however, *two* proper ligaments connecting the vertebral column with the pelvis; these are, the

Lumbo-sacral,

Lumbo-iliac.

The *lumbo-sacral* or *sacro-vertebral ligament* is a thick triangular fasciculus of ligamentous fibres, connected above with the transverse process of the last lumbar vertebra, and below with the posterior part of the upper border of the sacrum.

The *lumbo-iliac* or *ilio-lumbar ligament* passes from the apex of the transverse process of the last lumbar vertebra to that part of the crest of the ilium which surmounts the sacro-iliac articulation. It is triangular in form.

10. *Articulations of the Pelvis.*—The ligaments of the articulations of the pelvis are divisible into four groups:—1, those connecting the *sacrum* and *ilium*; 2, those passing between the *sacrum* and *ischium*; 3, between the *sacrum* and *coccyx*; and, 4, between the *two pubic bones*.

1st, *Between the sacrum and ilium.*

Sacro-iliac anterior,
Sacro-iliac posterior.

2d, *Between the sacrum and ischium.*

Sacro-ischiatric anterior (*short*),
Sacro-ischiatric posterior (*long*).

3d, *Between the sacrum and coccyx.*

Sacro-coccygean anterior,
Sacro-coccygean posterior.

4th, *Between the ossa pubis.*

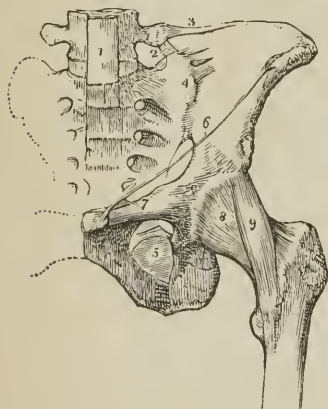
Anterior pubic,	Superior pubic,
Posterior pubic,	Sub-pubic,
Interosseous fibro-cartilage.	

1. *Between the Sacrum and Ilium.*—The *anterior sacro-iliac ligament* consists of numerous short ligamentous bands and fibres, which pass from bone to bone on the anterior surface of the joint.

The *posterior sacro-iliac or interosseous ligament* (ileo-sacrale breve) is composed of numerous strong fasciculi of ligamentous fibres, which pass horizontally between the rough surfaces of the *posterior half* of the sacro-iliac articulation, and constitute the principal bond of connexion between the sacrum and ilium. One fasciculus of this ligament, longer and larger than the rest, is distinguished, from its direction, by the name of *oblique sacro-iliac ligament* (ileo-sacrale longum). It is attached, by one extremity, to the posterior superior spine of the ilium; and, by the other, to the third transverse tubercle on the posterior surface of the sacrum.

The surfaces of the two bones forming the sacro-iliac articulation are partly covered with cartilage, and partly rough and connected by the interosseous ligament. The *anterior or auricular half* is coated with cartilage, which is thicker on the sacrum than on the ilium. The surface of the cartilage is uneven, and provided with a delicate synovial membrane, not demonstrable in the adult, but apparent in the young subject and in the female during pregnancy.

FIG. 129.



LIGAMENTS OF THE PELVIS AND HIP-JOINT. 1. Lower part of the anterior common ligament of the vertebrae, extending downwards over the front of the sacrum. 2. Lumbo-sacral ligament. 3. Lumbo-iliac ligament. 4. Anterior sacro-iliac ligament. 5. Obturator membrane. 6. Poupert's ligament. 7. Gimbernat's ligament. 8. Capsular ligament of the hip-joint. 9. Ilio-femoral or accessory ligament.

2. *Between the Sacrum and Ischium.*—The *anterior or lesser sacro-ischiatic ligament* (sacro-ischiadicum minus) is thin, and triangular in form; it is attached by its apex to the spine of the ischium; and by its broad extremity to the side of the sacrum and coccyx, interlacing its fibres with the greater sacro-ischiatic ligament.

The anterior sacro-ischiatic ligament is *in relation*, in front, with the coccygeus muscle; behind, with the posterior ligament, with which its fibres are intermingled. By its upper border it forms part of the lower boundary of the great sacro-ischiatic foramen, and by the lower, part of the lesser sacro-ischiatic foramen.

The *posterior or greater sacro-ischiatic ligament* (sacro-ischiadicum majus), larger, thicker, and posterior to the preceding, is narrower in the middle than at each extremity. It is attached, by the smaller end, to the inner margin of the tuberosity and ramus of the ischium; where it forms a falciform

process, which protects the internal pudic artery, and is continuous with the obturator fascia. By its larger extremity it is inserted into the side of the coccyx, sacrum, and posterior inferior spine of the ilium.

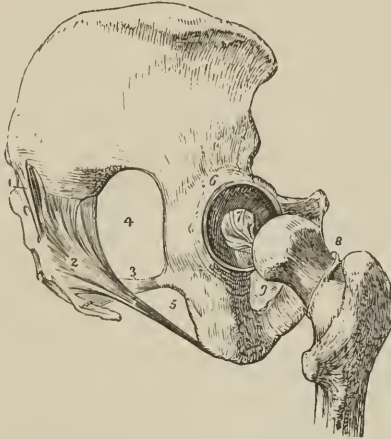
The posterior sacro-ischiatic ligament is *in relation*, in front, with the anterior ligament; behind, with the gluteus maximus, to some fibres of which it gives origin. By its superior border it forms part of the boundary of the lesser ischi-

atic foramen, and by its lower border, part of the boundary of the perineum. It is pierced by the coccygeal branch of the ischiatic artery. The two ligaments convert the sacro-ischiatic notches into foramina.

3. *Between the Sacrum and Coccyx.*—The *anterior sacro-coccygean ligament* is a thin fasciculus passing from the anterior surface of the sacrum to the front of the coccyx.

The *posterior sacro-coccygean ligament* is a thick ligamentous layer, which completes the lower part of the sacral canal, and connects the sacrum with the coccyx posteriorly, extending as far as the apex of the latter bone.

FIG. 130.



LIGAMENTS OF THE PELVIS AND HIP-JOINT; LATERAL VIEW. 1. Oblique sacro-iliac ligament. The other fasciculi of the posterior sacro-iliac ligament are not seen in this view of the pelvis. 2. Posterior sacro-ischiatic ligament. 3. Anterior sacro-ischiatic ligament. 4. Great sacro-ischiatic foramen. 5. Lesser sacro-ischiatic foramen. 6. Cotyloid ligament of the acetabulum. 7. Ligamentum teres. 8. Cut edge of the capsular ligament, showing its extent posteriorly, as compared with its anterior attachment. 9. Obturator membrane only partly seen.

Between the two bones is a thin disk of soft fibrous cartilage; and in females not unfrequently a synovial membrane. The articulation admits of a certain degree of movement backwards during parturition.

The ligaments connecting the different pieces of the coccyx consist of a few scattered *anterior* and *posterior* fibres, and a thin disk of interosseous cartilage; the latter exists only in the young subject, as in the adult the pieces become ossified.

4. *Between the Ossa Pubis.*—The *anterior pubic ligament* is composed of ligamentous fibres, which pass obliquely across the union of the two bones from side to side, and form an interlacement in front of the symphysis.

The *posterior pubic ligament* consists of a few irregular bands of fibres uniting the pubic bones posteriorly.

The *superior pubic ligament* is a thick band of fibres connecting the angles of the ossa pubis superiorly, and filling the inequalities of the surface of the bones.

The *sub-pubic ligament* is a thick arch of fibres connecting the two bones inferiorly, and forming the upper boundary of the pubic arch.

The *interosseous fibro-cartilage* unites the two surfaces of the pubic bones, in the same manner as the intervertebral substance connects the bodies of the vertebræ. It resembles the intervertebral substance also in being composed of oblique fibres disposed in concentric layers, which are more dense towards the

surface than near the centre. It is thick in front, and thin behind; and a synovial membrane is sometimes found in the posterior half of the articulation.

This articulation becomes movable towards the latter term of pregnancy, and admits of a slight degree of separation of its surfaces.

The *obturator ligament* (*membrana obturatoria*) is not a ligament of articulation, but simply a ligamentous membrane stretched across the obturator foramen. It gives attachment by its surfaces to the two obturator muscles, and leaves a space in the upper part of the foramen for the passage of the obturator vessels and nerve.

The numerous vacuities in the walls of the pelvis, and their closure by ligamentous structures, as in the case of the sacro-ischiatric fissures and obturator foramina, serve to diminish the pressure on the soft parts during the passage of the head of the fœtus through the pelvis in parturition.

LIGAMENTS OF THE UPPER EXTREMITY.

The *Ligaments of the upper extremity* may be arranged in the order of the articulations of the different bones: they are,

- | | |
|-------------------------------------|---|
| 1. Sterno-clavicular articulation. | 6. Radio-ulnar articulation. |
| 2. Scapulo-clavicular articulation. | 7. Wrist joint. |
| 3. Ligaments of the scapula. | 8. Articulation between the carpal bones. |
| 4. Shoulder joint. | 9. Carpo-metacarpal articulation. |
| 5. Elbow joint. | 10. Metacarpo-phalangeal articulation. |
| | 11. Articulation of the phalanges. |

1. *Sterno-clavicular Articulation*.—The sterno-clavicular is an arthrodial articulation; its ligaments are,

- | | |
|---------------------------------|---------------------------------------|
| Anterior sterno-clavicular, | Inter-clavicular, |
| Posterior sterno-clavicular, | Costo-clavicular (<i>rhomboid</i>). |
| Interarticular fibro-cartilage, | |
| Two synovial membranes. | |

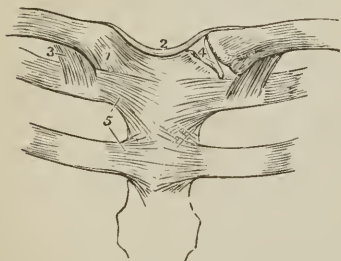
The *anterior sterno-clavicular ligament* is a broad ligamentous layer, extending obliquely downwards and inwards, and covering the anterior aspect of the articulation. This ligament is *in relation* by its anterior surface with the integument and sternal origin of the sterno-mastoid muscle; and behind with the interarticular fibro-cartilage and synovial membranes.

The *posterior sterno-clavicular ligament* is a broad band covering the posterior surface of the articulation. It is *in relation* by its anterior surface with the interarticular fibro-cartilage and synovial membranes; and behind, with the sterno-hyoid and sterno-thyroid muscle.

The anterior and posterior ligament are continuous at the upper and lower part of the articulation, so as to form a capsule around the joint.

The *inter-clavicular ligament* is a cord-like band which crosses from the one, and is closely adherent to the

FIG. 131.



LIGAMENTS OF THE STERNO-CLAVICULAR AND COSTO-STERNAL ARTICULATIONS. 1. Anterior sterno-clavicular ligament. 2. Inter-clavicular ligament. 3. Costo-clavicular or rhomboid ligament; seen on both sides. 4. Interarticular fibro-cartilage, brought into view by the removal of the anterior and posterior ligaments. 5. Anterior costo-sternal ligaments of the first and second rib.

extremity of one clavicle to that of the

upper border of the sternum. It is separated by cellular tissue from the sternothyroid muscles.

The *costo-clavicular ligament (rhomboides)* is a thick fasciculus of fibres, connecting the sternal extremity of the clavicle with the cartilage of the first rib. It is placed obliquely between the rib and under surface of the clavicle; and is *in relation*, in front with the tendon of origin of the subclavius muscle, and behind with the subclavian vein. [There is, nearly always, a synovial membrane between the clavicle and first costal cartilage, constituting an arthrodia].

The rupture of the rhomboid ligament in dislocation of the sternal end of the clavicle gives rise to the peculiar deformity of that accident.

The *interarticular fibro-cartilage* is nearly circular in form, and thicker at the edges than in the centre. It is attached above, to the clavicle; below, to the cartilage of the first rib; and throughout the rest of its circumference to the anterior and posterior sterno-clavicular ligament. It divides the joint into two cavities, which are lined by separate *synovial membranes*; is sometimes pierced through its centre, and not unfrequently deficient, to a greater or less extent, at its lower part.

Actions.—The movements of the sterno-clavicular articulation are, a *gliding movement* of the fibro-cartilage with the clavicle, on the articular surface of the sternum, in the directions, forwards, backwards, upwards, and downwards; and *circumduction*. This articulation is the centre of the movements of the shoulder.

2. *Scapulo-clavicular Articulation.*—The ligaments of the scapular end of the clavicle are,

- Superior acromio-clavicular,
- Inferior acromio-clavicular,
- Coraco-clavicular (*trapezoid* and *conoid*),
- Interarticular fibro-cartilage,
- Two synovial membranes.

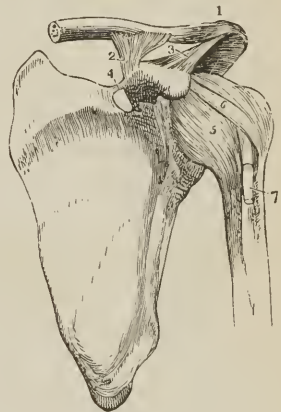
The *superior acromio-clavicular ligament* is a moderately thick plane of fibres passing between the extremity of the clavicle and the acromion, on the upper surface of the joint.

The *inferior acromio-clavicular ligament* is a thin plane situated on the under surface. These two ligaments are continuous with each other in front and behind, and form a capsule around the articulation.

The *coraco-clavicular ligament (trapezoides, conoides)* is a thick fasciculus of ligamentous fibres, passing obliquely between the base of the coracoid process and under surface of the clavicle, and holding the end of the clavicle in firm connexion with the scapula. Seen from *before*, it has a quadrilateral form; hence its name *trapezoid*; examined from *behind*, it is triangular, the base being upwards; hence its other name, *conoid*. [Sometimes quite a perfect joint, furnished with a synovial membrane, is found between the coracoid process and the clavicle].

The *interarticular fibro-cartilage* is often indistinct, from having partial connexions with the fibro-cartilaginous surfaces of the two bones between which it is

FIG. 132.



LIGAMENTS OF THE SCAPULA AND SHOULDER-JOINT. 1. Superior acromio-clavicular ligament. 2. Coraco-clavicular ligament; this aspect of the ligament is named trapezoid. 3. Coraco-acromial ligament. 4. Transverse ligament. 5. Capsular ligament. 6. Coraco-humeral ligament. 7. The long tendon of the biceps issuing from the capsular ligament, and entering the bicipital groove.

placed; and is not unfrequently absent. When partial, it occupies the upper part of the articulation. The *synovial membranes* are thin; and when the fibro-cartilage is incomplete, there is but one.

Actions.—The acromio-clavicular articulation admits of two movements, *gliding* of the surfaces on each other, and *rotation* of the scapula on the extremity of the clavicle.

3. The *proper ligaments of the scapula* are,

Coraco-acromial, Transverse.

The *coraco-acromial ligament* (triangulare) is a broad and thick triangular band, which forms a protecting arch over the shoulder joint. It is attached by its apex to the point of the acromion process, and by its base to the external border of the coracoid process its whole length. This ligament is *in relation* above with the under surface of the deltoid muscle; and below with the tendon of the supra-spinatus muscle, a bursa mucosa being usually interposed.

The *transverse or coracoid ligament* (supra-scapulare) is a narrow but strong fasciculus, which crosses the notch in the upper border of the scapula, from the base of the coracoid process, and converts it into a foramen. The supra-scapular nerve passes through this foramen, the artery over it.

4. *Shoulder Joint.*—The scapulo-humeral articulation is an enarthrosis, or ball-and-socket joint; its ligaments, are,

Capsular, Coraco-humeral, Glenoid.

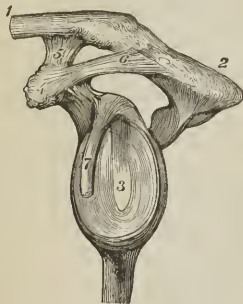The *capsular ligament* incloses the articulating head of the scapula and head of the humerus, and is attached to the neck of each bone. It is thick above, where resistance is most required, and strengthened by the tendons of the supra-spinatus, infra-spinatus, teres minor, and subscapularis, muscles: below it is thin and loose. The capsule is incomplete at the point of contact of the tendons, which consequently obtain on their inner surface a lining of synovial membrane.

The *coraco-humeral ligament* is a broad band which descends obliquely outwards from the border of the coracoid process to the greater tuberosity of the humerus, and serves to strengthen the superior and anterior part of the capsular ligament.

The *glenoid ligament* is the prismoid band of fibro-cartilage, which is attached around the margin of the glenoid surface for the purpose of protecting its edge and deepening its cavity. It divides superiorly into two slips which are continuous with the long tendon of the biceps; hence the ligament is sometimes described as being formed by the splitting of that tendon. The cavity of the articulation is traversed by the long tendon of the biceps which is inclosed in a sheath of synovial membrane in its passage through the joint.

The *synovial membrane* of the shoulder joint is extensive; it communicates anteriorly through an opening (foramen ovale) in the capsular ligament with a large bursal sac, which lines the under surface of the tendon of the subscapularis muscle. Superiorly it frequently communicates through another opening in the capsular

[FIG. 133.



LIGAMENTS OF THE CLAVICLE AND SCAPULA; LEFT SIDE. The shoulder joint has been opened, and the humerus removed. 1. Clavicle. 2. Acromion process of the scapula. 3. Glenoid cavity surrounded by the glenoid ligament. 4. Coracoid process. 5. Coraco-clavicular ligament; trapezoid portion. 6. Coraco-acromial ligament. 7. Long head of the biceps. 8. Superior acromio-clavicular ligament.]

ligament with a bursal sac belonging to the infra-spinatus muscle; and it moreover forms a sheath around that portion of the tendon of the biceps which is included within the joint.

The muscles immediately surrounding the shoulder joint are, the subscapularis, supra-spinatus, infra-spinatus, teres minor, long head of the triceps, and deltoid; the long tendon of the biceps is within the capsular ligament.

Actions.—The shoulder joint is capable of every variety of motion, viz., of movement forwards and backwards, of abduction and adduction, of circumduction and rotation.

5. *Elbow Joint.*—The elbow is a ginglymoid articulation; and its ligaments four in number, namely,

Anterior,	Internal lateral,
Posterior,	External lateral.

The *anterior ligament* is a broad and thin membranous layer, descending from

FIG. 134.



LIGAMENTS OF THE ELBOW JOINT; INNER SIDE.

1. Anterior ligament.
- 2, 2. Internal lateral ligament.
3. Orbicular ligament.
4. Oblique ligament.
5. Interosseous ligament.
6. Internal condyle of the humerus, which conceals the posterior ligament.

the anterior surface of the humerus immediately above the joint, to the coronoid process of the ulna and orbicular ligament. It is connected on each side with the lateral ligaments; and is composed of fibres which pass in three different directions, vertical, transverse, and oblique, the latter being extended downwards and outwards to the orbicular ligament, into which they are inserted inferiorly. This ligament is covered in by the brachialis anticus muscle.

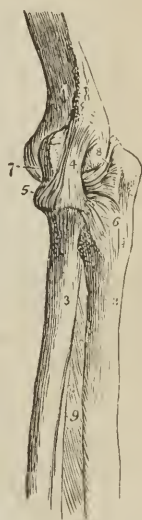The *posterior ligament* is a broad and loose layer passing between the posterior surface of the humerus and the anterior surface of the base of the olecranon, and connected at each side with the lateral ligaments. It is covered in by the tendon of the triceps.

The *internal lateral ligament* (brachio-cubitale) is a thick triangular layer, attached above, by its apex, to the internal condyle of the humerus; and below, by its expanded border, to the margin of the greater sigmoid cavity of the ulna, extending from the coronoid process to the olecranon. At its insertion it is intermingled with some transverse fibres;

and posteriorly is in relation with the ulnar nerve.

The *external lateral ligament* (brachio-radiale) is a strong and narrow band, which descends from the external condyle of the humerus, to be inserted into the orbicular ligament and the ridge on the ulna with which the posterior part of the latter ligament is connected. This ligament is closely united with the tendon of origin of the supinator brevis muscle.

FIG. 135.



EXTERNAL VIEW OF THE

- ELBOW JOINT. 1. Humerus. 2. Ulna. 3. Radius. 4. External lateral ligament inserted inferiorly into (5) the orbicular ligament. 6. Posterior extremity of the orbicular ligament, spreading out at its insertion into the ulna. 7. Anterior ligament, scarcely apparent in this view of the articulation. 8. Posterior ligament, thrown into folds by the extension of the joint.

The *synovial membrane* is extensive, and is reflected from the cartilaginous surfaces of the bones upon the inner surface of the ligaments. It surrounds inferiorly the head of the radius, and forms an articulating sac between it and the lesser sigmoid notch.

The muscles immediately surrounding, and in contact with, the elbow joint are, *in front*, *brachialis anticus*; *inner side*, *pronator radii teres*, *flexor sublimis digitorum*, and *flexor carpi ulnaris*; *externally*, *extensor carpi radialis brevis*, *extensor communis digitorum*, *extensor carpi ulnaris*, *anconeus*, and *supinator brevis*; *behind*, *triceps*.

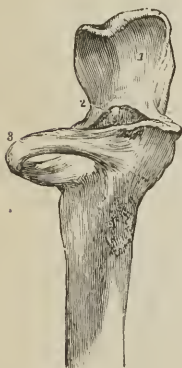Actions. — The movements of the elbow joint are *flexion* and *extension*; the extent of these movements being limited, in front by the coronoid process, and behind by the olecranon.

6. *Radio-ulnar Articulation.* — The radius and ulna are firmly held together by ligaments, connected with both extremities of the bones, and with the shaft; they are,

Orbicular,	Anterior inferior,
Oblique,	Posterior inferior,
Interosseous,	Interarticular fibro-cartilage.

The *orbicular ligament* (*annulare, coronale*) is a firm band several lines in breadth, which surrounds the head of the radius, and is attached by each end to an extremity of the lesser sigmoid cavity. It is strongest behind where it receives the external lateral ligament, and is lined on its inner surface by a reflection of the synovial membrane of the elbow joint.

[FIG. 136.



ORBICULAR LIGAMENT.—

1. Articular surface of olecranon process of the ulna.
2. Coronoid process.
3. Orbicular ligament which surrounds the neck of the radius.]

The rupture of this ligament permits the dislocation of the head of the radius.

The *oblique ligament* (called also *ligamentum teres*, in contradistinction to the interosseous ligament) is a narrow slip of ligamentous fibres, descending obliquely from the base of the coronoid process of the ulna to the inner side of the radius, a little below its tuberosity.

The *interosseous ligament* (*membrana interossea*) is a broad and thin plane of aponeurotic fibres passing obliquely downwards from the sharp ridge on the radius to that on the ulna. It is deficient superiorly, broader in the middle than at each extremity, and perforated at its lower part for the passage of the anterior interosseous artery. The posterior interosseous artery passes backwards between the oblique ligament and upper border of the interosseous ligament.

The interosseous ligament affords an extensive surface for the attachment of muscles; and is *in relation in front*, with the *flexor profundus digitorum*, *flexor longus pollicis*, *pronator quadratus*, and anterior interosseous artery and nerve; *behind*, with the *supinator brevis*, *extensor ossis metacarpi pollicis*, *extensor primi internodii pollicis*, *extensor secundi internodii pollicis*, *extensor indicis*, and near the wrist with the anterior interosseous artery and posterior interosseous nerve.

The *anterior inferior ligament* is a thin band of fibres, passing transversely between the radius and ulna.

The *posterior inferior ligament*, also thin and loose, has the same disposition on the posterior surface of the articulation.

The *interarticular*, or *triangular fibro-cartilage*, acts the part of a ligament

between the lower extremity of the radius and ulna. It is inserted by its apex into a depression on the inner surface [radial aspect] of the styloid process of the ulna, and attached by its base to the edge of the radius. This fibro-cartilage is lined on the upper surface by a synovial membrane, which forms a remarkably loose capsule between the radius and ulna, and is called the *membrana saciformis*. By its lower surface it enters into the articulation of the wrist joint.

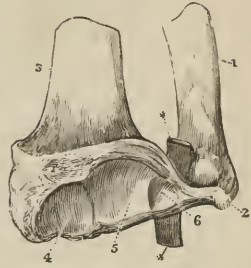
Actions. — The movements taking place between the radius and ulna are, rotation of the former upon the latter; rotation forwards being termed *pronation*, and rotation backwards *supination*. In these movements the head of the radius turns upon its axis, within the orbicular ligament and lesser sigmoid notch of the ulna; while inferiorly, the radius presents a concavity which moves on the rounded head of the ulna. The movements of the radius are chiefly limited by the anterior and posterior inferior ligaments; hence these are not unfrequently ruptured in great muscular efforts.

7. *Wrist Joint.* — The wrist is a ginglymoid articulation; the articular surfaces entering into its formation being the radius and triangular fibro-cartilage above, and the rounded surface of the scaphoid, semilunar, and euneiform bone, below; its ligaments are *four* in number, —

Anterior,
Posterior,

Internal lateral,
External lateral.

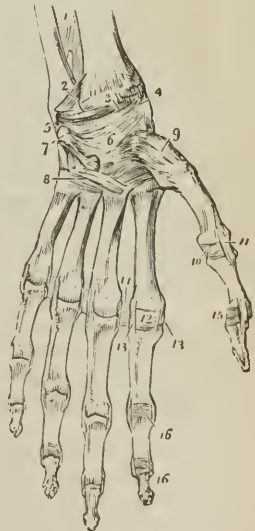
[FIG. 137.]



THE LOWER ENDS OF THE RADIUS AND ULNA, WITH THE TRIANGULAR FIBRO-CARTILAGE CONNECTING THEM. 1. Ulna. 2. Its styloid process. 3. Radius. 4. Its articular surface for the scaphoid bone, and 5, that for the semilunar. 6. The triangular fibro-cartilage; its lower surface. A piece of whalebone (*) has been passed between the upper surface and the head of the ulna.]

LIGAMENTS OF THE ANTERIOR ASPECT OF THE WRIST AND HAND. 1. Lower part of the interosseous membrane. 2. Antero-inferior radio-ulnar ligament. 3. Anterior ligament of the wrist joint. 4. External lateral ligament. 5. Internal lateral ligament. 6. Palmar ligaments of the carpus. 7. Pisiform bone, with its ligaments. 8. Ligaments connecting the second range of carpal bones with the metacarpal, and the metacarpal with each other. 9. Capsular ligament of the carpo-metacarpal articulation of the thumb. 10. Anterior ligament of the metacarpo-phalangeal articulation of the thumb. 11. One of the lateral ligaments of that articulation. 12. Anterior ligament of the metacarpo-phalangeal articulation of the index finger; this ligament has been removed in the other fingers. 13, 13. Lateral ligaments of the same articulation; the corresponding ligaments are seen in the other articulations. 14. Transverse ligament connecting the heads of the metacarpal bones of the index and middle finger; the same ligament is seen between the other fingers. 15. Anterior and one lateral ligament of the phalangeal articulation of the thumb. 16, 16. Anterior and lateral ligaments of the phalangeal articulations of the index finger; the anterior ligaments are removed in the other fingers, but the lateral ligaments remain.

FIG. 138.



The *anterior ligament* is a broad and membranous layer consisting of three fasciculi, which pass between the lower part of the radius and the scaphoid, semilunar, and cuneiform bone.

The *posterior ligament*, also thin and loose, passes between the posterior surface of the radius, and the posterior surface of the semilunar and cuneiform bone.

The *internal lateral ligament* extends from the styloid process of the ulna to the cuneiform and pisiform bone.

The *external lateral ligament* is attached by one extremity to the styloid process of the radius, and by the other to the side of the scaphoid bone, some of its fibres being prolonged to the trapezium. The radial artery rests on this ligament as it passes backwards to the first metacarpal space.

The *synovial membrane* of the wrist joint lines the under surface of the radius and interarticular cartilage above, and the first row of bones of the carpus below.

The *relations* of the wrist joint are the flexor and extensor tendons, by which it is surrounded, and the radial and ulnar artery.

Actions. — The movements of the wrist joint are, *flexion, extension, adduction, abduction, and circumduction*. In these motions the articular surfaces glide upon each other.

8. *Articulations between the Carpal Bones*. — These are amphiarthrodial joints, with the exception of the conjoined head of the os magnum and unciforme, which is received into a cup formed by the scaphoid, semilunar, and cuneiform bone, and constitutes an enarthrosis. The ligaments are,

Dorsal,	Interosseous fibro-cartilages,
Palmar,	Annular.

The *dorsal ligaments* are ligamentous bands, that pass transversely and longitudinally from bone to bone on the dorsal surface of the carpus.

The *palmar ligaments* are fasciculi of the same kind, but stronger than the dorsal, having the like disposition on the palmar surface.

The *interosseous ligaments* are fibro-cartilaginous lamellæ situated between the adjoining bones in each range: in the upper range they close the upper part of the space between the scaphoid, semilunar, and cuneiform bones; in the lower range they are stronger than in the upper, and connect the os magnum on the one side to the unciforme, on the other to the trapezoides, leaving intervals through which the synovial membrane is continued to the bases of the metacarpal bones.

The *proper annular ligament* (lig. carpi volare proprium) is a firm ligamentous band, which connects the bones of the two sides of the carpus. It is attached by one extremity to the trapezium and scaphoid, by the other to the unciform process of the unciforme and base of the pisiform bone, and forms an arch over the anterior surface of the carpus, beneath which the tendons of the long flexors and the median nerve pass into the palm of the hand.

The *articulation of the pisiform bone* with the cuneiform is provided with a separate synovial membrane, protected by fasciculi of ligamentous fibres, which form a kind of capsule around the joint; they are inserted into the cuneiforme, unciforme, and base of the metacarpal bone of the little finger.

Synovial Membranes. — There are *five* synovial membranes entering into the composition of the articulations of the carpus: —

The *first* is situated between the lower end of the ulna and the interarticular fibro-cartilage; it is called *sacciform*, from forming a sacculus between the ulna and radius.

The *second* is situated between the lower surface of the radius and interarticular fibro-cartilage *above*, and the first range of bones of the carpus *below*.

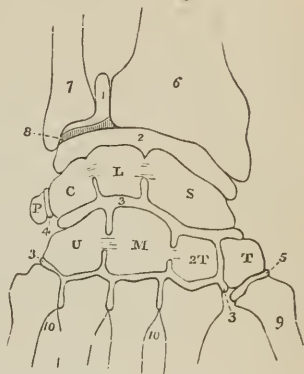
The *third*, the most extensive of the synovial membranes of the wrist, is situated between the two rows of carpal bones, and passes between the bones of the second range, to invest the carpal extremities of the four metacarpal bones of the fingers.

The *fourth* is the synovial membrane of the articulation of the metacarpal bone of the thumb with the trapezium.

The *fifth* is situated between the pisiform and cuneiform bone.

FIG. 139.

DIAGRAM SHOWING THE DISPOSITION OF THE FIVE SYNOVIAL MEMBRANES OF THE WRIST JOINT. [One of these (2) only, belongs to the wrist joint proper; the others are, more correctly, in relation with it.] 1. Sacciform membrane. 2. Second synovial membrane. 3, 3. Third, or large synovial membrane. 4. Synovial membrane between the pisiform and cuneiform bone. 5. Synovial membrane of the metacarpal articulation of the thumb. 6. Lower extremity of the radius. 7. Lower extremity of the ulna. 8. Interarticular fibro-cartilage. *S.* Scaphoid bone. *L.* Semilunare. *C.* Cuneiforme; interosseous ligaments are seen passing between these three bones and separating the articulation of the wrist (2) from that of the carpal bones (3). *P.* Pisiforme. *T.* Trapezium. *T 2.* Trapezoides. *M.* Os magnum. *U.* Unciforme; interosseous ligaments are seen connecting the os magnum with the trapezoides and unciforme. 9. Base of the metacarpal bone of the thumb. 10, 10. Bases of the other metacarpal bones.



Actions. — Very little movement exists between the bones in each range, but more is permitted between the two ranges. The motions of the latter are those of flexion and extension.

9. *Carpo-metacarpal Articulations.* — The second row of bones of the carpus articulates with the metacarpal bones of the four fingers by *dorsal* and *palmar* ligaments; and the metacarpal bone of the thumb with the trapezium by a *capsular ligament*. There is also in the carpo-metacarpal articulation a thin *interosseous* band, which passes from the ulnar edge of the os magnum to the bases of the third and fourth metacarpal bones at their point of connexion.

The *dorsal ligaments* are strong fasciculi which pass from the second range of carpal to the metacarpal bones; with the exception of the little finger there are two fasciculi to each bone, namely, to the index finger, one each from the trapezium and trapezoides; to the middle finger, one each from the trapezoides and os magnum; to the ring finger, one each from the os magnum and unciforme; and to the little finger, one from the unciforme.

The *palmar ligaments* are thin fasciculi arranged according to the same plan on the palmar surface.

The *synovial membrane* is a continuation of the great synovial membrane of the two rows of carpal bones.

The *capsular ligament* of the thumb is one of the three true capsular ligaments of the skeleton; the other two belong to the shoulder joint and hip joint. The articulation has a proper *synovial membrane*.

The *metacarpal bones* of the four fingers are firmly connected at their bases by means of *dorsal* and *palmar* ligaments, which extend transversely from one bone to the other, and by *interosseous* ligaments which pass between their contiguous surfaces. Their lateral articular facets are lined by a reflection of the great synovial membrane of the two rows of carpal bones.

Actions.—The movements of the metacarpal on the carpal bones are restricted to a slight degree of sliding motion, with the exception of the articulation of the metacarpal bone of the thumb with the trapezium. In the latter, the movements are *flexion, extension, adduction, abduction, and circumduction.*

10. *Metacarpo-phalangeal Articulation.*—The metacarpo-phalangeal articulation is a ginglymoid joint; and its ligaments four in number,—

Anterior, Two lateral, Transverse.

The *anterior ligaments*, thick and fibro-cartilaginous, form part of the articulating surface of the joints. They are grooved externally for the lodgment of the flexor tendons, and by their internal aspect form part of the articular surface for the head of the metacarpal bone. At each side they are continuous with the lateral ligaments.

The *lateral ligaments* are strong narrow fasciculi, holding the bones together at each side.

The *transverse ligament* is a strong ligamentous band passing across the heads of the metacarpal bones of the four fingers, and connected with the anterior ligaments.

The expansion of the extensor tendon over the back of the fingers takes the place and performs the office of a posterior ligament.

Actions.—This articulation admits of movement in four different directions, viz., *flexion, extension, adduction, and abduction*; it is also capable of *circumduction.*

11. *Articulation of the Phalanges.*—These articulations are ginglymoid joints; and furnished with three ligaments,

Anterior, Two lateral.

The *anterior ligament*, firm and fibro-cartilaginous, forms part of the articular surface for the head of the phalanges; while externally it is grooved for the reception of the flexor tendons.

The *lateral ligaments* are very strong; and the principal bond of connexion between the bones.

The extensor tendon takes the place and performs the office of a posterior ligament.

Actions.—The movements of the phalangeal joints are *flexion* and *extension*, these movements being more free between the first and second, than between the second and third.

In connexion with the phalanges it will be proper to examine certain fibrous bands termed *thecæ* or *vaginal ligaments*, which serve to retain the tendons of the flexor muscles against the flat surface of the bones. These fibrous bands are attached at each side to the lateral margins of the phalanges; they are thick in the interspaces of the joints, thin where the tendons lie upon the joints, and are lined on their inner surface by synovial membrane.

LIGAMENTS OF THE LOWER EXTREMITY.

The *ligaments of the lower extremity*, like those of the upper, may be arranged in the order of the joints to which they belong; these are,

1. Hip joint.
2. Knee joint.
3. Articulation between the tibia and fibula.
4. Ankle joint.

5. Articulation of the tarsal bones.
6. Tarso-metatarsal articulation.
7. Metatarso-phalangeal articulation.
8. Articulation of the phalanges.

1. *Hip Joint*. — The articulation of the head of the femur with the acetabulum constitutes an enarthrosis, or ball-and-socket joint. The articular surfaces are, the cup-shaped cavity of the acetabulum and the rounded head of the femur; the ligaments are *five* in number, viz.,

Capsular,	Cotyloid,
Ilio-femoral,	Transverse.
Teres,	

The *capsular ligament* (*membrana capsularis*, fig. 129, 8) is a strong ligamentous capsule, embracing the acetabulum superiorly, the neck of the femur below, and connecting the two bones firmly together. It is much thicker on the upper part of the joint, where more resistance is required, than on the under part, and extends further along the neck of the femur on the anterior and superior than on the posterior and inferior side, being attached to the intertrochanteric line in front, to the base of the great trochanter above, and to the middle of the neck of the femur behind.

The *ilio-femoral ligament* (fig. 129, 9) is an accessory and radiating band, which descends obliquely from the anterior inferior spinous process of the ilium to the anterior intertrochanteric line, and strengthens the anterior portion of the capsular ligament.

The *ligamentum teres*, [*interarticular ligament*] (fig. 130, 7), triangular in shape, is attached by a round apex to the depression just below the middle of the head of the femur, and by its base, which separates into two fasciculi, into the borders of the notch of the acetabulum. It is formed by a fasciculus of fibres of variable size, surrounded by synovial membrane; sometimes the synovial membrane is present without the fibres, or the ligament is wholly absent. [Its only use seems to be to support the vessels which pass to and from the head of the femur.]

The *cotyloid ligament* (fig. 130, 6) is a prismoid cord of fibro-cartilage, attached around the margin of the acetabulum, and serving to deepen that cavity and protect its edges. It is thicker at the upper and posterior border of the acetabulum than in front, is inclined inwards towards the acetabulum, and consists of fibres which arise from the whole circumference of the brim, and interlace with each other at acute angles.

The *transverse ligament* is a strong fasciculus of ligamentous fibres, continuous with the cotyloid ligament, and stretching across the notch of the acetabulum. It converts the notch into a foramen, through which the articular branches of the internal circumflex and obturator artery enter the joint.

The fossa at the bottom of the acetabulum is filled with a mass of fat, covered by synovial membrane, which serves as an elastic cushion for the head of the bone during its movements. This was described by Havers as the synovial gland.

The *synovial membrane* is extensive; it invests the head of the femur, and is continued around the ligamentum teres into the acetabulum, whence it is reflected on the inner surface of the capsular ligament back to the head of the bone.

The muscles immediately surrounding and in contact with the hip joint are, *in front*, psoas and iliacus, separated from the capsular ligament by a large synovial bursa; *above*, short head of the rectus and gluteus minimus; *behind*, pyramiformis, gemellus superior, obturator internus, gemellus inferior, and quadratus femoris; and at the *inner side*, obturator externus and pectineus.

Actions.—The movements of the hip joint are very extensive; they are *flexion, extension, adduction, abduction, circumduction, and rotation.*

2. *Knee Joint.*—The knee [formed by the condyles of the femur, the glenoid cavities of the tibia, and the posterior surface of the patella] is a ginglymoid articulation of large size, and provided with numerous ligaments; the latter are thirteen in number, namely:

Anterior, or ligamentum patellæ,
 Posterior, or ligamentum posticum Winslowii,
 Internal lateral,
 Two external lateral,
 Anterior or external crucial,
 Posterior or internal crucial,
 Transverse,
 Two coronary,
 Ligamentum mucosum, } *false ligaments.*
 Ligamenta alaria [two], }
 Two semilunar fibro-cartilages,
 Synovial membrane.

The first *five* are *external* to the articulation; the next *five* are *internal*; the remaining three are mere folds of synovial membrane, and have no title to the name of ligaments. In addition to the ligaments, there are two fibro-cartilages, and a synovial membrane.

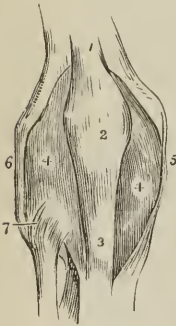
The *anterior ligament*, or *ligamentum patellæ*, is the prolongation of the tendon of the extensor muscles of [the leg, which are placed upon] the thigh, downwards to the tubercle of the tibia. It is, therefore, no ligament; and, as the patella is simply a sesamoid bone developed in the tendon of the extensor muscles for the defence of the front of the knee joint, the ligamentum patellæ has no title to consideration, either as a ligament of the knee joint or as a ligament of the patella.

A small *bursa mucosa* is situated between the ligamentum patellæ near its insertion and the front of the tibia; and another of larger size between the anterior surface of the patella and fascia lata. It is the latter which is enlarged in housemaid's knee.

The *posterior ligament*, *ligamentum posticum Winslowii*, is a broad expansion of ligamentous fibres, which covers the whole of the posterior aspect of the joint. It is divisible into two lateral portions, which invest the condyles of the femur, and a central portion which is depressed, and formed by the interlacement of fasciculi passing in different directions. The strongest of these fasciculi is derived from the tendon of the semi-membranosus, and passes obliquely upwards and outwards from the posterior part of the inner tuberosity of the tibia to the external condyle of the femur. Other accessory fasciculi are given off by the tendon of the popliteus and heads of the gastrocnemius. The middle portion of the ligament supports the popliteal artery and vein, and is perforated by several openings for the passage of branches of the azygos articular artery and the nerves of the joint.

The *internal lateral ligament* is a broad and trapezoid layer of ligamentous fibres, attached above to the tubercle on the internal

FIG. 140.



ANTERIOR VIEW OF THE
 LIGAMENTS OF THE KNEE
 JOINT. 1. Tendon of the
 quadriceps extensor muscle
 of the leg. 2. Patella. 3. An-
 terior ligament, or ligamen-
 tum patellæ, near its inser-
 tion. 4. 4. Synovial mem-
 brane. 5. Internal lateral
 ligament. 6. Long external
 lateral ligament. 7. Antero-
 superior tibio-fibular liga-
 ment.

condyle of the femur, and below to the inner tuberosity of the tibia. It is crossed at its lower part by the tendons of the inner hamstring, from which it is separated by a synovial bursa, and it covers in the anterior slip of the semi-membranosus tendon and the inferior internal articular artery.

External lateral ligaments.—The *long* external lateral ligament is a strong and round cord, which descends from the posterior part of the tubercle on the external condyle of the femur to the outer part of the head of the fibula.

The *short* external lateral ligament is an irregular fasciculus situated behind the preceding, arising from the external condyle near the origin of the head of the gastrocnemius muscle, and inserted into the posterior part of the head of the fibula. It is firmly connected with the external semilunar fibro-cartilage, and appears principally intended to connect that cartilage with the fibula; sometimes it is lost superiorly in the capsular ligament without reaching the femur.¹

The long external lateral ligament is covered in by the tendon of the biceps, and has passing beneath it the tendon of origin of the popliteus muscle, and the inferior external articular artery.

The true ligaments *within the joint* are the crucial, transverse, and coronary.

The *anterior*, or *external crucial ligament*, arises from the depression on the head of the tibia in front of the spinous process, and passes upwards and backwards to be inserted into the inner surface of the outer condyle of the femur, as far back as its posterior border. It is smaller than the posterior.

The *posterior*, or *internal crucial ligament*, arises from the depression on the head of the tibia behind the spinous process, and passes upwards and forwards to be inserted into the [outer surface of the] inner condyle of the femur. This ligament is less oblique and larger than the anterior.

The *transverse ligament* is a small slip of fibres which extends transversely from the external semilunar fibro-cartilage, near its anterior extremity, to the anterior convexity of the internal cartilage.

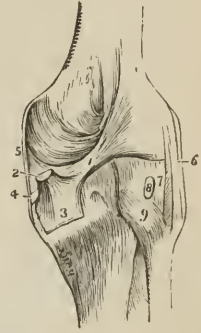
The *coronary ligaments* are the short fibres by which the convex borders of the semilunar cartilages are connected to the head of the tibia and ligaments surrounding the joint.

The *semilunar fibro-cartilages* are two falciform plates of fibro-cartilage, situated on the head of the tibia around its margin, and serving to deepen the surface of articulation for the condyles of the femur. They are thick along their convex border; thin and sharp along their concave edge.

The *internal semilunar fibro-cartilage* forms an oval cup for the reception of the internal condyle of the femur; it is connected by its convex border with the head of the tibia and internal and posterior ligaments, by means of its coronary ligament; and by its two extremities is firmly implanted into the depression before and behind the spinous process. The *external semilunar fibro-cartilage* bounds a circular fossa for the external condyle; it is connected by its convex border with the head of the tibia, and to the external and posterior ligaments by

¹ Professor Retzius considers the short external lateral ligament as part of the tendon of origin of the popliteus muscle.

FIG. 141.

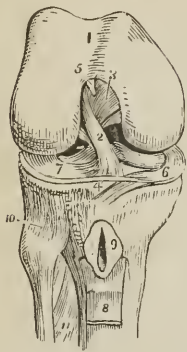


POSTERIOR VIEW OF THE LIGAMENTS OF THE KNEE JOINT.

1. Fasciculus of the ligamentum posticum Winslowii, derived from 2, the tendon of the semi-membranosus muscle; the latter is cut through.
2. The process of the tendon which spreads out in the fascia of the popliteus muscle.
3. The process which is sent forwards beneath the internal lateral ligament.
4. The posterior part of the internal lateral ligament.
5. Long external lateral ligament.
6. Short external lateral ligament.
7. Tendon of the popliteus muscle cut through.
8. Postero-superior tibio-fibular ligament.
- 9.

its coronary ligament; by its two extremities it is inserted into the depression between the two projections which constitute the spinous process of the tibia. The two extremities of the external cartilage being inserted into the same fossa, form an almost complete circle, and the cartilage being somewhat broader than the internal, nearly covers the articular surface of the tibia.

FIG. 142.



THE RIGHT KNEE JOINT LAID OPEN FROM THE FRONT, IN ORDER TO SHOW THE INTERNAL LIGAMENTS. 1. Cartilaginous surface of the lower extremity of the femur with its two condyles; the figure 5 rests on the external; the figure 3 on the internal condyle. 2. Anterior crucial ligament. 3. Posterior crucial ligament. 4. Transverse ligament. 5. Attachment of the ligamentum mucosum; the rest has been removed. 6. Internal semilunar fibrocartilage. 7. External semilunar fibrocartilage. 8. Part of the ligamentum patellæ turned down. 9. Bursa situated between the ligamentum patellæ, and head of the tibia; laid open. 10. Antero-superior tibio-fibular ligament. 11. Interosseous membrane; the opening above this membrane is for the passage of the anterior tibial artery.

surface of the patella; it covers both surfaces of the semilunar fibro-cartilages; and is reflected upon the crucial ligaments, and inner surface of the ligaments which form the circumference of the joint. On each side of the patella it lines the tendinous aponeuroses of the vastus internus and vastus externus muscle, and forms a pouch of considerable size between the extensor tendon and front of the femur. It also forms the folds in the interior of the joint, called "ligamentum mucosum," and "ligamenta alaria." The superior pouch of the synovial membrane is supported and raised during the movements of the limb by a small muscle, the *subcrureus*, which is inserted into it.

Between the ligamentum patellæ and synovial membrane is a considerable mass of fat, which presses the membrane towards the interior of the joint, and occupies the fossa between the condyles.

Besides the proper ligaments of the articulation, the joint is strengthened in front by the fascia lata, which is thicker at the outer than the inner side, by a tendinous expansion from the vastus internus, and some scattered ligamentous fibres inserted into the sides of the patella. This expansion has been termed the *capsular ligament*.

Actions.—The knee joint is one of the strongest of the articulations of the

The external semilunar fibro-cartilage, besides giving off a fasciculus from its anterior border to constitute the transverse ligament, is continuous by some of its fibres with the extremity of the anterior crucial ligament; posteriorly it divides into three slips; one, a strong cord, ascends obliquely forwards to be inserted into the anterior part of the inner condyle of the femur in front of the posterior crucial ligament; another is the fasciculus of insertion into the fossa of the spinous process; while the third, of small size, is continuous with the posterior part of the anterior crucial ligament.

The *ligamentum mucosum* is a slender conical process of synovial membrane inclosing a few ligamentous fibres which proceed from the transverse ligament. It is connected, by its apex, with the anterior part of the condyloid notch, and, by its base, is lost in the mass of fat which projects into the joint beneath the patella.

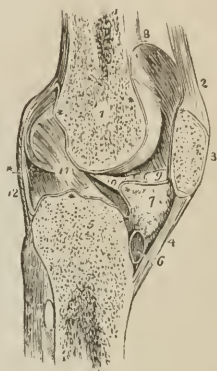
The *alar ligaments* are two fringed folds of synovial membrane, extending from the ligamentum mucosum, along the edges of the mass of fat to the sides of the patella.

The *synovial membrane* of the knee joint is by far the most extensive in the body. It invests the cartilaginous surfaces of the condyles of the femur, head of tibia, and inner

body, while, at the same time, it admits of the most perfect degree of movement in the direction of *flexion* and *extension*. During flexion the articular surface

LONGITUDINAL SECTION OF THE LEFT KNEE JOINT, SHOWING THE REFLECTIONS OF ITS SYNOVIAL MEMBRANE. 1. Cancellous structure of the lower part of the femur. 2. Tendon of the extensor muscles of the leg. 3. Patella. 4. Ligamentum patellæ. 5. Cancellous structure of the head of the tibia. 6. A bursa situated between the ligamentum patellæ and head of the tibia. 7. Mass of fat projecting into the cavity of the joint below the patella. * * * * * The synovial membrane. 8. The pouch of synovial membrane which ascends between the tendon of the extensor muscles of the leg, and front of the lower extremity of the femur. 9. One of the alar ligaments; the other has been removed with the opposite section. 10. Ligamentum mucosum left entire; the section being made to its inner side. 11. Anterior or external crucial ligament. 12. Posterior ligament of the joint. The plan of the synovial membrane, which is here presented to the student, is divested of all unnecessary complications. It may be traced from the sacculus (at 8), along the inner surface of the patella; then over the adipose mass (7) from which it throws off the mucous ligament (10); then over the head of the tibia, forming a sheath to the crucial ligaments; then upwards along the posterior ligament and condyles of the femur, to the sacculus whence its examination commenced.

FIG. 143.



of the tibia glides forwards on the condyles of the femur; the lateral ligaments, the posterior, and the crucial ligaments are relaxed; while the ligamentum patellæ, being on the stretch, serves to press the adipose mass behind it into the vacuity formed in front of the joint. In *extension* all the ligaments are put on the stretch, with the exception of the ligamentum patellæ. When the knee is semi-flexed, a partial degree of *rotation* is permitted.

3. *Articulation between the Tibia and Fibula.*—The tibia and fibula are held firmly connected by means of *seven* ligaments, namely,

Anterior,	} above.	Anterior,	} below.
Posterior,		Posterior,	
Interosseous membrane,		Transverse.	
Interosseous inferior.			

The *anterior superior tibio-fibular ligament* is a strong fasciculus of parallel fibres passing obliquely downwards and outwards from the outer tuberosity of the tibia, to the anterior surface of the head of the fibula.

The *posterior superior tibio-fibular ligament*, thicker and stronger than the anterior, is disposed in a similar manner on the posterior surface of the joint.

Within the articulation there is a *synovial membrane* which is sometimes continuous with that of the knee joint.

The *interosseous membrane*, or *superior interosseous ligament*, is a broad layer of aponeurotic fibres which pass obliquely downwards and outwards, from the sharp ridge on the tibia to the inner edge of the fibula, and are crossed at an acute angle by a few fibres taking the opposite direction. The ligament is deficient *above*, leaving a considerable interval between the bones, through which the anterior tibial artery takes its course forwards to the anterior aspect of the leg; and perforated *below*, near its lower third, for the anterior peroneal artery and vein.

The interosseous membrane is *in relation, in front*, with the tibialis anticus, extensor longus digitorum, extensor proprius pollicis, anterior tibial vessels and nerve, and anterior peroneal artery; *behind*, with the tibialis posticus, flexor longus digitorum, and posterior peroneal artery.

The *inferior interosseous ligament* consists of short and strong fibres, which hold the bones firmly together inferiorly, where they are nearly in contact. This articulation is so firm, that the fibula is broken when an attempt is made to rupture the ligament.

The *anterior inferior tibio-fibular ligament* is a broad band, consisting of two fasciculi of parallel fibres which pass obliquely across the anterior aspect of the articulation of the two bones at their inferior extremity, from tibia to fibula.

The *posterior inferior tibio-fibular ligament* is a similar band on the posterior surface of the articulation. Both ligaments project somewhat below the margin of the bones, and serve to deepen the cavity of articulation with the astragalus.

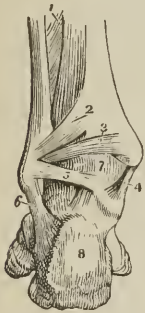The *transverse ligament* is a narrow band of ligamentous fibres, continuous with the preceding, and passing transversely across the back of the ankle joint, between the two malleoli.

The *synovial membrane* of the inferior tibio-fibular articulation, is a duplication of the synovial membrane of the ankle joint, reflected upwards for a short distance between the two bones.

Actions.—Between the tibia and fibula there exists a slight degree of movement, which is calculated to enable the latter to resist injury by yielding for a trifling extent to forcible pressure.

4. *Ankle Joint.*—The ankle is a ginglymoid articulation; the surfaces entering into its formation are the under surface of the tibia with its malleolus and the malleolus of the fibula, above; and the surface of the astragalus with its two lateral facets, below. The ligaments are three in number:

FIG. 144.



POSTERIOR VIEW OF THE ANKLE JOINT. 1. Lower part of the interosseous membrane. 2. Postero-inferior ligament connecting the tibia and fibula. 3. Transverse ligament. 4. Internal lateral ligament. 5. Posterior fasciculus of the external lateral ligament. 6. Middle fasciculus of the external lateral ligament. 7. Synovial membrane of the ankle joint. 8. Posterior tuberosity of the os calcis.

thicker fasciculus, which connects the apex of the internal malleolus with the side of the astragalus.

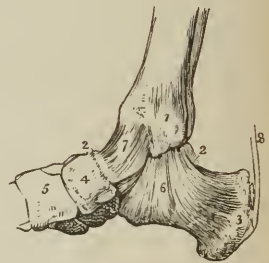The internal lateral ligament is covered in and partly concealed by the tendon

Anterior,
Internal lateral,
External lateral.

The *anterior ligament* is a thin, membranous layer, passing from the margin of the tibia, to the astragalus, in front of its articular surface. It is *in relation, in front*, with the tendons of the extensors of the great and lesser toes, tibialis anticus, peroneus tertius, and anterior tibial vessels and nerve. *Posteriorly* it lies in contact with a stratum of extra-synovial adipose tissue and the synovial membrane

The *internal lateral* or *deltoid ligament* is a triangular layer of fibres, attached superiorly, by its apex, to the internal malleolus; inferiorly, by an expanded base, to the astragalus, os calcis, and scaphoid bone. Beneath the superficial layer of this ligament is a stronger and

FIG. 145.



INTERNAL VIEW OF THE ANKLE JOINT. 1. Internal malleolus of the tibia. 2, 2. Astragalus. 3. Os calcis. 4. Scaphoid bone. 5. Internal cuneiform bone. 6. Internal lateral or deltoid ligament. 7. Anterior ligament. 8. Tendo Achillis; a small bursa is seen interposed between this tendon and the posterior tuberosity of the os calcis.

of the tibialis posticus, and, at its posterior part, is in relation with the tendon of the flexor longus digitorum, and flexor longus pollicis.

The *external lateral ligament* consists of three strong fasciculi, which proceed from the inner side of the external malleolus, and diverge in three different directions. The *anterior fasciculus* passes forwards to be attached to the astragalus; the *posterior*, backwards, to be connected with the astragalus posteriorly; and the *middle*, longer than the other two, descends to be inserted into the outer side of the os calcis.

"It is the strong union of this bone," says Sir Astley Cooper, "with the tarsal bones, by means of the external lateral ligaments, which leads to its being more frequently fractured than dislocated."

The transverse ligament of the tibia and fibula occupies the place of a posterior ligament of the ankle joint. It is *in relation, behind*, with the posterior tibial vessels and nerve, and tendon of the tibialis posticus muscle; *in front*, with the extra-synovial adipose tissue and synovial membrane.

The *synovial membrane* invests the cartilaginous surfaces of the tibia and fibula (sending a duplicature upwards between their lower ends), and the upper surface and two sides of the astragalus. It is then reflected upon the anterior and lateral ligaments, and on the transverse ligament posteriorly.

Actions. — The movements of the ankle joint are *flexion* and *extension* only, without lateral motion.

5. *Articulation of the Tarsal Bones.*—The ligaments which connect the seven bones of the tarsus to each other are of three kinds,—

Dorsal,

Plantar,

Interosseous.

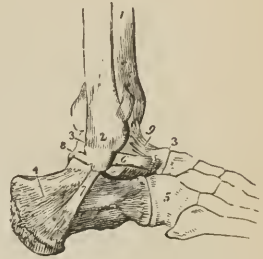
The *dorsal ligaments* are small fasciculi of parallel fibres, which pass from each bone to all the neighboring bones with which it articulates. The only dorsal ligaments deserving of particular mention are, the *external* and *posterior calcaneo-astragaloid*, which, with the interosseous ligament, complete the articulation of the astragalus with the os calcis; the *superior* and *internal calcaneo-cuboid* ligaments; and the *superior astragaloscapoid* ligament. The internal calcaneo-cuboid, and superior calcaneo-scaphoid ligament, which are closely united posteriorly in the deep groove which intervenes between the astragalus and os calcis, separate anteriorly to reach their respective bones; they form the principal bond of connexion between the first and second range of bones of the foot. It is the division of this portion of these ligaments that demands the careful attention of the surgeon in performing Chopart's operation.

The *plantar ligaments* have the same disposition on the plantar surface of the foot; — three of them, however, are of large size, and have especial names, viz., the

Calcaneo-scaphoid,
Long calcaneo-cuboid,
Short calcaneo-cuboid.

The *inferior calcaneo-scaphoid ligament* is a broad and fibro-cartilaginous

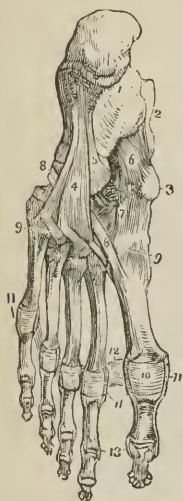FIG. 146.



EXTERNAL VIEW OF THE ANKLE JOINT. 1. Tibia. 2. External malleolus of the fibula. 3, 3. Astragalus. 4. Os calcis. 5. Cuboid bone. 6. Anterior fasciculus of the external lateral ligament attached to the astragalus. 7. Its middle fasciculus, attached to the os calcis. 8. Its posterior fasciculus, attached to the astragalus. 9. Anterior ligament of the ankle.

band of ligament, which passes forwards from the anterior and inner border of the os calcis to the edge of the scaphoid bone. Besides connecting the os calcis and scaphoid, it supports the astragalus, and forms part of the cavity in which the round head of the latter bone is received. It is lined on its upper surface by the synovial membrane of the astragalo-scaphoid articulation.

FIG. 147.



LIGAMENTS OF THE SOLE OF THE FOOT. 1. Os calcis. 2. Astragalus. 3. Tuberosity of the scaphoid bone. 4. Long calcaneo-cuboid ligament. 5. Part of the short calcaneo-cuboid ligament. 6. Calcaneo-scaphoid ligament. 7. Plantar tarsal ligaments. 8, 8. Tendon of the peroneus longus muscle. 9, 9. Plantar tarso-metatarsal ligaments. 10. Plantar ligament of the metatarso-phalangeal articulation of the great toe; the same ligament is seen on the other toes. 11, 11, 11. Lateral ligaments of the metatarso-phalangeal articulations. 12. Transverse ligament. 13. Lateral ligaments of the phalanges of the great toe; the same ligaments are seen on the other toes.

fourth, the large tarsal synovial membrane, for the articulations between the scaphoid and three cuneiform bones, the cuneiform bones with each other, the external cuneiform bone with the cuboid, and the two external cuneiform bones with the bases of the second and third metatarsal bones. The prolongation which reaches the metatarsal bones passes forwards between the internal and middle cuneiform bone. A small synovial membrane is sometimes met with between the contiguous surfaces of the scaphoid and cuboid bone.

Actions.—The movements permitted by the articulation between the astragalus and os calcis, are a slight degree of gliding, in the direction *forwards* and *back-*

The firm connexion of the os calcis with the scaphoid bone, and the feebleness of the astragalo-scaphoid articulation, are conditions favorable to the occasional dislocation of the head of the astragalus.

The *long calcaneo-cuboid*, or *ligamentum longum plantæ*, is a long band of ligamentous fibres, which proceeds from the under surface of the os calcis to the rough surface on the under part of the cuboid bone, its fibres being continued onwards to the base of the third and fourth metatarsal bones.

This ligament forms the inferior boundary of a canal in the cuboid bone, through which the tendon of the peroneus longus passes to its insertion into the base of the metatarsal bone of the great toe.

The *short calcaneo-cuboid*, or *ligamentum breve plantæ*, is situated closer to the bones than the long plantar ligament, from which it is separated by adipose tissue; it is broad and extensive, and ties the under part of the os calcis and cuboid bone firmly together.

The *interosseous ligaments* are five in number; they are short and strong ligamentous fibres, situated between adjoining bones, and firmly attached to their rough surfaces. One of these, *calcaneo-astragaloid*, is lodged in the groove between the upper surface of the os calcis and the lower of the astragalus. It is large and very strong, consists of vertical and oblique fibres, and serves to unite the os calcis and astragalus solidly together. The second interosseous ligament, also very strong, is situated between the sides of the scaphoid and cuboid bone; the three remaining interosseous ligaments connect strongly together the three cuneiform bones and the cuboid.

The *synovial membranes* of the tarsus are four in number: *one*, for the posterior calcaneo-astragaloid articulation; a *second*, for the anterior calcaneo-astragaloid and astragalo-scaphoid articulation; occasionally an additional small synovial membrane is found in the anterior calcaneo-astragaloid joint; a *third*, for the calcaneo-cuboid articulation; and a

wards, and *laterally* from side to side. The movements of the second range of tarsal bones are very trifling, being greater between the scaphoid and three cuneiform bones than in the other articulations. The movements occurring between the first and second range are the most considerable; they are *adduction* and *abduction*; and, in a minor degree, *flexion*, which increases the arch of the foot, and *extension*, which flattens the arch.

6. *Tarso-metatarsal Articulation*. — The ligaments of this articulation are,

Dorsal,	Plantar,	Interosseous.
---------	----------	---------------

The *dorsal ligaments* connect the metatarsal to the tarsal bones, and the metatarsal bones with each other. The base of the second metatarsal bone, articulating with the three cuneiform bones, receives a ligamentous slip from each, while the rest articulating with a single tarsal bone receive only a single tarsal slip.

The *plantar ligaments* have a similar disposition on the plantar surface.

The *interosseous ligaments* are situated between the bases of the metatarsal bones of the four lesser toes; also between the base of the second and third metatarsal bones and the internal and external cuneiform bone.

The metatarsal bone of the second toe being implanted by its base between the internal and external cuneiform bone, is the most strongly articulated of all the metatarsal bones. This disposition must be recollected in amputation at the tarso-metatarsal articulation [Hey's operation].

The *synovial membranes* of the tarso-metatarsal articulation are three in number; one for the metatarsal bone of the great toe; one for the second and third metatarsal bone, which is continuous with the great tarsal synovial membrane; and one for the fourth and fifth metatarsal bones.

Actions. — The movements of the metatarsal on the tarsal bones and on each other are very slight; they are such only as contribute to the strength of the foot, by permitting a certain degree of yielding to opposing forces.

7. *Metatarso-phalangeal Articulation*. — The ligaments of this articulation, like those between the first phalanges and metacarpal bones of the hand, are,

Inferior or plantar,	Two lateral,	Transverse.
----------------------	--------------	-------------

The *inferior or plantar ligaments*, thick and fibro-cartilaginous, form part of the articulating surface of the joint.

The *lateral ligaments*, short and very strong, are situated one on each side of the joint.

The *transverse ligament* is a strong band, which passes transversely between the plantar ligaments.

The expansion of the extensor tendon supplies the place of a dorsal ligament.

Actions. — The movements of the first phalanges on the rounded heads of the metatarsal bones, are *flexion*, *extension*, *adduction*, and *abduction*.

8. *Articulation of the Phalanges*. — The ligaments of the phalanges are the same as those of the fingers, and have the same disposition; their actions are also similar. They are,

Inferior or plantar, and, Two lateral.

CHAPTER IV.

OF THE MUSCLES.

MUSCLES are the moving organs of the animal frame; they constitute by their size and number the great bulk of the body, upon which they bestow form and symmetry. In the limbs they are situated around the bones, which they invest and defend, while they form to some of the joints a principal protection. In the trunk they are spread out to inclose cavities and constitute a defensive wall, capable of yielding to internal pressure, and again returning to its original position.

Their color presents the deep red which is characteristic of flesh, and their form is variously modified, to execute the varied range of movements which they are required to effect.

Muscle is composed of a number of parallel fibres placed side by side, and supported and held together by a delicate web of areolar tissue; so that, if it were possible to remove the muscular substance, we should have remaining a beautiful reticular framework, possessing the exact form and size of the muscle without its color and solidity. Towards the extremity of the organ the muscular fibre ceases, and the fibrous structure becomes aggregated, and modified, so as to constitute those glistening fibres and cords by which the muscle is tied to the surface of bone, and which are called *tendons*. Almost every muscle in the body is connected with bone [through the medium of the periosteum], either by tendinous fibres, or by an aggregation of those fibres constituting a tendon; and the union is so firm, that, under extreme violence, the bone itself breaks rather than permit the separation of the tendon from its attachment. In the broad muscles the tendon is spread out so as to form an expansion, called *aponeurosis* (ἀπό, longè; νεῦρον,¹ nervus, a nerve widely spread out).

Muscles present various modifications in the arrangement of their fibres in relation to their tendinous structure. Sometimes they are longitudinal, and terminate at each extremity in tendon, the entire muscle being *fusiform* in shape; in other situations they are disposed like the rays of a fan, converging to a tendinous point, as the temporal, pectoral, glutei, &c., and constitute a *radiate* muscle. Again, they are *penniform*, converging like the barbs of a feather to one side of a tendon, which runs the whole length of the muscle, as in the peronei; or *bipenniform*, converging to both sides of the tendon. In other muscles the fibres pass obliquely from the surface of a tendinous expansion spread out on one side, to that of another extended on the opposite side, as in the semi-membranosus; or, they are composed of penniform or bipenniform fasciculi, as in the deltoid, and constitute a compound muscle.

The nomenclature of muscles is defective and confused, and is generally derived from some prominent character which the muscle presents; thus, some are named from their situation, as the tibialis, peroneus, brachialis, temporali; others from their uses, as the flexors, extensors, adductors, abductors, levators, tensors, spincters, &c. Some again from their form, as the trapezius, triangularis, deltoid, rhomboideus, scalenus, orbicularis, &c.; and others from their direction, as the rectus, obliquus, transversalis, &c. Certain muscles have received names expressive of their attachments, as the sterno-mastoideus, sterno-hyoideus, &c.; and others, of their divisions, as the biceps, triceps, digastricus, complexus, &c.

In the description of a muscle we express its attachment by the words "origin" and "insertion"; the term *origin* is generally applied to the more fixed or central

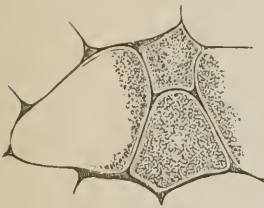
¹ The ancients named all the white fibres of the body νεῦρά: the term has since been limited to the nerves.

attachment, or to the point towards which the motion is directed, while *insertion* is assigned to the more movable point, or to that most distant from the centre; but there are exceptions to this principle, and as many muscles pull equally towards both extremities, the use of such terms must be regarded as arbitrary.

In structure, muscle is composed of bundles of fibres of variable size called fasciculi, which are inclosed in an areolar membranous investment or sheath, and the latter is continuous with the areolar framework of the fibres. Each *fasciculus* is composed of a number of smaller bundles, and these of single fibres, which, from their minute size and independent appearance, have been distinguished by the name of ultimate fibres. The *ultimate fibre* is found by microscopic investigation to be itself a fasciculus (ultimate fasciculus), made up of a number of *ultimate fibrils* inclosed in a delicate sheath, the myolemma or sarcolemma.¹ Two kinds of ultimate muscular fibre exist in the animal economy; viz., that of voluntary or animal life, striated muscle; and that of involuntary or organic life, smooth muscle.

The *ultimate fibre of animal life* is known by its size, by its uniformity of calibre, and especially by the transverse markings which occur at minute and regular distances. It also presents other markings or striæ, having a longitudinal direction, which indicate the existence of fibrillæ within the myolemma. The myolemma, or sarcolemma, the investing sheath of the ultimate fibre, is thin, homogeneous, transparent, and elastic.

FIG. 149.



TRANSVERSE SECTION OF ULTIMATE FIBRES OF THE BICEPS, after Bowman. In this figure the polyhedral form of the fibres is seen, and their composition of ultimate fibrils.

the human female is $\frac{1}{454}$, in the male $\frac{1}{332}$, the average of both being in round numbers $\frac{1}{400}$ [of an inch]. The largest fibres are met with in fishes, in which they average $\frac{1}{222}$; the next largest are found in man; while in other classes they range in the following order:—insects $\frac{1}{19}$; reptiles $\frac{1}{84}$; mammalia $\frac{1}{61}$; birds $\frac{1}{7}$ [of an inch].

¹ In the summer of 1836, while engaged with Dr. Jones Quain in the examination of animal tissues with a simple dissecting microscope, constructed by Powell, I first saw that the ultimate fibre of muscle was invested by a proper sheath, for which I proposed the term "Myolemma;" a term which was adopted by Dr. Quain in the fourth edition of his "Elements of Anatomy." We at that time believed that the transverse folding of that sheath gave rise to the appearance of transverse striæ, an opinion which subsequent examination proved to be incorrect. Mr. Bowman has since employed the term "Sarcolemma," as synonymous with Myolemma.

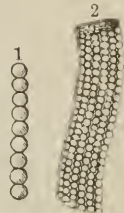
² On the Minute Structure and Movements of Voluntary Muscle. Philosophical Transactions, 1840.

FIG. 148.



A MUSCULAR FIBRE OF ANIMAL LIFE inclosed in its myolemma; the transverse and longitudinal striæ are seen.

FIG. 150.



1. ULTIMATE FIBRIL OF MUSCULAR FIBRE OF ANIMAL LIFE, according to the views of Bowman. 2. MUSCULAR FIBRE OF ANIMAL LIFE, more highly magnified. Its myolemma is so thin and transparent as to permit the ultimate fibrils to be seen.

The *ultimate fibrils* of animal life, according to Bowman, are beaded filaments, presenting a regular succession of segments and constrictions, the latter being narrower than the former, and the component substance probably less dense.

An ultimate fibre consists of a bundle of these fibrils, which are so disposed that all the segments and all the constrictions correspond, and in this manner

Fig. 151.



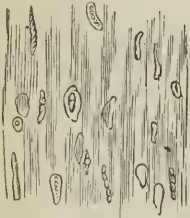ULTIMATE FIBRE, in which the transverse splitting into disks, in the direction of the constrictions of the ultimate fibrils, is seen. After Bowman.

give rise to the alternate light and dark lines of the transverse striæ. The fibrils are connected together with very different degrees of closeness in different animals; in man they are but slightly adherent, and distinct longitudinal lines of junction may be observed between them; they also separate easily when macerated for some time. Besides the more usual separation of the ultimate fibre into fibrils, it breaks when stretched, into transverse segments, corresponding with the dark lines of the striæ, and consequently with the constrictions of the fibrillæ. Where this division occurs with the greatest facility, the longitudinal lines are indistinct, or scarcely perceptible. "In fact," says Bowman, "the primitive fasciculus seems to consist of primitive component segments or particles, arranged so as to form, in one sense, fibrillæ, and in another sense, disks: and which of these two

may happen to present itself to the observer, will depend on the amount of adhesion, endways or sideways, existing between the segments. Generally, in a recent fasciculus, there are transverse striæ, showing divisions into disks, and longitudinal striæ, marking its composition by fibrillæ."

Bowman has observed that in the substance of the ultimate fibre there exist minute "oval or circular disks, frequently concave on one or both surfaces, and

Fig. 152.



MASS OF ULTIMATE FIBRES from the pectoralis major of the human fœtus, at nine months. These fibres have been immersed in a solution of tartaric acid, and their "numerous corpuscles, turned in various directions, some presenting nucleoli," are shown. After Bowman.

containing, somewhere near the centre, one, two, or three minute dots or granules." Occasionally they present irregularities of form, which he regards as accidental. They are situated between and connected with the fibrils, and distributed in pretty equal numbers through the fibre. These corpuscles are the nuclei of the nucleated cells out of which the muscular fibre was originally developed. Observing, however, that their "absolute number is far greater in the adult than in the fœtus, while their number, relatively to the bulk of the fasciculi, at these two epochs, remains nearly the same," Mr. Bowman believes that, "during development, and subsequently, a further and successive deposit of corpuscles" takes place. The corpuscles are brought into view only when the muscular fibre is acted upon by a solution of "one of the milder acids, as the citric."


According to my investigations,¹ the ultimate fibril of animal life is cylindrical when isolated, and probably polyhedral from pressure when forming part of an ultimate fibre or fasciculus. It measures in diameter $\frac{1}{200000}$ of an inch, and is composed of a succession of cells connected by their flat surfaces. The cells are filled with a transparent substance, which may be termed *myoline*. The myoline differs in density in different cells, and from this circumstance bestows a peculiarity of character on certain of the cells. For example, when a fibril in its passive state is examined, there will be seen a series

¹ These were made on dissections of fresh human muscle, prepared for me by Mr. Lealand, partner of the eminent optician, Mr. Powell.

of dark oblong bodies separated by light spaces of equal length; now, the dark bodies are each composed of a pair of cells containing the densest form of myo-

STRUCTURE OF THE ULTIMATE MUSCULAR FIBRIL AND FIBRE OF ANIMAL LIFE. — A. Ultimate muscular fibril in the state of partial contraction. B. The same in the state of ordinary relaxation. This fibril measured $\frac{1}{700000}$ of an inch in diameter. C. A similar fibril put upon the stretch, and measuring $\frac{1}{300000}$ of an inch in diameter. D. Plan of a portion of an ultimate fibre, showing the manner in which the transverse striæ are produced, by the collocation of the fibrils.

FIG. 153.



Nos. 1, 1. The pair of highly refractive cells; they form the dark parts of the single fibrils, but the bright parts of the fibre D. In the stretched fibril C, each cell has the appearance of being double. 2, 2. The pair of less refractive cells, light in the single fibrils, but forming the shaded striæ in D. The transverse septum between these cells is very conspicuous; and in C two other septa are seen to exist, making the number of transparent cells four. In D, the tier of cells immediately above the dark tier is partially illumined from the obliquity of the light. (By an error on the part of the engraver the boundary lines of the fibril are omitted in A B and C.)

line, and are hence highly refractive, while the transparent spaces are constituted by a pair of cells containing a more fluid myoline. When the fibrils are collected together so as to form an ultimate fibre or fasciculus, the appearance of the cell is altered; those which look dark in the single fibril, that is, the most refractive, being ranged side by side, constitute the bright band; while the transparent cells of the single fibril are the shaded striæ of the fibre.

When the ultimate fibril is very much stretched, the two highly refractive cells appear each to be double; while the transparent space is evidently composed of four cells.

The *ultimate fibre of organic life*, or smooth muscular fibre, is a single homogeneous filament much smaller than the fibre of animal life, flat, smooth, and without transverse markings. It is of a fusiform shape, and various length, and consists of a thin external membrane, blended with a soft, homogeneous or finely granular contained substance. These fibres were originally round nucleated cells, which have become elongated into a fusiform shape, and subsequently grown into the dimensions of fibres. When of small size they have a single nucleus; but in the longer fibre a succession of nuclei with corresponding swollen parts may be observed from point to point, and the nucleus is sometimes so much elongated as to deserve the title of columnar. The fusiform cells are united into little bundles or fasciculi by an adhesive interstitial substance, and the fasciculi, which are sometimes round and sometimes flat, are bound together into larger bundles by areolar tissue and fine elastic fibres; the interspaces of the bundles being occupied by vessels and nerves, the former in great abundance.

Organic or smooth muscle is distributed abundantly in the animal frame, and is met with in all situations where a distinct contractile power, independent of mere elasticity, is required; for example, in the alimentary canal, from the middle of the œsophagus to the internal sphincter ani; in the posterior segment of the trachea, and in the bronchial tubes to their finest ramifications; in the excretory ducts of various glands, as Wharton's duct, the ductus communis choledochus, the calices and pelvis of the kidneys; the ureters, bladder, and urethra; on the testes, around the vasa deferentia and vesiculæ seminales, the prostate, Cowper's glands, and in the substance of the corpora cavernosa; in the Fallopian tubes, uterus and vagina; in the middle coat of arteries, veins, and lymphatic vessels; in the iris; and in the corium of the skin, particularly in the areolæ and nipples

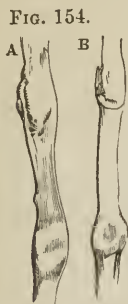of the mammary glands, in the dartos of the scrotum, and around the hair follicles, and many of the sudoriferous and sebiferous ducts.

The *development of muscular fibre* is effected by means of the formation of nucleated cells out of an original blastema, and the conversion of those cells into the tubuli of ultimate fibres, while their contents, by a subsequent developmental action, are transformed into ultimate fibrils. In the muscular fibre of organic life the process seems to stop short of the formation of fibrillæ; the cell-contents retaining their original homogeneous or granular character.

Muscles are divided into two great classes, voluntary and involuntary, to which may be added, as an intermediate and connecting link, the muscle of the vascular system, the heart.

ULTIMATE MUSCULAR FIBRE OF ORGANIC LIFE.

A. Muscular fibre of organic life from the urinary bladder, magnified 600 times, linear measure. Two of the nuclei are seen. B. Muscular fibre of organic life, from the stomach, magnified 600 times. The diameter of this and the preceding fibre, midway between the nuclei, was $\frac{1}{4750}$ of an inch.



The *voluntary, or system of animal life*, is developed from the external or serous layer of the germinal membrane, and comprehends the whole of the muscles of the limbs and trunk. The *involuntary, or organic system*, is developed from the internal or mucous layer, and constitutes the thin muscular structure of the intestinal canal, urinary passages, and internal organs of generation. At the commencement of the alimentary canal at the middle of the œsophagus, and near its termination at the anus, the muscular coat is formed by a blending of the fibres of both classes. The heart is developed from the middle, or vascular layer of the germinal membrane; and although involuntary in its action is composed of ultimate fibres, having the transverse striæ of the muscle of animal life. Striated muscle is also found around the venæ cavæ near the heart, in the upper half of the œsophagus, and in the round ligaments of the uterus.

THE MUSCLES may be arranged in conformity with the general division of the body into — 1. Those of the head and neck. 2. Those of the trunk. 3. Those of the upper extremity. 4. Those of the lower extremity.

MUSCLES OF THE HEAD AND NECK.

The muscles of the head and neck admit of subdivision into those of the head and face, and those of the neck.

MUSCLES OF THE HEAD AND FACE.

These muscles may be divided into groups corresponding with the natural regions of the head and face; the groups are eight in number, namely,

- | | |
|-------------------|---------------------------|
| 1. Cranial group. | 5. Superior labial group. |
| 2. Orbital group. | 6. Inferior labial group. |
| 3. Ocular group. | 7. Maxillary group. |
| 4. Nasal group. | 8. Auricular group. |

The muscles of each of these groups may be thus arranged :

- | | |
|--|--|
| 1. <i>Cranial group.</i>
Occipito-frontalis. | 3. <i>Ocular group.</i>
Levator palpebræ,
Rectus superior,
Rectus inferior,
Rectus internus,
Rectus externus,
Obliquus superior,
Obliquus inferior. |
| 2. <i>Orbital group.</i>
Orbicularis palpebrarum,
Corrugator supercillii,
Tensor tarsi. | |

4. *Nasal group.*

Pyramidalis nasi,
Compressor naris,
Dilatator naris,
Depressor alæ nasi,
[Levator labii superioris alæque nasi.]

5. *Superior labial group.*

(Orbicularis oris),
(Levator labii superioris alæque nasi),¹
Levator labii superioris proprius,
Levator anguli oris,
Zygomaticus major,
Zygomaticus minor.

6. *Inferior labial group.*

(Orbicularis oris),²
Depressor labii inferioris,
Depressor anguli oris,
Risorius Santorini,
Levator labii inferioris.

7. *Maxillary group.*

Masseter,
Temporalis,
Buccinator,
Pterygoideus externus,
Pterygoideus internus.

8. *Auricular group.*

Attollens aurem,
Attrahens aurem,
Retrahens aurem.

1. *Cranial Group.*

Occipito-frontalis.

Dissection. — The *occipito-frontalis* is to be dissected by making a longitudinal incision along the vertex of the head, from the tubercle on the occipital bone to the root of the nose; and a second incision along the forehead and around the side of the head, to join the two extremities of the preceding. Dissect the integument and superficial fascia carefully outwards, beginning at the anterior angle of the flap, where the muscular fibres are thickest, and remove it altogether. This dissection requires care; for the muscle is very thin and without attention would be raised with the integument. There is no deep fascia on the face or head, nor is it required; for here the muscles are closely applied against the bones, upon which they depend for support, whilst in the extremities the support is derived from the dense layer of fascia by which they are invested, and which forms for each muscle a distinct sheath.

The OCCIPITO-FRONTALIS (epicranium) is a broad musculo aponeurotic layer, which covers the whole side of the vertex of the skull, from the occiput to the eyebrow. It *arises* by tendinous fibres from the outer two-thirds of the superior curved line of the occipital, and from the mastoid portion of the temporal bone. Its *insertion* takes place by means of the blending of the fibres of its anterior portion with those of the orbicularis palpebrarum, corrugator supercillii, levator labii superioris alæque nasi, and pyramidalis nasi. The muscle is fleshy in front over the frontal bone (frontalis) and behind over the occipital (occipitalis), the two portions being connected by a broad aponeurosis. The two muscles, together with their aponeurosis, cover the whole vertex of the skull, hence their designation *galea capitis*; they are loosely adherent to the pericranium, but closely to the integument, particularly on the forehead. At the side of the head the aponeurosis (*galea aponeurotica*)³ is attached to the root of the mastoid process and processus auditorius, and, becoming thin over the temporal fascia, is connected with the zygoma, malar bone, and external boundary of the orbit.

Relations. — This muscle is in relation by its *external surface* with the frontal and supraorbital vessels, supraorbital and facial nerve, temporal vessels and auriculo-temporal nerve, occipital vessels and nerves, and integument, to which it is

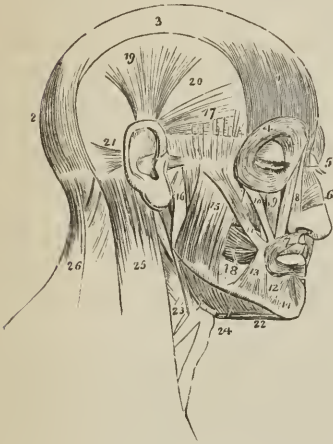
¹ [As this muscle belongs to two groups I have, following Mr. Wilson's plan, placed it in parentheses.]

² The orbicularis oris, from encircling the mouth, belongs necessarily to both the superior and inferior labial regions; it is therefore inclosed within parentheses.

³ [This lateral portion, which is an extension from the edge of the proper tendon, is sometimes called the superficial temporal fascia.]

closely adherent. Its *under surface* is attached to the pericranium by a loose cellular tissue which admits of considerable movement.

Fig. 155.



MUSCLES OF THE HEAD AND FACE. 1. Frontal portion of the occipito-frontalis. 2. Its occipital portion. 3. Its aponeurosis. 4. Orbicularis palpebrarum, which conceals the corrugator supercillii and tensor tarsi. 5. Pyramidalis nasi. 6. Compressor naris. 7. Orbicularis oris. 8. Levator labii superioris alæque nasi; the adjoining fasciculus between ciphers 8 and 9 is the labial portion of the muscle. 9. Levator labii superioris proprius; the lower part of the levator anguli oris is seen between the muscles 10 and 11. 10. Zygomaticus minor. 11. Zygomaticus major. 12. Depressor labii inferioris. 13. Depressor anguli oris. 14. Levator labii inferioris. 15. Superficial portion of the masseter. 16. Part of its deep portion. 17. Attrahens aurem. 18. Buccinator. 19. Attollens aurem. 20. Temporal fascia covering the temporal muscle. 21. Retrahens aurem. 22. Anterior belly of the digastricus; the tendon is seen passing through its aponeurotic pulley. 23. Stylo-hyoid muscle pierced by the posterior belly of the digastricus. 24. Mylo-hyoideus. 25. Upper part of the sterno-mastoid. 26. Upper part of the trapezius. The muscle between 25 and 26 is the splenius.

Action.—To raise the eyebrows, thereby throwing the integument of the forehead into transverse wrinkles. Some persons have the power of moving the entire scalp on the pericranium by means of these muscles.

2. Orbital Group.

Orbicularis palpebrarum, Corrugator supercillii, Tensor tarsi.

Dissection.—The dissection of the face is to be effected by continuing the longitudinal incision of the vertex of the previous dissection onwards to the tip of the nose, and thence downwards to the margin of the upper lip; then carry an incision along the margin of the lip to the angle of the mouth, and transversely across the face to the angle of the lower jaw. Lastly, divide the integument in front of the external ear upwards to the transverse incision which was made for exposing the occipito-frontalis. Dissect the integument and superficial fascia carefully from the whole of the region included by these incisions, and the present and two following groups of muscles will be brought into view.

The ORBICULARIS PALPEBRARUM is a sphincter muscle, surrounding the orbit and eyelids, and consists of two portions, external and internal. The *external or orbital portion*, arises from a short tendon, tendo palpebrarum (tendo oculi), situated at the inner angle of the eye, from the nasal process of the superior maxillary and angular process of the frontal bone; it encircles the orbit and is inserted into the inner border of the orbit and lower border of the tendo palpebrarum, some of its fibres being continuous with the upper segment. The *internal portion* (palpebralis) forms a curved plane of fibres on the eyelids, thinner and paler than the orbital portion; externally these fibres are attached to the external palpebral ligament and border of the orbit, some being continuous with the orbital portion; internally they are attached to the borders of the lacus lachrymalis and tendo palpebrarum. The borders of the palpebralis nearest the edges of the lids

are thicker than the rest, and termed *ciliaris*. Mr. Haynes Walton¹ remarks that the *ciliaris* is redder than the rest of the palpebralis, and continuous with the tensor tarsi; he conceives it to be the active cause in the production of entropium.

The *tendo palpebrarum* (*tendo oculi*), about two lines in length and one in breadth, is attached by one end to the nasal process of the superior maxillary bone, close to the edge of the orbit; the other end bifurcates to be inserted into the inner extremities of the tarsal cartilages; from its inner side is given off a process which spreads over the lachrymal sac, and is attached to the crest of the lachrymal bone; this is the reflected aponeurosis of the *tendo palpebrarum*, and serves to protect the lachrymal sac.

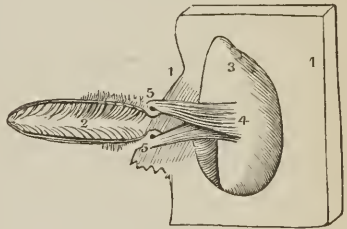
Relations.—By its *superficial surface* it is closely adherent to the integument, from which it is separated on the eyelids by a loose cellular tissue. By its *deep surface* it lies in contact, *above*, with the upper border of the orbit, corrugator supercillii muscle, frontal and supraorbital vessels, and supraorbital nerve; *below*, with the lachrymal sac, levator labii superioris alæque nasi, levator labii superioris proprius, zygomaticus major and minor muscles, and malar bone; *externally*, with the temporal fascia. On the eyelids it is in relation with the broad tarsal ligament and tarsal cartilages, and by its upper border is connected with the occipito-frontalis.

The CORRUGATOR SUPERCILII is a small, narrow, and pointed muscle, situated immediately above the orbit and beneath the upper segment of the orbicularis palpebrarum. It *arises* from the inner extremity of the superciliary ridge, and is *inserted* into the under surface of the orbicularis palpebrarum. Its connexion with the orbicularis commences near the supraorbital foramen and is continued outwards to the external angular process.

Relations.—By its *superficial surface*, with the pyramidalis nasi, occipito-frontalis and orbicularis palpebrarum; by its *deep surface*, with the supraorbital vessels and nerve.

The TENSOR TARSII (Horner's² muscle) is a thin plane of muscular fibres, about three lines in breadth, and six in length. It is best dissected by separating the eyelids from the eye, and turning them over the nose without disturbing the *tendo palpebrarum oculi*; then dissect away the small fold of mucous membrane called *plica semilunaris*, and some loose cellular tissue under which the muscle is concealed. It *arises* from the orbital surface of the lachrymal bone, and passing across the lachrymal sac, divides into two slips, which are continuous with the margin of the *ciliaris* along the edges of the lids;³ some few of its fibres being attached to the lachrymal canals, and then spread out on the aponeurosis of the lachrymal sac to be inserted into the crest and orbital surface of the lachrymal bone.

[FIG. 156.]



A DIAGRAM OF THE TENSOR TARSII MUSCLE. 1, 1. Bony margins of the orbit. 2. Palpebral fissure. 3. Orbital surface of the lachrymal bone. 4. Origin of the tensor tarsi. 5, 5. Insertion into the neighborhood of the puncta lachrymalia.]

Actions.—The palpebral portion of the orbicularis acts involuntarily in closing

¹ Medical Times and Gazette, May, 1852.

² W. E. Horner, M.D., Professor of Anatomy in the University of Pennsylvania. The notice of this muscle is contained in a work published in Philadelphia in 1827, entitled "Lessons in Practical Anatomy."

³ Haynes Walton, loc. cit.

the lids, and from the greater curve of the upper lid, upon that principally. The entire muscle constitutes a sphincter, drawing at the same time, by means of its osseous attachment, the integument and lids inwards towards the nose. The *corrugatores superciliarum* draw the eyebrows downwards and inwards, and produce the vertical wrinkles of the forehead. The *tensor tarsi*, or lachrymal muscle, is an auxiliary to the orbicularis, and draws the extremities of the lachrymal canals inwards, so as to place the puncta in the best position for receiving the tears. It serves also to keep the lids in relation with the surface of the eye. Dr. Horner is acquainted with two persons who have the voluntary power of drawing the lids inwards by these muscles so as to bury the puncta in the angle of the eye.

3. Ocular Group.

Levator palpebræ,	Rectus internus,
Rectus superior,	Rectus externus,
Rectus inferior,	Obliquus superior,
	Obliquus inferior.

Dissection. — To open the orbit (the calvaria and brain having been removed) the frontal bone must be sawn through at the inner extremity of the orbital ridge; and, externally, at its outer extremity. The roof of the orbit may then be comminuted with the hammer; a process easily accomplished, on account of the thinness of the orbital plate of the frontal bone and lesser wing of the sphenoid. The superciliary portion of the orbit may next be driven forwards by a smart blow, and the external angular process and external wall of the orbit outwards in the same manner; the broken fragments of the roof of the orbit should then be removed. By this means the periosteum will be exposed unbroken and undisturbed. Remove the periosteum from the whole of the upper surface of the exposed orbit, and examine the parts beneath.

The **LEVATOR PALPEBRÆ** is a long, thin, and triangular muscle, situated in the upper part of the orbit on the middle line; it *arises* from the upper margin of the optic foramen, and from the fibrous sheath of the optic nerve; and is *inserted* into the upper border of the superior tarsal cartilage.

Relations. — By its *upper surface* with the fourth nerve, supraorbital nerve and artery, periosteum of the orbit, and, in front, inner face of the broad tarsal ligament. By its *under surface* it rests on the superior rectus, globe of the eye, and conjunctiva; it receives its nerve and artery by this aspect.

The **RECTUS SUPERIOR** (*attollens*) *arises* from the upper margin of the optic foramen, and from the fibrous sheath of the optic nerve; and is *inserted* into the upper surface of the globe of the eye at a point somewhat more than three lines from the margin of the cornea.

Relations. — By its *upper surface* with the levator palpebræ muscle; by the *under surface* with the optic nerve, ophthalmic artery and nasal nerve, from which it is separated by the adipose tissue of the orbit, and, in front, with the globe of the eye, the tendon of the superior oblique muscle being interposed.

The **RECTUS INFERIOR** (*depressor*) *arises* from the inferior margin of the optic foramen by a tendon (ligament of Zinn) which is common to it, the internal and external rectus, and from the fibrous sheath of the optic nerve; it is *inserted* into the inferior surface of the globe of the eye, a little more than two lines from the margin of the cornea.

Relations. — By its *upper surface* with the optic nerve, inferior oblique branch of the third nerve, adipose tissue of the orbit, and under surface of the globe of the eye. By its *under surface* with the periosteum of the floor of the orbit, and inferior oblique muscle.

The **RECTUS INTERNUS** (*adductor*), the thickest and shortest of the straight muscles, *arises* from the common tendon, and from the fibrous sheath of the optic

nerve; and is *inserted* into the inner surface of the globe of the eye at two lines from the margin of the cornea.

Relations. — By its *internal surface* with the optic nerve, adipose tissue of the orbit, and eyeball. By its *outer surface* with the periosteum of the orbit; by its *upper border* with the anterior and posterior ethmoidal vessels, nasal and infra-trochlear nerve.

The RECTUS EXTERNUS (abductor), the longest of the straight muscles, *arises* by two heads, one from the common tendon, the other with the origin of the superior rectus from the margin of the optic foramen; the nasal, third, and sixth nerve, passing between them. It is *inserted* into the outer surface of the globe of the eye, a little more than two lines from the margin of the cornea.

Relations. — By its *internal surface* with the third, nasal, sixth, and optic nerve, ciliary ganglion and nerves, ophthalmic artery and vein, adipose tissue of the orbit, inferior oblique muscle, and eyeball. By its *external surface* with the periosteum of the orbit and lachrymal gland; by the *upper border* with the lachrymal vessels and nerve.

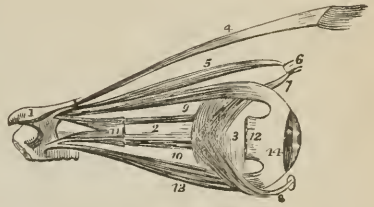
The recti muscles present several characters in common; thus, they are thin, have each the form of an isosceles triangle, bear the same relation to the globe of the eye, and are inserted in a similar manner into the sclerotica, at about two lines from the circumference of the cornea. The points of difference relate to thickness and length; the internal rectus is the thickest and shortest, the external the longest, and the superior the most thin. The insertion of the four recti into the globe of the eye forms a tendinous expansion, which is continued as far as the margin of the cornea, and is termed tunica albuginea.

The OBLIQUUS SUPERIOR (trochlearis) is a fusiform muscle *arising* from the margin of the optic foramen, and from the fibrous sheath of the optic nerve; it passes forwards to the pulley at the internal angular process of the frontal bone; its tendon is then reflected outwards beneath the superior rectus to the outer part of the globe of the eye, where it is *inserted* into the sclerotic coat, at about midway between the margin of the cornea and the optic nerve. The *trochlea* or *pulley* of the superior oblique muscle is a fibro-cartilaginous ring attached to the depression beneath the internal angular process of the frontal bone. The ring is flat, about a line in width, and provided with a synovial membrane, which is continued together with a fibrous sheath, for a short distance, upon the tendon. Sometimes the ring is supported, or in part formed, by a process of bone.

Relations. — By its *superior surface* with the fourth nerve, supra-trochlear nerve, and periosteum of the orbit. By the *inferior surface* with the adipose tissue of the orbit, upper border of the internal rectus and the vessels and nerves crossing that border.

The OBLIQUUS INFERIOR, a thin and narrow muscle, *arises* from the inner margin of the [orbital surface of the] superior maxillary bone, immediately external to the lachrymal groove, and passes beneath the inferior rectus, to be

FIG. 157.



MUSCLES OF THE EYEBALL; the view is taken from the outer side of the right orbit. 1. Fragment of that portion of the sphenoid bone through which the optic nerve passes to enter the orbit. 2. Optic nerve. 3. Globe of the eye. 4. Levator palpebræ muscle. 5. Superior oblique. 6. Its cartilaginous pulley. 7. Its reflected tendon. 8. Inferior oblique muscle; the small square knob at its commencement is a piece of its bony origin broken off. 9. Superior rectus. 10. Internal rectus partly concealed by the optic nerve. 11. Part of external rectus, showing its two heads of origin, 12. Extremity of external rectus at its insertion; the intermediate portion of the muscle having been removed. 13. Inferior rectus. 14. Tunica albuginea, formed by the expansion of the tendons of the four recti.

inserted into the outer and posterior part of the eyeball, at about two lines from the entrance of the optic nerve.

Relations. — By its *superior surface* with the inferior rectus muscle and eyeball; by the *inferior surface* with the periosteum of the floor of the orbit, and external rectus.

According to Mr. Ferrall¹ the muscles of the orbit are separated from the globe of the eyeball and structures immediately surrounding the optic nerve, by a fascia, which is continuous with the broad tarsal ligament and tarsal cartilages. This fascia the author terms *tunica vaginalis oculi*²; it is pierced anteriorly, for the passage of the six orbital muscles, by six openings, through which the tendons of the muscles play as through pulleys. The use assigned to it by Mr. Ferrall is to protect the eyeball from the pressure of its muscles during their action; by its means, also, the recti muscles are enabled to give a rotatory movement to the eyeball; and in brutes antagonize the retractor muscle.

Actions. — The levator palpebræ raises the upper eyelid. The four recti, acting singly, pull the eyeball in the four directions; upwards, downwards, inwards, and outwards. Acting by pairs, they carry the eyeball in the diagonal of these directions, viz., upwards and inwards, upwards and outwards, downwards and inwards, downwards and outwards. Acting all together, they directly retract the globe within the orbit. The superior oblique muscle, acting alone, rolls the globe inwards and forwards, and carries the pupil outwards and downwards to the lower and outer angle of the orbit. The inferior oblique acting alone, rolls the globe outwards and backwards, and carries the pupil outwards and upwards to the upper and outer angle of the eye. Both muscles acting together, draw the eyeball forwards, and give the pupil that slight degree of eversion which enables it to admit the largest field of vision.

[Tenon, as far back as 1806, described each rectus muscle as dividing near its anterior extremity into *two* tendons, one, the *ocular*, piercing the deep ocular fascia, (which he also described,) and being inserted into the sclerotica; the other, the *orbital*, quite slender, placed behind the fascia, and inserted into the orbit near its margin. By this means all compressive action upon the ball is prevented during the contraction of one or more of these muscles, the fixity of the orbital tendon elevating the more movable portion of the muscle during its action. Richet, more recently (1843), figured these muscles with their double insertions, as well as the deep ocular fascia. This fascia, in 1841, was described by Ferrall as the *tunica vaginalis oculi*. The existence of these tendons, it has been asserted, not only deprives the recti muscles of any compressive power, but also deters them from retracting the globe to any extent, so that they cannot be antagonists of the obliqui, which, possessing no orbital tendons, undoubtedly advance it. Hence, we must find some other agent to depress the globe in its socket than those generally indicated: this is the orbicularis palpebrarum. The inner and outer attachments of this muscle are on a plane posterior to its central palpebral portion, which, during contraction, is pressed against the globe; and its power is sustained by its close connexion with the subconjunctival layer of the tunica vaginalis oculi, especially at the inner angle of the eye. According to this statement, Dr. Hewson urges, that the protrusion of the globe, which follows the ordinary operation for convergent strabismus, is produced, not by disturbing the balance of power between the recti and obliqui, as ordinarily believed, but by weakening the connexion between the orbicularis and its retaining fascia at the inner portion, and thus diminishing its power.

The accompanying figure, (to which, by the author's permission, I have added the ciphers and description,) from a paper by Dr. Hewson, exhibits, in a transverse section, the orbital and ocular tendons of the internal and external rectus

¹ In a paper read before the Royal Society, on the 10th of June, 1841.

² First described by Dalrymple, "Anatomy of the Human Eye," 1834.

muscles and the folds of the ocular fascia, as exposed in dissections made by him, and which I have examined. The ocular fascia will be observed commencing upon the optic nerve, and can be traced forwards upon the globe as far as nearly to the insertion of the ocular tendon of the rectus, where this tendon perforates it; immediately anterior to this perforation the fascia splits into two portions, one passes in front of the orbital tendon to the edge of the orbit, where it becomes continuous with the broad tarsal ligament, the other covers the external surface (taking the globe as a centre) of the ocular tendon and passes as far forwards as $\frac{1}{2}$ of an inch from the cornea, where it is reflected beneath the ocular conjunctiva (and is called the subconjunctival layer), to unite with the portion last described, at the edge of the orbit. The subconjunctival portion is firmly connected by dense areolar tissue, not only with that covering the orbital tendon (so that towards the edge of the orbit they seem to form but one layer), but at the inner canthus with the reflected aponeurosis of the tendo palpebrarum so as to retain that tendon, firmly, in its place, and thus steady the depressing action of the orbicularis; but if this fascia is divided, the tendo oculi is allowed to advance during the action of the muscle, instead of holding the inner attachment of the muscle firmly in its proper place; and thus the depressing power of the orbicularis is diminished, and the obliqui are permitted to protrude the ball.

The correctness of these statements seems to be well supported by the results of Dr. Hewson's operative procedures, wherein subconjunctival tenotomy is performed without disturbing the ocular fascia.¹

4. *Nasal Group.*

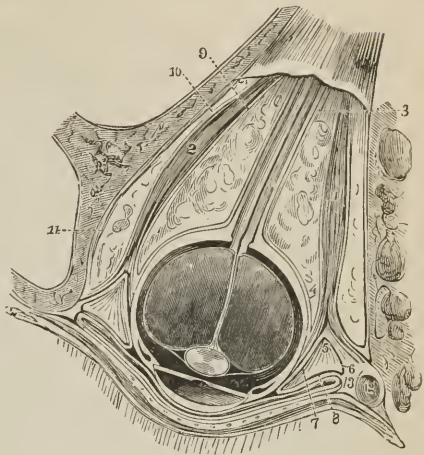
Pyramidalis nasi,
Compressor naris,

Dilatator naris,
Depressor alæ nasi,
[Levator labii superioris alæque nasi.]

The PYRAMIDALIS NASI (procerus) is a small pyramidal slip of muscular

¹ [For an excellent résumé of the entire subject, see an article in the N. Am. Med.-Chir. Review, March, 1858, "On the Prominence of the Eyeball, etc., following the ordinary operation for Strabismus. With an account of a pair of Scissors for performing the Subconjunctival Operation. By Addinell Hewson M. D. Philada."]

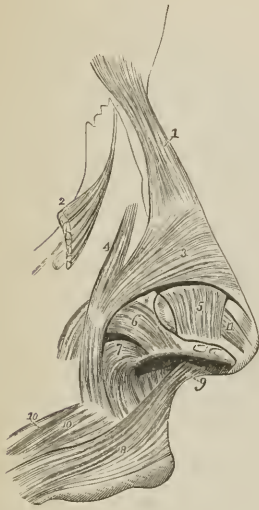
[FIG. 158.



TRANSVERSE SECTION OF THE RIGHT EYE, VIEWED FROM ABOVE, WITH ALL THE REFLEXIONS OF THE OCULAR FASCIA, AND ITS RELATIONS TO THE EYEBALL, MUSCLES, AND EYELIDS. 1. Internal rectus. 2. External rectus, each dividing anteriorly into its two tendons, orbital and ocular. 3, 4, 5, 6, 7, 8. Ocular fascia on the nasal side. 3, 4. Deep-seated portion forming a socket for the globe. 5. At this point, after being perforated by the ocular tendon, it divides into two layers, 6 and 7. 6 passes to the edge of the orbit in front of the orbital tendon to become connected with the broad tarsal ligament. 7 continues forwards upon the ocular tendon to about $\frac{1}{2}$ of an inch behind the cornea, where it is reflected (8) behind the ocular conjunctiva to the edge of the orbit where it is continuous with the layer 6. 9, 10. Muscular sheath of the rectus, adherent in front to the opening in the ocular fascia for the transit of the ocular tendon. 11. Periosteum of the orbit. The ocular and palpebral layers of the conjunctiva are seen in front between the lid and the globe. 12. Section of lachrymal sac. 13. Dense fibro-areolar tissue formed by the blending of the subconjunctival and deep ocular layer with the reflected aponeurosis of the tendo palpebrarum.]

fibres sent downwards on the bridge of the nose by the occipito-frontalis. It is inserted into the tendinous expansion of the compressor naris.

FIG. 159.



MUSCLES OF THE NOSE; after Arnold. 1. Pyramidalis nasi. 2. Upper part of the levator labii superioris alæque nasi, turned aside. 3. Compressor naris. 4. Musculus anomalus. 5. Levator proprius alæ nasi anterior. 6. Levator proprius alæ nasi posterior. 7. Part of the depressor alæ nasi. 8. Upper segment of the orbicularis oris. 9. Naso-labialis. 10, 10. Fasciculi accessorii of the orbicularis. 11. A small muscle, termed by Arnold compressor narium minor; it extends between the end of the nose and the alar cartilage. Its existence is doubtful.

terior half. These muscles are difficult of dissection, from the close adhesion of the integument with the nasal cartilages.

The DEPRESSOR ALÆ NASI (myrtiformis), [called, also, by some anatomists, from its connexion with the orbicularis oris, *depressor labii superioris alæque nasi*], is brought into view by drawing upwards the upper lip and raising the mucous membrane. It arises from the superior maxillary bone in front of the roots of the second incisor and canine tooth (myrtiform fossa), and passes upwards and inwards to be inserted into the posterior part of the columna and ala nasi. It is closely connected with the deep surface of the orbicularis.

Relations. — By its superficial surface with the mucous membrane of the mouth, orbicularis oris and levator labii superioris alæque nasi; by its deep surface with the superior maxillary bone.

[The *Levator labii superioris alæque nasi* is described, and its action detailed with the next group.]

Actions. — The pyramidalis nasi, as a point of attachment of the occipito-fron-

Relations. — By its upper surface with the integument; by its under surface with the periosteum of the frontal and nasal bone. Its outer border corresponds with the edge of the orbicularis palpebrarum; its inner border with its fellow, from which it is separated by a narrow cellular space.

The COMPRESSOR NARIS (*transversus nasi*) is a thin and triangular muscle; it arises by its apex from the canine fossa of the superior maxillary bone, and spreads out upon the side of the nose into a thin tendinous expansion, which is continuous across the ridge with the muscle of the opposite side. It is connected at its origin with a muscular fasciculus which is attached to the nasal process of the superior maxillary bone immediately below the origin of the levator labii superioris alæque nasi. This muscular slip was termed by Albinus, *musculus anomalus*, from its attachment to bone by both ends; and by Santorinus, *musculus rhomboideus*.

Relations. — By its superficial surface with the levator labii superioris proprius, levator labii superioris alæque nasi, and integument; by its deep surface with the superior maxillary and nasal bone, and with the alar and lateral cartilage of the nose.

The DILATATOR NARIS is a thin and indistinct muscular apparatus expanded on the ala of the nostril, and consisting of an anterior and posterior slip. The anterior slip (levator proprius alæ nasi anterior) arises from the upper border and surface of the alar cartilage, and is inserted into the integument of the border of the nostril. The posterior slip (levator proprius alæ nasi posterior) arises from the nasal process of the superior maxillary bone, and sesamoid cartilages, and is inserted into the integument of the border of the nostril, its posterior half.

talis, assists that muscle in its action; it also draws down the inner angle of the eyebrow, and by its insertion fixes the aponeurosis of the compressores narium, and tends to elevate the nose. The compressores narium appear to act in expanding rather than compressing the nares; hence probably the collapsed state of the nares from paralysis of these muscles in the last moments of life, or in compression of the brain. The dilatator naris is a dilator of the nostril, and the depressor alæ nasi draws downwards both the ala and column of the nose, the depression of the latter being assisted by the naso-labialis.

5. Superior Labial Group.

Orbicularis oris,	Levator anguli oris,
Levator labii superioris alæque nasi,	Zygomaticus major,
Levator labii superioris proprius,	Zygomaticus minor.

The ORBICULARIS ORIS is a sphincter muscle, completely surrounding the mouth, and possessing consequently neither origin nor insertion. It is composed of two thick semicircular planes of fibres, which embrace the rima of the mouth, and interlace at their extremities, where they are continuous with the fibres of the buccinator, and the other muscles connected with the angle of the mouth. The upper segment is attached by means of a small muscular fasciculus (naso-labialis) to the column of the nose; and other fasciculi connected with both segments, and attached to the maxillary bones, are termed "accessorii." Several anatomists consider the orbicularis as composed of two portions, *internal* or *marginal*, in immediate contact with the lips, and thick; and *external*, broad and thin; the separation between the two being indicated by the coronary arteries.

Relations.—By its *superficial surface* with the integument of the lips, with which it is closely connected. By its *deep surface* with the mucous membrane of the mouth, the labial glands and coronary arteries being interposed. By its *circumference* with the numerous muscles which move the lips, and by the *inner border* with the mucous membrane of the rima of the mouth.

The LEVATOR LABII SUPERIORIS ALÆQUE NASI (pyramidalis) is a thin triangular muscle; it *arises* from the upper part of the nasal process of the superior maxillary bone; and, becoming broader as it descends, is *inserted* by two portions, one into the ala of the nose, the other into the orbicularis oris and upper lip.

Relations.—By its *superficial surface* with the orbicularis palpebrarum, facial artery, and integument. By its *deep surface* with the superior maxillary bone, musculus anomalus, compressor naris, dilatator naris, and alar cartilage.

The LEVATOR LABII SUPERIORIS PROPRIUS (incisorius) is a thin quadrilateral muscle; it *arises* from the lower border of the orbit, and passing obliquely downwards and inwards, is *inserted* into the integument of the upper lip, its deep fibres being blended with those of the orbicularis.

Relations.—By its *superficial surface* with the lower segment of the orbicularis palpebrarum, facial artery, and integument. By its *deep surface* with the compressor naris, levator anguli oris, orbicularis oris, and infraorbital artery and nerve.

The LEVATOR ANGULI ORIS (caninus) *arises* from the canine fossa of the superior maxillary bone, and passes obliquely outwards to be *inserted* into the angle of the mouth; its fibres being continued into the inferior segment of the orbicularis, and depressor anguli oris.

Relations.—By its *superficial surface* with the levator labii superioris proprius, branches of the infraorbital artery and nerve, and inferiorly with the integument. By its *deep surface* with the superior maxillary bone and buccinator muscle.

The ZYGOMATIC muscles are two slender fasciculi of fibres which *arise* from the malar bone, and are *inserted* into the upper lip. The zygomaticus major descends to the angle of the mouth, and is continuous with the inferior segment

of the orbicularis, depressor anguli oris, and risorius Santorini. The zygomaticus minor, lying in front of the major, becomes connected with the outer border of the levator labii superioris proprius, and is attached to the integument of the upper lip. This muscle is often wanting.

Relations. — The *zygomaticus major* is in relation by its *superficial surface* with the lower segment of the orbicularis palpebrarum above, and with the fat of the cheek and integument for the rest of its extent. By its *deep surface* with the malar bone, masseter and buccinator muscles, and facial vessels. The *zygomaticus minor* being in front of the major, has no relation with the masseter; inferiorly it rests on the levator anguli oris.

Actions. — The orbicularis oris produces the direct closure of the lips by means of its continuity, at the angles of the mouth, with the fibres of the buccinator. When acting singly in the forcible closure of the mouth, the integument is thrown into wrinkles, in consequence of its firm connexion with the surface of the muscle; its naso-labial fasciculus draws downwards the columna nasi. The levator labii superioris alæque nasi lifts the upper lip with the ala of the nose, and expands the opening of the nares. The levator labii superioris proprius is the proper elevator of the upper lip; acting singly, it draws the lip a little to one side. The levator anguli oris lifts the angle of the mouth and draws it inwards, while the zygomatici pull it upwards and outwards, as in laughing, and produce the dimple in the cheek. In the movement of laughter the zygomatici are assisted by the risorius Santorini.

6. Inferior Labial Group.

[Orbicularis oris,
Depressor labii inferioris,
Depressor anguli oris,

Risorius Santorini,
Levator labii inferioris.

Dissection. — To dissect the inferior labial region, continue the vertical section from the middle of the lower lip to the point of the chin. Then carry an incision along the margin of the lower jaw to its angle. Dissect off the integument and superficial fascia from this surface, and the muscles of the inferior labial region will be exposed.

[The *Orbicularis oris*. This muscle has been described with the previous group.]

The DEPRESSOR LABII INFERIORIS (*quadratus menti*) arises from the oblique line by the side of the symphysis of the lower jaw, and passing upwards and inwards, is inserted into the orbicularis muscle and integument of the lower lip. Its inner fibres interlace with those of the opposite muscle, the outer fibres reach nearly to the angle of the mouth.

Relations. — By its *superficial surface* with the platysma myoides, part of the depressor anguli oris, and the integument of the chin with which it is closely connected. By the *deep surface* with the levator labii inferioris, labial glands, mucous membrane of the lower lip, and mental nerve and artery.

The DEPRESSOR ANGULI ORIS (*triangularis*) is a triangular plane of muscle arising by a broad base from the external oblique ridge of the lower jaw, and inserted by its apex into the angle of the mouth, where it is continuous with the levator anguli oris, zygomaticus major, and upper segment of the orbicularis. Near its insertion it is joined by the following muscle.

Relations. — By its *superficial surface* with the integument; by its *deep surface* with the depressor labii inferioris, buccinator, and branches of the mental nerve and artery.

The RISORIUS SANTORINI is a thin and triangular muscle, consisting of a few scattered fasciculi of fibres which arise from the fascia, covering the masseter muscle, and converge to the angle of the mouth, where they become connected with the outer border of the depressor anguli oris, and continuous with the

zygomaticus major. This muscle is generally regarded as a part of the platysma myoides.

The LEVATOR LABII INFERIORIS (levator menti) is a short but strong muscle arising from the incisive fossa of the lower jaw, and inserted into the integument of the chin. It is in relation with the mucous membrane of the mouth, with its fellow, and with the depressor labii inferioris.

Actions.—The depressor labii inferioris draws the lower lip directly downwards, and at the same time a little outwards. The depressor anguli oris, from the radiated direction of its fibres, will pull the angle of the mouth either downwards and forwards, or downwards and backwards, and be expressive of grief; or acting with the levator anguli oris, zygomaticus major, and risorius Santorini, will draw the angle of the mouth upwards and backwards, or directly backwards. The levator labii inferioris raises and protrudes the integument of the chin.

7. Maxillary Group.

Masseter,	Buccinator,
Temporalis,	Pterygoideus externus,
	Pterygoideus internus.

Dissection.—The masseter has been already exposed by the preceding dissection.

The MASSETER (*μασσαραι*, to chew,) is a short, thick, and somewhat quadrilateral muscle, composed of two planes of fibres, superficial and deep. The superficial layer arises by a strong aponeurosis from the malar process of the superior maxillary bone, lower border of the malar bone and zygoma; and passes downwards and backwards to be inserted into the ramus and angle of the inferior maxilla. The deep layer arises also from the zygomatic arch but extends further back upon the zygoma, and passes downwards and forwards, to be inserted into the upper half of the ramus. This muscle is tendinous and muscular in structure; and covered in by a fascia (fascia parotideo-masseterica) which is connected with the zygomatic arch above, and incloses the parotid gland behind.

Relations.—By its external surface with the zygomaticus major, risorius Santorini and platysma myoides, parotid gland and Stenon's duct, transverse facial artery, pes anserinus, and integument. By its internal surface with the temporal muscle, buccinator, from which it is separated by a mass of fat, and ramus of the lower jaw. By its posterior border with the parotid gland; by the anterior border with the facial artery and vein.

Dissection.—Make an incision along the upper border of the zygoma, for the purpose of separating the temporal fascia from its attachment. Then saw through the zygomatic process of the malar bone, and through the root of the zygoma near the meatus auditorius. Draw down the zygoma, and with it the origin of the masseter, and dissect the latter muscle away from the ramus and angle of the inferior maxilla. Now remove the temporal fascia from the rest of its attachment, and the whole of the temporal muscle will be brought into view.

The TEMPORALIS (crotaphytes) [*κρόταφος*, the temple], is a broad and radiating muscle, occupying a considerable extent of the side of the head, and filling the temporal fossa. It is covered in by a dense fascia (temporal fascia), which is attached along the temporal ridge on the side of the skull, extending from the external angular process of the frontal bone to the mastoid portion of the temporal; and inferiorly to the upper border of the zygoma. The muscle arises by tendinous fibres from the whole length of the temporal ridge, and by muscular fibres from the temporal fascia and entire surface of the temporal fossa. Its fibres converge to a strong and narrow tendon, which is inserted into the apex and internal surface of the coronoid process of the lower jaw.

Relations.—By its external surface with the temporal fascia (which separates

it from the attollens and attrahens aurem muscle, and temporal vessels and nerves) and with the zygoma and masseter. By its *internal surface* with the bones forming the temporal fossa, the external pterygoid muscle, part of the buccinator, and the internal maxillary artery with its deep temporal branches.

By sawing through the coronoid process near its base, and pulling it upwards, together with the temporal muscle, which may be dissected from the fossa, we obtain a view of the entire extent of the buccinator and external pterygoid muscle.

The BUCCINATOR (*buccina*, a trumpet; *alveolo-labialis*), the trumpeter's muscle, *arises* from the alveolar process of the superior maxillary bone, the external oblique line of the inferior maxillary as far forwards as the second bicuspid tooth, and the pterygo-maxillary ligament. This ligament is the raphé of union between the buccinator and superior constrictor muscle, and is attached by one extremity to the hamular process of the internal pterygoid plate, and by the other to the extremity of the molar [or mylo-hyoidean] ridge. The fibres of the muscle converge towards the angle of the mouth, where some are continuous with the levator and depressor anguli oris, and the rest cross each other, the superior being continuous with the inferior segment of the orbicularis oris, the inferior with the superior segment. The muscle is invested externally by a thin fascia (buccal) which extends backwards to the pharynx.

Relations. — By its *external surface*, posteriorly, with a large and rounded mass of fat, which separates the muscle from the ramus of the lower jaw, temporalis, and masseter: *anteriorly* with the risorius Santorini, zygomatici, levator anguli oris, and depressor anguli oris. It is also in relation with a part of Stenon's duct, (which pierces it opposite the second molar tooth of the upper jaw,) with the transverse facial artery, branches of the facial and buccal nerve, and facial artery and vein. By its *internal surface* with the buccal glands and mucous membrane of the mouth.

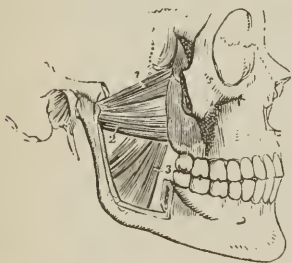The PTERYGOIDEUS EXTERNUS is a short and thick muscle, broader at its origin than at its insertion. It *arises* by two heads, *one* from the under surface of the great ala of the sphenoid, and pterygoid ridge; the *other* from the external pterygoid plate, tuberosity of the palate bone and tuberosity of the superior maxillary. The fibres pass backwards to be *inserted* into the neck of the lower jaw and into the interarticular fibro-cartilage. The internal maxillary artery passes between the two heads of this muscle.

Relations. — By its *external surface* with the ramus of the lower jaw, temporal muscle, and internal maxillary artery; by its *internal surface* with the internal pterygoid muscle, internal lateral ligament of the jaw, arteria meningea media, and inferior maxillary nerve; by its *upper border* with the muscular branches of the inferior maxillary nerve; the internal maxillary artery passes between its two heads, and its lower head is pierced by the buccal nerve.

The external pterygoid muscle must now be removed, the ramus of the lower jaw sawn through its lower third, and the head of the bone dislocated from its socket and withdrawn, for the purpose of seeing the pterygoideus internus.

The PTERYGOIDEUS INTERNUS is a thick quadrangular muscle. It *arises* from the pterygoid fossa and descends obliquely backwards, to be *inserted* into the ramus and angle of the lower jaw: it resem-

FIG. 160.



THE TWO PTERYGOID MUSCLES. The zygomatic arch and the greater part of the ramus of the lower jaw have been removed, in order to bring these muscles into view. 1. The sphenoid origin of the external pterygoid. 2. Its pterygoid origin. 3. The internal pterygoid.

bies the masseter in appearance and direction, and was named by Winslow, *internal masseter*.

Relations. — By its *external surface* with the external pterygoid, inferior maxillary nerve and branches, internal maxillary artery and branches, internal lateral ligament, and ramus of the lower jaw. By its *internal surface* with the tensor palati, superior constrictor and fascia of the pharynx; by its *posterior border* with the parotid gland.

Actions. — The maxillary muscles are the active agents in mastication, and form an apparatus admirably fitted for that office. The buccinator circumscribes the cavity of the mouth, and with the aid of the tongue keeps the food under the immediate pressure of the teeth. By means of its connexion with the superior constrictor, it shortens the cavity of the pharynx from before backwards, and becomes an auxiliary in deglutition. The temporal, the masseter, and the internal pterygoid are the bruising muscles, drawing the lower jaw against the upper with great force. The two latter, from the obliquity of their direction, assist the external pterygoid in grinding the food, by carrying the lower jaw forwards upon the upper; the jaw being brought back again by the deep portion of the masseter and posterior fibres of the temporal. The whole of these muscles, acting in succession, produce a rotatory movement of the teeth upon each other, which, with the direct action of the lower jaw against the upper, effects the mastication of the food.

8. Auricular Group.

Attollens aurem,

Attrahens aurem,

Retrahens aurem.

[These three muscles are the *extrinsic* muscles of the ear. The *intrinsic* muscles are described with the anatomy of the ear.]¹

Dissection. — The three small muscles of the ear may be exposed by removing a square of integument from around the auricula. This operation must be performed with care, otherwise the muscles, which are extremely thin, will be raised with the superficial fascia. They are best dissected by commencing with their tendons, and thence proceeding in the course of their radiating fibres.

The ATTOLLENS AUREM (superior auriculæ), the largest of the three, is a thin triangular plane of muscular fibres, *arising* from the lateral portion of the galea aponeurotica and aponeurosis of the occipito-frontalis, at about the middle of the temporal ridge, and *inserted* into the convexity of the fossa triangularis of the pinna.

It is *in relation* by its external surface with the integument, and by the internal with the galea aponeurotica and temporal fascia.

The ATTRAHENS AUREM (anterior auriculæ), also triangular, *arises* from the lateral portion of the aponeurosis of the occipito-frontalis above the zygoma, and is *inserted* into the spine of the helix.

It is *in relation* by its external surface with the integument; and by the internal with the galea aponeurotica, temporal fascia, and temporal artery and veins.

The RETRAHENS AUREM (posterior auriculæ), *arises* by two, (sometimes three) muscular slips from the root of the mastoid process. They are *inserted* into the posterior surface of the concha.

It is *in relation* by its external surface with the integument, and by its internal surface with the mastoid portion of the temporal bone.

Actions. — The *actions* of the auricular muscles are expressed in their names; they have but little power in man, but are important muscles in brutes.

¹ [The extrinsic muscles move the auricle as a whole; the intrinsic muscles move the different parts of the auricle upon each other.]

MUSCLES OF THE NECK.

The muscles of the neck may be arranged into eight groups, corresponding with the natural divisions of the region; they are, the

1. Superficial group.
2. Depressors of the os hyoides and larynx.
3. Elevators of the os hyoides and larynx.
4. Lingual group.
5. Pharyngeal group.
6. Palatine group.
7. Prævertebral group.
8. Laryngeal group.

The muscles in each group are as follow:—

- | | |
|---|---|
| <p>1. <i>Superficial group.</i>
Platysma myoides,
Sterno-cleido-mastoideus.</p> | <p>5. <i>Muscles of the pharynx.</i>
Constrictor inferior,
Constrictor medius,
Constrictor superior,
Stylo-pharyngeus,
(Palato-pharyngeus.)¹</p> |
| <p>2. <i>Depressors of the os hyoides and larynx.</i>
Sterno-hyoideus,
Sterno-thyroideus,
Thyro-hyoideus,
Omo-hyoideus.</p> | <p>6. <i>Muscles of the soft palate.</i>
Levator palati,
Tensor palati,
Azygos uvulæ,
(Palato-glossus),
(Palato-pharyngeus.)¹</p> |
| <p>3. <i>Elevators of the os hyoides and larynx.</i>
Digastricus,
Stylo-hyoideus,
Mylo-hyoideus,
Genio-hyoideus,
(Genio-hyo-glossus.)¹</p> | <p>7. <i>Prævertebral group.</i>
Rectus anticus major,
Rectus anticus minor,
Scalenus anticus,
Scalenus medius,
Scalenus posticus,
Longus colli.</p> |
| <p>4. <i>Muscles of the tongue.</i>
(Genio-hyo-glossus.)¹
Hyo-glossus,
Linguans,
Stylo-glossus,
(Palato-glossus.)¹</p> | <p>8. <i>Muscles of the larynx.</i>
Crico-thyroideus,
Crico-arytenoideus posticus,
Crico-arytenoideus lateralis,
Thyro-arytenoideus,
Arytenoideus.</p> |

First or Superficial Group.

Platysma myoides,

Sterno-cleido-mastoideus.

Dissection.—The dissection of the neck should be commenced by making an incision along the middle line of its fore part from the chin to the sternum, and bounding it superiorly and inferiorly by two transverse incisions; the superior being carried along the margin of the lower jaw, and across the mastoid process to the tubercle on the occipital bone, the inferior along the clavicle to the acromion process. The square flap of integument thus included should be turned back from the entire side of the neck, which brings into view the superficial fascia, and on the removal of a thin layer of superficial fascia the platysma myoides will be exposed.

¹ [As this muscle belongs to two groups I have inclosed it with parentheses.]

The *PLATYSMA MYOIDES* (*πλατύς μῦς ἰδός*, broad muscle-like lamella; *latissimus colli*; *subcutaneus colli*; *thoraco-facialis*) is a thin plane of muscular fibres, situated beneath the integument on the side of the neck; it *arises* from the fascia of the pectoralis major and deltoid muscle, and passes obliquely upwards and inwards to be *inserted* into the side of the chin, oblique line of the lower jaw, angle of the mouth, and cellular tissue of the face. The anterior fibres are continuous beneath the chin, with the muscle of the opposite side; the next interlace with the depressor anguli oris and depressor labii inferioris; the posterior fibres are disposed in a transverse direction across the lower part of the face, arising from the fascia of the parotid gland and masseter muscle, and inserted into the angle of the mouth (*risorius Santorini*). The entire muscle is analogous to the cutaneous muscle of brutes, the *panniculus carnosus*.

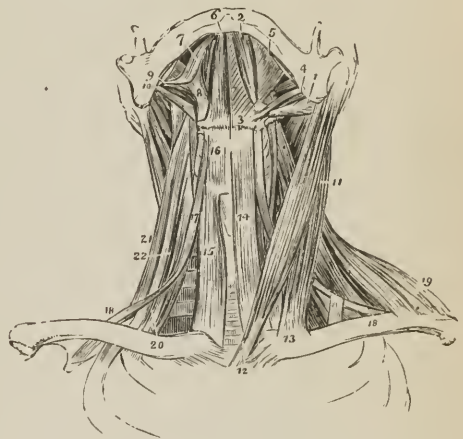
Relations. — By its *external surface* with the integument, with which it is closely adherent below, but loosely above. By its *internal surface*, below the clavicle, with the pectoralis major and deltoid; in the neck with the trapezius, sterno-mastoid, external jugular vein and deep cervical fascia; on the face, with the parotid gland, masseter, facial artery and vein, buccinator, depressor anguli oris, and depressor labii inferioris.

On raising the platysma throughout its whole extent, the sterno-mastoid is brought into view.

The *STERNO-CLEIDO-MASTOIDEUS* is the large oblique muscle of the neck, and is situated between two layers of the deep cervical fascia. It *arises*, as implied by its name, from the sternum and clavicle (*κλειδίον*), and passes obliquely upwards and backwards, to be *inserted* into the mastoid process of the temporal, and superior curved line of the occipital bone. The sternal portion arises by a rounded tendon, increases in breadth as it ascends, and spreads out to a considerable extent at its insertion. The clavicular portion is broad and fleshy, separate from the sternal portion below, but blended with the posterior surface of the latter as it ascends.

The two portions of this muscle are sometimes described as separate muscles under the names of *sterno-mastoides* (*nutator capitis internus, vel anticus*) and *cleido-mastoides* (*nutator capitis externus, vel posticus*). A sesamoid bone is sometimes found in the sternal tendon; this is regarded as the sternal rudiment of a cervical rib; and these

FIG. 161.



MUSCLES OF THE ANTERIOR ASPECT OF THE NECK; on the right side of the figure the superficial muscles are seen, on the left the deep. 1. Posterior belly of digastricus. 2. Its anterior belly. Aponeurotic pulley, through which its tendon is seen passing, attached to the body of the os hyoides. 3. 4. Stylo-hyoid muscle, transfixed by the posterior belly of the digastricus. 5. Mylo-hyoid. 6. Genio-hyoid. 7. Sterno-cleido-mastoid. 8. Hyo-glossus. 9. Stylo-glossus. 10. Stylo-pharyngeus. 11. Sterno-mastoid. 12. Its sternal origin. 13. Its clavicular origin. 14. Sterno-hyoid. 15. Sterno-thyroid of the right side. 16. Thyro-hyoid. 17. Hyoid portion of the omo-hyoid. 18, 19. Its scapular portion; on the left side, the tendon of the muscle is seen to be bound down by a portion of the deep cervical fascia. 19. Clavicular portion of the trapezius. 20. Scalenus anticus, of the right side. 21. Scalenus posticus. 22. Scalenus medius, seen between the two.

osseous formations have been described by Breschet under the name of *ossa suprasternalia vel episternalia*.

Relations. — By its *superficial surface* with the integument, platysma myoides, external jugular vein, superficial branches of the cervical plexus of nerves, and anterior layer of the deep cervical fascia. By its *deep surface* with the deep layer of the cervical fascia, sterno-clavicular articulation, sterno-hyoid, sterno-thyroid, omo-hyoid, scalmi, levator anguli scapulae, splenii, and posterior belly of the digastricus muscle; phrenic nerve, transversa colli and suprascapular artery; deep lymphatic glands, sheath of the common carotid artery and internal jugular vein, descendens noni nerve, external carotid artery with its posterior branches, and commencement of the internal carotid artery; cervical plexus of nerves, pneumogastric, spinal accessory, hypoglossal, sympathetic, and facial nerve, and parotid gland. It is pierced on this aspect by the spinal accessory nerve. The *anterior border* of the muscle is the posterior boundary of the great anterior triangle, the other two boundaries being the middle line of the neck in front, and the lower border of the jaw above. It is the guide to the operations for the ligation of the common carotid artery and arteria innominata, and, on the left side, for oesophagotomy. The *posterior border* is the anterior boundary of the great posterior triangle; the other two boundaries being the anterior border of the trapezius behind, and the clavicle below.

Actions. — The platysma produces a muscular traction on the integument of the neck, which prevents it from falling so flaccid in old persons as it would if the extension of the skin were the mere result of elasticity. It draws also on the angle of the mouth, and is one of the depressors of the lower jaw. The transverse fibres draw the angle of the mouth outwards. The sterno-mastoid muscles (*nutatores capitis*) are the great anterior muscles of connexion between the thorax and the head. Both muscles acting together bow the head directly forwards. The clavicular portions, acting more forcibly than the sternal, give stability and steadiness to the head in supporting great weights. Either muscle acting singly would draw the head towards the shoulder of the same side, and carry the face towards the opposite side.

Second Group. — Depressors of the Os Hyoides and Larynx.

Sterno-hyoideus,	Thyro-hyoideus,
Sterno-thyroideus,	Omo-hyoideus.

Dissection. — These muscles are brought into view by removing the deep fascia from off the front of the neck between the two sterno-mastoid muscles. The omo-hyoid to be seen in its whole extent requires that the sterno-mastoid muscle be divided from its origin and turned aside.

The STERNO-HYOIDEUS is a narrow, ribbon-like muscle, arising from the posterior surface of the first bone of the sternum and from the posterior sterno-clavicular ligament (sometimes from the inner extremity of the clavicle, and sometimes from the cartilage of the first rib). It is inserted into the lower border of the os hyoides. The sterno-hyoidei are separated by a considerable interval at the root of the neck, approach each other as they ascend, and are again separated on the thyroid cartilage; they are frequently traversed below by a tendinous intersection.

Relations. — By its *external surface* with the deep cervical fascia, platysma myoides and sterno-mastoid muscle; by its *internal surface* with the sterno-thyroid, and thyro-hyoid muscle, and superior thyroid artery.

The STERNO-THYROIDEUS, broader than the preceding, beneath which it lies, arises from the posterior surface of the upper bone of the sternum, and from the cartilage of the first rib; it is inserted into the oblique line on the great ala of the thyroid cartilage. The inner borders lie in contact along the middle line, and the muscles are marked by a tendinous intersection at their lower part. Some

of the fibres of this muscle are continued directly into the thyro-hyoideus without intervening attachment; others are continuous with the inferior constrictor.

Relations. — By its *external surface* with the sterno-hyoid, omo-hyoid, and sterno-mastoid muscle; by its *internal surface*, with the trachea, inferior-thyroid veins, thyroid gland, lower part of the larynx, sheath of the common carotid artery and internal jugular vein, subclavian vein, vena innominata, and, on the right side, arteria innominata. The middle thyroid vein lies along its inner border.

The THYRO-HYOIDEUS is the continuation upwards of the sterno-thyroid muscle. It *arises* from the oblique line on the thyroid cartilage, and is *inserted* into the lower border of the body, and great cornu of the os hyoides for one half its length.

Relations. — By its *external surface* with the sterno-hyoid and omo-hyoid muscle; by its *internal surface* with the great ala of the thyroid cartilage, thyro-hyoidean membrane, and superior laryngeal artery and nerve.

The OMO-HYOIDEUS (*ὤμος*, shoulder) is a double-bellied muscle passing obliquely across the neck from the scapula to the os hyoides; it forms an obtuse angle behind the sterno-mastoid, and is retained in that position by a process of the deep cervical fascia which forms a sheath for its tendon and holds it in connexion with the sternum and first rib. It *arises* from the upper border of the scapula and transverse ligament of the suprascapular notch; and is *inserted* into the os hyoides at the junction of the body and great cornu.

Relations. — By its *superficial surface* with the trapezius, subclavius, clavicle, deep cervical fascia, platysma myoides, sterno-mastoideus, and integument. By its *deep surface* with the brachial plexus, scaleni muscles, phrenic nerve, sheath of the common carotid artery and jugular vein, descendens noni nerve, sterno-thyroid and thyro-hyoid muscle, and the sterno-hyoid at its insertion.

The scapular portion of the muscle divides the great posterior triangle into a superior or *occipital triangle*, and an inferior or *subclavian triangle*; the latter contains the subclavian artery and brachial plexus of nerves; the other two boundaries of the subclavian triangle being the sterno-mastoid in front and the clavicle below. The hyoid portion of the muscle divides the great anterior triangle into an *inferior carotid triangle* situated below the muscle, and a superior triangle which lies above the muscle, and is again subdivided by the digastricus into the *submaxillary triangle* and *superior carotid triangle*. The other two boundaries of the inferior carotid triangle are the middle line of the neck in front and the anterior border of the sterno-mastoid behind. The other boundaries of the superior carotid triangle are the posterior belly of the digastricus above and the anterior border of the sterno-mastoid behind.

Actions. — The four muscles of this group are depressors of the os hyoides and larynx. The three former drawing these parts downwards in the middle line, and the two omo-hyoidei regulating their traction to the one or other side of the neck, according to the position of the head. The omo-hyoid muscles, by means of their connexion with the cervical fascia, are rendered tensors of that portion of the deep fascia which covers the lower part of the neck, between the two sterno-mastoid muscles.

Third Group. — Elevators of the Os Hyoides.

Digastricus,	Genio-hyoideus,
Stylo-hyoideus,	Genio-hyo-glossus.
Mylo-hyoideus,	

Dissection. — These are best dissected by placing a high block beneath the neck, and throwing the head backwards. The integument has been already dissected away and the removal of some cellular tissue and fat brings them clearly into view.

The DIGASTRICUS (*δῖς*, twice, *γαστήρ*, belly, biventer) is a small muscle situated immediately beneath the side of the body of the lower jaw; fleshy at each extremity, and tendinous in the middle. It *arises* from the digastric fossa and anterior border of the mastoid process of the temporal bone; pierces by its posterior belly the stylo-hyoideus muscle, and is *inserted* into a depression on the inner side of the lower jaw, close to the symphysis. The middle tendon is held in connexion with the body of the os hyoides by an aponeurotic loop, through which it plays as through a pulley; the loop being lubricated by a synovial membrane. A thin layer of aponeurosis is given off from the tendon of the digastricus at each side, which is connected with the body of the os hyoides, and forms a strong plane of fascia between the anterior portions of the two muscles. This fascia, the *supra-hyoidean*, is continuous with the deep cervical fascia.

Relations. — By its *superficial surface* with the platysma myoides, sternomastoid, anterior fasciculus of the stylo-hyoid muscle, parotid gland, and submaxillary gland. By its *deep surface* with the styloid muscles, hyo-glossus, mylo-hyoideus, external carotid artery, lingual and facial artery, internal carotid artery, jugular vein, and hypoglossal nerve. The digastric muscle forms the two inferior boundaries of the *submaxillary triangle*, the superior boundary being the side of the body of the lower jaw. In the posterior half of the submaxillary triangle are situated the submaxillary gland and facial artery.

The STYLO-HYOIDEUS is a small and slender muscle situated in immediate relation with the posterior belly of the digastricus, by which it is pierced. It *arises* from the middle of the styloid process, its outer side, and is *inserted* into the body of the os hyoides near the middle line.

Relations. — By its *superficial surface* with the posterior belly of the digastricus, parotid gland and submaxillary gland; its deep relations are similar to those of the posterior belly of the digastricus.

The digastricus and stylo-hyoideus must be removed from their connexion with the lower jaw and os hyoides, and turned aside in order to see the next muscle.

The MYLO-HYOIDEUS (*μύλη*, mola, *i. e.*, attached to the molar ridge of the lower jaw) is a broad and triangular plane of muscular fibres, forming, with its fellow of the opposite side, the inferior wall or floor of the mouth. It *arises* fleshy from the molar [or mylo-hyoidean] ridge of the lower jaw as far back as the last molar tooth, and proceeds inwards and backwards to the middle line, where its fibres are continuous with those of the opposite side, the posterior fibres being *inserted* into the lower border of the body of the os hyoides. At the middle line the union is tendinous on the upper surface in front, on the lower behind, the rest being fleshy.

Relations. — By its *superficial* or inferior *surface*, with the platysma myoides, digastricus, supra-hyoidean fascia, submaxillary gland, and submental artery. By its *deep* or superior *surface* with the genio-hyoideus, genio-hyo-glossus, hyo-glossus, stylo-glossus, gustatory nerve, hypoglossal nerve, Wharton's duct, sublingual gland, and mucous membrane of the floor of the mouth.

After the mylo-hyoideus has been examined, it should be cut away from its origin and insertion, and completely removed. The view of the next muscles would also be improved by dividing the lower jaw a little to the side of the symphysis, and drawing it outwards; or removing it altogether if the ramus have been already cut across in dissecting the internal pterygoid muscle. The tongue may then be drawn out of the mouth by means of a hook.

The GENIO-HYOIDEUS (*γένειον*, the chin) *arises* from a small tubercle on the inner side of the symphysis of the lower jaw, and is *inserted* into the body of the os hyoides. It is a short and slender muscle, closely connected with its fellow and with the border of the following.

Relations. — By its *superficial* or inferior *surface* with the mylo-hyoideus; by the *deep* or superior *surface* with the lower border of the genio-hyo-glossus.

The GENIO-HYO-GLOSSUS ($\gamma\lambda\omega\sigma\sigma\alpha$, the tongue) is a triangular muscle, narrow and pointed at its origin from the lower jaw, broad and fan-shaped at its attachment to the tongue. It *arises* from a tubercle immediately above that of the genio-hyoideus, and spreads out to be *inserted* into the whole length of the tongue, from base to apex, and into the os hyoides.

Relations.—By its *inner surface* with its fellow of the opposite side. By its *outer surface* with the mylo-hyoideus, hyo-glossus, stylo-glossus, lingualis, sublingual gland, lingual artery, and hypo-glossal nerve. By its *upper border* with the mucous membrane of the floor of the mouth, in the situation of the frænum linguæ; by its *lower border* with the genio-hyoideus.

Actions.—The whole of this group of muscles acts on the os hyoides when the lower jaw is closed, and on the lower jaw when the os hyoides is drawn downwards and fixed by the depressors of the os hyoides and larynx. The genio-hyo-glossus is, moreover, a muscle of the tongue; its action upon that organ will be considered with the next group.

Fourth Group. — Muscles of the tongue.

Genio-hyo-glossus,
Hyo-glossus,
Lingualis,
Stylo-glossus,
Palato-glossus.

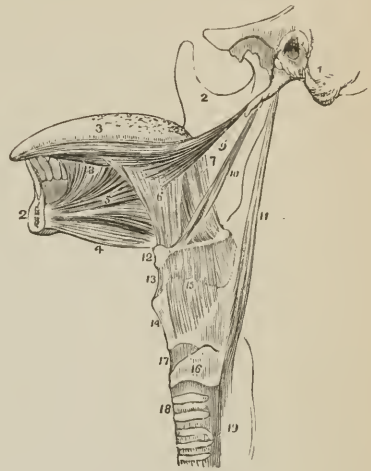
These are already exposed by the preparation we have just made; there remains, therefore, only to dissect and examine them.

[The genio-hyo-glossus, hyo-glossus, stylo-glossus, and palato-glossus are the *extrinsic* muscles of the tongue. The *intrinsic* muscles are described with the lingualis and with the organ of taste.]

The *Genio-hyo-glossus*, the first of these muscles, has been described with the last group.

The *HYO-GLOSSUS* is a square-shaped plane of muscle, *arising* from the whole length of the great cornu and from the body of the os hyoides; and *inserted* between the stylo-glossus and lingualis into the side of the tongue. The direction of the fibres of that portion of the muscle which arises from the body is obliquely backwards; that from the great cornu obliquely forwards; hence they are described by Albinus as two muscles, under the names of *basio-glossus* [$\beta\alpha\sigma\iota\sigma$, 'base'], and *cerato-glossus* [$\chi\epsilon\rho\alpha\sigma$, cornu], to which he added a third fasciculus, arising from the lesser cornu, and spreading along the side of the tongue, the *chondro-glossus*. The basio-glossus slightly overlaps the upper part of the

FIG. 162.



STYLOID MUSCLES AND MUSCLES OF THE TONGUE. 1. Portion of the temporal bone of the left side, with the styloid and mastoid process, and meatus auditorius externus. 2. The right side of the lower jaw, divided at its symphysis; the left side having been removed. 3. Tongue. 4. Genio-hyoideus. 5. Genio-hyo-glossus. 6. Hyo-glossus; its basio-glossus portion. 7. Its cerato-glossus portion. 8. Anterior fibres of the lingualis, issuing from between the hyo-glossus and genio-hyo-glossus. 9. Stylo-glossus, with part of the stylo-maxillary ligament. 10. Stylo-hyoideus. 11. Stylo-pharyngeus. 12. Os hyoides. 13. Thyro-hyoidean membrane. 14. Thyroid cartilage. 15. Thyro-hyoideus muscle, arising from the oblique line of the thyroid cartilage. 16. Cricoid cartilage. 17. Crico-thyroidean membrane, through which the operation of laryngotomy is performed. 18. Trachea. 19. Commencement of the œsophagus.

cerato-glossus, and is separated from it by the transverse portion of the stylo-glossus.

Relations. — By its *external surface* with the digastricus, stylo-hyoideus, stylo-glossus, mylo-hyoideus, gustatory nerve, hypoglossal nerve, Wharton's duct, and sublingual gland. By its *internal surface* with the middle constrictor of the pharynx, lingualis, genio-hyo-glossus, lingual artery, and glosso-pharyngeal nerve.

The LINGUALIS. — The fibres of this muscle (lingualis longitudinalis inferior) may be seen towards the apex of the tongue, issuing from the interval between the hyo-glossus and genio-hyo-glossus; and is best examined by removing the preceding muscle. It consists of a small fasciculus of fibres, running longitudinally from the base, where it is attached to the os hyoides, to the apex of the tongue. By the outer border its fibres reach the plane of longitudinal fasciculi of the stylo-glossus and lingualis superficialis; and by its under surface it is in relation with the ranine artery.

The other muscles entering into the structure of the tongue, are, the lingualis longitudinalis superior vel superficialis; and the lingualis transversus. The *lingualis superior* forms a thin plane on the upper surface of the organ, lying immediately beneath the mucous membrane. This layer is thicker in front than behind, and is covered posteriorly by a thin stratum of transverse fibres derived from the hyo-glossus. The *lingualis transversus* constitutes the chief bulk of the tongue; it lies between the lingualis superior and inferior, its fibres being attached at the middle line to the fibro-cartilaginous septum of the tongue, and laterally to the mucous membrane; some of its fibres are continuous with those of the stylo-glossus and hyo-glossus, and others are connected with the lesser cornua of the os hyoides.

The STYLO-GLOSSUS *arises* from the apex of the styloid process and from the stylo-maxillary ligament; it divides on the side of the tongue into two parts, one transverse, which passes transversely inwards between the two portions of the hyo-glossus, and is lost among the transverse fibres of the substance of the tongue — the other longitudinal, which spreads out upon the side of the tongue, and is prolonged forwards with the lingualis as far as its tip.

Professor Hyrtl of Prague has described a fasciculus of this muscle, which *arises* from the outer side of the styloid process, and is *inserted* into the cartilage of the meatus auris, under the name of *stylo-auricularis*. He states that it occurs once in every six bodies.

Relations. — By its *external surface* with the internal pterygoid muscle, gustatory nerve, parotid gland, sublingual gland, and mucous membrane of the floor of the mouth. By its *internal surface* with the tonsil, superior constrictor of the pharynx, and hyo-glossus.

The PALATO-GLOSSUS passes between the soft palate and the side of the base of the tongue, forming a prominence of the mucous membrane, which is called the anterior pillar of the soft palate. Its fibres are spread out superiorly among the muscular fibres of the palato-pharyngeus, and inferiorly among the fibres of the stylo-glossus upon the side of the tongue. This muscle with its fellow constitutes the *constrictor isthmi faucium*.

Actions. — The genio-hyo-glossus muscle effects several movements of the tongue. When the tongue is steadied and pointed by the other muscles, the posterior fibres of the genio-hyo-glossus would dart it from the mouth, while its anterior fibres would restore it to its former position. The whole length of the muscle acting on the tongue, would render it concave along the middle line, and form a channel for the current of fluid towards the pharynx, as in sucking. The apex of the tongue is directed to the roof of the mouth, and rendered convex from before backwards by the linguales. The hyo-glossi, by drawing down the sides of the tongue, render it convex along the middle line. It is drawn upwards at its base by the palato-glossi, and backwards or to either side by the stylo-glossi.

Thus the whole of the complicated movements of the tongue may be explained, by reasoning on the direction of the fibres of the muscles, and their probable actions. The palato-glossi muscles, assisted by the uvula, have the power of closing the fauces completely, an action which takes place in deglutition.

Fifth Group. — Muscles of the Pharynx.

Constrictor inferior,
Constrictor medius,
Constrictor superior,

Stylo-pharyngeus,
Palato-pharyngeus.

[The three constrictors, are the *intrinsic* muscles, and the stylo-pharyngeus, palato-pharyngeus, and salpingo-pharyngeus, the *extrinsic* muscles of the pharynx.]

Dissection. — To dissect the pharynx, the trachea and œsophagus are to be cut through at the lower part of the neck, and drawn upwards by dividing the loose cellular tissue which connects the back of the pharynx to the vertebral column. The saw is then to be applied behind the styloid processes, and the base of the skull sawn through. The vessels and loose structures should be removed from the preparation, and the pharynx stuffed with tow or wool for the purpose of distending it, and rendering the muscles more easy of dissection. The pharynx is invested by a proper pharyngeal fascia.

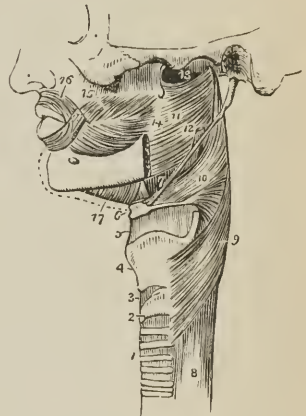
The CONSTRUCTOR INFERIOR, the thickest of the three constrictor muscles, *arises* from the cricoid cartilage, and the oblique line of the thyroid. Its fibres spread out, and are *inserted* into the middle line of the pharynx, the inferior fibres being almost horizontal, the superior oblique and overlapping the middle constrictor.

Relations. — By its *external surface* with the vertebral column, longus colli, sheath of the common carotid artery, sterno-thyroid muscle, thyroid gland, and some lymphatic glands. By its *internal surface* with the middle constrictor, stylo-pharyngeus, palato-pharyngeus, and mucous membrane of the pharynx. By its *lower border*, near the cricoid cartilage, it is in relation with the recurrent nerve; and by the *upper border* with the superior laryngeal nerve. The fibres of origin of this muscle are blended with those of the sterno-thyroid, thyro-hyoid, and crico-thyroid, and it frequently forms a tendinous arch across the latter; inferiorly it is blended with the circular fibres of the œsophagus.

The muscle must be removed before the next can be examined.

The CONSTRUCTOR MEDIUS *arises* from the great cornu of the os hyoides, and from the lesser cornu. It radiates, from its origin, and spreads out upon the side of the pharynx, the lower fibres descending and being overlapped by the constrictor inferior; the upper fibres ascending, so as to cover in the constrictor superior. It is *inserted* into the *raphé* of the

FIG. 163.



SIDE VIEW OF THE MUSCLES OF THE PHARYNX. 1. Trachea. 2. Cricoid cartilage. 3. Crico-thyroid membrane. 4. Thyroid cartilage. 5. Thyro-hyoidean membrane. 6. Os hyoides. 7. Stylo-hyoidean ligament. 8. Œsophagus. 9. Inferior constrictor. 10. Middle constrictor. 11. Superior constrictor. 12. Stylo-pharyngeus, passing down between the superior and middle constrictor. 13. Upper concave border of superior constrictor; at this point the muscular fibres of the pharynx are deficient. 14. Pterygo-maxillary ligament. 15. Buccinator. 16. Orbicularis. 17. Mylo-hyoideus.

pharynx, and by a fibrous aponeurosis into the basilar process of the occipital bone.

Relations. — By its *external surface* with the vertebral column, longus colli, rectus anticus major, carotid vessels, inferior constrictor, hyo-glossus, lingual artery, pharyngeal plexus of nerves, and some lymphatic glands. By its *internal surface*, with the superior constrictor, stylo-pharyngeus, palato-pharyngeus, and mucous membrane of the pharynx.

The upper portion of this muscle must be turned down, to bring the whole of the superior constrictor into view; in so doing, the stylo-pharyngeus muscle will be seen passing behind its upper border.

The CONSTRUCTOR SUPERIOR is a thin and quadrilateral plane of muscular fibres *arising* from the side of the tongue, the extremity of the molar ridge of the lower jaw, the pterygo-maxillary ligament, and lower third of the internal pterygoid plate; and *inserted* into the *raphé* of the pharynx and basilar process of the occipital bone. Its superior fibres are arched, leaving a concave interspace between its upper border and the basilar process; some of its lower fibres are continuous with those of the genio-hyo-glossus on the side of the tongue, and it is overlapped inferiorly by the middle constrictor.

Between the side of the pharynx and the ramus of the lower jaw is a triangular interval, the *maxillo-pharyngeal space*, which is bounded at the *inner* side by the superior constrictor muscle; at the *outer* side by the internal pterygoid muscle; and *behind* by the rectus anticus major and vertebral column. In this space are situated the internal carotid artery, internal jugular vein, glosso-pharyngeal, pneumogastric, spinal accessory, and hypoglossal nerve.

Relations. — By its *external surface* with the vertebral column and muscles of the latter, behind; with the vessels and nerves contained in the *maxillo-pharyngeal space* laterally, and with the middle constrictor, stylo-pharyngeus, and tensor palati. By its *internal surface* with the levator palati, palato-pharyngeus, tonsil, and mucous membrane of the pharynx.

The STYLO-PHARYNGEUS (levator seu dilatator pharyngis) is a long and slender muscle *arising* from the inner side of the base of the styloid process; it descends between the superior and middle constrictor muscle, and spreads out beneath the mucous membrane of the pharynx; it is *inserted* partly into the posterior border of the thyroid cartilage, and partly into the internal face of the inferior constrictor.

Relations. — By its *external surface* with the stylo-glossus muscle, external carotid artery, parotid gland, and middle constrictor. By its *internal surface* with the internal carotid artery, internal jugular vein, superior constrictor, palato-pharyngeus, and mucous membrane. Along its lower border is seen the glosso-pharyngeal nerve, which crosses it opposite the root of the tongue, to pass between the superior and middle constrictor and behind the hyo-glossus.

Associated in function with the preceding is a small muscle, not always present, the *salpingo*¹-*pharyngeus* (levator pharyngeus internus), which *arises* from the lower border of the Eustachian tube near its aperture, and passes down upon the inner surface of the side of the pharynx, where it becomes united with the palato-pharyngeus.

The *palato-pharyngeus* is described with the muscles of the soft palate. It *arises* from the soft palate, and is *inserted* into the inner surface of the pharynx and posterior border of the thyroid cartilage.

Actions. — The three constrictor muscles are important agents in deglutition; they contract upon the morsel of food as soon as it is received by the pharynx, and convey it downwards into the œsophagus. The stylo-pharyngei draw the pharynx upwards, and widen it laterally. The palato-pharyngei also draw it upwards, and with the aid of the uvula close the opening of the fauces. The *salpingo-pharyngei* are elevators of the upper part of the pharynx.

¹ σαλπιγξ, a tube.

Sixth Group. — Muscles of the soft Palate.

Levator palati,	Palato-glossus,
Tensor palati,	Palato-pharyngeus.
Azygos uvulæ,	

Dissection. — To examine these muscles, the pharynx must be opened from behind, and the mucous membrane carefully removed from off the posterior surface of the soft palate.

The **LEVATOR PALATI**, a moderately thick muscle, *arises* from the extremity of the petrous bone and from the posterior and inferior aspect of the Eustachian tube, and passing down by the side of the posterior nares spreads out between the fasciculi of origin of the palato-pharyngeus; it is *inserted* into the middle line, where it is continuous with the muscle of the opposite side, and is overlaid by the azygos uvulæ.

Relations. — *Externally* with the tensor palati and superior constrictor muscle; *internally* and *posteriorly* with the mucous membrane of the pharynx and soft palate; inferiorly it passes between the two fasciculi of origin of the palato-pharyngeus to reach its insertion.

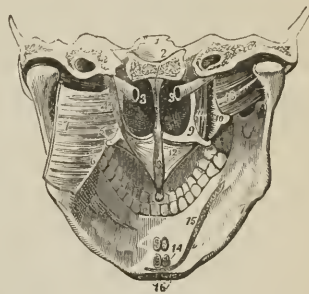This muscle must be turned down from its origin on one side, and removed, and the superior constrictor dissected away from its pterygoid origin, to bring the next muscle into view.

The **TENSOR PALATI** (circumflexus) is a slender and flattened muscle; it *arises* from the scaphoid fossa at the base of the internal pterygoid plate, from the spinous process of the sphenoid bone, and from the anterior aspect of the Eustachian tube. It lies between the internal pterygoid muscle and internal pterygoid plate, and winding around the hamular process of the latter, expands into a tendinous aponeurosis, which is *inserted* into the transverse ridge on the horizontal portion of the palate bone, and at the middle line is continuous with the aponeurosis of the opposite muscle.

Relations. — By its *external surface* with the internal pterygoid muscle; by its *internal surface* with the levator palati, internal pterygoid plate, and superior constrictor. In the soft palate, its tendinous expansion is placed in front of the other muscles, and in contact with the mucous membrane.

The **AZYGOS UVULÆ** is a pair of small muscles situated along the middle line of the soft palate. They *arise* from the spine of the palate bone, and are *inserted* into the uvula. By their anterior surface they are in relation with the

FIG. 164.



MUSCLES OF THE THE SOFT PALATE. 1. Transverse section through the middle of the base of the skull, dividing the basilar process of the occipital bone in the middle line, and the petrous portion of the temporal bone at each side. 2. The vomer covered by mucous membrane and separating the two posterior nares. 3, 3. Eustachian tubes. 4. Levator palati muscle, left side; the right has been removed. 5. Hamular process of the internal pterygoid plate of the left side, around which the aponeurosis of the tensor palati is seen turning. 6. Pterygo-maxillary ligament. 7. Superior constrictor, left side, turned aside. 8. Azygos uvulæ. 9. Internal pterygoid plate. 10. External pterygoid plate. 11. Tensor palati muscle. 12. Its aponeurosis expanding in the structure of the soft palate. 13. External pterygoid muscle. 14. The attachments of two pairs of muscles cut short: the superior pair belong to the genio-hyoglossi; the inferior, to the genio-hyoidei. 15. Attachment of the mylo-hyoideus of one side and part of the opposite. 16. Anterior attachment of the digastric muscles. 17. Depression on the lower jaw corresponding with the submaxillary gland. The depression above the mylo-hyoideus, on which the cipher 15 rests, corresponds with the situation of the sublingual gland.

levatores palati, palato-glossi and anterior fasciculus of the palato-pharyngei; posteriorly they have the thin posterior fasciculus of the palato-pharyngei and the mucous membrane.

The two next muscles are brought into view by raising the mucous membrane from off the pillars of the soft palate at each side.

The PALATO-GLOSSUS (constrictor isthmi faucium) [described also with the fourth group] is a small fasciculus of fibres, which *arises* in the soft palate as a radiated expansion continuous with its fellow of the opposite side; and descends to be *inserted* into the side of the tongue. It is the prominence of this small muscle, covered by mucous membrane, that constitutes the anterior pillar of the soft palate. It has been named constrictor isthmi faucium, from a function it performs in common with the palato-pharyngeus, viz., constricting the opening of the fauces.

The PALATO-PHARYNGEUS (constrictor isthmi faucium posterior) forms the posterior pillar of the fauces; it *arises* by two fasciculi from the raphé of the soft palate, where its fibres are continuous with those of the muscle of the opposite side; and is *inserted* into the inner surface of the pharynx and posterior border of the thyroid cartilage. This muscle is broad above where it forms the whole thickness of the lower half of the soft palate, narrow in the posterior pillar, and again broad and thin in the pharynx, where it spreads out previously to its insertion. The levator palati passes to its insertion between the two fasciculi of origin of this muscle.

Relations. — In the soft palate it is in relation with the mucous membrane both by its *anterior* and *posterior* surface; *above*, with the levator palati, and *below* with the mucous glands situated along the margin of the arch of the palate. In the posterior pillar, it is surrounded for two-thirds of its extent by mucous membrane. In the pharynx, it is in relation by its *outer surface* with the superior and middle constrictor muscle, by its *inner surface* with the mucous membrane.

Actions. — The azygos uvulæ shortens the uvula. The levator palati raises the soft palate, while the tensor spreads it out laterally so as to form a septum between the pharynx and posterior nares. Taking its fixed point from below, the tensor palati will dilate the Eustachian tube. The palato-glossus and palato-pharyngeus constrict the opening of the fauces, and drawing down the soft palate, serve to press the mass of food from the dorsum of the tongue into the pharynx.

Seventh Group. — Prævertebral Muscles.

Rectus anticus major,	Scalenus medius,
Rectus anticus minor,	Scalenus posticus,
Scalenus anticus,	Longus colli.

Dissection. — These muscles have already been exposed by the removal of the pharynx from the anterior aspect of the vertebral column; all that is further needed is the removal of the fascia by which they are invested.

The RECTUS ANTICUS MAJOR (trachelo-suboccipitalis), broad and thick above, narrow and pointed below, *arises* from the anterior tubercles of the transverse processes of the third, fourth, fifth, and sixth cervical vertebræ; and is *inserted* into the basilar process of the occipital bone.

Relations. — By its *anterior surface* with the pharynx, internal carotid artery, internal jugular vein, superior cervical ganglion and trunk of the sympathetic nerve, pneumogastric, and spinal accessory nerve. By its *posterior surface* with the rectus anticus minor, and superior cervical vertebræ; *internally* with the longus colli, and *externally* with the scaleni.

The RECTUS ANTICUS MINOR *arises* from the anterior border of the lateral mass of the atlas, and is *inserted* into the basilar process; its fibres being directed obliquely upwards and inwards.

Relations. — By its *anterior surface* with the rectus anticus major, and superior cervical ganglion of the sympathetic. By its *posterior surface* with the articulation of the condyle of the occipital bone with the atlas, and anterior occipito-atloid ligament.

The **SCALENUS ANTICUS** (*costo-trachelius*) is a triangular muscle, as its name implies, situated at the root of the neck, and appearing like a continuation of the rectus anticus major; it *arises*, by a flat and narrow tendon, from the upper and inner border of the first rib; and is *inserted* into the anterior tubercles of the transverse processes of the third, fourth, fifth, and sixth cervical vertebræ.

Relations. — By its *anterior surface* with the sterno-mastoid and omo-hyoid muscles, suprascapular and transversa colli artery, phrenic nerve, and subclavian vein, by which latter it is separated from the subclavius muscle and clavicle. By its *posterior surface* with the pleura, the nerves which form the brachial plexus, and below, the subclavian artery. By its *inner side* with the longus colli, being separated by the vertebral artery; by its *outer side* with the scalenus medius. Its relations with the subclavian artery and vein are important, the vein being before, the artery behind the muscle.¹

The **SCALENUS MEDIUS**, the largest of the three, *arises* from the first rib between the groove for the subclavian artery and the tuberosity [*i. e.* tubercle], and is *inserted* by separate tendons into the posterior tubercles of all the cervical vertebræ excepting the first.

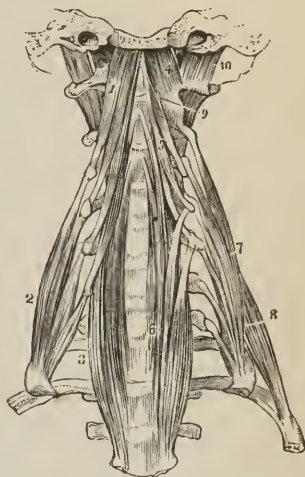
Relations. — By its *anterior surface* with the brachial plexus and subclavian artery; *posteriorly* with the scalenus posticus, levator anguli scapulæ, and cervicalis ascendens; *internally* with the pleura, intertransverse muscles, and cervical vertebræ; *externally* with the sterno-mastoid, omo-hyoid, suprascapular and transversa colli artery.

The **SCALENUS POSTICUS**, of small size, *arises* by a thin tendon from the second rib between its tubercle and angle, and divides superiorly into two or three tendons which are *inserted* into the posterior tubercles of the two or three lower cervical vertebræ. The scalenus posticus was formerly described with the scalenus medius as one muscle; while Albinus and Soëmmering make five scaleni.

Relations. — In *front* with the scalenus medius; *behind* with the two upper levatores costarum, and cervicalis ascendens.

The **LONGUS COLLI** (*prædorso-atloideus*) is a long and flat muscle, consisting of two portions. The *upper*, *arises* from the anterior tubercle of the atlas, and is *inserted* into the transverse processes of the third, fourth, and fifth cervical vertebræ. The *lower* portion *arises* from the bodies of the second, third, and fourth, and transverse processes of the fifth and sixth, and passes down the

FIG. 165.



PRÆVERTEBRAL GROUP OF MUSCLES OF THE NECK. 1. Rectus anticus major. 2. Scalenus anticus. 3. Lower part of the longus colli of the right side; it is concealed superiorly by the rectus anticus major. 4. Rectus anticus minor. 5. Upper portion of the longus colli. 6. Its lower portion; the figure rests on the seventh cervical vertebra. 7. Scalenus medius. 8. Scalenus posticus. 9. One of the intertransversales. 10. Rectus lateralis, left side.

¹ In a subject dissected in the school of the Middlesex Hospital during the winter of 1841, by Mr. Joseph Rogers, the subclavian artery of the left side was placed with the vein in front of the scalenus anticus muscle.

neck, to be *inserted* into the bodies of the three lower cervical and three upper dorsal vertebræ. We may thus arrange these attachments in a tabular form:—

	<i>Origin.</i>	<i>Insertion.</i>
Upper portion.	{ Atlas { 2d, 3d, and 4th bodies { 5th and 6th transverse processes . . .	{ 3d, 4th, and 5th transverse processes. { 3 lower cervical vertebræ, bodies. { 3 upper dorsal, bodies.
Lower portion.		

In general terms, the muscle is attached to the bodies and transverse processes of the six superior cervical vertebræ above, and to the bodies of the last three cervical and first three dorsal below.

Relations.—By its *anterior surface* with the pharynx, œsophagus; sheath of the common carotid, internal jugular vein and pneumogastric nerve; sympathetic nerve, inferior laryngeal nerve, and inferior thyroid artery. By its *posterior surface* it rests on the cervical and upper dorsal vertebræ.

*Transversalis colli anterior.*¹—Under this name Retzius has described a small muscle (rudimentary in man but large and important in mammiferous animals) situated on the anterior tubercles of the transverse processes of the cervical vertebræ between the rectus anticus major and scalenus anticus. It *arises* by small tendinous slips from the anterior tubercles of the fourth, fifth, and sixth cervical vertebræ; and is *inserted* into the corresponding tubercles of the second and third vertebræ, and sometimes into the transverse process of the atlas.

Actions.—The rectus anticus major and minor preserve the equilibrium of the head upon the atlas; and, acting with the longus colli, flex and rotate the head and the cervical portion of the vertebral column. The scaleni muscles are flexors of the vertebral column: and, acting from above, fix the first and second ribs for the inspiratory muscles.

Eighth Group.—*Muscles of the Larynx.*

These muscles are described with the anatomy of the larynx, in Chapter XI.

MUSCLES OF THE TRUNK.

The muscles of the trunk may be subdivided into four natural groups: viz.,

1. Muscles of the back.
2. Muscles of the thorax.
3. Muscles of the abdomen.
4. Muscles of the perineum.

MUSCLES OF THE BACK.

The *region of the back*, in consequence of its extent, is common to the neck, upper extremities, and abdomen; and its muscles, which are numerous, may be arranged into six layers.

First Layer.

Trapezius,
Latissimus dorsi.

Second Layer.

Levator anguli scapulæ,
Rhomboides minor,
Rhomboides major.

Third Layer.

Serratus posticus superior,
Serratus posticus inferior,
Splenius capitis,
Splenius colli.

¹ Oken's Isis, 1845. Transactions of the Scandinavian Naturalists, 1842.

Fourth Layer.

(Dorsal Group.)

Sacro-lumbalis,
Longissimus dorsi,
Spinalis dorsi.

(Cervical Group.)

Cervicalis ascendens,
Transversalis cervicis,
Trachelo-mastoideus,
Complexus.*Fifth Layer.*

(Dorsal Group.)

Semi-spinalis dorsi.
Semi-spinalis colli.

(Cervical Group.)

Rectus posticus major,
Rectus posticus minor,
Rectus lateralis,
Obliquus inferior,
Obliquus superior.*Sixth Layer.*Multifidus spinæ,
Interspinales,
Intertransversales,
Levatores costarum*First Layer.*

Trapezius,

Latissimus dorsi.

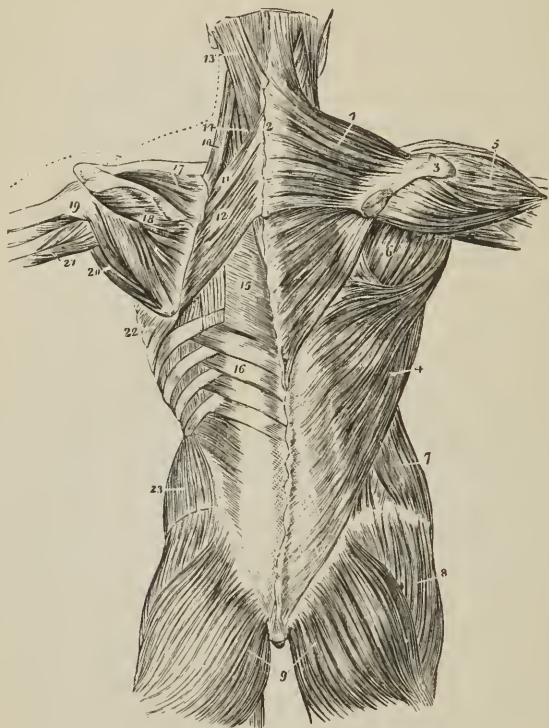
Dissection. — The muscles of this layer are to be dissected by making an incision along the middle line of the back, from the tubercle on the occipital bone to the coccyx. From the upper point of this incision carry a second transversely outwards to the back of the ear: inferiorly an incision must be made from the extremity of the sacrum, along the crest of the ilium, to about its middle. For convenience of dissection, a fourth may be carried from the middle of the spine to the acromion process. The integument and superficial fascia, together, are to be dissected off the muscles in the course of their fibres, over the whole of this region.

The TRAPEZIUS muscle (trapezium, a quadrangle with unequal sides) arises from the inner third of the superior curved line of the occipital bone, from the ligamentum nuchæ, and from the supraspinous ligament and spinous processes of the last cervical and all the dorsal vertebræ. The fibres converge from these various points, and are inserted into the scapular third of the clavicle, acromion process, and upper border of the spine of the scapula, as far back as its tubercle. The inferior fibres become tendinous, near the scapula, and glide over the triangular surface at the origin of the spine, upon some loose cellular tissue. When the trapezius is dissected on both sides, the two muscles resemble a trapezium, or diamond-shaped quadrangle, on the posterior part of the shoulders; hence the muscle was formerly named cucullaris (cucullus, a monk's cowl). The occipital portion of the muscle is extremely thin; and the origin of the cervical and upper part of the dorsal portion tendinous, forming, with the muscle of the opposite side, a tendinous trapezium.

Relations. — By its *superficial surface* with the integument and superficial fascia, to which it is closely adherent by its cervical portion, loosely by its dorsal portion. By its *deep surface*, from above downwards, with the complexus, splenius, levator anguli scapulæ, supra-spinatus, a small portion of the serratus posticus superior, rhomboideus minor, rhomboideus major, vertebral aponeurosis which separates it from the erector spinæ, and with the latissimus dorsi. The *anterior border* of the cervical portion forms the posterior boundary of the posterior triangle of the neck. Its clavicular insertion sometimes advances to the middle of the clavicle, or as far as the outer border of the sterno-mastoid, and occasionally it has been seen to overlap the latter. This is a point to be borne in mind in the operation for ligature of the subclavian artery. The spinal accessory nerve passes beneath the anterior border, near the clavicle, previously to its distribution to the under surface of the muscle.

The *ligamentum nuchæ* is a thin fibrous band extended from the tubercle and spine of the occipital bone, to the spinous process of the seventh cervical vertebra.

FIG. 166.



FIRST, SECOND, AND PART OF THE THIRD LAYER OF MUSCLES OF THE BACK; the first layer occupies the right, the second, the left side. 1. Trapezius. 2. Tendinous portion, forming, with a corresponding part of the opposite muscle, the tendinous ellipse on the back of the neck. 3. Acromion process and spine of the scapula. 4. Latissimus dorsi. 5. Deltoid. 6. Muscles of the dorsum of the scapula: infra-spinatus, teres minor, and teres major. 7. Obliquus externus abdominis. 8. Gluteus medius. 9. Glutei maximi. 10. Levator anguli scapulae. 11. Rhomboideus minor. 12. Rhomboideus major. 13. Splenius capitis; the muscle immediately above, and overlaid by the splenius, is the complexus. 14. Splenius colli, partially seen; the common origin of the splenius is seen attached to the spinous processes below the origin of the rhomboideus major. 15. Vertebral aponeurosis. 16. Serratus posticus inferior. 17. Supra-spinatus. 18. Infra-spinatus. 19. Teres minor. 20. Teres major. 21. Long head of triceps, passing between teres minor and major to the arm. 22. Serratus magnus proceeding forwards from its origin at the base of the scapula. 23. Obliquus internus abdominis.

tebra, where it is continuous with the supraspinous ligament. It is connected with the spinous processes of all the cervical vertebrae, excepting the atlas, by means of a series of small fibrous slips; and is the analogue of an important elastic ligament in animals.

The LATISSIMUS DORSI muscle covers the whole of the lower part of the back and loins. It arises from the spinous processes of the four or six inferior dorsal, and all the lumbar vertebrae, from the supraspinous ligament, spinous tubercles of the sacrum, posterior third of the crest of the ilium, and four lower ribs; the

latter origin taking place by muscular slips, which indigitate with the external oblique muscle of the abdomen. The fibres from this extensive origin converge as they ascend, and cross the inferior angle of the scapula; they then curve around the lower border of the teres major muscle, and terminate in a short quadrilateral tendon, which gets in front of the tendon of the teres, and is *inserted* into the bicipital groove. The tendinous origin of the muscle is united by its under surface with the posterior lamella of the fascia lumborum, and forms the posterior part of the sheath of the erector spinæ; it is also connected with the posterior aponeurosis of the obliquus internus. A synovial bursa is interposed between its upper border and the lower angle of the scapula, and another between the upper half of its tendon and that of the teres major; the two tendons being united inferiorly. The muscle frequently receives a small fasciculus from the scapula as it crosses its inferior angle; and sometimes by means of its tendon, a small muscular fasciculus from the pectoralis major, its tendon also gives off fibres to the deep fascia of the upper arm.

Relations.—By its *superficial surface* with the integument and superficial fascia, the latter being dense and fibrous in the lumbar region, and with the trapezius. By its *deep surface*, from below upwards, with the erector spinæ, serratus posticus inferior, posterior aponeurosis of the obliquus internus, obliquus externus, serratus magnus, intercostal muscles and ribs, rhomboideus major, inferior angle of the scapula, and teres major. The latissimus dorsi, with the teres major, forms the posterior border of the axilla.

Second Layer.

Levator anguli scapulæ,
Rhomboideus minor,
Rhomboideus major.

Dissection.—This layer is brought into view by dividing the two preceding muscles near their insertion, and turning them aside.

The LEVATOR ANGULI SCAPULÆ (trachelo-scapularis) *arises* by tendinous slips from the posterior tubercles of the transverse processes of the four upper cervical vertebræ; and is *inserted* into the upper angle and posterior border of the scapula, as far as the triangular smooth surface at the root of its spine. Being the principal elevator of the shoulder, the levator anguli scapulæ has been termed *musculus patientiæ*.

Relations.—By its *superficial surface* with the trapezius, sterno-mastoideus, and integument. By its *deep surface* with the splenius colli, transversalis cervicis, cervicalis ascendens, scalenus posticus, and serratus posticus superior. The tendons of origin are interposed between the attachments of the scalenus medius in front and the splenius colli and transversalis cervicis behind.

The RHOMBOIDEUS MINOR (dorso-scapularis; rhombus, a parallelogram with four equal sides) is a narrow slip of muscle, detached from the rhomboideus major by a slight cellular interspace. It *arises* from the spinous process of the last cervical vertebra and ligamentum nuchæ; and is *inserted* into the edge of the triangular surface, on the posterior border of the scapula.

The RHOMBOIDEUS MAJOR *arises* from the spinous processes and interspinous ligaments of the four upper dorsal vertebræ; and is *inserted* into the posterior border of the scapula as far as its inferior angle. The upper and middle portion of the insertion is effected by means of a tendinous band, which is attached in a longitudinal direction to the posterior border of the scapula.

Relations.—By their *superficial surface* the rhomboid muscles are in relation with the trapezius, and the rhomboideus major with the latissimus dorsi and integument; by their *deep surface* with the serratus posticus superior, erector spinæ, intercostal muscles and ribs.

Third Layer.

Serratus posticus superior,
Serratus posticus inferior,

Splenius capitis,
Splenius colli.

Dissection. — The *third layer* consists of muscles which arise from the spinous processes of the vertebral column, and pass outwards. It is brought into view by dividing the levator anguli scapulæ near its insertion, and reflecting the two rhomboid muscles upwards from their insertion into the scapula. The latter muscles should now be removed.

The **SERRATUS POSTICUS SUPERIOR** (dorso-costalis) is situated at the upper part of the thorax; it *arises* from the ligamentum nuchæ, and spinous processes of the last cervical and two upper dorsal vertebræ. The muscle passes obliquely downwards and outwards, and is *inserted* by four serrations into the upper border of the second, third, fourth, and fifth rib, a little beyond their angles.

Relations. — By its *superficial surface* with the trapezius, rhomboideus major and minor, and serratus magnus. By its *deep surface* with the splenius, erector spinæ, intercostal muscles and ribs.

The **SERRATUS POSTICUS INFERIOR** (lumbo-costalis) *arises* from the spinous processes and interspinous ligaments of the two lower dorsal and two or three upper lumbar vertebræ, and passing obliquely upwards, is *inserted* by four serrations into the lower border of the four inferior ribs. Both muscles consist of a thin aponeurosis for about half their extent.

Relations. — By its *superficial surface* with the latissimus dorsi, its tendinous origin being inseparably connected with the aponeurosis of that muscle. By its *deep surface* with the erector spinæ, intercostal muscles and lower ribs. The *upper border* is continuous with a thin tendinous layer, the vertebral aponeurosis.

The *Vertebral aponeurosis* (fascia lumbo-dorsalis) is a thin membranous expansion, composed of transverse and longitudinal fibres, extending from the upper border of the serratus posticus inferior upwards beneath the serratus posticus superior to the neck, where it is lost in the cervical fascia. It is attached along the middle line to the spinous processes of the dorsal vertebræ, externally to the angles of the ribs, and forms the posterior boundary of a triangular sheath, which contains the erector spinæ and deep muscles of the back. The other two boundaries of the triangular sheath, are the ribs and vertebræ in front and the spinous processes of the vertebræ at the middle line.

The serratus posticus superior must be removed from its origin and turned outwards, to bring into view the whole extent of the splenius muscle.

The **SPLЕНИUS** muscle is single at its origin, but divides soon after into two portions, which are destined to distinct insertions. It *arises* from the lower half of the ligamentum nuchæ, the spinous process of the last cervical, and spinous processes and interspinous ligaments of the six upper dorsal vertebræ; it divides as it descends the neck into the splenius capitis and splenius colli.

The *splenius capitis* (cervico-mastoideus) is *inserted* into the rough surface of the occipital bone between the two curved lines, into the mastoid portion of the temporal bone, and posterior border of the mastoid process.

The *splenius colli* (dorso-trachelius) is *inserted* into the posterior tubercles of the transverse processes of the three upper cervical vertebræ.

Relations. — By its *superficial surface* with the trapezius, sterno-mastoideus, levator anguli scapulæ, rhomboideus minor and major, and serratus posticus superior. By its *deep surface* with the spinalis dorsi, longissimus dorsi, semi-spinalis colli, complexus, trachelo-mastoideus, and transversalis cervicis. The tendons of insertion of the splenius colli are interposed between and united with the

tendons of the levator anguli scapulæ in front, and the transversalis cervicis behind.

The splenii of opposite sides of the neck leave between them a triangular interval, in which the complexus is seen.

Fourth Layer.

(Dorsal Group.)

Sacro-lumbalis,
Longissimus dorsi,
Spinalis dorsi.

(Cervical Group.)

Cervicalis ascendens,
Transversalis cervicis,
Trachelo-mastoideus,
Complexus.

Dissection. — The two serrati and two splenii muscles must be removed by cutting them away from their origin and insertion, and the vertebral aponeurosis laid open, to bring the fourth layer into view.

Three of these muscles: viz., sacro-lumbalis, longissimus dorsi, and spinalis dorsi, are associated under the name of *erector spinæ*. They occupy the lumbar and dorsal portion of the back. The remaining four are situated in the cervical region.

The SACRO-LUMBALIS and LONGISSIMUS DORSI arise by a common origin from the posterior third of the crest of the ilium, the oblique sacro-iliac ligament, articular and spinous tubercles of the sacrum, spinous processes of the lumbar vertebræ, and, deeply, from the posterior transverse tubercles of the lumbar vertebræ; the external portion being fleshy, the internal tendinous. The tendinous portion is broad and flat, and gives origin by its deep surface to a considerable part of the muscular fibres. In the lumbar region, the muscle proceeding from this extensive origin is a broad and thick musculo-tendinous mass, on the surface of which, opposite the last rib, a line of separation is apparent, the outer portion, about one third, being the sacro-lumbalis, the inner two thirds the longissimus dorsi.

The *sacro-lumbalis* (ilio-costalis, Theile) ascends upon the chest internally to the angles of the ribs, and is inserted by separate slips, the four upper tendinous, the two lower fleshy, into the angles of the six lower ribs.

If this muscle be turned a little outwards, a number of tendinous slips will be seen which take their origin from the

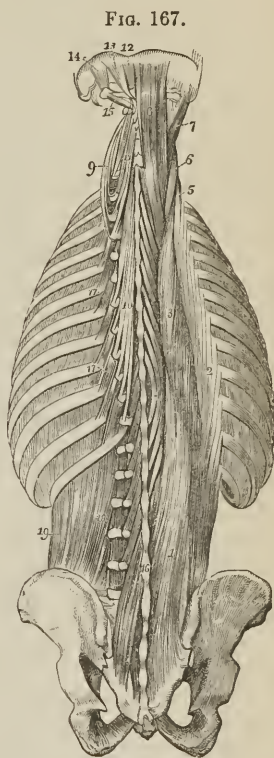


FIG. 167.
FOURTH AND FIFTH, AND PART OF THE SIXTH LAYER OF THE MUSCLES OF THE BACK.
1. Common origin of the erector spinæ.
2. Sacro-lumbalis. 3. Longissimus dorsi.
4. Spinalis dorsi. 5. Cervicalis ascendens.
6. Transversalis cervicis. 7. Trachelo-mastoideus. 8. Complexus. 9. Transversalis cervicis, showing its origin. 10. Semi-spinalis dorsi. 11. Semi-spinalis colli.
12. Rectus posticus minor. 13. Rectus posticus major. 14. Obliquus superior. 15. Obliquus inferior. 16. Multifidus spinæ.
17, 17. Levatores costarum. 18. Inter-transversales. 19. Quadratus lumborum.

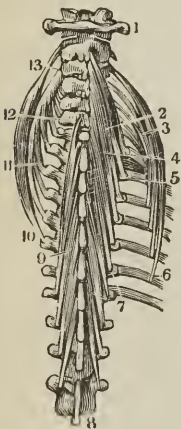
upper border of the ribs near their angles, and terminate in muscular fasciculi, which prolong the sacro-lumbalis to the upper part of the chest. This is the *musculus accessorius ad sacro-lumbalem*; it arises from the six lower ribs; and is inserted by separate tendons into the angles of the six upper ribs and transverse process of the seventh cervical vertebra.

Retzius, considering the separation of the accessorius as a difficulty to the student, treats it as the costal portion of the sacro-lumbalis, which latter he then describes as dividing into two sets of tendons, external or ascending, and internal or descending. These tendons cross each other in their course, and are inserted into the angles of all the ribs.

The *longissimus dorsi* is inserted by two series of tendons internal and external; the *internal* being implanted into the posterior transverse processes (processus accessorii) of the lumbar, and transverse processes of all the dorsal vertebræ; the *external* into the transverse processes (lumbar ribs) of the lumbar vertebræ, and all the ribs, excepting the first, between their tubercles and angles.

The SPINALIS DORSI arises from the spinous processes of the two upper lumbar and two lower dorsal vertebræ, and is inserted into the spinous processes of the upper dorsal vertebræ from the second to the sixth or eighth. It also receives several fasciculi from the longissimus dorsi and semi-spinalis dorsi. The two muscles form an ellipse, which embraces the spinous processes of the dorsal vertebræ.

[FIG. 168.



A PART OF THE FOURTH AND FIFTH LAYERS OF THE MUSCLES OF THE BACK. 1. Atlas. 8. Tenth dorsal vertebra. 3, 5, 6. Cervicalis ascendens; 5, 6, its origin; 3, its insertion. 10, 11, 12, 13. Transversalis cervicis; 10, 11, its origin; 12, 13, its insertion. 9. Semi-spinalis dorsi. 2, 4, 7. Semi-spinalis colli.]

Relations.—The erector spinæ muscle is in relation by its *superficial surface* (in the lumbar region) with the serratus posticus inferior, and latissimus dorsi; (in the dorsal region) with the vertebral aponeurosis, which separates it from the latissimus dorsi, trapezius, and serratus posticus superior, and with the splenius. By its *deep surface* (lumbar region) with the multifidus spinæ, transverse processes of the lumbar vertebræ, and middle layer of the lumbar fascia, which separates it from the quadratus lumborum; (dorsal region) with the multifidus spinæ, semi-spinalis dorsi, levatores costarum, intercostal muscles, and ribs as far as their angles. *Internally* or mesially, with the multifidus spinæ, and semi-spinalis dorsi, which separate it from the spinous processes and arches of the vertebræ.

The fascia lumborum, with the spinal column, aponeurosis of the latissimus dorsi, and ribs, forms a complete osseo-aponeurotic sheath for the erector spinæ.

The CERVICALIS ASCENDENS vel descendens is the continuation of the sacro-lumbalis upwards into the neck. It arises from the angles of the third, fourth, fifth, and sixth ribs, and is inserted by slender tendons into the posterior tubercles of the transverse processes of the third, fourth, fifth, and sixth cervical vertebræ. The term *descendens*, applied to this muscle, can only be correct when it is described as arising in the neck and passing downwards to the ribs.

Relations.—By its *superficial surface* with the levator anguli scapulæ; by its *deep surface* with the upper intercostal muscles, ribs, and intertransverse muscles; *externally* with the scalenus posticus and medius; *internally* with

the transversalis cervicis. The tendons of insertion are interposed between the attachments of the scalenus medius and posticus and transversalis cervicis, with which they are united.

The TRANSVERSALIS CERVICIS appears to be the continuation upwards into the neck of the longissimus dorsi; it *arises* from the transverse processes of the five or six upper dorsal vertebræ; and is *inserted* into the posterior tubercles of the transverse processes of the cervical vertebræ, from the second to the sixth. receives a fasciculus from the longissimus dorsi and several small slips from the trachelo-mastoideus.

Relations. — By its *superficial surface* with the levator anguli scapulæ, splenius, and longissimus dorsi. By its *deep surface* with the complexus, trachelo-mastoideus, and vertebræ; *externally* with the musculus accessorius ad sacrolumbalem and cervicalis ascendens; *internally* with the trachelo-mastoideus and complexus. The tendons of insertion of this muscle are interposed between the tendons of insertion of the cervicalis ascendens on the outer side, and those of origin of the trachelo-mastoid on the inner side.

The TRACHELO-MASTOIDEUS (complexus parvus) is likewise a continuation upwards from the longissimus dorsi. It is a slender and delicate muscle, *arising* from the transverse processes of the three upper dorsal and last cervical, and from the articular processes of the three next cervical vertebræ, its origin being similar to that of the complexus, with which and the origin of the transversalis cervicis it is closely connected. It receives a fasciculus from the longissimus dorsi, and is *inserted* into the posterior border and summit of the mastoid process.

Relations. — The same as the preceding muscle, excepting that it is interposed between the transversalis cervicis and complexus.

The COMPLEXUS (trachelo-occipitalis) is a large muscle, forming with the splenius the great bulk of the back of the neck. It crosses the direction of the splenius, *arising* from the transverse processes of the three upper dorsal and last cervical, and from the articular processes of the three next lower cervical vertebræ; and is *inserted* into the rough surface of the occipital bone between the two curved lines, as far as the occipital spine. The complexus is marked in the upper part of the neck by a transverse tendinous intersection.

A large fasciculus of the complexus lying superficially to that muscle, and remarkable for consisting of two fleshy bellies with an intermediate tendon, is usually described under the name of *biventer cervicis*. Considered as a separate muscle, it *arises* by three or four slips from the transverse processes of the dorsal vertebræ, from the fourth to the seventh; and is *inserted* into the inner portion of the superior curved line of the occipital bone. Its tendons of origin lie internally to the insertions of the longissimus dorsi, and are connected with those of the semi-spinalis colli; and its lower belly receives a fasciculus from the longissimus. The outer border of the upper belly is united with the complexus; in the rest of its course it is free.

Relations. — By its *superficial surface* with the trapezius, splenius, trachelo-mastoideus, transversalis cervicis, and longissimus dorsi. By its *deep surface* with the semi-spinalis dorsi and colli, recti and obliqui. It is separated from its fellow of the opposite side by the ligamentum nuchæ, and from the semi-spinalis colli by the profunda cervicis artery, princeps cervicis branch of the occipital, and posterior cervical plexus of nerves.

Fifth Layer.

(Dorsal Group.)

Semi-spinalis dorsi,
Semi-spinalis colli.

(Cervical Group.)

Rectus posticus major,
Rectus posticus minor,
Rectus lateralis,
Obliquus inferior,
Obliquus superior.

Dissection. — The muscles of the preceding layer are to be removed by dividing them transversely through the middle, and turning one extremity upwards, the other downwards. In this way the whole of the muscles of the fourth layer may be dissected off, and the remaining muscles of the spine brought into a state to be examined.

The *Semi-spinales muscles* are connected with the transverse and spinous processes of the vertebræ, spanning one-half the vertebral column; hence their name semi-spinales.

The SEMI-SPINALIS DORSI arises from the transverse processes of the dorsal vertebræ from the sixth to the tenth; and is inserted into the spinous processes of the four upper dorsal and two lower cervical vertebræ. It is united below with the spinalis dorsi, and above with the semi-spinalis colli; it also sends several small slips to the longissimus dorsi.

The SEMI-SPINALIS COLLI, larger than the preceding, arises from the transverse processes of the five or six upper dorsal vertebræ; and is inserted into the spinous processes of the cervical vertebræ from the second to the fifth.

Relations. — By their superficial surface the semi-spinales are in relation from below upwards with the spinalis dorsi, longissimus dorsi, complexus, splenius; profunda cervicis and princeps cervicis artery, and posterior cervical plexus of nerves. By their deep surface with the multifidus spinæ muscle.

On the middle line in the cervical region is a small muscle, the analogue of the spinalis dorsi, termed the *spinalis cervicis*. It is extremely irregular; arising from the spinous processes of the two upper dorsal or two lower cervical vertebræ; and inserted into the spinous process of the axis, and sometimes into the next one or two vertebræ.

Occipital Group. — This group of small muscles is intended for the movements of the cranium on the atlas, and of the atlas on the axis.

The RECTUS POSTICUS MAJOR (superficialis) arises from the spinous process of the axis; and is inserted into the inferior curved line of the occipital bone.

The RECTUS POSTICUS MINOR (profundus) arises from the spinous tubercle of the atlas; and is inserted into the rough surface of the occipital bone, beneath the inferior curved line.

The RECTUS LATERALIS arises from the transverse process of the atlas, and is inserted into the rough surface of the occipital bone, externally to the condyle.

The OBLIQUUS INFERIOR (major) arises from the spinous process of the axis, and passes obliquely outwards to be inserted into the extremity of the transverse process of the atlas.

The OBLIQUUS SUPERIOR (minor) arises from the extremity of the transverse process of the atlas, and passes obliquely inwards to be inserted into the rough surface of the occipital bone, between the curved lines, and directly behind the mastoid process.

Relations. — By their superficial surface the recti and obliqui are in relation

with a strong aponeurosis which separates them from the complexus. By their *deep surface*, with the atlas and axis. The rectus posticus major partly covers in the rectus minor. The rectus lateralis is in relation by its *anterior surface* with the internal jugular vein, and by its *posterior surface* with the vertebral artery.

Sixth Layer.

Multifidus spinæ,
Interspinales,

Intertransversales,
Levatores costarum.

Dissection. — The semi-spinales muscles must be removed to obtain a good view of the multifidus spinæ, which lies beneath them, and fills up the concavity between the spinous and transverse processes, the whole length of the vertebral column.

The MULTIFIDUS SPINÆ, consisting of about twenty-one small muscular fasciculi, extends along the vertebral groove from the sacrum to the axis. The muscle commences by tendinous fibres on the dorsum of the sacrum, proceeding from the lateral tubercles of the sacrum, and even from the lateral cornu of the coccyx, and passing obliquely upwards and inwards to the spinous tubercles. The fasciculi arise inferiorly from the sacrum, ilium, and tendon of the erector spinæ; in the lumbar region from the articular and posterior transverse processes of the vertebræ; in the dorsal region from the transverse processes; and in the cervical region from the articular processes of the four inferior vertebræ. They are inserted into the spinous processes and laminae of all the vertebræ from the sacrum to the axis. Of the twenty-two fasciculi, six are lumbar, twelve dorsal, and four cervical. Each fasciculus, separate below, spreads out as it ascends, and passing over the next vertebra, is inserted into the four or five immediately above it. The muscle is thick inferiorly; and the uppermost fasciculus larger than those immediately below it.

Under the name of *rotatores dorsi*, expressive of their action, Theile has described eleven pairs of small muscles, which appear to belong to the multifidus spinæ, though separated from it by cellular tissue. The rotatores arise from the apex and upper border of a transverse process; to be inserted into the lower border of the lamina of the vertebra above, as far as the base of the spinous process. The inferior rotatores are somewhat larger than the superior.

Relations. — By its *superficial surface* with the longissimus dorsi, semi-spinalis dorsi, and semi-spinalis colli. By its *deep surface* with the laminae and spinous processes of the vertebral column, and in the cervical region with the ligamentum nuchæ.

The INTERSPINALES are small muscular slips arranged in pairs and situated between the spinous processes of the vertebræ. In the *cervical region* there are six pairs of these muscles, the first being placed between the axis and third vertebra, the sixth between the last cervical and first dorsal; they are attached to the apices of the spinous processes, and are separated by the interspinous ligaments. In the *dorsal region*, rudiments of these muscles are occasionally met with between the upper and lower vertebræ, but are absent in the rest. In the *lumbar region* there are six pairs of interspinales, the first pair occupying the interspinous space between the last dorsal and first lumbar vertebra, the last, the space between the fifth lumbar and sacrum. They are thin, broad, and imperfectly developed. Rudimentary interspinales are occasionally met with between the sacrum and coccyx; these are the analogues of the caudal muscles of brutes; in man they are named collectively the *extensor coccygis* (sacro-coccygeus posticus).

The INTERTRANSVERSALES (intertransversarii) are small quadrilateral muscles

situated between the transverse processes of the vertebræ. In the *cervical region* they are arranged in pairs corresponding with the double conformation of the transverse processes, the vertebral artery and anterior division of a cervical nerve lying between them. The *rectus anticus minor* and *rectus lateralis* represent the intertransversales between the atlas and cranium. In the *dorsal region* the anterior intertransversales are represented by the intercostal muscles, while the posterior are mere tendinous bands, muscular only between the first and last vertebræ. In the *lumbar region*, the anterior intertransversales are thin, and occupy only part of the space between the transverse processes. Analogues of posterior intertransversales exist, in the form of small muscular fasciculi (*interobliqui, interaccessorii*) extended between the rudimentary posterior transverse processes of the lumbar vertebræ.

The *LEVATORES COSTARUM* (*supra-costales*) are divided into long and short. The *short* (*breves*), twelve in number at each side, *arise* from the apex and lower border of the transverse process of the last cervical and eleven upper dorsal vertebræ; and pass downwards and outwards, radiating in their descent, to be *inserted* into the upper border of all the ribs, between the tuberosity [*i. e.* tubercle] and angle. The uppermost muscle is the smallest, and their breadth increases from above downwards.

The *levatoros costarum longi*, four in number at each side, *arise* from the transverse processes of the dorsal vertebræ, the seventh to the tenth, and are *inserted* into the four lower ribs; each muscle passing over a rib in its descent, and being attached to the rib below as far as its angle. The *levatoros longi* lie superficially to the *levatoros breves* and increase in size from above downwards.

Relations. — By their *superficial surface* with the *sacro-lumbalis, longissimus dorsi* and *transversalis cervicis*. By their *deep surface* with the ribs and intercostal spaces; the *levatoros breves* close the intercostal spaces, and are united by their external border with the *intercostales externi*.

With regard to the origin and insertion of the muscles of the back, the student should be informed that no exact regularity attends their attachments. At the best, a knowledge of their precise connexions, even were it possible to retain it, would be but a barren information, if not absolutely injurious, as tending to exclude more valuable learning. I have therefore arranged a plan, by which they may be more easily recollected, placing them in a tabular form (pp. 210, 211), that the student may see at a glance, the origin and insertion of each, and compare the natural grouping and similarity of attachment of the various layers. In this manner their actions will also be better comprehended, and learnt with greater facility.

In examining the table, the student will observe the constant recurrence of the number *four* in the origin and insertion of the muscles. Sometimes the *four* occurs at the top or bottom of a region of the spine, and frequently includes part of two regions, taking two from each, as in the case of the *serrati*. Again, he will perceive that the muscles of the upper half of the table take their origin from spinous processes, and pass outwards to transverse, whereas the lower half arise mostly from transverse processes. To the student I commit these reflections, and leave it to the peculiar tenor of his own mind to make such arrangements as will be best retained in his memory.

Actions. — The upper fibres of the *trapezius* draw the shoulder upwards and backwards; the middle fibres, directly backwards; the lower, downwards and backwards. The lower fibres also act in producing rotation of the scapula on the chest. If the shoulder be fixed, the upper fibres will flex the spine towards the

corresponding side. The *latissimus dorsi* is a muscle of the arm, drawing it backwards and downwards, and at the same time rotating it inwards; if the arm be fixed, the *latissimus dorsi* will draw the spine to that side, and, raising the lower ribs, be an inspiratory muscle; and if both arms be fixed, the two muscles will draw the whole trunk forwards, as in climbing or walking on crutches. The *levator anguli scapulæ* lifts the upper angle of the scapula, and with it the entire shoulder; the *rhomboidei* carry the scapula and shoulder upwards and backwards.

The serrati are respiratory muscles acting in opposition to each other, the *serratus posticus superior* drawing the ribs upwards, and thereby expanding the chest; the *inferior* drawing the lower ribs downwards, and diminishing the cavity of the chest. The former is an inspiratory, the latter an expiratory muscle. The *splenii* muscles of one side draw the vertebral column backwards and to one side, and rotate the head towards the corresponding shoulder. The muscles of opposite sides acting together, draw the head directly backwards. They are direct antagonists of the sterno-mastoid muscles.

The *sacro-lumbalis* with its *accessory muscle*, the *longissimus dorsi* and *spinalis dorsi*, are known by the general term of *erector spinæ*, which sufficiently expresses their action. They keep the spine supported in the vertical position by their broad origin from below, and by their insertion, by distinct tendons, into the ribs and spinous processes. Being made up of a number of distinct fasciculi, which act alternately, the spine is kept erect without fatigue, even when the muscles have to counterbalance a corpulent abdomen. The continuation upwards of these muscles into the neck preserve the steadiness and uprightness of that region. When the muscles of one side act alone, the neck is rotated upon its axis. The *complexus*, being attached to the occipital bone, draws the head backwards, and counteracts the muscles of the anterior part of the neck. It assists also in the rotation of the head.

The *semi-spinales* and *multifidus spinæ* muscles act directly on the vertebrae, and contribute to the general action of supporting the vertebral column erect.

The four little muscles situated between the occiput and the first two vertebrae, effect the various movements between these bones; the *recti* producing the antero-posterior actions; the *obliqui* the rotatory motions of the atlas on the axis.

The actions of the remaining muscles of the spine, the *interspinales* and *intertransversales*, are expressed in their names. They approximate their attachments and assist the more powerful muscles in preserving the erect position of the body.

The *levatores costarum* raise the posterior parts of the ribs, and are probably more serviceable in preserving the articulation of the ribs from displacement, than in raising them in inspiration.

ORIGIN.				
Layers.	Spinous Processes.	Transverse Processes.	Ribs.	Additional.
<i>1st Layer.</i>				
Trapezius . . .	last cervical, 12 dorsal	}	}	{ occipital bone and ligamentum nuchæ
Latissimus dorsi .	4 or 6 lower dorsal, 5 lumbar			
<i>2d Layer.</i>				
Levator anguli scapulæ	4 upper cervical
Rhomboideus minor	lig. nuchæ and last cervical	}	}	}
Rhomboideus major	4 upper dorsal			
<i>3d Layer.</i>				
Serratus posticus superior . . .	lig. nuchæ, last cervical, 2 upper dorsal	}	}	}
Serratus posticus inferior . . .	2 lower dorsal, 2 upper lumbar			
Splenius capitis .	lig. nuchæ, last cervical,	}	}	}
Splenius colli . .	6 upper dorsal			
<i>4th Layer.</i>				
Sacro-lumbalis	ilium
Accessorius ad sacro-lumbalem	angles, 6 lower	}
Longissimus dorsi	
Spinalis dorsi . .	2 lower dorsal, 2 upper lumbar	}	}	}
Cervicalis ascendens			
Transversalis cervicis	5 or 6 upper dorsal . . .	}	}
Trachelo-mastoideus	3 upper dorsal, 1 lower cervical		
Complexus	3 upper dorsal, 1 lower cervical	}	{ articular processes } 4th, 5th, 6th cerv. articular processes } 4th, 5th, 6th cerv.
Biventer cervicis	dorsal 4th to 7th		
<i>5th Layer.</i>				
Semi-spinalis dorsi	6th to 10th dorsal
Semi-spinalis colli	5 or 6 upper dorsal . .	}	}
Rectus posticus major	axis		
Rectus posticus minor	atlas
Rectus lateralis	atlas
Obliquus inferior	axis
Obliquus superior	atlas
<i>6th Layer.</i>				
Multifidus spinæ	from sacrum to 4th cervical	}	{ Sacrum, ilium, tendon of erector spinæ, articular proc. }
Interspinales . .	cervical&lumbar		
Intertransversales	cervical&lumbar
Levatores costarum	last cervical and 11 upper dorsal	}	}

INSERTION.			
Spinous Processes.	Transverse Processes.	Ribs.	Additional.
.	} clavicle, acromion, and spine of scapula. bicipital groove of humerus.
.	
.	} angle and base of scapula.
.	
.	base of scapula.
.	base of scapula.
.	2d, 3d, 4th, and 5th.	
.	4 lower.	
.	3 upper cervical	} occipital and temporal bone, and mastoid process.
.	angles of 6 lower.	
.	last cervical .	angles of 6 upper.	
.	all the lumbar and dorsal	11 lower, between tubercles and angles.	
{ dorsal, 2d to 6th or 8th.	} 3d, 4th, 5th, 6th cervical.		
.		2d to 6th cervical.	
.	mastoid process.
.	} occipital bone between the curved lines.
.	
.	occipital bone, superior curved line.
{ 4 upper dorsal, 2 lower cervical.			
2d to 5th cervical			
.	occipital bone.
.	occipital bone.
.	occipital bone.
.	atlas.	occipital bone.
.	
all except atlas	} all the laminæ, except atlas.
cervical & lumbar.	cervical & lumbar		
.	} all, between tubercles and angles.	
.		

MUSCLES OF THE THORAX.

The principal muscles situated on the front and sides of the thorax belong in their actions to the upper extremity, with which they will be described. They are the pectoralis major and minor, subclavius and serratus magnus. The true thoracic muscles, which appertain exclusively to the actions of the ribs, are, the

Intercostales externi,	Subcostales,
Intercostales interni,	Triangularis sterni.

The intercostal muscles are two planes of muscular and tendinous fibres, directed obliquely between adjacent ribs and closing the intercostal spaces. They are seen partially on the reflection of the pectoral muscles, or on the inner surface of the chest. The triangularis sterni is within the chest, and requires the removal of the anterior part of the thorax to bring it into view.

The INTERCOSTALES EXTERNI, eleven on each side, commence posteriorly at the tubercles of the ribs, and advance forwards to the costal cartilages, where they terminate in a thin aponeurosis which is continued onwards to the sternum. Their fibres are directed obliquely downwards and inwards, pursuing the same line with those of the external oblique muscle of the abdomen. They are thicker than the internal intercostals, and more tendinous in structure.

The INTERCOSTALES INTERNI, also eleven on each side, commence anteriorly at the sternum, and extend backwards as far as the angles of the ribs, whence they are prolonged to the vertebral column by a thin aponeurosis. Their fibres are directed obliquely downwards and backwards, corresponding with those of the internal oblique muscle of the abdomen, and crossing those of the external intercostals.

In structure the intercostal muscles consist of an admixture of muscular and tendinous fibres. They *arise* from the two lips of the lower border of the rib, the external from the outer lip, the internal from the inner; and are *inserted* into the upper border of the rib below, encroaching somewhat on its surfaces.

The SUBCOSTALES (infracostales; intracostales) are nine or ten small muscles situated within the thorax at its posterior part, and lying upon the ribs. They increase in size from above downwards, and the direction of their fibres corresponds with that of the intercostales interni. Each muscle *arises* from the front of a rib, and is *inserted* into the front of the rib but one below; the first subcostalis is often absent.

Relations. — The external intercostals, by their *external surface*, with the muscles which immediately invest the chest, viz., pectoralis major and minor, serratus magnus, serratus posticus superior and inferior, scalenus posticus, sacrolumbalis and longissimus dorsi with their continuations, cervicalis ascendens and transversalis cervicis, levatores costarum, and obliquus externus abdominis. By their *internal surface* with the internal intercostals, intercostal vessels and nerves, and posteriorly with the pleura, a thin aponeurosis being interposed. The internal intercostals, by their *external surface* with the external intercostals, and intercostal vessels and nerves; by their *internal surface* with the pleura costalis, triangularis sterni, subcostales, and diaphragm.

The TRIANGULARIS STERNI (sterno-costalis), situated upon the inner wall of the front of the chest, *arises* by a thin aponeurosis from the side of the sternum, ensiform cartilage, and sternal extremities of the costal cartilages from the third to the sixth or seventh; it is *inserted* by fleshy digitations into the second, third, fourth, and fifth costal cartilages and corresponding ribs.

Relations. — By its *external surface* with the sternum, ensiform cartilage, costal cartilages, internal intercostal muscles, and internal mammary vessels. By its *internal surface* with the pleura costalis, cellular tissue of the anterior mediastinum, and diaphragm. The lower fibres of the triangularis sterni are continuous with those of the transversalis abdominis.

Actions. — The intercostal muscles raise the ribs when they act from above, and depress them when they take their fixed point from below. They are, therefore, both inspiratory and expiratory muscles. The triangularis sterni draws down the costal cartilages, and is therefore an expiratory muscle.

The muscles of respiration, according to Dr. Barelay, are as follows:—

Dilating or Inspiratory muscles.

Intercostales,	Subcostales,
Levatores costarum,	Diaphragma,
<i>assisted occasionally by the</i>	
Sterno-cleido-mastoidei,	Subclavii,
Scaleni,	Pectorales majores,
Serrati postici superiores,	Latissimi dorsi,
Pectorales minores,	Cervicales ascendentes,
Serrati magni,	Accessorii ad sacro-lumbales.

Contracting, or Expiratory muscles.

Triangulares sterni,	Transversales abdominis,
Obliqui externi,	Recti abdominis,
Obliqui interni,	Pyramidales,

assisted occasionally by the

Serrati postici inferiores,	Quadrati lumborum,
Longissimi dorsi,	Serrati magni.
Sacro-lumbales,	

To which may be added, as expiratory powers, the costal cartilages; acting by virtue of their elasticity.

MUSCLES OF THE ABDOMEN.

The muscles of the abdominal region are, the

Obliquus externus (descendens),	Rectus,
Obliquus internus (ascendens),	Pyramidalis,
Cremaster,	Quadratus lumborum,
Transversalis,	Psoas parvus,
Diaphragma.	

Dissection. — The dissection of the abdominal muscles is to be commenced by making three incisions:— The first, *vertical*, in the middle line, from over the lower part of the sternum to the pubes; the second, *oblique*, from the umbilicus, upwards and outwards, to the outer side of the chest, as high as the fifth or sixth rib; the third, *oblique*, from the umbilicus, downwards and outwards, to the crest of the ilium and along the crest to its middle. The three flaps included by these incisions should then be dissected back in the direction of the fibres of the external oblique muscle, beginning at the angle of each. The integument and superficial fascia should be dissected off together, so as to expose the fibres of the muscle at once.

When the external oblique muscle is dissected on both sides, a white tendinous line will be seen along the middle of the abdomen, extending from the ensiform cartilage to the pubes; this is the *linea alba*. A little external to it, on each side, two curved lines will be observed extending from the eighth rib to the spine of the pubes, and bounding the recti muscles; these are the *lineæ semilunares*. Some transverse lines, *lineæ transversæ*, three in number, connect the *lineæ*

semilunares with the linea alba at and above the umbilicus; [sometimes a fourth and even a fifth are found below the umbilicus].

The EXTERNAL OBLIQUE MUSCLE (*obliquus externus abdominis, descendens; costo-abdominalis*) is the external flat muscle of the abdomen. Its name is derived from the obliquity of its direction, and the descending course of its fibres. It *arises* by fleshy digitations from the external surface of the eight inferior ribs; the five upper digitations being received between corresponding processes of the serratus magnus, the three lower, of the latissimus dorsi. The fleshy fasciculi proceeding from this extensive origin terminate on the front of the abdomen in a broad aponeurosis, and posteriorly are *inserted* into the outer lip of the crest of the ilium, for two-thirds its length, and into the anterior superior spinous process. The aponeurosis is united, in front, by its under surface, with that of the obliquus internus, forming the anterior wall of the sheath of the rectus, and is *inserted* into the linea alba, front of the pubes, spine of the pubes and pectineal line.

The lower border of the aponeurosis, which is stretched between the anterior superior spinous process of the ilium, and the spine of the pubes, is round from being folded inwards, and forms *Poupart's ligament* (ligamentum Fallopii; arcus cruralis); the insertion into the pectineal line is *Gimbernat's ligament* [see fig. 129, 6, 7].

Just above the crest of the pubes is the *external abdominal ring* (annulus abdominalis externus), a triangular opening formed by the separation of the fibres of the aponeurosis of the external oblique. It is oblique in direction, and corresponds with the course of the fibres of the aponeurosis. It is bounded below by the crest of the pubes; on either side by the borders of the aponeurosis, which are termed *pillars*; and above by some curved fibres (*intercolumnar*) which originate from Poupart's ligament, and cross the upper angle of the ring, to give it strength. The *external pillar*, which is at the same time *inferior* from the obliquity of the opening, is inserted into the spine of the pubes; the *internal* or *superior pillar* forms an interlacement with its fellow of the opposite side over the front of the symphysis pubis. The external abdominal ring gives passage to the spermatic cord in the male, and the round ligament in the female; they are both invested in their passage through it by a prolongation of the fascia of the external oblique muscle, the *intercolumnar fascia*, or fascia spermatica.

The pouch of inguinal hernia, in passing through this opening, receives the *intercolumnar fascia* as one of its coverings.

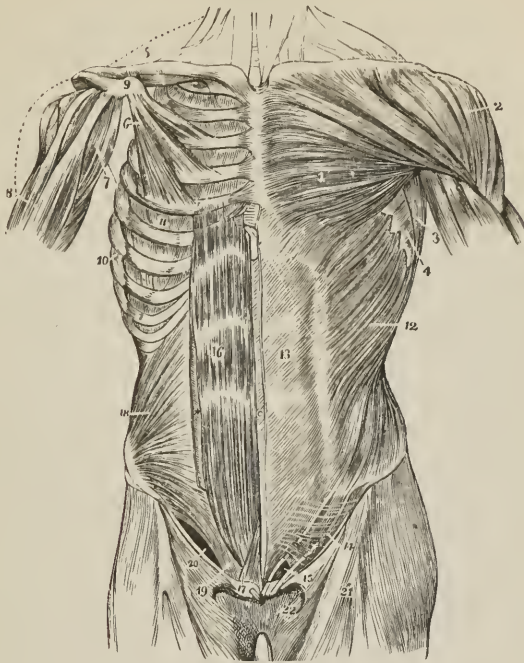
Relations.—By its *external surface* with the superficial fascia, integument, cutaneous vessels and nerves, particularly the superficial epigastric and superficial circumflexa ilii vessels, and latissimus dorsi, by which it is overlapped posteriorly. By its *internal surface* with the internal oblique, lower part of the eight inferior ribs and intercostal muscles, cremaster, spermatic cord in the male, and round ligament in the female. The upper border of the external oblique is continuous with the pectoralis major.

The external oblique is now to be removed by making an incision across the ribs, just below its origin, to its posterior border; and another along Poupart's ligament and the crest of the ilium. Poupart's ligament should be left entire, as it gives attachment to the next muscles. The muscle may then be turned forwards towards the linea alba, or removed altogether.

The INTERNAL OBLIQUE MUSCLE (*obliquus internus abdominis, ascendens; ilio-abdominalis*) is the middle flat muscle of the abdomen. It *arises* from the outer half of Poupart's ligament, from the middle of the crest of the ilium for two-thirds its length, and from the fascia lumborum [see p. 217]. Its fibres diverge from their origin, those from Poupart's ligament curving downwards, those from the anterior part of the crest of the ilium passing transversely, and the rest ascending obliquely. The muscle is *inserted* into the pectineal line and crest of the pubes, linea alba, and lower border of the four inferior ribs. At its origin

from the fascia lumborum it becomes the bond of union between the aponeurosis of the transversalis and that of the latissimus dorsi.

FIG. 169.



MUSCLES OF THE ANTERIOR ASPECT OF THE TRUNK; on the left side the superficial layer is seen, on the right the deeper layer. 1. Pectoralis major. 2. Deltoid; the interval between these muscles lodges the cephalic vein. 3. Anterior border of the latissimus dorsi. 4. Serratus magnus. 5. Subclavius, right side. 6. Pectoralis minor. 7. Coraco-brachialis. 8. Upper part of the biceps, showing its two heads. 9. Coracoid process of the scapula. 10. Serratus magnus, right side. 11. External intercostal muscle of the fifth intercostal space. 12. External oblique. 13. Its aponeurosis; the median line to the left of this number is the linea alba; the curved line to the right, the linea semilunaris; the transverse lines above and below the cipher, the lineæ transversæ. 14. Poupart's ligament. 15. External abdominal ring; the margin above the ring is the superior or internal pillar; the margin below the ring, the inferior or external pillar; the curved intercolumnar fibres are seen proceeding upwards from Poupart's ligament to strengthen the ring. The numbers 14 and 15 are placed on the fascia lata of the thigh; the opening immediately to the left of 15 is the saphenous opening. 16. Rectus muscle of the right side brought into view by the removal of the anterior segment of its sheath; * posterior segment of its sheath with the divided edge of the anterior segment. 17. Pyramidalis muscle. 18. Internal oblique. 19. Conjoined tendon of the internal oblique and transversalis, descending behind Poupart's ligament to the pectineal line. 20. The arch formed between the lower curved border of the internal oblique muscle and Poupart's ligament; it is beneath this arch that the spermatic cord and oblique inguinal hernia pass.

Along the upper three-fourths of the linea semilunaris, the aponeurosis of the internal oblique separates into two lamellæ, which pass, one in front, the other behind the rectus muscle to the linea alba, where they are inserted; along the lower fourth, the aponeurosis passes in front of the rectus without separation. The two layers, which thus inclose the rectus, consequently form for it a sheath, which is incomplete at its posterior and inferior part.

The lowest fibres of the internal oblique are inserted into the pectineal line of the pubes in common with those of the transversalis muscle. Hence the tendon of this insertion is called the *conjoined tendon of the internal oblique and transversalis*. This tendon is situated directly behind the external abdominal ring, and serves to strengthen what would otherwise be a weak point in the abdomen. Sometimes the tendon is insufficient to resist the internal pressure, and is forced through the external ring; it then forms the distinctive covering of *direct inguinal hernia*.

The spermatic cord passes beneath the arched border of the internal oblique muscle, between it and Poupart's ligament. During its passage some fibres are given off from the lower border of the muscle, which accompany the cord downwards to the testicle, and form loops around it; this is the cremaster muscle. In the descent of oblique inguinal hernia, which travels the same course as the spermatic cord, the cremaster muscle forms one of its coverings.

The CREMASTER, considered as a distinct muscle, *arises* from the middle of Poupart's ligament, and forms a series of loops upon the spermatic cord. A few of its fibres are inserted into the tunica vaginalis, the rest (*crus internum*) ascend along the inner side of the cord, to be *inserted*, with the conjoined tendon, into the pectineal line of the os pubis.

Relations.—The internal oblique is in relation by its *external surface* with the external oblique, latissimus dorsi, spermatic cord, and external abdominal ring. By its *internal surface* with the transversalis muscle, fascia transversalis, internal abdominal ring, and spermatic cord. By its *lower* and *arched border* with the spermatic cord; forming the upper boundary of the spermatic canal.

The cremaster is in relation by its *external surface* with the aponeurosis of the external oblique, and intercolumnar fascia; by its *internal surface* with the fascia propria of the spermatic cord.

The internal oblique muscle is to be removed by separating it from its attachment, to the ribs above, the crest of the ilium and Poupart's ligament below. It should be divided behind by a vertical incision extending from the last rib to the crest of the ilium, as its lumbar attachment cannot at present be examined. The muscle is then to be turned forwards. Some degree of care will be required in performing this dissection, from the difficulty of distinguishing between this muscle and the one beneath. A thin layer of cellular tissue is all that separates them for the greater part of their extent. Near the crest of the ilium the circumflexa ili artery ascends between the two muscles, and forms a guide to their separation; but just above Poupart's ligament they are so closely united, that separation is impossible.

The TRANSVERSALIS (lumbo-abdominalis) is the internal flat muscle of the abdomen; and is transverse in the direction of its fibres, as implied in its name. It *arises* from Poupart's ligament, somewhat less than the outer half, from the anterior two-thirds of the internal lip of the crest of the ilium; from the transverse processes of the lumbar vertebræ through the medium of the posterior aponeurosis, and from the inner surface of the six inferior costal cartilages. The superior fibres, proceeding from the cartilage of the seventh rib, are *inserted* into the ensiform cartilage; the inferior fibres, proceeding from Poupart's ligament, curve downwards to be *inserted* by means of a tendinous expansion common to it and the internal oblique, the *conjoined tendon of the internal oblique and transversalis*, into the pectineal line of the pubes; while the fibres intermediate between these points terminate near the outer border of the rectus in an aponeurosis which is continued onwards to the linea alba. The upper portion of the aponeurosis, closely united with the posterior lamella of the aponeurosis of the internal oblique, assists in forming the posterior wall of the sheath of the rectus, while the inferior portion, commencing at a point midway between the umbilicus and pubes is continued with the undivided aponeurosis of the internal oblique in front of the rectus.

The *posterior aponeurosis* of the transversalis divides into three lamellæ, anterior, middle, and posterior, which constitute the *fascia lumborum*. The *anterior* lamella, thin and membranous, is attached to the base of the transverse processes of the lumbar vertebræ; the *middle* lamella, of considerable thickness, to their apices; the *posterior* layer receives the attachment of the posterior aponeurosis of the internal oblique, and further back, near the border of the erector spinæ, becomes united with the aponeurosis of the latissimus dorsi. Between the anterior and middle lamella is lodged the quadratus lumborum; and between the middle and posterior layer, the erector spinæ and multifidus spinæ, which are thus furnished with aponeurotic sheaths.

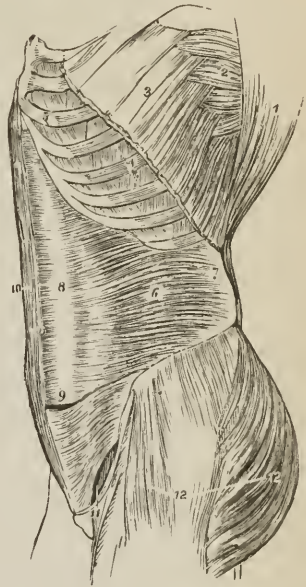
Relations.—By its *external surface* with the internal oblique, the internal surface of the six lower ribs, and internal intercostal muscles. By its *internal surface* with the transversalis fascia, which separates it from the peritoneum, with the psoas magnus, the lower part of the rectus, and pyramidalis. The spermatic cord and oblique inguinal hernia pass beneath the *lower border*, but have no direct relation with it. The *upper border* is continuous with the diaphragm and triangularis sterni.

To dissect the *rectus* muscle, its sheath should be opened by a vertical incision, extending over the cartilages of the lower ribs to the front of the os pubis. The sheath may then be dissected off and turned aside; this is easily done excepting at the *lineæ transversæ*, where a close adhesion subsists between the muscle and the external wall of the sheath. The sheath contains the rectus and pyramidalis muscle.

The RECTUS (sterno-pubius) arises by a double tendon from the front and crest of the os pubis, and is *inserted* by three broad digitations into the cartilages of the fifth, sixth, and seventh ribs. It is traversed by several tendinous intersections, called *lineæ transversæ* (inscriptiones tendineæ). One of these is situated at the umbilicus, one over the ensiform cartilage, and one midway between these points; when a fourth exists, it occurs below the umbilicus. The *lineæ transversæ* are vestiges of the abdominal ribs of reptiles, and rarely extend completely through the muscle.

Relations.—By its *external surface* with the anterior lamella of the aponeurosis of the internal oblique, below with the aponeurosis of the transversalis, and with the pyramidalis. By its *internal surface* with the ensiform cartilage, car-

FIG. 170.



LATERAL VIEW OF THE TRUNK, SHOWING ITS MUSCLES, particularly the transversalis abdominis. 1. Costal origin of the latissimus dorsi. 2. Serratus magnus. 3. Upper part of the external oblique, divided in the direction best calculated to show the muscles beneath without interfering with its indigitations with the serratus magnus. 4. Two of the external intercostal muscles. 5. Two of the internal intercostals. 6. Transversalis. 7. Its posterior aponeurosis. 8. Its anterior aponeurosis forming the posterior layer of the sheath of the rectus. 9. Lower part of the left rectus with the aponeurosis of the transversalis passing in front. 10. Right rectus muscle. 11. Arched opening left between the lower border of the transversalis muscle and Poupart's ligament, through which the spermatic cord and oblique inguinal hernia pass. 12. Tensor vaginae femoris, gluteus medius and maximus invested by fascia lata.

tilages of the ribs from the fifth to the ninth, posterior lamella of the internal oblique, peritoneum, and epigastric artery and veins.

The PYRAMIDALIS (pubio-subumbilicalis) *arises* from the crest of the os pubis in front of the rectus, and is *inserted* into the linea alba at about midway between the umbilicus and pubes. It is inclosed in the sheath with the rectus, and rests against the lower part of that muscle; it is sometimes absent.

The rectus may now be divided across the middle, and the two ends drawn aside for the purpose of examining the mode of construction of its sheath.

The *sheath of the rectus* is formed, *in front*, for the upper three-fourths of its extent, by the aponeurosis of the external oblique and anterior lamella of the internal oblique; *behind* by the posterior lamella of the internal oblique and aponeurosis of the transversalis. Midway between the umbilicus and the pubes, the posterior wall of the sheath terminates in a thin curved margin (plica semilunaris Douglasii) the aponeurosis of the three muscles passing, below this point, altogether in front of the rectus.

The next two muscles can be examined only when the viscera of the abdomen are removed. To see the quadratus lumborum, it is also necessary to divide and draw aside the psoas muscle and the anterior lamella of the posterior aponeurosis of the transversalis.

The QUADRATUS LUMBORUM (ilio-costalis) is concealed from view by the anterior lamella of the posterior aponeurosis of the transversalis muscle, which is inserted into the bases of the transverse processes of the lumbar vertebræ. When this lamella is divided, the muscle will be seen to consist of two portions: one, the *external*, *arising* from the ilio-lumbar ligament and outer lip of the crest of the ilium for two inches in extent, and *inserted* into the apices of the transverse processes of the four upper lumbar vertebræ (sometimes also last dorsal) and last rib; the other, the *internal* and anterior portion, *arises* by tendinous slips from the transverse processes of the three or four lower lumbar vertebræ, and passes upwards to be *inserted* into the lower border of the last rib. If the muscle be cut across or removed, the middle lamella of the aponeurosis of the transversalis will be seen, attached to the apices of the transverse processes; the quadratus being inclosed between the two lamellæ as in a sheath.

Relations. — Inclosed in the sheath formed by the aponeurosis of the transversalis muscle, it is in relation, *in front*, with the kidney, colon, psoas magnus, and diaphragm. *Behind*, but also separated by its sheath, with the erector spinæ.

The PSOAS PARVUS is a small and infrequent muscle which *arises* from the last dorsal and first lumbar vertebra and from the intervertebral substance between them, and terminates in a long slender tendon which expands inferiorly and is *inserted* into the ilio-pectineal line and eminence. The tendon is continuous by its outer border with the iliac fascia.

Relations. — It rests on the psoas magnus, and is covered in by the peritoneum; superiorly it passes beneath the ligamentum arcuatum internum of the diaphragm.

DIAPHRAGMA. — To obtain a good view of this important inspiratory muscle, the peritoneum should be dissected from its under surface. It is a transverse muscular septum between the thorax and abdomen, and is composed of two portions, thoracic and lumbar, the former being named the greater, the latter the lesser muscle. The *thoracic portion* *arises* from the ensiform cartilage by a distinct slip and from the internal surface of the six inferior ribs indigitating with the transversalis. The fibres converge to be *inserted* into the central tendon.

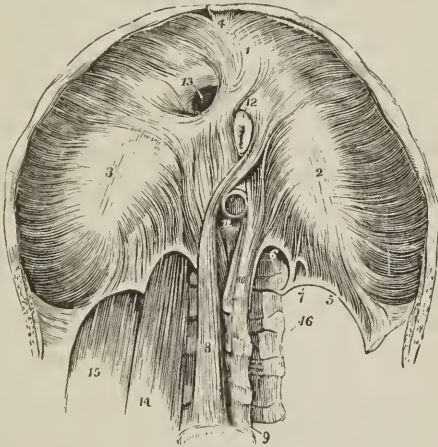
A triangular interval exists between the sternal and costal portion of the muscle at each side, closed by a few irregular muscular fibres and by the serous membranes of the cavity of the chest and abdomen. A protrusion of any portion of the contents of the abdomen through this opening constitutes phrenic or diaphragmatic hernia.

The *lumbar portion* consists of a right and left lateral half (*pillars, crura*); each of which is composed of *three* smaller pillars or crura, *internal, middle, and external*.

The *crura, arise* from the front and lateral aspect of the bodies of the first, second, and third lumbar vertebræ, from the intervertebral substance between the first, second, third, and fourth, from the transverse process of the first, ligamentum arcuatum internum and externum, and last rib. The *left crus* is shorter than the *right* by the breadth of a vertebra, and does not advance so far forwards on the front of the vertebral column. The crura are *inserted* into the whole length of the posterior border of the central tendon.

The origin of the crura takes place by a strong tendon, from which and from the other points of attachment muscular fibres proceed. The *internal pillar* of the crus is its anterior fasciculus, which proceeds from the third lumbar vertebra; the *middle pillar*, smaller than the others, proceeds from the second vertebra; the *external pillar*, the largest of the three, from the lumbar vertebra, ligamenta arcuata and last rib. The internal pillars approach each other as they ascend, the arched interval between them being the aortic opening; their internal fibres, consisting of several fasciculi, cross each other in front of the aortic

FIG. 171.



UNDER OR ABDOMINAL SIDE OF THE DIAPHRAGM. 1, 2, 3. The thoracic portion; figure 1 rests on the central leaflet of the tendinous centre; figure 2 on the left or smallest leaflet; figure 3 on the right leaflet. 4. Fasciculus from the ensiform cartilage; a small triangular space, closed only by the serous membranes of the abdomen and chest, is left on either side of this fasciculus. 5. Ligamentum arcuatum externum of the left side. 6. Ligamentum arcuatum internum. 7. A small arched opening occasionally found, through which the lesser splanchnic nerve passes. 8. Tendon of the right or larger crus; a muscular fasciculus from this tendon curves to the left side of the greater muscle between the œsophageal and aortic opening. 9. Fourth lumbar vertebra. 10. Tendon of the left or shorter crus. 11. Aortic opening occupied by the cylinder of the aorta. 12. Portion of the œsophagus issuing through the œsophageal opening; in this figure the œsophageal opening is tendinous at its anterior part, a state that is not uncommon. 13. Opening for the inferior vena cava, in the tendinous centre of the diaphragm. 14. Psoas magnus passing beneath the ligamentum arcuatum internum; it has been removed on the opposite to show the arch more distinctly. 15. Quadratus lumborum passing beneath the ligamentum arcuatum externum, the muscle has also been removed on the left side. 16. Intertransversales.

opening and form the lateral boundaries of another opening of elliptical shape (œsophageal), and are then lost in the central tendon. In the decussation between

the aortic and œsophageal opening the fibres of the right internal pillar are generally the most superficial. Between the lumbar and costal portion of the diaphragm at each side is a triangular interval like that between the costal and sternal portion, closed only by cellular tissue and the serous membranes of the two cavities.

The *ligamentum arcuatum internum* is a tendinous arch thrown across the upper part of the psoas muscle from the side of the body of the first lumbar vertebra to the apex of its transverse process, extending sometimes also to that of the second. Beneath this arch the psoas magnus emerges from the chest.

The *ligamentum arcuatum externum* is a tendinous band extended from the apex of the transverse process of the first lumbar vertebra to the lower border of the last rib. It forms an arch across the quadratus lumborum, and is continuous with the anterior wall of the sheath of that muscle derived from the posterior aponeurosis of the transversalis abdominis.

The *tendinous centre* of the diaphragm is shaped like a trefoil leaf, of which the central leaflet points to the ensiform cartilage, and is the largest; the lateral leaflets, right and left, occupy the corresponding portions of the muscle; the right being the larger and rounded, the left smaller and lengthened in its form.

The *openings in the diaphragm* are three: one, *quadrilateral*, in the tendinous centre, at the union of the right and middle leaflets, for the passage of the *inferior vena cava*; a muscular opening of an elliptical shape formed by the internal pillars of the crura, the *œsophageal*, for the transmission of the *œsophagus* and *pneumogastric nerves*; a third, the *aortic*, formed by a tendinous arch thrown from the tendon of one crus to that of the other, beneath which pass the *aorta* and *thoracic duct*. The great splanchnic nerve passes through the diaphragm between the internal and middle pillar of the crus; the trunk of the sympathetic and vena azygos between the middle and external pillar. The lesser splanchnic nerve escapes between those fibres of the external pillar which proceed from the *ligamentum arcuatum internum*.

Relations. — By its *superior surface* with the pleuræ, pericardium, heart, and lungs. By its *inferior surface* with the peritoneum; on the left with the stomach and spleen; on the right with the convexity of the liver; behind, with the kidneys, supra-renal capsules, duodenum, and solar plexus. By its *circumference* with the ensiform cartilage, ribs, intercostal muscles, and vertebral column.

Actions. — The external oblique muscle, acting singly, would draw the thorax towards the pelvis, and twist the body to the opposite side. Both muscles, acting together, flex the thorax directly on the pelvis. The internal oblique of one side draws the chest downwards and outwards; both together bend it directly forwards. Either transversalis muscle, acting singly, will diminish the size of the abdomen on its own side, and both together will constrict the entire cylinder of the cavity. The recti muscles, assisted by the pyramidales, flex the thorax towards the pelvis, and, through the medium of the lineæ transversæ, are enabled to act when their sheath is curved inwards by the action of the transversales. The pyramidales are tensors of the linea alba. The abdominal, are expiratory muscles, and chief agents in expulsion; by their action, the fœtus is expelled from the uterus, the urine from the bladder, fæces from the rectum, bile from the gall-bladder, ingesta from the stomach and bowels in vomiting, and mucous and irritating substances from the bronchial tubes, trachea, and nasal passages, during coughing and sneezing. To produce these effects, they all act together. Their violent and continued action produces hernia, and, acting spasmodically, they may occasion rupture of the viscera. The quadratus lumborum draws the last rib downwards, and is an expiratory muscle; it also serves to bend the vertebral column to one or the other side. The psoas parvus is a tensor of the iliac

fascia, and, taking its fixed origin from below, may assist in flexing the vertebral column forwards. The diaphragm is an inspiratory muscle, and the sole agent in tranquil inspiration. When in action, the muscle is drawn downwards, its plane being rendered oblique from the level of the ensiform cartilage, to that of the upper lumbar vertebra. During relaxation it is convex, and encroaches considerably on the cavity of the chest, particularly at the sides, where it corresponds with the lungs. It assists the abdominal muscles powerfully in expulsion, every act of that kind being preceded or accompanied by inspiration. Spasmodic action of the diaphragm produces hicough and sobbing, and its rapid alternation of contraction and relaxation, combined with laryngeal and facial movements, laughing and crying.

The actions of the muscles on the trunk, the neck and the head may be conveniently studied by means of a table arranged according to the plan of Dr. Barclay. Thus, the head, the neck and the trunk are moved forwards or flexed, backwards or extended, or laterally, that is abducted from the middle line, by the several muscles, as follows:—

HEAD.

Flexors.

Rectus anticus minor, Rectus anticus major,
Sterno-cleido-mastoideus,

*and, the jaw being fixed by the masseteres, temporales
and pterygoidei,*

Platysma myoides, Genio-hyoideus,
Digastricus, Genio-hyo-glossus.
Mylo-hyoideus,

Extensors.

Trapezius, Rectus posticus major,
Splenius capitis, Rectus posticus minor,
Complexus, Obliquus superior.
Trachelo-mastoideus,

Abductors.¹

Platysma myoides, Trachelo-mastoideus,
Sterno-cleido-mastoideus, Complexus,
Trapezius, Rectus posticus major,
Splenius capitis, Rectus lateralis.

NECK.

Flexors.

Platysma myoides, Sterno-thyroideus,
Sterno-cleido-mastoideus, Omo-hyoideus,
Digastricus, Rectus anticus major,
Mylo-hyoideus, Longus colli,
Genio-hyoideus, Scalenus anticus,
Genio-hyo-glossus, Scalenus medius.
Sterno-hyoideus,

¹ Muscles having broad and numerous attachments or an oblique position must necessarily act in several directions, and consequently occupy a place in different groups of this table.

Extensors.

Trapezius,	Transversalis cervicis,
Levator anguli scapulæ,	Cervicalis ascendens,
Rhomboideus minor,	Semi-spinalis colli,
Serratus posticus superior,	Multifidus spinæ,
Splenius capitis,	Interspinales,
Splenius colli,	Scalenus medius,
Complexus,	Scalenus posticus.
Trachelo-mastoideus,	

Abductors and Rotators.

The flexors and extensors of one side acting alone are abductors; acting in groups, they combine more or less flexion or extension with abduction, and are consequently rotators. The more direct abductors are:—

Trapezius,	Scaleni,
Sterno-cleido-mastoideus,	Intertransversales.

TRUNK.

Flexors.

Rectus abdominis,	Obliquus internus,
Pyramidalis,	Psoas magnus,
Obliquus externus,	Psoas parvus,
<i>and indirectly,</i>	
Pectoralis major,	Serratus magnus,
Pectoralis minor,	Transversalis abdominis.

Extensors.

Trapezius,	Longissimus dorsi,
Rhomboideus major,	Spinalis dorsi,
Latissimus dorsi,	Semi-spinalis dorsi,
Serratus posticus superior,	Multifidus spinæ,
Serratus posticus inferior,	Intertransversales,
Sacro-lumbalis,	Quadratus lumborum.

Abductors, or Lateral Flexors.

The whole of the muscles of the trunk acting on one side more forcibly than on the other.

MUSCLES OF THE PERINEUM.

The muscles of the perineum are situated in the outlet of the pelvis, and consist of two groups, one of which belongs especially to the organs of generation and urethra, the other to the termination of the alimentary canal. To these may be added the anterior muscles of the coccyx.

MALE PERINEUM.—The muscles of the perineal region in the male, are the

Accelerator urinæ,	Sphincter ani,
Erector penis,	Levator ani,
Transversus perinei,	Coccygeus,
Compressor urethræ,	Sacro-coccygeus anticus.

to the int
in the sup
of that bon
t — To dissect the perineum, the subject should be fixed in the posi-
tomy, that is, the hands should be bound to the soles of the feet,

and the knees kept apart. An easier plan is the drawing of the feet upwards by means of a cord passed through a hook in the ceiling. Both of these means of preparation have for their object the full exposure of the perineum. And as this is a dissection which demands some degree of delicacy and nice manipulation, a strong light should be thrown upon the part. Having fixed the subject, and drawn the scrotum upwards by means of a string or hook, carry an incision from the base of the scrotum along the ramus of the pubes and ischium and tuberosity of the ischium to a point parallel with the apex of the coccyx; then describe a curve over the coccyx to the same point on the opposite side, and continue the incision onwards along the opposite tuberosity and ramus of the ischium and pubes, to the opposite side of the scrotum, where the two extremities may be connected by a transverse incision. This incision will completely surround the perineum, following very nearly the outline of its boundaries. Now let the student dissect off the integument carefully from the whole of the included space, and he will expose the fatty cellular structure of the common superficial fascia, which resembles the superficial fascia in other situations. The common superficial fascia is then to be removed to the same extent, exposing the superficial perineal fascia. This layer is also to be turned aside, when the muscles of the genital region of the perineum will be brought into view.

The ACCELERATORES URINÆ (bulbo-cavernosi) arise from a tendinous point in the centre of the perineum [*perineal centre*], and from the fibrous raphé of the two muscles. From this origin the fibres diverge like the barbs of a pen; the posterior to be inserted into the triangular ligament and ramus of the pubes; the middle, to encircle the corpus spongiosum and meet on its upper side; the anterior to spread out on the corpus cavernosum at each side, and be inserted, partly into its fibrous structure, and partly into the fascia penis. The posterior and middle insertions of these muscles are best seen by carefully raising one muscle from the corpus spongiosum and tracing its fibres.

Relations. — By their *superficial surface* with their superficial perineal fascia, dartos, superficial vessels and nerves of the perineum, and, on each side, the erector penis. By their *deep surface* with the corpus spongiosum and bulb of the urethra.

The ERECTOR PENIS (ischio-cavernosus) arises from the tuberosity of the ischium and from the ramus of the pubes on each side of the crus, and curves around the root of the penis; to be inserted into the upper surface of the corpus cavernosum, where it is continuous with a strong fascia which covers the dorsum of the organ, the fascia penis.

Relations. — By its *superficial surface* with the superficial perineal fascia, dartos, and superficial perineal vessels and nerves. By its *deep surface* with the corpus cavernosum penis.

The TRANSVERSUS PERINEI arises from the ramus of the ischium at each side, and is inserted into the central tendinous point of the perineum;¹ where it is connected with the accelerator urinæ and sphincter ani.

A small slip of muscle is sometimes found in front of the transversus perinei: this is the *transversus perinei alter*. By its inner end it is continuous with the accelerator.

Relations. — By its *superficial surface* with the superficial perineal fascia, and superficial perineal vessels and nerves. By its *deep surface* with the triangular ligament and internal pudic artery and veins. By its *posterior border* it is in relation with that portion of the superficial perineal fascia which passes upwards and becomes continuous with the triangular ligament.

¹ I have twice dissected a perineum in which the transversus perinei was of the ordinary size, and spread out as it approached the middle line so as to become fan-shaped. The anterior fibres were continuous with those of the muscle of the opposite side; but those which were prolonged forwards upon the bulb and corpus spongiosum of the urethra, on each side of the middle of the penis, forming a broad layer which usurped the place and function of the accelerator urinæ.

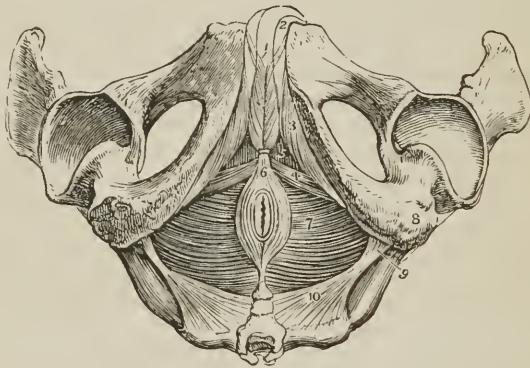
To dissect the *compressor urethræ*, the three preceding muscles should be removed, so as to render the glistening surface of the triangular ligament apparent. This ligament should then be carefully dissected away, and the corpus spongiosum penis divided through its middle, separated from the corpus cavernosum, and drawn forwards in order to put on the stretch the membranous portion of the urethra, with which the compressor muscles are connected. The compressor urethræ is, however, better seen in a dissection made from within the pelvis, after having turned down the bladder from its attachment to the ossa pubis, and removed a plexus of veins together with the pelvic fascia.

The COMPRESSOR URETHRÆ (constrictor urethræ membranaceæ, constrictor isthmi urethræ) directed transversely across the perineum above the triangular ligament *arises* from the rami of the pubes and ischium, their point of union, and from the anterior ligament of the bladder and prostate gland. Proceeding inwards it divides into two fan-shaped fasciculi, superior and inferior, which embrace the membranous portion of the urethra, and are continuous with the muscle of the opposite side. The *superior fasciculus* is continued forwards to the junction of the crura penis, and backwards to the prostate gland; on the upper surface of which it is spread out. The *inferior fasciculus* is attached to the bulb of the urethra in front, and extends to the prostate gland behind. A third fasciculus, closely united with the two preceding, consists of *circular fibres*, which inclose and form a muscular sheath for the membranous part of the urethra.

Under the name of Wilson's muscles, a fourth fasciculus has been described as descending vertically from the body of the pubes, near the symphysis, to unite with the superior fasciculus of the compressor urethræ. This fasciculus is inconstant and its existence doubtful.

The SPHINCTER ANI is a thin and elliptical plane of muscle closely adherent

FIG. 172.



MUSCLES OF THE MALE PERINEUM. 1. Acceleratores urinæ; the figure rests on the corpus spongiosum penis. 2. Corpus cavernosum of one side. 3. Erector penis of one side. 4. Transversus perinei of one side. 5. Triangular space, through which the triangular ligament is seen. 6. Sphincter ani; its anterior extremity cut off. 7. Levator ani of the left side; the deep space between the tuberosity of the ischium (8) and the anus, is the ischio-rectal fossa; the same fossa is seen on the opposite side. 9. Spine of the ischium. 10. Left coccygeus muscle. The boundaries of the perineum are well exhibited in this engraving.

to the integument, and surrounding the opening of the anus. It *arises* posteriorly in the superficial fascia around the coccyx, and by a fibrous raphé from the apex of that bone; and is *inserted* anteriorly into the tendinous centre of the perineum,

and into the raphé of the integument, nearly as far forwards as the commencement of the scrotum.

Relations. — By its *superficial surface* with the integument. By its *deep surface* with the internal sphincter, levator ani, cellular tissue and fat of the ischio-rectal fossa, and in front with the superficial perineal fascia.

The SPHINCTER ANI INTERNUS is a muscular band embracing the extremity of the intestine, and formed by an aggregation of the circular muscular fibres of the rectum.

Part of the levator ani may be seen during the dissection of the anal portion of the perineum by removing the fat which surrounds the termination of the rectum in the ischio-rectal fossa. But, to study the entire muscle, a lateral section of the pelvis must be made by sawing through the pubes a little to one side of the symphysis, separating the bones behind at the sacro-iliac symphysis, and turning down the bladder and rectum. The pelvic fascia is then to be carefully raised, beginning at the base of the bladder and proceeding upwards, until the whole extent of the muscle is exposed.

The LEVATOR ANI is a thin plane of muscular fibres, situated at each side of the pelvis. The muscle *arises* from the inner surface of the os pubis near the pubic arch, from the base and upper border of the spine of the ischium, and between those points, from a tendinous arch which occupies the line of division of the pelvic fascia into obturator fascia and recto-vesical fascia. Its fibres descend to be *inserted* into its fellow of the opposite side beneath the prostate gland, into the rectum, and behind the rectum into its fellow of the opposite side and the side of the extremity of the coccyx.

In the female this muscle has an additional insertion into the vagina.

Relations. — By its *external or perineal surface*, with a thin layer of fascia, by which, and by the obturator fascia, it is separated from the obturator internus muscle; with the fat in the ischio-rectal fossa, triangular ligament, sphincter ani, and posteriorly, gluteus maximus. By its *internal or pelvic surface* with the pelvic fascia, which separates it from the viscera of the pelvis and peritoncum.

The COCCYGEUS muscle, thin and triangular, *arises* from the spine of the ischium and lesser sacro-ischiatric ligament, and spreads out to be *inserted* into the side of the coccyx and lower part of the sacrum.

Relations. — By its *internal or pelvic surface* with the cavity of the pelvis; by its *external surface* with the lesser sacro-ischiatric ligament; and by its *borders*, with the pyriformis above, and levator ani below.

The SACRO-COCCYGEUS ANTICUS (*curvator coccygis*), the analogue of an important muscle in brutes, but rudimentary in man, and more tendinous than fleshy in structure, is a small muscle which *arises* from the side of the last piece of the sacrum and first of the coccyx; and is *inserted* into the front of the last piece of the coccyx in common with its fellow of the opposite side. Sometimes it gives lateral offsets to the outer side of the second and third piece of the coccyx.

FEMALE PERINEUM. — The muscles of the perineum in the female are the same as in the male, and have received analogous names. They are smaller in size, and are modified to suit the difference of form of the organs; they are

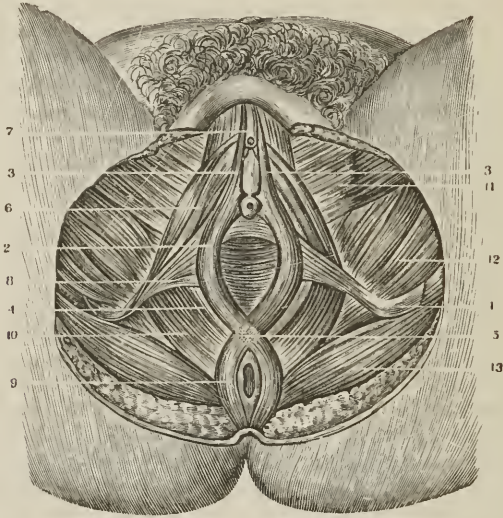
Constrictor vaginæ,	Sphincter ani,
Erector clitoridis,	Levator ani,
Transversus perinei,	Coccygeus,
Compressor urethræ,	Sacro-coccygeus anticus.

The CONSTRICTOR VAGINÆ is analogous to the accelerator urinæ of the male, it *arises* from the tendinous centre of the perineum, where it is continuous with the sphincter ani and transversus perinei; and passes forwards on each side of the entrance of the vagina, to be *inserted* into the corpus cavernosum clitoridis.

The **ERECTOR CLITORIDIS** arises from the ramus of the ischium, and is inserted on each side into the crus clitoridis. It is in relation by its inner border with the constrictor vaginae.

The **TRANSVERSUS PERINEI** is a small muscle arising on each side from the ramus of the ischium, and inserted into the side of the constrictor vaginae.

[FIG. 173.]



MUSCLES OF THE FEMALE PERINEUM. 1. Tuber ischii. 2. Constrictor vaginae. 3, 3. Its insertion into the clitoris. 4. Vaginal ring of the same muscle, which receives a part of the fibres of the levator ani. 5. Intercrossing of the sphincter ani and constrictor vaginae at the perineal centre. 6. Erector clitoridis. 7. The clitoris covered by its prepuce. 8. Transversus perinei. 9. Sphincter ani. 10. Levator ani. 11. Gracilis. 12. Adductor magnus. 13. Gluteus maximus.]

The **COMPRESSOR URETHRÆ** has the same origin and insertion, and exercises the same functions in the female as in the male.

The **SPHINCTER ANI** and **SPHINCTER ANI INTERNUS** surround the lower extremity of the rectum, as in the male.

The **LEVATOR ANI** is inserted into the side of the vagina and rectum.

The **COCYGEUS** and **SACRO-COCYGEUS ANTICUS** are identical with the same muscles in the male.

Actions.—The acceleratores urinæ being continuous at the middle line, and attached at each side to the triangular ligament, by means of their posterior fibres, support the bulbous portion of the urethra, and acting suddenly, propel the semen, or the last drops of urine from the canal. The posterior and middle fibres, according to Krause,¹ contribute to the erection of the corpus spongiosum, by compressing the venous structure of the bulb; and the anterior fibres, according to Tyrrell,² assist in the erection of the entire organ by compressing the vena dorsalis, by means of their insertion into the fascia penis. The erector penis becomes entitled to its name from spreading out on the dorsum of the organ into a membranous expansion (fascia penis), which, according to Krause, compresses the dorsal vein during the action of the muscle, and especially after the erection

¹ Müller, Archiv. für Anatomie, Physiologie, &c. 1837.

² Lectures in the College of Surgeons. 1839.

of the organ has commenced. The transverse muscles serve to steady the tendinous centre, that the muscles attached to it may obtain a firm point of support. According to Cruveilhier, they draw the anus backwards during the expulsion of the fæces, and antagonise the levatores ani, which carry the anus forwards. The compressor urethræ, taking its fixed point from the ramus of the ischium at each side, can, says Guthrie, "compress the urethra so as to close it; I conceive completely, after the manner of a sphincter." The *external sphincter*, being a cutaneous muscle, contracts the integument around the anus, and by its attachment to the tendinous centre of the perineum and point of the coccyx, assists the levator ani in giving support to the opening during expulsive efforts. The *internal sphincter* contracts the extremity of the cylinder of the intestine. The use of the levator ani is expressed in its name; it is the antagonist of the diaphragm, and abdominal expulsive muscles, and serves to support the rectum and vagina during their expulsive efforts. The levator ani acts in unison with the diaphragm, and rises and falls like that muscle in forcible respiration. Yielding to the propulsive action of the abdominal muscles, it enables the outlet of the pelvis to bear a greater force than a resisting structure, and, on the remission of such action, restores the perineum to its original form. The coccygei and sacro-coccygei muscles restore the coccyx to its natural position, after it has been pressed backwards during defecation or parturition.

Dr. Barclay styles the levatores ani, transversi perinei, sphincteres ani, coccygei and curvatores coccygis, *moderator muscles*, "which, after moderating the motor muscles, become motor muscles themselves; and, acting successively in compressing the rectum, expel any remains of the fæces that may be lodged towards the extremity of the canal."

MUSCLES OF THE UPPER EXTREMITY.

The muscle of the upper extremity may be arranged into groups corresponding with the respective regions of the limb, as follows:—

THORACIC REGION.

<i>Anterior Thoracic Region.</i>	<i>Lateral Thoracic Region.</i>
Pectoralis major, Pectoralis minor, Subclavius.	Serratus magnus.

SHOULDER.

<i>Anterior Scapular Region.</i>	<i>Posterior Scapular Region.</i>
Subscapularis.	Supra-spinatus, Infra-spinatus, Teres minor, Teres major.

Acromial Region.

Deltoides.

ARM

<i>Anterior Humeral Region.</i>	<i>Posterior Humeral Region.</i>
Coraco-brachialis, Biceps brachii, Brachialis anticus.	Triceps brachii.

FOREARM.

Anterior Brachial Region.
Superficial layer.

Pronator radii teres,
Flexor carpi radialis,
Palmaris longus,
Flexor sublimis digitorum,
Flexor carpi ulnaris.

Deep layer.

Flexor profundus digitorum,
Flexor longus pollicis,
Pronator quadratus.

Posterior Brachial Region.
Superficial layer.

Supinator longus,
Extensor carpi radialis longior,
Extensor carpi radialis brevior,
Extensor communis digitorum,
Extensor minimi digiti,
Extensor carpi ulnaris,
Anconeus.

Deep layer.

Supinator brevis,
Extensor ossis metacarpi pollicis,
Extensor primi internodii pollicis,
Extensor secundi internodii pollicis,
Extensor indicis.

HAND.

Radial Region (Thenar).

Abductor pollicis,
Flexor ossis metacarpi (opponens),
Flexor brevis pollicis,
Adductor pollicis.

Ulnar Region (Hypothenar).

Palmaris brevis,
Abductor minimi digiti,
Flexor brevis minimi digiti,
Adductor ossis metacarpi.

Palmar Region.

Lumbricales,

Interossei palmares,

Intercosci dorsales.

MUSCLES OF THE THORACIC REGION.

Anterior Thoracic Region.

Pectoralis major,

Pectoralis minor,

Subclavius.

Dissection. — Make an incision along the line of the clavicle, from the upper part of the sternum to the acromion process; a second along the lower border of the great pectoral muscle, from the lower end of the sternum to the insertion of its tendon into the humerus; and connect the two by a third, carried longitudinally along the middle of the sternum. The integument and superficial fascia are to be dissected together from off the fibres of the muscle, and always in the direction of their course. For this purpose the dissector, if he have the right arm, will commence with the lower angle of the flap; if the left, with the upper angle. He will thus expose the pectoralis major muscle in its whole extent.

The PECTORALIS MAJOR (sterno-humeralis) arises from the sternal half of the clavicle, from half the sternum its whole length, from the cartilages of all the true ribs, excepting the first and last, and from the aponeurosis of the external oblique muscle of the abdomen. From this extensive origin the fibres converge to be inserted by a broad and folded tendon into the anterior bicipital ridge of the humerus.

The pectoralis major admits of a division into three portions, *clavicular*, *sternal*, and *costal*; the two former are separated from each other by a well marked cellular interspace; the latter is distinguished not only by its origin, but also by forming a fold beneath the sternal portion, and lying behind it at its insertion. At the latter point the three portions are superimposed, the clavicular being in front, the sternal next, the costal behind; the clavicular portion being prolonged

at its insertion to the lower extremity of the bicipital ridge, the costal portion to its upper end.

Relations. — By its *external surface* with the fibres of origin of the platysma myoides, mammary gland, superficial fascia and integument. By its *internal surface*, on the thorax, with the clavicle, sternum, costal cartilages, intercostal muscles, subclavius, pectoralis minor, and serratus magnus; in the axilla, with the axillary vessels and glands. By its *external border* with the deltoid, from which it is separated above by a cellular interspace lodging the cephalic vein and descending branch of the thoracica acromialis artery. Its *lower border* forms the anterior boundary of the axillary space.

The pectoralis major is to be removed by dividing its fibres along the lower border of the clavicle, and then carrying the incision perpendicularly downwards, parallel to the sternum, and at about three inches from its border. Divide some loose cellular tissue, and several small branches of the thoracic arteries, and reflect the muscle outwards. We thus bring into view a region of considerable interest, in the middle of which is situated the pectoralis minor.

The PECTORALIS MINOR (costo-coracoideus) *arises* by three digitations from the front and upper border of the third, fourth, and fifth ribs near their cartilages; and is *inserted* by a broad tendon into the anterior border and apex of the coracoid process of the scapula. It is closely united at its insertion with the coraco-brachialis.

Relations. — By its *anterior surface* with the pectoralis major and superior thoracic vessels and nerves. By its *posterior surface* with the ribs, intercostal muscles, serratus magnus, axillary space, and axillary vessels and nerves. Its *upper border* forms the lower boundary of a triangular space, bounded above by the costo-coracoid membrane and internally by the ribs; in this space are found the axillary vessels and nerves.

The SUBCLAVIUS (costo-clavicularis) *arises* by a round tendon from the cartilage and adjacent osseous part of the first rib; it is *inserted* into the under surface of the clavicle as far as the costo-coracoid ligament [see p. 270]. This muscle is inclosed in a partial sheath by the costo-coracoid membrane, an extension of the deep cervical fascia.

Relations. — By its *upper surface* with the clavicle. By the *lower* with the subclavian artery and vein and brachial plexus, which separate it from the first rib. In *front* with the pectoralis major, the costo-coracoid membrane being interposed.

Actions. — The pectoralis major draws the arm against the thorax, while its upper fibres assist the upper part of the trapezius in raising the shoulder, as in supporting weights. The lower fibres depress the shoulder with the aid of the latissimus dorsi. Taking its fixed point from the shoulder, the pectoralis major assists the pectoralis minor, subclavius, and serratus magnus, in drawing up and expanding the chest. The pectoralis minor, in addition to this action, draws upon the coracoid process, and assists in rotating the scapula upon the chest. The subclavius draws the clavicle downwards and forwards, and thereby assists in steadying the shoulder. All the muscles of this group are agents in forced respiration, but are incapable of acting in that capacity until the shoulders are fixed.

Lateral Thoracic Region.

Serratus magnus.

The SERRATUS MAGNUS (serratus, indented like the edge of a saw; costo-scapularis) broad, thin, and trapezoid in shape, *arises* by nine fleshy serrations from the eight upper ribs, two of the serrations being attached to the second rib, and extends backwards upon the side of the chest, to be *inserted* into the whole length of the base of the scapula, its anterior aspect. In structure, the muscle is composed of three portions, *superior*, formed by the serrations of the first two ribs,

and inserted into the inner surface of the superior angle of the scapula; *middle*, composed of the serrations connected with the third and fourth ribs, and inserted into the greater part of the posterior border; *inferior*, consisting of the last five serrations, these latter indigitate with the obliquus externus and form a thick muscular fasciculus, which is inserted into the scapula near its inferior angle.

Relations. — By its *superficial surface* with the pectoralis major and minor, subscapularis, latissimus dorsi, and axillary vessels and nerves. By its *deep surface* with the ribs and intercostal muscles, to which it is connected by loose cellular tissue.

Actions. — The serratus magnus is the great external inspiratory muscle, raising the ribs when the shoulders are fixed, and thereby increasing the cavity of the chest. Acting upon the scapula it draws the shoulder forwards, as in the case of diseased lungs, where the chest has become almost fixed from apprehension of the expanding action of the respiratory muscles.

MUSCLES OF THE SHOULDER.

Anterior Scapular Region

Subscapularis.

The SUBSCAPULARIS *arises* from the whole of the under surface of the scapula excepting the superior and inferior angle, and terminates by a broad and thick tendon, which is *inserted* into the lesser tuberosity of the humerus, and by muscular fibres into the surface of bone immediately below that process. In structure the subscapularis is composed of eight or ten fasciculi, four or five of which *arise* from one side of as many aponeurotic processes attached to the ridges of the venter of the scapula; and four or five proceed from the other side of the aponeurotic processes and from the surface of bone intervening between them. Its tendon forms part of the capsule of the joint, glides over a large bursa which separates it from the base of the coracoid process, and is lined by a prolongation of the synovial membrane of the articulation.

Relations. — By its anterior surface with the serratus magnus, coraco-brachialis, and axillary vessels and nerves. By its *posterior surface* with the scapula, and shoulder joint.

Actions. — It rotates the head of the humerus inwards, and is a powerful defence to the joint. When the arm is raised, it draws the humerus downwards.

Posterior Scapular Region.

Supra-spinatus,
Infra-spinatus,

Teres minor,
Teres major.

The SUPRA-SPINATUS muscle (*supra*, above; *spina*, the spine) *arises* from the supra-spinous fossa, spine of the scapula, and proper investing fascia; and is *inserted* into the uppermost depression on the greater tuberosity of the humerus; the tendon being united near its attachment with that of the infra-spinatus. The tendon cannot be seen until the acromion process is removed.

Relations. — By its *upper surface* with the trapezius, clavicle, acromion, and coraco-acromial ligament. From the trapezius it is separated by a strong fascia. By its *lower surface* with the supra-spinous fossa, supra-scapular vessels and nerves, origin of the omohyoid muscle, and upper part of the shoulder joint, forming part of the capsular ligament.

The INFRA-SPINATUS (*infra*, beneath; *spina*, the spine) is covered in by a layer of tendinous fascia, which must be removed before the fibres of the muscle can be seen, the deltoid muscle having been previously turned down from its

scapular origin. It *arises* from the whole of the infra-spinous fossa, excepting a small portion near the neck of the bone, from the spine of the scapula, and from the investing fascia; it is *inserted* into the middle depression of the greater tuberosity of the humerus; its tendon being blended with that of the supra-spinatus above and the teres minor below.

Relations. — By its *posterior surface* with the deltoid, latissimus dorsi, trapezius and integument. By its *anterior surface* with the infra-spinous fossa, supra-scapular and dorsal scapular vessels, and shoulder joint; its tendon being lined by a prolongation from the synovial membrane. By its *upper border* it is in relation with the spine of the scapula; and by the *lower* with the teres major and minor, being closely united with the latter.

The TERES MINOR (*teres*, round) *arises* from the posterior surface of the lower border of the scapula for about the middle third of its extent; it is connected with the lower border of the preceding muscle, and is *inserted*

into the inferior depression of the greater tuberosity of the humerus. The tendons of the three preceding muscles, with that of the subscapularis, are in immediate contact with the shoulder joint, and form part of its ligamentous capsule, thereby preserving the solidity of the articulation. They are therefore the structures most frequently ruptured in dislocation of the head of the humerus.

Relations. — By its *posterior surface* with the deltoid, and integument. By its *anterior surface* with the inferior border and part of the dorsum of the scapula, dorsalis scapulæ vessels, scapular head of the triceps, and shoulder joint. By its *upper border* with the infra-spinatus; by the *lower* with the teres major, and long head of the triceps.

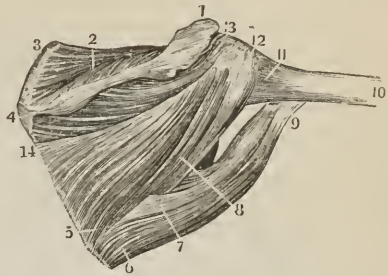
The TERES MAJOR muscle *arises* from the dorsal surface of the inferior angle of the scapula, and from its inferior border; it is *inserted* into the posterior bipitital ridge of the humerus, immediately behind the tendon of the latissimus dorsi. At its origin this muscle is covered by the latissimus dorsi, but the latter shortly afterwards curves around its lower border and become placed in front; the two tendons at their insertion, one lying behind the other, are separated by a bursa.

Relations. — By its *posterior surface* with the latissimus dorsi, scapular head of the triceps and integument. By its *anterior surface* with the subscapularis, latissimus dorsi, coraco-brachialis, short head of the biceps, axillary vessels, and nerves of the brachial plexus. By its *upper border* it is in relation with the teres minor, from which it is separated by the scapular head of the triceps; and by the *lower*, forms, with the latissimus dorsi, the lower and posterior border of the axilla.

A large triangular space exists between the two teres muscles, which is divided into two minor spaces by the long head of the triceps.

Actions. — The supra-spinatus raises the arm from the side; but feebly, from the disadvantageous direction of its force. The infra-spinatus and teres minor are rotators of the head of the humerus outwards. The most important use of these three muscles is the protection of the joint, and defence against displace-

[FIG. 174.]



THE MUSCLES OF THE POSTERIOR SCAPULAR REGION. 1. Acromion process of the scapula. 2. Supra-spinatus muscle. 3. Upper angle of the scapula. 1, 4. Spine of the scapula. 5, 14. Origin of the infra-spinatus muscle. 6, 7. Origin of the teres major. 8. Origin of the teres minor. 9. Insertion of the teres major. 10. Shaft of the humerus. 11. Lower part of the capsular ligament. 12. Insertion of the teres minor. 13. Insertion of the infra-spinatus.]

ment of the head of the humerus, in which action they co-operate with the subscapularis. The teres major combines, with the latissimus dorsi, in rotating the arm inwards, and at the same time carrying it towards the side, and somewhat backwards.

Acromial Region.

Deltoideus.

The DELTOIDEUS (Δ , delta; εἶδος, resemblance; attollens humeri; sub-acromio-humeralis) is the large triangular muscle which forms the convexity of the shoulder; it *arises* from the outer third of the clavicle, from the acromion process, and from the whole length of the spine of the scapula. The fibres from this broad origin converge to the middle of the outer side of the humerus, where they are *inserted* into a rough triangular elevation. In structure the deltoideus is composed of seven fasciculi, four of which are fleshy above and tendinous below; and three tendinous above and fleshy below. To bring the muscles beneath it into view, the deltoid must be cut away from its origin, and turned down; in so doing a large bursa will be seen between its under surface and the head of the humerus.

Relations. — By its *superficial surface* with the brachial fascia, a few fibres of the platysma myoides, the superficial fascia, and integument. By its *deep surface* with the shoulder joint (from which it is separated by a thin tendinous fascia and a synovial bursa), the coraco-acromial ligament, coracoid process, pectoralis minor, coraco-brachialis, both heads of the biceps, tendon of the pectoralis major, tendon of the supra-spinatus, infra-spinatus, teres minor, teres major, scapular and external head of the triceps, circumflex vessels anterior and posterior, and humerus. By its *anterior border* with the external border of the pectoralis major, from which it is separated by a cellular interspace, lodging the cephalic vein and descending branch of the thoracica acromialis artery. Its *posterior border* is thin and tendinous above, where it is connected with the aponeurotic covering of the infra-spinatus muscle, and thick below.

Actions. — The deltoid is the elevator muscle of the arm in a direct line, and, by means of its extensive origin, it can carry the arm forwards or backwards, so as to range with the hand a considerable segment of a large circle. The arm, raised by the deltoid, is an illustration of a lever of the *third* power, so common in the animal machine, by which velocity is gained at the expense of power. In this lever, the weight (hand) is at one extremity, the fulcrum (glenoid cavity) at the opposite end, the power (insertion of the muscle) between the two, but nearer to the fulcrum than to the weight.

MUSCLES OF THE ARM.

Anterior Humeral Region.

Coraco-brachialis,

Biceps brachii,

Brachialis anticus.

Dissection. — These muscles are exposed, on the removal of the integument and fascia from the anterior half of the upper arm, and the clearing away of the cellular tissue.

The CORACO-BRACHIALIS, a name suggestive of its points of origin and insertion, *arises* from the apex of the coracoid process in common with the short head of the biceps; and is *inserted* into a rough line on the inner side of the middle of the humerus.

Relations. — By its *anterior surface* with the deltoid and pectoralis major. By its *posterior surface* with the shoulder joint, humerus, subscapularis, teres major, latissimus dorsi, short head of the triceps, and anterior circumflex vessels. By its *internal border* with the axillary and brachial vessels and nerves, particu-

larly with the median and musculo-cutaneous nerve, by the latter of which it is pierced. By the *external border* with the short head of the biceps and brachialis anticus.

The BICEPS BRACHII (*bis* — κεφαλαί, two heads; flexor radii) arises by two tendons, one, the *short head*, from the coracoid process in common with the coraco-brachialis; the other, the *long head*, from the upper part of the glenoid cavity, where it is continuous with the glenoid ligament. The muscle is inserted by a rounded tendon into the back part of the tuberele of the radius. The long head, a long slender tendon, passes through the capsular ligament of the shoulder joint inclosed in a sheath of the synovial membrane; after leaving the cavity of the joint, it is lodged in the deep groove that separates the two tuberosities of the humerus, the bicipital groove. A small synovial bursa is interposed between the tendon of insertion and the tuberele of the radius. At the bend of the elbow, the tendon of the biceps gives off from its inner side a tendinous band, which protects the brachial artery, and is continuous with the fascia of the forearm.

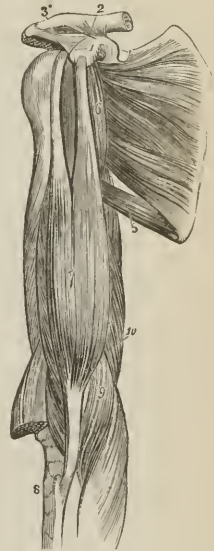Relations. — By its *anterior surface* with the deltoid, pectoralis major, superficial and deep fascia, and integument. By its *posterior surface* the short head rests on the subscapularis, from which it is separated by a bursa. In the rest of its extent the muscle is in relation with the humerus, teres major, latissimus dorsi, and brachialis anticus; from the latter it is separated by the musculo-cutaneous nerve. By its *inner border* with the coraco-brachialis, brachial artery and veins, and median nerve; the brachial vessels crossing its tendon at the bend of the elbow. By its *outer border*, with the deltoid and supinator longus.

The BRACHIALIS ANTICUS (humero-epitralis) is a broad muscle covering the whole of the anterior surface of the lower part of the humerus; it arises by two fleshy serrations, which embrace the insertion of the deltoid, from the anterior surface of the humerus, and from the inner intermuscular septum. Its fibres converge to be inserted into the coronoid process of the ulna, between two processes of the flexor digitorum profundus.

Relations. — By its *anterior surface* with the biceps, musculo-cutaneous nerve, brachial artery and veins, and median nerve. By its *posterior surface* with the humerus, anterior ligament of the elbow joint, and intermuscular aponeurosis. The latter separates it from the triceps. By its *external border* with the supinator longus, extensor carpi radialis longior, musculo-spiral nerve, and recurrent radial artery. By its *internal border* with the intermuscular aponeurosis (which separates it from the triceps and ulnar nerve), and with the pronator radii teres.

Actions. — The coraco-brachialis draws the humerus inwards, and assists in flexing it upon the scapula. The biceps and brachialis anticus are flexors of the forearm, and the former a supinator. The brachialis anticus is a powerful protector of the elbow joint.

FIG. 175.



MUSCLES OF THE ANTERIOR ASPECT OF THE UPPER ARM. 1. Coracoid process of the scapula. 2. Coraco-clavicular ligament (trapezoid), passing upwards to the scapular end of the clavicle. 3. Coraco-acromial ligament, passing outwards to the acromion. 4. Subscapularis. 5. Teres major; the triangular space above this muscle is that through which the dorsalis scapulae vessels pass. 6. Coraco-brachialis. 7. Biceps. 8. Upper end of the radius. 9. Brachialis anticus; a portion of the muscle is seen at the outer side of the tendon of the biceps. 10. Internal head of the triceps.

Posterior Humeral Region.

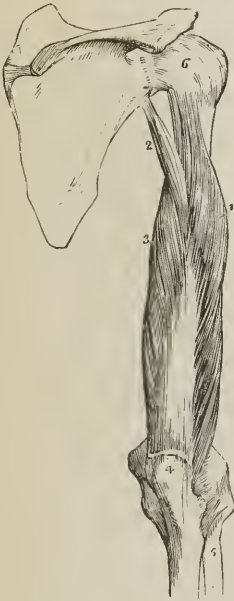
Triceps brachii.

Dissection. — Remove the integument and fascia from the posterior aspect of the upper arm.

The TRICEPS BRACHII (τρεις κεφαλαί, three heads; triceps extensor cubiti) arises by three heads; external, middle, and internal.

The *external head* (anconæus externus) proceeds from the whole length of the external and posterior aspect of the humerus, from the insertion of the teres

FIG. 176.



POSTERIOR VIEW OF THE UPPER ARM, AND TRICEPS MUSCLE. 1. External head. 2. Long or scapular head. 3. Internal or short head. 4. Olecranon process of ulna. 5. Radius. 6. Capsular ligament of the shoulder joint.

minor at the greater tuberosity to the external condyle, and also from the external intermuscular septum. The *internal head* (anconæus internus) arises from the inner and posterior aspect of the humerus, from the insertion of the teres major to the internal condyle, and from the internal intermuscular septum. The *middle* or long head (anconæus longus) arises from the lower part of the head and adjoining part of the border of the scapula, to the extent of about an inch. The three heads, passing downwards in different directions, unite to form a broad muscle, which is inserted into the olecranon process of the ulna, and sends an expansion to the deep fascia of the forearm. A small bursa is situated between the tendon of the muscle and the upper part of the olecranon.

The scapular head of the triceps passes between the teres minor and major, and divides the triangular interspace of those two muscles into two smaller spaces, one of which is triangular, the other quadrangular. The *triangular space* is bounded by the teres minor, teres major, and scapular head of the triceps; it gives passage to the dorsalis scapulæ artery and veins. The *quadrangular space* is bounded on three sides by the three preceding muscles, and on the fourth by the humerus. Through the latter space pass the posterior circumflex artery and veins, and circumflex nerve.

Beneath the lower part of the triceps are two small fasciculi arising from the humerus, and descending one on either side of the fossa of the olecranon to be inserted into the capsule¹ of the elbow joint. These have been named *subanconeus*, they are analogous to the suberureus.

Relations. — By its *posterior surface* with the deep and superficial fascia and integument. By its *anterior surface* with the superior profunda artery, musculospiral nerve, humerus, intermuscular aponeurosis which separates it from the brachialis anticus, and elbow joint. The *scapular head* is in relation posteriorly with the deltoid and teres minor; anteriorly with the subscapularis, teres major, and latissimus dorsi; and externally with the posterior circumflex vessels and nerve.

Actions. — The triceps brachii is an extensor of the forearm.

¹ [The ligaments of the elbow joint which form a continuous membrane around it, are sometimes called the capsule.]

MUSCLES OF THE FOREARM.

*Anterior Brachial Region.**Superficial layer.*

Pronator radii teres,
Flexor carpi radialis,
Palmaris longus,
Flexor sublimis digitorum,
Flexor carpi ulnaris.

Dissection.—These muscles are brought into view by making an incision through the integument along the middle line of the forearm, crossing each extremity by a transverse incision, and turning aside the flaps. The superficial and deep fascia are then to be removed.

The PRONATOR RADII TERES arises by two heads: one from the inner condyle of the humerus, fascia of the forearm, and intermuscular septum; the other from the coronoid process of the ulna; the median nerve passing between them. Its tendon is flat, and is inserted into the middle third of the oblique ridge of the radius. The two heads of this muscle are best examined by cutting through that which arises from the inner condyle, and turning it aside. The second head will then be seen with the median nerve lying across it.

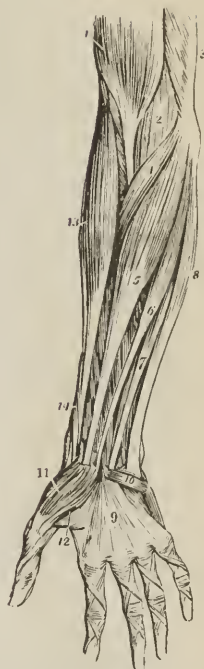Relations.—By its anterior surface with the deep fascia of the forearm, supinator longus, extensor carpi radialis longior and brevior, radial artery and veins, and radial nerve. By its posterior surface with the brachialis anticus, flexor sublimis digitorum, ulnar artery and veins, and the median nerve after it has passed between the two heads of the muscle. By its upper border it forms the inner boundary of the triangular space, in which the termination of the brachial artery is situated. By its lower border it is in relation with the flexor carpi radialis.

The FLEXOR CARPI RADIALIS arises from the inner condyle, deep fascia and intermuscular septa. Its tendon passes through a groove in the trapezium bone, to be inserted into the base of the metacarpal bone of the index finger.

Relations.—By its anterior surface with the deep fascia of the forearm, and at the wrist with the tendinous canal through which the tendon passes. By its posterior surface with the flexor sublimis digitorum, flexor longus pollicis, wrist joint, and groove in the trapezium bone. By its outer border with the pronator radii teres, radial artery and veins. By its inner border with the palmaris longus. The tendon is surrounded by synovial membrane, where it plays through the tendinous canal of the wrist.

The PALMARIS LONGUS is a small muscle which arises from the inner condyle,

FIG. 177.



SUPERFICIAL LAYER OF MUSCLES OF THE FOREARM. 1. Biceps, with its tendon. 2. Brachialis anticus, seen beneath biceps. 3. Part of triceps. 4. Pronator radii teres. 5. Flexor carpi radialis. 6. Palmaris longus. 7. One of the fasciculi of the flexor sublimis digitorum; the rest of the muscle is seen beneath the tendons of the palmaris longus and flexor carpi radialis. 8. Flexor carpi ulnaris. 9. Palmar fascia. 10. Palmaris brevis. 11. Abductor pollicis. 12. Flexor brevis pollicis; the leading line crosses part of the adductor pollicis. 13. Supinator longus. 14. Extensor ossis metacarpi and extensor primi internodii pollicis, curving around the lower border of the forearm.

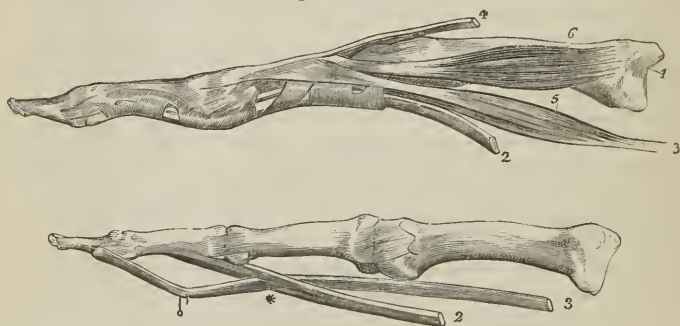
deep fascia, and intermuscular septa. Its tendon pierces the deep fascia and crosses the annular ligament to be *inserted* into the palmar fascia.

Relations. — By its *anterior surface* with the deep fascia of the forearm. By the *posterior surface* with the flexor sublimis digitorum; to the *external side* with the flexor carpi radialis; and to the *internal side* with the flexor carpi ulnaris.

Cut the flexor carpi radialis and palmaris longus from their origin, in order to obtain a good view of the whole extent of origin of the flexor sublimis digitorum.

The FLEXOR SUBLIMIS DIGITORUM (*perforatus*) *arises* from the inner condyle, intermuscular septa, internal lateral ligament, coronoid process of the ulna, and oblique line of the radius. The median nerve and ulnar artery pass between its heads. It divides into four tendons, which pass beneath the annular ligament [those for the median and ring fingers being here placed anteriorly to those for the index and little fingers], and are *inserted* into the base of the second phalanges of the fingers, splitting at their termination to give passage to the tendons of the deep flexor; hence its designation, *perforatus*. In the thecæ of the fingers [see p. 158], several small tendinous fasciuli are found, which pass between the phalanges and the edges of the tendons; these have been termed the *vincula accessoria*. [Beneath the proper annular ligament of the carpus, the tendons of the flexor sublimis, as well as those of the flexor profundus are enveloped in a common synovial membrane. The thecæ are also provided, each with a synovial membrane, which lines them and envelops the flexor tendons therein contained.]

[FIG. 178.]



THE METACARPAL AND PHALANGEAL BONES OF TWO FINGERS, WITH THE TENDONS. In the first figure the tendons of the flexor muscles are bound to the finger by the theca or vaginal ligament; in the second they are freed from that structure, as well as from the synovial membrane and the vincula accessoria. 1. Metacarpal bone. 2. Tendon of flexor sublimis. 3. Tendon of flexor profundus. * The perforation of the former by the latter. 4. Tendon of extensor digitorum communis. 5. A lumbricalis muscle. 6. An interosseous muscle.]

Relations. — In the forearm; by its *anterior surface* with the pronator radii teres, flexor carpi radialis, palmaris longus, flexor carpi ulnaris, and the deep fascia. By its *posterior surface* with the flexor profundus digitorum, flexor longus pollicis, ulnar artery, veins, and nerve, and median nerve. This muscle frequently sends a fasciculus to the flexor longus pollicis, or flexor profundus. In the hand: its tendons, after passing beneath the annular ligament, are in relation *superficially* with the superficial palmar arch, and palmar fascia; and *deeply* with the tendons of the deep flexor and lumbricales.

The FLEXOR CARPI ULNARIS *arises* by two heads, one from the inner condyle and intermuscular septa, the other from the olecranon and by means of a strong aponeurosis from two-thirds of the inner border of the ulna. Its tendon is *inserted* into the pisiform bone and base of the metacarpal bone of the little finger.

Relations. — By its *anterior surface* with the deep fascia of the forearm, with

which it is closely united superiorly. By its *posterior surface* with the flexor sublimis digitorum, flexor profundus, pronator quadratus, ulnar artery, veins, and nerve. By its *radial border* with the palmaris longus, and in the lower third of the forearm, the ulnar vessels and nerve. The ulnar nerve, and the posterior ulnar recurrent artery, pass between its two heads of origin.

Deep layer.

Flexor profundus digitorum, Flexor longus pollicis,
Pronator quadratus.

Dissection. — This group is brought into view by removing the flexor sublimis, and drawing aside the pronator radii teres.

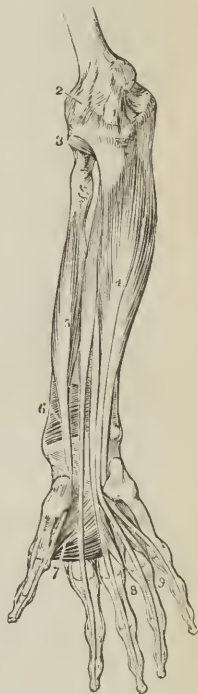The FLEXOR PROFUNDUS DIGITORUM (perforans) arises from the upper two-thirds of the ulna, its anterior and inner surface and posterior border, from the inner side of the olecranon, where it is connected with the aponeurotic expansion of the flexor carpi ulnaris, and from the ulnar half of the interosseous membrane. At the middle of the forearm it divides into four tendons which pass beneath the annular ligament, and along the fingers, between the two slips of the tendons of the flexor sublimis, to be inserted into the base of the last phalanges. In the groove of the carpus the tendons are inclosed in a synovial membrane and the three outer [*ulnar*] tendons communicate with each other by means of small slips, the tendon of the index finger remaining distinct. In the hand, the tendons give origin to the lumbricales muscles, and on the second phalanges are retained in position by two little tendinous slips, the *vincula accessoria*.

Relations. — In the forearm. By its *anterior surface* with the flexor sublimis digitorum, flexor carpi ulnaris, median nerve, and ulnar artery, veins, and nerve. By its *posterior surface* with the ulna, interosseous membrane, pronator quadratus, and wrist joint. By its *radial border* with the flexor longus pollicis, the anterior interosseous artery and nerve being interposed. By its *ulnar border* with the flexor carpi ulnaris. In the hand: its tendons are in relation *superficially* with the tendons of the superficial flexor; and *deeply* with the interossei, adductor pollicis, and deep palmar arch.

The FLEXOR LONGUS POLLICIS arises from the anterior surface of the radius for two-thirds of its extent, and from one-half the interosseous membrane. Its tendon passes beneath the annular ligament [where it is provided with a special synovial membrane] to be inserted into the base of the last phalanx of the thumb.

Relations. — By its *anterior surface* with the flexor sublimis digitorum, flexor carpi radialis, supinator longus, and radial artery and veins. By its *posterior surface* with the radius, interosseous membrane, pronator quadratus, and wrist joint. By its *ulnar border*, it is sepa-

FIG. 179.



DEEP LAYER OF MUSCLES OF THE FOREARM. 1. Internallateral ligament of the elbow joint. 2. Anterior ligament. 3. Orbicular ligament of the head of the radius. 4. Flexor profundus digitorum. 5. Flexor longus pollicis. 6. Pronator quadratus. 7. Adductor pollicis. 8. Dorsal interosseous of the middle, and palmar interossei of the ring finger. 9. Dorsal interosseous muscle of the ring finger, and palmar interosseous of the little finger.

rated from the flexor profundus digitorum by the anterior interosseous artery and nerve. In the hand: after passing beneath the annular ligament, it is lodged in the interspace between the two portions of the flexor brevis pollicis, and afterwards in the tendinous theca of the phalanx.

If the tendons of the last two muscles be drawn aside or divided, the third muscle of this group will be brought into view, lying across the lower part of the two bones.

The PRONATOR QUADRATUS (eubito-radialis) arises from the anterior and inner side of the ulna; and is inserted into the front of the radius. This muscle occupies about the lower fourth of the two bones, is broad at its origin, and narrower at its insertion.

Relations. — By its anterior surface with the tendons of the supinator longus, flexor carpi radialis, flexor longus pollicis, flexor profundus digitorum, and flexor carpi ulnaris, radial artery and veins, and ulnar artery, veins, and nerve. By its posterior surface with the radius, ulna, and interosseous membrane.

Actions. — The pronator radii teres and pronator quadratus rotate the radius upon the ulna, and render the hand prone. The remaining muscles are flexors: two flexors of the wrist, flexor carpi radialis and ulnaris; two of the fingers, flexor sublimis and profundus, the former flexing the second phalanges, the latter the last; one flexor of the last phalanx of the thumb, flexor longus pollicis. The palmaris longus is primarily a tensor of the palmar fasciæ, and secondly a flexor of the wrist and forearm.

Posterior Brachial Region.

Superficial layer.

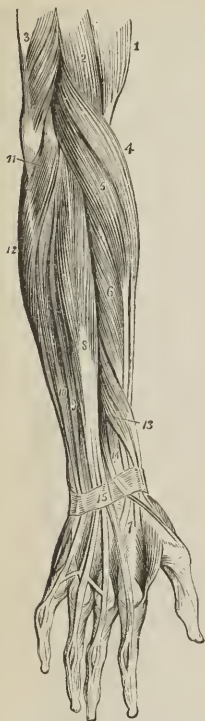Supinator longus,
Extensor carpi radialis longior,
Extensor carpi radialis brevior,
Extensor communis digitorum,
Extensor minimi digiti,
Extensor carpi ulnaris,
Anconeus.

Dissection. — The integument is to be divided and turned aside, and the fasciæ removed in the same manner as for the anterior brachial region.

The SUPINATOR LONGUS (braebio-radialis) is placed along the radial border of the forearm. It arises from the external condyloid ridge of the humerus, nearly as high as the insertion of the deltoid, and from the intermuscular septum; passes forwards to the anterior aspect of the elbow joint, and descends the forearm to be inserted into the base of the styloid process of the radius.

Relations. — By its superficial surface with the extensor ossis metacarpi

FIG. 180.



SUPERFICIAL LAYER OF MUSCLES OF THE POSTERIOR ASPECT OF THE FOREARM. 1. Biceps. 2. Brachialis anticus. 3. Lower part of the triceps, inserted into the olecranon. 4. Supinator longus. 5. Extensor carpi radialis longior. 6. Extensor carpi radialis brevior. 7. Tendons of insertion of these two muscles. 8. Extensor communis digitorum. 9. Extensor minimi digiti. 10. Extensor carpi ulnaris. 11. Anconeus. 12. Flexor carpi ulnaris. 13. Extensor ossis metacarpi and extensor primi internodii lying together. 14. Extensor secundi internodii; its tendon is seen crossing the tendons of the extensor carpi radialis longior and brevior. 15. Posterior annular ligament. The tendons of the common extensor are seen on the back of the hand, and their mode of distribution on the dorsum of the fingers.

pollicis, extensor primi internodii pollicis, and deep fascia of the forearm. By its *deep surface* with the brachialis anticus, extensor carpi radialis longior, tendon of the biceps, supinator brevis, pronator radii teres, flexor carpi radialis, flexor sublimis digitorum, flexor longus pollicis, pronator quadratus, radius, musculospiral nerve, radial and posterior interosseous nerve, and radial artery and veins.

This muscle must be divided through the middle, and the two ends turned aside to expose the next muscle.

The EXTENSOR CARPI RADIALIS LONGIOR *arises* from the external condyloid ridge, below the preceding, and from the intermuscular septum. Its tendon passes through a groove in the radius immediately behind the styloid process, to be *inserted* into the base of the metacarpal bone of the index finger.

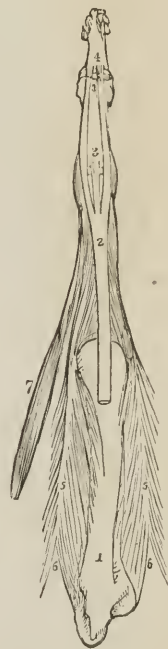
Relations.—By its *superficial surface* with the supinator longus, extensor ossis metacarpi pollicis, extensor primi internodii pollicis, extensor secundi internodii pollicis, radial nerve, fascia of the forearm, and posterior annular ligament. By its *deep surface* with the brachialis anticus, extensor carpi radialis brevior, radius, and wrist joint.

The EXTENSOR CARPI RADIALIS BREVIOR is seen by drawing aside the former muscle. It *arises* from the external condyle of the humerus and intermuscular septa, and is *inserted* into the base of the metacarpal bone of the middle finger. Its tendon is lodged in the same groove on the radius with that of the extensor carpi radialis longior.

Relations.—By its *superficial surface* with the extensor carpi radialis longior, extensor ossis metacarpi pollicis, extensor primi internodii pollicis, extensor secundi internodii pollicis, fascia of the forearm and posterior annular ligament. By its *deep surface* with the supinator brevis, tendon of the pronator radii teres, radius, and wrist joint. By its *ulnar border* with the extensor communis digitorum.

The EXTENSOR COMMUNIS DIGITORUM *arises* from the external condyle by a common tendon with the preceding and two following muscles, from the intermuscular septa, and deep fascia; and divides into four tendons, which are *inserted* into the second and third phalanges of the fingers. At the metacarpo-phalangeal articulation each tendon becomes narrow and thick, and sends a thin fasciculus upon each side of the joint. It then spreads out, and receiving the tendon of the lumbricalis and some tendinous fasciculi from the interossei, forms a broad aponeurosis, which covers the whole posterior aspect of the finger. At the first phalangeal joint the aponeurosis divides into three slips. The middle slip is inserted into the base of the second phalanx, and the two lateral portions are continued onwards at each side of the joint, to be inserted into the last. Little oblique tendinous slips connect the tendon of the ring with those of the middle and little finger as they cross the back of the hand.

[FIG. 181.]



THE ARRANGEMENT OF THE EXTENSOR TENDON UPON THE DORSAL SURFACE OF A FINGER.—1. The metacarpal bone of the middle finger. 2. The extensor tendon expanding into a broad aponeurosis, which divides into three slips. 3. The middle slip, inserted into the base of the second phalanx. 4. The two lateral slips, inserted into the base of the third phalanx. 5, 5. Two dorsal interossei, showing their bifid origin, 6, 6, and inserted by an aponeurotic expansion into the sides of the extensor tendon. 7. The second lumbricalis muscle, also inserted into the side of the extensor tendon.]

Relations.—By its *superficial surface* with the deep fascia of the forearm and hand, and posterior annular ligament. By its *deep surface* with the supinator brevis, extensor ossis metacarpi pollicis, extensor primi internodii, extensor secundi internodii, extensor indicis, posterior interosseous artery and nerve, wrist joint, metacarpal bones, interossei muscles, and phalanges. By its *radial border* with the extensor carpi radialis longior and brevior. By the *ulnar border* with the extensor minimi digiti, and extensor carpi ulnaris.

The EXTENSOR MINIMI DIGITI (auricularis) is an off-set from the extensor communis, with which it is connected by means of a tendinous slip. Passing down to the inferior extremity of the ulna, it traverses a distinct fibrous sheath, and at the metacarpo-phalangeal articulation unites with the tendon derived from the common extensor. The common tendon then spreads out into a broad expansion which divides into three slips to be *inserted* as in the other fingers into the last two phalanges. It is to this muscle that the little finger owes its power of separate extension; and, being called into action when the point of the finger is introduced into the meatus of the ear, for the purpose of removing unpleasant sensations or producing titillation, the muscle was called by the old writers "auricularis."

The EXTENSOR CARPI ULNARIS *arises* from the external condyle by the common tendon, from the border of the ulna, and from the deep fascia. Its tendon passes through the posterior groove in the lower extremity of the ulna, to be *inserted* into the base of the metacarpal bone of the little finger.

Relations.—By its *superficial surface* with the deep fascia of the forearm, and posterior annular ligament. By its *deep surface* with the supinator brevis, extensor ossis metacarpi pollicis, extensor secundi internodii, extensor indicis, ulna, and wrist joint. By its *radial border* it is in relation with the extensor communis digitorum and extensor minimi digiti, and by the *ulnar border* with the anconeus.

The ANCONEUS (anconæus parvus, vel quartus) is a small triangular muscle, having the appearance of being a continuation of the triceps; it *arises* from the outer condyle, and is *inserted* into the olecranon and triangular surface of the upper extremity of the ulna.

Relations.—By its *superficial surface* with a strong tendinous aponeurosis derived from the triceps. By its *deep surface* with the elbow joint, orbicular ligament, and slightly with the supinator brevis.

Deep layer.

Supinator brevis,
Extensor ossis metacarpi pollicis,
Extensor primi internodii pollicis,
Extensor secundi internodii pollicis,
Extensor indicis.

Dissection.—The muscles of the superficial layer should be removed in order to bring the deep group completely into view.

The SUPINATOR BREVIS cannot be seen in its entire extent, until the radial extensors of the carpus are divided from their origin. It *arises* from the external condyle, from the external lateral and orbicular ligament, and from the ulna, and winds around the upper part of the radius to be *inserted* into the upper third of its oblique line. The posterior interosseous artery and nerve perforate the lower border of this muscle.

Relations.—By its *superficial surface* with the pronator radii teres, supinator longus, extensor carpi radialis longior and brevior, extensor communis digitorum, extensor carpi ulnaris, anconeus, radial artery and veins, musculo-spiral nerve, radial and posterior interosseous nerve. By its *deep surface* with the elbow joint and ligaments, interosseous membrane, and radius.

The **EXTENSOR OSSIS METACARPI POLLICIS** (*abductor pollicis longus*) is placed immediately below the *supinator brevis*. It *arises* from the ulna, interosseous membrane, and radius, and is *inserted* into the base of the metacarpal bone of the thumb. Its tendon passes through the groove immediately in front of the styloid process of the radius.

Relations. — By its *superficial surface* with the *extensor carpi ulnaris*, *extensor minimi digiti*, *extensor communis digitorum*, fascia of the forearm and annular ligament. By its *deep surface* with the ulna, interosseous membrane, radius, tendons of the *extensor carpi radialis longior* and *brevior*, and *supinator longus*, and at the wrist with the radial artery. By its *upper border* with the edge of the *supinator brevis*; by its *lower border* with the *extensor secundi* and *primi internodii*. It is crossed by branches of the posterior interosseous artery and nerve.

The **EXTENSOR PRIMI INTERNODII POLLICIS** (*extensor pollicis brevis vel minor*) the smallest of the muscles in this layer, *arises* from the interosseous membrane and radius, and passes through the groove with the *extensor ossis metacarpi*, to be *inserted* into the base of the first phalanx of the thumb.

Relations. — The same as the preceding muscle, with the exception of the *extensor carpi ulnaris*. The muscle accompanies the *extensor ossis metacarpi*.

The **EXTENSOR SECUNDI INTERNODII POLLICIS** (*extensor pollicis longus vel major*) *arises* from the ulna, and interosseous membrane. Its tendon passes through a separate groove in the radius, and is *inserted* into the base of the last phalanx of the thumb.

Relations. — By its *external surface*, the same as the *extensor ossis metacarpi*. By its *deep surface* with the ulna, interosseous membrane, radius, wrist joint, radial artery, and metacarpal bone of the thumb. The muscle is placed between the *extensor primi internodii* and *extensor indicis*.

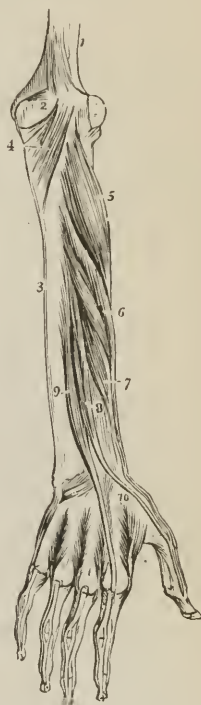
The **EXTENSOR INDICIS** (*indicator*) *arises* from the ulna, as high up as the *extensor ossis metacarpi pollicis*, and inferiorly from the interosseous membrane. Its tendon passes beneath the posterior annular ligament to be *inserted* into the aponeurosis of the common extensor tendon of the index finger.

Relations. — The same as the preceding muscle, with the exception of the hand, where the tendon rests on the metacarpal bone of the fore finger and second interosseous muscle, and has no relation with the radial artery.

The tendons of the extensors, as of the flexor muscles of the forearm, are provided with synovial bursæ as they pass beneath the annular ligament: those of the back of the wrist have separate sheaths, formed by the posterior annular ligament.

Actions. — The *anconeus* is associated in its action with the *triceps extensor*

FIG. 182.



DEEP LAYER OF MUSCLES OF THE POSTERIOR ASPECT OF THE FORE-ARM. 1. Humerus. 2. Olecranon. 3. Ulna. 4. Anconeus. 5. Supinator brevis. 6. Extensor ossis metacarpi pollicis. 7. Extensor primi internodii pollicis. 8. Extensor secundi internodii pollicis. 9. Extensor indicis. 10. First dorsal interosseous muscle. The other three dorsal interossei are seen between the metacarpal bones of their respective fingers.

cubiti: it assists in extending the forearm on the arm. The supinator longus and brevis effect the supination of the forearm, and antagonize the two pronators. The extensor carpi radialis longior and brevior and extensor carpi ulnaris, extend the wrist in opposition to the two flexors of the carpus. The extensor communis digitorum restores the fingers to the straight position after they have been flexed by the two flexors, sublimis and profundus. The extensor ossis metacarpi, primi internodii, and secundi internodii pollicis, are the special extensors of the thumb, and serve to balance the actions of the flexor ossis metacarpi, flexor brevis, and flexor longus pollicis. The extensor indicis produces extension of the index finger, and is therefore named "indicator," and the extensor minimi digiti supplies that finger with the power of exerting a distinct extension.

MUSCLES OF THE HAND.

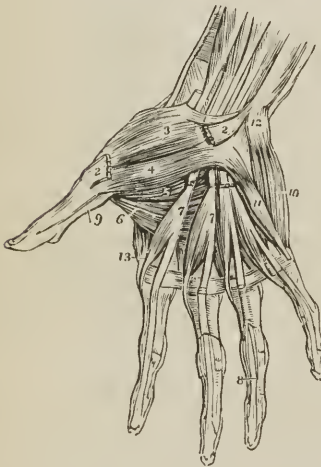
Radial or Thenar Region.

Abductor pollicis,
Flexor ossis metacarpi (opponens),

Flexor brevis pollicis,
Adductor pollicis.

Dissection.—The hand is best dissected by making an incision along the middle of the palm, from the wrist to the base of the middle finger, and crossing it at

Fig. 183.



MUSCLES OF THE HAND. 1. Annular ligament. 2, 2. Origin and insertion of the abductor pollicis muscle; its middle portion has been removed. 3. Flexor ossis metacarpi, or opponens pollicis. 4. Superficial portion of the flexor brevis pollicis. 5. Deep portion of the flexor brevis pollicis. 6. Adductor pollicis. 7, 7. The lumbricales muscles, arising from the deep flexor tendons, upon which the figures are placed. The tendons of the flexor sublimis have been removed. 8. One of the tendons of the deep flexor, passing between the two terminal slips of the tendon of the flexor sublimis to reach the last phalanx. 9. The tendon of the flexor longus pollicis, passing between the two portions of the flexor brevis to the last phalanx. 10. Abductor minimi digiti. 11. Flexor brevis minimi digiti. The edge of the adductor ossis metacarpi is seen projecting beyond the inner border of the flexor brevis. 12. Pisiform bone. 13. First dorsal interosseous muscle, the abductor indicis.

each extremity by a transverse incision, then turning aside the flaps of integument. For exposing the muscles of the radial region, the removal of the integument and fascia on the radial side will be sufficient.

The ABDUCTOR POLLICIS (brevis) is a small thin muscle, which *arises* from the trapezium bone and annular ligament. It is *inserted* into the base of the first phalanx of the thumb.

Relations.—By its *superficial surface* with the external portion of the palmar fascia; by its *deep surface* with the flexor ossis metacarpi. At its *inner side* it is separated by a narrow cellular interspace from the flexor brevis pollicis. This muscle must be divided from its origin, and turned aside, in order to see the next.

The FLEXOR OSSIS METACARPI (opponens pollicis) *arises* from the trapezium and annular ligament, and is *inserted* into the whole length of the metacarpal bone.

Relations.—By its *superficial surface* with the abductor pollicis. By its *deep*

surface with the trapezo-metacarpal articulation and metacarpal bone. *Internally* with the flexor brevis pollicis. The flexor ossis metacarpi may now be divided from its origin and turned aside, in order to show the next muscle.

The FLEXOR BREVIS POLLICIS consists of two portions, between which lies the tendon of the flexor longus pollicis. The external portion *arises* from the trapezium and annular ligament; the internal portion from the trapezoides and os magnum. They are both *inserted* into the base of the first phalanx of the thumb, having a sesamoid bone in each of their tendons to protect the joint.

Relations. — By its *superficial surface* with the external portion of the palmar fascia. By its *deep surface* with the adductor pollicis, tendon of the flexor carpi radialis, and trapezo-metacarpal articulation. By its *external surface* with the flexor ossis metacarpi and metacarpal bone. By its *inner surface* with the tendons of the long flexor muscles and first lumbricalis.

The ADDUCTOR POLLICIS is a triangular muscle; it *arises* by a broad origin from the metacarpal bone of the middle finger; the fibres converge to its *insertion* into the base of the first phalanx of the thumb, where it is united with the inner head of the flexor brevis.

Relations. — By its *anterior surface* with the flexor brevis pollicis, tendons of the deep flexor of the fingers, lumbricales, and deep palmar arch. By its *posterior surface* with the metacarpal bones of the index and middle finger, the interossei of the second interosseous space, and the abductor indicis. Its inferior border is subcutaneous.

Ulnar or Hypothenar Region.

Palmaris brevis,	Flexor brevis minimi digiti,
Abductor minimi digiti,	Adductor ossis metacarpi.

Dissection. — Turn aside the ulnar flap of integument from the palm of the hand; in doing this, a small subcutaneous muscle, the palmaris brevis, will be exposed. After examining this muscle, remove it with the deep fascia, in order to bring into view the muscles of the little finger.

The PALMARIS BREVIS is a thin plane of muscular fibres about an inch in width, which *arises* from the annular ligament and palmar fascia, and passes transversely inwards to be *inserted* into the integument of the inner border of the hand.

Relations. — By its *superficial surface* with the fat and integument of the ball of the little finger. By its *deep surface* with the ulnar portion of the palmar fascia, which separates it from the ulnar artery, veins, and nerve, and from the muscles of the inner border of the hand.

The ABDUCTOR MINIMI DIGITI is a small tapering muscle which *arises* from the pisiform bone, where it is continuous with the tendon of the flexor carpi ulnaris, and is *inserted* into the base of the first phalanx of the little finger, and into the expansion of the extensor tendon.

Relations. — By its *superficial surface* with the internal portion of the deep fascia and palmaris brevis; by its *deep surface* with the adductor ossis metacarpi and metacarpal bone. By its *inner border* with the flexor brevis minimi digiti.

The FLEXOR BREVIS MINIMI DIGITI is a small muscle *arising* from the unciform bone and annular ligament, and *inserted* into the base of the first phalanx. It is sometimes wanting.

Relations. — By its *superficial surface* with the internal portion of the palmar fascia, and palmaris brevis. By its *deep surface* with the adductor ossis metacarpi and metacarpal bone. *Externally* with the abductor minimi digiti, from which it is separated near its origin by the deep palmar branch of the ulnar nerve and communicating artery. *Internally* with the tendons of the flexor sublimis and profundus.

The ADDUCTOR OSSIS METACARPI (opponens), or abductor minimi digiti, *arises* from the unciform bone and annular ligament; and is *inserted* into the whole length of the metacarpal bone of the little finger.

Relations. — By its *superficial surface* with the flexor brevis and abductor minimi digiti. By its *deep surface* with the interossei muscles of the last metacarpal space, metacarpal bone, and flexor tendons of the little finger.

Palmar Region.

Lumbricales, Interossei palmares, Interossei dorsales.

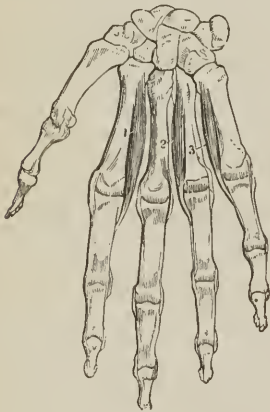The LUMBRICALES, four in number, are accessories to the deep flexor muscle. They *arise* from the tendons of the deep flexor; the first and second from the palmar side, the third from the ulnar, the fourth from the radial side; and are *inserted* into the aponeurotic expansion of the extensor tendons on the radial side of the fingers. The third, or that of the tendon of the ring finger, sometimes bifurcates, at other times it is inserted wholly into the extensor tendon of the middle finger.

Relations. — In the palm of the hand with the flexor tendons; at their insertion, with the tendons of the interossei and the metacarpo-phalangeal articulations.

The PALMAR INTEROSSEI, three in number, are placed upon the metacarpal bones, rather than between them. They *arise* from the base of the metacarpal bone of one finger, and are *inserted* into the base of the first phalanx and aponeurotic expansion of the extensor tendon of the same finger. The first belongs to the index finger; the second, to the ring finger; the third to the little finger; the middle finger being omitted.

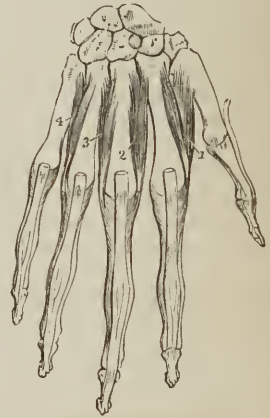Relations. — By their *palmar surface* with the flexor tendons and deep muscles in the palm of the hand. By their *dorsal surface* with the dorsal interossei. On one side with the metacarpal bone, on the other with the corresponding dorsal interosseous muscle.

[FIG. 184.]



PALMAR INTEROSSEOUS MUSCLES. 1. First palmar interosseous; adductor indicis. 2. Second palmar interosseous; adductor of the ring finger. 3. Third palmar interosseous; adductor of the little finger.]

[FIG. 185.]



DORSAL INTEROSSEOUS MUSCLES. 1. First dorsal interosseous muscle; abductor indicis. 2, 3. Second and third dorsal interossei; both abductors of the mid-finger. 4. Fourth dorsal interosseous; abductor of the ring finger.]

DORSAL INTEROSSEI. — Turning to the dorsum of the hand, the four *dorsal interossei* (bicipites) are seen in the four spaces between the metacarpal bones.

They are bipenniform muscles, and *arise* by two heads, from adjoining sides of the bases of the metacarpal bones. They are *inserted* into the base of the first phalanges, and into the aponeurosis of the extensor tendons.

The first is inserted into the index finger, and from its use is called abductor indicis; the second and third are inserted into the middle finger, compensating its exclusion from the palmar group; the fourth is attached to the ring finger; so that each finger is provided with two interossei, with the exception of the little finger, as may be shown by means of a table, thus:—

<i>Index finger</i>	{	one dorsal (abductor indicis), one palmar.
<i>Middle finger</i> ,		two dorsal.
<i>Ring finger</i>	{	one dorsal, one palmar.
<i>Little finger</i> ,		remaining palmar.

Relations.—By their *dorsal surface* with a thin aponeurosis, the fascia *dorsalis profunda*, which separates them from the tendons on the dorsum of the hand. By their *palmar surface* with the muscles and tendons in the palm of the hand. By one side with the metacarpal bone; by the other with the corresponding palmar interosseous. The abductor indicis is in relation by its palmar surface, with the adductor pollicis and flexor brevis pollicis. The radial artery passes into the palm of the hand between the two heads of the first dorsal interosseous muscle (abductor indicis); and the perforating branches of the deep palmar arch, between the heads of the other dorsal interossei.

Actions.—The actions of the muscles of the hand are expressed in their names. Those of the radial region belong to the thumb, and provide for three of its movements, *abduction*, *adduction*, and *flexion*. The ulnar group, in like manner, are subservient to the same motions of the little finger, and the interossei are abductors and adductors of the several fingers. The lumbricales are accessory in their actions to the deep flexors; they were called by the earlier anatomists *fidicinii*, *i. e.*, fiddlers' muscles, from an idea that they might effect the rapid movements by which the performer is enabled to produce the various notes on that instrument.

In relation to the axis of the hand, the four *dorsal* interossei are *abductors*, the three palmar *adductors*. It will therefore be seen that each finger is provided with its proper adductor and abductor, two flexors, and (with the exception of the middle and ring finger) two extensors. The thumb has moreover a flexor and extensor of the metacarpal bone; and the little finger a flexor of the metacarpal bone (opponens) without an extensor.

The actions of the muscles of the upper extremity, arranged after the plan of Dr. Barclay, are as follows:—

SCAPULA.

Elevators.

Trapezius,
Levator anguli scapulæ,
Rhomboidi.

Depressors.

Trapezius (lower part),
Pectoralis minor.

Attrahentes.

Pectoralis minor,
Serratus magnus.

Retrahentes.

Trapezius,
Rhomboidi.

HUMERUS.

Extensors (forwards).

Deltoid (anterior part),
Pectoralis major,
Biceps,
Coraco-brachialis.

Abductors.

Deltoid (middle part),
Supra-spinatus,
Infra-spinatus,
Subscapularis,
Teres minor.

Rotators (forwards).

Deltoid,
Subscapularis,
Pectoralis major,
Latissimus dorsi,
Teres major.

Flexors (backwards).

Deltoid (posterior part),
Teres minor,
Teres major,
Latissimus dorsi,
Triceps (long head).

Adductors.

Deltoid (anterior and posterior part),
Pectoralis major,
Latissimus dorsi,
Teres major.

Rotators (backwards).

Deltoid,
Supra-spinatus,
Infra-spinatus,
Teres minor,
Coraco-brachialis.

FOREARM.

Flexors.

Brachialis anticus,
Biceps,
Supinator longus,
Pronator radii teres,

Flexor carpi ulnaris,
Flexor carpi radialis,
Palmaris longus,
Flexor sublimis digitorum.

Extensors.

Triceps, Anconcus.

Pronators.

Pronator teres,
Pronator quadratus,
Flexor sublimis digitorum.

Palmaris longus,
Flexor carpi radialis,

Supinators.

Biceps,
Supinator brevis,

Extensor sec: internod: pollicis,
Supinator longus.¹

CARPUS.

Flexors.

Flexor carpi radialis,
Flexor carpi ulnaris
Palmaris longus,

Flexor sublimis digitorum,
Flexor profundus digitorum,
Flexor longus pollicis.

Extensors.

Extensor carpi radialis longior, Extensor indicis,
Extensor carpi radialis brevior, Extensor communis digitorum,
Extensor sec: internod: pollicis, Extensor minimi digiti.

¹ Barclay says: — "As for the muscle which has been called *supinator longus*, it co-operates with, and moderates alternately, pronators and supinators, bringing the radius to that middle state which is properly neither pronation nor supination."

Abductors.

Extensor ossis metacarpi pollicis,	Extensor carpi radialis longior,
Extensor primi internodii pollicis,	Extensor carpi radialis brevior,
	Flexor carpi radialis.

Adductors.

Extensor carpi ulnaris,	Flexor carpi ulnaris,
Extensor minimi digiti,	Flexor sublimis digitorum,
Extensor communis digitorum,	Flexor profundus digitorum.

The movements of the fingers and thumb have been already sufficiently discussed with the description of their muscles.

MUSCLES OF THE LOWER EXTREMITY.

The muscles of the lower extremity may be arranged into groups corresponding with the regions of the hip, thigh, leg, and foot, as in the following table:—

HIP.

Gluteal Region.

Gluteus maximus,	Obturator internus,
Gluteus medius,	Gemellus inferior,
Gluteus minimus,	Obturator externus,
Pyriformis,	Quadratus femoris.
Gemellus superior,	

THIGH.

Anterior Femoral Region.

Tensor vaginæ femoris,
Sartorius,
Rectus femoris,
Vastus internus,
Vastus externus,
Crureus.

Internal Femoral Region.

Iliacus internus,
Psoas magnus,
Pectineus,
Adductor longus,
Adductor brevis,
Adductor magnus,
Gracilis.

Posterior Femoral Region.

Biceps femoris,
Semi-tendinosus,
Semi-membranosus.

LEG.

Anterior Tibial Region.

Tibialis anticus,
Extensor longus digitorum,
Peroneus tertius,
Extensor proprius pollicis.

*Posterior Tibial Region.**Superficial group.*

Gastrocnemius,
Plantaris,
Soleus.

Deep group.

Popliteus,
Flexor longus pollicis,
Flexor longus digitorum,
Tibialis posticus.

Fibular Region.

Peroneus longus,
Peroneus brevis.

FOOT.

Dorsal Region.

Extensor brevis digitorum,
Interossei dorsales.

*Plantar Region.**1st Layer.*

Abductor pollicis,
Abductor minimi digiti,
Flexor brevis digitorum.

2d Layer.

Musculus accessorius,
Lumbricales.

3d Layer.

Flexor brevis pollicis,
Adductor pollicis,
Transversus pedis,
Flexor brevis minimi digiti,

4th Layer.

Interossei plantares.

MUSCLES OF THE HIP.

Gluteal Region.

Gluteus maximus,	Gemellus superior,
Gluteus medius,	Obturator internus,
Gluteus minimus,	Gemellus inferior,
Pyramidalis,	Obturator externus,
Quadratus femoris.	

Dissection.—The subject being turned on its face, and a block placed beneath the pubes to support the pelvis, the student commences the dissection of this region, by carrying an incision from the apex of the coccyx along the crest of the ilium to its anterior superior spinous process; or *vice versâ*, if he be on the left side. He then makes an incision from the posterior fifth of the crest of the ilium, to the apex of the trochanter major, this marks the upper border of the gluteus maximus; and a third incision from the apex of the coccyx along the fleshy margin of the lower border of the gluteus maximus, to the outer side of the thigh, about four inches below the apex of the trochanter major. He then reflects the integument, superficial fascia, and deep fascia, which latter is very thin over this muscle, from the gluteus maximus, following rigidly the course of its fibres; and having exposed the muscle in its entire extent, he dissects the integument and superficial fascia from off the deep fascia which binds down the gluteus medius, the other portion of the region.

The **GLUTEUS MAXIMUS** (*γλουτὸς*, nates; sacro-femoralis) is the thick, fleshy mass of muscle, of a trapezoid shape, which forms the convexity of the nates. In structure, it is coarse, being made up of large fibres, which are collected into fasciculi, and these again into distinct muscular masses, separated by deep cellular furrows. It *arises* from the posterior fifth of the crest and external surface of the ilium, from the posterior surface of the sacrum and coccyx, and from the great sacro-ischiatic ligament. It passes obliquely outwards and downwards, to be *inserted* into the rough line leading from the trochanter major to the linea aspera, and is continuous by means of its tendon with the fascia lata covering the outer side of the thigh, and with the external intermuscular ligament. Several bursæ are situated between this muscle and subjacent parts: one upon the tuberosity of the ischium, one between its tendon and the trochanter major, and one between it and the tendon of the vastus externus.

Relations.—By its *superficial surface* with a thin aponeurotic fascia, which separates it from the superficial fascia and integument, and near its insertion,

with the vastus externus. By its *deep surface* with the gluteus medius, pyriformis, gemelli, obturator internus, quadratus femoris, sacro-ischiatic foramina, great sacro-ischiatic ligament, tuberosity of the ischium, semi-membranosus, semi-tendinosus, biceps, and adductor magnus; gluteal vessels and nerves, ischiatic vessels and nerves, and internal pudic vessels and nerve. By its *upper border* it overlaps the gluteus medius; and by the *lower border* forms the lower margin of the nates. The gluteus maximus must be turned down from its origin, in order to bring the next muscles into view.

The GLUTEUS MEDIUS is placed in front of, rather than beneath the gluteus maximus; and is covered in by a process of the deep fascia, which is very thick and dense. It *arises* from the outer lip of the crest of the ilium for four-fifths its length, from the surface of bone between that border and the superior curved line of the dorsum ilii, and from the thick fascia above mentioned. Its fibres converge to the outer part of the trochanter major, into which its tendon is *inserted*.

Relations.—By its *superficial surface* with the tensor vaginæ femoris, gluteus maximus, and its own proper fascia. By its *deep surface* with the gluteus minimus and gluteal vessels and nerves. By its *lower border* with the pyriformis muscle. A bursa is interposed between its tendon and the upper part of the trochanter major. This muscle should now be removed from its origin and turned down, to expose the next, which is situated beneath it.

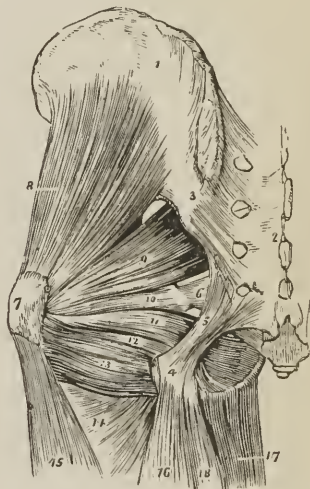
The GLUTEUS MINIMUS is a radiated muscle *arising* from the surface of the dorsum ilii, between the superior and inferior curved line; its fibres converge to the anterior border of the trochanter major, into which it is *inserted* by means of a rounded tendon. There is no distinct separation between the gluteus medius and minimus anteriorly.

Relations.—By its *superficial surface* with the gluteus medius, and gluteal vessels. By its *deep surface* with the ilium, long tendon of the rectus femoris, and capsule of the hip joint. A bursa is interposed between its tendon and the trochanter.

The PYRIFORMIS (pyrum, a pear, *i.e.* pear-shaped; iliacus externus) *arises* from the anterior surface of the sacrum, by three little slips interposed between the anterior sacral foramina from the first to the fourth, and from the adjoining surface of the ilium. It passes out of the pelvis through the great sacro-ischiatic foramen, and is *inserted* by a rounded tendon into the posterior border of the trochanter major.

Relations.—By its *superficial or external surface* with the sacrum and gluteus maximus. By its *deep or pelvic surface* with the rectum, sacral plexus of nerves, branches of the internal iliac artery, great sacro-ischiatic notch, and capsule of the hip joint. By its *upper border* with the gluteus medius and gluteal vessels and nerves. By its *lower border* with the gemellus superior, ischiatic vessels and nerves, and internal pudic vessels and nerve.

FIG. 186.



DEEP MUSCLES OF THE GLUTEAL REGION. 1. Ilium. 2. Sacrum. 3. Posterior sacro-iliac ligaments. 4. Tuberosity of the ischium. 5. Great or posterior sacro-ischiatic ligament. 6. Lesser or anterior sacro-ischiatic ligament. 7. Trochanter major. 8. Gluteus minimus. 9. Pyriformis. 10. Gemellus superior. 11. Obturator internus, passing out of the lesser sacro-ischiatic foramen. 12. Gemellus inferior. 13. Quadratus femoris. 14. Adductor magnus. 15. Vastus externus. 16. Biceps. 17. Gracilis. 18. Semi-tendinosus.

The GEMELLUS SUPERIOR (gemellus, double, twin) is a small slip of muscle situated immediately below the pyriformis; it *arises* from the spine of the ischium, and is *inserted* into the upper border of the tendon of the obturator internus, and into the digital fossa of the trochanter major. The gemellus superior is not unfrequently wanting.

Relations. — By its *superficial surface* with the gluteus maximus, ischiatic vessels and nerves, and internal pudic vessels and nerve. By its *deep surface* with the pelvis and capsule of the hip joint.

The OBTURATOR INTERNUS *arises* from the inner surface of the anterior wall of the pelvis, being attached to the margin of bone around the obturator foramen and to the obturator membrane. It passes out of the pelvis through the lesser sacro-ischiatic foramen, and is *inserted* by a flattened tendon into the digital fossa of the trochanter major. The lesser sacro-ischiatic notch, over which this muscle plays as through a pulley, is faced with cartilage, and provided with a synovial bursa to facilitate its movements. The tendon of the obturator is bordered above and below, by the gemelli muscles (hence their names), which are inserted into the sides of its tendon, and appear to be auxiliaries or superadded portions, external origins in fact of the obturator internus.

Relations. — By its *superficial or posterior surface* with the internal pudic vessels and nerve, the obturator fascia, which separates it from the levator ani and viscera of the pelvis, the sacro-ischiatic ligaments, gluteus maximus, and ischiatic vessels and nerves. By its *deep or anterior surface* with the obturator membrane and the margin of bone surrounding it, the cartilaginous pulley of the lesser sacro-ischiatic foramen, external surface of the pelvis, and capsular ligament of the hip joint. By its *upper border* within the pelvis, with the obturator vessels and nerve; externally to the pelvis, with the gemellus superior. By its *lower border* with the gemellus inferior.

The GEMELLUS INFERIOR *arises* from the posterior point of the tuberosity of the ischium, and is *inserted* into the lower border of the tendon of the obturator internus, and into the digital fossa of the trochanter major.

Relations. — By its *superficial surface* with the gluteus maximus, and ischiatic vessels and nerves. By its *deep surface* with the external surface of the pelvis, and capsule of the hip joint. By its *upper border* with the tendon of the obturator internus. By its *lower border* with the tendon of the obturator externus and quadratus femoris.

In this region the tendon only of the obturator externus can be seen; it is situated deeply between the gemellus inferior and upper border of the quadratus femoris. To expose the muscle fully, it is necessary to dissect it on the anterior part of the thigh, after the removal of the pectineus, adductor longus and adductor brevis.

The OBTURATOR EXTERNUS muscle (obturare, to stop up) *arises* from the obturator membrane and from the surface of the bone immediately surrounding it anteriorly, viz., from the ramus of the pubes and ischium; its tendon passes outwards behind the neck of the femur, to be *inserted* with the external rotator muscles, into the digital fossa of the trochanter major.

Relations. — By its *superficial or anterior surface* with the tendon of the psoas and iliacus, pectineus, adductor brevis and magnus, obturator vessels and nerve. By its *deep or posterior surface* with the obturator membrane and margin of bone which surrounds it, the lower part of the capsule of the hip joint and quadratus femoris.

The QUADRATUS FEMORIS (square-shaped) *arises* from the external border of the tuberosity of the ischium; and is *inserted* into a rough line on the posterior border of the trochanter major, which is thence named linea quadrati.

Relations. — By its *posterior surface* with the gluteus maximus, and ischiatic vessels and nerves. By its *anterior surface* with the tendon of the obturator externus and trochanter minor, a synovial bursa often separating it from the latter.

By its *upper border* with the gemellus inferior; and by the *lower border* with the adductor magnus.

Actions.—The glutei muscles are abductors of the thigh, when they take their fixed point from the pelvis. Taking their fixed point from the thigh, they steady the pelvis on the head of the femur; this action is peculiarly obvious in standing on one leg: they assist also in carrying the leg forwards, in progression. The gluteus minimus being attached to the anterior border of the trochanter major, rotates the limb slightly inwards. The gluteus medius and maximus, from their insertion into the posterior aspect of the bone, rotate the limb outwards; the latter is, moreover, a tensor of the fascia of the thigh. The other muscles rotate the limb outwards, everting the knee and foot; hence they are named external rotators.

MUSCLES OF THE THIGH.

Anterior Femoral Region.

Tensor vaginæ femoris,	Vastus internus,
Sartorius,	Vastus externus,
Rectus femoris,	Crureus.

Dissection.—Make an incision along the line of Poupart's ligament, from the anterior superior spinous process of the ilium to the spine of the pubes; and a second, from the middle of the preceding, down the inner side of the thigh, and across the inner condyle of the femur to the head of the tibia, where it may be bounded by a transverse incision. Turn back the integument from the whole of this region, and examine the superficial fascia; which is next to be removed in the same manner. After the deep fascia has been well considered, it is likewise to be removed, by dissecting it off in the course of the fibres of the muscles. As it might not be convenient to the junior student to expose so large a surface at once as ordered in this dissection, the vertical incision may be crossed by one or two transverse incisions, as may be deemed most proper.

The TENSOR VAGINÆ FEMORIS (stretcher of the sheath of the thigh) is a short flat muscle, situated on the outer side of the hip. It *arises* from the crest of the ilium, near its anterior superior spinous process, and is *inserted* between two layers of the fascia lata at about one-fourth down the thigh.

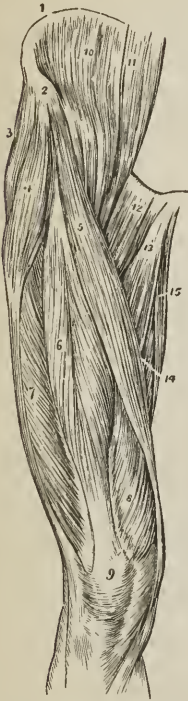
Relations.—By its *superficial surface* with the fascia lata and integument. By its *deep surface* with an internal layer of the fascia lata, gluteus medius, rectus, and vastus externus. By its *inner border* near its origin with the sartorius.

The SARTORIUS (tailor's muscle) is a long ribandlike muscle, *arising* from the anterior superior spinous process of the ilium, and from the notch immediately below that process; it crosses obliquely the upper third of the thigh, descends behind the inner condyle of the femur, and is *inserted* by an aponeurotic expansion into the inner tuberosity of the tibia [and sends a considerable process to the deep fascia of the leg]. This expansion covers in the insertion of the tendons of the gracilis and semi-tendinosus muscle. [The aponeurotic interlacement of these three tendons is called the 'goose's foot.'] The inner border of the sartorius muscle is the guide to the operation for tying the femoral artery in the middle of its course; and the outer boundary of Scarpa's triangular space.

Relations.—By its *superficial surface* with the fascia lata and cutaneous nerves. By its *deep surface* with the psoas and iliacus, rectus, sheath of the femoral vessels, vastus internus, adductor longus, adductor magnus, gracilis, long saphenous nerve, internal lateral ligament of the knee joint. By its expanded insertion with the tendons of the gracilis and semi-tendinosus, a synovial bursa being interposed. At the knee joint its *posterior border* is in relation with the internal saphenous vein. At the upper third of the thigh the sartorius forms, with the lower border of the adductor longus, an isosceles triangle (Scarpa's

triangular space), whereof the base corresponds with Poupart's ligament. A perpendicular line, drawn from the middle of the base to the apex of this triangle, immediately overlies the femoral artery with its sheath.

FIG. 187.



MUSCLES OF THE ANTERIOR FEMORAL REGION. 1. Crest of the ilium. 2. Its anterior superior spinous process. 3. Gluteus medius. 4. Tensor vaginae femoris; its insertion into the fascia lata is shown inferiorly. 5. Sartorius. 6. Rectus. 7. Vastus externus. 8. Vastus internus. 9. Patella. 10. Iliacus internus. 11. Psoas magnus. 12. Pectineus. 13. Adductor longus. 14. Part of the adductor magnus. 15. Gracilis.

The RECTUS FEMORIS (straight) is fusiform in shape and bipenniform in the disposition of its fibres. It arises by two round tendons, one from the anterior inferior spinous process of the ilium, the other from the upper lip of the acetabulum; and is inserted by a broad and strong tendon into the upper border of the patella. It is more correct to consider the patella as a sesamoid bone, developed within the tendon of the rectus; and the ligamentum patellæ as the continuation of the tendon to its insertion into the tubercle of the tibia.

Relations. — By its superficial surface with the gluteus medius, psoas and iliacus, sartorius; and for the lower three-fourths of its extent, with the fascia lata. By its deep surface with the capsule of the hip joint, external circumflex vessels, crureus, vastus internus and externus. The rectus must now be divided through its middle, and the two ends turned aside, to bring clearly into view the next muscles.

The three next muscles are generally considered collectively under the name of *triceps extensor cruris*. Adopting this view, the muscle surrounds the whole of the femur, excepting the rough line (*linea aspera*), at its posterior aspect. Its division into three parts is not well defined; the fleshy mass upon each side being distinguished by the names of vastus internus and externus, the middle portion by that of crureus.

The VASTUS EXTERNUS (*extensor cruris externus*) narrow below and broad above, arises from the base of the trochanter major, the outer surface of the femur, outer lip of the *linea aspera*, and intermuscular fascia; it passes down to be inserted into the outer border of the patella, or rather, by means of the ligamentum patellæ, into the tubercle of the tibia conjointly with the rectus and two following muscles.

Relations. — By its superficial surface with the fascia lata, rectus, biceps, semi-membranosus, and gluteus maximus, a synovial bursa being interposed between it and the latter. By its deep surface with the crureus and femur.

The VASTUS INTERNUS (*extensor cruris internus*), broad below and narrow above, arises from the anterior intertrochanteric line, inner surface of the femur, inner lip of the *linea aspera* and intermuscular fascia, and is inserted into the inner border of the patella. By its mesial border it is blended with the crureus.

Relations. — By its superficial surface with the psoas and iliacus, rectus, sartorius, femoral artery and vein, and saphenous nerve, pectineus, adductor longus, brevis, and magnus, and fascia lata. By its deep surface with the crureus and femur.

The CRUREUS (*crus, the leg*) arises from the anterior intertrochanteric line and anterior surface of the femur to within two inches of the patella. It is continuous by its inner border with the vastus internus, and is inserted into the upper border of the patella; its tendon occupying its cutaneous aspect.

When the erureus is divided from its insertion, a small muscle is seen upon the lower part of the femur; it generally consists of two fasciuli, external and internal, which are inserted into the pouch of synovial membrane that extends upwards from the knee joint, behind the patella; and is named, from its situation, *subcrureus*. It would seem to be intended to support the synovial membrane.

Relations.—By its *superficial surface* with the external circumflex vessels, rectus, vastus internus and externus. By its *deep surface* with the femur, subcrureus, and synovial membrane of the knee joint.

Actions.—The tensor vaginæ femoris renders the fascia lata tense, and slightly inverts the limb. The sartorius flexes the leg upon the thigh, and, continuing to act, the thigh upon the pelvis, at the same time carrying the leg across that of the opposite side, into the position in which tailors sit; hence its name. Taking its fixed point from below, it assists the extensor muscles in steadying the leg, for the support of the trunk. The other four muscles have been collectively named *quadriceps extensor*, from their similarity of action. They extend the leg upon the thigh, and obtain a great increase of power by their attachment to the patella, which acts as a fulcrum. Taking their fixed point from the tibia, they steady the femur upon the leg, and the rectus, being attached to the pelvis, serves to balance the trunk upon the lower extremity.

Internal Femoral Region.

Iliacus internus,	Adductor longus,
Psoas magnus,	Adductor brevis,
Pectineus,	Adductor magnus,
	Gracilis.

Dissection. — These muscles are exposed by the removal of the inner flap of integument recommended in the dissection of the anterior femoral region. The iliacus and psoas arising from within the abdomen can only be seen in their entire extent after the removal of the viscera from that cavity.

The ILIACUS INTERNUS is a flat radiated muscle. It *arises* from the fossa of the ilium, the internal lip of the crest, and anterior border of the bone; and after escaping beneath the crural arch and joining the tendon of the psoas, is *inserted* into the trochanter minor of the femur. A few fibres of this muscle are derived from the base of the sacrum, and others from the capsular ligament of the hip joint.

Theile, with several other anatomists, regards the iliacus internus and psoas magnus as a single muscle, arising by two heads; it has no proper tendon, its muscular fibres being inserted into that of the psoas. He describes the combined muscle under the name of *flexor femoris*.

Relations. — By its *anterior surface* within the pelvis, with the external cutaneous nerve, and iliac fascia, which latter separates it from the peritoneum, on the right from the cæcum, and on the left from the sigmoid flexure of the colon; *externally* to the pelvis, with the fascia lata, rectus, and sartorius. By its *posterior surface* with the iliac fossa, margin of the pelvis, and capsule of the hip joint, a synovial bursa of large size being interposed. This bursa sometimes communicates with the synovial membrane of the ilio-femoral articulation. By its *inner border*, with the psoas magnus and crural nerve.

The PSOAS MAGNUS (ῥόα, lumbus, a loin), situated by the side of the vertebral column in the loins, is a long fusiform muscle. It *arises* from the bodies, and bases of the transverse processes, of the last dorsal and all the lumbar vertebræ. It also takes its origin from the intervertebral substance, and from a series of tendinous arches attached to the vertebræ, and intended for the protection of the lumbar vessels and branches of the sympathetic nerve in their passage between the muscle and the bone. From this extensive origin the muscle passes along the margin of the brim of the pelvis, and beneath Poupert's ligament, to its

insertion. The tendon of the psoas magnus is joined by the iliacus, and *inserted* into the posterior part of the trochanter minor, a bursa being interposed.

Relations. — By its *anterior surface* with the ligamentum arcuatum internum of the diaphragm, kidney, psoas parvus, genito-crural nerve, sympathetic nerve, psoas fascia, peritoneum, colon, and along its pelvic border, the common and external iliac artery and vein. By its *posterior surface* with the lumbar vertebræ, lumbar arteries, quadratus lumborum (from which latter it is separated by the anterior layer of the aponeurosis of the transversalis), and crural nerve, which, near Poupart's ligament, reaches its outer side. The lumbar plexus of nerves is situated in the substance of the posterior part of the muscle. In the thigh the muscle is in relation with the fascia lata *in front*; the border of the pelvis and hip joint, from which it is separated by the synovial membrane, common to it and the preceding muscle, *behind*; the crural nerve and iliacus muscle to the *outer side*; and the femoral artery, by which it is slightly overlaid, to the *inner side*.

The PECTINEUS is a flat and quadrangular muscle; it *arises* from the pectineal line (pecten, a crest) of the os pubis, and from the surface of bone in front of that line. It is *inserted* into the ridge leading from the anterior intertrochanteric line to the linea aspera of the femur.

Relations. — By its *anterior surface* with the pubic portion of the fascia lata, which separates it from the femoral artery and vein and internal saphenous vein, and lower down with the profunda artery. By its *posterior surface* with the capsule of the hip joint, obturator externus and adductor brevis, the obturator vessels being interposed. By its *external border* with the psoas, the femoral artery resting on the line of interval. By its *internal border* with the outer edge of the adductor longus. Obturator hernia is situated directly behind this muscle, which forms one of its coverings.

The ADDUCTOR LONGUS (adducere, to draw to; caput longum tricipitis), the most superficial of the three adductors, *arises* by a round and thick tendon from the front surface of the os pubis, immediately below the angle of that bone; and, assuming a flattened and expanded form as it descends, is *inserted* into the middle third of the linea aspera.

Relations. — By its *anterior surface* with the pubic portion of the fascia lata, and near its insertion, with the femoral artery and vein. By its *posterior surface* with the adductor brevis and magnus, anterior branches of the obturator vessels and nerve, and, near its insertion, profunda artery and vein. By its *outer border* with the pectineus, by the *inner border* with the gracilis. The pectineus must be divided near its origin and turned outwards, and the adductor longus through its middle, turning its ends to either side, to bring into view the adductor brevis.

The ADDUCTOR BREVIS (caput breve tricipitis), placed behind the pectineus and adductor longus, is fleshy, and thicker than the adductor longus; it *arises* from the body of the os pubis, and is *inserted* into the line leading from the lesser trochanter to the linea aspera.

Relations. — By its *anterior surface* with the pectineus, adductor longus, and anterior branch of the obturator nerve and artery. By its *posterior surface* with the adductor magnus. By its *outer border* with the obturator externus, and tendon of the psoas and iliacus. By its *inner border* with the gracilis and adductor magnus. The adductor brevis is pierced near its insertion by the middle perforating artery. The adductor brevis may now be divided from its origin and turned outwards, or its inner two-thirds may be cut away entirely, when the adductor magnus muscle will be exposed in its entire extent.

The ADDUCTOR MAGNUS (caput magnum tricipitis) is a broad triangular muscle, forming a septum of division between the muscles situated on the anterior and those on the posterior aspect of the thigh. It *arises* by fleshy fibres from the ramus of the pubes and ischium and from the side of the tuber ischii; and radiating in its passage outwards, is *inserted* into the whole length of the linea aspera,

and inner condyle of the femur. The adductor magnus is pierced by five openings; the three superior, for the three perforating arteries; the fourth, for the termination of the profunda. The fifth is the large oval opening, in the tendinous portion of the muscle, that gives passage to the femoral vessels.

Relations.—By its *anterior surface* with the pectineus adductor brevis, adductor longus, femoral artery and vein and profunda artery and vein, with their branches. By its *posterior surface* with the semi-tendinosus, semi-membranosus, biceps, and gluteus maximus. By its *inner border* with the gracilis and sartorius. By its *upper border* with the obturator externus, and quadratus femoris.

The GRACILIS (slender; reetus internus) is situated along the inner border of the thigh. It *arises* by a broad but very thin tendon, from the body of the os pubis along the edge of the symphysis, and from the margin of the ramus of the pubes and ischium; it is *inserted* by a rounded tendon into the inner tuberosity of the tibia, beneath the expansion of the sartorius [and sends off an aponeurosis to the deep fascia of the leg.]

Relations.—By its *inner or superficial surface* with the fascia lata, and below with the sartorius and internal saphenous nerve; the internal saphenous vein crosses it lying superficially to the fascia lata. By its *outer or deep surface* with the adductor longus, brevis, and magnus, and the internal lateral ligament of the knee joint, from which it is separated by a synovial bursa common to it and the tendons of the gracilis and semi-tendinosus.

Actions.—The iliacus, psoas, pectineus, and adductor longus muscles bend the thigh upon the pelvis, and at the same time, from the obliquity of their insertion into the lesser trochanter and linea aspera, rotate the limb outwards; the pectineus and adductors adduct the thigh powerfully, and from the manner of their insertion into the linea aspera, assist in rotating the limb outwards. The gracilis is an adductor of the thigh; but contributes to the flexion of the leg, by its attachment to the inner tuberosity of the tibia.

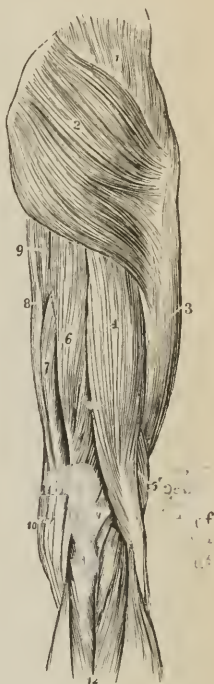
Posterior Femoral Region.

Biceps femoris, Semi-tendinosus,
Semi-membranosus.

Dissection.—Remove the integument and fascia on the posterior part of the thigh by two flaps, as on the anterior region, and turn aside the gluteus maximus from the upper part; the muscles may then be examined.

The BICEPS FEMORIS (bis, double, κεφαλή, head; flexor cruris externus vel fibularis) *arises* by two heads, one (caput longum) by a common tendon with the semi-tendinosus from the upper and back part of the tuber ischii; the other (caput breve) muscular and much shorter, from the lower two-thirds of the external border of the linea aspera.

FIG. 188.



MUSCLES OF THE POSTERIOR FEMORAL AND GLUTEAL REGION. 1. Gluteus medius. 2. Gluteus maximus. 3. Vastus externus covered in by fascia lata. 4. Long head of biceps. 5. Short head. 6. Semi-tendinosus. 7. Semi-membranosus. 8. Gracilis. 9. Part of the inner border of the adductor magnus. 10. Edge of sartorius. 11. Popliteal space. 12. Gastrocnemius; its two heads. The tendon of the biceps forms the outer hamstring; the sartorius, with the tendons of the gracilis, semi-tendinosus, and semi-membranosus, the inner hamstring.

The biceps forms the outer hamstring, and is *inserted* by a strong tendon into the head of the fibula; one portion of the tendon being continued downwards into the fascia of the leg, and another being attached to the outer tuberosity of the tibia.

Relations. — By its *superficial or posterior surface* with the gluteus maximus and fascia lata. By its *deep or anterior surface* with the semi-membranosus, adductor magnus, vastus externus, from which it is separated by the external intermuscular fascia, great ischiatic nerve, popliteal artery and vein, and near its insertion the external head of the gastrocnemius, and plantaris. By its *inner border* with the semi-tendinosus, and in the popliteal space with the popliteal artery and vein.

The SEMI-TENDINOSUS, remarkable for its long tendon, *arises* in common with the long head of the biceps, from the upper and back part of the tuberosity of the ischium: the two muscles being closely united for several inches below their origin. It is *inserted* into the inner tuberosity of the tibia, immediately below the insertion of the tendon of the gracilis, and sends an expansion to the fascia of the leg.

Relations. — By its *superficial surface* with the gluteus maximus, fascia lata, and at its insertion with the synovial bursa which separates its tendon from the expansion of the sartorius. By its *deep surface* with the semi-membranosus, adductor magnus, internal head of the gastrocnemius, and internal lateral ligament of the knee joint, the synovial bursa common to it and the tendon of the gracilis being interposed. By its *inner border* with the gracilis; by its *outer border* with the biceps.

These two muscles must be dissected from the tuberosity of the ischium, to bring into view the origin of the next.

The SEMI-MEMBRANOSUS, remarkable for the tendinous expansion upon its anterior and posterior surface, *arises* from the tuberosity of the ischium, in front of the common origin of the two preceding muscles. It is *inserted* [see fig. 191] into the posterior part of the inner tuberosity of the tibia; at its insertion the tendon splits into three portions, one of which is inserted in a groove on the inner side of the head of the tibia, beneath the internal lateral ligament. The second is continuous with an aponeurotic expansion that binds down the popliteal muscle, the popliteal fascia; and the third turns upwards and outwards to the external condyle of the femur, forming the middle portion of the posterior ligament of the knee joint (ligamentum posticum Winslowii).

The tendons of the semi-tendinosus, semi-membranosus, gracilis and sartorius, from the inner hamstring.

Relations. — By its *superficial surface* with the gluteus maximus, biceps, semi-tendinosus, fascia lata, and, at its insertion, the tendinous expansion of the sartorius. By its *deep surface* with the quadratus femoris, adductor magnus, internal head of gastrocnemius, knee joint from which it is separated by a synovial membrane, and popliteal artery and vein. By its *inner border* with the gracilis. By its *outer border* with the great ischiatic nerve, and in the popliteal space, the popliteal artery and vein.

If the semi-membranosus muscle be turned down from its origin, the student will bring into view the broad and radiated expanse of the adductor magnus, against which the three flexor muscles above described rest.

Actions. — The three hamstring muscles are flexors of the leg upon the thigh; and taking their fixed point from below, they balance the pelvis on the lower extremities. The biceps, from the obliquity of its direction, everts the leg when partly flexed, and the semi-tendinosus turns the leg inwards when in the same state of flexion.

MUSCLES OF THE LEG.

Anterior Tibial Region.

Tibialis anticus,
Extensor longus digitorum,

Peroneus tertius,
Extensor proprius pollicis.

Dissection. — The dissection of the anterior tibial region is to be commenced by carrying an incision along the middle of the leg, midway between the tibia and fibula, from the knee to the ankle, and bounding it inferiorly by a transverse incision extending from one malleolus to the other. And to expose the tendons on the dorsum of the foot, the longitudinal incision may be carried onwards to the outer side of the base of the great toe, and terminated by another incision directed across the heads of the metatarsal bones.

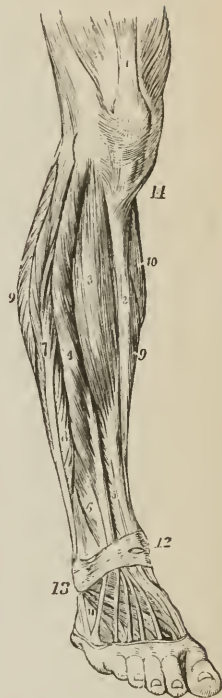The TIBIALIS ANTICUS (*flexor tarsi tibialis*) arises from the outer tuberosity and upper two-thirds of the tibia, the interosseous membrane, intermuscular fascia, and deep fascia; its tendon passes through a distinct sheath in the annular ligament, and is inserted into the inner and under side of the internal cuneiform bone, and base of the metatarsal bone of the great toe.

Relations. — By its *anterior surface* with the deep fascia, from which many of its superior fibres arise, and the anterior annular ligament. By its *posterior surface* with the interosseous membrane, tibia, ankle joint, and bones of the tarsus. By its *internal surface* with the tibia; by its *external surface* with the extensor longus digitorum, extensor proprius pollicis, and anterior tibial vessels and nerve.

The EXTENSOR LONGUS DIGITORUM (*extensor communis longus*) arises from the outer tuberosity of the tibia, the head and upper three-fourths of the fibula, the interosseous membrane, intermuscular fascia and deep fascia. Near the ankle it divides into four tendons, which pass beneath the annular ligament through a proper tendinous pulley (the sling ligament of Retzius), to be inserted into the second and third phalanges of the four lesser toes. The mode of insertion of the extensor tendons, both in the hand and in the foot, is remarkable; each tendon spreads into a broad aponeurosis over the first phalanx; this aponeurosis is strengthened on its borders by the tendons of the lumbricales and interossei, and divides into three slips; the middle slip is inserted into the base of the second phalanx, the two lateral slips are continued onwards, to be inserted into the base of the third.

Relations. — By its *anterior surface*, with the deep fascia of the leg and foot, and anterior annular ligament. By its *posterior surface* with the interosseous membrane, fibula, ankle joint, extensor brevis digitorum (which separates its tendons from the tarsus) metatarsus and phalanges

FIG. 189.

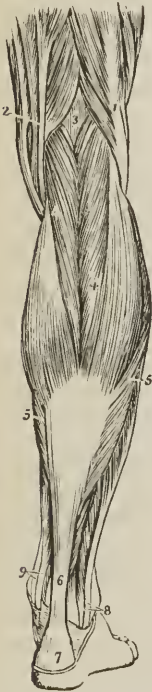

MUSCLES OF THE ANTERIOR TIBIAL REGION. 1. Quadriceps extensor inserted into the patella; the figure rests on the tendon of the rectus: the vastus internus and externus are situated one at each side. 2. Subcutaneous surface of the tibia. 3. Tibialis anticus. 4. Extensor longus digitorum. 5. Extensor proprius pollicis. 6. Peroneus tertius. 7. Peroneus longus. 8. Peroneus brevis. 9, 9. Borders of the soleus muscle. 10. Part of the inner belly of the gastrocnemius. 11. Extensor brevis digitorum; the tendon in front of the cipher is that of the peroneus tertius; that behind it, the peroneus brevis.

By its *inner surface*, with the tibialis anticus, extensor proprius pollicis, and anterior tibial vessels. By its *outer border* with the peroneus longus and brevis.

The PERONEUS TERTIUS (flexor tarsi fibularis) *arises* from the lower fourth of the fibula and intermuscular fascia, and is *inserted* into the base of the metatarsal bone of the little toe. Although apparently but a mere division or continuation of the extensor longus digitorum, this muscle may be looked upon as analogous to the flexor carpi ulnaris of the forearm. Sometimes it is wanting.

FIG. 190.



SUPERFICIAL MUSCLES OF THE POSTERIOR ASPECT OF THE LEG. 1. Biceps, forming the outer hamstring. 2. Tendons forming the inner hamstring. 3. Popliteal space. 4. Gastrocnemius. 5, 5. Soleus. 6. Tendo Achillis. 7. Posterior tuberosity of the os calcis. 8. Tendons of the peroneus longus and brevis passing behind the outer ankle. 9. Tendons of the tibialis posticus and flexor longus digitorum passing into the foot behind the inner ankle.

The EXTENSOR PROPRIUS POLLICIS (extensor hallucis longus) lies between the tibialis anticus and extensor longus digitorum. It *arises* from the lower two-thirds of the fibula and interosseous membrane. Its tendon passes through a distinct sheath in the annular ligament, and is *inserted* into the base of the last phalanx of the great toe.

Relations. — By its *anterior surface* with the deep fascia of the leg and foot, and anterior annular ligament. By its *posterior surface* with the interosseous membrane, fibula, tibia, ankle joint, extensor brevis digitorum, and bones and articulations of the great toe. It is crossed on this aspect by the anterior tibial vessels and nerve. By its *outer side* with the extensor longus digitorum, and in the foot with the dorsalis pedis artery and veins; the outer side of its tendon on the dorsum of the foot being the guide to these vessels. By its *inner side* with the tibialis anticus, and anterior tibial vessels.

Actions. — The tibialis anticus and peroneus tertius are direct flexors of the tarsus upon the leg; acting in conjunction with the tibialis posticus they direct the foot inwards, and with the peroneus longus and brevis outwards. They assist also in preserving the flatness of the foot during progression. The extensor longus digitorum and extensor proprius pollicis are extensors of the phalanges; and continuing their action, they assist the tibialis anticus and peroneus tertius, in flexing the foot upon the leg. Taking their origin from below, they increase the stability of the ankle joint.

Posterior Tibial Region.

Superficial Group.

Gastrocnemius, Plantaris, Soleus.

Dissection. — Make an incision from the middle of the popliteal space down the middle of the posterior part of the leg to the heel, bounding it inferiorly by a transverse incision passing between the two malleoli. Turn aside the flaps of integument and remove the fasciæ from the whole of this region; the gastrocnemius muscle will then be exposed.

The GASTROCNEMIUS (γαστροκνήμιον, the bellied part of the leg; gemellus suræ) *arises* by two heads (gemellus externus et internus) from the upper part of the two condyles of the femur, the inner head being the longest. They unite to form the beautiful

muscle so characteristic of this region of the limb. It is *inserted*, by means of the tendo Achillis, into the lower part of the posterior tuberosity of the os calcis, a synovial bursa being placed between the tendon and the upper part of the tuberosity. The gastrocnemius must be removed from its origin, and turned down in order to expose the next muscle.

Relations. — By its *superficial surface* with the deep fascia of the leg, which separates it from the external saphenous vein, and with the external saphenous nerve. By its *deep surface* with the lateral portions of the posterior ligament of the knee joint, the popliteus, plantaris, and soleus. The internal head of the muscle rests against the posterior surface of the internal condyle of the femur; the external head against the outer side of the external condyle. In the latter a sesamoid bone is sometimes found.

The PLANTARIS (planta, the sole of the foot), an extremely diminutive muscle situated between the gastrocnemius and soleus, *arises* from the upper part of the outer condyle of the femur; and is *inserted*, by its long and delicately slender tendon, into the inner side of the posterior tuberosity of the os calcis, by the side of the tendo Achillis; having crossed obliquely between the two muscles.

The SOLEUS (solea, a sole,) is the broad muscle upon which the plantaris rests. It *arises* from the head and upper half of the fibula, from the oblique line and middle third of the tibia, and from a tendinous arch thrown across between these two portions. Its fibres converge to the tendo Achillis, by which it is *inserted* into the posterior tuberosity of the os calcis. The tendinous arch gives passage to the popliteal vessels and nerve in their course to the leg.

Relations. — By its *superficial surface* with the gastrocnemius and plantaris. By its *deep surface* with the intermuscular fascia, which separates it from the flexor longus digitorum, tibialis posticus, flexor longus pollicis, posterior tibial vessels and nerve, and peroneal vessels.

Actions. — The three muscles (triceps suræ, extensor pedis) of the calf draw powerfully on the os calcis, and lift the heel; continuing their action they raise the entire body. This movement is attained by means of a lever of the second power, the fulcrum (the toes) being at one end, the weight (the body supported on the tibia) in the middle, and the power (these muscles) at the other extremity.

They are, therefore, the walking muscles, and perform all movements that require the support of the whole body from the ground, as dancing, leaping, &c. Taking their fixed point from below, they steady the leg upon the foot.

Deep Layer.

Popliteus,	Flexor longus digitorum,
Flexor longus pollicis,	Tibialis posticus.

Dissection. — After the removal of the soleus, the deep layer will be found bound down by an intermuscular fascia which is to be dissected away; the muscles may then be examined.

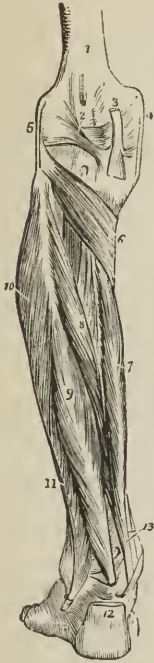The POPLITEUS muscle (poples, the ham of the leg) forms the floor of the popliteal region at its lower part, and is bound tightly down by a strong fascia derived from the middle slip of the tendon of the semi-membranosus muscle. It *arises* by a rounded tendon from a deep groove at the outer side of the external condyle of the femur, beneath the [long¹] external lateral ligament and within the capsular ligament of the joint; and spreading obliquely over the head of the tibia, is *inserted* into the surface of bone above its oblique line. This line is called, from being the limit of insertion of the popliteus muscle, the popliteal line.

Relations. — By its *superficial surface* with a thick fascia which separates it from the gastrocnemius, plantaris, and popliteal vessels and nerve. By its *deep surface* with the synovial membrane of the knee joint, and upper part of the tibia.

¹ [See note, p. 161.]

The FLEXOR LONGUS POLLICIS (flexor hallucis longus) is the most superficial of the next three muscles. It arises from the lower two-thirds of the fibula, and

FIG. 191.



DEEP LAYER OF MUSCLES OF THE POSTERIOR TIBIAL REGION.

1. Lower extremity of the femur. 2. Ligamentum posticum Winslowii. 3. Tendon of the semi-membranosus muscle dividing into three slips. 4. Internal lateral ligament of the knee joint. 5. External lateral ligament [long]. 6. Popliteus muscle. 7. Flexor longus digitorum. 8. Tibialis posticus. 9. Flexor longus pollicis. 10. Peroneus longus. 11. Peroneus brevis. 12. Tendo Achillis divided near its insertion into the os calcis. 13. Tendons of the tibialis posticus and flexor longus digitorum, just as they are about to pass beneath the internal annular ligament of the ankle; the interval between the latter tendon and the tendon of the flexor longus pollicis is for the posterior tibial vessels and nerve.

lation, to be inserted into the bone, a process of its tendon being prolonged outwards to the external cuneiform

and passes through a groove in the astragalus and os calcis, converted by tendinous fibres into a distinct sheath lined by synovial membrane, into the sole of the foot, to be inserted into the base of the last phalanx of the great toe.

Relations. — By its superficial surface with the intermuscular fascia, which separates it from the soleus and tendo Achillis. By its deep surface with the tibialis posticus, fibula, peroneal vessels, interosseous membrane, and ankle joint. By its outer border with the peroneus longus and brevis. By its inner border with the flexor longus digitorum. In the foot, the tendon of the flexor longus pollicis is connected with that of the flexor longus digitorum by a short tendinous slip.

The FLEXOR LONGUS DIGITORUM (perforans; flexor communis longus) arises from the surface of the tibia, immediately below the popliteal line. Its tendon passes through a sheath common to it and the tibialis posticus, behind the inner malleolus; it then passes through a second sheath which is connected with a groove in the astragalus and os calcis into the sole of the foot, where it divides into four tendons, which are inserted into the base of the last phalanx of the four lesser toes, perforating the tendons of the flexor brevis digitorum.

Relations. — By its superficial surface with the intermuscular fascia, which separates it from the soleus, and with the posterior tibial vessels and nerve. By its deep surface with the tibia and tibialis posticus. In the sole of the foot its tendon is in relation with the abductor pollicis and flexor brevis digitorum, which lie superficially to it, and it crosses the tendon of the flexor longus pollicis. At the point of crossing it receives a tendinous slip of communication.

The flexor longus pollicis must now be removed from its origin, and the flexor longus digitorum drawn aside, to bring into view the entire extent of the tibialis posticus.

The TIBIALIS POSTICUS (nauticus; extensor tarsi tibialis) lies upon the interosseous membrane, between the two bones of the leg. It arises by two heads from the adjacent sides of the tibia and fibula their whole length, from the interosseous membrane, and from an aponeurosis which binds it in its place. Its tendon passes inwards beneath the tendon of the flexor longus digitorum, and runs in the same sheath; it then passes through a proper sheath over the deltoid ligament, and beneath the astragalo-scaploid articulation, to be inserted into the

tuberosity of the scaphoid and internal cuneiform bone, a process of its tendon being prolonged outwards to the external cuneiform.

While in the common sheath behind the internal malleolus, the tendon of the tibialis posticus lies internally to that of the flexor longus digitorum, from which it is separated by a thin fibrous partition. A sesamoid bone is usually met with in the tendon close to its insertion.

Relations.—By its *superficial surface* with the intermuscular aponeurosis, flexor longus pollicis, flexor longus digitorum, posterior tibial vessels and nerve, peroneal vessels, and, in the sole of the foot, the abductor pollicis. By its *deep surface* with the interosseous membrane, fibula and tibia, ankle joint and astragalus. The anterior tibial artery passes between the two heads of the muscle.

The student will observe that the two latter muscles change their relative position to each other in their course. Thus, in the leg, the position of the three muscles from within outwards, is, flexor longus digitorum, tibialis posticus, flexor longus pollicis. At the inner malleolus, the relation of the tendons is, tibialis posticus, flexor longus digitorum, both in the same sheath; then a broad groove, which lodges the posterior tibial artery, venæ comites, and nerve; and lastly, the flexor longus pollicis.

Actions.—The popliteus is a flexor of the tibia upon the thigh, carrying it at the same time inwards so as to invert the leg. The flexor longus pollicis, and flexor longus digitorum, are the long flexors of the toes; their tendons are connected in the foot by a short tendinous band, hence they necessarily act together. The tibialis posticus is an extensor of the tarsus upon the leg, and an antagonist to the tibialis anticus. It combines with the tibialis anticus in adduction of the foot.

Fibular Region.

Peroneus longus,

Peroneus brevis.

Dissection.—These muscles are exposed by continuing the dissection of the anterior tibial region outwards beyond the fibula, to the border of the posterior tibial region.

The PERONEUS LONGUS (περόνη, fibula; extensor tarsi fibularis longior) arises from the head and upper half of the outer side of the fibula, from the deep fascia, and intermuscular septa, and terminates in a long tendon which passes behind the external malleolus, and obliquely across the sole of the foot, through the groove in the cuboid bone, to be inserted into the base of the metatarsal bone of the great toe. Its tendon is thickened where it glides behind the external malleolus, and a sesamoid bone is developed in that part which plays against the cuboid bone.

Relations.—By its *superficial surface* with the fascia of the leg and foot. By its *deep surface* with the fibula, peroneus brevis, os calcis, cuboid bone, and, near the head of the fibula, the external popliteal nerve. By its *anterior border* it is separated from the extensor longus digitorum by the attachment of the fascia of the leg to the fibula; and, by the *posterior border*, by the same medium from the soleus and flexor longus pollicis. The tendon of the peroneus longus is furnished with three fibrous sheaths and as many synovial membranes; the first is situated behind the external malleolus, and is common to this muscle and the peroneus brevis, the second at the outer side of the os calcis, the third on the cuboid bone.

The PERONEUS BREVIS (extensor tarsi fibularis brevior) lies beneath the peroneus longus; it arises from the lower half of the fibula and intermuscular septa, and terminates in a tendon which passes behind the external malleolus and through a groove in the os calcis, to be inserted into the base of the metatarsal bone of the little toe.

Relations.—By its *superficial surface* with the peroneus longus and fascia of the leg and foot. By its *deep surface* with the fibula, os calcis, and cuboid bone. The lateral relations of the muscle are the same as those of the peroneus longus.

The tendon of the peroneus brevis has but two tendinous sheaths and two synovial membranes, one being behind the external malleolus and common to both peronei, the other at the side of the os calcis.

Actions. — The peronei muscles are extensors of the foot, conjointly with the tibialis posticus. They antagonise the tibialis anticus and peroneus tertius, which are flexors of the foot. The whole of these muscles acting together, tend to maintain the flatness of the foot, so necessary to security in walking.

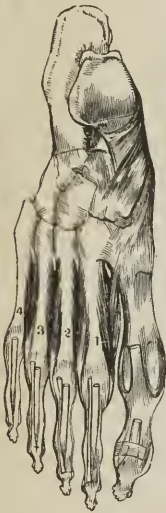MUSCLES OF THE FOOT.

Dorsal Region.

Extensor brevis digitorum,

Interossei dorsales.

[FIG. 192.]



DORSAL INTEROSSEOUS MUSCLES. 1. Adductor of the second toe. 2. Abductor of the second toe. 3. Abductor of the third toe. 4. Abductor of the fourth toe.]

The EXTENSOR BREVIS DIGITORUM muscle arises from the outer side of the os calcis, crosses the foot obliquely, and terminates in four tendons, the innermost of which is inserted into the base of the first phalanx of the great toe, and the other three into the sides of the long extensor tendons of the second, third, and fourth toes.

Relations. — By its upper surface with the tendons of the extensor longus digitorum, peroneus brevis, and the deep fascia of the dorsum of the foot. By its under surface with the tarsal and metatarsal bones. Its inner border is in relation with the dorsalis pedis artery, the innermost tendon crossing that artery just before its division.

The INTEROSSEI DORSALES (bicipites) are placed between the metatarsal bones; they resemble the analogous muscles in the hand in arising by two heads from the adjacent sides of the metatarsal bones; their tendons are inserted into the base of the first phalanx, and the digital expansion of the tendons of the long extensor.

The first dorsal interosseous is inserted into the inner side of the second toe, and is therefore an adductor: the other three are inserted into the outer side of the second, third, and fourth toe, and are consequently abductors.¹

Relations. — By their upper surface with a strong fascia which separates them from the extensor tendons. By their under surface with the plantar interossei. Each of the muscles gives passage to a small artery (posterior perforating) which communicates with the external plantar artery. And between the heads of the first interosseous muscle the dorsalis pedis takes its course.

Plantar Region.

First Layer.

Abductor pollicis,

Abductor minimi digiti,

Flexor brevis digitorum.

Dissection. — The sole of the foot is best dissected by carrying an incision around the heel, and along the inner and outer border of the foot, to the great

¹ [It would seem much better, following the example of many anatomists, to consider a line passing through the middle of the second toe as the antero-posterior axis of the foot (just as the centre of the middle finger is considered as the axis of the hand), when all the dorsal interossei would be abductors, and the plantar adductors, which is the arrangement of the analogous muscles of the hand. I have, however, made the description of the inserted figure to correspond with the description in the text.]

and little toe. This incision should divide the integument and superficial fascia, and both together should be dissected from the deep fascia, as far forwards as the base of the phalanges, where they may be removed from the foot altogether. The deep fascia should then be raised, and the first layer of muscles will be brought into view.

The ABDUCTOR POLLICIS (vel hallucis) lies along the inner border of the foot; it *arises* by two heads, between which the tendons of the long flexors, arteries, veins, and nerves, enter the sole of the foot. One head proceeds from the inner tuberosity of the os calcis, the other from the internal annular ligament and plantar fascia; it is *inserted* into the base of the first phalanx of the great toe, and into the internal sesamoid bone.

Relations. — By its *superficial surface* with the intercal portion of the plantar fascia. By its *deep surface* with the flexor brevis pollicis, musculus accessorius, tendons of the flexor longus digitorum, flexor longus pollicis, tibialis anticus and posticus, plantar vessels and nerves, and tarsal bones. At its *outer border* with the flexor brevis digitorum, from which it is separated by a vertical septum of the plantar fascia.

The ABDUCTOR MINIMI DIGITI (digiti quinti) lies along the outer border of the sole of the foot. It *arises* from the outer tuberosity of the os calcis, and from the plantar fascia, as far forwards as the base of the fifth metatarsal bone; and is *inserted* into the base of the first phalanx of the little toe.

Relations. — By its *superficial surface* with the external portion of the plantar fascia. By its *deep surface* with the musculus accessorius, flexor brevis minimi digiti, tarsal bones, and metatarsal bone of the little toe. By its *inner side* with the flexor brevis digitorum, from which it is separated by the vertical septum of the plantar fascia.

The FLEXOR BREVIS DIGITORUM (perforatus) is placed between the two preceding muscles. It *arises* from the under surface of the os calcis, from the plantar fascia, and intermuscular septa; and is *inserted* by four tendons into the base of the second phalanx of the four lesser toes. Each tendon divides, previously to its insertion, to give passage to the tendon of the long flexor; hence its cognomen *perforatus*.

Relations. — By its *superficial surface* with the plantar fascia. By its *deep surface* with a thin layer of fascia which separates it from the musculus accessorius, tendons of the flexor longus digitorum and flexor longus pollicis, and plantar vessels and nerves. By its *borders* with the vertical septa of the plantar fascia, which separate the muscle, on the one side from the abductor pollicis, on the other from the abductor minimi digiti.

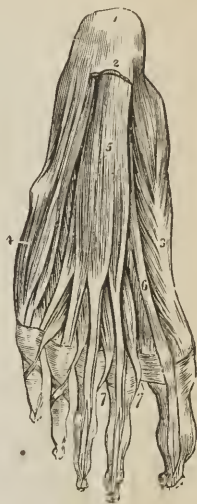Second Layer.

Musculus accessorius,

Lumbricales.

Dissection. — The three preceding muscles must be divided from their origin, and anteriorly through their tendons, and removed, in order to bring into view the second layer.

Fig. 193.



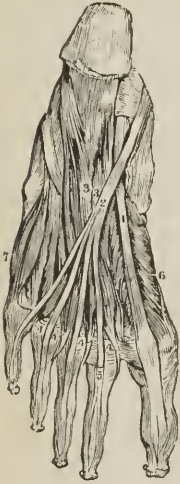FIRST LAYER OF MUSCLES OF THE SOLE OF THE FOOT: this layer is exposed by the removal of the plantar fascia. 1. Os calcis. 2. Posterior part of the plantar fascia divided transversely. 3. Abductor pollicis. 4. Abductor minimi digiti. 5. Flexor brevis digitorum. 6. Tendon of the flexor longus pollicis. 7, 7. Lumbricales. On the second and third toe, the tendons of the flexor longus digitorum are seen passing through the bifurcation of the tendons of the flexor brevis digitorum.

The **MUSCULUS ACCESSORIUS** [flexor accessorius] arises by two slips from either side of the under surface of the os calcis; the inner slip being fleshy, the outer tendinous and blended with the ligamentum longum plantæ. It is inserted into the outer side and upper surface of the tendon of the flexor longus digitorum; of which muscle it may be regarded as a second and short head. It has been named "massa carnea Jacobi Sylvii" and "caro quadratus Sylvii."

Relations.—By its *superficial surface* with the three muscles of the superficial layer, from which it is separated by their fascial sheaths, and with the external plantar vessels and nerve. By its *deep surface* with the under part of the os calcis and long calcaneo-euboid ligament.

The **LUMBRICALES** (lumbrius, an earthworm) are four little muscles arising from the tendons of the flexor longus digitorum at their point of bifurcation, and inserted into the expansion of the extensor tendons, and the base of the first phalanx of the four lesser toes on their tibial side. They pass between the digital slips of the plantar fascia to their insertion. The innermost lumbricalis is connected with only one tendon.

[FIG. 194.]



DEEP-SEATED MUSCLES IN THE SOLE OF THE FOOT. 1. Tendon of the flexor longus pollicis. 2. Tendon of the flexor communis digitorum. 3, 3. Musculus accessorius. 4, 4, 4, 4. Lumbricales. 5. A tendon of the flexor brevis digitorum. 6. Flexor brevis pollicis. 7. Flexor brevis minimi digiti.]

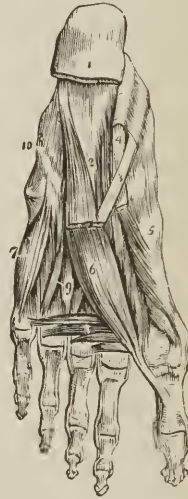Third Layer.

Flexor brevis pollicis,
Adductor pollicis,

Transversus pedis,
Flexor brevis minimi digiti.

Dissection.—The tendons of the long flexors and the muscles connected with them must be removed, to see clearly the attachments of the third layer.

FIG. 195



THIRD AND PART OF THE SECOND LAYER OF MUSCLES OF THE SOLE OF THE FOOT. 1. Divided edge of the plantar fascia. 2. Musculus accessorius. 3. Tendon of the flexor longus digitorum. 4. Tendon of the flexor longus pollicis. 5. Flexor brevis pollicis. 6. Adductor pollicis. 7. Flexor brevis minimi digiti. 8. Transversus pedis. 9. Interossei muscles, plantar and dorsal. 10. Convex ridge formed by the tendon of the peroneus longus in its oblique course across the foot.

The FLEXOR BREVIS POLLICIS arises by a pointed tendinous process from the side of the cuboid, external cuneiform bone, and expanded tendon of the tibialis posticus; it is inserted by two heads into the base of the first phalanx of the great toe. Two sesamoid bones are developed in the tendons of insertion of these two heads, and the tendon of the flexor longus pollicis lies in the groove between them.

Relations. — By its superficial surface with the abductor pollicis, tendon of the flexor longus pollicis, and plantar fascia. By its deep surface with the tarsal bones, metatarsal bone of the great toe, and insertion of the tendon of the peroneus longus. By its inner border with the abductor pollicis; and by its outer border with the adductor pollicis; with both of which muscles it is blended near its insertion.

The ADDUCTOR POLLICIS arises from the cuboid bone, the sheath of the tendon of the peroneus longus, and the base of the third and fourth metatarsal bones. It is inserted into the base of the first phalanx of the great toe, in conjunction with the outer head of the flexor brevis pollicis.

Relations. — By its superficial surface with the tendons of the flexor longus and flexor brevis digitorum, musculus accessorius, and lumbricales. By its deep surface with the tarsal bones and ligaments, external plantar artery and veins, interossei muscles, tendon of the peroneus longus, and metatarsal bone of the great toe. By its inner border with the flexor brevis pollicis; with which its fibres are blended.

The TRANSVERSUS PEDIS arises by fleshy slips, from the heads of the metatarsal bones of the four lesser toes. It passes transversely inwards to be inserted into the base of the first phalanx of the great toe, its tendon being blended with that of the adductor pollicis.

The transversus pedis is regarded by some anatomists as a short head of the adductor pollicis; in its action it is obviously an adductor; while the adductor pollicis is as much a flexor as an adductor.

Relations. — By its superficial surface with the tendons of the flexor longus and flexor brevis digitorum, and lumbricales. By its deep surface with the interossei muscles and ligaments of the metatarso-phalangeal articulations.

The FLEXOR BREVIS MINIMI DIGITI arises from the base of the metatarsal bone of the little toe, and the sheath of the tendon of the peroneus longus. It is inserted into the base of the first phalanx of the little toe at its outer side.

Relations. — By its superficial surface with the tendons of the flexor longus and flexor brevis digitorum, the fourth lumbricalis, abductor minimi digiti, and plantar fascia. By its deep surface with the plantar interosseous muscle of the fourth metatarsal space, and the fifth metatarsal bone.

Fourth Layer.

Interossei plantares.

The INTEROSSEI PLANTARES muscles are three in number, and are placed upon rather than between the metatarsal bones. They arise from the base of the metatarsal bone of the three outer toes, and are inserted into the inner side of the extensor tendon and base of the first phalanx of the same toes. In their action they are adductors

Relations. — By their superficial surface with the dorsal interossei, and meta-

[FIG. 196.]



PLANTAR INTEROSSEOUS MUSCLES. 1. Adductor of the third toe. 2. Adductor of the fourth toe. 3. Adductor of the little toe.]

tarsal bones. By their *deep surface* with the external plantar artery and veins, adductor pollicis, transversus pedis, and flexor minimi digiti.

Actions.—All the preceding muscles act upon the toes; and the movements which they are capable of executing may be referred to four heads, viz., flexion, extension, adduction, and abduction. In these actions they are grouped in the following manner:—

<i>Flexion.</i>	<i>Extension.</i>
Flexor longus digitorum, Flexor brevis digitorum, Flexor accessorius, Flexor minimi digiti.	Extensor longus digitorum, Extensor brevis digitorum.
<i>Adduction.</i>	<i>Abduction.</i>
Interossei, { one dorsal, ¹ { three plantar.	Interossei, three dorsal, ¹ Abductor minimi digiti.

The great toe, like the thumb in the hand, enjoys an independent action, and is provided with distinct muscles to perform its movements. These movements are precisely the same as those of the other toes, viz.:—

<i>Flexion.</i>	<i>Extension.</i>
Flexor longus pollicis, Flexor brevis pollicis.	Extensor proprius pollicis, Extensor brevis digitorum.
<i>Adduction.</i>	<i>Abduction.</i>
Adductor pollicis, Transversus pedis.	Abductor pollicis.

The only muscles excluded from this table are the lumbricales, four small muscles, which, from their attachments to the tendons of the long flexor, appear to be assistants in its action.

The actions of the muscles of the lower extremity, according to Dr. Barclay, are as follows:—

FEMUR.

Flexors.

Sartorius,	Adductor magnus (anterior part),
Gracilis,	Iliacus,
Tensor vaginæ femoris,	Psoas magnus,
Pectineus,	Obturator externus,
Adductor longus,	Gluteus minimus.
Adductor brevis,	

Extensors.

Gluteus maximus,	Quadratus femoris,
Gluteus medius (part),	Adductor magnus (posterior part),
Pyramiformis,	Biceps (long head),
Obturator internus,	Semi-tendinosus,
Gemelli,	Semi-membranosus.

¹ [See note, p. 262.]

Abductors.

Tensor vaginæ femoris,	Pyriformis,
Gluteus maximus,	Sartorius,
Gluteus medius,	Obturator internus,
Gluteus minimus,	Gemelli.

Adductors.

Pectineus,	Semi-membranosus,
Adductores (three),	Biceps (long head),
Quadratus femoris,	Obturator externus,
Gracilis,	Psoas magnus,
Semi-tendinosus,	Iliacus.

Rotatores externi.

Gluteus maximus,	Quadratus femoris,
Gluteus medius (part),	Iliacus,
Pyriformis,	Psoas magnus,
Gemelli,	Adductores (three),
Obturatores (both),	Biceps (assists).

Rotatores interni.

Tensor vaginæ femoris,	Gluteus minimus ;
Gluteus medius (part),	

assisted by,

Sartorius,	Semi-tendinosus.
Gracilis,	

LEG.

Flexors.

Gracilis,	Gastrocnemius,
Sartorius,	Plantaris,
Semi-tendinosus.	Popliteus,
Semi-membranosus,	Tensor vaginæ femoris,
Biceps,	Gluteus maximus.

Extensors.

Rectus,	Crureus,
Vastus internus,	Tensor vaginæ femoris,
Vastus externus,	Gluteus maximus.

Foot.

Flexors.

Tibialis anticus,	Extensor proprius pollicis,
Extensor longus digitorum,	Peroneus tertius.

Extensors.

Gastrocnemius,	Flexor longus pollicis,
Soleus,	Tibialis posticus,
Plantaris,	Peroneus longus,
Flexor longus digitorum,	Peroneus brevis.

<i>Abductors.</i>	<i>Adductors.</i>
Peroneus longus,	Tibialis posticus,
Peroneus brevis,	Extensor proprius pollicis,
Peroneus tertius,	Flexor longus digitorum,
Extensor longus digitorum.	Flexor longus pollicis.

The actions of the muscles of the foot and toes are sufficiently illustrated in the preceding description.

CHAPTER V.

OF THE FASCIÆ.

FASCIA (fascia, a bandage) is the name assigned to laminæ of various extent and thickness, which are distributed through the different regions of the body, for the purpose of investing or protecting the softer and more delicate organs. From a consideration of their structure, these fasciæ may be arranged into two groups: areolo-fibrous fasciæ and aponeurotic fasciæ.

The *areolo-fibrous fascia* is best illustrated by the common subcutaneous investment of the entire body, the superficial fascia. This structure is situated immediately beneath the integument over every part of the frame, and is the medium of connexion between that layer and the deeper parts. It is composed of areolar and elastic tissue, and contains in its areolæ an abundance of adipose cells. The fat being a bad conductor of caloric, serves to retain the warmth of the body; while it forms at the same time a yielding tissue, through which minute vessels and nerves pass to the skin without incurring the risk of obstruction from injury or pressure. By dissection, the superficial fascia may be separated into *two layers*, between which are found the superficial or cutaneous vessels and nerves; as, the superficial epigastric artery, saphenous veins, radial and ulnar veins, superficial lymphatic vessels, and the cutaneous muscles, as the platysma myoides, orbicularis palpebrarum, sphincter ani, &c. In other situations, the areolo-fibrous fascia is found condensed into a firm and dense membrane, as is exemplified in the deep fascia of the neck, the thoracic, transversalis, perineal fascia, and the sheaths of vessels.

The *aponeurotic fascia* is the strongest kind of investing membrane; it is composed of tendinous fibres running parallel with each other, and connected by other fibres of the same kind passing in different directions, together with areolar tissue and fine elastic fibres. When freshly exposed, it is white, glistening, and iridescent, and is firm, unyielding, and but little elastic. In the limbs it constitutes the deep fascia, inclosing and forming distinct sheaths to all the muscles and tendons. It is thick on the outer and least protected side of the limb, and thinner at its inner side. It is firmly connected to the bones, and to the prominent points of each region, as to the pelvis, knee, and ankle, in the lower, and to the clavicle, scapula, elbow, and wrist, in the upper extremity. It assists the muscles in their action, by keeping up a tonic pressure on their surface; aids materially in the circulation of the fluids in opposition to the laws of gravity: and in the palm of the hand and sole of the foot is a powerful protection to the structures which enter into the composition of those regions. In some situations its tension is regulated by muscular action, as by the tensor vaginæ femoris and gluteus maximus in the thigh, by the biceps in the leg, and by the biceps and palmaris longus in the arm; in other situations it affords an extensive surface for the origin of the fibres of muscles.

The fasciæ may be arranged, like the other components of the body, into—

1. Those of the head and neck. 2. Those of the trunk. 3. Those of the upper extremity. 4. Those of the lower extremity.

FASCIÆ OF THE HEAD AND NECK.

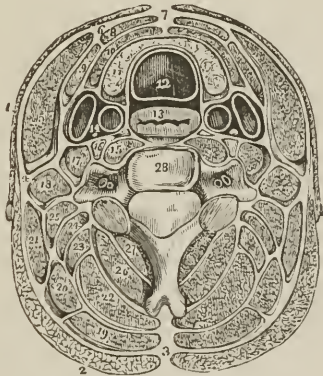
The **TEMPORAL FASCIA** is a strong aponeurotic membrane, which covers in the temporal muscle at each side of the head, and gives origin by its internal surface to some of its fibres. It is attached to the whole extent of the temporal ridge above, and to the zygomatic arch below; in the latter situation it is thick, and divided into two layers, the external being connected to the upper border of the arch; the internal to its inner surface. Some fat is found between these two layers and the orbital branch of the temporal artery. The temporal fascia is covered in by the aponeurosis (galea aponeurotica) of the occipito-frontalis muscle, which descends to be attached to the zygomatic arch.

CERVICAL FASCIÆ. — The fasciæ of the neck are the superficial and deep.

The *Superficial cervical fascia* is a part of the common superficial fascia of the entire body, and is only interesting from containing between its layers the platysma myoides muscle.

The *Deep cervical fascia* is a strong areolo-fibrous membrane, which invests the muscles of the neck, and retains and supports the vessels and nerves. It

FIG. 197.



TRANSVERSE SECTION OF THE NECK, SHOWING THE DEEP CERVICAL FASCIA and its numerous prolongations, forming sheaths for the different muscles. As the figure is symmetrical, the figures of reference are placed only on one side. 1. Platysma myoides. 2. Trapezius. 3. Ligamentum nuchæ, from which the fascia may be traced forwards beneath the trapezius, inclosing the other muscles of the neck. 4. The point at which the fascia divides, to form a sheath for the sterno-mastoid muscle (5). 6. The point of reunion of the two layers of the sterno-mastoid sheath. 7. The point of union of the deep cervical fascia of opposite sides of the neck. 8. Section of the sterno-hyoid. 9. Omo-hyoid. 10. Sterno-thyroid. 11. Lateral lobe of the thyroid gland. 12. Trachea. 13. Œsophagus. 14. The sheath containing the common carotid artery, internal jugular vein, and pneumogastric nerve. 15. Longus colli. The nerve in front of the sheath of this muscle is the sympathetic. 16. Rectus anticus major. 17. Scalenus anticus. 18. Scalenus medius. 19. Splenius capitis. 20. Splenius colli. 21. Levator anguli scapulæ. 22. Complexus. 23. Trachelo-mastoideus. 24. Transversalis cervicis. 25. Cervicalis ascendens. 26. Semi-spinalis colli. 27. Multifidus spinæ. 28. Cervical vertebra; the transverse processes are seen to be traversed by the vertebral artery and vein.

commences posteriorly at the ligamentum nuchæ, and passes forwards at each side beneath the trapezius muscle to the posterior border of the sterno-mastoid.

here it divides into two layers, which embrace that muscle and unite upon its anterior border, to be prolonged onwards to the middle line of the neck, where it is continuous with the fascia of the opposite side. Besides constituting a sheath for the sterno-mastoid, it also forms sheaths for the other muscles of the neck over which it passes. If the superficial layer (anterior layer) of the sheath of the sterno-mastoid be traced upwards, it will be found to pass over the parotid gland and masseter muscle (fascia parotideo-masseterica), to be inserted into the zygomatic arch; if it be traced downwards, it will be seen to pass in front of the clavicle, and become lost upon the pectoralis major muscle. If the deep layer (posterior layer) of the sheath be examined superiorly, it will be found attached to the styloid process, from which it is reflected to the angle of the lower jaw, forming the *stylo-maxillary ligament*; and if it be followed downwards, it will be found connected with the tendon of the omo-hyoid muscle, and may thence be traced behind the clavicle, where it incloses the subclavius muscle, and being extended from the cartilage of the first rib to the coracoid process, constitutes the *costo-coracoid membrane* or ligament (fascia costo-clavicularis). In front of the sterno-mastoid muscle, the deep fascia is attached to the border of the lower jaw, os hyoides, and anterior bellies of the digastricus (fascia supra-hyoidea), and forms a sheath for the submaxillary gland. Inferiorly it divides into two layers, one of which is attached to the inter-clavicular ligament and upper border of the sternum; the other to its inner border.

FASCIÆ OF THE TRUNK.

The THORACIC FASCIA¹ is a dense layer of areolo-fibrous membrane stretched horizontally across the superior opening of the thorax. It is firmly attached to the concave margin of the first rib, and to the inner surface of the sternum. In front it leaves an opening for the connexion of the cervical with the thoracic portion of the thymus gland, and behind, forms an arch across the vertebral column, to give passage to the œsophagus.

At the point where the great vessels and trachea pass through the thoracic fascia, it divides into an ascending and descending layer. The *ascending layer* is attached to the trachea, and becomes continuous with the sheath of the carotid vessels, and with the deep cervical fascia; the *descending layer* descends upon the trachea to its bifurcation, surrounds the large vessels arising from the arch of the aorta, and the upper part of the arch itself, and is continuous with the fibrous layer of the pericardium. It is connected also with the venæ innominatæ and superior cava, and is attached to the areolo-fibrous capsule of the thymus gland.

“The thoracic fascia,” according to Sir Astley Cooper, “performs three important offices:—

“1st. It forms the upper boundary of the chest, as the diaphragm does the lower.

“2d. It steadily preserves the relative situation of the parts which enter and quit the thoracic opening.

“3d. It attaches and supports the heart in its situation, through the medium of its connexion with the aorta and large vessels which are placed at its curvature.”

ABDOMINAL FASCIÆ. — The lower part of the parietes of the abdomen, and the cavity of the pelvis, are strengthened by a layer of fascia which lines their internal surface, and at the bottom of the latter cavity is reflected inwards upon the sides of the bladder. This fascia is continuous throughout the whole of the above-mentioned surface; but for convenience of description is considered under the several names of transversalis fascia, iliac fascia, and pelvic fascia; the two

¹ See Sir Astley Cooper's work on the “Anatomy of the Thymus Gland.”

former meet at the crest of the ilium and Poupart's ligament, the latter is confined to the cavity of the true pelvis.

The *FASCIA TRANSVERSALIS* (Fascia Cooperi)¹ is a thin fibrous membrane, which lines the inner surface of the transversalis muscle, and is interposed between that muscle and the peritoneum. It is thick and dense below, near the lower part of the abdomen; but becomes thinner as it ascends, and is gradually lost in the subserous areolar tissue. It is attached inferiorly to the reflected margin of Poupart's ligament and to the crest of the ilium; internally, to the pectineal line and border of the rectus muscle; and, at the inner part of the femoral arch [see p. 279] is continued beneath Poupart's ligament, and forms the anterior segment of the *crural canal*, or sheath of the femoral vessels.

The *internal abdominal ring* (annulus inguinalis internus, vel posterior) is situated in this fascia, at about midway between the symphysis pubis and anterior superior spine of the ilium, and half an inch above Poupart's ligament; it is oval in form, and bounded on its inner side by a well-marked falciform border, but is ill-defined around its outer margin. From the circumference of this ring is given off an *infundibuliform process* which surrounds the testicle and spermatic cord, constituting the *fascia propria* of the spermatic cord, and forms the first investment to the sac of oblique inguinal hernia. It is the strength of the transversalis fascia, in the interval between the tendon of the rectus and the internal abdominal ring, that defends the parietes against the frequent occurrence of direct inguinal hernia.

INGUINAL HERNIA.

Inguinal hernia is of two kinds, oblique and direct.

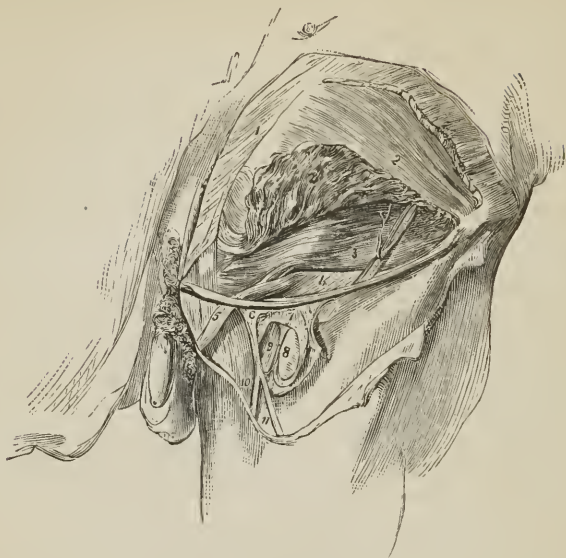
In *OBLIQUE INGUINAL HERNIA* the intestine escapes from the cavity of the abdomen into the *spermatic canal* (canalis inguinalis) through the *internal abdominal ring*, pressing before it a pouch of peritoneum, which constitutes the *hernial sac*, and distending the infundibuliform process of the transversalis fascia. After emerging through the internal abdominal ring it passes *firstly* beneath the lower and arched border of the transversalis muscle; *then* beneath the lower border of the internal oblique muscle; and *finally* through the *external abdominal ring* (annulus inguinalis externus, vel anterior) in the aponeurosis of the external oblique. From the transversalis muscle it receives no investment; while passing beneath the lower border of the internal oblique it obtains the cremaster muscle; and on escaping at the external abdominal ring, receives the intercolumnar fascia. So that the coverings of an oblique inguinal hernia, after it has emerged through the external abdominal ring, are, from the surface to the intestine, the

Integument,	Cremaster muscle,
Superficial fascia,	Transversalis, or infundibuliform fascia,
Intercolumnar fascia,	Peritoneal sac.

The *Spermatic Canal*, which in the normal condition of the abdominal parietes serves for the passage of the spermatic cord in the male, and the round ligament with its vessels in the female, is about one inch, and a half in length. It is bounded *in front* by the aponeurosis of the external oblique muscle; *behind* by the transversalis fascia, and the conjoined tendon of the internal oblique and transversalis; *above* by the arched border of the internal oblique and transversalis; *below* by the grooved border of Poupart's ligament: and at each extremity by one of the abdominal rings, the internal ring at the inner, the external ring

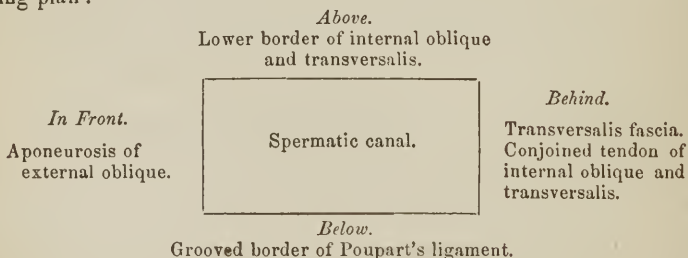
¹ Sir Astley Cooper first described this fascia in its important relation to inguinal hernia.

[Fig. 198.]



ANATOMY OF THE SPERMATIC CANAL. After the removal of the lower part of the external oblique (with the exception of a small slip including Poupart's ligament), the lower portion of the internal oblique was raised, and thereby the transversalis muscle and fascia have been brought into view. The femoral artery and vein are seen to a small extent, the iliac portion of the fascia lata having been turned aside and the sheath of the bloodvessels laid open.— 1. External oblique muscle. 2. Internal oblique muscle. 2'. Part of same turned up. 3. Transversalis muscle. Upon the last-named muscle is seen a branch of the circumflexa ilii artery, with its companion veins; and some ascending tendinous fibres are seen over the conjoined tendon of the two last-named muscles. 4. Transversalis fascia. 5. Spermatic cord covered with the infundibuliform fascia from preceding. 6. Upper angle of the iliac part of fascia lata. 7. The sheath of the femoral vessels. 8. Femoral artery. 9. Femoral vein. 10. Internal saphenous vein. 11. A vein joining it.]

at the outer extremity. These relations may be more distinctly illustrated by the following plan :



There are three¹ varieties of oblique inguinal hernia : common, congenital, and encysted.

Common oblique hernia is that which has been described above.

Congenital hernia results from the non-closure of the pouch of peritoneum carried downwards into the scrotum by the testicle, during its descent in the

¹ Velpeau describes a fourth, in which the protrusion takes place between the edge of the rectus and the umbilical ligament, and then takes the course of the spermatic canal.

fœtus. In consequence of this defect, the intestine at some period of life is forced into the peritoneal canal, and descends through it into the tunica vaginalis, where it lies in contact with the testicle; so that congenital hernia has *no proper sac*, but is contained within the tunica vaginalis. The other coverings are the same as those of common inguinal hernia.

Encysted hernia (hernia infantilis of Hey) is that form of protrusion in which the pouch of peritoneum forming the tunica vaginalis, being only partially closed, and remaining open externally to the abdomen, admits of the hernia passing into the scrotum, behind the tunica vaginalis. So that the surgeon, in operating upon this variety, requires to divide three layers of serous membrane; the first and second layer being those of the tunica vaginalis; the third the true sac of the hernia.

DIRECT INGUINAL HERNIA [ventro-inguinal] has received its name from passing *directly* through the external abdominal ring, and forcing before it the opposing parietes. This portion of the wall of the abdomen is strengthened by the conjoined tendon of the internal oblique and transversalis, which is pressed before the hernia, and forms one of its investments. Its coverings therefore are, the

Integument,	Conjoined tendon,
Superficial fascia,	Transversalis fascia,
Intercolumnar fascia,	Peritoneal sac.

Direct inguinal hernia differs from oblique, firstly, in never attaining the same bulk, in consequence of the resisting nature of the conjoined tendon of the internal oblique and transversalis and transversalis fascia; secondly, in its direction having a tendency to protrude *from* the middle line rather than towards it; thirdly, in making for itself a new passage through the abdominal parietes, instead of following a natural channel; and fourthly, in the relation of the neck of its sac to the epigastric artery; that vessel lying to the outer side of the opening of the sac of direct hernia, and to the inner side of that of oblique hernia.

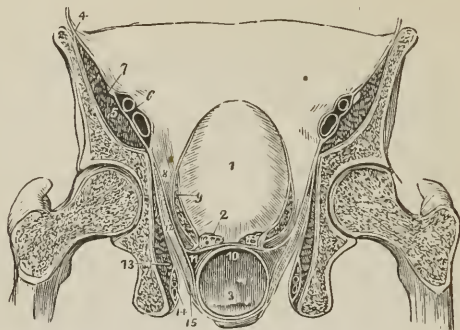
All the forms of inguinal hernia are designated *scrotal*, when they have descended into the cavity of the scrotum.

The FASCIA ILIACA (lumbo-iliaca) is the aponeurotic investment of the psoas and iliacus muscle; and like the fascia transversalis, is thick below, and becomes gradually thinner as it ascends. It is attached superiorly, along the edge of the psoas, to the anterior lamella of the aponeurosis of the transversalis muscle, to the ligamentum arcuatum internum, and to the bodies of the lumbar vertebræ, leaving arches, corresponding with the constricted part of the vertebræ, for the transit of the lumbar vessels. Lower down it passes beneath the external iliac vessels, and is attached along the margin of the true pelvis; externally it is connected to the crest of the ilium; and, inferiorly, to the outer two-thirds of Poupart's ligament, where it is continuous with the fascia transversalis. Passing beneath Poupart's ligament, it surrounds the psoas and iliacus muscle to its termination, and beneath the inner part of the femoral arch forms the posterior segment of the crural canal or sheath of the femoral vessels.

The FASCIA PELVICA is an aponeurotic layer situated beneath the peritoneum, forming a covering to the walls of the pelvis, and reflected from its walls upon the viscera. The pelvic fascia is attached to the internal surface of the ossa pubis near the symphysis, to the body of the pubes above the origin of the obturator internus muscle, to the ilio-pectineal line of the brim of the pelvis as far back as the sacro-iliac articulation, and to the margin of the great sacro-ischiatic foramen. Having descended upon the wall of the pelvis as low as the pubic arch in front, and the spine of the ischium behind, it divides in the direction of a line drawn between those points, into *two* layers, internal and external.

The *internal layer* (recto-vesical) is continued downwards to the prostate gland, neck of the bladder, (vagina), and rectum, to which it is closely attached;

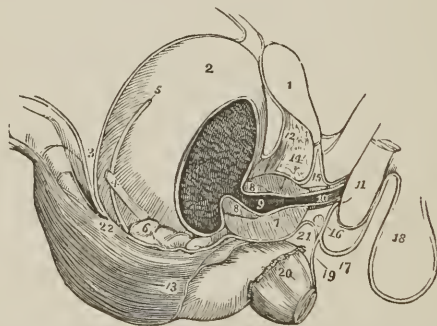
FIG. 199.



TRANSVERSE VERTICAL SECTION OF THE PELVIS, SHOWING THE DISTRIBUTION OF THE PELVIC FASCIA. 1. Bladder. 2. Vesicula seminalis of one side, divided. 3. Rectum. 4. Iliac fascia, covering in the iliacus and psoas (5); and forming a sheath for the external iliac vessels (6). 7. Anterior crural nerve excluded from the sheath. 8. Pelvic fascia. 9. Its ascending layer, forming the lateral ligament of the bladder of one side, and a sheath to the vesical plexus of veins. 10. A layer of fascia passing between the bladder and rectum. 11. A layer passing around the rectum. 12. Levator ani. 13. Obturator internus, covered in by the obturator fascia, which also forms a sheath for the internal pudic vessels and nerves (14). 15. Perineal fascia investing the under surface of the levator ani. Figures 14, 15, are placed in the ischio-rectal fossa.

and is reflected for a short distance upwards and downwards on those viscera. This layer is in contact, by its external surface, with the levator ani muscle and

FIG. 200.



SIDE VIEW OF THE VISCERA OF THE PELVIS, SHOWING THE DISTRIBUTION OF THE PELVIC FASCIA. 1. Symphysis pubis. 2. Bladder. 3. Recto-vesical fold of peritoneum, passing from the anterior surface of the rectum to the posterior part of the bladder; and from the upper part of the bladder to the abdominal parietes. 4. Ureter. 5. Vas deferens crossing behind the ureter. 6. Vesicula seminalis. 7, 7, 8. Prostate gland divided longitudinally. 9. Prostatic portion of the urethra. 10. Membranous portion embraced by the compressor urethrae muscle. 11. Commencement of the corpus spongiosum penis; the bulb. 12. Anterior ligaments of the bladder. 13. The pelvic fascia reflected on the rectum. 14. An interval between the pelvic fascia and triangular ligament occupied by a plexus of veins. 15. The triangular ligament. 16. Cowper's gland. 17. Superficial perineal fascia ascending in front of the root of the penis to become continuous with the dartos of the scrotum (18). 19. The fascia prolonged to the rectum. 20. Lower part of the levator ani. 21. A layer of fascia situated between the bladder and rectum.

coccygeus; and is prolonged backwards over the sacral nerves to the lower part of the sacrum and the coccyx, to which it is attached, meeting at the middle line the layer of the opposite side.

The *external* layer is the *obturator fascia*; it covers in the obturator muscle, and is attached to the ramus of the pubes and ischium in front, and to the tuberosity of the ischium and falciform border of the great sacro-ischiatic ligament below. The levator ani arises from the line of division of the two layers of the pelvic fascia.

The anterior border of the pelvic fascia is separated from its fellow of the opposite side by a narrow interval, and the fascia passing from the side of the symphysis to the upper part of the prostate gland and front of the neck of the bladder, constitutes the *anterior true ligament of the bladder* (pubio-vesicale); a little further outwards, the fascia passing to the side of the neck of the bladder constitutes its *lateral true ligament*; and reflected forwards from the neck of the bladder upon the prostate, it forms a sheath for that gland which incloses the prostatic plexus of veins. Upon the rectum and vagina it also forms a sheath. The posterior boundary of the pelvic fascia forms a free semilunar border in front of the pyriformis muscle.

PERINEAL FASCIÆ. — The fasciæ of the perineum are the superficial and the deep.

The *Superficial fascia* consists as in other situations of two layers, one lying next the skin and containing an abundance of fat, the other more condensed, lying in contact with the muscles.

The *superficial layer* in the perineum is connected with the raphé at the middle line and with the external border of the sphincter ani, and is continuous by its circumference with the dartos of the scrotum, or cellular tissue of the labia majora, in front, with the superficial fascia of the thighs at each side, and with the superficial fascia covering the glutei maximi and coccyx behind.

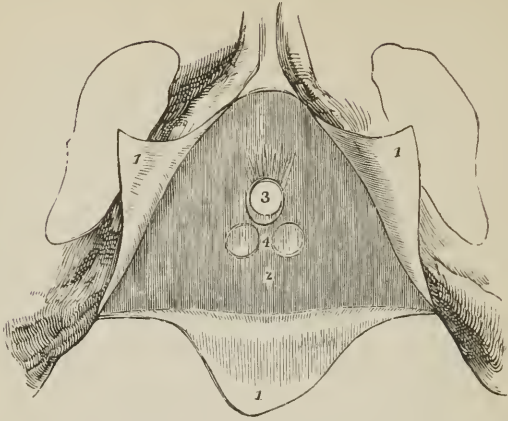
The *deep layer* or *proper perineal fascia* (fascia perinei superficialis) is divisible into two portions, anterior and posterior, the former investing the muscles of the perineum, the other the ischio-rectal fossa. The *anterior portion* (fascia ischio-pubica, Velpeau) is a thin aponeurotic layer which covers in the muscles of the genital region of the perineum and the root of the penis. It is firmly attached at each side to the ramus of the pubes and ischium; posteriorly it is reflected upwards behind the transversi perinei muscles to become continuous with the deep perineal fascia or triangular ligament; while, in front it is continuous with the dartos in the male, and is lost in the labia majora and nymphæ in the female. The continuation of the perineal fascia into the triangular ligament along the posterior border of the transversi perinei muscles, is a barrier to the extension of extravasation of urine backwards, and the chief cause of its advance into the scrotum and lower part of the abdomen.

The *posterior portion* of the perineal fascia (fascia analis; ischio-rectalis, Velpeau) lines the deep fossa (excavatio perinei) which surrounds the anus and levator ani muscles, and is bounded externally by the ischia and internal obturator muscles, and behind by the glutei maximi, the *ischio-rectal fossa*.¹ The ischio-rectal fascia is continuous with the anterior portion of the fascia perinei in front; invests the levatores ani as high as their origin, and the obturator fascia at each side, and is attached to the tuberosities of the ischia and great sacro-ischiatic ligaments. In the ischio-rectal fossa the two layers of the superficial fascia are separated by the masses of fat which fill that cavity.

The *Deep perineal fascia* (ligamentum triangulare; perineale; Camper's ligament) is a thin layer of aponeurosis stretched across the anterior portion of the outlet of the pelvis; it is attached at each side to the pelvic border of the ramus of the pubes and ischium, as far back as the origin of the erector penis muscle.

[There are, properly, two ischio-rectal fossæ, one on either side of the rectum.]

FIG. 201.



THE PUBIC ARCH AND PERINEAL FASCIÆ. 1, 1, 1. The superficial perineal fascia divided by a A shaped incision into three flaps; the lateral flaps are turned over the ramus of the pubes and ischium at each side, to which they are firmly attached; the posterior flap is continuous with the deep perineal fascia or triangular ligament. 2. The triangular ligament of Camper. 3. Opening for the passage of the membranous portion of the urethra, previously to the entrance of the latter into the bulb. 4. Two projections of the triangular ligament corresponding with the position of Cowper's glands.

Anteriorly, it is convex and closely connected with the sub-pubic ligament; while, posteriorly, it is concave, and turns forwards around the posterior border of the transversi perinei muscles, to become continuous with the superficial perineal fascia. At its middle, it is about an inch and a half in depth; at one inch below the pubic arch, it is pierced by the membranous portion of the urethra, and nearer the pubic arch, by the dorsal vein of the penis and internal pudic arteries.

Directly behind the triangular ligament are situated the compressor urethræ muscle, the arteries of the bulb, and Cowper's glands, and more deeply the pelvic fascia, which has been described as a posterior layer of the deep perineal fascia.

FASCIÆ OF THE UPPER EXTREMITY.

The *Superficial fascia* of the upper extremity contains between its layers the superficial veins and lymphatics, and superficial nerves.

The *Deep fascia* is thin over the deltoid and pectoralis major muscle, and in the axillary space, but thick on the dorsum of the scapula, where it binds down the infra-spinatus muscle. It is attached to the clavicle, coracoid process, acromion process, and spine of the scapula, and forms separate sheaths for all the muscles of the scapula and shoulder. In the *upper arm (fascia brachialis)* it is somewhat stronger, receives fibres from the lower border of the tendon of the pectoralis major, latissimus dorsi, as also from the costo-coracoid membrane and deltoid, and forms an anterior and posterior sheath for the muscles lying in front of and behind the humerus. It is attached to the condyloid ridges, by means of the *internal and external intermuscular septum (ligamenta intermuscularia)* and is inserted inferiorly into the two condyles, the olecranon, and posterior border of the ulna, being continuous between these points with the fascia of the forearm. Besides forming separate sheaths for the muscles, the anterior portion

of the brachial fascia gives a sheath likewise to the brachial vessels and median nerve.

The deep fascia of the forearm (*fascia antibrachialis*) is strong, and at the bend of the elbow is augmented in thickness by a broad band, which is given off from the inner side of the tendon of the biceps. It is firmly attached to the olecranon process, to the ulna, and to the prominent points about the wrist, forms sheaths for the muscles and vessels, gives origin to some of the fibres of the muscles, and is pierced a little above the wrist by the tendon of the palmaris longus. At the wrist the transverse fibres form the anterior and posterior annular ligament.

The *anterior annular ligament* is a narrow band of fibres attached externally to the scaphoid, and internally to the pisiform bone and tendon of the flexor carpi ulnaris; it is continuous above with the fascia antibrachialis, and below with the proper annular ligament of the wrist; being separated from the latter by the ulnar vessels and tendon of the flexor carpi radialis.

The *posterior annular ligament* [see fig. 180], thicker than the anterior, is an oblique band about half an inch in breadth, extending from the lower end and styloid process of the radius, to the cuneiform and pisiform bone at the border of the carpus. It is continuous above with the fascia of the forearm, below with the thin fascia of the dorsum of the hand, and sends processes inwards to be attached to the bones and form sheaths for the extensor tendons. There are six of these sheaths, the first on the radial side giving passage to the extensor ossis metacarpi and extensor primi internodii pollicis; the second, to the extensor carpi radialis longior and brevior; the third, to the extensor secundi internodii; the fourth, to the extensor indicis and extensor communis digitorum; the fifth, which is placed between the two bones, to the extensor digiti minimi; and the sixth, situated on the ulna, to the extensor carpi ulnaris. The tendons in passing through these sheaths are each provided with a synovial bursa.

On the back of the hand there are two fasciæ, superficial and deep. The *fascia dorsalis superficialis* is thin and covers in the extensor tendons; it is attached laterally to the metacarpal bones of the index and little finger, and is continuous above with the posterior annular ligament. The *fascia dorsalis profunda* is stretched across the metacarpal spaces, and covers in the interossei muscles.

The *palmar fascia* is divided into three portions. A central portion, which occupies the middle of the palm, and two lateral portions, which are thin and inclose the muscles of the borders of the hand, being continuous with the dorsal fascia. The central portion is strong and tendinous: it is narrow at the wrist, where it is attached to the annular ligament and receives the insertion of the tendon of the palmaris longus, and broad over the heads of the metacarpal bones, where it divides into four processes, each of which subdivides to embrace the root of the corresponding finger. These processes are attached at the middle line to the sheath of the tendons, and at the side of each finger to the lateral and transverse ligament. The fascia is strengthened at its point of division by strong fasciculi of transverse fibres; the arched interval caused by the bifurcation of each slip gives passage to the tendons of the flexor muscles, while the greater arches between the fingers transmit the digital vessels and nerves, and lumbrical muscles.

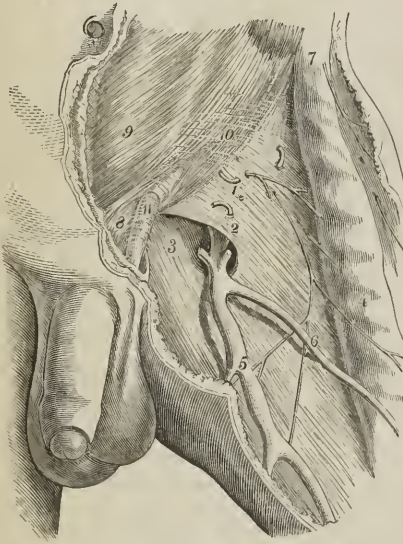
FASCIÆ OF THE LOWER EXTREMITY.

The *Superficial fascia* contains between its two layers the superficial vessels and nerves of the lower extremity. At the groin these two layers are separated from each other by the superficial lymphatic glands, and the deep layer is attached to Poupart's ligament, while the superficial layer is continuous with the superficial fascia of the abdomen.

The *Deep fascia of the thigh* is named, from its great extent, the *fascia lata*;

it is thick and strong upon the outer side of the limb, and thinner at its inner and posterior side. That portion of the deep fascia which invests the gluteus maximus is very thin, but that which covers in the gluteus medius is excessively thick, and gives origin, by its inner surface, to the superficial fibres of that muscle. The fascia lata is attached superiorly to Poupart's ligament, the crest of the ilium, sacrum, coccyx, tuberosity of the ischium, ramus of the ischium and pubes, body of the pubes, and pectineal line; it has also a deep attachment (ligamentum iliaceum) to the anterior border of the ilium, tendon of origin of the rectus muscle and border of the acetabulum. It forms sheaths for the muscles of the thigh and femoral vessels, and is connected with the linea aspera by means of two *intermuscular ligaments*, *external* and *internal*; the former extending from the insertion of the gluteus maximus to the external condyle, and separating the vastus externus from the biceps muscle; the internal being attached to the inner branch of the linea aspera for a short distance above the internal condyle,

[FIG. 202.]



SAPHENOUS OPENING IN THE FASCIA LATA.

1. The fascia lata; iliac portion; the figure indicates the position of the common femoral artery.
2. The falciform border of the saphenous opening.
3. Pubic portion of the fascia lata forming the inner and posterior boundary of the saphenous opening.
4. Sartorius covered by fascia lata.
5. Internal saphenous vein.
6. A tributary vein.
7. Anterior superior spinous process of ilium.
8. Spine of pubes.
9. Tendinous portion of obliquus externus abdominis.
10. The point where the fibres of the tendon begin to separate to form the pillars of the external ring.
11. Intercolumnar fascia.]

of the femoral vessels, and the lower extremity of the curve is continuous with the pubic portion.

The *pubic portion*, occupying the pubic side of the saphenous opening, is attached to the spine of the pubes and pectineal line; and, passing outwards

and separating the vastus internus from the adductor magnus. The fascia lata receives the attachment of two muscles, tensor vaginae femoris and gluteus maximus, and glides over the trochanter major on a bursa. Inferiorly it is inserted into the head of the tibia, and forms a bridge across the popliteal space (fovea poplitea), being continuous between its points of attachment with the fascia of the leg.

In addition to the smaller openings in the fascia lata which transmit the small cutaneous vessels and nerves, there exists at the upper and inner extremity of the thigh an oval opening (fovea ovalis), which gives passage to the superficial lymphatic vessels, and the large subcutaneous vein of the lower extremity, the internal saphenous vein, and is thence named the *saphenous opening*. The existence of this opening has given rise to the division of the upper part of the fascia lata into two portions, an iliac portion and a pubic portion.

The *iliac portion* is situated upon the iliac side of the opening. It is attached to the crest of the ilium, and along Poupart's ligament to the spine of the pubes, whence it is reflected downwards and outwards in an arched direction, and forms a *falciform border*, which constitutes the outer boundary of the saphenous opening. The edge of this border immediately overlies, and is adherent to, the sheath

behind the sheath of the femoral vessels, divides into two layers; the anterior layer is continuous with that portion of the iliac fascia which forms the sheath of the iliacus and psoas muscle, the posterior layer is lost upon the capsule of the hip joint.

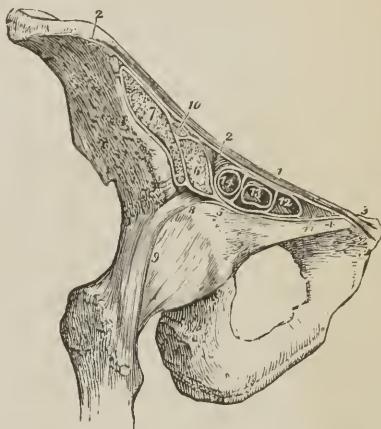The interval between the falciform border of the iliac portion and the opposite surface of the pubic portion is closed by an areolo-fibrous layer, derived from the superficial fascia, and pierced by numerous openings for the passage of lymphatic vessels, the *cribriform fascia* (lamina cribrosa). The cribriform fascia is connected with the sheath of the femoral vessels, and forms one of the coverings of femoral hernia. When the iliac portion of the fascia lata is removed from its attachment to Poupart's ligament and turned aside, the sheath of the femoral

vessels (the *Femoral* or *Crural Canal*) is brought into view; and if Poupart's ligament be carefully divided, the sheath may be isolated, and its continuation with the transversalis and iliac fascia demonstrated. In this view, the sheath of the femoral vessels is an infundibuliform continuation of the abdominal fascia, closely adherent to the vessels a little way down the thigh, but much larger than the vessels it contains at Poupart's ligament. If the sheath be opened, the artery and vein will be found lying side by side, and occupying the outer two-thirds of the sheath, leaving an infundibuliform interval between the vein and inner wall of the sheath. The superior opening of this space is named the *femoral* or *crural ring*; it is bounded in front by Poupart's ligament, behind by the os pubis, internally by Gimbernat's ligament, and externally by the femoral vein. The interval itself serves for the passage of the superficial lymphatic vessels from the saphenous opening to a lymphatic gland, which generally occupies the femoral ring, and from thence they proceed into the current of the deep lymphatics. The femoral ring is closed merely by a thin layer of subserous cellular tissue,¹ which retains the lymphatic gland in its position, and is named *septum crurale*, and by the peritoneum. It follows from this description that the femoral ring must be a weak point in the parietes of the abdomen, particularly in the female, in whom the *femoral arch*, or space included between Poupart's ligament and the border of the pelvis, is larger than in the male, while the structures which pass through it are smaller. It happens, consequently,

that if violent or continued pressure be made upon the abdominal viscera, a portion of intestine may be forced through the femoral ring into the infundibuliform

¹ This cellular tissue is sometimes very considerably thickened by a deposit of fat within its areolæ, and forms a thick stratum over the hernial sac.

FIG. 203.



SECTION OF THE STRUCTURES WHICH PASS BENEATH THE FEMORAL ARCH. 1. Poupart's ligament. 2, 2. Iliac portion of the fascia lata, attached along the margin of the crest of the ilium, and along Poupart's ligament, as far as the spine of the pubes (3). 4. Pubic portion of the fascia lata, continuous at 3 with the iliac portion, and passing outwards behind the sheath of the femoral vessels to its outer border at 5, where it divides into two layers; one is continuous with the sheath of the psoas (6), and iliacus (7); the other (8) is lost upon the capsule of the hip joint (9). 10. The crural nerve enclosed in the sheath of the psoas and iliacus. 11. Gimbernat's ligament. 12. The femoral ring, within the femoral sheath. 13. Femoral vein. 14. Femoral artery; the two vessels and the ring are surrounded by the femoral sheath, and thin septa are sent between the anterior and posterior wall of the sheath, dividing the artery from the vein, and the vein from the femoral ring.

space in the sheath of the femoral vessels, carrying before it the peritoneum and septum crurale,—this constitutes *Femoral Hernia*. If the causes which gave rise to the formation of the hernia continue, the intestine, unable to extend further down the sheath, from the close connexion of the latter with the vessels, will, in the next place, be forced forwards through the saphenous opening in the fascia lata, carrying before it two additional coverings, the sheath of the vessels or fascia propria, and the cribriform fascia; and, then curving upwards over Poupert's ligament, the hernia will become placed beneath the superficial fascia and integument.

The direction which femoral hernia takes in its descent is at first *downwards*, then *forwards*, and then *upwards*; and in endeavoring to reduce it, the application of the taxis must have reference to this course, and be directed in precisely the reverse order. The coverings of femoral hernia are, the

Integument,	Fascia propria,
Superficial fascia,	Septum crurale,
Cribriform fascia,	Peritoneal sac.

The *Deep fascia of the leg (fascia cruralis)* is attached to the inner and outer tuberosity of the tibia and head of the fibula, and receives an accession of fibres from the tendons of the sartorius, gracilis, [semi-tendinosus] and biceps. Between its points of attachment, and especially behind, it is continuous with the fascia of the thigh. In the front of the leg it incloses the tibialis anticus and extensor muscles, and affords origin to some of their fibres. On the outer side it forms a sheath for the peronei muscles; and behind, two sheaths superficial and deep; the former for the gastrocnemius and soleus with the tendo Achillis; the latter for the deep flexor muscles. At the ankle these four sheaths are differently arranged; the posterior superficial sheath terminates on the os calcis with the tendo Achillis; the posterior deep sheath is attached at one side to the border of the internal malleolus, at the other to the os calcis and inner side of the foot, being blended with the origin of the abductor pollicis. This portion of the deep fascia is the *internal annular ligament (laciniatum internum)*; it sends processes inwards to divide the tendons of the flexors and form sheaths for their passage into the foot. The sheath of the peronei muscles at the outer ankle is attached to the external malleolus on one side, and the border of the os calcis on the other, and forms the *external annular ligament (laciniatum externum)*. The anterior portion of the fascia forms at the ankle the anterior annular and the cruciform ligament. The *anterior annular ligament (transversum)* is a band of transverse fibres about an inch and a half in breadth, situated immediately above the joint, and attached to the tibia and fibula at either side. The *cruciform ligament (cruciatum)* is composed of two bands about half an inch in width, blended with each other at their point of union on the front of the joint. The internal band is attached above to the internal malleolus and below to the os calcis at the outer side of the foot; the external band to the external malleolus above, and the scaphoid and internal cuneiform bone at the inner border of the foot. The internal band at its origin consists of two layers, between which passes the tendon of the tibialis anticus. The tendons of the extensor longus digitorum and peroneus tertius have also a separate loop connected with the cruciform ligament, the *sling ligament (fundiforme)* of Retzius; this is a narrow band which embraces the tendons in a sling-shaped loop, and passes outwards and backwards to be attached to the sulcus tali and neighboring part of the calcaneum. The tendons passing through the loops and sheaths around the ankle are each furnished with a synovial bursa.

That portion of the fascia cruralis which forms a septum between the superficial and deep muscles of the back of the leg is sometimes called the *intermuscular fascia*; and in operations on the arteries of that region the *deep layer* of the deep fascia. There is besides another deep portion of fascia, above the preceding, the *popliteal fascia*, derived from the tendon of the semi-membranosus

muscle and binding down the popliteus muscle. By its inferior border this fascia is inserted into the popliteal line of the tibia.

The *fasciæ dorsales pedis* are three in number, superficial, middle and deep.

The *fascia dorsalis pedis* is thin and covers the dorsum of the foot, being continuous at the ankle with the cruciform ligament, and attached at either side to the borders of the foot, where it becomes united with the plantar fascia. A second or *middle layer* of fascia covers in the anterior part of the extensor brevis digitorum with its tendons; and a third or *deep layer* is found beneath the latter, and covering in the interossei muscles. On the interossei muscles the three layers are united, and the extensor tendons are consequently separated from each other in their course to the toes.

The PLANTAR FASCIA consists of three portions, middle and two lateral.

The *middle portion* (fascia plantaris media) is thick and dense, and composed of strong aponeurotic fibres, closely interwoven with each other. It is attached posteriorly to the inferior surface of the tuberosities of the os calcis, and terminates under the heads of the metatarsal bones in five fasciculi. Each of these fasciculi bifurcates to embrace the base of the corresponding toe, and is attached in the middle to the sheath of the flexor tendons, and at either side to the head of the metatarsal bone. The point of division of the fascia into fasciculi is strengthened by transverse bands, which preserve the solidity of the fascia at its broadest part. The intervals between the toes give passage to the digital arteries and nerves and lumbricales muscles.

The *lateral portions* (fascia interna et externa) are thin, and cover the sides of the sole of the foot; they are continuous behind with the internal and external annular ligament; and on the mesial side with the central portion. The *inner* portion is continuous along the border of the foot with the fascia of the dorsum; the *outer* portion is attached to the os calcis and base of the metatarsal bone of the little toe, forming between these points a thick band, which gives origin to part of the abductor minimi digiti muscle.

Besides constituting a strong layer of investment and defence to the soft parts situated in the sole of the foot, these three portions of fascia send processes inwards, which form sheaths for the different muscles. A strong septum is given off from each side of the middle portion of the plantar fascia, which is attached to the tarsal bones, and divides the muscles into three groups, middle and two lateral; and transverse septa are stretched between these to separate the layers. The superficial layer of muscles derive part of their origin from the plantar fascia.

CHAPTER VI.

OF THE ARTERIES.

THE arteries are the cylindrical tubes which convey the blood from the ventricles of the heart to every part of the body. They are dense in structure, and preserve for the most part the cylindrical form when emptied of their blood, which is their condition after death: hence they were considered by the ancients as the vessels for the transmission of the vital spirits,¹ and were therefore named arteries (*ἀρτή τρρεῖν*, to contain air).

The artery proceeding from the left ventricle of the heart contains the pure or arterial blood, which is distributed throughout the entire system, and constitutes with its returning veins the *greater* or *systemic circulation*. That which ema-

¹ To Galen is due the honor of having discovered that arteries contained blood, and not air.

nates from the right ventricle conveys the impure blood to the lungs; and with its corresponding veins establishes the *lesser* or *pulmonary circulation*.

The whole of the arteries of the systemic circulation proceed from a single trunk, named the *aorta*, from which they are given off as branches, and divide and subdivide to their ultimate ramifications, constituting the great arterial tree which pervades by its minute subdivisions every part of the animal frame. The mode in which the division into branches takes place is deserving of remark. From the aorta the branches, for the most part, pass off at right angles, as if for the purpose of checking the impetus with which the blood would otherwise rush along the cylinders from the main trunk; but in the limbs a very different arrangement is adopted; the branches are given off from the principal artery at an acute angle, so that no impediment may be offered to the free circulation of the vital fluid. The division of arteries is usually dichotomous, as of the aorta into the two common iliaes, common carotid into the external and internal, &c.; but in some few instances a short trunk divides suddenly into several branches which proceed in different directions; this mode of division is termed an *axis*, as the thyroid and cœliac axis.

In the division of an artery into two branches, it is observed that the combined area of the two branches is somewhat greater than that of the single trunk; and if the combined area of all the branches at the periphery of the body were compared with that of the aorta, it would be seen that the blood, in passing from the aorta into the numerous distributing branches, was flowing through a conical space, of which the apex might be represented by the aorta, and the base by the surface of the body. The advantage of this provision in facilitating the circulation is sufficiently obvious; for the increased channel which is thus provided for the current of the blood, serves to compensate for the retarding influence of friction, resulting from the distance of the heart and the division of the vessels.

Communications between arteries are free and numerous, and increase in frequency with the diminution in size of the branches; so that, through the medium of the minute ramifications, the entire body may be considered as one uninterrupted circle of *inosculations* or *anastomoses* (ἀνά, between, στόμα, mouth). This increase in the frequency of anastomosis in the smaller branches is a provision for counteracting the greater liability to impediment existing in them than in the larger branches. Where freedom of circulation is of vital importance, this communication of the arteries is very remarkable, as in the circle of Willis in the cranium, or in the distribution of the arteries of the heart. It is also strikingly seen in situations where obstruction is most likely to occur, as in the distribution to the alimentary canal, around joints, or in the hand and foot. Upon this free communication existing everywhere between arterial branches is founded the principle of cure by the ligature of large arteries; the ramifications of the branches given off from the artery above the ligature inosculate with those which proceed from the trunk of the vessel below the ligature; these anastomosing branches enlarge and constitute a *collateral circulation*, in which, as is shown in the preparations made by Sir Astley Cooper, several large branches perform the office of the single obliterated trunk.¹

The arteries do not terminate directly in veins; but in an intermediate system of vessels, which, from their minute size (about $\frac{1}{3000}$ of an inch in diameter,) are termed *capillaries* (capillus, a hair). The capillaries constitute a microscopic network, which is distributed through every part of the body,² so as to render it impossible to introduce the smallest needle-point beneath the skin without wounding several of these fine vessels. It is through the medium of the capillaries, that all the phenomena of nutrition and secretion are performed. They are remark-

¹ I have a preparation, showing the collateral circulation in a dog, in which I tied the abdominal aorta; the animal died from over-feeding nearly two years after the operation.

² The only organs in which capillaries are wanting, are the corpora cavernosa penis, and uterine placenta.

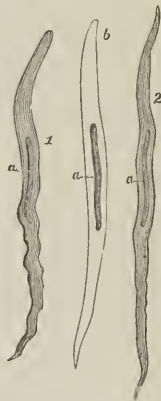
able for their uniformity of diameter, and for the constant divisions and communications which take place between them, without any alteration of size. They inosculate on the one hand with the terminal ramusculi of the arteries; and on the other with the minute radicles of the veins.

ARTERIES are composed of three coats, external, middle, and internal.

The *external coat* [tunica adventitia,] is firm and strong, and formed of tissues which take a longitudinal or oblique direction; it is thin in the large arteries, but thicker than the middle coat in arteries of small and medium size, and composed of areolar and elastic tissue. The *areolar tissue* consists of fine and coarse fasciculi and separate fibrils, among which are scattered numerous elongated nuclei; in arteries of the smallest size the areolar tissue is more nucleated and loses its fibrous character, and ultimately in the minutest vessel is changed into a delicate homogeneous membrane, in which the nuclei are gradually lost. The *elastic tissue* exists in small quantity in the large arteries, occupies the deep layer of the external coat, and is not distinctly separable from the middle coat. In arteries of medium size it is more abundant, consists of larger fibres, and is laminated, the laminæ approaching in character to elastic membrane. In small arteries the elastic tissue exists as a fine network in the deep layer of the external coat; in vessels still smaller it presents itself in a developmental form as fusiform cells, and in the smallest disappears altogether.

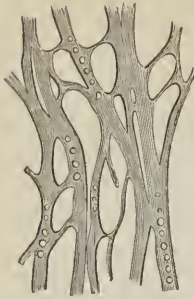The *middle or contractile coat* [tunica media,] is thick and laminated, and composed of structures which take a transverse or circular direction; hence it is brittle and easily cut through when a ligature is applied. In the small arteries it is wholly composed of smooth muscular fibres; in arteries of medium size, as the external and internal carotid, brachial, crural, and popliteal, of a mixture of smooth muscular and elastic tissue; and in the large arteries, as the aorta, common carotids and iliacs, chiefly of elastic tissue. The *smooth muscular tissue* is the only component structure of the middle coat of small arteries; in which there are two or three laminæ, the fibres about $\frac{1}{30,000}$ of an inch in diameter being arranged in rings; in smaller arteries there is but one muscular lamina, the elements of the fibres being shorter and in proportion as the arteries are more and more minute, becoming reduced to the earliest developmental form, namely, short elliptic cells with oblong nuclei; ultimately they are completely lost. In arteries of medium size, elastic fibres are superadded to the muscular fibres, the latter predominating for awhile, and in the large arteries the smooth muscular fibres are reduced to their cellular form and gradually diminished in number and importance, until they exist as mere rudimentary elements scattered among the layers of elastic tissue, of which the middle coat of large arteries is principally composed. The *elastic tissue* is absent altogether in the middle coat of small arteries, but makes its appearance in arteries of medium size as fine fibres disposed in a network of wide meshes. In the larger kind of medium-sized arteries, the elastic network is mingled with areolar tissue, and a tendency to the alternation of these tissues begins to be apparent; furthermore, in some of the largest of the medium arteries the elastic tissue is found, in parts of the vessel, to occupy the whole thickness of the

FIG. 204.



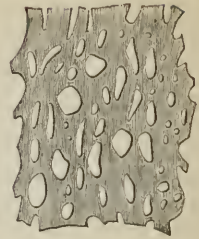
SMOOTH MUSCULAR FIBRE CELLS FROM THE MIDDLE COAT OF THE ARTERY: 1, from the popliteal; 2, from a twig of the anterior tibial, half a line in diameter, *a, a*, elongated or rod-like nucleus. The middle cell (*b*) has been rendered transparent by immersion in vinegar. Magnified 350 times; after Kölliker.

FIG. 205.



NETWORK OF COARSE ELASTIC TISSUE FROM THE MIDDLE COAT OF THE PULMONARY ARTERY of the horse; the fibres are pierced with circular openings. Magnified 350 times; after Kölliker.

FIG. 206.

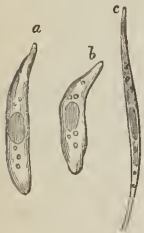

ELASTIC MEMBRANE OF THE FENESTRATED KIND, from the middle coat of the carotid artery of the horse. Magnified 350 times; after Kölliker.

middle coat, thus leading upwards to the large vessels in which the elastic tissue is the chief constituent. While thus encroaching as it were on the structure of the middle coat of arteries, the elastic tissue presents a corresponding series of transitional forms; at first it exists as fine fibres disposed singly or in a fine network with open meshes; then the fibres become larger and the meshes closer; and interlaced so as to form a fibrous membrane with narrow meshes; next by the increase of breadth of their fibres and their intimate union or fusion, a homogeneous membrane is formed, in which the meshes appear as simple perforations (fenestrated membrane). In medium-sized arteries the elastic tissue forms a single layer, lying exteriorly to the muscular fibres in the largest arteries of this class; it is mingled with areolar tissue, and exhibits a tendency to become laminated, the laminæ alternating with similar layers of areolar tissue. In the large arteries this is the common character of the middle coat; the elastic tissue is laminated, and between the laminæ are strata of areolar and muscular tissue. The presence of elastic tissue as a chief constituent of the middle coat of arteries, gives them a yellow color, while those arteries in which the muscular tissue is abundant have a reddish tint. In the aorta, the laminæ of the middle coat are forty or fifty in number.

The *internal coat* [tunica intima,] is the thinnest of the three, and easily broken in the transverse direction; it is composed of two layers, an internal layer or *epithelium*, and an external *elastic membrane*, which is either homogeneous or made up of elastic elements, disposed in a longitudinal direction. In the middle-sized and large arteries there is a third and *intermediate* layer, consisting of an imperfect areolar tissue provided with a network of elastic tissue, and presenting in certain situations a peculiar structure which has received the name of *striped lamellæ*. The *epithelium* is composed of slender fusiform cells with elongated nuclei, lying parallel with the axis of the vessel; they are more lengthened in the small than in the large arteries, and in those of the smallest calibre are only distinguishable by their nuclei. The *elastic layer* is a thin, homogeneous membrane of the fenestrated kind, perforated with minute oblong openings having a direction parallel with the axis of the

FIG. 207.



EPITHELIAL CELLS OF BLOODVESSELS; a, b, from a vein; c, from an artery. Magnified 350 times; after Kölliker.

vessel. It is folded into longitudinal rugæ when the vessel is empty, and becomes extremely delicate and is finally lost in the minute vessels. Exteriorly

this layer assumes a reticulated character, and is made up of a longitudinal network of elastic fibres. The *intermediate layer* of the internal coat, found only in the larger arteries, is lamellated and composed of elements which have a longitudinal direction. The *striped lamellæ* are situated in this layer, and consist of clear lamellæ, sometimes striped, sometimes nucleated, and sometimes homogeneous. They lie immediately beneath the epithelium, and when nucleated bear so close a resemblance to that layer, as to have been regarded as a metamorphosed epithelium; when homogeneous their nearest analogue is elastic membrane, to which tissue they appear to belong. In the internal coat of certain arteries, as of the axillary and popliteal, Kölliker has found smooth muscular fibres.

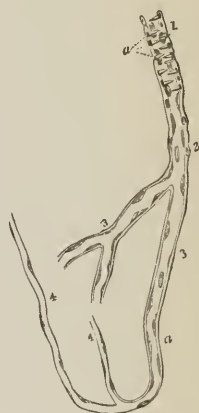In taking a summary survey of the constituent tissues of the three coats of arteries in their order of succession from without inwards, it will be seen that the external coat consists of areolar and elastic tissue; the middle coat of smooth muscular fibre, areolar and elastic tissue, and the internal coat of elastic tissue and epithelium.

CAPILLARIES or capillary vessels have only one coat, which is thin, transparent, and structureless; resembling, in this respect, cell-membrane and the sarcolemma of muscular fibre; in approaching the arteries and veins this coat becomes somewhat thicker, and is finally lost in the elastic membrane of the internal coat of the arteries, and in that of the middle coat of the veins. The increasing thickness of the coat of capillaries causes a distinction of these vessels into *fine* and *coarse*, and the latter gradually augmenting in size and complexity of structure, become the *transitional vessels*. On the inner surface of capillaries, and dispersed at short distances, are oblong nuclei; the nuclei become placed nearer together in the coarse capillaries and transitional vessels, and in the arteries and veins constitute the epithelial layer of the internal coat. In distribution, capillary vessels form plexuses by their frequent communication with each other; and these plexuses present considerable variety in the closeness of their meshes and the number and size of the vessels. They are most abundant and largest in the lungs, liver, kidneys, and other secreting glands, also in the skin and mucous membrane, where a secreting function has to be performed; and least abundant and smallest in the muscles, nerves, organs of sense, serous membranes and tendons, where nutrition only has to be accomplished. In the bones the capillaries are large, but the plexuses scanty.

The arteries, in their distribution through the body are included in a loose areolo-fibrous investment, which separates them from surrounding tissues, and is called a *sheath*. Around the principal vessels the sheath is an important structure; it is composed of areolar tissue, intermingled with aponeurotic fibres, and is continuous with the fasciæ of the region in which the arteries are situated, as with the thoracic and cervical fascia in the neck, transversalis and iliac fascia, fascia lata in the thigh, &c. The sheath of the arteries contains also their accompanying veins, and sometimes a nerve.

The coats of arteries are supplied with blood like other organs of the body, their vessels proceed from the neighboring small branches, and are named *vasa*

FIG. 208.



TRANSITION OF A MINUTE ARTERY INTO CAPILLARY VESSELS; from the brain: after Kölliker. 1. Minute artery. 2. Transitional capillary. 3, 3. Coarse capillaries with thick coat, represented by a double contour line. 4, 4. Fine capillaries, with single contour. The nuclei are seen widely scattered in 4 and 3: more closely congregated in 2; and still more so in 1; where they form an epithelium. a. The transverse elongated nuclei of muscular cells; the incipient muscular coat of the artery.

vasorum. The vasa vasorum or vasa nutritia are distributed in the external coat, some few making their way among the external layers of the middle coat. They are met with even on the smallest arteries, and form a rich capillary network with rounded meshes. The small veins which return the blood from the capillaries, open into the companion veins of the artery. The *nerves*, like the vasa vasorum, are found only in the external coat, and are wanting altogether in many arteries, as in those of the cerebral and spinal substance, the choroid membrane of the ovum, the placenta, and also in the arterics of some muscles, glands, and membranes.

In the consideration of the arteries, we shall first describe the aorta, and the branches of that trunk with their subdivisions, which together constitute the efferent portion of the systemic circulation; and then the pulmonary artery as the efferent trunk of the pulmonary circulation.

AORTA.

The AORTA arises from the base of the left ventricle, at the middle of the root of the heart, and presents at its commencement an enlargement (*bulbus aortæ*) caused by three dilatations of the walls of the vessel, the *sinus aortici* (*sinus Valsalvæ*) and corresponding with the three semilunar valves. It ascends at first forwards and to the right, then curves backwards and to the left, and descends on the left side of the vertebral column to the fourth lumbar vertebra. Hence it is divided into the arch and descending aorta.

The ARCH OF THE AORTA (*arcus aortæ*), commencing at a point corresponding with the articulation of the cartilage of the fourth rib with the sternum on the left side, crosses behind and near the sternum to a point corresponding with the upper border of the articulation of the second rib with the sternum on the right side. It then curves backwards and to the left, and descends to the left side of the body of the third dorsal vertebra, and at the lower border of the latter vertebra becomes the thoracic aorta.

The first or *ascending* portion of the arch (*aorta ascendens*), a little more than two inches in length, is almost wholly contained within the pericardium. It is crossed *in front* by the pulmonary artery; on its *left* side it has the left auricle and pulmonary artery; on its *right* the right auricle and superior vena cava; and *behind* the right pulmonary artery and veins.

The second or *transverse* portion of the arch is crossed *in front* by the left phrenic nerve, left *nervus superficialis cordis*, left inferior cardiac of the pneumogastric, and left pneumogastric nerve. *Behind* it is in relation with the trachea, œsophagus, thoracic duct, nerves to the deep cardiac plexus, and left recurrent nerve. *Above* it gives off the *arteria innominata*, left carotid and left subclavian artery, and supports the left vena innominata; and *below* is in relation with the superficial cardiac plexus, bifurcation of the pulmonary artery, cord of the ductus arteriosus, left bronchus, and left recurrent nerve.

The third or *descending* portion of the arch lies against the third dorsal vertebra, and is partially covered by the left pleura.

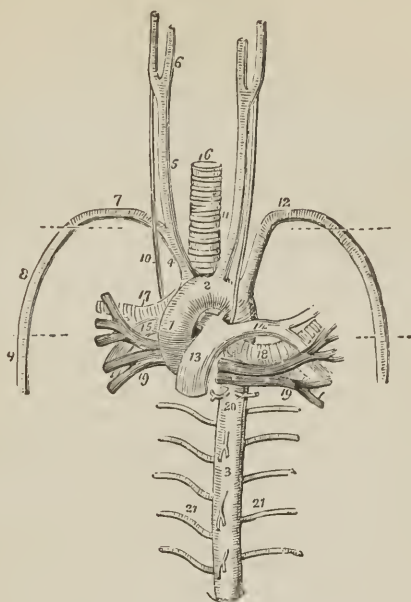
AORTA DESCENDENS. — The descending aorta is subdivided in correspondence with the two great cavities of the trunk, into the thoracic and abdominal aorta.

Aorta thoracica. — The thoracic aorta commencing at the lower border and left side of the third dorsal vertebra curves gently towards the right as it descends, and as it passes through the aortic opening of the diaphragm lies on the middle line of the vertebral column.

It is in relation *behind*, with the vertebral column and lesser vena azygos; *in front*, with the œsophagus and right pneumogastric nerve; to the *left side*, with the pleura; and to the *right* with the thoracic duct.

Aorta abdominalis. — The abdominal aorta enters the abdomen through the aortic opening of the diaphragm, and between the two pillars of that muscle. In

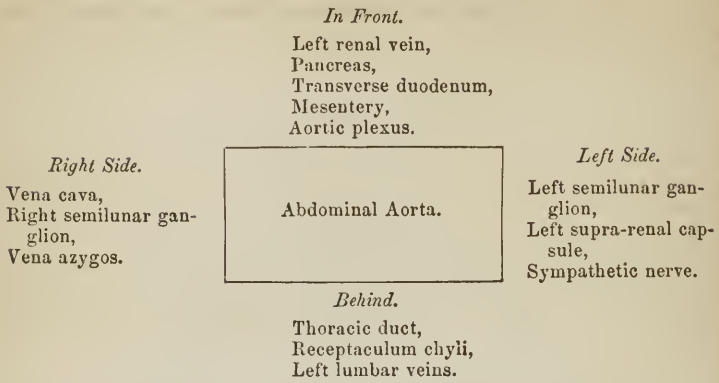
FIG. 209.



THE LARGE VESSELS OF THE ROOT OF THE HEART AND LUNGS. 1. Ascending aorta; the numeral is placed on the dilatation known as the sinus quartus vel maximus Valsalvæ. 2. Transverse portion of the arch. 3. Thoracic portion of the descending aorta. 4. Arteria innominata, dividing into, 5, the right common carotid, which again divides at 6, into the external and internal carotid; and 7, the right subclavian artery. 8. Axillary artery; its extent is designated by a dotted line. 9. Braehial artery. 10. Right pneumogastric nerve running by the side of the common carotid in front of the right subclavian artery, and behind the root of the right lung. 11. Left common carotid, having on its outer side the left pneumogastric nerve, which crosses the arch of the aorta, and as it reaches its lower border gives off the left recurrent nerve. 12. Left subclavian artery becoming axillary and braehial in its course, like the artery of the opposite side. 13. Trunk of the pulmonary artery connected to the concavity of the arch of the aorta by a fibrous cord, the remains of the ductus arteriosus. 14. Left pulmonary artery. 15. Right pulmonary artery. 16. Trachea. 17. Right bronchus. 18. Left bronchus. 19, 19. Pulmonary veins. 17, 15, 19, on the right side, and 14, 18, 19, on the left, constitute the roots of the corresponding lungs, and the relative position of the vessels is preserved. 20. Bronchial arteries. 21, 21. Intercostal arteries; the branches from the front of the aorta above and below the number 3 are pericardiac and cesophageal.

its course downwards, it lies on the vertebral column to the left of the middle line, and terminates on the fourth lumbar vertebra, by dividing into the two common iliac arteries. It is crossed *in front* by the left renal vein, pancreas, transverse duodenum, and mesentery, and is in relation *behind* with the thoracic duc, receptaculum chyli, and left lumbar veins. On its *left side* is situated the left semilunar ganglion, supra-renal capsule, and synpathetic nerve; on its *right*, the inferior vena cava, right semilunar ganglion, and commencement of the vena azygos.

Plan of the Relations of the Abdominal Aorta.



BRANCHES. — The branches of the aorta arranged in a tabular form, are as follows: —

Arch	{	ascending portion,	Coronary, right and left.
		transverse portion.	{ Arteria innominata, . { Right carotid, Left carotid, { Right subclavian. Left subclavian.
Thoracic aorta . . .	{		Pericardiac, Bronchial, Œsophageal, Intercostal. Phrenic.
			Cœliac axis { Gastric, { Hepatic, { Splenic.
Abdominal aorta . . .	{		Supra-renal, Renal, Superior mesenteric, Spermatic, Inferior mesenteric, Lumbar, Sacra media, Common iliacs.

The CORONARY ARTERIES (cardiacæ) arise from the aortic sinuses at the commencement of the ascending portion of the arch of the aorta, immediately above the free margin of the semilunar valves.

The *left coronary* (coronaria cordis sinistra) passes forwards, between the pulmonary artery and left appendix auriculæ, and divides into two branches; one of which (posterior) winds around the base of the left ventricle in the auriculo-ventricular groove, and inosculates with the right coronary, forming an arterial circle around the base of the heart; the other (anterior) passes along the groove of union of the two ventricles, on the anterior aspect of the heart, to its apex, where it anastomoses with the right coronary. The left coronary artery supplies the left auricle and anterior surface of both ventricles.

The *right coronary* (coronaria cordis dextra) passes forwards, between the root of the pulmonary artery and the right auricle, and winds along the auriculo-ventricular groove, to the posterior longitudinal furrow; it then descends along

the posterior aspect of the heart to its apex, and inosculates with the left coronary. It is distributed to the right auricle and ventricle, and posterior surface of both ventricles, and sends a large branch along the sharp margin of the right ventricle to the apex of the heart.

ARTERIA INNOMINATA.

The *Arteria innominata* [brachio-cephalic artery] (fig. 209, 4) is the first and largest artery given off by the arch of the aorta. It is an inch and a half in length, and ascends obliquely towards the right sterno-clavicular articulation, where it divides into the right carotid and right subclavian artery.

Relations.—It is in relation, *in front*, with the left vena innominata, sternum, and origin of the sterno-hyoid and sterno-thyroid muscle; *behind*, with the trachea and right pneumogastric nerve; to the *right* with the right vena innominata and pleura; to the *left*, with the left common carotid artery and remains of the thymus gland.

*Plan of the Relations of the Arteria Innominata.**In Front.*

Left vena innominata,
Sternum,
Sterno-hyoideus,
Sterno-thyroideus.

Right Side.

Right vena innominata.
Pleura.

Arteria Innominata.

Left Side.

Left carotid,
Remains of thymus.

Behind.

Trachea,
Right pneumogastric nerve.

The arteria innominata occasionally gives off a small branch, which ascends along the middle of the trachea to the thyroid gland. This branch was described by Neubauer, as the *thyroidea ima* (lowest thyroid artery), and Dr. Harrison names it the *middle thyroid artery*. A knowledge of its existence is important in performing the operation of tracheotomy.

COMMON CAROTID ARTERIES.

The common carotid arteries (*carotis communis vel primitiva*; *κάρα*, the head) arise, the *right* from the bifurcation of the arteria innominata opposite the right sterno-clavicular articulation, the *left* from the arch of the aorta. It follows, therefore, that the right carotid is shorter than the left; it is also more anterior; and, in consequence of proceeding from a branch instead of from the main trunk, is larger than its fellow.

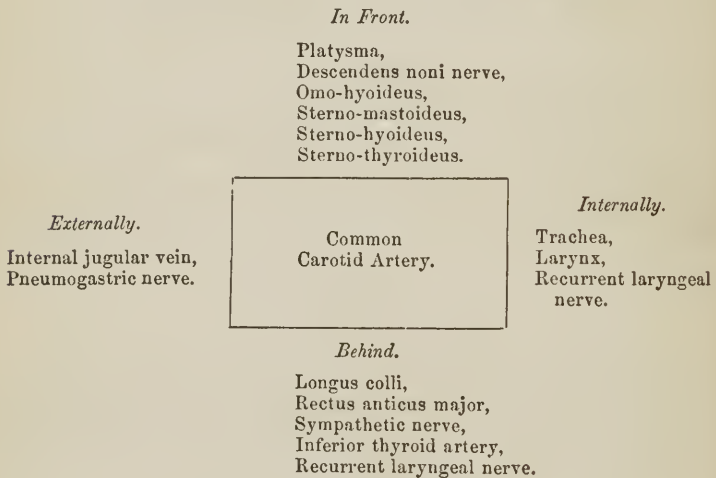
The *Right common carotid artery*, (fig. 209, 5) ascends the neck perpendicularly by the side of the trachea and larynx, from behind the right sterno-clavicular articulation to a level with the upper border of the thyroid cartilage, where it divides into the external carotid and internal carotid.

The *Left common carotid* (fig. 209, 11) passes somewhat obliquely outwards from the arch of the aorta to the side of the neck, and thence upwards by the side of the trachea and œsophagus to a level with the upper border of the thyroid cartilage, where it divides like the right common carotid into the external carotid and internal carotid.

Relations.—The common carotid artery, in the neck, is inclosed in a fibrous

sheath, which also contains the internal jugular vein, lying to the outer side of the artery, and the pneumogastric nerve, which lies between and behind both. The sheath rests on the vertebral column, having interposed the sympathetic nerve and anterior muscles of the vertebral column, namely, longus colli and rectus anticus major; and being crossed behind by the inferior thyroid artery and recurrent laryngeal nerve. To the *inner side* of the carotid is the trachea, recurrent laryngeal nerve, and larynx; to its *outer side*, and inclosed in its sheath, the jugular vein and pneumogastric nerve; and *in front*, the sterno-thyroid, sterno-hyoid, sterno-mastoid, omo-hyoid, and platysma muscles, and the descendens noni nerve. The left common carotid, in addition to the relations just enumerated, which are common to both, is crossed near its commencement by the left vena innominata, and supports the remains of the thymus gland; it lies on the trachea; then gets to its side, and is in relation with the œsophagus and thoracic duct: to facilitate the study of these relations, I have arranged them in a tabular form.

Plan of the Relations of the Common Carotid Artery.



Additional Relations of the Left Common Carotid.

<i>In Front.</i>	<i>Behind.</i>	<i>Internally.</i>	<i>Externally.</i>
Left vena innominata, Remains of thymus.	Trachea, Thoracic duct.	Arteria innominata, Æsophagus.	Pleura.

EXTERNAL CAROTID ARTERY.

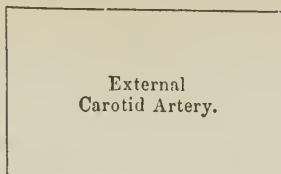
The *External carotid artery* (carotis externa) ascends nearly perpendicularly from opposite the upper border of the thyroid cartilage, to the space between the neck of the lower jaw and meatus auditorius, where it divides into two terminal branches, temporal and internal maxillary.

Relations. — *In front* it is crossed by the posterior belly of the digastricus, stylo-hyoideus, and platysma myoides; by the hypoglossal nerve near its origin; higher up it is situated in the substance of the parotid gland, and has in front the facial nerve and temporo-maxillary vein. *Behind*, it is separated from the internal carotid by the stylo-pharyngeus and stylo-glossus muscle, glosso-pharyngeal nerve, and part of the parotid gland.

Plan of the Relations of the External Carotid Artery.

In Front.

Platysma,
 Digastricus,
 Stylo-hyoideus,
 Hypoglossal nerve,
 Facial nerve,
 Temporo-maxillary
 vein,
 Parotid gland,



Behind.

Stylo-pharyngeus,
 Stylo-glossus,
 Glosso-pharyngeal
 nerve.
 Parotid gland.

BRANCHES.—The branches of the external carotid, ten in number, may be arranged into three groups, anterior, posterior, and ascending. They are as follows:—

Anterior.

Superior thyroid,
 Lingual,
 Facial.

Posterior.

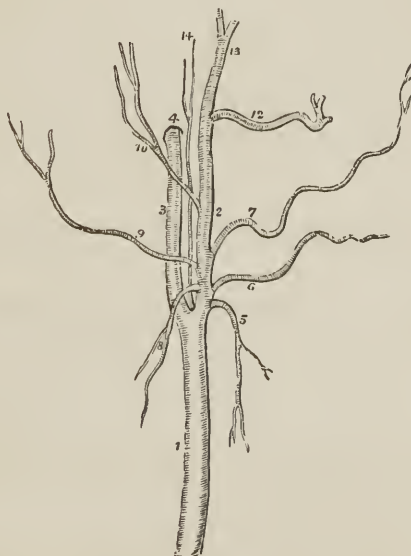
Sterno-mastoid,
 Occipital,
 Posterior auricular.

Ascending.

Ascending pharyngeal,
 Parotidcan,
 Temporal,
 Internal maxillary.

The anterior branches arise from the commencement of the external carotid, within a short distance of each other. The lingual and facial bifurcate, not unfrequently, from a common trunk.

FIG. 210.



CAROTID ARTERIES WITH THE BRANCHES OF THE EXTERNAL CAROTID. 1. Common carotid. 2. External carotid. 3. Internal carotid. 4. Carotid foramen in the petrous portion of the temporal bone. 5. Superior thyroid artery. 6. Lingual artery. 7. Facial artery. 8. Sterno-mastoid artery. 9. Occipital. 10. Posterior auricular. 12. Internal maxillary. 13. Temporal. 14. Ascending pharyngeal artery.

The SUPERIOR THYROID ARTERY (thyroidea superior) the first of the branches of the external carotid, arises from that trunk just below the great cornu of the os hyoides, and curves downwards to the thyroid gland. It is distributed by several large branches (rami thyroidei) to the anterior part of the gland, and anastomoses with its fellow of the opposite side, and with the inferior thyroid arteries. In its course it passes beneath the omo-hyoid, sterno-thyroid, and sterno-hyoid muscle.

Branches.— Hyoid, Inferior laryngeal,
Superior laryngeal, Muscular.

The *Hyoid branch* passes forwards beneath the thyro-hyoideus, and is distributed to the depressor muscles of the os hyoides near their insertion.

The *Superior laryngeal* (laryngea superior) pierces the thyro-hyoidean membrane, in company with the superior laryngeal nerve, and supplies the mucous membrane and muscles of the larynx, sending a branch upwards to the epiglottis.

The *Inferior laryngeal* (crico-thyroidea) is a small branch which crosses the crico-thyroidean membrane along the lower border of the thyroid cartilage. It sends branches through that membrane to supply the mucous lining of the larynx, and inosculates with its fellow of the opposite side.

The *Muscular branches* (rami musculares) are distributed to the depressor muscles of the os hyoides and larynx. One of these branches crosses the sheath of the common carotid to the under surface of the sterno-mastoid muscle.

The LINGUAL ARTERY (lingualis) ascends obliquely from its origin; it then passes forwards parallel with the great cornu of the os hyoides; thirdly, it ascends to the under surface of the tongue; and fourthly, runs forwards in a serpentine direction to its tip, under the name of *ranine artery* (profunda linguæ), where it terminates by inosculating with its fellow of the opposite side.

Relations.— The *first* part of its course rests on the middle constrictor muscle of the pharynx, being covered in by the tendon of the digastricus and the stylo-hyoid muscle; the *second* is situated between the middle constrictor and hyoglossus muscle, the latter separating it from the hypoglossal nerve; in the *third* part of its course it lies between the hyo-glossus and genio-hyo-glossus; and in the fourth (ranine), rests on the lingualis to the tip of the tongue.

Branches.— Hyoid, Dorsalis linguæ, Sublingual.

The *Hyoid branch* (hyoidea) runs along the upper border of the os hyoides, and is distributed to the elevator muscles of the os hyoides near their insertion, inosculating with its fellow of the opposite side.

The *Dorsalis linguæ* ascends along the posterior border of the hyo-glossus muscle to the dorsum of the tongue, and is distributed to the tongue, fauces, and epiglottis; anastomosing with its fellow of the opposite side.

The *Sublingual branch* (sublingualis) runs forwards on the genio-hyo-glossus muscle, and is distributed to the sublingual gland and muscles of the tongue. It is situated between the mylo-hyoideus and genio-hyo-glossus, generally accompanies Wharton's duct for a part of its course, and sends a branch to the frænum linguæ. The latter branch affords the considerable hemorrhage which sometimes follows the old operation of snipping the frænum in children.

FACIAL ARTERY.—The facial artery (maxillaris externa; labialis) arises immediately above the lingual and a little above the great cornu of the os hyoides, and passes forwards to the submaxillary gland, in which it lies imbedded. It then curves around the body of the lower jaw, close to the anterior inferior angle of the masseter muscle, ascends to the angle of the mouth, and thence to the angle of the eye, where it is named, *angular artery*. The facial artery is tortuous in its

course over the buccinator muscle, to accommodate itself to the movements of the jaws.

Relations. — Below the jaw it passes beneath the digastricus and stylo-hyoid muscle; on the body of the lower jaw it is covered by the platysma myoides, and at the angle of the mouth by the depressor anguli oris and zygomatic muscles. It rests on the submaxillary gland, lower jaw, buccinator, orbicularis oris, levator anguli oris, levator labii superioris proprius, and levator labii superioris alæque nasi.

Its *branches* may be grouped into those which are given off below the jaw, and those on the face; they may be thus arranged:—

Below the Jaw.

Inferior palatine,
Tonsillar,
Submaxillary,
Submental,
Muscular.

On the Face.

Buccal,
Inferior labial,
Inferior coronary,
Superior coronary,
Lateralis nasi.

The *Inferior palatine branch* (palatina ascendens; pharyngo-palatina) ascends between the stylo-glossus and stylo-pharyngeus muscle, to be distributed to the tonsil and soft palate, and anastomose with the descending palatine branch of the internal maxillary artery.

The *Tonsillar branch* (tonsillaris) ascends by the side of the pharynx, and pierces the superior constrictor muscle to be distributed to the tonsil.

The *Submaxillary* (submaxillares) are four or five branches which supply the submaxillary gland.

The *Submental branch* (submentalis) runs forwards on the mylo-hyoid muscle, under cover of the body of the lower jaw, and anastomoses with branches of the sublingual and inferior dental artery.

The *Muscular branches* (musculares) are distributed to the masseter, pterygoideus internus, digastricus, and stylo-hyoideus.

The *Buccal branches* (buccales), eight or ten in number, are given off upon the face, and are distributed to the buccinator, masseter, muscles of the upper lip, orbicularis palpebrarum, and integument of the cheek. They anastomose with the buccal branch of the internal maxillary, the transverse facial, and infra-orbital.

The *Inferior labial branch* (labialis inferior) passes forwards beneath the depressor anguli oris muscle, and is distributed to the muscles of the lower lip, inosculating with the labial branch of the inferior dental, and the inferior coronary.

The *Inferior coronary branch* (coronaria labii inferioris) is given off at the angle of the mouth, and passes inwards near the edge of the lower lip, lying between the orbicularis and mucous membrane; it inosculates with its fellow of the opposite side.

The *Superior coronary branch* (coronaria labii superioris), arising close to, or in common with the preceding, takes its course in the same manner along the upper lip, inosculating with its fellow of the opposite side. At the middle of the lip it sends a small branch upwards to the septum of the nose (arteria septi).

The *Lateral nasal branch* (nasalis lateralis vel externa) is given off near the ala nasi, and passes beneath the levator labii superioris alæque nasi, to be distributed to the nose. It inosculates with the nasal branch of the ophthalmic artery.

The *Inosculations* of the facial artery are numerous, namely, with the sublingual branch of the lingual, ascending pharyngeal artery, descending palatine artery, inferior dental at its escape from the mental foramen, infraorbital at the

infraorbital foramen, transverse facial on the side of the face, and nasal and frontal branch of the ophthalmic artery at the angle of the eye.

The facial artery is subject to variety in length; it not unfrequently terminates at the angle of the nose or mouth, and is rarely symmetrical on both sides of the face.

The STERNO-MASTOID ARTERY turns downwards from its origin, to be distributed to the sterno-mastoid muscle, and lymphatic glands of the neck; sometimes there are two branches.

The OCCIPITAL ARTERY (*occipitalis*), smaller than the anterior branches, passes backwards behind the parotid gland and beneath the posterior belly of the digastricus, trachelo-mastoideus, and sterno-mastoideus to the occipital groove in the mastoid portion of the temporal bone. It then ascends between the splenius and complexus, pierces the trapezius, and is distributed to the back of the head (*ramus occipitalis*), anastomosing with the opposite occipital, posterior auricular, and temporal artery. The hypoglossal nerve curves around this artery opposite the angle of the jaw and near its origin from the external carotid.

Branches.—It gives off several muscular branches (*cervicales*) to the sterno-mastoideus, digastricus, stylo-hyoideus, and deep muscles in its course, a small branch to the external ear, and two larger branches, inferior meningeal and *princeps cervicis*.

The *Inferior meningeal* ascends by the side of the internal jugular vein, and passes through the foramen lacerum posterius, to be distributed to the dura mater.

The *Arteria princeps cervicis* (*cervicalis profundus superior*) is a large and irregular branch. It descends the neck between the complexus and semi-spinalis colli, and inosculates with the *cervicalis profunda* of the subclavian and with branches of the vertebral. This branch is the means of establishing an important collateral circulation between the branches of the carotid and subclavian, after ligation of the common carotid artery.

The POSTERIOR AURICULAR ARTERY (*auricularis posterior*) arises from the external carotid, above the level of the digastricus and stylo-hyoideus muscle, and ascends by the side of the styloid process and behind the parotid gland, to the back part of the concha. It is distributed by two branches, to the external ear, *ramus auricularis*, and side of the head, *ramus occipitalis*, anastomosing with the occipital and temporal artery; some of its branches pass through fissures in the fibro-cartilage, to reach the anterior surface of the pinna. The anterior auricular arteries are branches of the temporal.

Branches.—The posterior auricular gives off a branch to the digastricus muscle, and several branches to the parotid gland; it then gives off the *stylo-mastoidea*, which enters the stylo-mastoid foramen to be distributed to the aquæductus Fallopii, labyrinth, mastoid cells, and tympanum; a twig accompanies the chorda tympani under the name of *tympanica superior*.

The ASCENDING PHARYNGEAL ARTERY (*pharyngea ascendens*), the smallest of the branches of the external carotid, arises from that trunk near its origin, and ascends between the internal carotid and side of the pharynx to the base of the skull, where it divides into two branches; *meningeal* (*meningea posterior*), which enters the foramen lacerum posterius, to be distributed to the dura mater; and *pharyngeal*. It supplies the pharynx, tonsils, soft palate, and Eustachian tube.

The PAROTIDEAN ARTERIES (*parotideæ*) are four or five large branches which are given off from the external carotid whilst in the parotid gland. They are

distributed to the structure of the gland, their terminal branches reaching the integument of the side of the face, and masseter muscle (rami masseterici posteriores).

The TEMPORAL ARTERY (temporalis) is one of the two terminal branches of the external carotid. It ascends over the root of the zygoma; and, at about an inch and a half above the zygomatic arch, divides into an anterior and posterior temporal branch. The *anterior temporal* (temporalis superficialis anterior, vel frontalis) is distributed over the front of the temple and arch of the skull, and anastomoses with the opposite anterior temporal, and with the supraorbital and frontal artery. The *posterior temporal* (temporalis superficialis posterior, vel occipitalis) curves upwards and backwards, and inosculates with its fellow of the opposite side, with the posterior auricular and occipital artery.

The trunk of the temporal artery is covered by the parotid gland and attrahens aurem muscle, and rests on the temporal fascia.

The *Branches* of the temporal artery are, some small offsets to the parotid gland and articulation of the lower jaw, and the following:

Anterior auricular,	Transversa faciei,
Orbital,	Middle temporal.

The *Anterior auricular branches* (auriculares anteriores), two in number, are distributed to the anterior portion of the pinna.

The *Orbital branch* (zygomatiko-orbitalis; supraorbitalis externa) passes forwards immediately above the zygoma, between the two layers of the temporal fascia, and inosculates beneath the orbicularis palpebrarum with the lachrymal branch of the ophthalmic artery.

The *Transversa faciei* arises from the temporal immediately below the zygoma, and runs transversely across the face, resting on the masseter muscle, and lying parallel with and a little above Stenon's duct. It anastomoses with the facial and infraorbital artery.

The *Middle temporal branch* (temporalis media) passes through an opening in the temporal fascia immediately above the zygoma, and supplies the temporal muscle inosculating with the deep temporal arteries.

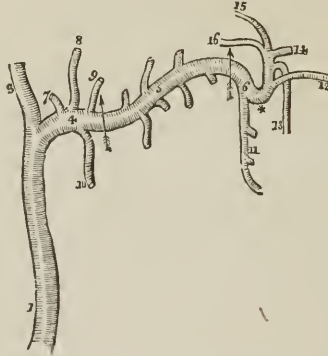
The INTERNAL MAXILLARY ARTERY (maxillaris interna), the other terminal branch of the external carotid, has next to be examined.

Dissection — The *internal maxillary artery* passes inwards behind the neck of the lower jaw to the deep structures in the face; we require, therefore, to remove several parts for the purpose of seeing it completely. To obtain a good view of the vessel, the zygoma should be sawn across in front of the external ear, and the malar bone near the orbit. Turn down the zygomatic arch with the masseter muscle. In doing this, a small artery and nerve will be seen crossing the sigmoid notch of the lower jaw, to enter the masseter muscle (masseteric). Cut away the tendon of the temporal muscle from its insertion into the coronoid process, and turn it upwards towards its origin; some vessels will be seen entering its under surface; these are the *deep temporal*. Then saw the ramus of the jaw across its middle, and dislocate it from its articulation with the temporal bone. Be careful in doing this to carry the blade of the knife close to the bone, lest any branches of nerves should be injured. Next raise this portion of bone, and with it the external pterygoid muscle. The artery, together with the deep branches of the inferior maxillary nerve, will be seen lying on the pterygoid muscles. These are to be carefully freed from fat and cellular tissue, and then examined.

The internal maxillary artery commences in the substance of the parotid gland, opposite the meatus auditorius externus; it passes in the first instance horizontally forwards behind the neck of the lower jaw; next, curves around the lower

border of the external pterygoid muscle near its insertion, and ascends obliquely forwards upon the outer side of that muscle; it then passes inwards between the two heads of the external pterygoid, and enters the spheno-maxillary fossa. Occasionally it takes its course between the two pterygoid muscles, without

[FIG. 211.]



INTERNAL MAXILLARY ARTERY.—1. The external carotid artery. 3, 4. The two terminal branches of the external carotid. 3. The temporal artery; and 4. The internal maxillary, the first or *maxillary portion* of its course; the limit of this portion is marked by an arrow. 5. The second, or *pterygoid portion*, of the artery; the limits are bounded by the arrows. 6. The third, or *spheno-maxillary portion*. The branches of the maxillary portion are, 7. A tympanic branch. 8. The arteria meningea media or magna. 9. The arteria meningea parva. 10. The inferior dental artery. The branches of the second portion are wholly muscular, the ascending ones being distributed to the temporal, and the descending to the four other muscles of the inter-maxillary region, viz., the two pterygoids, the masseter and buccinator. The branches of the spheno-maxillary portion of the artery are, 11. The superior dental artery. 12. The infraorbital artery. 13. The superior palatine. 14. The spheno-palatine or nasal. 15. The pterygo-palatine. 16. The Vidian. * The remarkable bend which the third portion of the artery makes as it turns inwards to enter the sphenomaxillary fossa.]

appearing on the outer surface of the external pterygoid. For the purposes of description it admits of division into three portions: maxillary, pterygoid, and spheno-maxillary.

Relations.—The *maxillary* portion is situated between the neck of the jaw and the internal lateral ligament and inferior dental nerve, and lies parallel with the auriculo-temporal nerve; the *pterygoid* portion between the external pterygoid muscle, and the masseter and temporal muscle. The *spheno-maxillary* portion lies between the two heads of the external pterygoid muscle, and, in the sphenomaxillary fossa, is in relation with Meckel's ganglion.

Branches.—*Maxillary Portion.*

Tympanic,
Inferior dental,
Arteria meningea media,
Arteria meningea parva.

Pterygoid Portion.

Deep temporal,
Pterygoid,
Masseteric,
Buccal.

Spheno-maxillary Portion.

Superior dental,
Infraorbital,
Pterygo-palatine,

Spheno-palatine,
Superior palatine,
Vidian.

The *Tympanic branch* (arteria cavi tympani) passes into the tympanum

through the fissura Glaseri, and is distributed to the laxator tympani, and membrana tympani; on the latter it inosculates with the stylo-mastoid, a branch of the posterior auricular artery.

The *Inferior dental* (maxillaris vel alveolaris inferior) descends to the dental foramen, and enters the canal of the lower jaw in company with the inferior dental nerve. Opposite the bicuspid teeth it divides into two branches, one of which is continued onwards within the bone as far as the symphysis, to supply the incisor teeth; while the other, *mentalis*, escapes with the nerve at the mental foramen, and anastomoses with the inferior labial and submental branch of the facial. It supplies the alveoli (rami alveolares) and teeth of the lower jaw, sending small branches along the canals in their roots. At the inferior dental foramen, it gives off a *mylo-hyoid* branch, which accompanies the mylo-hyoid nerve.

The *Arteria meningea media* [or magna] ascends behind the temporo-maxillary articulation to the foramen spinosum in the spinous process of the sphenoid bone, and entering the cranium, divides into an anterior and a posterior branch. The *anterior branch* crosses the greater ala of the sphenoid to the groove or canal in the anterior inferior angle of the parietal bone, and divides into branches which ramify on the external surface of the dura mater, and anastomose with corresponding branches from the opposite side. The *posterior branch* crosses the squamous portion of the temporal bone, to the posterior part of the dura mater and cranium.

The branches of the arteria meningea media are distributed chiefly to the bones of the skull; in the middle fossa it sends a small petrosal branch through the hiatus Fallopii to the facial nerve, and branches to the Gasserian ganglion.

The *Meningea parva* is a small branch which ascends to the foramen ovale, and passes into the skull to be distributed to the Gasserian ganglion and dura mater. It gives off a twig to the nasal fossæ and soft palate.

The *Muscular branches* (musculares) are distributed, as their names imply, to the five muscles of the maxillary region; the *temporal* branches (temporales profundæ) are two in number; they inosculate with the middle temporal. The *pterygoid* branches are distributed to the two muscles of that name. The *masseteric* artery passes outwards, behind the tendon of the temporal muscle and over the sigmoid notch, to the masseter muscle. The *buccal* branch, arising opposite the anterior part of the pterygoid muscle, passes downwards with the buccal nerve to the buccinator muscle. It inosculates with the facial and transverse facial artery.

The *Superior dental artery* (supramaxillaris vel alveolaris superior) is given off from the internal maxillary, just as that vessel is about to make its turn inwards to reach the spheno-maxillary fossa. It descends on the tuberosity of the superior maxillary bone, and sends its branches through several small foramina to supply the posterior teeth of the upper jaw, and the antruni. The terminal branches are continued forwards on the alveolar process, to be distributed to the gums and sockets of the teeth.

The *Infraorbitalis* appears, from its size, to be the proper continuation of the artery. It runs along the infraorbital canal with the superior maxillary nerve, sending branches upwards into the orbit, and downwards, through canals in the bone, to supply the mucous membrane of the antrum and the teeth of the upper jaw, and emerges on the face at the infraorbital foramen. The branch which supplies the incisor teeth is the *anterior dental artery*: on the face the infra-orbital inosculates with the facial and transverse facial artery.

The *Pterygo-palatine* (pharyngea suprema vel descendens) is a small branch which passes backwards through the pterygo-palatine canal, and supplies the mucous membrane of the posterior part of the nares, upper part of the pharynx, Eustachian tube, and sphenoidal cells.

The *Spheno-palatine*, or posterior nasal (nasalis posterior; spheno-palatina),

enters the superior meatus of the nose through the sphenopalatine foramen, in company with the nasal filaments of Meckel's ganglion, and divides into two branches; one branch, *arteria septi*, is distributed to the mucous membrane of the septum, and inosculates in the anterior palatine canal with the terminal branch of the descending palatine; the other, *nasalis posterior externa*, supplies the mucous membrane of the lateral wall of the nares, antrum, and sphenoid and ethmoid cells.

The *Superior* or *descending palatine artery* (*palatina superior vel descendens*) descends along the posterior palatine canal, in company with the palatine branches of Meckel's ganglion, to the posterior palatine foramen; it then bends forwards, lying in a groove of the bone, and is distributed to the palate. While in the posterior palatine canal it sends several twigs backwards through the small posterior palatine foramina to supply the soft palate; anteriorly it distributes a branch, *palatina anterior*, to the anterior palatine canal, which reaches the nares and inosculates with the *arteria septi*.

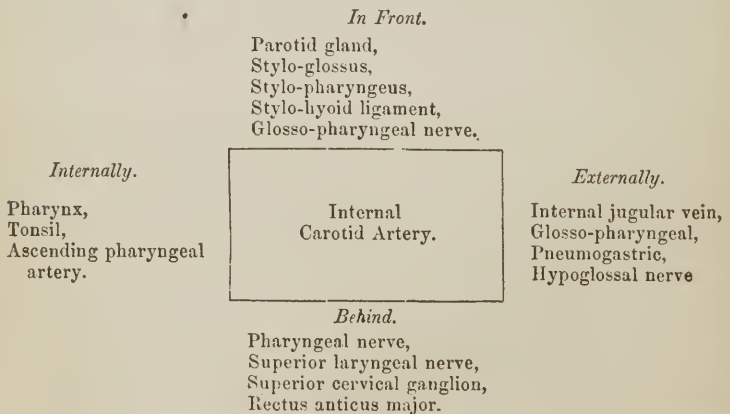
The *Vidian* or *pterygoid branch* passes backwards along the pterygoid canal, and is distributed to the sheath of the Vidian nerve, the Eustachian tube, and mucous membrane of the upper part of the pharynx.

INTERNAL CAROTID ARTERY.

The internal carotid artery (*carotis interna*) curves slightly outwards from the bifurcation of the common carotid, and ascends nearly perpendicularly by the side of the pharynx, to the carotid foramen in the petrous portion of the temporal bone. It next passes *inwards*, along the carotid canal, *forwards* by the side of the sella turcica, and *upwards* by the anterior clinoid process, where it pierces the dura mater, and divides into three terminal branches. The course of this artery is remarkable for the number of angular curves which it forms; one or two of these flexures are sometimes seen in the cervical portion, near the base of the skull; and, by the side of the sella turcica, it resembles the italic letter *s*, placed horizontally.

Relations. — In consideration of its connexions, the artery is divisible into a cervical, petrous, cavernous, and cerebral portion.

The *Cervical portion* is in relation *anteriorly* with the rectus anticus major, superior cervical ganglion of the sympathetic, and pharyngeal and superior laryngeal nerve which cross behind it. *Internally* it is in relation with the side of the pharynx, tonsil, and ascending pharyngeal artery. *Externally* with the internal jugular vein, glosso-pharyngeal, pneumogastric, and hypoglossal nerve; and *in front* with the stylo-glossus and stylo-pharyngeus muscle, stylo-hyoid ligament, glosso-pharyngeal nerve, and parotid gland.

Plan of the Relations of the Cervical Portion of the Internal Carotid Artery.

The *Petrous portion* is separated from the bony wall of the carotid canal by a periosteal lining derived from the dura mater; it is in relation with the carotid plexus, and is covered in by the Gasserian ganglion.

The *Cavernous portion* is situated in the cavernous sinus, and is in relation by its inner side with the lining membrane of the sinus, and by its outer side with the third, fourth, ophthalmic, and sixth nerve.

The *Cerebral portion* of the artery is inclosed in a sheath of the arachnoid, and is in relation with the optic nerve. At its point of division it is situated in the fissure of Sylvius.

Branches. — The cervical portion of the internal carotid gives off no branches: from the other portions are derived the following: —

Tympanic,	Anterior cerebral,
Arteriæ receptaculi,	Middle cerebral,
Ophthalmic,	Posterior communicating,
	Choroidea anterior.

The *Tympanie* is a small branch given off in the carotid canal; it enters the tympanum and inosculates with the tympanic branch of the internal maxillary, and with the stylo-mastoid artery.

The *Arteriæ receptaculi* anterior and posterior are two small branches given off in the cavernous sinus and distributed to the parts contained in the sinus, to the Casserian ganglion, and dura mater; one of the twigs distributed to the latter is the *anterior meningeal artery*.

The *Ophthalmic artery* (ophthalmica) arises from the internal carotid, just as that vessel pierces the dura mater, and enters the orbit through the foramen opticum, lying externally to the optic nerve. It then crosses the optic nerve to the inner wall of the orbit, and runs along the lower border of the superior oblique muscle, to the inner angle of the eye, where it divides into two terminal branches, frontal and nasal.

Branches. — The branches of the ophthalmic artery, ten in number, may be arranged into two groups: first, those distributed to the orbit and surrounding parts; and, secondly, those which supply the muscles and globe of the eye. They are —

First Group.

Lachrymal,
Supraorbital,
Posterior ethmoidal,
Anterior ethmoidal,
Palpebral,
Frontal,
Nasal.

Second Group.

Muscular, — anterior ciliary,
Ciliary, short and long,
Centralis retinae.

The *Lachrymal* (lachrymalis) is the first branch of the ophthalmic artery, and is usually given off immediately before that artery enters the optic foramen. It follows the course of the lachrymal nerve, above the upper border of the external rectus muscle, and is distributed to the lachrymal gland. The small branches which escape from the gland supply the conjunctiva and upper eyelid. The lachrymal artery gives off a *malar branch* which passes through the malar bone into the temporal fossa, and inosculates with the deep temporal arteries, while some of its branches become subcutaneous on the cheek, and anastomose with the transversa faciei.

The *Supraorbital artery* (supraorbitalis) follows the course of the frontal nerve, resting on the levator palpebræ muscle; it passes through the supraorbital foramen, and divides into a superficial and deep branch, which are distributed to

the muscles and integument of the forehead and to the pericranium. At the supraorbital foramen it sends a branch inwards to the diploë.

The *Ethmoidal arteries* (ethmoidales), *posterior* and *anterior*, pass through the ethmoidal foramina, and are distributed to the falx cerebri and to the ethmoidal cells and nasal fossæ. The latter accompanies the nasal nerve, and sends a branch to the frontal sinus.

The *Palpebral arteries* (palpebrales), *superior* and *inferior*, are given off from the ophthalmic, near the inner angle of the orbit; they encircle the eyelids, forming a superior and an inferior arch (arcus tarseus superior et inferior) near the borders of the lids, between the orbicularis palpebrarum and tarsal cartilage. At the outer angle of the eyelids, the superior palpebral inosculates with the orbital branch of the temporal artery. The inferior palpebral artery sends a branch to the nasal duct.

The *Frontal artery* (frontalis), one of the terminal branches of the ophthalmic, emerges from the orbit at its inner angle, and ascends along the middle of the forehead. It is distributed to the integument, muscles, and pericranium.

The *Nasal artery* (nasalis vel dorsalis nasi), the other terminal branch of the ophthalmic, passes out of the orbit above the tendo oculi, and divides into two branches; one of which (*angularis*) inosculates with the angular artery, while the other, *dorsalis nasi*, runs along the ridge of the nose, and is distributed to the integument of that organ. The nasal artery sends a small branch to the lachrymal sac.

The *Muscular branches* (rami musculares), usually two in number, *superior* and *inferior*, supply the muscles of the orbit; and at the anterior part of the globe of the eye give off the *anterior ciliary* arteries, which pierce the sclerotic near its margin of connexion with the cornea, and are distributed to the iris. It is the congestion of these vessels that gives rise to the vascular zone around the cornea in iritis.

The *Ciliary arteries* (ciliares) are divisible into three groups, short, long, and anterior.

The *short ciliary* (ciliares posticæ breves), from ten to fifteen in number, pierce the sclerotic around the entrance of the optic nerve, and supply the choroid coat and ciliary processes. The *long ciliary* (ciliares posticæ longæ), two in number, pierce the sclerotic at opposite sides of the globe of the eye, and pass forwards between it and the choroid, to the iris. They form an arterial circle around the circumference of the iris by inosculating with each other, and from this circle branches are given off which ramify in the substance of the iris, and form a second circle around the pupil. The *anterior ciliary* (ciliares anteriores), six to twelve in number, are branches of the muscular arteries; they terminate in the great arterial circle of the iris.

The *Centralis retinæ* artery pierces the optic nerve obliquely, and passes forwards in the centre of its cylinder to the retina, where it divides into branches, which ramify in the inner layer of that membrane. It supplies the retina, hyaloid membrane, and zonula ciliaris; and, by means of a branch sent forwards through the centre of the vitreous humour in a tubular sheath of the hyaloid membrane, the capsule of the lens.

The *Anterior cerebral artery* (cerebri anterior vel corporis callosi) [Fig. 212,] passes forwards in the great longitudinal fissure between the two hemispheres of the brain; then curves backwards along the corpus callosum to its posterior extremity. It gives branches to the olfactory and optic nerves, to the under surface of the anterior lobes, the third ventricle, corpus callosum, and inner surface of the hemispheres. The two anterior cerebral arteries are connected soon after their origin by a short anastomosing trunk, the *anterior communicating artery* (communicans anterior).

The *Middle cerebral artery* (*cerebri media vel fossæ Sylvii*), larger than the preceding, passes outwards along the fissure of Sylvius, and divides into three principal branches, which supply the anterior and middle lobes of the brain, and the island of Reil. Near its origin it gives off the numerous small branches which enter the *substantia perforata*, to be distributed to the *corpus striatum*.

The *Posterior communicating artery* (*communicans posterior*), variable in size, sometimes double, and sometimes altogether wanting, passes backwards and inosculates with the posterior cerebral, a branch of the basilar artery. Occasionally it is so large as to take the place of the posterior cerebral artery.

The *Choroidea anterior* is a small branch which is given off from the internal carotid, near the origin of the posterior communicating artery, and passes beneath the edge of the middle lobe of the brain to enter the descending cornu of the lateral ventricle. It is distributed to the choroid plexus, and to the walls of the middle cornu.

SUBCLAVIAN ARTERY.

The *Subclavian artery* (*subclavia*) [Fig. 213] on the right side, arises from the *arteria innominata*, opposite the sterno-clavicular articulation; on the left, from the arch of the aorta. The right is consequently shorter than the left, and situated nearer the anterior wall of the chest; it is also somewhat greater in diameter, from being a branch of a branch, in place of a division from the main trunk.

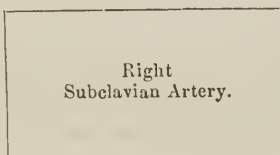
The course of the subclavian artery is divisible, for the sake of precision and surgical observation, into three portions. The first portion of the right and left arteries differs in its course and relations in correspondence with the dissimilarity of origin above referred to. The other two portions are alike on both sides.

The *first portion*, on the *right side*, ascends obliquely outwards to the inner border of the *scalenus anticus*. On the *left side* it ascends perpendicularly to the inner border of that muscle. The *second portion* curves outwards behind the *scalenus anticus*; the *third portion* passes downwards and outwards beneath the clavicle, to the lower border of the first rib, where it becomes the axillary artery.

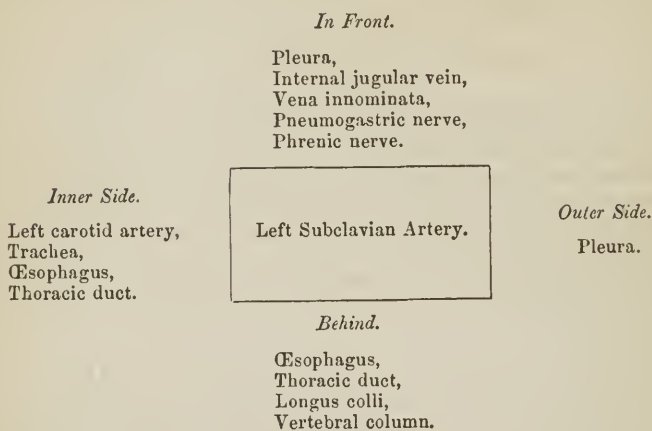
Relations. — The *first portion*, on the *right side*, is in relation, in *front*, with the internal jugular and vertebral vein, and is crossed by the pneumogastric nerve, phrenic nerve, and one or two branches of the sympathetic. *Behind and beneath* it is invested by the pleura, is crossed by the right recurrent laryngeal nerve, and is in relation further back with the sympathetic nerve, longus colli muscle, and transverse process of the seventh cervical vertebra. The *first portion* on the *left side* is in relation in front with the pleura, internal jugular vein, vena innominata, and pneumogastric and phrenic nerve (which lie parallel to it). To its *inner side* is the left carotid artery, trachea, œsophagus, and thoracic duct; to its *outer side* the pleura; and *behind*, the œsophagus, thoracic duct, longus colli, and vertebral column.

*Plan of the Relations of the First Portion of the Right Subclavian Artery**In Front.*

Internal jugular vein,
Vertebral vein,
Pneumogastric nerve,
Phrenic nerve,
Sympathetic filaments.

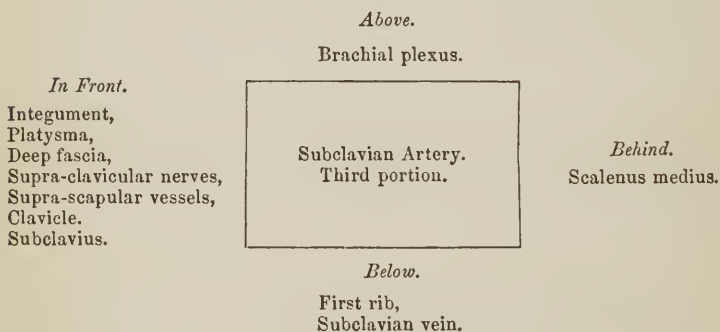
*Behind and Beneath.*

Pleura,
Recurrent nerve,
Sympathetic nerve,
Longus colli muscle,
Transverse process of
7th cervical vertebra.

Plan of the Relations of the First Portion of the Left Subclavian Artery.

The *second portion* of the artery has the scalenus anticus *in front*; the scalenus medius and two lower nerves of the brachial plexus *behind*; the upper nerves of the plexus *above*, and the pleura *below*. The scalenus anticus separates it from the phrenic nerve and subclavian vein, which latter is rather below the level of the artery.

The *third portion* of the artery is situated in the subclavian triangle, and is more superficial than the rest. *In front* it is covered by the integument, platysma, and deep fascia, and crossed by the supra-clavicular nerves. Lower down it is crossed by the supra-scapular artery and vein, and gets behind the subclavius muscle and clavicle. *Behind*, it has the scalenus medius; *above*, the brachial plexus; and *below*, the first rib and subclavian vein.

Plan of the Relations of the Third Portion of the Subclavian Artery.

Branches. — The branches of the subclavian artery are four, and sometimes five in number. Three are given off by the *first portion* of the artery; one, the superior intercostal, by the *second portion*; when a fifth artery exists, it arises from the third portion, and is the supra-scapular.

In a tabular form the branches are as follows :

Vertebral,	
Internal mammary,	
Thyroid axis	{
	Inferior thyroid,
	Supra-scapular,
	Transversa colli.
Superior intercostal, —	Cervicalis profunda.

The VERTEBRAL ARTERY (*vertebralis*), the first and largest of the branches of the subclavian artery, arises from the posterior aspect of that trunk; it ascends through the foramina in the transverse processes of all the cervical vertebræ, excepting the last; then winds backwards around the articulating process of the atlas; and, piercing the dura mater, enters the skull through the foramen magnum. The two arteries unite at the lower border of the pons Varolii, to form the *basilar artery*. In the foramina of the transverse processes of the vertebræ the artery lies in front of the cervical nerves, and, on the left side, it is crossed by the thoracic duct.

Dr. John Davy¹ has observed, that when the vertebral arteries differ in size, the left is generally the larger; thus in ninety-eight cases he found the left vertebral the larger twenty-six times, and the right only eight. In the same number of cases he found a small band stretching across the cylinder of the basilar artery, near the junction of the two vertebral arteries, seventeen times; and, in a few instances, a small communicating trunk between the two vertebral arteries previously to their union. I have several times seen this communicating branch.

The BASILAR ARTERY (*basilaris, meso-cephalica*), so named from its position at the base of the brain, runs forwards in the groove on the mid-line of the pons Varolii; and at the anterior border of the pons divides into four ultimate branches, two to either side.

Branches. — The branches of the vertebral and basilar artery are the following: —

<i>Vertebral.</i>	<i>Basilar.</i>
Lateral spinal,	Transverse,
Posterior meningeal,	Superior cerebellar,
Anterior spinal,	Posterior cerebellar.
Posterior spinal,	
Inferior cerebellar.	

The *Lateral spinal branches* (*spinales laterales*) enter the intervertebral foramina, and taking the course of the roots of the spinal nerves, are distributed to the spinal cord and vertebræ. Where the vertebral artery curves around the articular process of the atlas, it gives off several muscular branches (*rami musculares*).

The *Posterior meningeal* (*meningeæ posterior*) are one or two small branches which enter the cranium through the foramen magnum, to be distributed to the dura mater of the cerebellar fossæ, and to the falx cerebelli. One branch, described by Soemmering, passes into the cranium along the first cervical nerve.

The *Anterior spinal* (*spinalis anterior*) is a small branch which unites with its fellow of the opposite side, on the front of the medulla oblongata. * The artery formed by the union of these two vessels descends along the anterior aspect of the spinal cord, to which it distributes branches.

The *Posterior spinal* (*spinalis posterior*) winds around the medulla oblongata to the posterior aspect of the cord, and descends on either side to the cauda equina. It communicates very freely with the spinal branches of the intercostal

¹ Edinburgh Medical and Surgical Journal, 1839

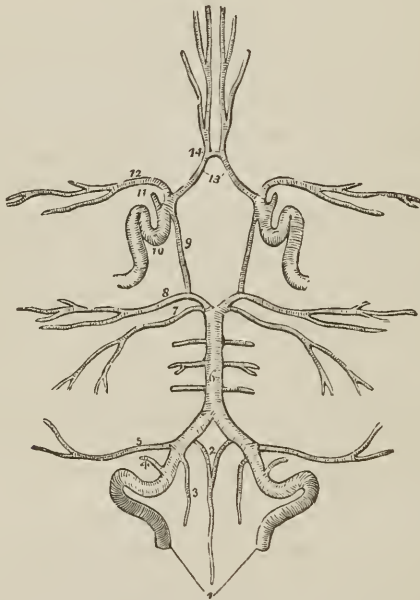
and lumbar arteries, and near its origin sends a branch upwards to the fourth ventricle.

The *Inferior cerebellar arteries* (*cerebelli inferior posterior vel magna*) wind around the upper part of the medulla oblongata to the under surface of the cerebellum, to which they are distributed. They pass between the filaments of origin of the hypoglossal nerve in their course, and anastomose with the superior cerebellar arteries.

The *Transverse* branches of the basilar artery supply the pons Varolii, and adjacent parts of the brain. One of these branches, larger than the rest, passes along the crus cerebelli to be distributed to the anterior border of the cerebellum (*a. cerebelli inferior, anterior*). This artery gives off a small branch, *auditiva interna*, which accompanies the facial and auditory nerves into the meatus auditorius internus; the auditory branch may be derived directly from the basilar.

The *Superior cerebellar arteries* (*cerebelli superior*), two of the terminal branches of the basilar, wind around the crus cerebri on each side, lying in rela-

FIG. 212.



CIRCLE OF WILLIS. The arteries being symmetrical have references on one side only. 1. Vertebral arteries. 2. Anterior spinal branches uniting to form a single vessel. 3. Posterior spinal artery. 4. Posterior meningeal. 5. Inferior cerebellar. 6. Basilar artery giving off transverse branches. 7. Superior cerebellar artery. 8. Posterior cerebral. 9. Posterior communicating branch of the internal carotid. 10. Internal carotid artery, showing its curves within the skull. 11. Ophthalmic artery divided across. 12. Middle cerebral artery. 13. Anterior cerebral arteries, connected by, 14, anterior communicating artery.

tion with the fourth nerve, and are distributed to the upper surface of the cerebellum inosculating with the inferior cerebellar.

The *Posterior cerebral arteries* (*cerebri posterior vel profunda*), the other two terminal branches of the basilar, wind around the crus cerebri at each side, and are distributed to the posterior lobes of the cerebrum. They are separated from the superior cerebellar arteries near their origin, by the third pair of nerves, and are in close relation with the fourth pair in their course around the crura cerebri.

Anteriorly, near their origin, they give off a tuft of small vessels which enter the locus perforatus, and they receive the posterior communicating arteries from the internal carotid. They also send a branch to the velum interpositum and plexus choroides, *choroidea posterior*.

The communications established between the anterior cerebral arteries in front, and the internal carotids and posterior cerebral arteries behind, by the communicating arteries, constitute the circle of Willis (circulus arteriosus Willisii). This remarkable vascular communication at the base of the brain is formed by the anterior communicating branch, anterior cerebrals, and internal carotid arteries in front, and by the posterior communicating, posterior cerebrals, and basilar artery behind.

The INTERNAL MAMMARY ARTERY (mammaria vel thoracica interna) arises from the under side of the subclavian, and passes down behind the subclavian vein to the cartilage of the first rib. It then descends by the side of the sternum, resting on the cartilages of the ribs, to the sheath of the rectus, where, under the name of superior epigastric, it terminates by inosculating with the epigastric branch of the external iliac. As the artery enters the chest it is crossed by the phrenic nerve; it then gets under cover of the pleura, and lower down lies between the triangularis sterni and internal intercostal muscles; in the sheath of the rectus it sends branches to the walls of the abdomen.

The *Branches* of the internal mammary are,—

Comes nervi phrenici,	Anterior intercostal,
Mediastinal,	Perforating,
Pericardiac,	Musculo-phrenic.

The *Comes nervi phrenici* (phrenica superior), a long and slender branch given off by the artery as it enters the chest, descends with the phrenic nerve between the pleura and pericardium to the diaphragm, to which it is distributed, inosculating with the musculo-phrenic and abdominal phrenic arteries.

The *Mediastinal* and *Pericardiac* branches are small vessels distributed to the anterior mediastinum, pericardium, and thymus gland (*thymicæ*). Some *sternal* branches are sent to supply the sternum and triangularis sterni muscle.

The *Anterior intercostals* (intercostales anteriores) supply the intercostal muscles of the front of the chest, and inosculate with the aortic intercostals; to each space there are two arteries which run along the borders of the ribs. Besides supplying the intercostal muscles, they send branches to the pectoral muscles and mammary gland.

The *Perforating arteries* (mammary) pass forwards to the front of the chest through the first six intercostal spaces; they then turn outwards, and after giving some branches to the front of the sternum, are distributed to the pectoral muscles and mammary gland. Those intended for the mammary gland are of larger size than the rest.

The *Musculo-phrenic artery*, proceeding from the internal mammary at the interspace between the sixth and seventh rib, passes downwards and outwards over the cartilages of the false ribs to the last intercostal space. It pierces the diaphragm at the attachment of that muscle to the eighth rib, and sends branches to its muscular structure, and others to the intercostal spaces of the false ribs.

“The mammary arteries,” says Dr. Harrison, “are remarkable for the number of their inosculations, and for the distant parts of the arterial system which they serve to connect. They anastomose with each other, and their inosculations with the thoracic aorta, encircle the thorax. On the parietes of this cavity their branches connect the axillary and subclavian arteries; on the diaphragm they form a link in the chain of inosculations between the subclavian artery and abdominal aorta; and in the parietes of the abdomen they form an anastomosis

most remarkable for the distance between those vessels which it serves to connect; namely, the arteries of the superior and inferior extremities."

The **THYROID AXIS** is a short trunk which arises from the front of the subclavian close to the inner border of the anterior scalenus, and divides almost immediately into three branches, inferior thyroid, supra-scapular and transversa colli.

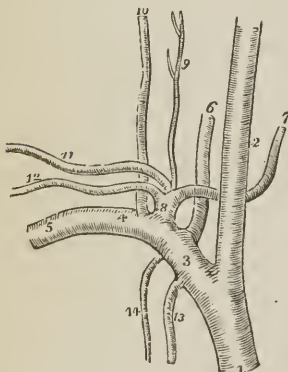
The **INFERIOR THYROID ARTERY** (thyroidea inferior) ascends obliquely in a serpentine course behind the sheath of the carotid vessels, and in front of the longus colli, to the inferior and posterior part of the thyroid gland, to which it is distributed. It is in relation with the middle cervical ganglion of the sympathetic, which lies in front of it; and sends branches to the trachea, larynx, and œsophagus. Near its origin it gives off the following branch.

The *Cervicalis ascendens*, a branch of the inferior thyroid, ascends upon the anterior tubercles of the transverse processes of the cervical vertebræ, lying in the groove between the scalenus anticus and rectus anticus major. It is distributed to the deep muscles and glands of the neck, and sends branches through the intervertebral foramina to supply the spinal cord and its membranes.

The **SUPRA-SCAPULAR ARTERY** (transversæ scapulæ; scapularis superior) passes obliquely outwards behind the clavicle, and over the ligament of the supra-scapular notch, to the supra-spinatus fossa. It crosses in its course the scalenus anticus muscle, phrenic nerve, and subclavian artery; is distributed to the muscles of the dorsum of the scapula, and inosculates with the posterior scapular, and beneath the acromion process with the dorsal branch of the subscapular artery.

At the supra-scapular notch it sends a large branch outwards, which pierces the trapezius muscle, and becomes cutaneous at the tip of the shoulder (*acromialis*). The supra-scapular artery sometimes arises directly from the subclavian.

FIG. 213.



BRANCHES OF THE RIGHT SUBCLAVIAN ARTERY. 1. Arteria innominata. 2. Right carotid. 3. First portion of the subclavian. 4. Second portion. 5. Third portion. 6. Vertebral artery. 7. Inferior thyroid. 8. Thyroid axis. 9. Cervicalis ascendens. 10. Cervicalis profunda. 11. Transversa colli. 12. Supra-scapular. 13. Internal mammary artery. 14. Superior intercostal.

The **TRANSVERSA COLLI ARTERY** (scapularis posterior) passes transversely across the subclavian triangle at the root of the neck, to the anterior border of the levator anguli scapulæ, where it divides into two terminal branches, the cervicalis superficialis and posterior scapular. In its course it lies above the supra-scapular artery, and crosses the scaleni muscles and brachial plexus of nerves, often passing between the latter. At its bifurcation it is covered in by the edge of the trapezius.

The *Cervicalis superficialis artery* (cervicalis posterior), its ascending branch, passes upwards under cover of the anterior border of the trapezius, and is distributed to the superficial muscles of the neck and deep cervical glands.

The *Posterior scapular artery* (dorsalis scapulæ, Tiedemann), the proper continuation of the transversa colli, passes backwards to the superior angle of the scapula, and then descends along the posterior border of that bone to its inferior angle, where it inosculates with the subscapular artery. In its course it lies under cover of the levator anguli scapulæ and rhomboidei muscles, distributes

branches to them and neighboring muscles, and inosculates with the arteries of the scapula and branches of the intercostal arteries.

The *cervicalis superficialis* and posterior scapular artery sometimes arise separately, the former from the thyroid axis, the latter from the third portion of the subclavian. By means of its numerous inosculation the *transversa colli* artery maintains an important anastomotic communication between the branches of the external carotid, subclavian, and axillary arteries.

The SUPERIOR INTERCOSTAL ARTERY (*intercostalis suprema*) arises from the upper and back part of the subclavian artery behind the scalenus anticus, and descending in front of the necks of the first two ribs, sends *intercostal* branches to the first two intercostal spaces, and *dorsal* branches to the muscles and integument of the back. The artery lies behind the pleura, to the outer side of the sympathetic nerve, and in the second intercostal space inosculates with the first aortic intercostal. It gives off the *cervicalis profunda*.

The *Cervicalis profunda artery* (*profunda cervicis*) arises by a common trunk with the preceding, or, more properly, is a branch of the superior intercostal, corresponding with the posterior branch of the other intercostal arteries. It passes backwards between the transverse processes of the seventh cervical and first dorsal vertebra, and ascends the back part of the neck, between the complexus and semi-spinalis colli muscle. It inosculates with the *princeps cervicis* of the occipital artery, and with branches of the vertebral.

Varieties of the Subclavian Arteries.—Varieties in these arteries are rare; that which most frequently occurs is the origin of the right subclavian from the left extremity of the arch of the aorta, below the left subclavian artery. The vessel, in this case, curves behind the œsophagus and right carotid artery, and sometimes between the œsophagus and trachea, to the upper border of the first rib on the right side of the chest, where it assumes its ordinary course. In a case of subclavian aneurism on the right side above the clavicle, which happened during the summer of 1839, Mr. Liston proceeded to perform the operation of tying the carotid and subclavian arteries at their point of division from the innominate. Upon reaching the spot where the bifurcation should have existed, he found that there was no subclavian artery. With his usual self-possession he continued his dissection more deeply, towards the vertebral column, and succeeded in securing the artery. It was ascertained after death, that the *arteria innominata* was extremely short, and that the subclavian was given off within the chest from the posterior aspect of its trunk, and pursued a deep course to the upper margin of the first rib. In a preparation which was shown me at Heidelberg, some years since, by Professor Tiedemann, the right subclavian artery arose from the thoracic aorta, as low down as the fourth dorsal vertebra, and ascended from that point to the border of the first rib. Varieties in the branches of the subclavian are not unfrequent; the most interesting is the origin of the left vertebral from the arch of the aorta.

AXILLARY ARTERY.

The *Axillary artery* (*axillaris*) passes outwards and downwards with a gentle curve through the axillary space from the lower border of the first rib to the lower border of the tendons of the *latissimus dorsi* and *teres major*, where it becomes the brachial.

Relations.—After emerging from beneath the margin of the costo-coracoid membrane, it is in relation with the axillary vein, which lies at first to the inner side, and then in front of the artery. Near the middle of the axilla it is embraced by the two heads of the median nerve, and covered in by the pectoral muscles. On the *inner or thoracic side* it is in relation, first, with the first

intercostal muscle; it next rests on the first serration of the serratus magnus; and is then separated from the chest by the brachial plexus of nerves. By its *outer* or *humeral side* it is at first separated from the brachial plexus by a triangular interval of cellular tissue; it next rests against the tendon of the subscapularis muscle; and thirdly, upon the coraco-brachialis muscle.

The *relations* of the axillary artery may be thus arranged:—

<i>In Front.</i>	<i>Inner or Thoracic Side.</i>	<i>Outer or Humeral Side.</i>
Pectoralis major, Pectoralis minor, Pectoralis major.	First intercostal muscle, First serration of serratus magnus, Plexus of nerves.	Plexus of nerves, Tendon of subscapularis, Coraco-brachialis.

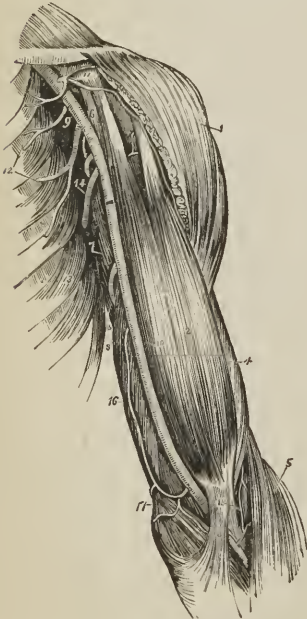
Branches.—The branches of the *Axillary artery* are seven in number:—

Superior thoracic, Thoracica acromialis, Long thoracic, Thoracica alaris,	Subscapular, Circumflex anterior, Circumflex posterior.
--	---

The superior thoracic and thoracica acromialis are found in the triangular space above the pectoralis minor. The inferior thoracic and thoracica alaris, below the pectoralis minor. And the three remaining branches below the lower border of the subscapularis.

The *Superior thoracic* (suprema; short thoracic), the highest of the branches of the axillary, and sometimes derived from the next, passes inwards to the chest in front of the pectoralis minor muscle, and is distributed to the pectoral

FIG. 214.



AXILLARY AND BRACHIAL ARTERY, WITH THEIR BRANCHES. 1. Deltoid. 2. Biceps. 3. Tendonous process given off from the tendon of the biceps, to the deep fascia of the forearm; this process separates the median basilic vein from the brachial artery. 4. Outer border of the brachialis anticus. 5. Supinator longus. 6. Coraco-brachialis. 7. Middle portion of the triceps. 8. Its inner head. 9. Axillary artery. 10. Brachial artery;—a dark bar marks the limit between these two vessels. 11. Thoracica acromialis artery dividing into its three branches: the figure rests on the coracoid process. 12. The superior and long thoracic arteries. 13. Serratus magnus muscle. 14. Subscapular artery. The posterior circumflex and thoracica alaris branches are seen in the figure between the inferior thoracic and subscapular. The anterior circumflex is observed between the two heads of the biceps, crossing the neck of the humerus. 15. Superior profunda. 16. Inferior profunda. 17. Anastomotica magna inosculating inferiorly with the anterior ulnar recurrent. 18. Termination of the superior profunda, inosculating with the radial recurrent in the interspace between the brachialis anticus and supinator longus.

muscles and walls of the chest. It anastomoses with the intercostal and mammary arteries

The *Thoracica acromialis* (thoracica humeraria) is a short trunk which proceeds from the axillary in the space above the pectoralis minor muscle, and divides into three sets of branches: *pectoral*, which are distributed to the pectoral muscles, serratus magnus, and mammary gland; *acromial* (r. transversus), which pass outwards to the acromion, and inosculate with branches of the supra-scapular artery; and *descending* (r. deltoideus), a single branch, which follows the interspace between the deltoid and pectoralis major muscle, and is in relation with the cephalic vein.

The *Long thoracic* (thoracica inferior; mammae externa) descends along the lower border of the pectoralis minor to the side of the chest. It is distributed to the pectoralis major and minor, serratus magnus, and mammary gland; inosculating with the superior thoracic, intercostal and mammary arteries.

The *Thoracica alaris* is a small branch distributed to the plexus of nerves and glands in the axilla. It is frequently wanting; its place being supplied by a branch derived from one of the other thoracic branches.

The *Subscapular artery* (scapularis inferior), the largest of the branches of the axillary, runs along the lower border of the subscapularis muscle, to the inferior angle of the scapula, where it inosculates with the posterior scapular, a branch from the subclavian. It supplies the muscles of the under surface and inferior border of the scapula, and the side of the chest. At about an inch and a half from the axillary, it gives off a large branch, the *dorsalis scapulæ* (circumflexa scapulæ), which passes backwards through the triangular space bounded by the teres minor, teres major, and scapular head of the triceps, and beneath the infra-spinatus muscle to the dorsum of the scapula, where it is distributed, inosculating with the supra-scapular and posterior scapular artery.

The *Circumflex arteries* (circumflexæ humeri) wind around the neck of the humerus. The *Anterior*, very small, passes beneath the coraco-brachialis and short head of the biceps, and sends a branch upwards along the bicipital groove to supply the shoulder joint.

The *Posterior circumflex*, of larger size, passes backwards through the quadrangular space bounded by the teres minor and major, the scapular head of the triceps, and humerus, and is distributed to the deltoid muscle and shoulder joint. Sometimes this artery is a branch of the superior profunda of the brachial. It then ascends behind the tendon of the teres major, and is distributed to the deltoid without passing through the quadrangular space.

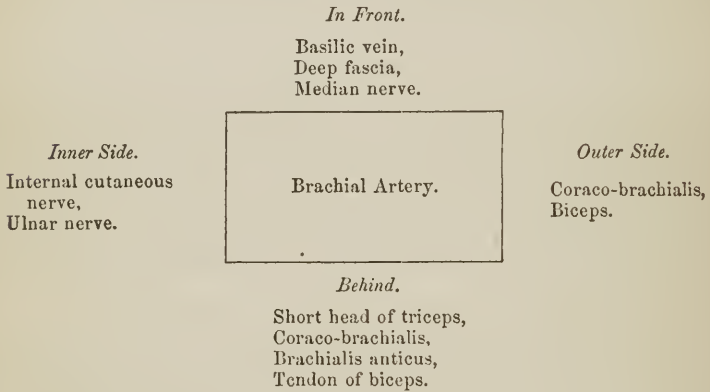
Varieties of the Axillary Artery.—The most frequent peculiarity of this kind is the division of the vessel into two trunks of equal size: a muscular trunk, which gives off some of the ordinary axillary branches and supplies the upper arm, and a continued trunk, which represents the brachial artery. The next most frequent variety is the high division of the ulnar which passes down the arm by the side of the brachial artery, and superficially to the muscles proceeding from the inner condyle, to its ordinary distribution in the hand. In this course it lies immediately beneath the deep fascia of the forearm, and may be seen and felt pulsating beneath the integument. The high division of the radial from the axillary is rare. In one instance, I saw the axillary artery divide into three branches of nearly equal size, which passed together down the arm, and at the bend of the elbow resolved themselves into radial, ulnar, and interosseous. But the most interesting variety, both in a physiological and surgical sense, is that described by Dr. Jones Quain, in his "Elements of Anatomy." "I found in the dissecting-room, a few years ago, a variety not hitherto noticed; it was at first taken for the ordinary high division of the ulnar artery. The two vessels descended from the point of division at the border of the axilla, and lay parallel with one another in their course through the arm; but instead of diverging, as is usual, at the bend of the elbow, they converged, and united so as to form a short trunk, which soon divided again into the radial and ulnar arteries in the

regular way." In a subject dissected by myself, this variety existed in both arms; and I have seen several instances of a similar kind.

BRACHIAL ARTERY.

The *Brachial artery* (brachialis; humeraria) passes down the inner side of the arm, from the lower border of the tendons of the latissimus dorsi and teres major, to a little below the bend of the elbow, where it divides into the radial and ulnar artery.

Relations. — In its course downwards, it rests on the triceps, coraco-brachialis, brachialis anticus, and tendon of the biceps. To its inner side is the internal cutaneous and ulnar nerve; to the outer side, the coraco-brachialis and biceps; in front it has the basilic vein, and is crossed by the median nerve. Its relations, within its sheath, are the venæ comites.

Plan of the Relations of the Brachial Artery.

The *Branches* of the brachial artery are, the

Superior profunda, Inferior profunda,	Anastomotica magna, Muscular, and Nutrient.
--	--

The *Superior profunda* (brachialis profunda; profunda humeri) arises opposite the lower border of the tendon of the latissimus dorsi, and winds around the humerus, between the triceps and the bone, to the space between the brachialis anticus and supinator longus, where it inosculates with the radial recurrent artery. It accompanies the musculo-spiral nerve. In its course it gives off the *posterior articular* artery, which descends to the elbow joint, and a more *superficial branch*, which descends by the side of the external intermuscular septum and inosculates with the interosseous articular artery. The inferior muscular branches of the superior profunda inosculate with the inferior profunda, anastomotica magna and ulnar recurrent.

The *Inferior profunda* (collateralis ulnaris superior) arises from about the middle of the brachial artery, and descends with the ulnar nerve to the space between the inner condyle and olecranon, where it inosculates with the posterior ulnar recurrent. In its course it pierces the intermuscular septum.

The *Anastomotica magna* (collateralis ulnaris inferior) is given off nearly at right angles from the brachial, at about two inches above the joint. It passes directly inwards upon the brachialis anticus muscle, pierces the intermuscular septum, and winds around the humerus to inosculate with the superior profunda. On the brachialis anticus it divides into two branches, which inosculate

with the anterior and posterior ulnar recurrent arteries and with the inferior profunda.

The *Muscular branches* are distributed to the muscles in the course of the artery, namely, coraco-brachialis, biceps, deltoideus, brachialis anticus, and triceps.

The *Nutrient branch* (nutritia humeri) is given off at about the middle of the arm, and passes into the medullary foramen near the insertion of the coraco-brachialis muscle.

Varieties of the Brachial Artery. — The most frequent peculiarity in the distribution of branches from this artery is the high division of the radial, which arises generally from about the upper third of the brachial artery, and descends to its normal position at the bend of the elbow. The ulnar artery sometimes arises from the brachial at about two inches above the elbow, and pursues either a superficial or deep course to the wrist; and, in more than one instance, I have seen the interosseous artery arise from the brachial a little above the bend of the elbow. The two profunda arteries occasionally arise by a common trunk, or there may be two superior profundæ.

RADIAL ARTERY.

The *Radial artery* (radialis), one of the divisions of the brachial, appears, from its direction, to be the continuation of that trunk. It runs along the radial side of the forearm, from the bend of the elbow to the wrist; it then turns backwards around the base of the thumb, beneath its extensor tendons, and passes between the two heads of the first dorsal interosseous muscle, into the palm of the hand. It next crosses the metacarpal bones to the ulnar side of the hand, forming the *deep palmar arch*, and terminates by inosculating with the superficial palmar arch.

In the upper half of its course, the radial artery is situated between the supinator longus muscle, by which it is slightly overlapped, and the pronator radii teres; in the lower half, between the tendons of the supinator longus and flexor carpi radialis. It rests in succession on the supinator brevis, pronator radii teres, radial origin of the flexor sublimis, flexor longus pollicis, and pronator quadratus; and is covered in by the integument and fasciæ. At the wrist it lies against the external lateral ligament and beneath the extensor tendons of the thumb; and, in the palm of the hand, beneath the flexor tendons. It is accompanied by venæ comites; and is in relation with the radial nerve which lies to the outer side of its middle third.

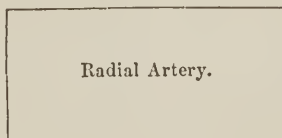
Plan of the Relations of the Radial Artery in the Forearm.

In Front.

Deep fascia,
Supinator longus.

Inner Side.

Pronator radii teres,
Flexor carpi radialis.



Outer Side.

Supinator longus,
Radial nerve (middle third).

Behind.

Supinator brevis,
Pronator radii teres,
Flexor sublimis digitorum,
Flexor longus pollicis,
Pronator quadratus,
Wrist joint.

The *Branches* of the radial artery may be arranged into three groups, corresponding with the three regions — forearm, wrist, and hand; they are —

Forearm.

Recurrent radial,

Muscular.

Wrist.

Superficialis volæ,
Carpea anterior,
Carpea posterior,

Metacarpea,
Dorsales pollicis,
Dorsalis indicis.

Hand.

Princeps pollicis,
Radialis indicis,
Interosseæ,

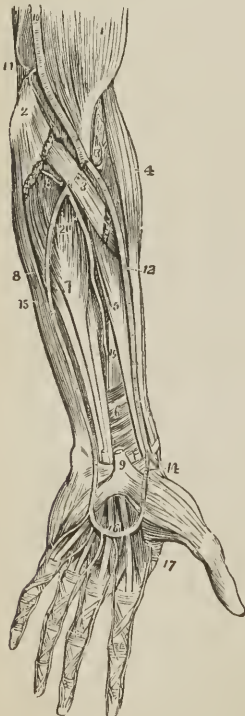
Perforantes,
Recurrentes.

The *Radial recurrent branch* (radialis recurrens) is given off immediately below the elbow; it ascends in the space between the supinator longus and brachialis anticus, sends branches to the muscles arising from the external condyle, and inosculates with the terminal branches of the superior profunda.

The *Muscular branches* are distributed to the muscles of the radial border of the forearm.

The *Superficialis volæ* (radio-palmaris) is given off by the radial artery while

FIG. 215.



ARTERIES OF THE FOREARM. 1.

Lower part of biceps. 2. Inner condyle of humerus with the humeral origin of the pronator radii teres and flexor carpi radialis divided across. 3. Deep portion of pronator radii teres. 4. Supinator longus. 5. Flexor longus pollicis. 6. Pronator quadratus. 7. Flexor profundus digitorum. 8. Flexor carpi ulnaris. 9. Annular ligament with the tendons passing beneath it into the palm of the hand; the figure is placed on the tendon of the palmaris longus, divided close to its insertion. 10. Brachial artery. 11. Anastomotica magna inosculating superiorly with the inferior profunda and inferiorly with the anterior ulnar recurrent. 12. Radial artery. 13. Radial recurrent inosculating with the superior profunda. 14. Superficialis volæ. 15. Ulnar artery. 16. Superficial palmar arch giving off digital branches to three fingers and a half. 17. Magna pollicis and radialis indicis. 18. Posterior ulnar recurrent. 19. Anterior interosseous. 20. Posterior interosseous, passing through the interosseous membrane.

at the wrist. It passes between the fibres of the abductor pollicis muscle, and inosculates with the termination of the ulnar artery, completing the superficial

palmar arch. This artery is variable in size, being sometimes as large as the continuation of the radial, at other times a mere muscular twig, or entirely wanting; when of large size it supplies the palmar side of the thumb and radial side of the index finger.

The *Carpea anterior* passes inwards along the lower border of the pronator quadratus, and forms an arch by inosculating with the anterior carpal branch of the ulnar artery. From this arch twigs are given off to supply the wrist joint.

The *Carpea posterior* crosses the carpus posteriorly, and inosculates with the posterior carpal branch of the ulnar artery. Superiorly it inosculates with the termination of the anterior interosseous artery; inferiorly it gives off *dorsal interosseous branches*, which anastomose with the perforating branches of the deep palmar arch, and run forwards upon the dorsal interossei muscles of the third and fourth metacarpal spaces.

The *Metacarpea* or *first dorsal interosseous branch* runs forwards to the metacarpal space between the index and middle finger. At the cleft of the fingers it inosculates with the palmar digital artery, and gives off dorsal collateral branches. It is joined opposite the heads of the interosseous muscle by the perforating branch from the deep palmar arch.

The *Dorsales pollicis* are two small branches which run along the sides of the dorsal aspect of the thumb.

The *Dorsalis indicis* is a very small branch which runs along the radial border of the metacarpal bone and phalanges of the index finger.

The *Princeps pollicis*, the great artery of the thumb, passes along the metacarpal bone of the thumb, between the first dorsal interosseous (abductor indicis) and flexor brevis pollicis to the base of the first phalanx; and, between the two heads of the latter muscle, in the groove of the tendon of the flexor longus, it divides into two collateral branches for the palmar borders of the thumb.

The *Radialis indicis*, the digital branch of the radial side of the index finger, is directed inwards, between the abductor indicis and flexor brevis and adductor pollicis, to the side of the finger, along which it runs, forming its radial collateral artery. Near its origin it gives off a small branch (more frequently a direct branch of the radial), which inosculates with the superficial palmar arch.

The *Interossee palmares*, three or four in number, are branches of the deep palmar arch; they pass forwards upon the interossei muscles, and inosculate with the digital branches of the superficial arch, opposite the heads of the metacarpal bones.

The *Perforantes*, three in number, pass directly backwards between the heads of the dorsal interossei muscles, and inosculate with the dorsal interosseous arteries.

The *Recurrent* branches of the deep palmar arch pass upwards in front of the wrist joint, and inosculate with the arterial arch formed by the anterior carpal arteries.

ULNAR ARTERY.

The *Ulnar artery* (ulnaris; cubitalis), the other and larger division of the brachial, crosses the forearm obliquely to the commencement of its middle third; it then runs down the ulnar side of the forearm to the wrist, crosses the annular ligament into the hand, and forms the superficial palmar arch (arcus volaris superficialis), which terminates by inosculating with the superficialis volæ.

Relations. — In the upper or oblique portion of its course it lies upon the brachialis anticus and flexor profundus digitorum, and is covered in by the superficial layer of muscles of the forearm and median nerve. In the second part of its course, it is placed upon the flexor profundus and pronator quadratus, lying between the flexor carpi ulnaris and flexor sublimis digitorum. While crossing the annular ligament it is protected from injury by a strong tendinous arch,

layer of muscles; it then ascends between the two heads of the flexor carpi ulnaris, lying beneath the ulnar nerve, and inosculates with the inferior profunda, anastomotica magna, and interosseous recurrent.

The INTEROSSEOUS ARTERY is a short trunk which arises from the ulnar, opposite the bicipital tuberosity of the radius, and passes backwards to the interosseous membrane, where it divides into the anterior and posterior interosseous artery.

The *Anterior interosseous* (interossea interna) passes down the forearm upon the interosseous membrane, between the flexor profundus digitorum and flexor longus pollicis, and behind the pronator quadratus; it then passes through an opening in the interosseous membrane to the back of the wrist, where it inosculates with the posterior carpal branches of the radial and ulnar. The anterior interosseous artery gives off several *muscular* branches; *nutrient* branches to the radius and ulna; a *companion branch* to the median nerve; and at the upper border of the pronator quadratus, a small branch, which descends behind that muscle to inosculate with the anterior carpal arteries. The *median* artery is sometimes of large size, and occasionally takes the place of the superficial palmar arch.

The *Posterior interosseous artery* (interossea externa; perforans suprema) passes backwards through an opening between the upper part of the interosseous membrane and the oblique ligament, and descends between the superficial and deep layer of muscles of the forearm to the back of the wrist, where it inosculates with the anterior interosseous and posterior carpal branches of the radial and ulnar. At its upper part it gives off a recurrent branch, *posterior interosseous recurrent*, which returns upon the elbow between the anconeus, extensor carpi ulnaris and supinator brevis, and anastomoses with the posterior terminal branches of the superior profunda.

The *Muscular branches* of the ulnar artery are distributed to the muscles of the ulnar border of the forearm.

The *Carpea anterior*, a branch of small size, passes outwards upon the front of the wrist joint, and contributes to form the *anterior carpal arch* by inosculating with the anterior carpal branch of the radial artery.

The *Carpea posterior*, larger than the preceding, passes beneath the tendon of the flexor carpi ulnaris muscle to the back of the wrist joint, where it inosculates with the posterior carpal branch of the radial artery, and forms a *posterior carpal arch*.

The *Metacarpea*, often a branch of the preceding, passes along the inner border of the metacarpal bone of the little finger, and forms the dorsal collateral branch of that finger.

The *Communicating* or deep branch arises close to the annular ligament, and dips between the abductor minimi digiti and flexor brevis to inosculate with the termination of the deep palmar arch. It is accompanied by the deep palmar branch of the ulnar nerve.

The *Digital branches*, four in number, are given off from the convexity of the superficial palmar arch. The first and smallest is distributed to the ulnar side of the little finger. The other three are short trunks, which divide between the heads of the metacarpal bones, and form the collateral branch of the radial side of the little finger, the collateral branches of the ring and middle finger, and the collateral branch of the ulnar side of the index finger. On the last phalanx, the collateral arteries communicate and form an arch, from which numerous branches are given off to the tip of the finger.

The arteries of the hand are subject to frequent variety of distribution.

BRANCHES OF THE THORACIC AORTA.

Pericardiac,
 Bronchial,
 Œsophageal,
 Posterior mediastinal,
 Intercostal.

The *Pericardiac* arteries are a few small and irregular branches distributed to the pericardium.

The **BRONCHIAL ARTERIES**, generally three in number, one for the right lung and two for the left, vary both in size and origin; the right often proceeding from a short trunk common to it and one of the left bronchial branches, or from the first aortic intercostal. They take their course to the back of the root of the lung, and accompany the ramifications of the bronchial tubes through its substance; giving twigs also to the bronchial glands, œsophagus, and pericardium.

The **ŒSOPHAGEAL ARTERIES** (œsophageæ), five or six in number, arise from the anterior part of the aorta, and are distributed to the œsophagus, establishing a chain of anastomoses along that tube: the superior inosculate with the bronchial arteries, and with œsophageal branches of the inferior thyroid arteries; the inferior with similar branches of the phrenic and gastric arteries.

The *Posterior mediastinal* arteries are small twigs distributed to the lymphatic glands and cellular tissue of the posterior mediastinum.

The **INTERCOSTAL**, or posterior intercostal arteries (*intercostales inferiores*), arise from the posterior part of the aorta; they are ten in number at each side, the first intercostal space being supplied by the superior intercostal artery, a branch of the subclavian. The right intercostals are longer than the left, on account of the position of the aorta. They ascend somewhat obliquely from their origin, and cross the vertebral column behind the thoracic duct, vena azygos major, and sympathetic nerve, to the intercostal spaces; the left passing beneath the superior intercostal vein, vena azygos minor and sympathetic. In the intercostal space, or rather on the external intercostal muscle, each artery gives off a *dorsal branch*, which passes back between the transverse processes of the vertebræ, lying internally to the middle costo-transverse ligament, and divides into a *spinal branch*, which supplies the spinal cord and vertebræ, and a *muscular branch*, distributed to the muscles and integument of the back. The intercostal artery then comes into relation with its vein and nerve, the former being above, the latter below, and ascends obliquely to the lower border of the rib, [see note, p. 101], with which it comes into relation near the angle of the bone. It then runs along the lower border of the rib, lying between the two planes of intercostal muscles to the front of the chest, where it inosculates with the superior anterior intercostal branch of the internal mammary.

Besides the *dorsal branch* and several small muscular branches, the intercostal artery, at about the middle of its course, gives off a large *inferior branch*, which runs along the upper border of the rib below to the fore part of the chest, and inosculates with the inferior anterior intercostal branch of the internal mammary.

While between the two planes of intercostal muscles, the intercostal artery is protected from pressure by little tendinous arches thrown across it and attached by each extremity to the bone. The upper pair of intercostal arteries inosculate with the superior intercostals of the subclavian; the lower intercostals anastomose with the lumbar and epigastric arteries in the parietes of the abdomen.

BRANCHES OF THE ABDOMINAL AORTA.

Phrenic,
 Cœliac axis, { Gastric,
 { Hepatic,
 { Splenic,
 Superior mesenteric,
 Spermatic,
 Inferior mesenteric,
 Supra-renal,
 Renal,
 Lumbar,
 Sacra media.

The PHRENIC ARTERIES (phrenicæ; diaphragmaticæ) are given off (frequently by a common trunk) from the anterior part of the aorta as soon as that vessel has emerged through the aortic opening. Passing obliquely outwards on the under surface of the diaphragm, each artery divides into two branches, an *internal branch*, which runs forwards and inosculates with its fellow of the opposite side in front of the œsophageal opening; and an *external branch*, which proceeds outwards towards the great circumference of the muscle, and sends branches to the supra-renal capsules. The phrenic arteries inosculate with branches of the internal mammary, intercostal, epigastric, œsophageal, gastric, hepatic, and supra-renal arteries. They are not unfrequently derived from the cœliac axis, or from one of its divisions, and sometimes they give origin to the supra-renal arteries.

The CÆLIAC AXIS (cœliaca; κοιλία, ventriculus) is the first single trunk given off by the abdominal aorta. It arises opposite the upper border of the first lumbar vertebra, is about half an inch in length, and divides into three large branches, gastric, hepatic, and splenic.

Relations.—The trunk of the cœliac axis has in relation with it, *in front* the lesser omentum; on the *right side*, the right semilunar ganglion and lobus Spiegelii of the liver; on the *left side*, the left semilunar ganglion and cardiac portion of the stomach; and *below*, the upper border of the pancreas and lesser curve of the stomach. It is completely surrounded by the solar plexus.

The GASTRIC ARTERY (coronaria ventriculi), the smallest of the three branches of the cœliac axis, ascends between the two layers of the lesser omentum to the cardiac orifice of the stomach, then runs along the lesser curvature to the pylorus, and inosculates with the pyloric branch of the hepatic. It is distributed to the lower extremity of the œsophagus and lesser curve of the stomach; and anastomoses with the œsophageal arteries, vasa brevia of the splenic artery, and pyloric branch of the hepatic artery.

The HEPATIC ARTERY (hepatica) curves forwards, and ascends along the right border of the lesser omentum to the liver, where it divides into two branches (right and left), which enter the transverse fissure, and are distributed along the portal canals to the right and left lobes.¹ It is in relation, in the right border of the lesser omentum, with the ductus communis choledochus and portal vein, and is surrounded by the hepatic plexus of the nerves, and numerous lymphatics. There are sometimes two hepatic arteries, in which case one is derived from the superior mesenteric.

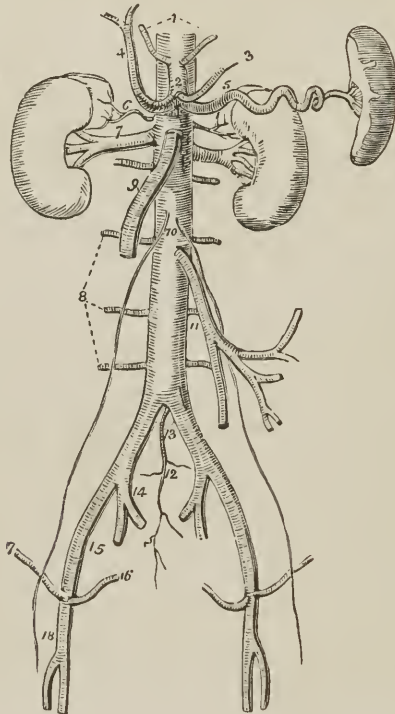
¹ For the mode of distribution of the hepatic artery within the liver, see the "Structura. Anatomy" of that organ in the Chapter on the Viscera.

The *Branches* of the hepatic artery are, the

Pyloric,	} Gastro-epiploica dextra, Pancreatico-duodenalis.
Gastro-duodenalis,	
Cystic.	

The *Pyloric branch*, given off from the hepatic near the pylorus, is distributed to the commencement of the duodenum and to the lesser curve of the stomach, where it inosculates with the gastric artery.

FIG. 216.



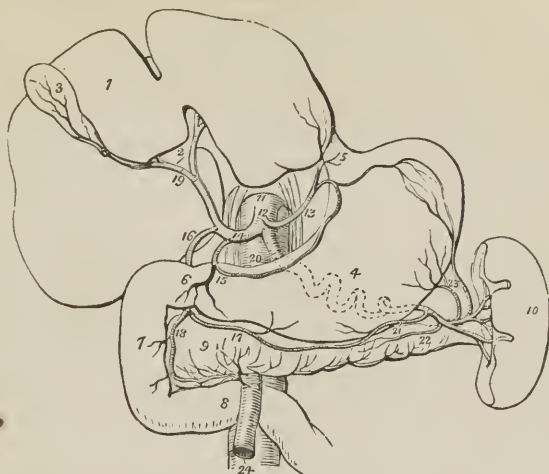
ABDOMINAL AORTA WITH ITS BRANCHES. 1. Phrenic arteries. 2. Celiac axis. 3. Gastric artery. 4. Hepatic artery, dividing into right and left hepatic branches. 5. Splenic artery, passing outwards to the spleen. 6. Supra-renal artery of the right side. 7. Right renal artery, longer than the left, passing outwards to the right kidney. 8. Lumbar arteries. 9. Superior mesenteric artery. 10. The two spermatic arteries. 11. Inferior mesenteric artery. 12. Sacra media. 13. Common iliacs. 14. Internal iliac, right side. 15. External iliac. 16. Epigastric artery. 17. Circumflexa ilii. 18. Common femoral artery, dividing into femoralis superficialis and profunda.

The *Gastro-duodenalis artery* is a short but large trunk, which descends behind the pylorus, and divides into two branches, the *gastro-epiploica dextra*, and *pancreatico-duodenalis*. Previously to its division it gives off some *inferior pyloric* branches to the small end of the stomach.

The *Gastro-epiploica dextra* runs along the great curve of the stomach lying between the two layers of the great omentum, and inosculates at about its middle with the *gastro-epiploica sinistra*, a branch of the splenic artery. It supplies the greater curve of the stomach and great omentum; hence its name.

The *Pancreatico-duodenalis* curves along the fixed border of the duodenum, partly concealed by the attachment of the pancreas, and is distributed to the

FIG. 217.



BRANCHES OF THE CŒLIAC AXIS. 1. Liver. 2. Its transverse fissure. 3. Gall-bladder. 4. Stomach. 5. Œsophagus. 6. Pylorus. 7. Duodenum, descending portion. 8. Transverse portion of the duodenum. 9. Pancreas. 10. Spleen. 11. Aorta. 12. Cœliac axis. 13. Gastric artery. 14. Hepatic artery. 15. Its pyloric branch. 16. Gastro-duodenalis. 17. Gastro-epiploica dextra. 18. Pancreatico-duodenalis, inosculating with the inferior pancreatico-duodenalis. 19. Division of the hepatic artery into right and left branches; the right giving off the cystic branch. 20. Splenic artery, traced by dotted lines behind the stomach to the spleen; the figure rests on the aorta. 21. Gastro-epiploica sinistra, inosculating along the great curvature of the stomach with the gastro-epiploica dextra. 22. Pancreatica magna. 23. Vasa brevia to the great end of the stomach, inosculating with the gastric artery. 24. Superior mesenteric artery, emerging from between the pancreas and transverse portion of the duodenum.

pancreas and duodenum, It inosculates inferiorly with the inferior pancreatico-duodenalis and pancreatic branches of the superior mesenteric artery.

The *Cystic artery*, generally a branch of the right hepatic, is of small size, and ramifies between the coats of the gall-bladder, previously to its distribution to the mucous membrane.

The **SPLenic ARTERY** (*splenica*; *lienalis*), the largest of the three branches of the cœliac axis, passes horizontally to the left along the upper border of the pancreas, and divides into five or six large branches (*r. splenici*), which enter the hilum of the spleen, and are distributed to its structure. In its course the vessel is tortuous and serpentine, frequently making a complete turn upon itself. It lies in a narrow groove in the upper border of the pancreas, and is accompanied by the splenic vein which lies beneath it, and by the splenic plexus of nerves.

The *Branches* of the splenic artery are, the

Pancreaticæ parvæ,
Pancreatica magna,

Vasa brevia,
Gastro-epiploica sinistra.

The *Pancreaticæ parvæ* are numerous small branches distributed to the pancreas, as the splenic artery runs along its upper border. One of these,

larger than the rest, follows the course of the pancreatic duct, and is called *Pancreatica magna*.

The *Vasa brevia* (gastricæ breves) are five or six branches of small size which pass from the extremity of the splenic artery and its terminal branches, between the layers of the gastro-splenic omentum, to the great end of the stomach, to which they are distributed, inosculating with branches of the gastric artery and gastro-epiploica sinistra.

The *Gastro-epiploica sinistra* appears to be the continuation of the splenic artery; it passes forwards from left to right, along the great curve of the stomach, lying between the layers of the great omentum, and inosculates with the gastro-epiploica dextra. It is distributed to the greater curve of the stomach and great omentum.

The SUPERIOR MESENTERIC ARTERY (*mesenterica vel mesaraica superior*), the second of the single trunks, and next in size to the cœliac axis, arises from the aorta immediately below that vessel, and behind the pancreas. It passes forwards between the pancreas and transverse duodenum, and descends within the layers of the mesentery, to the right iliac fossa, where it terminates, much reduced in size. In its course it forms a curve, the convexity being to the left, the concavity to the right; is in relation near its commencement with the portal vein; and is accompanied by two veins, and the superior mesenteric plexus of nerves.

The *Branches* of the superior mesenteric artery are—

Pancreatico-duodenalis inferior,	Ileo-colica,
Vasa intestini tenuis,	Colica dextra, Colica media.

The *Pancreatico-duodenalis inferior* is a small branch which arises from the superior mesenteric while behind the pancreas, and curves upwards along the line of junction of the pancreas and duodenum. It supplies both those organs, and inosculates with the pancreatico-duodenalis branch of the hepatic.

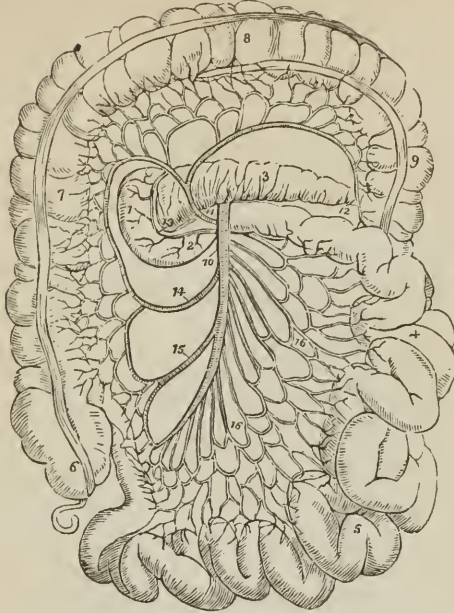
The *Vasa intestini tenuis* arise from the convexity of the superior mesenteric artery. They vary from fifteen to twenty in number, and are distributed to the small intestine from the duodenum to the termination of the ileum. In their course between the layers of the mesentery, they form a series of arches by the inosculation of their larger branches; from these are developed secondary arches, and from the latter a third series of arches, from which the branches arise which are distributed to the coats of the intestine. From the middle branches a fourth and sometimes even a fifth series of arches is produced. By means of these arches a direct communication is established between all the branches given off from the convexity of the superior mesenteric artery; the upper branch inosculates with the inferior pancreatico-duodenalis; the lower with the ileo-colica.

The *Ileo-colic artery* is the last branch given off by the concavity of the superior mesenteric. It descends to the right iliac fossa, and divides into branches which communicate and form arches, from which branches are distributed to the termination of the ileum, cæcum, and commencement of the colon. This artery inosculates on the one hand with the termination of the mesenteric trunk; on the other, with the colica dextra.

The *Colica dextra* arises from about the middle of the concavity of the superior mesenteric, and passing outwards behind the peritoneum, divides into branches which form arches, and are distributed to the ascending colon. Its descending branches inosculate with the ileo-colica, the ascending with the colica media.

The *Colica media* arises from the upper part of the concavity of the superior mesenteric, and passes forwards between the layers of the transverse meso-colon, where it forms arches, and is distributed to the transverse colon. It inosculates on the right with the colica dextra; on the left, with the colica sinistra, a branch of the inferior mesenteric artery.

FIG. 218.



COURSE AND DISTRIBUTION OF THE SUPERIOR MESENTERIC ARTERY. 1. Descending portion of the duodenum. 2. Transverse portion. 3. Pancreas. 4. Jejunum. 5. Ileum. 6. Cæcum and appendix vermiformis. 7. Ascending colon. 8. Transverse colon. 9. Descending colon. 10. Superior mesenteric artery. 11. Colica media. 12. The branch which inosculates with the colica sinistra. 13. Pancreatico-duodenalis inferior. 14. Colica dextra. 15. Ileocolica. 16, 16. Vasa intestini tenuis.

The SPERMATIC ARTERIES (*spermaticæ internæ*) are two small vessels which arise from the front of the aorta below the superior mesenteric; from their origin each artery passes obliquely outwards, and accompanies the corresponding ureter along the front of the psoas muscle to the border of the pelvis, where it is in relation with the external iliac artery. It is then directed outwards to the internal abdominal ring, and follows the course of the spermatic cord along the spermatic canal and through the scrotum to the testicle, to which it is distributed. The right spermatic artery lies in front of the vena cava, and both vessels are accompanied by veins and by the spermatic plexuses of nerves.

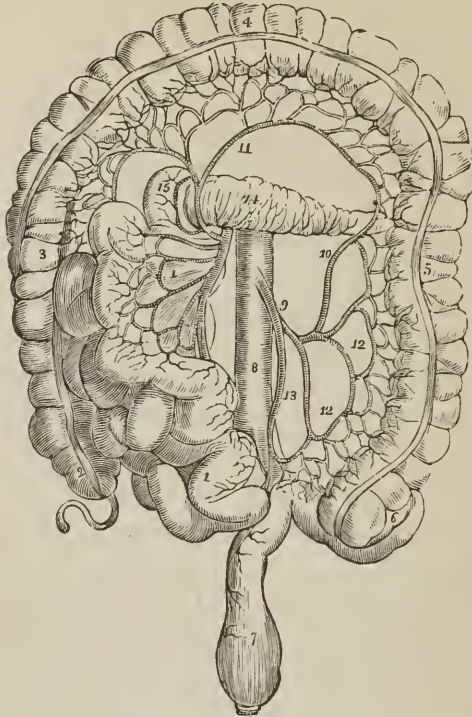
The spermatic arteries in the female (*ovarian*) descend into the pelvis and pass between the two layers of the broad ligaments of the uterus, to be distributed to the broad ligaments, ovaries, Fallopian tubes, and round ligaments; along the latter they are continued to the inguinal canal and labium at each side. They inosculate with the uterine arteries.

The INFERIOR MESENTERIC ARTERY (*mesenterica inferior*), smaller than the superior, arises from the abdominal aorta, about two inches below the origin of the latter vessel, and descends between the layers of the left meso-colon, to the left iliac fossa, where it divides into three *branches*:

Colica sinistra, Sigmoidea,
Hæmorrhoidalis superior

The *Colica sinistra* (superior) is distributed to the descending colon; it passes upwards and outwards behind the peritoneum, and divides into two branches, one

FIG. 219.



BRANCHES OF THE INFERIOR MESENTERIC ARTERY. 1, 1. The superior mesenteric, and small intestines turned over to the right side. 2. Cæcum and appendix cæci. 3. Ascending colon. 4. Transverse colon raised upwards. 5. Descending colon. 6. Sigmoid flexure. 7. Rectum. 8. Aorta. 9. Inferior mesenteric artery. 10. Colica sinistra, inosculating with, 11, colica media. 12, 12. Sigmoid branches. 13. Superior hæmorrhoidal artery. 14. Pancreas. 15. Descending portion of the duodenum.

of which (ramus anastomoticus) ascends to inosculate with the colica media, while the other descends to communicate with the sigmoid branch. The inosculation of the colica sinistra with the colica media is the largest arterial anastomosis in the body.

The *Sigmoid artery* (colica sinistra inferior) passes obliquely outwards behind the peritoneum and divides into branches which form arches, and are distributed to the sigmoid flexure of the colon. The superior branch inosculates with the colica sinistra, the inferior with the superior hæmorrhoidal artery.

The *Superior hæmorrhoidal artery* is the continuation of the inferior mesenteric. It crosses the ureter and left common iliac artery, and descending between the two layers of the meso-rectum, is distributed to the rectum as far as its middle, anastomosing with the middle and inferior hæmorrhoidal arteries.

The SUPRA-RENAL (suprarenales; capsulares) are two small vessels which arise from the aorta immediately above the renal arteries, and are distributed to the supra-renal capsules. They are sometimes branches of the phrenic or of the renal arteries.

The RENAL ARTERIES (renales; emulgentes) are two large trunks given off from the sides of the aorta immediately below the superior mesenteric artery; the right is longer than the left, on account of the position of the aorta, and passes behind the vena cava to the kidney of that side. The left is somewhat higher than the right. They divide into several large branches previously to entering the kidney, and ramify very minutely in its vascular portion. The renal arteries supply several small branches to the supra-renal capsules, and one to the ureter.

The LUMBAR ARTERIES (lumbales) correspond with the intercostals in the chest; they are four or five in number at each side, curve around the bodies of the lumbar vertebræ beneath the psoas muscles, and divide into two branches; one, *dorsal branch*, passes backwards between the transverse processes, and is distributed to the vertebræ and spinal cord and muscles of the back; the other, *parietal branch*, taking its course behind the quadratus lumborum, supplies the abdominal muscles, and inosculates with branches of the internal mammary and epigastric artery. The first lumbar artery runs along the lower border of the last rib; the last, along the crest of the ilium. In passing between the psoas muscle and the vertebræ, they are protected by a series of tendinous arches, which defend them and the communicating branches of the sympathetic nerve from pressure, during the action of the muscle.

The SACRA MEDIA arises from the posterior part of the aorta at its bifurcation, and descends along the middle of the anterior surface of the sacrum to the first piece of the coccyx, where it terminates by inosculating with the lateral sacral arteries. It distributes branches to the rectum and anterior sacral nerves, and inosculates at either side with the lateral sacral arteries.

Varieties in the Branches of the Abdominal Aorta.—The phrenic arteries are very rarely both derived from the aorta. One or both may be branches of the celiac axis; one may proceed from the gastric artery, from the renal, or from the upper lumbar. There are occasionally three or more phrenic arteries. The celiac axis is variable in length, and gives off its branches irregularly. There are sometimes two or even three hepatic arteries, one of which may be derived from the gastric or from the superior mesenteric. The colica media is sometimes derived from the hepatic artery. The spermatic arteries are variable both in origin and number. The right spermatic may be a branch of the renal; the left, of the inferior mesenteric. The supra-renal arteries may be derived from the phrenic or renal arteries. The renal arteries present several varieties in number; there may be three or even four on one side, and one only on the other. When there are several renal arteries on one side, one may arise from the common iliac artery, from the front of the aorta near its lower part, or from the internal iliac.

COMMON ILIAC ARTERIES.

The abdominal aorta divides opposite the fourth lumbar vertebra into the two common iliac arteries. Sometimes the bifurcation takes place as high as the third, and occasionally as low as the fifth. The common iliac arteries (*iliacæ communes vel primitivæ*) are about two inches in length; they diverge from the termination of the aorta, and pass downwards and outwards at each side to the margin of the pelvis, opposite the sacro-iliac symphysis, where they divide into the internal and external iliac. In old persons the common iliac arteries are more or less dilated and curved in their course. The *right artery* is somewhat longer than the left, and forms a more obtuse angle with the termination of the aorta; the angle of bifurcation is greater in the female than in the male.

Relations.—The relations of the two arteries are different at the two sides of the body. The *right common iliac* is in relation in front with the peritoneum, and is crossed at its bifurcation by the ureter. It is in relation behind with the two common iliac veins, and externally with the psoas magnus. The *left* is in

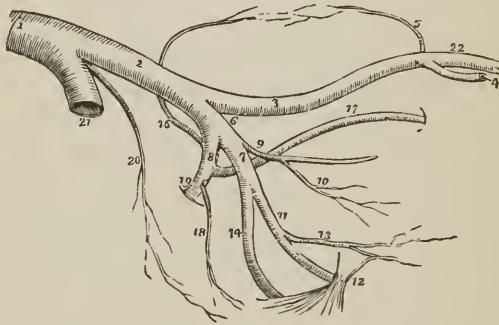
relation in front with the peritoneum, and is crossed by the rectum and superior hæmorrhoidal artery, and, at its bifurcation, by the ureter. It is in relation behind with the left common iliac vein, and externally with the psoas magnus.

INTERNAL ILIAC ARTERY.

The *Internal iliac artery* (*iliaca interna; hypogastrica*), is a short trunk, varying in length from an inch to two inches. It descends obliquely forwards to a point opposite the upper margin of the great sacro-ischiatic foramen, where it divides into an anterior and a posterior trunk. In the fœtus, the internal iliac artery under the name of *hypogastric* or *umbilical* is continued onwards by the side of the fundus of the bladder to near its apex, whence it ascends by the side of the linea alba and urachus to the umbilicus, where it becomes the true umbilical artery. After birth, this artery ceases to be pervious beyond the side of the bladder, and the obliterated portion is converted into a fibrous cord. The projection of the two cords on the inner wall of the abdomen causes the depression at each side, which goes by the name of *peritoneal fossa*.

Relations. — This artery rests externally on the sacral plexus and origin of

FIG. 220.



ILIAC ARTERIES. 1. Aorta. 2. Left common iliac artery. 3. External iliac. 4. Epi-gastric artery. 5. Circumflexa ilii. 6. Internal iliac artery. 7. Its anterior trunk. 8. Its posterior trunk. 9. The pervious portion of the umbilical artery giving off (10) the superior vesical artery. 11. Internal pudic artery passing behind the spine of the ischium (12) and lesser sacro-ischiatic ligament. 13. Middle hæmorrhoidal artery. 14. Ischiatic artery, also passing behind the anterior sacro-ischiatic ligament to escape from the pelvis. 16. Ilio-lumbar, ascending to inosculate with the circumflexa ilii artery (5) and form an arch along the crest of the ilium. 17. Obturator artery. 18. Lateral sacral. 19. Gluteal artery passing through the upper part of the great sacro-ischiatic foramen. 20. Sacra media. 21. Right common iliac artery cut short. 22. Femoral artery.

the pyriformis muscle; posteriorly it is in relation with the internal iliac vein, and anteriorly with the ureter.

Branches. — The branches of the anterior trunk are, the

Superior vesical,	Vaginal,
Inferior vesical,	Obturator,
Middle hæmorrhoidal,	Ischiatic,
Uterine,	Internal pudic.

The branches of the posterior trunk are, the

Ilio-lumbar,	Lateral sacral,
Gluteal.	

Branches of the Anterior Trunk

The *Superior vesical* arteries are three or four small branches, which proceed from the pervious portion of the umbilical artery. They are distributed to the upper and middle part of the bladder. From one of these there passes off a small artery, the *deferential*, which accompanies the vas deferens along the spermatic cord.

The *Inferior vesical*, somewhat larger than the preceding, passes down upon the side of the bladder to its base, and is distributed to that region, the vesiculæ seminales, and prostate gland.

The *Middle hæmorrhoidal artery*, frequently a branch of the preceding, passes downwards to the rectum, to which it is distributed, inosculating with the superior and inferior hæmorrhoidal arteries. In the female it distributes branches to the vagina.

The *Uterine artery* passes inwards between the layers of the broad ligament to the neck of the uterus, and ascends in a tortuous course along its lateral border. It gives branches to the vagina, lower part of the bladder, Fallopian tube (*tubaria*), ovary (*ovaria*), and round ligament, and inosculates with the spermatic or ovarian artery. According to Weber the ovarian branch of the uterine is the special artery of the ovary.

The *Vaginal artery* corresponds in position with the inferior vesical, and is distributed to the vagina, and neighboring parts of the bladder and rectum.

The **OBTURATOR ARTERY** (*obturatoria*; arising frequently from the posterior trunk of the internal iliac) passes forwards from the anterior trunk, a little below the brim of the pelvis, to the upper border of the obturator foramen. Escaping from the pelvis through a tendinous arch formed by the obturator membrane, it divides into two branches, internal and external.

Its *branches* within the pelvis are: an *iliac* branch, which supplies the bone of the iliac fossa, and inosculates with the ilio-lumbar artery; and a *pubic* branch which is given off close to the obturator foramen, and inosculates with its fellow of the opposite side, behind the pubes, and with the pubic branch of the epigastric artery.

The *internal* branch curves inwards around the bony margin of the obturator foramen, and distribute twigs to the obturator and adductor muscles, inosculating with the internal circumflex artery of the femoral.

The *external* branch winds around the outer margin of the obturator foramen to the space between the gemellus inferior and quadratus femoris, where it inosculates with the ischiatic artery. In its course it inosculates also with the internal circumflex, and sends a small branch through the notch in the acetabulum (*ramus acetabuli*) to supply the ligamentum teres.

The **ISCHIATIC ARTERY** (*ischiadica*; *glutæa inferior*) is the larger of the two terminal branches of the anterior division of the internal iliac. It passes downwards in front of the pyriformis and sacral plexus of nerves, lying internally to the pudic artery, to the lower part of the great ischiatic foramen, where it escapes from the pelvis between the inferior border of the pyriformis and coccygeus. It then descends in the space between the trochanter major and tuberosity of the ischium in company with the ischiatic nerves, and divides into several branches, the principal of which are, coccygeal, comes nervi ischiatici, and muscular.

The *Coccygeal* branch pierces the great sacro-ischiatic ligament, and is distributed to the coccygeus and levator ani, and to the integument around the anus and coccyx.

The *Comes nervi ischiatici* is a slender branch, which accompanies the great ischiatic nerve extending as far as the lower part of the thigh.

The *Muscular* branches supply the muscles of the posterior part of the hip and thigh, and inosculate with the internal and external circumflex arteries,

obturator, and superior perforating; some branches are also sent to the hip joint.

The INTERNAL PUDIC ARTERY (pudenda interna) the other terminal branch of the anterior trunk of the internal iliac, descends externally to the ischiatic artery to the lower part of the great sacro-ischiatic foramen. It emerges from the pelvis through the great sacro-ischiatic foramen between the lower border of the pyriformis and coccygeus, crosses the spine of the ischium, and re-enters the pelvis through the lesser sacro-ischiatic foramen; in the next place it passes forwards on the internal obturator muscle to the ramus of the ischium, being situated at about an inch from the margin of the tuberosity, and bound down by the obturator fascia; it then ascends by the side of the ramus of the ischium and pubes, and near the symphysis pubis pierces the triangular ligament of the perineum and divides into two terminal branches, arteria corporis cavernosi, and arteria dorsalis penis.

Branches. — The branches of the internal pudic artery within the pelvis are several small ramuscules to the levator ani and sacral nerves; and occasionally a branch which takes the place of the inferior vesical or middle hæmorrhoidal artery.

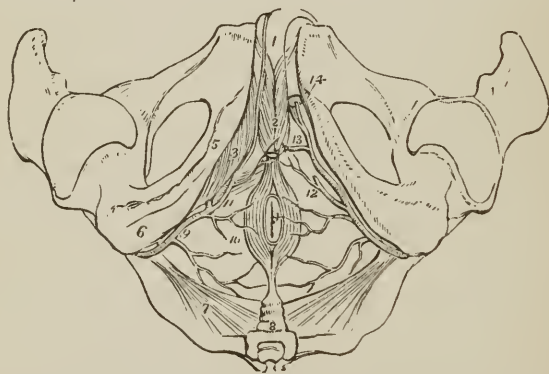
The *branches* given off externally to the pelvis are, the

Inferior hæmorrhoidal,
Superficialis perinei,
Transversa perinei,

Arteria corporis bulbosi,
Arteria corporis cavernosi,
Arteria dorsalis penis.

The *Inferior hæmorrhoidal arteries* (externæ) are three or four small branches, given off by the internal pudic while behind the tuberosity of the ischium. They cross the ischio-rectal fossa, and are distributed to the anus and to the muscles and integument of the anal region of the perineum.

FIG. 221.



ARTERIES OF THE PERINEUM; on the right side the superficial arteries are seen, on the left the deep. 1. The penis; the crus penis of the left side is cut through. 2. Acceleratores urinae muscles, inclosing the bulbous portion of the corpus spongiosum. 3. Erector penis, spread out upon the crus penis of the right side. 4. Anus, surrounded by the sphincter ani. 5. Ramus of ischium and pubes. 6. Tuberosity of ischium. 7. Lesser sacro-ischiatic ligament, attached by its small extremity to the spine of the ischium. 8. Coccyx. 9. Internal pudic artery, crossing the spine of the ischium, and entering the perineum. 10. Inferior hæmorrhoidal branches. 11. Superficialis perinei artery, giving off a small branch, transversa perinei, upon the transversus perinei muscle. 12. The same artery on the left side cut off. 13. Artery of the bulb. 14. The two terminal branches of the internal pudic artery; one is seen entering the divided extremity of the crus penis, the artery of the corpus cavernosum; the other, dorsalis penis, ascends to the dorsum of the organ.

The *Superficial perineal artery* (perinæa) is given off near the attachment of the crus penis; it pierces the connecting layer of the perineal fascia and triangular ligament, and runs forwards across the transversus perinei muscle, and along the groove between the accelerator urinæ and erector penis to the septum scroti, upon which it ramifies under the name of *arteria septi*. It distributes branches to the scrotum (scrotales posteriores) and perineum. One of the latter, larger than the rest, crosses the perineum, resting on the transversus perinei muscle, and is named the *Transversa perinei*. There are often two superficial perineal arteries.

The *Artery of the bulb* (bulbo-urethralis) is given off from the pudic nearly opposite the opening for the transmission of the urethra; it passes almost transversely inwards behind the triangular ligament, and pierces that ligament to enter the corpus spongiosum at its bulbous extremity. It is distributed in the corpus spongiosum.

The *Artery of the corpus cavernosum* (profunda penis) pierces the crus penis, and runs forwards in the interior of the corpus cavernosum, by the side of the septum pectiniforme. It ramifies in the parenchyma of the venous structure of the corpus cavernosum.

The *Dorsal artery of the penis* (dorsalis penis) ascends between the two crura and symphysis pubis to the dorsum penis, and runs forwards through the suspensory ligament, in the groove of the corpus cavernosum, to the glans, distributing branches in its course to the body of the organ and integument.

The INTERNAL PUDIC artery in the female is smaller than in the male; its branches, with their distribution, are, in principle, the same. The superficial perineal artery supplies the analogue of the lateral half of the scrotum, namely, the greater labium. The artery of the bulb supplies the commencement of the vagina; the artery of the corpus cavernosum, the cavernous body of the clitoris, and the arteria dorsalis clitoridis, the dorsum of that organ.

Branches of the Posterior Trunk.

The ILIO-LUMBAR ARTERY (ileo-lombalis) ascends beneath the external iliac vessels and psoas muscle, to the posterior part of the crest of the ilium, where it divides into two branches, a *lumbar branch* which supplies the psoas and quadratus lumborum, and sends a ramuscle through the fifth intervertebral foramen to the spinal cord and its membranes; and an *iliac branch* (r. transversalis) which crosses the iliac fossa to the crest of the ilium, and inosculates with the lumbar arteries and circumflexa ili; in its course it distributes branches to the iliacus and abdominal muscles.

The LATERAL SACRAL ARTERIES (sacrales laterales) are generally two in number on each side, superior and inferior. The *superior* passes inwards to the first sacral foramen, and is distributed to the contents of the spinal canal, from which it escapes by the posterior sacral foramen, and supplies the integument of the dorsum of the sacrum. The *inferior* passes down by the side of the anterior sacral foramina to the coccyx; it first pierces and then rests on the origin of the pyriformis, and sends twigs into the sacral canal to supply the sacral nerves. Both arteries inosculate with each other and with the sacra media.

The GLUTEAL ARTERY (glutæa superior) is the continuation of the posterior trunk of the internal iliac: it passes backwards between the lumbo-sacral and first sacral nerve through the upper part of the great sacro-ischiatic foramen and above the pyriformis muscle, and divides into three branches, superficial, deep superior, and deep inferior; while within the pelvis it gives off some muscular twigs to the iliacus and pyriformis, and at its escape from the pelvis, a *nutritious* artery to the ilium.

The *Superficial branch* passes backwards between the gluteus maximus and medius, and is distributed to the gluteus maximus and to the integument of the gluteal and sacral region.

The *Deep superior branch* passes forwards along the superior curved line of the ilium, between the gluteus medius and minimus to the anterior superior spinous process, where it inosculates with the superficial circumflexa ilii and external circumflex of the femoral. There are frequently two arteries occupying the place of this branch.

The *Deep inferior branches*, two or three in number, cross the gluteus minimus obliquely to the trochanter major, where they inosculate with branches of the external circumflex and ischiatic artery, and send branches through the gluteus minimus to supply the capsule of the hip joint.

Varieties in the Branches of the Internal Iliac.—The most important of the varieties occurring among these branches is the origin of the dorsal artery of the penis from the internal iliac or ischiatic. The artery in this case passes forwards by the side of the prostate gland, and through the upper part of the transverse ligament of the perineum. It would be endangered in the operation of lithotomy. The dorsal artery of the penis is sometimes derived from the obturator, and sometimes from one of the external pudic arteries. The artery of the bulb, in its normal course, passes almost transversely inwards to the corpus spongiosum. Occasionally, however, it is so oblique in direction as to render its division in lithotomy unavoidable. The obturator artery may be very small or altogether wanting, its place being supplied by a branch from the external iliac or epigastric.

EXTERNAL ILIAC ARTERY.

The *External iliac artery* (*iliaca externa; cruralis iliaca*), of each side, passes obliquely downwards along the inner border of the psoas muscle, from opposite the sacro-iliac symphysis to the femoral arch, where it becomes the femoral artery.

Relations.—It is in relation *in front* with the spermatic vessels, peritoneum, and a thin layer of fascia, derived from the iliac fascia which surrounds the artery and vein. At its commencement it is crossed by the ureter, and near its termination by the genital branch of the genito-crural nerve and the circumflexa ilii vein. *Externally* it lies against the psoas muscle, from which it is separated by the iliac fascia; and *posteriorly* it is in relation with the external iliac vein, which, at the femoral arch, becomes placed to its inner side. The artery is surrounded by lymphatic vessels and several glands.

Branches.—Besides several small twigs which supply the lymphatic glands and psoas muscle, the external iliac gives off two branches, the

Epigastric,

Circumflexa ilii.

The **EPIGASTRIC ARTERY** (*epigastrica*) arises from the front of the external iliac near Poupart's ligament; and passing inwards between the peritoneum and transversalis fascia, ascends obliquely to the sheath of the rectus. It enters that sheath near its lower third, passes upwards behind the rectus muscle, to which it is distributed, and, in the substance of that muscle, inosculates, near the ensiform cartilage, with the termination (*superior epigastric*) of the internal mammary artery. It lies internally to the internal abdominal ring and immediately above the femoral ring, and is crossed near its origin by the vas deferens in the male, and the round ligament in the female.

The branches of the epigastric artery are,

A *cremasteric* branch (*spermaticea externa*) which accompanies the spermatic cord, and after supplying the cremaster muscle inosculates with the spermatic artery.

A *pubic* branch which is distributed behind the pubes, and sends a small branch of communication downwards to the obturator artery.

Muscular branches which pass outwards between the abdominal muscles, and inosculate with the circumflexa ilii, lumbar, and inferior intercostal arteries.

Superficial branches which pierce the rectus muscle, and are distributed to the integument of the abdomen.

The epigastric artery forms a prominence of the peritoneum, which divides the inguinal fossa into an internal and external portion; it is from the former that direct inguinal hernia issues, and from the latter, oblique inguinal hernia.

The CIRCUMFLEXA ILII arises from the outer side of the external iliac, a little below the epigastric artery. It ascends obliquely along Poupart's ligament, and curving around the crest of the ilium, inosculates with the ilio-lumbar and inferior lumbar artery. In its course the artery pierces the crural sheath and then lies between the transversalis muscle and fascia; near its termination it pierces the transversalis muscle and becomes placed between it and the internal oblique. Opposite the anterior superior spinous process of the ilium, it gives off a large *ascending branch*, which passes upwards between the internal oblique and transversalis, and divides into numerous branches which supply the abdominal muscles, and inosculate with the inferior intercostal and the lumbar arteries.

Varieties in the Branches of the External Iliac. — The epigastric artery not unfrequently¹ gives off the obturator, which descends in contact with the external iliac vein, to the obturator foramen. In this situation the artery would lie to the outer side of the femoral ring, and would not be endangered in the operation of dividing the stricture of femoral hernia. But occasionally the obturator passes along the free margin of Gimbernat's ligament in its course to the obturator foramen, and would completely encircle the neck of the hernial sac, a position in which it could scarcely escape the knife of the operator. In a preparation now before me, the branch of communication between the epigastric and obturator artery is much enlarged, and takes this dangerous course.

FEMORAL ARTERY.

Emerging from beneath Poupart's ligament, the external iliac artery enters the thigh and becomes the femoral. The femoral artery (*femoralis*; *cruralis*) passes down the inner side of the thigh, from Poupart's ligament, at a point midway between the anterior superior spinous process of the ilium and the symphysis pubis, to the opening in the adductor magnus, at the junction of the middle with the inferior third of the thigh, where it becomes the popliteal artery.

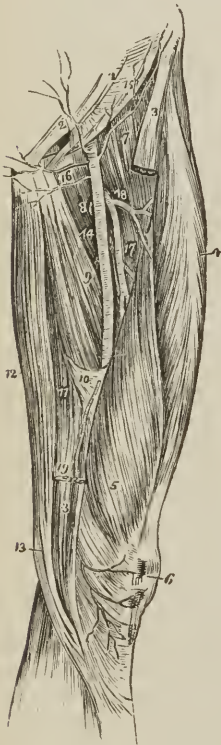
The femoral artery and vein are inclosed in a strong sheath, *femoral sheath*, which is formed for the greater part of its extent by fibrous and areolar tissue, and by a process of fascia sent inwards from the fascia lata. Near Poupart's ligament this sheath is much larger (infundibuliform) than the vessels it contains, and is continuous with the transversalis and iliac fascia. If the sheath be opened at this point, the artery will be seen in contact with the outer wall of the sheath. The vein lies next the artery, being separated from it by a fibrous septum, and between the vein and the inner wall of the sheath, and divided from the vein by another thin fibrous septum, is a triangular interval (*femoral or crural canal*), into which the sac is protruded in femoral hernia. This space is occupied in the normal state of the parts by loose cellular tissue,

¹ The proportion in which high division of the obturator artery from the epigastric occurs, is stated to be one in three. In two hundred and fifty subjects examined by Cloquet with a view to ascertain how frequently the high division took place, he found the obturator arising from the epigastric on both sides one hundred and fifty times; on one side twenty-eight times, and six times it arose from the femoral artery.

and by lymphatic vessels which pierce the inner wall of the sheath to make their way to a gland, situated in the femoral or *crural* ring.

Relations.—The upper third of the femoral artery is superficial, being covered only by the integument, inguinal glands, and superficial and deep fascia. The lower two-thirds are covered by the sartorius muscle. To its *outer side* the artery is in relation with the psoas, and vastus internus. *Behind*, it rests on the inner border of the psoas; it is next separated from the pectineus by the femoral vein, profunda vein and artery, and then lies on the adductor longus to its termination; near the lower border of the adductor longus it is placed in an aponeurotic sheath or canal, formed by an arch of tendinous fibres, thrown from the border of the adductor longus and the border of the opening in the adductor magnus, to the side of the vastus internus. To its *inner side* it is in relation at its upper part with the femoral vein, and lower down with the pectineus, adductor longus, and sartorius.

FIG. 222.



ANTERIOR AND INNER ASPECT OF THE THIGH, WITH THE FEMORAL ARTERY.

1. Lower part of the tendon of the external oblique muscle; its inferior margin is Poupart's ligament. 2. External abdominal ring. 3, 3. Upper and lower part of the sartorius muscle; its middle portion being removed. 4. Rectus. 5. Vastus internus. 6. Patella. 7. Iliacus and psoas; the latter being nearest the artery. 8. Pectineus. 9. Adductor longus. 10. Tendinous canal for the femoral artery, formed by the adductor magnus and vastus internus. 11. Adductor magnus. 12. Gracilis. 13. Tendon of the semi-tendinosus. 14. Femoral artery. 15. Superficial circumflexa ilii artery, taking its course along the line of Poupart's ligament, to the crest of the ilium. 16. Superficial epigastric artery. 17. The two external pudic arteries, superior and inferior. 18. Profunda artery, giving off, 18, its external circumflex branch; and lower down the three perforantes. A small bend of the internal circumflex artery (8) is seen behind the inner margin of the femoral, just below the inferior external pudic artery. 19. The anastomotica magna, descending to the knee, upon which it ramifies (6).

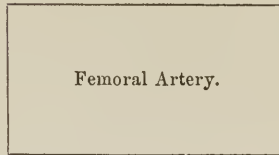
The immediate relations of the artery are the femoral vein, long saphenous nerve, and muscular nerve to the vastus internus. The vein at Poupart's ligament lies to the inner side of the artery; but lower down gets behind it, and inclines to its outer side. The muscular nerve lies to the outer side, and somewhat upon the sheath for the lower two-thirds of its extent; and the long saphenous nerve is situated within the sheath, and in front of the artery for the same extent.

*Plan of the Relations of the Femoral Artery.**In Front.*

Fascia lata,
Long saphenous nerve,
Sartorius,
Aponeurotic canal.

Inner Side.

Femoral vein,
Pectineus,
Adductor longus,
Sartorius.

*Outer Side.*

Psoas,
Vastus internus.

Behind.

Psoas muscle,
Femoral vein,
Adductor longus.

Branches.—The branches of the Femoral Artery are, the

Superficial circumflexa ilii,
Superficial epigastric,
Superior external pudic,
Inferior external pudic,
Profunda, { External circumflex,
 { Internal circumflex,
 { Three perforating.
Muscular,
Anastomotica magna.

The *Superficial circumflexa ilii artery* (circumflexa ilii externa) arises from the femoral immediately below Poupart's ligament, and passes obliquely outwards towards the crest of the ilium, where it pierces the fascia lata. It supplies the integument of the groin, superficial fascia, and inguinal glands.

The *Superficial epigastric* (epigastrica superficialis) arises from the femoral immediately below Poupart's ligament, pierces the fascia lata, and ascends obliquely towards the umbilicus between the two layers of superficial fascia. It distributes branches to the inguinal glands and integument, and inosculates with branches of the deep epigastric and internal mammary artery.

The *Superior external pudic* (pudenda externa, superior) arises near the superficial epigastric artery; it pierces the fascia lata at the saphenous opening, and passes transversely inwards, crossing the spermatic cord, to be distributed to the integument of the penis and serotum (rami scrotales anteriores) in the male, and to the labia (rami labiales anteriores) in the female.

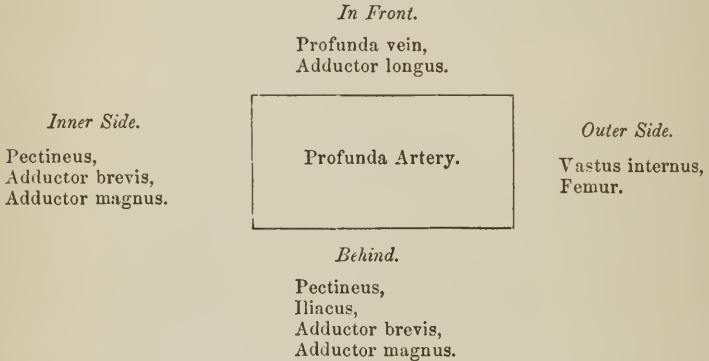
The *Inferior external pudic* (pudenda externa, inferior) arises from the femoral a little below, and sometimes in common with, the preceding; it crosses the femoral vein immediately below the termination of the internal saphenous vein, and resting on the pectineus muscle reaches the inner border of the thigh, where it pierces the fascia lata, and is distributed to the integument of the external organs of generation and perineum. Both external pudics inosculate with the internal pudic artery.

The **PROFUNDA FEMORIS** (femoralis profunda) arises from the outer and posterior side of the femoral artery about one inch and a half below Poupart's liga-

ment; it passes downwards and backwards and a little outwards, behind the adductor longus muscle, pierces the adductor magnus, and is distributed to the flexor muscles on the posterior part of the thigh.

Relations. — In its course downwards it rests successively on the pectineus, iliacus, adductor brevis, and adductor magnus. To its *outer side* the tendinous insertion of the vastus internus muscle intervenes between it and the femur; on its *inner side* it is in relation with the pectineus, adductor brevis, and adductor magnus; and *in front* it is separated from the femoral artery, *above* by the profunda and femoral vein, and *below* by the adductor longus muscle.

Plan of the Relations of the Profunda Artery.



Branches.—The branches of the profunda artery are, the external circumflex, internal circumflex, and three perforating arteries.

The *External circumflex artery* (circumflexa femoris externa) passes outwards beneath the sartorius and rectus and in front of the crureus muscle, crossing between the divisions of the crural nerve, and divides into three sets of branches; *ascending*, which pass upwards beneath the sartorius, rectus, and tensor vaginae femoris, and inosculate with the terminal branches of the gluteal artery; *descending*, which pass downwards beneath the rectus muscle to inosculate with the superior articular arteries of the popliteal; and *middle*, which continue the original course of the artery around the thigh, pierce the vastus externus, and anastomose with branches of the ischiatic, internal circumflex, and superior perforating artery. It supplies the muscles of the anterior and outer side of the thigh.

The *Internal circumflex artery* (circumflexa femoris interna) winds around the inner side of the neck of the femur, passing between the pectineus and psoas, and over the upper border of the adductor brevis to the tendon of the obturator externus, which it accompanies to the space between the quadratus femoris and upper border of the adductor magnus. While on the obturator externus it gives off a branch which is distributed to that muscle, the adductor brevis, and gracilis, and anastomoses with the obturator artery. It next gives off an *articular* branch, which enters the hip joint through the notch in the acetabulum; and terminates in several branches which inosculate with the ischiatic, external circumflex, and superior perforating artery.

The *Superior perforating artery* passes backwards near the lower border of the pectineus, pierces the adductor brevis and magnus near the femur, and is distributed to the posterior muscles of the thigh; inosculating with the circumflex, ischiatic, and middle perforating artery.

The *Middle perforating artery* pierces the tendons of the adductor brevis and magnus, and is distributed like the superior; inosculating with the superior and inferior perforating. From this branch is given off the *nutritious* artery of the femur.

The *Inferior perforating artery* is given off below the adductor brevis, and pierces the tendon of the adductor magnus, supplying it and the flexor muscles, and inosculating with the middle perforating artery above, and the articular branches of the popliteal below. It is through the medium of the branches of the profunda which inosculate above with branches of the internal iliac, and below with those of the popliteal artery, that the collateral circulation is maintained in the limb after ligature of the femoral artery.

The *Muscular branches* are given off by the femoral artery throughout the whole of its course. They supply the muscles in immediate proximity with the artery, particularly those of the anterior aspect of the thigh. One of these branches, larger than the rest, arises from the femoral immediately below the origin of the profunda, and passing outwards between the sartorius and rectus, divides into branches which are distributed to all the muscles of the anterior aspect of the thigh. This may be named the *superior muscular artery*.

The *Anastomotica magna* (articularis genu superficialis) arises from the femoral near its termination at the opening in the adductor magnus, and divides into a superficial and deep branch. The *superficial branch* accompanies the internal saphenous nerve to the knee, and piercing the fascia lata is distributed to the integument. The *deep branch* passes onwards through the substance of the vastus internus muscle, resting on the tendon of the adductor magnus, to the knee; where it inosculates with the internal articular branches of the popliteal, and the recurrent of the anterior tibial. It also sends a branch through the vastus internus, which supplies the synovial membrane of the joint, and inosculates with the superior external articular artery and external circumflex.

POPLITEAL ARTERY.

The popliteal artery (*poplitea*, Fig. 224) commences from the termination of the femoral at the opening in the adductor magnus muscle, and passes obliquely outwards through the middle of the popliteal space to the lower border of the popliteus muscle, where it divides into the anterior and posterior tibial artery. In structure the popliteal artery is remarkable for the thickness of its walls.

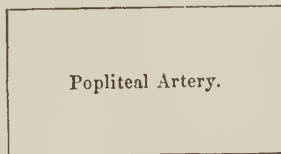
Plan of the Relations of the Popliteal Artery.

Superficially.

Semi-membranosus,
Popliteal nerve,
Popliteal vein,
Gastrocnemius,
Plantaris,
Soleus.

Inner Side.

Semi-membranosus,
Internal condyle,
Gastrocnemius.



Outer Side.

Biceps,
External condyle,
Gastrocnemius,
Plantaris,
Soleus.

Deeply.

Femur,
Ligamentum posticum Winslowii,
Popliteal fascia.

Relations. — In its course downwards it rests on the femur, then on the posterior ligament of the knee joint, then on the fascia covering the popliteus muscle. *Superficially* it is in relation with the semi-membranosus muscle, next

with a quantity of fat which separates it from the deep fascia, and near its termination with the gastrocnemius, plantaris, and soleus; superficial and external to it is the popliteal vein, and still more superficial and external the internal popliteal nerve. By its *inner side* it is in relation with the semi-membranosus, internal condyle of the femur, and inner head of the gastrocnemius; and by its *outer side* with the biceps, external condyle of the femur, outer head of the gastrocnemius, plantaris, and soleus.

Branches. — The branches of the popliteal artery are, the

Superior external articular,	Inferior external articular,
Superior internal articular,	Inferior internal articular,
Azygos articular,	Sural.

The *Superior articular arteries* (articulares genu superiores), *external* and *internal*, wind around the femur, immediately above the condyles, to the front of the knee joint, anastomosing with each other, with the external circumflex, anastomotica magna, inferior articular, and recurrent of the anterior tibial. The external passes beneath the tendon of the biceps, and the internal through an arched opening beneath the tendon of the adductor magnus. They supply the knee joint and lower part of the femur, and give branches to the vasti muscles.

The *Azygos articular artery* (articularis genu media) pierces the posterior ligament of the joint, the ligamentum posticum Winslowii, and supplies the crucial ligaments and synovial membrane. There are, frequently, several posterior articular arteries.

The *Inferior articular arteries* (articulares genu inferiores) wind around the head of the tibia immediately below the joint, and anastomose with each other, the superior articular arteries, and the recurrent of the anterior tibial. The *external* passes beneath the two external lateral ligaments of the joint, the *internal* beneath the internal lateral ligament. They supply the knee joint and the heads of the tibia and fibula.

The *Sural arteries* (surales; sura, the calf) are two muscular branches of large size, distributed to the two heads of the gastrocnemius muscle. Other *muscular* branches are given off from the upper part of the popliteal artery to supply the hamstring muscles.

ANTERIOR TIBIAL ARTERY. 268

The anterior tibial artery (*tibialis antica*) passes forwards between the two heads of the tibialis posticus muscle, and through the opening in the upper part of the interosseous membrane, to the anterior tibial region. It then runs down the anterior aspect of the leg to the ankle joint, where it becomes the dorsalis pedis.

Relations. — In its course it rests on the interosseous membrane (to which it is connected by a little tendinous arch which is thrown across it), the lower part of the tibia, and the anterior ligament of the joint. In its upper third it is situated between the tibialis anticus and extensor longus digitorum, lower down between the tibialis anticus and extensor proprius pollicis; and just before it reaches the ankle it is crossed by the tendon of the extensor proprius pollicis, and becomes placed between that tendon and the tendons of the extensor longus digitorum. Its immediate relations are the venæ comites and anterior tibial nerve; the latter lies at first to its outer side, at about the middle of the leg it is placed superficially to the artery, and at the ankle is again at its outer side.

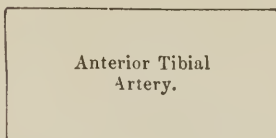
Plan of the Relations of the Anterior Tibial Artery.

In Front.

Deep fascia.
Tibialis anticus,
Extensor longus digitorum,
Extensor proprius pollicis,
Anterior tibial nerve.

Inner Side.

Tibialis anticus,
Tendon of extensor
proprius pollicis.



Outer Side.

Anterior tibial nerve.
Extensor longus digitorum
Extensor proprius pollicis,
Tendons of extensor longus
digitorum.

Behind.

Interosseous membrane,
Tibia (lower fourth),
Ankle joint.

Branches.—The branches of the Anterior Tibial Artery are, the

Recurrent,
Muscular,

External malleolar,
Internal malleolar.

The *Recurrent branch* (tibialis recurrens) passes upwards beneath the origin of the tibialis anticus muscle to the front of the knee joint, upon which it is distributed, anastomosing with the articular arteries.

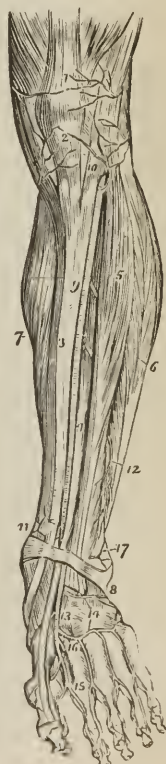The *Muscular branches* are numerous, they supply the muscles of the anterior tibial region.

The *Malleolar arteries* (malleolares anteriores) are distributed to the ankle joint; the *external*, passing beneath the tendons of the extensor longus digitorum and peroneus tertius, inosculates with the anterior peroneal artery and dorsalis pedis; the *internal*, beneath the tendons of the extensor proprius pollicis and tibialis anticus, inosculates with branches of the posterior tibial and internal plantar artery. They supply branches to the ankle joint.

The DORSALIS PEDIS ARTERY is continued forwards along the tibial side of the dorsum of the foot, from the ankle to the base of the metatarsal bone of the great toe where it gives off a branch, *dorsalis hallucis*; it then dips

ANTERIOR ASPECT OF THE LEG AND FOOT, SHOWING THE ANTERIOR TIBIAL AND DORSALIS PEDIS ARTERY; the tibialis anticus has been removed. 1. Tendon of insertion of the quadriceps extensor muscle. 2. Insertion of the ligamentum patellæ into the lower border of the patellæ. 3. Tibia. 4. Extensor proprius pollicis muscle. 5. Extensor longus digitorum. 6. The peronei. 7. Inner belly of the gastrocnemius and soleus. 8. Annular ligament. 9. Anterior tibial artery. 10. Its recurrent branch inosculating with (2) inferior articular, and (1) superior articular arteries, branches of the popliteal. 11. Internal malleolar artery. 17. External malleolar inosculating with the anterior peroneal artery 12. 13. Dorsalis pedis artery. 14. Tarsæa and metatarsæa; the tarsæa is nearest the ankle, the metatarsæa is seen giving off the interosseæ. 15. Dorsalis hallucis artery. 16. Continuation of the dorsalis pedis into the sole of the foot.

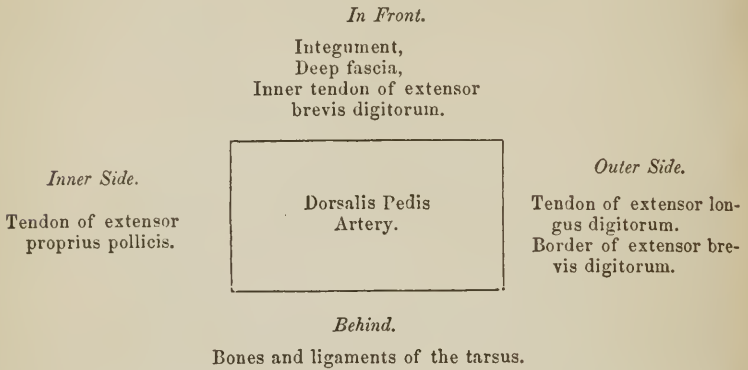
FIG. 228.



between the two heads of the first dorsal interosseous muscle into the sole of the foot and becomes continuous with the deep plantar arch.

Relations.—The dorsalis pedis is situated along the outer border of the tendon of the extensor proprius pollicis; at its fibular side is the innermost tendon of the extensor longus digitorum, and near its termination it is crossed by the inner tendon of the extensor brevis digitorum. It is accompanied by venæ comites, and has the continuation of the anterior tibial nerve to its outer side.

Plan of the Relations of the Dorsalis Pedis Artery.



Branches.—The branches of this artery are, the

Tarsea,
Metatarsæa,

Dorsalis hallucis,
Magna pollicis.

The *Tarsea* (externa) arches transversely across the tarsus, beneath the extensor brevis digitorum muscle, and supplies the articulations of the tarsal bones and outer side of the foot: it anastomoses with the external malleolar, peroneal arteries, and external plantar.

The *Metatarsæa* forms an arch (arcus tarseus vel dorsalis pedis) across the base of the metatarsal bones, and supplies the outer side of the foot; anastomosing with the tarsea and external plantar artery. From its convex side the metatarsæa gives off three branches, *interosææ*, which pass forwards upon the dorsal interossei muscles, and divide into branches (*dorsal collateral*) for the supply of the sides of the toes between which they are placed. At their commencement these interosseous branches receive the posterior perforating arteries from the plantar arch, and opposite the heads of the metatarsal bones are joined by the anterior perforating branches from the digital arteries. The interosseous artery of the fourth interosseous space, in addition to the two dorsal collateral branches into which it bifurcates, sends a third branch to the outer side of the little toe.

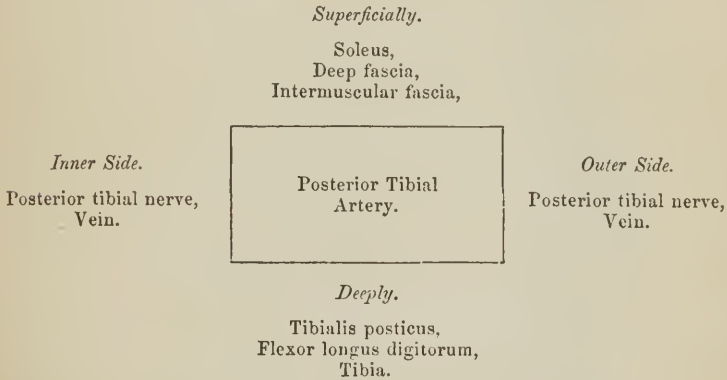
The *Dorsalis hallucis* (interossea dorsalis prima) runs forwards upon the first dorsal interosseous muscle, and at the base of the first phalanx divides into two branches, one of which passes inwards beneath the tendon of the extensor proprius pollicis, and is distributed to the inner border of the great toe, while the other bifurcates into two *dorsal collateral digital* branches for the adjacent sides of the great and second toe.

The *Arteria magna pollicis* arises from the dorsalis pedis, while in the metatarsal space and just before its inosculation with the external plantar artery. It sends a *digital* branch to the inner border of the great toe on its plantar aspect, and bifurcates to supply the *plantar collateral digital branches* of the great and second toe.

POSTERIOR TIBIAL ARTERY.

The posterior tibial artery (*tibialis postica*) passes obliquely downwards along the tibial side of the leg from the lower border of the popliteus muscle to the concavity of the os calcis, where it divides into the internal and external plantar artery.

Relations.—In its course it lies first on the *tibialis posticus*, next on the *flexor longus digitorum*, then on the tibia; it is covered in by the intermuscular fascia which separates it above from the soleus, below from the deep fascia and integument. It is accompanied by *venæ comites*, and by the posterior tibial nerve, which lies to its inner side at first, and to its outer side for the rest of its course.

Plan of the Relations of the Posterior Tibial Artery.

Branches.—The branches of the posterior tibial artery are, the

Peroneal,	Internal calcanean,
Nutritious,	Internal plantar,
Muscular,	External plantar.

The PERONEAL ARTERY (*peronæa*; *fibularis*) is given off from the posterior tibial at about two inches below the lower border of the popliteus muscle; it is nearly as large as the anterior tibial artery, and passes obliquely outwards to the fibula. It then runs downwards along the inner border of the fibula to its lower third, where it divides into the anterior and posterior peroneal.

Relations.—The peroneal artery rests on the *tibialis posticus* muscle, and is covered in by the soleus, intermuscular fascia, and *flexor longus pollicis*, having the fibula to its outer side.

Branches.—The branches of the peroneal artery are, *muscular* to the soleus and neighboring muscles; *nutrient* to the fibula; and two terminal branches, anterior and posterior peroneal.

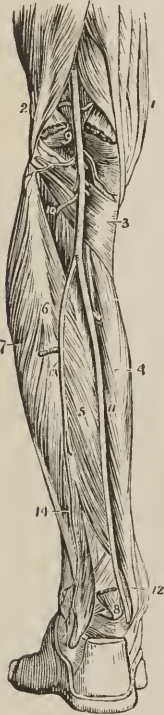
The *Anterior peroneal artery* (*peronæa antica*, vel *perforans*) pierces the interosseous membrane at the lower third of the leg, and is distributed on the front of the outer malleolus, anastomosing with the external malleolar and tarsal artery.

The *Posterior peroneal* continues onwards along the posterior aspect of the outer malleolus to the side of the os calcis, to which and to the muscles arising from it, it distributes *external calcanean* branches. It anastomoses with the anterior peroneal, tarsal, external plantar, and posterior tibial artery; with the latter by means of a small transverse branch (*ramus anastomoticus transversus*).

The *Nutritious artery* (*nutritia tibiæ*) of the tibia arises from the trunk of the posterior tibial, frequently above the origin of the peroneal, and proceeds to the nutritious canal, which it traverses obliquely from below upwards.

The *Muscular branches* of the posterior tibial artery are distributed to the soleus and deep muscles of the posterior aspect of the leg. One of these branches is deserving of notice, a *recurrent branch*, which arises from the posterior tibial above the origin of the peroneal artery, pierces the soleus, and is distributed on the inner side of the head of the tibia, anastomosing with the inferior internal articular.

FIG. 224.



POSTERIOR VIEW OF THE LEG, SHOWING THE POPLITEAL AND POSTERIOR TIBIAL ARTERY. 1. Tendons of the inner hamstring. 2. Tendon of the biceps, forming the outer hamstring. 3. Popliteus muscle. 4. Flexor longus digitorum. 5. Tibialis posterior. 6. The fibula; immediately below the figure is the origin of the flexor longus pollicis; the muscle has been removed in order to expose the peroneal artery. 7. Peronei muscles, longus and brevis. 8. Lower part of the flexor longus pollicis muscle with its tendon. 9. Popliteal artery giving off articular and muscular branches; the two superior articular are seen in the upper part of the popliteal space passing above the two heads of the gastrocnemius muscle, which are cut through near their origin. The two inferior are in relation with the popliteus muscle. 10. Anterior tibial artery passing through the angular interspace between the two heads of the tibialis posterior muscle. 11. Posterior tibial artery. 12. The relative position of the tendons and artery at the inner ankle from within outwards, previously to their passing beneath the internal annular ligament. 13. Peroneal artery, dividing a little below the figure, into two branches; the anterior peroneal is seen piercing the interosseous membrane. 14. Posterior peroneal.

The *Internal calcanean branches*, three or four in number, proceed from the posterior tibial artery immediately before its division; they are distributed to the integument, to the inner side of the os calcis, and to the muscles which arise from its inner tuberosity; and anastomose with the external calcanean branches of the posterior peroneal, and with all the neighboring arteries, forming around the heel a network of inosculations, *rete calcaneum*.

PLANTAR ARTERIES.

The *Internal plantar artery* (*plantaris interna*) proceeds from the bifurcation of the posterior tibial at the inner malleolus, and passes along the inner border of the foot beneath the abductor pollicis, supplying the inner border of the foot and great toe.

The *External plantar artery* (*plantaris externa*), much larger than the internal, passes obliquely outwards between the first and second layer of the plantar

muscles to the fourth metatarsal space. It then turns transversely inwards between the second and third layer, to the first metatarsal space, where it inosculates with the dorsalis pedis. The transverse portion of the artery describes a slight curve, having the convexity forwards; this is the *plantar arch* (arcus plantaris).

Branches.—The branches of the external plantar artery are, the

Muscular,
Articular,
Digital, { collateral,
 { anterior perforating.
Posterior perforating.

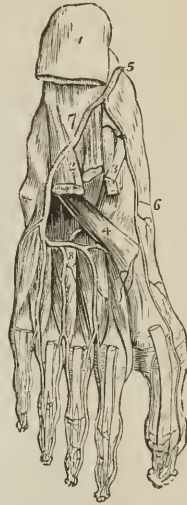The *Muscular* and *articular branches* are distributed to the muscles of the sole of the foot and to the articulations of the tarsus.

The *Digital branches* (interossee plantares) are four in number: the first is distributed to the outer side of the little toe; the three others pass forwards to the cleft between the toes, and divide into *collateral branches*, which supply the adjacent sides of the three external toes, and the outer side of the second. At the bifurcation of the toes, a small branch is sent upwards from each digital artery, to inosculate with the interosseous branches of the metatarsæ; these are the *anterior perforating* arteries.

The *Posterior perforating* are three small branches which pass upwards between the heads of the three external dorsal interossei muscles, to inosculate with the arch formed by the metatarsæ artery.

Varieties in the Arteries of the Lower Extremity.—The femoral artery occasionally divides at Poupart's ligament into two branches, and sometimes into three; the former is an instance of the high division of the profunda artery; and in a case of the latter kind which occurred during my dissections, the branches were the profunda, superficial femoral, and internal circumflex. Dr. Jones Quain, in his "Elements of Anatomy," records an instance of high division of the femoral artery, in which the two vessels became again united in the popliteal region. The point of origin of the profunda artery varies considerably in different subjects, being sometimes nearer to and sometimes further from Poupart's ligament, but more frequently the former. The branches of the popliteal artery are very liable to variety in size; and in all these cases the compensating principle, so constant in the vascular system, is manifested. When the anterior tibial is of small size, the peroneal is large; and, in place of dividing into two terminal branches at the lower third of the leg, descends to the lower part of the interosseous membrane, and emerges upon the front of the ankle, to supply the dorsum of the foot; or the posterior tibial and plantar arteries are large, and the external plantar is continued between the heads of the first dorsal interosseous muscle, to be distributed to

Fig. 225.



ARTERIES OF THE SOLE OF THE FOOT; the first and part of the second layer of muscles having been removed. 1. Under and posterior part of the os calcis; to which the origins of the first layer of muscles remain attached. 2. Musculus accessorius. 3. Long flexor tendons. 4. Tendon of the peroneus longus. 5. Termination of the posterior tibial artery. 6. Internal plantar. 7. External plantar artery. 8. The plantar arch giving off four digital branches, which pass forwards on the interossei muscles. Three of these arteries are seen dividing, near the heads of the metatarsal bones, into collateral branches for adjoining toes.

the dorsal surface of the foot. Sometimes the posterior tibial artery is small and thread-like; and the peroneal, after descending to the ankle, curves inwards to the inner malleolus, and divides into the two plantar arteries. If, in this case, the posterior tibial be sufficiently large to reach the ankle, it anastomoses with the peroneal previously to the division of the latter. The internal plantar artery sometimes takes the distribution of the external plantar, which is short and diminutive, and the latter not unfrequently replaces a deficient *dorsalis pedis*.

The varieties of arteries are interesting in the practical application of a knowledge of their principal forms to surgical operations; in their transcendental anatomy, as illustrating the normal type of distribution in animals; or, in many cases, as diverticula permitted by Nature, to teach her observers two important principles:—*first*, in respect to herself, that, however in her means she may indulge in change, the end is never overlooked, and a limb is as surely supplied by a leash of arteries, various in their course, as by those which we are pleased to consider normal in distribution; and *secondly*, with regard to us, that we should be keenly alive to whatever is passing beneath our observation, and ready in the most serious operation to deviate from our course, and avoid—or give eyes to our knife, that it may see—the concealed dangers which it is our pride to be able to contend with and vanquish.

PULMONARY ARTERY.

The pulmonary artery (*arteria pulmonalis*) arises from the left side of the base of the right ventricle in front of the origin of the aorta, and ascends obliquely for the space of two inches to the under surface of the arch of the aorta, where it divides into the right and left pulmonary artery. In its course upwards and backwards it inclines to the left side, crossing the commencement of the aorta, and is connected by its left branch to the under surface of the arch by a thick and impervious cord (ligamentum arteriosum; chorda ductus arteriosi), the remains of the ductus arteriosus of the fœtus.

Relations.—It is inclosed for nearly the whole of its extent by the pericardium, and receives the attachment of the fibrous portion of that membrane by its upper portion. Behind, it rests against the ascending portion of the arch of the aorta, and left auricle, on either side is the appendix of the corresponding auricle with a coronary artery; and above, the superficial cardiac plexus, and the cord of the ductus arteriosus.

The *Right pulmonary artery*, longer and somewhat larger than the left, passes transversely outwards behind the ascending aorta and superior vena cava to the root of the right lung, where it divides into three branches for the three lobes. In its course it lies parallel with and in front of the right bronchus.

The *Left pulmonary artery*, shorter and smaller than the right, crosses the descending aorta and left bronchus to the root of the left lung, where it divides into two branches for the two lobes.

The pulmonary arteries divide and subdivide in the structure of the lungs, and terminate in capillary vessels which form a network around the air-passages and cells, and become continuous with the radicles of the pulmonary veins.

Relations.—In the root of the *right lung*, examined from above downwards, the pulmonary artery is situated between the bronchus and pulmonary veins, the former being above, the latter below; in the root of the *left lung* the artery is highest, next the bronchus, and then the veins. On both sides, from before backwards, the artery is situated between the veins and bronchi, the former being in front, the latter behind.

CHAPTER VII.

OF THE VEINS.

THE veins are the vessels which return the blood to the auricles of the heart, after it has been circulated by the arteries through the various tissues of the body. They are much thinner in structure than the arteries, so that when emptied of their blood they become flattened and collapsed. The veins of the systemic circulation convey the dark-colored and impure or *venous blood* from the capillary system to the right auricle of the heart, and they are found after death to be more or less distended with that fluid. The veins of the pulmonary circulation resemble the arteries of the systemic circulation in containing during life the pure or arterial blood, which they transmit from the capillaries of the lungs to the left auricle.

The veins commence by minute radicles in the capillaries which are everywhere distributed through the textures of the body, and converge to constitute larger and larger branches, till they terminate in the main trunks which convey the venous blood directly to the heart. In diameter they are larger than the arteries, and, like those vessels, their combined area would constitute a hollow cone, whereof the apex is placed at the heart, and the base at the surface of the body. It follows from this arrangement, that the blood in returning to the heart is passing from a larger into a smaller channel, and therefore that it increases in rapidity during its course.

Veins admit of a threefold division into superficial, deep, and sinuses.

The *Superficial veins* return the blood from the integument and superficial structures, and take their course between the layers of the superficial fascia; they then pierce the deep fascia in the most convenient and protected situations, and terminate in the deep veins. They are unaccompanied by arteries, and are the vessels usually selected for venesection.

The *Deep veins* are situated among the deeper structures of the body, and generally in relation with the arteries; in the limbs they are inclosed in the same sheath with those vessels, and they return the venous blood from the capillaries of the deep tissues. In company with all the smaller, and also with the secondary arteries, as the brachial, radial, and ulnar in the upper, and the tibial and peroneal in the lower extremity, there are two veins, placed one at each side of the artery, and named *venæ comites*. The larger arteries, as the axillary, subclavian, carotid, popliteal, femoral, are accompanied by a single venous trunk; and certain veins, such as those of the cranium, spinal canal, liver, and larger veins of bones, run apart from arteries.

Sinuses differ from veins in their structure; and also in their mode of distribution, being confined to especial organs and situated within their substance. The principal venous sinuses are those of the dura mater, diploë, cancellous structure of bones, and uterus.

The communications between veins are more frequent than those of arteries, and they take place between the larger as well as the smaller vessels; the *venæ comites* communicate with each other in their course by means of short transverse branches which pass across from one to the other. These communications are strikingly exhibited in the frequent inosculations of the spinal veins, and in the various venous plexuses, as the spermatic plexus, and vesical plexus. The office of these inosculations is very apparent, as tending to obviate the obstructions to which veins are particularly liable from the thinness of their coats, and from their inability to overcome much impediment by the force of their current.

Veins, like arterics, are composed of three coats, external, middle, and internal.

The *External coat* [tunica adventitia] is the thickest of the three, increasing by degrees from the smallest to the largest; in the former gradually diminishing until it is lost altogether, and nothing remains but the one coat of the capillary; in the veins of medium size acquiring double the thickness of the middle coat, and in some of the large veins attaining four or five times its thickness. In structure it resembles the external coat of arteries, consisting of areolar tissue interwoven with a network of elastic fibres of the finer and coarser kind. In some of the larger veins, as the inferior vena cava, the trunks of the hepatic veins, and vena portæ, there exists besides, a layer of longitudinal smooth muscular fibres, occupying the inner half or two-thirds of the external coat, and, where the middle coat is absent, lying in contact with the internal coat. This muscular stratum is met with in its highest state of development in that portion of the inferior vena cava which is imbedded in the liver, the muscular fibres being intermingled with a fine network of elastic fibres.

The *Middle or contractile coat* [tunica media] is thin but firmer than the external, and composed of areolar tissue, elastic tissue, and smooth muscular fibres; the two latter being less in quantity than in the corresponding coat of arteries, and the muscular fibres being more abundant in the medium-sized than in the larger veins. The especial character of the middle coat of veins is, however, the presence of *longitudinal* as well as *transverse* fibres; the longitudinal fibres consisting of closely-reticulated elastic tissue, occurring in layers and alternating with the circular layers composed of smooth muscular fibres intermingled with areolar tissue and fine elastic fibres. The number of layers constituting the middle coat varies, according to the size and thickness of the vessel, from five to ten; and they are so disposed that the inner and outer layers are muscular, while the longitudinal elastic layers are more abundant towards the inner than the outer portion of the coat, and, although stratified, communicate with each other at different points so as to form one continuous whole. In the veins of the lower extremity the middle coat is thicker than elsewhere, and in certain of the veins of the lower limb, as the popliteal, profunda, and saphenæ, there exists an additional layer on the inner aspect of the middle coat, a layer composed of areolar tissue intermingled with fine elastic fibres and having a longitudinal fibrillation; the *longitudinal lamina of the middle coat*. In tracing the veins downwards to those of the smallest size, the layers of areolar tissue mingled with fine elastic fibres are the first to disappear; then the muscular element is reduced to a single layer, while the elastic cells are separated and scanty and finally cease; the elastic element consisting of a network of fine elastic fibres is continued further and becomes continuous with the coat of the capillaries. In that portion of the inferior vena cava which is imbedded in the liver and in the larger hepatic veins, the middle coat is without muscular fibres, and the external and internal coat are in contact.

The *Internal coat* [tunica intima], stronger than that of arteries, is composed of an epithelium and an elastic membrane, between which is situated a striated nuclear lamella. The *epithelium* consists of nucleated cells, which are elongated in veins of large and medium size; elliptical and almost round in the smallest veins, and cease altogether in the transitional veins. The *elastic membrane* is not homogeneous and fenestrated as in arteries, but composed of a closely areolated longitudinal network of coarse and fine elastic fibres. In the smallest veins this membrane is lost and its place supplied by a layer of homogeneous or sub-fibrous areolar tissue.

The veins which open into the heart, have an external annular layer of muscular fibres similar to those of the heart and presenting the same anastomosing structure. They are met with on the superior and inferior vena cava and around the pulmonary veins. Smooth muscular fibres are found in the veins of the gravid uterus in great abundance and highly developed, in all the three coats;

while in other veins the muscular element is altogether absent, as in the maternal portion of the placenta; the greater part of the veins of the cerebral substance and pia mater; the sinuses of the dura mater and of the bones; the veins of the corpora cavernosa; probably those of the spleen; and the veins of the retina. These veins are simply composed of condensed areolar tissue more or less completely developed and lined by epithelium; the sinuses of the dura mater have besides some fine elastic fibres.

The *Valves of veins* are composed of a thin stratum of nucleated areolar tissue mingled with fine elastic fibres, and coated on the two surfaces with an epithelium of less elongated cells. The segments or flaps of the valves of veins are semilunar in form, and arranged in pairs, one upon either side of the vessel; in some instances there is but a single flap, which has a spiral direction, and occasionally there are three. The free border of the valvular flaps is concave, and directed forwards, so that while the current of blood is permitted to flow freely towards the heart, the valves are distended, and the current intercepted, if the stream become retrograde in its course. On the cardiac side of each valve the vein is expanded into two pouches (sinuses), corresponding with the flaps of the valves, which give to the distended or injected vein a knotted appearance. The valves are most numerous in the veins of the extremities, particularly in the deeper veins, and they are generally absent in the very small veins, and in the veins of the viscera, as in the portal and cerebral veins; they are also absent in the large trunks, as in the *venæ cavæ*, *venæ azygos*, *innominatæ*, and *iliac* veins.

Sinuses are venous channels, excavated in the structure of an organ, and lined by the internal coat of the veins; of this structure are the sinuses of the dura mater, whose external covering is the fibrous tissue of the membrane. The external investment of the sinuses of the uterus is the tissue of that organ and that of the bones, the lining membrane of the cells and canals.

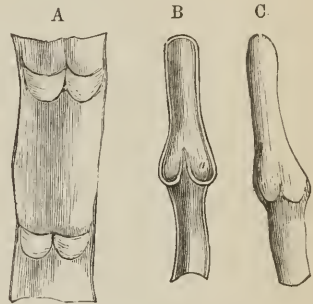
Veins, like arteries, are supplied with nutritious vessels, the *vasa vasorum*; the nervous filaments, few in number and of small size, are derived from the sympathetic and spinal system; they have been found only on the larger veins; as, the *venæ cavæ*, *iliacæ*, *crural*, *jugal*, *vertebral*, and sinuses of the dura mater.

I shall describe the veins according to the primary division of the body taking first, those of the head and neck; next, those of the upper extremity, then, those of the lower extremity; and lastly, the veins of the trunk.

VEINS OF THE HEAD AND NECK.

The veins of the head and neck may be arranged into three groups, namely, veins of the exterior of the head, veins of the diploë and interior of the cranium, veins of the neck.

[FIG. 226.



DIAGRAMS SHOWING VALVES OF VEINS.
 A. Part of a vein laid open, and spread out, with two pairs of valvular flaps.
 B. Longitudinal section of a vein, showing the apposition of the edges of the valvular flaps in their closed state.
 C. Pouch or sinus on the cardiac side of the flap of the valve. c. Portion of a distended vein, exhibiting a swelling in the situation of a valve.]

VEINS OF THE EXTERIOR OF THE HEAD.

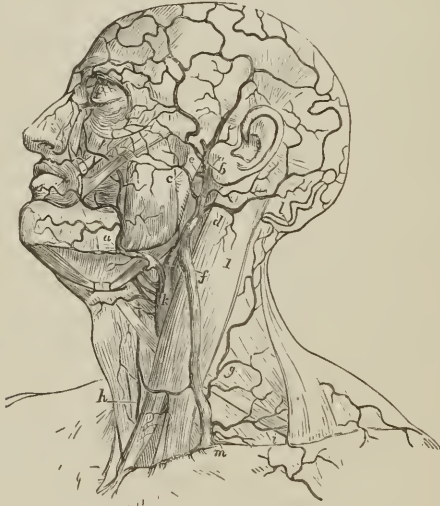
The veins of the exterior of the head are, the

Facial,	Temporo-maxillary,
Internal maxillary,	Posterior auricular,
Temporal,	Occipital.

The *Facial vein* (facialis anterior) commences on the anterior part of the head in a venous plexus, formed by the communications of the branches of the temporal, and descends along the middle line of the forehead, under the name of *frontal vein*, to the root of the nose, where it is connected with its fellow of the opposite side by a communicating trunk, the *nasal arch*. There are usually two frontal veins, which communicate by a transverse inosculation; but sometimes the vein is single and bifurcates at the root of the nose, into the two angular veins. From the nasal arch the frontal is continued downwards by the side of the root of the nose, and near the angle of the eye, under the name of *angular vein*; it then passes beneath the zygomatic muscles, becomes the facial vein, and descends along the anterior border of the masseter muscle, crossing the body of the lower jaw by the side of the facial artery, to the submaxillary gland, and from thence to the internal jugular vein, in which it terminates.

The *branches* which the facial vein receives in its course are, the *supraorbital*, which joins the frontal vein; the *dorsal veins* of the nose, which terminate in

[Fig. 227.



VEINS OF THE HEAD, FACE AND NECK. 1. Sterno-cleido-mastoideus muscle. a. Facial vein. b. Temporal vein. c. Transverse facial vein. d. Posterior auricular. e. Internal maxillary vein. f. External jugular. g. Posterior cervical branches of external jugular. h. Anterior jugular. i. Supra- and posterior scapular veins. k. Internal jugular. l. Occipital vein. m. Termination of external jugular in the subclavian.]

the nasal arch; the *ophthalmic*, which communicates with the angular vein; the *palpebral* and *nasal*, which open into the angular vein; a considerable trunk, the *deep facial* (maxillaris interna anterior), which returns the blood from the spheno-maxillary fossa, from the infraorbital, palatine, Vidian, and spheno-palatine veins, and joins the facial beneath the zygomatic process of the superior

maxillary bone; and the veins corresponding with the branches of the facial artery.

The *Internal maxillary vein* receives the veins from the zygomatic and pterygoid fossa; these are so numerous and communicate so freely as to constitute a *pterygoid plexus*. Passing backwards behind the neck of the lower jaw, the internal maxillary joins the temporal vein.

The *Temporal vein* commences on the vertex of the head by a plexiform network, which is continuous with the frontal, opposite temporal, auricular, and occipital vein. The ramifications of this plexus form an anterior and posterior branch which unite immediately above the zygoma; the trunk is here joined by another large vein, the *middle temporal*, which collects the blood from the temporal muscle and outer segment of the orbit, and pierces the temporal fascia near the root of the zygoma. The temporal vein then descends in the substance of the parotid gland to the angle of the lower jaw, where it divides into two trunks, one of which, mounting upon the sterno-mastoideus muscle, constitutes the external jugular vein; while the other, uniting with the facial vein, becomes the temporo-maxillary vein. The temporal vein receives the *anterior auricular, masseteric, transverse facial, and parotid veins*.

The *Temporo-maxillary vein*, a short trunk formed by the union of the temporo-maxillary trunk and facial vein, sends a branch to the anterior jugular, and terminates in the internal jugular vein. It receives the *lingual, laryngeal, and superior thyroid vein*.

The *Posterior auricular vein* communicates with the plexus of the vertex of the head, and descends behind the ear to join the external jugular vein near its origin. It receives in its course the veins of the external ear and the *stylo-mastoid vein*.

The *Occipital vein* commencing posteriorly in the plexus of the vertex of the head, follows the direction of the occipital artery, and passing deeply beneath the muscles of the back part of the neck, terminates in the external or internal jugular vein. This vein communicates with the lateral sinus by means of a large branch which passes through the mastoid foramen, the *mastoid vein*.

VEINS OF THE DIPLOË.

The diploë of the bones of the head is furnished in the adult with irregular sinuses (*venæ diploeticæ*), which are formed by a continuation of the internal coat of the veins into the osseous canals in which they are lodged. At the middle period of life these sinuses are confined to separate bones; but in old age, after the ossification of the sutures, they may be traced from one bone to the next. They receive their blood from the capillaries supplying the cellular structure of the diploë, and terminate externally in the veins of the pericranium, internally, in the veins and sinuses of the dura mater; they are separated from the bony walls of the canals by a thin layer of medulla.

Breschet describes four of these diploetic veins, namely, *frontalis, temporalis anterior, temporalis posterior, and occipitalis*. The *diploetica frontalis*, the smallest of the four, escapes from the frontal bone at the supraorbital notch, and opens into the supraorbital vein. The *temporalis anterior* also collects the blood from the frontal bone, and terminates either in the deep temporal veins or in the cavernous sinus. The *temporalis posterior* commences in the parietal bone, and opens into the lateral sinus, sometimes sending a branch outwards to the veins of the scalp. The *occipitalis*, the largest of the four, originates in the occipital bone, and terminates in the occipital sinus, or externally in the occipital vein.

CEREBRAL AND CEREBELLAR VEINS.

The cerebral veins are remarkable for the absence of valves, and for the extreme tenuity of their coats. They may be arranged into the superficial, and deep or ventricular veins.

The *Superficial cerebral veins* are situated on the surface of the hemispheres lying in the grooves formed by the convexities of the convolutions. They are named from the position which they may chance to occupy on the surface of the brain, either superior or inferior, internal or external, anterior or posterior.

The *Superior cerebral veins*, seven or eight in number at each side, pass obliquely forwards, and terminate in the superior longitudinal sinus, in the opposite direction to the course of the stream of blood in the sinus. In the infant the direction of these veins is nearly transverse.

The *Deep or Ventricular veins* commence within the lateral ventricles by the veins of the *corpora striata* and those of the *choroid plexus*, which unite to form the two *venæ Galeni*.

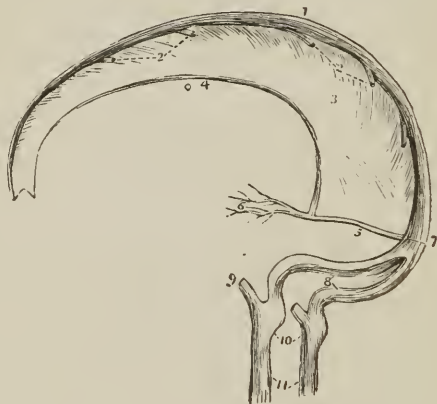
The *Venæ Galeni* pass backwards in the structure of the velum interpositum; and escaping through the fissure of Bichât, terminate in the straight sinus.

The *Cerebellar veins* are disposed, like those of the cerebrum, on the surface of the lobes of the cerebellum; they are situated, some on the superior, some on the inferior surface, while others occupy the borders of the organ. They terminate in the lateral and petrosal sinuses.

SINUSES OF THE DURA MATER.

The sinuses of the dura mater are irregular channels formed by the splitting of the layers of that membrane, and lined on their inner surface by a continua-

FIG. 228.



SINUSES OF THE UPPER AND BACK PART OF THE SKULL. 1. Superior longitudinal sinus. 2, 2. Cerebral veins opening into the sinus from behind forwards. 3. Falx cerebri. 4. Inferior longitudinal sinus. 5. Straight or fourth sinus. 6. *Venæ Galeni*. 7. Torcular Herophili. 8. The lateral sinuses, with the occipital sinuses between them. 9. The termination of the inferior petrosal sinus of one side. 10. Bulbs of the internal jugular veins, corresponding with the jugular fossæ. 11. Internal jugular veins.

tion of the internal coat of the veins. They may be divided into two groups—those situated at the upper and back part of the skull, and those of the base of the skull.

The former are, the

Superior longitudinal sinus,
Inferior longitudinal sinus,
Straight sinus,

Occipital sinuses,
Lateral sinuses.

The *Superior longitudinal sinus* is situated in the attached margin of the falx cerebri, and extends along the middle line of the arch of the skull, from the foramen cæcum in the frontal, to the inner tuberosity of the occipital bone, where it divides into the two lateral sinuses. It is triangular in form, small in front, and increases gradually in size as it passes backwards; it receives the superior cerebral veins which open into it obliquely, numerous small veins from the diploë, and near the posterior extremity of the sagittal suture the *parietal veins*, from the pericranium and scalp. Examined in its interior, it presents numerous transverse fibrous bands (trabeculæ) the *chordæ Willisii*, which are stretched across its inferior angle; and some small white granular masses, the *glandulæ Pacchioni*; the oblique openings of the cerebral veins, with their valve-like margin, are also seen on the walls of the sinus.

The termination of the superior longitudinal sinus in the two lateral sinuses forms a considerable dilatation, into which the straight sinus opens from the front, and the occipital sinuses from below. This dilatation is named the *toreular Herophili*,¹ and is the point of communication of six sinuses, the superior longitudinal, two lateral, two occipital, and the straight.

The *Inferior longitudinal sinus* is situated in the free margin of the falx cerebri; it is cylindrical in form, and extends from near the crista galli to the anterior border of the tentorium, where it terminates in the straight sinus. It receives in its course several veins from the falx, and sometimes one or two from the internal surface of the hemispheres.

The *Straight or fourth sinus* (sinus tentorii) is the sinus of the tentorium; it is situated at the line of union of the falx with the tentorium; is prismoid in form, and extends across the tentorium, from the termination of the inferior longitudinal sinus to the *toreular Herophili*. It receives the *venæ Galeni*, the cerebral veins from the inferior part of the posterior lobes, and the superior cerebellar veins.

The *Occipital sinuses* (occipitales posteriores) are two canals of small size, situated in the attached border of the falx cerebelli; they commence by several small veins around the foramen magnum, and terminate by separate openings in the *toreular Herophili*. Not unfrequently they communicate with the termination of the lateral sinuses.

The *Lateral sinuses* (sinus transversi, vel laterales), commencing at the *toreular Herophili*, pass horizontally outwards, in the attached margin of the tentorium, and then curve downwards and inwards along the base of the petrous portion of the temporal bone, at each side, to the foramina lacera posteriora, where they terminate in the internal jugular veins. Each sinus rests in its course on the transverse groove of the occipital bone, posterior inferior angle of the parietal, mastoid portion of the temporal, and again on the occipital bone. They receive the cerebral veins from the inferior surface of the posterior lobes, the inferior cerebellar veins, superior petrosal sinuses, mastoid and posterior condyloid vein. These sinuses are often unequal in size, the right being larger than the left.

The sinuses of the base of the skull are, the

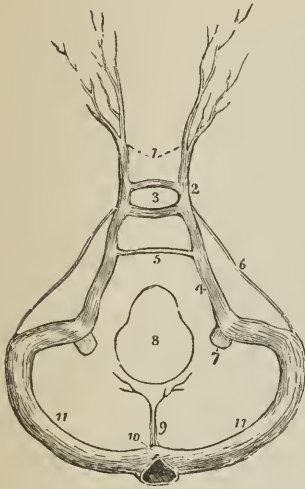
Cavernous,
Inferior petrosal,
Circular,

Superior petrosal,
Transverse.

¹ *Toreular* (a press), from a supposition entertained by the older anatomists that the column of blood, coming in different directions, compressed each other at this point.

The *Cavernous sinuses* are named from presenting a structure similar to that of the corpus cavernosum penis. They are situated at each side of the sella

FIG. 229.



SINUSES OF THE BASE OF THE SKULL. 1. Ophthalmic veins. 2. Cavernous sinus of one side. 3. Circular sinus; the figure occupies the position of the pituitary gland in the sella turcica. 4. Inferior petrosal sinus. 5. Transverse or anterior occipital sinus. 6. Superior petrosal sinus. 7. Internal jugular vein. 8. Foramen magnum. 9. Occipital sinuses. 10. Torcular Herophili. 11. Lateral sinuses.

turcica, receiving, anteriorly, the ophthalmic veins through the sphenoidal fissures, and terminating posteriorly in the inferior petrosal sinuses. In the cavernous sinus is the internal carotid artery, several filaments of the carotid plexus, the third, fourth, ophthalmic, and sixth nerve. The artery is separated from the blood flowing through the sinus, by the lining membrane of the latter. Besides the ophthalmic vein the cavernous sinus receives the cerebral veins of the under part of the anterior lobe, a vein from the posterior border of the orbit (*sinus spheno-parietalis*) and the vein of the middle fossa of the cranium. The cavernous sinuses communicate by means of the ophthalmic with the facial veins, by the circular sinus with each other, and by the superior petrosal with the lateral sinuses.

The *Inferior petrosal sinuses* are the continuations of the cavernous sinuses backwards along the lower border of the petrous portion of the temporal bone at each side of the base of the skull, to the foramina laeera posteriora, where they terminate with the lateral sinuses in the commencement of the internal jugular veins.

The *Circular sinus* (*sinus of Ridley*; ellipticus) is situated in the sella turcica, surrounding the pituitary gland, and communicating on each side with the cavernous sinus. The posterior segment is larger than the anterior.

The *Superior petrosal sinuses* pass obliquely backwards along the attached border of the tentorium, on the upper margin of the petrous portion of the temporal bone, and establish a communication between the cavernous and lateral sinus at each side. They receive one or two cerebral veins from the inferior part of the middle lobes, and a cerebellar vein from the anterior border of the cerebellum. Near the extremity of the petrous bone these sinuses cross the oval aperture which transmits the fifth nerve.

The *Transverse sinus* (*basilaris*; *occipitalis anterior*) passes transversely across the basilar process of the occipital bone, forming a communication between the two inferior petrosal sinuses. Sometimes there are two sinuses in this situation, or, more properly, a plexus.

VEINS OF THE NECK.

The veins of the neck which return the blood from the head are,

External jugular,
Anterior jugular,

Internal jugular,
Vertebral.

The *External jugular vein*, the continuation of the superficial division of the temporo-maxillary, augmented by the junction of the posterior auricular and

sometimes of the occipital, commences at the lower border of the parotid gland, in front of the sterno-mastoid muscle. It descends the neck in the direction of a line drawn from the angle of the lower jaw to the middle of the clavicle, crosses the sterno-mastoid, and terminates near the posterior and inferior attachment of that muscle, in the subclavian vein. In its course downwards, it lies on the anterior lamella of the deep cervical fascia, which separates it from the sterno-mastoid muscle, and is covered in by the platysma myoides and superficial fascia; at the root of the neck it pierces the deep cervical fascia. It is accompanied, for the upper half of its course, by the auricularis magnus nerve. The *branches* which it receives are the occipital cutaneous and posterior cervical cutaneous, and, near its termination, the supra-scapular and posterior scapular.

The external jugular vein is variable in size, and occasionally replaced by two veins.

The *Anterior jugular vein* commences on the os hyoides by several small veins, and by a branch from the temporo-maxillary, and passes downwards along the mid-line of the neck to the sternum; it then turns outwards behind the lower part of the sterno-mastoideus and opens into the subclavian vein, near the termination of the external jugular. The two veins communicate with each other, and with the external and internal jugular vein.

The *Internal jugular vein*, formed by the convergence of the lateral and inferior petrosal sinus, commences at the foramen lacerum posterius on each side of the base of the skull, by a dilatation (bulbus venæ jugularis), and descends the side of the neck, lying, in the first instance, to the outer side of the internal carotid, then on the outer side of the common carotid artery to the root of the neck, where it unites with the subclavian, and constitutes the vena innominata. At its commencement, the internal jugular vein is posterior and external to the internal carotid artery and eighth pair of nerves, the hypoglossal nerve being behind it; lower down, the vein and artery are on the same plane, the glossopharyngeal and hypoglossal nerve passing forwards between them, the pneumogastric being between and behind in the same sheath, and the nervus accessorius crossing obliquely behind or before the vein at its upper part.

The *branches* which the internal jugular receives in its course are, *pharyngeal, occipital, deep division of the temporo-maxillary, and middle thyroid.*

The *Vertebral vein* descends by the side of the vertebral artery in the canal formed by the foramina in the transverse processes of the cervical vertebræ, and at the root of the neck opens into the subclavian vein close to its termination. In the lower part of the vertebral canal it frequently divides into two branches, one of which advances forwards, while the other passes through the foramen in the transverse process of the seventh cervical vertebra, before opening into the subclavian vein.

The *branches* which it receives in its course are the *posterior condyloid vein, muscular veins, cervical meningo-rachidian veins, and near its termination, the superficial and deep cervical veins.*

The *Inferior thyroid veins*, two, and frequently more in number, are situated one on each side of the trachea, and receive the venous blood from the thyroid gland. They communicate with each other, and with the middle and superior thyroid veins, and form a plexus on the front of the trachea. The right vein terminates in the right vena innominata, just at its union with the superior cava; the left in the left vena innominata.

VEINS OF THE UPPER EXTREMITY.

The veins of the upper extremity are deep and superficial.

The *Deep veins* accompany the branches and trunks of the arteries, and constitute their *venæ comites*. The venæ comites of the radial and ulnar artery are

inclosed in the same sheath, with those vessels, and terminate at the bend of the elbow in the brachial veins. The brachial venæ comites are situated one at each side of the artery, and open into the axillary vein; the axillary becomes the subclavian, and the subclavian unites with the internal jugular to form the vena innominata.

The *Superficial veins* of the arm are, the

Anterior ulnar vein,	Cephalic vein,
Posterior ulnar vein,	Median vein,
Basilic vein,	Median basilic,
Radial vein,	Median cephalic.

The *Anterior ulnar vein* collects the venous blood from the inner and palmar border of the hand and ascends along the anterior aspect of the inner side of the forearm to the bend of the elbow, where it receives the median basilic, and becomes the basilic vein.

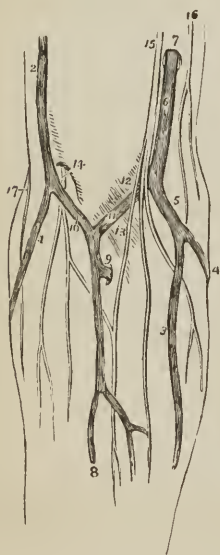
The *Posterior ulnar vein* commences on the dorsum of the hand by the ulnar termination of the *venous arch* which receives the *digital veins* from the fingers, and, after being joined by a large vein, the *vena salvatella*, from the little finger, ascends along the posterior aspect of the forearm to the bend of the elbow, where it turns forwards and terminates in the anterior ulnar vein.

The *Basilic vein* (βασιλικός, royal, or principal) ascends from the common ulnar vein formed by the two preceding, along the inner side of the upper arm, and near its middle pierces the fascia; it then passes upwards to the axilla, and becomes the axillary vein.

The *Radial vein* commences on the dorsum of the hand, by the radial termination of the *venous arch*, which receives the veins of the fingers. This origin is increased by the junction of some small veins from the thumb. The radial vein ascends the dorsal side of the forearm to a little below its middle, then lies on its anterior aspect to the bend of the elbow, where it receives the median cephalic, and becomes the cephalic vein.

The *Cephalic vein* (κεφαλή, the head) ascends along the outer side of the upper

FIG. 230.



VEINS OF THE FOREARM AND BEND OF THE ELBOW. 1. Radial vein. 2. Cephalic vein. 3. Anterior ulnar vein. 4. Posterior ulnar vein. 5. The trunk formed by their union. 6. Basilic vein, piercing the deep fascia at 7. 9. Communicating branch between the deep veins of the forearm and the upper part of the median vein. 10. Median cephalic vein. 11. Median basilic. 12. A slight convexity of the deep fascia, formed by the brachial artery. 13. The process of fascia, derived from the tendon of the biceps, which separates the median basilic vein from the brachial artery. 14. External cutaneous nerve, piercing the deep fascia, and dividing into two branches, which pass behind the median cephalic vein. 15. Internal cutaneous nerve, dividing into two branches, which pass in front of the median basilic vein. 16. Intercosto-humeral nerve. 17. Spiral cutaneous nerve, a branch of the musculo-spiral.

arm to its superior third; it then enters the groove between the pectoralis major and deltoid muscle, where it is in relation with the descending branch of the thoracica acromialis artery, and terminates beneath the clavicle in the axillary vein. A large communicating branch sometimes crosses the clavicle between the external jugular and this vein, which gives it the appearance of being derived directly from the head — hence its appellation.

The *Median vein* is intermediate in position between the anterior ulnar and radial vein; it begins at the wrist by the junction of branches from the palm of the hand, and collects the blood from the anterior aspect of the forearm communicating with the two preceding. At the bend of the elbow it receives a branch from the deep veins, and divides into two branches, the median cephalic and median basilic.

The *Median cephalic vein*, longer and somewhat smaller than the median basilic, passes obliquely outwards, in the groove between the biceps and supinator longus, to unite with the radial and form the cephalic vein. The branches of the external cutaneous nerve pass behind it.

The *Median basilic vein*, larger than the median cephalic, passes obliquely inwards, in the groove between the biceps and pronator radii teres, and unites with the common trunk of the ulnar veins to form the basilic vein. This vein is crossed by one or two filaments of the internal cutaneous nerve, and overlies the brachial artery from which it is separated by the aponeurotic slip given off from the tendon of the biceps.

AXILLARY VEIN. — The axillary vein is formed by the union of the venæ comites of the brachial artery with the basilic vein. It lies to the inner side of the artery, receives numerous branches from the collateral veins of the branches of the axillary artery; and at the lower border of the first rib becomes the subclavian vein. Above the pectoralis minor it receives the cephalic vein.

SUBCLAVIAN VEIN. — The subclavian vein crosses the first rib and beneath the clavicle, and unites with the internal jugular vein to form the vena innominata. It lies at first in front of the subclavian artery, and then in front of the scalenus anticus, which separates it from that vessel. The phrenic and pneumogastric nerve pass between the artery and vein. The veins opening into the subclavian are the external and anterior jugular externally to the scalenus anticus, and the vertebral internally to that muscle.

VEINS OF THE LOWER EXTREMITY.

The veins of the lower extremity are deep and superficial.

The *Deep veins* accompany the branches of the arteries in pairs, and form the venæ comites of the anterior and posterior tibial and peroneal artery. These veins unite in the popliteal region to form a single vessel of large size, the popliteal, which successively becomes in its course the femoral and the external iliac vein.

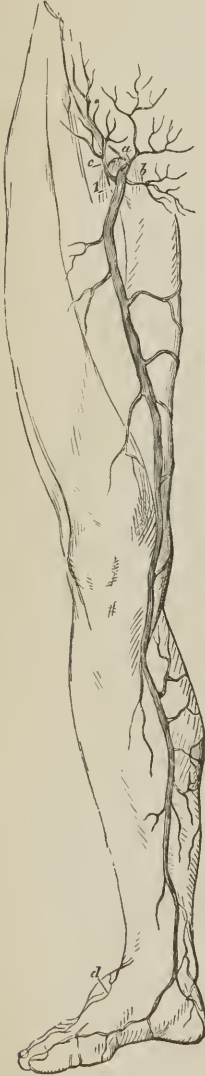POPLITEAL VEIN. — The popliteal vein ascends through the popliteal region, lying, in the first instance, directly upon the artery, and then getting somewhat to its outer side; and, passing through the oval opening in the tendon of the adductor magnus, becomes the femoral vein. It receives several muscular and articular branches, and the external saphenous vein. The valves in this vein are four or five in number.

FEMORAL VEIN. — The femoral vein, commencing at the opening in the adductor magnus muscle, ascends the thigh in the sheath of the femoral artery, and entering the pelvis beneath Poupart's ligament, becomes the external iliac

vein. In the lower part of its course it is situated on the outer side of the artery; it then becomes placed behind that vessel, and at Poupart's ligament, lies to its inner side. It receives the muscular veins and profunda, and, through the saphenous opening, the internal saphenous vein. The valves in this vein are four or five in number.

The *Profunda vein* is formed by the convergence of the numerous small veins which accompany the branches of the artery: it is a vein of large size, lies in front of the profunda artery, and terminates in the femoral at about two inches below Poupart's ligament.

[FIG. 231.]



INTERNAL SAPHEOUS VEIN.

1. Saphenous opening in the fascia lata. a. Superficial epigastric vein. b. External pudic vein. c. Superficial circumflexa ilii. d. Beginning of external saphenous vein.]

SUPERFICIAL VEINS.—The superficial veins are the external or short, and the internal or long saphenous. They commence on the dorsum of the foot in a *venous arch* which lies across the metatarsus; this venous arch receives the *digital veins* by its convex side.

The *External saphenous vein* commences at the outer extremity of the venous arch and on the outer border of the foot. It passes behind the outer ankle, ascends along the posterior aspect of the leg, lying in the groove between the two bellies of the gastrocnemius muscle, and pierces the deep fascia in the popliteal region to join the popliteal vein. It receives several cutaneous branches in the popliteal region previously to perforating the deep fascia, and is in relation in its course with the external saphenous nerve.

The *Internal saphenous vein* commences at the inner extremity of the venous arch of the dorsum and on the inner side of the foot and great toe. It ascends in front of the inner ankle, and along the inner side of the leg; it then passes behind the inner condyle of the femur and along the inner side of the thigh to the saphenous opening, where it pierces the sheath of the femoral vessels, and terminates in the femoral vein, at about one inch and a half below Poupart's ligament.

It receives in its course the cutaneous veins of the leg and thigh, and communicates freely with the deep veins. At the saphenous opening it is joined by the superficial epigastric and circumflexa ilii vein, and by the external pudic. The situation of this vein in the thigh is not unfrequently occupied by two or even three trunks of nearly equal size.

VEINS OF THE TRUNK.

The veins of the trunk may be divided into, 1. The superior vena cava, with its formative branches. 2. The inferior vena cava, with its formative branches. 3. The azygos veins. 4. The vertebral and spinal veins. 5. The cardiac veins. 6. The portal vein. 7. The pulmonary veins.

SUPERIOR VENA CAVA, WITH ITS FORMATIVE BRANCHES.

The *Venæ innominatæ* [brachio-cephalic veins] are two large trunks, formed by the union of the internal jugular and subclavian vein at each side of the root of the neck.

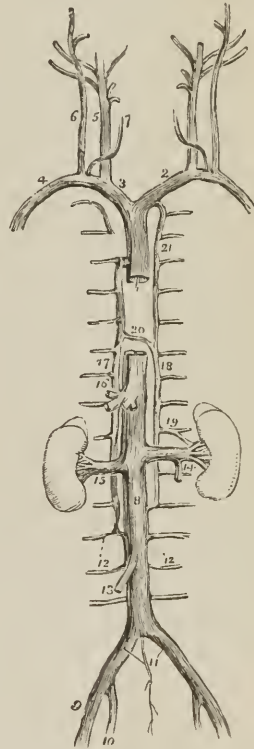
The *Right vena innominata*, about an inch and a quarter in length, lies superficially and externally to the arteria innominata, and descends almost vertically to unite with its fellow of the opposite side in the formation of the superior cava. At the junction of the jugular and subclavian vein it receives from behind the ductus lymphaticus dexter, and lower down it has opening into it the *right internal mammary*, and *right inferior thyroid vein*.

The *Left vena innominata*, considerably longer than the right, extends almost horizontally across the roots of the three great arteries arising from the arch of the aorta, to the right side of the mediastinum, where it unites with the right vena innominata, to constitute the superior vena cava.

FIG. 232.

VEINS OF THE TRUNK AND NECK.

1. Superior vena cava. 2. Left vena innominata. 3. Right vena innominata. 4. Right subclavian vein. 5. Internal jugular vein. 6. External jugular. 7. Anterior jugular. 8. Inferior vena cava. 9. External iliac vein. 10. Internal iliac vein. 11. Common iliac veins; the small vein between these is the vena sacra media. 12, 12. Lumbar veins. 13. Right spermatic vein. 14. The left spermatic, opening into the left renal vein. 15. Right renal vein. 16. Trunk of the hepatic veins. 17. The greater vena azygos, commencing inferiorly in the lumbar veins. 18. The lesser vena azygos, also commencing in the lumbar veins. 19. A branch of communication with the left renal vein. 20. Termination of the lesser in the greater vena azygos. 21. Left superior intercostal vein; communicating inferiorly with the lesser vena azygos, and terminating superiorly in the left vena innominata.



It is in relation in front with the left sterno-clavicular articulation and first piece of the sternum. At its commencement it receives the thoracic duct which opens into it from behind, and in its course is joined by the *left inferior thyroid*, *left mammary*, and *left superior intercostal vein*. It also receives some small veins from the mediastinum and thymus gland. There are no valves in the venæ innominatæ.

SUPERIOR VENA CAVA.

The superior cava (*descendens*) is a short trunk about three inches in length, formed by the junction of the two venæ innominatæ. It descends perpendicularly on the right side of the arch of the aorta and entering the pericardium terminates in the upper part of the right auricle.

It is in relation *in front* with the pericardium; *behind* with the right pulmonary artery; *internally* with the ascending aorta; *externally* with the pleura and right phrenic nerve. Immediately before entering the pericardium it receives the vena azygos major.

INFERIOR VENA CAVA, WITH ITS FORMATIVE BRANCHES.

The *External iliac vein* lies to the inner side of the corresponding artery at the os pubis; but gradually gets behind it as it passes upwards along the brim of the pelvis; it terminates opposite the sacro-iliac symphysis by uniting with the internal iliac, to form the common iliac vein. Immediately above Poupert's ligament it receives the epigastric and circumflexa ilii vein; it has no valves.

The *Internal iliac vein* is formed by vessels which correspond with the branches of the internal iliac artery; it receives the returning blood from the gluteal, ischiatic, internal pudic, and obturator vein, externally to the pelvis; and from the vesical and uterine plexuses within the pelvis. The vein lies to the inner side of the internal iliac artery, and terminates by uniting with the external iliac vein, to form the common iliac.

The *vesical and prostatic plexus* is an important plexus of veins which surrounds the neck and base of the bladder and prostate gland, and receives its blood from the great dorsal vein of the penis and the veins of the external organs of generation. It is retained in connexion with the sides of the bladder by a reflection of the pelvic fascia.

The *uterine plexus* is situated around the vagina, and at the sides of the uterus, between the two layers of the broad ligaments. The veins forming the vesical and uterine plexuses are peculiarly subject to the production of calcareous concretions termed *phlebolites*.

The *Common iliac veins* are formed by the union of the external and internal iliac vein at each side of the pelvis. The *right* common iliac, shorter than the left, ascends obliquely behind the corresponding artery; and on the intervertebral substance of the fourth and fifth lumbar vertebra, unites with the vein of the opposite side, to form the inferior cava. The *left* common iliac, longer and more oblique than the right, ascends behind and a little internally to the corresponding artery, and passes beneath the right common iliac artery, near its origin, to unite with the right vein in the formation of the inferior vena cava. The right common iliac vein has no branch; the left receives the vena sacra media. These veins have no valves.

INFERIOR VENA CAVA.

The inferior vena cava [*ascendens*] is formed by the union of the two common iliac veins, on the intervertebral substance of the fourth and fifth lumbar vertebra. It ascends along the front of the vertebral column, to the right of the abdominal aorta, and passing through the fissure in the posterior border of the liver and the quadrilateral opening in the tendinous centre of the diaphragm, terminates in the inferior and posterior part of the right auricle. There are no valves in this vein.

It is in relation from below upwards, *in front* with the mesentery, transverse

duodenum, portal vein, pancreas, and liver, which latter nearly and sometimes completely surrounds it; *behind* it rests on the vertebral column and right crus of the diaphragm, from which it is separated by the right renal artery and right lumbar arteries; to the *right* it has the peritoneum and sympathetic nerve; to the *left* the aorta.

The *Branches* which the inferior vena cava receives in its course, are, the

Lumbar,	Supra-renal.
Right spermatic,	Phrenic,
Renal,	Hepatic.

The *Lumbar veins*, three or four in number at each side, collect the venous blood from the muscles and integument of the loins, and spinal veins; the left are longer than the right on account of the position of the vena cava.

The *Right spermatic vein* is formed by the two veins which return the blood from the venous plexus of the spermatic cord. These veins follow the course of the spermatic artery, and unite to form the single trunk which opens into the inferior vena cava. The *left spermatic vein* terminates in the left renal vein.

The *Ovarian veins* represent the spermatic veins of the male, and collect the venous blood from the ovaries, round ligaments, Fallopian tubes, and communicate with the uterine sinuses. They terminate as in the male.

The *Renal or emulgent veins* return the blood from the kidneys; their branches are situated in front of the divisions of the renal arteries, and the left opens into the vena cava somewhat higher than the right. The *left* is longer than the right in consequence of the position of the vena cava, and crosses the aorta immediately below the origin of the superior mesenteric artery. It receives the *left spermatic vein*, which terminates in it at right angles: hence the more frequent occurrence of varicocele on the left than on the right side.

The *Supra-renal veins* terminate partly in the renal veins, and partly in the inferior vena cava.

The *Phrenic veins* return the blood from the ramifications of the phrenic arteries; they open into the inferior vena cava.

The *Hepatic veins* form two principal trunks and numerous smaller channels which open into the inferior vena cava, while that vessel is situated in the posterior border of the liver. The hepatic veins commence in the liver by minute venules, the *intralobular veins*, in the centre of each lobule; these pour their blood into larger vessels, the *sublobular veins*; and the sublobular veins constitute, by their convergence and union, the hepatic trunks, which terminate in the inferior vena cava.

AZYGOS VEINS.

The azygos veins (Fig. 232) form a system of communication between the superior and inferior vena cava, and serve to return the blood from that part of the trunk of the body in which those vessels are deficient, on account of their connexion with the heart. This system consists of four vessels—namely,

- Vena azygos major,
- Vena azygos minor,
- Two superior intercostal veins.

The *Vena azygos major* commences in the lumbar region by a communication with the lumbar veins; sometimes it is joined by a branch directly from the inferior vena cava, or by one from the renal vein. It passes through the right crus of the diaphragm, or through the aortic opening, and ascends along the right side of the vertebral column to the third dorsal vertebra, where it arches forwards over the right bronchus, and terminates in the superior vena cava. It receives all the intercostal veins of the right side with the exception of those of the first and second space, the vena azygos minor, and right bronchial vein.

The *Vena azygos minor* commences in the lumbar region, on the left side, by a communication with one of the lumbar veins or with the renal vein. It enters the chest through the left crus of the diaphragm and ascends the left side of the vertebral column, crosses the fifth or sixth dorsal vertebra and opens into the *vena azygos major*. It receives the six or seven lower intercostal veins of the left side. The azygos veins have no valves.

The *Right superior intercostal vein* receives the veins of the first and second intercostal space, and opens into the subclavian vein of the same side.

The *Left superior intercostal vein* is the trunk formed by the union of the five or six upper intercostal veins of the left side. It communicates below with the *vena azygos minor*, and crosses the arch of the aorta to terminate in the left *vena innominata*. It receives the left bronchial vein.

VERTEBRAL AND SPINAL VEINS.

The numerous venous plexuses of the vertebral column and spinal cord may be arranged into three groups:—

Dorsi-spinal, Meningo-rachidian, Medulli-spinal.

The *Dorsi-spinal veins* form a plexus around the spinous, transverse, and articular processes, and arches of the vertebræ. They receive the returning blood from the dorsal muscles and surrounding structures, and transmit it, in part to the meningo-rachidian, and in part to the vertebral, intercostal, lumbar, and sacral veins.

The *Meningo-rachidian veins* are situated between the *dura mater spinalis* and the vertebræ. They communicate freely with each other by means of a complicated plexus. In front they form two longitudinal trunks (*longitudinal spinal sinuses*), extending the whole length of the column on each side of the posterior common ligament, and are joined on the body of each vertebra by transverse trunks, which pass beneath the ligament, and receive the large basi-vertebral veins from the interior of each vertebra. The meningo-rachidian veins communicate superiorly through the anterior condyloid foramina with the internal jugulars; in the neck they pour their blood into the vertebral veins; in the thorax, into the intercostals; and in the loins and pelvis into the lumbar and sacral veins, the communications being made through the intervertebral foramina.

The *Medulli-spinal veins* are situated between the *pia mater* and arachnoid; they communicate freely with each other to form plexuses; and send branches through the intervertebral foramina with each of the spinal nerves, to join the veins of the trunk.

CARDIAC VEINS.

The veins (*cardiacæ vel coronariæ cordis*) returning the blood from the substance of the heart are, the

Great cardiac vein, Anterior cardiac veins,
Posterior cardiac vein, Venæ Thebesii.

The *Great cardiac vein* (*vena cordis magna*; *coronaria magna*) commences at the apex of the heart, and ascends along the anterior ventricular groove to the base of the ventricles; it then curves around the left auriculo-ventricular groove to the posterior part of the heart, where it terminates in the right auricle. It receives in its course the left cardiac veins from the left auricle and ventricle, and the posterior cardiac veins from the posterior ventricular groove.

The *Posterior cardiac vein* (*vena cordis media*), frequently two in number, commences also at the apex of the heart, and ascends along the posterior ven-

tricular groove, to terminate in the great cardiac vein. It receives the veins at right angles from the posterior aspect of the two ventricles.

The *Anterior cardiac veins* (*venæ parvæ*), collect the blood from the anterior surface of the right ventricle; one larger than the rest runs along the right border of the heart and joins the trunk formed by these veins, which curves around the right auriculo-ventricular groove, to terminate in the great cardiac vein near its entrance into the right auricle; others cross the groove, and open directly into the auricle.

The *Venæ Thebesii* (*venæ minimæ*) are numerous minute venules which convey the venous blood directly from the substance of the heart into the right auricle. The cardiac veins have no valves, excepting that at the orifice of the great vein.

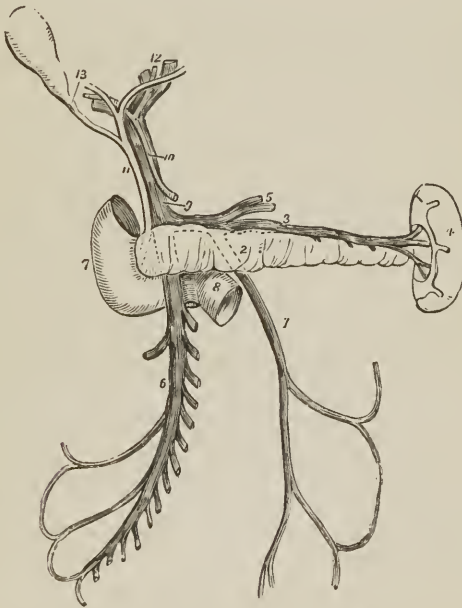
PORTAL SYSTEM.

The portal system is composed of four large veins which return the blood from the chylopoietic viscera; they are the

Inferior mesenteric vein,	Splenic vein,
Superior mesenteric vein,	Gastric veins.

The *Inferior mesenteric vein* receives its blood from the rectum by means of the hæmorrhoidal veins, and from the sigmoid flexure and descending colon, and

FIG. 233.



THE PORTAL VEIN. 1. Inferior mesenteric vein; it is traced by means of dotted lines behind the pancreas (2) to terminate in the splenic vein (3). 4. Spleen. 5. Gastric veins, opening into the splenic vein. 6. Superior mesenteric vein. 7. Descending portion of the duodenum. 8. Its transverse portion, crossed by the superior mesenteric vein and part of the trunk of the superior mesenteric artery. 9. Portal vein. 10. Hepatic artery. 11. Ductus communis choledochus. 12. Division of the duct and vessels at the transverse fissure of the liver. 13. Cystic duct leading to the gall-bladder.

ascends behind the transverse duodenum and pancreas, to terminate in the splenic vein. Its hæmorrhoidal branches inosculate with branches of the internal iliac vein, and thus establish a communication between the portal and general venous system.

The *Superior mesenteric vein* is formed by branches which collect the venous blood from the capillaries of the superior mesenteric artery; they constitute by their junction a large trunk, which ascends by the side of the corresponding artery, crosses the transverse portion of the duodenum, and unites behind the pancreas with the splenic in the formation of the portal vein.

The *Splenic vein* commences in the structure of the spleen, and quits that organ by several large branches; it is larger than the splenic artery, and perfectly straight in its course. It passes horizontally inwards behind the pancreas, and terminates near its greater end by uniting with the superior mesenteric and forming the portal vein. It receives in its course the gastric and pancreatic veins, and near its termination the inferior mesenteric vein.

The *Gastric veins* correspond with the gastric, gastro-epiploic, and vasa brevia arteries, and terminate in the splenic vein.

The *VENA PORTÆ*, formed by the union of the splenic and superior mesenteric vein behind the pancreas, ascends through the right border of the lesser omentum to the transverse fissure of the liver, where it divides into two branches, one for each lateral lobe. In the right border of the lesser omentum it is situated behind and between the hepatic artery, and ductus communis choledochus, and is surrounded by the hepatic plexus of nerves and lymphatics. At the transverse fissure each primary branch divides into numerous secondary branches which ramify through the portal canals, and give off vaginal and interlobular veins, and the latter terminate in the lobular venous plexus of the lobules of the liver. The portal vein within the liver receives the venous blood from the capillaries of the hepatic artery.

PULMONARY VEINS.

The pulmonary veins (*venæ pulmonales*), four in number, return the arterial blood from the lungs to the left auricle of the heart; they differ from veins in general, in the area of their cylinders being but little larger than that of the corresponding arteries, and in accompanying singly each branch of the pulmonary artery. They commence in the capillaries upon the parietes of the intercellular passages and air-cells, and unite to form a single trunk for each lobe. The vein of the middle lobe of the right lung unites with the superior vein, so as to form the two trunks which open into the left auricle. Sometimes they remain separate, and then there are three pulmonary veins on the right side. The right pulmonary veins behind pass behind the right auricle to the left auricle; the left pass in front of the descending aorta; they both pierce the pericardium. Within the lung the branches of the pulmonary veins are behind the bronchial tubes, and those of the pulmonary artery in front; but at the root of the lungs the veins are in front, next the arteries, and then the bronchi. There are no valves in the pulmonary veins.

CHAPTER VIII.

OF THE LYMPHATICS.

THE lymphatic vessels, or absorbents, have received their double appellation from certain phenomena which they present; the former name being derived from the appearance of the limpid fluid (lymp^ha, water) which they convey; the latter from their supposed property of absorbing foreign substances into the system. They are minute, delicate, and transparent vessels, remarkable for their general uniformity of size, a knotted appearance which is due to the presence of numerous valves, their frequent dichotomous divisions, and their division into several branches immediately before entering a gland. Their office is to collect the products of digestion and the detrita of nutrition, and convey them into the venous circulation near the heart.

Lymphatic vessels commence in a delicate network which is distributed in the cutaneous surface of the body, on the various surfaces of organs, and throughout their internal structure; and from this network the lymphatic vessels proceed, nearly in straight lines, in a direction towards the root of the neck. In their course they are intercepted by numerous small, spheroid or oblong, or flattened bodies, *lymphatic glands*. The lymphatic vessels entering these glands are termed *vasa inferentia* or *afferentia*, and those which quit them, *vasa efferentia*. The *vasa inferentia* vary in number from two to six, they divide at the distance of a few lines from the gland into several smaller vessels, and enter it by one of its flattened surfaces.¹ The *vasa efferentia* escape from the gland at the opposite, but not unfrequently on the same surface; they consist, like the *vasa inferentia* at their junction with the gland, of several small vessels which unite after a course of a few lines to form from one to three trunks, often double the size of the *vasa inferentia*.

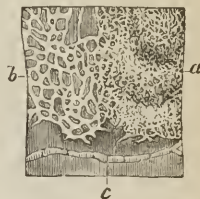
Lymphatic Vessels admit of a threefold division, into superficial, deep, and lacteals.

The *Superficial lymphatic vessels*, on the surface of the body, follow the course of the veins, and pierce the deep fascia in convenient situations, to join the deep lymphatics. On the surface of organs they converge to the nearest lymphatic trunks. The *superficial lymphatic glands* are placed in the most protected situations of the superficial fascia, as in the hollow of the ham and groin in the lower extremity; on the inner side of the arm in the upper extremity.

The *Deep lymphatics*, fewer in number and somewhat larger than the superficial vessels, accompany the deeper veins; those from the lower parts of the body converging to the numerous glands seated around the iliac veins and inferior vena cava, and terminating in a large trunk situated on the vertebral column, the thoracic duct. From the upper part of the trunk of the body on the left side, and from the left side of the head and neck, they also proceed to the thoracic duct. Those on the right side of the head and neck, right upper extremity, and right side of the thorax, form a distinct duct [*ductus lymphaticus dexter*] which terminates at the point of junction of the subclavian with the internal jugular vein on the right side of the root of the neck.

¹ See Mr. Lane's article on the "Lymphatic System," in the Cyclopædia of Anatomy and Physiology.

[FIG. 234.]



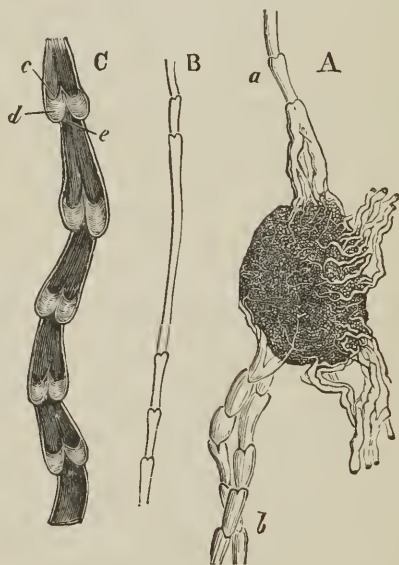
LYMPHATIC VESSELS OF THE SKIN OF THE BREAST injected; after Breschet. *a.* Superficial plexus. *b.* Deeper plexus. *c.* A lymphatic vessel, which proceeded to the axillary glands.]

The *Lacteals* are the lymphatic vessels of the small intestines; they have received their distinctive appellation from conveying the milk-like product of digestion, the chyle, to the great centre of the lymphatic system, the thoracic duct. They are situated in the mesentery, and open into the numerous mesenteric glands in their course.

Lymphatic vessels are very generally distributed through the animal tissues; there are, nevertheless, certain structures in which they have not been detected; for example, the brain and spinal cord, the eye, bones, cartilages, tendons, the membranes of the ovum, umbilical cord, and placenta. Anastomoses between these vessels are less frequent than between arteries, and veins; they are effected by means of vessels of equal size with the vessels which they connect, and no increase of calibre results from their junction. The lymphatic vessels are smallest in the neck, larger in the upper extremities, and larger still in the lower limbs.

For the purpose of effecting the movement of their fluids in a proper direction, lymphatic vessels are furnished with valves, and it is to these that the appearance of constrictions around the cylinders of the vessels, at short distances, is due. Like the valves of veins, the valves of lymphatic vessels are each composed of two semilunar flaps attached by their convex border to the sides of the

[Fig. 235.]



LYMPHATIC GLAND AND VESSELS. A. One of the inguinal lymphatic glands injected with mercury; *a*, afferent lymphatic vessels from the lower extremity; *b*, efferent vessels—others are also seen. B. One of the superficial lymphatic trunks of the thigh. C. One of the femoral lymphatic trunks laid open longitudinally to display the valves within it; *c*, sinus between the flap of the valve and the wall of the vessel. *d*, Surface of one flap directed towards the opposite; *e*, semicircular attached margin of the flap.]

vessel and free by their concave border. This is the general character of the valves, but, as in veins, there are exceptions in their form and disposition; sometimes one flap is so small as to be merely rudimentary, while the other is large in proportion; sometimes the flap runs all the way round the tube, leaving a central aperture, which can only be closed by a contractile power in the valve

itself; and sometimes, instead of being circular, the aperture is elliptical, and the arrangement of the flaps like that of the ileo-cæcal valve.¹ These peculiarities are most frequently met with at and near the anastomoses of the lymphatic vessels. The valves occur most numerously near the lymphatic glands; next in frequency they are found in the neck and upper extremities where the vessels are small, and least numerously in the lower limbs where the lymphatics are large. In the thoracic duct an interspace of two or three inches frequently occurs between the valves. Connected with the presence of valves in the lymphatic vessels are two lateral dilatations or pouches, analogous to the valvular *sinuses* of veins. The sinuses are situated on the cardiac side of the valves; they receive the valves when the latter are thrown back by the current of the lymph; and when reflux occurs they become distended with a body of fluid which makes pressure on the flaps. These pouch-like dilatations and the constrictions corresponding with the line of attachment of the convex borders of the flaps are the cause of the knotted appearance of distended lymphatic vessels.

Like arteries and veins, lymphatic vessels are composed of three coats, external, middle, and internal. The *external* or *areolar coat* is thin, but very strong, and serves to connect the vessel to surrounding tissues, at the same time that it forms a protective covering. It is composed of a network of areolar tissue mingled with fine fibres of elastic tissue and fibres of smooth muscle, arranged in a longitudinal direction; the latter serving to distinguish lymphatics, as Kölliker observes, from small veins. The *middle* or *muscular coat*, also thin and elastic, consists of a layer of smooth muscular fibres mingled with elastic fibres. These fibres are described by Mr. Lane as longitudinal; by Kölliker as transverse or circular, and analogous to the middle coat of arteries. The *internal coat*, less elastic and more liable to rupture than the other coats, is composed of a longitudinal network of elastic tissue, generally single, but sometimes double, supporting a layer of tessellated epithelium, consisting of nucleated slightly elongated cells. *Capillary* and *minute lymphatics* have a single, delicate, structureless, transparent coat, with imperfect longitudinal nuclei; the *minute lacteals* have a similar structure, but are somewhat thicker. The valves are composed of a very thin layer of areolar tissue coated on its two surfaces by epithelium.

The *Lymphatic Glands* (conglobate, absorbent) are small oval or bean-shaped, flattened or rounded bodies of a pale red color, and inclosed in a firm but thin sheath of areolar tissue mingled with fine fibres of elastic tissue. On the exterior the gland has the appearance of being composed of minute lobules, and on the face of a section the lobules are represented by *alveolar spaces*, bounded by a delicate areolar network, sent inwards by the sheath, and permeating the entire gland. Some difference of color and texture may also be perceived between the central and external part of the gland, which has determined its division into a *cortical* and *medullary portion*, the former being firmer in texture than the latter, which is soft and more or less pulpy. Moreover, the cortical portion appears to be composed of round, ovate, apparently glandular bodies, while the alveolar spaces of the medullary portion are filled with a grayish-white alkaline pulp, containing free nuclei with homogeneous contents, pale nucleated cells, and larger cells with vesicular nuclei and nucleoli, and occasionally some fat granules. The areolar structure of the gland is traversed by vessels, which frequently enter its substance through a hilum-like spot, and dividing into a capillary plexus in the walls of the alveoli, constitute, with the globular bodies of the cortex and the cells of the medulla, a porous glandular tissue, through which the lymph or chyle makes its way in its passage through the gland, and finally escapes by the vasa efferentia, carrying with it part of the cellular contents of the alveoli.² At their entrance into the gland the vasa inferentia terminate abruptly, and their contained fluid is emptied into the alveoli; and as the alveoli

¹ Mr. Lane, loc. cit.

² Ludwig and Noll.

communicate freely with each other, forming so many fine anastomosing canals, it is enabled to make its way to the vasa efferentia, probably undergoing some important nutritive change in its course, and receiving the nuclei and nucleated cells of the pulp as its future lymph corpuscles.¹ The bronchial glands differ in appearance from other lymphatic glands, as being more or less mottled with black, and sometimes filled with a black pigment. Lymphatic glands are larger in the young subject than in the adult, and are smallest in old age; they, as well as their vessels, are supplied with arteries, veins, and nerves, like other structures.

The *vasa vasorum* of lymphatics are the same as those of veins; but they are deficient of nerves.

I shall describe the lymphatic vessels and glands according to the arrangement adopted for the veins, commencing with those of the head and neck, and proceeding next to those of the upper extremity, lower extremity, and trunk.

LYMPHATICS OF THE HEAD AND NECK.

GLANDS.—The *Superficial lymphatic glands of the head and face* are small, few in number, and isolated; they are, the *occipital*, which are situated near the origin of the occipito-frontalis muscle; *posterior auricular*, behind the ear; *parotid*, in the parotid gland; *zygomatic*, in the zygomatic fossa; *buccal*, on the buccinator muscle; and *submaxillary*, beneath the margin of the lower jaw. There are no deep lymphatic glands within the cranium.

The *Superficial cervical lymphatic glands* are few in number and small; they are situated in the course of the external jugular vein, between the sterno-mastoid and trapezius muscle, at the root of the neck, and about the larynx.

The *Deep cervical glands* (glandulæ concatenatæ) are numerous and of large size; they are situated around the internal jugular vein and sheath of the carotid artery, by the side of the pharynx, œsophagus, and trachea, and extend from the base of the skull to the root of the neck, where they are in communication with the lymphatic vessels and glands of the thorax.

VESSELS.—The *Superficial lymphatic vessels of the head and face* are disposed in three groups; *occipital*, which take the course of the occipital vein to the occipital and deep cervical glands; *temporal*, which follow the branches of the temporal vein to the parotid and deep cervical glands, and *facial*, which accompany the facial vein to the submaxillary lymphatic glands.

The *Deep lymphatic vessels of the head* are the *meningeal* and *cerebral*; the former are situated in connexion with the meningeal veins, and escape through foramina at the base of the skull, to join the deep cervical glands. The *cerebral lymphatics*, according to Fohmann, are situated on the surface of the pia mater, none having as yet been discovered in the substance of the brain. They pass most probably through the foramina at the base of the skull, to terminate in the deep cervical glands.

The *Deep lymphatic vessels of the face* proceed from the nasal fossæ, mouth, and pharynx, and terminate in the submaxillary and deep cervical glands.

The *Superficial and Deep cervical lymphatic vessels* accompany the jugular veins, passing from gland to gland; at the root of the neck they communicate with the thoracic lymphatic vessels, and terminate, on the right side, in the ductus lymphaticus dexter; on the left, in the thoracic duct, near its termination.

¹ Brücke, 1853.

LYMPHATICS OF THE UPPER EXTREMITY.

GLANDS. — The *Superficial lymphatic glands* of the arm are not more than four or five in number, and of very small size. One or two are situated near the median basilic and median cephalic vein, at the bend of the elbow; and one or two near the basilic vein, on the inner side of the upper arm, immediately above the elbow.

The *Deep glands* in the forearm are excessively small and infrequent; two or three may be found in the course of the radial and ulnar vessels. In the upper arm there is a chain of small glands, accompanying the brachial artery.

The *Axillary glands* are numerous and of large size. Some are closely adherent to the vessels, others are dispersed in the loose cellular tissue of the axilla, and a small chain may be observed extending along the lower border of the pectoralis major to the mammary gland. Two or three subclavian glands are situated beneath the clavicle, and serve as the medium of communication between the axillary and deep cervical lymphatic glands.

VESSELS. — The *Superficial lymphatic vessels* of the upper extremity commence on the fingers and take their course along the forearm to the bend of the elbow. The greater part reach their destination by passing along the dorsal surface of the fingers, wrist, and forearm, and then curving around the borders of the latter; but some few are met with in the palm of the hand, which take the direction of the median vein. At the bend of the elbow the lymphatics arrange themselves into two groups; an internal and larger group, which communicates with a gland situated just above the inner condyle, and then accompanies the basilic vein upwards to the axilla to enter the axillary glands; and a smaller group which follows the course of the cephalic vein. Several of the vessels of this group cross the biceps muscle at its upper part to reach the axillary glands, while the remainder, two or three in number, ascend with the cephalic vein in the interspace of the deltoid and pectoralis major; these latter usually join a small gland in this space, and then cross the pectoralis minor muscle to become continuous with the subclavian lymphatics.

Besides the lymphatic vessels of the arm, the axillary glands receive those from the integument of the chest, its anterior, posterior, and lateral aspect, and the lymphatics of the mammary gland.

The *Deep lymphatics* accompany the vessels of the upper extremity, and communicate occasionally with the superficial lymphatics. They enter the axillary and subclavian glands, and, at the root of the neck, terminate on the left side in the thoracic duct, and on the right side in the ductus lymphaticus dexter.

LYMPHATICS OF THE LOWER EXTREMITY.

GLANDS. — The *Superficial lymphatic glands* of the lower extremity are those of the groin, *inguinal*; and one or two situated in the superficial fascia of the posterior aspect of the thigh, just above the popliteal region.

The *Inguinal glands* are divisible into two groups; a superior group of small size, situated along the line of Poupart's ligament, and receiving the lymphatic vessels from the parietes of the abdomen, gluteal region, perineum, and genital organs; and an inferior group of larger glands clustered around the internal saphenous vein near its termination, and receiving the superficial lymphatic vessels from the lower extremity.

The *Deep lymphatic glands* are the *anterior tibial, popliteal, deep inguinal, gluteal, and ischiatic*.

The *Anterior tibial* is generally a single gland, placed on the interosseous membrane, by the side of the anterior tibial artery in the upper part of its course.

The *Popliteal glands*, four or five in number, and small, are imbedded in the loose cellular tissue and fat of the popliteal space.

The *Deep inguinal glands*, less numerous and smaller than the superficial, are situated near the femoral vessels in the groin, beneath the fascia lata.

The *Gluteal* and *ischiatric glands* are placed near the vessels of that name, above and below the pyriformis muscle at the great ischiatic foramen.

VESSELS. — The *Superficial lymphatic vessels* are divisible into two groups, internal and external; the *internal* and principal group, commencing on the dorsum and inner side of the foot, ascend the leg by the side of the internal saphenous vein, and passing behind the inner condyle of the femur follow the direction of that vein to the groin, where they join the saphenous group of superficial inguinal glands. The greater part of the efferent vessels from these glands pierce the cribriform fascia of the saphenous opening and the sheath of the femoral vessels, to join the lymphatic gland situated in the femoral ring, which serves to establish a communication between the lymphatics of the lower extremity and those of the trunk. The other efferent vessels pierce the fascia lata to join the deep glands. The vessels which pass upwards from the outer side of the dorsum of the foot ascend along the outer side of the leg, and curve inwards across the front of the leg just below the knee, to unite with the lymphatics of the inner side of the thigh. The *external group* consists of a few lymphatic vessels which commence on the outer side of the foot and posterior part of the ankle, and accompany the external saphenous vein to the popliteal region, where they enter the popliteal glands.

The *Deep lymphatic vessels* accompany the deep veins, and communicate with the various glands in their course. After joining the deep inguinal glands they pass beneath Poupart's ligament, to communicate with the numerous glands situated around the iliac vessels. The deep lymphatics of the gluteal region follow the course of the branches of the gluteal and ischiatic veins. The former join the glands situated on the upper border of the pyriformis muscle, and the latter, after communicating with the lymphatics of the thigh, enter the ischiatic glands.

LYMPHATICS OF THE TRUNK.

The lymphatics of the trunk may be arranged under three heads, superficial, deep, and visceral.

The *Superficial lymphatic vessels* of the upper half of the trunk pass upwards and outwards at each side, and converge, some to the axillary glands, others to the glands at the root of the neck. The lymphatics from the mammary glands follow the lower border of the pectoralis major, communicating, by means of a chain of lymphatic glands, with the axillary glands. The superficial lymphatic vessels of the lower half of the trunk, gluteal region, perineum, and external organs of generation, converge to the superior group of superficial inguinal glands. One or two small glands are situated at each side of the dorsal vein of the penis, near the suspensory ligament; from these, as from the superficial lymphatics, the efferent vessels pass into the superior group of superficial inguinal glands.

GLANDS.—The *Deep lymphatic glands of the thorax* are the intercostal, anterior mediastinal, and œsophageal.

The *Intercostal glands*, of small size, are situated on each side of the vertebral column, near the articulations of the heads of the ribs, and in the course of the intercostal arteries.

The *Anterior mediastinal glands* are situated along the course of the internal mammary arteries; they are six or seven in number at each side, and receive the lymphatic vessels from the anterior wall of the chest, the mediastinum, thymus gland, and pericardium.

The *Æsophageal glands*, fifteen or twenty in number, are situated in the

course of the œsophagus, and receive the lymphatics of that tube; they communicate above with the deep cervical glands, on each side with the intercostal, and below with the abdominal glands.

VESSELS.—The *Deep lymphatic vessels of the thorax* are the intercostal, internal, mammary, and diaphragmatic.

The *Intercostal* lymphatic vessels follow the course of the veins of the same name; and reaching the vertebral column, curve downwards, to terminate in the thoracic duct.

The *Internal mammary* lymphatics commence in the parietes of the abdomen, communicating with the epigastric lymphatics. They ascend by the side of the internal mammary vessels, being joined in their course by the anterior intercostals, and terminate at the root of the neck, on the right side in the tributaries of the ductus lymphaticus dexter; on the left, in the thoracic duct. The *diaphragmatic* lymphatics pursue the direction of their corresponding veins, and terminate some *in front*, in the internal mammary vessels, and some *behind*, in the posterior mediastinal lymphatics.

GLANDS.—The *Deep lymphatic glands of the abdomen* are the lumbar glands; they are numerous, and seated around the common iliac vessels, the aorta, and vena cava.

The deep lymphatic glands of the pelvis are the external iliac, internal iliac, and sacral.

The *External iliac* are placed around the external iliac vessels, being in continuation by one extremity with the femoral lymphatics; by the other, with the lumbar glands.

The *Internal iliac* glands are situated in the course of the internal iliac vessels, and the *Sacral* glands rest on the concave surface of the sacrum.

VESSELS.—The *Deep lymphatic vessels* are continued upwards from the thigh beneath Poupart's ligament, and along the external iliac vessels to the lumbar glands, receiving in their course the epigastric, circumflexa ilii, and ilio-lumbar lymphatic vessels. Those from the parietes of the pelvis, and from the gluteal, ischiatic, and obturator vessels, follow the course of the internal iliac veins, and unite with the lumbar lymphatics. And the lumbar lymphatic vessels, after receiving all the lymphatics from the lower extremities, pelvis, and loins, terminate by several large trunks in the receptaculum chyli.

LYMPHATICS OF THE VISCERA.

LUNGS.—The *Lymphatic vessels of the lungs*, of large size, are distributed over every part of the surface, and through the texture of those organs: they converge to the *bronchial glands*, ten or twelve in number, situated around the bifurcation of the trachea and roots of the lungs. Some of these glands, of small size, may be traced in connexion with the bronchial tubes into the substance of the lungs. The efferent vessels from the bronchial glands unite with the tracheal and œsophageal glands, and terminate principally in the thoracic duct at the root of the neck, and partly in the ductus lymphaticus dexter. The bronchial glands, in the adult, present a variable tint of brown, and in old age a deep black color. In infancy they have none of this pigment, and are not to be distinguished from lymphatic glands in other situations.

HEART.—The *Lymphatic vessels of the heart* originate in the subserous areolar tissue of the surface, and in the deeper tissues of that organ, and follow the course of the vessels, principally, along the right border of the heart to the glands situated around the arch of the aorta and to the bronchial glands, whence they proceed to the root of the neck, and terminate in the thoracic duct. The *cardiac glands* are three or four in number.

The *pericardiac* and *thymic* lymphatic vessels proceed to join the anterior mediastinal and bronchial glands.

LIVER.—The *Lymphatic vessels of the liver* are divisible into deep and superficial. The former take their course through the portal canals, and through the right border of the lesser omentum, to the lymphatic glands situated in the course of the hepatic artery and along the lesser curve of the stomach. The *superficial* lymphatics are situated in the areolar structure of the proper capsule, over the whole surface of the liver. The lymphatics of the convex surface are divided into two sets:—1. Those which pass from before backwards; 2. Those which advance from behind forwards. The former unite to form trunks, which enter between the folds of the lateral ligaments at the right and left extremities of the organ, and of the coronary ligament in the middle. Some of these pierce the diaphragm and join the posterior mediastinal glands; others converge to the lymphatic glands situated around the inferior cava. Those which pass from behind forwards consist of two groups: one ascends between the folds of the broad ligament, and perforates the diaphragm, to terminate in the anterior mediastinal glands; the other curves around the anterior margin of the liver to its concave surface, and from thence to the glands in the right border of the lesser omentum. The lymphatic vessels of the concave surface are variously distributed, according to their position; those from the right lobe terminate in the lumbar glands; those from the gall-bladder, which are large, and form a remarkable plexus, enter the glands in the right border of the lesser omentum; and those from the left lobe converge to the lymphatic glands situated along the lesser curve of the stomach.

SPLEEN AND PANCREAS.—The *Lymphatic glands of the spleen* are situated around its hilum, and those of the *pancreas* in the course of the splenic vein. The *lymphatic vessels* of these organs pass through their respective glands, and join the aortic glands, previously to terminating in the thoracic duct.

STOMACH.—The *Lymphatic glands of the stomach*, of small size, are situated along the lesser and greater curve of that organ. The *lymphatic vessels*, as in other viscera, are superficial and deep, the former originating in the subserous, the latter in the submucous tissue; they pass from the stomach in four different directions: some ascend to the glands situated along the lesser curve; others descend to those occupying the greater curve; a third set pass outwards to the splenic glands, and a fourth to the glands situated near the pylorus, and to the aortic glands.

INTESTINES.—The *Lymphatic glands of the small intestine* are situated between the layers of the mesentery, in the meshes formed by the superior mesenteric artery, and are thence named *mesenteric glands*. These glands are most numerous and largest, superiorly, near the duodenum; and, inferiorly, near the termination of the ileum.

The *Lymphatic vessels* of the small intestines are of two kinds: those of the structure of the intestine, which run upon its surface previously to entering the mesenteric glands; and those which commence in the villi, in the substance of the mucous membrane, and are named lacteals.

The *Lacteals*, according to Henle, commence in the centre of each villus as a caecal tubulus, which opens into a fine network, situated in the submucous tissue. From this network the lacteal vessels proceed to the mesenteric glands, and from thence to the thoracic duct, in which they terminate.

The *Lymphatic glands of the large intestines* are situated along the attached margin of the intestine, in the meshes formed by the colic and hæmorrhoidal arteries previously to their distribution. The *lymphatic vessels* take their course in two different directions; those of the cæcum, ascending colon and transverse colon, after traversing their proper glands, proceed to the mesenteric glands, and those of the descending colon and rectum to the lumbar glands.

KIDNEY.—The *Lymphatic vessels of the kidney* follow the direction of the bloodvessels to the lumbar glands situated around the aorta and inferior vena

cava; those of the supra-renal capsules, which are very large and numerous, terminate in the renal lymphatics.

PELVIS. — The *Lymphatic vessels of the viscera of the pelvis* terminate in the sacral and lumbar glands.

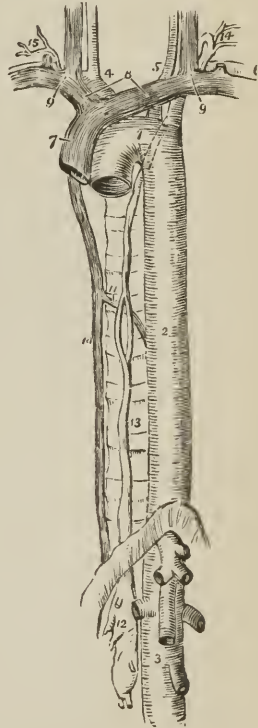
The *Lymphatic vessels of the testicle* take the course of the spermatic cord, in which they are of large size; they terminate in the lumbar glands.

THORACIC DUCT.

The thoracic duct,¹ the great trunk of the lymphatic and chylous system, commences in the abdomen, by a considerable and somewhat triangular dilatation, the *receptaculum chyli*, which is situated on the front of the body of the second lumbar vertebra, behind and between the aorta and inferior vena cava, and close to the tendon of the right crus of the diaphragm. From the upper part of the receptaculum chyli the thoracic duct ascends through the aortic opening of the diaphragm, and along the front of the vertebral column, lying between the tho-

FIG. 236.

THE COURSE AND TERMINATION OF THE THORACIC DUCT. 1. Arch of the aorta. 2. Thoracic aorta. 3. Abdominal aorta; showing its principal branches divided near their origin. 4. Arteria innominata, dividing into right carotid and right subclavian. 5. Left carotid. 6. Left subclavian. 7. Superior cava, formed by the union of, 8, the two venæ innominatæ; and these by the junction, 9, of the internal jugular and subclavian vein at each side. 10. Greater vena azygos. 11. Termination of the lesser in the greater vena azygos. 12. Receptaculum chyli; several lymphatic trunks are seen opening into it. 13. Thoracic duct, dividing opposite the middle of the dorsal vertebræ into two branches which reunite; the course of the duct behind the arch of the aorta and left subclavian artery is shown by a dotted line. 14. The duct making its turn at the root of the neck and receiving several lymphatic trunks previously to terminating in the posterior aspect of the junction of the internal jugular and subclavian vein. 15. Termination of the trunk of the ductus lymphaticus dexter.



racic aorta and vena azygos and upon the right intercostal arteries, to the fourth dorsal vertebra. It then inclines to the left side, passes behind the arch of the aorta, and ascends by the side of the œsophagus and behind the perpendicular

¹ The thoracic duct was discovered by Eustachius, in 1563, in the horse; he regarded it as a vein, and called it the vena alba thoracis. The lacteals were first seen by Asellius, in 1622, in the dog; and within the next ten years by Veslingius in man.

portion of the left subclavian artery to the root of the neck opposite the seventh cervical vertebra, where it makes a sudden curve forwards and downwards, and terminates at the point of junction of the left subclavian with the left internal jugular vein.

The thoracic duct is about eighteen or twenty inches in length, and near its origin as large as a goose-quill; as it ascends it diminishes in size; and near its termination again becomes dilated. At the middle of the thorax it frequently divides into two branches of equal size, which reunite after a short course; and sometimes it gives off several branches, which assume a plexiform arrangement in this situation. Occasionally the thoracic duct bifurcates at the upper part of the thorax into two branches, one of which opens into the point of junction between the right subclavian and jugular vein, while the other proceeds to the normal termination of the duct on the left side. In rare instances the duct has been found to terminate in the vena azygos, which is its normal destination in some mammalia.

The thoracic duct presents fewer valves in its course than lymphatic vessels generally; at its termination it is provided with a pair of semilunar valves, to prevent the admission of venous blood.

Branches.—The thoracic duct receives at its commencement four or five large lymphatic trunks, which unite to form the receptaculum chyli; it next receives the trunks of the lacteal vessels. Within the thorax it is joined by a large lymphatic trunk from the liver, and in its course through the posterior mediastinum, receives the lymphatic vessels both from the viscera and parietes of the thorax. At its curve forwards in the neck it is joined by lymphatic trunks from the left side of the head and neck, left upper extremity, upper part of the thorax, and thoracic viscera.

The *Ductus lymphaticus dexter* is a short trunk which receives the lymphatic vessels from the right side of the head and neck, right upper extremity, right side of the thorax, right lung, and one or two branches from the liver. It terminates at the junction of the right subclavian with the right internal jugular vein, at the point where these veins unite to form the right vena innominata; and is provided at its termination with a pair of semilunar valves, which prevent the entrance of blood from the veins.

CHAPTER IX.

OF THE NERVOUS SYSTEM.

THE nervous system consists of a central organ, the cerebro-spinal centre or axis, and numerous rounded and flattened white cords, the nerves, which are connected by one extremity with the cerebro-spinal centre, and by the other are distributed to all the textures of the body. The sympathetic system is an exception to this description; for in place of one it has many small centres which are called ganglia, and which communicate very freely with the cerebro-spinal axis and with its nerves.

The cerebro-spinal axis consists of two portions, the brain, an organ of large size, situated within the skull, and the spinal cord, a lengthened portion of the nervous centre continuous with the brain, and occupying the canal of the vertebral column.

The most superficial examination of the brain and spinal cord shows them to be composed of fibres, which in some situations are ranged in a longitudinal

direction, and in others are interlaced by cross fibres. It is also observed that the cerebro-spinal axis presents two substances differing from each other in density and color; a gray or cineritious or cortical substance, and a white or medullary substance. The *gray substance* forms a thin lamella over the surface of the convolutions of the cerebrum, and of the laminae of the cerebellum; hence it has been named cortical: but the gray substance is not confined to the surface of the brain, as this term would imply; it is likewise situated in the centre of the spinal cord its entire length, and may be thence traced through the medulla oblongata, crura cerebri, thalami optici, and corpora striata: it enters also into the composition of the locus perforatus, tuber cinereum, commissura mollis, pineal gland, pituitary gland, and corpora rhomboidea. Two kinds of gray substance are described by Rolando as existing in the spinal cord; the one (*substantia cinerea spongiosa vasculosa*) is the ordinary gray matter of the cord, the other (*substantia cinerea gelatinosa*) is found along the edge and at the extremity of the posterior cornua.

The *elementary constituents* of the nervous system are *nerve-fibres* and *nerve-cells*; and associated with the latter, a *finely granular, pale matrix substance*, and *free cell-nuclei*.

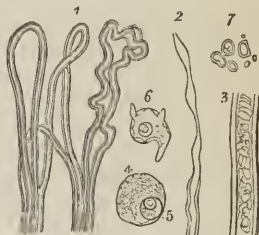
The NERVE-FIBRES (nerve tubes; primitive fibres and tubes) are the chief components of the nerves and of the white substance of the brain and spinal cord, and are also found, but in less number, in the gray substance and ganglia. They are soft and cylindrical, clear and transparent when seen by transmitted light; white, glittering, and opaline when the light is reflected, and bounded by simple, dark, contour lines. They present great variety of size and some degree of variety of texture, being coarse or fine, fragile or firm; their measurement varies between $\frac{1}{1200}$ and $\frac{1}{2400}$ of an inch; and they undergo a structural change after death or under the influence of chemical reagents, which converts them from simple cylinders into cylinders with *double* boundary lines or contours.

In *structure* the nerve-fibre is composed of three parts; namely, an external coat or sheath, a medulla or pulp, and a central solid filament or axis-cylinder.

The *sheath* is excessively fine and transparent; so fine and transparent as to be almost invisible, or demonstrable only by chemical means, and of doubtful existence even, in the finer fibres. It is elastic and structureless, and corresponds in general and chemical characters with the sarcolemma of muscular fibre.

The *medulla* or pulp (medullary sheath) is the mid-layer of the nerve-fibre; it is a viscous, transparent, clear, homogeneous fluid, easily susceptible of coagulation, and converted in its coagulated state into an opaque, granular, white substance. The coagulation of the medulla commences from the exterior, and gives rise to the appearance of double boundary lines in the fibre (dark-bordered fibres); and the greater or less extent of the coagulum determines the depth of the interval between the double lines. In the *fine* nerve-fibres with a more delicate sheath, the medulla is apt to undergo another change, namely, that of collecting from point to point into elliptical masses, and producing *varicose nerve-fibres*. In chemical composition the medulla consists chiefly of oily and albuminous

FIG. 237.



NERVE-FIBRES AND NERVE-CELLS. 1. Nerve-fibres, with double contours, or dark-bordered nerve-fibres, showing their parallel arrangement in the nerves and their mode of termination in loops. 2. A dark-bordered nerve-fibre terminating in a varicose fibre. 3. A dark-bordered nerve-fibre, showing the granular coagulum of the medulla. 4. A nerve-cell with nucleus, and 5, nucleolus. 6. A nerve-cell, giving off three processes. 7. Granules and free nuclei.

matter; its cognomen, *medullary sheath*, is derived from its position, encircling the central filament as in a sheath; and it is absent in the finest nerve-fibres.

The *central filament*, or *axis-fibre* (axis-cylinder, Purkinje; primitive band, Remak), is a pale, transparent, homogeneous, slightly flattened or cylindrical filament, which occupies the centre of the nerve-fibre. It is about one-third the thickness of the nerve-fibre; is solid and elastic, sometimes finely granular or striated, and is only brought into view when the fibre is broken up or the medulla dissolved by chemical means. It is also met with in an isolated form, and divested both of sheath and medulla. According to Kölliker, the central filament exists in all nerve-fibres, coarse or fine; but Valentin and Henle, among other histologists, regard it as simply the uncoagulated portion of the medullary sheath. Kölliker adduces, in support of his views, the constancy of appearance of the filament, its chemical constitution as a protein compound allied to coagulated albumen, and its presence in nerves still warm with life; his opinion is probably correct.

Besides the *medullated* or *dark-bordered nerve-fibres*, now described, there are others which contain no medulla, *non-medullated fibres*, and which consist only of the central filament invested by the nerve-sheath. The non-medullated nerve-fibres are pale in color, and bounded by single contour lines; they are more or less transparent and consistent, and sometimes nucleated; in a word, they present those conditions which distinguish them as nerve-fibres in process of development, and, as such, are the chief constituent of the embryonic brain. According to this view, the contents of the embryonic fibres separate into two parts, of which the exterior, fluid and viscous, is the medulla, while the unaltered interior, firm and solid, is the central filament. *Pale non-medullated fibres* are found in connexion with nerve-cells, constituting the processes of those cells, and sometimes forming the bond of union between the nerve-cells and medullated fibres; they are found also as peripheral continuations of the medullated fibres in the cornea; in the Pacinian corpuscles; and as nucleated fibres in the terminal expansion of the olfactory nerves.

The NERVE-CELLS (nerve-corpuseles) are nucleated cells, occurring in great numbers in the gray or colored portion of the brain and spinal cord, in ganglia, occasionally in the trunks of certain nerves, and in nervous expansions, as of the optic and auditory nerve. In *structure* they are composed of a delicate structureless membrane, containing soft pulpy grayish contents, and a central nucleated nucleus. In size the nerve-cells vary between $\frac{1}{200}$ and $\frac{1}{8000}$ of an inch in diameter, and the nuclei between $\frac{1}{1500}$ and $\frac{1}{8000}$. The contents of the cells are a clear, homogeneous, colorless, or slightly yellowish matrix, having diffused through it a multitude of minute round granules of nearly uniform size. Sometimes the granules are pale and colorless, or have intermingled with them a small number which are slightly tinged with yellow or gray, and constitute *colorless nerve-cells*. At other times the granules have a brownish or blackish tint, and have mingled with them others of a darker and larger kind; these are the *colored* or *pigmentary nerve-cells*. Occasionally, the colored granules are diffused equally through the mass of the contents, while in other cells they are congregated near the nucleus, and form a considerable mass. The *nucleus* is a clear spherical vesicle with a distinct membrane and transparent contents, with one and sometimes two or more large opaque *nucleoli*. The soft elastic contents of the nerve-cells are a protein compound, analogous to that of the central filament of the nerve-fibres; the opaque granules consisting chiefly of fatty matter and pigment.

Nerve-cells present some variety in structure and form; they may have *thin* walls, like the cells above described, found in the brain and spinal cord; or *thick* walls, as in the cells of ganglia. They may be *independent cells*, or they may be furnished with pale filamentary processes, and be termed according to the number of such processes, *unipolar*, *bipolar*, or *multipolar* cells, the cells with-

out processes being *apolar*. The processes given off by these cells resemble the non-medullated nerve-fibres, and are sometimes continuous with the medullated fibres; at other times they are branched.

The *finely granular pale matrix substance* is found chiefly in the gray matter of the brain and spinal cord; it is identical with the contents of the nerve-cells. The *free cell-nuclei* correspond with the nuclei of the nerve-cells, and in certain situations are accumulated in considerable number.

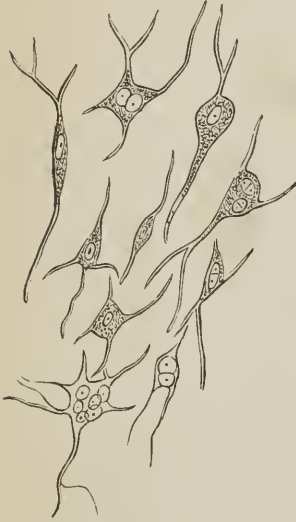
These being the elementary constituents of the nervous system, we may now proceed to inquire into their mode of distribution in the spinal cord, the brain, the cerebro-spinal nerves, and sympathetic system.

SPINAL CORD.—In the spinal cord the *white* or *medullary substance* occupies the exterior of that organ, [see fig. 258] while the interior is composed of gray substance. The spinal cord is divided into two lateral halves, by an anterior and posterior fissure, and each lateral half is marked into three parts or columns (*funiculi*) by an anterior and posterior lateral groove corresponding with the line of attachment of the anterior and posterior roots of the spinal nerves. At the bottom of the anterior fissure the white substance of one half is continuous with that of the other, constituting the anterior or *white commissure*. Behind, at the posterior fissure, the white substance of the two halves is in apposition, the fissure being indicated, for the greater part of its extent, by the perforations of bloodvessels merely, and existing as a distinct separation only in the upper part of the cervical and in the lumbar region. The *gray substance* (nucleus), occupying the interior of the spinal cord, consists of a transverse portion, which crosses from one half into the other, and two processes which project from the transverse portion forwards and backwards in each lateral half of the cord, so as to present on the face of a section the appearance of a dumb-bell or two irregular crescents, connected by their convex borders. The transverse portion is the *gray commissure*, and the anterior and posterior projections of the lateral portion the *anterior* and *posterior cornua*.

The *white substance* of the cord is composed of parallel *longitudinal fibres*, of uniform size, and diminishes in bulk from above downwards in consequence of the deeper fibres passing inwards to the gray substance, and assuming a *transverse* or oblique direction; and subsequently, after undergoing certain alterations of character and size, issuing from the cord as the roots of the spinal nerves. The particular course of these fibres is as follows: proceeding from the brain, the deep fibres of the anterior column of one side of the spinal cord cross the bottom of the anterior fissure, enter the gray substance of the anterior cornu of the opposite side, and become continuous with the fibres of origin of the anterior root of a spinal nerve. The anterior commissure is, therefore, the decussation of the fibres of the anterior columns, and is thickest and broadest where the spinal nerves are largest and most numerous, namely, at the cervical and lumbar swelling of the cord. The deep fibres of the lateral column passing inwards, enter the anterior and posterior cornu of the gray substance; those of the anterior half passing forwards through the anterior cornu, and becoming continuous with the fibres of the anterior root of a spinal nerve; and those which pass backwards through the posterior cornu becoming continuous with the posterior root. The deep fibres of the posterior column, after entering in the same manner the posterior cornu, divide into two sets, one of which curves outwards and backwards, and enters the posterior root of a spinal nerve; while the other set passes inwards through the central gray substance to the opposite posterior column, constituting the posterior or gray commissure. In this manner, the anterior root of a spinal nerve is shown to be a continuation of the fibres of the anterior part of the lateral column of its own side, and the anterior column of the opposite side; while the posterior root is a continuation of the fibres of the posterior part of the lateral and part of the posterior column of its own side, and part of the lateral and posterior column of the opposite side.

The *gray substance* (*substantia grisea*; *gray nucleus*) of the cord is most abundant in the lumbar swelling, next in the cervical swelling, then in the dorsal portion, and, at the extremity

FIG. 238.

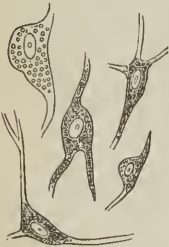

MULTI-NUCLEATED CELLS FROM THE CENTRAL GRAY SUBSTANCE of the spinal cord; magnified 350 times; after Kölliker. These cells measure between $\frac{1}{3000}$ and $\frac{1}{1500}$ of an inch in diameter.

processes, which terminate in fine fibrils. They are fusiform or polygonal in shape, contain a brown pigment, and are found in the anterior and posterior

cornua of the gray substance; in the former composing two groups, which are traversed by the internal and external division of the anterior roots of the spinal nerves. The processes of the cells are fine pale fibrils, resembling axis-fibres of the finest kind.

FIG. 239.



CELLS FROM THE SUBSTANTIA GELATINOSA of the posterior horn of the spinal cord; magnified 350 times; after Kölliker.

The *nerve-fibres of the gray substance* of the spinal cord constitute about half its bulk, and are referable to three sources, namely, to the roots of the spinal nerves, to the gray substance itself, and to the processes of the nerve-cells. The *fibres of the roots of the spinal nerves* may be traced through the longitudinal fibres of the white substance into the gray; they diminish in size as they enter the gray, and become still smaller in the gray substance, being reduced to half their former size; leaving the gray substance, they increase in dimensions, and finally join the deep longitudinal fibres of the white substance, restored to their original bulk. The *anterior roots*, at their entrance into the cord, divide into two fasciculi, inner and outer; the inner fasciculus, entering the inner side of the

apex of the anterior cornu, passes through the inner group of large multipolar pigmentary cells, and, following the inner half of the cornu, reaches the anterior commissure, through which it attains the opposite side of the cord, and, turning

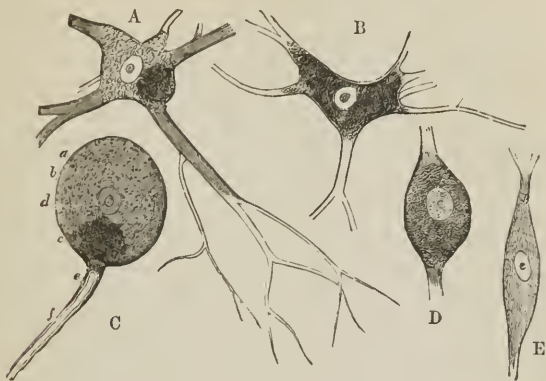
the anterior cornua are short and thick and of an uniform gray color; the posterior cornua, longer and thinner and less uniform in color, are surrounded by the *substantia gelatinosa* of Rolando, which is most abundant at their extremity, and streaked by the fasciculated posterior roots of the spinal nerves. The gray substance is composed of nerve-cells and transverse fibres; the latter, of medium size and fine, extending into the lateral halves of the cord constituting the posterior commissure.

The *nerve-cells of the gray substance* present three principal forms, namely, cells of the central gray substance; cells of the *substantia gelatinosa*; and large pigmentary cells. Between the two former, every possible gradation of size and form is also met with. The *cells of the central gray substance* are pale, finely granular, contain several nuclei, and give off pale branching processes. The *cells of the substantia gelatinosa* have a yellowish colour, contain single nuclei, and give off smaller processes, from one to three in number.

The *pigmentary cells* are of large size, and are multipolar or many-rayed cells, giving off numerous, from two to nine or more, branched

upwards, becomes continuous with the longitudinal fibres of the anterior columns. The outer fasciculus, the larger of the two, passes through the outer part of the anterior cornu and outer group of large multipolar pigmentary cells, and then

FIG. 240.



VARIOUS FORMS OF NERVE-CELLS. A, B. Large nerve-cells, with branching processes from the anterior cornu of the spinal cord; after Kölliker. The pigment granules are collected into a mass in one of the cells; but are more generally distributed in the other. The cells measure between $\frac{1}{400}$ and $\frac{1}{200}$ of an inch in diameter; and their nuclei $\frac{1}{2500}$ to $\frac{1}{1500}$. [c. Nerve-cell with its connected fibre; from the anastomosis of the facial and auditory nerves at the meatus auditorius internus of the ox. a. Cell-wall. b. Cell-contents. c. Pigment. d. Nucleus. e. Continuation of the sheath upon the nerve-fibre. f. Nerve-fibre. n. Nerve-cell from the substantia ferruginea of man. e. Smaller cell from the spinal cord. Magnified 350 diameters.]

curves outwards to become continuous with the longitudinal fibres of the anterior part of the lateral column. The *posterior roots*, after penetrating the white fibres of the exterior of the cord, collect into small fasciculi, which enter the substantia gelatinosa, and then, divided into fibres, pass into the posterior cornu; in the posterior cornu they separate into two portions, posterior and anterior; the posterior portion bends directly backwards, and becomes continuous with the longitudinal fibres of the posterior columns and posterior part of the lateral columns; while the anterior portion passes in part outwards to become continuous with the posterior part of the lateral columns, and in part inwards to become continuous with the fibres of the posterior column, and cross into the other half of the cord, constituting the posterior commissure, and thence become continuous with the posterior and lateral columns of the opposite side. In pursuing this course the nerve-fibres become diminished in size, their sheath is more delicate, they are more fragile, and they acquire the property of becoming varicose, and in their finest state they appear to lose their sheath entirely and become reduced to their central axis-cylinder; besides which they are mingled with the nerve-cells of the gray substance, the large multipolar pigmentary cells of the anterior cornua, the small cells of the substantia gelatinosa, and the medium-sized cells with the gray pulpy matrix and free nuclei of the substantia grisea.

MEDULLA OBLONGATA.—In the medulla oblongata the columns of the spinal cord undergo some change of position; the *anterior columns* separate from each other and ascend to the outer side of the corpora pyramidalia. A small portion of the anterior column constitutes the outer part of the corpus pyrami-

dale, while the larger portion (*funiculus olivaris*) divides into two fasciculi, *funiculi siliquæ*, which embrace the *corpus olivare*, and are then continued through the pons Varolii above the second stratum of transverse fibres, one of the two bundles becoming the *laqueus* and entering the corpora quadrigemina, where it meets its fellow of the opposite side, the other passing into the upper division, *tegmentum*, of the crus cerebri. The *lateral columns* divide into three portions; anterior, middle, and posterior. The *anterior portion*, advancing into the space left by the divergence of the anterior columns, constitutes the *corpora pyramidalia*, the one corpus pyramidale, decussating with the other at the middle line by means of two or three fasciculi. The corpora pyramidalia are continued through the pons Varolii between its first and second transverse layers and enter the lower segment of the crus cerebri. The *middle portion*, *fasciculi innominati*, continued upwards, make their appearance in the floor of the fourth ventricle under the name of eminentiæ teretes, and are thence prolonged into the tegmentum of the crura cerebri. The *posterior portion* unites with the corpus restiforme and enters the crus cerebelli. The *posterior columns* constitute the fasciculi cuneati and fasciculi graciles; the former enter the crura cerebelli, while some of their fibres, with the fasciculi graciles, are continued forwards by the side of the eminentiæ teretes to the tegmentum of the crura cerebri. The tegmentum cruris cerebri therefore becomes the recipient of fibres from the anterior, middle, and posterior column.

Besides these, which are the longitudinal fibres of the medulla oblongata, there are *transverse fibres*, which are disposed in three sets; namely, *fibræ arciformes* (superficial cerebellar fibres, Solly), which curve superficially to the corpus pyramidale and olivare and take their course to the crus cerebelli; *antero-posterior fibres*, which pass from before backwards through the middle of the medulla oblongata, forming its raphé; and *lateral fibres*, which pass outwards from the raphé into the lateral halves of the medulla; the most posterior of these fibres (deep cerebellar fibres, Solly) taking their course through the posterior funiculi siliquæ and fasciculi cuneati into the crura cerebelli.

The *gray substance* of the medulla oblongata is collected into three principal masses, which are situated respectively in the corpora olivaria, corpora restiformia, and floor of the fourth ventricle; and, in addition to those, there are smaller collections of gray matter in the corpora pyramidalia and funiculi siliquæ. In the *corpus olivare* the gray matter forms a crumpled oblong capsule of a yellowish-brown color, open behind, the *nucleus olivæ* (*corpus dentatum*); and posteriorly to this and on a plane with its upper two-thirds, another yellowish lamella, the *nucleus olivæ accessorius* (Stilling). The gray substance of the *corpora restiformia* (*nucleus cinereus*) is a prolongation upwards of the posterior cornua of the spinal cord, and occupies the interior of the fasciculi laterales, cuneati, and graciles. The gray substance of the *floor of the fourth ventricle* is a prolongation upwards of the central substance of the spinal cord; it forms a thick layer in the floor of the ventricle, extending from the calamus scriptorius to the aqueduct of Sylvius.

The gray substance of the medulla oblongata, like that of the spinal cord, is composed of nerve-cells and nerve-fibres. The *nerve-cells* of the nucleus olivæ are small, round, contain yellowish granules which give color to the nucleus, and have from three to five processes; the nerve-cells of the nucleus cinereus of the corpora restiformia are similar in size to those of the nucleus olivæ, and have similar processes, but are either wanting in pigment or have pigment granules of a brownish hue; the nerve-cells of the corpora pyramidalia and funiculi siliquæ are large and caudate, while those of the gray substance of the floor of the fourth ventricle are partly caudate, presenting every gradation of size, and partly large with an abundance of pigment granules and finely-branched processes.

The *nerve-fibres* of the gray substance of the medulla oblongata are the

transverse fibres, which proceed from the raphé, and take their course into, through, and around the nucleus olivæ and between the deep longitudinal fibres of the corpora pyramidalia and funiculi siliquæ; the nerve-fibres are for the most part of the finer kind.

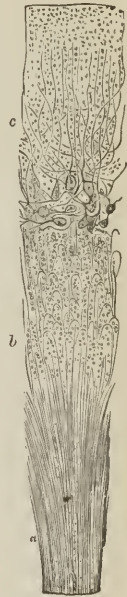PONS VAROLII. — The pons Varolii, or great commissure of the cerebellum, is composed of successive layers of white and gray substance, the former consisting of transverse parallel nerve-fibres, the latter of ordinary gray substance, traversed by the longitudinal nerve-fibres of the corpora pyramidalia and funiculi siliquæ, the corpora pyramidalia passing between the first and second transverse layers, into the inferior segment of the crura cerebri, the funiculi siliquæ above the second transverse layer into the upper segment or tegmentum. The gray substance is continuous with that of the medulla oblongata below, and the substantia nigra of the crura cerebri above.

CEREBELLUM. — The great bulk of the cerebellum is composed of white nerve-fibres, the fibres presenting every gradation of magnitude, from the dark-bordered to the softer non-medullated nerve-fibre, and the slender filaments apparently consisting of the axis-cylinder alone. The gray substance is found in three situations, namely, on the surface, constituting the cortical substance of the convolutions, in the centre of each lateral half of the white substance, forming the corpus dentatum; and in small quantity in the velum medullare inferius of the roof of the fourth ventricle.

The cortical substance presents the appearance of two layers of nearly equal thickness, the outer being gray, the inner yellowish-red, *substantia ferruginea*. The intimate components of the cortical substance are, nerve-fibres, nerve-cells, free cell-nuclei, and a pale yellowish granular substance, which is identical in character with the granular matrix of the nerve-cells. The *nerve-fibres* proceed from the white medullary substance; they become reduced in the cortical substance to the dimensions of the finest nerve-fibres, form a close plexus by mutual interlacement in the substantia ferruginea and deep layer of the gray substance, and are finally lost towards the middle of the latter. The *nerve-cells* are of two kinds, small and large; both are found in the deep layer of the substantia grisea, near the substantia ferruginea. The smaller nerve-cells, the least numerous of the two, are pale, with delicate processes. The large nerve-cells are round, oval, or pyriform in shape, contain a finely-granular colorless substance, and give off from their peripheral side two or three branched processes of considerable size, which take their course towards the granular superficial layer. The cell-nuclei are found in great numbers in the substantia ferruginea imbedded among the nerve-fibres, and also in the deep layer of the gray substance among the large and small cells; and the pale yellowish granular substance, exists throughout the whole of the substantia grisea, but chiefly in its deep layer.

The *corpus dentatum* is a grayish-red crumpled capsule, containing a large number of yellow pigmentary cells of medium size, each cell being provided with four or five processes; and the *gray substance* of the

FIG. 241.



SECTION OF THE CORTICAL SUBSTANCE OF THE CEREBELLUM; after Kölliker. a. Medullary substance, showing its fibres. b. The substantia ferruginea, composed of fibres and cell-nuclei. c. The gray substance; granular at the surface, and containing large multipolar branching cells near the substantia ferruginea.

velum medullare inferius of the *fourth ventricle* consists of brownish pigmentary cells, intermingled with nerve-fibres.

CEREBRUM.—The cerebrum has entering into its composition three pairs of ganglia, namely, corpora quadrigemina, thalami optici, and corpora striata; and the hemispheres; and each of these parts is composed of white and gray substance.

The gray substance of the cerebral ganglia is similar in structure to that of the gray substance of other parts; it is separate and isolated in the corpora striata, but continuous with the gray substance of the pons Varolii and medulla oblongata in the thalami optici and corpora quadrigemina; it is also somewhat deeper in color in the thalami optici than in the corpora quadrigemina, and inseparably commingled with the white fibres. The corpora quadrigemina and thalami receive their white fibres from the processus cerebelli ad testes, funiculi siliquæ, fasciculi innominati, and partly from the corpora restiformia; while the base of the thalami is traversed by the crura cerebri.

The *corpus striatum* contains two large nuclei of gray substance, *nucleus caudatus*, which is superior and anterior, and *nucleus lenticularis*, inferior and posterior, though both are connected in front; and two smaller and secondary portions, *nucleus teniaformis* and *amygdala*. The gray substance is composed of nerve-cells and fine nerve-fibres; the nerve-cells being partly colorless and partly pigmentary, and provided with from two to five processes. The *white nerve-fibres* are derived from the corpus pyramidale and lower segment of the crura cerebri. Entering the corpus striatum they collect into fasciculi, which penetrate the first division of the lenticular nucleus and anterior and thicker portion of the nucleus caudatus; they then divide into smaller fasciculi, and, spreading out in a radiated manner, pass successively through the second and external layer of the nucleus lenticularis. In their course they are reduced in size to an extreme degree of fineness, and terminate by forming a plexiform interlacement in which they are finally lost.

Connected with the central ganglia are other smaller collections of gray substance, namely, the substantia nigra of the crura cerebri, the commissura mollis, pineal gland, floor of the third ventricle, corpora mamillaria, tuber cinereum, and pituitary gland. The *substantia nigra* is composed of pigmentary nerve-cells similar to those of the substantia ferruginea of the cerebellum, but smaller and possessed of fewer processes. In the *commissura mollis* the nerve-cells are smaller and paler, with from one to three processes, and mingled with fine plexiform nerve-fibres, and a few of the coarser kind. The *pineal gland* is made up of pale round nerve-cells without processes and scattered nerve-fibres, and contains in addition the sabulous matter peculiar to that organ. The peduncles of the gland consist of an admixture of coarse and fine nerve-fibres. In the *floor* of the *third ventricle* there are large and small nerve-cells imbedded in the meshes of fine nerve-fibres; the cells are pale, and furnished with from one to four processes, often very large. The *corpus mamillare* is a hollow capsule of white substance, containing gray substance similar to that of the floor of the third ventricle, but with nerve-cells somewhat less in size. The *tuber cinereum* is composed of small cells with not more than one or two processes.

The *pituitary gland* has a small quantity of fine granular substance, with cell-nuclei and fine fibres in its posterior lobe; but no nervous elements in the anterior or larger lobe. The gray matter and the nerve-fibres communicate with the tuber cinereum through the medium of the infundibulum.

HEMISPHERES.—The hemispheres are composed of white nerve-fibres, which take a radiated course from the corpus callosum and cerebral ganglia to the surface, where they are invested with gray substance. The fibres are parallel, independent, and undivided, and their average diameter $\frac{1}{80000}$ of an inch.

The *gray or cortical substance* presents the appearance of three layers; ex-

ternal, white; middle, gray; and internal, yellowish-red. The internal layer occupies about half the thickness of the cortical substance, and is marked horizontally by two clear whitish streaks consisting of nerve-fibres, one of these streaks being situated at about its middle; the other at its junction with the gray layer; hence, the section of the cortical substance may be said to exhibit six laminae, distinguished by their color, as follows: white or external layer; gray or middle layer; the four remaining constituting the internal layer, namely, clear whitish streak, yellowish-red lamina, clear whitish streak, yellowish-red lamina.

In structure the *cortical substance* is composed of nerve-cells, nerve-fibres and a pale granular substance or matrix, which alone constitutes the external layer. The *nerve-cells* are provided with processes, and vary somewhat in the different layers. In the external or white layer, they are few in number and small, with one or two fine processes, and imbedded in the pale granular substance. In the middle or gray layer they are abundant and closely aggregated, present every gradation of size from cell-nuclei to large cells, are pyriform, fusiform, triangular and polygonal in shape, and provided with three, four, or five branching processes. In the internal or yellowish-red layer they are less numerous than in the middle layer, somewhat paler, but otherwise similar in character, while some contain pigment granules which give the peculiar tint to the layer, especially its deepest stratum.

The *nerve-fibres* of the cortical substance proceed from the medullary substance, and after penetrating the yellowish-red layer in parallel fasciculi and becoming greatly reduced in size, separate from each other and run in every direction, some becoming horizontal and constituting the clear whitish streak, and others passing onwards into the gray layer and superficial layer. In the gray layer, the white fibres, still more and more attenuated in size, form an intricate plexus among the nerve-cells, while in the external or white layer, they cross each other in every direction, forming several superimposed strata, and become so minute as to be ultimately lost to the eye, appearing to terminate in fine loops.

The *corpus callosum*, *anterior commissure*, and *fornix* are composed of nerve-fibres like those of the medullary substance of the hemispheres. In the corpus callosum, a few grayish streaks and thin deposits of gray substance occur, consisting of cell-nuclei and clear vesicles deposited among the white fibres. And the fornix, although containing no gray substance, is closely connected with that substance in various places, as in the thalami optici, corpora mamillaria, floor of the third ventricle, and at its junction with the septum lucidum. The *septum lucidum* contains nerve-cells like those of the tuber cinereum, and numerous plexuses of the finest nerve-fibres.

The *hippocampus major* and *minor* are composed of nerve-fibres like those of the medullary substance of the hemispheres; and also contain gray substance.

The olfactory nerves, as a part of the hemispheres, and the optic nerves, as proceeding from the corpora quadrigemina and thalami optici, also call for a passing notice in connexion with the histological structure of the cerebrum. The *tractus* and *bulbus olfactorius* are composed of fine non-medullated and medullated nerve-fibres, with nerve-cells and a finely granular matrix; in the bulb the nerve-cells are small and large, the latter provided with branching processes. The *optic nerves*, besides their origin from the corpora quadrigemina, corpora geniculata, and thalami optici, are in their course connected with the

FIG. 242.



CORTICAL SUBSTANCE OF THE HEMISPHERES; after Kölliker. *a.* Medullary substance. *b.* Reddish-gray layer. *c.* Clear white streak, composed of horizontal fibres. *d.* Gray layer. *e.* External white layer.

erura cerebri, substantia perforata, tuber cinereum, and lamina cinerea, and decussate each other in the commissure. They consist for the most part of dark-bordered nerve-fibres.

Origin of nerve-fibres. — The origin of nerve-fibres is still an unsettled question; they are presumed to arise from the nerve-cells, to be in fact continuations of the processes of those cells; but in their course in the gray substance they are so minute as to cease to be traceable to their source. Kölliker has seen in the frog the origin of the dark-bordered nerves from the nerve-cells, and this observation has been corroborated by Wagner and others, among fishes. Thus the nerve-fibres of the corpus callosum may be considered as arising from the nerve-cells of the gray substance of one hemisphere and terminating in the other.

SPINAL NERVES. — The roots of the spinal nerves are composed of parallel nerve-fibres, which are larger in the anterior or motor than in the posterior or sensitive roots; they are invested by a thin sheath of pia mater in their course across the sub-arachnoidean space, and the pia mater not only gives them an external sheath, but penetrates into their substance, and forms septa between their individual fasciculi; moreover, at their escape from the dura mater they receive an additional sheath or neurilemma from that membrane. On each of the posterior roots, at a short distance from the spinal cord, and for the most part externally to the dura mater and vertebral canal, is situated a swelling or ganglion, and beyond this ganglion the anterior and posterior root are united, the fibres of both being collected together into the same sheath. After the union of the two roots, the fibres run parallel with each other without division, exchanging fasciculi and fibres so as to form plexuses where they are associated in the supply of a separate region, as the neck, the upper and lower extremity, and finally terminating in loops, in free extremities, and in reticular anastomosing plexuses. In the roots of the nerves, the nerve-fibres are various in size, some being large and some small, and beyond the ganglion of the posterior root their number is augmented by the addition of ganglionic fibres. They maintain a general uniformity of bulk and are undulated in their course, and, in their peripheral termination, no difference of size is perceptible between the fibres of the motor and sensitive roots. It is, further, to be remarked that communications are not infrequent between the posterior roots of the nerves, and especially in the cervical region.

The *sheath* of the nerve, or *neurilemma* [*νεῦρον*, a nerve, *λέμμα*, a coat or sheath] is a firm membranous layer of areolar tissue which incloses the nerve and sends septa into its interior, forming sheaths for its separate fasciculi and fibres; in the smallest branches the neurilemma becomes homogeneous and nucleated, and in the large nerves the areolar tissue assumes a fibrous character and is intermingled with simple and reticulated filaments of elastic tissue. In the smaller fasciculi the neurilemma is remarkable for its smooth and polished appearance, and is marked by a peculiar oblique or zig-zag line.

The connexion of a nerve with the cerebro-spinal axis is called, for convenience of description, its *origin*; this term must not, however, be taken literally, for each nerve is developed in the precise situation which it occupies in the body, and with the same relations that it possesses in after life. Indeed, we not unfrequently meet with instances in anencephalous fœtuses, where the nerves are completely formed, while the brain and spinal cord are wanting. In their *distribution* the spinal nerves for the most part follow the course of the arteries, particularly in the limbs, where they lie almost constantly to the outer side of and superficially to the vessels, as if for the purpose of receiving the first intimation of danger, and communicating it to the muscles, that the latter may instantly remove the arteries from impending injury.

The cerebral nerves, from the third to the hypoglossal, resemble in histological characters the spinal nerves, the motor nerves corresponding with the anterior

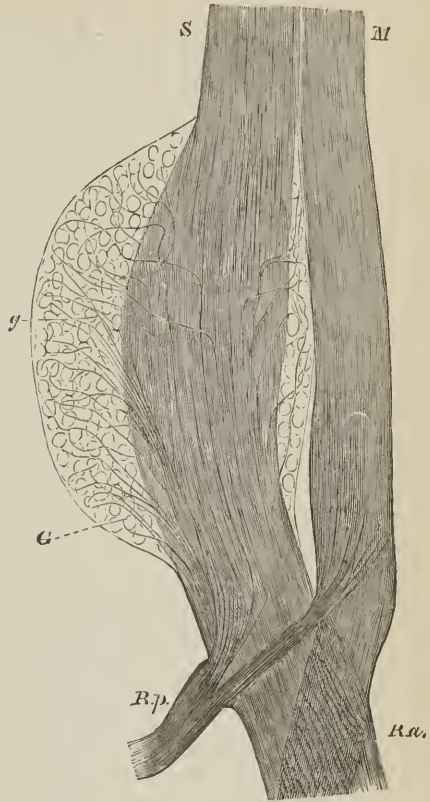roots, the sensitive nerves with the posterior roots; but it is to be remarked that the motor nerves receive sensitive fibres from the nerves of sensation previously to their escape from the cranium. The fifth, glosso-pharyngeal and pneumogastric nerves have both a motor and a sensitive root, with a ganglion on the latter like the posterior root of the spinal nerve.

The *ganglion* [γαγγλιον, a knot] of a spinal nerve is formed by the accumulation of nerve-cells (*ganglion-cells*, or *globules*) around and between the nerve-fibres of the posterior root. The ganglion-cells are round, a little flattened by mutual compression, elongated or pyriform in shape, and inclosed in a thin layer of imperfect areolar tissue which forms a sheath for the ganglion, and septa for the ganglion-cells, frequently supplying the latter with individual sheaths. The nerve-fibres take their course through the ganglion in one or several plexiform fasciculi, and are joined on their escape from its substance by the *ganglionic fibres* derived from the ganglion-cells. The ganglion-cells are composed of an outer coat, consisting of two layers, a fine granular matrix substance containing yellowish or brownish pigment cells in greater or less number, and a nucleolated nucleus; besides which they give off for the most part one, and frequently two, pale processes, the commencement of the ganglionic fibres, a few of the cells appearing to have no processes.

The external portion of the coat of the ganglion-cell is a thick nucleated layer, composed of a more or less homogeneous or fibrous and imperfect areolar tissue, and continued on the ganglionic fibre to its point of exit from the ganglion; the internal layer is a thin proper membrane. The pigment cells are frequently aggregated into a rounded mass near the nucleus, and deepen in color with age.

The *ganglionic fibres* are pale, consisting of tubular prolongations of the nucleated and proper coat of the ganglion-cell, inclosing a granular substance identical with that of the cell-matrix. They take their course to the exterior of the nervous fasciculi, interlacing them in various directions and seeming to hold them together, and frequently making one or more turns around the ganglion-cells before proceeding to join the nerve-fibres. They are at first fine, but

FIG. 243.



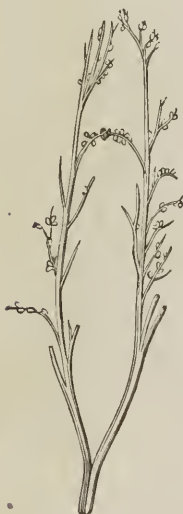A LUMBAR GANGLION OF A PUPPY, made transparent by soda; after Kölliker. *S.* Posterior root, *M.* Anterior root. *G.* Ganglion on the posterior root, with (*g*) the cells and ganglion-fibres. *R, p.* *R, a.* Junction of the fibres of the anterior and posterior roots, with those coming from the ganglion; *R, p.* is the posterior trunk of the spinal nerve; *R, a.* its anterior trunk.

soon increase in size, and are gradually converted by the development of a medullary sheath into dark-bordered nerve-fibres of medium size. The ganglionic fibres are probably distributed with the bloodvessels to the integuments, muscles, bones, joints, tendons, membranes, and glands, while the fibres of the motor roots are destined for the voluntary muscles, and the sensitive nerves for the exposed parts of the mucous membrane and skin.

In their *ultimate distribution*, nerve-fibres terminate in loops, in fine plexuses, and in free extremities, instances of all these modes of termination, together with division of fibres, being met with in the skin: loops are well seen in the papillæ of that membrane, terminal plexuses in the conjunctiva scleroticæ, and free extremities in the conjunctiva and Pacinian bodies.

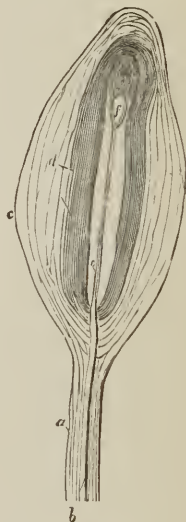The *Pacinian bodies*¹ are small oval or pyriform masses, varying in size from half a line to three lines in length, situated on the peripheral extremities of the nerve-fibres, chiefly in the palm of the hand and sole of the foot, but also found in other parts, as the perineum, glans penis, bulb of the urethra, on the intercostal nerves, on the cutaneous nerves of the neck, arm, and leg, and dorsum of the hand and foot, and on the filaments of the sympathetic nerve in various

FIG. 244.



PACINIAN CORPUSCLES. Portion of digital nerve, rather less than natural size, showing the disposition of the Pacinian corpuscles.

FIG. 245.



A PACINIAN CORPUSCLE; after Kölliker. *a.* Its peduncle. *b.* The nerve-fibre. *e.* The axis-cylinder contained in the cavity of the corpuscle. *f.* Subdivision and termination of the same. *c, d.* The laminated sheath.

localities. It has been calculated that in the palm of the hand and palmar surface of the fingers there are six hundred of these bodies, and at the extremities of the fingers they are especially numerous. They are situated for the most part in the subcutaneous areolar tissue, are clear, transparent, and glistening in appearance, and traversed internally with white streaks. In structure a Pacinian body is composed of from twenty to sixty concentric layers or capsules of areolar tissue, separated by spaces containing a serous fluid, and having a central cavity

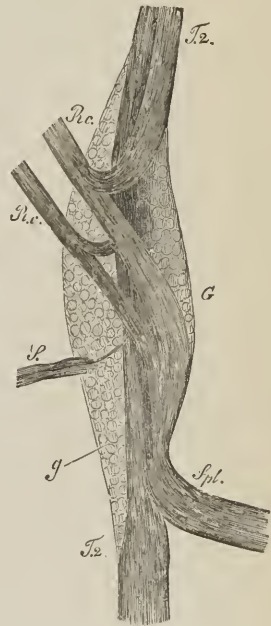¹ [First noticed by Pacini, an Italian, in 1830, and described by him more particularly, in 1840, and by Henle and Kölliker in 1844. They had however been previously noticed, although their nature had not been recognized.]

also filled with serous fluid, which contains the free extremity of a nerve-fibre, divested of its sheath and medulla, and reduced to the condition of an axis-cylinder. The intercapsular spaces are wider between the external than the internal layers, and closing around the nerve-fibre at its entrance into the corpuscle are continued for some distance on the fibre to constitute its sheath. The nerve-fibre included within the central cavity ends in a small rounded tubercle, and not unfrequently is bifid or even trifid. The Pacinian corpuscles are first apparent during the sixth month of foetal life.

SYMPATHETIC NERVE. — The sympathetic or ganglionic nerve, or system of organic nerves, has received its various designations from its numberless communications and anastomoses, from its composition of a series of ganglia, and from its distribution chiefly to the viscera of the body. It consists [on each side] of a cord of moderate thickness, which extends from the head to the coccyx, lying by the side of the vertebral column, of a series of ganglia, some of which are fusiform and others flattened and multangular, of short branches of communication from the spinal nerves, and, peripheral branches, which for the most part follow the trunks of arteries, are distributed to the viscera, after uniting with ganglia in their course, or forming smaller ganglia in their distribution. The elementary constituents of the ganglionic nerve are; white nerve-fibres of every degree of magnitude from coarse to fine; ganglionic nerves and nerve-cells. The ganglia resemble in structure those of the posterior roots of the spinal nerves, but the nerve-cells are smaller, more uniformly round, pale and colorless or slightly tinged with pigment, and provided with a single process, sometimes two, and more rarely none; the *ganglionic nerve*. After one or two turns around and between the nerve-cells, the ganglionic nerve takes its course to the periphery of the ganglion, and united with other fibres constitutes the nervous cords. The ganglionic nerves are dark-bordered and pale. The *white nerve-fibres* are derived from the anterior and posterior roots of the spinal nerves, chiefly from the latter; entering the ganglion, they divide into an ascending and descending fasciculus, which pass upwards and downwards along the main trunk of the nerve, or pass off with the larger branches in company with ganglionic nerves.

The branches of the sympathetic nerve present some difference of color, having reference to the greater or less preponderance of the white or ganglionic fibres; thus the splanchnic nerves are white, the mesenteric branches grayish-white; and the filaments occupying the branches of the carotid arteries reddish-gray and soft (*nervi subrufi, molles*); the cardiac branches and pelvic plexuses are also gray and soft. Some part of the grayness

FIG. 246.



SIXTH THORACIC GANGLION on the left side of the sympathetic nerve of the rabbit, seen from behind, and treated with soda; magnified 40 diameters; after Kölliker. *T2*, *T2*. Trunk of the sympathetic nerve. *Rc*, *Rc*. Communicating branches from a spinal nerve; these branches divide into two fasciculi, which take their course upwards and downwards in the trunk. *Spl.* Splanchnic nerve (a visceral branch). *S.* Twigs of the ganglion with two stronger fibres and finer filaments, probably going to vessels. *G.* The ganglion, composed of (*g*) ganglion-cells.

of these nerves is also due to the presence of certain peculiar fibres, the gray fibres of Remak (gelatinous fibres, Henle). The *gray fibres of Remak* are pale flat fibres, indistinctly striated, granular or homogeneous, and presenting elongated or fusiform nuclei, in fact presenting characters similar to imperfectly-formed areolar tissue, to which substance they probably belong. Remak finds them in great abundance in the impregnated uterus, indeed more numerous than the nerve-fibres, and they seem to constitute the basis of many of the nerves. They are probably derived from the neurilemma of the finer branches.

In their peripheral terminations the branches of the sympathetic nerve present numerous minute, almost microscopic ganglia, which are especially remarkable on the carotid arteries, in the pharyngeal plexus, upon the heart, around the root and in the substance of the lungs, upon the supra-renal capsule, on the lymphatic glands, on the posterior wall of the urinary bladder, and occasionally in the kidneys. In structure these ganglia are identical with the larger ganglia. The nerve-fibres, like those of the cerebro-spinal system, terminate in loops, in fine plexuses, and in free ends, the latter being present in the Pacinian corpuscles of the mesentery. In their ultimate terminations they probably cease to be medullated, and become reduced to their axis-fibres.

DEVELOPMENT.—*Nerve-cells* and nerve-fibres are developed from the primary cells of which the embryo is originally composed; the nerve-cells increase in size, and either retain the character of simple cells or throw out processes which become connected with nerve-fibres. Some of the nerve-cells, provided with two nuclei, appear to increase by division. *Nerve-fibres* are produced from fusiform nucleated cells, which are united into pale, flattened, nucleated tubules or fibres; and at about the middle period of foetal life they become white from the development of the medullary sheath. In the peripheral plexuses, the anastomosis of fibres results from their development by fusiform or stellate cells, the processes of which unite with each other; while in the trunks of the nerves, the tubules attain a large size and their contents become split up into a fasciculus of fibres, as occurs in the development of muscular fibre.

In the cerebro-spinal centre, nerve-fibres are first perceptible in the embryo at the end of the second month, at which time they are intermingled with an abundance of fusiform cells with fine lengthened ends. At the fourth month the gray and the white substance are distinct; but dark contours to the fibres do not make their appearance until the mid-period of foetal life, and are first discoverable in the spinal cord. The subsequent changes are, increase of size of the fibres, the number of primitive fibres existing in the foetus being as great as in the adult.

VESSELS.—The brain and spinal cord are very moderately supplied with blood by small arteries which enter their substance from the pia mater, and divide into branches at acute angles. In the medullary substance they form a network of fine capillaries with wide meshes; but the network is closer and the capillaries more abundant in the gray substance. The ganglia of the nerves possess a delicate capillary plexus which pervades their structure, encircling each cell in a special web; the arteries of the nerves are more scanty and for the most part longitudinal, forming an open network with elongated interstices, which invests the fasciculi but does not penetrate to the nerve-fibres. In the Pacinian corpuscles, bloodvessels reach the interior of the central cavity.

The NERVOUS SYSTEM may be divided for convenience of description into.
 1. The brain. 2. The spinal cord. 3. The cranial nerves. 4. The spinal nerves. 5. The sympathetic system.

THE BRAIN.

The brain is a collective term which signifies those parts of the nervous system, exclusive of the nerves themselves, which are contained within the cranium; they are, the cerebrum, cerebellum, and medulla oblongata.¹ These are invested and protected by the membranes of the brain, and the whole together constitute the encephalon (*ἐν κεφαλῇ*, within the head).

MEMBRANES OF THE ENCEPHALON.

Dissection.—To examine the encephalon with its membranes, the upper part of the skull must be removed, by sawing through the external table and breaking the internal table with the chisel and hammer. After the calvaria has been loosened all round, it will require a considerable degree of force to tear the bone away from the dura mater. This adhesion is particularly firm at the sutures, where the dura mater is continuous with a membranous layer, interposed between the edges of the bones; in other situations the connexion results from numerous vessels which permeate the inner table of the skull. The adhesion subsisting between the dura mater and bone is greater in the young subject and in old persons than in the adult. On being torn away, the internal table will present numerous deeply-grooved and ramified channels, corresponding with the branches of the *arteria meningea media*. Along the middle line will be seen a groove corresponding with the superior longitudinal sinus, and on either side may be frequently observed some small fossæ, corresponding with the Pacchionian bodies.

The membranes of the encephalon and spinal cord are the *dura mater*, *arachnoid membrane*, and *pia mater*.

Dura Mater.

The *Dura Mater*² is the firm, whitish or grayish layer which is brought into view when the calvaria is removed. It is a strong fibrous membrane, somewhat laminated in texture, and composed of white fibrous tissue. Lining the interior of the cranium, it serves as the internal periosteum of that cavity; it is prolonged also into the spinal column, but is not adherent to the bones in that canal as in the cranium. From the internal surface of the dura mater, processes are directed inwards for the support and protection of parts of the brain; while from its exterior, other processes are prolonged outwards to form sheaths for the nerves as they quit the skull and spinal column. Its external surface is rough and fibrous, and corresponds with the internal table of the skull. The internal surface is smooth, and lined by the thin varnish-like lamella of the arachnoid membrane. The latter is a serous membrane. Hence the dura mater becomes a *fibro-serous* membrane, being composed of its own proper fibrous structure, and the serous layer derived from the arachnoid. There are two other instances of fibro-serous membrane in the body, formed in the same way, namely, the pericardium, and tunica albuginea of the testicle.

On the external surface of the dura mater the branches of the middle meningeal artery may be seen ramifying; and in the middle line is a depressed groove, formed by the subsidence of the upper wall of the superior longitudinal sinus

¹ The average weight of the human brain is three pounds for the male, and four or five ounces less for the female; the medium weight for the male ranging between forty-six and fifty-three ounces, and for the female between forty-one and forty-seven. Cuvier's brain weighed sixty-four ounces, and Dupuytren's sixty-three and a half.

² So named from a supposition that it was the parent source of all the fibrous membranes of the body.

If the sinus be opened along its course, it will be found to be a triangular channel, crossed at its lower angle by numerous white bands, called chordæ Willisii;¹ granular bodies are also occasionally seen in its interior, these are the glandulæ Pacchioni.

The *Glandulæ Pacchioni*² are small, round, whitish granulations, occurring singly or in clusters, and forming small groups of various size along the margin of the longitudinal fissure of the cerebrum, and more particularly near the summit of the latter. These bodies would seem to be of morbid origin; they are absent in infancy, increase in numbers in adult life, and are abundant in the aged. They are generally associated with opacity of the arachnoid around their bases, but in some instances are wanting even in the adult. They have their point of attachment in the pia mater, from which they seem to spring, carrying with them the arachnoid membrane, and then, in proportion to their size, producing various effects upon contiguous parts. For example, when small, they remain free or constitute a bond of adhesion between the visceral and parietal layer of the arachnoid; when of larger size they produce absorption of the dura mater, and as the degree of absorption is greater or less, they protrude through that membrane, and form depressions on the inner surface of the cranium, or simply render the dura mater thin and cribriform. Sometimes they cause absorption of the wall of the longitudinal sinus, and projecting into its cavity, give rise to the granulations described in connexion with that channel. In intimate structure they are composed of immature areolar and elastic tissue containing corpuscula amylacea.

If the student cut through one side of the dura mater, in the direction of his incision through the skull, and turn it upwards towards the middle line, he will observe the smooth internal surface of this membrane. He will perceive also the large veins of the hemispheres filled with dark blood, and passing from behind forwards to open into the superior longitudinal sinus; and the firm connexion, by means of these veins and the Pacchionian bodies, between the opposed surfaces of the arachnoid membrane. If he separate these adhesions with his scalpel, he will see a vertical layer of dura mater descending between the hemispheres; and if he draw one side of the brain a little outwards, he will be enabled to perceive the extent of the process of membrane, which is called the *falx cerebri*.

The processes of the dura mater which are sent inwards towards the interior of the skull, are the *falx cerebri*, *tentorium cerebelli*, and *falx cerebelli*.

The *Falx cerebri* (falx, a sickle), so named from its sickle-like appearance, narrow in front, broad behind, and forming a sharp curved edge below, is attached in front to the crista galli process of the ethmoid bone, and behind to the tentorium cerebelli.

The *Tentorium cerebelli* (tentorium, a tent) is a roof of dura mater, thrown across the cerebellum and attached at each side to the margin of the petrous portion of the temporal bone; behind, to the transverse ridge of the occipital bone, which lodges the lateral sinuses; and to the clinoid processes in front. It supports the posterior lobes of the cerebrum and prevents their pressure³ on the cerebellum, leaving a small opening anteriorly, for the transmission of the crura cerebri.

The *Falx cerebelli* is a small process, generally double, attached to the vertical ridge of the occipital bone beneath the lateral sinus, and to the tentorium.

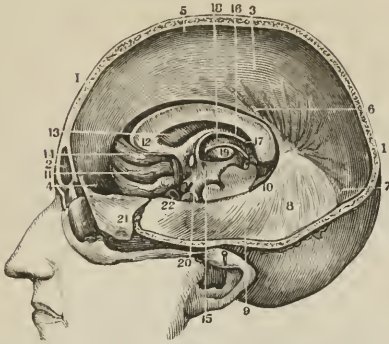
¹ Willis lived in the seventeenth century; he was a great defender of the opinions of Harvey.

² These bodies are incorrectly described as conglobate glands by Pacchioni, in an epistolatory dissertation, "De Glandulis conglobatis Duræ Meningis indeque ortis Lymphaticis et Piam Matrem productis," published at Rome, in 1705.

³ In leaping animals, as the feline and canine genera, the tentorium forms a bony tent.

It is received into the indentation between the two hemispheres of the cerebellum.

[FIG. 247.]



VERTICAL SECTION OF THE HEAD TO SHOW THE PROCESSES OF THE DURA MATER, ETC.

1, 1. Vertical section of the head. 2. The frontal sinus. 3. The falx cerebri. 4. Its attachment to the crista galli. 5. Its attachment along the sagittal suture. 6. The lower or concave edge of the falx. 7. Its continuation to the tentorium. 8. The tentorium. 9. Its attachment to the petrous portion of the temporal bone. 10. The free edge of the same part. 11. The convolutions of the right anterior lobe of the cerebrum. 12. The anterior extremity of the corpus callosum. 13. The septum lucidum. 14. Section of the anterior commissure. 15. Anterior crus of the fornix. 16. Middle of the fornix. 17. Its posterior extremity joining the corpus callosum. 18. Internal side of the thalamus nervi optici. 19. Section of the corpus striatum. 20. Lateral parietes of the third ventricle. 21. A portion of the dura mater turned off. 22. Section of the internal carotid artery.]

The layers of the dura mater separate in several situations, so as to form irregular channels which receive the venous blood. These are the *sinuses* of the dura mater, already described; page 346.

The student cannot see the tentorium and falx cerebelli until the brain is removed; but he should consider the attachments of the former on the dried skull, for he will have to incise it in the removal of the brain. He should now proceed to that operation, for which purpose the dura mater is to be divided all round, on a level with the section through the skull, and the scissors are to be carried deeply between the hemispheres of the brain in front, to cut through the anterior part of the falx; then draw the dura mater backwards, and leave it hanging by its attachment to the tentorium. Raise the anterior lobes of the brain carefully with the hand, and lift the olfactory bulbs from the cribriform fossæ with the handle of the scalpel. Then cut across the two optic nerves and internal carotid arteries. Next divide the infundibulum and third nerves, and carry the knife along the margin of the petrous bone at each side, so as to divide the tentorium near its attachment. Cut across the fourth, fifth, sixth, seventh, and eighth nerves in succession with a sharp knife, and pass the scalpel as far down as possible into the vertebral canal, to sever the spinal cord, cutting first to one side and then to the other, in order to divide the vertebral arteries and first cervical nerves. Then let him press the cerebellum gently upwards with the fingers of the right hand, the hemispheres being supported with the left, and the brain will roll into his hand.

The *Arteries* of the dura mater are, the *anterior meningeal* from the ethmoidal, ophthalmic, and internal carotid. The *middle meningeal* and *meningeal parva* from the internal maxillary. The *inferior meningeal* from the ascending pharyngeal and occipital artery; and the *posterior meningeal* from the vertebral.

Its *Nerves* are derived from the *nervi molles* and vertebral plexus of the sympathetic, from the Casserian ganglion, the ophthalmic nerve, and sometimes from the fourth. The branches from the two latter are given off while those nerves are situated by the side of the sella turcica; they are recurrent, and pass backwards between the layers of the tentorium, to the lining membrane of the lateral sinus. Purkinje describes a sympathetic plexus of considerable size, as being situated around the vena Galeni at its entrance into the fourth sinus. The filaments from this plexus are distributed to the tentorium.

Kölliker describes the dura mater as composed of two lamellæ, *periosteal* and *proper fibrous*, the former adheres to the bones, the latter forms the internal processes, whilst the sinuses result from the separation of the two. He finds nothing to indicate the lining of the internal surface by the arachnoid as a separate membrane; but shows that the tessellated epithelium of the free surface is in contact with and bedded upon the fibrous structure.

Arachnoid membrane.

The *Arachnoid*, (*ἀράχνη εἶδος*, like a spider's web), so named from its extreme tenuity, is the serous membrane of the cerebro-spinal centre; and, like other serous membranes, a shut sac. It envelops the brain and spinal cord, *visceral layer*, and is reflected on the inner surface of the dura mater, *parietal layer*, giving to that membrane its serous investment.

On the upper surface of the hemispheres the arachnoid is transparent, but may be demonstrated as it passes across the sulci from one convolution to another by injecting with a blow-pipe a stream of air beneath it. At the base of the brain the membrane is opalescent and thicker than in other situations, and more easily demonstrable from the circumstance of stretching across the interval between the middle lobes of the hemispheres. The space which is included between this layer of membrane and those parts of the base of the brain which are bounded by the optic commissure and fissures of Sylvius in front, and the pons Varolii behind, is termed the *anterior sub-arachnoidean space*. Another space formed in a similar manner, between the under part of the cerebellum and the medulla oblongata, is the *posterior sub-arachnoidean space*; and a third space, situated over the corpora quadrigemina, may be termed the *superior sub-arachnoidean space*. These spaces communicate freely with each other, the anterior and posterior across the crura cerebelli, the anterior and the superior around the crura cerebri, and the latter and the posterior across the cerebellum in the course of the vermiform processes. They communicate also with a still larger space formed by the loose disposition of the arachnoid around the spinal cord, the *spinal sub-arachnoidean space*. The whole of these spaces, with the lesser spaces between the convolutions of the hemispheres, constitute one large and continuous cavity which is filled with a limpid, serous secretion, the *sub-arachnoidean* or *cerebro-spinal fluid*,¹ a fluid which is necessary for the regulation of pressure, and protection of the cerebro-spinal mass. The quantity of the cerebro-spinal fluid is determined by the relative size of the cerebro-spinal axis and that of the containing cavity, and is consequently variable. It is smaller in youth than in old age, and in the adult has been estimated at about two ounces. The visceral layer of the arachnoid is connected to the pia mater by a delicate areolar tissue, which in the sub-arachnoidean spaces is loose and filamentous. The serous secretion of the true cavity of the arachnoid is very small in quantity as compared with the sub-arachnoidean fluid.

The arachnoid does not enter into the ventricles of the brain, as imagined by

¹ The presence of a serous fluid beneath the arachnoid has given rise to the conjecture that a sub-arachnoid serous membrane may exist in that situation. Such a supposition is quite unnecessary to explain the production of the secretion, since the pia mater is fully adequate to the function.

Bichât, but is reflected inwards upon the venæ Galeni for a short distance only, and returns upon those vessels to the dura mater of the tentorium. It surrounds the nerves as they originate from the brain, and forms a sheath around them to their point of exit from the skull. It is then reflected back upon the inner surface of the dura mater.

According to Mr. Rainey,¹ *vessels* of considerable size, but few in number, and branches of cranial *nerves*, are found in the arachnoid. He also describes, in this membrane, numberless plexuses and ganglia, which he considers to be analogous to those of the sympathetic nerve; but which are most probably, as Kölliker observes, reticular, anastomosing fasciculi of areolar tissue. These fasciculi united into lamellæ are the constituent structure of the arachnoid membrane, and many of the fasciculi have fibres of elastic tissue twined around them. The external [free] surface of the arachnoid is furnished with a *tesselated epithelium* identical with that of the dura mater.

Pia mater.

The *Pia mater* is an areolo-vascular membrane composed of innumerable vessels held together by immature areolar tissue. It invests the whole surface of the brain, dipping into the sulci between the convolutions, and forming a fold in its interior called *velum interpositum*. It also forms folds in other situations, as in the third and fourth ventricles, and in the longitudinal fissures of the spinal cord.

This membrane differs in structure in different parts of the cerebro-spinal axis. Thus, on the surface of the cerebrum, in contact with the soft gray matter of the brain, it is extremely vascular, forming remarkable loops of anastomosis in the interspaces of the convolutions, and distributing multitudes of minute straight vessels (*tomentum cerebri*) to the gray substance. In the *substantia perforata*, again, and *locus perforatus*, it gives off tufts of small arteries, which pierce the white matter to reach the gray substance in the interior. But upon the *crura cerebri*, *pons Varolii*, and spinal cord, its vascular character seems almost lost. It has become a *dense fibrous membrane*, difficult to tear off, and forming the proper sheath of the spinal cord.

The *pia mater* is the nutrient membrane of the brain, and derives its blood from the internal carotid and vertebral arteries. Lymphatics have also been described as entering into its structure.

Its *Nerves* are the minute filaments of the sympathetic, and filaments from the sensory cranial nerves; they accompany the branches of the arteries.

CEREBRUM.

The *Cerebrum* presents on its surface a number of slightly convex elevations, the convolutions (*gyri*), which are separated from each other by sulci of various depth.² It is divided superiorly into two hemispheres by the great longitudinal fissure, which lodges the *falx cerebri*, and marks the original development of the brain by two symmetrical halves.

Each hemisphere, on its under surface, admits of division into three lobes, anterior, middle, and posterior. The *anterior lobe* rests on the roof of the orbit, and is separated from the middle by the fissure of Sylvius.³ The *middle lobe* is received into the middle fossa of the base of the skull, and is separated from

¹ Medico-Chirurgical Transactions, vol. 29.

² In estimating the surface of the brain, which, according to Baillarger, averages in round numbers, 670 square inches, these convolutions and the laminæ of the cerebellum are supposed to be unfolded.

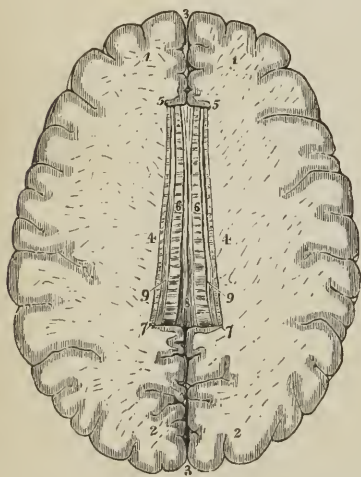
³ James Dubois, a celebrated professor of anatomy in Paris, where he succeeded Vidius in 1550, although known much earlier by his works and discoveries, but particularly by his violence in the defence of Galen. His name was Latinized to *Jacobus Sylvius*.

the posterior by a slight impression produced by the ridge of the petrous bone. The *posterior lobe* is supported by the tentorium.

If the upper part of one hemisphere, at about one-third from its summit, be removed with a scalpel, a centre of white substance will be observed, surrounded by a narrow border of gray, which follows the line of the sulci and convolutions, and presents a zigzag form. This section, from exhibiting the largest surface of medullary substance demonstrable in a single hemisphere, is called *centrum ovale minus*; it is spotted by numerous small red points (*puncta vasculosa*), which are produced by the escape of blood from the cut ends of minute arteries and veins.

Separate carefully the two hemispheres of the cerebrum, and a broad band of white substance (*corpus callosum*) will be seen to connect them; it will be seen

FIG. 248.



SECTION OF THE BRAIN SHOWING THE CENTRUM OVALE MAJUS AND CORPUS CALLOSUM.

1, 1. Anterior lobes of the brain. 2, 2. Posterior lobes. 3, 3. Longitudinal fissure for the reception of the falx cerebri. 4, 4. Roof of the lateral ventricles. 5, 5. Genu of the corpus callosum. 6, 6. Its body, upon which the lineæ transversæ are seen. 7, 7. Splenium corporis callosi. 8. Raphé. 9, 9. Striæ longitudinales laterales, or covered bands of Reil.

be traced downwards to the base of the brain in front of the commissure of the optic nerves. Posteriorly it forms a thick rounded fold, *splenium*, which is continuous with the fornix. The length of the corpus callosum is about four inches.

Beneath the posterior rounded border of the corpus callosum is the *transverse fissure* of the cerebrum, which extends between the hemispheres and crura cerebri from near the fissure of Sylvius on one side, to the same point on the opposite side of the brain. It is through this fissure that the pia mater communicates with the velum interpositum. And it was here that Bichât conceived the arachnoid to enter the ventricles; hence it is also named the *fissure of Bichât*.

also that the surface of the hemisphere, where it comes in contact with the corpus callosum, is bounded by a large convolution (*gyrus fornicatus*) which lies horizontally on that body, and may be traced forwards and backwards to the base of the brain, terminating by each extremity at the fissure of Sylvius. The sulcus between this convolution and the corpus callosum has been termed the "ventricle of the corpus callosum," and some longitudinal fibres (*striæ longitudinales laterales*), which are brought into view when the convolution is raised, were called by Reil the "covered band." If the upper part of each hemisphere be removed to a level with the corpus callosum, a large expanse of medullary matter, surrounded by a zigzag line of gray substance corresponding with the convolutions and sulci of the two hemispheres, will be seen; this is the *centrum ovale majus* of Vieussens.

The **CORPUS CALLOSUM** (*callosus*, hard) is a thick layer of medullary fibres passing transversely between the two hemispheres, and constituting their *great commissure*, (*trabs cerebri*, beam of the brain). It is situated in the middle line of the *centrum ovale majus*, but nearer the anterior than the posterior part of the brain, and terminates anteriorly in a rounded border, *genu*, which may

Along the middle line of the corpus callosum is the *raphé*, a linear depression between two slightly elevated longitudinal bands (chordæ longitudinales Lancisii); and, on either side of the *raphé*, may be seen the *lineæ transversæ*, which mark the direction of the fibres of which the corpus callosum is composed. These fibres may be traced into the hemispheres on either side, and they will be seen to be crossed at about an inch from the *raphé* by the longitudinal fibres of the covered band of Reil. Anteriorly and posteriorly the fibres of the corpus callosum curve forwards and backwards into their corresponding lobes.

If a superficial incision be made through the corpus callosum on either side of the *raphé*, two irregular cavities will be opened, which extend from one extremity of the hemispheres to the other: these are the *lateral ventricles*. To expose them completely, their upper boundary should be removed with the scissors. In making this dissection the thin and diaphanous membrane of the ventricles may frequently be seen.

LATERAL VENTRICLES. — Each lateral ventricle is divided into a *central cavity* and three smaller cavities called *cornua*. The *anterior cornu* curves forwards and outwards in the anterior lobe; the *middle cornu* descends into the middle lobe; and the *posterior cornu* passes backwards in the posterior lobe, converging towards its fellow of the opposite side. The central cavity is triangular in form, being bounded above (*roof*) by the corpus callosum; internally by the septum lucidum, which separates it from the opposite ventricle; and below (*floor*) by the following parts, taken in their order of position from before backwards: —

Corpus striatum,
Tenia semicircularis,
Thalamus opticus,

Choroid plexus,
Corpus fimbriatum,
Fornix.

The *Corpus striatum* is named from the striated lines of white and gray matter which are seen upon cutting into its substance. It is gray on the exterior, and of a pyriform shape. The broad end, directed forwards, rests against the corpus striatum of the opposite side: the small end, backwards, is separated from its fellow by the interposition of the thalami optici. The corpora striata are the superior ganglia of the cerebrum.

The *Tenia semicircularis* (tenia, a fillet) is a narrow band of medullary substance, extending along the posterior border of the corpus striatum, and serving as a bond of connexion between that body and the thalamus opticus. It is transparent and dense at the surface, and received from Tarinus¹ the name of *horny band*. The tenia is partly concealed by a large vein (*vena corporis striati*), which receives numerous small veins from the corpus striatum and thalamus opticus, and terminates in the vena Galeni of its own side.

The *Thalamus opticus* (thalamus, a bed) is an oblong body, having a thin coating of white substance on its surface; and has received its name from giving origin to one root of the optic nerve. It is the inferior ganglion of the cerebrum. Part only of the thalamus is seen in the floor of the lateral ventricle; we must, therefore, defer its further description until we can examine it in its entire extent.

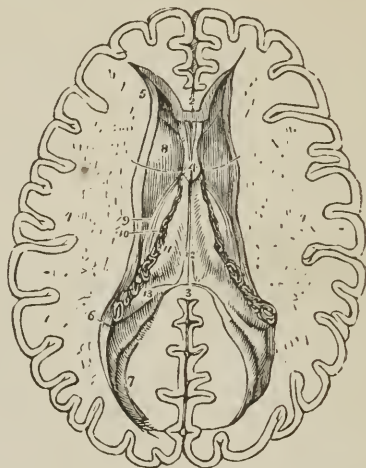
The *Choroid plexus* (χόριον είδος, resembling the chorion)² is a vascular fringe extending obliquely across the floor of the lateral ventricle, and sinking into the middle cornu. Anteriorly, it is small and tapering, and communicates with the choroid plexus of the opposite ventricle, through a large oval opening, the *foramen of Monro*, or foramen commune anterius. This foramen may be seen by

¹ Peter Tarin, a French anatomist; his work, entitled "Adversaria Anatomica," was published in 1750.

² See the note appended to the description of the choroid coat of the eyeball.

pulling slightly on the plexus, and pressing aside the septum lucidum with the handle of the knife. It is situated between the under surface of the fornix, and the anterior extremities of the thalami optici, and forms a communication

FIG. 249.



LATERAL VENTRICLES OF THE CEREBRUM. 1,1. The two hemispheres cut down to a level with the corpus callosum so as to constitute the centrum ovale majus. The surface is seen to be studded with the small vascular points, *puncta vasculosa*; and surrounded by a narrow margin which represents the gray substance. 2. A small portion of the anterior extremity (*genu*) of the corpus callosum. 3. Its posterior boundary (*splenium*); the intermediate portion forming the roof of the lateral ventricles has been removed so as to expose completely those cavities. 4. Part of the septum lucidum, showing an interspace between its layers, the fifth ventricle. 5. Anterior cornu of one side. 6. Commencement of the middle cornu. 7. Posterior cornu. 8. Corpus striatum of one ventricle. 9. *Tenia semicircularis* partly covered by the *vena corporis striati*. 10. A small part of the thalamus opticus. 11. The dark fringe-like body to the left of the cipher is the choroid plexus. This plexus communicates with that of the opposite ventricle through the foramen of *Monro*, or *foramen commune anterius*; a bristle is passed through this opening (under figure 4), and its extremities are seen resting on the corpus striatum at each side. The figure 11 rests on the edge of the fornix, on that part of it which is called *corpus fimbriatum*. 12. Fornix. 13. Commencement of the hippocampus major descending into the middle cornu. The rounded oblong body, directly behind figure 13, is the *pes accessorius*, and further back, immediately under figure 7, the hippocampus minor.

transversely between the lateral ventricles, and perpendicularly with the third ventricle.

The choroid plexus presents on its surface a number of minute vascular processes, which are termed *villi*. They are invested by an epithelium consisting of a single layer of nucleated polygonal cells surmounted by cilia, which have been seen in motion in the embryo. Besides the nucleus the cells contain numerous yellow granules and one or two dark oil drops; and, according to Henle, give off from their angles spine-like processes, which are connected with the bed of homogeneous areolar tissue on which they rest. The vessels composing the plexus are connected by a transparent interstitial substance without areolar tissue; and the latter is often interspersed with calcareous particles. Sometimes the plexuses present on their surface an assemblage of small serous cysts.

The *Corpus fimbriatum* is a narrow white band, situated immediately behind the choroid plexus, and extending with it into the descending cornu of the late-

ral ventricle. It is, in fact, the lateral thin edge of the fornix, and being attached to the hippocampus major in the descending horn of the lateral ventricle, is also termed, *tenia hippocampi*.

The *Fornix* is a white layer of medullary substance, of which a portion only is seen in this view of the ventricle.

The *Anterior cornu* is triangular in form, sweeping outwards, and terminating by a point in the anterior lobe of the brain, at a short distance from its surface.

The *Posterior cornu* or *digital cavity* curves inwards, as it extends back into the posterior lobe of the brain, and likewise terminates near the surface. An elevation corresponding with a deep sulcus between two convolutions, projects into the area of this cornu, and is called the *hippocampus minor*.

The *Middle* or *descending cornu*, in descending into the middle lobe of the brain, forms a very considerable curve, and alters its direction several times as it proceeds. Hence it is described as passing backwards and outwards and downwards, and then turning forwards and inwards. This complex expression of a very simple curve has given origin to a symbol, formed of the primary letters of the terms, by which the student is enabled to recollect more easily the course of the cornu, BODFI. It is the largest of the three cornua, and terminates close to the fissure of Sylvius, after having curved around the crus cerebri.

The middle cornu should now be laid open, by inserting the little finger into its cavity, and making it serve as a director for the scalpel in cutting away the side of the hemisphere, so as to expose it completely.

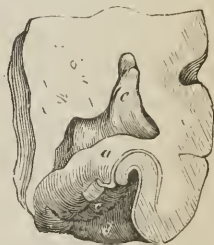
The *superior boundary* of the middle cornu is formed by the under surface of the thalamus opticus, upon which are the two projections called corpus geniculatum internum and externum; and the *inferior wall* by the following parts:—

Hippocampus major,
Pes hippocampi,
Pes accessorius,
Corpus fimbriatum,
Choroid plexus,
Fascia dentata,
Transverse fissure.

The *Hippocampus major* or *cornu Ammonis*, so called from its resemblance to a ram's horn, the famous crest of Jupiter Ammon, is a considerable projection from the inferior wall, and extends the whole length of the middle cornu. Its extremity is likened to the foot of an animal, from its presenting a number of knuckle-like elevations on the surface, and is named *pes hippocampi*. The hippocampus major is the internal surface of the convolution (*gyrus fornicatus*) of the lateral edge of the hemisphere, the convolution which has been previously described as lying on the corpus callosum and extending downwards to the base of the brain to terminate at the fissure of Sylvius. If it be cut across, the section will be seen to resemble the extremity of a convoluted scroll, consisting of alternate layers of white and gray substance. The hippocampus major is continuous superiorly with the fornix and corpus callosum, and derives its medullary layer from the corpus fimbriatum.

The *Pes accessorius* (*eminentia collateralis*) is a swelling somewhat resembling the hippocampus major, but smaller in size, and situated in the angular interval between it and the hippocampus minor. Like the latter, it is formed by the protrusion of one of the sulci of the convolutions.

[Fig. 250.]



SECTION OF THE HIPPOCAMPUS MAJOR, to show the arrangement of its gray and white substance. *a.* White layer on its surface. *b.* Gray substance which becomes rolled up. *d.* White reticulated substance, on the surface of *gyrus fornicatus*. *c.* Fascia dentata. *e.* Cavity of lateral ventricle.]

The *Corpus fimbriatum* (tenia hippocampi) is the narrow white band which is prolonged from the central cavity of the ventricle, and is attached along the inner border of the hippocampus major. It is lost inferiorly in the hippocampus.

Fascia dentata. — If the corpus fimbriatum be carefully raised, a narrow serrated band of gray substance, the margin of the gray substance of the middle lobe, will be seen beneath it; this is the fascia dentata. Beneath the corpus fimbriatum will be likewise seen the *transverse fissure* of the brain, which has been before described as extending from near the fissure of Sylvius on one side, across to the same point on the opposite side. It is through this fissure that the pia mater communicates with the *choroid plexus*, and the latter obtains its supply of blood. The fissure is bounded on one side by the corpus fimbriatum, and on the other by the under surface of the thalamus opticus.

The internal boundary of the lateral ventricle is the *septum lucidum*. This septum is thin, semi-transparent, and consists of two laminae of cerebral substance attached above to the under surface of the corpus callosum at its anterior part, and below to the fornix. Between the two layers is a narrow space, the FIFTH VENTRICLE, which is lined by a proper membrane. The *fifth ventricle* may be shown, by snipping through the septum lucidum transversely with the scissors.

The corpus callosum should now be cut across towards its anterior extremity, and the two ends carefully dissected away. The anterior portion will be retained only by the septum lucidum, but the posterior will be found incorporated with the white layer beneath, which is the fornix.

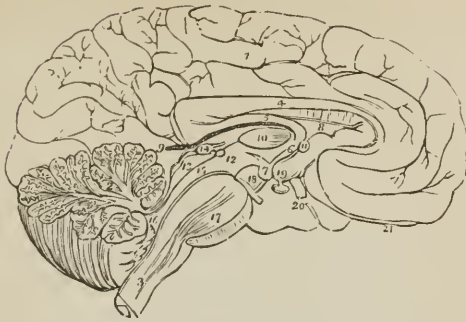
FORNIX.—The fornix (arch) is a triangular lamina of white substance, broad behind, and extending into each lateral ventricle: narrow in front, where it terminates in two crura, which arch downwards to the base of the brain. The two crura descend in a curved direction to the base of the brain, imbedded in gray substance, in the lateral walls of the third ventricle, and lying directly behind the anterior commissure. At the base of the brain they make a sudden curve upon themselves and constitute the corpora albicantia, from which they may be traced upwards to their origin in the thalami optici. Opening transversely beneath these two crura, just as they are about to arch downwards, is the foramen of communication between the lateral and the third ventricle, the *foramen of Monro*; or *foramen commune anterius*. The choroid plexuses communicate, and the veins of the corpora striata pass through this opening.

The lateral thin edges of the fornix are continuous *posteriorly* with the concave border of the hippocampus major at each side, and form the narrow white band called *corpus fimbriatum* (posterior crus of the fornix). In the middle line the fornix is continuous with the corpus callosum, and at each side with the hippocampus major and minor. On the under surface of the fornix towards its posterior part some transverse lines are seen passing between the diverging corpora fimbriata; this appearance is termed the *lyra* (corpus psalloides), from a fancied resemblance to the strings of a harp.

The fornix may now be removed by dividing it across anteriorly, and turning it backwards, at the same time separating its lateral connexions with the hippocampi. If the student examine its under surface, he will perceive the lyra above described.

Beneath the fornix is the *velum interpositum* (tela choroidea), a duplicature of pia mater introduced into the interior of the brain, through the transverse fissure. The velum is continuous at each side with the choroid plexus, and contains in its inferior layer two large veins (the *venæ Galeni*) which receive the blood from the corpora striata and choroid plexuses, and terminate posteriorly after uniting into a single trunk, in the straight sinus. On the under surface of the velum interpositum are two fringe-like bodies, which project into the third ventricle. These are the *choroid plexuses* of the *third ventricle*; pos-

FIG. 251.



MESIAL SURFACE OF A LONGITUDINAL SECTION OF THE BRAIN. The incision has been carried along the middle line; between the two hemispheres of the cerebrum, and through the middle of the cerebellum and medulla oblongata. 1. Inner surface of left hemisphere. 2. Divided surface of cerebellum, showing arbor vitæ. 3. Medulla oblongata at junction with the spinal cord. 4. Corpus callosum curving downwards in front to terminate at the base of the brain, and rounded behind to become continuous with, 5, fornix. 6. Crus of the fornix descending to 7, corpus albicans. 8. Septum lucidum. 9. Velum interpositum, communicating with the pia mater of the convolutions through the fissure of Bichât. 10. Section of middle commissure situated in the third ventricle. 11. Section of anterior commissure. 12. Section of posterior commissure; the commissure is somewhat above and to the left of the figure. The interspace between 10 and 11 is the foramen commune anterius, in which the crus of the fornix (6) is situated. The interspace between 10 and 12 is the foramen commune posterius. 13. Corpora quadrigemina, upon which is seen resting the pineal gland, 14. 15. Iter a tertio ad quartum ventriculum, or aqueduct of Sylvius. 16. Fourth ventricle. 17. Pons Varolii, through which are seen passing the fibres of the corpora pyramidalia. 18. Crus cerebri of left side, with the third nerve arising from it. 19. Tuber cinereum, from which projects the infundibulum, having the pituitary gland appended to its extremity. 20. One of the optic nerves. 21. The left olfactory nerve terminating anteriorly in a rounded bulb.

teriorly these fringes inclose the pineal gland. The velum interpositum is coated with an epithelium identical with that of the choroid plexuses; and around the pineal gland the areolar tissue is abundant and strong.

If the velum interpositum be raised and turned back, an operation to be conducted with care, particularly at its posterior part, where it invests the pineal gland, the thalami optici and the cavity of the third ventricle will be brought into view.

THALAMI OPTICI.—The thalami optici are two oblong, square-shaped bodies, of a white color superficially, inserted between the two diverging portions of the corpora striata. In the middle line a fissure exists between them which is called the *third ventricle*. Posteriorly and inferiorly, they form the superior wall of the descending cornu of the lateral ventricle, and present two rounded elevations called *corpus geniculatum externum* and *internum*. The *corpus geniculatum externum*, the larger of the two, and of a grayish color, is the principal origin of the optic nerve. Anteriorly, the thalami are connected with the corpora albicantia by means of two white bands, which appear to originate in the white substance (*tenia semicircularis*) uniting the thalami to the corpora striata. Externally they are in relation with the corpora striata and hemispheres. In their interior the thalami are composed of white fibres mixed with gray substance. They are essentially the *inferior ganglia of the cerebrum*.

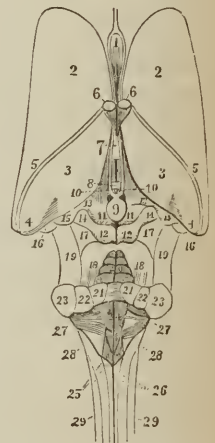
THIRD VENTRICLE.—The third ventricle is the fissure between the two thalami optici. It is bounded above by the under surface of the velum inter-

positum, from which are suspended the choroid plexuses of the third ventricle. Its *floor* is formed by the gray substance of the anterior termination of the corpus callosum, called lamina cinerea, the tuber cinereum, corpora albicantia, and locus perforatus. *Laterally* it is bounded by the thalami optici; *anteriorly* by the anterior commissure, and crura of the fornix; and *posteriorly* by the posterior commissure and the iter a tertio ad quartum ventriculum. The third ventricle is crossed by three commissures, anterior, middle, and posterior; and between these are two spaces, called foramen commune anterius and foramen commune posterius.

The *anterior commissure* is a small rounded white cord, which enters the corpus striatum at either side, and reaches the substance of the hemispheres; the *middle*, or *soft commissure* consists of gray substance, which is continuous with the gray lining of the ventricle, it connects the adjacent sides of the thalami

THIRD AND FOURTH VENTRICLE. 1. Fifth ventricle, between the layers of the septum lucidum. 2, 2. Corpora striata. 3, 3. Thalami optici; the figures are placed on the part termed "colliculus." 4, 4. The pulvinar. 5, 5. Tenia semicircularis. 6, 6. Crura of the fornix, cut across. 7. Middle commissure of the third ventricle. 8. Posterior commissure of the third ventricle; the space between the thalami optici (3, 3), in which the commissures (7, 8) are placed, is the third ventricle. 9. Pineal gland. 10, 10. Peduncles of the pineal gland, prolonged forwards as streaks (striae medullares colliculi nervorum opti-
corum) to the crura of the fornix, 6, 6. 11, 11. Nates. 12, 12. Testes. 11, 11, and 12, 12, are the corpora quadrigemina. 13. Brachium anterius. 14. Brachium posterius. 15. Corpus geniculatum internum. 16. Corpus geniculatum externum. 17, 17. The laqueus. 18, 18. Processus e cerebello ad testes. 19, 19. Crura cerebri. 20. Valvo of Vicussens. 21. Section of the processus e cerebello ad testem, or superior peduncle of the cerebellum. 22. Section of the corpus restiforme, or middle peduncle. 23. Section of the crus cerebelli or inferior peduncle. 24. Fourth ventricle; the two bodies on which the figure is placed are the eminentiae teretes. 25. Alæ cinereæ of the floor of the fourth ventricle; this part of the ventricle is termed the calamus scriptorius. 26. Fasciculi graciles at their upper part, where they constitute the enlargements known as the processus clavati. They are separated by the posterior median fissure, and the dark aperture at the top of this fissure is the ventricle of Arantius. 27, 27. Striae medullares, the origin of the portio mollis nerve. 28, 28. Fasciculi laterales of the spinal cord. 29, 29. Fasciculi cuneati.

FIG. 252



optici; the *posterior commissure*, smaller than the anterior, is a flattened white cord, connecting the two thalami optici posteriorly.

The space between the anterior and middle commissure is called the *foramen commune anterius*, and is that to which Monro has given his name (*foramen of Monro*). It is the medium of communication between the two lateral and third ventricle, and transmits superiorly the choroid plexus and venæ corporum striatorum. The foramen commune anterius is also termed, *iter ad infundibulum*, from leading downwards to the funnel-shaped cavity of the infundibulum. The crura of the fornix are imbedded in the lateral walls of the foramen commune, and are concealed from view in this situation by the layer of gray substance which lines the interior of the third ventricle. If the crura be slightly separated, the anterior commissure will be seen immediately in front of them, crossing from one corpus striatum to the other. The space between the middle and posterior commissure is the *foramen commune posterius*; it is much shallower than the preceding, and is the origin of a canal, the aqueduct of Sylvius or *iter a tertio ad quartum ventriculum*, which leads backwards beneath the posterior commis-

sure and through the base of the corpora quadrigemina to the upper part of the fourth ventricle.

CORPORA QUADRIGEMINA.—The corpora quadrigemina, or optic lobes, are situated immediately behind the third ventricle and posterior commissure; and beneath the posterior border of the corpus callosum. They form, indeed, at this point, the inferior boundary of the transverse fissure of the hemispheres, the fissure of Bichât. The anterior pair of these bodies, gray in color, are named *nates*; the posterior pair, white and much smaller than the anterior, are termed *testes*. From the nates on each side may be traced a rounded process (brachium anterius) which passes obliquely outwards into the thalamus opticus; and from the testis a similar but smaller process (brachium posterius) which has the same destination. The corpus geniculatum internum lies in the interval of these two processes where they enter the thalamus, and behind the brachium posterius is a prominent band (laqueus) which marks the course of the superior division of the fasciculus olivaris. The corpora quadrigemina are perforated longitudinally through their base by the aqueduct of Sylvius; they are covered in partly by the pia mater and partly by the velum interpositum, and the nates support the pineal gland.

PINEAL GLAND.—The pineal gland is a small reddish-gray body of a conical form (hence its synonym *courarium*), situated on the anterior part of the nates, and invested by a duplicature of pia mater derived from the under part of the velum interpositum. The pineal gland, when pressed between the fingers, is found to contain a gritty matter¹ (acervulus) composed chemically of phosphate and carbonate of lime, and phosphate of magnesia and ammonia, with some organic matter; and is sometimes hollow in the interior. It is connected to the brain by means of two medullary cords called *peduncles* and a thin lamina derived from the posterior commissure; the peduncles of the pineal gland are attached to the thalami optici, and may be traced along the upper and inner margin of those bodies to the crura of the fornix with which they become blended. From the close connexion subsisting between the pia mater and the pineal gland, and the softness of texture of the latter, the gland is liable to be torn away in the removal of the pia mater.

Behind the corpora quadrigemina is the cerebellum, and beneath the cerebellum the fourth ventricle. The student must therefore divide the cerebellum down to the fourth ventricle, and turn its lobes aside to examine that cavity.

FOURTH VENTRICLE.—The fourth ventricle (sinus rhomboidalis) is the ventricle of the cerebellum. It is situated on the posterior surface of the medulla oblongata and pons Varolii, is lozenge-shaped in its form, and *bounded on each side* by a thick cord passing between the cerebellum and corpora quadrigemina, called the *processus e cerebello ad testes*, and by the *corpus restiforme*. It is covered in *behind* by the cerebellum, and by a thin lamella of medullary substance, stretched between the two *processus e cerebello ad testes*, termed the *valve of Vieussens*.²

That portion of the cerebellum which forms the posterior boundary of the fourth ventricle presents four small prominences or lobules, and a thin layer of medullary substance, the *velum medullare posterius*. Of the lobules two are placed in the middle line, the *nodulus* and *uvula*, the former being before the

¹ This gritty matter, the brain sand, consists of round, mulberry-shaped, opaque, concentrically striated granules; also, of angular, stalactiform, clavate or irregular bodies, having an uneven, botryoidal, scaly surface; also, of simple cylindrical rigid fibres branched or reticular; also, of fine particles. It is sometimes found in the choroid plexuses, and in the pia mater and arachnoid.

² Raymond Vieussens, a great discoverer in the anatomy of the brain and nervous system. His "Neurographia Universalis" was published at Lyons, in 1685.

latter; the remaining two are named *amygdalæ*, or tonsils, and are situated one on either side of the uvula. They all project into the cavity of the fourth ventricle, and the *velum medullare posterius* is situated in front of them. The *valve of Vieussens* or *velum medullare anterius* is an extremely thin lamella of medullary substance, prolonged from the white matter of the cerebellum to the testes, and attached on each side to the *processus e cerebello ad testes*. This lamella is overlaid for a short distance by a thin, transversely-grooved lobule of gray substance (*linguetta laminosa*) derived from the anterior border of the cerebellum, and its junction with the testes is strengthened by a narrow slip given off by the commissure of those bodies, the *frænulum veli medullaris anterioris*. The *anterior wall*, or *floor* of the fourth ventricle is formed by two slightly convex bodies, *fasciculi teretes* (innominati), separated by a longitudinal groove which is continuous inferiorly with the posterior median fissure of the spinal cord. On these bodies the gray substance (*fasciolæ cineræ*) derived from the interior of the medulla is spread out, and at the lower part of the ventricle forms several eminences or nuclei, from which, according to Stilling, the eighth and ninth nerves, and probably also the fifth, take their origin. Higher up the *fasciculi teretes* are crossed by several white striæ (*linæ transversæ*), the origin of the auditory nerves. Upon the lower part of the floor of this ventricle is an impression resembling the point of a pen, and hence named *calamus scriptorius*; the lateral boundaries of the calamus are the *processus clavati* of the posterior pyramids. *Above*, the fourth ventricle is bounded by the *corpora quadrigemina* and aqueduct of Sylvius; and *below* by a layer of pia mater and arachnoid, called the valve of the arachnoid. Beneath this valve a communication exists between the ventricles of the brain and the sub-arachnoidean space. Within the fourth ventricle, and lying against the uvula and tonsils, are two small vascular fringes formed by the pia mater, the *choroid plexuses* of the fourth ventricle.

LINING MEMBRANE OF THE VENTRICLES.

The lining membrane of the ventricles, *ependyma ventriculorum*, is a serous layer distinct from the arachnoid; it lines the whole of the interior of the lateral ventricles, and is connected above and below with the attached border of the choroid plexus, so as to exclude all communication between the lateral ventricles and the exterior of the brain. From the lateral ventricles it is reflected through the foramen of Monro on each side into the third ventricle, which it invests throughout. From the third it is conducted into the fourth ventricle, through the *iter a tertio ad quartum ventriculum*, and after lining its interior becomes continuous inferiorly with the sub-arachnoidean space of the spinal cord. The lining membrane of the ventricles is provided with a ciliated epithelium, and is the source of the secretion which moistens and lubricates their interior. The fifth ventricle has a separate lining membrane.

The epithelium of the *ependyma ventriculorum* is for the most part bedded on the medullary substance, but where a substratum of areolar tissue exists, as in the walls of the lateral ventricles, and on the *septum lucidum*, and particularly where the sub-ependymic tissue is thickened, certain small bodies, *corpuscula amylacea*, are found as a pathological formation. These bodies resemble starch-granules, are round and biscuit-shaped, yellowish in color, and marked by concentric striæ.

CEREBELLUM.

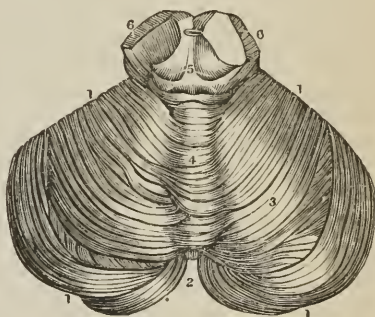
The *Cerebellum* (figs. 251, 254, 256), seven times smaller than the cerebrum, is situated beneath the posterior cerebral lobes, being lodged in the posterior fossa of the base of the cranium, and protected from the superincumbent pressure of the cerebrum by the *tentorium cerebelli*. Like the cerebrum, it is com-

posed of gray and white substance, the former occupying the surface, the latter the interior, and its surface is formed of parallel lamellæ separated by sulci, and here and there by deeper sulci. In form the cerebellum is oblong and flattened, its greater diameter being from side to side, its two surfaces looking upwards and downwards, and its borders being anterior, posterior, and lateral. In consideration of its shape the cerebellum admits of a division into two hemispheres, into certain prominences termed processes and lobules, and into certain divisions of its substance called lobes, formed upon the hemispheres by the deeper sulci above referred to. The two hemispheres are separated from each other on the upper surface of the cerebellum by a longitudinal ridge, which is termed the *superior vermiform process*, and which forms a commissure between them. On the anterior border of the organ there is a semilunar notch, *incisura cerebelli anterior*, which embraces the corpora quadrigemina. On the posterior border there is another notch, *incisura cerebelli posterior*, which receives the upper part of the falx cerebelli: and on the under surface of the cerebellum is a deep fissure corresponding with the medulla oblongata, and termed the *vallecula* (valley).

Each hemisphere of the cerebellum is divided by means of a fissure (sulcus horizontalis) which runs along its free border, into an upper and a lower portion, and upon each of these portions certain lobes are marked out. Thus on the upper portion there are two such lobes separated by a sulcus, somewhat more strongly marked than the rest, and extending deeper into the substance of the cerebellum; they are the *lobus superior anterior* and *lobus superior posterior*. On the under portion of the hemisphere there are three such lobes, namely, *lobus inferior anterior*, *medius*, and *posterior*, and two additional ones of peculiar form, the *lobus inferior internus* or *tonsil*, and the *flocculus*. The *tonsil* (amygdala) is situated on the side of the vallecula, and projects into the fourth ventricle. The *flocculus* or pneumogastric lobule, long and slender, extends from the side of the vallecula around the corpus restiforme to the crus cerebelli, lying behind the filaments of the eighth pair of nerves.

The commissure between the two hemispheres is termed the *worm* (vermis), that portion of the worm which occupies the upper surface of the cerebellum as far back as the horizontal fissure being the *processus vermiformis superior*, and that which is lodged within the vallecula being the *processus vermiformis inferior*. The *superior vermiform process* is a prominent longitudinal ridge, extending from the incisura anterior to the incisura posterior. In imitation of the hemispheres, it is divided into lobes, of which three have received names, namely, the *lobulus centralis*, a small lobe situated in the incisura anterior; the *monticulus cerebelli*, a longer lobe, having its peak and declivity; and a small lobe near the incisura posterior, the *commissura simplex*. The lobes of the *inferior vermiform process* are four in number, namely, the *commissura brevis*, situated in the incisura posterior, below the horizontal fissure; the *pyramid*, a small obtusely-pointed eminence; a larger prominence, the *uvula*, situated between the tonsils, and connected with them by means of a commissure; and

[FIG. 253.]



THE CEREBELLUM, viewed on its upper surface. 1, 1, 1, 1. Sulcus horizontalis. 2. Incisura cerebelli posterior. 3. The right hemisphere. 4. Superior vermiform process. 5. Corpora quadrigemina embraced by the incisura cerebelli anterior. 6, 6. Section of the crura cerebri.]

in front of the uvula, the *nodulus*. In front of the nodulus is a thin lamina of medullary substance consisting of a central and two lateral portions, the *velum medullare posterius* (valvula Tarini), and between this velum and the nodulus and uvula is a deep fossa which is known as the *swallow's nest* (nidus hirundinis). The *velum medullare anterius* is the valve of Vieussens, described with the fourth ventricle; both these vela proceed from the same point in the roof of that ventricle, and separate from each other at an angle, the one passing obliquely forwards, the other obliquely backwards.

When a vertical incision is made into the cerebellum, that appearance is seen which has been denominated *arbor vitæ cerebelli*; the white substance in the centre of such a section resembles the trunk of a tree, from which branches are given off, and from the branches branchlets and leaves, the two latter being coated by a moderately thick and uniform layer of gray substance. If the incision be made somewhat nearer to the commissure than to the lateral border of the organ, a yellowish-gray dentated line, inclosing medullary substance traversed by the openings of numerous vessels, will be seen in the centre of the white substance. This is the ganglion of the cerebellum, the *corpus rhomboidum* or dentatum, from which the peduncles of the cerebellum proceed. The reddish-gray line is dense and horny in structure, and is the cut edge of a thin capsule, open towards the medulla oblongata.

The cerebellum is associated with the rest of the encephalon by means of three pairs of rounded cords or peduncles, superior, middle, and inferior. The superior peduncles, or *processus e cerebello ad testes*, proceed from the cerebellum forwards and upwards to the testes, in which they are lost. They form the anterior part of the lateral boundaries of the fourth ventricle, and give attachment by their inner borders to the valve of Vieussens, which is stretched between them. At their junction with the testes they are crossed by the fourth pair of nerves. The middle peduncles, or *crura cerebelli ad pontem*, the largest of the three, issue from the cerebellum through the anterior extremity of the sulcus horizontalis, and are lost in the pons Varolii. The inferior peduncles, or *crura ad medullam oblongatam*, are the corpora restiformia, which descend to the posterior part of the medulla oblongata, and form the inferior portion of the lateral boundaries of the fourth ventricle.

BASE OF THE BRAIN.

The student should now prepare to study the base of the brain: for this purpose the organ should be turned upon its incised surface; and if the dissection have hitherto been conducted with care, he will find the base uninjured. The arachnoid membrane, some parts of the pia mater, and the circle of Willis, must be carefully cleared away, in order to expose all the parts to be examined. These he will find arranged in the following order from before backwards:—

Longitudinal fissure,	Commencement of the transverse fissure, ¹
Olfactory nerves,	Optic commissure,
Fissure of Sylvius, ¹	Tuber cinereum,
Substantia perforata; ¹	Infundibulum;
Corpora albicantia,	Pons Varolii,
Locus perforatus,	Crura cerebelli,
Crura cerebri;	Medulla oblongata.

The *Longitudinal fissure* is the space separating the two hemispheres; it is continued downwards to the base of the brain, and divides the two anterior lobes. In this fissure the anterior cerebral arteries ascend towards the corpus callosum; and if the two lobes be slightly drawn asunder, the anterior border (genu) of the corpus callosum will be seen descending to the base of the brain. Arrived

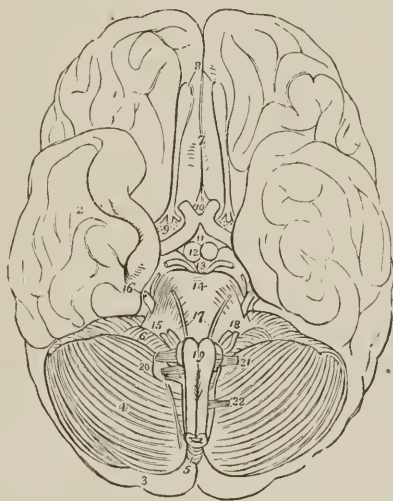
¹ [On each side.]

at the base of the brain, the corpus callosum terminates by a concave border, which is prolonged to the commissure of the optic nerves by a thin layer of gray substance, the *lamina cinerea*. The lamina cinerea is the anterior part of the inferior boundary of the third ventricle. On each side of the lamina cinerea the corpus callosum is continued into the substantia perforata and crura cerebri, and, upon the latter, forms a narrow medullary band lying externally to, and slightly overlapping, the optic tract, the *medulla innominata*.

On the under surface of each anterior lobe, on either side of the longitudinal fissure, is the *olfactory nerve*, with its bulb.

The *Fissure of Sylvius* bounds the anterior lobe posteriorly, and separates it from the middle lobe; it lodges the middle cerebral artery. If this fissure be followed outwards, a small isolated cluster of five or six convolutions (*gyri operi*) will be observed; these constitute the *island of Reil*. The island of Reil, together with the substantia perforata, forms the base of the corpus striatum.

FIG. 254.



UNDER SURFACE OR BASE OF THE BRAIN. 1. Anterior lobe of one hemisphere of the cerebrum. 2. Middle lobe. 3. Posterior lobe almost concealed by (4) the hemisphere of the cerebellum. 5. Pyramidal lobe of the inferior vermiform process of the cerebellum. 6. Pneumogastric lobule. 7. Longitudinal fissure. 8. Olfactory nerves, with their bulbous expansion. 9. Substantia perforata at the inner termination of the fissure of Sylvius; the three roots of the olfactory nerve are seen on the substantia perforata. The commencement of the transverse fissure at each side is concealed by the inner border of the middle lobe. 10. Commissure of the optic nerves; the figure is placed between the optic nerves as they diverge from the commissure, and rests on the lamina cinerea of the corpus callosum. 11. Tuber cinereum, from which the infundibulum is seen projecting. 12. Corpora albicantia. 13. Locus perforatus, bounded at each side by the crura cerebri, and third nerve. 14. Pons Varolii. 15. Crus cerebelli of one side. 16. Fifth nerve emerging from the side of the pons Varolii; the small nerve close to it is the fourth. 17. Sixth pair of nerves. 18. Facial and auditory nerve. 19. Corpora pyramidalia of the medulla oblongata; the corpus olivare and part of the corpus restiforme are seen at each side. Just below the figure is the decussation of the fibres of the corpora pyramidalia. 20. Glosso-pharyngeal, pneumogastric, and spinal accessory nerve. 21. Hypoglossal nerve. 22. Anterior root of the first cervical spinal nerve.

The *Substantia perforata* (*locus perforatus anticus*) is a triangular plane of white substance, situated at the inner extremity of the fissure of Sylvius. It is

named *perforata* from being pierced by a number of openings for small arteries, which enter the brain in this situation to supply the gray substance of the corpus striatum.

Passing backwards on each side beneath the edge of the middle lobe, is the commencement of the *great transverse fissure*, which extends beneath the hemisphere of one side to the same point on the opposite side. A probe passed into this fissure between the crus cerebri and middle lobe will enter the middle cornu of the lateral ventricle.

The *Optic commissure* is situated on the middle line; it is the point of communication between the two optic nerves.

The *Tuber cinereum* is an eminence of gray substance situated immediately behind the optic commissure, and in front of the corpora albicantia. From its centre there projects a small conical body of gray substance, apparently a prolongation of the tuber cinereum, the *infundibulum*. The infundibulum is hollow, inclosing a short caecal canal, which communicates with the cavity of the third ventricle; and below the termination of the canal, the conical process becomes connected with the pituitary gland. The infundibulum and tuber cinereum form part of the floor of the third ventricle.

The *Pituitary gland* (hypophysis cerebri) is a small, flattened, reddish-gray body, situated in the sella tureica, and closely retained in that situation by the dura mater and arachnoid. It consists of two lobes, closely pressed together, the anterior lobe being the larger of the two and oblong in shape, the posterior round. Both lobes are connected with the infundibulum, but the latter is so soft in texture as to be generally torn through in the removal of the brain. Indeed, for the purposes of the student, it is better to effect this separation with the knife, and leave the pituitary body in situ, to be examined with the base of the cranium.

The *Corpora albicantia* (mamillaria, pisiformia, bulbi forniceis) are two white convex bodies, having the shape and size of peas, situated behind the tuber cinereum, and between the crura cerebri. They are a part of the crura of the fornix, which, after their origin from the thalami optici, descend (radix descendens) to the base of the brain, and making a sudden curve upon themselves previously to their ascent (radix ascendens) to the lateral ventricles, constitute the corpora albicantia. When divided by section, these bodies will be found to be composed of a capsule of white substance, containing gray matter, the gray matter of the two corpora being connected by means of a commissure.

The *Locus perforatus* (posticus) is a layer of whitish-gray substance, connected in front with the corpora albicantia, behind with the pons Varolii, and on each side with the crura cerebri, between which it is situated. It is perforated by several thick tufts of arteries, which are distributed to the thalami optici and third ventricle, of which latter it assists in forming the floor. It is also called the pons Tarini.

The *Crura cerebri* (peduncles of the cerebrum) are two thick white cords, which issue from the anterior border of the pons Varolii, and diverge to enter the thalami optici and corpora striata. By their outer side the crura cerebri are continuous with the corpora quadrigemina, and, above, they constitute the lower boundary of the aqueduct of Sylvius. Within, they contain gray matter, which has a semilunar shape when the crus is divided transversely, and has been termed the *locus niger*. The third nerve will be observed to arise from the inner side of each crus, and the fourth nerves wind around their outer border from above.

The *Pons Varolii*¹ (protuberantia annularis, nodus encephali) is the broad

¹ Constant Varolius, Professor of Anatomy in Bologna: died in 1578. He dissected the brain, in the course of its fibres, beginning from the medulla oblongata; a plan which has since been perfected by Vieussens, and by Gall and Spurzheim. The work containing his mode of dissection, "De Resolutione Corporis Humani," was published after his death, in 1591.

transverse band of white fibres which arches like a bridge across the upper part of the medulla oblongata; and, contracting on each side into a thick rounded cord, enters the substance of the cerebellum under the name of the crus cerebelli. There is a groove along its middle which lodges the basilar artery. The pons Varolii is the commissure of the cerebellum, and associates the two lateral lobes in their common function. Resting against the pons, near its posterior border, is the sixth pair of nerves. On the anterior border of the crus cerebelli, at each side, is the thick bundle of filaments belonging to the fifth nerve, and lying against its posterior border, the seventh pair of nerves. The upper surface of the pons forms part of the floor of the fourth ventricle.

MEDULLA OBLONGATA.

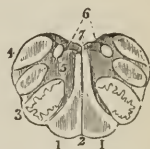
The medulla oblongata (*bulbus rachidicus*), is the upper enlarged portion of the spinal cord. It is somewhat conical in shape, and a little more than an inch in length, extending from the pons Varolii to a point corresponding with the upper border of the atlas. On the middle line in front and behind, the medulla oblongata is marked by two vertical fissures, the anterior and posterior median fissures, which divide it superficially into two symmetrical lateral cords or columns; whilst each lateral column is subdivided by shallow grooves into three smaller cords, namely, the *corpora pyramidalia*, *corpora olivaria*, and *corpora restiformia*.

The *Corpora pyramidalia* are two narrow convex cords, tapering slightly from above downwards, and situated one on either side of the anterior median fissure. At about an inch below the pons the *corpora pyramidalia* communicate across the fissure by a decussation of their fibres, and at their point of entrance into the pons are constricted into round cords. The fissure is somewhat enlarged by this constriction, and the enlarged space has received the name of *foramen cæcum* (*Vicq d'Azyr*) of the medulla oblongata.

The *Corpora olivaria* (named from some resemblance in shape to an olive) are two oblong, oval-shaped, convex bodies, of about the same breadth as the *corpora pyramidalia*, about half an inch in length, and somewhat larger above than below. The *corpus olivare* is situated immediately external to the *corpus pyramidale*, from which, and from the *corpus restiforme*, it is separated by a groove. In this groove some longitudinal fibres are seen which inclose the base of the *corpus olivare*, and have been named *funiculi siliquæ*, those which lie to its inner side being the *funiculus internus*, and those to its outer side the *funiculus externus*. Besides these there are other fibres which cross the *corpus olivare* obliquely, these are the *fibræ arciformes*. When examined by section the *corpus olivare* is found to be a ganglion deeply imbedded in the medulla oblongata, and meeting its fellow at the middle line behind the *corpus pyramidale*. The ganglion of the *corpus olivare* (*corpus dentatum*, *nucleus olivæ*), like that of the cerebellum, is a yellowish-gray dentated capsule, open behind, and containing gray substance and transverse white fibres. The nervous filaments which spring from the groove on the anterior border of the *corpus olivare*, are those of the hypoglossal nerve; and those on its posterior border are the glosso-pharyngeal and pneumogastric.

The *Corpora restiformia* (*restis*, a rope) comprehend the whole of the posterior half of each lateral column of the medulla oblongata. They are separated from the *corpora olivaria* by the grooves already spoken of; posteriorly they are

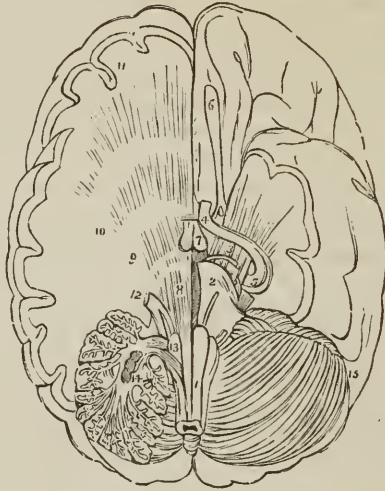
FIG. 255.



SECTION OF THE MEDULLA OBLONGATA made across the lower part of the corpora olivaria; after Arnold. 1, 1. Corpora pyramidalia. 2. Anterior median fissure. 3. Corpus olivare; with the zigzag outline of the corpus dentatum. 4. Corpus restiforme. 5. Gray substance of the corpus restiforme. 6. Corpora pyramidalia posteriora, or fasciuli graciles. 7. Floor of the fourth ventricle.

divided from each other by the posterior median fissure and fourth ventricle, and superiorly they diverge and curve backwards to enter the cerebellum, and con-

FIG. 256.



BASE OF THE BRAIN, UPON WHICH SEVERAL SECTIONS HAVE BEEN MADE, showing the distribution of the longitudinal or diverging fibres. 1. Medulla oblongata. 2. One half of the pons Varolii. 3. Crus cerebri crossed by the optic nerve (4), and spreading out into the thalamus opticus and corpus striatum to form the corona radiata. 5. Optic nerve near its origin: the nerves about the crus cerebri and cerebelli are the same as in figure 254. 6. Olfactory nerve. 7. Corpora albicantia. On the left side of the figure a portion of the brain has been removed to show the distribution of the diverging fibres. 8. Fibres of the corpus pyramidale passing through the pons Varolii. 9. Fibres passing through the thalamus opticus. 10. Fibres passing into the corpus striatum. 11. Fibres of the hemispheres. 12. The fifth nerve: its two roots. 13. Fibres of the corpus pyramidale passing outwards with the corpus restiforme into the substance of the cerebellum; arciform fibres of Solly. The fibres referred to are those below the figure, the figure itself rests on the corpus olivare. 14. Section through one hemisphere of the cerebellum, showing the corpus rhomboideum in the centre of its white substance; the arbor vitæ is also seen. 15. Opposite hemisphere of the cerebellum.

stitute its inferior peduncles. Along the posterior border of each corpus restiforme, and marked off from that body by a groove, is a narrow white cord, separated from its fellow by the posterior fissure. This pair of narrow cords are termed the *posterior pyramids* (fasciculi graciles). Each fasciculus forms an enlargement (processus clavatus) at its upper end, and is then lost in the corresponding corpus restiforme. The processus clavati are the lateral boundaries of the nib of the calamus scriptorius. The corpus restiforme is crossed near its entrance into the cerebellum by the auditory nerve, the choroid plexus of the fourth ventricle, and the pneumogastric lobule.

The remaining portions of the medulla oblongata visible from the exterior, are the two slightly convex columns which enter into the formation of the floor of the fourth ventricle. These columns are the fasciculi teretes (innominati).

SPINAL CORD.

The dissection of the spinal cord requires that the spinal column should be opened throughout its entire length by sawing through the laminæ of the verte-

bræ, close to the roots of the transverse processes, and raising the arches with a chisel; the muscles of the back having been removed as a preliminary step.

The *Spinal column* contains the *spinal cord*, or *medulla spinalis*; the *roots of the spinal nerves*; and the membranes of the cord, viz., the *dura mater*, *arachnoid*, *pia mater*, and *membrana dentata*.

The *Dura mater spinalis* [see fig. 269] is a cylindrical sheath of fibrous membrane, identical in structure with the *dura mater* of the skull, and continuous with that membrane. At the margin of the occipital foramen it is closely adherent to the bone; by its anterior surface it is attached to the posterior common ligament, and below, by means of its pointed extremity, to the coccyx. In the rest of its extent it is comparatively free, being connected, by a loose areolar tissue, to the walls of the spinal canal. In this areolar tissue there exists a quantity of reddish, oily, adipose substance, somewhat analogous to the marrow of long bones. On either side and below, the *dura mater* forms a sheath for each of the spinal nerves, to which it is closely adherent. Upon its inner surface it is smooth, being lined by the *arachnoid*; and on its sides may be seen double openings for the two roots of each of the spinal nerves.

The *Arachnoid* is a continuation of the serous membrane of the brain. It incloses the cord very loosely, being connected to it only by long slender filaments of areolar tissue, and by a longitudinal lamella which is attached to the posterior aspect of the cord. The areolar tissue is most abundant in the cervical region, and diminishes in quantity from above downwards; and the longitudinal lamella is complete only in the dorsal region. The *arachnoid* passes off from the cord on either side with the spinal nerves, to which it forms a sheath; and is then reflected on the *dura mater*. A connexion exists in several places between the *arachnoid* and *dura mater*. The space between the *arachnoid* and the spinal cord is identical with that already described as existing between the same parts in the brain, the *sub-arachnoidean space*. It is occupied by a serous fluid, sufficient in quantity to expand the *arachnoid*, and fill completely the cavity of the *dura mater*. The *sub-arachnoidean* or *cerebro-spinal fluid* keeps up a constant and gentle pressure on the entire surface of the brain and spinal cord, and yields with the greatest facility to the various movements of the cord, giving to those delicate structures the advantage of the principles so usefully applied by Dr. Arnott in the hydrostatic bed.

The *Pia mater* is the immediate investment of the cord; and, like the other membranes, is continuous with that of the brain. It is not, however, like the *pia mater cerebri*, a vascular membrane; but is dense and fibrous in structure, and contains but few vessels. It invests the cord closely, and sends a duplication into the anterior median fissure, and another, extremely delicate, into the posterior median fissure. It forms a sheath for each of the fasciculi of the nerves, and for the nerves themselves; and, inferiorly, at the conical termination of the cord, is prolonged downwards as a slender ligament (*filum terminale*), which descends through the centre of the *cauda equina*, and is attached to the *dura mater* lining the canal of the coccyx. This attachment is a rudiment of the original extension of the spinal cord into the canal of the sacrum and coccyx. The *pia mater* has, distributed to it, a number of nervous plexuses.

The *Membrana dentata* (*ligamentum dentatum*) is a thin process of *pia mater* sent off from each side of the cord throughout its entire length, and separating the anterior from the posterior roots of the spinal nerves. The number of serrations on each side is about twenty, the first being situated on a level with the occipital foramen, and having the vertebral artery and hypoglossal nerve passing in front and the spinal accessory nerve behind it, and the last opposite the first or second lumbar vertebra. Below this point the *membrana dentata* is lost in the *filum terminale* of the *pia mater*. The use of this membrane is to maintain the position of the spinal cord in the midst of the fluid by which it is surrounded.

The *Spinal cord* of the adult, somewhat less than eighteen inches in length, extends from the pons Varolii to opposite the first or second lumbar vertebra, where it terminates in a conical point, retained in position by the filum terminale; in the child, at birth, the cone reaches the middle of the third lumbar vertebra, and in the embryo is prolonged as far as the coccyx. It presents a difference of diameter in different parts of its extent, and has three enlargements. The uppermost of these is the *medulla oblongata*; the next corresponds with the origin of the nerves destined to the upper extremities (brachial); and the lower enlargement (lumbar) is situated near its termination, and corresponds with the attachment of the nerves which are intended for the supply of the lower limbs. The brachial enlargement is flattened from before backwards, and extends from the third cervical vertebra to the first dorsal; the lumbar enlargement is flattened from side to side, and is smaller than the brachial. The spinal cord gives off near its termination that assemblage of nerves which has received the name of *cauda equina*; the cauda equina being the roots of the lumbar and sacral nerves elongated by the growth of the spine, the ganglia of the posterior roots being held in connexion with the intervertebral foramina through which the nerves pass.

In form, the spinal cord is a flattened cylinder, and presents on its anterior surface a fissure, which extends into the cord to the depth of one-third its diameter. This is the *anterior median fissure*. If the sides of the fissure be gently separated, they will be seen to be connected at the bottom by a layer of medullary substance, the *anterior white commissure*. In the middle line behind and corresponding with the fissura anterior is the *posterior median fissure*, which exists as a fissure only in the upper part of the cervical and in the lumbar portion of the cord. Between these points its place is occupied by a series of perforations which transmit the bloodvessels to the gray substance. It extends more deeply into the cord than the anterior fissure, and reaches the gray substance of the interior. These two fissures divide the

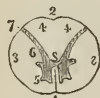medulla spinalis into two lateral portions, which are connected to each other by the white commissure which forms the bottom of the anterior fissure, and by a commissure of gray matter situated behind the former. On either side of the posterior median fissure is a slight line which bounds on each side the posterior median columns. These columns are most apparent at the upper part of the cord, in the medulla oblongata, where they have received the name of posterior pyramids, or funiculi graciles.

Two other lines are observed on the medulla, the anterior and posterior lateral sulci, corresponding with the attachment of the anterior and posterior roots of the spinal nerves. The *anterior lateral sulcus* is a mere trace, marked only by the attachment of the filaments of the anterior roots; the *posterior lateral sulcus* is somewhat more evident.

These fissures and sulci indicate a division of the spinal cord into three pairs of columns, namely, anterior, lateral, and posterior; or, as they are frequently described, into antero-lateral and posterior. The anterior and part of the lateral columns are the columns of motion; the posterior part of the lateral, and the posterior columns, the columns of sensation.

If a transverse section of the spinal cord be made, its internal structure may be seen and examined. It will then appear to be composed of two hollow cylinders of white substance placed

FIG. 257.



SECTION OF THE SPINAL CORD made between the third and fourth cervical nerves. 1. Anterior median fissure. 2. Indentation corresponding in situation with the posterior median fissure, which latter is not distinguishable at this part of the cord. 3, 3. Antero-lateral columns of the spinal cord. 4, 4. Posterior columns. 5. Anterior cornu of gray matter. 6. Posterior cornu, terminating at 7, sulcus lateralis posterior. 8. Isthmus or commissure connecting the gray matter of the two sides of the cord.

side by side, and connected by a narrow *white commissure*. Each cylinder is filled with gray substance, which is connected by a commissure of the same matter (*gray commissure*). The form of the gray substance, as observed in the section, is that of two irregularly curved or crescentic lines joined by a transverse band. The extremities of the curved lines corresponding with the sulci of origin of the anterior and posterior roots of the nerves, are termed *cornua*; the *anterior cornu* is short and thick; the *posterior cornu*, long and slender, reaches nearly to the surface of the sulcus lateralis posterior.

CRANIAL NERVES.

The PAIRS of cranial nerves are *nine* or *twelve* in number, according as the arrangement of Willis or Soemmering is adopted; the former has been generally used in this country; but is greatly inferior to the latter, which is universally employed on the continent. Willis numbered the pairs of nerves in correspondence with the openings in the base of the cranium, and included amongst them, as the tenth pair, the sub-occipital or first cervical nerve, now considered as a spinal nerve. Soemmering, more properly, treats the facial and the auditory nerve as separate pairs, under the name of seventh and eighth; the glosso-pharyngeal as the ninth pair; the pneumogastric the tenth; the spinal accessory the eleventh; and the hypoglossal the twelfth. They may be arranged in a tabular form, as follows:—

	1st. Olfactory.	
	2nd. Optic.	
	3rd. Motores oculorum.	
	4th. Pathetici (trochleares).	
	5th. Trifacial (trigemini).	
	6th. Abducentes.	
7th.	{ Facial (portio dura).	7th. Soemmering.
	{ Auditory (portio mollis).	8th. “
	{ Glosso-pharyngeal.	9th. “
8th.	{ Pneumogastric (vagus, par vagum).	10th. “
	{ Spinal accessory.	11th. “
9th.	Hypoglossal (lingual).	12th. “

Functionally or physiologically the cranial nerves admit of division into three groups, namely, nerves of special sense, nerves of motion, and compound nerves, that is, nerves which contain fibres both of sensation and motion. The nerves belonging to these groups are the following:—

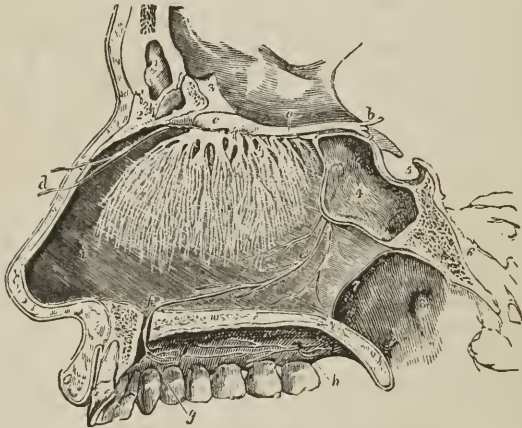
Special sense.	{ 1st. Olfactory.
	{ 2nd. Optic.
	{ 7th. Auditory.
Motion. . . .	{ 3rd. Motores oculorum.
	{ 4th. Pathetici.
	{ 6th. Abducentes.
	{ 7th. Facial.
	{ 9th. Hypoglossal.
Compound. .	{ 5th. Trifacial.
	{ 8th. Glosso-pharyngeal.
	{ “ Pneumogastric.
	{ “ Spinal accessory.

The fourth, facial, and three nerves of the eighth pair were considered by Sir Charles Bell to form a system apart from the rest, and to be allied in the func-

tions of expression and respiration. In consonance with this view he termed them *respiratory nerves*, and he gave to that part of the medulla oblongata from which they arise the name of *respiratory tract*.

FIRST PAIR. OLFACTORY. — The olfactory nerve *arises* by three roots; an *inner* or *short root* from the inner and posterior part of the anterior lobe close to the *substantia perforata*; a *middle root* from a papilla of gray matter (*caruncula mamillaris*), imbedded in the anterior lobe, its white fibres being derived from the *corpus striatum*; and an *external* or *long root*, which may be traced as a white streak along the fissure of Sylvius into the middle lobe, where it is continuous with the fibres of the anterior commissure and the exterior white substance of the *thalamus opticus*. The nervous cord formed by the union of the three roots is soft in texture, prismoid in shape, and imbedded in a sulcus between two convolutions on the under surface of each anterior lobe of the brain, lying between the *pia mater* and *arachnoid*. As it passes forwards it

FIG. 258.



OLFACTORY NERVE, WITH ITS DISTRIBUTION ON THE SEPTUM NASI. The nares have been divided by a longitudinal section made immediately to the left of the septum, the right naris being preserved entire. 1. Frontal sinus. 2. Nasal bone. 3. Crista galli process of ethmoid bone. 4. Sphenoidal sinus of left side. 5. Sella turcica. 6. Basilar process of sphenoid and occipital bone. 7. Posterior opening of the right naris. 8. Opening of the Eustachian tube in the upper part of the pharynx. 9. Soft palate divided through its middle. 10. Cut surface of the hard palate. *a.* Olfactory nerve. *b.* Its three roots of origin. *c.* Its bulb, from which the filaments are seen to proceed which spread out in the substance of the pituitary membrane. *d.* Nasal nerve, a branch of the ophthalmic, descending into the left naris from the anterior foramen of the cribriform plate, and dividing into its external and internal branch. *e.* Naso-palatine nerve, a branch from the spheno-palatine ganglion, distributing twigs to the mucous membrane of the septum nasi in its course to (*f.*) the anterior palatine foramen. *g.* Branches of the naso-palatine nerve to the palate. *h.* Anterior and posterior palatine nerves. *i.* Septum nasi.

increases in breadth and swells at its extremity into an oblong mass of gray and white substance, the *bulbus olfactorius*, which rests on the cribriform lamella of the ethmoid bone. From the under surface of the *bulbus olfactorius* are given off the nerves which pass through the cribriform foramina, and supply the mucous membrane of the nares; they are arranged into three groups, an inner group, reddish in color and soft, which spread out upon the septum narium; an outer group, whiter and more firm, which descend through bony canals in the

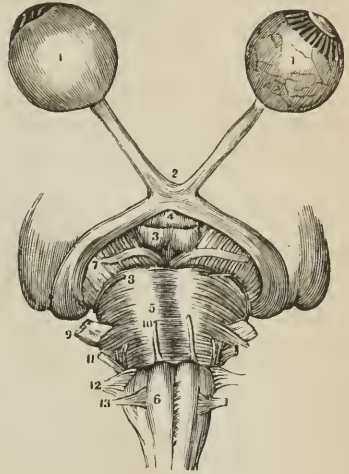
outer wall of the nares, and are distributed on the superior and middle turbinated bones; and a middle group, which supply the mucous membrane of the roof of the nasal fossæ.

SECOND PAIR. OPTIC.—The optic nerve, a nerve of large size, *arises* from the corpora geniculata on the posterior and inferior aspect of the thalamus opticus, from the thalamus itself, and from the nates. Proceeding from this origin it winds around the crus cerebri as a flattened band, under the name of *tractus opticus*, and joins with its fellow in front of the tuber cinereum to form the *optic commissure* (chiasma). The tractus opticus is united with the crus cerebri and tuber cinereum, and is covered in by the pia mater; the commissure is also connected with the tuber cinereum, from which it receives fibres, and the nerve beyond the commissure diverges from its fellow, becomes rounded in form, and is inclosed in a sheath derived from the arachnoid. In passing through the optic foramen the optic nerve receives a sheath from the dura mater, which splits at this point into two layers; one, which becomes the periosteum of the orbit; the other, the one in question, which forms a sheath for the nerve, and is lost in the sclerotic coat of the eyeball. After a short course within the orbit, the optic nerve pierces the sclerotic and choroid coats and expands into the nervous membrane of the eyeball, the retina. Near the globe, the nerve is pierced by a small artery, *arteria centralis retinæ*, which runs through the central axis of the nerve and reaches the internal surface of the retina, to which it distributes branches.

The *optic commissure* rests on the process olivaris of the sphenoid bone; is bounded by the lamina cinerea of the corpus callosum in front, by the substantia perforata at each side, and by the tuber cinereum behind. Within the commissure the innermost fibres of the optic nerves cross each other to pass to opposite eyes, the outer fibres continue their course uninterruptedly to the eye of the corresponding side; some fibres pass in an arched direction from one nerve to the other behind, and others taking a similar course in front connect the two retinæ. The neurilemma of the commissure, as well as that of the nerves, is formed by the pia mater.

THIRD PAIR. MOTORES OCULORUM.—The motor oculi, a nerve of moderate size, *arises* from the inner side of the crus cerebri, close to the pons Varolii, and passes forwards between the posterior cerebral and superior cerebellar artery. It pierces the dura mater immediately in front of the posterior clinoid process; descends obliquely in the external wall of the cavernous sinus; and divides into two branches which enter the orbit through the sphenoidal fissure

[FIG. 259.]

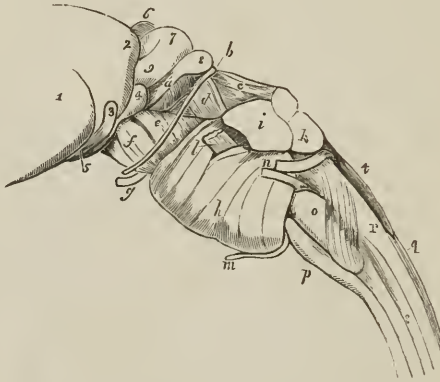

A VIEW OF THE SECOND PAIR OR OPTIC, and the origins of seven other pairs. 1, 1. Globe of the eye; the one on the left hand is perfect, but that on the right has the sclerotic and choroid removed to show the retina. 2. The chiasm of the optic nerves. 3. The corpora albicantia. 4. The infundibulum. 5. The pons Varolii. 6. The medulla oblongata. The figure is on the right corpus pyramidale. 7. Third pair, motores oculorum. 8. Fourth pair, pathetici. 9. Fifth pair, trigemini. 10. Sixth pair, abducentes. 11. Seventh pair, auditory and facial. 12. Eighth pair, pneumogastric, spinal accessory, and glosso-pharyngeal. 13. Ninth pair, hypoglossal.]

and between the two heads of the external rectus muscle. The *superior* branch ascends, and supplies the superior rectus and levator palpebræ. The *inferior* sends a branch beneath the optic nerve to the internal rectus, another to the inferior rectus, and a long branch to the inferior oblique muscle. From the latter a short thick branch is given to the ophthalmic ganglion, forming its inferior root. The branches of the third nerve enter the muscles on their ocular side.

The fibres of origin of this nerve may be traced into the gray substance of the crus cerebri,¹ into the longitudinal fibres of the pons Varolii or motor tract,² into the corpora quadrigemina and valve of Vieussens, and to a gray nucleus in

FIG. 260.



ISTHMUS ENCEPHALI, showing thalamus opticus, corpora quadrigemina, pons Varolii, and medulla oblongata, viewed from the side. 1. Thalamus opticus. 2. Posterior prominence of this body, tuberculum superius posterius or pulvinar. 3. Corpus geniculatum externum. 4. Corpus geniculatum internum. 5. Tractus opticus. 6. Pineal gland. 7. Nates. 8. Testis of one side. 9. Brachium anterius. *a*. Brachium posterius. *b*. Origin of fourth nerve, which may be seen descending over the crus cerebri. *c*. Processus cerebelli ad testem, or superior peduncle of the cerebellum. *d*. The band of fibres termed laqueus, the superior division of the fasciculus olivaris, crossing the superior peduncle of the cerebellum to enter the corpora quadrigemina. Through the small triangular space in front of this band, crossed by the fourth nerve, some of the fibres of the superior peduncle of the cerebellum may be seen. *e*. Superior portion of crus cerebri, termed tegmentum. *f*. Its inferior portion. *g*. Third nerve. *h*. Pons Varolii. *i*. Crus cerebelli, or middle peduncle of the cerebellum. *k*. Inferior peduncle derived from the corpus restiforme. The mass lying in the angular interval upon these is the superior peduncle. *l*. Fifth nerve issuing from between the transverse fasciculi of the pons Varolii. *m*. Sixth nerve. *n*. Facial and auditory nerve. *o*. Corpus olivare crossed inferiorly by the superficial arciform fibres. *p*. Corpus pyramidale. *q*. Posterior pyramids of the medulla oblongata. *r*. Corpus restiforme. *t*. Fourth ventricle.

the floor of the aqueduct of Sylvius.³ In the cavernous sinus it receives one or two filaments from the carotid plexus, and one from the ophthalmic nerve.

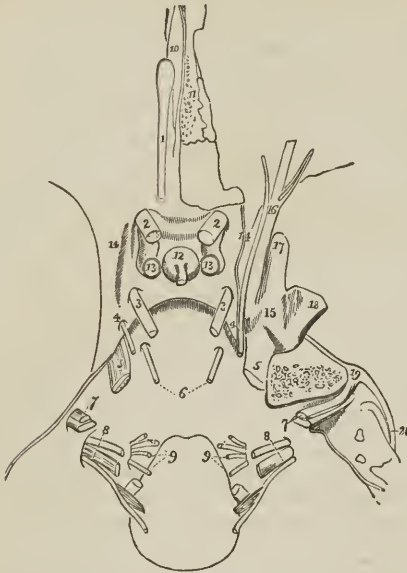
FOURTH PAIR PATHETICI (trochlearis). — The fourth is the smallest cerebral nerve; it *arises* from the valve of Vieussens close to the testis, and winding around the crus cerebri to the extremity of the petrous portion of the temporal bone, pierces the dura mater below the third nerve, and passes forwards in the outer wall of the cavernous sinus to the sphenoidal fissure. In its course in the outer wall of the sinus it is situated at first below the motor oculi, but afterwards ascends and becomes the highest of the nerves entering the orbit by

¹ Mayo.² Solly.³ Stilling.

the sphenoidal fissure. On entering the orbit the nerve crosses the levator palpebræ muscle near its origin, and is distributed on the orbital surface of the superior oblique or trochlearis muscle; hence its synonym *trochlearis*.

The fibres of origin of the two nerves communicate with each other forming a kind of commissure, while those of the deep origin of the nerve may be traced in two fasciculi to a gray nucleus in the floor of the aqueduct of Sylvius in front; and to a similar nucleus in the floor of the fourth ventricle behind.

FIG. 261.



CEREBRAL NERVES WITHIN THE CRANIUM. 1. Olfactory nerve swelling at its anterior extremity into the bulbus olfactorius. 2, 2. Optic nerves, passing through the optic foramina. 3, 3. Motores oculorum, piercing the dura mater near the posterior clinoid processes. 4, 4. Pathetici; the nerve of the left side is seen piercing the dura mater; on the right side the dura mater is removed, and the nerve may be traced through the cavernous sinus. 5, 5. The trigeminus; on the left side the nerve is seen merely passing through the dura mater; on the right, the Gasserian ganglion and its three divisions are seen. 6. Abducens. 7, 7. Facial and auditory nerve; on the right side the nerves are traced into the petrous portion of the temporal bone. 8, 8. Glosso-pharyngeal, pneumogastric, and spinal accessory nerve. 9, 9. Hypoglossal nerve, consisting of several fasciculi piercing the dura mater at the anterior condyloid foramen. 10. Dura mater attached to crista galli. 11. Cribiform plate of ethmoid bone. 12. Pituitary gland and infundibulum. 13, 13. Internal carotid arteries. 14, 14. Cavernous sinus. 15. Gasserian ganglion. 16. Ophthalmic nerve. 17. Superior maxillary nerve passing through the foramen rotundum. 18. Inferior maxillary nerve passing through the foramen ovale. 19. Intumescencia gangliformis of the facial nerve; the nerve joining it from the front is the nervus petrosus superficialis major. 20. Course of the facial nerve along the aquæductus Fallopii to the stylo-mastoid foramen.

Branches. — While in the cavernous sinus the fourth nerve gives off a recurrent branch, and sends a branch of communication to the ophthalmic nerve, the *recurrent branch*, consisting of sympathetic filaments derived from the carotid plexus, passes backwards between the layers of the tentorium, and divides into two or three filaments, which are distributed to the lining membrane of the lateral sinus. This recurrent nerve is sometimes a branch of the ophthalmic,

and occasionally proceeds directly from the carotid plexus. Sometimes the communication with the ophthalmic takes place in the orbit, in which case the lachrymal nerve has the appearance of arising by two roots.

FIFTH PAIR. TRIFACIAL (trigeminus.)—The fifth nerve, the great sensitive nerve of the head and face, and the largest cranial nerve, is analogous to the spinal nerves in its origin by two roots from the anterior and posterior columns of the spinal cord, and in the existence of a ganglion on the posterior root. It *arises*, or rather makes its appearance at the surface of the brain, on the anterior part of the lateral and constricted portion of the pons Varolii, and consists of a large and small fasciculus, separated by a narrow interspace, the larger fasciculus being the posterior or sensitive root; the smaller one, the anterior or motor root. The sensitive root is composed of from seventy to a hundred filaments, each inclosed in a neurilemma of pia mater, and the entire bundle is bound together into a single nerve and connected with the motor root by a sheath of arachnoid membrane. The nerve then passes through an oval opening in the border of the tentorium, near the extremity of the petrous bone, and spreads out into a large semilunar ganglion, the Gasserian. If the ganglion be turned over, it will be seen that the anterior root lies against its under surface without having any connexion with it, and may be followed onwards to the inferior maxillary nerve. The Gasserian ganglion divides into three branches, ophthalmic, superior maxillary, and inferior maxillary.

Following the nerve to its *deep origin*, the *posterior root* may be traced between the transverse layers of the pons Varolii, behind the corpus olivare, and between the corpus restiforme and fasciculus innominatus to the gray substance of the floor of the fourth ventricle; the *anterior root* being lost among the longitudinal fibres prolonged upwards from the corpus pyramidale, or, according to Stilling, also pursuing its course to the gray substance of the floor of the fourth ventricle. When the posterior root is torn from its attachment a cone of medullary substance is left behind, occasioned by the deeper embrace of the filaments by the pia mater at the periphery than in the centre of the fasciculus.

The **OPHTHALMIC NERVE** is the nerve of sensation of the eyeball, lachrymal gland, mucous membrane of the eye and nose, integument of the forehead and nose, and muscles of the eyebrow and forehead. It arises from the upper part of the Gasserian ganglion by a short trunk, about three-quarters of an inch in length; passes forwards in the outer wall of the cavernous sinus, lying externally to the other nerves, and divides into three branches. Previously to its division it receives several filaments from the carotid plexus, and gives off a small *recurrent nerve*, which passes backwards with the recurrent branch of the fourth nerve between the two layers of the tentorium to the lining membrane of the lateral sinus.

The *Branches* of the ophthalmic nerve are, the—

Frontal,	Lachrymal,	Nasal.
----------	------------	--------

The *Frontal nerve* enters the orbit immediately to the outer side of the fourth nerve, and passing forwards, for some distance, upon the levator palpebræ muscle, divides into a supraorbital and supra-trochlear branch.

The *supraorbital branch*, the proper continuation of the nerve, passes out of the orbit through the supraorbital notch, in company with the supraorbital artery, and after giving filaments to the upper eyelid, muscles of the forehead and perieranium, divides into two cutaneous branches, internal and external. The *internal branch* pierces the oecipito-frontalis and is distributed to the integument as far as the summit of the head. The *external branch* of larger size communicates with the facial nerve, and piercing the oecipito-frontalis supplies the integument as far back as the oeciput.

The *supra-trochlear* branch passes inwards to the angle of the orbit, above the pulley of the superior oblique muscle, and is distributed to the inner angle

FIG. 262.

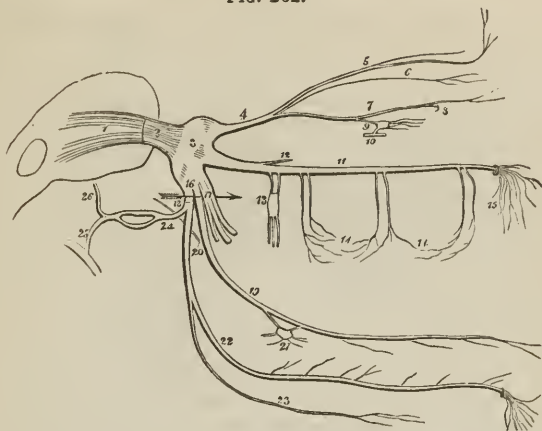


DIAGRAM SHOWING THE FIFTH PAIR OF NERVES WITH ITS BRANCHES. 1. Origin of the nerve by two roots. 2. The nerve escaping from the pons Varolii. 3. Gasserian ganglion. 4. Ophthalmic nerve. 5. Frontal nerve giving off the supra-trochlear branch, and escaping on the forehead through the supraorbital foramen. 6. Lachrymal nerve. 7. Nasal nerve, passing at 8 through the anterior ethmoidal foramen, and giving off the infra-trochlear branch. 9. Communication (superior root) of the nasal nerve with the ophthalmic ganglion. 10. A small portion of the third nerve with which the ganglion is seen communicating (inferior root); the ganglion gives off the ciliary nerves from its anterior aspect. 11. Superior maxillary nerve. 12. Orbital branch. 13. Spheno-palatine nerves communicating with Meckel's ganglion; the three branches from the lower part of the ganglion are the palatine nerves. 14, 14. Superior dental nerves, posterior, middle, and anterior, forming by their communications the superior maxillary plexus. 15. Infraorbital branches distributed to the cheek. 16. Inferior maxillary nerve. 17. Its anterior or muscular trunk. 18. The posterior trunk; the two divisions are separated by an arrow. 19. Gustatory nerve. 20. Chorda tympani joining it at an acute angle. 21. Submaxillary ganglion. 22. Inferior dental nerve. 23. Mylo-hyoidean branch. 24. Auriculo-temporal nerve, dividing behind the articulation of the lower jaw, to reunite and form a single trunk. 25. Its branch of communication with the facial nerve. 26. Continuation of its trunk to the temple.

of the eye, root of the nose, and integument of the middle line of the forehead. It communicates with the infra-trochlear branch of the nasal nerve.

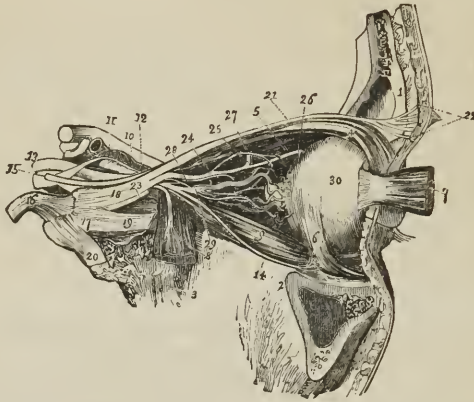
The *Lachrymal nerve*, the smallest of the three branches of the ophthalmic, enters the orbit on the outer side of the frontal, but inclosed in a separate sheath of dura mater; and passes forwards, above the upper border of the external rectus muscle, and in company with the lachrymal artery to the lachrymal gland, where it divides into two branches, superior and inferior. The *superior branch* passes over the gland which it supplies on the upper surface, and traversing a foramen in the malar bone, communicates with the subcutaneous malæ and facial nerve. The *inferior branch* supplies the under surface of the gland, upper lid and outer angle of the eye.

The lachrymal nerve sometimes receives the branch of the fourth nerve destined for the ophthalmic, and appears to arise by two roots.

The *Nasal nerve* (naso-ciliaris) enters the orbit between the two heads of the external rectus and between the two branches of the third nerve. It crosses the optic nerve in company with the ophthalmic artery, and, passing over the inter-

nal rectus, enters the anterior ethmoidal foramen, by which it is conducted to the cribriform plate of the ethmoid bone. It then passes through the slit-like

FIG. 263.



NERVES OF THE ORBIT SEEN FROM THE OUTER SIDE; after Arnold. 1. Section of frontal bone; immediately behind the cipher is the frontal sinus, and in front, the integument. 2. Superior maxillary bone; the section in front of the cipher exhibits the maxillary sinus. 3. Part of sphenoid bone. 4. Levator palpebræ and superior rectus muscle. 5. Superior oblique muscle. 6. Inferior oblique. 7. Ocular half of the external rectus drawn forwards. 8. Orbital half of the external rectus turned downwards. On this muscle the sixth nerve is seen dividing into branches. 9. Inferior rectus. 10. Optic nerve. 11. Internal carotid artery emerging from the cavernous sinus. 12. Ophthalmic artery. 13. Third nerve. 14. Branch of the third nerve to the inferior oblique muscle. Between this and the sixth nerve (8) is seen the branch which supplies the inferior rectus; its branch to the ophthalmic ganglion is seen proceeding from the upper side of the trunk of the nerve, at the bottom of the orbit. 15. Fourth nerve. 16. Trunk of the fifth nerve. 17. Gasserian ganglion. 18. Ophthalmic nerve. 19. Superior maxillary nerve. 20. Inferior maxillary nerve. 21. Frontal nerve. 22. Its division into branches to supply the integument of the forehead. 23. Lachrymal nerve. 24. Nasal nerve; the small nerve seen in the bifurcation of the nasal and frontal, is one of the branches of the upper division of the third nerve. 25. Nasal nerve passing over the internal rectus muscle to the anterior ethmoidal foramen. 26. Infra-trochlear nerve. 27. A long ciliary branch of the nasal; another long ciliary branch is seen proceeding from the lower aspect of the nerve. 28. Long root of the ophthalmic ganglion, proceeding from the nasal nerve, and receiving the sympathetic root which joins it at an acute angle. 29. Ophthalmic ganglion, giving off from its fore-part, the short ciliary nerves. 30. Globe of the eye.

opening by the side of the crista galli, and descends into the nose, where it divides into an internal and external branch. The *internal branch* is distributed to the mucous membrane; the *external branch*, passing outwards between the nasal bone and cartilage, supplies the integument of the exterior of the nose as far as its tip.

The *Branches* of the nasal nerve are, *ganglionic*, *ciliary*, and *infra-trochlear*.

The *ganglionic branch*, about half an inch in length and of small size, enters the upper angle of the ophthalmic ganglion, and constitutes its superior or long root.

The *long ciliary branches* are two or three filaments given off from the nerve as it crosses the optic nerve. They pierce the sclerotic coat near the short ciliary nerves, and passing through the globe of the eye between the sclerotic and choroid, are distributed to the iris.

The *infra-trochlear branch* is given off close to the anterior ethmoidal foramen. It passes forwards along the upper border of the internal rectus to the

inner angle of the eye, where it communicates with the supra-trochlear nerve, and is distributed to the lachrymal sac, and inner angle of the orbit.

The SUPERIOR MAXILLARY NERVE, larger than the preceding, is the nerve of sensation of the teeth of the upper jaw, the hard and soft palate, tonsils, antrum maxillare, and muscles and integument of the lower eyelid, cheek, and upper lip. Proceeding from the middle of the Gasserian ganglion, it passes forwards through the foramen rotundum, crosses the spheno-maxillary fossa, and enters the canal in the floor of the orbit, along which it runs to the infraorbital foramen. Emerging on the face, beneath the levator labii superioris muscle, it divides into a number of branches, which form a plexus with the facial nerve.

The *Branches* of the superior maxillary nerve are divisible into three groups: namely, those given off in the spheno-maxillary fossa; those given off in the infraorbital canal; and those given off on the face. They may be thus arranged:

Spheno-maxillary fossa,	{	Orbital, or temporo-malar,
		Spheno-palatine, Posterior dental.
Infraorbital canal, .	{	Middle dental, Anterior dental.
		Muscular, Cutaneous.
On the face, . . .	{	

The *Orbital* or *temporo-malar branch* enters the orbit through the spheno-maxillary fissure, and divides into two branches, temporal and malar; the *temporal branch* ascends along the outer wall of the orbit, and after receiving a branch from the lachrymal nerve, passes through a canal in the malar bone, and enters the temporal fossa; it then pierces the temporal muscle and fascia, and is distributed to the integument of the temple and side of the forehead, communicating with the facial and anterior temporal nerve. In the temporal fossa it communicates with the deep temporal nerves. The *malar*, or inferior branch (subcutaneous malæ) takes its course along the lower angle of the outer wall of the orbit, and emerges on the cheek through an opening in the malar bone, passing between the fibres of the orbicularis palpebrarum muscle. It communicates with branches of the infraorbital and facial nerve.

The *Spheno-palatine branches*, two in number, pass downwards to the spheno-palatine or Meckel's ganglion.

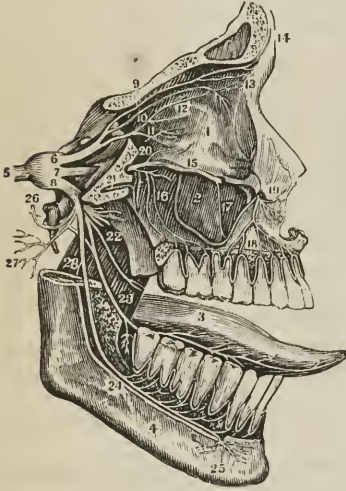
The *Posterior dental branches*, two in number, pass downwards upon the tuberosity of the superior maxillary bone, where *one* enters a canal in the bone, and is distributed to the molar teeth and lining membrane of the antrum, and communicates with the anterior dental nerve; while the *other*, lying externally to the bone, is distributed to the gums and buccinator muscle.

The *Middle* and *anterior dental branches* descend to the corresponding teeth and gums; the former beneath the lining membrane of the antrum, the latter through distinct canals in the walls of the bone. Previously to their distribution, the dental nerves form a plexus (superior maxillary plexus) in the outer wall of the superior maxillary bone immediately above the alveolus. From this plexus filaments are given off which supply the pulps of the teeth, gums, mucous membrane of the floor of the nares, and palate. Some gangliform bodies have been described in connexion with this plexus, one being placed over the canine, another over the second molar tooth.

The *Muscular* and *cutaneous branches* are the terminating filaments of the nerve; they supply the muscles, integument, and mucous membrane of the lower eyelid, cheek, nose, and upper lip, and form a plexus by their communications with the facial nerve.

The INFERIOR MAXILLARY NERVE is a nerve both of sensation and motion, and is distributed to the teeth and gums of the lower jaw, to the tongue, which

[FIG. 264.]



THE DISTRIBUTION OF THE TRIFACIAL OR FIFTH PAIR. — 1. Orbit. 2. Antrum of Highmore. 3. Tongue. 4. Lower maxilla. 5. Root of 5th pair forming the ganglion of Gasser. 6. 1st branch, Ophthalmic. 7. 2d branch, Superior maxillary. 8. 3d branch, Inferior maxillary. 9. Frontal branch, dividing into external and internal frontal at 14. 10. Lachrymal branch, dividing before entering the lachrymal gland. 11. Nasal branch. Just under the figure is the long root of the lenticular or ciliary ganglion, and a few of the ciliary nerves. 12. Internal nasal, disappearing through the anterior ethmoidal foramen. 13. External nasal. 14. External and internal frontal. 15. Superior maxillary nerve. 16. Posterior dental branches. 17. Middle dental branch. 18. Anterior dental branch. 19. Terminating branches of superior maxillary, called labial and palpebral. 20. Orbital or temporo-malar branch. 21. Pterygoid branch, or Vidian nerve, from Meckel's ganglion. 22. Five anterior branches of inferior maxillary nerve, being nerves of motion, and called masseteric, temporal, pterygoid and buccal. 23. Gustatory branch joined at an acute angle by the chorda tympani. 24. Inferior dental nerve terminating in, 25. Mental branches. 26. Auriculo-temporal nerve. 27. Auricular branches. 28. Mylohyoid branch.]

it supplies with the sense of taste, to the integument of the temple, external ear, lower part of the face and lower lip, and to the muscles of mastication. It proceeds from the inferior angle of the Gasserian ganglion, is the largest of the three divisions of the fifth nerve, and is increased in size by the anterior or motor root, which, passing behind the ganglion, unites with the inferior maxillary as it escapes through the foramen ovale. Emerging at the foramen ovale the nerve divides into two trunks, external and internal, separated from each other by the external pterygoid muscle.

The *External division*, into which may be traced nearly the whole of the motor root, immediately separates into five or six branches, distributed to the muscles of the temporo-maxillary region; they are, masseteric, temporal, buccal, internal pterygoid, and external pterygoid.

The *Masseteric branch* passing over the external pterygoid muscle, and behind the tendon of the temporal, crosses the sigmoid notch with the masseteric artery to the masseter muscle. It sends a small branch to the temporal muscle, and a filament to the temporo-maxillary articulation.

The *Deep temporal branches*, two in number, *anterior* and *posterior*, pass between the upper border of the external pterygoid muscle and the temporal bone to the temporal muscle. Two or three filaments from these nerves pierce the temporal fascia, and communicate with the lachrymal, subcutaneous malar, superficial temporal, and facial nerve.

The *Buccal branch* is of large size, and pierces the lower fibres of the external pterygoid muscle at its anterior part. It sends a branch to the external pterygoid muscle, and is distributed to the buccinator, and mucous membrane and integument of the cheek, communicating with the facial nerve.

The *Internal pterygoid branch* is a long and slender nerve which passes inwards to the internal pterygoid muscle, and gives filaments in its course to the

tensor palati and tensor tympani. This nerve is remarkable for its connexion with the otic ganglion, to which it is closely adherent.

The *External pterygoid branch* is commonly derived from the buccal nerve.

The *Internal division* of the inferior maxillary nerve splits into three branches—

Auriculo-temporal,

Inferior dental,

Gustatory.

The AURICULO-TEMPORAL NERVE originates by two roots, between which the arteria meningea media takes its course, and passes directly backwards behind the articulation of the lower jaw. It then ascends between that articulation and the meatus auris, and, escaping from beneath the parotid gland, divides into two temporal branches. While behind the temporo-maxillary articulation, it forms a kind of plexus, and sends off several branches.

Its *branches* are, a small branch to the temporo-maxillary articulation; two or three to the parotid gland; two to the meatus auris, which enter the canal between the fibro-cartilage and processus auditorius; two auricular branches to the pinna; a communicating branch to the otic ganglion; two communicating branches to the facial nerve, and the temporal branches.

The *auricular branches, superior and inferior*, are distributed to the pinna above and below the meatus. The inferior branch communicates with the sympathetic.

The branches which communicate with the facial nerve embrace the external carotid artery in their course.

The *temporal branches* are anterior and posterior; the *anterior* accompanies the anterior temporal artery, and supplies the integument of the temporal region, communicating with branches of the facial, supraorbital, subcutaneous maxillæ and lachrymal nerve; the *posterior* is distributed to the upper part of the pinna, attrahens aurem muscle, and integument of the posterior part of the temple.

The INFERIOR DENTAL NERVE, the largest of the three branches of the internal division of the inferior maxillary, passes downwards with the inferior dental artery, at first between the two pterygoid muscles, then between the internal lateral ligament and ramus of the lower jaw, to the dental foramen, next it runs along the canal in the inferior maxillary bone, distributing branches (inferior maxillary plexus) to the teeth and gums, and divides into two terminal branches, incisive and mental.

The *branches* of the inferior dental nerve, besides those given to the teeth, are the mylo-hyoidean and the two terminal branches.

The *Mylo-hyoidean branch* leaves the nerve just as it is about to enter the dental foramen; it then pierces the insertion of the internal lateral ligament, and descends along a groove in the bone to the inferior surface of the mylo-hyoid muscle, to which, and to the anterior belly of the digastricus, it is distributed.

The *Incisive branch* is continued forwards to the symphysis of the jaw, to supply the incisor teeth.

The *Mental or labial branch* emerges from the jaw at the mental foramen, beneath the depressor anguli oris, and divides into branches which supply the muscles and integument of the lower lip and chin, and communicate with the facial nerve.

The GUSTATORY NERVE descends between the two pterygoid muscles, and makes a gentle curve forwards to the side of the tongue, along which it takes its course to the tip. On the side of the tongue it is flattened, and gives off numerous branches, which are distributed to the mucous membrane and papillæ

In the upper part of its course the gustatory nerve lies between the external

pterygoid muscle and the pharynx, next between the two pterygoid muscles, then between the internal pterygoid and ramus of the jaw, and between the stylo-glossus muscle and the submaxillary gland; lastly, it runs along the side of the tongue, resting against the hyo-glossus muscle and crossing the duct of the submaxillary gland, and is covered in by the mylo-hyoideus and mucous membrane.

The gustatory nerve, while between the pterygoid muscles, often receives a communicating branch from the inferior dental; lower down it is joined at an acute angle by the chorda tympani, a small nerve which, arising from the facial in the aquæductus Fallopii, crosses the tympanum, and escapes from that cavity through the fissura Glaseri. Having joined the gustatory nerve, the chorda tympani is continued downwards in its sheath to the submaxillary ganglion.

One or two *branches* are given by the gustatory nerve to the submaxillary ganglion.

On the hyo-glossus muscle several *branches* of communication join with branches of the hypoglossal nerve, and others are sent to the sublingual gland, Wharton's duct, and mucous membrane of the mouth and gums.

SIXTH PAIR. ABDUCENTES. — The abducens nerve, about half the size of the motor oculi, *arises* by several filaments from the upper constricted part of the corpus pyramidale, and by a few fibres from the pons Varolii. Proceeding forwards from this origin, it lies parallel with the basilar artery, and, piercing the dura mater on the clivus Blumenbachii of the sphenoid bone, ascends between the two layers of that membrane to the cavernous sinus. It then runs forwards through the sinus below the level of the other nerves, and resting against the internal carotid artery, to the sphenoidal fissure. Entering the orbit through the sphenoidal fissure it passes between the two heads of the external rectus, and is distributed to that muscle. At the sphenoidal fissure it lies upon the ophthalmic vein, from which it is separated by a lamina of dura mater; and in the cavernous sinus is joined by several filaments from the carotid plexus.

Mayo traced the deep origin of this nerve between the fasciculi of the corpora pyramidalia to the posterior part of the medulla oblongata; and it appears to arise from the gray substance of the fourth ventricle.

SEVENTH PAIR. — The seventh pair of nerves, of Willis, consists of two nervous cords which lie side by side on the posterior border of the crus cerebelli. The smaller and most internal of these, and at the same time the most dense in texture, is the facial nerve or portio dura. The external nerve, which is soft and pulpy, and often grooved by contact with the preceding, is the auditory nerve or portio mollis.¹

FACIAL NERVE; portio dura; SEVENTH PAIR of Soemmerring. — The facial nerve, the motor nerve of the face, *arises* from the upper part of the groove between the corpus olivare and corpus restiforme close to, and by a few fibres from, the pons Varolii; its deep origin being traced through the corpus restiforme to the side of the floor of the fourth ventricle. The nerve passes forwards, resting on the crus cerebelli, and comes into relation with the auditory nerve, with which it enters the meatus auditorius internus, lying at first to the inner side of, and then upon that nerve. At the bottom of the meatus, the facial nerve enters

¹ A third nerve of small size, *portio intermedia* of Wrisberg, is brought into view by separating these two cords. The researches of Morgagni render it probable that the portio intermedia is connected, at its origin in the corpus restiforme, with the auditory nerve; that it is the posterior or sensitive root of the facial; that the intumescentia gangliformis of the facial is the ganglion of this root; that it bestows the principal part of the sensitive function on the facial; and that the chorda tympani is partly derived from the intumescentia gangliformis.

the aquæductus Fallopii, and takes its course forwards to the hiatus Fallopii, in the anterior wall of the petrous bone, where it forms a gangliform swelling (intumescencia gangliformis, ganglion geniculare), and receives the petrosal branch of the Vidian nerve. It then curves backwards towards the tympanum, and descends in the inner wall of that cavity to the stylo-mastoid foramen. Emerging at the stylo-mastoid foramen, it passes forwards within the parotid gland, crossing the external carotid artery, to the ramus of the lower jaw, where it splits into two trunks, *temporo-facial* and *cervico-facial*. These trunks divide into numerous branches, which escape from the anterior border of the parotid gland, and are distributed in a radiated manner over the side of the face, from the temple to below the lower jaw; on the masseter muscle the branches communicate and form loops, and the whole arrangement over the side of the face has been termed *pes anserinus*.

In the meatus auditorius, the facial nerve communicates with the auditory nerve by one or two filaments; the intumescencia gangliformis receives the nervus petrosus superficialis major and minor, and sends a twig back to the auditory nerve; behind the tympanum, the nerve receives one or two twigs from the auricular branch of the pneumogastric; at its exit from the stylo-mastoid foramen it receives a twig from the glosso-pharyngeal, and in the parotid gland one or two large branches from the auriculo-temporal nerve. Besides these, the facial nerve has numerous peripheral communications, with the branches of the fifth nerve on the face, with the cervical nerves in the parotid gland and on the neck, and with the sympathetic. The numerous communications of the facial nerve have obtained for it the designation of *nervus sympatheticus minor*.

The *Branches* of the facial nerve are —

Within the aquæductus Fallopii . . .	{ Tympanic, Chorda tympani.
After emerging at the stylo-mastoid foramen	{ Posterior auricular, Stylo-hyoid, Digastric.
On the face	{ Temporo-facial, Cervico-facial.

The *Tympanic branch* is a small filament given off by the facial while in the petrous bone, and distributed to the stapedius muscle.

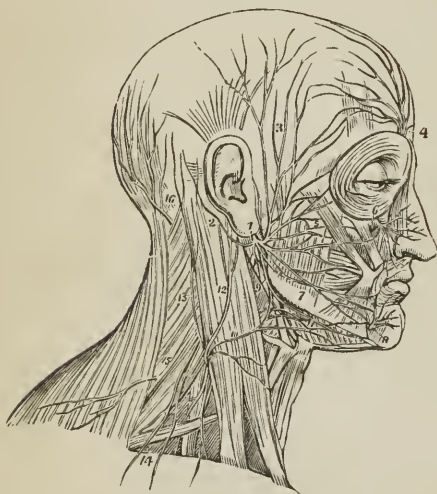
The *Chorda tympani* quits the facial immediately above the stylo-mastoid foramen, and ascends by a distinct canal to the upper part of the posterior wall of the tympanum, where it enters that cavity through an opening situated between the base of the pyramid and the attachment of the membrana tympani, and becomes invested by mucous membrane. It then crosses the tympanum between the handle of the malleus and long process of the incus to its anterior inferior angle, and escapes through an opening in the fissura Glaseri, to join the gustatory nerve at an acute angle between the two pterygoid muscles. Inclosed in the sheath of the gustatory nerve, it descends to the submaxillary gland, where it enters the submaxillary ganglion.

The *Posterior auricular branch* ascends behind the ear, between the meatus and mastoid process, and divides into an anterior or auricular, and a posterior or occipital, branch. The *auricular* branch receives a filament of communication from the auricular branch of the pneumogastric nerve, and distributes filaments to the retrahens aurem muscle and pinna. The *occipital* branch communicates with the auricularis magnus and occipitalis minor, and is distributed to the occipital portion of the occipito-frontalis.

The *Stylo-hyoid branch* is distributed to the stylo-hyoid muscle, and communicates with the sympathetic plexus of the external carotid artery.

The *Digastric branch* supplies the posterior belly of the digastricus muscle, and communicates with the glosso-pharyngeal and pneumogastric nerve.

FIG. 265.



DISTRIBUTION OF THE FACIAL NERVE AND BRANCHES OF THE CERVICAL PLEXUS.

1. Facial nerve, escaping from the stylo-mastoid foramen, and crossing the ramus of the lower jaw: the parotid gland has been removed in order to see the nerve distinctly. 2. Posterior auricular branch; the digastric and stylo-hyoid twigs are seen near the origin of this branch. 3. Temporal branches, communicating with (4) branches of the supraorbital nerve. 5. Infraorbital branches, communicating with (6) the infraorbital nerve. 7. Supra-maxillary branches, communicating with (8) the mental nerve. 9. Infra-maxillary branches communicating with (10) the superficialis colli nerve, and forming a plexus (11) over the submaxillary gland. The distribution of the branches of the facial in a radiated direction over the side of the face and their looped communications constitute the pes anserinus. 12. Auricularis magnus nerve, one of the ascending branches of the cervical plexus. 13. Occipitalis minor ascending along the posterior border of the sterno mastoid. 14. Superficial and deep descending branches of the cervical plexus. 15. Spinal accessory nerve, giving off a branch to the external surface of the trapezius muscle. 16. Occipitalis major nerve, the posterior branch of the second cervical.

The **TEMPORO-FACIAL DIVISION**, while in the parotid gland, sends a branch of communication along the carotid artery to the auriculo-temporal nerve, and divides into temporal, malar, and infraorbital branches.

The *Temporal branches* ascending upon the temporal region supply the *atrahens aurem*, *occipito-frontalis*, and *orbicularis palpebrarum*; and communicate with the supraorbital nerve and temporal branch of the superior maxillary.

The *Malar branches* cross the malar bone to the outer angle of the eye, and supply the *orbicularis palpebrarum*, *corrugator supercilii*, and eyelids. They communicate with the subcutaneous malæ branch of the superior maxillary nerve, and with branches of the ophthalmic nerve in the eyelids.

The *Infraorbital branches* cross the masseter muscle, and are distributed to the buccinator, elevator muscles of the upper lip and *orbicularis oris*. They communicate with the terminal branches of the infraorbital nerve, infra-trochlear and nasal nerve. Two or more of these branches are found by the side of Stenon's duct.

The **CERVICO-FACIAL DIVISION**, smaller than the temporo-facial, communicates in the parotid gland with the *auricularis magnus* nerve, and divides into branches which admit of arrangement into three sets; buccal, supra-maxillary, and infra-maxillary.

The *Buccal branches* pass forwards across the masseter muscle towards the mouth, and distribute branches to the *orbicularis oris* and buccinator. They

communicate with branches of the temporo-facial, and with the buccal branch of the inferior maxillary nerve.

The *Supra-maxillary branches* are destined to the muscles of the lower lip, and take their course along the body of the lower jaw. Beneath the depressor anguli oris, they have a plexiform communication with the inferior dental nerve.

The *Infra-maxillary branches* (subcutanei colli) take their course below the lower jaw, pierce the deep cervical fascia, and are distributed to the platysma; communicating with the superficialis colli nerve.

AUDITORY NERVE; portio mollis; EIGHTH PAIR of Soemmering.—The auditory nerve takes its origin in the lineæ transversæ (striæ medullares) of the anterior wall or floor of the fourth ventricle, and winds around the corpus restiforme, from which it receives fibres, to the posterior border of the crus cerebelli. It then passes forwards on the crus cerebelli in company with the facial nerve, which lies in a groove on its superior surface, enters the meatus auditorius internus, and at the bottom of the meatus divides into two branches, *cochlear* and *vestibular*. The auditory nerve is soft and pulpy in texture, and receives in the meatus auditorius several filaments from the facial nerve.

EIGHTH PAIR of Willis; ninth, tenth, and eleventh pairs of Soemmering; consists of three nerves, glosso-pharyngeal, pneumogastric, and spinal accessory.

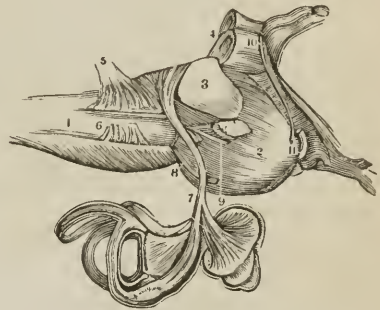
GLOSSO-PHARYNGEAL NERVE.—The glosso-pharyngeal nerve, as its name implies, is the nerve of sensation of the mucous membrane of the tongue and pharynx, but it also gives branches to some of the muscles of these organs. It *arises* by five or six filaments from the groove between the corpus olivare and restiforme, or rather from the anterior border of the latter, and escapes from the skull at the innermost extremity of the jugular foramen through a distinct opening in the dura mater, lying anteriorly to the sheath of the pneumogastric and spinal accessory nerve, and internally to the jugular vein. It then passes forwards between the jugular vein and internal carotid artery, and crosses the artery to reach the posterior border of the stylo-pharyngeus. Following the posterior border of this muscle for a short distance, it next passes across it and the middle constrictor and behind the hyo-glossus muscle, to be distributed to the mucous membrane of the tongue, pharynx, and tonsil.

While in the jugular fossa, the nerve presents two gangliform swellings; one *superior*, the *ganglion jugulare* (Müller), of small size, and involving only the posterior fibres of the nerve; the other *inferior*, nearly half an inch below the preceding, of larger size, and occupying the whole diameter of the nerve, the *ganglion petrosum* or ganglion of Andersch.¹

The fibres of origin of this nerve may be traced through the fasciuli of the corpus restiforme to the gray substance of the floor of the fourth ventricle.

¹ Charles Samuel Andersch. "Tractatus Anatomico-Physiologicus de Nervis corporis Humani Aliquibus, 1797."

[Fig. 266.



ORIGIN AND DISTRIBUTION OF THE PORTIO MOLLIS of the seventh pair, or auditory nerve. 1. The medulla oblongata. 2. The pons Varolii. 3 and 4. The crura cerebelli of the right side. 5. Eighth pair. 6. Ninth pair. 7. The auditory nerve distributed to the labyrinth. 8. The sixth pair. 9. The portio dura of the seventh pair. 10. The fourth pair. 11. The third pair.]

The *branches* of the glosso-pharyngeal nerve are branches of communication and branches of distribution.

The *Branches of communication* proceed chiefly from the ganglion of Andersch; they are, one to join the auricular branch of the pneumogastric; one to the ganglion of the pneumogastric; one to the superior cervical ganglion of the sympathetic; and one, which arises below the ganglion and pierces the posterior belly of the digastricus muscle, to join the facial nerve.

The *Branches of distribution* are —

Tympanic,	Pharyngeal,
Carotid,	Tonsillitic,
Muscular,	Lingual.

The *Tympanic branch* (Jacobson's nerve) proceeds from the ganglion of Andersch, or from the trunk of the nerve immediately above the ganglion; it enters a small bony canal in the jugular fossa (page 66), and divides into six branches, which are distributed on the inner wall of the tympanum, and establish a plexiform communication (tympanic plexus) with the sympathetic and fifth pair of nerves. The *branches of distribution* supply the fenestra rotunda, fenestra ovalis, and Eustachian tube; those of communication join the carotid plexus in the carotid canal, the petrosal branch of the Vidian nerve, and the otic ganglion.

The *Carotid branches* are several filaments which follow the trunk of the internal carotid artery, and communicate with the nervi molles of the sympathetic.

The *Muscular branch* divides into filaments, which are distributed to the posterior belly of the digastricus, stylo-hyoideus, stylo-pharyngeus, and constrictor muscles.

The *Pharyngeal branches* are two or three filaments which are distributed to the pharynx and unite with the pharyngeal branches of the pneumogastric and sympathetic nerve to form the *pharyngeal plexus*.

The *Tonsillitic branches* proceed from the glosso-pharyngeal nerve, near its termination; they form a plexus (circulus tonsillaris) around the base of the tonsil, from which numerous filaments are given off to the mucous membrane of the fauces and soft palate. These filaments communicate with the descending palatine branches of Meckel's ganglion.

The *Lingual branches* enter the substance of the tongue beneath the hyoglossus and stylo-glossus muscle, and are distributed to the mucous membrane of the side and base of the tongue, and to the epiglottis and fauces.

PNEUMOGASTRIC or VAGUS NERVE; *par vagum*; TENTH PAIR of Soemmering. —The pneumogastric is the nerve of the respiratory organs and upper part of the alimentary canal, supplying branches to the larynx, trachea, lungs, pharynx, œsophagus, and stomach, and also giving branches to the heart. It *arises* by ten or fifteen filaments from the groove between the corpus olivare and corpus restiforme, or rather from the anterior border of the latter, immediately below the glosso-pharyngeal, and passes out of the skull through the inner extremity of the jugular foramen, inclosed in a sheath of dura mater common to it and the spinal accessory. The nerve then takes its course down the side of the neck, lying at first between the internal jugular vein and internal carotid artery, and lower down behind and between that vein and the common carotid artery, and inclosed in the same sheath. At the root of the neck the course of the nerve on the two sides is different. The *right nerve* enters the chest by passing between the subclavian artery and vein, and descends by the side of the trachea to the posterior part of the root of the right lung; it then proceeds as a double cord along the posterior aspect of the œsophagus to the corresponding side of the stomach; the two cords reuniting at the lower part of the œsophagus. The

left nerve enters the chest between the left common carotid and subclavian artery lying behind the left vena innominata; it then crosses the arch of the aorta, and reaches the posterior part of the root of the left lung, whence it descends, by one or two cords, along the anterior aspect of the œsophagus to the front part of the stomach.

In the jugular foramen, the pneumogastric nerve presents a small round ganglion, the *superior* or *jugular ganglion*; and immediately at its exit a gangliform swelling, nearly an inch in length, the *inferior ganglion* (plexus gangliiformis).

The fibres of origin of the pneumogastric nerve, like those of the glosso-pharyngeal, may be traced through the fasciculi of the corpus restiforme to the gray substance of the floor of the fourth ventricle.

The *branches* of the pneumogastric nerve are branches of communication and branches of distribution.

The *Branches of communication* proceed from the ganglia: from the superior ganglion one or two branches pass to the spinal accessory; one or two to the superior ganglion of the sympathetic; and one to the inferior ganglion of the glosso-pharyngeal. From the inferior ganglion there pass off branches to the hypoglossal; branches to the superior cervical ganglion of the sympathetic, and branches to the loop between the first and second cervical nerve.

The *Branches of distribution* are —

Auricular,	Pulmonary anterior,
Pharyngeal,	Pulmonary posterior,
Superior laryngeal,	Œsophageal,
Cardiac,	Gastric.
Inferior or recurrent laryngeal,	

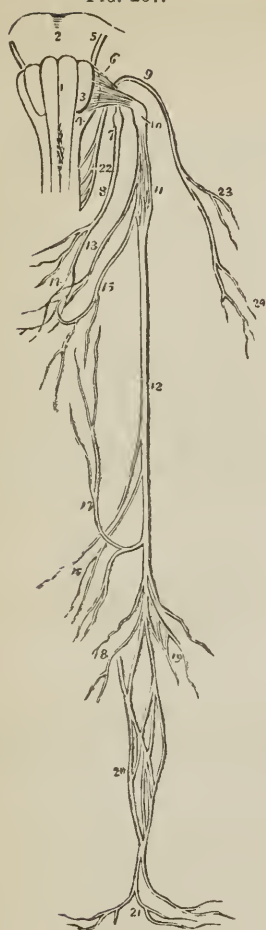The *Auricular* nerve is given off from the lower part of the jugular ganglion, or from the trunk of the nerve immediately below it, and receives immediately after its origin a small branch of communication from the glosso-pharyngeal. It then passes outwards behind the jugular vein, and at the outer side of that vessel enters a small canal (page 67), in the petrous portion of the temporal bone near the stylo-mastoid foramen. Guided by that canal it reaches the descending part of the aquæductus Fallopii and joins the facial nerve. In the aquæductus Fallopii the auricular nerve gives off two small filaments, one of which communicates with the posterior auricular branch of the facial, while the other is distributed to the pinna.

The *Pharyngeal* nerve arises from the upper part of the superior ganglion and crosses behind the internal carotid artery to the upper border of the middle constrictor, upon which it forms the *pharyngeal plexus* assisted by branches from the glosso-pharyngeal, superior laryngeal, and sympathetic. The pharyngeal plexus is distributed to the muscles and mucous membrane of the pharynx.

The *Superior laryngeal* nerve arises from the inferior ganglion and descends behind the internal carotid artery to the opening in the thyro-hyoidean membrane, through which it passes with the superior laryngeal artery, and is distributed to the mucous membrane of the larynx and arytenoideus muscle. On the latter, and behind the cricoid cartilage, it communicates with the recurrent laryngeal nerve. Behind the internal carotid it gives off the *external laryngeal branch*, which sends a twig to the pharyngeal plexus, and then descends to supply the inferior constrictor, crico-thyroid muscle and thyroid gland. This branch communicates inferiorly with the recurrent laryngeal and sympathetic nerve.

The *Cardiac branches*, two or three in number, arise from the upper and lower part of the cervical portion of the nerve. Those from above communicate

FIG. 267.



ORIGIN AND DISTRIBUTION OF THE GLOSSO-PHARYNGEAL, PNEUMOGASTRIC, AND SPINAL ACCESSORY NERVE. 1, 3, 4. Medulla oblongata. 1. Corpus pyramidale. 3. Corpus olivare. 4. Corpus restiforme. 2. Pons Varolii. 5. Facial nerve. 6. Origin of the glosso-pharyngeal. 7. Ganglion of Andersch. 8. Trunk of the nerve. 9. Spinal accessory nerve. 10. Superior ganglion of the pneumogastric. 11. Inferior ganglion. 12. Trunk. 13. Pharyngeal branch forming the pharyngeal plexus (14), assisted by a branch from the glosso-pharyngeal (8), and one from the superior laryngeal nerve (15). 16. Cardiac branches. 17. Recurrent laryngeal branch. 18. Anterior pulmonary and cardiac branches. 19. Posterior pulmonary branches. 20. Oesophageal plexus. 21. Gastric branches. 22. Origin of the spinal accessory nerve. 23. Branch to the sternomastoid muscle. 24. Branches to the trapezius.

with cardiac branches of the sympathetic. One large branch (*inferior cardiac*) is given off just before the nerve enters the chest; on the *right* this branch descends by the side of the arteria innominata to the deep cardiac plexus; on the *left* it passes in front of the arch of the aorta to the superficial cardiac plexus. One or two cardiac branches also proceed from the thoracic portion of the right pneumogastric nerve.

The *Inferior laryngeal*, or recurrent laryngeal nerve, curves around the subclavian artery on the right, and the arch of the aorta on the left side. It ascends in the groove between the trachea and oesophagus, and piercing the lower fibres of the inferior constrictor muscle enters the larynx close to the articulation of the inferior cornu of the thyroid with the cricoid cartilage. It is distributed to all the muscles of the larynx, with the exception of the crico-thyroid, and communicates on the arytenoideus muscle with the superior laryngeal nerve. As it curves around the subclavian artery and aorta it gives branches (cardiac) to the heart and root of the lungs; and as it ascends the neck it distributes filaments to the oesophagus and trachea, and communicates with the external laryngeal nerve and sympathetic.

The *Anterior pulmonary branches*, two or three in number, are distributed upon the anterior aspect of the root of the lungs, forming, with branches from the cardiac plexuses, the *anterior pulmonary plexus*.

The *Posterior pulmonary branches*, more numerous and larger than the anterior, are distributed on the posterior aspect of the root of the lungs; they are joined by filaments from the third and fourth thoracic ganglia of the sympathetic, and form the *posterior pulmonary plexus*.

Oesophageal branches are given off by the pneumogastric nerves above the root of the lungs; below that point, the trunks of the nerves, divided into several cords, form a plexus around the oesophagus, the right and left nerves communicating with each other. This plexus accompanies the oesophagus to the stomach, and is the *oesophageal plexus* (*plexus gulæ*).

The *Gastric branches* are the terminal filaments of the pneumogastric nerves; they are spread out upon the anterior and

posterior surface of the stomach, and are likewise distributed to the omentum, spleen, pancreas, liver, and gall-bladder. The branches of the anterior aspect of the stomach proceed from the left nerve and communicate with the hepatic plexus in the lesser omentum; those of the posterior aspect are derived from the right nerve and communicate with the solar plexus.

SPINAL ACCESSORY NERVE; ELEVENTH PAIR of Soemmering. — The spinal accessory, a nerve of motion, *arises* by several filaments from the side of the spinal cord as low down as the fifth or sixth cervical nerve, and ascends behind the ligamentum dentatum, and between the anterior and posterior roots of the spinal nerves, to the foramen lacerum posterius. It communicates in its course with the posterior root of the first cervical nerve, and, entering the foramen lacerum, becomes applied against the posterior aspect of the superior ganglion of the pneumogastric, being contained in the same sheath of dura mater. The nerve then passes outwards and downwards, behind and sometimes in front of the internal jugular vein, to the upper and under part of the sterno-mastoid, pierces that muscle obliquely, and descends across the posterior triangle of the neck to the under surface of the trapezius to which it is distributed, its branches being continued downwards to near the lower border of the muscle.

The *Branches of communication* of the spinal accessory are one or two small branches from the superior ganglion of the pneumogastric, and a large branch which joins the pneumogastric between the two ganglia.

Its *Branches of distribution* are muscular branches to the sterno-mastoid and trapezius. In the substance of the sterno-mastoid it communicates with branches of the cervical plexus, and in the posterior triangular space with the third and fourth cervical nerve.

The pneumogastric and spinal accessory nerve together (*nervus vagus cum accessorio*) resemble a spinal nerve, of which the former with its ganglion is the posterior and sensitive root, the latter the anterior and motor root. The deep origin of the spinal accessory may be traced into the gray substance of the floor of the fourth ventricle.

NINTH PAIR of Willis; TWELFTH PAIR of Soemmering. HYPOGLOSSAL NERVE; lingual. — The hypoglossal is a nerve of motion, distributed to all the muscles of the tongue, most of those attached to the os hyoides, and the sterno-thyroid. It *arises* from the groove between the corpus pyramidale and corpus olivare by ten or fifteen filaments, which are collected into two bundles, and escape from the cranium through the anterior condyloid foramen. At its exit from the cranium, the nerve lies behind the internal carotid artery and internal jugular vein, then passing forwards between the artery and vein it descends to a point parallel with the angle of the lower jaw. It next curves forwards around the occipital artery, with which it forms a loop, and crossing the external carotid and lower part of the hyo-glossus muscle to the genio-hyo-glossus, sends filaments onwards with the anterior fibres of that muscle as far as the tip of the tongue. While resting on the hyo-glossus muscle it is flattened, and beneath the mylo-hyoideus communicates with the gustatory nerve.

At its origin, the hypoglossal nerve sometimes communicates with the posterior root of the first cervical nerve. Its *deep origin* may be traced to one of the nuclei of gray substance, in the floor of the fourth ventricle, where it decussates with its fellow of the opposite side.

The *branches* of the hypoglossal nerve are branches of communication and branches of distribution.

The *Branches of communication* of the hypoglossal nerve are, several to the pneumogastric, with which nerve it is closely united; one or two with the supe-

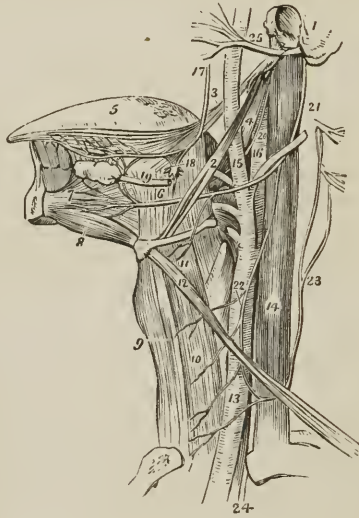
rior cervical ganglion of the sympathetic ; and one or two with the loop between the first and second cervical nerve.

The *Branches of distribution* are —

Descendens noni, Thyro-hyoidean, Muscular.

The *Descendens noni* is a long and slender nerve, which quits the hypoglossal just as it is about to form its arch around the occipital artery, and descends on

FIG. 268.



ANATOMY OF THE SIDE OF THE NECK, SHOWING THE NERVES OF THE TONGUE. 1. Fragment of the temporal bone containing the meatus auditorius externus, mastoid, and styloid process. 2. Stylo-hyoid muscle. 3. Stylo-glossus. 4. Stylo-pharyngeus. 5. Tongue. 6, 18. Hyo-glossus muscle; its two portions. 7. Genio-hyo-glossus. 8. Genio-hyoideus; both arise from the inner surface of the symphysis of the lower jaw. 9. Sterno-hyoid muscle. 10. Sterno-thyroid. 11. Thyro-hyoid, upon which the thyro-hyoidean branch of the hypoglossal nerve is seen ramifying. 12. Omo-hyoid crossing the common carotid artery (13), and internal jugular vein (14). 15. External carotid giving off its branches. 16. Internal carotid. 17. Gustatory nerve giving a branch to the submaxillary ganglion (18), and communicating a little further on with the hypoglossal nerve. 19. Submaxillary, or Wharton's duct, passing forwards to the sublingual gland. The submaxillary ganglion is the small round body between figures 18 and 19. 20. Glosso-pharyngeal nerve, passing in behind the hyo-glossus muscle. 21. Hypoglossal nerve curving around the occipital artery. 22. Descendens noni nerve, forming a loop with (23) the communicans noni, which is seen arising by filaments from the upper cervical nerves. 24. Pneumogastric nerve, emerging from between the internal jugular vein and common carotid artery, and entering the chest. 25. Facial nerve, emerging from the stylo-mastoid foramen and crossing the external carotid artery.

the sheath of the carotid vessels. Just below the middle of the neck it forms a loop with a long branch (*communicans noni*) derived from the second and third cervical nerve. From the convexity of this loop branches are sent to the sterno-hyoideus, sterno-thyroideus, and both bellies of the omo-hyoideus; sometimes also a twig is given off to the cardiac plexus, and occasionally one to the phrenic nerve. If the descendens noni be traced to its origin, it will be found to be composed of a branch from the hypoglossal, and one from the first and second

cervical nerve; occasionally it receives also a filament from the pneumogastric.

The *Thyro-hyoidæan* nerve is a small branch, distributed to the thyro-hyoidæus muscle. It is given off by the trunk of the hypoglossal near the posterior border of the hyo-glossus, and descends obliquely over the great cornu of the os hyoides.

The *Muscular branches* are given off where the nerve is covered in by the mylo-hyoidæus muscle, and rests on the hyo-glossus; several large branches take their course across the fibres of the genio-hyo-glossus to reach the substance of the tongue. Moreover, on the hyo-glossus muscle, the branches of the hypoglossal nerve communicate with those of the gustatory nerve.

SPINAL NERVES.

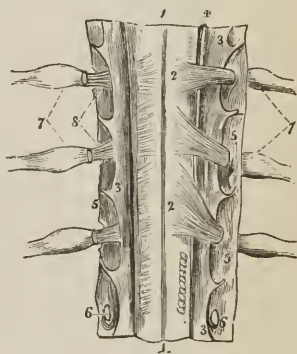
There are thirty-one pairs of spinal nerves, each arising by two roots, an anterior or motor root, and a posterior or sensitive root.

The anterior roots proceed from the anterior lateral sulcus, which marks the division of the anterior from the middle column of the spinal cord, and gradually approach towards the anterior median fissure as they descend.

The posterior roots, more regular than the anterior, proceed from the posterior lateral sulcus; they are larger, and the filaments of origin more numerous than

PART OF THE CERVICAL PORTION OF THE SPINAL CORD, VIEWED ON ITS POSTERIOR ASPECT; showing its membranes and the posterior roots of the spinal nerves. 1, 1. Posterior median fissure. 2, 2. Posterior roots of the cervical nerves; on the opposite side the corresponding roots are cut through near their origin. 3, 3. Membrana dentata. 4. Nervus accessorius, ascending between the posterior roots and membrana dentata; on the opposite side this nerve has been removed. 5, 5. Dura mater. 6, 6. Openings in the dura mater for the passage of the roots of the nerve. 7, 7. Ganglia on the posterior roots of the spinal nerves. 8. Anterior roots of the spinal nerves. The posterior roots have been cut away in order to show each anterior root proceeding to join the nerve beyond the ganglion.

FIG. 269.



those of the anterior roots; and in the intervertebral foramina there is a ganglion on each of their roots. The first cervical nerve forms an exception to these characters; its posterior root is smaller than the anterior; it often joins, in whole or in part, the spinal accessory nerve, and sometimes the hypoglossal: it has frequently no ganglion, and when the ganglion exists, it is often situated within the dura mater, the latter being the usual position of the ganglia of the last two pairs of spinal nerves.

After the formation of a ganglion, the two roots unite, and constitute a spinal nerve, which escapes through the intervertebral foramen, and separates into an *anterior cord* for the supply of the front aspect of the body, and a *posterior cord* for the posterior aspect. In the first cervical, last sacral, and coccygeal nerve this division takes place within the dura mater and in the upper four sacral nerves externally to that cavity, but within the sacral canal. The anterior cords, with the exception of the first two cervical nerves, are larger than the posterior; an arrangement which is proportioned to the larger extent of surface they are required to supply.

The SPINAL NERVES are classed as follows:—

Cervical	8	pairs
Dorsal	12	“
Lumbar	5.	“
Sacral	5	“
Coccygeal.	1	“

The cervical nerves pass off transversely from the spinal cord; the dorsal are oblique in direction; the lumbar and sacral, vertical; the latter from the large assemblage of nerves, at the termination of the cord, called *cauda equina*. The cauda equina occupies the lower third of the spinal canal.

CERVICAL NERVES.

The cervical nerves increase in size from above downwards; the first (sub-occipital) passes out of the spinal canal between the occipital bone and atlas; the second between the posterior ring of the atlas and the lamina of the axis; and the last between the last cervical and first dorsal vertebra. Each nerve, at its escape from the intervertebral foramen, divides into an anterior and a posterior cord. The anterior cords of the four upper cervical nerves form the *cervical plexus*; the posterior cords, the *posterior cervical plexus*. The anterior cords of the four inferior cervical together with the first dorsal form the brachial plexus.

ANTERIOR CERVICAL NERVES.—The anterior cord of the *first cervical* or *sub-occipital nerve* escapes from the vertebral canal through the groove on the posterior arch of the atlas, which supports the vertebral artery, lying beneath that vessel. It descends in front of the transverse process of the atlas, sends twigs to the rectus lateralis and rectus anticus minor, and forms an anastomotic loop by communicating with an ascending branch of the second nerve. Branches from this loop communicate with the pneumogastric nerve, hypoglossal nerve, and first cervical ganglion of the sympathetic.

The anterior cord of the *second cervical nerve*, at its exit from the intervertebral foramen between the atlas and axis, gives twigs to the rectus anticus major, scalenus medius, and levator anguli scapulæ, and divides into three branches: *ascending* branch, which completes the arch of communication with the first nerve; and two *descending* branches, which form loops with corresponding branches of the third nerve.

The anterior cord of the *third cervical nerve*, double the size of the preceding, divides at its exit from the intervertebral foramen into several branches, some of which are distributed to the rectus major, longus colli, and scalenus medius, while others communicate and form loops and anastomoses with the second and fourth nerve.

The anterior cord of the *fourth cervical nerve*, equal in size with the preceding, sends twigs to the rectus major, longus colli, and levator anguli scapulæ, communicates by anastomosis with the third, and sends a small branch downwards to the fifth nerve. Its principal branches pass downwards and outwards across the posterior triangle of the neck, towards the clavicle and acromion.

The anterior cords of the *fifth, sixth, seventh, and eighth* cervical nerves will be described with the brachial plexus, of which they form a part.

CERVICAL PLEXUS.—The cervical plexus is constituted by the loops of communication and anastomoses which take place between the anterior cords of the first four cervical nerves. The plexus rests on the levator anguli scapulæ, pos-

terior and middle scalenus, and splenius colli muscle, and is covered in by the sterno-mastoid and platysma.

The *Branches* of the cervical plexus [fig. 265] may be arranged into three groups, superficial ascending, superficial descending, and deep:—

Superficial .	{	<i>Ascending,</i>	{	Superficialis colli,
				Auricularis magnus,
				Occipitalis minor.
		<i>Descending,</i>	{	Acromiales,
				Claviculares.
Deep	{	Communicating branches,		
		Communicans noni,		
		Muscular,		
		Phrenic.		

The *Superficialis colli* is formed by communicating branches from the second and third cervical nerves; it curves around the posterior border of the sterno-mastoid and crosses obliquely behind the external jugular vein to the anterior border of that muscle, where it pierces the deep cervical fascia and divides into an ascending and a descending branch.

The *ascending branch* passes upwards to the submaxillary region, and divides into four or five filaments, some of which pierce the platysma myoides, and supply the integument as high as the chin and lower part of the face; while others form a plexus with the infra-maxillary branches of the facial nerve beneath the platysma. One or two filaments from this branch accompany the external jugular vein.

The *descending branch* pierces the platysma and is distributed to the integument of the front of the neck as far downwards as the sternum.

The *Auricularis magnus*, the largest of the three ascending branches of the cervical plexus, also proceeds from the second and third cervical nerve; it curves around the posterior border of the sterno-mastoid, and ascends upon that muscle, lying parallel with the external jugular vein, to the parotid gland, where it divides into an anterior and a posterior branch.

The *anterior branch* is distributed to the integument over the parotid gland, and to the gland itself, communicating with the facial nerve.

The *posterior branch* ascends behind the ear where it divides into *auricular branches*, supplying the pinna; and a *mastoid branch* which communicates with the posterior auricular branch of the facial and is distributed to the integument behind the ear. The auricular branches communicate with the auricular offsets of the facial nerve, pneumogastric nerve, and occipitalis minor.

The *Occipitalis minor* arises from the second cervical nerve; it curves around the posterior border of the sterno-mastoid above the preceding, and ascends upon that muscle, parallel with its posterior border, to the lateral and posterior aspect of the cranium. It is distributed to the integument, to the occipital portion of the occipito-frontalis and attollens aurem, and communicates with the occipitalis major, auricularis magnus, and posterior auricular branch of the facial.

Superficial descending branches.—The *Acromiales* and *Claviculares* are two or three large nerves which proceed from the fourth cervical nerve, and pass downwards in the posterior triangle of the neck; they pierce the deep fascia, and, crossing the clavicle, are distributed to the integument of the front of the chest from the sternum to the acromion: hence their designation, *claviculares* and *acromiales*. The most anterior of the branches is named *sternal*, from its destination, and the outermost branch passes over the clavicular attachment of the trapezius, to reach the shoulder.

Deep branches.—The *communicating branches* are filaments which arise from the loop between the first and second cervical nerve, and pass inwards to com-

municate with the sympathetic, pneumogastric, and hypoglossal nerve. The first three cervical nerves send branches to the first cervical ganglion; the fourth sends a branch to the trunk of the sympathetic, or to the middle cervical ganglion. From the second cervical nerve a large branch is given off, which joins the spinal accessory nerve.

The *Communicans noni* is a long and slender branch of communication between the cervical plexus and descendens noni; it is formed by filaments from the second and third cervical nerve; descends at the outer side of the internal jugular vein, and forms a loop with the descendens noni over the sheath of the carotid vessels.

The *Muscular branches* of the cervical plexus are distributed to the muscles of the front of the vertebral column and side of the neck. From the loop, between the first and second nerve, branches are given to the anterior recti; from the *second* cervical nerve a branch proceeds to the sterno-mastoid; from the *third* and *fourth* nerve branches are distributed to the trapezius, levator anguli scapulæ, scalenus medius, and scalenus posticus. The branch to the trapezius communicates with the spinal accessory nerve.

The *Phrenic nerve* (internal respiratory of Bell) is formed by the union of filaments from the third, fourth, and fifth cervical nerve, and one from the sympathetic. It descends to the root of the neck, resting on the scalenus anticus muscle, crosses the first portion of the subclavian artery, and enters the chest between it and the subclavian vein. Within the chest it passes downwards through the middle mediastinum, lying between the pleura and pericardium, and in front of the root of the lung, to the diaphragm; near the diaphragm it divides into branches which pierce that muscle, and are distributed on its under surface. Some of its filaments reach the abdomen through the openings for the œsophagus and vena cava, and communicate with the phrenic and solar plexus, and on the right side with the hepatic plexus. The *left phrenic nerve* is longer than the right, from the inclination of the heart to the left side, and crosses the arch of the aorta. The *right nerve* is situated more deeply in the upper part of the chest than the left, and lies in contact with the right vena innominata and superior vena cava. Both nerves cross in front of the origin of the internal mammary artery at their entrance into the chest.

POSTERIOR CERVICAL NERVES. — The posterior cords of the *cervical nerves* issue from between the transverse processes, and divide into an internal and external branch. The *internal* branch is directed inwards towards the middle of the spine, and, becoming cutaneous near the spinous processes of the vertebræ, is then reflected outwards to supply the integument. The *external* branch, smaller than the internal, is distributed to the muscles of the outer portion of the vertebral groove.

The posterior cord of the *first cervical nerve* (sub-occipital), larger than the anterior, escapes from the vertebral canal through the opening for the vertebral artery, lying posteriorly to that vessel, and emerges in the triangular space formed by the rectus posticus major, obliquus superior, and obliquus inferior. It is distributed to the recti, obliqui and complexus, and sends a branch downwards to communicate with the second cervical nerve; it has no external branch.

The posterior cord of the *second cervical nerve* is three or four times larger than its anterior cord, and exceeds in size the other posterior cervical nerves. Its *internal branch* is the *occipitalis major nerve*.

The posterior cord of the *third cervical nerve* is smaller than the second, but larger than the fourth; its *internal branch* gives off a cutaneous branch to the back of the cranium.

The posterior cords of the remaining cervical nerves go on progressively decreasing in size to the seventh.

The *internal branches* of the *second, third, fourth and fifth* nerve lie on the semi-spinalis colli muscle, and are closely connected with a fascia which separates that muscle from the complexus. The second and third, with a branch from the first, constitute the *posterior cervical plexus*; and all the branches in their course to the surface pierce the complexus and trapezius and some the splenius.

The *internal branches* of the *sixth, seventh, and eighth* nerve pass beneath the semi-spinalis colli, and are lost in the muscles without reaching the integument.

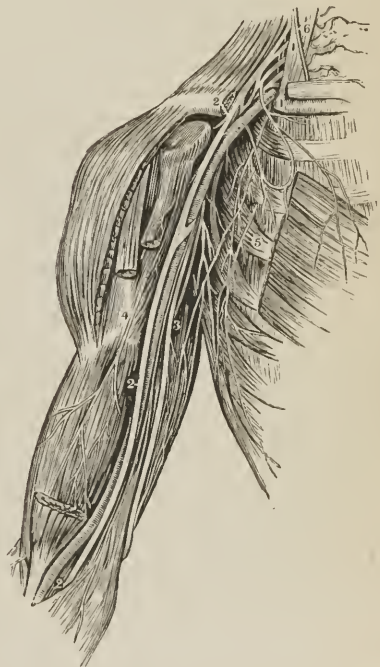
The *Occipitalis major nerve*, the internal branch of the posterior cord of the second cervical nerve, ascends obliquely inwards, between the obliquus inferior and complexus, pierces the complexus and trapezius after passing for a short distance between them, and ascends the posterior aspect of the head in company with the occipital artery. Soon after its escape from the trapezius, it receives a branch from the third cervical, and divides into numerous branches, which are distributed to the occipitalis muscle and to the integument as far as the summit of the head. It communicates with the occipitalis minor nerve, and sends an *auricular branch* to the back of the ear.

BRACHIAL PLEXUS.

The *Brachial or axillary plexus* of nerves is formed by communications between the anterior cords of the four lower cervical nerves and first dorsal. These nerves are alike in size, and their mode of disposition in the formation of the plexus as follows: the fifth and sixth unite to form a common trunk; the last cervical and first dorsal also unite to form a single trunk; the seventh cervical nerve lies for some distance apart from the rest, and then divides into two branches, which join the other cords. At the point of junction the plexus consists of two cords, from which a third is given off, and the three become placed, one to the inner side of the axillary artery, one behind, and one to its outer side. Lower down, each of the lateral cords gives off a branch which unites with its fellow in front of the artery, and surrounds the vessel; the trunk formed by the union of the two branches being the median nerve. The plexus is broad in the neck, narrows as it descends into the axilla, and again enlarges at its lower part, where it divides into its terminal branches.

The brachial plexus communicates with the cervical plexus by means of a branch from the fourth to the fifth nerve; and receives branches from the two inferior cervical ganglia of the sympathetic.

[FIG. 270.]



THE BRACHIAL PLEXUS OF NERVES AND BRANCHES TO THE ARM. 1, 1. Scalenus anticus muscle, behind and to the outer side of which are the roots of the plexus. 2, 2. Median nerve. 3. Ulnar nerve. 4. Musculo-cutaneous nerve. 5. The thoracic nerves. 6. The phrenic, from the third, fourth, and fifth cervical nerves.]

The plexus is in relation in the neck with the scaleni muscles; lower down it is placed between the clavicle and subclavius muscle above, and the first rib and first serration of the serratus magnus muscle below. In the axilla, it is situated at first to the outer side of and then behind the axillary artery, resting by its outer border against the tendon of the subscapularis muscle. Lower down it completely surrounds the artery.

The *Branches* of the brachial plexus are: from the *outer cord*, one of the anterior thoracic nerves, the musculo-cutaneous nerve, and the outer head of the median; from the *inner cord*, the other anterior thoracic nerve, inner head of the median, internal cutaneous, lesser internal cutaneous of Wisberg, and ulnar; from the *posterior cord*, the subscapular nerves, circumflex, and musculo-spiral.

Besides these, the brachial plexus, while in the neck, gives off several *superior muscular branches*; one to the subclavius muscle, one to the rhomboid muscles and levator anguli scapulæ; one of large size, the *supra-scapular*; and a long and slender nerve which passes down the thoracic wall of the axilla, the *posterior thoracic*, or external respiratory nerve of Bell.

In reference to their distribution, the branches of the brachial plexus may be arranged in three groups, *thoracic*, *scapular*, and *brachial*, as follows:—

<i>Thoracic.</i>	<i>Scapular.</i>
Anterior thoracic, .. Posterior thoracic.	Superior muscular, Supra-scapular, Subscapular.
<i>Brachial.</i>	
Musculo-cutaneous, Internal cutaneous, Lesser internal cutaneous, Median, Ulnar, Musculo-spiral, Circumflex.	

The *Anterior thoracic nerves*, two in number, proceed, one from the external cord of the plexus, the other from the internal cord. The former, the *external* or superficial branch, crosses the axillary artery in the space above the pectoralis minor to the front of the chest, and is distributed to the pectoralis major muscle. The *internal* or deeper branch issues from between the axillary artery and vein, and after forming a loop of communication with the preceding, is distributed to the under surface of the pectoralis minor and major.

The *Posterior thoracic*, or external respiratory of Bell, is formed by the junction of two offsets, one from the fifth, the other from the sixth cervical nerve; it crosses behind the brachial plexus to reach the side of the chest, and descends on the serratus magnus to the lower part of that muscle, to which it is distributed.

The *Superior muscular nerves* are small branches to the longus colli and scaleni; and branches to the rhomboidei and subclavius.

The *Rhomboid branch* proceeds from the fifth cervical nerve, and passing backwards through the fibres of the scalenus medius, and beneath the levator anguli scapulæ, is distributed to the under surface of the rhomboid muscles. In its course it sometimes gives a branch to the levator anguli scapulæ.

The *Subclavian branch*, proceeding from the cord formed by the fifth and sixth nerve, descends in front of the subclavian artery to the subclavius muscle. This nerve usually communicates with the phrenic at its entrance into the chest.

The *Supra-scapular nerve* arises from the fifth cervical nerve, and proceeds obliquely outwards to the supra-scapular notch; it passes through the notch, crosses the supra-spinous fossa beneath the supra-spinatus muscle, and running in front of the concave margin of the spine of the scapula enters the infra-spinous fossa, to be distributed to the supra-spinatus and infra-spinatus muscle, and send two or three filaments to the shoulder joint.

The *Subscapular nerves* are three in number; one arises from the brachial plexus above the clavicle, the others from the posterior cord of the plexus within the axilla. The first or smallest supplies the upper part of the subscapularis muscle; the second and largest (*long subscapular*) follows the course of the subscapular artery, and is distributed to the latissimus dorsi; the third supplies the lower part of the subscapularis muscle and teres major.

BRACHIAL NERVES. — The brachial branches of the plexus are arranged in the following order: musculo-cutaneous, and one head of the median to the outer side of the artery; the other head of the median, internal cutaneous, lesser internal cutaneous, and ulnar, to its inner side; the circumflex and musculo-spiral behind.

The **MUSCULO-CUTANEOUS NERVE** (external cutaneous, perforans Casserii) arises from the brachial plexus in common with the external head of the median; pierces the coraco-brachialis muscle, and passes between the biceps and brachialis anticus to the outer side of the bend of the elbow, where it perforates the deep fascia, and divides into an anterior and posterior branch. These branches pass behind the median cephalic vein, the *anterior* the larger of the two, taking the course of the radial vein and communicating with the radial nerve on the back of the hand; the *posterior* and smaller following the direction of the supinator longus, communicating with the internal cutaneous, and at the lower third of the forearm sending off an arterial twig, which accompanies the radial artery to the wrist, and distributes filaments to the synovial membranes of the joint.

The musculo-cutaneous nerve supplies the coraco-brachialis, biceps, and brachialis anticus in the upper arm, and the integument of the outer side of the forearm as far as the wrist and hand.

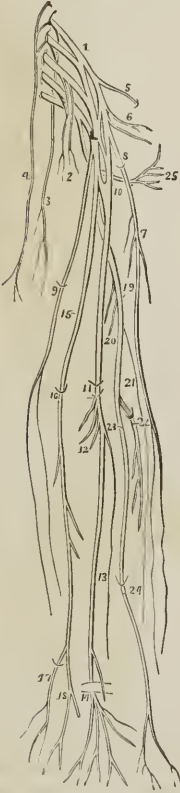
The **INTERNAL CUTANEOUS NERVE**, one of the internal and smaller branches of the axillary plexus, arises from the plexus in common with the ulnar and internal head of the median, and passes down the inner side of the arm in company with the basilic vein, giving off several cutaneous filaments in its course. At about the middle of the upper arm it pierces the deep fascia by the side of the basilic vein and divides into two branches, external and internal. The *external branch*, the larger of the two, divides into several branches which pass in front of, and sometimes behind, the median basilic vein at the bend of the elbow, and descend in the course of the palmaris longus muscle to the wrist, distributing filaments to the integument in their course and communicating with the anterior branch of the musculo-cutaneous on the outer side, and its own internal branch on the inner side of the forearm. The *internal branch* sends off several twigs to the integument over the inner condyle and olecranon, passes behind the inner condyle, and descends the forearm in the course of the ulnar vein as far as the wrist, supplying the integument of the inner side of the forearm, and communicating with the external branch of the same nerve in front, and the dorsal branch of the ulnar nerve at the wrist.

The **LESSER INTERNAL CUTANEOUS NERVE** or *nerve of Wrisberg*, the smallest of the brachial nerves, arises with the preceding from the inner cord of the plexus, and issuing from beneath the axillary vein, descends the inner side of the arm, to the middle of its posterior aspect, where it pierces the fascia and is

distributed to the integument of the lower third of the upper arm as far as the olecranon. While in the axilla, the nerve of Wrisberg communicates with the intercosto-humeral nerve, and sometimes its place is taken by the latter.

The **MEDIAN NERVE**, named from its median position in the arm and forearm, arises by two heads which proceed from the outer and inner cord of the

FIG. 271.



BRACHIAL PLEXUS OF NERVES WITH ITS BRANCHES AND THEIR DISTRIBUTION. 1. Brachial plexus. 2. Anterior thoracic nerves. 3. Posterior thoracic or external respiratory of Bell. 4. Phrenic nerve. 5. Supra-scapular nerve. 6. Subscapular nerves. 7. Musculo-cutaneous nerve. 8. The point at which it pierces the coraco-brachialis muscle. 9. Internal cutaneous nerve; the point at which it pierces the deep fascia. 10. Origin of the median nerve by two heads. 11. Bend of the elbow where the median passes between the two heads of the pronator radii teres, and flexor sublimis digitorum. 12. Its muscular branches. 13. Anterior interosseous branch. 14. The point at which the nerve passes beneath the annular ligament and divides into six terminal branches. The branch which crosses the annular ligament is the superficial palmar. 15. Ulnar nerve. 16. The point at which it passes between the two heads of the flexor carpi ulnaris. 17. Its dorsal branch. 18. Termination of the nerve, dividing into a superficial and deep palmar branch. 19. Musculo-spiral nerve. 20. Muscular branches to the triceps. 21. Cutaneous nerve. 22. Posterior interosseous nerve piercing the supinator brevis muscle. 23. Radial nerve. The last two nerves are the terminal branches of the musculo-spiral. 24. The point at which the radial nerve pierces the deep fascia. 25. Circumflex nerve.

plexus and embrace the axillary artery. The nerve lies at first to the outer side of the brachial artery, but crosses it in the middle, sometimes in front and sometimes behind, and getting to its inner side descends to the bend of the elbow. It next passes between the two heads of the pronator radii teres and beneath the flexor sublimis digitorum, and runs down the middle of the forearm, lying between the latter muscle and the flexor profundus to the wrist. It then dips beneath the annular ligament and enters the palm of the hand. Just above the wrist it is superficial, lying by the outer border of the tendons of the flexor sublimis digitorum.

The *Branches* of the median nerve are —

Muscular,
Anterior interosseous,
Superficial palmar,
Digital.

The *Muscular branches* are given off by the nerve at the bend of the elbow; they are distributed to all the muscles of the anterior aspect of the forearm, with the exception of the flexor carpi ulnaris, and ulnar half of the flexor profundus. The branch to the pronator radii teres sends off reflected filaments to the elbow joint.

The *Anterior interosseous* is a large branch accompanying the anterior interosseous artery, and supplying the deep layer of muscles of the forearm; being lost inferiorly in the pronator quadratus.

The *Superficial palmar branch* arises from the median at about the lower fourth of the forearm; it crosses the annular ligament, and is distributed to the integument of the palm of the hand, and ball of the thumb.

The median nerve at its termination in the palm of the hand is spread out and flattened, and divides into six branches, one muscular and five digital.

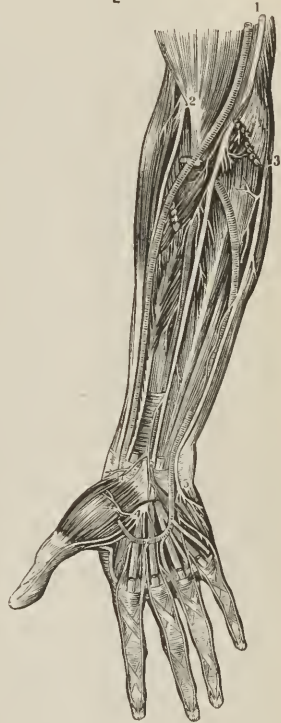The *muscular branch* is distributed to the muscles of the ball of the thumb.

The *Digital branches* are arranged as follows: *two* pass outwards to the thumb and supply its borders; the *third* runs along the radial side of the index finger, sending a twig to the first lumbricalis, in its course; the *fourth* subdivides for the supply of the adjacent sides of the index and middle finger, and gives a twig to the second lumbricalis; the *fifth* receives a filament of communication from the ulnar nerve, and supplies the collateral branches of the middle and ring finger.

Opposite the base of the first phalanx, each nerve gives off a *dorsal branch* which runs along the border of the dorsum of the finger. Near its extremity the nerve divides into a *palmar* and a *dorsal branch*; the former supplying the sentient extremity of the finger; the latter the structures around and beneath the nail. The digital nerves in their course along the fingers lie to the inner side of and superficially to the arteries; and the nerve of one side of a finger has no communication with that of the opposite side.

The **ULNAR NERVE** is somewhat smaller than the median, behind which it lies, gradually diverging from it in its course. It arises from the inner cord of the brachial plexus in common with the internal head of the median and internal cutaneous nerve, and runs down the inner side of the arm, to the groove between the internal condyle and olecranon, resting on the internal head of the triceps, and accompanied by the inferior profunda artery. At the elbow it is superficial, and supported by the inner condyle, against which it may be compressed, giving rise to the thrilling sensation along the inner side of the forearm and little finger, popularly ascribed to striking the "funny bone." It then passes between the two heads of the flexor carpi ulnaris, and descends along the inner side of

[FIG. 272.]



THE NERVES ON THE FRONT OF THE FOREARM. — 1. The median nerve. 2. Anterior branch of the musculo-spiral, or radial nerve. 3. The ulnar nerve. 4. Division of the median nerve in the palm to the thumb, fore-, mid-, and radial side of the ring finger. 5. Division of the ulnar nerve to the ulnar side of the ring, and both sides of the little finger.]

the forearm, crosses the annular ligament, and divides into two branches, superficial and deep palmar. At the commencement of the middle third of the forearm it comes into relation with the artery, and lies to the ulnar side of that vessel, as far as the hand.

The *Branches* of the ulnar nerve are —

Articular,	Dorsal branch,
Muscular,	Superficial palmar,
Cutaneous,	Deep palmar.

The *Articular branches* are several filaments to the elbow joint, given off from the nerve while lying in the groove between the inner condyle and olecranon.

The *Muscular branches* are distributed to the flexor carpi ulnaris and ulnar half of the flexor profundus digitorum.

The *Cutaneous branch* proceeds from about the middle of the nerve, and descends upon the ulnar artery to the hand, giving twigs to the integument in its course. One branch from its upper part, sometimes a separate offset from the nerve and sometimes absent, pierces the fascia, and communicates with the internal cutaneous nerve.

The *Dorsal branch* passes backwards beneath the tendon of the flexor carpi ulnaris, at the lower fourth of the forearm, and divides into branches which supply the integument and two fingers and a half on the posterior aspect of the hand, communicating with the radial nerve, with which it forms an arch.

The *Superficial palmar branch*, after giving some twigs to the palmaris brevis and inner border of the hand, divides into three filaments, two of which are distributed, *one* to the ulnar side of the little finger, and *one* to the adjoining borders of the little and ring finger, while the third, a *communicating branch*, joins the median nerve.

The *Deep palmar branch* passes between the abductor and flexor minimi digiti, to the deep palmar arch, supplying the muscles of the little finger, interossei, two ulnar lumbricales, adductor pollicis, and inner head of the flexor brevis pollicis.

The MUSCULO-SPIRAL NERVE, the largest branch of the brachial plexus, arises from its posterior trunk in common with the circumflex, and, descending behind the axillary and brachial artery, winds around the humerus between the triceps and the bone, and in company with the superior profunda artery, to the space between the brachialis anticus and supinator longus, and thence onwards to the bend of the elbow, where it divides into two branches, radial and posterior interosseous.

The *Branches* of the musculo-spiral nerve are —

Muscular,	Radial,
Cutaneous,	Posterior interosseous.

The *Muscular branches* are distributed to the triceps, anconeus, brachialis anticus, supinator longus, and extensor carpi radialis longior.

The *Cutaneous branches* are three in number, internal and two external. The *internal branch* arises from the nerve in the axilla, and piercing the deep fascia in the upper third of the arm on its posterior aspect, communicates with the intercosto-humeral nerve, and is distributed to the integument of the posterior aspect of the upper arm, as far as the olecranon.

The *external cutaneous branches* pass through the substance of the external head of the triceps, and pierce the deep fascia; one, *upper*, near the insertion of the deltoid, the other, *lower*, at about the middle of the upper arm. The *upper branch* follows the course of the cephalic vein, supplying the integument

of the outer and forepart of the upper arm as far as the bend of the elbow. The *lower branch* passes down the outer side of the forearm, reaches the posterior aspect at about its middle, and is continued onwards to the wrist, where it communicates with the posterior branch of the musculo-cutaneous.

The *Radial nerve* runs along the radial side of the forearm to the commencement of its lower third; it there passes beneath the tendon of the supinator longus, and, at about two inches above the wrist joint, pierces the deep fascia and divides into an external and internal branch.

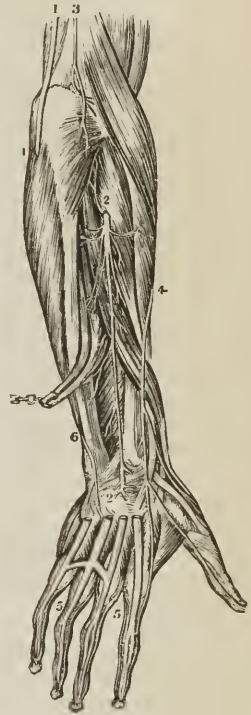
The *external branch*, the smaller of the two, is distributed to the outer border of the thumb, and communicates with the posterior branch of the musculo-cutaneous nerve. The *internal branch* crosses the direction of the extensor tendons of the thumb, and divides into several filaments for the supply of the ulnar border of the thumb, radial border of the index finger, and adjacent borders of the index and middle finger. It communicates above the wrist with the posterior branch of the musculo-cutaneous nerve, and on the back of the hand forms an arch by joining with the dorsal branch of the ulnar nerve. On the backs of the fingers the digital branches communicate with those of the median nerve.

In the upper third of the forearm the radial nerve lies beneath the border of the supinator longus muscle; in the middle third it is in relation with the radial artery, lying to its outer side; and in the lower third it quits the artery, and passes beneath the tendon of the supinator longus to reach the back of the hand.

The *Posterior interosseous nerve*, somewhat larger than the radial, separates from the latter at the bend of the elbow, pierces the supinator brevis muscle, and emerges from its lower border on the posterior aspect of the forearm, where it divides into branches which supply all the muscles of the posterior aspect of the forearm, with the exception of the anconeus, supinator longus, and extensor carpi radialis longior. One branch, longer than the rest, descends upon the interosseous membrane to the posterior part of the wrist, and forms a gangliform swelling (a common character of nerves which supply joints), from which numerous filaments are distributed to the wrist joint.

The CIRCUMFLEX NERVE arises from the posterior cord of the brachial plexus in common with the musculo-spiral. It passes downwards over the border of the subscapularis muscle, winds around the neck of the humerus with the posterior circumflex artery, and splits into an upper and lower division; the upper division is continued onwards beneath the deltoid, and distributed to the anterior part of that muscle, some of its branches piercing the muscular fibres and becoming cutaneous. The lower division sends a branch (remarkable for a gangliform swelling) to the teres minor, several branches to the posterior part of the deltoid, and mounting upon the border of that muscle becomes *cutaneous*, supplying the integument over its lower half by means of several filaments. Besides its muscular and cutaneous branches, the trunk of the nerve gives off

[FIG. 273.]



THE NERVES ON THE DORSAL ASPECT OF THE FOREARM AND HAND. 1, 1. The ulnar nerve. 2, 2. The posterior interosseous nerve. 3. A humeral cutaneous branch. 4. The radial nerve. 5, 5. A back view of the digital nerves. 6. Dorsal branch of the ulnar nerve.]

an *articular* branch, which enters the shoulder joint at its posterior and under part.

DORSAL NERVES.

The dorsal nerves are twelve in number at each side; the first appearing between the first and second dorsal vertebra; the last between the twelfth dorsal and first lumbar. They are smaller than the lower cervical nerves; diminish gradually in size from the first to the tenth, and then increase to the twelfth. Each nerve, as soon as it has escaped from the intervertebral foramen, separates into an anterior and posterior cord; the anterior cords being the intercostal nerves, the posterior the dorsal branches of the dorsal nerves.

The *Dorsal branches* pass directly backwards between the transverse processes of the vertebræ, lying internally to the anterior costo-transverse ligament, and each nerve divides into an *internal* and *external* branch. The *internal branches* diminish in size from the first to the last. The six upper branches pass inwards between the semi-spinalis dorsi and multifidus spinæ, and, piercing the rhomboid, trapezius and latissimus dorsi, become cutaneous close to the spinous processes, and are then reflected outwards to supply the integument. The six lower branches are lost in the muscles of the spine.

The *external branches* increase in size from above downwards, and make their appearance in the line of separation between the longissimus dorsi and sacro-lumbalis. The six upper branches are distributed to those muscles and the levatores costarum. The six lower, after supplying the same muscles, pierce the serratus posticus inferior and latissimus dorsi in a line with the angles of the ribs, and becoming *cutaneous*, are directed downwards and forwards over the side of the trunk.

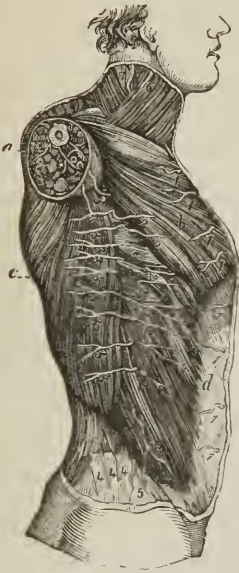INTERCOSTAL NERVES.—The *anterior cords* of the dorsal nerves, twelve in number at each side, are the *intercostal nerves*. Each intercostal nerve passes outwards in the intercostal space in company with the intercostal vessels, below which it lies; at the commencement of its course it rests on the external intercostal muscle, further outwards it is placed between the two planes of intercostal muscles; beyond the middle of the rib it enters the substance of the internal intercostal and reaches its inner surface, being in contact with the pleura; finally, at the anterior extremity of the intercostal space, it crosses in front of the triangularis sterni and internal mammary vessels and piercing the internal intercostal muscle and pectoralis major, is distributed to the integument of the front of the chest and mammary gland, under the name of *anterior cutaneous*. The intercostal nerve, near its origin, sends one or two filaments to the neighboring dorsal ganglion of the sympathetic, and midway between the vertebral column and sternum, while situated between the intercostal muscles, gives off a *lateral cutaneous branch* which pierces the external intercostal muscle and divides into an anterior and posterior twig for the supply of the integument of the side of the thorax.

This description applies in full only to the six upper intercostal nerves; the six lower, with the exception of the last, cross the cartilages of the ribs where the thorax is deficient, and take their course between the internal oblique and transversalis muscle to the sheath of the rectus, and, after supplying that muscle, to the linea alba, by the side of which they reach the integument constituting the *anterior cutaneous nerves* of the abdomen.

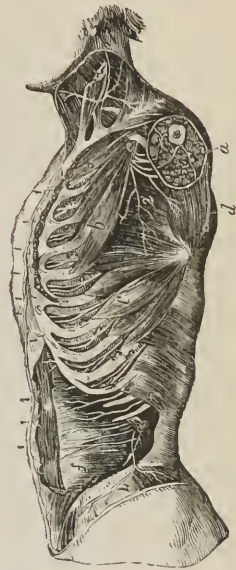
The first and the last intercostal nerve are exceptions to this general scheme of distribution. The *first* ascends over the first rib to join the brachial plexus, and gives off only a small branch, to take the usual course of the other intercostal nerves. The *last* or *twelfth nerve* lies below the last rib, and after crossing the quadratus lumborum takes its course between the internal oblique and transver-

salis muscle like the other inferior intercostals. Near its origin it sends a branch, the *dorsi-lumbar*, downwards to join the first lumbar nerve.

[FIG. 274.]



[FIG. 275.]



PLAN OF THE CUTANEOUS NERVES OF THE CHEST AND ABDOMEN. *a.* Section of the arm. *b.* Pectoralis major muscle. *c.* Latissimus dorsi. *d.* External oblique. *e.* Serratus magnus. 1, 1, 1. Anterior cutaneous nerves of the thorax and abdomen. 2, 2, 2. Anterior branches of the lateral cutaneous nerves of the thorax and abdomen. 3, 3, 3. Posterior branches of the same. 4, 4, 4. Cutaneous branches of the posterior divisions of the lumbar nerves. 5. Ilio-hypogastric nerve.]

PLAN OF THE INTERCOSTAL NERVES. *a.* Cut surface of the arm. *b.* Pectoralis minor muscle. *c.* Serratus magnus muscle. *d.* Subscapular muscle. *f.* Transversalis abdominis. 1, 1, 1. Anterior cutaneous nerves of the thorax and abdomen. 2. Posterior thoracic nerve. 3, 3, 3. Intercostal nerves. 4. Lateral cutaneous branch of the last intercostal nerve.]

The *branches* of the intercostal nerves are, muscular, lateral cutaneous, and anterior cutaneous.

The *Muscular branches* are small twigs distributed to the intercostal and neighboring muscles.

The *Lateral cutaneous nerves* given off from the intercostals at about the middle of the lateral half of the thorax, pierce the external intercostal muscle and pass between the fibres of the serratus magnus above and the obliquus externus below to reach the surface. The lateral cutaneous nerve then divides into an anterior and posterior branch. The *anterior branches* are directed forwards to supply the integument of the antero-lateral aspect of the trunk, some of the superior branches turning around the inferior border of the pectoralis major to the mammary gland. The *posterior branches* take their course backwards to supply the integument of the postero-lateral aspect of the trunk, some of the superior turning around the posterior border of the axilla to reach the integument over the lower part of the scapula and latissimus dorsi; and that from the third intercostal being distributed to the integument of the axilla and neighboring part of the arm.

The first intercostal gives off no lateral cutaneous nerve; the lateral cutaneous branch of the second intercostal nerve will be presently described, under the name of *intercosto-humeral nerve*. The lateral cutaneous branch of the last intercostal nerve pierces the internal and external oblique muscle, crosses the crest of the ilium just behind the tensor vaginae femoris, and is distributed to the integument of the anterior part of the gluteal region as low down as the trochanter major.

The *Anterior cutaneous nerves* are divided according to their position into those of the thorax and those of the abdomen. Having reached the surface they are reflected outwards to supply the integument of the front of the trunk. The anterior cutaneous branches of the third and fourth intercostal nerve are distributed to the mammary gland.

The *Intercosto-humeral nerve* is the lateral cutaneous branch of the second intercostal nerve; after piercing the external intercostal muscle, it passes downwards into the axilla, and communicates with a branch of the lesser internal cutaneous nerve of Wrisberg. It then perforates the deep fascia and is distributed to the integument of the inner and back part of the arm to about the middle, and to the integument covering the lower part of the scapula. On the back of the arm it communicates with the internal cutaneous branch of the musculo-spiral nerve. This nerve sometimes takes the place of the nerve of Wrisberg.

LUMBAR NERVES.

There are five pairs of lumbar nerves, of which the first makes its appearance between the first and second lumbar vertebra; the last between the fifth lumbar and the base of the sacrum. The *anterior cords* increase in size from above downwards. They communicate at their origin with the lumbar ganglia of the sympathetic, and pass obliquely outwards behind the psoas magnus, or between its fasciculi, sending twigs to that muscle and to the quadratus lumborum. In this situation each nerve divides into two branches, a superior branch which ascends to form a loop of communication with the nerve above; and an inferior branch which descends to join in like manner the nerve below. The communications and anastomoses which are thus established constitute the lumbar plexus.

The *posterior cords* diminish in size from above downwards; they pass backwards between the transverse processes of the corresponding vertebrae, and each nerve divides into an internal and external branch. The *internal branch*, the smaller of the two, passes inwards to be distributed to the multifidus spinæ and inter-spinales. The *external branches* communicate with each other by several loops, and, after supplying the deeper muscles, pierce the sacro-lumbalis to reach the integument to which they are distributed. The external branches of the three upper lumbar nerves descend over the posterior part of the crest of the ilium, and are distributed to the integument of the gluteal region.

LUMBAR PLEXUS.

The *Lumbar plexus* is formed by the communications and anastomoses which take place between the anterior divisions of the four upper lumbar nerves, and between the latter and the last dorsal. It is narrow above, increases in breadth inferiorly, and is situated between the transverse processes of the lumbar vertebrae and quadratus lumborum behind, and the psoas magnus muscle in front.

The *Branches* of the *lumbar plexus* are the —

Ilio-hypogastric,
Ilio-inguinal,
Genito-crural,

External cutaneous,
Obturator,
Anterior crural.

The **ILIO-HYPOGASTRIC NERVE** (superior musculo-cutaneous) proceeds from the first lumbar nerve, and passes obliquely outwards between the fibres of the psoas magnus and across the quadratus lumborum to about the middle of the crest of the ilium. It then pierces the transversalis muscle, and between it and the internal oblique divides into its two terminal branches, iliac and hypogastric.

The *iliac branch* pierces the internal and external oblique muscles close to their attachment, and a little behind the middle of the crest of the ilium; it is distributed to the integument of the outer part of the hip.

The *hypogastric branch* continues its course onwards, piercing first the internal oblique, and just above the external abdominal ring the aponeurosis of the external oblique. It is distributed to the integument of the hypogastric region and mons pubis.

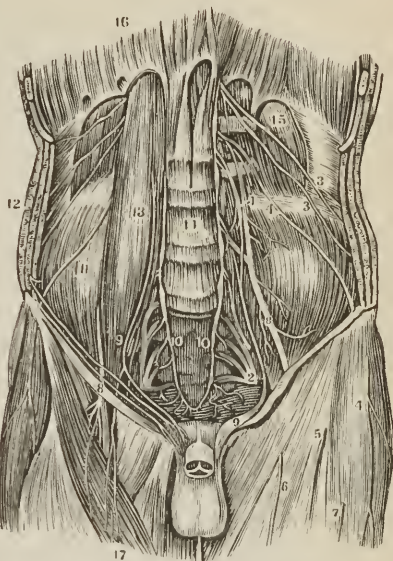The **ILIO-INGUINAL NERVE** (inferior musculo-cutaneous), smaller than the preceding, also arises from the first lumbar nerve. It passes obliquely downwards and outwards below the ilio-hypogastric nerve, and crosses the quadratus lumborum and iliacus muscle to the anterior part of the crest of the ilium; it then pierces the transversalis muscle, and between that muscle and the obliquus internus communicates with the hypogastric nerve.

It next pierces the obliquus internus, and following the course of the spermatic cord, escapes at the external abdominal ring to be distributed to the scrotum and to the integument of the upper part of the thigh, internally to the saphenous opening; and in the female to that of the pudendum.

The **GENITO-CRURAL NERVE** proceeds from the second lumbar and by a few filaments from the loop between it and the first. It traverses the psoas magnus from behind forwards, and runs down the anterior surface of that muscle, lying beneath its fascia, to near Poupart's ligament, where it divides into a genital and a crural branch.

The *genital branch* (n. spermaticus seu pudendus externus) crosses the external iliac artery to the internal abdominal ring, and descends along the spermatic canal, lying behind the cord, to the scrotum, where it distributes twigs to the spermatic cord and cremaster muscle. In the female it gives twigs to the round ligament and external labium. At the internal abdominal ring this nerve

[FIG. 276.]

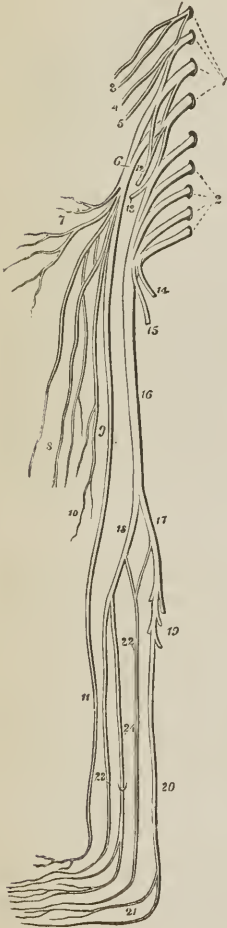


A VIEW OF THE LUMBAR AND SACRAL PLEXUSES AND THE BRANCHES OF THE FORMER.—1. The lumbar plexus. 2. The sacral plexus. 3, 3. Ilio-hypogastric and ilio-inguinal nerves. 4, 4. External musculo-cutaneous nerve. 5, 6, 7. Cutaneous branches from 8, The anterior crural nerve. 9. The genito-crural nerve. 10, 10. The lower termination of the great sympathetic. 11. The iliacus internus muscle. 12. The three broad muscles of the abdomen. 13. The psoas magnus muscle. 14. The bodies of the lumbar vertebrae. 15. The quadratus lumborum muscle. 16. The diaphragm. 17. The sartorius.]

sends off a branch, which, after supplying the lower border of the internal oblique and transversalis, is lost in the integument of the groin.

The *crural branch* (lumbo-inguinalis), the most external of the two, descends

FIG. 277.



A DIAGRAM SHOWING THE LUMBAR AND SACRAL PLEXUSES, WITH THE NERVES OF THE LOWER EXTREMITY. 1. The first four lumbar nerves; which, with a branch from the last dorsal, constitute the lumbar plexus. 2. The four upper sacral nerves; which, with the last lumbar, form the sacral plexus. 3. The two musculo-cutaneous nerves, branches of the first lumbar nerve. 4. Genito-crural nerve. 5. External cutaneous nerve. 6. Anterior crural or femoral nerve. 7. Its muscular branches. 8. Middle cutaneous branches. 9, 10. Internal cutaneous branches. 11. The long or internal saphenous. 12. Obturator nerve. 13. Gluteal nerve; a branch of the lumbo-sacral. 14. Internal pudic nerve. 15. Lesser ischiatic nerve. 16. Greater ischiatic nerve. 17. Internal popliteal nerve. 18. External popliteal nerve. 19. Muscular branches. 20. Posterior tibial nerve; dividing at 21, into the two plantar nerves. 22. External saphenous nerve. 23. Anterior tibial nerve. 24. Musculo-cutaneous nerve, piercing the deep fascia, and dividing into two cutaneous branches, for the supply of the dorsum of the foot.

along the outer border of the external iliac artery, and, crossing the origin of the circumflexa ilii, enters the sheath in front of the femoral vessels in front of the femoral artery. It pierces the sheath below Poupart's ligament, and is distributed to the integument of the anterior aspect of the thigh as far as its middle. This nerve communicates with the middle cutaneous branch of the crural nerve, and is often very small.

The EXTERNAL CUTANEOUS NERVE (inguino-cutaneous) proceeds from the second lumbar, and from the loop between it and the third. It pierces the posterior fibres of the psoas muscle; and crossing the iliacus on the iliac fascia, to the anterior superior spinous process of the ilium, passes into the thigh, beneath Poupart's ligament, where it divides into two branches, anterior and posterior.

The *posterior branch* crosses the tensor vaginæ femoris muscle to the outer and posterior side of the thigh, and supplies the integument in that region.

The *anterior nerve*, after passing for three or four inches down the thigh in a sheath formed by the fascia lata, becomes superficial, and divides into two branches, which are distributed to the integument of the outer border of the thigh, and to the articulation of the knee.

The OBTURATOR NERVE is formed by a branch from the third, and another from the fourth lumbar nerve, and is distributed to the obturator externus and adductor muscles of the thigh, the hip and knee joint, the femoral and popliteal artery, and sometimes to the integument of the upper and inner part of the leg. From its origin it takes its course among the fibres of the psoas muscle, through the angle of bifurcation of the common iliac vessels, and along the inner border

of the brim of the pelvis, to the obturator foramen, where it joins the obturator artery. Having escaped from the pelvis, it divides into an anterior and posterior branch.

The *anterior branch* passes downwards in front of the adductor brevis, supplies that muscle together with the pectineus, gracilis, and adductor longus, and at the lower border of the latter unites with the internal cutaneous and long saphenous nerve, to form a plexus. It then passes onwards to the femoral artery, to which it distributes filaments. In its course this nerve gives off an *articular* branch to the hip joint; and a *cutaneous* branch, which pierces the fascia lata at the knee, communicates with the long saphenous nerve, and is distributed to the integument of the inner side of the leg as far as its middle. The cutaneous branch is often wanting, its place being supplied by the internal cutaneous nerve, and sometimes by the accessory obturator.

The *posterior branch* pierces the obturator externus muscle, to which and to the adductor magnus it distributes branches; it also gives off an *articular branch* which pierces the adductor magnus muscle, and accompanies the popliteal artery to the knee joint.

The *Accessory obturator nerve*, small and inconstant, is a high division of the obturator, being sometimes derived from it near its origin, and sometimes by separate filaments from the third and fourth lumbar nerve. It passes down the inner border of the psoas muscle, crosses the os pubis, and dips beneath the pectineus, where it divides into branches. One of its branches is distributed to the pectineus, another supplies the hip joint, while a third communicates with the anterior branch of the obturator nerve, and when of large size constitutes its *cutaneous* branch. As already stated, the existence of the accessory obturator nerve is uncertain.

The ANTERIOR CRURAL or FEMORAL NERVE, is the largest of the divisions of the lumbar plexus; it is formed by the union of branches from the second, third, and fourth lumbar nerve, and is distributed to the integument of the front and inner side of the thigh, leg, and foot, to all the muscles of the front of the thigh (excepting one) to the iliacus, pectineus, femoral artery, and knee joint. Emerging from beneath the psoas, the nerve passes downwards in the groove between that muscle and the iliacus, and beneath Poupart's ligament into the thigh, where it spreads out and divides into numerous branches. At Poupart's ligament it is separated from the femoral artery by the breadth of the psoas muscle, which at this point is scarcely more than half an inch in diameter, and by the iliac fascia, beneath which it lies.

Branches. — Within the pelvis, the anterior crural nerve gives off three or four twigs to the iliacus muscle, and a *branch to the femoral artery*. The latter divides into filaments which entwine about the artery, and follow its course downwards in the thigh. Below Poupart's ligament the crural nerve becomes flattened out, and divides into numerous branches, which may be arranged into two principal groups, superficial and deep. The separate branches of these groups are as follows:—

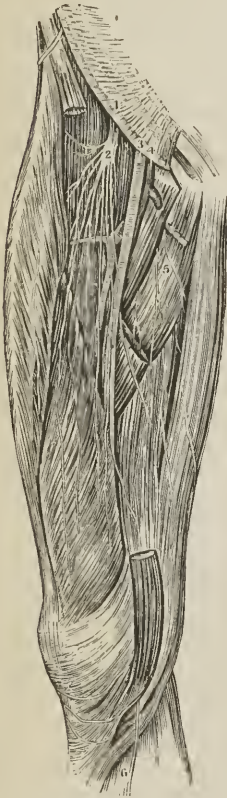<i>Superficial.</i>	<i>Deep.</i>
Middle cutaneous,	Muscular,
Internal cutaneous,	Articular
Long or Internal saphenous,	

The *Middle cutaneous nerve* pierces the fascia lata at about three inches below Poupart's ligament, and divides into two branches, which pass down the inner and front part of the thigh, and are distributed to the integument as low as the

knee joint. At its upper part the external branch communicates with the crural branch of the genito-crural nerve; and below, the internal branch communicates with the internal cutaneous. One or both of these branches sometimes pierce the sartorius muscle.

The *Internal Cutaneous nerve* passes inwards in front of the sheath of the femoral artery, and divides into an *anterior* and an *inner* branch. Previously

[FIG. 278.]



THE ANTERIOR CRURAL NERVE AND ITS BRANCHES.

1. Place of emergence of the nerve under Poupart's ligament. 2. Division of the nerve into branches. 3. Femoral artery. 4. Femoral vein. 5. Branches of the obturator nerve. 6. Long or internal saphenous nerve.]

to its division it gives off three cutaneous filaments, which pierce the fascia near the internal saphenous vein, and following the course of that vessel, are distributed to the integument of the inner side of the thigh as low down as the knee. The uppermost of these filaments passes through the saphenous opening, the middle becomes subcutaneous at about the middle of the thigh, and the lowest pierces the fascia at its lower third.

The *anterior branch* passes down the inner side of the thigh, and pierces the fascia at its lower third, near the internal saphenous vein. It then divides into two twigs, one of which continues onwards to the inner side of the knee; while the other curves outwards to its outer side, communicating in its course with a branch of the long saphenous nerve.

The *inner branch* descends along the inner and posterior border of the sartorius muscle to the knee, where it pierces the fascia lata, and gives off several cutaneous twigs. It then sends a small branch of communication to the long saphenous nerve, and passes downwards along the inner side of the leg, to which it is distributed. While beneath the fascia lata it aids in the formation of a plexus by uniting with branches of the long saphenous nerve and descending branch of the obturator. When the latter is large the inner branch of the internal cutaneous nerve is small, and may terminate in the plexus, or merely give off a few cutaneous filaments.

The *Long or internal saphenous nerve* inclines inwards to the sheath of the femoral vessels, and passes downwards in front of the sheath and beneath the aponeurotic expansion which covers the sheath, to the opening in the adductor magnus. It then quits the femoral vessels, and continuing to descend, passes between the tendons of the sartorius and gracilis, and reaches the internal saphenous vein. By the side of the latter it passes down the inner side of the leg, in front of the inner ankle, and along the inner side of the foot as far as the great toe; being distributed to the integument in its course.

The branches of the long saphenous nerve in the thigh are: one or two to join the plexus formed by the obturator and internal cutaneous nerve; and a large branch, the *cutaneus patellæ*, which pierces the sartorius and fascia lata at the inner side of the knee, and divides into many twigs, which are distributed to the integument of the front of the knee. Above the patella this branch communicates with the anterior branch of the internal

cutaneous nerve, and with the terminal twigs of the middle, and external cutaneous. Below the patella it communicates with other branches of the long saphenous; the whole of these communications constituting a kind of plexus (plexus patellæ).

The branches of the long saphenous nerve below the knee are distributed to the integument of the front and inner side of the leg. By one of these branches it communicates with the cutaneous branch of the obturator nerve.

The *Muscular branches* of the anterior crural nerve supply all the muscles of the front of the thigh (with the exception of the tensor vaginæ femoris, which obtains its nerve from the superior gluteal) and the pectineus. The branch to the *pectineus* passes behind the sheath of the femoral vessels; the branches to the *sartorius*, three or four in number, arise with the cutaneous nerves, and sometimes are supplied by the latter. The branch to the *rectus* enters the deep surface of that muscle. The branch to the *vastus externus* follows the course of the descending branch of the external circumflex artery; the branch to the *crureus* passes directly to that muscle; and the branch to the *vastus internus*, remarkable for its length, descends by the side of the sheath of the femoral vessels.

The *Articular branches* are distributed to the knee joint; one enters the joint at its outer side, being derived from the nerve of the vastus externus; the other, proceeding from the nerve of the vastus internus, descends with the anastomotica magna to a level with the joint, and then pierces the capsular ligament.

The LUMBO-SACRAL NERVE.—The anterior division of the fifth lumbar nerve, conjoined with a branch from the fourth, constitutes the lumbo-sacral nerve, which descends over the base of the sacrum into the pelvis, and assists in forming the sacral plexus.

SACRAL NERVES.

There are five pairs of sacral nerves; the first four escape from the vertebral canal through the sacral foramina, the last between the sacrum and coccyx. The *posterior sacral nerves* are small, and diminish in size from above downwards; they communicate with each other by means of anastomosing loops immediately after their escape from the posterior sacral foramina, and divide like the other spinal nerves into external and internal branches. The *external branches* pierce the gluteus maximus, to which they give filaments, and are distributed to the integument of the posterior part of the gluteal region. The *internal branches* supply the multifidus spinæ muscle and the integument over the sacrum and coccyx.

The *anterior sacral nerves* diminish in size from above downwards; the *first* is large, and unites with the lumbo-sacral nerve; the *second*, of equal size, unites with the first; and the *third*, scarcely one-fourth so large as the second, joins with the two preceding nerves in the formation of the sacral plexus.

The *fourth sacral nerve* divides into two branches, one of which assists in forming the sacral plexus, the other separates into three branches: a *communicating branch* to unite with the fifth sacral nerve; a *visceral branch*, to join with the hypogastric plexus and supply the bladder and prostate gland, and in the female, the vagina; and a *muscular branch* which sends filaments to the levator ani and coccygeus and a *hæmorrhoidal branch* to the sphincter ani and integument behind the anus.

The *fifth sacral nerve*, issuing from between the sacrum and coccyx, pierces the coccygeus muscle, and receives the communicating branch from the fourth;

it then communicates with the coccygeal nerve, and piercing the coccygeus a second time, is distributed to the integument over the dorsal surface of the coccyx.

The *Coccygeal nerve* pierces the coccygeus muscle, and unites with the fifth sacral nerve, in which it is lost.

Each of the anterior cords of the sacral nerves communicates with the sympathetic, at its point of escape from the sacral canal.

SACRAL PLEXUS.

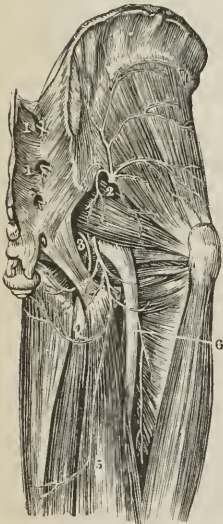
The *Sacral plexus* is formed by the union of the lumbo-sacral and the anterior cords of the three upper sacral nerves and one-half the fourth. The plexus is triangular in form, its base corresponding with the whole length of the sacrum, and its apex with the lower part of the great ischiatic foramen. It is in relation behind with the pyriformis muscle; and in front with the pelvic fascia, which separates it from the internal iliac vessels and the viscera of the pelvis.

The *Branches* of the sacral plexus are,

Visceral,
Muscular,
Superior gluteal,

Pudic,
Lesser ischiatic,
Greater ischiatic.

[FIG. 279.



THE BRANCHES OF THE SACRAL PLEXUS TO THE HIP AND BACK OF THE THIGH. 1, 1'. Posterior sacral nerves. 2. Superior gluteal nerve. 3. The pudic nerve. 5. The lesser ischiatic nerve, giving off, 4. The inferior pudendal. 6. The great ischiatic nerve.]

The *Visceral nerves* are three or four large branches derived from the fourth and fifth sacral nerves: they ascend by the side of the rectum and bladder; in the female by the side of the rectum, vagina, uterus, and bladder; and interlace with branches of the hypogastric plexus, sending in their course numerous filaments to the pelvic viscera.

The *Muscular branches* are one or two twigs to the *levator ani*; an *obturator branch*, which curves around the spine of the ischium to reach the internal surface of the obturator internus muscle; two twigs to the *pyriformis*; a branch to the *gemellus superior*; and a branch of moderate size, which descends between the gemelli muscles and the ischium, and is distributed to the *gemellus inferior*, *quadratus femoris*, and capsule of the *hip joint*.

The **SUPERIOR GLUTEAL NERVE** arises from the lumbo-sacral near its junction with the first sacral nerve; it passes out of the pelvis with the gluteal artery, through the great sacro-ischiatic foramen, and divides into a superior and an inferior branch.

The *superior branch* follows the direction of the superior curved line of the ilium, accompanying the deep superior branch of the gluteal artery, and sends filaments to the *gluteus medius* and *minimus*.

The *inferior branch* passes obliquely downwards and forwards between the *gluteus medius* and *minimus*, distributing numerous filaments to both, and terminates in the *tensor vaginæ femoris* muscle.

The PUDIC NERVE arises from the lower part of the sacral plexus and passes out of the pelvis through the great sacro-ischiatic foramen below the pyriformis muscle. It crosses the spine of the ischium, and re-entering the pelvis through the lesser sacro-ischiatic foramen, accompanies the internal pudic artery along the outer wall of the ischio-rectal fossa, lying inferiorly to the artery and inclosed in the same sheath. Near its origin it gives off the *inferior hæmorrhoidal* nerve, and in the ischio-rectal fossa divides into a superior and inferior branch.

The *Inferior hæmorrhoidal nerve*, often a branch of the sacral plexus, passes through the lesser sacro-ischiatic foramen, and descends to the termination of the rectum to be distributed to the sphincter ani and integument.

The *Dorsalis penis nerve*, the superior division of the internal pudic, ascends along the posterior surface of the ramus of the ischium, pierces the triangular ligament, and accompanies the arteria dorsalis penis to the glans, to which it is distributed. At the root of the penis the nerve gives off a cutaneous branch which runs along the side of the organ, gives filaments to the corpus cavernosum, and with its fellow of the opposite side supplies the integument of the upper two-thirds of the penis.

The *Perineal nerve*, or inferior terminal branch, larger than the preceding, pursues the course of the superficial perineal artery in the perineum and divides into cutaneous and muscular branches.

The *cutaneous branches* (superficial perineal), two in number, *posterior* and *anterior*, enter the ischio-rectal fossa and pass forwards with the superficial perineal artery to be distributed to the integument of the perineum, scrotum, and under part of the penis. The *posterior* superficial perineal nerve sends a few filaments to the integument of the anus and sphincter ani; while the *anterior* gives off one or two twigs to the levator ani.

The *muscular branches* proceed from a single trunk, which passes inwards behind the transversus perinei muscle; they are distributed to the transversus perinei, accelerator urinæ, and erector penis. The perineal nerve also sends two or three filaments to the *corpus spongiosum*.

In the female the pudic nerve is distributed to the parts analogous to those of the male. The *superior branch* supplies the clitoris; the *inferior*, the vulva and perineum.

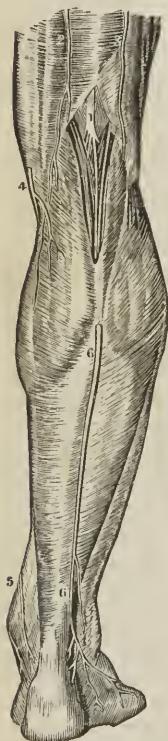
The LESSER ISCHIATIC NERVE passes out of the pelvis through the great sacro-ischiatic foramen below the pyriformis muscle, and continues its course downwards through the thigh to the lower part of the popliteal region, where it pierces the fascia and becomes subcutaneous. It then accompanies the external saphenous vein to the lower part of the leg, and communicates with the external saphenous nerve.

The *branches* of the lesser ischiatic nerve are, muscular and cutaneous. The *muscular* or *inferior gluteal* are several large branches distributed to the gluteus maximus.

The *cutaneous branches* are divisible into external, internal, and middle. The *external cutaneous branches* are several filaments which turn around the lower border of the gluteus maximus, and are distributed to the integument over the hip and outer side of the thigh. The *internal cutaneous branches* are distributed to the integument of the upper and inner part of the thigh. One of these, larger than the rest, *inferior pudental*, curves around the tuberosity of the ischium, pierces the fascia lata near the ramus of that bone, and, after communicating with one of the superficial perineal nerves, is distributed to the integument of the scrotum and penis. The *middle cutaneous branches*, two or three in number, are derived from the lesser ischiatic in its course down the thigh, and are distributed to the integument.

The GREAT ISCHIATIC NERVE is the largest nervous cord in the body; it is formed by the sacral plexus, or rather is a prolongation of the plexus, and at its exit from the great sacro-ischiatic foramen beneath the pyriformis muscle measures three-quarters of an inch in breadth. It descends through the middle of the space between the trochanter major and tuberosity of the ischium, and along the posterior part of the thigh to its lower third, where it divides into two large terminal branches, internal and external popliteal. This division sometimes takes place at the plexus, and the two nerves descend side by side; occasionally they are separated at their commencement by a part or by the whole of the pyriformis muscle. The nerve in its course down the thigh rests on the gemellus superior, tendon of the obturator internus, gemellus inferior, quadratus femoris, and adductor magnus, and is covered in by the gluteus maximus and biceps.

[FIG. 280.



SOME OF THE BRANCHES OF THE INTERNAL POPLITEAL NERVE. 1. The internal popliteal nerve. 2. The terminations of posterior femoral cutaneous nerves. 1, 5. The internal or long saphenous nerve. 6, 6. The external or short saphenous nerve.]

[FIG. 281.



THE POSTERIOR TIBIAL NERVE in the back of the leg. 1. The internal popliteal nerve becoming the posterior tibial. 1 and 2, indicate its course, the upper part of the external popliteal nerve being seen to the right.]

The *Branches* of the great ischiatic nerve, previously to its division, are, muscular and articular.

The *Muscular branches* are given off from the upper part of the nerve and supply both heads of the biceps, the semi-tendinosus, semi-membranosus, and adductor magnus.

The *Articular branch* descends to the upper part of the external condyle of the femur, and divides into filaments, which are distributed to the fibrous capsule and synovial membrane of the knee joint.

The INTERNAL POPLITEAL NERVE passes through the middle of the popliteal space, from the division of the great ischiatic nerve to the lower border of the popliteus muscle, accompanies the artery beneath the arch of the soleus, and becomes the posterior tibial nerve. It is superficial in the whole of its course, and lies externally to the vein and artery.

The *Branches* of the internal popliteal nerve are, muscular or sural, articular, and a cutaneous branch, the external saphenous.

The *Muscular branches*, of considerable size, and four or five in number, are distributed to the two heads of the gastrocnemius, to the soleus, plantaris, and popliteus.

The *Articular branches*, two or three in number, supply the knee joint, two of the twigs accompanying the internal articular arteries.

The *External or short saphenous nerve* (eomunicans poplitei, vel tibialis) proceeds from the middle of the internal popliteal, and descends in the groove between the two

bellies of the gastrocnemius muscle to the middle of the leg; it then pierces the fascia, and, after receiving the communicans peronei, comes into relation with the external saphenous vein, and follows the course of that vein to the outer ankle, to which, and to the integument of the heel and outer side of the foot (cutaneus dorsi pedis externus), it distributes branches.

The POSTERIOR TIBIAL NERVE is continued along the posterior aspect of the leg from the lower border of the popliteus muscle to the posterior part of the inner ankle, where it divides into the internal and external plantar nerve. In the upper part of its course it lies to the inner side of the posterior tibial artery; it then becomes placed superficially to that vessel, and at the ankle is situated to its outer side; in the lower third of the leg it lies parallel with the inner border of the tendo Achillis.

The *Branches* of the posterior tibial nerve are, three or four *muscular* twigs to the deep muscles of the posterior aspect of the leg, the branch to the flexor longus pollicis accompanies the fibular artery; one or two filaments which entwine around the artery, and then terminate in the integument; and a *plantar cutaneous branch* which pierces the internal annular ligament and is distributed to the integument of the heel, and inner border of the sole of the foot.

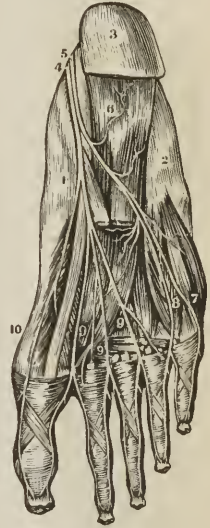
The INTERNAL PLANTAR NERVE, larger than the external, crosses the posterior tibial vessels to enter the sole of the foot, and becomes placed between the abductor pollicis and flexor brevis digitorum; it then enters the sheath of the latter muscle, and divides opposite the base of the metatarsal bones into three digital branches; *one* to supply the adjacent sides of the great and second toe; the *second* the adjacent sides of the second and third toe; the *third* the corresponding sides of the third and fourth toe. This distribution is precisely similar to that of the digital branches of the median nerve in the hand.

In its course the internal plantar nerve gives off *cutaneous branches* to the integument of the inner side and sole of the foot; *muscular branches* to the muscles forming the inner and middle group of the sole; a *digital branch* to the inner border of the great toe; and *articular branches* to the articulations of the tarsal and metatarsal bones.

The EXTERNAL PLANTAR NERVE, the smaller of the two, follows the course of the external plantar artery to the outer border of the musculus accessorius, beneath which it sends several deep branches to supply the adductor pollicis, interossei, transversus pedis and the articulations of the tarsal and metatarsal bones. It then gives branches to the integument of the outer border and sole of the foot, and sends forwards two digital branches to supply the little toe and half the next.

¹ It is extremely interesting, in a physiological point of view, to observe the mode of distribution of these arterial filaments. They seem to be *monitors* to the artery of the presence or approach of danger.

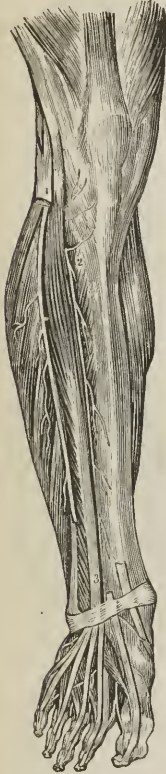[FIG. 282.]



THE TERMINATION OF THE POSTERIOR TIBIAL NERVE IN THE SOLE OF THE FOOT. 1. Inner side of the foot. 2. Outer side of the foot. 3. Heel. 4. Internal plantar nerve. 5. External plantar nerve. 6. Branch to flexor brevis. 7. Branch to outside of little toe. 8. Branch to space between fourth and fifth toes. 9, 9, 9. Digital branches of the internal plantar to remaining spaces. 10. Branch of internal plantar to inner border of great toe.]

The **EXTERNAL POPLITEAL NERVE** (n. peroneus) one half smaller than the internal, passes downwards by the side of the tendon of the biceps, and crosses the inner head of the gastrocnemius and the head of the soleus, to the neck of the fibula, it then pierces the peroneus longus muscle, and divides into two branches, anterior tibial and musculo-cutaneous.

[Fig. 283.]



THE MUSCULO-CUTANEOUS AND THE ANTERIOR TIBIAL NERVE. — 1. The musculo-cutaneous nerve. 2, 3. The anterior tibial nerve accompanying the anterior tibial artery.]

cutaneous nerves of the foot. In its course it gives off several branches to the peronei muscles.

The *internal branch*, the smaller of the two, is distributed to the inner side of the foot and great toe, and communicates with the anterior tibial and internal saphenous. The *external*, or larger branch, supplies the adjacent sides of the second and third, third and fourth, and fourth and fifth toes, and communicates with the external saphenous.

The *Branches* of the external popliteal nerve are, communicans peronei, cutaneous, and articular.

The *Communicans peronei*, proceeding from the external popliteal near the head of the fibula, crosses the external origin of the gastrocnemius muscle, and piercing the deep fascia, descends to the middle of the leg, where it joins the external saphenous nerve. It gives off one or two cutaneous filaments in its course.

The *Cutaneous* branch passes down the outer side of the leg, supplying the integument.

The *Articular* branches follow the external articular arteries to the knee joint.

The **ANTERIOR TIBIAL NERVE** (n. interosseus, vel peroneus profundus) commences at the bifurcation of the external popliteal on the neck of the fibula, and passes beneath the upper part of the extensor longus digitorum, to reach the outer side of the anterior tibial artery, just as that vessel has emerged through the opening in the interosseous membrane. It descends the leg with the artery; lying at first to its outer side, then in front of it, and near the ankle becoming again placed to its outer side. Reaching the ankle it passes beneath the annular ligament; accompanies the dorsalis pedis artery, supplies the adjacent sides of the great and second toe, and communicates with the internal division of the musculo-cutaneous nerve.

The *Branches* given off by the anterior tibial nerve are, *muscular* to the muscles in its course; and at the ankle a *tarsal* branch which may be considered as one of the terminal divisions of the nerve. This branch passes outwards upon the dorsum of the foot, becomes ganglionie like the posterior interosseous nerve at the wrist, and supplies the extensor brevis digitorum muscle and the articulations of the tarsus and metatarsus.

The **MUSCULO-CUTANEOUS NERVE** (n. peroneus superficialis) passes downwards along the fibula, in the substance of the peroneus longus; it then gets between the peroneus longus and brevis, next between the peronei and extensor longus digitorum, and at the lower third of the leg pierces the deep fascia, and divides into the internal and external

SYMPATHETIC NERVES.

The *Sympathetic* consists of a vertebral and prævertebral portion; the *vertebral portion* is composed of a series of ganglia united by a longitudinal cord, it descends along each side of the vertebral column from the head to the coccyx, communicates with the cranial and spinal nerves, and distributes branches to the internal organs and viscera. The *prævertebral portion* is that part of the sympathetic which appertains to the viscera, comprising the numerous ganglia and plexuses of the head, chest, abdomen, and pelvis.

The sympathetic nerve communicates with the cerebro-spinal nerves immediately at their exit from the cranium and vertebral canal. With the fourth and sixth nerve, however, it unites in the cavernous sinus; with the olfactory in the nose; and with the auditory in the meatus auditorius internus.

The branches of distribution accompany the arteries which supply the different organs, and form communications around them which are called *plexuses*, and take the name of the artery with which they are associated; thus we have the mesenteric plexus, hepatic plexus, and splenic plexus. All the *internal organs* of the head, neck, and trunk are supplied with branches from the sympathetic, and some of them exclusively; hence it is denominated the nerve of *organic life*.

It is called the *ganglionic nerve*, from being constituted of a number of *ganglia*; and from the constant disposition which it evinces in its distribution, to communicate and form small knots or ganglia.

There are four sympathetic ganglia in the head; namely, the ophthalmic or lenticular, the sphenopalatine or Meckel's, the otic or Arnold's, and the submaxillary; three in the neck, superior, middle, and inferior cervical; twelve in the dorsal region; four in the lumbar region; and four or five in the sacral region.

Each ganglion [see fig. 246,] may be considered as a *distinct centre*, receiving and giving branches in four different directions, viz., *superior*, or *ascending*, to communicate with the ganglion above; *inferior*, or *descending*, to communicate with the ganglion below; *external*, to communicate with the spinal nerves; and *internal*, to communicate with the sympathetic filaments of the opposite side, and be distributed to the viscera.

As regards the spinal nerves, it receives as well as gives; the white fibres of the sympathetic being derived from the cerebro-spinal nerves.

CRANIAL PORTION OF THE SYMPATHETIC NERVE.

Cranial Ganglia.

Ophthalmic, or lenticular ganglion,
Sphenopalatine, or Meckel's ganglion,
Otic, or Arnold's ganglion,
Submaxillary ganglion.

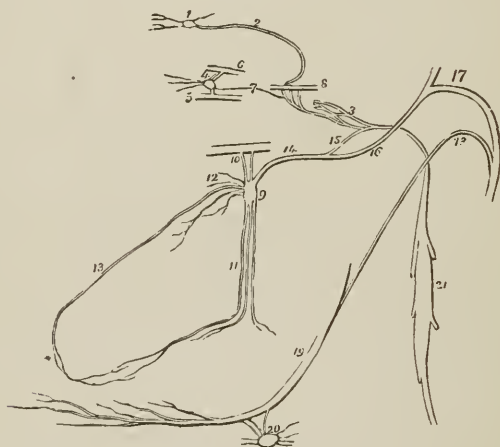
The OPHTHALMIC GANGLION (*ciliary*; *lenticular*) is a small quadrangular and flattened ganglion situated within the orbit, between the optic nerve and external rectus muscle; it is in close relation with the optic nerve, and generally with the ophthalmic artery; and is surrounded by adipose tissue, which renders its dissection somewhat difficult. It is of a reddish-gray color, like other sympathetic ganglia

Its *branches of distribution* are the *short ciliary* nerves, which arise from its anterior angles in two groups: the upper group consisting of about four filaments; the lower, of five or six. They accompany the ciliary arteries in a waving course, and divide into filaments which pierce the sclerotic around the optic nerve, to supply the tunics of the eyeball. A small filament is said, by

Tiedemann, to accompany the arteria centralis retinae into the centre of the globe of the eye.

Its *branches of communication* are three: one, the *long root*, proceeds from the *nasal branch* of the ophthalmic nerve, and joins its superior angle; a short and thick branch, the *short root*, from the inferior division of the third nerve to its inferior angle; and a slender filament, the *sympathetic root*, from the carotid plexus. Occasionally the ophthalmic ganglion receives also a filament of communication from the spheno-palatine ganglion; and sometimes from the abducent nerve.

Fig. 284.



CRANIAL GANGLIA OF THE SYMPATHETIC NERVE. 1. Ganglion of Ribes. 2. Filament by which it communicates with the carotid plexus (3). 4. Ophthalmic or lenticular ganglion, giving off ciliary branches. 5. Part of the inferior division of the third nerve communicating with the ganglion by means of a short thick branch (short root). 6. Part of the nasal nerve, connected with the ganglion by means of a longer branch (long root). 7. A slender filament (the sympathetic root) sent directly backwards from the ganglion to the carotid plexus. 8. Part of the sixth nerve in the cavernous sinus, receiving two branches from the carotid plexus. 9. Meckel's ganglion (spheno-palatine). 10. Spheno-palatine nerves. 11. Descending or palatine branches. 12. Its internal or nasal branches. 13. Naso-palatine branch, one of the nasal branches. 14. Posterior branch of the ganglion, the Vidian nerve. 15. Its carotid branch (n. petrosus profundus) communicating with the carotid plexus. 16. Its petrosal branch (n. petrosus superficialis major), joining the intumescencia gangliformis of the facial nerve. 17. Facial nerve. 18. Chorda tympani nerve, descending to join the gustatory nerve. 19. Gustatory nerve. 20. Submaxillary ganglion, receiving the chorda tympani, and other filaments from the gustatory. 21. Superior cervical ganglion of the sympathetic. * Naso-palatine ganglion, or ganglion of Cloquet.

The SPHENO-PALATINE GANGLION (Meckel's), the largest of the cranial ganglia of the sympathetic, is situated in the spheno-maxillary fossa, a little below the superior maxillary nerve. It is of small size, of a reddish-gray color, and triangular in shape; and is placed on the posterior part of the spheno-palatine nerves, which it only partially involves. Its branches are divisible into four groups; ascending, descending, internal, and posterior.

The *ascending* branches are three or four small filaments which are distributed to the periosteum of the orbit. One of these branches sometimes joins the ophthalmic ganglion; one the sixth nerve; and two the optic nerve.

The *descending* branches are the three palatine nerves, anterior, middle, and posterior.

The *anterior* or *large palatine nerve* descends from the ganglion through the posterior palatine canal, and emerges at the posterior palatine foramen. It then passes forwards in the substance of the hard palate to which it is distributed, and communicates with the naso-palatine nerve. While in the posterior palatine canal, this nerve gives off several branches (*inferior nasal*), which enter the nose through openings in the palate bone, and are distributed to the middle and inferior meatus, inferior spongy bone, and antrum.

The *middle* or *external palatine nerve* descends externally to the preceding to the posterior palatine foramen, and distributes branches to the tonsil, soft palate, and uvula.

The *posterior* or *small palatine nerve*, quits the other nerves to enter a distinct canal, from which it emerges by a separate opening behind the posterior palatine foramen. It is distributed to the hard palate and gums near the point of its emergence, and also to the tonsil, soft palate, and uvula.

The *internal branches* are the superior nasal and naso-palatine. The *superior nasal nerves*, four or five in number, enter the nasal fossa through the sphenopalatine foramen, and are distributed to the mucous membrane of the superior meatus, and superior and middle spongy bone.

The *naso-palatine nerve* (Scarpa) enters the nasal fossa with the nasal nerves, and crosses the roof the nares to reach the septum, to which it gives filaments. It then curves downwards and forwards to the naso-palatine canal, and passes through that canal to the palate, to which and to the papilla behind the incisor teeth it is distributed. This nerve was described by Cloquet as uniting with its fellow in the naso-palatine canal and constituting the *naso-palatine ganglion*. The existence of this ganglion is disputed.

The *posterior branches* are the Vidian or pterygoid nerve, and the pharyngeal.

The *Vidian*¹ nerve passes directly backwards from the sphenopalatine ganglion, through the pterygoid or Vidian canal, to the foramen lacerum basis cranii, where it divides into two branches, *carotid* and *petrosal*. The *carotid branch* (n. petrosus profundus) crosses the foramen lacerum, surrounded by the cartilaginous substance which closes that opening, and enters the carotid canal to join the carotid plexus. The *petrosal branch* (n. petrosus superficialis major) enters the cranium through the foramen lacerum basis cranii, piercing the cartilaginous substance, and passes backwards beneath the Gasserian ganglion and dura mater, imbedded in a groove on the anterior surface of the petrous bone, to the hiatus Fallopii. In the hiatus Fallopii it receives a branch from Jacobson's nerve, and terminates in the intumescencia gangliformis of the facial nerve.

The *pharyngeal* nerve is a small branch which passes backwards through the pterygo-palatine canal with the pterygo-palatine artery, to be distributed to the mucous membrane of the Eustachian tube and neighboring part of the pharynx.

The OTIC GANGLION (Arnold's)² is a small oval-shaped and flattened ganglion, lying against the inner surface of the inferior maxillary nerve, close to the foramen ovale; it is in *relation, externally*, with the trunk of that nerve, just at the point of union of the motor root; *internally* it rests against the cartilage of the Eustachian tube and tensor palati muscle; and *posteriorly* is in contact with the arteria meningea media. It is closely adherent to the internal pterygoid nerve, and appears like a swelling of that branch.

The branches of the otic ganglion are six in number; two of distribution, and four of communication.

¹ Guido Guidi Latinized into Vidus Vidius, was Professor of Anatomy and Medicine in the College of France in 1542. His work is posthumous, and was published in 1611.

² Frederick Arnold, "Dissertatio Inauguralis de Parte Cephalicâ Nervi Sympathetici." Heidelberg, 1826; and "Ueber den Ohrknoten," 1828.

The *branches of distribution* are, a small filament to the tensor tympani muscle, and one or two to the tensor palati.

The *branches of communication* are, one or two filaments from the inferior maxillary nerve (short root); one or two filaments from the auriculo-temporal nerve; filaments from the *nervi molles* of the *arteria meningea media*, and the *nervus petrosus superficialis minor* (long root). The latter nerve ascends from the ganglion to a small canal situated between the foramen ovale and foramen spinosum, and passes backwards on the petrous bone to the hiatus Fallopii, where it divides into two filaments. One of these filaments enters the hiatus and joins the *intumescencia gangliformis* of the facial; the other passes to a minute foramen nearer the base of the petrous bone, and enters the tympanum, where it communicates with a branch of Jacobson's nerve.

The SUBMAXILLARY GANGLION is a small round or triangular ganglion situated on the submaxillary gland, in close relation with the gustatory nerve, and near the posterior border of the mylo-hyoideus muscle.

Its *branches of distribution*, six or eight in number, divide into many filaments, which supply the side of the tongue, the submaxillary gland, sublingual gland, and Wharton's duct.

Its *branches of communication* are, two or three from and to the gustatory nerve; one from the chorda tympani; two or three which form a plexus with branches of the hypoglossal nerve; and one or two filaments which pass to the facial artery, and communicate with the *nervi molles* from the cervical portion of the sympathetic.

CAROTID PLEXUS.—The ascending branch of the superior cervical ganglion enters the carotid canal with the internal carotid artery, and divides into two branches, which form several loops of communication with each other around the artery. These branches, together with those derived from the carotid branch of the Vidian, constitute the *carotid plexus*. They also form frequently a small gangliform swelling at the under part of the artery, which is called the *carotid ganglion*. The latter, however, is not constant. The continuation of the carotid plexus onwards with the artery by the side of the sella turcica, is the *cavernous plexus*.

The *carotid plexus* is the centre of communication between all the cranial ganglia, and, being derived from the superior cervical ganglion, between the cranial ganglia and those of the trunk; it also communicates with the greater part of the cerebral nerves, and distributes filaments with each of the branches of the internal carotid, to accompany those branches to their ultimate ramifications. The branches which accompany the anterior cerebral artery at each side, unite upon the anterior communicating artery, and, according to Ribes, form a small ganglion, the *ganglion of Ribes*. The existence of this ganglion is disputed.

The *ophthalmic ganglion* communicates with the plexus by means of the long branch which reaches it from the cavernous plexus. The *spheno-palatine* joins the plexus by means of the carotid branch of the Vidian. The *submaxillary ganglion* is brought into connexion with it by means of the otic ganglion, and the *otic ganglion* by means of the tympanic nerve and Vidian.

It communicates with the third nerve in the cavernous sinus, and through the ophthalmic ganglion; frequently with the fourth in the formation of the nerve of the tentorium; with the Gasserian ganglion; with the *ophthalmic* division of the fifth in the cavernous sinus, and by means of the ophthalmic ganglion; with the superior maxillary, through the spheno-palatine ganglion; and with the inferior maxillary, through the otic ganglion. It sends two branches directly

to the sixth nerve, which unite¹ with it as it crosses the cavernous sinus; it communicates with the facial and auditory nerve, through the medium of the petrosal branch of the Vidian; and with the glosso-pharyngeal by means of two filaments to the tympanic nerve.

CERVICAL PORTION OF THE SYMPATHETIC NERVE.

The *Superior cervical ganglion* is long and fusiform, of a reddish-gray color, smooth, and of considerable thickness, extending from within an inch of the carotid foramen in the petrous bone to opposite the lower border of the third cervical vertebra. It is in relation, in front, with the sheath of the internal carotid artery and internal jugular vein; and, behind, with the rectus anticus major muscle.

Its *branches* are divisible into *superior, inferior, external, and internal*; to which may be added, as proper to this ganglion, *anterior*.

The *superior* (carotid nerve) is a single branch which ascends by the side of the internal carotid, and divides into two branches; one lying to the outer, the other to the inner side of that vessel. The two branches enter the carotid canal, and, by their communications with each other and with the carotid branch of the Vidian, constitute the *carotid plexus*.

The *inferior* or descending branch, sometimes two, is the cord of communication with the middle cervical ganglion.

The *external branches* are numerous, and may be divided into two sets; those which communicate with the glosso-pharyngeal, pneumogastric, and hypoglossal nerve; and those which communicate with the first four cervical nerves.

The *internal branches* are three in number: *pharyngeal*, to assist in forming the pharyngeal plexus; *laryngeal*, to join the superior laryngeal nerve and its branches; and, *superior cardiac nerve*, or *nervus superficialis cordis*.

The *anterior branches* accompany the external carotid artery with its branches, around which they form plexuses, and here and there small ganglia; they are named, from the softness of their texture, *nervi molles*, and, from their reddish hue, *nervi subrufi*. The branches accompanying the facial artery are conducted by that vessel to the submaxillary ganglion, and those which accompany the internal maxillary artery reach the otic ganglion through the medium of the *arteria meningea media*.

The *Middle cervical ganglion* (thyroid ganglion) is small, and sometimes wanting. It is situated opposite the fifth cervical vertebra, and rests against the inferior thyroid artery. This relation is so constant, as to have induced Haller to name it the "*thyroid ganglion*."

Its *superior branch*, or branches, ascend to communicate with the superior cervical ganglion.

Its *inferior branches* descend to join the inferior cervical ganglion; one of these frequently passes in front of the subclavian artery, the other behind it.

Its *external branches* communicate with the fifth and sixth cervical nerve.

Its *internal branches* are filaments which accompany the inferior thyroid artery, *inferior thyroid plexus*; and the *middle cardiac nerve*, *nervus cardiacus magnus*.

The *Inferior cervical ganglion* (vertebral ganglion) is much larger than the preceding, and constant in its existence. It is of a semilunar form, and situated on the base of the transverse process of the seventh cervical vertebra, immediately behind the vertebral artery; hence its designation "*vertebral ganglion*."

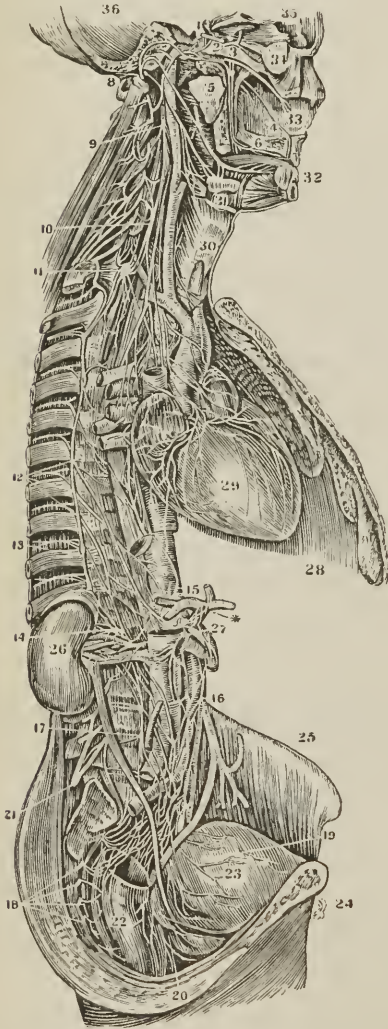
¹ Panizza, in his "Experimental Researches on the Nerves," denies this communication, and states very vaguely that "they are merely lost and entwined around it."—*Edinburgh Medical and Surgical Journal*, Jan. 1836.

Its *superior branches* communicate with the middle cervical ganglion.

The *inferior branches* pass some before and some behind the subclavian artery, to join the first thoracic ganglion.

The *external branches* consist of two sets; one which communicates with the sixth, seventh, and eighth cervical, and first dorsal nerve, and one which accompanies the vertebral artery along the vertebral canal, forming the *vertebral plexus*. The plexus sends filaments to all the branches given off by that

[FIG. 285.]



THE GREAT SYMPATHETIC NERVE. 36. The cavity of the cranium. 34. The globe of the eye. 33. The septum of the nose. 32. The incisor teeth. 31. The submaxillary gland. 30. The larynx. 29. The heart. 28. The left lung. * The cœliac axis. 27. The ascending vena cava. 26. The kidney. 25. The crista of the ilium. 24. The pubes. 23. The bladder. 22. The rectum. 1. Plexus on the carotid artery in the carotid foramen. 2. Sixth nerve, (abduens.) 3. First branch of the fifth, or ophthalmic nerve. 4. Nasopalatine nerve on the septum narium, connecting Meckel's ganglion with Cloquet's in the incisive foramen. 5. Immediately above the figure is the recurrent branch, pterygoid, or Vidian nerve, dividing into the carotid and petrosal branches. 6. Anterior or large palatine branch of Meckel's ganglion. 7. Gustatory nerve joined by the chorda tympani. 8. The portio dura of the seventh pair, or facial nerve. 9. The superior cervical ganglion. 10. The middle cervical ganglion. 11. The inferior cervical ganglion. 12. The roots of the great splanchnic nerve, arising from the thoracic ganglia. 13. The lesser splanchnic nerve. 14. The renal plexus. 15. The solar plexus. 16. The mesenteric plexus. 17. The lumbar ganglia. 18. The sacral ganglia. 19. The vesical plexus. 20. The rectal plexus. 21. The lumbar plexus, (cerebro-spinal.)]

artery, and communicates in the cranium with the filaments of the internal carotid plexus accompanying the branches of the internal carotid artery.

The *internal branch* is the *inferior cardiac nerve*, *nervus cardiacus minor*.

CARDIAC NERVES. — The cardiac nerves are three in number at each side, namely, superior, middle, and inferior.

The *Superior cardiac nerve* (*nervus superficialis cordis*) proceeds from the lower part of the superior cervical ganglion; it descends the neck behind the common carotid artery and parallel with the trachea, crosses the inferior thyroid artery, and running by the side of the recurrent laryngeal nerve, enters the chest. The nerve of the right side passes either in front of or behind the subclavian artery and along the posterior aspect of the arteria innominata to the deep cardiac plexus. The left superior cardiac nerve runs by the side of the left carotid artery, and crosses the arch of the aorta to the superficial cardiac plexus.

In its course it receives branches from the pneumogastric nerve, and sends filaments to the thyroid gland and trachea.

The *Middle cardiac nerve* (*nervus cardiacus magnus*) proceeds from the middle cervical ganglion, or, in its absence, from the cord of communication between the superior and inferior ganglion. It is the largest of the three nerves, and lies parallel with the recurrent laryngeal. At the root of the neck it divides into several branches, which pass some before and some behind the subclavian artery, communicates with the superior and inferior cardiac, pneumogastric and recurrent nerve, and descends to the bifurcation of the trachea, to join the *deep cardiac plexus*.

The *Inferior cardiac nerve* (*nervus cardiacus minor*) arises from the inferior cervical ganglion, communicates with the recurrent laryngeal and middle cardiac nerve, and descends to the front of the bifurcation of the trachea, to the *deep cardiac plexus*.

The SUPERFICIAL CARDIAC PLEXUS is situated immediately beneath the arch of the aorta, and in front of the right pulmonary artery. It receives the superior cardiac nerve of the *left* side and the inferior cardiac branch of the *left* pneumogastric nerve, both of which cross the arch of the aorta between the left phrenic and pneumogastric nerve. It receives besides several filaments from the deep cardiac plexus, and sometimes a cardiac branch from the right pneumogastric nerve. Connected with the plexus is a small ganglion (sometimes wanting), the *cardiac ganglion of Wisberg*, which lies close to the right side of the fibrous cord of the ductus arteriosus. The superficial cardiac plexus gives off filaments which pass along the front of the left pulmonary artery to the root of the left lung, where they communicate with the anterior pulmonary plexus; while the principal part of the plexus descends in the groove between the pulmonary artery and aorta to the anterior longitudinal *sulcus* of the heart, where it comes into relation with the anterior coronary artery, and becomes the *anterior coronary plexus*. At the base of the heart, the anterior coronary plexus receives several filaments from the deep cardiac plexus. Its branches are distributed to the substance of the heart in the course of the left or anterior coronary artery.

The DEEP or GREAT CARDIAC PLEXUS is situated on the bifurcation of the trachea, above the right pulmonary artery and behind the transverse portion of the arch of the aorta. It receives, on the *right* side, the three cardiac nerves of the sympathetic of the same side, and the cardiac branches of the right pneumogastric and right recurrent nerve. On the *left* side it receives the middle and inferior cardiac nerves of the sympathetic of the left side; the cardiac branches of the left pneumogastric (excepting the inferior), and several cardiac branches from the left recurrent nerve. In other words, it receives all the cardiac filaments of the sympathetic, pneumogastric, and recurrent nerves, with the exception of the left superior cardiac of the sympathetic (*nervus superficialis cordis*) and the inferior cervical cardiac of the left pneumogastric, these two nerves being destined to the superficial cardiac plexus.

The *branches* of the deep cardiac plexus, proceeding from its right and left division, pass downwards to join the coronary arteries, and outwards to the pulmonary plexuses.

From the *right division* of the plexus the branches proceed before and behind the right pulmonary artery. Those which pass in front descend upon the trunk of the pulmonary artery to the left coronary artery, and help to form the *anterior coronary plexus*; those which pass behind the right pulmonary artery are distributed to the right auricle; a third set of filaments, proceeding from the right division of the deep cardiac plexus, follow the course of the right pulmonary artery to the anterior pulmonary plexus.

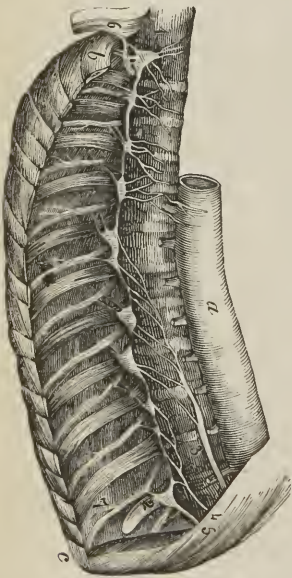
From the *left division* of the plexus branches proceed beneath the arch of the aorta immediately to the right of the ligament of the ductus arteriosus to join the superficial cardiac plexus; others pass outwards with the pulmonary artery to the pulmonary plexus; a few descend to the left auricle; but the chief bulk pass on to the right coronary artery and form the *posterior coronary plexus*.

The *Anterior coronary plexus* proceeds from the superficial cardiac plexus, and receives other filaments from the deep cardiac plexus. It is distributed with the branches of the coronary artery on the anterior aspect of the heart.

The *Posterior coronary plexus* proceeds from the deep cardiac plexus and principally from its left division. It follows the course of the arteries distributed to the posterior aspect of the heart.

THORACIC PORTION OF THE SYMPATHETIC NERVE.

[FIG. 286.]



THE GANGLIA OF THE SYMPATHETIC IN THE CHEST; (the ganglia are represented larger than natural); from part of a plate in Mr. Swan's work. *a.* Aorta. *b.* First rib. *c.* Eleventh rib. *1.* First thoracic ganglion. *2.* Last thoracic ganglion. *3.* The great splanchnic nerve. *4.* The lesser splanchnic nerve. *5.* Third or renal splanchnic nerve. *6.* Part of the brachial plexus.]

The *thoracic portion of the sympathetic nerve* is the trunk of the sympathetic in its course through the cavity of the thorax. It lies by the side of the vertebral column on the heads of the ribs and intercostal spaces; but at its lowest part comes into relation with the sides of the bodies of the last two dorsal vertebrae.

The *Thoracic ganglia* are twelve in number at each side. They are flattened and triangular, or irregular in form, and present the peculiar reddish-gray color and pearly lustre of sympathetic ganglia in general; they rest against the heads of the ribs, and are covered by the pleura costalis. The first two ganglia and the last are usually the largest; the latter being situated on the side of the body of the last dorsal vertebra.

Their *branches* are branches of communication and branches of distribution. Some ascending filaments from the first ganglion assist in the formation of the vertebral plexus.

The *external or communicating branches*, usually two in number for each ganglion, communicate with the intercostal nerves.

The *internal or visceral branches* proceeding from the five or six upper ganglia, are of small size, and distributed to the aorta, œsophagus, vertebral column, and lungs. The branches to the lungs proceed from the third and fourth ganglia, and go to join the posterior pulmonary plexus. The visceral branches of the six lower ganglia unite to form the three splanchnic nerves.

The *Great splanchnic nerve* proceeds from the sixth dorsal ganglion, and receiving the

branches of the seventh, eighth, ninth, and tenth, passes downwards along the front of the vertebral column, and, piercing the crus of the diaphragm, terminates in the semilunar ganglion.

The *Lesser splanchnic nerve* is formed by filaments which issue from the tenth and eleventh ganglia; it pierces the crus of the diaphragm, and joins the solar plexus near the middle line.

The *Third or renal splanchnic nerve* proceeds from the last thoracic ganglion, and, piercing the diaphragm, terminates in the renal plexus. When absent, the place of this nerve is supplied by the lesser splanchnic.

The *Semilunar ganglion* is a large, irregular, gangliform body, pierced by numerous openings, and appearing like the aggregation of a number of smaller ganglia, having spaces between them. It is situated by the side of the cœliac axis and root of the superior mesenteric artery, and extends outwards to the supra-renal capsule. The ganglia communicate both above and below the cœliac axis and form a gangliform circle, from which branches pass off in all directions, like rays from a centre. Hence the entire circle has been named the *solar plexus*.

The *Solar or epigastric plexus* receives the great and lesser splanchnic nerves; the termination of the right pneumogastric nerve; some filaments from the right phrenic nerve; and sometimes one or two from the left. It sends forth numerous filaments which accompany, under the name of *plexuses*, all the branches given off by the abdominal aorta. Thus we have, derived from the solar plexus, the —

Phrenic, or diaphragmatic plexuses,
Gastric plexus,
Hepatic plexus,
Splenic plexus,
Supra-renal plexuses,

Renal plexuses,
Superior mesenteric plexus,
Aortic plexus,
Spermatic plexuses,
Inferior mesenteric plexus.

In connexion with the *phrenic plexus* of the right side, there is described a small *ganglion diaphragmaticum*, which is situated near the supra-renal capsule. In this ganglion branches of the right phrenic nerve communicate with those of the sympathetic.

The *Supra-renal plexuses* are remarkable for their large size, and for a ganglion, which has received the name of *ganglion supra-renalale*.

The *Renal plexuses* are large, and receive the third splanchnic nerve.

The *Superior mesenteric plexus* has several small ganglia at the root of the artery; and its nerves, which are whiter than those of the other plexuses, form a kind of nervous sheath to the artery and its branches.

The *Aortic plexus* is a continuation of the solar plexus downwards on the aorta, for the supply of the inferior branches of that trunk; it receives also branches from the renal plexuses and lumbar ganglia. It is the source of origin of the inferior mesenteric plexus and part of the spermatic plexus, and terminates below in the hypogastric plexus. It likewise distributes branches on the inferior vena cava.

The *Spermatic plexus* is derived from the renal plexus, but receives filaments from the aortic plexus.

The *Inferior mesenteric plexus* is derived chiefly from the aortic plexus.

LUMBAR PORTION OF THE SYMPATHETIC NERVE.

The *lumbar* portion of the trunk of the sympathetic is situated on the vertebral column, close to the anterior border of the psoas magnus muscle. It is continuous above under the edge of the diaphragm, with the thoracic portion of the nerve, and below it descends upon the sacrum, in front of the anterior

sacral foramina, to the coccyx. It presents four small ganglia and an intermediate cord.

The *Lumbar ganglia*, four in number at each side, of a pearly-gray color and fusiform shape, are situated on the anterior part of the bodies of the lumbar vertebræ.

The *branches* of the lumbar ganglia are branches of communication and branches of distribution.

The *external* or *communicating branches*, two or three in number from each ganglion, and longer than in the other regions, communicate with the lumbar nerves.

The *internal* or *visceral branches* consist of two sets; the upper pass inwards in front of the abdominal aorta, and join the *aortic plexus*; the lower cross the common iliac arteries, and unite over the promontory of the sacrum, to form the hypogastric plexus.

The *Hypogastric plexus* is formed by the termination of the aortic plexus, and by the union of branches from the lower lumbar ganglia. It is situated over the promontory of the sacrum, between the two common iliac arteries, and bifurcates inferiorly into two lateral portions, *inferior hypogastric plexuses*, which communicate with branches from the third and fourth sacral nerves. It distributes branches to the viscera of the pelvis, and sends filaments which accompany the branches of the internal iliac artery.

SACRAL PORTION OF THE SYMPATHETIC NERVE.

The *Sacral ganglia* are four or five in number at each side. They are situated on the sacrum, close to the anterior sacral foramina, and resemble the lumbar ganglia in form and mode of connexion, although much smaller in size.

The *external* or *communicating branches* are two from each ganglion, which pass outwards to communicate with the anterior sacral nerves and with the coccygeal nerve.

The *internal* or *visceral branches* communicate very freely with the inferior hypogastric plexuses, and are distributed to the pelvic viscera. The last pair of sacral ganglia give off branches which join a small ganglion, situated on the first bone of the coccyx, called the *ganglion impar*, or *azygos*. This ganglion serves to connect the extremities of the two sympathetic nerves. It gives off a few small branches to the coccyx and rectum, and communicates with the coccygeal nerve.

CHAPTER X.

ORGANS OF SENSE.

THE organs of sense, the instruments by which the animal frame is brought into relation with surrounding nature, are five in number. Four of these organs are situated within the head: viz., the apparatus of smell, sight, hearing, and taste; the remaining organ, that of touch, is resident in the skin, and distributed over the surface of the body.

ORGAN OF SMELL.

The organ of smell consists essentially of two parts: one external, the *nose*; the other internal, the *nasal fossæ*.

NOSE.

The nose is the triangular pyramid which projects from the centre of the face, immediately above the upper lip. Superiorly it is connected with the forehead by means of a narrow bridge; inferiorly, it presents two openings, the *nostrils*,¹ [*anterior nares*,] which overhang the mouth, and are so constructed that the odor of all substances must be received by the nose before they can be introduced within the lips. The septum between the openings of the nostrils is called the *columna*. Their entrance is guarded by a number of stiff hairs (*vibrissæ*) which project across the openings, and act as a filter in preventing the introduction of foreign substances, such as dust or insects, with the current of air intended for respiration.

The anatomical elements of which the nose is composed, are, 1. Integument. 2. Muscles. 3. Bones. 4. Fibro-cartilages. 5. Mucous membrane. 6. Vessels and nerves.

1. The *Integument* forming the tip (*lobulus*) and wings (*alæ*) of the nose is extremely thick and dense, so as to be with difficulty separated from the fibro-cartilage. It is furnished with an abundance of *sebiparous glands*, which, by their oily secretion, protect the extremity of the nose under alternations of temperature. The sebaceous matter of these glands becomes of a dark color near the surface, from altered secretion, and also from attraction of the carbonaceous matter floating in the atmosphere; hence the spotted appearance which the tip of the nose presents in large cities. When the integument is firmly compressed, the inspissated sebaceous secretion is squeezed out, and, taking the cylindrical form of the excretory ducts of the glands, has the appearance of small white maggots (grubs; comedones) with black heads.

2. The *Muscles* are brought into view by reflecting the integument; they are the *pyramidalis nasi*, *compressor naris*, *dilatator naris*, *levator labii superioris alæque nasi*, and *depressor alæ nasi*. They have been already described with the muscles of the face.

3. The *Bones* of the nose are, the nasal, and nasal processes of the superior maxillary.

4. The *Fibro-cartilages* give form and stability to the nose, providing, at the same time, by their elasticity against injuries. They are five in number, namely, the—

Fibro-cartilage of the septum,
Two lateral fibro-cartilages,
Two alar fibro-cartilages.

The *Fibro-cartilage of the septum*, somewhat triangular in form, divides the nose into its two nostrils. It is connected above with the nasal bones and lateral fibro-cartilages; behind, with the ethmoidal septum and vomer; and below, with the palate processes of the superior maxillary bones. The alar fibro-cartilages and *columna* move freely on the fibro-cartilage of the septum, being but loosely connected with it by perichondrium.

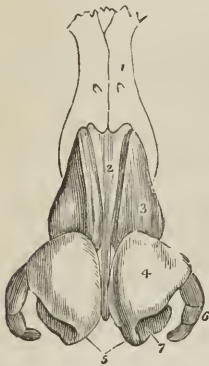
The *Lateral fibro-cartilages* are also triangular; they are connected, *in front*, with the fibro-cartilage of the septum; *above*, with the nasal bones; *behind*, with the nasal processes of the superior maxillary bones; and *below*, with the alar fibro-cartilages.

Alar fibro-cartilages.—Each of these cartilages is curved so as to correspond with the walls of the nostril, to which it forms a kind of rim. The inner portion is loosely connected with the same part of the opposite cartilage, to form the *columna*. It is expanded and thickened at the point of the nose, to consti-

¹ [The word *nostril* is employed in a somewhat more extended sense than "aperture," and would seem properly to refer to each lateral cavity of the nose, forming a vestibule to its appropriate nasal fossa.]

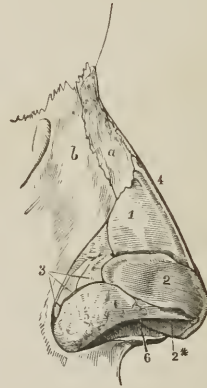
tute the *lobe* [*lobulus*]; and on the side makes a curve corresponding with that of the ala. This curve is prolonged backwards and downwards in the direction of the posterior border of the ala by three or four small fibro-cartilaginous plates (sesamoid cartilages, *cartilagines minores*), which are appendages of the alar fibro-cartilage.

Fig. 287.



THE FIBRO-CARTILAGES OF THE NOSE.
1. One of the nasal bones. 2. Cartilage of the septum. 3. Lateral cartilage. 4. Alar cartilage. 5. Central portions of the alar cartilages which constitute the columna. 6. *Cartilagines minores* or sesamoid cartilages. 7. The nostril.

Fig. 288.



THE FIBRO-CARTILAGES AND BONES OF THE NOSE, viewed from the side; after Arnold. *a.* Nasal bone. *b.* Nasal process of the superior maxillary bone. 4. Cartilage of the septum. 1. Lateral cartilage. 2. Alar cartilage. 2*. Inner portion of the alar cartilage. 3. Sesamoid cartilages. 5. Areolar tissue of the ala nasi. 6. Aperture of the nostril.

The whole of these fibro-cartilages are connected with each other, and to the bones, by perichondrium, which, from its membranous structure, permits of the freedom of motion existing between them.

5. The *Mucous membrane* lining the interior of the nose, is continuous with the skin externally, and with the pituitary membrane of the nasal fossæ within. Around the entrance of the nostrils it is provided with the *vibrissæ*.

6. *Vessels and Nerves*. — The *Arteries* of the nose are the *lateralis nasi* from the facial, and the *nasalis septi* from the superior coronary.

Its *Nerves* are, the facial, infraorbital, and nasal branch of the ophthalmic.

N A S A L F O S S Æ .

To obtain a good view of the *nasal fossæ*, the face must be divided through the nose by a vertical incision, a little to one side of the middle line.

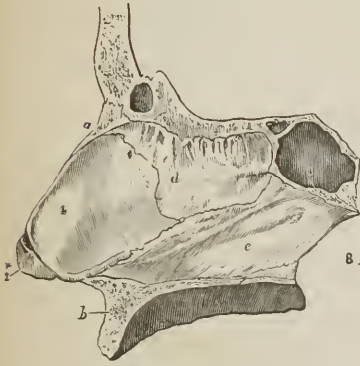The *Nasal fossæ* [*nares internæ*] are two irregular, compressed cavities, extending backwards from the nose to the pharynx. They are [each] bounded *superiorly* by the lateral cartilage of the nose, and by the nasal, ethmoid, and sphenoid bone; *inferiorly*, by the hard palate; and, in the *middle* line, they are separated by a bony and fibro-cartilaginous septum. A plan of the boundaries of the nasal fossæ will be found at page 91.

On the outer wall of each fossa, in the dried skull, are three projecting processes, termed spongy bones. The two superior belong to the ethmoid, the inferior is a separate bone. In the fresh fossæ these are covered with mucous membrane, and serve to increase the surface of that membrane by their prominence and convoluted form. The space intervening between the superior and

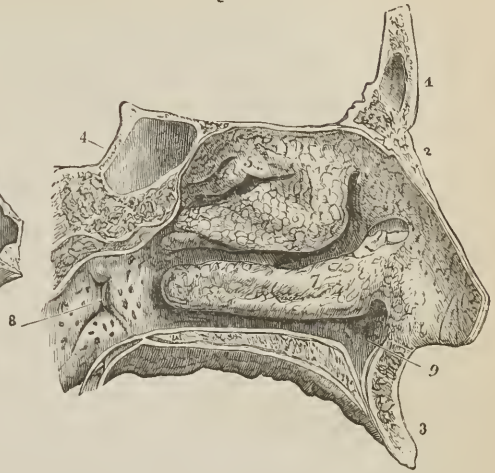
middle spongy bone is the *superior meatus*; the space between the middle and inferior, the *middle meatus*; and that between the inferior and the floor of the fossa, the *inferior meatus*.

[FIG. 290.]

[FIG. 289.]



OSSEOUS AND FIBRO-CARTILAGINOUS SEPTUM OF THE NASAL FOSSÆ, seen from the left side; after Arnold.—*a.* Nasal bone. *b.* Superior maxillary bone. *c.* Sphenoidal sinus. *d.* Central or perpendicular plate of the ethmoid bone. *e.* Vomer. 2*. Inner part of the right alar fibro-cartilage of the nose. 4. Fibro-cartilage of the septum.]



THE OUTER WALL OF THE LEFT NASAL FOSSA covered with the pituitary membrane. 1. Frontal bone. 2. Nasal bone. 3. Superior maxillary. 4. Sphenoid. 5. The superior turbinated or spongy bone. 6. Middle turbinated bone. 7. Inferior turbinated bone. The three meatuses of the nose are seen below the three last-named bones. 8. The opening of the Eustachian tube.]

These *meatuses* are passages which extend from before backwards, and it is in circulating through and amongst them that the atmosphere deposits its odorous particles upon the mucous membrane. There are several *openings* into the nasal fossæ: thus, in the *superior meatus* are the openings of the sphenoidal and posterior ethmoidal cells; in the *middle*, the anterior ethmoidal cells, frontal sinuses, and antrum maxillare; and, in the inferior meatus, the termination of the nasal duct. In the dried bones there are two additional openings, the sphenopalatine and the anterior palatine foramen; the former being situated in the superior, the latter in the inferior meatus.

The *Mucous membrane* of the nasal fossæ is called *pituitary*, or *Schneiderian*.¹ The former name being derived from the nature of its secretion [*pituita*, phlegm, mucus,] the latter from Schneider, who was the first to show that the secretion of the nose proceeded from the mucous membrane, and not from the brain, as was previously imagined. It is closely adherent to the periosteum, constituting what is called a fibro-mucous membrane, and is continuous with the general gastro-pulmonary mucous membrane. From the nasal fossæ it may be traced through the openings in the meatuses, into the sphenoidal and ethmoidal cells; into the frontal sinuses; into the antrum maxillare; through the nasal duct to the surface of the eye, where it is continuous with the conjunctiva; along the Eustachian tubes into the tympanum and mastoid cells, to which it forms the lining membrane; and through the posterior nares into the pharynx and mouth, and thence through the lungs and alimentary canal.

¹ Conrad Victor Schneider, Professor of Medicine at Wittenberg. His work, entitled "De Catarrhis," &c. was published in 1661.

The surface of the membrane is furnished with a laminated epithelium near the apertures of the nares, and in the rest of its extent with a columnar epithelium supporting vibratile cilia.

Vessels and Nerves. — The *Arteries* of the nasal fossæ are the anterior and posterior ethmoidal, from the ophthalmic; and sphenopalatine and pterygopalatine from the internal maxillary.

The *Nerves* are, olfactory, sphenopalatine and naso-palatine from Meckel's ganglion, and nasal branch of the ophthalmic. The ultimate filaments of the olfactory nerve terminate in papillæ.

ORGAN OF VISION.

THE form of the eyeball is that of a sphere, of about one inch in diameter, having the segment of a smaller sphere engrafted on its anterior surface, which increases its antero-posterior diameter. The axes of the two eyeballs are parallel with each other, but not so with the axes of the orbits, which are directed outwards. The optic nerves follow the direction of the orbits, and therefore enter the eyeballs at their nasal side.

GLOBE OF THE EYE.

The *globe of the eye* is composed of *tunics*, and of refracting media called *humors*. The *tunics* are three in number,

1. Sclerotic and Cornea,
2. Choroid, [Ciliary ligament,] Iris, and Ciliary processes,
3. Retina and Zonula ciliaris.

The *humors* are also three —

Aqueous,	Crystalline (lens),	Vitreous.
----------	---------------------	-----------

FIRST TUNIC.—The Sclerotic and Cornea form the external tunic of the eyeball, and give it its peculiar form. Four-fifths of the globe are invested by the sclerotic, the remaining fifth by the cornea.

The *Sclerotic* (*σκληρός*, hard) is a dense fibrous membrane, thicker behind than in front. It is continuous, posteriorly, with the sheath of the optic nerve derived from the dura mater, and is pierced by that nerve as well as by the ciliary nerves and arteries. Anteriorly it presents a bevelled edge, which receives the cornea as a watch-glass is received by the groove of its case. Its anterior surface is covered by a thin tendinous layer, the *tunica albuginea*, derived from the expansion of the tendons of the four recti muscles; and by its posterior surface it gives attachment to the two oblique muscles. The *tunica albuginea* is covered, for part of its extent, by the mucous membrane of the front of the eye, the conjunctiva; and, by reason of the brilliancy of its whiteness, gives occasion to the common expression, “the white of the eye.”

At the entrance of the optic nerve, the sclerotic forms a thin *cribriform lamella* (*lamina cribrosa*), which is pierced by a number of minute openings for the passage of the nervous filaments. One of these openings, larger than the rest, and situated in the centre of the lamella, is the *porus opticus*, through which the *arteria centralis retinæ* enters the eyeball.

The *Cornea* (*corneus*, horny) is the transparent prominent layer which constitutes the anterior fifth of the globe of the eye. In its form it is circular, concavo-convex, and resembles a watch-glass. It is received by its edge, which

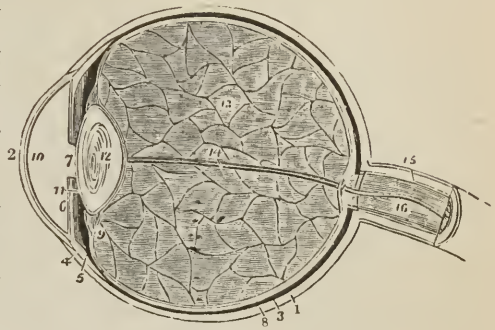
is sharp and thin, within the bevelled border of the sclerotic, to which it is very firmly attached, and it is somewhat thicker than the anterior portion of that tunic. When examined from the exterior, its vertical diameter is seen to be about one-sixteenth shorter than the transverse, in consequence of the overlapping above and below of the margin of the sclerotica; on the interior, however, its outline is perfectly circular.

The cornea is composed of four layers: namely, the *conjunctiva*; the *cornea propria*, which consists of several thin lamellæ connected together by an extremely fine areolar tissue; the *cornea elastica*, a "fine, elastic, and exquisitely transparent membrane, exactly applied to the inner surface of the cornea proper;" and the *lining membrane* of the anterior chamber of the eyeball. The cornea elastica is remarkable for its perfect transparency, even when submitted for many days to the action of water or alcohol; while the cornea propria is rendered opaque by the same immersion. To expose this membrane, Dr. Jacob suggests that the eye should be placed in water for six or eight days, and then, that all the opaque cornea should be removed layer by layer. Another character of the cornea elastica is its great elasticity, which causes it to roll up when divided or torn, in the same manner as the capsule of the lens. The use of this layer, according to Dr. Jacob, is to "preserve the requisite permanent correct curvature of the flaccid cornea proper."

The opacity of the cornea, produced by pressure on the globe, results from the infiltration of fluid into the areolar tissue connecting its layers. This appearance cannot be produced in a sound living eye, although a small quantity of serous fluid (*liquor corneæ*) is said to occupy the spaces of the areolar tissue.

Dissection.—The sclerotic and cornea are now to be dissected away from the second tunic; this, with care, may be easily performed, the only firm connexions subsisting between them being at the circumference of the iris, the entrance of the optic nerve, and the perforation of the ciliary nerves and arteries. Pinch up a fold of the sclerotic near its anterior circumference, make a small opening through it, then raise the edge of the tunic, and with a pair of fine blunt-pointed scissors, divide the entire circumference of the sclerotic, and cut it away bit by bit. Then separate it from its attachment around the circumference of the iris

FIG. 291.



LONGITUDINAL SECTION OF THE GLOBE OF THE EYE.

1. Sclerotic, thicker behind than in front. 2. Cornea, received within the anterior margin of the sclerotic, and connected with it by means of a bevelled edge. 3. Choroid, connected anteriorly with (4) ciliary ligament, and (5) ciliary processes. 6. Iris. 7. Pupil. 8. Third layer of the eye, the retina, terminating anteriorly by an abrupt border at the commencement of the ciliary processes. 9. Canal of Petit, which encircles the lens (12); the thin layer in front of this canal is the zonula ciliaris, a prolongation of the vascular layer of the retina to the lens. 10. Anterior chamber of the eye, containing the aqueous humor; the lining membrane by which the humor is secreted is represented in the diagram. 11. Posterior chamber. 12. The lens, more convex behind than before, and inclosed in its proper capsule. 13. Vitreous humor inclosed in the hyaloid membrane, and in cells formed in its interior by that membrane. 14. Tubular sheath of the hyaloid membrane, for the passage of the artery of the capsule of the lens. 15. Neurilemma of the optic nerve. 16. Arteria centralis retinae, imbedded in the centre of the optic nerve.

by a gentle pressure with the edge of the knife. The dissection of the eye must be conducted under water.

In the course of this dissection, the *ciliary nerves* and *long ciliary arteries* will be seen passing forwards between the sclerotic and choroid, to be distributed to the iris.

SECOND TUNIC.—The second tunic of the eyeball is formed by the *choroid*, *ciliary ligament*, and *iris*, the *ciliary processes* being an appendage developed from its inner surface.

The *Choroid*¹ is a vascular membrane of a rich chocolate-brown color upon its external surface, and of a deep black color within. It is connected to the sclerotic externally, by an extremely fine areolar tissue (*membrana fusca*), and by nerves and vessels. Internally it is in simple contact with the third tunic of the eye, the retina. It is pierced posteriorly for the passage of the optic nerve, and is connected anteriorly with the iris, ciliary processes, and the line of junction of the cornea and sclerotic, by a dense white structure, the *ciliary ligament*, which surrounds the circumference of the iris like a ring.

[FIG. 292

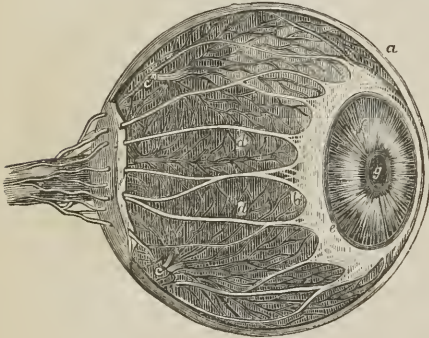
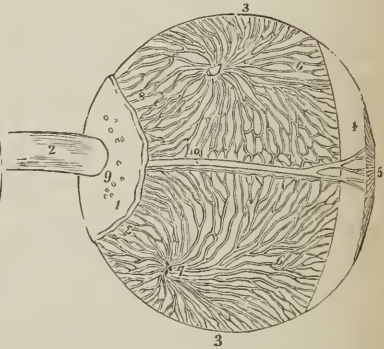


FIG. 293.



CILIARY NERVES.—*a.* Sclerotica. *b.* Venæ vorticosæ, and outer surface of choroid. *c, c.* Two of the chief trunks of the venæ vorticosæ as they leave the choroid. *d, d.* Ciliary nerves. *e.* Annulus albidus, or ciliary ligament. *f.* Iris. *g.* Pupil.]

DISSECTION OF THE EYEBALL, SHOW-

ING ITS SECOND TUNIC, AND THE MODE

OF DISTRIBUTION OF THE VENÆ VORTI-

COSÆ OF THE CHOROID; after Arnold.

1. Part of the sclerotic coat. 2. Optic

nerve. 3, 3. Choroid coat. 4. Ciliary

ligament. 5. Iris. 6, 6. Venæ vorticosæ.

7, 7. Trunks of the venæ vorticosæ at

the point where they have pierced the

sclerotica. 8, 8. Posterior ciliary veins,

which enters the eyeball in company with

the posterior ciliary arteries, by piercing

the sclerotic at 9. 10. One of the long

ciliary nerves, accompanied by a long

ciliary vein.

The choroid membrane is composed of three layers:—an *external* or *venous* layer, which consists principally of veins arranged in a peculiar manner: hence they have been named *venæ vorticosæ*. The marking on the surface of the membrane produced by these veins resembles so many centres to which a number of curved lines converge. It is this layer which is connected with

¹ The word *choroid* has been very much abused in anatomical language; it was originally applied to the membrane of the fœtus called chorion, from the Greek word *χόριον* domicilium, that membrane being, as it were, the abode or receptacle of the fœtus. *Χόριον* comes from *χωρέω*, to take or receive. Now, the chorion in the ovum is a vascular membrane of peculiar structure. Hence the term choroid, *χόριον είδος*; like the chorion, has been used to signify vascular structures, as the choroid membrane of the eye, the choroid plexus, &c., and we find Cruveilhier, in his work on *Anatomy*, vol. iii. p. 463, saying in a note, “Choroïde est synonyme de vasculaire.”

the ciliary ligament. The *middle* or *arterial layer* (*tunica Ruyschiana*)¹ is formed principally by the ramifications of minute arteries. It is reflected inwards at its junction with the ciliary ligament, so as to form the ciliary processes. The *internal layer* is a delicate membrane (*membrana pigmenti*) composed of several laminae of nucleated hexagonal cells, which contain the granules of pigmentum nigrum, and are arranged like the tiles of a tessellated pavement.

In animals, the pigmentum nigrum of the posterior wall of the eyeball, is replaced by a layer of considerable extent, and of metallic brilliancy, called the tapetum.

The *Ciliary ligament*, or circle (*annulus albidus*), is the bond of union between the external and middle tunic of the eyeball, and serves to connect the cornea and sclerotic, at their line of junction, with the iris and external layer of the choroid. It is also the point to which the ciliary nerves and vessels proceed previously to their distribution, and it receives the anterior ciliary arteries through the anterior margin of the sclerotic. A minute vascular canal is situated within the ciliary ligament, called the ciliary canal, or canal of Fontana,² from its discoverer.

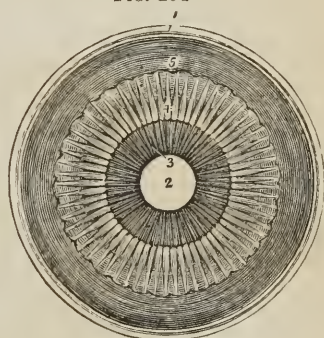
The *Iris* (iris, a rainbow) is so named from its variety of color in different individuals; it forms a septum between the anterior and posterior chamber of the eye, and is pierced somewhat to the nasal side of its centre by a circular opening, which is called the *pupil*. By its periphery it is connected with the ciliary ligament, and by its inner circumference forms the margin of the pupil; its anterior surface looks towards the cornea, the posterior towards the ciliary processes and lens.

The iris is composed of two layers, an *anterior* or *muscular layer*, consisting of *radiating* fibres which converge from the circumference towards the centre, and have the power of dilating the pupil; and *circular* fibres which surround the pupil like a sphincter, and by their action produce contraction of its area. The *posterior layer* is of a deep purple tint, and is thence named *uvea*, from its resemblance in color to a ripe grape.

The *Ciliary processes* (*corpus ciliare*) may be seen in two ways, either by removing the iris from its attachment to the ciliary ligament, when a front view of the processes will be obtained, or by making a transverse section through the globe of the eye, when they may be examined from behind, as in Fig. 294.

They consist of a number of triangular folds, formed apparently by the plaiting of the middle and internal layer of the choroid. According to Zinn, they are about sixty in number, and may be divided into large and small, the latter being situated in the spaces between the former. Their periphery is connected with the ciliary ligament, and is continuous with the middle and internal layer of the choroid. The central border is free, and rests against the circumference

FIG. 294



ANTERIOR SEGMENT OF A TRANSVERSE SECTION OF THE GLOBE OF THE EYE, SEEN FROM WITHIN. 1. Divided edge of the three tunics; sclerotic, choroid (the dark layer), and retina. 2. Pupil. 3. Iris, the surface presented to view in this section being the uvea. 4. Ciliary processes. 5. The scalloped anterior border of the retina.

¹ Ruysch was born at the Hague in 1638, and was appointed Professor of Anatomy at Amsterdam in 1665. His whole life was employed in making injected preparations, for which he is justly celebrated, and he died at the advanced age of ninety-three years; having come to the conclusion that the body was entirely made up of vessels.

² Felix Fontana, an anatomist of Tuscany. His "Description of a New Canal in the Eye" was published in 1778, in a Letter to the Professor of Anatomy in Upsal.

of the lens. The anterior surface corresponds with the uvea; the posterior receives the folds of the zonula ciliaris between its processes, and thus establishes a connexion between the choroid and the third tunic of the eye. The ciliary processes are covered with a thick layer of pigmentum nigrum, which is more abundant on them and the anterior part of the choroid, than at the posterior part of the latter. When the pigment is washed off, the processes are of a whitish color.

THIRD TUNIC. — The third tunic of the eye is the *retina*, which is prolonged forwards to the lens by the *zonula ciliaris*.

Dissection. — If, after the preceding dissection, the choroid membrane be carefully raised and removed, the eye being kept under water, the retina may be seen very distinctly. [To do this, a small opening is to be made in the choroid coat, near the entrance of the optic nerve, with the point of the scalpel, being careful not to incise the retina. If the edges of this opening are now seized by two pairs of forceps, and traction be gently made, the choroid will peel off from the retina beneath, sometimes without additional aid, but occasionally the scissors may be used to clip off detached portions; as the anterior part of the ball is reached, the ciliary processes will be drawn out from the zonula of Zinn, and the second tunic will be entirely removed, leaving behind the third tunic fully exposed.]

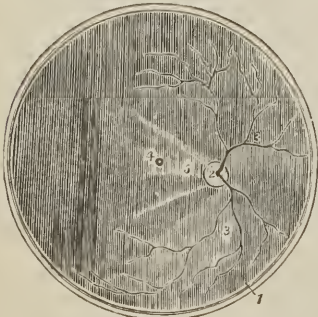The *Retina* is composed of three layers:—

<i>External,</i>	or Jacob's membrane,
<i>Middle,</i>	Nervous membrane,
<i>Internal,</i>	Vascular membrane.

Jacob's membrane is extremely thin, and is seen as a mere film when the freshly-dissected eye is suspended in water. Examined by the microscope, it is found to be composed of cells having a tessellated arrangement. Dr. Jacob considers it to be a serous membrane.

The *Nervous membrane* is the expansion of the optic nerve, and forms a thin semi-transparent bluish-white layer, which envelops the vitreous humor, and extends forwards to the commencement of the ciliary processes, where it terminates by an abrupt scalloped margin [*margo dentatus*]. According to Trevisanus, this layer is composed of cylindrical fibres, which proceed from the optic nerve, and, near their termination, bend abruptly inwards, to form the internal papillary layer, which lies in contact with the hyaloid membrane; each fibre constituting by its extremity a distinct papilla.

FIG. 295.



POSTERIOR SEGMENT OF A TRANSVERSE SECTION OF THE GLOBE OF THE EYE, SEEN FROM WITHIN. 1. Divided edge of the three tunics. The membrane covering the whole internal surface is the retina. 2. The entrance of the optic nerve with the arteria centralis retinae piercing its centre. 3, 3. Ramifications of the arteria centralis. 4. Foramen of Soemmering, in the centre of the axis of the eye; the shade from the sides of the section obscures the limbus luteus which surrounds it. 5. A fold of the retina, which generally obscures the foramen of Soemmering after the eye has been opened.

The *Vascular membrane* consists of the ramifications of a minute artery, arteria centralis retinae, and its accompanying vein; the artery pierces the optic

nerve, and enters the globe of the eye through the porus opticus, in the centre of the lamina cribrosa. This artery may be seen by making a transverse section of the eyeball. Its branches are continued anteriorly into the zonula ciliaris. The vascular layer forms distinct sheaths for the nervous papillæ, which constitute the inner surface of the retina.

In the centre of the posterior part of the globe of the eye, the retina presents a circular spot, which is called the *foramen of Soemmering*;¹ it is surrounded by a yellow halo, the *limbus luteus*, and is frequently obscured by an elliptical fold of the retina, which has been regarded as a normal condition of the membrane. The term foramen is misapplied to this spot, for the vascular layer and the membrana Jacobi are continued across it; the nervous substance alone appearing to be deficient. It exists only in animals having the axes of the eyeballs parallel with each other, as man, quadrumana, and some saurian reptiles, and is said to give passage to a small lymphatic vessel.

The *Zonula ciliaris* (zonula of Zinn)² is a thin vascular layer, which connects the anterior margin of the retina with the anterior surface of the lens, near its circumference. It presents at its surface a number of small folds corresponding with the ciliary processes, between which they are received. These processes are arranged in the form of rays around the lens, and the spaces between them are stained by the pigmentum nigrum of the ciliary processes; they derive their vessels from the vascular layer of the retina. The under surface of the zonula is in contact with the hyaloid membrane, and around the lens forms the anterior fluted wall of the *canal of Petit*.

The connexion between these folds and the ciliary processes may be demonstrated by dividing an eye transversely into two portions, then raising the anterior half, and allowing the vitreous humor to separate from its attachment by its own weight. The folds of the zonula will be seen to be drawn out from between the folds of the ciliary processes.

HUMORS.—The *Aqueous humor* is situated in the anterior and posterior chamber of the eye; it is a weakly-albuminous fluid, with an alkaline reaction, and a specific gravity very little greater than that of distilled water. According to Petit, it scarcely exceeds four or five grains in weight.

The *anterior chamber* is the space intervening between the cornea in front, and the iris and pupil behind. The *posterior chamber* is the narrow space less than half a line in depth,³ bounded by the posterior surface of the iris and pupil in front, and by the ciliary processes, zonula ciliaris, and lens behind. The two chambers are lined by a thin layer, the *secreting membrane of the aqueous humor*.

The *Vitreous humor* forms the principal bulk of the globe of the eye. It is an albuminous and highly transparent fluid, inclosed in a delicate membrane, the *hyaloid*. From the inner surface of this membrane, numerous thin lamellæ are directed inwards, and form compartments in which the fluid is contained. According to Hannover, these lamellæ have a radiated arrangement, like those of the transverse section of an orange, and are about 180 in number. In the centre of the vitreous humor is a tubular canal, through which a minute artery is conducted from the arteria centralis retinae to the capsule of the lens. This vessel is injected without difficulty in the fœtus.

¹ Samuel Thomas Soemmering is celebrated for the beautiful and accurate plates which accompany his works. The account "De Foramine Centrali Retinae Humanæ, Limbo Luteo cincto," was published in 1779, in the *Commentationes Soc. Reg. Scient. Göttingensis*.

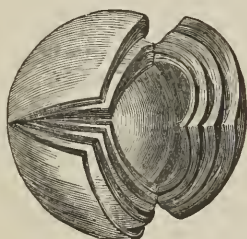
² John Gottfried Zinn, Professor of Anatomy in Göttingen: his "Descriptio Anatomica Oculi Humani," was published in 1755; with excellent plates. It was republished by Wrisberg in 1780.

³ Winslow and Lieutaud thought the iris to be in contact with the lens; it frequently adheres to the capsule of the latter in iritis. The depth of the posterior chamber is greater in old than in young persons.

The *Crystalline humor* or *lens* is situated immediately behind the pupil, and surrounded by the ciliary processes, which slightly overlap its margin. It is more convex on the posterior than on the anterior surface, and is imbedded in the anterior part of the vitreous humor, from which it is separated by the hyaloid membrane. It is invested by a peculiarly transparent and elastic membrane, the capsule of the lens, which contains a small quantity of fluid, called *liquor Morgagni*,¹ and is retained in its place by the attachment of the zonula ciliaris. Dr. Jacob is of opinion that the lens is connected to its capsule by means of areolar tissue, and that the liquor Morgagni is the result of a cadaveric change.

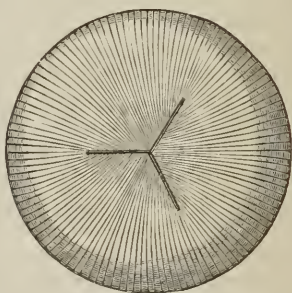
The lens consists of concentric layers, of which the external are soft, the next firmer, and the central form a hardened nucleus. They are best demonstrated

[FIG. 296.]



CRYSTALLINE LENS hardened in spirit and partially divided along the three interior planes, as well as into lamellæ — Magnified $3\frac{1}{2}$ diameters.]

[FIG. 297.]



TRIPLE DIVISION OF THE LENS AND THE COURSE OF ITS FIBRES.]

by boiling, or by immersion in alcohol, when they separate easily from each other. Another division of the lens takes place at the same time: it splits into three triangular segments, having the sharp edge directed towards the centre, and the base towards the circumference. The concentric lamellæ are composed of minute parallel fibres, united with each other by means of scalloped borders, the convexity of one border fitting the concave scallop of the other.

Immediately around the circumference of the lens is a triangular canal, the *canal of Petit*,² about a line and a half in breadth. It is bounded, in front, by the flutings of the zonula ciliaris; behind, by the hyaloid membrane; and within, by the border of the lens.

VESSELS AND NERVES. — The *Vessels* of the globe of the eye are the long, short, and anterior ciliary arteries, and the arteria centralis retinae. The *long ciliary arteries*, two in number, pierce the posterior part of the sclerotic, and pass forwards on each side, between that membrane and the choroid, to the ciliary ligament, where each divides into two branches, which are distributed to the iris. The *short ciliary arteries* pierce the posterior part of the sclerotic coat, and are distributed to the middle layer of the choroid membrane. The *anterior ciliary* are branches of the muscular arteries. They enter the eye through the anterior part of the sclerotic, and are distributed to the iris. It is the increased number of these latter arteries, in iritis, that gives rise to the peculiar red zone around the circumference of the cornea.

The *Arteria centralis retinae* enters the optic nerve at about half an inch from

¹ John Baptist Morgagni was born in 1682. He was appointed Professor of Medicine in Bologna, and published the first part of his "Adversaria Anatomica," in 1706. He died in 1771.

² John Louis Petit, a celebrated French surgeon: he published several surgical and anatomical Essays, in the early part of the 18th century. He died in 1750.

the globe of the eye, and passing through the porus opticus, is distributed on the inner surface of the retina, forming its vascular layer; one branch pierces the centre of the vitreous humor, and supplies the capsule of the lens.

The *Nerves* of the eyeball are, the optic, two ciliary nerves from the nasal branch of the ophthalmic, and the ciliary nerves from the ophthalmic ganglion.

Observations.—The sclerotic is a tunic of protection, and the cornea a medium for the transmission of light. The choroid supports the vessels destined for the nutrition of the eye, and by its pigmentum nigrum absorbs all scattered rays that might confuse the image impressed on the retina. The iris, by means of its powers of expansion and contraction, regulates the quantity of light admitted through the pupil. If the iris be thin, and the rays of light pass through its substance, they are absorbed by the uvea; and if that layer be insufficient, they are taken up by the black pigment of the ciliary processes. In Albinoes, where there is an absence of pigmentum nigrum, the rays of light traverse the iris, and even the sclerotic, and so overwhelm the eye with light, that sight is destroyed, except in the dimness of evening or at night. In the manufacture of optical instruments, care is taken to color their interior black, with the same object, the absorption of scattered rays.

The transparent lamellated cornea and the humors of the eye have for their office the refraction of the rays in such proportion as to direct the image in the most favorable manner upon the retina. Where the refracting medium is too great, as in over convexity of the cornea and lens, the image falls short of the retina; (myopia, near-sightedness); and where it is too little, the image is thrown beyond the nervous membrane (presbyopia, far-sightedness). These conditions are rectified by the use of spectacles, which provide a differently refracting medium externally to the eye, and thereby correct the transmission of light.

APPENDAGES OF THE EYE.

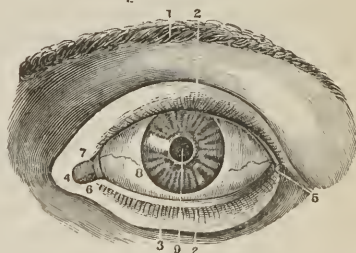
The *Appendages of the Eye* (*tutamina oculi*) are, the eyebrows, eyelids, eyelashes, conjunctiva, caruncula lachrymalis, and the lachrymal apparatus.

The *Eyebrows* (*supercilia*) are two prominent arches of integument covered with short thick hairs, which form the upper boundary of the orbits. They are connected beneath with the orbiculares, occipito-frontales, and corrugatores superciliorum muscles; their use is to shade the eyes from too vivid a light, or protect them from particles of dust and moisture rolling down the forehead.

The *Eyelids* (*palpebræ*) are two valvular layers placed in front of the eye, serving to defend it from injury by their closure. When drawn open, they leave between them an elliptical space (*fissura palpebrarum*), the angles of which are called *canthi*. The outer canthus is formed by the meeting of the two lids at an acute angle. The inner canthus is prolonged for a short distance inwards towards the nose, and a triangular space is left between the lids in this situation, which is called the *lacus lachrymalis*.

At the commencement of the lacus lachrymalis upon each of the two lids is a small angular projection, the *lachrymal papilla* or *tubercle*: and at the apex of

[FIG. 298.]



A FRONT VIEW OF THE LEFT EYE, MODERATELY OPENED.—1. The supercilia. 2. The cilia of each eyelid. 3. The inferior palpebra. 4. The internal canthus. 5. The external canthus. 6. The caruncula lachrymalis. 7. The plica semilunaris. 8. The eyeball. 9. The pupil.]

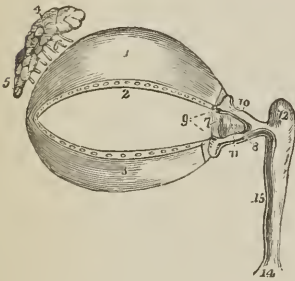
each papilla a small orifice (punctum lachrymale), the commencement of the lachrymal canal.

The eyelids have, entering into their structure, *integument, orbicularis muscle, tarsal cartilages, Meibomian glands, and conjunctiva.*

The tegumentary areolar tissue of the eyelids is remarkable for its looseness and absence of adipose substance; it is particularly liable to serous infiltration. The fibres of that portion (palpebralis) of the orbicularis muscle which covers the eyelids are thin and pale.

The *Tarsal cartilages* are two thin lamellæ of fibro-cartilage, about an inch in length, which give form and support to the eyelids. The *Superior* is of a semi-lunar form, about one-third of an inch in breadth at its middle, and tapering to each extremity. Its lower border is broad and flat, its upper thin, and gives attachment to the levator palpebræ and to the fibrous membrane of the lids.

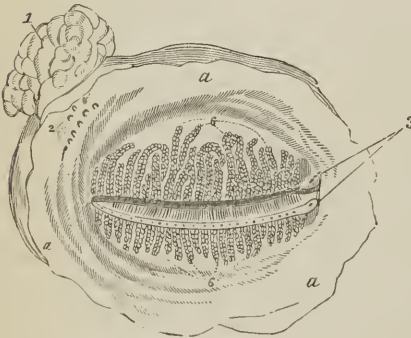Fig. 299.



APPENDAGES OF THE EYE. 1. Superior tarsal cartilage. 2. Lower border of the cartilage on which are seen the openings of the Meibomian glands. 3. Inferior tarsal cartilage; along the upper border of this cartilage the openings of the Meibomian glands are likewise seen. 4. Lachrymal gland; its superior or orbital portion. 5. Inferior or palpebral portion. 6. Lachrymal ducts. 7. Plica semilunaris. 8. Caruncula lachrymalis. 9. Puncta lachrymalia of the lachrymal canals. 10. Superior lachrymal canal. 11. Inferior lachrymal canal. 12. Lachrymal sac. 14. Dilatation of the nasal duct, where it opens into the inferior meatus of the nose. 15. Nasal duct.

The *Inferior fibro-cartilage* is an elliptical band, narrower than the superior, and situated in the substance of the lower lid. Its upper border is flat, and corresponds with the flat edge of the upper cartilage. The lower is held in its place by the fibrous membrane.

Fig. 300.



MEIBOMIAN GLANDS, SEEN FROM THE INNER OR OCULAR SURFACE OF THE EYELIDS, WITH THE LACHRYMAL GLAND—THE LEFT SIDE. a, a, a. Palpebral conjunctiva. 1. Lachrymal gland. 2. Openings of lachrymal ducts. 3. Lachrymal puncta. 6, 6. Meibomian glands; their apertures are seen forming a row along the free border of each eyelid.

Near the inner canthus the tarsal cartilages terminate, at the commencement of the lacus lachrymalis, and are attached to the margin of the orbit by the tendo oculi. At their outer extremity they terminate at a short distance from the angle of the canthus, and are retained in position by means of a decussation of the fibrous structure of the broad tarsal ligament, called the *external palpebral* or *external tarsal ligament.*

The *Fibrous membrane* of the lids is firmly attached to the periosteum, around the margin of the orbit, by its circumference, and to the tarsal cartilages by its central margin. It is thick and dense for the outer half of the orbit, but becomes thin to its inner side. Its use is to retain the tarsal cartilages in their place, and give support to the lids; hence it is named the *broad tarsal ligament.*

The *Meibomian glands*¹ are imbedded in the substance of the cartilages, and are distinctly seen on examining the inner aspect of the lids. They have the appearance of parallel strings of pearls, about thirty in number in the upper cartilage, and somewhat fewer in the lower; and open by minute foramina on the edges of the lids. They correspond in length with the breadth of the cartilage, and are consequently longer in the upper than in the lower lid.

Each gland consists of a single lengthened follicle or tube, into which a number of small clustered glandular vesicles open; the latter being so numerous as almost to conceal the tube by which the secretion is poured out on the margin of the lids. Occasionally an arch is formed between two of the follicles, and produces a graceful appearance.

The edges of the eyelids are furnished with a triple row of long thick hairs, which curve upwards from the upper lid, and downwards from the lower, so as not to interlace with each other in the closure of the eyelids, and prove an impediment to the opening of the eyes. These are the *eyelashes (cilia)*, important organs of defence to the sensitive surface of so delicate a structure as the eye. Their follicles are supplied with sebiparous glands like those of other hairs.

The *Conjunctiva* is the mucous membrane of the eye. It covers the whole of its anterior surface, and is then reflected upon the lids so as to form their internal layer. The duplicatures formed between the globe of the eye and the lids are called the *superior and inferior palpebral sinuses*, the former being deeper than the latter. Where it covers the cornea, the conjunctiva is thin and closely adherent, and no vessels can be traced into it. On the sclerotica it is thicker and less adherent, and on the inner surface of the lids is very closely connected, and exceedingly vascular. It is continuous with the general gastro-pulmonary mucous membrane, and sympathizes in its affections, as may be observed in various diseases. From the surface of the eye it may be traced through the lachrymal ducts into the lachrymal gland; along the edges of the lids it is continuous with the mucous lining of the Meibomian glands, and at the inner angle of the eye it may be followed through the lachrymal canals into the lachrymal sac, and thence downwards through the nasal duct into the inferior meatus of the nose.

The *Caruncula lachrymalis* is the small reddish body which occupies the lacus lachrymalis at the inner canthus of the eye. In health it presents a bright pink tint; in sickness it loses its color, and becomes pale. It consists of an assemblage of follicles similar to the Meibomian glands, imbedded in a fibro-cartilaginous tissue, and is the source of the whitish secretion which so constantly forms at the inner angle of the eye. It is covered with minute hairs, which are sometimes so long as to be visible to the naked eye.

Immediately to the outer side of the caruncula is a slight duplicature of the conjunctiva, called *plica semilunaris*, which contains a minute plate of cartilage, and is the rudiment of the third lid of animals, the *membrana nictitans* of birds.

Vessels and Nerves.—The palpebræ are supplied internally with *arteries* from the ophthalmic, and externally from the facial and transverse facial. Their *nerves* are branches of the fifth and facial.

Lachrymal Apparatus.

The *Lachrymal apparatus* consists of the lachrymal gland with its excretory ducts; the puncta lachrymalia and lachrymal canals; the lachrymal sac and nasal duct.

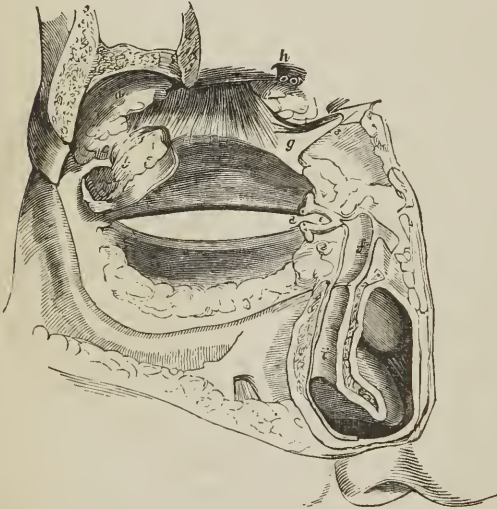
The *Lachrymal gland* is situated at the upper and outer angle of the orbit, and consists of two portions, orbital and palpebral. The *orbital portion*, about

¹ Henry Meibomius, "De Vasis Palpebrarum Novis," 1666.

three-quarters of an inch in length, is flattened and oval in shape, and occupies the lachrymal fossa of the orbital plate of the frontal bone. It is in contact superiorly with the periosteum, with which it is closely connected by its upper and convex surface; by its inferior or concave surface it is in relation with the globe of the eye, and the superior and external rectus; and by its anterior border with the broad tarsal ligament. By its posterior border it receives its vessels. The *palpebral portion*, smaller than the preceding, is situated in the upper eyelid, extending downwards to the superior margin of the tarsal cartilage. It is connected with the orbital portion above, and is inclosed in an investment of dense fibrous membrane. The secretion of the lachrymal gland is conveyed away by from eight to twelve small ducts which run for a short distance beneath the conjunctiva, and open on its surface by a series of pores, about one-twentieth of an inch apart, situated in a curved line a little above the upper border of the tarsal cartilage.

Lachrymal canals [canaliculi lachrymales].—The lachrymal canals commence at the minute openings, puncta lachrymalia, seen on the lachrymal papillæ of the lids at the outer extremity of the lacus lachrymalis, and proceed inwards to

[FIG. 301.]



LACHRYMAL APPARATUS AND NASAL DUCT. — *a, b, c.* Lachrymal gland and its appendage. *d.* Puncta lachrymalia. *e.* Lachrymal canals. *f.* Nasal duct laid open. *g.* Tendon of superior oblique muscle after being reflected. *h.* Supraorbital foramen; the artery, vein, and nerve have been cut across. *i.* Interior of nasal duct near its termination in the inferior meatus.]

The *Lachrymal sac* is the upper extremity of the nasal duct, and is scarcely more dilated than the rest of the canal. It is lodged in the groove of the lachrymal bone, and is often distinguished internally, from the nasal duct, by a semi-lunar or circular valve. The sac consists of mucous membrane, but is covered in and retained in its place by a fibrous expansion, derived from the tendon of the orbicularis, which is inserted into the ridge of the lachrymal bone; it is also covered by the tensor tarsi muscle, which arises from the same ridge, and in its action on the lachrymal canals makes pressure on the lachrymal sac.

The *Nasal duct* [ductus ad nasum,] is a short canal, about three-quarters of an inch in length, directed downwards, backwards, and a little outwards to the

the lachrymal sac, where they terminate beneath a valvular semilunar fold of the lining membrane. The *superior duct* at first ascends, and then turns suddenly inwards towards the sac, forming an abrupt angle. The *inferior duct* forms the same kind of angle, by descending at first, and then turning abruptly inwards. They are dense and elastic in structure, and, being constantly open, act like capillary tubes in absorbing the tears from the surface of the eye. The two fasciculi of the tensor tarsi muscle are inserted into these ducts, and serve to draw them inwards.

The *Lachrymal sac* is the upper extremity of the nasal duct, and is scarcely more dilated than the rest of the canal. It is lodged in the groove of the lachrymal bone, and is often distinguished internally, from the nasal duct, by a semi-

inferior meatus of the nose, where it terminates by an expanded orifice [often guarded by a valvular fold of the lining membrane]. It is lined by mucous membrane, which is continuous with the conjunctiva above, and with the pituitary membrane of the nose below. Obstruction, from inflammation and suppuration of this duct, constitutes the disease termed *fistula lachrymalis*.

Vessels and Nerves.—The lachrymal gland is supplied with blood by the lachrymal branch of the ophthalmic artery, and with nerves by the lachrymal branch of the ophthalmic nerve.

ORGAN OF HEARING.

The apparatus of hearing is composed of three parts, external ear, middle ear or tympanum, and internal ear or labyrinth.

EXTERNAL EAR.

The *external ear* consists of two portions, the *pinna* and *meatus*; the former representing a kind of funnel which collects the vibrations of the atmosphere producing sounds, and the latter a tube which conveys the vibrations to the tympanum.

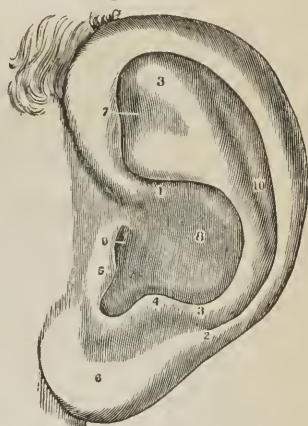
The PINNA [or auricle], presents a number of folds and hollows on its surface, which have different names assigned to them. Thus, the external folded margin is the *helix* (ἑλιξ, a fold). The elevation parallel with and in front of the helix is the *antihelix* (ἀντι, opposite). The pointed process, projecting like a valve over the opening of the ear, from the face, is the *tragus* (τράγος, a goat), probably from being sometimes covered with bristly hair like that of a goat; and, a tubercle opposite this, is the *antitragus*; [the notch between them is the *incisura intertragica* or notch of the concha]. The lower dependent and fleshy portion of the pinna is the *lobulus*. The space between the helix and antihelix is named the *fossa innominata* (*scaphoidea*). Another depression at the upper extremity of the antihelix, produced by a bifurcation of that ridge, is the *fossa triangularis* (*ovalis*); and the large central space, to which all the channels converge, the *concha*, which opens directly into the *meatus*.

The pinna is composed of *integument*, *fibro-cartilage*, *ligaments*, and *muscles*.

The *Integument* is thin, contains an abundance of sebiparous glands and is closely connected with the fibro-cartilage.

The *Fibro-cartilage* gives form to the pinna, and is folded so as to produce the various convexities and grooves which have been described on its surface. The *helix* begins in the concha, and partially divides that cavity into two parts; on its anterior border, where it commences its curve upwards, is a tubercle or spine, and a little above this a small vertical fissure, the *fissure of the helix*. The termination of the helix and antihelix forms a lengthened process, the *processus caudatus*, which is separated from the concha by an extensive fissure.

[FIG. 302.]



THE PINNA OF THE EXTERNAL EAR. 1. The origin, and 2, the termination of the helix. 3, 3. Antihelix. 4. Antitragus. 5. Tragus. 6. Lobulus. 7. Fossa triangularis; the cipher is on the front and top of the pinna. 8. Concha. 9. Meatus auditorius externus. 10. Fossa innominata. The incisura intertragica, extends between 4 and 5.]

On the anterior surface of the tragus is another fissure, the *fissure of the tragus*; and, in the lobulus, the fibro-cartilage is wanting. The fibro-cartilage of the meatus is divided from the concha by several fissures (fissures of Santorinus), and at the upper and anterior part of the cylinder is a considerable space, which is closed by muscular and ligamentous fibres; it is firmly attached at its termination to the processus auditorius.

The *Ligaments* of the external ear are those which attach the pinna to the side of the head [extrinsic], viz, anterior, posterior, and ligament of the tragus; and those of the fibro-cartilage [intrinsic], which serve to preserve its folds and connect the opposite margins of the fissures. The latter are two in number, the ligament between the concha and processus caudatus, and the broad ligament which extends from the upper margin of the fibro-cartilage of the tragus to the helix, and completes the meatus.

The proper [or intrinsic] *Muscles* of the pinna are the—

Major helicis,
Minor helicis,
Tragicus,

Antitragicus,
Transversus auriculæ,
Obliquus auris,

Dilatator conchæ.

FIG. 303.

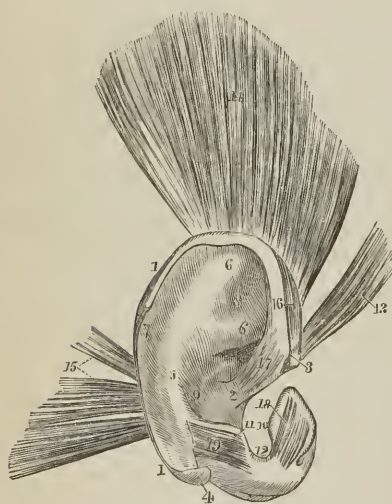
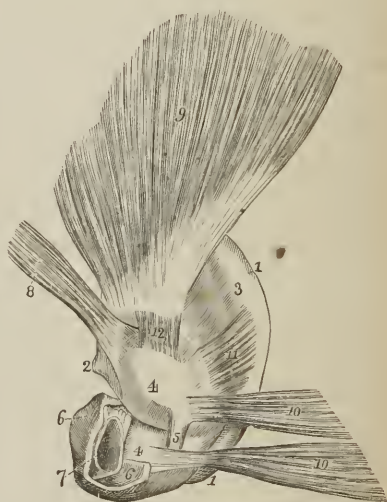


FIG. 304.



THE PINNA AND ITS MUSCLES; after Arnold. 1, 1. Helix. 2. Crus helicis. 3. Spina helicis. 4. Processus caudatus helicis. 5. Antihelix. 6, 6. Crura antihelicis. 7. Fossa innominata or scaphoidea. 8. Fossa triangularis. 9. Concha. 10. Tragus. 11. Antitragus. 12. Incisura intertragica. 13. Attrahens aurem. 14. Attollens aurem. 15. Retrahens aurem. 16. Major helicis muscle. 17. Minor helicis. 18. Tragicus. 19. Antitragicus.

THE PINNA AND ITS MUSCLES, AS SEEN FROM BEHIND; after Arnold. 1, 1. Border of the helix. 2. Spine of the helix. 3. Convexity corresponding with the fossa scaphoidea. 4, 4. Convexity of the concha; the fissure between the numbers corresponds with the crus helicis. 5. Ponticulus conchæ. 6, 6. Cartilage of the meatus. 7. Aperture of the meatus. 8. Attrahens aurem. 9. Attollens aurem. 10, 10. Retrahens aurem. 11. Transversus auriculæ. 12. Obliquus auriculæ.

The *Major helicis* is a narrow band of muscular fibres situated on the anterior border of the helix. It arises from the spine of the helix and is inserted into the anterior border of that fold.

The *Minor helix* is placed upon the anterior extremity (crus) of the helix, at its commencement in the fossa of the concha.

The *Tragicus* is a thin quadrilateral layer of muscular fibres, situated on the tragus.

The *Antitragicus* arises from the antitragus, and is inserted into the posterior surface of the processus caudatus of the helix.

The *Transversus auriculæ*, partly tendinous and partly muscular, extends transversely from the convexity of the concha to that of the helix, on the posterior surface of the pinna.

The *Obliquus auris* (Tod) is a small band of fibres passing between the upper part of the convexity of the concha and the convexity immediately above it.

The *Dilatator conchæ* is a thin band of muscular fibres which crosses the fissure between the cartilage of the meatus and tragus on its anterior aspect.

Tod¹ describes, besides, a contractor meatûs, or trago-helicus muscle.

The MEATUS AUDITORIUS [externus] is a canal, partly cartilaginous and partly osseous, about an inch in length, which extends inwards and a little forwards from the concha to the tympanum. It is narrower in the middle than at each extremity, forms an oval cylinder, the long diameter being vertical, and is slightly curved on itself, the concavity looking downwards.

It is lined by an extremely thin pouch of epithelium, which, when withdrawn after maceration, preserves the form of the meatus. Some stiff short hairs are also found in its interior, which stretch across the tube, and prevent the ingress of insects and dust. In the substance of its lining membrane are a number of *ceruminous glands*, which secrete the wax of the ear.

Vessels and Nerves.—The pinna is plentifully supplied with *arteries*: by the anterior auricular from the temporal, by the posterior auricular from the external carotid, and by a branch from the occipital artery.

Its *Nerves* are derived from the auriculo-temporal of the fifth, the posterior auricular of the facial, and the auricularis magnus of the cervical plexus.

MIDDLE EAR, OR TYMPANUM.

The *tympanum* is an irregular bony cavity, compressed from without inwards, and situated within the petrous bone. It is bounded *externally* by the meatus and membrana tympani; *internally*, by the base of the petrous bone, [labyrinth]; *behind*, by the mastoid cells; and, throughout the rest of its circumference, by the thin osseous layer which connects the petrous with the squamous portion of the temporal bone.

The *Membrana tympani* is a thin and semi-transparent membrane of an oval shape, its long diameter being vertical. It is inserted into a groove situated around the circumference of the meatus, near its termination, and is placed obliquely across the area of that tube, the direction of the obliquity being downwards and inwards. It is concave towards the meatus, convex towards the tympanum, and composed of *three layers*, *external*, or epithelial; *middle*, fibrous and muscular; and *internal*, mucous, derived from the mucous lining of the tympanum.

The tympanum contains three small bones, *ossicula auditûs*, viz., the malleus, incus, and stapes.

The *Malleus* (*hammer*) consists of a head, neck, handle (*manubrium*), and two processes, *long* (*processus gracilis*) [*process of Raw*], and *short* (*processus brevis*). The manubrium is connected with the membrana tympani by its whole length, extending below the central point of that membrane. It lies beneath the mucous layer of the membrane, and serves as a point of attachment to which

¹ "The Anatomy and Physiology of the Organ of Hearing," by David Tod. 1832.

the radiating fibres of the fibrous layer converge. The long process descends to a groove near the fissura Glaseri, and gives attachment to the laxator tympani muscle. Into the short process is inserted the tendon of the tensor tympani; and the head of the bone articulates with the incus.

FIG. 305.

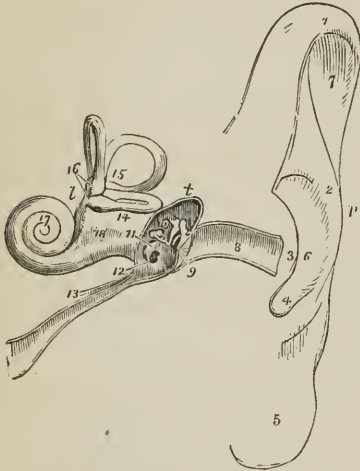


DIAGRAM OF THE EAR. *p.* Pinna. *t.* Tympanum. *l.* Labyrinth. 1. Upper part of the helix. 2. Antihelix. 3. Tragus. 4. Antitragus. 5. Lobulus. 6. Concha. 7. Upper part of the fossa scaphoidea. 8. Meatus. 9. Membrana tympani, divided by the section. 10. The three little bones, crossing the area of the tympanum, malleus, incus, and stapes; the foot of the stapes blocks up the fenestra ovalis of the inner wall of the tympanum. 11. Promontory. 12. Fenestra rotunda; the dark opening above the ossicula leads into the mastoid cells. 13. Eustachian tube; the little canal upon this tube contains the tensor tympani muscle in its passage to the tympanum. 14. Vestibule. 15. Three semicircular canals, horizontal, perpendicular, and oblique. 16. Ampullæ of the perpendicular and horizontal canal. 17. Cochlea. 18. Depression between the two tubuli which communicate with the tympanum and vestibule; the one is the scala tympani, terminating at 12, the other the scala vestibuli.

The *Incus* (*anvil*) is named from an imagined resemblance to an anvil. It has also been likened to a bicuspid tooth, having one root longer than, and widely separated from, the other. It consists of two processes, united nearly at right angles, and at their junction forming a flattened body, which articulates with the head of the malleus. The short process is attached to the margin of the opening of the mastoid cells by means of a ligament; the long process descends nearly parallel with the handle of the malleus, and curves inwards, near its termination. At its extremity is a small globular projection, the *os orbiculare*, which in the fœtus is a separate piece, but becomes ankylosed to the long process of the incus in the adult; this process articulates with the head of the stapes.

The *Stapes* is shaped like a stirrup, to which it bears a close resemblance. Its head articulates with the os orbiculare, and the two branches (*crura*) are connected by their extremities with a flat, oval-shaped plate, representing the foot of the stirrup. The foot of the stirrup is received into the fenestra ovalis, to the margin of which it is connected by means of a ligament; it is in contact, by its surface, with the membrana vestibuli, and is covered in by the mucous lining of the tympanum. The neck of the stapes gives attachment to the stapedius muscle.

The ossicula auditûs are retained in position, and moved upon themselves, by means of ligaments and muscles.

The *Ligaments* are three in number: the *suspensory ligament* of the malleus, which is attached by one extremity to the upper wall of the tympanum, and by the other to the head of the malleus; the *posterior ligament* of the incus, a short and thick band, which serves to attach the extremity of the short process of that bone to the margin of the opening of the mastoid cells; and the *annular ligament* which connects the margin of the foot of the stapes with the circumference of the fenestra ovalis. These ligaments have been described as muscles, by Tod, under the names of superior capitis mallei, obliquus incudis externus posterior, and musculus vel structura stapedii inferior. Arnold adds, as a fourth, a suspensory ligament of the incus.

The *Muscles* of the *tympaanum* are four in number, the—

Tensor tympani, ¹	Laxator tympani minor,
Laxator tympani,	Stapedius.

The *Tensor tympani* (*musculus internus mallei*), *arises* from the spinous process of the sphenoid, the petrous portion of the temporal bone, and the Eustachian tube, and passes forwards in a distinct canal, separated from the tube by the *processus cochleariformis*, to be *inserted* into the handle of the malleus, immediately below the root of the *processus gracilis*.

The *Laxator tympani* (*musculus externus mallei*), *arises* from the spinous process of the sphenoid bone, and passes through an opening in the *fissura Glaseri*, to be *inserted* into the neck of the malleus, just above the root of the *processus gracilis*. This is regarded as a ligament (anterior ligament of the malleus) by some anatomists.

The *Laxator tympani minor* (posterior ligament of the malleus), *arises* from the upper margin of the meatus, and is *inserted* into the handle and *processus brevis* of the malleus. This is regarded as a ligament by some anatomists.

The *Stapedius*, *arises* from the interior of the pyramid, and escapes, from its summit to be *inserted* into the neck of the stapes.

Foramina.—The openings in the tympanum are ten in number, *five large* and *five small*; they are—

Large openings.

Meatus auditorius [externus],
Fenestra ovalis,
Fenestra rotunda,
Mastoid cells,
Eustachian tube.

Small openings.

Entrance of chorda tympani,
Exit of chorda tympani,
For the laxator tympani,
For the tensor tympani,
For the stapedius.

The opening of the *meatus auditorius [externus]*, has been already described.

The *Fenestra ovalis* (*fenestra vestibuli*) is a reniform opening, situated at the bottom of a small oval fossa (*pelvis ovalis*), in the upper part of the inner wall of the tympanum, directly opposite the meatus. The long diameter of the fenestra is horizontal, and its convex borders directed upwards. It is the opening of communication between the tympanum and vestibule, and is closed by the foot of the stapes and by the lining membrane of both cavities.

The *Fenestra rotunda* (*fenestra cochleæ*) is somewhat triangular in form, and situated in the inner wall of the tympanum, below and rather posteriorly to the fenestra ovalis, from which it is separated by a bony elevation, called the *promontory*. It serves to establish a communication between the tympanum and cochlea. In the fresh subject it is closed by a proper membrane (*m. tympani secundaria*) as well as by the lining of both cavities.

The *Mastoid cells* are numerous, and occupy the whole of the interior of the mastoid process and part of the petrous bone. They communicate by a large irregular opening with the upper and posterior circumference of the tympanum.

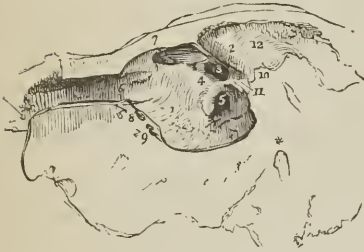
The *Eustachian tube* is a short canal about an inch and three-quarters in length, extending obliquely between the pharynx and the anterior circumference of the tympanum. In structure it is partly fibro-cartilaginous and partly osseous, is broad and expanded at its pharyngeal extremity, and narrow and compressed at the tympanum.

The *Smaller openings* serve for the transmission of the chorda tympani nerve, and three of the muscles of the tympanum.

¹[The proper nomenclature of these muscles would seem to be that of Soemmering, viz: *tensor membranæ tympani*, &c.]

The *opening* by which the *chorda tympani* enters the tympanum is at about the middle of its *posterior wall*, and near the root of the pyramid. The *opening of exit* for the *chorda tympani* is at the *fissura Glaseri* in the *anterior wall* of the tympanum.

[Fig. 306.]



THE TYMPANUM OF THE LEFT EAR.—1. Its inner wall. 2. A convex ridge marking the situation of the aquæductus Fallopii; the star shows its termination on the face of the section, in its course downwards to the stylo-mastoid foramen. 3. The fenestra ovalis. 4. The promontory. 5. The fenestra rotunda. Anteriorly, 6, is the entrance of the Eustachian tube. 7. The opening for the tensor tympani. 8. The opening for the laxator tympani. 9. The opening of exit for the *chorda tympani* nerve. Posteriorly, 10, is the opening of entrance for the *chorda tympani*; and, 11, the pyramid with the small opening at its apex which gives passage to the tendon of the stapedius muscle. Superiorly is a large opening, 12, leading backwards to the mastoid cells.]

The *opening* for the *laxator tympani* muscle is also situated in the *fissura Glaseri*, in the *anterior wall* of the tympanum. The *opening* for the *tensor tympani* muscle is in the *inner wall*, immediately above the opening of the Eustachian tube. The *opening* for the *stapedius* muscle is at the apex of a conical bony eminence, the pyramid, which is situated on the *posterior wall* of the tympanum, immediately behind the fenestra ovalis.

Directly above the fenestra ovalis is a rounded ridge formed by the projection of the aquæductus Fallopii. Beneath the fenestra ovalis and separating it from the fenestra rotunda is the promontory, a rounded prominence formed by the projection of the first turn of the cochlea. It is channeled on its surface by three small grooves, which lodge the three tympanic branches of Jacobson's nerve.

The *Foramina* and *processes of the tympanum* may be arranged, according to their situation, into four groups.

1. In the *External wall* is the *mcatus auditorius [externus]*, closed by the *membrana tympani*.

2. In the *Inner wall*, from above downwards, are the—

Opening for the tensor tympani,
Ridge of the aquæductus Fallopii,
Fenestra ovalis,
Promontory, with the grooves for Jacobson's nerve,
Fenestra rotunda.

3. In the *Posterior wall* are the—

Opening of the mastoid cells,
Pyramid, and opening for the stapedius,
Opening for Jacobson's nerve,
Apertura chordæ (entrancee).

4. In the *Anterior wall* are the —

Eustachian tube,
Fissura Glaseri,
Opening for laxator tympani,
Apertura chordæ (exit).

The tympanum is lined by a *vascular mucous membrane*, which invests the ossicula and chorda tympani, and forms the internal layer of the membrana tympani. From the tympanum it is reflected into the mastoid cells, which it lines throughout, and it passes through the Eustachian tube to become continuous with the mucous membrane of the pharynx. In the Eustachian tube its epithelium is furnished with vibratile cilia.

Vessels and Nerves. — The *Arteries* of the tympanum are derived from the internal maxillary, internal carotid, and posterior auricular.

Its *Nerves* are — 1. Minute branches from the *facial*, distributed to the stapedius muscle. 2. The *chorda tympani*, which leaves the facial nerve near the stylo-mastoid foramen, and arches upwards to enter the tympanum at the root of the pyramid; it then passes forwards between the handle of the malleus and long process of the incus, to its proper opening in the fissura Glaseri. 3. The *tympanic branches of Jacobson's nerve*, which are distributed to the membranes of the fenestra ovalis and fenestra rotunda, and to the Eustachian tube, and form a plexus by communicating with the carotid plexus, otic ganglion, and Vidian nerve. 4. A filament from the otic ganglion to the tensor tympani muscle.

INTERNAL EAR, OR LABYRINTH.

The *Internal ear* is called *labyrinth*, from the complexity of its communications; it consists of a membranous and an osseous portion.

The OSSEOUS LABYRINTH presents a series of cavities, which are channeled through the substance of the petrous bone, and is situated between the cavity of the tympanum and the meatus auditorius internus. It is divisible into the—

Vestibule,

Semicircular canals,

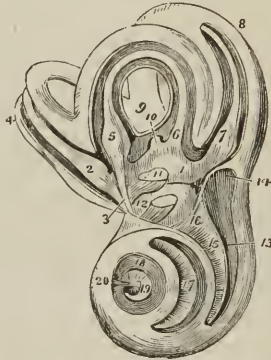
Cochlea.

The VESTIBULE is a small three-cornered cavity, compressed from without inwards, and situated immediately within the inner wall of the tympanum. The three corners, which are named *ventricles* or *cornua*, are placed, one anteriorly, one superiorly, and one posteriorly.

The Anterior ventricle receives the oval aperture of the scala vestibuli; the superior, the ampullary openings of the superior and horizontal semicircular canal; the posterior, the ampullary opening of the oblique semicircular canal, the common aperture of the oblique and perpendicular canal, the termination of the horizontal canal, and the aperture of the aquæductus vestibuli. In the *anterior ventricle* is a small depression, which corresponds with the posterior segment of the cul-de-sac of the meatus auditorius internus; it is called the *fovea hemispherica*, and is pierced by a cluster of small openings, the *macula cribrosa*. In the *superior ventricle* of the vestibule is another small depression, the *fovea elliptica*, which is separated from the fovea hemispherica by a projecting crest, the *eminentia pyramidalis*. The latter is pierced by numerous minute openings for the passage of nervous filaments. The *posterior ventricle* presents a third small depression, the *fovea sulciformis*, which leads upwards to the ostium aquæductus vestibuli. The *internal wall* of the vestibule corresponds with the bottom of the cul-de-sac of the meatus auditorius internus, and is pierced by numerous small openings for the transmission of nervous filaments. In the *ex-*

(*scalæ*) by means of a thin and porous lamina of bone (*zonula ossea laminae spiralis*), which is wound spirally around the modiolus in the direction of the canal. The bony septum extends for about two-thirds across the diameter of the canal, and in the fresh subject is prolonged to the opposite wall by means of a membranous layer, so as to constitute a complete partition, the *lamina spiralis*.¹ The osseous lamina spiralis consists of two thin lamellæ, between which, and through the perforations on their surfaces, the filaments of the cochlear nerve reach the membrane of the cochlea. At the apex of the cochlea, the [osseous] lamina spiralis terminates by a pointed, hook-shaped process, the

FIG. 309.



LABYRINTH OF THE LEFT EAR, SHOWING ITS CAVITIES AND THE MEMBRANOUS LABYRINTH; after Breschet. 1. Cavity of the vestibule; the figure rests on the common saccule of the membranous labyrinth, the saccus communis. 2. Ampulla of the perpendicular semicircular canal, receiving a fasciculus from the superior branch of the vestibular nerve, 3. 4. Perpendicular canal with its contained membranous canal. 5. Ampulla of the horizontal semicircular canal, receiving a fasciculus from the superior branch of the vestibular nerve. 6. Termination of the membranous canal of the horizontal semicircular canal in the saccus communis. 7. Ampulla of the oblique semicircular canal, receiving a fasciculus from the inferior branch of the vestibular nerve. 8. Oblique semicircular canal with its membranous canal. 9. The common canal, resulting from the union of the perpendicular with the oblique semicircular canal. 10. Membranous common canal terminating in the saccus communis. 11. The otoconite of the saccus communis seen through the membranous parietes. A fasciculus from the inferior branch of the vestibular nerve distributed to the saccus communis near the otoconite. The portion of the saccus above the otoconite is lodged in the superior ventricle of the vestibule, and that below it in the inferior ventricle. 12. Saccus proprius situated in the anterior ventricle; its otoconite is seen through its membranous parietes, and a fasciculus derived from the middle branch of the vestibular nerve is distributed to it. The spaces around the membranous labyrinth are occupied by the aqua labyrinthi. 13. First turn of the cochlea; the figure points to the scala tympani. 14. Extremity of the scala tympani, the fenestra rotunda. 15. Lamina spiralis; the figure is situated in the scala vestibuli. 16. Opening of the scala vestibuli into the vestibule. 17. Second turn of the cochlea; the figure is placed on the lamina spiralis, and therefore in the scala vestibuli, the scala tympani being beneath the lamina. 18. Remaining half-turn of the cochlea; the figure is placed in the scala tympani. 19. Lamina spiralis terminating in its falciform extremity. The dark space included within the falciform curve of the extremity of the lamina spiralis is the helicotrema. 20. Infundibulum.

hamulus laminae spiralis. The two *scalæ* of the cochlea, which are completely separated throughout their length in the living ear, communicate superiorly, over the hamulus laminae spiralis, by means of an opening common to both, the

¹ [The osseous portion is called the *lamina spiralis ossea*; the membranous portion is the *lamina spiralis membranacea*.]

helicotrema (ἑλιξ ἐλίσσω volvere—τροῦμα¹). Inferiorly, one of the two scalæ, the scala vestibuli, terminates by means of an oval aperture in the anterior ventricle of the vestibule; while the other, the scala tympani, becomes somewhat expanded, and opens into the tympanum through the fenestra rotunda (fenestra cochleæ). Near the termination of the scala tympani is the small opening of the aquæductus cochleæ.

The internal surface of the osseous labyrinth is lined by a *fibro-serous membrane*, which is analogous to the dura mater in performing the office of a periosteum by its exterior, whilst it fulfils the purpose of a serous membrane by its internal layer, secreting a limpid fluid, the aqua labyrinthi (perilymph, liquor Cotunnii), and sending a reflection inwards upon the nerves distributed to the membranous labyrinth. In the cochlea, the membrane of the labyrinth invests the two surfaces of the bony lamina spiralis, and being continued from its border across the diameter of the canal to its outer wall, forms the membranous lamina spiralis, and completes the separation between the scala tympani and scala vestibuli. The fenestra ovalis and fenestra rotunda are closed by an extension of this membrane across them, assisted by the membrane of the tympanum and a proper intermediate layer. Besides lining the interior of the osseous cavity, the membrane of the labyrinth sends two delicate processes along the aqueducts of the vestibule and cochlea to the internal surface of the dura mater, with which they are continuous. These processes are the remains of a communication originally subsisting between the dura mater and the cavity of the labyrinth.²

The MEMBRANOUS LABYRINTH is smaller in size, but a perfect counterpart with respect to form, of the vestibule and semicircular canals. It consists of a small elongated sac, sacculus communis (utriculus communis); of three semicircular membranous canals, which correspond with the osseous canals, and communicate with the sacculus communis; and of a small round sac (sacculus proprius), which occupies the anterior ventricle of the vestibule, and lies in close contact with the external surface of the sacculus communis. The membranous semicircular canals are two-thirds smaller in diameter than the osseous canals.

The membranous labyrinth is retained in position by means of the numerous nervous filaments which are distributed to it from the openings in the inner wall of the vestibule, and is separated from the lining membrane of the labyrinth by the aqua labyrinthi. In structure it is composed of four layers; an external, or *serous layer*, derived from the lining membrane of the labyrinth; a *vascular layer*, in which an abundance of minute vessels are distributed; a *nervous layer*, formed by the expansion of the filaments of the vestibular nerve; and an *internal* and serous membrane, by which the limpid fluid which fills its interior is secreted. Some patches of pigment have been observed by Wharton Jones in the tissue of the membranous labyrinth of man. Among animals such spots are constant.

The membranous labyrinth is filled with a limpid fluid, the liquor Scarpæ³ (endolymph, vitreous humor of the ear), and contains two small calcareous masses, called otoconites. The *otoconites* (οἶς, ὠτός, κόρις, car-dust) consist of an assemblage of minute, crystalline particles of carbonate and phosphate of lime,

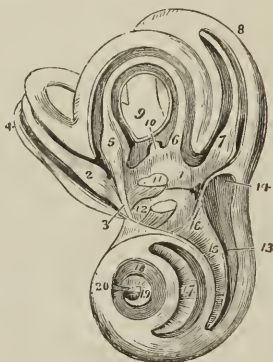
¹ [A foramen.]

² Cotunnii regarded these processes as tubular canals, through which the superabundant aqua labyrinthi might be expelled into the cavity of the cranium. Wharton Jones also describes them as tubular canals terminating beneath the dura mater of the petrous bone in a small dilated pouch. In the ear of a man deaf and dumb from birth, he found the termination of the aqueduct of the vestibule of unusually large size in consequence of irregular development.

³ Antonio Scarpa is celebrated for several admirable surgical and anatomical monographs; as, for example, his work on "Aneurism," "De Auditu et Olfactu," &c. An account of the aqua labyrinthi will be found in his anatomical observations "De Structura Fenestræ Rotundæ. et de Tympano Secundario."

(scalæ) by means of a thin and porous lamina of bone (*zonula ossea laminae spiralis*), which is wound spirally around the modiolus in the direction of the canal. The bony septum extends for about two-thirds across the diameter of the canal, and in the fresh subject is prolonged to the opposite wall by means of a membranous layer, so as to constitute a complete partition, the *lamina spiralis*.¹ The osseous lamina spiralis consists of two thin lamellæ, between which, and through the perforations on their surfaces, the filaments of the cochlear nerve reach the membrane of the cochlea. At the apex of the cochlea, the [osseous] lamina spiralis terminates by a pointed, hook-shaped process, the

FIG. 309.



LABYRINTH OF THE LEFT EAR, SHOWING ITS CAVITIES AND THE MEMBRANOUS LABYRINTH; after Breschet. 1. Cavity of the vestibule; the figure rests on the common saccule of the membranous labyrinth, the *sacculus communis*. 2. Ampulla of the perpendicular semicircular canal, receiving a fasciculus from the superior branch of the vestibular nerve, 3. 4. Perpendicular canal with its contained membranous canal. 5. Ampulla of the horizontal semicircular canal, receiving a fasciculus from the superior branch of the vestibular nerve. 6. Termination of the membranous canal of the horizontal semicircular canal in the *sacculus communis*. 7. Ampulla of the oblique semicircular canal, receiving a fasciculus from the inferior branch of the vestibular nerve. 8. Oblique semicircular canal with its membranous canal. 9. The common canal, resulting from the union of the perpendicular with the oblique semicircular canal. 10. Membranous common canal terminating in the *sacculus communis*. 11. The otoconite of the *sacculus communis* seen through the membranous parietes. A fasciculus from the inferior branch of the vestibular nerve distributed to the *sacculus communis* near the otoconite. The portion of the *sacculus* above the otoconite is lodged in the superior ventricle of the vestibule, and that below it in the inferior ventricle. 12. *Sacculus proprius* situated in the anterior ventricle; its otoconite is seen through its membranous parietes, and a fasciculus derived from the middle branch of the vestibular nerve is distributed to it. The spaces around the membranous labyrinth are occupied by the *aqua labyrinthi*. 13. First turn of the cochlea; the figure points to the *scala tympani*. 14. Extremity of the *scala tympani*, the *fenestra rotunda*. 15. *Lamina spiralis*; the figure is situated in the *scala vestibuli*. 16. Opening of the *scala vestibuli* into the vestibule. 17. Second turn of the cochlea; the figure is placed on the *lamina spiralis*, and therefore in the *scala vestibuli*, the *scala tympani* being beneath the *lamina*. 18. Remaining half-turn of the cochlea; the figure is placed in the *scala tympani*. 19. *Lamina spiralis* terminating in its falciform extremity. The dark space included within the falciform curve of the extremity of the *lamina spiralis* is the *helicotrema*. 20. *Infundibulum*.

hamulus laminae spiralis. The two *scalæ* of the cochlea, which are completely separated throughout their length in the living ear, communicate superiorly, over the *hamulus laminae spiralis*, by means of an opening common to both, the

¹ [The osseous portion is called the *lamina spiralis ossea*; the membranous portion is the *lamina spiralis membranacea*.]

helicotrema (ἑλιξ ἑλίσσω *volvere*—*τρήμα*¹). Inferiorly, one of the two *scalae*, the *scala vestibuli*, terminates by means of an oval aperture in the anterior ventricle of the vestibule; while the other, the *scala tympani*, becomes somewhat expanded, and opens into the tympanum through the *fenestra rotunda* (*fenestra cochleæ*). Near the termination of the *scala tympani* is the small opening of the *aquæductus cochleæ*.

The internal surface of the osseous labyrinth is lined by a *fibro-serous membrane*, which is analogous to the *dura mater* in performing the office of a *periotestium* by its exterior, whilst it fulfils the purpose of a serous membrane by its internal layer, secreting a limpid fluid, the *aqua labyrinthi* (*perilymph*, *liquor Cotunnii*), and sending a reflection inwards upon the nerves distributed to the membranous labyrinth. In the cochlea, the membrane of the labyrinth invests the two surfaces of the bony *lamina spiralis*, and being continued from its border across the diameter of the canal to its outer wall, forms the membranous *lamina spiralis*, and completes the separation between the *scala tympani* and *scala vestibuli*. The *fenestra ovalis* and *fenestra rotunda* are closed by an extension of this membrane across them, assisted by the membrane of the tympanum and a proper intermediate layer. Besides lining the interior of the osseous cavity, the membrane of the labyrinth sends two delicate processes along the aqueducts of the vestibule and cochlea to the internal surface of the *dura mater*, with which they are continuous. These processes are the remains of a communication originally subsisting between the *dura mater* and the cavity of the labyrinth.²

The MEMBRANOUS LABYRINTH is smaller in size, but a perfect counterpart with respect to form, of the vestibule and semicircular canals. It consists of a small elongated sac, *sacculus communis* (*utricle communis*); of three semicircular membranous canals, which correspond with the osseous canals, and communicate with the *sacculus communis*; and of a small round sac (*sacculus proprius*), which occupies the anterior ventricle of the vestibule, and lies in close contact with the external surface of the *sacculus communis*. The membranous semicircular canals are two-thirds smaller in diameter than the osseous canals.

The membranous labyrinth is retained in position by means of the numerous nervous filaments which are distributed to it from the openings in the inner wall of the vestibule, and is separated from the lining membrane of the labyrinth by the *aqua labyrinthi*. In structure it is composed of four layers; an external, or *serous layer*, derived from the lining membrane of the labyrinth; a *vascular layer*, in which an abundance of minute vessels are distributed; a *nervous layer*, formed by the expansion of the filaments of the vestibular nerve; and an *internal* and serous membrane, by which the limpid fluid which fills its interior is secreted. Some patches of pigment have been observed by Wharton Jones in the tissue of the membranous labyrinth of man. Among animals such spots are constant.

The membranous labyrinth is filled with a limpid fluid, the *liquor Scarpæ*³ (*endolymph*, vitreous humor of the ear), and contains two small calcareous masses, called *otoconites*. The *otoconites* (οἶς, ὠτός, κόνις, ear-dust) consist of an assemblage of minute, crystalline particles of carbonate and phosphate of lime,

¹ [A foramen.]

² Cotunnius regarded these processes as tubular canals, through which the superabundant *aqua labyrinthi* might be expelled into the cavity of the cranium. Wharton Jones also describes them as tubular canals terminating beneath the *dura mater* of the petrous bone in a small dilated pouch. In the ear of a man deaf and dumb from birth, he found the termination of the aqueduct of the vestibule of unusually large size in consequence of irregular development.

³ Antonio Scarpa is celebrated for several admirable surgical and anatomical monographs; as, for example, his work on "Aneurism," "De Auditu et Olfactu," &c. An account of the *aqua labyrinthi* will be found in his anatomical observations "De Structura Fenestræ Rotundæ. et de Tympano Secundario."

held together by organic substance, and probably retained in form by a reflection of the lining membrane of the membranous labyrinth. They are found suspended in the liquor Searpæ; one in the saeculus communis, the other in the saeculus proprius, from that part of each sac with which the nerves are connected.

The AUDITORY NERVE divides into two branches at the bottom of the cul-de-sac of the meatus auditorius internus; a vestibular nerve and a cochlear nerve.

The *Vestibular nerve*, the posterior of the two, separates into three branches, superior, middle, and inferior. The superior vestibular branch gives off a number of filaments which pass through the minute openings of the eminentia pyramidalis and superior ventricule of the vestibule, and are distributed to the saeculus communis and ampullæ of the perpendicular and horizontal semicircular canal. The middle vestibular branch sends off numerous filaments, which pass through the openings of the macula eribrosa in the anterior ventricule of the vestibule, and are distributed to the saeculus proprius. The inferior and smallest branch takes its course backwards to the posterior wall of the vestibule, and gives off filaments which pierce the wall of the ampullary dilatation of the oblique canal to be distributed upon its ampulla. According to Stiefensand, there is in the situation of the point of entrance of the nervous filaments into the ampulla a deep depression on the exterior of the membrane, and on the interior a corresponding projection, which forms a kind of transverse septum, partially dividing the cavity of the ampulla into two chambers. In the substance of the saeculi and ampullæ, the nervous filaments radiate in all directions, anastomosing with each other and forming interlacements and loops, and terminate on the inner surface of the membrane in minute papillæ, resembling those of the retina.

The *Cochlear nerve* divides into numerous filaments which enter the foramina of the tractus spiralis foraminulentus in the base of the cochlea, and passing upwards in the canals of the modiolus, bend outwards at right angles, to be distributed in the tissue of the lamina spiralis. The central portion of the nerve passes through the tubulus centralis of the modiolus, and supplies the apical portion of the lamina spiralis. In the lamina spiralis the nervous filaments lying side by side on an even plane form numerous anastomosing loops, and spread out into a nervous membrane. According to Treviranus and Gottsche, the ultimate terminations of the filaments assume the form of papillæ.

The *Arteries* of the labyrinth are derived from the internal auditory branch of the superior cerebellar, or basilar artery, and from the stylo-mastoid.

ORGAN OF TASTE.

The *Tongue* is composed of muscular fibres [intrinsic muscles] which are distributed in layers arranged in various directions: thus, some are disposed *longitudinally* (lingualis superficialis); others *transversely* (lingualis transversus); others, again, *obliquely* and *vertically*. Between the muscular fibres is a considerable quantity of adipose substance, and in the middle of the organ a vertical septum of fibrous tissue.

The tongue is *connected*, posteriorly, with the os hyoides by muscular attachment; and to the epiglottis by mucous membrane, which forms the three glosso-epiglottic folds called *fræna epiglottidis*. At either side it is held in connexion with the lower jaw by mucous membrane; and in front, a fold of that membrane, which is named *frænum linguæ*, is formed beneath its under surface.

The surface of the tongue is covered by a dense layer, analogous to the corium of the skin, which gives support to papillæ. A *raphé* marks the middle line of the organ, and divides it into symmetrical halves.

The *Papillæ* of the *tongue* are, the—

Papillæ circumvallatæ,
Papillæ conicæ,

Papillæ filiformes,
Papillæ fungiformes.

The *Papillæ circumvallatæ* (p. lenticulares) are of large size, and from fifteen to twenty in number. They are situated on the dorsum of the tongue, near its root, and form a row at each side, which meets its fellow at the middle line, like the two branches of the letter A. Each papilla resembles a cone, attached by its apex to the bottom of a cup-shaped depression: hence they are also named *papillæ calyciformes*. This cup-shaped cavity forms a kind of fossa around the papilla, whence their name *circumvallatæ*. At the meeting of the two rows of these papillæ, upon the middle of the root of the tongue, is a deep mucous follicle, called *foramen cæcum*.

The *Papillæ conicæ* and *filiformes* cover the whole surface of the tongue in front of the *circumvallatæ*, but are most abundant towards its anterior part. They are conical and filiform in shape, and many of them are pierced at the extremity by a minute aperture. Hence, they may be regarded as follicles rather than sentient organs; the true sentient papillæ being extremely minute, and occupying their surface, as they do that of the other papillæ of the tongue.

The *Papillæ fungiformes* (p. capitatæ) are irregularly dispersed over the dorsum of the tongue, and are easily recognised among the other papillæ by their rounded heads, larger size, and red color. A number of these papillæ will generally be observed at the tip of the tongue.

Behind the *papillæ circumvallatæ*, at the root of the tongue, are a number of mucous glands (*lingual*), which open on the surface. There is also a small cluster beneath the tip of the tongue.

Vessels and Nerves.—The tongue is abundantly supplied with blood by the lingual arteries.

The *Nerves* are three in number, and of large size: the *gustatory* branch of the inferior maxillary, is distributed to the papillæ, and is the nerve of common sensation and taste; the *glosso-pharyngeal*, is distributed to the mucous membrane, glands, and papillæ *circumvallatæ*,¹ and the *hypoglossal*, the motor nerve of the tongue, is distributed to the muscles.

The *Mucous membrane* which invests the tongue is continuous with the derma along the margin of the lips. On either side of the *frænum linguæ* it may be traced through the sublingual ducts into the sublingual glands, and along Wharton's² ducts into the submax-

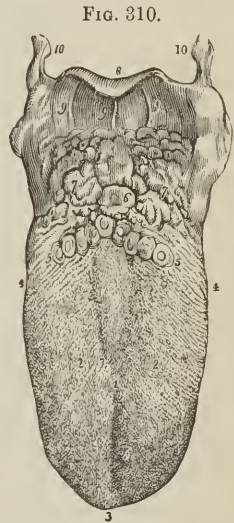


FIG. 310.

THE TONGUE WITH ITS PAPILLÆ.

1. The raphé, which sometimes bifurcates on the dorsum of the tongue, as in the figure. 2, 2. Lobes of the tongue; the rounded eminences on this part, and near its tip, are the papillæ fungiformes. The smaller papillæ, among which the former are dispersed, are the papillæ conicæ and filiformes. 3. Tip of the tongue. 4, 4. Its sides, on which are seen the lamellated and fringed papillæ. 5, 5. The A-shaped row of papillæ circumvallatæ. 6. Foramen cæcum. 7, 7. Mucous glands of the root of the tongue. 8. Epiglottis. 9, 9, 9. Fræna epiglottidis. 10, 10. Greater cornua of the os hyoides.

¹ [The glosso-pharyngeal is also regarded as a nerve of taste.]

² Thomas Wharton, an English physician, devoted considerable attention to the anatomy of the glands; his work, entitled "Adenographia," &c., was published in 1656.

illary glands; from the sides of the cheeks it passes through the opening of Stenon's¹ ducts to the parotid glands: in the fauces it forms the assemblage of follicles called tonsils, and may thence be traced downwards into the larynx and pharynx, where it is continuous with the general gastro-pulmonary mucous membrane.

Beneath the mucous membrane of the mouth are a number of small *glands*, which pour their secretion upon the surface. A considerable number of these bodies are situated within the lips, in the palate, and in the floor of the mouth. They are named, according to their position, *labial glands*, *palatal glands*, and *buccal glands*.

ORGAN OF TOUCH.

The *Skin* is the exterior investment of the body, which it serves to cover and protect. It is continuous at the apertures of the internal cavities with the lining membrane of those cavities, the internal skin or mucous membrane, and is composed essentially of two layers, *derma* and *epidermis*.

The *DERMA* or cutis is chiefly composed of areolo-fibrous tissue, besides which it has entering into its structure elastic tissue and smooth muscular fibre, together with bloodvessels, lymphatic vessels and nerves. The areolo-fibrous tissue exists in greatest abundance in the deeper stratum of the derma, which is consequently dense, white, and coarse; the superficial stratum, on the other hand, is fine in texture, reddish in color, soft, raised into minute papillæ, and highly vascular and sensitive. These differences in structure have given rise to a division of the derma into the deep stratum, or *corium*, and the superficial, or *papillary* layer.

In the *Corium* the areolo-fibrous tissue is collected into fasciæ, which are small and closely interwoven in the superficial strata, large and coarse in the deep strata; in the latter forming an areolar network, with large areolæ, which are occupied by adipose tissue. These areolæ are the channels through which the branches of vessels and nerves find a safe passage to the papillary layer, in which and in the superficial strata of the corium they are principally distributed. The yellow elastic tissue is found chiefly in the superficial strata, the smooth muscular tissue in the deep. It is to the latter that the nipples and serotum owe their contractile power, and the general surface of the skin the contraction which is known by the name of *cutis anserina*. The corium presents some variety in thickness in different parts of the body. Thus in the more exposed regions, as the back, the outer sides of the limbs, the palms, and the soles, it is remarkable for its thickness; while on protected parts it is comparatively thin, and on the eyelids, penis and serotum is peculiarly delicate. It is connected by its under surface with the common superficial fascia of the body.

The *Papillary* layer of the derma is raised in the form of conical prominences or papillæ. On the general surface of the body the papillæ are short and exceedingly minute; but in other situations, as the palmar surface of the hands and fingers, and the plantar surface of the feet and toes, they are long and of large size. They also differ in arrangement; for, on the general surface, they are distributed at unequal distances and without order; whereas, on the palms and soles, and on the corresponding surfaces of the fingers and toes, they are collected into little square clumps, containing from ten to twenty papillæ; and these little clumps are disposed in parallel rows. It is this arrangement in rows that gives rise to the characteristic parallel ridges and furrows which are met with on the hands and feet. The papillæ in these little square clumps are for the most part uniform in size and length, but every here and there one papilla

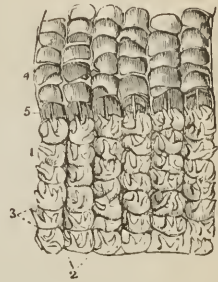
¹ Nicholas Stenon, a Danish anatomist: he was made Professor in Copenhagen in 1672.

may be observed which is longer than the rest. The largest papillæ of the derma are those which produce the nail; in the dermal follicle of the nail they are long and filiform, while beneath its concave surface they form longitudinal and parallel plications which extend for nearly the entire length of that organ. In structure the papilla is composed of homogeneous, nucleated, and fibrillated areolar tissue, bounded by a structureless limitary membrane, and containing transverse elastic fibres with a capillary and nervous loop; besides which, in some papillæ, are certain peculiar bodies, called by Wagner *corpusecula tactûs*.

The EPIDERMIS or cuticle (scarfskin) is a product of the derma, which it serves to envelop and defend. That surface of the epidermis which is exposed to the influence of the atmosphere and exterior sources of injury, is hard and horny in texture, while that which lies in contact with the papillary layer is soft and cellular. Hence the epidermis, like the derma, is divisible into two layers, external and internal, the latter being termed the *rete mucosum*. Moreover, the epidermis is laminated in structure, and the laminæ present a progressively increasing tenuity and density as they advance from the inner to the outer surface. This difference of density is dependent on the mode of growth of the epidermis, for as the external surface is constantly subjected to destruction from attrition and chemical action, so the membrane is continually reproduced on its internal surface; new layers being successively formed on the derma to take the place of the old.

The theory of growth of the epidermis, deduced from the observations of Schwann, is as follows: a stratum of plastic lymph (*liquor sanguinis*) is poured out on the surface of the derma. This fluid, by virtue of the vital force inherent in itself, and communicated to it by contact with a living tissue, is converted into granules, which are termed cell-germs or *cytoblasts*. By endosmosis, these cytoblasts imbibe serum from the plastic lymph and adjacent tissues, and the outermost layer or pellicle of the cytoblast becomes

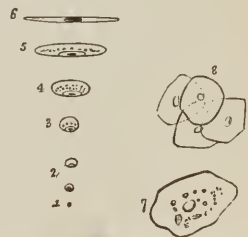
FIG. 311.



PORTION OF SKIN FROM THE PALM OF THE HAND. 1. Papillary layer. 2. Longitudinal furrows, marking the arrangement of the papillæ into ridges. 3. Transverse furrows dividing the ridges into small quadrangular clumps. In the figure a few only of the papillæ are shown. 4. Rete mucosum raised from the papillary layer; its under surface presents an exact impression of the papillary layer. 5. Perspiratory ducts drawn out straight by the separation of the rete mucosum from the papillary layer; the point at which each perspiratory duct issues from the papillary layer, and pierces the rete mucosum, is the middle of the transverse furrow between the quadrangular clumps.

DIAGRAM ILLUSTRATIVE OF THE DEVELOPMENT OF THE EPIDERMIS AND OF EPITHELIA IN GENERAL, ACCORDING TO THE THEORY OF SCHWANN. 1. A granule or cytoblast. 2. The cell seen rising on the cytoblast; the latter is now a nucleus, and a nucleolus may be detected in its interior. 3. The spheroidal cell. 4. The oval cell. 5. The elliptical cell. 6. The flattened cell; which, by contact of its walls, is speedily converted into a scale in which the nucleus is lost. 7. A nucleated scale as seen on its flat surface. 8. A cluster of such scales.

FIG. 312.



imbibed fluid. The cytoblast has now become a cell, and the solid portion of the cytoblast, which always remains adherent to some one point of the internal

surface of the cell-membrane is the *nucleus* of the cell. Moreover, within the nucleus one or several nuclei are formed, which are termed *nucleoli*. By a continuance of the process of imbibition, the cell becomes more or less spherical; so that, after a time, every part of the surface of the papillary layer of the derma is coated by a thin stratum, consisting of spherical cells lying closely pressed together, and corresponding with every irregularity of the papillæ. But, as this production of cells is a function constantly in operation, a new layer is formed before the first is completed, and the latter is separated by subsequent formations further and further from the surface of the papillary layer. As a consequence of loss of contact with the derma, the vital force is progressively diminished; the cell becomes subject to the influence of physical laws, and evaporation of its fluid slowly ensues. In consequence of this evaporation, the cell becomes collapsed and flattened, and assumes an elliptical form; the latter is by degrees converted into the flat cell with parallel and contiguous layers, and an included nucleolated nucleus; and lastly, the flattened cell desiccates into a thin membranous scale, in which the nucleus is scarcely apparent.

My own investigations¹ have shown that, after the original granules of the liquor sanguinis have become aggregated into a granular nucleus, other granules are formed in successive circles, around the circumference of the nucleus, until the entire breadth of the epidermal scale is attained; that the cell never acquires a greater thickness than that of the original nucleus, and, that the formation of the scale results from the desiccation of the cell, as it is gradually pushed outwards from the derma towards the surface. Consequently, the cell never possesses any other than the flattened form; all its phases of growth are perfected in the deepest layer of the epidermis; and, in its internal structure, it is a parent cell containing secondary and tertiary cells and granules, its growth being the result of the growth of these secondary formations.

The under surface of the epidermis is accurately modelled on the papillary layer of the derma, each papilla having its appropriate sheath in the newly-formed epidermis or rete mucosum, and each irregularity of surface of the former having its representative in the soft tissue of the latter. On the external surface, this character is lost; the minute elevations corresponding with the papillæ are, as it were, polished down, and the surface is rendered smooth and uniform. The palmar and plantar surface of the hands and feet are, however, an exception to this rule; for here, in consequence of the large size of the papillæ and their peculiar arrangement in rows, ridges corresponding with the papillæ are strongly marked on the superficial surface of the epidermis. The epidermis is remarkable for its thickness in situations where the papillæ are large, as in the palms and soles. In other situations, it assumes a character which is also due to the nature of the surface of the derma; namely, that of being marked by a network of linear furrows, which trace out the surface into small polygonal and lozenge-shaped arææ. These lines correspond with the folds of the derma produced by its movements, and are most numerous where those movements are greatest, as in the flexures and on the convexities of joints.

The dark color of the skin among the natives of the South is due to the coloration of the primitive granules of which the cell is composed, especially the nucleus. As the cells desiccate, the color of the granules is lost; hence the deeper hue of the rete mucosum.

The *pores* of the epidermis are the openings of the perspiratory ducts, hair follicles, and sebiparous glands.

Vessels and Nerves.—The *Arteries* of the derma, which enter its structure through the areolæ of the under surface of the corium, divide into innumerable intermediate vessels, which form a rich capillary plexus in the superficial strata of the skin and in its papillary layer. In the papillæ of some parts of the derma, as in the longitudinal plications beneath the nail, the capillary vessels form

¹ Diseases of the Skin.

simple loops, but in other papillæ they are convoluted to a greater or less degree in proportion to the size and importance of the papillæ. The *Lymphatic* vessels probably form, in the superficial strata of the derma, a plexus, the meshes of which are interwoven with those of the capillary and nervous plexus. No lymphatics have as yet been discovered in the papillæ.

The *Nerves* of the derma, after entering the areolæ of the deeper part of the corium, divide into minute fasciculi, which form a terminal plexus in the upper strata of the corium. From this plexus the primitive fibres pass off to their distribution as loops, in the papillæ. In the less sensitive parts of the skin, the loops are simple and more or less acute in their bend, in conformity with the figure of the papillæ. In the sensitive parts, and especially in the tactile papillæ of the pulps of the fingers, there are two loops, which are, moreover, associated with a peculiar body imbedded in the substance of the papilla, the *corpusculum tactûs* of Wagner.

APPENDAGES OF THE SKIN.

The appendages of the skin are the nails, hairs, sebiparous glands, and perspiratory [or sudoriparous] glands and ducts.

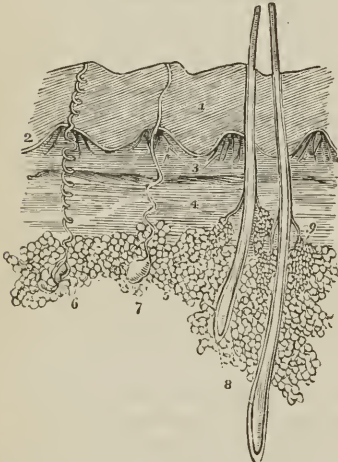
The **NAILS** are horny appendages of the skin, identical in formation with the epidermis, of which they are a part. A nail is convex on its external surface, concave within, and implanted by means of a thin margin or root in a fold of the derma, which is nearly two lines in depth, and acts the part of a follicle to the nail. At the bottom of the groove of the follicle are a number of filiform papillæ, which produce the margin of the root, and, by the successive formation of new cells, push the nail onwards in its growth. The concave surface of the nail is in contact with the derma, and the latter is covered by papillæ, which perform the double office of retaining the nail in its place, and giving it increased thickness by the addition of newly-formed cells to its under surface. It is this constant change occurring in the under surface of the nail, co-operating with the continual formation taking place along the margin of the root, which ensures the growth of the nail in the proper direction. The nail derives a peculiarity of appearance from the disposition and form of the papillæ on the unguis surface of the derma (matrix). Thus, beneath the root, and for a short distance onwards towards its middle, the derma is covered by papillæ which are more minute, and consequently less vascular than the papillæ somewhat further on. This patch of papillæ is bounded by a semilunar line, and that part of the nail covering it being lighter in color than the rest, has been termed *lunula*. Beyond the lunula the papillæ are raised into longitudinal plaits, which are exceedingly vascular, and give a deeper tint of redness to the nail. These plait-like papillæ of the derma are well calculated by their form to offer an extensive surface both for the adhesion and formation of the nail. The granules and cells are developed on every part of their surface, both in the grooves between the plaits and on their sides, and a horny lamina is formed between each pair of plaits. When the under surface of a nail is examined, these longitudinal laminæ, corresponding with the longitudinal papillæ of the unguis portion of the derma, are distinctly apparent, and if the nail be forcibly detached, the laminæ may be seen in the act of parting from the grooves of the papillæ. It is this structure that gives rise to the ribbed appearance of the nail. The papillary substance of the derma, which produces the nail, is continuous around the circumference of the attached part of that organ with the derma of the surrounding skin, and the horny structure of the nail is consequently continuous with that of the epidermis.

HAIRS are horny appendages of the skin, produced by the involution and subsequent evolution of the epidermis; the involution constituting the follicle in which the hair is inclosed, and the evolution the shaft of the hair. Hairs

vary much in size and length in different parts of the body; in some they are so short as not to appear beyond the follicle; in others, they grow to a great length, as on the scalp; while along the margins of the eyelids, and in the whiskers and beard, they are remarkable for their thickness. Hairs are generally more or less flattened in form, and when the extremity of a transverse section is examined, it is found to possess an elliptical or reniform outline. This examination also demonstrates that the centre of the hair is porous and loose in texture, while its periphery is dense; thus affording ground for its division into a *cortical* and a *medullary* portion. The free extremity of a hair is generally pointed, and sometimes split into two or three filaments. Its attached extremity is implanted deeply in the integument, extending through the derma into the subcutaneous areolar tissue, where it is surrounded by adipose cells. The central extremity of a hair is larger than its shaft, and is called the root or bulb. It is rounded or conical in shape.

The process of formation of a hair by its follicle is identical with that of the formation of the epidermis by the papillary layer of the derma. Plastic lymph is in the first instance exuded by the capillary plexus of the follicle, the lymph undergoes conversion, first into granules, then into cells, and the latter are elongated into fibres. The cells which are destined to form the surface of the hair

FIG. 313.



SECTION OF THE SKIN. 1. Epidermis. 2. Rete Mucosum, or deep layer of the epidermis. 3. Two of the quadrilateral papillary clumps, such as are seen in the palm of the hand or sole of the foot; they are composed of conical papillæ. 4. Deep layer of the derma, the corium. 5. Adipose cells. 6. A sudoriparous gland with its spiral duct, such as is seen in the palm of the hand or sole of the foot. 7. Another sudoriparous gland with a straighter duct, such as is seen in the scalp. 8. Two hairs from the scalp, inclosed in their follicles; their relative depth in the skin is preserved. 9. A pair of sebiparous glands, opening by short ducts into the follicle of the hair.

go through a different process. They are converted into flat scales, which inclose the fibrous structure of the interior. These scales, as they are successively produced, overlap those which precede and give rise to the prominent and waving lines which may be seen around the circumference of a hair. It is this overlapping line that is the cause of the roughness which we experience in drawing a hair, from its point to its bulb, between the fingers. The bulb is the newly-formed portion of the hair: its expanded form is due to the greater bulk of the fresh cells compared with the fibres and scales into which they are subsequently converted in the shaft.

The color of the hair, like that of the epidermis, is due to the coloration of the primitive granules of the cells.

The SEBIPAROUS GLANDS are imbedded in the substance of the derma, and present every degree of complexity, from the simplest follicle to the compound lobulated gland. In some situations their excretory ducts open independently on the surface of the epidermis; while in others, they terminate in the follicles of the hairs. The sebiparous glands associated with the hairs are racemiform and lobulated, consisting of glandular vesicles which open by short pedunculated tubuli into a common excretory duct, and the latter, after a short course, into the hair-follicle. In the scalp there are two of these glands to each hair-follicle. On the nose and face the glands are of

large size, and constantly associated with small hair-follicles. In the meatus auditorius the *ceruminous* glands are also large; in the eyelids the cilia are supplied like other hairs with sebiparous glands, but the Meibomian glands may also be regarded as belonging to this class. The excretory ducts of sebiparous glands offer some diversity in different parts of the body; in many situations they are short and straight, in others, as in the palms of the hands and soles of the feet, where the epidermis is thick, they assume a spiral course. The sebiferous ducts are lined by an inversion of the epidermis, which forms a thick and funnel-shaped cone at its commencement, but soon becomes uniform and soft. Sebiparous glands are met with in all parts of the body, but are most abundant in the skin of the face, and in those situations which are naturally exposed to the influence of friction.

The sebaceous substance, when it collects in inordinate quantities within the excretory ducts, becomes the habitat of a remarkable parasitic animal, the *steatozoon folliculorum*.

The SUDORIPAROUS GLANDS are situated deeply in the corium and also in the subcutaneous areolar tissue, where they are surrounded by adipose cells. They are small round or oblong bodies, composed of one or more convoluted tubuli, or of a congeries of glandular vesicles, which open into a common efferent duct. The latter ascends from the gland through the derma and epidermis, and terminates on the surface by a funnel-shaped and oblique aperture or pore. The efferent duct presents some variety in its course upwards; within the derma it is straight, or curved and serpentine, and if the epidermis be thin, proceeds more or less directly to the excreting pore. Sometimes it is spirally curved within the derma, and having passed the latter, is regularly and beautifully spiral in its passage through the epidermis, the last turn forming an oblique and valvular opening on the surface. The spiral course of the duct is especially remarkable in the thick epidermis of the palm of the hand and sole of the foot. On those parts of the skin where the papillæ are irregularly distributed, the efferent ducts of the sudoriparous glands open on the surface also irregularly, while on the palmar and plantar surfaces of the hands and feet, the pores are situated at regular distances along the ridges, at points corresponding with the intervals of the small, square-shaped, clumps of papillæ. Indeed the apertures of the pores, seen on the surface of the epidermal ridges, give rise to the appearance of small transverse furrows, which intersect the ridges from point to point.

The efferent duct and the glandular vesicles and tubuli of the sudoriparous gland are lined by an inflection of the epidermis. This inflection is thick and infundibuliform in the upper stratum of the derma, but soon becomes uniform and soft. The infundibuliform projection is drawn out from the duct when the epidermis is removed, and may be perceived on the under surface of the latter as a nipple-shaped cone. A good view of the sudoriferous ducts is obtained by gently separating the epidermis of a portion of decomposing skin; or they may be better seen by scalding a piece of skin, and then withdrawing the epidermis from the derma. In both cases it is the lining sheath of epidermis, in other words, the epithelium which is drawn out from the duct.

CHAPTER XI.

OF THE VISCERA.

THAT part of the science of anatomy which treats of the viscera is named splanchnology, from the Greek words, *σπλάγχνον*, viscus, and *λόγος*. The viscera of the human body are situated in the three great internal cavities; cranio-spinal, thorax, and abdomen. The viscera of the cranio-spinal cavity, namely, the brain, and spinal cord, with the principal organs of sense, have been already described, in conjunction with the nervous system. The viscera of the chest are: the central organ of circulation, the heart; the organs of respiration, the lungs; and the thymus gland. The abdominal viscera admit of a subdivision into those which properly belong to that cavity, viz., the alimentary canal, liver, pancreas, spleen, kidneys, and supra-renal capsules; and those of the pelvis, the bladder and internal organs of generation.

THORAX.

The thorax is the conical cavity, situated at the upper part of the trunk of the body: it is narrow above, and broad below, and is bounded in *front*, by the sternum, six superior costal cartilages, ribs, and intercostal muscles; *laterally*, by the ribs and intercostal muscles; and, *behind*, by the ribs, intercostal muscles, and vertebral column, as low down as the upper border of the last rib and first lumbar vertebra; *superiorly*, by the first rib at each side, the upper part of the sternum in front and the first dorsal vertebra behind; and, *inferiorly*, by the diaphragm. The superior opening of the thorax is closed by the thoracic fascia, and gives passage to the following parts, namely, the sterno-hyoid, sterno-thyroid, and longi colli muscles; the trachea and œsophagus; the carotid and subclavian arteries and veins, and thoracic duct; the pneumogastric, phrenic, and sympathetic nerves; and the upper part of the lungs and pleuræ. The cavity of the thorax is much deeper on the posterior than on the anterior wall, in consequence of the obliquity of the diaphragm, and contains the heart inclosed in its pericardium, with the great vessels; the lungs, with their serous coverings, the pleuræ; the œsophagus; some important nerves; and, in the fœtus, the thymus gland.

THE HEART.

The central organ of circulation, the heart, is situated between the two layers of pleura which constitute the mediastinum, and is inclosed in a proper membrane, the pericardium.

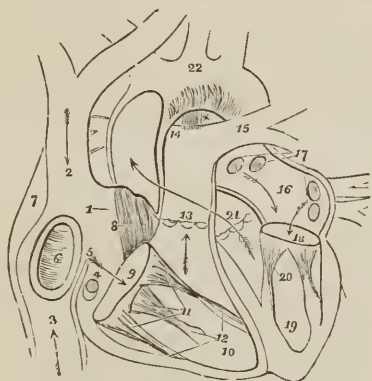
Pericardium.—The pericardium is a fibro-serous membrane like the dura mater, and resembles that membrane also in deriving its serous layer from the reflected serous membrane of the viscus which it incloses. It consists of two layers, external, fibrous; and internal, serous. The *fibrous* layer is attached above, to the great vessels proceeding from the heart, on which it is continuous with the thoracic fascia; and below, to the tendinous portion of the diaphragm. The *serous* membrane invests the heart with the commencement of its great vessels as high as the arch of the aorta, and is then reflected upon the internal surface of the fibrous layer.

In intimate structure the fibrous layer is composed of arcular tissue; the serous layer consisting of a thin stratum of elastic tissue disposed in a network,

adherent by one surface to the fibrous layer, and smooth on the free surface, where it gives support to a single or double lamina of tessellated epithelium. The bag of the pericardium has few vessels and nerves, the latter being derived from the phrenic and recurrent branch of the right pneumogastric.

The HEART is placed obliquely in the chest, the *base* being directed upwards and backwards towards the right shoulder; the *apex* forwards and to the left, pointing to the space between the fifth and sixth ribs, at about two or three inches from the sternum.¹ Its *under side* is flattened, and rests on the tendinous portion of the diaphragm; its *upper side* is rounded and convex, and formed principally by the right ventricle, and partly by the left. Surmounting the ven-

FIG. 314.



ANATOMY OF THE HEART. 1. Right auricle. 2. Entrance of the superior vena cava. 3. Entrance of the inferior cava. 4. Opening of the coronary vein, half-closed by the coronary valve. 5. Eustachian valve. 6. Fossa ovalis, surrounded by the annulus ovalis. 7. Tuberculum Loweri. 8. Musculi pectinati of the appendix auriculæ. 9. Auriculo-ventricular opening. 10. Cavity of the right ventricle. 11. Trienspid valve, attached by the chordæ tendineæ to the carnæ columnæ (12). 13. Pulmonary artery, guarded at its commencement by three semilunar valves. 14. Right pulmonary artery, passing beneath the arch and behind the ascending aorta. 15. Left pulmonary artery, crossing in front of the descending aorta. * Remains of the ductus arteriosus, acting as a ligament between the pulmonary artery and arch of the aorta. The arrows mark the course of the venous blood through the right side of the heart. Entering the auricle by the superior and inferior cavæ, it passes through the auriculo-ventricular opening into the ventricle, and thence through the pulmonary artery to the lungs. 16. Left auricle. 17. Openings of the four pulmonary veins. 18. Auriculo-ventricular opening. 19. Left ventricle. 20. Mitral valve, attached by its chordæ tendineæ to two large columnæ carneæ, which project from the walls of the ventricle. 21. Commencement and course of the ascending aorta behind the pulmonary artery, marked by an arrow. The entrance of the vessel is guarded by three semilunar valves. 22. Arch of the aorta. The comparative thickness of the two ventricles is shown in the diagram. The course of the pure blood through the left side of the heart is marked by arrows. The blood is brought from the lungs by the four pulmonary veins into the left auricle, and passes through the auriculo-ventricular opening into the left ventricle, whence it is conveyed by the aorta to every part of the body.

tricles are the corresponding auricles, whose auricular appendages are directed forwards, and slightly overlap the root of the pulmonary artery. The pulmonary artery is the large anterior vessel at the root of the heart; it crosses obliquely

¹ The size of the heart is about five inches in length, three and a-half inches in greatest breadth, and two and a-half in thickness. Its weight is about eleven ounces in the male, and nine ounces in the female.

the commencement of the aorta. The heart consists of two auricles and two ventricles, which are respectively named, from their position, right and left. The right is the venous side of the heart; it receives into its auricle the venous blood from every part of the body, by the superior and inferior cava and coronary vein. From the auricle the blood passes into the ventricle, and from the ventricle through the pulmonary artery, to the capillaries of the lungs. From these it is returned as arterial blood to the left auricle; from the left auricle it passes into the left ventricle; and from the left ventricle is carried through the aorta, to be distributed to every part of the body, and again returned to the heart by the veins. This constitutes the course of the *adult circulation*.

The heart is best studied *in situ*. If, however, it be removed from the body, it should be placed in the position indicated by the above description of its situation. A transverse incision should then be made along the ventricular margin of the right auricle, from the appendix to its right border, and crossed by a perpendicular incision, carried from the side of the superior to the inferior cava. The blood must then be removed. Some fine specimens of white fibrin are frequently found with the coagula; occasionally they are yellow and gelatinous. The older anatomists called these substances "polypus of the heart;" they are usually met with in the right ventricle, and sometimes in the left cavities.

The RIGHT AURICLE is larger than the left, and consists of a principal cavity or sinus, and an appendix auriculæ. The interior of the sinus presents for examination five openings; two valves; two relicts of foetal structure; and two peculiarities in the proper structure of the auricle. To facilitate remembrance they may be thus arranged:—

Openings	{	Superior cava, Inferior cava, Coronary vein, Foramina Thebesii, Auriculo-ventricular.
Valves	{	Eustachian valve, Coronary valve.
Relicts of foetal structure	{	Annulus ovalis, Fossa ovalis.
Structure of the auricle .	{	Tuberculum Loweri, Musculi pectinati.

The *Superior vena cava* returns the blood from the upper half of the body, and opens into the upper and back part of the auricle.

The *Inferior vena cava* returns the blood from the lower half of the body, and opens through the lower and posterior wall, close to the partition between the auricles (septum auricularum). The direction of these two vessels is such, that a stream forced through the superior cava would rush towards the auriculo-ventricular opening. In like manner, a jet issuing from the inferior cava would dash its stream against the septum auricularum; this is the proper direction of the two currents during foetal life.

The *Coronary vein* returns the venous blood from the substance of the heart; it opens into the auricle between the inferior cava and auriculo-ventricular opening, under cover of the coronary valve.

The *Foramina Thebesii*¹ are minute pore-like openings of small veins (venæ minimæ) which issue directly from the muscular structure of the heart, without entering the venous current. These openings are also found in the left auricle,

¹ Adam Christian Thebesius. His description of the openings now known by his name is contained in his "Dissertatio Medica de Circulo Sanguinis in Corde," 1708.

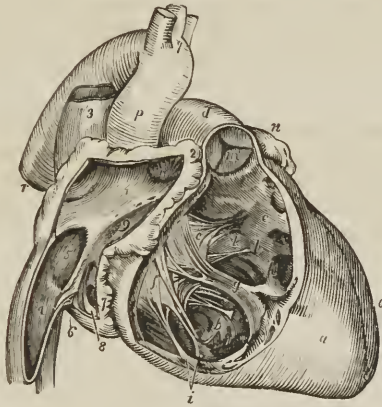
and in the right and left ventricles, but, in the latter, are generally believed to be mere cæcal depressions.

The *Auriculo-ventricular opening* is the large opening of communication between the auricle and ventricle.

The *Eustachian*¹ *valve* is a part of the apparatus of foetal circulation, and serves to direct the placental blood from the inferior cava, through the foramen ovale into the left auricle. In the adult it is a mere vestige and imperfect, though sometimes it remains of large size. It is formed by a fold of the lining membrane of the auricle, containing some muscular fibres, is situated between the aperture of the inferior cava and the auriculo-ventricular opening, and is generally connected with the coronary valve.

The *Coronary valve* is a semilunar fold of the lining membrane, stretching across the mouth of the coronary vein, and preventing the reflux of blood in the vein during contraction of the auricle.

Fig. 315.



ANATOMY OF THE HEART; RIGHT SIDE. 1. Cavity of right auricle. 2. Appendix auriculæ, in its cavity are seen the musculi pectinati. 3. Superior vena cava, opening into the upper part of right auricle. 4. Inferior vena cava. 5. Fossa ovalis; the prominent ridge surrounding it is the annulus ovalis. 6. Eustachian valve. 7. Opening of the coronary vein. 8. Coronary valve. 9. Entrance of the auriculo-ventricular opening. Between the figures 1 and 9, two or three foramina Thebesii are seen. *a*. Right ventricle. *b, c*. Cavity of right ventricle, on the walls of which the columnæ carneæ are seen; *c* is placed in the channel leading upwards to the pulmonary artery, *d*. *e, f*. Tricuspid valve; *e* is placed on the anterior curtain, *f* on the right curtain. *g*. Long columnæ carneæ, to the apex of which the anterior and right curtain are connected by chordæ tendineæ. *h*. The "long moderator band." *i*. The two columnæ carneæ of the right curtain. *k*. Attachment by chordæ tendineæ of the left limb of the anterior curtain. *l, l*. Chordæ tendineæ of the "fixed curtain" of the valve. *m*. Valve of the pulmonary artery. The letter of reference is placed on the inferior semilunar segment. *n*. Apex of left appendix auriculæ. *o*. Left ventricle. *p*. Ascending aorta. *q*. Its transverse portion, with the three arterial trunks which arise from the arch. *r*. Descending aorta.

The *Annulus ovalis* is situated on the septum auricularum, opposite the termination of the inferior cava. It is the rounded margin of the septum, which occupies the place of the foramen ovale of the foetus.

The *Fossa ovalis* is an oval depression corresponding with the foramen ovale

¹ Bartholomew Eustachius, born at San Severino, in Naples, was Professor of Medicine in Rome, where he died in 1570. He was one of the founders of modern anatomy, and the first to illustrate his works with good engravings on copper.

of the fœtus. This opening is closed at birth by a thin valvular layer, which is continuous with the left margin of the annulus, and is frequently imperfect at its upper part. The depression or fossa in the right auricle results from this arrangement. There is no fossa ovalis in the left auricle.

The *Tuberculum Loweri*¹ is the portion of auricle intervening between the openings of the superior and inferior cava. Being thicker than the walls of the veins, it forms a projection, which was supposed by Lower to direct the blood from the superior cava into the auriculo-ventricular opening.

The *Musculi pectinati* are small muscular columns situated in the appendix auriculæ. They are numerous, and arranged parallel with each other; hence their cognomen, "*pectinati*," like the teeth of a comb.

The RIGHT or ANTERIOR VENTRICLE is triangular and prismoid in form. Its anterior side is convex, and forms the larger portion of the front of the heart. The posterior side, which is also inferior, is flat, and rests on the diaphragm; the inner side corresponds with the partition between the two ventricles, septum ventriculorum. Superiorly, where the pulmonary artery arises, there is a dilatation of the ventricle, termed the *infundibulum*, or conus arteriosus.

The right ventricle is to be laid open by making an incision parallel with, and a little to the right of, the anterior longitudinal furrow, from the pulmonary artery in front, to the apex of the heart, and thence by the side of the posterior longitudinal furrow behind to the auriculo-ventricular opening.

It contains, to be examined, two openings, the auriculo-ventricular and that of the pulmonary artery; two apparatus of valves, tricuspid and semilunar; and a muscular and tendinous apparatus belonging to the tricuspid valves. They may be thus arranged:—

Auriculo-ventricular opening,
Opening of the pulmonary artery,

Tricuspid valves,
Semilunar valves,

Chordæ tendinæ,
Carnæ columnæ.

The *Auriculo-ventricular opening* is surrounded by a fibrous ring, covered by the lining membrane (endocardium) of the heart. It is the opening of communication between the right auricle and ventricle.

The *Opening of the pulmonary artery* is situated at the summit of the conus arteriosus, close to the septum ventriculorum, on the left side of the right ventricle, and upon the anterior aspect of the heart.

The *Tricuspid valves*² are three triangular folds of the lining membrane, strengthened by a thin layer of fibrous tissue. They are connected by their base around the auriculo-ventricular opening; and by their sides and apices, which are thickened, they give attachment to a number of slender tendinous cords, called chordæ tendinæ. The *chordæ tendinæ* are the tendons of the thick muscular columns (*columnæ carnæ*) which stand out from the walls of the ventricle, and serve as muscles to the valves. A number of these tendinous cords converge to a single muscular attachment. The tricuspid valves prevent the regurgitation of blood into the auricle during the contraction of the ventricle,

¹ Richard Lower, M. D. "Tractatus de Corde; item de Motu et Colore Sanguinis," 1669. His dissections were made upon quadrupeds, and his observations relate rather to animals than man.

² [This structure is generally denominated the *tricuspid valve*, and sometimes the triglochin valve (*τρεις*, *tres*, three; and *γλωχίς*, *cuspis*, a point), from its appearance as a whole; its divisions being called segments, flaps, or tongues.]

and they are prevented from being themselves driven back by the chordæ tendinæ and their muscular attachments.

This connexion of the muscular columns of the heart to the valves has caused their division into active and passive. The *active* valves are the tricuspid and mitral; the *passive*, the semilunar and coronary.

The valves consist, according to King,¹ of *curtains*, *cords*, and *columns*. The *anterior valve* or *curtain* is the largest, and is so placed as to prevent the filling of the pulmonary artery during the distension of the ventricle. The *right valve* or *curtain* is of smaller size, and is situated on the right side of the auriculo-ventricular opening. The third valve, or "*fixed curtain*," is connected by its cords to the septum ventriculorum. The *cords* (chordæ tendinæ) of the anterior curtain are attached, principally to a long *column* (columna carnea), which is connected with the "right or thin and *yielding wall* of the ventricle." From the lower part of this column a transverse muscular band, the "*long moderator band*," is stretched to the septum ventriculorum, or "*solid wall*" of the ventricle. The right curtain is connected, by means of its *cords*, partly with the long column, and partly with its own proper column, the *second column*, which is also attached to the "*yielding wall*" of the ventricle. A third and smaller column is generally connected with the right curtain. The "*fixed curtain*" is so named from its attachment to the "*solid wall*" of the ventricle, by means of cords only, without fleshy columns.

From this arrangement of the valves it follows, that if the right ventricle be over distended, the thin or "*yielding wall*" will give way, and carry with it the columns of the anterior and right valve. The cords connected with these columns will draw down the edges of the corresponding valves, and produce an opening between the curtains, through which the superabundant blood may escape into the auricle, and the ventricle be relieved from over-pressure. This mechanism is therefore adapted to fulfil the function of a "*safety valve*."

The *Columnæ carneæ* (fleshy columns) is a name expressive of the appearance of the internal walls of the ventricles, which, with the exception of the infundibulum, seem formed of muscular columns interlacing in almost every direction. They are divided, according to the manner of their connection, into three sets. 1. The greater number are attached by the whole of one side, and merely form convexities into the cavity of the ventricle. 2. Others [trabeculæ carneæ] are connected by both extremities, being free in the middle. 3. A few (columnæ papillares) are attached by one extremity to the walls of the heart, and by the other give insertion to the chordæ tendinæ.

The *Semilunar valves*, [sigmoid valves], three in number, are situated around the commencement of the pulmonary artery, being formed by a folding of its lining membrane, strengthened by a thin layer of fibrous tissue. They are attached by their convex borders, and free by the concave, which are directed upwards in the course of the vessel, so that, during the current of the blood along the artery, they are pressed against the sides of the cylinder; but if regurgitation ensue, they are immediately expanded, and effectually close the entrance of the tube. The margins of the valves are thicker than the rest of their extent, and each valve presents in the centre of this margin a small fibro-cartilaginous tubercle or nodule, called *corpus Arantii*,² which locks in with the other two during the closure of the valves, and secures the triangular space which would otherwise be left by the approximation of three semilunar folds. On either side of the nodule, the edge of the valve is folded and thin. and to

¹ "Essay on the Safety-Valve Function in the Right Ventricle of the Human Heart," by T. W. King. Guy's Hospital Reports, vol. ii.

² Julius Cæsar Arantius, Professor of Medicine in Bologna. He was a disciple of Vesalius, one of the founders of modern anatomy. His treatise *De Humano Fœtu*, was published at Rome, in 1564.

this part the term *lunula* has been applied. When the valves are closed, the *lunulæ* are brought in contact with each other by their surfaces.

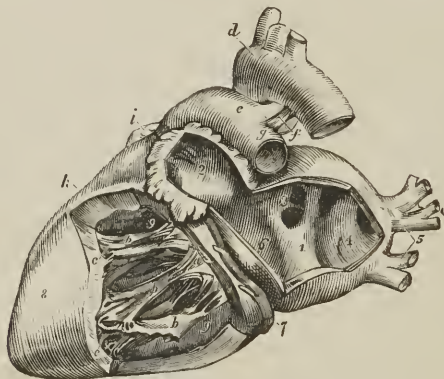
Between the semilunar valves and the cylinder of the artery are three pouches, called the *pulmonary sinuses* (sinuses of Valsalva). Similar sinuses are situated behind the valves at the commencement of the aorta, and are larger and more capacious than those of the pulmonary artery.

The *Pulmonary artery* commences by a scalloped border, corresponding with the three valves which are attached along its edge. It is connected to the ventricle by muscular fibres, and by the lining membrane of the heart.

The LEFT or POSTERIOR AURICLE is somewhat smaller, but thicker, than the right; of a cuboid form, and situated more posteriorly. The *appendix auriculæ* is constricted at its junction with the auricle, and has a foliated appearance; it is directed forwards towards the root of the pulmonary artery, to which the auriculæ of both sides appear to converge.

The left auricle is to be laid open by a **L** shaped incision, the horizontal section being made along the border which is attached to the base of the ventricle

FIG. 316.



ANATOMY OF THE HEART; LEFT SIDE. 1. Cavity of left auricle. The figure is placed on that portion of the septum auricularum corresponding with the centre of the fossa ovalis. 2. Cavity of the appendix auriculæ, near the apex of which are seen muscoli pectinati. 3. Opening of the two right pulmonary veins. 4. The sinus, into which the left pulmonary veins open. 5. Left pulmonary veins. 6. Auriculo-ventricular opening. 7. Coronary vein, lying in the auriculo-ventricular groove. 8. Left ventricle. 9, 9. Cavity of the left ventricle; the figures rest on the septum ventriculorum. a. Mitral valve; its flaps are connected by chordæ tendinæ to b, b, b, Columnæ carneæ. c, c. Fixed columnæ carneæ, forming part of the internal surface of the ventricle. d. Arch of the aorta, from the summit of which the three arterial trunks of the head and upper extremities are seen arising. e. Pulmonary artery. f. Obliterated ductus arteriosus; the letter is placed in the cleft formed by the bifurcation of the pulmonary artery. g. Left pulmonary artery. h. Right ventricle. i. Point of the appendix of right auricle.

It presents for examination five openings, and the muscular structure of the appendix; the fossa ovalis, as previously observed, is not to be seen on the left side of the septum auricularum. The parts to be examined, are, —

Four pulmonary veins,
Auriculo-ventricular opening,
Muscoli pectinati.

The *Pulmonary veins*, two from the right and two from the left lung, open into the corresponding sides of the auricle. The two left pulmonary veins terminate frequently by a common opening.

The *Auriculo-ventricular opening* is the aperture of communication between the auricle and ventricle.

The *Musculi pectinati* are fewer in number than in the right auricle, and are situated only in the appendix auriculæ.

LEFT VENTRICLE.—The left ventricle is to be opened by making an incision a little to the left of the septum ventriculorum, and continuing it around the apex of the heart to the auriculo-ventricular opening behind.

The left ventricle is conical, both in external figure and in the shape of its internal cavity. It forms the apex of the heart, by projecting beyond the right ventricle, while the latter has the advantage in length towards the base. Its walls are about seven lines in thickness, those of the right ventricle being about two lines and a half.

It presents for examination, in its interior, two openings, two [apparatus of] valves, and the tendinous cords and muscular columns; they may be thus arranged:—

Auriculo-ventricular opening,
Aortic opening,

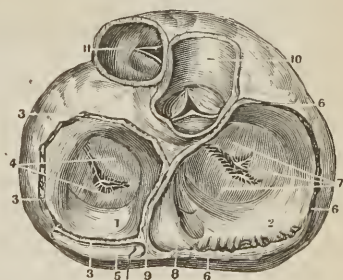
Mitral valves,
Semilunar valves,

Chordæ tendinæ,
Columnæ carneæ.

The *Auriculo-ventricular opening* is a dense fibrous ring, covered by the endocardium, but smaller in size than that of the right side. Its fibrous structure is closely connected with that of the right auriculo-ventricular and aortic

A VERTICAL VIEW OF THE AURICULO-VENTRICULAR AND ARTERIAL VALVES, AS GIVEN BY A TRANSVERSE SECTION OF THE HEART THROUGH THE AURICLES, AND OF THE ARTERIES ABOVE THEIR VALVES.—1. The left auricle. 2. The right auricle. 3, 3, 3. Section of the parietes of the left auricle. 4. Superior or auricular surface of the two folds of the mitral valve. 5. Section of the coronary vein. 6, 6, 6. Section of the parietes at the base of the right auricle. 7. Auricular surface of the three folds of the tricuspid valve. 8. Orifice of the coronary vein. 9. Septum of the auricles. 10. A section of the aorta to show its semilunar valves. 11. The pulmonary artery with its semilunar valves.]

[FIG. 317.]



rings; at the junction of the three there is a fibro-cartilaginous mass, and, in some animals, a portion of bone.

The *Mitral valves*¹ are attached around the auriculo-ventricular opening, as are the tricuspid in the right ventricle. They are thicker than the tricuspid, and consist of two segments, of which the larger is placed between the auriculo-ventricular opening and the commencement of the aorta, and acts the part of a valve to that foramen during the filling of the ventricle. The difference in size

¹[This membranous structure, like the tricuspid valve, is also most frequently spoken of as a single valve, and called *mitral*, from its appearance as a whole; the two segments, flaps, or tongues giving the appearance described in the text. It is also called "bicuspid valve" (*bis*, twice, *cuspis*, a point).]

of the two valves, both being triangular, and the space between them, has given rise to the idea of a "*bishop's mitre*," after which they were named. These valves, like the tricuspid, are furnished with an apparatus of tendinous cords, *chordæ tendineæ*, which are attached to two very large *columnæ carneæ*.

The *Columnæ carneæ* admit of the same arrangement into three kinds, as on the right side. Those which are free by one extremity, the *columnæ papillares*, are two in number, and larger than those on the opposite side; one being placed on the left wall of the ventricle, the other at the junction of the septum ventriculorum with the posterior wall.

The *Semilunar valves* [sigmoid valves] are placed around the commencement of the aorta, like those of the pulmonary artery; they are similar in structure, and are attached to the scalloped border by which the aorta is connected with the ventricle. The nodule in the centre of each fold is larger than those of the pulmonary valves, and it was these that Arantius particularly described; but the term "*corpora Arantii*," is now applied indiscriminately to both. The fossæ between the semilunar valves and the cylinder of the artery are larger than those of the pulmonary artery; and are called the "*sinus aortici*" (sinuses of Valsalva).

STRUCTURE OF THE HEART.

The arrangement of the fibres of the heart has been made the subject of careful investigation by Mr. Searle, to whose article, "Fibres of the Heart," in the Cyclopædia of the Anatomy and Physiology, I am indebted for the following summary of their distribution:—

Fibres of the Ventricles.—For the sake of clearness of description, the fibres of the ventricles have been divided into *three layers*, superficial, middle, and internal, all of which are disposed in a spiral direction around the cavities of the ventricles. The mode of formation of these three layers will be best understood by adopting the plan pursued by Mr. Searle in tracing the course of the fibres from the centre of the heart towards its periphery.

The left surface of the septum ventriculorum is formed by a broad and thick layer of fibres, which proceed backwards in a spiral direction around the posterior aspect of the left ventricle, and become augmented on the left side of that ventricle by other fibres derived from the bases of the two *columnæ papillares*. The broad and thick band formed by the fibres from these two sources, curves around the apex and lower third of the left ventricle to the anterior border of the septum, where it divides into two bands, a short or apical band, and a long or basal band.

The *Short or apical band* is increased in thickness at this point by receiving a layer of fibres (derived from the root of the aorta and *earnæ columnæ*) upon its internal surface, from the right surface of the septum ventriculorum; it is then continued onwards in a spiral direction from left to right, around the lower third of the anterior surface, and the middle third of the posterior surface of the right ventricle to the posterior border of the septum. From the latter point, the short band is prolonged around the posterior and outer border of the left ventricle to the anterior surface of the base of that ventricle, and is inserted into the anterior border of the left auriculo-ventricular ring and anterior part of the root of the aorta and pulmonary artery.

The *Long or basal band*, at the anterior border of the septum, passes directly backwards through the septum (forming its middle layer), to the posterior ventricular groove, where it becomes joined by fibres derived from the root of the pulmonary artery. It then winds spirally around the middle and upper third of the left ventricle to the anterior border of the septum, where it is connected by means of its internal surface with the superior fibres derived from the aorta, which form part of the right wall of the septum. From this point it is continued

around the upper third of the anterior and posterior surface of the right ventricle to the posterior border of the septum, where it is connected with the fibres constituting the right surface of the septum ventriculorum. At the latter point the fibres of this band begin to be twisted upon themselves, like the strands of a rope, the direction of the twist being from below upwards. This arrangement of fibres is called by Mr. Searle "the rope;" it is continued spirally upwards, forming the brim of the left ventricle, to the anterior surface of the base of that ventricle, where the twisting of the fibres ceases. The long band then curves inwards towards the septum, and spreads out upon the left surface of the septum into the broad and thick layer of fibres with which this description commenced.

The most inferior of the fibres of the left surface of the septum ventriculorum, after winding spirally around the internal surface of the apex of the left ventricle, so as to close its extremity, form a small fasciculus, which is excluded from the interior of the ventricle, and expands in a radiated manner over the surface of the heart, constituting its superficial layer of fibres. The direction of these fibres is, for the most part, oblique, passing from left to right on the anterior, and from right to left on the posterior surface of the heart, becoming more longitudinal near its base, and terminating by being inserted into the fibrous rings of the auriculo-ventricular openings, and of the pulmonary artery and aorta. Over the right ventricle, the superficial fibres are increased in number by the addition of accessory fibres from the right surface of the septum, which pierce the middle layer, and take the same direction as the superficial fibres from the apex of the left ventricle, and of other accessory fibres from the surface of both ventricles.

From this description it will be perceived that the *superficial layer* of fibres is very scanty, and is pretty equally distributed over the surface of both ventricles. The *middle layer* of both ventricles is formed by the two bands, short and long. But the *internal layer* of the two ventricles is very differently constituted; that of the left is formed by the spiral expansion of the fibres of the rope, and of the two columnæ papillares; that of the right remains to be described. The septum ventriculorum also consists of three layers, a *left layer*, the radiated expansion of the rope and carneæ columnæ; a *middle layer*, the long band; and a *right layer*, belonging to the proper wall of the right ventricle, and continuous both in front and behind with the long band, and in front also with the short band, and with the superficial layer of the right ventricle.

The *Internal layer* of the *right ventricle* is formed by fasciculi of fibres which arise from the right segment of the root of the aorta, from the entire circumference of the root of the pulmonary artery, and from the bases of the columnæ papillares. The fibres from the root of the aorta, associated with some from the carneæ columnæ, constitute a layer which passes obliquely forwards upon the right side of the septum. The superior fibres coming directly from the aorta join the internal surface of the long band at the anterior border of the septum, while the lower two-thirds of the layer are continuous with the internal surface of the short band, some of its fibres piercing that band to augment the number of superficial fibres. The fibres derived from the root of the pulmonary artery, conjoined with those from the base of one of the columnæ papillares, curve forwards from their origin, and wind obliquely downwards and backwards around the internal surface of the wall of the ventricle to the posterior border of the septum, where they become continuous with the long band, directly that it has passed backwards through the septum.

Fibres of the Auricles. — The fibres of the auricles are disposed in *two layers*, external and internal. The *Internal layer* is formed of fasciculi which arise from the fibrous rings of the auriculo-ventricular openings, and proceed upwards to enlace with each other, and constitute the appendices auricularum. These

fasciculi are parallel in their arrangement, and in the appendices form projections and give rise to the appearance which is denominated *musculi pectinati*. In their course they give off branches which connect adjoining fasciculi, and form a columnar interlacement between them.

External Layer.—The fibres of the right auricle having completed the appendix, wind from left to right around the right border of this auricle, and along its anterior aspect, beneath the appendix, to the anterior surface of the septum. From the septum they are continued to the anterior surface of the left auricle, where they separate into three bands, superior, anterior, and posterior. The *superior band* proceeds onwards to the appendix, and encircles the apex of the auricle. The *anterior band* passes to the left, beneath the appendix, and winds as a broad layer completely around the base of the auricle, and through the septum to the root of the aorta, to which it is partly attached, and from this point is continued onwards to the appendix, where its fibres terminate by interlacing with the *musculi pectinati*. The *posterior band* crosses the left auricle obliquely to its posterior part, and winds from left to right around its base, encircling the openings of the pulmonary veins; some of its fibres are lost on the surface of the auricle, others are continued onwards to the base of the aorta; and a third set, forming a small band, are prolonged along the anterior edge of the appendix to its apex, where they are continuous with the *superior band*. The septum auricularum has four sets of fibres entering into its formation; 1. The fibres arising from the auriculo-ventricular rings at each side; 2. Fibres arising from the root of the aorta, which pass upwards to the transverse band, and to the root of the superior cava; 3. Those fibres of the anterior band that pass through the lower part of the septum in their course around the left auricle; and, 4. A slender fasciculus, which crosses through the septum from the posterior part of the right auriculo-ventricular ring to the left auricle.

It will be remarked, from this description, that the left auricle is considerably thicker and more muscular than the right.

FIG. 318.



EPITHELIUM OF THE ENDOCARDIUM. 1. Nucleated cells assuming the fusiform figure. 2. Polygonal nucleated cells. Magnified 350 times. After Kölliker.

MINUTE STRUCTURE.—The *Pericardium* is a thin layer, composed of a network of fine elastic fibres, adherent by the deep surface to the muscular structure of the heart, and supporting on its free surface a single or double lamina of tessellated epithelium. Beneath the pericardium, especially in the grooves of the heart, is more or less adipose tissue, which is sometimes distributed more extensively over the surface of the organ.

The *Endocardium*, or lining membrane of the heart, is also thin, but thicker in the auricles than in the ventricles, and especially in the left auricle. It consists of three layers, namely, 1, a thin stratum of white fibrous areolar tissue, which connects it to the muscular structure: 2, a middle layer, composed of elastic tissue, which is so abundant in the auricles as to constitute a thin elastic membrane possessed of several laminae: and, 3, an epithelium, consisting of a single or double layer of more or less elongated or polygonal, flattened nucleated cells. The surface of the middle layer, on which the epithelium is imbedded, presents a smooth stratum of fine elastic fibres, arranged longitudinally, while the chief thickness of the layer is made up of fine and coarse elastic networks, connected by a matrix of areolar tissue, in the meshes of which are numerous scattered nuclei. In the ventricles the endocardium is transparent; in the auricles, particularly the left, it is opaque and white, and continuous with the lining membrane of the vessels which open into the heart.

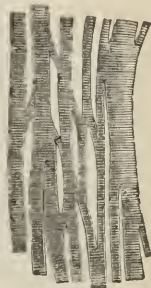
The *Muscular Fibres* are more slender and friable than those of the rest of the muscular system; the sarcolemma is more delicate; the longitudinal markings and nuclei more apparent; the fibres, more closely united together, have less intervening areolar tissue, are inextricably interlaced, and form innumerable anastomosing plexuses, a character peculiar to the muscular structure of the heart. The nuclei are placed in the axis of the fibre and in the same situation are found rows of minute fatty granules, which are excessively multiplied in fatty degeneration of the heart.

The *auriculo-ventricular valves* are composed of two layers of endocardium, connected in the body of the valve by areolar tissue, mingled with a network of elastic fibres; towards the edges of the valve, the two layers become blended with each other, and form a single membrane. The *chordæ tendineæ* consist of a fasciculus of tendinous fibres invested by a thin layer of endocardium. The *semilunar valves* are composed of a thin stratum of elastic and areolar tissue, the elastic tissue forming a fine network in the substance of the latter, and the free surface being invested by a single or double layer of epithelium.

Vessels and Nerves.—The *arteries* of the heart are derived from the left and right coronary; the *capillaries* form a fine network around the muscular fasciculi as in other muscles; the *veins* accompany the arteries, and empty themselves by the common coronary vein into the right auricle; the *venæ minimæ* or *venæ Thebesii* discharging their blood directly into the auricle. The semilunar valves are an exception to the rest of the valves of the heart, in having no bloodvessels. *Lymphatic vessels* are scanty in the bag of the pericardium, but numerous beneath the membrana propria; they follow the grooves of the heart, and terminate in the glands situated beneath the arch of the aorta, and upon the bifurcation of the trachea.

The *Nerves* of the heart are numerous, and derived from the cardiac plexuses, which are formed by filaments from the sympathetic and pneumogastric nerve, and reach the substance of the organ by means of the anterior and posterior coronary plexus. The nervous filaments partly accompany the vessels, partly cross their course, anastomose with each other at acute angles, and pierce the surface of the heart to reach its substance and the endocardium. The nerves are gray, being composed of fine pale fibres, a few only of the larger nerves containing in addition an admixture of nucleated fibres. The minute fusiform enlargements on the external branches are not ganglia, but mere thickenings of the neurilemma.

FIG. 319.



ANASTOMOISING MUSCULAR FIBRES OF THE HEART. After Kölliker.

ORGANS OF RESPIRATION AND VOICE.

The organs of respiration are the two lungs, with their air-tube, the trachea, to the upper part of which is adapted an apparatus of cartilages, constituting the organ of voice, or larynx.

THE LARYNX.

The *Larynx* is situated at the fore-part of the neck, between the trachea and base of the tongue. It is a short tube, of an hour-glass form, and composed of *cartilages, ligaments, muscles, vessels, nerves, and mucous membrane.*

The *Cartilages* are the —

Thyroid,	Two cornicula laryngis,
Cricoid,	Two cuneiform,
Two arytenoid,	Epiglottis.

The *Thyroid* (θυρεὸς εἶδος, like a shield) is the largest cartilage of the larynx: it consists of two lateral portions, or *alæ*, which meet at an angle in front, and form the projection which is known by the name of *pomum Adami*. In the male, after puberty, the angle of union of the two *alæ* is acute; in the female, and before puberty in the male, it is obtuse. Where the *pomum Adami* is prominent, a *bursa mucosa* is often found between it and the skin.

Each *ala* is quadrilateral in shape, and forms a rounded border posteriorly, which terminates above, in the *superior cornu*, and below, in the *inferior cornu*. On the side of the *ala* is an *oblique line*, or *ridge*, directed downwards and forwards, and bounded at each extremity by a tubercle. Into this line the sterno-thyroid muscle is inserted; and from it the thyro-hyoid and inferior constrictor take their origin. In the *receding angle*, formed by the meeting of the two *alæ*, on the inner side of the cartilage, and near its lower border, are attached the epiglottis, chordæ vocales, thyro-arytenoid and thyro-epiglottidean muscles.

The *Cricoid* (κρίκος, εἶδος, like a ring) is a ring of cartilage, narrow in front, and broad behind, where it is surmounted by *two rounded surfaces*, which articulate with the arytenoid cartilages. At the middle line, posteriorly, is a *vertical ridge* which gives attachment to the œsophagus, and at each side of the ridge are the depressions which lodge the crico-arytenoidei postici muscles. On either side of the ring is a *glenoid cavity*, which articulates with the inferior cornu of the thyroid cartilage.

The *Arytenoid cartilages* (ἀρρταινα,¹ a pitcher), two in number, are triangular and prismoid in form. They are broad and thick below, where they articulate with the upper border of the cricoid cartilage; pointed above, and prolonged by two small pyriform fibro-cartilages, *cornicula laryngis* (*capitula Santorini*), which are curved inwards and backwards, and they each present three surfaces, anterior, posterior, and internal. The posterior surface is concave, and lodges part of the arytenoideus muscle; the internal surface is smooth, and forms part of the lateral wall of the larynx; the anterior or external surface is rough and uneven, and gives attachment to the chorda vocalis, thyro-arytenoideus, crico-arytenoideus lateralis and posticus, and, above these, to the base of the cuneiform cartilage.

The *Cuneiform cartilages* are two small cylinders of yellow fibro-cartilage, about seven lines in length, and enlarged at each extremity. By the lower end, or base, the cartilage is attached to the middle of the external surface of the arytenoid, and by its upper extremity forms a prominence in the border of the aryteno-epiglottidean fold of membrane. They are sometimes wanting.

In the male, the cartilages of the larynx are more or less ossified, particularly in old age.

The *Epiglottis* (ἐπιγλωττίς, upon the tongue) is a fibro-cartilage of a yellowish color, studded with a number of small mucous glands, which are lodged in shallow pits on its surface. It is shaped like a cordate leaf, and placed immediately in front of the opening of the larynx, which it closes completely when the larynx is drawn up beneath the base of the tongue. It is attached by its point to the *receding angle* of the thyroid cartilage.

¹ This derivation has reference to the appearance of both cartilages taken together and covered by mucous membrane. In animals, which were the principal subjects of dissection among the ancients, the opening of the larynx with the arytenoid cartilages bears a curious resemblance to the mouth of a pitcher with a large spout.

Ligaments.—The *ligaments* of the larynx are numerous, and may be arranged into four groups: 1. Those which articulate the thyroid with the os hyoides. 2. Those which connect it with the cricoid. 3. Ligaments of the arytenoid cartilages. 4. Ligaments of the epiglottis.

1. The ligaments which connect the thyroid cartilage with the os hyoides are three in number.

Two *Thyro-hyoidean ligaments* pass between the superior cornua of the thyroid and the extremities of the greater cornua of the os hyoides: a sesamoid bone or cartilage is found in each.

The *Thyro-hyoidean membrane* is a broad membranous layer, occupying the entire space between the upper border of the thyroid cartilage and the upper and inner border of the os hyoides. It is pierced by the superior laryngeal nerve and artery.

2. The ligaments connecting the thyroid to the cricoid cartilage are also three in number.

Two *Capsular ligaments*, with their synovial membranes, which form the articulation between the inferior cornua of the thyroid and the sides of the cricoid; and the crico-thyroidean membrane.

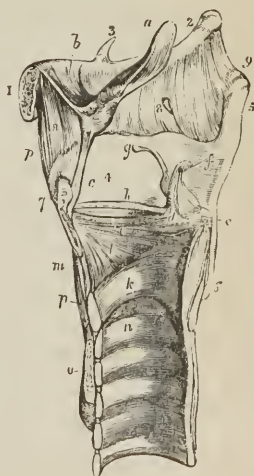
The *Crico-thyroidean membrane* is a fan-shaped layer of yellow elastic tissue, thick in front (middle crico-thyroidean ligament) and thinner at each side (lateral crico-thyroidean ligament). It is attached by its apex to the lower border and receding angle of the thyroid cartilage, and by its expanded margin to the upper border of the cricoid and base of the arytenoid cartilages. Superiorly it is continuous with the inferior margin of the chordæ vocales. The front of the crico-thyroidean membrane is crossed by a small artery, the inferior laryngeal, and is the spot selected for the operation of laryngotomy. Laterally it is covered in by the crico-thyroidei and crico-arytenoidei laterales muscles.

3. The ligaments of the arytenoid cartilages are eight in number.

Two *Capsular ligaments*, with synovial membranes, which articulate the arytenoid cartilages with the cricoid, strengthened behind by two *posterior crico-arytenoid bands* or ligaments; and the superior and inferior thyro-arytenoid ligaments.

VERTICAL SECTION OF THE LARYNX, SHOWING ITS LIGAMENTS. 1. Body of os hyoides. 2. Its great cornu. 3. Lesser cornu. 4. Ala of the thyroid cartilage. 5. Superior cornu. 6. Inferior cornu. 7. Pomum Adami. 8. Thyro-hyoidean membrane; the opening in the membrane immediately above the posterior figure is for the passage of the superior laryngeal nerve and artery. 9. Thyro-hyoidean ligament; the figure is placed immediately above the sesamoid bone or cartilage. a. Epiglottis. b. Hyo-epiglottic ligament. c. Thyro-epiglottic ligament. d. Arytenoid cartilage; inner surface. e. Outer angle of base of arytenoid cartilage. f. Corniculum laryngis. g. Cuneiform cartilage. h. Superior thyro-arytenoid ligament. i. Inferior thyro-arytenoid ligament, or chorda vocalis, the elliptical space between the two thyro-arytenoid ligaments is the ventricle of the larynx. k. Cricoid cartilage. l. Lateral portion of the crico-thyroidean membrane. m. Central portion of the same membrane. n. Upper ring of trachea. o. Section of isthmus of thyroid gland. p. p. Levator glandulæ thyroideæ.

FIG. 320.



The *superior thyro-arytenoid ligaments* are two thin bands of yellow elastic tissue attached in front to the receding angle of the thyroid cartilage, and behind

to the anterior and inner border of each arytenoid cartilage. The lower border of this ligament constitutes the upper boundary of the ventricle of the larynx, and the fold of mucous membrane caused by its prominence has been called the superior or false chorda vocalis.

The *inferior thyro-arytenoid ligaments* or true *chordæ vocales*, are thicker than the superior, and like them composed of yellow elastic tissue. Each ligament is attached in front to the receding angle of the thyroid cartilage, and behind to the anterior angle of the base of the arytenoid. The inferior border of the chorda vocalis is continuous with the lateral expansion of the crico-thyroid ligament. The superior border forms the lower boundary of the ventricle of the larynx. The space between the two chordæ vocales is the glottis or rima glottidis.

4. The ligaments of the epiglottis are five in number, namely, three glosso-epiglottic, hyo-epiglottic, and thyro-epiglottic.

The *glosso-epiglottic ligaments* (fræna epiglottidis) are three folds of mucous membrane, which connect the anterior surface of the epiglottis with the root of the tongue. The middle of these contains elastic tissue. The *hyo-epiglottic ligament* is a band of yellow elastic tissue passing between the anterior aspect of the epiglottis near its apex, and the upper margin of the body of the os hyoides. The *thyro-epiglottic ligament* is a long and slender fasciculus of yellow elastic tissue, which embraces the apex of the epiglottis, and is inserted into the receding angle of the thyroid cartilage immediately below the anterior fissure and above the attachment of the chordæ vocales.

Muscles.—The muscles of the larynx are eight in number; the five larger are the muscles of the chordæ vocales and rima glottidis; the three smaller are muscles of the epiglottis.

[These are the *intrinsic* muscles (the *extrinsic* muscles which move the larynx as a whole have been previously described). They exist in pairs, with the exception of the arytenoideus, which is a single muscle.]

The five muscles of the chordæ vocales and rima glottidis, are—

Crico-thyroid,	Thyro-arytenoideus,
Crico-arytenoideus posticus,	Arytenoideus.
Crico-arytenoideus lateralis,	

The *Crico-thyroid* muscle *arises* from the anterior surface of the cricoid cartilage, and passes obliquely outwards and backwards to be *inserted* into the lower and inner border of the ala of the thyroid, from its tubercle as far back as the inferior cornu.

The *Crico-arytenoideus posticus*, *arises* from the depression on the posterior surface of the cricoid cartilage, and passes upwards and outwards to be *inserted* into the outer angle of the base of the arytenoid.

The *Crico-arytenoideus lateralis*, *arises* from the upper border of the side of the cricoid, and passes upwards and backwards to be *inserted* into the outer angle of the base of the arytenoid cartilage.

The *Thyro-arytenoideus*, *arises* from the receding angle of the thyroid cartilage, close to the outer side of the chorda vocalis, and passes backwards parallel with the cord, to be *inserted* into the base and outer surface of the arytenoid cartilage.

The *Arytenoideus* muscle occupies the posterior concave surface of the arytenoid cartilages, between which it is stretched. It consists of three planes of transverse and oblique fibres; hence it was formerly considered as several muscles, under the names of *transversi* and *obliqui*.

The three muscles of the epiglottis are—

Thyro-epiglottideus,
Aryteno-epiglottideus superior,
Aryteno-epiglottideus inferior.

The *Thyro-epiglottideus* appears to be formed by the upper fibres of the thyro-arytenoideus muscle; they spread out on the external surface of the sacculus laryngis, and in the aryteno-epiglottidean fold of mucous membrane, on which they are lost; a few of the anterior fibres being continued onwards to the side of the epiglottis (*depressor epiglottidis*).

Fig. 321.

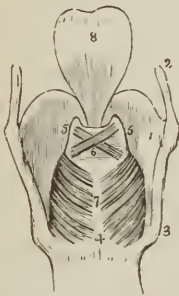
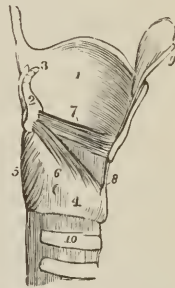


Fig. 322.



POSTERIOR VIEW OF THE LARYNX. 1. Thyroid cartilage, right ala. 2. Ascending cornu. 3. Descending cornu. 4, 7. Cricoid cartilage. 5, 5. Arytenoid cartilages. 6. Arytenoideus muscle, consisting of oblique and transverse fasciculi. 7. Crico-arytenoidei postici muscles. 8. Epiglottis.

SIDE VIEW OF LARYNX, ONE ALA OF THE THYROID CARTILAGE REMOVED. 1. Left ala of thyroid cartilage. 2. Right arytenoid cartilage. 3. Corniculum laryngis. 4. Cricoid cartilage. 5. Crico-arytenoideus posterior muscle. 6. Crico-arytenoideus lateralis. 7. Thyro-arytenoideus. 8. Crico-thyroidean membrane. 9. One half the epiglottis. 10. Upper part of trachea.

The *Aryteno-epiglottideus superior* consists of a few scattered muscular fibres, which pass forwards in the fold of mucous membrane forming the lateral boundary of the entrance into the larynx, from the apex of the arytenoid cartilage to the side of the epiglottis.

The *Aryteno-epiglottideus inferior*, described by Hilton, and closely connected with the sacculus laryngis, may be seen by raising the mucous membrane immediately above the ventricle of the larynx. It *arises* by a narrow and fibrous origin from the arytenoid cartilage, just above the attachment of the chorda vocalis; and passing forwards and a little upwards, expands over the upper half or two-thirds of the sacculus laryngis; it is *inserted* by a broad attachment into the side of the epiglottis.

Actions.—From a careful examination of the muscles of the larynx, Bishop¹ concludes that the crico-arytenoidei postici open the glottis, while all the rest close it. The arytenoideus approximates the arytenoid cartilages posteriorly, and the crico-arytenoidei laterales and thyro-arytenoidei anteriorly; the latter, moreover, close the glottis mesially. The crico-thyroidei are tensors of the chordæ vocales, and these muscles, together with the thyro-arytenoidei, regulate the tension, position, and vibrating length of the vocal cords.

The crico-thyroid muscles effect the tension of the chordæ vocales by rotating the cricoid on the inferior cornua of the thyroid; by this action the anterior portion is drawn upwards, and made to approximate the inferior border of the

¹ Cyclopædia of Anatomy and Physiology, art. Larynx.

thyroid, while the posterior and superior border of the cricoid, together with the arytenoid cartilages, is carried backwards. The crico-arytenoidei postici separate the chordæ vocales by drawing the outer angles of the arytenoid cartilages outwards and downwards. The crico-arytenoidei laterales, by drawing the outer angles of the arytenoid cartilages forwards, approximate the anterior angles to which the chordæ vocales are attached. The thyro-arytenoidei draw the arytenoid cartilages forwards, and, by their connexion with the chordæ vocales, act upon the whole length of those cords.

The thyro-epiglottideus acts principally by compressing the glands of the sacculus laryngis and the sacculus itself; by its attachment to the epiglottis it would act feebly upon that valve. The aryteno-epiglottideus superior serves to keep the mucous membrane of the sides of the opening of the glottis tense, when the larynx is drawn upwards and the opening closed by the epiglottis. Of the aryteno-epiglottideus, the "functions appear to be," writes Mr. Hilton, "to compress the subjacent glands which open into the pouch; to diminish the capacity of that cavity, and change its form; and to approximate the epiglottis and the arytenoid cartilage."

Mucous Membrane.—The aperture of the larynx is a triangular or cordiform opening, broad in front and narrow behind; bounded anteriorly by the epiglottis, posteriorly by the arytenoideus muscle, and on either side by a fold of mucous membrane stretched between the side of the epiglottis and the apex of the arytenoid cartilage. On the margin of this *aryteno-epiglottidean* fold the cuneiform cartilage forms a prominence more or less distinct. The cavity of the larynx is divided into two parts by an oblong constriction produced by the prominence of the chordæ vocales. That portion of the cavity which lies above the constriction is broad and triangular above, and narrow below; that which is below it, is narrow above and broad and cylindrical below, the circumference of the cylinder corresponding with the ring of the cricoid; while the space included by the constriction is a narrow, triangular fissure, the *glottis* or *rima glottidis*. The form of the glottis is that of an isosceles triangle, bounded on the sides by the chordæ vocales and inner surface of the arytenoid cartilages, and behind by the arytenoideus muscle. Its length is greater in the male than in the female, and in the former measures somewhat less than an inch. Immediately above the prominence caused by the chorda vocalis, and extending nearly its entire length on each side of the cavity of the larynx, is an elliptical fossa, the *ventricle of the larynx*. This fossa is bounded below by the chorda vocalis, which it serves to isolate, and above by a border of mucous membrane folded upon the lower edge of the superior thyro-arytenoid ligament (superior or false chorda vocalis). The whole of the cavity of the larynx, with its prominences and depressions, is lined by mucous membrane, which is continuous superiorly with that of the mouth and pharynx, and inferiorly is prolonged through the trachea and bronchial tubes into the lungs. In the ventricles of the larynx the mucous membrane forms a cæcal pouch of variable size, termed by Hilton the *sacculus laryngis*.¹ The sacculus laryngis is directed upwards, sometimes extending as

¹ This sac was described by Mr. Hilton before he was aware that it had already been pointed out by the older anatomists. I myself made a dissection, of the same sac in an enlarged state, during the month of August, 1837, without any knowledge of either Mr. Hilton's labors or Morgagni's account. The sac projected considerably above the upper border of the thyroid cartilage, and the extremity had been snipped off at one side in the removal of the muscles. The larynx was sent to me by Dr. George Moore; he had obtained it from a child who died of bronchial disease; and he conceived that this peculiar disposition of the mucous membrane might possibly explain some of the symptoms by which the case was accompanied. Cruveilhier made the same observation in ignorance of Morgagni's description, for we read in a note at page 677, vol. ii. of his *Anatomie Descriptive*, — "J'ai vu pour la première fois cette arrière cavité chez un individu affecté de phtisie laryngée, où elle était très-développée. Je fis des recherches sur le larynx l'autres individus, et je trouvai que cette disposition était constante. Je ne savais pas alors

high as the upper border of the thyroid cartilage, and occasionally above that border. When dissected from the interior of the larynx it is found covered by the aryteno-epiglottideus muscle and a fibrous membrane, which latter is attached to the superior thyro-arytenoid ligament below; to the epiglottis in front; and to the upper border of the thyroid cartilage above. If examined from the exterior of the larynx, it will be seen to be covered by the thyro-epiglottideus muscle. On the surface of its mucous membrane are the openings of sixty or seventy small racemose glands, which are situated in the submucous tissue, and give to its external surface a rough and ill-dissected appearance. The secretion from these glands is intended for the lubrication of the chordæ vocales, and is directed upon them by two small valvular folds of mucous membrane, which are situated at the entrance of the sacculus. The mucous membrane is closely connected to the epiglottis and to the chordæ vocales, on the latter being remarkable for its thinness. It is invested by a columnar ciliated epithelium as high up as the superior folds of the ventricle of the larynx and lower half of the epiglottis.

Glands.—The mucous membrane of the larynx is furnished with an abundance of mucous glands; many of these are situated on the epiglottis, in the sacculus laryngis, and in the aryteno-epiglottidean folds, where they are termed *arytenoid*. The body known as the epiglottic gland is merely a mass of areolar and adipose tissue, situated in the triangular space between the front surface of the apex of the epiglottis, the hyo-epiglottidean and the thyro-hyoidean ligament.

Vessels and Nerves.—The *Arteries* of the larynx are derived from the superior and inferior thyroid. The *Nerves* are the superior laryngeal and recurrent laryngeal; both branches of the pneumogastric. The two nerves communicate with each other; but the superior laryngeal is distributed principally to the mucous membrane at the entrance of the larynx; the recurrent, to the muscles.

THE TRACHEA.

The TRACHEA or wind-pipe is cylindrical for about two-thirds of its circumference, and flattened on the posterior third, where it rests on the œsophagus; it extends from opposite the fifth cervical vertebra to opposite the third dorsal, where it divides into the two bronchi. The length of the trachea is about four inches, and its diameter from side to side nearly an inch; it is somewhat larger in the male than in the female. The *right bronchus*, larger than the left, passes off nearly at *right angles*, to the upper part of the corresponding lung. The *left* descends *obliquely*, and passes beneath the arch of the aorta, to reach the left lung.

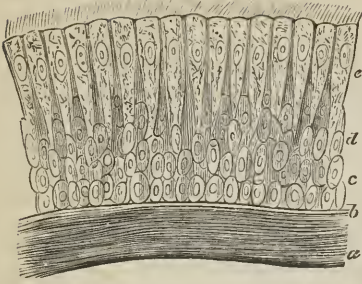
It is composed of cartilaginous rings, fibrous membrane, muscular fibres, elastic tissue, and is lined by mucous membrane.

The *Cartilaginous rings* are from fifteen to twenty in number, and extend for two-thirds around its cylinder, being deficient at the posterior part. The first ring is received within the lower margin of the cricoid cartilage, and is broader than the rest; the last is broad at the middle in consequence of the prolongation of the lower border into a triangular process which curves backwards at the point of bifurcation. The posterior extremities of the rings are rounded, and occasionally one or two rings will be found to bifurcate.

The *Fibrous membrane* connects the rings and forms a thin covering to them on the outer surface. Internally it does not reach the surface, and the rings have in consequence an appearance of greater prominence. It also stretches across between the rings on the posterior part of the trachea.

que Morgagni avait indiqué et fait représenter la même disposition." Cruveilhier compares its form very aptly to a "*Phrygian casque*," and Morgagni's figure, *Advers.* 1. *Epist. Anat.* 3. plate 2. fig. 4, has the same appearance. But neither of these anatomists notice the glands described by Mr. Hilton.

FIG. 323.



CILIATED EPITHELIUM FROM THE TRACHEA; after Kölliker. *a.* External layer of longitudinal elastic fibres. *b.* Homogeneous surface layer of the mucous membrane. *c.* Round cells. *d.* Oval and oblong cells. *e.* Ciliated cells.

substance of the fibrous membrane between the rings. Their ducts open upon the mucous membrane.

The *Muscular fibres* are disposed transversely across the space, between the extremities of the rings behind. They are placed internally to the fibrous membrane.

The *Elastic tissue* is disposed in longitudinal bundles, within the rings; and, internally to the muscular layer behind.

The *Mucous membrane*, which is pale, forms the internal lining of the tube, and has opening upon its surface the excretory tubes of numerous mucous glands; it is furnished with a ciliated columnar epithelium, which is continuous with that of the larynx above and the bronchial tubes below.

The *Mucous glands* are small ovoid bodies situated externally to the fibrous membrane, between that membrane and the muscular layer behind, and in the

THYROID GLAND.

The thyroid gland or body is a *blood-vascular gland*; in other words, it secretes into the numerous cells of which it is composed, a peculiar fluid, which, originally separated from the blood, is again taken up by the veins or lymphatic vessels or both, and conveyed into the circulation, in this way performing some function in connexion with the formation or renovation of the blood. It is situated on the trachea, and may therefore be considered in this place, although bearing no part in the function of respiration.

This gland consists of two lobes, which are placed one on each side of the trachea, and are connected with each other by means of an *isthmus*, which crosses its upper rings, usually the third and fourth; but in this respect there is some variety, a point necessary to be remembered in operations on the trachea. The lobes are somewhat conical in shape, being larger below than above, and the smaller end is continued upwards to the side of the thyroid cartilage. The isthmus is connected with the lower third of the two lobes, and [its upper part] often gives origin to a process of variable length and size, called the *pyramid* or third lobe. The pyramid is generally situated on the left side of the isthmus, and is sometimes derived from the left lobe. The left lobe is somewhat smaller than the right, the weight of the entire gland being about one ounce and a half. It is, however, larger in young persons and females than in adult males, and undergoes a slight increase during menstruation. Its permanent enlargement constitutes bronchocele, goitre, or the Derbyshire neck.

The structure of the thyroid is of a brownish-red color, and is composed of a dense aggregation of minute and independent membranous cavities or vesicles inclosed by a plexus of capillary vessels, and connected together by areolar tissue. The vesicles are composed of a *membrana propria* lined by a *tesselated epithelium* of nucleated cells, and contain a clear yellowish fluid, in which are found cytoblasts and cells; the latter measuring $\frac{1}{14,000}$ of an inch in diameter.

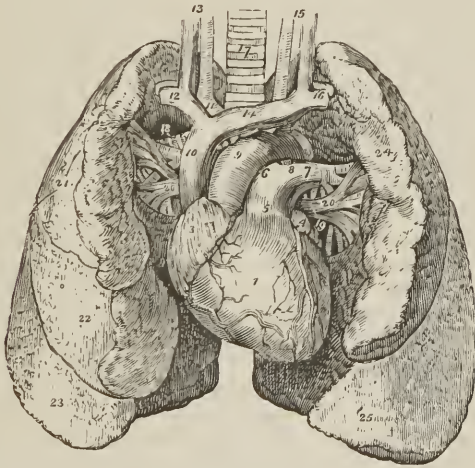
A muscle is occasionally found connected with its isthmus, or with the pyramid, and is attached, superiorly, to the body of the os hyoides, or to the thyroid cartilage. It was named by Soemmering, "*levator glandulæ thyroideæ*," fig. 320

Vessels and Nerves. — It is abundantly supplied with blood by the superior and inferior thyroid arteries. Sometimes an additional artery [see p. 289,] is derived from the arteria innominata, and ascends upon the front of the trachea to be distributed to the gland. The wounding of the latter vessel, in tracheotomy, might be fatal to the patient. The *nerves* are derived from the superior laryngeal and from the middle and inferior cervical ganglia of the sympathetic.

THE LUNGS.

The lungs are two conical organs, situated one at each side of the chest, embracing the heart, and separated from each other by that organ and by a membranous partition, the mediastinum. On the external or thoracic side they are convex, and correspond with the form of the cavity of the chest; internally they are concave, to receive the convexity of the heart. Superiorly they terminate in a tapering cone, which extends above the level of the first rib into the root of the neck, and inferiorly they are broad and concave, and rest on the convex surface of the diaphragm. Their posterior border is rounded, broad and long; the anterior, sharp, short, and marked by one or two deep fissures; and the inferior border which surrounds the base is also sharp. The color of the lungs is pinkish-gray, mottled, and variously marked with black. The surface is figured with irregularly polyhedral outlines, which represent the lobules of the organ, and the area of each of these polyhedral spaces is crossed by lighter lines representing smaller lobules. The weight of the lungs is about forty ounces, the right lung being two ounces heavier than the left.

FIG. 324.



HEART AND LUNGS. 1. Right ventricle; the vessels to the left of the figure are the middle coronary artery and veins; those to its right, the left coronary artery and veins. 2. Left ventricle. 3. Right auricle. 4. Left auricle. 5. Pulmonary artery. 6. Right pulmonary artery. 7. Left pulmonary artery. 8. Ligament of the ductus arteriosus. 9. Arch of the aorta. 10. Superior vena cava. 11. Arteria innominata, and, in front of it, the right vena innominata. 12. Right subclavian vein, and, behind it, its corresponding artery. 13. Right common carotid artery and vein. 14. Left vena innominata. 15. Left carotid artery and vein. 16. Left subclavian vein and artery. 17. Trachea. 18. Right bronchus. 19. Left bronchus. 20, 20. Pulmonary veins; 18, 20, form the root of the right lung; and 7, 19, 20, the root of the left. 21. Superior lobe of the right lung. 22. Middle lobe. 23. Inferior lobe. 24. Superior lobe of the left lung. 25. Inferior lobe.

Each lung is divided into two lobes, by a long and deep fissure, which extends from the posterior surface of the upper part of the organ, downwards and forwards to near the anterior angle of its base. In the right lung the upper lobe is subdivided by a second fissure, which extends obliquely forwards from the middle of the preceding to the anterior border of the organ, and marks off a small triangular lobe. The left lung presents a deep notch in its anterior border, at a point corresponding with the apex of the heart.

The right lung is larger than the left, in consequence of the inclination of the heart to the left side. It is also shorter, from the great convexity of the liver, which presses the diaphragm upwards on the right side of the chest, considerably above the level of the left; and it has three lobes. The left lung is smaller, has only two lobes, but is longer than the right.

Each lung is retained in its place by its *root*, which is formed by the pulmonary artery, pulmonary veins, and bronchial tubes, together with the bronchial vessels and pulmonary plexuses of nerves. The groove on the surface of the lung where the vessels enter its substance is the hilum pulmonis; and the position of the large vessels in the root of the lung, as follows: from before, backwards, they are placed in a similar order on both sides, viz.,

Pulmonary veins,

Pulmonary artery,

Bronchus.

From above downwards, on the *right* side, this order is exactly reversed; but on the *left* side, the bronchus has to stoop beneath the arch of the aorta, which alters its position to the vessels. They are thus disposed on the two sides:—

Right, {
 Bronchus,
 Artery,
 Veins.

Left, {
 Artery,
 Bronchus,
 Veins.

The special relations of the roots of the lung are, for the right, the descending aorta, which lies in front, and the vena azygos, which arches over it from behind to terminate in the superior vena cava. The root of the left lung has the descending aorta lying behind it.

Structure — The lungs are composed of the ramifications of the bronchial tubes (*bronchia*), which terminate in intercellular passages and air-cells, of the ramifications of the pulmonary arteries and veins, bronchial arteries and veins, lymphatics, and nerves; the whole of these structures, being held together by areolar tissue, constitute the *parenchyma*. The parenchyma of the lungs, when examined on the surface or by means of a section, is seen to consist of small polyhedral divisions, or lobules, which are connected to each other by an interlobular areolar tissue. These lobules again consist of smaller lobules, and the latter are formed by a cluster of air-cells, in the parietes of which the capillaries of the pulmonary artery and pulmonary veins are distributed. Each lobule, taken alone, is provided with its separate bronchial tube, pulmonary artery, and vein, and is isolated from surrounding lobules by a process of areolar membrane derived from the subserous tissue; the entire lung is an assemblage of these lobules, so separated and so connected, held together by the pleura.

The serous investing membrane of the lungs or pleura is connected with the surface of the lobules by means of a *subserous areolar tissue*, which forms a distinct layer, and being prolonged between the lobules, is the bond of adhesion between them. This layer contains elastic tissue, and is a chief source of the elasticity of the lungs; its interstices are moistened by a serous secretion, and are unnumbered with fat.

Bronchial Tubes.—The two bronchi proceed from the bifurcation of the trachea opposite the third dorsal vertebra to their corresponding lungs. The right, about an inch long, takes its course nearly at right angles with the

trachea, and enters the upper part of the right lung; while the left, two inches in length, and smaller than the right, passes obliquely beneath the arch of the aorta, and enters the lung at about the middle of its root. Upon entering the lungs, they divide into two branches, and each of these divides and subdivides dichotomously to their ultimate termination in the intercellular passages and air-cells.

According to Rainey,¹ the bronchial tubes continue to diminish in size until they attain a diameter of $\frac{1}{50}$ to $\frac{1}{30}$ of an inch, and arrive within $\frac{1}{8}$ of an inch of the surface of the lung. They then become changed in structure, and are continued onwards in the midst of air-cells, under the name of *intercellular passages*. Lastly, the intercellular passages, after several bifurcations, terminate each by a caecal extremity or air-cell. The intercellular passages are at first cylindrical, like the bronchial tubes, but soon become irregular in shape from the great number of air-cells which open into them on all sides. The *air-cells* in the adult lung measure between $\frac{1}{200}$ and $\frac{1}{70}$ of an inch, they are irregular in shape, and, most frequently, four-sided cavities, separated by thin septa, and communicating freely with the intercellular passages, and sparingly with the bronchial tubes.

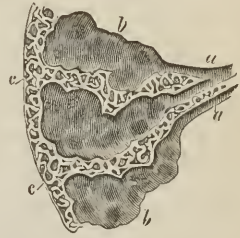
In structure the bronchial tubes are composed of cartilages, fibrous membrane, muscular fibres, elastic fibres, and mucous membrane. The *cartilages* in the primary bronchi are six or eight in number in the right bronchus, and ten or twelve in the left [and like those of the trachea are imperfect behind]. In the subsequent divisions of the bronchial tubes, which are cylindrical in figure, the cartilages assume the form of thin plates of irregular shape and size, adapted to each other by their edges, and completely surrounding the tubes. The plates are most strongly developed around the bifurcations of the tubes, and the point of division is furnished with a cartilage of a semilunar form. They are found entering into the structure of the bronchial tubes until the latter are reduced to a quarter of a line in diameter, and are then lost.

The *fibrous membrane*, which enters largely into the formation of the trachea and bronchial tubes, is the principal coat of the smallest tubes, and is continued to their terminations in the intercellular passages and air-cells.

The *muscular fibres*, belong to the class of non-striated, smooth, or organic muscle, they are arranged in rings around the tube, and form a muscular coat which is placed externally to the cartilaginous plates and is continued as far as the extremity of the tubes, being absent in the intercellular passages and air-cells. The *elastic fibres*, arranged in longitudinal fasciculi, form a thin stratum next the mucous lining; this elastic coat is prolonged to the ends of the tubes, and scattered fibres are found around the intercellular passages and air-cells. The *mucous membrane*, lining the bronchial tubes, is provided with a ciliated columnar epithelium as far as their termination; but in the intercellular passages and air-cells it is altered in its characters, is thin and transparent, and coated with a squamous epithelium.

The capillaries of the lungs form plexuses which occupy the walls and septa of the air-cells and the walls of the intercellular passages, but are not continued into the bronchial tubes. The septa between the air-cells consist of a single layer of the capillary plexus inclosed in a fold of the mucous lining membrane.

FIG. 325.



A DIAGRAM SHOWING THE DILATATION OF THE ULTIMATE BRONCHIAL TUBES INTO INTERCELLULAR PASSAGES, and the enlargement of the latter near the surface of the lung. *a, a.* Bronchial tubes *b, b.* Intercellular passages, on the walls of which are seen opening the air-cells. *c, c.* Air-cells near the surface of the lung.

¹ Medico-Chirurgical Transactions, vol. xxviii.

The air-cells of the central parts of the lung are most vascular, and at the same time smallest, whilst those of the periphery are less vascular and larger.

The pigmentary matter of the lungs is contained in the air-cells, as well as in the areolar tissue of the interlobular spaces and bloodvessels; it is composed chiefly of carbon.

The *Pulmonary artery*, conveying the dark and impure venous blood to the lungs, terminates in capillary vessels, which form a dense network in the parietes of the intercellular passages and air-cells, and then converge to form the pulmonary veins, by which the arterial blood, purified in its passage through the capillaries, is returned to the left auricle of the heart.

The *Bronchial arteries*, branches of the thoracic aorta, ramify on the parietes of the bronchial tubes, and terminate partly in bronchial veins which convey the venous blood to the vena azygos on the right side, and the superior intercostal vein on the left; and partly in the pulmonary capillaries.

The *Lymphatics*, commencing on the surface and in the substance of the lungs, terminate in the bronchial glands. These glands, very numerous and often of large size, are placed at the roots of the lungs, around the bronchi, and at the bifurcation of the trachea. In early life they resemble lymphatic glands in other situations; but in old age, and often in the adult, are black, and filled with carbonaceous matter, and occasionally with calcareous deposits.

The *Nerves* are derived from the pneumogastric and sympathetic. They form two plexuses: *anterior pulmonary plexus*, situated upon the front of the root of the lungs, and composed chiefly of filaments from the deep cardiac plexus; and *posterior pulmonary plexus*, on the posterior aspect of the root of the lungs, composed principally of branches from the pneumogastric. The branches from these plexuses follow the course of the bronchial tubes, and are distributed to the intercellular passages and air-cells.

PLEURÆ.

Each lung is inclosed, and its structure maintained, by a serous membrane, the pleura [*πλευρα*, the side], which invests it as far as the root, and is then reflected on the parietes of the chest. That portion of the membrane which is in relation with the lung is called *pleura pulmonalis*, and that in contact with the parietes, *pleura costalis*. The reflected portion, besides forming the internal lining to the ribs and intercostal muscles, also covers the diaphragm and thoracic surface of the vessels at the root of the neck, extending for somewhat more than an inch above the margin of the first rib. At the lower border of the root of the lung is a fold of the pleura, which extends down by the side of the posterior mediastinum to the diaphragm, and serves to retain the lower part of the lung in position. This fold is the broad ligament of the lung, *ligamentum latum pulmonis*.

On its external surface, where the pleura is connected with surrounding parts, it is rough; on its inner surface, smooth. At the right side, where the diaphragm is pressed upwards by the liver, the pleura is shorter than on the left, but extends higher into the neck; while the left pleura, in consequence of the encroachment of the heart on the left side of the chest, is narrower than the right.

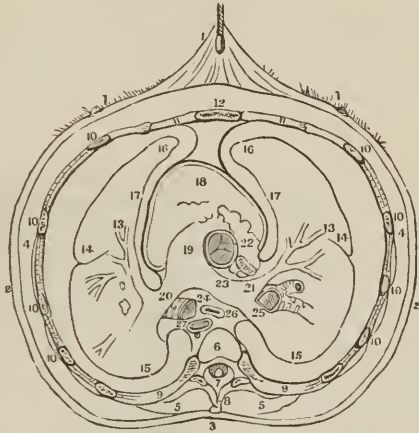MEDIASTINUM.

The approximation of the two reflected pleuræ in the middle line of the thorax forms a septum, which divides the chest into the two pulmonary cavities. This is the mediastinum. The two pleuræ are not, however, in contact with each other at the middle line in the formation of the mediastinum, but have a space between them which contains all the viscera of the chest with the excep-

tion of the lungs. The mediastinum is divided into an *anterior*, *middle*, and *posterior* portion.

The *Anterior mediastinum* is a triangular space, bounded in front by the sternum, and at each side by the pleura. It contains a quantity of loose areolar

[FIG. 326.



AN OUTLINE OF A TRANSVERSE SECTION OF THE CHEST, SHOWING THE RELATIVE POSITION OF THE PLEURÆ TO THE THORAX AND ITS CONTENTS. 1, 1, 2, 3. The skin covering the chest. 4, 4. The subcutaneous fat, and muscles on the outside of the thorax. 5, 5. Muscles in the vertebral grooves. 6. Fifth dorsal vertebra. 7. The Spinal canal. 8. Spinous process. 9, 9, 10, 10. Sections of the ribs and intercostal muscles. 11, 11. Costal cartilages. 12. The sternum. 13. The division of the pulmonary artery. 14. The external surface of the lungs. 15. Posterior border of the lungs. 16. Anterior border of the lungs. 17. Inner surface of the lungs. 18. Anterior surface of the heart covered by the pericardium. 19. Pulmonary artery. 20, 21. Its division into right and left branches. 22. Portion of the right auricle. 23. Descending aorta cut off at the right auricle. 24. Section of the left bronchus. 25. Section of the right bronchus. 26. The œsophagus. 27. The thoracic aorta. The space between figures 12 and 18 and the two 16's is the anterior mediastinum, and the space which contains 26 and 27 is the posterior mediastinum. The middle mediastinum is between the anterior and posterior mediastina. These spaces are formed by the reflexions of the pleuræ.]

tissue, in which are found some lymphatic vessels passing upwards from the liver, the remains of the thymus gland, the origin of the sterno-hyoid, sterno-thyroid, and left triangularis sterni muscle, and the left internal mammary vessels.

The *Middle mediastinum* contains the heart inclosed in its pericardium; the ascending aorta; superior vena cava; pulmonary arteries and veins; bifurcation of the trachea; and phrenic nerves.

The *Posterior mediastinum* is bounded behind by the vertebral column, in front by the pericardium, and at each side by the pleura. It contains the aorta; the greater and lesser azygos vein, and superior intercostal veins; the thoracic duct; œsophagus and pneumogastric nerves; and the great splanchnic nerves.

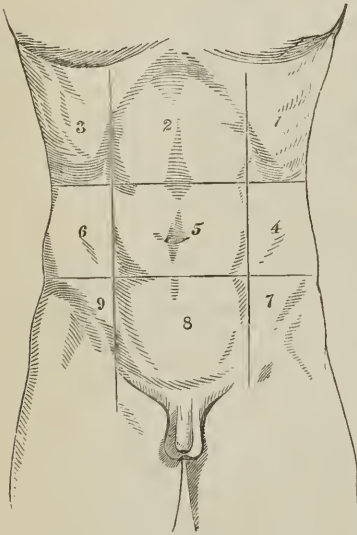
ABDOMEN.

The abdomen is the inferior cavity of the trunk of the body; it is bounded *in front* and *at the sides* by the lower ribs and abdominal muscles; *behind*, by the vertebral column and abdominal muscles; *above*, by the diaphragm; and, *below*, by the pelvis; and contains, the alimentary canal, the organs subservient

to digestion, viz., the liver, pancreas, and spleen; and the organs of excretion, the kidneys, with the supra-renal capsules.

Regions. — For convenience of description of the viscera, and of reference to the morbid affections of this cavity, the abdomen is divided into certain districts or regions. Thus, if two transverse lines be carried around the body, the one parallel with the cartilages of the eighth ribs, the other with the highest point of the crests of the ilia, the abdomen will be divided into three zones. Again, if a perpendicular line be drawn, at each side, from the cartilage of the eighth rib to the middle of Poupart's ligament, the three primary zones will each be subdivided into three compartments or regions, middle and two lateral.

[FIG. 327.]

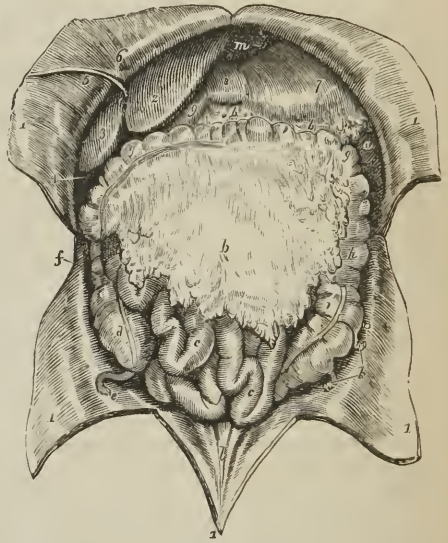


REGIONS OF THE ABDOMEN. 1. Left hypochondriac. 2. Epigastric. 3. Right hypochondriac. 4. Left lumbar. 5. Umbilical. 6. Right lumbar. 7. Left iliac. 8. Hypogastric. 9. Right iliac.]

The middle region of the upper zone being immediately over the small end of the stomach, is called *epigastric* (ἐπί γαστήρ, over the stomach). The two lateral regions being under the cartilages of the ribs, are called *hypochondriac* (ὑπὸ χόνδροι, under the cartilages). The middle region of the middle zone is the *umbilical*; the two lateral, the *lumbar*. The middle region of the inferior zone is the *hypogastric* (ὑπὸ γαστήρ, below the stomach); and the two lateral, the *iliac*. In addition to these divisions, we employ the term *inguinal region*, in reference to the vicinity of Poupart's ligament.

Position of the Viscera.—In the upper zone will be seen the liver, extending

FIG. 328.



VISCERA OF THE ABDOMEN IN SITU. 1, 1. Flaps of the abdominal parietes turned aside. 2. Liver, its left lobe. 3. Right lobe. 4. Fundus of the gall-bladder. 5. Round ligament of the liver, issuing from the cleft of the longitudinal fissure, and passing along the parietes of the abdomen to the umbilicus. 6. Part of the broad ligament of the liver. 7. Stomach. 8. Its pyloric end. 9. Commencement of the duodenum. a. Lower extremity of spleen. b, b. Greater omentum. c, c. Small intestines. d. Cæcum. e. Appendix cæci. f. Ascending colon. g, g. Transverse colon. h. Descending colon. i. Sigmoid flexure of colon. k. Appendices epiploicæ connected with the sigmoid flexure. l. Three ridges representing the cords of the urachus and hypogastric arteries ascending to the umbilicus. m. Diaphragm.

across from the right to the left side; the stomach and spleen on the left, and the pancreas and duodenum behind. In the *middle zone* is the transverse portion of the colon, with the upper part of the ascending and descending colon, omentum, small intestines, mesentery, and, behind, the kidneys and supra-renal capsules. In the *inferior zone* is the lower part of the omentum and small intestines, the cæcum, ascending colon, descending colon with the sigmoid flexure, and ureters.

The smooth and polished surface, which the viscera and parietes of the abdomen present, is due to the peritoneum.

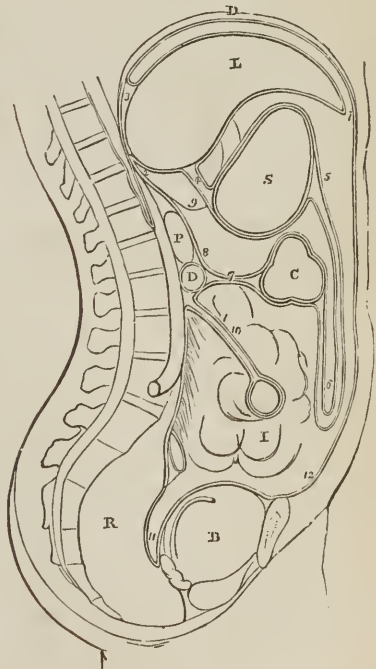
PERITONEUM.

The *Peritoneum* (*περιτεινειν*, to extend around) is a serous membrane, and therefore, a shut sac: a single exception exists in the human subject to this character, viz., in the female, where the peritoneum is perforated by the open extremities of the Fallopian tubes, and is continuous with their mucous lining.

The simplest idea that can be given of a serous membrane, which will apply equally to all, is, that it invests the viscus or viscera, and is then reflected on the parietes of the containing cavity. If the cavity contain only a single viscus, the consideration of the serous membrane is extremely simple. But in the abdomen, where there are a number of viscera, the serous membrane passes from one to the other until it has invested the whole, before it is reflected on the parietes. Hence its reflexions are a little more complicated.

REFLEXIONS OF THE PERITONEUM. D. Diaphragm. L. Liver. S. Stomach. C. Transverse colon. D. Transverse duodenum. P. Pancreas. I. Small intestines. R. Rectum. B. Urinary bladder. 1. Anterior layer of peritoneum, lining the under surface of the diaphragm. 2. Posterior layer. 3. Coronary ligament, formed by the passage of these two layers to the posterior border of the liver. 4. Lesser omentum; the two layers passing from the under surface of the liver to the lesser curve of the stomach. 5. The two layers meeting at the greater curve, then passing downwards and returning upon themselves, forming (6) the greater omentum. 7. Transverse mesocolon. 8. Posterior layer traced upwards in front of D, transverse duodenum, and P, pancreas, to become continuous with the posterior layer (2). 9. Foramen of Winslow; the dotted line bounding this foramen inferiorly marks the course of the hepatic artery forwards, to enter between the layers of the lesser omentum. 10. Mesentery encircling the small intestine. 11. Rectovesical fold, formed by the descending anterior layer. 12. Anterior layer traced upwards on the inner surface of the abdominal parietes to the layer (1), with which the examination commenced.

FIG. 329.



In tracing the reflexions of the peritoneum, in the middle line, we commence with the diaphragm, which is lined by two layers, one from the parietes in

front, *anterior*, and one from the parietes behind, *posterior*. These two layers of the same membrane, at the posterior part of the diaphragm, descend to the upper surface of the liver, forming the *coronary* and *lateral ligaments* of the liver. They then surround the liver, one going in front, the other behind that viscus, and meeting at its under surface, pass to the stomach, forming the *lesser omentum*. They then, in the same manner, surround the stomach, and meeting at its lower border, descend for some distance in front of the intestines, and return to the transverse colon, forming the *great omentum*; they then surround the transverse colon, and pass directly backwards to the vertebral column, forming the transverse *meso-colon*. Here the two layers separate; the *posterior* ascends in front of the pancreas and aorta, and returns to the posterior part of the diaphragm, where it becomes the posterior layer with which we commenced. The *anterior* descends, invests all the small intestines, and returning to the vertebral column, forms the *mesentery*. It then descends into the pelvis in front of the rectum, which it holds in its place by means of a fold called *meso-rectum*, forms a pouch, the *recto-vesical fold*, between the rectum and the bladder, ascends upon the posterior surface of the bladder, forming its false ligaments, and returns upon the anterior parietes of the abdomen to the diaphragm, whence we first traced it.

In the female, after descending into the pelvis in front of the rectum, it is reflected upon the posterior surface of the vagina and uterus. It then descends on the anterior surface of the uterus, and forms at either side the broad ligaments of that organ. From the uterus it ascends upon the posterior surface of the bladder, and anterior parietes of the abdomen, and is continued, as in the male, to the diaphragm.

In this way the continuity of the peritoneum, as a whole, is distinctly shown, and it matters not where the examination commence or where it terminate, still the same continuity of surface will be discernible throughout. If we trace it from side to side of the abdomen, we may commence at the umbilicus; we then follow it outwards, lining the inner side of the parietes to the ascending colon; it surrounds that intestine; it then surrounds the small intestine, and, returning on itself, forms the mesentery. It then invests the descending colon, and reaches the parietes on the opposite side of the abdomen, whence it may be traced to the exact point from which we started.

The viscera, which are thus shown to be invested by the peritoneum in its course from above downwards, are the—

Liver,	Transverse colon,
Stomach,	Small intestines,
Pelvic viscera.	

The folds formed between these and between the diaphragm and the liver, are—

(Diaphragm.)

Broad, coronary, and lateral ligaments.

(Liver.)

Lesser omentum.

(Stomach.)

Greater omentum.

(Transverse colon.)

Transverse meso-colon,

Mesentery,
 Meso-rectum,
 Recto-vesical fold,
 False ligaments of the bladder.

And in the female, the —

Broad ligaments of the uterus.

The ligaments of the liver will be described with that organ.

The *Lesser omentum* (gastro-hepatic) is the duplicature which passes between the liver and the upper border of the stomach. It is extremely thin, excepting at its right border, where it is free, and contains between its layers, the —

Hepatic artery,	Portal vein,
Ductus communis choledochus,	Lymphatics,
Hepatic plexus of nerves.	

These structures are inclosed in a loose areolar tissue, called *Glisson's capsule*.¹ The relative position of the three vessels is, the artery to the left, the duct to the right, the vein between and behind.

If the finger be introduced behind this right border of the lesser omentum, it will be situated in an opening called the *foramen of Winslow*.² In *front* of the finger will lie the right border of the lesser omentum; *behind* it, the diaphragm, covered by the ascending or posterior layer of the peritoneum; *below*, the hepatic artery, curving forwards from the cœliac axis; and *above*, the lobus Spigelii. These, therefore, are the *boundaries of the foramen of Winslow*, which is nothing more than a constriction of the general cavity of the peritoneum at this point, arising out of the necessity for the hepatic and gastric arteries to pass forwards from the cœliac axis to reach their respective viscera.

If air be blown through the foramen of Winslow, it will descend behind the lesser omentum and stomach to the space between the descending and ascending pair of layers, forming the great omentum. This is sometimes called the lesser cavity of the peritoneum, and that external to the foramen the greater cavity; in which case the foramen is considered as the means of communication between the two. It may be objected to this division that it tends to lead the inexperienced to believe that there are two cavities, while, in reality, there is but one, the foramen of Winslow being merely a constriction of that one, to facilitate the communication between the nutrient arteries and the viscera of the upper part of the abdomen.

The *Great omentum* (gastro-colic) consists of *four layers of peritoneum*, the two which descend from the stomach, and the same two, returning upon themselves to the transverse colon. A quantity of adipose substance is deposited around the vessels which ramify through its structure. It would appear to perform a double function in the economy: namely, protecting the intestines from cold; and, facilitating the movement of the intestines on each other during their vermicular action.

The *Transverse meso-colon* (*μέσος*, middle, being attached to the middle of the cylinder of the intestine,) is the medium of connexion between the transverse colon and the posterior wall of the abdomen. It affords to the nutrient arteries a passage to reach the intestine, and incloses between its layers, at the posterior

¹ Francis Glisson, Professor of Medicine in the University of Cambridge. His work, "De Anatomia Hepatis," was published in 1654.

² Jacob Benignus Winslow: his "Exposition Anatomique de la Structure du Corps Humain" was published in Paris in 1732.

part, the transverse portion of the duodenum. It also forms a transverse septum across the abdominal cavity.

The *Mesentery* (μέσον έντερον, connected to the middle of the cylinder of the small intestine,) is the medium of connexion between the small intestines and the posterior wall of the abdomen. It is oblique in direction, being attached to the posterior wall, from the left side of the second lumbar vertebra to the right iliac fossa; retains the small intestines in their place, and gives passage to the mesenteric arteries, veins, nerves, and lymphatics.

The *Meso-rectum*, in like manner, retains the rectum in connexion with the front of the sacrum. Besides this, there are some minor folds in the pelvis, as the *recto-vesical fold*, the *false ligaments of the bladder*, and the *broad ligaments of the uterus*.

The *Appendices epiploicæ* are small irregular pouches of the peritoneum, filled with fat, and attached like fringes to the large intestine.

Three other duplicatures of the peritoneum are situated in the sides of the abdomen; they are the *gastro-phrenic ligament*, the *gastro-splenic omentum*, the *ascending and descending meso-colon*. The *gastro-phrenic ligament* is a small duplicature of the peritoneum, which descends from the diaphragm to the extremity of the œsophagus, and lesser curve of the stomach. The *gastro-splenic omentum* (ligamentum gastro-lienale) is the duplicature which connects the spleen to the stomach. The *ascending meso-colon* is the fold which connects the upper part of the ascending colon with the posterior wall of the abdomen; and the *descending meso-colon*, that which retains the sigmoid flexure in connexion with the abdominal wall.

Structure of Serous Membrane.—Serous membrane consists of two layers, an external or areolar layer, and an internal layer or epithelium. The *areolar layer* is composed of areolar and elastic tissue; is smooth, transparent, and non-vascular on its free surface; and rough and vascular on the exterior, being connected to adjacent structures by means of a subserous areolar tissue, which contains fat, and gives support to the vessels of the membrane. The *epithelium* [see fig. 110] consists of a simple tessellated layer of nucleated cells, which are flattened and polygonal, and about $\frac{1}{1200}$ of an inch in diameter.

The general characters of a serous membrane are its resemblance to a shut sac, and its secretion of a peculiar fluid, similar to the serum of the blood; but the former of these characters is not absolutely essential to the identity of a serous membrane; for, as we have shown above, the peritoneum in the female is perforated by the extremities of the Fallopian tubes; while in some aquatic reptiles there is a direct communication between its cavity and the medium in which they live.

From the variable nature of the secretion of these membranes, they have been divided into two classes, the true serous membranes, viz., the arachnoid, pericardium, pleuræ, peritoneum, and tunicæ vaginales, which pour out a secretion containing but a small portion of albumen; and the synovial membranes and bursæ, which secrete a fluid containing a larger quantity of albumen.

ALIMENTARY CANAL.

The *Alimentary canal* is a musculo-membranous tube, extending from the mouth to the anus. It is variously named in the different parts of its course; and is divided into, the

Mouth,
Pharynx,
Œsophagus,
Stomach,

Small intestine	{	Duodenum, Jejunum, Ileum.
Large intestine	{	Cæcum, Colon, Rectum.

M O U T H .

The *Mouth* (cavum, seu, cavitas oris) is the irregular cavity which contains the organ of taste and the principal instruments of mastication. It is bounded, *in front*, by the lips and fissura oris; on either *side*, by the internal surface of the cheeks; *above*, by the hard palate and teeth of the upper jaw; *below*, by the tongue, the mucous membrane stretched between the arch of the lower jaw and the under surface of the tongue, and by the teeth of the inferior maxilla; and *behind*, by the soft palate and fauces. The space between the teeth and fleshy walls of the face is the *vestibulum oris*.

The *Lips* (labium superius et inferius) are two fleshy folds formed externally by common integument and internally by mucous membrane, and containing between these two layers, muscles, a quantity of fat, and numerous small *labial glands*. They are attached to the surface of the upper and lower jaw, and each lip is connected to the gum in the middle line by a fold of mucous membrane, the *frænum labii superioris* and *frænum labii inferioris*, the latter being very small.

The *Cheeks* (buccæ) are continuous with the lips, and form the sides of the face; they are composed of integument, a large quantity of fat, muscles, mucous membrane, and *buccal glands*.

The mucous membrane lining the cheeks is reflected above and below on the sides of the jaws, and is attached posteriorly to the anterior margin of the ramus of the lower jaw. At about its middle, opposite the second molar tooth of the upper jaw, is a papilla, on which may be observed a small opening, the aperture of the duct of the parotid gland.

The *Hard palate* (palatum durum, seu, osteum) is a dense structure, composed of mucous membrane, *palatine glands*, areolar tissue, vessels, and nerves, and firmly connected to the palate processes of the superior maxillary and palate bones. It is bounded in front and at each side by the alveolar processes and gums, and is continuous behind with the soft palate. Along the middle line it is marked by an elevated raphé, and presents at each side of the raphé a number of transverse ridges and grooves. Near its anterior extremity, and immediately behind the middle incisor teeth, is a papilla which corresponds with the termination of the anterior palatine canal, and receives the naso-palatine nerves.

The *Gums* (gingivæ) are composed of a thick and dense mucous membrane, which is closely adherent to the periosteum of the alveolar processes, and embraces the necks of the teeth. They are remarkable for their hardness and insensibility; and for their close contact, without adhesion, to the surface of the tooth. From the neck of the tooth they are reflected into the alveolus, and become continuous with the periosteal (peridental) membrane of that cavity.

The *Tongue* has been already described as an organ of sense; it is invested by mucous membrane, which is reflected from its under part upon the inner surface of the lower jaw, and constitutes with the muscles beneath, the floor of the mouth. On the under surface of the tongue, near its anterior part, the mucous membrane forms a considerable fold, which is called the *frænum linguæ*; and on each side of the frænum is a large papilla, *caruncula sublingualis*, the termination of the duct (Wharton's duct) of the submaxillary gland. Running back from this papilla is a ridge, occasioned by the prominence of the sublingual gland; and opening along the summit of this ridge, a number of small

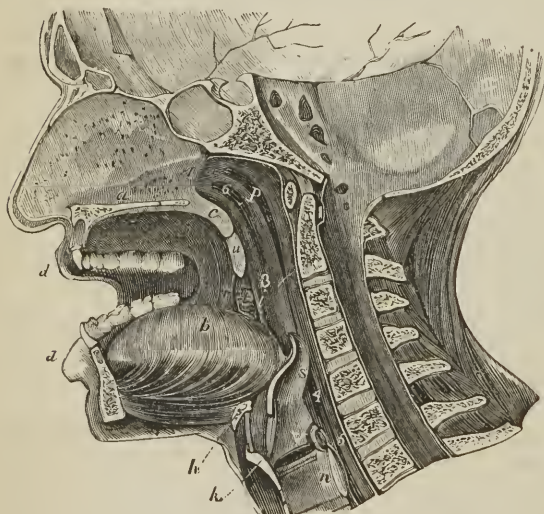
openings, the apertures of the excretory ducts of the gland. Posteriorly the tongue is connected with the os hyoides by muscle, and to the epiglottis by three folds of mucous membrane, the *fræna epiglottidis*.

The *Soft palate* (palatum molle; velum pendulum palati) is a fold of mucous membrane situated at the posterior part of the mouth. It is continuous, superiorly with the hard palate, and is composed of mucous membrane, *palatine glands*, and muscles. Hanging from the middle of its inferior border is a small rounded process, the *uvula*; and passing outwards from the uvula at each side are two curved folds of the mucous membrane, the arches or pillars of the palate. The *anterior pillar* (arcus palatinus inferior; glosso-palatinus) is continued downwards to the side of the base of the tongue, and is formed by the prominence of the palato-glossus muscle. The *posterior pillar* (arcus palatinus superior; pharyngo-palatinus) is prolonged downwards and backwards into the pharynx, being formed by the convexity of the palato-pharyngeus muscle. These two pillars, closely united above, are separated below by a triangular interval or niche, in which the tonsil is lodged.

The space included between the soft palate and the root of the tongue is the *isthmus of the fauces*. It is bounded *above* by the soft palate; on each *side* by the pillars of the soft palate and tonsil; and *below* by the root of the tongue. It is the opening between the mouth and pharynx.

The *Tonsils* (amygdalæ) are two glandular organs, about half an inch in length, shaped like almonds, and situated between the anterior and posterior

[FIG. 330.]



MEDIAN SECTION OF THE NOSE, MOUTH, PHARYNX, AND LARYNX.—*a.* Septum of the nose; below it is the section of the hard palate. *b.* The tongue. *c.* Section of velum pendulum palati. *d, d.* Lips. *u.* Uvula. *r.* Anterior arch or pillar of the fauces. *i.* Posterior arch or pillar. *t.* Tonsil. *p.* Pharynx. *h.* Hyoid bone. *k.* Thyroid cartilage. *n.* Cricoid cartilage. *s.* Epiglottis. *v.* Glottis. 1. Posterior opening of nares. 2. Isthmus faucium (before the cipher.) 3. Superior opening of larynx. 4. Superior opening of larynx. 5. Passage into œsophagus. 6. Mouth of the right Eustachian tube.]

pillar of the soft palate, at each side of the fauces. They are composed of an assemblage of mucous follicles, which open on the surface by twelve or fifteen apertures. Externally, they are invested by the pharyngeal fascia, which separates them from the superior constrictor muscle and internal carotid artery, and prevents an abscess from opening in that direction. In relation to surrounding parts, each gland corresponds with the angle of the lower jaw

The *Mucous glands* of the mouth (orales) are racemose or lobulated glands; they are yellowish or whitish in color, rounded or multangular in form, and situated in the submucous areolar tissue. The *labial glands* vary in size from

half a line to one line and a half in diameter, and form an almost continuous layer around the mouth. The *buccal glands* are numerous, but smaller than the labial; a few of larger size being located near the aperture of Stenon's duct. The *molar glands* are placed between the masseter and buccinator, and pierce the latter with their ducts opposite the molar teeth. The *palatine glands* are situated in the posterior half of the hard palate and in the soft palate; in the latter forming a layer several lines in breadth. They are also numerous but small on the posterior part of the soft palate. The *lingual glands* form a thick stratum in the submucous tissue beneath the mucous follicles at the root of the tongue; this layer extends completely across the tongue, and their ducts, several lines in length, open by infundibuliform expansions, some into the mucous follicles, others into the foramen cæcum, others into the fossæ of the papillæ circumvallatæ, and others between the papillæ. Mucous glands of the same kind are also dispersed on other parts of the tongue, but are smaller and few in number; a small group is found between the vertical folds on the sides of the tongue, and a considerable group on its under surface near the tip and on either side of the frænum linguæ.

In *minute structure* the glandular organs of the mucous membrane of the mouth are divisible into *follicles* or *follicular glands*; and *racemose* or *lobulated glands*. The follicular glands are *simple*, as those of the root of the tongue; or *compound*, like the tonsil, which is merely an aggregation of simple follicular glands. The racemose or lobulated glands may be of the simplest construction, consisting of from four to eight lobules, which open directly into an excretory duct like the smaller oral glands, or of an aggregation of smaller and larger lobules, forming primary and secondary lobes, and finally a gland of considerable size, as the salivary.

The *follicular gland*, in external appearance, is a mere crypt or pouch of mucous membrane, but the wall of the pouch is thickened, and presents two layers, superficial and deep, with an intermediate fibro-vascular matrix, in which are lodged a number of *closed vesicles* or *capsules*. These capsules are round or oblong, and whitish, from $\frac{1}{120}$ to $\frac{1}{30}$ of an inch in diameter, and composed of an external coat of homogeneous areolar tissue, containing a grayish white pulpy substance, consisting of small nucleated cells ($\frac{1}{3000}$ of an inch), free nuclei, and a small quantity of alkaline fluid. The follicular glands of the root of the tongue form a continuous layer, stretching from the papillæ circumvallatæ backwards to the epiglottis, and from the tonsil on one side to that on the other side of the fauces. They are lenticular and globular in figure, from

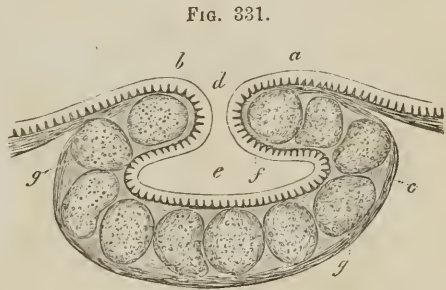


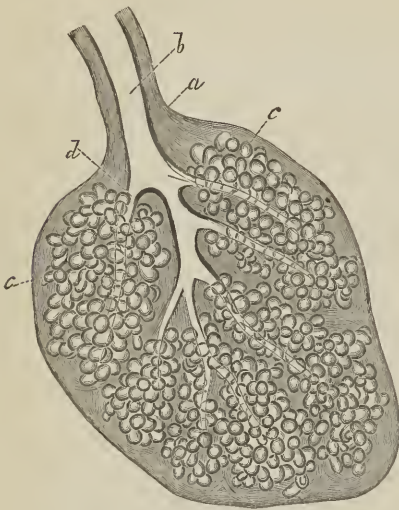
FIG. 331.

FOLLICULAR GLAND FROM THE ROOT OF THE TONGUE; (magnified thirty diameters); after Kölliker. *a, f.* Epithelium. *b.* Papillæ of the mucous membrane. *d.* Central aperture. *e.* Cavity of the follicle. *c.* Investing coat of the gland, composed of areolar tissue. *g, g.* The closed capsules contained in the fibro-vascular matrix, which forms the parenchyma of the gland.

They are lenticular and globular in figure, from half a line to two lines in diameter, and placed superficially so as to form prominences on the surface of the membrane. Each gland is furnished with a central aperture which opens into its cavity; the cavity being lined with mucous membrane and epithelium, and containing a grayish mucus. The deep layer of the follicular gland is firmly adherent to the submucous tissue, and overlies the proper mucous glands, which form a stratum beneath the follicular glands.

The tonsil is a compound follicular gland, consisting of an aggregation of fifteen or twenty simple follicular glands, intimately united and held together so as to constitute a single organ. They are inclosed in a thick investing capsule of areolar tissue, with a certain proportion of elastic tissue. The capillary vessels of the follicular glands form a fine and close network around their bases.

FIG. 332.

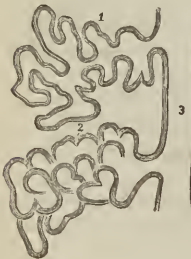


RACEMOSE MUCOUS GLAND FROM THE FLOOR OF THE MOUTH; after Kölliker. *a.* Sheath of areolar tissue. *b.* Excretory duct. *c.* Glandular vesicles, or acini. *d.* Ducts of the lobes. Magnified 50 diameters.

proper color to the glands. The excretory ducts are composed of areolar and elastic tissue, and lined by a layer of *columnar epithelium*.

The smallest racemose gland consists of several lobules, and the lobules are held together by areolar tissue, and by an external investing coat of the same tissue intermingled with elastic fibres. The capillary vessels of the glands form a close network around the glandular vesicles; and the secretion of the glands is a clear yellowish mucus, with an occasional and accidental admixture of granules, nuclei, and remains of cells.

FIG. 333.



PLAN OF THE STRUCTURE OF A RACEMOSE GLAND; after Kölliker. 1. An excretory tube unraveled, to show the composition of the lobule, of diverticula, and caecal terminations of the duct. 2. Appearance of the glandular vesicles, when grouped together in their normal state. 3. The main excretory duct.

Salivary Glands.

Communicating with the mouth are the excretory ducts of three pairs of salivary glands (*glandulae salivales*), the parotid, submaxillary, and sublingual.

The PAROTID GLAND (*παρά*, near, *ὄψ*, ὄρος, the ear), the largest of the three, is situated immediately in front of the external ear, and extends superficially for a short distance over the masseter muscle, and deeply behind the ramus of the lower jaw. It reaches inferiorly to below the level of the angle of the jaw, and posteriorly to the mastoid process, slightly overlapping the insertion of the sterno-mastoid muscle. Imbedded in its substance are the external carotid artery, temporal vein, and facial nerve; emerging from its anterior

border, the transverse facial artery and branches of the facial nerve; and above, the temporal artery and auriculo-temporal nerve.

The duct of the parotid gland (Stenon's¹ duct), about two inches in length, and about the diameter of a crow's quill, issues from the anterior part of the gland, just below the zygoma, and crosses the masseter muscle; it then curves inwards over the anterior border of the muscle, and pierces the buccinator opposite the second molar tooth of the upper jaw; its opening in the mouth being indicated by a prominent papilla.

The duct is dense in structure, and its walls of considerable thickness in proportion to the area of the tube, which is remarkably small. A small glandular appendage, the *socia parotidis*, is connected with the upper part of the duct on the masseter muscle, and opens into it by one or several small ducts.

The SUBMAXILLARY GLAND, rounded in its form, is situated in the posterior part of the submaxillary triangle of the neck. It rests on the hyo-glossus, stylo-glossus, and mylo-hyoideus muscle, and is covered in by the body of the lower jaw, and the deep cervical fascia. It is separated from the parotid gland by the stylo-maxillary ligament, and from the sublingual gland by the mylo-hyoideus muscle. Imbedded among its lobules are the facial artery and submaxillary ganglion.

Its excretory duct, *Wharton's duct*, about two inches in length, issues from the middle of the gland, and passes between the mylo-hyoideus and hyo-glossus to the frænum linguæ, by the side of which it terminates at the apex of a papilla, *caruncula sublingualis*. A process of the gland is prolonged with the duct for a short distance behind the mylo-hyoideus.

The SUBLINGUAL is a long and flattened gland, situated beneath the mucous membrane of the floor of the mouth, at each side of the frænum linguæ. It is in relation at the frænum with its fellow of the opposite side, and in the rest of its course lies between the lower jaw and genio-hyo-glossus, being bounded below by the mylo-hyoideus. It is in relation also with the duct of the submaxillary gland and the hypoglossal nerve.

Its secretion is poured into the mouth by from seven to twenty short ducts, *ductus Riviniani*, which open on the ridge made by the gland in the floor of the mouth; the larger openings being situated by the side of the frænum linguæ. One of the ducts longer than the rest, and opening close to Wharton's duct, has been named *ductus Bartholini*.

Structure. — The salivary glands are of the conglomerate kind, consisting of lobes, which are made up of polyhedral lobules; and these of smaller lobules; in minute structure they correspond with the racemose mucous glands.

The smallest lobule is composed of glandular vesicles, *acini*, which are minute cæcal pouches, formed by the convolution and dilatation of the extreme ramifications of the ducts. These minute ducts unite to form lobular ducts, and the lobular ducts constitute by their union a single excretory duct. The glandular vesicles are connected by areolar tissue, so as to form a minute lobule; and the lobules and larger lobes are held together by a more condensed, but lax areolar tissue. The submaxillary and sublingual glands are looser in structure and their lobules larger than those of the parotid gland.

The *glandular vesicles*, about $\frac{1}{500}$ of an inch in diameter, consist of a proper external coat or *membrana propria*, lined by a single layer of *spheroidal epithelial cells*. The cells are nucleolo-nucleated and contain granules, some of which are fatty and others pigmentary. The excretory ducts are thick and dense, composed of areolar and elastic tissue, and lined by a layer of *columnar epithelium*; and Wharton's duct is additionally provided with a longitudinal layer of smooth muscular fibre. The secretion of the salivary glands is a clear fluid,

¹Nicholas Stenon, an anatomist of great research. He discovered the parotid duct while in Paris. He was appointed Professor of Medicine in Copenhagen in 1672. His work, "De Musculis et Glandulis Observationes," was published in 1664.

sometimes containing a small quantity of mucus and the detrita of epithelial cells.

Vessels and Nerves. — The parotid gland is abundantly supplied with *arteries* by the external carotid; the submaxillary, by the facial and lingual; and the sublingual, by the sublingual and submental branches of the lingual artery. The capillaries form networks around and in contact with the glandular vesicles.

The *Nerves* of the parotid gland are derived from the auriculo-temporal branch of the inferior maxillary, from the auricularis magnus, and from the nervi molles accompanying the external carotid artery. The submaxillary gland is supplied by the branches of the submaxillary ganglion, sympathetic, and filaments from the mylo-hyoidean nerve; and the sublingual, by filaments from the submaxillary ganglion and gustatory nerve.

PHARYNX.

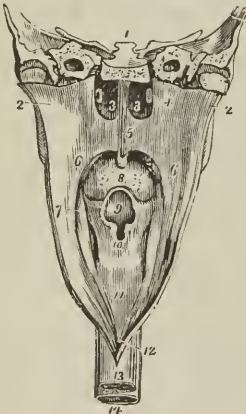
The pharynx (*φάρυγξ*, the throat) is a musculo-membranous sac, about four inches in length, situated on the cervical portion of the vertebral column, and extending from the base of the skull to a point corresponding with the ericoid cartilage in front, and the fifth cervical vertebra behind. It is composed of mucous membrane, muscles, and a strong aponeurosis; and communicates in front with the cavity of the nose, mouth, and larynx. Above it is attached partly by muscle, but chiefly by aponeurosis, to the basilar process of the occipital bone and petrous portion of the temporal bones, and below it is continuous with the œsophagus.

At its anterior part it has opening into it seven foramina, viz.—

Posterior nares, two,	Larynx,
Eustachian tubes, two,	Œsophagus.
Mouth,	

The *Posterior nares* (choanæ narium) are the two large openings at the upper and front part of the pharynx. On each side of these openings, and parallel

FIG. 334.



PHARYNX LAID OPEN FROM BEHIND.

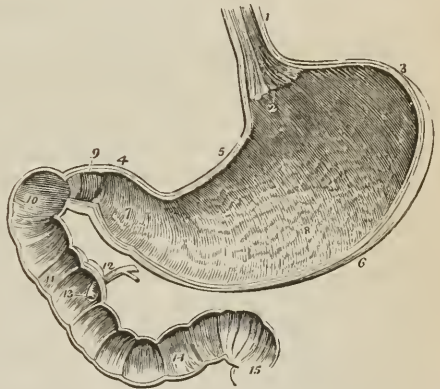
1. Section carried transversely through the base of the skull.
- 2, 2. Walls of the pharynx drawn aside.
- 3, 3. Posterior nares, separated by the vomer.
4. Extremity of one Eustachian tube.
5. Soft palate.
6. Posterior pillar of the soft palate.
7. Anterior pillar; the tonsil is seen in the niche between the two pillars.
8. Root of the tongue, partly concealed by the uvula.
9. Epiglottis, overhanging (10) the cordiform opening of the larynx.
11. Posterior part of the larynx.
12. Opening of the œsophagus.
13. Œsophagus.
14. Trachea.

with the posterior termination of the inferior turbinated bone, is the slit-like opening in the mucous membrane, marking the aperture of the *Eustachian tube*. Beneath the posterior nares is the isthmus faucium, the large opening into the *mouth*, partly veiled by the soft palate; and beneath the root of the tongue, the cordiform opening of the larynx, *aditus ad glossidem*. The *œsophageal* opening is the lower constricted portion of the pharynx.

ŒSOPHAGUS.

The *œsophagus* (ὄειν, to bear, φάγειν, to eat) is a slightly flexuous canal, inclining to the left in the neck, to the right in the upper part of the thorax,¹ and again to the left in its course through the posterior mediastinum; it commences at the termination of the pharynx, opposite the lower border of the cricoid cartilage and fifth cervical vertebra, and descends the neck behind, and rather to the left of the trachea. It then passes behind the arch of the aorta and left bronchus, and along the posterior mediastinum, lying in front of the thoracic aorta, to the œsophageal opening in the diaphragm, where it enters the abdomen, and terminates at the cardiac orifice of the stomach opposite the ninth or tenth dorsal vertebra. The œsophagus is flattened and narrow in the cervical region, and cylindrical in the rest of its course; its largest diameter being met with near the lower part; it is connected by loose areolar tissue to surrounding structures.

FIG. 335.



STOMACH.

The stomach is an expansion of the alimentary canal, situated in the left hypochondriac and epigastric region, and, for a small extent, in the right hypochondriac region. It is directed somewhat obliquely from above downwards, from left to right, and from behind forwards; and in the female, as a result of tight-lacing, is longer than in the male. On account of the peculiarity of its form, it is divided into a middle part or *body*, a *greater* or *splenic*, and a *lesser* or *pyloric end*; a *lesser curvature* above, and a *greater curvature* below; an *anterior* and a *posterior surface*; a *cardiac orifice*, and a *pyloric orifice*. The great end (*fundus*) is not only of large size, but expands beyond the point of entrance of the œsophagus, and is embraced by the concave surface of the spleen; it presents superiorly a funnel-shaped expansion, leading to the cardiac orifice. The pylorus (*janitor*) is the small and contracted extremity of the organ; it is situated on a plane anterior and inferior to the cardiac orifice, and lies in contact with the under surface of the liver, often reaching to the gall-bladder. Near the lesser end is a dilatation, the antrum of the pylorus. The two curvatures give attachment to the peritoneum; the upper curve to the lesser omentum, the lower, to the great omentum. The anterior

VERTICAL AND LONGITUDINAL SECTION OF THE STOMACH AND DUODENUM, made in a direction to include the two orifices of the stomach. 1. Œsophagus; on its internal surface the plicated arrangement of the mucous membrane is shown. 2. Cardiac orifice of the stomach, around which the serrated border of the epithelium is seen. 3. Great end of the stomach. 4. Lesser or pyloric end. 5. Lesser curve. 6. Greater curve. 7. Dilatation at the lesser end of the stomach, the antrum of the pylorus. This may be regarded as the rudiment of a second stomach. 8. Rugæ of the stomach formed by the mucous membrane: their longitudinal direction is shown. 9. Pylorus. 10. Oblique portion of the duodenum. 11. Descending portion. 12. Pancreatic duct and ductus communis choledochus close to their termination. 13. Papilla upon which the ducts open. 14. Transverse portion of duodenum. 15. Commencement of jejunum. In the interior of the duodenum and jejunum, the valvulæ conniventes are seen.

¹ Cruveilhier remarks that this inflection explains the obstruction which a bougie sometimes meets with, in its passage along the œsophagus, opposite the first rib.

surface looks upwards and forwards, and is in relation with the diaphragm, (which separates it from the viscera of the thorax and six lower ribs,) with the left lobe of the liver, and in the epigastric region with the abdominal parietes. The posterior surface looks downwards and backwards, and is in relation with the diaphragm, pancreas, third portion of the duodenum, transverse meso-colon, left kidney, and left supra-renal capsule; this surface forms the anterior boundary of that cul-de-sac of the peritoneum which is situated behind the lesser omentum and extends into the greater omentum. In a state of distension, as after a meal, the anterior surface becomes superior, and the greater curvature is directed forwards against the abdominal parietes. Meekel estimates the capacity of the stomach at one foot square; when moderately full it is capable of holding from five to ten pints of fluid.

SMALL INTESTINE.

The small intestine, *intestinum tenue*, is about twenty or twenty-five feet in length, and is divisible into three portions, *duodenum*, *jejunum*, and *ileum*.

The *Duodenum*, (called δωδεκάδακτυλον by Herophilus,) larger and more deeply seated than the rest of the small intestine, has received its name from being about equal in length to the breadth of twelve fingers (eight or ten inches). In its course it presents a horse-shoe curve; commencing at the pylorus, it ascends *obliquely* backwards to the under surface of the liver; it next descends *perpendicularly* in front of the right kidney as low as the fourth lumbar vertebra, and then passes nearly *transversely* across the third lumbar vertebra; terminating in the jejunum at the left side of the second lumbar vertebra, where it is crossed by the superior mesenteric artery and vein. It is connected with the portal eminence of the liver by means of a band of peritoneum called *ligamentum hepatico-duodenale*; and to the right kidney by another band, the *ligamentum duodeno-renalē*.

The *first* or *oblique portion* (*pars transversa superior*) of its course, between two and three inches in length, is completely inclosed by the peritoneum: it is in relation, *above* with the liver and neck of the gall-bladder; *in front* with the great omentum and abdominal parietes; and *behind* with the right border of the lesser omentum and its vessels.

The *second* or *perpendicular portion* (*pars descendens*) is situated altogether behind the peritoneum: it is in relation by its *anterior surface* with the commencement of the arch of the colon; by its *posterior surface* with the concave margin of the right kidney, the inferior vena cava, and ductus communis choledochus; by its *right border* with the ascending colon; and by its *left border* with the pancreas. The ductus communis choledochus and pancreatic duct open into the internal and posterior side of the perpendicular portion, a little below its middle.

The *third* or *transverse portion* (*pars transversa inferior*) of the duodenum, the longest and narrowest of the three, lies between the diverging layers of the transverse meso-colon, with which and with the stomach it is in relation *in front*; *above*, it is in contact with the lower border of the pancreas, the superior mesenteric artery and vein being interposed; and, *behind*, it rests on the inferior vena cava and aorta.

The *Jejunum* (*jejunus*, empty) is named from being generally found empty. It forms the upper two-fifths of the small intestine: commencing at the bend of the duodenum, *flexura duodeno-jejunalis*, on the left side of the second lumbar vertebra, and terminating in the ileum. It is thicker to the touch than the rest of the intestine, has a pinkish tinge from containing more mucous membrane than the ileum, and is situated in the umbilical region and left iliac fossa.

The *Ileum* (*εἰλεῖν*, to twist, to convolute) includes the remaining three-fifths

of the small intestine. It is somewhat smaller in calibre, thinner in texture, and paler than the jejunum; but there is no mark by which to distinguish the termination of the one or the commencement of the other. It is situated in the umbilical and hypogastric region and pelvic cavity, and terminates in the right iliac fossa, by opening at an obtuse angle into the commencement of the colon. At its entrance into the large intestine it has a cunciform shape.

The small intestines form in their course a double curve resembling the letter S, the upper curve to the right representing that of the duodenum; and the lower to the left that of the jejunum and ileum to the termination of the latter in the colon.

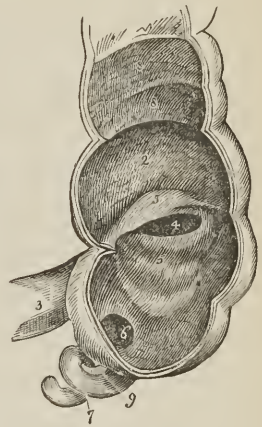
The jejunum and ileum are surrounded, above and at the sides, by the colon; in front they are in relation with the omentum and abdominal parietes; they are retained in position by the mesentery, which connects them with the posterior wall of the abdomen; and below they descend into the cavity of the pelvis. At about the lower third of the ileum a pouch-like process or diverticulum of the intestine is occasionally seen. This is a vestige of embryonic structure, and results from the obliteration of the omphalo-mesenteric or vitelline duct at a short distance from the cylinder of the intestine.

LARGE INTESTINE.

The large intestine (intestinum crassum vel amplum) five or six feet and sometimes more in length, prismoid in form, sacculated and thicker than the small intestine, tapers gradually from above downwards, and is divided into, *cæcum*, *colon*, and *rectum*.

The *Cæcum* (*caput coli*) is the blind pouch, or cul-de-sac, about two inches and a half in length, situated at the commencement of the large intestine. It is lodged in the right iliac fossa, and retained in its place by the peritoneum which passes over its anterior surface; its posterior surface is connected by loose areolar tissue with the iliac fascia. Attached to its extremity is the *appendix vermiformis*, a long worm-shaped tube, the rudiment of the lengthened cæcum found in all mammiferous animals except man and the higher quadrumana. The appendix varies in length from one to five or six inches; it is about equal in diameter to a goose-quill, and is connected with the posterior and left aspect of the cæcum near the extremity of the ileum. It is usually more or less coiled upon itself, and retained in that coil by a falciform duplicature of peritoneum. Its canal is extremely small, and the orifice by which it opens into the cæcum not unfrequently provided with an incomplete valve. Occasionally the peritoneum invests the cæcum so completely as to constitute a meso-cæcum, which permits of an unusual degree of movement in this portion of the intestine, and serves to explain the occurrence of hernia of the cæcum on the right side. The cæcum is the most dilated portion of the large intestine; and is distinguished from the colon externally by the constriction corresponding with the entrance of the ileum, and internally by the ileo-cæcal or ilco-colic valve.

FIG. 336.



THE CÆCUM, showing its appendix, entrance of the ileum, and ileo-cæcal valve. 1. Cæcum. 2. Commencement of colon 3. Ileum 4. Aperture of entrance of the ileum into the large intestine. 5, 5. Ileo-cæcal valve. 6. Aperture of appendix vermiformis cæci. 7. Appendix vermiformis. 8, 8. Sacculi of the colon, separated by valvular septa. 9. Falciform frænum of appendix vermiformis.

The *Colon* is divided into, *ascending*, *transverse*, and *descending*. The *ascending colon* passes upwards from the right iliac fossa, through the right lumbar region, to the under surface of the liver. It then bends inwards, *flexura dextra vel hepatica*, and crosses the upper part of the umbilical region under the name of *transverse colon*; and, on the left side, *flexura sinistra vel lienalis*, descends, *descending colon*, through the left lumbar region to the left iliac fossa, where it makes a remarkable curve upon itself, which is called the *sigmoid flexure*, *flexura iliaca*.

The *ascending colon*, the most dilated portion of the large intestine, next the cæcum, is retained in position in the abdomen either by the peritoneum passing simply in front of it or by a narrow meso-colon. It is in relation *in front* with the small intestine and abdominal parietes; *behind* with the quadratus lumborum muscle and right kidney; *internally* with the small intestine and perpendicular portion of the duodenum; and by its *upper extremity* with the under surface of the liver and gall-bladder.

The *transverse colon*, the longest portion of the large intestine, forms a curve across the cavity of the abdomen, the convexity of the curve looking forwards and sometimes downwards. It is in relation, by its *upper surface*, with the liver, gall-bladder, stomach, and lower extremity of the spleen; by its *lower surface*, with the small intestine; by its *anterior surface*, with the anterior layers of the great omentum and abdominal parietes; and, by its *posterior surface*, with the transverse meso-colon.

The *descending colon* is smaller in calibre, and situated more deeply than the ascending colon; its relations are similar.

The *sigmoid flexure*, the narrowest part of the colon, curves upwards and to the right, then downwards and to the left, and is retained in its place by a meso-colon. It is in relation, *in front*, with the small intestine and abdominal parietes; and *behind* with the iliac fossa.

The *Rectum*, the termination of the large intestine, seven or eight inches in length, has received its name, not so much from the direction of its course, as from the straightness of its form in comparison with the colon. It descends, from opposite the left sacro-iliac symphysis, in front of the sacrum, forming a gentle curve to the right side, and then returning to the middle line; opposite the extremity of the coccyx it curves backwards to terminate in the anus at about an inch in front of the apex of that bone. The rectum, therefore, forms a double flexure in its course, the one being directed from side to side, the other from before backwards. It is smaller in calibre at its upper part than the sigmoid flexure, but becomes gradually larger as it descends, and its lower extremity, previously to its termination at the anus, forms a dilatation of considerable, but variable magnitude.

With reference to its relations, the rectum is divided into three portions; the *first*, including half its length, extends to about the middle of the sacrum, is completely surrounded by peritoneum, and connected to the sacrum by means of the meso-rectum. This portion is in relation, above, with the left sacro-iliac symphysis; and, below, with the branches of the internal iliac artery, sacral plexus of nerves and left ureter; one or two convolutions of the small intestine are interposed between the front of the rectum and the bladder, in the male; and between the rectum and the uterus with its appendages, in the female. The *second portion*, about three inches in length, is closely attached to the surface of the sacrum, and covered by peritoneum only in front; it is in relation by its lower part with the base of the bladder, vesiculæ seminales, and prostate gland; and in the female with the vagina. The *third portion* curves backwards from opposite the prostate gland and tip of the coccyx to terminate in the anus; it is embraced by the levatores ani, and is about one inch and a half in length. This portion is separated from the membranous part of the urethra by a trian-

gular space; in the female the triangular space intervenes between the vagina and rectum, and constitutes by its base the perineum.

The *Anus* is situated at a little more than an inch in front of the extremity of the coccyx. The integument around it is covered with hairs, and is thrown into numerous radiated plaits which are obliterated during the passage of fæces. The margin of the anus is provided with an abundance of sebiparous glands, and the epidermis may be seen terminating by a fringed and scalloped border, at a few lines above the extremity of the opening.

STRUCTURE OF THE INTESTINAL CANAL.

The intestinal canal has four coats:—*mucous*, *submucous* or *arcolar*, *muscular*, and an external coat, which, in the pharynx and œsophagus, is *areolofibrous*, and in the abdominal cavity *serous*, being derived from the peritoneum.

MUCOUS COAT.—The mucous membrane of the *mouth* is thick, of a pinkish-red color, semi-transparent, furnished with an abundance of papillæ, and rich in vessels and nerves. It lines the whole interior of the oral cavity, and is closely adherent to the boundaries of that cavity, in some parts muscle, in others, as upon the jaws and hard palate, bone. It commences, in front, at the junction of the red margin with the skin of the lips, is continuous with the lining membrane of the parotid, submaxillary and sublingual ducts, forms the fræna of the lips, tongue, and epiglottis, lines the follicular glands of the tongue and tonsils, and is continuous with the mucous membrane of the pharynx.

The mucous membrane of the *pharynx* is pale in its lower or alimentary part, but red and thick in its upper or respiratory portion; the division of the two parts corresponding with the lower border of the soft palate; the respiratory portion, moreover, is more thickly studded with glands, but is divested of papillæ. The mucous membrane of the pharynx is continuous with the mucous lining of the Eustachian tubes, nares, mouth, larynx, and œsophagus.

In the *œsophagus*, the mucous membrane is pale red above and whitish below. It has but few papillæ, is loosely connected with the muscular coat by means of the submucous coat, and is disposed in *longitudinal plicæ*.

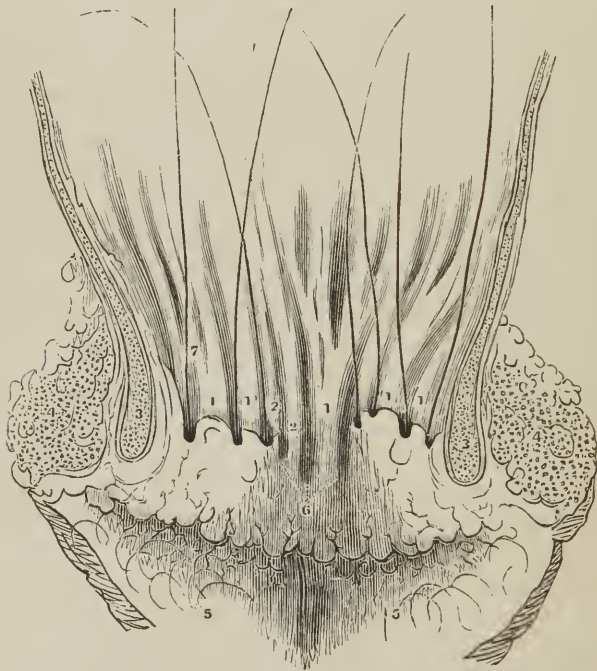
In the *stomach* the mucous membrane is soft and loose, thinner at the cardiac than at the pyloric end, and of a grayish or reddish-gray color, heightened to a bright red during digestion. It is redder in infancy than in the adult, and least red in old age. It is disposed on the surface in plaits or *rugæ*, which around the cardiac orifice have a radiated arrangement, take a longitudinal direction in the body of the organ, and at the pylorus form a circular or spiral fold, which constitutes with the muscular coat the *pyloric valve*. The *rugæ* are most numerous and largest at the pyloric end of the stomach.

In the *small intestine* the mucous membrane is thinner than in the stomach; it is smooth in the upper fourth of the *duodenum*, but raised into crescentic folds, *valvulæ conniventes* [valvulæ Kerkringii], in its lower three-fourths; the *valvulæ conniventes* being continued throughout the jejunum, and extending as far as the middle of the ileum. On the posterior and inner side of the descending portion of the duodenum is a longitudinal ridge or crest, *plica longitudinalis*, about an inch in length, caused by the oblique passage through the walls of the intestine, of the ductus communis choledochus; and at the lower and most prominent part of this crest is the aperture of termination of that duct and the ductus pancreaticus. The *valvulæ conniventes* are narrow at their commencement, but quickly become larger, and at the lower part of the duodenum and upper part of the jejunum, where they are largest, have a breadth of several lines. In the lower part of the jejunum and upper part of the ileum they become narrower and more scanty, and are finally lost altogether at about the

middle of the latter. Each fold or valve extends for about one-half or three-fourths around the cylinder of the intestine; and as they spring from all sides of its circumference, have the appearance of circular septa. The jejunum owes its considerable thickness to these valves; and as they are small in the upper half of the ileum, and wanting in its lower half, the thinness of the ileum is due to their absence.

At the termination of the ileum in the large intestine, the mucous membrane forms two semilunar folds, strengthened by the muscular coat. The termination of the ileum is oblique and flattened, and constitutes the division between the cæcum and colon, the two folds of mucous membrane being the *ileo-cæcal* or *ileo-colic valve* (valvula Bauhini). The position of these folds is such that one belongs to the cæcum, the other to the colon, the opening between them being oblong, and oval, and not inaptly compared to a button-hole; moreover, the colic flap somewhat overlaps the cæcal flap, and is so disposed in relation to the entrance of the ileum, that the contents of the small bowel are necessarily discharged into the cæcum. In the *cæcum* and *colon*, the mucous membrane is smooth, and lines the surfaces of the *plicæ sigmoideæ* which form the bounda-

[Fig. 337.]



A VERTICAL SECTION OF THE ANTERIOR PARIETES OF THE ANUS, with the rectum displayed so as to show the relations of the rectal pouches to the surrounding parts, their orifices being marked with bristles. 1, 1. Columns of the rectum. 2, 2. Rudiments of columns. 3, 3. Internal sphincter. 4, 4. External sphincter. 6. Imperfect pouches. 5, 5. Radiated folds of the skin, terminating on the surface of the nates. 7. A bristle in one of the pouches.]

ries of the sacculi of the large intestine. In the *rectum*, it forms three valvular folds,¹ one of which is situated near the commencement of the intestine; the

¹ Houston, "On the Mucous Membrane of the Rectum." Dublin Hospital Reports, vol. v.

second, extending from the side of the tube, is placed opposite the middle of the sacrum; and the third, which is the largest and most constant, projects from the anterior wall of the bowel opposite the base of the bladder. Besides these folds, the membrane in the empty state of the intestine is thrown into longitudinal plaits, somewhat similar to those of the œsophagus; these have been named the *columns* of the rectum. [The intervals between these columns, observed as the ordinary natural condition, by Horner, become closed near the anus, so as to form small pouches of from two to four lines in depth, the orifices of which present upwards. These pouches occasionally become the seat of disease, and, being enlarged, produce a painful itching.] The mucous membrane of the rectum is connected to the muscular coat by a loose areolar tissue, as in the œsophagus.

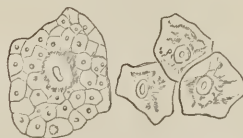
STRUCTURE OF MUCOUS MEMBRANE.—In intimate structure, mucous membrane is composed of three layers, *epithelium*, *true mucous membrane* or *corium*, and *submucous tissue*.

EPITHELIUM² is analogous to the epidermis in forming a layer of protection to the structure which it invests; it constitutes the surface of the mucous membrane, and indeed of all the other internal membranes of the body, namely, the serous and synovial membranes, the heart, the bloodvessels, and lymphatics. Like the epidermis, also, it is composed of minute cells, generated on the surface of the corium in a soft, transparent, jelly-like substance, filled with small granules, the *blastema*, which serves besides the purpose of a matrix in connecting the cells together. The blastema, originally fluid, soon becomes filled with organic granules; these granules, congregating together in small masses, constitute the *nucleus*, or original part of the cell, the separate granules being the *nucleoli*. Around the nucleus other granules accumulate and grow, a boundary membrane is formed about them, and the cell is complete, consisting of its *nucleus* with included *nucleoli*, the *cavity* of the cell, which is composed of granules and secondary cells, and the *cell-membrane*. This process of cell-formation being in constant operation on all the surfaces of the body, the old cells of the surface of the epithelium are regularly cast off, while young cells take their place from below. A section of epithelium would, therefore, like the epidermis, show cells in successive stages of formation and growth, namely, as simple granules, aggregated granules or nuclei, small cells, and larger and complete cells.

The cells of epithelium present some differences of form and arrangement which have given rise to their division into four varieties, namely, squamous, columnar, spheroidal, and ciliated.

The *Squamous epithelium* is so named from the conversion of its superficial cells into thin, flattened, polyhedral squamæ or scales, in which the original structure of the cell, together with its nucleus, is more or less effaced. On the serous membranes of the cavities of the body and on that of the blood and lymph vessels, the squamæ form a single layer, but on the mucous membrane, as on

Fig. 338.



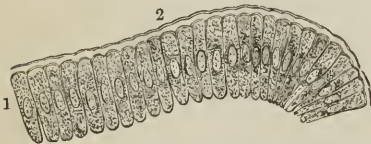
EPITHELIAL SCALES FROM THE MOUTH; the large scale magnified 310 times, exhibits the structure of the scale, as consisting of a nucleus with nucleolus in the centre; and secondary nucleated cells, forming the body of the scale. In the other scales, magnified 155 times, the nucleus and nucleolus are alone seen distinctly: the secondary cells being reduced to the appearance of a few granules dispersed through the scale.

¹ [Vide Horner's Special Anat. and Histol., vol. ii., p. 47. Philadelphia, 1851. Also, Am. Cyclop. Pract. Med. and Surg., vol. ii., 1836. Article *Anus*.]

² [*Ἐπί, upon; and θηλή, a nipple.*]

the skin, there are several superimposed layers; hence the names *lamellated*, *tessellated*, *stratified*, and *pavement epithelium* have been given to this variety. The squamous epithelium is found on the conjunctiva; in the cavity of the nose near its external apertures; in the mouth, fauces, and lower half of the pharynx; in the œsophagus, where it forms a thick layer, and terminates at the cardiac orifice of the stomach by a serrated border, *ora serrata*; in the vulva, vagina, cervix uteri, and entrance of the urethra.

FIG. 339.



PORTION OF THE COLUMNAR EPITHELIUM from one of the villi of the small intestine. 1. Nucleus of the cell. 2. Membrane of the cell raised from its contents by the absorption of water. From the rabbit: after Kölliker.

side by side like columns, and their interstices are filled with a transparent jelly-like matrix, similar to that which connects the cells of the squamous epithelium.

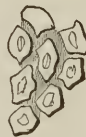Each column contains near its middle a *nucleus*, which gives it a swollen appearance, and the nucleus possesses one or more nucleoli; from the transparency of the column the nucleus may be seen through its base. The columnar epithelium occurs in the stomach and bowels, urethra, gall-bladder, and ducts of glands. In the gall-bladder the nucleus is less apparent than in other parts.

FIG. 340.



COLUMNAR EPITHELIUM from the small intestine; after Henlé. Separate columns, showing nucleus and nucleolus.

FIG. 341.



APPEARANCE OF THE SURFACE formed by the apposition of the bases of several columns.

FIG. 342.



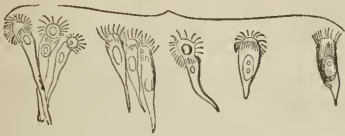CELLS OF SPHEROIDAL EPITHELIUM from the walls of a hair tube, magnified 155 times.

The *Spheroidal epithelium* is composed of cells, which are spheroidal in shape, and more or less polyhedral from compression; in other respects they resemble in structure the cells of the preceding varieties. They are found in situations where the squamous and columnar epithelium are continuous, and on that account have been named by Henlé *transitional epithelium*. The spheroidal epithelium also occurs in the excretory passages of the kidney, the bladder, and in the excretory ducts of the glands which open on the mucous membrane and skin.

The *Ciliated epithelium* is characterized by the presence of minute conical vibratile filaments (*cilia*) mounted on the broad ends of the columnar cells, or upon the free surface of those of the spheroidal kind. The cilia are in constant

action, and produce a wave-like motion, which carries the secretions in contact with them towards the outlet of the organ in which they exist. They are found

FIG. 343.



CELLS OF THE COLUMNAR CILIATED EPITHELIUM of the nose, magnified 310 times.

FIG. 344.



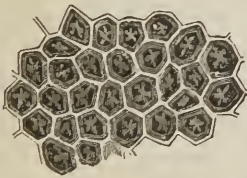
APPEARANCE OF THE SURFACE formed by the apposition of the bases of the columnar ciliated epithelium.

in the nose, and sinuses communicating with the nose; in the nasal duct; upper or respiratory part of the pharynx; Eustachian tubes; larynx, trachea, and bronchial tubes; uterus and Fallopian tubes; and serous membrane of the ventricles of the brain.

The epithelium of the mucous membrane of the alimentary canal is, therefore, *squamous* in the mouth, guttural part of the pharynx, and œsophagus; and *columnar* in the stomach, intestines, and mucous glands. In the upper or nasal portion of the pharynx the epithelium is *columnar* and *ciliated*, as belonging to the apparatus of the air passages. In the mouth it is thin and continuous at the outer edge of the lips with the epidermis; in the œsophagus it is thick, and terminates by an abrupt and serrated border, *ora serrata*, at the cardiac orifice of the stomach; below this point the epithelium is thin and transparent.

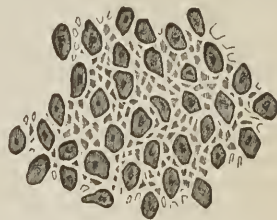
The TRUE MUCOUS MEMBRANE or CORIUM is analogous to the corium of the skin, and is that part of the mucous coat on which its thickness chiefly depends. In structure it consists of two portions; of a thin transparent surface-layer, the *limitary membrane* (*membrana propria*; basement membrane), and an *areolo-vascular portion*, which constitutes its chief bulk. It is rich in bloodvessels, and its areolar element varies in quantity in different membranes, and also in different parts of the same membrane; thus, it is thick in the œso-

FIG. 345.



PORTION OF THE MUCOUS MEMBRANE OF THE STOMACH, magnified 75 times. The alveoli measured $\frac{1}{200}$ of an inch in length, by $\frac{1}{30}$ in breadth; the width of the septa being $\frac{1}{30}$ of an inch. The smaller alveoli measured $\frac{1}{35}$ of an inch in length, and $\frac{1}{30}$ in breadth. The trifid or quadrifid division of a small artery is seen at the bottom of each alveolus, and in the depressions between the divisions of the artery, the apertures of the gastric follicles; two, three, or four, in each depression.

FIG. 346.

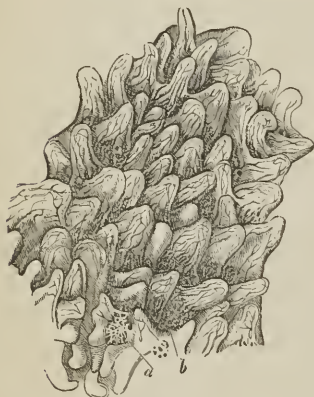

PORTION OF THE MUCOUS MEMBRANE OF THE LARGE INTESTINE, magnified 75 times. The alveoli measured $\frac{1}{250}$ of an inch in length, by $\frac{1}{30}$ in breadth; the septa between the alveoli measuring $\frac{1}{30}$ of an inch in width. The alveoli are less regular in form and shallower than those of the stomach; and in the bottom of each is a gland with a central excretory aperture. In some of the larger alveoli there are two glands.

phagus, thin in the stomach and intestines, and thickest in the bladder and vagina.

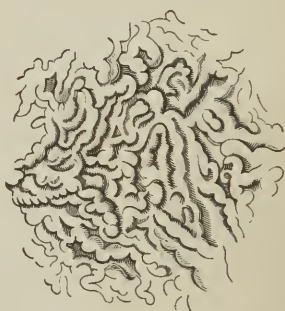
In the liminary membrane and in that part of the corium immediately beneath it, the areolar tissue is in its amorphous and undeveloped condition; the liminary portion is transparent and structureless, while that immediately beneath it is a transparent matrix containing nuclei and undeveloped cells. The papillæ and villi are formed of this material, but have also entering into their structure, smooth muscular fibre and bloodvessels. The smooth muscular fibre forms a thin layer in the deep portion of the mucous membrane in contact with the sub-mucous coat, and is more developed in animals than in man. In the alimentary canal, the surface of the mucous layer presents some diversity of appearance, having reference to the mode of arrangement of the liminary membrane. Thus in the stomach it is raised into a delicate network, the minute openings included within the frame of the network being termed alveoli, and this form of mucous membrane *alveolar*. The alveolar mucous membrane is also found in the large intestine, where the alveoli are smaller and the septa thicker than those of the stomach; in the vesiculæ seminales, where they are larger; and in the gall-

FIG. 347.



PORTION OF THE MUCOUS MEMBRANE OF THE SMALL INTESTINE, MAGNIFIED 19 TIMES, SHOWING CONICAL VILLI. In the hollows between the villi are seen the apertures of simple follicles (*b*); and near the bottom of the figure is a zone of follicles (*a*), surrounding what has been described as a solitary gland. These villi measured $\frac{1}{60}$ of an inch in length, by $\frac{1}{60}$ in breadth at the base, and from $\frac{1}{125}$ to $\frac{1}{150}$ of an inch near the summit.

FIG. 348.



PORTION OF THE MUCOUS MEMBRANE OF THE JEJUNUM, lying between the valvule conniventes, magnified 19 times, and showing the lamellated and convoluted form of villi; the breadth of the lamellæ is $\frac{1}{250}$ of an inch.

bladder, where they are large and coarse. The alveoli of the stomach are polyhedral, for the most part hexagonal in form, and have opening into their floor the mouths of the gastric follicles; in the pyloric end of the stomach, they are oblong in form, and their walls are rendered uneven by the presence of numerous flattened papillæ or villi, *plicæ villosæ*.

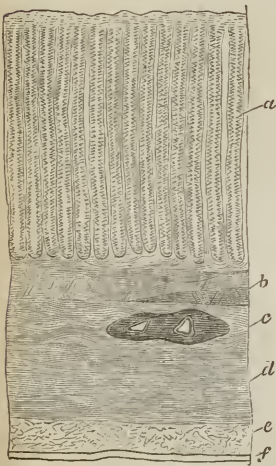
In the small intestine, the liminary membrane and subjacent tissue, instead of forming a raised network, is prolonged into papillæ, which are termed *villi*. The villi vary in form, some being conical; others cylindrical, and enlarged at the extremity; others again triangular or flat and lamellated. They measure in length about $\frac{1}{60}$ of an inch, and in thickness taper from $\frac{1}{60}$ to $\frac{1}{125}$ or $\frac{1}{150}$ of an inch, and are so numerous that Krause counted from fifty to ninety within the limits of a square line in the upper part of the intestine; and lower down from forty to seventy; the entire number of villi in the small intestine he estimated at four millions. The villi are situated on every part of the surface of the membrane, both on the valvulæ conniventes and between those folds, and when

immersed in water they give it the appearance of a fine velvet. There are no villi in the large intestine.

The rete of the stomach and large intestine and the villi of the small intestine are both highly vascular; and, besides the limiting membrane and subliminary substance, have entering into their structure capillary and lymphatic vessels. The villi have each a small artery and vein, with an intermediate capillary plexus; but no nerves have as yet been traced into them. The lymphatic or *lacteal* of each villus probably commences, as Henlé has described, by a single caecal vessel. Krause thinks it begins both as a plexus and by several caecal tubes.

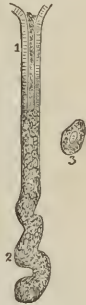AREOLAR COAT.—The *Submucous* or *areolar coat* (vascular, nervous) is a moderately thick stratum of areolar tissue which sustains the vessels, nerves, and glands of the mucous membrane, and connects it to the muscular coat; it is thin and dense in the oesophagus; thicker and more distinct in the stomach; and thicker than the other coats in the small intestine, where it is loose in texture, devoid of fat, and easily distended with air, excepting at Peyer's glands, where it is closely adherent. It is also thicker in the upper part of the small intestine than below, and is one cause of the greater thickness of the duodenum and jejunum; moreover, it enters into the structure of the *valvulae conniventes*.

FIG. 349



PERPENDICULAR SECTION OF THE STOMACH, IN THE PYLORIC REGION; showing its coats and the gastric glands; from the pig; after Kölliker. *a.* Gastric glands. *b.* Muscular layer of the mucous membrane. *c.* Submucous coat, in which a vessel has been divided. *d.* Transverse fibres of the muscular coat. *e.* Longitudinal fibres of the muscular coat. *f.* Serous coat.

FIG. 350.



A TUBULAR GASTRIC GLAND. 1. Columnar epithelium occupying its upper third. 2. Flexuous and twisted deeper portion, filled with nucleated cells. 3. One of the nucleated cells. After Kölliker.

Glands.—In the corium and in the loose areolar tissue of the submucous coat, are situated the glands of the mucous membrane. These glands like those of the mucous membrane of the mouth, are of three kinds; *tubular glands* or simple follicles; *follicular* or saccular glands; and *racemose* or lobulated glands.

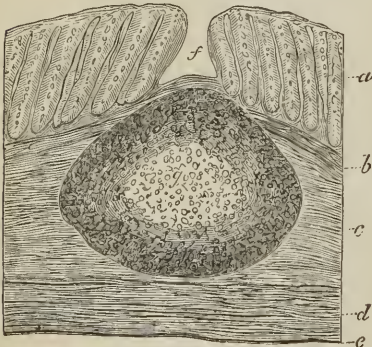
The *Tubular glands* or *simple follicles* are minute caecal tubuli, closely set together, and occupying the whole thickness of the mucous membrane. They are composed of a *membrana propria* of limiting membrane, and lined by a columnar epithelium, which either invests them throughout as in the simple follicles of the small and large intestine, the *cryptae mucosae* of Lieberkuhn; or occupies only the upper third of their extent, as in the gastric or pepsiniferous glands; the remainder of the tubule being filled with pale finely granular polygonal nucleated cells. The tubular glands of the small and large intestine have the same diameter throughout, while those of the stomach, and especially those at the pyloric end, are dilated at the extremity, sometimes flexuous and twisted, occasionally bifurcated, and always filled in the deeper

part with nucleated cells. The mucous membrane of the pyloric end of the stomach owes its greater thickness to the large size and considerable number of these glands. In the small intestine the tubular glands are so numerous as to give to the surface of the membrane between the villi the appearance of a sieve, and around the solitary follicular glands, and the follicular glands of Peyer's patches, they are arranged in circles of six or ten, *coronæ tubulorum*. In the large intestine, they are very closely set, and are also somewhat larger and longer than the tubular glands of the small intestine.

The *Follicular* or *saccular glands*, called also from the shape of their sac, *lenticular*, and *vesicular* from their structure, resemble the follicular glands of the tongue already described. They are found in the roof of the pharynx in considerable numbers, and behind the apertures of the Eustachian tubes; sparingly in the stomach, *lenticular glands*; and more numerous in the small intestines, where they constitute the *glandulæ solitariæ* and Peyer's glands; and in the large intestine, where they are termed solitary glands. In structure the follicular gland is a closed follicle, sacculus, or vesicle, globular or lenticular in shape, composed of a thick and moderately strong coat of nucleated areolar tissue, and containing in its interior a soft grayish pulp, consisting of nucleated cells, cell-nuclei, and a small quantity of fluid; to which may be added, the probable existence of a plexus of fine capillary vessels; a structure, in fact, very closely resembling that of a lymphatic gland. These sacculi are imbedded in the substance of the mucous membrane, by which they are surrounded on all sides, and they form a prominence on the surface, which in the small intestine is studded with villi, and surrounded by a zone of simple follicles.


The *glandulæ solitariæ*, under the name of lenticular glands, are more commonly found in the stomach of children than the adult; and in the small intestine are also most frequent in children. They are met with in every part of the cylinder of the bowel, sometimes singly and sometimes in groups, and more

FIG. 351.



SOLITARY GLAND FROM THE COLON OF A CHILD, as shown in a section of the intestine. *a*. Tubular glands. *f*. Depression on the surface of the membrane corresponding with the central prominence of the gland. *g*. The gland. *b*. Muscular layer of the mucous coat. *c*. Submucous coat. *d*. Muscular coat. *e*. Serous coat. After Kölliker.

FIG. 352.



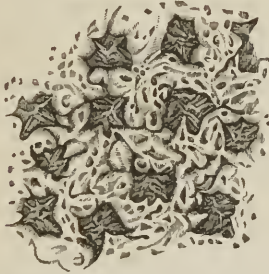
PROMINENCE OF THE MUCOUS MEMBRANE OF THE LARGE INTESTINE, PRODUCED BY A SOLITARY GLAND, magnified 19 times. The alveoli are deep and large, measuring $\frac{1}{7}$ of an inch by $\frac{1}{25}$, and the septa narrow, $\frac{1}{100}$. The alveoli within the crater are smaller and the septa thicker. In the floor there is a vascular network, and the openings of simple follicles.

numerously in the jejunum than in the ileum. In the large intestine, they are grouped closely together in the appendix vermiformis, and are abundant in the

cæcum and rectum, but less numerous in the colon; they are larger in the large than in the small intestine.

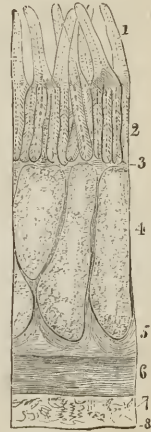
The *glandulæ ayminatæ* (aggregatæ; Peyer's glands) are oval and oblong patches of lighter color than the surrounding mucous membrane, and situated in the ileum and lower part of the jejunum, but principally at the lower part of the former, where they are larger than above. They are found in that portion of the intestine which is opposite the attachment of the mesentery, and vary in size from half an inch to several inches in length, and from a quarter to half an inch in breadth. To the naked eye they have the appearance of pale disks pierced with numerous small irregular fissures; but, under the microscope, they are found to be composed of a reticular and alveolar structure. The *reticular structure*, forming the septa between the alveoli, measures between $\frac{1}{120}$ and $\frac{1}{70}$ of an inch in breadth; it is highly vascular, and presents on its surface the numerous small angular and oval openings of shallow pits. The *alveoli* are quadrangular and oblong in form, and measure in longest diameter about $\frac{1}{50}$ of an inch. Their floor is somewhat raised in the centre by a vascular network, and in the foveolæ formed by the radiating branches of this vascular network

FIG. 353.



PORTION OF ONE OF PEYER'S GLANDS, magnified 19 times. The alveoli are deep; measuring $\frac{1}{45}$ by $\frac{1}{70}$ of an inch (a smaller one measured $\frac{1}{80}$ by $\frac{1}{75}$); and the septa between the alveoli measured from $\frac{1}{120}$ to $\frac{1}{70}$ of an inch. A vascular network and the openings of numerous simple follicles are seen in the floor of the alveoli; and the septa are marked by numerous circular and elongated sulci.

FIG. 354.



SECTION OF THE LOWER PART OF THE ILEUM OF THE CALF, THROUGH A PEYER'S GLAND; after Kölliker. 1. Villi. 2. Tubular glands or Lieberkühn's follicles. 3. Muscular stratum of the mucous membrane. 4. Sacculi of Peyer's gland. 5. Deep portion of the submucous coat. 6. Circular layer of the muscular coat. 7. Longitudinal layer of the muscular coat. 8. Serous coat.

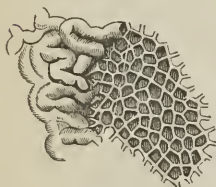
are the openings of numerous simple follicles. The alveoli are considerably less vascular than the reticular structure; and immediately beneath their floor are the closed vesicles or sacculi which constitute the essential part of the gland. There are commonly twenty or thirty of these sacculi in each patch, in some as many as fifty or sixty; they are imbedded in the mucous membrane and submucous tissue, and are bounded externally by the muscular coat of the intestine; generally producing a prominence on the exterior of the intestine. Peyer's glands are richly supplied with capillary vessels and lymphatics, which form a plexus around the sacculi, the lymphatics, or rather lacteals, being probably associated with them in function.

The *Racemose* or *lobulated glands* are small yellowish and flattened glands, each surrounded by a small capsule of areolar tissue, and situated in the submucous coat of the alimentary canal. They are identical in structure with the

racemose glands of the mouth (page 524, figs. 332, 333), and open on the surface of the mucous membrane by means of an excretory duct. They are met with abundantly in the upper part of the *pharynx* and posterior surface of the soft palate, and around the apertures of the Eustachian tubes, and measure from one-third of a line to a line in diameter. In the *œsophagus* they are isolated and smaller, and, with the exception of the duodenum, are wanting in the rest of the intestinal canal, namely, the stomach, small intestine, and large intestine. In the *duodenum*, however, they are very numerous, extending from the pylorus, where they are most abundant, to the entrance of the ductus communis chole-dochus. Von Brunn compared them to a second pancreas, and after him they have been named *Brunner's glands* or *duodenal glands*. They are situated in the submucous coat of the intestine, immediately beneath the mucous membrane, and each gland is inclosed in a separate capsule of areolar tissue. Their average size is a quarter to half a line, and they secrete a clear alkaline mucus, in which no formed elements, such as cells or nuclei, are present. They take no part in digestion.

Besides the above, which are the usually recognised racemose glands of the intestine, I have found others in the small intestine and large intestine, which have hitherto apparently escaped observation. The glands in question are distinctly racemose, have an excretory duct, and are placed so near the surface of the mucous membrane as to be seen distinctly through it; moreover the thin layer of mucous membrane which immediately covers them is non-vascular, or at any rate remained uninjected in the highly-injected preparations on which my observations were made. In the large intestine these glands, which I have termed *muciparous*, occupy the arææ of the reticular surface of the mucous membrane (fig. 346), and in the small intestine they are found in patches, in which a similar reticular structure prevails.

FIG. 355.



PORTION OF THE FREE BORDER OF ONE OF THE VALVULÆ CONNIVENTES OF THE JEJUNUM, magnified 19 times, SHOWING AN ALVEOLAR AND GLANDULAR STRUCTURE. The mode of transition of the lamellated into the alveoli structure is seen. The alveoli measured $\frac{2}{3} \frac{1}{10}$ of an inch by $\frac{1}{3} \frac{1}{10}$, being as large as those of the stomach, and somewhat larger than those of the large intestine; the septa measured between $\frac{1}{8} \frac{1}{10}$ and $\frac{1}{4} \frac{1}{10}$ of an inch in width; the alveoli were shallow, and contained in their floor a mucous gland with an excretory opening.

The *muciparous glands* of the large intestine occupy the alveoli of the mucous membrane, and constitute the floor of those cavities. They are white, semi-transparent, obscurely lobulated, and provided with an excretory aperture. Commonly, each alveolus has its separate gland; but occasionally, and especially where the alveolus is longer than usual, there may be two glands and two excretory apertures. The gland fills the alveolus, rising almost to the level of its brim, and thereby rendering the cavity of the alveolus shallow; the excretory aperture is surrounded by a protuberant lip.

The *muciparous glands* of the small intestine seem to exist chiefly in the lamellated mucous membrane, and especially on the valvulæ conniventes, where they appear to take the place of simple follicles. They occur in patches as large as a lentil, but perfectly flat and identical in structure with the mucous membrane of the large intestine, consisting of a reticular framework and alveoli. The septa, somewhat thicker than those of the large intestine, measure about $\frac{1}{5} \frac{1}{10}$ of an inch in breadth, and contain from two to four rows of minute capillaries, which form a plexus with close meshes. The alveoli

are polygonal, for the most part hexagonal in form, and somewhat larger than those of the large intestine, measuring between $\frac{1}{3} \frac{1}{10}$ and $\frac{1}{2} \frac{1}{10}$ of an inch in longest diameter. Each contains a muciparous gland, which forms its floor,

and the gland is furnished with a central excretory opening. Around the circumference of the glandular patch the reticular structure is imperceptibly lost in the lamellated villi of the mucous membrane.

Vessels.—The distribution of the finer arterial vessels and capillaries in the mucous membrane of the intestinal canal, in relation to the glands, is worthy of attention. The small arteries divide into fine capillaries in the submucous coat; these fine capillaries enter the spaces between the tubular glands, and form by their communications a plexus around the glands, in their course to the surface. Having reached the surface of the mucous membrane, the capillaries become increased in size, and form a horizontal plexus around the apertures of the glands, and these larger capillaries taking a retrograde course, unite to form small venous trunks, by which the blood is returned to the venous circulation. Hence the glands are provided for their secreting function with fine capillaries, while the capillaries which contribute to the nutrition and secretion of the surface of the mucous membrane are of a coarser kind.

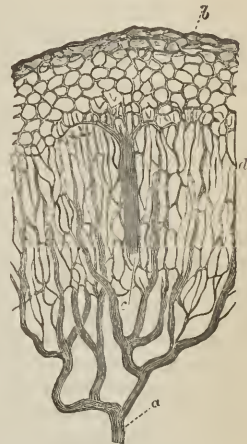
MUSCULAR COAT.—The muscular coat of the pharynx consists of five pairs of muscles, which have been already described. The muscular coat of the rest of the alimentary canal is composed of two planes of fibres, external or *longitudinal*, and internal or *circular*.

The *Œsophagus* is very muscular; its *longitudinal fibres* commence by three fasciculi, two lateral, which are continuous with the inferior constrictor, and one anterior which is attached to the vertical ridge of the cricoid cartilage. The *circular fibres* are attached superiorly to the cricoid cartilage; they are transverse in their arrangement above and below, but spiral in the middle of the *œsophagus*. Below, both sets of fibres are continued upon the stomach.

In addition to the proper muscular fibres of the *œsophagus*, Hyrtl has described two special muscles in connexion with this tube, broncho-*œsophageal* and pleuro-*œsophageal*. The *Broncho-œsophageal* muscle arises as a broad fasciculus from the posterior surface of the left bronchus, and is lost, after a course of two or three inches in length, among the longitudinal fibres of the left side of the *œsophagus*. The *Pleuro-œsophageal* muscle arises from the left wall of the posterior mediastinum, behind the commencement of the descending aorta, and curves around that vessel to mingle its fibres with the longitudinal fibres of the *œsophagus*.

On the *Stomach*, the *longitudinal fibres*, descending from the *œsophagus*, spread out in a radiated manner around the cardiac orifice and great end of the organ, and take their course towards the lesser end; they are most apparent along the lesser curve. The *circular fibres* are most abundant at the lesser end, and at the pylorus are aggregated into a thick circular ring, which, with the spiral fold of mucous membrane found in that situation, constitutes the *pyloric valve*. At the great end of the stomach a new order of fibres is introduced, having for their object to strengthen and compress that extremity of the organ. They are directed more or less horizontally from the great end towards the lesser end, and are generally lost upon the sides of the stomach at about its

Fig. 356.



CIRCULATION IN THE MUCOUS MEMBRANE OF THE INTESTINE; after Kölliker. *a.* Artery. *d.* Fine capillary network, proceeding from the artery and surrounding the tubular glands. *b.* Superficial capillary network around the mouths of the tubular glands. *c.* Vein formed by the union of capillaries returning the blood of the superficial capillary network.

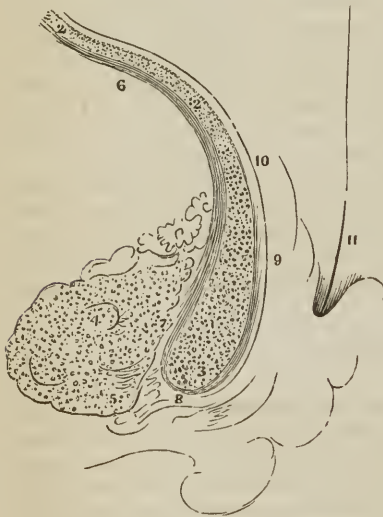
middle; these are the *oblique fibres*. They are the most internal of the three layers, and most numerous at the upper part of the cul-de-sac, near the cardiac orifice.

In the *Small intestine*, the muscular coat is thicker in the duodenum and jejunum than in the ileum; the *longitudinal fibres* are most numerous along the free border of the intestine; and the *circular fibres* are more or less oblique in direction. At the termination of the ileum, the circular fibres are continued into the two folds of the ileo-cæcal valve, while the longitudinal fibres pass onwards to the large intestine.

In the *Large intestine*, the *longitudinal fibres* commence at the appendix vermiformis, and are collected into three bands, anterior, broad; and two posterior and narrower bands. These bands, the *ligamenta coli*, are nearly one-half shorter than the intestine, and serve to maintain the sacculated structure of the cæcum and colon. In the *descending colon* the posterior bands usually unite and form a single band. From this point the bands are continued downwards upon the sigmoid flexure to the rectum, around which they spread out and form a thick and very muscular longitudinal layer. The *circular fibres* in the cæcum and colon are thin; in the rectum they are thicker, and near its lower extremity are aggregated into the thick muscular band which is known as the internal sphincter ani. Between the latter and the mucous membrane are several narrow fasciculi of longitudinal muscular fibres, somewhat more than an inch in length, which have been described by Horner of Philadelphia.

[Horner states that the longitudinal fibres, having reached the lower edge of the internal sphincter, curve under this margin, between it and the external sphincter, and then ascend for an inch or two in contact with the areolar substratum of the mucous membrane, into which they are inserted by fasciculi, which form the body of the columns of the rectum; many of the fibres, however, terminating between the fasciculi of the circular fibres.¹]

[Fig. 357.



A VERTICAL SECTION OF THE PARIETES OF THE ANUS, passing through the middle line of one of the columns of the rectum, and the neighboring parts. 1. The internal sphincter, with its arched fibres transversely divided. 2, 2. The plane of arched fibres of the muscular coat, similarly divided. 3. The point of greatest contraction of the internal sphincter. 4. The external sphincter. 5. The point of greatest contraction of the same muscle. 6. The plane of longitudinal fibres of the muscular coat, longitudinally divided. 7. Some of these fibres terminating in the internal sphincter. 8. Others terminating in the external sphincter. 9. The remaining longitudinal fibres, collected into a semi-tendinous fasciculus, passing over the lower margin of the internal sphincter, to be reverted upwards within the duplicature of the column. 10. These reverted fibres again becoming muscular, and terminating in the mucous coat. 11. The mucous coat. 11. A bristle in one of the pouches.]

The *muscular fibres* of the alimentary canal are of the *smooth* kind, excepting at the commencement and termination, where they are striated; the *striated fibres* form the chief bulk of the muscular coat of the œsophagus, as far as the

¹ [Vide Horner's Special Anat. and Histol., vol. ii., p. 46. Philadelphia, 1851. Also Am. Cyc. Pract. Med. and Surg., vol. ii., Philad., 1836. Article *Anus*.]

thorax, they then become smooth, first in the circular and then in the longitudinal layer. In the lower fourth, the smooth muscular fibres predominate, but a few isolated striated fibres are met with as low down as the cardia. In the lower part of the rectum, the striated fibres again make their appearance, and increase in numbers to its extremity.

SEROUS COAT.—The pharynx and œsophagus have no covering of serous membrane, but in its place a strong fibrous membrane composed of areolar tissue and elastic fibres. The alimentary canal within the abdomen has a serous layer, derived from the peritoneum.

The *stomach* is completely surrounded by peritoneum, excepting along the line of attachment of the great and lesser omentum. The *first* or *oblique portion of the duodenum* is also completely included by the serous membrane, with the exception of the points of attachment of the omenta. The *descending portion* has only a partial covering on its anterior surface, derived from the right meso-colon. The *transverse portion* is also behind the peritoneum, being situated between the two layers of the transverse meso-colon, and has but a partial covering. The rest of the *small intestine* is completely invested by it, excepting along the concave border, *margo-mesenterialis*, to which the mesentery is attached. The *cæcum* is more or less invested by the peritoneum, the more frequent disposition being that in which the intestine is surrounded for three-fourths only of its circumference. The *ascending* and *descending colon* are covered by the serous membrane only in front. The *transverse colon* is invested completely, with the exception of the lines of attachment of the greater omentum and transverse meso-colon. And the *sigmoid flexure* is entirely surrounded, with the exception of the part corresponding with the junction of the left meso-colon. The upper third of the rectum is completely inclosed by the peritoneum; the middle third has an anterior covering only, and the inferior third none whatsoever.

Vessels and Nerves.—The *Arteries* of the alimentary canal, as they supply the tube from above downwards, are the pterygo-palatine, ascending pharyngeal, superior thyroid, and inferior thyroid, in the neck; œsophageal in the thorax; gastric, hepatic, splenic, superior and inferior mesenteric, in the abdomen; and inferior mesenteric, internal iliac, and internal pudic, in the pelvis. The *veins* from the abdominal alimentary canal unite to form the vena portæ. The *lymphatics* and *lacteals* open into the thoracic duct.

The *Nerves* of the pharynx and œsophagus are derived from the glosso-pharyngeal, pneumogastric, and sympathetic. The nerves of the stomach are the pneumogastric, and sympathetic branches from the solar plexus; and those of the intestinal canal are the superior and inferior mesenteric and hypogastric plexuses. The extremity of the rectum is supplied by the inferior sacral nerves from the spinal cord.

THE LIVER

The liver is a conglomerate gland of large size, appended to the alimentary canal, and performing the double office of separating impurities from the venous blood of the chylopoietic viscera previously to its return into the general venous circulation, and of secreting a fluid necessary to chylofication, the bile. It is the largest organ in the body, weighing about four pounds, and measuring through its longest diameter about twelve inches. It is situated in the right hypochondriac region, and extends across the epigastrium into the left hypochondrium, frequently reaching, by its left extremity, the upper end of the spleen. It is placed obliquely in the abdomen; its convex surface looking upwards and forwards, the concave downwards and backwards. The anterior border is sharp and free, and marked by a deep notch, and the posterior rounded

and broad. It is in relation, superiorly and posteriorly, with the diaphragm; inferiorly with the stomach, ascending portion of the duodenum, transverse colon, right supra-renal capsule, and right kidney; and corresponds, by its free border, with the lower margin of the ribs.

Ligaments.—The liver is retained in its place by five ligaments, four of which are duplicatures of the peritoneum, situated on the convex surface of the organ; the fifth is a fibrous cord which passes through a fossa in its under surface, from the umbilicus to the inferior vena cava. They are the—

Longitudinal,
Two lateral

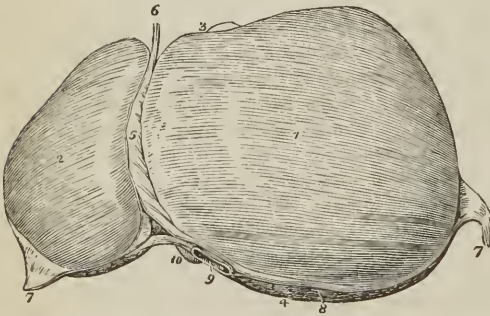
Coronary,
Round.

The *Longitudinal ligament* (broad, ligamentum suspensorium hepatis) is an antero-posterior fold of peritoneum, extending from the notch in the anterior margin of the liver to its posterior border. Between its two layers, in the anterior and free margin, is the round ligament.

The *Lateral ligaments* are formed by the two layers of peritoneum, which pass from the under surface of the diaphragm to the posterior border of the liver; they correspond with its lateral lobes.

The *Coronary ligament* is formed by the separation of the two layers forming the lateral ligaments near their point of convergence. The posterior layer is continued unbroken from one lateral ligament to the other; but the anterior quits the posterior at each side, and is continuous with the corresponding layer of the longitudinal ligament. In this way a large oval surface on the posterior border of the liver is left uncovered by peritoneum, and is connected to the diaphragm by areolar tissue. This space is formed principally by the right

FIG. 358.



UPPER SURFACE OF THE LIVER. 1. Right lobe. 2. Left lobe. 3. Anterior or free border. 4. Posterior or rounded border. 5. Broad ligament. 6. Round ligament. 7, 7. The two lateral ligaments. 8. The space left uncovered by the peritoneum, and surrounded by the coronary ligament. 9. Inferior vena cava. 10. Point of the lobus Spigelii. 3. Fundus of the gall-bladder seen projecting beyond the anterior border of the right lobe.

lateral ligament, and is pierced near its left extremity by the inferior vena cava, previously to the passage of that vessel through the tendinous opening in the diaphragm.

The *Round ligament* is a fibrous cord resulting from the obliteration of the umbilical vein, and situated between the two layers of peritoneum in the anterior border of the longitudinal ligament. It may be traced from the umbilicus through the longitudinal fossa of the under surface of the liver to the inferior vena cava, to which it is connected.

Fossæ.—The under surface of the liver is marked by five fossæ [or fissures], which divide its surface into five compartments or lobes, two principal and three minor lobes; they are the—

Fossæ.

Longitudinal fossa,
 Fossa for the ductus venosus,
 Transverse fossa,
 Fossa for the gall bladder,
 Fossa for the vena cava.

Lobes.

Right lobe,
 Left lobe,
 Lobus quadratus,
 Lobus Spigelii,
 Lobus caudatus.

The *Longitudinal fossa* or *fissure* is a deep groove running from the notch, *incisura umbilicalis*, in the anterior margin of the liver, to the posterior border of the organ. At about one-third from its posterior extremity it is joined by a short but deep fossa, the transverse, which meets it transversely from the under part of the right lobe.

The longitudinal fossa in front of this junction lodges the fibrous cord of the umbilical vein, and is generally crossed by a band of hepatic substance called the *pons hepatis*.

The *Fossa for the ductus venosus* is the shorter portion of the longitudinal fossa, extending from the junctional termination of the transverse fossa to the posterior border of the liver, and containing a small fibrous cord, the remains of the ductus venosus. This fossa is therefore but a part of the longitudinal fossa.

The *Transverse fossa* is the short and deep fossa, about two inches in length, through which the hepatic ducts quit and the hepatic artery and portal vein enter the liver. Hence this fossa was considered by the older anatomists as the gate of the liver, *porta hepatis*; and the large vein entering the organ at this point, the portal vein. At their entrance into the transverse fossa the branches of the hepatic duct are the most anterior, next those of the artery, and most posteriorly the portal vein.

The *Fossa for the gall-bladder* is a shallow depression extending forwards, parallel with the longitudinal fossa, from the right extremity of the transverse fossa to the free border of the liver, where it frequently forms a notch, *incisura vesicalis*.

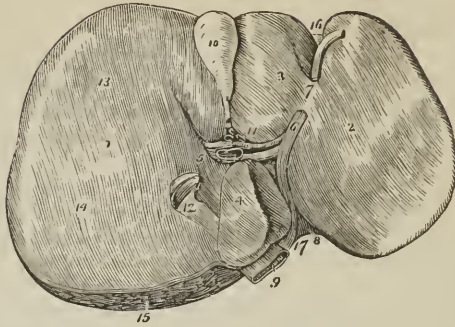
The *Fossa for the vena cava* is a deep and short fissure, occasionally a circular tunnel, which proceeds from a little behind the right extremity of the transverse fossa to the posterior border of the liver, and lodges the inferior vena cava.

These five fossæ taken collectively resemble an inverted ∇ , the base corresponding with the free margin of the liver, and the apex with its posterior border. Viewing them in this way, the two anterior branches represent the longitudinal fossa on the left, and the fossa for the gall-bladder on the right side; the two posterior, the fossa for the ductus venosus on the left, and the fossa for the vena cava on the right; and the connecting bar, the transverse fossa.

Lobes.—The *right lobe* is four or six times larger than the left, from which it is separated, on the concave surface, by the longitudinal fossa, and, on the convex, by the longitudinal ligament. It is marked on its under surface by the transverse fossa, and by the fossæ for the gall-bladder and vena cava; and presents three depressions, one, in front, for the curve of the ascending colon, *impressio colica*, and two behind, for the right supra-renal capsule and kidney, *impressio renalis*. Not unfrequently several small irregular fissures, *rimæ cæcæ*, are found on the under surface of this lobe.

The *Left lobe* is small and flattened, convex on its upper surface and concave below, where it lies in contact with the anterior surface of the stomach. It is sometimes in contact by its extremity with the upper end of the spleen, and is in relation, by its posterior border, with the cardiac orifice of the stomach and left pneumogastric nerve.

FIG. 359.



UNDER SURFACE OF THE LIVER. 1. Right lobe. 2. Left lobe. 3. Lobus quadratus. 4. Lobus Spigelii. 5. Lobus caudatus; the fissure in front of 5, and running parallel with the gall-bladder is a rima cæca. 6. Longitudinal fossa; the figure is placed on the rounded cord, the remains of the umbilical vein. 7. Pons hepatis. 8. Fossa of the ductus venosus; the obliterated cord of the ductus is seen passing backwards to be attached to the coats of the inferior vena cava (9). 10. Gall-bladder lodged in its fossa. 11. Transverse fossa, containing, from before backwards, hepatic duct, hepatic artery, and portal vein. 12. Vena cava. 13. Depression corresponding with the curve of the colon. 14. Double depression produced by the right kidney and its supra-renal capsule. 15. Rough surface on the posterior border of the liver left uncovered by peritoneum; the cut edge of the peritoneum surrounding this surface forms part of the coronary ligament. 16. Notch on the anterior border, separating the two lobes. 17. Incisura vertebralis or notch on the posterior border, corresponding with the vertebral column.

The *Lobus quadratus* is a quadrilateral lobe situated on the under surface of the right lobe; it is bounded, *in front*, by the free border of the liver; *behind*, by the transverse fossa; to the *right*, by the gall-bladder; and to the *left*, by the longitudinal fossa.

The *Lobus Spigelii*¹ is a small triangular lobe, also situated on the under surface of the right lobe: it is bounded, *in front*, by the transverse fossa; and, *on the sides*, by the fossæ for the ductus venosus and vena cava.

The *Lobus caudatus* is a small tail-like appendage of the lobus Spigelii, from which it runs outwards like a crest into the right lobe, and serves to separate the right extremity of the transverse fossa from the commencement of the fossa for the vena cava. In some persons this lobe is well marked, in others it is small and ill-defined.

Reverting to the comparison of the fossæ with an inverted ∇ , it will be observed, that the quadrilateral interval, in front of the transverse bar, represents the lobus quadratus; the triangular space behind the bar, the lobus Spigelii; and the apex of the letter, the point of union between the inferior vena cava and the obliterated cord of the ductus venosus.

Vessels and Nerves.—The vessels entering into the structure of the liver are also *five* in number; they are the—

Hepatic artery,
Portal vein,

Hepatic veins,
Hepatic ducts,

Lymphatics.

The *Hepatic artery*, *Portal vein*, and *Hepatic duct*, enter the liver at the transverse fossa, and ramify through portal canals to every part of the organ; so

¹ Adrian Spigel, a Belgian physician, Professor at Padua after Casserius in 1616. He assigned considerable importance to this little lobe, but it had been described by Sylvius full sixty years before his time.

that their general direction is from below upwards, and from the centre towards the circumference.

The *Hepatic veins* commence at the circumference, and proceed from before backwards, to open into the vena cava at the posterior border of the liver. Hence the branches of the two veins cross each other in their course.

The portal vein, hepatic artery, and hepatic duct are moreover enveloped in a loose areolar tissue, the capsule of Glisson, which permits them to contract upon themselves when emptied of their contents; the hepatic veins, on the contrary, are closely adherent by their parietes to the surface of the canals in which they run, and are unable to contract. By these characters the anatomist is enabled, in any section of the liver, to distinguish at once the most minute branch of the portal vein from an hepatic vein; the former will be found more or less collapsed, and always accompanied by an artery and duct, and the latter widely open and solitary.

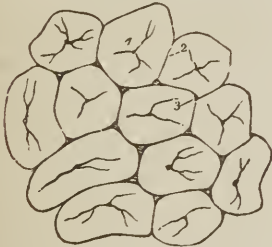
The *Lymphatics* of the liver are described in the Chapter dedicated to those vessels.

The *Nerves* of the liver are derived from the spinal and sympathetic system; the former proceed from the right phrenic and right pneumogastric nerve, the latter from the hepatic plexus.

Structure and Minute Anatomy of the Liver.

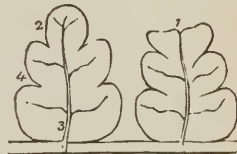
The *Liver* is composed of *lobules*, of a connecting medium called *Glisson's capsule*, of the ramifications of the *portal vein*, *hepatic duct*, *hepatic artery*, *hepatic veins*, *lymphatics*, and *nerves*, and is inclosed and retained in its situation by the peritoneum.

FIG. 360.



LOBULES OF THE LIVER. The lobules as they are seen on the surface of the liver, or when divided transversely. 1. Intralobular vein in the centre of each lobule. 2. Interlobular fissure. 3. Interlobular space.

FIG. 361.

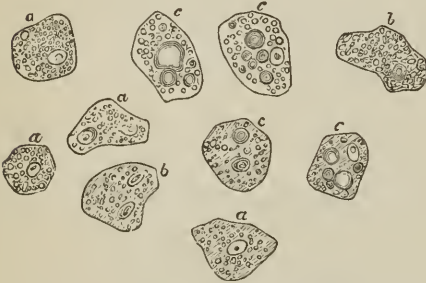


LONGITUDINAL SECTION OF TWO LOBULES.
1. A superficial lobule, terminating abruptly, and resembling a section at its extremity. 2. A deep lobule, showing the foliated appearance of its section. 3. Intralobular vein, with its converging venules; the vein terminates in a sublobular vein. 4. External, or capsular surface of the lobule.

The *Lobules* are small granular bodies of about the size of a millet seed, of irregular form, and presenting a number of rounded prominences on their surface. When divided longitudinally, they have a foliated appearance, and transversely, a polygonal outline, with sharp or rounded angles, according to the smaller or greater quantity of Glisson's capsule contained in the liver. Each lobule is divided on its exterior into a base and a capsular surface. The *base* corresponds with one extremity of the lobule, is flattened, and rests on an hepatic vein, which is thence named *sublobular*. The *capsular surface* includes the rest of the periphery of the lobule, and has received its designation from being inclosed in an areolar capsule derived from the capsule of Glisson. In the centre of each lobule is a small vein, the *intralobular*, which is formed by the convergence of six or eight minute venules from the rounded prominences of the peri-

phery. The intralobular vein thus constituted takes its course through the centre of the longitudinal axis of the lobule, pierces the middle of its base, and opens into the sublobular vein. The periphery of the lobule, with the exception of its base, which is always closely attached to a sublobular vein, is connected by means of its areolar capsule, with the capsular surface of surrounding lobules. The interval between the lobules is the *interlobular fissure*, and the angular interstices formed by the apposition of several lobules are the *interlobular spaces*.

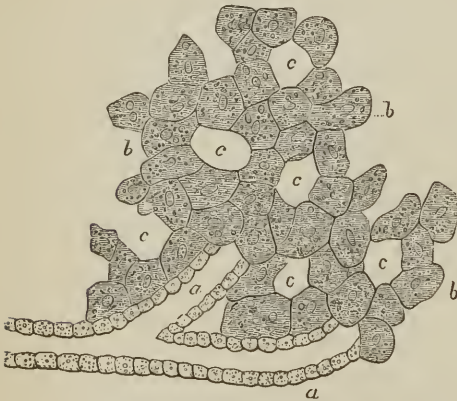
FIG. 362.



HEPATIC CELLS OF MAN; after Kölliker. a. The more normal cells. b. With pigment. c. With fat. Magnified 400 diameters.

hepatic vein; no ducts are found in the lobule; these latter, with the branches of the hepatic artery, being situated in the intervals of the lobules or interlobular fissures.

FIG. 363.



ARRANGEMENT OF THE HEPATIC CELLS IN A CELL NETWORK, and the mode of origin of the hepatic ducts; after Kölliker. a, a. Hepatic ducts, commencing by cæcal extremities, and formed by epithelial cells without limiting membrane. b, b. Hepatic cells, disposed in solid columns. c, c. Vascular spaces occupied by the capillary plexus.

The lobules of the centre of the liver are angular, and somewhat smaller than those of the surface, from the greater compression to which they are submitted. The superficial lobules are incomplete, and give to the surface of the organ the appearance of a transverse section.

In *ultimate structure*, the lobule is composed of *hepatic cells* or *corpuseles*, and a *vascular plexus*, which receives its blood exteriorly from an interlobular branch of the portal vein and transmits it internally to the intralobular vein, the radicle of the

hepatic vein; no ducts are found in the lobule; these latter, with the branches of the hepatic artery, being situated in the intervals of the lobules or interlobular fissures. The *hepatic cells* or *corpuseles* are nucleolo-nucleated cells, of a polyhedral figure, measuring about $\frac{1}{1000}$ of an inch in diameter, and of a pale amber color. They are composed of a thin proper membrane, inclosing granular, semi-fluid contents, which are yellowish in color, and the essential constituents of the bile; moreover, there are often found within the hepatic cell, besides the nucleus, a greater or less number of brownish-yellow pigment granules, and one or more globules of fat. The hepatic cells are arranged in the form of a network, the meshes of the network corresponding with the vascular plexus, and the columns or solid portions of the network constituting the secretory portion of the gland. The lobules are, therefore, composed of cells and capillary vessels, closely applied to each other, and the secretion of bile is effected by the exudation of the fluid elements of the bile from the vessels into the cells. The biliary ducts originate by cæcal extremities among the hepatic cells of the exterior of the lobule, and

the next step in the process of secretion is the transmission of the bile from the hepatic cells to the biliary ducts.

Glisson's capsule is the areolar tissue which envelops the hepatic artery, portal vein, and hepatic duct, during their passage through the transverse fossa, and which continues to surround them to the interlobular fissures. It connects all the lobules together, and constitutes the proper capsule of the entire organ. Glisson's capsule "is to the liver what the pia mater is to the brain; it is a cellulo-vascular membrane, in which the vessels divide and subdivide to an extreme degree of minuteness; which lines the portal canals, forming sheaths for the larger vessels contained in them, and a web in which the smaller vessels ramify;"¹ and which enters the interlobular fissures. Hence arises a division of the capsule into two portions, *vaginal* and *interlobular*.

The vaginal portion is that which invests the hepatic artery, hepatic duct, and portal vein, in the portal canals; in the large canals it completely surrounds these vessels, but in the smaller is situated only on that side which is occupied by the artery and duct; while the interlobular portion occupies the interlobular fissures and spaces.

The *Portal vein*, entering the liver at the transverse fossa, ramifies through its structure in canals, which resemble, by their surfaces, the external superficies of the liver, and are formed by the capsular surface of the lobules. These are the portal canals, and contain, besides the portal vein with its ramifications, the artery and duct with their branches.

In the larger canals, the vessels are separated from the parietes by a web of Glisson's capsule; but in the smaller, the portal vein is in contact with the surface of the canal for about two-thirds of its cylinder, the opposite third being in relation with the artery and duct and their investing capsule. If, therefore, the portal vein were laid open by a longitudinal incision in one of these smaller canals, the coats being transparent, the outline of the lobules, bounded by their interlobular fissures, would be as distinctly seen as on the external surface of the liver, and the smaller venous branches would be observed entering the interlobular spaces.

The branches of the portal vein are, vaginal, interlobular, and lobular. The *vaginal branches* are those which, being given off in the portal canals, have to pass through the sheath (vagina) of Glisson's capsule, previously to entering the interlobular spaces. In this course they form an intricate plexus, *vaginal plexus*, in the capsule of Glisson, and this plexus surrounds the vessels, as does the capsule in the larger canals, and occupies the capsular side only in the smaller canals. The *interlobular branches* are given off from the vaginal portal plexus where it exists, and directly from the portal veins, in that part of the smaller canals where the coats of the vein are in contact with the walls of the canal. They then enter the interlobular spaces and divide into branches, which cover with their ramifications every part of the surface of the lobules, with the exception of their bases and those extremities of the superficial lobules which appear on the surfaces of the liver. The *lobular branches* are derived from the interlobular veins; they form a plexus within each lobule, and converge from the circumference towards the centre, where they terminate in the minute radicles of the intralobular vein. "This plexus, interposed between the interlobular portal veins and the intralobular hepatic vein, constitutes the venous part of the lobule, and may be called the *lobular venous plexus*." The regular islets of the substance of the lobules, seen between the meshes of this plexus by means of the microscope, are the acini of Malpighi, and are the network of hepatic cells.

The portal vein returns the venous blood from the chylopoietic viscera, to be

¹ "The Anatomy and Physiology of the Liver," by Kiernan, "Phil. Trans.," 1833, from which this and the other paragraphs within inverted commas, on the structure of the liver, are quoted.

circulated through the lobules; it also receives the blood which results from the distribution of the hepatic artery.

The *Hepatic duct*, entering the liver at the transverse fossa, divides into branches, which ramify through the portal canals, with the portal vein and hepatic artery, to terminate in the interlobular fissures; its branches are, vaginal and interlobular.

The *vaginal branches* ramify through the capsule of Glisson, and form a *vaginal biliary plexus*, which, like the vaginal portal plexus, surrounds the

[FIG. 364.]

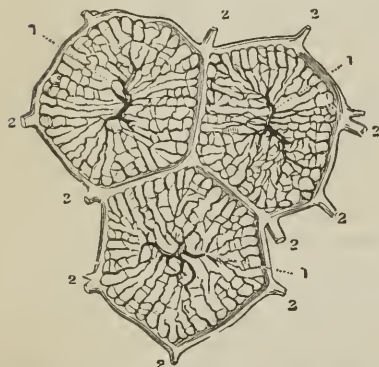
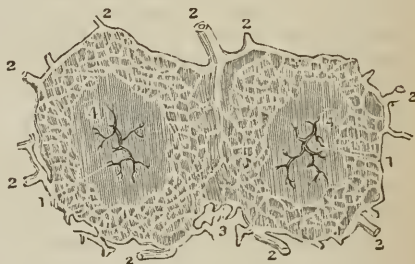

DIAGRAM SHOWING THE ARRANGEMENT OF THE TWO PRINCIPAL SYSTEMS OF BLOOD-VESSELS within and between the lobules. (Kiernan.) 2, 2. Interlobular branches of portal vein, forming the lobular venous plexus, connecting the portal veins (2, 2) with the intralobular vein (1) in the centre, which is the commencing branch of the hepatic vein.]

[FIG. 365.]



HORIZONTAL SECTION OF TWO SUPERFICIAL LOBULES, SHOWING THE INTERLOBULAR PLEXUS OF BILIARY DUCTS: (Kiernan). 1, 1. Intralobular veins; 2, 2, Trunks of biliary ducts. 3. Interlobular tissue; 4, 4. Parenchyma of the lobules.]

vessels in the large canals, but is deficient on that side of the smaller canals against which the duct is placed. The *interlobular branches* proceed from the vaginal biliary plexus, where it exists, and directly from the hepatic duct on that side of the smaller canals against

which the duct is placed. They enter the interlobular spaces, and ramify between the lobules in the interlobular fissures, where they end by caecal extremities.

The coats of the duct are very vascular, and supplied with a number of mucous glands, which are distributed irregularly in the larger, but are arranged in two parallel longitudinal rows in the smaller ducts.

The *Hepatic artery* enters the liver with the portal vein and hepatic duct, and ramifies with those vessels through the portal canals. Its branches are, vaginal and interlobular. The *vaginal branches*, like those of the portal vein and hepatic duct, form a *vaginal plexus*, which exists throughout the whole extent of the portal canals, with the exception of that side of the smaller canals which corresponds with the artery. The *interlobular branches*, arising from the vaginal plexus and from the parietal side of the artery (in the smaller canals), ramify through the interlobular fissures, and are principally distributed to the coats of the interlobular ducts.

“From the superficial interlobular fissures small arteries emerge, and ramify in the *proper capsule*, on the convex and concave surface of the liver, and in the ligaments. These are the *capsular arteries*.” Where the capsule is well developed, “these vessels cover the surfaces of the liver with a beautiful plexus, and anastomose with branches of the phrenic, internal mammary, and supra-

renal arteries," and with the epigastric. The venous blood resulting from the distribution of the hepatic artery is returned into the portal vein.

The *Hepatic veins* commence in the substance of each lobule by minute venules, which receive the blood from the lobular venous plexus, and converge to form the intralobular vein. The *intralobular vein* passes through the central axis of the lobule, and through the middle of its base, to terminate in a sublobular vein; and the union of the sublobular veins constitutes the hepatic trunks, which open into the inferior vena cava. The hepatic venous system consists, therefore, of three sets of vessels; intralobular veins, sublobular veins, and hepatic trunks.

The *sublobular veins* are contained in canals formed solely by the bases of the lobules, with which, from the absence of Glisson's capsule, they are in immediate contact. Their coats are thin and transparent; and, if they be laid open by a longitudinal incision, the bases of the lobules will be distinctly seen, separated by interlobular fissures, and perforated through the centre by the opening of the intralobular vein.

The *hepatic trunks* are formed by the union of the sublobular veins; they are contained in canals (hepatic venous) similar in structure to the portal canals, and lined by a prolongation of the proper capsule. They proceed from before backwards, and terminate, by two large openings (corresponding with the right and left lobe of the liver) and several smaller apertures, in the inferior vena cava.

Summary.—The liver has been shown to be composed of *lobules*; the lobules (excepting at their bases) are connected together, the vessels supported, and the whole organ inclosed, by *Glisson's capsule*; and they are so arranged, that the base of every lobule in the liver is in contact with an hepatic vein (sublobular).

The *Portal vein* distributes its numberless branches through portal canals, which are channeled through every part of the organ; it brings the returning blood from the chylopoietic viscera; it collects also the venous blood from the ultimate ramifications of the hepatic artery in the liver itself. It gives off branches in the canals, which are called *vaginal*, and form a venous *vaginal plexus*; these give off *interlobular branches*, and the latter enter the lobules and form *lobular venous plexuses*, from the blood circulating in which the bile is secreted.

The *Bile* is received from the hepatic cells by the *interlobular ducts*; it is thence poured into the biliary *vaginal plexus* of the portal canals, and thence into the excreting ducts, by which it is carried to the duodenum and gall-bladder, after being mingled in its course with the mucous secretion from numberless muciparous glands in the walls of the ducts.

The *Hepatic artery* distributes branches through every portal canal; gives off *vaginal branches* which form a vaginal hepatic plexus, from which the *interlobular branches* arise, and these latter terminate ultimately in the lobular venous plexuses of the portal vein. The artery ramifies abundantly in the coats of the hepatic ducts, enabling them to provide their mucous secretion; and supplies the vasa vasorum of the portal and hepatic veins, and the nutrient vessels of the entire organ.

The *Hepatic veins* commence in the centre of each lobule by minute radicles, which collect the impure blood from the lobular venous plexus, and convey it into the *intralobular veins*; these open into the *sublobular veins*, and the sublobular veins unite to form the large hepatic trunks by which the blood is carried into the vena cava.

Physiological and pathological deductions.—The physiological deduction arising out of this anatomical arrangement is, that the *bile is wholly secreted*

from venous blood, and not from a mixed venous and arterial blood, as stated by Müller; for although the portal vein receives its blood from two sources, viz., from the chylipoietic viscera, and from the capillaries of the hepatic artery, yet the fact of the blood of the latter vessel having passed through its capillaries into the portal vein, or in extremely small quantity into the capillary network of the lobular venous plexus, is sufficient to establish its venous character.¹

The pathological deductions depend on the following facts:—Each lobule is a perfect gland, of uniform structure, of uniform color, and possessing the same degree of vascularity throughout. It is the seat of a double venous circulation, the vessels of the one (*hepatic*) being situated in the centre of the lobule, and those of the other (*portal*) in the circumference. Now the color of the lobule, as of the entire liver, depends chiefly on the proportion of blood contained within these two sets of vessels; and so long as the circulation is natural, the color will be uniform. But the instant that any cause is developed which shall interfere with the free circulation of either, there will be an immediate diversity in the color of the lobule.

Thus, if there be any impediment to the free circulation of the venous blood through the heart or lungs, the circulation in the hepatic veins will be retarded, and the sublobular and the intralobular veins will become congested, giving rise to a more or less extensive redness in the centre of each of the lobules, while the marginal or non-congested portion presents a distinct border of a yellowish-white, yellow, or green color, according to the quantity and quality of the bile it may contain. “This is ‘*passive congestion*’ of the liver, the usual and natural state of the organ after death;” and, as it commences with the hepatic vein, it may be called the first stage of *hepatic-venous* congestion.

But if the causes which produced this state of congestion continue, or be from the beginning of a more active kind, the congestion will extend through the lobular venous plexuses “into those branches of the portal vein situated in the *interlobular fissures*, but not to those in the *spaces*, which being larger, and giving origin to those in the fissures, are the last to be congested.” In this second stage the liver has a mottled appearance, the non-congested substance is arranged in isolated, circular, and ramose patches, in the centres of which the spaces and parts of the fissures are seen. This is an extended degree of *hepatic-venous congestion*; it is “*active congestion*” of the liver, and very commonly attends disease of the heart and lungs.

These are instances of *partial congestion*, but there is sometimes *general congestion* of the organ. “In general congestion the whole liver is of a red color, but the central portions of the lobules are usually of a deeper hue than the marginal portions.”

GALL-BLADDER.

The Gall-bladder (Fig. 233) is the reservoir of the bile; it is a pyriform sac, situated in a fossa on the under surface of the right lobe of the liver, and extending from the right extremity of the transverse fossa to the free margin. It is divided into a body, fundus, and neck: the fundus, or broad extremity in the natural position of the liver, is placed downwards, and frequently projects beyond the free margin of the liver, while the neck, small and constricted, is directed upwards. This sac is composed of three coats, serous, fibrous, and mucous. The *serous coat* is partial, is derived from the peritoneum, and covers that side only which is unattached to the liver. The *middle or fibrous coat* is thin but strong fibrous layer, composed of dense areolar tissue, and connected on the one side with the liver, on the other with the peritoneum. There also exists in this layer a stratum of smooth muscular fibres, which are longitudinal

¹ For arguments on this contested question, see the article “Liver,” in the “Cyclopædia of Anatomy and Physiology.”

and circular in direction. The *internal* or *mucous coat* is but loosely attached to the fibrous layer; it is everywhere raised into minute rugæ, which give it a beautifully reticulated appearance; and it forms, at the neck of the sac, a spiral valve. It is continuous through the hepatic duct with the mucous membrane lining the ducts of the liver, and through the ductus communis choledochus, with the mucous membrane of the alimentary canal. It is coated on its surface with a columnar epithelium.

The *Biliary ducts* are, the hepatic, cystic, and ductus communis choledochus.

The *Hepatic duct*, nearly two inches long, is formed in the transverse fossa of the liver by the junction of two ducts which proceed from the right and left lobe. It joins the cystic duct at an acute angle, and the common duct resulting from their union is the ductus communis choledochus.

The *Cystic duct*, about an inch in length, passes inwards from the neck of the gall-bladder, and unites at an acute angle with the preceding.

The *Ductus communis choledochus* (χολή, bilis, δέχομαι, recipio) is the common excretory duct of the liver and gall-bladder; it is about three inches in length, and is formed by the junction of the hepatic with the cystic duct. It descends through the right border of the lesser omentum, and behind the descending portion of the duodenum to the inner side of that intestine, where it terminates by passing obliquely between the muscular and mucous coat, and opening on the summit of a papilla which is common to it and the pancreatic duct. The papilla is situated near the lower part of the descending portion of the duodenum at its inner side; and the duct is constricted in size during its passage between the coats of the intestine.

The coats of the biliary ducts are an external or fibrous, and an internal or mucous coat. The *external coat* is composed of dense areolar tissue, containing many nuclei, and elastic tissue. The *mucous coat*, continuous on the one hand with the lining membrane of the hepatic ducts and gall-bladder, and on the other with that of the duodenum, is furnished with a columnar epithelium. A few smooth muscular fibres have been observed in the mucous coat; but there is no special muscular coat.

Vessels and Nerves. — The gall-bladder is supplied with blood by the cystic artery, a branch of the hepatic. Its veins return their blood into the portal vein. The nerves are derived from the hepatic plexus.

THE PANCREAS.

The pancreas [πᾶν κρέας, all flesh,] is a long, flattened, conglomerate gland, analogous to the salivary glands. It is about six inches in length, and between three and four ounces in weight; is situated transversely across the posterior wall of the abdomen, behind the stomach, and rests on the aorta, vena portæ, inferior vena cava, the origin of the superior mesenteric artery, and the left kidney and supra-renal capsule; opposite the first and second lumbar vertebra. It is divided into a body, a greater, and a smaller extremity; the great end or head is placed towards the right, and surrounded by the curve of the duodenum; the lesser end [or tail] extends to the left as far as the spleen. The anterior surface of the body of the pancreas is covered by the ascending posterior layer of peritoneum, and is in relation with the stomach, the first portion of the duodenum, and the commencement of the transverse arch of the colon. The posterior surface is grooved for the splenic vein, and tunneled by a complete canal for the superior mesenteric and portal vein, and superior mesenteric artery. The upper border presents a deep groove, sometimes a canal, for the splenic artery and vein, and is in relation with the oblique portion of the duodenum, lobus Spigelii, and cœliac axis. And the lower border is separated from the transverse portion of the duodenum by the superior mesenteric artery and vein. On the posterior part of the head of the pancreas is a lobular fold of the gland which

completes the canal of the superior mesenteric vessels, and is called the *lesser pancreas*.

The pancreatic duct (duct of Wirsung) commences at the small extremity of the organ by two branches, which converge and unite after a course of about one-third the length of the gland. The duct is then continued onwards from left to right, gradually increasing in size, and lying nearer the anterior than the posterior surface of the organ, to the lower part of the descending duodenum, where it terminates on the papilla of mucous membrane, common to it and the ductus communis choledochus. The duct receives numerous branches which open into it on all sides from the lobules of the gland, and at its termination is slightly dilated and passes obliquely between the muscular and mucous coat of the intestine to reach the papilla. The duct which receives the secretion from the lesser pancreas is called the *ductus pancreaticus minor*; it opens into the principal duct near the duodenum, and sometimes passes separately into that intestine. As a variety, two pancreatic ducts are occasionally met with.

In structure the pancreas presents the ordinary composition of a *compound racemose gland*, being made up of lobes, and these of reddish-yellow polyhedral lobules, which latter consist of smaller lobules, and the smallest lobules of the ramifications of minute ducts, terminating in *glandular vesicles*. The glandular vesicles are rounded in form (Fig. 332), and composed of a *membrana propria*, lined by a *spheroidal epithelium* of nucleated cells; the cells being somewhat opaque from the presence of fat granules as part of their contents. The *ducts* are composed of areolar and elastic tissue, and lined by a *columnar epithelium*. In the walls of the ducts are numerous small racemose mucous glands like those in the hepatic ducts. The secretion of the pancreas is a clear fluid, without formed elements.

Vessels and Nerves. — The arterics of the pancreas are branches of the splenic, hepatic, and superior mesenteric; the *veins* open into the splenic vein; the *lymphatics* terminate in the lumbar glands. The *nerves* are filaments of the splenic plexus.

THE SPLEEN.

The spleen [*σπλήν*, lien,] is an oblong flattened organ, of a dark bluish-red color, situated in the left hypochondriac region. It is variable in size and weight,¹ spongy and vascular in texture, and exceedingly friable. The external surface is convex, the internal slightly concave, indented along the middle line, and pierced by several large and irregular openings for the entrance and exit of vessels; this is the *hilum lienis*. The upper extremity is somewhat larger than the lower, and rounded; the inferior is flattened; the posterior border is obtuse, the anterior sharp, and marked by several notches. The spleen is in relation by its external or *convex* surface with the diaphragm, which separates it from the ninth, tenth, and eleventh ribs; by its *concave* surface, with the great end of the stomach, small extremity of the pancreas, gastro-splenic omentum with its vessels, left kidney and supra-renal capsule, and left crus of the diaphragm; by its *upper end* with the diaphragm, and sometimes with the extremity of the left lobe of the liver; and, by its *lower end*, with the left extremity of the transverse arch of the colon. It is connected to the stomach by the gastro-splenic omentum, and to the diaphragm by a fold of the peritoneum, called the *suspensory ligament*.

A second spleen (*lien sucenturiatus*) is sometimes found appended to one of the branches of the splenic artery, near the great end of the stomach; when it exists, it is round and of small size, rarely larger than a hazel-nut. There are sometimes two, and even three, of these bodies.

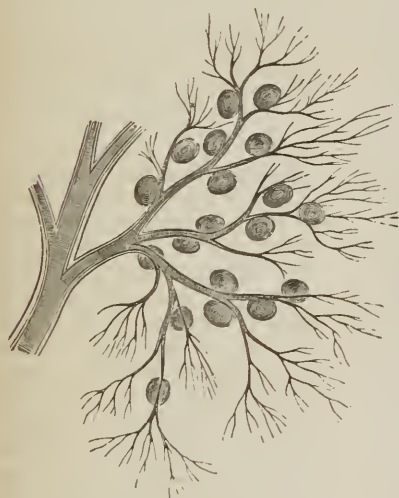The spleen is a blood-vascular gland, concerned in the renovation of the blood, and probably in the preparation of the blood for the secretion of bile. In *structure* it is composed of a *serous* and *fibrous coat* and *parenchyma*; the paren-

¹ Its ordinary length is about five inches; and its weight six ounces.

chyma consisting of a network of fibrous bands, or *trabeculæ*, inclosing in their areas a bright red pulpy substance, the *splenic pulp*; and the latter containing an abundance of vessels and numerous small white corpuscles, the *splenic* or *Malpighian corpuscles*. The fibrous coat, *tunica albuginea* vel *propria*, is composed of areolar and elastic tissue, and besides investing the exterior, sends processes into the interior of the gland with the bloodvessels; these fibrous sheaths (*vaginæ vasorum*) accompany the vessels to their ultimate terminations, and finally constitute a fine areolar network in the substance of the splenic pulp. The fibrous coat also sends inwards from every part of its internal surface, a number of white, glistening, flattened or cylindrical bands, the *splenic trabeculæ*, which traverse the substance of the gland in all directions, and are attached by their inner ends to each other and to the fibrous sheaths of the vessels.

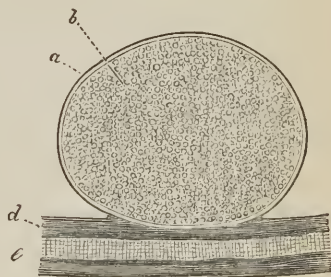
The *splenic* or *Malpighian corpuscles* or *vesicles* are small white roundish bodies, imbedded in the splenic pulp, and connected with the twigs of the small arteries. They are found only in the fresh and healthy spleen, and are more constant in children than the adult; their average size is one-sixth of a line, and they are found in numbers varying from five to ten on each small arterial twig. In intimate structure, the splenic corpuscle is a *vesicle* composed of a *membrana propria* and grayish pulpy granular contents. The *membrana propria* is transparent and colorless, moderately thick, consisting of homogeneous areolar tissue with elastic fibrils, and closely connected with the fibrous sheath of the artery. The grayish contents are thick and viscid, and made up of pale round nucleated cells, free nuclei, and a small proportion of clear albuminous

FIG. 366.



ARTERIAL TWIGS OF THE SPLENIC ARTERY, showing the connection of the splenic corpuscles with the small vessels. From the spleen of the dog; after Kölliker.

FIG. 367.



A SINGLE SPLENIC CORPUSCLE, from the spleen of the ox; after Kölliker. *a.* External tunic, or *membrana propria*. *b.* Granular contents. *c.* Part of a small artery. *d.* Its sheath, derived from the exterior tunic of the spleen, with which the corpuscle is closely connected.

fluid. The splenic corpuscles would seem to be analogous to the closed vesicles of the follicular glands, as the tonsils, solitary glands, and Peyer's gland; and to the lymphatic glands. In support of this view, Kölliker thinks that he saw a vascular plexus in the splenic corpuscles of the cat; like that which has been described as existing in the vesicles of Peyer's glands. On the other hand, there is no apparent relation between the lymphatic vessels and these corpuscles.

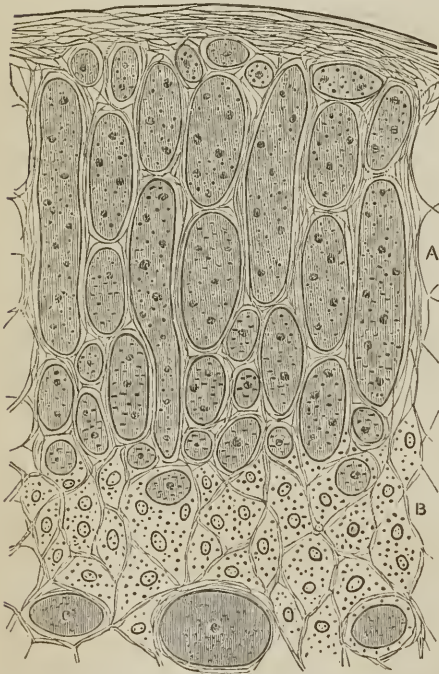
The *splenic pulp* fills the interstices of the *trabeculæ*, is of a bright red color,

like currant jelly, and is composed of a *delicate areolar network*, formed by the smaller trabeculæ and vascular sheaths; of *minute bloodvessels*; and of nucleated cells (parenchyma cells) similar to those of the splenic corpuseles, and free nuclei. Besides which there are also met with other cells with single and multiple nuclei, and of various size, intermingled with blood-corpuseles in various stages of degradation; and pigmentary granules. The cells are for the most part collected together into small aggregated masses of various dimensions.

Vessels and Nerves.—The *splenic artery* is of a very large size in proportion to the bulk of the spleen; it is a division of the cœliac axis. The branches which enter the spleen are distributed to distinct sections of the organ, and anastomose very sparingly with each other; they terminate in elegant bundles or *penicilli* of minute straight arteries, which end in a capillary network, and the latter forms a plexus throughout the substance of the parenchyma, and around the splenic corpuseles. The *veins*, by their numerous dilatations, constitute the principal part of the bulk of the spleen; they pour their blood into the splenic vein, which is one of the two great formative trunks of the portal vein. The *lymphatics*, few in number, are superficial and deep; the former are situated between the coats of the gland; the latter issue from its substance through the hilum, and terminate by means of a trunk in the thoracic duct. The *nerves* are, the splenic plexus, derived from the solar plexus.

THE SUPRA-RENAL CAPSULES.

[Fig. 368.¹



TRANSVERSE SECTION OF A HUMAN SUPRA-RENAL CAPSULE; (Harley). A. Cortical substance. B. Medullary substance. c, c. Venous sinuses.]

in the fœtus will be found in the succeeding chapter.

¹ [This and the succeeding cut from an excellent article in the *Lancet* for June 5 and 12, 1858, on the Histology of the Supra-Renal Capsules, by Geo. Harley, M. D., F. C. S., Lecturer in University College, London.]

The supra-renal capsules or *glandulæ supra-renales* are two small yellowish and flattened bodies surmounting the kidneys, and inclining inwards towards the vertebral column. The right is somewhat three-cornered in shape, the left semi-lunar; they are connected to the kidneys by the common investing areolar tissue, and each capsule is marked on its anterior surface by a fissure or *hilum* which appears to divide it into two lobes. The right supra-renal capsule is closely adherent to the posterior and under surface of the liver, the left lies in contact with the pancreas and spleen. Both capsules rest against the crura of the diaphragm on a level with the tenth dorsal vertebra, and by their inner border are in relation with the great splanchnic nerve and semilunar ganglion. They are larger in the fœtus than in the adult, and appear to perform some office specially connected with embryonic life. The anatomy of these organs

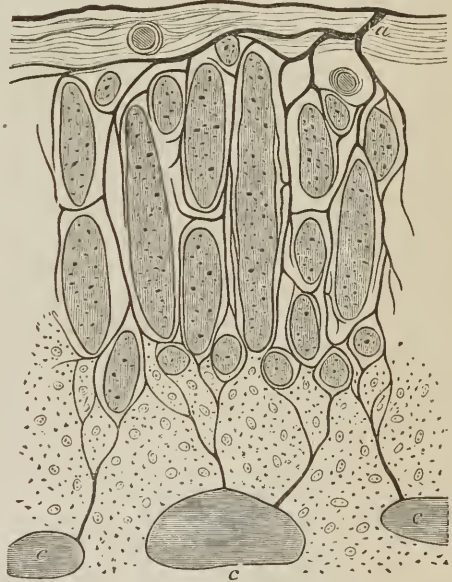In structure the supra-renal capsule is composed of a cortical and medullary substance, and invested by a firm but thin coat of areolar tissue, which sends fine processes inwards through its interior. The *cortical substance* is of a yellowish-white color externally, and brownish within, consists of straight parallel columns arranged perpendicularly to the surface, and is somewhat friable, breaking in the direction of these columns. The *medullary substance*, twice or three times the thickness of the cortical substance, is soft, of a grayish-white or pale red color, darker when the venous plexus is congested, and easily detached from the cortical layer, being connected with it only by the vessels and thin processes of areolar tissue sent inwards by the fibrous tunic. Moreover in the centre of the medullary substance is the trunk of a large vein, the *vena supra-renal*. After death the medullary substance speedily runs into a state of decomposition, and is converted into a dirty brownish pulp.

In *intimate structure*, the columns of the *cortical substance* are found to be composed of a series of round and oblong cavities invested and separated by areolar tissue. These cavities have been compared to the closed follicles of the follicular glands, and their contents are not unlike, namely, a granular substance with nuclei and cells, together with oil granules and pigment granules; whether these contents are inclosed in a *membrana propria* is not yet determined,¹ and no vessels have been detected within them as occurs in the closed follicles of Peyer's glands. The *medullary substance* is composed of a fine network or *stroma* of areolar tissue, continuous with that of the cortical substance, and containing within its meshes a pale granular substance, and cells resembling nerve-cells, pale, with nucleus and nucleolus, fine granular contents, fat and pigment granules, and fine processes simple and branched. The peculiar structure of the supra-renal capsule has caused its two parts to be compared, the cortical substance to a blood-vascular, or ductless gland; the medullary substance to a sympathetic ganglion, bearing the same relation to the sympathetic system as the pituitary gland to the brain. In confirmation of this view is the great number of nerves which ramify through it, and the observation of Leydig, that in the salamander he had detected nerve-fibres proceeding from its bipolar cells.

The *bloodvessels* of the supra-renal capsules are very numerous. The *arteries*, about twenty in number, proceed from the aorta, phrenic, cœliac and renal trunks; they enter the cortical substance at every point of its surface, the greater number dividing into minute twigs and forming a plexus in the cortical layer; while others continue onwards

[Harley has shown that they are. *Lancet*, June, 1858, p. 557.]

[FIG. 369.



DISTRIBUTION OF THE BLOODVESSELS OF A HUMAN SUPRA-RENAL CAPSULE, shown in a transverse section; (Harley). *a*. Artery. *b, b*. Veins. *c, c, c*. Venous sinuses.]

to the medullary substance, and either terminate in the medullary plexus or cross the medullary substance to re-enter the cortical layer and contribute to the formation of its capillary plexus. In the cortical substance the capillaries are straight, occupy the intercolumnar spaces, and communicate with each other across the columns by transverse branches, forming oblong meshes; in the medullary substance the capillary plexus is a close network and the meshes rounded. The *veins* take their origin from the capillary plexus by minute venules, which unite to form the supra-renal vein. The *supra-renal vein* runs through the centre of the medullary substance, and issues from the supra-renal capsule at the *hilum* on its anterior surface, to terminate, on the right side in the inferior vena cava, on the left in the renal vein. Smaller veins take their course by the side of the arterial twigs, and leave the capsule at various points of its surface, and terminate in the renal and phrenic veins and inferior vena cava. The *lymphatic vessels* are numerous, and belong to the exterior of the organ; they terminate in the lumbar glands.

The *nerves* are very numerous, and derived from the renal and phrenic plexus; Kölliker counted as many as thirty-three trunks, composed of dark-bordered nerve-fibres and provided with isolated ganglia. They are distributed to the medullary substance only, in which they form a rich nervous plexus.

THE KIDNEYS.

The kidneys, the secreting organs of the urine, are situated in the lumbar regions, behind the peritoneum, and at each side of the vertebral column, extending from the eleventh rib to near the crest of the ilium, and approaching the vertebral column by their upper end. Each kidney is between four and five inches in length, about two inches and a half in breadth, somewhat more than one inch in thickness, and weighs between three and five ounces. The kidneys are usually surrounded by fat; they rest on the crura of the diaphragm, on the anterior lamella of the aponeurosis of the transversalis muscle, which separates them from the quadratus lumborum, and on the psoas magnus. The *right kidney* is somewhat lower than the left, from the position of the liver; it is in relation, by its anterior surface, with the liver and descending portion of the duodenum, which rest against it; and is covered in by the ascending colon. The *left kidney*, higher than the right, is covered, in front, by the great end of the stomach, the spleen, and descending colon. The anterior surface of the kidney is convex, the posterior is flat; the superior extremity is in relation with the supra-renal capsule; the convex border is turned outwards towards the parietes of the abdomen; the concave border looks inwards towards the vertebral column, and presents a deep notch (*hilum renale*), which leads to a cavity, or *sinus*, within the organ. In the *sinus renalis* are situated the vessels and nerves of the kidney and the expansion of the excretory duct called *pelvis renalis*. At the hilum these vessels are so placed that the renal vein is in front of the artery, and the pelvis and ureter behind.

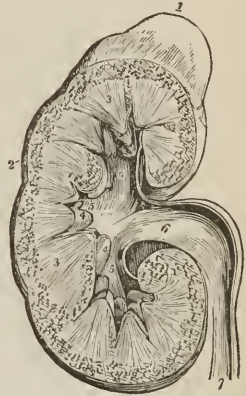The kidney is surrounded by a thick layer of fat, contained in the meshes of a loose areolar tissue, the *adipose capsule*; and immediately inclosed in a *proper fibrous capsule*, which is thin, firm and whitish, and composed of dense areolar tissue intermingled with elastic fibres. The capsula propria is adherent by its inner surface to a thin layer, formed by the condensed areolar stroma of the organ, from which it may be easily torn. The substance of the kidney is dense and fragile, and when divided by a longitudinal incision, exhibits two structures, different in color and texture, — an external *vascular or cortical portion*; and an internal, *tubular or medullary portion*. The *tubular portion* consists of from eight to fifteen pale reddish-colored conical masses, having their apices or *papillæ* directed towards the sinus renalis, and their bases to the cortical substance; these conical masses are the *pyramids of Malpighi*, and are composed

of an assemblage of straight tubuli, the *tubuli recti*, which open on the surface of the papilla and divide into branches at acute angles as they proceed from the apex to the base of the pyramid; moreover, the surface of the pyramid is marked by minute vascular streaks caused by the straight vessels of the tubular structure, the *arteriola et venæ rectæ*. The *vascular* or *cortical portion*, distinguished by its red color and softer texture, forms the surface of the organ, surrounding the base of each pyramid and penetrating between them to the sinus renalis. It therefore forms septa between the pyramids, (*septa vel columnæ Bertini*) and marks the original composition of the kidney of separate lobes. It is composed of bloodvessels, with the cortical fasciculi and ultimate terminations of the tubuli uriniferi, held together by a delicate stroma of areolar tissue.

The *tubuli uriniferi* commence on the surface of the papillæ by from two hundred to five hundred openings and take their course in straight lines, *tubuli recti*, through the pyramids, dividing dichotomously in their course, and separated by thin long straight vessels, *arteriola et venæ rectæ*. At the base of the pyramids of Malpighi the tubuli break up into numerous¹ small fasciculi, which enter the cortical substance, *cortical fasciculi*, and having a pyramidal form, have received the name of *pyramids of Ferrein*; from the latter, the separate tubuli pass off on all sides, and especially at their extremity, and after a tortuous course (*tubuli contorti*) during which they form plexuses and anastomoses with similar tubuli, terminate in small globular bodies, the *corpora Malpighiana*. The tubuli uriniferi vary somewhat in size in their course; they are largest in the papillæ, diminish in size towards the base of the pyramid in consequence of giving off branches, and enlarge in the pyramids of Ferrein and *tubuli contorti*, to become again constricted immediately before joining the *corpora Malpighiana*. The tubulus is cylindrical and composed of two layers, a thin homogeneous and elastic *membrana propria*, and an *epithelium* consisting of a single layer of polygonal nucleated cells. The epithelium is equal in thickness to two-thirds the diameter of the tubulus, the remaining third representing its area. The cells of the epithelium contain a finely granular substance occasionally intermingled with fatty and pigmentary granules; and near the Malpighian body are furnished, according to Bowman, with vibratile cilia.

The *corpora Malpighiana* are small globular bodies about $\frac{1}{100}$ of an inch in diameter, situated on the branches of small arterics, like fruit upon its stalk, in the vascular portion of the kidney immediately around the pyramids of Ferrein and in the *septa renum*. Each Malpighian corpuscle consists of a *capsule*, the expanded extremity of the uriniferous tubule, and contains in its

FIG. 370.

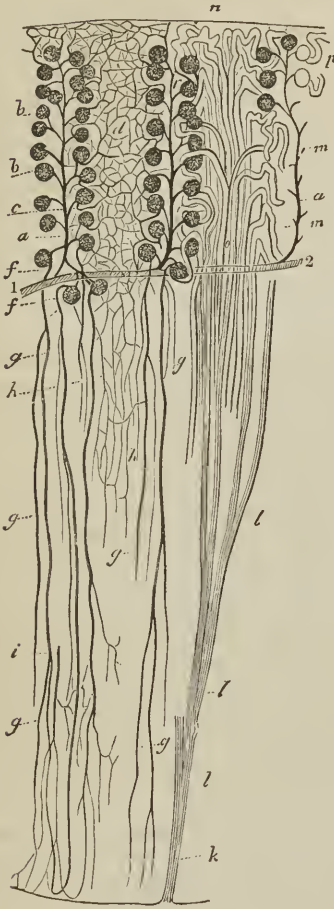

SECTION OF THE KIDNEY, surmounted by the supra-renal capsule; the swellings on the surface mark the original constitution of the organ of the lobes. 1. Supra-renal capsule. 2. Vascular portion of the kidney. 3, 3. Tubular portion, consisting of cones. 4, 4. Two of the papillæ projecting into their corresponding calices. 5, 5, 5. The three infundibula; the middle 5 is situated in the mouth of a calyx. 6. Pelvis. 7. Ureter.

¹ Huschke estimates the number of tubuli in each fasciculus corticalis at 200; and the number of cortical fasciculi to each pyramid at 700. Consequently fifteen pyramids would represent upwards of two millions of tubuli. Further, as there are 500 orifices upon each papilla, and the tubuli recti divide about ten times, it is probable that each tubulus rectus is the excretory duct of a separate cortical fasciculus.

interior a plexiform tuft of minute vessels, the *glomerulus Malpighianus*, imbedded in epithelium; the cells of the epithelium being smaller than those which line the tubule. The Malpighian corpuscle is therefore the origin of the uriniferous tubule, which is remarkable for its contorted course, first passing outwards and then suddenly bending inwards before joining with the cortical fasciculus; and the glomerulus is the vascular source of the urinary secretion.

FIG. 371.



PLAN OF THE STRUCTURE OF THE KIDNEY; after Kölliker. *k*. Tubulus rectus, dividing into branches *l, l, l*, as it ascends. *n, o*. Pyramid of Ferrein; with, *m*, the tubuli contorti. *p*. Origin of two tubules from their respective Malpighian bodies. 1, 2. Branch of an artery. *a, r, a*. Three interlobular arteries giving off afferent twigs to, *b, b*, the Malpighian bodies. *d*. Capillary plexus formed by the efferent vessels, of which one is seen at *c*. *f, f*. Efferent vessels, proceeding to the tubular structure of the pyramids and constituting the arteriolæ rectæ *g, g, g*. *h*. Capillary plexus of the tubular structure of the pyramid. *i*. One of the venulæ rectæ.

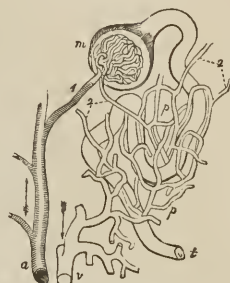
The renal artery, derived from the aorta, divides into several large branches, which, entering the hilum, make their way into the vascular substance of the septa renum and thence to the peripheral part of the cortical substance, surrounding each of the pyramids of Malpighi with a fine ramification of small vessels. From this ramification are given off small arteries which pass outwards between the cortical fasciculi, and have received the name of *interlobulares*; and from the interlobular arteries the small afferent arteries proceed, which enter the Malpighian bodies and constitute the *glomerulus*. In the Malpighian body the afferent artery divides into from five to eight branches, and each of these branches into a bundle of capillaries, and the latter, re-uniting in the same manner, constitute the *efferent vessel*. The *efferent vessel*, quitting the Malpighian body by the side of the afferent artery, divides into capillary vessels, which form a rich capillary plexus throughout the whole of the cortical substance, and eventually terminate in the renal veins. Those efferent vessels which are nearest to the base of the pyramids take a straight course (*arteriola rectæ*) between the tubuli recti, and giving off but few branches in their course, also pass into a capillary plexus which surrounds the tubuli and terminates in the *venulæ rectæ*.

Bowman, who regards the efferent vessels, not as arteries, but as veins, remarks that, "there are in the kidney two perfectly distinct systems of capillary vessels, through both of which the blood passes in its course from the arteries into the veins; the first, that" which forms the vascular tuft in the Malpighian bodies, and is "in immediate

connexion with the arteries; the second, that enveloping the convolutions of the tubes, and communicating directly with the veins. The efferent vessels

PLAN OF THE RENAL CIRCULATION; after Bowman. *a*. Branch of the renal artery giving off several Malpighian twigs. 1. An afferent twig to the capillary tuft contained in the Malpighian body, *m*; from the Malpighian body the uriniferous tube is seen taking its tortuous course to *t*. 2, 2. Efferent vessels; that which proceeds from the Malpighian body is smaller than the corresponding artery. *p, p*. The capillary plexus, ramifying on the uriniferous tube. This plexus receives its blood from the efferent vessels, 2, 2, and transmits it to the branch of the renal vein, *v*.

FIG. 372.



of the Malpighian bodies, that carry the blood between these two systems, may collectively be termed the portal system of the kidney." The inferences drawn by Bowman from his investigations are, that the capillary tufts of the Malpighian bodies are the part of the kidney specially acted on by diuretics; that they are the medium by which water, certain salts, and other substances, pass out of the system; that they are, moreover, the means of escape of certain morbid products, such as sugar, albumen, and the red particles of blood. Respecting the capillary venous plexus, we have proof that the principal proximate constituents of urine, such as urea, lithic acid, &c., are, like the bile, derived from venous (portal) blood.

The *Veins* of the kidney commence at the surface by minute converging venules, the *stellated vessels*, in the cortical substance where they form the *interlobular veins*, and in the pyramids of Malpighi, where they constitute the *venulæ rectæ*; proceeding from these three sources, they unite to form the branches of the renal vein, which terminates in the vena cava by a single large trunk at each side; the left renal vein receiving the left spermatic vein. Injections thrown into the renal artery, and returning by the tubuli uriniferi, make their way into those tubes by rupture. The *lymphatic vessels* accompany the deep bloodvessels, and terminate in the lumbar glands.

The *Nerves* are derived from the renal plexus, which is formed partly by the solar plexus, and partly by the third splanchnic nerve. The renal plexus gives branches to the spermatic plexus, and branches which accompany the ureters: hence the morbid sympathies which exist between the kidney, ureter, and testicle: and by communications with the solar plexus, with the stomach and diaphragm, and indeed with the whole system. In the intimate structure of the kidney, the nerve-fibres are, according to Toynebee, continuous with the nucleated cells of the parenchyma of the organ.

The *cavity of the kidney* is occupied by a membranous bag, the *pelvis renalis*, which gives off three processes, the *infundibula*, one for each extremity, and one for the middle of the organ; and the infundibula give off smaller processes termed *calices*, which embrace the papillæ and form a separate pouch around each; the calyx being firmly attached to the base of the papilla, and continuous with the fibrous capsule. Externally the sac of the *pelvis renalis* contracts into its excretory duct, the ureter.

The *Ureter* (ὄρον, urine, ἄρπειν, to keep,) is a membranous tube, of about the diameter of a goose-quill, and nearly eighteen inches in length, continuous superiorly with the pelvis of the kidney, and constricted inferiorly, where it lies in an oblique direction between the muscular and mucous coat of the base of the bladder, and opens on its mucous surface. Lying along the posterior wall of

the abdomen, it is situated behind the peritoneum, and is crossed by the spermatic vessels; in its course downwards it rests against the anterior surface of the psoas, and crosses the common iliac artery and vein, and then the external iliac vessels. Within the pelvis it crosses the hypogastric cord and vas deferens in the male; and runs by the side of the cervix uteri and upper part of the vagina in the female. There are sometimes two ureters to one kidney. The ureter, the pelvis, the infundibula, and the calices, are composed of three coats, external or fibrous, middle or muscular, and internal or mucous. The *fibrous coat* consists of condensed areolar tissue, intermingled with fine elastic fibres. The *muscular coat* is made up of muscular fibres of the smooth kind, disposed in two layers, external longitudinal, and internal circular; while towards the bladder there are besides internal longitudinal fibres. The muscular coat is thick in the ureter and pelvis renalis, thin on the calices, and ceases altogether at the attachment of the latter to the papillæ. The *mucous coat* is thin, vascular, and without villi; on the papillæ it is connected with the substance of the pyramids, and is continuous with the uriniferous tubuli, while inferiorly it becomes blended with the mucous membrane of the bladder. The *epithelium* of the mucous coat is thick, and composed of several layers of nucleated cells, which are small and round next the membrane; of larger size, and cylindrical or conical in the middle; and large and spheroidal at the surface, sometimes measuring $\frac{1}{60}$ of an inch in breadth, and not unfrequently containing two nuclei.

PELVIS.

The cavity of the pelvis is that portion of the great abdominal cavity which is included within the bones of the pelvis, below the level of the linea-ilio-pectinea and the promontory of the sacrum. It is bounded by the cavity of the abdomen above, and by the perineum below; its internal parietes are formed, in front, below, and at the sides, by the peritoneum, pelvic fascia, levatores ani, and obturator muscles; and behind, by the coccygei muscles, sacro-ischiatic ligaments, pyriformes muscles, sacral plexus of nerves, sacrum, and coccyx.

MALE PELVIS.

The *Viscera of the pelvis* in the male are, the urinary bladder, prostate gland, vesiculæ seminales, and rectum.

BLADDER.

The *Bladder* is a hollow membranous viscus, triangular and flattened against the pubes when empty, ovoid when distended, situated behind the pubes and in front of and upon the rectum. It is larger in its vertical diameter than from side to side; and its long axis is directed from above, obliquely downwards and backwards. It is divided into body, fundus, base, and neck. The *body* comprehends the middle zone of the organ; the *fundus*, superior fundus, its upper segment; the *base*, inferior fundus, the lower broad extremity which rests on the rectum; and the *neck*, the narrow constricted portion which is applied against the prostate gland.

It is retained in position by ligaments which are divisible into true and false; the *true ligaments* are five in number, two anterior, two lateral, and the cord of the urachus; the *false ligaments* are folds of the peritoneum, and are also five in number, two posterior, two lateral, and one superior.

The *anterior ligaments* are formed by the recto-vesical fascia in its passage from the inner surface of the pubes, at each side of the symphysis, to the neck of the bladder and prostate gland.

The *lateral ligaments* are also formed by the recto-vesical fascia in its passage from the levatores ani muscles to the sides of the prostate gland and neck of the bladder.

The *ligament of the urachus* is a fibrous cord resulting from the obliteration of a tubular canal (urachus) existing in the embryo. It proceeds from the summit of the bladder, and ascends along the linea alba to the umbilicus.

The *posterior false ligaments* are the fold of peritoneum formed at each side of the pelvis by the obliterated hypogastric artery; this fold also contains the ureter, and the vessels and nerves of the bladder.

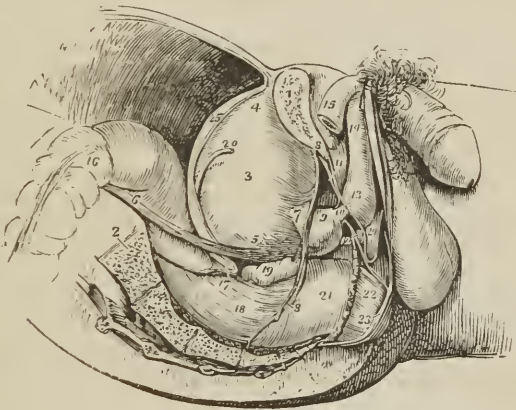
The *lateral false ligaments* are formed by the passage of the peritoneum from the side of the pelvis to the side of the bladder. The obliterated hypogastric artery lies along the line of reflection of the membrane.

The *superior or suspensory false ligament* is the fold of peritoneum caused by the prominence of the cord of the urachus and the cords of the obliterated hypogastric arteries.

The bladder is composed of four coats, external or serous, muscular, areolar, and mucous.

The *Serous coat* is partial, and derived from the peritoneum; it invests the posterior surface and sides of the bladder, from about opposite the point of ter-

FIG. 373.



SIDE VIEW OF THE VISCERA OF THE MALE PELVIS, in situ. The right side of the pelvis has been removed by a vertical section made through the os pubis near the symphysis; and another through the middle of the sacrum. 1. Divided surface of the os pubis. 2. Divided surface of the sacrum. 3. Body of the bladder. 4. Its fundus; from the apex is seen passing upwards the urachus. 5. Base of the bladder. 6. Ureter. 7. Neck of the bladder. 8, 8. Pelvic fascia; the fibres immediately above 7 are given off from the pelvic fascia, and represent the anterior ligaments of the bladder. 9. Prostate gland. 10. Membranous portion of the urethra. 11. Triangular ligament. 12. One of Cowper's glands lying beneath the membranous portion of the urethra. 13. Bulb of corpus spongiosum. 14. Body of corpus spongiosum. 15. Right crus penis. 16. Upper part of first portion of the rectum. 17. Recto-vesical fold of peritoneum. 18. Second portion of rectum. 19. Right vesicula seminalis. 20. Vas deferens. 21. The rectum covered by the descending layer of the pelvic fascia, just as it is making its bend backwards to constitute the third portion. 22. Part of the levator ani muscle investing the lower part of the rectum. 23. External sphincter ani. 24. Interval between the superficial perineal fascia and triangular ligament; they are seen to be continuous beneath the figure.

mination of the ureters to its summit, whence it is guided to the anterior wall of the abdomen by the hypogastric cords and urachus.

The *Muscular coat* consists of three layers, external or longitudinal, middle or circular, and internal, which is also longitudinal. The *external layer*, or *detrusor urinæ*, consists of parallel longitudinal fasciculi which take their origin from the anterior ligaments of the bladder, thence named tendons of the detrusor urinæ; they spread out upon the upper surface of the prostate gland (levator prostatae) and ascend upon the anterior surface of the bladder to the fundus, where they are inserted into the subserous tissue, some being continuous with the longitudinal fibres of the posterior surface of the organ, and others prolonged upon the urachus. The longitudinal fasciculi of the posterior surface and sides of the bladder, attached superiorly to the subserous tissue and partly continuous with those of the opposite aspect, while some are prolonged upon the urachus, are attached inferiorly to the prostate gland, those in the middle line being lost in the deep muscular layer of the neck of the bladder. The detrusor urinæ is thickest on the anterior surface of the bladder; it communicates by an interchange of fasciculi with the middle layer, and in the female its posterior fibres are inserted into the vagina. The *middle layer* consists of circular fibres which are most numerous at the cervix, where they form a moderately thick stratum, the *sphincter vesicæ*, and are then continued onwards around the prostatic urethra.

The *internal layer* (submucous layer; Ellis¹), thinner than the preceding, is composed of fibres which are oblique and scattered in the fundus and body of the bladder, but become longitudinal in its lower part and base, and are continued through the cervix and along the urethra to its termination at the meatus urinarius. At the base of the bladder this layer is strengthened by the longitudinal fibres of the ureters, which, after perforating the external and middle muscular layer, spread out in a radiated manner, and are continuous with the internal longitudinal layer, the increment of fibres in this situation constituting the *muscles of the ureters* of Sir Charles Bell. The three muscular layers communicate with each other by means of a frequent interchange of fasciculi, and are thus enabled to act in unison as a single muscle. In the trigonum, the radiating fibres of the ureters have a transverse direction, and the muscular structure is intermingled with areolar and elastic tissue.

The *Areolar* or *submucous* coat is the thick layer of areolar tissue interposed between the mucous and muscular coat, and forming the bond of union between them.

The *Mucous coat* is thick and smooth, of a pale rose color, and exactly moulded on the muscular coat, to which it is connected by the areolar coat; it has no papillæ, but numerous mucous glands which are most abundant in the cervix and fundus, and are either simple pyriform follicles or small aggregations of follicles constituting small racemose glands. The mucous membrane is continuous through the ureters with the lining membrane of the uriniferous ducts, and through the urethra with that of the seminiferous ducts, prostate gland and Cowper's glands. It is provided with a laminated epithelium, the deeper cells of which are conical or fusiform; the superficial, spheroidal or flattened, and of unequal size. In the mucous glands the epithelium is columnar. The mucous membrane is rich in vessels which are most abundant, as are the nerves, in the cervix and fundus; the nerves are not numerous.

On the internal surface of the base of the bladder is a triangular smooth plane, the *trigonum vesicæ* or *trigone vesicale* (Fig. 377), on which the mucous membrane is paler and thinner than the rest. Calculi resting on this part give rise to much suffering on account of the greater number of nerves distributed to the

¹ "An Account of the Arrangement of the Muscular Substance in the Urinary and certain of the Generative Organs of the Human Body," by George Viner Ellis, Professor of Anatomy in University College. *Medico-Chirurgical Transactions*, vol. xxxix., 1856. Mr. Ellis's description is so clear and apparently faithful, that I have not hesitated to adopt his views.

cervix vesicæ. The trigonum is bounded at each side by the raised ridge, corresponding with the muscles of the ureters, at each posterior angle by the openings of the ureters, and, in front, by a slight elevation of the mucous membrane at the entrance of the urethra, called *uvula vesicæ*.

The external surface of the base of the bladder corresponding with the trigonum is also triangular, and separated from the rectum by a thin layer of areolofibrous membrane, derived from the recto-vesical fascia. It is bounded behind by the recto-vesical fold of peritoneum; and at each side by the vas deferens and vesicula seminalis, which converge almost to a point at the base of the prostate gland. It is through this space that the opening is made in the recto-vesical operation for puncture of the bladder.

Vessels and Nerves.—The *arteries* of the urinary bladder are the *superior vesical*, three or four small branches which proceed from the commencement of the hypogastric artery, previously to its complete obliteration; and *inferior vesical*, from the internal iliac. The latter is distributed to the base of the bladder, vesiculae seminales, and prostate gland. The *veins* are numerous and of large size, and form a plexus around the neck and at the base of the bladder; the plexus communicates with the prostatic plexus and hæmorrhoidal veins. The *nerves* of the bladder are derived from the inferior hypogastric plexuses, and their communications with the third and fourth sacral nerves.

PROSTATE GLAND.

The prostate gland (*προιόντημι*, præponere) is situated in front of the neck of the bladder, behind the triangular ligament and pelvic fascia, and upon the rectum, through which latter it may be felt with the finger. It surrounds the commencement of the urethra for a little more than an inch of its extent, and resembles a Spanish chestnut both in size and form; the base being directed backwards towards the neck of the bladder, the apex forwards, and the convex side towards the rectum. It is retained firmly in position by the anterior and lateral ligaments of the bladder, and by a process of the recto-vesical fascia, which forms a sheath around it. It consists of three lobes, two lateral and a middle lobe or isthmus; the lateral lobes are distinguished by an indentation at the base of the gland, and a slight furrow on its upper and lower surface. The third lobe or isthmus is a small transverse band which passes between the two lateral lobes at the base of the organ.

In structure the prostate is composed of smooth muscle and glandular tissue, the latter being not more than one-third or one-fourth of the whole, and consisting of from thirty to fifty compound racemose glands, of a pyriform shape. It is of a grayish-red color, and dense in texture, splits easily in the course of its ducts, and is surrounded by a proper fibrous covering, and by a plexus of veins inclosed in a sheath derived from the recto-vesical fascia. Its secretion is poured into the prostatic portion of the urethra by fifteen or twenty excretory ducts. The ducts of the lateral lobes open into the urethra at each side of the veru montanum; those of the third lobe open upon and behind the veru. The urethra, in passing through the prostate, lies one-third nearer its upper, than its lower, surface.

Ellis regards the prostate as "essentially a muscular body, consisting of circular or orbicular involuntary fibres, with one large central hole for the passage of the urethra," the circular fibres being continuous behind with those of the middle muscular layer of the bladder, and prolonged in front upon the membranous portion of the urethra as a stratum, $\frac{1}{30}$ of an inch thick. This muscular layer he proposes to call *orbicularis vel sphincter urethrae*. The longitudinal fibres of the detrusor urinæ continued forwards on the upper surface of the prostate, and attached to it laterally and behind, therefore represent the external muscular coat of the prostate, while the longitudinal fibres inclosing the urethra

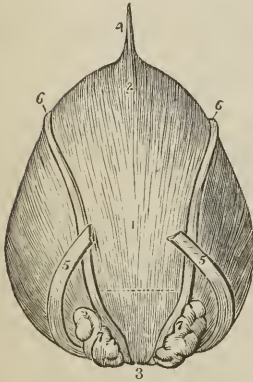
within the prostate constitute an internal muscular layer, corresponding and continuous with that of the bladder. The small secreting glands contained in the prostate are but an appendage of the mucous membrane projecting amongst the muscular fibres, and occupy but a small portion of the organ, chiefly at its base.

The *arteries* of the prostate are small and derived from the inferior vesical and middle hæmorrhoidal; they distribute numerous capillaries to the glandular structure of the organ. The *veins* form a rich plexus in the submucous tissue of the urethra, and another of larger vessels on the exterior of the gland; the latter receives from the front the veins of the penis, and terminates in the vesical plexus

VESICULÆ SEMINALES.

On the under surface of the base of the bladder, and converging towards the base of the prostate gland, are two lobulated and somewhat pyriform bodies, about two inches in length, the vesiculæ seminales.

FIG. 374.



POSTERIOR ASPECT OF THE MALE BLADDER; the serous covering is removed in order to show the muscular coat. 1. Body of the bladder. 2. Fundus. 3. Inferior fundus or base. 4. Urachus. 5, 5. Ureters. 6, 6. Vasa deferentia. 7, 7. Vesiculæ seminales. The triangular area, bounded by the vasa deferentia and vesiculæ seminales at either side, a dotted line above, and the figure 3 below, is the space corresponding with the trigonum vesicæ. It is this part of the bladder which is pierced, in puncturing the bladder through the rectum. The dotted line, forming the base of this triangular area, marks the extent of the recto-vesical fold of peritoneum.

Their upper surface is in contact with the base of the bladder; the under side rests on the rectum, separated only by a process derived from the recto-vesical fascia; the larger extremities are directed backwards and outwards, and the smaller ends almost meet at the base of the prostate. They inclose between them a triangular space, which is bounded posteriorly by the recto-vesical fold of peritoneum, and corresponds with the trigonum vesicæ on the interior of the bladder. Each vesicula is formed by the convolutions of a single tube, which gives off several irregular cæcal sacculi and branches. It is inclosed in a thin fibrous membrane, and is constricted beneath the isthmus of the prostate gland into a small excretory duct. The vas deferens, somewhat enlarged and sacculated, lies along the inner border of each vesicula, and is included in its fibrous investment. It communicates with the duct of the vesicula beneath the isthmus of the prostate, and forms the ejaculatory duct.

The ejaculatory duct is about three-quarters of an inch in length, and running forwards, first between the base of the prostate and the isthmus, and then through the tissue of the veru montanum, opens on the mucous membrane of the urethra, by the side of or within the aperture of the sinus pocularis.

The vesiculæ seminales and vasa deferentia are partly covered in by a muscular layer, *compressor vesiculæ et ductus seminalis* (Ellis); which is brought into view on raising the recto-vesical fascia. This muscular layer consists of transverse and longitudinal fibres, the *transverse fibres* being the most superficial, and continuous with the posterior border of the prostate gland; the *longitudinal fibres* lying in contact with the vesiculæ and vasa deferentia. The longitudinal fibres form a continuous fleshy plane for the space of half an inch behind the prostate, and are prolonged for a short distance backwards on the vesiculæ and vasa deferentia,

lying chiefly along their borders; while anteriorly the fibres accompany the ejaculatory ducts to the termination of the latter in the urethra, and are continuous with the internal longitudinal coat of the prostatic urethra. "This muscular layer will compress and shorten the vesiculæ seminales, and the lower dilated ends of the vasa deferentia;" and most forcibly when the bladder is distended.

In *structure* the vesiculæ seminales are composed of three coats: *external*, a thin *fibrous* membrane, made up of condensed areolar tissue; *middle*, a *muscular* coat, consisting of smooth muscular fibres arranged in two layers, longitudinal and circular; and *internal*, a thin *mucous* membrane, vascular, marked by a delicate reticulation of ridges and alveoli, and coated with a squamous epithelium of cells containing yellowish pigment granules. The vesiculæ are covered externally and their convolutions held together by a thin membrane of areolar tissue, and they are further invested by the recto-vesical fascia, and the muscular stratum already described.

MALE ORGANS OF GENERATION.

The organs of generation in the male are, the penis and testes, with their appendages.

PENIS.

The *Penis* is divisible into a body, root, and extremity. The *body* is surrounded by a thin integument, which is remarkable for the looseness of its connexion with the deeper parts of the organ, and for containing no adipose tissue. The *root* is broad, and firmly adherent to the rami of the pubes and ischium by means of two strong processes, the erura, and connected to the symphysis pubis by an elastic fibrous membrane, the ligamentum suspensorium. The *extremity* or *glans penis* resembles an obtuse cone, somewhat compressed from above downwards, and of a deeper red color than the surrounding skin. At its apex is a small vertical slit, the *meatus urinarius*, which is bounded by two, more or less protuberant, labia; and, extending backwards from the meatus, a grooved raphé, to which a loose fold of mucous membrane, the *frænum præputii*, is attached. The base of the glans is marked by a projecting collar, the *corona glandis*, upon which are seen a number of small papillary elevations, the *glandulæ odoriferae* Tysoni. Behind the corona is a deep fossa, *fossa glandis* (cervix), bounded by a circular fold of integument, *præputium*, which, in the collapsed state of the organ, may be drawn over the glans, but, in its distended state, is obliterated, and serves to facilitate its enlargement. The internal surface of the prepuce is lined by mucous membrane, covered by a thin epithelium; this membrane, on reaching the cervix glandis, is reflected over the glans, and, at the meatus urinarius, is continuous with the mucous lining of the urethra.

The *superficial fascia* of the penis is thin, and its areolar structure free from fat; it is continuous with the superficial fascia of the abdomen above, and with the dartos and superficial fascia of the perineum below.

The *ligamentum suspensorium penis* is an elastic fibrous membrane of triangular form, attached by its apex to the symphysis pubis; and, by its base, to the body of the penis. Near the latter attachment it separates into two layers, to give passage to the dorsal vessels and nerves of the penis.

The penis is composed of the corpus cavernosum and corpus spongiosum, and contains in its interior the longest portion of the urethra.

The *Corpus cavernosum* is distinguished into two lateral portions (corpora cavernosa) by an imperfect septum and a superior and inferior groove, and is divided posteriorly into two erura. It is firmly adherent, by means of its erura, to the rami of the pubes and ischium; and each erus, previously to its junction

with its fellow, presents a slight enlargement, which was named by Kobelt, the *bulb*. The corpus cavernosum forms, anteriorly, a single rounded extremity, which is received into a fossa in the base of the glans; the superior groove lodges the dorsal vessels of the penis, and the inferior receives the corpus spongiosum. Its fibrous tunic is thick, elastic, and extremely firm, and sends a number of fibrous bands and cords (*trabeculæ*) inwards from the inferior groove, which cross the interior in a radiating direction, and are inserted into the inner walls of the tunic. These *trabeculæ* are most abundant at the middle line, where they are ranged vertically, side by side, somewhat like the teeth of a comb, and constitute the imperfect partition of the corpus cavernosum, called *septum pectiniforme*. The septum is more complete at its posterior than towards its anterior part.

The tunic of the corpus cavernosum consists of two layers of fibrous fasciculi, the *external* being longitudinal and forming a kind of close net by the frequent interchange of their fibrous bundles; the *internal*, less thick, being disposed in a circular direction, and constituting the *septum pectiniforme*. From its anterior extremity it gives off small fibrous bands, which are prolonged into the substance of the glans penis.¹ The cavity of the corpus cavernosum is occupied by the spongy mass of its erectile tissue.

The *Corpus spongiosum* is situated along the under surface of the corpus cavernosum, in its inferior groove. It commences by its posterior extremity, between and beneath the crura penis, where it forms an enlargement, the *bulb*, and terminates anteriorly by another expansion, the *glans penis*. Its middle portion, or body, is nearly cylindrical, and tapers gradually from the posterior to the anterior extremity. The bulb is adherent to the triangular ligament by means of a prolongation of fibrous membrane; in the rest of its extent the corpus spongiosum is attached to the corpus cavernosum by areolar tissue, and by veins which pass upwards to reach the dorsal vein. It is composed of erectile tissue, inclosed in a dense fibrous layer much thinner than that of the corpus cavernosum, and contains the spongy portion of the urethra, which lies nearer its upper than its lower wall. The bulb shows a tendency to division into two lobes, an appearance which is due to the existence of a thin longitudinal septum in its interior.

The fibrous tunic of the corpus spongiosum, unlike that of the corpus cavernosum, consists only of circular fibres which are reflected inwards along the middle line, forming a septum which is complete only in the bulb; the reflected fibres of this septum embrace the urethra throughout its entire length, and exclude the latter from the proper structure of the corpus spongiosum.


Erectile tissue is a peculiar cellulo-vascular structure, entering in considerable quantity into the composition of the organs of generation. It consists essentially of a plexus of veins so closely convoluted and interwoven, as to give rise to a cellular appearance when examined by means of a section. The veins forming this plexus are smaller in the glans penis, corpus spongiosum, and circumference of the corpus cavernosum, than in the central part of the latter, where they are large and dilated. They have no other coat than the internal lining prolonged from the neighboring veins; and the interstices of the plexus are occupied by a reddish smooth muscular tissue. The arteries are convoluted in the passive state of the penis, but straightened in its distended condition; they terminate in large capillaries, which do not form a plexus, as in other situations, but open directly into these dilated veins. Some of the finer twigs of the arteries have a peculiar, twisted, and dilated or tendril-like appearance, first described by Müller under the name of *arteriæ helicinæ*. The *helicine* arteries were supposed by Müller to end by caecal terminations; but Kölliker finds a minute artery to proceed from the bulbous extremity of each of these dilated vessels, and terminate like the other capillaries in the veins. Arnold regards

¹ Ellis: loc. citat.

the helicine arteries as mere vascular loops. The venous plexus conveys the blood into the efferent veins of the penis, by which it is returned to the general circulation.

Vessels and Nerves.—The arteries of the penis are derived from the internal pudic; they are, the arteries of the bulb, arteries of the corpus cavernosum, and dorsales penis. Its *veins* are superficial and deep. The deep veins run by the side of the deep arteries, and terminate in the internal pudic veins. The superficial veins escape in considerable number from the base of the glans, and converge on the dorsum penis, to form a large dorsal vein, which receives other veins from the corpus cavernosum and spongiosum in its course, and passes backwards between two layers of the ligamentum suspensorium, and through the triangular ligament beneath the arch of the pubes, to terminate in the prostatic plexus.

The *Lymphatics* terminate in the upper group of inguinal glands, while some of the deeper lymphatics take the course of the urethra and end in the pelvic glands. The *nerves* are derived from the pudic nerve, sacral plexus, and hypogastric plexus.



PORTION OF THE ERECTILE TISSUE OF THE CORPUS CAVERNOSUM, magnified to show the areolar structure and the distribution of the arteries (Müller). *a.* A small artery, supported by the larger trabeculae, and branching out on all sides. *c.* The tendril-like arterial tufts, or helicine arteries of Müller. *d.* The areolar structure formed by the finer trabeculae.]

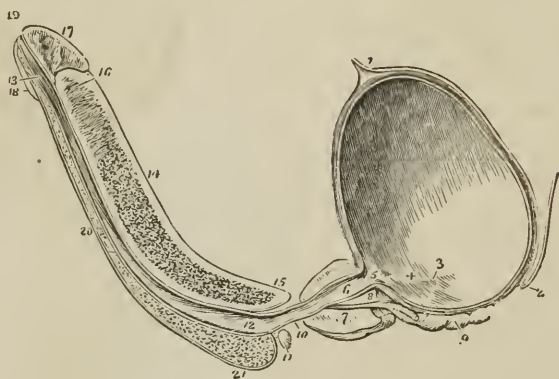
URETHRA.

The urethra is the membranous canal extending from the neck of the bladder to the meatus urinarius. It is curved in its course, and composed of three layers, a mucous coat, submucous coat, and muscular coat. The *mucous coat* is thin and smooth; it is continuous internally, with the mucous membrane of the bladder; externally, with the investing membrane of the glans; and at certain points of its extent, with the lining membrane of the numerous ducts which open into the urethra, namely, those of Cowper's glands, prostate gland, vasa deferentia, and vesiculæ seminales. It is provided with a squamous epithelium corresponding with that of the bladder. The *submucous coat* is loose, and contains numerous racemose mucous glands, which open on the surface of the mucous membrane. The *muscular coat* consists of longitudinal fibres, intermingled with areolar and elastic tissue, and is derived from the internal muscular layer of the bladder. The urethra is about eight inches in length, and divided into a prostatic, membranous, and spongy portion.

The *Prostatic portion*, a little more than an inch in length, is situated in the prostate gland, about one-third nearer its upper than its lower surface, and extending from its base to its apex. On its lower circumference or floor is a longitudinal ridge or crest, the *veru montanum*, or caput gallinaginis, formed by a fasciculus of the longitudinal muscular fibres of the urethra; and at each side of the veru, a shallow fossa, the *prostatic sinus*, in which are seen the numerous openings (15 to 20) of the prostatic ducts.

The *veru montanum* is most prominent in the centre; and immediately in front of the prominent part is the opening of a small cæcal sac, the *sinus pocularis*.

FIG. 376.



LONGITUDINAL SECTION OF THE BLADDER, PROSTATE GLAND, AND PENIS, SHOWING THE URETHRA. 1. Urachus attached to the upper part of the fundus of the bladder. 2. Rectovesical fold of peritoneum, at its point of reflexion from the base of the bladder, upon the anterior surface of the rectum. 3. Opening of the right ureter. 4. A slight ridge, formed by the muscle of the urcter, and extending from the termination of the ureter to the commencement of the urethra. This ridge forms the lateral boundary of the trigonum vesicæ. 5. Commencement of the urethra; the elevation of mucous membrane immediately below the figure is the *uvula vesicæ*. The constriction of the bladder at this point is the neck of the bladder. 6. Prostatic portion of the urethra. 7. Prostate gland; the difference of thickness of the gland, above and below the urethra, is shown. 8. Isthmus, or third lobe of the prostate; immediately beneath which the ejaculatory duct is seen passing. 9. Right vesicula seminalis; the *vas deferens* is seen to be cut short off, close to its junction with the ejaculatory duct. 10. Membranous portion of the urethra. 11. Cowper's gland of the right side, with its duct. 12. Bulbous portion of the urethra; throughout the whole length of the urethra of the *corpus spongiosum* numerous lacunæ are seen. 13. Fossa navicularis. 14. *Corpus cavernosum*, cut somewhat obliquely to the right side, near its lower part. The character of the venous-cellular texture is well shown. 15. Right crus penis. 16. Near the upper part of the *corpus cavernosum*, the section has fallen a little to the left of the middle line; a portion of the *septum pectiniforme* is consequently seen. This figure also indicates the thickness of the fibrous investment of the *corpus cavernosum*, and its abrupt termination at the base of (17) the *glans penis*. 18. Lower segment of the glans. 19. *Meatus urinaris*. 20. *Corpus spongiosum*. 21. *Bulb* of the *corpus spongiosum*.

laris, or *utriculus prostaticus*. This sac is the analogue of the uterus; it is nearly half an inch in length, extends back beneath the third lobe of the prostate, and by its approach to the surface contributes to the prominence of the *veru montanum*. Its walls, of a yellowish-white color, are composed of areolar and elastic tissue, mingled towards its fundus with smooth muscular fibre, and it is lined within by a columnar epithelium. The ejaculatory ducts, enveloped in longitudinal smooth muscular fibre, take their course forwards by the side of the *sinus pocularis*, and terminate within its aperture by slit-like openings.

The prostatic portion of the urethra, when distended, is the most dilated part of the canal; but, excepting during the passage of urine, is completely closed by its muscular tissue. In the contracted state of the urethra, the *veru montanum* acts as a valve, being pressed upwards against its roof; but, during the action of the *detrusor muscle* of the bladder, the canal is dilated.

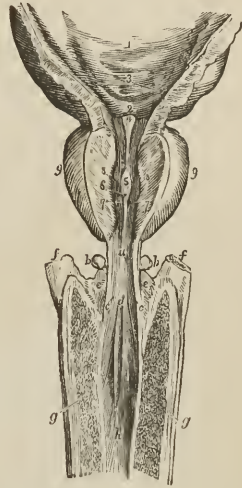
The *Membranous portion*, the narrowest part of the canal, measures about

three lines in diameter, and is somewhat less than an inch in length. It extends from the apex of the prostate gland to the bulb of the corpus spongiosum, and

FIG. 377

THE BULBOUS, MEMBRANOUS, AND PROSTATIC URETHRA, WITH PART OF THE BLADDER.

1. Part of the urinary bladder; its internal surface. 2. Trigonum vesicæ. 3. Openings of the ureters. 4. Uvula vesicæ. 5. Veru montanum. 6. Opening of the sinus pocularis. 7, 7. Apertures of the ejaculatory ducts. 8, 8. Openings of the prostatic ducts. The figures 7, 7, and 8, 8, are placed on the cut surface of the supra-urethral portion of the prostate gland. 9, 9. Lateral lobes of the prostate gland. a. Membranous portion of the urethra. b, b. Cowper's glands. c, c. Apertures of the excretory ducts of Cowper's glands. d. Commencement of the bulbous portion of the urethra. e, e, Upper surface of the bulb of the corpus spongiosum. f, f. Crura penis. g, g. Corpus cavernosum. h. Spongy portion of the urethra.



passes through the triangular ligament. Its coats are, the mucous membrane, longitudinal muscular coat, and compressor urethræ muscle. The submucous tissue is richly supplied with vessels.

The *Spongy portion*, about six inches in length, forms the rest of the extent of the canal, and is lodged in the corpus spongiosum from its commencement at the triangular ligament to the meatus urinarius. It is narrowest in the body, and dilated at each extremity, posteriorly in the bulb, where it is named the *bulbous portion*, and anteriorly in the glans penis, where it forms the *fossa navicularis*. The meatus urinarius is the most constricted part of the canal; so that a catheter, which will enter that opening, may be passed freely through the whole extent of a normal urethra. Opening into the bulbous portion are two small excretory ducts about an inch in length, which may be traced backwards, between the coats of the urethra and the bulb, to the under part of the membranous portion behind the triangular ligament, where they originate in two small, lobulated, and somewhat compressed glands, of about the size of peas, *Cowper's glands*. These glands are inclosed in a thin membrana propria, their glandular structure being held together by areolar tissue and smooth muscular fibre; smooth muscular fibre is also found as a longitudinal layer around their excretory ducts. Their glandular vesicles are lined by a tessellated epithelium, the epithelium of the excretory ducts being of the columnar kind. They are situated immediately beneath the membranous portion of the urethra, and are inclosed by the lower segment of the compressor urethræ muscle, so as to be subject to muscular compression. On the whole internal surface of the spongy portion of the urethra, and especially along its lower surface, are numerous small openings of lacunæ, the apertures of mucous glands situated in the submucous areolar tissue. The openings of the lacunæ are directed forwards, and are liable occasionally to intercept the point of a small catheter in its passage to the bladder. At about an inch and a half from the opening of the meatus, in the upper wall of the urethra, one of the lacunæ is generally found much larger than the rest, and is named the *lacuna magna*. In a preparation of this lacuna, made by Sir Astley Cooper, the extremity of the canal presents several large primary ramifications.

TESTES.

The testes are two small glandular organs suspended from the abdomen by the spermatic cords, and inclosed in an external tegumentary covering, the scrotum.

The SCROTUM is distinguished into two lateral halves or hemispheres by a *raphé*, which is continued anteriorly along the under surface of the penis, and posteriorly along the middle line of the perineum to the anus. Of these two lateral portions the left is somewhat longer than the right, and corresponds with the greater length of the spermatic cord on the left side.

The scrotum is composed of two layers, integument, and a proper covering, the dartos; the integument is thin, devoid of fat, semi-transparent, possesses numerous large sebiparous and sudoriparous glands, is beset with hairs which issue obliquely from the skin, and have prominent roots, and has usually a dark color from the presence of pigment in the epidermis. The *tunica dartos* is a thin reddish layer composed of smooth muscular tissue; it forms the proper tunic of the scrotum, and sends inwards a septum, *septum scroti*, which divides the cavity into two sacs for the two testes. The dartos is continuous around the base of the scrotum with the common superficial fascia of the abdomen and perineum, and in an attenuated form is prolonged upon the penis to the prepuce.

The SPERMATIC CORD is the medium of communication between the testes and the interior of the abdomen; and is composed of arteries, veins, lymphatics, nerves, the excretory duct of the testicle, and investing tunics. It commences at the internal abdominal ring, where the vessels of which it is composed converge, and passes obliquely along the spermatic canal: the cord then escapes at the external abdominal ring, and descends through the scrotum to the posterior border of the testicle. The left cord is somewhat longer than the right, and permits the left testicle to reach a lower level than its fellow.

The *Arteries* of the spermatic cord are, the spermatic artery from the aorta; the deferential artery, accompanying the vas deferens, from the superior vesical; and, the cremasteric, from the epigastric artery. The *spermatic veins* form a plexus, which constitutes the chief bulk of the cord; they are provided with valves at short intervals, and the smaller veins have a peculiar tendril-like arrangement, which has obtained for them the name of *vasa pampiniformia*. The *lymphatics* are of large size, and terminate in the lumbar glands. The *nerves* are the spermatic plexus, which is derived from the aortic and renal plexus, the genital branch of the genito-crural nerve, and the scrotal branch of the ilio-inguinal.

The *Vas deferens*, the excretory duct of the testicle, is situated along the posterior border of the cord, where it may be distinguished by the hard and cordy sensation which it communicates to the fingers. It is about a line or a line and a half in thickness; its parietes are thick and tough, and its canal from one-fourth to one-third the diameter of the entire duct. In *structure* it is composed of three coats, an *external* or *fibrous coat*, which is thin; a *middle* or *muscular coat*, which is remarkable for its thickness, and consists of three layers of smooth muscular fibre, namely, external longitudinal, middle circular, and internal longitudinal; and an *internal* or *mucous coat*, the mucous membrane being pale in color, disposed in longitudinal plaits, and coated with a squamous epithelium, composed of cells containing yellowish pigment granules. In the dilated portion, near its extremity, it presents a reticular appearance, like that of the *vesiculæ seminales*.

The *Coverings of the spermatic cord* are, the spermatic fascia, cremaster muscle, and fascia propria. The spermatic fascia is a prolongation of the inter-

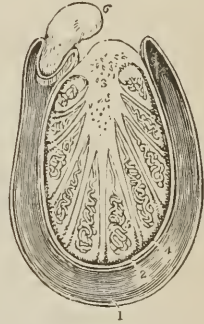
columnar fascia, derived from the borders of the external abdominal ring during the descent of the testicle in the fœtus. The cremasteric covering, *erythroïd*, is the thin muscular expansion formed by the spreading out of the fibres of the cremaster, which is likewise carried down by the testis during its descent. The fascia propria is a continuation of the infundibuliform process from the transversalis fascia, which immediately invests the vessels of the cord, and is also obtained during the descent of the testis.

The TESTIS (testicle) is a small oblong and rounded gland, about an inch and a half in length, somewhat compressed at the sides and behind, and suspended in the cavity of the scrotum by the spermatic cord.

Its position in the scrotum is oblique, so that the upper extremity is directed upwards and forwards, and a little outwards; the lower, downwards and backwards, and a little inwards; the convex border looks forwards and downwards, and the flattened border, to which the cord is attached, backwards and up-

TRANSVERSE SECTION OF THE TESTICLE. 1. Cavity of the tunica vaginalis; the most external layer is the parietal layer; and that in contact with the organ, the visceral layer. 2. Tunica albuginea. 3. Mediastinum testis giving off numerous fibrous cords in a radiated direction to the internal surface of the tunica albuginea. The cut extremities of the vessels below the figure belong to the rete testis; and those above to the arteries and veins of the organ. 4. Tunica vasculosa, or pia mater testis. 5. One of the lobules, consisting of the convolutions of the tubuli seminiferi, and terminating by a single duct, the vas rectum. Corresponding lobules are seen between the other fibrous cords of the mediastinum. 6. Section of the epididymis.

FIG. 378.



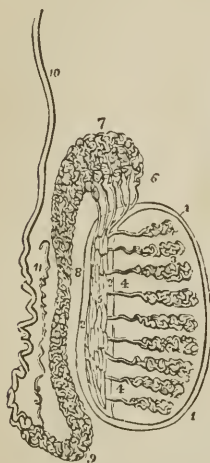
wards. Lying against its outer and posterior border is a flattened body which follows the course of the testicle, and extends from its upper to its lower extremity; this body is named, from its relation to the testis, *epididymis* (*ἐπί*, upon, *διδυμος*, the testicle); it is divided into a central part or body, an upper extremity or *globus major*, and a lower extremity, *globus minor* (cauda) epididymis. The *globus major* [or head] is situated against the upper end of the testicle, to which it is closely adherent; the *globus minor* [or tail] is placed at its lower end, is attached to the testis by areolar tissue, and curves upwards, to become continuous with the vas deferens. The testis is invested by three tunics, tunica vaginalis, tunica albuginea, and tunica vasculosa, and is connected to the inner surface of the dartos by a large quantity of extremely loose areolar tissue, in which fat is never deposited, but which is very susceptible of serous infiltration.

The *Tunica vaginalis* is a pouch of serous membrane derived from the peritoneum in the descent of the testis, and afterwards obliterated from the abdomen to within a short distance of the gland. Like other serous coverings, it is a shut sac, investing the organ, *visceral portion*, and then reflected so as to form a bag around its circumference, *parietal portion*. The visceral portion, tunica vaginalis propria, covers the surface of the tunica albuginea, and surrounds the epididymis, connecting it to the testis by means of a duplicature. The parietal portion, tunica vaginalis communis, is attached by its external surface, through the medium of a quantity of loose areolar tissue, to the inner surface of the dartos. Between the two layers is the smooth surface of the shut sac, moistened by its proper secretion.

The *Tunica albuginea* (*dura mater testis*) is a thick areolo-fibrous membrane,

of a bluish-white color, and the proper tunica of the testicle. It is adherent externally to the tunica vaginalis propria, and, from the union of a serous with a fibrous membrane, is regarded as a fibro-serous membrane, like the dura mater and pericardium. After surrounding the testicle, the tunica albuginea is reflected from its posterior border into the interior of the gland, and forms a projecting longitudinal ridge, the *mediastinum testis* (corpus Highmorianum),¹ from which numerous fibrous cords (trabeculæ, septula) are given off, to be inserted into the inner surface of the tunica. The medi-

FIG. 379.



ANATOMY OF THE TESTIS. 1, 1. Tunica albuginea. 2, 2. Mediastinum testis. 3, 3. Lobuli testis. 4, 4. Vasa recta. 5. Rete testis. 6. Vasa efferentia, of which six only are represented in this diagram. 7. Coni vasculosi, constituting the globus major epididymis. 8. Body of the epididymis. 9. Globus minor epididymis. 10. Vas deferens. 11. Vasculum aberrans.

astinum serves to contain the vessels and ducts of the testicle in their passage into the substance of the organ, and the fibrous cords are adapted to prevent compression of the gland. If a transverse section of the testis be made, and the surface of the mediastinum examined, it will be observed that the bloodvessels of the substance of the organ are situated near the posterior border of the mediastinum, while the divided ducts of the rete testis occupy a place nearer the free margin.

The *Tunica vasculosa* (pia mater testis) is the nutrient membrane of the testis; it is situated immediately within the tunica albuginea, and incloses the substance of the gland, sending processes inwards between the lobules, in the same manner that the pia mater is reflected between the convolutions of the brain.

The substance of the testis consists of numerous conical flattened *lobules* (lobuli testis), the bases being directed towards the surface of the organ, and the apices towards the mediastinum. Krause found between four and five hundred of these lobules in a single testis. Each lobule is invested by a distinct sheath formed of two layers, one being derived from the tunica vasculosa, the other from the tunica albuginea. The lobule is composed of from one to three minute tubuli, *tubuli seminiferi*,² exceedingly convoluted, anastomosing frequently with each other near their extremities, terminating in loops or in free cæcal ends, and of the same diameter ($\frac{1}{170}$ of an inch, Lauth) throughout. The tubuli seminiferi are of a bright yellow color; they become less convoluted in the apices of the lobules, and terminate by forming between twenty and thirty small straight ducts of about twice the diameter of the tubuli seminiferi, the *vasa recta*. The vasa recta enter the substance of the mediastinum, and terminate in from seven to thirteen ducts, smaller in diameter than the vasa

recta. These ducts pursue a waving course from below upwards through the fibrous tissue of the mediastinum; they communicate freely with each other, and constitute the *rete testis*. At the upper extremity of the mediastinum, the ducts of the rete testis terminate in from nine to thirty small ducts, the *vasa efferentia*,³ which form by their convolutions a series of conical masses, the

¹Nathaniel Highmore, a physician of Oxford, in his "Corporis Humani Disquisitio Anatomica," published in 1651, considers the corpus Highmorianum as a duct formed by the convergence of the fibrous cords, which he mistakes for smaller ducts.

²Lauth estimates the whole number of tubuli seminiferi in each testis at 840, and their average length at 2 feet 3 inches. According to this calculation, the entire length of the tubuli seminiferi would be 1890 feet.

³Each vas efferens with its cone measures, according to Lauth, about 8 inches. The entire length of the tubes composing the epididymis, according to the same authority, is about 21 feet.

coni vasculosi; from the bases of these cones tubes of larger size proceed, which constitute, by their complex convolutions, the body of the epididymis. The tubes become gradually larger towards the lower end of the epididymis, and terminate in a single large and convoluted duct, the *vas deferens*.

The *Epididymis* is formed by the convolutions of the excretory seminal ducts, externally to the testis, and previously to their termination in the *vas deferens*. The more numerous convolutions and the aggregation of the *coni vasculosi* at the upper end of the organ constitute the *globus major*; the continuation of the convolutions downwards is the *body*; and the smaller number of convolutions of the single tube at the lower extremity, the *globus minor*. The tubuli are connected together by filamentous areolar tissue, and are inclosed by the *tunica vaginalis*.

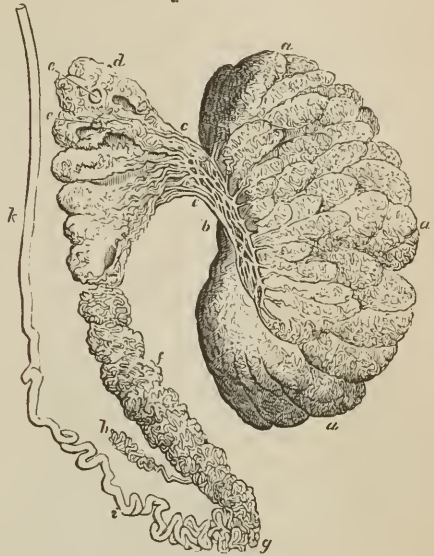A small convoluted duct, of variable length, is generally connected with the duct of the epididymis, just at the commencement of the *vas deferens*. This is the *vasculum aberrans* of Haller; it is attached to the epididymis by the areolar tissue in which that body is enveloped. Sometimes it becomes dilated towards its extremity, but more frequently retains the same diameter throughout.

The *Vas deferens* may be traced upwards, from the *globus minor* of the epididymis along the posterior part of the spermatic cord, and along the spermatic canal to the internal abdominal ring. From the ring it is reflected inwards to the side of the fundus of the bladder, and descends along its posterior surface, crossing the direction of the ureter, to the inner border of the *vesicula seminalis*. In the latter situation it becomes somewhat larger in size and sacculated, and terminates at the base of the prostate gland, by uniting with the duct of the *vesicula seminalis*, and constituting the ejaculatory duct. The ejaculatory duct, which is thus formed by the junction of the duct of the *vesicula seminalis* with the *vas deferens*, passes forwards in the outer wall of the *sinus pularis*, and terminates by a slit-like opening close to or just within the aperture of the sinus.

FEMALE PELVIS.

The peculiarities in form of the female pelvis have already been examined with the anatomy of the bones (p. 118). Its lining boundaries are the same as those of the male.

[FIG. 380.]



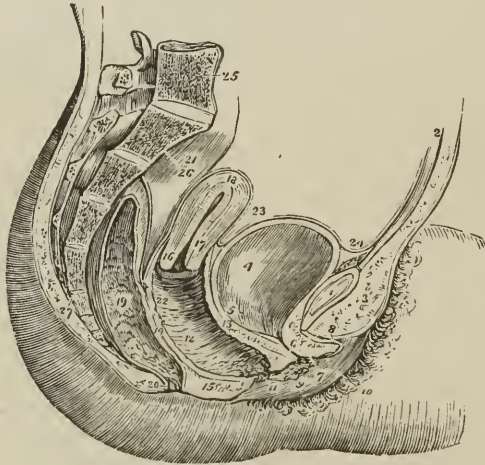
GLANDULAR STRUCTURE OF THE TESTIS, DISPLAYED BY MERCURIAL INJECTION; after Lauth. *a, a, a*. Glandular substance of the testis subdivided into lobes, each lobe being composed of convoluted tubuli closely packed. *b*. Rete testis. *c, c*. Vasa efferentia. *d*. Inflected part of the vasa efferentia forming the *coni vasculosi*. *e, e*. Dilatations of the efferent vessels. *f*. Body of the epididymis. *g*. Tail of the epididymis. *h*. Vasculum aberrans. *i*. Convoluted part of the *vas deferens*. *k*. Straight part of the *vas deferens*.]

The contents are the bladder, vagina, uterus with its appendages, and rectum. Some portion of the small intestine also occupies the upper part of its cavity.

The **BLADDER** is in relation with the pubes in front, with the uterus behind, from which it is usually separated by a convolution of small intestine, and with the neck of the uterus and vagina beneath. The form of the female bladder corresponds with that of the pelvis, being broad from side to side, and often bulging more on one side than on the other. This is particularly evident after parturition. The *coats* of the bladder are the same as those of the male.

The **URETHRA**, about an inch and a half in length, is lodged in the upper and anterior wall of the vagina, in its course downwards and forwards, beneath

FIG. 381.



SIDE VIEW OF THE VISCERA OF THE FEMALE PELVIS. 1. Symphysis pubis; to the upper part of which the tendon of the rectus muscle is attached. 2. Abdominal parietes. 3. Collection of fat, forming the prominence of the mons Veneris. 4. Urinary bladder. 5. Entrance of left ureter. 6. Canal of the urethra, converted into a mere fissure by the contraction of its walls. 7. Meatus urinarius. 8. Clitoris, with its præputium, divided through the middle. 9. Left nymphæ. 10. Left labium majus. 11. Meatus of the vagina, narrowed by the contraction of its sphincter. 12, 22. Canal of the vagina, on which the transverse rugæ are apparent. 13. Thick wall of separation between the base of the bladder and the vagina. 14. Wall of separation between vagina and rectum. 15. Perineum. 16. Os uteri. 17. Cervix. 18. Fundus uteri. The *cavitas uteri* is seen along the centre of the organ. 19. Rectum, showing the disposition of its mucous membrane. 20. Anus. 21. Upper part of rectum invested by peritonæum. 23. Utero-vesical fold of peritonæum. The recto-uterine fold is seen between the rectum and posterior wall of the vagina. 24. Reflexion of peritonæum, from the apex of the bladder upon the urachus to the internal surface of the abdominal parietes. 25. Last lumbar vertebra. 26. Sacrum. 27. Coccyx.

the arch of the pubes, to the meatus urinarius. It is composed of three coats, mucous, submucous, and muscular: the *mucous coat* is vascular, and disposed in longitudinal folds, and is continuous internally with the mucous membrane of the bladder and externally with that of the vulva. It is provided with a

squamous epithelium, having a deep stratum of elongated cells, like the mucous membrane of the bladder, and near its extremity has, opening on its surface, the ducts of numerous racemose mucous glands, the glands of Littre. The *submucous coat* is loose, and provided with a considerable plexus of veins, and in its areolar tissue are situated the racemose mucous glands, which open into the urethra near its termination. The *muscular coat* consists of two layers, which are continuous with the muscular structure of the bladder, the internal layer being longitudinal, and mingled with areolar and elastic tissue; the external circular, and continuous with the middle layer of the muscular coat. The female urethra is remarkable for its distensibility, which is only restricted at the meatus by a ring of dense areolar tissue; hence, in distending the urethra for surgical purposes, it is often necessary to divide the margin of the meatus with the knife.

INTERNAL ORGANS OF GENERATION.

VAGINA.

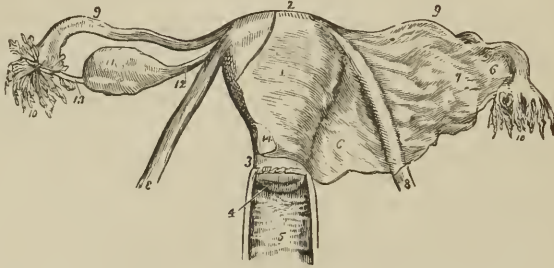
The *Vagina* is a membranous canal, leading from the vulva to the uterus, and corresponding in direction with the axis of the outlet of the pelvis. It is constricted at its commencement, but near the uterus becomes dilated, and is closed by the contact of the anterior with the posterior wall. Its length is variable; but it is always longer on the posterior than on the anterior wall, the former being usually about five or six inches in length, the latter about four. It is attached to the cervix of the uterus, which latter projects into the upper extremity of the canal. Its upper fourth is covered posteriorly by the peritoneum, while anteriorly the peritoneum is reflected from the cervix uteri without reaching so low as the vagina; it is firmly connected to the bladder in front, and loosely to the rectum behind; while at the sides it receives the attachment of the posterior layer of the broad ligaments above, and that of the pelvic fascia and levatores ani below. Its close connexion with the bladder occasions the prolapsus of that organ in cases of prolapsus uteri, while its looser connexion with the rectum preserves the latter from a similar accident.

The vagina, about one line in thickness, is composed of three coats, external, fibrous; middle, muscular; and internal, mucous. The *externa*, or *fibrous coat*, is thin and white, and consists of condensed areolar tissue, with an admixture of elastic fibres. It is firm around the upper part of the tube, and lax inferiorly, and contains in its tissue, especially below, an abundant venous plexus. By its inner surface it is blended with the muscular coat without any distinct separation. The *middle*, or *muscular coat*, is composed of smooth muscular fibre, arranged in longitudinal and circular bundles, and intermingled with areolar tissue and a considerable plexus of veins. The *internal*, or *mucous coat*, is of a pale red color, and disposed in numerous plaits or folds, *columnæ rugosæ*; which diverge transversely from a middle line, or raphé, situated on the anterior and posterior wall of the vagina; the rugæ are most strongly developed on the anterior wall, and the median raphé are termed *columns of the vagina*. In intimate structure the mucous membrane consists of areolar and elastic tissue, to which its firmness and elasticity are due, and presents numerous conical papillæ imbedded in a squamous epithelium. The *epithelium* is thick and laminated, resembling that of the œsophagus, its upper scales measuring about $\frac{1}{1000}$ of an inch in diameter; it is continuous externally with the epithelium of the vulva, and terminates internally at about the middle of the cervix uteri.

UTERUS.

The *Uterus* is a flattened organ of a pyriform shape, having the base directed upwards and forwards, and the apex downwards and backwards, in the line of

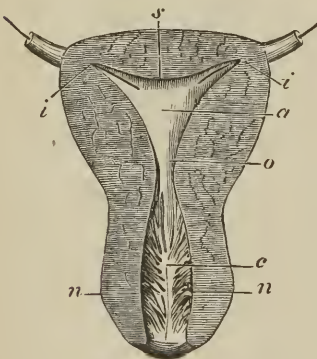
FIG. 382.



UTERUS WITH ITS APPENDAGES VIEWED FROM THE FRONT. 1. Body of the uterus. 2. Fundus. 3. Cervix. 4. Os uteri. 5. Vagina; the cipher is placed on the posterior raphé or column, from which the transverse rugæ are seen passing off at each side. 6, 6. Broad ligament of the uterus. 7. Convexity of the broad ligament formed by the ovary. 8, 8. Round ligaments of the uterus. 9, 9. Fallopian tubes. 10, 10. Fimbriated extremities of the Fallopian tubes; on the left side of the figure, the mouth of the tube is turned forwards in order to show its ostium abdominale. 11. Ovary. 12. Utero-ovarian ligament. 13. Fallopio-ovarian ligament, on which some small fimbriæ are continued for a short distance. 14. Peritoneum of anterior surface of uterus. This membrane is removed at the left side of the figure, but on the right is continuous with the anterior layer of the broad ligament.

the axis of the inlet of the pelvis, and forming a considerable angle with the course of the vagina. It is convex

[FIG. 383.]



SECTION OF VIRGIN OR NULLIPAROUS UTERUS. a. Cavity of the body. o. Orificium internum and inferior angle of the cavity. i, i. The two superior angles of the cavity and orifices of the Fallopian tubes, through which bristles are passed. s. Fundus. c. Cavity of the cervix. n, n. Plicæ palmatæ.]

what less thick. The opening of

on its posterior surface, and somewhat flattened in front; in the unimpregnated state it is about three inches in length, two in breadth across its broadest part, and one in thickness; and is divisible into fundus, body, cervix, and os uteri. At the period of puberty, the uterus weighs about one ounce and a half; after parturition, from two to three ounces; and at the ninth month of utero-gestation, from two to four pounds.

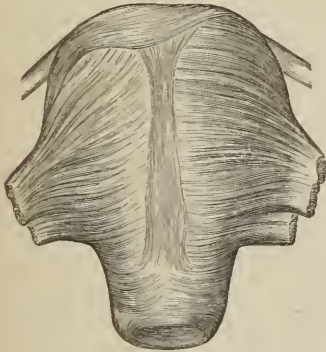
The *fundus* and *body* are enclosed in a duplicature of peritoneum, which is connected with the sides of the pelvis, and forms a transverse septum between the bladder and rectum. The folds formed by this duplicature of peritoneum at either side of the organ are the *broad ligaments*. The *cervix* is the lowest portion of the uterus; it is distinguished from the body by a well-marked constriction; around its circumference is attached the upper end of the vagina, and at its extremity is an opening which is nearly round in the virgin, and transverse after parturition, the *os uteri* (*os tinææ*), bounded before and behind by two labia; the posterior labium being somewhat longer than the anterior, and somewhat less thick. The opening of the os uteri is of considerable size, and is

named the *orificium uteri externum*; the canal then becomes narrowed, and at the upper end of the cervix is constricted into a smaller opening, the *orificium internum*.¹ Beyond this point the canal of the cervix expands into the shallow triangular cavity of the uterus, the inferior angle corresponding with the *orificium internum*, and the two superior angles, which are funnel-shaped, and represent the original bicornute condition of the organ, with the commencement of the Fallopian tubes.

The uterus is composed of three tunics: of an *external or serous coat*, derived from the peritoneum, which constitutes the duplicatures at each side of the organ called the broad ligaments; of a *middle or muscular coat*, which gives thickness and bulk to the uterus; and of an *internal or mucous membrane*, which lines its interior, and is continuous on the one hand with the mucous lining of the Fallopian tubes, and on the other with that of the vagina.

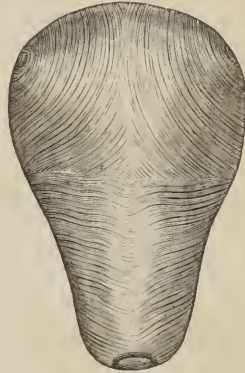
In the unimpregnated state the *muscular coat* is exceedingly dense in texture, offers resistance to section with the scalpel, and appears to be composed of whitish fibres inextricably interlaced and mingled with bloodvessels. In the impregnated uterus the fibres are of large size, distinct, and separable into three

[FIG. 384.]



EXTERNAL LAYER OF UTERINE MUSCULAR FIBRES.]

[FIG. 385.]



INTERNAL LAYER OF UTERINE MUSCULAR FIBRES.]

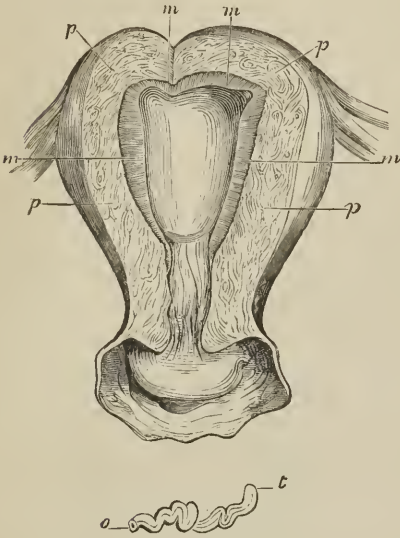
layers: *external*, which are longitudinal and transverse, the former constituting a thin plane on the anterior and posterior surface and fundus of the organ, the latter being prolonged outwards on the Fallopian tubes, and into the round and ovarian ligaments; *middle*, a thick layer consisting of flat bundles of transverse, longitudinal, and oblique fibres, complexly interlaced, and traversed by a plexus of large veins, which give this portion of the substance of the uterus a spongy appearance; and an *internal layer* of longitudinal, transverse, and oblique fibres. The longitudinal fibres of the internal or deep layer are thin and slender, the transverse stronger and continued as an annular stratum upon the Fallopian tubes, while around the os uteri they form a circular ring, the *sphincter uteri*. The formative elements of the muscular coat are short, fusiform fibre-cells, about $\frac{1}{500}$ of an inch long, with long oval nuclei, intermingled with a considerable quantity of immature nucleated areolar tissue.

The *mucous membrane*, of a whitish or pale red color, is closely connected, or more correctly, is blended with the muscular coat; it is composed of immature nucleated areolar tissue without elastic fibres, is smooth on the surface, and

¹ The *orificium internum* is not unfrequently obliterated in old persons; indeed, this obliteration is so common, as to have induced Mayer to regard it as normal.

coated by a *ciliated epithelium*, the direction of the vibrations of the cilia being from without inwards. In the cervix uteri the mucous membrane is somewhat thicker than in the fundus, and on the anterior and posterior surface of its canal is disposed in folds,

[FIG. 386.]



MULTIPAROUS UTERUS laid open by removing a part of its anterior wall. *m, m.* Mucous membrane. *p, p.* Substance of the uterine walls. Below is shown a single gland from the mucous membrane. *o.* Mouth of the gland. *t.* Cæcal extremity.]

bothi, seen in the canal of the cervix, around the os uteri, and sometimes in its cavity.

Vessels and Nerves. — The *Arteries* of the uterus are, the uterine from the internal iliac, and the ovarian from the aorta; they ramify through the muscular and mucous coat, forming a plexus of larger vessels in the deep portion of the latter, and of smaller vessels in its superficial portion; from the smaller vessels are given off the capillaries, which constitute a fine plexus around the glands and a coarse plexus at the surface, the blood from the latter passing into the veins. The *Veins* take the course of the arteries, and terminate in the venous plexus situated on each side of the body of the uterus. In the impregnated womb, the veins are so much dilated as to deserve the name of *sinuses*; they are thin in structure, and devoid of valves, and their great number in the muscular coat gives a spongy appearance to the walls of the pregnant uterus. The *Lymphatics* are numerous, the deep commencing in the mucous membrane, the superficial taking their course in the subserous tissue; they follow the direction of the bloodvessels, and terminate in the pelvic and lumbar glands.

The *Nerves* of the uterus are derived from the hypogastric and spermatic plexuses, and from the sacral plexus. They have been made the subject of special investigation by Dr. Robert Lee, who has successfully repaired the omission made by Dr. William Hunter, in this part of the anatomy of the organ. In his numerous dissections of the uterus, both in the unimpregnated and gravid state, Dr. Lee has made the discovery of several large nervous ganglia and plexuses. The principal of these, situated at each side of the cervix uteri

received the name of *arbor vitæ uterina*. In the lower part of the cervix, moreover, are found filiform papillæ, invested by a ciliated epithelium.

The *mucous glands* of the uterus, or *uterine glands*, are minute follicles corresponding in length with the thickness of the mucous membrane, very numerous, sometimes simple, sometimes bifid, and sometimes spirally twisted. Their structure resembles other mucous glands, namely, a membrana propria, an epithelium of spheroidal cells in the fundus of the follicle, and of columnar cells in the excretory duct. They become much enlarged during pregnancy. In the cervix uteri, between the plicæ palmatæ, are found other *mucous* follicles which secrete the peculiar, transparent, vitreous or crystalline mucus of that region. It is these follicles in an imperforate state which constitute the small transparent vesicles termed *ovula Na-*

immediately behind the ureter, he terms the *hypogastric ganglion*; it receives the greater number of the nerves from the hypogastric and sacral plexuses, and distributes branches to the uterus, vagina, bladder, and rectum. Of the branches to the uterus, a large fasciculus proceeds upwards by the side of the organ towards its angle, where they communicate with branches of the spermatic plexus, and form another large ganglion, which he designates the *spermatic ganglion*, and which supplies the fundus uteri. Besides these, Dr. Lee describes *vesical* and *vaginal ganglia*, and anterior and posterior *subperitoneal ganglia* and *plexuses*, which communicate with the preceding, and constitute an extensive nervous network over the entire uterus. Dr. Lee concludes his observations by remarking:—“These dissections prove that the human uterus possesses a great system of nerves, which enlarges with the coats, bloodvessels, and absorbents, during pregnancy, and which returns after parturition to its original condition before conception takes place. It is chiefly by the influence of these nerves that the uterus performs the varied functions of menstruation, conception, and parturition, and it is solely by their means that the whole fabric of the nervous system sympathises with the different morbid affections of the uterus. If these nerves of the uterus could not be demonstrated, its physiology and pathology would be completely inexplicable.”¹

APPENDAGES OF THE UTERUS.

The *Appendages of the uterus* are inclosed by the lateral duplicatures of peritoneum, called the broad ligaments. They are the *Fallopian tubes* and *ovaries*.

The FALLOPIAN² TUBES or oviducts, the *uterine trumpets* of the French writers, are situated in the upper border of the broad ligaments, and are connected with the superior angles of the uterus. They are somewhat trumpet-shaped, being smaller at the uterine than at the free extremity, and narrower in the middle than at either end. Each tube is about four or five inches in length, and more or less flexuous in its course. The canal of the Fallopian tube is exceedingly minute; its inner extremity opens by means of the *ostium uterinum* into the upper angle of the cavity of the uterus, and the opposite end into the cavity of the peritoneum. The free or expanded extremity of the Fallopian tube presents a double and sometimes a triple series of small processes or fringes, which surround the margin of the trumpet or funnel-shaped opening, the *ostium abdominale*. This fringe-like appendage to the end of the tube has gained for it the appellation of the *fimbriated extremity*; and the remarkable manner in which this circular fringe applies itself to the surface of the ovary during sexual excitement, the additional title of *morsus diaboli*. A short ligamentous cord proceeds from the fimbriated extremity to be attached to the distal end of the ovary, and serves to guide the tube in its seizure of that organ.

The Fallopian tube is composed of three tunics, an *external* and *serous* investment derived from the peritoneum; a *middle* or *muscular coat*, consisting of circular (internal) and longitudinal (external) fibres, continuous with those of the uterus; and an *internal* or lining *mucous* membrane, which is continuous on the one hand with the mucous membrane of the uterus, and at the opposite extremity with the peritoneum. The fibres of smooth muscle are mingled, as in

¹ Philosophical Transactions for 1842.

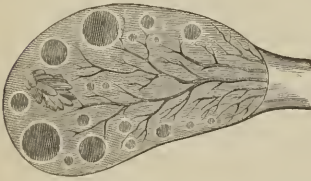² Gabriel Fallopius, a nobleman of Modena, was one of the founders of modern anatomy. He was Professor at Ferrara, then at Pisa, and afterwards succeeded Vesalius at Padua. His principal observations are collected in a work, “*Observationes Anatomicæ*,” which he published in 1561.

the uterus, with immature nucleated areolar tissue. The mucous membrane is thin, pale, and soft, without villi or glands, and disposed in longitudinal plaits. It is invested by an *epithelium* consisting of a single layer of conical or filiform ciliated cells, the direction of the vibrations of the cilia being towards the cavity of the uterus.

The OVARIES, *testes muliebres*, are two oblong, flattened and oval bodies, of a whitish color and uneven surface, [about half an inch thick, three-quarters of an inch wide, and from an inch to an inch and a half long,] situated in the posterior layer of peritoneum of the broad ligaments. They are connected to the upper angles of the uterus at each side by means of a rounded cord, consisting of fibrous tissue, and a few muscular fibres derived from the uterus, the *ligament of the ovary*. By the opposite extremity they are connected by another and a shorter ligament to the fimbriated aperture of the Fallopian tube.

In *structure* the ovary is composed of a spongy fibrous parenchyma or stroma of a grayish-red color, containing a number of small cells traversed by bloodvessels, and inclosed in a capsule consisting of two tunics, *external* or *serous*, derived from the peritoneum, and investing it completely, with the exception of its lower border where the vessels enter; and *internal* or *fibrous*, called also *tunica propria* and *tunica albuginea*, the latter from its analogy with the fibrous coat of the testis. By its inner surface the tunica albuginea blends with the substance of the ovary. The stroma is composed of immature nucleated and fibrous areolar tissue, and, traced from the lower border of the organ, its fibres radiate from the lower border and centre towards the circumference

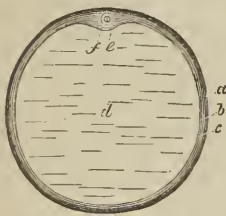
[FIG. 387.]



SECTION OF HUMAN OVARY, showing the formation of Graafian vesicles; about twice the natural size.]

in small bundles, between which and near the surface of the ovary, are seen a number of small cells or vesicles termed *ovisacs* or *Graafian vesicles*. The peripheral position of the larger ovisacs has caused a division of the stroma into *medullary* and *cortical*, in the latter of which, the ovisacs are chiefly found. The number of ovisacs in a single ovary has been estimated at from 30 to 100 or even 200; and their size varies from a quarter of a line to three lines in diameter.

[FIG. 388.]



GRAAFIAN FOLLICLE OF THE sow; after Kölliker. Magnified about 10 diameters. *a*. External, *b*, internal layer of the fibrous membrane of the follicle. *c*. Membrana granulosa. *d*. Liquor folliculi. *e*. Germinal eminence, a projection of the membrana granulosa. *f*. Ovulum with a zona pellucida, vitellus, and germinal vesicle.]

The *Ovisac* or *Graafian vesicle* [or *follicle*], is a vesicle consisting of an external membrane and fluid contents. The membrane is composed of an outer coat, the *tunica fibrosa*, the theca folliculi of Von Baer; and an internal lining or *epithelium*. The tunica fibrosa is highly vascular, is connected to the stroma of the ovary by means of a loose areolar tissue, and is composed of condensed immature areolar tissue. Externally, it is whitish and firm; internally, reddish and soft. The epithelium consists of round or polygonal cells with large nuclei, and a greater or less number of fatty granules; the cells quickly lose their definition after death, and then the epithelium assumes the appearance which has gained for it the name of *membrana granulosa*, namely, a granular layer with numerous nuclei.

The membrana granulosa forms an uniform lining to the ovisacs, excepting on

the side nearest the surface of the ovary, where the cells are accumulated into a small eminence, termed *cumulus proligerus* or *germinal eminence*. This germinal eminence contains a minute globular nucleated vesicle, the *ovulum*. The fluid contents of the ovisac, *liquor folliculi*, are a clear yellowish fluid resembling serum, and a few free nuclei detached from the *membrana granulosa*.

The *ovulum*, or future ovum, measuring in its mature state about $\frac{1}{100}$ of an inch in diameter, is a globular vesicle consisting of a cell membrane, the *membrana vitellina*, a *yelk*, or *vitellus*, and a vesicular nucleated nucleus, the vesicular nucleus being the *germinal vesicle*, and the nucleolus the *germinal spot*. The cell membrane is clear and transparent, and has received the name of *zona pellucida*, and the yelk yellowish and viscid, consisting of numerous minute granules intermingled with fat granules; the fluid of the germinal vesicle is clear and colorless.

As the ovisac attains maturity, it approaches nearer and nearer the capsule of the ovary, and, pressing against the capsule, renders it so thin that moderate pressure, such as that made by the fimbriated extremity of the Fallopian tube, causes the protrusion and rupture both of the ovisac and the capsule of the ovary. By this rupture the ovulum is expelled, carrying with it the germinal eminence and part of the *membrana granulosa*, which in its new relation is termed the *germinal disk*, *discus proligerus*. The ovisac, now emptied of its contents, is quickly filled with a sanguineous fluid, resulting from the tearing of its vessels, the internal portion of the *tunica fibrosa* becomes thickened and plicated, and converted into a yellow vascular tissue, while the external layer of the tunic retains its character of a white fibrous membrane. This is the *corpus luteum*, a yellowish mass with fast diminishing cavity, plicated structure, vascular, and inclosed in a thin fibrous layer. It retains these characters up to the second or third month of pregnancy, and then slowly diminishes in size, being gradually lost some months after parturition is complete, or reduced to a small whitish or dark-colored mass, *corpus albicans vel nigrum*. The *corpora lutea*, which are independent of pregnancy, *false corpora lutea*, disappear in the course of one or two months, and leave behind them a scarcely perceptible trace of their existence.

Vessels and Nerves.—The *Arteries* of the ovaries are branches of the uterine; the spermatic or ovarian artery being distributed to the broad ligaments, according to Weber, and not specially to the ovaries. The arteries enter the ovary along its inferior border by numerous minute trunks, which pass in a serpentine course through its stroma, to be distributed chiefly to the walls of the ovisacs, forming an exterior coarse and interior fine capillary plexus. The *Veins* constitute an ovarian plexus, which terminates in the uterine plexus. The *Lymphatics*, few in number, terminate in the pelvic and lumbar glands. The *Nerves* are derived from the spermatic plexus, and take the course of the arteries.

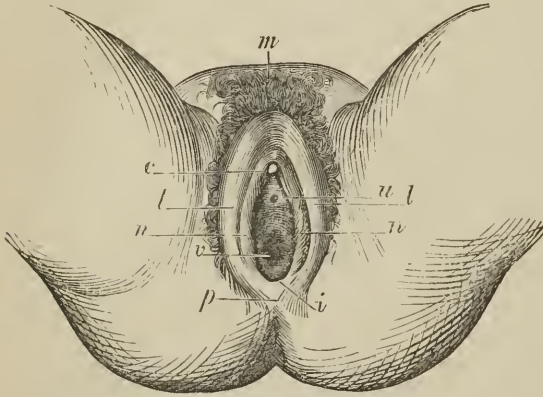
The **ROUND LIGAMENTS** are two musculo-fibrous cords between four and five inches long, situated within the layers of the broad ligaments, and extending from the upper angles of the uterus, and along the spermatic canals to the labia majora, in which they are lost. They are composed of smooth muscular fibre and areolar tissue, but towards the internal abdominal rings, have also numerous fasciculi of striated muscular fibres. The round ligaments are accompanied by a small artery, by several filaments of the spermatic plexus of nerves, by a plexus of veins, and by a process of the peritoneum which represents the serous membrane investing the spermatic cord in the male. In the young subject, this process extends for a short distance along the spermatic canal, and is denominated the *canal of Nuck*; it is sometimes pervious in the adult. The plexus of veins occasionally becomes varicose, and forms a small tumor at the external abdominal ring, which has been mistaken for inguinal hernia.

The round ligaments serve to retain the uterus in position in the pelvis, and, during utero-gestation, to draw the anterior surface of the organ against the abdominal parietes.

EXTERNAL ORGANS OF GENERATION.

The female organs of generation are divisible into internal and external; the internal are contained within the pelvis, and have been already described; they

[FIG. 389.



FEMALE EXTERNAL ORGANS OF GENERATION. *m.* Mons Veneris. *p.* Perineum. *l, l.* Labia majora. *i.* Fourchette, or inferior commissure of the vulva. *n, n.* Nymphæ, or labia minora. *c.* Clitoris. *u, u.* Meatus urinarius; the space between the meatus and the clitoris is the vestibule. *v.* Vaginal orifice.]

are the vagina, uterus, ovaries, and Fallopian tubes. The external organs are the mons Veneris, labia majora, labia minora, clitoris, meatus urinarius, and opening of the vagina.

The *Mons Veneris* is the eminence of integument, situated on the front of the pubes. Its areolar tissue is loaded with adipose substance, and the surface covered with hairs.

The *Labia majora* are two large longitudinal folds of integument, containing areolar tissue, fat, and a tissue resembling the dartos. They inclose an elliptical fissure, the common urino-sexual opening or *vulva*. The vulva receives the inferior opening of the urethra and vagina, and is

bounded anteriorly by the *commissura superior*, and posteriorly by the *commissura inferior*. Stretching across the posterior commissure is a small transverse fold, the *frænulum labiorum*, or fourchette, which is ruptured during parturition; and immediately within this fold a small cavity, the *fossa navicularis*. The length of the perineum is measured from the posterior commissure to the margin of the anus, and is usually not more than an inch. The external surface of the labia is covered with hairs; the inner surface is smooth, and lined by mucous membrane, which contains a number of large sebiparous glands, and is covered by a thin cuticular epithelium. The use of the labia majora is to favor the expansion of the vulva during parturition; for, in the passage of the head of the fœtus, the labia are unfolded and completely effaced.

The *Labia minora*, or *nymphæ*, are two smaller folds, situated within the labia majora. Superiorly they are divided into two processes, which surround the glans clitoridis, the superior fold forming the *præputium clitoridis*, the inferior its *frænulum*. Inferiorly, they diminish gradually in size, and are lost on the sides of the opening of the vagina. The nymphæ consist of mucous membrane, covered by a thin cuticular epithelium. They are provided with a number of sebiparous glands, and contain, in their interior, a plexus of blood-vessels.

The *Clitoris* is a small elongated organ situated in front of the pubes, and supported by a suspensory ligament. It is formed by a small body, analogous to the corpus cavernosum penis, and, like it, arises from the ramus of the os pubis and ischium at each side by two *crura*. At the extremity of the clitoris

is a small accumulation of erectile tissue which is highly sensitive, and is termed the *glans*. The corpus cavernosum clitoridis, like that of the penis, is composed of erectile tissue inclosed in a dense layer of fibrous membrane, and is susceptible of erection. Like the penis, also, it is provided with two small muscles, the *erectores clitoridis*.

At about an inch behind the clitoris is the *entrance of the vagina*, an elliptical opening, marked by a prominent margin. The entrance to the vagina is closed in the virgin by a duplicature of mucous membrane of a semilunar form, which is stretched across the opening; this is the *hymen*. Sometimes the membrane forms a complete septum, and gives rise to inconvenience by preventing the escape of the menstrual effusion. It is then called an *imperforate hymen*. The *hymen* must not be considered a necessary accompaniment of virginity, for its existence is uncertain. When present, it assumes a variety of appearances: it may be a membranous fringe, with a round opening in the centre; or a semilunar fold, leaving an opening in front; or a transverse septum, having an opening both in front and behind; or a vertical band with an opening at each side.

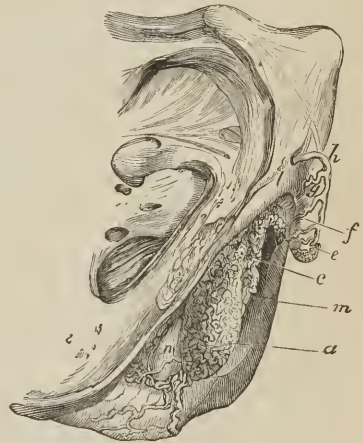The rupture of the hymen, or its rudimentary existence, gives rise to the appearance of a fringe of papillæ around the opening of the vagina; these are called *carunculæ myrtiformes*.

The triangular smooth surface between the clitoris and the entrance of the vagina, which is bounded at each side by the upper portions of the nymphæ, is the *vestibule*.

At the posterior part of the vestibule and near the margin of the vagina is the opening of the urethra, the *meatus urinarius*; and around the meatus an elevation of the mucous membrane formed by the aggregation of numerous mucous glands. This prominence serves as a guide to finding the meatus in the operation of introducing the female catheter. Beneath the vestibule at each side, and extending from the clitoris to the side of the vagina, are two oblong or pyriform bodies, consisting of erectile tissue inclosed in a thin layer of fibrous membrane. These bodies are narrow above, pars intermedia, broad and rounded below, and are termed by Kobelt, who considers them analogous to the bulb of the male urethra, the *bulbi vestibuli*. Behind these bodies and lying against the outer wall of the vagina are two small glands analogous to Cowper's glands in the male subject; they are the *glands of Bartholine*. Each gland opens by means of a long excretory duct on the inner side of the corresponding nymphæ.

The *mucous membrane* of the external organs, about a quarter of a line in thickness, is composed of areolar and elastic tissue, without fat, and rich in capillary vessels. It is furnished with numerous papillæ, which are large on the labia minora, smaller on the clitoris, and is invested by a squamous epithelium. On the internal surface of the labia majora, on the labia minora, and occasionally around the meatus urinarius and entrance of the vagina, there exist *sebiparous*

[FIG. 390.]



THE ERECTILE STRUCTURES OF THE EXTERNAL ORGANS OF GENERATION IN THE FEMALE, the skin and mucous membrane being removed; lateral view. (Kobelt).—*a*. Bulbus vestibuli. *c*. Plexus of veins named pars intermedia. *e*. Glans of the clitoris. *f*. Body of the clitoris. *h*. Dorsal vein. *l*. Right crus of clitoris. *m*. Vulva. *n*. Right gland of Bartholine.]

glands; while on the vestibule, around the meatus urinarius and around the entrance of the vagina, there is an abundance of *racemose mucous glands*, opening on the surface of the membrane by shorter and longer ducts. The *glands of Bartholine* are common racemose mucous glands, nearly half an inch in diameter, and made up of pyriform glandular vesicles, lined by squamous epithelium, and surrounded by a dense nucleated areolar tissue. Their excretory ducts, more than half an inch in length, are invested by columnar epithelium, and surrounded by a thin layer of smooth-muscle cells, disposed longitudinally. The secretion of these glands is a clear, yellowish, viscous mucus.

Vessels and Nerves.—The external organs of generation are abundantly supplied with *arteries*, chiefly by the internal pudic; they terminate in a deep and superficial capillary plexus, as in other mucous membranes. Valentin has described helicine arteries in the clitoris. The *veins* returning the blood from the capillaries form a rich plexus, which is especially abundant in the bulbi vestibuli of Kobelt. The *lymphatics* are numerous, and communicate partly with the inguinal and partly with the pelvic glands. The *nerves* are derived partly from the hypogastric plexus and partly from the sacral plexus.

MAMMARY GLANDS.

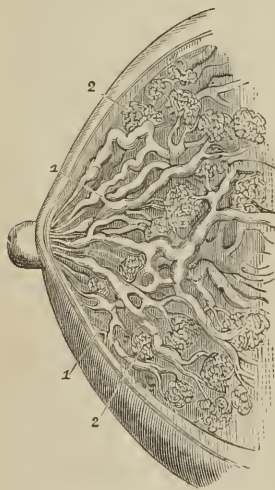
The *Mammæ* are situated in the pectoral region, and are separated from the pectoralis major muscle by a thin layer of superficial fascia. Their base is somewhat elliptical, the long diameter corresponding with the direction of the fibres of the pectoralis major muscle; and the left mamma is generally a little larger than the right. They exist in the male, but in a rudimentary state, unless excited into growth by some peculiar or morbid action, such as the loss or atrophy of the testes.

Near the centre of the convexity of each mamma is a small prominence of the integument, called the *nipple* (mamilla), which is surrounded by an *areola* having a colored tint. In females of fair complexion before impregnation, the color of the areola is a delicate pink; after impregnation, it enlarges and assumes a brownish hue, which deepens in color as pregnancy advances; and after the birth of a child, the brownish tint continues through life.

The areola is furnished with a number of *sebiparous glands*, which secrete a peculiar fatty substance for the protection of the delicate integument around the nipple. During suckling these glands increase in size, and have the appearance of small pimples, projecting from the skin. At this period they serve by their secretion to defend the nipple and areola from the excoriating action of the mouth of the infant.

In *structure*, the mamma is a compound racemose or conglomerate gland, consisting of *lobes*, *lobules*, and *gland-vesicles*. The lobes, from 15 to 25 in number, have each a separate system of lobules and gland-vesicles, and a distinct excretory duct; hence, the mamma may be regarded as being composed of a number of separate glands, their excretory ducts converging to the mamilla, and terminating at its extremity by distinct apertures. The lobes are irregular in size and form, flattened, and bounded by rounded angles; they are made up of smaller lobes or lobules,

[FIG. 391.]



SECTION OF MAMMARY GLAND.

1, 1. Galactophorous ducts. 2, 2. Lobuli.]

and the lobules of other lobules still more diminutive, the smallest lobules consisting of round or pyriform gland-vesicles.

The *gland-vesicles*, about $\frac{1}{200}$ of an inch in diameter, are composed of a structureless membrane, or *membrana propria*, lined with an *epithelium* of spheroidal nucleated cells. The gland-vesicles communicate with an excretory duct, and the excretory ducts of all the lobules unite to form a common excretory duct or canal for each lobe, *ductus lactiferus*, ductus galactophorus. The ductus lactiferus taking its course beneath the areola, dilates into an elongated sac or ampulla, *sacculus vel sinus lactiferus*, and reaching the base of the mamilla, contracts in size and bends outwards into that process to terminate at its extremity by a small aperture. At the point of escape from the lobe, the lacteal duct measures from one to two lines in diameter; the lacteal sac is double that size: within the mamilla the duct measures between half a line and a line, and the excretory aperture about one quarter of a line. There are from 15 to 25 ducts in the nipple, a number corresponding with the number of lobes composing the gland.

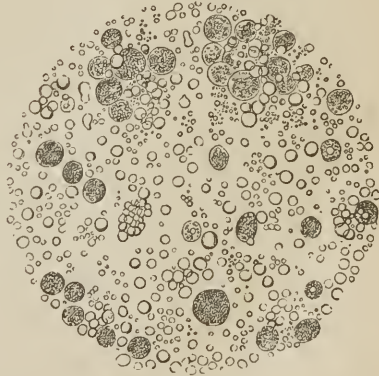
The gland-vesicles are held together by a dense white areolar tissue, which unites the lobules into lobes, and connects the different lobes with each other, forming a covering for the whole, and being itself surrounded with adipose tissue. The lactiferous ducts are composed of areolar tissue, which is homogeneous internally, and fibrillated and nucleated and mingled with elastic fibres externally. Moreover, according to Henlé, there is an indication of longitudinal smooth muscular fibre. The fibrous coat of the lactiferous tubes is plaited, and their interior lined by a columnar epithelium.

The *mamilla* or *nipple* is covered by a thin epidermis, presenting more or less pigment in its rete mucosum; it possesses at the extremity a number of papillæ, between which are the lactiferous openings, and it is composed internally of the lactiferous ducts, united together and surrounded by areolar and smooth muscular tissue, the latter giving the nipple the faculty of erection and retraction. The integument of the *areola*, besides possessing a colored epidermis with numerous large sudoriparous and sebiparous glands, the latter associated with fine hairs, is also provided with a layer of smooth muscular fibre, which gives it a power of contraction.

The *secretion of milk* is effected by the formation of oil-globules in the epithelial cells of the gland-vesicles; the epithelial cells being perfected, are pushed outwards and displaced by a new layer of similar cells which form beneath them; they are thus carried forwards into the lacteal ducts, where the cell bursts and gives exit to its oil-globules, now become *milk-globules*; and the cell-membrane and nucleus are lost. These milk-globules suspended in a fluid, the *milk-plasma*, constitute the *milk*. Previously to conception, the mammæ only secrete a yellowish viscid mucus, and at the commencement of lactation the milk is imperfect and termed *colostrum*, having entering into its composition a number of cells filled with yellow fat-globules, named *colostrum-corpuscles*.

The *mammary gland of the male* is rudimentary; it varies in size from a quarter of an inch to two inches in breadth, by one to three lines in thickness.

[FIG. 392.]



MILK. Milk-globules and colostrum-corpuscles, the latter being the largest.]

It is firm in texture, presents no division into lobes, and its ducts are small without dilatations, and terminate in gland-vesicles larger than those of the female.

The *development* of the mammary gland commences at the fourth or fifth month of embryonic life, at first by a papilla of the rete mucosum, which subsequently gives off primary and secondary branches; the papilla and its branches are for a time solid, but as development advances they become hollow and invested externally by a fibrous membrane. At birth the gland measures between two and four lines in breadth, and presents from twelve to fifteen lobular divisions, and then goes on gradually, but very slowly, increasing in bulk. True gland-vesicles do not make their appearance until the period of menstruation, and are not fully developed throughout the entire gland until the first pregnancy. After the period of child-bearing, the gland gradually degenerates, the gland-vesicles disappear, and in old age the organ passes into a state of atrophy, the ducts, with their epithelium in a state of fatty degeneration alone remaining, surrounded by a cushion of fat which takes the place of the glandular tissue.

Vessels and Nerves. — The mammæ are supplied with *Arteries* from the thoracic branches of the axillary, the intercostals, and internal mammary; having entered the substance of the gland they divide into capillaries, which constitute a close network around the gland-vesicles. The *Veins* form an incomplete circle around the base of the nipple, *circulus venosus Halleri*, from which larger veins conduct the blood to the circumference of the gland, and by these communications form a plexus on its surface. They terminate in the axillary vein, internal mammary, intercostals, and jugular veins.

The *Lymphatics* are abundant in the integument covering the mammæ, but have not yet been observed in the structure of the gland; they take the course of the veins, inwards, to the anterior mediastinal glands; and outwards along the border of the pectoralis major to the axillary glands.

The *Nerves* of the mammary gland are derived from the anterior cutaneous branches of the second, third, and fourth intercostal nerves; and from the lateral cutaneous branches of the same nerves.

CHAPTER XII.

ANATOMY OF THE FŒTUS.

THE medium weight of a child of the full period, at birth, is seven pounds, and its length seventeen inches; the extremes of weight are four pounds and three-quarters, and ten pounds; and the extremes of measurement fifteen and twenty inches. The head is of large size, and lengthened from before backwards; the face small. The upper extremities are greatly developed, and the thorax expanded and full. The upper part of the abdomen is large, from the great size of the liver; the lower part is conical and small. And the lower extremities are diminutive in proportion to the rest of the body. The external genital organs are large, and fully developed, and the attachment of the umbilicus is one inch further from the vertex of the head than from the soles of the feet; and one inch further from the ensiform cartilage than from the symphysis pubis.

OSSEOUS SYSTEM. — The development of the osseous system has been treated of in the first chapter.

The **LIGAMENTOUS SYSTEM** presents no peculiarity deserving of remark.

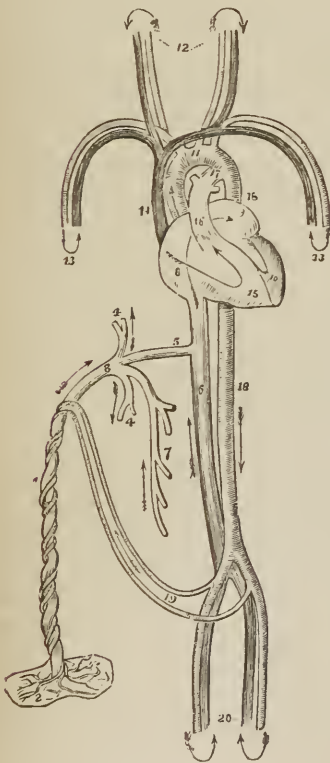
MUSCULAR SYSTEM. — The muscles of the fœtus at birth are large and fully formed. They are of a lighter color than those of the adult, and of softer texture. The transverse striæ on the fibres of animal life are not distinguishable until the sixth month of fœtal life.

VASCULAR SYSTEM. — The circulating system presents several peculiarities: 1stly, in the heart; there is a communication between the two auricles by means of the *foramen ovale*. 2ndly, in the arterial system; there is a communication between the pulmonary artery and arch of the aorta, by means of a large trunk, the *ductus arteriosus*. 3rdly, also in the arterial system; the internal iliac arteries, under the name of hypogastric and *umbilical*, are continued from the fœtus to the placenta, to which they return the blood which has circulated in the system of the fœtus. 4thly, in the venous system; there is a communication between the umbilical vein and inferior vena cava, called the *ductus venosus*.

FŒTAL CIRCULATION.

The pure blood is brought from the placenta by the *umbilical vein*. The umbilical vein passes through the umbilicus, and enters the liver, where it

FIG. 393.



FŒTAL CIRCULATION. 1. Umbilical cord, consisting of umbilical vein and two umbilical arteries; proceeding from the placenta (2). 3. Umbilical vein, dividing into branches; two (4, 4), to be distributed to the liver; and one (5), the ductus venosus, which enters the inferior vena cava (6). 7. Portal vein, returning the blood from the intestines, and communicating with the right hepatic branch. 8. Right auricle; the course of the blood is denoted by the arrow, proceeding from 8, to 9, the left auricle. 10. Left ventricle; the blood following the arrow to the arch of the aorta (11), to be distributed through the branches given off by the arch to the head and upper extremities. The arrows 12 and 13, represent the return of the blood from the head and upper extremities through the jugular and subclavian veins, to the superior vena cava (14), to the right auricle (8), and in the course of the arrow through the right ventricle (15), to the pulmonary artery (16). 17. Ductus arteriosus, which appears to be a proper continuation of the pulmonary artery; the offsets at each side are the right and left pulmonary artery; these are of extremely small size as compared with the ductus arteriosus. The ductus arteriosus joins the descending aorta (18, 18), which divides into the common iliacs, and these into the internal iliacs, or hypogastric arteries (19), and return the blood along the umbilical cord to the placenta; while the other divisions, the external iliacs (20), are continued into the lower extremities. The arrows at the terminations of these vessels mark the return of the venous blood by the veins to the inferior cava.

divides into several branches; two or three of these branches are distributed to the left lobe; one branch communicates with the portal vein in the transverse

fissure, and supplies the right lobe; and a large branch, the *ductus venosus*, passes directly backwards, and joins the inferior vena cava. In the inferior cava the pure blood becomes mixed with that which is returning from the lower extremities and abdominal viscera, and is carried through the right auricle (guided by the Eustachian valve) and through the *foramen ovale*, into the left auricle. From the left auricle it passes into the left ventricle, and from the left ventricle into the aorta, whence it is distributed by means of the carotid and subclavian arteries, principally to the head and upper extremities. From the head and upper extremities, the impure blood is returned by the superior vena cava to the right auricle; from the right auricle, it is propelled into the right ventricle; and from the right ventricle into the pulmonary artery. In the adult, the blood would now be circulated through the lungs, and oxygenated; but in the fœtus the lungs are solid, and almost impervious. Only a small quantity of blood passes therefore into the lungs; the greater part courses through the *ductus arteriosus*, into the commencement of the descending aorta, where it becomes mingled with that portion of the pure blood which is not sent through the carotid and subclavian arteries.

Passing along the aorta, a small quantity of this mixed blood is distributed by the external iliac arteries to the lower extremities; the greater portion is conveyed by the internal iliac or hypogastric, and umbilical arteries to the placenta; the hypogastric arteries pass forwards by the side of the fundus of the bladder, and upwards along the anterior wall of the abdomen to the umbilicus, where they become the umbilical arteries.

From a careful consideration of this circulation, we perceive —

1st. That the pure blood from the placenta is distributed in considerable quantity to the liver, before entering the general circulation. Hence arises the abundant nutrition of that organ, and its enormous size in comparison with other viscera.

2dly. That the right auricle is the scene of meeting of a double current; the one coming from the inferior cava, the other from the superior, and that they must cross each other in their respective course. How this crossing is effected, a cursory examination of the fœtal heart will show; for the direction of entrance of the two vessels is so opposite, that they may discharge their currents through the same cavity without admixture. The inferior cava opens almost directly into the left auricle; and, by the aid of the Eustachian valve, the current in the inferior cava is almost entirely excluded from the right auricle.

3dly. That the blood which circulates through the arch of the aorta comes directly from the placenta; and, although mixed with the impure blood of the inferior cava, yet is propelled in such abundance to the head and upper extremities, as to provide for the increased nutrition of those parts, and prepare them, by their greater size and development, for the functions which they are required to perform at the instant of birth.

4thly. That the blood circulating in the descending aorta is very impure, being obtained principally from the returning current in the superior cava; a small quantity only being derived from the left ventricle. Yet it is from this impure blood that the nutrition of the lower extremities is provided. Hence we are not surprised at their insignificant development at birth; while we perceive the providence of nature, which directs the nutrient current, in abundance, to the organs of sense, prehension, and deglutition, organs so necessary, even at the instant of birth, to the safety and welfare of the creature.

After birth, the *foramen ovale* becomes gradually closed by a membranous layer, which is developed from the margin of the opening from below upwards, and completely separates the two auricles. The situation of the foramen is seen in the adult heart, on the septum auricularum, and is called the *fossa ovalis*; the prominent margin of this opening is the *annulus ovalis*.

As soon as the lungs have become inflated by the first act of inspiration, the

blood of the pulmonary artery courses through its right and left branches into the lungs, to be returned to the left auricle by the pulmonary veins. Thus the pulmonary circulation is established. Then the *ductus arteriosus* contracts and degenerates into an impervious fibrous cord, serving in after life simply as a bond of union between the left pulmonary artery and the concavity of the arch of the aorta.

The current through the umbilical cord being arrested, the *hypogastric arteries* likewise contract and become impervious. The *umbilical vein* and *ductus venosus*, also deprived of their circulating current, become reduced to fibrous cords, the former being the *round ligament* of the liver, and the latter a fibrous band which may be traced along the fissure of the ductus venosus to the inferior vena cava.

NERVOUS SYSTEM. — The brain is very soft, almost pulpy, and has a reddish tint throughout; its weight at birth, relatively to the entire body, is as one to six, and the difference between the white and gray substance is imperfectly marked. The nerves are firm and well developed.

ORGANS OF SENSE.

Eye. — The eyeballs are of large size and well developed at birth. The pupil is closed by a vascular membrane called the *membrana pupillaris*, which disappears at about the seventh month. Sometimes it remains permanently, and produces blindness. It consists of two thin membranous layers, between which the ciliary arteries are prolonged from the edge of the iris, and form arches and loops by returning to it again, without anastomosing with those of the opposite side.

The removal of the membrane takes place by the contraction of these arches and loops towards the edge of the pupil. The capsule of the lens is extremely vascular.

Ear. — The ear is remarkable for its early development; the labyrinth and ossicula auditûs are ossified at an early period, and the latter are completely formed before birth. The only parts remaining incomplete are the mastoid cells, and meatus auditorius. The *membrana tympani* in the fœtal head is very oblique, occupying almost the basilar surface of the skull; hence probably arises a deficient acuteness in the perception of sound. It is also extremely vascular.

Nose. — The sense of smell is imperfect in the infant, as may be inferred from the small capacity of the nasal fossæ, and the non-development of the ethmoid, sphenoid, frontal, and maxillary sinuses.

THYROID GLAND.

The *Thyroid gland* is of large size in the fœtus, and is developed by two lateral halves, which approach and become connected at the middle line so as to constitute a single gland. It is doubtful whether it performs any special function in fœtal life.

THYMUS GLAND.

The *Thymus gland*¹ consists "of a thoracic and a cervical portion on each side. The former is situated in the anterior mediastinum, and the latter is placed in the neck just above the first bone of the sternum and behind the

¹ In the description of this gland I have followed the account of it given by Sir Astley Cooper in his celebrated monograph "On the Anatomy of the Thymus Gland," 1822.

sterno-hyoidei and sterno-thyroidei museles." It extends upwards from the fourth rib as high as the thyroid gland, resting against the pericardium, separated from the arch of the aorta and great vessels by the thoracic fascia, and lying at each side of the trachea in the neck.

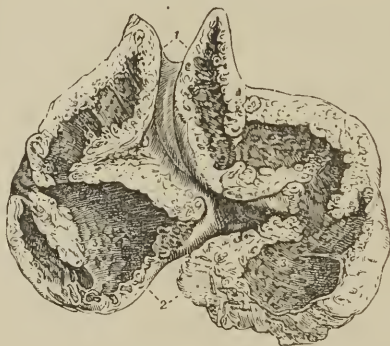Although described usually as a single gland, it consists actually of two lateral, almost symmetrical glands, connected with each other by areolar tissue only, and having no structural communication; they may therefore be "properly called a right and left thymus gland."

The thymus is perceptible as early as the seventh week of embryonic existence, and continues gradually increasing with the growth of the fœtus until the seventh month. At the eighth month it is large; during the ninth, it undergoes a sudden change, assumes a greatly increased size, and at birth weighs 240 grains. After birth it continues to enlarge until the expiration of the second year, when it ceases to grow, and begins to diminish between the eighth and twelfth year; being often well developed at the age of twenty, and only disappearing entirely before forty.

The thymus is a blood-vascular gland, composed of lobules disposed in a spiral form around a central canal. The lobules are held together by a firm areolar tissue ("reticulated"), and the entire gland is inclosed in a coarse areolar capsule.

The *Lobules*, somewhat more than a quarter of an inch in diameter, of a rounded and pyriform shape, are composed of smaller lobules, and the *smaller*

FIG. 394.



SECTION OF THE THYMUS GLAND AT THE EIGHTH MONTH. (This figure, and the succeeding, were drawn with the kind permission of Sir Astley Cooper from two of his preparations; the references were made by Sir Astley himself.) 1. Cervical portions of the gland; the independence of the two lateral glands is shown. 2. Secretory cells seen on the cut surface of the section; these are observed in all parts of the section. 3, 3. Pores or openings of the secretory cells and pouches; they are seen dispersed on the whole internal surface of the great central cavity or reservoir. The continuity of the reservoir in the lower or thoracic portion of the gland, with the cervical portion, is seen in the figure.

lobules, which are hollow in the interior, are made up of small round or polygonal solid masses, the *gland-granules* or *acini*. The gland-granules, separate externally, are adherent by their inner borders, and inclose the cavity of the smaller lobule, the "*secretory cell*;" the secretory cells open into the "*pouch*" or cavity of the lobules, and the pouches of the lobules open into the central canal or cavity, "*the reservoir of the thymus*."

The substance of the thymus is contained in the gland-granules, of which the

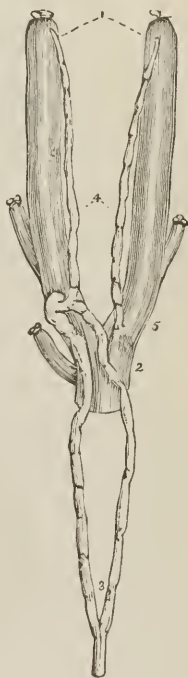walls of the organ are constructed; this substance is of a grayish-white color, soft, about a quarter of a line in thickness, and placed between two membranes, a thin fibrous, almost homogeneous *membrana propria* externally, which invests each separate lobule, and is continued over the entire gland; and a thin vascular membrane internally, consisting of a plexus of bloodvessels held together by a small quantity of areolar tissue. The proper substance of the gland is composed of *cells*, *free nuclei*, *bloodvessels*, and a small quantity of *areolar tissue*. The cells are pale, sometimes nucleated, and sometimes without nuclei, containing a few scattered fat-granules, and sometimes filled with fat. The free nuclei, more numerous than the cells, are round and slightly flattened, filled with homogeneous clear contents, and sometimes furnished with a nucleolus. The arterics form a plexus near the surface of the internal cavity, from which branches are sent into the lobules, and from the lobules into the smaller lobules and granules, the vessels always preserving their position at the internal part of the glandular wall, and terminating in a close capillary network.

When either gland is carefully unravelled by removing the areolar capsule and vessels, which retain the lobules in contact, the reservoir, from being folded in a serpentine manner upon itself, admits of being drawn out into a lengthened tubular *cord*,¹ around which the lobules are clustered in a spiral manner, and resemble knots on a cord, or a string of beads.

The *internal cavity*, or *reservoir*, which is most commonly a lengthened canal, but sometimes a space of moderate breadth, has a similar structure to the walls of the lobules, the external fibrous membrane being thicker and stronger, and the granular substance thinner, and provided with a plexus of large vessels. On its internal surface are seen the apertures or "*pores*" of the "*pouches*" and "*secretory cells*," each pore being surrounded by a vascular mesh, which forms a slightly prominent rim; but there is no epithelium, and nothing analogous in structure to a mucous membrane.

The *contents* of the cavity of the thymus are a whitish and milky albuminous fluid, slightly acid, and containing in suspension an abundance of *free nuclei*, with isolated *cells*, and when the gland is on the decline, certain peculiar bodies, first noticed by Hassall, and named *concentric corpuscles*. The free nuclei are globular and oval in form, uneven in outline, various in size, and provided with a small central nucleus. The concentric corpuscles, which appear with the decline of the gland, have a thick concentrically striated cell-membrane and granular contents, while others, much larger, consist of several of the former inclosed in a common envelop, also

FIG. 395.



COURSE AND TERMINATION OF THE "ABSORBENT DUCTS" OF THE THYMUS OF THE CALF; from one of Sir Astley Cooper's preparations. 1. Internal jugular veins. 2. Superior vena cava. 3. Thoracic duct, dividing into two branches, which reunite previously to their termination in the root of the left jugular vein. 4. The two thymic ducts; that on the left side opens into the thoracic duct, that on the right into the root of the right jugular vein.

¹ See Plates in Sir Astley Cooper's work.

concentrically striated. They are met with near the wall of the cavity, and probably result from some alteration of the elements of the granular substances associated with the degeneration of the gland. They are allied to the bodies termed *corpora amylacea*, found in the brain.

In the human fœtus, the thymic fluid was found by Sir Astley Cooper in too small proportion to be submitted to chemical analysis. But the thymic fluid of the fœtal calf, which exists in great abundance, gave the following analytical¹ results: one hundred parts of the fluid contained sixteen parts of solid matter, which consisted of, —

Incipient fibrine,
Albumen,
Mucous and muco-extractive matter,
Muriate and phosphate of potass,
Phosphate of soda,
Phosphoric acid, a trace.

The *Arteries* of the thymus gland are derived from the internal mammary, superior thyroid and inferior thyroid. The *Veins* terminate in the left vena innominata, and some small branches in the thyroid veins. The *Nerves* are minute, and derived chiefly, through the internal mammary plexus, from the superior thoracic ganglion of the sympathetic. Sir Astley Cooper also saw a branch from the junction of the pneumogastric and sympathetic pass to the side of the gland.

The *Lymphatics* terminate in the general union of the lymphatic vessels at the junction of the internal jugular and subclavian vein. Sir Astley Cooper injected them once only in the human fœtus, but in the calf he finds two large lymphatic ducts, which commence in the upper extremities of the glands, and pass downwards to terminate at the junction of the jugular and subclavian vein at each side. These vessels he considers to be the "*absorbent ducts* of the glands, '*thymic ducts*;' they are the carriers of the fluid from the thymus into the veins."

Sir Astley Cooper concludes his anatomical description of this gland with the following observations: — "As the thymus secretes all the parts of the blood, viz., albumen, fibrine, and particles, is it not probable that the gland is designed to prepare a fluid well fitted for the fœtal growth and nourishment from the blood of the mother, before the birth of the fœtus, and, consequently, before chyle is formed from food? — and this process continues for a short time after birth, the quantity of fluid secreted from the thymus gradually declining as that of chylification becomes perfectly established."

FÆTAL LUNGS.

The *Lungs*, previously to the act of inspiration, are dense and solid in structure, and of a deep red color. Their specific gravity is greater than water, in which they sink to the bottom; whereas lung which has respired will float upon that fluid. The specific gravity is, however, no test of the real weight of the lung, the respired lung being actually heavier than the fœtal. Thus the weight of the fœtal lung, at about the middle period of uterine life, is to the weight of the body as 1 to 60.² But, after respiration, the relative weight of the lung to the entire body is 1 to 30.

¹ This analysis was conducted by Dr. Dowler of Richmond.

² Cruveilhier, "Anatomie Descriptive," vol. ii. p. 621

FŒTAL HEART.

The *Heart* of the fœtus is large in proportion to the size of the body; it is also developed very early, representing at first a simple vessel, and undergoing various degrees of complication, until it arrives at the compound character which it presents after birth. The two ventricles form, at one period, a single cavity, which is afterwards divided into two by the septum ventriculorum. The two auricles communicate up to the moment of birth, the septum being incomplete, and leaving a large opening between them, the *foramen ovale* (foramen of Botal).¹

The *Ductus arteriosus* is another peculiarity of the fœtus connected with the heart; it is a communication between the left pulmonary artery and the arch of the aorta. It degenerates into a fibrous cord after birth, from the double cause, of a diversion in the current of the blood towards the lungs, and from the pressure of the left bronchus, caused by its distension with air.

VISCERA OF THE ABDOMEN.

At an early period of uterine life, and sometimes at the period of birth, as I have twice observed in the imperfectly-developed fœtus, two minute fibrous threads may be seen passing from the umbilicus to the mesentery. These are the remains of the omphalo-mesenteric vessels.

The *Omphalo-mesenteric* are the first developed vessels of the germ: they ramify on the vesicula umbilicalis, or yelk-bag, and supply the newly-formed alimentary canal of the embryo. From them, as from a centre, the general circulating system is produced. After the establishment of the placental circulation they cease to carry blood, and dwindle to the size of mere threads, which may be easily demonstrated in the early periods of uterine life; but are completely removed, excepting under peculiar circumstances, at a later period.

The *Alimentary canal* is developed from the inferior and middle layer of the germinal membrane; the former, producing the mucous membrane with its epithelium and glands; the latter, the muscular and serous coats, together with the vessels and nerves.

The *Stomach* is of small size, and the great extremity but little developed. It is also more vertical in direction the earlier it is examined, a position that would seem due to the enormous magnitude of the liver, and particularly of its left lobe.

The *Appendix vermiformis cæci* is long and of large size, and is continued directly from the central part of the cul-de-sac of the cæcum, of which it appears to be a constricted continuation. This is the character of the appendix cæci in the higher quadrumana.

The large intestines are filled with a dark green viscous secretion, called *meconium* (*μήκων*, poppy), from its resemblance to the inspissated juice of the poppy.

The *Pancreas* is comparatively larger in the fœtus than in the adult.

The *Spleen* is comparatively smaller in the fœtus than in the adult. It is developed at the end of the second month in the fœtal meso-gastrium, from the

¹ Leonard Botal, of Piedmont, was the first of the moderns who gave an account of this opening, in a work published in 1565. His description is very imperfect. The foramen was well known to Galen.

middle layer of the germinal membrane; it is somewhat lobulated at first, and whitish in color, but soon becomes red and abundant in vessels.

FŒTAL LIVER.

The *Liver* is the first formed organ in the embryo, consisting primarily of two small masses of cells, appertaining, the one to the epithelial, the other to the fibrous coat of the intestine. The cells rapidly increase in number, the epithelial cells forming solid cylinders which ramify and anastomose with each other, and finally constitute the secretory portion of the gland; the other cells, included within the network of the former, constituting the areolar and vascular structure of the organ. Subsequently the solid cylinders are hollowed in their interior, and form the biliary ducts. Dr. Handfield Jones considers the liver to take its origin independently of the intestine, namely, from the gall-bladder, which is at first solid, like the columns of cells above described, and gives off two branches, one to join the intestine, while the other is developed into the liver. At the third week the liver fills the whole abdomen, and is one-half the weight of the entire embryo. At the fourth month the liver is of immense size in proportion to the bulk of the fœtus. At birth, it is of very large size, and occupies the whole upper part of the abdomen. The left lobe is as large as the right, and the falciform ligament corresponds with the middle line of the body. The liver diminishes rapidly after birth, probably from obliteration of the umbilical vein.

KIDNEYS AND SUPRA-RENAL CAPSULES.

The *Kidneys* present a lobulated appearance in the fœtus, which is their permanent type among some animals, as the bear, the otter, and cetacea.

The *Supra-renal capsules* are organs which appear, from their early and considerable development, to belong especially to the economy of the fœtus. They are distinctly formed at the second month of embryonic life, and are greater in size and weight than the kidneys. At the third or fourth month, they are equalled in bulk by the kidneys; and at birth are about one-third less than those organs.

VISCERA OF THE PELVIS.

The *Bladder* in the fœtus is long and conical, and situated altogether above the upper border of the ossa pubis, which are as yet small and undeveloped. It is, indeed, an abdominal viscus, and is connected superiorly with a fibrous cord, called the *urachus*, of which it appears to be an expansion.

The *Urachus* is continued upwards to the umbilicus, and becomes connected with the umbilical cord. In animals it is a pervious duct, and is continuous with one of the membranes of the embryo, the *allantois*. It has been found pervious in the human fœtus; and the urine has been known to pass through the umbilicus. Calculous concretions have also been found in its course.

The *Uterus*, in the early periods of embryonic existence, appears bifid, from the large size of the Fallopian tubes, and the small development of the body of the organ. At the end of the fourth month, the body assumes a larger bulk, and the bifid appearance is lost. The cervix uteri in the fœtus is larger than the body of the organ.

The *Ovaries* are situated, like the testicles, in the lumbar region, near the kidneys, and descend from thence, gradually, into the pelvis.

TESTES.

The *Testicles* in the embryo are situated in the lumbar regions, immediately in front of and somewhat below the kidneys. They have, connected with them inferiorly, a peculiar structure, which assists in their descent, and is called the gubernaculum testis.

The *Gubernaculum* is a soft and conical cord, composed of areolar tissue, containing in its areolæ a gelatiniform fluid. In the abdomen it lies in front of the psoas muscle, and passes along the spermatic canal, which it serves to distend for the passage of the testis. It is attached by its superior and larger extremity to the lower end of the testis and epididymis, and by the inferior extremity to the bottom of the scrotum. The gubernaculum is surrounded by a thin layer of muscular fibres, the cremaster, which pass upwards upon this body to be attached to the testis. Inferiorly the muscular fibres divide into three processes, which, according to Curling,¹ are thus attached: "The external and broadest is connected to Poupart's ligament in the inguinal canal; the middle forms a lengthened band, which escapes at the external abdominal ring, and descends to the bottom of the scrotum, where it joins the dartos; the internal passes in the direction inwards, and has a firm attachment to the os pubis and sheath of the rectus muscle. Besides these a number of muscular fibres are reflected from the internal oblique on the front of the gubernaculum."

FIG. 396.

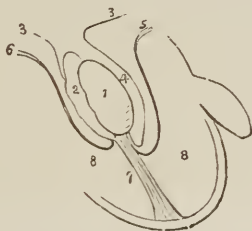


FIG. 397.

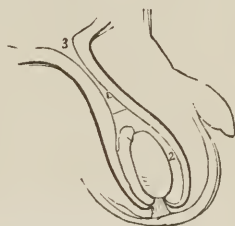


FIG. 396. — DIAGRAM ILLUSTRATING THE DESCENT OF THE TESTIS. 1. Testis. 2. Epididymis. 3, 3. Peritoneum. 4. Pouch formed around the testis by the peritoneum, the future cavity of the tunica vaginalis. 5. Pubic portion of the cremaster attached to the lower part of the testis. 6. Portion of the cremaster attached to Poupart's ligament. The mode of eversion of the cremaster is shown by these lines. 7. Gubernaculum attached to the bottom of the scrotum, and becoming shortened by the contraction of the muscular fibres which surround it. 8, 8. Cavity of the scrotum.

FIG. 397. — IN THIS FIGURE THE TESTIS HAS COMPLETED ITS DESCENT. The gubernaculum is shortened to its utmost, and the cremaster completely everted. The pouch of peritoneum above the testis is compressed so as to form a tubular canal, z. A dotted line marks the point at which the tunica vaginalis will terminate superiorly; and the figure 2 its cavity. 3. Peritoneal cavity.

The *Descent of the testicle* is gradual and progressive. Between the fifth and sixth month it has reached the lower part of the psoas muscle, and, during the

¹"On the Structure of the Gubernaculum," &c., by Mr. Curling, Lecturer on Morbid Anatomy in the London Hospital. *Lancet*, vol. ii. 1840-41, p. 70.

seventh, makes its way through the spermatic canal, and descends into the scrotum.

While situated in the lumbar region, the testis and gubernaculum are placed behind the peritoneum by which they are invested upon their anterior surface and sides. As they descend, the investing peritoneum is carried downwards with the testis into the scrotum, forming a lengthened pouch, which by its upper extremity opens into the cavity of the peritoneum. The upper part of this pouch, being compressed by the spermatic canal, is gradually obliterated, the obliteration extending downwards along the spermatic cord nearly to the testis. That portion of the peritoneum which immediately surrounds the testis is, by the above process, cut off from its continuity with the peritoneum, and is termed the tunica vaginalis; and as this membrane must be obviously a shut sac, one portion of it investing the testis, and the other being reflected so as to form a loose bag around it, its two portions have received the appellations of tunica vaginalis propria, and tunica vaginalis reflexa.

The descent of the testis is effected by means of the traction of the muscle of the gubernaculum, the cremaster. "The fibres," writes Mr. Curling, "proceeding from Poupart's ligament and the obliquus internus, tend to guide the gland into the inguinal canal; those attached to the os pubis, to draw it below the abdominal ring; and the process descending to the scrotum, to direct it to its final destination." During the descent, "the muscle of the testis is gradually everted, until, when the transition is completed, it forms a muscular envelope external to the process of peritoneum, which surrounds the gland and the front of the cord." "The mass composing the central part of the gubernaculum, which is so soft, lax, and yielding as in every way to facilitate these changes, becomes gradually diffused, and, after the arrival of the testicle in the scrotum, contributes to form the loose cellular tissue which afterwards exists so abundantly in this part." The attachment of the gubernaculum to the bottom of the scrotum is indicated throughout life by distinct traces.

INDEX.

A.

Abdomen, 515
 Abdominal regions, 516
 Abdominal ring, 214, 271
 Abductor oculi, 177
 Acervulus, 395
 Acetabulum, 116
 Acini, 524, 549
 Acromion, 105
 Adductor oculi, 176
 Adipose tissue, 135
 Air-cells, 512
 Albino, 469
 Alimentary canal, 520
 Allantois, 596
 Amphi-arthritis, 130
 Ampulla, 480
 Amygdalæ cerebelli, 395, 397
 faucium, 522
 Anastomosis, 282
 Andersch, notice of, 419
 Annulus abdominalis, 214, 271
 albidus, 465
 membranæ tympani, 66
 ovalis, 495 590
 Antihelix, 473
 Antitragus, 473
 Antrum of Highmore, 73
 pylori, 527
 Anus, 531
 Aorta, 286
 Aortic sinuses, 286, 500
 Aponeurosis, 135, 168
 Apophysis, 47
 Apparatus ligamentosus colli, 141
 Appendices epiploicæ, 520
 Appendix auriculæ, 494, 498
 vermiformis, 529, 595
 Aqua labyrinthi, 483
 Aquæductus cochleæ, 483
 Aquæductus vestibuli, 480
 Aqueduct of Sylvius, 394
 Aqueous humor, 467
 Arachnoid membrane, 386, 408
 Arantius, notice of, 497
 Arbor vitæ cerebelli, 398
 uterina 580
 Arch, femoral, 279
 palmar, superficial, 313
 plantar, 338
 Arciform fibres, 374, 401
 Arcus aortæ, 286
 cruralis, 214
 Areola, 586
 Areolar tissue, 134
 Arnold, Frederick, researches, 451

ARTERIES, 281

 general anatomy, 281
 structure, 283
 anastomotica brachialis, 310
 femoralis, 333
 angular, 292
 aorta, 286
 articulares genu, 334
 auditiva, 303
 auricular anterior, 295
 posterior, 294
 axillary, 307
 basilar, 303
 brachial, 310
 bronchial, 316, 514
 bulbo-urethralis, 327
 calcanean, 338
 capsulares, 322
 cardiacæ, 288, 344
 carotid common, 289
 external, 290
 internal, 298
 carpal radial, 311
 ulnar, 315
 cavernosi, 327
 centralis retinæ, 300, 468
 cerebellar, 304
 cerebral, 300, 304
 cervicalis ascendens, 306
 profunda, 307
 superficialis, 306
 choroidean, 301, 305
 ciliary, 300, 468
 circumflex femoris, 332
 humeri, 309
 ili, 323, 331
 coccygeal, 325
 cœliac, 317
 colic, 320, 322
 comes nervi ischiatici, 325
 comes nervi phrenici, 305
 communicans cerebri, 301
 coronaria cordis, 288
 labii, 293
 ventriculi, 317
 corporis bulbosi, 327
 cavernosi, 327
 cremasteric, 328
 crico-thyroid, 292
 cubitalis, 313
 cystic, 319
 dental, 297
 diaphragmaticæ, 317
 digitales manûs, 315
 pedis, 339
 dorsales pollicis, 313
 dorsalis hallucis, 336

ARTERIES — *continued.*

- dorsalis indicis, 313
 - linguæ, 292
 - nasi, 300
 - pedis, 335
 - penis, 327
- dorsalis scapulæ, 306, 309
- emulgent, 323
- epigastric, 328
 - superficial, 331
- ethmoidal, 300
- facial, 292
- femoral, 329
- frontal, 300
- gastric, 317, 320
- gastro-duodenalis, 318
- gastro-epiploica dextra, 318
 - sinistra, 320
- gluteal, 325, 327
- hæmorrhoidal, 322, 325, 326
 - external, 326
- helicine, 568
- hepatic, 317, 546, 550
- hypogastric, 324, 589
- ileo-colic, 320
- iliac, common, 323
 - external, 328
 - internal, 324
- ilio-lumbar, 327
- infra-orbital, 297
- innominata, 289
- intercostal, 316
 - anterior, 305
 - superior, 307
- interosseous, 315
- intestini tenuis, 320
- ischiatric, 325
- labial, 293
- lachrymal, 299
- laryngeal, 292
- lateralis nasi, 293
- lienalis, 319
- lingual, 292
- lumbar, 323
- magna pollicis, 336
- mallolar, 335
- mammary, 588
 - internal, 305
- masseteric, 297
- mastoid, 294
- maxillary internal, 295
- mediastinal, 305, 316
- meningeæ, anterior, 299, 385
 - inferior, 294, 385
 - media, 297, 385
 - parva, 297, 385
 - posterior, 294, 303, 385
- mesenteric, 320
 - inferior, 321
- metacarpal, 313, 315
- metatarsal, 336
- musculo-phrénic, 305
- nasal, 293, 297, 300, 460
- nutritia humeri, 311
 - tibiæ, 338
- obturator, 325
- occipital, 294

ARTERIES — *continued.*

- œsophageal, 316
- ophthalmic, 299
- orbital, 295
- ovarian, 320, 580
- palatina descendens, 298
 - inferior, 293
- palatina superior, 298
- palpebral, 300
- pancreatica magna, 319
- pancreaticæ parvæ, 319
- pancreatico-duodenalis, 319, 320
- parotidean, 294
- perforantes, femoral, 332
 - palmares, 313
 - plantares, 339
- pericardiac, 305, 316
- perineal superficial, 326
- peroneal, 337
- pharyngea ascendens, 294
- phrenic, 317
- plantar, 338
- popliteal, 333
- princeps cervicis, 294
 - pollicis, 313
- profunda cervicis, 307
 - femoris, 331
 - humeri, 310
 - penis, 327
- prostatic, 566
- pterygoid, 297, 298
- pterygo-palatine, 297
- pubic external, 331
 - internal, 326, 327
- pulmonary, 340, 514
- pyloric, 318
- radial, 311
- radialis indicis, 313
- ranine, 292
- recurrens interosseæ, 315
 - radialis, 312
 - tibialis, 335, 338
 - ulnaris, 314
- renal, 323, 560
- sacra lateralis, 327
 - media, 323
- scapular posterior, 306
- sigmoid, 322
- spermatic, 321, 328
- spheno-palatine, 297
- spinal, 303
- splenic, 319
- sterno-mastoid, 294
- stylo-mastoid, 294
- subclavian, 301
- sublingual, 292
- submaxillary, 293
- submental, 293
- subscapular, 309
- superficialis volæ, 312
- supraorbital, 299
- supra-renal, 322, 556
- supra-scapular, 306
- sural, 334
- tarsea, 336
- temporal, 295
- temporales profundæ, 297

ARTERIES — *continued.*

- thoracic, 308
 - thymic, 594
 - thyroidea ima, 289
 - inferior, 306
 - media, 289
 - superior, 292
 - tibialis antica, 334
 - postica, 337
 - transversa colli, 306
 - faciei, 295
 - humeri, 308
 - perinei, 327
 - scapulæ, 306
 - tympanic, 296, 299
 - ulnar, 313
 - umbilical, 324, 589
 - uterine, 325, 580
 - vaginal, 325
 - vasa brevia, 320
 - intestini tenuis, 320
 - vertebral, 303
 - vesical, 324, 564
 - Vidian, 298
- Arthrodia, 130, 151
- Articulations, 131, 136
- Arytenoid cartilages, 504
 - glands, 509
- Auricles of the heart, 494, 498
- Auriculo-ventricular openings, 496, 499
- Axis, cœliac, 317
 - thyroid, 306
- Axis-cylinder, 370

B.

- Bartholine's duct, 525
 - glands, 585
- Base of the brain, 398
- Bauhini, valvula, 532
- Bertini, columns of, 559
- Berzelius, analysis of bone, 41
- Biliary ducts, 550, 553
- Bladder, 562, 576, 596
- Blastema, 533
- BONES, asymmetrical, 42
 - azygos, 42
 - chemical composition, 41
 - corresponding, 42
 - development, 44
 - general anatomy, 41
 - lateral, 42
 - number of, 48
 - structure, 42
 - symmetrical, 42
- astragalus, 124
- atlas, 49
- axis, 50
- calcis, 124
- capitatum, 111
- carpus, 109
- clavicula, 102
- coccyx, 57
- costæ, 100
- coxæ, 113
- cuboides, 126
- cuneiforme carpi, 110

BONES — *continued.*

- cuneiforme tarsi externum, 125
 - internum, 126
 - medium, 128
- episternalia, 188
- ethmoides, 70
- femur, 119
- fibula, 122
- frontale, 61
- humerus, 105
- hyoides, 98
- ilium, 114
- innominatum, 113
- ischium, 115
- jugale, 76
- lachrymale, 75
- magnum, 111
- malare, 76
- maxillare inferius, 80
 - superius, 72
- metacarpus, 112
- metatarsus, 127
- multangulum majus, 110
 - minus, 110
- nasi, 72
- naviculare, 108, 125
- occipitale, 57
- orbiculare, 476
- palati, 77
- parietale, 60
- patella, 121
- phalanges manûs, 113
 - pedis, 128
- pisiforme, 110
- pubes, 115
- radius, 108
- sacrum, 55
- scaphoides carpi, 109
 - tarsi, 125
- scapula, 103
- semilunarc, 109
- sesamoidea manûs, 129
 - pedis, 129
- sphenoides, 67
- sternum, 99
- suprasternalia, 100, 187
- tali, 124
- tarsus, 124
- temporale, 63
- tibia, 121
- trapezium, 110
- trapezoides, 110
- triquetra, 82
- turbinatum inferius, 79
 - superius, 71
- tympanicum, 66
- ulna, 107
- unciforme, 111
- unguis, 75
- vertebra dentata, 50
 - prominens, 50
- vertebræ cervical, 49
 - dorsal, 51
 - lumbar, 51
- vomer, 79
- Wormiana, 82
- Total, foramen of, 595

- Botal, notice of, 595
 Brachia cerebri, 395
 Brain, 383
 sand, 395
 Bronchi, 509, 512
 Bronchial cells, 512
 tubes, 509, 512
 Bronchocele, 510
 Brunner's glands, 540
 Bulb, corpus spongiosum, 568
 Bulbi fornicis, 400
 Bulbous part of the urethra, 571
 Bulbus aortæ, 286
 olfactorius, 406
 rachidicus, 401
 venæ jugularis, 345
 Bursæ mucosæ, 136
- C.
- Cæcum, 529
 Calamus scriptorius, 396
 Calcigerous cells, 44
 Calices, 561
 Camper's ligament, 275
 Canal of Fontana, 465
 Nuck, 583
 Petit, 467, 468
 Sylvius, 394
 Canals of Havers, 43
 Canthi, 469
 Capillaries, 282, 285
 Capitula laryngis, 504
 Capsule of Glisson, 519, 547, 549
 Capsules, supra-renal, 556
 Caput coli, 529
 gallinaginis, 569
 Cardia, 527
 Carpus, 105, 112
 Cartilage, 45, 132
 interarticular of clavicle, 151
 interarticular of jaw, 143
 interarticular of wrist, 155
 semilunar, 161
 xiphoid, 100
 Cartilages, costal, 101, 146
 Cartilagification, 45
 Caruncula lachrymalis, 471
 mamillaris, 406
 sublingualis, 525
 Carunculæ myrtiformes, 585
 Casserian ganglion, 410
 Cauda equina, 404
 Cava, vena, 354
 Cells, bone, 44
 calcigerous, 44
 hepatic, 548
 Cellular tissue, 134
 Jementum, 93
 Centrum ovale, 388
 Cerebellum, 375, 396
 Cerebro-spinal axis, 368
 fluid, 386, 403
 Cerebrum, 376, 387
 Ceruminous glands, 475, 491
 Cervical ganglia, 453
 Chambers of the eye, 467
- Cheeks, 521
 Chemical elements, 28
 Chiasma nervorum opticum, 407
 Choanæ narium, 526
 Chorda ductus arteriosi, 340
 Chordæ longitudinales, 389
 tendineæ, 496, 500
 vocales, 506
 Willisii, 347
 Choroid membrane, 464
 plexus, 389, 392, 396
 Cilia, 471
 Ciliated epithelium, 534
 Ciliary canal, 465
 Ciliary ligament, 465
 processes, 465
 Circle of Willis, 305
 Circulation, adult, 281, 494
 fœtal, 589
 Circulus tonsillaris, 420
 venosus Halleri, 588
 Willisii, 305
 Clitoris, 584
 Clivus Blumenbachii, 66
 Cochlea, 481
 Cœliac axis, 317
 Colon, 580
 Colostrum, 587
 Columna nasi, 459
 Columnæ carneæ, 496, 500
 papillares, 497
 Columnar epithelium, 534
 Comedones, 459
 Commissures, 394
 great, 388
 Conarium, 395
 Concha, 473
 Congestion of the liver, 552
 Coni renales, 559
 vasculosi, 574
 Conjunctiva, 471
 Connective tissue, 134
 Conus arteriosus, 496
 Coracoid process, 105
 Corium, 486, 535
 Cornea, 462
 Cornicula laryngis, 504
 Cornu Ammonis, 391
 Cornua of the ventricles, 391
 Corona glandis, 567
 Coronæ tubulorum, 538
 Coronary valve, 495
 Corpora albicantia, 400
 Arantii, 497, 500
 cavernosa, 567
 geniculata, 393
 Malpighiana, 555, 559
 mamillaria, 400
 olivaria, 401
 pisiformia, 400
 pyramidalia, 373, 401
 quadrigemina, 395
 restiformia, 401
 striata, 389
 Corpus albicans, 583
 callosum, 377, 388
 cavernosum, 567

CORPUS — *continued.*

- ciliare, 465
- dentatum, 374, 379, 398, 401
- fimbriatum, 390, 392
- geniculatum, 393
- Highmorianum, 574
- luteum, 583
- nigrum, 583
- psaloides, 392
- rhomboideum, 398
- spongiosum, 568
- striatum, 389
- Corpuscles of Purkinje, 42
- Corpuscula amylacea, 396
 - tactus, 487, 489
- Costal cartilages, 101
- Cotunnus, notice of, 481
- Cotyloid cavity, 116
- Cowper's glands, 571
- Cranial nerves, 405
- Cranium, 83
 - area of, 89
- Cribriform fascia, 279
- Cricoid cartilage, 504
- Crico-thyroid membrane, 505
- Crura cerebelli, 398, 401
 - cerebri, 400
 - diaphragmatis, 218
 - penis, 567
- Crural canal, 279
 - ring, 279
- Cryptæ mucosæ, 537
- Crystalline lens, 468
- Cumulus proligerus, 583
- Cuneiform cartilages, 504
- Cupola, 482
- Curling, researches of, 597
- Cuticle, 487
- Cutis, 486
- Cystic duct, 553
- Cytoblast, 33, 487

D.

- Dartos, 572
- Derbyshire neck, 510
- Derma, 486
- Detrusor urinæ, 564
- Diaphragm, 218
- Diaphysis, 47
- Diarthrosis, 130
- Digital cavity, 391
- Dorsi-spinal veins, 356
- Ductus ad nasum, 473
 - arteriosus, 589, 595
 - Bartholini, 525
 - communis choledochus, 553
 - cysticus, 553
 - ejaculatorius, 566, 576
 - galactophorus, 586
 - hepaticus, 553
 - lactiferus, 587
 - lymphaticus dexter, 368
 - pancreaticus, 554
 - prostaticus, 565, 569
 - Riviniani, 525
 - Stenonis, 525

DUCTUS — *continued.*

- thoracicus, 367
- thymic, 594
- venosus, 589
- Duodenum, 528
- Dura mater, 383, 403

E

- Ear, 473, 591
- Ejaculatory duct, 566, 576
- Elastic tissue, 131, 283
- Ellis, researches of, 564, 565
- Enamel, 93
- Enarthrosis, 130
- Encephalon, 383
- Endocardium, 502
- Endolymph, 483
- Ensiform cartilage, 100
- Entozoon folliculorum, 491
- Ependyma ventriculorum, 396
- Epidermis, 487
- Epididymis, 573, 574
- Epigastric region, 516
- Epiglottic gland, 509
- Epiglottis, 504
- Epiglottic-hyoidean ligament, 506
- Epiphysis, 47
- Epithelium, 533
- Erectile tissue, 568
- Eustachian tube, 447, 526
 - valve, 495
- Eustachius, notice of, 495
- Eye, 462, 591
- Eyebrows, 469
- Eyelashes, 471
- Eyelids, 469

F.

- Falciform process, 278
- Fallopian tubes, 581
- Fallopian, notice of, 581
- Falx cerebelli, 384
 - cerebri, 384
- FASCIA, general anatomy of, 268
 - abdominal, 270
 - anal, 275
 - antibrachial, 277
 - brachial, 276
 - cervical, 269
 - Cooperi, 271
 - costo-clavicular, 270
 - cribriform, 279
 - cruralis, 280
 - dentata, 392
 - iliaca, 273
 - intercolumnar, 214, 271
 - ischio-pubica, 275
 - ischio-rectal, 275
 - lata, 277
 - lumbar, 216
 - lumbo-dorsalis, 202
 - manus dorsalis, 277
 - obturator, 275
 - ocular, 178
 - palmar, 277

- FASCIA — *continued*
 parotid, 269
 pelvica, 273
 perincal, 275, 276
 plantar, 281
 popliteal, 280
 propria, 280
 recto-vesical, 274
 spermatica, 214, 572
 supra-hyoidean, 189, 270
 temporal, 269
 thoracic, 270
 transversalis, 271
- Fasciculi cuneati, 374
 graciles, 374, 402
 innominati, 374, 396, 402
 siliquæ, 374, 401
 teretes, 396, 402
- Fasciolæ cinereæ, 396
- Fauces, 522
- Femoral arch, 279
 canal, 279
 hernia, 280
 ring, 279
- Fenestra ovalis, 477
 rotunda, 477
- Fenestrated membrane, 135, 284
- Ferrein, pyramids of, 559
- Fibræ arciformes, 374, 401
- Fibres of the heart, 500
- Fibrous cartilage, 133
 interarticular of the clavicle, 151
 jaw, 143
 knee, 161
 wrist, 155
- Fibro-cellular tissue, 134
- Fibrous tissue, 134
- Filamentous tissue, 36, 134
- Filum terminale, 403
- Fimbriæ, Fallopiæ, 581
- Fissure of Bichât, 388
 longitudinal, 398
 of Sylvius, 387, 399
 transverse, 400
- Fissures of the spinal cord, 404
- Flocculus, 397
- Fœtal circulation, 589
- Fœtus, anatomy of, 588
- Follicles, structure of, 523
- Follicles of Lieberkuhn, 537
- Follicular glands, 523
- Fontana, notice of, 465
- Fontanel, anterior, 62
 posterior, 59
- Foramen, of Botal, 595
 cæcum, 62, 401, 485
 commune anterius, 392, 394
 posterius, 394
 Monro, of, 389, 392, 394
 obturator, 116
 ovale, 589, 595
 saphenum, 278
 Soemmering, of, 467
 thyroid, 116
 Winslow of, 519
- Foramina Thebesii, 494
- Forceps cerebri, 404
- Fornix, 377, 392
- Fossa innominata, 473
 ischio-rectalis, 275
 navicularis urethræ, 571
 pudendi, 584
 ovalis, 495
 scaphoidea, 473
- Fovea ovalis, 278
 poplitea, 278
- Fourchette, 584
- Fræna epiglottidis, 484, 506, 522
- Frænulum labiorum, 584
 veli medullaris, 396
- Frænulum labii, 521
 linguæ, 484, 521
 præputii, 567
- Funiculi graciles, 374, 402
 siliquæ, 373, 401
- Funiculus olivaris, 373
- G.
- Galea aponeurotica, 178
 capitis, 173
- Galen, 281
- Gall-bladder, 552
- Ganglia, cerebrum, of the, 393
 cervical, 453
 lumbar, 458
 sacral, 458
 semilunar, 457
 structure of, 379, 382
 thoracic, 456
- Ganglion of Andersch, 410
 Arnold's, 451
 azygos, 458
 cardiac, 455
 carotid, 452
 Casserian, 410
 ciliary, 449
 Cloquet's, 451
 diaphragmatic, 457
 geniculare, 417
 impar, 458
 jugular, 419, 421
 lenticular, 449
 Meckel's, 450
 Müller's, 419
 naso-palatine, 451
 ophthalmic, 449
 otic, 451
 petrous, 419
 Ribes, of, 452
 semilunar, 457
 spheno-palatine, 450
 submaxillary, 452
 thyroid, 353
 vertebral, 453
- Ganglion-cells, 379
- Gastro-colic omentum, 519
- Gastro-hepatic omentum, 519
- Gastro-splenic omentum, 520
- Genu corporis callosi, 388, 398
- Germinal disk, 583
 eminence, 583
 vesicle, 583

- Gimbernat's ligament, 214
 Ginglymus, 130
 Gland, epiglottic, 509
 pineal, 395
 pituitary, 376, 400
 prostate, 565
 thymus, 591
 thyroid, 510, 591.
 Glands, absorbent, 361
 aggregate, 539
 arytenoid, 509
 Bartholini, 585
 bronchial, 514
 Brunner's, 540
 ceruminous, 475
 concatenatæ, 362
 conglobate, 361
 Cowper's, 571
 duodenal, 540
 follicular, 523, 538
 gastric, 537
 inguinal, 363
 lachrymal, 471
 lenticular, 538
 Lieberkuhn's, 537
 lingual, 485, 523
 lobulated, 524, 539
 lymphatic, 359
 mammary, 586
 mesenteric, 366
 Meibomian, 471
 muciparous, 540
 odoriferæ, 567
 oesophageal, 540
 Pacchionian, 347, 384
 parotid, 524
 pepsiniferous, 537
 Peyer's, 539
 pharyngeal, 540
 racemose, 524, 539
 saccular, 538
 salivary, 524
 sebiparous, 490
 solitary, 538
 sublingual, 525
 submaxillary, 525
 sudoriparous, 491
 tracheal, 510
 tubular, 537
 uterine, 580
 vesicular, 538
 Glandulæ odoriferæ, 567
 Pacchioni, 347, 384
 Tysoni, 567
 Glandular vesicles, 524
 Glans clitoridis, 585
 penis, 567
 Glenoid cavity, 104
 Glisson, notice of, 519
 Glisson's capsule, 519, 549
 Globus major epididymis, 573
 minor epididymis, 573
 Glomeruli, 560
 Glottis, 508
 Goodsir, researches of, 94
 Goitre, 510
 Gomphosis, 130
 Graafian vesicles, 582
 Gubernaculum testis, 597
 Gums, 521
 Gyri operati, 399
 Gyurus fornicatus, 388, 391

H.

 Hair, 489
 Harmonia, 82, 129
 Haversian canals, 43
 Heart, 492, 595
 Helicine arteries, 568
 Helicotrema, 482
 Helix, 473
 Hemispheres, cerebral, 376, 387
 cerebellar, 375, 397
 Hepatic cells, 548
 duct, 550, 553
 Hernia, congenital, 272
 diaphragmatic, 218
 direct, 273
 encysted, 273
 femoral, 280
 infantilis, 273
 inguinal, 271
 scrotal, 273
 Hewson on ocular muscles and fascia, 178
 Highmore, notice of, 574
 Hilton's muscle, 507
 Hilum lienis, 554
 renale, 558
 Hippocampus major, 391
 minor, 391
 Histology, 32
 Horner's muscle, 175
 Humors of the eye, 467
 Hyaloid membrane, 467
 Hymen, 585
 Hypochondriac regions, 516
 Hypogastric region, 516
 Hypophysis cerebri, 400

I.

 Ileo-cæcal valve, 532
 Ileo-colic valve, 532
 Ileum, 528
 Iliac regions, 516
 Immediate principles, 28
 Incus, 476
 Infundibula, 561
 Infundibulum, 400, 496
 Inguinal canal, 271
 region, 516
 Inosculation, 282
 Inscriptioes tendineæ, 217
 Interarticular cartilages of the clavicle, 151
 jaw, 143
 knee, 161
 wrist, 155
 Intercolumnar fibres, 214
 Intervertebral substance, 138
 Intestinal canal, 528
 Intestine, large, 542
 small, 542
 Intumescencia gangliformis, 417

Iris, 465
 Isthmus of the fauces, 522
 Iter ad infundibulum, 394
 ad quartum ventriculum, 394

J.

Jacob's membrane, 466
 Jejunum, 528
 Joint, ankle, 164
 elbow, 153
 hip, 159
 lower jaw, 142
 knee, 160
 shoulder, 152
 wrist, 155
 Jones, Wharton, researches of, 483

K.

Kidneys, 558, 596
 Krause, researches of, 226, 574

L.

Labia majora, 584
 minora, 584
 Labyrinth, 479, 483
 Lachrymal canals, 472
 gland, 471
 papillæ, 469, 472
 puncta, 469, 472
 sac, 472
 tubercles, 469, 472
 Lacteals, 360, 366
 Lacunæ, 571
 Lacus lachrymalis, 469
 Lamina cinerea, 399
 cribrosa, 279, 462
 spiralis, 481
 Laqueus, 374, 395
 Laryngotomy, 505
 Larynx, 503
 Lateral ventricles, 396
 Lauth, researches of, 574
 Lee, Dr., researches of, 580
 Lens, 468
 Lenticular ganglion, 449
 Levers, 232, 259
 Lieberkuhn's follicles, 537
 Lien succenturiatus, 554
 Ligament, 134
 LIGAMENTS, 129, 134
 accessory, 145
 acromio-clavicular, 151
 alar, 141, 162
 ankle, of the, 164
 annular, of the ankle, 280
 radius, 154
 wrist, anterior, 157
 posterior, 277
 apicum, 139
 arcuatum externum, 220
 internum, 220
 arteriosum, 340
 astragalo-scaploid, 165

LIGAMENTS — *continued.*

atlo-axoid, 141
 bladder, of the, 274, 562
 brachio-cubitale, 153
 radiale, 153
 breve plantæ, 166
 calcaneo-astragaloid, 165
 cuboid, 165
 scaphoid, 165
 Camper's, 275
 capsular of the hip, 159
 jaw, 143
 rib, 144
 shoulder, 152
 thumb, 157
 carpal, 156
 carpi volare, 156
 carpo-metacarpal, 157
 common anterior, 137
 posterior, 138
 condylo-atloid, 140
 conoid, 151
 coracoid, 152
 coraco-acromial, 152
 clavicular, 151
 humeral, 152
 coronale, 154
 coronary, 154
 of the knee, 161
 corruscantia, 147
 costo-clavicular, 151
 coracoid, 270
 sternal, 145
 transverse, 144
 vertebral, 144
 xyphoid, 147
 cotyloid, 159
 crico-thyroidean, 505
 crucial, 161
 cruciatum, 280
 cruciform, 142, 280
 deltoid, 164
 dentatum, 403
 elbow, of the, 153
 Fallopii, 214
 fundiforme, 280
 Gimbernât's, 214
 glenoid, 152
 glosso-epiglottic, 506
 hip-joint, of the, 159
 hyo-epiglottic, 506
 ilio-femoral, 159
 ilio-lumbar, 147
 interarticular of ribs, 144
 inter-clavicular, 150
 intermuscular, 276, 278
 interosseous calcaneo-astragaloid, 163
 carpal, 156
 peroneo-tibial, 163
 radio-ular, 154
 interspinous, 139
 intertransverse, 139
 intervertebral, 138
 jaw, of the, 142
 knee, of the, 160
 laciniatum, 280
 larynx, of the, 505

LIGAMENTS — *continued.*

- lateral, of the ankle, 164
 - elbow, 153
 - jaw, 142
 - knee, 160
 - phalanges, foot, 167
 - phalanges, hand, 158
 - wrist, 156
- liver, of the, 518, 544
- longum plantæ, 166
- lumbo-iliac, 147
- lumbo-sacral, 147
- metacarpal, 157
- metatarsal, 167
- mucosum, 162
- nuchæ, 200
- oblique, 154
- obturator, 150
- occipito-atloid, 140
 - axoid, 141
- odontoid, 141
- orbicular, 154
- palpebral, 470
- patellæ, 160
- perineal, 275
- peroneo-tibial, 163
- phalanges, of the foot, 167
- phalanges of the hand, 158
- plantar, long, 166
 - short, 166
- posticum Winslowii, 160
- Poupart's, 214
- processuum obliquorum, 139
- pterygo-maxillary, 184, 194
- pubic, 149
- pubio-vesicale, 275
- radio-ulnar, 154
- rhomboid, 151
- rotunda uteri, 583
- rotundum, hepatis, 545
- sacro-coccygean, 149
- sacro-iliac, 148
- sacro-ischiatic, 148
- sacro-vertebral, 147
- spheno-maxillary, 142
- stellate, 144
- sternal, 147
- sterno-clavicular, 150
- sterno-xyphoid, 147
- stylo-maxillary, 143, 270
- subflava, 139
- sub-pubic, 149
- supra-scapular, 152
- supraspinous, 139
- supensorium
 - dentis, 141
 - hepatis, 544
 - penis, 567
- tarsal, 165
- tarsometatarsal, 167
- teres, 154, 159
- thyro-arytenoid, 505
- thyro-epiglottic, 506
- thyro-hyoidean, 505
- tibio-fibular, 163
- transverse of the acetabulum, 159
 - ankle, 164
 - atlas, 141

LIGAMENTS — *continued.*

- transverse of the knee, 161
 - metacarpus, 157
 - metatarsus, 167
 - scapula, 152
 - semilunar cartilages, 161
- trapezoid, 151
- triangular, 153, 275
- tympanum, of the, 475
- uterus, of the, 578, 584
- vaginal, 158
- wrist, of the, 155
- Zinn, of, 176
- Ligamentum nuchæ, 200
- Limbus luteus, 467
- Linea alba, 213
- Lineæ semilunares, 213
 - transversæ, 214, 389, 396
- Linguetta laminosa, 396
- Lips, 521
- Liquor Cotunnii, 483
 - Morgagni, 468
 - Scarpa, of, 483
- Littre, glands of, 577
- Liver, 543, 596
- Lobules of the liver, 547
- Lobuli testis, 574
- Lobulus auris, 473
- Lobulus pneumogastricus, 397
- Lobus caudatus, 546
 - quadratus, 546
 - Spigelii, 546
- Locus niger, 400
 - perforatus, 399, 400
- Lower, notice of, 496
- Lumbar fascia, 217
 - regions, 516
- Lungs, 511, 594
- Lunula, 489, 497
- Lymphatic glands and vessels, 359
 - axillary, 363
 - bronchial, 365
 - cardiac, 365
 - cervical, 362
 - concatenatæ, 362
 - head and neck, 362
 - heart, 365
 - iliac, 365
 - inguinal, 363
 - intestines, 366
 - kidneys, 366, 561
 - lacteals, 360, 366
 - liver, 366
 - lower extremity, 363
 - lungs, 365, 514
 - mammary, 365, 588
 - mediastinal, 364
 - mesenteric, 366
 - pancreas, 366
 - pelvic viscera, 367
 - popliteal, 364
 - spleen, 366
 - stomach, 366
 - testicle, 367
 - thymic, 594
 - trunk, 364

LYMPHATICS—*continued.*

- upper extremity, 363
- uterus, of the, 580
- viscera, 365

Lyra, 392

M

- Malleus, 475
- Malpighian corpuscles, 555, 559
 - glomeruli, 559
 - pyramids, 559
- Mammæ, 586
- Mammary gland, 586
- Mastoid cells, 477
- Matrix, 489
- Maxillo-pharyngeal space, 194
- Meatus auditorius, 64, 475
 - urinarius, female, 576, 585
 - male, 567
- Meatuses of the nares, 91, 461
- Meckel's ganglion, 450
- Meconium, 595
- Mediastinum, 514
 - testis, 574
- Medulla of bones, 44
 - innominata, 399
 - oblongata, 374, 401
- Medullary membrane, 44
- Meibomian glands, 471
- Meibomius, notice of, 471
- Membrana dentata, 403
 - fusca, 464
 - interossea, 154, 163
 - nictitans, 471
 - pigmenti, 465
 - pupillaris, 591
 - sacciformis, 155
 - tympani, 475
- Membrane, choroid, 464
 - hyaloid, 467
 - Jacob's, 466
 - of the ventricles, 396
- Membranous urethra, 570
- Meniscus, 133
- Mesenteric glands, 366
- Mesentery, 520
- Meso-colon, 519
- Meso-rectum, 520
- Metacarpus, 112
- Metatarsus, 127
- Milk, secretion of, 587
- Mitral valves, 499
- Modiolus, 481
- Mons Veneris, 584
- Morgagni, notice of, 468
- Morsus diaboli, 581
- Mouth, 521
- Mucous membrane, structure, 531
- MUSCLES, actions of, 213, 221, 245, 266
 - general anatomy of, 168
 - development, 172
 - structure, 169
 - abdomen, of the, 213
 - abductor indicis, 245
 - minimi digiti, 243, 263
 - oculi, 177

MUSCLES—*continued.*

- abductor pollicis, 241, 242, 263
- accelerator urinæ, 223
- accessorii, 181
- accessorius, 204, 264
- adductor brevis, 254
 - longus, 254
 - magnus, 254
 - minimi digiti, 243
 - oculi, 176
 - pollicis, 243, 265
- alveolo-labialis, 184
- anconeus, 240
- anomalus, 180
- anterior auriculæ, 185
- antitragicus, 475
- arytenoideus, 506
- aryteno-epiglottideus, 507
- attollens aurem, 185
 - humeri, 232
 - oculi, 176
- atrahens aurem, 185
- auricularis, 239
- azygos uvulæ, 195
- back, of the, 198
- basio-glossus, 191
- biceps flexor cruris, 255
 - cubiti, 233
- bicipites, 244, 262
- biventer cervicis, 205
- brachialis anticus, 233
- brachio-radialis, 238
- broncho-œsophagealis, 541
- buccinator, 184
- bulbo-cavernosus, 223
- caninus, 181
- cerato-glossus, 191
- cervicalis ascendens, 204
 - descendens, 204
- cervico-mastoideus, 202
- chondro-glossus, 191
- ciliaris, 175
- circumflexus palati, 195
- cleido-mastoideus, 187
- coccygeus, 225
- complexus, 204
 - parvus, 204
- compressor naris, 180
 - urethræ, 224
 - vesiculæ seminalis, 566
- constrictor isthmi faucium, 192, 196
 - pharyngis, 193
 - urethræ, 224
 - vaginæ, 225
- coraco-brachialis, 232
- corrugator supercillii, 175
- costo-abdominalis, 214
- clavicularis, 229
- coracoideus, 229
- scapularis, 229
- trachelius, 197
- cremaster, 216
- crico-arytenoideus lateralis, 506
 - posticus, 506
- crico-thyroideus, 506
- crotaphytes, 183
- crureus, 252

MUSCLES—*continued.*

- cubito-radialis, 238
- cucullaris, 199
- curvator coccygis, 225
- deltoid, 232
- depressor alæ nasi, 180
 - anguli oris, 182
 - labii inferioris, 182
 - oculi, 176
- detrusor urinæ, 564
- diaphragma, 218
- digastricus, 190
- dilatator conchæ, 475
 - naris, 180
 - pharyngis, 194
- dorso-costalis, 202
- dorso-scapularis, 201
- dorso-trachelius, 202
- epicranius, 173
- erector clitoridis, 226
 - penis, 223
 - spinæ, 203
- extensor carpi radialis, 239
 - carpi ulnaris, 239
 - coccygis, 207
 - cruris, ext. et int., 252
 - digiti minimi, 239
 - digit. rum brevis, 262
 - communis, 239
 - longus, 257
 - indicis, 241
 - ossis metacarpi, 241
 - pollicis internodii, 241
 - proprius, 258
- face, of the, 172
- fidicini, 245
- flexor accessorius, 264
 - brevis digiti min., 243, 265
 - carpi radialis, 235
 - ulnaris, 236
- digitorum brevis, 263
 - profundus, 237
 - sublimis, 236
- longus digitorum pedis, 260
 - pollicis, 237, 260
- ossis metacarpi, 242
- pollicis brevis, 243, 265
 - longus, 237, 260
- frontalis, 173
- gastrocnemius, 258
- gemellus, 250
- genio-hyo-glossus, 191
- genio-hyoideus, 190
- gluteus maximus, 248
 - medius, 249
 - minimus, 249
- gracilis, 255
- helicis major, 474
 - minor, 475
- humero-cubitalis, 233
- hyo-glossus, 191
- iliacus internus, 257
- ilio-abdominalis, 214
- ilio-costalis, 203, 218
- incisorius, 181
- indicator, 241
- infracostales, 212

MUSCLES—*continued.*

- infra-spinatus, 230
- interaccessorii, 208
- intercostales, 212
- inter-obliqui, 208
- interossei, 244, 262, 265
- interspinales, 207
- intertransversales, 207
- infracostales, 212
- ischio-cavernosus, 223
- larynx, of the, 506
- latissimus colli, 187
- latissimus dorsi, 200
- laxator tympani, 477
- levator alæ nasi, 180
 - anguli oris, 181
 - scapula, 201
- ani, 225
- glandulæ thyroideæ, 510
- labii inferioris, 183
 - superioris, 181
- menti, 183
- palati, 195
- palpebræ, 176
- pharyngis, 194
- prostatæ, 563
- levatores costarum, 208
- lingualis, 192
- longissimus dorsi, 203
- longus colli, 197
- lower extremity, 247
- lumbo-abdominalis, 216
- lumbo-costalis, 202
- lumbricales, 244, 264
- mallei externus, 477
 - internus, 477
- masseter, 183
- multifidus spinæ, 207
- mylo-hyoideus, 190
- myrtiformis, 180
- naso-labialis, 181
- nauticus, 260
- neck, of the, 186
- nutator capitis, 187
- obliquus abdominis, 214
 - auris, 475
 - capitis, 206
 - oculi, 177
- obturator, 250
- occipitalis, 173
- occipito-frontalis, 173
- omo-hyoideus, 189
- opponens digiti minimi, 243
 - pollicis, 242
- orbicularis oris, 181
 - palpebrarum, 174
 - urethræ, 565
- palato-glossus, 192, 196
- palato-pharyngeus, 196
- palmaris brevis, 243
 - longus, 235
- palpebralis, 174
- patientiæ, 201
- pectineus, 254
- pectoralis major, 228
 - minor, 229
- perineum, of the, 222

MUSCLES — *continued.*

- peroneus brevis, 261
 longus, 261
 tertius, 258
- pharynx, of the, 193
- plantaris, 259
- platysma myoides, 187
- pleuro-oesophagealis, 541
- popliteus, 259
- posterior auriculæ, 185
- prædorso-atloideus, 197
- procerus, 179
- pronator quadratus, 238
 radii teres, 235
- psaos magnus, 253
 parvus, 218
- pterygoideus, 184
- pubio-subumbilicalis, 218
- pyramidalis abdominis, 218
 labii, 181
 nasi, 179
- pyriformis, 249
- quadratus femoris, 250
 lumborum, 218
 menti, 182
- quadriceps femoris, 253
- rectus abdominis, 217
 capitis anticus major, 196
 minor, 196
 lateralis, 206
 posticus major, 206
 minor, 206
- femoris, 252
- oculi externus, 177
 inferior, 176
 internus, 176
 superior, 176
- retrahens aurem, 185
- rhomboideus faciei, 180
 major et minor, 201
- risorius Santorini, 182, 187
- rotatores dorsi, 207
- sacro-coccygeus anticus, 226
 posticus, 207
- femorals, 248
 lumbalis, 203
- salpingo-pharyngeus, 194
- sartorius, 251
- scalenus anticus, 197
 medius, 197
 posticus, 197
- semi-spinalis dorsi et colli, 206
 membranosus, 256
 tendinosus, 256
- serratus magnus, 229
 posticus, 202
- soleus, 259
- sphincter ani, 224
 urethræ, 565
 vaginæ, 225
 vesicæ, 564
- spinalis cervicis, 206
 dorsi, 204
- splenius, 202
- stapedius, 477
- sterno-costalis, 212
 humeralis, 228

MUSCLES — *continued.*

- sterno-hyoideus, 188
 mastoideus, 187
 pubius, 217
 thyroideus, 188
- stylo-auricularis, 192
 glossus, 192
 hyoideus, 190
 pharyngeus, 194
- sub-acromio-humeralis, 232
- subclavius, 229
- subcostales, 212
- suberureus, 253
- subcutaneus colli, 187
- subscapularis, 230
- superior auriculæ, 185
- supinator brevis, 240
 longus, 238
- supra-costales, 208
- supra-spinatus, 230
- temporalis, 183
- tensor palati, 195
 tarsi, 175
 tympani, 477
 vaginæ femoris, 251
- teres major, 231
 minor, 231
- thoraco-facialis, 187
- thorax, of the, 212
- thyro-arytenoideus, 506
 epiglottideus, 507
 hyoideus, 189
- tibialis anticus, 257
 posticus, 260
- tongue, extrinsic, of the, 191
- trachelo-mastoideus, 205
 occipitalis, 205
 scapularis, 201
 suboccipitalis, 196
- tragicus, 475
- transversalis abdominis, 216
 cervicis, 205
 colli anterior, 198
- transversus auriculæ, 475
 nasi, 180
 pedis, 265
 perinei, 223, 226
- trapezius, 199
- triangularis oris, 182
 sterni, 212
- triceps brachii, 234
 extensor cruris, 252
 cubiti, 234
 suræ, 259
- trochlearis, 177
- upper extremity, of the, 227
- ureters, of the, 564
- vastus externus, 252
 internus, 252
- Wilson's, 224
- zygomaticus, 181
- Muscular fibre, 169
- Musculi pectinati, 496
- Myolemma, 169
- Myoline, 170
- Myopia, 468

N.

Naboth, ovula of, 580
 Nails, 489
 Nares, 90, 460, 526
 Nasal duct, 473
 fossæ, 90, 460
 Nasmyth, researches of, 93
 Nates cerebri, 395
 Nerve-cells, 370
 fibres, 369
 NERVES, general anatomy, 368
 abducentes, 416
 accessorius, 423
 acromiales, 427
 auditory, 419, 484
 auricularis inferior, 415
 magnus, 427
 posterior, 417
 superior, 415
 vagi, 421
 auriculo-temporal, 415
 brachial, 431
 buccal, 414, 418
 cardiac, 421, 503
 carotid, 420, 451
 cervical, 426
 cervico-facial, 418
 chorda tympani, 417, 479
 ciliary, 411, 449, 468
 circumflex, 435
 claviculares, 427
 coccygeal, 444
 cochlear, 419, 484
 communicans noni, 424, 428
 peronei, 448
 poplitei, 446
 tibialis, 446
 cranial, 405
 crural, 441
 cutaneus externus, brachialis, 431
 femoralis, 440
 internus, brachialis, 431
 femoralis, 442
 medius, femoralis, 441
 patellæ, 442
 spiralis, 434
 dental, 413, 415
 descendens noni, 424
 digastric, 418
 dorsal, 436
 dorsalis penis, 445
 eighth pair, 419
 eleventh pair, 423
 facial, 416
 femoral, 441
 fifth pair, 410
 first pair, 406
 fourth pair, 408
 frontal, 410
 gastric, 422
 genito-crural, 539
 glosso-pharyngeal, 419, 485
 gluteal, 444
 inferior, 445
 gustatory, 415, 485
 hæmorrhoidal, 443, 445

NERVES — *continued.*

hypoglossal, 423, 485
 ilio-inguinal, 439
 ilio-hypogastric, 439
 inferior maxillary, 414
 infra-maxillary, 419
 infraorbital, 418
 infra-trochlear, 412
 inguino-cutaneous, 440
 intercostal, 436
 intercosto-humeral, 438
 interosseous anterior, 433
 cruris, 448
 posterior, 435
 ischiaticus major, 446
 minor, 445
 Jacobson's, 420, 479
 labial, 415
 lachrymal, 411
 laryngeal inferior, 422, 509
 recurrent, 422, 509
 superior, 421, 509
 lingual, 420, 485
 lumbar, 438
 lumbo-inguinal, 440
 lumbo-sacral, 443
 malar, 413, 418
 mammæ, 588
 masseteric, 414
 maxillaris inferior, 414
 superior, 413
 median, 432
 mental, 415
 molles, 453
 motores oculorum, 407
 musculo-cutaneous, arm, 431
 leg, 440, 448
 musculo-spiral, 434
 mylo-hyoidean, 415
 nasal, 411, 451, 461
 naso-ciliaris, 411
 naso-palatine, 451
 ninth pair, 419, 423
 obturator, 440
 occipitalis major, 429
 minor, 427
 œsophageal, 422
 olfactory, 406
 ophthalmic, 410
 optic, 407
 orbital, 413
 palatine, 451
 palmar, 433, 434
 par vagum, 420
 pathetici, 408
 perforans Casserii, 431
 perineal, 445
 peroneal, 448
 petrosal, 451
 pharyngeal, 420, 421
 phrenic, 428
 plantar, 447
 pneumogastric, 420
 popliteal, 446, 448
 portio dura, 416
 intermedia, 416
 mollis, 419

NERVES — *continued.*

pterygoid, 414, 451
 pudendalis inferior, 445
 pudendus externus, 440
 pudic, 445
 pulmonary, 422
 radial, 435
 recurrent, 422
 renal, 457, 561
 respiratory external, 430
 internal, 428
 rhomboid, 430
 sacral, 443
 saphenous external, 446
 long or internal, 442
 short, 446
 second pair, 407
 seventh pair, 416
 sixth pair, 416
 spermatic, 440
 spheno-palatine, 413, 450
 spinal, 425
 spinal accessory, 423
 splanchnic, 456
 sternal, 427
 stylo-hyoid, 417
 subclavian, 430
 subcutanei colli, 419
 subcutaneus malæ, 413
 sub-occipital, 426
 subrufi, 453
 subscapular, 431
 superficialis colli, 427
 cordis, 455
 superior maxillary, 413
 supra-maxillary, 419
 supraorbital, 410
 supra-scapular, 431
 supra-trochlear, 411
 sympathetic major, 381, 449
 minor, 417
 temporal, 413, 414, 415, 418
 temporo-facial, 418
 temporo-malar, 413
 tenth pair, 420
 third pair, 407
 thoracic, 430
 thyro-hyoidean, 425
 tibialis anticus, 448
 posticus, 447
 tonsillitic, 420
 trifacial, 410
 trigeminus, 410
 trochlearis, 404
 twelfth pair, 423
 tympanic, 417, 420, 479
 ulnar, 433
 vagus, 420
 vesical, 565
 vestibular, 419, 484
 Vidian, 451
 Wrisberg, of, 431
 Neurilemma, 378
 Nidus hirundinis, 398
 Nipple, 586
 Nodus, 395, 398

Nodus encephali, 400
 Nose, 459, 591
 Nuck, canal of, 583
 Nucleolus cellæ, 33, 44
 Nucleus cellæ, 33, 44
 cinereus, 374
 lenticularis, 376
 olivæ, 374, 401
 teniaformis, 376
 Nymphæ, 585

O.

Obturator foramen, 116
 Œsophagus, 527
 Omentum, gastro-colic, 519,
 gastro-hepatic, 519
 gastro-splenic, 520
 great, 519
 lesser, 519
 Omphalo-mesenteric vessels, 595
 Optic commissure, 407
 thalami, 389, 393
 Orbiculare, os, 476
 Orbits, 89
 Os tinæ, 578
 Ossicula auditûs, 475
 Ossification, 45
 Osteo-genesis, 45
 Osteology, 41
 Ostium abdominale, 581
 uterinum, 581
 Otoconites, 483
 Ovaries, 582, 597
 Oviducts, 581
 Ovisacs, 582
 Ovula Graafiana, 582
 Naboth, of, 580
 Ovulum, 583

P.

Pacchionian glands, 347, 384
 Pacinian corpuscles, 380
 Palate, 94, 521
 Palmar arch, 313
 Palpebræ, 469
 Palpebral ligaments, 470
 sinuses, 471
 Pancreas, 553
 Panizza, researches of, 453
 Papillæ of the nail, 489
 skin, 486
 tongue, 485
 calyciformes, 485
 capitatae, 485
 circumvallatæ, 485
 conicæ, 485
 filiformes, 485
 fungiformes, 485
 lenticulares, 485
 Parotid gland, 524
 Pedunculi cerebri, 400
 Pelvis, 113, 117, 562, 575

- Pelvis, viscera of, 562, 576
 Penis, 566
 Pericardium, 492, 502
 Perichondrium, 44
 Pericranium, 44
 Perilymph, 483
 Perineum, muscles of, 222, 225
 Periosteum, 44
 Peritoneum, 517
 Perspiratory ducts, 491
 Pes accessorius, 391
 anserinus, 417
 hippocampi, 391
 Petit, notice of, 468
 Peyer's glands, 539
 Phalanges, 118, 128
 Pharynx, 526
 Pia mater, 387, 403
 Pigmentum nigrum, 465
 Pillars of the abdominal ring, 214
 diaphragm, 218
 palate, 522
 Pineal gland, 395
 Pinna, 473
 Pituitary gland, 376, 400
 membrane, 461
 Pleura, 514
 Plexus, general anatomy, 378
 aortic, 457
 axillary, 429
 brachial, 429
 cardiac, 455
 carotid, 452
 cavernous, 452
 cervical, 426, 429
 choroid, 389, 392, 396
 coeliac, 457
 coronary, 456
 epigastric, 457
 gangliformis, 421
 gastric, 457
 gulæ, 422
 hepatic, 457
 hypogastric, 458
 lumbar, 438
 maxillary, 413, 415
 mesenteric, 457
 oesophageal, 422
 patellar, 443
 pharyngeal, 420, 421, 453
 phrenic, 457
 prostatic, 354, 565
 pterygoid, 345
 pulmonary, 422, 514
 renal, 457
 sacral, 443
 solar, 457
 spermatic, 458
 splenic, 457
 submaxillary, 427
 supra-renal, 457, 558
 tonsillitic, 420
 tympanic, 420
 uterine, 354, 580
 vertebral, 454
 vesical, 354, 565
 Plica semilunaris, 218, 471
 Plicæ longitudinales, 531, 582
 palmatæ, 580
 sigmoideæ, 532
 Pneumogastric lobule, 397
 Polypus of the heart, 494
 Pomum Adami, 504
 Pons Tarini, 400
 Varolii, 375, 400
 Pores, 488, 491
 Portal vein, 358, 546, 549
 Portio dura, 416
 mollis, 419, 484
 Porus opticus, 462
 Poupert's ligament, 214
 Prepuce, 567
 Presbyopia, 468
 Processus e cerebello ad testes, 398
 clavatus, 402
 vermiformes, 397
 Promontory, 477
 Prostate gland, 565
 Prostatic urethra, 569
 Protuberantia annularis, 400
 Pulmonary artery, 340, 514
 plexuses, 422, 514
 sinuses, 498
 veins, 358, 514
 Puncta lachrymalia, 469, 471
 vasculosa, 388
 Punctum ossificationis, 45
 Pupil, 465
 Purkinje, corpuscles of, 42
 Pylorus, 527
 Pyramid, 397, 477
 Pyramids, anterior, 374, 401
 Ferrein, of, 559
 Malpighi, of, 559
 posterior, 402

R.

 Rainey, Mr., researches of, 387, 513
 Raphé, corporis callosi, 389
 Receptaculum chyli, 367
 Rectum, 530
 Horner's observations on the, 533, 542
 Regions, abdominal, 515
 Reil, island of, 399
 Respiratory muscles, 213
 nerves, 405
 tract, 405
 Rete mucosum, 487
 testis, 574
 Retina, 466
 Ribes, ganglion of, 452
 Ribs, 100
 Rima glottidis, 508
 Ring, external abdominal, 214, 271
 femoral, 279
 internal abdominal, 271
 Rivinian ducts, 525
 Rugæ, 531
 Ruysch, notice of, 465

S.

- Sacculus communis, 483
 laryngis, 508
 proprius, 483
 Salivary glands, 524
 Saphenous opening, 278
 veins, 352
 Sarcolemma, 169
 Scala tympani, 483
 vestibuli, 483
 Scarf-skin, 487
 Scarpa, notice of, 483
 Schindylesis, 82, 129
 Schneider, notice of, 461
 Schneiderian membrane, 461
 Sclerotic coat, 462
 Scrotum, 572
 Searle, researches of, 500
 Sebiparous glands, 490
 Semicircular canals, 480
 Semilunar fibro-cartilages, 161
 valves, 497, 500
 Septum auricularum, 494
 crurale, 279
 lucidum, 392
 pectiniforme, 568
 scroti, 572
 Serous membrane, structure, 520
 Sesamoid bones, 129
 Sheath of arteries, 285
 rectus, 218
 Sigmoid valves, 497, 500
 Sinus ampullaceus, 480
 lactiferus, 587
 Sinuses, structure, 348
 aortic, 286, 500
 basilar, 348
 cavernous, 348
 circular, 348
 fourth, 347
 lateral, 347
 longitudinal inferior, 347
 superior, 347
 occipital anterior, 348
 posterior, 347
 petrosal inferior, 348
 superior, 348
 pocularis, 570
 prostatic, 569
 pulmonary, 498
 rectus, or straight, 347
 rhomboidalis, 395
 transverse, 348
 uterine, 580
 Valsalva, of, 286, 497, 500
 Skeleton, 48
 Skin, 486
 Skull, 57
 Socia parotidis, 525
 Soemmering, notice of, 467
 Soft palate, 522
 Spermatic canal, 271
 cord, 572
 Spheno-maxillary fossa, 84
 Spheno-palatine ganglion, 450
 Spheroidal epithelium, 534
 Spigel, notice of, 546
 Spinal cord, 371, 402
 nerves, 378
 veins, 356
 Spleen, 554, 595
 Splenium corporis callosi, 388
 Spongy part of the urethra, 571
 Squamous epithelium, 533
 Stapes, 476
 Stenon, notice of, 525
 Stenon's duct, 525
 Steatozoon folliculorum, 491
 Stœchiology, 28
 Stomach, 527
 Striæ longitudinales, 395
 medullares, 419
 muscular, 169
 Structural elements, 32
 Sub-arachnoidean fluid, 386, 403
 space, 386, 403
 tissue, 386, 403
 Sublingual gland, 525
 Submaxillary gland, 525
 Substantia cinerea, 369
 ferruginea, 375
 nigra, 376
 ostoidea, 93
 perforata, 399
 Sudoriferous ducts, 491
 Sudoriparous glands, 491
 Sulci of the spinal cord, 404
 Supercilia, 469
 Superficial fascia, 268
 Supra-renal capsules, 556, 596
 Suspensory ligament, liver, 544
 penis, 567
 Sutures, 82, 129
 Sylvius, notice of, 387
 Sympathetic system, 381, 456
 Symphysis, 115, 130
 Synarthrosis, 129
 Synovia, 136
 Synovial membrane, 136

 T.
 Tapetum, 465
 Tarin, Peter, notice of, 389
 Tarsal cartilages, 470
 Tarsus, 124, 127
 Teeth, 91
 Tegmentum, 374
 Tela choroidea, 392
 Temporal fossa, 83
 Tendo Achillis, 259
 oculi, 175
 palpebrarum, 175
 Tendon, 134, 168
 Tenia hippocampi, 391
 semicircularis, 389
 Tarini, 389
 Tenon on ocular muscles and fascia, 178
 Tentorium cerebelli, 384
 Testes cerebri, 395
 Testicles, 573, 597

Testicles, descent, 597
 Thalami optici, 389, 393
 Thebesius, notice of, 494
 Thecæ, 159
 Thoracic duct, 367
 Thorax, 99, 492
 Thymus gland, 591
 Thyro-hyoid membrane, 505
 Thyroid axis, 306
 cartilage, 504
 foramen, 116
 gland, 510, 591
 Tissues, 35
 Tomentum cerebri, 387
 Tongue, 484, 521
 Tonsils, 522
 cerebelli, 395, 397
 Torcular Herophili, 347
 Trachea, 509
 Tractus opticus, 407
 spiralis, 481
 respiratorius, 405
 Tragus, 474
 Triangles of the neck, 188, 189
 Tricuspid valve, 496
 Trigonum vesicæ, 564
 Trochanter major et minor, 119
 Trochlea, 177
 Trochlearis, 177
 Tuber cinereum, 400
 Tubercula quadrigemina, 395
 Tuberculum Loweri, 496
 Tubuli galactophori, 587
 lactiferi, 587
 seminiferi, 574
 uriniferi, 559
 Tunica albuginea oculi, 177, 462
 testis, 573
 erythroides, 573
 nervea, 537
 Ruyschiana, 465
 vaginalis, 574
 oculi, 178
 vasculosa testis, 574
 Tutamina oculi, 469
 Tympanic bone, 66
 Tympanum, 475
 Tyson's glands, 567

U.

Umbilical region, 516
 Urachus, 563, 596
 Ureter, 561
 Urethra, female, 576
 male, 569
 Uterus, 578, 596
 Utriculus communis, 483
 prostaticus, 570
 Uvea, 465
 Uvula cerebelli, 395, 397
 palati, 522
 vesicæ, 564

V.

Vagina, 577
 medullaris, 369
 Vallecule, 397
 Valsalva, sinuses of, 498, 500
 Valve arachnoid, 396
 Bauhini, 532
 coronary, 495
 Eustachian, 495
 ileo-cæcal, 532
 mitral, 499
 pyloric, 531, 541
 rectum, of the, 532
 semilunar, 497, 500
 Tarin, of, 398
 tricuspid, 496
 Vieussens, of, 395
 Valves of veins, 343
 Valvulæ conniventes, 531
 Varolius, notice of, 400
 Vasa afferentia, 359
 efferentia, 359, 574
 inferentia, 359
 lactea, 586
 lymphatica, 359
 pampiniformia, 572
 recta, 574
 Vasa vasorum, 285
 Vasculum aberrans, 575
 Vas deferens, 572, 575
 VEINS, 341
 structure, 342
 angular, 344
 auricular, 345
 axillary, 351
 azygos, 355
 basilic, 350
 cardiac, 356
 cava inferior, 354
 superior, 354
 cephalic, 350
 cerebellar, 346
 cerebral, 346
 comites, 341, 349, 351
 coronary, 356
 corporis striati, 346, 389
 diploë, 345
 dorsal penis, 354
 dorsi-spinal, 356
 emulgent, 355
 facial, 344
 femoral, 351
 frontal, 344
 Galenî, 346, 392
 gastric, 358
 hepatic, 355, 547, 551
 iliac, 354
 innominatæ, 353
 intercostal superior, 356
 jugular, 348
 lumbar, 355
 mammary, 588
 mastoid, 345
 maxillary internal, 345

VEINS — *continued.*

- median, 351
 - basilic, 351
 - cephalic, 351
- medulli-spinal, 356
- meningo-rachidian, 356
- mesenteric, 357
- occipital, 345
- ovarian, 355
- parietal, 347
- popliteal, 351
- portal, 357, 546, 549
- profunda femoris, 352
- prostatic, 354, 566
- pulmonary, 358
- radial, 350
- renal, 355, 361
- salvatella, 350
- saphenous, 352
- spermatie, 355, 572
- spinal, 356
- splenic, 358
- subclavian, 351
- temporal, 345
- temporo-maxillary, 345
- Thebesii, 357
- thymic, 594
- thyroid, 349
- ulnar, 350
- umbilical, 589
- uterine, 354, 580
- vena cava, 354
- vertebral, 349, 356
- vesical, 354, 565
- Velum interpositum, 387, 392
 - medullare, 395, 398
 - pendulum palati, 522
- Venæ comites, 341, 349, 351
 - Galenii, 346, 392
 - Thebesii, 357
 - vorticosa, 464
- Ventricles of the brain, fifth, 392
 - fourth, 395
 - lateral, 389
 - third, 393
- heart, 496, 499
- Ventricles of the larynx, 508
- Vermiform processes, 397
- Vertebra, characters of, 48
- Vertebral aponeurosis, 202
 - column, 48
- Veru montanum, 569
- Vesicula umbilicalis, 595
- Vesiculæ seminales, 566
- Vestibule, 479
- Vestibulum vaginæ, 585
- Vibrissæ, 459
- Vidius, Vidus, notice of, 451
- Vieussens, notice of, 395
- Villi, 536
- Vincula accessoria, 236
- Vitreous humor, 467
- Vulva, 584

W.

- Wharton's duct, 485, 525
- Willis, notice of, 384
- Wilson's muscles, 224
- Winslow, notice of, 519
- Wirsung, duct of, 554
- Wrisberg, nerve of, 431

X.

- Xyphoid cartilage, 100

Y.

- Yellow fibrous tissue, 135

Z.

- Zinn, notice of, 467
- Zona pellucida, 583
- Zonula ciliaris, 467
 - of Zinn, 467
- Zygoma, 63
- Zygomatic fossa, 84

THE END.

BLANCHARD & LEA'S MEDICAL AND SURGICAL PUBLICATIONS.

TO THE MEDICAL PROFESSION.

The prices on the present catalogue are those at which our books can generally be furnished by booksellers throughout the United States, who can readily procure any which they may not have on hand. To physicians who have not convenient access to bookstores, we will, as long as the existing rates of postage remain unchanged, forward them at these prices, *free* by mail, to any post office in the United States under 1,500 miles. As we open accounts only with booksellers, the amount must in every case, without exception, accompany the order, and we assume no risks of the mail, either on the money or on the books; and as we deal only in our own publications, we can supply no others. Gentlemen desirous of purchasing will, therefore, find it more advantageous to deal with the nearest booksellers whenever practicable.

BLANCHARD & LEA.

PHILADELPHIA, March, 1862.

* * We have now ready a new edition of our ILLUSTRATED CATALOGUE of Medical and Scientific Publications, forming an octavo pamphlet of 80 large pages, containing specimens of illustrations, notices of the medical press, &c. &c. It has been prepared without regard to expense, and will be found one of the handsomest specimens of typographical execution as yet presented in this country. Copies will be sent to any address, by mail, free of postage, on receipt of nine cents in stamps.

Catalogues of our numerous publications in miscellaneous and educational literature forwarded on application.

The attention of physicians is especially solicited to the following important new works and new editions, just issued or nearly ready:—

Ashton on the Rectum,	See page	3
Bumstead on Venereal,	"	5
Barwell on the Joints,	"	6
Condie on Diseases of Children,	"	8
Churchill's Midwifery,	"	9
Druitt's Surgery,	"	10
Dalton's Human Physiology, 2d edition,	"	11
Dunglison's Medical Dictionary,	"	12
Erichsen's System of Surgery,	"	14
Flint on the Heart,	"	14
Fownes' Manual of Chemistry,	"	15
Gross's System of Surgery,	"	16
Gray's Anatomy, Descriptive and Surgical, 2d edition,	"	17
Hamilton on Fractures and Dislocations,	"	18
Hodge on Diseases of Women,	"	19
Lyons on Fever,	"	21
Meigs on Diseases of Women,	"	21
Morland on Uræmia,	"	23
Parri-h's Practical Pharmacy,	"	25
Stillé's Therapeutics and Materia Medica,	"	27
Simpson on Diseases of Women,	"	27
Sargent's Minor Surgery, new edition,	"	28
Taylor's Medical Jurisprudence,	"	28
Toynbee on the Ear,	"	29
Watson's Practice of Physic,	"	30
Walsh on the Lungs,	"	30
Winlow on Brain and Mind,	"	32
West on Diseases of Women,	"	32

TWO MEDICAL PERIODICALS, FREE OF POSTAGE.

Containing over Fifteen Hundred large octavo pages,
FOR FIVE DOLLARS PER ANNUM.

THE AMERICAN JOURNAL OF THE MEDICAL SCIENCES, subject to postage, when not paid for in advance, - - - - - \$5 00
 THE MEDICAL NEWS AND LIBRARY, invariably in advance, - - - - - 1 00
 OR, BOTH PERIODICALS mailed, FREE OF POSTAGE (as long as the existing rates are maintained), to any post-office in the United States, for Five Dollars remitted in advance.

THE AMERICAN JOURNAL OF THE MEDICAL SCIENCES, EDITED BY ISAAC HAYS, M. D.,

is published Quarterly, on the first of January, April, July, and October. Each number contains at least two hundred and eighty large octavo pages, handsomely and appropriately illustrated.

wherever necessary. It has now been issued regularly for more than FORTY years, and it has been under the control of the present editor for more than a quarter of a century. Throughout this long period, it has maintained its position in the highest rank of medical periodicals both at home and abroad, and has received the cordial support of the entire profession in this country. Its list of Collaborators will be found to contain a large number of the most distinguished names of the profession in every section of the United States, rendering the department devoted to

ORIGINAL COMMUNICATIONS

full of varied and important matter, of great interest to all practitioners.

As the aim of the Journal, however, is to combine the advantages presented by all the different varieties of periodicals, in its

REVIEW DEPARTMENT

will be found extended and impartial reviews of all important new works, presenting subjects of novelty and interest, together with very numerous

BIBLIOGRAPHICAL NOTICES,

including nearly all the medical publications of the day, both in this country and Great Britain, with a choice selection of the more important continental works. This is followed by the

QUARTERLY SUMMARY,

being a very full and complete abstract, methodically arranged, of the

IMPROVEMENTS AND DISCOVERIES IN THE MEDICAL SCIENCES.

This department of the Journal, so important to the practising physician, is the object of especial care on the part of the editor. It is classified and arranged under different heads, thus facilitating the researches of the reader in pursuit of particular subjects, and will be found to present a very full and accurate digest of all observations, discoveries, and inventions recorded in every branch of medical science. The very extensive arrangements of the publishers are such as to afford to the editor complete materials for this purpose, as he not only regularly receives

ALL THE AMERICAN MEDICAL AND SCIENTIFIC PERIODICALS,

but also twenty or thirty of the more important Journals issued in Great Britain and on the Continent, thus enabling him to present in a convenient compass a thorough and complete abstract of everything interesting or important to the physician occurring in any part of the civilized world.

To their old subscribers, many of whom have been on their list for twenty or thirty years, the publishers feel that no promises for the future are necessary; but those who may desire for the first time to subscribe, can rest assured that no exertion will be spared to maintain the Journal in the high position which it has occupied for so long a period.

By reference to the terms it will be seen that, in addition to this large amount of valuable and practical information on every branch of medical science, the subscriber, by paying in advance, becomes entitled, without further charge, to

THE MEDICAL NEWS AND LIBRARY,

a monthly periodical of thirty-two large octavo pages. Its "NEWS DEPARTMENT" presents the current information of the day, while the "LIBRARY DEPARTMENT" is devoted to presenting standard works on various branches of medicine. Within a few years, subscribers have thus received, without expense, many works of the highest character and practical value, such as "Watson's Practice," "Todd and Bowman's Physiology," "Malgaigne's Surgery," "West on Children," "West on Females, Part I.," "Haber-nhon on the Alimentary Canal," &c.

While the work at present appearing in its columns is

CLINICAL LECTURES ON THE DISEASES OF WOMEN.

BY PROFESSOR J. Y. SIMPSON, of Edinburgh.

WITH NUMEROUS HANDSOME ILLUSTRATIONS.

These Lectures, published in England under the supervision of the Author, carry with them all the weight of his wide experience and distinguished reputation. Their eminently practical nature, and the importance of the subject treated, cannot fail to render them in the highest degree satisfactory to subscribers, who can thus secure them without cost. These Lectures are continued in the "News" for 1862.

It will thus be seen that for the small sum of FIVE DOLLARS, paid in advance, the subscriber will obtain a Quarterly and a Monthly periodical,

EMBRACING NEARLY SIXTEEN HUNDRED LARGE OCTAVO PAGES.

Those subscribers who do not pay in advance will bear in mind that their subscription of Five Dollars will entitle them to the Journal only, without the News, and that they will be at the expense of their own postage on the receipt of each number. The advantage of a remittance when ordering the Journal will thus be apparent.

Remittances of subscriptions can be mailed at our risk, when a certificate is taken from the Postmaster that the money is duly inclosed and forwarded.

Address **BLANCHARD & LEA, PHILADELPHIA.**

ASHTON (T. J.),

Surgeon to the Blenheim Dispensary, &c.

ON THE DISEASES, INJURIES, AND MALFORMATIONS OF THE RECTUM AND ANUS; with remarks on Habitual Constipation. From the third and enlarged London edition. With handsome illustrations. In one very beautifully printed octavo volume, of about 300 pages. (*Just Issued.*) \$2 00.

INTRODUCTION. CHAPTER I. Irritation and Itching of the Anus. II. Inflammation and Excoriation of the Anus. III. Excrescences of the Anal Region. IV. Contraction of the Anus. V. Fissure of the Anus and lower part of the Rectum. VI. Neuralgia of the Anus and extremity of the Rectum. VII. Inflammation of the Rectum. VIII. Ulceration of the Rectum. IX. Hemorrhoidal Affections. X. Enlargement of Hemorrhoidal Veins. XI. Prolapsus of the Rectum. XII. Abscess near the Rectum. XIII. Fistula in Ano. XIV. Polypi of the Rectum. XV. Stricture of the Rectum. XVI. Malignant Diseases of the Rectum. XVII. Injuries of the Rectum. XVIII. Foreign Bodies in the Rectum. XIX. Malformations of the Rectum. XX. Habitual Constipation.

The most complete one we possess on the subject.

Medico-Chirurgical Review.

We are satisfied, after a careful examination of the volume, and a comparison of its contents with those of its leading predecessors and contemporaries, that the best way for the reader to avail himself of

the excellent advice given in the concluding paragraph above, would be to provide himself with a copy of the book from which it has been taken, and diligently to read its instructive pages. They may secure to him many a triumph and fervent blessing.—*Am. Journal Med. Sciences.*

ALLEN (J. M.), M. D.,

Professor of Anatomy in the Pennsylvania Medical College, &c.

THE PRACTICAL ANATOMIST; or, The Student's Guide in the Dissecting-ROOM. With 266 illustrations. In one handsome royal 12mo. volume, of over 600 pages, leather. \$2 25.

We believe it to be one of the most useful works upon the subject ever written. It is handsomely illustrated, well printed, and will be found of convenient size for use in the dissecting-room.—*Med. Examiner.*

However valuable may be the "Dissector's Guides" which we, of late, have had occasion to

notice, we feel confident that the work of Dr. Allen is superior to any of them. We believe with the author, that none is so fully illustrated as this, and the arrangement of the work is such as to facilitate the labors of the student. We most cordially recommend it to their attention.—*Western Lancet.*

ANATOMICAL ATLAS.

By Professors H. H. SMITH and W. E. HORNER, of the University of Pennsylvania. 1 vol. 8vo., extra cloth, with nearly 650 illustrations. See SMITH, p. 331

ABEL (F. A.), F. C. S. AND C. L. BLOXAM.

HANDBOOK OF CHEMISTRY, Theoretical, Practical, and Technical; with a Recommendatory Preface by Dr. HOFMANN. In one large octavo volume, extra cloth, of 662 pages, with illustrations. \$3 25.

ASHWELL (SAMUEL), M. D.,

Obstetric Physician and Lecturer to Guy's Hospital, London.

A PRACTICAL TREATISE ON THE DISEASES PECULIAR TO WOMEN

Illustrated by Cases derived from Hospital and Private Practice. Third American, from the Third and revised London edition. In one octavo volume, extra cloth, of 528 pages. \$3 00.

The most useful practical work on the subject in the English language.—*Boston Med. and Surg. Journal.*

The most able, and certainly the most standard and practical, work on female diseases that we have yet seen.—*Medico-Chirurgical Review.*

ARNOTT (NEILL), M. D.

ELEMENTS OF PHYSICS; or Natural Philosophy, General and Medical.

Written for universal use, in plain or non-technical language. A new edition, by ISAAC HAYS, M. D. Complete in one octavo volume, leather, of 484 pages, with about two hundred illustrations. \$2 50.

BIRD (GOLDING), A. M., M. D., &c.

URINARY DEPOSITS: THEIR DIAGNOSIS, PATHOLOGY, AND THERAPEUTICAL INDICATIONS. Edited by EDMUND LLOYD BIRKETT, M. D. A new American, from the fifth and enlarged London edition. With eighty illustrations on wood. In one handsome octavo volume, of about 400 pages, extra cloth. \$2 00. (*Just Issued.*)

The death of Dr. Bird has rendered it necessary to entrust the revision of the present edition to other hands, and in his performance of the duty thus devolving on him, Dr. Birkett has sedulously endeavored to carry out the author's plan by introducing such new matter and modifications of the text as the progress of science has called for. Notwithstanding the utmost care to keep the work within a reasonable compass, these additions have resulted in a considerable enlargement. It is, therefore, hoped that it will be found fully up to the present condition of the subject, and that the reputation of the volume as a clear, complete, and compendious manual, will be fully maintained.

BENNETT (J. HUGHES), M. D., F. R. S. E.,

Professor of Clinical Medicine in the University of Edinburgh, &c.

THE PATHOLOGY AND TREATMENT OF PULMONARY TUBERCULOSIS, and on the Local Medication of Pharyngeal and Laryngeal Diseases frequently mistaken for or associated with, Phthisis. One vol. 8vo., extra cloth, with wood-cuts. pp. 130. \$1 25.

BUDD (GEORGE) M. D., F. R. S.,

Professor of Medicine in King's College, London.

ON DISEASES OF THE LIVER. Third American, from the third and enlarged London edition. In one very handsome octavo volume, extra cloth, with four beautifully colored plates, and numerous wood-cuts. pp. 500. \$3 00

Has fairly established for itself a place among the classical medical literature of England.—*British and Foreign Medico-Chir. Review.*

Dr. Budd's Treatise on Diseases of the Liver is now a standard work in Medical literature, and during the intervals which have elapsed between the successive editions, the author has incorporated into the text the most striking novelties which have characterized the recent progress of hepatic physiology and pathology; so that although the size of the book

is not perceptibly changed, the history of liver diseases is made more complete, and is kept upon a level with the progress of modern science. It is the best work on Diseases of the Liver in any language.—*London Med. Times and Gazette.*

This work, now the standard book of reference on the diseases of which it treats, has been carefully revised, and many new illustrations of the views of the learned author added in the present edition.—*Dublin Quarterly Journal.*

BY THE SAME AUTHOR.

ON THE ORGANIC DISEASES AND FUNCTIONAL DISORDERS OF THE STOMACH. In one neat octavo volume, extra cloth. \$1 50.

BUCKNILL (J. C.), M. D., AND **DANIEL H. TUKE, M. D.,**

Medical Superintendent of the Devon Lunatic Asylum. Visiting Medical Officer to the York Retreat.

A MANUAL OF PSYCHOLOGICAL MEDICINE; containing the History, Nosology, Description, Statistics, Diagnosis, Pathology, and Treatment of INSANITY. With a Plate. In one handsome octavo volume, of 536 pages. \$3 00.

The increase of mental disease in its various forms, and the difficult questions to which it is constantly giving rise, render the subject one of daily enhanced interest, requiring on the part of the physician a constantly greater familiarity with this, the most perplexing branch of his profession. At the same time there has been for some years no work accessible in this country, presenting the results of recent investigations in the Diagnosis and Prognosis of Insanity, and the greatly improved methods of treatment which have done so much in alleviating the condition or restoring the health of the insane. To fill this vacancy the publishers present this volume, assured that the distinguished reputation and experience of the authors will entitle it at once to the confidence of both student and practitioner. Its scope may be gathered from the declaration of the authors that "their aim has been to supply a text book which may serve as a guide in the acquisition of such knowledge, sufficiently elementary to be adapted to the wants of the student, and sufficiently modern in its views and explicit in its teaching to suffice for the demands of the practitioner."

BENNETT (HENRY), M. D.

A PRACTICAL TREATISE ON INFLAMMATION OF THE UTERUS, ITS CERVIX AND APPENDAGES, and on its connection with Uterine Disease. To which is added, a Review of the present state of Uterine Pathology. Fifth American, from the third English edition. In one octavo volume, of about 500 pages, extra cloth. \$2 00.

BROWN (ISAAC BAKER),

Surgeon-Accoucheur to St. Mary's Hospital, &c.

ON SOME DISEASES OF WOMEN ADMITTING OF SURGICAL TREATMENT. With handsome illustrations. One vol. 8vo., extra cloth, pp. 276. \$1 60.

Mr. Brown has earned for himself a high reputation in the operative treatment of sundry diseases and injuries to which females are peculiarly subject. We can truly say of his work that it is an important addition to obstetrical literature. The operative suggestions and contrivances which Mr. Brown describes, exhibit much practical sagacity and skill,

and merit the careful attention of every surgeon-accoucheur.—*Association Journal*

We have no hesitation in recommending this book to the careful attention of all surgeons who make female complaints a part of their study and practice.—*Dublin Quarterly Journal.*

BOWMAN (JOHN E.), M. D.

PRACTICAL HANDBOOK OF MEDICAL CHEMISTRY. Second American, from the third and revised English Edition. In one neat volume, royal 12mo., extra cloth, with numerous illustrations. pp. 288. \$1 25.

BY THE SAME AUTHOR.

INTRODUCTION TO PRACTICAL CHEMISTRY, INCLUDING ANALYSIS Second American, from the second and revised London edition. With numerous illustrations. In one neat vol., royal 12mo., extra cloth. pp. 350. \$1 25.

BEALE ON THE LAWS OF HEALTH IN RELATION TO MIND AND BODY. A Series of Letters from an old Practitioner to a Patient. In one volume, royal 12mo., extra cloth. pp. 296. 80 cents.

BUSHNAN'S PHYSIOLOGY OF ANIMAL AND VEGETABLE LIFE; a Popular Treatise on the Functions and Phenomena of Organic Life. In one handsome royal 12mo. volume, extra cloth, with over 100 illustrations. pp. 234. 80 cents.

BUCKLER ON THE ETIOLOGY, PATHOLOGY, AND TREATMENT OF FIBRO-BRONCHITIS AND RHEUMATIC PNEUMONIA. In one 8vo. volume, extra cloth. pp. 150. \$1 25.

BLOOD AND URINE (MANUALS ON); BY JOHN WILLIAM GRIFFITH, G. OWEN REESE, AND ALFRED MARKWICK. One thick volume, royal 12mo., extra cloth, with plates. pp. 460. \$1 25.

BRODIE'S CLINICAL LECTURES ON SURGERY. 1 vol. 8vo. cloth. 350 pp. \$1 25.

BUMSTEAD (FREEMAN J.) M. D.,

Lecturer on Venereal Diseases at the College of Physicians and Surgeons, New York, &c.

THE PATHOLOGY AND TREATMENT OF VENEREAL DISEASES,

including the results of recent investigations upon the subject. With illustrations on wood. In one very handsome octavo volume, of nearly 700 pages, extra cloth; \$3 75. (*Now Ready.*)

The object of the author has been to prepare a complete work, which should present the results of the most recent researches and modern experience on all branches of the subject, with special reference to the wants of the practitioner, theoretical disquisitions being rendered subordinate to practical utility. To show the thoroughness of the outline which is thus filled up, a condensed synopsis of the contents is subjoined.

CONTENTS.

INTRODUCTION.

PART I.—GONORRHOEA AND ITS COMPLICATIONS.—CHAPTER I. Urethral Gonorrhœa in the Male. II. Gleet III. Balanitis IV Phymosis. V. Paraphymosis. VI. Swelled Testicle. VII. Inflammation of the Prostate. VIII. Inflammation of the Bladder. IX. Gonorrhœa in Women. X. Gonorrhœal Ophthalmia. XI. Gonorrhœal Rheumatism. XII. Vegetations. XIII. Stricture of the Urethra.

PART II.—THE CHANCROID AND ITS COMPLICATIONS: SYPHILIS.—CHAP. I. Introductory remarks. II. Chancres. III. Affections of the Lymphatic Vessels and Ganglia attendant upon Primary Sores. IV. General Syphilis—Introductory remarks. V. Treatment of Syphilis. VI. Syphilitic Fever—State of the Blood—Affections of Lymphatic Ganglia. VII. Syphilitic Affections of the Skin VIII Syphilitic Alopecia, Onychia, and Paronychia. IX. Mucous Patches. X. Gummy Tumors. XI Syphilitic Affections of Mucous Membranes. XII. Syphilitic Affections of the Eye. XIII. Syphilitic Affections of the Ear. XIV. Syphilitic Orchitis. XV. Syphilitic Affections of the Muscles and Tendons. XVI. Syphilitic Affections of the Nervous System. XVII. Syphilitic Affections of the Periosteum and Bones. XVIII. Congenital Syphilis.

BARCLAY (A. W.), M. D.,

Assistant Physician to St. George's Hospital, &c.

A MANUAL OF MEDICAL DIAGNOSIS; being an Analysis of the Signs and Symptoms of Disease. In one neat octavo volume, extra cloth, of 424 pages. \$2 00. (*Lately issued.*)

The task of composing such a work is neither an easy nor a light one; but Dr. Barclay has performed it in a manner which meets our most unqualified approbation. He is no mere theorist; he knows his work thoroughly, and in attempting to perform it, has not exceeded his powers.—*British Med. Journal.*

We venture to predict that the work will be deservedly popular, and soon become, like Watson's Practice, an indispensable necessity to the practitioner.—*N. A. Med. Journal.*

An inestimable work of reference for the young practitioner and student.—*Nashville Med. Journal.*

We hope the volume will have an extensive circulation, not among students of medicine only, but practitioners also. They will never regret a faithful study of its pages.—*Cincinnati Lancet.*

An important acquisition to medical literature. It is a work of high merit, both from the vast importance of the subject upon which it treats, and also from the real ability displayed in its elaboration. In conclusion, let us bespeak for this volume that attention of every student of our art which it so richly deserves—that place in every medical library which it can so well adorn.—*Pennsular Medical Journal.*

BARLOW (GEORGE H.), M. D.

Physician to Guy's Hospital, London, &c.

A MANUAL OF THE PRACTICE OF MEDICINE. With Additions by D.

F. CONDIE, M. D., author of "A Practical Treatise on Diseases of Children," &c. In one handsome octavo volume, leather, of over 600 pages. \$2 75.

We recommend Dr. Barlow's Manual in the warmest manner as a most valuable vade-mecum. We have had frequent occasion to consult it, and have found it clear, concise, practical, and sound. It is eminently a practical work, containing all that is essential, and avoiding useless theoretical discussion. The work supplies what has been for some time wanting, a manual of practice based upon modern discoveries in pathology and rational views of treatment of disease. It is especially intended for the use of students and junior practitioners, but it

will be found hardly less useful to the experienced physician. The American editor has added to the work three chapters—on Cholera Infantum, Yellow Fever, and Cerebro-spinal Meningitis. These additions, the two first of which are indispensable to a work on practice destined for the profession in this country, are executed with great judgment and fidelity, by Dr. Condie, who has also succeeded happily in imitating the conciseness and clearness of style which are such agreeable characteristics of the original book.—*Boston Med. and Surg. Journal.*

BARTLETT (ELISHA), M. D.

THE HISTORY, DIAGNOSIS, AND TREATMENT OF THE FEVERS

OF THE UNITED STATES. A new and revised edition. By ALONZO CLARK, M. D., Prof. of Pathology and Practical Medicine in the N. Y. College of Physicians and Surgeons, &c. In one octavo volume, of six hundred pages, extra cloth. Price \$3 00.

It is a work of great practical value and interest, containing much that is new relative to the several diseases of which it treats, and, with the additions of the editor, is fully up to the times. The distinctive features of the different forms of fever are plainly and forcibly portrayed, and the lines of demarcation carefully and accurately drawn, and to the American practitioner is a more valuable and safe guide than any work on fever extant.—*Ohio Med. and Surg. Journal.*

This excellent monograph on febrile disease, has

stood deservedly high since its first publication. It will be seen that it has now reached its fourth edition under the supervision of Prof. A. Clark, a gentleman who, from the nature of his studies and pursuits, is well calculated to appreciate and discuss the many intricate and difficult questions in pathology. His annotations add much to the interest of the work, and have brought it well up to the condition of the science as it exists at the present day in regard to this class of diseases.—*Southern Med. and Surg. Journal.*

BARWELL (RICHARD,) F. R. C. S.,

Assistant Surgeon Charing Cross Hospital, &c.

A TREATISE ON DISEASES OF THE JOINTS. Illustrated with engravings on wood. In one very handsome octavo volume, of about 500 pages, extra cloth; \$5 00. (Now Ready.)

"A treatise on Diseases of the Joints equal to, or rather beyond the current knowledge of the day, has long been required—my professional brethren must judge whether the ensuing pages may supply the deficiency. No author is fit to estimate his own work at the moment of its completion, but it may be permitted me to say that the study of joint diseases has very much occupied my attention, even from my studentship, and that for the last six or eight years my devotion to that subject has been almost unremitting. . . . The real weight of my work has been at the bedside, and the greatest labor devoted to interpreting symptoms and remedying their cause."—AUTHOR'S

PREFACE.

At the outset we may state that the work is worthy of much praise, and bears evidence of much thoughtful and careful inquiry, and here and there of no slight originality. We have already carried this notice further than we intended to do, but not to the extent the work deserves. We can only add, that the perusal of it has afforded us great pleasure. The author has evidently worked very hard at his subject, and his investigations into the Physiology and Pathology of Joints have been carried on in a manner which entitles him to be listened to with attention and respect. We must not omit to mention the very admirable plates with which the volume is enriched. We seldom meet with such striking and faithful delineations of disease.—*London Med. Times and Gazette*, Feb. 9, 1861.

We cannot take leave, however, of Mr. Barwell, without congratulating him on the interesting amount of information which he has compressed into his book. The work appears to us calculated

to be of much use to the practising surgeon who may be in want of a treatise on diseases of the joints, and at the same time one which contains the latest information on articular affections and the operations for their cure.—*Dublin Med. Press*, Feb. 27, 1861.

This volume will be welcomed, both by the pathologist and the surgeon, as being the record of much honest research and careful investigation into the nature and treatment of a most important class of disorders. We cannot conclude this notice of a valuable and useful book without calling attention to the amount of *bonâ fide* work it contains. In the present day of universal book-making, it is no slight matter for a volume to show laborious investigation, and at the same time original thought, on the part of its author, whom we may congratulate on the successful completion of his arduous task.—*London Lancet*, March 9, 1861.

CARPENTER (WILLIAM B.), M. D., F. R. S., &c.,

Examiner in Physiology and Comparative Anatomy in the University of London.

PRINCIPLES OF HUMAN PHYSIOLOGY; with their chief applications to

Psychology, Pathology, Therapeutics, Hygiene, and Forensic Medicine. A new American, from the last and revised London edition. With nearly three hundred illustrations. Edited, with additions, by FRANCIS GURNEY SMITH, M. D., Professor of the Institutes of Medicine in the Pennsylvania Medical College, &c. In one very large and beautiful octavo volume, of about nine hundred large pages, handsomely printed and strongly bound in leather, with raised bands. \$4 25.

In the preparation of this new edition, the author has spared no labor to render it, as heretofore, a complete and lucid exposition of the most advanced condition of its important subject. The amount of the additions required to effect this object thoroughly, joined to the former large size of the volume, presenting objections arising from the unwieldy bulk of the work, he has omitted all those portions not bearing directly upon HUMAN PHYSIOLOGY, designing to incorporate them in his forthcoming Treatise on GENERAL PHYSIOLOGY. As a full and accurate text-book on the Physiology of Man, the work in its present condition therefore presents even greater claims upon the student and physician than those which have heretofore won for it the very wide and distinguished favor which it has so long enjoyed. The additions of Prof. Smith will be found to supply whatever may have been wanting to the American student, while the introduction of many new illustrations, and the most careful mechanical execution, render the volume one of the most attractive as yet issued.

For upwards of thirteen years Dr. Carpenter's work has been considered by the profession generally, both in this country and England, as the most valuable compendium on the subject of physiology in our language. This distinction it owes to the high attainments and unwearied industry of its accomplished author. The present edition (which, like the last American one, was prepared by the author himself), is the result of such extensive revision, that it may almost be considered a new work. We need hardly say, in concluding this brief notice, that while the work is indispensable to every student of medicine in this country, it will amply repay the practitioner for its perusal by the interest and value of its contents.—*Boston Med. and Surg. Journal*.

This is a standard work—the text-book used by all medical students who read the English language. It has passed through several editions in order to keep pace with the rapidly growing science of Physiology. Nothing need be said in its praise, for its merits are universally known; we have nothing to say of its defects, for they only appear where the science of which it treats is incomplete.—*Western Lancet*.

The most complete exposition of physiology which any language can at present give.—*Brit. and For. Med.-Chirurg. Review*.

The greatest, the most reliable, and the best book on the subject which we know of in the English language.—*Stethoscopa*.

To eulogize this great work would be superfluous. We should observe, however, that in this edition the author has remodelled a large portion of the former, and the editor has added much matter of interest, especially in the form of illustrations. We may confidently recommend it as the most complete work on Human Physiology in our language.—*Southern Med. and Surg. Journal*.

The most complete work on the science in our language.—*Am. Med. Journal*.

The most complete work now extant in our language.—*N. O. Med. Register*.

The best text-book in the language on this extensive subject.—*London Med. Times*.

A complete cyclopædia of this branch of science.—*N. Y. Med. Times*.

The profession of this country, and perhaps also of Europe, have anxiously and for some time awaited the announcement of this new edition of Carpenter's Human Physiology. His former editions have for many years been almost the only text-book on Physiology in all our medical schools, and its circulation among the profession has been unsurpassed by any work in any department of medical science.

It is quite unnecessary for us to speak of this work as its merits would justify. The mere announcement of its appearance will afford the highest pleasure to every student of Physiology, while its perusal will be of infinite service in advancing physiological science.—*Ohio Med. and Surg. Journ.*

CARPENTER (WILLIAM B.), M. D., F. R. S.,

Examiner in Physiology and Comparative Anatomy in the University of London.

THE MICROSCOPE AND ITS REVELATIONS. With an Appendix containing the Applications of the Microscope to Clinical Medicine, &c. By F. G. SMITH, M. D. Illustrated by four hundred and thirty-four beautiful engravings on wood. In one large and very handsome octavo volume, of 724 pages, extra cloth, \$4 00; leather, \$4 50.

Dr. Carpenter's position as a microscopist and physiologist, and his great experience as a teacher, eminently qualify him to produce what has long been wanted—a good text-book on the practical use of the microscope. In the present volume his object has been, as stated in his Preface, “to combine, within a moderate compass, that information with regard to the use of his ‘tools,’ which is most essential to the working microscopist, with such an account of the objects best fitted for his study, as might qualify him to comprehend what he observes, and might thus prepare him to benefit science, whilst expanding and refreshing his own mind.” That he has succeeded in accomplishing this, no one acquainted with his previous labors can doubt.

The great importance of the microscope as a means of diagnosis, and the number of microscopists who are also physicians, have induced the American publishers, with the author's approval, to add an Appendix, carefully prepared by Professor Smith, on the applications of the instrument to clinical medicine, together with an account of American Microscopes, their modifications and accessories. This portion of the work is illustrated with nearly one hundred wood-cuts, and, it is hoped, will adapt the volume more particularly to the use of the American student.

Those who are acquainted with Dr. Carpenter's previous writings on Animal and Vegetable Physiology, will fully understand how vast a store of knowledge he is able to bring to bear upon so comprehensive a subject as the revelations of the microscope; and even those who have no previous acquaintance with the construction or uses of this instrument, will find abundance of information conveyed in clear and simple language.—*Med. Times and Gazette.*

Although originally not intended as a strictly

medical work, the additions by Prof. Smith give it a positive claim upon the profession, for which we doubt not he will receive their sincere thanks. Indeed, we know not where the student of medicine will find such a complete and satisfactory collection of microscopic facts bearing upon physiology and practical medicine as is contained in Prof. Smith's appendix; and this of itself, it seems to us, is fully worth the cost of the volume.—*Louisville Medical Review.*

BY THE SAME AUTHOR.

ELEMENTS (OR MANUAL) OF PHYSIOLOGY, INCLUDING PHYSIOLOGICAL ANATOMY. Second American, from a new and revised London edition. With one hundred and ninety illustrations. In one very handsome octavo volume, leather. pp. 566. \$3 00.

In publishing the first edition of this work, its title was altered from that of the London volume, by the substitution of the word “Elements” for that of “Manual,” and with the author's sanction the title of “Elements” is still retained as being more expressive of the scope of the treatise.

To say that it is the best manual of Physiology now before the public, would not do sufficient justice to the author.—*Buffalo Medical Journal.*

In his former works it would seem; that he had exhausted the subject of Physiology. In the present, he gives the essence, as it were, of the whole.—*N. Y. Journal of Medicine.*

Those who have occasion for an elementary treatise on Physiology, cannot do better than to possess themselves of the manual of Dr. Carpenter.—*Medical Examiner.*

The best and most complete exposé of modern Physiology, in one volume, extant in the English language.—*St. Louis Medical Journal.*

BY THE SAME AUTHOR.

PRINCIPLES OF COMPARATIVE PHYSIOLOGY. New American, from the Fourth and Revised London edition. In one large and handsome octavo volume, with over three hundred beautiful illustrations. pp. 752. Extra cloth, \$4 80; leather, raised bands, \$5 25.

This book should not only be read but thoroughly studied by every member of the profession. None are too wise or old, to be benefited thereby. But especially to the younger class would we cordially commend it as best fitted of any work in the English language to qualify them for the reception and comprehension of those truths which are daily being developed in physiology.—*Medical Counsellor.*

Without pretending to it, it is an encyclopedia of the subject, accurate and complete in all respects—a truthful reflection of the advanced state at which the science has now arrived.—*Dublin Quarterly Journal of Medical Science.*

A truly magnificent work—in itself a perfect physiological study.—*Ranking's Abstract.*

This work stands without its fellow. It is one of the few men in Europe could have undertaken; it is one

no man, we believe, could have brought to so successful an issue as Dr. Carpenter. It required for its production a physiologist at once deeply read in the labors of others, capable of taking a general, critical, and unprejudiced view of those labors, and of combining the varied, heterogeneous materials at his disposal, so as to form an harmonious whole.

We feel that this abstract can give the reader a very imperfect idea of the fulness of this work, and no idea of its unity, of the admirable manner in which material has been brought, from the most various sources, to conduce to its completeness, of the lucidity of the reasoning it contains, or of the clearness of language in which the whole is clothed. Not the profession only, but the scientific world at large, must feel deeply indebted to Dr. Carpenter for this great work. It must, indeed, add largely even to his high reputation.—*Medical Times.*

BY THE SAME AUTHOR. (*Preparing.*)

PRINCIPLES OF GENERAL PHYSIOLOGY, INCLUDING ORGANIC CHEMISTRY AND HISTOLOGY. With a General Sketch of the Vegetable and Animal Kingdom. In one large and very handsome octavo volume, with several hundred illustrations.

BY THE SAME AUTHOR.

A PRIZE ESSAY ON THE USE OF ALCOHOLIC LIQUORS IN HEALTH AND DISEASE. New edition, with a Preface by D. F. CONDIE, M. D., and explanations of scientific words. In one neat 12mo. volume, extra cloth. pp. 178. 50 cents.

CONDIE (D. F.), M. D., &c.

A PRACTICAL TREATISE ON THE DISEASES OF CHILDREN. Fifth edition, revised and augmented. In one large volume, 8vo., leather, of over 750 pages. \$3 25. (*Just Issued*, 1859.)

In presenting a new and revised edition of this favorite work, the publishers have only to state that the author has endeavored to render it in every respect "a complete and faithful exposition of the pathology and therapeutics of the maladies incident to the earlier stages of existence—a full and exact account of the diseases of infancy and childhood." To accomplish this he has subjected the whole work to a careful and thorough revision, rewriting a considerable portion, and adding several new chapters. In this manner it is hoped that any deficiencies which may have previously existed have been supplied, that the recent labors of practitioners and observers have been thoroughly incorporated, and that in every point the work will be found to maintain the high reputation it has enjoyed as a complete and thoroughly practical book of reference in infantile affections.

A few notices of previous editions are subjoined.

Dr. Condie's scholarship, acumen, industry, and practical sense are manifested in this, as in all his numerous contributions to science.—*Dr. Holmes's Report to the American Medical Association.*

Taken as a whole, in our judgment, Dr. Condie's Treatise is the one from the perusal of which the practitioner in this country will rise with the greatest satisfaction.—*Western Journal of Medicine and Surgery.*

One of the best works upon the Diseases of Children in the English language.—*Western Lancet.*

We feel assured from actual experience that no physician's library can be complete without a copy of this work.—*N. Y. Journal of Medicine.*

A veritable pædiatric encyclopædia, and an honor to American medical literature.—*Ohio Medical and Surgical Journal.*

We feel persuaded that the American medical profession will soon regard it not only as a very good, but as the VERY BEST "Practical Treatise on the Diseases of Children."—*American Medical Journal.*

In the department of infantile therapeutics, the work of Dr. Condie is considered one of the best which has been published in the English language.—*The Stethoscope.*

We pronounced the first edition to be the best work on the diseases of children in the English language, and, notwithstanding all that has been published, we still regard it in that light.—*Medical Examiner.*

The value of works by native authors on the diseases which the physician is called upon to combat, will be appreciated by all; and the work of Dr. Condie has gained for itself the character of a safe guide for students, and a useful work for consultation by those engaged in practice.—*N. Y. Med Times.*

This is the fourth edition of this deservedly popular treatise. During the interval since the last edition, it has been subjected to a thorough revision by the author; and all new observations in the pathology and therapeutics of children have been included in the present volume. As we said before, we do not know of a better book on diseases of children, and to a large part of its recommendations we yield an unhesitating concurrence.—*Buffalo Med. Journal.*

Perhaps the most full and complete work now before the profession of the United States; indeed, we may say in the English language. It is vastly superior to most of its predecessors.—*Transylvania Med. Journal.*

CHRISTISON (ROBERT), M. D., V. P. R. S. E., &c.

A DISPENSATORY; or, Commentary on the Pharmacopœias of Great Britain and the United States; comprising the Natural History, Description, Chemistry, Pharmacy, Actions, Uses, and Doses of the Articles of the *Materia Medica*. Second edition, revised and improved, with a Supplement containing the most important New Remedies. With copious Additions, and two hundred and thirteen large wood-engravings. By R. EGLESFELD GRIFFITH, M. D. In one very large and handsome octavo volume, leather, raised bands, of over 1000 pages. \$3 50.

COOPER (BRANSBY B.), F. R. S.

LECTURES ON THE PRINCIPLES AND PRACTICE OF SURGERY. In one very large octavo volume, extra cloth, of 750 pages. \$3 00.

COOPER ON DISLOCATIONS AND FRACTURES OF THE JOINTS.—Edited by BRANSBY B. COOPER, F. R. S., &c. With additional Observations by Prof. J. C. WARREN. A new American edition. In one handsome octavo volume, extra cloth, of about 500 pages, with numerous illustrations on wood. \$3 25.

COOPER ON THE ANATOMY AND DISEASES OF THE BREAST, with twenty-five Miscellaneous and Surgical Papers. One large volume, imperial 8vo., extra cloth, with 252 figures, on 36 plates. \$2 50.

COOPER ON THE STRUCTURE AND DISEASES OF THE TESTIS, AND ON THE THYMUS GLAND. One vol. imperial 8vo., extra cloth, with 177 figures on 29 plates. \$2 00.

COPLAND ON THE CAUSES, NATURE, AND TREATMENT OF PALSY AND APOPLEXY. In one volume, royal 12mo., extra cloth. pp. 326. 50 cents.

CLYMER ON FEVERS; THEIR DIAGNOSIS, PATHOLOGY, AND TREATMENT. In one octavo volume, leather, of 600 pages. \$1 50.

COLOMBAT DE L'ISERE ON THE DISEASES OF FEMALES, and on the special Hygiene of their Sex. Translated, with many Notes and Additions, by C. D. MEIGS, M. D. Second edition, revised and improved. In one large volume, octavo, leather, with numerous wood-cuts. pp. 720. \$3 50.

CARSON (JOSEPH), M. D.,

Professor of *Materia Medica* and Pharmacy in the University of Pennsylvania.

SYNOPSIS OF THE COURSE OF LECTURES ON MATERIA MEDICA AND PHARMACY, delivered in the University of Pennsylvania. Second and revised edition. In one very neat octavo volume, extra cloth, of 208 pages. \$1 50.

CURLING (T. B.), F. R. S.,

Surgeon to the London Hospital, President of the Hunterian Society, &c.

A PRACTICAL TREATISE ON DISEASES OF THE TESTIS, SPERMATIC CORD, AND SCROTUM. Second American, from the second and enlarged English edition. In one handsome octavo volume, extra cloth, with numerous illustrations. pp. 420. \$2 00.

CHURCHILL (FLEETWOOD), M. D., M. R. I. A.
ON THE THEORY AND PRACTICE OF MIDWIFERY. A new American from the fourth revised and enlarged London edition. With Notes and Additions, by D. FRANCIS CONDIE, M. D., author of a "Practical Treatise on the Diseases of Children," &c. With 194 illustrations. In one very handsome octavo volume, leather, of nearly 700 large pages. \$3 50. (Just Issued.)

This work has been so long an established favorite, both as a text-book for the learner and as a reliable aid in consultation for the practitioner, that in presenting a new edition it is only necessary to call attention to the very extended improvements which it has received. Having had the benefit of two revisions by the author since the last American reprint, it has been materially enlarged, and Dr. Churchill's well-known conscientious industry is a guarantee that every portion has been thoroughly brought up with the latest results of European investigation in all departments of the science and art of obstetrics. The recent date of the last Dublin edition has not left much of novelty for the American editor to introduce, but he has endeavored to insert whatever has since appeared, together with such matters as his experience has shown him would be desirable for the American student, including a large number of illustrations. With the sanction of the author he has added in the form of an appendix, some chapters from a little "Manual for Midwives and Nurses," recently issued by Dr. Churchill, believing that the details there presented can hardly fail to prove of advantage to the junior practitioner. The result of all these additions is that the work now contains fully one-half more matter than the last American edition, with nearly one-half more illustrations, so that notwithstanding the use of a smaller type, the volume contains almost two hundred pages more than before.

No effort has been spared to secure an improvement in the mechanical execution of the work equal to that which the text has received, and the volume is confidently presented as one of the hand-omest that has thus far been laid before the American profession; while the very low price at which it is offered should secure for it a place in every lecture-room and on every office table.

A better book in which to learn these important points we have not met than Dr. Churchill's. Every page of it is full of instruction; and the opinion of all writers of authority is given on questions of difficulty, as well as the directions and advice of the learned author himself, to which he adds the result of statistical inquiry, putting statistics in their proper place and giving them their due weight, and no more. We have never read a book more free from professional jealousy than Dr. Churchill's. It appears to be written with the true design of a book on medicine, viz: to give all that is known on the subject of which he treats, both theoretically and practically, and to advance such opinions of his own as he believes will benefit medical science, and insure the safety of the patient. We have said enough to convey to the profession that this book of Dr. Churchill's is admirably suited for a book of reference for the practitioner, as well as a text-book for the student, and we hope it may be extensively purchased amongst our readers. To them we most strongly recommend it.—*Dublin Medical Press*, June 20, 1860.

To bestow praise on a book that has received such marked approbation would be superfluous. We need only say, therefore, that if the first edition was thought worthy of a favorable reception by the medical public, we can confidently affirm that this will be found much more so. The lecturer, the practitioner, and the student, may all have recourse to its pages, and derive from their perusal much interest and instruction in everything relating to theoretical and practical midwifery.—*Dublin Quarterly Journal of Medical Science*.

A work of very great merit, and such as we can confidently recommend to the study of every obstetric practitioner.—*London Medical Gazette*.

This is certainly the most perfect system extant. It is the best adapted for the purposes of a text-book, and that which he whose necessities confine him to one book, should select in preference to all others.—*Southern Medical and Surgical Journal*.

BY THE SAME AUTHOR. (Lately Published.)

ON THE DISEASES OF INFANTS AND CHILDREN. Second American Edition, revised and enlarged by the author. Edited, with Notes, by W. V. KEATING, M. D. In one large and handsome volume, extra cloth, of over 700 pages. \$3 00, or in leather, \$3 25.

In preparing this work a second time for the American profession, the author has spared no labor in giving it a very thorough revision, introducing several new chapters, and rewriting others, while every portion of the volume has been subjected to a severe scrutiny. The efforts of the American editor have been directed to supplying such information relative to matters peculiar to this country as might have escaped the attention of the author, and the whole may, therefore, be safely pronounced one of the most complete works on the subject accessible to the American Profession. By an alteration in the size of the page, these very extensive additions have been accommodated without unduly increasing the size of the work.

BY THE SAME AUTHOR.

ESSAYS ON THE PUERPERAL FEVER, AND OTHER DISEASES PECULIAR TO WOMEN. Selected from the writings of British Authors previous to the close of the Eighteenth Century. In one neat octavo volume, extra cloth, of about 450 pages. \$2 50.

The most popular work on midwifery ever issued from the American press.—*Charleston Med. Journal*.

We were reduced to the necessity of having but one work on midwifery, and permitted to choose, we would unhesitatingly take Churchill.—*Western Med. and Surg. Journal*.

It is impossible to conceive a more useful and elegant manual than Dr. Churchill's Practice of Midwifery.—*Provincial Medical Journal*.

Certainly, in our opinion, the very best work on the subject which exists.—*N. Y. Annalist*.

No work holds a higher position, or is more deserving of being placed in the hands of the tyro, the advanced student, or the practitioner.—*Medical Examiner*.

Previous editions, under the editorial supervision of Prof. R. M. Huston, have been received with marked favor, and they deserved it; but this, reprinted from a very late Dublin edition, carefully revised and brought up by the author to the present time, does present an unusually accurate and able exposition of every important particular embraced in the department of midwifery. * * The clearness, directness, and precision of its teachings, together with the great amount of statistical research which its text exhibits, have served to place it already in the foremost rank of works in this department of remedial science.—*N. O. Med. and Surg. Journal*.

In our opinion, it forms one of the best if not the very best text-book and epitome of obstetric science which we at present possess in the English language.—*Monthly Journal of Medical Science*.

The clearness and precision of style in which it is written, and the great amount of statistical research which it contains, have served to place it in the first rank of works in this department of medical science.—*N. Y. Journal of Medicine*.

Few treatises will be found better adapted as a text-book for the student, or as a manual for the frequent consultation of the young practitioner.—*American Medical Journal*.

CHURCHILL (FLEETWOOD), M. D., M. R. I. A., &c.
ON THE DISEASES OF WOMEN; including those of Pregnancy and Child-bed. A new American edition, revised by the Author. With Notes and Additions, by D. FRANCIS CONDIE, M. D., author of "A Practical Treatise on the Diseases of Children." With numerous illustrations. In one large and handsome octavo volume, leather, of 768 pages. \$3 00.

This edition of Dr. Churchill's very popular treatise may almost be termed a new work, so thoroughly has he revised it in every portion. It will be found greatly enlarged, and completely brought up to the most recent condition of the subject, while the very handsome series of illustrations introduced, representing such pathological conditions as can be accurately portrayed, present a novel feature, and afford valuable assistance to the young practitioner. Such additions as appeared desirable for the American student have been made by the editor, Dr. Condie, while a marked improvement in the mechanical execution keeps pace with the advance in all other respects which the volume has undergone, while the price

It comprises, unquestionably, one of the most exact and comprehensive expositions of the present state of medical knowledge in respect to the diseases of women that has yet been published.—*Am. Journ. Med. Sciences.*

This work is the most reliable which we possess on this subject; and is deservedly popular with the profession.—*Charleston Med. Journal*, July, 1857.

We know of no author who deserves that approbation, on "the diseases of females," to the same

extent that Dr. Churchill does. His, indeed, is the only thorough treatise we know of on the subject; and it may be commended to practitioners and students as a masterpiece in its particular department.—*The Western Journal of Medicine and Surgery.*

As a comprehensive manual for students, or a work of reference for practitioners, it surpasses any other that has ever issued on the same subject from the British press.—*Dublin Quart. Journal.*

DICKSON (S. H.), M. D.,

Professor of Practice of Medicine in the Jefferson Medical College, Philadelphia.

ELEMENTS OF MEDICINE; a Compendious View of Pathology and Therapeutics, or the History and Treatment of Diseases. Second edition, revised. In one large and handsome octavo volume, of 750 pages, leather. \$3 75. (*Just Issued.*)

The steady demand which has so soon exhausted the first edition of this work, sufficiently shows that the author was not mistaken in supposing that a volume of this character was needed—an elementary manual of practice, which should present the leading principles of medicine with the practical results, in a condensed and perspicuous manner. Disencumbered of unnecessary detail and fruitless speculations, it embodies what is most requisite for the student to learn, and at the same time what the active practitioner wants when obliged, in the daily calls of his profession, to refresh his memory on special points. The clear and attractive style of the author renders the whole easy of comprehension, while his long experience gives to his teachings an authority everywhere acknowledged. Few physicians, indeed, have had wider opportunities for observation and experience, and few, perhaps, have used them to better purpose. As the result of a long life devoted to study and practice, the present edition, revised and brought up to the date of publication, will doubtless maintain the reputation already acquired as a condensed and convenient American text-book on the Practice of Medicine.

DRUITT (ROBERT), M. R. C. S., &c.

THE PRINCIPLES AND PRACTICE OF MODERN SURGERY. A new and revised American from the eighth enlarged and improved London edition. Illustrated with four hundred and thirty-two wood-engravings. In one very handsomely printed octavo volume, leather, of nearly 700 large pages. \$3 50. (*Just Issued.*)

A work which like DRUITT'S SURGERY has for so many years maintained the position of a leading favorite with all classes of the profession, needs no special recommendation to attract attention to a revised edition. It is only necessary to state that the author has spared no pains to keep the work up to its well earned reputation of presenting in a small and convenient compass the latest condition of every department of surgery, considered both as a science and as an art; and that the services of a competent American editor have been employed to introduce whatever novelties may have escaped the author's attention, or may prove of service to the American practitioner. As several editions have appeared in London since the issue of the last American reprint, the volume has had the benefit of repeated revisions by the author, resulting in a very thorough alteration and improvement. The extent of these additions may be estimated from the fact that it now contains about one-third more matter than the previous American edition, and that notwithstanding the adoption of a smaller type, the pages have been increased by about one hundred, while nearly two hundred and fifty wood-cuts have been added to the former list of illustrations.

A marked improvement will also be perceived in the mechanical and artistic execution of the work, which, printed in the best style, on new type, and fine paper, leaves little to be desired as regards external finish; while at the very low price affixed it will be found one of the cheapest volumes accessible to the profession.

This popular volume, now a most comprehensive work on surgery, has undergone many corrections, improvements, and additions, and the principles and the practice of the art have been brought down to the latest record and observation. Of the operations in surgery it is impossible to speak too highly. The descriptions are so clear and concise, and the illustrations so accurate and numerous, that the student can have no difficulty, with instrument in hand, and book by his side, over the dead body, in obtaining a proper knowledge and sufficient tact in this much neglected department of medical education.—*British and Foreign Medico-Chirurg. Review*, Jan. 1850.

In the present edition the author has entirely rewritten many of the chapters, and has incorporated the various improvements and additions in modern surgery. On carefully going over it, we find that

nothing of real practical importance has been omitted; it presents a faithful epitome of everything relating to surgery up to the present hour. It is deservedly a popular manual, both with the student and practitioner.—*London Lancet*, Nov. 19, 1859.

In closing this brief notice, we recommend as cordially as ever this most useful and comprehensive hand-book. It must prove a vast assistance, not only to the student of surgery, but also to the busy practitioner who may not have the leisure to devote himself to the study of more lengthy volumes.—*London Med. Times and Gazette*, Oct. 22, 1859.

In a word, this eighth edition of Dr. Druiitt's Manual of Surgery is all that the surgical student or practitioner could desire.—*Dublin Quarterly Journal of Med. Sciences*, Nov. 1859.

DALTON, JR. (J. C.), M. D.

Professor of Physiology in the College of Physicians, New York.

A TREATISE ON HUMAN PHYSIOLOGY, designed for the use of Students and Practitioners of Medicine. Second edition, revised and enlarged, with two hundred and seventy-one illustrations on wood. In one very beautiful octavo volume, of 700 pages, extra cloth, \$4 00; leather, raised bands, \$4 50. (*Just Issued, 1861.*)

The general favor which has so soon exhausted an edition of this work has afforded the author an opportunity in its revision of supplying the deficiencies which existed in the former volume. This has caused the insertion of two new chapters—one on the Special Senses, the other on Imbibition, Exhalation, and the Functions of the Lymphatic System—besides numerous additions of smaller amount scattered through the work, and a general revision designed to bring it thoroughly up to the present condition of the science with regard to all points which may be considered as definitely settled. A number of new illustrations has been introduced, and the work, it is hoped, in its improved form, may continue to command the confidence of those for whose use it is intended.

It will be seen, therefore, that Dr. Dalton's best efforts have been directed towards perfecting his work. The additions are marked by the same features which characterize the remainder of the volume, and render it by far the most desirable text-book on physiology to place in the hands of the student which, so far as we are aware, exists in the English language, or perhaps in any other. We therefore have no hesitation in recommending Dr. Dalton's book for the classes for which it is intended, satisfied as we are that it is better adapted to their use than any other work of the kind to which they have access.—*American Journal of the Med. Sciences*, April, 1861.

It is, therefore, no disparagement to the many books upon physiology, most excellent in their day, to say that Dalton's is the only one that gives us the science as it was known to the best philosophers throughout the world, at the beginning of the current year. It states in comprehensive but concise diction, the facts established by experiment, or other method of demonstration, and details, in an understandable manner, how it is done, but abstains from the discussion of unsettled or theoretical points. Herein it is unique; and these characteristics render it a text-book without a rival, for those who desire to study physiological science as it is known to its most successful cultivators. And it is physiology thus presented that lies at the foundation of correct pathological knowledge; and this in turn is the basis of rational therapeutics; so that pathology, in fact, becomes of prime importance in the proper discharge of our every-day practical duties.—*Cincinnati Lancet*, May, 1861.

Dr. Dalton needs no word of praise from us. He is universally recognized as among the first, if not the very first, of American physiologists now living. The first edition of his admirable work appeared but two years since, and the advance of science, his

own original views and experiments, together with a desire to supply what he considered some deficiencies in the first edition, have already made the present one a necessity, and it will no doubt be even more eagerly sought for than the first. That it is not merely a reprint, will be seen from the author's statement of the following principal additions and alterations which he has made. The present, like the first edition, is printed in the highest style of the printer's art, and the illustrations are truly admirable for their clearness in expressing exactly what their author intended.—*Boston Medical and Surgical Journal*, March 29, 1861.

It is unnecessary to give a detail of the additions; suffice it to say, that they are numerous and important, and such as will render the work still more valuable and acceptable to the profession as a learned and original treatise on this all-important branch of medicine. All that was said in commendation of the getting up of the first edition, and the superior style of the illustrations, apply with equal force to this. No better work on physiology can be placed in the hand of the student.—*St. Louis Medical and Surgical Journal*, May, 1861.

These additions, while testifying to the learning and industry of the author, render the book exceedingly useful, as the most complete exposé of a science, of which Dr. Dalton is doubtless the ablest representative on this side of the Atlantic.—*New Orleans Med. Times*, May, 1861.

A second edition of this deservedly popular work having been called for in the short space of two years, the author has supplied deficiencies, which existed in the former volume, and has thus more completely fulfilled his design of presenting to the profession a reliable and precise text-book, and one which we consider the best outline on the subject of which it treats, in any language.—*N. American Medico-Chirurg. Review*, May, 1861.

DUNGLISON, FORBES, TWEEDIE, AND CONOLLY.

THE CYCLOPÆDIA OF PRACTICAL MEDICINE: comprising Treatises on the Nature and Treatment of Diseases, Materia Medica, and Therapeutics, Diseases of Women and Children, Medical Jurisprudence, &c. &c. In four large super-royal octavo volumes, of 3254 double-columned pages, strongly and handsomely bound, with raised bands. \$12 00.

*** This work contains no less than four hundred and eighteen distinct treatises, contributed by sixty-eight distinguished physicians, rendering it a complete library of reference for the country practitioner.

The most complete work on Practical Medicine extant; or, at least, in our language.—*Buffalo Medical and Surgical Journal*.

For reference, it is above all price to every practitioner.—*Western Lancet*.

One of the most valuable medical publications of the day—as a work of reference it is invaluable.—*Western Journal of Medicine and Surgery*.

It has been to us, both as learner and teacher, a work for ready and frequent reference, one in which modern English medicine is exhibited in the most advantageous light.—*Medical Examiner*.

The editors are practitioners of established reputation, and the list of contributors embraces many of the most eminent professors and teachers of London, Edinburgh, Dublin, and Glasgow. It is, indeed, the great merit of this work that the principal articles have been furnished by practitioners who have not only devoted special attention to the diseases about which they have written, but have also enjoyed opportunities for an extensive practical acquaintance with them and whose reputation carries the assurance of their competency justly to appreciate the opinions of others, while it stamps their own doctrines with high and just authority.—*American Medical Journal*.

DEWEES'S COMPREHENSIVE SYSTEM OF MIDWIFERY. Illustrated by occasional cases and many engravings. Twelfth edition, with the author's last improvements and corrections, in one octavo volume, extra cloth, of 600 pages. \$3 20.

DEWEES'S TREATISE ON THE PHYSICAL

AND MEDICAL TREATMENT OF CHILDREN. The last edition. In one volume, octavo, extra cloth, 548 pages. \$2 80

DEWEES'S TREATISE ON THE DISEASES OF FEMALES. Tenth edition. In one volume, octavo extra cloth, 532 pages, with plates. \$3 00

DUNGLISON (ROBLEY), M. D.,

Professor of Institutes of Medicine in the Jefferson Medical College, Philadelphia.

NEW AND ENLARGED EDITION.

MEDICAL LEXICON; a Dictionary of Medical Science, containing a concise

Explanation of the various Subjects and Terms of Anatomy, Physiology, Pathology, Hygiene, Therapeutics Pharmacology, Pharmacy, Surgery, Obstetrics, Medical Jurisprudence, Dentistry, &c. Notices of Climate and of Mineral Waters; Formulæ for Official, Empirical, and Dietetic Preparations, &c. With French and other Synonymes. Revised and very greatly enlarged. In one very large and handsome octavo volume, of 992 double-columned pages, in small type; strongly bound in leather, with raised bands. Price \$4 00.

Especial care has been devoted in the preparation of this edition to render it in every respect worthy a continuance of the very remarkable favor which it has hitherto enjoyed. The rapid sale of FIFTEEN large editions, and the constantly increasing demand, show that it is regarded by the profession as the standard authority. Stimulated by this fact, the author has endeavored in the present revision to introduce whatever might be necessary "to make it a satisfactory and desirable—if not indispensable—lexicon, in which the student may search without disappointment for every term that has been legitimated in the nomenclature of the science." To accomplish this, large additions have been found requisite, and the extent of the author's labors may be estimated from the fact that about SIX THOUSAND subjects and terms have been introduced throughout, rendering the whole number of definitions about SIXTY THOUSAND, to accommodate which, the number of pages has been increased by nearly a hundred, notwithstanding an enlargement in the size of the page. The medical press, both in this country and in England, has pronounced the work indispensable to all medical students and practitioners, and the present improved edition will not lose that enviable reputation.

The publishers have endeavored to render the mechanical execution worthy of a volume of such universal use in daily reference. The greatest care has been exercised to obtain the typographical accuracy so necessary in a work of the kind. By the small but exceedingly clear type employed, an immense amount of matter is condensed in its thousand ample pages, while the binding will be found strong and durable. With all these improvements and enlargements, the price has been kept at the former very moderate rate, placing it within the reach of all.

This work, the appearance of the fifteenth edition of which, it has become our duty and pleasure to announce, is perhaps the most stupendous monument of labor and erudition in medical literature. One would hardly suppose after constant use of the preceding editions, where we have never failed to find a sufficiently full explanation of every medical term, that in this edition "about six thousand subjects and terms have been added," with a careful revision and correction of the entire work. It is only necessary to announce the advent of this edition to make it occupy the place of the preceding one on the table of every medical man, as it is without doubt the best and most comprehensive work of the kind which has ever appeared.—*Buffalo Med. Journ.*, Jan. 1858.

The work is a monument of patient research, skilful judgment, and vast physical labor, that will perpetuate the name of the author more effectually than any possible device of stone or metal. Dr. Dunglison deserves the thanks not only of the American profession, but of the whole medical world.—*North Am. Medico-Chir. Review*, Jan. 1858.

A Medical Dictionary better adapted for the wants of the profession than any other with which we are acquainted, and of a character which places it far above comparison and competition.—*Am. Journ. Med. Sciences*, Jan. 1858.

We need only say, that the addition of 6,000 new terms, with their accompanying definitions, may be said to constitute a new work, by itself. We have examined the Dictionary attentively, and are most happy to pronounce it unrivalled of its kind. The erudition displayed, and the extraordinary industry which must have been demanded, in its preparation and perfection, redound to the lasting credit of its author, and have furnished us with a volume *indispensable* at the present day, to all who would find themselves *au niveau* with the highest standards of medical information.—*Boston Medical and Surgical Journal*, Dec. 31, 1857.

Good lexicons and encyclopedic works generally, are the most labor-saving contrivances which literary men enjoy; and the labor which is required to produce them in the perfect manner of this example is something appalling to contemplate. The author

tells us in his preface that he has added about six thousand terms and subjects to this edition, which, before, was considered universally as the best work of the kind in any language.—*Silliman's Journal*, March, 1858.

He has razed his gigantic structure to the foundations, and remodelled and reconstructed the entire pile. No less than six thousand additional subjects and terms are illustrated and analyzed in this new edition, swelling the grand aggregate to beyond sixty thousand! Thus is placed before the profession a complete and thorough exponent of medical terminology, without rival or possibility of rivalry.—*Nashville Journ. of Med. and Surg.*, Jan. 1858.

It is universally acknowledged, we believe, that this work is incomparably the best and most complete Medical Lexicon in the English language. The amount of labor which the distinguished author has bestowed upon it is truly wonderful, and the learning and research displayed in its preparation are equally remarkable. Comment and commendation are unnecessary, as no one at the present day thinks of purchasing any other Medical Dictionary than this.—*St. Louis Med. and Surg. Journ.*, Jan. 1858.

It is the foundation stone of a good medical library, and should always be included in the first list of books purchased by the medical student.—*Am. Med. Monthly*, Jan. 1858.

A very perfect work of the kind, undoubtedly the most perfect in the English language.—*Med. and Surg. Reporter*, Jan. 1858.

It is now emphatically the Medical Dictionary of the English language, and for it there is no substitute.—*N. H. Med. Journ.*, Jan. 1858.

It is scarcely necessary to remark that any medical library wanting a copy of Dunglison's Lexicon must be imperfect.—*Cin. Lancet*, Jan. 1858.

We have ever considered it the best authority published, and the present edition we may safely say has no equal in the world.—*Peninsular Med. Journal*, Jan. 1859.

The most complete authority on the subject to be found in any language.—*Va. Med. Journal*, Feb. '58.

BY THE SAME AUTHOR.

THE PRACTICE OF MEDICINE. A Treatise on Special Pathology and Therapeutics. Third Edition. In two large octavo volumes, leather, of 1,500 pages. \$6 25.

DUNGLISON (ROBLEY), M. D.,

Professor of Institutes of Medicine in the Jefferson Medical College, Philadelphia.

HUMAN PHYSIOLOGY. Eighth edition. Thoroughly revised and extensively modified and enlarged, with five hundred and thirty-two illustrations. In two large and handsomely printed octavo volumes, leather, of about 1500 pages. \$7 00.

In revising this work for its eighth appearance, the author has spared no labor to render it worthy a continuance of the very great favor which has been extended to it by the profession. The whole contents have been rearranged, and to a great extent remodelled; the investigations which of late years have been so numerous and so important, have been carefully examined and incorporated, and the work in every respect has been brought up to a level with the present state of the subject. The object of the author has been to render it a concise but comprehensive treatise, containing the whole body of physiological science, to which the student and man of science can at all times refer with the certainty of finding whatever they are in search of, fully presented in all its aspects; and on no former edition has the author bestowed more labor to secure this result.

We believe that it can truly be said, no more complete repository of facts upon the subject treated, can anywhere be found. The author has, moreover, that enviable tact at description and that facility and ease of expression which render him peculiarly acceptable to the casual, or the studious reader. This facility, so requisite in setting forth many graver and less attractive subjects, lends additional charms to one always fascinating.—*Boston Med. and Surg. Journal.*

The most complete and satisfactory system of Physiology in the English language.—*Amer. Med Journal.*

The best work of the kind in the English language.—*Silliman's Journal.*

The present edition the author has made a perfect mirror of the science as it is at the present hour. As a work upon physiology proper, the science of the functions performed by the body, the student will find it all he wishes.—*Nashville Journ of Med*

That he has succeeded, most admirably succeeded in his purpose, is apparent from the appearance of an eighth edition. It is now the great encyclopædia on the subject, and worthy of a place in every physician's library.—*Western Lancet.*

BY THE SAME AUTHOR. (A new edition.)

GENERAL THERAPEUTICS AND MATERIA MEDICA; adapted for a Medical Text-book. With Indexes of Remedies and of Diseases and their Remedies. SIXTH EDITION, revised and improved. With one hundred and ninety-three illustrations. In two large and handsomely printed octavo vols., leather, of about 1100 pages. \$6 00.

In announcing a new edition of Dr. Dunglison's General Therapeutics and Materia Medica, we have no words of commendation to bestow upon a work whose merits have been heretofore so often and so justly extolled. It must not be supposed, however, that the present is a mere reprint of the previous edition; the character of the author for laborious research, judicious analysis, and clearness of expression, is fully sustained by the numerous additions he has made to the work, and the careful revision to which he has subjected the whole.—*N. A. Medico-Chir. Review*, Jan. 1858.

The work will, we have little doubt, be bought and read by the majority of medical students; its size, arrangement, and reliability recommend it to all; no one, we venture to predict, will study it without profit, and there are few to whom it will not be in some measure useful as a work of reference. The young practitioner, more especially, will find the copious indexes appended to this edition of great assistance in the selection and preparation of suitable formulæ.—*Charleston Med. Journ. and Review*, Jan. 1858.

BY THE SAME AUTHOR. (A new Edition.)

NEW REMEDIES, WITH FORMULÆ FOR THEIR PREPARATION AND ADMINISTRATION. Seventh edition, with extensive Additions. In one very large octavo volume, leather, of 770 pages. \$3 75.

Another edition of the "New Remedies" having been called for, the author has endeavored to add everything of moment that has appeared since the publication of the last edition.

The articles treated of in the former editions will be found to have undergone considerable expansion in this, in order that the author might be enabled to introduce, as far as practicable, the results of the subsequent experience of others, as well as of his own observation and reflection; and to make the work still more deserving of the extended circulation with which the preceding editions have been favored by the profession. By an enlargement of the page, the numerous additions have been incorporated without greatly increasing the bulk of the volume.—*Preface.*

One of the most useful of the author's works.—*Southern Medical and Surgical Journal.*

This elaborate and useful volume should be found in every medical library, for as a book of reference, for physicians, it is unsurpassed by any other work in existence, and the double index for diseases and for remedies, will be found greatly to enhance its value.—*New York Med. Gazette.*

The great learning of the author, and his remarkable industry in pushing his researches into every source whence information is derivable, have enabled him to throw together an extensive mass of facts and statements, accompanied by full reference to authorities; which last feature renders the work practically valuable to investigators who desire to examine the original papers.—*The American Journal of Pharmacy.*

ELLIS (BENJAMIN), M. D.

THE MEDICAL FORMULARY: being a Collection of Prescriptions, derived from the writings and practice of many of the most eminent physicians of America and Europe. Together with the usual Dietetic Preparations and Antidotes for Poisons. To which is added an Appendix, on the Endermic use of Medicines, and on the use of Ether and Chloroform. The whole accompanied with a few brief Pharmaceutical and Medical Observations. Eleventh edition, revised and much extended by ROBERT P. THOMAS, M. D., Professor of Materia Medica in the Philadelphia College of Pharmacy. (*Preparing.*)

ERICHSEN (JOHN),

Professor of Surgery in University College, London, &c.

THE SCIENCE AND ART OF SURGERY; BEING A TREATISE ON SURGICAL

INJURIES, DISEASES, AND OPERATIONS. New and improved American, from the second enlarged and carefully revised London edition. Illustrated with over four hundred engravings on wood. In one large and handsome octavo volume, of one thousand closely printed pages, leather, raised bands. \$4 50. (Just Issued.)

The very distinguished favor with which this work has been received on both sides of the Atlantic has stimulated the author to render it even more worthy of the position which it has so rapidly attained as a standard authority. Every portion has been carefully revised, numerous additions have been made, and the most watchful care has been exercised to render it a complete exponent of the most advanced condition of surgical science. In this manner the work has been enlarged by about a hundred pages, while the series of engravings has been increased by more than a hundred, rendering it one of the most thoroughly illustrated volumes before the profession. The additions of the author having rendered unnecessary most of the notes of the former American editor, but little has been added in this country; some few notes and occasional illustrations have, however, been introduced to elucidate American modes of practice.

It is, in our humble judgment, decidedly the best book of the kind in the English language. Strange that just such books are not often produced by public teachers of surgery in this country and Great Britain. Indeed, it is a matter of great astonishment, but no less true than astonishing, that of the many works on surgery republished in this country within the last fifteen or twenty years as text-books for medical students, this is the only one that even approximates to the fulfilment of the peculiar wants of young men just entering upon the study of this branch of the profession.—*Western Jour. of Med. and Surgery.*

Its value is greatly enhanced by a very copious well-arranged index. We regard this as one of the most valuable contributions to modern surgery. To one entering his novitiate of practice, we regard it the most serviceable guide which he can consult. He will find a fulness of detail leading him through every

step of the operation, and not deserting him until the final issue of the case is decided.—*Sethscape.*

Embracing, as will be perceived, the whole surgical domain, and each division of itself almost complete and perfect, each chapter full and explicit, each subject faithfully exhibited, we can only express our estimate of it in the aggregate. We consider it an excellent contribution to surgery, as probably the best single volume now extant on the subject, and with great pleasure we add it to our text-books.—*Nashville Journal of Medicine and Surgery.*

Prof. Erichsen's work, for its size, has not been surpassed; his nine hundred and eight pages, profusely illustrated, are rich in physiological, pathological, and operative suggestions, doctrines, details, and processes; and will prove a reliable resource for information, both to physician and surgeon, in the hour of peril.—*N. O. Med. and Surg. Journal.*

FLINT (AUSTIN), M. D.,

Professor of the Theory and Practice of Medicine in the University of Louisville, &c.

PHYSICAL EXPLORATION AND DIAGNOSIS OF DISEASES AFFECT-

ING THE RESPIRATORY ORGANS. In one large and handsome octavo volume, extra cloth, 636 pages. \$3 00.

We regard it, in point both of arrangement and of the marked ability of its treatment of the subjects, as destined to take the first rank in works of this class. So far as our information extends, it has at present no equal. To the practitioner, as well as the student, it will be invaluable in clearing up the diagnosis of doubtful cases, and in shedding light upon difficult phenomena.—*Buffalo Med. Journal.*

A work of original observation of the highest merit. We recommend the treatise to every one who wishes to become a correct auscultator. Based to a very large extent upon cases numerically examined, it carries the evidence of careful study and discrimination upon every page. It does credit to the author, and, through him, to the profession in this country. It is, what we cannot call every book upon auscultation, a readable book.—*Am. Jour. Med. Sciences.*

BY THE SAME AUTHOR. (Now Ready.)

A PRACTICAL TREATISE ON THE DIAGNOSIS, PATHOLOGY, AND TREATMENT OF DISEASES OF THE HEART. In one neat octavo volume, of about 500 pages, extra cloth. \$2 75.

We do not know that Dr. Flint has written anything which is not first rate; but this, his latest contribution to medical literature, in our opinion, surpasses all the others. The work is most comprehensive in its scope, and most sound in the views it enunciates. The descriptions are clear and methodical; the statements are substantiated by facts, and are made with such simplicity and sincerity, that without them they would carry conviction. The style is admirably clear, direct, and free from dryness. With Dr. Walshe's excellent treatise before us, we have no hesitation in saying that Dr. Flint's book is the best work on the heart in the English language.—*Boston Med. and Surg. Journal.*

We have thus endeavored to present our readers with a fair analysis of this remarkable work. Preferring to employ the very words of the distinguished author, wherever it was possible, we have essayed to condense into the briefest space a general view of his observations and suggestions, and to direct the attention of our brethren to the abounding stores of valuable matter here collected and arranged for their use and instruction. No medical library will hereafter be considered complete without this volume; and we trust it will promptly find its way into the hands of every American student and physician.—*N. Am. Med. Chir. Review.*

This last work of Prof. Flint will add much to his previous well-earned celebrity, as a writer of

great force and hearty, and, with his previous work, places him at the head of American writers upon diseases of the chest. We have adopted his work upon the heart as a text-book, believing it to be more valuable for that purpose than any work of the kind that has yet appeared.—*Nashville Med. Journ.*

With more than pleasure do we hail the advent of this work, for it fills a wide gap on the list of text-books for our schools, and is, for the practitioner, the most valuable practical work of its kind.—*N. O. Med. News.*

In regard to the merits of the work, we have no hesitation in pronouncing it full, accurate, and judicious. Considering the present state of science, such a work was much needed. It should be in the hands of every practitioner.—*Chicago Med. Journal.*

But these are very trivial spots, and in no wise prevent us from declaring our most hearty approval of the author's ability, industry, and conscientiousness.—*Dublin Quarterly Journal of Med. Sciences.*

He has labored on with the same industry and care, and his place among the first authors of our country is becoming fully established. To this end, the work whose title is given above, contributes in no small degree. Our space will not admit of an extended analysis, and we will close this brief notice by commending it without reserve to every class of readers in the profession.—*Peninsular Med. Journ.*

FOWNES (GEORGE), PH. D., &c.

A MANUAL OF ELEMENTARY CHEMISTRY; Theoretical and Practical.

From the seventh revised and corrected London edition. With one hundred and ninety-seven illustrations. Edited by ROBERT BRIDGES, M. D. In one large royal 12mo. volume, of 600 pages. In leather, \$1 65; extra cloth, \$1 50. (*Just Issued.*)

The death of the author having placed the editorial care of this work in the practised hands of Drs. Bence Jones and A. W. Hoffman, everything has been done in its revision which experience could suggest to keep it on a level with the rapid advance of chemical science. The additions requisite to this purpose have necessitated an enlargement of the page, notwithstanding which the work has been increased by about fifty pages. At the same time every care has been used to maintain its distinctive character as a condensed manual for the student, divested of all unnecessary detail or mere theoretical speculation. The additions have, of course, been mainly in the department of Organic Chemistry, which has made such rapid progress within the last few years, but yet equal attention has been bestowed on the other branches of the subject—Chemical Physics and Inorganic Chemistry—to present all investigations and discoveries of importance, and to keep up the reputation of the volume as a complete manual of the whole science, admirably adapted for the learner. By the use of a small but exceedingly clear type the matter of a large octavo is compressed within the convenient and portable limits of a moderate sized duodecimo, and at the very low price affixed, it is offered as one of the cheapest volumes before the profession.

Dr. Fownes' excellent work has been universally recognized everywhere in his own and this country, as the best elementary treatise on chemistry in the English tongue, and is very generally adopted, we believe, as the standard text-book in all our colleges, both literary and scientific.—*Charleston Med Journ. and Review.*

A standard manual, which has long enjoyed the reputation of embodying much knowledge in a small space. The author has achieved the difficult task of condensation with masterly tact. His book is concise without being dry, and brief without being too dogmatical or general.—*Virginia Med. and Surgical Journal.*

The work of Dr. Fownes has long been before the public, and its merits have been fully appreciated as the best text-book on chemistry now in existence. We do not, of course, place it in a rank superior to the works of Brande, Graham, Turner, Gregory, or Gmelin, but we say that, as a work for students, it is preferable to any of them.—*London Journal of Medicine.*

A work well adapted to the wants of the student. It is an excellent exposition of the chief doctrines and facts of modern chemistry. The size of the work, and still more the condensed yet perspicuous style in which it is written, absolve it from the charges very properly urged against most manuals termed popular.—*Edinburgh Journal of Medical Science.*

FISKE FUND PRIZE ESSAYS — THE EFFECTS OF CLIMATE ON TUBERCULOUS DISEASE. By EDWIN LEE, M. R. C. S., London, and **THE INFLUENCE OF PREGNANCY ON THE DEVELOPMENT OF TUBERCLES** By

EDWARD WARREN, M. D., of Edenton, N. C. Together in one neat 8vo volume, extra cloth, \$1 00. **FRISK ON RENAL AFFECTIONS;** their Diagnosis and Pathology. With illustrations. One volume, royal 12mo., extra cloth 75 cents

FERGUSON (WILLIAM), F. R. S.,

Professor of Surgery in King's College, London, &c.

A SYSTEM OF PRACTICAL SURGERY. Fourth American, from the third and enlarged London edition. In one large and beautifully printed octavo volume, of about 700 pages, with 393 handsome illustrations, leather. \$3 00.

GRAHAM (THOMAS), F. R. S.

THE ELEMENTS OF INORGANIC CHEMISTRY, including the Applications of the Science in the Arts. New and much enlarged edition, by HENRY WATTS and ROBERT BRIDGES, M. D. Complete in one large and handsome octavo volume, of over 800 very large pages, with two hundred and thirty-two wood-cuts, extra cloth. \$4 00.

** Part II., completing the work from p. 431 to end, with Index, Title Matter, &c., may be had separate, cloth backs and paper sides. Price \$2 50.

From Prof. E. N. Horsford, *Harvard College.*

It has, in its earlier and less perfect editions, been familiar to me, and the excellence of its plan and the clearness and completeness of its discussions, have long been my admiration.

No reader of English works on this science can

afford to be without this edition of Prof. Graham's Elements.—*Silliman's Journal*, March, 1858.

From Prof. Wolcott Gibbs, *N. Y. Free Academy.*

The work is an admirable one in all respects, and its republication here cannot fail to exert a positive influence upon the progress of science in this country.

GRIFFITH (ROBERT E.), M. D., &c.

A UNIVERSAL FORMULARY, containing the methods of Preparing and Administering Official and other Medicines. The whole adapted to Physicians and Pharmacutists. SECOND EDITION, thoroughly revised, with numerous additions, by ROBERT P. THOMAS, M. D., Professor of Materia Medica in the Philadelphia College of Pharmacy. In one large and handsome octavo volume, extra cloth, of 650 pages, double columns. \$3 00; or in sheep, \$3 25.

It was a work requiring much perseverance, and when published was looked upon as by far the best work of its kind that had issued from the American press. Prof. Thomas has certainly "improved," as well as added to this Formulary, and has rendered it additionally deserving of the confidence of pharmacutists and physicians.—*Am. Journal of Pharmacy.*

We are happy to announce a new and improved edition of this, one of the most valuable and useful works that have emanated from an American pen. It would do credit to any country, and will be found of daily usefulness to practitioners of medicine; it is better adapted to their purposes than the dispensatories.—*Southern Med. and Surg. Journal.*

It is one of the most useful books a country practitioner can possibly have.—*Medical Chronicle.*

This is a work of six hundred and fifty one pages, embracing all on the subject of preparing and administering medicines that can be desired by the physician and pharmacist.—*Western Lancet.*

The amount of useful, every-day matter for a practicing physician, is really immense.—*Boston Med and Surg. Journal.*

This edition has been greatly improved by the revision and ample additions of Dr. Thomas, and is now, we believe, one of the most complete works of its kind in any language. The additions amount to about seventy pages, and no effort has been spared to include in them all the recent improvements. A work of this kind appears to us indispensable to the physician, and there is none we can more cordially recommend. *N Y Journal of Medicine.*

GROSS (SAMUEL D.), M. D.,

Professor of Surgery in the Jefferson Medical College of Philadelphia, &c.

Enlarged Edition—Now Ready, January, 1862.

A SYSTEM OF SURGERY: Pathological, Diagnostic, Therapeutic, and Operative. Illustrated by TWELVE HUNDRED AND TWENTY-SEVEN ENGRAVINGS. Second edition, much enlarged and carefully revised. In two large and beautifully printed octavo volumes, of about twenty-two hundred pages; strongly bound in leather, with raised bands. Price \$12.

The exhaustion in little more than two years of a large edition of so elaborate and comprehensive a work as this is the best evidence that the author was not mistaken in his estimate of the want which existed of a complete American System of Surgery, presenting the science in all its necessary details and in all its branches. That he has succeeded in the attempt to supply this want is shown not only by the rapid sale of the work, but also by the very favorable manner in which it has been received by the organs of the profession in this country and in Europe, and by the fact that a translation is now preparing in Holland—a mark of appreciation not often bestowed on any scientific work so extended in size.

The author has not been insensible to the kindness thus bestowed upon his labors, and in revising the work for a new edition he has spared no pains to render it worthy of the favor with which it has been received. Every portion has been subjected to close examination and revision; any deficiencies apparent have been supplied, and the results of recent progress in the science and art of surgery have been everywhere introduced; while the series of illustrations has been enlarged by the addition of nearly three hundred wood-cuts, rendering it one of the most thoroughly illustrated works ever laid before the profession. To accommodate these very extensive additions, the work has been printed upon a smaller type, so that notwithstanding the very large increase in the matter and value of the book, its size is more convenient and less cumbersome than before. Every care has been taken in the printing to render the typographical execution unexceptionable, and it is confidently presented as a work in every way worthy of a place in even the most limited library of the practitioner or student.

A few testimonials of the value of the former edition are appended.

Has Dr. Gross satisfactorily fulfilled this object? A careful perusal of his volumes enables us to give an answer in the affirmative. Not only has he given to the reader an elaborate and well-written account of his own vast experience, but he has not failed to embody in his pages the opinions and practice of surgeons in this and other countries of Europe. The result has been a work of such completeness, that it has no superior in the systematic treatises on surgery which have emanated from English or Continental authors. It has been justly objected that these have been far from complete in many essential particulars, many of them having been deficient in some of the most important points which should characterize such works. Some of them have been elaborate—too elaborate—with respect to certain diseases, while they have merely glanced at, or given an unsatisfactory account of, others equally important to the surgeon. Dr. Gross has avoided this error, and has produced the most complete work that has yet issued from the press on the science and practice of surgery. It is not, strictly speaking, a Dictionary of Surgery, but it gives to the reader all the information that he may require for his treatment of surgical diseases. Having said so much, it might appear superfluous to add another word; but it is only due to Dr. Gross to state that he has embraced the opportunity of transferring to his pages a vast number of engravings from English and other authors, illustrative of the pathology and treatment of surgical diseases. To these are added several hundred original wood-cuts. The work altogether commends itself to the attention of British surgeons, from whom it cannot fail to meet with extensive patronage.—*London Lancet*, Sept. 1, 1860.

BY THE SAME AUTHOR.

ELEMENTS OF PATHOLOGICAL ANATOMY. Third edition, thoroughly revised and greatly improved. In one large and very handsome octavo volume, with about three hundred and fifty beautiful illustrations, of which a large number are from original drawings. Price in extra cloth, \$4 75; leather, raised bands, \$5 25. (*Lately Published.*)

The very rapid advances in the Science of Pathological Anatomy during the last few years have rendered essential a thorough modification of this work, with a view of making it a correct exponent of the present state of the subject. The very careful manner in which this task has been executed, and the amount of alteration which it has undergone, have enabled the author to say that "with the many changes and improvements now introduced, the work may be regarded almost as a new treatise," while the efforts of the author have been seconded as regards the mechanical execution of the volume, rendering it one of the handsomest productions of the American press.

We most sincerely congratulate the author on the successful manner in which he has accomplished his proposed object. His book is most admirably calculated to fill up a blank which has long been felt to exist in this department of medical literature, and as such must become very widely circulated amongst all classes of the profession.—*Dublin Quarterly Journ. of Med. Science*, Nov. 1857.

BY THE SAME AUTHOR.

A PRACTICAL TREATISE ON FOREIGN BODIES IN THE AIR-PASSAGES. In one handsome octavo volume, extra cloth, with illustrations. pp. 468. \$2 75.

Of Dr. Gross's treatise on Surgery we can say no more than that it is the most elaborate and complete work on this branch of the healing art which has ever been published in any country. A systematic work, it admits of no analytical review; but, did our space permit, we should gladly give some extracts from it, to enable our readers to judge of the classical style of the author, and the exhausting way in which each subject is treated.—*Dublin Quarterly Journal of Med. Science*.

The work is so superior to its predecessors in matter and extent, as well as in illustrations and style of publication, that we can honestly recommend it as the best work of the kind to be taken home by the young practitioner.—*Am. Med. Journ.*

With pleasure we record the completion of this long-anticipated work. The reputation which the author has for many years sustained, both as a surgeon and as a writer, had prepared us to expect a treatise of great excellence and originality; but we confess we were by no means prepared for the work which is before us—the most complete treatise upon surgery ever published, either in this or any other country, and we might, perhaps, safely say, the most original. There is no subject belonging properly to surgery which has not received from the author a due share of attention. Dr. Gross has supplied a want in surgical literature which has long been felt by practitioners; he has furnished us with a complete practical treatise upon surgery in all its departments. As Americans, we are proud of the achievement; as surgeons, we are most sincerely thankful to him for his extraordinary labors in our behalf.—*N. Y. Monthly Review and Buffalo Med. Journal*.

We have been favorably impressed with the general manner in which Dr. Gross has executed his task of affording a comprehensive digest of the present state of the literature of Pathological Anatomy, and have much pleasure in recommending his work to our readers, as we believe one well deserving of diligent perusal and careful study.—*Montreal Med. Chron.*, Sept. 1857.

GROSS (SAMUEL D.), M. D.,

Professor of Surgery in the Jefferson Medical College of Philadelphia, &c.

A PRACTICAL TREATISE ON THE DISEASES, INJURIES, AND MALFORMATIONS OF THE URINARY BLADDER, THE PROSTATE GLAND, AND THE URETHRA. Second Edition, revised and much enlarged, with one hundred and eighty-four illustrations. In one large and very handsome octavo volume, of over nine hundred pages. In leather, raised bands, \$5 25; extra cloth, \$4 75.

Philosophical in its design, methodical in its arrangement, ample and sound in its practical details, it may in truth be said to leave scarcely anything to be desired on so important a subject.—*Boston Med. and Surg. Journal*

Whoever will peruse the vast amount of valuable practical information it contains, will, we think,

agree with us, that there is no work in the English language which can make any just pretensions to be its equal.—*N. Y. Journal of Medicine*

A volume replete with truths and principles of the utmost value in the investigation of these diseases.—*American Medical Journal*.

GRAY (HENRY), F. R. S.,

Lecturer on Anatomy at St. George's Hospital, London, &c.

ANATOMY, DESCRIPTIVE AND SURGICAL. The Drawings by H. V.

CARTER, M. D., late Demonstrator on Anatomy at St. George's Hospital; the Dissections jointly by the AUTHOR and Dr. CARTER. Second American, from the second revised and improved London edition. In one magnificent imperial octavo volume, of over 800 pages, with 388 large and elaborate engravings on wood. Price in extra cloth, \$6 25; leather, raised bands, \$7 00. (Now Ready, 1862.)

The speedy exhaustion of a large edition of this work is sufficient evidence that its plan and execution have been found to present superior practical advantages in facilitating the study of Anatomy. In presenting it to the profession a second time, the author has availed himself of the opportunity to supply any deficiencies which experience in its use had shown to exist, and to correct any errors of detail, to which the first edition of a scientific work on so extensive and complicated a science is liable. These improvements have resulted in some increase in the size of the volume, while twenty-six new wood-cuts have been added to the beautiful series of illustrations which form so distinctive a feature of the work. The American edition has been passed through the press under the supervision of a competent professional man, who has taken every care to render it in all respects accurate, and it is now presented, without any increase of price, as fitted to maintain and extend the popularity which it has everywhere acquired.

With little trouble, the busy practitioner whose knowledge of anatomy may have become obscured by want of practice, may now resuscitate his former anatomical lore, and be ready for any emergency. It is to this class of individuals, and not to the student alone, that this work will ultimately tend to be of most incalculable advantage, and we feel satisfied that the library of the medical man will soon be considered incomplete in which a copy of this work does not exist.—*Madras Quarterly Journal of Med. Science*, July, 1861.

This edition is much improved and enlarged, and contains several new illustrations by Dr. Westmacott. The volume is a complete companion to the dissecting-room, and saves the necessity of the student possessing a variety of "Manuals."—*The London Lancet*, Feb. 9, 1861.

The work before us is one entitled to the highest praise, and we accordingly welcome it as a valuable addition to medical literature. Intermediate in fulness of detail between the treatises of Sharpey and of Wilson, its characteristic merit lies in the number and excellence of the engravings it contains. Most of these are original, of much larger than ordinary size, and admirably executed. The various parts are also lettered after the plan adopted in Holden's Osteology. It would be difficult to over-estimate the advantages offered by this mode of pictorial illustration. Bones, ligaments, muscles, bloodvessels, and nerves are each in turn figured, and marked with their appropriate names; thus enabling the student to comprehend, at a glance, what would otherwise often be ignored, or at any rate, acquired only by prolonged and irksome application. In conclusion, we heartily commend the work of Mr. Gray to the attention of the medical profession, feeling certain that it should be regarded as one of the most valuable contributions ever made to educational literature.—*N. Y. Monthly Review*. Dec. 1859.

In this view, we regard the work of Mr. Gray as far better adapted to the wants of the profession, and especially of the student, than any treatise on anatomy yet published in this country. It is destined, we believe, to supersede all others, both as a manual of dissections, and a standard of reference to the student of general or relative anatomy.—*N. Y. Journal of Medicine*, Nov. 1859.

For this truly admirable work the profession is indebted to the distinguished author of "Gray on the Spleen." The vacancy it fills has been long felt

to exist in this country. Mr. Gray writes throughout with both branches of his subject in view. His description of each particular part is followed by a notice of its relations to the parts with which it is connected, and this, too, sufficiently ample for all the purposes of the operative surgeon. After describing the bones and muscles, he gives a concise statement of the fractures to which the bones of the extremities are most liable, together with the amount and direction of the displacement to which the fragments are subjected by muscular action. The section on arteries is remarkably full and accurate. Not only is the surgical anatomy given to every important vessel, with directions for its ligation, but at the end of the description of each arterial trunk we have a useful summary of the irregularities which may occur in its origin, course, and termination.—*N. A. Med. Chir. Review*, Mar. 1859.

Mr. Gray's book, in excellency of arrangement and completeness of execution, exceeds any work on anatomy hitherto published in the English language, affording a complete view of the structure of the human body, with especial reference to practical surgery. Thus the volume constitutes a perfect book of reference for the practitioner, demanding a place in even the most limited library of the physician or surgeon, and a work of necessity for the student to fix in his mind what he has learned by the dissecting knife from the book of nature.—*The Dublin Quarterly Journal of Med. Sciences*, Nov. 1858.

In our judgment, the mode of illustration adopted in the present volume cannot but present many advantages to the student of anatomy. To the zealous disciple of Vesalius, earnestly desirous of real improvement, the book will certainly be of immense value; but, at the same time, we must also confess that to those simply desirous of "cramming" it will be an undoubted godsend. The peculiar value of Mr. Gray's mode of illustration is nowhere more markedly evident than in the chapter on osteology, and especially in those portions which treat of the bones of the head and of their development. The study of these parts is thus made one of comparative ease, if not of positive pleasure; and those bugbears of the student, the temporal and sphenoid bones, are shorn of half their terrors. It is, in our estimation, an admirable and complete text-book for the student, and a useful work of reference for the practitioner; its pictorial character forming a novel element, to which we have already sufficiently alluded.—*Am. Journ. Med. Sci.*, July, 1859.

GIBSON'S INSTITUTES AND PRACTICE OF SURGERY. Eighth edition, improved and altered. With thirty-four plates. In two handsome octavo volumes, containing about 1,000 pages, leather, raised band. \$6 50

GARDNER'S MEDICAL CHEMISTRY, for the use of Students and the Profession. In one royal 12mo. vol., cloth, pp. 396, with wood-cuts. \$1.

GLUGE'S ATLAS OF PATHOLOGICAL HISTOLOGY. Translated, with Notes and Addi-

tions, by JOSEPH LEIDY, M. D. In one volume, very large imperial quarto, extra cloth, with 320 copper-plate figures, plain and colored, \$5 00.

HUGHES' INTRODUCTION TO THE PRACTICE OF AUSCULTATION AND OTHER MODES OF PHYSICAL DIAGNOSIS IN DISEASES OF THE LUNGS AND HEART. Second edition. 1 vol. royal 12mo., ex. cloth, pp. 304. \$1 00.

HAMILTON (FRANK H.), M. D.,
Professor of Surgery in the Long Island College Hospital.

A PRACTICAL TREATISE ON FRACTURES AND DISLOCATIONS. In one large and handsome octavo volume, of over 750 pages, with 289 illustrations. \$4 25. (Now Ready, January, 1860.)

Among the many good workers at surgery of whom America may now boast not the least is Frank Hastings Hamilton; and the volume before us is (we say it with a pang of wounded patriotism) the best and handiest book on the subject in the English language. It is in vain to attempt a review of it; nearly as vain to seek for any sins, either of commission or omission. We have seen no work on practical surgery which we would sooner recommend to our brother surgeons, especially those of "the services," or those whose practice lies in districts where a man has necessarily to rely on his own unaided resources. The practitioner will find in it directions for nearly every possible accident, easily found and comprehended; and much pleasant reading for him to mure over in the after-consideration of his cases.—*Edinburgh Med. Journ* Feb 1861.

This is a valuable contribution to the surgery of most important affections, and is the more welcome, inasmuch as at the present time we do not possess a single complete treatise on Fractures and Dislocations in the English language. It has remained for our American brother to produce a complete treatise upon the subject, and bring together in a convenient form those alterations and improvements that have been made from time to time in the treatment of these affections. One great and valuable feature in the work before us is the fact that it comprises all the improvements introduced into the practice of both English and American surgery, and though far from omitting mention of our continental neighbors, the author by no means encourages the notion—but too prevalent in some quarters—that nothing is good unless imported from France or Germany. The latter half of the work is devoted to the consideration of the various dislocations and their appropriate treatment, and its merit is fully equal to that of the preceding portion.—*The London Lancet*, May 5, 1860.

It is emphatically the book upon the subjects of which it treats, and we cannot doubt that it will continue so to be for an indefinite period of time. When we say, however, that we believe it will at once take its place as the best book for consultation by the practitioner; and that it will form the most complete, available, and reliable guide in emergencies of every nature connected with its subjects; and also that the student of surgery may make it his textbook with entire confidence, and with pleasure also, from its agreeable and easy style—we think our own

opinion may be gathered as to its value.—*Boston Medical and Surgical Journal*, March 1, 1860.

The work is concise, judicious, and accurate, and adapted to the wants of the student, practitioner, and investigator, honorable to the author and to the profession.—*Chicago Med. Journal*, March, 1860.

We regard this work as an honor not only to its author, but to the profession of our country. Were we to review it thoroughly, we could not convey to the mind of the reader more forcibly our honest opinion expressed in the few words—we think it the best book of its kind extant. Every man interested in surgery will soon have this work on his desk. He who does not, will be the loser.—*New Orleans Medical News*, March, 1860.

Now that it is before us, we feel bound to say that much as was expected from it, and onerous as was the undertaking, it has surpassed expectation, and achieved more than was pledged in its behalf; for its title does not express in full the richness of its contents. On the whole, we are prouder of this work than of any which has for years emanated from the American medical press; its sale will certainly be very large in this country, and we anticipate its eliciting much attention in Europe.—*Nashville Medical Record*, Mar. 1860.

Every surgeon, young and old, should possess himself of it, and give it a careful perusal, in doing which he will be richly repaid.—*St. Louis Med. and Surg. Journal*, March, 1860.

Dr. Hamilton is fortunate in having succeeded in filling the void, so long felt, with what cannot fail to be at once accepted as a model monograph in some respects, and a work of classical authority. We sincerely congratulate the profession of the United States on the appearance of such a publication from one of their number. We have reason to be proud of it as an original work, both in a literary and scientific point of view, and to esteem it as a valuable guide in a most difficult and important branch of study and practice. On every account, therefore, we hope that it may soon be widely known abroad as an evidence of genuine progress on this side of the Atlantic, and further, that it may be still more widely known at home as an authoritative teacher from which every one may profitably learn, and as affording an example of honest, well-directed, and untiring industry in authorship which every surgeon may emulate.—*Am. Med. Journal*, April, 1860.

HOBLYN (RICHARD D.), M. D.

A DICTIONARY OF THE TERMS USED IN MEDICINE AND THE COLLATERAL SCIENCES. A new American edition. Revised, with numerous Additions, by ISAAC HAYS, M. D., editor of the "American Journal of the Medical Sciences." In one large royal 12mo. volume, leather, of over 500 double columned pages. \$1 50.

To both practitioner and student, we recommend this dictionary as being convenient in size, accurate in definition, and sufficiently full and complete for ordinary consultation.—*Charleston Med. Journ.*

We know of no dictionary better arranged and adapted. It is not encumbered with the obsolete terms of a bygone age, but it contains all that are now in

use; embracing every department of medical science down to the very latest date.—*Western Lancet*.

Hoblyn's Dictionary has long been a favorite with us. It is the best book of definitions we have, and ought always to be upon the student's table.—*Southern Med. and Surg. Journal*.

HOLLAND'S MEDICAL NOTES AND REFLECTIONS. From the third London edition. In one handsome octavo volume, extra cloth. \$3.

HORNER'S SPECIAL ANATOMY AND HIS-

TOLOGY. Eighth edition. Extensively revised and modified. In two large octavo volumes, extra cloth, of more than 1000 pages, with over 300 illustrations. \$6 00.

HODGE (HUGH L.), M. D.,

Professor of Midwifery and the Diseases of Women and Children in the University of Pennsylvania, &c.

ON DISEASES PECULIAR TO WOMEN, including Displacements of the Uterus. With original illustrations. In one beautifully printed octavo volume, of nearly 500 pages, extra cloth. \$3 25. (*Now Ready.*)

We will say at once that the work fulfils its object capillary well; and we will moreover venture the assertion that it will inaugurate an improved practice throughout this whole country. The secrets of the author's success are so clearly revealed that the attentive student cannot fail to insure a goodly portion of similar success in his own practice. It is a credit to all medical literature; and we add, that the physician who does not place it in his library, and who does not faithfully con its pages, will lose a vast deal of knowledge that would be most useful to himself and beneficial to his patients. It is a practical work of the highest order of merit; and it will take rank as such immediately.—*Maryland and Virginia Medical Journal*, Feb. 1861.

This contribution towards the elucidation of the pathology and treatment of some of the diseases peculiar to women, cannot fail to meet with a favorable reception from the medical profession. The character of the particular maladies of which the work before us treats; their frequency, variety, and obscurity; the amount of malaise and even of actual suffering by which they are invariably attended; their obstinacy, the difficulty with which they are overcome, and their disposition again and again to recur—these, taken in connection with the entire competency of the author to render a correct account of their nature, their causes, and their appro-

priate management—his ample experience, his matured judgment, and his perfect conscientiousness—invest this publication with an interest and value to which few of the medical treatises of a recent date can lay a stronger, if, perchance, an equal claim.—*Am. Journ. Med. Sciences*, Jan. 1861.

Indeed, although no part of the volume is not eminently deserving of perusal and study, we think that the nine chapters devoted to this subject, are especially so, and we know of no more valuable monograph upon the symptoms, prognosis, and management of these annoying maladies than is constituted by this part of the work. We cannot but regard it as one of the most original and most practical works of the day; one which every accoucheur and physician should most carefully read; for we are persuaded that he will arise from its perusal with new ideas, which will induce him into a more rational practice in regard to many a suffering female, who may have placed her health in his hands.—*British American Journal*, Feb. 1861.

Of the many excellences of the work we will not speak at length. We advise all who would acquire a knowledge of the proper management of the maladies of which it treats, to study it with care. The second part is of itself a most valuable contribution to the practice of our art.—*Am. Med. Monthly and New York Review*, Feb. 1861.

The illustrations, which are all original, are drawn to a uniform scale of one-half the natural size.

HABERSON (S. O.), M. D.,

Assistant Physician to and Lecturer on Materia Medica and Therapeutics at Guy's Hospital, &c.

PATHOLOGICAL AND PRACTICAL OBSERVATIONS ON DISEASES OF THE ALIMENTARY CANAL, ŒSOPHAGUS, STOMACH, CÆCUM, AND INTESTINES. With illustrations on wood. In one handsome octavo volume of 312 pages, extra cloth \$1 75. (*Now Ready.*)

JONES (T. WHARTON), F. R. S.,

Professor of Ophthalmic Medicine and Surgery in University College, London, &c.

THE PRINCIPLES AND PRACTICE OF OPHTHALMIC MEDICINE AND SURGERY. With one hundred and ten illustrations. Second American from the second and revised London edition, with additions by EDWARD HARTSHORNE, M. D., Surgeon to Wills' Hospital, &c. In one large, handsome royal 12mo. volume, extra cloth, of 500 pages. \$1 50.

JONES (C. HANDFIELD), F. R. S., & EDWARD H. SIEVEKING, M. D.,
Assistant Physicians and Lecturers in St. Mary's Hospital, London.

A MANUAL OF PATHOLOGICAL ANATOMY. First American Edition, Revised. With three hundred and ninety-seven handsome wood engravings. In one large and beautiful octavo volume of nearly 750 pages, leather. \$3 75.

As a concise text-book, containing, in a condensed form, a complete outline of what is known in the domain of Pathological Anatomy, it is perhaps the best work in the English language. Its great merit consists in its compactness and brevity, and in this respect it supplies a great desideratum in our literature. Heretofore the student of pathology was

obliged to glean from a great number of monographs, and the field was so extensive that but few cultivated it with any degree of success. As a simple work of reference, therefore, it is of great value to the student of pathological anatomy, and should be in every physician's library.—*Western Lancet*.

KIRKES (WILLIAM SENHOUSE), M. D.,

Demonstrator of Morbid Anatomy at St. Bartholomew's Hospital, &c.

A MANUAL OF PHYSIOLOGY. A new American, from the third and improved London edition. With two hundred illustrations. In one large and handsome royal 12mo. volume, leather. pp. 586. \$2 00. (*Lately Published.*)

This is a new and very much improved edition of Dr. Kirkes' well-known Handbook of Physiology. It combines conciseness with completeness, and is, therefore, admirably adapted for consultation by the busy practitioner.—*Dublin Quarterly Journal*.

One of the very best handbooks of Physiology we possess—presenting just such an outline of the science as the student requires during his attendance upon a course of lectures, or for reference whilst preparing for examination.—*Am. Medical Journal*.

Its excellence is in its compactness, its clearness,

and its carefully cited authorities. It is the most convenient of text-books. These gentlemen, Messrs. Kirkes and Paget, have the gift of telling us what we want to know, without thinking it necessary to tell us all they know.—*Boston Med and Surg. Journal*.

For the student beginning this study, and the practitioner who has but leisure to refresh his memory, this book is invaluable, as it contains all that it is important to know.—*Charleston Med. Journal*.

KNAPP'S TECHNOLOGY; or, Chemistry applied to the Arts and to Manufactures. Edited by Dr. RONALDS, Dr. RICHARDSON, and Prof. W. R. JOHNSON. In two handsome 8vo. vols., with about 500 wood engravings. \$6 00.

LAYCOCK'S LECTURES ON THE PRINCIPLES AND METHODS OF MEDICAL OBSERVATION AND RESEARCH. For the Use of Advanced Students and Junior Practitioners. In one royal 12mo. volume, extra cloth. Price \$1.

LALLEMAND AND WILSON.

A PRACTICAL TREATISE ON THE CAUSES, SYMPTOMS, AND TREATMENT OF SPERMATORRHOEA. By M. LALLEMAND. Translated and edited by HENRY J. McDOUGALL. Third American edition. To which is added — ON DISEASES OF THE VESICULÆ SEMINALES; AND THEIR ASSOCIATED ORGANS. With special reference to the Morbid Secretions of the Prostatic and Urethral Mucous Membrane. By MARRIS WILSON, M. D. In one neat octavo volume, of about 400 pp., extra cloth. \$2 00. (*Just Issued.*)

LA ROCHE (R.), M. D., &c.

YELLOW FEVER, considered in its Historical, Pathological, Etiological, and Therapeutical Relations. Including a Sketch of the Disease as it has occurred in Philadelphia from 1699 to 1854, with an examination of the connections between it and the fevers known under the same name in other parts of temperate as well as in tropical regions. In two large and handsome octavo volumes of nearly 1500 pages, extra cloth. \$7 00.

From Professor S. H. Dickson, Charleston, S. C., September 18, 1855.

A monument of intelligent and well applied research, almost without example. It is, indeed, in itself, a large library, and is destined to constitute the special resort as a book of reference, in the subject of which it treats, to all future time.

We have not time at present, engaged as we are, by day and by night, in the work of combating this very disease, now prevailing in our city, to do more than give this cursory notice of what we consider as undoubtedly the most able and erudite medical publication our country has yet produced. But in view of the startling fact, that this, the most malig-

nant and unmanageable disease of modern times, has for several years been prevailing in our country to a greater extent than ever before; that it is no longer confined to either large or small cities, but penetrates country villages, plantations, and farm-houses; that it is treated with scarcely better success now than thirty or forty years ago; that there is vast mischief done by ignorant pretenders to knowledge in regard to the disease, and in view of the probability that a majority of southern physicians will be called upon to treat the disease, we trust that this able and comprehensive treatise will be very generally read in the south.—*Memphis Med. Recorder.*

BY THE SAME AUTHOR.

PNEUMONIA; its Supposed Connection, Pathological and Etiological, with Autumnal Fevers, including an Inquiry into the Existence and Morbid Agency of Malaria. In one handsome octavo volume, extra cloth, of 500 pages. \$3 00.

LAWRENCE (W.), F. R. S., &c.

A TREATISE ON DISEASES OF THE EYE. A new edition, edited, with numerous additions, and 243 illustrations, by ISAAC HAYS, M. D., Surgeon to Will's Hospital, &c. In one very large and handsome octavo volume, of 950 pages, strongly bound in leather with raised bands. \$5 00.

LUDLOW (J. L.), M. D.

A MANUAL OF EXAMINATIONS upon Anatomy, Physiology, Surgery, Practice of Medicine, Obstetrics, Materia Medica, Chemistry, Pharmacy, and Therapeutics. To which is added a Medical Formulary. Third edition, thoroughly revised and greatly extended and enlarged. With 370 illustrations. In one handsome royal 12mo. volume, leather, of 816 large pages. \$2 50.

We know of no better companion for the student during the hours spent in the lecture room, or to refresh, at a glance, his memory of the various topics

crammed into his head by the various professors to whom he is compelled to listen.—*Western Lancet*, May, 1857.

LEHMANN (C. G.)

PHYSIOLOGICAL CHEMISTRY. Translated from the second edition by GEORGE E. DAY, M. D., F. R. S., &c., edited by R. E. ROGERS, M. D., Professor of Chemistry in the Medical Department of the University of Pennsylvania, with illustrations selected from Funke's Atlas of Physiological Chemistry, and an Appendix of plates. Complete in two large and handsome octavo volumes, extra cloth, containing 1200 pages, with nearly two hundred illustrations. \$6 00.

The work of Lehmann stands unrivalled as the most comprehensive book of reference and information extant on every branch of the subject on which it treats.—*Edinburgh Journal of Medical Science.*

The most important contribution as yet made to Physiological Chemistry.—*Am. Journal Med. Sciences*, Jan. 1856.

BY THE SAME AUTHOR. (*Lately Published.*)

MANUAL OF CHEMICAL PHYSIOLOGY. Translated from the German, with Notes and Additions, by J. CHESTON MORRIS, M. D., with an Introductory Essay on Vital Force, by Professor SAMUEL JACKSON, M. D., of the University of Pennsylvania. With illustrations on wood. In one very handsome octavo volume, extra cloth, of 336 pages. \$2 25.

From Prof. Jackson's Introductory Essay.

In adopting the handbook of Dr Lehmann as a manual of Organic Chemistry for the use of the students of the University, and in recommending his original work of PHYSIOLOGICAL CHEMISTRY for their more mature studies, the high value of his researches, and the great weight of his authority in that important department of medical science are fully recognized.

LYONS (ROBERT D.), K. C. C.,

Late Pathologist in-chief to the British Army in the Crimea, &c.

A TREATISE ON FEVER; or, selections from a course of Lectures on Fever. Being part of a course of Theory and Practice of Medicine. In one neat octavo volume, of 362 pages, extra cloth; \$2 00. (*Now Ready.*)

From the Author's Preface.

"I am induced to publish this work on Fever with a view to bring within the reach of the student and junior practitioner, in a convenient form, the more recent results of inquiries into the Pathology and Therapeutics of this formidable class of diseases.

"The works of the great writers on Fever are so numerous, and in the present day are scattered in so many languages, that they are difficult of access, not only to students but also to practitioners. I shall deem myself fortunate if I can in any measure supply the want which is felt in this respect.

We have great pleasure in recommending Dr. Lyons' work on *Fever* to the attention of the profession. It is a work which cannot fail to enhance the author's previous well-earned reputation, as a diligent, careful, and accurate observer.—*British Med. Journal*, March 2, 1861.

Taken as a whole we can recommend it in the highest terms as well worthy the careful perusal and study of every student and practitioner of medi-

cine. We consider the work a most valuable addition to medical literature, and one destined to wield no little influence over the mind of the profession.—*Med. and Surg. Reporter*, May 4, 1861.

This is an admirable work upon the most remarkable and most important class of diseases to which mankind are liable.—*Med. Journ. of N. Carolina*, May, 1861.

MEIGS (CHARLES D.), M. D.,

Professor of Obstetrics, &c. in the Jefferson Medical College, Philadelphia.

OBSTETRICS: THE SCIENCE AND THE ART. Third edition, revised and improved. With one hundred and twenty-nine illustrations. In one beautifully printed octavo volume, leather, of seven hundred and fifty-two large pages. \$3 75.

Though the work has received only five pages of enlargement, its chapters throughout wear the impress of careful revision. Expunging and rewriting, remodelling its sentences, with occasional new material, all evince a lively desire that it shall deserve to be regarded as improved in manner as well as matter. In the matter, every stroke of the pen has increased the value of the book, both in expungings and additions.—*Western Lancet*, Jan. 1857.

The best American work on Midwifery that is accessible to the student and practitioner.—*N. W. Med. and Surg. Journal*, Jan. 1857.

This is a standard work by a great American Obstetrician. It is the third and last edition, and, in the language of the preface, the author has "brought the subject up to the latest dates of real improvement in our art and Science."—*Nashville Journ. of Med. and Surg.*, May, 1857.

BY THE SAME AUTHOR. (*Just Issued.*)

WOMAN: HER DISEASES AND THEIR REMEDIES. A Series of Lectures to his Class. Fourth and Improved edition. In one large and beautifully printed octavo volume, leather, of over 700 pages. \$3 60.

In other respects, in our estimation, too much cannot be said in praise of this work. It abounds with beautiful passages, and for conciseness, for originality, and for all that is commendable in a work on the diseases of females, it is not excelled, and probably not equalled in the English language. On the whole, we know of no work on the diseases of women which we can so cordially commend to the student and practitioner as the one before us.—*Ohio Med. and Surg. Journal*.

which cannot fail to recommend the volume to the attention of the reader.—*Ranking's Abstract*.

It contains a vast amount of practical knowledge, by one who has accurately observed and retained the experience of many years.—*Dublin Quarterly Journal*.

Full of important matter, conveyed in a ready and agreeable manner.—*St. Louis Med. and Surg. Jour.*

The body of the book is worthy of attentive consideration, and is evidently the production of a clever, thoughtful, and sagacious physician. Dr. Meigs's letters on the diseases of the external organs, contain many interesting and rare cases, and many instructive observations. We take our leave of Dr. Meigs, with a high opinion of his talents and originality.—*The British and Foreign Medico-Chirurgical Review*.

There is an off-hand fervor, a glow, and a warm-heartedness infecting the effort of Dr. Meigs, which is entirely captivating, and which absolutely hurries the reader through from beginning to end. Besides, the book teems with solid instruction, and it shows the very highest evidence of ability, viz., the clearness with which the information is presented. We know of no better test of one's understanding a subject than the evidence of the power of lucidly explaining it. The most elementary, as well as the obscurest subjects, under the pencil of Prof. Meigs, are isolated and made to stand out in such bold relief, as to produce distinct impressions upon the mind and memory of the reader.—*The Charleston Med. Journal*.

Every chapter is replete with practical instruction, and bears the impress of being the composition of an acute and experienced mind. There is a terseness, and at the same time an accuracy in his description of symptoms, and in the rules for diagnosis,

BY THE SAME AUTHOR.

ON THE NATURE, SIGNS, AND TREATMENT OF CHILDBED FEVER. In a Series of Letters addressed to the Students of his Class. In one handsome octavo volume, extra cloth, of 365 pages. \$2 50.

The instructive and interesting author of this work, whose previous labors have placed his countrymen under deep and abiding obligations, again challenges their admiration in the fresh and vigorous, attractive and racy pages before us. It is a de-

lectable book. * * * This treatise upon child-bed fevers will have an extensive sale, being destined, as it deserves, to find a place in the library of every practitioner who scorns to lag in the rear.—*Nashville Journal of Medicine and Surgery*.

BY THE SAME AUTHOR; WITH COLORED PLATES.

A TREATISE ON ACUTE AND CHRONIC DISEASES OF THE NECK OF THE UTERUS. With numerous plates, drawn and colored from nature in the highest style of art. In one handsome octavo volume, extra cloth. \$4 50.

MACLISE (JOSEPH), SURGEON.

SURGICAL ANATOMY. Forming one volume, very large imperial quarto.

With sixty-eight large and splendid Plates, drawn in the best style and beautifully colored. Containing one hundred and ninety Figures, many of them the size of life. Together with copious and explanatory letter-press. Strongly and handsomely bound in extra cloth, being one of the cheapest and best executed Surgical works as yet issued in this country. \$11 00.

* * The size of this work prevents its transmission through the post-office as a whole, but those who desire to have copies forwarded by mail, can receive them in five parts, done up in stout wrappers. Price \$9 00.

One of the greatest artistic triumphs of the age in Surgical Anatomy.—*British American Medical Journal*.

No practitioner whose means will admit should fail to possess it.—*Ranking's Abstract*.

Too much cannot be said in its praise; indeed, we have no language to do it justice.—*Ohio Medical and Surgical Journal*.

The most accurately engraved and beautifully colored plates we have ever seen in an American book—one of the best and cheapest surgical works ever published.—*Buffalo Medical Journal*.

It is very rare that so elegantly printed, so well illustrated, and so useful a work, is offered at so moderate a price.—*Charleston Medical Journal*.

Its plates can boast a superiority which places them almost beyond the reach of competition.—*Medical Examiner*.

Country practitioners will find these plates of immense value.—*N. Y. Medical Gazette*.

A work which has no parallel in point of accuracy and cheapness in the English language.—*N. Y. Journal of Medicine*.

We are extremely gratified to announce to the profession the completion of this truly magnificent work, which, as a whole, certainly stands unrivalled, both for accuracy of drawing, beauty of coloring, and all the requisite explanations of the subject in hand.—*The New Orleans Medical and Surgical Journal*.

This is by far the ablest work on Surgical Anatomy that has come under our observation. We know of no other work that would justify a student, in any degree, for neglect of actual dissection. In those sudden emergencies that so often arise, and which require the instantaneous command of minute anatomical knowledge, a work of this kind keeps the details of the dissecting-room perpetually fresh in the memory.—*The Western Journal of Medicine and Surgery*.

MILLER (HENRY), M. D.,

Professor of Obstetrics and Diseases of Women and Children in the University of Louisville.

PRINCIPLES AND PRACTICE OF OBSTETRICS, &c.; including the Treatment of Chronic Inflammation of the Cervix and Body of the Uterus considered as a frequent cause of Abortion. With about one hundred illustrations on wood. In one very handsome octavo volume, of over 600 pages. (Lately Published.) \$3 75.

We congratulate the author that the task is done. We congratulate him that he has given to the medical public a work which will secure for him a high and permanent position among the standard authorities on the principles and practice of obstetrics. Congratulations are not less due to the medical profession of this country, on the acquisition of a treatise embodying the results of the studies, reflections, and experience of Prof. Miller. Few men, if any, in this country, are more competent than he to write on this department of medicine. Engaged for thirty-five years in an extended practice of obstetrics, for many years a teacher of this branch of instruction in one of the largest of our institutions, a diligent student as well as a careful observer, an original and independent thinker, wedded to no hobbies, ever ready to consider without prejudice new views, and to adopt innovations if they are really improvements, and withal a clear, agreeable writer, a practical treatise from his pen could not fail to possess great value.—*Buffalo Med Journal*.

In fact, this volume must take its place among the standard systematic treatises on obstetrics; a posi-

tion to which its merits justly entitle it. The style is such that the descriptions are clear, and each subject is discussed and elucidated with due regard to its practical bearings, which cannot fail to make it acceptable and valuable to both students and practitioners. We cannot, however, close this brief notice without congratulating the author and the profession on the production of such an excellent treatise. The author is a western man of whom we feel proud, and we cannot but think that his book will find many readers and warm admirers wherever obstetrics is taught and studied as a science and an art.—*The Cincinnati Lancet and Observer*.

A most respectable and valuable addition to our home medical literature, and one reflecting credit alike on the author and the institution to which he is attached. The student will find in this work a most useful guide to his studies; the country practitioner, rusty in his reading, can obtain from its pages a fair résumé of the modern literature of the science; and we hope to see this American production generally consulted by the profession.—*Va. Med. Journal*.

MACKENZIE (W.), M. D.,

Surgeon Oculist in Scotland in ordinary to Her Majesty, &c. &c.

A PRACTICAL TREATISE ON DISEASES AND INJURIES OF THE

EYE. To which is prefixed an Anatomical Introduction explanatory of a Horizontal Section of the Human Eyeball, by THOMAS WHARTON JONES, F. R. S. From the Fourth Revised and Enlarged London Edition. With Notes and Additions by ADDINELL HEWSON, M. D., Surgeon to Wills Hospital, &c. &c. In one very large and handsome octavo volume, leather, raised bands, with plates and numerous wood-cuts. \$5 25.

The treatise of Dr. Mackenzie indisputably holds the first place, and forms, in respect of learning and research, an Encyclopædia unequalled in extent by any other work of the kind, either English or foreign.—*Dixon on Diseases of the Eye*.

Few modern books on any department of medicine or surgery have met with such extended circulation, or have procured for their authors a like amount of European celebrity. The immense research which it displayed, the thorough acquaintance with the subject, practically as well as theoretically, and the

able manner in which the author's stores of learning and experience were rendered available for general use, at once procured for the first edition, as well on the continent as in this country, that high position as a standard work which each successive edition has more firmly established. We consider it the duty of every one who has the love of his profession and the welfare of his patient at heart, to make himself familiar with this the most complete work in the English language upon the diseases of the eye.—*Med. Times and Gazette*.

MAYNE'S DISPENSATORY AND THERAPEUTICAL REMEMBRANCER. With every Practical Formula contained in the three British Pharmacopœias. Edited, with the addition of the Formulæ of the U. S. Pharmacopœia, by R. E. GRIFFITH, M. D. 12mo. vol. ex. cl., 300 pp. 75 c.

MALGAIGNE'S OPERATIVE SURGERY, based on Normal and Pathological Anatomy. Translated from the French by FREDERICK BRITTON, A. B., M. D. With numerous illustrations on wood. In one handsome octavo volume, extra cloth, of nearly six hundred pages. \$3 00.

MILLER (JAMES), F. R. S. E.,
Professor of Surgery in the University of Edinburgh, &c.

PRINCIPLES OF SURGERY. Fourth American, from the third and revised Edinburgh edition. In one large and very beautiful volume, leather, of 700 pages, with two hundred and forty illustrations on wood. \$3 75.

The work of Mr. Miller is too well and too favorably known among us, as one of our best text-books, to render any further notice of it necessary than the announcement of a new edition, the fourth in our country, a proof of its extensive circulation among us. As a concise and reliable exposition of the science of modern surgery, it stands deservedly high—we know not its superior.—*Boston Med. and Surg. Journal.*

The work takes rank with Watson's Practice of Physic; it certainly does not fall behind that great work in soundness of principle or depth of reasoning and research. No physician who values his reputation, or seeks the interests of his clients, can acquit himself before his God and the world without making himself familiar with the sound and philosophical views developed in the foregoing book.—*New Orleans Med. and Surg. Journal.*

BY THE SAME AUTHOR. (Just Issued.)

THE PRACTICE OF SURGERY. Fourth American from the last Edinburgh edition. Revised by the American editor. Illustrated by three hundred and sixty-four engravings on wood. In one large octavo volume, leather, of nearly 700 pages. \$3 75.

No encomium of ours could add to the popularity of Miller's Surgery. Its reputation in this country is unsurpassed by that of any other work, and, when taken in connection with the author's *Principles of Surgery*, constitutes a whole, without reference to which no conscientious surgeon would be willing to practice his art.—*Southern Med. and Surg. Journal.*

It is seldom that two volumes have ever made so profound an impression in so short a time as the "Principles" and the "Practice" of Surgery by Mr. Miller—or so richly merited the reputation they have acquired. The author is an eminently sensible, practical, and well-informed man, who knows exactly what he is talking about and exactly how to talk it.—*Kentucky Medical Recorder.*

By the almost unanimous voice of the profession,

his works, both on the principles and practice of surgery have been assigned the highest rank. If we were limited to but one work on surgery, that one should be Miller's, as we regard it as superior to all others.—*St. Louis Med. and Surg. Journal.*

The author has in this and his "Principles," presented to the profession one of the most complete and reliable systems of Surgery extant. His style of writing is original, impressive, and engaging, energetic, concise, and lucid. Few have the faculty of condensing so much in small space, and at the same time so persistently holding the attention. Whether as a text-book for students or a book of reference for practitioners, it cannot be too strongly recommended.—*Southern Journal of Med. and Physical Sciences.*

MORLAND (W. W.), M. D.,

Fellow of the Massachusetts Medical Society, &c.

DISEASES OF THE URINARY ORGANS; a Compendium of their Diagnosis, Pathology, and Treatment. With illustrations. In one large and handsome octavo volume, of about 600 pages, extra cloth. (Just Issued.) \$3 50.

Taken as a whole, we can recommend Dr. Morland's compendium as a very desirable addition to the library of every medical or surgical practitioner.—*Erit and For. Med.-Chir. Rev.*, April, 1859.

Every medical practitioner whose attention has been to any extent attracted towards the class of diseases to which this treatise relates, must have often and sorely experienced the want of some full, yet concise recent compendium to which he could

refer. This desideratum has been supplied by Dr. Morland, and it has been ably done. He has placed before us a full, judicious, and reliable digest. Each subject is treated with sufficient minuteness, yet in a succinct, narrational style, such as to render the work one of great interest, and one which will prove in the highest degree useful to the general practitioner.—*N. Y. Journ. of Medicine.*

BY THE SAME AUTHOR.—(Now Ready.)

THE MORBID EFFECTS OF THE RETENTION IN THE BLOOD OF THE ELEMENTS OF THE URINARY SECRETION. Being the Dissertation to which the Fiske Fund Prize was awarded, July 11, 1861. In one small octavo volume, 83 pages, extra cloth. 75 cents.

MONTGOMERY (W. F.), M. D., M. R. I. A., &c.,

Professor of Midwifery in the King and Queen's College of Physicians in Ireland, &c.

AN EXPOSITION OF THE SIGNS AND SYMPTOMS OF PREGNANCY.

With some other Papers on Subjects connected with Midwifery. From the second and enlarged English edition. With two exquisite colored plates, and numerous wood-cuts. In one very handsome octavo volume, extra cloth, of nearly 600 pages. (Lately Published.) \$3 75.

A book unusually rich in practical suggestions.—*Am. Journal Med. Sciences*, Jan. 1857.

These several subjects so interesting in themselves, and so important, every one of them, to the most delicate and precious of social relations, controlling often the honor and domestic peace of a family, the legitimacy of offspring, or the life of its parent, are all treated with an elegance of diction, fulness of illustrations, acuteness and justice of reasoning, unparalleled in obstetrics, and unsurpassed in medicine. The reader's interest can never flag, so

fresh, and vigorous, and classical is our author's style; and one forgets, in the renewed charm of every page, that it, and every line, and every word has been weighed and reweighed through years of preparation; that this is of all others the book of Obstetric Law, on each of its several topics; on all points connected with pregnancy, to be everywhere received as a manual of special jurisprudence, at once announcing fact, affording argument, establishing precedent, and governing alike the jurymen, advocate, and judge.—*N. A. Med.-Chir. Review.*

MOHR (FRANCIS), PH. D., AND REDWOOD (THEOPHILUS).

PRACTICAL PHARMACY. Comprising the Arrangements, Apparatus, and Manipulations of the Pharmaceutical Shop and Laboratory. Edited, with extensive Additions, by Prof. WILLIAM PROCTER, of the Philadelphia College of Pharmacy. In one handsomely printed octavo volume, extra cloth, of 570 pages, with over 500 engravings on wood. \$2 75.

NEILL (JOHN), M. D.,

Surgeon to the Pennsylvania Hospital, &c.; and

FRANCIS GURNEY SMITH, M. D.,

Professor of Institutes of Medicine in the Pennsylvania Medical College.

AN ANALYTICAL COMPENDIUM OF THE VARIOUS BRANCHES OF MEDICAL SCIENCE; for the Use and Examination of Students. A new edition, revised and improved. In one very large and handsomely printed royal 12mo. volume, of about one thousand pages, with 374 wood-cuts. Strongly bound in leather, with raised bands. \$3 00.

The very flattering reception which has been accorded to this work, and the high estimate placed upon it by the profession, as evinced by the constant and increasing demand which has rapidly exhausted two large editions, have stimulated the authors to render the volume in its present revision more worthy of the success which has attended it. It has accordingly been thoroughly examined, and such errors as had on former occasions escaped observation have been corrected, and whatever additions were necessary to maintain it on a level with the advance of science have been introduced. The extended series of illustrations has been still further increased and much improved, while, by a slight enlargement of the page, these various additions have been incorporated without increasing the bulk of the volume.

The work is, therefore, again presented as eminently worthy of the favor with which it has hitherto been received. As a book for daily reference by the student requiring a guide to his more elaborate text-books, as a manual for preceptors desiring to stimulate their students by frequent and accurate examination, or as a source from which the practitioners of older date may easily and cheaply acquire a knowledge of the changes and improvement in professional science, its reputation is permanently established.

The best work of the kind with which we are acquainted.—*Med. Examiner.*

Having made free use of this volume in our examinations of pupils, we can speak from experience in recommending it as an admirable compend for students, and as especially useful to preceptors who examine their pupils. It will save the teacher much labor by enabling him readily to recall all of the points upon which his pupils should be examined. A work of this sort should be in the hands of every one who takes pupils into his office with a view of examining them; and this is unquestionably the best of its class.—*Transylvania Med. Journal*

In the rapid course of lectures, where work for

the students is heavy, and review necessary for an examination, a compend is not only valuable, but it is almost a *sine qua non*. The one before us is, in most of the divisions, the most unexceptionable of all books of the kind that we know of. The newest and soundest doctrines and the latest improvements and discoveries are explicitly, though concisely, laid before the student. There is a class to whom we very sincerely commend this cheap book as worth its weight in silver—that class is the graduates in medicine of more than ten years' standing, who have not studied medicine since. They will perhaps find out from it that the science is not exactly now what it was when they left it off.—*The Stethoscope*

NELIGAN (J. MOCRE), M. D., M. R. I. A., &c.

(A splendid work. Just Issued.)

ATLAS OF CUTANEOUS DISEASES. In one beautiful quarto volume, extra cloth, with splendid colored plates, presenting nearly one hundred elaborate representations of disease. \$4 50.


This beautiful volume is intended as a complete and accurate representation of all the varieties of Diseases of the Skin. While it can be consulted in conjunction with any work on Practice, it has especial reference to the author's "Treatise on Diseases of the Skin," so favorably received by the profession some years since. The publishers feel justified in saying that few more beautifully executed plates have ever been presented to the profession of this country.

Neligan's Atlas of Cutaneous Diseases supplies a long existing desideratum much felt by the largest class of our profession. It presents, in quarto size, 16 plates, each containing from 3 to 6 figures, and forming in all a total of 90 distinct representations of the different species of skin affections, grouped together in genera or families. The illustrations have been taken from nature, and have been copied with such fidelity that they present a striking picture of life; in which the reduced scale aptly serves to

give, at a *coup d'œil*, the remarkable peculiarities of each individual variety. And while thus the disease is rendered more definable, there is yet no loss of proportion incurred by the necessary concentration. Each figure is highly colored, and so truthful has the artist been that the most fastidious observer could not justly take exception to the correctness of the execution of the pictures under his scrutiny.—*Montreal Med. Chronicle.*

BY THE SAME AUTHOR.

A PRACTICAL TREATISE ON DISEASES OF THE SKIN. Third American edition. In one neat royal 12mo. volume, extra cloth, of 334 pages. \$1 00.

 The two volumes will be sent by mail on receipt of *Five Dollars*.

OWEN ON THE DIFFERENT FORMS OF THE SKELETON, AND OF THE TEETH.

One vol. royal 12mo., extra cloth with numerous illustrations. \$1 25

PIRRIE (WILLIAM), F. R. S. E.,

Professor of Surgery in the University of Aberdeen.

THE PRINCIPLES AND PRACTICE OF SURGERY. Edited by JOHN NEILL, M. D., Professor of Surgery in the Penna. Medical College, Surgeon to the Pennsylvania Hospital, &c. In one very handsome octavo volume, leather, of 780 pages, with 316 illustrations. \$3 75.

We know of no other surgical work of a reasonable size, wherein there is so much theory and practice, or where subjects are more soundly or clearly taught.—*The Stethoscope.*

Prof. Pirrie, in the work before us, has elabo-

ately discussed the principles of surgery, and a safe and effectual practice predicated upon them. Perhaps no work upon this subject heretofore issued is so full upon the science of the art of surgery.—*Nashville Journal of Medicine and Surgery.*

PARRISH (EDWARD),

Lecturer on Practical Pharmacy and Materia Medica in the Pennsylvania Academy of Medicine, &c.

AN INTRODUCTION TO PRACTICAL PHARMACY. Designed as a Text-Book for the Student, and as a Guide for the Physician and Pharmacist. With many Formulæ and Prescriptions. Second edition, greatly enlarged and improved. In one handsome octavo volume of 720 pages, with several hundred Illustrations, extra cloth. \$3 50. (*Just Issued.*)

During the short time in which this work has been before the profession, it has been received with very great favor, and in assuming the position of a standard authority, it has filled a vacancy which had been severely felt. Stimulated by this encouragement, the author, in availing himself of the opportunity of revision, has spared no pains to render it more worthy of the confidence bestowed upon it, and his assiduous labors have made it rather a new book than a new edition, many portions having been rewritten, and much new and important matter added. These alterations and improvements have been rendered necessary by the rapid progress made by pharmaceutical science during the last few years, and by the additional experience obtained in the practical use of the volume as a text-book and work of reference. To accommodate these improvements, the size of the page has been materially enlarged, and the number of pages considerably increased, presenting in all nearly *one-half more* matter than the last edition. The work is therefore now presented as a complete exponent of the subject in its most advanced condition. From the most ordinary matters in the dispensing office, to the most complicated details of the vegetable alkaloids, it is hoped that everything requisite to the practising physician, and to the apothecary, will be found fully and clearly set forth, and that the new matter alone will be worth more than the very moderate cost of the work to those who have been consulting the previous edition.

That Edward Parrish, in writing a book upon *practical Pharmacy* some few years ago—one eminently original and unique—did the medical and pharmaceutical professions a great and valuable service, no one, we think, who has had access to its pages will deny; doubly welcome, then, is this new edition, containing the added results of his recent and rich experience as an observer, teacher, and practical operator in the pharmaceutical laboratory. The excellent plan of the first is more thoroughly, and in detail, carried out in this edition.—*Peninsular Med. Journal*, Jan. 1860.

Of course, all apothecaries who have not already a copy of the first edition will procure one of this; it is, therefore, to physicians residing in the country and in small towns, who cannot avail themselves of the skill of an educated pharmacist, that we would especially commend this work. In it they

will find all that they desire to know, and should know, but very little of which they do really know in reference to this important collateral branch of their profession; for it is a well established fact, that, in the education of physicians, while the science of medicine is generally well taught, very little attention is paid to the art of preparing them for use, and we know not how this defect can be so well remedied as by procuring and consulting Dr. Parrish's excellent work.—*St. Louis Med. Journal*, Jan. 1860.

We know of no work on the subject which would be more indispensable to the physician or student desiring information on the subject of which it treats. With Griffith's "Medical Formulæ" and this, the practising physician would be supplied with nearly or quite all the most useful information on the subject.—*Charleston Med. Jour. and Review*, Jan. 1860

PEASLEE (E. R.), M. D.,

Professor of Physiology and General Pathology in the New York Medical College.

HUMAN HISTOLOGY, in its relations to Anatomy, Physiology, and Pathology; for the use of Medical Students. With four hundred and thirty-four illustrations. In one handsome octavo volume, of over 600 pages. (*Lately Published.*) \$3 75.

It embraces a library upon the topics discussed within itself, and is just what the teacher and learner need. Another advantage, by no means to be overlooked, every thing of real value in the wide range which it embraces, is with great skill compressed into an octavo volume of but little more than six hundred pages. We have not only the whole subject of Histology, interesting in itself, ably and fully discussed, but what is of infinitely greater interest to the student, because of greater practical value, are its relations to Anatomy, Physiology, and Pathology, which are here fully and satisfactorily set forth.—*Nashville Journ. of Med. and Surgery*.

We would recommend it to the medical student and practitioner, as containing a summary of all that is known of the important subjects which it treats; of all that is contained in the great works of Simon and Lehmann, and the organic chemists in general. Master this one volume, we would say to the medical student and practitioner—master this book and you know all that is known of the great fundamental principles of medicine, and we have no hesitation in saying that it is an honor to the American medical profession that one of its members should have produced it.—*St. Louis Med. and Surg. Journal*.

PEREIRA (JONATHAN), M. D., F. R. S., AND L. S.

THE ELEMENTS OF MATERIA MEDICA AND THERAPEUTICS.

Third American edition, enlarged and improved by the author; including Notices of most of the Medicinal Substances in use in the civilized world, and forming an Encyclopædia of Materia Medica. Edited, with Additions, by JOSEPH CARSON, M. D., Professor of Materia Medica and Pharmacy in the University of Pennsylvania. In two very large octavo volumes of 2100 pages, on small type, with about 500 illustrations on stone and wood, strongly bound in leather, with raised bands. \$9 00.

* * * Vol. II. will no longer be sold separate.

PARKER (LANGSTON),

Surgeon to the Queen's Hospital, Birmingham.

THE MODERN TREATMENT OF SYPHILITIC DISEASES, BOTH PRIMARY AND SECONDARY; comprising the Treatment of Constitutional and Confirmed Syphilis, by a safe and successful method. With numerous Cases, Formulæ, and Clinical Observations. From the Third and entirely rewritten London edition. In one neat octavo volume, extra cloth, of 316 pages. \$1 75.

ROYLE'S MATERIA MEDICA AND THERAPEUTICS; including the

Preparations of the Pharmacopœias of London, Edinburgh, Dublin, and of the United States. With many new medicines. Edited by JOSEPH CARSON, M. D. With ninety-eight illustrations. In one large octavo volume, extra cloth, of about 700 pages. \$3 00.

RAMSBOTHAM (FRANCIS H.), M. D.

THE PRINCIPLES AND PRACTICE OF OBSTETRIC MEDICINE AND SURGERY, in reference to the Process of Parturition. A new and enlarged edition, thoroughly revised by the Author. With Additions by W. V. KEATING, M. D., Professor of Obstetrics, &c., in the Jefferson Medical College, Philadelphia. In one large and handsome imperial octavo volume, of 650 pages, strongly bound in leather, with raised bands; with sixty-four beautiful Plates, and numerous Wood-cuts in the text, containing in all nearly 200 large and beautiful figures. \$5 00.

From Prof. Hodge, of the University of Pa.

To the American public, it is most valuable, from its intrinsic undoubted excellence, and as being the best authorized exponent of British Midwifery. Its circulation will, I trust, be extensive throughout our country.

It is unnecessary to say anything in regard to the utility of this work. It is already appreciated in our country for the value of the matter, the clearness of its style, and the fulness of its illustrations. To the physician's library it is indispensable, while to the student as a text-book, from which to extract the material for laying the foundation of an education on obstetrical science, it has no superior.—*Ohio Med and Surg. Journal*.

The publishers have secured its success by the

truly elegant style in which they have brought it out, excelling themselves in its production, especially in its plates. It is dedicated to Prof. Meigs, and has the emphatic endorsement of Prof. Hodge, as the best exponent of British Midwifery. We know of no text-book which deserves in all respects to be more highly recommended to students, and we could wish to see it in the hands of every practitioner, for they will find it invaluable for reference.—*Med. Gazette*.

RICORD (P.), M. D.

A TREATISE ON THE VENEREAL DISEASE. By JOHN HUNTER, F. R. S.

With copious Additions, by PH. RICORD, M. D. Translated and Edited, with Notes, by FREEMAN J. BUMSTEAD, M. D., Lecturer on Venereal at the College of Physicians and Surgeons, New York. Second edition, revised, containing a *résumé* of RICORD'S RECENT LECTURES ON CHANCERE. In one handsome octavo volume, extra cloth, of 550 pages, with eight plates. \$3 25. (*Just Issued*.)

In revising this work, the editor has endeavored to introduce whatever matter of interest the recent investigations of syphilographers have added to our knowledge of the subject. The principal source from which this has been derived is the volume of "Lectures on Chancre," published a few months since by M. Ricord, which affords a large amount of new and instructive material on many controverted points. In the previous edition, M. Ricord's additions amounted to nearly one-third of the whole, and with the matter now introduced, the work may be considered to present his views and experience more thoroughly and completely than any other.

Every one will recognize the attractiveness and value which this work derives from thus presenting the opinions of these two masters side by side. But, it must be admitted, what has made the fortune of the book, is the fact that it contains the "most complete embodiment of the veritable doctrines of the Hôpital du Midi," which has ever been made public. The doctrinal ideas of M. Ricord, ideas which, if not universally adopted, are incontestably dominant, have heretofore only been interpreted by more or less skilful

secretaries, sometimes accredited and sometimes not.

In the notes to Hunter, the master substitutes himself for his interpreters, and gives his original thoughts to the world in a lucid and perfectly intelligible manner. In conclusion we can say that this is incontestably the best treatise on syphilis with which we are acquainted, and, as we do not often employ the phrase, we may be excused for expressing the hope that it may find a place in the library of every physician.—*Virginia Med. and Surg. Journal*.

BY THE SAME AUTHOR.

RICORD'S LETTERS ON SYPHILIS. Translated by W. P. LATIMORE, M. D.

In one neat octavo volume, of 270 pages, extra cloth. \$2 00.

SLADE (D. D.), M. D.

DIPHTHERIA; its Nature and Treatment, with an Account of the History of its Prevalence in various countries. Being the Dissertation to which the Fiske Fund Prize was awarded, July 11, 1860. In one small octavo volume, extra cloth; 75 cents. (*Now Ready, 1861*.)

ROKITANSKY (CARL), M. D.,

Curator of the Imperial Pathological Museum, and Professor at the University of Vienna, &c.

A MANUAL OF PATHOLOGICAL ANATOMY. Four volumes, octavo,

bound in two, extra cloth, of about 1200 pages. Translated by W. E. SWAINE, EDWARD SIEVEKING, C. H. MOORE, and G. E. DAY. \$5 50.

The profession is too well acquainted with the reputation of Rokitansky's work to need our assurance that this is one of the most profound, thorough, and valuable books ever issued from the medical press. It is *sui generis*, and has no standard of comparison. It is only necessary to announce that it is issued in a form as cheap as is compatible with its size and preservation, and its sale follows as a matter of course. No library can be called complete without it.—*Buffalo Med. Journal*.

An attempt to give our readers any adequate idea of the vast amount of instruction accumulated in these volumes, would be feeble and hopeless. The effort of the distinguished author to concentrate in a small space his great fund of knowledge, has

so charged his text with valuable truths, that any attempt of a reviewer to epitomize is at once paralyzed, and must end in a failure.—*Western Lancet*.

As this is the highest source of knowledge upon the important subject of which it treats, no real student can afford to be without it. The American publishers have entitled themselves to the thanks of the profession of their country, for this timely and beautiful edition.—*Nashville Journal of Medicine*.

As a book of reference, therefore, this work must prove of inestimable value, and we cannot too highly recommend it to the profession.—*Charleston Med. Journal and Review*.

This book is a necessity to every practitioner.—*Am. Med. Monthly*.

RIGBY (EDWARD), M. D.,

Senior Physician to the General Lying-in Hospital, &c.

A SYSTEM OF MIDWIFERY. With Notes and Additional Illustrations.

Second American Edition. One volume octavo, extra cloth, 422 pages. \$2 50.

BY THE SAME AUTHOR. (*Lately Published*.)

ON THE CONSTITUTIONAL TREATMENT OF FEMALE DISEASES.

In one neat royal 12mo. volume, extra cloth, of about 250 pages. \$1 00.

STILLE (ALFRED), M. D.

THERAPEUTICS AND MATERIA MEDICA; a Systematic Treatise on the Action and Uses of Medicinal Agents, including their Description and History. In two large and handsome octavo volumes, of 1789 pages. (*Just Issued.*) \$8 00.

This work is designed especially for the student and practitioner of medicine, and treats the various articles of the *Materia Medica* from the point of view of the bedside, and not of the shop or of the lecture-room. While thus endeavoring to give all practical information likely to be useful with respect to the employment of special remedies in special affections, and the results to be anticipated from their administration, a copious Index of Diseases and their Remedies renders the work eminently fitted for reference by showing at a glance the different means which have been employed, and enabling the practitioner to extend his resources in difficult cases with all that the experience of the profession has suggested.

Rarely, indeed, have we had submitted to us a work on medicine so ponderous in its dimensions as that now before us, and yet so fascinating in its contents. It is, therefore, with a peculiar gratification that we recognize in Dr. Stillé the possession of many of those more distinguished qualifications which entitle him to approbation, and which justify him in coming before his medical brethren as an instructor. A comprehensive knowledge, tested by a sound and penetrating judgment, joined to a love of progress—which a discriminating spirit of inquiry has tempered so as to accept nothing new because it is new, and abandon nothing old because it is old, but which estimates either according to its relations to a just logic and experience—manifests itself everywhere, and gives to the guidance of the author all the assurance of safety which the difficulties of his subject can allow. In conclusion, we earnestly advise our readers to ascertain for themselves, by a study of Dr. Stillé's volumes, the great value and interest of the stores of knowledge they present. We have pleasure in referring rather to the ample treasury of undoubted truths, the real and assured conquest of medicine, accumulated by Dr. Stillé in his pages; and commend the sum of his labors to the attention of our readers, as alike honorable to our science, and creditable to the zeal, the candor, and the judgment of him who has garnered the whole so carefully.—*Edinburgh Med. Journal.*

Our expectations of the value of this work were based on the well-known reputation and character of the author as a man of scholarly attainments, an elegant writer, a candid inquirer after truth, and a philosophical thinker; we knew that the task would be conscientiously performed, and that few, if any, among the distinguished medical teachers in this country are better qualified than he to prepare a systematic treatise on therapeutics in accordance with the present requirements of medical science. Our preliminary examination of the work has satis-

fied us that we were not mistaken in our anticipations.—*New Orleans Medical News*, March, 1860.

The most recent authority is the one last mentioned, *Stillé*. His great work on "*Materia Medica and Therapeutics*," published last year, in two octavo volumes, of some sixteen hundred pages, while it embodies the results of the labor of others up to the time of publication, is enriched with a great amount of original observation and research. We would draw attention, by the way, to the very convenient mode in which the *Index* is arranged in this work. There is first an "*Index of Remedies*;" next an "*Index of Diseases and their Remedies*." Such an arrangement of the Indices, in our opinion, greatly enhances the practical value of books of this kind. In tedious, obstinate cases of disease, where we have to try one remedy after another until our stock is pretty nearly exhausted, and we are almost driven to our wit's end, such an index as the second of the two just mentioned, is precisely what we want.—*London Med. Times and Gazette*, April, 1861.

We think this work will do much to obviate the reluctance to a thorough investigation of this branch of scientific study, for in the wide range of medical literature treasured in the English tongue, we shall hardly find a work written in a style more clear and simple, conveying forcibly the facts taught, and yet free from turgidity and redundancy. There is a fascination in its pages that will insure to it a wide popularity and attentive perusal, and a degree of usefulness not often attained through the influence of a single work. The author has much enhanced the practical utility of his book by passing briefly over the physical, botanical, and commercial history of medicines, and directing attention chiefly to their physiological action, and their application for the amelioration or cure of disease. He ignores hypothesis and theory which are so alluring to many medical writers, and so liable to lead them astray, and confines himself to such facts as have been tried in the crucible of experience.—*Chicago Medical Journal.*

SMITH (HENRY H.), M. D. AND HORNER (WILLIAM E.), M. D.
AN ANATOMICAL ATLAS, illustrative of the Structure of the Human Body.

In one volume, large imperial octavo, extra cloth, with about six hundred and fifty beautiful figures. \$3 00.

These figures are well selected, and present a complete and accurate representation of that wonderful fabric, the human body. The plan of this Atlas, which renders it so peculiarly convenient for the student, and its superb artistic execution, have been already pointed out. We must congratulate

the student upon the completion of this Atlas, as it is the most convenient work of the kind that has yet appeared; and we must add, the very beautiful manner in which it is "got up" is so creditable to the country as to be flattering to our national pride.—*American Medical Journal.*

SHARPEY (WILLIAM), M. D., JONES QUAIN, M. D., AND RICHARD QUAIN, F. R. S., &c.

HUMAN ANATOMY. Revised, with Notes and Additions, by JOSEPH LEIDY, M. D., Professor of Anatomy in the University of Pennsylvania. Complete in two large octavo volumes, leather, of about thirteen hundred pages. Beautifully illustrated with over five hundred engravings on wood. \$6 00.

SIMPSON (J. Y.), M. D.,

Professor of Midwifery, &c., in the University of Edinburgh, &c.

CLINICAL LECTURES ON THE DISEASES OF FEMALES. With numerous illustrations.

This valuable series of practical Lectures is now appearing in the "*MEDICAL NEWS AND LIBRARY*" for 1860, 1861, and 1862, and can thus be had without cost by subscribers to the "*AMERICAN JOURNAL OF THE MEDICAL SCIENCES.*" See p. 2.

SOULLY ON THE HUMAN BRAIN; its Structure, Physiology, and Diseases. From the Second and much enlarged London edition. In one octavo volume, extra cloth, of 500 pages, with 120 woodcuts. \$2 00.

SKEY'S OPERATIVE SURGERY. In one very

handsome octavo volume, extra cloth, of over 650 pages, with about one hundred woodcuts. \$3 25.
SIMON'S GENERAL PATHOLOGY, as conducive to the Establishment of Rational Principles for the prevention and Cure of Disease. In one octavo volume, extra cloth, of 212 pages. \$1 25.

SARGENT (F. W.), M. D.

ON BANDAGING AND OTHER OPERATIONS OF MINOR SURGERY.

New edition, with an additional chapter on Military Surgery. One handsome royal 12mo. vol., of nearly 400 pages, with 184 wood cuts. Extra cloth, \$1 40; leather, \$1 50.

The value of this work as a handy and convenient manual for surgeons engaged in active duty in the field and hospital, has induced the publishers to render it more complete for those purposes by the addition of a chapter on gun-shot wounds and other matters peculiar to military surgery. In its present form, therefore, with no increase in price, it will be found a very cheap and convenient vade-mecum for consultation and reference in the daily exigencies of military as well as civil practice.

Sargent's Minor Surgery has always been popular, and deservedly so. It furnishes that knowledge of the most frequently requisite performances of surgical art which cannot be entirely understood by attending clinical lectures. The art of bandaging, which is regularly taught in Europe, is very frequently overlooked by teachers in this country; the student and junior practitioner, therefore, may often require that knowledge which this little volume so tersely and happily supplies.—*Charleston Med. Journ. and Review.*

A work that has been so long and favorably known to the profession as Dr. Sargent's Minor Surgery, needs no commendation from us. We would remark, however, in this connection, that minor surgery seldom gets that attention in our schools that its importance deserves. Our larger works are also very defective in their teaching on these small practical points. This little book will supply the void which all must feel who have not studied its pages.—*Western Lancet.*

SMITH (W. TYLER), M. D.,

Physician Accoucheur to St. Mary's Hospital, &c.

ON PARTURITION, AND THE PRINCIPLES AND PRACTICE OF OBSTETRICS. In one royal 12mo. volume, extra cloth, of 400 pages. \$1 25.

BY THE SAME AUTHOR.

A PRACTICAL TREATISE ON THE PATHOLOGY AND TREATMENT OF LEUCORRHOEA. With numerous illustrations. In one very handsome octavo volume, extra cloth, of about 250 pages. \$1 50.

TANNER (T. H.), M. D.,

Physician to the Hospital for Women, &c.

A MANUAL OF CLINICAL MEDICINE AND PHYSICAL DIAGNOSIS.

To which is added The Code of Ethics of the American Medical Association. Second American Edition. In one neat volume, small 12mo., extra cloth, 87½ cents.

TAYLOR (ALFRED S.), M. D., F. R. S.,

Lecturer on Medical Jurisprudence and Chemistry in Guy's Hospital.

MEDICAL JURISPRUDENCE. Fifth American, from the seventh improved and enlarged London edition. With Notes and References to American Decisions, by EDWARD HARTSHORNE, M. D. In one large 8vo. volume, leather, of over 700 pages. (*Now Ready.*) \$3 25.

This standard work having had the advantage of two revisions at the hands of the author since the appearance of the last American edition, will be found thoroughly revised and brought up completely to the present state of the science. As a work of authority, it must therefore maintain its position, both as a text-book for the student, and a compendious treatise to which the practitioner can at all times refer in cases of doubt or difficulty.

No work upon the subject can be put into the hands of students either of law or medicine which will engage them more closely or profitably; and none could be offered to the busy practitioner of either calling, for the purpose of casual or hasty reference, that would be more likely to afford the aid desired. We therefore recommend it as the best and safest manual for daily use.—*American Journal of Medical Sciences.*

It is not excess of praise to say that the volume before us is the very best treatise extant on Medical Jurisprudence. In saying this, we do not wish to be understood as detracting from the merits of the excellent works of Beck, Ryan, Traill, Guy, and others; but in interest and value we think it must be conceded that Taylor is superior to anything that has preceded it.—*N. W. Medical and Surg. Journal.*

It is at once comprehensive and eminently practical, and by universal consent stands at the head of

American and British legal medicine. It should be in the possession of every physician, as the subject is one of great and increasing importance to the public as well as to the profession.—*St. Louis Med. and Surg. Journal.*

This work of Dr. Taylor's is generally acknowledged to be one of the ablest extant on the subject of medical jurisprudence. It is certainly one of the most attractive books that we have met with; supplying so much both to interest and instruct, that we do not hesitate to affirm that after having once commenced its perusal, few could be prevailed upon to desist before completing it. In the last London edition, all the newly observed and accurately recorded facts have been inserted, including much that is recent of Chemical, Microscopical, and Pathological research, besides papers on numerous subjects never before published.—*Charleston Med. Journal and Review.*

BY THE SAME AUTHOR. (*New Edition, just issued.*)**ON POISONS, IN RELATION TO MEDICAL JURISPRUDENCE AND MEDICINE.** Second American, from a second and revised London edition. In one large octavo volume, of 755 pages, leather. \$3 50.

Since the first appearance of this work, the rapid advance of Chemistry has introduced into use many new substances which may become fatal through accident or design—while at the same time it has likewise designated new and more exact modes of counteracting or detecting those previously treated of. Mr. Taylor's position as the leading medical jurist of England, has during this period conferred on him extraordinary advantages in acquiring experience on these subjects, nearly all cases of moment being referred to him for examination, as an expert whose testimony is generally accepted as final. The results of his labors, therefore, as gathered together in this volume, carefully weighed and sifted, and presented in the clear and intelligible style for which he is noted, may be received as an acknowledged authority, and as a guide to be followed with implicit confidence.

TODD (ROBERT BENTLEY), M. D., F. R. S.,

Professor of Physiology in King's College, London; and

WILLIAM BOWMAN, F. R. S.,

Demonstrator of Anatomy in King's College, London.

THE PHYSIOLOGICAL ANATOMY AND PHYSIOLOGY OF MAN. With about three hundred large and beautiful illustrations on wood. Complete in one large octavo volume, of 950 pages, leather. Price \$4 50.

☞ Gentlemen who have received portions of this work, as published in the "MEDICAL NEWS AND LIBRARY," can now complete their copies, if immediate application be made. It will be furnished as follows, free by mail, in paper covers, with cloth backs.

PARTS I., II., III. (pp. 25 to 552), \$2 50.

PART IV. (pp. 553 to end, with Title, Preface, Contents, &c.), \$2 00

Or, PART IV., SECTION II. (pp. 725 to end, with Title, Preface, Contents, &c.), \$1 25.

A magnificent contribution to British medicine, and the American physician who shall fail to peruse it, will have failed to read one of the most instructive books of the nineteenth century.—*N. O. Med and Surg. Journal.*

It is more concise than Carpenter's Principles, and more modern than the accessible edition of Muller's Elements; its details are brief, but sufficient; its descriptions vivid; its illustrations exact and copious; and its language terse and perspicuous.—*Charleston Med. Journal.*

We know of no work on the subject of physiology

so well adapted to the wants of the medical student. Its completion has been thus long delayed; that the authors might secure accuracy by personal observation.—*St. Louis Med. and Surg. Journal.*

Our notice, though it conveys but a very feeble and imperfect idea of the magnitude and importance of the work now under consideration, already transcends our limits; and, with the indulgence of our readers, and the hope that they will peruse the book for themselves, as we feel we can with confidence recommend it, we leave it in their hands.—*The Northwestern Med. and Surg. Journal.*

• **TODD (R. B.) M. D., F. R. S., &c.**

CLINICAL LECTURES ON CERTAIN DISEASES OF THE URINARY ORGANS AND ON DROPSIES. In one octavo volume, 284 pages. \$1 50.

BY THE SAME AUTHOR. (*Now Ready.*)

CLINICAL LECTURES ON CERTAIN ACUTE DISEASES. In one neat octavo volume, of 320 pages, extra cloth. \$1 75.

TOYNBEE (JOSEPH), F. R. S.,

Aural Surgeon to, and Lecturer on Surgery at, St. Mary's Hospital.

A PRACTICAL TREATISE ON DISEASES OF THE EAR; their Diagnosis, Pathology, and Treatment. Illustrated with one hundred engravings on wood. In one very handsome octavo volume, extra cloth, \$3 00. (*Just Issued.*)

The work, as was stated at the outset of our notice, is a model of its kind, and every page and paragraph of it are worthy of the most thorough study. Considered all in all—as an original work, well written, philosophically elaborated, and happily illustrated with cases and drawings—it is by far the ablest monograph that has ever appeared on the anatomy and diseases of the ear, and one of the most valuable contributions to the art and science of surgery in the nineteenth century.—*N. Amer. Medic-Chirurg. Review*, Sept. 1860.

To recommend such a work, even after the mere hint we have given of its original excellence and value, would be a work of supererogation. We are speaking within the limits of modest acknowledg-

ment, and with a sincere and unbiassed judgment, when we affirm that as a treatise on Aural Surgery, it is without a rival in our language or any other.—*Charleston Med. Journ and Review*, Sept. 1860.

The work of Mr. Toynbee is undoubtedly, upon the whole the most valuable production of the kind in any language. The author has long been known by his numerous monographs upon subjects connected with diseases of the ear, and is now regarded as the highest authority on most points in his department of science. Mr Toynbee's work, as we have already said, is undoubtedly the most reliable guide for the study of the diseases of the ear in any language, and should be in the library of every physician.—*Chicago Med. Journal*, July, 1860.

WILLIAMS (C. J. B.), M. D., F. R. S.,

Professor of Clinical Medicine in University College, London, &c.

PRINCIPLES OF MEDICINE. An Elementary View of the Causes, Nature, Treatment, Diagnosis, and Prognosis of Disease; with brief remarks on Hygienics, or the preservation of health. A new American, from the third and revised London edition. In one octavo volume, leather, of about 500 pages. \$2 50. (*Just Issued.*)

We find that the deeply-interesting matter and style of this book have so far fascinated us, that we have unconsciously hung upon its pages, not too long, indeed, for our own profit, but longer than reviewers can be permitted to indulge. We leave the further analysis to the student and practitioner. Our judgment of the work has already been sufficiently

expressed. It is a judgment of almost unqualified praise.—*London Lancet.*

A text-book to which no other in our language is comparable.—*Charleston Medical Journal.*

No work has ever achieved or maintained a more deserved reputation.—*Va. Med. and Surg. Journal.*

WHAT TO OBSERVE

AT THE BEDSIDE AND AFTER DEATH, IN MEDICAL CASES.

Published under the authority of the London Society for Medical Observation. A new American, from the second and revised London edition. In one very handsome volume, royal 12mo., extra cloth. \$1 00.

To the observer who prefers accuracy to blunders and precision to carelessness, this little book is invaluable.—*N. H. Journal of Medicine.*

One of the finest aids to a young practitioner we have ever seen.—*Peninsular Journal of Medicine.*

New and much enlarged edition—(Just Issued.)

WATSON (THOMAS), M. D., &c.,

Late Physician to the Middlesex Hospital, &c.

LECTURES ON THE PRINCIPLES AND PRACTICE OF PHYSIC.

Delivered at King's College, London. A new American, from the last revised and enlarged English edition, with Additions, by D. FRANCIS CONDIE, M. D., author of "A Practical Treatise on the Diseases of Children," &c. With one hundred and eighty-five illustrations on wood. In one very large and handsome volume, imperial octavo, of over 1200 closely printed pages in small type; the whole strongly bound in leather, with raised bands. Price \$4 25.

That the high reputation of this work might be fully maintained, the author has subjected it to a thorough revision; every portion has been examined with the aid of the most recent researches in pathology, and the results of modern investigations in both theoretical and practical subjects have been carefully weighed and embodied throughout its pages. The watchful scrutiny of the editor has likewise introduced whatever possesses immediate importance to the American physician in relation to diseases incident to our climate which are little known in England, as well as those points in which experience here has led to different modes of practice; and he has also added largely to the series of illustrations, believing that in this manner valuable assistance may be conveyed to the student in elucidating the text. The work will, therefore, be found thoroughly on a level with the most advanced state of medical science on both sides of the Atlantic.

The additions which the work has received are shown by the fact that notwithstanding an enlargement in the size of the page, more than two hundred additional pages have been necessary to accommodate the two large volumes of the London edition (which sells at ten dollars), within the compass of a single volume, and in its present form it contains the matter of at least three ordinary octavos. Believing it to be a work which should lie on the table of every physician, and be in the hands of every student, the publishers have put it at a price within the reach of all, making it one of the cheapest books as yet presented to the American profession, while at the same time the beauty of its mechanical execution renders it an exceedingly attractive volume.

The fourth edition now appears, so carefully revised, as to add considerably to the value of a book already acknowledged, wherever the English language is read, to be beyond all comparison the best systematic work on the Principles and Practice of Physic in the whole range of medical literature. Every lecture contains proof of the extreme anxiety of the author to keep pace with the advancing knowledge of the day, and to bring the results of the labors, not only of physicians, but of chemists and histologists, before his readers, wherever they can be turned to useful account. And this is done with such a cordial appreciation of the merit due to the industrious observer, such a generous desire to encourage younger and rising men, and such a candid acknowledgment of his own obligations to them, that one scarcely knows whether to admire most the pure, simple, forcible English—the vast amount of useful practical information condensed into the Lectures—or the manly, kind-hearted, unassuming character of the lecturer shining through his work.—*London Med. Times and Gazette.*

Thus these admirable volumes come before the profession in their fourth edition, abounding in those distinguished attributes of moderation, judgment, erudite cultivation, clearness, and eloquence, with which they were from the first invested, but yet richer than before in the results of more prolonged observation, and in the able appreciation of the latest advances in pathology and medicine by one of the most profound medical thinkers of the day.—*London Lancet.*

The lecturer's skill, his wisdom, his learning, are equalled by the ease of his graceful diction, his eloquence, and the far higher qualities of candor, of courtesy, of modesty, and of generous appreciation of merit in others. May he long remain to instruct us, and to enjoy, in the glorious sunset of his declining years, the honors, the confidence and love gained during his useful life.—*N. A. Med. Chir. Review.*

Watson's unrivalled, perhaps unapproachable work on Practice—the copious additions made to which (the fourth edition) have given it all the novelty and much of the interest of a new book.—*Charleston Med. Journal.*

Lecturers, practitioners, and students of medicine will equally hail the reappearance of the work of Dr. Watson in the form of a new—a fourth—edition. We merely do justice to our own feelings, and, we are sure, of the whole profession, if we thank him for having, in the trouble and turmoil of a large practice, made leisure to supply the hiatus caused by the exhaustion of the publisher's stock of the third edition, which has been severely felt for the last three years. For Dr. Watson has not merely caused the lectures to be reprinted, but scattered through the whole work we find additions or alterations which prove that the author has in every way sought to bring up his teaching to the level of the most recent acquisitions in science.—*Brit. and For. Medico-Chir. Review.*

WALSHE (W. H.), M. D.,

Professor of the Principles and Practice of Medicine in University College, London, &c.

A PRACTICAL TREATISE ON DISEASES OF THE LUNGS; including the Principles of Physical Diagnosis. A new American, from the third revised and much enlarged London edition. In one vol. octavo, of 468 pages. (Just Issued, June, 1860.) \$2 25.

The present edition has been carefully revised and much enlarged, and may be said in the main to be rewritten. Descriptions of several diseases, previously omitted, are now introduced; the causes and mode of production of the more important affections, so far as they possess direct practical significance, are succinctly inquired into; an effort has been made to bring the description of anatomical characters to the level of the wants of the practical physician; and the diagnosis and prognosis of each complaint are more completely considered. The sections on TREATMENT and the Appendix (concerning the influence of climate on pulmonary disorders), have, especially, been largely extended.—*Author's Preface.*

* * * In press, by the same author, a volume on Diseases of the Heart and Aorta, to match the above.

WILSON (ERASMUS), F. R. S.,

Lecturer on Anatomy, London.

THE DISSECTOR'S MANUAL; or, Practical and Surgical Anatomy. Third American, from the last revised and enlarged English edition. Modified and rearranged, by WILLIAM HUNT, M. D., Demonstrator of Anatomy in the University of Pennsylvania. In one large and handsome royal 12mo. volume, leather, of 582 pages, with 154 illustrations. \$2 00.

New and much enlarged edition—(Just Issued.)

WILSON (ERASMUS), F. R. S.

A SYSTEM OF HUMAN ANATOMY, General and Special. A new and revised American, from the last and enlarged English Edition. Edited by W. H. GOBRECHT, M. D., Professor of Anatomy in the Pennsylvania Medical College, &c. Illustrated with three hundred and ninety-seven engravings on wood. In one large and exquisitely printed octavo volume, of over 600 large pages; leather. \$3 25.

The publishers trust that the well earned reputation so long enjoyed by this work will be more than maintained by the present edition. Besides a very thorough revision by the author, it has been most carefully examined by the editor, and the efforts of both have been directed to introducing everything which increased experience in its use has suggested as desirable to render it a complete text-book for those seeking to obtain or to renew an acquaintance with Human Anatomy. The amount of additions which it has thus received may be estimated from the fact that the present edition contains over one-fourth more matter than the last, rendering a smaller type and an enlarged page requisite to keep the volume within a convenient size. The author has not only thus added largely to the work, but he has also made alterations throughout, wherever there appeared the opportunity of improving the arrangement or style, so as to present every fact in its most appropriate manner, and to render the whole as clear and intelligible as possible. The editor has exercised the utmost caution to obtain entire accuracy in the text, and has largely increased the number of illustrations, of which there are about one hundred and fifty more in this edition than in the last, thus bringing distinctly before the eye of the student everything of interest or importance.

It may be recommended to the student as no less distinguished by its accuracy and clearness of description than by its typographical elegance. The wood-cuts are exquisite.—*Brit. and For. Medical Review.*

An elegant edition of one of the most useful and accurate systems of anatomical science which has been issued from the press. The illustrations are really beautiful. In its style the work is extremely concise and intelligible. No one can possibly take up this volume without being struck with the great

beauty of its mechanical execution, and the clearness of the descriptions which it contains is equally evident. Let students, by all means examine the claims of this work on their notice, before they purchase a text-book of the vitally important science which this volume so fully and easily unfolds.—*Lancet.*

We regard it as the best system now extant for students.—*Western Lancet.*

It therefore receives our highest commendation.—*Southern Med. and Surg. Journal.*

BY THE SAME AUTHOR. (Just Issued.)

ON DISEASES OF THE SKIN. Fourth and enlarged American, from the last and improved London edition. In one large octavo volume, of 650 pages, extra cloth, \$2 75.

The writings of Wilson, upon diseases of the skin, are by far the most scientific and practical that have ever been presented to the medical world on this subject. The present edition is a great improvement on all its predecessors. To dwell upon all the great merits and high claims of the work before us, *seriatim*, would indeed be an agreeable service; it would be a mental homage which we could freely offer, but we should thus occupy an undue amount of space in this *Journal*. We will, however, look

at some of the more salient points with which it abounds, and which make it incomparably superior in excellence to all other treatises on the subject of dermatology. No mere speculative views are allowed a place in this volume, which, without a doubt, will, for a very long period, be acknowledged as the chief standard work on dermatology. The principles of an enlightened and rational therapeia are introduced on every appropriate occasion.—*Am. Jour. Med. Science*, Oct. 1857.

ALSO, NOW READY,

A SERIES OF PLATES ILLUSTRATING WILSON ON DISEASES OF THE SKIN; consisting of nineteen beautifully executed plates, of which twelve are exquisitely colored, presenting the Normal Anatomy and Pathology of the Skin, and containing accurate representations of about one hundred varieties of disease, most of them the size of nature. Price in cloth \$4 25.

In beauty of drawing and accuracy and finish anything of the kind as yet issued in this country.

The plates by which this edition is accompanied leave nothing to be desired, so far as excellence of delineation and perfect accuracy of illustration are concerned.—*Medico-Chirurgical Review.*

Of these plates it is impossible to speak too highly. The representations of the various forms of cutaneous disease are singularly accurate, and the coloring exceeds almost anything we have met with in point of delicacy and finish.—*British and Foreign Medical Review.*

We have already expressed our high appreciation of Mr. Wilson's treatise on Diseases of the Skin. The plates are comprised in a separate volume, which we counsel all those who possess the text to purchase. It is a beautiful specimen of color printing, and the representations of the various forms of skin disease are as faithful as is possible in plates of the size.—*Boston Med. and Surg. Journal*, April 8, 1855.

BY THE SAME AUTHOR.

ON CONSTITUTIONAL AND HEREDITARY SYPHILIS, AND ON SYPHILITIC ERUPTIONS. In one small octavo volume, extra cloth, beautifully printed, with four exquisite colored plates, presenting more than thirty varieties of syphilitic eruptions. \$2 25.

BY THE SAME AUTHOR.

HEALTHY SKIN; A Popular Treatise on the Skin and Hair, their Preservation and Management. Second American, from the fourth London edition. One neat volume, royal 12mo., extra cloth, of about 300 pages, with numerous illustrations. \$1 00; paper cover, 75 cents.

WHITEHEAD ON THE CAUSES AND TREATMENT OF ABORTION AND STERILITY.

Second American Edition. In one volume, octavo extra cloth, pp. 308. \$1 75.

WINSLOW (FORBES), M. D., D. C. L., &c.

ON OBSCURE DISEASES OF THE BRAIN AND DISORDERS OF THE

MIND; their incipient Symptoms, Pathology, Diagnosis, Treatment, and Prophylaxis. In one handsome octavo volume, of nearly 600 pages. (Just Issued.) \$3 00.

We close this brief and necessarily very imperfect notice of Dr. Winslow's great and classical work, by expressing our conviction that it is long since so important and beautifully written a volume has issued from the British medical press.—*Dublin Med. Press*, July 25, 1860.

We honestly believe this to be the best book of the season.—*Ranking's Abstract*, July, 1860.

It carried us back to our old days of novel reading, it kept us from our dinner, from our business, and from our slumbers; in short, we laid it down only when we had got to the end of the last paragraph, and even then turned back to the repeal of several passages which we had marked as requiring further study. We have failed entirely in the above notice to give an adequate acknowledgment of the profit and pleasure with which we have perused the above work. We can only say to our readers, study it

yourself; and we extend the invitation to unprofessional as well as professional men, believing that it contains matter deeply interesting not to physicians alone, but to all who appreciate the truth that: "The proper study of mankind is man."—*Nashville Medical Record*, July, 1860.

The latter portion of Dr. Winslow's work is exclusively devoted to the consideration of Cerebral Pathology. It completely exhausts the subject, in the same manner as the previous seventeen chapters relating to morbid psychical phenomena left nothing unnoticed in reference to the mental symptoms premonitory of cerebral disease. It is impossible to overrate the benefits likely to result from a general perusal of Dr. Winslow's valuable and deeply interesting work.—*London Lancet*, June 23, 1860.

It contains an immense mass of information.—*Brit. and For. Med.-Chir. Review*, Oct. 1860.

WEST (CHARLES), M. D.,

Accoucheur to and Lecturer on Midwifery at St. Bartholomew's Hospital, Physician to the Hospital for Sick Children, &c.

LECTURES ON THE DISEASES OF WOMEN. Second American, from the second London edition. In one handsome octavo volume, extra cloth, of about 500 pages; price \$2 50. (Now Ready, July, 1861.)

* * * Gentlemen who received the first portion, as issued in the "Medical News and Library," can now complete their copies by procuring Part II, being page 309 to end, with Index, Title matter, &c., 8vo., cloth, price \$1.

We must now conclude this hastily written sketch with the confident assurance to our readers that the work will well repay perusal. The conscientious, painstaking, practical physician is apparent on every page.—*N. Y. Journal of Medicine*, March, 1858.

We know of no treatise of the kind so complete and yet so compact.—*Chicago Med. Journal*, January, 1858.

A fairer, more honest, more earnest, and more reliable investigator of the many diseases of women and children is not to be found in any country.—*Southern Med. and Surg. Journal*, January 1858.

We gladly recommend his Lectures as in the highest degree instructive to all who are interested in obstetric practice.—*London Lancet*.

We have to say of it, briefly and decidedly, that it is the best work on the subject in any language; and that it stamps Dr. West as the facile princeps of British obstetric authors.—*Edinb. Med. Journ.*

As a writer, Dr. West stands, in our opinion, second only to Watson, the "Macaulay of Medicine;" he possesses that happy faculty of clothing instruction in easy garments; combining pleasure with profit, he leads his pupils, in spite of the ancient

proverb, along a royal road to learning. His work is one which will not satisfy the extreme on either side, but it is one that will please the great majority who are seeking truth, and one that will convince the student that he has committed himself to a candid, sure, and valuable guide. We anticipate with pleasure the appearance of the second part of the work, which, if it equals this part, will complete one of our very best volumes upon diseases of females.—*N. A. Med.-Chirurg. Review*, July, 1858.

Happy in his simplicity of manner, and moderate in his expression of opinion, the author is a sound reasoner and a good practitioner, and his book is worthy of the handsome garb in which it has appeared from the press of the Philadelphia publishers.—*Virginia Med. Journal*.

We must take leave of Dr. West's very useful work, with our commendation of the clearness of its style, and the industry and sobriety of judgment of which it gives evidence.—*London Med Times and Gazette*

Sound judgment and good sense pervade every chapter of the book. From its perusal we have derived unmingled satisfaction.—*Dublin Quart. Journ.*

BY THE SAME AUTHOR. (Just Issued.)

LECTURES ON THE DISEASES OF INFANCY AND CHILDHOOD.

Third American, from the fourth enlarged and improved London edition. In one handsome octavo volume, extra cloth, of about six hundred and fifty pages. \$2 75.

The three former editions of the work now before us have placed the author in the foremost rank of those physicians who have devoted special attention to the diseases of early life. We attempt no analysis of this edition, but may refer the reader to some of the chapters to which the largest additions have been made—those on Diphtheria, Disorders of the Mind, and Idiocy, for instance—as a proof that the work is really a new edition; not a mere reprint. In its present shape it will be found of the greatest possible service in the every-day practice of practitioners of the profession.—*Med. Times and Gazette*, London, Dec. 10, 1859.

All things considered this book of Dr. West is by far the best treatise in our language upon such modifications of morbid action and disease as are witnessed when we have to deal with infancy and childhood. It is true that it confines itself to such disorders as come within the province of the physician, and even with respect to these it is unequal as regards minuteness of consideration, and some

diseases it omits to notice altogether. But those who know anything of the present condition of pædiatrics will readily admit that it would be next to impossible to effect more, or effect it better, than the accoucheur of St. Bartholomew's has done in a single volume. The lecture (XVI.) upon Disorders of the Mind in children is an admirable specimen of the value of the later information conveyed in the Lectures of Dr. Charles West.—*London Lancet*, Oct. 22, 1859.

Since the appearance of the first edition, about eleven years ago, the experience of the author has doubled; so that, whereas the lectures at first were founded on six hundred observations, and one hundred and eighty dissections made among nearly fourteen thousand children, they now embody the results of nine hundred observations, and two hundred and eighty-eight post-mortem examinations made among nearly thirty thousand children, who, during the past twenty years, have been under his care.—*British Med. Journal*, Oct. 1, 1859.

BY THE SAME AUTHOR.

AN ENQUIRY INTO THE PATHOLOGICAL IMPORTANCE OF ULCERATION OF THE OS UTERI. In one neat octavo volume, extra cloth. \$1 00.





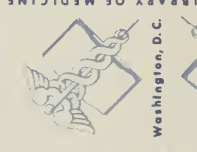U.S. Department of Health, Education, and Welfare, Public Health Service



NATIONAL LIBRARY OF MEDICINE



NATIONAL LIBRARY OF MEDICINE



NATIONAL LIBRARY OF MEDICINE



NATIONAL LIBRARY OF MEDICINE



NATIONAL LIBRARY OF MEDICINE

U.S. Department of Health, Education, and Welfare, Public Health Service



NATIONAL LIBRARY OF MEDICINE




NATIONAL LIBRARY OF MEDICINE



NATIONAL LIBRARY OF MEDICINE



NATIONAL LIBRARY OF MEDICINE



NATIONAL LIBRARY OF MEDICINE


U.S. Department of Health, Education, and Welfare, Public Health Service




NATIONAL LIBRARY OF MEDICINE



NATIONAL LIBRARY OF MEDICINE



NATIONAL LIBRARY OF MEDICINE

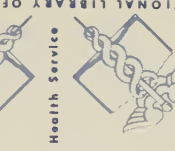

NATIONAL LIBRARY OF MEDICINE



NATIONAL LIBRARY OF MEDICINE

U.S. Department of Health, Education, and Welfare, Public Health Service



NATIONAL LIBRARY OF MEDICINE



NATIONAL LIBRARY OF MEDICINE



NATIONAL LIBRARY OF MEDICINE

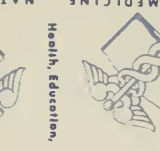

NATIONAL LIBRARY OF MEDICINE

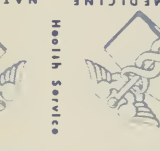

NATIONAL LIBRARY OF MEDICINE

U.S. Department of Health, Education, and Welfare, Public Health Service



NATIONAL LIBRARY OF MEDICINE




NATIONAL LIBRARY OF MEDICINE



NATIONAL LIBRARY OF MEDICINE



NATIONAL LIBRARY OF MEDICINE



NATIONAL LIBRARY OF MEDICINE

NATIONAL LIBRARY OF MEDICINE



NLM 03289969 7