

*Kelly (H. H.)*

REPRINTED FROM

**ANNALS OF GYNAECOLOGY AND PÆDIATRY**  
 A Monthly Review of Gynaecology, Obstetrics, Abdominal Surgery, and the Diseases of Children.

EDITED BY  
 ERNEST W. CROSSLAND, M.D., Boston,  
 ASSOCIATE EDITOR,  
 RICHARD C. MORRIS, M.D., Philadelphia.

THE ASSOCIATE EDITORS ARE

DR. J. W. CROSSLAND, Philadelphia	DR. LEONARD P. STIMP, Philadelphia
DR. W. H. ALLEN, New York	DR. THOMAS LEITCH, Philadelphia
DR. J. C. BROWN, Philadelphia	DR. W. C. PETERS, London
DR. J. B. BURNETT, Philadelphia	DR. J. W. P. LITTLE, Philadelphia
DR. W. H. CROSSLAND, Philadelphia	DR. W. H. P. LITTLE, Philadelphia
DR. J. W. CROSSLAND, Philadelphia	DR. W. H. P. LITTLE, Philadelphia
DR. J. W. CROSSLAND, Philadelphia	DR. W. H. P. LITTLE, Philadelphia
DR. J. W. CROSSLAND, Philadelphia	DR. W. H. P. LITTLE, Philadelphia
DR. J. W. CROSSLAND, Philadelphia	DR. W. H. P. LITTLE, Philadelphia

Subscription Price, \$3.00 a year in advance.  
 For Foreign Countries, \$5.00.  
 Sent by subscription to University of Pennsylvania Press, Philadelphia, Pa.  
 Published by the UNIVERSITY OF PENNSYLVANIA PRESS, PHILADELPHIA.

JANUARY, 1894

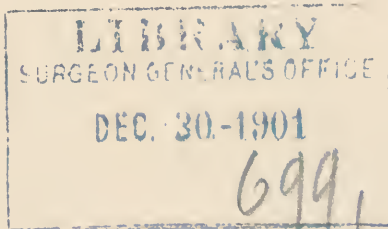
# THE DIAGNOSIS OF PELVIC INFLAMMATORY DISEASES.

BY HOWARD A. KELLY, M.D.,

Professor of Gynaecology and Obstetrics in the Johns Hopkins University, Baltimore, Md.

LIBRARY  
 SURGEON GENERAL'S OFFICE  
 DEC 31-1901  
 6991





## The Diagnosis of Pelvic Inflammatory Diseases.<sup>1</sup>

BY HOWARD A. KELLY, M.D.,

*Professor of Gynæcology and Obstetrics in the Johns Hopkins University,  
Baltimore, Md.*

So much attention has been paid to the treatment of pelvic inflammatory diseases that I feel it will not be amiss to devote my remarks on this occasion exclusively to the diagnosis. To the general practitioner the importance of appreciating the grounds upon which the diagnosis of these affections is made, is a matter of the greatest importance, and to him I desire especially to speak.

That a consideration of this subject from this stand-point is called for at present, cannot be questioned, for I find upon analyzing the last 200 cases in my private case-book, many of which have been referred to me by physicians at a distance, that thirty-two, or 15.5 per cent., had no pelvic disease at all; in other words, an error in diagnosis had been made.

We will consider, therefore, first, in what way pseudo-pelveo-peritonitis simulates true pelveo-peritonitis; and, second, what are the means of mak-

ing a differential diagnosis between *pseudo-pelveo-peritonitis* and true *pelveo-peritonitis*.

The term "pelvic inflammatory disease" includes all affections of the tubes and ovaries resulting from infection of these organs or the pelvic peritoneum, also all inflammatory conditions resulting from traumatism or other causes not directly traceable to infection.

As the result of this inflammatory process plastic lymph is thrown out, forming adhesions between the uterine appendages and the adjacent peritoneum and pelvic walls, pelvic floor, posterior surfaces of broad ligaments or uterus; *it is by means of these adhesions that true pelvic inflammatory disease is diagnosed.*

This concomitant inflammation of the peritoneum is called according to its location perisalpingitis, peri-öphoritis or perimetritis. The more common affections of the tubes and ovaries exciting this inflammation of the peritoneum are salpingitis, pyo-

<sup>1</sup> An address delivered before the Southern Surgical and Gynæcological Association.

salpinx, tuberculosis and abscess of the ovary, and hydrosalpinx is often associated with it.

#### PSEUDO-PELVEO-PERITONITIS.<sup>1</sup>

Pseudo-pelveo-peritonitis is usually found in hysterical women who furnish many of the symptoms of, and present a history often closely analogous to, true pelvic peritonitis.

Such cases have usually been long under the family doctor's charge, when they are referred to the specialist. Their history is one of dysmenorrhœa, extending over many years, intense enough in some instances to confine the patient to bed for two or three days at each period. Many of these patients are regularly addicted to opium or the bromides and the milder sedatives. Douches, plasters, blisters and topical applications, per vaginam, have usually entered largely into the treatment.

As a consequence of the opium habit a well-marked cachexia is often present, which may prove misleading. A certain number of these patients have spent days or weeks in bed on account of pains in the lower abdomen, simulating and thought to be peritonitis.

From these symptoms the medical attendant often concludes that his patient has "ovaritis," "salpingitis" or "pyosalpinx;" and if, upon a superficial examination of the lower abdomen, the patient complains upon pressure over one or both ovarian regions, and a digital examination discloses marked tenderness at the vaginal vault, sometimes amounting to

"excruciating pain," the doctor considers the diagnosis well established.

The irresistible impression made by such a complex of symptoms as these—constant or frequently recurring pain in the lower abdomen, extreme tenderness, cachexia, and loss of health—is that a serious pelvic inflammatory affection is present.

Upon such grounds, therefore, the diagnosis of "inflammation involving the tube and ovary," and often of "pyosalpinx," is erroneously made.

The correct method of making a diagnosis of pelvic inflammatory disease is the following:

#### TRUE PELVEO-PERITONITIS.

All these symptoms just detailed must be considered as of subsidiary value in making a diagnosis, for it is often true that in the most aggravated cases, in which there is a large accumulation of pus, dysmenorrhœa may not be present, and the patient may be free from pain for long intervals.

Fever is a sign of value, but it is more frequently absent than present, only being observed when there is absorption from the diseased area. A collection of pus well encapsulated, as a rule, gives rise to no fever whatever. Although in these pus cases emaciation and cachexia are sometimes extreme, it is possible, on the other hand, for a patient to have a pelvic abscess, and yet remain in blooming health in spite of the abscess.

Even when the patient gives a history of free discharge of "pus" from the vagina, this is not significant unless it has been carefully inspected by the physician, for patients often

<sup>1</sup> The prefix "pseudo" is not used in a strictly scientific sense. It is employed as a convenient catchword to designate affections which convey the impression of being what they are not.

confuse muco-purulent leucorrhœal discharges with the discharge of an abscess.

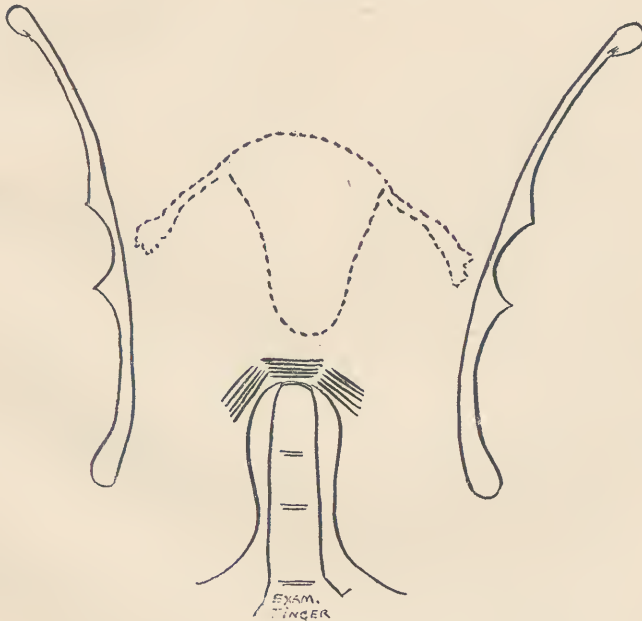
*The essential points in the diagnosis of pelvic inflammatory disease are discovered by a direct examination of the diseased organs by rectum, vagina and lower abdomen.* In every case the lower bowel must be freely evacuated before the examination is made. In the course of this investigation the examiner must demonstrate evidences

The inferior and posterior surfaces of resisting masses detected through the vagina can be most distinctly felt by the rectum, filling out an area corresponding to the base of one or both broad ligaments.

A peculiar roofed-in, board-like hardness on one or both sides of the vaginal vaults often characterizes pyosalpinx and ovarian abscess.

Where the evidences of disease are not so distinct as in the cases just de-

FIG. 1.



Area of board-like induration indicated by heavy parallel lines.

of alterations in the *size, consistency or mobility* of ovary and tube. If the cervix uteri cannot be easily displaced upwards, but is more or less immobile, and hard resisting surfaces are felt lateral to the uterus, the diagnosis of pelvic inflammatory disease may be made. (Fig. 1.)

Marked pain or wincing under the examination, and an ill-defined sense of resistance do not justify a diagnosis of any kind.

tailed, and by digital examination through the vagina one is not able to detect more than a small mass of doubtful identity lateral to the uterus, a bimanual examination through the rectum and abdomen will often demonstrate this to be an inflamed adherent mass attached to the broad ligament.

In making examinations by the rectum, it is necessary, in order to palpate the pelvic structures clearly,

to introduce the finger up beyond the ampulla or rectal pouch, through the utero-sacral ligaments behind the uterus.

Still more exact than the method just described is the *bimanual examination under anæsthesia*.<sup>1</sup>

Several hundred cases are anæsthetized in my clinic at the Johns Hopkins Hospital yearly, for the sole purpose of making an exact diagnosis, and I cannot sufficiently commend this method for the increased facilities of investigation which it affords.

#### THE TRIMANUAL EXAMINATION.

Where the ovary or the ovary and the tube are bound down by velamentous or delicate bands of adhesions, there are often no alterations in the size of these organs, and the amount of mobility still retained may be so great as to prove deceptive to the ordinary vaginal or rectal examination.

Under these circumstances the most perfect method of examining the pelvic structures at our disposal must be employed to establish the diagnosis, and we have recourse to the *trimanual examination conducted at the same time by the vagina, rectum and abdomen, under anæsthesia*. To avoid giving the anæsthetic twice, not infrequently in my hospital practice the minute examination is made immediately before the operation. Several times I have returned patients from the operating table to the ward with the note, "structures sound, operation not called for." It had appeared, from the history and the ordinary bimanual examination in these cases,

that there was serious pelvic disease present. The efficiency of the trimanual examination depends upon the fact that *the normal uterus can be drawn down to the vaginal outlet without harm, and the tubes and ovaries also becoming displaced in proportion to the displacement of the uterus, are thus brought within easy touch*. To dispense with an assistant, I have devised a third hand for the examiner in the form of a flat tenaculum, corrugated on one side to prevent its slipping under the fingers. The tenaculum is introduced into the vagina and hooked in the anterior lip of the cervix, which is now drawn gently down toward the outlet. (Fig. 2.)

If resistance is felt at any point, the traction must not be carried further until the cause of the resistance is ascertained. The corrugated handle is now grasped between the ball of the thumb and the last phalanges of the third and fourth fingers, and the uterus is thus detained in its artificial descensus, while the index finger of the same hand is inserted into the rectum and easily carried up to the top of the uterus and laterally over the broad ligament, ovaries and tubes. The ovaries are detected in doubtful cases by means of the utero-ovarian ligaments, always recognizable as prominent cords in the broad ligament immediately below the cornua uteri. (Fig. 3.) Upon running the finger out one of these cords, 1.5 to 2.5 centimetres (one-half to one inch), it comes in contact with an abrupt enlargement, which is always the ovary. If this is large, ill-defined in outline and more or less fixed, the diagnosis of inflammatory disease may be made at once. In order to

<sup>1</sup> v. Johns Hopkins Hospital Reports, Gynæcological Fasciculus, No. II.

exclude inflammatory conditions, the finger must be passed around the ovary, clearly outlining its border and surfaces as it is lifted on the palpating finger. In this way the most delicate adhesions will be discovered.

In conclusion, let me briefly recapitulate:

(1) The history of the patient, associated with pain in the ovarian regions produced by deep abdominal or

pelvis at the sides and behind the uterus.

(4) It is possible in this way sometimes to mistake a retroflexed fundus, an extra-uterine pregnancy or a myoma, for inflammatory disease. This error on the part of the general practitioner, however, is in the right direction, calling for a more exact investigation or consultation with a specialist, and is therefore not detrimental to the patient.

FIG. 2.



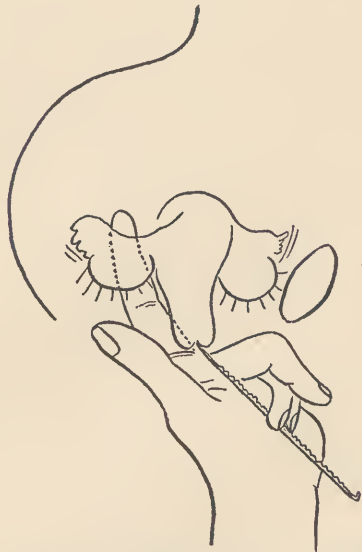Position A.—Tenaculum caught in cervix. Position B.—Uterus drawn down into vagina.

vaginal palpation, cannot *per se* establish a diagnosis of pelvic inflammatory disease.

(2) An attempt to make a diagnosis without directly palpating the pelvic organs is at best but more or less clever guess-work.

(3) The diagnosis can be made with certainty when resisting masses are felt choking the posterior half of the

FIG. 3.



Utero-ovarian ligament used as a landmark in locating ovary. All surfaces of ovary brought into easy touch by means of corrugated tenaculum.

(5) For a more delicate appreciation of the exact condition of the pelvic organs, and in many cases in order to make any diagnosis at all, a bimanual examination by rectum and abdomen under anæsthesia is necessary.

(6) The writer's trimanual method of examination by rectum, vagina and abdomen, is the most accurate of all, serving to detect the slightest irregularities of the uterus and ovaries, as well as the most delicate adhesions.











