











JAMES LEMON,  
BOOKBINDER,  
HONGKONG.





A SERIES  
OF  
ANATOMICAL PLATES;

WITH REFERENCES AND PHYSIOLOGICAL COMMENTS,

ILLUSTRATING

THE STRUCTURE OF THE DIFFERENT PARTS

OF

THE HUMAN BODY.

BY JONES QUAIN, M.D.

PROFESSOR OF ANATOMY AND PHYSIOLOGY IN THE UNIVERSITY OF LONDON.

AND


W. J. E. WILSON, M.D.

LECTURER ON PRACTICAL AND SURGICAL ANATOMY AND PHYSIOLOGY.

Third Edition Revised, with Additional Notes,

BY JOSEPH PANCOAST, M.D.

PROFESSOR OF GENERAL, DESCRIPTIVE, AND SURGICAL ANATOMY IN JEFFERSON MEDICAL COLLEGE OF PHILADELPHIA,  
LECTURER ON CLINICAL SURGERY AT THE PHILADELPHIA HOSPITAL, ETC. ETC.



PHILADELPHIA:  
CAREY AND HART, CHESNUT STREET,  
FOR G. N. LOOMIS.

1845.

QS  
Q/s  
8/1845

---

---

Entered according to act of Congress, in the year 1842, by CAREY & HART, in the Clerk's Office of the District Court of the Eastern District of Pennsylvania.

---

---

---

STEREOTYPED BY L. JOHNSON.  
PRINTED BY T. R. & P. G. COLLINS, PHILADELPHIA.

---



# ADVERTISEMENT

TO THE AMERICAN EDITION.

---

THE American publishers of this work, for the purpose of rendering it more extensively useful by bringing down the price so as to place it within the reach of almost every one interested in the study of Anatomy, have reduced it from the folio to the quarto form. By this means, it is believed, the work will more than repay what it loses in magnitude and pretension by the greater convenience and facility for reference that it will afford the student. In usefulness and accuracy, the American publishers consider this will be found in no respect behind the English edition. Portions of the body which are minute or complicated in structure, as the organs of the senses, the head, brain, &c., are represented of the same size as in the original edition, whilst such drawings as were too large for the quarto form have been reduced to the requisite size, with care to observe as far as possible the proper proportion of the different parts. The figures have been in general carefully compared with the original sources referred to in the advertisement to the London edition, and especially with the recent extensive work of Messrs. Bourguery and Jacob, from which many of the English copies have been drawn. Considerable attention has been given to the correction of the references to the plates, which almost necessarily in a work that has had to pass through so many hands, and where the references are so numerous, must be found more or less defective. Many synonyms and additional references have been introduced without mark through the body of the work, for the purpose of rendering it more useful to the American student, whilst the text of the accomplished English anatomists, Messrs. Jones Quain and W. J. Erasmus Wilson has been published without abbreviation. It has not been the desire of the American publishers to have the work loaded with notes, but such have been added as it is believed will render the work more useful to the students of this country.

JOSEPH PANCOAST.

*Philadelphia, August 1, 1842.*

# ADVERTISEMENT

## TO THE ENGLISH EDITION.

---

THIS publication consists of a series of the most approved Anatomical Drawings, selected from monograph treatises or from systematic works. The highest place in the former class is deservedly conceded to the works of Scarpa and Tiedemann, and in the latter, to those of Mascagni and Caldani; but, from their size, and the style in which they are executed, the expense of publication is necessarily such as to confine their usefulness to comparatively few persons. It may, however, be fairly admitted, that the collections of Cloquet and Loder, though not of equal pretension, are no less valuable to students, as a guide to the knowledge of that complex fabric, whose composition they seek to investigate; and to those of maturer age, as a means of reviving impressions received during their earlier studies. As, however, even the works last named, from their price, are inaccessible to some, and to others from the descriptions and references being given in a foreign language, the want of a similar publication in an English garb has been for some time complained of.

To supply the want here noticed, and at a moderate price, is the object of the present undertaking. The plates are accompanied by letter-press, containing detailed references to the various objects delineated, the names being set down in English, Latin, and French. But with a view to render them intelligible to a greater number of persons, a running comment on each Plate is given, stating in general terms, and divested (as far as can be) of all technicality, the uses and purposes which the different objects serve in the animal economy. The drawings are taken on stone by Mr. W. Fairland, and the printing executed by Hullmandel, and Graff and Soret.

The work consists of Five Divisions, as follows :

The Bones and Ligaments.

The Muscles.

The Heart and Blood Vessels, (Arteries and Veins,) with the Lymphatic and Lacteal Vessels

The Brain and Spinal Marrow; the Nerves and Organs of Sense.

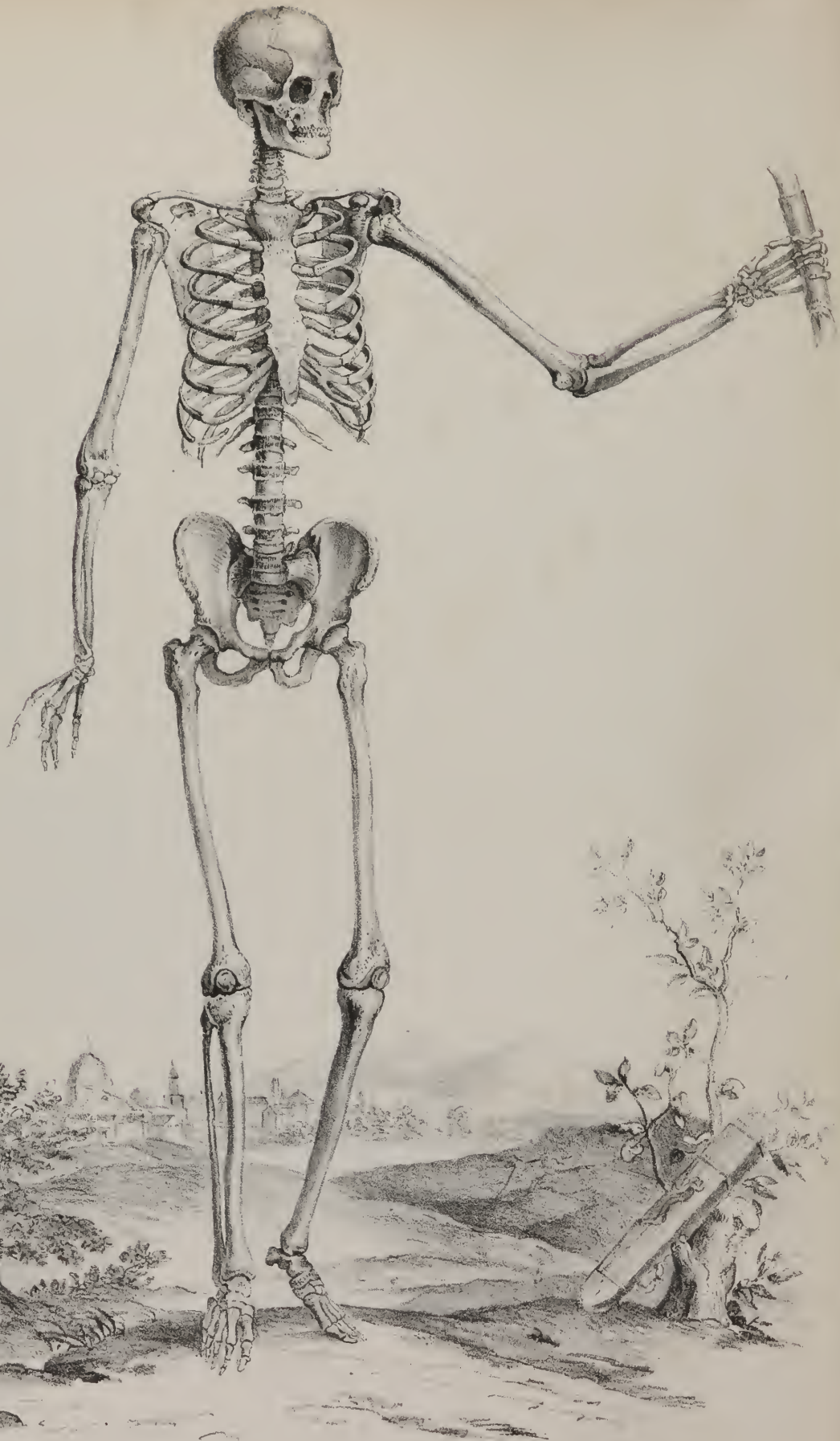
Organs of Digestion, Respiration, and Secretion.



THE  
BONES AND LIGAMENTS  
OF  
THE HUMAN BODY.







# OSSEOUS SYSTEM.

---

THE Osseous System (*système osseux*, *ossa*, *οσσεια*) is peculiarly fitted, by its solidity and hardness, not only to give support to the soft parts, but also to furnish points of attachment to the muscles, by which the different movements are executed. This solid frame-work of the body is made up of a number of separate pieces, the aggregate of which has been termed "*the skeleton*." It is a favourite opinion with some persons, that bones determine the form of parts, as well as the direction of the body. But we find, that in their development they just keep pace with that of the soft parts, particularly of the central nervous masses. If these proceed regularly to their completion, so will the arches of the vertebræ, and the bones of the head; but, if their growth be retarded or deranged, the bones will not arch inwards, and so the spinal and cranial cavities will remain open. Again, if we descend through the series of animals, the skeleton becomes gradually more simple and rudimentary, until it is reduced to its fundamental part—the spine; and even this may be composed of cartilage, with scarcely a trace of calcareous matter. A few grades lower down in the scale, we find multitudes of animals altogether destitute of a skeleton, either internal or external, so that the muscular structure alone remains as the means of locomotion. Bone is, then, the passive instrument—muscle the active agent; muscle is, moreover, prior in its appearance and importance in the animal series, bone being secondary in both respects. It may be asked, are we still to persist in drawing such a broad line of distinction as has been hitherto done, between the hard calcareous parts of crustacea and insects, and the osseous system of higher animals, as that the latter alone should be considered to merit the name of skeleton, whilst the former is treated as a mere shell, or outward tegument? To put the question in a different way, is it more conformable with what we know of the economy of nature—is it more philosophic, to admit, at once and without examination, that these so-called shells or crusts are altogether new organs given to the animals they invest, (and as such destitute of any analogy with the structures observed in higher grades of beings, and with which we are in general more familiar,) or to scrutinize these different parts attentively, and carefully note the points of similitude, if any, which may exist between them, with a view to determine whether they are not really modifications, or repetitions, of what occurs in other tribes, and so trace out (what analogy goes a great way to establish) a unity of plan throughout the animal series? The researches of Geoffroy Saint-Hilaire and others have thrown much light on this important question. The mere position of parts, whether internal or external, is a matter of little moment: a consideration of their structure, and adaptation to purpose and use, can alone determine whether any correspondence exists between them. The internal skeleton of a vertebrate animal, and the external one of the articulata, appear to be really analogous parts in the economy of these classes of animals, notwithstanding the vast distance which separates them in the scale of being; and the difference, though confessedly a considerable one, which exists between the rachis of a crustaceous animal and that of a fish, reptile, bird, or quadruped, seems to arise from the circumstance that a spinal marrow exists in the one, but not in the other, a special conformation of the osseous system being required in each case.

*Situation.*—The osseous structure is situated deeply, being covered by the soft parts and common integuments; at least, this is the case in the vertebrate animals.

The *number* of bones is differently stated by writers, the difference arising from the period of life at which the enumeration is made: in early age the number is greatest, and subsequently diminishes, when, by the process of ossification, two or more

## PLATE I.

Skeleton of an adult male, anterior aspect. This figure is copied from Cheselden's beautiful plate. In his description of the figure, Cheselden observes that it is "in the same proportions and attitude with the Belvidere Apollo."



previously distinct pieces become united into one. Their *form* and *size* present a considerable degree of variety. They are usually divided into long, short, flat, and mixed.

The *long* or *cylindrical* bones belong in general to the parts intended for locomotion, and represent so many levers, to be moved by the muscles in various directions. When examined from the superior part to the inferior, viz. from the humerus or femur, to the phalanges of the fingers or toes, they are found to increase successively in number as they diminish in size—a disposition which gives to the superior division of each limb the great extent of motion it enjoys, whilst it allows to the inferior and terminal ones a variety of rapid movements within restricted limits.

Each long bone presents a body, or middle part, and two extremities. The shaft or body is round and cylindrical in some, prismatic in others, but somewhat bent or twisted on its axis, so that the direction of its superior extremity does not exactly correspond with that of the inferior. Whatever difference of outward form may obtain, there is little or none in that of the internal canal; it is circular in the tibia as well as in the femur. This canal is not intended merely to lodge and protect the medulla; it contributes very much to increase the strength of the bone, as has been satisfactorily shown by direct experiment. If two cylinders contain the same quantity of matter, one being solid, the other hollow, the power of resistance of the latter is greater than that of the former, owing to its greater diameter. By this conformation, also, bones, without being increased in weight, require an adequate degree of lightness, together with sufficient superficial extent to afford a more expanded surface for the attachment of muscles, which are important requisites in what may be considered as the passive organs of locomotion.

The *short* bones are usually situated in parts in which solidity and firmness are required to be combined with freedom of motion; for instance, in the carpus, tarsus, and vertebral column. Their external conformation is necessarily influenced and determined by that of the parts into whose composition they enter; and as they are intended to co-operate in certain common functions, they present a number of articulating surfaces, prominences, and depressions, suited to their mode of adaptation and mutual connexion.

The *flat* or *broad* bones for the most part serve to form the walls of cavities, or to enclose spaces. They present two surfaces, one convex, and the other concave; which conformation, by giving them an arched form, increases their power of resistance, and affords additional security to the organs they enclose. The bones of the skull and pelvis come under this denomination.

Some are so irregular in their form as not to be referrible to either of these heads. These are situated along the median line, as the occipital, the sphenoid, and ethmoid bones, and the vertebræ.

In addition to these divisions into classes, adopted by all writers, those who treat expressly of descriptive anatomy are obliged to have recourse to others. Thus, in order to facilitate the description of irregular bones, such as the ethmoid, or the sphenoid, they are considered as being divisible into a central part or body, and processes; the anatomical situation of the parts forming the ground of division. In other instances it is supplied by the mode of development, as of the os innominatum into ilium, ischium, and os pubis. Finally, in some, the division is founded on the situation and relations of their parts, as when the frontal bone is resolved into a frontal, nasal, and orbital portions.

The *surfaces* of bones are marked by eminences and depressions adapted to various purposes. The eminences may be ranged under four heads. 1st, those of articulation; 2nd, insertion; 3rd, impression; 4th, reflection. Those for articulation vary according as they are movable or immovable, and shall be described in the next chapter. Those for insertion are variously adapted for the attachment of muscles, or for tendons and ligaments. They present numerous differences in their degree of projection, according to the sex, age, and muscular development of each individual. Their form is equally various; some consisting of diffused asperities, others extending along the surface like rough lines, whilst others project more or less from the bone, and are intended not only to give insertion to muscles, but also to serve the purpose of increasing their power of action, by removing their line of direction farther from the axis of the bone.

The eminences of impression are certain prominent lines interposed between depressions on the surfaces of bones. Thus, the shallow pits on the cranial bones corresponding with the convolutions of the brain, and the depressions on the external surface, marking the insertion of muscles, are separated by prominent lines, termed eminences of impression. The expression appears not to have been well chosen; it was originally founded on the supposition that the action of contiguous organs, by depressing certain parts of the surface of the bone, served to elevate others; but it is far more conformable to what occurs in other structures, to refer to the laws of nutrition and growth (by which different parts are mutually adapted to one another) the inequalities here alluded to, as well as those more prominent points to which muscles are attached. The latter are usually attributed to the action of the muscles drawing them out, and as it were moulding them; but, as Bichât observes, such an opinion, founded on what occurs in soft and inorganic substances, ill accords with the known phenomena of vitality. We observe eminences for the insertion of ligaments, which project more than those which give attachment to muscles; for instance, the spinous process of the ischium; there is, moreover, no proportion between the elongation of different apophyses, and the power of the muscles attached to them, viz. between the styloid process of the temporal bone and its muscles.

The term or phrase “eminence of reflection,” is not often used. It expresses a fact which we occasionally observe, viz. that tendons slide upon elevations at the ends of bones, by which their direction is changed. As an instance, we may cite the case of



the peronei muscles, and the flexors, which run behind the malleolar projections of the tibia and fibula, by which these tendons take a new direction, and modify the line of traction of their respective muscles.

The prominences on the surface of bones are variously named, according to their form, degree of elevation, and the uses which they serve. When of considerable size, they are called *apophyses*, (processus, apophysis, ἀπο from, φέρω to grow.) These, in most instances, are appendices to the body or shaft of long bones, in infancy and in early life, when they are called *epiphyses*: but as the process of ossification proceeds to its completion, they become, as it were, soldered to the rest of the bones. The term *tuberosity* (tuber) denotes an eminence, rather broad and rough, but not much projecting; *tubercle* (tuberculum) expresses something still smaller. A process which is thin and tapering, is called *styloid*, from its resemblance to the Roman writing instrument, (stylus.) A sharp thin projection is called *spine*, (spina.) But one which runs along like a ridge, is called a *crest*, (crista.) An apophysis, when rounded, is usually called a *head*, (caput,) and the constricted part supporting it represents its *neck*, (cervix, column.) *Condyle* is a compressed apophysis, which forms part of an articulation.

The depressions and cavities on the external surface of bones are divisible into the articular and non-articular. The former shall be treated of in the section on articulations; the latter, being very numerous, may be ranged under the following heads. 1st, those for insertion; 2d, for reception; 3d, gliding; 4th, transmission; 5th, nutrition. Those for "insertion" are well adapted for the attachment of muscle, ligament, &c., by increasing the extent of space allotted for that purpose, inasmuch as a concave surface presents a greater extent than a plane one bounded by the same line. Some of these, as the digastric and pterygoid fossæ, by the greater depth at which they allow the muscles to be inserted, increase their power, by permitting an elongation of their fibres.

The bones of the skull and face present several instances of "cavities of reception." Some correspond with the whole extent of a bone, as in the case of the parietal bone. Some occur in a particular part only, as the fossa in the nasal process of the superior maxillary bone, and os unguis for the lachrymal sac.

The depressions for "gliding" are situated about the heads of long bones, being grooves, in which tendons slide, as they pass to their destinations. The formation of these has been attributed to the influence of the mechanical pressure and friction of tendons. But such a rationale is inadmissible; for they are found in subjects paralytic from infancy, and are by no means proportioned in depth to the force of the muscular exertion which bears upon them. The different configuration of bones should rather be considered as the result of the laws of ossification which preside over the growth and development of the osseous system, and by which its different parts are adapted to their appropriate purposes.

The cavities for "transmission" give passage to vessels and nerves; their form is various, some being mere fissures, others tubular, &c.; to this head are referable most of the apertures at the base of the skull.

The foramina of "nutrition" transmit the vessels intended for the support of the substance of the bones and of the medulla; they are divisible into three orders. The first usually receive the name of foramina of nutrition, though in strictness it does not belong to them more than to the others, the only difference between them being, that they transmit vessels to supply the medullary membrane, whilst the others give passage to those which are distributed to the substance of the bone. The first set, considerably the largest, are situated towards the middle of the long bones, and penetrate their substance in an oblique direction. The second order of foramina are much smaller, but very numerous; they are most perceptible towards the extremities of long bones, and generally all over the surface of the short and thick ones. But the third are so minute as to be perceptible only by the aid of a glass, by which we can discern them all over the surface.

The depressions and cavities in bones differ so much in form, size, and use, that it has been deemed necessary to devise certain terms to mark these differences. A deep pit which receives the globular head of a bone, is called a *cotyloid*, or cup-shaped cavity, (κοτύλη a cup,) or an *acetabulum*, (an ancient cup or measure,) *ex gr.* the socket which receives the head of the thigh-bone. If shallow and superficial, it is said to be *glenoid*, (γληνη a shallow pit;) the articular surface of the scapula upon which the head of the humerus plays, is an instance. A large hollow or cavity in the interior of a bone, is termed a *cave*, (antrum,) such as that seen in the upper maxillary bone; when of a size smaller, it is known as a *hollow*, (sinus,) as in the body of the sphenoid bone: and if still smaller, as a *cell*, (cellula,) as in the orbital process of the palate bone. A small depression is a *fovea* or *fossa*. The meaning of the terms canal, (canalis,) fissure, (fissura,) notch, (incisura,) and groove, (sulcus,) is sufficiently obvious.

*Structure.*—The proper structure of bone is fibrous in its character; the fibres, in some parts, by being closely aggregated together, constitute a firm and compact substance; but in others they lie so far apart as to enclose spaces or cells, on which depends the porous and spongy appearance of some bones.

The compact substance is so close in its texture, that the naked eye can discover no interstices in it; yet by the aid of a microscope a great number of minute vascular canals become perceptible. In the long bones, these canals are all longitudinal, and maintain a communication laterally with the great medullary canal, and externally with the vessels on the surface of the bone.

The spongy or cellular part presents a multitude of spaces, of various forms and size, all of which communicate with one another, as may be proved by the following experiment; if the end of a long bone, or the surface of a flat one, be perforated, and some mercury poured in, it will be found not only to descend through the cells, but also to flow out through the vascular foramina on the surface. The interior of flat and short bones, then, does not differ so decidedly from that of cylindrical ones, as

would at first sight appear. Each presents a cavity, which, at least in the one towards its centre, is a hollow tube, but in the other is divided by a number of intersecting laminæ, into minute spaces communicating freely with one another.

Some peculiarities are observable in the arrangement of the compact and cellular structurè in the different classes of bones. The body of long bones consists chiefly of compact substance, but the inner side of the tube is rendered rough by projecting filaments and lamellæ; towards their extremities, the compact substance is gradually reduced to a thin lamella, or layer, encasing the bone, the interior of which consists altogether of cells communicating freely with the central cavity.

The two surfaces of the broad and flat bones are compact in their texture, the interval between them being made up of areolar or spongy substance. This is usually called *diploë*. In its original acceptation the term *diploë* (*διπλοῦς* double) was applied to the two plates or tables of the cranial bones, together with the intervening cellular structure; subsequently it was restricted to the latter part alone; but it is now commonly extended to the loose tissue of all broad and flat bones. The internal table of the cranial bones is more dense than the external, and, from being also more thin and brittle, it is called *vitreous*, (*tabula vitrea*.) The short bones are made up for the most part of spongy substance, encased by a thin lamella of compact tissue. These differences arise altogether from the mode of aggregation and arrangement of the osseous particles; for, on examination, the composition of both is found to be the same, being made up of the same elements, viz. a cellular base, in the areolæ of which is deposited a peculiar earthy salt.

These constituents may be separated, so that each may be examined by itself. If a bone be macerated for some days in a dilute acid, the saline or inorganic part is removed, whilst the organic remains; the bone is thus rendered soft and flexible, but retains its form, its weight being diminished in proportion to the quantity of saline matter taken up by the acid: when reduced to this state, it presents no appearance of any particular arrangement of fibres, but by a continued maceration in water it may be resolved into layers, each of which will be found to consist of a series of fibres aggregated together. If the process be still continued, the fibres become swollen and softened, and present an areolar texture, analogous to that of cellular tissue in other parts of the body. This then may be considered as forming the nidus for the deposition of that inorganic substance on which the solidity and firmness of bone depend. If a cylindrical bone be examined in this way, its central portion is found to consist of several laminæ, super-imposed one on the other: the external one is continuous throughout its whole extent, forming its general envelope; but those subjacent to it, as they pass from the centre, become gradually thinner, and turn inwards towards the axis of the bone, becoming continuous with the lamellæ which divide it into areolæ or cells, (*cancelli*, lattice-work.) In the flat and irregular bones, the compact structure which encloses them externally sends off filaments and plates to divide their interior into cells.

Examined beneath the microscope, bone is seen to be composed of lamellæ, which are concentric in long, and parallel in flat bones. Between the lamellæ are situated numerous small longitudinal canals, and minute oval corpuscles. The longitudinal canals, named, after their discoverer, "the canals of Havers," contain medullary substance and vessels, and communicate with each other. They also communicate with the medullary canal in the shaft, and with the cells of the cancellous structure in the extremities of long bones and in the interior of flat bones. The canals of Havers are surrounded by minute concentric laminæ, and the latter appear to be crossed by delicate lines which radiate from the area of the canal, to the circumference of the concentric laminæ of each canal. These lines were first observed by Deutsch, who imagines them to be tubes of a prismoid form, and filled with the calcareous substance of bone. In the extremities of long bones, in short, and in flat bones, the cells are the representatives of the Haversian canals, and are analogous in structure, being each surrounded by concentric lamellæ. In like manner, the medullary canal of long bones may be regarded as analogous to one of these Haversian canals, and as representing one of these tubes exceedingly dilated. The oval corpuscles discovered by Purkinje are minute cells, measuring in their long diameter about  $\frac{1}{60}$ th of a line. From the surface of these cells are given off a number of radiating and branching tubuli, which anastomose with the corresponding tubuli of neighbouring cells. The tubuli were first accurately described by Müller: their larger trunks are about  $\frac{1}{3000}$ th of a line in diameter; they are, nevertheless, very distinctly seen by means of the microscope. The cells of Purkinje and these tubuli are filled with calcareous substance; hence they have been most appropriately named calcigerous cells and tubuli.

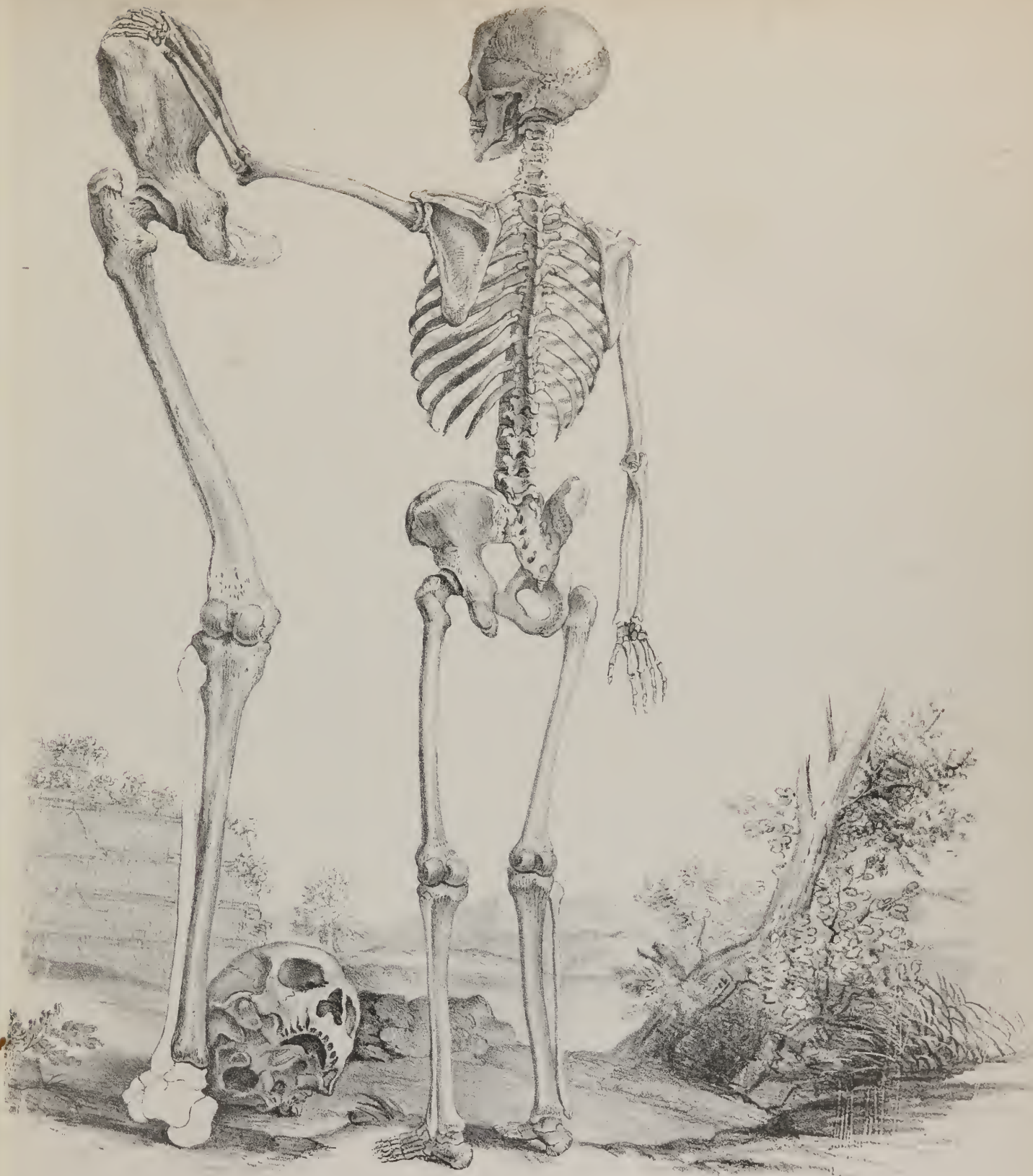
By long-continued boiling, as is well known, a large part of the animal matter of bone is extracted, and a solution obtained, which concretes on cooling into a gelatinous mass. Again, if a bone be exposed to heat so as to expel all the animal matter, it is

## PLATE II.

Skeleton of an adult male, posterior aspect; after Cheselden. In describing this figure, Cheselden remarks that it was delineated from "the skeleton of a man five feet and a half high; the left hand resting on the hip of another skeleton, which was near eight feet high." The latter represents a posterior view "of some of the bones of the lower limb of a man near eight feet high." The skull lying upon the ground he states to have belonged to the same man.

In introducing the bones of the lower extremity in the position represented in the plate, Cheselden seems to have evinced a desire of directing the attention of the student to the obliquity of the femur in relation to the tibia; in order to explain in this way the reason for the greater length of the inner than of the outer condyle.







rendered brittle and light, but still retains its form; but if the heat be raised until the bone becomes red, it undergoes a semi-fusion, as occurs in other earthy substances under the same circumstances. The analysis of bone affords the following results:

<i>According to Fourcroy and Vauquelin.</i>		<i>According to Berzelius.</i>	
Animal matter	51	Cartilage	32.17
Phosphate of lime	37.7	Blood-vessels	1.13
Carbonate of lime	10	Fluate of lime	2
Phosphate of magnesia	1.3	Phosphate of lime	51.04
	100	Carbonate of lime	11.30
	100	Phosphate of magnesia	1.16
	100	Soda, muriate of soda, and water	1.20
	100		100

The general rules of these analyses serve to show that the fibrillæ into which bone may be divided by maceration, consist of a cellular tissue, containing in its areolæ a quantity of earthy salts.

Respecting its ultimate fibre, several fanciful notions have been entertained by different persons. Thus it was considered by some to consist of absorbent vessels, filled with phosphate of lime. Others thought it to be made up of lamellæ and fibres, between which was interposed an osseous juice, &c. Such gratuitous assumptions serve no other end than to lead inquiry out of the true path, and to retard, instead of promoting, the progress of useful knowledge.

*Process of Ossification.*—Of all the systems of organs, the osseous is that which arrives latest at its full period of development, the progress of ossification not being fully completed in the different parts of the skeleton until about the sixteenth or eighteenth year; sometimes even still later. From its first commencement to its final completion, the ossific process runs through three distinct states or conditions, viz. the mucous, cartilaginous, and, finally, that of solid bone. But though these succeed one another regularly, it would be a mistake to suppose that the mucous becomes hardened into cartilage, or the latter solidified into bone, by any process similar to transformation; the facts observed by no means warrant such an inference. The change coincides with an alteration in the mode of nutrition in the part, in consequence of which bone is deposited in place of cartilage.\*

The embryo, at the earliest periods in which it has been examined, presents no distinction of parts, all being equally soft and homogeneous. So, at least, it has appeared to the greater number of those who have investigated the subject. Sir E. Home, however, states that certain parts are distinguishable, even so early as the eighth day after conception. Towards the fourth week, the consistence of the parts corresponding to the future skeleton is sufficiently increased to admit of their being distinguishable from all others, and their outline defined. The vessels, at this period, convey and deposit gelatine, the basis of the cartilaginous state, which appears to be completed about the eighth week, for it is about this period that the deposition of bone begins in some places. The cartilages being temporary substitutes for bone, differ from it in many respects. They present no appearance of

\* With regard to the manner in which the cartilaginous mould of a bone undergoes that modification of structure by which bone is formed, we have not yet, notwithstanding the labour of the microscopists, a perfectly clear or satisfactory explanation. The following account of cartilage and its changes will briefly display all that is as yet known upon the subject. The cartilage of bone, (temporary or ossific cartilage,) though much resembling, is not perfectly the same as the cartilages, or fibro-cartilages, which are to remain in general flexible during life. The cartilage of bone, previous to the commencement of ossification, yields only, after long boiling in water, a substance called *chondrin*, which differs from *gelatin* in not being precipitated by tannic acid, and in giving precipitates with salts which do not disturb a solution of gelatine, such as acetic acid, alum, acetate of lead, and protosulphate of iron; whilst the perfectly formed elastic and fibro-cartilages yield only gelatine when subjected to the same process, or gelatine with but a minute portion of chondrin. The original chemical constitution of all the cartilages is thought to be the same. Their primitive physical formation is cellular, like that of other tissues of the body: between these cells there is interposed a *hyaline*, or transparent *intercellular substance*, and the cells themselves are filled with a softish, granular matter. As the cartilage increases in growth, new cells are developed in the hyaline substance, by which the older ones are pushed farther and farther from each other. The original cells produce two or more young or secondary cells from their granular nuclei; between these secondary cells is also formed a secondary hyaline substance, and thus the original cells form each one a little group of cells enclosed within it, and each group is known under the name of cartilage corpuscle.

The fixed character of the cartilage depends upon the ulterior development in it. If fibro-cartilage be formed, the intercellular or hyaline substance is developed in the form of fibre, and the cells disappear altogether. If elastic cartilage, the fibres are developed around the cells, forming a kind of net-work. If ossific cartilage, a new set of corpuscles are developed in the secondary hyaline substance, called bone corpuscles, which are the nuclei of the bone cells, of which the microscope has shown all bony structure in reality to consist. As this process is going on, the cluster of cartilage cells called cartilage corpuscles become compressed together: the secondary hyaline substance becomes dissolved and transudes through the walls of the primary or parent cell. It coagulates, and, in this state of *cytoblastema*, constitutes the proper ossific cartilage. In it arise the bone corpuscles *cytoblasts*, from which are formed the bone cells. These follow the same mode of development as the embryonic cartilage cells; that is, new cells are forming in the cytoblastema, while those recently produced are growing; the cartilage corpuscles, ever more closely compressed together, disappear; radiated points, nutrient vessels, &c., make their appearance; the nuclei of the bone cells acquire all the while calcareous salts, and become opaque; the bone cells themselves appropriate salts of the same kind, and the formation of bone is achieved. It is, according to this, from a peculiar substance, not ordinary cartilage, that bone is produced; and we well know that the effused fluid of which the callus in fractures is formed, is in many respects different from the original cartilaginous mould of the bone, and that in fact true bone is developed, in many parts of the body, without the existence of any previous cartilaginous basis. Vide Miescher. Diss. de Os. Genes. Struc. et Vit. Berol. 1836; Gerber's General and Minute Anatomy, Lond. 1842; and Carpenter's Human Physiology, 1842.—J. P.



fibres or vessels, have no internal cavity or medullary tissue; they are solid and homogeneous in their whole extent, but possess the outward form of bone, and are invested by a fibrous envelope analogous to that of bone, (perichondrium.) There is another peculiarity which deserves notice: all those parts of the cartilage which are intended to be replaced by flat bones, viz. of the skull, face, and pelvis, represent a continuous layer, without any perceptible boundary or distinction, and the fibrous envelope passes uninterruptedly over the entire surface; but the femur, tibia, clavicle, and humerus are quite distinct and accurately defined: the latter, it will be recollected, are ultimately to be connected by ligaments, and contribute to form the movable articulations; the former still continue to be united by cartilage. About the eighth week, the cartilage, which for a certain time, more or less in different instances, occupies the place and performs the functions of bone, becomes hollowed into irregular cavities, and shortly afterwards into canals lined by vascular membranes, and filled by a mucilaginous or viscid fluid; at this period a red dot appears at some particular point, and ossification immediately commences. The spot first ossified (*punctum ossificationis*) is always situated within the substance of the cartilage, never at its surface. Bichât was of opinion that the vessels were not developed at this period; that they existed before, but circulated only white fluids, and then, for the first time, began to admit red globules; but, be that as it may, the change is marked by the admission of blood into the interior of the cartilage, and the deposition of calcareous matter, both appearing to be coincident. The cartilage appears red and injected, where it is in close contact with the ossified points; more externally it is somewhat opaque, and marked by grooves or canals; in the next remove it retains its original character, presenting, however, in a few points, some vascular canals directed towards the centre of ossification. As the process proceeds, the osseous point increases, as well by additions externally, as by interstitial depositions; whilst the cartilage, as it becomes excavated by canals and cavities lined by vascular lamellæ, diminishes gradually as the bone increases, and finally disappears, being as it were supplanted.

This is to be considered as the general outline of the process of ossification. The time of its commencement and completion varies considerably in different parts of the skeleton. The bones first formed are those which enclose the central organs of circulation, and of the nervous system, the vertebræ and ribs being developed very early. The long bones, viz. clavicle, femur, and tibia,\* present along the centre of their shaft a broad ring of bone at the earliest moment at which their outline can be traced, constituting an exception to the general principle, that bone is deposited in the first instance in a bed of cartilage. The jaw-bones and clavicle are also ossified at a very early period; the sternum, pelvis, and extremities being later, which corresponds with the order of their appearance and the date of their growth in the animal series. From the class of fishes, upwards, maxillæ are developed so rapidly as to be completed very early; so are the clavicles when they exist; whilst the sternum, pelvis, and limbs grow tardily, and in many instances remain in a comparatively rudimentary state through life.

In reasoning on the phenomena of ossification, too much has been attributed to the periosteum: its importance and utility cannot be questioned, when we consider how frequently partial exfoliations, or even total necrosis of bones, follow as a consequence of injuries of their fibrous investment. Some persons have, however, gone farther than this, and have even contended that it is the periosteum which produces bone, as if the fibrous membrane acted as its secreting organ; but it may be said that it is its vessels which secrete, and not the membrane. The vessels, however, belong to the bone, not to the periosteum; and moreover, in many parts, the first ossific deposits take place in the centre of cartilage, and therefore at a distance from that membrane.

## THE SKELETON.

THE osseous structure is peculiarly fitted, by its solidity and hardness, not only to give support to the soft parts, but also to furnish points of attachment to the muscles, by which the different movements are excited. This solid frame-work of the body is made up of a number of separate pieces, the aggregate of which has been termed "*the skeleton*" (*sceletum*, σκελετω, *to dry*.) The vertebral column may be considered as the central or fundamental part of the whole, both because it exists in all animals which possess an internal osseous skeleton, and also because the different parts of the osseous system are either immediately or mediately connected with it as a common centre. Thus, on its superior extremity or apex it supports the skull; laterally it gives attachment to the ribs, which arch forwards, to form, with the sternum, a bony case for the lodgment of the organs of respiration and circulation, at the same time that they furnish externally points of support for the superior extremities: inferiorly the column is immovably connected with the pelvic bones, which are articulated with those of the lower extremity.

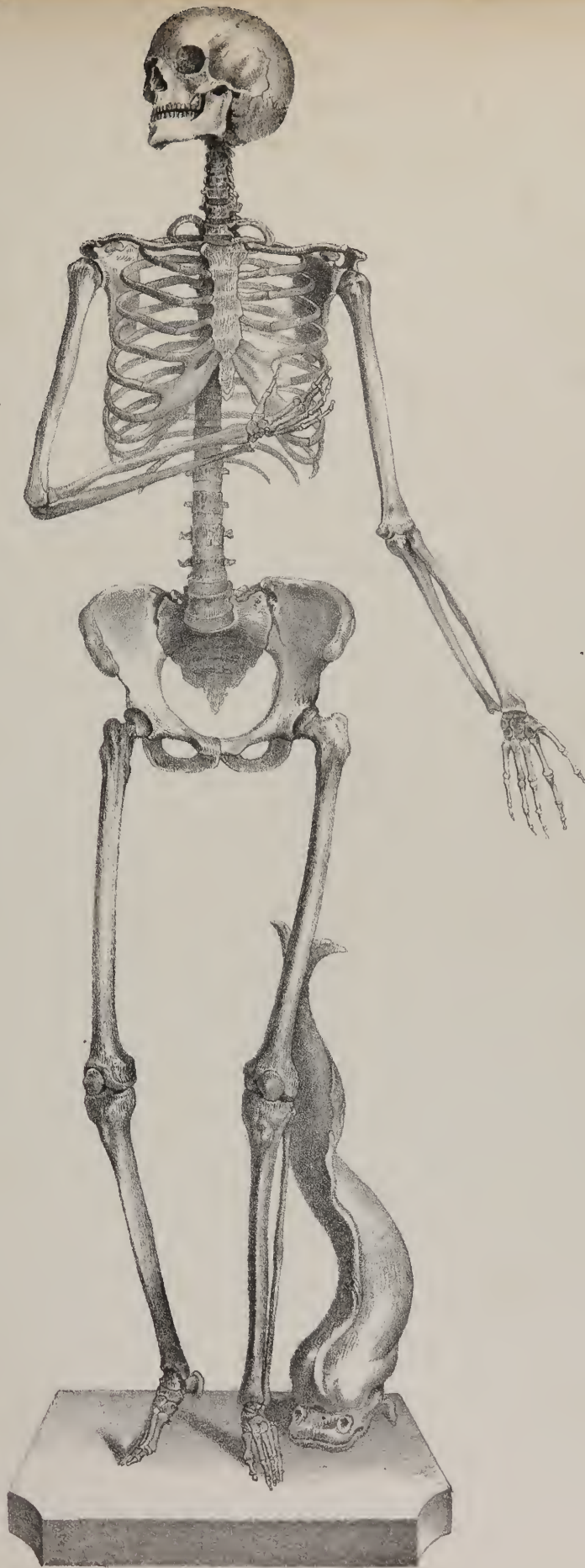
When proceeding with the description of the human body, it is usual to consider it as divisible into head, trunk, and extremities, which is sufficient for the purposes of a regional division; but the skeleton must be viewed in a different way, particularly

## PLATE III.

Skeleton of an adult female, after Cheselden. This author, in his description of the plate, observes that it presents "the same proportions as the Venus de Medicis."

\* Howship, Med. Chir. Transactions.

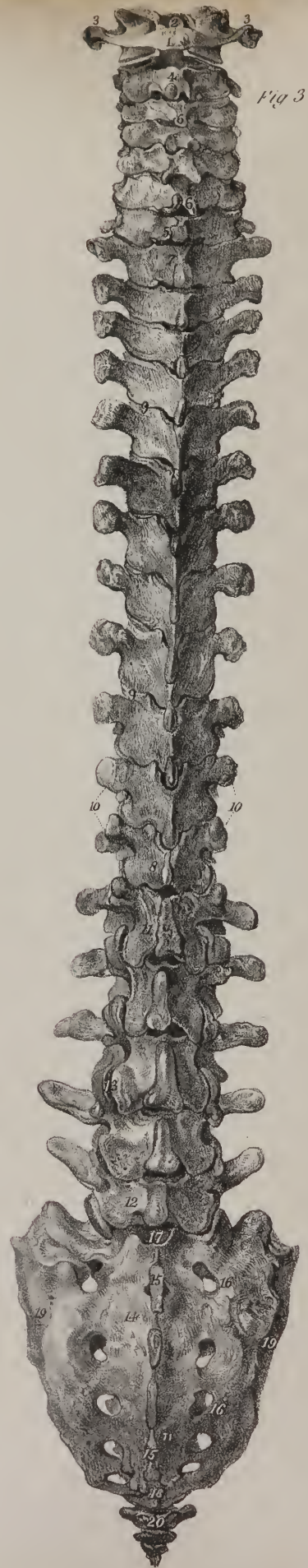
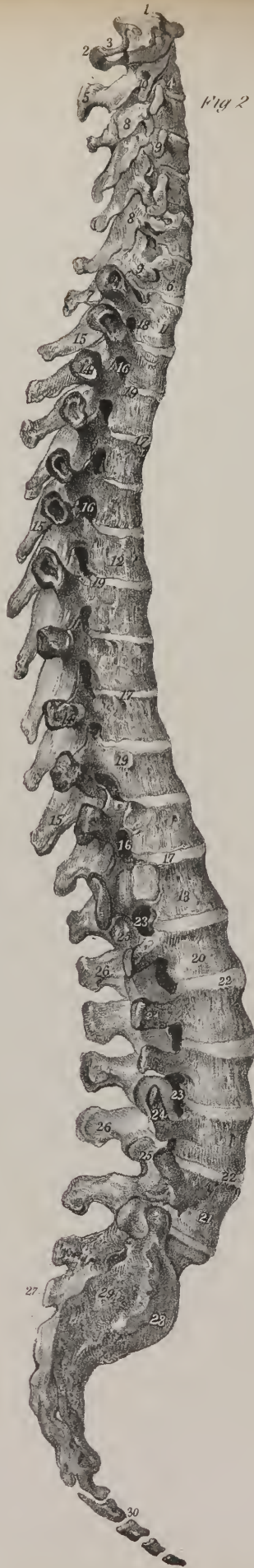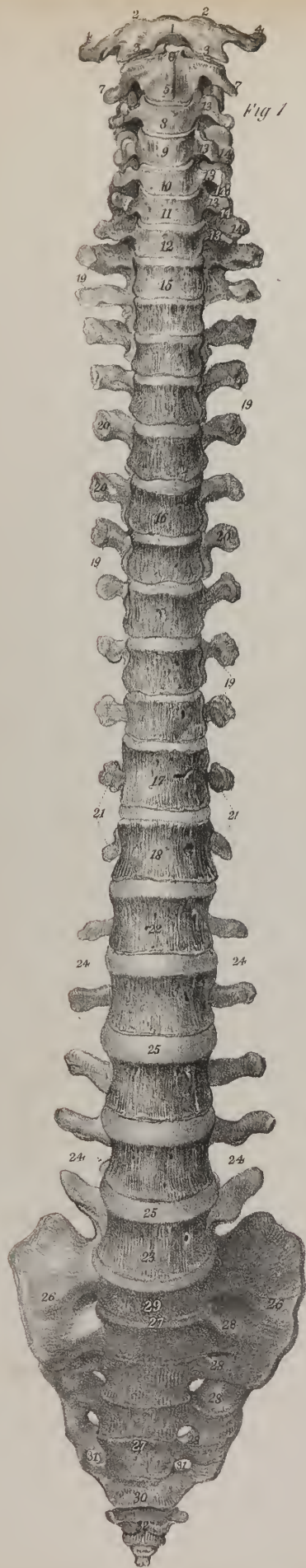












if reference is made to its conformation in the various orders of animals—to its developement—and to the subordination of its component parts. The spine being its essential constituent, all the others (viz. the ribs and sternum, clavicle, scapula, and upper extremities, the pelvic bones and lower extremities) rank as accessories. The sacrum and coccyx are obviously parts of the spine, so likewise are the cranial bones; for, though in outward appearance they differ so much in man and the higher animals from the bones of the spine which are placed beneath them, and with which they are articulated, they still are but modifications of similar organic elements—repetitions, in fact, of like parts differently developed to suit the peculiar relations into which they enter, and the purposes which they are designed to serve.

The number of pieces which compose the osseous system varies in the different ages of life; for some, which in the first instance are divided into two or more portions, become soldered together as the process of ossification goes on. But authors are far from being unanimous as to the number of bones which they recognise even in the adult. Do the sesamoid bones form part of the skeleton, or are they mere accessory structures developed in tendons? Are the teeth, os hyoides, and ossicula auditûs, to be enumerated as components or accessories? Monro and Sæmmering reckon 260 bones; and Meckel, who takes the number at 253, includes the teeth, patellæ, ossa sesamoidea, os hyoides as five pieces, sternum as three, coccyx as four, and the small bones of the ear. If, however, we omit those just named, as being either accessories or connected with special organs, the whole number of pieces found in the ordinary skeleton will be 197, as follow:—

The spinal column, properly so called, consists of 24 vertebræ, the sacrum and the coccyx, (26.)

The skull is made up of eight cranial bones, viz. the occipital, two parietal, two temporal, the frontal, the ethmoid and sphenoid:

## PLATE IV.

The bones of the vertebral column articulated.

FIG. 1. The vertebral column seen from the front.

No. 1. The atlas; the number is placed on the anterior arch of this bone. 2, 2. Its superior articular processes. 3, 3. Its inferior articular processes. 4, 4. Its transverse processes. 5. The axis. 6. The base of the odontoid process. 7, 7. The transverse processes, remarkable for their small size as compared with those of the atlas. 8. The body of the third cervical vertebra. 9. The body of the fourth. 10. The body of the fifth cervical vertebra. 11. The sixth cervical vertebra. 12. The seventh cervical vertebra. 13. The anterior tubercles of the transverse processes of the cervical vertebræ. 14. Their posterior tubercles. 15. The body of the first dorsal vertebra. 16. The body of the sixth. 17, 18. The bodies of the eleventh and twelfth dorsal vertebræ. 19, 19. The transverse processes of the dorsal vertebræ. 20, 20. Articular surfaces upon the extremity of the transverse processes. These surfaces are formed on all the transverse processes with the exception of the two last. 21, 21. The transverse processes of the two last dorsal vertebræ, which are remarkable for their small size. 22. The body of the first lumbar vertebra. 23. The last lumbar vertebra. 24, 24. The transverse processes of the lumbar vertebræ, which are long and sharp. 25. The intervertebral substances of the lumbar vertebræ; the same substance is seen between the other vertebræ composing the column. 26, 26. The sacrum. 27, 27. The transverse lines on the sacrum, marking its original conformation of separate pieces. 28, 28. The anterior sacral foramina of one side; the same foramina are seen on the opposite side. 29. The promontory of the sacrum. 30. The first piece of the coccyx, ankylosed to the extremity of the sacrum, and forming a fifth pair of sacral foramina. 31. 32. The lower portion of the coccyx, consisting of three pieces and a rudiment of a fourth.

FIG. 2. A side view of the vertebral column, showing its curves.

No. 1. The atlas. 2. The posterior arch of the atlas. 3. The groove upon which the vertebral artery rests. 4. The axis. 5. The spinous process of the axis, remarkable for its great size. 6. The seventh and last cervical vertebra. 7. The long spinous process of the seventh cervical vertebra. 8, 8. The laminae of the cervical vertebræ. 9, 9. Their transverse processes. 10. The foramen for the vertebral artery in the transverse process of the axis. 11. The body of the first dorsal vertebra. 12. The body of the sixth dorsal vertebra. 13. The body of the twelfth. 14, 14. The transverse processes of the dorsal vertebræ, upon which the articular depression for the tubercles of the ribs is seen. 15, 15. The spinous processes of the dorsal vertebræ. 16. The intervertebral foramina in the dorsal region of the spine. 17, 17. The intervertebral substances in the dorsal region. 18. Depression upon the side of the body of the first dorsal vertebra, for the first rib. 19, 19. Depressions upon the sides of the bodies of the vertebræ for other ribs. 20. The first lumbar vertebra. 21. The fifth or last lumbar vertebra. 22, 22. The intervertebral substances connecting the bodies of the lumbar vertebræ. 23, 23. Intervertebral foramina in the lumbar region. 24, 24. The transverse processes of the lumbar vertebræ. 25, 25. Articular processes of the lumbar vertebræ. 26, 26. Spinous processes of the lumbar vertebræ. 27. The rudimentary spinous processes of the sacrum. 28. The surface of the sacrum, which articulates with the ilium. 29. The rough portion of the sacro-iliac articulation which gives attachment to the posterior sacro-iliac ligaments. 30. The four pieces of the coccyx.

FIG. 3. Posterior view of the vertebral column.

No. 1. The atlas. 2. The odontoid process of the axis seen articulating with the anterior arch of the atlas. 3, 3. Transverse processes of the atlas. 4. The axis. 5. The seventh cervical vertebra. 6, 6. The bifid spinous processes of the cervical vertebræ. 7. The first dorsal vertebra. 8. The last dorsal vertebra. 9, 9. The articulating processes of the dorsal vertebræ. 10, 10. The short transverse processes of the eleventh and twelfth dorsal vertebræ. 11. The first lumbar vertebra. 12. The fifth lumbar vertebra. 13, 13. The articular processes of the lumbar vertebræ. 14, 14. The sacrum. 15, 15. Its rudimentary spinous processes. 16, 16. The posterior sacral foramina. 17. The commencement of the sacral canal. 18. The termination of the sacral canal. 19, 19. The articular borders of the sacrum. 20. The coccyx.



and of fourteen facial, viz. two nasal, two lachrymal, two superior maxillary, two malar, two palatal, two turbinated, one vomer, and the inferior maxillary bone, (22.)

The ribs are 24 in number, (twelve on each side,) with the sternum, (25.)

The two superior extremities consist each of a clavicle and scapula, humerus, radius, and ulna, eight carpal bones, five metacarpal, and fourteen in the digital rows, (64.)

The two inferior extremities comprise, each, one pelvic bone, (innominatum,) one femur, tibia, and fibula, seven tarsal bones, five metatarsal, and fourteen digital, (60.)

In the skeleton we recognise two great cavities, (which are again variously subdivided;) one anterior and inferior, comprising the thorax and abdomen; the other posterior and superior, formed by the union of the vertebral canal with the cranial cavity

*Vertebral column.*—The *vertebral column* (columna vertebralis, rachis, spina) is situated along the median line, at the posterior part of the trunk, the length of which it determines. Anteriorly it presents the form of an irregular pyramid—posteriorly, a series of elongated processes, (spinæ,) disposed regularly one beneath the other, from which circumstance the term “spine” is derived. Viewed as a whole, it resembles at first sight the shape of a long bone, but it is very differently constructed. As it receives the weight of the head and trunk, and transmits it to the base on which it rests, it requires to be firm and resisting, its power of resistance increasing gradually from above downwards. Being the centre of all the movements of the body, it must be as pliant and flexible as a bow, but yet firm, in order to give adequate protection to the spinal cord which it encloses. All these conditions are attained by its being made up of several small pieces united by an elastic substance, the motion permitted between each pair being slight, while the aggregate of all is considerable.

The *vertebræ*, or separate pieces of which the column is made up, are so named from their mobility, (vertere, to turn.) They are divided into *true* and *false*; the former term being applied to those which remain separate in the adult, and retain their mobility—the latter to such as become united into one mass, (viz., the sacrum,) or degenerate, as it were, and lose all the ordinary characters of *vertebræ*, (viz., the coccyx.) The size of the *vertebræ* increases from above downwards as far as the first pieces of the sacrum, from which it diminishes towards the end of the coccyx, where it terminates by a point; so that the column may be said to consist of two pyramids applied to one another at their bases. The superior, or moveable one, however, does not taper regularly from above downwards in its entire length; it becomes somewhat narrowed and constricted as it were at the third dorsal vertebra, after which it gradually enlarges towards its base.

## PLATE V.

The *vertebræ* of the three regions of the spine, with separate *vertebræ* from the cervical region; after Cheselden.

FIG. 1. A front view of the seven cervical *vertebræ* articulated.

No. 1. The atlas. 2. The axis. 3. The seventh and last cervical vertebra.

FIG. 2. An atlas seen upon its upper surface.

No. 1. The anterior arch of the atlas. 2. Its anterior tubercle. 3. The posterior arch. 4. The posterior tubercle, or rudimentary spinous process. 5, 5. The intervertebral notch, which supports the vertebral artery at each side. 6, 6. The transverse processes. 7, 7. The foramen for the transmission of the vertebral artery. 8, 8. The superior articular surfaces of the atlas. 9, 9. The tubercles to which the extremities of the transverse ligament are attached.

FIG. 3. The atlas seen from below.

The references to the preceding figure are equally applicable to this: the additional points exhibited in the present view are, 10. The articular surface for the odontoid process of the axis, on the posterior part of the anterior arch. 11, 11. The inferior articular surfaces, which are flat and nearly horizontal.

FIG. 4. A lateral view of the axis.

No. 1. The body of the axis. 2. The odontoid process of the axis. 3. The smooth articular surface corresponding with the posterior aspect of the anterior arch of the atlas. 4, 4. The laminae. 5. The spinous process. 6. The transverse process. 7. The foramen for the vertebral artery. 8. One of the superior articular processes. 9. One of the inferior articular processes.

FIG. 5. One of the middle cervical *vertebræ*, seen upon its upper surface.

No. 1. The body. 2, 2. The transverse processes. 3, 3. The anterior tubercles of the transverse processes. 4, 4. The posterior tubercles. 5, 5. Foramina for the vertebral arteries. 6, 6. The pedicles, rendered concave by the intervertebral notches. 7, 7. Superior articular processes. 8. The outer surface of one of the inferior articular processes. 9, 9. Laminae of the vertebra. 10. The spinous process. 11. The bifid termination of the spinous process. 12. The ring of the vertebra for the location of the spinal cord with its membranes.

FIG. 6. A cervical vertebra seen upon its under surface.

No. 1. The anterior surface of the body. 2. Its under surface. 3, 3. Transverse processes. 4, 4. The inferior articular processes. 5. The spinous process. 6. Its bifid extremity. 7, 7. The pedicles of the laminae.

FIG. 7. The seventh cervical vertebra, or vertebra prominens, seen upon its upper surface.

No. 1. The upper and concave surface of the body of the vertebra. 2. Its posterior surface, upon which foramina are seen for the veins of the vertebra. 3, 3. Transverse processes. 4, 4. The pedicles of the laminae. 5, 5. The laminae. 6, 6. The superior articular processes. 7. The long spinous process.

FIG. 8. A lateral view of the twelve dorsal *vertebræ*.

FIG. 9. The five lumbar *vertebræ*. The *vertebræ* in the three figures, 1, 8, and 9, constitute together the same vertebral column.



Fig 3

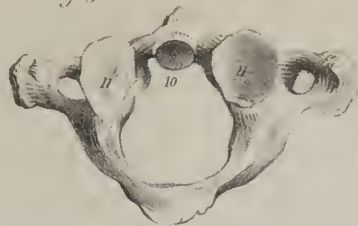

Fig 4

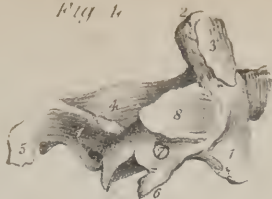

Fig 2

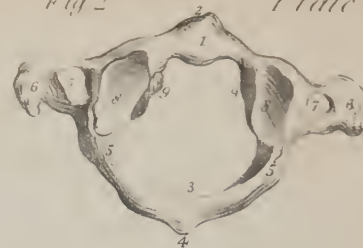

Fig 8

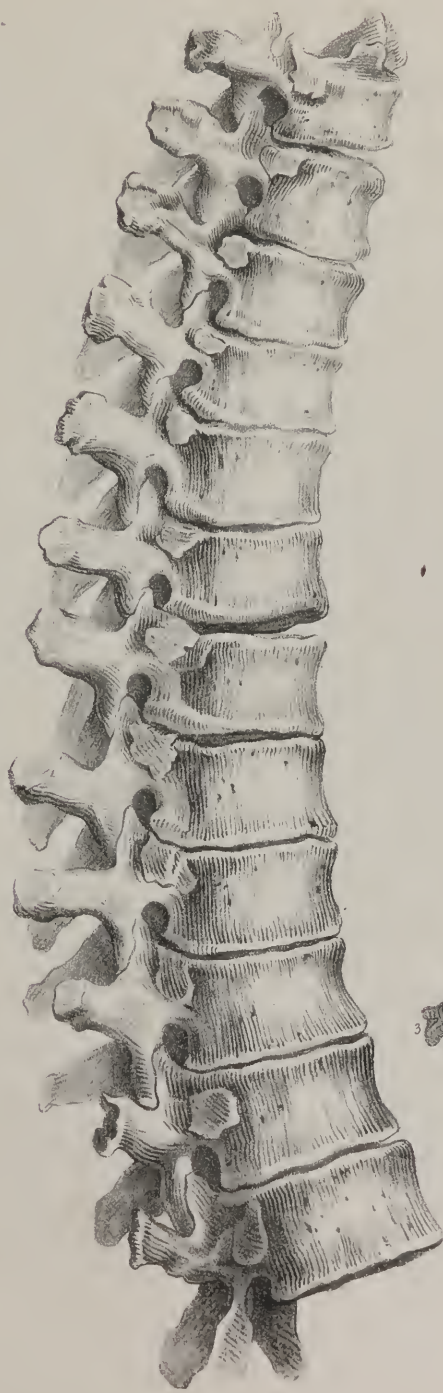


Fig 5

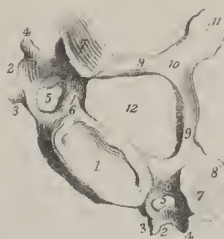

Fig 1

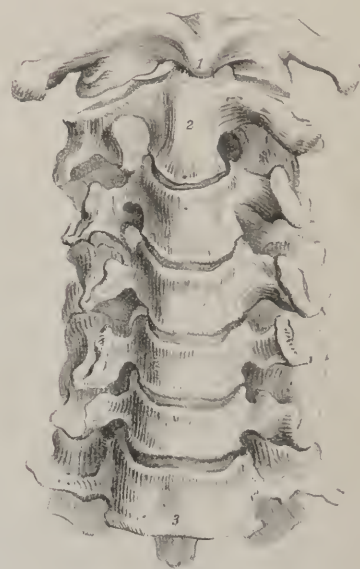


Fig 6

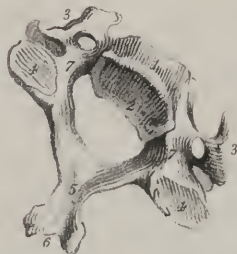

Fig 9

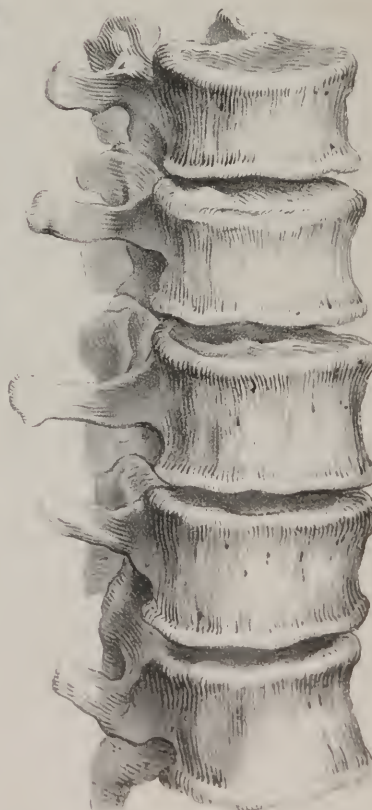
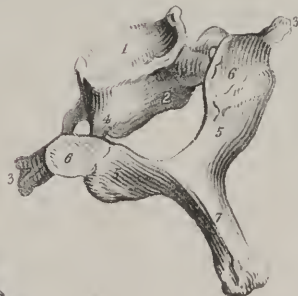
Fig 7





*Vertebræ, division of.*—The true vertebræ are divided into three sets, named from the regions which they occupy, *cervical, dorsal, lumbar*. The sacrum and coccyx, which form the remaining part of the column, shall be described with the bones of the pelvis, as they enter into the composition of that cavity, and maintain important relations with the organs which it contains.

The true vertebræ present, 1, certain general characters by which they may at once be distinguished from bones of any other class; 2, those of each region, (*cervical, dorsal, lumbar,*) exhibit peculiar characters by which they are severally distinguished.

*General characters of a vertebra.*—It is usual to say that a vertebra consists of body and processes—the body being the primary or fundamental part. The objects presented by each of these bones are, a body, a ring, articulating processes, transverse and spinous processes, and notches: of these, the ring, or foramen, merely to suit the purposes of methodical description, may be considered the central part. As the whole series of vertebræ is intended to form a pillar of support, each, with the exception of the first, presents in front a convex mass, (the body,) which is a section of a cylinder, and which, by being piled one over the other, form the pillar. As each bone must be securely joined with the one above it, and that below it, there exist certain prominences for articulation with them. The column being flexible, and partaking in the several movements of the body, it is required that there be levers for the attachment of the muscles or moving powers. Finally, it is necessary that a free communication should be allowed for the nerves with the nervous centre contained in the canal.

The *ring* (foramen vertebrale, rachidium) is formed in front by the body, and posteriorly by what is named the *arch* of the vertebra, from which latter the several processes project. As the vertebræ are piled one over the other, the rings are arranged so as to form, with the aid of the interposed ligamentous structures, a flexible canal for the lodgment and protection of the spinal cord.

The *body* forms the anterior and most considerable part of the bone. Rounded before, and marked in the middle by a transverse groove, which gives it a constricted appearance, it is slightly hollowed posteriorly, where it contributes to the formation of the vertebral canal, and in most instances is flat on the superior and inferior surfaces, by which, through the medium of a layer of fibro-cartilage, it is connected with the contiguous bones. Its outer surface all round presents numerous foramina for the passage of nutritious vessels. From the body, at its lateral margins, two processes pass backwards called “pedicles.” The pedicles join with the lamellæ, or plates; and these, by inclining inward, meet at the median line posteriorly, so as to complete the “arch” of the vertebra. From the point of junction of the pedicles with the lamellæ at each side, the articulating and transverse processes project, and from the union of the two lamellæ the spinous processes take their origin.

*Articulating processes.*—For maintaining the connexion between the contiguous vertebræ, there are four processes,—two superior, and two inferior,—which project, one on each side, from the junction of the lamella with the pedicle. Two of these processes project upwards, and two downwards; the smooth surfaces of the upper pair look backwards, those of the lower, forwards; they are coated with cartilage, and articulate with corresponding processes of the next vertebræ. Their margins are rough for the attachment of ligaments.

The *transverse* and *spinous* processes form a series of levers for the attachment of muscles. The transverse processes, two in number, (one on each side,) and named from their direction, project laterally from the arch near the articulating processes, between which their bases are interposed. The *spinous* process is a single projection, situated posteriorly in the median line; this process, or rather the appearance presented by the aggregation of those of the several vertebræ, has given to the entire column one of its designations, (spine.) The parts of the arch which intervene between the bases of the spinous and the transverse processes are named *laminae* or *plates*. Lastly, the processes which extend from the lamellæ to the body of the bone, are called “pedicles,” as above stated. In each pedicle are seen two excavations, or *notches*, (*incisuræ*), one on the upper, the other on the lower border, the latter being deeper than the former. When the vertebræ are placed in their natural position, the notches in the contiguous margins of each pair of them form rounded apertures, which communicate with the vertebral canal, and give transmission to the spinal nerves and to the entering and emerging vessels. From their position and mode of formation they are called the *inter-vertebral foramina*, (*trous de conjugaison*.)

These remarks apply generally to all the vertebræ; but as each class presents peculiar characters which distinguish those included within it from others, and as there are peculiarities which mark certain individuals of each class, it becomes necessary to examine them more in detail.

The *cervical* vertebræ are seven in number; they are smaller than those in the other regions, which results from the size of the body and processes being less than that of the corresponding parts in the dorsal and lumbar class. The vertebral foramen is of a triangular form, and larger proportionally than in the other classes. The body, elongated transversely, is thicker anteriorly than posteriorly; for the under and fore part of each dips down a little. The upper surface is broader than the under one, and is rendered concave from side to side, by two little plates, which project upwards from its margins. The lower surface is slightly convex, and rounded off at the sides. The superior articular processes are flat and oblique in their direction, so as to look backwards and upwards, whilst the inferior incline downwards and forwards. The transverse processes, short, and bifid at their extremities, present a groove superiorly for the transmission of the nerves, and at their base a foramen, through which in most of them the vertebral artery passes. It will be observed, that these processes have two roots or points of connexion with the vertebra. The posterior one springs from the junction of the pedicle with the arch, and therein corresponds with the transverse



processes in the back and loins. The anterior one is attached to the side of the body of the vertebra, and ranges with the ribs, of which it is a rudiment. The formation of the foramen can, from these facts, be readily indicated. The osseous points, which here represent the ribs, not being required for any special purpose, remain in their rudimentary condition, and merely incline backwards, so as to become ankylosed with the true transverse processes which lie behind them. They thus enclose a space, viz., the foramen, which, however, cannot be said to be intended to lodge the vertebral vessels, as it exists in the seventh cervical vertebra, through which they do not pass, and in the sixth and fifth in those cases in which the artery enters at the fourth. The spinous process is short, projects horizontally backwards, and is bifid at its extremity. The plates are narrower and longer than in the other regions. The notches are deeper and larger in the upper than in the lower border of the pedicles, in all except the second. They lie behind the articular processes in the first, but before them in the rest.

The *dorsal* vertebræ, twelve in number, are intermediate in size, as well as in situation, between the cervical and the lumbar. The foramen is smaller than in the cervical or lumbar region, and is nearly circular in its form. The lateral notches, and consequently the inter-vertebral foramina which they form, are larger than those in the neck; and those at the lower margin of the pedicles are much larger and deeper than those on the upper. The depth of the body, taken from before backwards, is greater than its breadth from side to side; it is convex and prominent on the anterior surface, flat and plain at the upper and lower; at each side of the body may be observed a slight notch, in the superior as well as in the inferior border,—these, when the vertebra is placed in apposition with the adjacent ones, form oval depressions for the reception of the heads of the corresponding ribs. The articulating processes are nearly vertical in their direction; the superior looking backwards, the inferior forwards. The transverse processes are long and inclined backwards, and on the anterior surface of each of their tubercular terminations is situated a slight excavation, which, in the fresh state, is tipped with cartilage, and articulates with the tubercle of the rib. The spinous processes, elongated and triangular, are directed downwards, and terminate in a tubercle. The plates are broad and thick, but shorter than those in the neck.

The *lumbar* vertebræ, five in number, are larger than either of the other sets. The foramen of each vertebra in this region

## PLATE VI.

Section of the vertebral column, showing the texture of the divided surfaces, and the direction of the vertebral canal; with views of the dorsal and lumbar vertebræ: after Cheselden.

FIG. 1. The sixteen superior vertebræ.

No. 1. The atlas. 2. The axis. 3. The seventh cervical vertebra, or vertebra prominens. 4. The first dorsal vertebra. 5. The ninth dorsal vertebra. 6. The most projecting of the spinous processes of the cervical vertebræ, belonging to the vertebra prominens. 7, 7. The oblique direction and imbricated position of the spinous processes of the dorsal vertebræ is here shown. 8, 8. The inter-vertebral foramina, formed by the approximation of the intervertebral notches. 9, 9. The vertebral canal.

FIG. 2. The eight inferior vertebræ of the spinal column, with the sacrum.

No. 1. The tenth dorsal vertebra. 2. The last dorsal vertebra. 3. The first lumbar vertebra. 4. The last lumbar vertebra. 5, 5. The short and nearly horizontal spinous processes of the last dorsal vertebræ. 6, 6. The broad spinous processes of the lumbar vertebræ. 7, 7. The intervertebral foramina. 8, 8. The vertebral canal. 9, 9. The sacrum. 10. A part of its anterior surface, upon which two of the anterior sacral foramina, 11, 11, are seen. 12, 12. Fissures in the body of the sacrum, marking its original construction of four pieces. 13. Section of the rudimentary spinous processes of the sacrum. 14, 14. The sacral canal, in which several of the posterior sacral foramina, 15, 15, are seen. 16. The termination of the sacral canal. 17. The coccyx, consisting of four pieces.

FIG. 3. A dorsal vertebra seen upon its under surface.

No. 1. The anterior surface of its body. 2. The under surface. 3, 3. Transverse processes. 4, 4. The inferior articular process. 5. One of the superior articular processes. 6, 6. Laminæ of the vertebra. 7. The vertebral ring. 8. The spinous process. 9. Its tubercle.

FIG. 4. A dorsal vertebra seen from above.

No. 1. The superior surface of the body. 2. Its lateral surface. 3. Part of its posterior surface. 4, 4. The transverse processes. 5, 5. Superior articular processes. 6, 6. Posterior surface of the laminæ. 7. The spinous process, directed downwards and terminated inferiorly by the tubercle.

FIG. 5. The last dorsal vertebra, approaching in appearance to the characters of the lumbar vertebræ.

No. 1. Its body. 2. The depression on the side of the body for the articulation of the last rib. 3, 3. The superior articular processes. 4. One of the inferior articular processes. 5. The pedicle. 6. The superior intervertebral notch. 7. The inferior intervertebral notch. 8, 8. The transverse process of the vertebra. 9. Its spinous process.

FIG. 6. One of the lumbar vertebræ turned upwards so as to show its under surface.

No. 1. Its body. 2. One of its pedicles. 3, 3. The transverse processes. 4. One of the superior articular processes. 5, 5. The inferior articular processes. 6. The spinous process. 7. The vertebral ring. 8. The under surface of the body.

FIG. 7. One of the lumbar vertebræ seen from above and behind.

No. 1. The upper surface of the body of the vertebra. 2. Its posterior surface, on which openings for the transmission of several large veins are seen. 3. The pedicle of one of the laminæ, immediately above which the superior intervertebral notch is seen. 4, 4. Transverse processes. 5, 5. The superior articular processes. 6. One of the inferior articular processes. 7, 7. Laminæ of the vertebra. 8. The spinous process.

Fig 1

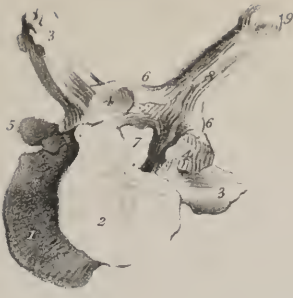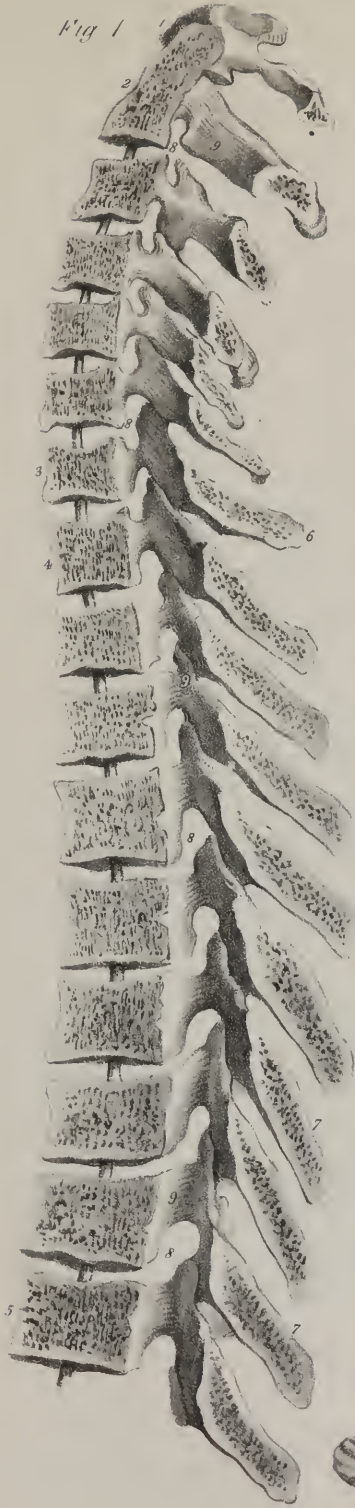


Fig 4

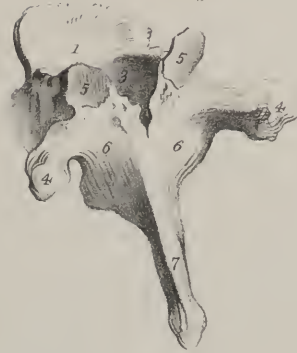

Fig 5

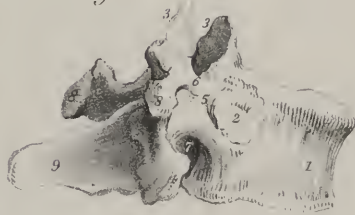

Fig 6

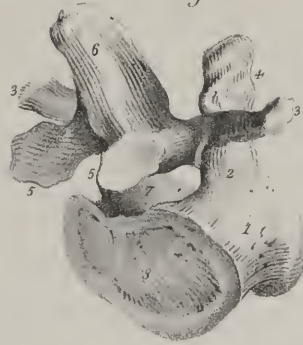

Fig 7

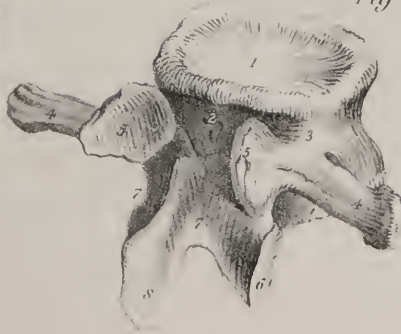
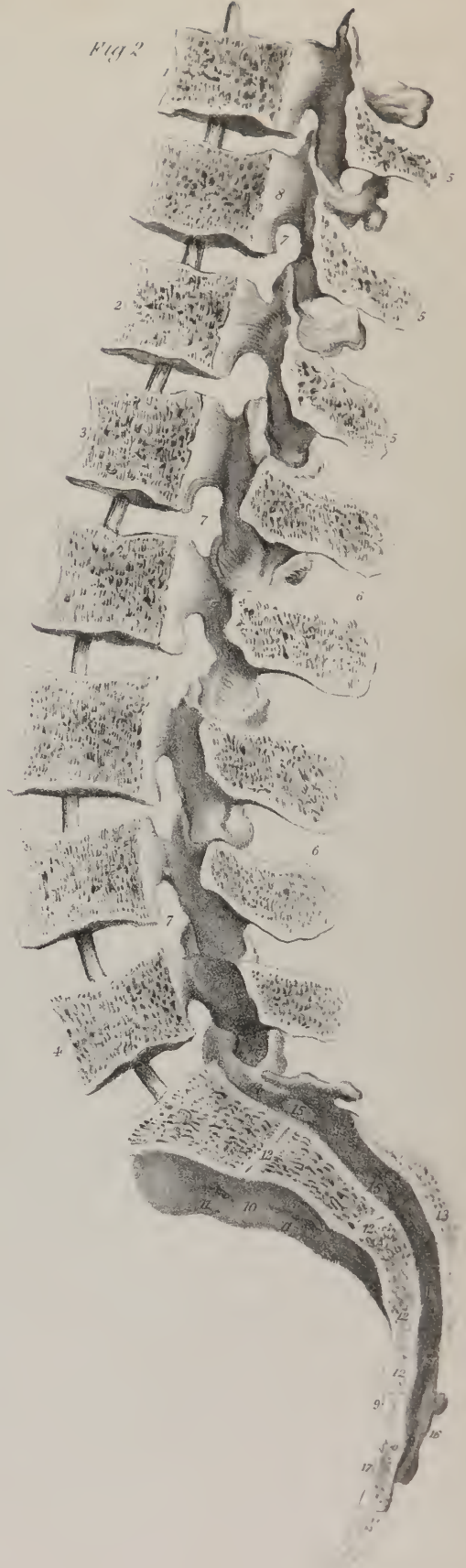
Fig 2







is large and triangular. The notches for the formation of the intervertebral foramina are very deep, especially the inferior pair. The body, broader from side to side than from before backwards, is flat on its superior and inferior surfaces. It is not so convex anteriorly as that of the dorsal vertebræ. The articulating processes are thick, strong, and disposed vertically; the superior pair, concave, look inwards and backwards; the inferior, convex, outwards and forwards; the former are farther apart than the latter, hence they receive and in a manner embrace the lower articulating processes of the vertebra above them. The transverse processes, long, thin, and horizontal, do not project backwards like those of the dorsal vertebræ. The spinous process is broad, flat, and nearly of a square form, so that it terminates not by a pointed extremity, like those in the dorsal region, but presents rather a compressed and rough border. The plates, though shorter, are deeper and thicker than those of the dorsal vertebræ.

The general characters of the vertebræ, and the differences which characterize those of different regions, being considered, it remains to point out certain peculiarities presented by some individual bones in each set. It may be here stated generally, that the vertebræ situated at the extremities of each region assimilate in some degree to the characters of those in whose vicinity they are placed. Thus, for instance, the lower pieces of the cervical region begin to resemble the dorsal vertebræ, and the latter become, by a similar transition, assimilated to the lumbar,—the characters peculiar to each region being best displayed by the bones situated towards its middle point.

*Peculiarities of certain vertebræ.*—The first, second and seventh cervical vertebræ present some characters which distinguish them from the others.

The first, or *atlas*, (so called from supporting the head,) is an irregular ring of bone, which presents nothing analogous either to the bodies or spines of the other vertebræ. The ring, in the fresh state, is divided into two parts, by a transverse ligament,—the anterior one being occupied by the odontoid process of the axis, the posterior by the spinal cord,—it presents in front a small arch of bone, the anterior surface of which is marked by a tubercle; the posterior by a smooth depression, adapted to the odontoid process of the axis. The posterior segment of the ring is considerably larger than the anterior; at its middle point it presents a tubercle, which is the analogue of the spinous processes; it is thick and round in the greater part of its extent; but at its junction with the rest of the vertebra there exists on the upper border at each side a smooth groove, which lies behind the superior articular process, and marks the tortuous course pursued by the vertebral artery previously to entering the cranium. This groove is analogous to the notches in the other vertebræ, for it transmits the first spinal nerve as well as the vertebral artery; it is sometimes converted into a foramen by a spicula of bone.—The articulating surfaces are horizontal and large; the superior pair receive the condyles of the occipital bone; they converge in some sort towards the forepart of the bone; and as their form is oval, and their surface concave from before backwards, they look towards one another; at the inner margin of each is a rough surface, which gives attachment to the transverse ligament. The inferior pair, on the contrary, are flat, and nearly circular in their form. The parts of the vertebra (*lateral masses*) on which these processes are situated are of very considerable thickness, because the weight of the head, which in others is received by the bodies, rests here on the articular surfaces. The transverse processes project considerably on each side, and terminate in a rounded point; at the root of each is situated the foramen, which transmits the vertebral artery.

The second vertebra, or *axis*, (so called from forming the pivot on which the head rotates,) is somewhat triangular in its form. The body presents anteriorly a vertical ridge, bounded on each side by a depression for the attachment of the longus colli muscle; superiorly it is surmounted by a process, (*odontoid, p. dentatus*; whence is derived the name *vertebra dentata*.) presenting two smooth surfaces, one for its articulation with the atlas, the other with the transverse ligament which retains it in its situation; being constricted inferiorly, and somewhat enlarged towards the summit, these parts of the process are called respectively its *neck* and *head*. The superior articulating processes are of considerable size, and nearly horizontal; they are close to the body, so as to communicate to it the weight of the head, transmitted to them by the articular processes of the atlas; the inferior pair are oblique, and of the same size as in the vertebræ beneath them. The transverse processes are neither grooved nor bifurcated, and the foramen at their root is inclined obliquely outwards. The spinous process is very large, and gives attachment to several muscles; it is deeply grooved on its inferior surface; the plates which support it are of proportionate size.

The *seventh*, or prominent vertebra, approaches in its characters to those of the dorsal region; its spinous process terminates in a tubercle, and is so long as to be, in the natural condition, felt underneath the skin, whilst the other cervical spines lie more deeply, and are covered by muscles; hence the term “prominent,” so commonly applied to this vertebra. The transverse process, though pierced by a foramen, presents but a slight appearance of a groove on its upper surface, and seldom more than a trace of a bifurcation at its extremity.

The *first dorsal* vertebra is marked at each side by a complete articular surface for the first rib, and on its inferior border by a slight excavation, which receives half the head of the second: the upper articular processes are oblique, and the spinous more nearly horizontal than those below it.

The *tenth* dorsal vertebra is usually marked by an articular surface, which receives the entire of the head of the corresponding rib.

The *eleventh* is distinguished by its transverse processes not presenting an articulating surface for the tubercle of the rib, whilst the form of its spinous process, of its lamellæ and body, approaches that of the lumbar vertebræ.

The *twelfth* dorsal vertebra resembles the eleventh in most of its characters; but its transverse processes are shorter, and the

lower articular pair convex and directed outwards, so that its conformation resembles that of the lumbar vertebræ in these particulars.

Amongst the *lumbar* vertebræ, the fifth only is distinguishable by any peculiarity deserving of notice, its body being thicker anteriorly than posteriorly, and its transverse process short, thick, and rounded.

The bones just described, when ranged in their natural position, form a pyramid, the length of which is equal to about two feet two or three inches; taken as a whole it presents an anterior and posterior surface, two lateral surfaces, a base, and a summit, each deserving a particular notice.

The anterior surface is broad in the cervical, narrow in the dorsal, and again expanded in the lumbar region; it is marked by a series of transverse grooves corresponding with the centre of the bodies of the vertebræ, and in the fresh state is covered by the anterior common ligament. When viewed in profile, it presents three curves depending on the different degrees of thickness of the anterior and posterior part of the bodies of the vertebræ in the different regions, but still more on that of the intervertebral substance. In the neck and loins the convexity of the curve is forwards; in the back it is in the opposite direction. A slight degree of lateral curvature is also observable in most cases in the dorsal region, the convexity of which is directed towards the right side. The older anatomists imagined this to be produced by the action of the aorta beating against the left side of the column; but Bichât attributed it to the effect of muscular action, and explained it in the following way:—As most persons are disposed to use the right arm in preference to the left, the muscles of that side become stronger, and act with more power on the points to which they are attached; when making efforts, as in pulling, the body is curved to the left, which gives an additional advantage to the muscles; and the habitual use of this position gives rise to some degree of permanent curvature. In support of this explanation of the fact, Bécлар has stated that he found in one or two individuals, who were known to have been left-handed, the convexity of the lateral curve directed to the left side.

The posterior surface presents along the median line the spinous processes, varying in form and direction, as has been

## PLATE VII.

The ligaments of the vertebral column, and of the costo-vertebral and costo-sternal articulations.

FIG. 1. The ligaments situated upon the anterior aspect of the vertebral column, in the dorsal region.

Nos. 1, 1. The anterior common ligament. 2, 2. The intervertebral substances. 3, 3. The anterior costo-vertebral or stellate ligaments. 4, 4. The anterior costo-transverse ligaments.

FIG. 2. The ligaments of the posterior aspect of the vertebral column.

Nos. 1, 1. The supra-spinous ligaments. 2, 2. The ligamenta subflava. 3, 3. The posterior costo-transverse ligaments. 4, 4. The anterior costo-transverse ligaments.

FIG. 3. A posterior view of the bodies of three of the dorsal vertebræ.

Nos. 1, 1. The cut surfaces of the pedicles of the vertebræ. 2, 2. The posterior common ligament. 3, 3. The intervertebral substances. 4, 4. Foramina for the transmission of the venæ basis vertebræ.

FIG. 4. Arches of three of the dorsal vertebræ.

Nos. 1, 1. The cut surfaces of the pedicles. 2. Superior articular processes of the uppermost of the three. 3, 3. Transverse processes. 4, 4. Ligamenta subflava.

FIG. 5. The intervertebral substance between two vertebræ, showing its composition of oblique fasciculi of fibres.

FIG. 6. The surface of a section of the intervertebral substance.

Nos. 1, 1. Concentric circles of fibrous structure. 2. The pulpy fibro-cartilaginous tissue of the centre of the intervertebral substance.

FIG. 7. A lateral view of the ligaments of the vertebral column, with those of the costo-vertebral articulation.

Nos. 1, 1. The anterior common ligament. 2, 2. The intervertebral substances. 3, 3. The anterior costo-vertebral or stellate ligaments; the numbers are placed on the middle fasciculi. 4. The superior fasciculus of the stellate ligament. 5. Its inferior fasciculus. 6, 6. The anterior costo-transverse ligaments. 7. The articular facets of two adjoining vertebræ, serving for the articulation of a single rib. The numeral is placed upon the intervertebral substance, which serves for the attachment of the interarticular ligament. 8. The articular surface at the extremity of the transverse process, for the attachment of the same rib. 9. The supra-spinous ligaments. 10. One of the inter-spinous ligaments.

FIG. 8. A vertebra, with its articulated ribs, seen from above, in order to show the middle costo-transverse ligament.

No. 1. The surface of the body of the vertebra, coated with intervertebral substance. 2, 2. The ribs divided through their middle. 3, 3. The middle costo-transverse ligaments. 4, 4. The posterior costo-transverse ligaments. On the left side, at 5, the articulation of the tubercle of the rib with the transverse process is partly laid open.

FIG. 9. Section of a vertebra with the head of a rib, through the costo-vertebral articulation.

No. 1. Part of the anterior common ligament. 2. The intervertebral substance. 3, 3. The two synovial cavities of the costo-vertebral articulation, separated by 4, the interarticular ligament.

FIG. 10. The costo-sternal articulation seen from the front.

Nos. 1, 1. Cartilages of the ribs. 2, 2. Anterior costo-sternal ligaments. 3, 3. Articular surfaces of the sternum, for the costal cartilages of the opposite side.

FIG. 11. The costo-sternal articulation, seen from behind.

Nos. 1, 1. Costal cartilages. 2, 2. Posterior costo-sternal ligaments. 3, 3. Longitudinal tendinous fibres on the posterior surface of the sternum. 4, 4. Articular surfaces of the opposite border of the sternum.



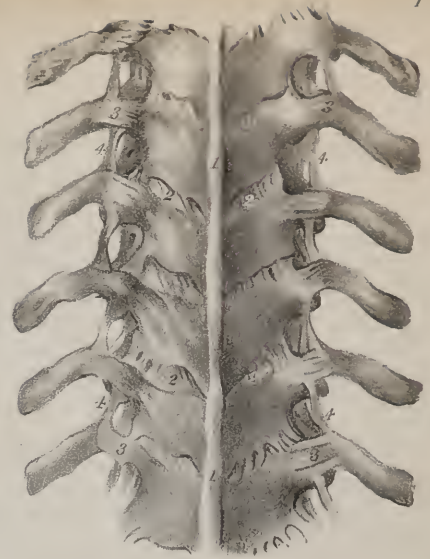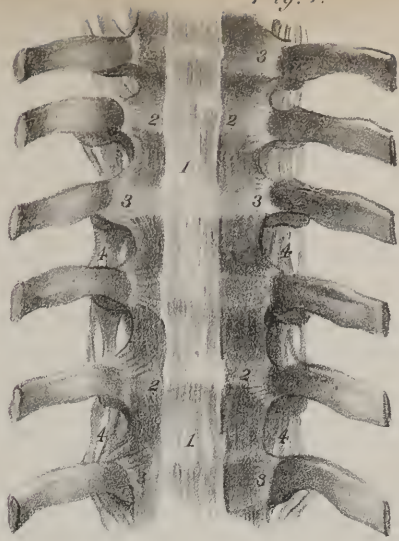


Fig. 3.

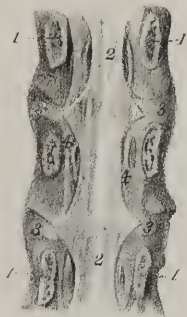

Fig. 8.

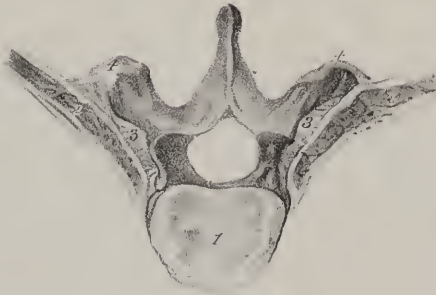


Fig. 1.

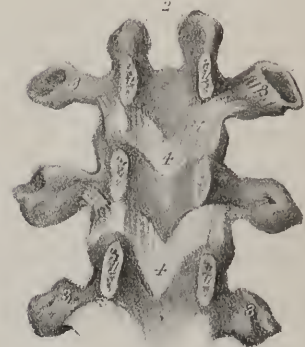

Fig. 7.

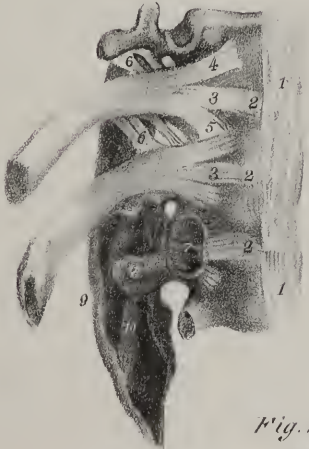

Fig. 6.

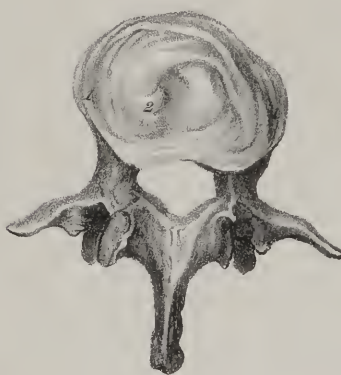

Fig. 9.




Fig. 10.

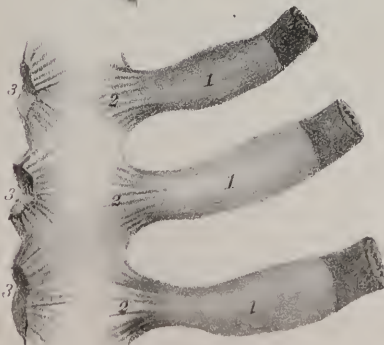
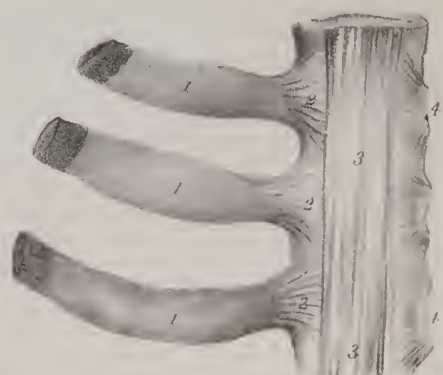
Fig. 11.







already stated ; being horizontal in the cervical and lumbar regions, and nearly vertical in the dorsal. Those in the cervical and dorsal regions correspond pretty exactly with the middle line, but in the back the spines will be observed in many instances to incline, some to one side, some to the other. On each side of these are the vertebral grooves, extending from the base of the skull to the sacrum ; their breadth corresponds with that of the laminæ ; they are broad but shallow in the neck, and become deep and narrow lower down. Along the grooves are seen the spaces between the laminæ, which in the natural condition are filled up by the yellow ligaments. The breadth of these intervals is very trifling in the neck and in the greater part of the back ; it increases in the lower third of the dorsal, and still more in the lumbar region. The interval between the occipital bone and the atlas is considerable, and so is that between the last lumbar vertebra and the sacrum.

The lateral surfaces of the column present the transverse processes, varying in form and character in the different regions : before these are situated the intervertebral foramina, and more anteriorly still, in the dorsal region, the articulating surfaces which receive the heads of the ribs.

The summit is articulated with the occipital bone, and supports the head ; whilst the base, or broader extremity, rests on the sacrum. Along the entire extent of the column runs the vertebral canal, which is broad and triangular in the cervical and lumbar regions, circular and contracted in the dorsal. The canal may be said to expand at its upper extremity into the cranial cavity, and at its lower end to be prolonged into that of the sacrum.

*Developement.*—In the description here given of the vertebræ, each of them is considered as a single bone ; and so it is when fully formed. But in the fœtal state and in early infancy each consists of at least three pieces, representing so many centres of ossification, one corresponding with the body and one for each lateral mass. The spinous process has even been observed to commence by a separate point, and analogy would lead to the inference that the anterior and posterior segments of the body are produced from distinct centres. Are we to go farther still, and admit that the body in the first instance consists of two lateral halves ? If so, instead of three, we should have eight incipient osseous points in each of these bones. The atlas has three osseous nodules from which its ring is completed, one at each side for the lateral masses, and one in front for the anterior arch. Bichât found in some cases two additional points in the posterior arch. The second vertebra commences by five points at least, two of them being in its odontoid process.

*Of the Skull.*—The skull is of a spheroidal figure, compressed on the sides, broader behind than before, and supported by its base on the vertebral column. It is divided by anatomists into two parts, the cranium and the face ; the former being composed of eight bones, viz., the *occipital*, two *parietal*, the *frontal*, two *temporal*, the *sphenoid*, and the *ethmoid* ; the latter is made up of fourteen bones, viz. two *superior maxillary*, two *malar*, two *ossa nasi*, two *ossa palati*, two *ossa unguis*, two *inferior turbinated* bones, the *vomer*, and *inferior maxilla* ; the frontal bone is so situated as to be common to the cranium and face. The bones of the ear are not included in this enumeration, as they belong rather to a special organ than to the skeleton considered as the frame-work of the body.

*The Occipital Bone.*—The occipital bone (os occipitis) is situated at the posterior part of the base of the skull, broad behind, narrowed to a point before, of a trapezoid figure, presenting two surfaces, four borders, and four angles. To place the bone in its natural position, hold it so that the great foramen and the articulating processes beside it shall look directly downwards ; the thick process in front of the foramen will then project forwards into the base of the skull, whilst the broad expanded part behind it arches upwards and a little forwards, forming the posterior wall of the cavity. *External surface* : this is convex in its general outline, and presents a little above its centre a rough prominence, the *occipital protuberance*, the part between which and the superior angle is smooth. Extending obliquely outwards at each side from the protuberance is a rough line, called the *superior curved line*, to distinguish it from another which is lower down between it and the great foramen, called the *inferior curved line* ; both are prominent, and give attachment to muscles, as also do the rough depressions between them. These are crossed by a vertical line, extending forwards from the protuberance to the foramen.

The *occipital foramen*, (foramen magnum,) which is of an oval figure, (its long diameter extending from before backwards,) gives transmission to the spinal cord, the vertebral arteries, and spinal accessory nerves.

At each side of the foramen, but nearer its anterior part, are situated the articulating processes, (*condyles*,) two oblong eminences, which articulate with the first vertebra. These converge from behind forwards ; their inferior surface, which in the fresh state is smooth, covered with cartilage, and convex in its general outline, looks downwards and outwards, and is adapted for moving on the concave surface presented by the articulating processes of the atlas. The inner border of each condyle is rough, and receives the insertion of the check ligaments, which extend up from the odontoid process of the axis ; the outer border, depressed and not so well marked, gives attachment to the ligament connecting it with the atlas.

External to the fore part of the condyles are two fossæ, in the bottom of which are two foramina, (*anterior condyloid*,) which look outwards and forwards, and transmit the hypoglossal nerves ; behind them are also two larger pits, in which are generally, but not always, found foramina, (*posterior condyloid*,) which give passage to a vein and small artery ; sometimes a foramen exists at one side, and not at the other. External to each condyle is a rough surface, which overhangs the transverse processes of the vertebræ, and of which it may be regarded as the “analogue ;” it gives insertion to the rectus lateralis muscle.

The *internal surface* of the bone is marked by two lines—one vertical, extending from the upper angle of the bone to the

great foramen, and the other transverse from one lateral angle to the other. These intersect towards the central point, (internal occipital protuberance,) and mark off four pits, of which the upper pair (superior occipital fossæ) receive the posterior lobes of the brain, and the lower (inferior occipital fossæ) lodge the lateral lobes of the cerebellum: the superior line and the two transverse ones are generally grooved, and correspond with the course of the longitudinal and lateral sinuses. The inferior one gives attachment to the falx cerebelli. The anterior border of the foramen magnum is slightly excavated, and becomes continuous with the *basilar groove*, a shallow excavation on the surface of the basilar process, which supports the medulla oblongata; close to the margin of the foramen are the anterior condyloid foramina, and a little external to it are two fossæ, marking the terminations of the lateral sinuses.

The thick triangular process, which projects forward into the base of the skull from the foramen, is called the *basilar process*; its margins are rough, and contiguous to the pars petrosa of the temporal bone; its under surface presents slight depressions for the insertion of muscles, and the upper one the shallow groove just noticed.

## PLATE VIII.

Ligaments of the articulations between the occipital bone, the atlas and the axis, and of the lower jaw.

FIG. 1. The ligaments connecting the occipital bone, the atlas and the axis, seen from the anterior aspect.

No. 1. Section of the basilar process of the occipital bone. 2, 2. Sections of the extremity of the petrous portion of the temporal bones. 3, 3. The transverse processes of the atlas. 4, 4. The axis. 5, 5. The third cervical vertebra. 6. The round, or accessory anterior occipito-atloidean ligament. 7, 7. The broad anterior occipito-atloidean ligament. 8, 8. Capsular ligaments of the occipito-atloidean articulation. 9, 9. The anterior atlo-axoid ligament. 10, 10. Capsular ligaments of the atlo-axoid articulation: on the right side the articulation is laid open, in order to show the articulating surfaces. 11, 11. Capsular ligaments of the articulation between the second and third vertebræ. 12. The commencement of the anterior common ligament.

FIG. 2. The ligaments of the occipital bone, the atlas, and the axis, seen from behind.

No. 1. A part of the occipital bone. 2. The posterior arch of the atlas. 3, 3. Its transverse processes. 4. The spinous process of the axis. 5, 5. Its laminae. 6, 6. Its rudimentary transverse processes. 7, 7. The third cervical vertebra. 8. The posterior occipito-atloidean ligament. 9, 9. The vertebral arteries, passing beneath an arch at each side, formed by this ligament. 10. The posterior atlo-axoidean ligament. 11, 11. The atlo-axoidean capsular ligaments. 12. One of the capsular ligaments of the articulation between the second and third vertebræ; the other, 13, is laid open.

FIG. 3. The upper part of the vertebral canal, opened from behind by removing a part of the arches of the vertebræ, in order to show the occipito-axoidean ligament.

No. 1. The basilar portion of the sphenoid bone. 2, 2. The foramen lacerum posterius. 3, 3. The anterior condyloid foramina. 4, 4. The occipito-axoidean ligament. 5. A slight projection of this ligament, formed by the odontoid process. 6, 6. The cut surfaces of the posterior arch of the atlas. 7, 7. The transverse processes of the atlas. 8, 8. The capsular ligaments of the occipito-atloidean articulation. 9, 9. The cut extremities of the laminae of the axis. 10, 10. The capsular ligaments of the articulation between the atlas and the second cervical vertebra.

FIG. 4. The ligaments brought into view on the removal of the occipito-axoidean ligament. The section is the same as in the preceding figure.

No. 1. A small portion of the occipito-axoidean ligament. 2. The transverse ligament of the atlas. 3, 3. The vertical fibres of the transverse ligament, which have gained for it the designation of the cruciform ligament. 4, 4. The odontoid ligaments, connecting the apex of the odontoid process with the inner surface of the condyles of the occipital bone. 5, 5. Occipito-atloidean capsular ligaments. 6, 6. Capsular ligaments of the articulation between the atlas and the second cervical vertebra.

FIG. 5. The ligaments of the occipital bone, atlas, and axis, examined by means of a vertical section.

No. 1. The internal surface of a part of the base of the skull lined by dura mater. 2. One of the anterior condyloid foramina. 3. Section of the basilar process of the occipital bone. 4. Section of the posterior part of the occipital bone. 5. The cut surface of the anterior arch of the atlas. 6. The cut surface of the posterior arch. 7. Vertical section of the body of the axis and of the odontoid process. 8. Cut surface of its arch. 9, 9. Section of the third cervical vertebra. 10. Section of the anterior occipito-atloid ligament. 11. Section of the transverse ligament. 12. The superior vertical fasciculus of the transverse ligament. 13. The inferior vertical fasciculus of the transverse ligament. 14, 14. The occipito-axoidean ligament. 15. The fan-shaped insertion of the right odontoid ligament. 16. The posterior occipito-atloidean ligament. 17. The right vertebral artery, passing beneath a tendinous arch formed by the posterior occipito-atloidean ligament. 18. Section of the anterior atlo-axoidean ligament. 19. The posterior atlo-axoidean ligament. 20. The commencement of the anterior common ligament. 21. Intervertebral substance between the bodies of the second and third cervical vertebræ. 22. The first ligamentum subflavum.

FIG. 6. The atlas, seen from above, showing the situation of the transverse ligament, and the opening for the reception of the odontoid process of the axis.

No. 1. The anterior arch of the atlas. 2. Its posterior arch. 3, 3. The lateral masses upon which the articular surfaces for the reception of the condyles of the occipital bone are seen. 4, 4. The transverse processes pierced by the foramina for the passage of the vertebral arteries. 5. The transverse ligament. 6. The opening for the reception of the odontoid process. 7. The posterior opening of the ring of the atlas for the transmission of the spinal cord and its membranes.

FIG. 7. The articulation of the lower jaw seen from the external surface.

No. 1. A portion of the malar bone. 2. The zygoma. 3. The tubercle of the zygoma, which gives attachment to the external lateral ligament. 4. The external lateral ligament. 5. The neck of the lower jaw. 6. Its ramus. 7. Its coronoid process. 8. A part



Fig. 1.

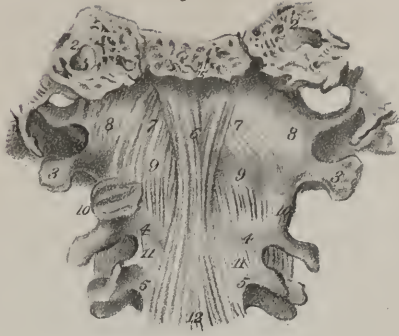

Fig. 7.

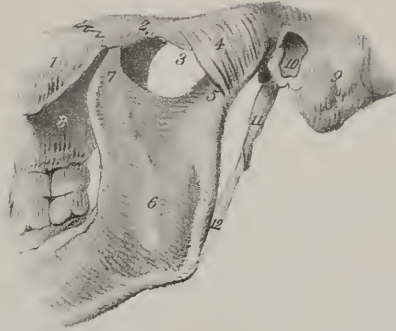


Fig. 2.

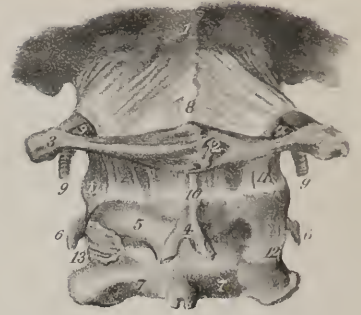


Fig. 4.

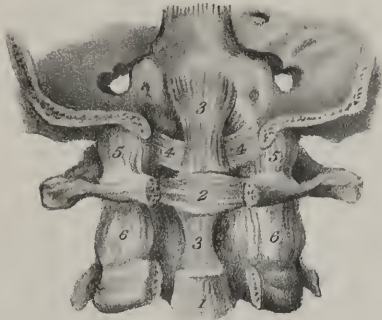


Fig. 8.

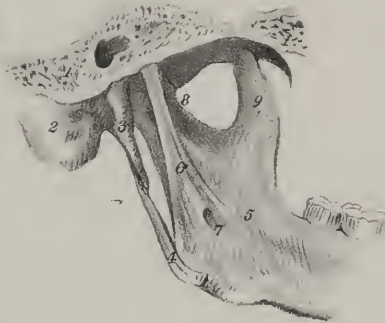

Fig. 3.

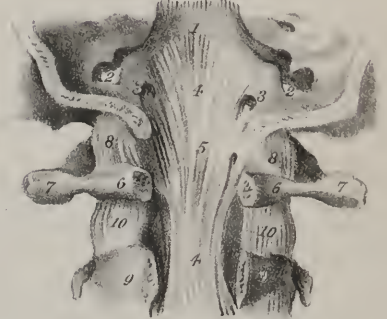

Fig. 5.



Fig. 9.

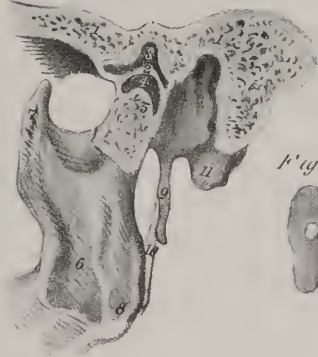

Fig. 6.

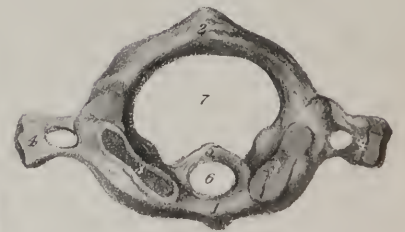

Fig. 10.



Fig. 11.







The *superior borders* of the occipital bone are dentated and converge to a point, but are frequently interrupted by bony islets, (*ossa triquetra*—Wormiana;) the inferior border at each side is divided into two parts by a prominent piece of bone, the *jugal eminence*, which surmounts an excavation contributing with the temporal bone to form the jugular fossa. The superior angle is acute, and received into the retiring angle formed by the posterior border of the parietal bones; the anterior is represented by the extremity of the basilar process; the lateral angles, not very prominent, correspond with the line at which the postero-inferior angle of the parietal bone joins with the mastoid part of the temporal.

*Articulations.*—The occipital articulates with six bones, viz., with the two parietal by its superior borders—the two temporal by the inferior—with the sphenoid by its basilar process—and with the atlas by the condyles.

*Attachments of muscles.*—The posterior third of the superior curved line gives attachment to the trapezius; its anterior two-thirds to the occipito-frontalis above, and to the sterno-mastoid below: the inner part of the space between the curved lines to the complexus: the external part to the splenius capitis: the space between the lower ridge and the great foramen to the recti majores and minores, and more outwardly to the obliquus superior: the under surface of the jugal eminences to the recti laterales: the fossæ at the inferior surface of the basilar process to the recti antici, (majores and minores,) and still more anteriorly to the superior constrictor of the pharynx.

*Development.*—In the fœtus at birth this bone consists of four distinct pieces, of which one represents the basilar process, two the lateral or condyloid portions, and one the posterior or expanded part. Hence it is usually said to commence by four points of ossification. Meckel, however, is of opinion that it has no fewer than eleven separate centres, eight of them being in the broad (squamous) part. This doubtless has existed in some specimens which he examined; but ordinarily in the early stages of the development there are found two ossific points in the lateral parts as above stated, one in the anterior or basilar, and four in the posterior broad part.

*The Parietal Bones.*—The parietal bones (*ossa parietalia*) form a principal part of the roof of the skull; they are of a square form, convex externally, concave internally, and present each two surfaces and four borders. The external surface rises towards its middle, where it presents a slight elevation, called the *parietal eminence*, below which is a curved line, forming part of the temporal ridge, and bounding a flat surface, which forms a part of the temporal fossa. At the upper and back part of the bone, usually about two lines from the sagittal suture, is a small hole, (*foramen parietale*,) which transmits a communicating vein; its position is exceedingly variable; even its existence is not constant.

The internal surface of the bone is marked by branching lines, corresponding with the course of the middle meningeal artery, and by depressions for the convolutions of the brain. Towards its middle is a depression, “*parietal fossa*,” corresponding with the eminence (*parietal*) on the outside. Along the superior border is a slight depression, which, with a similar one in the corresponding bone, forms a groove adapted to the course of the longitudinal sinus; and in the same situation (in most skulls, particularly those of old persons) are some small pits corresponding with the so-named *glandulæ Pacchioni*.

The superior border is straight, and articulated with its fellow by a series of dentations; the inferior border, concave and bevelled off at its outer margin, is overlapped by the squamous portion of the temporal bone; the anterior unites with the frontal bone, and posterior with the occipital.

The anterior inferior angle dips down to the great wing of the sphenoid bone, and presents a groove internally for the middle meningeal artery: the posterior inferior angle articulates with the mastoid part of the temporal bone, and presents internally a small part of the groove which lodges the lateral sinus.

Each parietal bone gives attachment to the temporal muscle by that part of its surface which lies beneath the temporal ridge: the remainder of its outer surface is covered by the aponeurosis of the occipito-frontalis.

*Articulations.*—It articulates with its fellow of the opposite side, and with the frontal, the sphenoid, the temporal, and the occipital bones.

*Development.*—Its growth proceeds from one ossific centre which corresponds with the parietal eminence. At birth the

of the superior maxillary bone. 9. The mastoid process of the temporal bone. 10. The meatus auditorius externus. 11. The styloid process. 12. The stylo-maxillary ligament.

FIG. 8. The articulation of the lower jaw seen from within.

Nos. 1, 1. The cut surface of a section, including a part of the occipital, the petrous portion of the temporal, and the spinous process of the sphenoid bone. 2. The internal surface of the mastoid process. 3. The styloid process. 4. The stylo-maxillary ligament. 5. The ramus of the lower jaw. 6. The internal lateral ligament of the articulation of the lower jaw. 7. The small arched opening which transmits the mylo-hyoidean nerve. 8. The neck of the lower jaw. 9. Its coronoid process.

FIG. 9. A vertical section carried through the middle of the articulation of the lower jaw.

Nos. 1, 1. Section of the temporal bone. 2. The interarticular fibro-cartilage dividing the joint into two synovial cavities. 3. The superior synovial cavity. 4. The inferior synovial cavity. 5. Cut surface of the head of the lower jaw. 6. Ramus of the lower jaw. 7. Its coronoid process. 8. Its angle. 9. The styloid process of the temporal bone. 10. The stylo-maxillary ligament. 11. The internal surface of the mastoid process.

FIG. 10. An interarticular fibro-cartilage removed from the articulation.

FIG. 11. An interarticular fibro-cartilage pierced through its middle by a foramen, as is sometimes observed.

antero-superior angles of these bones are not developed; hence there exists an interstice between them and the still divided os frontis, which is called the "fontanelle," (fons, bregma.)

*The Frontal Bone.*—The frontal bone, (os frontis, coronale,) situated at the anterior part of the skull, and upper part of the face, is divisible into two parts, (frontal and orbital,) differing in size and position; of these, one extends upwards towards the vertex, forming three fourths of the extent of the bone; the other, inferior and horizontal in its direction, forms the roof of the orbits. To place the bone in its natural position, hold it so that the orbital plates shall look downwards, and the smooth convex surface forwards.

## PLATE IX.

In this plate several views of the cranium are exhibited.

FIG. 1. An anterior view of the cranium and face.

No. 1. The frontal bone. 2, 2. The parietal bone. 3, 3. The coronal suture uniting the frontal with the parietal bones. 4, 4. The upper part of the great ala of the sphenoid bone. 5, 5. The squamous portion of the temporal bone. 6, 6. The frontal eminence. 7, 7. The superciliary ridge. 8. The nasal tuberosity. 9, 9. The supra-orbital ridge. 10. The supra-orbital notch of the right orbit. 11. The internal angular process. 12. The external angular process. 13. The commencement of the temporal ridge.—The numbers 2, 4, and 5, are situated in the temporal fossa.—14. The orbital plate of the frontal bone. 15. The nasal bones. 16. The superior maxillary bone. 17. Its nasal process. 18. The infra-orbital foramen. 19. Its malar process. 20. The canine fossa. 21. The incisive fossa. 22. The nasal spine. 23. The harmonia suture uniting the two superior maxillary bones. 24. The alveolar process. 25. Median incisor tooth. 26. Lateral incisor. 27. Canine tooth. 28. The two bicuspides or small molars. 29. The great molars. 30. The lachrymal bone. 31. The malar bone. 32. Its frontal process. 33. Its maxillary process. 34. Its zygomatic process. 35. Its orbital process. 36. The orbital surface of the great ala of the sphenoid. 37. The sphenoidal fissure of the orbit. 38. The depression on the orbital plate of the frontal bone beneath its external angular process for the lachrymal gland. 39. The depression beneath the internal angular process, for the pulley of the trochlearis muscle. 40. The middle turbinated bone. 41. The inferior turbinated bone. 42. The vomer. 43. The body of the lower jaw. 44. Its symphysis. 45. The depression by the side of the symphysis for the origin of the depressor labii inferioris muscle. 46. The incisive fossa, for the levator labii inferioris. 47. The mental foramen. 48. The alveolar process; the teeth are the same as in the upper jaw. 49. The ramus of the lower jaw. 50. The angle of the lower jaw.

FIG. 2. A side view of the cranium and face.

The numbers of reference, from 1 to 50, are the same as in the preceding figure. No. 51. The sagittal suture, connecting the two parietal bones. 52. The temporal ridge upon the parietal bone. 53. The anterior inferior angle of the parietal bone. 54. The posterior inferior angle. 55. The squamous suture. 56. The zygoma. 57. Its tubercle. 58. Its superior root, continuous with the temporal ridge. 59. The meatus auditorius externus. 60. The mastoid process. 61. The styloid process. 62. The occipital bone. 63. The lambdoidal suture. 64. The additamentum suturæ lambdoidalis. 65. The additamentum suturæ squamosæ. 66. Condyle of the lower jaw. 67. Coronoid process of the lower jaw. 68. Semilunar notch of the lower jaw.

FIG. 3. Base of the skull.

No. 1, 1. The body of the lower jaw. 2, 2. The depressions near the symphysis, for the attachment of the digastric muscles. 3. Tubercles for the attachment of the genio-hyoid and genio-hyo-glossi muscles. 4, 4. The molar ridge of the lower jaw, seen upon one side. 5. The angle. 6. The condyle. 7. Part of the malar bone. 8. The zygomatic arch. 9, 9. The palatal processes of the superior maxillary bones. 10. The naso-palatine foramen. 11, 11. The palatal processes of the palate bones. 12, 12. The posterior palatine foramina. 13. The palate spine. 14. The vomer. 15, 15. The posterior nares. 16, 16. The internal pterygoid plates of the sphenoid bone. 17, 17. The hamular processes. 18, 18. The external pterygoid plates; the figures are placed in the pterygoid fossæ. 19. The zygomatic fossa of one side. 20. The foramen ovale. 21. The foramen lacerum basis cranii. 22. The petrous portion of the temporal bone. 23. The carotid foramen. 24, 24. The foramen lacerum posterius. 25. The vaginal process. 26. The stylo-mastoid foramen. 27. The meatus auditorius externus. 28. The mastoid process. 29. The digastric fossa. 30. Part of the additamentum suturæ lambdoidalis. 31. The transverse process of the occipital bone. 32. The anterior condyloid foramen. 33, 33. The condyles of the occipital bone. 34. The posterior condyloid foramen. 35. The foramen magnum. 36. The basilar process of the occipital bone. 37, 37. The inferior curved line of the occipital bone. 38, 38. The superior curved line. 39. The occipital tuberosity. 40, 40. The occipital spine. 41. The occipital bone. 42, 42. Part of the lambdoidal suture. 43. The parietal bone. 44. Mastoid portion of the temporal bone.

FIG. 4. Vertical and longitudinal section of the cranium.

No. 1. The frontal bone. 2. The frontal sinus. 3. Nasal bone. 4. Crista galli. 5. Central lamella of the ethmoid bone. 6. Vomer. 7. The inferior turbinated bone. 8. The palate. 9. The naso-palatine canal. 10. Pterygoid process. 11. Section of the basilar process of the occipital bone. 12. Sphenoidal cells. 13. Anterior clinoid process. 14. Roof of the right orbit. 15, 15. Grooves for the lodgment of the branches of the arteria meningea media. 16. Parietal bone, divided through the sagittal suture. 17. The occipital bone. 18. Border of the foramen magnum. 19. Petrous portion of the temporal bone. 20. The meatus auditorius internus. 21. Foramen lacerum posterius or jugular foramen. 22. The groove for the lateral sinus. 23. The mastoid process.

FIG. 5. A section showing the right nasal fossa.

No. 1. Part of the frontal bone. 2. Frontal sinus. 3. Nasal bone. 4. Crista galli. 5, 5. The upper part of the central lamella of the ethmoid. 6. Sphenoid cells. 7. Opening of the sphenoid cells into the superior meatus of the nose. 8. Anterior clinoid process. 9. Basilar process of the occipital bone. 10. Superior meatus of the nares. 11. The speno-palatine foramen. 12. The middle turbinated bone. 13, 13. The middle meatus of the nasal fossa. 14. The inferior turbinated bone. 15. The inferior meatus. 16. The pterygoid process. 17. The cut edge of the palate. 18. The naso-palatine canal. 19. The under surface of the palate.



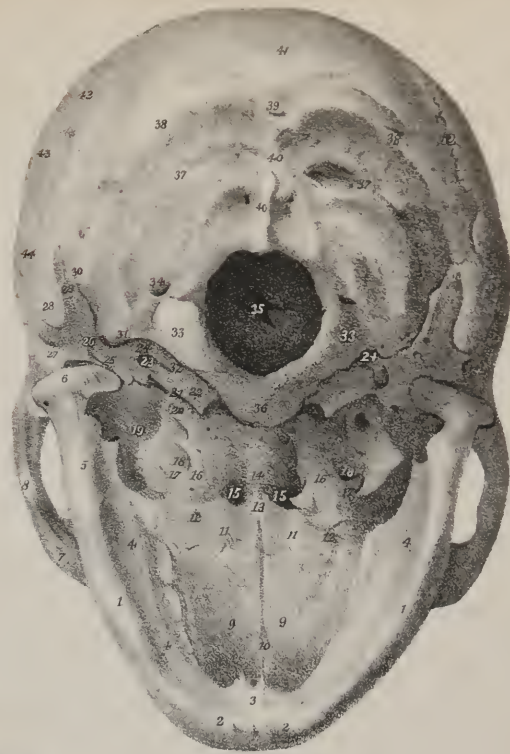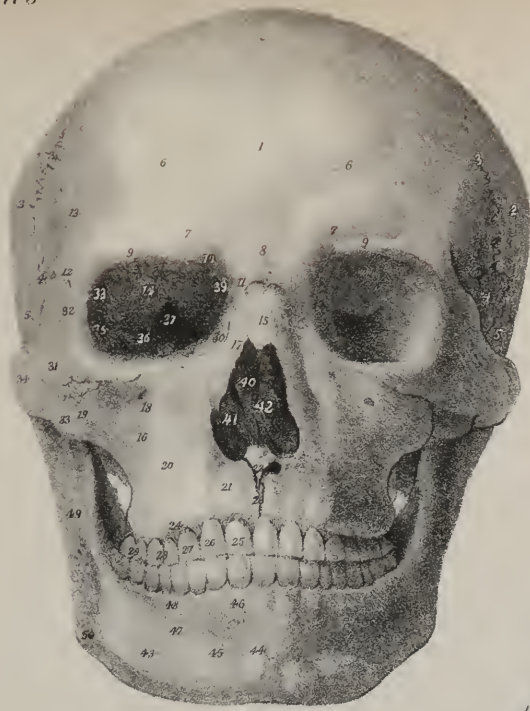


Fig 5

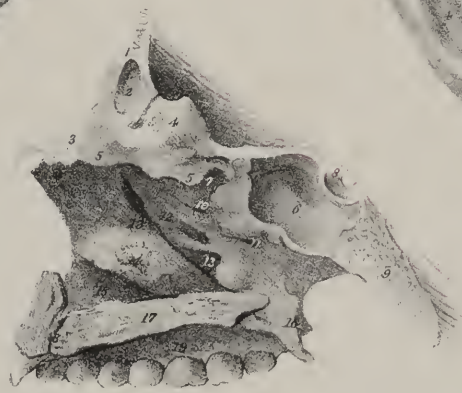
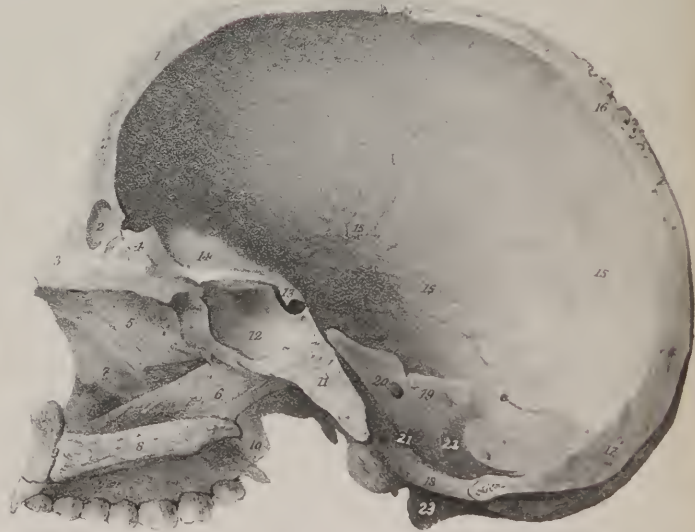


Fig 2

Fig 4


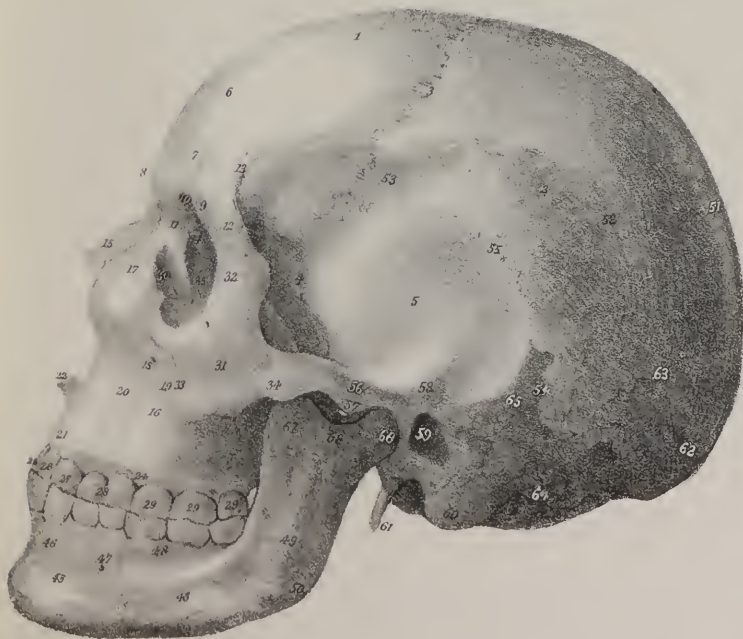









Fig 1

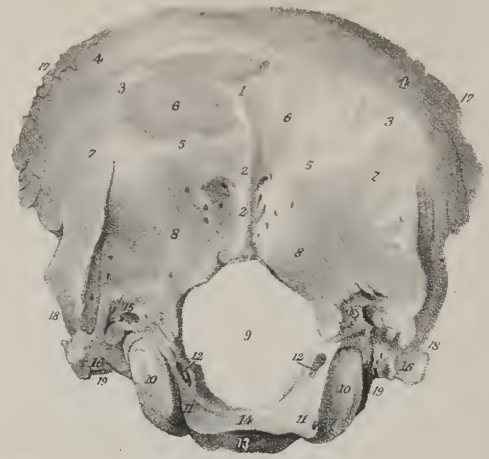


Fig 5

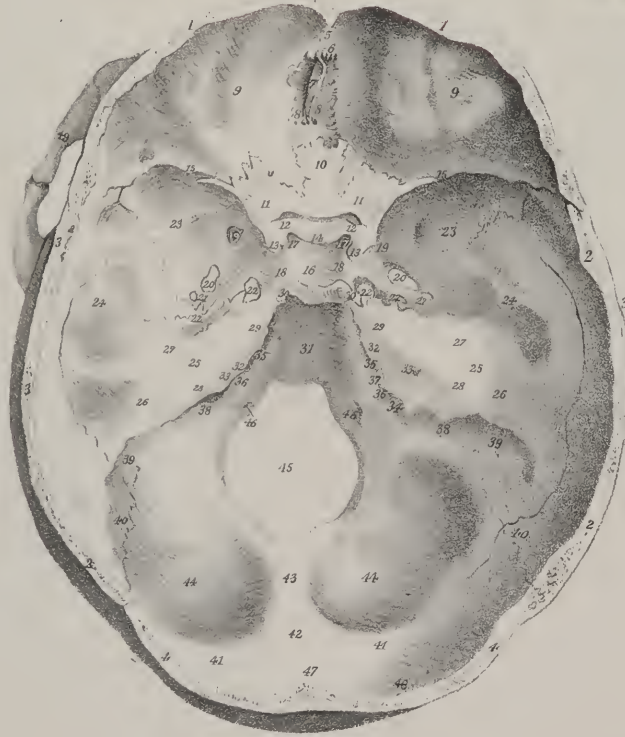


Fig 2

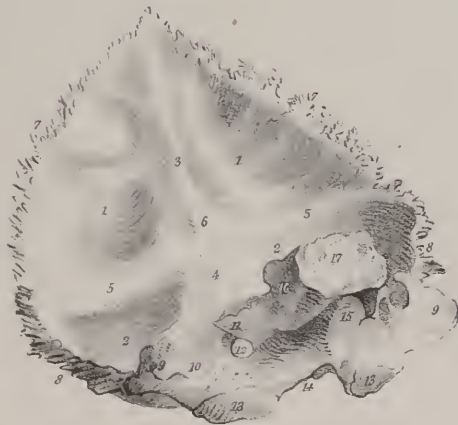
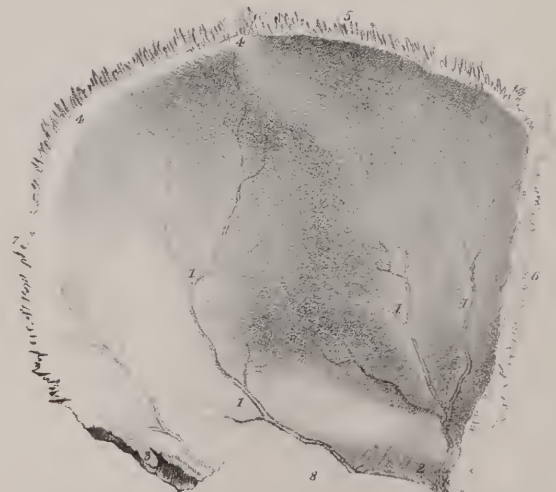


Fig 4



The external surface of the frontal part is smooth, and presents on each side a slight elevation, named *frontal eminence*, which corresponds with the most prominent part of the forehead: beneath this is an arched depression, bounded below by a prominent curved line, called the *superciliary ridge*, or arch, which is more or less prominent in different individuals. Immediately beneath this is the margin of the orbit (*orbital arch*), which is better defined towards its outer part, where it curves down to the malar bone, and forms the external angular process, than at its inner portion, where it gradually subsides towards the root of the nose. Towards the inner third of the orbital arch is a small foramen, (*supra-orbital*), or sometimes a notch crossed by a ligament, which transmits the supra-orbital nerve and artery.

Between the superciliary ridges is the *nasal eminence*, or glabella, which is prominent in proportion to the size of the frontal sinuses; it is bounded inferiorly by a rough surface which articulates with the nasal bones and the ascending processes of the superior maxilla. From this surface projects downwards in the median line a flat thin process, called the *nasal spine*; it articulates in front with the nasal bones, and behind with the perpendicular lamella of the ethmoid.

The internal surface of this part of the bone is concave, and presents along the median line a groove corresponding with the longitudinal sinus. The margins of the groove gradually approach towards the fore part of the bone, and in some cases unite so as to form a ridge; but in others the groove, narrowed almost to a line, continues apparent down to the foramen cæcum. In either case it gives attachment to the falx; this ridge terminates in a minute foramen, called *foramen cæcum*, from its having been supposed to be merely a cul-de-sac, but it is in reality pervious, and lodges a small spurlike process of the dura mater, and transmits a vein which enters the sinus from the nasal fossæ.

The orbital plates or processes are smooth and concave at their inferior surface; the superior or cerebral is convex, and marked more or less in different instances by elevations and depressions corresponding with the sulci and convolutions of the anterior lobes of the brain which rest upon them. They are separated by a deep excavation, (*ineisura ethmoidalis*), which receives within it the cribriform plate of the ethmoid bone, and round its margins are several cells which complete the cavities lodged within the lateral parts of the last-named bone. In this margin may also be observed two foramina, (*anterior and posterior orbital*), which are common to the frontal and ethmoid bones, as their contiguous margins contribute to their formation. The anterior one transmits the nasal twig of the ophthalmic nerve, and the anterior ethmoidal artery; the other, the posterior ethmoidal artery and vein. Each orbital plate is bounded externally by a thick well-marked prominence, called the *external angular process*; and internally by a depressed and smooth one, (*internal angular process*.) Near the inner one is a slight depression, to which is attached the cartilaginous pulley of the trochlearis musele; near the outer and within the orbit, is a depression for the lodgment of the lachrymal gland; the external side of this process is slightly hollowed, and forms part of the temporal fossa.

The thickness of the frontal bone varies considerably in different parts of it. The orbital plates are thin and translucent; the nasal and external angular processes are thick and prominent. The upper or broad part is thinner at the frontal eminences than elsewhere, if these are well-marked, so as to indicate a full developement of the corresponding cerebral parts. In childhood the two tables are separated only by the diploë, as in other bones; but, in adult age, an interval exists between them at the middle line over the nasal process, and extending outwards for some way under the superciliary ridges. This interval, the extent of which varies in different individuals, is divided by a ridge of bone into two parts or cavities called the *frontal sinuses*; they are lined by mucous membrane, and communicate with the anterior ethmoidal cells.

*Articulations.*—The frontal articulates with twelve bones; superiorly with the two parietal, laterally and behind with the sphenoid, inferiorly with the ethmoid; with the nasal bones by the nasal spine; with the ossa unguis; with the ascending process of the superior maxillary bones; and with the malar bones. The mode of articulation differs in different parts of its circumference. Thus, the superior border is found to overlap and rest on the parietal bones, whilst towards the lateral and inferior parts the exterior table of the bone is bevelled off, and is covered in by the parietal. The posterior border of the orbital plates, straight and squamous, is in a manner inserted between the margins of the two alæ of the sphenoid bone, with each of which it articulates.

## PLATE X.

This plate exhibits the occipital and parietal bones, with the interior of the base of the skull.

FIG. 1. The external surface of the occipital bone.

No. 1. The protuberance of the occipital bone. 2, 2. Its spine. 3, 3. The superior curved line. 4, 4. The surface above the superior curved line to which the occipito-frontalis muscles are attached. 5, 5. The inferior curved line. 6, 6. The rough surface to which the complexi muscles are attached. 7, 7. The rough surface to which the splenii capitis are attached. 8, 8. The rough surface for the recti postici and obliqui superiores. 9. The foramen magnum. 10, 10. The condyles of the occipital bone. 11, 11. The rough surface within the condyles, to which the odontoid ligaments are attached. 12, 12. The inner openings of the anterior condyloid foramina. 13. The basilar process, its under surface. 14. Its upper and concave surface, upon which the medulla oblongata rests. 15, 15. The posterior condyloid foramina. 16, 16. The transverse process of the occipital bone. 17, 17. The superior borders of the bone. 18, 18. Its inferior borders. 19, 19. The notches corresponding with the jugular foramina.

FIG. 2. The internal surface of the occipital bone; after Cheselden.

Nos. 1, 1. The cerebral fossæ, for lodging the posterior lobes of the cerebrum. 2, 2. The cerebellar fossæ, for the lateral lobes of the



*Attachment of muscles.*—It gives attachment to the corrugator supercili— to a small part of the temporal and of the orbicularis palpebrarum.

*Development.*—This bone begins by two osseous points corresponding with the frontal eminences. The lateral pieces formed by the spreading of the ossification ultimately become united along the middle by a straight suture, which runs from the vertex, where it is continuous with the sagittal suture, down to the nose. It is generally obliterated at an early period.

*The Temporal Bone.*—The temporal bones, two in number, are so named because they occupy that part of the head on which the hair first becomes white, and thus indicates the ravages of time, (*ossa temporis*.)

The *temporal* bone (*os temporis*) is placed at the side and basis of the skull. When viewed in its natural position, it presents two portions, one at the side of the skull, towards its middle and lower part, which is flat and vertical in its direction; whilst the

cerebellum. 3. The superior arm of the crucial ridge: this ridge is grooved for the superior longitudinal sinus, and to the borders of the groove the falx cerebri is attached. 4. The inferior arm of the crucial ridge, for the falx cerebelli and cerebellar sinuses. 5, 5. The transverse ridge, for the tentorium cerebelli and lateral sinuses. 6. The internal occipital protuberance. 7, 7. The superior borders of the bone. 8, 8. Its inferior borders. 9, 9. The jugular eminences. 10. The jugular fossa of the right side. 11. The border of the bone which articulates with the petrous portion of the temporal bone. 12. The anterior condyloid foramen of the right side. 13, 13. The condyles. 14. The anterior margin of the foramen magnum. 15. The under surface of the basilar process. 16. Its lateral surface. 17. The surface which articulates with the sphenoid bone.

FIG. 3. The external surface of the right parietal bone.

No. 1. The parietal eminence. 2, 2. The temporal ridge. 3, 3. The rough surface above the ridge, upon which the aponeurosis of the occipito-frontalis muscle rests. 4, 4. The smooth surface below the ridge, that gives attachment to the temporal muscle. 5. The superior or sagittal border of the bone. 6. The parietal foramen. 7. The anterior and concave border of the parietal bone. 8. The posterior and somewhat convex border. 9. The inferior or squamous border. 10, 10. The grooves upon this part of the bone correspond with ridges upon the squamous border of the temporal. 11. The anterior and inferior angle of the bone. 12. The posterior and inferior angle.

FIG. 4. The left parietal bone seen upon its internal surface; after Cheselden.

Nos. 1, 1. The grooves for lodging the ramifications of the arteria meningea media. 2. At the anterior and inferior angle of the bone, the groove for the main trunk of this artery is converted into a canal. 3. A groove upon the posterior and inferior angle for the lodgment of the lateral sinus. 4, 4. A partial groove, completed by the articulation of the two parietal bones, and serving for the lodgment of the superior longitudinal sinus. 5. The superior or sagittal border of the bone. 6. The anterior or coronal border; the formation of the serrations at the expense of the outer table is well exhibited. 7. The posterior or lambdoidal border. 8. The inferior or squamous border.

FIG. 5. A view of the interior of the base of the skull; the calvarium having been removed.

Nos. 1, 1. The cut surface of the frontal bone; in this section, the structure of the cranial bones, consisting of two tables and an intervening cellular part, the diploë is well seen. 2, 2. The parietal bone. 3, 3. The squamous part of the temporal bone; in this bone the diploë is not present. 4, 4. The occipital bone. 5. A part of the ridge on the internal surface of the frontal bone, which gives attachment to the falx cerebri, and supports the commencement of the longitudinal sinus. 6. The foramen cæcum. 7. The crista galli process of the ethmoid bone. 8, 8. The cribriform plates with their foramina. 9, 9. The orbital plates of the frontal bone; the depressions on these plates are the digital fossæ. 10. The ethmoidal spine of the sphenoid bone. 11, 11. The lesser wings of the sphenoid. 12, 12. The optic foramina. 13, 13. The anterior clinoid processes. 14. The processus olivaris.—The whole of the preceding figures, from No. 4, are situated in the anterior fossa of the base of the cranium. Nos. 15, 15, with 13, 13, and 14, form the posterior boundary of this fossa, and the anterior boundary of the middle fossa of the base of the cranium. The border, 15, 15, is received into the fissure of Sylvius on each side of the base of the brain.—16. The cella Turcica. 17, 17. The depression upon each side of the cella Turcica, which lodges the last turn of the internal carotid artery. 18, 18. The depression upon each side of the cella Turcica, which supports the internal carotid artery and the cavernous sinuses. 19, 19. The foramen rotundum of the sphenoid bone. 20, 20. The foramen ovale. 21, 21. The foramen spinosum. 22, 22. The foramen lacerum basis cranii. 23, 23. The cerebral surface of the greater ala of the sphenoid bone. 24, 24. The internal surface of the squamous portion of the temporal bone. 25, 25. The anterior surface of the petrous portion of the temporal bone. 26, 26. The eminence upon the anterior surface of the petrous portion of the temporal bone, which marks the situation of the superior or perpendicular semicircular canal. 27, 27. The groove which leads to the hiatus Fallopii.—The whole of the preceding figures, from No. 16, are situated in the middle fossa of the base of the cranium.—28, 28. The superior border of the petrous portion of the temporal bone, for the attachment of the tentorium cerebelli. 29, 29. The notch near the extremity of the petrous portion of the temporal bone, which supports the fifth nerve. 30, 30. The posterior clinoid processes.—The figures 28, 29, and 30, at each side, mark the posterior boundary of the middle fossa of the base of the cranium and the anterior boundary of the posterior fossa.—31. The basilar portion of the sphenoid and occipital bones, rendered concave for the support of the pons Varolii and medulla oblongata. 32, 32. The posterior surface of the petrous portion of the temporal bone. 33, 33. The meatus auditorius internus. 34. The aqueductus vestibuli on the right petrous bone. 35, 35. The groove for the inferior petrosal sinus. 36, 36. The jugular fossa. 37. A part of the jugular foramen of the right side. 38, 38. The groove for the lateral sinus, on the occipital bone. 39, 39. The same groove on the mastoid portion of the temporal bone. 40, 40. The same groove upon the posterior and inferior angle of the parietal bone. 41, 41. The groove upon the occipital portion of the occipital bone. 42. The internal occipital protuberance. 43. The inferior arm of the crucial ridge of the occipital bone. 44, 44. Cerebellar fossæ. 45. The foramen magnum. 46, 46. The anterior condyloid foramen.—The whole of the preceding figures, from No. 31, are situated in the posterior fossa of the base of the cranium; the numbers 40, 41, and 42, forming its posterior boundary.—47. The superior arm of the crucial ridge of the occipital bone. 48. The cerebral fossa of the right side of the occipital bone. 49. The arch of the zygoma.





Fig 1

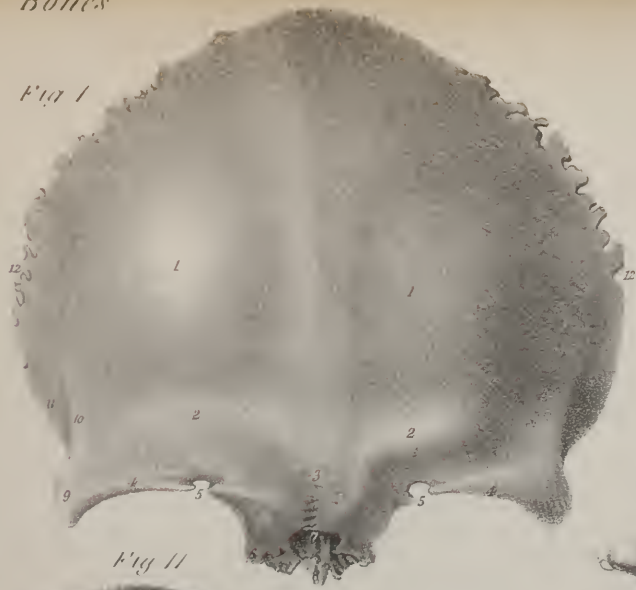


Fig 2

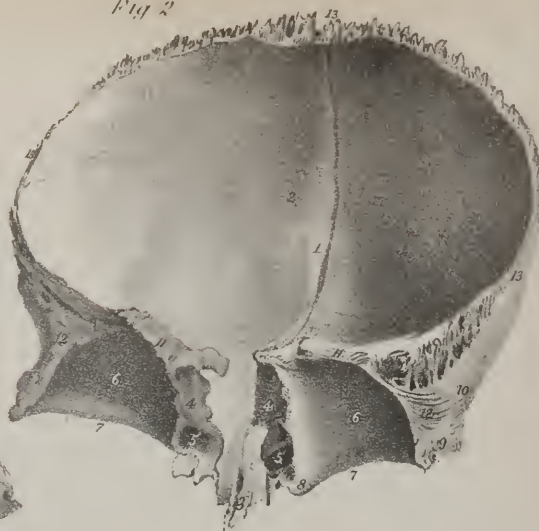


Fig 9



Fig 11

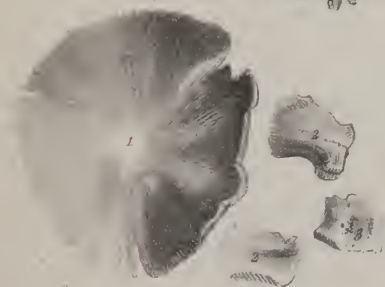

Fig 4

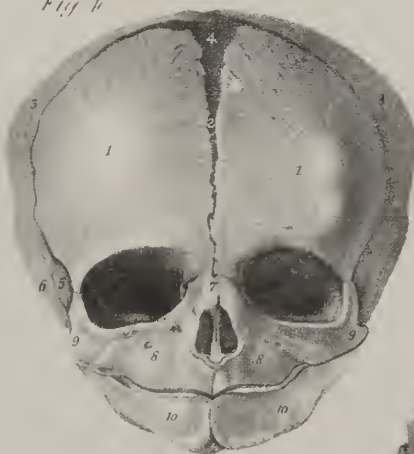


Fig 8

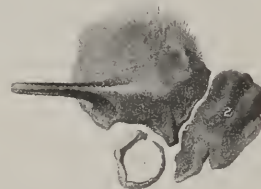

Fig 10




Fig 6



Fig 7

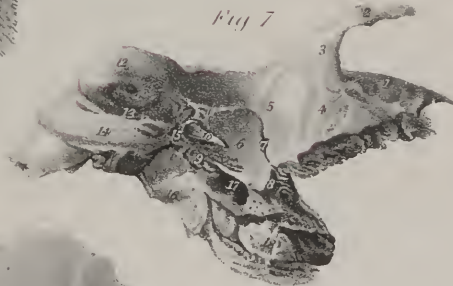

Fig 5



Fig 3



other is horizontal and projects inwards so as to be wedged between the occipital and sphenoid bones. But to facilitate its description, it may be divided into three parts, adopting the division which obtains in infancy before the ossification is complete. One is superior, flat, scale-like, and named the squamous portion, (squama, a scale;) another posterior, thick at its base, but tapering downward like a nipple, the mastoid part; the third, called petrous from its hardness, is internal and intermediate, projecting into the basis of the skull.

The *squamous* portion, (pars squamosa,) by its external surface which is smooth, forms part of the temporal fossa, and is bounded above by an arched border, below by a horizontal process called "zygoma." The inner surface of the squamous part of the bone, slightly concave in its general outline, is marked by cerebral impressions like the other bones of the head, and by

## PLATE XI.

The frontal and temporal bones in the adult and in the fœtus.

FIG. 1. The frontal bone seen upon its anterior aspect: after surgery.

Nos. 1, 1. The frontal eminences. 2, 2. The superciliary ridges. 3. The nasal eminence or tuberosity. 4, 4. The supra-orbital ridges. 5, 5. The supra-orbital notches. 6. The internal angular process of one side. 7. The rough surface for articulation with the nasal bones. 8. The nasal spine. 9. The external angular process. 10. The temporal ridge. 11. A part of the temporal fossa. 12, 12. The border which articulates with the parietal bones.

FIG. 2. The frontal bone seen upon its internal aspect: after Cheselden.

No. 1. The longitudinal ridge which gives attachment to the falx cerebri. The dark line in the course of this ridge indicates the existence of a median suture in this bone. 2. Depressions for glandulæ Pacchioni. 3. The nasal spine. 4, 4. The borders of the ethmoidal fissure. 5, 5. The openings into the frontal sinuses. 6, 6. The orbital plates. 7, 7. The supra-orbital ridges. 8. The internal angular process of one side. 9. The external angular process. 10. A part of the temporal fossa. 11, 11. The border which articulates with the lesser wing of the sphenoid. 12, 12. The border which articulates with the greater wing of the sphenoid. 13, 13. The border which articulates with the parietal bones.

FIG. 3. The frontal bones seen upon its inferior or orbito-nasal aspect: after Cheselden.

Nos. 1, 1. The frontal portion of the bone. 2. A line indicating the existence of a frontal suture. 3. The nasal eminence or tuberosity. 4. The rough surface which articulates with the nasal bones, and the nasal spine. 5. The ethmoidal fissure. 6, 6. The borders of the ethmoidal fissure. 7, 7. The orbital plates. 8, 8. The supra-orbital ridges. 9. The internal angular process of one side. 10. The depression for lodging the cartilaginous pulley of the trochlearis muscle. 11. Two supra-orbital foramina. 12. The external angular process. 13. The lachrymal fossa. 14. The temporal ridge. 15. Part of the temporal fossa. 16, 16. The border which articulates with the sphenoid bone.

FIG. 4. An anterior view of the fœtal skull, showing the mode of development of the frontal bone by two lateral portions.

Nos. 1, 1. The lateral portions of the frontal bone. 2. The line of approximation of the two lateral portions; when union is incomplete in the adult, a frontal suture is met with in this situation. 3, 3. The parietal bones. 4. The anterior fontanelle. 5. The extremity of the great ala of the sphenoid of one side. 6. The temporal bone of the same side. 7. The nasal bones. 8, 8. The superior maxillary bones. 9, 9. The malar bones. 10, 10. The inferior maxillary bone consisting of two lateral portions.

FIG. 5. The temporal bone of the right side, viewed upon its external surface: after Bourguery.

No. 1. The squamous portion. 2. The zygoma. 3. The tubercle of the zygoma. 4. The superior root of the zygoma, which serves to mark the separation of the squamous from the mastoid portion of the temporal bone. 5. The middle root of the zygoma. 6. The eminentia articularis, with which the anterior root is continuous. 7. The mastoid portion of the temporal bone. 8. The mastoid process. 9. The mastoid foramen. 10. The meatus auditorius externus. 11. The processus auditorius. 12. The styloid process. 13. The vaginal process. 14. The glenoid fossa.

FIG. 6. The temporal bone of the right side, seen upon its internal aspect: after Cheselden.

No. 1. The squamous portion. 2. A groove for the posterior branch of the arteria meningea media. 3, 3. The squamous border, which articulates with the lower border of the parietal bone. 4. The extremity of the zygoma seen projecting beyond the anterior border of the temporal bone. 5. The mastoid portion of the bone. 6, 6. The groove for the lateral sinus. 7. The internal termination of the mastoid foramen. 8. The petrous portion of the temporal bone. 9. The meatus auditorius internus. 10. A small notch for the insertion of a process of dura mater. 11. The opening of the aquæductus vestibuli. 12. Groove for the superior petrosal sinus. 13. The elevation corresponding with the superior semicircular canal. 14. Groove for the inferior petrosal sinus. 15. The irregular notch which forms the anterior boundary of the jugular foramen. 16. The extremity of the styloid process.

FIG. 7. The inferior or basial surface of the right temporal bone.

No. 1. The squamous portion. 2. The zygoma. 3. Its tubercle. 4. The eminentia articularis. 5. The glenoid fossa; its condyloid portion. 6. Its parotid portion. 7. The glenoid fissure. 8. The opening for the Eustachian tube. 9. The vaginal process. 10. The styloid process. 11. The lower border of the processus auditorius. 12. The mastoid process. 13. The digastric fossa. 14. The occipital groove. 15. The stylo-mastoid foramen. 16. The jugular fossa. 17. The carotid foramen. 18. The petrous portion of the temporal bone.

FIG. 8. The left temporal bone of the fœtus, showing three of the pieces of which it consists at an early period.

No. 1. The squamous portion. 2. The mastoid portion. 3. The auditory portion.

FIG. 9. The petrous portion of the temporal bone of a fœtus: after Cheselden.

FIG. 10. The parietal bone of a fœtus, showing the radiated disposition of the osseous fibres of which it is composed at this early period: after Cheselden.

FIG. 11. The occipital bone of a fœtus, showing the four pieces of which it consists at an early period: after Cheselden.

No. 1. The occipital portion. 2, 2. The condyloid portions. 3. The basilar portion.



slight linear grooves for the branches of the middle meningeal artery. Its upper edge is bevelled off so as to form a thin scale which overlies the parietal bone.

The *zygoma*, or zygomatic process, (*ζευγνυμι*, to connect or yoke together,) forms a yoke connecting the temporal with the malar bone, and under which the temporal muscle passes; it is broad posteriorly at its base, where it projects outward from the squamous part of the bone, but soon narrows, and turns forward; its outer surface is convex and subcutaneous, the inner surface is concave and bounds the temporal fossa; the superior margin, very thin, gives attachment to the temporal fascia; the inferior one is thicker and shorter, owing to the end of the process being bevelled off so as to rest on the malar bone, with which it articulates. At its base the upper surface is concave, and supports the posterior border of the temporal muscle. The under surface

## PLATE XII.

Bones of the head and face.

FIG. 1. An anterior view of the sphenoid bone: after Cheselden.

No. 1. The ethmoidal spine. 2. The lesser wing of one side. 3. The sphenoidal spongy bone of one side closing the sphenoidal cells. 4. The sphenoidal cells exposed upon the opposite side. 5. The rostrum. 6. The sphenoidal fissure. 7. The orbital surface of the great ala of the sphenoid bone. 8. The temporal surface. 9. The pterygoid crest. 10. The zygomatic portion of the external surface of the great ala of the sphenoid. 11. The foramen rotundum. 12. The Vidian foramen. 13. The smooth surface upon the anterior surface of the root of the pterygoid process against which Meckel's ganglion rests. 14. The pterygo-palatine canal. 15. The internal pterygoid plate of the pterygoid process. 16. Its hamular process. 17. The external pterygoid plate. 18. The triangular notch between the pterygoid plates for the reception of the tuberosity of the palate bone. 19. The foramen ovale. 20. A notch, which in this bone would seem to represent the spinous foramen.

FIG. 2. The sphenoid bone seen upon its posterior aspect: after Cheselden.

No. 1. The basilar portion of the sphenoid bone. 2. The surface which articulates with the basilar process of the occipital bone. 3, 3. The posterior clinoid processes. 4, 4. The anterior clinoid processes. 5, 5. The lesser wings of the sphenoid. 6. The optic foramen on the right side. 7, 7. The sphenoidal fissure. 8. The great ala of the sphenoid of one side; its cerebral surface. 9. The spinous process. 10. The posterior opening of the Vidian canal. 11. The pterygo-palatine canal. 12. The pterygoid fossa. 13. The internal pterygoid plate of the pterygoid process. 14. The hamular process. 15. The external pterygoid plate.

FIG. 3. The superior or cerebral surface of the sphenoid bone: after Cheselden.

No. 1. The ethmoidal spine. 2. The olivary process. 3, 3. The lesser wings. 4, 4. The anterior clinoid processes. 5, 5. The optic foramina. 6, 6. The depression for the last turn of the internal carotid artery. 7. The sella Turcica. 8, 8. The posterior clinoid processes. 9. The basilar portion of the bone. 10. The surface which articulates with the basilar process of the occipital bone. 11, 11. The groove upon the side of the body of the sphenoid bone for the horizontal portion of the internal carotid artery. 12. The sphenoidal fissure of one side. 13. The foramen rotundum. 14. The foramen ovale. 15. The foramen spinosum. 16. The spinous process of the sphenoid. 17. The spine at the extremity of the spinous process. 18. The great ala of the sphenoid; its cerebral surface. 19. The internal pterygoid plate of the pterygoid process. 20. The hamular process. 21. The external pterygoid plate.

FIG. 4. Cerebral surface of the sphenoid bone of a fœtus.

No. 1. The anterior portion of the body. 2, 2. The rudimentary lesser wings. 3. The posterior portion of the body. 4, 4. Rudimentary pterygoid processes. 5, 5. Rudimentary greater wings. 6, 6. Rudimentary spinous processes.

FIG. 5. The ethmoid bone, seen upon its upper and lateral surface: after Cheselden.

No. 1. The crista galli process. 2, 2. The cribriform plate. 3, 3. The superior borders of the bone. 4. The os planum. 5. The anterior cells, completed by the lachrymal bone. 6, 6. Posterior ethmoidal cells. 7. The anterior extremity of the central lamella.

FIG. 6. The ethmoid bone, seen upon its inferior and lateral surface: after Cheselden.

Nos. 1, 1. The central perpendicular lamella. 2. The os planum. 3. The superior turbinated bone. 4. The middle turbinated bone. 5. The superior meatus of the nose.

FIG. 7. The ethmoid bone, seen upon its posterior surface.

No. 1. The crista galli. 2, 2. The cribriform plates. 3, 3. The upper borders of the bone. 4, 4. The os planum. 5, 5. The lateral masses. 6. The central lamella. 7, 7. The superior turbinated bones. 8, 8. The middle turbinated bones. 9, 9. The superior meatuses.

FIG. 8. The two nasal bones, articulated and seen upon their under surface: after Cheselden.

No. 1. The upper thick extremity of the bones. 2, 2. The irregular free margin. 3, 3. The lateral borders which articulate with the superior maxillary bones. 4, 4. The groove upon the under surface of each nasal bone, for the external branch of the nasal nerve.

FIG. 9. The lachrymal bone; its external surface: after Cheselden.

No. 1. The crest which divides the bone into two portions. 2. The orbital portion. 3. The lachrymal portion, grooved for the reception of the lachrymal sac.

FIG. 10. The lachrymal bone; its internal surface: after Cheselden.

No. 1. A part of the vertical crest of the external surface.

FIG. 11. The inferior turbinated bone, seen upon its convex surface.

FIG. 12. The malar bone of the right side, seen upon its external surface.

No. 1. The frontal process. 2. The superior maxillary process. 3. The zygomatic process. 4. One of the foramina for the transmission of the filaments of nerves and small arterics.

FIG. 13. The malar bone of the right side, seen upon its internal surface: after Cheselden.

Fig 5



Fig 1

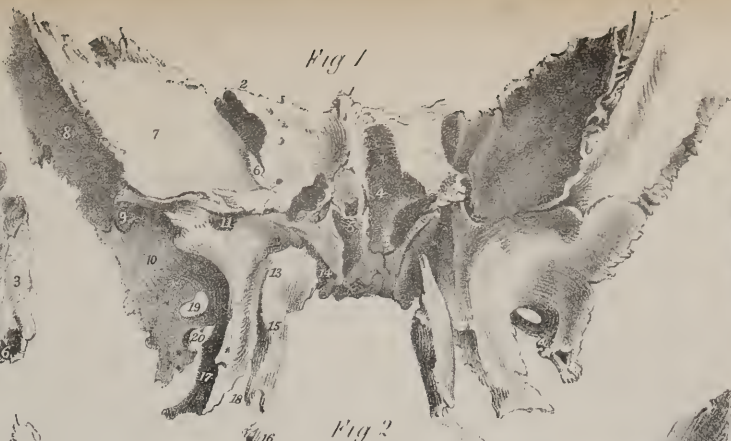

Fig 6



Fig 12



Fig 2

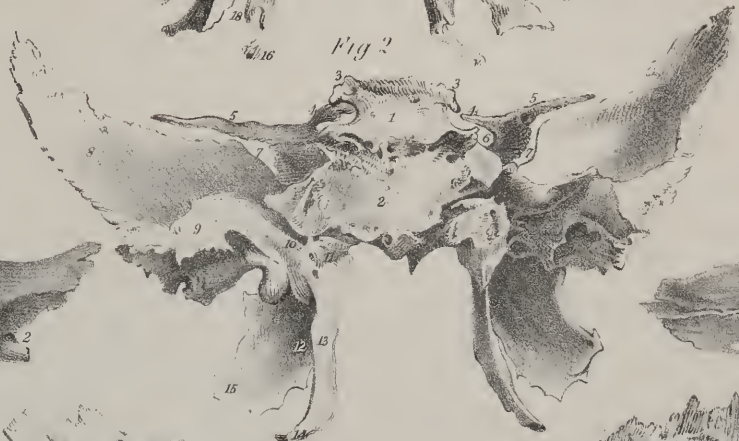

Fig 18



Fig 11

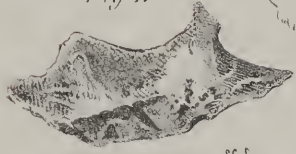

Fig 3

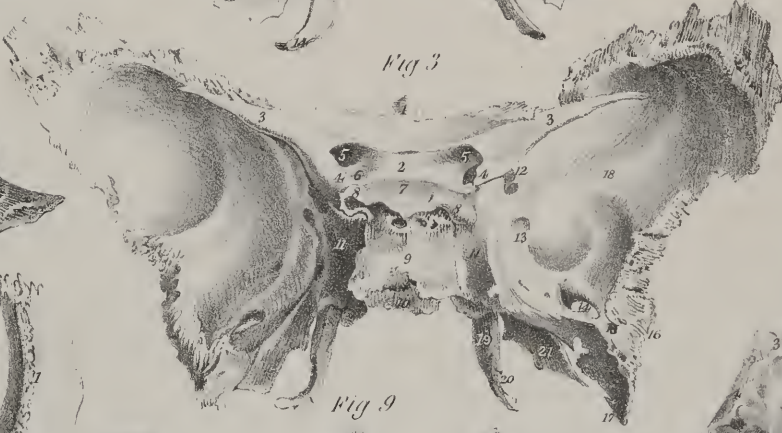

Fig 8



Fig 13

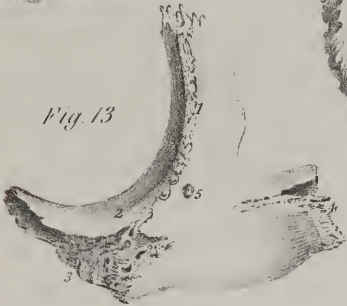

Fig 9



Fig 10



Fig 7

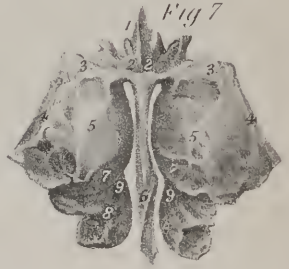

Fig 14

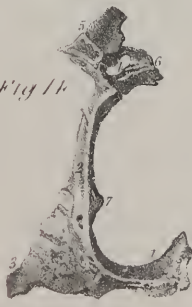

Fig 16



Fig 4

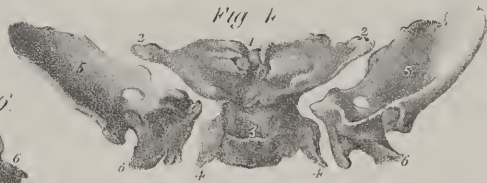


Fig 15

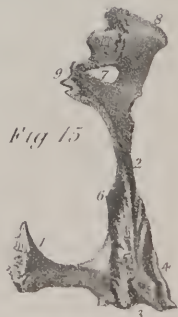
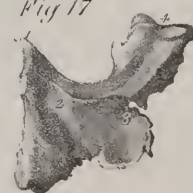
Fig 17







forms the border of the glenoid cavity; here it presents two roots, of which one runs horizontally backwards, forming the outer margin of the glenoid cavity, whilst the other turns inwards and forms the anterior border of that cavity. At the point of division is a slight tubercle, which gives attachment to the external lateral ligament of the lower jaw. Now the anterior root widens and subsides, becoming concave from without inwards and convex from before backwards, as it forms part of the articular surface upon which the lower jaw-bone moves; in its natural condition it is covered with cartilage. The other root, which is continued horizontally backwards, bifurcates, one part turning inwards to the *fissura Glasseri*, whilst the other gradually subsides as it passes backwards over the auditory tube, yet marks the separation between the squamous and mastoid portions of the bone. The *glenoid fossa*, ( $\gamma\lambda\eta\eta$ , a shallow pit,) marked off as here indicated, is elongated from without inwards, and divided into two parts by a fissure, (*fissura Glasseri*), which transmits the chorda tympani nerve, laxator tympani muscle, and gives attachment to the process gracilis of the malleus. The part before the fissure is smooth, and articulates with the lower jaw; the remainder lodges a process of the parotid gland.

The *mastoid* part of the bone externally is rough, for the attachment of muscles, and prolonged downwards, forming the mastoid or nipple-shaped process, ( $\mu\alpha\sigma\tau\omicron\varsigma$ , a nipple:  $\epsilon\iota\delta\omicron\varsigma$ ), from which this division of the bone is named. This process overhangs a groove, (*digastric fossa*), for the attachment of the digastric muscle; close to this is a slight groove, the occipital groove. When viewed at its inner surface, the mastoid part presents a broad and generally a deep groove, which curves forwards and downwards; it here supports part of the lateral sinus. It is usually pierced by a foramen, (mastoideum,) which opens into the sinus from the outer surface, commencing near the posterior border of the bone. The size and position of this hole vary in different instances; it sometimes exists at one side and not at the other.

The *petrous* part, pars petrosa, ( $\pi\epsilon\tau\omicron\varsigma$ , a stone,) forms a triangular pyramid (pyramis trigona) which projects into the base of the skull forwards and inwards; it presents a base, an apex, (truncated,) three surfaces, and three borders. In the base is situated the orifice of the auditory canal, which is bounded above by the posterior root of the zygoma; inferiorly, and in the greatest part of its circumference, by a curved uneven lamella, (*auditory process*), to which the cartilage of the ear is attached: this process is in the fœtus a separate piece. The canal itself, (*meatus auditorius externus*), narrower in the middle than at its extremities, is directed obliquely forwards and inwards, and leads into the tympanum. The apex or inner end of the pars petrosa, rough, irregular, and, as it were, truncated, forms part of the foramen lacerum medium, and is pierced by the termination of the carotid canal, (canalis caroticus:)—this canal commences in the inferior surface of the bone anterior and internal to the jugular fossa, ascends at first perpendicularly, but soon turns horizontally forwards and inwards to the apex, where it ends.

The anterior surface of the petrous portion forms part of the middle fossa in the base of the skull, where it looks obliquely upwards and forwards. Towards the apex it is slightly grooved, where it corresponds with the ganglion of the fifth pair of nerves, (Casserian.) A narrow groove is seen to run obliquely backwards and outwards; it lodges a small nerve, (the Vidian;) it is named the *hiatus Fallopii*, and leads to the aqueduct of Fallopius. Farther back is a rounded eminence indicating the situation of the superior semicircular canal. The *aqueduct* of Fallopius just alluded to commences at the internal auditory meatus; it is a small osseous tube lodged in the interior of the bone, and passing at first in an arched direction, outwards and upwards, then backwards and downwards towards the basis of the skull, where it ends in the stylo-mastoid foramen; it transmits the portio dura, and receives, through the hiatus Fallopii, the Vidian nerve. The posterior surface looks obliquely backwards, and forms part of the third or posterior fossa at the base of the skull. In it will be observed a large orifice, leading to a short canal, (*meatus auditorius internus*.) The canal is oblique in its direction, having an inclination outwards and forwards. It conveys the auditory and facial nerves. Its fundus is formed by a lamella of bone, (*lamina cribrosa*), divided into two parts by a crest or

No. 1. The frontal process. 2. The orbital process. 3. The superior maxillary process. 4. The zygomatic process. 5. One of the foramina for the transmission of filaments of nerves and small arteries to the integument of the face.

FIG. 14. An anterior view of the palate bone.

No. 1. The horizontal portion of the palate bone. 2. Its perpendicular portion. 3. Its tuberosity. 4. The spheno-palatine foramen. 5. The orbital portion. 6. The sphenoidal portion. 7. The ridge that gives attachment to the inferior turbinated bone.

FIG. 15. A posterior view of the palate bone.

No. 1. The horizontal portion. 2. The perpendicular portion. 3. The tuberosity. 4. The surface which articulates with the external pterygoid plate. 5. The surface which articulates with the internal pterygoid plate. 6. The ridge that gives attachment to the inferior turbinated bone. 7. The spheno-palatine foramen. 8. The orbital portion. 9. The sphenoidal portion.

FIG. 16. An external view of the palate bone.

No. 1. The perpendicular portion. 2. The posterior palatine groove. 3. The posterior palatine foramen. 4. The tuberosity. 5. The spheno-palatine foramen. 6. The orbital portion. 7. The sphenoidal portion.

FIG. 17. The under surface of the palate portion of the palate bone.

No. 1. The palate spine. 2. The transverse ridge which gives attachment to the aponeurosis of the tensor palati muscle. 3. The posterior palatine foramen. 4. The tuberosity.

FIG. 18. The vomer.

No. 1. The broad and concave extremity, which articulates with the rostrum of the sphenoid bone. 2. The antero-superior border, which articulates with the central lamella of the ethmoid bone and with the cartilage of the septum. 3. The inferior border for articulation with the palate processes of the superior maxillary and palate bones. 4. The posterior and free border of the vomer.

ridge; the upper or smaller part is pierced by a foramen which transmits the facial nerve, whilst the lower presents several very small apertures through which the fibrillæ of the auditory nerve pass. About three lines further back than the orifice of the meatus is a narrow fissure, oblique in its direction. It is the termination of the aquæductus vestibuli. Between the

## PLATE XIII.

The bones of the upper and lower jaw; the teeth, the os hyoides, and the anatomical characteristics of a rib, are shown in this plate.

FIG. 1. The two superior maxillary bones articulated: after Cheselden.

No. 1. The body of the bone. 2. The canine fossa. 3. The infra-orbital foramen. 4. The incisive fossa. 5. The harmonial suture of the two bones. 6. The nasal spine. 7. The semi-lunar notch, forming the lateral boundary of the anterior nares. 8. The nasal process. 9. The concavity for the articulation of the lachrymal bone. 10. The malar process. 11. The tuberosity of the superior maxillary bone. 12. The median incisor of the right bone. 13. The lateral incisor. 14. The canine tooth. 15. The two bicuspидati, or small molars. 16. The three large molars. 17, 17. The alveolar process. 18. The left superior maxillary bone. 19. The opening of termination of the nasal duct. 20. The opening of the antrum of Highmore. 21. The notch for the reception of the nasal bones. 22. The palate process of the superior maxillary bone.

FIG. 2. The superior maxillary bone of the left side; a part of the bone has been removed in order to show the cavity of the antrum: after Cheselden.

The references from 1 to 16 are the same as in the preceding figure. 17, 17. The alveolar process. 18. The cavity of the antrum Highmore, laid open by the removal of a part of the anterior wall of the bone. 19. The orbital process. 20. The lachrymal tubercle.

FIG. 3. The left superior maxillary bone, with the pale and inferior turbinated bone; seen upon their nasal aspect: after Cheselden.

No. 1. The nasal surface of the superior maxillary bone. 2. The opening of the antrum. 3. The inferior turbinated bone, remaining attached to this surface. 4. The inferior meatus of the nose, into which the nasal duct opens. 5. The nasal process of the bone. 6. The semi-lunar notch for the articulation of the lachrymal bone. 7. The border of the orbital plate which articulates with the ethmoid bone. 8. The nasal surface of the perpendicular lamella of the palate bone. 9. The nasal spine. 10, 10. The palate process of the superior maxillary bone. 11, 11. The alveolar process. 12, 12. The palate process of the palate bone. 13. The palate spine. 14. The tuberosity of the palate bone. 15. Its hamular process. 16. The groove forming part of the nasopalatine canal.

FIG. 4. The inferior maxillary bone: after Cheselden.

No. 1. The body of the bone. 2. The symphysis. 3. The mental foramen. 4, 4. The alveolar process. 5, 5. The ramus of the lower jaw. 6, 6. Its angle. 7, 7. The coronoid process. 8, 8. The sigmoid notch. 9. Its condyle. 10. The neck of the condyle. 11. The inferior dental foramen. 12. The mylo-hyoidean ridge. 13. The median incisors. 14. The lateral incisor. 15. The canine. 16. The bicuspидati or small molars. 17. Two of the large molars, the third molar or dens sapientie has not yet appeared.

FIG. 5. The inferior maxillary bone; seen from within.

Nos. 1, 1. The body of the bone. 2. The symphysis. 3, 3. The rough surfaces for the attachment of the digastric muscles. 4. Tubercles for the attachment of the genio-hyoidei and genio-hyo-glossi muscles. 5, 5. The mylo-hyoidean ridge, at each side. 6, 6. The smooth surface against which the sublingual gland rests. 7, 7. The surface against which the submaxillary gland rests. 8, 8. The ramus of the inferior maxillary bone. 9, 9. Its angle. 10, 10. The inferior dental foramen. 11, 11. The mylo-hyoidean groove. 12, 12. The coronoid process. 13, 13. The sigmoid notch. 14, 14. The condyle. 15, 15. The neck of the condyle.

FIG. 6. The teeth of the upper and lower jaw: after Cheselden.

Nos. 1, 1. Median incisors. 2, 2. Lateral incisors. 3, 3. Canines. 4, 4. First bicuspидati. 5, 5. Second bicuspидati. 6, 6. First molars. 7, 7. Second molars. 8, 8. Third molars, or dentes sapientie. A. The second and third molars of the lower jaw closely locked together, and showing the recurved form of the fang which occasionally occurs. B. Section of a molar tooth, showing its anatomical structure. 1. The crown. 2. The neck. 3, 3. The roots or fangs. 4. The cavitas pulpæ.

FIG. 7. The os hyoides, viewed from the front.

No. 1. The body. 2, 2. The greater cornua. 3, 3. The lesser cornua.

FIG. 8. The os hyoides, viewed upon its inner aspect.

No. 1. The body. 2, 2. The greater cornua. 3, 3. The lesser cornua.

FIG. 9. The sixth rib: after Cheselden.

No. 1. Its shaft. 2. Its head. 3. Its neck. 4. Its tubercle. 5. The articular surface upon the tubercle. 6. The angle of the rib. 7. The groove along its lower border for the lodgment of the intercostal vessels and nerve. 8. The extremity which articulates with the costal cartilage.

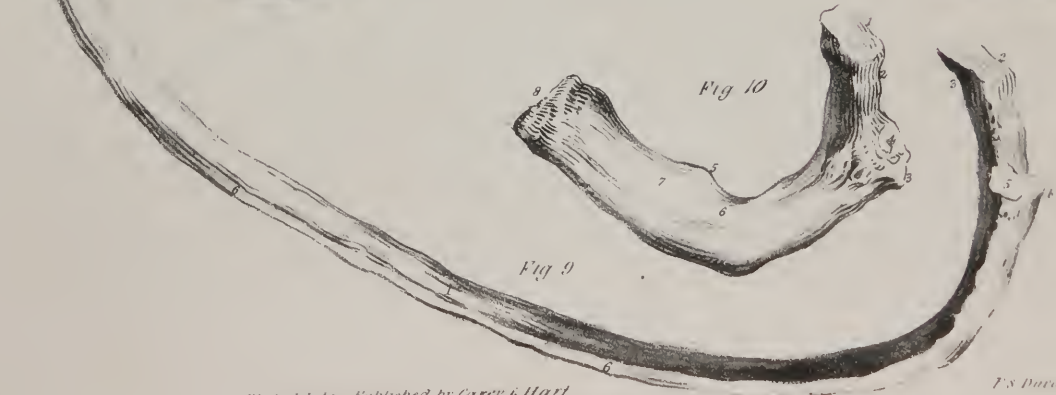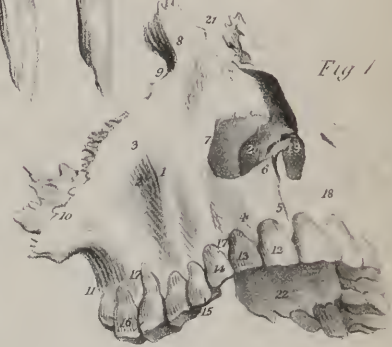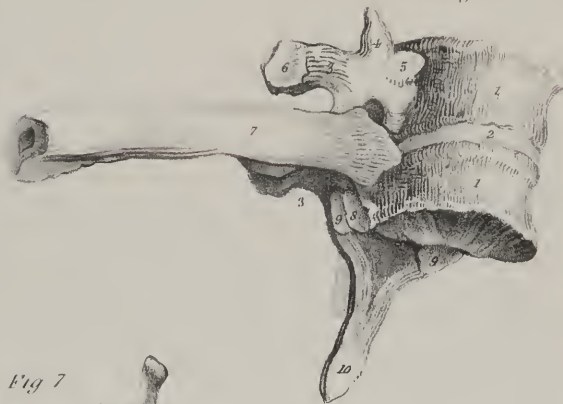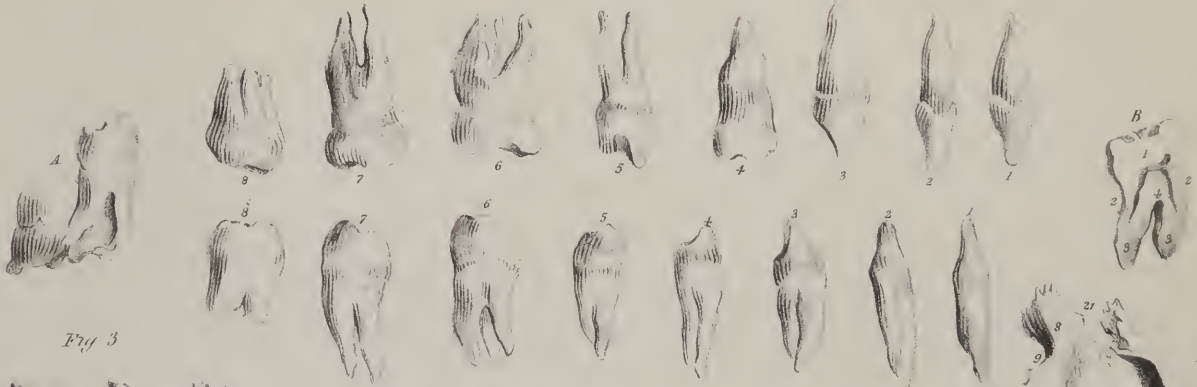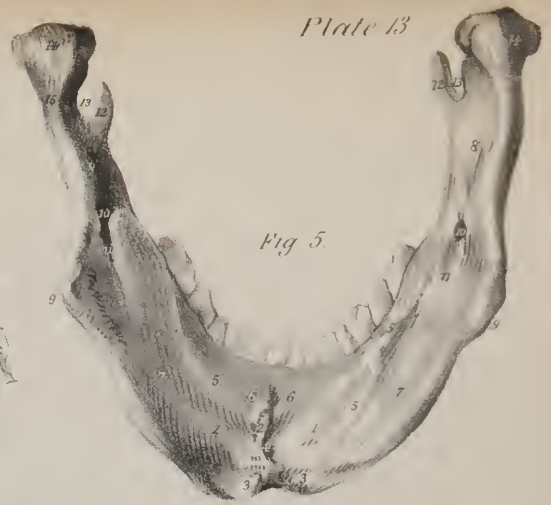
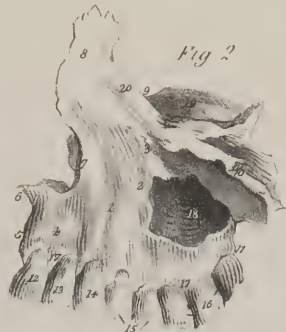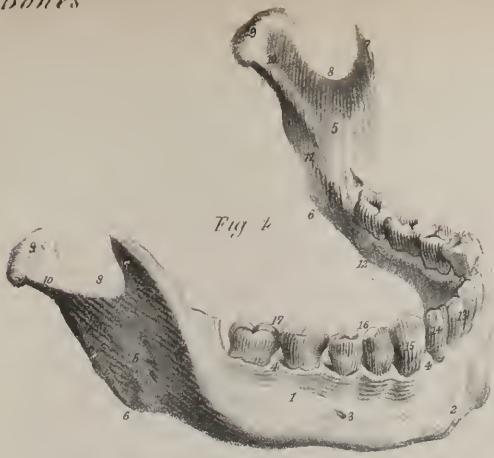
FIG. 10. The first rib: after Cheselden.

No. 1. Its head. 2. The neck. 3. The tubercle. 4. The articular surface upon the tubercle. 5. The projection for the attachment of the tendon of the scalenus anticus muscle. 6. The groove for the subclavian artery. 7. The groove for the subclavian vein. 8. The extremity for articulation with the costal cartilages.


FIG. 11. Two of the dorsal vertebræ, with which a rib is articulated; the figure is intended to show the mode of articulation of these bones: after Cheselden.

Nos. 1, 1. The bodies of the vertebræ. 2. The intervertebral substance. 3, 3. The transverse processes. 4. An articular process. 5. A half facet for the head of a rib. 6. The articular surface upon the extremity of the transverse process for the articulation of the tubercle of a rib. 7. A rib articulated with the vertebræ. 8. Another half facet for the articulation of the head of a rib. 9, 9. Inferior articular processes. 10. A spinous process.









aperture of the aqueduct and that of the meatus is an irregular depression, into which a small process of the dura mater is fixed.

On the inferior surface of the pars petrosa, which is exceedingly irregular, we observe, proceeding from within outwards and backwards, a rough surface, giving attachment to the levator palati and tensor tympani muscles, the carotid foramen, the jugular fossa, the vaginal and styloid processes; lastly, the stylo-mastoid foramen. The carotid foramen leads into the curved canal (canalis caroticus) already noticed. The *jugular fossa* (fossa bulbi venæ jugularis internæ) is named by some the "thimble-like" cavity, also the "foramen lacerum posterius." It is of large size, and formed in the contiguous margins of the temporal and occipital bones. It is in some cases divided into two parts, but unequally, by a spicula of bone; the anterior and inner portion gives passage to the glosso-pharyngeal, vagus, and spinal accessory nerves, whilst the posterior and larger one transmits the jugular vein. External to the margin of the fossa is the styloid or pencil-like process, long and tapering, with an inclination downwards and forwards. Its length varies from an inch to an inch and a half; it gives attachments to three muscles and two ligaments. Close before the base of the styloid process is a compressed bony plate, the free surface of which looks obliquely forwards and forms the back part of the glenoid or articular cavity. This is named the *vaginal* process, (vagina processûs styloidei.) Between the root of the styloid process and the mastoid is the *stylo-mastoid foramen*, (f. stylo-mastoideum,) so called from its position with regard to the processes just named. It forms the outlet or termination of the aqueduct of Fallopius, and gives exit to the facial nerve.

The superior border of the pars petrosa is grooved for the petrosal sinus; the anterior, which is very short, forms, with the squamous part, an angle at their point of junction, in which is situated the orifice of the Eustachian tube, a canal which leads from the pharynx to the tympanum: above this, and separated from it by a thin horizontal lamella, (*processus cochleariformis*.) is another osseous tube, that gives passage to the tensor tympani muscle. The posterior border articulates with the basilar process of the occipital bone and forms with it the jugular fossa. About the middle of this edge or border is a minute foramen, the opening of a small canal leading from the cochlea, (*aquæductus cochleæ*.)

*Articulations.*—The temporal bone articulates with the parietal, malar, inferior maxillary, sphenoid, and occipital bones.

*Attachments of muscles.*—To the zygoma is attached the masseter; to the squamous portion, the temporal; to the mastoid process, the retrahens aurem, the sterno-mastoid, splenius capitis, and trachelo-mastoideus; to the digastric fossa, the digastricus; to the styloid process, the stylo-glossus, stylo-hyoideus, and stylo-pharyngeus; to the apex of the petrous portion, the levator palati and tensor tympani.

*Development.*—The squamous, mastoid, and petrous parts of the bone have each a separate ossific centre. So have the processes, viz., the zygomatic, styloid, and auditory.

*The Sphenoid Bone.*—The sphenoid is a single bone placed transversely at the base of the skull, and articulated with all the bones of the cranium and several of those of the face, between which it is inserted somewhat like a wedge, whence its name (*σφην*, a wedge; *ειδος*, like;) its form has been likened to that of a bat with its wings extended; and the comparison is not very far-fetched, particularly if the ethmoid bone remains attached, as often happens. Like other irregular bones, it may be divided into body and processes.

To place this bone in its proper position so as to perceive clearly the relations of its different parts, observe that it has two thick processes somewhat like legs. Hold it so that these shall project downwards, as if from beneath the body and wings, and let those edges of the processes which are channelled into vertical grooves look backwards.

*Of the body*, or central part of the bone.—To give precision to its description, we say that it presents six aspects or surfaces, each of which looks in a different direction and has distinct relations:—The superior surface, which forms part of the basis of the skull, is of limited extent, yet is hollowed into a deep pit, which lodges the pituitary gland: hence this excavation is called *pituitary fossi*, and sometimes "sella Turcica," from some resemblance to a Turkish saddle, (ephippium.) On either side of the fossa the surface is depressed, and corresponds with the cavernous sinus; farther back are two superficial grooves, directed from behind forwards, which correspond with the internal carotid arteries. Before the fossa, is a slightly depressed portion of the bone, on a level with the optic foramina, on which rests the commissure of the optic nerves;—behind it is a prominent ascending lamella, of a square form, and sloping backwards, so as to be continuous with the basilar groove of the occipital bone: the corners of this lamella project over the fossa, and are called the *posterior clinoid processes*, (*κλινη*, a bed.)

The inner surface is the narrow interval between the pterygoid processes; it is intersected by a prominent spine, called the *rostrum* or *azygos* process, which dips downwards and forwards to join the vomer. At each side are two small and slightly everted lamellæ, (projecting from the base of the pterygoid processes,) which articulate with the margins of the vomer. Farther out is a small groove, which contributes with the head of the palate bone to form the *pterygo-palatine canal*.

The anterior surface is very irregular, and presents the openings of two deep sinuses, into which the bone is hollowed: these sinuses (*sphenoidal*) do not exist in young children; in the adult, in whom they are of considerable size, they are separated by a thin partition, (septum sphenoidale,) which is continuous inferiorly with the rostrum, and in the front articulates with the central lamella of the ethmoid bone. The sinuses are covered in anteriorly by two thin osseous plates, the *sphenoidal spongy bones*, (cornua sphenoidalia, cornets sphenoidaux;) these do not, however, altogether seal up the sphenoidal sinuses, but leave a

circular aperture, by which they communicate with the posterior ethmoidal cells. In early life they are distinct, and easily separable; but in the adult they become united either with the margins of the sinuses or with the ethmoid or the palate bone.

The posterior surface is flat, and united with the basilar process of the occipital bone,—in early life by cartilage, but in adult age by osseous matter.

The lateral surfaces are continuous with the great wings, which branch out from them on either side.

*Of the Processes.*—The principal processes are, the great wings, the small wings, and the pterygoid processes; the minor ones are the ethmoid spine, processus olivaris, clinoid processes, the rostrum, the hamular and spinous processes.

The *great wings* (*alæ majores*) project outwards, forwards, and upwards, from the sides of the body of the bone, and are so formed as to present each three surfaces, looking in different directions; one, anterior, (*orbital*), is square, smooth, inclined obliquely forwards, and forms part of the outer wall of the orbit; the second, (superior or *cerebral*), of much greater extent, is elongated from behind forwards, and concave, so as to form part of the middle fossa of the basis of the skull, which supports the middle lobe of the brain; the third (*external* or *temporal*) looks outwards into the temporal fossa, where it forms part of the side of the cranium. It is elongated from above downwards, and slightly hollowed. But it will be observed that this surface, taken as a whole from the top of the wing down to the root of the pterygoid process, presents two parts divided by a slight ridge; of these the upper and longer one just noticed forms part of the temporal fossa, and the inferior or smaller division, of the zygomatic fossa.

The *small wings*, (*alæ minores*), called also wings of Ingrassias, are triangular in form, horizontal in direction, and extended forwards and outwards, on a level with the upper surface of the body—its fore part. Their upper surface, plain and flat, supports part of the anterior cerebral lobes, the inferior one overhangs the back part of the orbit and the sphenoidal fissure. The anterior border, sharp, thin, and rough, articulates in the greater part of its extent with the orbital plate of the frontal bone, and internally, at the middle line, where the bases of the two processes are united, there is a slight angular process, (*ethmoidal spine*), which articulates with the cribriform lamella of the ethmoid bone. The posterior border, rounded and smooth, is free and unattached, and corresponds with the fissure (*fissura Sylvii*) which separates the anterior from the middle lobe of the brain. The external and anterior ends of these processes are sharp and pointed, whilst posteriorly they terminate in two blunt tapering productions, which incline obliquely backwards, towards the pituitary fossa, and overlie the cavernous sinuses. These are called *anterior clinoid processes*.

The *pterygoid* processes are seen at the inferior surface of the bone, from which they project down like legs rather than wings, though the name given to them would indicate the reverse, (*πτερυξ*, a wing.) Each of these consists of two narrow plates, (*pterygoid lamellæ*), united at an angle in front, and diverging behind, so as to form an angular groove, (*pterygoid fossa*.) The internal plate, longer and narrower than the external, is prolonged into a slight round process, named, from its crooked form, the hook-like or *hamular process*, round which plays the tendon of the tensor palati muscle. The external lamella looks outwards, and somewhat forwards, bounds the zygomatic fossa, and gives attachment to the external pterygoid muscle. At the root of the internal lamella is situated a slight depression, (*fossa navicularis*), which gives attachment to the tensor palati muscle; in the groove or fossa, between the two plates, arises the internal pterygoid muscle. The groove is incomplete at its lower part when the sphenoid bone is examined by itself; for an angular interstice exists between the pterygoid lamellæ. This, however, is filled up by a part of the pyramidal process of the palate bone, which is inserted between the margins of the lamellæ.

The *ethmoid spine*, already noticed, is a very small angular plate, which projects forward on a level with the upper surface of the lesser wings in the middle line, and articulates with the cribriform lamella of the ethmoid bone.

The *processus olivaris* is a minute elevation seen on that depressed piece of bone on a level with the optic foramina, and which supports the commissure of the optic nerves.

The *clinoid* processes are two pair, one before, the other behind the pituitary fossa; therefore called anterior and posterior. A spicula of bone often passes from the anterior to the posterior clinoid process at one or both sides; and occasionally one dips down from this to the body of the bone.

The *rostrum* is the prominent angular ridge, which projects downwards from the under or guttural surface of the bone, dividing it into two parts.

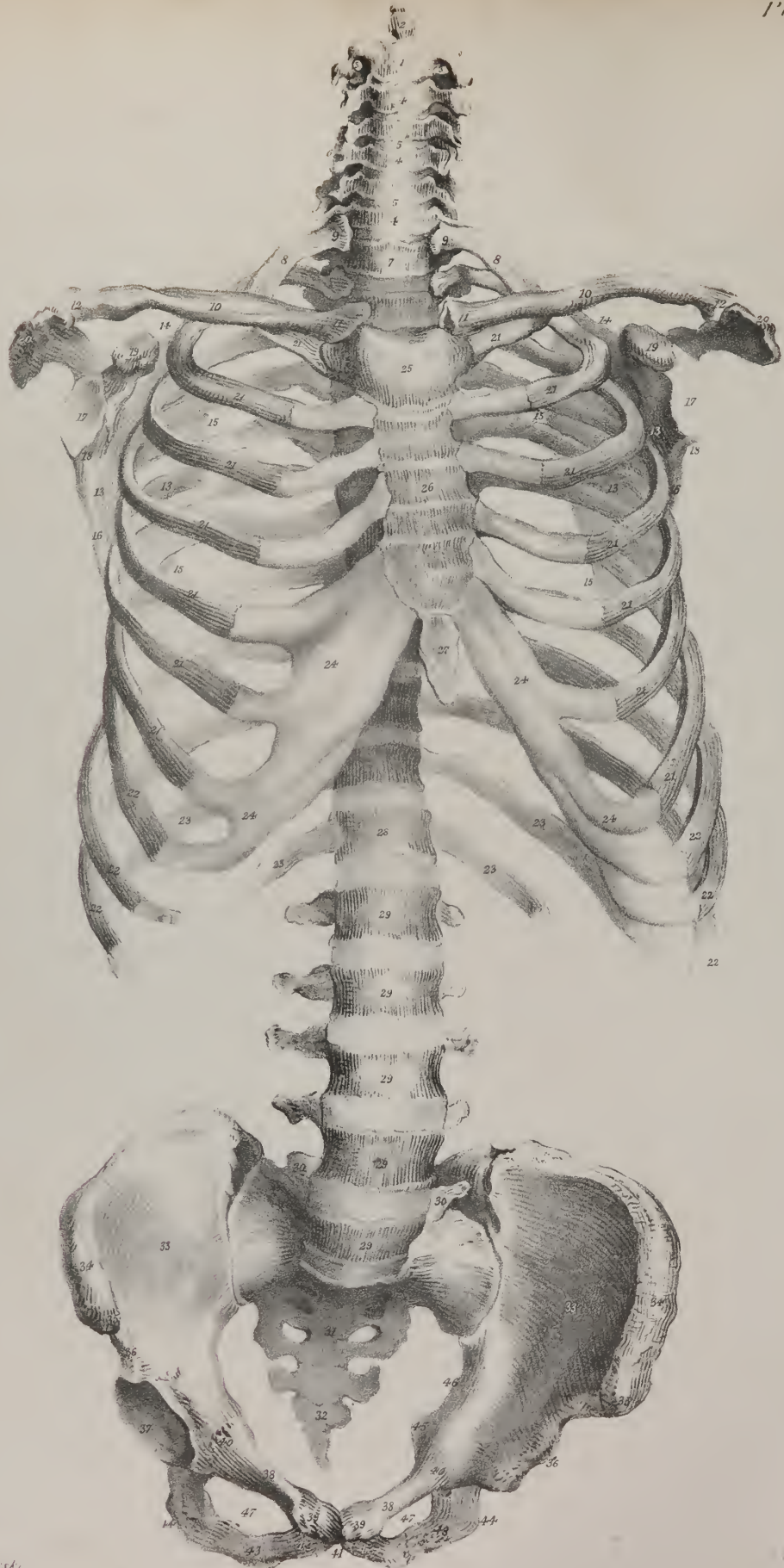
The *hamular* processes projects from the termination of the internal pterygoid plate, is thin, constricted, and curved in the greater part of its extent, but ends in a small blunted tubercle.

The *spinous* process are placed at the posterior and inner terminations of the great wings, from which they project downwards about two lines.

Each lateral half of the bone presents a fissure, four foramina, and a canal. The fissure, (*fissura sphenoidalis*), triangular and elongated, is placed between the lesser and greater wings, opens into the orbit, (hence sometimes named foramen lacerum orbitale,) and transmits the third, the fourth, and the sixth nerves, the ophthalmic branch of the fifth and the ophthalmic vein. This fissure is separated at its base from the foramen opticum by a narrow plate of bone which passes from the under surface of the anterior clinoid process (at its root) obliquely down to the body of the sphenoid bone; to this is attached a small tendon, common to the inferior, internal, and external recti muscles of the eye. Of the foramina,—the optic foramen inclines outwards







On Stone by S. Creharski.

W. S. Davis Lith. Eng.

and forwards on a level with the fore-part of the body of the bone; it transmits the optic nerve and the ophthalmic artery. Farther back and on a lower plane, inasmuch as it is situated in the great wing, is a round aperture, leading forwards; it is the *foramen rotundum*, which transmits the superior maxillary branch of the fifth pair of nerves: a little farther back and more external is a larger foramen, of an oval form, hence called *foramen ovale*; it gives passage to the inferior maxillary branch: near the posterior angle of the ala is the *foramen spinosum*; it is very small, and transmits the middle meningeal artery. The root, or base, of each internal pterygoid process is pierced by a circular foramen, (*pterygoideum*,) more properly a canal, extending horizontally from before backwards, slightly expanded before, narrowed behind, and giving passage to the posterior branch from Meckel's ganglion, (*Vidian, pterygoid*.)

*Articulations*.—The body of the sphenoid bone articulates posteriorly with the basilar process of the occipital, anteriorly with the ethmoid; with the orbital processes of the frontal by the lesser and greater alæ; with the anterior inferior angles of both parietal, and the squamous portion of the two temporal, by the great alæ, and by the spinous processes with the angles between the petrous and squamous portions of that bone: with the vomer it articulates by the rostrum; with the malar bones by means of the external border of the orbital plates, and with the palate bones by the pterygoid processes;—in all, twelve bones.

*Attachments of muscles*.—Round the optic foramen in each orbit are attached the four recti, the obliquus superior, and levator palpebræ muscles; to the external surface of the great ala at each side, the temporal muscle; to the external pterygoid process, the external pterygoid muscle; to the pterygoid fossa, the internal pterygoid; to the inferior half of the internal pterygoid plate, the superior constrictor of the pharynx; and to the fossa navicularis, the circumflexus palati; and to the spinous process, the laxator tympani.

*Development*.—There are two osseous centres in the great wings, two in the pterygoid processes, and two in the small wings. The anterior and posterior segments of the body of the bone commence by distinct points; and as these in some instances unite, one with the great wings and the other with the small ones, before they become joined to one another, this condition of the bone presents an analogy with its permanent state in fishes, reptiles, and most mammalia, in which we find an anterior and posterior sphenoid bone. There appear also two osseous points at the inner borders of the optic foramina.

*Ethmoid Bone*.—The *ethmoid*, or sieve-shaped bone, ( $\sigma\theta\mu\omicron\varsigma$ , a sieve;  $\epsilon\iota\delta\omicron\varsigma$ , like; os ethmoides,) is common to the cranium, the orbits, and the nasal fossæ; it is placed at the fore part of the base of the skull, from which it projects downwards, and is inserted between the orbital plates of the frontal bone, lying behind the nasal and superior maxillary bones, before the sphenoid and above the vomer. It is exceedingly light and thin, considering its size; and seems, at first, but a collection of irregular cells, enclosed between plates of bone as thin as paper. It is of a cuboid figure, symmetrical, and composed of two lateral masses, between which is interposed a central vertical plate. This points out a mode of dividing the bone for the purpose of description, but it is more convenient to consider it as a whole, and examine separately each of its six surfaces.

To place the bone in its proper position, observe that its upper surface is the one from which arises a smooth angular process like a cock's comb. The short border of this looks forward, and the long sloping one backwards.

The superior, or *cerebral* surface of the bone, is at once recognised by its presenting a triangular process, which projects upwards from it, in the middle line; this process, from some resemblance to a cock's comb, is called *crista galli*. The surface of the crista is smooth and compact, its form triangular, the base being horizontal, and on a level with the cribriform plate, below which it is continuous with the perpendicular lamella forming the septum narium; the posterior border of this process is long, and slopes backwards, but the anterior is short, and nearly perpendicular; at its junction with the base two small bony masses sometimes project forwards, leaving between them a fissure which forms part of the "foramen cæcum," placed in the middle line at the junction of this bone with the frontal. The *crista galli* is usually perpendicular, but occasionally inclines to one side; it is

## PLATE XIV.

An anterior view of the trunk of the skeleton: after Cheselden.

- No. 1. The axis. 2. Its odontoid process. 3, 3. The foramen in its transverse process for the passage of the vertebral artery. 4, 4. The bodies of the cervical vertebræ. 5, 5. Their intervertebral substance. 6, 6. The transverse processes, with their anterior and posterior tubercles. 7. The body of the first dorsal vertebra. 8, 8. The first rib. 9, 9. The head of the first rib, which in this subject would seem to articulate with the last cervical vertebra. 10, 10. The clavicle. 11, 11. Its rounded or sternal extremity. 12, 12. Its flattened or scapular end. 13, 13. The anterior surface of the scapula. 14, 14. Its superior or short border. 15, 15. Its posterior border or base. 16, 16. Its anterior border. 17, 17. Glenoid cavity. 18, 18. The neck of the scapula. 19, 19. The coracoid process. 20, 20. The acromion process. 21, 21. The seven true ribs. 22, 22. The false ribs. 23, 23. The two floating ribs. 24, 24. The costal cartilages. 25. The first piece of the sternum. 26. The middle piece. 27. The ensiform cartilage. 28. The last dorsal vertebra. 29, 29. The bodies of the five lumbar vertebræ. 30, 30. Their transverse processes. 31. The sacrum. 32. The coccyx. 33, 33. The os ilium. 34, 34. Its crest. 35, 35. The anterior and superior spinous process. 36, 36. The anterior inferior spinous process. 37. The acetabulum of the right side. 38, 38. The body of the os pubis. 39, 39. Its crest. 40, 40. The ilio-pectineal eminence. 41. The symphysis pubis. 42, 42. The ramus of the pubis at each side. 43, 43. The ramus of the ischium. 44. The tuberosity of the ischium. 45. The spine of the ischium. 46. The great sacro-ischiatic notch. 47, 47. The obturator foramen.



sometimes bulged a little at the sides, and is then found to enclose a small sinus; it gives attachment to the *falx cerebri*, the two layers of which in a manner embrace it.

Beside and behind the *crista* is the sieve-like or *cribriform lamella*, (*lamella cribrosa*.) It consists of a narrow plate of bone, pierced by a number of holes, from which it derives its name; posteriorly this plate of bone is, for a very little way, even and horizontal; it then becomes depressed into two grooves, beside the *crista*, which lodge the ganglia of the olfactory nerves. This part of the surface is narrow, elongated from behind forwards, and pierced by numerous foramina, for the transmission of the filaments of the olfactory nerves. The foramina in it are of three sorts: those which lie along the middle of the groove are mere holes or perforations which permit the filaments of the nerves, with their membranous investments, to pass down to the roof of the nares; the external and internal rows are larger, and form the orifices of small canals, which are grooved in the bone, and subdivide as they descend into the septum and spongy bones. In the anterior border of the *cribriform lamella*, and close to the *crista galli*, is a fissure at each side of its base, which transmits the nasal filament of the ophthalmic nerve. Along the outer margin of the *cribriform* plate we observe several small cellules, which are open, and, as it were, incomplete when the bone is detached from its natural situation, but are closed in by the orbital plates of the frontal bone, and completed by a junction with the cells observed in their border. At the posterior margin of this surface, and in the middle line, is a slight notch, which receives the ethmoid spine of the sphenoid bone.

The anterior surface of the bone presents in the middle the edge of the perpendicular or nasal lamella; at the sides of this are narrow grooves which separate it from the lateral masses, and form the upper part of the nasal fossæ; still farther out are some open cellules, which when the bone is in its place are closed by the ascending process of the superior maxillary bone.

The posterior surface presents also in the middle the edge of the perpendicular lamella, then the grooved posterior margins of the ethmoidal turbinate bones, and still more externally large open cellules which are closed by the sphenoid bone and its turbinate bones, and lower down by the head of the palate bones.

The lateral or orbital surfaces are smooth and plain; each is formed of a thin plate of bone, (*lamella plana, os planum*,) which lies in the inner wall of the orbits.

Thus far we can proceed with our description of the bone as if it were a single piece, which presented several aspects, each requiring to be noticed; but when we look at it from below we find it expedient to consider it as divisible into a central or median plate, and two lateral parts or masses.

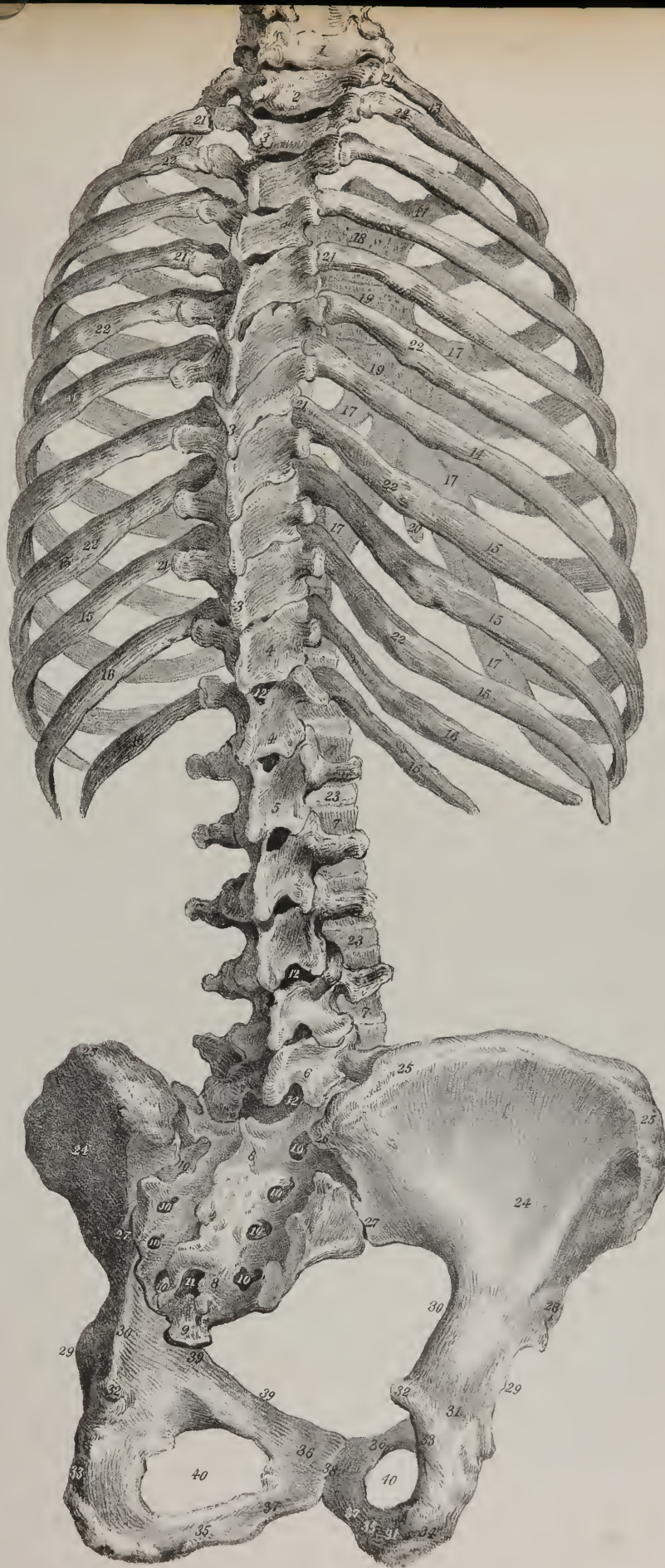
The inferior, or *nasal* surface of the bone, is of considerable extent, and presents in the middle line a flat plate of bone, and two lateral masses separated from it by a narrow interval: these lateral parts are formed of thin plates, enclosing cellules, which appear so complex as to be likened by some persons to a labyrinth. The descending or *nasal* plate, (*lamella nasalis*,) called also the perpendicular plate, though it frequently inclines to one side, forms a considerable part of the septum nasi; it is continuous above with the base of the *crista galli*, as already stated; below, it articulates with the vomer and the triangular cartilage of the nose; its anterior margin joins by its upper part with the nasal process of the frontal bone, and lower down supports the *ossa nasi*; the posterior margin articulates with the septum sphenoidale. This plate presents a number of grooves and minute canals, leading from the foramina of the *cribriform lamella*, for the transmission of the olfactory nerves: in the natural condition it is covered by the pituitary membrane.


*Lateral masses.*—The external surface of each of these consists of a thin, smooth, and nearly vertical plate of bone, (*lamella plana, os planum*,) which closes in the ethmoidal cells, and forms a considerable part of the inner wall of the orbit: it articulates above with the orbital plate of the frontal bone; below, with the superior maxilla and palate bone; in front, with the *os unguis*; and behind, with the sphenoid. At its anterior and posterior margins, the ethmoidal cells are open when the bone is detached

## PLATE XV.

A posterior view of the trunk of the skeleton: after Cheselden.

- No. 1. The last cervical vertebra. 2. The first dorsal vertebra. 3, 3. The spinous processes of the dorsal vertebræ, showing their imbricated position. 4, 4. The two last dorsal vertebræ, showing their approximation in form to the lumbar vertebræ and their exceedingly short transverse processes. 5. The first lumbar vertebra. 6. The last lumbar vertebra. 7, 7. The bodies of the lumbar vertebræ. 8, 8. The sacrum. 9. The first piece of the coccyx. 10, 10. The posterior sacral foramina. 11. The termination of the sacral canal. 12, 12. The spaces between the arches of the vertebræ, which are closed in the fresh subject by the ligamenta subflava. 13, 13. The first rib. 14, 14. The seventh and last true rib. 15, 15. The three upper false ribs. 16, 16. The two last false ribs,—the floating ribs. 17, 17. The costal cartilages. 18. The first piece of the sternum. 19, 19. The sternum. 20. The ensiform cartilage. 21, 21. The tubercles of the ribs articulating with the extremities of the transverse processes of the ten upper dorsal vertebræ. 22, 22. The angles of the ribs; the surface between the tubercles and the angles is rough for the attachment of muscles. 23, 23. The inter-vertebral substance, situated between the vertebræ. 24. The ilium. 25, 25. Its crest. 26. The posterior superior spinous process. 27. The posterior inferior spinous process. 28. The anterior inferior spinous process. 29. The border of the acetabulum. 30. The great sacro-ischiatic notch. 31, 31. The ischium. 32. The spine of the ischium. 33. The lesser sacro-ischiatic notch. 34. The tuberosity of the ischium. 35. The ramus of the ischium. 36. The *os pubis*. 37. Its ramus. 38. The symphysis pubis. 39, 39. The ilio-pectineal line. 40. The obturator foramen.







from its connexions; in the former situation they are closed by the os unguis; in the latter by the sphenoid spongy bones. In its upper margin are two grooves, which are formed into foramina by similar indentations in the frontal bones, and so form the internal orbital foramina, (*foramen orbitarium internum, anterius et posterius.*)

The inner surface of each lateral mass forms part of the external wall of the corresponding nasal fossa, and consists of a thin osseous plate, connected above with the cribriform lamella, from which it hangs down, and below ends in a free margin, which is convoluted a little, and represents the middle spongy bone. At its upper and fore part is a square, flat, but rough surface, which is pierced by a number of grooves, leading from the foramina of the cribriform lamella; posteriorly are placed two thin and also rough osseous plates, curved a little, so as to represent small bivalve shells, from which circumstance they are called ethmoidal *turbinate* bones; but from their texture, being cellular and porous on the surface, they are named spongy bones. Of these, the first or upper one, (*concha superior,*) which is also placed farther back, is very small; by the curve or coil which it makes it arches over, and forms a groove or channel, (*meatus naris superior:*) this is of small extent from before backwards, not being more than half that of the ethmoid bone; it communicates with the posterior ethmoidal cells, and the sphenoidal sinuses. Still lower down is another osseous lamella, thin, rough, and convoluted, which is the second ethmoidal spongy or turbinate bone. Its lower margin is more rough and prominent than that of the upper one, and its extent from before backwards nearly double. Beneath this is a groove or channel which it overhangs so as to form the second *meatus naris*, which communicates with the anterior ethmoidal cells and the frontal sinuses.

The osseous rough plate here described gives attachment by its outer surface to a number of osseous lamellæ, thin and delicate, which pass across the space between it and the lamella plana, dividing it into a number of cells, (*ethmoidal.*) These do not all communicate: they are separated into two sets by a sort of transverse partition, the posterior being small and few in number—from four to five,—whilst the anterior, larger and more numerous, communicate with the frontal sinus. The cellule, which directly communicates with the middle meatus, is prolonged, in a curved direction, upwards and forwards, opening by a small aperture into the anterior ethmoidal cells, and by another, farther on, into the frontal sinus; and, as it is broad below and tapering above, it assumes somewhat the form of a funnel, and hence is named *infundibulum*.

The superior border of each lateral mass presents some incomplete cells, before noticed, when describing the cribriform plate; the inferior gives off some irregular lamellæ, which articulate with the side of the maxillary sinus and the inferior turbinate bone; the anterior also exhibits some incomplete cells, which are closed in by the os unguis and the nasal process of the superior maxillary bone.

*Articulations.*—The ethmoid articulates with thirteen bones—the frontal, the sphenoid, and vomer, two nasal, two ossa unguis, two superior maxillary, two palatal, and two inferior spongy bones.

*Developement.*—There is an ossific centre in each lateral mass, and one in the perpendicular lamella.

*Ossa triquetra.*—Accidental, or supernumerary bones, are not unfrequently found in skulls. From their form, which is very variable, they are sometimes called triquetra, at others, triangularia, or ossa Wormii, from Wormius the anatomist, who is said to have given the first detailed description of them. They are osseous plates, with serrated margins, inserted, as it were, between two cranial bones, and appearing like islets placed in the sutures. Their most ordinary position is in the lambdoid suture, next in the sagittal, seldom if ever in the coronal, never in the squamous. The superior angle of the occipital bone sometimes occurs as an accessory piece; so does the anterior inferior angle of the parietal. They are not found before the sixth or eighth month after birth; and, whatever varieties of size and appearance they may present, the principle of their formation is the same in all cases. As the broad bones grow by successive deposits, extending from their central points towards the margins, whenever the natural process is retarded or interrupted, the mode of osseous deposition takes a new direction, a new centre is established in the layer of cartilage between the margins of the bones, and therefore in the situation of the suture, from which it extends outwards until it comes into contact with the margins of the contiguous bones, with which it becomes united in the usual way by suture.

*Bones of the face.*—The bones of the face are fourteen in number.

*The superior maxillary bone.*—This bone (*maxilla superior*) is very irregular; it presents an external convex surface, corresponding with the anterior and lateral parts of the face; another, internal, of considerable extent, corresponding with the nasal cavity; one, superior, smooth, and inclined inwards, forming the floor of the orbit, and surmounted internally by a triangular process, forming the side of the nose; lastly, a surface which projects horizontally inwards, to form the arch of the palate. The external surface is bounded inferiorly by a thick dependent border, (*alveola,*) for the lodgment of the teeth; to this, as to a common point of union, all the other parts of the bone may be referred.

The alveolar border, thick, semicircular, convex externally, concave internally, is pierced along its margin by a number of deep pits, (*alveoli,*) into which the teeth are inserted. The pits or sockets vary in form and depth, conforming in these particulars to the roots of the teeth which they receive. From this border the external side ascends upwards to the margin of the orbit, presenting some depressions and elevations; but at its fore part it is interrupted and excavated so as to present a deeply concave margin, which, with a similar one in the corresponding bone, forms the anterior nares. This excavation is surmounted by a process, (*ascending or nasal,*) prolonged as far as the frontal bone, with which it articulates. The external surface of this process,

slightly grooved, gives attachment to the orbicularis palpebrarum muscle and the levator labii superioris *alæque nasi*. The internal, or nasal surface, somewhat concave, presents a rough line, running from before backwards, which articulates with the inferior spongy bone; above this is a depression corresponding with the middle meatus of the nose, and, towards the summit, a rough surface, which closes in the anterior ethmoidal cells. The anterior border is rough, for its attachment to the nasal bone; the posterior presents a well-marked groove, running from above downwards, and a little backwards with a slight curve, and which is completed into a canal by a similar one in the os unguis, for the lachrymal sac.

The part of the external surface a little above the molar teeth is elevated into a rough projection, (*malar eminence*), for its articulation with the malar bone. Anterior and inferior to this is observed a fossa, (*fossa canina*), which gives attachment to the levator anguli oris. Between this fossa and the margin of the orbit is the infra-orbital foramen, which transmits the superior maxillary nerve. A little above the sockets of the incisor teeth is a slight depression, (*myrtiform fossa*), which gives attachment

## PLATE XVI.

The clavicle and scapula, with the ligaments of the sterno-clavicular articulation and shoulder joint.

FIG. 1. The clavicle of the left side of the skeleton.

No. 1. The sternal extremity. 2. Its articulating surface. 3. Its scapular end. 4. The surface which articulates with the acromion process.

FIG. 2. The under surface of the same clavicle.

No. 1. The surface which articulates with the sternum. 2. The rough surface for the attachment of the rhomboid ligament. 3, 3. The grooved surface for lodging the subclavius muscle. 4. The rough surface for the attachment of the coraco-clavicular ligament. 5. The scapular end of the clavicle.

FIG. 3. The scapula of the left side; its dorsal aspect.

No. 1. The superior border of the scapula. 2. The superior angle of the scapula. 3, 3. Its posterior border. 4, 4. The spine. 5. The triangular smooth surface at the commencement of the spine, over which the trapezius glides upon a bursa. 6. The acromion process. 7. The supra-spinatus fossa. 8. The infra-spinatus fossa. 9. The neck of the scapula. 10. The glenoid fossa. 11. The apex of the glenoid fossa, to which the long tendon of the biceps is attached. 12. The coracoid process. 13. The anterior or inferior border of the scapula. 14. The rough surface from which the middle head of the triceps muscle arises. 15. The surface for the attachment of the teres minor muscle. 16. The surface for the attachment of the teres major muscle. 17. The inferior angle of the scapula.

FIG. 4. The anterior surface of the scapula of the left side.

No. 1. The superior border of the scapula. 2. The supra-scapular notch. 3. The superior angle of the bone. 4, 4. Its posterior border. 5. The inferior angle. 6, 6. The anterior or inferior border. 7, 7. The concave surface of the venter of the scapula. 8. The neck of the scapula. 9. Its glenoid cavity. 10. The rough ridge which gives attachment to the long head of the triceps muscle. 11. The coracoid process. 12. The acromion process. 13. The smooth surface which articulates with the scapular end of the clavicle. 14. The spine of the scapula.

FIG. 5. An anterior view of the sterno-clavicular and costo-sternal articulations.

Nos. 1, 1. The sternal extremities of the clavicles. 2, 2. The anterior sterno-clavicular ligaments. 3. The interclavicular ligament. 4, 4. The costo-clavicular or rhomboid ligaments. 5, 5. The first rib at each side. 6, 6. The costal cartilages of the second and third ribs. 7, 7. Anterior costo-sternal ligaments.

FIG. 6. A posterior view of the sterno-clavicular and costo-sternal articulations.

Nos. 1, 1. The posterior sterno-clavicular ligaments. 2. The inter-clavicular ligament. 3, 3. The costo-clavicular or rhomboid ligaments. 4, 4. The posterior costo-sternal ligaments. 5, 5. The superior costo-sternal ligaments. 6, 6. The inferior costo-sternal ligaments.

FIG. 7. An anterior view of the ligaments of the shoulder joint.

No. 1. A part of the scapula. 2. The upper part of the humerus. 3. A part of the scapular end of the clavicle. 4. The scapulo-clavicular articulation. 5. Its inferior ligament. 6. The coracoid process. 7. The coraco-clavicular or trapezoid ligament. 8. The under surface of the acromion process. 9. The coraco-acromial ligament. 10. The transverse or coracoid ligament, converting the supra-scapular notch into a foramen. 11. The capsular ligament of the shoulder joint. 12. The coraco-humeral ligament. 13. The tendon of the sub-scapularis muscle. 14. The tendon of the long head of the biceps, escaping from the shoulder joint.

FIG. 8. A posterior view of the shoulder joint.

No. 1. The spine of the scapula. 2. Its acromion process. 3. The scapular extremity of the clavicle. 4. The superior scapulo-clavicular ligament. 5. The coracoid process. 6. The coraco-clavicular ligament, or conoid ligament. 7. The transverse or coracoid ligament crossing the supra-scapular notch. 8. The supra-scapular foramen. 9. The superior border of the scapula. 10. The coraco-acromial ligament. 11. The capsular ligament of the shoulder joint. 12. The tendon of the supra-spinatus muscle. 13. The tendon of the infra-spinatus. 14. The tendon of the teres minor. 15. The neck of the humerus.

FIG. 9. A portion of the scapula, showing the glenoid cavity and ligament.

No. 1. The acromion process. 2. The coracoid process. 3. The glenoid cavity. 4, 4. The glenoid ligament. 5. The tendon of the long head of the biceps.

FIG. 10. A section of the shoulder joint, showing the interior of its cavity.

No. 1. The anterior surface of the scapula. 2. The head of the humerus. 3. Part of the glenoid cavity. 4, 4. The cut border of the capsular ligament. 5. The tendon of the long head of the biceps, passing through the cavity of the joint. 6. Part of the glenoid ligament.



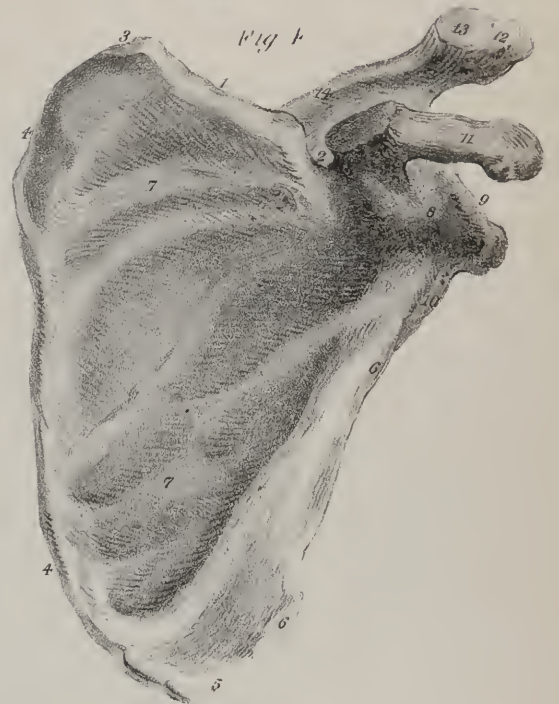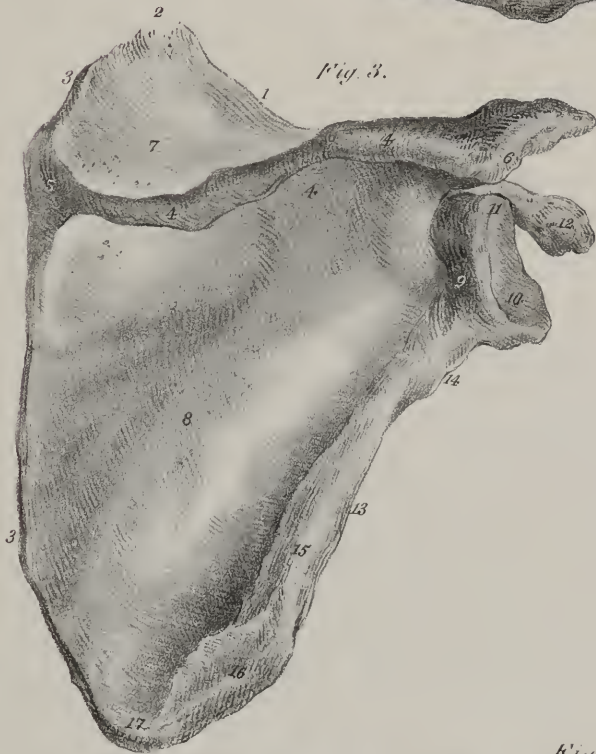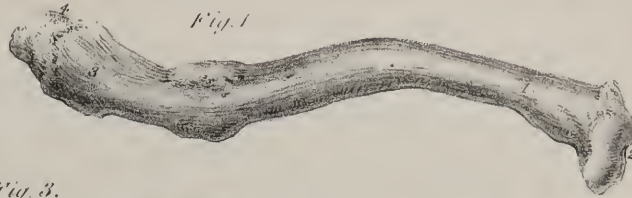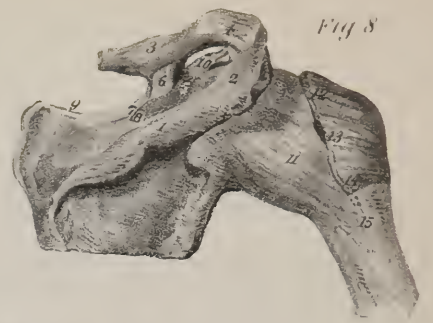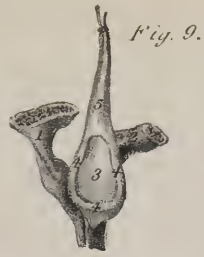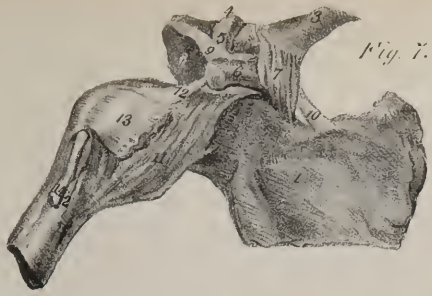


Fig. 2.

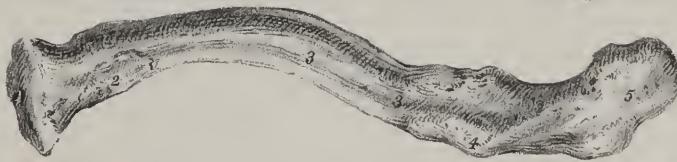

Fig. 5.

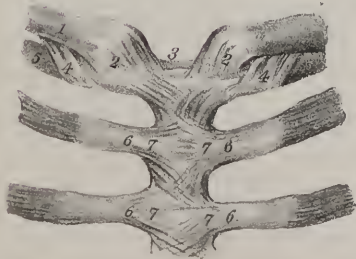


Fig. 6.

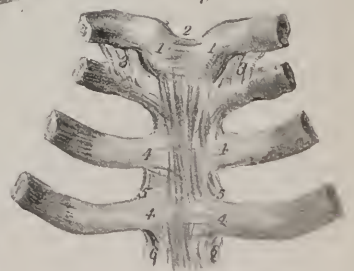
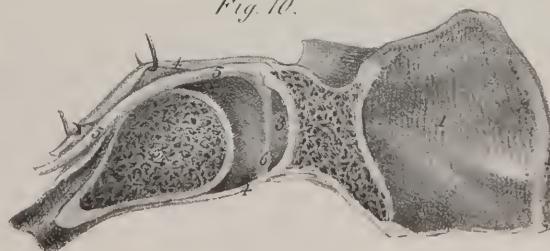
Fig. 10.







to the depressor muscle of the ala of the nose. Behind the malar tuberosity the surface is slightly excavated, and forms part of the zygomatic fossa; towards the posterior border it is plain, and forms one side of the spheno-maxillary fissure; and, at its junction with the orbital plate, it is rounded off and leads to the entrance of the infra-orbital canal. This surface is pierced by a number of foramina, which transmit the superior dental nerves; it terminates by a slight tuberosity, which projects behind the last molar tooth. The inner surface of its posterior border is rough, for its attachment to the tuberosity of the palate bone, and presents also a slight groove, contributing to the formation of the *posterior palatine canal*, which transmits the descending palatine branches from Meckel's ganglion.

From the upper border of the external surface, the *orbital plate* projects inwards, forming the floor of the orbit; its surface is smooth, being merely interrupted by the groove which leads to the infra-orbital canal; and at its inner and fore part near the lachrymal groove is a minute depression, which gives origin to the inferior oblique muscle of the eye.

The horizontal or *palate* plate of the bone projects inwards, forming the roof of the mouth, and the floor of the nares. Its nasal surface is concave from side to side, and smooth; externally it is continuous with the body of the bone, internally it presents a rough surface, which is articulated with the corresponding bone, and surmounted by a ridge, which completes the septum narium by articulating with the vomer and nasal cartilage; in front it is prolonged a little, so as to form a small process, (anterior nasal spine;) beside it is the foramen, leading into the anterior palatine canal, which lodges the naso-palatine ganglion. The inferior surface of the palate plate is rough, arched, and overhangs the mouth.

The body of the bone is hollowed into a large cavity, *antrum Highmori*, or *maxillare*, which in the fresh state is lined by mucous membrane and communicates with the middle meatus of the nose. Its orifice appears of great size in the dried bone when detached from its connexions, but it is considerably diminished when the contiguous bones are in their natural position, viz. the ethmoid, the inferior turbinate, and the palatal.

*Articulations.*—With the corresponding bone; with the frontal, by its nasal process; also with the ethmoid and os nasi; with the palate bone; with the malar, by the malar eminence; with the os unguis, the vomer, the inferior spongy bone, and the nasal cartilage.

*Attachments of muscles.*—Proceeding from below upwards;—above the border of the alveolar arch, the buccinator, and the depressor labii superioris *alæque nasi*; to the canine fossa, the levator anguli oris, and the compressor nasi; to the margin of the orbit, part of the levator labii superioris; to the nasal process, the orbicularis palpebrarum, and the common elevator of the lip and ala of the nose; and just within the orbit, the inferior oblique muscle of the eye.

*Development.*—In this case there are several ossific centres,—one in the nasal process, one in the orbital, one in the body, and one or two in the palate process. If the growth be interrupted, the fore part of the alveolar border with a portion of the palatal arch may remain separate from the rest of the bone, and represent an inter-maxillary bone.

*The Malar Bone.*—The malar bone, (os *malæ*), common to the face and orbit, forms the most prominent point of the side of the former, and the greater part of the outer border of the latter. Its form is quadrangular. The facial or anterior surface, pierced by some foramina for small vessels, is convex, and gives attachment to the zygomatic muscles;—the posterior overlies the zygomatic fossa, and is rough at its fore part for its articulation with the superior maxillary bone. The superior surface, smooth, narrow, and lunated, extends into the orbit, and articulates with the frontal, sphenoid, and superior maxillary bones.

The superior border forms the outer margin of the orbit; the inferior is on a line with the zygomatic arch, which it contributes to form; the anterior articulates with the maxillary bone; the posterior, curved, gives attachment to the temporal aponeurosis.

*Articulations.*—It articulates with the frontal, superior maxillary, temporal, and sphenoid bones.

*Attachments of muscles.*—The zygomatici, to its anterior surface; the masseter, to its inferior border; to its anterior angle, part of the levator labii superioris.

*Development.*—It grows from a single ossific point.

*The Nasal Bones.*—The nasal bones, (ossa *nasi*), situated beneath the frontal bone, and between the ascending processes of the superior maxillary, are small, and irregularly quadrilateral, and form what is called the “bridge” of the nose. They are thick and narrow in their upper part, but gradually become wider and thinner lower down. The anterior surface of each, concave from above downwards, convex from side to side, presents a minute vascular foramen; the posterior, or nasal, is marked by the passage of a branch of the nasal nerve; the superior border articulates with the frontal bone; the inferior with the nasal cartilage; the external with the ascending process of the maxillary bone; the internal with its fellow of the opposite side, and is supported by the nasal spine of the frontal bone, and the perpendicular plate of the ethmoid.

They give attachment to the pyramidales and compressores *nasi*; and are developed each from a single osseous centre.

*Os Unguis—Os Lachrymale.*—This small bone is named “unguis” from a resemblance, if not in form, at least in thinness and size, to a finger-nail, (unguis;) it is also called the “lachrymal” bone, from its presenting a groove which, with a similar excavation in the nasal process of the superior maxilla, forms the lachrymal groove. Placed at the inner and anterior part of the orbit, it presents two surfaces and four borders; its external or orbital surface, plain in the greater part of its extent, is hollowed anteriorly by a groove which runs from above downwards, and contributes, as above stated, to lodge the lachrymal sac. Part of the

internal surface, which is rough, corresponds with the anterior ethmoidal cells, the rest with the middle meatus narium. The superior border is articulated with the orbital process of the frontal bone; the inferior with the superior maxillary bone; and where it dips down, to form a part of the lachrymal canal, it joins the inferior spongy bone; anteriorly, it rests on the nasal processes of the superior maxillary bone, and posteriorly on the os planum of the ethmoid.

It is developed from one osseous centre.

*The Palate Bone.*—The palate bone, (os palati,) wedged in between the superior maxillary and sphenoid bones, is common to the cavity of the mouth, nares, and orbit. In its form this bone somewhat resembles that of the letter L, one part being horizontal, the other vertical.

The horizontal or *palate* plate of the bone, which is nearly square, and forms the back part of the roof of the mouth and of the floor of the nares, articulates anteriorly with the palate plate of the maxillary bone; internally, it presents a rough thick border which rises up into a ridge, which joins with its fellow of the opposite side, and with it forms a groove which receives the lower border of the vomer; externally it unites at right angles with the vertical portion of the bone; posteriorly it presents a thin free border, forming the limit of the hard palate, and giving attachment to the velum or soft palate which projects downwards from it; it is slightly concave, and has at the inner angle a pointed process, (*the palate spine.*) The superior surface of this plate or process is smooth, and forms the back part of the floor of the nasal cavity: the inferior, which forms part of the roof

## PLATE XVII.

The bones of the upper extremity.

FIG. 1. The bones of the left upper extremity, in their natural relations: after Cheselden.

No. 1. The anterior surface or venter of the scapula. 2. Its superior angle. 3. Its inferior angle. 4. The posterior border of the same bone. 5. Its anterior or inferior border. 6. The superior border. 7. The supra-scapular notch. 8. The neck of the scapula. 9. The coracoid process. 10. A part of the spine of the scapula. 11. The clavicle articulated with the acromion process of the scapula. 12. Its sternal end. 13. The shaft of the humerus. 14. The head of the humerus. 15. Its neck. 16. Its surgical neck. 17. The lesser tuberosity of the humerus. 18. The internal condyle. 19. The shaft of the ulna. 20. The olecranon process. 21. The coronoid process. 22. The interosseous ridge of the ulna. 23. Its styloid process. 24. The radius. 25. Its head. 26. Its tuberosity. 27. Its interosseous ridge. 28. The styloid process of the radius. 29. The scaphoid bone of the carpus. 30. The semi-lunar bone. 31. The cuneiform bone. 32. The pisiform bone. 33. The trapezium. 34. The trapezoides. 35. The os magnum. 36. The unciform bone. 37, 37. The metacarpal bones. 38, 38. The first row of phalanges. 39, 39. The second row of phalanges. 40, 40. The third or last phalanges. 41. The neck of the radius.

FIG. 2. A posterior view of the bones of the left upper extremity, in their natural relations.

No. 1. The dorsum of the scapula; its infra-spinous fossæ. 2. The supra-spinous fossa. 3. The spine of the scapula. 4. The smooth surface at the commencement of the spine, over which the tendon of the trapezius muscle plays. 5. The acromion process; articulating, by its extremity, with the clavicle. 6. The clavicle. 7. Its sternal end. 8. The base of the coracoid process. 9. The apex of the coracoid process. 10. The superior border of the scapula. 11. The supra-scapular notch. 12. The superior angle of the bone. 13. Its inferior angle. 14, 14. Its posterior border. 15. Its anterior border. 16. The shaft of the humerus. 17. The rough eminence for the attachment of the tendon of the deltoid muscle. 18. The bicipital groove, upon the head of the bone. 19. The greater tuberosity of the humerus. 20. The lesser tuberosity. 21. The trochlea of the humerus. 22. The internal condyle. 23. The rounded articular surface for articulation with the head of the radius. 24. The external condyle. 25. The depression for the reception of the coronoid process of the ulna, during flexion of the forearm. 26. The radius. 27. The grooves on the posterior surface of the lower extremity of the radius, for the passage of the extensor tendons to the back of the hand. 28. The ulna. 29. Its coronoid process. 30. The lower extremity of the ulna. 31. Its styloid process. 32. The scaphoid bone of the carpus. 33. The semi-lunar bone. 34. The trapezium. 35. The trapezoides. 36. The os magnum. 37. The unciform bone.

FIG. 3. A posterior view of the bones of the left upper extremity of a fœtus: after Cheselden.

No. 1. The scapula. 2, 2. The rim of cartilage which completes the posterior border of the scapula. 3. The spine of the scapula. 4. The acromion process, which is as yet cartilage. 5. The cartilaginous coracoid process. 6. The cartilaginous head of the humerus. 7. The cartilaginous lower extremity of the humerus. 8. The radius and ulna, which are cartilaginous at both extremities. 9. The bones of the carpus, chiefly cartilaginous.

FIG. 4. A fœtal clavicle, cartilaginous at both extremities.

FIG. 5. Section of an adult clavicle, showing its cancellous structure: after Cheselden.

FIG. 6. A scapula, seen upon its anterior and external aspect.

No. 1. The glenoid cavity. 2. The rough surface for the attachment of the long tendon of the biceps. 3. The coracoid process. 4. The spine of the scapula. 5. The acromion process. 6. The dorsal aspect of the bone. 7. Its ventral aspect. 8. The rough surface on the anterior border of the bone, for the attachment of the long head of the triceps. 9. The surface of attachment of the teres minor muscle. 10. The surface of attachment of the teres major. 11. The inferior angle of the bone.

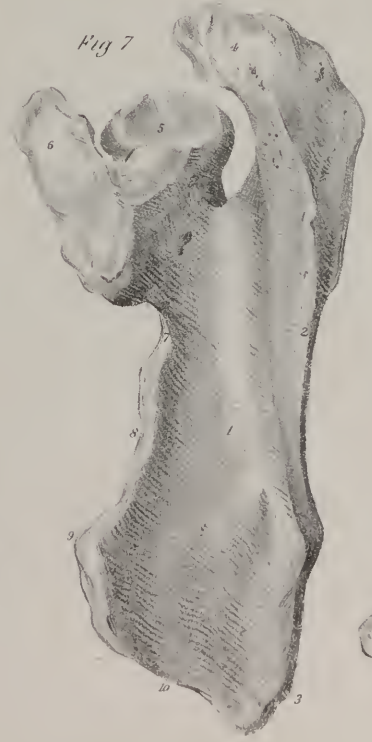
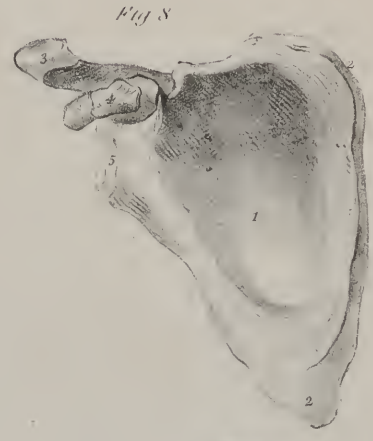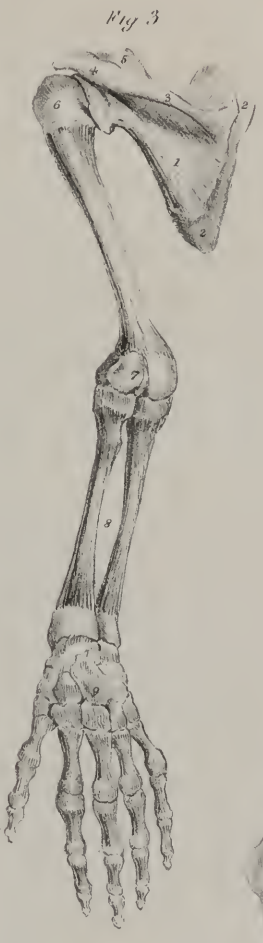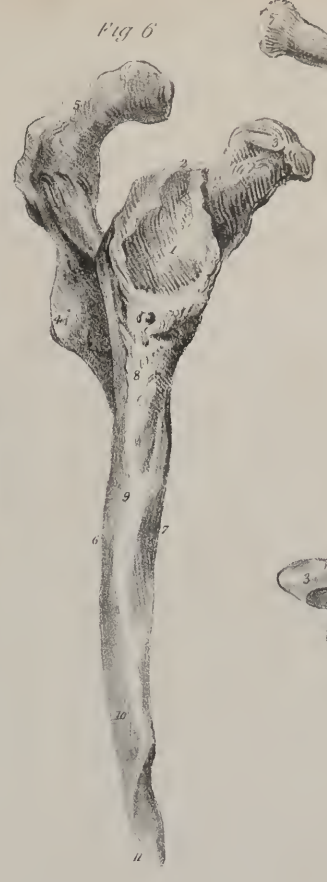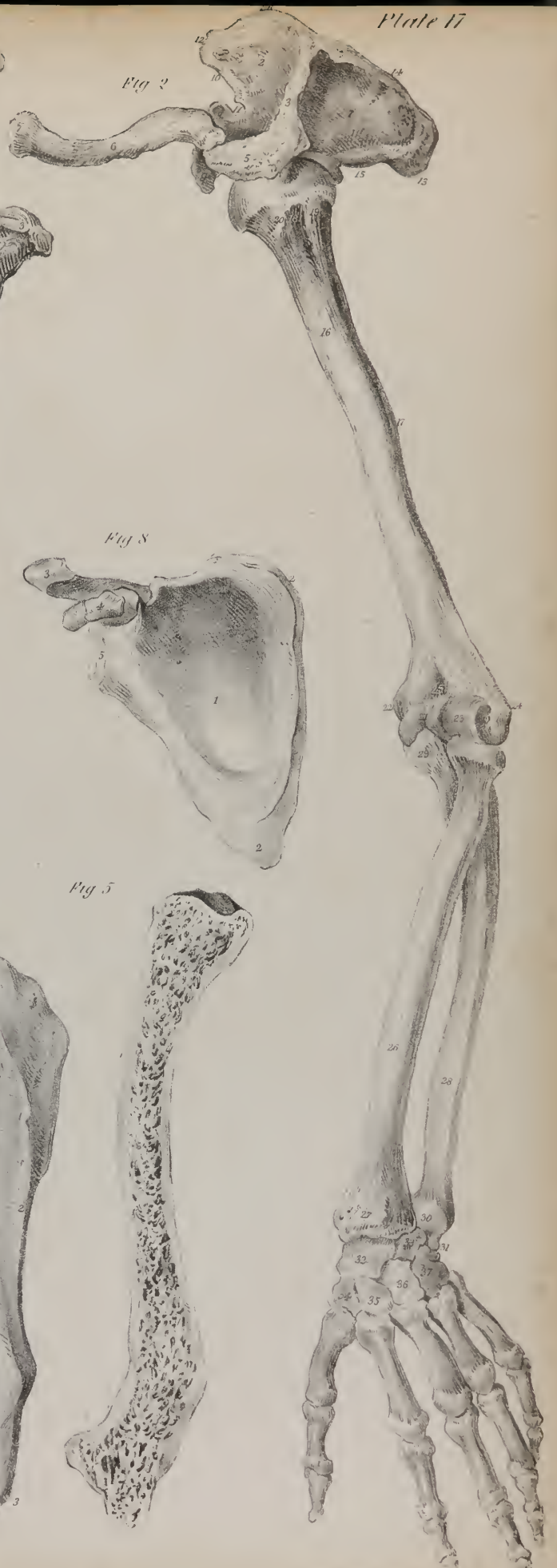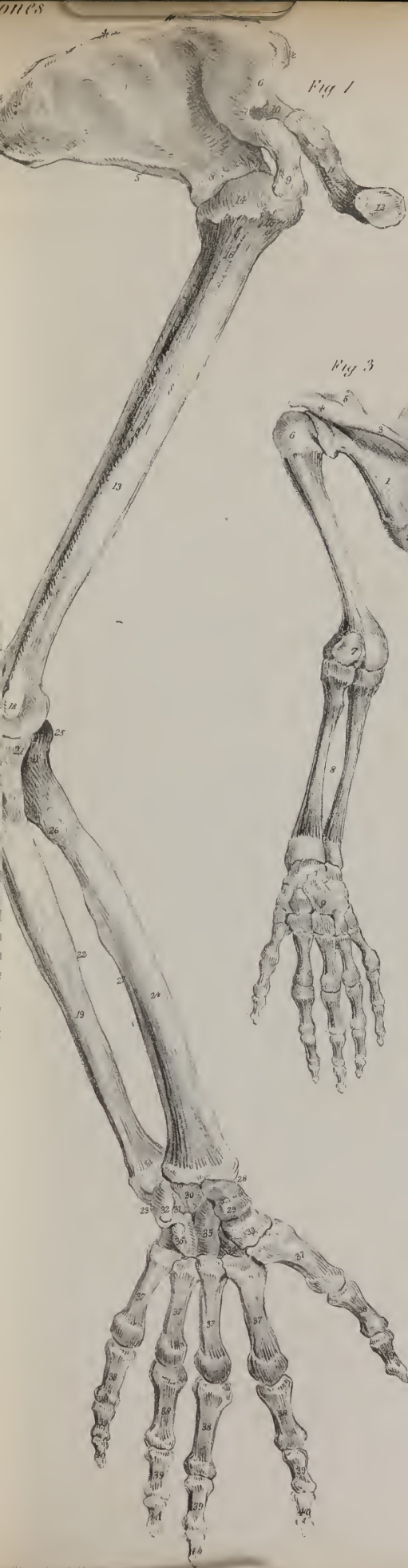
FIG. 7. The scapula, seen upon its superior aspect.

No. 1. The supra-spinous fossa. 2. The spine of the scapula. 3. The smooth surface at the commencement of the spine for the tendon of the trapezius muscle. 4. The acromion process. 5. The glenoid cavity. 6. The coracoid process. 7. The supra-scapular notch. 8. The superior border of the scapula. 9. The superior angle of the bone. 10. A part of the posterior border.

FIG. 8. A fœtal scapula, showing the process of ossification: after Cheselden.

No. 1. The venter of the scapula. 2, 2. The rim of cartilage forming its posterior border and inferior angle. 3. The acromion process. 4. The coracoid process, osseous in the centre, cartilaginous at both extremities. 5. The cartilaginous head of the scapula.







of the mouth, is unequal, and marked by a transverse ridge, into which the tendinous fibres of the circumflexus palati muscle are inserted; it presents also an oval foramen, being the inferior termination of the posterior palatine canal, which transmits the large descending palatine nerve and accompanying vessels; and farther back, another of smaller size, which transmits the middle palatine nerve.

At the junction of the horizontal and vertical portions, is situated a thick, rough tubercle, (*tuberosity, pyramidal process*), projecting downwards and backwards. This is marked by three vertical grooves; the two lateral ones are rough, and receive the inferior borders of the pterygoid plates of the sphenoid bone; the middle one, smooth, corresponds with and completes the fossa between the pterygoid plates.

The vertical portion of the bone is flat and thin; it presents two surfaces; the internal one (*nasal*) is divided into two parts by a transverse ridge, which articulates with the inferior spongy bone; the space below the ridge forms part of the inferior meatus, that above it of the middle meatus. The external surface, rough and unequal, is divided by a vertical groove, which is completed into a canal (*posterior palatine canal*) by the maxillary bone. The posterior part of this surface articulates with the rough border and nasal surface of the maxillary bone; and the anterior, thin and scaly, with the side of the antrum.

The superior border of the vertical portion of the palate bone presents a notch, forming the greater part of a foramen, which is completed by the sphenoid bone when the parts are in their natural position. This is called the *spheno-palatine* foramen; and outside it is placed the nervous ganglion of the same name, (*Meckel's ganglion*.) This notch divides the border of the bone into two processes or heads, the sphenoidal and the orbital.

The *sphenoidal* process, smaller and not so prominent, presents three surfaces, of which one, internal, looks to the nasal fossa; another, external, forms a small part of the zygomatic fossa; and the third, superior, grooved on its upper surface, articulates with the under surface of the sphenoid bone, and with it forms part of the *pterygo-palatine* canal.

The *orbital* process inclines outwards and forwards, and has five surfaces, two of which are free, and three articulated; of the latter, the internal one rests against the ethmoid bone, and covers some of its cellules; the anterior articulates with the superior maxillary bone; and the posterior (which is hollow) with the sphenoid. Of the non-articular surfaces, one superior, smooth, and oblique, forms a small part of the floor of the orbit; the other, external, looks into the zygomatic fossa.

*Articulations*.—With the corresponding palate bone; with the maxillary, ethmoid, sphenoid, vomer, and inferior spongy bone.

*Muscular attachments*.—To its spine, the azygos uvulæ; to the centre groove on its tuberosity, a small part of the internal pterygoid; and to the transverse ridge on the palate plate, the aponeurosis of the circumflexus palati.

*Developement*.—From the position and complex relations of this bone, its mode of growth is difficult to be determined. It appears at first like a single osseous plate slightly curved, and produced from one centre of ossification.

*The Vomer*.—The vomer, so called from its resemblance to a ploughshare, is flat, irregularly quadrilateral, and placed vertically between the nasal fossæ, presenting two surfaces and four borders. The lateral surfaces form part of the inner wall of the nasal fossæ; the superior border, thick and deeply grooved, receives the rostrum of the sphenoid bone; the margins of the groove expand and are articulated with two small lamellæ at the roots of the pterygoid processes of the sphenoid bone. The anterior border, also grooved, presents two portions, into one of which is implanted the descending plate of the ethmoid, and into the other the nasal cartilage. The posterior border, dividing the posterior nares, is thin and unattached: the inferior is received into the fissure formed by the palate plates of the superior maxillary and palate bones. It is developed from a single osseous centre.

*The Inferior Turbinate Bone*.—The *inferior turbinate*, or *spongy bone*, (so called from its texture in the latter case, in the former from some resemblance to the lateral half of an elongated bivalve shell,) extends from before backwards, along the side of the nasal fossa:—it appears as if appended to the side of the superior maxillary and palate bones. It is slightly convoluted, and presents an internal convex surface, projecting into the nasal fossa; and an external concave one, which arches over the inferior meatus. Its superior border articulates with the ascending process of the maxillary bone before, with the palate bone behind, and in the centre with the os unguis; it presents also a hooked process, which curves downwards and articulates with the side of the antrum; the inferior border is free, slightly twisted, and dependent. It has one point of ossification.

*The Inferior Maxillary Bone*.—The inferior maxilla (os maxillæ inferior) is of considerable size, and forms a large portion of the sides and fore part of the face. It is convex in its general outline, and shaped somewhat like a horse-shoe. It is usually considered as divisible into a middle larger portion—its body, and two branches or rami. The *body* is placed horizontally; its external surface is convex, and marked at the middle by a vertical line, indicating the original division of the bone into two lateral parts, and thence named its *symphysis*. On each side of the symphysis, and just below the incisor teeth, is a superficial depression, (*the incisor fossa*), which gives origin to the levator menti muscle; and, more externally, a foramen, (*foramen mentale*), which transmits the terminal branches of the dental nerve and artery. A raised line may be observed to extend obliquely upwards and outwards from near the symphysis to the anterior border of the ramus; it is named the *external oblique* line, and is intended to give attachment to muscles. The internal surface of the body of the bone is concave in its general outline, and marked at its centre by a depression corresponding with the symphysis; at each side of which are two prominent tubercles placed in pairs, one above the other, and affording attachment,—the upper pair to the genio-hyo-glossi, and the lower to the genio-hyoidei



muscles; beneath these are two slight depressions for the digastric muscles. An oblique prominent line (the *mylo-hyoidean ridge*) will be observed leading from the lower margin upwards and outwards to the ramus; above the line is a smooth depression for the sublingual gland, and beneath it, but situated more externally, is another for the submaxillary gland. The superior border of the body is horizontal, and marked by notches, corresponding with the alveoli, or sockets of the teeth. The inferior border, thicker at its anterior than at its posterior part, is slightly everted, so as to project somewhat forwards.

The branches (*rami*) project upwards from the posterior extremity of the body of the bone, with which they form nearly a right angle in the adult, an obtuse one in infancy,—the “angle” of the jaw. They are thinner somewhat, and appear as if compressed. The external surface of each ramus is flat, and marked by slight inequalities; the internal surface presents at its middle a foramen, (*inferior dental*), leading into a canal (dental) contained within the bone, and lodging the dental nerve and vessels. Beneath the foramen, a slight groove marks the passage of some vessels and a nerve, the rest of the surface being rough, for the insertion of the pterygoideus internus. The anterior border of each ramus is nearly vertical in its direction, and terminates in a pointed extremity, named the *coronoid process*; it is grooved at its commencement, for the attachment of the buccinator muscle. The posterior border is also almost vertical in adults; but in children and edentulous subjects it departs considerably from this direction, and approaches that of the base of the bone. This border is surmounted by a constricted part, which appears as if compressed from before backward, and is called the *neck* of the bone. It is slightly depressed at its fore part, and gives insertion to the external pterygoid muscle. Now the neck supports the articular head of the bone, (the *condyle*), which is convex and oblong, its greatest diameter being from without, inwards; the direction of its axis is oblique, so that, if prolonged, it would meet with that of its fellow of the opposite side at the anterior margin of the foramen magnum. The interval between the condyle and the coronoid process, deeply excavated, is called the *sigmoid notch*, and if viewed when the bones are *in situ*, it will be found to form a complete circle with the arch of the zygoma.

*Attachments of muscles.*—To the incisor fossa, the levator menti; to the external oblique line, the depressor labii inferioris, depressor anguli oris, and a small part of the platysma myoides. To the upper tubercles on the inner surface of the symphysis, the genio-hyo-glossi; to the inferior ones, the genio-hyoidei; to the depression beneath these, the digastricus; to the internal oblique line, the mylo-hyoideus, and posteriorly a small part of the superior constrictor of the pharynx. To the external surface of the ramus, the masseter; to the lower part of the inner surface, the pterygoideus internus; to the neck of the condyle, the pterygoideus externus; to the coronoid process, the temporal.

## PLATE XVIII.

### Anatomy of the humerus.

FIG. 1. An anterior view of the humerus of the right arm: after Cheselden.

No. 1. The shaft of the humerus. 2. The rough surface upon its outer side, which gives attachment to the tendon of the deltoid muscle. 3. The head of the bone. 4, 4. Its neck. 5. The greater tuberosity. 6. The lesser tuberosity. 7, 7. The bicipital groove. 8. The surgical neck of the bone. 9. The anterior bicipital ridge. 10. The posterior bicipital ridge. 11. The lower extremity of the bone. 12. The pulley-like surface which articulates with the ulna. 13. The rounded articular surface for the articulation of the head of the radius. 14. The external condyle. 15. The external condyloid ridge. 16. The internal condyle. 17. The internal condyloid ridge. 18. The fossa which receives the coronoid process of the ulna during flexion of the arm.

FIG. 2. A posterior view of the humerus of the right arm: after Cheselden.

No. 1. The shaft of the bone. 2. The prominence which corresponds with the insertion of the deltoid muscle. 3, 3. The musculo-spiral groove. 4. The head of the bone. 5, 5. Its neck. 6. The greater tuberosity; the number rests upon the surface for the attachment of the infra-spinatus muscle. 7. The surface for the attachment of the teres minor. 8. The surgical neck of the bone. 9. The lower extremity of the humerus. 10. The pulley-like surface for the articulation of the ulna. 11. The external condyle. 12. The external condyloid ridge. 13. The internal condyle. 14. The internal condyloid ridge. 15. The fossa for the reception of the olecranon process of the ulna.

FIG. 3. Section of the humerus, showing its internal structure: after Cheselden.

No. 1. The head of the bone. 2, 2. The line of junction of the epiphysis of the head with the shaft of the bone. 3. The greater tuberosity. 4, 4. The medullary canal of the bone. 5, 5. The solid walls of the bone. 6. The bottom of the fossa for the reception of the olecranon. 7. The external condyle. 8. The internal condyle. 9. The articular surface of the lower extremity of the bone.

FIG. 4. The head of the humerus, seen upon the superior aspect of the bone.

No. 1. The head. 2, 2. A part of the neck. 3. The greater tuberosity; the number rests upon that surface which gives attachment to the tendon of the infra-spinatus muscle. 4. The surface for the attachment of the supra-spinatus. 5. The surface for the attachment of the teres minor muscle. 6. The lesser tuberosity of the humerus. 7. The bicipital groove.

FIG. 5. The lower extremity of the humerus.

No. 1. The trochlear surface for the articulation of the greater sigmoid notch of the ulna. 2. The round articular surface for the head of the radius. 3. The ridge dividing these articular surfaces. 4. The external condyle. 5. The internal condyle. 6. The fossa for the reception of the olecranon process of the ulna.

FIG. 6. An anterior view of the humerus of the right arm of a fetus.

No. 1. Its shaft. 2. Its cartilaginous head and upper extremity. 3. The cartilaginous lower extremity.




Fig 1




Fig 3




Fig 2



Fig 6




Fig 4

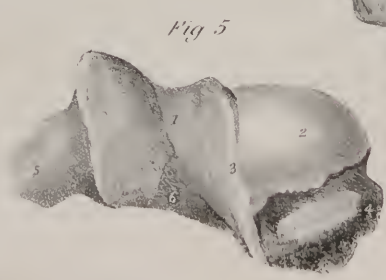

Fig 5










Fig. 3.

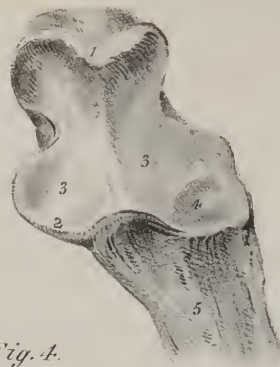

Fig. 4.

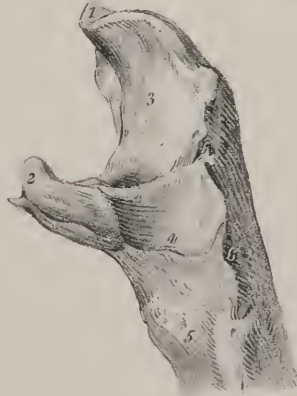

Fig. 5.

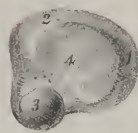


Fig. 6.

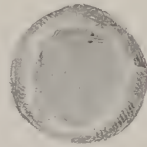


Fig. 7.




Fig. 8.


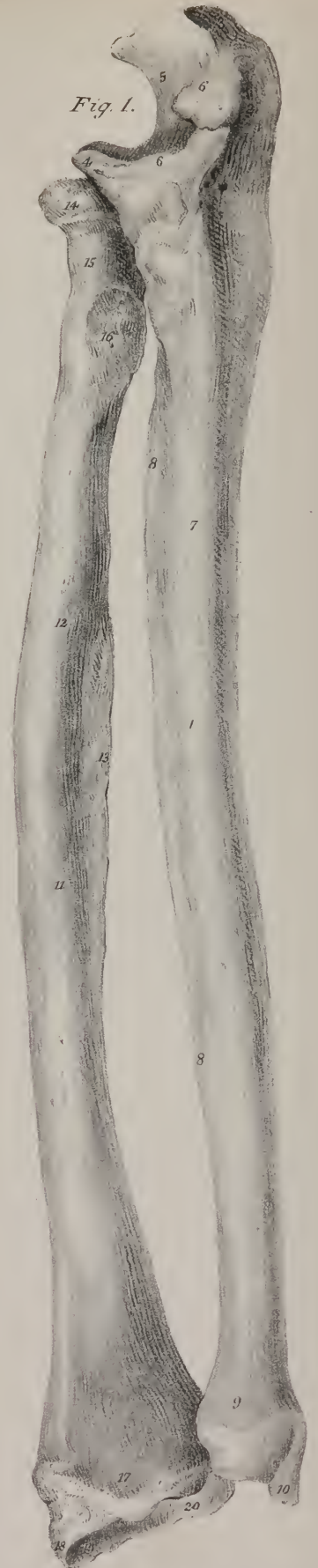


Fig. 1.



*Development.*—The growth is here effected from two osseous points, one in each lateral half.

*Os Hyoides.*—This is the u-shaped bone, so named from some resemblance to the Greek letter υ. It is occasionally called the lingual bone, from its important relations with the tongue; it is situated at the base of the tongue, and may be felt between the chin and the thyroid cartilage. It consists of a body, two cornua, and two cornicula. The body or central piece is small, quadrilateral in its form, and appearing as if compressed from before backwards; hence the direction of its plane is nearly vertical; but the great cornua seem as if compressed from above downwards, so that their plane appears horizontal. The anterior surface of the body is convex, and marked at the middle by a vertical line, on each side of which are depressions for the attachment of muscles; its posterior surface is concave, and corresponds with the epiglottis. The cornua project backwards, and in a rounded point. The cornicula, short, irregularly conical in their form, and oblique in their direction, are placed at the junction of the body with the cornua, and give attachment to the stylo-hyoid ligament; they continue for a long time movable, as the cartilage which connects them remains unossified to an advanced period of life.

*Attachments of muscles and ligaments.*—The stylo-hyoid ligaments, to the cornicula; the thyro-hyoid, to the cornua. The anterior surface gives attachment to the stylo-hyoid, sterno-hyoid, and digastric muscles; the superior border, to the mylo-hyoid, genio-hyoid, genio-hyo-glossi, lingualis, hyo-glossus, and the middle constrictor of the pharynx; its lower border, to the omo-hyoid and thyro-hyoid muscles, and more internally to the thyro-hyoid membrane.

*The sutures.*—The bones of the skull, and those of the face, are joined together by seams or sutures. The cranial sutures are commonly said to be five in number, of which three are termed true, as the margins of the bones are, in a manner, dove-tailed one into another; and two are called false, or squamous, as they merely overlap one another, like the scales of fishes. The true sutures are, the coronal, the lambdoidal, and the sagittal. These names are obviously ill-chosen; they convey no notion of the position which the sutures occupy in the skull or of the bones which they connect.

The *coronal* suture (*sutura coronalis*) has been so named from being situated where the ancients wore their garlands, (*coronæ*.) It connects the frontal with the two parietal bones, and hence it may with more propriety called “fronto-parietal.” It commences at each side about an inch behind the external orbital process of the frontal bone, where the anterior inferior angle of the parietal articulates with the great wing of the sphenoid bone. From this point it mounts rather obliquely up towards the vertex, having an inclination backwards. The dentations are better marked at the sides than at the summit of the head, for in the latter situation the suture approaches somewhat the squamous character, to allow the frontal bone to overlap the parietal. A similar change takes place at its lower part or commencement, with this difference, that there the parietal bones are made to overlie the frontal.

The *lambdoid* suture (*sutura lambdoidalis*) is situated between the occipital and the parietal bones, its form resembling somewhat that of the Greek letter  $\Lambda$ , whence its name has been taken. It begins at each side on a line with the posterior inferior

## PLATE XIX.

The bones of the fore-arm.

FIG. 1. An anterior view of the bones of the right fore-arm: after Cheselden.

No. 1. The shaft of the ulna. 2. The head of the bone. 3. The olecranon process. 4. The coronoid process. 5. The greater sigmoid notch. 6, 6. The rough border to which the broad extremity of the internal lateral ligament is attached. 7. The medullary foramen; upon the shaft of the bone. 8, 8. The interosseous ridge of the ulna. 9. The lower extremity of the bone. 10. Its styloid process. 11. The shaft of the radius. 12. The medullary foramen. 13. The interosseous ridge. 14. The head of the bone. 15. Its neck. 16. The tuberosity into which the tendon of the biceps muscle is inserted. 17. The lower extremity of the bone. 18. Its styloid process. 19. The surface which articulates with the scaphoid bone of the carpus. 20. The surface which articulates with the semilunar bone.

FIG. 2. An ulna of the left arm, viewed upon its external or radial side: after Cheselden.

No. 1. The shaft of the ulna. 2. The olecranon process of the head of the bone. 3, 3. The greater sigmoid notch, for articulation with the trochlea of the humerus. 4. The lesser sigmoid notch, for articulation with the head of the radius. 5. The coronoid process. 6. The surface for the attachment of the anconeus muscle. 7, 7. The interosseous ridge. 8. The inferior extremity of the ulna. 9. Its styloid process.

FIG. 3. A front view of the head of the left ulna.

No. 1. The upper part of the olecranon. 2. The coronoid process. 3, 3. The greater sigmoid notch, for articulation with the humerus. 4. The lesser sigmoid notch, for articulation with the head of the radius. 5. The upper part of the shaft of the bone.

FIG. 4. The head of the ulna, viewed upon its antero-external aspect.

The references are the same as for the preceding figure, with the addition of 6. The surface for the attachment of the anconeus.

FIG. 5. The lower extremity of the ulna, viewed from below.

No. 1. The surface which articulates with the inter-articular fibro-cartilage. 2, 2. The surface which articulates with the lower extremity of the radius. 3. The styloid process of the ulna.

FIG. 6. The head of the radius, viewed from above; and showing the cup-like form of the head of the bone.

FIG. 7. The lower extremity of the radius.

No. 1. Its styloid process.

FIG. 8. The radius and ulna of a fœtus, showing the cartilaginous epiphyses of the bones.



angle of the parietal bone, and thence inclines upwards and forwards to the point at which the two parietal bones are joined by the sagittal suture. It thus represents two sides of a triangle. It is often interrupted by accessory osseous deposits, (*ossa Wormiana*.) From its position and relation this suture may be named "occipito-parietal."

The *sagittal* suture (*s. sagittalis*—*sagitta*, an arrow) extends directly backwards, from the middle of the coronal to that of the lambdoid suture, and connects the two parietal bones, from which circumstance it may be called the "inter-parietal" suture: in children, and occasionally in adults, it is prolonged through the frontal bone, even to the root of the nose. The serrated appearance of the sutures is perceptible only on the external surface of the bones; the internal surface, or table of each, as it is called, being merely in apposition with the contiguous bone.

The line of union between the occipital and the temporal bone at each side used to be considered as a continuation of the lambdoid suture, or as an appendix to it, and was accordingly named *additamentum suturæ lambdoidalis*. It may, however, be named *tempora-occipital*, as it connects the mastoid and petrous parts of the temporal bone with the occipital—principally its basilar and condyloid portions. In this suture there are no regular dentations; in a great part of its extent the margins of the bones are merely in apposition.

The *squamous* sutures (*suturæ squamosæ*) are arched, and mark the junction of the lower borders of the parietal bones with the squamous parts of the temporal, their edges being so bevelled off as to allow the latter to overlie the former. At the point of junction between the squamous and mastoid parts of the temporal bone, the true squamous suture ceases; but from thence a short suture runs backwards to the lambdoid, connecting the mastoid part of the temporal with the postero-inferior angle of the parietal. This is termed *additamentum suturæ squamosæ*:—both together form the "temporo-parietal" suture.

The line of direction of the sutures (particularly the lambdoid and sagittal) is not unfrequently interrupted by additional bones, inserted between those hitherto enumerated. These, from being sometimes of a triangular form, are called *ossa triquetra*, and also *Wormiana*.

The cranial bones are joined to those of the face by sutures, which are common to both sets of bones. The *transverse* suture, observable at the root of the nose, extends across the orbits, and connects the frontal with the nasal, superior maxillary,

## PLATE XX.

The bones of the wrist and hand.

FIG. 1. A front view of the right wrist and hand: after Cheselden.

No. 1. The scaphoid bone. 2. The semilunar bone. 3. The cuneiform bone. 4. The pisiform bone. 5. The os trapezium. 6. The os trapezoides. 7. The os magnum. 8. The unciform bone. 9. Its hook-like process. 10. The metacarpal bone of the thumb. 11. The metacarpal bone of the index finger. 12. Its broad base, articulating with three bones of the carpus; the rough surface immediately below the figure is for the insertion of the tendon of the flexor carpi radialis. 13. The metacarpal bone of the middle finger. 14. The metacarpal bone of the ring finger with its small base. 15. The metacarpal bone of the little finger. 16. The first phalanx of the thumb. 17, 17. The first phalanges of the four fingers. 18, 18. The second phalanges of the fingers. 19, 19. The last phalanges of the fingers. 20. The last phalanx of the thumb.

FIG. 2. A posterior view of the right wrist and hand: after Cheselden.

No. 1. The scaphoid bone. 2. The semilunar bone. 3. The cuneiform bone. 4. The os trapezium. 5. The os trapezoides. 6. The os magnum. 7. Its rounded head. 8. The unciform bone. 9. The metacarpal bone of the thumb, articulating with the os trapezium. 10. The metacarpal bone of the index finger, articulating with the os trapezium, os trapezoides, and os magnum. 11. The depression for the insertion of the tendon of the extensor carpi radialis longior. 12. The metacarpal bone of the middle finger, articulating with the os magnum only. 13. The depression for the insertion of the tendon of the extensor carpi radialis brevior. 14. The metacarpal bone of the ring finger. 15. The metacarpal bone of the little finger, articulating with the os unciforme. 16. The depression of insertion for the tendon of the extensor carpi ulnaris. The other numbers of reference are the same as in the preceding figure.

FIG. 3. The bones of the carpus; showing the surfaces of the second row, which articulate with the metacarpal bones: after Cheselden.

No. 1. The surface of the os trapezium, which articulates with the metacarpal bone of the thumb. 2. The process on the palmar surface of the os trapezium, which overhangs the groove for the tendon of the flexor carpi radialis. 3. The os trapezoides. 4. The os magnum. 5. Its rounded head. 6. The unciform bone. 7. Its hook-like process. 8. The scaphoid bone. 9. The semilunar bone. 10. The cuneiform bone. 11. The pisiform bone.

FIG. 4. Separate bones of the carpus.

No. 1. The scaphoid bone. 2. Its concave surface. 3. Its broad extremity. 4. Its pointed extremity or tuberosity. 5. The semilunar bone. 6. The concave articular surface of the bone. 7. Its convex articular surface. 8. Its palmar extremity. 9. The cuneiform bone. 10. Its broad extremity. 11. Its apex. 12. The pisiform bone. 13. Its articular facet. 14. The os trapezium, viewed upon its dorsal aspect. 15. The surface which articulates with the metacarpal bone of the thumb. 16. The os trapezoides. 17. The os magnum. 18. Its rounded head. 19. Its dorsal surface. 20. The surface which articulates with the middle metacarpal bone. 21. The unciform bone. 22. Its hook-like process.

FIG. 5. The hand and wrist of the fetus: after Cheselden.

The carpus is wholly cartilaginous, as are the extremities of the metacarpal bones and phalanges.

FIG. 6. A sesamoid bone, viewed upon its convex and upon its articular surface.

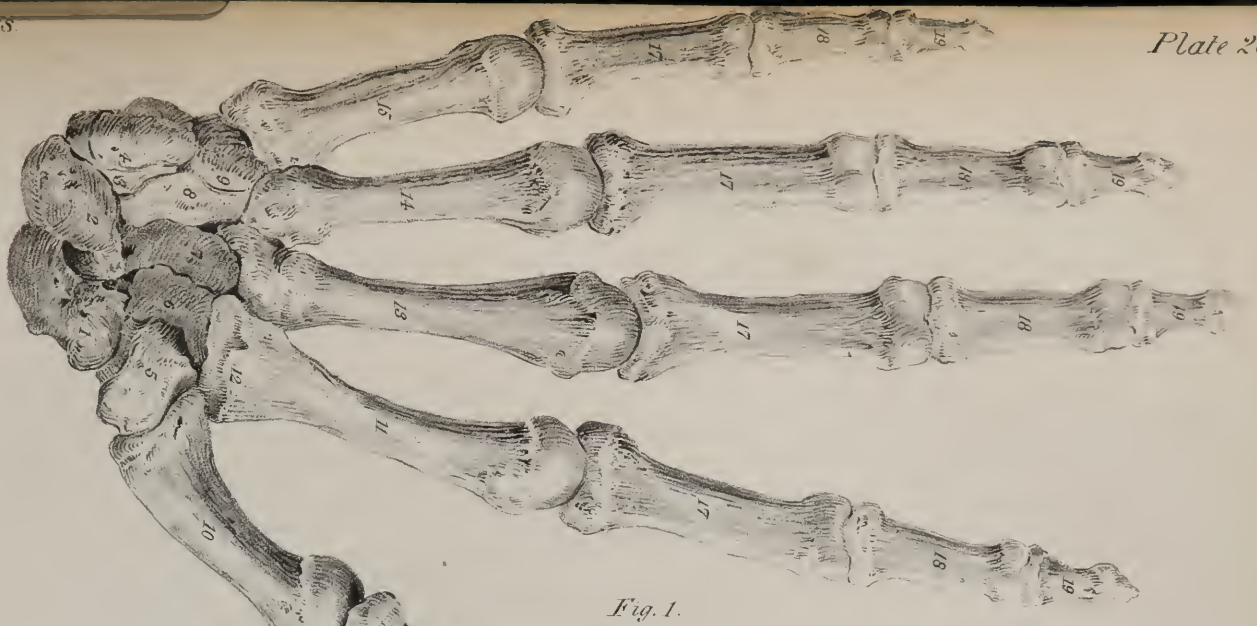

Fig. 1.

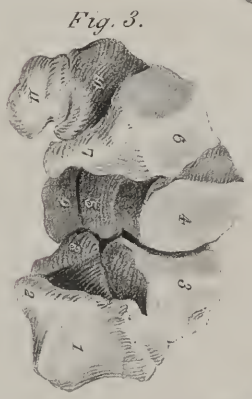

Fig. 3.

Fig. 6.

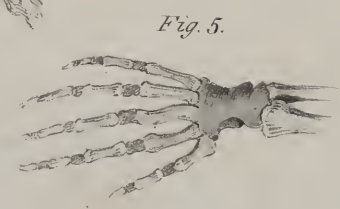



Fig. 5.

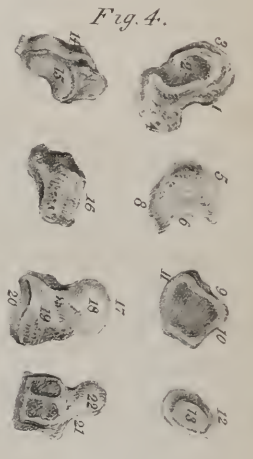

Fig. 4.

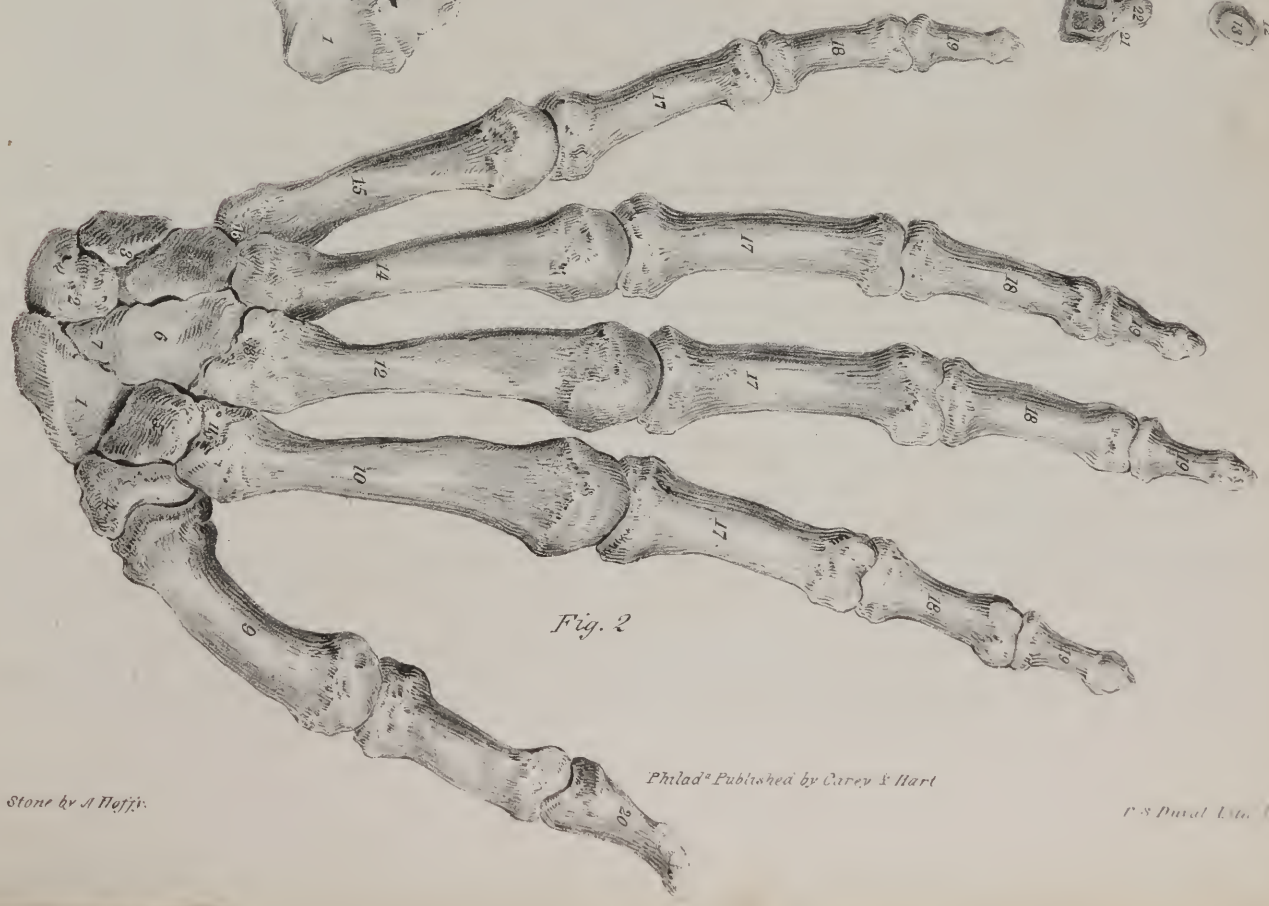

Fig. 2.





ossa unguis, ethmoid, sphenoid, and malar bones. The *zygomatic* sutures are very short; they are directed obliquely downwards and backwards, and join the zygomatic processes of the temporal with the malar bones. The *ethmoid* suture surrounds the bone of the same name; so does the *sphenoid*; they are necessarily complex in consequence of the many relations of these bones. The lines of connexion between the nasal and maxillary bones, though sufficiently marked, have not received particular names; but those observable between the horizontal lamellæ of the latter, and those of the palate bones, may be termed the palato-maxillary sutures.

*Remarks on the general conformation of the Skull.*—After having described, in detail, the separate bones of the head and face, it becomes necessary to review them collectively. The description of these bones forms the most difficult part of human, as well as of comparative osteology, as they are the most complex in the whole skeleton; but a correct knowledge of them is indispensable, in consequence of the many important parts which they serve to sustain and enclose; viz. the cerebral mass, with its nerves and vessels; the organs of sight, hearing, smell, and taste; part of those of mastication and deglutition, as well as of voice. To facilitate the description of the numerous eminences, depressions, cavities, and foramina of the skull, anatomists examine successively its external and internal surface: the former may be considered as divisible into five regions, three being somewhat of an oval figure, and situated, one superiorly, another at the base, the third in front, including the face; the others comprise the lateral parts, and are somewhat flat and triangular.

The *superior region* extends from the frontal eminences to the occipital protuberance, and, transversely, from one temporal ridge to the other; it thus includes the upper broad part of the frontal, almost all the parietal, and the superior third of the occipital bone, which together form the vaulted arch of the skull. It is divided into two symmetrical parts by the sagittal suture and its continuation when it exists; it presents no aperture or other inequality deserving of particular notice; it is covered by the common integument and occipito-frontalis muscle, on which ramify branches of the temporal, occipital, and auricular arteries, as well as filaments of nerves from the frontal branches of the fifth and portio dura, and also from the occipital nerve.

The *inferior region*, also oval in its outline, is the most complex of all, as it includes the entire base of the skull, extending from the incisor teeth to the occipital protuberance, and, transversely, from the mastoid process and dental arch on one side, to the corresponding points on the other. It may be considered as divisible into three parts. Of these, one corresponds with the extent of the arch of the palate; it is divided into two parts, by a line extending from before backwards, and marking the junction of the palate processes of the superior maxillary and palate bones; this is intersected by another, running transversely between each palate bone and the corresponding maxillary bone. Anteriorly, and in the middle line, is a foramen, (the *anterior palatine*,) which in the floor of the nares is double, but becomes single inferiorly, and transmits the naso-palatine nerve; posteriorly, on each side, and at the base of the alveolar border, is another foramen, (*posterior palatine*,) for the posterior palatine nerves and artery. The middle, or guttural region, is bounded at each side by a line extended from the pterygoid process as far as the mastoid process, thus including the posterior aperture of the nares, and the central part of the base of the skull. In the centre is situated the basilar process of the occipital bone, marked by slight inequalities for the attachment of muscles, and towards its posterior extremity the anterior condyloid foramina, which transmit the ninth pair of nerves. On each side is the pars petrosa of the temporal bone, in which may be observed the styloid and vaginal processes; more posteriorly is the jugular fossa, which is completed into a foramen (*foramen lacerum posterius basis cranii*) by the border of the occipital bone. This is divided into two parts by a spicula of bone, or a fibrous band, the internal and anterior one serving to transmit the glosso-pharyngeal, par vagum, and spinal accessory nerves; the other the jugular vein. Between the apex of the pars petrosa, and the side of the basilar process, and the body of the sphenoid bone, is the *foramen lacerum anterius basis cranii*, which is closed inferiorly by a thin plate of cartilage: across its area, as viewed at its upper or cerebral aspect, runs the internal carotid artery in its passage from the carotid canal in the temporal bone to the side of the sphenoid, and also the Vidian nerve, after it has passed backwards through the pterygoid foramen, and is proceeding to reach the groove in the upper surface of the pars petrosa. Between the contiguous margins of the pars petrosa and the great ala of the sphenoid bone is a groove, which leads backwards and outwards, and lodges the cartilaginous part of the Eustachian tube; and above the osseous part of that tube, and separated from it by a thin lamella of bone, is the orifice of the canal which transmits the tensor tympani muscle. The foramina of this region, taken in their order, from within outwards and backwards, are, the foramen ovale, foramen spinosum, foramen caroticum, and stylo-mastoideum.

The anterior part of this region is continuous with the posterior aperture of the nares, which is divided into two parts by the vomer. It is bounded above by the body of the sphenoid bone, below by the palate plates of the ossa palati, and on the sides by the pterygoid processes. The pterygoid groove, in each of these processes, is completed inferiorly by the pyramidal process of the palate bone; near its junction with the body of the bone is the scaphoid fossa, for the origin of the circumflexus palati; and at its inferior termination is the hamular process, round which the tendon of that muscle is reflected. Between the base of this process and the posterior palatine foramen is situated a smaller foramen, leading down from the posterior palatine canal, and which transmits the middle palatine nerve.

The posterior part of the inferior region includes all that is situated between the occipital protuberance and a line connecting the mastoid processes. It is divided into two lateral parts by a ridge, extending to the foramen magnum from the occipital protuberance, from which two rough curved lines branch outwards, giving attachment to muscles; so does the space between the lines,

and that between the inferior one and the foramen magnum. At the margin of the foramen, but nearer to its anterior termination, are the condyles of the occipital bone which articulate with the first vertebra; behind each is a depression, (*condyloid fossa*), and usually a foramen, (*posterior condyloid foramen*), which transmits a small vein and artery. Before and a little to the outer side of each, in a spot also retiring and depressed, is the opening of the *anterior condyloid foramen*, which looks obliquely outwards and forwards, and transmits the lingual nerve.

## PLATE XXI.

The ligaments of the elbow-joint, fore-arm, and wrist-joint.

FIG. 1. The ligaments of the elbow-joint and fore-arm, seen from the front.

No. 1. The lower part of the humerus. 2. The internal condyle. 3. The external condyle. 4. The projection formed by the head of the radius. 5. The coronoid process of the ulna. 6. The border of the greater sigmoid notch. 7, 7. The anterior ligament of the elbow-joint. 8. The internal lateral ligament. 9. The orbicular ligament of the head of the radius. 10. Some few of the anterior fibres of the external lateral ligament passing down to be inserted into the orbicular ligament. 11. The radius. 12. The ulna. 13. The oblique ligament. 14, 14. The interosseous ligament. 15. The opening which transmits the anterior interosseous artery. 16. The anterior ligament of the inferior radio-ulnar articulation. 17. The triangular fibro-cartilage of the inferior radio-ulnar articulation.

FIG. 2. The ligaments of the elbow-joint and fore-arm, seen from behind.

No. 1. The lower extremity of the humerus. 2. The internal condyle. 3. The external condyle. 4. The olecranon process of the ulna. 5. A projection made by the head of the radius. 6. The posterior ligament thrown into folds by the extension of the joint. 7. A part of the posterior ligament. 8. The external lateral ligament of the elbow. 9. Its posterior fibres, which are inserted into the ulna. 10. The orbicular ligament of the superior radio-ulnar articulation. 11. The radius. 12. The ulna. 13, 13. The interosseous ligament. 14. The opening in the interosseous ligament for the passage of the anterior interosseous artery. 15. The posterior ligament of the inferior radio-ulnar articulation.

FIG. 3. Ligaments of the elbow-joint, viewed from the inner side.

No. 1. The lower extremity of the humerus. 2. Its internal condyle. 3. The olecranon. 4. The ulna. 5. The radius. 6. The internal lateral ligament of the elbow. 7. Its anterior fibres continued downwards on the coronoid process of the ulna. 8. Its posterior fibres going to be attached to the side of the olecranon. 9. The anterior ligament of the articulation. 10. The orbicular ligament surrounding the head of the radius. 11. The tendon of the biceps curving around the radius to its insertion. 12. The upper part of the interosseous ligament.

FIG. 4. Ligaments of the elbow-joint, viewed from the outer side.

No. 1. The lower extremity of the humerus. 2. The outer condyle. 3. The olecranon process of the ulna. 4. The ulna. 5. The radius. 6. Its tuberosity, seen from behind. 7. The neck of the radius. 8. The external lateral ligament. 9. Its posterior fibres passing backwards to be inserted into the border of the olecranon. 10. The orbicular ligament. 11. The anterior ligament of the joint. 12. The posterior ligament. 13. The interosseous ligament.

FIG. 5. The elbow-joint, flexed, and seen from behind.

No. 1. The lower extremity of the humerus. 2. The internal condyle. 3. The external condyle. 4. The upper part of the olecranon. 5. The posterior ligament of the articulation. 6. The posterior part of the internal lateral ligament. 7. The external lateral ligament.

FIG. 6. The elbow-joint laid open from the front, in order to show the reflections of the synovial membrane.

No. 1. The lower extremity of the humerus. 2. Its internal condyle. 3. Its external condyle. 4. Its articular surface covered with cartilage. 5. The ulna. 6. The radius. 7. The external lateral ligament. 8. The internal lateral ligament. 9, 9. The anterior ligament drawn up. 10. The pouch of synovial membrane which intervenes between the head of the radius and the orbicular ligament. 11. The pouch of synovial membrane which is reflected between the head of the radius and the lesser sigmoid notch of the ulna. 12. The oblique ligament.

FIG. 7. The ligaments of the wrist-joint, viewed from the radial aspect.

No. 1. The lower part of the radius. 2. Grooves for the tendons of the extensor muscles of the thumb and of the wrist. 3. The styloid process of the radius. 4. The external lateral ligament of the wrist-joint. 5. The posterior ligament of the wrist. 6. The anterior ligament. 7, 7. The dorsal ligaments connecting the carpal bones. 8. The small end of the scaphoid bone. 9. The ligament connecting the scaphoid with the trapezium bone. 10. The external border of the trapezium. 11, 11. The palmar ligaments of the carpal bones. 12. The pisiform bone. 13. The unciform bone. 14. The dorsal carpo-metacarpal ligaments. 15. The transverse hands connecting the metacarpal bones with each other. 16. The tendon of the extensor carpi radialis longior cut off close to its insertion. 17. The tendon of the extensor carpi radialis brevior. 18, 18. The capsular carpo-metacarpal ligament of the thumb. 19. The tendon of the extensor ossis metacarpi pollicis divided close to its insertion. 20. Part of the metacarpal bone of the thumb. 21. Part of the metacarpal bone of the fore-finger.

FIG. 8. The ligaments of the wrist-joint, viewed from the ulnar aspect.

No. 1. The lower part of the ulna. 2. Its styloid process. 3. The internal lateral ligament of the wrist-joint. 4. The pisiform bone. 5. The cuneiform bone. 6. The hook-like process of the unciform bone. 7. The anterior ligament of the wrist. 8. The posterior ligament. 9, 9. The dorsal ligaments of the carpal bones. 10. The palmar ligaments of the carpal bones. 11, 11. The dorsal carpo-metacarpal ligaments. 12, 12. Transverse bands connecting the bases of the metacarpal bones. 13. The tendon of the extensor carpi ulnaris, divided close to its insertion. 14, 14. The internal lateral ligaments connecting the two ranges of the carpal bones and the latter with the fifth metacarpal bone. 15. Part of the metacarpal bone of the little finger. 16. Part of the metacarpal bone of the thumb. 17. The capsular carpo-metacarpal ligament of the thumb.



Fig 7

Fig 1

Fig 3

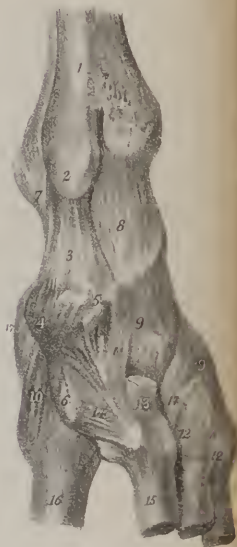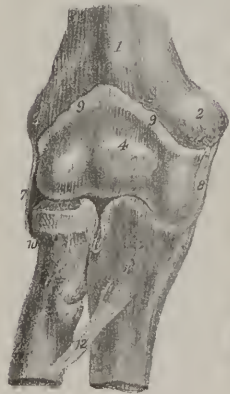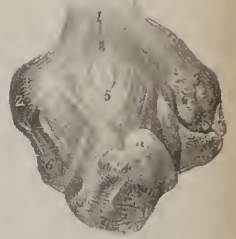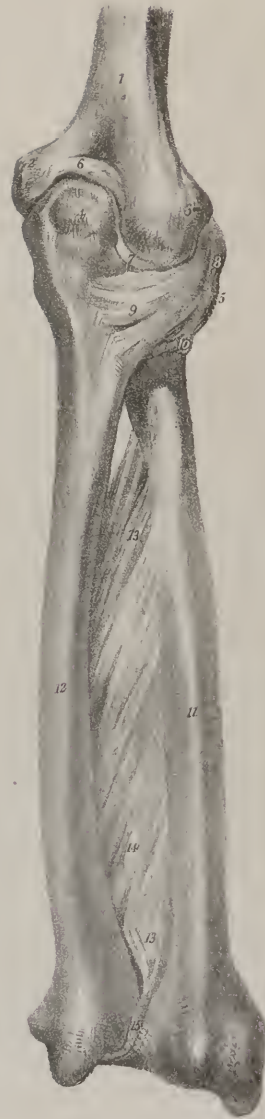

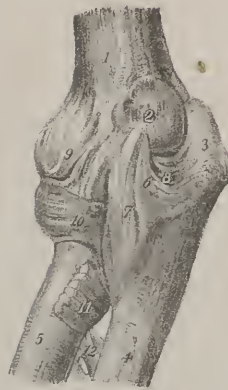Fig 2

Fig 5


Fig 8

Fig 6

Fig 4







The *anterior region* of the skull is of an oval form, and extends from the frontal eminences to the chin, and from the external border of the orbit and ramus of the jaw, on one side, to the corresponding points on the other, so as to include the whole of the face. The eminences, depressions, fossæ, and foramina, observable in this region, are as follow, viz. the frontal eminences, more or less prominent in different individuals, bounded inferiorly by two slight depressions, which separate them from the superciliary ridges; these curve outwards, from the nasal process of the frontal bone. Beneath the superciliary ridge, on each side, is the margin of the orbit, marked at its inner third by a groove, or a foramen, which transmits the frontal nerve and supra-orbital artery; and also by a slight depression, which gives attachment to the cartilaginous pulley of the trochlearis muscle. At an interval corresponding with the breadth of the orbit is another ridge, forming its inferior margin; under which is situated the infra-orbital foramen, for the passage of the superior maxillary nerve; and still lower down, the fossa canina, which gives attachment to the levator anguli oris muscle; it is bounded below by the alveolar border of the upper jaw, and surmounted by the malar tuberosity. Towards the middle line, and corresponding with the interval between the orbits, is the nasal eminence of the frontal bone, which is prominent in proportion to the development of the frontal sinuses over which it is situated. This is bounded by the transverse suture, marking the root of the nose. Beneath the nasal, and between the contiguous borders of the superior maxillary bones, is a triangular opening which leads into the nasal fossæ; it is broad below, and there its edge is surmounted by a prominent process, the nasal spine. Latterly it presents two sharp curved borders, which gradually incline inwards as they ascend to the nasal bones, so as to narrow it somewhat. Below the nasal aperture is a slight depression (myrtiform fossa) at each side of the middle line over the alveolus of the second incisor tooth. Farther down is the transverse rima of the mouth, between the alveolar borders of the jaws. In the inferior maxillary bone, besides some muscular impressions, is the mental foramen, which transmits the terminal branches of the dental nerve and artery.

The two *lateral* regions of the skull are somewhat of a triangular figure, the apex of the triangle being at the angle of the lower jaw, the base at the temporal ridge, and the sides formed by two lines drawn, one upwards and forwards, over the external orbital process, the other upwards and backwards over the mastoid process. In consequence of the great irregularity of the surface, it is necessary to subdivide each of these regions into three; the part above the zygoma being called the temporal region or fossa, that beneath it the zygomatic, the remainder being named the mastoid.

The *temporal* region, or fossa, being bounded by the temporal ridge above, and by the zygomatic arch below, is of a semi-circular form, and extends from the external angular process of the frontal bone to the base of the mastoid process. It is filled up by the temporal muscle, lodges the deep temporal vessels and nerves, and is formed by the temporal, parietal, frontal, sphenoid, and malar bones.

The *mastoid* region is bounded before by the transverse root of the zygoma, above by the horizontal one and the additamentum suturæ squamosæ, behind and inferiorly by the additamentum suturæ lambdoidalis. Proceeding from behind forwards, we observe the mastoid foramen, the process of the same name, anterior to which is the aperture of the meatus auditorius externus, which is circular in young subjects and somewhat oval in adults, the greatest diameter being from above downwards. The osseous tube continuous, externally, with the fibro-cartilage of the ear, and bounded, internally, by the membrana tympani, is directed, obliquely, forwards and inwards, and is somewhat broader at its extremities than in the middle. Anterior to the meatus is the glenoid fossa, which is bounded before by the transverse root of the zygoma, behind by the meatus, and internally by the spinous process of the sphenoid bone. It is divided into two parts by a transverse fissure, (*fissura Glasseri*,) the anterior portion being smooth, for its articulation with the condyle of the lower jaw; the posterior, rough, lodges part of the parotid gland. This fissure gives entrance to the laxator tympani muscle and a small artery, and transmits outwards the chorda tympani nerve.

The *zygomatic* region, situated deeply behind and beneath the orbit, is bounded before by the convex part of the superior maxillary bone, and is enclosed between the zygoma and the pterygoid process. The posterior surface of the maxillary bone is pierced by some small foramina, opening into canals, for the transmission of the superior dental nerves. Between the superior border of this bone, and the great ala of the sphenoid, is a fissure, (*spheno-maxillary*,) which is directed forwards and outwards, and communicates with the orbit; and between its posterior border and the pterygoid process is another, (*pterygo-maxillary*,) whose direction is vertical. The angle formed by the union of these fissures constitutes the *spheno-maxillary fossa*, which is situated before the base of the pterygoid process, behind the summit, or posterior termination, of the orbit, and immediately external to the nasal fossæ, from which it is separated by the perpendicular plate of the palate bone. Into this narrow spot five foramina open, viz. the foramen rotundum, which gives passage to the second branch of the fifth pair; the foramen pterygoideum, to the Vidian or pterygoid nerve and artery; the pterygo-palatine, to a small artery of the same name, (sometimes called also the superior pharyngeal;) the posterior palatine foramen, leading to the canal of the same name; and the spleno-palatine, which transmits the spleno-palatine nerve and artery.

The *internal surface* of the skull may be divided into its arch and its base. The arch extends from the base of the perpendicular part of the frontal bone, as far as the transverse ridge on the inner surface of the occipital bone. Along the middle line, and corresponding with the direction of the sagittal suture, is a shallow groove, marking the course of the superior longitudinal sinus. Several slight irregular depressions may also be observed, for the cerebral convolutions, and some tortuous lines for the

branches of the meningeal artery; and in many cases irregular depressions over the points occupied by glandulæ Pacchioni. The surface is more or less depressed so as to form fossæ at the points corresponding with the frontal and parietal eminences, and also above the internal occipital ridge, where the posterior lobes of the brain are lodged.

The *base* of the skull presents the several eminences, depressions, and foramina, which have been already enumerated in the description of the separate bones. Three fossæ may be observed at each side, differing in size and depth.

The *anterior fossa*, formed by the orbital plate of the frontal bone and the smaller wing of the sphenoid, serves to support the anterior lobe of the brain: it is marked by eminences and depressions corresponding with the cerebral convolutions and sulci; and, posteriorly, by a transverse line, indicating the junction of the bones just mentioned.

The *middle fossa*, formed by the great ala of the sphenoid, the squamous part of the temporal, and the anterior surface of the pars petrosa, lodges the middle lobe of the brain. It is marked by linear impressions for the meningeal artery, and by shallow pits for the cerebral convolutions; anteriorly it opens into the orbit by the sphenoidal fissure, sometimes called foramen lacrum anterius to distinguish it from those placed farther back, and already noticed; it transmits the third, the fourth, and the sixth

## PLATE XXII.

The ligaments of the wrist and hand.

FIG. 1. The ligaments of the anterior aspect of the wrist and fingers.

No. 1. The lower part of the radius. 2. The lower part of the ulna. 3. The inferior part of the interosseous ligament. 4. The anterior ligament of the inferior radio-ulnar articulation. 5. The anterior ligament of the wrist-joint. 6. The external lateral ligament. 7. The internal lateral ligament. 8. The pointed extremity of the scaphoid bone. 9. The ridge of the trapezium. 10. The pisiform bone. 11. The hook-like process of the unciform bone. 12. The anterior prominence of the os magnum. 13, 13. Anterior ligaments of the carpal bones. 14, 14. Lateral ligaments of the carpus. 15, 15. Anterior ligament of the carpo-metacarpal articulation. 16. The capsular ligament of the carpo-metacarpal articulation of the thumb. 17. A strong ligament passing between the pisiform bone and the hook-like process of the unciform bone. 18. The tendon of the extensor ossis metacarpi pollicis, divided close to its insertion. 19. One of the lateral ligaments of the metacarpo-phalangeal joint of the thumb. 20, 20. Sesamoid bones of this articulation. 21. One of the lateral ligaments of the phalangeal articulation of the thumb. 22. Anterior ligament of the metacarpo-phalangeal articulation of the index finger. 23, 23. Lateral ligaments of the metacarpo-phalangeal articulation of the index finger. 24, 24. Transverse ligaments. 25, 25. Anterior ligaments of the phalangeal articulations of the index finger. 26, 26. Lateral ligaments of the phalangeal articulations of the index finger. 27, 27. The theca of the flexor tendons laid open through its entire extent in the middle finger. 28. The theca of the flexor tendons unopened: farther onwards, the theca is laid open, and the tendons are exhibited. 29, 29. The tendon of the deep flexor, bifurcating into two slips, between which the tendon of the superficial flexor passes on to the last phalanx. 30. The tendon of the superficial flexor. 31. The tendon of the deep flexor muscle, dividing into two slips.

FIG. 2. The ligaments of the posterior aspect of the wrist and fingers.

No. 1. The lower part of the radius. 2. Its styloid process. 3. The lower part of the ulna. 4. Part of the interosseous ligament. 5. The posterior ligament of the inferior radio-ulnar articulation. 6. The posterior ligament of the wrist-joint. 7. The internal lateral ligament. 8. The external lateral ligament. 9, 9. The posterior ligaments of the carpus. 10, 10. The dorsal carpo-metacarpal ligaments. 11, 11. Transverse bands connecting the bases of the metacarpal bones of the fingers. 12. The capsular ligament of the carpo-metacarpal articulation of the thumb. 13. The tendon of the extensor ossis metacarpi pollicis, divided close to its insertion. 14. One lateral ligament of the metacarpo-phalangeal articulation of the thumb. 15. One of the sesamoid bones of the metacarpo-phalangeal articulation of the thumb. 16. One of the lateral ligaments of the phalangeal articulation of the thumb. 17. The tendon of the extensor secundi internodii pollicis muscle, divided close to its insertion. 18, 18. The lateral ligaments of the metacarpo-phalangeal articulation of the index and middle fingers. 19. The cavity of the articulation of the index finger. 20. The synovial membrane drawn aside in order to show the cavity of the articulation in the middle finger. 21, 21. The lateral ligaments of the phalangeal articulations of the index and middle fingers. 22, 22. The cavity of the articulation exposed in the middle finger by drawing aside the synovial membrane. 23, 23. The transverse ligament connecting the heads of the metacarpal bones. 24, 24. The tendon of the extensor communis digitorum muscle covering the dorsal surface of the ring and little fingers, and concealing the articulations.

FIG. 3. Vertical section of the carpus, showing the interosseous ligaments connecting the different bones, with the synovial cavity between them.

No. 1. The scaphoid bone. 2. The os semilunare. 3. The os cuneiforme. 4. The os trapezium. 5. The os trapezoides. 6. The os magnum. 7. The os unciforme. 8. The base of the metacarpal bone of the index finger. 9, 9. The bases of the metacarpal bones of the three other fingers. 10, 10. The synovial cavity between the first and second range of carpal bones. 11, 11. The synovial cavity between the second range and the metacarpal bones. 12, 12. The carpal portion of the synovial membrane of the wrist-joint. 13. The interosseous ligament connecting the scaphoid with the semilunar bone. 14. The interosseous ligament connecting the os semilunare with the os cuneiforme. 15. The ligament connecting the os magnum with the scaphoid bone and os trapezoides. 16. The ligament connecting the os magnum with the os unciforme. 17, 17. The interosseous ligaments connecting the bases of the metacarpal bones.

FIG. 4. The inferior articular surface of the bones of the fore-arm, showing the triangular fibro-cartilage.

No. 1. The articular surface of the radius. 2. The triangular fibro-cartilage. 3. The styloid process of the ulna.

FIG. 5. Vertical section of a finger, showing the lateral ligaments and the cavities of its articulations.

Nos. 1, 1. Lateral ligaments. 2, 2. Cavities of the articulations.



Fig 1

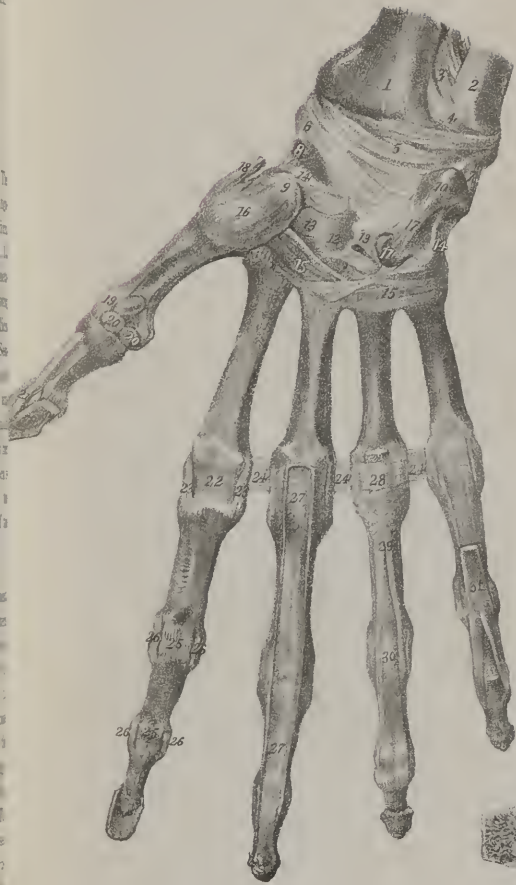


Fig 4



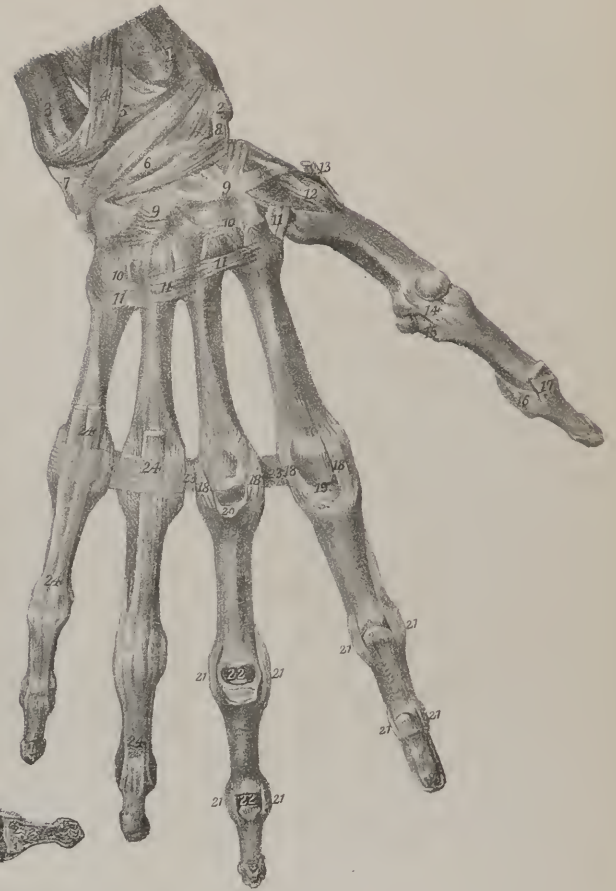
Fig 3

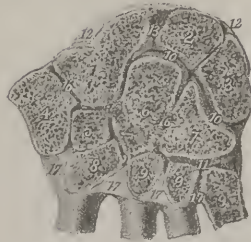


Fig 5



Fig 2





nerves, together with the ophthalmic branch of the fifth and the ophthalmic vein. Behind this is situated the foramen rotundum for the second branch of the fifth, the foramen ovale for the third, and, lastly, the foramen spinosum for the middle meningeal artery. Where the summit of the pars petrosa approaches the body of the sphenoid bone, there the internal orifice of the carotid canal opens. On the anterior surface of the pars petrosa, and directed obliquely backwards, there is a slight groove, leading to the hiatus Fallopii, and transmitting the Vidian nerve.

The *posterior fossa*, deeper and broader than the others, gives lodgment to the lateral lobes of the cerebellum. In the posterior surface of the pars petrosa, which forms the boundary of this fossa, may be observed the internal auditory foramen, and, within a few lines of it, a triangular fissure, which opens into the aquæductus vestibuli, and towards its inferior margin part of the groove for the lateral sinus, which leads down to the foramen lacerum posterius. Along the middle line, and taking the parts situated in the base of the skull from before backwards, we observe the crista galli of the ethmoid bone, and on each side the cribriform lamella of that bone; farther back, a slightly depressed surface, which supports the commissure of the optic nerves; and on each side the optic foramina. Behind this is the pituitary fossa, situated on the body of the sphenoid bone, bounded before and behind by the clinoid processes. Leading downwards and backwards from these is the basilar groove, which supports the pons Varolii and medulla oblongata, and terminates at the foramen magnum: at each side of this foramen are the condyloid foramina, and behind it a crista, leading upwards to the occipital ridge, and giving attachment to the falx cerebelli.

*The Orbits.*—The form of the orbits is that of a quadrilateral pyramid, whose base is directed forwards and outwards, and apex backwards and inwards, so that if their axes were prolonged backwards they would decussate on the body of the sphenoid bone.

The *roof* of each orbit forms part of the floor for the brain; it is concave, and composed of the orbital process of the frontal, and the smaller wing of the sphenoid bone: at its anterior and inner border may be observed a depression for the attachment of the pulley of the trochlearis muscle; externally, and immediately within the margin of the orbit, a shallow depression for the lachrymal gland; at the anterior border, a groove, sometimes a foramen, which transmits the supra-orbital or frontal nerve and artery; and posteriorly, at the apex of the cavity, the optic foramen, transmitting the optic nerve and ophthalmic artery. The *floor* forms the roof of the maxillary sinus: it consists of the orbital processes of the malar and maxillary bones, and of the small portion of the palate bone which rests on the latter; towards the inner and anterior border, near the lachrymal canal, may be observed a slight roughness, for the attachment of the obliquus inferior muscle; posteriorly, a groove, terminating in the infra-orbital canal, which runs nearly horizontally forwards. The inner side or wall of the orbit runs directly backwards, being parallel with the corresponding side of the other orbit, and is composed of the ascending process of the maxillary bone, the os unguis, the os planum of the ethmoid, and part of the body of the sphenoid bone. Near the anterior border is situated the *lachrymal canal*, which is formed, for the most part, between the ascending process and body of the maxillary bone, the remainder being made up by the groove in the os unguis, and a small process of the inferior spongy bone; this canal, a little expanded at its extremities, is directed downwards, backwards, and a little outwards. The *outer* side of the orbit, composed of the orbital plates of the malar and sphenoid bones, presents some minute foramina, which transmit small nerves from the orbit to the temporal fossa.

The *superior internal angle*, formed by the junction of the orbital process of the frontal bone with the os unguis and os planum, presents two foramina, (*foramen orbitale internum, anterius, et posterius,*) which give transmission, the anterior to the nasal twig of the ophthalmic nerve, the posterior to the ethmoidal artery. The *internal inferior angle* is rounded off so as to be scarcely recognised; it is formed by the union of the os unguis and os planum with the orbital plates of the superior maxillary and palate bones. In the *external superior angle*, formed by the malar, frontal, and sphenoid bones, is observed the sphenoidal fissure, of a triangular form, situated obliquely, its base being internal and inferior, the apex external and superior. In the *inferior external angle*, formed by the malar, the great ala of the sphenoid, the maxillary and palate bones, is situated the sphenomaxillary fissure, inclined at an angle with the former, and communicating with it, but of a different form, being broad at its extremities, and narrow at the centre.

The *anterior extremity, or base*, of the orbit, is directed outwards and forwards; and, as if to provide for a free range of lateral vision, the external wall retreats in some degree, and does not extend as far forward as the internal. The inner termination of the cavity, representing the summit of a pyramid, to which it has been likened, corresponds with the optic foramen. In each orbit, parts of seven bones are observed, viz. the frontal, ethmoid, sphenoid, os unguis, malar, maxillary, and palate bones; but as three of these, viz. the ethmoid, sphenoid, and frontal, are common to both, there are only eleven bones for the two orbits.

*The Nasal Fossæ.*—These fossæ are two cavities, placed one at each side of the median line, separated by a flat vertical septum. They communicate, by foramina, with the various sinuses lodged in the frontal, the ethmoid, and superior maxillary bones, and open anteriorly, on the surface, by the nares, and posteriorly into the pharynx. The roof, the floor, the inner and the outer walls of these cavities, require a separate consideration.

The *roof* is flat at its middle part, and sloped before and behind; it is formed in front by the inner surface of the nasal bones, behind by the body of the sphenoid, and in the middle by the horizontal or cribriform lamella of the ethmoid bone. The *floor*, smooth, concave from side to side, and formed by the palate plates of the maxillary and palate bones, extends backwards, and a little downwards, from the nares to the pharynx. Towards the anterior opening may be observed the superior orifice of the



anterior palatine canal. The *internal wall*, or septum narium, which extends from the roof to the floor of the cavity, is flat, nearly vertical, (the deviation, if any, being usually to the left side,) and composed of the perpendicular plate of the ethmoid bone, the vomer, and the nasal cartilage. The *external wall* is formed by the ethmoid, superior maxillary, os unguis, inferior spongy, and palate bones. The posterior and inferior parts of this surface are marked by a number of inequalities, whilst the superior and anterior are comparatively even. In the latter situation may be observed, first, the smooth surface just mentioned; and, secondly, passing downwards and backwards, three, and frequently four, arched and convoluted bones, (spongy bones,) beneath which are grooves (*meatus*) leading from before backwards. The superior spongy bone is much shorter than the others. beneath it is the *superior meatus*, into which will be found opening, anteriorly, a foramen from the posterior ethmoidal cells, and, posteriorly, the sphenopalatine foramen. The middle spongy bone overhangs the *middle meatus*, which communicates with the anterior ethmoidal cells; one of these curves forwards and upwards, and is continuous with the frontal sinus; more posteriorly is situated the opening of the maxillary sinus. The *inferior meatus* situated below the inferior spongy bone, between it and the floor of the nasal cavity, is necessarily longer than the others; it presents anteriorly the orifice of the nasal canal.

*The Frontal, Sphenoidal, and Maxillary Sinuses.*—The *frontal sinuses* correspond with the superciliary eminences of the frontal bone. Of considerable size in the adult, but varying in different individuals, they are not at all developed in the fœtus. They are divided into two, sometimes three compartments.

The *sphenoidal sinuses*, two in number, are placed within the body of the sphenoid bone; these also cannot be said to exist in infancy. They are separated by a partition. Above, behind, and on each side, they are bounded by the body of the sphenoid bone, and in front by two small spongy bones, (cornua sphenoidalia.)

The *maxillary sinus* (antrum Highmori) is a large excavation in the body of the superior maxillary bone. It appears at an earlier period than any of the other sinuses, the development commencing about the fourth month of fœtal life. Its form is irregularly pyramidal, the base being towards the nasal cavity, the apex corresponding with the malar tuberosity. Superiorly, it is

## PLATE XXIII.

Anatomy of the os innominatum.

FIG. 1. The os innominatum of the left side: after Cheselden.

No. 1. The ilium; its external or convex surface. 2, 2. The superior curved line of the ilium. 3, 3. The inferior curved line. 4, 4. That part of the surface of the bone from which the gluteus medius arises. 5, 5. The rough surface from which the gluteus maximus arises. 6, 6. The surface for the origin of the gluteus minimus. 7. The rough surface which gives origin to one head of the rectus muscle. 8, 8. The superior part of the lip of the acetabulum, which forms the inferior boundary of the ilium. 9, 9. The crest of the ilium. 10. Its anterior superior spinous process. 11. Its posterior superior spinous process. 12. The notch from the upper part of which the sartorius muscle arises. 13. The anterior inferior spinous process. 14. The posterior inferior spinous process. 15, 15. The great sacro-ischiatic notch. 16. The spine of the ischium. 17. The lesser sacro-ischiatic notch. 18. The body of the ischium. 19, 19. The posterior part of the lip of the acetabulum, which is formed by the ischium. 20. The tuberosity of the ischium. 21. The facet upon this tuberosity which gives origin to the semi-tendinosus muscle and the long head of the biceps. 22. The facet which gives origin to the semi-membranosus muscle. 23. The ramus of the ischium. 24. The body of the os pubis. 25. The crest of this bone. 26. The spine, or tuberosity of the os pubis. 27. The angle of the bone. 28. The edge of the articular surface of the os pubis. 29. The rough surface immediately beneath the angle from which the tendon of the adductor longus muscle arises. 30. The ilio-pectineal line. 31. The ilio-pectineal eminence. 32. The anterior portion of the lip of the acetabulum formed by the os pubis. 33. The notch in the acetabulum. 34, 34. The articular surface of the acetabulum. 35. The depression at the bottom of the acetabulum which lodges the cushion of fat of the ilio-femoral articulation. 36. The obturator foramen. 37. The groove upon the under surface of the os pubis which gives passage to the obturator vessels.

FIG. 2. The os innominatum of the right side, seen upon its internal aspect: after Cheselden.

No. 1. The concavity of the ilium, which lodges the iliacus muscle. 2, 2. The crista ilii. 3. The anterior superior spinous process. 4. The posterior superior spinous process. 5. The anterior inferior spinous process. 6. The notch between the anterior spinous processes. 7. The posterior inferior spinous process. 8. The ilio-pectineal eminence. 9. The upper margin of the acetabulum. 10, 10. The ilio-pectineal line. 11, 11. The auricular portion of the ilium, which articulates with the sacrum. 12, 12. The rough portion of the bone, which is connected with the sacrum by means of interosseous ligaments. 13. The ischium. 14, 14. The great sacro-ischiatic notch. 15. The spine of the ischium. 16. The lesser sacro-ischiatic notch. 17. The tuberosity of the ischium. 18. The border of the tuberosity of the ischium to which the great sacro-ischiatic ligament is attached. 19. The ramus of the ischium. 20. The body of the os pubis. 21. Its crest. 22. The spine or tuberosity. 23. The angle. 24, 24. The articular surface of the bone. 25. The ramus of the os pubis. 26. The obturator foramen.

FIG. 3. A portion of the os innominatum, from which the external table of the bone has been removed, in order to show its cellular or cancellous structure: after Cheselden.

FIG. 4. The os innominatum of the young subject, showing the mode of development of the bone by three portions, corresponding with the ilium, ischium, and os pubis, and their cartilaginous union at the acetabulum: after Cheselden.

No. 1. The ilium. 2, 2. The crest of the bone, which is as yet cartilaginous. 3. The ischium. 4. The os pubis. 5, 5. The cartilage connecting these three pieces of the acetabulum. 6, 6. The cartilaginous rim of the tuberosity of the ischium, and rami of the ischium and pubis. 7. The cartilaginous union between the two rami.

FIG. 5. The os innominatum of a fœtus, showing the bone at a still earlier stage of development: after Cheselden.

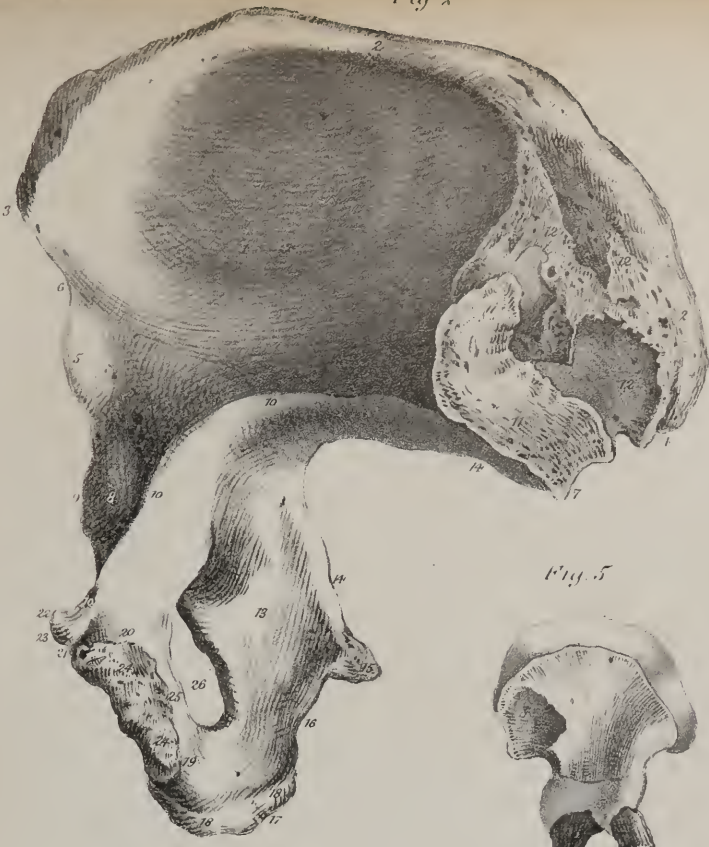


Fig 4

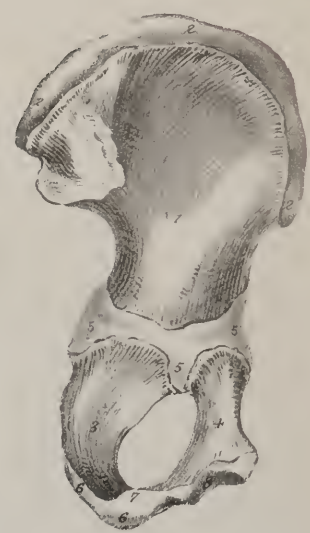

Fig 5




Fig 3

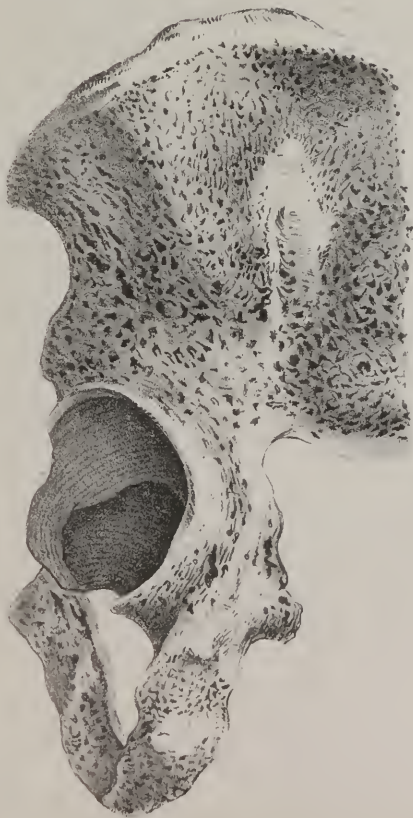
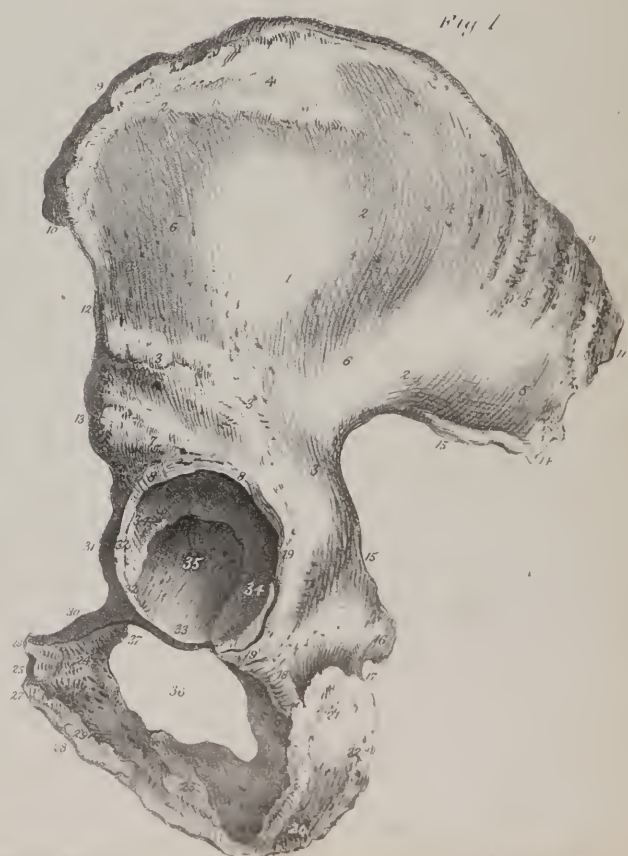
Fig 1







enclosed by the orbital plate of the maxillary bone; and inferiorly by its palate plate: internally, it opens into the middle meatus of the nasal cavity by a foramen, which, though it appears very large in the dry bone when separated from its connexions, is in the natural state small, being little more than sufficient for the admission of a probe; this diminution of size is caused by the lower edge of the ethmoid, the inferior spongy and the palate bones, and also by a fold of the mucous membrane.

*Analogy between Cranial Bones and Vertebræ.*—Anatomists have at all times perceived and recognised the analogy between the movable and motionless pieces of the spine—between those of the lumbar and dorsal regions, and those of the sacrum and coccyx: in the one, as well as in the other, similar organic elements are observed to exist, variously modified, in order to suit special purposes; but it is only of late years that any adequate attention has been directed to the points of similitude which exist between vertebræ, properly so called, and the cranial bones. Many persons who adopt, without hesitation, the terms false or pelvic vertebræ, as applied to the sacrum and coccyx, feel a repugnance to use the word false or cranial, as applied to the pieces of the skull; and deny, perhaps without examination, the analogy upon which it is founded, as being unnatural, or far-fetched. We have numerous instances of the harmony that subsists between containing and contained parts throughout the economy; in no case is it more striking than in the relation that obtains between the fundamental part of the osseous structure and the central mass of the nervous system. The spinal canal is accurately adapted in its different parts to the nervous cord which it encloses. In the pelvic region, the canal, at least in the human subject, becomes narrow, as it merely encloses nerves, whilst the body and processes take on a particular development to meet a special purpose, that of forming a basis of support for the rest of the column. This seems to result from the working of what may be termed a principle of compensation in the growth, as well as in the action of parts; for when one part of a given whole is developed to excess or to a maximum, others will remain at a minimum or atrophied: thus the spinal canal and the arches are at their minimum in the sacrum and coccyx, for the contained parts are there at a low point of development; but at the opposite end of the column the reverse obtains; the contained parts, viz. the central parts of the nervous system, are evolved in the human subject to the greatest extent, and so must the containing parts also be. The portion of the osseous system which corresponds with the bodies of the vertebræ can, therefore, hardly be recognised; whilst that which is analogous to the arches is expanded so much as to retain but a slight similitude to them.

If we take the occipital bone, and examine it attentively, we shall readily perceive in it all the elements of a vertebra. The foramen magnum is the counterpart of the ring of a vertebra, and has a similar relation to the spinal cord; the basilar process represents the body; the condyles are true articulating processes; the rough surfaces external to them, and which give attachment to the recti laterales, correspond to the transverse processes; the vertical ridge extended backwards along the median line, from the foramen to the occipital protuberance is, in the human subject, merely a rudiment of a spinal process; but in the dog, bear, and badger, it forms a sharp prominence well deserving the name of spine, and the likeness is still more striking in osseous fishes; finally, the broad plates on each side of the spine represent the arches. In this view of the matter, the occipital bone forms the first false vertebra of the cranial region.

In the second cranial piece or vertebra, it must be admitted that the analogies are not so striking; but when we recollect that the cavity of the skull, if examined in the different orders of animals, enlarges in proportion as the brain acquires an increase of development, and that this enlargement attains its maximum in the human subject, we shall at once find sufficient reason to expect that the parts corresponding with the vertebral arches should, in this region, be greatly evolved, while the rest are in a manner atrophied. The parietal bones, with the squamous part of the temporal and the great wings of the sphenoid, taken together, represent the arches, whilst the posterior part of the sphenoid bone (such as it exists in the human fœtus before its ossification is complete, and such as it continues permanently in several lower animals) is the counterpart of the body; the mastoid processes of the temporal bones with the glenoid fossæ serve as transverse and articulating processes. These, together, form the middle cranial piece, which may be termed the sphenotemporo-parietal cranial false vertebra.

The frontal bone, the ethmoid, and the anterior division of the sphenoid, (which is that part of the body that sustains the smaller wings,) form the third vertebra; the part of the sphenoid just named, together with the crista galli and the perpendicular plate of the ethmoid bone, form the body, which is here reduced to a rudimentary state, just as the coccygeal bones are at the opposite end of the column, of which it may be considered a repetition. The lateral and expanded parts of the frontal bone are the arches, and the external orbital processes may be likened to transverse processes.

We have here used the term false vertebra as applied to the cranial pieces; perhaps it would be better to use the word zone, as sanctioned by the authority of Cuvier. The passage in which he recognises the principle of development here indicated, as well as the application of it, (which appears to have been first inculcated by Dumeril, and traced in all its details by Geoffroy Saint-Hilaire, is as follows:—"Le crâne se subdivise comme en trois ceintures, formées—le antérieure par les deux frontaux et l'éthmoïde, l'intermédiaire par les pariétaux et le sphénoïde, la postérieure par l'occipital."\*)

*Man adapted to the erect posture.*—Every part of the conformation of the human subject indicates its adaptation to the erect position. The feet are broader than those of any other animal proportionally to its size; the tarsal and metatarsal bones admit of very little motion; and the great toe is on the same plane with the others, and cannot be brought into opposition with them. The foot is thus fitted to sustain the weight of the body, but not to grasp or seize objects presented to it. The hands, on the con-

\* Règne Animal, tom. i. p. 63.

trary, though so well adapted for these purposes, are ill calculated for affording support; so that man is truly "bimanous" and "biped."\* The tibia rests perpendicularly on the astragalus, and the os calcis projects backwards for the purpose of increasing the base, and also of lengthening the lever to which the strong muscles of the calf of the leg are attached. The whole extent of the tarsus, metatarsus, and phalanges, in man, rests on the ground, which does not obtain even in apes, the end of whose os calcis is somewhat raised, so as to form an acute angle with the bones of the leg. In dogs and digitated quadrupeds, the carpus and tarsus are considerably elevated from the ground, so that the body rests on the toes; and in the horse, and other solid-hoofed animals, the third phalanges only rest on the ground, the os calcis being raised nearly to the perpendicular direction.

The femur, placed securely beneath the pelvis, affords a firm support during progression. The great breadth of the pelvis serves to enlarge the base on which the trunk rests; and this is farther increased by the length of the cervix femoris. This peculiarity in the neck of the femur renders it necessary that the body of the bone should incline inwards, in order that its axis should approach the central line, and so support the centre of gravity. If its articular head be viewed in profile, it will be observed that the cartilaginous coating is distributed for the most part on its upper and inner aspect, showing its adaptation as a pillar of support in the erect position.

The bones of the pelvis in the human subject are distinguished from those of other animals by some marked peculiarities. The sacrum is remarkably broad and expanded, so as to form a firm support for the spinal column which rests upon it; its lower part is curved and articulated with the coccyx, so that both incline forwards and enclose the pelvic cavity, constituting a support

## PLATE XXIV.

Bones of the lower extremity.

FIG. 1. Femur of the right thigh, seen upon its anterior aspect: after Cheselden.

No. 1. The shaft of the bone. 2. Its head. 3. The indentation on the head of the femur for the insertion of the ligamentum teres. 4. The neck of the bone, somewhat forc-shortened. 5. The trochanter major. 6. The rough surface for the attachment of the tendon of the gluteus minimus muscle. 7, 7. The anterior inter-trochanteric line. 8. The trochanter minor. 9, 9. Foramina upon the neck of the bone for the passage of nutrient vessels. 10. The internal and longer condyle of the femur. 11. The tubercle which gives attachment to the tendon of the adductor magnus muscle. 12. The tubercle for the attachment of the internal lateral ligament of the knee-joint. 13. The external condyle. 14. The tubercle for the attachment of the external lateral ligament of the knee-joint. 15. The groove for the tendon of origin of the popliteus muscle. 16. Foramina for the passage of nutritious vessels into the cancellous structure of the lower extremity of the femur.

FIG. 2. The left femur, seen upon its posterior surface: after Cheselden.

No. 1. The shaft of the bone. 2. Its head. 3. The depression for the insertion of the ligamentum teres. 4. The neck of the femur. 5. The trochanter major. 6. A part of the surface for the attachment of the tendon of the gluteus medius. 7. The linea quadrati, for the attachment of the quadratus femoris muscle. 8. The posterior inter-trochanteric line. 9. The trochanter minor. 10, 10. The trochanteric or digital fossa. 11, 11. The line leading from the base of the greater trochanter to the linea aspera, for the attachment of the gluteus maximus. 12. The ridge for the attachment of the upper part of the adductor magnus muscle. 13, 13. The line passing down from the anterior inter-trochanteric line to the linea aspera, for the attachment of the pectineus muscle. 14, 14. The linea aspera. 15. The nutritious foramen of the femur. 16. The outer lip of the linea aspera, continued downwards to the external condyle. 17, 17. The continuation of the internal lip of the linea aspera down to the internal condyle. 18. A slight groove on the bone, at which the internal lip of the linea aspera is deficient. This groove supports the femoral artery at the point of its passage through the tendon of the adductor magnus. 19. The surface of the femur which forms part of the floor of the popliteal space. 20. The external condyle. 21. The tubercle for the attachment of the external lateral ligament of the knee-joint. 22. The internal condyle. 23. The tubercle for the attachment of the internal lateral ligament. 24. The tubercle for the insertion of the tendon of the adductor magnus muscle. 25. Foramina for the transmission of nutritious vessels to the cancellus structure of the inferior extremity of the bone. 26. The inter-condyloid fossa.

FIG. 3. Vertical section of the shaft of the femur of a young subject: after Cheselden.

No. 1. The head of the bone. 2. The osseous centre by which the cartilage of the head of the bone is being converted into bone. 3. The trochanter major, consisting of cartilage without any ossific centre. 4, 4. The line of separation between the epiphysis and diaphysis of the bone. 5, 5. The cancellus structure of the upper extremity of the diaphysis. 6, 6. The dense structure of the shaft of the diaphysis of the bone. 7, 7. The medullary canal. 8, 8. The cancellus structure of the lower extremity of the diaphysis. 9. The epiphysis of the lower extremity of the bone. 10, 10. Its cartilaginous portion. 11, 11. Its ossifying centre.

FIG. 4. The bones of the left lower extremity of a fetus; showing their epiphysis and diaphysis.

No. 1. The superior epiphysis of the femur, as yet in the state of cartilage. 2. The diaphysis. 3. The inferior epiphysis. 4. The patella, in the state of cartilage. 5. The superior epiphysis of the tibia. 6. The diaphysis of that bone. 7. The inferior epiphysis. 8. The superior epiphysis of the fibula. 9. The diaphysis of the fibula. 10. Its inferior epiphysis.

FIG. 5. A front view of the patella of the left leg: after Cheselden.

No. 1. The upper border of the bone. 2. Its inferior part or apex.

FIG. 6. The patella, seen upon its articular surface: after Cheselden.

No. 1. The upper border. 2. The apex. 3. The rough surface, to which the ligamentum patellæ is attached. 4. The surface for articulation with the external condyle of the femur. 5. The surface for articulation with the internal condyle.

FIG. 7. Section of the patella, showing its cancellous structure.

\* Règne Animal, tom. i. p. 82.



Fig 1

Fig 2

Fig 7

Fig 4

Fig 3

Fig 6

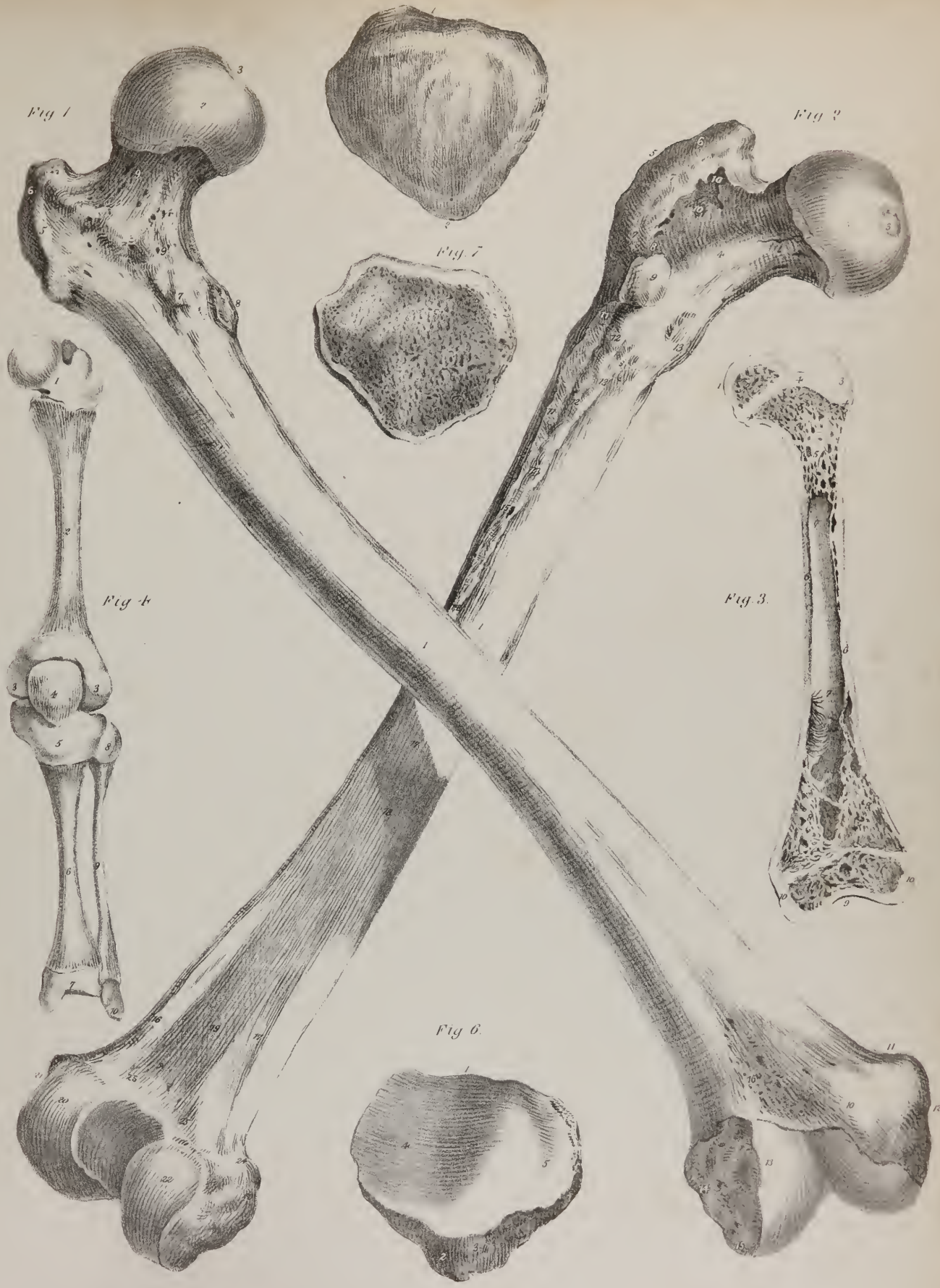







Fig 1

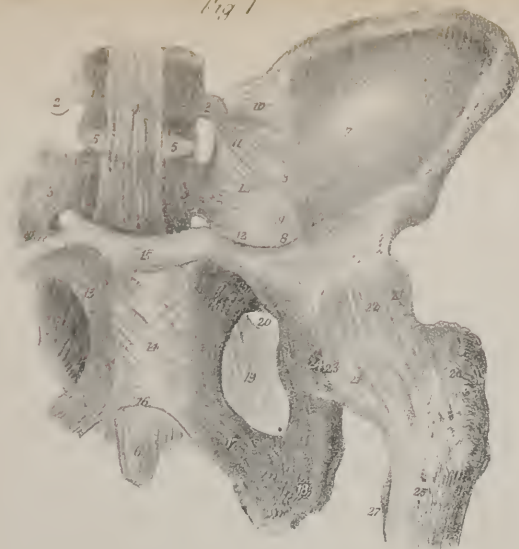


Fig 2

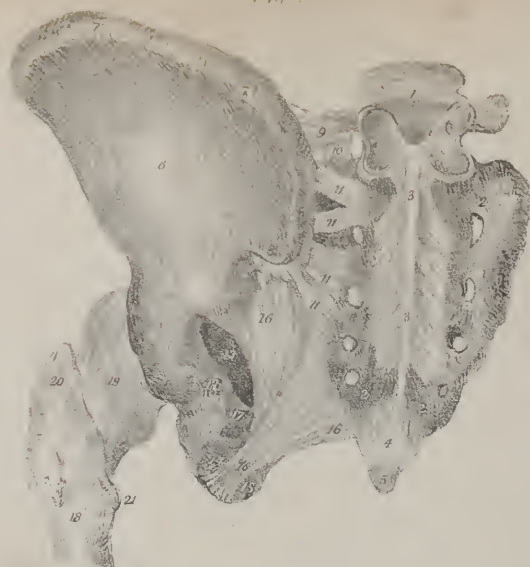


Fig 3

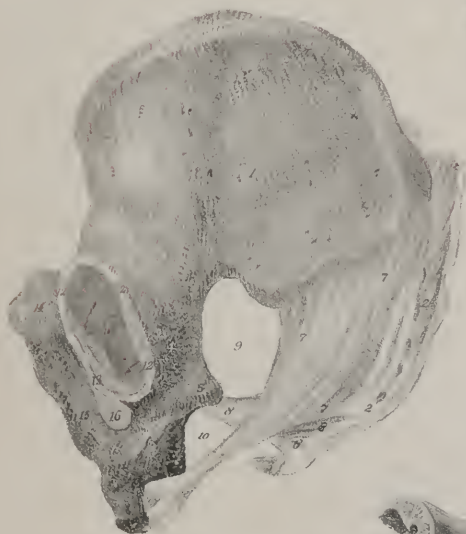


Fig 6



Fig 4

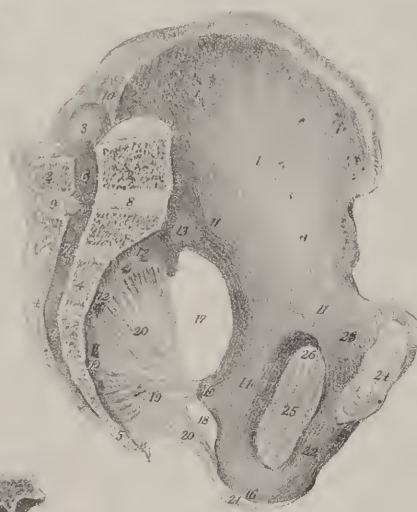

Fig 5

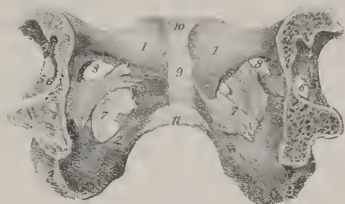

Fig 8

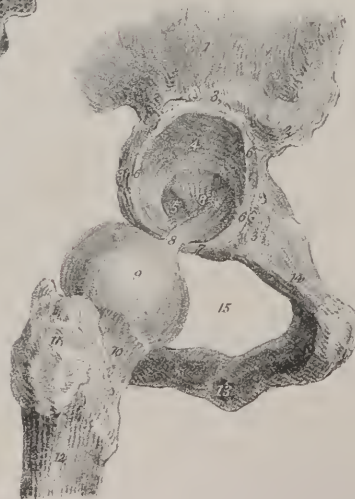
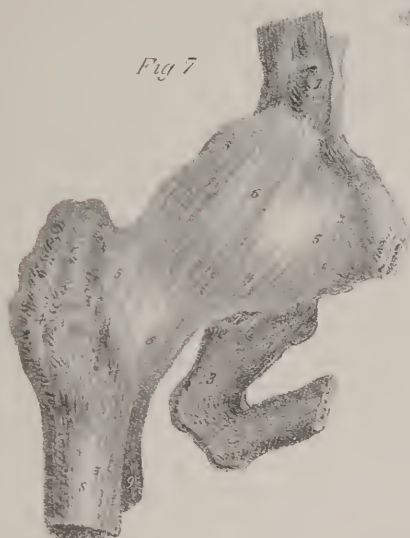
Fig 7





for the viscera when pressed down by muscular action. If a different arrangement of these bones obtained—if they were continued downwards in a straight line, they would project beyond the ischia and render the sitting posture irksome or impossible.

The spinal column, which is supported on the pelvis, is peculiarly adapted to the erect attitude. Its pyramidal form and enlarged base fit it to sustain the superincumbent weight; and by means of the different curvatures which it presents, a considerable range of motion is allowed to the trunk, the centre of gravity being still supported within the base. The form of the thorax is also peculiar. Shallow and compressed from before backwards, it is broad and expanded from side to side; by which means the preponderance of the trunk forwards is considerably lessened. The sternum, though broad, is very short, so that a considerable space intervenes between it and the pubes, which is occupied solely by muscular parts. But in quadrupeds, the thorax is compressed and flattened laterally, becoming gradually narrower towards the sternum, which is prominent and keel-shaped, so that the breadth from this latter bone to the spine is much greater than that from side to side. This conformation, together with the absence of clavicles in true quadrupeds, enables the anterior extremities to approach closely together, and fall perpendicularly downwards beneath the trunk, so as to give it a steady support. The sternum is elongated in these animals, and the ribs pass from the spine to that bone so directly, without making any angle, that they approach near to the crista of the ilia, and thereby increase the extent of firm support necessary to sustain the weight of the viscera. Even with these advantages, the muscles of the abdomen would be inadequate to the support of its contents, were they not assisted by a layer of elastic substance, which is placed over their entire extent, and which of itself marks their destination for the prone position.

Though the upper and lower extremities present several points of similitude, they yet may be contrasted so as to show that they are adapted to totally different purposes. It is quite obvious that the scapula and os innominatum, the humerus and the femur, the bones of the fore-arm and those of the leg, the hand and the foot, are respectively constructed on the same plan; but the differences which they present indicate a difference of function.

The scapulæ, placed on the supero-posterior part of the trunk, are borne off by the clavicles; their glenoid cavities are directed forwards and outwards, so that the arms, which are, as it were, appended to them, are fitted to enjoy a considerable degree of motion in the anterior and lateral directions. But in true quadrupeds the glenoid cavities look downwards, and are approximated closely together, so that the thoracic limbs, which are articulated with them, descend beneath the fore part of the trunk; and, as they are thus calculated to support its weight, they possess little lateral motion. The glenoid cavity in man is quite shallow, so that the globular head of the humerus is merely applied to its surface; but the acetabulum is a deep cup-like cavity, indicating a quite different destination in the two joints. The breadth of the articular surfaces of the knee-joint, and the peculiar conformation of the ankle-joint, as contrasted with the elbow and wrist, are abundantly sufficient to show that fixity and strength have been designed in the one, mobility in the other. This difference is, if possible, more strongly marked in the conformation in the hand and foot: the latter, as has been already observed, being intended to support the body, is placed at right angles beneath the leg; the former is continuous with the line of direction of the fore-arm, otherwise it could not be guided with sufficient precision to the different objects which it is intended to seize. The tarsal bones are large, firm and strong; those of the metatarsus are also thick and large, and placed all in a line. That which supports the great toe being the stoutest of all, and almost immovable, ranges with the others. But the metacarpal bones are quite differently disposed; that which supports the thumb admits of considerable motion in every direction, so as to perform a complete circumduction, and is placed so much out of line with the others that it can be opposed to them, as in grasping different objects. The hand and foot may be considered as divisible each into two parts, differing in their degrees of mobility, viz. the digital phalanges, and the row of bones which sustains them. The movable phalanges of the hand are as long as the carpal and metacarpal bones taken together; but in the foot, they are not a third of the length of the tarsal and metatarsal bones.

## PLATE XXV.

The ligaments of the pelvis and hip-joint.

FIG. 1. The left side of the pelvis, showing its ligaments and the capsular ligament of the hip-joint, seen from the front.

No. 1. The last lumbar vertebra. 2, 2. The transverse processes of this vertebra. 3, 3. The front surface of the sacrum. 4. The anterior common ligament of the vertebral column. 5, 5. The intervertebral substance between the body of the last lumbar vertebra and the base of the sacrum. 6. The anterior sacro-coccygean ligament. 7. The internal and concave surface of the ilium, or iliac fossa. 8, 8. The ilio-pectineal line. 9. The internal surface of the ischium. 10. The ilio-lumbar ligament. 11. The sacro-vertebral ligament. 12, 12. The anterior sacro-iliac ligaments. 13, 13. The anterior surface of the ossa pubis. 14. The anterior pubic ligament. 15. The superior pubic ligament. 16. The inferior or sub-pubic ligament. 17. The ramus of the pubis and ischium. 18. The tuberosity of the ischium. 19. The obturator ligament or membrane. 20. The aperture left between the upper border of this ligament and the os pubis for the passage of the obturator vessels and nerve. 21, 21. The capsular ligament of the hip-joint. 22. A ligamentous band which strengthens this capsule,—the ilio-femoral ligament. 23. The border of the transverse ligament of the acetabulum. 24. The notch in the acetabulum for the transmission of vessels and nerves. 25. The head of the femur. 26. The great trochanter. 27. The lesser trochanter.

No part of the osseous system of man affords more striking evidence of his adaptation for the erect posture than the cranium. Resting on the summit of the vertebral column, the line of its base forms a right angle with that of the column itself, which thus affords it a firm support. The condyles, or points of articulation, are situated very near the centre of its base, being, however, a little nearer to the occipital protuberance than to the anterior surface of the jaws; by this arrangement, very little active power is required to maintain it *in equilibrio*.\* In other animals the condyles are placed much further back; so that, instead of resting on the column, the skull is, as it were, appended to its extremity, and is sustained by an elastic substance, (ligamentum nuchæ,) which is attached by one extremity to the spinous processes of the vertebræ, and by the other to the occipital protuberance. The head, as has been already observed, is composed of two parts, the cranium and face; the one being intended to contain the brain—the material instrument of the mind; the other to enclose the organs of sight, smell, and taste. The more the organs of smell and taste are developed, the greater is the size of the face, and the greater its relative proportion to the cranium. On the contrary, the larger the brain, the greater must be the capacity of the skull, and the greater its proportion to the face. On this principle, a large

FIG. 2. The ligaments of the pelvis and the capsular ligament of the hip-joint, seen from behind.

No. 1. The last lumbar vertebra. 2, 2. The posterior surface of the sacrum. 3, 3. The continuation of the supra-spinous ligament of the vertebræ. 4. The posterior sacro-coccygean ligament. 5. The tip of the coccyx. 6. The ilium, seen upon its external and convex surface. 7, 7. The crest of the ilium. 8. The posterior and superior spinous process of the ilium. 9. The ilio-lumbar ligament. 10. The sacro-vertebral ligament. 11, 11. Posterior sacro-iliac ligaments. 12. The posterior part of the body of the ischium. 13. The great sacro-ischiatic foramen. 14. The lesser sacro-ischiatic foramen. 15. The tuberosity of the ischium. 16, 16. The great sacro-ischiatic ligament. 17. The spine of the ischium, to which the lesser sacro-ischiatic ligament is attached. 18. The upper extremity of the femur. 19. The capsular ligament of the hip-joint. 20. The greater trochanter of the femur. 21. The lesser trochanter.

FIG. 3. A side view of the pelvis, seen from its external aspect, and showing its ligaments.

No. 1. The external surface of the ilium. 2, 2. The posterior surface of the sacrum. 3. The coccyx. 4. The ischium. 5. Its spine. 6. Its tuberosity. 7, 7. The great sacro-ischiatic ligament. 8, 8. The lesser sacro-ischiatic ligament. 9. The great sacro-ischiatic foramen. 10. The lesser sacro-ischiatic foramen. 11. The acetabulum. 12, 12. The cotyloid ligament of the articulation of the hip-joint. 13. The transverse ligament. 14. The os pubis. 15. The ramus of the pubis and ischium. 16. The obturator membrane.

FIG. 4. A side view of the pelvis, seen from within. This view has been made by means of a section carried through the middle line of the cavity, and dividing the sacrum and coccyx behind, and the symphysis pubis in front.

No. 1. The inner surface of the ilium, or iliac fossa. 2, 2. A section of the last lumbar vertebra. 3. Its transverse process. 4, 4. Section of the sacrum. 5. Section of the coccyx. 6. The lower part of the spinal canal. 7, 7. The sacral canal. 8. The intervertebral ligament connecting the body of the last lumbar vertebra with the superior articular surface of the sacrum. 9. The interspinous ligament between the spinous process of the last lumbar vertebra and the superior spinous process of the sacrum. 10. The ilio-lumbar ligament. 11, 11. The ilio-pectineal line. 12, 12. The anterior surface of the sacrum. 13. The anterior sacro-iliac ligaments. 14. The internal surface of the ischium. 15. The spine of the ischium. 16. The tuberosity of the ischium. 17. The great sacro-ischiatic foramen. 18. The lesser sacro-ischiatic foramen. 19. The lesser sacro-ischiatic ligament. 20, 20. The great sacro-ischiatic ligament. 21. That portion of the great sacro-ischiatic ligament which is attached to the inner border of the tuberosity of the ischium. 22. The ramus of the pubis and ischium. 23. The internal surface of the os pubis. 24. The articular surface of the pubis, which unites with its fellow of the opposite side at the symphysis. 25. The obturator membrane. 26. The aperture between the upper border of the obturator membrane and the bone which gives passage to the obturator vessels and nerve.

FIG. 5. The ossa pubis and their articulation, seen from the inner aspect of the pelvis.

Nos. 1, 1. The inner surface of the ossa pubis. 2, 2. The ramus of the pubis and ischium at each side. 3, 3. The tuberosity of the ischium at each side. 4, 4. A part of the acetabulum at either side. 5, 5. The transverse ligament of the acetabulum. 6, 6. The notch of the acetabulum, converted into a foramen by the transverse ligament. 7, 7. The obturator membrane. 8, 8. The opening for the passage of the obturator vessels and nerve. 9. The symphysis pubis; its internal ligament. 10. The superior pubic ligament. 11. The sub-pubic ligament.

FIG. 6. A section carried through the anterior part of the bodies of the ossa pubis, in order to show the fibrous tissue which connects the articular surfaces of these bones.

Nos. 1, 1. The cut surface of the pubic bones. 2. The fibrous tissue connecting the articular surfaces of the ossa pubis.

FIG. 7. The capsular ligament of the hip-joint, and the bones entering into the formation of this articulation.

No. 1. The anterior inferior spinous process of the ilium. 2. A part of the os pubis. 3. A part of the ischium. 4. The great trochanter of the femur. 5, 5. The capsular ligament of the hip-joint. 6, 6. The ilio-femoral ligament. 7. The notch in the acetabulum for the passage of the vessels and nerves of the hip-joint. 8. The upper part of the shaft of the femur. 9. The lesser trochanter.

FIG. 8. The hip-joint laid open, and the capsular ligament removed: from Cheselden.

No. 1. A part of the ilium. 2. The anterior and inferior spinous process of the ilium. 3, 3. The lip of the acetabulum. 4. The cup of the acetabulum. 5. The fossa of the bottom of the acetabulum. 6, 6. The cotyloid ligament. 7. The transverse ligament. 8, 8. The ligamentum teres. 9. The head of the femur covered with cartilage. 10. The neck of the femur. 11. The trochanter major. 12. The upper part of the shaft of the femur. 13. The ramus of the pubis and ischium. 14. The body of the os pubis. 15. The obturator foramen.

\* Lawrence on the Characters of the Human Head, passim.





Fig 1




Fig 4

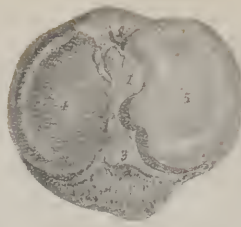


Fig 5

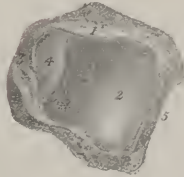


Fig 6



Fig 2




Fig 3



cranium and a small face indicate a large brain with a restricted development of the sense of smell and taste; but a small cranium and a large face mark an opposite conformation. The character and nature of animals is determined by the degree of energy with which their different functions are performed; they are guided and impelled by some leading propensity or disposition; and as the cranium and face bear to the brain and organs of sense the relation of containing and contained parts, the study of their relative proportions is one of great interest to the naturalist, inasmuch as they serve as indices of the faculties, instincts, and capabilities of different individuals as well as of classes.

Several methods have been suggested for determining the proportion of the cranium to the face; the simplest is that of Camper. If a line be drawn upwards from the side of the chin over the most prominent part of the forehead, it will form an angle with a horizontal line drawn backwards over the external auditory foramen from the margin of the anterior nares; the size of the angle will indicate the degree of development of the cranium and brain, as compared with that of the face and organs of sense. In the crocodile these lines are so nearly coincident, that there is scarcely any appreciable angle.

In the Horse it measures*	- - - - -	23°
Ram	- - - - -	30
Dog	- - - - -	35
Ouran-outang	- - - - -	56 to 60
European adult	- - - - -	85

## PLATE XXVI.

The bones and ligaments of the leg.

FIG. 1. The tibia and fibula of the left leg in their articulated position: after Cheselden.

No. 1. The head of the tibia. 2. Its spinous process. 3. The surface of the head of the bone, for articulation with the inner condyle of the femur. 4. The external tuberosity of the tibia. 5. The internal tuberosity. 6. The tubercle of the tibia for the attachment of the ligamentum patellæ. 7. A smooth surface immediately above the tubercle, corresponding with the situation of a bursa mucosa. 8, 8. The subcutaneous surface of the shaft of the tibia. 9, 9. The concave external surface, which gives attachment to the tibialis anticus muscle. 10. The ridge for the attachment of the interosseous membrane. 11. The surface behind this ridge, which gives attachment to one head of the tibialis posticus muscle. 12. The inferior extremity of the tibia. 13. The internal malleolus of the tibia. 14. The upper extremity of the fibula. 15. That portion of the head of the fibula which gives attachment to the external lateral ligament of the knee-joint. 16, 16. The shaft of the fibula; its external surface. 17, 17. The internal surface of the fibula. 18. The lower extremity of this bone, forming the external malleolus of the ankle. 19, 19. The subcutaneous surface of the external malleolus.

FIG. 2. The tibia of the right leg, seen upon its posterior surface: after Cheselden.

No. 1. The head of the bone. 2. The spinous process of the tibia. 3. The surface of articulation for the inner condyle of the femur. 4. The surface of articulation for the external condyle of the femur. 5. The inner tuberosity of the tibia. 6. The fossa upon this tuberosity for the insertion of the tendon of the semimembranosus muscle. 7. The outer tuberosity of the tibia. 8. The smooth surface on this tuberosity for articulation with the head of the fibula. 9. The oblique line of the tibia. 10. The surface above the oblique line for the attachment of the popliteus muscle. 11, 11. The posterior surface of the shaft of the tibia. 12. The nutritious foramen of the tibia. 13, 13. The interosseous line upon the external aspect of the tibia. 14. The surface of the tibia which gives origin to the internal head of the tibialis posticus muscle. 15, 15. The external surface of the shaft of the tibia, corresponding with the anterior muscles of the leg. 16. The lower extremity of the tibia. 17. The surface at the lower extremity of the tibia for articulation with the fibula. 18. A slight groove for the support of the tendon of the flexor longus pollicis. 19. A deeper groove for the tendons of the tibialis posticus and flexor longus digitorum. 20. The internal malleolus of the tibia. 21. The surface which articulates with the astragalus.

FIG. 3. The fibula of the right leg, viewed upon its external side: after Cheselden.

No. 1. The upper extremity or head of the bone. 2. The spine which gives attachment to the tendon of the biceps muscle. 3. The rough surface which gives attachment to the external lateral ligament of the knee-joint. 4, 4. The external surface of the shaft of the fibula. 5, 5. A part of the posterior surface of the shaft of the fibula. 6, 6. The lower extremity of the bone; its subcutaneous surface. 7. The point of the external malleolus. 8. The anterior or sharp border of the external malleolus. 9. The posterior border, deeply grooved for the passage of the tendons of the peronei muscles.

FIG. 4. A view of the articulating surface of the head of the tibia.

No. 1. The spinous process of the tibia. 2. The fossa in front of this process for the attachment of the anterior crucial ligament. 3. The fossa behind this ligament for the posterior crucial ligament. 4. The articulating surface for the internal condyle of the femur. 5. The articular surface for the external condyle of the femur.

FIG. 5. The inferior articulating surface of the tibia, seen from beneath.

No. 1. The anterior border of this extremity of the bone. 2. The surface which articulates with the astragalus. 3. The malleolus of the tibia. 4. The external surface of this malleolus, which articulates with the side of the astragalus. 5. The border of the surface, which articulates with the fibula.

FIG. 6. The tibia and fibula of the right leg, with their connecting ligaments: after Bourgerly.

No. 1. The spinous process of the tibia. 2. The ligamentum patellæ. 3, 3. Portions of the capsular ligament of the knee-joint. 4. The shaft of the tibia. 5. The shaft of the fibula. 6. The articulation between the head of the fibula and the external tuberosity of the tibia. 7, 7. The interosseous membrane. 8. The aperture in the upper part of the interosseous membrane for the passage of the anterior tibial vessels. 9. The anterior tibio-fibular ligament of the inferior articulation between these two bones.

\* Cuvier, Leçons d'Anatomie Comparée, tom. ii. p. 8.



Thus we find man at the top of the scale of animated beings, distinguished from all the rest as well by his external conformation as by his internal organization. When the mind has passed in review the many links of the chain which connects the lowest with the highest—the mere animated dot, with man, the lord of the creation, it cannot fail to be struck with astonishment at the immense chasm which separates them. Yet, when each link of the chain is compared with that which precedes and follows it, the transition from the one to the other is found to be so gradual as to be almost imperceptible. So easy are the steps of ascent from the organization of the higher orders of the quadrumana, up to the human species, that even Linnæus felt it difficult to assign the specific characters by which man is distinguishable from all others; but any doubt that may have existed on this subject has been long since removed. The physical and moral attributes of man are universally recognised as sufficient to elevate him much further from the higher mammalia than these are from the classes beneath them; and in the opinion of Cuvier,\* the zoologist, we consider the physical conformation of man as compared with that of other animals, or, with the moralist, reflect on his mental powers and high destination, we can scarcely refrain from saying, with the poet,

Sanctius his animal mentisque capaciùs altæ  
Deerat adhuc, et quod dominari in cætera possit,  
Natus est homo.

## PLATE XXVII.

The ligaments of the knee-joint.

FIG. 1. The ligaments of the front of the knee-joint: after Bourguery.

No. 1. The lower part of the femur. 2. The tibia. 3. The fibula. 4. The patella. 5. The tendon of the rectus muscle. 6. The ligamentum patellæ. 7, 7. The internal lateral ligament. 8. A ligamentous band passing inwards from the inner border of the patella, and expanding over the synovial membrane. 9. A similar band proceeding from the outer border of the patella. 10. The external lateral ligament. 11. The upper part of the interosseous membrane. 12. The aperture of transmission for the anterior tibial artery.

FIG. 2. The ligaments of the knee-joint, seen from behind: after Bourguery.

Nos. 1, 2, 3. The femur, tibia, and fibula. 4, 4. The posterior ligament,—ligamentum posticum Winslowii. 5, 5. Openings in this ligament for the passage of vessels and nerves. 6, 6. The two heads of the gastrocnemius muscle. 7, 7. The internal lateral ligament. 8, 8. The two external lateral ligaments. 9. The tendon of origin of the popliteus muscle. 10. The tendon of the semimembranosus muscle, cut short. 11. The posterior ligament of the peroneo-tibial articulation. 12. The interosseous ligament.

FIG. 3. The ligaments of the knee, seen upon the outer aspect of the joint: after Bourguery.

Nos. 1, 2, 3. The femur, tibia, and fibula. 4. The patella. 5. The common tendon of the quadriceps extensor muscle. 6. The ligamentum patellæ. 7, 7. Bands of ligament which strengthen the antero-lateral portions of the articulation. 8, 8. The synovial membrane. 9. The long external lateral ligament. 10. The short external lateral ligament. 11. The external head of the gastrocnemius. 12. The tendon of the biceps. 13. The interosseous membrane.

FIG. 4. The ligaments of the knee, seen upon the inner aspect of the joint: after Bourguery.

Nos. 1, 2, 3. The femur, tibia, and fibula. 4. The patella. 5. The tendon of the rectus muscle. 6. The ligamentum patellæ. 7. A ligamentous band, protecting the front of the articulation. 8, 8. The internal lateral ligament. 9. The internal head of the gastrocnemius muscle. 10, 10. The synovial membrane.

FIG. 5. The interior of the knee-joint, opened from the front and viewed previously to dissection: after Bourguery.

No. 1. The external condyle of the femur. 2. Its internal condyle. 3, 3. The synovial membrane, raised and turned back. 4. The internal surface of the patella. 5. The mucous ligament. 6, 6. The alar ligaments.

FIG. 6. The ligaments of the interior of the knee-joint, brought into view by dissecting away a part of the synovial membrane; the joint is viewed from the front: after Bourguery.

No. 1. The external condyle. 2. The internal condyle. 3, 3. The synovial membrane, turned back. 4. The mucous ligament, lifted upwards. 5. The anterior crucial ligament. 6, 6. The posterior crucial ligament. 7, 7. The semilunar fibro-cartilages. 8. The transverse ligament. 9. The tibia. 10. The fibula. 11. The lower part of the ligamentum patellæ. 12. The interosseous ligament. 13. The tendon of the biceps.

FIG. 7. The floor of the articulation of the knee-joint, showing the semilunar fibro-cartilages, and the inferior attachments of the crucial ligaments: after Bourguery.

No. 1. The anterior part of the head of the tibia. 2, 2. The external semilunar fibro-cartilage. 3, 3. The internal semilunar fibro-cartilage. 4. The anterior crucial ligament. 5. The posterior crucial ligament. 6. A part of the coronary ligament on the outer side of the joint. 7. The head of the fibula. 8, 8. Part of the internal lateral ligament.

FIG. 8. A vertical section of the knee-joint upon the middle line, showing the reflections of the synovial membrane of the articulation: after Bourguery.

No. 1. The femur. 2. The tibia. 3. The fibula. 4. The patella. 5. The tendon of the quadriceps extensor muscle. 6. The ligamentum patellæ. 7. The bursa of the ligamentum patellæ. 8. The articular mass of fat situated behind the ligamentum patellæ. 9. The anterior crucial ligament. 10. The pouch of synovial membrane situated between the tendon of the quadriceps extensor muscle and the front of the lower part of the femur. 11. The mucous ligament. 12. The alar ligament. 13. The posterior ligament.

\* Règne Animal, tom. i. p. 81.



Fig 2

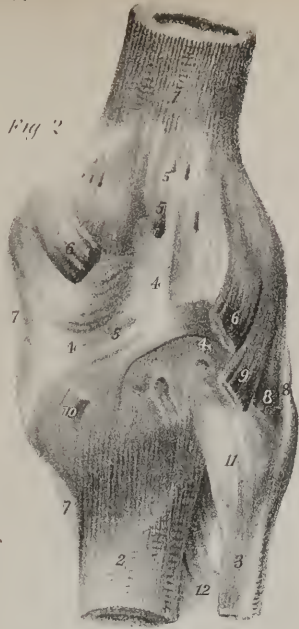

Fig 1

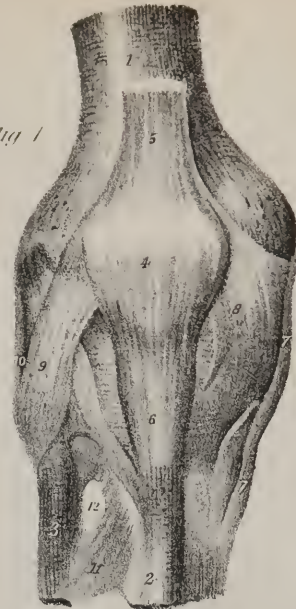

Fig 5

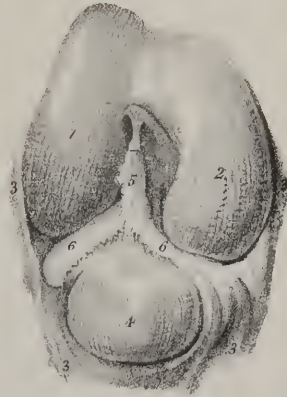


Fig 3

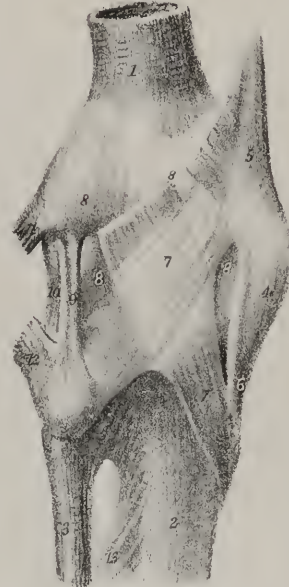

Fig 4

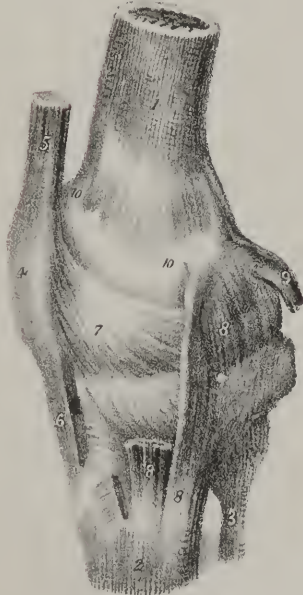

Fig 7

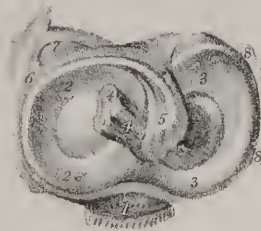


Fig 6

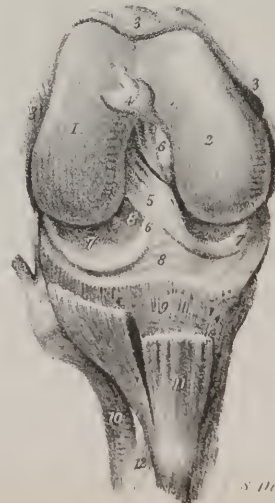
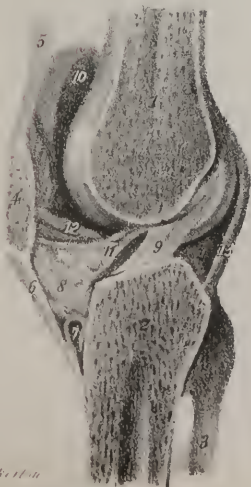


Fig 8





*The Teeth.*—The adult human subject is furnished with thirty-two teeth, sixteen in each jaw, arranged so that eight are placed on each side of the symphysis, in the upper and lower maxillæ. To facilitate their description, it is usual to consider a tooth as divisible into its *crown*, or that part projecting externally; the *root*, or that contained within the alveolus; and the *neck*, or part intermediate between the two. The root and central part of each tooth are composed of dense and hard osseous matter; and the projecting part, or crown, is, moreover, encased by a layer of white and excessively hard laminated substance, called enamel; at the superior and lateral parts of the crown the layer of enamel deposited upon it is thick, but gradually becomes thin at the neck, and disappears at the commencement of the root. The root and body of each tooth present a cavity, lined by a membrane, (*pulpa dentis*), on which the nutritious vessels and nerves ramify, after having entered through the foramina in the apices of the roots.

The teeth differ in size, form, manner of insertion, and mode of action, so that they are divisible into four sets, each of which has received a particular denomination, viz. *incisores*, *cuspidati*, *bicuspidati*, and *molares*.

The *incisor* or cutting teeth, (*dentes incisores*), four in number in each jaw, are placed at the fore part of the mouth, forming the convex prominent part of the dental arch; their projecting part is wedge-shaped, the anterior and posterior surfaces being compressed, so that their free border is thin and sharp; this part of the tooth is convex in front, flat or concave behind, where it slopes upwards and forwards from a small elevation, which surmounts the neck. Those in the upper jaw, particularly the central pair, are larger than those of the lower. The roots of all are single, elongated, and tapering: the inserted as well as the projecting part of an incisor tooth is wedge-shaped, the former being compressed from side to side, the latter from before backwards.

The *canine* teeth (*dentes cuspidati*, *canini*) are two in number in each jaw, and come next in order after the lateral incisors. In these the projecting part is convex anteriorly, concave and sloping behind, and tapers towards its summit, where it ends in a blunted point: the root is longer and sinks deeper into the alveolus than that of any other teeth; it is single, conical, compressed at the sides, and marked by a slight groove, running its whole length from its apex to its summit. This is a trace or a rudiment of that division into processes which obtains in the molar teeth.

The *small molar* or *bicuspid* teeth, (*dentes bicuspidati*), four in number in each jaw, are so named from usually having a divided root. They are intermediate in size as well as in situation between the *cuspidati* and *molares*. Their crown, compressed laterally where it is in apposition with the other teeth, is rounded on the external and internal sides, so that its depth from without inwards is greater than that of the *incisores* or *cuspidati*, whilst its breadth from side to side is less. The cutting extremities present two tubercles, one internal, the other external; in the lower jaw the internal tubercle is but very slightly prominent. A section of the neck presents an oval form; the root is single till near the apex, where it is usually bifid, particularly in the posterior *bicuspidati*; the groove at its sides is deeper than in the *cuspidati*.

The *large molar* or true grinding teeth (*dentes molares*) are larger and placed farther back than the others; the crown, or projecting part, is compressed from before backwards, as well as at the sides, so as to assume a cuboid form; its free surface, which is intended for trituration, is surmounted by four tubercles, separated by depressions, which so intersect one another as generally to assume a crucial form. There are six molares in each jaw when the set is completed: the first and second are the largest of all the teeth, and in the upper jaw are usually furnished with three roots, very seldom with four, whilst in the lower jaw there are but two. The disposition of the roots deserves attention. In the upper jaw two of the roots are placed external, and parallel in their direction, whilst the third projects inwards from them at a slight angle; in the lower jaw the roots are placed one anterior, the other posterior. The last of these molar teeth are the smallest, and, as they appear at an advanced period of life, are named *dentes sapientiæ*. The root is often single and tapering, but marked by two grooves, indicating, as it were, a tendency to separation; in the upper jaw we frequently find it bifid, with traces of a still further subdivision.

The dental formula for the adult is as follows:—incisors  $\frac{4}{4}$ , canine  $\frac{2}{2}$ , bicuspidati  $\frac{4}{4}$ , molares  $\frac{6}{6}$ .

What has been here stated applies altogether to the permanent teeth. The temporary or deciduous teeth which precede them are fewer in number, being twenty in all when complete; they are also smaller, and more delicate in their texture.

The formula for these is thus expressed:—incisors  $\frac{4}{4}$ , canine  $\frac{2}{2}$ , molares  $\frac{4}{4}$ .

The *incisores* and *cuspidati* are supplanted by permanent teeth of the same name: the bicuspid, which do not previously make their appearance, occupy the place of the temporary molares, so that the permanent molares will necessarily protrude at points farther back. The sockets into which the teeth are inserted are called *alveoli*; their form, number, and size being determined by that of the roots, which they lodge and receive; the alveolus being divided into two or three pits when the insertion of the tooth requires it, and being but a simple tapering fossa when a simple conformation obtains. The texture of the bone along the alveolar arches is porous and open, particularly in the transverse plates which separate the alveoli. In the natural state each of these cavities is lined by a prolongation of the periosteum, which invests the maxillary bones, and which extends into them as far as their apices, where it is reflected on the roots of the teeth so as to form a special investment for them.

*The Thorax.*—Into the composition of the thoracic portion of the skeleton enter the sternum and ribs, which are proper and peculiar to it, and the vertebræ, which are common to it and other parts.

*The Sternum and Ensiform cartilage.*—The sternum is situated in the median line, at the fore part of the thorax: it is flat and narrow, but not of equal width in its entire extent, being broad at its upper part, then narrowed somewhat, after which it



widens a little; finally it becomes compressed and narrow where it joins the ensiform cartilage. Its direction is oblique from above downwards and forwards; which, together with the curve backwards in the dorsal part of the vertebral column, causes a considerable increase in the antero-posterior diameter of the thorax inferiorly. We have to consider successively its surfaces, extremities, and borders.

The anterior surface, slightly convex, and subjacent to the skin, gives attachment to the aponeurosis of the pectoralis major and to the sterno-mastoid muscles, and is marked by four transverse lines, indicating its original division into five pieces. The union between the first and second of these pieces (corresponding with the insertion of the second costal cartilages) is frequently cartilaginous even in adult age.

The posterior surface looks backwards, towards the cavity of the thorax, and gives attachment, superiorly, to the sterno-hyoideus and sterno-thyroideus muscles; inferiorly, to the triangularis sterni. Along the middle line it corresponds with the interval left by the divergence of the two pleuræ, (anterior mediastinum.)

The borders are thick, and marked on each side by seven angular depressions for the reception of the cartilages of the true ribs, which give them a notched or serrated appearance.

The superior extremity, broad and thick, is slightly excavated from side to side, and presents at each corner a depression for the reception of the sternal end of the clavicle.

The sternum, in early infancy, is divided into several pieces, but in adult age two only remain distinct. The first division of the sternum is larger and thicker than the other; its form is nearly square; its lateral margins, thin and oblique, present each an oblong depression, which receives the cartilage of the first rib; and at each inferior angle may be observed an articular half

## PLATE XXVIII.

The bones of the foot in their articulated position and in the fetal state.

FIG. 1. The right foot, seen upon its upper surface: after Cheselden.

No. 1. The superior articular surface of the astragalus. 2. The anterior portion of that bone. 3, 3. The os calcis. 4. The commencement of the groove in which the interosseous ligament is lodged. 5. The scaphoid bone. 6. Its tuberosity. 7. The internal cuneiform bone. 8. The middle cuneiform bone. 9. The external cuneiform bone. 10. The cuboid bone. 11, 11. The metatarsal bones. 12, 12. The first row of phalanges. 13, 13. The second row of phalanges. 14, 14. The last phalanges.

FIG. 2. The under surface of the same foot: after Cheselden.

No. 1. The under part of the os calcis. 2. The posterior tuberosity of the os calcis. 3. The internal tuberosity of that bone. 4. Its external tuberosity. 5. The concave surface of the os calcis, which supports the tendons and vessels which pass into the sole of the foot. 6. The groove in which the tendon of the flexor longus digitorum muscle plays. 7. The side of the astragalus. 8. The rounded head of the astragalus. 9. The under surface of the scaphoid bone. 10. The tuberosity of the scaphoid bone. 11. The internal cuneiform bone. 12, 12. The apex of the middle cuneiform bone. 13. The external cuneiform bone. 14. The cuboid bone. 15, 15. The groove in this bone for the tendon of the peroneus longus muscle. 16. The metatarsal bone of the great toe. 17. The tubercle at its base which gives insertion to the tendon of the peroneus longus. 18, 18. The remaining metatarsal bones. 19. The tubercle on the base of the metatarsal bone of the little toe. 20, 20. The first row of phalanges. 21, 21. The second row of phalanges. 22, 22. The last phalanges.

FIG. 3. The inner border of the left foot: after Cheselden.

No. 1. The superior articular surface of the astragalus. 2. The lateral surface, which articulates with the inner malleolus of the tibia. 3. The inner and concave side of the os calcis. 4. The posterior tuberosity of the os calcis. 5. The internal tuberosity of that bone. 6. The process which supports the anterior portion of the astragalus. 7. The anterior part of the astragalus. 8. Its articular surface. 9. The scaphoid bone. 10. Its tuberosity. 11. The internal cuneiform bone. 12. A smooth facet which gives attachment to the tendon of the tibialis anticus muscle. 13. The base of the middle cuneiform bone. 14. The metatarsal bone of the great toe. 15, 15. The metatarsal bones of the other toes. 16. The first phalanx of the great toe. 17. The last phalanx of the same toe.

FIG. 4. The left foot, seen upon its outer side: after Bourguery.

No. 1. The superior articular surface of the astragalus. 2. The triangular lateral surface which articulates with the external malleolus. 3. The anterior portion of the astragalus. 4, 4. The os calcis. 5. Its posterior tuberosity. 6. Part of the smooth surface which supports the bursa of the tendo Achillis. 7. The external tuberosity of the os calcis. 8. The smooth pulley-like surface against which the tendons of the peronei muscles play. 9. The cuboid bone. 10. A notch upon the cuboid, which marks the commencement of the groove for the tendon of the peroneus longus muscle. 11. The scaphoid bone. 12. The external cuneiform bone. 13. The middle cuneiform bone. 14, 14. The metatarsal bones. 15. The tuberosity at the base of the metatarsal bone of the little toe. 16, 16. The first row of phalanges. 17, 17. The second row of phalanges. 18, 18. The last phalanges.

FIG. 5. A single toe, showing the four bones which enter into its formation: after Cheselden.

No. 1. The metatarsal bone. 2. A smooth surface by which the base of this bone articulates with the adjoining bone. 3. The head of the metatarsal bone. 4. The first phalanx. 5. Its base. 6. Its head. 7. The second phalanx. 8. The third and last phalanx.

FIG. 6. The two sesamoid bones of the metatarso-phalangeal articulation of the great toe.

FIG. 7. The foot of a fœtus at an early period: after Cheselden. The tarsus is wholly cartilaginous, and the metatarsal bones and phalanges only partly developed.

FIG. 8. The foot of a fœtus at a more advanced period: after Cheselden.

Fig 2

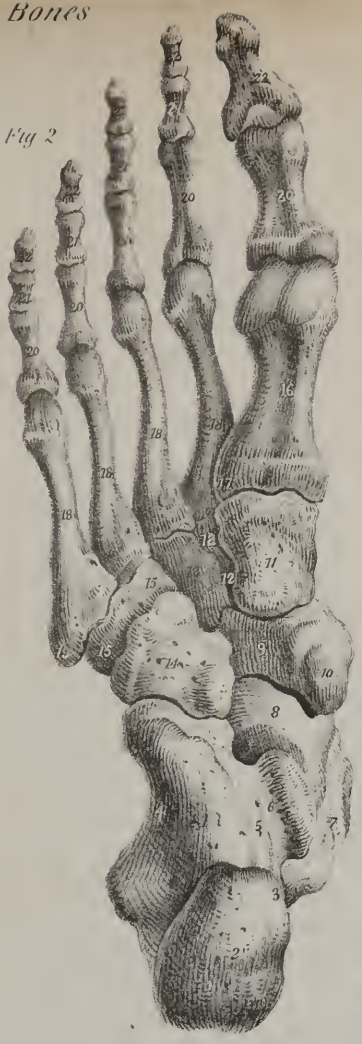

Fig 7



Fig 6




Fig 8

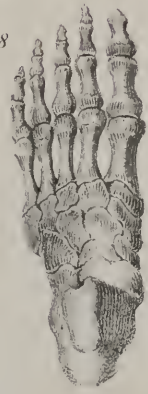

Fig 1

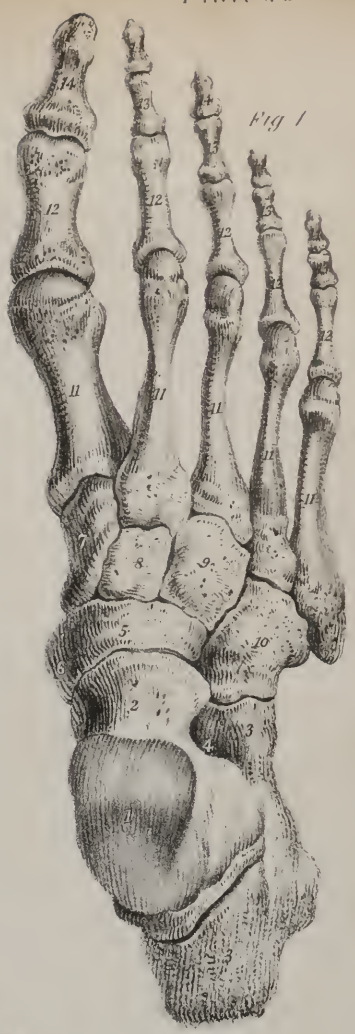

Fig 5

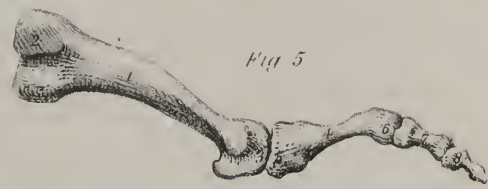


Fig 3

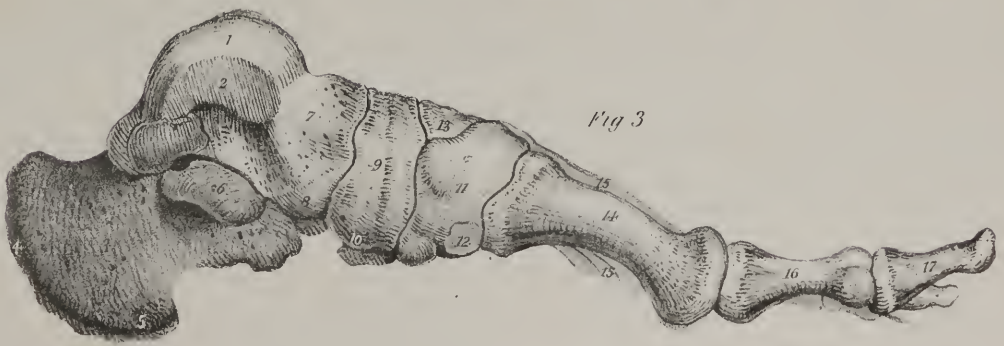
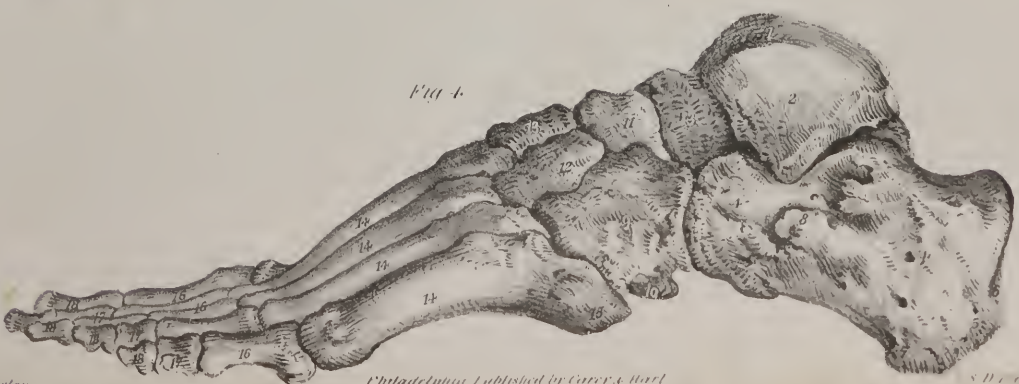
Fig 4







notch, which articulates with the second rib. The superior border is hollowed, and at the angles which bound it are the *fossæ*, which articulate with the clavicles, as has been already stated; the inferior is straight, and united to the extremity of the second piece.

The second piece, much longer than the first, is marked on its anterior surface by some transverse lines, which indicate its original division into separate portions. Both surfaces are nearly flat. The upper border is narrow, corresponding in breadth with the termination of the first bone, with which it is connected by cartilage. The lateral margins present each five notches for the reception of the cartilages of the five lower true ribs, and a half notch superiorly, which, with a similar depression in the first piece, forms a cavity for the second costal cartilage. The five inferior notches approach one another more closely in proportion as they are situated lower down, and part of the last is occasionally made up by the ensiform cartilage.

The inferior extremity of the sternum, thin and elongated, gives attachment to a cartilaginous appendix, called the *ensiform* or *xiphoid* (ξίφος, a sword; εἶδος) cartilage, which in most cases remains in the cartilaginous state until an advanced period of life. It is sometimes bent forwards, sometimes in the opposite direction, and sometimes pierced by a hole at its centre. Its form varies considerably in different individuals: it gives attachment to the aponeuroses of the abdominal muscles.

*Articulations.*—This bone articulates by its sides with the true ribs,—by its upper angles with the clavicles, and by its lower end with the ensiform cartilage. When examined at an early period, it exhibits usually eight or nine ossific centres. When sawed across, the sternum presents a considerable quantity of loose spongy texture in its interior, with a very thin lamella of compact tissue on its outside;—hence it is very light.

*The Ribs and their cartilages.*—The *ribs* (*costæ*) extend from the dorsal portion of the vertebral column to the sternum, forming arches, which enclose the lateral parts of the thorax. They are twelve in number at each side, of which the seven superior pairs, which are united by means of cartilaginous prolongations to the sternum, are called *sternal* or *true ribs*; the remaining five, which are not prolonged to the sternum, being denominated *asternal* or *false ribs*.

The ribs do not arch uniformly from the vertebral column towards the sternum; the greater number consist of parts of two circles or arches of different diameters, the anterior being much the larger. Thus the rib, directed at first backwards from its connexion with the bodies of the vertebræ, reaches and is supported by the transverse process, (which in the dorsal region is inclined backwards;) after leaving the extremity of this process it turns abruptly outwards, and finally is directed forward towards the sternum.

In their length, breadth, and direction, these bones present several varieties. From the first to the eighth their length successively increases, whilst from the ninth to the twelfth they gradually decrease, so that the last is very little longer than the first.

Their breadth, considered in the whole series, diminishes gradually from the first to the twelfth; but in each rib it is greatest towards its sternal extremity.

As to their direction in reference to the vertebral column, the first forms almost a right angle with it, and the succeeding ones gradually incline downwards, so that their anterior extremity is lower than the posterior. The body of all the ribs, except the first, is, as it were, twisted on itself, so that their two extremities cannot be made to rest at the same time on a plane surface.

These bones present two surfaces, two borders, and two extremities.

The external surface is convex and smooth. The internal is concave, and corresponds with the pleura.

The superior border, smooth and rounded, gives attachment to the intercostal muscles; the inferior is marked on its inner aspect by a groove, which is commonly said to be for the lodgment of the intercostal vessels, and also gives attachment to the intercostal muscles.

The posterior extremity, somewhat rounded and thicker than the other parts of the rib, and hence denominated its *head*, presents (except in the instances to be presently stated) two articular faces (separated by a slight ridge) which articulate with the corresponding small surfaces on the bodies of the dorsal vertebræ; the head is supported by a narrow round part, or *neck*, terminated externally by a tubercle, which is smooth in one part for its articulation with the transverse process of the lower of the two vertebræ to which the head is connected, and rough in the other for the insertion of the posterior costo-transverse ligament.

The anterior extremity is broad, flat, and hollowed at its tip into an oval pit, into which is implanted the costal cartilage.

Between the tuberosity and the most convex part of the body of each rib is a rough line, marking what is termed its *angle*. The distance of the angle from the tuberosity increases gradually from the second to the eleventh inclusive. In the last it is not perceptible: in the first it is not distinguishable from the tuberosity.

The first two and the last two ribs present some peculiarities deserving of notice.

The *first* rib is shorter and broader than either of the succeeding ones, its direction is nearly horizontal; its body not being twisted, as is the case in other ribs, it lies evenly when placed on a plain surface. One surface looks upwards, and is marked by two very slight depressions, (over which slide the subclavian vessels,) and an intervening roughness, sometimes well marked, which indicates the attachment of the scalenus anticus muscle. The other surface looks downwards, towards the cavity of the thorax. The external border, convex and rounded, is surmounted by the tuberosity; the internal is thin, and forms the margin

of the superior aperture of the thorax. The anterior extremity is broad and thick; the *head*, which articulates with the first dorsal vertebra, is small, presents an undivided articular surface, and is supported by a slender neck.

## PLATE XXIX.

The ligaments of the ankle, and bones of the tarsus.

FIG. 1. The os calcis of the right foot,—its upper surface.

No. 1. The posterior tuberosity. 2, 2. The two surfaces which articulate with the under part of the astragalus. 3. The groove for the interosseous ligament. 4. The outer border. 5. The cuboid surface.

FIG. 2. The under part of the astragalus of the right foot.

Nos. 1, 1. The surfaces which articulate with the os calcis. 2. The groove for the interosseous ligament. 3. The groove for the tendon of the flexor longus pollicis muscle. 4. The rounded head of the astragalus.

FIG. 3. The scaphoid bone of the right foot,—its anterior surface.

No. 1. The upper border. 2. The facet which articulates with the external cuneiform bone. 3. The facet for the middle cuneiform bone. 4. The facet for the internal cuneiform bone. 5. The under surface. 6. The tuberosity. 7. The broad extremity.

FIG. 4. The posterior surface of the scaphoid bone of the right foot.

No. 1. The concave surface which articulates with the head of the astragalus. 2. The upper border. 3. The lower border. 4. The broad extremity. 5. The tuberosity.

FIG. 5. The internal cuneiform bone of the right foot.

A. The anterior border of this bone.

No. 1. Its upper extremity. 2. Its lower extremity. 3. The outer surface. 4. The inner or subcutaneous surface. 5. The facet which gives attachment to the tendon of the tibialis anticus muscle. 6. The metatarsal surface.

B. The posterior border of the same bone.

No. 1. The facet which articulates with the scaphoid bone. 2. The facet which articulates with the middle cuneiform bone. 3. A small facet for articulation with the base of the metatarsal bone of the second toe. 4. The apex of the bone. 5. Its base. 6. Its external surface. 7. Its internal or subcutaneous surface.

FIG. 6. The middle cuneiform bone of the right foot.

A. The internal surface of this bone.

Nos. 1, 1. The facet which articulates with the internal cuneiform bone. 2. The upper surface of the bone. 3. Its inferior border. 4. Its anterior border. 5. Its posterior border.

B. The same bone, viewed upon its external aspect.

No. 1. The facet which articulates with the external cuneiform bone. 2. The rough surface for attachment to interosseous ligaments. 3. The upper surface of the bone. 4. The inferior border. 5. The anterior border. 6. The posterior border.

C. The posterior border of the same bone.

No. 1. The facet which articulates with the scaphoid bone. 2. The base of the bone. 3. Its inferior border. 4. The internal surface. 5. Its external surface.

FIG. 7. The external cuneiform bone of the right foot.

A. The external surface of this bone.

No. 1. The facet for articulation with the cuboid bone. 2. A rough surface for the attachment of the interosseous ligaments. 3. The superior border of the bone. 4. Its inferior border. 5. The anterior border of the bone. 6. Its posterior border.

B. The internal surface of the same bone.

No. 1. The upper surface of the bone. 2. Its inferior border. 3. The anterior border. 4. The posterior border. 5, 5. The metatarsal surface. 6. The facet which articulates with the middle cuneiform bone.

C. The anterior border of the same bone.

No. 1. The facet which articulates with the base of the metatarsal bone of the third toe. 2. The dorsal surface of the bone. 3. The inferior border. 4, 4. The facet which articulates with the base of the metatarsal bone of the second toe. 5. The outer surface of the bone.

FIG. 8. The cuboid bone of the right foot.

No. 1. Its dorsal surface. 2. Its plantar surface. 3. The peroneal groove. 4. A smooth facet for a bursa mucosa. 5. The outer border of the bone. 6. The anterior or metatarsal surface. 7. The posterior surface of the cuboid bone.

FIG. 9. The ankle-joint, seen upon its anterior aspect: after Bourguery.

No. 1. The tibia. 2. The fibula. 3. The interosseous ligament. 4. The anterior ligament of the inferior peroneo-tibial articulation. 5, 5. The anterior ligament of the ankle-joint. 6. The internal lateral ligament. 7. The external lateral ligament. 8. A prominence formed by the astragalus. 9. The scaphoid bone. 10. The cuboid bone.

FIG. 10. The ankle-joint, viewed from behind: after Bourguery.

No. 1. The tibia. 2. The fibula. 3. The interosseous membrane. 4. The posterior ligament of the inferior peroneo-tibial articulation. 5. The groove for the peronei tendons. 6. The groove for the tendons of the flexor longus digitorum, and the tibialis posticus muscle. 7. The posterior ligament. 8. The transverse ligament. 9. The internal lateral ligament. 10. The external lateral ligament,—its middle fasciculus. 11, 11. Its posterior fasciculi. 12. The groove upon the astragalus for the tendon of the flexor longus pollicis muscle. 13. The posterior tuberosity of the os calcis.

FIG. 11. The ankle-joint, viewed from the internal aspect: after Bourguery.

No. 1. The tibia. 2. The fibula. 3, 3. The internal lateral ligament. 4. The scaphoid bone. 5. A groove for the tendon of the tibialis posticus muscle. 6. The groove for the tendons of the flexor longus digitorum and flexor longus pollicis muscles. 7, 7. The os calcis. 8. The tendo Achillis.



Fig. 3.

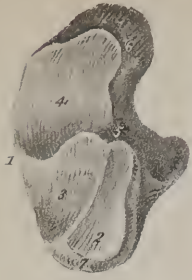

Fig. 4.

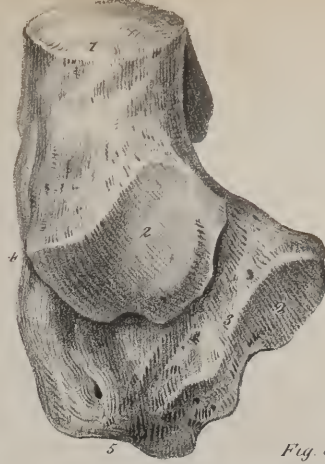
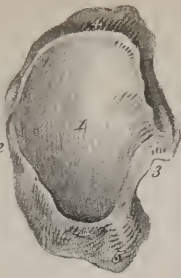
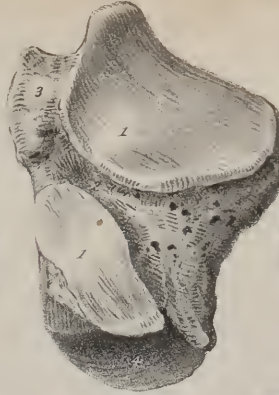
Fig. 2.



B. A.

Fig. 5.



B.

Fig. 6.



Fig. 8.

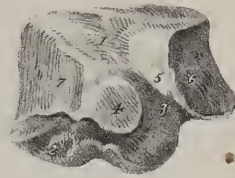

Fig. 7.




Fig. 10.

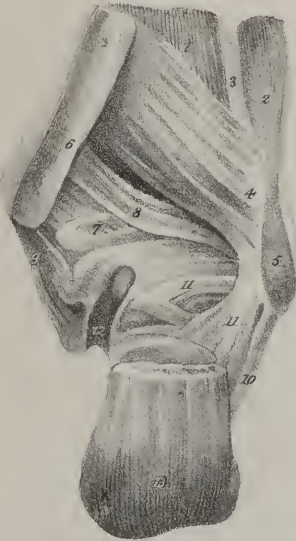

Fig. 6. C.




Fig. 7. A.

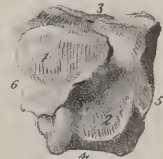

Fig. 13.

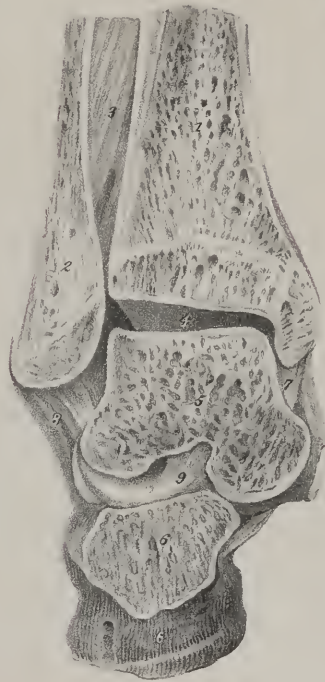


Fig. 9.

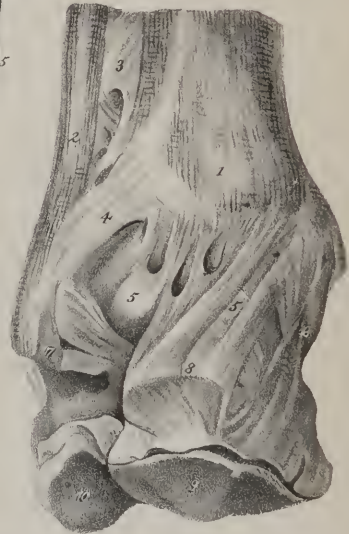

Fig. 12.

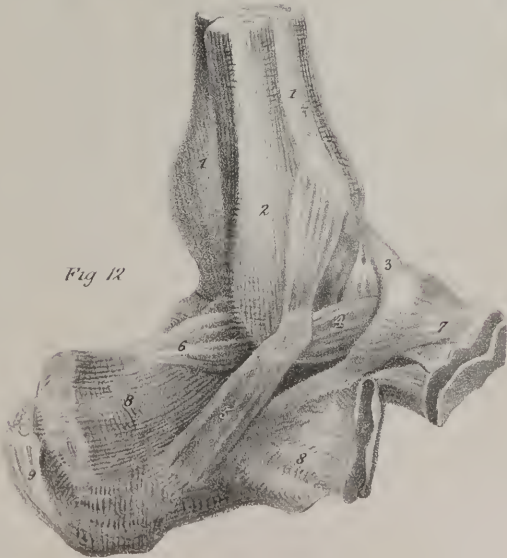
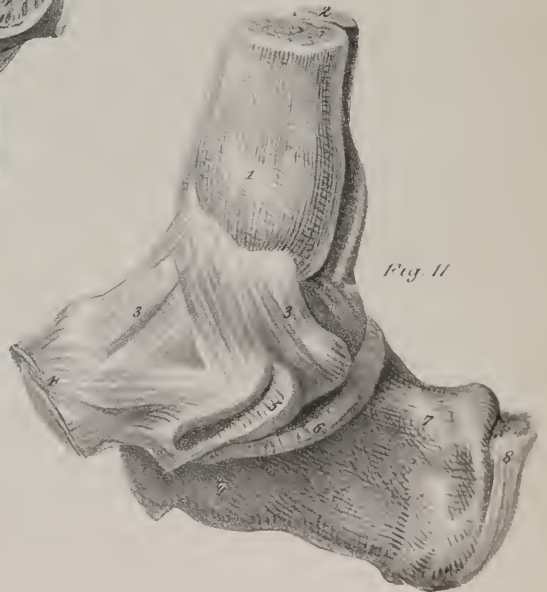


Fig. 11.







The *second* is longer than the first, and presents externally a prominent line for the attachment of the serratus magnus; its internal surface is somewhat grooved posteriorly.

The *eleventh* has no groove on its inferior border, nor a tubercle, as it is not articulated with the transverse process; its angle is scarcely perceptible, and the head has but one articulating surface.

The *twelfth* differs little from the preceding one, except in being shorter; it has neither angle, tubercle, nor groove, and as its anterior extremity, which is pointed, seems loose and unattached, it is called the floating rib.

The ribs grow from three osseous points; one in the body, one in the head, the third being at the tuberosity.

*Costal cartilages.*—These cartilages are twelve in number, like the ribs, of which they form the elastic continuation; their breadth diminishes gradually from the first to the last, whilst the length increases as far as to the seventh, after which it becomes less in each succeeding one. Their line of direction also varies considerably. The second is horizontal, the first descends a little, and all the rest ascend more and more as they are situated lower down. The external or costal extremity, convex and unequal, is implanted into the end of the corresponding rib. The internal extremities of the cartilages of the true ribs, smaller than the external, and somewhat pointed, are articulated with corresponding angular surfaces on the sides of the sternum; each of the cartilages of the first three false ribs, becoming slender towards its extremity, is attached to and blended with the lower border of that which is next above it; in the two last it is pointed, and unattached.

*Attachment of muscles.*—The two layers of intercostals, to the contiguous borders of all the ribs; the scaleni, to the first and second; the pectoralis major, to the cartilages of the true ribs, except the first; pectoralis minor, to the bodies of the third, fourth, and fifth; rectus abdominis, to the cartilages of the last three true ribs and ensiform cartilage; obliquus externus, to the last three true ribs and all the false; the internal oblique and transversalis, to the cartilages of the four or five false ribs; the diaphragm, to the ensiform cartilage, and to those of the last six ribs.

The serratus magnus, to the nine superior ribs; latissimus dorsi, to the four inferior; serratus posticus superior, to the third, fourth, and fifth true ribs; serratus posticus inferior, to the three last; sacro-lumbalis, to the angles of all the ribs; levatores costarum, a little beyond the tuberosities.

*Bones of the superior extremity.*—The upper extremity consists of the shoulder, the arm, the fore-arm, and the hand. The shoulder consists of the scapula and clavicle; the arm, of the humerus; the fore-arm, of the radius and ulna; and the hand, of the carpus, metacarpus, and fingers.

*Scapula.*—This bone [plate XVI.] is placed upon the upper and back part of the thorax, occupies the space from the second to the seventh rib, and forms the posterior part of the shoulder.

Its form is irregularly triangular and flat. It presents for examination two surfaces, three borders, and three angles.

The anterior surface, called also *fossa subscapularis*, looks towards the ribs, is triangular, slightly concave, intersected by prominent lines directed from within outwards and upwards, and therefore crossing the direction of the ribs.

The posterior surface (*dorsum scapulae*) is divided into two parts, but unequally, by a prominent ridge, (the spine:) of these, the superior one is called fossa supra-spinata; the inferior, fossa infra-spinata.

*Of the spine.*—The spine of the scapula is a prominent ridge of bone, flattened from above downwards, commencing at the posterior border of the scapula, with a smooth flat triangular surface, from which it becomes gradually more elevated as it proceeds forwards, until it terminates in an elongated process, (acromion,) which surmounts the shoulder-joint. The form of the spine considered by itself apart from the acromion is triangular; hence we have to notice its two surfaces and three borders. Its superior surface is concave, and, conjointly with the superior part of the dorsum of the scapula, forms the fossa supra-spinata. The inferior surface is irregularly triangular, constitutes part of the infra-spinous fossa, and in its middle may be observed a small foramen for a nutritious vessel. On the projecting border of the spine, which is rough and broad, may be noticed two margins, of which the superior one gives attachment to the trapezius, the inferior to the deltoid muscle,—the intervening edge is subcutaneous. The anterior or attached border, or base, is united with the dorsum of the bone. The external border, which is short, round, and somewhat concave, approaches the neck of the bone, and is continuous with the under surface of the acromion.

*Of the acromion process.*—This considerable eminence is flattened in the direction opposite to that of the spine, and, projecting outwards and forwards, forms the summit of the shoulder-joint; hence its designation, *ακρον*, a summit; *ωμος*, the shoulder.) Its posterior and upper surface, convex and somewhat rough, is subcutaneous; the anterior and inferior one, concave and smooth, is in relation with the supra-spinatus muscle, and overlies the capsular ligament of the shoulder-joint; the superior border pre-

FIG. 12. The ankle-joint, viewed upon its external aspect: after Bourgery.

No. 1. The tibia. 2. The fibula. 3. The anterior ligament. 4. The anterior fasciculus of the external lateral ligament. 5. Its middle fasciculus. 6. Its posterior fasciculus. 7. The scaphoid bone. 8, 8. The os calcis. 9. The tendo Achillis.

FIG. 13. A vertical section of the ankle-joint, showing the cavity of the articulation and the interosseous ligament of the calcaneo-astragaloid articulation: after Bourgery.

No. 1. The tibia. 2. The fibula. 3. The interosseous ligament. 4. The cavity of the ankle-joint. 5. The astragalus. 6, 6. The os calcis. 7. The internal lateral ligament of the ankle. 8. The external lateral ligament. 9. The calcaneo-astragaloid interosseous ligament.

sents, anteriorly, a narrow oval surface for its articulation with the external extremity of the clavicle, and its summit affords attachment to the coraco-acromion ligament.

The *fossa supra-spinata*, wider towards its vertebral than the other extremity, is filled up by the supra-spinatus muscle. The *fossa infra-spinata*, much larger than the preceding, is convex in the middle, somewhat concave, or rather grooved, inferiorly. Between the latter part and the axillary border is a slightly raised and elongated ridge, which extends from the glenoid cavity obliquely downwards to within an inch of the posterior angle of the bone, where it subsides into a flat and nearly quadrilateral surface. This latter part it is that gives origin to the teres major muscle, and over it slides the latissimus dorsi. Along the upper and rounded part arise the fibres of the teres minor; whilst the line of division between them marks the attachment of an aponeurosis, common to these muscles and to the infra-spinatus, which occupies the remainder of the fossa.

Of the three *borders* of the scapula, or *costæ*, (as they are sometimes called,) the *superior* is the shortest; at its outer part is situated a lunated notch, (lunula; incisura semi-lunaris,) which is converted into a foramen by a ligament, and is traversed sometimes by the supra-scapular vessels and nerve, but usually by the nerve alone. In front of this opening it is surmounted by the *caracoid* process, which, being thick, elongated, and curved on itself, is named from some fancied resemblance to a crow's beak, (*κροαξ*, a crow; *ειδος*, like.) This process, superiorly convex and unequal, gives attachment to the coraco-clavicular ligament; anteriorly to the pectoralis minor muscle; posteriorly to the coraco-acromion ligament; and by its extremity to the biceps and coraco-brachialis muscles. The *posterior*, or vertebral border, named also the "base" of the scapula, is the longest of the three; superiorly it approaches to the vertebral column, inferiorly it is more removed from it. The portion of this border which is above the spine will be observed to incline a little outwards. For the purpose of more easily assigning the attachments of the several muscles which are connected with it, we may regard it, though very thin, as divisible into two margins, with an inter-space; these are stated in the enumeration of the muscular attachments. The *axillary* border is inclined downwards and backwards from the lower margin of the glenoid cavity to the inferior angle of the bone; hence it is named the *inferior costa* of the scapula. It is of considerable thickness, being surmounted posteriorly by the ridge above noticed as giving origin to the teres minor. The edge itself presents a shallow groove running along the greater part of its extent. It corresponds with the lower border of the sub-scapular muscle. For about an inch beneath the glenoid fossa there is a well-marked linear impression, which gives origin to the long head of the triceps muscle.

## PLATE XXX.

The ligaments of the foot.

FIG. 1. The superficial ligaments of the dorsum of the foot: after Bourguery.

No. 1. The astragalus. 2. The os calcis. 3. The tendo Achillis. 4, 4. Calcaneo-astragaloid ligaments. 5, 5. Dorsal ligaments of the tarsus. 6. The tendon of the peroneus longus. 7. The tendon of the tibialis posticus. 8. The internal cuneiform bone. 9. The external cuneiform bone. 10. The cuboid bone. 11, 11. Tarso-metatarsal ligaments. 12, 12. Metatarsal ligaments. 13, 13. Lateral ligaments of the metatarso-phalangeal articulation. 14, 14. A band of the deep fascia of the foot. 15. A metatarso-phalangeal articulation laid open. 16, 16. The transverse ligaments. 17, 17. The lateral ligaments of the phalangeal articulations. 18. The tendon of the extensor proprius pollicis. 19. One tendon of the extensor communis digitorum.

FIG. 2. Deep ligaments of the dorsum of the foot: after Bourguery.

No. 1. The astragalus. 2, 2. The os calcis. 3, 3. Ligaments connecting these two bones. 4. The tendo Achillis. 5. The scaphoid bone. 6. The articulation between the astragalus and the scaphoid bone. 7. A calcaneo-scaphoid ligament. 8, 9, 10. The three cuneiform bones. 11. The cuboid bone. 12, 12. The scaphoideo-cuneiform articulation. 13, 13. Ligaments of the cuneiform bones. 14. The cuboideo-cuneiform articulation. 15. A calcaneo-cuboid ligament. 16, 16. The tarso-metatarsal articulations. 17, 17. The lateral metatarsal articulations. 18, 18. The metatarsal bones.

FIG. 3. The superficial ligaments of the sole of the foot: after Bourguery.

No. 1, 2. The os calcis. 3. The groove for the tendon of the flexor longus pollicis. 4, 4. The calcaneo-scaphoid ligament. 5. The tendon of the tibialis posticus. 6, 7. Prominences caused by the scaphoid and the internal cuneiform bones. 8, 8. The greater calcaneo-cuboid ligament. 9, 9. The deep calcaneo-cuboid ligament. 10, 10. The tendon of the peroneus longus. 11, 11. Inferior tarso-metatarsal ligaments. 12, 12. Metatarso-metatarsal ligaments. 13, 13. The metatarsal bones. 14, 14. A part of the plantar fascia. 15, 15. Ligamentous bands which serve to retain the tendons of the flexor muscles. 16, 16. The transverse ligament of the metatarso-phalangeal articulation. 17, 17. The inferior ligament of this articulation. 18, 18. Lateral ligaments of the metatarso-phalangeal articulations. 19. One of the metatarso-phalangeal articulations laid open. 20, 20. Lateral phalangeal ligaments. 21, 21. Inferior phalangeal ligaments. 22. One of the phalangeal articulations laid open.

FIG. 4. The deep ligaments of the sole of the foot: after Bourguery.

Nos. 1, 1. The os calcis. 2. The groove for the tendon of the flexor longus pollicis. 3, 3. The inferior calcaneo-scaphoid ligament. 4. The deep calcaneo-cuboid ligament. 5, 5. Cuboideo-cuneiform ligament. 6, 6. Metatarso-metatarsal ligaments. 7. The inferior tarso-metatarsal ligament of the great toe. 8. The tendon of the peroneus longus muscle. 9, 9. Metatarsal bones.

FIG. 5. A vertical section of the foot, showing the interosseous ligaments: after Bourguery.

No. 1. The tibia. 2. The astragalus. 3, 3. The interior of the ankle-joint. 4. The anterior ligament of this articulation. 5. The posterior ligament. 6. The os calcis. 7. The tendo Achillis. 8. The scaphoid bone. 9. The calcaneo-astragaloid interosseous ligament. 10. Part of the calcaneo-scaphoid ligament. 11. The internal cuneiform bone. 12. The metatarsal bone of the great toe. 13, 13. The phalanges of the great toe. 14. One of the sesamoid bones. 15. Metatarsal bones. 16. The great or superficial calcaneo-cuboid ligament.



Fig 4.

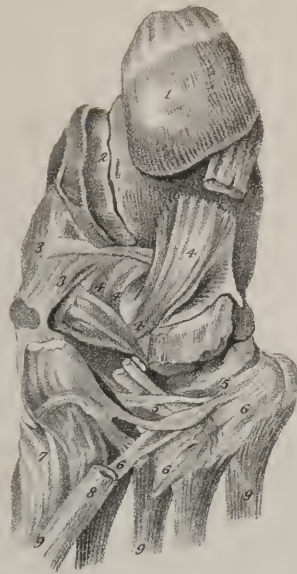

Fig 1

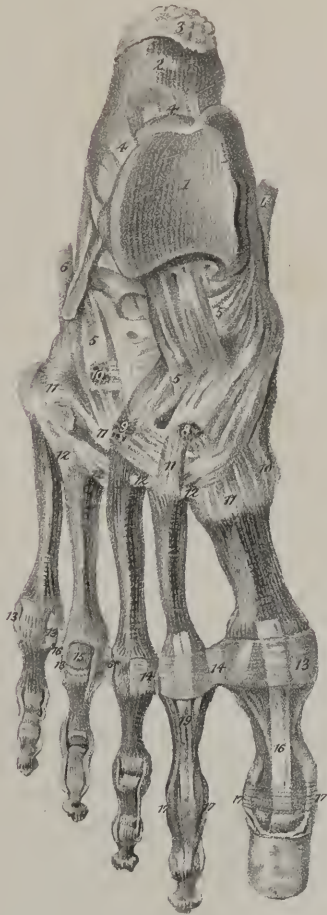


Fig 3

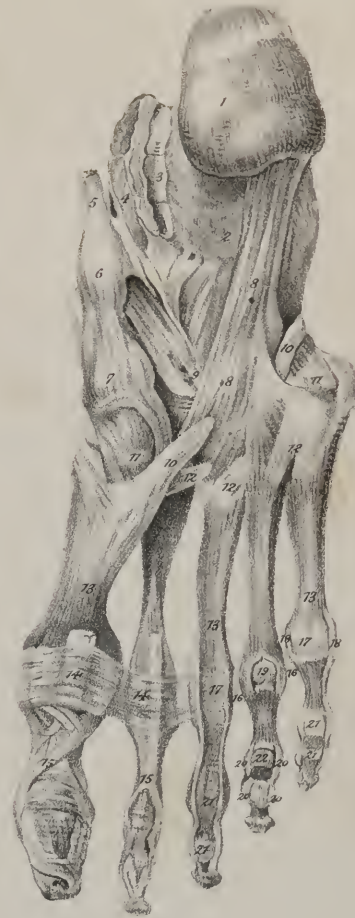

Fig 2

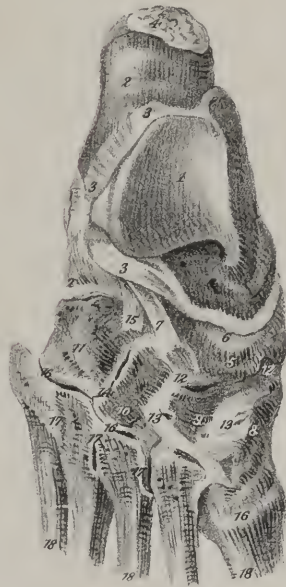
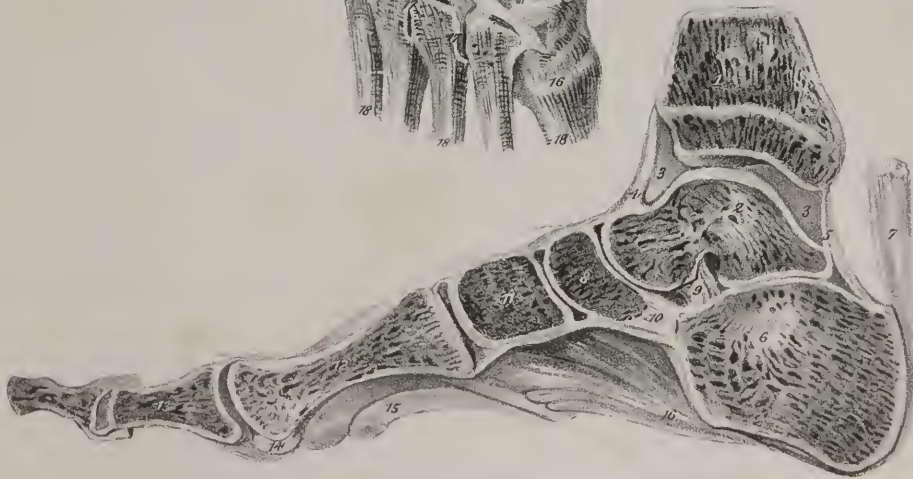
Fig 5





The postero-superior *angle* is formed by the junction of the base with the superior costa of the scapula; it is somewhat inclined outwards. The inferior angle is placed at the union of the base with the axillary or inferior border of the bone; upon it may be observed an elongated flat surface which gives origin to the *teres major*, and over which slides the *latissimus dorsi* muscle. At the convergence of the superior and inferior borders may be observed a narrow constricted part, denominated the *neck*, (*cervix scapulæ*.) The neck is bounded by a slightly-raised rim, which gives attachment to the fibrous capsule of the shoulder-joint; and finally the rim surrounds the articular surface of the bone, which is called the *glenoid* cavity, ( $\gamma\lambda\eta\eta\gamma$ , a superficial cavity;  $\epsilon\iota\delta\omicron\varsigma$ .) This is a shallow, oval depression, broader below than above, covered with cartilage in the fresh state, and deepened somewhat by a fibro-cartilaginous margin, which passes round it from the long tendon of the *biceps* muscle, whose origin is at its upper margin; its greatest diameter is perpendicular, its direction outwards and forwards. In this last respect, however, it varies considerably; for, during the more extended motions of the humerus, the scapula is made to turn, as it were, on a pivot driven through the centre of its dorsum, by which means the *glenoid* cavity is kept constantly in apposition with the head of the humerus, which is the chief security against its dislocation.

The scapula articulates by its *glenoid* cavity with the humerus, and by the *acromion* process with the *clavicle*; it affords attachment to the following muscles:—

The *subscapular fossa*, (the anterior or costal surface of the bone,) to the *subscapularis* muscle. Posterior or dorsal surface,—the spine (by its border and the *acromion*) superiorly to the *trapezius*, inferiorly to the *deltoid*: the *fossa supra-spinata*, by its posterior two-thirds, to the muscle of the same name: the *fossa infra-spinata*, in the greater part of its extent, to the *infra-spinatus*; by a slight oblique line situated near the inferior angle, to the *aponeurosis* common to the *infra-spinatus*, *teres minor*, and *teres major*; by a narrow rounded surface, near the axillary border, to the *teres minor*; by the flat surface, at its inferior angle, to the *teres major*.

The superior border, near the margin of its notch, to the *omo-hyoideus*: the *coracoid* process, anteriorly, to the *pectoralis minor*; by its summit, to the *biceps* and *coraco-brachialis*. The posterior border or base, anteriorly, to the *serratus magnus*; posteriorly, to the *supra-spinatus* and *infra-spinatus*; in the interspace, to the *rhomboidei* and to the *levator anguli scapulæ*. The inferior or axillary border, at its upper part, by a rough ridge, to the long portion of the *triceps extensor*; posteriorly, by an unequal surface, to some fibres of the *teres minor*; inferiorly, to the *teres major*.

The inferior angle, to the *teres major*, and occasionally to some fibres of the *latissimus dorsi*; the anterior angle, (*glenoid* cavity,) by its upper margin, to the long head of the *biceps* muscle.

*Development*.—When the scapula is examined at a very early period, it appears as a thin lamella without any elevation corresponding with the spine. Soon after, an osseous centre is seen towards the middle of its dorsum, one in the *coracoid* process, and in the *acromion*. The base and the inferior angle also commence by separate points.

*The Clavicle*.—The *clavicle*, (*clavis*, a key,) (plate XVI. figs. 1, 2; plate XVII. figs. 4, 5;) or, as it is popularly called, the collar-bone, is extended, transversely, between the *acromion* process of the scapula and the summit of the sternum, which it serves to connect; its direction, however, is not exactly horizontal, the *acromial* end being slightly elevated. This bone is curved somewhat like an italic *f*, the degree of the curvature being less in young and female subjects than in male adults; it is rather thick and somewhat triangular towards its sternal end, but broad and flat towards the scapular extremity; it presents for our consideration a body and two extremities. The superior surface of the body is principally subcutaneous. The inferior surface presents, near the sternal extremity, inequalities for the attachment of the *costo-clavicular* ligament; in the centre, a longitudinal depression, giving attachment to the *subclavius* muscle, the foramen for the entrance of the medullary vessels, and, more externally, a rough oblique line, to which the *coraco-clavicular* ligaments are attached; this surface corresponds internally to the first rib, externally to the *coracoid* process and the shoulder-joint, and in the middle to the axillary vessels and *brachial plexus* of nerves. The anterior border is broad and convex towards the sternal, thin and concave towards the scapular extremity; the posterior border presents, of course, the opposite arrangement of curvatures. The internal extremity is inclined downwards and forwards; it is considerably thicker than the other parts of the bone, and terminates in a triangular unequal surface, which is convex from above downwards, concave from behind forwards: this is tipped with cartilage, and articulates with the sternum, the articular surface of which it much exceeds in size; its entire circumference gives attachment to ligaments. The external or scapular extremity, compressed and flattened, inclines a little backwards and upwards, and articulates with the *acromion* by a narrow oblong surface which is covered with cartilage.

*Attachments of muscles*.—The *clavicle* gives attachment, by the superior surface of its sternal extremity, to the *sterno-cleido-mastoid*; the longitudinal depression on its inferior surface, to the *subclavius*; the anterior border, by its sternal half, to the *pectoralis major*; by its *acromial* third, to the *deltoid*; the posterior border, by its *acromial* third, to the *trapezius*.

*Articulations*.—The *clavicle* articulates with the sternum and the *acromion* process of the scapula.

*Development*.—The division of the bone above indicated into body and extremities is merely technical, being intended to facilitate its description. It consists of one piece, and grows from one ossific centre.

*The Humerus*.—The humerus or arm-bone, (plate XVII. figs. 1, 2, 3; plate XVIII., *os humeri*,) the largest bone of the upper extremity, extends from the scapula to the bones of the fore-arm, with each of which it is articulated. Its direction is ver-



tical, with an inclination inwards towards the lower end. Long and irregularly cylindrical in form, the humerus is divisible into a body and two extremities.

The *body* or shaft of the bone, thick and rounded superiorly, is somewhat expanded, and triangular inferiorly. It is divided into two nearly equal surfaces by two longitudinal lines, of which one is external and anterior, the other internal and posterior. These lines may be considered as rising, the former from the external, the latter from the internal condyle, near to which they are well marked, but gradually subside as they proceed upwards on the body of the bone; they afford attachment to the inter-muscular aponeuroses. The external one is interrupted about the middle by an oblique depression, or groove, which runs from above downwards, and marks the course of the musculo-spiral nerve and superior profunda artery; the surfaces separated by these lines are named posterior and anterior. The *posterior* surface is round superiorly, and inclined a little inwards; in the lower part it is broad, flat, and turned rather outwards; it is covered in the entire of its extent by the triceps extensor muscle, and towards its middle may be observed a small foramen for the medullary vessels. The *anterior* surface is divided superiorly into two unequal portions by a longitudinal groove, directed obliquely downwards and inwards, for about one-fourth of the length of the bone; this lodges the long tendon of the biceps muscle, and is therefore named the *bicipital* groove; its anterior margin gives attachment to the pectoralis major; the posterior, to the latissimus dorsi and teres major. The portion of the anterior surface which is internal to this groove is smooth in the greater part of its extent, and presents, towards its middle, a linear elevation for the insertion of the coraco-brachialis, and lower down an oblique medullary foramen; externally to the groove, and a little above the middle of the bone, may be observed a broad rough eminence, for the insertion of the deltoid muscle, beneath which runs the oblique depression already noticed as corresponding to the course of the musculo-spiral nerve and the accompanying artery.

The *superior extremity* of the bone presents a large hemispherical eminence, covered with cartilage in the fresh state, and directed backwards and inwards to the glenoid cavity of the scapula, with which it articulates; this is called the *head* of the humerus. It is bounded by a slightly depressed groove, sufficiently marked on the upper, not on the under aspect, denominated the *neck* of the bone. A little beneath, and to the outside of the head, are two eminences, which project from the ends of the shaft of the bone, and from their relative size, are named the greater and lesser *tuberosities*, (tubercula.) The greater tuberosity is external and posterior in its situation, convex in its outline, and marked on its upper border by three flat surfaces for the insertion of the external rotator muscles. The smaller tuberosity, rounded and more prominent than the other, gives attachment to the subscapularis muscle. They are separated by the bicipital groove. Towards its lower third the bone widens, and appears compressed and somewhat twisted from behind forward; its greatest diameter is transverse; it presents internally a considerable projection, the *inner condyle*, which is inclined backwards, and gives attachment to the internal lateral ligament of the elbow-joint, and to a tendon common to the greater number of the anterior muscles of the forearm. Externally is situated another smaller process, (*external condyle*,) to which are attached the external lateral ligament and a tendon common to the muscles of the posterior and external surfaces of the fore-arm. Between the condyles is placed the inferior articular surface, which is inclined somewhat forwards. Proceeding in the enumeration of the parts which enter into its composition from the radial to the ulnar side, we observe a rounded eminence placed rather on the anterior surface of the bone, and articulating with a cavity observable on the superior extremity of the radius, calculated to allow of all that freedom of motion which the radius enjoys, viz., flexion and extension on the humerus, and pronation and supination by rotation on its own axis;—a slight groove or depression corresponding with the circumference of this eminence, a semicircular ridge, which is lodged in the space intervening between the radius and ulna;—a wide and deep groove, which receives the prominent part of the larger sigmoid cavity of the ulna; and, lastly, a prominent ridge, which is received into the internal part of the same cavity. This prominence descends much lower than the external portion of the articular surface, and determines an obliquity in the direction of the humerus, when its lower extremity is made to rest on a plain surface. The groove, with its margins, forms a well-marked pulley-like surface, on which the sigmoid cavity of the ulna moves in flexion and extension; hence it is termed the *trochlea*. At the fore part of the inferior extremity of the bone, and immediately above the trochlea, is a superficial depression, which receives the coronoid process of the ulna during flexion; and posteriorly a more considerable fossa, which lodges the olecranon during the extension of the fore-arm.

A modification of the nomenclature applied to these different eminences has been proposed by Chaussier; retaining the term *trochlea* for the surface of articulation with the ulna, he calls that which articulates with the radius, the condyle; (it is sometimes called the *small head*;) and for the two lateral eminences of insertion, now named condyles, he substitutes the terms *epi-trochlea* and *epi-condyle*.

*Attachments of muscles.*—The posterior surface gives attachment to the triceps; the anterior, (by the posterior margin of the bicipital groove,) to the teres major and latissimus dorsi; in the middle, by a slightly-marked line, to the coraco-brachialis; inferiorly, to the brachialis anticus;—the external portion of the same surface, superiorly, by a rough eminence, to the deltoid; by the anterior margin of the bicipital groove, to the pectoralis major. The greater tuberosity gives attachment, by the three flat surfaces on its upper border, to the supra-spinatus, infra-spinatus, and teres minor muscles; the lesser tuberosity, to the subscapularis. The inferior extremity, by its outer border, to the supinator radii longus, and, by its external condyle, to the extensor carpi radialis longior and brevior, extensor communis digitorum, extensor carpi ulnaris, anconeus and supinator radii brevis; by the internal

condyle, to a tendon common to the pronator radii teres, flexor carpi radialis, palmaris longus, flexor carpi ulnaris, and flexor digitorum sublimis.

*Articulations.*—The humerus articulates with the glenoid cavity of the scapula, and with the ulna and radius.

*Development.*—The shaft of the bone grows from one ossific centre; the head and two tuberosities have each their own points. So have the two condyles and the trochlea.

*The Radius.*—The radius, (plate XVII. figs. 1, 2, 3; plate XIX. fig. 1,) shorter than the ulna by the length of the olecranon process, is placed at the external side of the fore-arm, extending from the humerus to the carpus. It is broader below than above, slightly curved in its form, and divided into a body and two extremities. As the body is somewhat triangular, we observe on it three surfaces, bounded by three margins or ridges. The *anterior* surface expands towards the lower part, and is marked along its middle by a longitudinal groove for the flexor pollicis longus; superiorly is situated the foramen for the medullary vessels, its direction being from below upwards; and inferiorly a flat surface, corresponding with the pronator quadratus. The *posterior* surface, convex in the greater part of its extent, is grooved at its central third, for the origin of the extensors of the thumb; the *external* surface, round and convex, is marked towards its middle by a rough impression, which gives insertion to the pronator radii teres. Of the margins separating these surfaces, the posterior is distinct only at the middle part; the external is round, and becomes smooth towards the lower extremity; whilst the internal is acute and sharp, for the attachment of the interosseous ligament. The body is terminated superiorly by a rough prominence, (tuber radii,) termed the *bicipital tuberosity*, from its giving insertion to the biceps muscle.

Above the tuberosity the bone becomes narrowed and constricted into the form of a *neck*, which is again surmounted by the *head*, intended by its extremity to articulate with the round convex part of the lower extremity of the humerus, its small head, (condyle, Chauss.) while its margin rolls on the lesser sigmoid cavity of the ulna. The margin is smooth and convex; the upper surface, also smooth, is a shallow cup-like cavity; and both are covered with cartilage in the recent state.

The radius at its lower part becomes broad and thick; the anterior surface is flat and expanded, being covered by the pronator quadratus muscle; it is bounded below by a prominent line, which gives attachment to the anterior ligament of the wrist-joint. The posterior surface is convex, and marked by grooves which transmit the tendons of the extensor muscles; of these, one, which is very narrow and oblique in its direction, and nearly in the middle line, lodges the tendon of the extensor pollicis, (secundi internodii.) At the inner or ulnar side of this is placed another, much broader, which transmits the tendons of the extensor communis and indicator; and at its outer side, a third, divided into two parts by a linear impression, marks the passage of the flexor carpi radialis, longior and brevior. Corresponding with the external border of the bone is another groove, directed obliquely forwards, and divided into two parts, for the tendons of the extensores—primi internodii, and ossis metacarpi pollicis. The outer side of the bone, particularly the part corresponding with the ridge which separates the two latter grooves, is prolonged downwards, and named the *styloid process*; it affords attachment to the external lateral ligament of the wrist-joint. On the inner side of the bone is situated a small cavity, (semilunar,) covered by cartilage, which articulates with the inferior extremity of the ulna. At its inferior extremity the radius presents its carpal articulating surface, (scaphoid; navicular,) which is included between the base of the styloid process and the oval cavity just mentioned, bounded before and behind by two rough margins for the attachment of the radio-carpal ligaments. It is divided from before backwards, by a line, into two unequal portions, of which the external is triangular, and articulates with the scaphoid bone; the internal is square, and articulates with the semilunar.

*Attachments of muscles.*—The anterior surface of the body, by its grooved part, to the flexor longus pollicis; by the oblique line, leading from the tuberosity to the insertion of the pronator; radii teres, to the supinator brevis and flexor sublimis; its inferior fifth, to the pronator quadratus; the posterior surface, by a slight concavity in the middle, to the extensores pollicis; the external margin, by a rough surface, to the pronator teres; inferiorly, to the pronator quadratus and the supinator radii longus; whilst the posterior part of the bicipital tuberosity gives attachment to the biceps muscle.

*Articulations.*—The radius articulates with the humerus, the ulna, the scaphoid and semilunar bones.

*Development.*—It has a centre of ossification for its body, and one for each extremity.

*The Ulna.*—The ulna (plate XVII. figs. 1, 2, 3; plate XIX., *ωλενη*, cubitus) is placed at the inner side of the fore-arm; it is a long and rather irregular bone, larger at the upper than at the lower extremity,—a conformation the reverse of that which obtains in the radius. Its body, or shaft, is marked off into three surfaces by three prominent lines. These are all broader above than below, in consequence of the decreasing size of the bone. The anterior surface, slightly depressed, is grooved longitudinally for the origin of the flexor profundus, and marked at its upper third by a foramen, directed obliquely upwards for the medullary vessels. The internal surface, smooth and somewhat excavated superiorly, is covered in the greater part of its extent by the flexor profundus muscle; it becomes round inferiorly, where it is subcutaneous. The external surface, rough and irregular, is divided into two parts, of which one, of small extent, corresponds with the superior extremity of the bone, and forms an elongated depression for the anconeus muscle; the other, reaching to the lower extremity, gives origin to the extensors of the thumb and the supinator radii brevis. Of the three margins, the internal and posterior are round, and for the most part smooth; the external is sharp, and gives attachment to the interosseous ligament.



At the superior extremity of the bone are situated two eminences, so placed as to bound the cavity by which it articulates with the humerus. Of these, one, called *olecranon*, (*ωλενη*, ulna; *κρανιον*, the head,) is nearly on a line with the shaft of the bone; the other, the *coronoid process*, (*χορωνη*, a crow's beak; *ειδος*, like,) projects from its anterior surface. The olecranon terminates in a rough tuberosity and an obtuse point; the former giving insertion to the triceps extensor; the latter being lodged, when the arm is extended, in the posterior cavity at the end of the humerus. Anteriorly, this process is smooth and hollowed out, to form part of the surface of articulation with the humerus; posteriorly, it presents a flat triangular surface, which is subcutaneous. The coronoid process, by a gentle ascent, rises upwards and forwards from the anterior surface of the bone, and terminates in a sharp ridge, which overhangs the articular surface, and is received during the flexion into the anterior depression in the humerus; its anterior surface, rough and triangular, gives insertion to the brachialis anticus muscle; its upper aspect is smooth and excavated; its inner border gives attachment to the internal lateral ligament; the external is hollowed into a smooth depression, the *smaller sigmoid cavity*, which articulates with the head of the radius. The *great sigmoid cavity*, formed by the junction of the smooth surfaces of these two processes, has been so named from some supposed resemblance to the form of the Greek letter  $\Sigma$  (*σιγμα*, *ειδος*, like,) as it was originally written. Covered by cartilage in its entire extent, it is divided into two parts (but unequally, the inner one being the larger,) by a smooth ridge running downwards from the peak or point of the olecranon to that of the coronoid process. This ridge and the concavities beside it correspond, the one with the groove, the others with the lateral parts of the trochlea. At the margins of the sigmoid cavity may be observed two notches, which mark off the parts of the surface which belong to the olecranon and the coronoid process respectively.

At the inferior extremity of the bone, which is small and rounded, are situated two eminences, of which the external one, named the *head* of the ulna, round and covered with cartilage, presents two aspects, of which one, nearly circular in its form, looks towards the wrist-joint, and corresponds with the triangular fibro-cartilage of that articulation; whilst the external one, narrow and convex, is received into the semilunar cavity in the contiguous border of the radius. The internal eminence, named the *styloid process*, projects on a line with the posterior and inner surface of the bone; it is elongated in its form, and gives attachment to the internal lateral ligament of the joint. The head and the styloid process are separated posteriorly by a groove, which is traversed by the tendon of the extensor carpi ulnaris, and inferiorly by a depression at the base of the styloid process into which the triangular fibro-cartilage is inserted.

*Attachments of muscles.*—The anterior surface, superiorly and in the middle, gives attachment to the flexor digitorum profundus; inferiorly, to the pronator quadratus; the posterior surface, to the anconeus, the extensor carpi ulnaris, supinator radii brevis, the extensores pollicis, and the extensor indicis; by the posterior longitudinal line, to an aponeurosis common to the flexor carpi ulnaris, flexor digitorum profundus, and extensor carpi ulnaris. The superior extremity, by the summit of the olecranon to the triceps brachialis; the coronoid process, by its anterior rough surface, to the brachialis anticus; and by its internal side, to the second origin of the pronator teres.

*Articulations.*—The ulna articulates with the humerus and the radius; it has no point of contact with the carpal bones, but it is brought into relation with the cuneiform bone by means of the inter-articular fibro-cartilage.

*Development.*—The shaft of the ulna, as in other long bones, has its own osseous centre; so has the lower extremity or head, as well as the olecranon process.

*Hand.*—The hand (plate XX.) is composed of the carpus, metacarpus, and fingers.

*Carpus.*—The first or superior part of the hand is named the carpus or wrist; it is placed between the fore-arm and the metacarpus, and composed of eight small bones, which are disposed in two ranges, each consisting of an equal number. Proceeding in the enunciation from the radial to the ulnar side, the bones which constitute the first or superior range are thus named from their shape—scaphoid, semilunar, cuneiform, and pisiform; those of the second or inferior range are the trapezium, trapezoid, os magnum, and unciform. The dorsal surface of the carpus is convex, the palmar concave and irregular, and marked by four bony prominences, across which is stretched the anterior annular ligament, so as to form a canal for the transmission of the flexor tendons.

*Bones of the first row.*—*The Scaphoid bone.*—The scaphoid or boat-shaped bone (plate XX.) (*σκαφη*, a boat) is the first of this row, and the largest. Its position is oblique, so that its broad end is directed towards the trapezium and root of the thumb, whilst the narrow one inclines inwards and upwards to the middle of the articular surface of the radius. It is convex on one side, concave on the other. The concave or hollowed surface (scaphoid) looks obliquely inwards and forwards, and is that which determines the form and gives name to the bone. Its upper articular surface, convex and triangular, is applied to the radius; the lower, also convex, articulates with the trapezium and the trapezoid bone. Its concavity receives part of the head of the os magnum; close to this is a narrow articular surface which is in contact with the semilunar bone; on its radial side is a rough surface, to which is attached the external lateral ligament of the wrist-joint; posteriorly is a narrow grooved surface for the attachment of ligaments; and anteriorly is a rough surface, the inner or ulnar half of which is narrow and slightly grooved, whilst the outer is prominent and tuberculated for the attachment of ligaments. It articulates with five bones.

*The Semilunar bone.*—The name of this bone (plate XX.) is taken from its being concave or crescentic on its inferior surface. Irregularly triangular in its form, convex superiorly, it articulates with the square part of the articular surface of the



radius; inferiorly concave, with the os magnum and the unciform; on the ulnar side, with the cuneiform; on the radial side, with the scaphoid; anteriorly and posteriorly it gives attachments to ligaments. It articulates with five bones.

*The Cuneiform bone.*—This is the “wedge-shaped” bone, (plate XX.) sometimes also it is named from its form “pyramidal:” superiorly it is in relation with the inter-articular fibro-cartilage of the wrist-joint; inferiorly it articulates with the unciform bone; on the ulnar side, gives attachment to ligaments; on the radial side, articulates with the semilunar bone; anteriorly it affords attachment to ligaments, and presents a small articular surface for the pisiform bone. It articulates with three bones.

*The Pisiform bone.*—The “pea-shaped” bone (plate XX.) is placed on a plane, anterior to the other bones of the carpus. Its form is indicated by its name, (*pisum*, a pea.) It presents but one articular surface, which is situated on the posterior part, or base, and rests on the anterior surface of the cuneiform bone; it affords attachment to the annular ligament of the carpus, to the flexor carpi ulnaris muscle, and to the abductor of the little finger.

The first three carpal bones form, when in apposition, a rounded convex surface, which corresponds with the concavity presented by the radius and the inter-articular cartilage; but their lower surface constitutes a deep hollow, which receives the head of the os magnum and the unciform bone.

*Bones of the second row.—The Trapezium.*—The name of this bone (plate XX.) is taken from its presenting four unequal edges at its posterior aspect. It is placed at the radial border of the carpus, between the metacarpal bone of the thumb and the scaphoid bone. It is known by the angular appearance of its dorsal surface, and by the tubercle and groove at its palmar aspect. Superiorly concave, it articulates with the scaphoid bone; inferiorly concave from behind forward, and convex transversely, with the first metacarpal bone; on the ulnar side, with the trapezoid bone, and, by a small surface situated more inferiorly, with the edge of the second metacarpal bone; on the radial and posterior sides it gives attachment to ligaments; anteriorly it presents a groove traversed by the tendon of the flexor carpi radialis, and a tubercle to which the annular ligament of the carpus is attached. It articulates with four bones.

*The Trapezoid bone.*—This is a small bone, (plate XX.,) compared with those between which it is placed, viz. the trapezium, scaphoid, and os magnum; in form and position it has some resemblance to a wedge, and but little to a trapezium, except that its posterior surface is bounded by four equal edges. It articulates superiorly with the scaphoid bone; inferiorly, with the second metacarpal bone; on the ulnar side, with the os magnum; on the radial side, with the trapezium: the anterior and posterior surfaces afford attachment to ligaments. It articulates with four bones.

*Os magnum.*—This (plate XV.) is the largest of the carpal bones; its form is oblong, round superiorly, cubic inferiorly; the superior surface, named its “head,” (whence it is sometimes called os capitatum,) is supported by a narrowed portion, named the “neck;” its greatest convexity is in the antero-posterior direction, where it is received into a cavity formed by the scaphoid and the semilunar bone; it articulates, inferiorly, by three distinct surfaces, of which the middle is the largest, with the second, third, and fourth metacarpal bones; on the ulnar side, with the unciform bone; on the radial side, with the trapezoid bone: the anterior and posterior aspects are rough (particularly the former) for the attachment of ligaments. It articulates with seven bones.

*The Unciform bone.*—The “hooked-shaped” bone (plate XX.) (*uncus*, a hook) is readily distinguished from the rest by the curved process upon its palmar surface: it articulates, superiorly, with the semilunar bone; inferiorly, by two distinct surfaces, with the fourth and fifth metacarpal bones; on the ulnar side, with the cuneiform bone; on the radial side, with the os magnum: anteriorly its hooked process affords attachment to the anterior annular ligament of the carpus; posteriorly a rough surface also gives attachment to ligaments. It articulates with five bones.

*The Metacarpus.*—This (plate XX.) forms the second or middle portion of the hand, being situated between the carpus and the phalanges; it is composed of five bones, which are named first, second, &c., in their numerical order, the enumeration being commenced at the radial side. These bones are placed parallel one with the other, and nearly on the same plane, with the exception of the first, which is more anterior than the rest, and alters its relative position to them in its various movements. They vary in size, the first being thicker and shorter than the others; and these gradually diminish in length from the second to the fifth. They are all slightly concave on the palmar surface, convex on the dorsal, larger at their extremities than in the bodies or middle part, terminated at the carpal extremity by an unequal eminence, and at the digital by a rounded head.

The bodies are lengthened and somewhat compressed, but may, in each, be regarded as presenting a palmar, a dorsal, and two lateral surfaces. The palmar surface is narrow, and presents in the middle a prominent line, which separates the attachments of the interosseous muscles, and corresponds with the tendons of the flexor muscles; as also, in the first, to the opponens and flexor brevis pollicis, and in the third to the origin of the adductor pollicis.

The dorsal surface, convex and smooth in the first, presents in the second, third, and fourth a longitudinal line, which, bifurcating, forms the sides of a triangular surface, extending over two-thirds of their length; in the fifth, also, is observed a prominent longitudinal line, directed obliquely from the ulnar to the radial side. The lateral surfaces afford attachment to the dorsal interosseous muscles; broad in the four last bones, these surfaces are narrowed, and form merely borders in the first.

The carpal extremity presents, in each, some peculiarities which render a separate description necessary: on the first is observed a surface, which is concave in the antero-posterior and convex in the opposite direction, which articulates with the

trapezium;—in the second, a concave surface articulates with the trapezoid bone, and on the radial side, a small surface, with the trapezium; at the ulnar side, its margin is extended obliquely backwards, so as to become wedged in between the trapezium and the third metacarpal bone, and articulates by its tip with the os magnum;—on the third, a nearly plain surface articulates with the os magnum; on the radial and ulnar sides are surfaces for articulation with the contiguous metacarpal bones; on the fourth two articular surfaces move upon the os magnum and unciform, on the radial side there are two surfaces, and on the ulnar side one, for articulation with the corresponding surfaces of the bones on each side;—on the fifth, a concave surface, directed outwards, corresponding with the unciform bone; and, on the radial side, a surface for the fourth metacarpal bone.

The anterior or digital extremities of all are convex, and articulated with the phalanges, the smooth surfaces extending farther on the palmar than on the dorsal aspect of the bones; and on the margins of these are inequalities for the attachment of ligaments.

*Bones of the Fingers.*—These (plate XX.) are fourteen in number; each, with the exception of the thumb, having three separate pieces, (*phalanges, internodia.*) Of these the first is longer than the second, and the second than the third. Like other long bones, each is divided into a body and two extremities, of which one represents the base and the other the head. Winslow and some other anatomists reckon three phalanges in the thumb, as they conceive that its posterior or most movable bone resembles the first phalanges of the fingers, rather than the metacarpal bones. But if its conformation be examined with attention, more especially that of its anterior extremity, and also its mode of articulation with the bone in front of it, its analogy with the metacarpal range will appear more striking than with the first digital phalanges; and so it is considered by Meckel, Portal, H. and J. Cloquet. The bodies of the first row or phalanx are convex on the dorsal surface, and flat from side to side on the palmar, but arched from before backwards; the palmar surface is bounded by two margins which give insertion to the fibrous sheaths of the flexor tendons. The larger or posterior extremities present an oval smooth surface, whose greatest diameter is from side to side, intended to receive the convex heads of the corresponding metacarpal bones. The anterior extremities, smaller than the other, end in two small lateral condyles, with a slight groove between them, both being adapted to the base of the contiguous bones, so as to form ginglymoid or hinge-joints. The articular surface is prolonged farther on the palmar than on the dorsal aspect, which allows a more free range to the motion of flexion. The margins of the articular surfaces are rough and prominent for the attachment of ligaments.

The second row consists of four bones, the thumb having only two pieces corresponding with those of the first and last phalanx. Smaller than the preceding set, they still resemble them in their general outline. The broader or posterior extremity ends in an articular surface, divided by a slight ridge extending from before backwards, the lateral parts being concave for the reception of the two eminences on the contiguous bone; the anterior extremity is divided into two lateral convex surfaces, which are lodged in depressions in the base of the last phalanx.

The third row (*phalanges unguium, Sæmm.*) consists of five pieces, that of the thumb being the largest. They are convex on the dorsal, flat on the palmar surface; rough at the summit, which corresponds with the points of the fingers, and at the base, for the attachment of ligaments and the flexor tendons. The articular surface, at the base, resembles that of the base of the second phalanx in having two shallow concavities divided by a central convex line.

*Attachments of muscles.*—1. To the carpal bones. The *pisiform* bone gives origin to the abductor minimi digiti, and insertion to the flexor carpi ulnaris; the *trapezium*, to the opponens and abductor pollicis; the *trapezoid*, to part of the flexor brevis pollicis; the *os magnum*, to part of the same; the *unciform*, to the flexor brevis (minimi digiti) and to the adductor.

2. To the metacarpal bones. The *first*, or that of the thumb, gives insertion to the extensor ossis metacarpi pollicis and to the opponens pollicis, and origin to part of the abductor indicis: the *second*, or that of the forefinger, to the flexor carpi radialis at its palmar end, and to the extensor carpi radialis longior on the dorsal surface of its base, and, by its lateral surfaces, to the two first dorsal interossei muscles and one palmar: the *third*, to the extensor carpi radialis brevior, to the adductor pollicis, and also to two dorsal interossei: the *fourth*, to two dorsal interossei and one palmar: the *fifth*, to the extensor carpi ulnaris, and the adductor or opponens minimi digiti, to one dorsal and one palmar interosseous muscle.

3. To the bones of the fingers. Those of the *first* range of the four fingers give attachment by their lateral borders to the tendinous sheaths of the flexor tendons; their dorsal surface is covered by the expansion of the extensor tendons. The bones of the *second* row give insertion at their dorsal surface to the tendons of the extensor communis; the tendons of the flexor sublimis are inserted into their bases at the palmar surface. The *third* set gives insertion to the tendons of the flexor profundus; the fibres of the extensor communis are also continued on their dorsal aspect.

The *first* phalanx of the thumb gives insertion to the extensor primi internodii, to the flexor brevis, to the adductor and abductor pollicis: the *second* phalanx to the flexor longus, and to the extensor secundi internodii.

*Of the Pelvis.*—The pelvis, or “basin-shaped” cavity (plate XV.) is placed at the lower extremity of the trunk, being formed by the union of the ossa innominata, the sacrum, and the coccyx. Its form is somewhat circular; its size presents many varieties, dependent on the sex and age of the subject, as well as on individual conformation. In young subjects the two large lateral bones, the ossa innominata, are divided each into three pieces, the ilium, ischium, and os pubis; the sacrum consists of five



pieces, resembling in some respects the bones of the vertebral column, and hence called false vertebræ: these in adult age become united into one. The coccyx, or caudal prolongation, consists of four pieces.

*The Sacrum.*—The sacrum, (plates IV. VI. XIV. XV.,) when the body is in the erect position, is placed at the superior and posterior part of the pelvis, beneath the last lumbar vertebra, above the coccyx, and between the ossa innominata, between which it is inserted in some measure like a keystone into an arch.

Its figure is triangular in its general outline; concave anteriorly, convex posteriorly. We consider successively its surfaces, borders, and extremities.

The anterior or pelvic surface is nearly flat from side to side, concave from above downwards, and marked by four transverse lines, indicating its original division into five pieces; laterally it presents four foramina, (anterior sacral,) for the transmission of the anterior branches of the sacral nerves. These are directed outwards, and diminish gradually in size from above downwards; external to these the surface gives attachment to the pyramidalis muscle.

The posterior or spinal surface is convex and presents along the median line four small eminences, usually connected so as to form a ridge; these are rudiments of the spinous processes; and beneath them is a triangular groove, or rather an opening, marking the termination of the sacral canal. The margins of the opening present two tubercles, which give attachment to the ligament that closes in the canal. The inferior pair (sacral cornua) articulate with the horns of the coccyx. At each side of the median line are two grooves, pierced by the posterior sacral foramina, which are much smaller than the anterior, and transmit the posterior branches of the sacral nerves.

The borders, or lateral surfaces of the sacrum, present two distinct parts, one superior, (iliac,) large and irregular, which in the fresh state is covered with cartilage, and articulated with the ilium; the other inferior, thin, and narrowing to a point, gives attachment to the sacro-sciatic ligaments. A small indentation terminates this border, which, with the corresponding extremity of the coccyx, forms a notch for the transmission of the fifth sacral nerve.

The *base*, or superior extremity, broad and expanded, presents, 1st, towards the middle line, an oval surface, cut off obliquely, and tipped with cartilage for its articulation with the last lumbar vertebra; behind this is a triangular aperture marking the orifice of the sacral canal. 2d, On each side a smooth convex surface, inclined forwards, and continuous with the iliac fossa; an articular process, concave from side to side, which looks backwards and inwards, and receives the inferior articular process of the last lumbar vertebra. Before each articular process is a groove, forming part of the last intervertebral foramen, and behind them is a curved, sharp, and depressed border, which bounds the sacral canal, and therefore corresponds with the lateral arches of the vertebræ, and gives attachment to the last ligamentum subflavum.

The *apex*, or inferior extremity, directed downwards and forwards, presents an oval convex surface, which articulates with the coccyx.

The sacrum in its interior contains much loose spongy substance, and its exterior layer is but moderately compact. Its central part is also hollowed into a canal, (sacral,) which curves from above downwards as the bone does; hence it is of a triangular form, and gradually narrows as it descends.

*Attachments of muscles.*—The sacrum gives attachment, by the lateral parts of its anterior surface, to the pyramidales muscles; by its posterior surface at each side, to the gluteus maximus, sacro-lumbalis, longissimus dorsi, and multifidus spinæ; by the inferior part of each border, to part of the coccygeus.

*Articulations.*—The sacrum articulates with the last lumbar vertebra, the two iliac bones, and the coccyx.

*Development.*—In the first three pieces there are found five bony points, one being in the body, two at the sides in front, and two posteriorly in the arches. Analogy would lead us to admit two more in each body corresponding with its upper and lower surfaces, and one in the spinous process, in all eight. In the two lower false vertebræ there appear to be but three, one being in the body and one at each side.

*Ossa Coccygis.*—These bones, (plates IV. VI. XIV.,) when united together, which is usually the case in advanced life, are supposed to resemble a cuckoo's bill, and are therefore called coccygeal, (*κοκκυβή*, a cuckoo.) Most commonly there are four of them, sometimes but three; in a few instances five have been found. They diminish gradually in size from above downwards, which gives them, when taken together, a pyramidal form. As they are placed in a continuous line with the inferior third of the sacrum, they form a slightly concave surface anteriorly, a convex one posteriorly.

The first of these bones resembles, in some measure, the last false vertebra of the sacrum. Its body is small and concave at its upper aspect, which articulates with the extremity of the sacrum; posteriorly, two small processes, termed cornua, project, which rest upon the sacral cornua. The second bone of the coccyx is somewhat square, the third oblong, and the fourth a small rounded nodule of bone.

*Attachments of muscles.*—The coccyx gives attachment to the gluteus maximus, and to the coccygeus of each side, and by its point to the sphincter ani. Its base articulates with the sacrum.

Each of these pieces has a separate osseous centre.

*Os innominatum.*—This bone (plates XIV. XV. XXIII.) is of so complex and irregular a form, that it bears no perceptible resemblance to any other known object, and therefore remains "unnamed" and unnameable. The two bones thus distinguished



by the negation of a name are situated at the inferior and lateral parts of the trunk, extending from the sacrum forwards to the median line, where they are connected together. Through the intervention of the sacrum, which is wedged in between them, they receive the weight of the body from the vertebral column, and transmit it to the lower extremities: thus placed, and being somewhat curved in their general outline, they circumscribe the greater part of the cavity of the pelvis, the sides and fore-part of which they form.

To facilitate the description of this very irregular bone, it is convenient to consider separately each of the parts into which it is found divided in early life, viz. the ilium, os pubis, and ischium.

The *ilium*, (os ilii,) or iliac portion of the os innominatum, constitutes the upper part of the bone where it is broad and expanded; it is situated at the superior and lateral part of the pelvis. Its surfaces, borders, and angles must be considered successively.

The external surface, (*dorsum*,) convex before, concave posteriorly, is marked by two curved lines running from before backwards; the superior one, commencing at the anterior-superior spinous process, arches downwards to the margin of the sacro-sciatic notch. A space, narrowed before, and wider posteriorly, is included between the line just noticed, the margin of the crista ilii, and the border of the rough surface for the attachment of the gluteus maximus; from this space the gluteus medius arises. The inferior curved line is shorter and less strongly marked than the superior; it commences at the anterior-inferior spinous process, and inclines backward to the sacro-sciatic notch. The space between these lines gives origin to the gluteus minimus. On its posterior and superior part is observed a rough surface, which gives attachment to the gluteus maximus muscle. The internal surface of the ilium is divided into three parts. One anterior, smooth, concave, and of considerable extent, is called the *iliac fossa*; the posterior one is rough and uneven, and serves for its articulation with the sacrum; whilst the third is smooth, much smaller than the others, and is the only part that enters into a formation of the true pelvis.

The superior border, (*crista ilii*,) extending from before backwards, is convex and arched; it forms an epiphysis in infancy, and is sometimes called the *spine* of the ilium, but more properly its crista; its anterior extremity curves inwards, the posterior outwards. This border presents an external and internal lip, (*labium*,) and a rough interval, to each of which muscles are attached.

The anterior border, depressed and excavated, descends from the superior border or crista towards the os pubis, with which it is continuous: its junction with the crista is marked by a prominent point, called the *anterior-superior spinous process*; and that with the pubis, by an obtuse elevation, common to the two bones, called the *ilio-pectineal* eminence. This border presents two excavations, separated by a prominent point, called the *anterior-inferior spinous process*. The interval between the latter and the ilio-pectineal eminence gives transmission to the iliacus and psoas muscles; and that between the spinous processes transmits the external cutaneous nerve, and gives origin to some fibres of the sartorius.

The posterior border also presents two notches, separated by a prominent point of bone, called the *posterior-inferior spinous process*; above which is another bony eminence, called the *posterior-superior spinous process*: of the notches, the inferior and larger one contributes to form the sacro-sciatic notch.

Of the three angles of the bone, the two superior ones correspond with the spinous processes, (anterior and posterior;) the inferior is represented by the constricted part of the bone. Here we observe three surfaces, (when the ilium is separated from the os pubis and ischium:) one external, smooth, concave, forming part of the *acetabulum*, the deep cavity which receives the head of the femur; one anterior, small and triangular, marking the junction with the os pubis; a third posterior, the junction with the ischium.

*Attachments of muscles.*—To the interval between the crista and the superior curved line on the dorsal surface is attached the gluteus medius; to the space between the curved lines, the gluteus minimus; to the posterior rough surface, the gluteus maximus; to the internal surface, or iliac fossa, the iliacus muscle.

To the anterior half of the external lip of its crista is attached the obliquus externus abdominis; to the posterior third of the same lip, the latissimus dorsi; to the anterior two-thirds of the interval between the lips, the obliquus internus; and to the remainder, the erector spinæ; to the anterior three-fourths of the inner lip, the transversalis abdominis; to the posterior fourth of the same lip, the quadratus lumborum.

To the external surface of the anterior-superior spinous process is attached the tensor vaginæ femoris; to the process and the notch beneath it, the sartorius; to the anterior-inferior spine, the straight tendon of the rectus femoris; and to the brim of the acetabulum, the external tendon of that same muscle.

*Articulations.*—This bone articulates with the sacrum, and joins by bony union with the os pubis and the ischium.

*Os Pubis.*—The pubic bone (plate XXIII.) forms the anterior and inner part of the os innominatum; and is usually divided into two portions, one superior and thick, called the body, the other inferior and thin, the ramus.

The *body*, horizontal in its direction, presents three surfaces, separated by three prominent lines. The superior surface, slightly depressed, is covered by the pectineus muscle; the internal is smooth, and forms part of the pelvic cavity; the external or inferior is somewhat grooved transversely, overhangs the obturator foramen, and looks downwards to the top of the thigh.

The external extremity of the bone is thick, and presents three faces; one, concave, forms part of the acetabulum; another,

superior, connects it with the ilium, (the junction being marked by a rounded elevation, called the *ilio-pectineal eminence*;) the third, inferior, is joined with the ischium. The internal extremity, flat and compressed, is joined to the corresponding part of the opposite bone by an intervening cartilage, the junction being termed the *symphysis pubis*, (*συμφυσις*, to grow together.) Leading outwards from the symphysis, whose direction is vertical, may be observed another margin, nearly an inch in length, which is placed horizontally, and named the *crista*. The angle formed by the crista and symphysis is termed the angle of the pubes; the crista is terminated externally by a projecting nodule of bone—the *tuberosity* or spine, from which runs outwards a sharp line, (*ilio-pectineal line*,) giving attachment to Gimbernat's ligament and to the pectineus muscle, and marking the margin or upper boundary of the true pelvis.

The *ramus*, or branch of the bone, inclines outwards and downwards from the body, forming an angle with it, becomes thin, and unites with the ascending ramus of the ischium. Its inner surface is smooth; the external is rough, for the attachment of muscles. One of its borders, thick and rough and somewhat everted, forms with the opposite bone an arch, called the *arch of the pubes*; the other border, sharp and thin, forms part of the margin of the obturator foramen.

*Attachments of muscles.*—To the crista are attached the pyramidalis and rectus abdominis; to the tuberosity and anterior surface, the obliquus externus; to the pectineal line, the pectineus and Gimbernat's ligament; to the crista, and part of the same line, the obliquus internus and transversalis.

To the external surface, at the angle, the adductor longus; to the space between this and the border of the obturator foramen, the adductor brevis; to the line of the symphysis and the ramus, the gracilis; and to the whole margin of the foramen, the obturator externus. To the inner surface, part of the obturator internus and levator ani.

*Ischium.*—The *ischium* (plate XXIII.) forms the posterior and lowest part of the os innominatum; it consists of two parts, a body and a ramus, united at an angle, so as to give the bone somewhat the figure of a hook. The *body*, or larger part, short, thick, and somewhat triangular in form, presents three surfaces or aspects which look in different directions; there are three borders and two extremities. On its external surface may be observed a smooth concave part, which forms more than two-fifths of the acetabulum, and is surrounded by a curved prominent line, which forms the lower border of that cavity; beneath this is a groove, directed horizontally backwards, corresponding with the tendon of the obturator externus muscle; and still lower a rough line, which bounds the tuberosity of the ischium, and gives attachment to the quadratus femoris. The external surface of this portion of the bone is smooth, and forms part of the cavity of the pelvis. This is broad at its upper part, as it comprises the interval between the spine, or spinous process, and the margin of the obturator foramen. Below this process it becomes narrowed, constricted, and rounded off at its back, so as to form a pulley-like surface in the interval between the spine and the tuberosity where the obturator internus muscle winds round its border. The posterior surface, broad at its upper part where it comprises the space between the spine and the margin of the acetabulum, then becomes narrowed and depressed, finally ends in a rough and rather prominent surface bounded by well-defined borders, which is the tuberosity of the ischium.

The *tuberosity*, (*tuber ischii*), thick and rounded, forms the part on which the body is supported in the sitting position. This rough prominence presents three impressions upon it, corresponding with the points of attachment of the three long flexor muscles of the leg.

The superior extremity of the bone (if it be examined in early life, when the bone can be detached from the ilium and os pubis, or after a section has been made of the os innominatum, so as to divide it into its three parts,) presents three surfaces, of which two are flat and triangular, and mark its junction with the ilium and os pubis; the other, concave and smooth, forms part of the acetabulum. The inferior extremity of the body of the bone is identified with the tuberosity. The *ramus* of the ischium is the flat, thin part, which ascends forwards and inwards from the tuberosity, towards the ramus of the os pubis with which it is united. One margin of the ramus, thick, rough, and somewhat everted, forms part of the inferior outlet of the pelvis; the other, thin and sharp, bounds the obturator foramen; its external surface looks outwards and downwards, is rough for the attachment of the muscles; the inner surface forms part of the lower circumference of the pelvis.

*Attachments of muscles.*—To the outer border of the tuberosity and the contiguous part of the ramus, the adductor magnus; to the inner margin of the tuberosity at its fore part, the erector penis; to the adjacent margin of the ramus, the transversus perinæi; the internal obturator muscle to the inner surface of the bone behind the thyroid or obturator foramen.

To the posterior surface of the tuberosity, the three flexors of the leg, *scil.* the biceps, semitendinosus, and semimembranosus; to the rough line on the outer surface which bounds the tuberosity, the quadratus femoris; to the external surface of the spine, the gemellus superior; to the adjacent border of the tuberosity, the gemellus inferior; to the internal surface of the bone, the levator ani; and to the spinous process, the coccygeus.

*Development.*—The three pieces which form the os innominatum commence each with a separate point of ossification, and the extension of the osseous deposit proceeds in each towards the acetabulum as a common centre, so that when completed it is found to consist of a portion of each. Besides these, the spine of the ilium and the tuberosity of the ischium are formed separately.

*Acetabulum.*—At the junction of the three pieces of the os innominatum is situated the cavity which articulates with the



head of the femur. It is called *acetabulum*, also the *cotyloid* or cup-shaped cavity, (*κοτύλη*, a cup; *εἶδος*, like.) Of this the ischium forms somewhat more than two-fifths, the ilium somewhat less than two-fifths, the remainder being made up by the os pubis. It is surrounded in the greater part of its extent by a margin or supercilium, which is most prominent towards the superior and external part; but at the opposite point, or towards the obturator foramen, it is deficient, leaving a notch, (*cotyloid notch*, sometimes also called *incisura acetabuli*.) The greater part of the cavity is covered with cartilage in the natural condition; but towards the notch there is a part depressed beneath the rest, and which corresponds with the passage of the round ligament, and lodges some synovial cryptæ: this has no cartilaginous coating.

When we examine the pelvis as a whole, we observe that these articulating cavities, placed in the lateral walls of the pelvis, look outwards and forwards, and that they rest, when the body is erect, upon the globular heads of the thigh-bones, which they lodge. The margin of each cavity is rough and uneven; but in the recent state it is rendered smooth, and the depth of the cavity is increased, by a fibro-cartilaginous rim, which runs round it, and increases its depth. Where the osseous margin is deficient, (at the cotyloid notch,) its place is supplied by a fibrous band, so stretched across as not altogether to fill it up, but rather to bridge it over, leaving a space beneath it for the entrance of vessels into the interior of the joint.

To the inner side of the acetabulum is found, in the dried bone, a large aperture, which, however, in the natural condition, is almost completely closed by a fibrous membrane. It is called *foramen obturatorium*, perhaps more properly *obturatorum*, from the circumstance of its being closed by a membrane or ligament. It is also called *foramen thyroideum* (shield-shaped; *θυρεος*, a shield) from its shape; and not unfrequently *foramen ovale*. It is somewhat of an oval form in the male, its greatest diameter being extended obliquely downwards and outwards; in the female it is a three-sided figure with rounded angles.

*General conformation of the Pelvis.*—The *pelvis*, or basin-shaped cavity, which is thus made up of the ossa innominata, the sacrum, and coccyx, deserves to be attentively examined, not merely as to the details of the parts which compose it, but as to its general conformation. Taking the objects which are deserving of notice on the external surface, from before backwards, and beginning at the median line, we observe the *symphysis pubis*, or the line of junction between the two bones of that name; its direction is vertical, its depth greater in the male than in the female; beneath it is an angular space, the *pubic or sub-pubic arch*, bounded by the rami of the ossa pubis and ischia at each side. On each side of the arch is the *thyroid or obturator foramen* above noticed, and still more laterally the *acetabulum*, above which rises the broad convex part of the ilium, (*dorsum ilii*.) Posteriorly, along the middle line, are situated the tubercles or spinous processes of the sacrum; external to these, the posterior sacral foramina, and next, a broad, unequal surface, to which the sciatic ligaments and gluteus maximus are attached; and lastly, the large deep excavation (*sacro-sciatic notch*), bounded by the margins of the sacrum and os innominatum.

The internal surface is divided into two parts by a prominent line, (*linea ilio-pectinea*), leading from the tuberosities of the ossa pubis, outwards and backwards, to the prominent point of the sacrum, (*promontorium*.) This constitutes the margin or brim of the *true pelvis*, all the part above it being called the *false pelvis*; as in reality it belongs to the abdomen.

The superior circumference of the false pelvis is formed on each side of the crista ilii; posteriorly may be observed a deep notch, which is divided into two parts by the base of the sacrum, and anteriorly (in the interval between the anterior-superior spinous processes of the ilia) the margin of the bone subsides, so as to present a deep excavation, which in the natural condition is filled up by the soft parietes of the abdomen. Along this margin are placed the anterior-inferior spinous processes of the ilia, the ilio-pectineal eminences, the spines or tuberosities of the ossa pubis, with their cristæ and angles.\* The inferior circumference or outlet of the pelvis presents three bony eminences, (the tuberosities of the ischia on the sides, and the coccyx behind in the middle line.) These are like so many promontories, separated by deep excavations. The anterior one, (*pubic arch*), triangular in its form, is bounded on each side by the rami of the ischia and ossa pubis, extending upwards and inwards, from the tuberosities of the ischia to the symphysis pubis. The two other notches (*sacro-sciatic*) are placed behind and above the tuberosities, and correspond with the interval between the sacrum and os innominatum. When examined in the dried bones, their extent is considerable; but in the natural condition they are divided into lesser spaces by the sacro-sciatic ligaments.

The size and conformation of the pelvis differ very remarkably in the two sexes. In the female the bones are thinner, more smooth on the surface, the muscular impressions being less strongly marked, and, though its perpendicular depth is less, its breadth and capacity are greater. The alæ of the iliac bones are more expanded; the upper aperture is more nearly circular, the projection of the sacrum less perceptible; and the space between the tuberosities of the ischia greater. The depth of the symphysis pubis is less in the female than in the male, whilst the breadth of the pubic arch is greater.

In the erect attitude of the body, the direction of the pelvis is oblique, its upper aperture being inclined forwards; so much so, that if a line be drawn from the upper border of the symphysis pubis, backwards to the sacrum, it rests against the middle of that bone. In consequence of this inclination, the central line, or axis of the inlet, differs very decidedly from that of the outlet; the former, if drawn from above downwards, reaches the lower third of the sacrum; the latter, if drawn from below, backwards and upwards, touches the promontory of the sacrum; both therefore decussate towards the centre of the pelvic cavity. The different dimensions of the male and female pelvis are stated as follows, by Meckel, Cloquet, and Burns:—

\* The superficial depression of this margin of bone, just at the outside of the pectineal protuberance, and between the anterior spinous processes of the ilium, has been pointed out by T. D. Mütter, M.D., Prof. Surg. in Jefferson Medical College, as the site of the head of the bone in a *sixth* luxation of the os femoris, (directly upwards,) which he has described in the 51st No. of the Philadelphia Medical Examiner.—J. P.



	MECKEL.		CLOQUET.	BURNS.
	In the Male Pelvis.	In the Female Pelvis.	Female.	Female.
	inch. lines.	inch. lines.	inch. lines.	inch. lines.
Between the anterior-superior spinous processes of the ilia . . . . .	7 8	8 6	10 0	10 0
Between the middle points of the cristæ of the ilia . . . . .	8 3	9 4	11 1	11 1
The transverse diameter . . . . .	4 6	5 0	5 6	5 6
The oblique . . . . . of the inlet . . . . .	4 5	4 5	4 7	5 5
The antero-posterior . . . . .	4 0	4 4	4 4	4 0
The transverse diameter . . . . .	4 0	4 8	—	—
The oblique . . . . . of the cavity . . . . .	5 0	5 4	—	—
The antero-posterior . . . . .	5 0	4 8	—	—
The transverse . . . . . of the outlet . . . . .	3 0	4 5	4 4	4 0
The antero-posterior . . . . .	3 3	4 4	4 4	4 0

The last may be increased to five inches in consequence of the mobility of the coccyx.

*Bones of the Lower extremity.*—The lower extremity is made up of three parts: the thigh, leg, and foot.

The osseous part of the first consists of one bone—the femur; that of the leg, of two—the tibia and fibula. The adjacent extremities of these, together with the patella, (a sort of sesamoid bone,) form the knee.

The foot is composed of three parts, the tarsus, metatarsus, and phalanges.

*The Femur.*—The femur or thigh-bone, (plate XXIV., *os femoris*,) the longest bone of the skeleton, is situated between the pelvis and the tibia. In the erect position of the body, its general direction is not vertical; it gradually inclines inwards towards the lower part, so that the bones of opposite sides, though separated at a considerable distance where they are connected with the pelvis, approach each other inferiorly, and come nearly in contact. The degree of this inclination varies in different persons, and is more marked in the female than the male. The femur presents a central part, or body, and two extremities.

The *body*, or shaft, as it is sometimes called, compressed, but nearly cylindrical towards the centre, and at the same time slightly convex or arched forwards, is expanded superiorly and inferiorly. Its anterior surface, convex and smooth, is broader towards the lower than the upper extremity. Both its lateral surfaces are compressed and somewhat flat; but it may be observed that the external is somewhat concave; it affords attachment to the vastus externus muscle. The surface, which superiorly looks inwards, is, in the lower third of the bone, inclined somewhat backwards, and gives attachment to the vastus internus. The anterior surface is separated, though not in a very marked degree, from the lateral surfaces by two lines, which may be traced upwards from the condyles towards the superior extremity of the bone; but posteriorly, at the union of the two lateral surfaces, is a rough and prominent line, (*linea aspera*,) which gives attachment to several muscles.

The *Linea aspera*, is most prominent towards the centre of the bone, and when examined with attention, presents two margins and a rough interstice, each giving attachment to muscles. Above and below the centre, it subsides as it were towards the extremities, and also becomes bifurcated. The two superior divisions or branches of the line terminate, the one (internal and somewhat shorter) at the lesser trochanter; the other, external, at the greater trochanter; in the course of the latter a rough strongly-marked impression exists, which gives insertion to the gluteus maximus. The inferior divisions spread more asunder, and terminate at the condyles, enclosing between them and the margins of these prominences, a flat triangular portion of the bone, which corresponds with the popliteal vessels. Towards the superior part of the linea aspera may be observed a foramen directed from below upwards, which transmits the medullary vessels.

At the superior extremity of the bone is placed its neck, which is directed upwards and inwards, so as to form an obtuse angle with the body or shaft; at its point of union with the latter are two eminences, (*trochanter*, major and minor,) one on the outer, the other on the inner side; it is from between these that the neck arises.

The *Trochanter major* is prolonged from the external surface of the body of the bone, and nearly in a line with its axis. This apophysis, quadrilateral in its form, is convex and rough on its external surface, which is marked by a line directed obliquely downwards and forwards for the attachment of the gluteus medius; the internal surface, of less extent, presents at its base a pit, (*trochanteric* or *digital fossa*,) which receives the external rotator muscles; its superior or terminal border is flat and straight, and the posterior thick and rounded. At the posterior aspect of the great trochanter may be observed an oblique and prominent line, directed downwards and inwards, and terminating in the trochanter minor.

The *Trochanter minor*, a conical rounded eminence, projects from the posterior and inner side of the bone, and gives attachment to the tendon of the psoas and iliacus muscles.

The *neck* of the femur, which is so named from its constricted appearance and supporting the head, forms an obtuse angle with the body of the bone; it is compressed from before backwards, so that its diameter in this is much less considerable than in the vertical direction, in which greater power of resistance is required for sustaining the weight of the body; its anterior surface is broad and smooth; the superior, inclined upwards, is short and somewhat concave; the inferior is the most extensive. The union of the neck with the rest of the bone is marked by the trochanters and two intervening oblique lines, (*inter-trochanteric*,) of which, the anterior one is rough and but slightly prominent; the other, situated posteriorly, forms a smooth projecting ridge, which overhangs the trochanteric fossa.

The neck is surmounted by the globular *head*, which forms a considerable segment of a sphere, is tipped with cartilage in the fresh state, and lodged in the acetabulum. A little beneath its most prominent part is a small cavity, which gives attachment to the round ligament.

The *inferior extremity* of the bone, much thicker and broader than the superior, is terminated by two eminences, separated posteriorly by a deep fossa; these are named *condyles*, of which one is internal, the other external.

The external condyle is larger, and projects forwards more than the internal; its articulating surface also is broader, and mounts higher up anteriorly; its external surface, rough and unequal, presents a deep pit inferiorly, which gives attachment to the tendon of the popliteus muscle; and immediately above it a projection, (*external tuberosity*), which gives attachment to the external lateral ligament of the knee-joint.

The internal condyle appears longer, and also to descend lower down than the other; but this is rather apparent than real for by means of the obliquity of the shaft of the bone both condyles are brought to the same plane. The internal condyle presents at its inner side a tuberosity which gives attachment to the internal lateral ligament of the knee-joint and the tendon of the adductor magnus. In the fossa, between the condyles, posteriorly, are implanted the crucial ligaments.

The articular surfaces of both condyles, covered with cartilage in the fresh state, are united anteriorly where they form a pulley-like surface, concave from side to side, on which the patella glides. Inferiorly, these surfaces diverge as they pass backwards, and, when they terminate at the posterior surface of the bone, are separated by a considerable interval.

*Articulations*.—The femur articulates superiorly with the acetabulum; by its condyles with, inferiorly, the tibia, and, anteriorly, the patella.

*Attachments of muscles*.—To the anterior surface, the crureus; to the two lateral and to both lips of the linea aspera are attached the vastus internus and externus; to the centre of that line, the adductors and the short head of the biceps flexor; to the superior border of the trochanter major, the gluteus medius; to its anterior border, the gluteus minimus; to the fossa, at its posterior surface, the external rotators; to the lesser trochanter, the tendon of the psoas and iliacus; to the line between the trochanters, posteriorly, the quadratus femoris; to the line below the lesser trochanter, the pectineus; to the rough impression beneath the great trochanter, the gluteus maximus; just above the inner and outer condyle, the corresponding heads of the gastrocnemius; to the external condyle, the plantaris; to the fossa beneath the external tuberosity, the popliteus.

*Development*.—The femur grows from five osseous centres; one being in the middle of the shaft, which appears very early; the two trochanters and the head commence by separate points; and there is one at the lower extremity, which is evolved into the two condyles.

*The Patella*.—The patella (plate XXIV., *rotula*, knee-pan) is situated at the anterior part of the knee-joint, being attached by a ligament (*ligamentum patellæ*) to the tibia, so that its position with regard to the joint varies according to the movements of that bone. Compressed and somewhat triangular in its form, its anterior surface is convex, and covered by the expanded fibres of the extensor tendons; the posterior, smooth and covered with cartilage for its articulation with the condyles of the femur, is divided into two parts by a vertical line, the external being the broader. Beneath these is situated a small irregular depression, corresponding with the apex, or narrowest part of the bone, which gives attachment to the ligamentum patellæ. The superior extremity, broad and rounded off at its margin, gives attachment to the extensor muscles; the inferior, narrow and pointed, to the ligament already named; the lateral borders are convex, the external being thinner than the internal.

*The Tibia*.—The tibia, (plate XXVI.,) next to the femur, is the longest bone in the skeleton; situated at the anterior and inner side of the leg, it alone receives from the femur (under which it is placed vertically) the weight of the trunk, and communicates it to the foot. Like the other long bones, it is divided into a body and two extremities.

The *superior extremity*, much thicker and more expanded than any other part of the bone, (being proportioned in size to the lower extremity of the femur,) is broader from side to side than from before backwards; its circumference is somewhat rounded and convex in front and at the sides, but slightly hollowed posteriorly; at the fore part, a little below the head, is situated an eminence, sometimes called the anterior tuberosity, more properly the *tubercle*, which is somewhat rough at its lower part, for the attachment of the ligament of the patella, and smooth superiorly, where it corresponds to a small synovial bursa, intervening between that ligament and the bone. On the sides, and above this, are two rounded eminences, (*tuberosities*), the external one being somewhat smaller than the other, and marked posteriorly by a flat surface, which articulates with the head of the fibula; these processes give attachment to the lateral ligaments of the knee-joint. On the superior aspect of this portion of the bone may be observed two concave cartilaginous surfaces, (*condyles*), which sustain the condyles of the femur; the internal one is somewhat the deeper, its greatest diameter is from before backwards; the external one is nearly circular. In the interval between the articular surfaces is situated a pyramidal eminence, the summit of which is usually divided into two tubercles; it is named the spine or spinous process of the tibia; before and behind this are two irregular depressed surfaces, which give attachment to the crucial ligaments and to the semi-lunar cartilages.

The *lower or tarsal* extremity of the bone is much smaller than the upper, and nearly quadrilateral in its form; the anterior surface, convex and smooth, is bounded below by a slightly rough margin which gives attachment to the anterior tibio-tarsal ligament; the posterior is flat, and marked by a groove for the flexor longus pollicis; the external, slightly concave, is rough



superiorly, for the attachment of the transverse ligament, and smooth below, to receive the extremity of the fibula. From the inner border of this end of the bone projects downwards a triangular apophysis, the *internal malleolus*; the inner surface of which is convex, and covered merely by the skin, the external is smooth, and articulates with the side of the astragalus; the anterior forms a rounded border, whilst the posterior is marked by two grooves for the tendons of the tibialis posticus, and flexor longus digitorum; to the most dependent part of the process is attached the internal lateral ligament. The lower articular surface of the tibia, or that part which enters into the formation of the ankle-joint, consists of two parts, one vertical, just described as being situated at the outer side of the malleolus; the other horizontal in its direction, concave and quadrilateral in its form, divided into two parts by a slightly raised line; of these two surfaces, which are united at a right angle, and tipped with cartilage in the fresh state, the latter rests on the dorsum of the astragalus, the former is applied to its inner flat border.

The *body* of the tibia, triangular in its form, diminishes gradually in size for about two-thirds of its length, after which it increases somewhat towards its lower extremity. The internal surface is convex and subcutaneous, except at the upper part of its extent, where it is covered by the tendons of the sartorius, semi-tendinosus, and gracilis muscles. The external surface, slightly hollowed above, where it gives origin to the tibialis anticus, is convex, and somewhat inclined forwards below, where it is covered by the extensor tendons. The posterior surface is very deeply seated; not so uniform in its outline as the others, it is marked at its upper third by a line extending upwards and outwards to the external tuberosity; the part above this is triangular, and gives attachment to the popliteus muscle, that below it to the tibialis posticus and flexor digitorum, and from the line itself arises the soleus. Near this line may be observed a medullary foramen of large size, whose direction is from above downwards.

The surfaces here indicated are separated by an equal number of borders. The anterior border, more or less sinuous in direction, sometimes considerably curved, is for the most part subcutaneous; sharp and prominent, especially towards the middle, and hence named the *crista* or *spine* of the tibia, it subsides towards the lower end of the bone, as if to allow a smooth surface for the passage forwards of the vessels and muscles, which superiorly are placed on the outer side. The inner border, thick and rounded, gives attachment to the soleus and flexor longus digitorum; whilst the external, somewhat sharp, divides inferiorly into two lines, which diverge towards the surface of articulation with the fibula. The interosseous ligament is inserted into this external border. The body of the tibia is slightly twisted, so that the internal tuberosity inclines a little backwards, and the internal malleolus forwards, which conformation deserves attention in the diagnosis and adjustment of fractures.

*Articulations.*—The tibia articulates with the femur, the fibula, and the astragalus.

*Attachments of muscles.*—To the external surface and external tuberosity, the tibialis anticus; to the latter also, the head of the extensor longus digitorum; to the inner surface, the sartorius, gracilis, semi-tendinosus, and semi-membranosus; the popliteus, to the triangular space on the posterior surface; the soleus, tibialis posticus, and flexor longus digitorum, to the rest of its extent, and, through the medium of the patella and its ligament, it may be said to give insertion to the extensors of the leg.

*Development.*—There is an osseous centre in the body of the bone, and one at each extremity.

*The Fibula.*—This bone (plate XXVI., *fibula*, *peroné*, *περονή*, a clasp) is situated at the external side of the leg; it is nearly equal to the tibia in length, but is much more slender. When the fibula is placed beside the tibia in its natural position, its lower extremity will be found a little farther forward than the upper one, and its shaft inclined backwards and a little inwards, so as to be convex in that direction.

The *body* of the bone, irregularly triangular in its form, presents three prominent lines bounding three surfaces; the anterior, or most prominent line, gives origin to muscles in the superior part of its extent, and bifurcates towards its lower extremity, so as to enclose a slightly concave triangular surface, which is subcutaneous; the internal one also gives attachment to muscles, and inferiorly, where it inclines forwards, to the interosseous ligament. The *internal* surface looks backwards for about a third of its extent, and somewhat forwards in the rest, and is divided, but unequally, into two parts, by a slightly-marked longitudinal line, to which the interosseous ligament is attached for about two-thirds of its length; the part of the surface behind this is grooved,—it gives attachment to the tibialis posticus muscle; the anterior portion, the smaller, to muscles placed in front of the leg. The *external* surface, concave in the greatest part of its extent, gives origin to muscles;—towards its lower extremity, this surface is inclined backwards, conforming with the peronei muscles, which are connected with the superior part of the bone, and incline in that direction to pass behind the external malleolus. The *posterior* surface, convex and smooth, affords attachment to muscles, and presents towards its middle a small foramen, directed obliquely downwards for the transmission of the medullary vessels; in the lower part it inclines inwards, and is terminated by a rough surface connected with the tibia.

The *superior* extremity of the bone, called also the head, is smaller than the inferior one; it presents on the supero-internal part a small oval and nearly flat surface, for its articulation with the corresponding part of the external tuberosity of the tibia; the remainder is unequal, and gives insertion to the biceps flexor cruris, to the external lateral ligament of the knee-joint, and to those which connect the tibia and fibula. The *inferior* or tarsal *extremity* forms the external malleolus, which is longer and more prominent than the internal one; in front it receives the insertion of ligaments; behind is situated a shallow groove traversed by the tendons of the peronei muscles; the outer side is convex and subcutaneous; the inner presents a small triangular surface, convex in the perpendicular, and nearly plain in the antero-posterior direction, which articulates with the astragalus, and is



bounded posteriorly by a rough depression, affording attachment to the transverse ligament of the ankle-joint, whilst the apex gives origin to the external lateral ligament.

*Articulations.*—The fibula articulates at both extremities with the tibia, and at the inferior one with the outer border of the astragalus.

*Attachments of muscles.*—The internal surface, by its anterior portion, to the extensor communis digitorum, extensor proprius pollicis, and peroneus tertius; by the depression on its posterior part, to the tibialis posticus: the external surface, to the peronei; the posterior surface, to the soleus and flexor longus pollicis; its head, to the biceps flexor cruris.

*Development.*—The fibula has an osseous centre for its body, and one for each extremity.

*Bones of the foot.*—The foot is composed, like the hand, of three parts, viz. the tarsus, metatarsus, and toes.

*Tarsus.*—The tarsus is composed of seven bones, viz. the os calcis, astragalus, naviculare, cuneiforme internum, cuneiforme medium, cuneiforme externum, and cuboides.

*The Calcaneum.*—This bone (plates XXVIII. XXIX., *os calcis—calcaneum*) is situated at the posterior and inferior part of the tarsus, and forms the heel by its projection backwards; elongated in that direction, and compressed laterally, it is the largest of the bones of the foot. Superiorly it presents (taking the objects successively from behind forwards) a concave portion, intervening between the insertion of the tendo Achillis into its posterior border, and the surface which articulates with the astragalus; then the last-named surface, which is bounded by a rough depression for the insertion of a ligament, (interosseous;) and lastly a narrow concave surface, which also articulates with the astragalus. On the inferior surface, which is narrower than the preceding, and broader behind than before, are observed posteriorly two tubercles, (the internal being the larger,) serving for the attachment of the plantar fascia and the superficial plantar muscles; between them a depression for the origin of the long plantar ligament, and in front another eminence, giving attachment to the inferior ligament (calcaneo-scaploid) connecting this bone with the scaphoid. The anterior surface, the smallest, is slightly concave, and articulates with the cuboid bone. The posterior surface, convex, presents, inferiorly, inequalities, for the attachment of the tendo Achillis; and, superiorly, a smooth surface, separated from that tendon by a synovial bursa. The external surface, broader behind than before, presents in the latter direction, superficial grooves, for the tendons of the peronei muscles, and is subcutaneous in the rest of its extent. The inner surface, deeply concave, is traversed by the plantar vessels and nerves, and the tendons of the flexor muscles. A groove runs along at its upper edge, and under the tubercle which surmounts it, for the tendon of the flexor longus pollicis. The calcaneum articulates with the astragalus and the cuboid bone.

*The Astragalus.* (*αστραγάλος*, a die.)—The astragalus (plates XXVIII. XXIX.) is situated at the superior part of the tarsus; its form is irregular, it appears as if twisted on itself. The upper surface presents, in front, a rough and slightly excavated part, serving for the attachment of ligaments; and behind it a large convex cartilaginous surface, which is longer and more prominent on the outer than on the inner side, broader before than behind, and articulated with the lower extremity of the tibia. On the outer and inner sides are situated two smooth surfaces, (the former the larger,) which are continuous with the preceding, and articulated with the inferior extremities of the tibia and fibula, (the *malleoli*.) On the inferior surface are observed, in front, and somewhat internally, a narrow convex surface, and behind, a broad concave one, both articulating with the os calcis; these are separated by a groove, which receives the ligament that proceeds upwards from the last-named bone. The anterior surface, convex, is received into the hollow in the scaphoid bone; it is called the *head*, and the constricted part by which it is supported, the *neck* of the astragalus. The posterior surface, or rather border, is grooved and traversed by the tendon of the flexor longus pollicis. The astragalus articulates with the tibia and fibula above, with the os calcis below, and with the scaphoid in front.

*The Cuboid bone.*—This bone (*os cuboides, cuboideum*) (plates XXVIII. XXIV.) is situated at the external side of the tarsus; its form is indicated by its name. The superior surface, rather rough, inclined obliquely outwards and upwards, gives attachment to ligaments. The inferior surface presents, in front, a depression traversed by the tendon of the peroneus longus muscle, in the middle a transverse ridge, (tuberosity,) and behind it an irregular surface, both of which give attachment to the calcaneo-cuboid ligament; the former also to some fibres of the ligamentum longum plantæ. At the anterior aspect of the bone is a smooth surface, directed from without inwards and forwards, and divided into two parts, the internal one being square, the external triangular, and articulated, the former with the fourth, the latter with the fifth metatarsal bone; at the posterior is a surface by which it articulated with the os calcis. The external border, which is short and rounded, presents a groove, continuous with that on the inferior surface, and serving for the transmission of the tendon of the peroneus longus muscle. On the internal surface may be observed, towards its middle, an elongated smooth and nearly flat portion, which articulates with the third cuneiform bone, the part before and behind it being rough, for the attachment of ligaments. The cuboid articulates with the fourth and fifth metatarsal bones before, with the os calcis behind, with the external cuneiform, and sometimes with the scaphoid.

*The Scaphoid bone.*—The scaphoid or navicular bone, (plates XXVIII. XXIX,) so named from its excavated form, (*σκαφή, navis*.) is placed at the inner border of the foot, between the astragalus and the cuneiform bones. It presents a concave surface which looks backwards, and a convex one which is turned forwards. Its inner margin projects in the form of a tubercle toward the sole of the foot. Upon its upper and inner surface are inequalities for the attachment of ligaments,—behind, a concavity for the head of the astragalus,—in front, three distinct surfaces for articulation with the three cuneiform bones; at its lower and inner

border is the prominence or tubercle, above noticed, which gives attachment to the tibialis posticus muscle; on the outer side, in some instances, is a small articular surface, by which it is united to the cuboid bone. It articulates with the three cuneiform bones, with the astragalus, and sometimes with the cuboid.

*The Cuneiform bones.*—These bones (plates XXVIII. XXIX., *ossa cuneiformia*, wedge-shaped) constitute the anterior and inner part of the tarsus; the name expresses their form. In number three, they are distinguished by their numerical order from within outwards. The first is the largest, and has its base or broad border turned down into the sole of the foot,—the second, or middle, the smallest. The base, or broad border, of the second and third is at the upper or dorsal surface of the foot, and contributes to give it its arched form. They articulate behind with the navicular, and in front with the first, second, and third metatarsal bones. In consequence of their excess in length over the second, the first and third, in addition to articulating laterally with the corresponding sides of that bone, are in apposition with the base of the second metatarsal bone, which is inserted between them. The inner side of the first is subcutaneous, and the outer side of the third articulates by a smooth flat surface with the cuboid, and by a small linear facette with the fourth metatarsal bone.

*Attachments of muscles.*—The os calcis, by its dorsal surface, to the extensor brevis digitorum pedis; the inferior half of the posterior surface, to the common tendon of the gastrocnemius and soleus, (*tendo Achillis*), and to that of the plantaris; the inferior surface on the inner side, to the flexor accessorius, and part of the abductor pollicis; on the outer side, to the abductor digiti minimi; and between the two abductors, to the flexor brevis digitorum.

The cuboid bone, by the inferior surface, to a portion of the adductor pollicis.

The scaphoid bone, by its tuberosity, to a portion of the tendon of the tibialis posticus.

The cuneiform bones. The first, by its base, to portions of the tendons of the tibialis anticus and posticus, and the second and third to part of the flexor brevis pollicis.

*Development.*—These bones have each a separate centre of ossification. The os calcis has a second in its posterior part or tuberosity.

*The Metatarsus.*—The second or middle portion of the foot (plate XXVIII.) is analagous to the corresponding portion of the hand, (metacarpus,) and like it is composed of five bones placed parallel one with the other. They are named according to their numerical order, from within outwards. The first, or that supporting the great toe, is the shortest, but it exceeds all the others very considerably in thickness. The second is the longest, and the rest decrease successively in length. In all, the thickness of the extremities, particularly of the tarsal ends, is greater than that of the bodies. The bodies of these bones, elongated and somewhat compressed, like the metacarpal bones, may be considered as presenting a dorsal, a plantar, and two lateral surfaces. The dorsal surface of all is covered by the tendons of the extensor muscles, the extensor brevis digitorum, and the vessels and nerves; that of the first is broad, inclined inwards, and bounded externally by a prominent line; in the last it looks outwards, and is bounded on the inner side by a like line. In the others are observed analogous lines, placed in the middle, and separating the attachments of the interossei muscles. The plantar surface corresponds to the deep-seated muscles of the foot, and to ligaments serving to connect those bones. That of the first is broader than any of the others. The lateral surfaces form the interosseous spaces, and give attachment to the interosseous muscles. The tarsal extremity presents, in the first, an oval concave surface, broader above than below, articulating with the first cuneiform bone, and inferiorly a tuberosity for the attachment of the peroneus longus; that of the second metatarsal bone, triangular in its form, is, in consequence of the shortness of the corresponding cuneiform bone, impacted between the two other bones of that name; it gives attachment to ligaments, articulates behind with the second cuneiform bone, on the inner side with the first metatarsal bone, and on the outer with the second. The tarsal end of the third, also triangular, and smaller than the preceding, receives the insertion of ligaments on its upper and under surfaces, and articulates posteriorly with the third cuneiform bone, on the inner side with the second metatarsal bone, on the outer with the fourth. The extremity of the fourth metatarsal bone, cubical in its form, is connected by ligaments to the adjacent bones, and articulates with the cuboid posteriorly, on the inner side with the third metatarsal and third cuneiform bones, on the outer with the fifth metatarsal. The posterior extremity of the fifth metatarsal bone, pyramidal in its form, articulates behind, by an oblique surface, with the cuboid, and on the inner side with the fourth metatarsal bone; on its external and lower side is a rough tuberosity, which forms a considerable projection on the external border of the foot, and gives attachment to the peroneus brevis, and to part of the abductor minimi digiti.

The anterior extremities of the metatarsal bones are convex, and rounded into the form of heads, flattened at the sides and elongated from above downwards. The head is bounded by a groove, or neck, better marked on the upper than on the under surface. These extremities are received into shallow depressions in the first phalanges, with which they are articulated.

*Phalanges of the Toes.*—The toes, which form the last part of the foot, are composed each of three phalanges or rows, except the first, which has but two. The body of the *first* presents three surfaces: one inferior, or plantar, is flat; the others, lateral, are smooth and convex, and meet on the dorsum in a rounded border; they are contracted towards the middle, somewhat rough and broad at the extremities for the attachment of ligaments; concave towards the sole of the foot, and convex superiorly. The posterior extremities, broader than the anterior, are concave, and receive the head of the metatarsal bones. The anterior



terminate in two rounded heads, with an intervening pulley-like surface, the lateral parts being received into depressions, in the contiguous extremities of the second phalanges, whilst the middle groove lodges a prominent line marked on the latter.

The bones of the *second phalanx*, much smaller than the first, are somewhat hollowed on the lower surface, and convex on the upper one; their borders are flat and compressed. The posterior extremities are terminated by two small concave articular surfaces separated by a prominent line, by which means they are adapted to the inequalities observed on the contiguous extremities of the first phalanges. The anterior extremities present two small condyles, which articulate with the third phalanges.

The third set are somewhat conical in their figure; the posterior extremities, or base, being hollow for their articulations with the ends of the second phalanges, whilst the anterior is rough and scabrous.

*Attachments of muscles.*—To the metatarsal bones. The *first* gives attachment to the prolonged tendon of the peroneus longus, to the transversalis pedis, and the first dorsal interosseous muscle; the *second*, to the first and second dorsal interossei; the *third*, to part of the adductor pollicis, to three interossei, and part of the transversalis pedis; the *fourth*, to three interossei also; the *fifth*, to the peroneus brevis and tertius, the transversalis pedis, part of the flexor brevis minimi digiti, to the fourth dorsal and third plantar interosseous muscle.

To the bones of the toes. The *first* phalanx of the great toe gives insertion to the abductor, flexor brevis, and adductor pollicis; the *second* phalanx, to the extensor proprius pollicis and flexor pollicis longus; the *second* phalanges of the other toes receive the insertion of the tendons of the flexor sublimis; and the *third*, those of the flexor profundus and of the extensors.

*Ossa Sesamoidea.*—These do not properly form part of the skeleton; they may be considered as accessories to the tendons of muscles, and are found only in the limbs, never in the trunk. In the superior extremity, two are always found in the articulation of the metacarpal bone of the thumb with its first phalanx. In the lower extremity, two are frequently found behind the femoral condyles, and constantly beneath the first joint of the great toe, as well as in the tendons of the tibialis posterior and peroneus longus. They are situated in the direction of flexion, (the only exception being the patella, which belongs to this class of bones,) and serve the purpose of increasing the power of muscles, by removing them farther from the axis of the bone on which they are intended to act.

## LIGAMENTOUS SYSTEM.

*Articulations.*—The different pieces of the osseous system being connected together so as to form a skeleton, their modes of union must be as various as their forms and uses. When the union is not immediate, as in the case in the cranial bones, it is effected by means of different substances, such as ligament, cartilage, fibro-cartilage, and fibrous membrane, variously arranged and disposed, so as to permit, in some instances, no perceptible motion; whilst in others a free and extended range is allowed in every direction. Still, all the varieties, however numerous, are usually included under the general term “articulation.”

The articulations are divided into three classes, viz. the immovable, the movable, and mixed; the last being intermediate in degree between the others. The first form obtains where flat and broad bones are united to enclose cavities for the lodgment of important organs, as in the cranium and pelvis. In some instances the surfaces are indented and reciprocally impacted one into the other, so that complete solidity is insured by the structure of the part; and as this mode of union occurs only amongst flat bones, their deficiency in extent of contact is compensated by the indentations in their margins. There is another set of immovable articulations, in which the surfaces are merely in apposition with one another, yet total immobility is secured by what may be termed a mechanical contrivance. Thus, though the squamous part of the temporal bone merely rests against the inferior border of the parietal, no motion can exist between them, in consequence of the manner in which the petrous portion of the former bone projects into the base of the skull.

All the bones of the head and face, except the lower jaw, are joined by immovable articulation, or *synarthrosis*, (*συν, together; αρθρον, articulation*), of which there are several forms.

1. The first is called *suture*, (*sutura, a seam*.) In the true suture the union is effected by indentations in the contiguous margins of bones which are mutually received into one another, as may be seen between the two parietal, the occipital, and frontal bones; any varieties that occur being referable to the form of the prominences. Thus, when they are tooth-shaped, the suture is termed *sutura dentata*; if like the teeth of a saw, *sutura serrata*; if the adjacent borders be bevelled off, as where the temporal and parietal bones are applied to one another, it is called a squamous suture, (*sutura squamosa*.) In some parts it may be observed that the mode of union and adaptation are alternated, in order to increase their power of resistance. Thus, at the superior part of the arch of the skull, the frontal overlies the parietal bones, and rests on them; but inferiorly and laterally the reverse takes place, where the parietal rests against the frontal.

When the surfaces are merely placed in apposition with one another, as in the superior maxillary bones, the union is called *harmonia*, (*ἁρμω, to adapt*.)

When a ridge in one bone is received into a groove in another, the articulation is called *schindylesis*, (*σχινδύλεσις, a slit or fissure*.) The rostrum of the sphenoid, and the descending plate of the ethmoid bone, are joined in this way with the vomer. When a conical surface is impacted into a cavity, the term *gomphosis* (*γομφος, a nail*) is adopted, which may be exemplified by the manner in which the teeth are lodged in the alveoli.



In the mixed form of articulation, or *amphi-artrosis*, the bones are connected by an intermediate substance, which allows some degree of motion. The articulations between the bodies of the vertebræ, the union of the pubic symphysis, and that between the two first bones of the sternum, are all constructed on this principle. As the surfaces in these cases are flat and plain, they possess in themselves no mechanical advantage; so that their union is maintained partly by the cartilages interposed between them, and partly by ligamentous and fibrous structures disposed round the articulations.

In the movable articulations, or *diarthrosis*, (*δια, through; αρθρον, articulation,*) as the surfaces are merely in contact with one another, the connexion between the parts is maintained by means of ligaments and fibrous membranes; for, though cartilages are interposed between their adjacent extremities, they do not form a bond of union between them; on the contrary, they are calculated to facilitate motion, rather than to restrain it. But the muscles which surround the different movable articulations contribute materially to retain the articular surfaces in their natural situations, and to prevent displacement. This is particularly evident in the shoulder-joint, in which the head of the humerus is kept in contact with the glenoid cavity of the scapula not so much by the fibrous capsule, which is weak and loose, as by the surrounding muscles; for if these be weakened by paralysis, luxation may be readily produced. The joints in the extremities are all referable to the movable class; so is that of the lower jaw with the skull, and of the latter with the vertebral column. In the greater number of instances one of the articular surfaces is convex, the other concave; but each of these forms exhibits some varieties of conformation, which are marked by particular names. Thus, an articulating surface, which is rounded and globular, so as to represent a segment of a sphere, is called a *head*; but, if it be elongated, the term *condyle* is used. These are in some cases supported by a contracted or thin portion, (*neck*), which connects them with the body of the bone. If two condyles be placed in apposition, so as to leave a fossa between them, and constitute a pulley-like surface, it is termed *trochlea*. When plain even surfaces articulate, it is not necessary to mark them by any particular name; in describing them they are referred to generally as articulating surfaces. Some of the articulating depressions have also received names taken from certain peculiarities in their conformation. Thus, the superior extremity of the ulna, which receives the trochlea of the humerus, is called the sigmoid cavity, from some resemblance to the Greek letter Σ, (*σιγμα, ειδος, like*;) others are denominated from their greater or less degree of depth or shallowness. The deep cup-shaped cavity which receives the head of the femur is called cotyloid, (from *κοτυλη, a cup*, and *ειδος, like*;) and the shallow oval depression to which the head of the humerus is applied, receives the name of *glenoid cavity*, (from *γληνη, a shallow cavity*, and *ειδος, like*.)

The varieties of diarthrosis are:—1. *Enarthrosis*, (*εν, in; αρθρον, a joint*), which in common language is called the “ball-and-socket” joint; such as we see in the hip and shoulder. In these great freedom of motion is provided for.—2. *Arthrodia*, which comprises joints with a limited motion, as in the case of the carpal and tarsal bones, which merely slide for a little way upon each other. The articulations between the tubercles of the ribs and the transverse processes of the vertebræ, and those between the articular processes of the last-named bones, also come under this head.

As the extent and form of the articulating surfaces of joints, as well as their ligamentous connexions, vary in different instances, so must their degrees of solidity and mobility: and, on a review of the whole of the articulations, it may be laid down as a general principle, that the greater their mobility, the less their solidity; or, in other words, that the one is inversely as the other. All the motions, however, which are admissible in joints may be arranged under four heads, viz. motions of gliding, angular movement or opposition, circumduction, and rotation.

1st. The contiguous surfaces of every movable articulation admit a certain degree of *gliding* motion upon one another, so that it may be regarded as common to all; but in some cases it is the only one which takes place, for instance, between the different bones of the carpus and tarsus. We thus observe that some joints admit of all the motions here indicated; some are deprived of rotation, retaining the rest; whilst in others nothing more than a mere gliding can take place between the surfaces; so that a regular gradation is established in their degrees of mobility between the most movable and those which are least so. The shoulder-joint admits of the greatest extent and variety of movement; those between the carpal and tarsal bones are exceedingly limited in these particulars; and finally, between the latter and those which are altogether immovable, an intermediate grade may be traced, of which the pubic symphysis presents an example.

2d. The *angular* movement, or opposition, can only take place between long bones. If these be made to move in opposite directions, as from extension to flexion, or from abduction to adduction, they form with one another angles varying in degree according to the extent of the motion. This, in some cases, as in the elbow and knee, is confined to flexion and extension, which makes them strictly ginglymoid or hinge-joints, (*γυγγλυμος, a hinge*;) in others the motion is general, and extends to four opposite directions, including each of the points intermediate between them, as may be observed in the shoulder, in the hip, and the meta-carpal joint of the thumb, all which joints admit of a circumduction in the part to which they belong.

3d. The motion of *circumduction* is performed when the shaft of a bone is made to describe a cone, its summit corresponding with the superior articulation, the base being at the inferior extremity of the bone. While this motion is being executed, the limb passes successively through the states of elevation, abduction, depression, adduction, and of course through all the intermediate points; and if a pencil be held between the fingers, and its point applied to any plain surface, such as a wall, it will trace a circle corresponding with the base of a cone, whose summit is at the shoulder-joint, whilst its side coincides with the line described by the out-stretched limb as it traverses the different points just enumerated.

4th. *Rotation* differs altogether from circumduction. In the latter the bone suffers a change of place as it moves from one point to another; in the former, it merely turns on its own axis, and therefore retains the same relative situation with respect to the adjacent parts. This movement, however, admits of two varieties; in one, it is performed on a pivot, as in the motion of the axis on the vertebra dentata; in the other there is a sort of compound motion, for instance, where the radius rolls on its own axis at one end, whilst at the other it moves upon the extremity of the ulna, by which its lower part describes a segment of a circle, and therefore changes place to a certain extent. The femur and humerus also admit of a rotatory motion; in the latter, as the head is closely applied upon the shaft, the axis of motion nearly coincides with that of the bone; but in the former, in consequence of the length of the neck, and of the angle which it forms with the bone, the rotation is performed round an imaginary axis, which may be conceived to pass from the globular head to the condyles.

There are but two articulations in which all the motions of opposition, circumduction, and rotation can be performed, namely, the hip and the shoulder joint. In these a convex surface is applied to one which is concave, the former being hemispherical, which is essentially necessary to such a freedom of motion. As joints constructed on this principle are more liable to displacement than any others, their security is in a great measure provided for by their being placed at the superior extremity of the limb, by which they are withdrawn from the influence of external forces. This arrangement is made subservient, not to the security of the joints solely, but also to a very important purpose in the functions of the limb; for, as these free and extended motions are performed in the superior articulation, their effect is communicated to the whole limb, so as to compensate for the more restricted movements in the lower joints.

Though all the motions above mentioned take place in the hip and shoulder joints, each of them, considered singly, is not performed with equal facility in both. Thus, circumduction is executed with greater ease in the shoulder than in the hip. Rotation, on the contrary, is more free and perfect in the latter than in the former. Circumduction can be executed with ease only when the axis of motion coincides (or very nearly so) with that of the lever to be moved, as is the case in the humerus; but, in the femur, the length of the neck of the bone removes the axis of motion considerably from that of the shaft, and thereby impedes circumduction in proportion as it facilitates the rotation of the limb. These differences of structure in the superior joints of the two extremities bear a direct relation to the conformation of their other articulations, and to the purposes for which they are adapted. For, as the inferior extremity is intended to sustain the weight of the body and for progression, the bones of the leg must be securely fixed, which could be effected only by diminishing their mobility; on this account no rotation or supination is allowed between the tibia and fibula; but, to compensate for this deficiency, rotation is permitted in the hip. But as the superior extremity, on the contrary, is fitted for the prehension of objects, and for quick and varied movements, free motion is allowed between the bones of the fore-arm, and between the latter and the carpus, in order that the hand and fingers may be more readily directed and applied to such objects as are required to be seized for different purposes; and the power of pronation and supination, thus conferred, more than compensates for any deficiency in the rotatory motion of the humerus.

It has been already observed, that rotatory motion in a bone presupposes the existence of a globular head, placed so that its axis shall form an angle with the shaft. Wherever this requisite is wanted, motion is confined to opposition and circumduction, as occurs in the articulation of the thumb with the carpus, in the phalanges with the metacarpal bones, and in the clavicle with the sternum. In these joints, the articulating surfaces are placed at the ends of the more movable bones; and, as their axes coincide with that of motion, rotation is prevented; but circumduction and opposition are freely performed. When these are limited in extent, as in the sterno-clavicular articulation, it arises rather from the accessory ligaments of the part than from any impediment in the surface of the bones; and if motion in one direction be more free than in another, as in the digital phalanges with the metacarpus, where flexion and extension are more free than abduction and adduction, it proceeds partly from the existence of the lateral ligaments, and partly from the great power possessed by the flexor and extensor muscles compared with those which perform the other movements. Though in the knee and elbow the axis of motion coincides with that of the bones, yet their movement is confined to two directions, viz. to flexion and extension. In these joints all other motions besides those just mentioned are prevented by the breadth of the articulating surfaces, and by their mode of adaptation: however, when they are flexed, some degree of lateral motion, and also of circumduction, can be performed; as any individual may ascertain by resting his elbow on a table, when he will find that the fore-arm may be made to describe a cone with its summit at the olecranon and base towards the fingers.

The structures entering into the composition of the articulations, are ligaments, fibro-cartilage, cartilage, elastic fibrous tissue, and synovial membrane.

*Ligaments* (ligamenta; λεγιω, to bind) form the chief means by which the numerous pieces of the osseous system are bound together, so as to constitute one whole—the skeleton. Their form and size must vary considerably in different parts, some being flat bands, some rounded cords, and others short but wide tubes, attached at both ends to bones which admit of free movement upon one another, as we see in the capsular ligaments of the hip and the shoulder. Viewing ligaments in this way, we may divide them into two groups, the funicular or cord-like, and the capsular; they are also called, from a mere consideration of their position in relation to their respective joints, anterior and posterior, internal and external, lateral. Most ligaments enter into the formation of joints, and are therefore articular; some, however, merely fill up spaces, as the interosseous ligaments in the fore-arm



and leg; or connect parts between which no motion exists, at the same time that they diminish vacuities, of which the sacro sciatic, and the two proper ligaments of the scapula, furnish examples. The term "false ligaments" is frequently applied to certain folds of serous and synovial membranes, from their being supposed to confine the parts to which they are attached. The broad processes of peritonæum extended from the bladder and uterus to the sides of the pelvis, also the so-called ligamentum mucosum in the knee-joint, may be cited as instances: the expression is obviously ill-chosen, and should be discontinued.

*Fibro-cartilage*, as the name implies, is a structure intermediate between fibrous tissue and cartilage, and partakes of the qualities of both, viz. firmness and elasticity. Being calculated to serve different purposes in the economy, it presents not a few varieties both of appearance and structure. Thus, we find it in the form of broad thin plates in the pieces of the larynx and epiglottis, in the pinna of the ear, in the lateral and median cartilages of the nose, and in the tarsal cartilages of the eye-lids; for in these parts it forms their basis of support, and determines their form; whilst in the trachea it consists of narrow plates curved round the tube, forming a series of rings. In the immovable articulations, fibro-cartilage is interposed between the contiguous surfaces of bones, in layers of various forms and thickness, constituting in some instances the principal means of connecting them together, as we see at the junction of the ossa pubis, and also of the bodies of the vertebræ, in which instances the elastic property is of considerable utility. In some of the movable articulations, pieces of this structure are also placed, their form and size necessarily varying in each instance. In the knee-joint,—in the articulation of the lower jaw-bone, and in that of the clavicle with the sternum, they diminish the effects of jarring motions by their elasticity, and by a certain degree of mobility, which allows them to give way as the bones move upon them, they keep up a perfect adaptation between the parts, notwithstanding the many inequalities of their surfaces. In the hip and shoulder joints they are so disposed as to deepen the articulating cavities, and lessen the liability to dislocation.

*Cartilage* (cartilago, tissu cartilagineux, χονδρος) is much more dense and solid than any of the preceding textures; it is highly elastic, and by its resiliency resumes its original position when any compressing force, to which it may be exposed, is removed. Its colour is in general a silvery white, and not unfrequently presents that of mother-of-pearl; its density is such, that all trace of its cellular nature, or of its being a modification of cellular tissue, is lost. Mr. Hatchett considers its chemical composition to be albumen, and a small quantity of phosphate of lime. It contains a considerable quantity of water, consequently soon dries on exposure to the air, becomes yellow, semi-transparent, and loses its elasticity; it resists maceration, and the action of cold water, for a long time, but is soon acted on by acids, or by boiling water, and converted into a gelatinous pulp.

Cartilage serves as an adjunct to bone, or a substitute for it. In early infancy the different pieces of the skeleton are cartilaginous; but, in the progress of growth, bone becomes deposited in their places, and gradually supplants them altogether; such cartilages are termed *temporary*. The articulating extremities of bones are covered with layers of cartilage, not merely to smoothen them, but also, by their elasticity, to lessen the effects of concussion. The thickness of these layers varies from half a line, or even less, to two lines; it will generally be found greatest along the margins of concave surfaces, and towards the centre of those which are convex. The free surface of each articular cartilage is covered by the synovial membrane of the joint, from which it is impossible to separate it: the attached surface is in equally intimate union with the bone on which it rests.\*

\* There are two subjects of some importance in the general anatomy of the joints, about which there is much difference of opinion, 1. As to whether the synovial membrane of the joints lines the free surfaces of the articular cartilages, or is arrested at their margin after leaving the fibrous capsule of the joint. 2. Whether the articular cartilages are penetrated by blood-vessels, so minute as to escape detection in their healthy state, and yet be capable of conveying the liquor sanguinis, or colourless portion of the blood, or whether they are wholly non-vascular, and receive the innutritive fluids by imbibition through the cells of which they are composed from the blood-vessels in their immediate vicinity. The negative side of the question on both of these points, has found, latterly, many earnest supporters among anatomists and operating surgeons. An amputation of the knee-joint, which I performed during the last winter before the class of the Jefferson Medical College, at the Philadelphia Hospital, gave me an opportunity of observing the changes produced by morbid causes in the articular cartilages, which would seem to favour the same negative view of the subject. From the diseased condition of the integuments of the leg, there was a scantiness of flap for covering the stump, which left the condyles of the femur partly exposed to view. From round the margin of the cartilage and the place of attachment of the crucial ligaments, in front of which the synovial membrane passes, there was, in the course of a fortnight, inflammation, secretion, and a rapid growth of vigorous granulations. On the surface of the cartilage of the condyles there was not the slightest trace of inflammation or secretion. The cartilage remained for many days unchanged, having its natural polished aspect, and totally insensible to the contact of an instrument. It then lost its polish, became soft and pulpy, like a joint exposed to maceration in a dissecting room, and separated flake after flake, till the compact layer of bone covering the cells of the epiphysis below was exposed to view. This was at first dark-coloured, on the separation of the last layers of the cartilage, but it soon became red and sensitive to the touch; small, firm, whitish conical elevations appeared over its surface, which grew into strong and healthy granulations, to which the margins of the flaps at the end of six weeks were firmly connected, leaving the patient a solid and serviceable stump. The patient suffered none of the constitutional irritation common to synovial inflammation, and it would be difficult to believe from the progress of this case, and analogous ones reported by Velpcau and others, either that the synovial membrane is spread over the cartilages of joints, or that the cartilages are themselves vascular.

At an early period of fetal life, the synovial membrane, with a layer of vessels below it, as asserted by Mr. Toynbee, (Memoir on the Non-vascular Tissues, Philos. Trans. 1841,) is spread over the articular cartilages. Towards the period of birth the sub-synovial vessels gradually recede from the surface of the articular cartilage, and form a zone around its margin. There are several minutely injected preparations in the College Museum, taken from young subjects, showing this zone of vessels, of which the general plan of arrangement is as follows—an arterial ramuscule of considerable size, is found concentric with the outer margin of the cartilage, below the synovial membrane, and just where the latter rises up to be lost on the side of the cartilage. From this ramuscule, branches are given off and secondary loops formed, somewhat like the arrangement of the mesenteric arches, forming on the side of the epiphysis an irregular network of vessels. The terminal branches are exceedingly minute radiated vessels, which mount up and are lost on the sides



The *costal* cartilages form so many elastic prolongations of the ribs, serving not merely to complete the arch from the spine to the sternum, but also, by means of their elasticity, to restore the ribs to their original position, after having been elevated by the effort of inspiration.

*Elastic fibrous tissue* (tissu jaune élastique—tissu fibreux jaune,—ligamenta flava—subflava) consists of pale yellow fibres placed parallel, whether their general direction is perpendicular or oblique, no decussation or crossing being observed between them; they are easily separable from one another, as but little cellular tissue connects them. As its name implies, elasticity is the chief property of this structure wherever it occurs, being developed to such a degree as to render it well calculated to form suspensory ligaments, or to invest parts which are subject to considerable alternations of distension and contraction. Thus, in quadrupeds a strong band of elastic tissue (*ligamentum nuchæ*) extends from the spinous processes of the neck, and from some of those of the back, to the skull, the weight of which it supports without producing that sense of fatigue which would necessarily arise were muscle the sustaining power. The corresponding structure in man is reduced to a rudimentary state, the balanced position of the head on the spinal column rendering any further provision unnecessary. The same material enters into the composition of the ligaments which connect the arches of the vertebræ, (*ligamenta subflava*.)

*Synovial membrane*, (*membrana synovialis*, tissu synovial.)—Under this head are included the lining membranes of all the articulations in the body, together with a great number of secreting sacs, (*bursæ mucosæ*), which occur in various parts, more particularly in those which are subject to motion and pressure. The secretion poured out by both is quite the same, though the names given to them would imply a difference; and the purposes which they serve in the economy are also the same, viz., that of facilitating motion, and preventing the injurious effects of friction, by means of the fluid which they secrete. Synovial membranes, like those of the serous class, are shut sacs, without perforation or interruption of their continuity.

Each *articular* synovial membrane lines the fibrous structures which connect the component parts of the joint, and is reflected over the smooth extremities of the bones. If a tendon passes across a joint, as that of the biceps muscle does in the shoulder, or if a ligament lies within it, as we see in the hip-joint, it is enclosed within a tubular sheath derived from the synovial membrane. Membranous processes and prolongations are found in some joints, attached by one extremity, the other being loose and floating. They consist of duplicatures of the synovial membrane enclosing some adipose tissue, together with delicate vessels. These were at one time called “glands of Havers,” after an anatomist of that name, who supposed them to be of a glandular structure, and to secrete synovia; but this fluid is now known to be produced from the whole surface, and not by any particular glands or follicles. As to the properties of the tissue under consideration, we find it to be, wherever it is situated, soft, thin, pale, and semi-transparent, admitting of distension by the effusion of fluid, as in hydrocs articulari, and capable of a slow contraction when absorption takes place. It possesses little or no sensibility in its natural condition, but produces severe suffering when attacked by acute inflammation.

*Articulations of the Spine*.—The different pieces of the vertebral column are connected together by ligaments, by fibro cartilage, and in some parts by synovial membranes; the former serving to retain them in their situation, the latter to facilitate motion between the different bones. The bodies are joined by two ligamentous bands, extending the whole length of the chain, and also by the intervertebral substances.

1. The *anterior common ligament* (plate VII. figs. 1, 7; *ligamentum commune anterius*, Sæmmering; *fascia longitudinalis anterior*, Weitbrecht) is a strong band of fibres which is placed on the front of the bodies of the vertebræ, and reaches from the axis to the first bone of the sacrum, becoming broader as it descends. It consists of longitudinal fibres, which are dense, firm, and well-marked. The superficial fibres extend from a given vertebra to the fourth or fifth below it; the set subjacent to these passes from the body of one to about the third beneath it; whilst the deeper ones pass only from one vertebra to that next it. The fibres are thicker towards the middle of the bodies of the vertebræ than at their margins, or over the intervertebral cartilages; by which means their transverse depressions are filled up, and the surface of the column rendered even. It may also be observed that they

of the bevelled edges of the cartilages. They are reflected back from this point in the form of veins, according to Mr. Toynbee, but my observations have not yet been sufficiently extended to prove this clearly; but whether the synovial membrane recedes with these vessels, or, losing its vascularity, is so altered in character as to form a smooth insensitive covering to the cartilage, has not yet been shown. In the fœtus there is no distinction between the cartilage that is to become the bone of the epiphysis, and that which is to remain as articular cartilage. This distinction is established, when ossification is going on in the epiphysis. In my preparations above referred to, a careful dissection shows branches running from the zone of vessels across the head of the bone, isolating the articular cartilage from the epiphysal. These have beds of bone formed around them, communicate freely with the vessels of the epiphysis, but appear to send no vertical branches towards the free surface of the articular cartilage. The portion of the articular cartilage immediately overlaying them, is, however, more tough and periosteal in character than that on the free surface of the cartilage, and has been described by Mr. Liston as cellular tissue connecting the cartilage and bone. It is well known that the articular cartilage in young subjects is thick, and the compact layer of the epiphysis below it, thin and fragile; whilst in old persons, the compact layer of the epiphysis is thick and strong, and the cartilage covering it thin, rigid, and so firmly united to the bone below, as to be with difficulty removed from it by the ordinary process of cleaning. It would seem from this that while the cartilage gets its nutritive fluids by imbibition from the epiphysal vessels and the marginal zone, some change is effected by their passage into its structure during the progress of life, by which the inner portions of the articular cartilages are gradually converted into bone. Though in the healthy state no vessels can be injected in cartilage, in some diseases of the joints blood-vessels and granulations may shoot up into the place of the cartilage, as in the instance mentioned above, where the cartilage was softened and removed after amputation at the knee-joint. It has been in cases of this description most probably that the appearance of vascularity in the cartilages has been observed; that of Mr. Liston, detailed in a late number of the *Medico-Chirurgical Transactions* was from a diseased joint.—J. P.

adhere more closely to the margins of the bones than to the middle of their bodies, and still more closely to the intervertebral cartilages. Upon the sides of the vertebræ there are some fibres which are thin and scattered, and reach from one bone to the other.

2. The *posterior common ligament* (plate VII. fig. 3; *ligamentum commune posterius*, Sæmm.; *fascia longitudinalis postica*, Weit.) is situated within the spinal canal, and attached to the posterior surface of the bodies of the vertebræ, extending from the axis to the sacrum. It is smooth, shining, and broader opposite the intervertebral cartilages than opposite the bodies of the bones, so that its margins present a series of points or dentations with intervening concave spaces. In the greater part of its extent it adheres firmly to the fibro-cartilages and to the bodies of the vertebræ, and is separated by loose cellular tissue from the prolongation of the dura mater which lines the canal.

3. The *intervertebral substance* (*ligamenta inter-vertebralia*, Weit.) is a plate or disc of fibro-cartilage, (plate VII. figs. 5, 6,) placed between the bodies of each pair of vertebræ, from the axis to the base of the sacrum. They correspond in shape to the parts of the vertebræ between which they are interposed, and, like them, increase in thickness from the upper to the lower end of the column. The thickness of these plates is not, however, uniform in their entire circumference. As they contribute to the production and maintenance of the curves which naturally exist in the spine, they are thinnest anteriorly, in the dorsal region, where its concavity looks forwards, and, on the contrary, thicker in front, in the neck and loins, where the convexity of the column looks in that direction. They are covered anteriorly and posteriorly by the common ligaments, which are intimately adherent to them; in the dorsal region they are connected laterally, by short ligaments, to the heads of all the ribs, which articulate with two vertebræ. The intervertebral substance is composed, towards its circumference, of thin plates of fibro-cartilage, resting on their edges, and placed one within the other, as it were concentrically. Thus the outer plate like a rim runs round the disc, its lower edge resting on the vertebra beneath it; its anterior or convex surface being subjacent to the anterior common ligament, whilst its concave surface is in apposition with the plate next within it. They are not, however, so broad as that their upper edges may reach the vertebra above them, nor are they exactly perpendicular; they incline inwards a little, so as to allow other plates to be in a manner piled upon them: each cartilage being in fact composed of two or three tiers of very narrow plates thus disposed. The interstices between the plates are filled by a pulpy and apparently elastic substance; and as the number of the plates gradually decreases towards the centre, whilst the pulpy matter increases, the quantity of the latter is such, that, when the pressure which confines it is taken off by cutting through the intervertebral substance, it will rise up so as to assume a conical form.

The *articulating processes* of the vertebræ are connected by irregular fibrous bands, (*ligamenta processuum obliquorum*, Weit.) forming a capsule outside the synovial membranes. These are longer and more loose in the cervical than in the dorsal or lumbar regions.

The arches, or plates of the vertebræ, are connected by the *ligamenta subflava*, (plate VII. figs. 2, 4; *ligamenta vertebrarum subflava*, Weit.) as their bodies are by the intervertebral cartilages. These consist of yellow elastic fibres, almost perpendicular in their direction, as they pass from the inferior border of one arch to the adjacent border of that immediately below it. They extend from the root of the transverse processes at each side backwards to the point where the two arches converge at the origin of the spinous processes, where the margins of each lateral half of the ligament may be observed to be merely in contact. The superior border of the ligament is attached, not to the margin exactly of the arch, but rather higher up on its anterior surface; whilst the inferior border is prolonged a little on the posterior surface, as well as the margin of its corresponding arch. They do not exist between the occiput and the atlas, or between the latter and the axis; common fibrous membrane supplies their place in these two spaces. They are most distinctly seen when the pedicles and arches are detached from the bodies of the vertebræ, so that they may be viewed from within the theca vertebralis. At the posterior aspect of the spine they appear short, and, as it were, overlaid by the arches.

The *articulation of the Spinous processes* (plate VII. figs. 2, 7) is effected by means of the supra-spinous and inter-spinous ligaments. 1. The *supra-spinous ligament* consists of small, compressed bundles of longitudinal fibres, which connect the summits of the spinous processes, and form a continuous chain from the seventh cervical vertebra to the spine of the sacrum. The posterior fibres pass down from a given vertebra to the third or fourth below it; those more deeply seated reach only from one to the next, or the second beneath it. 2. The *inter-spinous ligaments*, thin and rather membranous, extend from the root to near the summit of each spinous process, connecting the inferior border of one with the superior border of that next below it. They exist in the dorsal and lumbar regions only, and are intimately connected with the extensor muscles of the spine. The *inter-transverse ligaments* are found only between the transverse processes of the inferior dorsal vertebræ, and even there very indistinctly, for they are united so intimately with the sacro-lumbalis muscle, that their fibres are quite confused.

*Articulations of the two upper Vertebræ.*—The articulation of the axis with the atlas (plate VIII. figs. 1—6) is effected by means of their articulating processes, also (in the place of intervertebral substance, which would be altogether incompatible with the requisite movements) by the odontoid process of the former, which is connected in a particular manner with the arch of the latter, and constitutes the pivot on which the head turns in its rotatory motions. There are three ligaments and four synovial membranes in this articulation.

The *transverse ligament* (*ligamentum atlantis transversum*, Weit. Sæmm.) is a strong, thick fasciculus of fibres, compressed



from before backwards, arched in its direction, and attached on each side to the inner border of the superior articulating processes of the atlas. It is broader and thicker at the middle than at its extremities. From the middle of its posterior surface a short thin bundle of fibres passes down to be attached to the root of the odontoid process, whilst another passes up to the basilar process. These appendages form a cross with the transverse ligament, and serve to bind the occiput to the two first vertebræ; from this is derived the term *cruciform*, which is sometimes applied to the transverse ligament. To bring these structures into view, the posterior part of the vertebral arches must be removed.

The *anterior Atlo-axoid ligament* passes from the border of the anterior arch of the atlas, and its tubercle, to the body of the axis and the root of its odontoid process. It is thin and membranous.

The *posterior Atlo-axoid ligament* connects the posterior arch of the atlas with the plates of the axis. Thus the interstices between the plates or arches, which in all the other vertebræ are filled by the ligamenta subflava, are occupied by a loose membrane between the second and first, as well as between the latter and the occiput. The edges of the articulating processes are connected by irregular fibres passing from one to the other.

Two synovial membranes are placed between the articulating processes of the atlas and axis. One between the odontoid process and the transverse ligament, another between it and the arch of the atlas.

*Articulations of the Cranium.*—The cranium is articulated, 1, with the atlas; 2, with the axis; 3, with the lower jaw.

The articulation of the cranium with the atlas (plates VIII. figs. 1—6) takes place between the condyles of the occipital bone and the superior articulating processes of that vertebra, which are connected by ligaments and synovial membranes; it is also connected with the same by the two following ligaments.

The *anterior Occipito-atloidean ligament* (*membrana annuli anterioris vertebræ primæ*) extends from the anterior border of the occipital foramen, between the condyles, to the margin of the arch of the atlas between its superior articulating processes. This is thin, broad, and membranous; but in the median line a sort of accessory ligament is placed in front of it, which is thick, round, and composed of vertical fibres, attached above to the surface of the basilar process, and below to the small tubercle on the front of the atlas. The anterior surface of these ligaments is covered by the *recti antici* muscles, the posterior covers the odontoid process and its ligaments.

The *posterior Occipito-atloidean ligament*, also broad and membranous, is attached superiorly to all that part of the margin of the occipital foramen which is behind the condyles, and inferiorly to the adjacent border of the posterior arch of the atlas. It consists of two lamellæ, which are united at their superior attachment, but soon divide, one becoming blended with the *dura mater*, which lines the vertebral canal, whilst the other is inserted into the arch of the atlas. The posterior surface of the ligament is in apposition with the posterior *recti* and superior oblique muscles, the anterior looks towards the vertebral canal; at each side, near the articular processes, the ligament forms part of the foramina through which the sub-occipital nerves and vertebral arteries pass.

The articulation of the occipital bone with the axis is effected through the medium of ligaments, as no part of their surfaces comes into contact.

The *Odontoid ligaments* (*ligamenta alaria*) are two thick bundles of fibres attached below to each side of the summit of the odontoid process, and passing up diverging to be implanted into the rough depressions at the inner side of the condyles of the occiput, and also to a small part of the margin of the occipital foramen. Their direction, therefore, is obliquely upwards and outwards; the triangular interval which they thus leave is filled by some thin fibres passing almost perpendicularly from the margin of the foramen to the summit of the process. These are strictly check ligaments; the middle set, last described, prevent what may be termed a retroversion of the head, whilst the lateral pair check its rotatory motions.

The *Occipito-axoidcan ligament* seems to be a prolongation of the posterior common ligament; it is attached above to the inner surface of the basilar groove, from which it descends perpendicularly, becoming narrow, and opposite the axis is blended with the posterior common ligament. It covers the odontoid process and its check ligaments, and is intimately connected with the transverse ligament.

*Articulation of the Lower Jaw.*—The lower jaw articulates (plate VIII. figs. 7—11) at each side by one of its condyles with the glenoid cavity in the temporal bone; hence it is called the temporo-maxillary articulation. By means of an inter-articular cartilage a double joint is formed at each side, with distinct synovial membranes.

The *External lateral ligament* is a short fasciculus of fibres, attached above to the external surface of the zygoma, and to the tubercle at the bifurcation of its root; below, to the external surface and posterior border of the neck of the condyle, its fibres being directed downwards and backwards. Externally it is covered by the parotid gland, internally it is in relation with the inter-articular cartilage and synovial membranes.

The *internal lateral ligament*, thin, loose, and elongated, extends from the spinous process of the sphenoid bone downwards, and a little forwards, to be attached to the inferior maxillary bone at the lower border of the dental foramen, where it is somewhat expanded. Its external surface is in relation superiorly with the external pterygoid muscle, and in the rest of its extent with the ramus of the jaw, from which it is separated by the internal maxillary artery and dental nerve. Its inner surface is concealed by the internal pterygoid muscle.



The *Stylo-maxillary ligament*, thin and aponeurotic, passes from near the point of the styloid process to the inferior border of the angle of the jaw, where it is inserted between the masseter and internal pterygoid muscles.

The *inter-articular fibro-cartilage* is a thin plate, placed horizontally between the articular surfaces of the bones; it is of an oval form, and somewhat thicker at its margins than at its centre, where it is sometimes perforated. Its inferior surface, which is in contact with the condyle, is concave; the superior is alternately concave and convex when taken from before backwards, conforming in some way with the outline of the articular cavity. Its circumference is connected at the outside with the external lateral ligament, anteriorly with the external pterygoid muscle.

The synovial membrane, after lining the superior surface of the inter-articular cartilage, is reflected upwards on the external lateral ligament, and over the smooth part of the glenoid cavity; a similar membrane is interposed between the inferior surface of the cartilage and the condyle, so as to constitute a double joint.

*Articulations of the Ribs.*—The ligaments of the ribs (plate VII., figs. 1, 2, 7, 8, 9) may be divided into three sets: those which connect them—1, with the bodies of the vertebræ; 2, with their transverse processes; 3, with the sternum.

The *Costo-vertebral ligaments* (lig. capitulorum costarum) consist: 1. Of an anterior ligament which connects the head of each rib with the sides of the bodies of the vertebræ; its fibres, flat and radiated, are divided into three bundles, of which the middle one passes horizontally forwards upon the corresponding intervertebral cartilage, whilst the superior ascends to the body of the vertebra above it, and the inferior descends to that below. From the divergence of its fibres, this is usually called the *Stellate ligament*. 2dly. Of an *inter-articular ligament*, which is a thin and short band of fibres which passes transversely from the ridge separating the two articular surfaces on the head of the rib to the intervertebral substance, and dividing the articulation into two parts, each lined by a separate synovial membrane. This ligament does not exist in the articulation of the first, eleventh, or twelfth ribs, and in consequence there is in them but one synovial capsule.

The *Costo-transverse ligaments* connect the tubercles of the ribs with the transverse processes of the vertebræ; from their position they are named posterior, middle, and anterior. 1. The *posterior costo-transverse ligament*, (lig. transversum externum costarum, Weit.) consists of a very short thick fasciculus of fibres which passes from the posterior surface of the summit of the transverse process to the rough unarticulated part of the tubercle of the rib. Those of the superior ribs ascend, those of the inferior descend somewhat. 2. The *middle costo-transverse ligament* consists of a series of very short parallel fibres, which unite the neck of the rib to the anterior surface of the contiguous transverse process. These fibres are seen by removing horizontally a portion of the rib and transverse process, and forcibly drawing one from the other. 3. The *anterior costo-transverse ligament* (lig. transversum internum costarum, Weit.) is usually divided into two fasciculi of fibres, both nearly in apposition, and on the same plane. They pass from the neck of the rib obliquely upwards and outwards to the lower margin of the transverse process next above it. These do not exist in the articulations of the first and last ribs. The articulations between the tubercles of the ribs and the transverse processes are provided with synovial capsules.

The *Costo-sternal articulations*, (plate VII., figs. 10, 11,) situated between the anterior extremities of the cartilages of the ribs and the fossæ, in the margins of the sternum, are covered and supported by, 1, an anterior set of ligamentous fibres, thin, scattered, and radiated, passing from the extremity of the cartilage to the anterior surface of the sternum, where they interlace with those of the opposite side, and are blended with the aponeurosis of the pectoralis major muscle; 2, a posterior set of fibres similarly disposed, but not so thick or numerous, connecting the thoracic surfaces of the same parts; 3, a synovial membrane, interposed between the ends of each true rib and the sternum, and also between the margins of each pair of false ribs, where they articulate with one another. These can be readily demonstrated by slicing off a little of the anterior surface of the sternum and cartilages. A thin fasciculus of fibres connects the cartilage of the seventh rib with the xiphoid cartilage, and is thence called the *Costo-xiphoid ligament*. The pieces of the sternum are connected by a layer of fibro-cartilage placed between their contiguous borders; and, on the anterior and posterior surfaces, some scattered ligamentous fibres may be observed running longitudinally, which serve to strengthen their connexion. These are sometimes called the anterior and posterior sternal ligaments.

*Articulations of the Superior Extremities.*—These may be arranged under the following heads, taking them in their anatomical order, from above downwards: 1, the articulation between the sternum and clavicle; 2, that of the scapula and humerus; 3, of the elbow; 4, of the wrist; 5, of the hand; 6, of the fingers.

The superior extremity has but one point of bony attachment to the trunk, namely, that at the sterno-clavicular articulation, the scapula being connected with the trunk by muscles only. The clavicle articulates with the first bone of the sternum, and is connected with its fellow of the opposite side, and the first rib, by ligaments.

The *Sterno-clavicular articulation* (plate XVI., figs. 5, 6) consists of an anterior and posterior ligament, an inter-articular cartilage, and two synovial membranes.

The *anterior Sterno-clavicular ligament* passes from the inner extremity of the clavicle, downwards and inwards, upon the surface of the sternum. It is broad, and consists of parallel fibres, and corresponds, internally, with the synovial membranes of the articulation, and with the inter-articular cartilage to which it is adherent; externally, with the sternal origin of the sterno-mastoid muscle.

The *posterior Sterno-clavicular ligament*, of similar conformation with the last, but not so broad or strongly marked, is

placed between the same bones lying at the thoracic aspect of the joint. Its posterior surface is in relation with the sterno-hyoideus and sterno-thyroideus muscles.

The *inter-articular fibro-cartilage*, nearly circular in its form, and thicker at its border than at the centre, is interposed between the articulating surfaces of the sternum and clavicle. Towards its superior and posterior part it is attached to the margin of the clavicle, and at the opposite point of the cartilage of the first rib. In the latter situation it is thin and somewhat prolonged, so that the inferior border of the clavicle rests upon it.

*Synovial membranes*.—In this articulation, as in that of the lower jaw, there are two synovial membranes, of which one is reflected over the sternal end of the clavicle and adjacent surface of the fibro-cartilage, the other is disposed similarly between the cartilage and the articulating surface of the sternum.

The *Inter-clavicular ligament* is a dense fasciculus of fibres, placed transversely between the contiguous extremities of the clavicles. Its fibres do not pass directly across from one to the other; they dip down, and are attached to the upper margin of the sternum, by which it is rendered concave from side to side.

The *Costo-clavicular ligament* (ligamentum rhomboides, Weit. Sæmm.) does not properly form part of the articulation, yet it contributes materially to retain the clavicle in its situation. It is attached inferiorly to the cartilage of the first rib near its sternal end, and passes obliquely backwards and upwards, to be fixed to a roughness at the under surface of the clavicle.

The *Scapulo-clavicular articulation* (plate XVI., figs. 7, 8) is effected between the acromion process of the scapula and the external end of the clavicle. These points are connected, 1st, by a *superior ligament*, which is a strong broad band of fibres, passing from the superior surface of the acromion to the adjacent extremity of the clavicle; 2dly, by an *inferior ligament* similar to the preceding, and placed at the under surfaces of the same bones; 3dly, by a synovial membrane lining the two articular surfaces of the bones. As there is an inter-articular cartilage, there are sometimes two narrow synovial sacs, disposed in the same way as those in the sterno-clavicular articulation.

The *Coraco-clavicular ligament*, which connects the clavicle with the coracoid process of the scapula, presents two parts, each marked by a particular name. There is, however, no division between them, nor other distinction than that they look different ways.

The *posterior or internal fasciculus*, (conoid ligament,) broad above, narrow below, is attached, inferiorly, to the root of the coracoid process; superiorly, to a rough space at the inferior surface of the clavicle, its fibres being directed backwards and upwards. The *anterior or external fasciculus* (trapezoid ligament) passes from the superior surface of the coracoid process upwards, to an oblique line extending outwards from the tuberosity into which the conoid ligament is inserted; with the latter it unites at an angle, one of its aspects being directed forwards and upwards, the other downwards and backwards.

There are two ligaments (plate XVI. figs. 7, 8) proper to the scapula: 1. The *Coracoid ligament* (ligamentum proprium posterius) is a thin flat band of fibres, attached by its extremities to the opposite margins of the notch at the root of the coracoid process, which it thus converts into a foramen for the transmission of the supra-scapular nerve, the artery most commonly passing external to it. The *Coraco-acromion* ligament (ligamentum proprium anterius) is a broad, firm, triangular fasciculus, attached by its broader extremity to the coracoid process, and by the narrower to the acromion, between which it is stretched almost horizontally. Its inferior surface looks downwards upon the shoulder-joint, the superior is covered by the deltoid muscle.

The *Shoulder-joint*.—The globular head of the humerus and the glenoid cavity of the scapula are the osseous parts which compose this articulation, (*scapulo-humeral*.) As the head of the humerus is large and prominent, whilst the cavity is merely a superficial depression, it must be evident that they are retained in their situation not by any mechanical contrivance, but by the capsular ligament, and the muscles which are attached to the two tuberosities of the humerus.

The *Capsular ligament* (plate XVI. figs. 7, 8, 10) is attached superiorly round the margin of the glenoid cavity, and inferiorly round the neck of the humerus. It is broader in the latter than in the former situation; and its laxity is such, that if the muscular connexions of the humerus be detached, this bone drops away from the glenoid cavity. The superior and inner part of this membrane is covered and strengthened by a bundle of fibres, passing outwards and forwards from the coracoid process to the great tuberosity of the humerus, (*coraco-humeral ligament*.) Besides this, it receives additions from the tendons of the supra and infra spinatus muscles, from the teres minor and sub-scapularis, which are intimately connected with it, as they proceed to be attached to the tuberosities of the humerus. Thus its superior part is thick and firm, the inferior comparatively thin and weak. Its internal surface is lined by the synovial membrane; the external, besides the muscles already mentioned, is covered by the deltoid; inferiorly, it is in relation with the long head of the triceps and the circumflex vessels. The insertion of its inferior border is interrupted to give passage to the long tendon of the biceps muscle.

The *Glenoid ligament* (fig. 9) appears to be continuous with the tendon of the long head of the biceps muscle: this at its point of attachment to the superior margin of the glenoid cavity, separates into two sets of fibres, which, after encircling it, meet and unite inferiorly. These fibres, by elevating the border of the cavity, render it a little deeper.

The *synovial membrane* lines the glenoid cavity, and is reflected over its lower margin until it reaches the inner surface of the fibrous capsule, on which it is prolonged as far as the neck of the humerus, where it separates from the capsule, and is applied upon the articular surface of the head of that bone, giving it a smooth investment. Viewed in this way, it appears a simple shut



sac; and such it would be but for the peculiar relation of the long tendon of the biceps muscle to the shoulder-joint. The tendon is in fact enclosed in a tubular sheath, formed by an offset or process of the synovial membrane, which is reflected upon it where it is about to pass through the fibrous capsule, and is thence continued up to the summit of the glenoid cavity, where it is continuous with that part of the membrane which invests it. By this provision the integrity of the articulation and of the membrane is preserved.

On the superior and external surface of the capsule a considerable bursa mucosa is situated, by means of which the contiguous surfaces of the coracoid and acromion processes, and of the coraco-acromion ligament, are rendered smooth and lubricated, to facilitate their movements on the subjacent capsule.

The *Coraco-humeral* or accessory ligament, above noticed, extends obliquely over the upper and outer part of the articulation; it is attached to the coracoid process, and thence descends, intimately connected with the capsule, to the greater tuberosity of the humerus.

*The Elbow-joint.*—The lower extremity of the humerus is connected with the ulna and radius at the elbow, so as to form a hinge-joint. The sigmoid cavity of the ulna articulates with the trochlea of the humerus, so as to admit of flexion and extension only, while the cup-shaped depression on the head of the radius can turn freely on the rounded tuberosity to which it is applied. The bones are connected by four ligaments and a synovial membrane. (Plate XXI. figs. 1—6.)

The *internal lateral ligament*, composed of diverging and radiated fibres, presents two parts, each with a different aspect, one looking obliquely forwards, the other backwards. The anterior part is attached above, where it is narrow and pointed, to the front of the internal condyle of the humerus; its fibres, as they descend, become broad and expanded, and are inserted into the coronoid process, along the inner margin of the sigmoid cavity. The posterior part, of the same form, (triangular,) passes from the under and back part of the same process of bone downwards to the inner border of the olecranon; the superior fibres of this portion extend transversely between the points just named, the rest become successively more and more oblique.

The *external lateral ligament*, shorter and much narrower than the internal, is attached superiorly to the external condyle of the humerus, and inferiorly becomes blended with the annular ligament of the radius; none of its fibres are prolonged to the surface of that bone, for if they were, they would check its rotatory motion. It is intimately connected with the tendinous attachment of the extensor muscles, on which account, when dissected, it presents a jagged, irregular appearance.

The *anterior ligament* is a broad thin membrane, placed in front of the joint, extending from the rough margin of the fossa, which receives the coronoid process during flexion, downwards to the anterior border of the coronoid process, and to the annular ligament of the radius. Some of its fibres are directed obliquely downwards and outwards, others are vertical.

The *posterior ligament*, loose and weak, consists of fibres proceeding in opposite directions; thus some pass transversely between the adjacent margins of the fossa which receives the head of the olecranon; whilst others, subjacent to these, but not very well marked, pass vertically from the superior concave margin of that fossa to the extremity of the olecranon.

Though these structures are described and named as separate ligaments, it will be found, on examination, that they form a continuous membrane placed round the joint, as fibrous capsules usually are, except only that the irregularity of the surfaces to which they are attached prevents their continuity from being readily perceived, and gives them the appearance of distinct ligamentous connexions passing from one point of bone to another.

*The upper Radio-ulnar articulation.*—The head of the radius articulates with the small sigmoid cavity of the ulna, on which it rolls when it is made to turn on its axis. These surfaces are covered with cartilage, and invested by the synovial membrane of the elbow-joint. The radius is connected to the ulna by an annular ligament.

The *annular or orbicular ligament* (plate XXI. figs. 2, 3, 4) is a strong band of circular fibres, which, by being attached to the borders of the small sigmoid cavity, forms a ring, encircling the head of the radius, and binding it firmly in its situation. Its external surface is in apposition with the external lateral ligament of the elbow, whose fibres are inserted into it; the internal is smooth and lined by the synovial membrane.

The *synovial membrane* of the elbow-joint, after having covered the articular extremity of the humerus, is prolonged a little on the anterior surface of that bone, as far as the attachment of the anterior ligament, where it is reflected, and applied to the internal surface of that membrane, lining it as far as its radio-cubital insertion; at that point the synovial membrane leaves the fibrous one, and invests the articular surfaces of the radius and ulna, and is extended over them until it comes into apposition with the posterior ligament, by which it is guided to the extremity of the humerus; in the same way, it lines the lateral ligaments. Besides these reflections, the membrane forms two pouches, one by being prolonged into the small sigmoid cavity, the other where it passes between the annular ligament and the contiguous surface of the head of the radius.

When the joint is laid open, and the bones extended, it will be observed that the head of the radius is not in contact with the rounded articulating process of the humerus. On which account, in the extended state of the limb, the rotatory motions of this bone are performed with much less ease than in that of flexion, from its wanting support at its upper end. The part of the humerus here referred to is moreover covered with cartilage only on its anterior aspect, indicating that the radius moves on it only when in the flexed position.

*The middle Radio-ulnar articulation.*—The interval between the radius and ulna in the fore-arm is filled up by an



interosseous ligament and a round ligament, which serve to connect them together, and form what is called the middle radio-ulnar articulation.

The *interosseous ligament* (plate XXI. figs. 1, 2; *membrana interossea*) is a thin, flat, fibrous membrane, the direction of its fibres being obliquely downwards and inwards, from the inner sharp border of the radius to the contiguous one of the ulna. It does not reach the whole length of the bones, as it commences about an inch below the tubercle of the radius. The surfaces of this membrane are intimately connected with the deep-seated muscles of the fore-arm, serving to increase their points of origin as well as to connect the bones. Inferiorly, it leaves an opening for the transmission of the anterior interosseous vessels; superiorly, there is another, but much larger interval, through which the posterior interosseous vessels pass.

The *round or oblique ligament* (figs. 1, 6) in some measure supplies the deficiency left by the interosseous ligament at the superior part of the arm. It is a thin narrow fasciculus of fibres, extending obliquely from the coronoid process, downwards and outwards, to be attached to the radius, about half an inch below its tubercle. The direction of its fibres is therefore altogether different from that of the fibres of the interosseous ligament.

*The lower Radio-ulnar articulation.*—At the lower or carpal ends of the radius and ulna, (plate XXI. figs. 1, 2; plate XXII. 1, 2, 4,) the former rotates on the latter as its point of support, the articulating surface of the radius being concave, that of the ulna convex. The bones are connected anteriorly and posteriorly by some fibres passing between their extremities, so thin and scattered as scarcely to admit or require description, but internally they are joined by a fibro-cartilage and a synovial membrane.

The *fibro-cartilage*, placed transversely between the bones, is attached by its base to a rough line separating the carpal from the ulnar articulating surface of the radius, and by its summit to a depression at the root of the styloid process of the ulna. Its superior surface looks towards the head of the ulna, the inferior to the cuneiform bone; both are smooth, and lined by synovial membrane; the inferior one by the large membrane of the wrist-joint, the superior by a small one peculiar to the radio-ulnar articulation. Its two borders are connected with the carpal ligaments. As the radius rolls on the ulna, this cartilage is carried with it, and forms its chief bond of union with the latter bone.

The *synovial membrane* is frequently called *membrane sacciformis*, though there is nothing in its conformation which distinguishes it from other synovial sacs. It may be considered as presenting two parts, one projecting perpendicularly upwards into the articulation of the radius and ulna, lining the contiguous surfaces of each; the other placed horizontally between the head of the ulna and the corresponding surface of the fibro-cartilage, lining them also; both, however, are formed by a continuous membrane.

*The Wrist-joint.*—This articulation (*radio-carpal*) (plate XXI. figs. 7, 8; plate XXII. figs. 1, 2, 4) is formed above by the radius and triangular fibro-cartilage, and the first three bones of the carpus below. The articular aspect of the former, when viewed in the fresh state, presents an oval and slightly concave surface, its greatest breadth being from side to side. The surface of the radius is divided into two parts, by a line extending from before backwards; so that these, together with the cartilage, present three articular surfaces, one for each carpal bone. The scaphoid, semilunar, and cuneiform bones are articulated together, so as to form a rounded convex surface, which is received into the concavity above described. Four ligaments and a synovial membrane retain these parts in their situation, as follow:—

The *internal lateral ligament* passes directly downwards, from the extremity of the styloid process of the ulna, to be attached to the cuneiform bone; it also sends some fibres to the anterior annular ligament and the pisiform bone. Its form is that of a rounded cord; its inner surface is in contact with the synovial membrane of the radio-carpal articulation.

The *external lateral ligament* extends from the styloid process of the radius to a rough surface on the outer side of the scaphoid bone, some of the fibres being prolonged to the trapezium, and also to the annular ligament of the wrist.

The *anterior ligament*, (*radio-carpal*,) broad and membranous, is attached to the rough border of the carpal extremity of the radius, and to the base of its styloid process, from which its fibres pass down to be inserted into the anterior surface of the scaphoid, semilunar, and cuneiform bones. It is pierced by several foramina for the transmission of vessels: one of its surfaces is lined by the synovial membrane of the joint, the other is in contact with the tendons of the flexor muscles.

The *posterior ligament* extends obliquely downwards and inwards, from the extremity of the radius to the posterior surface of the semilunar and cuneiform bones; its fibres appear to be prolonged for some way on the carpal bones. One surface is in contact with the synovial membrane, the other with the extensor tendons.

The *synovial membrane*, after having lined the articular surface of the radius, and the triangular fibro-cartilage, is reflected on the anterior and posterior ligaments, and thence over the surface of the carpal bones.

*Articulation of the carpal bones.*—The bones of the carpus consist of two sets, each united by its proper connexions, so as to form a row; and the two rows are connected by fibrous bands and a synovial membrane, so as to form between them a joint. (Plate XXII. figs. 1, 2, 3.) The connexions proper to the first row are interosseous fibro-cartilages, and ligaments placed on their dorsal and palmar surfaces.

The *interosseous fibro-cartilages* are two lamellæ, one placed at each side of the semilunar bone, connecting it with the scaphoid and cuneiform bones. The carpal extremity of these is smooth, and lined by the synovial membrane of the wrist-joint.

The *palmar ligaments* are two, one extending from the scaphoid bone to the semilunar, the other from the semilunar to the cuneiform, their direction being transverse, and as their fibres are partly united, they may be considered as a continuous band connecting these bones.

The *dorsal ligaments* are also two, disposed similarly and connecting the same bones on their posterior surfaces. The pisiform bone stands out of the range, and rests on the palmar surface of the cuneiform, with which it is articulated by an irregular fibrous capsule and a synovial membrane.

The carpal bones of the second range are also connected by similar means. Three *dorsal* and *palmar ligaments* pass transversely from one bone to the other. There are, however, but two *interosseous fibro-cartilages*, placed one at each side of the os magnum, connecting it with the trapezoid externally, and the unciform internally. Such are the means of connexion peculiar to each row.

The ligaments which connect the upper to the lower row of bones are placed at their palmar, dorsal, and lateral aspects.

The *lateral ligaments* are placed one at the radial, the other at the ulnar border of the carpus; the former connects the scaphoid bone with the trapezium, the latter the cuneiform with the unciform.

The *palmar* or *anterior ligament* consists of short fibres, which pass obliquely from the bones of the first to those of the second range. The *posterior* is similar in structure and arrangement.

*Synovial membrane.*—It may be observed, that the first range of carpal bones forms a concavity; the second, particularly the os magnum and unciform, a convexity, which is received within it: by these means a ball-and-socket joint is formed, which is completed by a synovial membrane reflected over the articular surfaces of the different osseous pieces which compose it. The membrane, moreover, sends two processes between the three bones of the first row, and three between those of the second, so as to facilitate their respective motions.

*Carpo-metacarpal articulations.*—The last four metacarpal bones (plate XXII. figs. 1, 2, 3) are connected with those of the carpus by means of two sets of fibrous bands, situated, one on the palmar, the other on the dorsal surface, the latter being better marked. All but the fifth metacarpal bone receive two bands. Thus, to the second, or that of the fore-finger, a thin fasciculus of fibres passes from the trapezium, another from the trapezoid bone; the third receives one from the latter, and also from the os magnum; the fourth from the os magnum and also from the unciform; but the fifth is connected to the latter only. On the palmar surface a similar mode of connexion exists, but the fibres are not so well defined.

The *carpal extremities* of the last four metacarpal bones are bound together by three transverse fibrous bands on the palmar, and the same on the dorsal surface, passing from one to the other; they are slight, and often ill-defined.

The *digital extremities* of these metacarpal bones are connected at their palmar aspect by a flat band passing across them, and closely connected with the head of each; this is called the *transverse ligament*.

The *metacarpal bone of the thumb* is articulated on quite a different principle from the others; for, as it admits of all the motions except rotation, it is connected to the trapezium by a capsular ligament, which passes from the rough border bounding its articular surface to the trapezium: these parts are lined by a synovial membrane.

*Articulation of the Phalanges with the Metacarpal bones.*—The rounded head of each of the last four metacarpal bones being received into the slight concavity situated in the extremity of the first phalanx, is maintained *in situ* by two lateral ligaments, an anterior ligament, and a synovial membrane. (Plate XXII.)

The *lateral ligaments* consist of dense fasciculi of fibres, attached by one extremity to the sides of the metacarpal bones, by the other to the contiguous extremity of the phalanges, the direction of the fibres being forwards and downwards. The *anterior* ligaments occupy the intervals between these on the palmar aspect of the joints; they are thin and membranous. The synovial membrane invests the surfaces of the heads of the bones, and is reflected on the ligaments which connect them.

The phalanges are articulated with one another, on the same principle as that which obtains in the articulation between their bases and the metacarpal bones; it is therefore unnecessary to repeat what has been just stated on that subject.

There are some other fibrous and ligamentous structures which deserve to be noticed in this place, but not as being connected immediately with the joints; they are rather accessories to the tendons of the muscles. Thus, along the margins of the phalanges, on their palmar aspect, are attached the *vaginal ligaments*, which form sheaths for the flexor tendons, and bind them securely in their situation; these are thick and firm along the body of the phalanges, but over the flexures of the joints they are thin, so as not to impede their movements; their inner surface is lined by a fine membrane resembling the synovial class, which is reflected over the tendons, giving to each a smooth and shining appearance.

The *posterior annular ligament* of the wrist is continuous with the fascia of the fore-arm, of which it may be considered a part. It extends from the extremity of the radius, at its outer border, to the inner border of the ulna and the pisiform bone, and serves to bind down the extensor tendons.

The *anterior annular ligament* is a dense fasciculus of fibres, extended across the carpus from the pisiform and unciform bones to the trapezium and scaphoides, so as to form a canal which transmits the flexor tendons, retains them in their situation, and modifies their direction and power of action on the hand.



*Articulations of the Pelvis.*—The os sacrum, considered as the common point of support of the vertebral column above, the os coccygis below, and ossa innominata on each side, is connected with each of these in the following manner:—

*Sacro-vertebral articulation.* (Plate XXV. figs. 1, 2, 4.)—The base of the sacrum is articulated with the last lumbar vertebra by means similar to those which connect the different pairs of vertebræ throughout the column; 1, by an inter-vertebral substance placed between their oval surfaces; 2, by the continuation of the anterior and posterior common ligaments; 3, a ligamentum subflavum connecting the arches of the last vertebra with the posterior border of the sacral canal; 4, an inter-spinous ligament; 5, two synovial membranes between the articulating processes; and lastly, a sacro-vertebral ligament. All these, except the last, being similar to the connecting media throughout the column, require no farther description in this place.

The *Sacro-vertebral ligament* extends obliquely from the transverse process of the last lumbar vertebra downwards to the depressed lateral surface at the base of the sacrum; its form is triangular, as its fibres diverge and expand towards the sacro-iliac symphysis.

The *Ilio-lumbar ligament* is extended horizontally between the summit of the transverse process of the last lumbar vertebra and the posterior extremity of the crista of the ilium, where its fibres expand somewhat, so as to give it a triangular form. This is the only bond of union between the true vertebræ and the os ilium.

The *Sacro-coccygean articulation* (plate XXV. figs. 1, 2) is effected by, 1, an *anterior ligament*, consisting of irregular fibres, placed in front of these bones, subjacent to the rectum; 2, by a *posterior ligament* more strongly marked, composed of fibres which descend upon the bones of the coccyx, from the margin of the inferior orifice of the sacral canal, which it serves to close in and complete; 3, by a thin *fibro-cartilage* interposed between the contiguous extremities of the sacrum and coccyx with a synovial membrane which continues in the female to an advanced period of life.

The several pieces of the coccyx are connected one to the other by a continuation of the anterior and posterior ligaments which unite the sacrum and coccyx, and by very thin interposed fibro-cartilages. In the adult male the union between the sacrum and coccyx, and that between the pieces of the latter, are usually ossific; but in the female this change most commonly does not occur till a very advanced period of life, and the mobility increases during pregnancy.

The *Sacro-iliac articulation*, (plate XXV. figs. 1, 2,) often named the sacro-iliac symphysis, or synchondrosis, is formed between the rough lateral surfaces of the sacrum and ilium closely applied to one another, and connected by an irregular lamella of a cartilaginous structure. In addition to these means of union, the pelvic bones are connected by the following ligaments:—

The *posterior Sacro-sciatic ligament*, (plate XXV. figs. 1—4; ligam. sacro-ischadicum majus, Weit., Sæmm.) elongated, broad, and triangular, is placed at the inferior and posterior part of the pelvis, whose lower aperture it assists materially in closing. Its base or broader part is attached to the postero-inferior spine of the ilium and to the side of the sacrum and coccyx; whilst its other extremity is fixed along the inner margin of the tuber ischii, where it expands somewhat, and sends upwards and forwards along the margin of the ramus of that bone a falciform process, which presents one surface looking towards the perinæal space, and the other resting on the internal obturator muscle and pudic artery. The posterior surface of this ligament gives origin to part of the gluteus maximus; the anterior is covered partly by the small sacro-sciatic ligament.

The *anterior or small Sacro-sciatic ligament* (plate XXV. figs. 1—4; lig. sacro-ischadicum minus, internum, Weit., Sæmm.) is attached by its base to the side of the sacrum and coccyx, where its fibres are blended with those of the great ligament, and by its apex to the spinous process of the ischium; its form is triangular, the direction of its fibres forwards and outwards. The spinous process of the ischium, its tuberosity, and these two ligaments, bound an oval interval, through which pass the obturator internus muscle, and the internal pudic vessels and nerve; but above the border of the anterior ligament is a large oval opening, (bounded before and above by the margin of the ilium and ischium, and behind by the great ligament,) which transmits the pyramidalis muscle, the great sciatic nerve, the gluteal and ischiadic vessels and nerves.

The *posterior Sacro-iliac ligaments* (plate XXV. fig. 2) consist of three or four sets of short irregular fibres, extended between the posterior rough portion of the surface on the side of the sacrum and the corresponding part of the ilium. Some of the fibres pass horizontally between the bones, others obliquely: of the latter, one band, extending downwards from the posterior superior spine of the ilium to the tubercles on the third or fourth piece of the sacrum, is described separately, under the name of (from its direction) the *oblique*, or (from being situated superficially to the others) the *posterior sacro-iliac ligament*. They are all placed deeply in the groove formed by the ilium and sacrum, and covered by the origin of the lumbar muscles. The *anterior sacro-iliac ligament* consists of some thin irregular fibres, placed at the anterior aspect of the sacro-iliac symphysis, and attached to the pelvic surfaces of the sacrum and ilium.

The *Pubic articulation* (symphysis pubis) (plate XXV. figs. 1, 4, 5, 6) is formed by the conjunction of the ossa pubis in the median line anteriorly. This is effected by an elongated piece of fibro-cartilage, interposed between their surfaces, and connected to each. It consists of concentric lamellæ, is thicker anteriorly than posteriorly, and frequently projects beyond the level of the bones in the latter direction. A provision is made in this part for a slight degree of movement, which, however, is more perceptible in the female than in the male. Each pubic bone, properly speaking, has its own plate of fibro-cartilage. These plates are connected by fibres passing transversely from one to the other at the fore part as well as at the upper and lower border; but at the middle and back part they are smooth, and often lined by a slight synovial membrane. The union between the bones is



strengthened, 1st, by an *anterior pubic ligament*, which consists of irregular fibres, passing obliquely across from one bone to the other, and decussating on the anterior surface of the fibro-cartilage; the fibres are intermixed with those of the aponeuroses of the external oblique muscles of the abdomen; 2dly, the *sub-pubic ligament*, (ligamentum triangulare, arcuatum,) thick and triangular, which is placed beneath the symphysis, its sides being attached to the rami of the pubis, its base free and slightly concave, directed downwards and backwards to the perinæal space; 3dly, by some indistinct fibres which are situated on the posterior surface of the articulation, and others placed on its upper border: these may be named from their position.

The *Obturator ligament* (plate XXV. figs. 1, 4, 5; membrana obturans foraminis thyrcœidis, Sæmm.) is properly a fibrous membrane, inserted into the border of the obturator foramen, which it closes in its entire extent, except at the upper and outer part of its circumference, where a small oval aperture is left for the exit of the obturator vessels. The obturator muscles are attached to its surfaces.

*The Hip-joint.*—This is a true ball-and-socket joint, in which the globular head of the femur is received into the acetabulum or cotyloid cavity. The articulating surfaces are covered by cartilage in the greater part of their extent. It is deficient, however, at the bottom of the cavity, and also a little beneath the central point of the head of the femur; the latter marking the insertion of the round ligament, the former a shallow fossa for the lodgment of the structure which has been called the synovial gland. The connecting means in this articulation are three ligaments, (plate XXV. figs. 1, 3, 7, 8,) viz. a capsular, cotyloid, and inter-articular ligament, together with a synovial membrane.

The *Capsular ligament*, dense and firm in its texture, represents a fibrous tube, whose direction is downwards and outwards; being attached by one extremity round the margin of the cotyloid cavity, by the other to the neck of the femur. Its superior circumference, in the greater part of its extent, is attached to the bone, within two or three lines of the cotyloid ligament; but opposite the notch, where the margin of the cavity is deficient, it is attached to the transverse ligament. Its inferior circumference is inserted in front into the oblique line leading from one trochanter to the other; but superiorly and behind, its fibres are implanted into the neck of the bone, within a quarter of an inch of the trochanteric fossa, and about the same distance from the posterior inter-trochanteric line. The ligament is most dense and firm towards the superior and anterior part of the articulation; inferiorly, its fibres are comparatively thin. A firm fasciculus of fibres extends obliquely downwards in front of the joint, intimately connected with the capsule, being calculated to strengthen it, hence it is called its "accessory" ligament; but as one extremity of it is attached to the anterior inferior spinous process of the ilium, and the other to the anterior trochanteric line, it may be called the *ilio-femoral ligament*.

The *Cotyloid ligament* is a fibro-cartilaginous ring, placed round the cavity, and serving the purpose of increasing its depth, and completing its border, where it is deficient. The broader part or base of this structure is attached to the bone, its thin edge is free, and both its surfaces are covered by the synovial membrane, the external being in contact with the capsular ligament, the internal with the head of the femur. Its fibres are not continued all round; they rather pass obliquely from without inwards, over the margin of the cavity, one extremity being attached to the outer, the other to its inner surface. At the cotyloid notch these fibres are continued from side to side, crossing one another, so as to render the circumference complete. Some additional fibres are superadded in this part; from which circumstance, as well as its being stretched across from one margin of the notch to the other, it is usually named the *transverse ligament*. Subjacent to the transverse portion an interval is left for the admission of the articular vessels.

The *inter-articular ligament* is not unfrequently called the "round" ligament, (ligamentum teres capitis femoris, Weit., Sæmm.) It is a thick dense fasciculus of fibres, implanted by one extremity, which is round, into the fossa in the head of the femur; by the other, where it is broad, flat, and bifid, into the margins of the cotyloid notch, where its fibres become blended with those of the transverse ligament.

The *synovial membrane* lines the contiguous surfaces of all the parts which enter into the composition of the articulation, giving them a smooth and shining appearance. From the margin of the articular surface of the femur, it may be traced along the neck of that bone as far as the insertion of the capsular ligament, the inner surface of which it lines as far as its superior attachment. There it turns inwards over the cotyloid ligament, and dips into the cavity, lining its entire extent, and finally guided as it were by the inter-articular ligament, (which it invests by a funnel-shaped process,) it reaches the head of the femur, and invests it as far as the border of its cartilage, whence we proceeded in tracing its reflections.

*The Knee-joint.*—This is a ginglymus, or hinge-joint, formed by the condyles of the femur above, the head of the tibia below, and the patella in front, the contiguous surfaces of each being tipped with cartilage, and invested by a common synovial membrane. The following ligaments (plate XXVII.) enter into the composition of the articulation: the ligamentum patellæ, the external and internal lateral, a posterior, a transverse, and two crucial ligaments; besides these, may be enumerated two semilunar fibro-cartilages, and some folds of the synovial membrane, which have received names, viz., the ligamenta alaria and mucosum; but the term ligament cannot with propriety be applied to any other than fibrous structures which connect parts together.

The *ligamentum Patellæ* is a flat strong band of tendinous fibres, which connects the patella with the anterior tuberosity of the tibia. Its superior extremity is attached to the apex of the patella, and to a depression on its posterior surface; its superficial fibres pass upwards on the anterior aspect of the bone, and become continuous with those of the tendon of the rectus femoris; the

inferior extremity is a little expanded; towards the middle its borders are slightly tucked in. The anterior surface of this ligament is subcutaneous in its whole extent; the posterior rests on the synovial membrane of the knee-joint, from which it is separated by some adipose substance, as it is inferiorly from the head of the tibia by a synovial bursa.

The *internal lateral ligament*; broad and flat, connects the tuberosity of the internal condyle of the femur with the inner surface of the head of the tibia. It becomes broad inferiorly, where it is covered by the tendons of the sartorius, gracilis, and semi-tendinosus muscles; internally it rests on the synovial membrane, and is attached to the internal semilunar cartilage.

The *external lateral ligament* is a rounded cord-like fasciculus of fibres, which passes from the tuberosity of the external condyle of the femur, to the head of the fibula; its direction is almost vertical; it is placed nearer the posterior than the anterior surface of the joint; its internal surface corresponds with the synovial membrane and the external articular arteries, the external being covered by the tendon of the biceps flexor cruris, and the expanded fascia of the extensor muscles. Posterior to this, but parallel with it, another ligament is placed, connecting the same points of the femur and fibula; it is called the *short external lateral ligament*.

The *posterior ligament*, (ligamentum posticum Winslowi,) broad and expanded, is a flat plane of fibres, stretched obliquely behind the articulation, from the internal tuberosity of the tibia to the external condyle of the femur. The direction of the greater part of its fibres is from below upwards and outwards, running diagonally across the joint, being evidently continuous with the tendon of the semi-membranosus muscle, of which they may be regarded as a prolongation. This ligament, however, cannot be considered as formed solely by a reflection of the tendon of the semi-membranosus, or merely as the third insertion of that muscle; for several transverse and perpendicular fibres are observed in it, distinct from those of the reflected tendon. Some apertures may be observed between its fibres, which transmit the posterior articular vessels.

The *crucial or oblique ligaments* (ligamenta cruciata) are placed at the posterior part of the joint, external to the synovial membrane, but partially invested by it. As the name imports, their direction is oblique, so that they cross or decussate somewhat like the lines of the letter X; the posterior one, however, approaches more nearly a perpendicular direction: of these one is anterior, the other posterior. The *anterior ligament* is fixed by its lower extremity to a pit, situated before the spine of the tibia, where it is connected with the anterior cornu of the internal semilunar cartilage; its upper extremity is inserted into the inner side of the external condyle of the femur; hence its direction is upwards, backwards, and outwards. The *posterior ligament* is attached inferiorly to the pit behind the spine of the tibia, (where it is intimately connected with the posterior cornu of the external semilunar cartilage,) and superiorly, to the side of the inner condyle; its fibres being directed upwards and a little forwards. Its interior surface is in contact with the last-mentioned ligament, and the posterior with the ligamentum posticum. Both are thus implanted into the fossa between the condyles.

The *semilunar cartilages* are two crescent-shaped lamellæ of the fibro-cartilage, placed on the articulating surfaces of the head of the tibia, interposed between them and the condyles of the femur. The outer border of each is thick and convex, the inner thin and concave, leaving the central part of the superior surface of the tibia uncovered.

The *internal semilunar cartilage*, elongated from before backwards, is nearly of a semicircular form; its anterior cornu is connected with the anterior crucial ligament, and is inserted into the pit before the spine of the tibia; the posterior is attached behind the spine, and is in relation with the posterior crucial ligament; its thick border is connected with the internal lateral ligament, the thin one is free and unattached.

The *external semilunar cartilage* forms nearly a complete circle; its two cornua, fixed one before, the other behind the spine of the tibia, are so close at their insertion, that they may be said to be interposed between the insertions of the internal semilunar cartilage. Its external border is connected behind with the tendon of the popliteus muscle, and in the middle with the external lateral ligament. Towards the front of the joint the convex borders of the inter-articular cartilages are connected by a slight transverse band, (*transverse ligament*.) The superior surface of the fibro-cartilages is concave, and in apposition with the condyles of the femur; the inferior plane rests on the head of the tibia; both surfaces are invested in nearly their entire extent by the synovial membrane.

The *synovial membrane*, like all similar structures, forms a shut sac, whose surface is continuous throughout its entire extent, and as it lines the contiguous surfaces of all the parts entering into the composition of the knee-joint, it must necessarily present rather a complex arrangement. This complexity is increased by the existence of a small funnel-shaped fold, (improperly named *ligamentum mucosum*;) which is stretched across the joint from the lower border of the patella to the margin of the fossa, between the condyles of the femur. In order to exhibit the arrangement of the membrane, the joint should be laid open by a vertical incision carried along the inner margin of the patella and its ligament, leaving the ligamentum mucosum untouched. A lateral view of the joint being thus obtained, all the parts remaining in their natural position, it will be observed that the synovial sac is intersected and in a manner divided into two parts by a transverse funnel-shaped process, (*ligamentum mucosum*;) the superior one elongated and pyramidal, projects by its summit more than an inch above the patella, its base corresponding with the breadth of the process just named. The inferior division of the membrane is quadrilateral, one side being made up of the lower border of the same process, and the smooth surface of the femur with which it is continuous; another by the articulating surface of the tibia;



posteriorly it corresponds with the posterior crucial ligament, and anteriorly with the part of the membrane reflected on the ligamentum patellæ.

If we commence at the superior border of the patella to trace the reflections of the membrane, we find that it descends, lining its articulating surface; below its inferior border it corresponds with the ligamentum patellæ, from which it is separated by a considerable quantity of adipose matter; on reaching the margin of the tibia, it is reflected over its articulating surfaces, and also on both aspects of the semilunar cartilages, giving them a smooth investment; round the crucial ligaments also it forms partial investments, enclosing them as far as their attachments to the femur. The membrane will thus be found to be guided to the articulating surface of that bone at several points, viz., by the two crucial ligaments, by the funnel-shaped process, and by the external margin of the semilunar cartilages; from these points it expands over the condyles, and after ascending for some way in front of the femur, (forming a cul-de-sac between it and the tendon of the extensor muscles,) it passes downwards to the margin of the patella, from which we proceeded to trace its reflections. At the sides of the patella the membrane forms two slight folds which are named "*alar*" ligaments, (ligamenta alaria.)

In the enumeration of the ligaments of the knee-joint, no mention has been here made of a fibrous capsule, as an investment distinct from the other fibrous structures of the joint. It is not usually described in anatomical demonstrations, and no notice of it occurs in the works of Meckel, Portal, Cloquet, or B. Cooper. A capsular ligament is, however, attributed to this articulation by Sæmmering, Weitbrecht, and Fyfe. The capsular ligament or membrane (*membrana capsularis articuli genu*) is said to arise in front from the whole circumference of the articulating extremity of the femur, at some distance from its cartilaginous coating, and behind from the border of the inter-condyloid fossa, from which it descends, to be inserted into the rough border which surrounds the head of the tibia. The membrane is also inserted into the margins of the patella and its superior and inferior ligamentous connexions, so that this bone forms part of the capsule of the joint. "It is very thin, but is strengthened by the fascia of the limb, and the surrounding aponeurotic structures."

These are pretty nearly the words employed by Fyfe; the last clause approaches somewhat to a correct expression of the fact. The fascia lata is prolonged from the lower part of the thigh to the head of the tibia, and extends backwards upon the condyles, and forwards to the margins of the patella and its ligament; thus forming an exterior investment for the joint and its synovial membrane. The ligamentum posticum supplies its place at the back of the articulation.

*Peroneo-tibial articulation.*—The superior and inferior extremities of the tibia and fibula are connected by ligaments and synovial membranes, (plates XXVI. XXVII.,) and the shafts of these bones are moreover maintained in relation by an interosseous ligament.

The contiguous extremities of the bones present superiorly two flat oval surfaces covered with cartilage, which are closely applied to one another, and retained *in situ*, 1, by an *anterior ligament*, which is a broad flat band of fibres, passing obliquely upwards and inwards, from the head of the fibula to the internal tuberosity of the tibia; it is covered and strengthened by the tendon of the biceps flexor curis; 2, by a *posterior ligament*, similarly disposed behind the articulation, but stronger and thicker; 3, by a *synovial membrane*, which lines the articulating surfaces of the bones and ligaments.

The *interosseous ligament*, (plate XXVI. fig. 6,) which connects the bodies of the tibia and fibula, flat and membranous, is composed of a series of parallel fibres, extending obliquely between the external ridge of the tibia, and the ridge on the adjacent surface of the fibula. Most of the fibres run outwards and downwards, others cross them, and the membrane they compose is broader above than below, and presents in the former situation an elongated opening for the transmission of the anterior tibial vessels, and inferiorly a smaller aperture for the passage of the anterior branch of the fibular artery.

The inferior extremities of the tibia and fibula present two articulating surfaces, of which that of the former is concave, and receives the latter, which is convex, both being for a little way covered with cartilage; these are connected by four ligaments and a synovial membrane.

1. The *anterior ligament* (tibio-fibular) is a flat band of fibres, extended obliquely between the heads of the bones, the direction of its fibres being downwards from the tibia to the fibula.

2. The *posterior ligament*, somewhat triangular, is similarly disposed behind the articulation; its external surface is covered by the peronei muscles.

3. The *transverse ligament*, longer but narrower than the former, with which its fibres are closely connected, extends from the head of the fibula to that of the tibia; it forms the posterior boundary of the ankle-joint.

4. The *inferior interosseous ligament* consists of some short dense fibres, which connect the heads of the bones, as the great interosseous ligament does their bodies; it cannot be seen until the anterior and posterior ligaments are removed, and the bones in some degree separated.

*The Ankle-joint.*—This articulation (plate XXIX. figs. 9—13) consists of the inferior extremities of the tibia and fibula, united so as to form an arch, into which the superior convex surface of the astragalus is received. Their contiguous surfaces are covered with cartilage, lined by a synovial membrane, and retained in contact by the following ligaments. The *internal lateral ligament* (ligamentum deltoides) is a broad flat fasciculus of fibres, one extremity of which is attached to the inferior border of



the internal malleolus, the other to the inner side of the astragalus and os calcis. It is broader below than above; its cutaneous surface is covered by the tendon of the tibialis posticus muscle; the articular one is lined by the synovial membrane.

The *external lateral ligament* consists of three distinct fasciculi of fibres, separated by intervals and disposed in different directions. 1. The central one (*ligamentum fibulæ medium*) descends perpendicularly from the extremity of the fibula, and is inserted into the middle of the external surface of the os calcis. 2. The anterior fasciculus (*ligamentum fibulæ anterioris*) passes obliquely forwards from the inferior extremity of the fibula, to the anterior border of the articular surface of the astragalus; it is the shortest of the three. 3. The posterior, (*ligamentum fibulæ posterioris*), the strongest of the three ligaments, passes obliquely backwards from the extremity of the fibula, towards the posterior surface of the astragalus, where it is inserted into the border of the groove for the tendon of the flexor longus pollicis.

At the anterior aspect of the joint is a broad thin membranous band, composed of irregular fibres, extended obliquely from the border of the articulating surface of the tibia to the margin of the pulley-like surface of the astragalus. This is usually called the *Tibio-tarsal ligament*; it is covered by the tendons of the extensor muscles.

The *synovial membrane*, after having invested the articulating surface of the astragalus, is reflected upwards at each side upon the lateral ligaments, and at the anterior and posterior part of the joint, upon the corresponding fibrous structures, so as to reach the articulating surfaces of the tibia and fibula by several points at once. These it lines in their entire extent, and also sends upwards between the bones a process which reaches as far as the inferior interosseous ligament; so that the inferior articulation between these bones may be said to form part of the ankle-joint, as both are lined by the same synovial membrane.

*Articulations of the Foot.*—The foot is constructed on the principle of an arch, being concave inferiorly, where it rests on the ground, and convex superiorly, where it receives the weight of the body, transmitted to it by the bones of the leg. The posterior extremity, or heel, is narrow, thick, and rounded; the anterior, flat, thin, and expanded, being composed of the digital phalanges. The internal border, longer than the external, thick, and nearly straight, is composed of the inner border of the calcaneum, the scaphoid, first cuneiform, and first metatarsal and digital bones of the great toe: the external, shorter and thinner, consists of the calcaneum, the cuboid, the fifth metatarsal, and corresponding digital bones.

The foot being divided into the tarsus, metatarsus, and phalanges, its different parts are respectively bound together by ligaments, and all are united so as to form a whole.

The seven bones of which the tarsus consists may be divided into two sets, the os calcis and astragalus forming the first, the scaphoid, cuboid, and three cuneiform bones, the second.

*Articulation of the Astragalus with the Calcaneum.*—The astragalus is connected to the calcaneum by three ligaments, (plate XXIX. fig. 13, plate XXX.,) the chief of which is situated between the bones, and unites them somewhat after the manner that bivalve shells are connected by their muscle. This is termed the *interosseous ligament*; its breadth from side to side is more than an inch; the fibres of which it is composed pass perpendicularly between the bones, one extremity being fixed to the groove between the articulating surfaces of the calcaneum, the other to a corresponding depression in the astragalus. The *posterior ligament* connects the posterior border of the astragalus with the upper surface of the calcaneum; its fibres are oblique, its length and breadth not more than three or four lines. The *external ligament* is a slight fasciculus which descends perpendicularly from the under surface of the astragalus to the external side of the calcaneum; its direction is parallel with the external lateral ligament of the ankle-joint. It may be farther observed, that as the astragalus is wedged in between the malleoli, and as the lateral ligaments pass downwards from these to the os calcis, they must contribute somewhat to retain the astragalus in its proper position with regard to the latter bone.

*Articulation of the Calcaneum with the Scaphoid bone.*—This is effected by means of two ligaments, (plate XXX.,) their surfaces not being in contact. Of these ligaments, the inferior or plantar one, (*ligamentum calcaneo-scaphoideum inferius*, Meckel,) much the largest, passes forwards and inwards from the extremity of the calcaneum to the inferior surface of the scaphoid bone; its fibres are flat and horizontal, and in contact inferiorly with the tendon of the tibialis posticus muscle; superiorly they form part of the fossa which receives the head of the astragalus. The *external* or *dorsal ligament* (lig. calcaneo-scaphoideum externum) forms the external boundary of the cavity just mentioned; its fibres, very short, are directed from behind forwards between the contiguous extremities of the bones.

*Articulation of the Astragalus with the Scaphoid bone.*—The astragalus forms with the scaphoid bone a ball-and-socket joint. (Plate XXX.) The anterior articulating surface of the calcaneum, and the inferior calcaneo-scaphoid ligament, also may be said to enter into this articulation, as all the parts here mentioned are lined by a common synovial membrane. On the dorsum of the foot the astragalus is retained in its situation by the *ligamentum astragalo-scaphoideum*, a broad band of fibres extending obliquely forwards from the anterior extremity of the astragalus to the superior surface of the scaphoid bone. It is covered by the extensor tendons. The necessity for an inferior ligament between these bones is removed by the existence of the calcaneo-scaphoid ligament. The *synovial membrane* lines the concave surface of the scaphoid bone, the calcaneo-scaphoid ligament, and the elongated articulating surface of the calcaneum; from these it is reflected to the under surface of the astragalus and its scaphoid ligament, and so to the bone of that name from which we began to trace it.

*Articulation of the Calcaneum with the Cuboid bone.*—The connexion between these bones is maintained by three liga-

ments (plate XXX.) and a synovial membrane. The *superior calcaneo-cuboid ligament* is a broad flat band of fibres, which connects the anterior and superior surface of the calcaneum with the adjacent part of the cuboid bone. The *inferior* ligament consists of two distinct fasciculi of fibres, differing in form and attachments, of which one is superficial, the other deep-seated. The superficial one, called the *long plantar ligament*, (ligamentum longum plantæ,) is the longest of the tarsal ligaments. Its fibres, attached posteriorly to the inferior surface of the calcaneum, pass horizontally forwards, and become intimately connected with the rough tuberosity on the under surface of the cuboid bone; the greater number of them are continued forwards, and terminate at the base of the third and fourth metatarsal bones. The *deep-seated calcaneo cuboid ligament* lies close to the bones, being separated from the former by some cellular tissue; its breadth is considerable; its length scarcely an inch, one extremity being attached to the calcaneum before the long ligament, the other (somewhat expanded) to the under surface of the cuboid bone. A synovial membrane lines the contiguous surfaces of the two bones, and is necessarily reflected upon the articular aspects of the superior calcaneo-cuboid ligament and the deep-seated ligament just noticed.

*Articulations between the second set or range of Tarsal bones.*—The second range of the tarsal bones, viz. the scaphoid, cuboid, and three cuneiform, are connected together in the following manner, so as to form separate articulations between each pair of them. (Plate XXX.)

1. The *scaphoid* and *cuboid* bones, when in contact, which is not always the case, present two small articulating surfaces, at their edges covered with cartilage, and lined by a synovial membrane. They are connected by a *dorsal ligament*, composed of short thin fibres, extended obliquely between the two bones; and a *plantar*, situated in the solc of the foot, and composed of transverse fibres.

2. The *cuboid* and the *external cuneiform bones* are connected by a *dorsal ligament*, which is a thin fasciculus of fibres extended between them, and a *plantar ligament*, whose fibres are transverse.

3. The *scaphoid* and the *cuneiform bones* are held together by dorsal and plantar ligaments. It will be recollected that the scaphoid bone articulates with the three cuneiform by the smooth faces on its anterior surface. The *dorsal ligaments*, three in number, pass from the superior surface of the scaphoid to the first, second, and third cuneiform bones, into which they are inserted. The *plantar ligaments* are similarly disposed on the under surface of the bones, but not so strongly marked.

4. The three *cuneiform bones* are connected by two dorsal and two plantar ligaments extended transversely from side to side; the internal one is broader and stronger than the other. The contiguous flat surfaces of the bones are lined by synovial membranes.

*Articulation of the Tarsus and Metatarsus.*—The four anterior bones of the tarsus, viz. the three cuneiform and the cuboid, articulate with the metatarsus. (Plate XXX.) The first and third cuneiform bones project beyond the others; so that the anterior extremity of the tarsus is very irregular. The first metatarsal bone articulates with the internal cuneiform; the second is wedged in between the first and third cuneiform; the third metatarsal bone articulates with the extremity of the corresponding cuneiform, and the two last with the cuboid bone. The articular surfaces of the bones are lined by synovial membranes, and they are held in contact by *dorsal* and *plantar* ligaments. These are flat, thin bands of parallel fibres, which pass from behind forwards, connecting the contiguous extremities of the bones just mentioned. Thus the first metatarsal bone receives a broad thin band from the corresponding cuneiform bone; the second receives three, which converge to its upper surface, one passing from each cuneiform bone; the third has one from the third bone of that name; and, finally, the two last are bound by a broad fasciculus to the cuboid bone. The plantar set is similarly disposed; the first and second are more strongly marked than the corresponding ligaments on the dorsal surface.

*Articulations of the Metatarsal bones with one another.*—The five elongated bones which form the metatarsal are connected by ligaments, (plate XXX.) so as to form an integrant part of the foot. At their posterior or tarsal extremity, two sets of ligaments are situated, one on the dorsal, the other on the plantar surface. These consist of three short thin bands of fibres, which pass transversely across the contiguous extremities of the four last metatarsal bones; the plantar set is similarly disposed; but no such connexion exists between the first and second bones. At the anterior or digital extremity the five bones are connected by a *transverse ligament*, which is a flat thin band of fibres passing across from the extremity of one bone to the other; it is situated on the plantar surface of the metatarsus.

*Articulations of the Metatarsal bones with the Digital phalanges.*—The anterior extremities of the metatarsal bones are connected (plate XXX.) with those of the phalanges by two lateral ligaments, an inferior ligament, and a synovial membrane, similar in every respect to those of the hand.

The articulations of the phalanges with one another are also constructed on the same principle as those of the superior extremity. In each, the bones are held in contact by two lateral ligaments, and an anterior ligament which is thin and membranous; the surfaces being lined by a synovial membrane.





# INDEX.

---

- Acetabulum, page 63.  
Acromion process of the scapula, page 53.  
Amphi-arthritis, page 71.  
Analogy between cranial bones and vertebræ, page 43.  
Antrum of Highmore, pages 31, 42. (Pl. XIII.)  
Apophysis, page 5.  
Arthrodia, page 71.  
Articulations, page 70.  
    ankle, page 85. (Pl. XXIX.)  
    atlas and axis, of the, page 75. (Pl. VIII.)  
    carpal bones, of the, page 81. (Pl. XXII.)  
    costo-sternal, page 77. (Pl. VII.)  
    cranium, with the first vertebræ, of the, page 76.  
    elbow-joint, of the, page 79. (Pl. XXI.)  
    foot, of the, page 86. (Pls. XXIX. XXX.)  
    hand, of the, page 81. (Pl. XXII.)  
    hip-joint, page 83. (Pl. XXV.)  
    knee-joint, page 83. (Pl. XXVII.)  
    lower jaw, page 76. (Pl. VIII.)  
    pelvis, of the, page 82. (Pl. XXV.)  
    peroneo-tibial, page 85. (Pls. XXVI. XXVII.)  
    radio-ulnar, page 79. (Pl. XXI.)  
    ribs, of the, page 77. (Pl. VII.)  
    scapulo-clavicular, page 78. (Pl. XVI.)  
    shoulder-joint, of the, page 78. (Pl. XVI.)  
    sterno-clavicular, page 77. (Pl. XVI.)  
    vertebræ, of the, page 75. (Pl. VII.)  
    wrist-joint, page 80. (Pls. XXI. XXII.)  
Asternal ribs, *see* False ribs.  
Astragalus, page 68. (Pls. XXVIII. XXIX.)  
Atlas, page 13. (Pls. IV. V.)  
Axis, page 13. (Pls. IV. V.)  
Base of the skull, page 37. (Pl. IX.)  
Bone, general anatomy of, page 3.  
    structure of, page 5.  
Bursæ muscosæ, page 74.  
Calcaneum, page 68. (Pls. XXVIII. XXIX.)  
Camper's facial angle, page 47.  
Canals of Havers, page 6.  
Carpus, page 58. (Pl. XX.)  
Cartilage, page 73.  
Cells of Purkinje, page 6.  
Clavicle, page 55. (Pls. XVI. XVII.)  
Clinoid processes, page 26.  
Coccyx, page 61. (Pls. IV. VI. XIV.)  
Columna vertebralis, *see* Vertebral column.  
Coracoid process, *see* Scapula.  
Coronoid process, *see* Ulna.  
Costal cartilages, page 53. (Pl. XIV.)  
Cribriform lamella, page 28.  
Crista galli, page 28.  
Cuboid bone, page 68. (Pls. XXVIII. XXIX.)  
Cuneiform bone, of the carpus, page 59. (Pl. XX.)  
Cuneiform bones, of the tarsus, page 69. (Pls. XXVIII. XXIX.)  
Diarthrosis, page 71.  
Diploë, page 6.  
Elastic fibrous tissue, page 74.  
Enarthrosis, page 71.  
Ensiform cartilage, page 51. (Pl. XIV.)  
Epiphysis, page 5.  
Ethmoid bone, page 27. (Pls. IX. X. XII.)  
Facial, angle of Camper, page 47.  
False ribs, page 51.  
Femur, page 65. (Pl. XXIV.)  
Fibro-cartilage, page 73.  
Fibro-cartilages—  
    of the coccyx, page 82.  
    of the jaw, page 76. (Pl. VIII.)  
    of the knee, page 83. (Pl. XXVII.)  
    of the scapulo-clavicular articulation, page 78.  
    of the sterno-clavicular articulation, page 77. (Pl. XVI.)  
    of the wrist, page 80. (Pl. XXII.)  
Fibrous tissue, elastic, page 74.  
Fibula, page 67. (Pl. XXVI.)

**Foramen magnum**, page 15.  
**Frontal sinuses**, pages 19, 42. (Pl. IX.)  
**Frontal bone**, page 18. (Pls. IX. XI.)  
**Ginglymus**, page 71.  
**Glands of Havers**, page 74.  
**Gomphosis**, page 70.  
**Hand, bones of the**, page 58. (Pl. XX.)  
**Harmonia**, page 70.  
**Haversian canals**, page 6.  
**Humerus**, page 55. (Pls. XVII. XVIII.)  
**Inferior maxillary bone**, page 33. (Pls. IX. XIII.)  
**Innominatum, os**, page 61. (Pls. XIV. XV. XXIII.)  
**Ischium**, page 63. (Pl. XXIII.)  
**Jugular fossa**, page 25.  
**Lachrymal bones**, page 31. (Pls. IX. XII.)  
**LIGAMENOUS SYSTEM—**  
   *general considerations*, page 70.  
   *ligaments, general anatomy of*, page 72.  
   *acromio-clavicular*, page 78. (Pl. XVI.)  
   *alar, of the axis*, page 76. (Pl. VIII.)  
     *of the knee*, page 85. (Pl. XXVII.)  
   *ankle, of the*, page 85. (Pl. XXIX.)  
   *annular, of the radius*, page 79. (Pl. XXI.)  
     *wrist, anterior*, page 81.  
     *posterior*, page 81.  
   *arcuatum pubis*, *see* subpubic.  
   *astragalo-calcanean*, page 86. (Pls. XXIX. XXX.)  
   *astragalo-scaphoid*, page 86. (Pl. XXX.)  
   *atlantis transversum*, page 75. (Pl. VIII.)  
   *atlo-axoid*, page 76. (Pl. VIII.)  
   *breve plantæ*, page 87. (Pl. XXX.)  
   *calcaneo-astragaloid*, page 86. (Pls. XXIX. XXX.)  
     *cuboid*, page 86. (Pl. XXX.)  
     *scaphoid*, page 86. (Pl. XXX.)  
   *capitulum costarum*, page 77. (Pl. VII.)  
   *capsular, of the hip*, page 83. (Pl. XXV.)  
     *knee*, page 85.  
     *shoulder*, page 78. (Pl. XVI.)  
     *thumb*, page 81. (Pl. XXII.)  
   *carpal*, page 80. (Pl. XXII.)  
   *carpo-metacarpal*, page 81. (Pl. XXII.)  
   *common anterior*, page 74. (Pl. VII.)  
     *posterior*, page 75. (Pl. VII.)  
   *conoid*, page 78. (Pl. XVI.)  
   *coracoid*, page 73. (Pl. XVI.)  
   *coraco-acromial*, page 78. (Pl. XVI.)  
     *clavicular*, page 78. (Pl. XVI.)  
     *humeral*, page 79. (Pl. XVI.)  
   *costo-clavicular*, page 78. (Pl. XVI.)  
     *sternal*, page 77. (Pl. VII.)  
     *transverse*, page 77. (Pl. VII.)  
     *vertebral*, page 77. (Pl. VII.)  
     *xiphoid*, page 77. (Pl. VII.)

**LIGAMENOUS SYSTEM—**  
   *cotyloid*, page 83. (Pl. XXV.)  
   *crucial*, page 84. (Pl. XXVII.)  
   *cruciata*, *see* crucial.  
   *cruciform*, page 76. (Pl. VIII.)  
   *deltoid*, page 85. (Pl. XXIX.)  
   *elbow, of the*, page 79. (Pl. XXI.)  
   *fibula, of the*, page 86. (Pl. XXIX.)  
   *glenoid*, page 78. (Pl. XVI.)  
   *hip-joint, of the*, page 83. (Pl. XXV.)  
   *ilio-femoral*, page 82. (Pl. XXV.)  
   *ilio-lumbar*, page 82. (Pl. XXV.)  
   *inter-articular, of the hip*; *see* *teres*.  
     *of the ribs*, page 77. (Pl. VII.)  
   *inter-clavicular*, page 78. (Pl. XVI.)  
   *interosseous—*  
     *calcaneo-astragaloid*, page 86. (Pl. XXIX.)  
     *peroneo-tibial*, page 85. (Pl. XXVI.)  
     *radio-ulnar*, page 79. (Pls. XXI. XXII.)  
   *inter-spinous*, page 75. (Pl. VII.)  
   *inter-transverse*, page 75. (Pl. VII.)  
   *intervertebral*, page 75. (Pl. VII.)  
   *knee, of the*, page 83. (Pl. XXVII.)  
   *lateral, of the ankle*, page 85. (Pl. XXIX.)  
     *elbow*, page 79. (Pl. XXI.)  
     *jaw*, page 76. (Pl. VIII.)  
     *knee*, page 83. (Pl. XXVII.)  
     *phalanges, foot*, page 87. (Pl. XXX.)  
     *phalanges, hand*, page 81. (Pl. XXII.)  
     *wrist*, page 80. (Pls. XXI. XXII.)  
   *longum plantæ*, page 87. (Pl. XXX.)  
   *lumbo-iliac*, *see* *ilio-lumbar ligament*.  
   *lumbo-sacral*, *see* *sacro-vertebral ligament*.  
   *metacarpal*, page 81. (Pl. XXII.)  
   *metacarpophalangeal*, page 81. (Pl. XXII.)  
   *metatarso-phalangeal*, page 87. (Pl. XXX.)  
   *mucosum*, page 84. (Pl. XXVII.)  
   *oblique of the fore-arm*, page 80. (Pl. XXI.)  
     *of the knee*, page 84. (Pl. XXVII.)  
   *obturator*, page 83. (Pl. XXV.)  
   *occipito-atloidean*, page 76. (Pl. VIII.)  
   *occipito-axoid*, page 76. (Pl. VIII.)  
   *odontoid*, page 76. (Pl. VIII.)  
   *orbicular*, page 79. (Pl. XXI.)  
   *patellæ*, page 83. (Pl. XXVII.)  
   *peroneo-tibial*, page 85. (Pls. XXVI. XXVII.)  
   *phalanges of the foot*, page 87. (Pl. XXX.)  
     *of the hand*, page 81. (Pl. XXII.)  
   *plantar, long*, page 87. (Pl. XXX.)  
     *short*, page 87. (Pl. XXX.)  
   *posticum Winslowii*, page 84. (Pl. XXXVII.)  
   *processum obliquorum*, page 75.  
   *proprium anterius scapulæ*, page 78.  
     *posticum scapulæ*, page 78.  
   *pubic*, page 82. (Pl. XXV.)

## LIGAMENOUS SYSTEM—

- radio-carpal, page 80. (Pls. XXI. XXII.)  
 radio-ulnar, page 79. (Pls. XXI. XXII.)  
 rhomboid, page 78. (Pl. XVI.)  
 round, or oblique, page 80. (Pl. XXI.)  
 sacro-coccygean, page 82. (Pl. XXV.)  
 sacro-iliac, page 82. (Pl. XXV.)  
 sacro-ischiadicum, *see* sacro-sciatic.  
 sacro-vertebral, page 82. (Pl. XXV.)  
 sacro-sciatic anterior, page 82. (Pl. XXV.)  
     posterior, page 82. (Pl. XXV.)  
 scapulo-clavicular ligaments, page 78. (Pl. XVI.)  
 shoulder-joint, of the, page 78. (Pl. XVI.)  
 stellate, page 77. (Pl. VII.)  
 sterno-clavicular, page 77. (Pl. XVI.)  
 stylo-maxillary, page 77. (Pl. VIII.)  
 subflava, page 75. (Pl. VII.)  
 subpubic, page 83. (Pl. XXV.)  
 supra-spinous, page 75. (Pl. VII.)  
 tarsal, page 86. (Pl. XXX.)  
 tarso-metatarsal, page 87. (Pl. XXX.)  
 teres, page 83. (Pl. XXV.)  
 tibio-fibular, page 85. (Pls. XXVI. XXVII.)  
 tibio-tarsal, page 86.  
 transverse of the acetabulum, page 83. (Pl. XXV.)  
     atlas, page 75. (Pl. VIII.)  
     metacarpus, page 81. (Pl. XXII.)  
     metatarsus, page 87. (Pl. XXX.)  
     scapula, *see* coracoid ligament.  
     semilunar cartilages, page 84.  
 transversum internum costarum, page 77.  
     externum costarum, page 77.  
 trapezoid, page 78. (Pl. XVI.)  
 triangulare, page 83. (Pl. XXV.)  
 vaginal, of the phalanges, page 81.  
 wrist, of the, page 80. (Pls. XXI. XXII.)  
 Linea aspera, page 65.
- Magnum, os, page 59. (Pl. XX.)  
 Malar bones, page 31. (Pls. IX. XII.)  
 Man, his adaptation to the erect posture, page 43.  
 Mastoid process, page 23.  
 Maxillary sinus, *see* Antrum of Highmore.  
 Meatus auditorius, page 23.  
 Membrana interossea, peroneo-tibial, page 85. (Pl. XXVI.)  
     radio-ulnar, page 79.  
     sacciformis, page 80.  
     obturans foraminis thyreæidis, page 83.  
 Metacarpus, page 59. (Pl. XX.)  
 Metatarsus, page 69. (Pl. XXVIII.)  
 Nasal bones, page 31. (Pls. IX. XII.)  
 Nasal fossæ, page 41. (Pl. IX.)  
 Navicular bone, page 68. (Pls. XXVIII. XXIX.)  
 Obturator foramen, page 64.  
 Occipital bone, page 15. (Pls. IX. X.)  
 Olecranon, page 58.  
 Orbits, page 41. (Pl. IX.)  
 Os calcis, page 63. (Pls. XXVIII. XXIX.)  
 Os hyoides, page 35. (Pl. XIII.)  
 Os planum, page 28.  
 Ossa triquetra or Wormiana, pages 17, 29.  
 OSSEOUS SYSTEM, page 3.  
 Ossification, process of, page 7.  
 Os unguis, *see* Lachrymal bones.
- Palate bones, page 32. (Pls. IX. XII.)  
 Parietal bones, page 17. (Pls. IX. X.)  
 Patella, page 66. (Pl. XXIV.)  
 Pelvis, page 60. (Pl. XV.)  
     general conformation of, page 64.  
     measurements of the, page 65.  
 Phalanges of the foot, page 69. (Pl. XXVIII.)  
     hand, page 60. (Pl. XX.)  
 Pisiform bone, page 59. (Pl. XX.)  
 Processus cochleariformis, page 25.  
 Pterygoid processes, page 26.  
 Pubic symphysis, page 82.  
 Pubis, os, page 62. (Pl. XXIII.)  
 Punctum ossificationis, page 8.  
 Purkinjean corpuscles, page 6.  
 Pyramidal bone *see* Cuneiform bone.
- Radius, page 57. (Pls. XVII. XIX.)  
 Ribs, page 51. (Pls. XIII. XIV. XV.)
- Sacro-iliac symphysis or synchondrosis, page 82.  
 Sacrum, page 61. (Pls. IV. VI. XIV. XV.)  
 Scaphoid bone, hand, page 58. (Pl. XX.)  
 Scaphoid bone, foot, page 68. (Pls. XXVIII. XXIX.)  
 Scapula, page 54. (Pls. XVI. XVII.)  
 Schindylesis, page 70.  
 Semilunar bone, page 58. (Pl. XX.)  
 Sesamoid bones, page 70. (Pls. XX. XXVIII.)  
 Skeleton, pages 3, 8. (Pls. I. II. III.)  
 Skull, page 15. (Pls. IX. X. XI.)  
     conformation of the, page 37.  
 Sphenoid bone, page 25. (Pls. IX. X. XII.)  
 Sphenoidal sinuses, page 42. (Pl. IX.)  
 Sphenoidal spongy bones, page 25.  
 Spheno-maxillary fossa, page 39.  
 Spine, page 10. (Pl. IV.)  
 Spongy bones, *see* Turbinate bones.  
 Sternum, page 49. (Pl. XIV.)  
 Superior maxillary bone, page 29. (Pls. IX. XIII.)  
 Sutures, pages 35, 70. (Pl. IX.)  
 Symphysis pubis, page 82. (Pl. XXV.)  
     sacro-iliac, page 82.  
 Synarthrosis, page 70.  
 Synovial membrane, page 74.
- Tarsus, page 68.  
 Teeth, anatomy of, page 49.



Temporal bones, page 20. (Pls. IX. X. XI.)  
 Temporal fossa, page 39. (Pl. IX.)  
 Thorax, page 49.  
 Tibia, page 66. (Pl. XXVI.)  
 Trapezium, page 59. (Pl. XX.)  
 Trapezoid bone, page 59. (Pl. XX.)  
 Trochanter, major and minor, page 65.  
 Tuber ischii, page 63. (Pl. XXIII.)  
 Turbinate bones, page 33. (Pls. IX. XII.)  
 Ulna, page 57. (Pls. XVII. XIX.)  
 Uneiform bone, page 59. (Pl. XX.)

Vertebra dentata, *see* Axis.  
 Vertebra prominens, page 13. (Pls. IV. V.)  
 Vertebrae, page 11. (Pls. IV. V. VI.)  
 Vertebral column, page 10. (Pl. IV.)  
 Vomer, page 33. (Pls. IX. XII.)

Wormian bones, pages 17, 29.

Xiphoid cartilage *see* Ensiform cartilage.

Zygoma, page 22.

Zygomatic fossa, page 39.

END OF THE BONES AND LIGAMENTS.

THE  
MUSCLES  
OF  
THE HUMAN BODY.

THE UNIVERSITY OF CHICAGO

PHYSICS DEPARTMENT



# THE MUSCLES

OF

## THE HUMAN BODY.

---

THE muscles of the body are the agents by which its different efforts and movements are performed. In ordinary language they are known by the name flesh, and as such they differ considerably in colour and consistence in different classes of animals. A muscle is a compound structure made up of cellular tissue for its basis, which encloses in its areolæ fibrine as the essential constituent. Tendinous fibres are superadded in most muscles, particularly at their extremities, forming the means of attachment to the periosteum and the bones.

When we look at a muscle dissected, it evidently appears made up of fibres arranged in a defined direction; several of these are observed to be aggregated into bundles, (fasciculi,) each of which is detached from the rest by a thin lamella of delicate cellular tissue. Each fasciculus admits again of being separated into fibres, and these into fibrillæ; and the separation may be continued until we at length arrive at some so minute as to be incapable of farther division; these may be regarded, therefore, as ultimate fibres, at least in reference to our methods of analysis.

The muscles thus formed of bundles or groups of fibres, either singly or in various combinations, draw upon the different parts of the skeleton to which they are attached, and put them in motion, or steady and fix them as circumstances may require. As the skeleton, or frame-work of the body, consists of more than two hundred separate pieces, the muscles which move them are proportionally numerous, being about two hundred and twenty pairs. The bones may be considered as so many passive instruments, and the muscles as active agents; for they possess a peculiar property, by virtue of which their fibres contract and shorten themselves in obedience to the will, or on the application of some stimulant. Most muscles are under the direction of the will, which acts upon them through the brain and nerves. Others, however, as the heart, and the muscular coat of the stomach and bowels, are withdrawn from the control of the will, though still they are influenced by and through the nervous system. Hence it is that the former are termed *voluntary*, and the latter *involuntary* muscles, whilst those which are connected with the movements of respiration deserve the name of *mixed* muscles; for though they are subject to our volition, it is only to a limited extent, and they continue their action when the will is suspended, as in sleep.

The nomenclature of muscles is confessedly intricate and confused, owing, in a great measure, to its being the work of different individuals acting without concert, and adopting each a different basis for the construction of the terms employed, so that no scientific or general principle runs through it. Thus the names of some are taken from the mere circumstance of their occurring or appearing in a certain order—first, second, third—taken from a particular point of view. The earlier anatomists adopted this simple plan of naming the different objects, perhaps as they presented themselves in their dissections. But these terms were soon found to be so vague and uncertain, that it became necessary to take into consideration the form of the muscles, and to name them, as far as could be done, from their likeness to particular figures, calling one triangular, another rhomboid, quadrilateral, or pyramidal; and this appeared sufficient for the purpose intended, as far as it went, but comparatively few objects could be brought within its limit. When anatomists began to understand the powers and uses of the different muscles, they naturally sought to name them from a consideration of their actions, calling some flexors, others extensors,—some adductors; others abductors;—and lastly, we find some muscles named from the direction of their fibres—orbicular, transverse, oblique, or ascending; and not a few from the points to which their ends are attached, ex. gr. sterno-mastoid, sterno-hyoid.

Muscles seldom act singly,—two or more usually conspire to execute movements apparently simple. Those which act together are called associates; and when one group habitually reverses the action of another, they are called antagonists. The muscles seen on the fore-arm, and which, by several tendons or white cords, are prolonged through the palm of the hand to the bones of the fingers, curve or bend the joints of the latter, and are therefore named flexors; whilst those at the back part straighten or extend them, and are called extensors. Whilst either of these motions is being executed, it might be supposed that only one group of muscles, ex. gr. the flexors, is in action, the extensors being quiescent: but this is not exactly the case; for when we desire to bend the fore-arm, the will directs through the nerves, towards the flexor muscles placed upon the fore-part of the upper arm (and where they are readily felt as they come into action), a sufficient quantity of nervous influence to enable them to move the limb from point to point, through the arch of a circle, which it describes in passing from the straight to the bent position. Now, during the progress of this motion, the extensors also are kept in a state of tension, though in a less degree; for they are made to give way just so many points as the action of the flexors requires, yet still to hold on so as to moderate it, and at the same time give steadiness to the whole limb.

By referring to plates XLVIII. and XLIX., each of the long muscles will be found attached by its extremities to particular points of the bones. The upper end is that by which they most usually hold fast while they pull on the lower; hence the latter point is technically called the point of insertion, the former of origin. This line of action, however, is very often reversed. For instance, in the standing posture, a continued effort is required to keep the leg erect upon the foot; and to effect this, the muscles on the fore-part of the limb take their fixed points below, upon the back of the foot and toes, from which they draw upon the bones of the leg, so as to hold them forward and retain them erect upon the arch of the foot.

How easy and simple a movement that appears to be by which we rise from the sitting posture and assume the erect attitude! and yet it is executed by a series of efforts, requiring the co-operation of a great many muscles, and this, too, after a preparatory movement not a little complex in itself. In the first place, the foot is thrown backwards, and the body inclined forwards, in order to bring the centre of gravity directly over the basis of support: then the flexor muscles in the sole of the foot draw on the toes, and press them against the floor, so as to fix the foot; after which, by a simultaneous effort of several muscles, the leg is made to move backwards, and the thigh forwards, until both become erect. During this change of position, the leg moves through an arch of a circle, whose centre is at the ankle-joint, the bones of the leg representing its radius. As in this case the centre is fixed, the arch described is a part of the circumference of a circle. But the thigh-bone is differently circumstanced; its centre is at the knee, and necessarily changes place so as to pass from point to point through the arch *b c*, whilst its change of position is being effected. Hence, if it is considered as a radius, it will tend to describe as many circles as there are points in the arch *b c*; but it will really describe, not a part of a circle, but a curve, indicated by a line drawn through those points of the circumferences of the circles here indicated, which lie along the interval between its previous position *d*, and its present one *e*. If from *d* a line be drawn obliquely forwards, so as to represent the position of the body during the preparatory movement, it will be evident that the spine also resembles a radius attached to a moving centre at the hip-joint, and that the head, as it is ascending, will move in a curved line, similar to that here indicated, but described in the opposite direction.

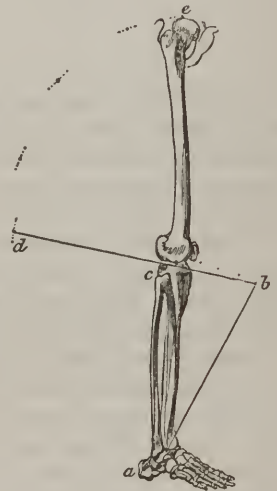


PLATE I. is intended to exhibit the intimate composition of muscle, with a view to explain the theory of its action. Fig. 1, 2, 3, are taken from the plate which accompanies the Memoir on Muscular Action, by MM. Prevost and Dumas, (*Journal de Physiologie*, tom. iii.) Fig. 4, 5, 6, and 7 are drawn from preparations in the Museum of the University. Each muscle, however simple its action may be, is in itself a compound structure: it has arteries, which convey to it blood for its growth and nutrition,—veins, which return the residue of the blood,—nerves, forming cords of communication with the brain, or spinal marrow,—and absorbing vessels, which perform an important part in the different changes which the process of growth and nutrition require. All these are held together by a delicate animal substance, called cellular tissue, which also forms their bond of connexion with the proper fibres of the muscle. Fig. 4 and 7 represent back and front views of the flexor muscle of the arm. The muscular, or fleshy part, forms a tapering body, from which white tendons, or cords, pass upwards over the shoulder-joint to the blade-bone, or scapula, and downwards over the elbow, to the bone of the fore-arm: it is called biceps, from having two heads, or extremities, at its upper end; between these the nerve is seen branching off into filaments amongst the muscular fibres. In fig. 5 the fibres run obliquely into one side of a tendon, upon which they act like so many cords attached to a rope passing over a pulley. In fig. 6 they are placed at both sides of the tendon, like the fibrillæ on a quill-feather. If the dark lines in the drawings were coloured red, so as to resemble flesh, the tendons at the end being made of a pearl white, they would represent, as nearly as may be, the muscles in their natural condition. When by an act of the will, propagated along the nerve, a muscle,—the biceps, for instance, (fig. 4)—is put in action, its body shortens and swells, its ends are brought nearer, and the fore-arm is drawn upwards into the bent position. This can be felt and seen whilst the effort is being made. It will very naturally be







Fig 2




Fig 4



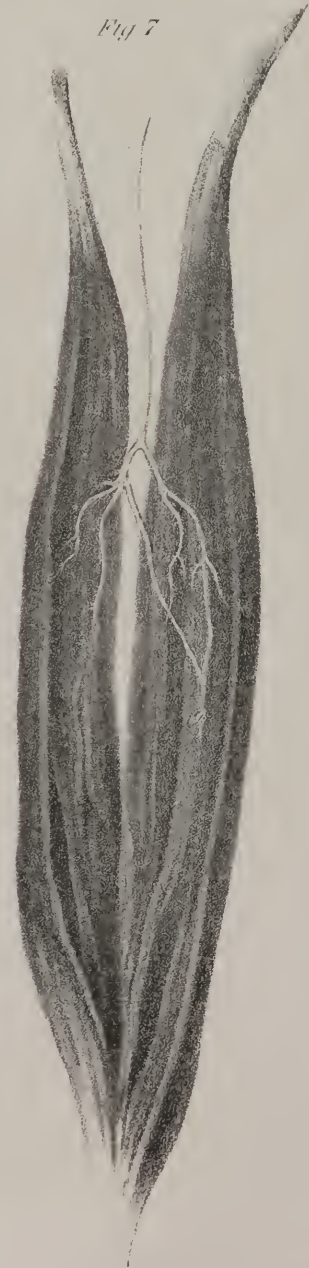Fig 5



Fig 6



Fig 7



asked, what is the change of state which occurs in a muscle whilst thus passing from repose into action, and what produces the change? Many expedients have been resorted to, and many efforts have been made at different times, to determine these points; but the best conducted and most recent researches are those of MM. Prevost and Dumas, (*Journal de Physiologie*, tom. iii.); yet even these are far from conclusive. A thin, flat muscle, (rectus abdominis,) taken from a frog, and placed under the object-glass of a microscope, appears to consist of fibres, cylindrical in their form, and straight whilst in the quiescent state, fig. 1; but when they are irritated, or acted on by electricity, they are thrown into waving, zig-zag lines, and necessarily shortened. By frequently repeating this observation, it is found that the angles, or points of inflexion, always occur at those places in which the muscular fibres are crossed by nervous filaments, (fig. 3.) Here a new question arises—what is the relation which subsists between the nerve and the muscle? When a nerve is traced into a muscle, it gives off delicate branches, most of which pass across the muscular fibres; but they soon become so small as to escape our unassisted vision, particularly in the large muscles of the higher animals, (fig. 7.) But when with the aid of a microscope, as in the experiment already noticed, the muscle of one of the lower animals—for instance, the frog—is examined, nervous filaments will be found at first running between the muscular fibres, and at intervals giving off filaments, which pass across them, and finally returning back in the form of loops, or joining with a neighboring branch, (fig. 2.) Most nerves convey two endowments, the power of motion and sensation; or rather, they are the means of imparting to muscles, not only the impulse which determines motion, but also of carrying back from them intimations of their condition and of their various changes of state. The former of these is effected by nervous filaments connected with the fore-part of the spinal marrow, and the latter by those attached to the back part; for it has been fully proved, that the power of motion is lost when the anterior roots of the nerves, or the corresponding part of the medulla, is injured, and that sensation is destroyed if the like happens to the posterior. The nerves then as chordæ internunciarum may be likened to conductors, along which an influence flows from the brain and spinal marrow to the muscles, determining their contraction, and in the opposite direction from the muscles to the brain, conveying impressions and exciting sensations. So far we can proceed securely enough; but a step farther leads at once into the region of hypothesis, where our only guide is a forced and questionable analogy. Observation, as above stated, having shown that when a muscle is irritated, its fibres are thrown into zig-zag lines, the angles of inflexion being at the points where they are crossed by the nervous filaments, and the experiments of M. Ampere having determined the fact, that two parallel wires will approach one another when voltaic currents pass along them in the same direction, Prevost and Dumas place these two pieces of information together, and found upon them a rationale of muscular action:—reasoning in this way, that as the wires approach one another when the voltaic agent passes along them, so the transverse filaments of the nerves become approximated when they become the conductors of the nervous influence; and that as they incline towards one another, they ripple and shorten the muscular fibres. It is, however, fairly admitted, that in this mode of viewing the subject, the muscle itself appears to be passive and the nerves alone active.

It may be further added, that as we should not in any case take analogy for identity, so when reasoning on phenomena so widely dissimilar, we are not warranted in rigorously transferring a rule from the one to the other.

We have spoken of the bones as passive instruments; they in fact resemble levers acted on by the muscles, and in the human skeleton we can point out instances of the three orders of levers described by writers on dynamics. When we observe how the base of the skull rests on the spine as its support, and how the muscles attached to the occiput can raise the face which

## PLATE I.

- Fig. 1, gives a magnified view of muscular fibres in the state of repose. The white lines indicate the course of the nerves: as they run along, they give off delicate filaments which cross the fibres of the muscle.
- Fig. 2, shows how the ultimate filaments of the nerves are disposed. After branching out for some way, as in Fig. 1, they become curved, and return into themselves, forming loops; or they incline towards a neighbouring branch, and form inverted arches.
- Fig. 3, represents the fibres in the state of contraction, when they are thrown into waving zig-zag lines. The transverse nervous filaments will be seen crossing them at the angles of inflexion.
- Fig. 4, is a front view of the biceps flexor. Fig. 7, a back view of the same. The branches of the nerve are seen ramifying amongst the muscular fibres.
- Fig. 5, is a semi-penniform muscle.
- Fig. 6, is a double penniform muscle, the fibres being placed at each side of a central tendon, like the fibrillæ of a quill-feather. In Fig. 5, the fibres are at one side only.

## PLATES XLVIII. & XLIX.

Plate XLVIII. forming the frontispiece to this work, and Plate XLIX. with which this section of the work concludes, exhibit the muscles as they are brought into view by the removal of the skin, with the membranous and adipose layers placed beneath it. Back and front views are given, and in each the deeper seated as well as the superficial muscles are shown.



projects in front, we recognise a lever of the first order, the moving power being at one end, the weight at the other, and the prop between them; again the leg rests on the foot, and the strong muscles of the calf of the leg are fixed to the heel, so as to raise the body forward on the toes, so that the prop is at one end, (the toes,) the power at the other, and the weight in the middle, —being an instance of the second sort of lever. Lastly, the muscle (biceps flexor) which runs along the upper arm is fixed into the outer bone of the fore-arm a little below the bend of the elbow, so as to act on the fore-arm and draw it into the bent position. In this case, the weight or resistance (viz. the hand and arm) is at one end, the prop at the other, (in the elbow-joint,) and the moving power between them, exemplifying the arrangement which obtains in levers of the third order. A loss of power necessarily results from the adoption of this principle, but it is more than compensated by the increased quickness of movement which is acquired.

## PLATE II.

THE first drawing in this plate gives a front view of the muscles of the face, the skin and cellular tissue which lies under it, —and the vessels and nerves being removed in order to show distinctly the direction of the muscular fibres and their points of attachment. At the right side of the face all the muscles are allowed to remain in their natural position; but at the left, some of them are removed so as to bring into view some which would otherwise remain concealed either wholly or in part. The occipito-frontalis muscle No. 1, is reflected obliquely upwards from off the forehead so as to expose No. 4. The orbicularis palpebrarum No. 3, is taken away to show the eye-lids, and their tendon No. 20, as well as the tendon of the muscle which raises the upper lid, (levator palpebræ superioris.) Nearly the whole length of this muscle is concealed within the orbit; a small part, however, No. 5, projects beyond its margin and is fixed into the cartilage of the upper lid. Nos. 8, 9, 10, and 11 are here also left out, in order to show more distinctly Nos. 7, 12, and 13. The second figure shows the back part of the head, covered by the occipito-frontalis muscle No. 1. Both are taken from Cloquet.

As the two lateral halves of the body are symmetrical, the muscles and other structures at each side of the middle line so perfectly correspond, that such remarks or references as are made with regard to the one will necessarily apply to the other.

Each bundle or layer of fibres, here exhibited and marked with figures, is a muscle or moving power capable of acting in obedience to the will, and, when put into action, of contracting and shortening itself. As all these muscles are in intimate connection with the skin which rests upon them like a thin covering, they can so act on it as to make it assume various changes dependent on their form and size, on the direction of their fibres, and still more on their acting singly or in combination. Thus No. 1 consists of fibres which run down from the top of the forehead to the eye-brow. They are obviously continuous at their upper ends with a thin tendon, which, in the form of a layer of white membrane, rests upon the arch of the skull, and extends

## PLATE II.

FIG. 1. No. 1. The fore-part of the occipito-frontal muscle, (m. epicranius.) 2. The same, detached and everted, so as to expose the bone. 3. The orbicular muscle of the eye-lids, (m. orbicularis palpebrarum; m. orbiculaire des paupières.) 4. The corrugator of the eye-brow, (m. corrugator supercilii; m. sourcilier.) 5. Part of the elevator of the eye-lid seen as it projects beyond the border of the orbit, and descending to be inserted into the cartilage of the lid, (m. levator palpebræ superioris; m. éleveur de la paupière supérieure.) 6. The pyramidal muscle of the nose, (m. pyramidalis nasi; m. fronto-nasal.) It appears like a continuation of the occipito-frontal muscle. 7. The triangular muscle of the nose, (m. compressor nasi; m. sus-maxillo-nasal.) 8. The elevator of the upper lip and wing of the nose, (m. levator labii superioris alæque nasi; m. grand sus-maxillo-labial.) 9. The elevator of the upper lip, (m. levator labii superioris; m. moyen sus-maxillo-labial.) 10. The small zygomatic muscle, m. zygomaticus minor; m. petit zygomato-labial.) 11. The large zygomatic muscle, (m. zygomaticus major; m. grand zygomato-labial.) 12. The elevator of the angle of the mouth, (m. levator anguli oris; m. caninus; m. petit sus-maxillo-labial.) This is distinctly seen at the left side as it descends from the upper jaw-bone to the angle of the mouth. 13. The buccal or cheek muscle, called also the buccinator or trumpeter's muscle, (m. buccinator; m. alveolo-labial;) it is more distinctly shown at the left side. 14. The masseter muscle, (m. masseter; m. zygomato-maxillaire;) it is one of the elevator muscles of the lower jaw. 15, 15. The orbicular muscle of the mouth, (m. orbicularis oris; m. labial;) its form is properly that of an ellipse, and the two references are used to mark its upper and lower segments. 16. The depressor muscle of the angle of the mouth, (m. depressor anguli oris; m. triangulaire des lèvres.) 17. The depressor of the lower lip, (m. depressor labii inferioris; m. quadratus menti; m. mento-labial.) 18. The elevator of the chin, (m. levator menti; levator labii inferioris.) 19. The bones of the side of the head. 20. The tendon of the eye-lids, and of their orbicular muscle. The muscle is removed to show the tendon and the lids more distinctly.

FIG. 2. Gives a view of the back of the head. The occipito-frontal muscle remains in its natural position at one side, No. 1. At the other it is detached and drawn upwards. 2. The thin aponeurosis, which connects the occipital with the frontal part of the muscle as seen in fig. 1, No. 1, rests upon the skull, and slides smoothly over it. 3. The posterior muscle of the ear, (m. retrahens aurem; m. mastoïdo-auriculaire.)



Fig 1.

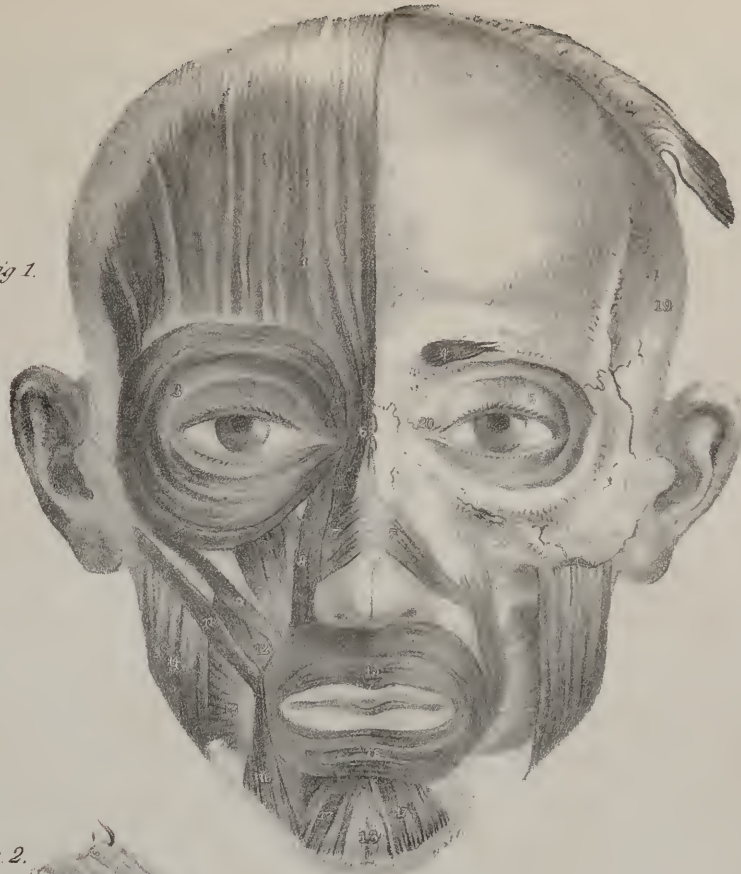
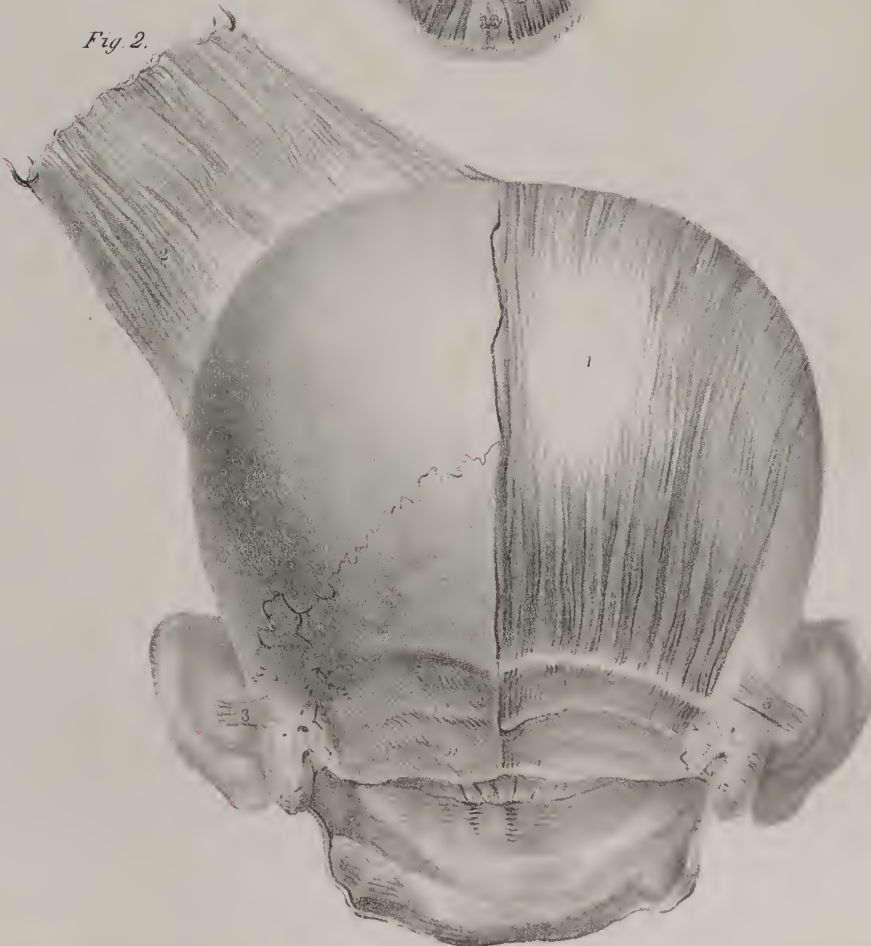



Fig 2.





to the back of the head, where by means of muscular fibres it is attached to the curved ridge seen on the bone, on a level with the ear, fig. 2, No. 1. Now, when this muscle is put into action, in the first instance it draws up the eye-brow, and if its effort is carried further it throws the skin of the forehead into transverse folds or wrinkles.

The lower end of these fibres will be observed to be connected along the line of the eye-brow with those of No. 3, and there they conceal a little muscle such as is seen at the left side No. 4; at the root of the nose the fibres of No. 1 are prolonged down for some way, and become attached to the bone. To form a clear idea of the form, extent, and structure, of this muscle, just for a moment suppose a piece of wire, or a long needle, to be introduced beneath its inner border, half an inch above the root of the nose, and pushed outwards close to the bone until it protrudes at the temple; and this can be readily done when the parts are dissected, as it merely rests on the bone. Then, by holding the two ends of the wire, it may be made to pass from before backwards, so as to slide under the muscle as far back as the occiput. By this expedient it may be shown that the muscle consists of two fleshy portions connected by a thin tendinous membrane. One fleshy part rests on the forehead, (fig. 1, No. 1,) and the other on the occiput, (fig. 2, No. 1.) All the parts of this muscle are intimately connected with the skin, while they slide smoothly over the skull; and, as the fleshy fibres at its opposite ends can be put alternately in action, we can readily conceive how it is that persons in whom it is much developed can move the hairy scalp, and draw it forwards and backwards at pleasure.

No. 3 (*orbicularis palpebrarum*) is a flat plane of circular or elliptic fibres placed round the eye-lids, but extending at the same time upwards on the brow and downwards on the cheek. Between the upper and lower segments of the muscle is the transverse fissure which separates the eye-lids, and through which the globe of the eye projects. This muscle is not connected with the bones of the face at any point of its extent except towards the inner border of the orbit, where it becomes attached by means of a small white tendon, (similar to that seen at the left side No. 20,) and also by some of its own fibres, which are fixed a little above the tendon. But the upper part of the muscle which lies along the eye-brow is intimately connected with the fibres of No. 1 which lies above it, and with No. 4 which is placed under cover of it. The corrugator supercilii No. 4, when brought into view by removing No. 3, appears in the form of a small tapering bundle of muscular fibres, attached by its inner end to the bone, whilst the other becomes blended with the two preceding muscles. Now, when No. 3 is thrown slightly into action, it contracts and shortens in such a way that the fibres of the upper and lower segments become straight and approach one another so as to close the eye-lids. If this action is continued and becomes forcible, the lids become wrinkled and drawn at the same time inwards to the root of the nose, by which means the tears, and any extraneous matters which may rest upon the eye-ball, are carried to the inner angle of the orbit, whence the lachrymal ducts lead to the nose. If No. 1 raises the brow and wrinkles the skin of the forehead transversely, this muscle can draw it downwards and undo the creases.

Let the reader for a moment conceive that he can lift up this muscle from the parts on which it lies by passing a wire under its external border, where it rests on the cheek-bone, and then gradually detaching the lower segment of it from the bone and the muscles 8, 9. The upper segment may also be separated along the eye-brow, although with more difficulty, as it is connected intimately with No. 1. If a piece of card be then placed under it, it will represent what we have stated it to be: viz. a flat plane of elliptic fibres, which are not connected with the bones of the face at any part of their extent except at the inner border of the orbit. At this point will be observed a small white line, representing a tendon, which runs horizontally outwards from the side of the nose to the fissure of the eye-lids. It is marked at the left side No. 20; it can be readily felt under the skin by drawing the lids outwards, so as to make it tense. To this tendon some of the muscular fibres are attached, and others are connected with the bone higher up towards the root of the nose.

No. 4, by its direction and point of attachment, is enabled to draw the eye-brow inwards, and throw it into vertical folds, as in frowning: but in this action the inner part of the upper segment of No. 3 exerts a considerable influence; for the brow is obviously drawn downwards in the direction of the tendon or fixed point of this muscle, as well as inwards to the root of the nose.

We proceed in the next place to the muscles of the mouth. The transverse fissure between the lips is here observed to be surrounded by a flat plane of elliptic fibres, (*orbicularis oris*), No. 15, in most respects similar to those of the eye-lids. By a slight degree of contraction they close the lips, and when they act a little more forcibly they crease the skin, and render the aperture small and circular, like the mouth of a purse, when its string is drawn tightly. To this, as to a common centre, several bundles of fibres, forming so many separate muscles, will be observed to converge from different points. Nos. 8 and 9 run downwards from the margin of the orbit; Nos. 10 and 11 incline obliquely from the cheek-bone. No. 13 inwards from the cheeks. Nos. 16 and 17 upwards from the lower jaw-bone. The ends of these muscles which are most distant from the mouth are attached to the bones here named, as to so many fixed points; but the other ends are united to the circular muscle round the mouth. Now all these may be considered as so many retractors, which can draw the lips either upwards, downwards, outwards, or obliquely upwards. If No. 8 acts by itself, it draws up the lip and the wing of the nose, for three or four of its fibres will be seen attached to the most prominent part of the side of the nose. No. 9 draws the middle of the lip also upwards: No. 12 elevates its angle: Nos. 10 and 11 draw the angle outwards and upwards, whilst 16 depresses it: No. 17 draws down the lower lip. It is by the agency of these different moving powers that the face can exhibit all that variety of expression of which it is susceptible. The forehead and brow, now calm and placid, can instantly be made to assume the frown of aversion or contempt.



And the lips which slightly move as we speak, or at times open into a smile, may with the rapidity of thought exhibit all the varieties of expression which characterise joy and grief, hope and despair, the tenderness of affection, or the bitterness of scorn.

The different muscles here noticed receive branches from a nerve (facial,) which serves as the means of connecting them with the brain, and placing them under the control of the will. This nerve, after passing down through the base of the skull, lies at first deeply in the interval between the ear and the angle of the jaw, where it soon divides into long filaments, which branch out upon the side of the face, some mounting upwards upon the temple, others inclining down along the lower jaw and the throat, whilst more proceed across to the cheek, nose, and lips. To this nervous cord and its branches, the muscles of expression owe their power of action. If it be compressed by a tumour, or divided during the progress of a surgical operation, the muscles become paralyzed, and lose the power of motion and of expression. Whenever this occurs, the muscles of the sound side being no longer counteracted, will draw on the mouth and lips, and cause a permanent deviation. The influence of nervous action upon the muscles is thus rendered obvious. Now, as the expressions of the face are put on in obedience to the promptings of the will, or the impulse of passion, they form so many outward indications of inward feeling; and as in many instances they are so often repeated as to become habitual, they give a certain cast to the countenance indicative of the prevailing habits of the mind.

In the features of an empassioned countenance, (observes Sir C. Bell, Anatomy of Expression,) it is not upon a single feature that the emotion operates,—there is a consent and accordance between different parts,—the whole face is marked with expression, and all its movements are consentaneous. “Hence when the angles of the mouth are depressed in grief, the eye-brows are not elevated at the outer angles, as in laughter. When a smile plays around the mouth, or the cheek is elevated in laughter, the brows are not ruffled, as in grief. The character of such opposite passions are so distinct that they cannot be combined, where there is true and genuine emotion. When we see them united by those who can, at will, control the actions of their muscles, the expression is farcical and ludicrous.”

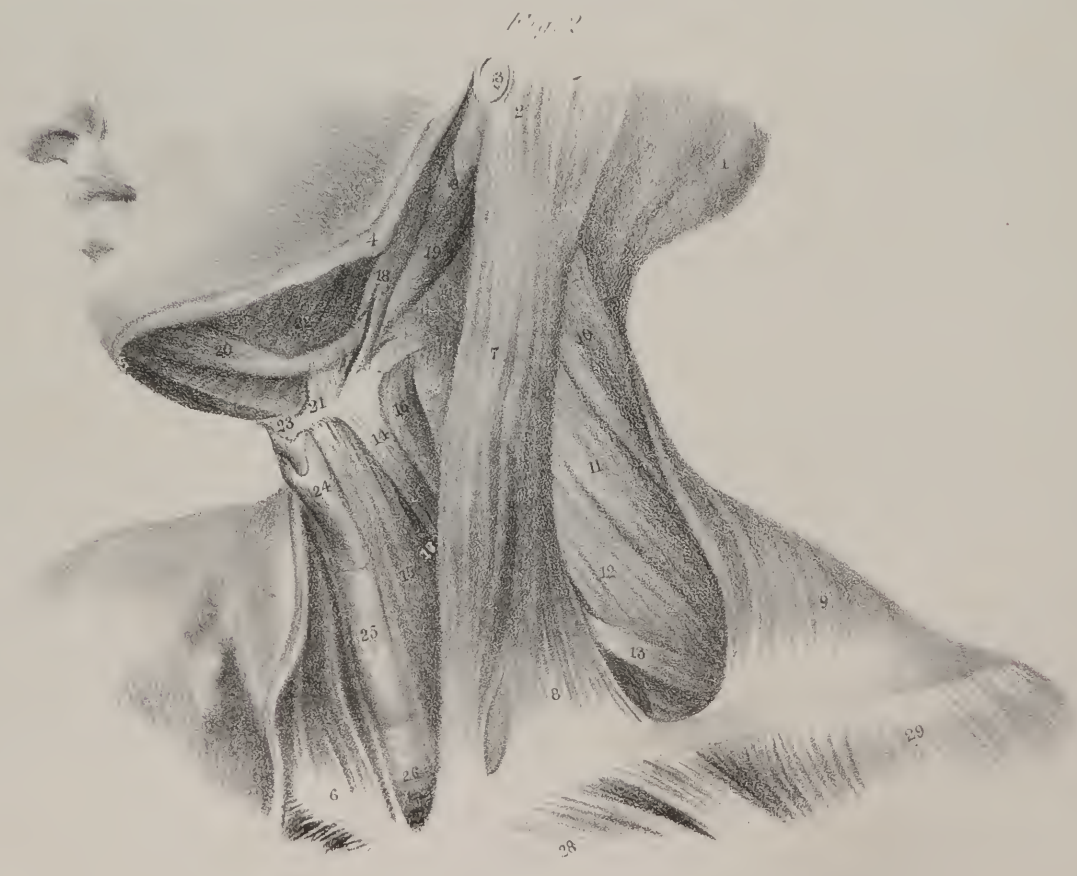
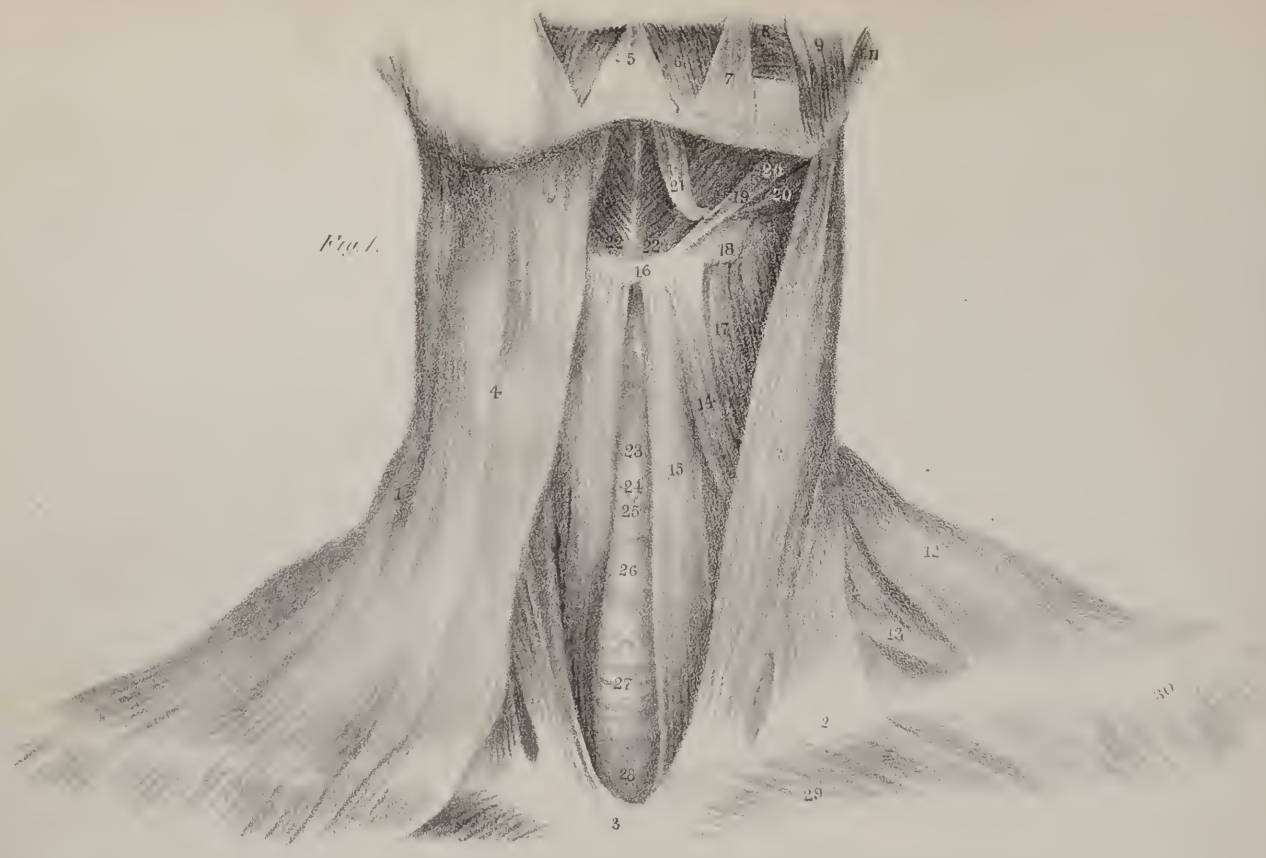
### PLATE III.

THE third plate gives a view of the muscles which lie immediately beneath the skin, upon the front and side of the neck. To render these apparent, the tegument and the superficial fascia are removed, and the cellular tissue which fills the interstices between the muscles is dissected out; moreover, the deep or proper cervical fascia is taken away, in order to exhibit the form and size of the different muscles, as well as the direction of their fibres.

In fig. 1, a broad but very thin layer of pale fibres, No. 4, will be observed to run up from the top of the chest and front of the shoulder, over the clavicle, and along the side of the neck, to the lower jaw and the cheek. From the paleness and thinness of its fibres, it is evident that its power is very little in the human subject; it may be considered a rudiment of the extensive fleshy layer which lies under the skin in lower animals, and enables them to move it to and fro, as well as to wrinkle it, and thereby remove any irritating substances which may rest upon it. It is called *platysma myoides*—the broad muscle-like lamella, (*πλατυν* a muscle, *ειδος* like.) Underneath this, and partly concealed by it, the extremities alone being uncovered, is a long, thick (and towards the middle, rounded) muscle, which lies obliquely along the neck at each side, being stretched from the sternum and clavicle, (the breast-bone, and collar-bone,) up to the bony prominence the mastoid or nipple-shaped process, (*μαστος* a nipple, *ειδος* like,) behind the ear. Its name expresses its three points of attachment, viz. sterno-cleido-mastoid. Its lower end consists of two parts, differing in their form as they do in the parts to which they are fixed; one being rounded and cord-like, the other flat and somewhat triangular; the former arises from the sternum, the latter from the clavicle. These are at first separated by a slight interval filled by cellular tissue, but they soon become united. The two muscles of this name will be observed to be close together at their lower ends, fig. 1, No. 3, and widely apart at the upper ends, where they are fixed to the base of the skull. When they both act together they bow the head, by drawing it downwards and forwards towards the chest, which is the point from which they act; if one of them acts by itself, it draws the head downwards to its own side, but it is also enabled by the obliquity of its direction to give a horizontal movement to the base of the skull, so as to turn the chin round towards the shoulder of the opposite side. Thus the right sterno-mastoid muscle, fig. 1, No. 13, can rotate the head, and turn the chin to the left side, until it comes into the position seen in fig. 2.

Two flat, ribbon-shaped muscles are here shown, No. 15, lying beside one another, at the front and side of the windpipe, 27, and organ of voice, (larynx,) No. 23. They stretch upwards from the sternum (its inner surface) to the tongue-bone, (os linguale, also called hyoides, or U-shaped, from some likeness to the Greek letter  $\psi$ .) Hence they are named sterno-hyoid muscles. Their action is obvious; they draw down the base of the tongue, and are therefore the antagonists of the muscles, which, by being stretched from the lower jaw to the tongue-bone, are so many elevators, (22, 23.) Close to the outer border of 15 is another flat, but still narrower band, 14; part of it is seen running obliquely up from behind 16, to the tongue-bone; part is concealed by







16, and another part, marked 13, lies still lower down, where it is deeply seated, and runs behind the clavicle to the upper border of the scapula, or blade-bone; it is named omo-hyoideus, (*ωμος* the shoulder:) it too is a depressor of the tongue-bone. At the external border of 14, and partly concealed by it, is a short, flat muscle, which extends from the side of the thyroid cartilage, (24,) to the side of the tongue-bone; its name expresses its attachments—thyro-hyoïd. It draws down the root of the tongue, if the thyroid cartilage is previously fixed, or it will carry the latter upwards, when the tongue-bone is drawn up by the action of the muscles, which connect it with the lower jaw and the base of the skull.

We shall, by and by, see the importance of this movement during the effort of swallowing: it will be found that it draws the entrance into the air-passages upwards, in such a way as to place it securely under the protection of a valve, or coverlid, (the epiglottis,) which prevents the descent of food or fluids into it. Part of a muscle is here also seen at the outer border of the sterno-hyoid, by which it is overlapped; it comes up from the sternum, and is fixed to the side of the thyroid, or shield-shaped cartilage, (*θυροειδ* a shield,) which it draws down if previously elevated.

Beneath the lower jaw are seen three muscles, which differ in form and size, as well as in the direction of their fibres. Two of them incline down from the base of the skull to the tongue-bone. In fig. 2, they appear deeply placed behind the angle of the jaw. One of them, fig. 2, No. 18, is round and tapering, its upper end is attached to a long bony process, which from some resemblance to the ancient stylus, or writing-instrument, has been called "styloid." The lower end of the muscle is fixed to the hyoid bone; hence its name stylo-hyoid. Close to the stylo-hyoid muscle, is one which consists of two parts or bellies united by a round tendon, and which is called digastric or double-bellied. One part, No. 20, is inserted close under the chin; the other lies deeply, being concealed by the sterno-mastoid muscle: the tendon which connects the two runs through a slit in the fibres of the stylo-hyoid muscle, by which means, as well as by some dense white fibres, it is connected with the hyoid bone. The whole muscle thus forms an arch whose concavity looks up to the jaw-bone. Suppose the jaw to be fixed as when the mouth is closed in the preparatory effort of swallowing, and that this muscle is put in action, its fibres when contracted and shortened will bring both its parts from the curved into the straight direction, by which means it will draw up the tongue-bone; the stylo-hyoid muscle will assist in the effort. The anterior part of the digastric muscle is seen to rest upon a flat plane of muscular fibres which pass down from the lower jaw, inclining obliquely inwards as they descend. Close under the chin, the fibres belonging to the muscles of opposite sides meet and join; and this convergence and union takes place along the whole interval between the chin and the tongue-bone, into which the longest fibres are inserted. The upper end of the fibres is fixed to the inside of the jaw-bone, the lower into the tongue-bone; whilst in the interval between the latter and the chin, the fibres

### PLATE III.

FIG. 1, exhibits the muscles seen upon the front of the neck, after the skin and fascia have been removed. No. 1, the border of the lower jaw-bone seen in front. 2. The clavicle of the right side; that of the left is partly concealed by the platysma muscle. 3. The sternum. 4. The platysma myoides muscle, (*musculus latissimus colli*; *m. peaucier*.) 5. The elevator muscle of the chin, (*m. levator menti*.) 6. The depressor of the lower lip, (*m. quadratus menti*; *m. mento-labial*.) 7. The depressor of the angle of the mouth, (*m. triangularis oris*.) 8. The buccinator muscle, (*m. buccinator*: *alveolo-labial*.) 9. The masseter, (*m. masseter*; *zygomato-maxillaire*.) 10. The sterno-cleido-mastoid muscle. 11. Jaw-bone. 12. Part of the trapezius muscle, (*m. cucullaris*; *occipito-dorsissus-acromien*.) 13. The lower part of the omo-hyoideus muscle, (*m. scapulo-hyoideus*.) 14. The upper part of the same muscle, the intervening portion being concealed by the sterno-cleido-mastoid. 15. The sterno-hyoid muscle, (*m. sterno-hyoideus*.) 16. The tongue-bone, (*os hyoides*; *os linguale*.) 17. The thyro-hyoid muscle, (*m. thyro-hyoideus*.) 18. The large wing, (*cornu*,) of the hyoid bone. 19. Part of the stylo-hyoid muscle. 20. The posterior part of the digastric muscle, (*m. digastricus*; *m. mastoïdementale*.) 21. The anterior part or belly of the same muscle. 22, 22. The mylo-hyoid muscles of the opposite sides, (*m. mylo-hyoideus*;) their fibres are seen converging, so as to form a seam by their junction, along the interval between the chin and the hyoid bone. 23. The shield-shaped, or thyroid cartilage, (*θυροειδ* a shield, *ειδος* like,) forming the most prominent part of the organ of voice. 24. The cricoid, or ring-shaped cartilage, (*κρηκοειδ* a circle,) which forms also a part of the organ of voice. 25. A small plate of membrane, (*crico-thyroid*,) connecting the two parts last named. 26. The thyroid gland. 27. The windpipe or trachea. 28. The inter-clavicular ligament, a strong band stretched across the top of the sternum from one clavicle to the other. 29. Part of the great pectoral muscle. 30. Part of the deltoid muscle.

FIG. 2. Shows the muscles upon the side and front of the neck; the cutaneous or platysma muscle, together with the integument, have been taken away. No. 1. The occipital bone. 2. The mastoid or nipple-shaped process of the temporal bone, in great part concealed by the insertion of the sterno-cleido-mastoid muscle. 3. The tube of the ear. 4. The angle of the lower jaw-bone. 5. The symphysis or junction of the same bone. 6. The clavicle. 7. The sterno-cleido-mastoid muscle. 8. Its clavicular part or region. 9. Part of the trapezius muscle. 10. The splenius muscle (*m. splenius colli et capitis*; *m. cervico-mastoïde et dorso-trachelien*.) 11. Part of the elevator of the scapula (*m. levator anguli scapulae*; *m. trachelo-anguli-scapulaire*.) 12. The posterior scalenus muscle. 13. The lower part of the omo-hyoid muscle. 14. The upper part of the same muscle. 15. The sterno-hyoid muscle. 16. The thyro-hyoid muscle. 17. Part of the sterno-thyroid muscle. 18. The stylo-hyoid muscle. 19, 20. The two parts or bellies of the digastric muscle. 21. Some tendinous fibres which connect it to the hyoid bone. 22. The mylo-hyoid muscle. 23. The hyoid or lingual bone. 24. The thyroid cartilage. 25. The thyroid gland. 26. The trachea or windpipe. 27. The inter-clavicular ligament. 28. Part of the great pectoral muscle. 29. Part of the deltoid muscle.

converging from opposite sides of the middle line join so as to form a sort of seam, (see plate V. fig. 4.) Its name "mylo-hyoid," expresses its points of attachment to a slight ridge at the inner side of the jaw near the grinder teeth (*μυλος*, a grinder) and the hyoid bone. It assists other muscles in drawing up the base of the tongue; and as it is placed immediately under the lining membrane of the mouth, it may be said to form a floor for that cavity, which, by the relaxation of its fibres, permits it to descend and become deep, and by their contraction draws it up again when circumstances require, so as to make it nearly a plane surface.

At the outer border of the sterno-mastoid muscle, fig. 2, Nos. 7, 8, is a deep interval intervening between it and the trapezius, No. 9. In this space will be seen, towards its lower part, the omo-hyoid muscle 13, resting on another, the middle scalenus 12; higher up are the fibres of the splenius and levator scapulae, (Nos. 10, 11.) These shall be commented on in a subsequent age.

## PLATE IV.

THESE drawings exhibit different views of the canal or passage which leads from the mouth and nose downwards into the stomach and lungs: it is, in technical language, called the pharynx; it is thin and membranous in its structure, being made up of two layers, the one a mucous membrane continuous with that which lines the mouth and nose, and which is prolonged throughout the whole alimentary canal—the other a layer of muscular fibres, disposed in a very peculiar way, which not only supports the lining membrane, but also gives to the tube itself a contractile power. The pharynx thus formed may be called a

## PLATE IV.

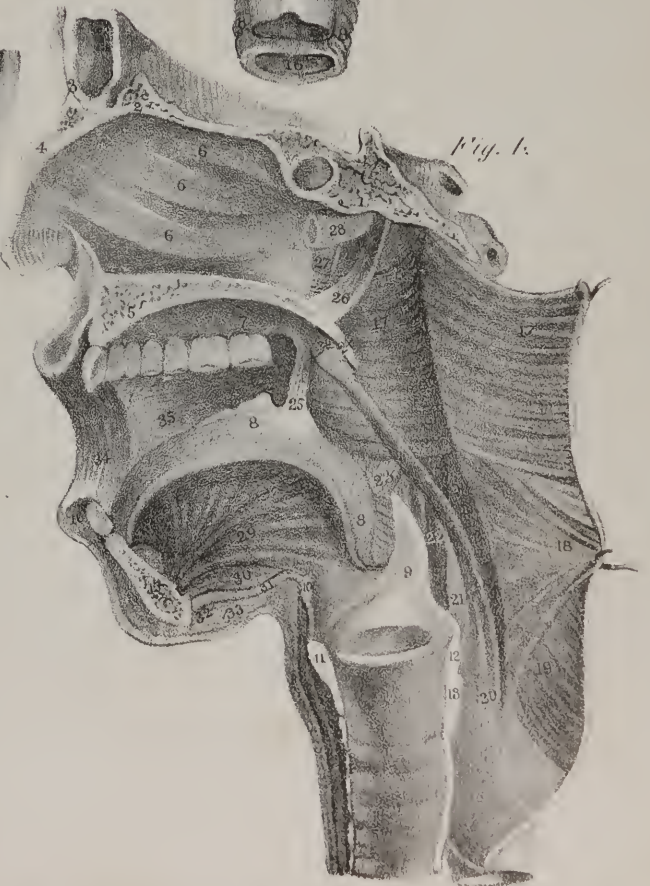
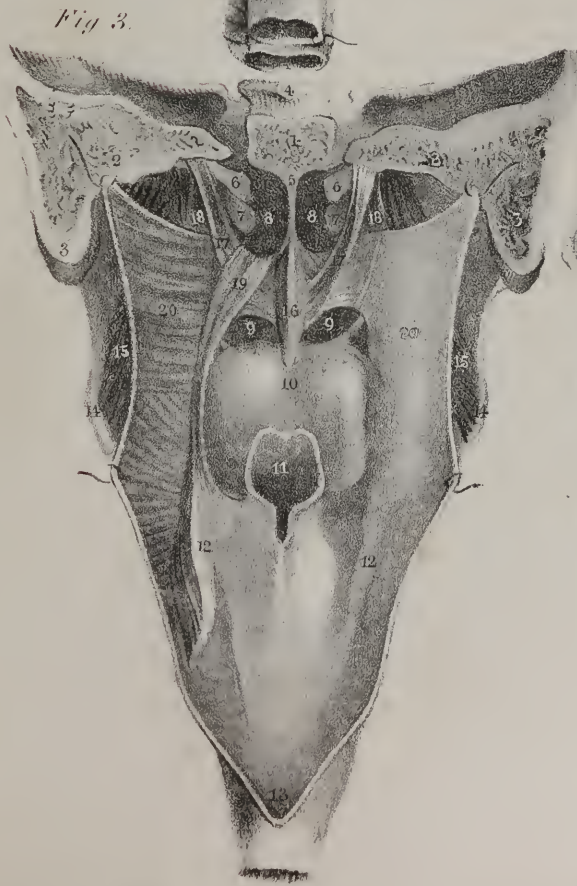
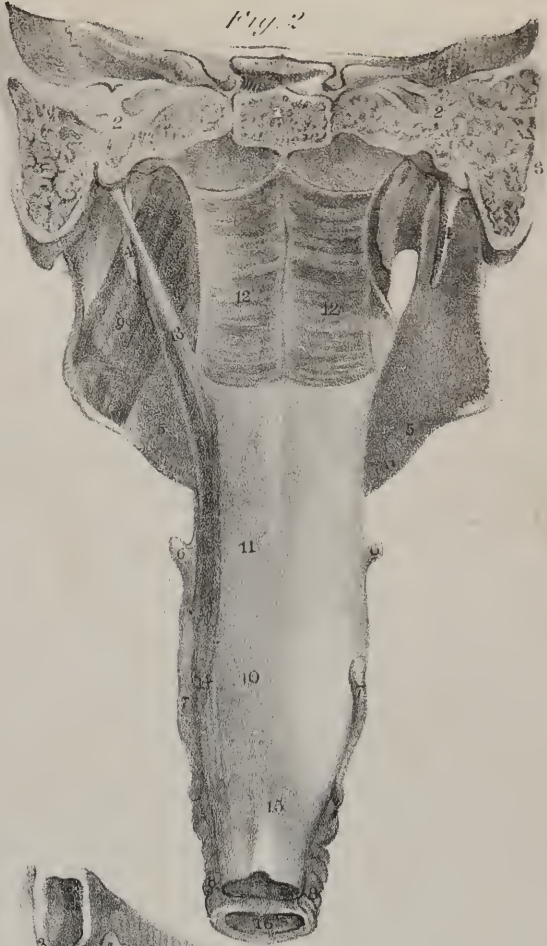
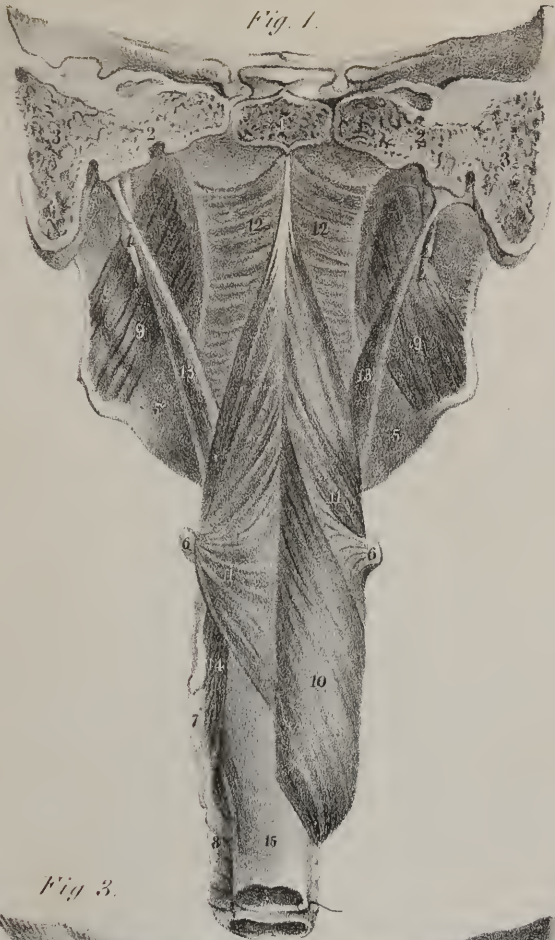FIGS. 1 and 2. Exhibit the pharynx and its muscles, as seen from the back. The arch of the skull is altogether removed, and only a part of its base remains. In order to obtain this view of the pharynx, it must be detached from the spine, in front of which it lies, and the fore-part of the skull must be separated from the back-part, in such a way as to leave the pharynx hanging down from the base of the skull. For this purpose, the trachea and oesophagus must be cut across at the lower part of the neck, near the sternum, and then drawn forwards and upwards; after which there is no difficulty in detaching the pharynx from the muscles in front of the spine, as it is connected with them merely by some loose cellular tissue. In the next place, a piece of linen, or calico, to serve as a retractor and guard to the pharynx, is to be passed down into the narrow interval between it and the top of the spine, and drawn tightly forwards, so as to protect the pharynx. The saw is to be inserted close to the cloth, in such a way that its edge shall rest immediately behind the roots of the styloid processes, and cut through the base of the skull from below upwards. By these means the pharynx, with that part of the base of the skull to which it is attached, is severed from its connexions with all contiguous structures, and can be examined by itself.

One such section will furnish readily the three views seen in figs. 1, 2, 3, and a very little management will suffice to obtain the lateral view given in fig. 4.

FIG. 1. No. 1. Part of the basilar process of the occipital bone. 2, 2. The petrous part of the temporal bone. 3, 3. The mastoid process of each side. 4, 4. The styloid process of each side. 5, 5. The lower jaw-bone. 6, 6. The extremities of the horn-shaped processes of the tongue-bone. 7. The border of the thyroid cartilage. 8. The rings of the windpipe. 9. The internal pterygoid muscles passing down from the groove between the pterygoid processes of the sphenoid bone, to be inserted into the angle of the lower jaw-bone. 10. The inferior constrictor muscle of the pharynx, (*m. constrictor inferior*.) At the opposite side the muscle is removed, in order to expose the lower part of the middle constrictor, which it conceals, and also the insertion of the stylo-pharyngeus muscle into the thyroid cartilage. 11. The middle constrictor muscle, its fibres spreading away like the ribs of a fan from their common origin at the tongue-bone, and passing back to unite with the corresponding muscle of the opposite side, and form a raphe, or seam, which is here seen to run from below upwards to the base of the skull. 12, 12. The superior constrictor muscles of each side, (*m. constrictor superior*.) The upper border of each is observed to be slightly curved, and as the upper fibres pass from the pterygoid process to the base of the skull, they necessarily leave a small part of the mucous membrane uncovered. 13, 13. The stylo-pharyngeal muscle of each side, (*m. stylo-pharyngeus*.) As the fibres descend they are observed to spread out a little; they become concealed by the middle constrictor, and also by the inferior constrictor; they finally terminate, 14, at the border of the thyroid cartilage. 15. The commencement of the oesophagus, where it passes down from the pharynx.

FIG. 2. Shows nearly the same parts, the inferior and middle constrictor being taken away so as to expose the mucous membrane of the pharynx in the points which correspond with them, (10, 11.) By these means the stylo-pharyngeus muscle is shown in its entire length, and also the superior constrictor. The stylo-pharyngeus of the right side is also taken away, in order to show the attachment which the superior constrictor has to the inside of the lower jaw-bone, and to the ligament which is extended from that bone to the internal pterygoid plate. No. 1. The basilar process of the occipital bone. 2, 2. The petrous part of the temporal bone. 3, 3. The mastoid process. 4, 4. The styloid process. 5, 5. The lower jaw-bone. 6, 6. The extremity of the horn-shaped process of the tongue-bone. 7, 7. The borders of the thyroid cartilage. 8. The rings of the windpipe. 9. The internal pterygoid muscle of the left side. 12, 12. The superior constrictor muscles of the pharynx; their fibres unite to form a seam along the middle line, and those highest up are fixed into the basilar process. 13. The left stylo-pharyngeus muscle. 14. The insertion of the same into the border









musculo-membranous tube; it extends from the centre of the basis of the skull as far as the fifth cervical vertebra, where it terminates in the œsophagus—the lengthened passage which leads thence downwards to the stomach. As the pharynx contracts towards its lower part, it has been likened to a funnel, and the comparison would be sufficiently correct were it not that it is wider in the middle than at its upper extremity: it lies along the neck before the spine, between the great blood-vessels of the neck, and behind the cavities of the nose, of the mouth, and of the larynx or organ of voice, all of which open into it. Figs. 1 and 2 show that it is closed at its back part and sides, in which situation it is found to be but loosely connected with surrounding structures, so that it admits of ascent and descent in the different efforts which are required in swallowing food and drink, and also in modulating the voice. If it be laid open as in fig. 3, by an incision made from below upwards along its back part, then it will be seen that it communicates with the nose by two apertures,—with the mouth by an arched interval situated between the roof of the tongue and the palate; also, that two lengthened ducts, called Eustachian tubes, lead outwards from it to the cavities of the ears: that, in the next place, it communicates with the larynx by a narrowed aperture surmounted by a valve called the epiglottis; and finally, that it narrows into a tube as it becomes continuous with the œsophagus. Its connexion with the base

of the thyroid cartilage. 15. The tube of the œsophagus, continuous with the lower end of the pharynx, from which it is prolonged down to the stomach. 16. The tube of the windpipe cut across.

FIG. 3. Brings into view the different openings and passages which communicate with the pharynx. This is readily done by laying open the pharynx along its entire length, beginning below at No. 15, fig. 1, and running the blade of a pair of scissors upwards to the basilar process. The sides are then drawn asunder, and retained so by hooks. By these means we see the posterior openings of the nose, 8, 8, with the partition between them, 5. 9, 9. The opening into the mouth, the tongue 10, and the opening 11, into the windpipe and organ of voice. The lining membrane is left on at the right side, but at the left it is removed so as to expose the muscular fibres of the pharynx, 20, and of the soft palate. The muscles of the latter at first appear complex, but their relative position and uses are soon rendered intelligible. The soft palate hangs down from the back part of the roof of the mouth, and is likened to a movable curtain; it presents at the middle a pointed process, 16, called the uvula, and at each side an arched border. Two thin bundles of muscular fibres, 17, 17, (*levator palati*,) run down to it from the base of the skull, which, when put into action, readily draw it up. One at each side, No. 19, (*palato-pharyngeus*,) descends from it to the pharynx, which can draw it downwards. Another pair, 18, (*tensor palati*,) after running for some way vertically downwards, change their direction by coiling round a process of bone, and turn horizontally inwards, by which means they can stretch it from side to side and make it tense. Two little muscles are placed in the uvula, No. 16,\* which shorten it. In fig. 4, a side view is given of the hard palate, No. 5, and of the soft palate hanging down from its back part, No. 24. (See plate V. fig. 3.)

Having premised thus much upon the objects of the drawing, we shall now give the references seriatim. No. 1. The basilar process of the occipital bone. 2, 2. The petrous part of the temporal bone. 3, 3. The mastoid processes. 4. Part of the sphenoid bone. 5. The partition between the right and left cavities of the nose. 6, 6. The extremities of the tubes which lead from the throat outwards, into the cavities of the ears. They are called Eustachian tubes, from the anatomist Eustachius. 7, 7. The extremities of the spongy bones of the nose; these are seen in fig. 4. 6, 6. 8, 8. The posterior openings of the nose. 9, 9. The fauces or narrowed communication from the mouth into the pharynx. 10. The upper surface of the tongue. 11. The epiglottis, and the opening into the air-passage, which it overhangs and protects. 12, 12. The borders of the thyroid cartilage. 13. The tube of the œsophagus or gullet leading down from the pharynx. 14, 14. The angle of the lower jaw-bone. 15, 15. The internal pterygoid muscle. 16. The azygos uvulæ muscle. 17, 17. The elevators of the soft palate. 18, 18. The tensors of the soft palate. 19. The palato-pharyngeus muscle. 20. The superior constrictor muscle everted.

FIG. 4. Exhibits a side view of the parts which are seen from behind in fig. 3. It is obtained by making a vertical section running from before backwards, of the base of the skull, of the roof of the mouth, of the lower jaw, and of the larynx. No. 1. Part of the body of the sphenoid bone, and behind it a part of the basilar process of the occipital bone. 2. The crest or cockscomb process of the ethmoid bone. 3. Part of the frontal bone. 4. The nasal bone. 5. The hard palate or bony roof of the mouth. 6. The three turbinate bones which overhang and form the passages (meatus) of the nose. 7. The inner side of the dental arch. 8. The upper surface of the tongue, and its papillæ. 9. The epiglottis. 10. Part of the tongue-bone. 11. The thyroid cartilage. 12. The arytenoid or ewer-shaped cartilage: between these will be observed an oval depression in the side of the larynx or organ of voice, which represents the ventricle of the larynx; it is bounded above and below by white lines, indicating the position of the vocal cords. 13. Is the back part of the ring-shaped (cricoid) cartilage. 14. The section of the rings of the windpipe. 15. The lower jaw cut through at its fore-part or symphysis. 16. The lower lip. 17, 17. The superior constrictor muscles of the pharynx, that of the left side being held back by a hook. 18. The middle constrictor of the left side everted. 19. The inferior constrictor muscle. 20. The palato-pharyngeus muscle, (m. pharyngo-staphylin.) 21. The great horn of the thyroid cartilage. 22. The lower part of the stylo-pharyngeus muscle. 23. Part of the middle constrictor muscle of the right side. 24. The soft palate and uvula. 25. The palato-glossus muscle (m. glosso-staphylin, constrictor Isthmii faucium,) of the right side. 26. The elevator muscle of the soft palate, (m. levator palati; m. peri-staphylin interne.) 27. Part of the tensor muscle of the soft palate, (m. circumflexus vel tensor palati; m. peri-staphylin externe.) 28. The Eustachian tube. 29. The genio-hyo-glossus muscle; its name expresses its three attachments: viz. to the inner side of the chin, (*γυελωρ*), to the hyoid or tongue-bone, and to the tongue itself. It is very narrow at its commencement at the chin, but its fibres soon spread out like the ribs of a fan, as they are inserted into the under surface of the tongue from its point as far back as its root. 30. The genio-hyoid muscle; its name expresses its points of attachment to the chin and tongue-bone. 31. The mylo-hyoid muscle. 32. A small part of the digastric muscle. 33. The skin beneath the jaw-bone. 34. Part of the orbicular muscle of the lips. 35. The inner side of the buccinator muscle.

\* Formerly described as a single muscle, *azygos uvulæ*.

of the skull at its upper part is effected not merely by its lining membrane, but also by its muscular fibres, many of which are attached to the bones of the skull, and take their fixed points from them when they are called into action. These muscular fibres are disposed in a very peculiar way at the sides and back part of the pharynx; there are three plates of them at each side, as may be seen in fig. 1, also in plate V. fig. 1. One plate, situated low down, consists of fibres which are fixed along the side of the larynx, from which they pass obliquely backwards and upwards, until they are met, along the middle line, by a similar set of fibres derived from the opposite side, where they join, forming a sort of seam, (raphè;) thus they are made to enclose the tube: the lowest of these fibres will be observed to arise from the first rings of the windpipe, and to run almost directly backwards, so as to surround the commencement of the œsophagus, whilst the upper fibres are very oblique in their course, so as to become nearly vertical in their direction, and these will be observed to cross and overlap part of the middle plate. Now the middle plate just mentioned consists of fibres which spread out from a common point, like the ribs of a fan, some upwards, some downwards, the rest with various degrees of obliquity, but all tending towards the back part of the tube, where they unite with similar fibres derived from the opposite side, just as we saw in the case of the preceding muscle. The common point of origin of this muscle is from the side of the tongue-bone, (see plate V. fig. 1;) and as they diverge whilst passing backwards, some of them will be observed to get under cover of the inferior constrictor and to be overlapped by it, whilst those placed higher up overlay in their turn the fibres of the superior one. The third or highest of these muscular lamellæ will be observed to embrace the top of the tube; some of its fibres commence at the inside of the lower jaw, some higher up from a thin ligament, (pterygo-maxillary, plate V. fig. 1, No. 20,) which passes from the internal pterygoid plate of the sphenoid bone to

## PLATE V.

- FIG. 1. Gives a side view of the muscles of the pharynx, showing their different points of attachment to the side of the larynx, to the tongue-bone, to the lower jaw, and to a ligament, No. 20, stretched between the latter and the pterygoid process, 21. The lower jaw is cut across near its angle, and its ascending part or branch removed. No. 1. The side of the skull. 2. The forehead. 3. The cheek-bone. 4. The zygomatic process. 5. The mastoid process. 6. The styloid process. 7. The lower jaw-bone. 8. The upper jaw-bone. 9. The tongue-bone. 10. The thyroid cartilage. 11. The great cornu, or horn-shaped process of the thyroid cartilage. 12. The cricoid, or ring-shaped cartilage. 13. The rings of the windpipe. 14. The commencement of the œsophagus, or gullet. 15. A broad membrane (thyro-hyoid) which connects the thyroid cartilage with the hyoid, or tongue-bone. 16. A round ligament, which connects the cornua of the parts last named. 17. The mylo-hyoid muscle. 18. The buccal, or buccinator muscle. 19. The orbicular muscle of the lips. 20. The pterygo-maxillary ligament. 21. The attachment of the superior constrictor muscle to the inner plate of the pterygoid process. 22. The external plate of the pterygoid process. 23. Part of the circumflex, or tensor muscle of the soft palate. 24. The superior constrictor muscle of the pharynx. 25. The middle constrictor muscle. 26. The inferior constrictor muscle.
- FIG. 2. Gives a side view of the tongue and its muscles; also of those which descend from the styloid process to the side of the tongue, to the tongue-bone, and to the thyroid cartilage. No. 1. The side of the skull. 2. The forehead. 3. The cheek-bone. 4. The zygomatic process. 5. The mastoid process. 6. The styloid process. 7. The branch of the lower jaw drawn up. The bone has been cut through at the chin, 7; also at its angle, and part removed, so as to expose the cavity of the mouth. 8. The upper jaw-bone. 9. The tongue-bone. 10. The thyroid cartilage. 11. Its horn-shaped process. 12. The cricoid cartilage. 13. The rings of the windpipe. 14. The œsophagus. 15. The external lateral ligament of the lower jaw-bone. 16. The stylo-maxillary ligament, extended between the styloid process and the angle of the lower jaw-bone. 17. The stylo-hyoid ligament, passing from the styloid process to the small process of the tongue-bone. 18. The stylo-glossus muscle. 19. The stylo-hyoideus muscle. 20. The stylo-pharyngeus muscle. 21. The superior constrictor muscle of the pharynx. 22. Part of the inferior constrictor muscle; the rest having been removed, so as to expose the insertion of the stylo-pharyngeus muscle into the border of the thyroid cartilage. 23. The thyro-hyoideus muscle. 24. The hyo-glossus muscle. 25. The tongue. 26. The genio-hyo-glossus muscle. 27. The genio-hyoideus muscle. The names of these muscles indicate their respective points of attachment.
- FIG. 3. Exhibits the muscles of the soft palate, as seen from behind:—the upper jaw-bones, with the roof of the mouth, and a small part of the base of the skull, are retained. No. 1. Part of the basilar process of the occipital bone. 2, 2. The extremity of the petrous portion of the temporal bone. 3, 3. Part of the sphenoid bones. 4, 4. The posterior borders of the upper jaw-bones. 5. The partition between the cavities of the nose. 6, 6. The hook-shaped (hamular) processes of the sphenoid bone. 7, 7. The external pterygoid plates of the same bone. 8, 8. The palate plates of the upper jaw-bones. 9, 9. The Eustachian tubes. 10. The elevator muscle of the soft palate (*m. levator palati*; *peri-staphylin interne*;) at the right side; that of the left is removed in order to show the entire extent of—11, 11, the tensor or circumflex muscles of the soft palate (*tensor vel circumflexus palati*; *peri-staphylin externe*.) 12, 12. The inner or reflected part of these muscles. 13, 13. The muscles of the uvula, (*azygos uvulæ*; *palato-staphylin*.) The circumflex muscles will be observed to turn round the hooked processes, which changes their direction, and gives them the mechanical advantage of a pulley, and enables them to stretch the soft palate from side to side and render it tense; the elevator muscles can draw up the soft palate so as to bring it to a level with the roof of the mouth or the hard palate; the little muscles of the uvula draw up and shorten that process.
- FIG. 4. Shows the mylo-hyoid muscle which forms the floor of the mouth. No. 1, 1. The inner side of the lower jaw-bone. 2, 2. Its condyles. 3, 3. Its coronoid processes. 4, 4. The mylo-hyoid muscles. 5. The body of the tongue-bone. 6, 6. Its great cornua or processes.



Fig 2

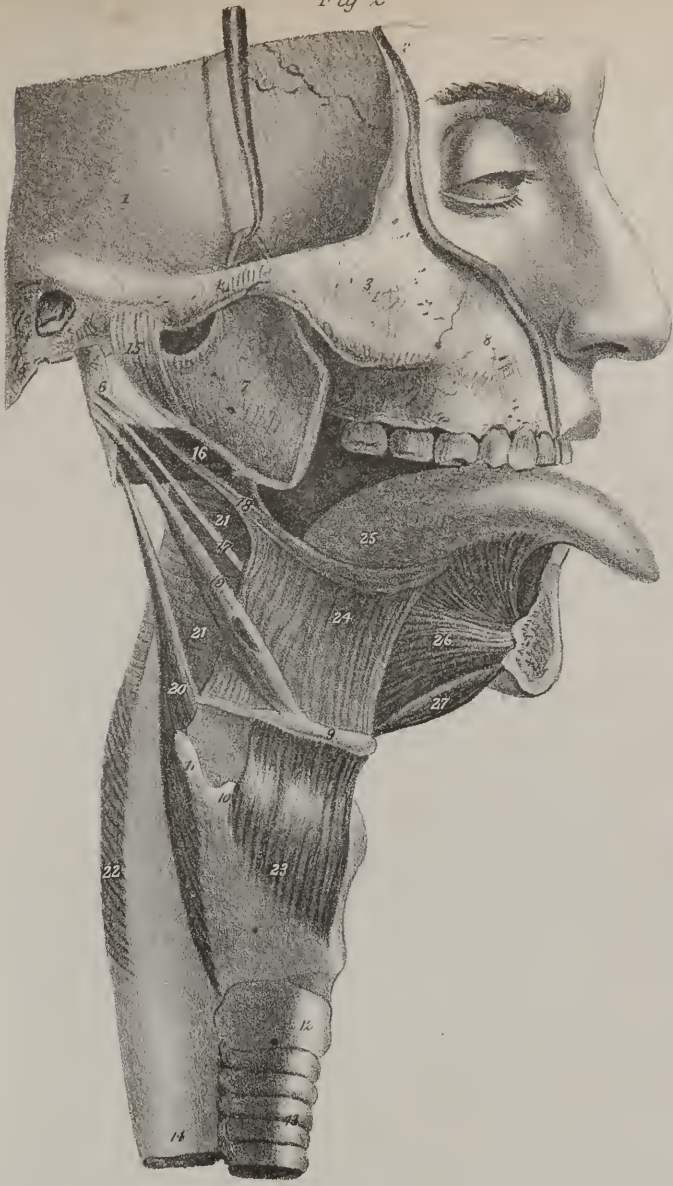

Fig. 1.

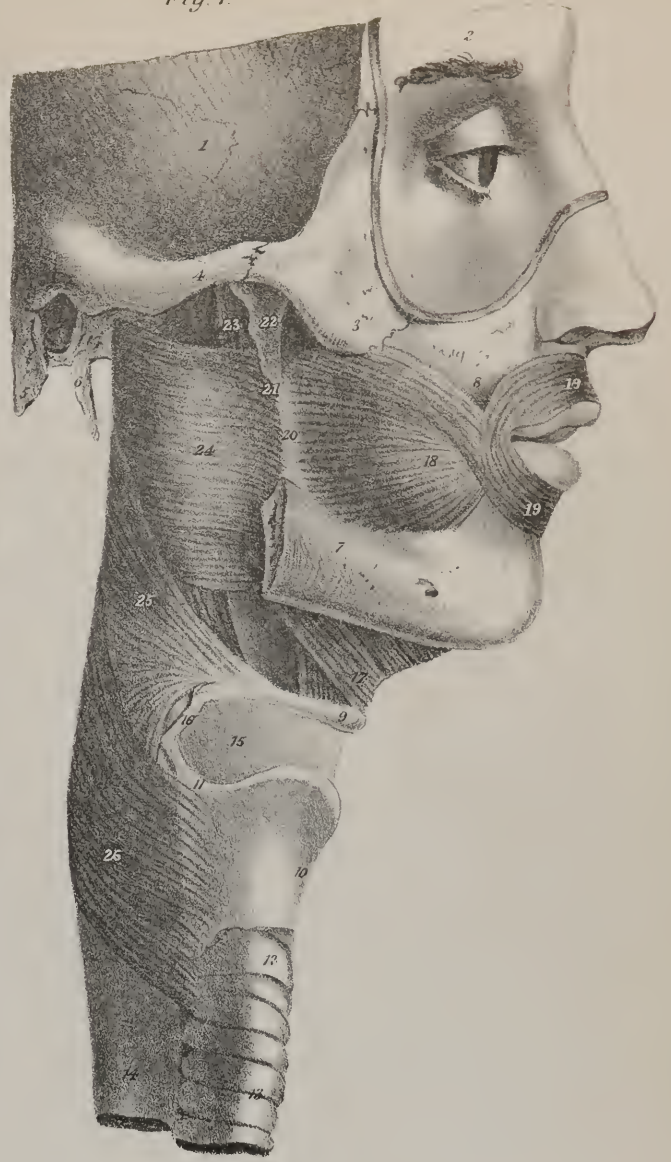

Fig 4.

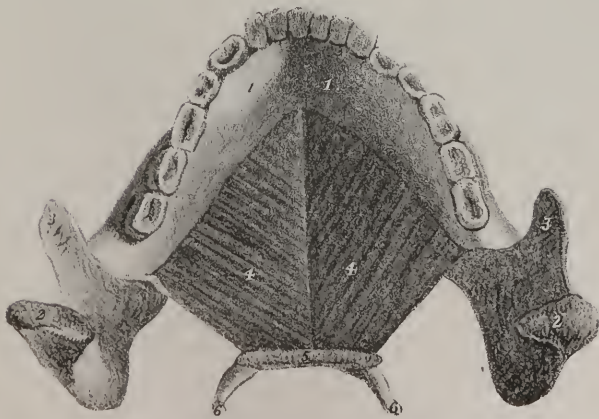
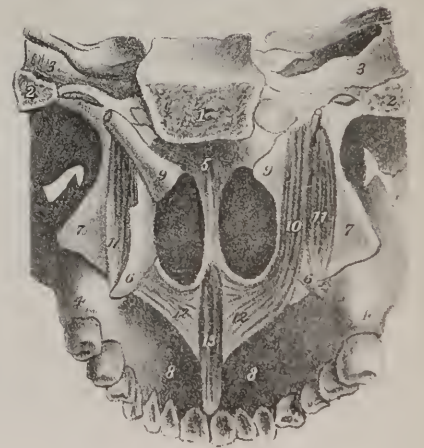


Fig 3.







the lower jaw, and others still higher from the plate of bone just named. From these different points the fibres pass backwards, coiling round the tube, and join with those of the opposite side, whilst those highest up are fixed into the basis of the skull, forming a slightly-arched border as they curve upwards; this is seen in figs. 1, 2. When these muscles are called into action, they will compress the sides and back part of the tube, thereby diminishing its capacity; hence they are called constrictors of the pharynx, and they are named in their order from above downwards, superior, middle, and inferior; but in describing them and in noting their peculiarities, we begin with that which is lowest down, for it overlaps the middle one, and the latter in its turn overlays that which is still higher up. The attachment of some of the fibres of the superior constrictor to the pterygo-maxillary ligament deserves particular attention, for it shows how the side of the mouth is connected with that of the pharynx, the ligament forming a bond of connexion between the muscular fibres of both. The square muscle which occupies the side of the cheek arises in part from the ligament just alluded to; so that from it, as a common point, the fibres can be traced forwards into the cheek, and backwards into the pharynx, (see plate V. fig. 1, Nos. 18, 20, 24.)

The constrictors are not the only muscular fibres found in the pharynx; two long tapering muscles will be observed to pass down converging into its sides. The upper ends of these muscles are attached to the styloid processes of the temporal bone, and as their fibres descend they get under cover of the middle constrictors, so as to lie between them and the lining membrane; their lower extremities are fixed into the borders of the thyroid cartilage; from their connections, they are named stylo-pharyngeal. There is another pair of muscles connected with the pharynx of a much smaller size, which can only be seen when the cavity is laid open, as is seen in fig. 3, where a thin fasciculus, (No. 19,) is seen descending from the side of the soft palate, along the side of the pharynx immediately under cover of the mucous membrane: its name expresses its attachments, viz. palato-pharyngeus.

The muscles here described are the principal agents in deglutition, or swallowing. When a portion of food has been reduced to a pulp, it is collected into a mass upon the surface of the tongue, the tip or point of which is (see plate V. fig. 2) raised to the roof of the mouth, and then, by a succession of efforts, each part of its surface is pressed upwards against the palate, by which means the food is forced from before backwards, having no other way to escape. In its progress it comes into contact with the depending soft palate, and raises it up, so as to bring it into the horizontal position on a level with the roof of the mouth, or hard palate; when thus placed the soft palate forms a valve which prevents the mass of food from being pushed up towards the nasal cavities, and as it has the power of contraction within itself, its muscles, particularly the palato-pharyngeal, may even assist in propelling the mass downwards. In swallowing, we are always conscious of a preparatory movement; the mouth is closed by the apposition of the jaws, immediately after which the pharynx is drawn upwards. But this is not the only change which it sustains; it is shortened and widened at the same time. The increase of its breadth from side to side, is effected by the stylo-pharyngei muscles. These, from their points of attachment, are evidently elevators of the pharynx; but the direction of their fibres just as clearly shows, that as they draw it up they will stretch its sides apart, or in other words widen it, for their points of origin at the styloid processes are farther asunder than their insertions into the sides of the pharynx. Now during this ascent, the tongue-bone and the larynx ascend also; and at the same time are drawn a little forwards, carrying with them the fore part of the pharynx, by which means this tube is prepared for receiving the mass of food which is pressed backwards into it, by the action of the tongue already noticed. As soon as it receives the morsel of food, these muscular efforts cease, the tube descends to its previous position, the fibres of the constrictors begin to act and compress the mass which they surround, forcing it from above downwards into the œsophagus; the upper part of this latter tube being dilated, its circular fibres are stimulated to contract, so as to press the mass onwards in its course, until by a succession of such muscular efforts it is finally conveyed into the stomach. A slight consideration of this mechanism will enable us readily to understand how a mass of food can be made to ascend contrary to its gravity in animals, which feed with their heads to the ground, and how it is kept still in its globular form throughout its passage. The muscular fibres which correspond with its middle, or projecting points, are relaxed, those above it and those below it being in action, so as to keep it for a moment confined;—then the lower fibres are made gradually to give way, as if overcome by the action of the superior ones, and as they relax they will come into apposition with the most projecting part of the mass—that degree of contraction which is necessary for its support and confinement being taken on by the fibres still lower down, so that a state of contraction and relaxation being assumed successively by a series of circular fibres placed along the whole length of the tube, they will sustain and propel its contents, at the same time that they limit the rapidity of its passage, and impress upon it the globular form. Fluids whilst being swallowed are controlled by the same agency; they do not trickle along the canal or run in a stream. In animals which drink with their heads downwards, we see that each portion of fluid which is taken up by the mouth is made to pass along the œsophagus in a globular form, as if it were solid; for the contractile fibres which surround the tube apply themselves to the surface of the fluid so as to grasp it at all points, and retain it in that form; and such is the consent and harmony between them, that they can give way and contract by so nice an adjustment, that they will convey it to its destination in the same form as they received it. It is by calling these muscular powers into action, that a mountebank is enabled to swallow fluids when standing on his head. We have spoken here of the œsophagus and pharynx as being the agents of deglutition; they differ much, however, not merely in form, but in structure; that of the œsophagus being more simple and uniform, as its muscular structure consists of fibres disposed, some in the longitudinal, and others in a circular



direction ; but in the pharynx they are arranged, as we have seen, in a very different manner, and are also more highly developed, which renders it probable, that this part of the canal performs some other functions besides that of receiving and propelling such substances as are to be conveyed into the stomach. It appears to exert an important influence in the modulation of the voice, more particularly in the production of its higher notes ; for if the fore-finger and the thumb be placed at the opposite sides of the throat, so as to embrace the tube of the pharynx, and if, at the same time, an effort be made to produce the different notes of the musical scale in the ascending order from the lowest to the highest, it will be found that the sides of the tube, which are at first soft and relaxed, gradually become tense, and finally rigid, when the higher notes are produced.

## PLATE VI.

WE have here several drawings of the muscles which move the globe of the eye, intended to illustrate their relative positions, their points of attachment, and actions. In fig. 1, the globe of the eye with its muscles is seen from the side, and it is obvious that they do not fill the whole of the orbit or socket in which they are placed ; considerable space is left, which is occupied by arteries, veins, and nerves, and a large quantity of adipose substance, which fills up the interstices—the eye is thus supported, and as it were cushioned in its natural position, admitting of rotation upon its axis, and of being directed to every point in the field of view which lies before it. The muscles are closely collected together at the back part of the orbit where it is very narrow ; they spread apart from one another where they embrace the globe of the eye, and are inserted into its outer coat or membrane. It will be observed that there are seven in all : one however belongs to the upper eye-lid, (fig. 1, 2, No. 1,) the rest appertain solely to the globe of the eye. Four of these are called straight muscles, from their direction, (fig. 2, No. 4, 5, 6, 7,) and two are oblique, (fig. 2, No. 2, 8.) The four straight muscles are attached behind to the sphenoid bone, round the aperture which transmits the optic nerve ; their opposite ends are inserted into the outer membrane of the globe of the eye, at opposite points of its circumference, as may be seen in fig. 4, one lying above it, another beneath it, and one on each side.

In fig. 1, the muscles which move the globe of the eye are seen in their natural position whilst kept enclosed within the orbit, the outer half of which is cut away. In fig. 2, the muscles and the eye are more distinctly seen, for no part of the osseous

## PLATE VI.

The muscles which move the globe of the eye.

- FIG. 1. is a vertical section of the orbit at the right side, the muscles and the globe of the eye being left in their natural positions. No. 1. The elevator muscle of the upper eyelid, (*m. levator palpebræ superioris*; *m. releveur de la paupière supérieure*.) 2. The superior oblique muscle, running through its pulley and reflected (3) backwards and outwards to the globe of the eye, (*m. obliquus superior, trochlearis*; *m. grand oblique*.) 4. The superior straight muscle, (*m. rectus superior*; *m. droit supérieur*.) 5. Part of the internal straight muscle; (*m. rectus internus*.) 6. The external straight muscle, (*m. rectus externus*.) 7. The lower straight muscle, (*m. rectus inferior*.) 8. The inferior oblique muscle, (*m. obliquus inferior*.) 9. The optic nerve at its entrance into the orbit.
- FIG. 2. The same structures as in the preceding, detached from their connexions with the orbit, so as to be more distinctly seen. No. 1. The elevator of the upper eyelid. 2. The superior oblique muscle with its pulley. 3. Its reflected tendon. 4. The superior straight muscle. 5. The internal straight muscle, partly concealed by the optic nerve. 6. The external straight muscle; its origin and insertion are retained, but the middle part is cut away to show the position of the optic nerve. 7. The inferior straight muscle. 8. The inferior oblique muscle. 9. A small piece of the superior maxillary bone from which it arises.
- FIG. 3. The globe of the eye and its muscles seen from behind. No. 1. The optic nerve cut across. 2. The superior oblique muscle. 3. A sheath of synovial membrane which surrounds it as it passes through its pulley to facilitate its movements. 4. The superior straight muscle. 5. The internal straight muscle. 6. The external straight muscle. 7. The inferior straight muscle. 8. The inferior oblique muscle. 9. A small piece of the bone from which it arises.
- FIG. 4. The same parts viewed in front, the straight muscles being drawn out of their natural position, in order to show their insertion at the fore part of the globe of the eye, at opposite points. No. 1. The superior oblique muscle, its pulley and a part of the frontal bone (2) to which it is attached. 3. The superior straight muscles. 4, 5, 7. The other three straight muscles. 8. The inferior oblique muscles. 9. The part of the bone from which it arises.
- FIG. 5. The elevator muscle of the upper eyelid seen by itself. It arises by a pointed process at the back part of the roof of the orbit a little above the aperture which transmits the optic nerve; it widens (4) as it passes forward over the globe of the eye, and is inserted into the cartilage (5) of the upper eyelid. 6. The eye-lashes.
- FIG. 6. Exhibits the two oblique muscles of the eye-ball in their natural position when viewed from before, and also some small muscles of the face which were not shown in the previous drawings. No. 1, 2. The superior oblique muscle of the eye running through its pulley. 4. The inferior oblique muscle, its direction being backwards and outwards to the globe of the eye from near the lower margin of the orbit. 5. The elevator muscle of the upper lip. 6. Part of the orbicular muscle of the lips. 7. The depressor muscle of the wing of the nose. 8, 8. The elevator muscles of the lower lip.

Fig 3

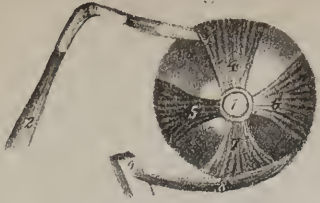


Fig 1

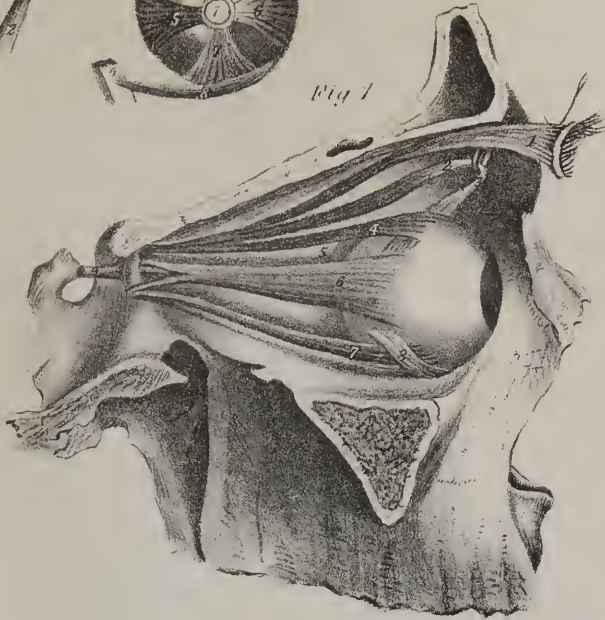


Fig 4


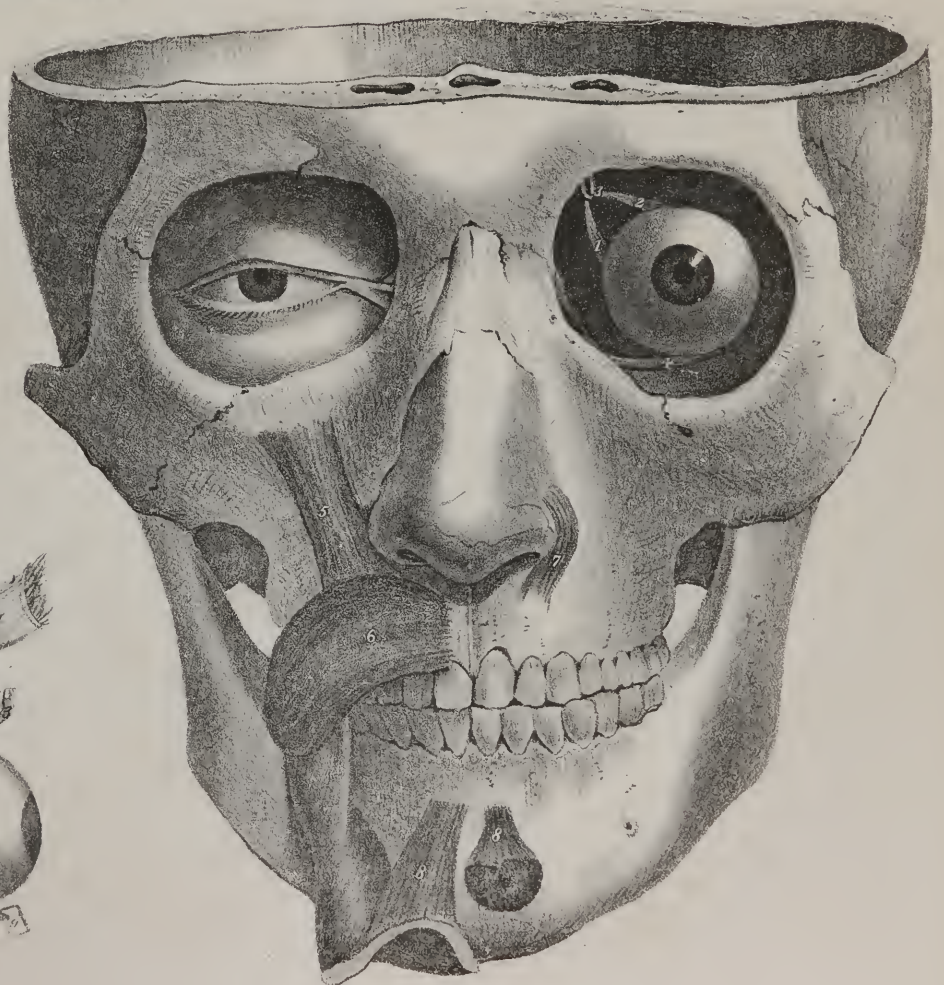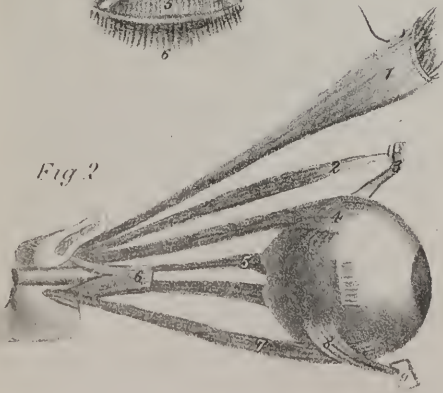


Fig 6

Fig 5



Fig 2









structure is retained, except a small piece of the sphenoid bone, near the entrance of the optic nerve. One of those here seen, and which is drawn separately in fig. 5, acts upon the upper eye-lid, and raises it, so as to uncover the front of the eye; it is therefore called the elevator of the lid, and is the antagonist of the orbicular muscle, which closes the eye-lids; it is marked 1, figs. 1, 2. The four straight muscles are composed of fleshy fibres in the greater part of their extent; but opposite the middle of the globe of the eye, they end in thin tendons which are fixed into the sclerotic coat, about two lines and a half behind the margin of the cornea and at opposite points, as may be seen in fig. 4. These muscles are under the control of the will—they receive their nervous influence from the third cerebral nerve.\* As their points of insertion are anterior to the transverse diameter of the globe of the eye, and as each, before it reaches its point of insertion, curves over the rounded surface of the eye, it requires but little consideration to perceive that, when in action, their effect must be to turn or rotate the ball of the eye, as it were upon an axis—the superior one will turn the transparent part of the eye, and with it the aperture of the pupil upwards, the inferior one downwards; that which lies to the external side, will incline it outwards as in lateral vision, and that at the opposite side will turn it inwards; the effect of this will be rendered more apparent if a needle be passed through the transparent cornea, and the upper and lower muscle be alternately pulled, either with the fingers, or a pair of forceps. If two of the straight muscles act together, for instance, the superior and the external one, the pupil will not be turned directly upwards or outwards, but to the point intermediate between these, viz. upwards and outwards. In the same way, the combined actions of the internal and inferior straight muscles will turn it downwards and inwards. By this succession, combination, and alternation of action of the four straight muscles, we are enabled to direct the transparent part of the eye, and the pupil, with the most minute precision to every point within our field of view, so as to receive the rays of light reflected from them upon the most sentient part of the retina.

These muscles are in absolute dependence upon the will. There also subsists between them and the retina a close sympathy; for when the nerve is paralysed as in amaurosis, so that it is no longer capable of being influenced by its appropriate stimulus, those transverse motions cease by which it is directed to the different objects within its field of vision, and it loses that peculiar expression which is indicative of watchfulness and intelligence. The oblique differ from the straight muscles in several particulars. They are inserted into the ball of the eye, behind its middle part; the direction of the inferior one is backwards and outwards, its fixed point being near the anterior margin of the orbit. The superior oblique muscle commences at the back part of the orbit near the origin of the straight muscles, but it passes through a cartilaginous ring or pulley attached to the upper margin of the orbit, by which it changes its direction, and runs backwards and outwards, to reach the back part of the ball of the eye, into which it is inserted about three or four lines from the entrance of the optic nerve. Both the oblique muscles may therefore be said to act upon the eye from the fore part of the orbit, as the recti do from the back part. On this was founded the opinion once entertained, that one set were the antagonists of the other—the straight muscles when in action tending to draw the eye back into the orbit, and the oblique preventing the retraction going too far. But this opinion is no longer tenable: we know that in quadrupeds, besides the straight muscles, a retractor muscle of great power is fixed to the back of the eye, yet the oblique muscles are not more strongly developed in these creatures than those that have got no retractor; and they exist in others where retraction cannot take place; inasmuch as the eye is supported not by adipose substance, but by cartilage. From what we have above observed concerning the powers of the straight muscles, it might be thought that all the necessary movements of the eye were provided for, and effected by them alone; but merely to move and direct the organ is not sufficient,—a provision is required to secure it from the injurious influences to which it is exposed. When any irritating particles come into contact with the eye, the lids are made to close, not merely to exclude these, but as it were to brush or wash them off; but this of itself would not suffice, if the eye-ball were motionless. In order to be effectual, the latter must be made to revolve and turn upwards as the lid descends, so that they shall move one upon another in opposite directions; and this is what invariably takes place in all winking, involuntary, or spasmodic motions; in these cases the straight muscles, which are the voluntary powers, cease to exercise any control, and the oblique muscles assume the direction and turn the organ upwards. It is matter of observation, that those muscles which are strictly voluntary, and which under ordinary circumstances are most readily controlled by the will, lose their power the soonest when the cerebral influence upon them is weakened or impaired. We may perceive this, says Sir C. Bell, “in the progressive stages of debility in the drunkard, when successively the muscles of the tongue, of the eyes, the face, and the limbs, become unmanageable; and under the same circumstances, the muscles which have a double office, as those of the chest, lose their voluntary motions, and retain their involuntary motions.” In the case which we are now considering, the straight muscles being voluntary, lose their power before the oblique muscles, so that the latter, assuming the sole direction of the organ, roll it upon its axis, and place the transparent part of the eye under cover of the lid; the white or opaque part alone appearing in the

\* The third pair of nerves (motor communis) supplies three of the straight muscles only; the rectus externus receiving a distinct nerve, called the sixth, (motor externus.) Each of the recti muscles is inserted upon the sclerotic, not by a point, but by a slip of tendon 8-20 to 7-20 of an inch broad. The fibres of the muscles which are attached to the lateral margins of the tendon, must therefore, where they act separately, incline the ball slightly in the same direction. The three recti which are supplied by the third pair of nerves, when they act together under the stimulus of that nerve, will have a tendency to sink the ball of the eye somewhat, and turn the cornea towards the inner canthus, as we find it in strabismus convergens. Here we find one of the probable causes that makes the internal form of strabismus of so much more frequent occurrence than the external. It is well to observe, too, that the same third pair which supplies these muscles, sends a branch through the ophthalmic ganglion, which is believed to be the nerve of motion to the iris.

interval between the lids, if they are partially open. This is the state in which the organ is found in the quiescence of sleep, or in the insensibility which precedes the approach of death. By means of the great variety and freedom of motion given to the eye, to which its globular form contributes not a little, and for which there is such ample provision in the number of its muscles, it is rendered capable of being an agent in the expression of desires and wants, as well as of passions and feelings. A movement of the eye accompanies that of the hand, when raised to supplicate or denounce, and in each case it assumes an appropriate expression. In persons born dumb, the eye is so constantly made the outward index of their feelings, that they become in a manner concentrated to it, giving it a character and a brilliancy quite peculiar. Do we not see the eye at one time tremblingly agitated in violent passion, then softened into pity, or glancing with anger or disdain? As these states are capable of being controlled by an effort of the will, so they admit of being simulated—the skilful actor can put them on with the characters he assumes, and delineate their workings, as if they were prompted by real passion.\*

## PLATE VII.

THE first and second figures represent the pterygoid muscles which are principal agents in the movements of the lower jaw. The articulation of the lower jaw with the base of the skull is so constructed as to allow not only the hinge-like movement by which the mouth is alternately opened and shut, but also a lateral or horizontal motion, by which the lower teeth are made to rub across those of the upper jaw, in order to crush and triturate the food. The jaw may be depressed, so as to open the mouth slightly, by the relaxation of its elevator muscles, but it is drawn down so as to dilate the aperture fully by the action of those muscles which proceed upwards to it from the tongue-bone; and it is drawn up so as to close the mouth by means of the masseter and the temporal muscles which are seen in plate VIII., and the internal pterygoid which is shown in plate VII., fig. 1, 2, No. 9. In carnivorous animals these muscles exhibit their maximum of development. In these creatures, the teeth, instead of flat crowns, present sharp cutting edges, and the movement of the lower jaw upon the upper is somewhat like that of the blades of a pair of scissors. The zygoma is strong, and inclines upwards so as to give additional power to the masseter muscle, and it moreover arches forward considerably, to accommodate itself to the great mass of the temporal muscle which lies behind it. This conformation is seen at its maximum in the head of the lion and tiger; but in the human subject the zygoma is thin, small, and very slightly arched. On referring to plate VII., it will be seen that the lower jaw represents a lever of the third order, the fulcrum being at one end, viz. in the socket, (No. 5,) the resistance being at the other, and constituted by whatever is placed between the teeth to be cut or crushed, whilst the moving power, at least in the elevation of the jaw, is between these, viz. the internal pterygoid muscle No. 9, as seen in plate VII., and the masseter as seen in plate X., fig. 1, 19. It is not a little remarkable that this is the mechanical contrivance most commonly employed in the living fabric; it is necessarily accompanied by a loss of power, for which, however, there is ample compensation in the velocity of movement which is acquired. The direct elevation of the lower jaw is effected by the temporal muscle; the masseter and the internal pterygoid are also powerful agents in effecting this end. The obliquity of the anterior fibres of the two latter enables them also to draw the angle of the jaw somewhat forwards; and the posterior fibres of the temporal muscle run so obliquely downwards and forwards to their insertion into the coronoid process, that they seem calculated not only to elevate the jaw-bone, but also to draw it backwards; but in continued and strong efforts, for instance, when we seek to support or draw up anything by catching it between the teeth, the different lines of direction here indicated are decomposed, when the muscles all act together, and the jaw is drawn directly upwards.

\* The doctrine that the oblique muscles of the eyes are provided for the purpose of drawing the ball forwards, and opposing the retractive action of the recti, is as old as the time of Boerhaave, and has still many supporters. It is, however, without foundation; and besides the reasons alleged against it above, it may be added among others, that in many animals, as the sheep and the horse, the oblique, if they act in either way upon the ball, must draw it backward, for the trochlea of the superior and the origin of the inferior oblique are much posterior to the insertion of their tendons upon the sclerotic coat. Since the operation for strabismus, by dividing the tendon of one of the muscles of the eye, has become so common, and found so generally successful when judiciously performed, it is a matter of considerable interest to ascertain the exact office of the oblique muscles, which are found so uniformly existing in the various classes of animals. It has not yet been satisfactorily done. In the course of about one hundred and thirty operations for this affection I have several times divided both the oblique muscles. But in no instances were the voluntary movements or the position of the ball apparently affected by their section. In two cases, where there was presbyopia, or farsightedness, the division of the obliques was attended with a manifest improvement in vision. In one strongly marked case, that of Mr. Jacob Phillips, of this city, æt. twenty-one, so presbyopic as to require the constant use of glasses suited to persons of sixty or seventy years of age, the operation practised for the purpose almost immediately restored the eyes to the degree of vision usual at his age; and the improvement has been permanent. On the same individual I had previously divided, without the least remaining deformity, the two internal recti for double strabismus. It appears to me that the oblique muscles, besides the offices mentioned in the text, rotate the ball on its axis from side to side, and very possibly, by acting in combination with the recti, so modify its shape as to aid the eye in accommodating itself to vision at different distances. *Vide* a paper on vision by Dr. D. Hosack, Lond. Philos. Trans. 1794. Each of the obliques, I have found by experiments upon the dead body, is capable of giving the ball a quarter rotation, the one antagonising the other, and moving the organ upon a middle oblique axis, which from the external border of the cornea runs obliquely backwards and inwards. The great oblique by an internal rotation carries the pupil downwards and outwards; the inferior oblique by an external rotation of the ball carries the pupil upwards and outwards.—J. P.





Fig 2

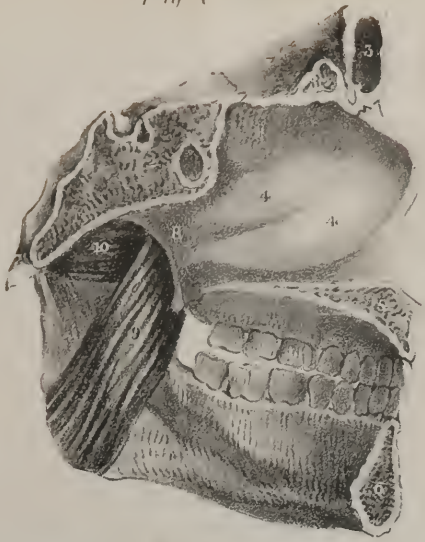

Fig 1

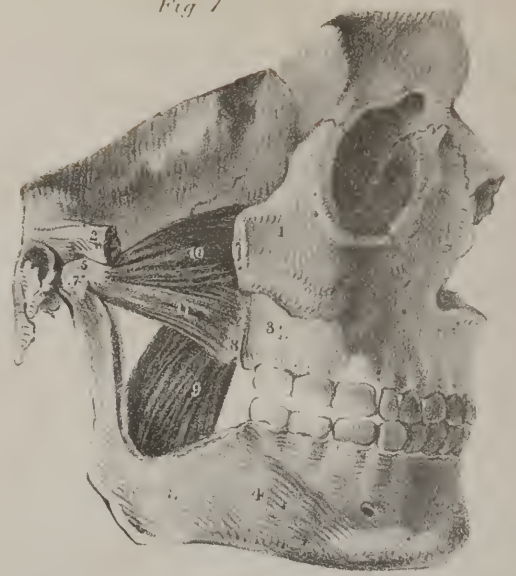


Fig 5

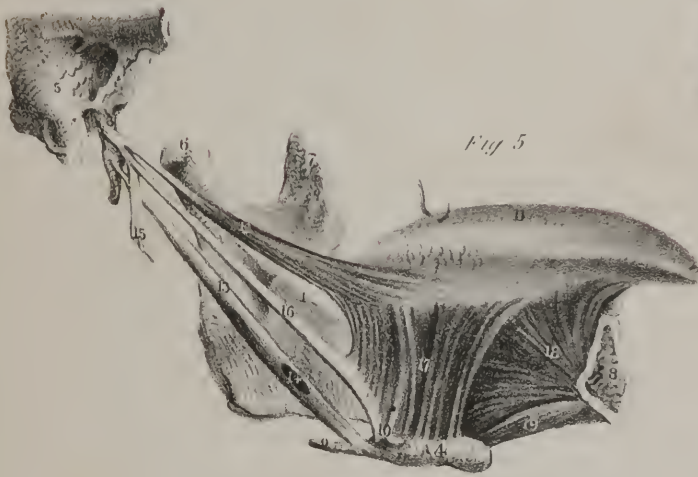


Fig 6

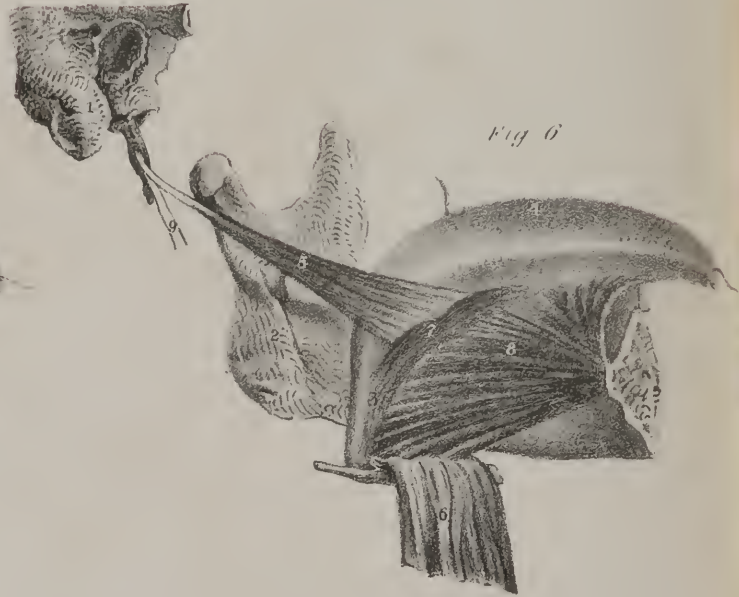


Fig 3

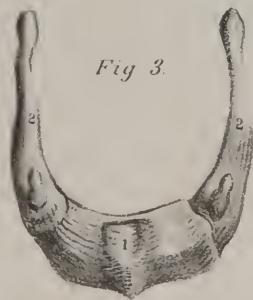

Fig 4



We can readily push the lower jaw forwards, and make the teeth project beyond the upper dental arch by means of the external pterygoid muscle of each side, which, when they act together, will draw the condyles directly forwards. The digastric muscle draws the chin backwards, and replaces the bone acting as a retractor. In plate VII., fig. 1, No. 8, the external pterygoid muscle of the right side is seen running backwards, and outwards, to be fixed to the neck of the lower jaw-bone and its inter-articular cartilage; it obviously can pull the condyle directly forwards towards its point of fixed attachment; and if the muscle of the right side acts in this way, whilst the condyle at the left side remains in its socket, the chin is made to deviate to the left side, and the lower teeth are rubbed horizontally across the upper ones. If this effort be discontinued, and the muscle of the opposite side be brought into action, the movement of the jaw is reversed, and this alternation of action by the two external pterygoids will produce that triturating motion by which any substance placed between the teeth is crushed or comminuted. The most perfect provision for this movement is made in herbivorous and ruminating animals, which are furnished with broad crowned teeth adapted to crush and triturate their food.

## PLATE VIII.

THE movements and actions of the muscles of the forehead, eyebrows, cheeks and mouth, of which a side-view is given in this plate, have been sufficiently dwelt upon in our remarks on expression, page 7; and the uses of the masseter, (fig. 1, 19,) and of the temporal muscle (fig. 2, No. 1,) have been stated in the observations just made on mastication. The muscles which are attached to the external ear have seldom any power of action in the human subject; but in several of the lower animals they are highly developed and obedient to the will, which enables these creatures to turn the hollow of their ears towards that point from which sounds issue, or from which they apprehend danger or surprise.

## PLATE VII.

Shows some of the muscles which move the lower jaw and the tongue.

- FIG. 1. Exhibits two of the muscles of the lower jaw, as seen from the outside, with their points of attachment. No. 1. The malar or cheek-bone. 2. The root of the zygomatic process, the intervening portion of the zygoma being cut away to expose the two pterygoid muscles. 3. The superior maxillary bone. 4. The lower jaw-bone. 5. The inter-articular cartilage, which is placed between the condyle of the lower jaw, and the glenoid fossa with which it articulates. 7. The condyle. 8. The external pterygoid muscle, consisting of two portions, of which one is attached to the external pterygoid plate of the sphenoid bone, and to the tuberosity of the palate bone, and the other higher up to the lower part of the great wing of the same bone: both become narrow and unite previously to their insertion into the neck of the condyle of the lower jaw, and the inter-articular cartilage. 9. The internal pterygoid muscle, to expose which part of the branch of the lower jaw with its coronoid process has been cut away. 10. The superior portion of the external pterygoid muscle. 11. The inferior portion of the same muscle.
- FIG. 2. Shows the same parts when viewed from the inside. No. 1, 2. A vertical section of the sphenoid and occipital bones. 3. The frontal bone cut through, its sinus being laid open. 4, 4, 4. The turbinate bones of the nose. 5. The hard palate cut through. 6. The lower jaw-bone sawed at its symphysis. 7. A small piece of the external pterygoid plate of the sphenoid bone. 8. The internal pterygoid plate. 9. The internal pterygoid muscle which is attached above to the groove between the pterygoid plates, and below to the branch, and the angle of the lower jaw. 10. Part of the external pterygoid muscle.
- FIG. 3. The tongue-bone, (os hyoides, os linguale,) its upper surface as seen from before. No. 1. The body of the bone. 2, 2. Its great horns or processes, (cornua.) 3, 3. Its small horns or processes, (cornicula.)
- FIG. 4. A lateral view of the same bone. No. 1. Its body. 2. Its great processes. 3. Its small processes.
- FIG. 5. A lateral view of the tongue and its principal muscles. The left side of the lower jaw-bone and the tongue-bone, being retained in their natural positions, together with part of the temporal bone of the right side. No. 1. The lower jaw-bone. 2. Part of the temporal bone. 3. The styloid process. 4. The tongue-bone. 5. The mastoid process. 6. The condyle of the lower jaw. 7. Its coronoid process. 8. The section of the lower jaw at its symphysis. 9. The great process (cornu,) of the tongue-bone. 10. Its small process. 11. The upper surface of the tongue. 12. The stylo-glossus muscle. 13. The stylo-hyoid muscle extending from the styloid process to the tongue-bone. 14. A slit in its fibres through which the tendon of the digastric muscle passes. 15. Part of the stylo-maxillary ligament. 16. The stylo-hyoid ligament. 17. The hyo-glossus muscle. 18. The genio-hyo-glossus muscle, its name expresses its three points of attachment, viz. to the inside of the lower jaw at the chin, to the tongue-bone, and to the under surface of the tongue, along its entire length, from its root to its point; it is composed of diverging, or rather radiating fibres. 19. The genio-hyoid muscle.
- FIG. 6. Another view of the same parts,—the hyo-glossus muscle being thrown down, so as to expose more fully the genio-hyo-glossus and the lingualis. No. 1. The mastoid process of the temporal bone. 2. The lower jaw-bone. 3. The lingualis muscle. 4. The tongue. 5. The stylo-glossus muscle. 6. The hyo-glossus muscle reflected downwards so as to expose (3. 7.) the lingualis and (6.) the genio-hyo-glossus. 9. Part of the stylo-hyoideus muscle.



## PLATE IX.

THE uses of the different muscles here exhibited have been already detailed in our remarks on the movements of the jaw, the tongue, and the larynx, in deglutition and mastication.

*Dislocations of the lower jaw.*—The different pieces which compose the skeleton, are connected one to the other in various ways,—no motion whatever is admitted between some, a restricted movement takes place in other cases, whilst in some a free motion is provided for in various directions. It often happens that the bones which form the joints, particularly in the limbs, are thrown by various accidents into new situations, so as to lose their natural position and relation with regard to one another; in other words, they are displaced, or to use the technical phrase, dislocated. In studying the dislocations of a particular joint, it is usual to enquire in how many ways they may occur; and this includes a consideration of the form and mutual adaptation of the articulating surfaces of the bones,—of the arrangement and form of the ligaments which connect them,—the direction of the shafts of the bones themselves, and above all, the direction, power, and modes of action of the different muscles placed round the joint. Dislocation occurs much more frequently in some joints than in others, arising from the great variety and freedom of motion which they admit of; and also from the effects of pressure being more frequently transmitted to them: for instance, the shoulder-joint is so constructed, that the head of the arm-bone moves in every direction upon a small and shallow surface in the scapula or blade-bone, from off which it may pass in different directions with great freedom, so far as the form of the articulating surfaces and the structure of the ligaments are concerned; and this natural liability to displacement is increased by the circumstance that persons instinctively throw out their hands whilst falling, in order to protect themselves, and so the pressure and the concussion become propagated by the bones to the shoulder-joint, and dislocation is produced. To this natural liability to such accidents, there is further added, in many instances, what may be termed an acquired one, owing to a laxity of the ligaments produced either by effusion into the joints, or by previous dislocations, and still more by weakness of the surrounding muscles, resulting from previous dislocations, or caused by paralysis. When such a state of muscle and ligament exists at the shoulder-joint, dislocation often occurs from slight causes; and owing to a similar state of relaxation in the articulation of the lower jaw, dislocation has occurred in some individuals whilst yawning. The lower jaw-bone admits of three displacements: first, both its articulating processes are thrown forwards under the zygomatic arch; secondly, one of them is brought forward, whilst the other remains in its natural state; lastly, it may slip before the inter-articular cartilage, owing to relaxation of the ligaments. The last is termed subluxation of the jaw; the first is the complete dislocation; the second is termed partial: all, however, take place in one direction, viz. forwards. The head of the bone cannot go backwards, for that would require that its dental arch should ascend to a level above its position when the teeth are closed, which is quite impossible: it is opposed, moreover, by the osseous plate of the auditory tube, and is not promoted by the action of any muscle; on the contrary, it is opposed by the external pterygoid muscles. Displacement directly inwards is prevented by the structure of the articulating surface, and by the spine of the sphenoid bone: and as it could only be produced by a blow upon the cheek, a force so applied would break the bone more readily than it could displace its articulating extremity. Dislocation of the lower jaw cannot occur in infants, for in them the branch of the bone forms an obtuse angle with its body, so that the neck which supports the condyle is nearly in the same direction as the body of the bone. While such a conformation exists, the action of elevator muscles would tend to press the bone

## PLATE VIII.

FIG. 1. Gives a side view of the muscles of the external ear, of the cranium, and of the face. 1, 1. The occipito-frontal muscle. 2. The fascia which binds down the temporal muscle, and conceals it. 3. The elevator muscle of the external ear, (*m. attollens aurem*; *m. auriculaire supérieure*.) 4. The anterior muscle of the ear, (*m. attrahens aurem*; *m. auriculaire antérieure*.) 5. The posterior muscle of the ear, (*m. retrahens aurem*; *m. auriculaire postérieure*.) 6. The orbicular muscle of the eyelids. 7. The pyramidalis nasi muscle. 8. Part of the triangular muscle of the nose, commonly called the compressor. 9. The elevator of the lip and nose. 10. The elevator of the upper lip. 11. The small zygomatic muscle. 12. The great zygomatic muscle. 13. The elevator muscle of the angle of the mouth. 14. The orbicular muscle of the lips. 15. The elevator of the lower lip. 16. The depressor of the lower lip. 17. The depressor of the angle of the lip. 18. The buccinator muscle. 19. The masseter muscle, its external or large portion. 20. The smaller or deep-seated portion of the same muscle. 21. The external lateral ligament of the lower jaw-bone.

FIG. 2. Gives a side view of the temporal muscle exposed by removing the strong membrane called the temporal fascia seen in fig. 1, No. 2, and by removing the masseter muscle, together with the zygoma. No. 1. The temporal muscle, (*m. temporalis*.) which is broad and radiating at its upper part, and narrowed almost to a point at its lower extremity, where it is inserted into the coronoid process (2) of the lower jaw-bone. 3. The external lateral ligament of the lower jaw-bone.



Fig 1

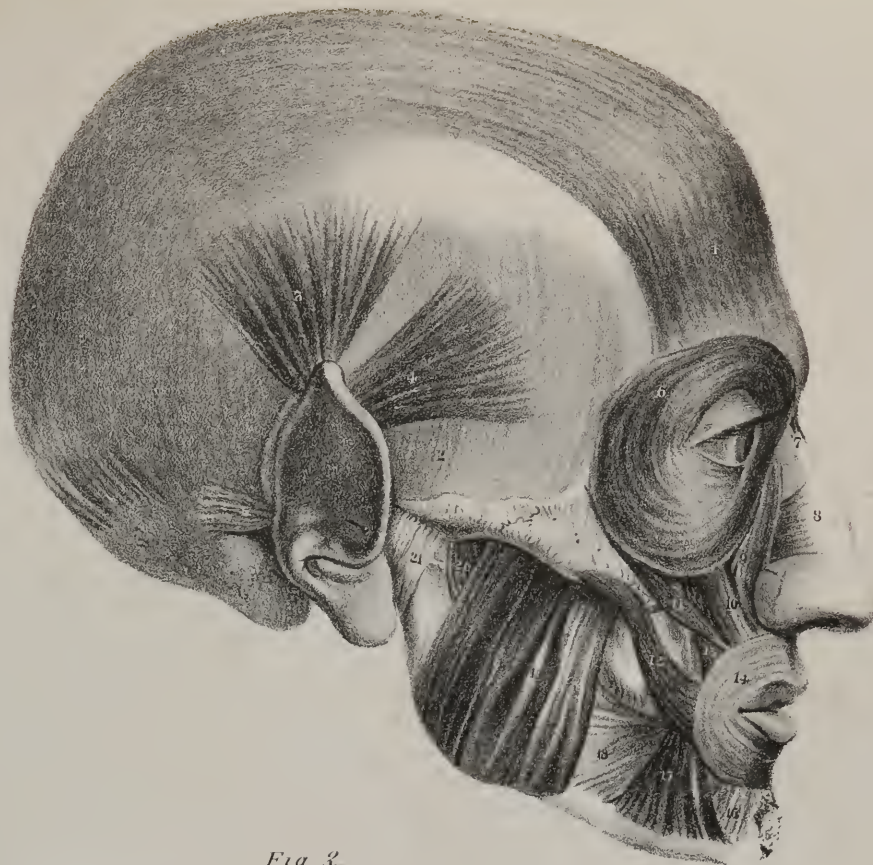
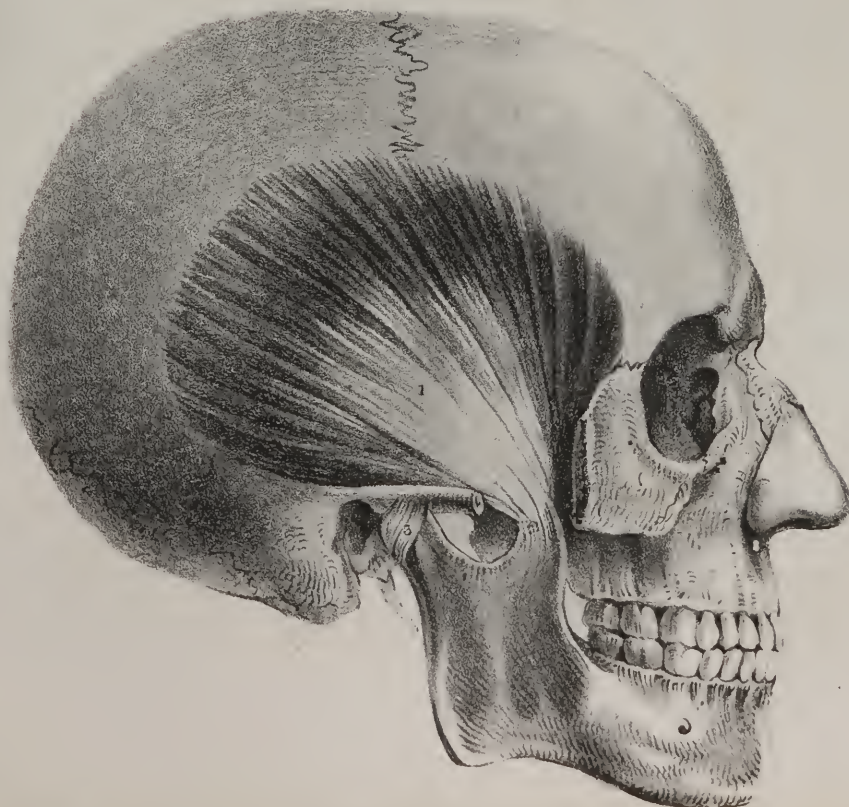


Fig. 2





more closely to its socket rather than draw it forwards out of its place. This accident can occur only when the bone is fully formed, and when its branch, or ascending part, forms nearly a right angle with its body, as is here delineated, (plate VIII., fig. 2.) When the jaw is alternately depressed and elevated, it moves as it were upon an imaginary centre, corresponding with the middle of its branch, which is the flat square projecting upwards, nearly at a right angle with its body or horizontal part. If a pivot be driven through the bone at this point, it will at once be perceived on depressing the jaw, that its angle passes backwards and upwards, whilst its head moves downwards and forwards, describing small arcs of circles. If this motion be carried to a considerable extent, as in gaping, the direction of the masseter muscle, (plate VIII., fig. 1, No. 19,) is rendered more oblique than in the natural state, so is the internal pterygoid muscle, and the masseter will be observed under such circumstances to be stretched downwards and backwards towards the angle of the jaw. Now, if in such a state of things, a slight blow be given to the jaw, the muscles may be made to contract suddenly, and concentrating their force upon the angles of the bone, they are enabled to draw them forwards, and thereby press the condyles under the arch of the zygoma. It is very likely that the depressor muscles at the same time give a certain degree of fixity to the chin; and also that the external pterygoid muscles draw the condyles forwards, thus contributing to produce the displacement. When this accident occurs, the appearance of the patient is that of forced and continued yawning; the mouth gapes, the cheeks and temples are flattened, for the masseter, the temporal, and buccal muscles are lengthened, and in a state of tension; the external pterygoid muscles are relaxed. The elevator muscles are the antagonists which oppose our efforts to replace the bone in its natural position. To overcome their resistance, the surgeon avails himself of an expedient, which enables him to act on the jaw itself, as if it were a lever of the first order; and it can be rendered such by placing a fulcrum, or prop, at each side, behind the last grinder teeth, at the angle formed by the body and the branch of the bone; and a piece of firm cork will suffice for this purpose. If the patient be placed in the horizontal position, with his head supported on a pillow, and the corks are inserted between the jaws as just stated, by placing the hand under the chin, and drawing it steadily upwards, the angles of the bone will be pressed backwards and downwards, the muscles will be kept still more on the stretch, fatigue will be induced in them, and their resistance will gradually cease, and the bone will pass backwards into its place. Some of the fibres of the opposing muscles may assist in promoting this end; for those which form the lower part of the temporal muscle, (plate VIII. fig. 2, No. 1,) by reason of their direction, are enabled to draw the coronoid process of the bone backwards, and some of the deep-seated fibres of the masseter can give the branch of the bone a similar direction. When the power is applied in the way above directed, to the chin or front of the bone, the resistance is at the opposite end, and the fulcrum between both; the process of reduction becomes a mechanical contrivance by which we convert the jaw into a lever of the first order.

Partial dislocation of the jaw consists in the displacement of one of its condyles, which is drawn forwards under the zygomatic arch, whilst the other remains in its place. The chin, in such accidents, necessarily deviates to the side opposite to that in which the dislocation has occurred; so does the dental arch of the lower jaw, which also protrudes beyond that of the upper one. The mode of reduction is the same in this case as when the dislocation is complete, save only that one fulcrum placed between the jaws will suffice.

The subluxation of the jaw arises from relaxation of the ligaments, and consists of a displacement of the condyle from its inter-articular cartilage, by which the jaw becomes motionless for a time, the mouth being kept slightly opened. Surgical assistance is seldom required in such cases, as the patient's muscular efforts alone generally succeed in righting the displacement.

## PLATE X.

WE have here given Cloquet's dissection of the pectoral muscles, with part of the deltoid and of the biceps. The insertion of the pectoral muscle into the humerus not being perceptible in fig. 1, it is shown in fig. 2, No. 6, where it appears in the form of a flat tendon, doubled on itself previously to its insertion into the anterior border of the groove which lodges the long tendon of the biceps muscle. The great pectoral muscle, fig. 1, No. 8, consists of fleshy fibres in the greater part of its extent; its insertion is tendinous, its points of attachment along the sternum are aponeurotic, and along the clavicle it is slightly aponeurotic. It reaches from the last-named bone down to the cartilage of the seventh rib, along which it arises by an oblique border. The middle fibres of the muscle extend transversely outwards; those which come from the clavicle descend, whilst the inferior fibres ascend, and as they pass to their insertion they lie posterior to the others; by this arrangement they become folded along the anterior margin of the axilla. This muscle is subjacent to the skin and superficial fascia, the mamma alone interposing towards its middle, and some fibres of the platysma myoides towards its upper part. The deltoid muscle, fig. 1, No. 9, forms a fleshy cap, which covers the shoulder-joint; its fibres are arranged into thick and coarse bundles; it overlays the tendinous insertion of the pectoral muscle, and conceals those different structures which lie around the joint, and which can be exposed only by its removal, as is seen in fig. 2. When the pectoral muscle is brought into action, it draws the shaft of the humerus inwards to the side, and then forwards upon the chest if its efforts be continued. If the arm be previously everted, this muscle, by its mode of



insertion, is enabled to assist in rotating it inwards; and when the arm is elevated into the vertical direction, the lower or ascending fibres of the pectoral muscle will draw it downwards. If the humerus be fixed, then this muscle can be made to reverse its mode of action, so as to draw upon the chest, by taking its fixed point upon the arm. Thus when, by elevating his arms, an individual catches an object placed above him, and seeks to elevate his body as in climbing, the pectoral muscles will combine with others, to draw the body upwards. This power of acting on the chest when the arms are fixed, enables it to dilate the walls of the cavity in the efforts of forced inspiration. When the arm of a crutch is placed under the axilla, and the lower margin of the pectoral and latissimus, fig. 1. 12, are made to rest upon it, these muscles, by taking their fixed points at the humerus, which is rendered steady as soon as the hand grasps the crutch, will act upon the chest, and pull it upwards towards the fulcrum upon which they rest. In this way the body is lifted and supported, at the same time a slight effort sufficing to carry the legs onwards in progression.

The deltoid muscle draws the arm outwards from the side, so as to bring it into the horizontal position, and by a continuance of its effort it can lift the arm upwards nearly into the vertical direction. When the arm is thrown outwards from the side, the anterior fibres of the deltoid can assist the pectoral muscle in drawing it forwards towards the chest, and the posterior fibres, (which, however, are not seen in this drawing, as they come from the spine of the scapula,) can move it backwards.

Fig. 2. exhibits the subclavius muscle, 7, and the small pectoral muscle, 9, in such a way as to render their actions readily intelligible. The subclavius is a long and narrow muscle, stretched obliquely from the cartilage of the first rib outwards, to be fixed to the under surface of the clavicle. When in action, it will depress the clavicle, and assist in drawing it forwards; but if the shoulder is fixed, then it will act on the first rib and steady it, assisting thereby to make it the point towards which the other ribs are drawn in inspiration.

The small pectoral muscle, 9, extends obliquely upwards and outwards, to be fixed to the coracoid process of the scapula. It therefore crosses the axilla and axillary vessels, and when the parts are in their natural position it is covered by the great pectoral muscle. It was sometimes called the small anterior serrate muscle, in consequence of its attachment to the ribs by angular processes. When in action, it can draw the coracoid process downwards and forwards, giving thereby a similar inclination to the shoulder-joint; in which movement the inferior angle of the scapula is made to move backwards and a little upwards. If, however, the lower part of the serratus magnus is in action at the same time, the shoulder is made to come directly forwards. This muscle can assist in dilating the chest, for if the shoulder be previously fixed, it will act from the coracoid process and draw upon the ribs to which it is attached.

## PLATE IX.

The second layer of muscles placed at the front of the neck is here shown in the position in which they are ordinarily seen during dissection, when the middle of the neck is supported by a block, and the head is extended backwards. The sterno-mastoid and the platysma muscles are taken away, together with the cervical fascia.

- No. 1. The lower jaw-bone. 2, 2. The mastoid processes of the temporal bone at each side. 3, 3. The clavicles. 4. The under surface of the acromion process of the scapula. 5. The extremity of the coracoid process. 6. The glenoid or articulating cavity of the scapula. 7. The first bone of the sternum. 8, 9, 10. The three upper ribs. 11. The digastric muscle. 12. The stylo-hyoid muscle. 13. The mylo-hyoid muscle of the left side, which is attached to 14, The tongue-bone. 15. The oblique fibres of the muscle just named, inclining inwards to meet those of its fellow of the opposite side, which, however, is here taken away to expose the two following muscles, viz. 16, The genio-hyoideus, and 17, The hyo-glossus. 18. The sterno-hyoideus muscle. 19. The sterno-thyroideus muscle of the right side, partly covered by the preceding muscle. 20. The sterno-thyroid muscle of the left side, which is here exposed by removing the sterno-hyoideus. 21. The thyroid cartilage. 22. The thyro-hyoideus muscle, which is continued upwards from the oblique line into which the sterno-thyroid is inserted almost as if it were a prolongation of it. 23. The omo-hyoideus muscle, seen in its entire length. The upper part lies parallel, and on the same plane with the sterno-hyoideus muscle, whilst the lower part extends downwards and backwards to the upper border of the scapula, into which its fibres are fixed as well as into the ligament (24) which crosses the supra-scapula notch. 25. The anterior scalenus muscle. 26. The posterior scalenus muscle. 27. The rectus anticus major muscle. 28. Part of the levator anguli scapulae muscle. 29. Part of the splenius muscle. 30. The membrane (thyro-hyoid) which connects the thyroid cartilage with the tongue-bone. 31. The membrane (crico-thyroid) which connects the cricoid with the thyroid cartilage. 32. The first ring of the wind-pipe. 33. The cricoid cartilage. 34. The thyroid gland. 35. The rings of the wind-pipe. 36. The upper intercostal spaces.
- Fig. 2. The first bone of the sternum is here seen detached in order to show the points of origin of the sterno-hyoid and sterno-thyroid muscles, which can only be seen in part, as in fig. 1.—18, 20, so long as the sternum is in its natural position. 1. The posterior surface of the first bone of the sternum. 2, 2. Parts of the clavicles. 4, 4. The cartilage of the first rib at each side. 5. The sterno-thyroid muscle. 6. Part of the left sterno-hyoid muscle. 7. The right sterno-hyoid muscle.
- Fig. 3. This gives a side view of the thyroid cartilage and the hyoid bone, together with the membrane and the muscle which connect them. 1. The hyoid, or tongue-bone. 2, 2. Its small horns or processes. 3. The large horns. 4. The thyro-hyoid membrane. 5. The thyro-hyoid ligament. 6. The thyroid cartilage. 7. Its upper cornu, or process. 8. Its lower cornu, or process. 9. The oblique ridge on the side of the thyroid cartilage, which gives insertion to, 10, The sterno-thyroid muscle, and origin to, 11, The thyro-hyoid muscle. Behind these is a part of the inferior constrictor muscle of the pharynx, spread out from its attachment to the side of the thyroid cartilage.

Fig 1

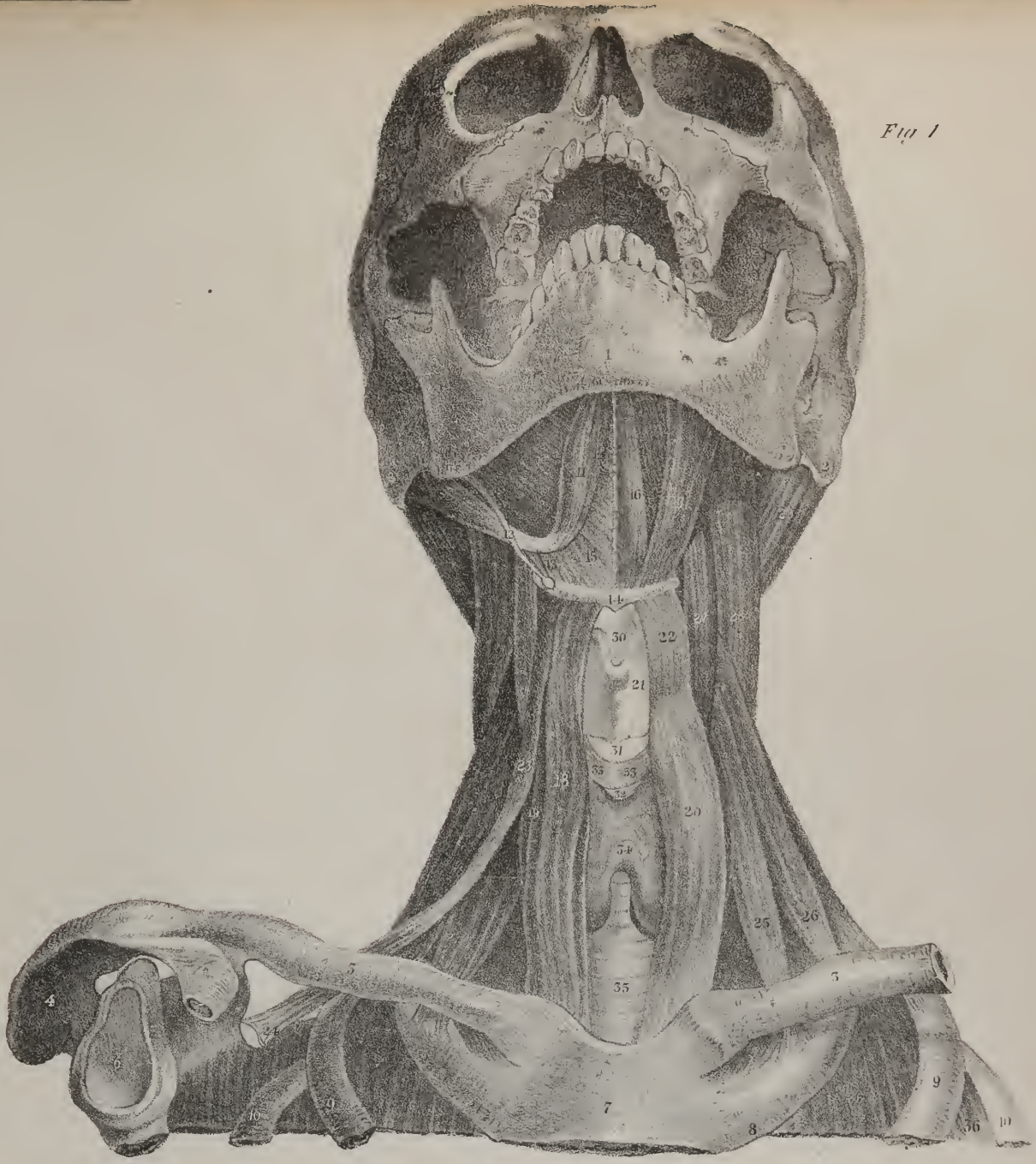


Fig 3

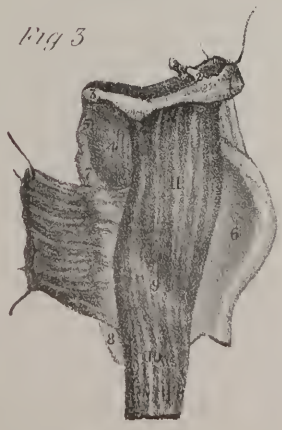

Fig 2

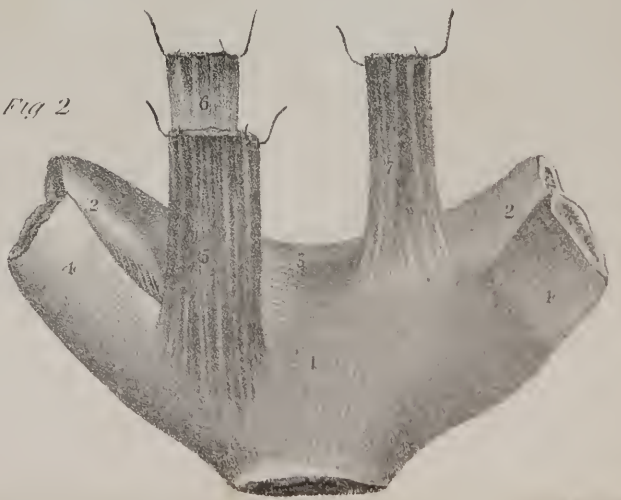










Fig 1

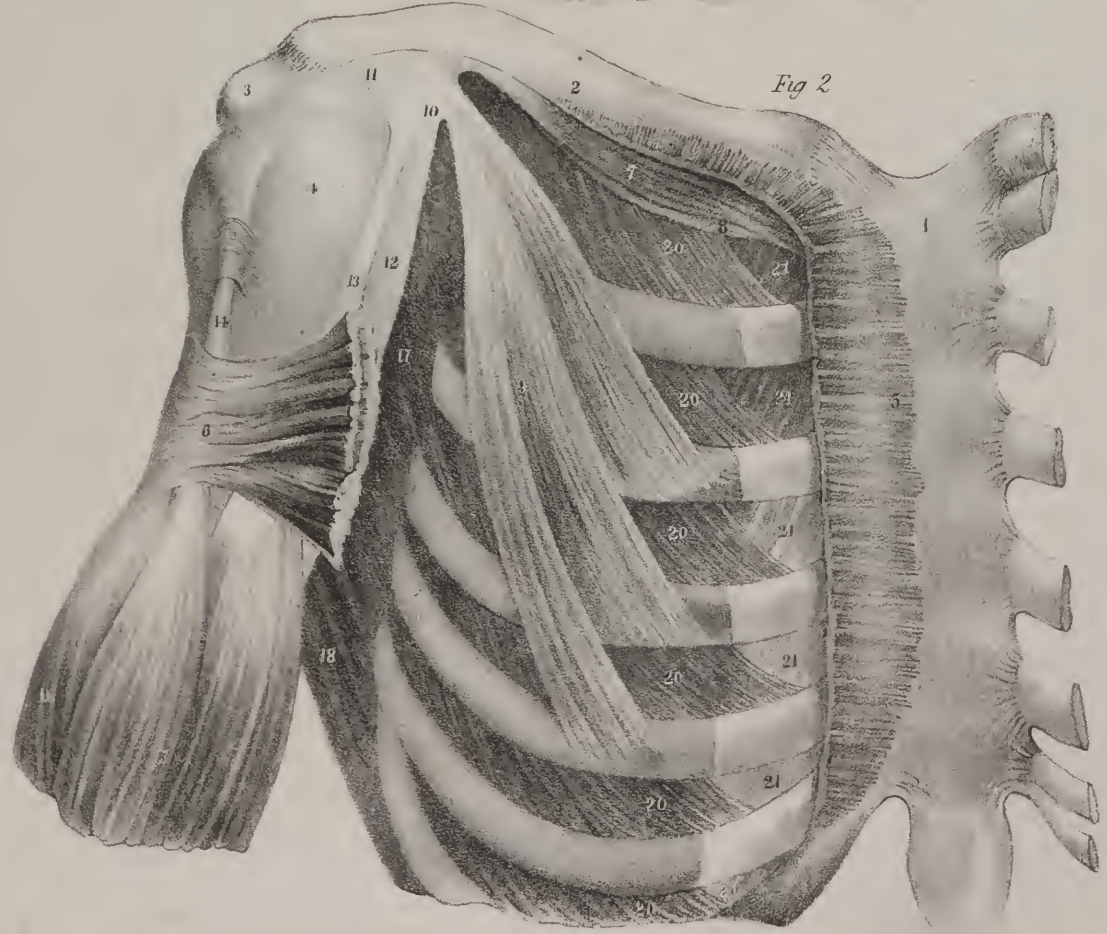


Fig 2



## PLATE XI.

WE have here some muscles shown in connexion with the chest and shoulder, which are still more deeply seated than those seen in the previous drawings. Along the side of the chest, and resting upon the ribs and intercostal spaces, is a muscle of considerable extent, (25,) which reaches from the first, but sometimes from the second rib, as far down as to the ninth. To expose it, the clavicle is sawed through, and the shoulder, with the scapula, drawn backwards. It is attached to the ribs by nine angular points, like the teeth of a saw, from which circumstance it has been called "serratus;" the other ends of its fibres are fixed along the posterior border of the scapula, a considerable number of them being concentrated towards its inferior angle. When in action, it draws the scapula forwards, and at the same time, by a slight effort, it can elevate the point of the shoulder, for it gives the scapula a rotatory motion, by means of which, whenever its inferior angle is drawn forwards, the glenoid cavity is necessarily turned a little upwards, and with it the shoulder-joint. It is in this way that the serratus contributes to support the shoulder when a heavy burden is placed upon it. In every effort which we make when pushing anything forwards, this muscle is necessarily in action in order to fix the scapula, and make it a steady support for the humerus. When such efforts as these are about to be made, the ribs must be rendered immoveable by a preparatory adjustment, in order that the muscle may have fixed points, from which to act along the side of the chest. This can be done by taking a full inspiration so as to distend the chest, after which the lower border of the cavity is kept fixed by the abdominal muscles and the diaphragm, and the air is prevented from escaping by the closing of the chink in the larynx. The necessity of this preparatory effort is rendered apparent in persons who have a fistulous opening in the wind-pipe, which allows the air to escape, for they cannot fix the chest so long as the aperture remains open. M. Bourdon some time since ascertained the fact to be as here stated, by direct experiment. He made an opening into the wind-pipe of a dog that was accustomed to jump and tumble about when bidden; after the operation the animal was no

## PLATE X.

This plate commences the delineation of the muscles which move the upper extremity.

FIG. 1. Shows the great pectoral muscle, which is extended outwards to the arm from the breast-bone, and the cartilages of the ribs; also a part of the deltoid muscle, which lies over the point of the shoulder. No. 1. The right clavicle. 2. The acromion process of the scapula. 3. Part of the left clavicle. 4. The sternum or breast-bone. 5. Its cartilaginous appendage, (called, from its shape, xiphoid or ensiform.) 6. The cartilages of the true-ribs. 7. The cartilage of the seventh rib of the right side. 8. The great pectoral muscle (m. pectoralis major; le grand pectoral.) 9. The anterior part of the deltoid muscle, which is broad above at its attachment to the clavicle, to the acromion and the spine of the scapula, and narrow at its insertion into the humerus, giving it a triangular form, not unlike that of the Greek letter Delta, from which circumstance its name is taken. 10. Part of the subclavius muscle; placed deeply under cover of the clavicle, but perceptible in the interval between the two preceding. 11. Part of the small pectoral muscle, which is also deeply seated. 12. Part of the great muscle of the back (latissimus dorsi,) which is here seen forming the posterior fold of arm-pit; the lower margin of the great pectoral muscle forms the anterior one. 13. Some fibres of the great serratus muscle, seen in the interval between 12 and 8. 14, 15. The fleshy part of the biceps, or two-headed flexor muscle of the arm. 16. The origin of the anterior brachial muscle, just below the insertion of the deltoid.

FIG. 2. Shows the parts which are seen after the removal of the pectoral and deltoid muscles. 1. The sternum. 2. The right clavicle. 3. The acromion process. 4. The capsular ligament of the shoulder-joint, covering the head of the humerus. 5. Part of the fibres of the great pectoral muscle, left at their connexion with the sternum. 6. The external part of the same muscle, which becomes flat and tendinous at its insertion into the humerus. 7. The subclavian muscle, lying along beneath the clavicle, to the under surface of which it is attached; its inner extremity is fixed to the cartilage of the first rib, (8.) 9. The small pectoral muscle, (m. pectoralis minor; petit pectoral,) which is attached by separate processes to the third, fourth, and fifth ribs, from which its fibres pass upwards and outwards, to be inserted into the coracoid process of the scapula (10.) 11. The triangular ligament stretched from the coracoid to the acromion process, so as to overhang the shoulder-joint. 12. The coraco-brachial muscle, (m. coraco-brachialis.) Its name expresses its points of attachment to the coracoid process and the humerus. 13. The inner, or short head of the biceps muscle, which is attached above to the coracoid process conjointly with the preceding muscle, in apposition with which it descends along the fore part of the humerus. 14. The external, or long head of the biceps muscle, seen after it has emerged from under cover of the capsular ligament of the shoulder-joint; the upper part of the tendon runs over the articulating head of the humerus, and is fixed to the top of the glenoid cavity of the scapula. As it runs through the joint it is surrounded by a tubular process of its synovial or lining membrane. Some of the fibres of the capsular ligament are here shown arching across the groove in the bone which lodges the tendon, so as to allow it to pass down freely. 15. The fleshy body of the muscle placed at the fore part of the upper arm, where it makes a considerable projection. 16. Some fibres of the anterior brachial muscle. 17. Part of the subscapular muscle, lying deep in the axilla. 18. Part of the great teres muscle, lying below the preceding. 20. The external intercostal muscles, placed between the ribs. 21. Part of the internal intercostal muscles.



longer able to make any similar effort, though evidently willing to do so; but when the wound was closed the lost power was immediately restored. The serratus muscle can, like most others, reverse its line of action; instead of acting as it ordinarily does upon the scapula, it can readily be made, if this bone be fixed, to act on the ribs, and draw them upwards and outwards, by which means it becomes a powerful agent in forcible inspiration.

The subscapular muscle, (24,) acts upon the humerus, and makes it turn upon its own axis, rotating it inwards. It assists in drawing the arm towards the side if it has been previously thrown outwards, and also contributes to keep the head of the bone in close apposition with the surface of the shallow cavity with which it articulates.

The scalenus anticus, (22,) can slightly bend the vertebral column laterally, and if the two muscles of opposite sides act together, they will contribute to maintain it in the erect position. If the neck be fixed, these muscles, acting from above, will draw on the first ribs, so as to fix them, and make them the point towards which the other ribs will move in inspiration.

The posterior scalenus, (21,) exerts the same influence upon the vertebræ and ribs, which the anterior one does. The elevator of the angle of the scapula, (No. 20.) draws upwards the superior angle of the scapula, particularly if it has been previously depressed; by this movement the glenoid cavity and the shoulder are inclined downwards. When the shoulder and scapula are fixed, it can act on the cervical vertebræ, and draw the spine towards the side.

*Dislocations of the Clavicle.*—The clavicle is more frequently the subject of fracture than of dislocation. Boyer says these accidents occur in the proportion of six to one. Yet were we to look at the structure of the sternal or acromial articulations of the bone, we should at first be disposed to think that dislocations frequently occur in them. The inner extremity of the clavicle rests upon a shallow notch in the upper angle of the sternum, beyond which it projects considerably, and the external extremity is connected with the acromion by a narrow plane surface, both conditions being apparently favourable to dislocation. The comparative infrequency of the accident is owing not merely to the ligaments which form the joints just named, but also to the accessory ligaments which connect the clavicle with the coracoid process (coraco-clavicular) and with the first rib, (costo-clavicular.) Moreover, in the concussion produced by a fall either on the hands or on the shoulder, a thin long bone such as the clavicle, will, when bent much beyond its natural curve, give way and suffer fracture towards its middle more easily than be displaced at either extremity. The inner end of the bone may, however, be thrown forwards upon the sternum. Dislocation downwards is altogether impossible, for the first rib lies beneath it; there is no case recorded of dislocation directly upwards; and though most writers admit the possibility of the displacement backwards, they do not cite any case in which it occurred as the result of violence. When the clavicle is dislocated forwards upon the sternum, the shoulder is depressed a little, and its point brought a little nearer to the central line of the body than that of the sound limb, for it is no longer borne off by the clavicle. The patient experiences difficulty in the movement of the arm, particularly in the direction upwards or forwards, his head inclines towards the affected side, and the clavicle no longer retains its natural position. It should be recollected that the line of that bone is not exactly horizontal; its outer extremity is raised a little, so that its direction is from without inwards, downwards, and a little forwards. When dislocated, the slight degree of obliquity which it naturally possesses is much increased, owing to its inner extremity being pressed downwards and forwards upon the sternum, where it forms a prominent tumour. This dislocation is more likely to happen in females and in young male subjects than in adult males. It may be produced by a forcible retraction of the shoulders or by a fall upon the point of the shoulder. Its reduction is easily effected, by placing the knee between the scapulæ, and then drawing the shoulders backwards, when the bone will drop into its natural position; but it will slip out of its place again if the arm be not supported, and the shoulder borne off from the side by the application of a pad in the axilla supported by a proper bandage, the arm being at the same time kept in a sling. Boyer expresses a decided opinion, that the sternal end of the clavicle cannot be dislocated backwards, at least by any of the ordinary causes which produce such accidents. Sir A. Cooper says he has never known this dislocation to occur from violence, and that, if ever it did happen, it could only be from a blow upon the fore part of the bone, which would rupture the sterno-clavicular and costo-clavicular ligaments, and force the bone directly backwards; but of this there is no instance on record. This displacement was, however, produced by a slow and gradual process in a person whose spine was distorted so much as to cause the scapula at one side to advance forwards and press the clavicle constantly backwards and inwards. In process of time the posterior sterno-clavicular ligament gave way, and the end of the bone slipped back behind the sternum, so as to produce considerable distress by its pressure on the œsophagus,—so much so that nothing but its removal could have saved the life of the individual.

The external or scapular end of the clavicle may be displaced from its connexion with the acromion process by a fall on the point of the shoulder, which will press the scapula downwards and inwards so as to separate it from its connexion with the clavicle. The shoulder of the affected side is necessarily depressed and inclined a little inwards. By making pressure along the spine of the scapula with the fingers, it is readily ascertained that the acromion process is no longer on the same plane with the end of the clavicle, but is sunk somewhat beneath it. The depression of the shoulder causes the skin to be drawn tightly over the projecting end of the clavicle, which renders every movement of the part painful. Finally, if the shoulders be drawn steadily back, so that the acromion may be carried outwards and upwards to its proper level, the displacement is at once reduced, but it will speedily recur if the shoulders be left without support. From this it follows, that in the management of such an

accident, adequate means should be devised to raise the scapula and bear it off from the side, the arm being at the same time supported so as to prevent its weight from depressing the scapula.\*

*Dislocations of the Shoulder.*—The head of the humerus may be displaced from the glenoid cavity of the scapula, in either of three directions; it may be forced downwards into the axilla, or forwards and upwards, so as to be placed on the sternal side of the coracoid process, or backwards, so as to rest upon the posterior surface of the scapula:—finally, a partial displacement may occur, in which the head of the bone does not entirely leave the glenoid cavity, but rests partly on its inner border, and partly on the outer side of the coracoid process. The displacement backwards is a rare occurrence; it often occurs in the direction forwards; but by far the most frequent form of the accident is that in which the bone is pressed downwards.

When dislocation into the axilla has occurred, the limb is necessarily lengthened, which is rendered obvious if the patient is viewed from behind, and the position of the elbows be compared one with the other. The arm is thrown somewhat outwards, so that the elbow is removed from the side, and on examining attentively the direction of the axis of the arm, it will be found that, instead of passing upwards from the elbow to the point of the shoulder, it inclines inwards, so as to terminate about two inches below that point that is a little beneath the border of the glenoid cavity. The shoulder no longer presents that rounded form which naturally marks it, and which depends on the support which the deltoid muscle receives from the head of the humerus. In the new state of parts consequent on the displacement of the bone, a depression exists instead of a fulness, and the want of support is readily perceived, if the fingers are pressed from point to point along the shaft of the humerus upwards, to where the deltoid appears sunk in. As the muscle last named is stretched, owing to its points of attachment being farther apart than in their natural condition, the border of the acromion process is rendered prominent, giving an appearance of sharpness to the shoulder. On searching for the head of the bone, it will very readily be found in the axilla, and can be distinctly felt, if the arm is drawn outwards a little. The power of voluntary motion is in a great degree lost; the patient can no longer move his arm upwards, or raise it towards his head; he can, however, move the limb a little forwards and backwards as it hangs by his side. The limb may be drawn outwards, and elevated a little, without causing much pain; but any effort to depress it, so as to bring it nearer to the side, is strongly opposed by the action of the deltoid, and productive of much pain, owing to the pressure of the head of the bone upon the nerves; hence it is that to relieve the pain and lessen the tension of the muscles, the patient instinctively inclines his head, and even his body, to the affected side, and supports and steadies the limb, by holding the fore-arm or elbow with the other hand.

This displacement may be produced by a fall on the point of the shoulder, or by falling on the side with the elbow thrown outwards, or by falling forwards with the hands outstretched. In the two latter cases, it results partly from external violence, but still more from muscular action. For when the body comes to the ground with the elbow thrown out from the side, the line of the arm is inclined to that of the body at a considerable angle; the lower end of the arm becomes fixed by its pressure against the ground, the upper end rests obliquely against the glenoid cavity of the scapula, and the muscles which form the folds of the arm-pit, are stretched across from the body to the humerus into which they are inserted. Under such circumstances, it represents a lever of the third order, the fulcrum being at the lower end, the resistance being at the upper, and the power, viz. the muscles, being between both; from which it follows, that if the muscles are thrown into action, they will instantly overcome the slight resistance given to them at the shoulder joint, and draw the bone downwards into the axilla.

The capsular ligament is torn not only at the lower part of the glenoid cavity, but also along the whole length of its inner margin. The head of the bone rests on the lower border of the scapula to the inner side of the long head of the triceps muscle. The tendon of the subscapular muscle is also torn, the deltoid is stretched, and its fibres elongated, the supra and infra spinatus muscles are necessarily stretched too; the *teres major* and *minor* muscles suffer little change; but the *coraco-brachialis*, the *biceps*, and the long head of the *triceps* muscles are all stretched.

If it is admitted as a general principle, that in the management of dislocations the muscles should be relaxed as much as possible, more particularly those which are in any way put on a stretch by the new condition into which the bones are placed, there can be little doubt as to the position into which the arm and fore-arm should be put in order to reduce with most ease the form of dislocation we are now considering. The deltoid and supra-spinatus muscles are most effectually relaxed by drawing the arm outwards and upwards from the side until it is brought into the horizontal position, so as to form a right angle with the body. Again, the biceps muscle is relaxed by bending the fore-arm upon the arm so as to form an acute angle with it. Yet this is not the position most commonly adopted; the dislocation is often reduced by placing the arm at full length parallel with the body, fixing the heel in the axilla, and pulling at the wrist, in which position every muscle which is placed in an unnatural degree of tension by the dislocation of the bone is rendered still more tense, and necessarily gives much more resistance than it would do if the limb were placed in the position above indicated. The same remark applies to the practice of reducing the

\* If care be not exercised in treating dislocation of the humeral end of the clavicle, to keep the scapula well out as directed in the text, by means of a pad in the axilla, the end of the clavicle will ride over the acromion, and the usefulness of the upper extremity be much impaired. A mismanaged case of this description, is now under my notice. The arm cannot be brought freely round upon the chest; the clavicle no longer serving its purpose of a moveable stay, with a joint at each end, the fulcrum being at the sternum; but slides over the acromion in the attempt, so as to make an unusual prominence under the skin, and excite considerable pain.—J. P.



dislocation by placing the knee in the axilla. The objection is lessened in some degree, when extension is made from the arm above the elbow, the fore-arm being flexed. Both modes of practice, however, succeed in recent dislocations with sufficient facility, but if they produce much more pain than accompanies the reduction, when care is taken to relax the muscles, then the motive for their continuance must be that they require little apparatus, and that success justifies their continuance.\*

The humerus may be thrown forwards and inwards off the glenoid cavity; in which case its head will be lodged at the inner side of the neck of the scapula; it is also drawn upwards so as to be placed upon a level with the second rib at the inner side of the coracoid process, and beneath the clavicle. In this dislocation, the arm is necessarily shortened; the elbow is thrown outwards from the side and also backwards. The margin of the acromion process is prominent, and the depression beneath it is more perceptible than in the dislocation downwards. On tracing the direction of the axis of the arm, it will be seen to drop to the inner side, and above the glenoid cavity; and if the hand be placed beneath the clavicle, a tumour can be felt under the pectoral muscle, which will be found to move or roll if the elbow be rotated. The movements of the limb are very much restricted; the arm is with difficulty drawn outwards from the side, for it is checked by the coracoid process: if it be drawn forwards, its head is pressed against the venter of the scapula, and the rotator muscles restrict its motion backwards. The diagnostic marks of this dislocation are thus briefly summed up by Sir A. Cooper: "The head of the bone is below the clavicle, the elbow is separated from the side, and thrown backwards; and rotation of the arm gives motion to the head of the bone in its new position."

Though the movements of the limb are thus restricted, the pain which is felt is not so great as in the other dislocation, for the nerves are not so much compressed. This accident commonly results from a fall when the arm is thrown out from the side, and a little backwards, by which means the head of the bone is forced forwards and upwards, tearing through the inner side of the capsular ligament. The bone in its new situation has in front of it the pectoralis minor as well as major; its outer side is in immediate contact with the venter of the scapula—the subscapular muscle is partly detached from the latter surface—its inner surface is separated from the ribs by the fibres of the subscapular muscle, and the serratus magnus. The rotator muscles are stretched, as well as the posterior fibres of the deltoid muscle; the part of the latter which arises from the clavicle is relaxed, so is the pectoralis major. This dislocation may be reduced by placing the heel in the axilla, and making extension from the arm immediately above the elbow, having previously placed the limb in a state of flexion, in order to relax the biceps muscle; but this method is not so often resorted to in the present case, as in the dislocation downwards. Counter-extension is effected by means of a bandage or girth, so applied as to fix the scapula; and extension is made from the arm above the elbow, the fore-arm being bent, so as to relax the biceps; the limb should be drawn downwards and a little backwards, corresponding with the line

## PLATE XI.

Shows the deep-seated muscles at the side of the neck and the chest; also the subscapular muscle, to expose which all the parts in the axilla must be removed, and the scapula drawn backwards out of its place.

No. 1. Part of the occipital bone. 2. The mastoid process of the temporal bone. 3. The styloid process. 4. The bodies of the cervical vertebrae. 5, 5. The inner and outer ends of the clavicle, the intermediate part being cut away. 6. The acromion process of the scapula. 7. The coracoid process. 8. The ligaments which connect it with the under surface of the clavicle. 9. The upper angle of the scapula. 10. The upper part of the humerus. 11. The lower border of the scapula. 12. The ligament connecting the first rib with the clavicle. 13. The sternum. 14. Its cartilaginous appendage. 15. The sternal or true ribs. 16. Three of the asternal or false ribs. 17. The line of the base of the scapula. 18. Part of the complexus muscle. 19. Part of the splenius. 20. The elevator muscle of the angle of the scapula, (*m. levator anguli scapulae*; *l'angulaire*), which is attached at one end by three or four tendinous points to the transverse processes of the upper cervical vertebrae, and by the lower to that part of the base of the scapula which lies above its spine. 21. The posterior scalenus muscle, which is extended from the first and second ribs at their back part to the transverse processes of the six lower cervical vertebrae. 22. The anterior scalenus muscle, extending from the inner border and upper surface of the first rib upwards, to the transverse processes of the cervical vertebrae, from the third to the sixth. 23. The part of the first rib which is included between the scaleni muscles, and over which slides the subclavian artery as it passes from the neck into the axilla. 24. The subscapular muscle, (*m. subscapularis*), which in the natural position of the parts lies deeply in the axilla under cover of the scapula.—(Plate X., fig. 2, No. 17.)—It is here thrown forwards by the eversion of the shoulder, which shows its points of origin from the concave surface and the base of the scapula 17, and its insertion into the small tubercle of the humerus. 25. The great serratus muscle, so called from its mode of attachment to the ribs by a series of angular processes resembling the teeth of a saw. The muscle is of considerable extent; it rests upon the external surface of the nine upper ribs and the intercostal spaces, and is inserted into the whole length of the base of the scapula, the greater number of its fibres being concentrated at the lower and upper angles of the bone. 26. The intercostal muscles.

\* M. Malgaigne, of Paris, has lately introduced the following method for reducing the luxation into the axilla, which, more effectually than any other, relaxes the two resisting muscles, the supra-spinatus and deltoides. The patient lies down upon the side. The surgeon is seated above and behind him. The scapula is well fixed, by placing one hand or foot upon the shoulder, or passing a jack towel over it, and fixing it to the opposite corner of the bed. The elbow is then to be raised up from the side, and drawn straight up by the head, till the head of the bone, reaching the level of the socket, slips into its place.—J. P.



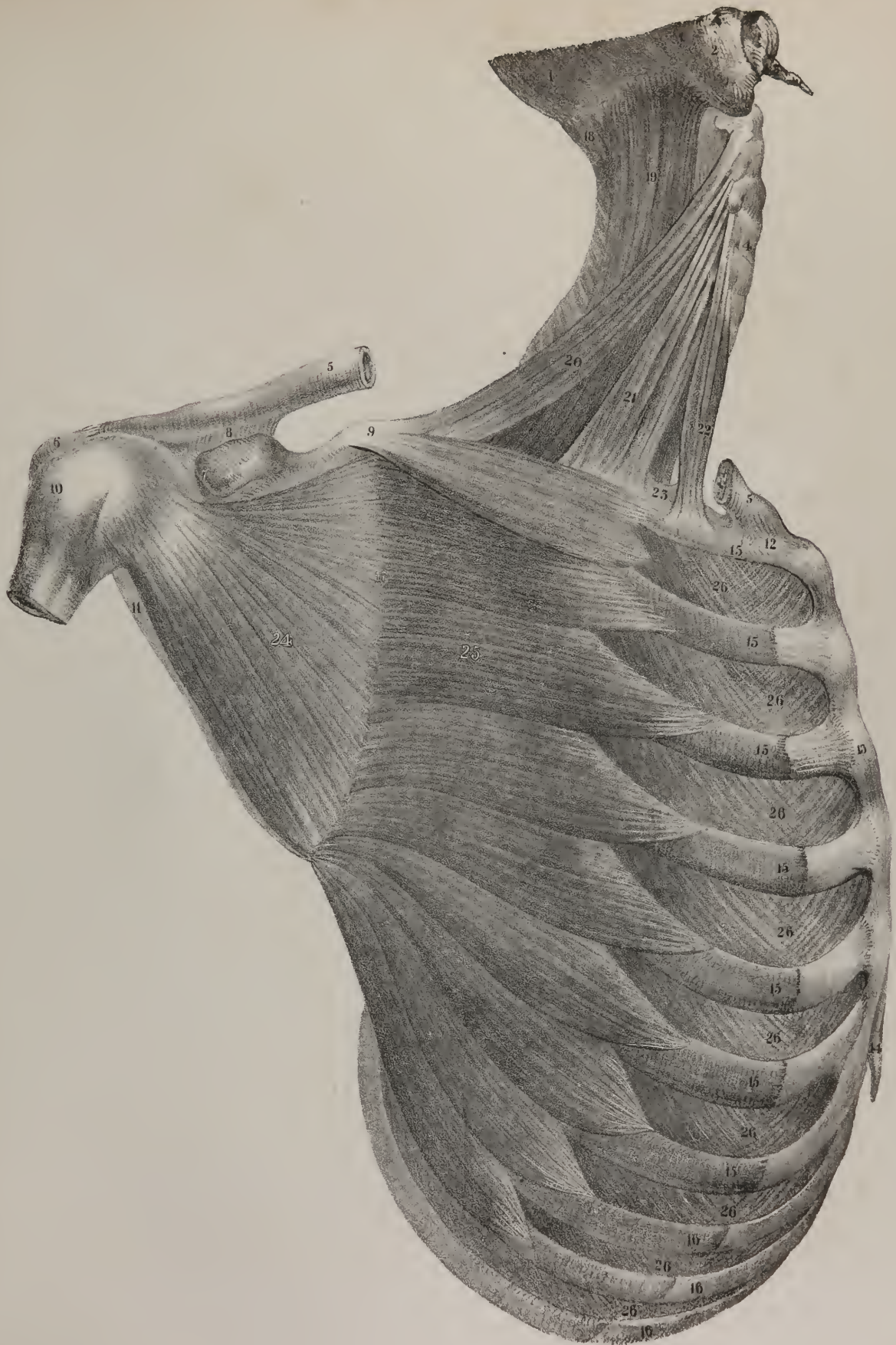








Fig. 1.

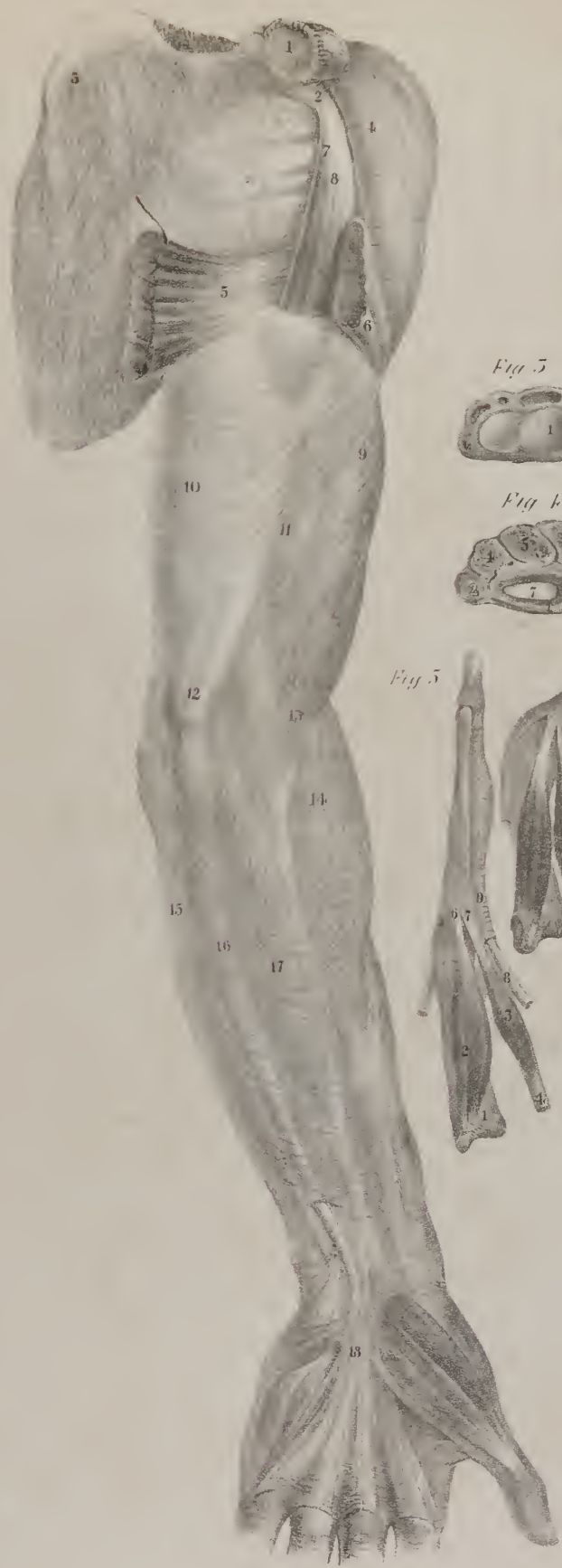

Fig. 2.

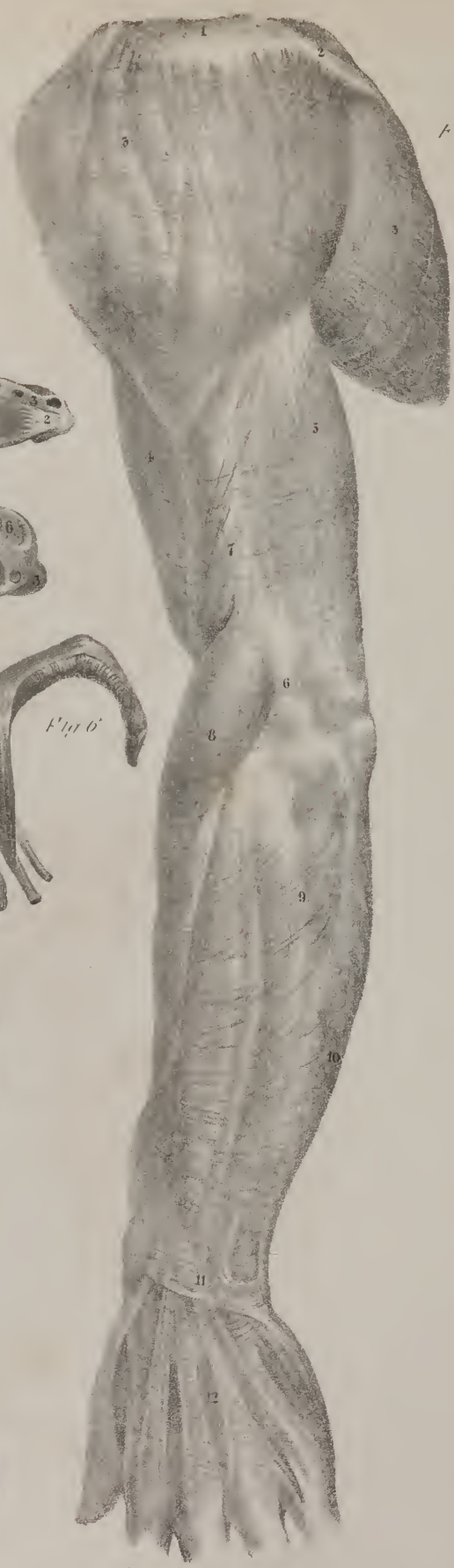


Fig. 3.



Fig. 4.




Fig. 5.





Fig. 6.



which its axis represents in the new position in which it is placed by the dislocation. By observing this precaution, the head of the bone is drawn clear of the coracoid process of the scapula, but when it is moved downwards a little, so as to approach the glenoid cavity, the arm should be drawn forwards at the elbow, so as to facilitate the passage of the head of the bone backwards into the glenoid cavity.

The head of the humerus may be thrown backwards upon the dorsum of the scapula, where it will necessarily form a considerable tumour beneath the spine of that bone, and behind the glenoid cavity. The depression beneath the acromion in this case is not so great as in the dislocation downwards: the direction of the axis of the limb is forwards and inwards, the arm being closely applied to the side, and, as it were, inverted. When the elbow is rotated, the protuberance formed by the head of the bone in its new situation can be readily felt beneath the spine, and farther back than the point of the acromion process. In one case cited by Sir A. Cooper, free motion was practicable backward and forward, but the limb could not be raised, or carried from the side without great difficulty, (on Dislocations, p. 416:)—whilst in another, p. 404, the arm could be moved considerably either upwards or downwards, but the motion in the anterior, or posterior direction, was very limited. In the few cases of this accident which we find reported, the reduction was easily effected. The counter-extension is made in the same way as in the other dislocations: by a gradual extension the limb is drawn directly outwards, so as to dislodge the bone from the dorsum of the scapula; if the elbow be then inclined a little backwards, the head of the bone will readily slip into its place.

A partial dislocation of the humerus has been known to occur in a few instances. In these, the head of the bone was not thrown altogether off the glenoid cavity; it rested partly upon its inner margin, and partly upon the contiguous portion of the coracoid process. The position of the bone thus placed, distinguishes the accident from the complete dislocation; for in the latter

## PLATE XII.

FIG. 1. Shows the fascia of the arm, and of the palm of the hand. No. 1. The inner end of the clavicle, the bone being fore-shortened in an extreme degree. 2. The coracoid process. 3. The subscapular muscle, its fibres being partly concealed by a thin membrane or fascia. 4. The anterior part of the deltoid muscle. 5. The tendon of the latissimus dorsi. 6. Part of the pectoralis major muscle: between the two last are seen, 7. The coraco-brachialis, and 8. The short head of the biceps muscle, passing down from their attachment to the coracoid process. 9. The fascia rendered prominent by the projection of the belly of the biceps muscle. 10. Indicates the place of the triceps. 11. Lies over the point into which the coraco-brachialis is inserted. 12. The position of the inner condyle. 13. Fibres given off from the tendon of the biceps muscle, which strengthen the fascia. 14, 15, 16, 17. Indicate the points at which the fascia is stretched over the supinator longus, flexor carpi ulnaris, palmaris longus, and flexor carpi radialis. 18. The palmar fascia: farther on it widens and presents distinct points of attachment to the extremities of the metacarpal bones. External to it are seen the muscles of the thumb. Those of the little finger lie to its inner border.

FIG. 2. Shows the fascia on the posterior and external part of the arm and fore-arm.

No. 1. The acromion process. 2. The spine of the scapula. 3. The thin part of the fascia covering the deltoid muscle. 3. bis. The dense fascia covering the infra-spinatus muscle. 4. The fascia, where it covers the biceps muscle. 5. The place of the triceps. 6. The place of attachment of the fascia to the external condyle:—7. To the external ridge of the humerus. 8, 9, 10. The fascia strained over the supinator, the common extensor, and the ulnar extensor. 11. The posterior annular ligament of the wrist. 12. The fascia covering the back of the hand, which is so thin as to allow the tendons of the extensor muscles to be seen through it.

FIG. 3. Shows the posterior annular ligament of the wrist, and the sheaths which it forms for the transmission of the tendons of the extensor muscles. The wrist joint has been cut across, and the radius and ulna sawed through immediately above it.

No. 1. The articulating surface of the radius. 2. The triangular ligament, which connects its inner border with the styloid process of the ulna. 3. The posterior annular ligament of the carpus. 4. The canal for the extensors of the metacarpal bone and first phalanx of the thumb. 5. One which is common to the tendons of the extensor carpi radialis, longior and brevior. 6. The canal for the transmission of the extensor of the second phalanx of the thumb. 7. One for the common extensor, and the indicator muscle. 8. That for the extensor of the little finger. 9. The sheath, or rather canal, which transmits the tendon of the flexor carpi ulnaris muscle.

FIG. 4. Shows the anterior annular ligament of the wrist, as it is stretched across from its inner to its outer border, forming with the carpal bones a ring or canal, for the transmission of the flexor tendons.

No. 1. The anterior annular ligament of the wrist. 2. The pisiform bone. 3. The trapezium. 4. The cuneiform bone. 5. The semi-lunar. 6. The scaphoid bone. 7. The ring which transmits the flexor tendons, near which is the small ring for the tendon of the flexor carpi radialis.

FIG. 5. Gives a side view of one of the fingers, in order to show the fibrous band or sheath which binds down the tendons of the flexor muscles; and the manner in which the interosseus and lumbricales muscles become fixed into the expanded tendon of the extensor muscle.

No. 1. A metacarpal bone. 2. The fleshy fibres of an interosseus muscle. 3. A lumbricalis muscle arising from 4, one of the tendons of the deep flexor muscle. 5. The extensor tendon running along the dorsal surface of the bone, and prolonged upon the phalanges of the finger. 6, 7. The insertion of the interosseous and lumbricalis into the border of the extensor tendon. 8. The tendon of the superficial flexor entering the sheath. 9. The fibrous sheath, which binds down the flexor tendons as they run along the palmar aspect of the finger.

FIG. 6. The same finger placed in the bent position, in order to show how the sheath binds down the flexor tendons, and increases their power; also how the lumbricales and interossei may become flexors of the first joints of the fingers.



it lies at the sternal side of the coracoid process, and in the former at the scapular side. It may be produced by a fall on the shoulder; after which, the shoulder no longer retains its usual roundness: a depression exists over the back part of the shoulder joint, so that the posterior half of the glenoid cavity can be perceived to be unoccupied by the head of the bone. When the upper extremity of the bone is thus thrown forwards and inwards, its axis will necessarily incline from above downwards, and a little backwards and outwards: the limb cannot be raised directly from the side, for by that movement the head of the bone is made to strike against the coracoid process, but if the elbow be drawn a little forwards, it may then be carried upwards. This form of dislocation is easily reduced; but it has a tendency to slip forwards again. The extension and counter-extension are made in this case in the same manner as in the dislocation forwards; but it is "necessary to draw the shoulders backwards, in order to bring the head of the bone to the glenoid cavity: immediately when the reduction is completed, the shoulders should be bound back by a clavicle bandage, else the bone will immediately slip forwards against the coracoid process." (Sir A. Cooper on Dislocations, p. 410.) If the clavicle bandage cannot conveniently be procured, a moderately sized pad may be placed in the axilla, and the elbow drawn forwards and inwards to the side of the chest, and retained in that position by a circular bandage, carried round the body. When the arm is thus placed, it must be obvious that the head of the bone is directed backwards and outwards, and thereby kept in apposition with the glenoid cavity of the scapula.\*

## PLATE XII.

THIS plate gives back and front views of the thin firm membrane which invests the muscles of the arm and fore-arm; it binds down the muscles like a band or sheath, from which circumstance it is called fascia; it is placed immediately beneath the skin, with which it is connected by cellular tissue, by small blood vessels and filaments of nerves, which must pierce this membrane before they can reach the tegument. The fascia resembles a web composed of white shining fibres, which run in various directions, some transversely, and others longitudinally, so as to form a layer of membrane; the outline of the muscles can be distinctly traced, even while they are covered by the fascia, for the membrane is closely adherent to them, and also gives off from its inner surface thin plates, which project into the interstices between several of the muscles, like so many partitions. The membrane is not of uniform thickness throughout its entire extent; it is thicker and firmer on the back part and outer side of the limb, than on the inner and fore part. At the bend of the elbow, the fascia is intimately connected with the condyles of the humerus, and also with the two ridges which extend upwards along the bone from these prominent processes; the latter connexion is effected by means of two firm plates of membrane, similar in structure to the fascia, which pass from its inner surface to the bone, so as to form partitions between the extensor and flexor muscles; from which circumstance they are termed inter-muscular ligaments. They serve, however, another purpose; they give an increased surface of attachment to the muscles, for several of the fibres of these arise from them. The inter-muscular septum at the outside of the arm, reaches from the external condyle to the insertion of the deltoid; that at the inner side, from the corresponding condyle upwards to where the coracobrachialis muscle is inserted.

At the outer side of the arm, the fascia is intimately connected with the insertion of the deltoid muscle, at which point it is strong and firm; but when traced upwards over the muscle, it becomes thin, so as to resemble a slight layer of condensed cellular tissue, rather than an investing membrane. In this altered form, it reaches as far as the spine of the scapula, and the outer part of the clavicle; behind the border of the deltoid it becomes blended with a very dense and firm membrane, which covers the infra-spinatus muscle. At the inner side of the limb it gradually becomes weak as it approaches the axilla; but it can be traced upon the pectoral muscle, and the latissimus dorsi, where they form the folds of the axillary space, for it is stretched across from the one to the other: from this point it gradually degenerates into mere cellular tissue, as it reaches the side and fore part of the thorax.

The fascia of the fore-arm is very dense and firm, particularly at the back part, and along the ulnar border; at the wrist, it is inserted into the annular ligaments. Its outer surface is separated from the tegument by the superficial veins, nerves, and lymphatics; its inner surface is intimately connected with the fibres of the muscles which arise from the condyles, and moreover gives off thin layers, which lie between them like so many septa, at the same time that they increase their points of attachment, for several of the muscular fibres arise from them.

The *anterior annular ligament* of the wrist is a strong firm band of white shining fibres, stretched across from one border

\* Young children are particularly liable to this form of subluxation of the humerus, a fact which I believe has not been noted. Four cases of the kind have come under my notice in the last three years, resulting from falls upon the shoulder. Slight efforts sufficed to replace the bone in each case, and the recovery of the perfect use of the limb was so speedy as to make it probable that in these instances the capsular ligament had been stretched but not torn in the displacement of the head of the bone. In one case the diagnosis was at first rendered obscure by a slight crepitation, resulting from an inflammatory thickening of the tissues about the joint.—J. P.





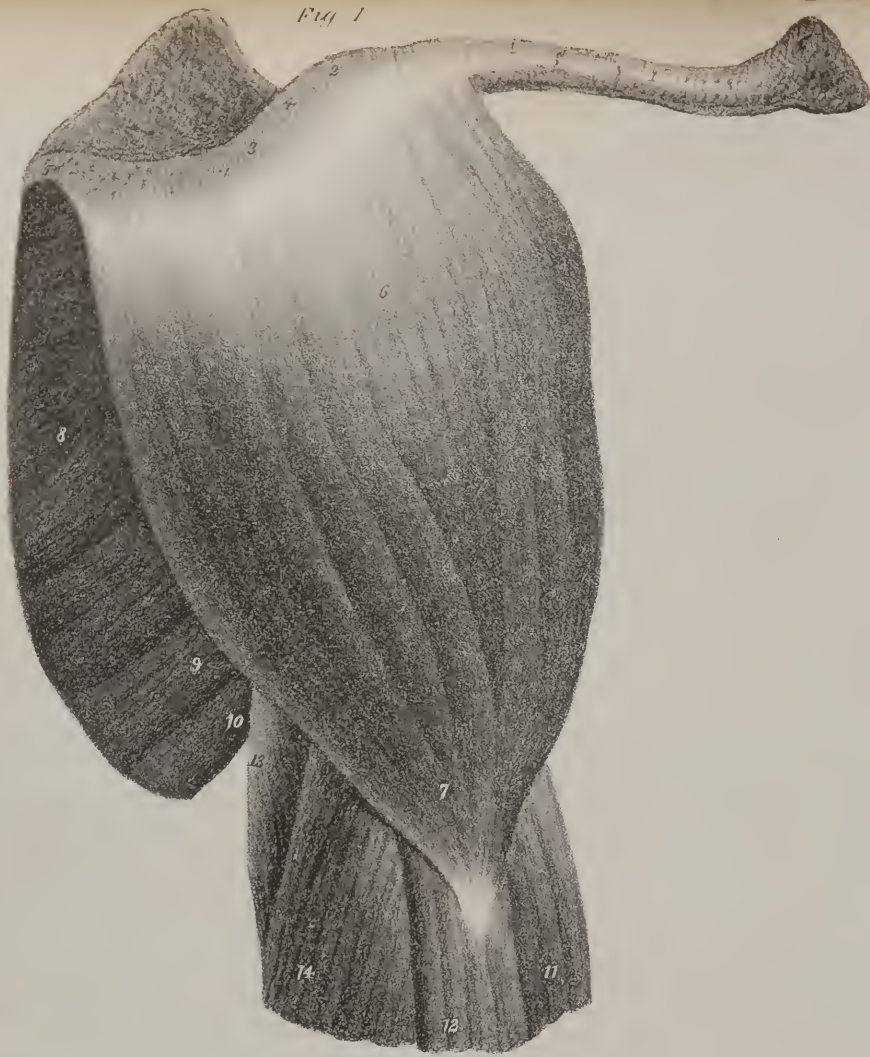
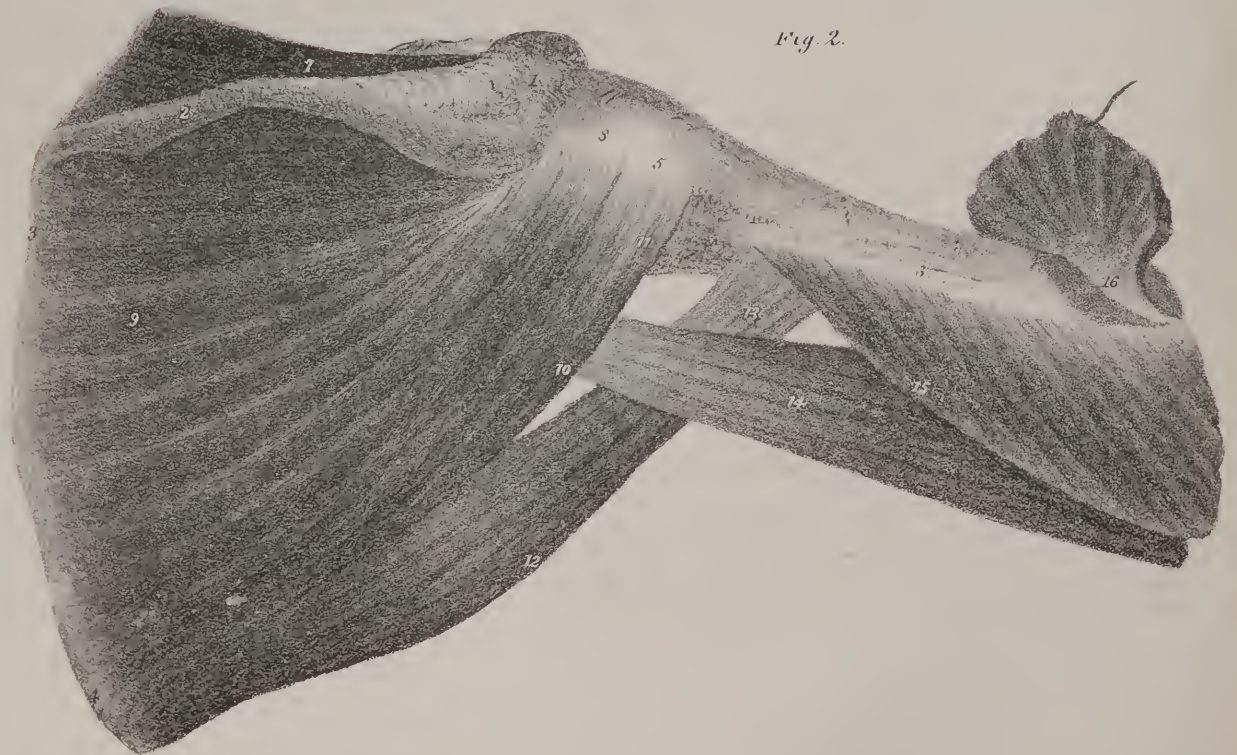
Fig 2.



of the carpal bones to the other, so as to convert the groove which these bones form into a canal. (Plate XII. fig. 4.) Its outer end is attached to the fore part of the trapezium and scaphoid bones, the inner to the pisiform bone, and the unciform. The fascia of the arm is attached to its upper edge, and to the lower is fixed the palmar fascia: its anterior or superficial surface gives attachment to some of the muscles of the thumb, and of the little finger; the posterior is in apposition with the tendons of the flexor muscles which slide beneath it. This surface is lined by a synovial membrane, which is prolonged upwards and downwards upon the flexor tendons, and dips in between them so as to facilitate their various movements; the tendon of the long flexor of the thumb has a distinct synovial sheath.

The *posterior annular ligament* of the wrist is stretched obliquely across the extensor tendons, and retains them in their situation. It is not by any means as strong or firm as the anterior ligament; its external extremity is attached to the outer part of the radius, from whence it is stretched inwards, and turning round the inner border of the wrist becomes attached to the pisiform bone, and the anterior annular ligament. Its upper border gives attachment to the fascia of the arm, (Plate XII. fig. 2, No. 11;) from the lower extends a thin fascia which covers the back of the hand, No. 12. Its posterior surface is subjacent to the skin; and from the anterior, bands are given off which are interposed between the tendons of the muscles, and by becoming fixed to the different prominent points upon the surface of the bones, convert into canals the shallow grooves which are marked upon the lower ends of the radius and ulna. (Plate XII. fig. 3.) These canals are lined by synovial membranes, which are reflected upon the tendons for some way both upwards and downwards.

The *palmar fascia*, (Plate XII. fig. 1, No. 18,) is a dense firm layer of fibrous structure, and of a triangular form, which extends from the anterior annular ligament of the wrist to the extremities of the four metacarpal bones, which support the fingers. Its narrow part or commencement is attached to the anterior annular ligament of the wrist, and to the tendon of the palmaris longus muscle. When traced forwards over the metacarpal bones, its fibres divide into four separate bundles, which are directed towards the extremities of the metacarpal bones: there each divides into two slips which diverge so as to leave a free passage for the transmission of the flexor tendons, and of the nerves and vessels. The slips or processes here alluded to, as they turn backwards, become fixed to the transverse and anterior metacarpal ligaments. The fibres, which in this arrangement run forward from the anterior ligament to the metacarpal bones, are interwoven with others which run in a transverse direction, so as to prevent their being separated or torn. From the edges of the palmar fascia thus disposed, a thin lamella projects inwards over the muscles of the little finger, and outwards over those of the thumb. The superficial surface of the fascia is subjacent to the skin; the deep one rests upon the flexor tendons and the palmar nerves and vessels, which it binds down and conceals.

## PLATE XIII.

These two drawings show the muscles which are in intimate relation with the shoulder joint.

FIG. 1. No. 1. The clavicle. 2. Its outer end. 3. The acromion process of the scapula. 4. The ligament which connects these two bones. 5. The spine of the scapula, which is here greatly fore-shortened as the parts are viewed laterally: part of the supra-spinatus muscle is seen above it. 6. The deltoid muscle. 7. Its insertion into the humerus. 8. Part of the infra-spinatus muscle. 9. Part of the teres minor muscle. 10. The origin of the teres major muscle. 11. Part of the biceps muscle. 12. The origin of the brachialis anticus muscle, immediately below the insertion of the deltoid. 13. The long head of the triceps muscle. 14. The second or external head of the same muscle.

FIG. 2. Shows the external rotator muscles as they are seen from behind; the deltoid is removed in order to expose their insertions, as well as the points of attachment of the teres major muscle, and the origin of the two heads of the triceps.

No. 1. The acromion process. 2. The spine of the scapula. 3. The base of the scapula. 4. Its inferior angle. 5. The great tuberosity of the humerus. 6. The shaft of the bone drawn obliquely outwards and forwards. 7. The supra-spinatus muscle. 8. Its tendinous insertion into the upper part of the great tuberosity of the humerus. 9. The infra-spinatus muscle. 10. The teres minor muscle. 11. Its insertion into the lower part of the great tuberosity of the humerus. 12. The teres major muscle. 13. Its insertion into the posterior border of the bicipital groove of the humerus. 14. The long head of the triceps muscle; its fibres coming downwards from the lower border of the scapula; its origin, however, is here concealed by the teres minor. 15. The second or middle head of the triceps muscle, arising from the shaft of the os humeri; its upper fibres form a pointed process, which reaches nearly as far as the insertion of the teres minor into the great tuberosity of the humerus. 16. Part of the deltoid remaining at its insertion, the rest being cut away.



## PLATE XIV.

THE drawings in this fasciculus are intended to show the muscles which act upon the fore-arm, and bring it forwards, so as to form an angle with the upper arm, and those which carry it back again, so as to bring the whole limb into a straight position. These movements are termed flexion and extension. The elbow-joint is constructed on the principle of a hinge, the movements of the fore-arm upon the arm being limited to those here stated. The two muscles which bend the fore-arm upon the arm, are shown in Plate XIV. fig. 1. They are placed upon the fore part of the shaft of the bone. The first of these is placed in the greater part of its extent immediately beneath the skin and the fascia of the arm as is seen delineated in Plate XII. fig. 1, No. 9. It extends from the scapula down to the radius or outer bone of the fore-arm, and is named the two-headed flexor of the fore-arm, (biceps flexor cubiti.) This term expresses the fact, that it flexes the fore-arm, and that at its upper extremity it presents two heads or distinct points of attachment: one of these is observed to be fixed to the coracoid process of the scapula conjointly with another muscle which lies along its inner border, and which, from being attached by one end to the process just named, and by the other to the arm-bone about its middle, is named coraco-brachialis; the other head of the biceps runs over the upper extremity of the humerus in a groove which lodges it, and through the capsular ligament of the shoulder-joint, as may be seen in fig. 2, No. 7, its extremity being fixed to the upper border of that shallow pit in the scapula with which the head of the humerus articulates. These parts of the muscle are compressed and narrow; they are here shown of a white colour, for they consist of tendinous fibres. They gradually approach as they descend, forming a very acute angle, and widen somewhat as they become continuous with the fleshy part or body of the muscle, which will be observed to enlarge and swell out, becoming convex and prominent at its middle; but towards the lower part it again narrows, and its fibres run into a tendon which slides over the elbow-joint, and is fixed to a prominent nodule of bone which projects from the inner side of the radius. When the fleshy fibres of the biceps muscle are brought into action, they contract and shorten, by which means its ends are necessarily brought nearer to one another. But, as the upper end is for the most part fixed, the power of the muscle is concentrated upon the lower one, by which means the radius is drawn forward, so as to form an angle with the humerus. The action of the muscle, however, is not confined to one of the bones of the fore-arm; by a simple piece of mechanism, it is made to extend in effect to the other also; for from the inner border of its tendon a fibrous band is stretched obliquely inwards, and becomes fixed upon the surface of the muscles of the fore-arm. This fact is expressed in Plate XII. fig. 1, No. 13. By means of this process, and of the connexion which it establishes, whenever the muscle contracts, so as to pull upon the radius, part of its effort is directed at the same time

## PLATE XIV.

FIG. 1. Shows the two flexor muscles of the fore-arm, and the extensor as seen from the inner side of the limb. The subscapular muscle is also brought into view; to effect which the scapula and arm are detached from their connexions with the body.

No. 1. The acromion process of the scapula. 2. The coracoid process. 3. The upper border of the scapula. 4. Its upper angle. 5. The base. 6. The lower angle. 7. The small tubercle of the humerus. 8. The inner condyle. 9. The outer condyle. 10. The tubercle of the radius. 11. Part of the shaft of the radius. 12. Part of the ulna. 13. Part of the supra-spinatus muscle. 14. The subscapular muscle. 15. Part of the teres minor muscle, deeply shaded where it crosses behind the long head of the triceps muscle. 16. The teres major muscle. 17. Part of the latissimus dorsi muscle. 18. Part of the pectoralis major drawn forwards out of its place. 19. The external or long head of the biceps muscle. 20. The inner or short head arising from the coracoid process, together with the coraco-brachialis muscle, which lies along its inner border. 21. The rounded tapering body of the biceps muscle. 22. Its tendon of insertion into the tubercle of the radius. 23. The posterior or long head of the triceps muscle. 24. Its inner or short head: between the latter and the biceps appears the brachialis anticus muscle, marked 23, but which ought to be 25; its insertion into the coronoid process of the ulna is seen further down.

FIG. 2. Shows the capsular ligament of the shoulder-joint laid open, in order to bring into view the tendon of the biceps muscle—its relation to the head of the bone, and its origin, from the upper border of the glenoid fossa.

No. 1. The hollowed or under surface of the scapula. 2. The coracoid process. 3. The acromion. 4, 5. The globular head of the humerus. 6. The glenoid ligament surrounding the margin of the articular cavity of the scapula, and connected with 7, the tendon of the biceps muscle. 6. Is the shaft of the humerus. 8. The capsular ligament of the joint laid open. 9. The tendon of the biceps after having passed beneath the border of the capsular ligament.

FIG. 3. Exhibits in its entire length the supra-spinatus muscle; the scapula and shoulder joint being viewed from behind.

No. 1. The posterior surface of the scapula. 2. The spine; the acromion is removed where it overlaps the supra-spinatus muscle. 3. The upper part of the base of the scapula. 4. The neck of the bone. 5. The capsular ligament where it covers the head of the humerus. 6. Part of the shaft of the humerus. 7. The supra-spinatus muscle. 8. The insertion of the infra-spinatus muscle into the great tubercle of the humerus.



Fig 1

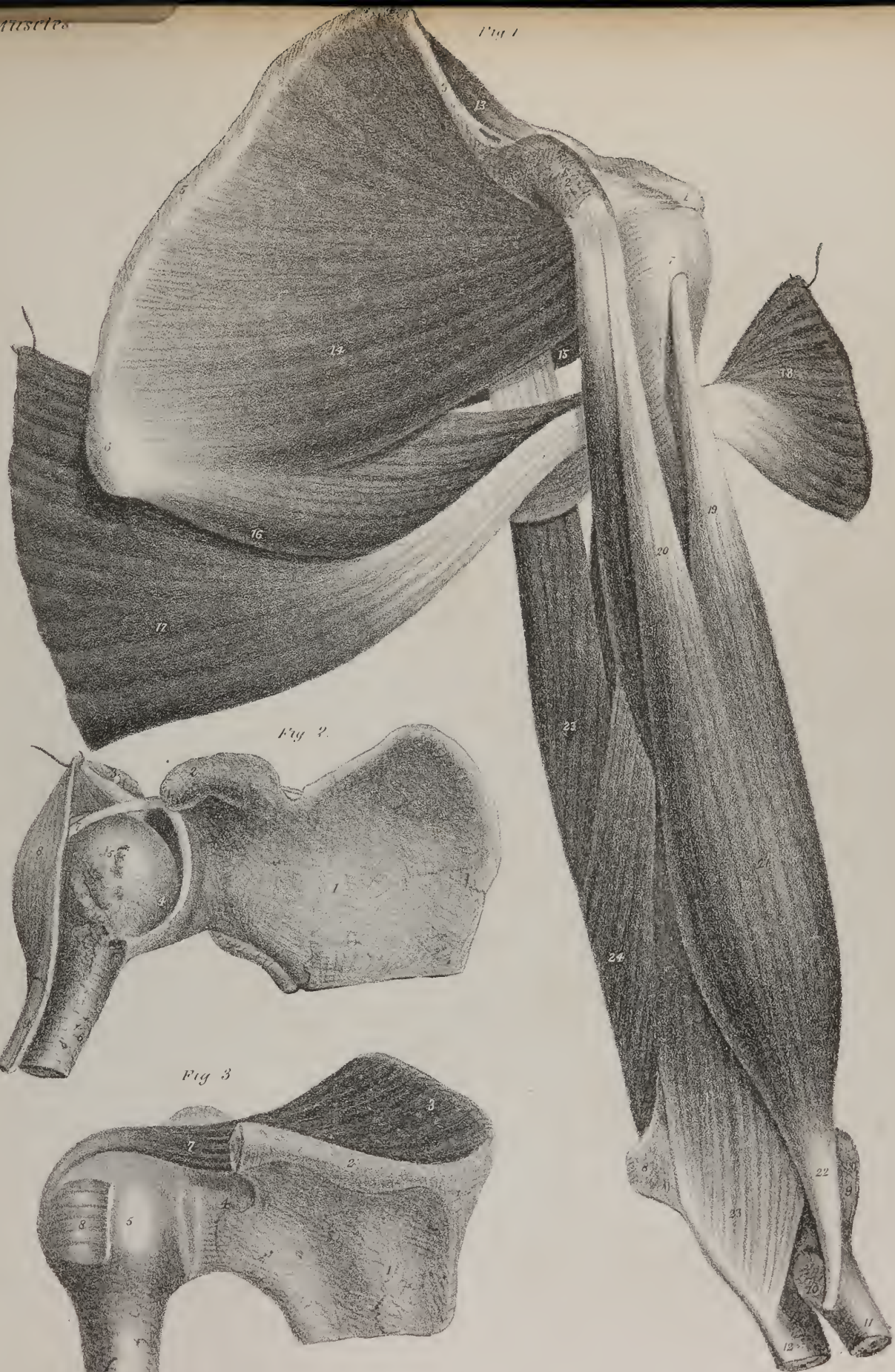


Fig 2

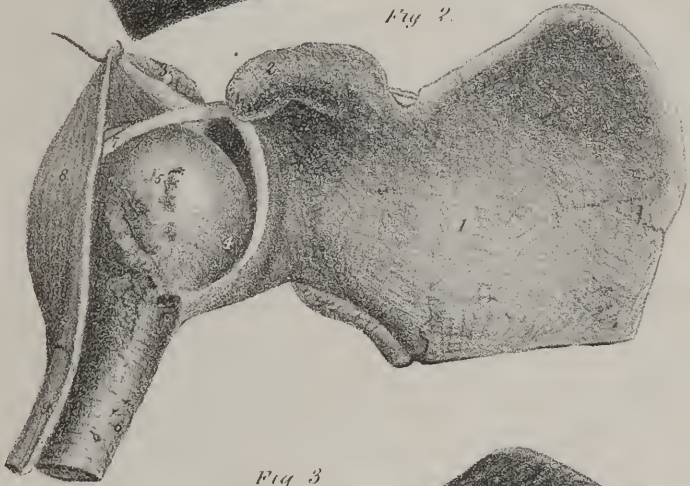
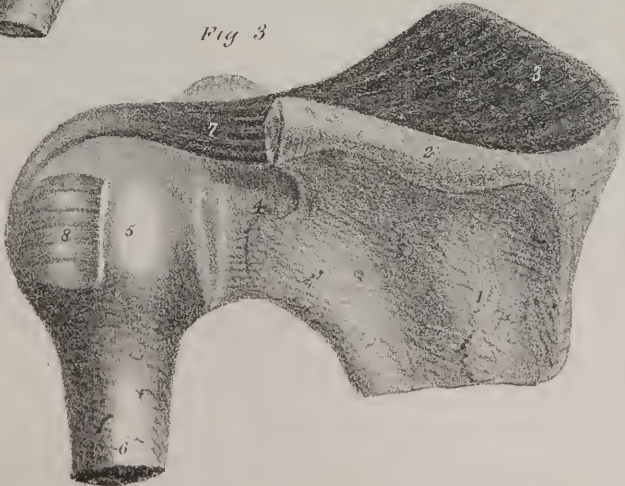


Fig 3







upon the inner side of the fore-arm. Another simple contrivance gives to this muscle an additional power over the radius besides that of flexion. If it were intended to give it the latter power alone, its tendon would have been fixed into the anterior surface of the bone: its fibres, however, are prolonged backwards, and fixed towards the posterior aspect of a nodule of bone called its tubercle which projects from the side of the radius, so that it is thrown inwards from the axis or shaft of the bone. Now, if the radius is rotated inwards, as when we turn the hand and fore-arm prone, the biceps muscle is enabled to rotate it upon its axis, and turn the arm and hand outwards, bringing thereby the palm of the hand from the prone into the supine position.

When we consider the changes which occur in this muscle during its actions, it is obvious that a loss of power results, not only from the mechanical contrivance employed, but also from the circumstance, that part of its force is expended upon the scapula; for when the fleshy fibres contract, they ripple and concentrate themselves towards the middle of the muscle, thereby pulling upon both ends—the upper as well as the lower. But though some force is thus directed away from the fore-arm, it cannot be considered as either lost or misplaced, when we take into account the influence which it exerts upon the state of the limb generally. The power applied in this direction, has the effect of drawing the articulating cavity of the scapula into closer apposition with the humerus, and the latter bone is at the same time prevented from sliding upwards, during the action of the muscle, by which adjustment the humerus is made to constitute a sufficiently steady point of support for the arm-bones. The mechanism by which this is effected will readily be perceived, by looking at fig. 1, in the plate; it shows how an associated movement is established between the three bones—the radius, the humerus and the scapula. Other muscles, as well as the biceps, are concerned in these movements, and are made to perform, either together or separately, various parts in the changes which take place, and in the efforts which are made; it too fulfils its own purposes in the ways here pointed out.

As to the other mode in which power is lost, for it, also, ample compensation is afforded. In the movements of the arm, the radius is made to serve as a lever, the muscles being the moving power by which it is acted on. The fulcrum or point upon which it rests or moves is in the elbow-joint, where the head of the bone rests against the humerus; the resistance is at the opposite end, viz. at the hand, the power being between both, so that it represents a lever of the third order; moreover, in originating the motion, the muscle acts in a direction nearly parallel with the axis of the radius. A loss of power obviously results from this contrivance; but a considerable degree of velocity is acquired in the movements of the limb, which is a sufficient equivalent for the loss.

The biceps muscle has a powerful assistant in the muscle (*brachialis anticus*,) which is placed immediately under it, and part of which is in this plate seen, fig. 1, No. 23, projecting from under its inner border, and extending downwards, to be fixed into the fore part of the ulna at its coronoid process. The muscle extends from the middle of the humerus to the point just named; it commences (see Plate XV. fig. 1, No. 13, where it is shown in its entire length, the biceps being removed,) just below the insertion of the deltoid muscle, which it in a manner embraces by its bifid extremity, and its fibres take their points of attachment from thence downwards along the surface of the humerus; its insertion is into the fore part of the coronoid process of the ulna. The direct action of the muscle is to draw the ulna forwards on the humerus, thereby conspiring with the biceps muscle in flexing the fore-arm.

The antagonist of the flexor muscles is in part seen in this drawing; it is called the three-headed extensor muscle, (*triceps extensor cubiti*.) The parts which it here presents, are indicated by the figures, 23, 24. It is fully shown in Plate XV. fig. 2. Its points of attachment and action shall be given in our comments upon the latter.

Two muscles are here shown, which exert considerable influence on the movements of the arm; one of these is seen in fig. 1, No. 14, another, No. 16; the former is triangular in its figure, taking the form of the scapula, and under cover of which it is placed, from which circumstance it is called the subscapular muscle. Its fibres are attached by one extremity to that surface of the bone just named where it overlays the ribs, by the other they are fixed to the humerus through the medium of a tendon, towards which they are seen to converge:—the tendon, previously to its insertion into a nodule upon the bone, called its small tuberosity, is intimately connected with the fibrous capsule of the shoulder-joint. This muscle when brought into action will, in the first instance, press the head of the humerus closely to the articular cavity of the scapula, and continuing its action it rotates the bone inwards, making it to turn upon its axis. The subscapular muscle and the three others which extend to the humerus from the posterior surface of the scapula, and which are seen in Plate XIV. fig. 2, No. 7. 9. 10, are the principal agents in keeping the head of the humerus in its place, as well as in rotating it. The weight of the limb tends constantly to draw it downwards, and the capsular ligament which connects it with the scapula, would be altogether insufficient to sustain it, but for the contractile force and power of these muscles. This is proved by the facility with which dislocations are known to occur, in cases in which paralysis has weakened or destroyed the power of the muscular fibres, and by the readiness with which displacement is known to recur in certain individuals, owing to a state of atony induced by previous dislocation.

Below the subscapular muscle is seen another called the *teres major*, No. 16, a name which is obviously ill-chosen, for it does not correctly express what its form is; and resting upon it is seen part of the broad muscle of the back, (*latissimus dorsi*, No. 17.) These muscles when put in action can draw the shaft of the humerus inwards to the side, and, if the arm has been previously rotated outwards, their mode of attachment to the humerus is such as to enable them to turn it upon its axis, and rotate it inwards.

Fig. 3, shows the supra-spinatus muscle in its entire extent; the acromion process of the scapula being cut away in order to bring its insertion into view. It extends outwards from the scapula to the large tubercle of the humerus, into which it is fixed by a tendinous insertion. When this muscle is coming into action, it will press the upper extremity of the humerus against the glenoid cavity of the scapula; continuing its effort, it will make the rounded head of the bone slide downwards, and at the same time project its axis outwards from the side, making the bone to pass from the position in which it is seen in fig. 3, to that in which it is placed in fig. 2. Thus when we desire to move the arm from the side and carry it upwards into the horizontal position, this muscle commences the effort and can effect it to a certain extent; but the deltoid is called into action, takes up the movement at a particular point, and continues it until completed.

## PLATE XV.

THE coraco-brachial muscle is here shown in its entire length, fig. 1, No. 17, also the anterior brachial muscle, fig. 1, No. 13. In order to expose both of these fully, the biceps muscle has been removed; but the principal object of both figures is to show the extensor muscle, which is placed at the back part of the humerus, for it is opposed in situation, as it is the antagonist in action, to the biceps and anterior brachial muscle. It is called the three-headed extensor muscle, (*triceps extensor cubiti*), the name being intended to express its action upon the fore-arm, and also because at its upper extremity it has three points, or heads. One of these heads is fixed to the lower border of the scapula, immediately behind its articulating cavity. (Fig. 1, No. 15; also fig. 2, No. 15.) At first it is flat and tendinous, but lower down it enlarges and becomes fleshy. The second head lies along the outer border of the bone just noticed; it commences by a pointed tendinous process immediately below the great tubercle of the humerus; the muscular fibres which are placed lower down, commence from the surface of the humerus, to which they are fixed from point to point, even to its lower extremity. The short head lies along the inner side of the first, as may be seen in fig. 1, No. 14. Its fleshy fibres, too, take points of attachment along the surface of the humerus. It would be more correct to say, that in this case as well as in others, the muscular fibres are attached to the periosteum or fibrous investment of the bone, rather than to the osseous texture itself. The muscular fibres here noticed, extend, some directly downwards, others downwards and backwards, and become continuous with the fibres of a broad aponeurosis seen at fig. 2, No. 11, which narrows at its lower part, and is fixed to the posterior surface of the olecranon process of the ulna.

When the fore-arm is brought into a state of flexion by the action of the biceps and anterior brachial muscle, the triceps can readily draw it backwards, so as to bring it again into a right line with the humerus, or, in other words, extend it. If the fore-arm and arm be fixed, the long head of this muscle can move the scapula upon the humerus, and in the extended state of the limb it may assist in drawing the arm backwards.

*Dislocations of the elbow-joint.*—The bones which form the elbow-joint may be displaced from one another in different directions. The radius and ulna may be thrown backwards behind the humerus, or they may be forced inwards or outwards; but the luxation backwards is the most ordinary occurrence, owing to the manner in which the force is applied. The accident most commonly occurs when a person, in falling forwards, puts out his hands to protect his body. In such circumstances, the palm of the hand comes first to the ground, so that the force of the fall is transmitted to the fore-arm, tending to press the upper ends of the radius and ulna backwards behind the humerus, whilst at the same time the weight of the body presses the lower extremity of the humerus obliquely downwards and forwards. In this way the bones are made to ride one upon the other, their ends being driven by opposing forces in the directions just indicated. There is also something in the structure of the joint which renders this dislocation more frequent than the others; for the coronoid process of the ulna projects but little forwards, and opposes only a slight resistance to the humerus when it is pushed downwards and forwards by the fall. Another form of dislocation occurs, in which the ulna alone is displaced from its connexion with the pulley-like surface of the humerus, and thrown behind it, the radius remaining in its usual position. And lastly, the radius by itself may be forced either forwards or backwards, the ulna remaining in its place. These are the simple dislocations (as distinguished from those that are compound or complicated) which may take place at the elbow-joint; one, however, occasionally occurs which is not included in this list:—it is that form of accident in which the radius and ulna are both dislocated forwards, which is necessarily complicated with fracture of the olecranon process.

When both bones are thrown backwards, the coronoid process of the ulna is lodged in the pit at the lower part of the humerus, so that the olecranon projects backwards, and also much above its usual position. In the natural state of the parts, this process of the ulna is on a level with the external condyle of the humerus; but in its new position, it projects nearly an inch and a half above it. As to the radius, its position is at the back part of the external condyle of the humerus; whilst the last-named bone necessarily forms a considerable prominence at the fore part of the arm. Owing to this change in the relative position of the bones, the shape of the limb at the elbow-joint is greatly altered. There is a considerable projection at the back part, con-








Fig. 2.

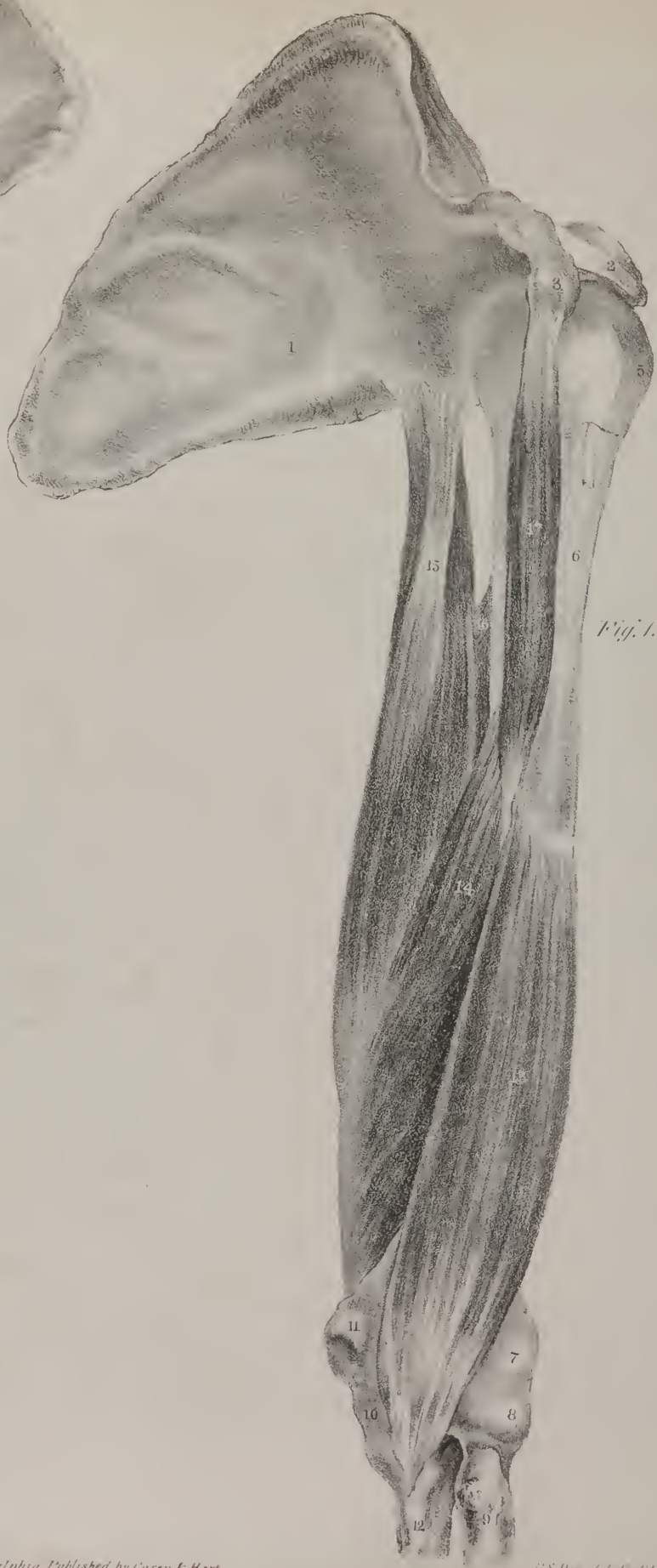

Fig. 1.

sisting of the olecranon process and the head of the radius; the articular surface of the humerus forms a prominence at the front, but, laterally, there is a depression at each side, corresponding with the borders of the olecranon. Motion is nearly lost; the limb is a little flexed, the fore-arm inclining to the supine position. The anterior ligament of the joint is necessarily torn through; the biceps muscle is somewhat stretched; and the brachialis anticus is considerably so, for it is made to run over the articular surface of the humerus, and then curves backwards to the coronoid process. The triceps muscle, on the contrary, is relaxed, inasmuch as the olecranon process, into which it is inserted, is situated higher up than in its natural condition. When the state of the two flexor muscles is considered, particularly that of the brachialis anticus, it will be obvious that they will begin to assist in drawing the bones forward, as soon as the coronoid process is dislodged from its position in the supra trochlear fossa; to effect this primary object, a simple expedient will suffice. The patient sits on a chair, and the surgeon placing his foot upon it also, rests his knee against the inner side of the elbow-joint in which the dislocation has occurred. He then takes hold of the wrist, and draws the fore-arm forcibly forwards. At the moment of doing this, the pressure of the knee is directed against the radius and ulna, with a view to force them backwards from the humerus; and when this is once effected, the action of the flexor muscles will draw the bones forwards into their natural position. Sir Astley Cooper once reduced a dislocation by the aid of the muscles alone, in the case of a person who had the elbow dislocated backwards, and also laterally inwards: "Finding (to use his own words) that the tendon of the biceps and the brachialis anticus were put upon the stretch, I thought I might make use of them to draw the os humeri backwards, as by the string of a pulley; so I forcibly extended the arm, and the dislocation was immediately reduced."—(On Dislocations, p. 437.) The muscles, under such circumstances, doubtless exercise some influence in pressing the humerus backwards, but their principal force will be made to act in drawing the ulna and radius forwards. When the reduction is effected, the fore-arm should be bent, so as to form an angle somewhat less than a right angle with the upper arm, and should be retained in that position, and supported in a sling. There are various modes of effecting the reduction of this dislocation. It is a common practice to place the patient beside a bed-post, round which he places his arm; the fore-arm is then drawn steadily forwards, and at the same time bent, but the upper-arm must necessarily be fixed, else the counter-extension will not be adequately maintained; again, the counter-extension may be made by an assistant, who takes hold of the middle of the arm, whilst another assistant makes extension from the wrist. In the dislocation backwards, it sometimes happens that the annular ligament, which retains the head of the radius in apposition with the side of the ulna, is torn, so that when the chief dislocation is reduced, the radius has a tendency to slip out of its place, and pass before the ulna. If such an accident should take place, it must be dealt with as if it were a primary dislocation of the radius forwards, which we shall notice in the sequel.

The bones of the fore-arm may be thrown inwards or outwards, constituting the lateral dislocations; these are commonly the consequence of considerable force or violence, for none of the ordinary movements of the arm tend to favour their production, and their occurrence is opposed by the mode of adaptation which exists between the articulating surfaces of the bones. It should also be observed, that these dislocations are seldom complete, which is owing, no doubt, to the great extent of the articulating surfaces in the transverse direction. The accident has been produced by the arm being accidentally caught between the spokes of the wheel of a carriage as it rolled along, by which means the fore-arm was drawn outwards, and the upper-arm inwards; it has been produced also by the passage of a wheel over the arm of an individual who had fallen with the limb outstretched. In either case, the lateral ligaments of the joint are torn, and those upon the front and back part are partially, if not entirely so. The fibres of the muscles, too, suffer more or less injury; hence it is that the limb seldom presents that fixity which exists in the posterior dislocation. When the bones of the fore-arm are thrown outwards, the coronoid process will rest against the back part of the external condyle of the humerus, so that the olecranon forms a greater projection than it does in the dislocation backwards. The head of the radius necessarily lies behind, and to the outer side of the humerus, where it can be readily

## PLATE XV.

FIG. 1. Shows the brachialis anticus muscle in its entire extent; and two portions of the triceps are seen from the inner side of the limb.

No. 1. The scapula—its hollowed or under surface. 2. The coraco-acromial ligament inserted into the acromion process. 3. The coracoid process. 4. The lower border of the scapula. 5. The great tubercle of the humerus. 6. The shaft of the bone. 7. The external condyle of the humerus. 8. The head of the radius. 9. Part of the shaft of the radius. 10. The coronoid process of the ulna. 11. The inner condyle of the humerus. 12. Part of the shaft of the ulna. 13. The brachialis anticus muscle. 14. The inner or short head of the triceps muscle. 15. Its long head. 16. A small part of the external head of the triceps, seen in the interstice between the long head and the humerus. 17. The coraco-brachialis muscle.

FIG. 2. Exhibits the triceps muscle in its entire extent, as seen from the back of the limb. The scapula is drawn up in order to put the long head of the muscle on the stretch.

No. 1. The dorsal surface of the scapula. 2. Its lower border. 3. The coracoid process. 4. The large tubercle of the humerus. 5. The small tubercle. 6. The inner condyle. 7. The border of the sigmoid cavity of the ulna. 8. The external condyle. 9. The head of the radius. 10. Part of the ulna. 11. The lower or tendinous part of the triceps muscle. 12. The fleshy body of the muscle. 13, 14. The inner or short head of the triceps. 15. The long head of the triceps muscle. 16. The external head of the muscle.



felt by rotating the hand. At the inside of the articulation the condyle of the humerus forms a projection, and there will necessarily be a depression above the one and beneath the other of these prominent points. When the bones are thrown inwards, the olecranon process will rest against the back part of the inner condyle of the humerus, where it forms a considerable projection. The head of the radius corresponds with the posterior fossa of the humerus, which ordinarily receives the olecranon. In such circumstances, the external condyle of the humerus is rendered very prominent at the outer side of the joint, and beneath it there is a depression, owing to the retrocession of the head of the radius; at the inner side of the limb there is a depression also, but it is above the end of the olecranon. These circumstances, together with the inclination of the hand and arm outwards, coupled with the want of power and of motion in the limb, constitute the distinguishing characters of the accident. In whatever direction the dislocation has occurred, the reduction is easily effected by making counter-extension from the arm and extension from the wrist; there being little resistance to overcome, save what is offered by the friction of the projecting ends of the bones against one another. Or the expedient above indicated, in the case of the dislocation backwards, may be resorted to, viz. that of "bending the arm over the knee, even without particularly paying attention to the direction of it, inwards or outwards; for as soon as the radius and ulna are separated from the os humeri, by the pressure of the knee, the muscles will give them the proper direction for reduction."—(Op. cit. p. 436.)

## PLATE XVI.

SOME of the muscles of the fore-arm are brought distinctly into view as soon as the skin and fascia are removed, others are placed more deeply; the two figures in this plate indicate the fact. Several of the muscles are attached to the prominent points of the humerus, so that one group will be observed to arise from the inner condyle of that bone, and another from the outer condyle. In the interval between these the biceps and brachialis anticus muscles are seen to dip down in order to reach their points of attachment to the radius and ulna. Into this interval also the brachial vessels descend as they are passing from the arm into the fore-arm. The names of the muscles express their ordinary actions and uses; one is observed to stretch obliquely from the inner condyle, downwards and outwards, to the middle of the radius, fig. 1—7, 8. It is called the pronator of the radius, (pronator radii teres,) for it can turn the radius upon its axis, so as to place the fore-arm and hand in the prone position, if it has been previously in the opposite state. If, after having effected so much by its contraction, it be made to continue its efforts, it

## PLATE XVI.

The muscles at the front of the fore-arm are exhibited in these drawings; the superficial set, those which lie immediately under the skin and fascia, are represented in Fig. 1. In Fig. 2, some of these are removed in order to bring others into view, which they in part conceal.

FIG. 1, No. 1. The lower part of the biceps muscle. 2. Its tendon; at its inner edge is seen part of the aponeurosis given off from the tendon, and which, when prolonged inwards, covers the brachial artery and median nerve. 3. Its insertion into the tubercle of the radius. 4. The lower part of the brachialis internus muscle projecting at each side of the tendon of the biceps. 5. Part of the triceps muscle. 6. The fleshy fibres of the brachialis anticus muscle. 7. The pronator radii teres muscle. 8. Its lower part becoming tendinous as it approaches the radius. 9. The flexor carpi radialis muscle. 10. Its tendon. 11. The continuation of the same into the palm of the hand. 12. The palmaris longus muscle. 13. The termination of its tendon in the annular ligament and palmar fascia. 14. The tendon of the flexor carpi ulnaris muscle, which is seen running along the inner border of the fore-arm. 15, 15. The fleshy fibres of the superficial flexor muscle of the fingers; the tendons of this muscle are drawn a little to the inner side in order to expose, 17, the tendons of the deep-seated flexor muscles. 16. Part of the pronator quadratus muscle. 18. The anterior annular ligament of the wrist. 19. The palmar fascia. 20. Metacarpal bone of the thumb. 21. The small muscles of the little finger. 22. The abductor muscle of the index finger; the muscles of the thumb having been removed in order to expose it. Along the outer side of the fore-arm, extending from above the elbow down to the end of the radius, is seen the supinator longus muscle. At its upper part it is fleshy, but lower down it ends in a flat narrow tendon, which is inserted into the outer border of the radius, a little above its styloid process; the point of attachment of the tendon is overlapped and concealed by the tendons of two of the abductor muscles of the thumb; between the tendon of the supinator muscle and that of the flexor carpi radialis, (10,) is seen a part of the long flexor muscle of the thumb.

FIG. 2, No. 1. The lower part of the humerus. 2. The inner condyle. 3. The inner side of the trochlea. 4. The olecranon process. 5. The superficial flexor muscle of the fingers. 6. Its tendons prolonged downwards to the palm of the hand. 7. The flexor carpi ulnaris muscle. 8. Its tendon of insertion; this muscle at its upper end presents two pointed processes by which it is attached to the inner condyle of the humerus, and the olecranon process of the ulna; between these is an angular interval, through which passes the ulnar nerve; some transverse fibres are observed to pass across from the one to the other. 9. The tendon of the abductor muscle of the metacarpal bone of the thumb. 10. The lower extremity of the radius. 11. The tendon of the long flexor muscle of the thumb. 12. The lower extremity of the ulna. 13. The insertion of the tendon of the flexor carpi ulnaris muscle into the pisiform, or pea-shaped bone. 14. Part of the anterior annular ligament of the wrist.



Fig. 1.

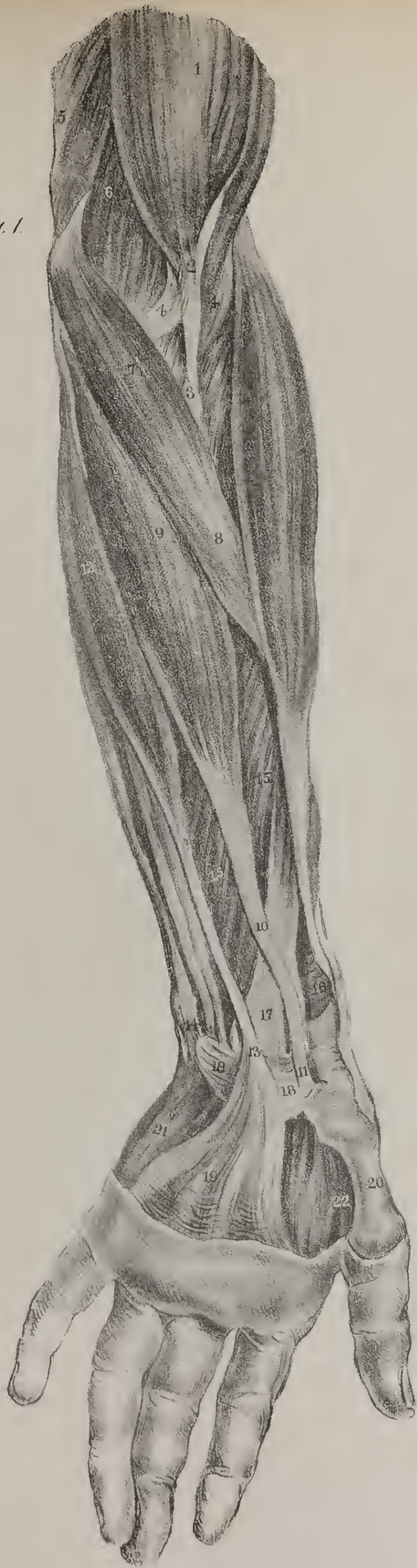

Fig. 2.









Fig 2

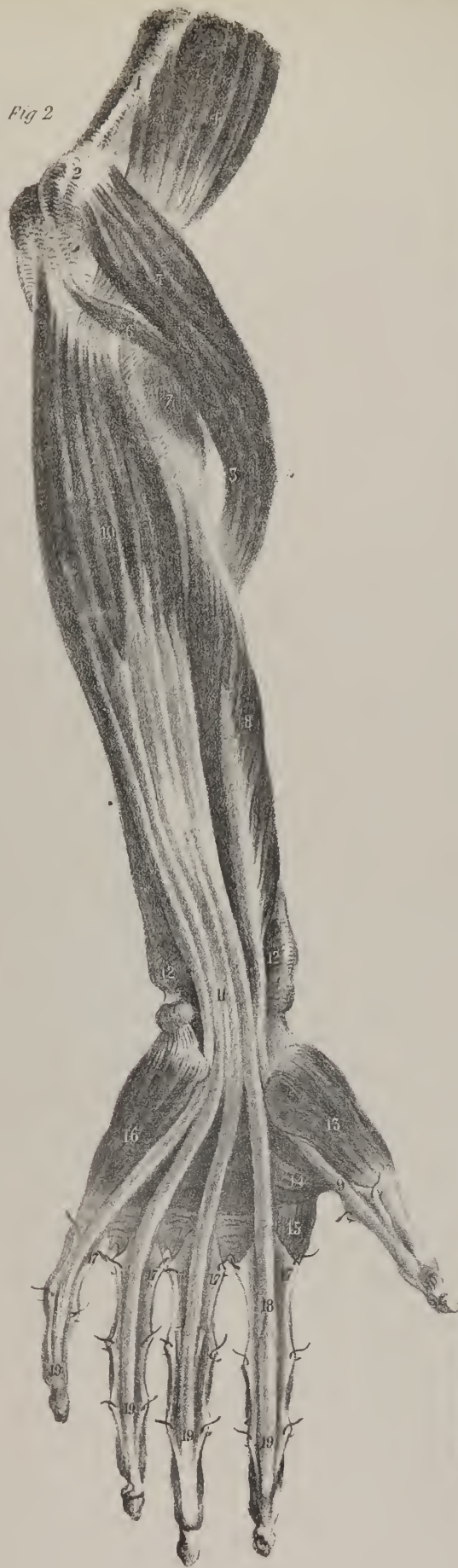
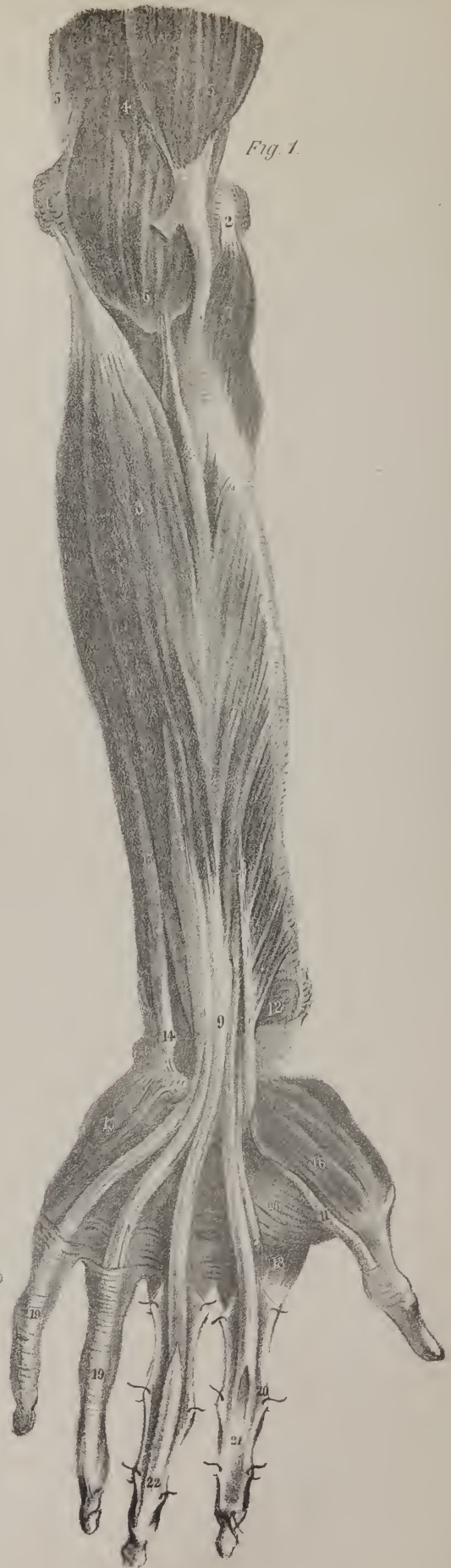
Fig. 1.



will assist in drawing the fore-arm forwards, so as to place it in the flexed position. There is one case in which it may be even in the first instance a flexor muscle, viz. if the supinator muscles are previously put into action so as to prevent it from rotating the radius. Along the inner side of the muscle here noticed, lies another, which is considerably longer, as it extends from the inner condyle to the metacarpal bone of the fore-finger. The tendon, which is prolonged from its fleshy fibres, passes under the anterior annular ligament of the wrist, and slides through a groove in the trapezium bone, previously to reaching its insertion. It is called the radial, or outer flexor muscle of the wrist, (*flexor carpi radialis*,) not because it runs along the radial border of the arm, but merely from its direction towards the radial, or outer side of the hand, upon which it is made to act. The tendon of this muscle serves as the guide to the position of the radial artery in the ordinary operation of feeling the pulse at the wrist. Along the inner or ulnar border of the *flexor radialis*, lies a thin small muscle, which is prolonged to the annular ligament and palmar fascia, in which its tendon (13) terminates; hence it is termed *palmaris longus*: in many subjects it does not exist. Along the inner border of the fore-arm, and taking the direction of the ulna in its entire length, is placed the *flexor carpi ulnaris* muscle; its tendon, (No. 14,) and part of its fleshy fibres, are seen in fig. 1, but in fig. 2 it is fully shown; its fleshy fibres (No. 7) proceed obliquely forwards from the ulna to reach the tendon, which lies along the fore part of the muscle. Its upper extremity is attached by two distinct points to the inner condyle and the olecranon process, in the interval between which the ulner nerve is placed, as it proceeds to the fore-arm. The superficial flexor muscle of the fingers is seen only at two points (15, 15) in fig. 1, as it is overlaid by the other muscles; but in fig. 2 it is brought more fully into view by their removal. At the outer border of the fore-arm is placed a long muscle, with a considerable fleshy body, which ends in a flat tendon; it is called the long supinator of the radius, to distinguish it from another muscle possessed of a similar power, but which is deeply placed at the upper part of the fore-arm: underneath the long supinator are two extensor muscles, which are in great part concealed by it.

Now, when we consider the power of these muscles, it is obvious that they can be made to act upon the bones of the fore-arm, the hand, and the fingers; the action of the pronator teres has been already noticed; the flexors of the wrist, as their name implies, can draw the hand forwards so as to bend it upon the fore-arm. The flexors of the fingers pull on their tendons like so many cords, and curve the joints so as to close the hand; and having proceeded so far, they can be made to act upon the wrist too, and flex it upon the fore-arm. The pronator muscle is directly assisted in its action on the fore-arm, by a short square plate of muscular fibres stretched across from the radius to the ulna, close to their lower extremities: from its shape it is called *pronator quadratus*, by which it is distinguished from the other, which is named "teres," or round. The direct antagonists of the pronator muscles are the long and the short supinators, of which the former alone is seen in this plate; the biceps muscle, it will also be recollected, has a similar power over the radius.

The head of the radius may be displaced from its natural position, and thrown either backwards or forwards: of the latter dislocations Sir Astley Cooper met with six instances, but none of the former in the living subject. He had, however, an opportunity of examining the state of the joint in the dead body of a man brought for dissection to St. Thomas' Hospital, in whom this dislocation existed, without being reduced, for a considerable time previous to his death. The coronary ligament was torn

## PLATE XVII.

The deep-seated muscles of the fore-arm and hand are here brought into view by the removal or displacement of the superficial set which conceal them.

FIG. 1, No. 1. Internal condyle of the humerus. 2. The external condyle. 3. The fleshy part of the biceps muscle. 4. The *brachialis anticus* muscle projecting to the inner side of the biceps. 5. Part of the *triceps extensor* muscle. 6. The insertion of the *brachialis anticus* into the coronoid process of the ulna. 7. The *supinator radii brevis* muscle. 8. The superficial flexor muscle; its attachment above is to the inner condyle of the humerus, lower down its fibres are fixed to the radius; sometimes a pointed process, as here, is derived from the coronoid process of the ulna. 9. The tendons of the superficial flexor muscle, which are placed closely together, but diverge to their insertions after having got into the palm of the hand. 10. The long flexor muscle of the thumb. 11. Its tendon. 12. A few fibres of the *pronator quadratus* muscle. 13. The *flexor carpi ulnaris*. 14. Its tendon. 15. The muscles of the little finger. 16. The muscles of the thumb. 17. Its abductor muscle. 18. Part of the abductor of the index finger. 19. The sheaths which bind down the flexor tendons. 20. The sheath laid open in order to expose the tendon. 21. The tendon of the superficial flexor muscle at its insertion into the second bone of the fore-finger. 22. The tendon of the deep flexor muscle, after having passed through the fissure and groove in the superficial flexor, is prolonged to the last bone of the finger.

FIG. 2, No. 1. The inner border of the humerus. 2. The inner condyle. 3. The olecranon process. 4. Part of the *brachialis anticus* muscle. 5. The *pronator radii teres* muscle, which is here drawn forcibly out of its position, in order to show its two origins, and the interval between them; one being from the inner condyle, the other (No. 6.) from the coronoid process of the ulna. 7. Some fibres of the *supinator radii brevis* muscle. 8. The long flexor muscle of the thumb. 9. Its tendon. 10. The deep-seated flexor muscle of the fingers. 11. Its tendons. 12, 12. The two extremities of the *pronator quadratus* muscle seen where they project beyond the preceding muscles. 13. The muscles which form the ball of the thumb. 14. Its abductor muscle. 15. The abductor of the index finger. 16. The muscles of the little finger. 17, 17, 17, 17. The sheaths which bind down the flexor tendons laid open and inverted. 18. The tendon of the superficial flexor muscle remaining in its position. 19, 19, 19, 19. The tendons of the deep flexor muscle running on to their insertion into the last bones of the fingers.



through at its fore part, the oblique one had also given way. The "capsular ligament was partially torn, and the head of the radius would have receded much more, had it not been supported by the fascia, which extends over the muscles of the fore-arm." When the arm was extended, the head of the radius could be seen as well as felt behind the external condyle of the os humeri. Professor Langenbeck, of Gottingen, met with two cases of this accident; in one, a man twenty years of age, it was of six weeks' standing; in the other, a child five years old, it had occurred on the day previous to his admission into the hospital. The symptoms in both were so well marked, that the nature of the injury became manifest, even on the first inspection. The peculiar form of the radial side of the fore-arm, owing to the ulna not being displaced, indicated the nature of the mischief. At the origin of the supinator radii longus, and the extensors carpi from the external condyle, there was a marked prominence; the outline of the arm was somewhat like that which exists in rickety persons, in whom the radius is generally bent. On examination of the joint, the head of the radius was found thrown backwards and outwards from the external condyle of the humerus, and could be immediately detected. The hand was prone, and could not be brought into the state of supination. The fore-arm was moderately bent, in which position it was fixed, for the arm admitted neither of flexion nor extension. At the inner side of the internal condyle the skin was loose, and presented a depression, in which the internal articulating surface could be felt. On tracing the radius from below, upwards, the finger came against the external condyle, behind which, in the adult, the articular surface only of the radius could be felt, and next to it the olecranon. When the finger was placed on this spot, and the radius was moved as far as it admitted, its motion was distinctly felt. In the other case, the glenoid cavity of the head of the radius could be felt behind and beneath the external condyle of the humerus. In the child, moderate extension only, with pressure on the end of the radius, sufficed for its reduction. In the adult, though the dislocation was of such long standing, it was reduced also. The "principal means to be adopted appeared to me, a powerful but gradual extension of the fore-arm, in order to draw the head of the radius towards the articulating surface of the humerus; at the same time making counter-extension at the upper arm, I pressed the dislocated head inwards. As in this case very strong and long-continued extension was necessary, I could, after a while, completely stretch out the fore-arm, which was before impracticable, and thus push the head of the radius inwards. The limb was kept in this situation by splints and bandages, and the patient was soon able to move the fore-arm in the four directions."—(Lancet, 1827, Vol. I. p. 248.) Though the extension was made from the fore-arm, in these cases it succeeded. In the first instances of the dislocation of the radius forwards which Sir A. Cooper met with, the efforts failed, even though long continued, as the force was expended for the most part on the ulna, which remained in its natural position. On considering the subject, it became obvious that this defect in the means of reduction could be remedied by making extension from the hand, for then all the force would be concentrated upon the radius.

Boyer never met with the dislocation of the radius forwards, and expresses doubts of its ever occurring. Sir Astley Cooper reports six cases of this form of accident. It was produced, at least in some of these, by a fall upon the hand with the arm extended; the radius received, under such circumstances, the weight of the body, and was forced upwards and inwards so as to get in front of the coronoid process of the ulna. When this accident occurs, the fore-arm is slightly bent, but cannot be brought to a right angle with the upper arm, nor can it be completely extended. When it is suddenly bent, the head of the radius strikes against the fore part of the os humeri, and checks the motion. The hand is in the half-supine position. If the thumb be pressed into the middle of the bend of the elbow, the head of the radius can be felt, particularly if it be slightly rotated. "On dissection, the head of the radius is found resting in the hollow, above the external condyle of the os humeri; the ulna being in its natural position. The coronary ligament of the radius, the oblique ligament, and the anterior ligament of the elbow joint, are torn through. The biceps muscle is shortened."—(On Dislocations, p. 440.)

## PLATE XVII.

THE first drawing in this plate shows the two pronator muscles of the fore-arm, and the short supinator, all the other muscles being removed, in order that the mode of action of those just named may be more clearly perceived. Having already noticed the pronator teres, and its action, it will suffice here to say, that it is assisted in the effort of turning the hand and fore-arm into the prone position by the flat square muscle placed immediately above the wrist, in close contact with the radius and ulna, No. 7; from its form and its action it is named pronator quadratus. The direction of its fibres is transverse, being extended outwards from the border of the ulna to that of the radius; when in action, they take their fixed point of attachment at the ulna, and then by drawing on the radius, they make it rotate upon the ulna as a fixed point, and so bring it and the hand into the prone position.

The short supinator muscle, which is seen here, No. 3, is the direct antagonist, as its name implies, of the pronators; its fixed points of attachment are the external condyle of the humerus, the external lateral ligament of the elbow-joint, and a ridge upon the posterior surface of the ulna. The fibres of the muscle are directed from these points downwards and forwards, lying close





Fig 1

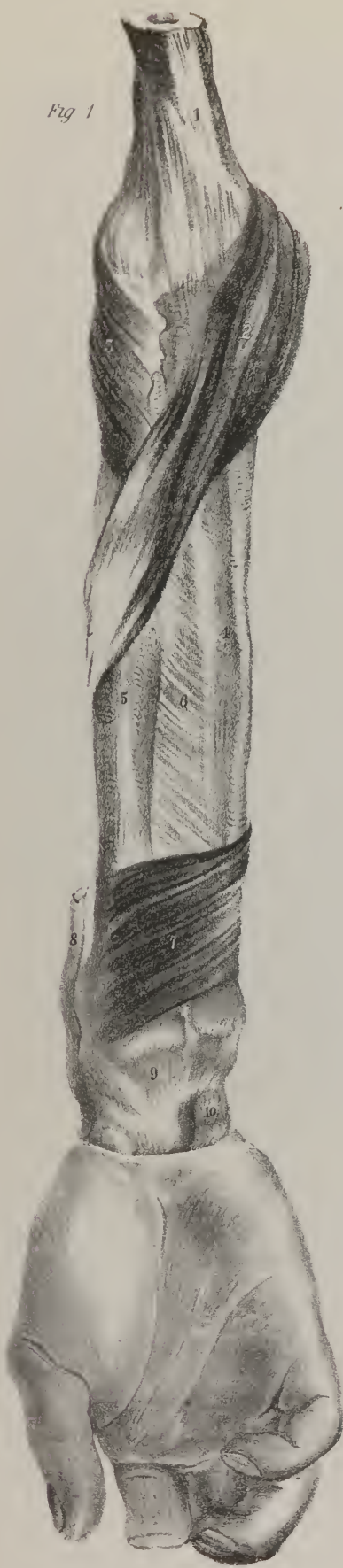

Fig 2



Fig 3



Fig 4



Fig 5



Fig 6



Fig 7

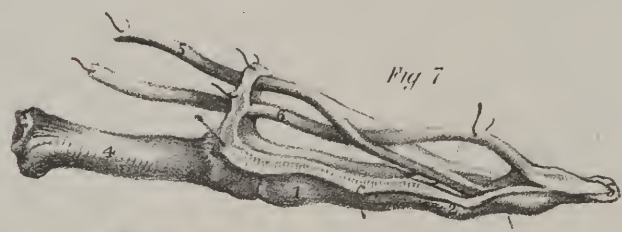

Fig 9

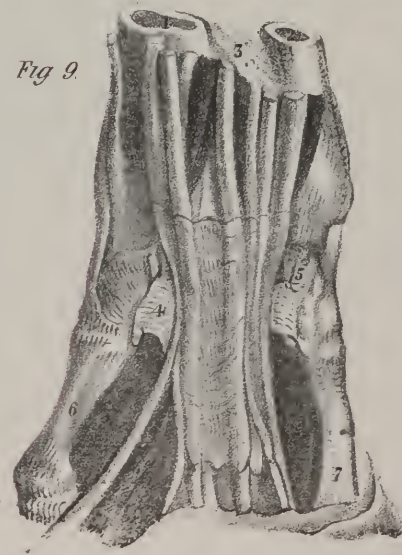

Fig 8



upon the radius, to which they become inserted along an oblique line which extends from the bicipital tubercle down to the insertion of the pronator teres. When the hand and the fore-arm are placed in the prone position, this muscle, by means of the obliquity of its fibres, and by having its fixed points of attachment above and behind, is enabled to act on the radius, making it to turn upon its axis so as to pass from the prone to the supine position. It will be obvious, even from a cursory inspection of these muscles, that they must tend to displace the pieces of the radius in cases of fracture in that bone. When the accident occurs towards the upper part, the pronator will tend to draw the lower piece forwards, whilst the supinator carries the upper fragment somewhat backwards. If the fracture occurs at the lower part, the pronator quadratus, by reason of its transverse direction, approximates the bones when both are fractured, or draws the radius to the ulna when the former alone has suffered injury; and if this tendency on the part of the muscle be not prevented by placing the limb in a proper position, and by a careful adaptation of the fractured pieces, false ankylosis will be very likely to occur.

The other figures in this plate exhibit the arrangement of the flexor tendons of the fingers, their points of attachment to the bones, their mutual adaptation the one to the other, the provisions devised for facilitating their movements by diminishing friction, and for securing their power without increasing their bulk. The flexure, or bending of the different joints of the four fingers, is effected by means of two muscles (flexor sublimis and profundus,) which are seen in plate 17, fig. 1, No. 8; fig. 2, No. 10. From each, four cords or tendons are prolonged into the palm of the hand, where they diverge a little from one another towards the fingers; two tendons proceed to each finger, one derived from the superficial, the other from the deep flexor, both being in close contact, as seen in plate 18, fig. 8. As they run along the palmar surface of the bones of the fingers, they are retained in their position by a sheath of fibrous structure, which is stretched from one border of the finger bones to the other, so as to bind them down. When the sheath is cut open and reflected, as in fig. 7, so as to bring the tendons into view, that of the deep flexor will be found to run on to the last bone of the finger, whilst the superficial one is fixed to the second bone, fig. 6, 7, No. 6. The palmar surface of the first and second bones of each finger is slightly grooved, and in the natural condition of parts that groove is converted into a canal by the fibrous sheath above noticed, which is attached along the edges of the bones, and stretched over the two tendons, fig. 8; the fibres of this sheath are closely aggregated together, opposite the central parts or bodies of the bones, but towards their extremities, where they form the joints, the fibres become thin and scattered, so as not to impede or restrict motion. The surfaces of the tendons and of the sheath are lined by a synovial membrane, which secretes a fluid necessary to keep them at all times smooth and pliant. The contrivance adopted to permit the deep flexor tendon to pass beyond

## PLATE XVIII.

- FIG. 1, No. 1. The lower extremity of the os humeri. 2. The pronator radii teres muscle. 3. The supinator radii brevis. 4. The ulna. 5. The radius. 6. The interosseous ligament. 7. The pronator quadratus muscle. 8. Part of the tendon of the supinator radii longus muscle. 9. The carpus. 10. The pisiform bone.
- FIG. 2. One of the tendons of the deep flexor muscle (flexor digitorum profundus,) detached from its connections so as to show its insertion into the last bone of the finger. No. 1. The flexor tendon. 2. The second bone, or phalanx of the finger. 3. The last bone of the finger. 4. The insertion of the tendon into its base.
- FIG. 3. No. 1. The deep flexor tendon seen at its posterior aspect. 2. The articulating extremity of the last bone of the finger.
- FIG. 4. One of the superficial flexor tendons, detached from its connections, so as to show the mode in which each of them is inserted into the second bone of the fingers, and also the fissure in its fibres, for the transmission of the deep flexor tendon. No. 1. A tendon of the superficial flexor muscle (flexor sublimis perforatus—m. fléchisseur superficiel.) 2. The fissure through which the perforating tendon is transmitted. 3. The groove upon its palmar surface upon which the perforating tendon slides. 4. The second bone of the finger into which the perforated tendon is inserted by two pointed processes. 5. The third bone of the finger.
- FIG. 5. The perforated tendon detached from all its connections, as seen at its posterior aspect. No. 1. The tendon previous to its bifurcation. 2. The groove which it presents at its posterior surface, by which it is accommodated to the deep flexor tendon. 3. The fibres of the tendon united again, after having diverged to form the fissure. 4. Their ultimate subdivision into two pointed processes at their insertion into the second bone of the finger.
- FIG. 6. The two flexor tendons as they proceed to their points of insertion. No. 1, 2, 3. The first, second, and third bones of the finger. 4. The metacarpal bone. 5. The perforated tendon of the flexor muscle. 6. The deep, or perforating tendon. 7. The same continued onwards to its insertion.
- FIG. 7. The flexor tendons as seen when the sheath is laid open which binds them down in their situation; the references are the same as in the preceding.
- FIG. 8. Gives a lateral view of the flexor tendons and of their sheath. No. 1, 2, 3. The bones of the finger. 4. The metacarpal bone. 5. The fibrous sheath which binds down the flexor tendons. 6, 7. The superficial and the deep flexor tendons.
- FIG. 9. The flexor tendons are here shown as they pass from the fore-arm into the hand through the canal formed for them by the anterior annular ligament and the carpal bones. No. 1, 2. The radius and ulna. 3. The interosseous ligament. 4. The anterior annular ligament cut through at its middle and drawn aside, the ends being held apart by hooks. 5. The pisiform bone. 6. The metacarpal bone of the thumb. 7. The metacarpal bone of the little finger. The flexor tendons form a cluster, and are in a manner compressed together under the annular ligament. Upon their surface rests a delicate synovial membrane, which is prolonged upwards and downwards a little; upon them its points of reflection are distinctly indicated.



the superficial one deserves attention. The fibres of the latter separate into two narrow bands opposite the first bone of the finger, so as to leave between them an angular fissure; they soon unite again (fig. 4, 5,) and proceed onwards, to be inserted by two pointed processes into the second bone of the finger. The deep flexor tendon, fig. 6, 7, No. 6, passes through the fissure here noticed, and is continued onwards to its insertion into the last bone. From this circumstance it is that they are called—the one, flexor perforatus; the other, flexor perforans: this, however, is not all; the superficial tendon is grooved at its posterior aspect, where it forms the fissure, for at that point it rests upon the other tendinous cord, but farther on it is grooved upon its palmar or anterior surface, so as to accommodate itself to its new relation to the perforating tendon, which at this point lies upon it.

Fig. 9 is intended to show the provision adopted for facilitating the movement of the flexor tendons, one upon the other. They are compressed closely together as they pass under the annular ligament of the wrist: in this situation, a thin synovial membrane invests them, capable of secreting a fluid which smoothens their surface; it extends upwards and downwards a little; the points of its reflection are here distinctly seen: one membrane is common to the different flexor tendons of the fingers; the long flexor of the thumb has a synovial sheath distinct from the others. In order to expose the tendons and their synovial sheath, the anterior annular ligament is cut through at its middle, and reflected; this thick strong fibrous band is stretched across from the pisiform bone, and the projecting process of the unciform to the scaphoid and the trapezium; and after being fixed into the latter, some of its fibres are continued onwards, so as to form a sheath for the flexor carpi radialis muscle. Its upper border gives attachment to the fascia of the fore-arm; the lower gives attachment to the palmar fascia; from its anterior surface towards its inner border several of the fleshy fibres of the muscles of the little finger arise, and at its outer border some of those of the thumb. This ligament forms half a ring, or canal (the remaining half being made up by the carpal bones) of an elliptic form, which transmits the flexor tendons of the fingers and of the thumb, also the median nerve.

The ulna may be dislocated by itself at the elbow joint, or at the wrist, without any displacement of the radius, notwithstanding the intimate connection which exists between these bones at their extremities, as well as along their shafts. When the sigmoid cavity of the ulna is separated from the trochlea, or pulley-like surface of the humerus at the elbow-joint, and when the radius still remains in its position, the fore-arm and hand are much twisted inwards, giving rise to a considerable degree of deformity. The arm cannot be extended completely, nor can it be bent to more than a right angle. By tracing the line of the ulna from below upwards, the olecranon will be found prominent, behind the humerus, projecting higher up than its proper position; but the radius will be found before the external condyle of the humerus. These circumstances, taken together with the twisting of the arm inwards, will determine the nature of the accident. In a case of this sort, which had remained a long time unreduced before the death of the individual, the coronoid process of the ulna was found on dissection to have been lodged in that pit at the back part of the humerus which receives the olecranon when the limb is extended; the olecranon projected considerably behind the humerus; the radius was in a manner hitched upon the external condyle of the humerus, where a new joint was formed for it, which admitted of some rotatory motion; the orbicular and oblique ligaments were ruptured, and also some fibres of the interosseous ligament. The brachialis anticus muscle was stretched over the extremity of the humerus; the triceps was of course relaxed. This dislocation may be reduced by resorting to the expedient which is practised in cases of dislocation of both bones backwards, viz. that of bending the arm over the knee, and drawing the fore-arm downwards. As soon as the coronoid process of the ulna is dislodged from the fossa into which it is thrown, the brachialis anticus muscle will direct the bone into its proper position.

The lower extremity of the ulna may be separated from the radius, and be thrown either backwards or forwards. Most writers now agree in considering this accident as a dislocation of the ulna, though it arises from a twisting of the radius, and the force which produces it is applied to the latter bone, or to the hand, causing in effect a displacement of the radius from the ulna. In cases of dislocation of the lower end of the ulna backwards, which more frequently occurs than that in the opposite direction, the fore-arm and hand are in a state of forced pronation, the shaft of the radius instead of being in a line with that of the ulna, crosses it in front at an acute angle, so that the breadth of the fore-arm at its lower part is much diminished; the fore-arm and the hand are somewhat flexed, and the tendons of the flexor muscles pressed inwards present a peculiar appearance along the inner side of the radius, and the lower end of the ulna forms a considerable prominence at the back of the hand, so that it is no longer on a level with the cuneiform bone, nor is its styloid process in a line with the metacarpal bones of the little finger. In the dislocation forwards the same sort of narrowing of the limb and crossing of the bones exist, but in a less degree; the ulna is on a plane anterior to the radius, the fore-arm and hand are necessarily placed in a state of fixed supination; the flexor tendons are pressed outwards, and the lower extremity or head of the ulna forms a prominence at the fore part of the wrist. This dislocation has been caused from a violent twist, or a wrenching movement given unexpectedly to the hand, by which it is turned outwards suddenly into the supine position. The pain, the deformity, the position of the limb, and the projection of the ulna, leave no doubt as to the nature of the accident. The dislocation backwards may be produced by a sudden wrenching or twisting movement in the opposite direction, by which the hand and fore-arm are brought into the state of forced pronation. It occurred in this way to a laundress, whose case Desault has recorded. She was engaged in wringing or twisting clothes with another woman, and whilst in the act she twisted the wrist so violently forwards as to produce the luxation of the head of the ulna back





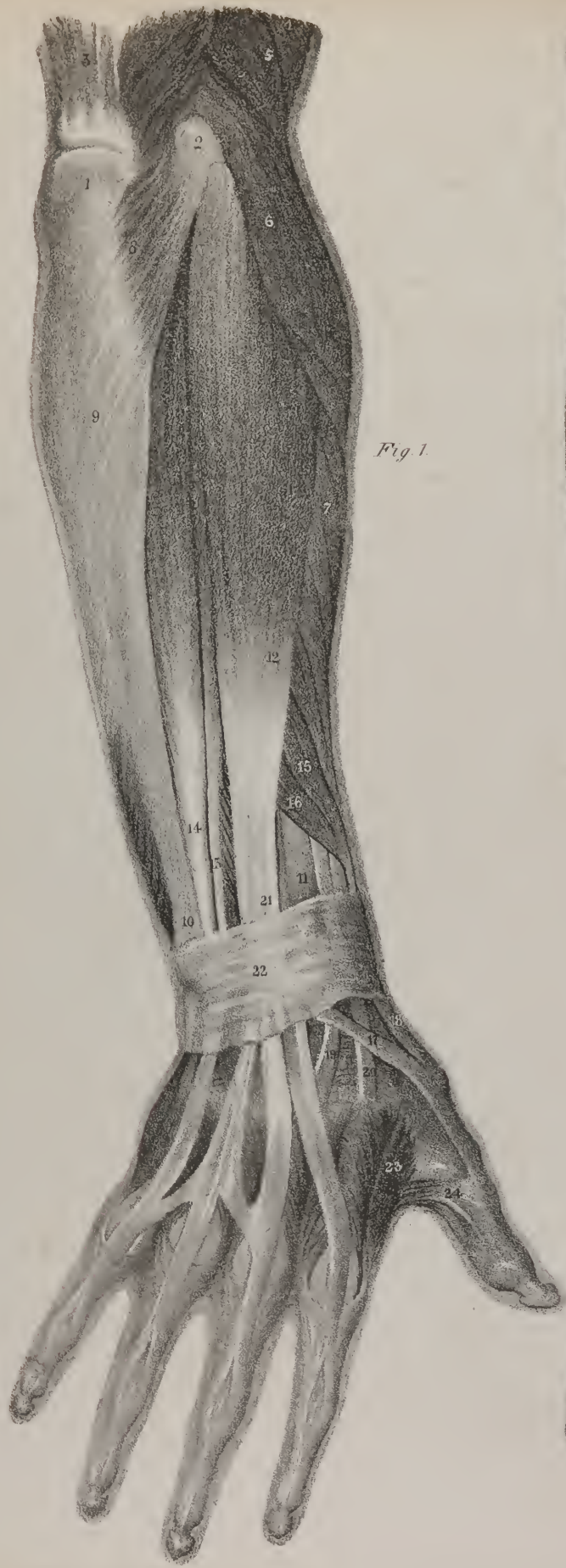

Fig. 1.

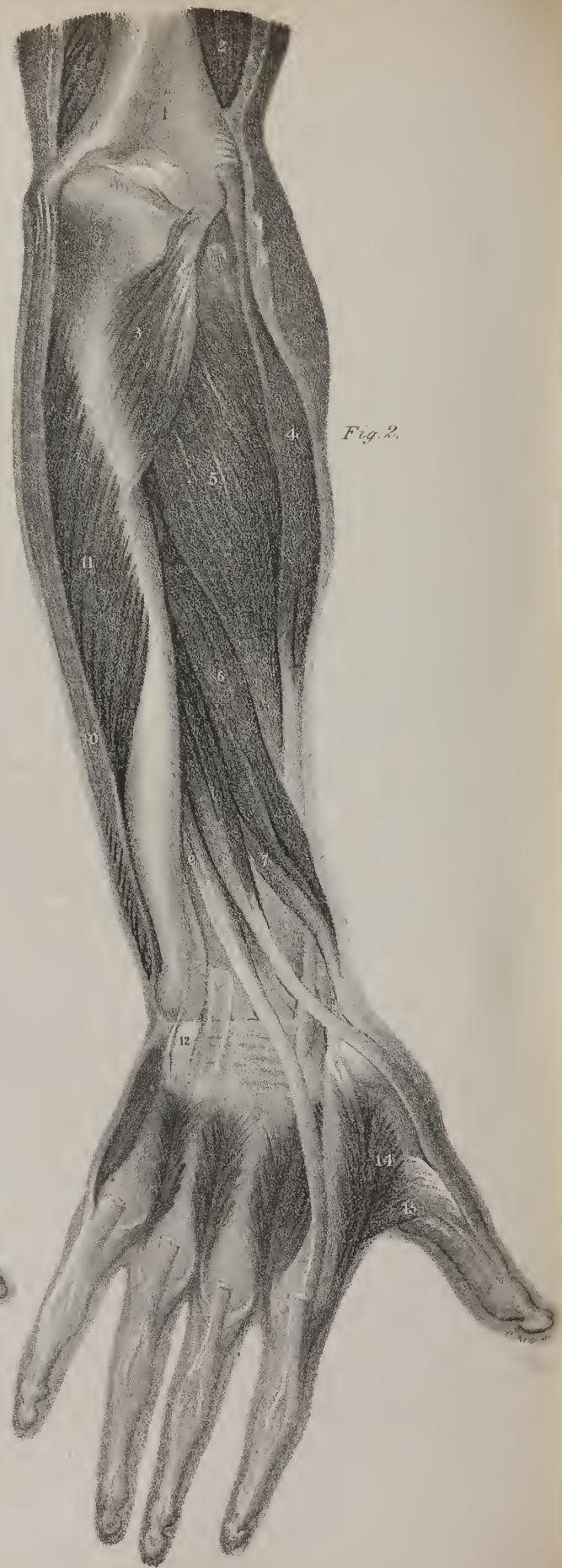


Fig. 2.



wards. The accident may also be produced by a force applied to the hand whilst falling. Boyer gives the dissection of a case of dislocation of the end of the ulna forwards, which had remained unreduced for some time before the death of the individual. In front of the lower part of the fore-arm a hard prominence was observed, and a depression at the opposite point. This attracted attention, and suggested the expediency of examining it carefully. The hand was œdematous; the flexor tendons were pressed outwards, and had become adherent to one another and to the skin; the sigmoid cavity of the radius was filled up by a new deposit, occupying the place of the cartilage which naturally covers it; the triangular fibro-cartilage which connects the radius with the ulna was torn from the latter bone, and accompanied the radius in its movement backwards; the head of the ulna lay on a plane anterior to the sigmoid cavity of the radius, and rested upon a sesamoid bone, with which it was connected by a capsular ligament. In attempting the reduction of these dislocations, it is necessary, in the first place, to lessen the pressure which the end of the ulna makes against the radius, before any attempt is made to force it in its proper position. The patient being placed sitting on a chair, an assistant steadily supports the fore-arm, and another the hand; the surgeon then placing himself at the outside of the limb, takes hold of its lower part with both hands, placing them in such a way upon it that the thumbs shall meet at the interosseous space, and at that side of it towards which the dislocation has occurred, viz. in front, where the dislocation of the ulna has taken place forwards, and *vice versa*. He then makes an effort to draw the bones in opposite directions, as if with a view to separate them from one another; and as soon as he finds them to give way a little, the assistant who holds the hand endeavours to turn it into the supine position, in the case of dislocation backwards, whilst the surgeon presses the head of the bone with both his thumbs forwards. When the bone is dislocated forwards, the same plan is followed; the movements, with a view to its restoration, being made in the opposite direction.

The radius and ulna may be displaced from their connection with the carpal bones in either of four directions, viz. backwards, forwards, or laterally to either side. The first two occur much more frequently than the others, which is partly owing to the circumstance that the extent of articulating surface is less from before backwards than from side to side, but chiefly because the greater number of efforts which we make, tend to throw it backwards or forwards, and not inwards or outwards; owing to this latter cause, and also to the extent of the articular surfaces in the transverse direction, the lateral dislocations are almost always incomplete. When in falling, a person puts out his hand to save himself, and strikes with the palm against any resisting body, the

## PLATE XIX.

The first and second planes of muscles, situated at the back of the fore-arm and hand, are seen in these drawings. The outline of the limb is traced by a line indicating the section of the skin, with a view to render its appearance more natural.

- FIG. 1, No. 1. The olecranon process of the ulna. 2. The external condyle of the humerus. 3. The triceps extensor muscle, (its tendon into which the fleshy fibres are seen to pass obliquely backwards.) 4. Part of the flexor muscles—the biceps and brachialis anticus. 5. The long supinator muscle, (supinator radii longus.) 6. The long radial extensor muscle, (extensor carpi radialis longior.) 7. The short radial extensor muscle, (extensor carpi radialis brevior.) 8. The anconeus muscle. 9. The internal or ulnar flexor muscle of the wrist, (flexor carpi ulnaris:) its attachment by aponeurotic fibres along the inner border of the ulna is here shown. 10. The lower part of the ulna. 11. The lower part of the radius. 12. The common extensor muscle of the fingers, (extensor digitorum communis.) 13. The extensor muscle of the little finger, (extensor digiti minimi.) 14. The inner or ulnar extensor muscle of the wrist, (extensor carpi ulnaris.) 15. The long abductor muscle of the thumb, or the extensor of its metacarpal bone, (extensor ossis metacarpi pollicis.) 16. The short extensor of the thumb, or the extensor of the first phalanx, (extensor primi internodii pollicis, seu, extensor minor pollicis manus.) 17. The tendon of the long extensor of the thumb, (extensor major pollicis manus,) in the fore-arm it is covered by the common extensor muscle of the fingers. 18. The tendons of the two muscles of the thumb (15, 16) running together along the outer border of the wrist. 19. The tendon of the short radial extensor at its insertion into the third metacarpal bone. 20. The tendon of the long radial extensor muscle at its insertion into the second metacarpal bone. 21. The tendons of the extensor muscle of the fingers as they are passing down towards the back of the wrist. 22. The posterior annular ligament of the wrist stretched over the extensor tendons, and binding them down in their proper situations. 23. The abductor muscle of the fore-finger. 24. The insertion of the abductor muscle of the thumb.
- FIG. 2, No. 1. The lower part of the arm-bone—os humeri. 2. The posterior fibres of the brachialis anticus muscle brought into view by the removal of the triceps extensor, as seen in fig. 1, No. 3. 3. The anconeus muscle. 4. The short radial extensor muscle; the long radial extensor, and the long supinator, as seen in fig. 1, No. 6, 7, being removed in order to show it more fully. 5. The short supinator muscle, (supinator radii brevis.) 6. The long abductor of the thumb, or the extensor of its metacarpal bone. 7. The extensor of the first bone (phalanx) of the thumb. 8. The long extensor of the thumb, or the extensor of its second bone, (phalanx.) 9. The extensor of the index finger. 10. Part of the flexor ulnaris muscle seen arising from the inner condyle of the humerus, and running along the inner border of the arm to reach the fore part of the wrist: its origin from the olecranon process and its aponeurotic attachment along the inner border of the ulna are removed, in order to bring into view No. 11, the deep flexor of the fingers, the fibres of which are seen attached along the inner side of the ulna. 12. A small part of the tendon of the extensor carpi ulnaris muscle, left at its insertion into the fifth metacarpal bone. Close to it is seen the groove which transmits the tendon of the extensor of the little finger. 13. The insertion of the adductor muscle of the thumb. 14. The external origin of the abductor muscle of the fore-finger—between it and the other part which is attached along the metacarpal bone of the fore-finger, is seen an angular interval, which transmits the radial artery as it passes to the palm of the hand.

rounded surface formed by the bones of the carpus is made to slide from behind forwards, so as to press against the anterior ligament of the wrist joint. If the force be considerable, the ligament will give way, and the carpal bones will be pressed forwards, so as to get before the lower extremity of the radius. In this case the hand inclines backwards, being in a state of unnatural extension: but the fingers are flexed. The carpus forms a marked projection at the fore part of the wrist, whilst at the back part there is a transverse depression or crease, corresponding with the lower end of the radius. The projection of the carpus renders the flexor tendons tense, and gives rise to the bending of the fingers. If the force of the fall is by any circumstance made to act upon the back of the hand, then the carpal bones will be made to glide from before backwards upon the articular surface of the radius, so as to press against the posterior radio-carpal ligament, and to rupture it. The carpus is thus thrown behind the bones of the fore-arm, constituting the dislocation backwards. In this case the hand, or rather the metacarpus, is drawn forwards or flexed, whilst the fingers are in the extended position. The carpus is very prominent at the back part of the joint, whilst at its palmar aspect there is a transverse depression or crease, corresponding with the lower border of the radius and ulna; the projection of the carpus forces back the extensor tendons, and renders them tense. There is seldom much difficulty in reducing these dislocations, and the mode of proceeding is the same, no matter in what direction the displacement has occurred. The fore-arm is placed in the flexed position, an assistant takes hold of the upper arm firmly with both hands just above the elbow, the surgeon then seizes the patient's hand and makes a steady extension, the assistant keeping a counter-extension, so that the bones of the fore-arm and hand are drawn in opposite directions. As soon as they cease to overlap, the one the other, the muscles will give the displaced part its proper direction, and draw it into its natural position.

## PLATE XX.

The drawings in this plate give different views of the hand, the skin and fascia being removed in order to exhibit the muscles more distinctly.

FIG. 1. The back of the hand.

No. 1. Part of the ulna. 2. The lower part of the radius. 3. The posterior annular ligament of the wrist joint. 4. The long abductor muscle of the thumb. 5. The extensor of the first phalanx of the thumb. 6. The tendon of the extensor of the second phalanx of the thumb. 7. The tendons of the common extensor muscle of the fingers, (extensor communis digitorum.) 8. The tendon of the extensor muscle of the little finger. 9. The tendon of the extensor ulnaris muscle. 10. The tendon of the long radial extensor muscle, (extensor carpi radialis longior,) at its insertion into the second metacarpal bone. 11. The tendon of the short radial extensor, (extensor carpi radialis brevior,) at its insertion into the third metacarpal bone. 12. The first dorsal interosseous muscle. The other three muscles of this name are seen in the greater part of their extent in the interstices between the extensor tendons.

FIG. 2. The muscles of the palm of the hand as seen when the palmar fascia is removed.

No. 1. Part of the fascia of the fore-arm. 2. The tendon of the flexor ulnaris muscle. 3. The tendon of the flexor carpi radialis muscle. 4. The palmaris longus. 5. The palmaris brevis. 6. The abductor muscle of the little finger. 7. The short flexor of the little finger, (flexor brevis minimi digiti.) 8. The short abductor muscle of the thumb. 9. The short flexor muscle of the thumb. 10. The insertion of the opponens pollicis muscle along the margin of the metacarpal bone of the thumb. 11. The tendinous sheath which binds down the tendon of the long flexor muscle of the thumb. 12. The first dorsal interosseous muscle, called also the abductor of the index finger. 13. Part of the adductor muscle of the thumb. 14. Is omitted. 15. The first lumbricalis muscle. The other muscles of this name are seen passing forwards from the flexor tendons towards the margins of the first bones of the fingers, and becoming tendinous as they are inserted into the edge of the extensor tendon of each finger at its radial border. 16. The commencement of the fibrous sheath which binds down the flexor tendons.

FIG. 3. The second plane of muscles in the palm of the hand.

No. 1. The pisiform bone. 2. The lower extremity of the radius. 3. The anterior annular ligament of the wrist joint. 4. The origin of the short abductor muscle of the thumb. 5. Its insertion, the intervening part being cut away in order to expose the subjacent muscle. 6. The short flexor muscle of the thumb. 7. The opponens of the thumb. 8. The tendon of the long flexor muscle of the thumb passing on to its insertion into the base of its second phalanx. 9. The adductor muscle of the thumb. 10. The abductor of the index finger, or first dorsal interosseous muscle. 11. The abductor muscle of the little finger. 12. The short flexor of the little finger, (flexor brevis digiti minimi.) 13. The tendons of the deep-seated flexor muscle of the finger, (flexor profundus perforans,) passing on to their insertions into the last phalanges of the fingers. To expose these, the tendons of the superficial flexor muscles are cut across as they emerge from under the annular ligament of the wrist, and also opposite the first joints of the fingers, and the intervening part taken away. This brings into view the deep flexor tendons in the palm of the hand, and also their accessories, viz. the four lumbricales, which are four tapering fasciculi that arise from the tendons of the flexor muscle, and proceed forwards to be inserted into the borders of the extensor tendons.

FIG. 4. Shows the third plane of muscles in the palm of the hand. The flexor muscles and their tendons, and the superficial muscles of the palm of the hand, are removed in order to bring those which are deep-seated into view.

No. 1. The pronator quadratus muscle. 2. The opponens muscle of the little finger. 3. Part of the tendon of the flexor carpi radialis muscle. 4. The tendon of the flexor carpi ulnaris muscle. 5. The opponens muscle of the thumb. 6. The sheath for the tendon of the flexor longus pollicis muscle, which partly conceals the tendon of the broad triangular muscle (adductor pollicis) converging towards it from the metacarpal bone of the middle finger. 7. Part of the first dorsal interosseous muscle. 8. The first palmar interosseous muscle. 9. The second dorsal interosseous muscle. 10. The third dorsal interosseous muscle. 11. The second palmar interosseous muscle. 12. The fourth dorsal interosseous muscle. 13. The third palmar interosseous muscle. 14. Some of the fibres of the sheaths of the tendons left on in order to retain the tendons in their positions; they are drawn a little too strong.



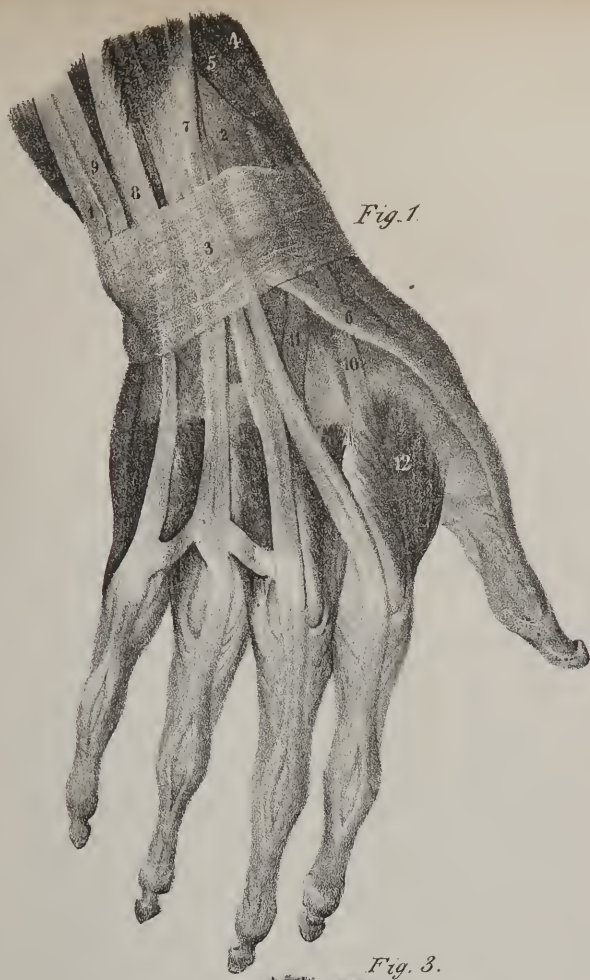


Fig. 1.

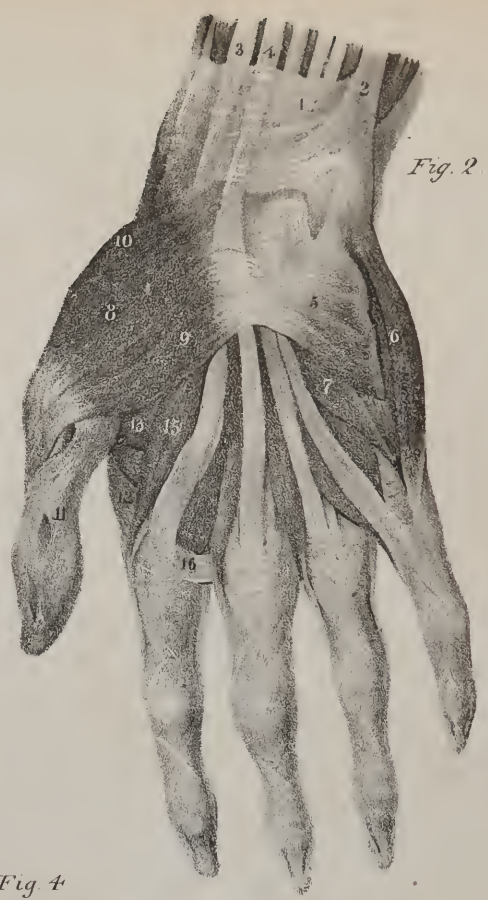

Fig. 2.

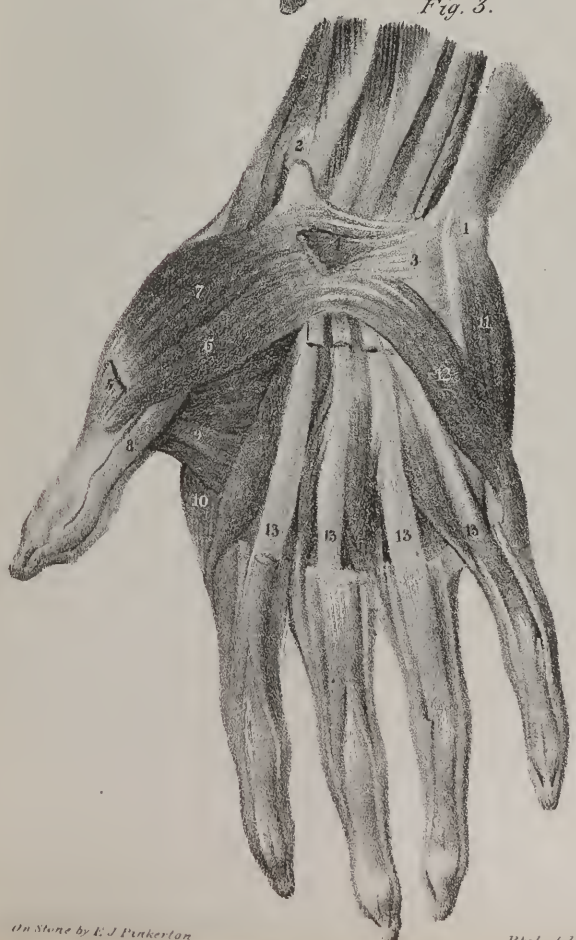


Fig. 3.

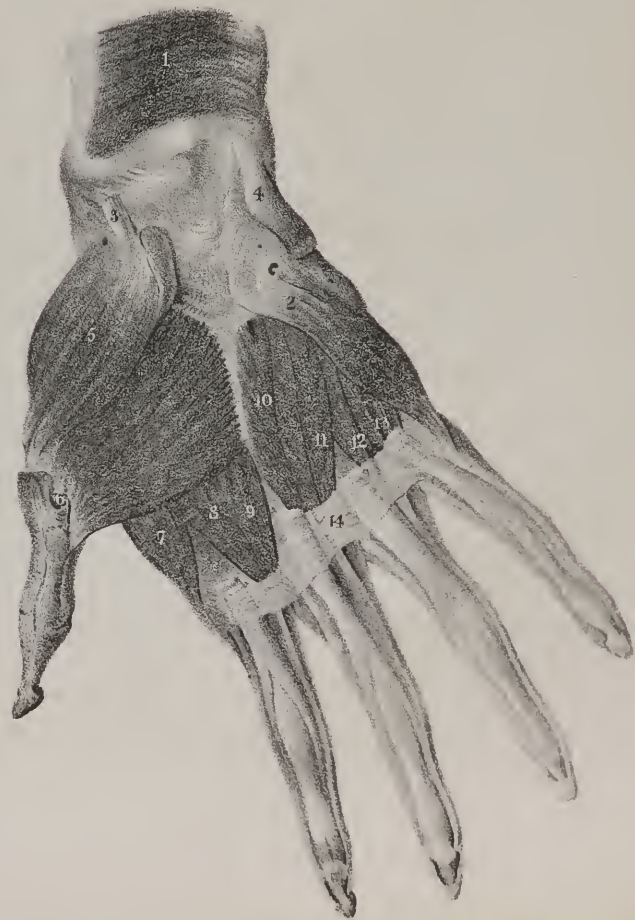


Fig. 4.





In cases of dislocation inwards, the carpus forms a projection towards the inner side of the joint, beneath the inferior extremity of the ulna; the outer edge of the hand is inclined towards the radial border of the fore-arm, as if in the state of forcible abduction. In the dislocation outwards, the carpus becomes prominent beneath the lower extremity of the radius, and the inner border of the hand is drawn towards the ulnar side of the fore-arm, so as to be placed in a state of forced adduction. These displacements being incomplete, are easily reduced; the plan above indicated in the cases of the other two dislocations will suffice for them.

## PLATE XIX.

THE muscles placed at the back part of the fore-arm and hand are here exhibited, the skin and fascia which bind them down having been removed in order to show more distinctly their relative position and points of attachment. They are divided into two sets, one of which is superficial in its entire extent, and overlays the others, so as wholly or in part to conceal them. The superficial set consists of the anconeus, the common extensor of the fingers, the extensor of the little finger, and the inner or ulnar extensor muscle. The deep-seated set consists of the long abductor and the two extensors of the thumb, the extensor of the index finger, and the short supinator muscle.

At the back part of the elbow is seen a small flat triangular muscle, No. 8, fig. 1; No. 3, fig. 2; it is termed anconeus from its position. It commences by a narrow tendon attached to the back part of the outer condyle of the humerus, the fibres of which are prolonged for some way along the outer border of the muscle. From these the fleshy part of the muscle arises, and the fibres of which it is composed will be seen to spread out as they proceed backwards and inwards to be inserted into the outer side of the olecranon process of the ulna, and into the posterior border of the ulna for a little way farther down; the upper fibres of the muscle are very short and nearly horizontal in their direction, but those which succeed them gradually increase in length. It is on the same plane with the triceps extensor muscle, fig. 1, No. 3, of which it often appears to be a continuation, and with which it conspires in its action upon the fore-arm, viz. in extending it so as to bring it into a right line with the humerus.

The common extensor muscle of the fingers, fig. 1, No. 12, extends from the external condyle of the humerus to the extremities of the fingers. It presents a rounded fleshy body, a narrow pointed commencement or origin, and at the middle of the fore-arm a tendinous prolongation, which soon branches out into four flat bands, which, after passing under the posterior annular ligament of the wrist, proceed along the back of the hand to reach the first joints of the fingers, over which they are continued uninterruptedly; whilst passing behind the first bones of the fingers, they receive the insertions of the interossei and lumbricales, which increase their breadth, and give them the appearance of broad aponeuroses covering the back part of the fingers. Near the second joint of each finger the fibres of the tendon appear to separate, so as to leave an elliptical interval between them; this is owing to the fact, that the fibres at the side are comparatively thick and strong, whilst the middle part is thin where it slides behind the joint, and becomes inserted into the extremity of the second bone of the finger; this arrangement of the tendon is calculated to facilitate the bending of the joint, for the knuckle is received in the interstice between the diverging fibres of the tendon. Further on, the parts of the tendon become united again into a flat band, which is inserted into the last bone of the finger; the tendon of the ring finger is observed to be connected with that of the middle one by a transverse slip, which passes from the one to the other; a similar connecting band passes off to the tendon over the little finger. In the present instance, the tendon for the little finger is but a small slip, formed of a few fibres which run along the margin of the tendon of the ring finger, and merely forms part of the oblique slip or connexion already noticed, but which here passes to the proper extensor of the little finger. This muscle is the direct antagonist of the flexors of the fingers, which are placed at the fore part of the limb, for it extends the bones of which they are composed, so as to bring them into the straight position, and when it has carried the fingers as far back as they will admit of, it can continue its action so as to extend the hand upon the fore-arm.

The proper extensor muscle of the little finger is a long and narrow slip, which lies along the ulnar border of the common extensor muscle, with which its fibres are united in a considerable part of their extent. From the external condyle it stretches down the middle of the fore-arm, and ends in a tendon, No. 13, which after passing under the posterior annular ligament of the wrist is continued over the fifth metacarpal bone, and finally, after becoming blended with the fourth tendon of the common extensor muscle, it is continued over the bones of the little finger, having the same relation and connexions with them which the other extensor tendons have, and like them it is inserted into the base of the last phalanx. The ulnar extensor muscle, No. 14, extends from the outer condyle of the humerus to the upper extremity of the fifth metacarpal bone; some of its upper fibres are attached to the fascia of the fore-arm, and an aponeurotic band between it and the common extensor muscle; and below the anconeus it also has attachments to the posterior surface of the ulna. The tendon into which its fibres run passes through a groove appropriated to it in the annular ligament, previously to its insertion into the fifth metacarpal bone, fig. 2, No. 12. This muscle, when in action, can extend the hand upon the fore-arm, and incline it towards the inner or ulnar side.

The muscles which we have here noticed, partly conceal from view those which lie immediately upon the bones and interos-

scous ligament, and which form the second plane. These are shown in their entire length in fig. 2, the superficial set being removed. The fibres of the short supinator of the radius, No. 5, represent a flat triangular plane, extended obliquely over the outer border of the radius. It has been already noticed in our comment on Plate XVIII. Immediately beneath its lower border is seen the long abductor muscle of the thumb, No. 6; its direction is obliquely downwards and outwards from the ulna, across the interosseous ligament and the radius, to both of which its fibres are attached. In this part of its extent it represents a rounded fleshy fasciculus, which at the lower part of the arm ends in a flat tendon, which after passing through a groove upon the outer border of the radius is fixed to the upper extremity of the metacarpal bone of the thumb; hence it is frequently called the extensor of the metacarpal bone. At its lower border, and partly concealed by it, is placed the extensor of the first bone of the thumb, No. 7, which is shorter and smaller than the preceding; its fibres are attached to the interosseous ligament and radius, and take the same oblique direction from above, downwards and outwards, to end in a narrow tendon which runs through the same groove in the radius that transmits the tendon of the extensor of the metacarpal bone, and is thence continued onwards to be inserted into the base of the first phalanx of the thumb. The extensor of the second bone of the thumb, No. 8, also runs an oblique course, but its tendon is separated by an interval from the preceding, and slides in a groove appropriated to itself at the back part of the radius. Its fibres arise from the middle third of the ulna and from the interosseous ligament, and the tendon in which they terminate, after passing through the groove in the radius just noticed, slides over the insertion of the two radial extensors, (fig. 1, 19, 20,) and is prolonged upon the dorsal surface of the thumb to the base of its last phalanx, into which it is inserted. Still lower down, and on the same plane, lies the extensor of the index finger, No. 9; its fibres are attached to the posterior surface of the ulna and the interosseous ligament. The tendon in which its fibres terminate will be found in the groove which transmits the common extensor muscle, and as it passes along the back of the hand it is in close contact with the band given by the common extensor to the index finger, with which it becomes identified.

The tendons of the extensor muscles, whilst running along the back of the hand, overlay and partly conceal from view some small muscles, which are deeply seated, inasmuch as they lie in the intervals between the metacarpal bones, from which circumstance they are termed the interosseous muscles. In order to bring them fully into view, the extensor muscles, with their tendons, are cut across over the first joints of the fingers, fig. 2, and removed, and the tendon of the indicator muscle is drawn slightly out of its place. There are four interosseous spaces, each of which at the dorsal aspect of the hand is occupied by a muscle. At the palmar aspect there are three, the tendons of which are here slightly seen as they are prolonged from the palm in the second, third, and fourth interosseous spaces, to be inserted into the margins of the extensor tendons. The first dorsal interosseous muscle is the largest of the set, and occupies the interval between the metacarpal bone of the thumb and that of the fore-finger; its fibres arise from the contiguous margins of these two bones, and at first appear as two bundles separated by an angular interval, but as they proceed forwards, each approaching the other, they unite and form a flat narrow muscle, and this ends in a tendon which is inserted into the base of the first bone of the fore-finger, and is also connected with the outer margin of the tendon over that finger; from its line of direction it is obvious that this muscle can draw the fore-finger away from the rest, on which account it is called the abductor of the index finger. The second and third dorsal interosseous muscles arise from the contiguous margins of the metacarpal bones, between which they lie; they also consist of oblique fibres, which converge towards a middle line; each ends in a narrow tendon, which is inserted into the margin of the extensor tendon, lying over the middle finger. These, when in action, can incline the finger laterally; the one drawing it inwards, the other outwards. The fourth dorsal interosseous muscle, similar in structure and mode of origin to the preceding, is inserted along the inner or ulnar side of the extensor tendon of the ring finger.

## PLATE XX.

THE drawings here given exhibit different views of the hand placed in the position in which it is usually examined by the anatomist. The skin and fascia are removed in order that the form, the lines of direction, and the points of attachment of the muscles may be distinctly seen. What a number of objects are here grouped together in a small space! the bones which form the substratum that gives support to the rest vary much in form and size, so do the muscles which move them, and their number is proportioned to the variety of motions which the hand can perform. In every part of the body, evidence of design and contrivance may be traced; in none is it more clearly demonstrable than in the hand, and the demonstration may be rendered more complete were we to extend our observation to the whole limb of which it forms a part. Observation shows us how well adapted it is for its different purposes and uses, and how infinitely various these are. Let us contrast it with the lower extremity: placing them side by side, we see that the parts of which they are composed, I mean the anatomical elements of which they are made up, are analogous in every particular. Just take the basis, or substratum, which gives support to the other structures,—the osseous part: laying them thus together, (fig. 1, 2,) we see that they consist of the same number of pieces, viz. the femur (*a*), and humerus (*a*\*), the two bones (*c*, *d*), of the leg, and those of the fore-arm (*c*\*. *d*\*), the different pieces in the tarsus (*e*) and

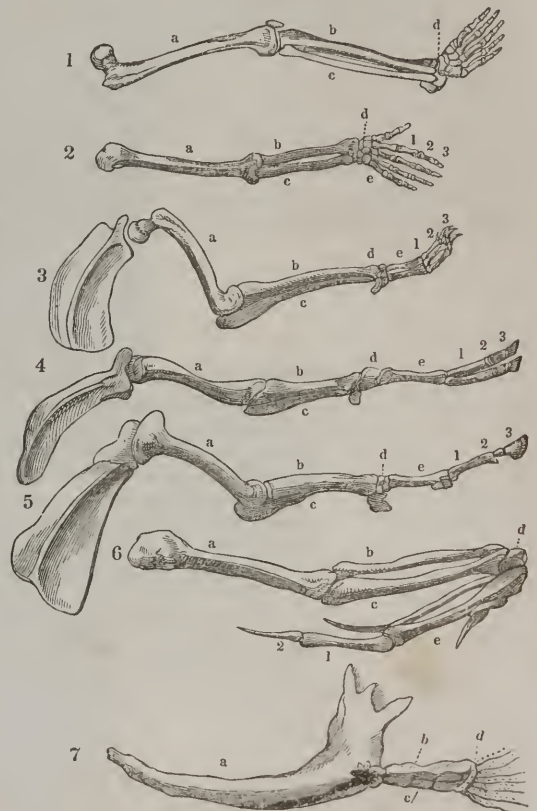


carpus ( $e^*$ ), those of the meta-tarsal row ( $f$ ), and in the meta-carpus ( $f^*$ ), and lastly those of the toes ( $g$ ), and of the fingers ( $g^*$ .) The femur, strongly made, is, at its upper part, lodged in a deep cup-shaped socket, by means of which the whole weight of the body is thrown on the limb; at its lower end it is expanded so as to increase the surface by which it rests on the leg. The bones of the leg are also firm in themselves, and closely bound together so as to admit of no motion upon one another; they rest securely on the foot, the upper bone of which is lodged in a socket, which they form. The humerus, on the contrary, is barely in contact with a superficial depression on which it moves, and so admits, at the shoulder, the utmost variety and latitude of movement; the bones of the fore-arm, too, are calculated for flexibility and motion, one rolling on the other, and both fitted with a perfect apparatus of muscles or moving powers, which, with the utmost ease and precision, turn the wrist, and guide the hand to any object to which it is to be applied. The bones, then, in arrangement and general plan, are similar, yet, by slight modifications, are fitted for totally different purposes.

The hand and the foot (2, 1,) agree in the elements of which they are composed, and in the number of them; but they are developed so differently in each, that they form totally distinct members, and serve for widely different purposes. The solid and the moveable parts in each are strongly contrasted; the pieces which compose the solid part of the foot (fig. 1,) are strong and large, those of the hand (2,) are comparatively diminutive, but the fingers, or flexible part, are largely developed, as compared with the toes. It is commonly said that this arises merely because the toes are less necessary for support and progression than the rest of the foot, whilst the fingers are more necessary for prehension and adjustment than the rest of the hand; it would be more correct to say that it is the result of a general law which pervades the whole animal kingdom, a law which establishes what may be termed a principle of compensation, by virtue of which, if any given part is increased above par, its increase is effected at the expense of some other; or, as it has been technically expressed, if the "formative effort" be strongly directed to one part, it will be less so to some neighbouring one. The arch of the foot is the more important part in reference to its general purpose of sustaining the body, the toes being obviously less so as a means of support or progression. It is just the reverse in the hand: the fingers, or flexible part, being the more important one, in reference to the various purposes which the hand has to perform, and therefore they are proportionally evolved or developed.

Again, when we direct our attention to a single part of the hand, viz. the thumb, and contrast it with the corresponding part of the foot, we see how a new instrument is produced by a mere modification of its constituents. The bones, the muscles, vessels, and nerves of the thumb, and of the great toe, are respectively analogous, yet how different are the purposes which they are intended to fulfil? The first bone of the toe is thick and strong, it ranges with those of the other toes, and admits of little more motion than they do, as it is one of the chief points on which the weight of the body is thrown in its different movements. The first bone of the thumb admits of every variety of motion; it does not range with those of the fingers, from which arises its most striking peculiarity, that of being brought into opposition with the rest. In its various uses it is not merely a part of the hand,—it is rather a new member, or a supplemental hand. Thus we see what a variety of results are obtained from a few materials, and how, by a modification in the form, proportion, and arrangement of the same constituents, new instruments are produced,—new powers created.

But let us not confine our attention to the structure of the human frame, let us glance at that of other animals, still for illustration, confining our attention to the instance already selected, viz. the upper or anterior extremity: take that in one of the lower animals, say the cat. Ordinarily it sustains the body, therefore, is an instrument of support; its parts move on one another, and, when acted on by the muscles, it becomes an instrument of progression; it is terminated by moveable phalanges, which may be flexed or extended, and so it becomes a means of prehension; finally, the last phalanges, which are usually turned back, may be pushed forward to a line with the rest, protruding the sharp nails with which they are armed, and so it becomes an instrument of attack or defence. In the monkey this limb serves for support and progression, but chiefly for the prehension of objects; it is not well calculated for defence or attack. In the dog and in hoofed animals it serves for support and progress; in birds for progression only; whilst in fishes it merely assists in progression, as that is effected chiefly by the movement of the hinder part of the body. Now, in the anterior limb in all these animals, we



find the same bones, muscles, nerves, vessels, &c.; and all the variety of purpose which they serve is attained by modification in the size, form, and mode of connexion of these components.\* We often speak of the simplicity of Nature's works, here that simplicity is fully exemplified. These limbs consist of the same parts,—the materials are identical; yet, as we have seen, they execute different functions, and so may be considered as different organs, which is sufficiently indicated by the different names by which they are popularly known. And all this is effected by one portion being largely developed, a contiguous one being less so,—some being evolved to a maximum, whilst others are left rudimentary, as if Nature were sparing of her materials, yet profuse in the results she would elaborate out of them: and this is what we really mean when we speak of the simplicity of Nature's works, as contrasted with the grandeur and comprehensiveness of her designs.

When we have inspected attentively the leading divisions of the animal kingdom, and examined the structure of its different orders, say from the fishes up to the mammalia, we see that, though variously modified, the proximate or anatomical constituents of the members, (as in the instances cited,) and also of the trunk, are analogous. Now, whilst we pass from link to link in this great chain, if the mind dwells sufficiently long on each of the natural families which it connects to retain an impression of its fundamental form, omitting the minor traits which give to each its individuality; if, in a word, as it passes from the lowest to the highest, it retains that which is essential in the form and composition of each, abstracting its peculiarities, it will gradually ascend to the contemplation of a form, which will be a type, or representative of all, divested of the peculiarities which mark each of them. Having thus ascended to the contemplation of a type, or abstract form, which may be conceived to contain within it the components, or anatomical elements, of each of the great classes (fishes, reptiles, birds, mammalia,) and retaining it for a while before the mind's eye, so as to fix the impression of it, we may readily reverse this process, and proceed to evolve the model which is thus present to the mind, and give to each limb, as well as to the body, such a degree of expansion or development as will make it represent the form which it presents in a fish, a reptile, a bird, or a quadruped. Thus, for example, the structures of the anterior extremity whilst in their rudimental state, are found aptly enough at the bottom of the scale in form of the fishes' fin. (In fig. 7, *a* represents the bones of the shoulder; *b*, *c*, the radius and ulna; *d*, the fin-rays, being so many digital processes.) We find the osseous structure very perfect in the limbs of the amphibia. In the ophidian reptiles it does not exist, but in the sauria and batrachia it is variously modified, to suit the habits of these animals. In the class of birds it is developed considerably to form the wing; fig. 6 shows part of the wing of a bird; *a*, the humerus; *b*, the radius; *c*, ulna; *d*, carpus; *e*, metacarpus; 1, 2, the great finger,—its two phalanges. And the same elements, by receiving their appropriate adjustment, are made to represent the limb as it is in the solidungula, (fig. 5;) in the bisulca, (fig. 4;) in the feline tribe, (fig. 3;) and finally the hand of man, (fig. 2.) Having thus sketched a part in each, we may, by a similar process, complete the figure by following it out through the posterior extremity, and then the body, spine, and head; the parts of the skull being analogous to vertebræ. It is in this way only that we can form any adequate conception of the plan or groundwork from which the different varieties of animal forms are deduced. For, when we look over a menagerie, or a great assemblage of animals, our first impression is that of variety and discrepancy; but, on a closer inspection, we find that some are nearly allied, and form groups or families, marked by certain

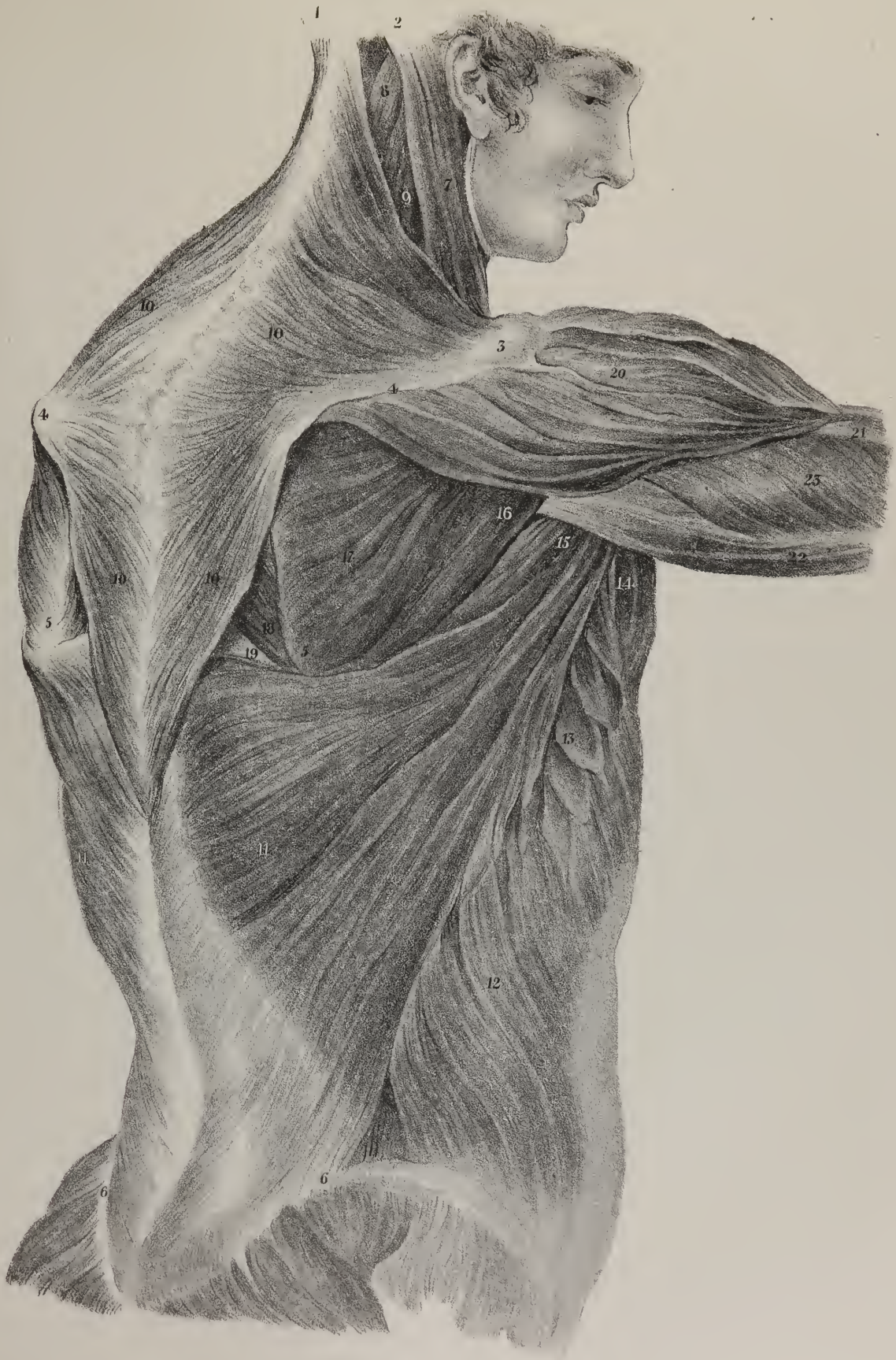
## PLATE XXI.

This drawing exhibits the first layer or plane of muscles placed along the back and side of the body; the skin and the cellular tissue being removed in order to show the direction of the fibres in each muscle, and their points of attachment.

No. 1. The protuberance of the occipital bone. 2. The mastoid process of the temporal bone. 3. The acromion process of the right scapula. 4, 4. The spinous processes of the two scapulae. 5, 5. The base of each scapula. 6, 6. The margins of the iliac bones. 7. The sterno-cleido-mastoid muscle. 8. Part of the splenius as seen between the margin of the preceding and of the trapezius. 9. Part of the levator scapulae. 10, 10. The trapezius muscle of each side; and as it is of very considerable extent, forming a flat angular plane which extends from the occiput to the spinous process of the last dorsal vertebra; the numbers 10, 10, are repeated in the lower part of it. 11, 11. The latissimus dorsi muscle of each side, which is also of considerable size. 12. The external oblique muscle of the abdomen. 13. Part of the border of the great serratus muscle, presenting angular points interposed between the fibres of the external oblique muscle. 14. A part of the lower border of the great pectoral muscle where it forms the anterior fold of the axilla. 15. The *teres major* muscle. 16. The *teres minor* muscle. 17. The *infra-spinatus* muscle. 18. A small part of the greater rhomboid muscle. 19. Some of the fibres of the *longissimus dorsi* muscle which are deeply seated, and exposed only when the scapula is drawn forwards, as here exhibited. 20. The *deltoid* muscle. 21. Part of the upper extremity of the *brachialis anticus* muscle where it arises below the insertion of the *deltoid*. 22. The long head of the *triceps extensor* muscle of the arm. 23. Its external or middle head.

\* The expression in the text must be taken with some limitation. For even in the fore foot of a monkey, so analogous as regards structure in other respects to the human hand, there is one very important muscle wanting, which belongs to man, the *flexor longus pollicis*. It is this muscle which, acting separately, places the thumb in opposition to the fingers, so that a grasp may be made between them, forming of the human hand the perfect instrument that it is. In the monkey and other animals endowed with clavicles, the thumb moves like an ordinary finger, and the two fore-extremities must be opposed to each other to enable them to perform perfectly the act of prehension.—J. P.















peculiarities and natural affinities. But we could never have supposed that any such uniformity of plan ran through them all, unless we had examined their intimate structure and composition. Then it is that we readily see the analogies by which they are associated, and trace the unity of design which runs through the whole scheme.

The muscles of the palm of the hand are necessarily numerous, owing to the variety of the movements which the hand and fingers are required to perform. Were we to arrange them according to their actions and uses, we should have a group consisting of flexors, another of adductors, a third of abductors; it is, however, found much more convenient to arrange them according to the positions which they occupy. Viewed in this way, they admit of being divided into three sets, those of the thumb, of the little finger, and those which occupy the intervening space in the middle of the palm. The palmar muscles of the thumb form that fleshy mass which, in popular language, is called the ball of the thumb; they are four in number, viz. the abductor, the opponens, the short flexor, and the adductor. The abductor is a flat thin muscle, fig. 2, No. 8; it is placed immediately under the skin, extended obliquely from the anterior annular ligament of the wrist and the scaphoid bone to the outer edge of the first phalanx of the thumb at its base; it is broader at its origin than at its insertion, as it gradually narrows to a short tendon near the latter point. It is covered merely by the skin and a thin membrane, derived from the palmar fascia.

The opponens muscle of the thumb, fig. 3, No. 7, is thicker than the preceding, under which it lies, so that in order to bring it into view, the abductor must be detached at its origin and reflected downwards, or the middle part may be removed and the attachments allowed to remain, as in the drawing before us, fig. 3, Nos. 4, 5. The opponens will then appear a small triangular muscle, extending from the outer part of the annular ligament and the surface of the trapezium bone to the metacarpal bone of the thumb, into the outer border of which its fibres are inserted along its entire length. It is aponeuretic at its extremities, and fleshy along its middle.

The short flexor muscle, fig. 3, No. 6, arises from the lower border of the annular ligament, and from the reflected part of it which binds down the tendon of the flexor carpi radialis; some of its fibres are also attached to the trapezium bone. The fibres of the muscle proceed outwards and forwards, gradually narrowing to a short tendon, which, after being attached to the external sesamoid bone, becomes fixed to the base of the first phalanx of the thumb. The contiguous fibres which arise from the os magnum, and are inserted into the internal sesamoid bone, are usually considered a part of the short flexor; we here join them to the adductor.

The adductor muscle of the thumb, fig. 4, No. 6, is broad and triangular in its form, representing a flat plane of fleshy fibres, placed deeply under cover of the preceding muscles, a part only of the anterior fibres projecting before them, fig. 3, No. 9. It arises from the anterior border of the third metacarpal bone, from the os magnum and the trapezoid bone, also by a few fibres from the trapezium. The anterior fibres pass transversely outwards, those higher up become more and more oblique, so that they converge, and become narrow towards their insertion, which is effected by means of a narrow tendon, which, after being connected with the internal sesamoid bone, is fixed to the inner side of the first phalanx of the thumb; the outer and upper part of the muscle is usually considered as forming a part of the flexor brevis.

*Actions.*—On taking a general view of the muscles of the thumb, which are eight in number, we perceive that, though all of them are attached to the three bones, they come from three different situations, and necessarily differ much from one another in form and length, as well as in direction of their fibres. Three of them lie along the back part of the fore-arm and hand, Plate XIX. fig. 2, Nos. 6, 7, 8; one will be found at the front of the fore-arm, part of which is seen in plate XX. fig. 3, No. 8; the remainder being the group of short muscles, which are shown here in Plate XX. figs. 2, 3, 4; the actions and powers of each of these muscles will readily be understood by considering their points of attachment, and the direction of their fibres. It should be recollected that there are three pieces of bone in the thumb, each of which is straightened or bent by appropriate muscles; that all are joined together so as to admit of four separate movements, for they may be drawn backwards, forwards, inwards, outwards, which movements are technically called extension, flexion, adduction, abduction. Now there are three extensor muscles, one for each bone, viz. the extensor of the metacarpal bone, that of the first and the second phalanx. These are the muscles above referred to as being placed at the back of the limb; their antagonists in action, the flexors, are also three in number, and lie at the palmar aspect of the hand. The opponens of the thumb may be considered a flexor of the metacarpal bone, the short flexor bends the first phalanx, and the long flexor the second. There remain the abductor and adductor, which are also opposed to one another in situation as well as in action; one being superficial and external, fig. 2, No. 8; whilst the

## PLATE XXII.

This drawing is intended to exhibit the external oblique muscle of the abdomen, and its different points of attachment; the skin and the fascia are removed, so as show its relations at its origin to the pectoral, serratus, and latissimus muscles.

No. 1. The sternum. 2. Linea alba. 3. Umbilicus. 4. The symphysis of the pubes. 5. The crest of the ilium. 6, 6. The lower part of the pectoral muscles. 7. Part of the latissimus dorsi. 8. Part of the great serratus muscle. 9. The external oblique muscle of the abdomen, (m. obliquus externus abdominis.)

other is deep-seated and internal, fig. 4, No. 6. The former is evidently fitted to draw the thumb away from the other fingers, in which it is powerfully assisted by the extensor of the metacarpal bone, which is frequently called from this circumstance the long abductor; the latter, as its name implies, and as is obvious from the number and direction of its fibres, draws the thumb towards the other fingers. If these moving powers be made to act successively upon the osseous pieces under their control, they will make the thumb move round as if in a circle, or perform what is technically termed circumduction; in which movement it describes a cone, whose summit is at the carpal articulation, whilst its base is represented by the line which its distal extremity traverses.

The four tapering fleshy fasciculi which are seen in fig. 2 and fig. 3, attached to the deep-seated flexor tendons, are called lumbricales, from some resemblance in their form to an earth-worm; they may be considered as appendages to the tendons of the deep muscle just named. The first lumbricalis arises from the outer border of the tendon, which goes to the fore-finger; the second from that of the middle finger; the third from the contiguous margins of the tendons going to the middle and ring-fingers; and the fourth from the latter and that of the little finger. As they proceed forwards they become round and tapering, and each ends in a tendinous process, which is fixed to the outer edge of the extensor tendons, lying over the fingers with which they correspond; they appear to assist in flexing the fingers by acting on their first joint.

*Muscles of the Little Finger.*—The fleshy mass placed along the inner border of the hand consists of four muscles, three of which act on the little finger, the other being merely cutaneous. The cutaneous muscle is that by which we are enabled to constrict and pucker the skin upon the inner border of the palm of the hand. It consists of a flat and very thin plane of fleshy fibres, which run obliquely inwards, from the anterior surface of the annular ligament and of the palmar fascia, and become fixed into the skin, along the inner border of the palm of the hand, for about an inch in length; it is usually called palmaris brevis, fig. 2, No. 5. The abductor muscle of the little finger, fig. 2, No. 6, lies along the inner edge of the hand; it is long and somewhat compressed, broader at its middle than at its extremities; it arises from the pisiform bone and from the tendinous fibres, which connect it with the annular ligament: its muscular fibres as they proceed forwards gradually end in a narrow tendon, which becomes attached to the inner border of the base of the first bone of the little finger, where its fibres are connected with those of the flexor brevis.

The short flexor of the little finger, fig. 2, No. 7, fig. 3, No. 12, varies much in form and size, and sometimes does not exist. It arises by short tendinous fibres from the annular ligament at its anterior border, and from the hook-shaped bone at the wrist, from whence it proceeds obliquely forwards to be inserted into the base of the first phalanx of the little finger. The opponens of the little finger, fig. 4, No. 2, is concealed by the preceding muscles, which must be removed in order to bring it into view; it may be considered an adductor of the fifth metacarpal bone, as the opponens of the thumb is of the first, fig. 4, No. 5. It arises from the hook-shaped bone and from the annular ligament of the wrist, and is inserted into the inner border of the fifth metacarpal bone, its fibres gradually spreading out as they proceed to their points of attachment. The names of these muscles sufficiently indicate their actions.

*The Interosseous Muscles.*—These are divided into two groups, one of which is seen at the dorsal aspect of the hand, between the metacarpal bones; from which circumstance they are called the dorsal interossei. They are four in number, and are shown in Plate XIX. figs. 1, 2; also in Plate XX. fig. 1. We have already described them in pp. 39, 40.

When the flexor tendons are removed, as in fig. 4, Plate XX. the deep-seated muscles of the palm of the hand are brought into view; all the interossei are seen, for the dorsal group dip downwards and become perceptible in the palm. Nos. 7, 9, 10, 12, mark the dorsal group, whilst Nos. 8, 11, 13, indicate the palmar set. The first palmar interosseous muscle, No. 8, is a thin, compressed, fleshy fasciculus, which rests upon the second metacarpal bone, at its inner side; it ends in a narrow tendon, which is fixed into the expansion of the extensor tendon over the fore-finger, at the inner side of the base of its first phalanx. The second palmar interosseous muscle, No. 11, lies along the fourth metacarpal bone at its outer border; it is inserted into the outer border of the extensor tendon, covering the ring-finger. The third, No. 13, lies upon the outer side of the fifth metacarpal bone, and is inserted into the corresponding border of the extensor tendon. The tendons of these muscles are also connected with the

## PLATE XXIII.

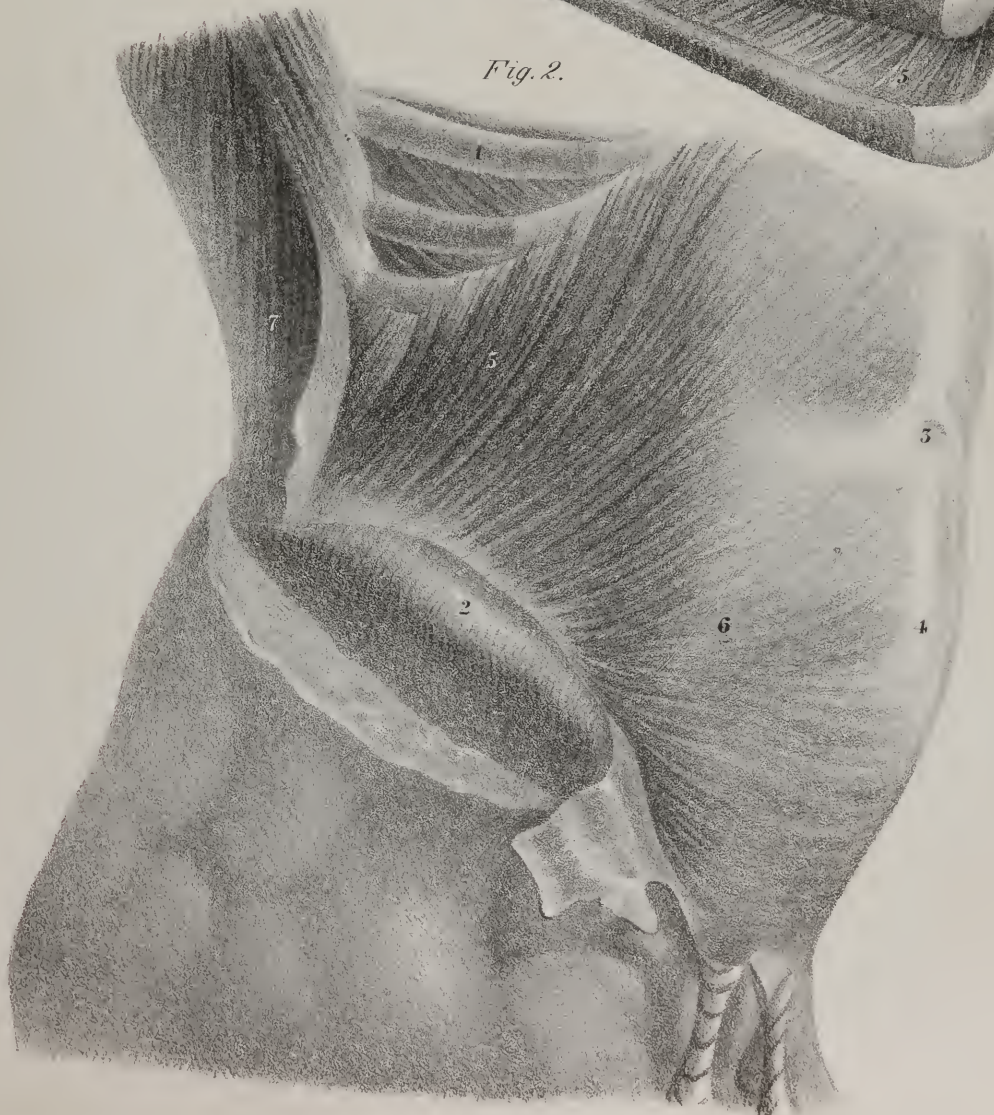
FIG. 1. Shows the two planes of intercostal muscles.

No. 1. The dorsal vertebræ. 2, 2. The heads of the ribs attached to them. 3, 3, 3. Ribs. 4. The external plane of intercostal muscle, the direction of its fibres being downwards and forwards. 5, 5. The internal plane of intercostal muscles, the fibres being directed downwards and backwards.

FIG. 2. Shows the internal oblique muscle, the direction of its fibres, and its different points of attachment.

No. 1. The lower ribs. 2. The crest of the ilium. 3. The umbilicus. 4. The linea alba. 5. The fleshy fibres of the internal oblique muscle (m. obliquus ascendens abdominis.) 6. Its aponeurosis, extending forwards to reach the linea alba. 7. Part of the latissimus dorsi muscle.









first phalanges of the fingers to which they belong. From the direction of the fibres of these fleshy fasciculi, it is obvious that they are enabled to incline the fingers to which they belong inwards or outwards, and, by a simultaneous movement, to separate them one from each other, or spread them out, and then draw them together again.

## PLATE XXI.

THE two broad muscles of the back are here seen in their entire extent, Nos. 10 and 11; the other references belong to muscles which we have previously noticed, or which will be given in subsequent drawings. The muscles of the back are generally considered as being arranged in layers just as we find them in prosecuting their dissection. The two which we here mark off form the first layer, for they lie immediately under the skin, one extending from the occiput to the lower part of the back, the other from the middle of the back downwards to the pelvis and lower part of the spine. The trapezius muscle, fig. 10, extends along the posterior part of the neck as well as of the back and shoulder. If the muscle of one side be taken by itself, its form is triangular; but both together represent a quadrilateral figure, whose four sides are not equal, and none of its sides parallel, from which circumstance its name is taken. The fibres of the trapezius muscle are attached to the external protuberance of the occipital bone, and for a short way to the oblique ridge leading outwards from it. Plate XXI. No. 1. In the neck the fibres of both muscles are united in the middle line, and are also connected with a tendinous band, which is attached to the spinous processes of the vertebra; lower down they take origin from the spinous process of the last cervical vertebra, and from all those of the dorsal region, as well as from the ligaments which connect them. From these different points the fibres proceed towards the spine of the scapula, the top of the shoulder, and the external part of the clavicle, into which they become inserted. The fibres which come from the last cervical and the upper dorsal vertebra pass horizontally outwards; those above them descend, while those below them ascend. The line of insertion into the upper border of the spine of the scapula and of the acromion process are marked 4 and 3. This muscle is fleshy in the greater part of its extent, but its points of attachment are tendinous.

The broad muscle of the back, latissimus dorsi, No. 11, is of very considerable extent, as its name implies. It extends from the lower half of the spine and from the back part of the pelvis obliquely outwards over the loins and the side, and across the axilla to the arm. Its lower and back part consists of a broad aponeurosis; the rest forms a flat plane of muscular fibres, which gradually become aggregated together so as to form a thick narrow fasciculus as it proceeds towards its insertion. Its commencing fibres are attached to the spinous processes of the six lower dorsal vertebræ, where they are covered by the trapezius; lower down they are attached to the spinous processes of the lumbar region and the sacrum, and to the supra-spinous ligaments; they are also seen to be attached to the crest of the ilium, No. 6. The broad aponeurosis which thus commences gives origin to the fleshy fibres which form the rest of the muscle; some of these, however, have a separate origin, for at its lower and outer border three or four points are seen, which, starting from the lower ribs, proceed obliquely upwards and forwards, and become blended with the rest of the muscle. The upper border of the latissimus muscle slides over the inferior angle of the scapula and the origin of the teres major, (15); the narrow fasciculus into which its fibres are collected forms the posterior fold of the axilla, where it turns upon the teres major so as to get in front of it, and then ends in a flat tendon about an inch and a half in breadth, which is inserted into the posterior border of the bicipital groove in the humerus.

*Actions.*—The trapezius muscle can be made to act on the head, on the shoulder, or on the spine. Thus, if the shoulders be fixed, the upper fibres are enabled to draw the head either backwards or to their own side; if the spine and head be fixed, the shoulder can be drawn backwards, particularly if another muscle, (the rhomboid,) which lies under it, and part of which is here seen, No. 18, be made to act at the same time. It raises the shoulder; but the scapula seldom moves directly backwards, or upwards, or downwards; these changes in its position are generally found accompanied by a movement of rotation, by which it is made to turn as if on a pivot driven through its centre.

When the latissimus muscle acts on the shaft of the humerus, it can obviously draw it downwards and bring the limb closely to the side; but at the same time it gives it a rotatory motion on its axis. If the shoulder and arm be fixed, the latissimus muscle can be made to assist in inspiration, by elevating the lower ribs; it also assists in drawing up the body in the effort of climbing. On the same principle this muscle and the pectoralis major enable a person to avail himself of the assistance of crutches; the top of the crutch serves as a fulcrum which supports the arm, and as the margins of these muscles rest upon it, they are enabled to draw the body upwards towards it as to a fixed point. When the shoulder and arm are fixed, the trapezius and latissimus muscles are enabled to act upon the spine, particularly in restoring the body to the erect position when it inclines to either side. On looking at the plate, it will be at once perceived that the fibres of the trapezius may be made to act from the shoulder upon the spine in a considerable part of its length, provided the shoulder is rendered fixed. The latissimus muscle can act in the same way upon the lower half of the spine if the arm be placed in the same position as is here represented, viz. thrown out from the side and steadily fixed by the action of its muscles; this preparatory movement would enable both muscles together to act upon

the spine. Suppose an individual when walking upon a narrow board finds himself inclining to the left side so much as to be in danger of losing his balance, he instinctively throws out his right arm in order to give these two muscles fixed points at their outer ends, which at once enables them to draw upon the spine and restore it to the erect posture. In the position here supposed, the spine for the moment forms a curve, whose concavity is to the left side, and convexity to the right, by which means the upper part of the trapezius and the lower part of the latissimus of the right are put into a state of tension, inasmuch as their points of attachment are farther separated than when in the condition of repose, whilst the middle fibres are somewhat relaxed; under such circumstances the fibres of the muscles which are attached to the upper and lower ends of the spine will be made by an effort of the will to pull upon them, and draw them to their own side: at the same moment those portions of the corresponding muscles of the opposite sides which are attached to the middle part of the spine, (which in the case here supposed are rendered tense,) are enabled not only to fix that part of the column so as to enable the muscles of the opposite side to act more steadily upon its extreme points, but by a continuance of their effort they can even draw that part towards their own side; by this combination of efforts it is that the spine, like a flexible column, is subjected to the influence of forces which act upon it from opposite sides, and restored to its equilibrium by a nice adjustment of power directed by a voluntary and instinctive impulse. To maintain himself erect the rope-dancer uses a pole, which he holds with both hands in the horizontal position, and which he inclines now to one side, now to the other; the pole is his only security, for by grasping it firmly he can render his arms fixed, and thereby give to the muscles points from which they may act upon the spine, so as to straighten the curves or lateral flexures into which it is necessarily thrown during his various evolutions.

## PLATE XXII.

A SIDE view of the body is here given in order to show the first stratum of muscular fibres which covers the abdomen. Its points of attachment to the ribs are disposed in a peculiar way with regard to the great pectoral muscle, the serratus, and the latissimus, which are here indicated; its insertion into the haunch-bone is also obvious, moreover, in the interval between the lower margin of the chest and the most projecting part of the haunch-bone; the muscular fibres end in a broad flat membrane or aponeurosis, which is prolonged inwards over the fore part of the abdomen, so as to become blended with a similar production from the muscle of the opposite side along the whole space from the lower extremity of the breast-bone to the pubes. The line of junction here indicated is termed the white line, (*linea alba*, No. 2); it is distinctly shown in plate XXIV. No. 14, in which the aponeuroses are cut away at each side, and a mere narrow cord left, which is formed by the junction of their fibres; it may be considered as the common point of junction of the three pairs of muscles which form the parietes of the abdomen; it is interposed between the two recti muscles, which in plate XXII. are seen somewhat to project in slight relief from under the aponeurosis which covers them; but in plate XXIV. the rectus of the left side is seen distinctly in its entire length, the aponeurosis being removed in order to expose it. The white line (*linea alba*) is broader at its upper than at its lower extremity, for there a wider interval exists between the recti muscles. At its middle the umbilicus or navel exists, which may be considered a cicatrix remaining after the closure of the aperture which gives passage to the umbilical cord during foetal life.

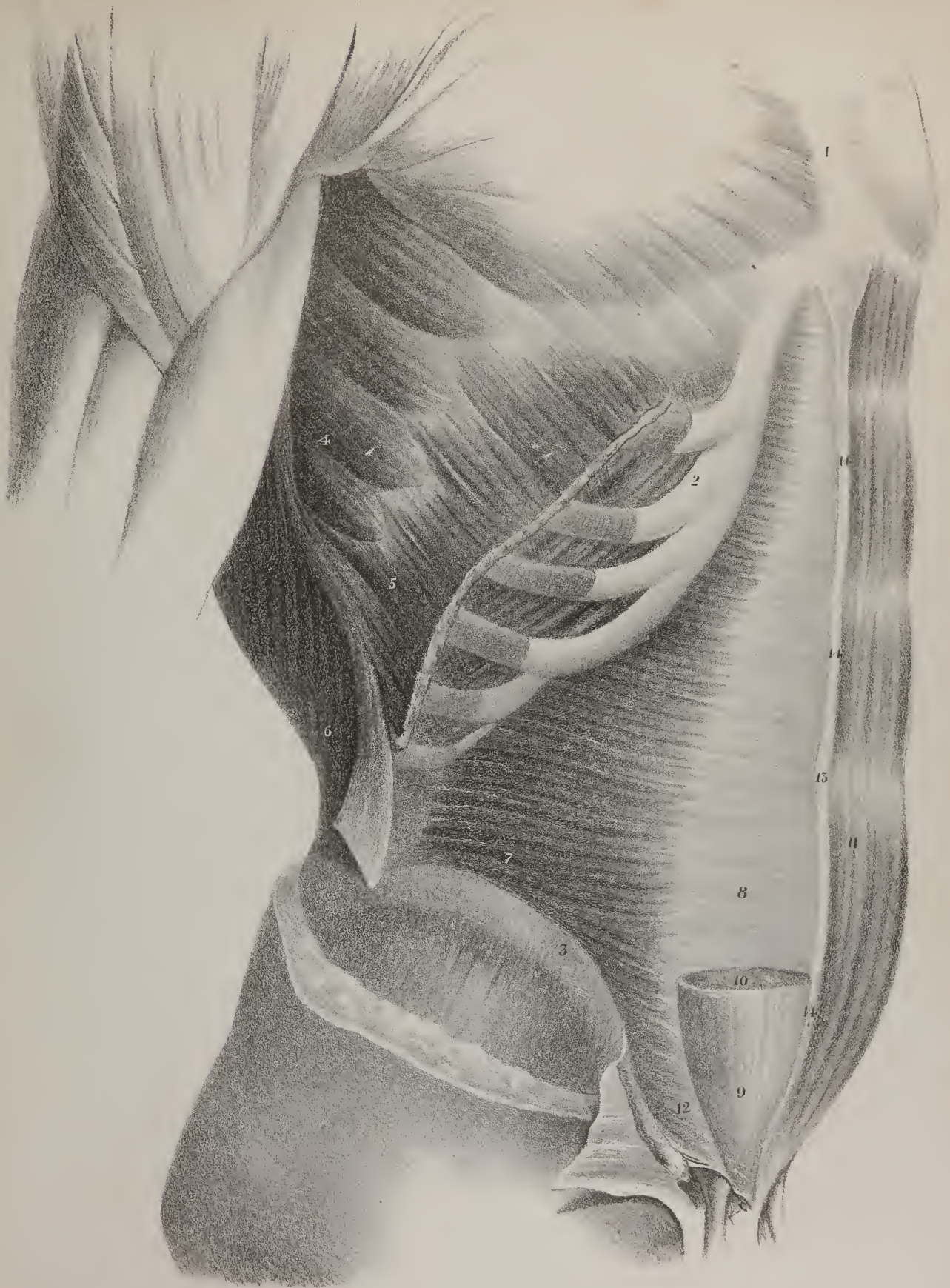
The muscles which cover the abdomen, and form the walls of that cavity from the ribs and sternum to the pelvis, at the front, at the sides, and backwards even to the lumbar part of the spine, are three broad flat planes composed of fleshy and

## PLATE XXIV.

This drawing represents the transversalis muscle of the abdomen, the external oblique muscle and the internal oblique having been removed in order to show it more fully; the greater part of the rectus muscle of the right side is also taken away with the same view, and also to show that at the lower part of the last named muscle the aponeurosis of the transversalis muscle passes in front of it, though higher up it passes behind it.

No. 1. The sternum. 2. The cartilages of the ribs. 3. The crest of the ilium. 4. The pointed processes by which the great serratus muscle arises. 5. A part of the external oblique muscle of the abdomen left upon the ribs, where its fibres will be seen insinuating themselves between those of the serratus. 6. Part of the latissimus dorsi muscle, its anterior edge being everted in order to expose the aponeurosis, which passes backwards from the transversalis muscle deeply into the lumbar region, where it becomes attached to the roots and points of the transverse processes of the vertebræ, after having formed a sheath for the quadratus muscle. 7. The transversalis muscle of the abdomen, (*m. transversus abdominis*, *m. lombo-abdominalis*.) 8. Its aponeurosis, where it lies behind the rectus muscle. 9. The lower part of its aponeurosis, where it passes in front of the muscle. 10. A transverse section of the rectus muscle of the right side, the upper two-thirds of it being removed. 11. The rectus muscle of the left side. 12. The lower part of the transversalis muscle, where it passes over the spermatic cord. 13. The umbilicus, or navel. 14, 14. The *linea alba*.

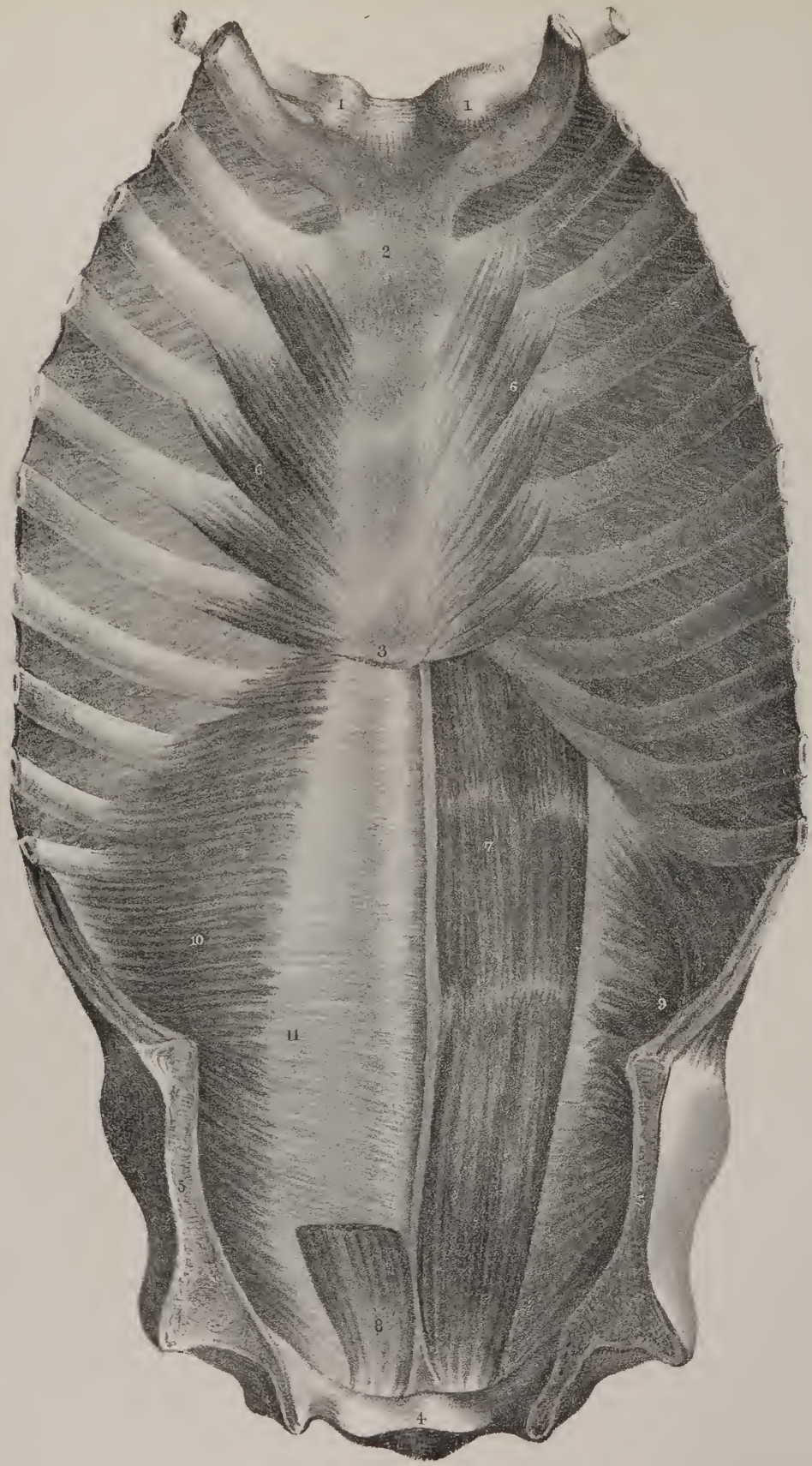












tendinous fibres, placed one over the other, the fibres of each running in a different direction from the others; from which circumstance, the external one, seen in plate XXII., is called the oblique muscle, with descending fibres: the next, seen in plate XXIII., is the oblique muscle, with ascending fibres: and the third, plate XXIV., No. 7, is the transverse muscle. In front there is a pair which extends from the lower part of the chest directly down to the pubes, and is thence called the recti muscles, plate XXIV. No. 11. We frequently find an accessory pair in the form of two small triangular muscles that rest upon the lower part of the recti, extending from the pubes about two inches, or two and a half inches upwards.

The external oblique muscle, as seen in plate XXIII. No. 9, is called also the descending oblique muscle, from the direction of its fibres; it is situated at the side and front of the abdomen, and represents a broad flat plane of muscular and aponeurotic fibres. It is very broad at its anterior margin, for it extends from the ensiform cartilage to the pubes; the posterior border is very narrow, oblique in its direction, and composed of fleshy fibres, extended from the last rib down to the ilium; the upper border is irregularly curved, and composed of seven or eight angular points, termed digitations, which are interposed between similar processes of the serratus magnus and the latissimus dorsi. The first or highest of these digitations is very thin, but still is prolonged, so that its border becomes blended with the lower edge of the great pectoral muscle, whilst its extremity is fixed to the fifth or sixth rib, beneath the corresponding point of the great serratus muscle; the second, third, and sometimes the fourth fleshy points are broader than the first, whilst the three last are very narrow and pointed. The digitations in each case are observed to commence with very short white tendinous fibres, to which the fleshy fibres soon succeed, and are thence prolonged obliquely downwards and forwards; those of the five upper digitations run into the broad aponeurosis, by which they are continued onwards into the linea alba, whilst those of the three last are inserted into the anterior half of the haunch-bone, (os ilii). The lower border of the muscle presents two parts: one fleshy, with a slight admixture of tendinous fibres, which are here seen inserted into the ilium; and the other tendinous, where the broad aponeurosis is stretched across from the prominent process (spinous) of the ilium to the pubes. This border, when detached from all its connexions, represents a flat tense band or cord, attached on the outside to the spine of the ilium, and on the inside to the spine of the pubes; by which arrangement provision is made for the passage of muscles, blood-vessels, and nerves downwards, from the abdomen into the thigh, through the space which intervenes between the under edge of the cord and the curved margin of the pelvic bones. From this circumstance the space is termed the crural arch; the lower fibres of the aponeurosis will be observed, moreover, to separate from one another so as to leave between them an angular interval, which transmits the spermatic cord in the male, or the round ligament in the female. It is, in fact, the outlet of a canal formed by a very peculiar arrangement of the lower part of these three muscles, the inlet or inner aperture being in a thin membrane, which lines the inner surface of the transversalis muscle, and is distant from the one here delineated by about one inch and a half. Provision is thus made for the security of the abdominal viscera, and for the prevention of their protrusion, inasmuch as the two apertures just noticed are not directly opposed to one another, which would render the egress of parts comparatively easy. The arrangement here indicated gives to the canal such a degree of obliquity in its course as to enable it to act on the principle of a valve in preventing protrusions. The outer aperture through which the cord passes will be observed to be somewhat of an angular form, being bounded by the diverging fibres of the aponeurosis of the external oblique muscle as they proceed to their insertion. Upon the aponeurosis some fibres will be observed to rest, but which run in a different direction, viz. upwards and inwards. They are well marked towards the outer angle of the aperture, and as they are interwoven with the subjacent fibres, they have the effect not merely of strengthening them in a part which requires some additional security, but also preventing the enlargement of the aperture. These transverse fibres, moreover, are continued downwards upon the cord as it escapes from the opening, but there they gradually become thin, so as to represent a smooth membrane, which shades off the margins of the aperture so as to render them indistinct until it is removed by dissection. Where this structure is continued downwards, it assumes a membranous form, and becomes one of the coverings of the cord.

Now there is much of technical language employed in the description of the parts here noticed. The tense cord, which represents the lower margin of the external oblique muscle, is called *Poupart's ligament*; the aperture is called the *ring*, (external abdominal,) notwithstanding its angular form; the fibres which form its sides are called *pillars*, (columnæ;) the trans-

## PLATE XXV.

This drawing gives a posterior view of the sternum and ribs, which form a covering for the chest, and of the transversalis and recti muscles, as they lie over the abdomen; the clavicles and ribs are cut through towards their anterior third, the incision is then continued downwards through the three planes of abdominal muscles, and through the iliac bones; the anterior third of the walls of the trunk are thus detached and everted, in order to show at one view their under or posterior surface.

Nos. 1, 1. The clavicles. 2. The sternum. 3. The ensiform cartilage. 4. The pubic bones at their symphysis. 5, 5. The iliac bones. 6, 6. The triangular muscle of the sternum, (m. triangularis sterni.) 7. The deep or under surface of the rectus muscle of the abdomen, which is here brought into view by the removal of the back part of the sheath, which the internal oblique and transversalis muscles form for it. 8. The lower part of the rectus muscle of the left side, where it is left uncovered by the aponeuroses of the muscles. 9. The transversalis muscle of the right side. 10. The transversalis muscle of the left side. 11. Its aponeurosis.



verse curved fibres which run across are called *intercolumnar* fibres; and finally, where the latter are prolonged down upon the cord, and assume the form of a thin membrane, they are said to form the *fascia* of the cord, or the spermatic fascia.

## PLATE XXIII.

Fig. 1. This drawing is intended to show the structure and the arrangement of the fibres of the intercostal muscles which fill up the spaces between the ribs, and assist materially in the respiratory movements. In each space there are two planes of fleshy and aponeurotic fibres, which differ in their direction, and also in the extent to which they are prolonged. The *external intercostal* muscle, or rather plane, of muscular fibres, No. 4, will be observed to have a direction downwards and forwards, from the lower margin of any given rib to the contiguous edge of that beneath it. Its extent is from opposite the transverse processes of the dorsal vertebræ to near the anterior extremities of the ribs, at which point the muscular fibres cease, and a thin layer of membrane is continued onwards to the sternum.

The *internal intercostal* muscle, placed under cover of or beneath the former, takes an opposite direction, the fibres running backwards and downwards, 5, 5; they may be said to commence at the sternum, to be attached by their extremities to the cartilages of the ribs, between which they lie, and to be then continued backwards between the bodies of the ribs themselves as far as their angles. Between the two planes of muscles here noticed, the intercostal nerves and vessels are placed. Their actions we shall notice when we comment on those of the Diaphragm.

Fig. 2. The second muscular layer which enters into the composition of the walls of the abdomen is here shown.

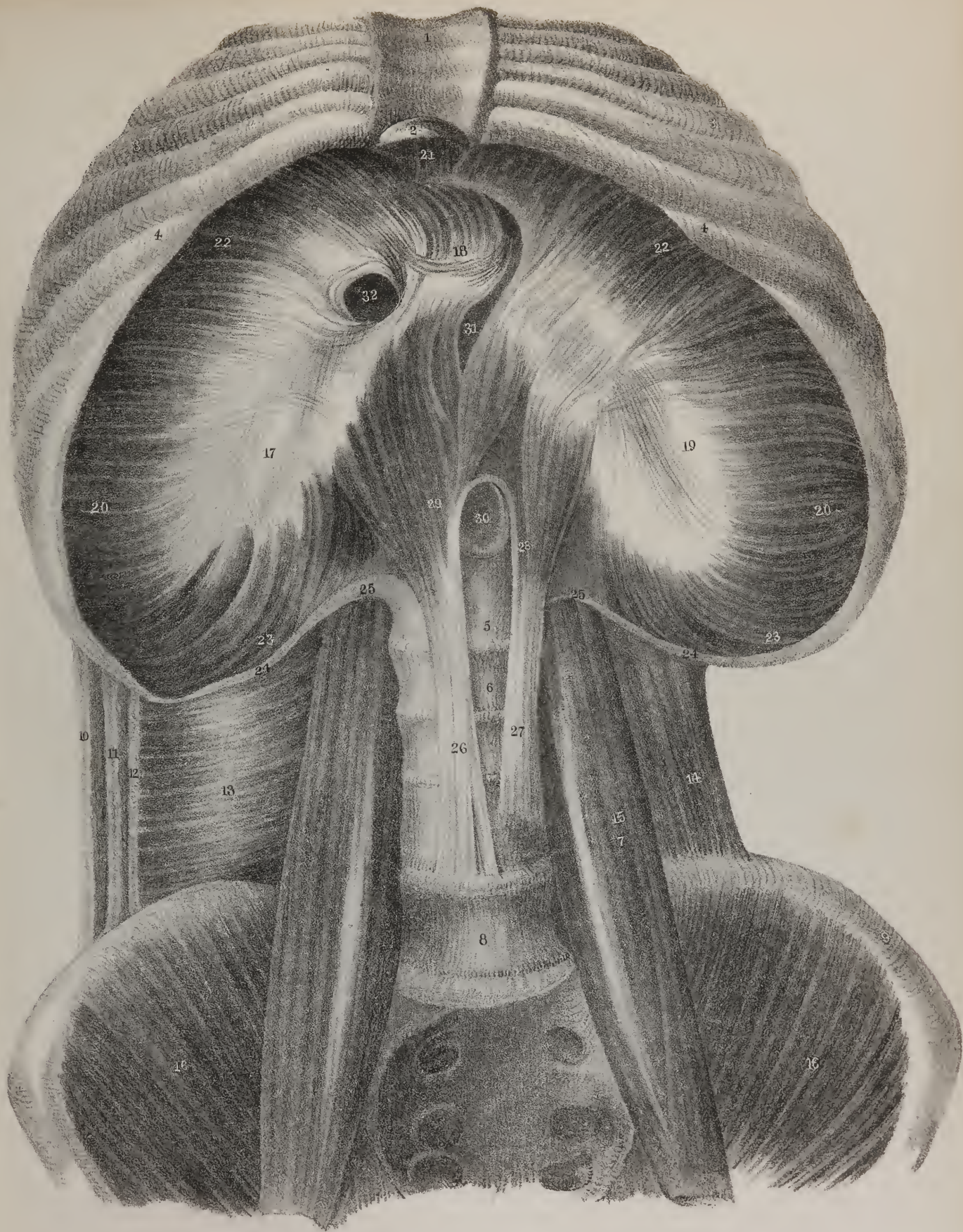
Fig. 2, No. 5. From its position, and from the direction of its fibres, this muscle is called the "internal oblique," and as most of its fibres incline upwards, it is not unfrequently called "obliquus ascendens." It is flat, broad, and thin, composed of fleshy fibres in a considerable part of its extent, but towards the fore part it becomes aponeurotic, No. 6; its fibres are attached along the crest of the ilium for two-thirds of its extent, and also to the outer two thirds of Poupart's ligament; this extent represents the lower border, or, as it is commonly termed, the origin of the muscle. Along its upper edge it will be seen to be fixed to the cartilage of the ribs, from the twelfth to the seventh, inclusive. The muscular fibres will be observed to pass into a broad aponeurosis, which at the outer border of the rectus muscle divides into two layers, of which one passes before and the other behind the flat muscle just named, so as to enclose it in a sheath. At its inner border they unite again, and become blended with the fibres of the corresponding muscle of the opposite side, from the ensiform cartilage to the pubic bone. Now the layer of aponeurosis which passes in front of the rectus muscle becomes identified with that of the external oblique muscle, as in Plate XXII., and that which passes behind the rectus unites with the aponeurosis of the transversalis muscle, as in Plate XXIV. The arrangement here indicated exists as far as from the ensiform cartilage to midway between the umbilicus and the pubic bone.

## PLATE XXVI.

The structure of the diaphragm, and its different points of attachment, are here exhibited as they are seen from the cavity of the abdomen after its soft parietes have been cut through and removed, together with the whole of its contained viscera.

No. 1. The sternum. 2. The ensiform cartilage. 3, 3. The ends of the true ribs. 4, 4. The cartilages of the false ribs. 5, 6, 7, 8, 9. The crest of the ilium. 10, 11, 12. The cut edges of the three layers of abdominal muscles of the right side, divided by an incision carried downwards from the ribs to the ilium. 13. The aponeurosis of the transversalis muscle, where it is prolonged inwards, and is about to form a sheath for the quadratus lumborum muscle. 14. The quadratus lumborum muscle of the left side, brought into view by the removal of the aponeurosis of the transversalis. 15. The great psoas muscle; it is seen to rest against the side of the lumbar vertebræ and to cross the brim of the pelvis, as it descends towards its insertion into the small trochanter of the thighbone; its upper end is crossed by the arched ligament (25) of the diaphragm (ligamentum arcuatum;) it then overlaps the quadratus muscle whilst in the lumbar region, and the inner edge of the iliacus whilst crossing the pelvis; lower down it becomes inseparably united with the latter previous to its insertion. 16, 16. The iliac muscles, so named from resting upon the hollow of the iliac bones. 17. The right division, or leaflet of the tendon of the diaphragm. 18, 19. The middle and the left divisions of the same. 20, 20. The muscular fibres of the diaphragm, where their direction is horizontal. 21. The anterior fibres of the same, their direction being backwards from the ensiform cartilage. 22, 22. The lateral part of the muscle, where the fibres are oblique. 23, 23. The deep or posterior part, the fibres of which pass forwards. 24, 24. The external arched ligament of the diaphragm; it is continuous with the anterior layer of the aponeurosis of the transversalis muscle, and gives attachment to the fibres last named of the diaphragm. 25, 25. The inner or proper arched ligament of the diaphragm, (ligamentum arcuatum proprium.) 26. The right crus or pillar of the diaphragm, commencing by a tendinous process from the lumbar vertebræ. 27. The left, or smaller crus. 28. The fleshy part of the left crus. 29. The fleshy part of the right crus. 30. The aorta passing down through the interval between the crura. 31. The œsophageal opening in the diaphragm. 32. The opening for the vena cava.









at which point both layers of the internal oblique, and also that of the transversalis muscle, pass in front of the rectus, Plate XXIV., Nos. 9, 10, also Plate XXV., No. 8, where the lower part of the rectus is left to show that the aponeuroses do not exist at its posterior or abdominal surface. The fibres of the internal oblique muscle which arise from Poupart's ligament become gradually thin and pale; they assume a direction downwards and inwards, arching over the spermatic cord, and become fixed to the crest of the pubic bone, and into that ridge upon it which is called the pectineal line. The latter part of the muscle becomes united with the subjacent fibres of the transversalis and assume the name of conjoined fibres or tendons of these muscles. The posterior border of the muscle is narrow, as it corresponds with the interval between the crest of the ilium and the last rib; at this point the fleshy fibres become attached to the aponeurosis of the latissimus dorsi muscle, which will be observed everted, in order to show the fascia here alluded to. At the lower part of the drawing a flat piece of white membrane will be observed turned out of its place and thrown down upon the thigh; it is a part of the aponeurosis of the external oblique muscle everted, in order to bring into view the relation which the lower border of the subjacent muscle bears to the cord.

The *cremaster* muscle rests upon the spermatic cord, and supports the testis, (*κρεμαω*, to suspend). It consists of a number of thin fibres disposed in curved lines, the concavities all looking upwards. They are indicated in Plates XXII. and XXIII.; they are on the same plane as the lower border of the internal oblique muscles and appear to have been originally continuous with it; their extremities have the same points of attachment, viz. to Poupart's ligament and the crest of the pubic bone, and they do not exist before the testis has descended. For these several reasons it may be considered a part of the internal oblique muscle drawn down with the testis, the direction of the fibres being determined by the traction exerted upon them during the descent of the organ just named.

## PLATE XXIV.

THE third muscular layer of the abdomen is here exhibited, viz. the transversalis muscle, No. 7, with its aponeurosis, No. 8, and the relation of that aponeurosis to the rectus muscle, both in the upper two thirds of its extent and in the lower third. The transversalis muscle, like the two oblique muscles previously noticed, consists of a broad thin plane of muscular and tendinous fibres. At first view its form appears to be triangular, one side being represented by the linea alba (14, 14,) extending from the ensiform cartilage to the pubic bone; another side, by the cartilages of the ribs, No. 2; and the third by the crest of the ilium, No. 3, and by Poupart's ligament. However, when we examine the muscle farther back, in the interval between the last rib and the ilium, it does not terminate in a point; its fleshy fibres become continuous with a membrane which is prolonged backwards, and becomes attached to the lumbar vertebræ in a very peculiar way, after having formed a sheath for the quadratus lumborum muscle. The fleshy fibres of the muscle may be said to arise above from the cartilages of the ribs, from the seventh to the twelfth, by their inner edges; below, from the inner edge of the crest of the ilium in three-fourths of its extent, and from the outer half of Poupart's ligament; and finally, in the interval between the last rib and the ilium, from the fascia just alluded to, and which shall be more particularly described when commenting on Plate XXVIII. The fleshy fibres proceed inwards and end in a broad aponeurosis, which soon becomes identified with the aponeurosis of the internal oblique muscle, with which it is prolonged to the linea alba, where it becomes blended with the fibres of the corresponding muscle of the opposite side, as well as with those of the oblique muscles, forming with them a seam, or common line of junction. The whole of the aponeurosis of the transversalis muscle lies behind the rectus muscle, in the upper two-thirds of its extent, No. 8, but passes in front of it in the lower third, No. 9; this relation is also indicated in Plate XXV. The lower border of the muscle, No. 12, where it arises from Poupart's ligament, becomes rather thin and weak; its fibres incline inwards over the spermatic cord, previously to their insertion into the crest and pectineal line of the pubic bone.

The rectus or straight muscle of the abdomen is here shown, extending from the lower margin of the chest to the crest of the pubic bone, gradually becoming narrow towards its lower attachment; see also Plate XXV., No. 7. Its upper attachment is effected by three points, of which one, the smallest, is fixed to the ensiform cartilage and the cartilage of the seventh rib; the second, to the cartilage of the sixth rib; and the third, to that of the fifth. The fibres, when traced downwards, will be found interrupted by two, three, or sometimes four zigzag tendinous lines (*lineæ transversæ*), which run across it, one of them being opposite the ensiform cartilage, one at the umbilicus, and the third in the interval between these; they are more distinct upon the anterior than the posterior surface. When traced downwards, the fibres of the muscle will be found to end in a flat tendon, which is inserted by two points into the upper edge of the pubic bone. The rectus muscle is enclosed in a sheath formed by the aponeurosis of the internal oblique muscle, which divides into two layers, so as to enclose it; the external layer being identified with and strengthened by the aponeurosis of the external oblique muscle, and the internal by that of the transversalis; but the sheath will be found deficient at its back part, towards the lower fourth or fifth of its extent, No. 8. Where the aponeurosis divides to enclose the rectus, it presents necessarily a curved line, corresponding with the outer border of the muscle, which is usually named *linea semi-lunaris*.



The *pyramidal* muscle (m. pyramidalis) is a small flat muscular bundle of a triangular form; when it exists, which is not always the case, it rests upon the lower extremity of the rectus muscle, is attached below to the pubic bone, near its symphysis, and above to the linea alba. Its surfaces are flat, the lower edge is tendinous and straight, the outer is oblique, the inner is also straight, the fibres being vertical, and parallel with the linea alba, close to which it lies, its power is necessarily very restricted; it may render the linea alba tense by drawing upon it.

*Actions.*—The three planes of muscular fibres here described are so arranged in the greater part of their extent as mutually to support and give strength to one another. The direction of the fibres of the internal oblique crosses that of the external, and that of the transversalis differs from both; hence, wherever this arrangement takes place, intestinal protrusions are prevented by the mode in which the fibres are super-imposed one upon the other. But towards the lower part of the abdomen, the fibres of all take nearly the same direction, being inclined downwards and inwards; there also, those of the internal oblique and transversalis become thin, and an interstice is moreover left beneath their lower margin for the transmission of the spermatic cord. Hence it is in this latter position that the intestines usually protrude, constituting hernia, or rupture. It would be limiting the use of these structures to say they serve merely to enclose and support the abdominal viscera. Their contracting power enables them to assist in many important functions, as well as in actions of the body; and as their position and points of attachment establish relations between them and the chest, the pelvis, and the cavity of the abdomen, we see how they can act upon either. Suppose their points of attachment to the chest and pelvis be rendered fixed by a preparatory effort of other moving powers, determined by the will, these muscles will be at once enabled to act upon the cavity of the abdomen, to diminish its capacity, and thereby the viscera it contains, particularly if an effort of inspiration be at the same time made, so that the diaphragm, as it descends, may force down the organs with which it is in contact. The combination of such movements as these is necessary in vomiting, and other expulsive efforts. The same agents, particularly the internal oblique and transversalis, can occasionally be made to compress the lower border of the chest, and thereby assist in expiration. When the lower attachment of these muscles becomes fixed, so as to give them a steady point from which to act, they can be made to move the trunk in various ways. Thus the two recti, by drawing on the lower part of the chest, can bend the body directly forwards, and so become flexors of the trunk. It will at once be perceived that the ribs into which they are fixed give them a great mechanical advantage in executing this office; for, as these bones project forwards from the spine, they resemble so many prolonged transverse processes, and in effect give to the muscles the mechanical advantage of levers, through the medium of which they can act upon the vertebral column. The two external oblique muscles can assist the recti in thus bending the body directly forwards, when both act together; but if either contracts by itself, it in the first instance tends to draw down the chest towards its own side, but a continuance of the effort enables it to turn the body upon its axis, and rotate it towards the opposite side; thus the right external oblique muscle rotates the body towards the left side, the centre of motion being in the lumbar vertebræ. If the chest be fixed, the oblique and recti muscles are enabled to concentrate their efforts upon the pelvis; this is exemplified in the ordinary effort of climbing, in which the arms are raised above the head and rendered fixed by seizing on some object; the ribs and chest are in the next place rendered motionless by taking a full inspiration, and by holding in the breath; then it is that the abdominal muscles can act upon the pelvis, and draw it upwards and forwards, thereby preparing for an upward movement of the legs. Though the moving powers here described are grouped together as belonging to the walls of the abdomen, sufficient has been said to show how important an influence they exert upon the thorax. The external oblique rests upon the same plane as the great serratus muscle, whilst the internal oblique and transversalis occupy the same relative position in the abdominal region which the intercostals do in the thoracic.

## PLATE XXVI.

This drawing is intended to exhibit the structure of the muscular partition, which in man and the higher animals separates the cavity of the chest from that of the abdomen; technically it is called the diaphragm, (*διαφραγμα*, to divide,) and in popular language it is known as the midriff. To bring it fully into view, all the viscera of the abdominal cavity must be removed, and the coating which the lining membrane or peritoneum gives to this, as well as to other parts, must be carefully dissected off. The vessels, too, which pass through it, as well as the œsophagus, are also cut across, in order that the form and position of the apertures which transmit them may be more distinctly seen. The great blood-vessels which lie upon the spine must also be taken away, in order to give a distinct view of the pointed processes, (footstalks, "legs," or "crura," as they are technically called,) by which the diaphragm is attached to the lumbar vertebræ. It is difficult to convey a correct or satisfactory impression of this structure by a single drawing, for its under surface, which is the one here seen, is concave, the upper surface being necessarily convex; moreover, the degrees of its curvature differ at the right and at the left sides, and they vary every moment of our lives, for, like a moveable floor, it descends with every inspiration which we make, and ascends with every expiration. This can be rendered clear only by a series of outline drawings, giving side views of sections of the body, which show at the same time



Fig 2

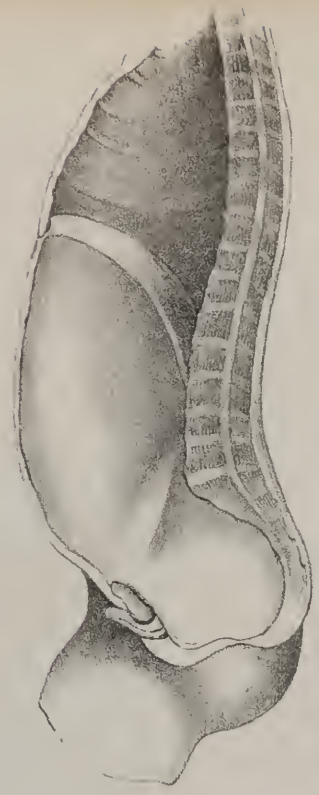


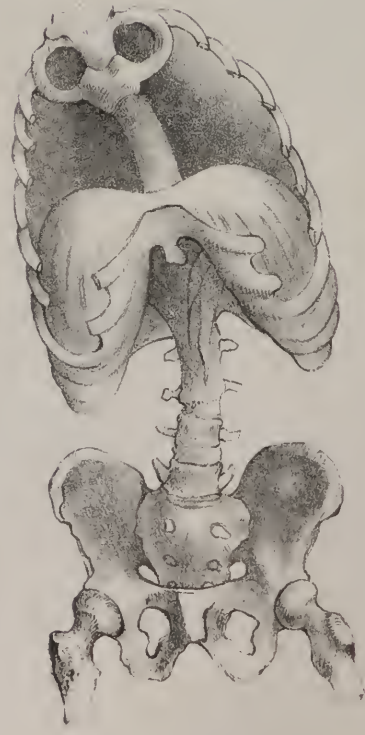
Fig 1

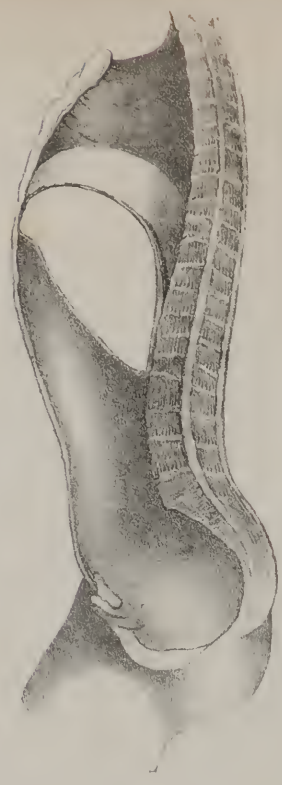

Fig 5

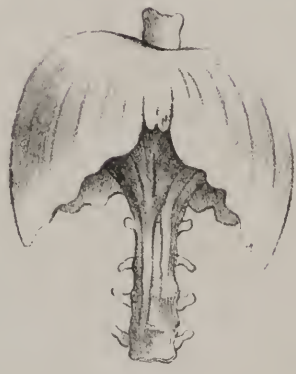

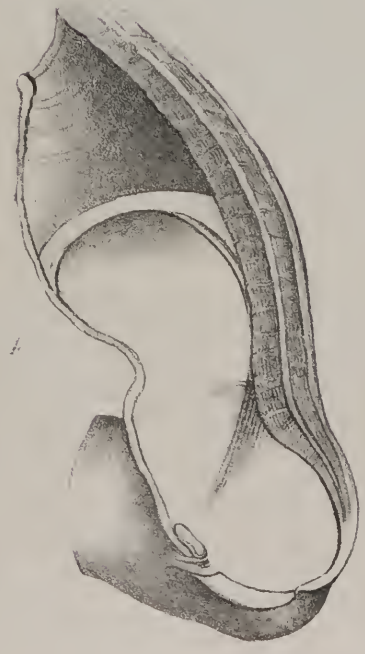Fig 5





the diaphragm in its different degrees of curvature, whilst it is descending in its contraction, and ascending in its relaxation; the import of these remarks will be more clearly perceived by reference to the different sketches given in Plate XXVII.

When placing the parts as prepared by dissection, in order to take this drawing, the lower ribs were drawn a little upwards, and also spread out somewhat at the sides, in order to make the fibres of the diaphragm tense. This gives the ribs necessarily somewhat of a formal appearance; the ensiform cartilage (No. 2) is also drawn up in order to show the fibres which are attached to it. Now, when viewed in this way from below, we perceive at once how the diaphragm is attached all round the lower rim of the chest, its fleshy fibres being fixed to the inside of the cartilages of the ribs from the seventh or last true rib, down to the last, (No. 24,) at each side; a small bundle is also attached to the ensiform cartilage. Two tapering processes, (crura, or legs,) one of which is larger and longer than the other, rest on the spine, and are fixed to it; finally, at each side of the spine, where, from the interposition of the psoas muscle, its fibres cannot be directly connected with any osseous structure, they are attached to a curved ligament, (No. 25,) which arches outwards from the spine to the transverse process of the first lumbar vertebra. The structure of the diaphragm is partly muscular and partly aponeurotic, or tendinous; the fleshy fibres which form the broad part, and which commence at the margin of the chest, are seen to terminate in white glistening fibres, which are interwoven so as to form a firm resisting membrane. The direction of the muscular fibrillæ necessarily varies, so does their length; those from the sides run transversely inwards, those from before are very short, and pass backwards, whilst the posterior sets ascend and come forward. The white or tendinous part, known as the "cordiform tendon," presents a right and a left branch, as well as a middle one, which are sometimes spoken of as leaflets, the whole being supposed to bear some resemblance to a trefoil leaf; the middle one, however, is here fore-shortened so much, and the shadow is thrown upon it in such a way, that it appears necessarily smaller and shorter than it really is. At the junction of the middle with the right division of the tendon a large square opening is observed, (No. 32,) which transmits the great vein, (vena cava,) that returns the blood from the lower parts of the body. Farther to the left and a little lower down is another opening, (31,) which gives passage to the œsophagus, or gullet, with the two great stom-achic nerves, (par vagum,—pneumogastric); it resembles a fissure, the long diameter of which is from above downwards; it is, however, elliptical in its form and fleshy in its structure, its margins being formed by the muscular fibres of the crura as they ascend to be fixed into the central tendon. Still farther back and towards the central line is another opening, which resembles a canal or a tunnel placed between the crura, (28, 29); it gives passage to the great artery (30) (the aorta,) to a large vein, (azygos,) and to the principal trunk of the absorbing system, (thoracic duct.)

The lower surface of the diaphragm is in apposition with the liver, the spleen, the upper extremity of the stomach, and farther back it supports part of the kidneys and their capsules. Its prolonged part (crura) is also in relation with the great vessels—aorta and vena cava, with the pancreas and the duodenum. The upper surface is in apposition at each side with the lungs, and between these with the heart and the pericardium.

*Actions.*—The position and the structure of the diaphragm would lead us at first sight to class it amongst the involuntary muscles; so also would the circumstance of its continuing to act when all volition is suspended during sleep or suppressed by an apoplectic seizure. Yet we are conscious of possessing a certain degree of control over its motions, for we can increase or diminish the extent of its movements, or hold it for a while at any particular state to which we have brought it by a previous effort. Seeing, then, that the muscle is thus allied to the two great classes of the voluntary and the involuntary, at the same time that it differs from each in some important particulars, we must associate it with those which form a group apart, and which are

## PLATE XXVII.

The outline figures here given are intended to show the different states of the diaphragm, and the influence which its changes exert upon the size of the cavities of the chest and abdomen, also the manner in which it can assist in compressing the abdominal viscera.

FIG. 1. The diaphragm is seen in the relaxed state in which it projects up into the thorax, thereby lessening its perpendicular depth, and diminishing its capacity during expiration. The abdomen is at the same time proportionally increased.

FIG. 2. When the diaphragm descends during inspiration, and increases the depth and the capacity of the chest, its curvature is lessened, for it approaches somewhat the state of an inclined plane. In its descent it also inclines forwards, which necessarily causes a certain degree of fullness at the umbilicus, towards which the abdominal viscera are pushed before it. This the drawing indicates.

FIG. 3. The curve of the upper surface of the diaphragm is sketched so as to show the difference in its degree at the right and left side. Also that it represents at once the floor of the chest and the roof of the abdomen.

FIG. 4. The manner in which the diaphragm and the abdominal muscles conspire to lessen the capacity of the abdomen is here shown. The oblique and transverse muscles, like broad belts, narrow its circumference, whilst the diaphragm presses downwards. When an effort is made to expel the contents of the intestinal canal, the body is inclined forwards, so that its axis may be made to coincide with that of the lower aperture of the pelvis. The fact is here expressed.

FIG. 5. This sketch shows how the diaphragm at times forces down the viscera towards the inguinal region, and may be the means of causing a hernia on one side or the other, according to the inclination which it is made to assume in different efforts. When, in lifting a heavy weight, a person inclines much towards the right side, as is here indicated, the viscera, particularly the small intestines, are pushed down towards the left groin, and if the resistance be not adequate, a protrusion is liable to occur.

termed mixed muscles. The changes of position which the diaphragm undergoes, as it passes alternately from a state of relaxation to contraction, materially influence the relative size of the two great compartments of the body between which it is placed. In fig. 1, Plate XXVII., the highest part of the curvature which its upper surface presents is on a level with the fourth intercostal space; it is then relaxed, which is the state corresponding with expiration, the cavity of the thorax being at the same time necessarily diminished in every direction by the subsidence of the ribs and sternum, which takes place concurrently with the ascent of the diaphragm. But when we commence the effort of inspiration, the muscular fibres of the diaphragm contract and shorten themselves, so as to bring it down from the curved and arched state which it exhibits in fig. 1, to nearly that of an inclined plane as seen in fig. 2. By this movement the viscera of the abdomen are pushed obliquely downwards and forwards, as if towards the umbilicus, thereby diminishing the perpendicular depth of the abdomen whilst that of the thorax is proportionally increased. Now as the ribs are at the same moment drawn upwards by the action of the intercostal muscles, (Plate XXIII., fig. 1,) their lower margins being at the same time slightly everted by a sort of twisting motion which they sustain, and as the sternum is pushed forward somewhat by the tendency of the ribs to come more into a straight line with their cartilages, aided by the elasticity of the latter, which is brought into play, we can see at once how the capacity of the chest is increased in every direction, viz. from above downwards by the descent of the diaphragm, from before backwards by the protrusion of the sternum, and from side to side by the ascent of the ribs, and the eversion of their lower margins. This change in the capacity of the chest necessarily gives rise to a diminution of the pressure upon the organs which it contains, or, in other words, to a tendency to the production of a vacuum, and as the pressure remains undiminished upon all the other parts of the body, fluids will necessarily rush in and restore equilibrium. It is in this way that the atmospheric air is made to pass through the mouth and air-passages downwards to the lungs, and may be said to be sucked into their vesicles. The same principle applies to the flow of venous blood. We see that it is retarded in its passage whilst the chest is contracted during expiration and the capacity of the lungs diminished, and that this obtains even in the case of the blood which flows in the veins of the neck and face, where its descent is not a little assisted by gravity. Still it accumulates and swells them in the state just noticed; but as soon as the inspiratory effort commences, and the cavity of the thorax thereby becomes increased, the venous blood finds a free passage towards the heart, being literally pumped into the chest by a mechanico-hydraulic contrivance.

The influence of the diaphragm upon the stomach and the other organs contained in the abdomen can be at once perceived, by paying a little attention to the sketch which is given of it, and of the muscles of the abdomen, in fig. 4, Plate XXVII. If, whilst the diaphragm descends in inspiration, the oblique and transverse muscles of the abdomen be made to contract, the contained organs will be placed between two compressing agents, which will assist materially their own contractile powers, in propelling their contents either downwards, as in the different expulsive efforts, or upwards, as in vomiting.

## PLATE XXV.

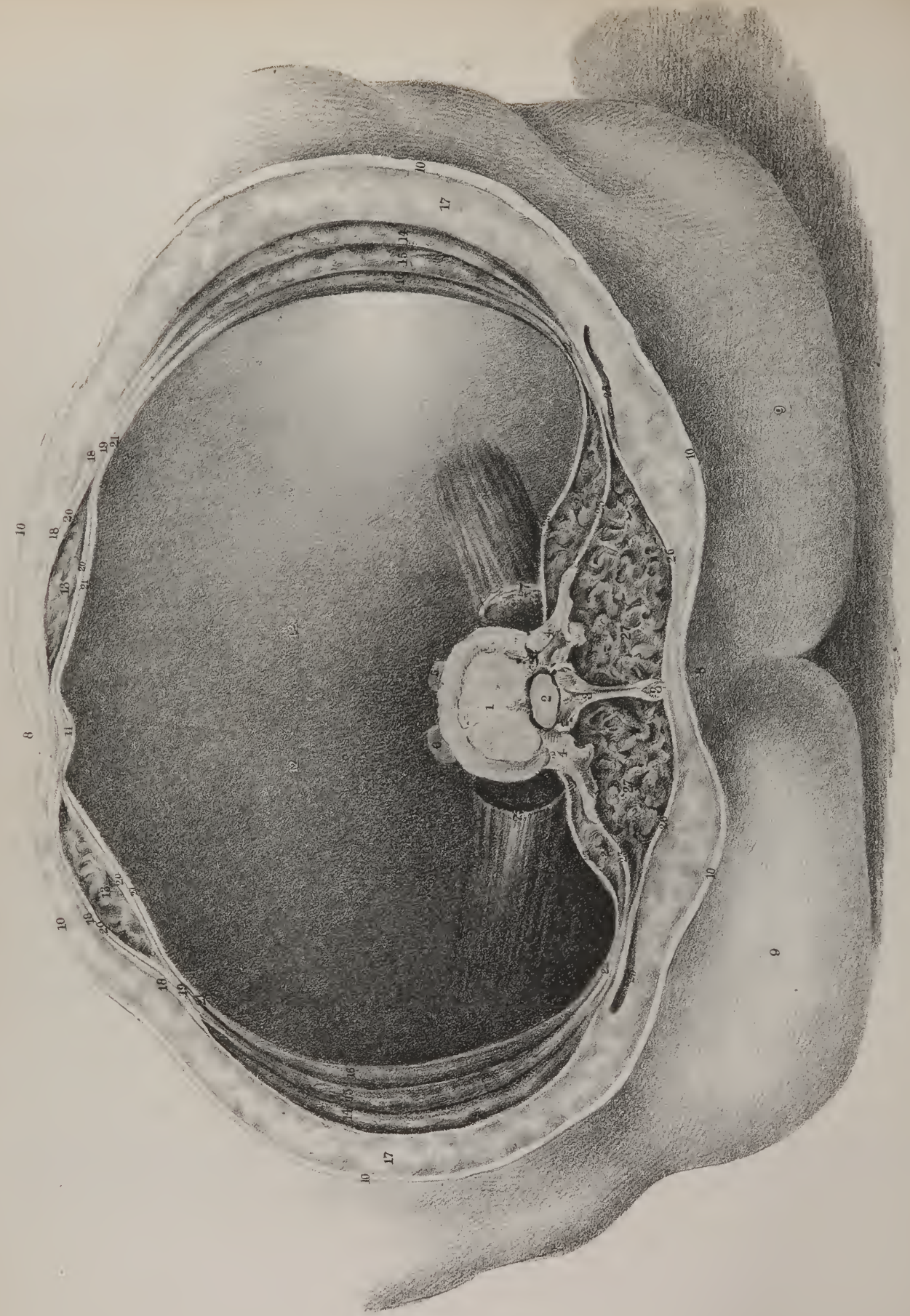
THE rectus muscle of the abdomen, 7, 8, and the transversalis, 9, 10, which are given in this drawing, have been already described in page 49. The flat thin muscle, 6, 6, which extends from the sternum to the ribs, and is in close apposition with their posterior or thoracic surface, requires to be briefly noticed. From its position, and the points to which its fibres are fixed, it may be termed *sterno-costal*, but is ordinarily named the *triangular* muscle of the sternum, (m. *triangularis sterni*;) it is thin and flat, and composed of a mixture of tendinous and fleshy fibres, the inner extremity of which is attached to the ensiform cartilage, and to the margin of the sternum as high up as the junction of the fourth costal cartilage, sometimes a little higher, whilst the outer end or insertion is fixed to the cartilages of the ribs, from the sixth to the third, or the second, as in the present case, forming thereby a series of points or digitations. The power of this muscle is necessarily very limited; its most obvious action is that of depressing or drawing down the cartilages of the ribs, by which means it assists in expiration.

## PLATE XXVII.

THE five figures given in this plate are to be considered merely as sketches, or as diagrams employed in the illustration of the movement and actions of the diaphragm. The various points to which they refer have been sufficiently indicated in the remarks made upon the action of the diaphragm, (pp. 51, 52,) and in the references given at the foot of page 51.









## PLATE XXVIII.

THIS drawing is intended to represent the different layers of muscles which enclose and support the abdominal viscera. Instead of looking at them layer after layer, as they are seen ordinarily in dissection, and as they have been exhibited in the preceding plates, their relations to one another are here shown by means of a transverse section carried through the whole body about the middle of the lumbar region. When this was effected, all the viscera were removed, and a drawing made of the soft parietes of the abdomen. At the sides will be observed the fleshy part of the three broad muscles overlaying one another; No. 14, 14, is the external oblique muscle of each side; 15, 15, the internal oblique muscle; 16, 16, the transversalis. Each of these is found, when traced forwards, to terminate in a white line which represents an aponeurotic membrane, which runs onwards from it to the fore part of the abdomen, where they all terminate, and become in a manner blended together, forming the *linea alba*, which we have previously described, (p. 47.) The white structures here noticed will be observed to form a sheath at each side which encloses the corresponding rectus muscle, 13, 13. The aponeurosis of the internal oblique muscle, 19, 19, on reaching the external border of the rectus, divides into two layers, 20, 20, which separate and diverge so as to leave between them an elliptical interval, which lodges the muscle. This aponeurosis it is which forms the immediate investment for the muscle just named. That layer of it, however, which passes in front of the rectus is further strengthened by the aponeurosis of the external oblique muscle, 18, 18, with which it becomes intimately united, so that their separation by dissection is rendered impracticable; and again, the deep-seated layer of the internal oblique, which passes behind the rectus, joins with and is strengthened by the aponeurosis of the transversalis muscle, 21, 21. At the inner margin of the recti muscles these different layers of aponeurosis coming from both sides will be observed to unite together at the *linea alba*, No. 11. The inside of the transversalis muscle is lined throughout by the serous membrane called peritoneum; towards the lower and fore part of the cavity it is supported by a thin layer of very different structure, called "*fascia transversalis*," which lying between the muscle and the peritoneum, represents a lining calculated to strengthen the abdominal parietes at the lower part, and to lessen the liability to intestinal protrusions. Between the layers of muscles, as here shown, two lines or interstices are observed, indicating the separation between them. This is effected by means of a thin stratum of cellular tissue, which is in intimate contact with each of the contiguous surfaces. Outside the external oblique muscle is a layer of cellular and adipose tissue, 17, 17, interposed between it and the common integument, 10, 10, from which circumstance it is commonly termed the sub-cutaneous cellular tissue. In some cases the quantity and thickness of this deposit are considerable, which is the case in the present instance; in others it is very thin, and contains no fatty matter. It may be traced upwards and downwards, forming a continuous layer all over the body: but in some places it becomes condensed or compressed into the form of a membranous layer, more or less firm; it is then named the "*superficial fasciæ*;" whilst in others it resembles a deposit intended to fill up interstices, viz. between muscles, in the ham and axilla.

Now at the posterior edges of two of these muscles certain aponeurotic layers are seen to extend backwards towards the spine, and to form connexions with it in such a way as to complete the circuit which encloses or circumscribes the abdominal

## PLATE XXVIII.

- No. 1. The lower surface of one of the lumbar vertebræ. 2. The vertebral foramen. 3, 3. The root and apex of the spinous process. 4, 4. The transverse processes. 5, 6. The crura of the diaphragm cut across where they lie upon the interval between this vertebra and the one beneath it. 7, 7. The psoas muscle at each side cut across. 8, 8. The middle line of the body, corresponding in front to the *linea alba*, and behind to the lumbar spines. 9, 9. The integument covering the lower part of the loins and nates. 10, 10, 10, 10, 10. The cut edge of the skin all round the trunk. 11. The *linea alba*, formed by the junction of the aponeuroses of the two oblique and transversalis muscles. 12, 12. The cavity of the abdomen deeply shaded to indicate its vacuity. 13, 13. The two recti muscles, lying one on each side of the *linea alba*, enclosed within their aponeurotic sheaths. 14, 14. The external oblique muscle of each side. 15, 15. The internal oblique muscle. 16, 16. The transversalis muscle. 17, 17. The layer of subcutaneous cellular and adipose substance interposed between the skin and the muscles. 18, 18. The aponeurosis of the external oblique muscle continued forwards to the *linea alba*. 19, 19. The aponeurosis of the internal oblique muscle. 20, 20. The two lamellæ into which this aponeurosis divides in order to enclose the rectus muscle. 21, 21. The aponeurosis of the transversalis muscle, prolonged inwards to the middle line behind the deeper seated layer of the aponeurosis of the internal oblique muscle, with which it becomes united. 22, 22. The posterior or lumbar aponeurosis of the transversalis muscle at each side. 23, 23. The two layers into which this aponeurosis divides so as to form a sheath for 24, the quadratus lumborum muscle. 25, 25. Part of the latissimus dorsi muscle at each side, cut across by the transverse section which has been made. 26, 26. The aponeurosis of the latissimus muscle continued back to the tip of the spinous process. 27, 27. The mass of the lumbar muscles, viz. sacro-lumbalis, longissimus dorsi, multifidus spinæ, as seen when divided by a transverse incision.

cavity. Here too a sheath is formed at each side by the aponeurotic prolongations which enclose a muscle (24,) constructed upon the same general principle as that which at the fore part surrounds the rectus; but there are points of difference which deserve notice. In the first place, the external oblique muscle has nothing to do with it, inasmuch as it terminates at the back part towards the lumbar region by a free margin which is altogether muscular in its structure, and consequently has no connexion with the aponeurotic bands which form the sheath just alluded to; secondly, the immediate investment of the muscle consists in this case of lamellæ given off from the transversalis muscle, and not from the internal oblique; lastly, it is much thinner, and its fibres are not so well developed as in the sheath of the rectus. The formation of the sheath may be thus stated:—the aponeurosis given off from the posterior edge of the transversalis muscle, 22, divides into two layers, 23, 23, at the outer edge of the quadratus lumborum muscle, 24, one passing anterior to it, and the other posterior; the former is prolonged inwards towards the spine, and becomes fixed near the root of the transverse process, 4, of each lumbar vertebra, whilst the other passes behind it, and reaches the apex of the transverse process. It is in the interval left between these two layers that the quadratus lumborum muscle is lodged. Now the posterior layer is intimately connected with the aponeurosis given off from the edge of the internal oblique muscle, and the latter in its turn contracting an adhesion to the aponeurosis of the latissimus dorsi muscle, is conjointly with it, continued backwards in the form of a strong aponeurotic lamella, 26, which will be observed to reach the apex of the spinous process, No. 3, and there to be fixed. Between the lamella just noticed and that of the transversalis which goes to the apex of the transverse process, a considerable interval necessarily exists, which is filled up by the mass of the lumbar muscles.

## PLATE XXIX.

THE quadratus muscle of the loins, 23, 23, exhibits some analogy to the scalenus in the neck, in so far as it bears the same relation to the last rib which the scalenus does to the first. The latter, from its points of attachment, may be termed the “costo-transverse” muscle, and the quadratus may be named “ilio-costal.” Two muscles of this name will be observed to lie one at each side of the lumbar part of the spine, and to extend from the crest of the ilium, its posterior fifth, to the lower edge of the last rib, which constitute its fixed points, or, in other words, its origin and insertion. Its fibres incline inwards a little as they ascend; it is flat, pretty thick, and quadrilateral in its form, as its name implies. Its origin is effected by short aponeuroses, some of which will be observed to come not only from the ilium, but from the ilio-lumbar ligament; those which form its outer border pass upwards to the last rib, but those at the inner margin form four processes or points, which are attached by short aponeuroses to the summit of the transverse processes of the four upper lumbar vertebræ. In the drawing the anterior surface of the quadratus appears to be in immediate apposition with the psoas which lies in front of it, whilst its posterior surface appears to rest upon the mass of the lumbar muscles, 24, 24, that lie behind it; but it will be recollected that this muscle is enclosed in a sheath formed by the posterior aponeurosis of the transversalis muscle, (Plate XXVIII., Nos. 23, 23,) one lamella of which passes before it interposed between it and the psoas, whilst the other lies behind it and separates it from the lumbar muscles.

## PLATE XXIX.

The muscles which lie at the sides of the lumbar part of the spine, and along the brim and fore part of the pelvis, are here exhibited, viz. the quadratus lumborum, the psoas major and minor, and the iliacus. As these muscles are deeply seated, being concealed by the abdominal viscera and their investing membrane, the quadratus being moreover covered by a special investment derived from the transversalis muscle, (Plate XXVIII., No. 23,) and the iliacus also by a special membrane, called fascia iliaca,—all these organs and structures must necessarily be removed, in order to bring the muscles fairly into view.

Nos. 1, 1. The eleventh rib at each side. 2, 2. The twelfth rib. 3, 4. The eleventh and twelfth dorsal vertebræ. 5, 6, 7, 8, 9. The five lumbar vertebræ indicated in their order from above downwards. 10. The junction of the fifth lumbar vertebra with the top of the sacrum, forming a projecting angle, (*sacro-vertebral*), and commonly termed the *promontory*. 11. The anterior concave or curved surface of the sacrum. 12, 12. The crest of the iliac bone at each side. 13. The great trochanter of the thigh-bone at the right side. 14. The upper part of the shaft of the right thigh-bone. 15. The ischium. 16, 16. The body of the pubic bone at each side. 17. The symphysis, or junction of these bones. 18, 18. The great psoas muscle at each side, (prelombo-trochantinien, Chauss.) 19. The small psoas of the left side, (psoas parvus.) 20. Its tendinous insertion into the ilio-pectineal line; this muscle sometimes does not exist. 21, 21. The iliacus muscle of each side, where it rests upon the anterior or hollowed surface (*fossa*), of the iliac bone. 22, 22. The junction of the iliacus with the psoas at each side, by which means they become united into one previous to their insertion into the small trochanter of the thigh-bone. 23. The quadratus lumborum muscle. 24, 24. Part of the lumbo-dorsal muscles lying behind the quadratus. 25. Part of the sartorius muscle of the thigh. 26. Part of the rectus muscle. 27. The tensor muscle of the thigh, (tensor vaginæ femoris.) 28. The fascia where it corresponds with the upper and outer part of the hip, forming an investment for the gluteus medius muscle. 29. Part of the pectineus muscle. 30. Part of the long adductor muscle.



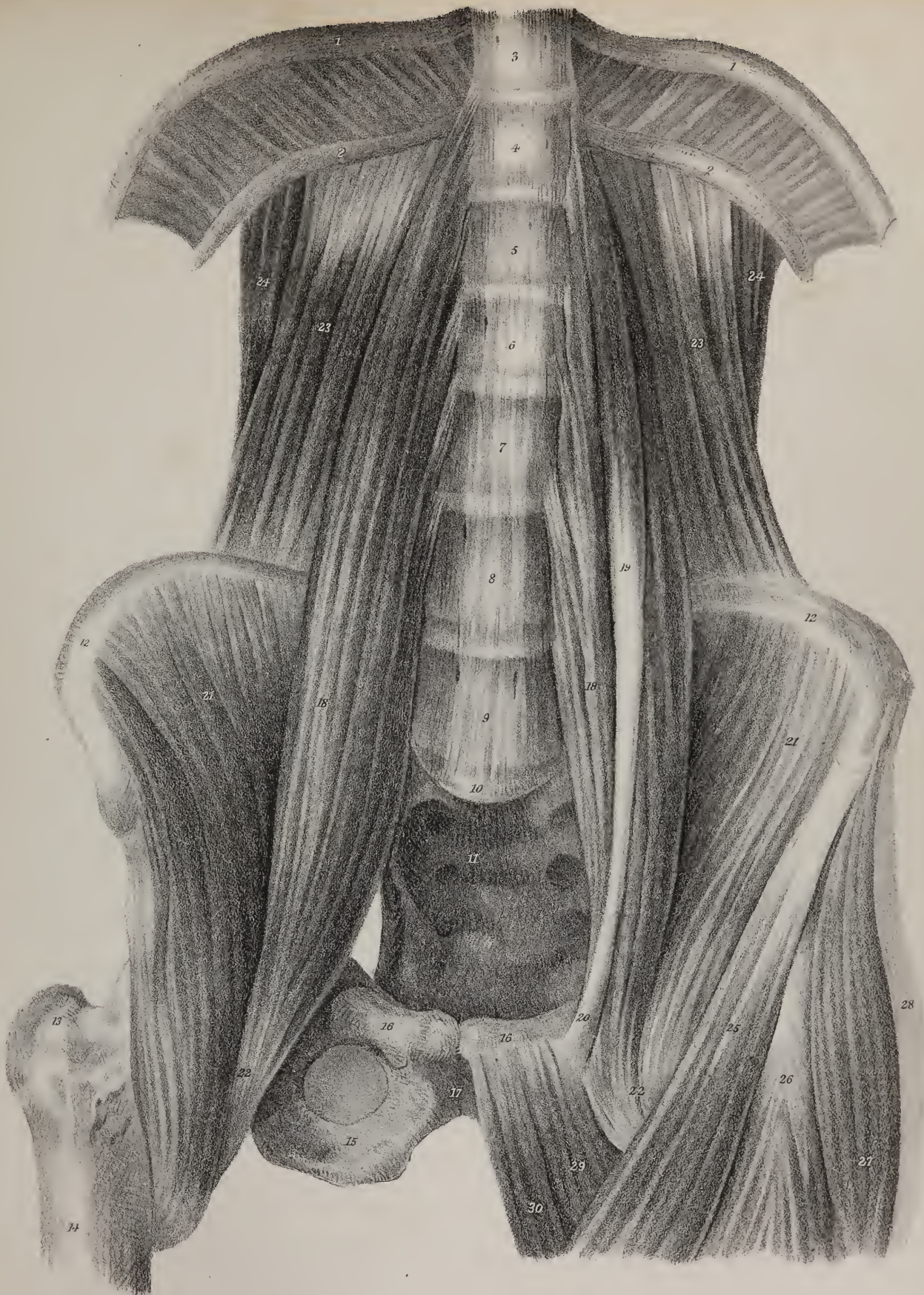








Fig 1

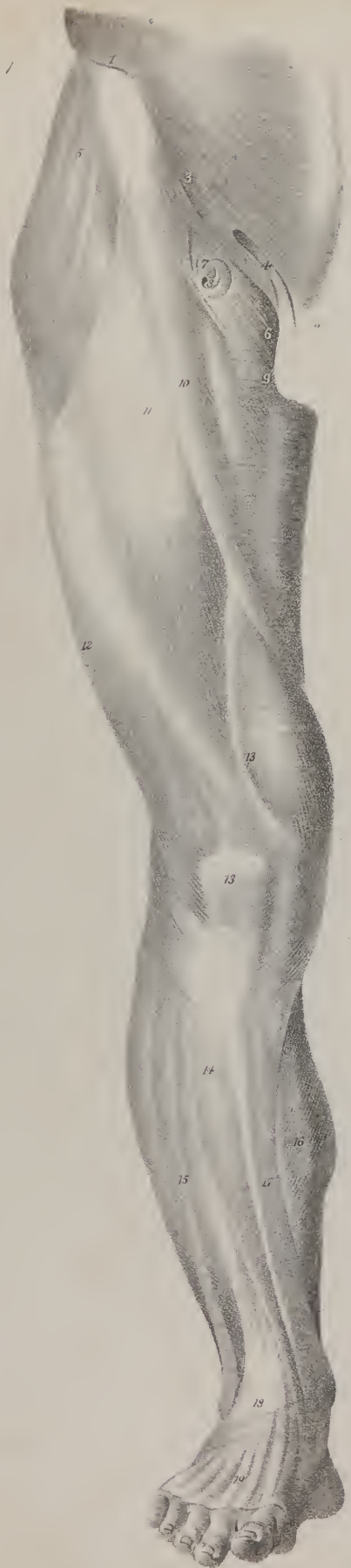



Fig 2



*Actions.*—The most obvious action of this pair of muscles is that of drawing down the last rib at each side, and rendering it fixed. When this is effected, the last intercostal muscle can be made to act upon the eleventh rib and depress it, which movement can be propagated simultaneously to the other ribs, by means of the intercostal muscles, so that all of them are together drawn downwards, and the capacity of the chest diminished. Thus the quadratus muscle may be made to commence a series of movements, all tending to effect a forcible expiration. Again, the separate points by which these muscles are fixed to the transverse processes of the lumbar vertebræ enable them to act upon the spinal column, so as to incline it now to one side, now to the other, or to steady and fix it when both act together. Their power in these particulars is not a little increased by their connexion with the last ribs, which may be regarded as two lengthened transverse processes, affording a longer lever with a proportionate increase of mechanical power to be directed upon the spine itself.

The great *psaos*, and the *iliacus* muscles, 18, 21, may be regarded as a single muscle, inasmuch as they are united, 22, previously to their insertion; but the more usual practice is to describe each separately. The *great psaos* muscle, (*psaos magnus*), No. 18, lies along the sides of the lumbar vertebræ, crosses the brim of the pelvis, and then descends into the thigh. It is therefore of considerable length, inasmuch as it reaches from the last dorsal vertebra to the small trochanter of the thigh bone, and may, if it were necessary to resort to much rigour in its description, be considered as divisible into three parts, which are here seen at a glance, viz. the lumbar, the pelvic, and the femoral. Its form is elongated, its anterior surface being rounded and convex, the posterior being compressed and flat; it tapers towards its extremities. Its fibres will be observed to arise by short aponeuroses from the sides of the bodies of the last dorsal vertebra, and of the four upper lumbar, also from the intervertebral fibro-cartilages; another set, more deeply seated, will be found attached to the transverse processes of the four lumbar vertebræ. The fibres of the muscles thus derived pass downwards, and altogether form a rounded thick fasciculus, which, passing over the brim of the pelvis, inclines outwards, downwards, and backwards, passing deeply into the upper and fore part of the thigh, where it is fixed to the small trochanter. The fleshy fibres of the *psaos* become fixed from point to point to the surface of the tendon, which is at first concealed between them, but afterwards becomes apparent towards the outer and fore part of the muscle, where it also gives attachment to a considerable number of the fibres of the *iliacus*, 22, 22. The anterior surface of the *psaos* corresponds at its upper extremity with the diaphragm, Plate 26, with the kidney and supra-renal capsule, with the smaller *psaos* when it exists, and the iliac fascia which covers it; with the femoral or crural arch, and the commencement of the femoral artery. The inner surface corresponds above with the spinal column, and lower down with the great iliac vessels.

The *iliac* muscle, 21, 21, (*M. iliacus*; *iliaco-trochantinien*), is so called from its relation and points of attachment to the ilium. The epithet "internal," or "anterior," is very commonly applied to it, which is no longer necessary, as the relative term "posterior," or "external," is no longer applied to any muscle. The *pyriformis* was at one time known as the posterior, or external, iliac muscle. The *iliacus* derives its form in a great degree, as well as its name, from the iliac bone, whose hollow or fossa it fills up; hence it is broad above, consisting of radiating fibres, and narrowed towards its lower extremity. It arises by short aponeuroses from the inner margin of the crest of the ilium, (its anterior two-thirds,) from the inner edge of the anterior spinous processes of the ilium, (superior and inferior,) and from that of the curved border of the bone between these points, also from the concave surface of the ilium by a great number of fleshy fibres, which are fixed to its upper three-fourths, and some are found attached to the broad part of the ilio-lumbar ligament. The fibres will be observed to incline inwards as they descend, and most of them become fixed to the outer edge of the tendon of the *psaos*. The fibres which correspond with the outer border of the *iliacus* descend lower down than the rest, and are inserted into the curved line which leads from the small trochanter of the thigh bone to the rough ridge on its back part, (*linea aspera*.) The anterior surface of this muscle is covered by the iliac

## PLATE XXX.

Back and front views of the fascia of the thigh and leg are here given. The subjacent muscles are to a certain extent seen through it, the numbers indicate their position.

FIG. 1. No. 1. The anterior superior spinous process of the ilium. 2. The pubes. 3. Poupart's ligament. 4. The external abdominal ring with the spermatic cord passing through it. 5. The part of the fascia which covers the tensor vaginae muscle. 6. The inner part which conceals the pectineus muscle. 7. The curved margin of the aperture [foramen saphenum] in the fascia for the transmission of the superficial vessels. 8. The lower part of the aperture where the vein enters. 9. The adductor longus. 10. The sartorius. 11. The rectus femoris. 12. The vastus externus. 13. The vastus internus. 13\*. The fibres of the fascia passing upon the patella and its ligament; lower down they become attached to the head of the tibia, and finally continuous with that which covers the leg. 14. The fascia covering the tibialis anticus muscle. 15. The peronei. 16. The gastrocnemius. 17. The tibia. 18. The anterior annular ligament of the ankle. 19. The thin part of the fascia covering the extensor tendons upon the dorsum of the foot.

FIG. 2. No. 1. The crista of the ilium. 2. Part of the tendinous structures which cover the side of the sacrum. 3. The part of the fascia which conceals the gluteus medius muscle. 4. The gluteus maximus; here it is very thin, and the coarse fibres of the muscles are distinctly seen through it. 5. The position of the vastus externus. 6. The biceps flexor. 7. That of the semi-tendinosus and semi-membranosus. 8. The fascia stretched from the flexor muscles so as to cover in the popliteal space. 9, 9. The fascia where it covers the muscles of the calf of the leg and their tendon.



fascia ; is crossed by the crural arch, and lower down by the sartorius and pectineus muscles ; its posterior surface rests on the iliac fossa, the brim of the pelvis, and the capsular ligament of the hip joint ; its inner border, which is in close apposition with the psoas, is however separated from it by the anterior crural nerve, which is lodged in the groove between them.

As these muscles conjointly slide over the brim of the pelvis and the capsule of the hip joint, and as a free and easy motion is necessary in this situation, provision for this purpose has been made. A synovial sac of considerable extent lies between the posterior surface of the muscles and the parts just named, which secretes a lubricating fluid, and by its looseness admits of every movement that can be required.

The *small psoas* muscle, (*psoas parvus*, No. 19,) when it exists, which is not always the case, extends from the last dorsal vertebra to the brim of the pelvis resting upon the great psoas muscle. It is a flat thin fasciculus, composed in the upper third of its length of fleshy fibres, the rest being a narrow tendon. It arises by short aponeurotic fibres from the body of the last dorsal vertebra, and from the intervertebral substance which connects it with the first lumbar ; and its tendon is fixed to the iliopectineal eminence, where it will be observed to widen previously to its termination.

*Actions.*—When the psoas and iliacus muscles of one side act together and take their fixed points above, they bend the thigh upon the pelvis, and at the same time rotate it outwards. This they are enabled to do by their passing so far backwards, and by the curve which they make previously to their insertion, as well as by the mechanical advantage which their connexion with the trochanter minor gives them. When the thigh bones are fixed, so that the muscles of both sides are enabled to act from below, they can be made to concentrate their force upon the spine and the pelvis, and when the muscles of opposite sides act together, they draw the spinal column forwards, and by continuing their effort become powerful agents in maintaining the body erect upon the legs. In the effort of standing on one leg also the psoas and iliacus act with great power in maintaining the pelvis and the spinal column erect, and in a manner poised upon the head of the thigh bone.

At the outside of the psoas, and in part overlaid by it, is a muscle (23, 23) of a very different form, being flat and compressed. This, from its shape and position, is usually called the square muscle of the loins, *quadratus lumborum* ; and from its points of attachment it is sometimes named *ilio-costalis*, as it is fixed below to the ilium, No. 12, and above to the last rib, 2. It is situated deeply in the lumbar region close to the vertebral column, and is of an irregular quadrilateral form, being broader below than above. It arises by tendinous fibres from the crista of the ilium for about one-fourth of its extent, and is inserted into the inferior border of the last rib for about half its length, and by four tendinous points into the transverse processes of the four superior lumbar vertebræ. This muscle is enclosed in a sheath, (*sheath of the quadratus*,) not unlike that of the rectus, but not so dense or firm in its structure. The posterior or lumbar aponeurosis of the transversalis muscle divides into two layers near the border of the quadratus, one of which is prolonged backward behind the latter muscle, to be attached to the apices of the transverse processes of the lumbar vertebræ, and the other before it, to be fixed at the roots of these processes. Now, the lower border of this layer is attached to the inner margin of the crista ilii, (its posterior fourth,) and the upper one is stretched across from the anterior surface of the last rib to the root of the transverse process of the first lumbar vertebra. This latter part, from its mode of attachment and relation to the broad muscle of the diaphragm, has been named by some *ligamentum arcuatum externum*.

The relation of this muscle to its sheath, and the mode in which this investment is formed, will be seen at once by referring to Plate XXVIII., where 24 is the quadratus, and 23, 23, the two layers of the sheath.

## PLATE XXX.

These drawings are intended to exhibit at one view a structure which forms the immediate investment of the muscles of the lower extremity. The outline of the muscles is indicated so as to convey to the mind the idea that they are covered by a thin veil drawn tightly upon them, allowing their form to be seen, but obscuring their colour and intimate texture. Most of the numbers are placed so as to indicate the position of the muscles as they lie under the membrane.

When the common integument has been dissected off and removed from the lower extremity, it will be found invested by another membrane of quite a different structure, being of a glistening white colour, close in its texture, and composed of fibres crossing in various directions. Anatomists have classed it amongst the fibrous membranes, and named it the broad swathing band, *fascia lata*, of the thigh. The leg is enclosed in a similar investment, and so is the foot. But each presents certain peculiarities, which require a separate consideration.

The *fascia lata* of the thigh may be considered as a special or immediate investment, which not only encloses it in its entire extent from the knee to the pelvis and Poupart's ligament, but also sends processes inwards in several situations, forming partitions between the muscles. The thickness of this membrane varies in different parts. It is considerable along the external



side of the thigh, where it lies upon the vastus externus muscle, fig. 2, No. 5, and higher up upon the gluteus medius, No. 3; it is less so on its posterior aspect over the flexor muscles, fig. 2, No. 6, 7; but superiorly, and at the inner side, it is in some places so thin as to require great care in dissecting off the skin, else the fascia will be removed with it. When examined towards the lower part of the thigh, it is found to be prolonged over the knee-joint, and to be continuous with the fascia of the leg. It has at the same time a connexion more or less intimate with all the bony prominences round the articulation, viz. with the condyles at each side; with the patella, 13, and its ligament, in front; with the tuberosities of the tibia below; with the head of the fibula to the outer side, to which it is guided by the biceps muscle; and finally, after being stretched across the popliteal space, fig. 2, No. 8, it is prolonged over the gastrocnemius muscle, fig. 2, No. 9, and so becomes blended with the fascia of the leg at the back part.

When traced upwards, over the thigh, it is found not only to encase it, but also to send processes inwards between the muscles. The most dense and remarkable of these is one which passes in between the vastus externus and the short head of the biceps, fig. 2, No. 6, and is attached to the linea aspera in its whole length, as far as the insertion of the gluteus maximus. Along the internal side of the thigh it invests the muscles, and merely gives attachment to some thin cellular lamellæ, which lie between them; but along the course of the sartorius, fig. 1, No. 10, particularly in the lower two-thirds of its extent, an investment or sheath is formed for it, which serves to maintain it in its place, notwithstanding the obliquity of its direction.

Its points of attachment at the superior part of the limb are so numerous, that it becomes necessary to examine each of them in detail. Thus, externally, after having been intimately connected with the insertion of the gluteus maximus, it is prolonged backwards and upwards on the cutaneous surface of that muscle, fig. 2, No. 4; and though very thin and weak, it may with care still be traced as far as to the side of the sacrum and coccyx, and also to the crista of the ilium, to which it is firmly attached, after having passed over the upper part of the gluteus medius, fig. 2, No. 3. The fascia in the latter situation becomes very dense and firm, and is intimately connected with the fibres of that muscle. Still more externally, it divides into two lamellæ, which embrace the inferior termination of the tensor vaginæ femoris, fig. 1, No. 5, to which it in this manner gives insertion. These two lamellæ become united into one along the posterior border of the muscle, which, by being prolonged over the gluteus medius (to whose fibres it gives attachment by its inner surface,) passes to be inserted into the crista of the ilium and its spinous process. Along the inner side of the thigh, the fascia passes upwards over the adductor muscles, fig. 1, No. 9, and becomes attached to the tuberosity of the ischium and its ramus, as well as to that of the os pubis, as far as its spinous process. The most important part of the membrane—that which has claimed the greatest share of attention from anatomists and surgeons, remains now to be considered, namely, the part immediately below Poupart's ligament, and which extends from the spinous process of the ilium to that of the os pubis.

It will be recollected that the membrane forms an uninterrupted sheath for the limb, until it comes within a little more than an inch of Poupart's ligament, fig. 1, No. 3. There a division takes place, and an opening is established for the transmission of the superficial vessels. The superficial vein, (vena saphena,) in its whole course, from the inner ankle to the knee, and thence to the top of the thigh, lies superficial to the fascia. The superficial lymphatic vessels are similarly situated; the superficial epigastric vessels also descend over the abdominal muscles; and as all these converge to one point, in order to communicate with the deep-seated vessels, an opening must be established for them in the fascia lata. The existence of this opening, (fig. 1, No. 8,) has caused a division of the anterior portion of the fascia into two parts, one external, the other internal.

The *external* or *iliac* portion passes upwards, lying on a plane anterior to the vessels, and becomes blended with the lower border of Poupart's ligament, with which it continues to be thus united as far as the spinous process of the pubes. Whilst it is being prolonged in front of the femoral vessels, this part of the membrane, by reason of its inclination from below upwards and inwards, must necessarily present a curved or falciform appearance, fig. 1, No. 7, one extremity of it being at the lower border of the opening, the other at the spinous process of the pubes. Now, as the membrane stretches between these two points, its border becomes folded on itself, not ceasing abruptly at the margin of the opening, as at first sight may appear. On the contrary, it is reflected on itself, and the reflected part becoming very thin, and degenerating into cellular tissue, passes outwards on the sheath of the deep femoral vessels, with which it is identified; but towards its superior termination it turns under the border of Poupart's ligament, and adheres to that of Gimbernat, with which it is inserted into the pectineal line.\*

The *pubic* or *inner* portion of the fascia, fig. 1, No. 6, so called from its situation, lies on the pectineus muscle, and therefore

\* The fascia lata is more commonly described, in the schools of this city, as having its origin from the pelvis and running down upon the lower extremity; and not its insertion there, as described in the text. Its *external* or *iliac* portion is called the *sartorial*, its *internal* or *pubic*, the *pectineal*, from the muscles which they respectively cover. The inner part of the sartorial, which is stretched along Poupart's ligament to the spine of the pubis, presents a crescentic edge downwards and inwards, and has been called in consequence by Allan Burns, the falciform process of the fascia lata. The internal termination of this falciform process, called Hey's ligament, or the femoral ligament, is folded as stated in the text, or half twisted on itself so as to present a cutting edge obliquely downwards; it crosses the crural ring in close connection with the sheath of the vessels, and running backwards is attached to the pubis just in front of Gimbernat's ligament, where it is continuous with the pectineal or inner portion of the fascia lata. Hey's ligament is considered a frequent seat of stricture in crural hernia; but in several cases where I have operated for crural hernia, with stricture at this point, the cause of strangulation has appeared to me to be rather in the thickening of the sheath of the vessels below the ligament than in the ligament itself. For a fuller account of the fascia, see Pancoast's Wistar, or Homer's Anatomy.—J. P.

is on a plane posterior to the femoral vessels. Superiorly it terminates at the pectineal line, to which it is guided, as it were, by the muscle of that name; externally, it passes behind the vessels and their sheath, and, on reaching the border of the psoas muscle and its tendon, divides into two lamellæ. Of these, one, rather dense and firm, passes deeply behind the tendon, and becomes attached to the fibrous capsule of the hip-joint; the other, lying more superficially, unites, along the border of the psoas magnus, with a membrane covering the muscle just named. This cannot be the fascia iliaca, as is usually stated. That membrane extends no farther than Poupart's ligament, in all that part between the spine of the ilium and the femoral vessels. In the rest of its extent, it forms part of the sheath of these vessels, behind which the pubic part of the fascia lata lies. The membranous structure then, with which the pubic part of the fascia lata becomes blended at the border of the psoas, is a deep-seated layer of the fascia lata, prolonged upwards upon the iliacus and psoas muscles, and which finally unites with the under surface of the fascia iliaca, where the latter turns forwards to be connected with Poupart's ligament.

The iliac and pubic parts of the fascia lata are continuous, and united at the lower border of the opening, which their junction serves to form, and over which slides the saphenous vein. Though the fascia, in the situation here referred to, appears to present a defined concave border, (the concavity looking upwards,) fig. 1, No. 8, it still will be found not to cease abruptly; on the contrary, it is folded on itself like the external margin of the opening, and reflected down on the sheath of the vessels, on which it is gradually lost. The oval aperture here described, from its transmitting the superficial vein, (v. saphena,) is called the *saphenous opening*, (*foramen saphenum*) of the fascia lata.\*

The lower part of the limb, from the knee to the ankle, is encased by a membrane similar in structure and use to that of the thigh. Posteriorly it is continuous with that part of the latter which covers the popliteal space, fig. 2, No. 6, 8; externally it contracts a firm adherence to the head of the fibula, where it is strengthened by additional fibres, sent down by the biceps muscle; and internally it receives an expansion from the sartorius. If traced down from these different points, the fascia will be found to invest the muscles, and also to send processes inwards between them, more particularly between the extensor communis and tibialis anticus (fig. 1, No. 14,) in front, and on the outside between the peroneal muscles, fig. 1, No. 15. These intermuscular septa serve to increase the number of points to which the muscles are attached; for it will be observed that their fibres arise from them, as well as from the inner surface of the fascia, for some way down the leg. The fascia is thin posteriorly over the gastrocnemius, fig. 2, No. 9; but is dense and firm where it covers the extensors, more particularly at the upper part; and will be found so firmly united along the anterior edge of the tibia, fig. 1, No. 17, that it cannot be detached so as to be traced over its cutaneous surface. If traced along the posterior aspect of the leg, the fascia will be observed to pass over the tendo Achillis, and to be connected with the malleoli at each side, and also with the fibrous sheaths which bind down the tendons passing behind them. At the inner side it joins the internal lateral ligament; externally it is continuous with the fascia covering the side of the foot, and in front becomes identified with the anterior fasciculus of the anterior annular ligament, fig. 1, No. 18.

The fasciæ of the foot consist of two parts, differing in density and texture as well as in situation, one being a dense fibrous structure, placed in the sole of the foot, the other a thin membrane covering its dorsum. Previously to examining the latter, it

## PLATE XXXI.

The superficial muscles at the front of the thigh are shown in Fig. 1, and those which lie deeply in Fig. 2.

FIG. 1. No. 1. The anterior superior spinous process of the ilium. 2. The pubes. 3. Part of the aponeurosis of the external oblique muscle of the abdomen. 4. The lower border of this aponeurosis, forming Poupart's ligament. 5. The tensor vaginæ muscle—its fleshy part. 6. Its lower extremity, where it is inserted into the fascia lata. 7. Part of the gluteus medius still covered by the fascia. 8. The sartorius muscle. 9. Its aponeurosis, where it spreads over the tendons of the gracilis and semi-tendinosus muscle, previously to its insertion. 10. The erectus femoris muscle. 11. Its tendon. 12. The patella. 13. The ligament of the patella. 14. Its insertion into the tubercle of the tibia. 15. The vastus externus muscle. 16. The vastus internus. 17. The psoas and iliacus muscles. 18. The pectineus. 19. The adductor longus. 20. The gracilis.

FIG. 2. No. 1. The crista and anterior superior spinous process of the ilium. 2. The anterior inferior spinous process. 3. The iliac fossa. 4. The ilio-pectineal eminence. 5. The upper surface of the os pubis. 6. Its angle. 7. The capsular ligament of the hip-joint covering the head and neck of the femur. 8. The trochanter major of the femur. 9. The trochanter minor. 10. The shaft or body of the femur. 11. Its inner condyle. 12. The outer condyle and tuberosity. 13. The adductor brevis muscle. 14. The adductor longus. 15, 15. The adductor magnus—its broad fleshy part forming a flat plane behind the two other adductors, which appears both above them and below them. 16. Its tendon, which is prolonged to the tuberosity upon the inner condyle. 17. The external obturator muscle. 18. The quadratus femoris muscle appearing just above the upper border of the adductor magnus, (15,) a slight fissure intervening.

\* Over this oval aperture, called by Scarpa the fossa ovalis, is spread in front of the sheath of the vessels a delicate fascia called the cribriform layer of the fascia lata; this connects the crescentic edge of the falciform process (which is never sharply defined except by the knife of the anatomist) with the pectineal portion of the same fascia lata.—J. P.



Fig 1

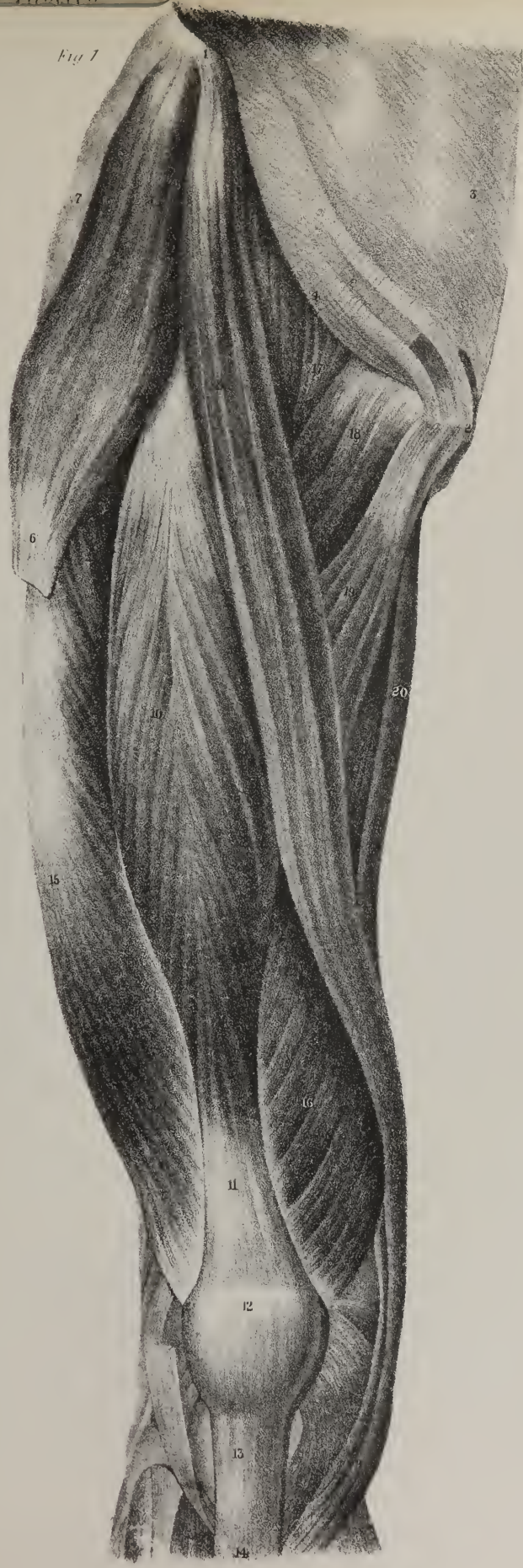
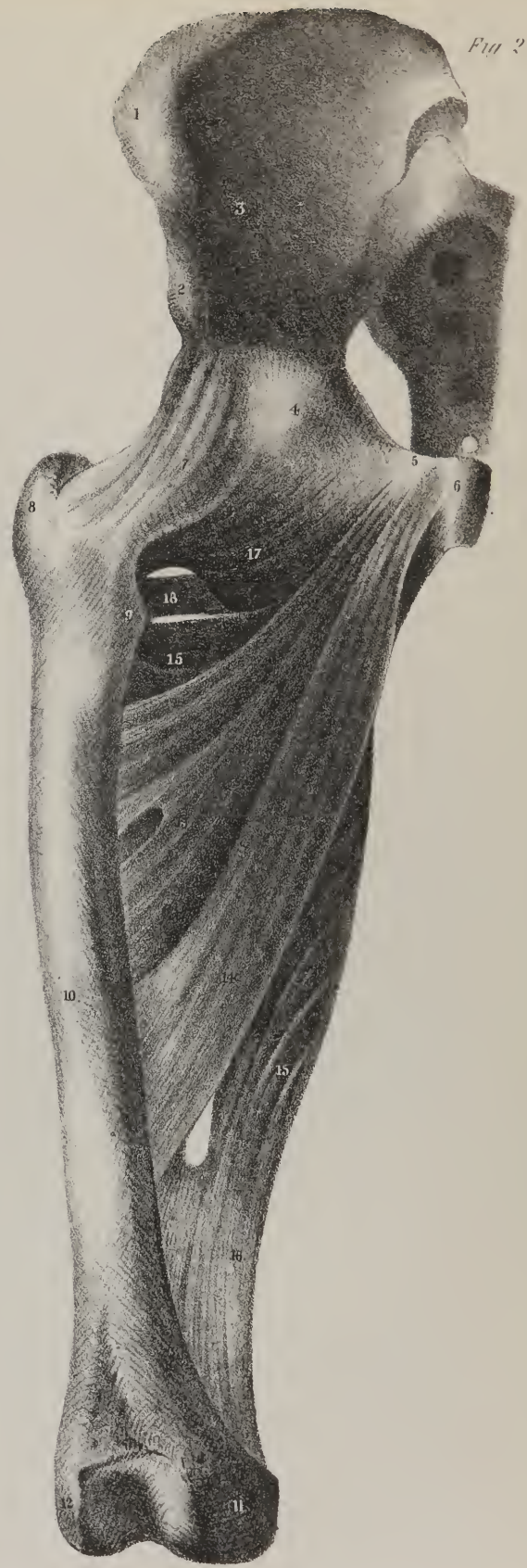

Fig 2







becomes necessary to describe a band of fibres which is strained across the bend of the ankle, and serves to bind down the tendons of the muscles.

The *anterior annular ligament*, fig. 1, No. 18, is attached by one extremity to the external malleolus and to the depression on the upper surface of the calcaneum, from which points the fibres of which it consists pass obliquely inwards, and divide into two fasciculi on reaching the border of the peroneus tertius and common extensor, one of them passing in front, the other behind the tendons of these muscles. At their inner border the fasciculi become united again, thus forming a tube or sheath for the transmission of the tendons. A similar arrangement of these fasciculi obtains as they cross the tendons of the extensor proprius pollicis and tibialis anticus, so that each is made to pass through a separate tube; and, finally, the fibres of the ligament, after having been thus successively separated and united again, are inserted into the internal malleolus. Now, the fasciculus of this band, or ligament, which lies in front of the tendons, is continuous by its upper border with the fascia of the leg, and by the lower with that on the dorsum of the foot, all three lying on the same plane beneath the skin. The *internal annular ligament* is attached, by one extremity, to the inner malleolus and the fibrous sheath of the muscles passing behind it, by the other to the inner margin of the calcaneum. Its superior border is continuous with the fascia of the leg, the inferior gives origin to part of the abductor pollicis; one surface is subcutaneous, the other is in contact with the vessels and tendons of the flexor muscles, which pass under cover of it into the sole of the foot.

The *fascia on the dorsum of the foot*, fig. 1, No. 19, is a thin lamella which covers the extensor tendons, being prolonged from the lower border of the annular ligament forwards to the digital phalanges. When traced towards the external border of the foot, it is found to be attached to the head of the fifth metatarsal bone. Behind this point it becomes blended with the corresponding margin of the plantar fascia, and before it, the membrane folds over the abductor and short flexor of the little toe, and unites with the digital process of the plantar fascia that lies beneath them. When traced along the inner border of the foot, we find the membrane passing over the fleshy fibres of the abductor pollicis. Posteriorly, it is attached to the calcaneum; but in all that part called the hollow of the foot, after covering the muscle just named, it is folded round its outer border, and, for part of its extent, passes deeply towards the tarsal bones, becoming blended with a septum sent upwards by the plantar fascia; farther forwards it unites with the first digital process of the fascia just named. The examination of the fascia in this situation is easily conducted by dissecting it from the tarsal bones, and tracing it over the border and plantar surface of the abductor muscle, when its termination and attachments will be found to be as above stated.

The *plantar fascia* is a dense fibrous structure, extended from the calcaneum to the heads of the metatarsal bones, along the sole of the foot. It is attached behind to the posterior tubercles on the plantar surface of the calcaneum, where its fibres (the greater number of which are longitudinal) are aggregated into a narrow thick fasciculus. From this point the fibres, as they proceed forwards, diverge and arrange themselves into two parts, separated by a depressed interval, one corresponding with the muscles of the little toe, the other with the middle of the tarsus, and the whole width of the metatarsus. The external, or narrow part, after being connected firmly with the fifth metatarsal bone, sends forwards some thin fibres which unite with the last digital process of the larger portion. By its outer border it gives attachment to the fascia of the dorsum of the foot, from the inner it sends a process upwards which contributes to form a septum between the plantar muscles. The broad portion of the fascia becomes thin as its fibres diverge, and ultimately resolves itself into five processes corresponding with the metatarsal bones. Each process, on reaching the digital extremity of these bones, divides into two fasciculi, which separate and become attached to their sides, thus leaving an angular interval for the transmission of the tendons and vessels to the phalanges of the toes. From each border of this part of the fascia a membranous partition is given off, which separates the mass of muscles placed in the middle of the foot from those that are situated along its borders and belong to the great and little toes.

## PLATE XXXII.

The muscles placed at the back of the hip are shown in these drawings just as they lie, layer after layer. At the right side, in fig. 1, the great gluteus muscle is brought into view by the removal of the skin and the fascia; at the left side of the same figure, the middle gluteus muscle, 14, of which part only is seen at the opposite side, is exposed by the removal of the great gluteus muscle. It is seen in its entire extent in Plate XXXIII. fig. 1, No. 13. Lower down are seen the external rotator muscles placed in a series one beneath the other, Nos. 16, 17, 18, 19, 20, 21. In fig. 2, in order to exhibit the third gluteus muscle, No. 9, the second muscle of that name is necessarily taken away:—We shall notice these separately.

The great gluteus muscle, (m. gluteus maximus,) fig. 1, No. 11, forms the prominence of the nates; its bulk and mass indicate at once the powerful action which it exerts. Its fibres are aggregated into thick and coarse fasciculi, and all are superficial, being covered merely by the skin and a thin layer of fascia. The direction of the fibres is oblique as they extend from above

downwards and outwards; they are attached above to the pelvic bones, viz. the ilium, the sacrum, and the coccyx, by means of short tendinous fibres. The three attachments here indicated are marked in the drawing by three numbers, 11, 11, 11. The fleshy fibres will be observed to end in a broad tendon, No. 12, which slides over the great trochanter of the thigh-bone, and is fixed into a rough impression beneath it. The line of insertion of the muscle is indicated at the left side, No. 13\*, where all the rest of the muscle is removed, its femoral attachment alone remaining. It will be observed that two of the borders of the muscle are fixed, and two are free and unattached, the upper one sliding in a manner over the gluteus medius, and the lower one, which forms the fold of the nates, overlaying the long flexor muscles, part of which is here shown. Where the gluteus slides over the great trochanter, provision is made for that degree of free motion which is necessary in this situation, by means of a large secreting membrane or synovial bursa, which lines the contiguous surfaces and enables them to slide smoothly one over the other.

The middle gluteus muscle, (*m. gluteus medius*), No. 14, is seen only in part until the great gluteus muscle is removed. When that is done, its lower part and its insertion, 15, are brought fully into view; it is of considerable extent, and by its mass is enabled to act with great power. Its fibres will be seen to take their points of attachment above upon the ilium, where they are in a manner expanded and radiating; they are fixed to almost every point of the crescent-shaped interval between the crest of the ilium and the origin of the third gluteus muscle, and which is shown in fig. 2, No. 8, where the bone is exposed by the removal of the muscle. The fibres of origin pass downwards and converge to a strong and broad tendon, No. 15, which is fixed into the upper border and external surface of the trochanter major.

The third gluteus muscle, (*gluteus minimus*), fig. 2, No. 9, lies close upon the bone in its entire extent, and it cannot be seen until the others are removed; it is broad and expanded at its upper part where it is composed of fleshy fibres, but it gradually narrows where its fibres run into a tendon, No. 10, previous to its insertion. It is fixed above to the external surface of the ilium, and below to the anterior border and outer surface of the trochanter major.

According to that system of nomenclature which has been constructed on the principle of making the names of muscles express their points of attachment, the great gluteus muscle is called "Ilio-sacro-femoral," the next muscle of that name becomes the great "Ilio-trochanteric," and the third is the small "Ilio-trochanteric."

*Actions.*—These muscles are enabled to act upon the femur and upon the pelvis according as the one or the other becomes relatively the more fixed point. When they act from above and concentrate their effort upon the thigh, they are enabled to draw it outwards, or in other words, they become abductors. The power of the great gluteus muscle in this particular is not a little increased by its being thrown outwards so far from the central line, where it slides over the great trochanter. Whilst executing this movement of abduction, the second and third glutei, by reason of the obliquity of their anterior and posterior fibres, are enabled to impress also a certain degree of rotatory motion upon the thigh-bone either forwards or backwards. Now, suppose the thighs to become the more fixed points, for instance in the standing posture; these muscles act upon the pelvis, and if the body is bent forwards as in the stooping posture, the great glutei, by acting upon the pelvis, draw it backwards, and retain it and the body erect upon the thighs. The bulk of these muscles is characteristic of the human subject; the only being which, in all particulars, is fitted to walk erect.

## PLATE XXXII.

These drawings exhibit the different muscles which lie at the back of the pelvis.

FIG. 1. No. 1. The back part of the sacrum covered by the aponeuroses of lumbar muscles. 2. The coccyx. 3, 3. The articulating processes of the last lumbar vertebra. 4, 4. Its transverse processes. 5, 5. The crista of the os ilium at each side. 6. The great sacro-sciatic ligament. 7. The tuber ischii. 8. The trochanter major. 9. The trochanter minor. 10. The shaft or body of the thigh-bone. 11, 11, 11. The great gluteus muscle, (*m. gluteus maximus*); the references indicate its three attachments to the ilium, to the sacrum and coccyx, and to the great sacro-sciatic ligament. 12. The broad tendon in which the fleshy fibres of the great gluteus muscle end, and which, after sliding over the great trochanter, are inserted into the rough impression which lies beneath it. 13, at the right side, indicates the connexion between the insertion of the muscle and the fascia lata of the thigh; and 13,\* at the left side, marks the line of insertion of the muscle into the thigh-bone. 14, 14. The second gluteus muscle, (*m. gluteus medius*); at the right side part of it only is seen, the rest being concealed by the great gluteus muscle; but at the left side this portion is brought into view by the removal of the great gluteus muscle, part of the fascia which covers it is still left on at the upper third of its extent. 15. The tendon by which the gluteus medius is inserted into the trochanter major. 16. The pyriformis muscle. 17. The superior gemellus. 18. The obturator internus. 19. The inferior gemellus muscle. 20. Small part of the external obturator muscle, (*m. obturator externus*.) 21. The quadratus femoris muscle.

FIG. 2. No. 1. The crista of the os ilium. 2. Its posterior superior spinous process. 3. The back part of the sacrum. 4. The great sacro-sciatic ligament. 5. The small sacro-sciatic ligament. 6. The tuberosity of the ischium. 7. The trochanter major of the thigh-bone. 8. The broad part of the os ilium left uncovered by the removal of the gluteus medius muscle. 9. The third gluteus muscle, (*m. gluteus minimus*.) 10. The tendon by which it is inserted into the trochanter major. 11. The pyriformis muscle. 12. Its tendon. 13. The superior gemellus muscle. 14. The obturator internus muscle. 15. The inferior gemellus muscle. 16. Part of the obturator externus muscle. 17. Quadratus femoris.



Fig. 1.

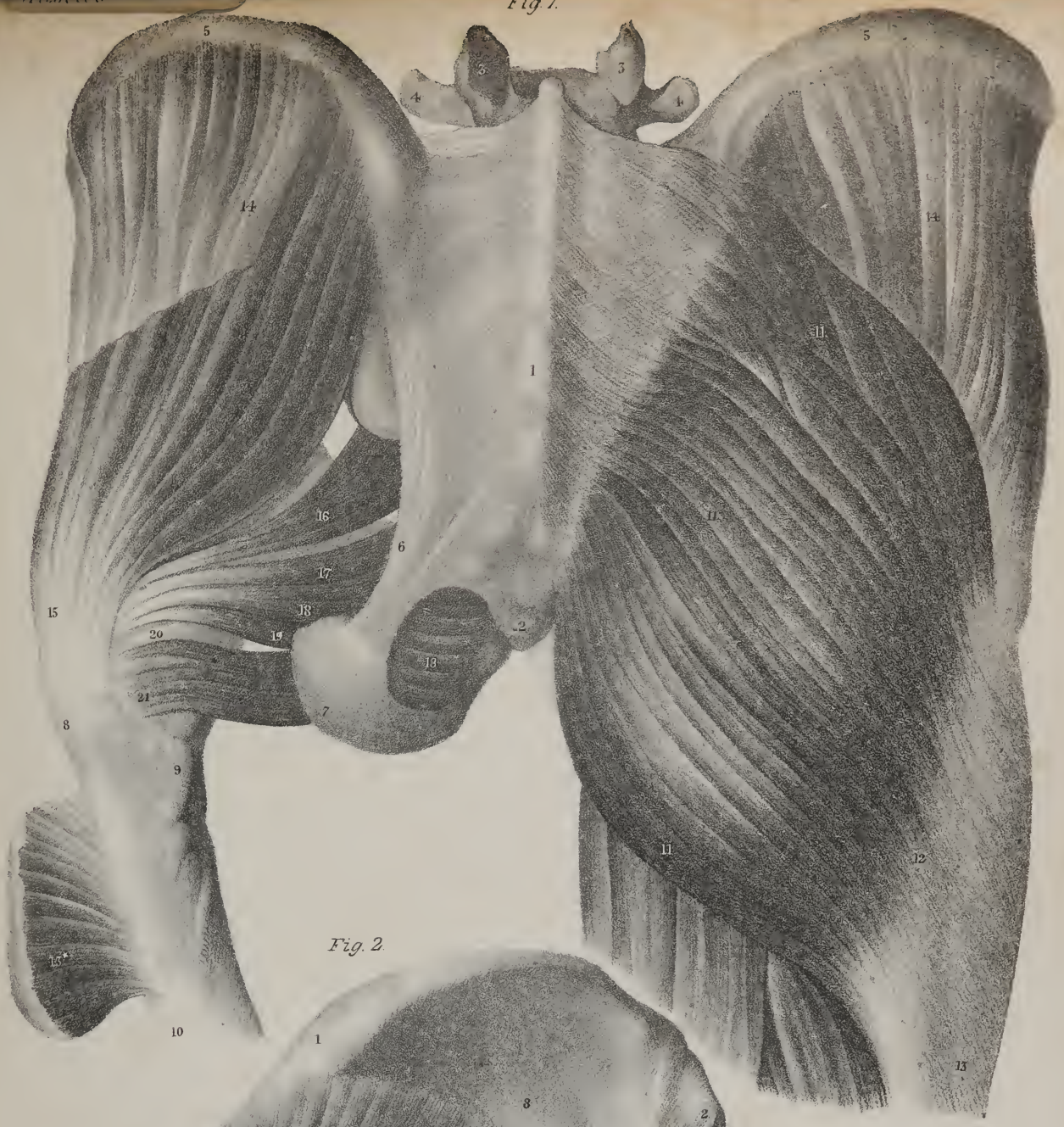
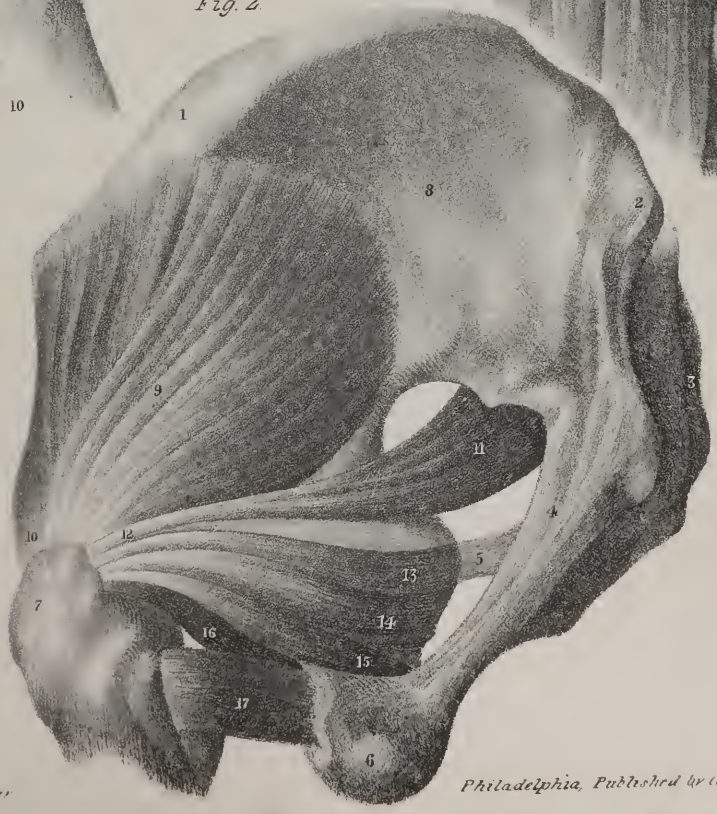

Fig. 2.









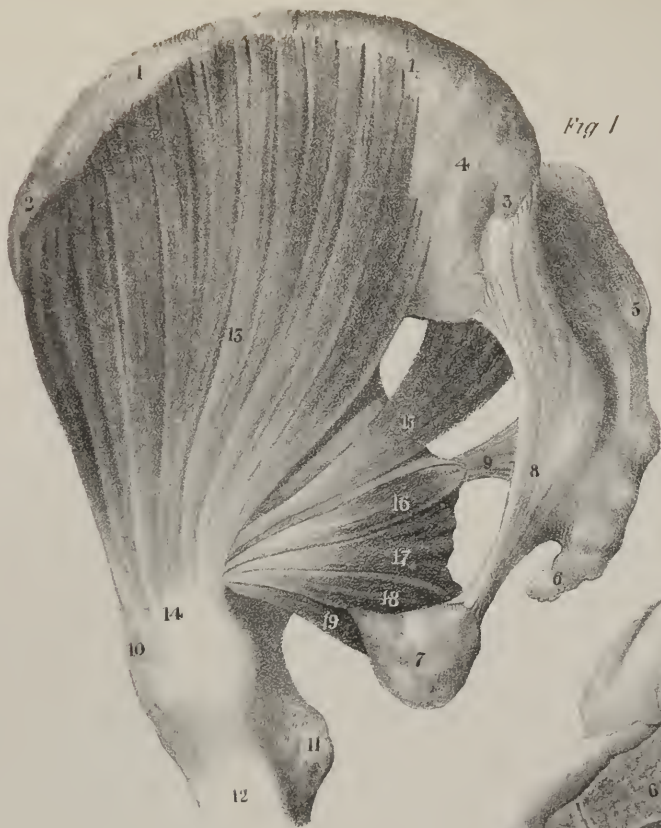

Fig 1

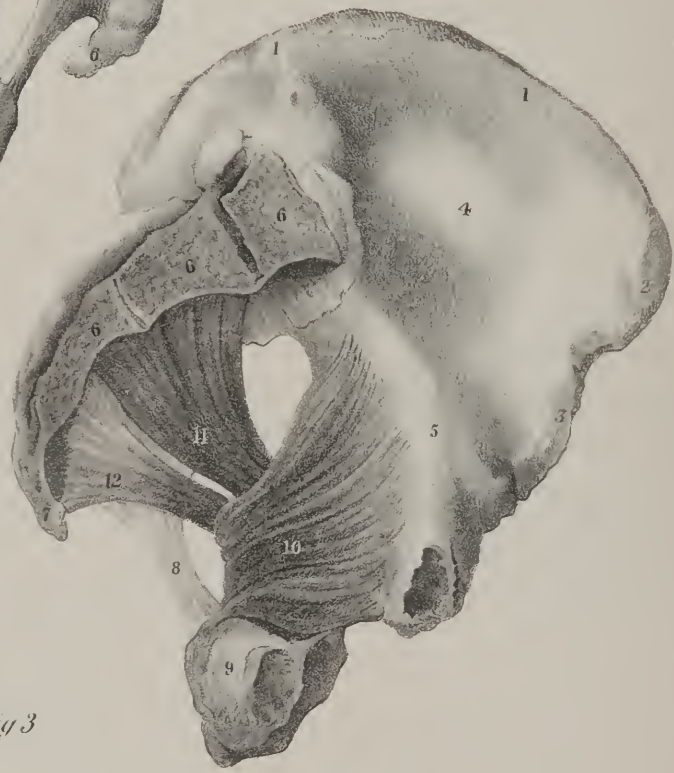


Fig 2

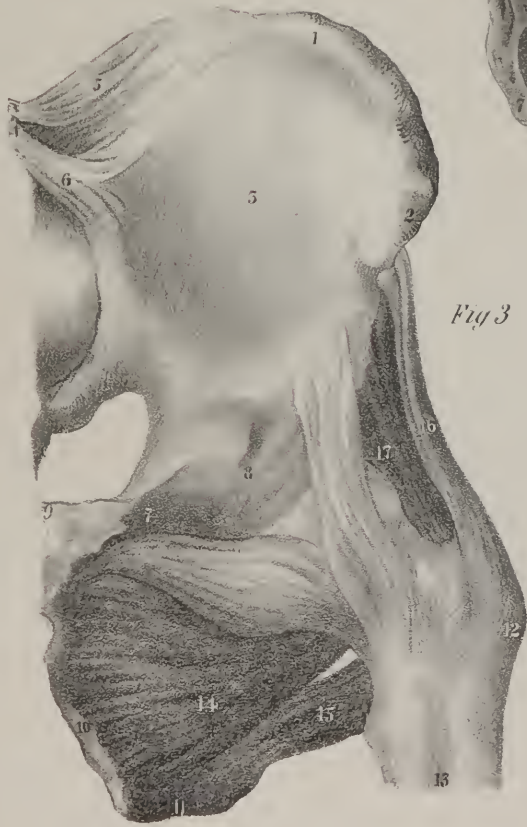

Fig 3

When the second and third glutei muscles take their fixed points below, and concentrate their effort upon their upper points of attachment, it is quite clear that they must influence the whole of the pelvis; for whatever motion is given to any one of its pieces is necessarily propagated to the rest, as they are all bound together and articulated with one another immoveably. Thus, in the effort to stand on one leg, the thigh-bone being rendered fixed, these two muscles act upon the pelvis and draw it in a manner outwards, so as to place it over the head of the bone, by which action they counterbalance the weight of the trunk, and maintain it erect upon the limb. Suppose this to be done at the left side, and the body be made to rest upon the left leg for an instant, if it be intended to advance a step, then the right leg will be carried, or in a manner swung forwards; the pelvis, and through it the whole body, being made to move as it were upon a pivot placed in the left hip joint. When in its turn the right leg is fixed upon the ground, the left is carried forwards in a similar manner, and the rotatory motion coinciding with its advance takes place in the right hip joint. In this way the centre of motion is changed from one joint to the other, and the sides of the pelvis are made to describe curves as they are alternately carried forwards in progression. It is this alternation of action in the muscles of opposite sides, and this change of the centre of motion from one joint to the other, which gives to the pelvis that sort of rotatory movement so perceptible in persons who walk irregularly, and which is so obvious in females in consequence of the great breadth of the pelvis.

*External Rotator Muscles.*—In figs. 1 and 2, Plate XXXII.; and in fig. 1, Plate XXXIII., six small muscles will be observed extending from the pelvis outwards to the upper part of the thigh-bone. They are all deeply seated, being concealed by the great gluteus muscle. These conspire in their action upon the thigh-bone; for they draw the great trochanter, No. 8, towards the tuberosity of the ischium, 7, as will be seen by referring to fig. 1; but as the neck of the bone prevents a direct approximation, a rotatory motion is given to its shaft, by which the whole limb is turned outwards, hence these muscles are named the external rotators of the thigh.

The pyriform muscle, (*m. pyriformis*; *pyramidalis*), fig. 1, No. 16; fig. 2, No. 11, is seen immediately below the border of the second gluteus muscle; it is tapering in its form, a fact which is expressed by its name. Its upper part or origin lies within the pelvis, its fibres being attached to the anterior surface of the sacrum, as may be seen by referring to Plate XXXIII., fig. 2, No. 11. This part of the muscle, which is termed its origin, is broad and fleshy; its fibres incline outwards and downwards, so as to pass out of the pelvic cavity through the great sacro-sciatic notch, and still continuing the same direction, they become narrowed into a tendon, which is inserted into the posterior border of the great trochanter of the thigh-bone, or into the upper part of the digital fossa immediately above the gemelli.

The two gemelli muscles are seen in fig. 1, Nos. 17, 19; fig. 2, Nos. 13, 15; and Plate XXXIII., fig. 1, Nos. 16, 18; these are small, narrow, and short muscles, which extend outwards from the ischium to the pit or fossa under the posterior margin of the great trochanter, enclosing between their contiguous margins part of the internal obturator muscle, fig. 1, No. 18; fig. 2, No. 14. The upper gemellus arises from the spinous process of the ischium, and the lower one from its tuberosity. As they pass

---

## PLATE XXXIII.

- FIG. 1. No. 1, 1. The crista of the os ilium. 2. Its anterior superior spinous process. 3. The posterior superior spinous process. 4. The rough part of the os ilium which gives attachment to the great gluteus muscle. 5. The sacrum. 6. The coccyx. 7. The tuberosity of the ischium. 8. The great sacro-sciatic ligament. 9. The small sacro-sciatic ligament. 10. The great trochanter of the thigh-bone. 11. The small trochanter. 12. Part of the shaft of the bone. 13. The middle gluteus muscle, (*m. gluteus medius*.) 14. Its tendinous insertion into the trochanter major. 15. The pyriformis muscle. 16. The superior gemellus. 17. The obturator internus. 18. The inferior gemellus muscle. 19. The obturator externus muscle.
- FIG. 2. No. 1, 1. The crista of the os ilium. 2. Its anterior superior spinous process. 3. The anterior inferior spinous process. 4. The hollow of the os ilium, (*fossa iliaca*.) 5. The margin of the true pelvis. 6, 6, 6. The sacrum, its different pieces divided in the middle line. 7. The coccyx. 8. The great sacro-sciatic ligament. 9. The tuberosity of the ischium. 10. The internal obturator muscle, (*m. obturator internus*), arising within the cavity of the pelvis, and passing out by the lower sacro-sciatic notch to be inserted into the trochanteric fossa of the thigh-bone between the two gemelli muscles; (see fig. 1, where 17 represents the external or reflected part of the obturator muscle as it lies between the gemellus superior, 16, and gemellus inferior, 18.) 11. The pyriformis muscle arising from the sacrum within the cavity of the pelvis, out of which it passes by the great sacro-sciatic notch to be inserted into the trochanteric fossa above the gemellus superior. (In fig. 1, 15 represents the external part of the pyriformis muscle.) 12. The coccygeus muscle.
- FIG. 3. No. 1. The crista of the ilium. 2. Its anterior superior spinous process. 3. Its concavity or fossa. 4. The transverse process of the last lumbar vertebra. 5. The ilio-vertebral ligament. 6. The ilio-sacral ligament. 7. The body of the os pubis. 8. The ilio-pectineal eminence. 9. The inner edge of the os pubis which forms its symphysis. 10. The ramus of the os pubis joining with that of the ischium. 11. The tuberosity of the ischium. 12. The trochanter major of the thigh-bone. 13. Part of the shaft of the thigh-bone. 14. The external obturator muscle, (*m. obturator externus*), which is broad and expanded at its origin, and gradually narrows as it passes behind the neck of the thigh-bone to be inserted into the lower part of the trochanteric fossa. (In fig. 1, No. 19 represents the prolonged part of the obturator externus muscle lying beneath the inferior gemellus.) 15. The quadratus femoris muscle. 16. Part of the anterior edge of the gluteus medius muscle. 17. Part of the gluteus minimus muscle.



outwards, each becomes narrow and tendinous, and at the same time contracts a more intimate connexion, or rather union, with the obturator muscle which lies between them, all three becoming inserted together into the fossa above indicated.

The internal obturator muscle, (*m. obturator internus*), fig. 1, No. 18; fig. 2, No. 14, is seen only in part in these drawings, the rest of it being concealed within the pelvis. When this cavity is laid open so as to obtain a side view of its interior, as in Plate XXXIII., fig. 2, No. 10, the muscle will be observed to be broad and expanded, its fibres being attached to a considerable extent along the side of the pelvis, for they are fixed to the inner surface of the os pubis, also to the obturator ligament, and to the ischium nearly as far back as the margin of the great sciatic notch. From these points they converge as they pass outwards, in order to issue from the pelvic cavity, through the lower or small sciatic notch. In this situation the direction of the muscle becomes changed, for it runs outwards and forwards, lying between the two gemelli, together with which it is inserted into the digital or trochanteric fossa in the upper part of the thigh-bone. This muscle acquires considerable increase of power by the change in its direction, for as it slides smoothly upon the border of the ischium, it moves upon a pulley-like surface, and in its action works with all the advantage which such a contrivance can give it.

The square muscle, (*m. quadratus femoris*), fig. 1, No. 21; fig. 2, No. 17, stretches outwards from the border of the tuber ischii, and is inserted into the posterior margin of the great trochanter; it is short, compressed, and flat, its form being that of an oblong square, and, as to its structure, it is almost all fleshy, there being but a slight admixture of tendinous fibres even at its attachments.

The external obturator muscle, (*m. obturator externus*), is seen only in a small part of its extent in plate XXXII. fig. 1, No. 20, fig. 2, No. 16; this is owing to the manner in which the muscle passes from the front of the pelvis behind the neck of the thigh-bone to reach its point of insertion, viz. the trochanteric fossa. By referring to plate XXXIII. fig. 3, No. 14, the position, form, and general direction of the muscle will be seen: it lies very deeply, being covered by all the muscles at the upper and inner part of the thigh; its direction is transversely outwards, its structure fleshy in the greater part of its extent, but it ends in a tendon previously to its insertion, and, at its origin, there are a few aponeurotic fibres. It is broad and expanded where it is attached to the pelvis, its fibres being fixed to the external flat surface of the os pubis, to the rami of the os pubis and ischium, and to part of the ligament which fills up the obturator foramen. As the fibres incline outwards they gradually become aggregated together so as to form a thick and narrow fasciculus, which necessarily is directed behind the neck of the thigh-bone, in order to reach the point of insertion above indicated.

*Actions.*—The six muscles included in this group conspire in their action upon the thigh-bone; they run outwards, so that the direction of the fibres in most of them forms a right angle with that of the shaft of the femur; this, together with the mechanical advantage given them by the length of the neck of the femur, enables them to concentrate their effort with much effect, so as to turn the whole limb upon its axis, and rotate it outwards. In their direction and mode of action, the muscles of this group bear a very close resemblance to those which are placed upon the back of the scapula, and are inserted into the great tuberosity of the os humeri.

## PLATE XXXIV.

FIG. 1. No. 1. The crest of the ilium. 2. Its anterior superior spinous process. 3. The tendinous origin of the sartorius muscle, (*m. couturier*.) 4. Its fleshy part. 5. The upper surface of the body of the os pubis. 6. Its angle. 7. The pectineus muscle. 8. The long adductor muscle, (*m. premier adducteur*.) 9. The tensor vaginae femoris muscle. 10. Its lower part, where it becomes inserted into the fascia lata of the thigh. 11. The anterior part of the gluteus medius muscle, (*m. moyen fessier*.) 12. Its tendinous insertion into the trochanter major. 13. Part of the gluteus maximus muscle, (*m. grand fessier*.) 14. Its tendon of insertion into the femur. 15. The middle fleshy part or body of the rectus femoris muscle, (*m. droit antérieur*.) 16. Its tendon passing down to be inserted into, 17, the patella; 18. part of the vastus internus muscle; 19. the vastus externus muscle; both these are seen to unite at their lower part with the tendon of the rectus muscle. 20. The long head of the biceps flexor cruris muscle. 21. The short head of the same muscle. 22. Its tendon of insertion where it becomes fixed to the head of the fibula. 23. The external head of the gastrocnemius muscle.

FIG. 2. No. 1. The external surface or dorsum of the ilium. 2. The trochanter major of the thigh-bone. 3. The tuberosity of the ischium. 4. The great sacro-sciatic ligament. 5. The superior gemellus muscle. 6. The internal obturator muscle. 7. The inferior gemellus muscle. 8. The quadratus femoris muscle. 9. The insertion of the great gluteus muscle: its fibres are shown as if cut off close to the bone, in order that its position at this point, and its relations to the adductor magnus and the vastus externus, may be clearly seen. 10, 10. The vastus externus muscle: the two references indicate its upper and lower part, for it extends from the base of the trochanter to the patella. 11. The long head of the biceps flexor cruris muscle. 12, 12. The short head of the same muscle: its fibres are seen to project, in this view, at each side of the tendon of the long head, into which they become inserted. 13. The tendon of the biceps flexor muscle near its insertion into the head of the fibula. 14. The semi-tendinosus muscle. 15. Its tendon. 16, 16. The semi-membranosus muscle, which is broader than the preceding, and projects on each side of it. 17. The tendon of the semi-membranosus muscle. 18. The posterior ligament of the knee-joint. 19. The gracilis muscle, (*m. droit interne*.) 20. Its tendon. 21. Part of the sartorius muscle. 22, 22. The upper part of the adductor magnus muscle.



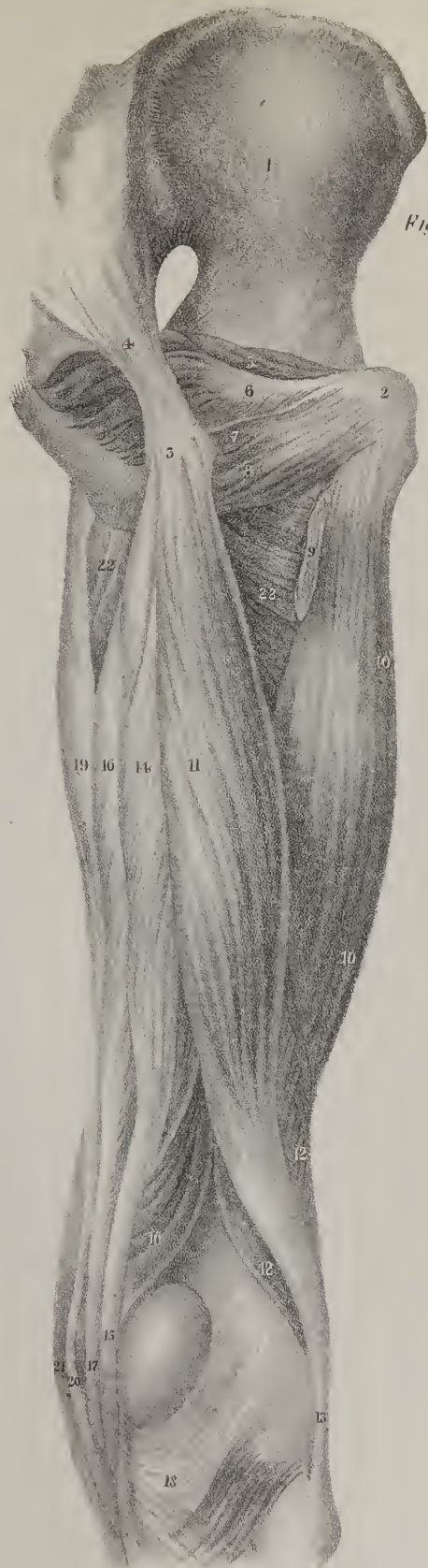

Fig 2.




Fig 1.



On reviewing the muscles exhibited in these drawings, it will at once be observed how many provisions there are for turning the thigh outwards. The psoas and iliacus muscles, which we have exhibited in a former number, are also to a certain extent rotators; and even the adductors of the thigh can turn the femur somewhat on its axis, and incline it outwards. Now, when so many moving powers conspire to produce such a result as this, it will be asked what are their opponents? We find that the antagonizing powers are few, and comparatively feeble. The tensor vaginae femoris is enabled, by its peculiar direction and mode of connexion with the fascia lata, to act upon the thigh, and rotate it inwards, and the anterior fibres of the gluteus medius muscle assist in producing the like result by reason of their oblique direction, and their insertion into the great trochanter. These are the only antagonists to the external rotator muscles, and accordingly we find that the power of turning the limb inwards is comparatively feeble, and that the effort is made with something of restraint, if not with awkwardness.

## PLATE XXXIII.

THE muscles exhibited in this plate have been already described with the two groups above noticed, viz. the glutei, and the external rotators; their names are given in the references at the foot of the page. One muscle, however, is here shown, which does not belong to either set, as it forms part of the deep perinæal, which we shall have to notice in a subsequent number: it is the coccygeus, fig. 2, No. 12; it may be called ischio-coccygeus, so as to make its name express the points to which it is attached. It is a flat triangular muscle placed at the outlet of the pelvic cavity at its outer and back part, which it assists in some degree to close, by being stretched from the spinous process of the ischium to the side of the coccyx and the contiguous part of the edge of the sacrum; it is composed of tendinous and fleshy fibres, and is so placed that its inner surface supports the rectum, and the external one is covered by the lesser sacro-sciatic ligament.

*Dislocations of the Hip-joint.*—We can scarcely dwell for any length of time upon the lines of direction of the different muscles round a joint, and their points of attachment to the bones which form it, without making an endeavour to determine what their several and combined actions are in the natural condition of the parts; and when we have made this step, and have fixed in our mind an accurate conception of the powers and influences of the muscles, we are insensibly led to inquire what is their state and condition when one of the bones is displaced. It is obvious that the muscles under such circumstances are thrown into a new relation with regard to the joint;—the line of direction of some is changed; the fibres of one set are put upon the stretch in consequence of their points of attachment being farther apart in the new position of the bones than previously; and this may be carried so far in particular instances, that laceration of the muscular structure, or of the tendons, may be produced. In other cases, on the contrary, the muscular fibres are relaxed, owing to their points of attachment being approximated. These various conditions of the muscles influence the state of the limb, and determine its line of direction, as well as the aspect and outline which the neighbouring region of the joint presents; hence the phenomena of dislocations form a proper sequel to the study of the actions of muscles, more particularly as they are the opponents which resist our efforts to restore the bones to their natural position.

Dislocation of the thigh-bone is not by any means so frequent as that of the humerus. It may take place in either of four directions; the most frequent form of the accident is that in which the head of the bone is thrown upwards and backwards on the dorsum of the os ilii; the next is that in which it is thrown downwards and inwards on the foramen ovale; the third is that in which it passes backwards into the ischiatic notch; and the fourth where it rests upon the body of the os pubis. Were we to endeavour to determine the relative frequency of these displacements by *a priori* considerations founded on the structure of the joint, and not by appealing to the results of experience, or were it left to a mere anatomist to determine the question, he would be very likely to say that the dislocation into the foramen ovale must be more frequent than that upon the dorsum ilii, for the margin of the articular cavity at its upper and outer part is more prominent than at the lower and inner,—the capsular ligament is thick and strong in the former situation, and comparatively thin and weak in the latter; added to this, the movement of abduction may be carried to a very considerable extent, which will make the head of the bone glide downwards and inwards, where the least resistance is opposed to it; yet, of twenty cases, the results of which have been noticed in Guy's Hospital, twelve presented the first form of dislocation, five that into the foramen ovale, three that on the os pubis, and one into the ischiatic notch.

When the bone is thrown backwards upon the dorsum ilii, the state of the limb is as follows: it is rendered shorter than its fellow by about two inches, so that the great toe rests upon the tarsus of the other foot: the foot and the leg are turned inwards, and the knee somewhat advanced before the opposite one: the hip loses its roundness and fulness, the nates appearing somewhat flattened when compared with that of the sound side; and the trochanter major is thrown upwards so as to be brought nearer the anterior superior spinous process of the ilium; the foot cannot be turned outwards without causing much pain, but its inclination inwards may be increased. The limb will not admit of being abducted, but it may be drawn slightly across that of the



other side. It is usually said that this accident may be confounded with fracture of the neck of the thigh-bone, but these accidents have but one circumstance in common, viz. the shortening of the limb. In the fracture just named, the knee and foot are turned outwards; the thigh may be raised up somewhat towards the abdomen, although the attempt to effect this causes pain; and lastly, by a slight degree of extension, the length of the limb can be restored to its usual length, but it will become shortened again when the extension is discontinued.

When we refer to the reports of cases\* of dislocation on the dorsum ilii, we find that this accident may occur under various circumstances. A man who worked as a labourer in a deep clay-pit "was in the act of stooping, with his left knee bent behind the other," when a large mass of clay fell upon him, so as to bury him in the earth. When removed from this position, the thigh-bone was found to be thrown upon the ilium. In another case, the displacement was occasioned "by a cart passing over the pelvis." A robust man "fell from a height of about four feet, and dislocated his hip." A carter, "in springing from the shaft of a wagon, slipped, and had his hip driven against the wheel with considerable force." The wheel of a cart "passed between a man's legs and over the upper part of the thigh, and produced dislocation on the dorsum ilii;" and the same accident occurred to a child, who, "whilst swinging on the shaft of a cart, which, being insecurely propped, suddenly gave way, and she fell to the ground upon her side." These different statements, taken from Sir A. Cooper's work on dislocations, merely make us acquainted with the circumstances under which the accident has occurred, and therefore might occur again, but do not furnish us with any adequate data from which we may infer how it is produced. It is not easy to perceive what they have in common, or why the same identical result should follow from accidents so various in their degree and character. Still, however vague and indeterminate they may be, they are of importance, inasmuch as they are taken from authentic reports of cases treated by competent persons. The following passage from Boyer† will show the risks which even the best-informed men incur of falling into error when they venture to decide upon subjects of this sort by *à priori* considerations. "When by a fall, from a place more or less elevated, on the soles of the feet, or on the knees, the thigh is pushed forwards and inwards, the head of the femur, forced towards the superior and external part of the acetabulum, breaks the internal and orbicular ligaments, escapes through a laceration in the latter, and ascends on the external face of the os ilium; but as the part of the os ilium immediately above and at the external side of the cavity is very convex, the head of the femur soon abandons its first position, and slides backwards and upwards into the external fossa of the os ilium, following the inclination of the plane towards the fossa, and obeying the action of the glutei muscles, which draw it in this direction. The head of the femur, in ascending thus on the external face of the os ilium, pushes upwards the gluteus minimus, which forms a sort of cap for it; and the gluteus maximus and medius are relaxed by the approximation of the points into which they are inserted. The pyriformis is nearly in its natural state; the gemini, obturatores, and quadratus femoris, are a little elongated. The psoas magnus and iliacus internus are relaxed, as are also the other muscles inserted into the trochanter minor. If to this description it be added that the orbicular ligament, torn at its superior part, is stretched over the acetabulum and covers it, an exact idea may be formed of the changes occasioned in the surrounding parts by this luxation of the femur."

The statement here given in the words of M. Boyer, has evidently been drawn up, not from any case of dislocation which this distinguished surgeon had observed himself, or from any "post mortem" examination which he had ever conducted. We cannot find any case in which luxation of the thigh-bone backwards and upwards was produced by a fall on the soles of the feet or on the knees, yet from the passage above cited it would appear to be the most ordinary cause of the accident; and the condition of the muscles round the joint appears to be indicated from anatomical considerations, and not founded on observation. In the third volume of the Dublin Hospital Reports a case is detailed at considerable length by Mr. Todd, which places in a clear point of view the condition of the different textures about the hip-joint in this form of dislocation. The nature of the accident was ascertained soon after its occurrence, and the efforts to effect the reduction of the dislocation were successful; but the patient died from the injuries which he had previously sustained. When proceeding with the dissection, Mr. Todd found, "after he had raised the gluteus maximus, a cavity filled with coagulated blood between it and the posterior part of the gluteus medius;" this obviously marked the position which the head of the bone had occupied; the glutei muscles were uninjured, but "the rotators, together with the pyriformis, were torn across." Some fibres of the pectineus also were torn; the capsular ligament of the joint remained entire at its upper and fore part, but was torn in all the rest of its extent. The round ligament was broken off near the head of the femur. Thus the condition of the muscles was found to be very different from that which Boyer had indicated. It is to be regretted that the report does not expressly say what was the state of the psoas and iliacus muscles: Boyer had inferred that they were relaxed as well as "the other muscles inserted into the trochanter minor," by which latter clause he doubtless alludes to the pectineus, which is inserted a little beneath it. But this muscle appears to have been stretched, so that "some of its fibres were even torn;" and such, we make no doubt, was the condition of the psoas and iliacus, both at the moment in which the head of the bone was sliding over the rim of the acetabulum, and even subsequently, when it rested upon the dorsum ilii; for the trochanter minor, though raised above its natural position, is carried so far back that the distance between the point of

\* A Treatise on Dislocation and Fractures, by Sir Astley Cooper, p. 41, et seq.

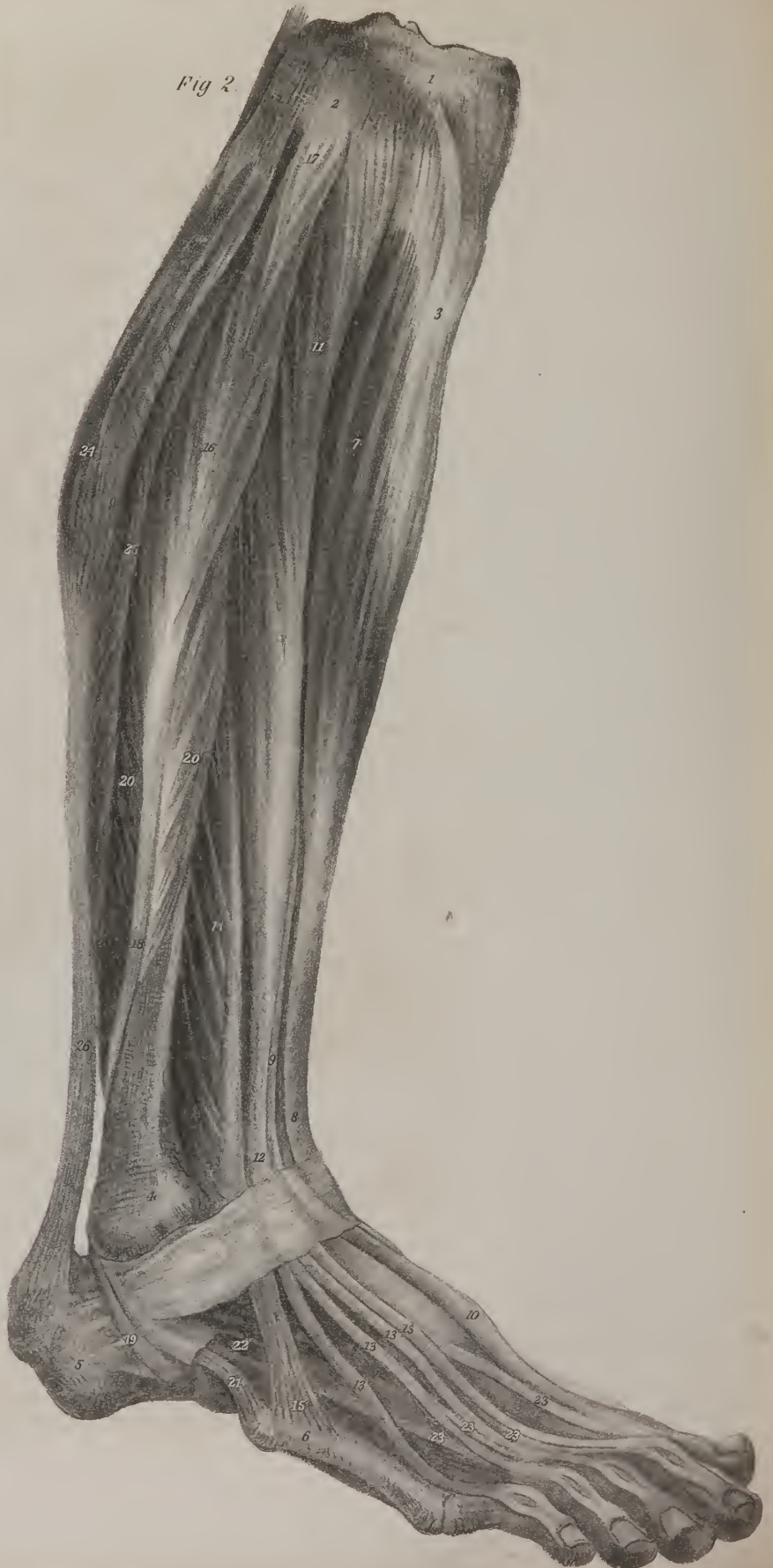† Lectures on Diseases of the Bones, vol. ii. p. 158.



Fig 1.



Fig 2.





insertion of the muscles, and the brim of the pelvis over which they slide, is greater in the new position of the limb than in its natural state; in other words, these two muscles as well as the pectineus are in a state of tension, and to this is owing the position in which the injured limb is found, viz. that it is drawn forwards and inwards, and in advance of that of the opposite side. Moreover, the mode in which the extension is made by all surgeons has reference to the condition of the psoas and iliacus muscles, for the limb is drawn, at least when the extension is being commenced, in that direction which is most likely to relax them.

It has often been asked how it comes to pass that the foot and limb are turned inwards in this form of dislocation. Boyer inclines to the opinion, that it depends on the external portion of the capsular ligament, which comes from the anterior inferior spine of the ilium; this portion, which is very thick, being stretched in the luxation upwards, draws the great trochanter forwards, and thereby turns the entire limb inwards. He had previously laid down the general principle, that the position of limbs when luxated is always "determined by the elongation of the muscles of the side opposite to that to which the luxated bone is carried;"—for instance, in the luxation of the arm downwards into the axilla, the deltoid and supra-spinatus muscles, being stretched by the separation of their points of attachment, give the arm an oblique direction, and cause the elbow to project outwards from the side. If he had followed up this view of the case, he would have concluded that the trochanter was drawn forwards, at the moment in which the head of the bone is slipping over the brim of the acetabulum, by the contractile effort of the anterior fibres of the gluteus medius, which are then put on the stretch, and that they are aided in this by the tensor vaginæ femoris. But the influence of these two muscles he overlooked, and dwelt on the power of the short external rotators, which he supposed to remain entire, and still to possess their ordinary power over the limb, were they not controlled by some superior agency. His words are, "the obturatores, gemini, and quadratus femoris, being elongated, the point of the foot ought to be turned outwards:" but finding in all cases the reverse to be the fact, he comes to the conclusion that the power of the muscles is contravened by the ilio-femoral ligament. Sir Astley Cooper gives a different explanation of the position of the limb; he says it may be caused "by a fall when the knee and foot of the patient are turned inwards, or by a blow whilst the limb is in that position, and the head of the bone is thus displaced upwards and turned backwards." It is difficult to conceive how the head of the bone could quit its articular cavity whilst the limb is in the extended position, so as to be forced upwards, unless the brim of the acetabulum were at the same time broken. It may be forced backwards by a sudden and violent blow given to the posterior edge of the trochanter when a person is unprepared for any such occurrence; for, under these circumstances, the head of the bone is made to glide backwards to the posterior lip of the acetabulum, and to press so forcibly against the capsular ligament as to tear through it and escape from the articulation. We can readily perceive that this luxation may be produced by a force applied to the outer side of the knee

## PLATE XXXV.

- FIG. 1. No. 1. The sacrum, divided along the middle line. 2. The coccyx. 3. The os pubis; the line of its symphysis. 4. Its ramus. 5. The tuberosity and ramus of the ischium. 6. The internal obturator muscle, as seen within the pelvis, from which it passes out through the small sacro-sciatic notch; its external portion is shown in several of the preceding plates; for instance, in plate XXXIV. fig. 2, No. 6. 7. The origin of the pyriformis muscle from the anterior surface of the sacrum. 8. The gracilis muscle lying along the inner side of the thigh, and ending in a tendon, 9, which is prolonged to the tibia. 10. The semi-tendinosus muscle. 11. Its tendon. 12. The semi-membranosus muscle. 13. The biceps flexor cruris muscle. 14. Its tendon passing to its insertion into the head of the fibula. 15. The lower part of the sartorius muscle. 16. Part of the vastus internus muscle. 17. A small portion of the rectus femoris muscle. 18. The adductor magnus muscle, which is seen to be attached above to the tuberosity and ramus of the ischium. 19. A small part of the same muscle which is fixed higher up to the ramus of the os pubis. 20. A small portion of the adductor brevis muscle. 21. The upper part of the adductor longus muscle, where it descends from its attachment to the angle of the os pubis. 22. The patella. 23. The popliteal space, being the deep interstice between the flexor or ham-string muscles. 24. The upper part of the gastrocnemius muscle.
- FIG. 2. No. 1. The outer head or tuberosity of the tibia. 2. The upper head of the fibula. 3. The anterior tubercle of the tibia. 4. The lower extremity of the fibula, forming the external ankle. 5. The posterior part of the os calcis. 6. The fifth metatarsal bone. 7. The tibialis anticus muscle. 8. Its tendon passing down under the annular ligament. 9. Part of the tendon of the extensor proprius pollicis muscle, as seen in the interstice between the tibialis anticus and the common extensor muscle. 10. The tendon of the extensor pollicis, where it rests on the dorsum of the foot, after having passed under the anterior annular ligament. 11. The upper fleshy portion of the common extensor muscle of the toes. 12. Its tendon passing down to the ankle and under the annular ligament. 13, 13, 13. The four tendons which are given off by the common tendon, and proceed over the foot to the four lesser toes. 14. The peroneus tertius muscle. 15. Its tendinous insertion into the fifth metatarsal bone. 16. The fleshy part of the peroneus longus muscle. 17. Its tendinous attachment to the head of the fibula. 18. Its tendon passing down behind the external ankle. 19. The same tendon, where it runs upon the outer side of the os calcis, and passes into the sole of the foot. 20, 20. The peroneus brevis muscle; the two references indicate that its fibres project on each side of the tendon of the peroneus longus. 21. The tendon of the peroneus brevis passing to its insertion into the posterior extremity of the fifth metatarsal bone. 22. The extensor brevis digitorum muscle. 23, 23, 23. The four tendons which it gives off to the four inner toes. 24. The upper fleshy part of the gastrocnemius muscle. 25. The outer border of the soleus muscle. The fleshy fibres of this muscle and of the gastrocnemius are seen passing with various degrees of obliquity to be inserted into the tendo Achillis, 26; and this descends to be fixed to the posterior extremity of the os calcis.

when the limb is in the semi-flexed position, for then the head of the bone, sliding backwards and upwards in the acetabulum, is forced against the capsular ligament and ruptures it. In this state the rotators have little power, for the line of direction of most of them nearly coincides with that of the femur; and this is the position in which the anterior fibres of the gluteus medius and the tensor vaginæ can act upon the trochanter major, and draw it forwards, thereby placing the head of the bone in the position which it is known to assume in the dislocation on the dorsum ilii.

*Dislocation into the foramen ovale.*—The head of the thigh-bone is in some cases displaced in the opposite direction from that which we have above stated, and thrown downwards into the situation of the foramen ovale. Were we to judge solely from the anatomical conformation of the joint and the movements of the limb, we should be disposed to conclude that this displacement would occur more frequently than that on the dorsum of the ilium; for the capsular ligament is weaker at the lower and inner part of its extent than elsewhere, and the round ligament, by reason of its attachment to the margins of the cotyloid notch, does not check the descent of the bone towards the foramen ovale: Boyer goes so far as to say that the rupture of the round ligament is not a necessary consequence of this form of dislocation; upon which point, however, he is at issue with Sir Astley Cooper, who states that “the ligamentum teres, as well as the lower and inner part of the capsular ligament, is torn through;”—finally, this form of accident is in a manner facilitated by the great extent to which the thigh may be abducted. Notwithstanding all these circumstances, the dislocation on the dorsum of the ilium is found to be of more frequent occurrence. The head of the bone cannot be thrown downwards and inwards unless when the thigh is in a state of forcible abduction, a position in which the limb is placed in many accidents to which persons are liable. When this displacement occurs, the limb is found to be about two inches longer than the other, the trochanter major is less prominent, the knee is carried forwards and separated from the other, so as not to admit of being brought into contact with it, or approximated to the axis of the body without great difficulty. In the standing posture the body is bent forwards; the foot, though widely separated from the other, is stated by Sir Astley Cooper to be turned neither outwards nor inwards; in his plate it is figured as if the toe were directed forwards, but he does not consider that the direction of the foot affords any diagnostic mark of the accident, as he found it to vary somewhat in different instances. The increased length of the limb, the separated knees, the bent position of the body, all point to the nature

## PLATE XXXVI.

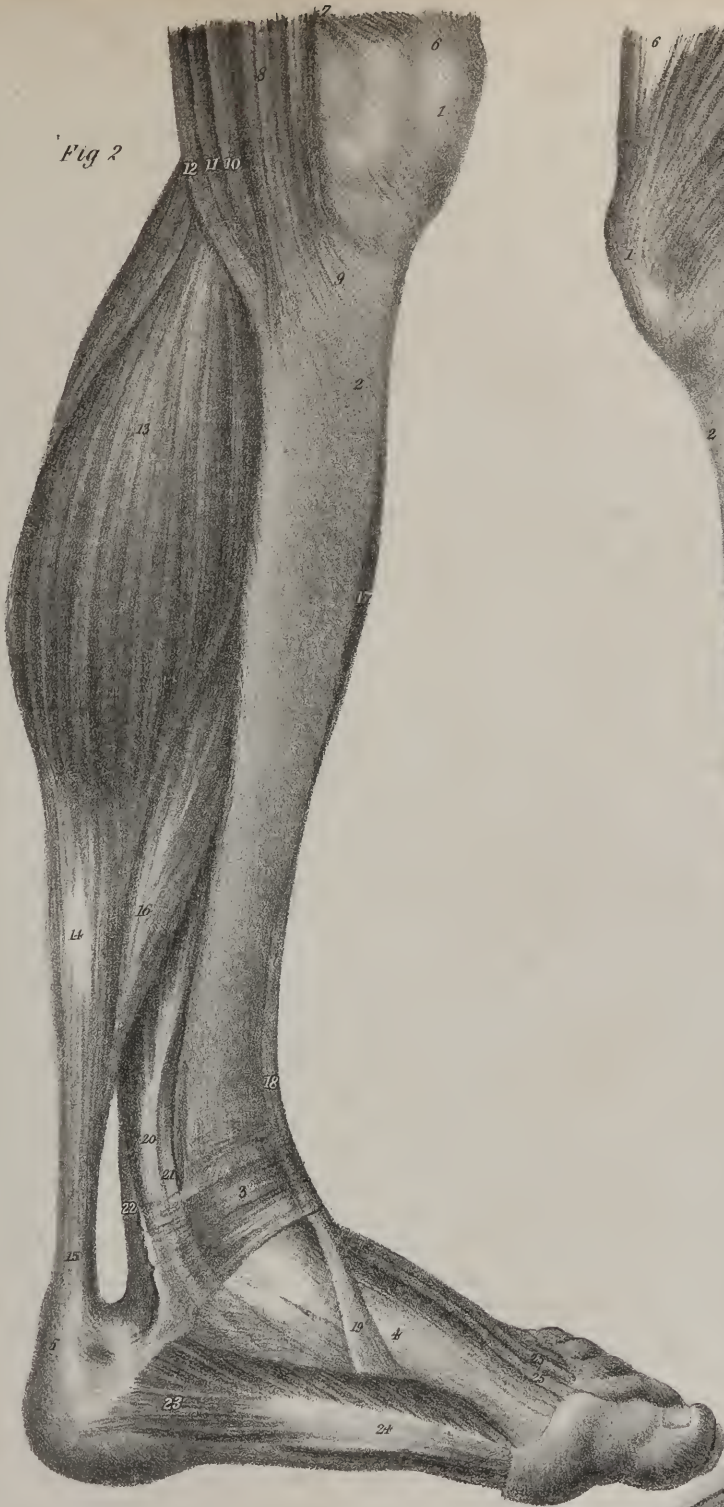FIG. 1. The muscles of the leg are here shown as they are seen at its outer side when the skin and the fascia are removed.

No. 1. The patella. 2. The upper extremity of the tibia. 3. The external ankle, formed by the lower extremity of the fibula. 4. The posterior extremity of the fifth metatarsal bone. 5. The os calcis. 6. Part of the tendon of the rectus femoris muscle, where it descends to its insertion into the patella. 7. Part of the vastus externus muscle. 8. The biceps flexor muscle. 9. The upper extremity, or origin, of the long peroneus muscle. 10. The fleshy part of the same muscle. 11, 11. Its tendon passing down behind the external malleolus, and upon the outer side of the os calcis, from which it is prolonged into the sole of the foot, after having turned round its outer border. 12, 12. The fleshy part of the peroneus brevis muscle; its fibres are seen projecting beyond the tendon of the peroneus longus. 12.\* The tendon of the peroneus brevis passing to its insertion into the fifth metatarsal bone. 13. The external head of the gastrocnemius muscle. 14. Its tendon,—tendo Achillis. 15. The lower part of the same tendon descending to its insertion into the os calcis. 16. The soleus muscle; its fibres are seen descending obliquely backwards to be inserted into the tendo Achillis. 17. The fleshy part of the tibialis anticus muscle. 18. Its tendon passing down towards the ankle. 19. The same tendon where it inclines towards the inner border of the foot: its position previously to its insertion is shown in fig. 2, No. 19. 20. The extensor communis digitorum muscle. 21. The tendon in which its fleshy fibres end. 22, 22, 22, 22. The digital processes into which this tendon divides, and which are prolonged over the dorsum of the foot to the four smaller toes. 23. The peroneus tertius muscle. 24. Its tendon at its insertion into the fifth metatarsal bone. 25. The tendon of the extensor muscle of the great toe (m. extensor pollicis longus,) appearing in the interstice between the tendons of the tibialis anticus and extensor communis digitorum: from this point it will be observed to descend in front of the ankle-joint, and from thence over the dorsum of the foot to the great toe. 26. The extensor brevis digitorum muscle; on the dorsum of the foot.

FIG. 2. The muscles of the leg and foot, as seen at the inner side, after the skin and fascia have been removed.

No. 1. The patella. 2. The front of the tibia. 3. The anterior annular ligament of the ankle-joint. 4. The articulation of the base of the first metatarsal bone. 5. The os calcis. 6. The tendon of the rectus muscle, close to its insertion into the patella. 7. A few fibres of the vastus internus muscle. 8. The sartorius muscle, as it passes by the inner side of the knee-joint. 9. The expanded aponeurosis in which this muscle terminates previously to its insertion into the tibia, and which will be observed to conceal the tendons of the gracilis and semi-tendinosus muscles. 10. The tendon of the gracilis muscle. 11. Part of the semi-membranosus muscle. 12. The semi-tendinosus muscle. 13. The inner head of the gastrocnemius muscle. 14. The upper broad part of the tendo Achillis, in which the fibres of the gastrocnemius and of the soleus terminate. 15. The lower part of the tendo Achillis, near its insertion into the os calcis. 16. The inner edge of the soleus muscle; its fibres are seen inclining obliquely backwards as they descend to be inserted into the tendo Achillis. 17. A few fibres of the anterior edge of the tibialis anticus muscle. 18. Its tendon, as it descends obliquely inwards. 19. The same tendon turning to reach the inner border of the foot, beneath which it is inserted into the internal cuneiform and first metatarsal bone. 20. The tendon of the flexor communis digitorum muscle; 21. the tendon of the tibialis posticus muscle:—these are observed passing down behind the internal ankle in order to reach the sole of the foot. 22. Part of the tendon of the flexor longus pollicis, which in this view can be but slightly seen. 23. The origin of the adductor pollicis muscle. 24. The tendon in which its fleshy fibres terminate. 25, 25. Two of the tendons of the extensor communis digitorum muscle.









of the accident; and if at the same time a hollow is perceived beneath Poupart's ligament, and the head of the bone be felt a little before and beneath the axis of the acetabulum, no doubt will remain as to the form of the dislocation. In a case of this sort, which Sir Astley Cooper had an opportunity of examining after death, he found the head of the thigh-bone lodged in the foramen ovale, the obturator externus muscle being entirely absorbed. The accident was evidently one of long standing, as the foramen ovale was filled up by bone, and osseous matter was deposited round its margin, so as to form a new socket for the head of the femur. The original acetabulum was nearly filled up with bony matter, the round ligament was torn through, and also the capsular ligament in part of its extent; the pectinalis muscle and the adductor brevis had been lacerated, but were united by tendinous fibres; the psoas and iliacus muscles, the glutei and the pyriformis, were all stretched. Sir Astley does not, however, say in what condition he found the gemelli and obturator internus muscles, or the quadratus femoris; but if the pyriformis is stretched, these must be much more so, and most likely are torn across at the moment that this accident occurs; and as the adductor brevis was found to have been torn, it is sufficiently obvious that the adductor longus and magnus must be elongated and stretched, in which condition they can readily be felt along the inner side of the thigh, forming a tense margin. This condition of the muscles necessarily tends to evert the toes, the only countervailing agent being the tensor vaginæ femoris, and perhaps a few fibres of the gluteus medius; hence, though in the general summary of the symptoms Sir Astley Cooper states that the toes are neither turned inwards nor outwards, in the first case, the history of which he details, page 60, "the toes were rather everted," and in the second case, page 62, "the foot was rather inclined outwards." When this dislocation remains unreduced, the limb is too long, and occasions a halt and a lameness, so that in progression the elongated extremity would be made to describe a curve outwards at each step which is taken.

In recent cases, the reduction of this dislocation is in general easily effected. Sir Astley Cooper directs the patient to be placed upon his back with his thighs separated as widely as possible; that a girth be passed round the flexure of the luxated thigh, and fixed to a staple in the wall or in the bedpost; the surgeon then takes hold of the ankle of the dislocated side, and draws it steadily inwards in front of the sound limb, by which means the head of the bone will be dislodged from its new position and forced backwards towards the acetabulum, into which it will pass with a jerk or snap, caused by the action of the muscles which were put on the stretch during the unnatural position of the limb. Whenever the dislocation has remained unreduced for two or three weeks, it is found necessary to place the patient in a different position in order to effect the reduction. He should be placed upon the sound side. The pelvis is then fixed by a bandage carried round it, and counter-extension is to be effected by a girth carried round the dislocated thigh, and fixed to a pulley suspended over the patient. Extension is then made by drawing the dislocated thigh directly upwards, the knee and the foot being pressed down so as to prevent the lower part of the limb from being elevated with the thigh-bone. In this way the thigh is made a lever of considerable force, by means of which the efforts of extension are directed upon the muscles which oppose the reduction, so as to overcome their resistance.

*Dislocation backward into the ischiatic notch.*—When the head of the femur is thrown backwards out of the acetabulum, it rests upon the pyriformis muscle, and occupies the interval between the small sacro-sciatic ligament and the margin of the ischiatic notch. This accident may be either primary or secondary; that is, it may be the direct and immediate result of force or violence so applied to the limb as to throw the bone from its articular cavity into the position here indicated, or it may follow and be a consequence of another mode of dislocation; not, however, in the manner in which Boyer\* states it, for he seems to think that the head of the femur, in a case of luxation upwards and outwards, may slide from the position which it at first occupies upon the external surface of the ilium downwards and backwards into the ischiatic notch, its passage in this direction being favoured by the bending of the thigh upon the pelvis. This mode of explaining the occurrence proceeds on the assumption that a second disturbing force is applied to the limb immediately after the dislocation on the dorsum ilii had occurred, somewhat in the same way as dislocation of the os humeri forwards under the pectoral muscle is made to supervene upon a primary displacement of the bone downwards into the axilla. It very seldom, if ever, happens that a second injury follows so quickly upon the first as to produce a secondary displacement of the femur in this way; but it may readily occur during the effort to reduce a primary dislocation upon the dorsum ilii, if the extension of the limb be discontinued before the head of the bone is drawn downwards to a level with the acetabulum; for if it be let go too soon, the muscles will draw it directly backwards into the ischiatic notch: this I have known to occur in one instance, and the secondary luxation was never reduced. It may also occur as a consequence of dislocation into the foramen ovale; for if the thigh is large and fleshy, it must necessarily incline somewhat forward during the effort to effect its reduction by drawing it across the sound limb, and so some risk is incurred of tilting the head of the bone backwards beneath the acetabulum into the ischiatic notch. To prevent the possibility of such an occurrence, Mr. Key, in a case, the particulars of which he transmitted to Sir Astley Cooper, (on Dislocations, p. 67,) "thought it advisable to carry the leg behind the sound one."

In the dislocation now under notice the limb is somewhat shortened, usually however not more than half an inch or an inch. The great toe rests against the inner side of that of the other foot; the knee and the foot are slightly turned inwards, the inclination in that direction being less than in the dislocation on the dorsum ilii; neither is the knee so much in advance of the sound

\* Lectures on Diseases of the Bones, vol. ii. p. 167.



limb as in the last-named accident. When the patient is in the standing posture, the toe, but not the heel, will touch the ground. On feeling for the trochanter major, it will be found behind its usual position, and having a very slight inclination towards the acetabulum; but the head of the bone is sunk so deeply into the ischiatic notch that it can scarcely be felt except in very thin persons.

Boyer appears to have formed his opinion as to the condition of the limb in this accident from merely anatomical considerations, and not from observation of cases which presented themselves to his notice. He says that when this luxation is primary, the limb is lengthened, the great trochanter by descending is removed farther from the spine of the ilium, and that the knee and foot are turned "outwards;" but if it be secondary, the knee and foot are turned "inwards." Sir Astley Cooper observes, that this error as to the state of the limb runs through the writings of every author who has treated of the subject, and he proceeds to point out the mistakes in practice to which such a description may give rise when it is unreservedly adopted. A gentleman wrote to him from the country to say that he had under his care a case of injury of the hip, which he would suppose to be a dislocation into the ischiatic notch, but that the limb was "shorter instead of being longer, as authors state it to be."

The circumstances under which this dislocation occurs are various. Thus, one person, whilst carrying a bag of sand, "stepped unexpectedly into a hollow in the road on which he walked, when his knee was turned inwards, at the same time that his body fell forwards with some violence." Another person, a sailor, rested his foot upon a chest raised a little way from the ground, when a box or basket fell upon his thigh, "striking the knee inwards." He fell; and when brought for examination, it was found that the head of the thigh-bone was thrown backwards into the ischiatic notch. In this latter case, the knee appears to have been pressed inwards whilst the thigh was placed at right angles with the abdomen; this position of the limb appears to be necessary to the production of the accident.

The reduction of this dislocation is confessed by all persons to be difficult, in consequence of the peculiar situation of the head of the bone with regard to the acetabulum; for it must be drawn towards the articular cavity, and also lifted over its margin. The patient is to be laid upon a table, resting on the sound side, and a girth placed between the pudendum and the inner part of the thigh, so as to fix the pelvis, and this is attached to a ring fixed behind the line of direction of the body; a wetted roller and strap should then be applied above the knee; to this a pulley is attached, which is fixed before the line of the body. The adjustment being thus made, the dislocated femur is drawn obliquely downwards across the other thigh; and whilst the extension is steadily kept up, an assistant passes a napkin under the upper part of the thigh, with which he lifts the bone as it is drawn towards the acetabulum over its brim. It is also found necessary to rotate the limb inwards, in order to facilitate the passage of the head of the bone over the margin of the articular cavity. As to the condition of the parts around the articulation, we are informed by Sir Astley Cooper that, in a case which he met with accidentally in the dissecting-room, and in which the luxation was not reduced, the original acetabulum was filled with a ligamentous substance; the capsular ligament was torn at its anterior and posterior part, but not at the superior and inferior; the round ligament was broken across, a part of it still remaining adherent to the head of the bone; the head of the femur, placed behind the acetabulum, rested upon the pyriformis, which muscle was diminished, but still there was no bony socket formed for the head of the bone: a new capsular ligament, however, was established, apparently consisting of condensed cellular membrane. It is to be regretted that all mention of the state of the muscles has been omitted in this report, more particularly as Boyer appears to have indicated their condition from anatomical or

## PLATE XXXVII.

FIG. 1. The superficial muscles of the calf of the leg are here shown as they are viewed from behind.

No. 1. The lower part of the thigh-bone. 2. Its inner condyle. 3. The outer condyle. 4, 4. The two heads of the gastrocnemius muscle. 5, 5. The broad fleshy part of the same muscle, where it forms the thick part of the calf of the leg. 6. The tendo Achillis, in which the fibres of the gastrocnemius muscle are inserted, and which is prolonged downwards to the os calcis. 7, 7. Some of the lower fibres of the soleus muscle, projecting on each side of the preceding muscle, and descending with an inclination backwards to be inserted into the anterior surface of the tendo Achillis. 8. The tendon of the tibialis posticus muscle, where it passes behind the inner ankle. 9. The tendon of the flexor communis digitorum muscle. 10. The tendon of the flexor pollicis longus muscle. 11. The peroneus longus muscle; its posterior border. 12. Its tendon passing behind the external ankle. 13. Part of the peroneus brevis muscle. 14. Its tendon. 15. Part of the fibrous band which binds down these tendons. 16. The cellular and adipose substance which forms the cushion of the heel, cut through. 17. The tegument covering the inner border of the foot. 18. The tegument at the outer border of the foot.

FIG. 2. No. 1. The lower part of the thigh-bone. 2. Its inner condyle. 3. The outer condyle. 4. The fleshy part of the plantaris muscle. 5. Its long thin tendon. 6. Part of the popliteus muscle. 7, 7. The broad fleshy portion of the soleus muscle. 8. The upper part of the tendo Achillis; this tendon will be observed to be cut across at its point of junction with the gastrocnemius, which muscle is altogether removed, in order to bring the soleus and plantaris into view. 9. The os calcis, giving insertion to the tendo Achillis. 10. The tendon of the tibialis posticus muscle. 11. The flexor communis digitorum muscle. 12. The tendon of the flexor longus pollicis muscle. 13. The posterior edge of the peroneus longus muscle. 14. Its tendon descending behind the external ankle. 15. Part of the peroneus brevis muscle. 16. Its tendon. 17. A few fibres of the flexor longus pollicis muscle. 18. The subcutaneous cellular and adipose substance which was cut through while making the dissection.







*a priori* views. He tells us that the muscles which cover the posterior part of the acetabulum, such as the pyriformis, gemelli, obturatores, and quadratus femoris, are raised up and stretched; and that the psoas magnus and iliacus are in a great state of tension, which explains the turning of the limb "outwards." In all the cases of which we have detailed statements, the foot is stated to have been turned "inwards;" and as to the condition of the rotator muscles, they are much more likely to be torn than merely "raised up and stretched."

*Dislocation forwards on the pubes.*—The head of the thigh-bone may be protruded from the acetabulum, and made to pass forwards towards the pubes, so as to rest upon the brim of the pelvis. When this has happened, the dislocated limb becomes shorter than the other by about an inch; the knee and foot are turned outwards, and cannot be rotated inwards; the great trochanter is approximated somewhat to the anterior superior spinous process of the ilium, and lies a little before it; the head of the bone, like a hard round ball, can be distinctly perceived to project above the level of Poupart's ligament, supported on the brim of the pelvis, lying to the outer side of the femoral vessels. Though this accident appears easy of detection, Sir A. Cooper met with three instances in which it was altogether overlooked, until it was too late to admit of being reduced. In a case of this kind, which was dissected after death, the capsular ligament was found to be extensively lacerated, and the round ligament broken through; the head of the thigh-bone had raised up Poupart's ligament, having slipped between it and the os pubis. In this position the tendon of the psoas and iliacus muscles was raised up and passed over the neck of the bone as they descended to their insertion. The crural nerve, lying between the iliacus and psoas, passed in front of the neck of the bone. The original acetabulum had become partly filled up by osseous deposit, and was greatly altered in form; so was the trochanter major, which lay upon it. A new articular cavity was formed upon the os pubis, which supported the neck of the bone, for its head projected above the brim of the pelvis. Poupart's ligament lay before the head of the bone; the femoral vessels to its inner side, and the anterior and inferior spinous process to its outer side.

This accident occurs in various ways. Sir A. Cooper gives the report of a case communicated to him by Mr. Tyrrell, in which this dislocation was produced by violence applied directly to the part. "A man, whilst standing at the corner of a street, was struck on the back part of the right hip by a cart-wheel, and knocked down by the blow." In this instance the head of the bone could be distinctly felt under Poupart's ligament, immediately to the outside of the femoral vessels. The limb was turned outwards, but was very little altered in its length; it could be rotated outwards, but not at all inwards, the thigh admitting only of a partial abduction and adduction. In a case which presented itself to Desault, the accident occurred in a very different way: the subject of it was a porter in one of the markets. This man's foot happened to slip whilst a heavy burden was being placed upon his shoulder: his leg and thigh were carried backwards, his body also became inclined a little backwards; and in the struggle to recover the erect position, the head of the femur was thrust forwards and upwards, so as to tear through its capsular ligament, and pass forwards into the fold of the groin, where it was distinctly perceptible.

When proceeding to effect the reduction of this dislocation, the patient is placed on a table, resting on the sound side, and a girth is passed between the pudendum and inner part of the thigh, and fixed to a staple placed a little before the line of the body; a roller and strap are then bound a little above the knee, in the usual way, to which a pulley is attached, in order to make extension. The traction should be made in such a way that the thigh-bone is drawn in the direction of a line a little behind that of the axis of the body. When extension is kept up for a short time, another bandage is to be applied around the upper part of the thigh, close to the perinæum, by means of which the head of the bone is raised. In this manner the reduction is accomplished without much difficulty in recent cases.

What, it will be asked, is the relative frequency of these different modes of dislocation of the thigh-bone? Sir A. Cooper gives, as the result of his extensive observation, the proportion in this way: out of twenty cases, he found twelve on the dorsum ilii, five in the ischiatic notch, two in the foramen ovale, one on the pubes.

## PLATE XXXI.

The muscles placed at the fore part of the thigh are exhibited in these drawings; the skin, the fascia, and the vessels being all removed.

*The Tensor muscle.*—At the upper and outer part of the limb a short muscle is seen, marked 5, 6, extending obliquely downwards from the point of the hip, and terminating a little below the prominence (trochanter major) of the thigh bone. This is the tensor muscle of the fascia of the thigh, (m. tensor vaginæ femoris.) It is compressed and flat in the greater part of its extent, narrow at its upper extremity, but becomes wider towards the lower. It arises from the anterior superior spinous process of the ilium, where it is fixed to the outer surface of the bone by tendinous fibres; to these the muscular fibres succeed, and spread out somewhat as they run downwards, and terminate by becoming inserted between two layers of the fascia lata of the thigh, which in a manner embrace them. The inner or anterior edge of the muscle is observed to be in apposition for a while with the



sartorius muscle, (No. 8,) but lower down an interval is left between them by their divergence, in which the rectus, No. 10, (which at its upper part is concealed by them,) comes forward into view.

*The Sartorius muscle.*—Along the anterior and inner aspect of the limb a lengthened strap-like muscle is seen to lie extended from the most prominent point of the hip, downwards and inwards, across the muscles of the thigh; then changing its direction, so as to descend by the inner side of the knee-joint, to terminate at the inner and upper part of the tibia. It is marked 8, 9, and is called the sartorius or tailor's muscle. It is fixed at its upper extremity, by tendinous fibres, to the anterior superior spinous process of the ilium, and to the curved margin of the bone beneath it: the fleshy fibres, which soon succeed to those that are white and tendinous, form a flat strap, about an inch or an inch and a quarter in width, which rests on the psoas and iliacus muscles, 17; on the pectineus, 18; and on the adductor longus, 19. Its outer side rests on the rectus femoris, 10; and on the vastus internus, 16. Beside the knee, it overlays the internal lateral ligament of the joint, and the tendons of the gracilis and semi-tendinosus muscles. Towards its lower part this muscle expands into a broad aponeurosis, which, after covering the tendons just named, becomes fixed to the upper and inner side of the tibia a little below its tuberosity.

*The Rectus muscle.*—Along the front of the thigh is stretched a muscle, which is broad and fleshy towards its middle, but narrow and tendinous at its extremity. It is marked 10, 11, and named the straight muscle of the thigh, (m. rectus femoris.) It is extended in a straight line downwards from the pelvis to the knee-pan, or patella. The middle fleshy portion, constituting the body of the muscle, swells out towards its central part, and tapers towards its extremities. The muscular fibres are arranged in two sets, one at each side; for they pass off obliquely towards the edges of the muscle, somewhat as the fibrillæ of a quill or feather do; muscles so constructed are said to be penniform. The muscular fibres at their lower end are seen to terminate in a tendon, 11, the fibres of which become fixed to the upper end and anterior surface of the patella; but they do not terminate upon this bone: they are found to be prolonged below its lower margin, where they constitute the ligament of the patella, 13, which is finally fixed into the tubercle in front of the tibia. In this way the straight muscle is made to act upon the tibia, and bring it (if it has been previously bent) into a direct line with the thigh-bone. The upper end of the straight muscle is concealed by the sartorius, 8, and the tensor, 5; it is tendinous in its structure, and is fixed by means of two processes, of which one is attached to the anterior inferior spinous process of the ilium, (fig. 2, No. 2,) whilst the other is reflected outwards, and is attached to the margin of the articular cavity of the thigh-bone.

*The Vastus Externus muscle.*—At the outer side of the thigh is a large and long muscle, which from its length and bulk is called vastus externus, 15. (It is shown also in plate XXXIV. fig. 1, No. 19; also in fig. 2, Nos. 10, 10.) It extends from the great trochanter of the thigh-bone downwards to the lower tendon of the rectus muscle, and the base of the patella, and forms the fleshy mass placed along the outer side of the thigh. The fibres of this muscle are observed to be attached as high up as the root of the great trochanter, from which point down as far as the middle of the oblique line leading to the outer condyle of the femur, the muscle takes points of attachment along the whole length of the linea aspera, as well as from the external surface of the bone. Hence the direction of the fibres varies considerably; some of them descend straight downwards, others become

## PLATE XXXVIII.

The deep-seated muscles of the leg are shown in these drawings. In order to expose them, the gastrocnemius, the soleus, and the plantaris have been removed, and also the deep fascia which is interposed between the superficial and deep-seated muscles.

- FIG. 1. No. 1. The lower extremity of the thigh-bone—its posterior surface, where it corresponds with the popliteal space. 2. The inner condyle. 3. The tendinous part of the popliteus muscle. 4. The fleshy part of the same muscle. 5. The head of the fibula. 6. Part of the tibialis posticus muscle, corresponding with the interval between the tibia and fibula. This muscle extends higher up than the common flexor of the toes and the flexor of the great toe, between which it is seen at its upper part; lower down it is overlapped by them and concealed. 7. The tendon of the tibialis posticus muscle, where it passes behind the inner ankle, and proceeds towards the sole of the foot. 8. The common flexor muscle of the toes, (m. flexor communis digitorum.) 9. Its tendon, where it passes behind the inner ankle, resting upon and partly concealing the tendon of the tibialis posticus. 10. The long flexor of the great toe, (m. flexor longus pollicis.) 11. Its tendon, where it passes behind the tibia to reach the sole of the foot. 12. The long peroneal muscle, (m. peroneus longus.) 13. Its tendon. 14. The short peroneal muscle, (m. peroneus brevis.) 15. Its tendon. 16. Part of the inner ankle. 17. The posterior surface of the os calcis. 18. The metatarsal bone of the great toe. 19, 20, 21, 22. The metatarsal bones of the small toes. 23, 23, 23, 23. The four tendons derived from the long flexor muscle proceeding to the small toes. 24. The tendon of the long flexor muscle of the great toe. 25. The tendon of the peroneus longus muscle, where it turns into the sole of the foot.
- FIG. 2. No. 1. The posterior surface of the head of the tibia. 2. The head of the fibula. 3. The tibialis posticus muscle: its fibres are seen arising from the tibia and fibula, and passing obliquely to be fixed into the tendon which lies along its posterior aspect. 4. The tendon of the tibialis posticus muscle passing behind the inner ankle. 5. Part of the inner ankle. 6. Part of the external ankle. 7. The posterior surface of the os calcis. 8, 9, 10, 11, 12. The metatarsal bones of the toes. 13. The fleshy part of the long peroneal muscle, (m. peroneus longus.) 14. Its tendon passing down behind the outer ankle. 15. The fleshy fibres of the short peroneal muscle, (m. peroneus brevis.) 16. The tendon of the same muscle proceeding to its insertion into the base of the fifth metatarsal bone.



Fig 1



Fig 2









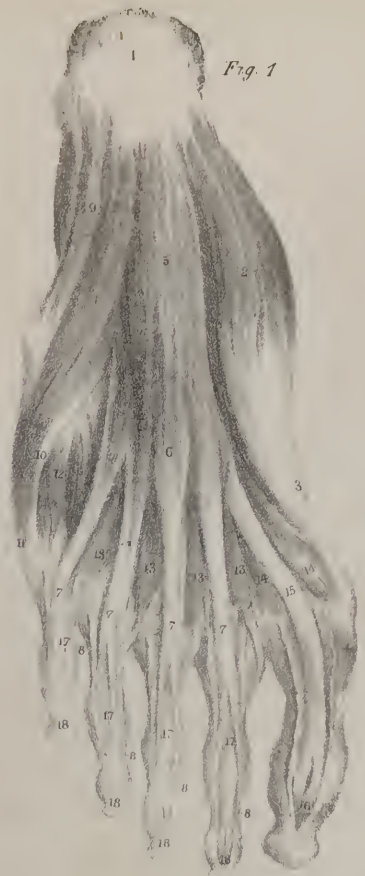


Fig. 1



Fig. 2.

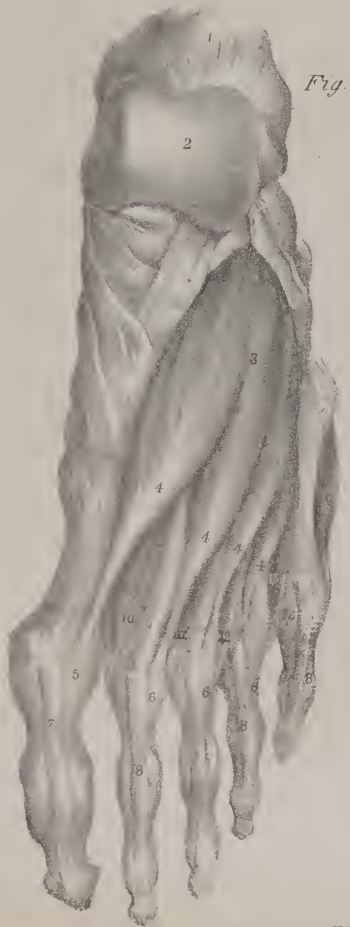


Fig. 4.

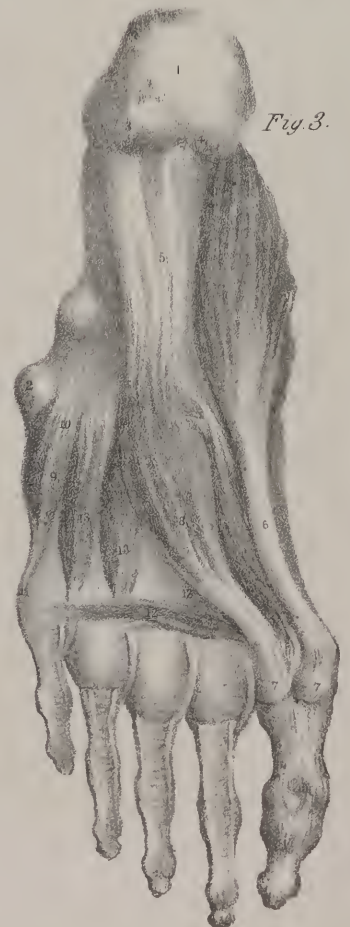

Fig. 3.

somewhat oblique, whilst those at its lower margin pass forwards, becoming almost transverse; and these latter are necessarily much shorter than those above them. The muscle becomes inserted at its lower extremity into the tendon of the rectus muscle, and into the base of the patella. There is a considerable mixture of tendinous fibre in this muscle, particularly at its upper part.

*The Vastus Internus muscle.*—Along the inner side of the thigh, a muscle somewhat similar to the preceding is placed, which, though not so large, still deserves the name of vastus internus; it is numbered 16: part only of it is seen in this drawing, the rest being concealed by the sartorius. It extends from a little below the small trochanter of the femur, (fig. 2, No. 9,) as far as to the base of the patella: its fibres are attached along the inner side of the thigh-bone and the margin of the linea aspera, as well as to part of the oblique ridge which leads from the latter to the inner condyle. The lower fibres are oblique in their direction, as they incline outwards and downwards to reach their insertion into the edge of the tendon of the rectus muscle and the base of the patella; there is a considerable admixture of tendinous fibres, particularly at its point of attachment.

*The Crureus muscle.*—In the interval between the two vasti above described, a muscle called crureus is placed, which is connected with them so intimately, that all three may be said to form one; and some persons have considered them in this way,

## PLATE XXXIX.

**FIG. 1.** The first layer of muscles in the sole of the foot is here brought into view by the removal of the skin and the plantar fascia. One of these muscles lies along the inner border of the foot, and is named the abductor of the great toe; it is marked by the figures 2, 3, 4: another occupies the middle of the foot, and is named the short flexor of the toes; it is marked 5, 6: the third muscle is the abductor of the little toe; it is marked 9, 10, 11.

**No. 1.** The under surface of the os calcis. 2. The fleshy part of the abductor muscle of the great toe, (m. abductor pollicis pedis.) 3. The tendon of the same muscle. 4. Its insertion into the inner border of the first phalanx of the great toe at its base. 5. The short flexor muscle of the small toes, arising from the under surface of the os calcis. 6. The anterior extremity of the muscle dividing into four processes, from each of which a tendon proceeds to the toes. 7, 7, 7, 7. The tendons of the short flexor muscle, proceeding beneath the toes, and dividing so as to leave a fissure, through which the tendons of the long flexor muscle pass: hence it is called flexor perforatus. 8, 8, 8, 8. The tendons of the short flexor muscle at their points of insertion into the bases of the second phalanges of the toes. 9. The abductor of the little toe, (m. abductor digiti minimi.) 10. Its tendon. 11. Its insertion into the base of the first phalanx of the little toe. 12. Part of the short flexor of the little toe. 13, 13, 13, 13. The four lumbricales muscles. 14, 14. The inner and outer heads of the short flexor of the great toe, (m. flexor brevis pollicis pedis.) 15. The tendon of the long flexor muscle of the great toe. 16. Its insertion. 17, 17, 17, 17. The tendons of the common flexor muscle of the toes, passing through slits in the tendons of the flexor brevis, and proceeding to their insertions into the last digital bones, which are marked 18, 18, 18, 18.

**FIG. 2.** The muscles which form the second plane in the sole of the foot are here brought into view by the removal of those which are shown in the preceding figure.

**No. 1.** The under surface of the os calcis. 2. The posterior extremity of the fifth metatarsal bone. 3. A part of the abductor pollicis muscle left attached by its tendon, its fleshy portion being cut away. 4, 4. The inner and outer heads of the flexor brevis pollicis muscle. 5. The tendon of the long flexor muscle of the great toe, where it passes into the sole of the foot; it is seen crossing the tendon of the common flexor muscle. 6. The continuation of the tendon of the long flexor muscle, passing between the two heads of the short flexor, and proceeding to its insertion into the great toe. 7. The tendon of the common flexor muscle passing obliquely along the hollow of the foot. 8. The tendon of the same muscle, at the point where it divides into four processes, (9, 9, 9, 9,) which proceed along the under surface of the toes, and are inserted into their last phalanges, (10, 10, 10, 10.) 11, 11, 11, 11. The four lumbricales muscles. 12. The two pointed processes by which the accessory muscle arises, (m. accessorius ad flexorem communem.) 13. The body or fleshy part of the accessory muscle, where it becomes attached to the tendon of the common flexor. 14. The short flexor muscle of the little toe. 15. The third plantar interosseous muscle. 16. Part of the fourth dorsal interosseous muscle, which here dips into the sole of the foot.

**FIG. 3.** The muscles which form the third or deepest layer in the sole of the foot are here seen, those in the second having been removed in order to bring them into view.

**No. 1.** The under surface of the os calcis. 2. The posterior extremity of the fifth metatarsal bone. 3, 4. The tubercles at the under surface of the os calcis. 5. The long plantar ligament. 6. The abductor muscle of the great toe, (m. abductor pollicis pedis.) 7, 7. The two sesamoid bones, with which the muscles are connected previously to their insertion. 8. The abductor pollicis pedis, which becomes connected with the outer head of the short flexor muscle previously to its insertion. 9. The short flexor muscle of the little toe. 10. Its point of attachment to the base of the fifth metatarsal bone. 11. Its insertion into the outer border of the first phalanx of the little toe at its base. 12. The transverse muscle of the foot, (m. transversus pedis.) 13, 13, 13. The three plantar interossei muscles.

**FIG. 4.** The upper surface or dorsum of the foot is here shown, with the short extensor muscle of the toes resting upon it.

**No. 1.** The os calcis. 2. The upper surface of the astragalus. 3. The posterior part or origin of the short extensor muscle of the toes, (m. extensor brevis digitorum pedis.) 4, 4, 4, 4. The pointed processes into which it divides; each of these ends in a tendon which is prolonged to the dorsal surface of the toes. 5. The insertion of the first tendon into the dorsal surface of the great toe. 6, 6, 6. The tendons of the other processes joining with those of the long extensor muscle. 7. A part of the tendon of the long extensor of the great toe. 8, 8, 8. The tendons of the common extensor muscle resting on the dorsal surface of the four small toes. 9. Part of the abductor of the little toe. 10. Part of the first dorsal interosseous muscle. 11. The second dorsal interosseous muscle. 12. The third dorsal interosseous muscle. 13. The fourth dorsal interosseous muscle.



as a single muscle made up of three parts or heads, and as such deserving the name of triceps femoris. The crureus taken by itself, and considered as a single muscle, extends the length of the body of the thigh-bone, as it reaches from the oblique line between the trochanters down to the patella; its fibres take points of attachment along the anterior surface of the femur, and are blended on each side of the vasti: it is concealed by the rectus, which lies in front of it.

*Actions.*—The name given to these muscles (extensors) at once indicates their most usual action, which is that of straightening the leg upon the thigh; and this they are enabled to do by reason of their connexion with the patella, for the ligament of this bone being fixed to the tibia, the whole force of the muscles is directed to the latter bone; they are the direct antagonists of the flexor muscles, and are called into play whenever any circumstance tends to bend the knees. Thus, in walking down a hill, they must make almost constant efforts to keep the limbs sufficiently straight for the performance of the required movements; which accounts for the sense of weariness so frequently induced when their action is too long continued. These muscles, like most others, can reverse their line of action so as to direct their force upon the thigh-bone and the pelvis. When the leg is fixed, as in the standing posture, and the tibia gives them their point of support, the two vasti will then draw upon the femur, and keep it erect upon the leg; and the rectus can also pull upon its upper points of attachment, and combine with the adductors, the psoas, and others in keeping the pelvis steady upon the thigh. The power of the sartorius over the leg cannot be much; it may bend it upon the thigh, and perhaps incline the knee a little outwards; its power can be more effectually exerted in maintaining the pelvis erect upon the thigh; for by taking its fixed point of attachment at the tibia, it is enabled to act upon the spine of the ilium, and assist other muscles in drawing the pelvis forwards, making it to rest steadily upon the thigh-bone.

Fig. 2. When the superficial muscles above noticed, viz. the tensor vaginæ, the sartorius, the rectus, and the vasti, have been removed, another group is brought into view, consisting of the adductor muscles, with two of the external rotators, viz. the obturator externus, 17; and quadratus femoris, 18. The adductor muscles are placed along the inner side of the thigh, extending obliquely from the pelvis to the femur; they are three in number, and differ in form and size; they are named the adductor longus, 14; the adductor brevis, 13; and the adductor magnus, 15, 15. With these we may associate another, which combines with them in their action, the general direction of its fibres being somewhat the same; it is named pectineus, and is shown partly in fig. 1, No. 18.

*The Pectineus muscle*, fig. 1, No. 18, is placed obliquely at the upper and fore part of the thigh, being extended from the upper surface of the pubic bone, downwards and outwards, to reach the thigh-bone a little below the small trochanter. It is flat and compressed; and consists of tendinous fibres at its attachments, the rest of it being fleshy.

*The long Adductor muscle*, (m. adductor longus,) fig. 2, No. 14, is placed in an oblique position at the inner part of the thigh, being extended from the angle of the pubic bone to about the middle of the femur. It is compressed and flat in the greater part of its extent, and irregularly triangular in its form; its middle part or body is fleshy, and the extremities tendinous. This muscle is narrow at its upper end, and is there fixed by tendinous fibres to the angle of the os pubis; its fibres spread out somewhat as they descend, and become inserted into the middle third of the rough line at the back of the thigh-bone.

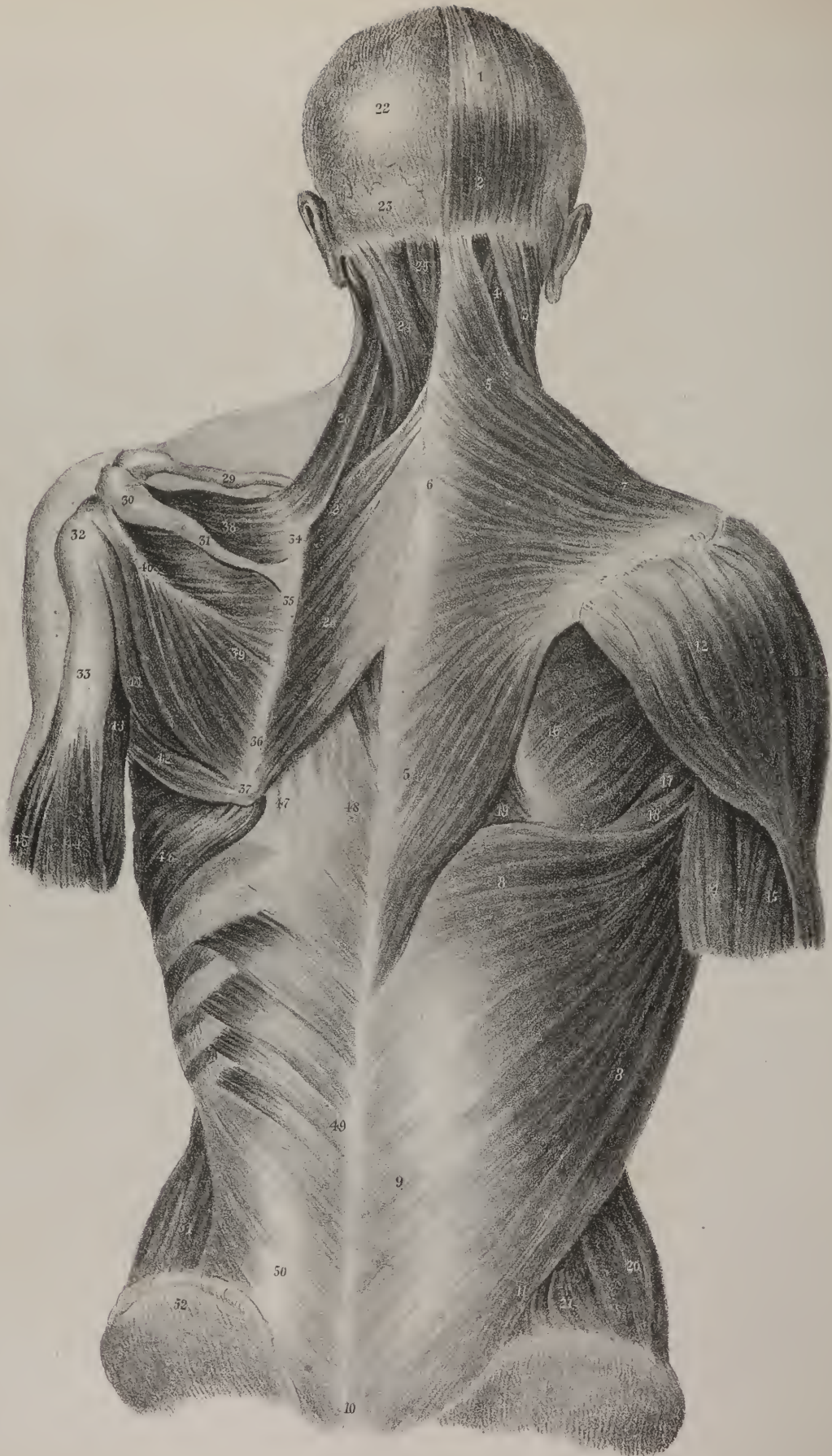
*The short Adductor muscle* (m. adductor brevis,—secundus,) is shorter than the preceding muscle, and lies higher up; it is overlaid at its origin, and also in some degree lower down, by the adductor longus. The form of the muscle is irregularly triangular: it is narrow at its upper end, where it is fixed by fleshy and tendinous fibres to the surface of the pubic bone, but widens gradually as it descends to its insertion, which takes place at the upper part of the linea aspera, and the oblique line which leads from it to the small trochanter.

*The great Adductor muscle*, (m. adductor magnus.) A flat plane of muscular fibres is shown here to lie behind and support the long and the short adductor muscles; part of it is observed to project above them, and a considerable part below them, marked 15, 15; and the lower portion is moreover observed to be prolonged to the inner condyle of the femur, the prolonged part being marked 16. The muscle is of very considerable extent, as it reaches nearly the whole length of the shaft of the thigh-bone, and may be likened to a flat plane of fleshy fibres, interposed between the muscles which lie in front of the thigh, and the long flexors which are placed behind it. Its form is obviously triangular; its base being represented by its line of insertion into the thigh-bone, whilst the apex corresponds with its origin or point of attachment to the ischium. Between the broad part of this muscle, which is inserted into the linea aspera of the thigh-bone, and the prolonged slip, 16, which goes down to the inner condyle, an aperture exists for the transmission of the femoral vessels as they pass backwards to reach the posterior aspect of the limb.

*Actions.*—These muscles are of considerable power. It is obvious, from their line of direction, that they draw the thigh-bone inwards, or adduct it, as their name expresses; for they take their fixed points of attachment above at the pelvis, and from thence concentrate their force upon the femur. Moreover, as they incline backwards somewhat, and are fixed to a projecting ridge (linea aspera,) at the back of the bone, they are enabled to turn it a little upon its axis so as to rotate it outwards, in which particular they conspire with another class of muscles, previously noticed, viz. the external rotators. The pectineus, also, owing to its line of direction, assists in bending the thigh upon the pelvis, in which effort it co-operates with the psoas and iliacus. These muscles may reverse their mode of action, and direct all their force upon the pelvis; but the thigh and the leg must, as a preparatory measure, be rendered steady and fixed, so as to give them secure points of attachment below, from which they can draw upon the pelvic bones. This mode of action is constantly required in the effort to stand upon one leg.







## PLATE XXXIV.

THE first drawing here given, fig. 1, shows the muscles of the hip and thigh as they appear when viewed from the outer side. The extensor muscles, viz. those which straighten the leg and bring it into a right line with the thigh, are placed upon the front and sides of the thigh-bone, where they form a considerable fleshy mass: they have a common point of attachment at their lower extremity, where they are fixed to the patella, or knee-pan; they are marked, 15, the rectus; 18, the vastus internus; 19, the vastus externus: their insertion is indicated by the numbers 16, 17. A front view of these muscles has been already given in Plate XXXI, fig. 1, where they are marked 10, 15, 16, and their connexion with the patella and tibia is farther indicated by the numbers 11, 12, 13, 14: their description is given in pages 71, 72. Behind the thigh-bone a group of muscles is placed, which, as they are opposed in situation to those just now alluded to, so they are also their antagonists in action; they are named the flexor muscles of the leg. In this view we see but one of them, which is marked 20, 21, 22, which is the two-headed flexor muscle. It is obvious that if the muscles placed upon the front of the thigh can act on the leg, so as to bring it into a straight line with the thigh, or extend it, this muscle and its assistants will draw the leg backwards and bend it upon the thigh.

In the upper part of this drawing, we see about a third of the sartorius muscle, marked 3, 4; the tensor muscle of the fascia of the thigh, marked 9, 10; a part of the gluteus medius, 11, 12; and the gluteus maximus, 13, forming the prominence of the nates; whilst its insertion into the thigh-bone is indicated at 14. A front view of the tensor and sartorius muscles is given in Plate XXXI, fig. 1, Nos. 5, 8; they are described in page 71: a full view of the glutei muscles is given in Plate XXXII, figs. 1, 2; their description will be found in pages 60, 61.

The flexor muscles are placed along the back part of the thigh, extending from the ischium to the upper part of the bones of the leg: their length is therefore considerable: they lie immediately under the skin and fascia in the greater part of their extent, their upper extremity being covered by the great gluteus muscle. They are shown in fig. 2 of this plate, and are marked 11, 14, 16, being three in number, and named the two-headed flexor, the semi-tendinous, and semi-membraneous muscle.

The *Two-headed Flexor muscle* (m. biceps femoris, biceps flexor cruris,) lies along the back part of the thigh, extending from the ischium, and then downwards to the head of the fibula. As its name implies, it consists of two parts or heads; of

## PLATE XL.

The first layer of the muscles of the back is shown at the right side in this figure, and the second at the left.

No. 1. The tendinous part of the occipito-frontal muscle. 2. Its fleshy fibres, where they arise from the occipital bone. 3. The upper attachment of the sterno-cleido-mastoid muscle. 4. Part of the splenius capitis muscle, seen in the interval between the preceding muscle and the trapezius. 5, 5. The cervical and dorsal parts of the trapezius muscle. 6. The tendinous fibres by which it arises at the lower part of the neck and upper part of the back are rather long, and join with the fleshy structure so as to represent an oval or elliptical outline, as here indicated. 7. The external part of the muscle, proceeding to its insertion into the clavicle, the acromion, and the spine of the scapula. 8, 8. The broad fleshy part of the latissimus dorsi muscle. 9. The tendinous part which arises from the spines of the lumbar vertebrae: 10. that which arises from the sacral spines. 11. The attachment to the crest of the ilium. 12. The back part of the deltoid muscle. 13. Its insertion into the humerus. 14. Part of the long head of the triceps extensor muscle. 15. Its external head. 16. The infra-spinous muscle. 17. Part of the smaller teres muscle. 18. Part of the larger teres muscle. 19. A small piece of the greater rhomboid muscle:—(it is seen in its entire extent at the opposite sides, No. 28.) 20. The back part of the external oblique muscle, stretching down from the last rib to the crest of the ilium. 21. A small piece of the internal oblique muscle, seen in the angular interval between the external oblique and the latissimus dorsi. 22. The parietal bone, exposed by the removal of the occipito-frontal muscle. 23. The upper part of the occipital bone. 24. The splenius muscle. 25. Part of the complexus muscle, seen above the edge of the splenius. 26. The elevator muscle of the angle of the scapula, (m. levator anguli scapulae.) 27. The smaller rhomboid muscle, (m. rhomboideus minor.) 28. The larger rhomboid muscle, (m. rhomboideus major.) 29. The clavicle. 30. The acromion process. 31. The spine of the scapula. 32. The greater tuberosity of the humerus. 33. Part of the humerus exposed by the removal of the deltoid muscle. 34. The upper part of the base of the scapula. 35. The part of the base of the scapula into which the smaller rhomboid muscle is inserted. 36. The lower part of the base of the scapula, into which the greater rhomboid muscle is inserted. 37. The lower angle of the scapula. 38. The supra-spinous muscle, (m. supra-spinatus.) 39. The broad fleshy part of the infra-spinous muscle; its fibres are seen converging to the tendon, 40, by which it is inserted. 41. The small teres muscle. 42. Part of the greater teres muscle. 43. The long head of the triceps muscle. 44. The external head of the triceps. 45. Part of the brachialis anticus muscle. 46. The lower part of the great serratus muscle. 47. Part of the sacro-lumbalis muscle. 48. Part of the longissimus dorsi:—these are indistinctly seen, as they are covered by a thin membrane called the vertebral aponeurosis. 49. The tendinous part of the serratus inferior; the four fleshy points by which it is inserted into the ribs are also shown. 50. The lower part of the lumbar muscles, viz. sacro-lumbalis and longissimus dorsi. 51. Part of the internal oblique muscle of the abdomen. 52. The spine of the ilium.



which one is attached to the ischium, and is therefore longer than the other, which is attached to the thigh-bone: the long head is marked No. 20, fig. 1, and 11, fig. 2; the short or femoral portion being indicated by No. 21, fig. 1, and 12, 12, fig. 2. The long head of the muscle is tendinous at its upper extremity, where it is attached to the tuberosity of the ischium; its fibres also for some way down are intimately connected with the semi-tendinous muscle: the short head is attached to the linea aspera of the femur, its fibres being interposed between those of the adductor magnus and vastus externus, where they reach as high up nearly as the insertion of the great gluteus. This head of the muscle is necessarily concealed by the long one, which lies behind it and overlays it, except in the neighborhood of the knee, where its fibres project somewhat on either side of the tendon which is common to both: this fact is expressed by the references 12, 12. The fibres of the short head incline backwards as they descend and join with those of the long head. A tendon (13,) common to both, is continued downwards, and becomes inserted into the head of the fibula.

*The Semi-tendinous muscle* (m. semi-tendinosus,) lies along the back part of the thigh, extending from the tuberosity of the ischium to the upper and inner part of the tibia; its fleshy part is marked 14, and the lower or tendinous portion 15. This muscle is attached by its upper extremity to the back part of the tuber ischii, and for some way down its fibres are connected with those of the long head of the biceps: lying along the inner side of the latter, it continues in close apposition with it as far as the lower third of the thigh, where the two muscles are observed to diverge; the one inclining to the outer, the other to the inner side of the ham or popliteal space. The tendon of the semi-tendinous muscle passes along the posterior and inner aspect of the knee-joint, and then turns forwards somewhat to be inserted into the upper part of the tibia, where its tendon rests a little below that of the gracilis, and under cover of the sartorius. The muscle is tendinous and fleshy at its upper part, fleshy in the middle, and altogether composed of a flat tendon in the rest of its extent; it rests in nearly its entire length upon the semi-membranous muscle, the posterior aspect of which is depressed and concave, as if it were adapted to it.

*The Semi-membranous muscle* (m. semi-membranosus) has the same extent as the preceding, being stretched from the tuberosity of the ischium to the upper end of the tibia: it is overlapped by the preceding muscle in a considerable part of its extent; but as its body is broader, particularly at the lower end, its fibres project farther into the popliteal space, so as to approach nearer to the biceps muscle; and higher up, towards the middle of the thigh, it projects inwards, so as to be seen between the semi-tendinous and gracilis: the double references, 16, 16, indicate these facts. The upper end of the semi-membranous muscle is fixed to the back part of the tuberosity of the ischium, where it is overlaid by the biceps and semi-tendinous muscles; the tendon of origin widens somewhat so as to become membranous, and the muscular fibres which arise from this descend with some degree of obliquity, forming a fleshy belly. From the outer border and lower end of the fleshy part a strong tendon is prolonged, which is fixed into the inner tuberosity of the tibia at its posterior surface; this tendon is marked 17; from it a considerable number of fibres are reflected, and pass obliquely behind the knee-joint, where they become blended with its posterior ligament, 18: a membranous expansion is also continued from it over the popliteal muscle: and a third tendinous process passes forwards upon the border of the inner tuberosity of the tibia into which it becomes fixed.

*Actions.*—The individuals of this group are commonly termed the ham-string muscles: they diverge from one another in such a way as to leave between them an interval, commonly known as the ham or popliteal space; the biceps forming its outer border, the semi-tendinous and semi-membranous muscles the inner one. When in action, by taking their fixed points of attachment above at the ischium, they concentrate their force upon the bones of the leg, to draw them directly backwards; so that the leg is made to form an angle with the thigh, or, in other words, is bent or flexed upon it. When they act together, the flexion is directly backwards; but a certain degree of inclination either inwards or outwards may be given to it, according as a greater degree of effort is made by the biceps or the others. These muscles can reverse their line of action, so as to draw upon the ischium and the femur; but, as a preparatory effort, the leg must become relatively the more fixed point, as is the case in the standing posture.

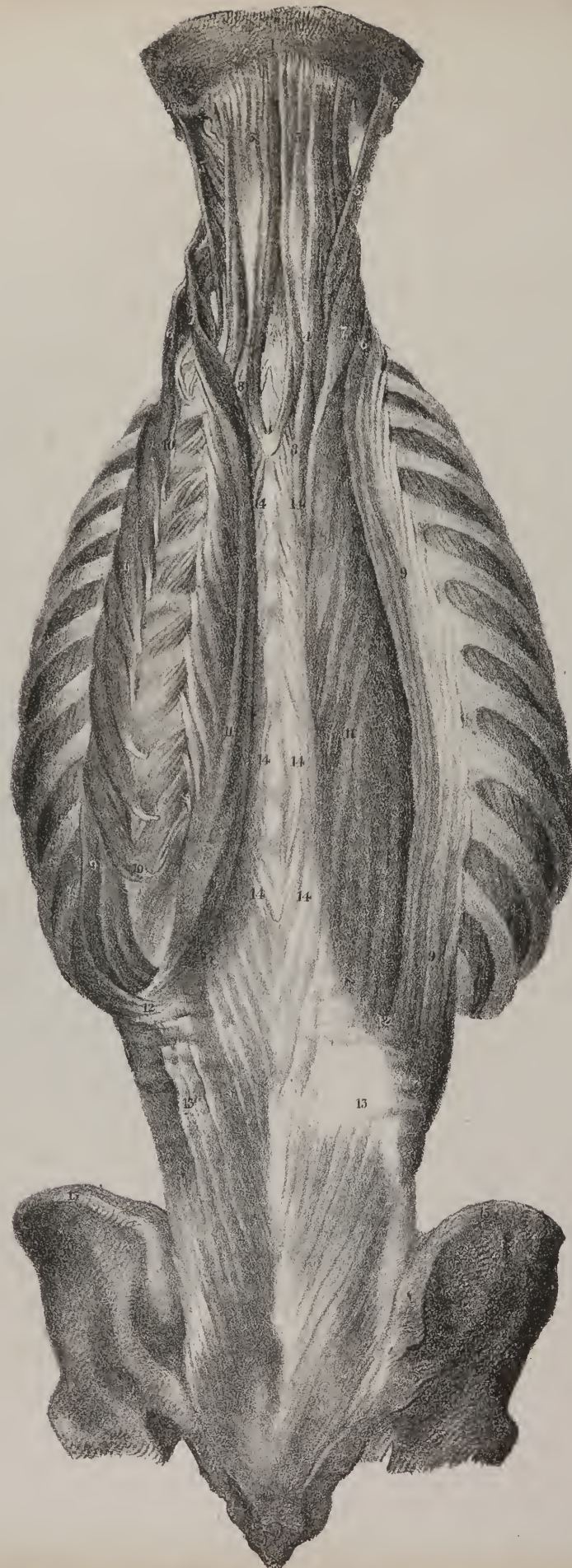
The external rotators are exhibited in this drawing, 5, 6, 7, 8; other views of them are given in Plate XXXII., figs. 1, 2, and in Plate XXXIII., figs. 1, 2, 3; they are described in pages, 62, 63.

## PLATE XXXV.

THE muscles placed along the inner and back part of the thigh are shown in fig. 1; also two of those which arise within the pelvis, viz. the internal obturator muscle, No. 6, and the pyriformis, No. 7. For the names of the other muscles see the references, page 65: they have been already described with the flexors, adductors, and rotators, to which they belong.

Fig. 2. The muscles placed at the fore part and outer side of the leg are here brought into view by removing the skin and the fascia which binds them down. When looked at in this way, it will be observed at once that they form three groups, the first occupying the interval between the two bones of the leg; viz. the anterior tibial muscle, 7, 8; the extensor of the great toe, 9, 10; the common extensor of the toes, 11, 12, and the third peroneal muscle, 14, 15: the second group consists of the two peronea







muscles, which rest upon the outer side of the peronè, or fibula; whilst the third, lying still farther back, and marked 24, 25, 26, forms the calf of the leg.

*The Anterior Tibial muscle*, 7, 8, (m. tibialis anticus,) extends from the upper part of the leg to the inner edge of the sole of the foot; its upper part consisting of rather a thick, fleshy, and tendinous body, the lower being a flat and rather strong tendon. The drawing shows that its fibres are attached to the outer tuberosity of the tibia, and to the flat surface of the bone beneath it, for a considerable way down; several fibres also are attached to the fascia of the leg, and to a tendinous process between this and the long extensor, whilst others more deeply placed are connected with the interosseous ligament. The tendon which extends from the fleshy fibres rests upon the lower end of the tibia, passes in front of the ankle-joint, inclining at the same time inwards, and becomes inserted into the inner side of the first cuneiform bone and the neighbouring part of the first metatarsal bone. Whilst passing in front of the ankle-joint, it is bound down by the annular ligament, which is here represented somewhat like a broad tape crossing the tendons and retaining them in their situation.

*The Long Extensor muscle* of the toes, 11, 12, 13, extends from the upper end of the tibia to the third row of digital bones: its upper extremity is fleshy, and somewhat aponeurotic; and the lower consists of a tendon which splits into four processes destined for the four smaller toes. The points to which its fleshy fibres are attached are,—the external tuberosity of the tibia, a little farther back than the anterior tibial muscle,—the head of the fibula, and the anterior surface of that bone for some way down; also the interosseous ligament, and the tendinous processes interposed between it and the tibialis anticus on one hand, and the peronei on the other. The fibres derived from these different points of attachment differ somewhat in their direction as they descend; the upper set descend vertically, those lower down incline obliquely forwards and downwards, all terminating in a tendon which gradually resolves itself into the processes already alluded to; these, as they pass over the upper surface of the foot, diverge a little as they proceed to their destination, and finally run upon the two first rows of the digital bones and become fixed into the third.

*The Third Peroneal muscle* (m. peroneus tertius) is placed along the fore part of the fibula in the lower third of its extent, being close to the edge of the common extensor muscle, with which it is intimately united at its origin and for some way down, so as to appear a part of it. It is not unfrequently called the anterior peroneal muscle, as it lies before the fibula, which separates it from the other two muscles of the same name: hence it is readily distinguished from these by its situation, and quite as decidedly in its action, for it bends the foot upon the leg; whilst they, on the contrary, carry it backwards by means of the change of direction which their tendons suffer whilst passing behind the lower end of the fibula. As, then, the third peroneal muscle is intimately united at its origin with the common extensor, and combines with it in its action on the foot, it may be considered a part of it. The fibres of this muscle will be observed to be fixed along the lower third of the fibula and the neighbouring part of the interosseous ligament; they incline obliquely forwards to a tendon which lies along the anterior edge of the muscle, and which, after passing under the annular ligament of the ankle-joint, becomes inserted into the fifth metatarsal bone.

*The Extensor muscle* of the great toe (m. extensor proprius pollicis) lies in the interval between the long extensor of the toes and the anterior tibial muscles, by which its upper part is altogether concealed; but its tendon, No. 9, comes forward, so as to be seen along the lower third of the leg, and also on the upper surface of the foot, where it is marked 10. From the situation which the muscle occupies, it is necessarily compressed and flat. It arises from the inner surface of the fibula, in the middle third of its extent, or a little higher up; also from the neighbouring part of the interosseous ligament for some way farther down; the fleshy fibres run obliquely forwards into a tendon which, as here shown, forms the anterior border of the muscle, and is the only

## PLATE XLI.

The fourth layer of the muscles of the back is here shown; the serratus posticus and splenii having been sufficiently indicated in the preceding plate.

No. 1. The occipital bone. 2, 2. The mastoid part of the temporal bone. 3, 3. The complexus muscle at each side. 4, 4. Its digastric portion, which is often considered a separate muscle, and named biventer cervicis. 5, 5. The trachelo-mastoideus muscle at each side; at the left side it is everted to show the tendinous points by which it arises. 6, 6. The cervicalis ascendens muscle at each side, forming a continuation of the sacro-lumbalis. 7, 7. The transversus cervicis muscle, forming a continuation of the longissimus dorsi. 8, 8. A slip of muscular fibre, usually passing from the longissimus dorsi to the complexus. 9, 9. The upper part of the sacro-lumbalis muscle at each side; at the right side, the tendinous points by which it is attached to the angles of the ribs are seen forming a series from below upwards; at the left side, the muscle is drawn outwards to show the series of accessory bundles of fibres derived from the ribs, and by which the muscle is strengthened and prolonged upwards: these are seen in the space from 10 to 10. 11, 11. The longissimus dorsi muscle at each side; at the left side it is drawn inwards to show its tendinous points of insertion. 12, 12. The point at which the sacro-lumbalis and longissimus dorsi of each side become separable from one another. 13, 13. The mass of tendinous and muscular fibres forming the deep-seated lumbar muscles—erectores spinae, and which higher up separate a little at 12, 12, so as to form the sacro-lumbalis and longissimus dorsi. 14, 14, 14, 14, 14. The series of tendinous and fleshy fibres, which lie close to the spinous processes, and are attached to them, forming, when taken together, the spinalis muscle. 15, 15. The crest of the ilium at each side. 16. The lower extremity of the spine.

part that can be seen in this view. The tendon passes beneath the annular ligament, and upon the upper surface of the foot, to reach the second bone of the great toe, into which it is fixed.

*Actions.*—The first effect of the long extensor muscle of the toes is to straighten or extend the different osseous pieces of which they consist, and at the same time to lift them from the ground: in these particulars it is the direct antagonist of the flexor muscles, which lie at the back of the leg, and whose tendons are prolonged through the sole of the foot to the digital bones. The power of the muscle is not, however, confined to the toes; it can be made to act upon the foot and draw it up so as to bend it upon the leg; this it is enabled to do by the change which is given in its direction as it passes under the annular ligament. In this latter effort it is assisted by the other muscles which lie beside it, for the anterior tibial and third peroneal muscles are the direct flexors of the foot; and the long muscle of the great toe, after having acted upon the digital bones, can, by continuing its effort, combine with those just named, so as to become a flexor of the foot. Finally, when the foot is rendered relatively the more fixed point, as in the standing posture, these muscles can be made to act from below, and draw upon the bones of the leg so as to bring them forward and maintain them erect over the foot. There is a short extensor muscle of the toes which is partly seen in this drawing: it consists of a narrow fleshy part, which rests far back upon the foot, No. 22, and of four tendinous processes, 23, 23, 23, 23, which are continued onwards to the four inner toes; it obviously assists the long extensor, but from the difference in its line of direction it is enabled not only to straighten the toes, but also to incline them a little outwards, or it may so modify the action of the long extensor, when both muscles act together, that they are simply extended and drawn backwards without receiving any inclination either inwards or outwards.

*The Long Peroneal Muscle* (m. peroneus longus, vel primus) is placed at the outer side of the leg, along which it descends to the outer ankle, behind which it passes; and, after resting upon the heel-bone, it runs obliquely across the sole of the foot, to be fixed into the first metatarsal bone: its fleshy part is marked 16, its upper attachment 17, the tendon which is prolonged from it in the middle and lower third of the leg 18; where it runs upon the calcaneum, after having passed behind the external ankle, its position is indicated by 19; below this point it is observed to turn round the border of the foot and pass deeply across its under or plantar surface. It is attached by its upper extremity to a small part of the tuberosity of the tibia, to the head of the fibula, and the outer surface of the bone in about one-third of its length; some of its fibres are also connected with the fascia of the leg, and the tendinous septa between it and the contiguous muscles. From the fleshy fibres thus arising, a flat tendon is prolonged downwards, resting for some way on the short peroneal muscle; it passes behind the outer ankle, where it is bound down by a fibrous band, which, with a groove in the bone, forms a sort of canal for its transmission; whilst passing over the heel-bone, (calcaneum,) it is also retained in its situation by a fibrous band. It then runs in a groove beneath the cuboid bone, where it is also confined by tendinous fibres; and finally it becomes fixed to the tubercle at the posterior extremity of the first metatarsal bone.

*The short Peroneal muscle* (m. peroneus brevis, vel secundus) is shorter than the preceding, and is overlapped by it, but not concealed, as its fibres project so as to be seen in the middle and lower part of the leg on each side of the tendon of the long peroneal muscle. This fact is expressed by the double references 20, 20; its tendon, 21, reaches to the fifth metatarsal bone. This muscle is attached to the outer surface of the fibula for half or a little more of its length; the fleshy fibres as they descend run, with varying degrees of obliquity, into a strong tendon which passes behind the external ankle, lying closer to the bone than the long peroneal muscle; it then inclines obliquely forwards to be fixed to the end of the fifth metatarsal bone.

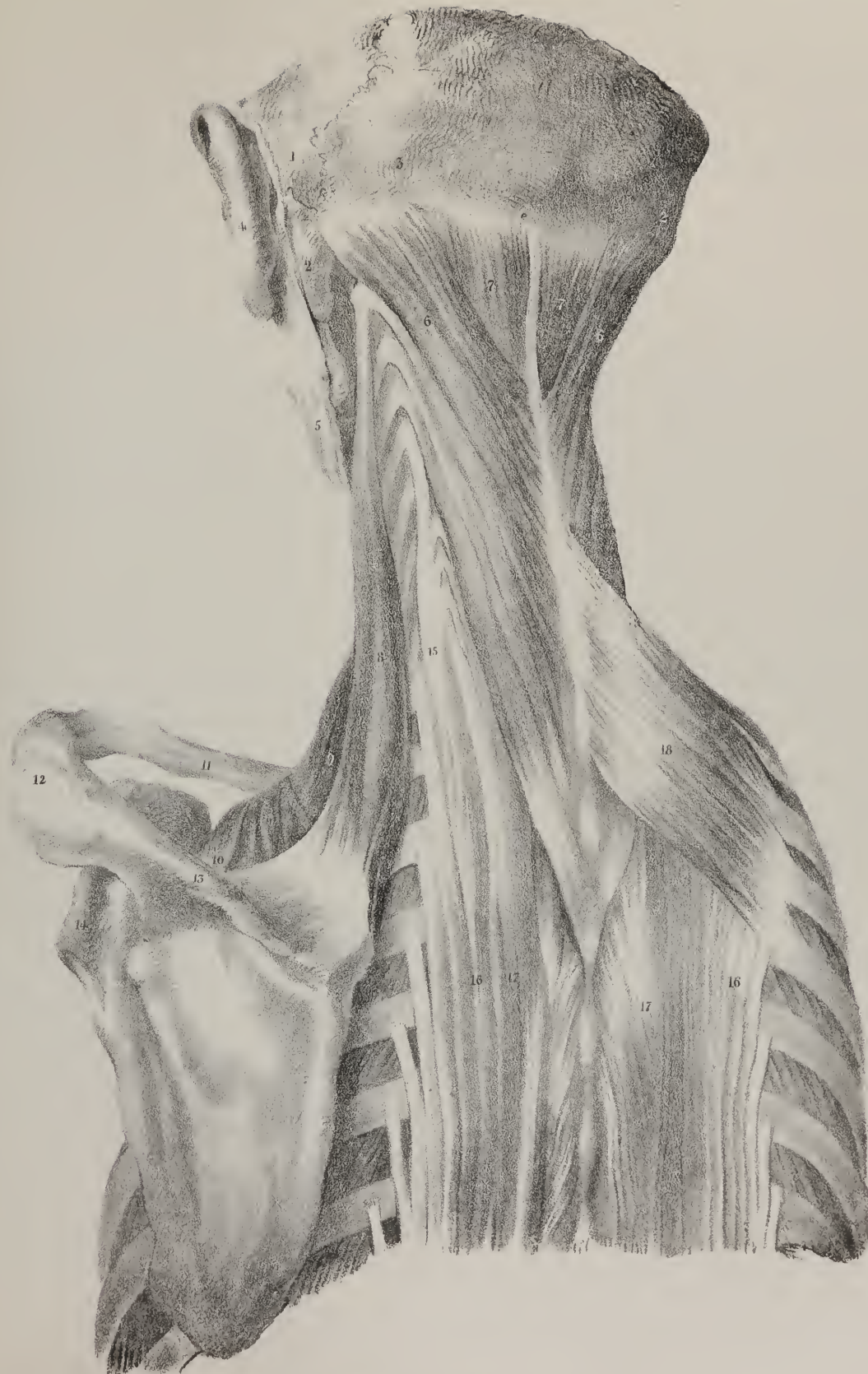
*Actions.*—When these muscles take their fixed points above, and draw upon the foot, they can readily extend it; this they are enabled to do by the change which occurs in their direction as they wind round the ankle: they can also elevate somewhat the outer border of the foot. When the foot is fixed by being pressed against the ground, these muscles will reverse their line of action, and draw upon the leg, so as to assist in maintaining it in the erect position. Thus, in the effort to stand upon one leg,

## PLATE XLII.

When the layers of muscles shown in the preceding plate are removed, the splenius, part of the complexus, and the serratus superior are brought into view.

- No. 1. The posterior part of the left parietal bone. 2, 2. The mastoid process of the temporal bone at each side. 3. The occipital bone. 4. The left ear. 5. The skin covering the lower jaw-bone. 6, 6. The splenius muscle at each side. 7, 7. The upper part of the complexus muscle at each side, seen in the interval left by the divergence of the splenii. 8. The elevator muscle of the angle of the scapula;—the four tendinous processes by which it arises from the transverse processes of the upper cervical vertebræ are shown by drawing the muscle a little outwards: lower down, three similar tendinous processes are seen; they form part of the attachment of the posterior scalenus muscle to the tubercles of the transverse processes of the cervical vertebræ. 9. Part of the posterior scalenus muscle. 10. Part of the omo-hyoideus muscle, arising from the upper border of the scapula. Between 9 and 10 a small part of the serratus magnus is seen. 11. The clavicle. 12. The acromion process. 13. The spine of the scapula. 14. The neck of the scapula. 15. The cervicalis ascendens muscle, being the cervical prolongation of the sacro-lumbalis. 16, 16. The sacro-lumbalis muscle at each side. 17, 17. The longissimus dorsi muscle at each side. 18. The upper serratus muscle, (m. serratus posticus superior.)









whenever it is desired to move it a little backwards or forwards upon the foot, the group of muscles placed before the bones, and those behind them, act alternately as motors and moderators; whilst the peroneal muscles act in a different way, and become in a manner fixors of the leg. The weight of the body in such a case as this tends to incline the leg and foot inwards; but the long peroneus, pulling as it were from its fixed point in the sole of the foot, and having its line of direction changed by turning round its outer border and behind the external ankle, is enabled to draw upon the outer side of the bones of the leg, and thereby counteract the influence of the weight of the body, which tends to press them inwards.

Behind the peroneal muscles, we see in this drawing the outer side or border of the great muscles which form the calf of the leg, viz. the gastrocnemius, 24, and the soleus, 25: other views are given of these same muscles in Plate XXXVI, fig. 2, and Plate XXXVII, figs. 1, 2.

## PLATE XXXVI.

THE muscles of the leg are here drawn as they are seen from its outer and inner sides. The position of the different tendons which pass in front of the ankle-joint are seen in fig. 1, where the annular ligament is removed in order to show their relative position at the point referred to. The tendon of the tibialis anticus is marked 18, 19; that of the extensor communis, 21, 22; of the peroneus tertius, 23, 24; and the extensor of the great toe, where it begins to be apparent, is marked 25; the position of the peroneal tendons, after passing behind the external ankle, is indicated by Nos. 11, 12. The tendons of the two inner hamstring muscles, with the gracilis and sartorius, are shown as they pass along the inner side of the knee, in fig. 2, Nos. 8, 10, 11, 12. The position and direction of the tendon of the anterior tibial muscle is indicated by the Nos. 18, 18; and the three muscles which pass behind the inner ankle are indicated by the Nos. 20, 21, 22.—See references page 66

## PLATE XXXVII.

IN fig. 1, the muscles of the calf of the leg are shown as they present themselves to view when the skin and fascia are dissected off: the gastrocnemius muscle is seen in its entire extent, 4, 4, 5, 5; and its long tendon, 6. Part of the soleus, where it projects behind the preceding, is indicated by No. 7, 7: the whole of this muscle is brought into view in fig. 2, No. 7, 7, by the removal of the gastrocnemius.

*The Gastrocnemius muscle* forms, as its name implies, the calf of the leg. It is thick and rounded at its posterior aspect, and plain in front, where it rests on the soleus. Its upper extremity consists of two processes or heads, 4, 4, which are attached to the back part of the condyles of the thigh-bone, leaving an interval between them for the passage of the popliteal vessels; lower down, they unite and form a considerable fleshy mass. Below the middle of the leg, the muscular part ends in a broad strong tendon called tendo Achillis, which grows narrower and thicker as it descends, and is finally fixed to the posterior extremity of the heel-bone.

*The Plantaris muscle*, fig. 2, No. 4, consists of a small tapering fleshy portion, and of a large narrow tendon, 5, which reaches as far as the heel-bone. It is attached at its upper extremity to the back part of the outer condyle of the thigh-bone, where it is concealed by the outer head of the gastrocnemius, and also to the posterior ligament of the knee-joint. It will be found to incline inwards as it descends, resting on the popliteus and soleus muscles: its tendon is inserted, together with the tendo Achillis, into the calcaneum.

*The Solcus muscle*, fig. 2, No. 7, 7, is thick and broad at its middle, but narrows towards its extremities, particularly the upper one, so as to assume the form of an elongated oval. It is attached to the tibia and fibula, and, in the interval between these bones, to a tendinous process stretched across from the one to the other: through this interstice the popliteal vessels pass downwards. The division of the muscle into two parts or heads is at first scarcely perceptible; but it will be found that the outer one is attached to the head of the fibula, and to the posterior surface of the bone for a third of its length, whilst the inner one is fixed to the middle third of the tibia as it commences below the border of the popliteus. The fleshy fibres converge as they descend, and become fixed into the tendo Achillis at its anterior surface.

*Actions.*—These muscles act powerfully in the different efforts which we are required to make in running, walking, and lifting burdens. They take their fixed points above, and pull on the heel bone, so as to lift it from the ground; thereby making the foot to represent an inclined plane, and give an impulse to the body upwards and forwards. When the body is in this way raised on one foot, the opposite limb can be carried forward without difficulty, and almost in a straight line. Were we not able

to make this preparatory movement, each leg should necessarily describe, whilst being carried forward in progression, a considerable arch of a circle, as may be seen in those who use a wooden leg. In the standing posture these muscles take their fixed points at the heel, and act on the bones of the leg, maintaining them in the erect position, and preventing them from obeying the influence of the weight of the body, which tends to incline them forwards.

## PLATE XXXVIII.

THE muscles which are situated deeply at the back of the leg, in close contact with the bones and the interosseous ligament, are shown here; they may be said to form a layer by themselves, as they are separated from the muscles of the calf of the leg by a layer of membrane, (the deep fascia of the leg,) and by the posterior tibial blood-vessels and nerves. When the membrane and vessels just named are removed, the muscles now to be described become exposed in their entire extent, so far as they are in relation with the bones of the leg; but, as part of them extends into the sole of the foot, some additional dissection is required in the latter situation. There are here placed four muscles; viz. the popliteal, or muscle of the ham, so called from its relation to the back part of the knee-joint; the long flexor of the toes, the flexor of the great toe, and the posterior tibial muscle.

*The Popliteal muscle*, (m. popliteus,) fig. 1, No. 3, is placed at the flexure of the knee-joint, extending obliquely across it from the external condyle of the thigh-bone downwards and inwards to the tibia. It commences by a flat, strong tendon, which is fixed to a depression at the outer side of the condyle; the muscular fibres spread out gradually as they descend from the tendon, and become inserted into a triangular space marked upon the upper part of the tibia, and which is seen in fig. 2, the fibres of the muscle being removed. This muscle is compressed and flat: its form is irregularly triangular; its upper part or origin consists of the tendon already spoken of, the lower being a mixture of fleshy and tendinous fibres; its posterior surface supports the popliteal vessels and nerves; the anterior is in close relation with the knee-joint, its tendon being connected with the external semi-lunar cartilage and the synovial or lining membrane of the joint.

*The long Flexor muscle of the toes*, (m. flexor longus digitorum pedis,) fig. 1, Nos. 8, 9, extends from the upper part of the tibia to the last row of digital bones. Its fibres commence to be fixed to the tibia immediately below the oblique line which marks the attachment of the soleus, and continue to arise from the bone for a considerable way downwards; the fleshy fibres will be observed to incline obliquely backwards as they descend, and to terminate in a tendon placed along the posterior edge of the muscle, and which, after running behind the inner ankle, is prolonged into the sole of the foot. When examined in the latter situation, the tendon is found to divide into four slips, which spread out towards the four smaller toes; each slip passes through a fissure formed for it in a similar tendinous process derived from the short flexor muscle, and finally becomes fixed to the last bone of the toe. Where the tendon slides behind the ankle, it overlays that of the posterior tibial muscle, No. 7; and both are retained in their proper situation by a fibrous sheath, which, however, is divided into two compartments, so that each tendon moves in a

## PLATE XLIII.

FIG. 1. The small complexus muscle is here shown.

No. 1. The mastoid part of the temporal bone of the right side. 2. The under part of the occipital bone. 3. The small complexus muscle, more usually called trachelo-mastoid, (m. trachelo-mastoideus.)

FIG. 2. The large complexus muscle is here given by itself.

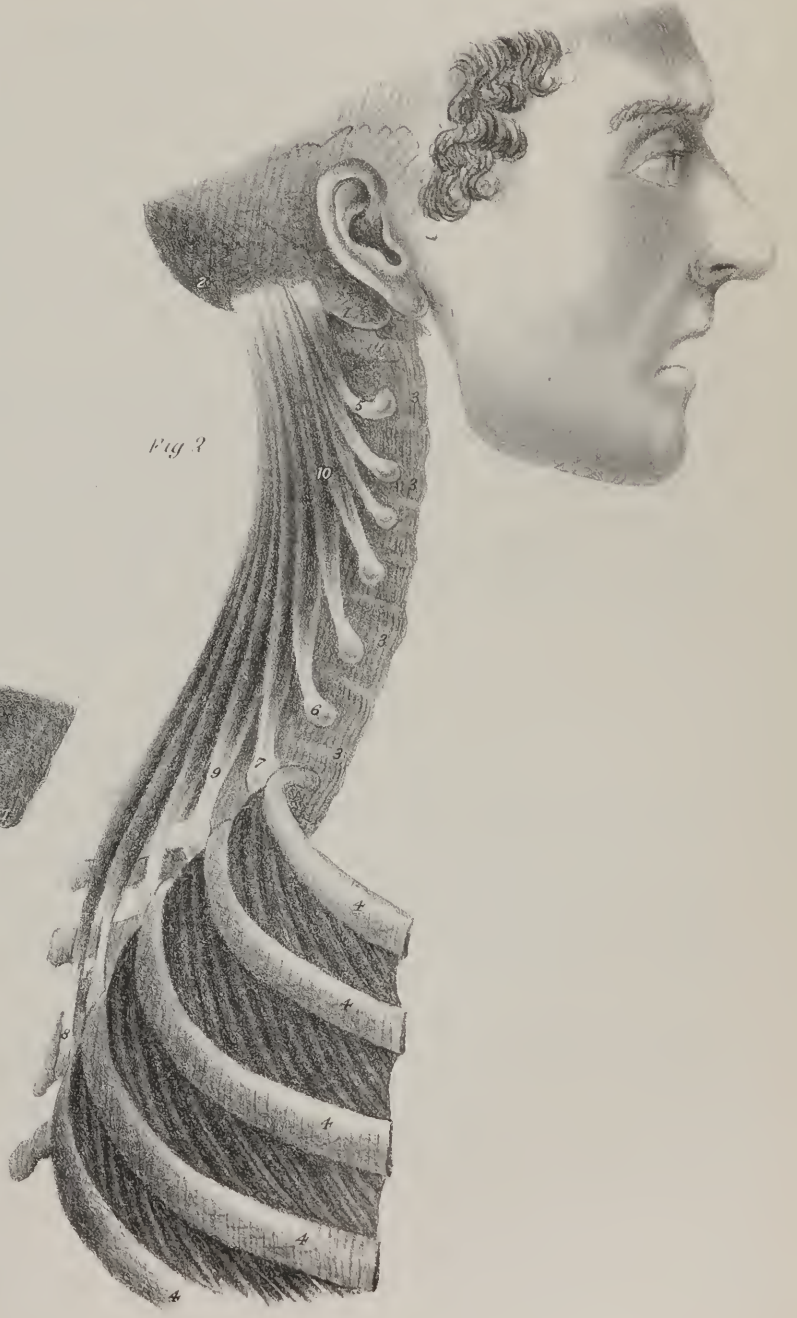
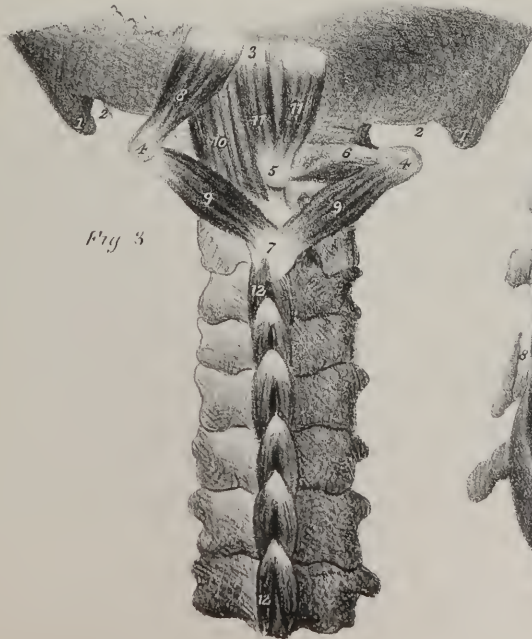
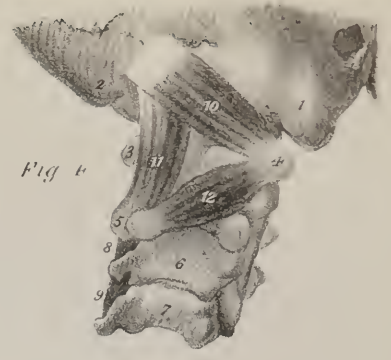
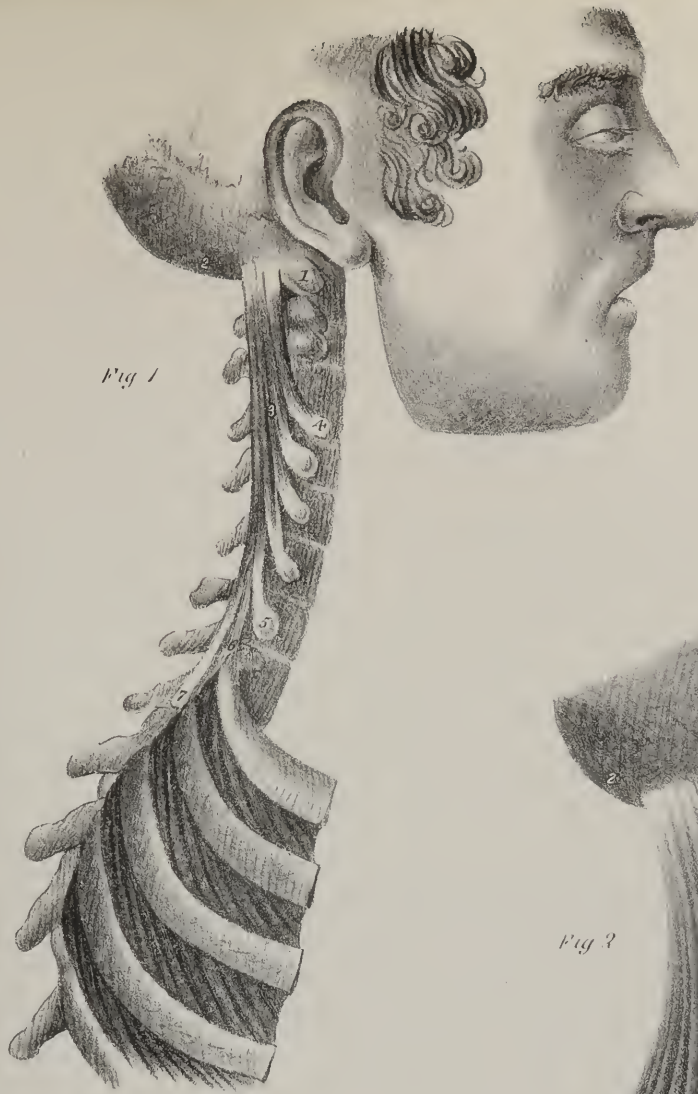
No. 1. The mastoid part of the temporal bone. 2. The under part of the occipital bone. 3, 3, 3, 3. The anterior surface of the bodies of the vertebrae. 4, 4, 4, 4. The upper ribs. From 5 to 6 are the pointed tendinous processes by which the great complexus muscle arises from the transverse processes of the cervical vertebrae. From 7 to 8 are the processes by which it arises from the transverse processes of the upper dorsal vertebrae. 9. The lower part of the body of the great complexus muscle, formed by the union of the several processes derived from the dorsal vertebrae;—10, the upper part, formed by the union of those derived from the cervical vertebrae.

The muscular apparatus connecting the two upper vertebrae of the neck with the base of the skull is shown in the drawings, figs. 3, 4.

FIG. 3. No. 1, 1. The mastoid process of the temporal bone at each side. 2, 2. The styloid process at each side. 3. The posterior surface of the occipital bone. 4, 4. The extremity of the transverse processes of the atlas, or first cervical vertebra. 5. The tubercle at the middle of the posterior arch of the atlas. 6. Part of the arch of the atlas at the right side, exposed by the removal of the superior rectus and superior oblique muscle. 7. The end of the spinous process of the second vertebra. 8. The superior oblique muscle, (m. obliquus superior.) 9, 9. The inferior oblique muscle at each side, (m. obliquus inferior.) 10. The greater straight muscle, (m. rectus major posticus.) 11, 11. The smaller straight muscle, (m. rectus minor posticus.) From 12 to 12 are seen the interspinal muscles, (m. interspinales.)

FIG. 4. No. 1. The mastoid process of the right temporal bone. 2. The under part of the occipital bone. 3. The posterior part of the arch of the atlas, or first cervical vertebra. 4. The transverse process of the atlas. 5. The end of the spinous process of the second vertebra. 6, 7. The arches of the third and fourth cervical vertebrae. 8, 9. The two upper interspinal muscles. 10. Superior oblique. 11. The greater straight muscle. 12. Inferior oblique.









separate groove or rather canal. The surfaces here in contact are lined by a membrane which secretes a fluid calculated to lessen the effects of friction.

*The Long Flexor muscle of the great toe*, Nos. 10, 11, (*m. flexor longus pollicis*,) lies along the posterior surface of the fibula, or outer bone of the leg, and is prolonged into the foot as far as the last bone of the great toe. Its fibres are fixed to the fibula for about two thirds of its length, and slightly to the interosseous ligament, from which they incline backwards to a tendon placed along its posterior border: the tendon inclines inwards, and runs along a groove marked upon the posterior surface of the tibia; it then passes behind the astragalus, or die-shaped bone, and under the inner edge of the calcaneum, thereby reaching the sole of the foot; in this latter situation it is connected with the long flexor muscle of the toes by a piece of tendon, and gradually inclines inwards, so as to pass beneath the first metatarsal bone, and between the two heads of the short flexor muscle of the great toe, after which it is inserted into its second bone.

*The Posterior Tibial muscle*, (*m. tibialis posticus*,) fig. 1, Nos. 6, 7; fig. 2, Nos. 3, 4, is partly concealed by the two preceding muscles, but its upper end extends higher in the leg, occupying the interstice between the two bones; this part is marked No. 6, in fig. 1; the rest is overlaid by Nos. 10 and 11; but its tendon, No. 7, is partly seen as it runs behind the inner ankle. The fibres of the posterior tibial muscle are attached to the surface of the tibia, commencing below the oblique line which bounds the insertion of the popliteal muscle, and continue to be fixed to the bone for some way down; many of them also arise from the posterior surface of the fibula for about two thirds of its length, and from the interosseous ligament. The fleshy fibres incline backwards to a tendon by which the muscle is prolonged into the sole of the foot: this tendon slides in a groove behind the inner ankle, and is fixed to a projection upon the under surface of the scaphoid bone; some of its fibres are prolonged to the inner cuneiform bone, and to the second and third metatarsal bones. As the fibres at the upper end of the muscle are attached to the tibia and the fibula, an interval necessarily exists between them, corresponding with an aperture in the interosseous ligament, for the transmission of the anterior tibial vessels: this fact is indicated in the drawings.

*Actions.*—The popliteal muscle, when it takes its fixed point above, can assist the flexor muscles in bending the leg upon the thigh; and by acting on the inner border of the tibia, it will incline the corresponding side of the leg and foot inwards: it can scarcely be said to flex the thigh upon the leg, but it may exert some influence in giving steadiness to the joint in the different movements of the limb.

The long flexor muscles, when first brought into action draw on the bones of the toes so as to bring them into the bent or curved position. By continuing their effort they extend the foot, or bring it (as nearly as the structure of the ankle-joint will admit) into a line with the leg; this they are enabled to do by the change of direction given to their tendons as they pass behind the projection of the ankle. The posterior tibial muscle is a principal agent in extending the foot upon the leg; so are the two peronei; and they can execute this movement in what is ordinarily considered the relaxed position of the limb, when the leg is bent on the thigh. In the extended state, the muscles of the calf of the leg act with great power on the foot, by drawing on the calcaneum. All these agents are employed in the effort to stand on tip-toe, and in every muscular exertion, such as jumping, which is an uplifting of the body from the feet as from a spring. In the standing posture these muscles are made, by an effort of the will, to reverse their mode of action and draw upon the bones of the leg, so as to assist in maintaining them erect upon the foot, or in bringing them into that state if they have been previously bent forwards.

## PLATE XXXIX.

THE muscles in the sole of the foot are shown in these drawings in the order in which they present themselves when dissected; they are arranged in layers, which are taken successively one after the other.

In fig. 1, are shown the muscles which form the first layer in the sole of the foot; they are three in number; one of them corresponds with the inner side of the foot and great toe; it is marked 2, 3, 4, and is named *abductor pollicis*: another lies along the outer border of the foot and little toe, and is marked 9, 10; it is the *abductor of the little toe*: the third occupies the interval between the two preceding muscles, and is marked 5, 6; it is named the *short flexor of the toes*:—these are brought into view by removing the skin and the plantar fascia.

*The Abductor muscle of the great toe*, (*m. abductor pollicis pedis*, 2, 3, is attached to the inner border of the calcaneum or heel-bone, where it forms a protuberance, and to the internal annular ligament; some of its fibres are also fixed to the plantar fascia; its fleshy fibres will be observed to end in a tendon which is fixed to the base of the first bone of the great toe at its inner border; it is also intimately connected with the inner division of the short flexor of the great toe, No. 14.

*The Abductor muscle of the little toe*, (*m. abductor digiti minimi*,) is attached to the outer border and under surface of the calcaneum, close to its outer tubercle, and also to the plantar fascia: the fleshy fibres end in a tendon which passes beneath the head of the fifth metatarsal bone, and is inserted into the first bone of the little toe at its base.

*The short Flexor of the toes*, (m. flexor brevis digitorum pedis—flexor perforatus,) 5, 6, lies along the middle of the sole of the foot: it is attached to the under surface of the calcaneum, close to its great tuberosity; its fibres are connected also with the plantar fascia, and with membranous partitions which separate it from the abductor of the great toe and that of the little toe; towards its fore part, the body of the muscle divides into four pointed processes, which are prolonged by means of separate tendons, 7, 7, 7, 7, to the second bones of the four smaller toes, into which they are fixed. Each tendon presents a fissure and a groove, through which a corresponding tendon of the long flexor tendon is transmitted, which is indicated by the references 17, 17; the points at which the tendons of the short flexor muscles terminate are indicated by the numbers, 8, 8, 8, 8.

Fig. 2.—The second layer of muscles in the sole of the foot consists of the tendon of the long flexor muscle of the great toe, 5, 6; the tendon of the long flexor muscle of the smaller toes, 7, 8, 9, with its accessories or assistants, viz. the accessory flexor 12, 13, and the lumbricales 11, 11, 11, 11. The long tendons here named have been already described with the muscles to which they belong, pp. 77, 78.

*The Accessory muscle*, (m. flexor accessorius,) 13, commences by two pointed processes, 12, 12, attached to the plantar surface of the calcaneum; they soon unite and form a flat fleshy mass, which at its termination becomes tendinous, and is fixed to the tendon of the long flexor muscle where it is about to divide into its digital processes.

*The Worm-like muscles* (m. lumbricales) are four in number: each is rounded and tapering, and is attached by one end to the tendon of the long flexor muscle near its point of division, and by the other is fixed to the base of the first bone of the corresponding toe at its inner side.

The other muscles in this figure are named in the references at page 71.

Fig. 3.—The third layer of plantar muscles is here shown, being brought into view by the removal of the long flexor tendons: they consist of the adductor muscle of the great toe; the short flexor; the transverse muscle of the foot, No. 12; and the short flexor of the little toe, No. 9.

*The Adductor muscle of the great toe*, (m. adductor pollicis,) No. 8, is placed obliquely in the sole of the foot, forming a thick fleshy bundle; it is attached to the external and middle cuneiform bones, and to the ends of the third and fourth metatarsal bones, as well as to the sheath of the long peroneal muscle: from these points it inclines inwards, and becomes tendinous; after which it joins with the outer head of the short flexor muscle, previously to its becoming fixed into the base of the first bone of the great toe: it is also connected with the external sesamoid bone, which may be considered an appendage to it.

*The Short Flexor muscle* (m. flexor brevis pollicis pedis) of the great toe is overlaid, and partly concealed in this and the preceding figure, by the abductor and the long flexor muscles: near its insertion it becomes divided into two processes or heads, which in fig. 1 are marked Nos. 14, 14; between these the tendons of the long flexor muscle, fig. 1, No. 15, lies as it proceeds to its insertion; the inner head of the short flexor muscle becomes inseparably connected with the abductor, and the outer with the adductor of the great toe, previously to its insertion; its posterior extremity is pointed and narrow, and is usually fixed to the inner border of the cuboid bone, also to the external cuneiform bone, and to the tendinous fibres prolonged into the foot from the

## PLATE XLIV.

The muscles in immediate connexion with the cervical part of the spine (its anterior surface) are shown in these drawings. The bones of the head and face are removed, with the exception of a small part of the basilar process of the occipital bone, and part, at each side, of the temporal bone.

FIG. 1. No. 1. Part of the basilar process of the occipital bone. 2, 2. The petrous portion of the temporal bone. 3, 3. The styloid process of the temporal bone. 4, 4. The transverse processes of the first vertebra. 5. The tubercle at the fore part of the first vertebra. 6. The ridge at the fore part of the second vertebra. 7, 8, 9, 10, 11, 12. The transverse processes of the cervical vertebræ, from the second to the seventh. 13, 14. The head and body of the first rib at the left side. 15. The first rib at the right side. 16. The second rib. 17, 18, 19. The bodies of the three upper dorsal vertebræ. 20. The great, or long anterior straight muscle of the head, (m. rectus capitis anticus major.) 21. The small, or short anterior straight muscle, (m. rectus capitis anticus minor) of the left side; it is brought into view by the removal of the long straight muscle, which overlays it. 22. The lateral straight muscle, (m. rectus lateralis.) 23. Part of the levator scapulæ muscle. 24, 24. The upper, or smaller division of the long muscles of the neck, (m. longi colli.) 25, 25. The lower, or long portion of the same muscles. 26. The posterior scalenus muscle of the right side. 27. The anterior scalenus muscle.

FIG. 2. No. 1. The basilar process of the occipital bone. 2, 2. The petrous portion of the temporal bone. 3, 3. The styloid process at each side. 4, 4. The transverse processes of the first cervical vertebra. 5. The tubercle at the fore part of the first vertebra. 6, 6. The transverse processes of the second cervical vertebra. 7. The great anterior straight muscle of the head (m. rectus capitis anticus major) at the right side, everted so as to show its mode of connexion with the transverse processes from which it arises. 8, 8. The recti laterales muscles. 9. The upper, or small portion of the longus colli muscle. 10, 11. Its middle and lower portions. 12. The lower part of the same muscle at the right side. 13. The anterior scalenus muscle at the right side. 14. The posterior scalenus muscle at the left side. 15. Its second origin, or attachment to the second rib. 16. Part of the tendinous attachment of the anterior scalenus muscle left in connexion with the first rib, the rest being removed in order to expose fully the posterior scalenus muscle.



Fig 1

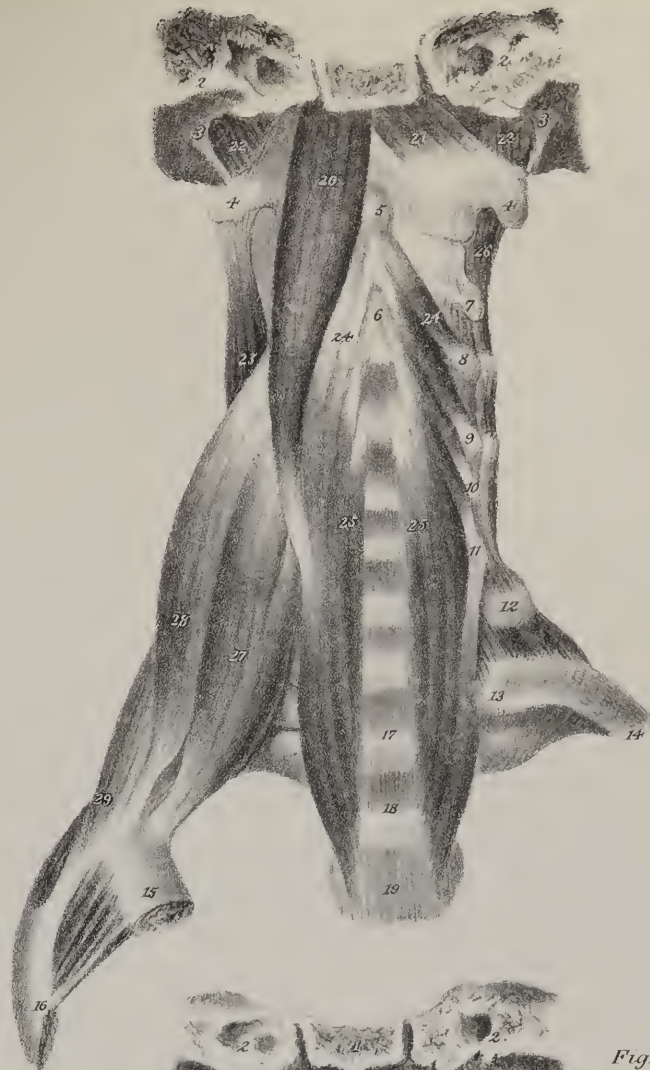
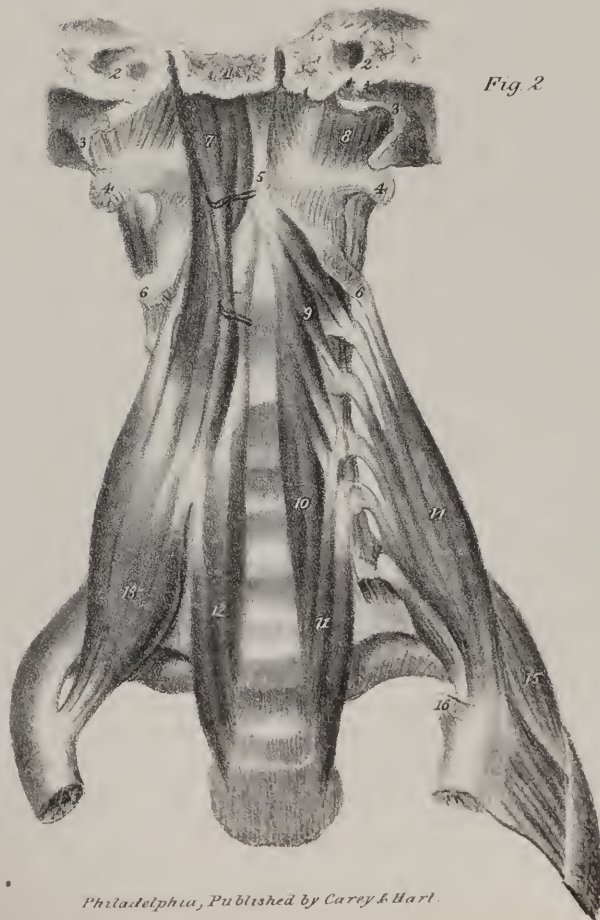
Fig 2







posterior tibial muscle: the two processes in which it terminates in front are fixed to the base of the first bone of the great toe, and also to the sesamoid bones.

*The Transverse muscle of the foot*, (m. transversus pedis,) 12, is a narrow flat band of fleshy fibres placed beneath the digital extremities of the metatarsal bones; its external extremity is attached to the lateral ligament connecting the fifth metatarsal bone with the first bone of the little toe, and, as it inclines inwards, its fibres are attached to the plantar ligaments connecting the second and third metatarsal bones with the digital bones; its inner extremity becomes blended with the adductor pollicis.

*The Short Flexor muscle of the little toe*, No. 9, lies beneath the fifth metatarsal bone; its posterior extremity, No. 10, is attached to the broad part or base of the bone just named, and to the sheath of the long peroneus muscle, whilst its anterior extremity becomes narrow and tendinous previously to its insertion into the base of the first bone of the little toe.

The fourth layer of muscles in the sole of the foot consists of the interossei. Three of these are seen in fig. 3, and are marked 13, 13, 13; they are the plantar interosseus muscles. Four are seen at the upper or dorsal surface of the foot in fig. 4, where they are numbered 10, 11, 12, 13; these are the dorsal interosseous muscles:—their name is taken from their occupying the interstices between the metatarsal bones.

*The Three Plantar Interosseous muscles*, fig. 3, No. 13, 13, 13, are placed not between the metatarsal bones, as their name would imply; they lie rather beneath the third, fourth, and fifth metatarsal bones, each inclining somewhat inwards. The first plantar interosseous muscle is attached along the under surface and inner border of the third metatarsal bone; it ends towards its fore part in a narrow tendon, which is fixed to the inner side of the first bone of the third toe at its base, and is also connected with the tendinous expansion of the common extensor muscle. The second and third plantar interosseous muscles are connected in the same way with the metatarsal and first digital bones of the fourth and fifth toes.

*The Dorsal Interosseous muscles* are four in number, and lie in the spaces between the metatarsal bones; their fibres are attached to the surfaces of the two bones between which they lie, and incline forward, converging to a thin tendon placed in the middle of each, so as to constitute it a double penniform muscle; their posterior extremities are necessarily bifid, and present slight interstices, through which perforating branches pass from the plantar to the dorsal arteries of the foot. The first dorsal interosseous muscle, fig. 4, No. 11, is inserted into the base of the first digital bone of the second toe, (at its inner side,) and into the tendon of the extensor muscle; the second dorsal interosseous muscle is fixed in the same way at the outer side of the same toe; and the third and fourth, Nos. 12, 13, are similarly disposed of at the outer sides of the corresponding bones.

*Actions.*—Several anatomists name the different interosseous muscles, not from their numerical order, first, second, third, &c., but from their actions and uses. Thus, the second, third, and fourth of the dorsal set are abductors of the corresponding toes, inasmuch as they are inserted into the external side of their phalanges; but the first dorsal and the three plantar muscles are adductors, so that if all four act together, they will draw the four lesser toes to the great one. Though the power of adduction and abduction is found in the digital phalanges of the foot, it is obviously very much restricted, as compared with the hand; and when we examine the rest of the muscular apparatus in this region, we shall see sufficient reason to admit, that, though it is constructed on the same general principle as that of the hand, and made up of analogous parts, its powers are modified and adapted to the peculiar uses of the foot, which forms a basis of support for the body, as well as an instrument of propulsion in its different movements. It may be observed, that from the analogy between the general construction of the great and little toes, and the thumb and little finger, the muscles of the former have received the same names as those of the latter, as if they could perform the same uses and exert the same actions. Thus the little toe has its abductor, flexor, and adductor (the third plantar interosseous), though these motions are so extremely restricted. The size of the muscles also shows that they are intended for some more important purpose than the movement of so small a part. The nomenclature of the muscles of the great toe has also been constructed on the supposition of its admitting of abduction and adduction like the thumb. But the mode in which its metatarsal bone is articulated with the first cuneiform bone, as well as the circumstance of its digital extremity being connected with the other toes, by the transverse ligament and transverse muscle, shows that these movements are, as it were, rudimentary, and have little to do with the proper functions of the part. Further, the three plantar muscles of the great toe are united so intimately together at their insertion, and for some way before it, that it is scarcely possible for them to act singly, or independently of one another; if so, they conspire in some common action, which is simply that of flexion. The bulk and power of these muscles are obviously disproportioned to the size of the part (the first phalanx) which they act on, as well as to the extent of any motions of which it admits. The same remark extends to the short muscles of the little toe, and generally to the flexors of all the toes, if a comparison be instituted between the moving powers and the things to be moved, supposing the phalanges to rank as the latter. Now, when we examine with attention the muscular apparatus of the foot, after having studied the structure and mode of adaptation of its different osseous pieces, we see abundant evidence of its being fitted to sustain strong and powerful efforts as a whole, rather than to admit of such free and varied motions amongst its parts as take place in the hand. Thus the oblique direction of the adductor and short flexor of the great toe, as well as of the little toe, enables them to draw the bones of the foot together, at the same time that they curve them downwards, and increase the arched form of the foot. These are not the only provisions for concentrating the metatarsal bones. The tendon of the peroneus longus passing across them from without inwards, and that of the tibialis posticus in the opposite direction, (at least that part of it which is prolonged to the third and fourth metatarsal bones,)

contribute to the same effect, as does also, but in a very minor degree, the crossing of the tendons of the flexor longus pollicis and flexor communis. All these facts tend to prove, that the aggregation and fixity of the different parts of the foot have been abundantly provided for, in order to render it a secure basis of support to the body, and that the muscular apparatus by which it is flexed and incurvated downwards, denotes it to be what we have here ventured to designate it,—a powerful instrument of propulsion in the different movements and actions of the lower extremity.

Fig. 4.—Upon the upper or convex surface of the foot, a single muscle is placed, which is here represented. It is the *Short Extensor muscle* of the toes, (m. extensor brevis digitorum pedis:) it is narrow and somewhat pointed at its posterior extremity, No. 3, but gradually becomes broad and thin as its fibres are traced forwards; it ends in four narrow processes, 4, 4, 4, 4, which become prolonged by tendons towards the upper surface of the toes. The first of these tendons, No. 5, is fixed to the upper surface of the first bone of the great toe at its base; whilst the other three, 6, 6, 6, become blended with the tendons of the long extensor as they run along the second, third, and fourth toes: the posterior extremity of this muscle is attached to the upper surface of the calcaneum, and to the ligament which connects it with the astragalus.

*Actions.*—The direct effect of this muscle is to straighten or extend the digital bones, and lift them from the ground; in which it assists the long extensor muscle.

## PLATE XL.

THIS drawing may be considered one of a series intended to show the structure, form, and relative position of the different muscles placed at the back of the trunk, and of the neck; they are arranged in layers lying one upon the other, and are readily distinguishable both by their size, form, and the direction of their fibres. At the right side, in this drawing, those muscles are exhibited which are brought into view by the removal of the skin and the subjacent cellular tissue. In performing the dissection, the texture of the muscles is rendered perfectly distinct by drawing the tegument so as to make it tense, and then directing the edge of the scalpel in the course of the muscular fibres.

*First Layer, or Dorsal muscles.*—Immediately beneath the skin there are two broad flat muscles, of which one extends from the occiput to the lower part of the back, and from the spine to the summit of the shoulder: it is marked 5, 6, 7, and named trapezius: the other extends from the middle of the back down to the pelvis, and from the spine to the humerus; it is marked 8, 8, 9, 10, and named from its great breadth, the broadest (latissimus) muscle of the back. Both these muscles have been already shown in Plate XXI., and their description will be found in pp. 45, 46.

*Second Layer of Dorsal muscles.*—At the left side, in this drawing, the second layer of muscles is brought into view by the removal of the trapezius and the latissimus; and those at the back part of the shoulder-joint are exposed by the removal of the deltoid muscle, which covers them, and gives to the shoulder its roundness and fullness, as may be seen at the right side, where it is marked No. 12.

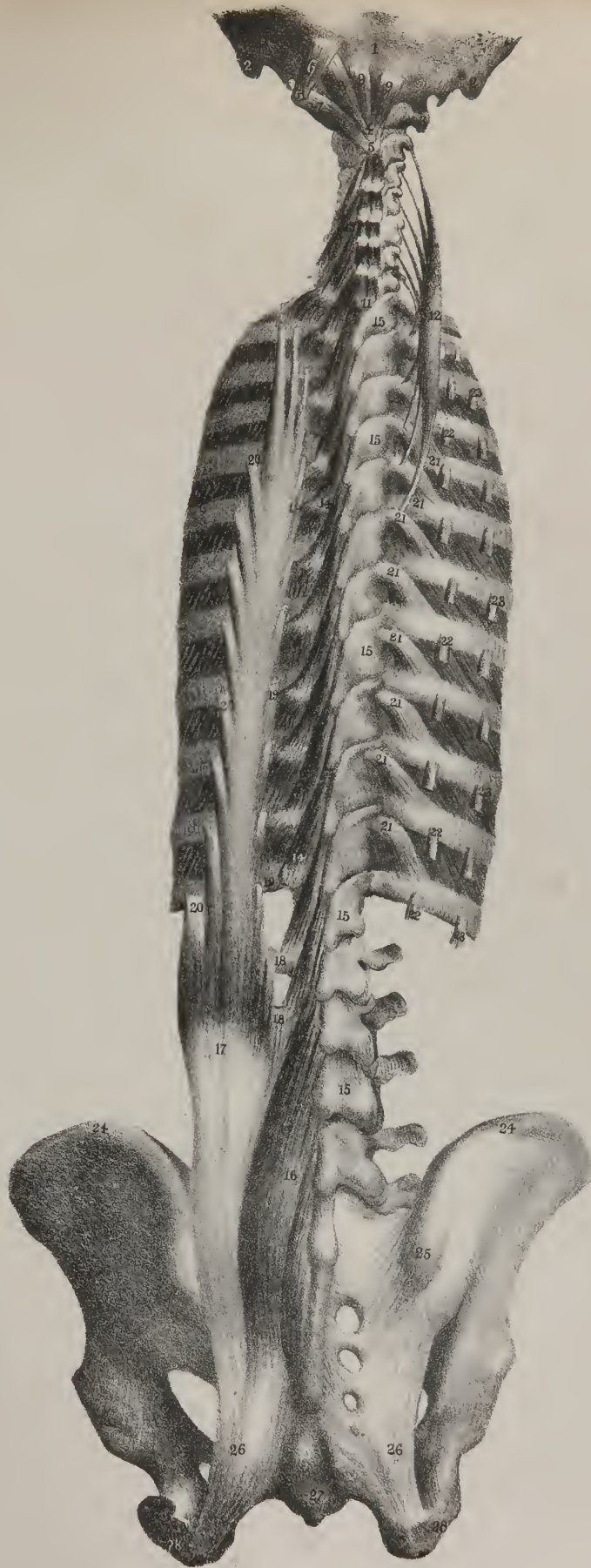
The second layer of muscles consists of three, which are covered by the trapezius, and are attached to the base of the scapula, where they lie on the same plane: they are the elevator muscle of the angle of the scapula, 26; the small rhomboid muscle, 27; and the large rhomboid muscle, 28.

*The Elevator muscle of the Scapula,* (m. levator anguli scapulæ,) is a flat narrow fasciculus, placed along the side and back

## PLATE XLV.

No. 1 The back part of the occipital bone. 2, 2. The mastoid process of the temporal bone at each side. 3, 3. The transverse processes of the first cervical vertebra. 4. The middle of its posterior segment. 5. The spinous processes of the second cervical vertebra. 6. The upper oblique muscle, (m. obliquus capitis superior.) 7. The lower oblique muscle, (m. obliquus inferior.) 8. The greater straight muscle (posterior), (m. rectus capitis posterior major.) 9, 9. The small straight muscle, (posterior), (m. rectus capitis posterior minor,) at each side of the middle line. 10. The rectus lateralis. 11. The spinous process of the seventh cervical vertebra:—in the interval between 11 and 5, (the spinous process of the second vertebra,) the interspinal muscles are seen. 12. The transversus cervicis muscle. 13. The cervical portion of the multifidus spinæ muscle. 14, 14. Its dorsal portion. 15, 15, 15, 15. The arches of the vertebræ at the right side, exposed by the removal of the multifidus spinæ muscle. 16. The lumbar portion of the multifidus spinæ muscle. 17. The lumbar portion of the longissimus dorsi muscle. 18, 18. Its points of attachment to the transverse processes of the lumbar vertebræ. 19, 19, 19, 19. Its points of attachment to the transverse processes of the dorsal vertebræ and to the tubercles of the ribs. 20, 20, 20. Its points of attachment to the ribs external to the tubercles. 21. Levatores costarum. 22, 22, 22, 22. The costal attachments of the longissimus dorsi muscle at the right side, the rest of its substance being removed. 23, 23, 23, 23. The points of attachment of the sacro-lumbalis muscle to the angles of the ribs. 24. The crest of the ilium at each side. 25. Its posterior spinous process. 26, 26. The great sacro-sciatic ligaments. 27. The os coccygis. 28, 28. The tuberosities of the ischia.

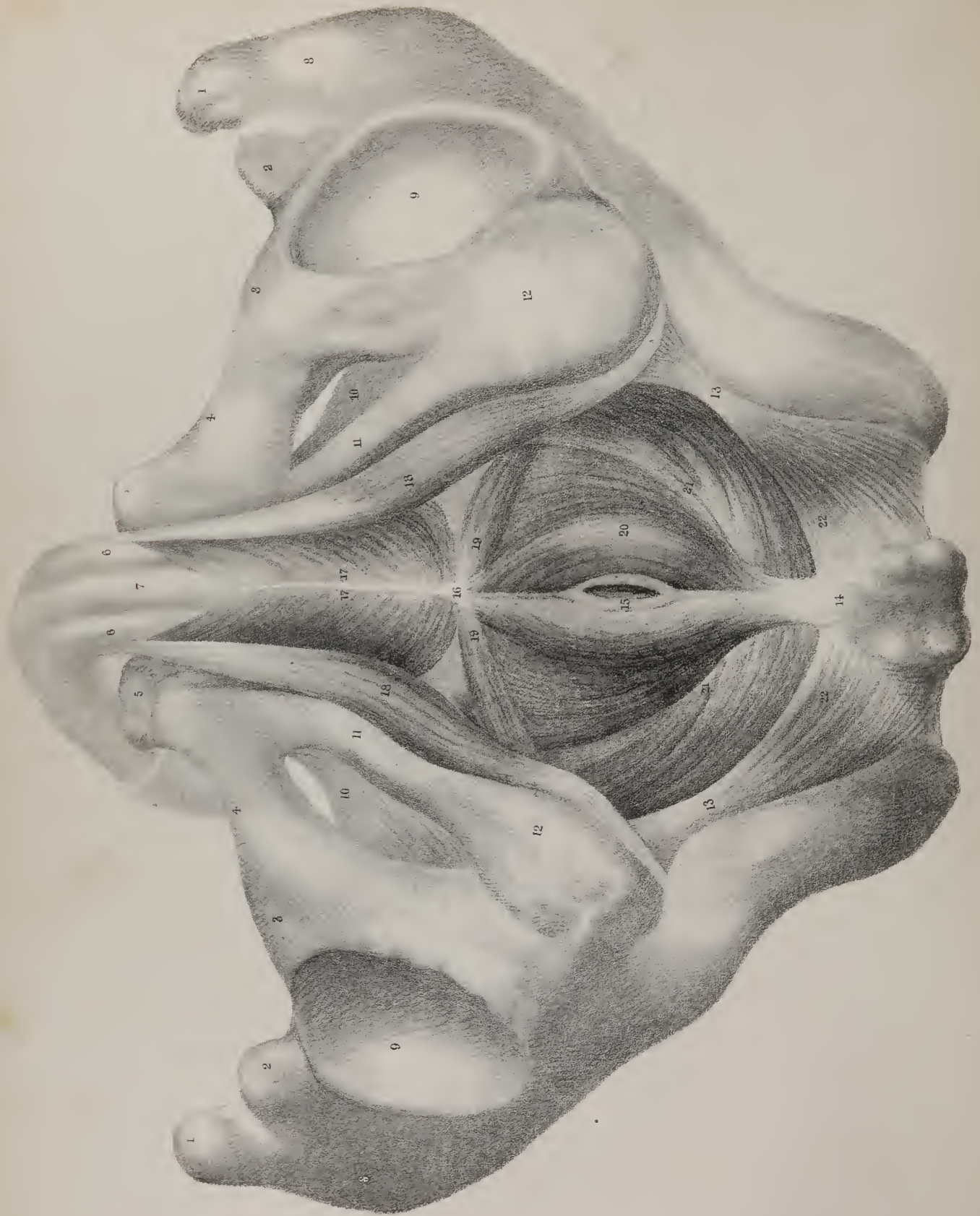











part of the neck: it is attached above to the posterior tubercles of three or four upper cervical vertebræ by separate tendinous points; from these the fleshy fibres descend, and form the body of the muscle. Its lower attachment is effected by means of tendinous fibres, which are fixed into that part of the base of the scapula which is included between the upper angle and the spine.

*The Smaller Rhomboid muscle* (m. rhomboideus minor,) No. 27, is a very narrow thin fasciculus, which is separated from the larger muscle of the same name by a very slight interval, which is filled with cellular tissue: both muscles lie on the same plane, and are similar in structure and in the direction of their fibres; the only assignable difference between them being in size. The smaller rhomboid muscle is attached by its upper extremity to the spinous process of the last cervical vertebra, and to the ligament of the neck (ligamentum nuchæ,) by short tendinous fibres; from these the fleshy structure inclines downwards and outwards, and becomes fixed to that part of the base of the scapula which corresponds with the triangular surface from which its spine arises.

*The Greater Rhomboid muscle* (m. rhomboideus major,) No. 28, four or five times larger than the other, is attached by tendinous fibres to the four or five upper dorsal vertebræ, and their interspinous ligaments, by tendinous fibres; it is inserted into the base, or posterior border of the scapula, for about two-thirds of its length, occupying the interval between its spine and lower angle.

*The Third Layer of muscles* consists of the splenii and the posterior serrati.

*The Splenius muscle* (m. splenius colli et capitis,) No. 24, is seen here in part of its extent, the rest being concealed by the rhomboid; the direction of its fibres is oblique, as it extends upwards and outwards from the spinous processes of the upper cervical vertebræ to the base of the skull. See Plate XLII., No. 6. It is usually considered as presenting two portions, which are described as separate muscles, inasmuch as one is attached to the base of the skull, and the other to the cervical vertebræ: it would be as well to treat it as a two-headed muscle, for the division occurs only at its upper part. The upper part of the muscle (splenius capitis) arises from the spinous processes of the two upper dorsal vertebræ, from that of the seventh cervical, and from the ligament of the neck; its fibres incline outwards as they ascend, and become fixed to the external surface of the mastoid process, and a little farther back into the occipital bone. The lower part of the muscle, viz. splenius colli, is neither so broad nor so thick as the preceding; it arises from the spinous processes of four dorsal vertebræ, from the third to the sixth, and is inserted by separate tendinous points into the transverse processes of three or four upper cervical vertebræ. The splenii are tendinous at their points of attachment, and fleshy in the rest of their extent; they are compressed and flat; the direction of their fibres is obliquely outwards and upwards.

The posterior serrati muscles are flat and thin; they are placed at a considerable distance from one another, as one of them rests upon the lower ribs, the other upon the upper.

*The Inferior Serratus muscle* (m. serratus posticus inferior,) No. 49, consists of fleshy and tendinous fibres, the latter forming the greater part of its extent; these will be observed to be attached to the spinous processes and the interspinous ligaments of the upper lumbar and two lower dorsal vertebræ; their direction is upwards and outwards; and the tendon terminates in four fleshy points, which are fixed to the bodies of the four lower ribs. The name given to the muscle is taken from the dentated appearance presented by its muscular attachment.

*The Upper Serratus* (m. serratus posticus superior) is altogether concealed by the rhomboid muscle; it is attached to the spinous processes of the two or three upper dorsal vertebræ, and to that of the last cervical; the direction of its fibres is downwards and outwards like the preceding muscle, becoming fleshy towards its termination. It is fixed by separate points into the bodies of the second, third, and fourth ribs, a little beyond their angles. Plate XLII., No. 18.

*Actions.*—The rhomboid muscles, when they take their fixed points at the spine, can act on the base of the scapula and

## PLATE XLVI.

The muscles of the perinæum are here shown, the skin and superficial fascia being removed:—the lateral parts of the pelvis and the os coccygis are so placed as to indicate the position of this region as it is seen in ordinary dissections.

No. 1, 1. The anterior superior spinous processes of the iliac bones. 2, 2. The anterior inferior spinous processes. 3, 3. The ilio-pectineal eminences. 4, 4. The bodies of the pubic bones. 5, 5. The cristæ or crests of the pubic bones. 6, 6. The corpora cavernosa penis. 7. The tube of the urethra. 8, 8. The outer surfaces of the iliac bones. 9, 9. The acetabula. 10. The obturator foramina, partly filled up by their ligaments. 11, 11. The rami of the pubic and ischial bones, forming the lateral boundaries of the perinæal space. 12, 12. The tuberosities of the ischium. 13, 13. Its spinous processes. 14. The end of the os coccygis. 15. The anal aperture. 16. The point between the anus and the bulb of the urethra, to which the fibres of some of the perinæal muscles converge. 17, 17. The accelerator urinæ muscle, (m. accelerator urinæ—m. bulbeux caverneux.) 18, 18. The erector penis muscle at each side (m. ischio-caverneux.) 19, 19. The transverse muscle of the perinæum at each side (m. transversus perinæi—m. ischio-perinæal.) 20, 20. The lateral parts of the sphincter ani muscle. 21, 21. Part of the levator ani muscle at each side. 22, 22. The coccygeus muscles at each side (m. ischio-coccygeal.)



draw it backwards, but not in a direct line, unless they conspire with the trapezius muscle; for the lower fibres of the latter ascend, whilst those of the rhomboid descend, so that their lines of direction decussate; hence, if they act together, the scapula will not be carried either upwards by the one, or downwards by the other, but directly backwards. It is in this way that we can approximate by a voluntary effort both the scapulæ, by drawing them backwards towards the spine. The elevator muscle of the angle of the scapula assists the rhomboid in one of its actions;—for instance, if the point of the shoulder be raised, the upper angle of the scapula is depressed, and the lower one is carried forwards; and when those muscles are relaxed which have effected this change, the elevator muscle restores the upper angle to its previous position, whilst the rhomboid effects the same purpose for the base and inferior angle. If the shoulder be fixed, the levator scapulæ muscle may incline the neck somewhat to its own side.

The inferior serratus muscle can act upon the lower ribs, and draw them downwards; its power, however, is very limited, owing to the shortness of its muscular fibres; still it may be classed amongst the muscles by which expiration is effected. The upper serratus muscle slightly elevates the ribs, and assists in inspiration.

The splenii muscles, when they act together can draw the head directly backwards, in which they conspire with the trapezius and complexus. When either splenius muscle acts by itself, it inclines the head laterally, and gives it at the same time a slight rotatory motion.

The complexus muscle, in addition to its more obvious power of drawing the head backwards, and of maintaining it steadily upon the spinal column, may also, by reason of the obliquity of its fibres, assist in rotating it, but in a direction contrary to that of the splenii, as may at once be seen by inspection of their fibres.

In this drawing, a thin layer of fibrous membrane is observed a little above the inferior serratus muscle, where it is marked 48: it is so thin, that some of the tendinous fibres of the long dorsal muscles, 47, are distinguishable through it. It appears as if stretched from the spinous processes of the vertebræ to the angles of the ribs, most of its fibres taking a transverse direction from within outwards; its lower border is continuous with the edge of the inferior serratus muscle, and the upper with that of the superior serratus, so that it occupies the interval between them; thus placed, it forms a partition between the long dorsal muscles and those which we have been hitherto examining: it is usually named the “vertebral aponeurosis.”

The superficial and deep muscles, which are shown in this drawing in the neighbourhood of the shoulder, have been already shown with the muscles of the shoulder and arm in Plate XIII. The deltoid muscle, its form, actions, &c., will be found indicated in pp. 19, 20; and the supra-spinatus p. 30.

## PLATE XLI.

*Fourth Layer of Dorsal muscles.*—This drawing exhibits at one view the muscles which form the fourth layer, taken in the order of their position. Some of these are very long, and reach from the bottom of the spine to the top; and, as their most obvious use is to maintain the body in the erect position by acting on the spine, they have received the name of erector, or *erectores spinæ*. At the lower part of these muscles they are inseparably united, so as to form at the loins, where they correspond with the small of the back, a thick mass consisting of tendinous and fleshy fibres. They are marked at each side of the spine 13, 13: a little below the first rib, the fibres begin to separate into two bundles, between which is merely a slight groove, commencing at 12, 12; now the outer division or bundle, marked 9, is called *sacro-lumbalis*, and the other, No. 11, *longissimus dorsi*; at the left, these muscles are fully separated from one another, and their edges everted, so as to show their points of attachment. The *erectores spinæ*, thus united at their lower part, are attached to the spinous processes of the sacrum, and to the irregular surface outside them; also to the spinous processes of the four lower lumbar vertebræ, and to the interspinous ligaments. If the *spinalis dorsi* be included as part, which it ought to be, the fibres may also be said to be attached to the spines of the two upper lumbar and two lower dorsal vertebræ. They are connected, moreover, with the crest of the ilium, and with the sacro-iliac ligament. The tendinous and fleshy mass thus attached fills up the depression at the lumbar part of the spine, and, opposite the upper lumbar vertebræ, becomes divided into three muscles, viz. *sacro-lumbalis*, *longissimus dorsi*, and *spinalis dorsi*.

The *Sacro-lumbalis muscle* is so called from its position in the loins, and its attachment to the sacrum; but as it runs upwards into the back, and is attached by tendinous points to the angles of the ribs, it may with more propriety be called *sacro-costalis*; it is marked 9, 9. In that part where it may be considered a distinct muscle, it will be observed to consist of tendinous and fleshy fibres, and gradually to diminish in breadth and thickness as it ascends; and that it is fixed by a series of pointed and tendinous processes into the angles of the ribs. At the left side, where the muscle is everted and drawn outwards, it will be found strengthened, and in a manner supported, by a series of tendinous and fleshy bundles, which, commencing at the angles of the ribs, pass upwards over one or two intercostal spaces in each case, and become fixed to the ribs placed above them: these constitute a set of accessory fibres to the muscle, and are commonly described under the name of “*musculus accessorius ad sacro-*



Fig. 1.

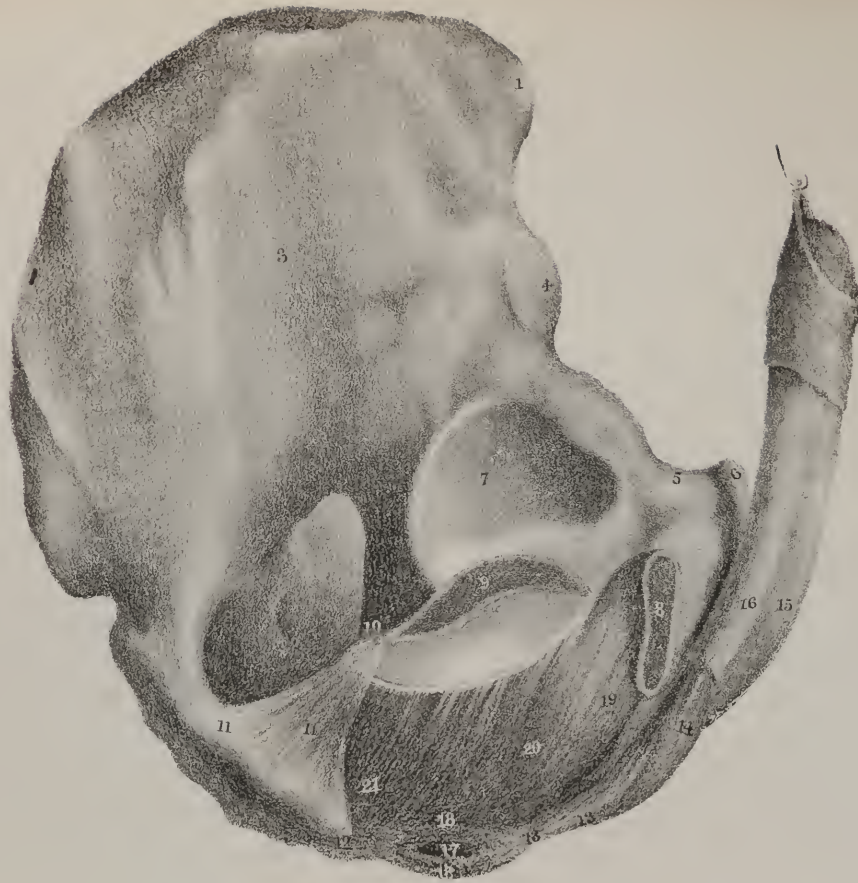
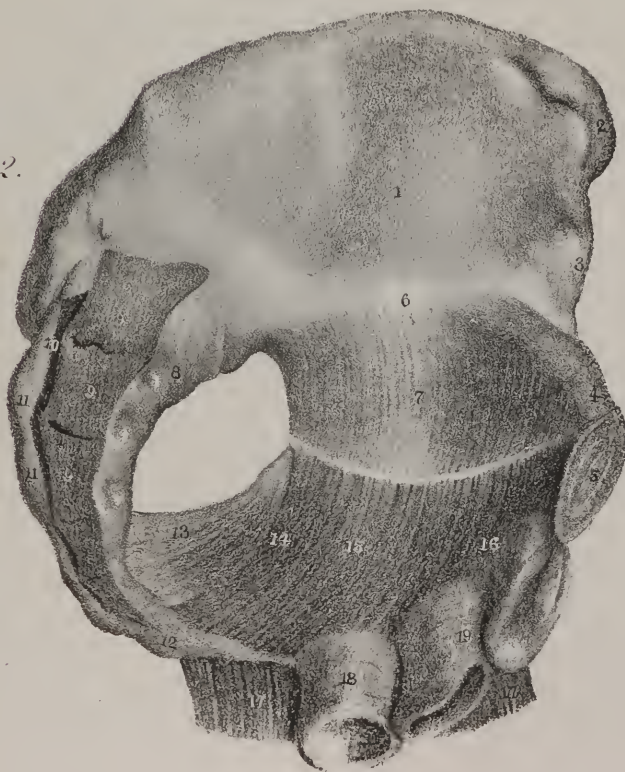

Fig. 2.





lumbalem." The upper fasciculus of these accessory fibres is commonly attached to the transverse process of the last cervical vertebra. Connected with the upper end of the sacro-lumbalis muscle will be found a narrow fasciculus of fleshy and tendinous fibres, marked here 6, 6, which form in a manner its cervical prolongation, and is commonly considered a separate muscle, and described under the name of "m. cervicalis ascendens:" it is attached by tendinous points to four ribs, from the third to the sixth; its fibres, as they ascend, form a narrow fleshy band, which is fixed by separate tendinous points into the transverse processes of the cervical vertebræ, from the third to the sixth inclusive.

*The Long Dorsal muscle* (m. longissimus dorsi,) reaches from the sacrum to the top of the thorax, where it is connected with two other small muscles, by which it is prolonged to the neck and the basis of the skull. The muscle itself is marked 11, 11; its cervical prolongation, 7, 7, is called "transversalis colli;" and its cranial prolongation, 5, 5, is called "trachelo-mastoid."

Viewing the long dorsal muscle thus, with its connections and relations, we shall take each of its parts separately. The long dorsal muscle itself lies in the middle of the vertebral groove, where it is interposed between the sacro-lumbar muscle, 9, and the spinalis dorsi muscle, 14, being separated from each though not very completely, by a groove or fissure, which lodges some loose cellular tissue; its posterior surface is smooth and even, as may be seen at the right side of the drawing; but at the left side, where it is everted, a series of tendinous processes are observed to be detached from it, and to become fixed to the transverse processes of the dorsal vertebræ at the tubercles, and also into their neighbouring parts of the ribs. The number of these processes varies in different instances from eight to eleven.

*The Transverse muscle of the Neck*, (m. transversalis colli,) 7, 7, does not properly deserve the name that it has received, as it does not express its direction, nor can it be so named from a consideration of its attachment, as several other muscles as well as it are attached to the transverse processes of the vertebræ. It is flat and thin at its middle, and irregularly pointed at its extremities, being fixed at its lower end, where it is blended with the fibres of the longissimus dorsi, to the transverse processes of four or five upper dorsal vertebræ, and by its upper extremity becomes attached, usually by four tendinous points, to the posterior tubercles of the transverse processes of the cervical vertebræ from the sixth to the second. Its position between the cervicalis ascendens, 6, and the trachelo-mastoid and complexus, 5 and 3, is here clearly indicated.

*The Trachelo-mastoid muscle*, (m. trachelo-mastoideus,) 5, extends from the transverse processes of the upper dorsal and lower cervical vertebræ upwards to the mastoid process of the occipital bone. It is flat and thin; its structure is tendinous and fleshy; and, from the manner in which its fibres are blended together, it occasionally receives the name of complexus minor. See Plate XLIII., fig. 1, No. 3.

*The Spinal muscle* (m. spinalis dorsi,) lies close to the spinous processes, occupying the interval between them and the longissimus dorsi; it is marked 14, 14, and will be found for the most part to consist of tendinous with a mixture of fleshy fasciculi, the lower ends of which are fixed to the two upper lumbar, and two or three lower dorsal vertebræ, whilst the upper are inserted into eight or nine superior dorsal spines. When the fibres of the two spinal muscles are viewed as they are here marked, they represent a narrow lengthened ellipsis.

*The Complexus muscle*, 3, 3, is placed deeply at the back of the neck, and forms a considerable mass of fleshy and tendi-

## PLATE XLVII.

FIG. 1. A lateral view of the perinæal muscles is given here in order to show the levator ani muscle. The greater part of the ischium, with part of the os pubis, is cut away at the right side, so as to expose the extent of the levator ani muscle and its points of connection: the cut surfaces of the bones are marked 8, 9.

No. 1. The anterior superior spinous process of the ilium. 2. The curved border of the bone. 3. The outer surface of the bone. 4. The anterior inferior spinous process. 5. The body of the pubic bone. 6. Its tuberosity and crista. 7. The acetabulum. 8, 9. The surfaces of the pubic and ischial bones where they have been cut through. 10. The spinous process of the ischium. 11. The coccygeus muscle. 12. The end of the os coccygis. 13. The central point in the perinæum between the anus and the bulb of the urethra. 14. The accelerator urinæ muscle. 15. The tube of the urethra. 16. The corpus cavernosum penis at the right side. 17. The anal aperture. 18, 18. The lateral parts of the sphincter ani muscle. 19, 20, 21. The levator ani muscle, the anterior portion of which will be seen attached to the os pubis at its inner surface, the posterior to the ischium, and the middle, or intervening portion, to the pelvic fascia and obturator membrane at their union, which is here indicated by a curved white line running from before backwards.

FIG. 2. A lateral section of the pelvis is here given, in order to show the muscles of the pelvis at the inner side. The pubic symphysis, 5, is divided; and the sacrum, 9, 9, is cut through from above downwards; the viscera are removed; a small part of the rectum, 18, of the vagina, 19, and of the bladder, 20, being left attached, in order to show the connexion of the levator ani muscle with them:—these parts are drawn over to the right side, and a portion of the right levator ani, 17, 17, is left connected with them.

No. 1. The inner concave surface of the ilium. 2. The anterior superior spinous process of the ilium. 3. The anterior inferior spinous process of the ilium. 4. The upper surface of the pubic bone. 5. The symphysis pubis cut through. 6. The margin of the true pelvis. 7. Part of the pelvic fascia. 8. The anterior surface of the sacrum. 9, 9, 9. The pieces of the sacrum as seen when sawed through from above downwards. 10. The canal of the sacrum. 11, 11. The spinal ridge of the sacrum. 12. The os coccygis. 13. The coccygeus muscle. 14, 15, 16. The posterior, middle, and anterior parts of the levator ani muscle. 17, 17. Part of the levator ani muscle of the right side everted. 18. The lower portion of the rectum. 19. The vagina. 20. Part of the bladder.

nous fibres blended together in a very intricate way, from which circumstance its name is taken. It arises from the transverse and articulating processes of four or five upper dorsal vertebræ, and four lower cervical; the inclination of each muscle is obliquely inwards as it ascends, converging towards its fellow, and becomes fixed to the depressed irregular surface between the curved lines marked on the occipital bone. Part of the inner border of this muscle usually appears separated from the rest by a furrow or groove, so as to present the appearance of a distinct muscle, and is often described as such under the name of "biventer cervicis." It is here marked 4, 4: its lower end is attached by tendinous points to the transverse processes of the six superior dorsal vertebræ; the upper becomes blended with the complexus, and forms virtually a part of it. A fleshy fasciculus is here seen, marked 8, 8, passing upwards from the longissimus dorsi, so as to connect it with the complexus or the biventer. See Plate XLIII., fig. 2, Nos. 9, 10.

*Actions.*—The long dorsal and the sacro-lumbar muscles, assisted by the spinalis dorsi, which is here seen, and the multifidus spinæ, which will be shown in Plate XLV., are the principal agents in giving fixity to the spine, and maintaining it in the erect position. They take their fixed point of attachment at the pelvic bones, and draw upon the transverse processes of the dorsal vertebræ, and on the ribs, which in effect are continuations of these, and so they can straighten or extend the spine. If the sacro-lumbalis muscle of one side act by itself, it may, by depressing the ribs, give a lateral inclination to the spinal column. When these muscles, and the prolongations which pass upwards from them to the neck and head, continue their action, they can draw the head, neck, and the whole spine backwards, so as to render it curved in that direction.

## PLATE XLII.

THE fourth layer of dorsal muscles is seen here at its upper part; also the splenius, serratus posticus superior, and levator scapulæ: their description is given in the preceding pages in the comment on Plate XLI., and their names are fully stated in the references to Plate XLII., at the foot of page 76.

## PLATE XLIII.

THE trachelo-mastoid muscle is shown in fig. 1, all the other parts being removed: it is marked No. 3.

In fig. 2, the complexus muscle is shown in its entire extent: it is marked 9, 10. These are described in page 85.

In figs. 3 and 4, the apparatus of small muscles placed between the two upper cervical vertebræ and the base of the skull, is drawn as they are seen from the back and from the side.—See the references at the foot of page 78.

## PLATE XLIV.

THE muscles placed at the fore part of the spine, in the cervical region, are here seen, viz. the recti antici, the longi colli, the scaleni, intertransversales, and recti laterales. They are disposed in pairs, one being at each side of the middle line.

*The Rectus Anticus major muscle*, fig. 1, No. 20; fig. 2, No. 7, extends from the transverse processes of four cervical vertebræ, from the third to the sixth, upwards to the basilar process of the occipital bone: it consists of tendinous and fleshy fibres.

*The Rectus Capitis Anticus minor*, fig. 1, No. 21, is very short, as it extends merely from the atlas to the basilar process of the occipital bone, and is partly concealed by the rectus major.

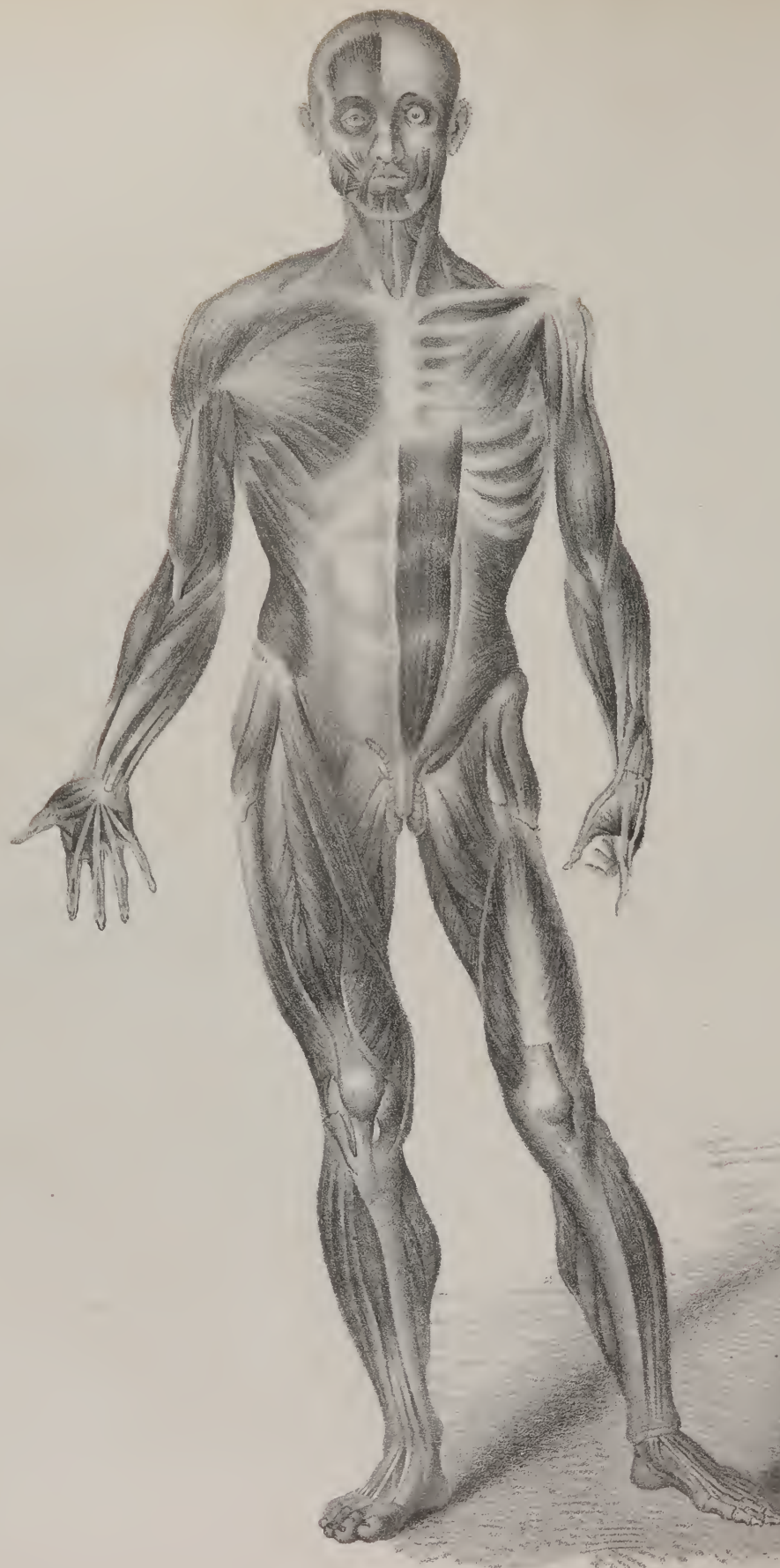
*The Rectus Lateralis muscle*, 22, 22, is also very short, as it extends from the transverse process of the first cervical vertebra upwards to the occipital bone, where it is fixed to a rough ridge outside its condyloid process.

*The Intertransversales* are necessarily short, as they occupy the intervals between the transverse processes.

*The Longi Colli muscles* reach from the first cervical vertebra to the third dorsal; they lie nearly parallel the one to the other, resting upon the bodies of the vertebræ: each of them appears to consist of two portions, differing in the direction of their fibres: the upper one is marked 24 in fig. 1, and 9 in fig. 2; it is attached by a narrow tendinous process to the fore part of the atlas, and is inserted into the transverse processes of the third, fourth, and fifth cervical vertebræ,—their anterior tubercles; the lower or longer part is marked 25 in fig. 1, and 10, 11, in fig. 2; at the left side, the bundles of fibres are separated from one







another as much as possible; at the right, they remain undisturbed, and are marked 12; this part of the muscle is attached to the body of the axis; also to the third and fourth cervical vertebræ, and to the transverse processes of the fourth and fifth: the general direction of the fibres is downwards, almost vertically; and, as they descend, they take points of attachment to the three lower cervical vertebræ and three upper dorsal, gradually diminishing so as to terminate in a point.

*The Anterior Scalenus muscle*, fig. 1, No. 27; fig. 2, No. 13, extends from the first rib upwards to the transverse processes of the cervical vertebræ, becoming fixed to their anterior tubercles from the third to the sixth.

*The Posterior Scalenus muscle*, fig. 1, No. 18; fig. 2, Nos. 13, 14, extends from the first and second ribs to the transverse processes of the cervical vertebræ, becoming inserted into their posterior tubercles from the second to the seventh: the fore part of this muscle, which in fig. 2 is marked 14, used to be considered as a middle scalenus muscle; and that part which lies farther back, arising from the second rib, and marked 13, was considered the posterior scalenus muscle.

*Actions.*—When the scaleni act together, they assist in maintaining the spine erect; in which case they take their fixed points of attachment at the ribs: if one of them acts by itself, it can incline the vertebræ to its own side; if the neck be fixed, these muscles concentrate their power upon the first ribs, and elevate them, as a preparatory step to a forcible inspiration.

The intertransversales and recti laterales incline the vertebræ laterally by drawing down the transverse processes; the anterior recti muscles incline the head forwards, and are from their position the direct antagonists of the muscles at the back of the neck: they are assisted by the longi colli.

## PLATE XLV.

THE fifth layer of dorsal muscles consists of the multifidus spinæ, semi-spinalis, (dorsi et colli,) interspinales muscles, with the posterior recti and obliqui. These are disposed at side of the middle line of the body close to the spine.

*The Multifidus Spinæ muscle* consists of a series of muscular and tendinous fibres, disposed in bundles, and extended obliquely from the transverse process of each of the vertebræ to the spinous process of the vertebra above it; thence it might be considered, not as a single muscle, but as an aggregate of several. Some fasciculi are found to extend over two or three spaces. The first fasciculus extends from the lateral mass of the sacrum to the spine of the fifth lumbar vertebra; this part, the lumbar portion of this muscle, is marked 16, the dorsal 14, and the cervical 15: the upper fasciculus of fibres will be found extending from the transverse process of the third cervical vertebra to the spinous process of the second.

*The Interspinales muscles* are short fleshy bundles placed between the spinous processes of the cervical vertebræ from the second to the seventh.

*The Semi-spinalis muscle* consists of a series of fleshy and tendinous fibres extended obliquely from the transverse processes of the vertebræ to the spinous processes a stage or two higher up. As they exist in the dorsal and cervical regions, they are usually considered as divisible into two muscles, viz. semi-spinalis dorsi and semi-spinalis colli.

*The Posterior Recti muscles* are two pair at each side, one being longer and larger than the other. *The Rectus major* (plate XLV. No. 8) extends from the spinous process of the second vertebra of the neck obliquely upwards and outwards to the posterior surface of the occipital bone.

*The Rectus minor muscle* (plate XLV. No. 9) reaches from the posterior part of the arch of the first vertebra almost directly upwards to the occipital bone, a little behind the foramen magnum.

*The Sacro-lumbalis muscle* is shown in this drawing, No. 17; it has been already described: also the elevator muscles of the ribs. These are small muscles, No. 21, 21, 21, consisting of fleshy and tendinous fibres, which extend from the extremity of the transverse process of each vertebra downwards and outwards, to be fixed into the rib below it in the interval between its tubercle and angle.

## PLATE XLVIII.

In this full-length figure the superficial muscles along the fore part of the body are shown at one side, and those deeper seated at the other.



## PLATE XLVI.

THE muscles of the perinæum are here shown; the skin, the superficial fascia, being removed. They may be considered as divisible into two groups,—those appertaining to the genital organs, and those connected with the termination of the alimentary canal.

The genital muscles are as follows:—

*The Erector Penis muscle*, (ischio-cavernosus, No. 18, 18,) is a thin, flat, long muscle placed on the ramus of the ischium at each side and on the crus of the penis, extending from the inner and upper part of the tuberosity of the ischium to the side of the penis. It is narrow at its extremities, but widens somewhat towards the middle. It arises from the inner border of the tuber ischii, from which its fleshy fibres proceed obliquely upwards and forwards, and become tendinous on reaching the corpus cavernosum, into whose fibrous sheath they are inserted. The inferior surface of the muscle is covered by the skin and the superficial fascia: the superior is in contact with the crus and body of the penis, whilst between its inner margin and the accelerator muscle a groove exists, in which the superficial perinæal vessels are lodged.

*The Accelerator Urinæ muscle*, (bulbo-cavernosus, No. 17, 17,) is so disposed as to surround the bulbous part of the urethra. We may consider it as a single muscle consisting of two symmetrical halves, united so as to form a tube surrounding a part of the urethra, and connected, anteriorly, by two diverging processes, with the corpora cavernosa, and posteriorly, at the central point of the perinæum, No. 16, with the sphincter ani and the transverse muscles, whilst its inferior fibres are extended obliquely outwards at each side to the rami of the ossa pubis. Its analogy with the constrictor vaginæ would lead us to consider it in this way. In conformity with usage, however, we shall describe each lateral half as a separate muscle.

The fibres of the accelerator muscle, forming a thin plane, are blended with those of the corresponding muscle along the middle line, beneath the bulb of the urethra. Their junction extends forwards for three quarters of an inch from the central point above referred to. The fibres from this line of origin proceed in three different directions: the inferior set pass obliquely outwards, and are attached to the angle of union formed by the deep perinæal fascia with the ramus of the pubes; the anterior set incline upwards and outwards, to be inserted into the corpus cavernosum; whilst the intervening or middle fibres coil round the canal of the urethra, and become tendinous on reaching its upper surface, upon which they unite with those of the corresponding muscle, thus forming a tube. If an incision be made over the bulb, so as to cut through the fibres of the muscle, and if one half be then carefully reflected outwards, its points of attachment will be readily seen; after which, if the urethra be cut across and reflected downwards, the union of the middle part of the muscle on its upper surface will be brought into view.

*The Transversus Perinæi muscle*, (ischio-perinæalis, No. 19, 19,) is a narrow fleshy fasciculus, which inclines forwards and inwards across the perinæum, being extended from the inner border of the tuber ischii at its junction with the ramus, to a point midway between the margin of the anus and the bulb of the urethra. The muscles of the opposite sides arise from the inner margin of the tuberosities and the rami of the ischia, and proceed with an inclination forwards, to the point just indicated, where they are blended with the sphincter ani and acceleratores urinæ. Another muscle of this name is occasionally found at each side, lying anterior to the one here described, and called *transversus perinæi alter*; the fibres of the latter are usually thin and pale.

The anal muscles are as follows:—

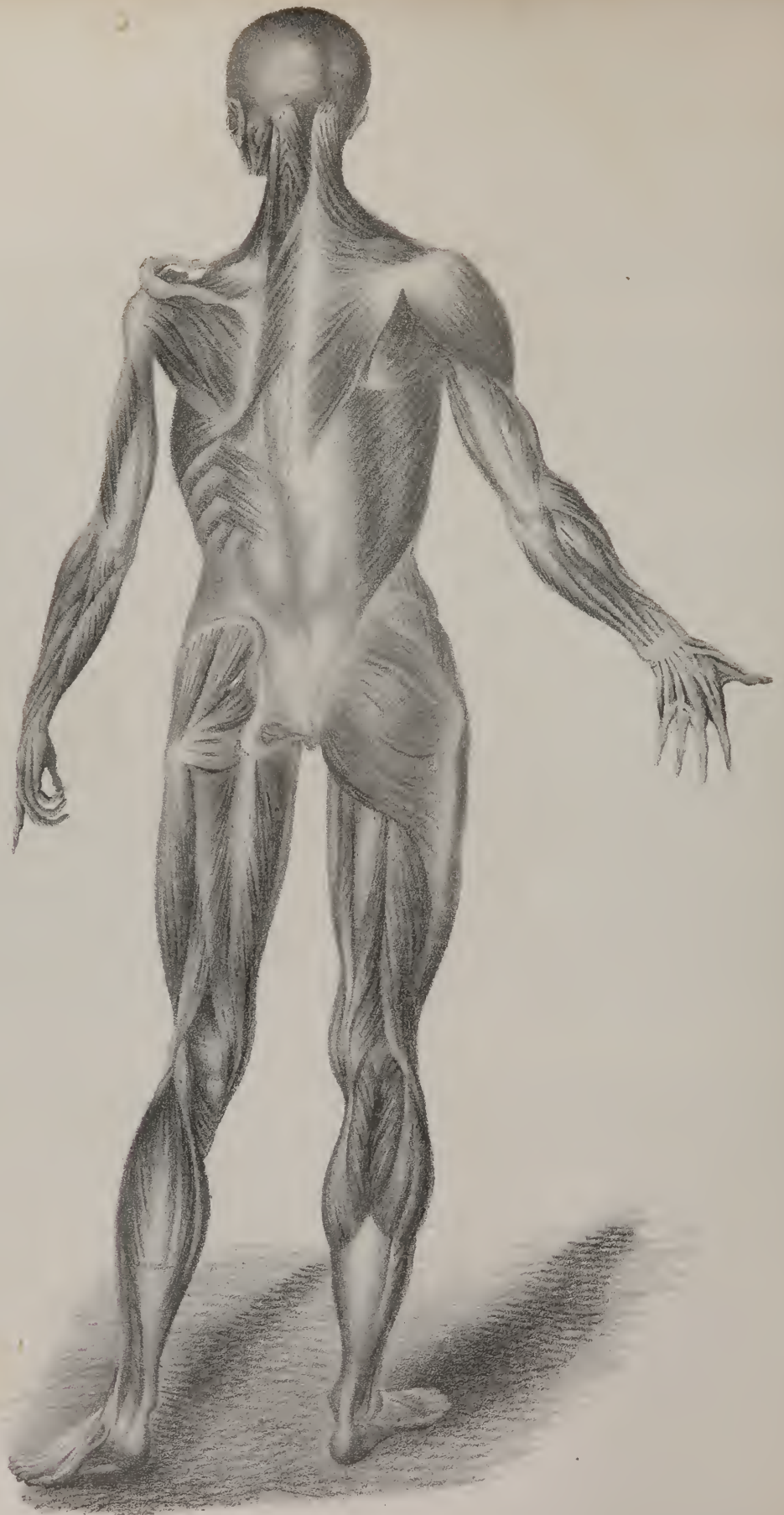
*The external Sphincter Ani*, (coccygeo-analis, No. 20,) is a flat elliptic muscle, placed immediately beneath the skin surrounding the margin of the anus, No. 15. It is attached posteriorly to the coccyx, 14, by a narrow fasciculus of tendinous fibres, and anteriorly becomes blended, about midway between the anus and the bulb, through the medium of a common fibrous point, with the transversi and acceleratores muscles, whilst the intervening part is disposed like orbicular muscles elsewhere, being composed of fleshy fibres curving round the intestine, and united by commissures before and behind it. One surface of the muscle is covered by the skin, the other rests on the internal sphincter, and on some cellular tissue which separates it from the levator ani.

*The internal Sphincter Ani* is a flat muscular ring, surrounding the anal extremity of the rectum; it is about four or five lines in breadth, and two thick. It obviously consists of the circular fibres of the intestine much more developed than elsewhere, and projecting lower down than the longitudinal fibres.

*The Levatores Ani* are two thin broad muscles, so placed at the outlet of the pelvis as to assist in closing it at the same time that they support the contained organs. They are seen only in part in plate XLVI. No. 21, 21; but they are brought fully into view in plate XLVII.—viz. that of the right side in fig. 1, Nos. 19, 20, 21, and that of the left side in fig. 2, Nos. 14, 15, 16. Each levator ani is attached at its fore part to the os pubis near its symphysis, and immediately above its arch; posteriorly, to the spine of the ischium, and along the intervening space to the angle formed by the union of the obturator and pelvic fascia. From this extensive origin the fibres proceed downwards and inwards, the posterior set being fixed to the side of the coccyx;







those next them in order unite by a raphé with the corresponding muscle, in the interval between the coccyx and the margin of the anus; the middle fibres are inserted into the extremity of the rectum, becoming connected with those of the internal sphincter, and the anterior ones pass on the side of the prostate, some of them uniting with those of the corresponding muscle beneath the membranous part of the urethra. In the female, the fibres of this muscle, previously to reaching the rectum, descend by the vagina, and become intimately connected with it.

*The Coccygeus muscle*, (ischio-coccygeus, No. 22, 22: also plate XLVII. fig. 1, No. 11; fig. 2, No. 13,) is placed deeply at the back part of the outlet of the pelvis, which it assists to close, by being stretched from the spinous process of the ischium to the side of the sacrum and coccyx. It is made up of tendinous and fleshy fibres, forming a flat triangular plane, the apex of which is attached to the spine of the ischium, and the base to the border of the coccyx and lower part of the sacrum. The internal, or pelvic surface, supports the rectum; the external is covered by the sacro-sciatic ligaments.

*Actions.*—The transverse muscles conspire to fix the common point of attachment of the perinæal muscles, and so increase their power. The action of the sphincter ani is sufficiently obvious. The accelerator muscle surrounds the bulbous part of the urethra, and, having points of attachment before and behind, is enabled forcibly to propel any fluid that may be lodged within the canal in that situation. The levator ani, in position and direction, is opposed to the diaphragm; and as the latter forces down the intestines by its descent, particularly in expulsive efforts, the levator as its name implies, can elevate at least the lower part of the intestinal canal.

## PLATE XLVII.

THE levator ani and coccygeus muscles are here brought more fully into view than in plate XLVI. The levator is marked in fig. 1, 19, 20, 21; and in fig. 2, 14, 15, 16. The coccygeus in fig. 1 is marked 11, and in fig. 2, 13. Their description is given in the remarks on the preceding plate.

*Dislocations of the Patella.*—This bone may be thrown either outwards or inwards off the pulley-like surface on which it rests. It may also be drawn upwards if the ligamentum patellæ be ruptured. The dislocation outwards is the most frequent. It may follow the application of force, or a blow, tending directly to press the bone outwards; or be the result of muscular effort during a twisting or wrenching movement in the joint, particularly in persons in whom the knees incline much inwards. The pain felt, the alteration in the form of the joint, the impossibility of effort or of walking, at once indicate the nature of the accident. The leg is in a state of extension; a tumour is perceived at the outer side of the femoral condyle: the tendon of the rectus muscle, and the ligamentum patellæ incline outwards, being drawn to the point where the patella is placed: the inner border of the pulley at the articular surface of the femur can be distinctly felt unless the tumefaction be very considerable; so can the inner edge of the patella, which from its position upon the external condyle turned somewhat forwards, whilst the anterior surface of the bone has an inclination outwards. In the dislocation inwards, the position of the limb, and other accompanying circumstances, are nearly the same as in the preceding case, except that the bone lies over the inner condyle. Another mode of displacement of the patella has occurred in a few instances: it has become inverted, so that one of its edges projected directly forwards under the skin, whilst the other rested perpendicularly upon the middle of the trochlea, or pulley-like surface of the femur. The reduction of these accidents should be effected as soon as possible. To relax all the muscles put into a state of action, extension is essential.

For this purpose, having placed the patient in the recumbent position, the leg should be drawn forwards or extended as much as possible, by which the triceps extensor will be relaxed, and all tension of the rectus muscle can be removed by raising the body a little, so as to bring the pelvis somewhat forwards upon the thigh. When relaxation of the muscles is thus effected, the bone should be pressed steadily towards the articular surface from which it has been displaced, taking care not to force it directly against the projecting margin of the condyle. To avoid this, the edge of the patella which is farthest from the articulation may be depressed a little, so as to raise the other over the border of the condyle.

*Dislocations of the Knee-joint.*—The tibia may be thrown inwards or outwards; but these lateral displacements are almost always incomplete, the extent of the articulating surfaces being sufficient to prevent their total separation. Again, the tibia may be forced backwards or forwards. In the dislocation inwards, the tuberosity of the tibia forms a considerable projection at the inner side of the joint, the inner condyle of the femur corresponds with the external articular surface of the tibia, and its semi-lunar cartilage: at the outer side of the joint there is a depression beneath the external condyle of the femur; and at the inner, a

## PLATE XLIX.

The muscles situated at the posterior aspect of the body are here shown at full length: the superficial layer at one side, and those deeper seated at the other.



similar depression above the projecting tuberosity of the tibia; the patella and its ligament are drawn somewhat inwards; all which circumstances give a great degree of deformity to the joint. In the dislocation outwards, the relative position of the bones, and of their projecting parts, will be the opposite of that just stated.

The dislocation of the tibia backwards is of rare occurrence. It has been produced by a fall from a height, during which the knee (the joint being in the bent position) was arrested by some projecting body, whilst the femur was pressed downwards and backwards by the weight of the body, and the force of the descent. In this way the tibia was forced back into the popliteal space, and the extremity of the femur formed a considerable projection in front. The leg under such circumstances, may be in the state of forced and permanent flexion. In a case noticed by Sir A. Cooper, the limb was found shortened, the condyles of the femur formed a considerable projection, the ligament of the patella was drawn back, and as it were sunk into a depression, and the leg, instead of being flexed, was rather bent forwards. The dislocation forwards can be produced only by extreme violence, sufficient to lacerate the posterior and crucial ligaments, and, perhaps, one or both lateral ligaments. It may be produced by the passing of a wheel over the lower part of the thigh, so as to force it backwards, the leg being fixed and supported so that it cannot give way at the same time.

These accidents are easily reduced, there being little resistance to be overcome: if moderate extension and counter-extension be kept up, the tibia can be pressed into its position without much force.

*Dislocations of the Ankle-joint.*—Three modes of displacement are liable to occur in this articulation, as the bones of the leg may be thrown off the astragalus, inwards, outwards, or forwards. In the first case, the internal malleolus is forced inwards so as to rest upon the inner side of the astragalus, where it forms a considerable projection under the integument; the foot is pressed outwards and somewhat everted, so that its inner border rests upon the ground; it is also easily moved in different directions. The fibula will be found fractured about three inches above the external ankle, at which point a crepitus is heard on slight motion, and a depression is perceived. In the second form of dislocation, the external malleolus is forced outwards and forms a considerable projection, the internal one is fractured near its summit; the foot is pressed inwards, and so altered in its direction that its outer border touches the ground. In the third form of dislocation, the tibia is forced forwards so as to rest on the navicular and internal cuneiform bones; the fibula is broken about two inches and a half above the joint, its lower end being retained in its position by the ligaments, whilst the upper piece is carried forward with the tibia. The foot appears shortened, the heel much more prominent than usual, and raised so that the toes are pointed towards the ground. A partial dislocation of the tibia has been known to occur in a few instances. The lower end of the bone rests partly on the astragalus, partly on the os naviculare: the fibula is broken; the foot appears a little shortened, the heel raised, and the toes pointed downwards. In all these cases the principal resistance to reduction is given by the muscles of the calf of the leg; hence they must be relaxed as much as possible. If the patient be placed on his back on a mattress, and the leg be bent to a right angle with the thigh, the latter being raised and supported, extension may be made by drawing on the foot, and counter-extension by an assistant holding steadily the lower part of the thigh.

In addition to the muscles of the perinæum described page 88, we have to notice the following:

*The compressor muscle*, (urethræ, Wilson; compressor prostatae, Sæmm.) is a narrow fasciculus that arises close by the pubic symphysis, immediately before the anterior fibres of the levator ani, and from which it is merely separated by a small vein and a little cellular tissue. The muscle descends close to its fellow of the opposite side, and beneath the membranous part of the urethra, both of them having become tendinous, unite so as to support it in a sling. Many persons consider this as but a part of the levator ani.

*The Compressor muscle* (venæ dorsalis penis) is a thin fasciculus, composed partly of tendinous, partly of fleshy fibres, placed beneath the pubic arch, and above the root of the penis. Its fleshy fibres are attached to the inner margin of the ramus of the os pubis, immediately above those of the erector penis; from this point the fibres ascend, at the same time inclining forwards and inwards, and end in a thin tendon, which unites with that of its fellow of the opposite side, at the median line, just over the dorsal vein. The perinæal muscles in the female correspond so nearly with those of the male in their number, general conformation, and attachments, that it is unnecessary to treat particularly of more than two of them.

*The Erector Clitoridis muscle*, (depressor, Meckel,) resembles the diminutive of the erector penis; it arises from the ramus of the pubis, and is inserted into the body of the clitoris.

*The Constrictor Vaginæ muscle* (perinæo-clitorius) resembles an orbicular muscle, being composed of two narrow fasciculi, united before and behind the vagina by two commissures, and leaving between them an elliptic interval corresponding with its circumference. The two muscles of this name may be said to arise posteriorly at a point which is common to them, to the sphincter ani and transversus muscles; after diverging to enclose the vagina, they unite in front of it into a tendinous process, which connects them to the corpus clitoridis.

Amongst the deep-seated muscles of the back already referred to, the following require to be noticed.

*The Cervicalis Ascendens muscle*, (plate XLI., No. 6; plate XLII., No. 15.) is prolonged upwards into the neck from the sacro-lumbalis, (m. cervicalis ascendens; cervicalis descendens;) it arises from the angles of the sixth, fifth, fourth, and third ribs, by a series of tendinous fasciculi, which are blended with the fibres of the sacro-lumbalis. These gradually unite to

form a thin, short, muscular band, which extends along the transverse processes of the sixth, fifth, fourth, and third cervical vertebræ, into which it is inserted by so many separate digitations or points.

*The Obliquus Capitis Inferior muscle* (axo-atloideus; plate XLIII., fig. 3, No. 9; fig. 4, No. 13; plate XLV., No. 7.) is placed obliquely between the first two cervical vertebræ. It arises from the spinous process of the axis, between the origin of the rectus posticus major and the insertion of the semi-spinalis colli, and is inserted into the extremity of the transverse process of the atlas.

*The Obliquus Capitis Superior muscle* (atlo-post-mastoideus; plate XLIII., fig. 3, No. 8; fig. 4, No. 10; plate XLV., No. 6.) extends from the atlas to the lateral and inferior part of the base of the skull. It arises from the extremity of the transverse process of the first cervical vertebra, inclines from thence obliquely upwards and inwards, expanding somewhat as it ascends, and is inserted, close behind the mastoid process, into the interval between the curved lines of the occipital bone. These two muscles are covered by the complexus, and correspond, the one with the first inter-vertebral space, the other with that between the atlas and occiput.

*The supra-spinales muscles.*—Some fasciculi of muscular fibres are found extended between the summits of the spinous processes, which are named as above: in position and attachment they are analogous to the recti postici.

The several muscles of the tongue, of the os hyoides, and the soft palate, though forming separate groups, are yet combined in the function of deglutition and in the modulation of the voice. Two of these are given in this plate L. viz. the palato-glossus and the palato-pharyngeus; the rest are shown in plates IV. and V. The muscles of the tongue and os hyoides consist of several pairs as follow.

*The Mylo-hyoideus muscle*, (plate III. No. 22; plate V. fig. 1, No. 17; fig. 4, Nos. 4, 4; plate IX. fig. 1, No. 15.) forms a flat plane of fleshy fibres extending from the lower jaw to the os hyoides. It arises from the mylo-hyoid ridge, along the inner surface of the lower jaw. The posterior fibres incline obliquely forwards as they descend to be inserted into the body of the os hyoides; the rest proceed, with different degrees of obliquity, to join at an angle with those of the corresponding muscle, forming, with them, a sort of raphé along the middle line, from the symphysis of the jaw to the os hyoides. The external surface of the mylo-hyoideus (which in the erect position of the head is inferior) is covered by the digastricus and sub-maxillary gland; the internal, which looks upwards and inwards to the mouth, conceals the genio-hyoideus and part of the hyo-glossus and stylo-glossus, and also the gustatory nerve; its posterior border alone is free and unattached, and behind it the duct of the submaxillary gland turns in its passage to the mouth.

The two muscles of this name, by their junction in front, and by the inclination of the plane which they form, support the mucous membrane of the mouth and the tongue, constituting a muscular floor for that cavity.

*The Genio-hyoideus muscle*, (plate V. fig. 2, No. 27; plate IX. fig. 1, No. 16.) is a narrow, rounded muscle, concealed by the preceding, and lying close to the median line. It arises from the inside of the symphysis of the chin, (its inferior sub-mental tubercle,) and thence descends (separated from the corresponding muscle only by a narrow cellular interval,) to be inserted into the body of the os hyoides. This pair of muscles lies between the mylo-hyoideus and the lower or free border of the genio-hyo-glossus.

*The Hyo-glossus muscle*, (plate V. fig. 2, No. 24, plate VII. fig. 5, No. 17.) is a flat, thin band of muscular fibres, extended upwards upon the side of the tongue from the lateral portion of the os hyoides. It arises from the great cornu of the os hyoides its whole length, and from part of the body of that bone. From this the muscular fibres incline upwards and outwards, to be inserted into the side of the tongue, where they expand, becoming blended with its substance: the direction of this muscle is almost vertically upwards, and that of the stylo-glossus horizontally forwards, so that they decussate upon the side of the tongue.

*The Genio-hyo-glossus muscle*, (plate V. fig. 2, No. 26; plate VII. fig. 5, No. 18; fig. 6, No. 8.) is so called from its triple connexion with the chin, os hyoides, and tongue. The muscle forms a flat, triangular plane of fleshy fibres, placed vertically in the median line, the apex of the triangle being represented by its origin from the inside of the symphysis of the lower jaw, the base by its insertion along the whole length of the tongue from its point to its root, for the fibres spread out radiating like the ribs of a fan; one of the sides (the lower one) corresponds with the border which extends from the symphysis to the os hyoides, the other (upper and anterior) with the frænum linguæ. Its inner surface is in contact with the corresponding muscle, the external being covered by those last described. It arises, by a short, pointed tendon, from the superior sub-mental tubercle on the inside of the symphysis of the chin. To this the fleshy fibres succeed, and diverge from one another; the inferior ones passing down to the os hyoides, the anterior forwards to the tip of the tongue, and all the rest proceeding with different degrees of obliquity to the under surface of the tongue, with which they are blended in its entire length from base to apex. The internal surface of the muscle is in contact with that of its fellow, from which it is at first separated slightly by some cellular tissue, but both become closely adherent towards their termination. The external surface is in contact with the lingualis, hyo-glossus, and stylo-glossus, the sub-lingual gland, and lingual artery.

*The Stylo-glossus muscle*, (plate V. fig. 2, No. 18; plate VII. fig. 5, No. 12; fig. 6, No. 5.) lies along the side of the tongue, to which it is extended from the styloid process. Its direction is forwards and a little downwards, so that it becomes nearly horizontal. It arises from the styloid process near its point, and from the stylo-maxillary ligament, to which the greater number



of its fibres are attached by a thin aponeurosis, and is inserted along the side of the tongue, its fibres expanding somewhat as they become blended with its substance; they overlay those of the hyo-glossus muscle.

*The Lingualis muscle*, (plate VII. fig. 6, No. 3, 7,) is a thin, narrow band of fleshy fibres, extended along the under surface of the tongue in its entire length. It lies close to the outer side of the genio-hyo-glossus, between it and the hyo-glossus; one extremity of its fibres is connected to the os hyoides, and the other prolonged to the tip of the tongue, being blended inseparably with its substance.

*Actions.*—The muscles that pass from the jaw-bone to the os hyoides are ordinarily employed in elevating the latter, and with it the base of the tongue, more particularly in deglutition. The genio-hyo-glossi, by means of their posterior and inferior fibres, can draw up the os hyoides, at the same time bringing it and the base of the tongue forwards, so as to make its apex protrude beyond the mouth. The anterior fibres will, subsequently, act in retracting the tongue within the mouth.\* The mylo-hyoidei may be compared to a moveable floor or bed, which closes in the inferior and anterior part of the mouth, at the same time serving to sustain the body of the tongue. The linguales resemble retractor muscles: they shorten the tongue, and draw its apex downwards, so as to make its dorsum convex.

The muscles of the soft palate consist of the following pairs; two are given here, the rest in preceding plates.

*The Elevator muscle of the Palate*, (m. levator palati; peri-staphylinus internus,  $\pi\epsilon\gamma\epsilon$ , about or near,  $\sigma\tau\alpha\phi\upsilon\lambda\eta$ , the uvula; plate IV. fig. 3, No. 17; fig. 4, No. 26; plate V. fig. 3, No. 10;) is a long, thin, flat muscle, placed at the posterior surface of the soft palate under cover of the mucous membrane, which arises from the extremity of the petrous portion of the temporal bone, before the orifice of the carotid canal, and from the cartilaginous part of the Eustachian tube. The two muscles converge, as they descend, to become blended at the middle of the soft palate with the other muscles, viz. the levator palati of the opposite side, the azygos uvulæ, and the tendon of the circumflexus palati.

*The Tensor muscle of the Palate*, (m. circumflexus; vel tensor palati, peri-staphylinus externus; plate IV. fig. 3, No. 18; fig. 4, No. 27, plate V. fig. 3, No. 11;) presents two portions which differ in their direction and relations. The muscle arises from the small fossa (navicularis) at the root of the internal pterygoid plate of the sphenoid bone, also from the anterior surface of the cartilage of the Eustachian tube. From these points it descends perpendicularly between the internal pterygoid muscle and the osseous lamella of the same name, and ends in a tendon, which winds round the hamular process; there it inclines inwards and expands at the same time into a broad aponeurosis, the fibres of which are inserted into the transverse ridge on the under surface of the palate process of the palate bone, and on reaching the middle line they unite with the aponeurosis of the corresponding muscle of the opposite side.

*The Azygos uvulæ muscle*, (palato-staphylinus; plate IV. fig. 3, No. 16; plate V. fig. 3, No. 13;) was so called from its having been supposed to be a single muscle; but there are really two thin fasciculi separated by a slight cellular interval above, which usually unites towards the lower part. Each arises from the pointed process (spine) of the palate plate, and descends vertically, becoming blended with the other structures in the uvula.

*The Palato-glossus muscle*, (constrictor isthmi faucium: plate IV. fig. 4, No. 25; plate L. fig. 10, No. 6;) inclines from the uvula forwards and outwards to the side of the tongue, where it may be considered as inserted. It is merely covered by the mucous membrane, which it renders prominent, so as to form the anterior arch of the palate.

*The Palato-pharyngeus muscle*, (plate IV. fig. 3, No. 19; fig. 4, No. 20; plate L. fig. 10, No. 7,) arches downwards and backwards, so as to leave an angular interval between it and the preceding. It commences at the uvula, and descends into the pharynx, being intimately connected with its muscles, and is prolonged as far as the cornu of the thyroid cartilage. It forms the posterior arch or pillar of the velum palati.

*Actions.*—When the mass of food is carried back towards the fauces, the soft palate is raised nearly to a level with the hard one, and not only serves to prevent the ingesta from passing into the nares, but also, by the contraction of its two arched muscles, assists in pressing them down into the pharynx. The circumflex muscles stretch the palate from side to side, and render it tense, whilst the proper elevators raise it up, and then the palato-glossi and palato-pharyngei, taking their fixed points below, are enabled, by depressing the palate, to force down the food into the cavity ready to receive it.

The stylo-hyoideus muscle and the stylo-pharyngeus may be considered here in connexion with the preceding group.

*The Stylo-hyoideus muscle*, (plate V. fig. 2, No. 19; plate VII. fig. 5, No. 13,) lies close to the posterior belly of the digastricus muscle, being a little behind and beneath it. It arises from the middle of the external surface of the styloid process of the temporal bone, from which it inclines downwards and forwards, to be inserted into the os hyoides at the union of its great cornu with the body. Its fibres are divided into two fasciculi near its insertion, for the transmission of the tendon of the digastricus. Its upper part lies deeply, being covered by the sterno-mastoid and digastricus muscles, and by part of the parotid gland: the middle crosses the carotid arteries; the insertion is comparatively superficial.

\* The spasmodic contraction of the genio-hyo-glossi muscles, in morbid association with the muscles of the larynx, may have the effect to keep the tongue low in the mouth, and prevent the free application of the tip to the palate, so necessary in speech, making a sort of muscular tongue tie. In this state of the parts, of which, though of rare occurrence, several cases have presented themselves to my notice, has been applied the operation for the cure of stammering, by dividing those muscles near their origin from the lower jaw bone. In two of these instances, there was also from the same cause considerable difficulty in deglutition.—J. P.



*The Stylo-pharyngeus muscle*, (plate IV. figs. 1, and 2, No. 13; plate V. fig. 2, No. 20,) is larger and longer than the other styloid muscles, and also more deeply seated; it extends from the styloid process downwards, along the side of the pharynx. It arises from the inner surface of the styloid process, near its root, from which it proceeds, downwards and inwards, to the side of the pharynx, where it passes under cover of the middle constrictor muscle, with which its fibres contract some connexion, but are finally prolonged to the posterior border of the thyroid cartilage, into which they are inserted. The external surface of the muscle is, in the upper part of its extent, in contact with the styloid process and stylo-hyoideus muscle and external carotid artery; in the lower, with the middle constrictor of the pharynx; the internal rests on the internal carotid artery and jugular vein; but, in the lower part of its extent, it is in contact with the mucous membrane of the pharynx.

*Actions.*—The stylo-hyoidei and stylo-pharyngei conspire in elevating the base of the tongue and the bag of the pharynx at the moment when deglutition is taking place, the latter pair of muscles tending at the same time to widen the pharynx. The peculiar mechanism of the digastric muscles enables them to contribute to the elevation of the os hyoides also; for when the two fleshy parts contract together they come nearly into a straight line, and thereby draw up the bone just named, by means of the connexion of the middle tendon of the muscle with its cornu. As a preparatory measure, the mouth must be closed, and the lower jaw fixed, which is one of the first steps in the process of deglutition. If the os hyoides be kept down by the sterno-hyoideus, the anterior belly of the digastricus will serve to depress the lower jaw. The stylo-glossi muscles retract the tongue; they also act on its margins, and elevate them: if the genio-hyo-glossi come into action at the same time, and draw down its raphé, or middle line, its upper surface will be converted into a groove, fitted to convey from before backwards to the fauces any substance required to be swallowed.

## PLATE L.

WE usually group together the several pairs of small muscles, which move the cartilages of the larynx, and are thereby concerned in the production of voice.

*The Crico-thyroid muscle*, (m. crico-thyroideus; fig. 1, Nos. 4, 4; fig. 3, No. 7,) is a short muscle, which, as its name implies, is attached to the cricoid and thyroid cartilages, its direction being obliquely upwards and outwards, diverging from its fellow of the opposite side. By this arrangement the crico-thyroid membrane is left uncovered, except by the skin and fascia, where it is to be punctured in the operation of laryngotomy. This muscle is concealed by the sterno-hyoideus and sterno-thyroideus.

*The posterior Crico-arytænoid muscles*, (m. crico-arytænoidei postici: fig. 2, Nos. 7, 7.)—These rest posteriorly on the broadest part of the cricoid cartilage, covering by their origin the whole of it, except the middle perpendicular line. Their fibres converge, as they proceed upward and outwards, to be inserted by a narrow process into the bases of the arytænoid cartilages by their external borders. They are merely covered by the mucous membrane.

*The lateral Crico-arytænoid muscles*, (m. crico-arytænoidei laterales; fig. 4, No. 7,) are extended obliquely backwards and upwards, from the upper border of the cricoid cartilage on each side, to the base of the arytænoid cartilage. They lie in the interval between the alæ of the thyroid cartilage and the glottis, concealed by the lining membrane.

*The Thyro-arytænoid muscles* (m. thyro-arytænoidei; fig. 4, No. 6) are placed immediately above the preceding, and are united with them at the point of insertion; they are stretched from before backwards, between the inner surface of the thyroid cartilage at its angle, and the base of the arytænoid cartilages at their anterior border. They lie parallel with the rima of the glottis.

*The Thyro-epiglottic muscles.*—Some muscular fibres may also be traced from near the origin of the preceding, which ascend to the margin of the epiglottis. These are described by some anatomists as thyro-epiglottidæi, or depressores epiglottidis; but it may be observed, that the closure of the aperture by means of the epiglottis, is effected by the ascent of the whole larynx, by which the rima is drawn as it were under cover of its operculum, and not by the descent of the latter upon it.

*The Arytæno-epiglottic muscles.*—Some muscular fibres are also occasionally found in the folds of mucous membrane stretched between the arytænoid cartilages and the epiglottis. These have been named arytæno-epiglottidæi.

*The Arytænoid muscle* (m. arytænoideus; fig. 2, No. 4) consists of oblique and transverse fibres intimately blended together, and laid upon the posterior concave surface of the arytænoid cartilages. Albinus and Winslow, from a consideration of the difference in the direction of its fibres, divided the muscle into three, viz. two oblique, and one transverse; but as all conspire in their actions, and are inseparably connected together, most modern anatomists describe them as a single muscle. The oblique fibres pass from the base of one cartilage towards the apex of the other, crossing in the middle. The transverse fibres pass from one border to the other, and are partly covered by the oblique.

*Actions.*—The arytænoideus muscle contracts the base or widest part of the rima, rendering it an elongated chink, and is therefore the direct antagonist of the posterior crico-arytænoid muscles, which draw the basis of the cartilages outwards and

widen the interval between them. These cartilages are, on the contrary, drawn forwards (and the antero-posterior extent of the aperture thereby diminished) by the lateral muscles, which pass to them from the cricoid and thyroid cartilages. It may easily be shown that the fibres of the thyro-arytænoid muscles are not merely stretched from before backwards, between the cartilages, but that some of them are attached at different points to the chordæ vocales, and so may act as stops on a musical string, limiting the extent of the part which vibrates at a given moment, and thereby modifying the sound.

Two small muscles of the lips are here indicated.

*The Depressor muscle of the upper lip and nose* (depressor labii superioris alæque nasi; m. myrtiformis; fig. 10, Nos. 9, 9) is a small flat muscle, extended from a slight pit (myrtiform fossa) near the alveolar border of the upper jaw, to the lateral cartilage of the nose; it lies between the mucous membrane and the muscular structure of the lip, with which its fibres are closely connected; this double connexion enables it to depress the lip as well as the nasal cartilage.

*The Elevator muscle of the lower lip* (m. levator labii inferioris; fig. 10, No. 10) arises from a slight pit a little below the alveolar border of the lower jaw, near the symphysis. This pair of muscles occupies the interval between the two depressors of the lower lip. They are small, short, and somewhat tapering, being narrow at their point of origin, from which they increase in breadth towards their insertion. They incline downwards and a little forwards to reach the tegument of the chin, into which they are inserted. The names of most of the muscles included in the three foregoing groups sufficiently indicate their actions.

## PLATE L.

The larynx and its muscles are here shown; also the muscles of the ear, and some of those of the mouth.

FIG. 1. Nos. 1, 1. The great or upper cornua of the thyroid cartilage. 2, 2. The alæ of the thyroid cartilage. 3. The cricoid cartilage. 4, 4. The crico-thyroid muscles.

FIG. 2. Nos. 1, 1. The great cornua of the thyroid cartilage. 2, 2. Its alæ. 3, 3. The arytænoid cartilages. 4. The arytænoid muscle. 5, 5. The posterior borders of the alæ of the thyroid cartilage. 6. The middle ridge at the posterior aspect of the cricoid cartilage. 7, 7. The crico-arytænoid posticus muscle. 8, 8. The inferior or smaller cornua of the thyroid cartilage. 9. The upper part of the trachea.

FIG. 3. A side view of the larynx and os hyoides is here given.

No. 1. The body of the os hyoides. 2. Its small cornua. 3. Its great cornu. 4. The thyro-hyoid membrane. 5. The great cornu of the thyroid cartilage. 6. Its ala. 7. The crico-thyroid muscle. 8. The cricoid cartilage.

FIG. 4. The ala of the thyroid cartilage is cut away at the right side, in order to bring into view the muscles in immediate apposition with the rima of the glottis.

No. 1. The great cornu of the thyroid cartilage. 2. The inner surface of its ala at the left side. 3. The surface of the incision made in order to remove the right ala. 4. The right arytænoid cartilage. 5. Part of the arytænoid muscle. 6. The thyro-arytænoid muscle. 7. The crico-arytænoid lateralis muscle. 8. The crico-arytænoid posticus muscle. 9. The right side of the cricoid cartilage. 10. The first ring of the trachea.

FIG. 5. The larynx is laid open at the back part, so as to expose its interior.

Nos. 1, 1. The small cornua of the os hyoides. 2, 2. The inner surface of the thyro-hyoid membrane. 3. The epiglottis. 4, 4. The arytænoid cartilages. 5, 5. The ventricles of the larynx. 6, 6. The lower or true chordæ vocales. 7, 7. The cut edges of the cricoid cartilage, divided by a vertical incision in the middle, and held apart. 8. The upper rings of the trachea.

FIG. 6. The temporal bone of the right side, the external meatus of the ear, and the membrana tympani, being cut away in order to show the chain of bones in the tympanum, and one of the muscles.

No. 1. The squamous part of the temporal bone. 2. Its zygomatic process. 3. The anterior root of this process. 4. The posterior one. 5. The mastoid process. 6. Part of the osseous lamella, forming the part of the glenoid fossa behind the fissura Glasseri. 7. The incus. 8. The stapes. 9. The malleus; being the three small bones of the ear. 10. The anterior muscle of the malleus, (m. anterior mallei, or laxator tympani.)

FIG. 7. An inner view of the tympanum and ossicula auditus.

No. 1. The squamous part of the temporal bone; its inner surface. 2. The malleus. 3. The incus. 4. The stapes. 5. The stapedius muscle. 6. The internal muscle of the malleus, (m. internus mallei, or tensor tympani.)

FIG. 8. The external ear and its muscles.

No. 1. The elevator muscle, (m. attollens aurem.) 2, 2. The helix. 3. The fossa innominata. 4, 4. The two limbs or branches of the anti-helix. 5. The fossa navicularis. 6. The greater muscle of the helix, (m. major helieis.) 7. The anterior muscle of the ear, (m. attrahens aurem.) 8. The smaller muscle of the helix, (m. minor helieis.) 9. The contractor meatûs muscle. 10. The anti-helix. 11. The tragus. 12. The tragus muscle. 13, 14. The lobule of the ear. 15. The anti-tragus muscle. 16. The retrahens aurem muscle.

FIG. 9. No. 1. The helix. 2. The transversus auris muscle. 3. The obliquus auris muscle. 4. Some fibres of the muscles of the helix, (major and minor.) 5. The contractor meatûs muscle. 6. The tragus muscle. 7. The tragus. 8. The anti tragus, seen at the back part. 9, 9. The retrahens aurem muscle. 10. The lobule of the ear.

FIG. 10. Nos. 1, 1. The ears. 2, 2. The lips, divided and drawn back. 3, 3. The mucous lining of the cheeks. 4. The hard palate. 5. The uvula, hanging down from the soft palate. 6, 6. The palato-glossus muscle at each side, (m. constrictor isthmi faucium.) 7, 7. The palato-pharyngeus muscle at each side. 8, 8. The tonsils. 9, 9. The depressor muscle of the upper lip, (m. depressor labii superioris alæque nasi.) 10, 10. The elevator muscle of the lower lip, (m. levator labii inferioris.)



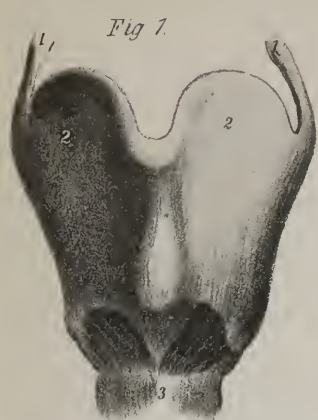


Fig. 1.

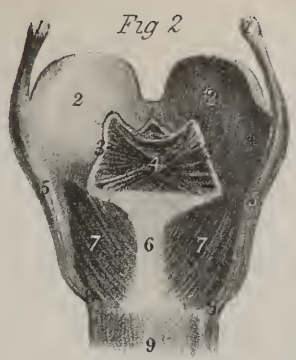


Fig. 2.

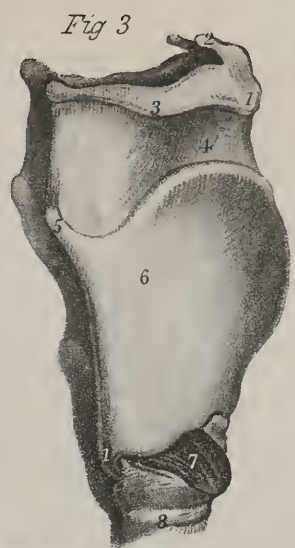


Fig. 3.

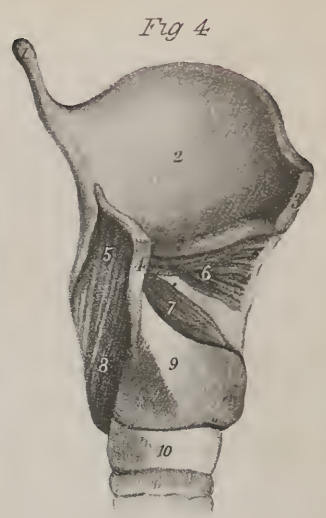


Fig. 4.

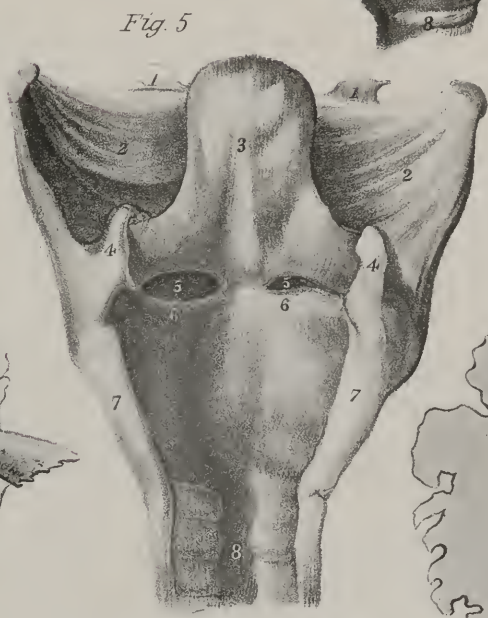


Fig. 5.

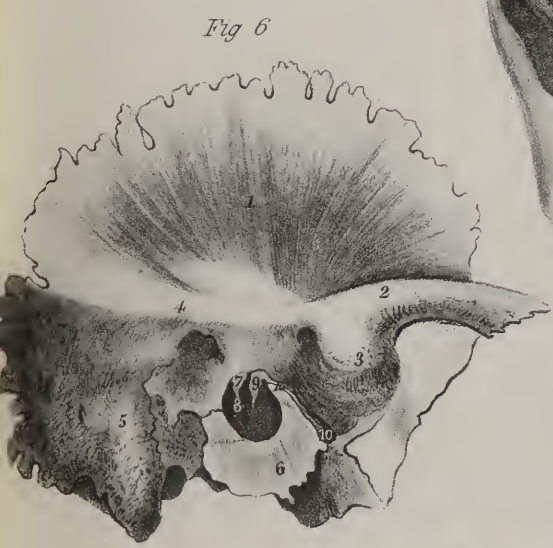

Fig. 6.

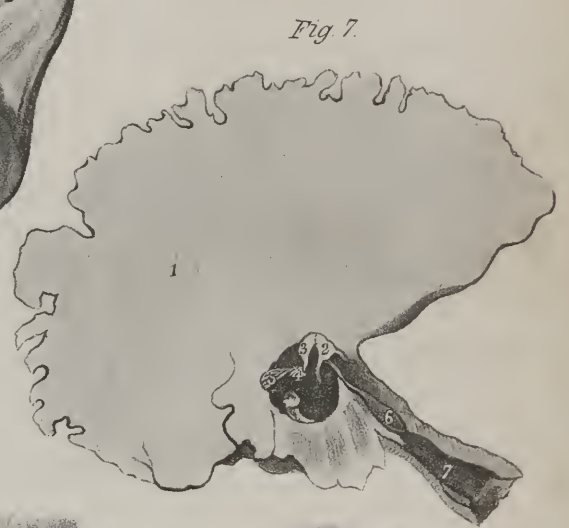

Fig. 7.



Fig. 9.

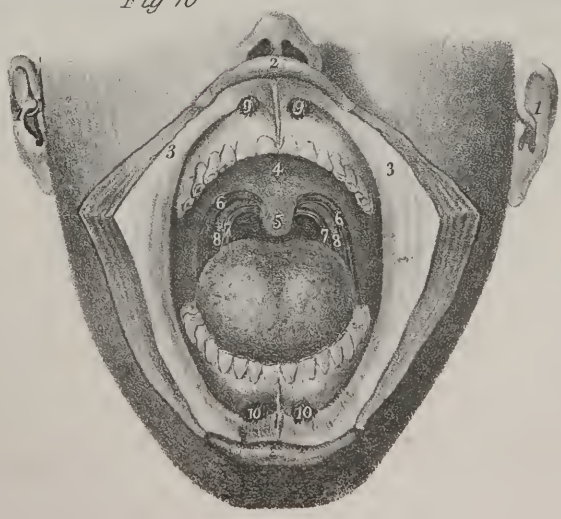


Fig. 10.

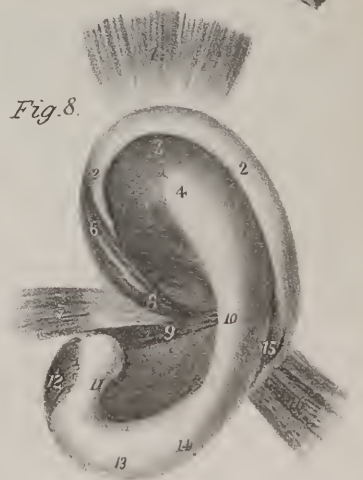


Fig. 8.





The external muscles of the ear may be divided into two groups, viz. those which move the pinna as a whole, and those which can act only on particular parts of it. The first group consisting of the superior, the posterior, and anterior muscles, will be found in plate X. fig. 1, Nos. 3, 4, 5; also in this plate, fig. 8, Nos. 1, 7, 16.

*The Superior muscle* (m. superior auris, attollens aurem, temporo-auricularis; fig. 8, No. 1; plate VIII. fig. 1, No. 3) is the largest. It arises from the temporal aponeurosis, where it expands on the side of the head, its fibres, though delicate, being broad and radiated. The muscle ends in a compressed tendon, which is inserted into the upper and anterior part of the cartilage of the ear.

*The Posterior muscle* (m. posterior auris, retrahens aurem, mastoido-auricularis; fig. 8, No. 16; plate VIII. fig. 1, No. 5) consists of two or three thin fasciculi, ranged one over the other; they arise from the mastoid process by short aponeurotic fibres, and are inserted into the back part of the concha.

*The Anterior muscle* (m. anterior auris, attrahens aurem, zygomato-auricularis; fig. 8, No. 7) is a narrow, fleshy, and tendinous fasciculus, which is attached to the temporal fascia above the zygoma, and passes backwards, to be inserted into the fore part of the helix.

The second group of muscles, viz. those which act on separate parts of the pinna, are the following:

*Musculus major helicis*, (fig. 8, No. 6,) arises just above the tragus, runs upwards upon the helix, and terminates where it is about to curve backwards.

*m. Minor helicis*, (fig. 8, No. 8,) commences in the concha close to the commencement of the helix, inclines upwards and forwards, and is lost upon the rim of the helix.

*m. Anti-tragicus*, (fig. 8, No. 15,) commences at the posterior surface of the anti-tragus, upon which it passes upwards and outwards to terminate upon the helix, crossing the fissure between it and the anti-tragus.

*m. Tragicus*, (fig. 8, No. 12,) consists of some fibres which are placed upon the tragus, extended from its base to its apex.

*m. Transversus Auriculæ* (fig. 9, No. 2,) stretches from the convexity of the concha to that of the fossa innominata.

*Musculus obliquus Auris* (fig. 9, No. 3,) extends from the dorsum of the concha to that of the scapha.

*m. Contractor meatûs* (trago-helicus; fig. 8, No. 9; fig. 9, No. 5;) ascends from the tragus obliquely to the anterior extremity of the helix.

The internal muscles of the ear are very small; only four are usually enumerated, of which three are attached to the malleus.

*The internal muscles of the Malleus* (m. internus mallei; tensor tympani; fig. 7, No. 6,) arises from the upper surface of the cartilage of the Eustachian tube, and also from the contiguous border of the pars petrosa of the temporal bone; it inclines outwards and backwards in the osseous canal that runs parallel with the Eustachian tube, and becomes tendinous on entering the tympanum, where it is inserted into the short process of the malleus.

*The Anterior muscle of the Malleus* (m. anterior mallei, laxator tympani major; fig. 6, No. 10,) arises from the spinous process of the sphenoid bone, and soon becoming tendinous, passes through the glenoid fissure to be inserted into the processus gracilis of the malleus.

*The External muscle of the Malleus* (m. externus mallei, laxator tympani minor,) is very small, and so indistinct, that many anatomists have omitted it altogether; it arises from the upper border of the osseous part of the auditory tube, and descends to be inserted into the manubrium of the malleus, near its short process.

*The muscle of the Stapes* (m. stapedius; fig. 7, No. 5;) arises from a deep sulcus at the back part of the tympanum, and runs forwards tapering to its termination, which is fixed to the neck of the stapes.





# INDEX.

---

- Abductor digiti minimi, page 44.  
 (Pl. XX. fig. 2, nos. 8, 11; Pl. XXXIX. fig. 1, nos. 9, 10, 11.)
- pedis, page 79.  
 (Pl. XXXIX. fig. 4, no. 9.)
- indicis, page 44.  
 (Pl. XVI. fig. 1, no. 22; Pl. XVII. fig. 1, no. 18, fig. 2, no. 15; Pl. XIX. fig. 1, no. 23, fig. 2, no. 14; Pl. XX. fig. 2, no. 12, fig. 3, no. 10.)
- pollicis, page 43.  
 (Pl. XVI. fig. 2, no. 9; Pl. XVII. fig. 1, no. 14; Pl. XX. fig. 2, no. 8, fig. 3, nos. 4, 5.)
- pedis, page 79.  
 (Pl. XXXVI. fig. 2, nos. 23, 24; Pl. XXXIX. fig. 1, nos. 2, 3, 4, fig. 2, no. 3, fig. 3, no. 6.)
- Accelerator urinæ, page 88.  
 (Pl. XLVI. fig. 1, no. 17; Pl. XLVII. fig. 1, no. 14.)
- Adductor brevis, page 72.  
 (Pl. XXXI. fig. 2, no. 13; Pl. XXXV. fig. 1, no. 20.)
- digiti minimi, page 44.
- longus, page 72.  
 (Pl. XXIX. fig. 1, no. 30; Pl. XXXI. fig. 1, no. 19, fig. 2, no. 14; Pl. XXXIV. fig. 1, no. 8; Pl. XXXV. fig. 1, no. 21.)
- magnus, page 72.  
 (Pl. XXXI. fig. 2, nos. 15, 16; Pl. XXXV. fig. 1, nos. 18, 19.)
- pollicis, page 43.  
 (Pl. XVII. fig. 1, no. 17; Pl. XIX. fig. 1, no. 24; Pl. XX. fig. 2, no. 13, fig. 3, no. 9, fig. 4, no. 6.)
- pedis, page 80.  
 (Pl. XXXIX. fig. 3, no. 8.)
- Anconeus, page 39.  
 (Pl. XIX. fig. 1, no. 8, fig. 2, no. 3.)
- Anti-tragicus, page 95.  
 (Pl. L. fig. 8, no. 15.)
- Arytænoideus, page 93.  
 (Pl. L. fig. 2, no. 4.)
- Arytæno-epiglottideus, page 93.
- Attollens aurem, page 95.  
 (Pl. VIII. fig. 1, no. 3; Pl. L. fig. 8, no. 1.)
- Attrahens aurem, page 95.  
 (Pl. VIII. fig. 1, no. 4; Pl. L. fig. 8, no. 7.)
- Azygos uvulæ, page 92.  
 (Pl. IV. fig. 3, no. 16; Pl. V. fig. 3, no. 13.)
- Biceps femoris, page 73.  
 (Pl. XXXIV. fig. 1, nos. 20, 21, 22, fig. 2, nos. 11, 12, 13; Pl. XXXV. fig. 1, nos. 13, 14; Pl. XXXVI. fig. 1, no. 8.)
- flexor cubiti, page 28.  
 (Pl. X. fig. 1, nos. 14, 15, fig. 2, nos. 13, 14, 15; Pl. XII. fig. 1, no. 8; Pl. XIII. fig. 1, no. 11; Pl. XIV. fig. 1, nos. 19, 20, 21, 22, fig. 2, nos. 7, 8; Pl. XVI. fig. 1, nos. 1, 2, 3; Pl. XVII. fig. 1, no. 3.)
- Biventer cervicis, page 86.  
 (Pl. XLI. fig. 1, no. 4.)
- Brachialis anticus, page 29.  
 (Pl. X. fig. 1, no. 16, fig. 2, no. 16; Pl. XIII. fig. 1, no. 12; Pl. XIV. fig. 1, no. 23; Pl. XV. fig. 1, no. 13; Pl. XVI. fig. 1, nos. 4, 6; Pl. XVII. fig. 1, nos. 4, 6; Pl. XVII. fig. 2, no. 4; Pl. XXI. fig. 1, no. 21; Pl. XL. fig. 1, no. 45.)
- Buccinator, page 6.  
 (Pl. II. fig. 1, no. 13; Pl. III. fig. 1, no. 8; Pl. IV. fig. 4, no. 35; Pl. V. fig. 1, no. 18; Pl. VIII. fig. 1, no. 18.)
- Cervicalis ascendens, page 90.  
 (Pl. XLI. no. 6; Pl. XLII. no. 15.)
- Circumflexus palati, *see* Tensor palati.
- Coccygeus, page 89.  
 (Pl. XXXIII. fig. 2, no. 12; Pl. XLVI. fig. 1, no. 22; Pl. XLVII. fig. 1, no. 11, fig. 2, no. 13.)

- Complexus, page 85.  
 (Pl. XI. fig. 1, no. 18; Pl. XL. fig. 1, no. 25; Pl. XLI. fig. 1, no. 3; Pl. XLII. fig. 1, no. 7; Pl. XLIII. fig. 2, nos. 5, 6, 7, 8, 9, 10.)
- Compressor narium, page 6.  
 (Pl. II. fig. 1, no. 7; Pl. VIII. fig. 1, no. 8.)
- urethræ, page 90.
- venæ dorsalis penis, page 90.
- Constrictor isthmi faucium, *see* Palato-glossus.
- pharyngis inferior, page 12.  
 (Pl. IV. fig. 1, no. 10, fig. 4, no. 19; Pl. V. fig. 1, no. 26, fig. 2, no. 22.)
- medius, page 12.  
 (Pl. IV. fig. 1, no. 11, fig. 4, nos. 18, 23; Pl. V. fig. 1, no. 25.)
- superior, page 13.  
 (Pl. IV. fig. 1, no. 12, fig. 2, no. 12, fig. 3, no. 20, fig. 4, no. 17; Pl. V. fig. 1, nos. 21, 24, fig. 2, no. 21.)
- vaginæ, page 90.
- Contractor meatûs, page 95.  
 (Pl. L. fig. 8, no. 9, fig. 9, no. 5.)
- Coraco-brachialis, page 28.  
 (Pl. X. fig. 2, no. 12; Pl. XII. fig. 1, no. 7; Pl. XV. fig. 1, no. 17.)
- Corrugator supercillii, page 7.  
 (Pl. II. fig. 1, no. 4.)
- Cremaster, page 49.
- Crico-arytænoideus lateralis, page 93.  
 (Pl. L. fig. 4, no. 7.)
- posticus, page 93.  
 (Pl. L. fig. 2, nos. 7, 7.)
- thyroideus, page 93.  
 (Pl. L. fig. 1, nos. 4, 4, fig. 3, no. 7.)
- Deltoides, page 19.  
 (Pl. III. fig. 1, no. 30, fig. 2, no. 29; Pl. X. fig. 1, no. 9; Pl. XII. fig. 1, no. 4; Pl. XIII. fig. 1, nos. 6, 7, fig. 2, no. 16; Pl. XXI. fig. 1, 20; Pl. XL. fig. 1, nos. 12, 13.)
- Depressor anguli oris, page 7.  
 (Pl. II. fig. 1, no. 16; Pl. III. fig. 1, no. 7; Pl. VIII. fig. 1, no. 17.)
- labii inferioris, page 7.  
 (Pl. II. fig. 1, no. 17; Pl. III. fig. 1, no. 6; Pl. VIII. fig. 1, no. 16.)
- superioris alæque nasi, page 94.  
 (Pl. L. fig. 10, no. 9.)
- Diaphragma, page 50.  
 (Pl. XXVI. fig. 1, nos. 17, 18, 19, 20, 21, 22, 23, 24, 25, 26, 27, 28, 29; Pl. XXVII. figs. 1, 2, 3, 4, 5.)
- Digastricus, page 9.  
 (Pl. III. fig. 1, nos. 20, 21, fig. 2, nos. 19, 20, 21, fig. 4, no. 32; Pl. IX. fig. 1, no. 11.)
- Erector clitoridis, page 90.  
 ——— penis, page 88.  
 (Pl. XLVI. fig. 1, no. 18.)
- spinæ, page 84.  
 (Pl. XLI. fig. 1, no. 13.)
- Extensor carpi radialis brevior, page 40.  
 (Pl. XIX. fig. 1, nos. 7, 19; Pl. XX. fig. 1, no. 11.)
- longior, page 40.  
 (Pl. XIX. fig. 1, nos. 6, 20; Pl. XX. fig. 1, no. 10.)
- ulnaris, page 39.  
 (Pl. XIX. fig. 1, no. 14; Pl. XX. fig. 1, no. 9.)
- digiti minimi, page 39.  
 (Pl. XIX. fig. 1, no. 13; Pl. XX. fig. 1, no. 8.)
- digitorum brevis, page 82.  
 (Pl. XXXV. fig. 2, nos. 22, 23; Pl. XXXIX. fig. 4, nos. 3, 4, 5, 6.)
- communis, page 39.  
 (Pl. XIX. fig. 1, nos. 12, 21; Pl. XX. fig. 1, no. 7; Pl. XXXVI. fig. 1, nos. 20, 21, 22.)
- longus, page 75.  
 (Pl. XXXV. fig. 2, nos. 11, 12, 13; Pl. XXXIX. fig. 4, no. 8.)
- indicis, page 40.  
 (Pl. XIX. fig. 2, no. 9.)
- ossis metacarpi pollicis, page 40.  
 (Pl. XIX. fig. 1, nos. 15, 18, fig. 2, no. 6; Pl. XX. fig. 1, no. 4.)
- pollicis proprius, page 75.  
 (Pl. XXXV. fig. 2, nos. 9, 10; Pl. XXXVI. fig. 1, no. 25; Pl. XXXIX. fig. 4, no. 7.)
- primi internodii pollicis, page 40.  
 (Pl. XIX. fig. 1, nos. 16, 18, fig. 2, no. 7; Pl. XX. fig. 1, no. 5.)
- secundi internodii pollicis, page 40.  
 (Pl. XIX. fig. 2, no. 8; Pl. XX. fig. 1, no. 6.)
- Flexor accessorius, page 80.  
 (Pl. XXXIX. fig. 2, nos. 12, 13.)
- brevis digiti minimi, page 44.  
 (Pl. XX. fig. 2, no. 7, fig. 3, no. 12.)
- pedis, page 80.  
 (Pl. XXXIX. fig. 1, no. 2, fig. 2, no. 14, fig. 3, nos. 9, 10, 11.)
- carpi radialis, page 32.  
 (Pl. XVI. fig. 1, nos. 9, 10, 11; Pl. XX. fig. 2, no. 3, fig. 4, no. 3.)

## Flexor carpi ulnaris, page 33.

(Pl. XVI. fig. 1, no. 14, fig. 2, nos. 7, 8; Pl. XVI. fig. 2, no. 13; Pl. XVII. fig. 1, nos. 13, 14; Pl. XIX. fig. 1, no. 9, fig. 2, no. 10; Pl. XX. fig. 2, no. 2, fig. 4, no. 4.)

## —— digitorum brevis, page 80.

(Pl. XXXIX. fig. 1, nos. 5, 6, 7, 8.)

## —— profundus, page 35.

(Pl. XVI. fig. 1, no. 17; Pl. XVII. fig. 1, no. 22, fig. 2, nos. 10, 11, 19; Pl. XVIII. fig. 2, no. 1, fig. 3, no. 1, fig. 6, no. 6; Pl. XIX. fig. 2, no. 11; Pl. XX. fig. 3, no. 13.)

## —— sublimis, page 35.

(Pl. XVI. fig. 1, no. 15, fig. 2, nos. 5, 6; Pl. XVII. fig. 1, nos. 8, 9, 21, fig. 2, no. 18; Pl. XVIII. fig. 4, nos. 1, 4, fig. 5, nos. 1, 2, 3, 4, fig. 6, no. 5.)

## —— longus digitorum pedis, page 78.

(Pl. XXXVI. fig. 2, no. 20; Pl. XXXVII. fig. 1, no. 9, fig. 2, no. 11; Pl. XXXVIII. fig. 1, nos. 8, 9, 23; Pl. XXXIX. fig. 1, no. 17, fig. 2, nos. 7, 8, 9.)

## —— pollicis pedis, page 79.

(Pl. XXXVI. fig. 2, no. 22; Pl. XXXVII. fig. 1, no. 10, fig. 2, nos. 12, 17; Pl. XXXVIII. fig. 1, nos. 10, 11, 24; Pl. XXXIX. fig. 1, nos. 15, 16, fig. 2, nos. 5, 6.)

## —— pollicis brevis, page 43.

(Pl. XX. fig. 2, no. 9, fig. 3, no. 6.)

## —— pedis, page 80.

(Pl. XXXIX. fig. 1, no. 14, fig. 2, no. 4.)

## —— longus, page 43.

(Pl. XVI. fig. 2, no. 11; Pl. XVII. fig. 1, nos. 10, 11, fig. 2, nos. 8, 9; Pl. XX. fig. 3, no. 8.)

## Gastrocnemius, page 77.

(Pl. XXXIV. fig. 1, no. 23; Pl. XXXV. fig. 1, no. 24, fig. 2, nos. 24, 26; Pl. XXXVI. fig. 1, nos. 13, 14, 15, fig. 2, no. 13; Pl. XXXVII. fig. 1, nos. 4, 5, 6.)

## Gemellus inferior, page 61.

(Pl. XXXII. fig. 1, no. 19, fig. 2, no. 15; Pl. XXXIII. fig. 1, no. 18; Pl. XXXIV. fig. 2, no. 7.)

## —— superior, page 61.

(Pl. XXXII. fig. 1, no. 17, fig. 2, no. 13; Pl. XXXIII. fig. 1, no. 16; Pl. XXXIV. fig. 1, no. 5.)

## Genio-hyo-glossus, page 91.

(Pl. IV. fig. 4, no. 29; Pl. V. fig. 2, no. 26; Pl. VII. fig. 5, no. 18, fig. 6, no. 8.)

## Genio-hyoideus, page 91.

(Pl. IV. fig. 4, no. 30; Pl. V. fig. 2, no. 27; Pl. VII. fig. 5, no. 19; Pl. IX. fig. 1, no. 16.)

## Gluteus maximus, page 59.

(Pl. XXXII. fig. 1, nos. 11, 12, 13; Pl. XXXIV. fig. 1, nos. 13, 14, fig. 2, no. 9.)

## —— medius, page 60.

(Pl. XXXI. fig. 1, no. 7; Pl. XXXII. fig. 1, nos. 14, 15; Pl. XXXIII. fig. 1, nos. 13, 14, fig. 3, no. 16; Pl. XXXIV. fig. 1, nos. 11, 12.)

## —— minimus, page 60.

(Pl. XXXII. fig. 2, nos. 9, 10; Pl. XXXIII. fig. 3, no. 17.)

## Gracilis, page 90.

(Pl. XXXI. fig. 1, no. 20; Pl. XXXIV. fig. 2, nos. 19, 20; Pl. XXXV. fig. 1, nos. 8, 9; Pl. XXXVI. fig. 2, no. 10.)

## Helicis major, page 95.

(Pl. L. fig. 8, no. 6.)

## —— minor, page 95.

(Pl. L. fig. 8, no. 8.)

## Hyo-glossus, page 91.

(Pl. V. fig. 2, no. 24; Pl. VII. fig. 5, no. 17, fig. 6, no. 6; Pl. IX. fig. 1, no. 17.)

## Iliacus, page 55.

(Pl. XXVI. fig. 1, no. 16; Pl. XXIX. fig. 1, nos. 21, 22.)

## Indicator, page 40.

## Infra-spinatus, page 29.

(Pl. XIII. fig. 1, no. 8, fig. 2, no. 9; Pl. XIV. fig. 3, no. 8; Pl. XXI. fig. 1, no. 17; Pl. XL. fig. 1, nos. 16, 39.)

## Inter-costales externi, page 48.

(Pl. X. fig. 2, no. 20; Pl. XI. fig. 1, no. 26; Pl. XXIII. fig. 1, no. 4.)

## —— interni, page 48.

(Pl. X. fig. 2, no. 21; Pl. XXIII. fig. 1, no. 4.)

## Inter-osseæ manûs dorsales, page 40.

(Pl. XX. fig. 1, no. 12, fig. 4, nos. 7, 9, 10, 12.)

## —— palmares, page 44.

(Pl. XX. fig. 4, nos. 8, 11, 13.)

## —— pedis dorsales, page 81.

(Pl. XXXIX. fig. 2, no. 16, fig. 4, nos. 10, 11, 12, 13.)

## —— plantares, page 81.

(Pl. XXXIX. fig. 2, no. 15, fig. 3, no. 13.)

## Inter-spinales, page 87.

(Pl. XLIII. fig. 3, no. 12, fig. 4, nos. 8, 9.)

## Inter-transversales, page 86.

## Latissimus dorsi, page 45.

(Pl. VI. fig. 1, no. 12; Pl. XI. fig. 1, no. 5; Pl. XIV. fig. 1, no. 17; Pl. XXI. fig. 1, no. 11; Pl. XXII. fig. 1, no. 7; Pl. XXIII. fig. 2, no. 7; Pl. XXVIII. fig. 1, nos. 25, 26; Pl. XL. fig. 1, nos. 8, 9, 10, 11.)



- Laxator tympani**, page 95.  
(Pl. L. fig. 6, no. 10.)
- **minor**, page 95.
- Levator anguli oris**, page 6.  
(Pl. II. fig. 1, no. 12; Pl. VIII. fig. 1, no. 13.)
- **scapulæ**, page 82.  
(Pl. III. fig. 2, no. 11; Pl. IX. fig. 1, no. 28; Pl. XI. fig. 1, no. 20; Pl. XXI. fig. 1, no. 9; Pl. XL. fig. 1, no. 26; Pl. XLII. fig. 1, no. 8; Pl. XLIV. fig. 1, no. 23.)
- **ani**, page 88.  
(Pl. XLVI. fig. 1, no. 21; Pl. XLVII. fig. 1, nos. 19, 20, 21, fig. 2, nos. 14, 15, 16, 17.)
- **labii inferioris**, page 94.  
(Pl. VI. fig. 6, no. 8; Pl. VIII. fig. 1, no. 15; Pl. L. fig. 10, no. 10.)
- **superioris**, page 6.  
(Pl. II. fig. 1, no. 9; Pl. VI. fig. 6, no. 5; Pl. VIII. fig. 1, no. 10.)
- **alæque nasi**, page 6.  
(Pl. II. fig. 1, no. 8; Pl. VIII. fig. 1, no. 9.)
- **menti**, page 7.  
(Pl. II. fig. 1, no. 18; Pl. III. fig. 1, no. 5.)
- **palati**, page 92.  
(Pl. IV. fig. 3, no. 17, fig. 4, no. 26; Pl. V. fig. 3, no. 10.)
- **palpebræ**, page 6.  
(Pl. II. fig. 1, no. 5; Pl. VI. fig. 1, no. 1, fig. 2, no. 1, fig. 5.)
- Levatores costarum**, page 87.  
(Pl. XLV. no. 21.)
- Lingualis**, page 92.  
(Pl. VII. fig. 6, nos. 3, 7.)
- Longissimus dorsi**, page 85.  
(Pl. XXI. fig. 1, no. 19; Pl. XL. fig. 1, nos. 48, 50; Pl. XLI. fig. 1, nos. 11, 12; Pl. XLII. fig. 1, no. 17; Pl. XLV. fig. 1, nos. 17, 18, 19, 20, 21, 22.)
- Longus colli**, page 86.  
(Pl. XLIV. fig. 1, nos. 24, 25, fig. 2, nos. 9, 10, 11, 12.)
- Lumbricales manûs**, page 44.  
(Pl. XX. fig. 2, no. 15, fig. 3, no. 13.)
- **pedis**, page 80.  
(Pl. XXXIX. fig. 1, no. 13, fig. 2, no. 11.)
- Massetericus**, pages 16, 17.  
(Pl. II. fig. 1, no. 14; Pl. III. fig. 1, no. 9; Pl. VIII. fig. 1, nos. 19, 20.)
- Multifidus spinæ**, page 87.  
(Pl. XLV. fig. 1, nos. 13, 14, 15, 16.)
- Mylo-hyoideus**, pages 9, 91.  
(Pl. III. fig. 1, no. 22, fig. 2, no. 22; Pl. V. fig. 1, no. 17, fig. 4, no. 4; Pl. IX. fig. 1, no. 15.)
- Obliquus abdominis externus**, page 47.  
(Pl. XXI. fig. 1, no. 12; Pl. XXII. fig. 1, no. 9; Pl. XXVIII. fig. 1, nos. 14, 18; Pl. XL. fig. 1, no. 20.)
- **internus**, page 48.  
(Pl. XXIII. fig. 2, no. 5; Pl. XXVIII. fig. 1, nos. 15, 19; Pl. XL. fig. 1, no. 21.)
- **auris**, page 95.  
(Pl. L. fig. 9, no. 3.)
- **capitis inferior**, page 91.  
(Pl. XLIII. fig. 3, no. 9, fig. 4, no. 13; Pl. XLV. no. 7.)
- **superior**, page 91.  
(Pl. XLIII. fig. 3, no. 8, fig. 4, no. 10; Pl. XLV. no. 6.)
- **oculi inferior**, page 14.  
(Pl. VI. fig. 1, no. 8, fig. 2, no. 8, fig. 3, no. 8, fig. 4, no. 8, fig. 6, no. 4.)
- **superior**, page 14.  
(Pl. VI. fig. 1, nos. 2, 3, fig. 2, nos. 2, 4, fig. 3, no. 2, fig. 4, no. 1, fig. 6, nos. 1, 2.)
- Obturator externus**, page 62.  
(Pl. XXXI. fig. 2, no. 17; Pl. XXXII. fig. 2, no. 16; Pl. XXXIII. fig. 1, no. 19, fig. 3, no. 14.)
- **internus**, page 62.  
(Pl. XXXII. fig. 1, no. 18, fig. 2, no. 14; Pl. XXXIII. fig. 1, no. 17, fig. 2, no. 10; Pl. XXXIV. fig. 2, no. 6; Pl. XXXV. fig. 1, no. 6.)
- Occipito-frontalis**, page 6.  
(Pl. II. fig. 1, nos. 1, 2, fig. 2, nos. 1, 2; Pl. VIII. fig. 1, no. 1; Pl. XL. fig. 1, nos. 1, 2.)
- Omo-hyoideus**, page 8.  
(Pl. III. fig. 1, nos. 13, 14, fig. 2, nos. 13, 14; Pl. IX. fig. 1, nos. 23, 24; Pl. XLII. fig. 1, no. 10.)
- Opponens digiti minimi**, page 44.  
(Pl. XX. fig. 4, no. 2.)
- **pollicis**, page 43.  
(Pl. XX. fig. 2, no. 10, fig. 3, no. 7, fig. 4, no. 5.)
- Orbicularis oris**, page 7.  
(Pl. II. fig. 1, no. 15; Pl. IV. fig. 4, no. 34; Pl. V. fig. 1, no. 19, fig. 6, no. 6; Pl. VIII. fig. 1, no. 14.)
- **palpebrarum**, page 6.  
(Pl. II. fig. 1, no. 3; Pl. VIII. fig. 1, no. 6.)
- Palato-glossus**, page 92.  
(Pl. IV. fig. 4, no. 25; Pl. L. fig. 10, no. 6.)
- **pharyngeus**, page 92.  
(Pl. IV. fig. 3, no. 19, fig. 4, no. 20; Pl. LIII. fig. 10, no. 7.)
- Palmaris brevis**, page 44.  
(Pl. XX. fig. 2, no. 5.)

- Palmaris longus, page 33.  
(Pl. XVI. fig. 1, nos. 12, 13; Pl. XX. fig. 2, no. 4.)
- Pectineus, page 72.  
(Pl. XXIX. fig. 1, no. 29; Pl. XXXI. fig. 1, no. 18; Pl. XXXIV. fig. 1, no. 7.)
- Pectoralis major, page 19.  
(Pl. III. fig. 1, no. 29, fig. 2, no. 28; Pl. X. fig. 1, no. 8, fig. 2, nos. 5, 6; Pl. XII. fig. 1, no. 6; Pl. XIV. fig. 1, no. 18; Pl. XXI. fig. 1, no. 14; Pl. XXII. fig. 1, no. 6.)
- minor, page 20.  
(Pl. X. fig. 1, no. 11, fig. 2, no. 9.)
- Peroneus brevis, page 76.  
(Pl. XXXV. fig. 2, nos. 20, 21; Pl. XXXVI. fig. 1, no. 12; Pl. XXXVII. fig. 1, nos. 13, 14, 15, fig. 2, nos. 15, 16; Pl. XXXVIII. fig. 1, nos. 14, 15, fig. 2, nos. 15, 16.)
- longus, page 76.  
(Pl. XXXV. fig. 2, nos. 16, 17, 18, 19; Pl. XXXVI. fig. 1, nos. 9, 10, 11; Pl. XXXVII. fig. 1, nos. 11, 12, fig. 2, nos. 13, 14; Pl. XXXVIII. fig. 1, nos. 12, 13, 25, fig. 2, nos. 13, 14.)
- tertius, page 75.  
(Pl. XXXV. fig. 2, nos. 14, 15; Pl. XXXVI. fig. 1, nos. 23, 24.)
- Plantaris, page 77.  
(Pl. XXXVII. fig. 2, nos. 4, 5.)
- Platysma myoides, page 8.  
(Pl. III. fig. 1, no. 4.)
- Popliteus, page 78.  
(Pl. XXXVII. fig. 2, no. 6; Pl. XXXVIII. fig. 1, nos. 3, 4.)
- Pronator quadratus, pages 33, 34.  
(Pl. XVI. fig. 1, no. 16; Pl. XVII. fig. 1, no. 12, fig. 2, no. 12; Pl. XVIII. no. 7; Pl. XX. fig. 4, no. 1.)
- radii teres, page 32.  
(Pl. XVI. fig. 1, nos. 7, 8; Pl. XVII. fig. 2, no. 5; Pl. XVIII. fig. 1, no. 2.)
- Psoas magnus, page 54.  
(Pl. XXVI. fig. 1, no. 15; Pl. XXIX. fig. 1, nos. 18, 22.)
- parvus, page 56.  
(Pl. XXIX. fig. 1, nos. 19, 20.)
- Pterygoideus externus, pages 17, 18.  
(Pl. VII. fig. 1, nos. 8, 10, fig. 2, no. 10.)
- internus, pages 16, 17.  
(Pl. IV. fig. 1, no. 9, fig. 2, no. 9, fig. 3, no. 15; Pl. VII. fig. 1, no. 9, fig. 2, no. 9.)
- Pyramidalis abdominis, page 50.  
———— nasi, page 6.  
(Pl. II. fig. 1, no. 6.)
- Pyriiformis, page 61.  
(Pl. XXXII. fig. 1, no. 16, fig. 2, nos. 11, 12; Pl. XXXIII. fig. 1, no. 15, fig. 2, no. 11; Pl. XXXV. fig. 1, no. 7.)
- Quadratus femoris, page 62.  
(Pl. XXXI. fig. 2, no. 18; Pl. XXXII. fig. 6, no. 21, fig. 2, no. 17; Pl. XXXIII. fig. 3, no. 15; Pl. XXXIV. fig. 2, no. 8.)
- lumborum, page 54.  
(Pl. XXVI. fig. 1, no. 14; Pl. XXIX. fig. 1, no. 23.)
- Rectus abdominis, page 49.  
(Pl. XXIV. fig. 1, nos. 10, 11; Pl. XXV. fig. 1, nos. 7, 8; Pl. XXVIII. fig. 1, no. 13.)
- capitis anticus major, page 86.  
(Pl. IX. fig. 1, no. 27; Pl. XLIV. fig. 1, no. 20, fig. 2, no. 7.)
- minor, page 86.  
(Pl. XLIV. fig. 1, no. 21.)
- posticus major, page 87.  
(Pl. XLIII. fig. 3, no. 10; Pl. XLV. fig. 1, no. 8.)
- minor, page 87.  
(Pl. XLIII. fig. 3, no. 11; Pl. XLV. fig. 1, no. 9.)
- femoris, page 70.  
(Pl. XXIX. fig. 1, no. 26; Pl. XXXI. fig. 1, nos. 10, 11; Pl. XXXIV. fig. 1, nos. 15, 16; Pl. XXXV. fig. 1, no. 17; Pl. XXXVI. fig. 1, no. 6, fig. 2, no. 6.)
- lateralis, page 86.  
(Pl. XLIV. fig. 1, no. 22, fig. 2, no. 8; Pl. XLV. fig. 1, no. 10.)
- oculi externus, page 14.  
(Pl. VI. fig. 1, no. 6, fig. 2, no. 6, fig. 3, no. 6.)
- inferior, page 14.  
(Pl. VI. fig. 1, no. 7, fig. 2, no. 7, fig. 3, no. 7.)
- internus, page 14.  
(Pl. VI. fig. 1, no. 5, fig. 2, no. 5, fig. 3, no. 5.)
- superior, page 14.  
(Pl. VI. fig. 1, no. 4, fig. 2, no. 4, fig. 3, no. 4, fig. 4, no. 3.)
- Retrahens aurem, page 95.  
(Pl. II. fig. 2, no. 3; Pl. VIII. fig. 1, no. 5; Pl. L. fig. 8, no. 16.)
- Rhomboideus major, page 83.  
(Pl. XXI. fig. 1, no. 18; Pl. XL. fig. 1, nos. 19, 28.)
- minor, page 83.  
(Pl. XL. fig. 1, no. 27.)
- Sacro-lumbalis, page 84.  
(Pl. XL. fig. 1, nos. 47, 50; Pl. XLI. fig. 1, nos. 9, 10, 12; Pl. XLII. fig. 1, no. 16; Pl. XLV. fig. 1, no. 23.)
- Sartorius, page 70.  
(Pl. XXIX. fig. 1, no. 25; Pl. XXXI. fig. 1, nos. 8, 9; Pl. XXXIV. fig. 1, nos. 3, 4, fig. 2, no. 21; Pl. XXXV. fig. 1, no. 15; Pl. XXXVI. fig. 2, nos. 8, 9.)

- Scalenus anticus, page 87.  
(Pl. IX. fig. 1, no. 25; Pl. XI. fig. 1, no. 22; Pl. XLIV. fig. 1, no. 27, fig. 2, nos. 13, 16.)
- posticus, page 87.  
(Pl. III. fig. 2, no. 12; Pl. IX. fig. 1, no. 26; Pl. XI. fig. 1, no. 21; Pl. XLII. fig. 1, no. 9; Pl. XLIV. fig. 1, no. 26, fig. 2, nos. 14, 15.)
- Semi-spinalis colli, 87.  
——— dorsi, page 87.
- Semi-membranosus, page 74.  
(Pl. XXXIV. fig. 2, nos. 16, 17; Pl. XXXV. fig. 1, no. 12; Pl. XXXVI. fig. 2, no. 11.)
- Semi-tendinosus, page 74.  
(Pl. XXXIV. fig. 2, nos. 14, 15; Pl. XXXV. fig. 1, nos. 10, 11; Pl. XXXVI. fig. 2, no. 12.)
- Serratus magnus, page 21.  
(Pl. X. fig. 1, no. 13; Pl. XI. fig. 1, no. 25; Pl. XXI. fig. 1, no. 13; Pl. XXII. fig. 1, no. 8; Pl. XL. fig. 1, no. 46.)
- posticus inferior, page 83.  
(Pl. XL. fig. 1, no. 49.)
- superior, page 83.  
(Pl. XLII. fig. 1, no. 18.)
- Solcus, page 77.  
(Pl. XXXV. fig. 2, nos. 25, 26; Pl. XXXVI. fig. 1, no. 16, fig. 2, no. 16; Pl. XXXVII. fig. 1, no. 7, fig. 2, nos. 7, 8.)
- Sphincter ani externus, page 88.  
(Pl. XLVI. fig. 1, no. 20; Pl. XLVII. fig. 1, no. 18.)
- internus, page 88.
- Spinalis dorsi, page 85.  
(Pl. XLI. fig. 1, no. 14.)
- Splenius capitis et colli, page 83.  
(Pl. III. fig. 2, no. 10; Pl. IX. fig. 1, no. 29; Pl. XI. fig. 1, no. 19; Pl. XXI. fig. 1, no. 8; Pl. XL. fig. 1, nos. 4, 24; Pl. XLII. fig. 1, no. 6.)
- Stapedius, page 95.  
(Pl. L. fig. 7, no. 5.)
- Sterno-cleido-mastoideus, page 8.  
(Pl. III. fig. 1, no. 10, fig. 2, nos. 7, 8; Pl. XXI. fig. 1, no. 7; Pl. XL. fig. 1, no. 3.)
- hyoideus, page 8.  
(Pl. III. fig. 1, no. 15, fig. 2, no. 15; Pl. V. fig. 2, no. 19; Pl. IX. fig. 1, no. 18.)
- thyroideus, page 8.  
(Pl. III. fig. 2, no. 17; Pl. IX. fig. 1, nos. 19, 20, 22, fig. 2, no. 5, fig. 3, no. 10.)
- Stylo-glossus, page 91.  
(Pl. V. fig. 2, no. 18; Pl. VII. fig. 5, no. 12, fig. 6, no. 5.)
- Stylo-hyoideus, page 92.  
(Pl. III. fig. 1, no. 19, fig. 2, no. 18; Pl. V. fig. 2, no. 19; Pl. VII. fig. 5, nos. 13, 14; Pl. IX. fig. 1, no. 12, fig. 2, nos. 6, 7.)
- pharyngeus, pages 13, 93.  
(Pl. IV. fig. 1, no. 13, fig. 2, nos. 13, 14, fig. 4, no. 22; Pl. V. fig. 2, no. 20.)
- Subclavius, page 20.  
(Pl. X. fig. 1, no. 10, fig. 2, no. 7.)
- Subscapularis, pages 22, 29.  
(Pl. X. fig. 2, no. 17; Pl. XI. fig. 1, no. 24; Pl. XII. fig. 1, no. 3; Pl. XIV. fig. 1, no. 14.)
- Supinator radii brevis, page 34.  
(Pl. XVII. fig. 1, no. 7, fig. 2, no. 7; Pl. XVIII. fig. 1, no. 3; Pl. XIX. fig. 2, no. 5.)
- longus, page 33.  
(Pl. XVIII. fig. 1, no. 8; Pl. XIX. fig. 1, no. 5.)
- Supra-spinales, page 91.  
——— spinatus, page 30.  
(Pl. XIII. fig. 2, nos. 7, 8; Pl. XIV. fig. 1, no. 13, fig. 3, no. 7; Pl. XL. fig. 1, no. 38.)
- Temporalis, pages 16, 17.  
(Pl. VIII. fig. 2, no. 1.)
- Tensor palatī, page 92.  
(Pl. IV. fig. 3, no. 18, fig. 4, no. 27; Pl. V. fig. 1, no. 23, fig. 3, nos. 11, 12.)
- tympani, page 95.  
(Pl. L. fig. 7, no. 6.)
- vaginæ femoris, page 69.  
(Pl. XXIX. fig. 1, no. 27; Pl. XXXI. fig. 1, nos. 5, 6; Pl. XXXIV. fig. 1, nos. 9, 10.)
- Teres major, page 29.  
(Pl. X. fig. 2, no. 18; Pl. XIII. fig. 1, no. 10, fig. 2, nos. 12, 13; Pl. XIV. fig. 1, no. 16; Pl. XXI. fig. 1, no. 15; Pl. XL. fig. 1, nos. 18, 42.)
- minor, page 29.  
(Pl. XIII. fig. 1, no. 9; Pl. XIV. fig. 2, nos. 10, 11; Pl. XXI. fig. 1, no. 16; Pl. XL. fig. 1, no. 17.)
- Thyro-arytænoideus, page 93.  
(Pl. L. fig. 4, no. 6.)
- epiglottideus, page 93.
- hyoideus, page 8.  
(Pl. III. fig. 1, no. 17, fig. 2, no. 16; Pl. V. fig. 2, no. 23; Pl. IX. fig. 3, no. 11.)
- Tibialis anticus, page 75.  
(Pl. XXXV. fig. 2, nos. 7, 8; Pl. XXXVI. fig. 1, nos. 17, 18, 19, fig. 2, nos. 17, 18, 19.)
- posticus, page 79.  
(Pl. XXXVI. fig. 2, no. 21; Pl. XXXVII. fig. 1, no. 8, fig. 2, no. 10; Pl. XXXVIII. fig. 1, nos. 6, 7, fig. 2, nos. 3, 4.)



- Trachelo-mastoideus, page 85.  
(Pl. XLI. fig. 1, no. 5; Pl. XLIII. fig. 1, no. 3.)
- Tragicus, page 95.  
(Pl. L. fig. 8, no. 12.)
- Transversalis abdominis, page 51.  
(Pl. XXIV. fig. 1, nos. 7, 12; Pl. XXV. fig. 1, nos. 9, 10; Pl. XXVIII. fig. 1, nos. 16, 21.)
- colli, page 85.  
(Pl. XLI. fig. 1, no. 7; Pl. XLV. fig. 1, no. 12.)
- Transversus pedis, page 80.  
(Pl. XXXIX. fig. 3, no. 12.)
- auriculæ, page 95.  
(Pl. L. fig. 9, no. 2.)
- perinæi, page 88.  
(Pl. XLVI. fig. 1, no. 19.)
- alter, page 88.
- Trapezius, page 45.  
(Pl. III. fig. 1, no. 12, fig. 2, no. 9; Pl. XXI. fig. 1, no. 10; Pl. XL. fig. 1, nos. 5, 6, 7.)
- Triangularis sterni, page 52.  
(Pl. XXV. fig. 1, no. 6.)
- Triceps extensor cubiti, page 30.  
(Pl. XIII. fig. 1, nos. 13, 14, fig. 2, nos. 14, 15; Pl. XIV. fig. 1, nos. 23, 24; Pl. XV. fig. 1, nos. 14, 15, 16, fig. 2, nos. 11, 12, 13, 14, 15, 16; Pl. XVI. fig. 1, no. 5; Pl. XVII. fig. 1, no. 5; Pl. XIX. fig. 1, no. 3; Pl. XXI. fig. 1, nos. 22, 23; Pl. XL. fig. 1, nos. 14, 15, 43, 44.)
- Vastus externus, page 70.  
(Pl. XXXIV. fig. 1, no. 19, fig. 2, no. 16; Pl. XXXVI. fig. 1, no. 7.)
- internus, page 71.  
(Pl. XXXI. fig. 1, no. 16; Pl. XXXIV. fig. 1, no. 18; Pl. XXXV. fig. 1, no. 16.)
- Zygomaticus major, page 6.  
(Pl. II. fig. 1, no. 11; Pl. VIII. fig. 1, no. 12.)
- minor, page 6.  
(Pl. II. fig. 1, no. 10; Pl. VIII. fig. 1, no. 11.)

END OF THE MUSCLES.

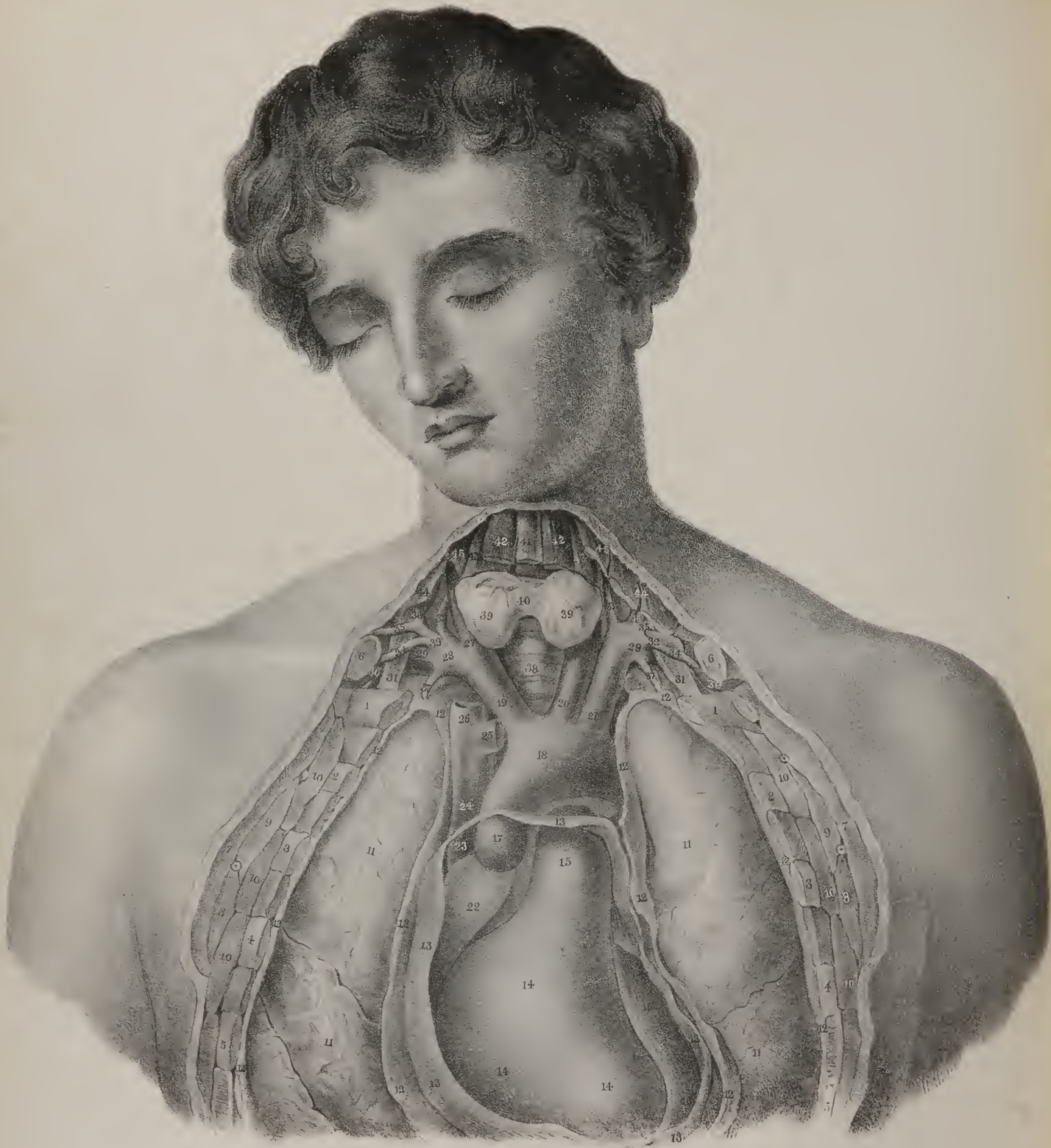

THE  
VESSELS  
OF  
THE HUMAN BODY.











# VASCULAR SYSTEM.

---

## CHAPTER I.

THE human body is made up of solid and fluid constituents, which bear to one another not only the more obvious relation of containing and contained parts, but also exert a mutual influence under the ever-varying conditions of health and disease. The proportion of the fluids to the solids is considerable; it may be estimated as nine to one: so that the mere circumstance of their quantity would demand for them an especial attention from the anatomist and physiologist; whilst the changes which their characters and properties undergo form a most important subject for the investigation of the pathologist.

The fluids, or, as they are frequently called, the humours, though very numerous, and differing much in composition, properties, and uses in the economy, may yet be arranged under three heads:—

## PLATE I.

This plate gives a view of the commencement of the great artery (aorta) as it issues from the heart, together with the leading branches, which carry the blood to the head and upper extremities; and the trunk of the great vein, (*vena cava vel magna*), which returns the blood from the same parts. In order to bring these different objects into view, the sternum and the fore-part of the ribs have been removed, together with part of the clavicle at each side; the pericardium, or heart-purse, is opened, and the front of it removed, so as to expose the heart itself.

Nos. 1, 2, 3, 4, 5. The upper ribs cut through. 6, 6. The clavicles. 7, 7. The great pectoral muscle at each side cut through, in order to expose the ribs previously to applying the saw to them. 8, 8. The reflected or folded part of the great pectoral muscle at each side. 9, 9. The small pectoral muscle. 10, 10, 10. The great serratus muscle at each side. 11, 11. At each side, the lungs. 12, 12, 12, 12. At each side, the investing membrane of the lungs, viz. the pleura, cut through. 13, 13, 13, 13. The pericardium cut through. 14, 14, 14. The right ventricle of the heart. 15. The pulmonary artery arising from the right ventricle. 16. The part of the left ventricle of the heart which is seen in this mode of viewing it. 17. The great artery, viz. the aorta, issuing from the left ventricle. 18. The transverse part of the curve or arch of the aorta. 19. The arterial trunk which carries blood to the right side of the neck and head, as well as to the right upper limb, and which from this circumstance is called the brachio-cephalic artery, (*arteria brachio-cephalica: arteria innominata.*) 20. The left carotid artery, (*arteria carotis sinistra.*) 21. The left subclavian artery, (*a. subclavia sinistra.*) 22. Part of the right auricle of the heart. 23. The great vein (*vena cava superior*) terminating in it: this part of the vessel will be observed to be within the pericardium. 24. The great vein outside the pericardium. 25. The left brachio-cephalic vein, (*v. brachio-cephalica sinistra: v. innominata sinistra,*) so named because it returns the blood from the left upper limb, and from the left side of the head. 26. The right brachio-cephalic vein, (*vena brachio-cephalica dextra: v. innominata dextra.*) 27. The right carotid artery, and, 28. the right subclavian artery, issuing from a common trunk, (the brachio-cephalic, No. 19.) 29. At each side, the subclavian artery, arching outwards to reach the anterior scalenus muscle. 30. At each side, the subclavian artery, where it turns down under the clavicle. 31. At each side, the anterior scalenus muscle. 32. At each side, the thyroid artery or axis, so called from its usually giving off several branches. 33. Its ascending branch going up to the thyroid gland, (*ramus thyroideus.*) 34. The supra-scapular branch, (*ramus supra-scapularis, vel transversalis humeri.*) 35. The posterior scapular branch, (*r. scapularis posterior, vel transversalis colli.*) 36. The ascending cervical branch, (*r. cervicalis ascendens.*) 37. At each side, the internal mammary artery, (*arteria mammaria interna.*) 38. The fore-part of the windpipe, (*trachea.*) 39, 39. The lateral lobes of the thyroid gland. 40. The transverse or connecting piece of the gland called its isthmus. 41. The fore-part of the thyroid cartilage of the larynx. 42. At each side, part of the sterno-hyoid muscle. 43. Part of the sterno-thyroid muscle at each side. 44. Part of the sterno-cleido-mastoid muscle at each side. 45. Part of the omo-hyoid muscle at each side.

First. The blood, or central mass, which constantly flows, as it were, in a circle, being alternately received into the heart, and propelled from it into all parts of the body.

Secondly. The various fluids which are separated from the blood by the different secreting organs: of these, some are intended to serve special purposes in the economy, for instance, the saliva, the mucous and gastric fluids; whilst others are eliminated from it, viz. the urine, perspiration, &c.

Thirdly. The fluids brought into the central mass from without:—these are the product of digestion and absorption; they are called chyle, and lymph, and are intended to supply the losses sustained by the processes of nutrition and secretion.

So long as life lasts, these solid as well as fluid constituents are subjected to a constant internal motion and change; some of the particles of which they consist, and which had lain a longer or shorter time within the system, being separated and cast out, whilst others are admitted to replace them. The form of the body remains the same, though its component parts are thus subjected to a perpetual mutation; but it will be at once perceived that these changes are molecular, having reference to the mere particles of which the textures and organs of our living fabric is made up. However minute and slow these changes may be, they present many important considerations to those who are engaged in examining the processes of nutrition and growth, as well as the various structural changes which occur in the intimate texture of organs.

It is now, and has been for a long time, almost universally known, that the blood, the proper nutrient fluid in the higher animals, moves, or rather is made to move, from point to point through a certain prescribed course, commencing from a given spot, and after a while returning to the same again, after having gone the round of its circuit. This could not occur with the requisite degree of precision and regularity, unless it were contained within tubes, and that the tubes were so fashioned as to allow the current to pass in one direction, and one only, at the same time that they were furnished with some provision to prevent its reflux. The ancients, from being unacquainted with these conditions, supposed the blood to move forwards and backwards in one set of vessels, having a sort of flux and reflux. The tubes here spoken of are the blood-vessels of the body; they branch out into every part of it. On referring to the diagram or plan of the vessels in Plate III. fig. 1, it will be seen that one set of these is coloured red, and that it commences by a large trunk at the heart. From this, as from a common conduit, offsets proceed to the head, to the arms, to the lower limbs, and to the various parts of the body. These offsets gradually diminish in size, but increase in number, until, finally, in the interior of our different organs and textures, they become as fine as hairs, and are thence termed capillary. The blood contained in this order of vessels is of a bright red colour, and possesses those properties which fit it for supplying materials for their growth and nutrition to the parts to which it is conveyed, as well as furnishing to secreting organs the materials of the secretions which they elaborate. A new order of tubes commences where those hitherto noticed may be said to terminate; they are coloured blue, and contain the blood, which is now changed in its characters and properties, after having parted with some of its constituents. The current within these vessels flows in the opposite direction from that in the preceding set; all the tributary streams which run into them being made to set towards the heart, to which they are in due time conveyed. Now, as the blood is thus made to issue from a particular spot—the heart, and to return again to the same, as if it flowed in a circle, (though the outline of its course in no one of its many gyrations approaches the form of an exact circle, ellipsis, or any other mathematical figure,) it is said to *circulate*, and the whole process is termed *circulation*.

The blood-vessels are divisible into two sets, which are termed arteries and veins. The former convey from the heart the pure blood, which is fitted for the purposes of the economy; the latter convey back to it that which is in a manner effete and exhausted. Now, the blood, brought back by the veins to the heart, is conveyed onwards from it, by the pulmonary artery, to the lungs, where it is exposed to the influence of the atmosphere, having previously received, through a most important inlet, the chyle, or nutritious substance extracted from the food by the process of digestion. This mixed fluid, viz. the venous blood and the chyle, having been duly aerated in the lungs, is returned to the heart again, to be propelled through the great arterial trunk into the system at large. Two streams may thus be said to begin and to terminate at the heart: one flowing from it to the lungs by the pulmonary artery, and returning by the pulmonary veins; the other extending through the whole body, and returning by two great veins which bring back the blood, the one from the upper part of the body, the other from the lower. The former has been termed, from its shorter course, the *lesser* circle, and, from its destination, the *pulmonary* circle; the latter is, with equal propriety, called the greater or aortic circle, and not unfrequently the *systemic*, from its connexion with the system at large. Though some of the older anatomists had conceived sufficiently correct notions of the course of the blood in some parts of the system, yet none of them were able to combine these together, so as to form a connected whole; that was reserved for Harvey, who, about the year 1619, first described the true course of the blood in the different orders of vessels, and demonstrated the correctness of his opinions by a complete series of proofs and experiments.

That the blood flows from the heart in the arteries, and that it returns again by the veins, may be proved by experiment, by observation, and by a consideration of certain contrivances called valves,—their structure, and the purposes which they serve in the economy,—in other words, their final causes. Harvey drew the proofs of his general propositions from each of these sources, and so combined them as to form a train of reasoning irresistibly cogent to any reflecting person. One of the experimental proofs consists in tying a thread tightly upon an artery as it runs along one of the limbs in an animal selected for



the purpose. It will be found that the thread or ligature acts like a stop-cock upon the current within the vessel; it literally shuts it off, so that the vessel becomes empty beyond the point at which it is applied, but is rendered turgid in the interval intercepted between the heart and the point indicated: the mode of applying the ligature is shown in Plate III. fig. 1, where it will be seen coiled round the artery at the right side.

If the vessel be punctured above the ligature, the blood will issue from the orifice in a stream and with force; but if the puncture be made below the ligature, none will issue from it. Again, if, instead of tying it in this way, the vessel be cut across, the blood will be projected in a jet from the part next the heart, and little, if any, will flow from the other segment or cut end of the vessel. These facts show that the blood flows from the heart in the arteries. In the next place, let the ligature be placed upon a vein; the vessel will be observed to swell as if distended in the part beyond the obstruction, and to collapse as if emptied in the part intercepted between this and the heart, or at all events up to the point at which some tributary stream is poured into it. As many veins of considerable size run immediately under the skin, particularly in the limbs of persons engaged in laborious employment, and as the coats of these vessels are thin and compressible, the experiment may be made by merely pressing upon one of them: it will at once be found to shrink in the part next the heart, and to swell beyond the finger; showing from which side the current comes, and whither it goes. These experiments and observations sufficiently demonstrate the direction of the current in the arteries and veins which form the greater circle: the proof is rendered complete when the arrangement and effects of the valves placed in the interior of the veins and at the commencement of the great arterial trunks are taken into account. The valves are folds or doublings of the lining membrane which project into the veins, where they represent so many small floodgates, for they are so adjusted as to allow the blood to flow freely towards the heart, whilst they effectually prevent its reflux. Again, at the commencement of the great artery, (the aorta or systemic trunk,) a valvular apparatus is also placed, which gives free transit to the blood as it is propelled from the heart into the vessel, but which as effectually resists its return, even when pressed by the recoil of the artery distended by the blood thrown into it. The form and arrangement of the valves in the veins are given in Plate III. fig. 2, and in the heart in fig. 4.

The course of the blood in the greater circuit being established, it remains for us to trace its current through the pulmonary circle, and to mark the place and mode of communication between the two circulations. Harvey distinctly noted the fact, that the heart's cavities alternately received blood into them and propelled it out of them. On opening the chest of a small animal,—for instance, a frog,—he saw the heart swell and enlarge when distended by the blood brought into it by the veins, and then diminish again when it emptied itself by expelling the contained fluid. Observations conducted in this way could merely determine the fact of the entrance and exit of the blood; they could not establish the line of its direction through the heart's cavities. This point can be cleared up satisfactorily only by examining the position and mechanism of the valves. In Plate III. fig. 4, the right auricle and ventricle are shown, and certain membranous folds are seen in the cavity of the latter, connected with its sides by small cords, which act like so many checks in preventing the folds from being pressed backwards into the auricle. A moment's consideration will show that these folds, which are the valves so often spoken of, are so constructed as to allow the blood to pass freely from the auricle into the ventricle, and at the same time effectually resist its return, acting on the principle of a floodgate. Again, when the ventricle opens into the artery (pulmonary) which issues from its upper part and reaches to the lungs, there also three folds or valves are placed, which give free transit to the current projected from the ventricle into the artery, but resist its return. From this it will at once appear that the blood which is brought back to the heart by the two great veins, (the upper one, fig. 4, No. 1, returning the venous blood from the head, neck, and upper limbs; and the lower one, No. 2, from the lower limbs and the inferior part of the body,) is received into a cavity, No. 3, which is the right auricle: when distended, this cavity, or rather its walls, being muscular and contractile, reacts upon the fluid so brought into it, and squeezes it through an oval aperture which leads into the ventricle, No. 4; and then the ventricle, which is much more muscular, instantly contracts when filled, and would inevitably force a considerable part of the fluid back into the auricle, but that the valvular folds, No. 5, are pressed down so as to form a complete impediment to any movement in this direction. There remains, however, a ready outlet, and there the blood escapes, viz. by the opening which leads into the pulmonary artery. Into this vessel the blood is projected with a force proportioned to the contractile power of the ventricle; and having once passed the valves, No. 6, its return is cut off. Hence it must proceed onwards to the minute branchings of the artery in the lungs: these terminal branches of the artery (See Plate III. fig. 5, No. 1) turn upon themselves, coiling round the air-vesicles, and open into the incipient radicles of the veins, No. 2, which receive the blood as it is being aërated, and bring it back to the left side of the heart; thus completing the smaller circle, or, as it is termed, the pulmonary circulation. Now, when the blood is thus conducted to the heart, it is received into the left auricle, from which it is pressed into the left ventricle. At the opening of communication between these cavities, there is another valvular apparatus which prevents the reflux of the blood, so that the fluid is forced upwards into the great artery, (aorta,) the orifice of which is also guarded by three valves similar to those at the commencement of the pulmonary artery. Hence, when the stream enters the artery, and its return is effectually prevented, it must proceed on its way, and go the round of the greater or systemic circulation.

The division of the circulation into the greater and the lesser, or the pulmonary and systemic, as established by Harvey, continued to be universally received, until Bichât (not by any means with a view to question its correctness or truth) adopted



another, on physiological grounds. The blood in the branches and trunks of the great veins, (*venæ cavæ*,) in the right side of the heart and pulmonary artery, being of a reddish-brown colour, (*venous*,) whilst that in the pulmonary veins, in the left side of the heart, and likewise in the aorta and its ramifications, is red, (*arterial*,) suggested to the mind of this great physiologist a corresponding division of the circulation into that of the *red* and that of the *dark* blood. According to Harvey, the heart, placed at the commencement of each circle, receives the blood, and propels it forwards, to describe the greater and the lesser course. According to Bichât, the heart must be conceived to be situated at a point intermediate between the origin and termination of each system; of which one (the dark-blooded) begins in the general capillary vessels of the body, and terminates in the capillaries of the lungs; whilst the red-blooded commences in the latter vessels, and ends in the capillaries diffused throughout the body. In this view of the subject, the actions of the lungs, and those going on in the body generally, may be considered as maintaining a constant antagonism, the one purifying and restoring the blood which becomes vitiated in the other.

Taking the heart as the centre of each circle, or the point from which each current starts, and to which it returns, we see the tubes which contain the blood commencing by two trunks, the aorta (Plate I. No. 17) and the pulmonary artery, (No. 15:) the former gives off branches, which divide and subdivide, until they become reduced to the minutest capillary tubes in the intimate texture of all parts of the body; the latter ramifies in the same way in the lungs. Thus there are two arterial trees, whose trunks arise from the heart; the branches of the one being intended to diffuse the materials of growth and nutrition through the body at large, whilst those of the other convey the exhausted and effete blood to the lungs, to be there renovated.

The modes in which arterial trunks branch off, and divide from stage to stage, are various: in the limbs, the branches generally form acute angles with the main artery, (Plate III. fig. 1;) within the body, we observe the aorta bifurcate into the common iliacs, and each of these into the two vessels of the same name, (internal and external;) the renal and lumbar arteries form right angles with the parent vessel; but the superior intercostals issue at obtuse angles. No assignable or fixed proportion seems to exist between the size of the vessel and its branches; from the aorta itself arise the spermatic arteries, which are exceedingly small, and the renal and carotid, which are very large; and between these extremes we see offsets of every variety of calibre. Where, however, a bifurcation occurs, the capacity of the two branches is always greater than of the vessel from which they proceed; so that the stream of blood, in proportion as it is subdivided, becomes also more diffused, as it flows from a narrower into a wider channel. This was made a subject of particular consideration by those physiologists who, soon after Harvey's time, sought to follow up his views of the mechanism of the circulation. Adopting the opinion which he had taught, that the heart was the sole agent in propelling the blood, it became interesting to ascertain the impediments and resistance which it had to overcome. With this view they examined—the angles formed by the branches at their points of origin,—the number

## PLATE II.

- IN this side-view of the face and neck, the principal arteries, together with the various muscles to which they have relation, are shown.
- No. 1, 1. The ear. 2, 2. The temporal fascia, which binds down the muscle of the same name, and supports the artery, (temporal.) 3, 3. The upper and lower segments of the orbicular muscle of the eye-lids. 4. The elevator muscle of the lip and nose. 5. The elevator muscle of the upper lip. 6. The elevator muscle of the angle of the mouth. 7. The smaller zygomatic muscle. 8. The larger zygomatic muscle. 9, 9. The upper and lower segments of the orbicular muscle of the lips. 10. The depressor muscle of the lower lip. 11. The depressor muscle of the angle of the mouth. 12. Part of the lower jaw-bone seen in the interval between the muscles. 13. The buccal, or buccinator muscle. 14, 14. The masseter muscle. 15, 15. The parotid gland. 16. The mastoid process of the temporal bone, where it gives insertion to the sterno-cleido-mastoid muscle. 17. The upper part of the splenius capitis muscle. 18. The upper part of the sterno-cleido-mastoid muscle. 19. The submaxillary gland. 20. The posterior part of the digastric muscle;—21. Its tendon, where it is attached to the side of the tongue-bone, (*os hyoides*.) 22. The anterior part of the digastric muscle. 23. The levator anguli scapulæ muscle. 24. The posterior scalenus muscle. 25. The upper part of the omo-hyoid muscle. 26. The sterno-thyroid muscle. 27. The sterno-hyoid muscle. 28. The prominent part of the thyroid cartilage of the larynx. 29. Part of the trapezius muscle. 30. The lower part of the omo-hyoid muscle. 31, 31, 31. The divisions of the brachial plexus of nerves. 32. Part of the anterior scalenus muscle. 33. The clavicular part of the sterno-cleido-mastoid muscle. 34. The sternal part of the same muscle. 35. The trachea. 36, 36. The clavicle. 37. Part of the deltoid muscle. 38. Part of the great pectoral muscle.
- A. The subclavian artery inclining downwards to get behind the clavicle.  
 a. The supra-scapular branch, (*ramus supra-scapularis: r. transversalis humeri*.) b. The posterior scapular branch, (*r. posterior scapulæ, vel transversalis humeri*.) c. The superficial cervical branch.  
 B. The trunk of the common carotid artery.  
 C. The external carotid artery.  
 D. The internal carotid artery.  
 e. The superior thyroid branch of the external carotid artery. d. The lingual branch. f, f, f. The facial artery. g. The transverse artery of the face. h. The posterior auricular branch. i. The occipital artery where it becomes superficial after having passed from under cover of the cervical muscles. k. The temporal artery ascending to the side of the head, having passed above the parotid gland, which covers the lower part of it. l. Its anterior branch. m. The posterior branch. n. The frontal branch of the ophthalmic artery as it emerges from the orbit.

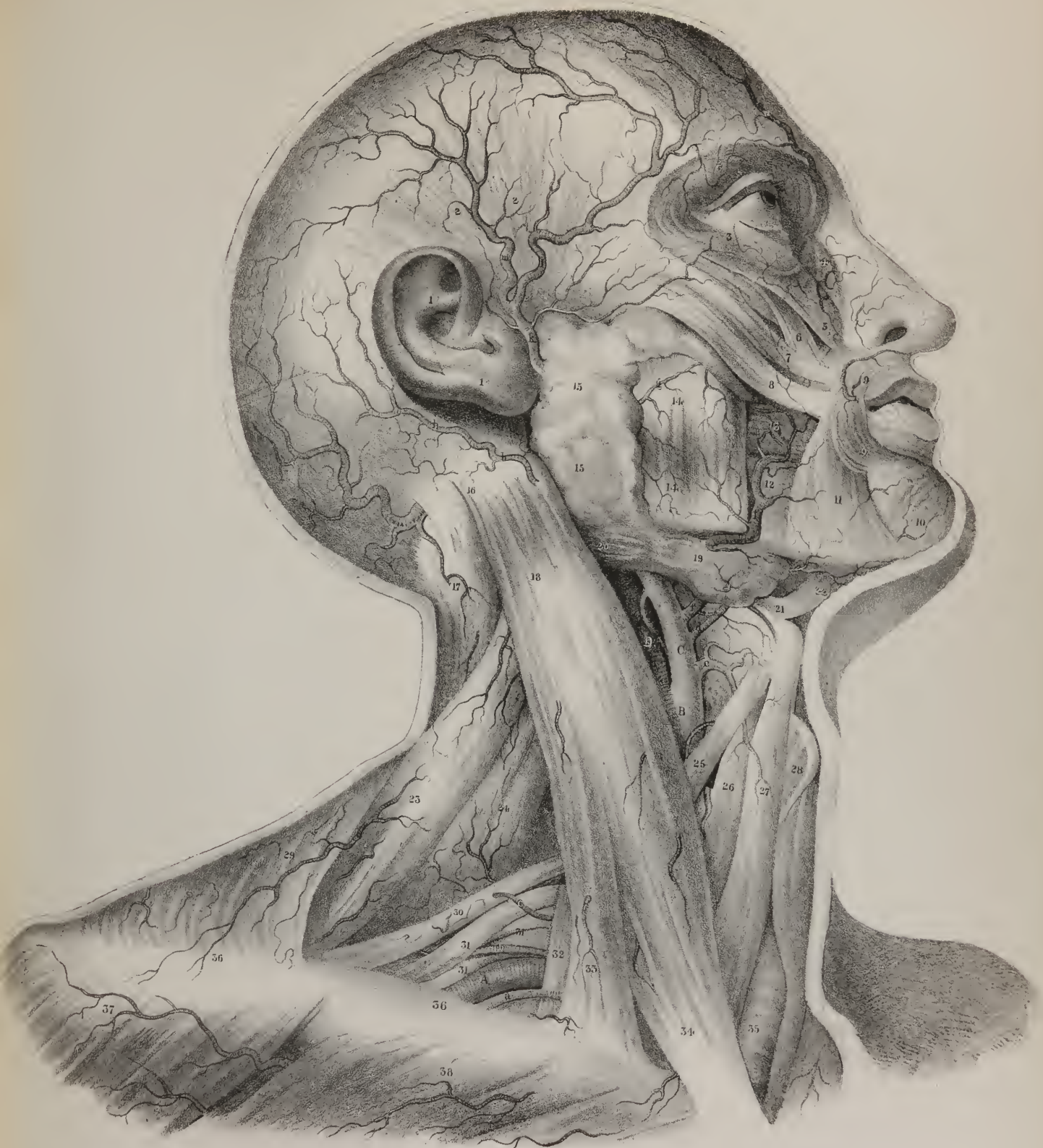










Fig. 1.

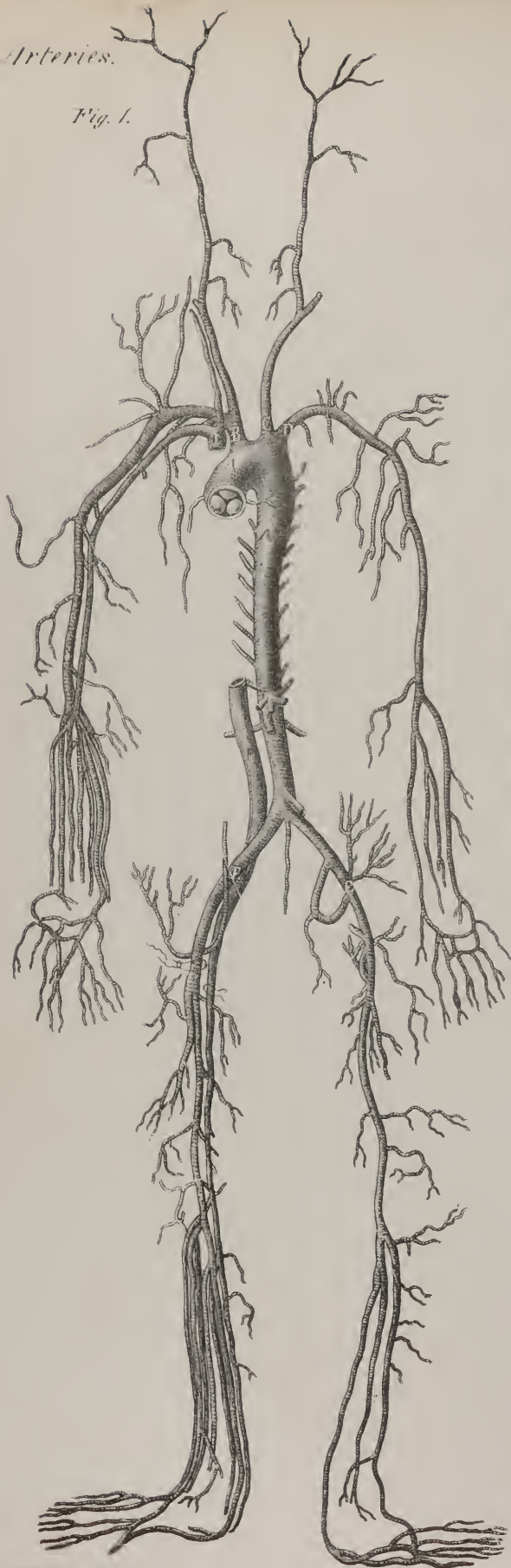


Fig. 2.



Fig. 3.




Fig. 4.

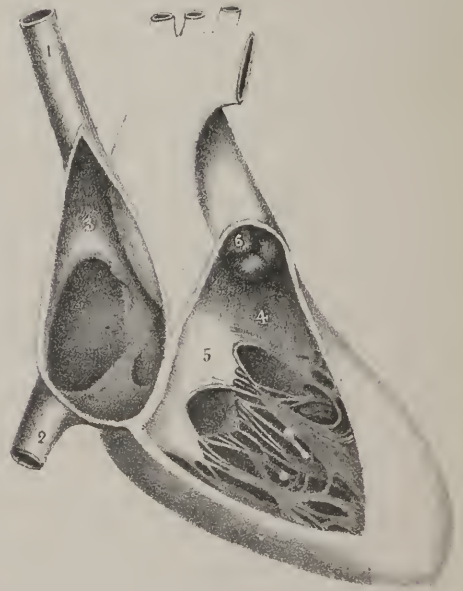
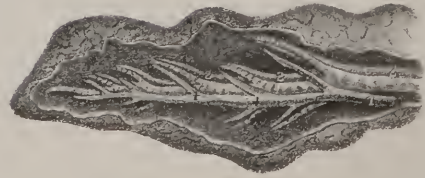


Fig. 5.



of divisions and subdivisions which took place down to their terminations in the veins,—the proportions subsisting between the calibre of the minor currents, as compared with those from which they proceed,—and, finally, the friction of the blood against the sides of the vessels was taken into account. But the calculations led to no satisfactory result; not perhaps because the problem to be solved was too complex, but that its conditions were too variable and uncertain.

The modes of communication between vessels are various; sometimes two of them, from points more or less distant, converge and meet, forming an arch by their junction, from which issue small ramusculi to the surrounding parts: we observe this along the intestinal canal, and about some of the joints. Very commonly arterial branches are connected only at their ultimate terminations; and under ordinary circumstances neither can be said to receive blood from the other, both being merely a means of supply to the parts to which they run; but if the direct flow in one be cut off, then it will become filled from the other, the current being in the opposite direction to what it was originally, viz. from the branches into the trunk. Another mode of junction is by a short canal extended between two parallel arteries, as in the case of the anterior cerebral arteries; or two of equal size join at an acute angle, and give rise to a third, as do the vertebals to form the basilar artery. These different communications are called anastomoses (*αναστομωω*, to communicate; *ανα, στωμα*, a mouth) or inosculation, which, literally, mean the same thing; yet in their technical application a difference is maintained between them; the latter being used where the union is free and open, the vessels themselves joining, so that it becomes difficult to say at what point their opposing currents meet, as is exemplified in the colic, epiploic, and coronary arteries; the former is generally employed when speaking of cases in which the minute branches communicate. When organs receive the materials of their growth and nutrition from two or more sources, the supply is less liable to disturbance or interruption than it otherwise would be; and should an obstruction happen to occur, or be placed designedly upon the current from one quarter, the deficiency will be made up by the others. It is by these means that the circulation is adequately carried on in a limb after the main artery has been tied; in such cases the blood is directed into a new or devious route, finding its way through the anastomoses existing between smaller vessels, and so what is termed “a collateral circulation” is established.

The veins, like arteries, present a ramified appearance; but as the blood flows in them from their extreme branches (which are continuous with those of the arteries) towards the main trunk, (vena cava,) which opens into the heart, and as the diameter of that vessel is considerably less than the sum of the diameters of the veins which pour their contents into it, the motion of the current within them increases from stage to stage of its progress, because it is made to run from a wider into a narrower channel.

### PLATE III.

THE drawings in this plate are intended to serve as diagrams, constructed so as to illustrate the different statements made in the text relative to the circulation of the blood.

- FIG. 1. This is a plan of the arteries. They will be observed to commence with the great trunk, which issues from the left ventricle of the heart, and to reach by their various branches to the different parts of the body. A sketch of the veins is given at the right side, sufficient to show the course of the current returned from the distant parts toward the heart.
- A, A. The great arterial trunk called the aorta. B. The great branch which passes up and divides into two vessels for the supply of the right side of the head and the upper extremity. C. The left carotid artery going to the left side of the neck and head. D. The left subclavian artery. E, E. The two iliac arteries passing down towards the lower extremities. F. The great vein (vena cava inferior) which returns the blood from the lower extremities, and from the pelvis and abdomen. G. The great vein which returns the blood from the upper extremities, and the right side of the neck and head.
- FIG. 2. A view of a vein laid open to show the arrangement of the valves within it; these are folds of the lining membrane, so arranged as to allow all the blood to pass freely towards the heart, and to prevent its reflux when once it has passed beyond them.
- FIG. 3. The three valves at the commencement of the pulmonary artery. A similar valvular apparatus is placed at the mouth of the aorta; both are crescent-shaped. When closed, they present the appearance indicated in fig. 1, where they are seen in the aorta, like three convex bulgings of the lining membrane.
- FIG. 4. This drawing taken from a preparation of the heart, shows the arrangement of the valves in the cavities of the right auricle and ventricle, and at the orifice of the pulmonary artery. They determine the course which the current of the blood must take.
- No. 1. The great vein (descending vena cava) which returns the blood from the head and the upper extremities. 2. The great vein (ascending vena cava) which returns the blood from the lower part of the body and the lower limbs. 3. The upper part of the cavity of the right auricle; lower down, a depression surrounded by a concave margin indicates the position of the aperture of communication between the right and left auricles of the heart during the fetal state. The position of the Eustachian valve ascending from the mouth of the vena cava is indicated, and near it the orifice of the great vein (coronary) of the heart. 4. The upper part of the right ventricle where it joins with the pulmonary artery: this part is smooth; the rest of the cavity contains a number of fleshy bundles, (*columnæ carneæ*), and some of them are connected with the points of the valve. 5. The three-pointed valve (tricuspid) placed at the opening of communication between the right auricle and ventricle. It allows the blood to pass freely from the auricle to the ventricle, but prevents its reflux. 6. The valves at the orifice of the pulmonary artery: they are represented in the position into which they are thrown when shut down by the distention of the artery. In their relaxed condition, as in fig. 3, they allow the blood to pass up into the artery; but in the state here shown they effectually prevent its reflux.
- FIG. 5. A sketch of an air-tube, accompanied by a branch of the pulmonary artery, Nos. 1, 1, 1, and of the pulmonary vein, 2, 2, 2.



The venous system, then, considered as a whole, seems to have been constructed on a hydraulic principle, which materially influences the passage of the blood it contains. It presents, on a general view, a series of cylindrical tubes, commencing in the interior of the different organs of the body, as well as in their remote or peripheral extremities. These, in the first instance, are so minute as to elude vision; but they gradually increase in size and diminish in number, forming successively vessels larger and larger, until finally all terminate in a large trunk. Though the calibre of any given vessel in the series is larger than that of either of the branches which open into it, yet its diameter is less than the sum of their diameters taken together; whence it follows, that the diameter of the common trunk is less than the sum of the diameters of the smaller vessels whose contents it receives. Now, when a current flows from a wider into a narrower bed, (its level remaining unaltered,) it necessarily becomes more rapid as it advances; and, by an extension of the same principle, when a number of tributary streams open into a channel whose width is less than that of these currents taken together, a certain impetus is given by the mere fact of such an arrangement, which materially aids any other collateral means that may have been devised for expediting its progress.

Having reviewed the circulating apparatus thus generally, it becomes necessary to notice the peculiarities of each of the three sets of vessels which compose it; as they exhibit not a few striking points of difference, more especially in structure and properties.

## ARTERIES.

**ARTERY**, arterial tissue, *arteria*.—The term “artery,” in its original acceptance, meant a tube containing air, (*αἴρ*, air; *τῆρεω*, to contain,) or some subtle agent, whether called archæus or vital spirits. It was at one time supposed that veins alone carried blood, as they were observed at all times to contain it, in the dead as well as the living; but as arteries were always found empty after death, they were imagined to be the conductors during life of something more refined and ethereal. Though this hypothesis has been long forgotten, the term to which it gave rise is retained even now, notwithstanding that centuries have elapsed since a very different doctrine has been completely established. Arteries are usually deep-seated, their form tubular, and each, if viewed from its commencement to its termination, will be found not to taper gradually, but from stage to stage to present a series of cylinders increasing in number, as they decrease in size; for a portion included between any two branches, whether it be one inch or three in length, retains its diameter throughout.

The outer surface of each arterial tube is connected with the surrounding structures by cellular tissue, and by vessels and nerves: these are derived from some of the contiguous small branches, and are termed *vasa vasorum*, because they circulate in the coats of the vessels, at least in the two exterior, not being traced into the inner one. Nerves also ramify upon and within their structure to the same extent, being derived, whilst in the cavities, from the sympathetic system, and in the limbs from the cerebro-spinal system. In many parts, as in the neck and extremities, the cellular structure becomes condensed, and forms a cylindrical investment (called “a sheath”) for it; which, however, is not a part of its proper structure, as the connexion between them is very slight.

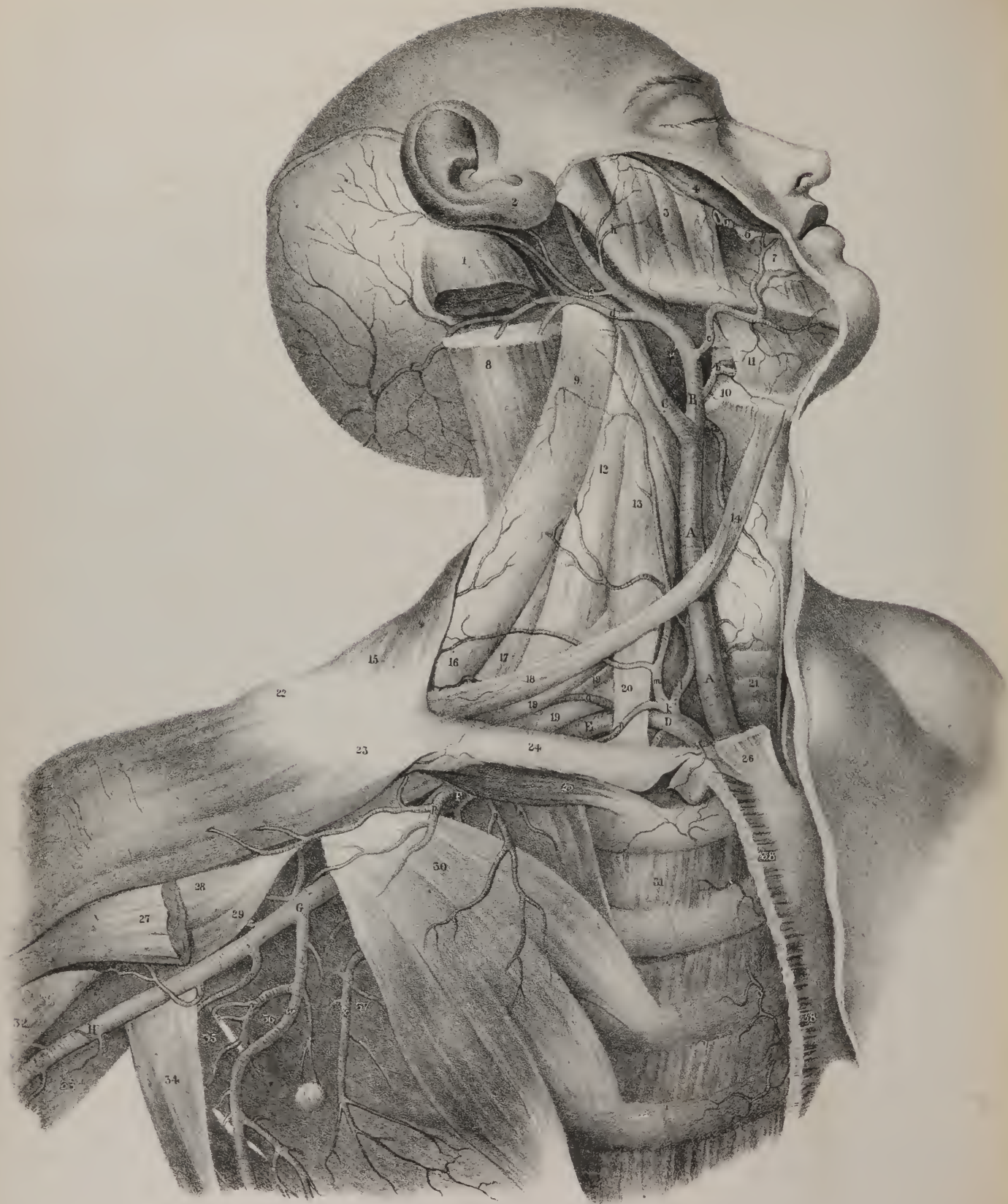
An artery is a cylindrical and highly elastic tube, composed of three coats or tunics, placed one within the other. The *external* coat is formed of cellular tissue, into which it may be reduced by maceration; its texture is closer where it is in contact with the middle coat, than externally, where it is somewhat loose and flocculent: it admits of considerable extension, and can retract when the distending cause is removed; and is so tough, as not to be divided by a hard ligature placed on the vessel, and so firm, as alone to resist the impulse of the current when the other coats are divided or torn.

The *internal* coat not only lines the arteries, but is continued into the ventricles of the heart; hence it is sometimes called the common membrane; and as it is smooth, and moistened by a fine halitus, which appears to be poured out upon its surface, it is by some considered analogous to serous membranes, and named accordingly. It is thin, homogeneous, and transparent, and so fragile as to be easily torn. Its inner surface is at all times in contact with the blood, the outer being in close union with the middle coat. At the ventricular openings it forms three folds, whose base, or line of attachment, which is convex, corresponds with the point of junction between the arteries and the ventricle; whilst their free and slightly concave border projects upward into the vessels, one surface looking towards its axis, the other resting against its side in the relaxed condition; but when distended with blood, they bulge or project downwards or forwards, so as to become convex when viewed from the ventricle, and concave from the artery. Each valvular fold thus disposed encloses a minute stratum of cellular tissue as its bond of union, and is bound down to the middle coat at the margin of one of the convex processes which it presents at its commencement: in the free margin of each is a small granule, called “*corpus Aurantii*” or “*sesamoideum*.” Such are the *sigmoid* or *semilunar* valves, which prevent the reflux of the blood from the arteries back into the ventricles.

The *middle* coat (called also fibrous, muscular, elastic) is that upon which the most striking peculiarities of arteries depend. At its commencement it presents, in both vessels, (aorta and pulmonary artery,) not a straight border, but rather one which is









scolloped by three notches into three processes, which pass down to the margin of the ventricle, but are not identified even by their tips with the fleshy fibres. It consists of pale, straw-coloured fibres, coiled obliquely round the circumference of the vessels, but none of them forming a complete circle. If an artery be stretched transversely, it will recoil and resume its original diameter; if elongated, it will retract. These are direct proofs of elasticity. When an artery no longer carries blood, as, for instance, when a ligature has been applied upon it, the part beyond the ligature will contract, its tubes will become obliterated, and finally, by an alteration in its mode of nutrition, will degenerate into a mere fibrous cord. This indicates a contractile power different from that resiliency which characterizes structures simply elastic, and has been termed contractility of tissue, to denote that it is in some sort a vital property. The coats of arteries resist the effects of maceration for a considerable time, and yield on decoction but little gelatine, and no fibrine: hence the structure of their middle coat has been assimilated to that peculiar substance called "tissu jaune"—"élastique," which forms the ligamenta subflava of the vertebræ, and the cervical ligaments in the lower animals. These physical and chemical properties constitute a marked line of distinction between the middle coat of arteries and muscle: but in some particulars, more especially in its vital properties, it manifests several points of resemblance to the muscular structure, so that it seems to constitute an intermediate link between it and the fibrous or fibro-cellular tissues.

That property of arteries which is here indicated, and which enables them to contract towards their centre, without having been previously distended, has been the subject of many controversies amongst physiologists. It has been variously denominated, by different persons,—tonicity, vital force, contractility, &c. The whole controversy may be reduced to this—are all the phenomena of extension and contraction that are presented by arteries attributable solely to their elasticity? Haller, Bichât, and Magendie, have taken the affirmative side of the question; Hunter, Sæmmering, Thomson, and Home, the opposite. A decided difference of opinion between such high authorities affords abundant evidence of the difficulty of the subject, particularly when we consider the great attention which they have severally paid to it, and the many experiments which they performed with a view to arrive at some satisfactory conclusion. Bichât's arguments against the irritability of arteries are as follow:—1. Mechanical or chemical irritants applied to their external or internal surface, determine no contraction in them; nor, when divided longitudinally, do the edges of the incision become everted, as occurs in the intestines, or other irritable tubes. 2. When separated from the body, they manifest no signs of contractility: if the finger be introduced into a vessel, it is not compressed. Galvanism produces no contraction; and if any is caused by the application of an acid, it is attributable rather to its chemical action on their coats than to any vital power in them. "The arteries," says Magendie,\* "nowhere present any indication of irritability; they remain immovable under the action of sharp instruments, of caustics, and of the galvanic current."

These results are not by any means conformable with those obtained by other physiologists. Dr. Thomson† "succeeded in

## PLATE IV.

THE direction, general relations, and the branches of the great arteries of the neck are here shown. The skin, the fascia, and the two superficial muscles, viz. the platysma and the sterno-mastoid, are removed in order to exhibit the arteries more clearly.

No. 1. The upper extremity or insertion of the sterno-mastoid muscle. 2. The lobe of the ear. 3. The masseter muscle. 3. The zygomaticus muscle. 5. Part of the parotid duct. 6. The buccinator muscle. 7. The depressor muscle of the angle of the mouth. 8. The splenius muscle. 9. The levator of the angle of the scapula. 10. The cornu of the os hyoides or tongue-bone. 11. The mylo-hyoid muscle. 12. The middle scalenus muscle. 13. The anterior scalenus muscle. 14. The upper part of the omo-hyoid muscle. 15. Part of the trapezius muscle. 16. The lower part of the levator of the angle of the scapula. 17. The third or posterior scalenus muscle. 18. The lower part of the omo-hyoid muscle. 19, 19, 19. Three of the divisions of the brachial plexus of nerves. 20. The lower part of the anterior scalenus muscle. 21. The trachea. 22. The outer end of the clavicle. 23. The clavicular part of the deltoid muscle. 24. The body of the clavicle. 25. The subclavius muscle. 26. The sternal origin of the sterno-mastoid muscle. 27. Part of the great pectoral muscle near its attachment to the humerus. 28. The short head of the biceps muscle. 29. The coraco-brachialis muscle. 30. The small pectoral muscle. 31. The intercostal muscles. 32. Part of the biceps muscle. 33. Part of the long head of the triceps muscle. 34. Part of the latissimus dorsi muscle. 35. The greater teres muscle. 36. The subscapular muscle. 37, 37. Part of the great serratus muscle. 38, 38. Sternal origin of the pectoral muscle.

A, A. The trunk of the common carotid artery. B. The external carotid artery. C. The internal carotid artery. a. The thyroid branch of the external carotid artery. b. The lingual artery. c. The facial artery. d. The occipital artery. e. The mastoid branch. f, f, f. Branches of the occipital artery. g. The auricular branch. h. The transverse artery of the face. i. A muscular branch of the zygomatic muscle and the orbicular muscle of the eyelids.

D. The subclavian artery in the inner part of its course. E. The subclavian artery in the third part of its course. F. The termination of the subclavian artery. G. The axillary artery. H. The commencement of the brachial artery. k. The thyroid axis from which issue three branches. l. The ascending thyroid branch. m. The ascending cervical branch. n. The transversalis humeri branch. o. The transversalis colli branch. p. The thoracico-acromial branch. q. The upper thoracic branch. r. The anterior circumflex branch. s. The posterior circumflex branch. t. The subscapular artery. v. The dorsal branch of the subscapular artery. w. Its continued branch. x. The long thoracic branch.

\* Physiology, p. 415.

† Lectures on Inflammation, p. 85.

producing complete contraction, by irritating, for some time, though gently, with the point of a needle, the small arteries in the web of a frog's foot." The same effect was also produced by weak volatile alkali; but when a saturated solution of common salt was applied with the point of a hair pencil, "the arteries, instead of being contracted, as they had so uniformly been by the application of ammonia, were actually and sensibly dilated."\* Again: "when the capillaries are stimulated by the direct rays of the sun, by the application of gentle friction, or of spirits of wine, the velocity of the blood in them is immediately increased."† The application of electricity has determined marked contractions in arteries, as has been observed by two Italian physiologists, Giulio and Rossi; and Sir E. Home succeeded in producing the same effect by irritating a neighbouring nerve. These direct proofs of the irritability of arteries derive additional support from several pathological facts. "The increased pulsation of the larger vessels supplying an inflamed part, sufficiently evinces their increased action."‡ Thus, if paronychia occur in one of the fingers, the corresponding radial artery will pulsate more strongly than that of the opposite hand. In cases of hemiplegia the force is considerably diminished at the affected side, though it remains quite natural at the other; a proof that the arteries possess

## PLATE V.

FIG. 1. In this plate the common external carotid artery and some of its branches are shown; these are seen at the inner and upper part of the neck, taking the course of the anterior edge of the sterno-mastoid muscle. A small part of the common carotid is also seen near its termination. The subclavian artery is also brought into view where it lies close above the middle of the clavicle. In order to expose the vessels, the skin, the platysma muscle, and the fascia of the neck, are dissected away.

No. 1. The occipital protuberance, where it gives attachment to the trapezius muscle. 2. The mastoid process giving attachment to the sterno-mastoid muscle. 3. The lobe of the ear. 4. The ramus of the jaw-bone. 5, 5. The lower border of the body of the jaw-bone. 6. The anterior fibres of the trapezius muscle inclining down to their insertion into the clavicle. 7. Part of the splenius muscle, seen in the interval between the trapezius and the sterno-mastoid. 8. The elevator muscle of the angle of the scapula. 9. The body of the sterno-cleido-mastoid muscle. 10. The great wing (cornu) of the tongue-bone, (os hyoides.) 11. The fibres of the mylo-hyoid muscle descending to their insertion. 12. The anterior belly of the digastric muscle, the rest being removed. 13. The fibres of the trapezius muscle descending towards the acromion and clavicle. 14. The posterior and middle scaleni muscles. 15. The sterno-cleido-mastoid muscle, where it overlays the omo-hyoid muscle. 16. The upper part of the omo-hyoid muscle proceeding to its insertion. 17. The lower part of the omo-hyoid muscle. 18, 19. Two of the divisions of the brachial plexus of nerves. 20. The anterior scalenus muscle, where it overlays the subclavian artery. 21. The clavicular origin of the sterno-cleido-mastoid muscle. 22. The sternal origin of the same muscle. 23. The thyroid cartilage. 24. The junction of the clavicle with the acromion process. 25. The body of the clavicle. 26. Part of the deltoid muscle. 27. A few fibres of the great pectoral muscle.

A, A. The external carotid artery running up by the edge of the sterno-mastoid muscle.

a. Superior thyroid artery, (ramus thyroideus superior vel descendens,) inclining downwards from the external carotid artery. b. The facial or labial artery, (ramus facialis vel labialis,) inclining upwards and inwards to its destination. c. Its submental branch. d. A transverse artery of the face. e. The termination of external carotid in the temporal, which proceeds upwards before the ear to reach the side of the head.

B. The subclavian artery, (arteria subclavia dextra,) descending from under cover of the scalenus muscle, and then proceeding behind the clavicle to reach the axilla.

f. The supra-scapular artery, (ramus supra-scapularis vel transversalis humeri.) g. The posterior scapular artery, (ramus posterior scapulæ vel transversalis colli.)

FIG. 2. This dissection shows the origin of the common carotid and subclavian arteries at the right side from the brachio-cephalic artery, also the course of the vertebral artery and the deep cervical. In order to expose these parts fully, the clavicle, with the sterno-mastoid and trapezius muscles, are removed, also the scaleni muscles in the greater part of their extent, as well as the levator scapulæ, splenius, trachelo-mastoid, and complexus, with the intertransversalis: we thus leave only the deep-seated muscles which lie close to the spine and at the basis of the skull.

No. 1. The superior oblique muscle. 2. The posterior rectus (major) muscle. 3. The inferior oblique muscle. 4, 4. The body of the sterno-cleido-mastoid muscle. 5, 5. The longus colli muscle. 6, 6. The semi-spinalis colli muscle. 7. Part of the middle scalenus muscle at its attachment to the first rib. 8. Part of the anterior scalenus muscle.

A. The brachio-cephalic artery, a little below its bifurcation. B. The common carotid artery, at its origin from the brachio-cephalic. C. The subclavian artery.

d. The thyroid artery or axis, giving origin, just as it rises from the subclavian, to three or four branches. e. The ascending thyroid artery, (ramus ascendens vel inferior,) passing upwards behind the common carotid artery to reach the thyroid gland. f. The ascending thyroid artery, which is here truncated near its origin. g, g, g, g. The whole course of the vertebral artery upwards to the base of the skull; the turn which it makes in order to get to a level with the great foramen of the base of the skull is seen in the triangular space bounded by the obliqui and recti muscles. h. The branch which gives off the deep cervical and the superior intercostal arteries. i. Superior intercostal artery. k. The deep cervical artery, (ramus profundus cervicis:;) it is exceedingly variable in its size, being sometimes very large, as in the present instance, at other times comparatively small; in the latter case, the descending branch of the sub-occipital artery acquires a proportionate increase. l. The origin of the internal mammary artery.

\* Eod. loco.

† Wilson Philip on the Vital Functions, p. 235.

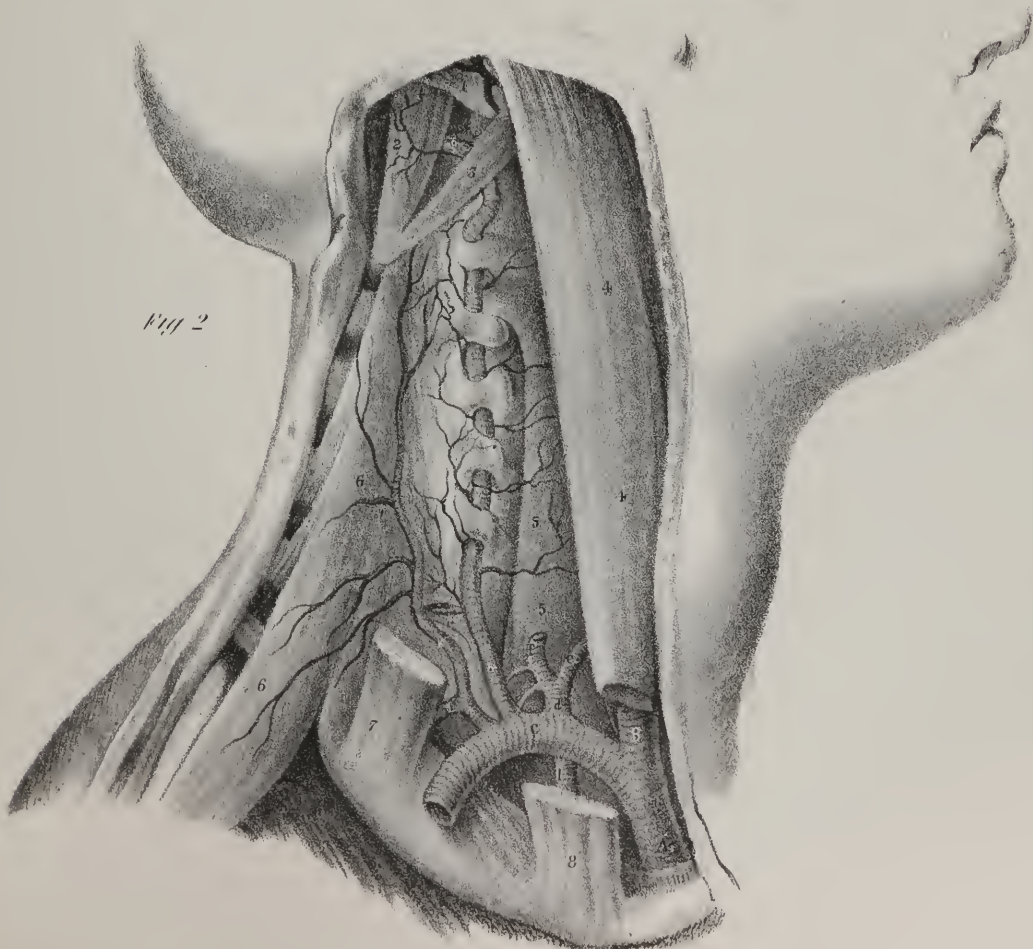
‡ Thomson, loc. cit.



Fig 1

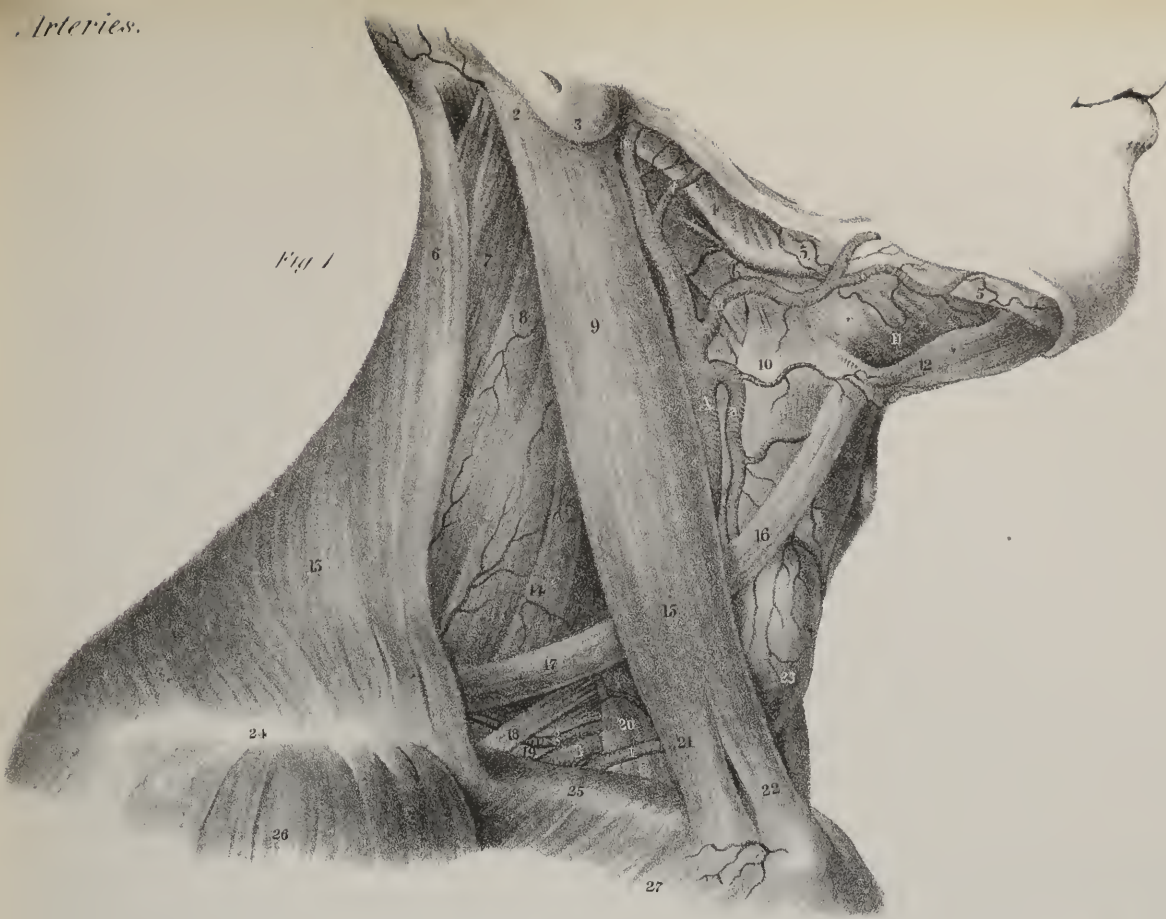

Fig 2







a power independent of the heart, and which is attributable to their irritability. The degree in which these two properties of arteries, elasticity and irritability, are manifested, differs according to the size of the vessels; the larger are more elastic, the smaller more irritable; and this latter property is more or less subjected to nervous influence.

The experiments of Dr. Thomson, above cited, cannot be considered as conclusive evidence that arteries are really irritable, at least in that sense in which muscles are known to be so. Even were it established that the capillaries are contractile on the application of stimuli, it would not follow that the arterial tubes which extend from the heart to these, are irritable or muscular. Pain is necessarily produced by irritating substances; pain and fear soon influence the circulation; the former will at first quicken it; the latter, from its depressing effect, will soon diminish its rapidity. Besides, it may be objected to all chemical agents, that they must act on the delicate tissues in which the vessels are enclosed, and upon their coats, if not upon their contents.

Whatever differences of opinion may exist on this much litigated subject, few will deny that arteries assist, in some degree, in carrying on the circulation; for we know that they appear before the heart in the human embryo; and in several of the lower animals, in which there is no heart, the vessels alone propel the fluids. In fishes there is no systemic ventricle; in reptiles the arteries contract, and propel the blood after the heart has been removed; and even in warm-blooded animals the blood has been observed moving freely in the capillaries, after all connection with the heart had been cut off by a ligature on the aorta.\* The circulation goes on in acephalous monsters, though they have not a heart. Inferences drawn from a consideration of the structure and functions of the lower animals cannot always be extended to those of a more complex and perfect organization, as the analogy between them may not be sufficiently close to warrant the application; but from a general view of what has been stated with regard to the circulating system, we may conclude, that when the heart exists, it exerts a decided influence on the circulation; that by its action the stream of blood in the arteries moves on, not continuously, but in jets; and that it flows uninterruptedly, though the leading arterial trunks have become ossified. The vessels also have a part to perform, as is evident from the fact that they can propel the blood after the heart has ceased to act; and so the heart and arteries may be considered as associated for the performance of a special function, each being to a certain extent endowed with an independent power: one acting by direct propulsion, the others assisting by their vital force and elasticity.

There are few subjects within the range of physiological research which have received more attention than the circulation of the blood at different times within the last two centuries. Considered even by itself, and altogether apart from the practical deductions which follow from it,—and they are many,—it carries sufficient interest to awaken the curiosity of any inquiring mind; but when it is taken in its various relations to the actions and movements of the different parts of the animated fabric, and to those derangements and disturbances of vital action and living structures which constitute disease, we cannot over-estimate its importance. When we turn over those pages in the history of medicine, in which are traced the different phases and mutations of opinion which have been exhibited during the progress of these researches which, from the first dawn of rational notions upon this subject, have gradually led to a complete evolution of all the phenomena of the circulation, and to the ascertainment of a satisfactory explanation of most, if not all, of them: though pleased with the general result, and gratified to find that so much has been reclaimed from the dominion of error and of ignorance and added to the sum of useful knowledge, we can scarcely help exclaiming, How slow and gradual is the progress of improvement! “So slow is it,” to use the words of Dugald Stewart, “that we are often tempted to doubt, whether the reason of the species is progressive. When our attention is limited to short periods of time, and becomes absorbed by the discussions and controversies which have agitated those who from time to time obtained sufficient ascendancy to give the tone to their contemporaries,—when we dwell on the ebb and flow of opinion, as traced in the writings of those sectaries who abetted the views and supported the doctrines of rival teachers or contending schoolmen, a doubt may perchance start across the mind, as to the reality of the progress which is made, or even to question the utility of some of the inquiries which are entered into; but when we enlarge the field of view, and extend the scope of inquiry, so as to look over the works of two or more succeeding generations, the reality of the progress, and the certainty of improvement becomes obvious.” It is now somewhat more than two centuries since Harvey gave to the world the results of his inquiries into the circulation of the blood. He was a native of Kent, having been born at Folkenstone in 1578: he went through the usual course of education in Cambridge, and then removed to the Continent, in order to prosecute (with more effect than he could do at home) his professional studies, having for some time previously resolved to make medicine his profession. Fortunately, he bent his steps to Padua, attracted, doubtless, by the well-merited celebrity of Jerom Fabricius, (generally known as Fabricius ab Aquapendente, from his birth-place,) the most eminent teacher of anatomy of his time. There he learned the principles of that science which his future life was destined to adorn: there he learned the advantages which result from the examination of the structure of lower animals, as well as that of man; and the necessity of tracing the growth of the different parts of the living system from their earliest stages to their full maturity. Fabricius attentively examined the development of the chick in the egg during the progress of incubation: he demonstrated the existence of valves in the veins; he inferred that they must exert some influence upon the blood contained within them, supposing it to be put in motion as a current. But there he stopped, as if the subject altogether eluded his research. When Harvey took it up, he found a few detached facts relative to the blood and its

\* Inquiry into the Laws of the Vital Functions, p. 219, by Wilson Philip.

movements scattered in the writings of Cæsalpinus, Columbus, and Fabricius, obscured by much that was hypothetical, or irrelevant if not erroneous. Fabricius not only knew of the valves in the interior of the veins and of the heart, but he thought the subject so well deserving of attention, that he delineated them in a series of drawings exhibiting their position and form. The existence of the valves was previously known to Sylvius, who appears to have been the first that noticed them; but Fabricius indicated clearly their form and direction. In one plate we see the valves in the basilic, axillary, and cephalic veins, as well as a double valve at the conflux of the internal jugular with the innominate vein: in another plate he shows the three valves at the origin of the aorta; and in five drawings he demonstrates the arrangement of the valves in the veins of the lower extremity. There is one drawing which forcibly arrests the attention: one would think that had he dwelt upon the facts which it represents, taken in connexion with his knowledge of the structure of the valves, and of their direction, viz., all pointing towards the heart, he could scarcely have failed to have arrived at a correct knowledge of the course of the blood in these vessels; still, though he had the facts before him, he did not draw the conclusion from them. The drawing to which I allude, is one which gives a view of the arm of a living person, the veins being rendered turgent by a ligature placed above the elbow; a consideration of the fact

## PLATE VI.

FIG. 1. The ramifications of arteries which branch out in the muscles and tegument of the face are here shown. They are derived from various sources: the temporal and labial arteries are derived from the external carotid; the frontal and supra-orbital are offshoots from the ophthalmic artery, which is a branch of the internal carotid; the infra-orbital artery comes from the internal maxillary; and the mental artery is derived from the dental artery, which also is a branch of the internal maxillary.

No. 1. The frontal muscle at the left side; at the right it is removed. 2, 2. The orbicular muscle of the eye-lids. 3, 3. The elevator muscle of the upper lip and nose at each side. 4. The elevator muscle of the upper lip. 5. The elevator muscle of the angle of the mouth. 6. The zygomatic minor muscle. 7. The zygomatic major muscle. 8. The parotid gland. 9. The masseter muscle. 10. Part of the buccinator muscle. 11. The depressor of the angle of the mouth. 12, 12. The depressors of the lower lip. 13, 13. The margin of the lower jaw-bone. 14, 14. The orbicular muscle of the mouth.

a. The frontal branch of the ophthalmic artery. b, b. The anterior branches of the temporal artery. c, c. The temporal artery. d. The transverse artery of the face, (ramus transversalis faciei.) e, e. The facial or labial artery, (ramus facialis vel labialis.) f. A branch given to the masseter muscle. g. The coronary artery of the lower lip, (ramus coronarius inferior.) h. The coronary artery of the upper lip, (ramus coronarius superior.) i. The lateral artery of the nose, (ramus nasalis lateralis;) it is the termination of the facial artery. k. A superficial branch of the submental artery running upon the chin. l. The mental or superficial branch of the dental artery as it emerges from the foramen mentale in the lower jaw. m. The facial artery of the right side ascending towards the nose, where it assumes the name of lateral nasal artery. n. The infra-orbital branch of the internal maxillary artery as it emerges from the foramen infra-orbitarium. o. The superficial nasal branch of the ophthalmic artery. p. The supra-orbital branch of the ophthalmic artery.

FIG. 2. The internal maxillary artery and its branches are shown in this drawing: in order to expose these, the zygoma, the greater part of the masseter muscle, and part of the lower jaw, are removed. The dura mater is also brought into view by the removal of part of the pericranium and skull, in order to expose its principal artery, viz. the middle meningeal.

Nos. 1, 1, 1. The arch of the skull divided by a vertical incision; a horizontal incision is made through it above the ear and the orbit: this piece being removed, the dura mater, 2, 2, 2, with its branching artery, is seen. 3. Part of the temporal muscle. 4, 4. The orbicular muscle of the eye-lids. 5, 5. The two extremities of the zygoma, where they are divided by the saw in order to allow the removal of the intervening piece. 6. Part of the external pterygoid muscle. 7. Part of the internal pterygoid muscle. 8. The ramus of the lower jaw-bone where it is sawed through. 9. The lower part of the masseter muscle, the rest being removed with the zygoma. 10. The buccinator muscle. 11. Part of the duct of the parotid gland. 12. The elevator muscle of the lip and nose. 13. The elevator muscle of the upper lip. 14. The zygomatic minor muscle. 15. The zygomatic major. 16, 16. The upper and lower attachments of the depressor of the angle of the mouth. 17, 17. The orbicular muscle of the lips. 18, 18. The upper and lower attachments of the depressor muscle of the lower lip, the intervening part being taken away in order to expose the mental artery.

A. The external carotid artery ascending to its point of division into the temporal and internal maxillary arteries. B, B. The internal maxillary artery in its deep and tortuous course. C, C. The temporal artery.

a. A small branch to the masseter muscle. b. A branch to the parotid gland, which is here cut off. c. The posterior auricular artery. d. Another auricular artery. e. A pterygoid branch going into the internal pterygoid muscle. f. The dental artery, (ramus dentalis inferior,) descending to reach the canal in the lower jaw-bone. g. The buccal artery, (ramus buccalis.) h. The superior dental or alveolar artery. i. An anterior temporal branch. k. The posterior temporal branch. l. The middle meningeal artery ascending to the base of the skull. 1\*, 1\*, 1\*. The branches of this vessel ramifying in the dura mater. m. A tympanic branch.

C, C. The temporal artery ascending in front of the ear.

n. An anterior auricular branch derived from the temporal artery; its superficial branches have been indicated in fig. 1.

D. The facial or labial artery.

o. A branch to the buccinator muscle. p. The continuation of the facial artery running up to the angle of the mouth. q. The same vessel passing under the zygomatici and ascending under the side of the nose. r. The coronary artery of the lower lip. s. A deep branch to the muscles of the lower lip, which anastomoses with the mental artery. t. The mental artery, (ramus mentalis.)



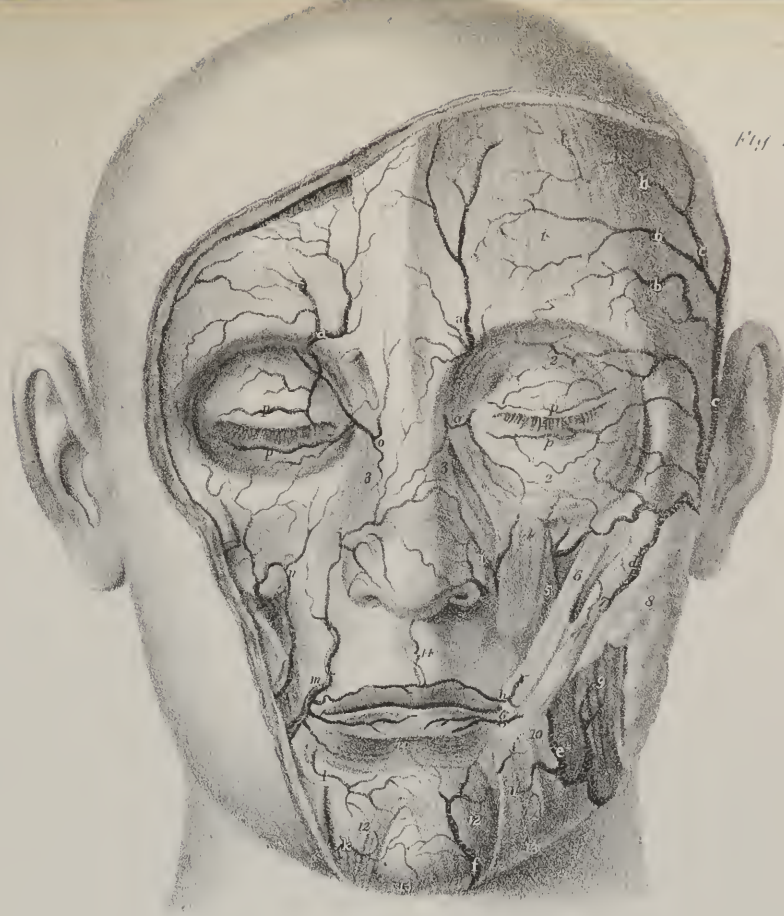


Fig 1

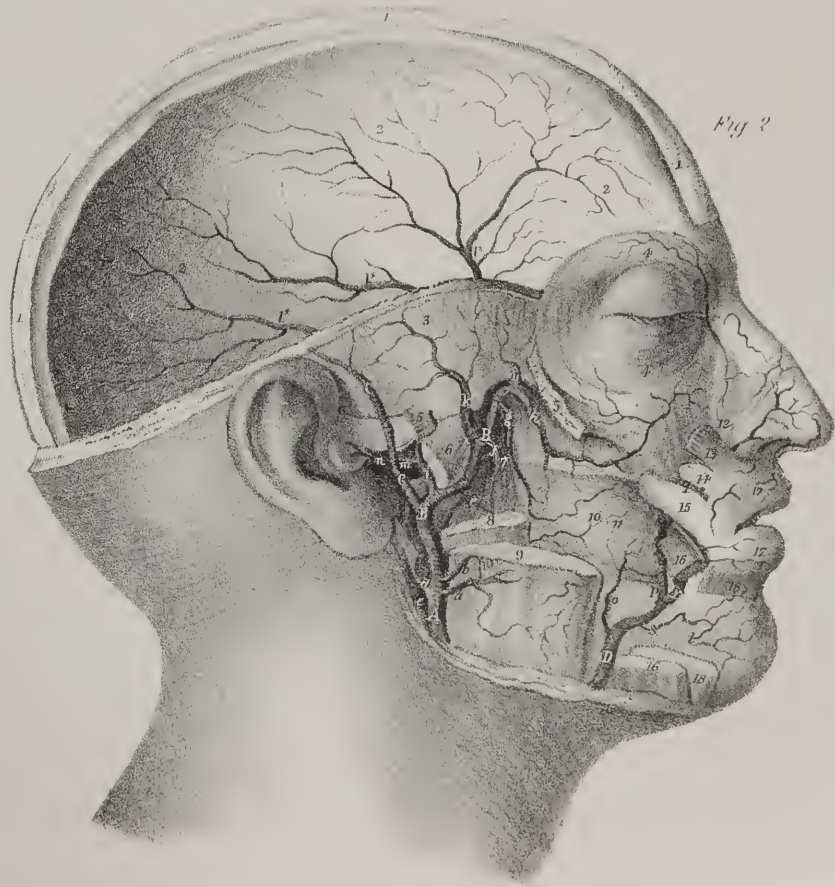


Fig 2



would show that the course of the blood was from the fingers upwards along the arm in the direction of the heart; but even Fabricius, with all his knowledge of the structure of the vessels, failed in achieving that discovery which has immortalized his more fortunate pupil. I made the remark just now that Sylvius knew of the existence of the valves; I find, however, on referring to that part of Fabricius, in which he treats of the nature of the valves, and replies distinctly to the question, "Ostiola venarum, quid?" and then proceeds to treat of the form of the valves, "ostiolearum forma," that he conceived himself to be the discoverer of the valves, and that he was decidedly under the impression, when he wrote his book, that no one had demonstrated them before his time. He first saw the valves, as he says, with great delight in 1574: "neque aliquis prius hæc viderit quam anno Domini septuagesimo quarto supra millesimum et quingentesimum quo a me summi cum lætitiâ inter dissecandum observata fuerunt."

Having treated formally of the structure and form of the valves, he proceeds to consider their use, and there shows that he had no correct notion whatever of the course of the blood, or the uses of the valves: his inference was, that the current of the blood flowed from the heart to the different parts of the body and to the limbs, whilst in the arteries it moved to and fro, as if it possessed something like a flux and a re-flux. Entertaining this opinion as to the course of the blood, he conceived that the valves were intended to break its force, and to retard it in its passage to the hands and feet; for if it went there in full stream it would unduly accumulate in the lower parts, and so leave the upper ones without sufficient means of nutrition: "Ea ratione, ut opinor, a naturâ genitæ, (ostioleæ,) ut sanguinem quadantenus remorentur, ne confertim et fluminis instar, aut ad pedes aut in manus et digitos universus influat colligaturque, duoque incommoda eveniant, tum ut superiores artuum partes alimenti penuriâ laborent, et pedes tumore perpetuo premantur." Farther on he speaks of varicose dilatation of veins, and repeats the opinion of the influence of the valves in retarding the flow of blood: "Imo, quod et ipsæ varices non aliâ de causâ fiant nisi quia sanguis crassior in ostiis diutius detentus, ostiola et venas dilatet." He conceived that they served no trivial purpose also in strengthening the veins: "Usus non contemnendus ut scilicet robur indatur ipsis venis." But why, it may be asked, are not the arteries furnished with valves? Fabricius has recorded his answer; namely, that they are not required for the purpose of preventing distention, because the coats of these vessels are sufficiently strong of themselves; nor are they wanted to retard the blood, for it but ebbs and flows: "Arteriis autem ostiola non fuere necessaria, neque ad distensionem prohibendam propter tunicæ crassitiem ac robur, neque ad sanguinem remorandum quia sanguinis fluxus refluxusque perpetuo fiat."

I make these references and extracts, not for the purpose of putting forward gratuitously the oversights of a really eminent man or in anywise of detracting from his merits; I do it merely for the purpose of directing the reader's attention to the actual state of knowledge as to matter of fact and to opinion, as to matter of inference relative to the circulation as it existed at the commencement of Harvey's career, and up to the moment in which he published his celebrated dissertation on the circulation, and which was entitled, "Exercitatio anatomica de motu cordis et sanguinis in animalibus." It occurred to me that it could only be done with fairness to all parties, by setting before the reader the doctrine as it was taught by one of the best informed men and the most distinguished teacher of the time. It is frequently said, that though the greater or systemic circulation was altogether unknown before Harvey's time, still the smaller or pulmonary circulation was known and distinctly described by two or three different persons; by Servetus, and still more distinctly by Columbus and Cæsalpinus: it is obvious that they knew that the blood could not pass from the right to the left cavity of the heart directly, inasmuch as there is no perforation in the partition between these cavities in their natural condition; if so, it must pass from the one to the other by going a devious course through the lungs: but if we refer to Fabricius, who is evidently well acquainted with all that was known upon these topics in his day, and who saw them through the medium in which they were presented by these authors themselves in their own works, or by their pupils and followers, but who saw them unaided by the additional light which was soon thrown upon the subject by the publication of Harvey's researches, we will see that even upon this point there existed little more than a glimmering of knowledge. Fabricius, in common with others, knew of the existence of three orders of vessels within the lungs, viz. the trachea, the arterious vein, (pulmonary artery,) and the venous arteries, (pulmonary veins:) he knew that the air entered the lungs by the trachea; but he supposed that it was carried from thence, to the left side of the heart, by the pulmonary vein, in order to be converted into vital spirits, and also to cool the heart, whilst the pulmonary artery conveyed a pure blood for the nutrition of the lungs:—

"Pulmones, cum publicum usum corpori præbent, tria illa vasorum genera in sui substantiam disseminata, scil. asperam arteriam, venam arterialem, et arteriam venalem, hoc modo administrant. Per asperam arteriam, aerem respiratione attractum primo rapiunt et recipiunt, qui postea a cordis pulsu per arteriam venalem in sinistrum cordis sinus defertur concoquendum et in spiritum vitalem commutandum, refrigeriumque cordi præstandum. Per tertium vero vas, quod vena arterialis dicitur, pulmones purissimo tenuissimoque sanguine enutriuntur."—*Fabricii Opera Anatomica*, p. 78, ch. viii.

When Harvey's book was published, the doctrines which it contained, and which were previously taught by him in his lectures for several years, were opposed as a violent innovation, which should be resisted as being altogether at variance with the doctrines taught by persons fully as competent as he could be to investigate facts and draw from them conclusions: not a few contended that it was a tissue of fallacy throughout; which is a sufficient proof that the doctrine was new, and, if tenable, deserved to be considered, as it has ever since been considered, one of the most important contributions to knowledge which the history of medicine records. When, however, the appeals which were made to experiment and observation, which arose on



these points, could not be resisted, Harvey's opponents adroitly shifted their ground, and put forward the allegation that his doctrine was not new or peculiar to himself, inasmuch as numerous traces of it could be detected in the writings of the ancients. It was alleged that even Hippocrates was acquainted with the circulation; but even if the passage upon which this opinion was founded be considered, it will not furnish any intelligible notion as to the circulation as taught by Harvey: in the Latin translation it runs thus, "Venæ per corpus diffusæ, spiritum et fluxum ac motum exhibent, ab una multæ germinantes; atque hæc una, unde oriatur et ubi desinat, non scio; circulo enim facto principium non invenitur." But even if we were for a moment

## PLATE VII.

FIG. 1. The lingual artery is here shown in its entire extent; also some of the branches of arteries on the septum of the nose and the palate.

No. 1. Frontal bone. 2. Crista galli. 3. The body of the sphenoid bone. 4. Its sinus. 5, 5. The nasal bone and cartilage divided. 6, 6. The septum of the nose. 7, 7. The superior maxillary and palate bones. 8. The upper lip. 9. The soft palate. 10, 10. The hard palate. 11. The lower lip. 12. The upper surface of the tongue. 13. Lower jaw-bone. 14, 14. The genio-hyo-glossus muscle. 15. The hyo-glossus muscle. 16. Part of the stylo-glossus. 17. The genio-hyoideus muscle. 18. The mylo-hyoideus. 19. Part of the omo-hyoid muscle. 20. Part of the sterno-hyoid muscle. 21. The anterior part of the thyroid cartilage. 22. Thyro-hyoid muscle. 23. Part of the lower constrictor muscle.

A. The common carotid artery. B. The external carotid artery. C. The internal carotid artery.  
a. The superior thyroid artery. b. Its superior laryngeal branch. c, c. The lingual artery. d. The dorsal branch given to the root of the tongue. e. The hyoid branch. f. The sublingual branch. g. The ascending part of the lingual artery. h. Its terminal part, usually called ranine artery. i. The labial or facial artery cut off. k. The external carotid artery cut off also. l. The palatine artery ramifying on the palatine arch. m. Branch of the posterior nasal artery ramifying on the septum of the nose. n. Branches of the ethmoidal artery derived from the ophthalmic. o. A branch of communication which passes down through the incisor foramen to the palate.

FIG. 2. The three upper ribs, with part of the sternum and of the spinal column, retained, in order to show the upper intercostal and the internal mammary artery: the parts are seen as within the cavity of the thorax.

No. 1. The body of the last cervical vertebra. 2, 3, 4, 5, 6. The bodies of the upper dorsal vertebræ. 7, 8, 9, 10, 11. The heads of the upper ribs. 12, 13, 14. The bodies of the three upper ribs. 15, 15, 15. The sternum, its inner surface. 16. The inner end of the clavicle. 17, 18, 19. Cartilages of the three upper ribs.

A. The subclavian artery.  
a. The cut extremity of the artery. b. The vertebral artery near its origin. c. A small trunk which gives origin to the first intercostal and the deep cervical arteries. d. The deep cervical artery. e. The trunk of the first intercostal artery turning down upon the rib. f. The branch which occupies the first intercostal space. g. The branch which occupies the second intercostal space. h, h. Two dorsal branches, which penetrate the intercostal spaces, and reach the deep muscles of the back. i, i. Branches of communication between the first intercostal and the intercostals which come from the aorta. k. The first intercostal branch derived from the aorta. l. Its continuation, running in the first intercostal space. m. The second intercostal branch derived from the aorta. n, n. The internal mammary artery. o, p. The two first anterior intercostal branches derived from the internal mammary artery. q, q. The inner or sternal branches.

FIG. 3. This drawing shows the basilar artery, formed by the conjunction of the two vertebral arteries, and terminating by giving off branches to the cerebellum and brain.

No. 1. The medulla oblongata. 2, 2. The small lobules of the eighth nerve. 3, 3. The anterior border of the cerebellum. 4, 4, 4, 4. The pons varolii. 5, 5. The sixth pair of nerves. 6, 6. The fifth pair of nerves. 7, 7. The crura cerebri. 8. The third pair of nerves. 9, 9. The mammillary bodies.

a. The right vertebral artery, which is here smaller than that of the opposite side. b. The posterior inferior branch given to the cerebellum. c. The anterior artery of the medulla spinalis. d. The left vertebral artery. e. The posterior and inferior branch to the cerebellum. f, f. The basilar artery. g, g. The anterior inferior arteries of the cerebellum. h, h. The superior arteries of the cerebellum. i, i. The posterior cerebral arteries. k, k. The communicating arteries.

FIG. 4. The arteries of the base of the brain are here seen.

No. 1, 1. The posterior lobes of the brain. 2, 2. The lobes of the cerebellum. 3, 3. The lobules of the eighth nerve, so called by Reil. 4, 4. The anterior border of the cerebellum. 5, 5. The fifth nerves. 6, 6. The sixth nerves. 7, 8. The facial and auditory nerves. 9, 9. The third nerves. 10, 10. The crura cerebri. 11, 11. The optic nerves. 12, 12. The tuber cinereum and infundibulum. 13, 13. The olfactory nerves. 14, 14. The anterior lobes of the cerebrum. 15, 15. The middle lobes of the brain.

a, a. The two vertebral arteries. b, b. The anterior arteries of the medulla spinalis. c, c. The posterior inferior arteries of the cerebellum. d, d. The basilar artery. e, e. The anterior inferior arteries of the cerebellum. f, f. Superior arteries of the cerebellum. g, g. The posterior cerebral arteries. h, h. The two communicating arteries. i, i. The trunks of the internal carotid arteries. k, k. The anterior cerebral arteries. l. The communicating arteries between them.

FIG. 5. The ophthalmic artery within the orbit.

No. 1, 1. Part of the upper eye-lid. 2. The elevator muscle of the upper eye-lid. 3. The lachrymal gland. 4. The superior oblique muscle. 5. The external rectus muscle. 6. The optic nerve.

a. The trunk of the internal carotid artery. b. The ophthalmic artery. c. Its lachrymal branch, going to the lachrymal gland, and giving branches to the external rectus muscle and the eye-lid. d. Continuation of the ophthalmic artery after having passed the inner

Fig 1.

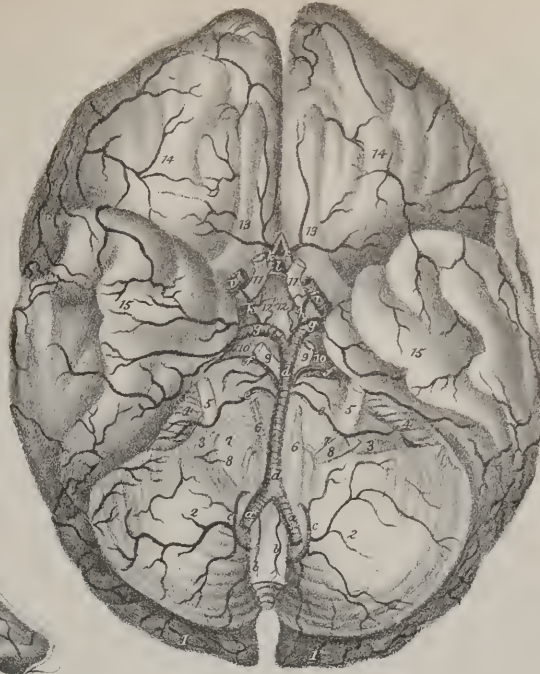

Fig 7

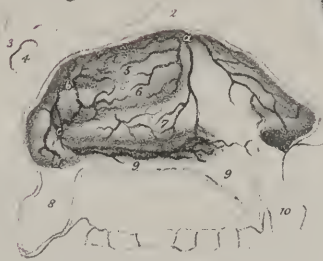


Fig 6



Fig 3

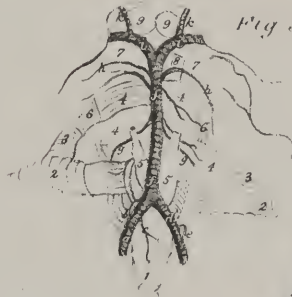

Fig 5



Fig 1

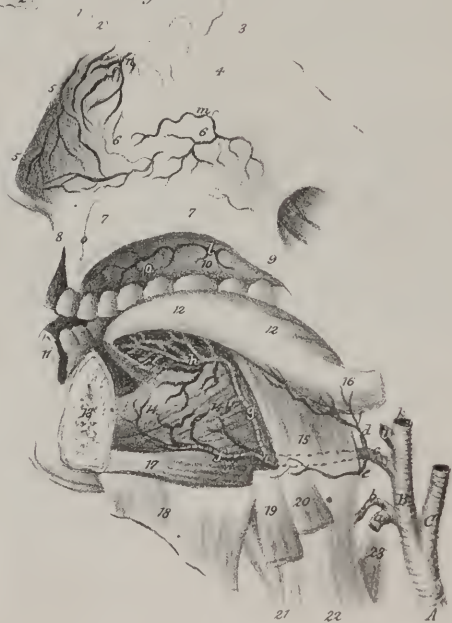
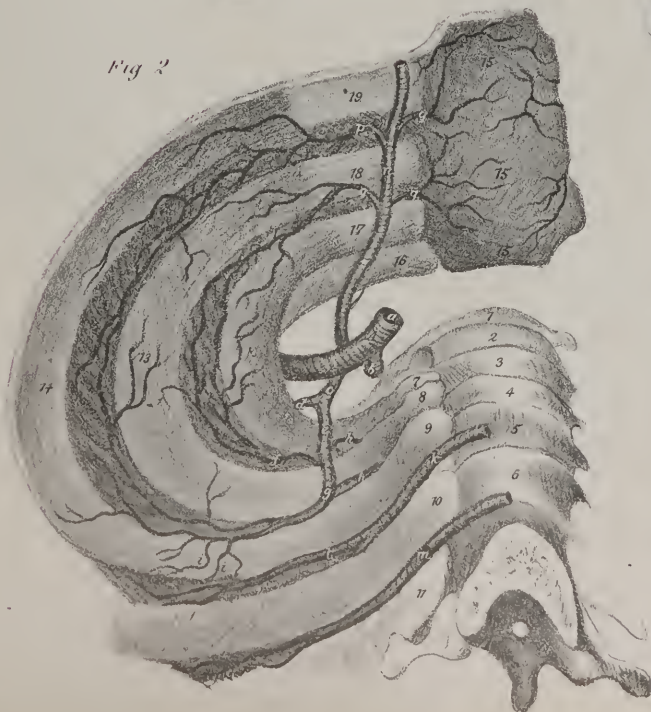


Fig 2







to admit that the seeds of knowledge of this point of doctrine were to be found in this passage, or in any other that can be cited, it must be confessed that they remained altogether unproductive; inasmuch as the best informed men up to the commencement of the seventeenth century failed to draw correct inferences from the facts before them, and, when they descended from vague generalities to special demonstrations, they supplied sufficient evidence to prove that their notions relative to the circulation were altogether erroneous.

I shall now proceed to describe the course of the different blood-vessels, beginning with the arteries.

The great artery, from which as from a common conduit all the other arteries issue, is called the aorta. In plate III. of the arteries, fig. 1, it is marked A, A. In plate I. it is numbered 17, 18. A single glance at the drawing first referred to will show that this vessel is the main trunk of a series of tubes which convey red blood to the different organs of the body. It commences at the left ventricle of the heart, with which it is connected by the lining membrane on the inside, by the serous pericardium externally, and by a cellulo-fibrous ring, which extends from the indented border of its middle coat to the margin of the ventricle. From the ventricle the vessel extends as far as the fourth lumbar vertebra, where it divides into the common iliac arteries. But though it remains an undivided trunk to the point just indicated, different parts of it have received different names, from their position and relations, as well as to facilitate their description.

The aorta, the primary systemic artery, arises from the upper part or base of the left ventricle of the heart, where its margin is guarded by three semi-lunar valves, which prevent the reflux of blood projected into the vessel. At its origin it is not exactly cylindrical, for there are three small bulgings externally, corresponding with as many dilatations within, each lying external to one of the valves. These dilatations are named *sinus minores*, or sinus Morgagni. If a probe be passed directly backwards from the upper border of the fourth costal cartilage of the left side, at its junction with the sternum, it will impinge on the junction of the vessel with the ventricle; and if pushed further back, it will touch the fourth dorsal vertebra a little to the left of the median line. The aorta at its origin lies behind the pulmonary artery which overlays it, and before the left auriculo-ventricular opening. Its course is at first upwards, forwards, and to the right side, until it gets on a level with the second costal cartilage; it then alters its direction, turning from right to left, becoming transverse, at the same time inclining backwards, being on a level with the second dorsal vertebra: but it soon makes another turn, and changes its direction so as to incline inwards and downwards upon the left side of the third dorsal vertebra, where the curved part of the artery (*arcus aortæ*) ceases.

Some persons restrict the term "arch" to the transverse portion, (*crosse de l'aorte*.) We, however, here apply it to the whole space included between the base of the ventricle and the lower border of the third dorsal vertebra; and between these points it will be observed that the artery describes a curve, whose convexity is directed upwards, forwards, and to the right side, the concavity of course in the opposite way. The terms "ascending" and "descending" aorta are not in strictness applicable to the conformation of the vessel in the human subject; they were adopted by some of the older anatomists, whose dissections were for the most part confined to inferior animals, in many of which the vessel, instead of forming a curve, divides into two trunks, one descending to supply the posterior parts, the other ascending to the head and anterior extremities. But in order to facilitate the description of the *arch*, and to mark more precisely its relations, it is convenient to consider it as divisible into three portions, an ascending, transverse, and descending.

The ascending part of the arch has before it, for a short way, the pulmonary artery, the right auricula also overlapping it; but as it ascends and comes forward, it approaches the sternum, from which it is separated by the pericardium and the cellular tissue lodged in the mediastinum. Posteriorly, it is supported by the right branch of the pulmonary artery; on its right, lies the descending vena cava; on the left, the pulmonary artery. This part, from two inches to two and a quarter in length, is enclosed within the pericardium. The transverse part lies behind the sternum, (at the junction of its first and second pieces,) from which it is separated, at least in part, by the left brachio-cephalic vein, which lies along its upper border, and overlaps it a little,—before the trachea, and above the bifurcation of the pulmonary artery, to which its concavity is connected by the ductus arteriosus: finally, at its left extremity, where it turns downwards, the vagus nerve crosses it in front, and the recurrent coils upwards

side of the orbit. e, e. Two ethmoidal branches. f. The tendon of the superior oblique muscle after having passed through its pulley. g. The dorsal artery of the nose. h. The palpebral branches.

FIG. 6. The trunk of the ophthalmic artery is here seen in its entire extent, the levator palpebræ and superior rectus being removed.

No. 1. The ball of the eye. 2. The external rectus muscle. 3. The tendon of the superior rectus cut across and drawn forwards.

4. The tendon of the superior oblique muscle. 5. The pulley through which it passes. 6. The body of the superior oblique muscle. 7. Part of the superior rectus muscle drawn inwards. 8. The optic nerve.

a. The trunk of the internal carotid artery. b. The ophthalmic artery continued onwards from it. c. One of its muscular branches.

d. Another muscular branch. e. The supra-orbital branch. f. The infra-trochlear branch. g. The ciliary branches.

FIG. 7. The branches which ramify on the outer side of the nasal fossa are here exposed, the cavity being exposed by a vertical incision.

No. 1. The frontal bone. 2. The crista galli. 3. The body of the sphenoid bone. 4. Its sinus. 5, 6, 7. The turbinate bones.

8. The soft palate. 9, 9. The hard palate. 10. The upper lip.

a. Branches of the ethmoidal artery passing down on the turbinate bones. b. Branches of the posterior nasal artery ramifying in the upper meatus, and upon the upper spongy bone. c. Branches to the inferior meatus, to the tonsil, and soft palate.

and inwards behind it. The descending part of the arch, as it sinks backwards, recedes from view, having before it the left bronchus and left pulmonary artery, behind it the body of the third dorsal vertebra, to the right the œsophagus and thoracic duct, and to the left the pleura, which is reflected upon it. If the pulmonary artery be cut across at its root and drawn upwards, it will be seen that the curve of the aorta in a manner encloses the right pulmonary artery, the left bronchus, the left auricula, the ductus arteriosus, and the recurrent nerve.

*Aorta—its branches.*—The branches given off by the arch of the aorta are five in number, viz. two to the heart, and three which supply the upper extremities, with the head and neck. The branches which go to the heart are called coronary, (à *corona*;) from the manner in which they encircle the base of the ventricles; and cardiac, (*καρδια*, the heart,) from their destination. They are named, the one right, the other left, from their direction. The other branches are, the brachio-cephalic or arteria innominata, which is distributed to the right upper extremity, and the corresponding side of the head and neck, the left carotid, and the left subclavian.

The description of the coronary arteries shall be given with that of the heart itself, as they are its proper nutritious vessel. I proceed to the larger vessels in their order.

*Brachio-cephalic artery*, (plate I. No. 19; plate III. fig. 1, B.)—The brachio-cephalic artery (a. brachio-cephalica, innominata) is a short trunk, which divides so as to supply the right upper extremity and the corresponding side of the head and neck; hence its name. There is no sufficient reason for continuing to call it the “unnamed” artery, when, so far from being unnameable, it has received a very appropriate name. Its diameter is greater than that of either of the vessels which arise from the arch of the aorta; its origin is at the junction of the ascending with the transverse parts of the arch, from which point it passes obliquely upwards, and to the right side, until it reaches the sterno-clavicular articulation, where it divides into the right subclavian and right carotid arteries. Its length is generally from an inch to an inch and a quarter; but in some cases it is a little longer, and ascends higher into the neck; its point of bifurcation may be transfixed by a probe passed backwards through the cellular interval between the sternal and clavicular portions of the sterno-mastoid muscle. This artery lies behind the first bone of the sternum, from which it is separated above by the sterno-hyoid and sterno-thyroid muscles, and below by the left brachio-cephalic vein, which crosses it. It rests on the trachea, over which it passes obliquely; to its right side is the right brachio-cephalic vein, and to the left the thymus gland, or the cellular tissue, into which it degenerates. No branches arise from this vessel in their ordinary or regular distribution: whenever any are seen to issue from it, they are found to be some which ordinarily come from other sources; for instance, the left carotid, or the thymic or inferior thyroid.

*Common carotid artery*, (plate I. No. 20—27, plate IV. A, A.)—The two vessels of this name, (a. carotides communes vel primitivæ,) whilst in the neck, are, as nearly as may be, similar in their course, size, and relations; but they differ in their length and mode of origin. The vessel on the right side commences opposite the sterno-clavicular articulation, being the point at which the brachio-cephalic divides into the carotid and subclavian arteries, whilst that of the left arises from the arch of the aorta, and is necessarily longer, and at first more deeply seated. That portion of the left carotid which intervenes between the arch of the aorta and the sterno-clavicular articulation is covered by the upper part of the sternum by the muscles arising from its posterior

## PLATE VIII.

The arteries of the back of the shoulder are here shown: in order to expose them, the deltoid muscle is reflected from its origin and drawn downwards, the trapezius is detached from its insertion and carried backwards, the rhomboidei and infra-spinatus are cut through and part removed.

No. 1, 1. The upper extremity of the trapezius muscle. 2, 2, 2. The trapezius muscle reflected and drawn to the left side. 3. The sterno-mastoid muscle. 4. The splenius capitis. 5. The splenius colli. 6, 6, 6. The elevator muscle of the angle of the scapula: it appears here as if it consisted of two fasciculi. 7. The lower part of the sterno-mastoid muscle. 8. Part of the serratus posticus superior. 9. The rhomboideus minor muscle. 10. The rhomboideus major. 11, 11. The vertebral aponeurosis. 12. The clavicle. 13. The acromion process. 14. The spine of the scapula. 15. Part of the infra-spinatus muscle. 16. The great tuberosity of the humerus. 17. The teres minor muscle. 18. The long head of the triceps extensor muscle. 19. The teres major muscle. 20. The deltoid muscle. 21, 21, 21. The great serratus muscle. 22. Part of the latissimus dorsi muscle.

a. The occipital artery where it ascends and becomes superficial. b, b. The transversalis colli artery where it turns backwards under the levator scapulae. c, c, c. The descending part of the artery where, from its relation to the base of the scapula, it assumes the name of posterior scapulae. d. The superficial cervical artery. e. Its posterior or muscular branches. f. A branch from the transversalis colli, which descends to the supra-spinous fossa. g. A muscular branch distributed to the supra-spinatus and the trapezius muscles. h. A branch which goes towards the clavicle and acromion. i, i. The transversalis humeri artery descending towards the dorsum of the scapula. k. The same vessel lower down, where it is covered by the infra-spinatus muscle: this situation it reaches by passing between the anterior border of the spine of the scapula, and the margin of the glenoid cavity: from its relation to the scapula, it is called the supra-scapular artery. l. The branches of arteries upon the acromion process forming a free anastomosis. m. The posterior circumflex artery. n, n. The dorsal branches of the sub-scapular artery. o, o. Penetrating branches derived from the intercostal arteries. p, p, p. Branches also derived from the intercostal arteries.



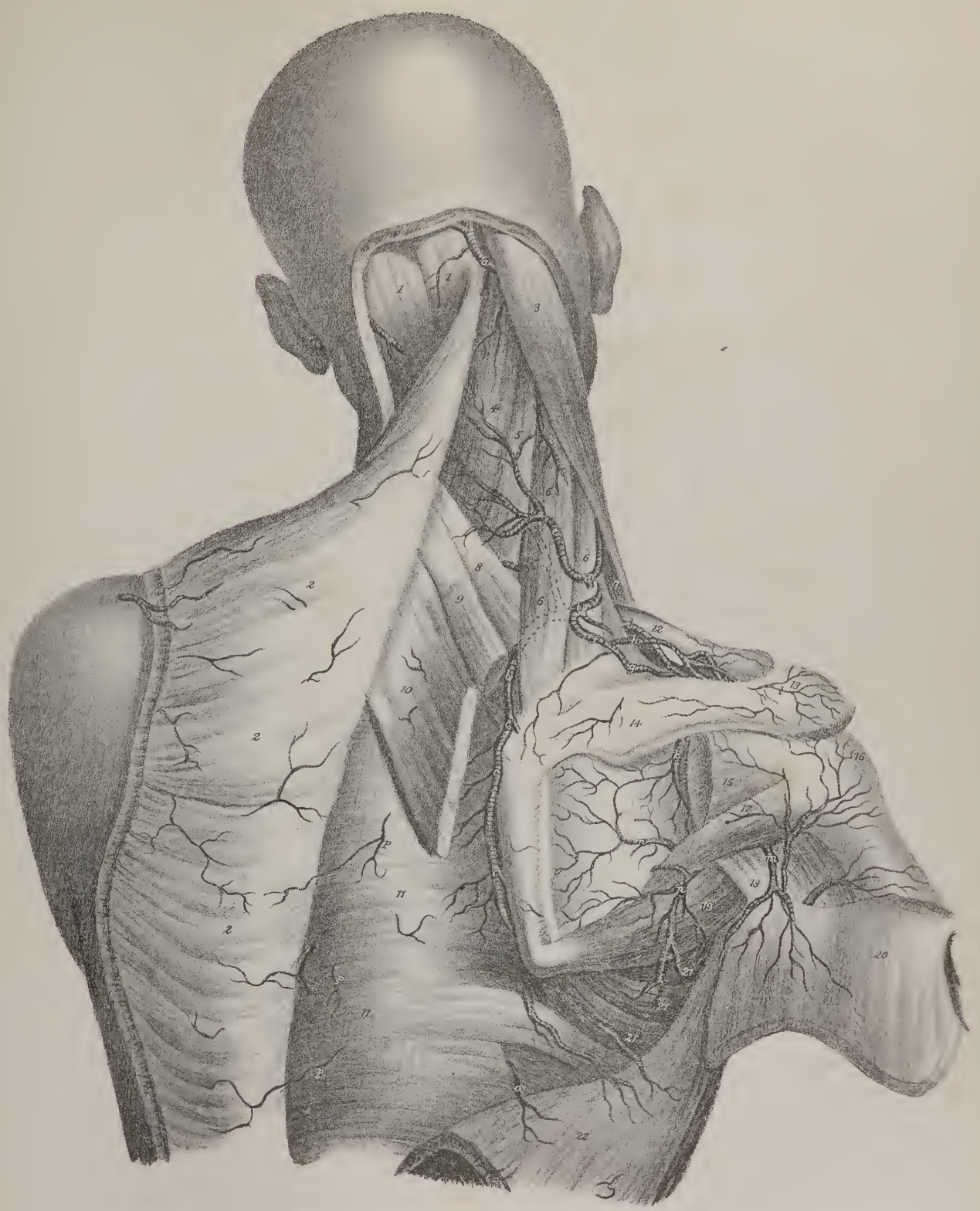







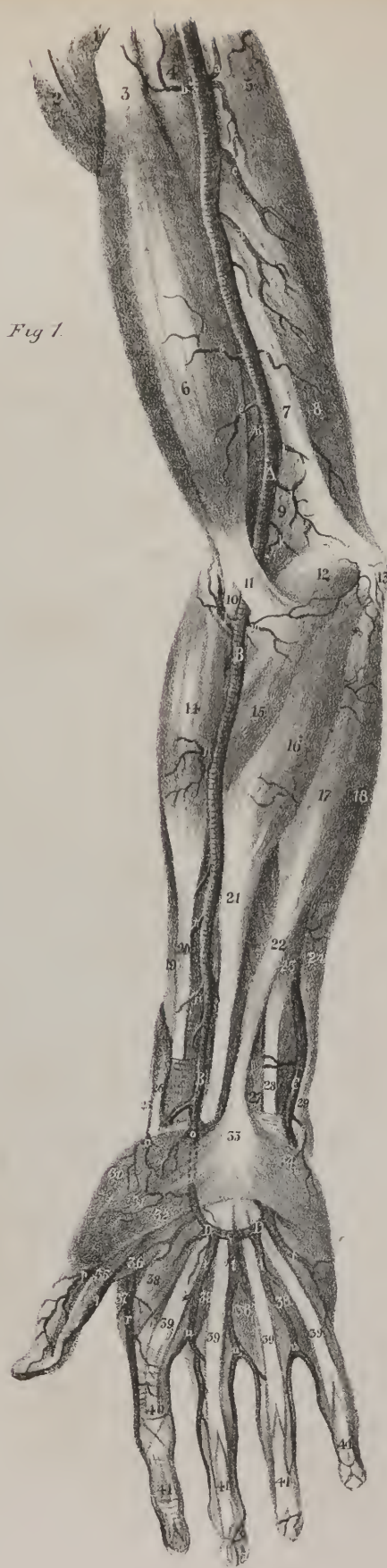


Fig 1.

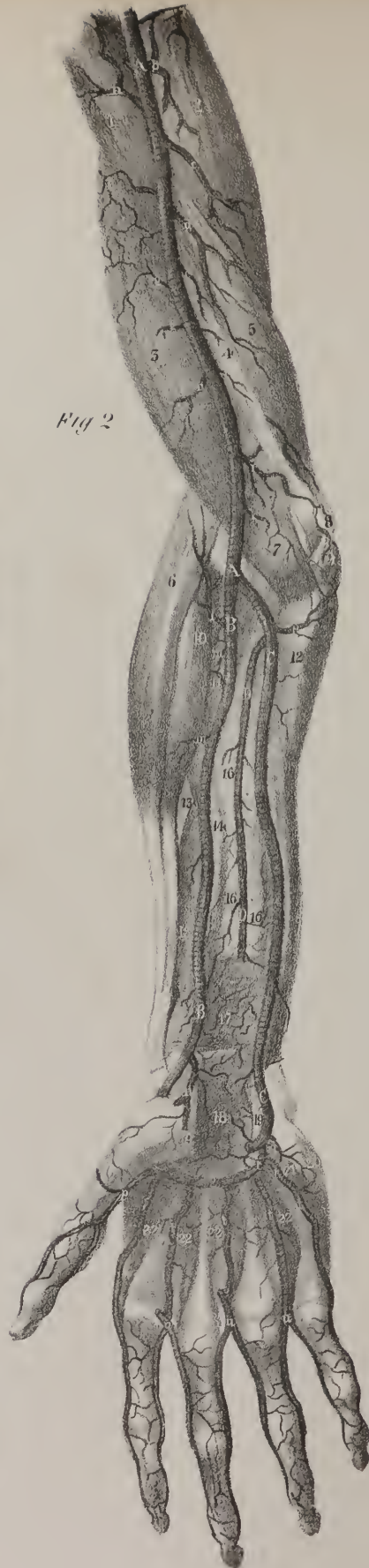

Fig 2.



aspect, and is crossed by the brachio-cephalic vein of the left side; posteriorly, it corresponds to the trachea, to the œsophagus, (which, in this situation, deviates to the left side,) and the thoracic duct. The description of the cervical portion of one artery will suffice for both.

The common carotid artery ascends obliquely upwards and outwards, its direction coinciding with that of a line drawn from the sterno-clavicular articulation to midway between the angle of the jaw and the mastoid process. Opposite the upper border of the thyroid cartilage, the vessel divides into two great branches, of which one is distributed by its ramifications to the cranium

## PLATE IX.

In these drawings the arteries of the arm, fore-arm, and hand are shown, as they lie along the anterior aspect of the limb. In the first figure the skin and fascia only are removed; in the second, some of the superficial muscles are cut away to bring the deep vessels into view.

FIG. 1. No. 1. A small part of the great pectoral muscle near its insertion. 2. Part of the deltoid muscle. 3. The upper part of the biceps flexor muscle. 4. The coraco-brachial muscle. 5. The long head of the triceps extensor muscle. 6. The middle part, or fleshy body, of the biceps flexor muscle. 7. The fibrous layer (inter-muscular septum) which separates the muscles on the fore part from that on the back part of the humerus. 8. The short head of the triceps extensor muscle. 9. The lower part of the brachialis anticus muscle. 10. The tendon of the biceps flexor muscle, dipping down between the muscles of the fore-arm to reach its insertion. 11. A fibrous layer or process which passes off from the tendon just named, and covers over the brachial artery at the bend of the fore-arm. 12. The pronator radii teres muscle. 13. The inner condyle of the humerus. 14. The long supinator muscle of the radius. 15. The lower part of the pronator teres muscle where it is passing to its insertion and becomes crossed by the radial artery. 16. The flexor carpi radialis muscle. 17. The fleshy part or body of the palmaris longus muscle. 18. The fleshy part or body of the flexor carpi ulnaris muscle. 19. A small part of one of the extensor muscles (scil. carpi radialis longior.) 20. The tendon of the long supinator muscle. 21. The tendon of the flexor carpi radialis. 22. The tendon of the palmaris longus. 23. Part of the superficial flexor muscle of the fingers. 24. The tendon of the flexor carpi ulnaris. 25. Part of the tendon of the extensor muscle of the first phalanx of the thumb. 26. The tendon of the extensor muscle of the metacarpal bone of the thumb. 27. A small part of the tendons of the deep flexor muscle of the fingers. 28. Part of the tendon of the superficial flexor muscle of the fingers. 29. The tendon of the flexor carpi ulnaris muscle where it becomes inserted into the pisiform bone. 30. Part of the opponens pollicis muscle. 31. The abductor muscle of the thumb. 32. Part of the short flexor muscle of the thumb. 33. Part of the palmar fascia. 34. The palmaris brevis muscle. 35. The tendon of the long flexor muscle of the thumb. 36. Part of the abductor muscle of the thumb. 37. The abductor muscle of the fore-finger. 38, 38, 38, 38. The four lumbricales muscles. 39, 39, 39, 39. The tendons of the superficial flexor muscle of the fingers. 40. The fibrous bands which bind down the flexor tendons as they run along the digital bones of the fore-finger: in the other fingers they are removed in order to show the flexor tendons. 41, 41, 41, 41. The tendons of the deep flexor muscle of the fingers passing to their insertions.

A, A. The brachial artery (*arteria brachialis vel humeralis*.)

a. Small muscular branch given to the triceps muscle. b. A branch to the coraco-brachialis muscle. c. The superior deep branch (*arteria profunda humeri*.) d. A branch to the triceps muscle. e and f, are branches also given to the triceps muscle: one of these is usually larger than is here represented, and descends to the inner and back part of the elbow-joint, where it assists in keeping up a free communication with branches derived from the vessels of the fore-arm; it is then called the inferior deep branch (*arteria profunda inferior*.) g and h, are muscular branches to the biceps and brachialis anticus muscles. i, is a muscular and communicating branch usually named *ramus anastomoticus*. k. A muscular branch to the brachialis anticus and pronator teres.

B, B. The radial artery (*arteria radialis*.)

l. Its recurrent branch (*ramus recurrens*.) m. A muscular branch to the pronator and flexor muscles. n, n, n, n. Muscular branches from the outer side of the artery as it passes along the fore-arm. o. Its superficial palmar branch (*ramus superficialis volæ*), which assists in forming the palmar arch of arteries.

C. The ulnar artery (*arteria ulnaris*) in the lower part of the fore-arm; higher up it is concealed by the muscles.

D, D. The superficial arch formed in the palm of the hand by the termination of the ulnar artery, joined by the superficialis volæ branch of the radial artery. p, q. The collateral branches of the thumb. r. The first collateral branch of the fore-finger. s. A small muscular branch given off by the ulnar artery to the muscles at the inner side of the palm of the hand. t, t, t, t. The digital branches derived from the palmar arch: each will be observed to divide into two offsets (u, u) at the roots of the fingers, which run along their borders, forming their collateral branches.

FIG. 2. No. 1. Part of the coraco-brachialis muscle. 2. The long head of the triceps muscle. 3. The brachialis anticus muscle. 4. The internal inter-muscular ligament. 5. The inner head of the triceps muscle. 6. The long extensor muscle (scil. extensor carpi radialis longior.) 7. The lower part of the brachialis anticus muscle at its insertion into the coronoid process of the ulna. 8. The inner condyle of the humerus. 9. Part of the flexor carpi ulnaris muscle; the rest, together with the flexor muscles arising from the inner condyle, being cut away to expose the ulnar artery. 10. The short extensor muscle (extensor carpi radialis brevior.) 11. Part of the supinator brevis muscle. 12. The upper part of the ulna. 13. The insertion of the pronator teres. 14, 15. The long flexor of the thumb. 16, 16, 16. The interosseous ligament. 17. The pronator quadratus muscle. 18. The wrist-joint,—its anterior radio-carpal ligament. 19, 19. The inner and outer extremities of the anterior annular ligament of the wrist; the intervening part being removed. 20. The abductor muscle of the little finger. 21. The opponens muscle. 22, 22, 22, 22. The interossei muscles.

A, A. The brachial artery.

and face, the other to the brain and the eye; hence, from their destination, they are named the external and internal carotid arteries. The common carotid artery is covered below by the skin and fascia, also by the sterno-mastoid, sterno-hyoid, and sterno-thyroid muscles, and crossed by the omo-hyoideus opposite the upper rings of the trachea, or the lower border of the cricoid cartilage. But from this point to its bifurcation the vessel is covered only by the skin, platysma, and fascia, owing to the fact that the sterno-mastoid and omo-hyoideus, by diverging to their respective destinations, cease to cover it, and so leave it comparatively superficial. It has behind it the vertebral column, from which, however, it is separated by the longus colli and rectus anticus muscles, and inferiorly by the recurrent laryngeal nerve and inferior thyroid artery. The inner side of the vessel is in close relation below with the trachea, higher up with the thyroid gland, (which often overlaps it,) the larynx, and pharynx; along its external side are placed the internal jugular vein and the vagus nerve, the latter being behind and between both vessels. The artery will be found enclosed in a sheath, composed of condensed cellular membrane, which forms an investment common to it, the internal jugular vein, and the nervus vagus. The descendens noni nerve usually rests on the fore part of the sheath; but in some instances part of the arch of anastomosis formed by this nerve will be found within the sheath, lying between the artery and vein. The sympathetic nerve lies between the sheath and the rectus anticus muscle.

If the subject be turned on its back, the two carotids will be seen separated, at the root of the neck, only by the interval between the sterno-clavicular articulations, but as they ascend they diverge, still they do not pass backwards, as may at first sight be supposed from viewing the parts in this position; their greater apparent depth at the upper than at the lower part of the neck is caused by the projection forwards of the larynx and os hyoides, which often protect them in attempted suicide. They send off no branches, and therefore retain their size undiminished as far as the upper border of the thyroid cartilage, where each divides into the external and internal carotid arteries.

*External Carotid artery*, (plate II. C, plate IV. B, plate V. fig. 1, A, A.)—This vessel, (a. carotis externa,) smaller than the other in infancy, but of equal size in adult age, extends from the point of division above indicated, to the neck of the condyle of the jaw, or a little lower, where it divides into the temporal and internal maxillary arteries. At first it lies before and to the inner side of the internal carotid, but soon crosses it, inclining backwards; after which it curves somewhat as it ascends to its point of division. For a quarter of an inch after its origin it is covered only by the skin, platysma, and fascia; it is then crossed by the stylo-hyoid and digastric muscles, also by the lingual nerve, and finally becomes embedded in the parotid gland. The stylo-glossus and stylo-pharyngeus muscles, with the glosso-pharyngeal nerve, run between it and the internal carotid artery, and support it, at least partially, until it reaches the gland, in the substance of which the artery is crossed by the portio dura, which is placed superficially to it. It gives off eight branches, including the pair into which it ultimately divides, which may be arranged into sets as follows:—1. The anterior branches, consisting of the superior thyroid, the lingual, and the facial. 2. The posterior set, viz. the occipital and posterior auris. 3. The internal, being the pharyngea ascendens. 4. The terminal ones, which are the temporal and internal maxillary.

*Thyroid artery*, (plate II. c, plate IV. a, plate V. fig. 1, a.)—This branch (a. thyroidea superior, vel descendens) is given off close to the commencement of the external carotid, immediately below the cornu of the os hyoides, and inclines downwards and inwards, somewhat in a serpentine manner, to the upper border of the thyroid cartilage. It then descends a little to reach the thyroid gland, and divides into three branches, one of which runs transversely to anastomose with the corresponding vessel of the opposite side, whilst the others ramify freely in the substance of the gland, and communicate with the ascending thyroid branch of the subclavian artery. The vessel is at first covered only by the platysma and fascia. Previously to its division into the proper thyroid, or terminal branches here noticed, it gives off the following:

The hyoid branch (*ramus hyoideus*)—a branch which passes just below or upon the os hyoides, and forms an arch with its fellow of the opposite side, sending at the same time ramusculi to the adjacent muscles and integuments.

*r. Descendens superficialis* passes down, and divides into several ramusculi, which supply the thyroid muscles, the sterno-mastoid, the platysma, and integument.

*r. Laryngealis* inclines inwards with the superior nerve of the same name, and in most instances pierces the thyro-hyoid membrane, but in some it passes through a foramen in the thyroid cartilage. In either case, on reaching the inside of the larynx, it divides into ramusculi, which take different directions for the supply of the small muscles and lining membrane of the organ.

a. Muscular branches to the triceps muscle. b. Offsets to the coraco-brachialis. c. The superior profunda artery. d. The inferior profunda artery. e, f, g, h. Muscular branches. i. The anastomotous branch. k. A muscular branch.

B, B. The radial artery.

l. Its recurrent branch. m, m. Muscular branches. n. Its superficial palmar branch (*ramus superficialis volæ.*) o. Its digital branch, (*arteria magna, vel princeps pollicis,*) dividing to supply both sides of the palmar aspect of the thumb.

C, C. The ulnar artery.

p. Its recurrent branch. q. A small branch to the muscles of the little finger. r. The deep branch, which joins with the termination of the radial artery, and completes the deep palmar arch (2.) s. The first collateral branch of the fore-finger. t, t, t. The interosseous branches derived from the deep palmar arch. u, u, u, u. The bifurcation of the digital branches of the fingers, derived from the superficial palmar arch: the palmar interosseous branches just noticed will be observed to join these at their points of bifurcation.

D. Anterior interosseal.



*Lingual artery*, (plate IV. b, plate VII. fig. 1, c, c.)—This branch (a. lingualis) inclines forwards and inwards to the upper margin of the cornu of the os hyoides, where it passes between the hyo-glossus and the middle constrictor of the pharynx. So far the direction of the vessel is horizontal, but it soon ascends almost perpendicularly, being covered by the digastric, mylo-hyoid, and genio-hyoid muscles; and finally changes its course, to run directly forwards beneath the tongue, where it assumes the name of ranine artery. Its branches are the following:

*The hyoid branch* (plate VII. fig. 1, e) takes the direction of the os hyoides, running on its upper border, and forming an arch by anastomosis with the corresponding vessel of the opposite side; it gives ramusculi to the contiguous muscles and the tegument.

*The dorsal branch of the tongue*, (r. dorsales linguæ, plate VII. fig. 1, d.)—One or two branches arise where the artery is deeply seated, and incline backwards and upwards, covered by the hyo-glossus muscle. These are called the “dorsal” branches, from their destination, for they supply the substance and upper part of the tongue, ramifying as far back as its root. At the anterior border of the hyo-glossus the lingual artery may be said to divide into the ranine and sublingual arteries.

*The ranine branch*, (r. raninus, plate VII. fig. 1, h,) in direction, is its proper continuation; it proceeds forwards beneath the lingualis muscle, and close to the outside of the genio-hyo-glossus; and, finally, near the tip of the tongue, forms an arch, by anastomosing with the corresponding artery of the opposite side. The ranine arteries of opposite sides are placed at each side of the frænum linguæ, under cover only of the mucous membrane.

*The sublingual branch* (r. sublingualis, plate VII. fig. 1, f) passes between the mylo-hyoid muscle and the sublingual gland, giving branches to both; one also reaches the chin, where it ramifies in small ramusculi. In its course it supplies the sublingual gland, as well as the muscles passing from the chin and jaw to the tongue; its size varies in different instances, so does its origin, for it often comes from the submental branch of the facial.

*Facial artery*, (plate IV. c, plate VI. fig. 1, e, e, and fig. 2, D.)—This vessel (a. facialis, labialis; maxillaris externa) extends from the carotid artery, along the side of the face, towards the root of the nose. It is usually the largest of the anterior branches, and arises higher up than the lingual. It ascends in rather a winding course, so as to get deeply under cover of the jaw-bone, and then inclines down, running in a groove in the upper surface of the submaxillary gland, as far as the margin of the jaw, over which it turns, to reach the side of the face. In its ascent, the artery is concealed by the platysma, the tendon of the digastricus, and the stylo-hyoideus; but where it rests on the external surface of the jaw-bone, it is covered only by the integument and platysma, lying close to the anterior border of the masseter, where its pulsation can readily be felt. The artery then ascends, inclining towards the angle of the mouth; it rests on the buccinator muscle, and is crossed by the zygomatici. And, finally, becoming much diminished in size by having given off several branches, it ascends under the name of *ramus angularis* by the side of the nose, covered by the common elevator muscle, and terminates at the angle of the eye by two or three very small ramusculi, which anastomose with the nasal branches of the ophthalmic artery.

Its branches are numerous, and may conveniently be divided into two sets; the first consisting of those given off before the vessel reaches the jaw, being usually three or four; the second of those distributed to the face, varying from five to six, as follows:

*The inferior palatine branch* (ramus palatinus inferior) ascends between the stylo-glossus and stylo-pharyngeus, reaching the pharynx close by the border of the internal pterygoid muscle. After having given small twigs to the tonsil, the styloid muscles, and Eustachian tube, it divides near the side of the levator palati into two ramusculi; of which one follows the course of the circumflexus palati muscle, and ramifies in the soft palate and its glands; whilst the other passes to the tonsil, supplying it, and anastomosing with the following branch.

*The tonsillar branch* (r. tonsillaris) ascends by the stylo-glossus to the side of the pharynx, and terminates by dividing into several ramusculi, which are distributed to the tonsil and side of the tongue.

*The glandular branches*, (r. glandulares,) a fasciculus of small branches, pass into the substance of the submaxillary gland, (plate II. No. 19,) whilst the artery is in contact with it; some of these are prolonged to the side of the tongue.

*The submental branch* (r. submentalis, plate V. fig. 1, c) departs from the artery near its turn round the jaw, and runs forward between the mylo-hyoideus and digastricus, close to the margin of the bone. At the symphysis of the chin it divides (after having previously given offsets to the submaxillary gland and muscles) into two branches, one of which, more superficial than the other, passes between the depressor labii inferioris and the skin, supplying both, whilst the other lies between this muscle and the bone, sending twigs to the substance of the lip, and communicating with the following branch. The submental artery will sometimes be found of considerable size, and then it gives off the sublingual.

*The inferior labial* (r. labialis inferior, vel superficialis; plate VI. fig. 2, s) inclines inwards, sending ramusculi to the muscles of the lower lip, and anastomosing with the r. coronarius inferior, with the submental, and the termination of the dental artery.

*The coronary artery of the lower lip* (r. coronarius labii inferioris; plate VI. fig. 1, g) arises near the angle of the mouth, and takes a transverse and tortuous course upon the mucous membrane, covered by the muscles of the lip, at the middle of which it inosculates with the corresponding artery of the opposite side. Some of its ramusculi are distributed to the orbicular and depressor muscles, others pass downwards to the chin, communicating with the branches that ramify there.



*r. Coronarius labii superioris* is larger and more tortuous than the preceding, above which it arises, taking a similar course as it proceeds inwards, across the upper lip, (plate VI. fig. 1, h.) It passes under cover of the zygomaticus and orbicularis, and forms an arch by inosculation with the corresponding artery of the opposite side. In addition to several small twigs to the muscles of the lip, it gives two or three to the nose. One of these (*r. nasalis septi*) proceeds along the septum to the extremity of the nose; the other (*r. nasalis lateralis*) ramifies on the side of the nose, and forms a minute net-work on its ala, to which the nasal branch of the ophthalmic artery also contributes.

The facial artery is the chief medium of communication between the superficial and deep branches of the external carotid, by means of its anastomoses with the infra-orbital, dental, and nasal branches; also between the external and internal carotids, by its anastomosis with the ophthalmic artery.

The *Ascending Pharyngeal artery*\* (a. pharyngea ascendens) lies deeply and concealed from view until some of the branches of the carotid artery and the stylo-pharyngeus muscle are drawn aside. It arises near the lingual artery, or even from the bifurcation of the common carotid, and is the smallest of the branches of the external carotid. It rests on the rectus capitis anticus major, close to the surface of the pharynx, and is directed up as if towards the foramen lacerum posterius. Its branches are necessarily small—they are mere ramusculi. We may, however, from a consideration of their destination, divide them into three sets.

*Pharyngeal branches.*—These pass inwards to the pharynx. One or two small and variable branches ramify in the middle

## PLATE X.

The arteries situated at the posterior aspect of the limb are here shown.

FIG. 1. No. 1. Part of the deltoid muscle. 2, 2. The triceps muscle. 3, 3. The biceps muscle. 4. The brachialis anticus. 5. The supinator longus muscle. 6. The extensor carpi radialis longior. 7. The extensor carpi radialis brevior: (these numbers are seen also at the back of the wrist, where they mark the tendons of the same muscles.) 8, 8, 8, 8. The common extensor muscle of the fingers, with its tendons. 9, 9. The extensor carpi ulnaris muscle. 10. The anconeus muscle. 11. Part of the flexor carpi ulnaris muscle. 12. The extensor of the metacarpal bone of the thumb. 13, 13. The extensor of its first phalanx. 14. The tendon of the extensor of the second phalanx. 15. The abductor indicis. 16. The abductor of the little finger.

a, a, a. Muscular branches which come forward from the arteria profunda. b, b. The arteria profunda. c, c. Muscular and cutaneous branches from the interosseous recurrent, communicating with the profunda and the radial recurrent. d, d, d. Twigs from the radial recurrent artery. e. A small branch from the superior perforating interosseous artery. f, f, f. Muscular and cutaneous twigs from the lower perforating artery. g, g. Cutaneous branches at the back of the wrist-joint, resting upon the posterior annular ligament. h. The dorsal carpal branch from the ulnar artery. i, i. The radial artery where it runs forwards at the back of the hand, previously to its getting deep, to reach its palmar aspect. k. The dorsal branch, which, with a similar branch (h) from the ulnar artery, forms an anastomosis upon the back of the hand. l. The dorsal digito-ulnar branch of the thumb. m. Its palmar digito-ulnar branch. n. The dorsal digito-radial branch of the fore-finger. o, o, o. Dorsal interosseous arteries. p, p, p. Dorsal arteries of the fingers. q, q, q. Small branches given by the palmar digital branches to the back of the fingers.

FIG. 2. shows the anastomosis between the arteries at the back of the elbow-joint.

No. 1. The posterior surface of the humerus. 2. Part of the brachialis anticus muscle. 3. The inner condyle of the humerus. 4. The olecranon process of the ulna. 5. The external condyle. 6. The external lateral ligament. 7. The orbicular ligament of the radius. 8. The radius. 9. The ulna.

a. The superior profunda artery. b. The inferior profunda. c, c. The anastomosing communications between these and the branches coming upwards from the arteries of the fore-arm. d. The posterior ulnar recurrent artery. e. The interosseous artery. f. Its recurrent branch: close beside this is a branch derived from the ulnar artery, and which, after passing through the interosseous space, ascends to join the anastomosis.

FIG. 3. The deep-seated branches of arteries at the posterior aspect of the limb are here shown.

No. 1. Part of the humerus. 2. The brachialis anticus muscle. 3. Part of the long supinator muscle. 4. The insertion of the triceps muscle. 5. The external lateral ligament of the elbow-joint. 6. The head of the radius covered by its orbicular ligament. 7, 7. The interosseous ligament. 8. The ulna. 9. The radius.

a, a. The superior profunda artery. b. The radial recurrent branch. c, c. The anastomosis at the back of the joint. d. The interosseous recurrent branch ascending to join the general anastomosis. e. The superior perforating branch of the interosseous artery. f, f, f. Smaller perforating branches. g. The inferior perforating branch. h, h. Branches descending to join the anastomosis of arteries at the back of the wrist-joint. i, i. The radial artery running forward to reach the cleft between the thumb and fore-finger, where it turns into the palm of the hand. k, k. Its dorsal carpal branch. l. The dorsal digito-radial branch of the thumb. m. The dorsal digito-ulnar branch of the thumb. n. The palmar digito-ulnar branch. o. The dorsal digito-radial branch of the fore-finger. p, p. The dorsal carpal branch of the ulnar artery. q. The dorsal digito-ulnar branch of the little finger. r, r, r. Perforating branches from the palmar arch, coming through the interosseous spaces, and joining the dorsal vessels. s, s, s. The dorsal interosseous branches. t, t, t. Their points of division into the digital branches.

\* This artery is frequently called *inferior* pharyngeal, in contradistinction to a small branch named *superior*, which comes off from the internal maxillary.—J. P.

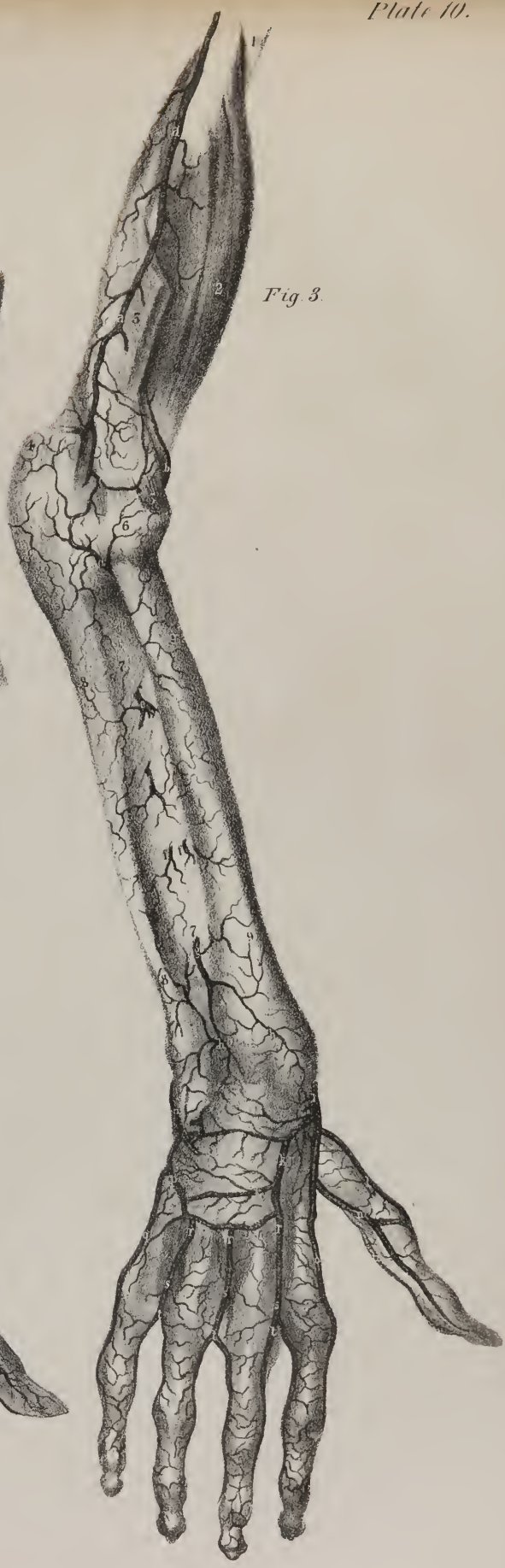
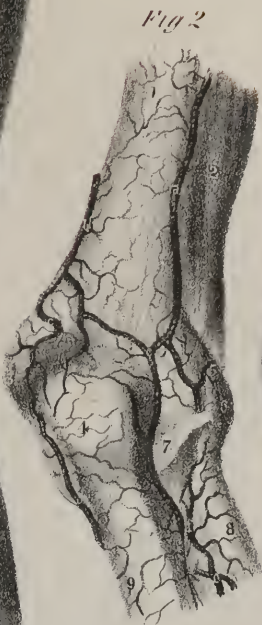
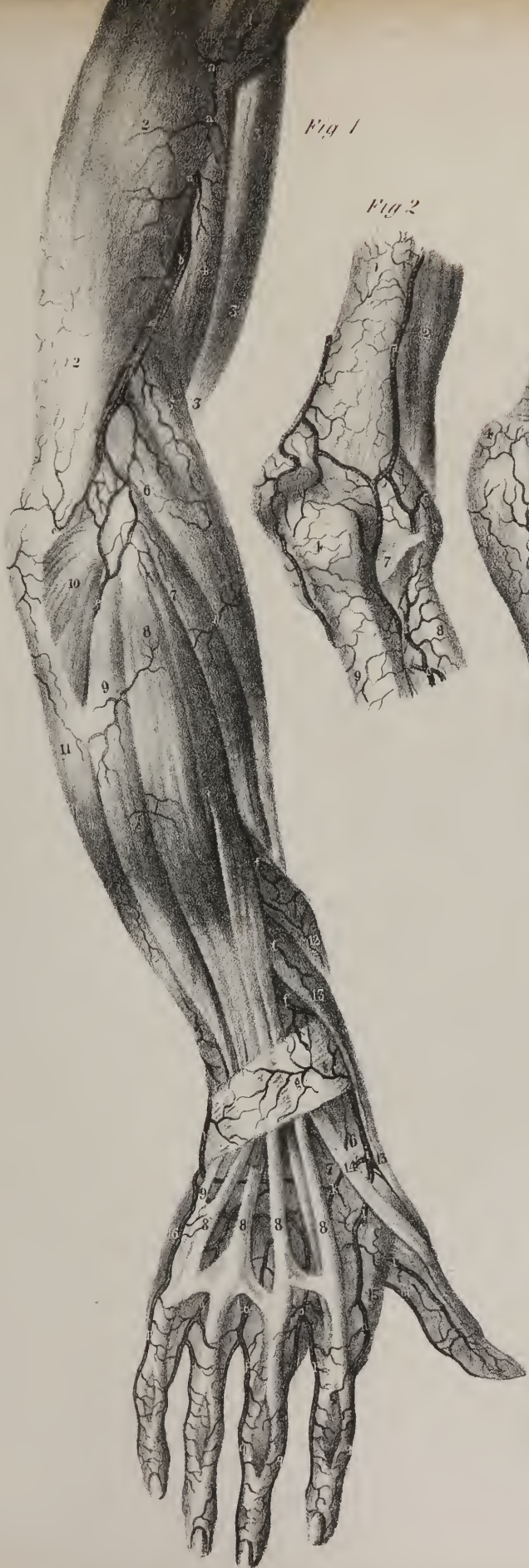





Fig. 1.



Fig. 2.

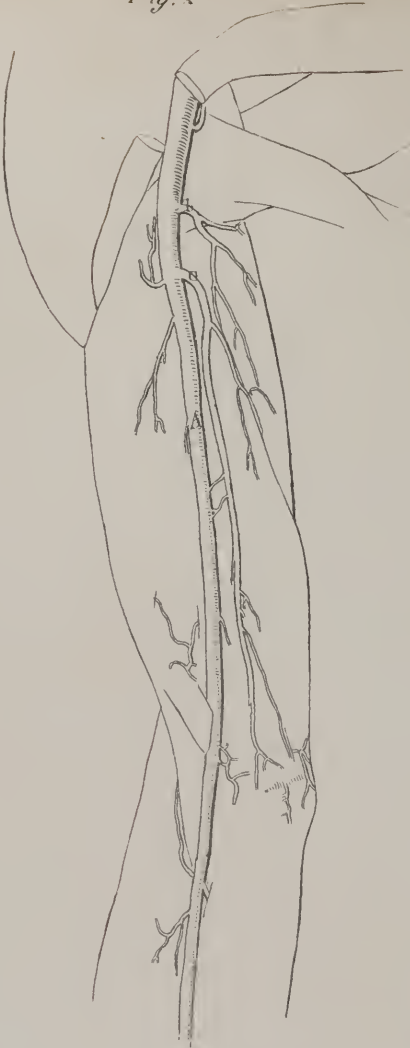

Fig. 3.



Fig. 4.

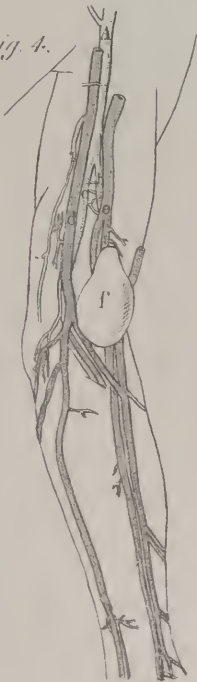

Fig. 5.

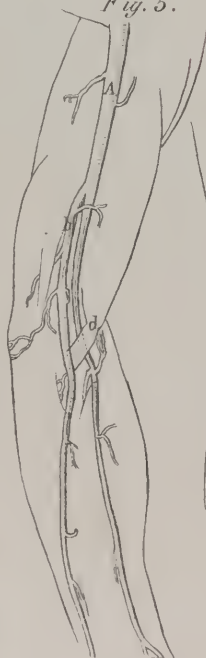

Fig. 6.

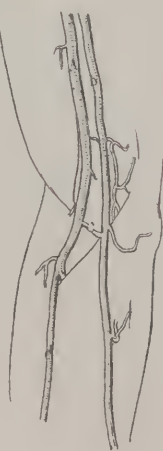
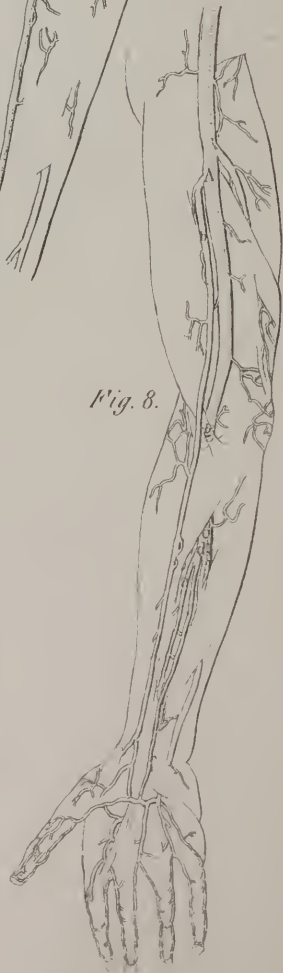
Fig. 7.



Fig. 8.



and inferior constrictors. Higher up than these is a larger and more regular branch, which runs upon the upper constrictor, and sends delicate ramifications to the Eustachian tube, the soft palate, and the tonsil.

The external branches consist of some small and irregular twigs, which are given to the first cervical ganglion, to some of the cerebral nerves as they issue from the skull, and to the conglobate glands of the neck.

*Meningeal branches.*—The terminating branches are those which pass through the holes at the base of the skull: one or two of them accompany the internal jugular vein through the foramen lacerum posterius, and ramify in the dura mater. Another passes through the foramen lacerum medium basis cranii, and is similarly disposed of.

*The Occipital artery* (a. occipitalis, plate IV. f; plate VIII. a) runs a long and tortuous course deeply at the upper part of the neck and base of the skull, and finally arches up towards the vertex, ramifying beneath the pericranium. This vessel passes backwards from the external carotid, opposite either to the lingual or facial artery, and takes the direction of the posterior belly of the digastricus, to reach the interval between the atlas and mastoid process, where it runs in a groove behind the latter. In this course it crosses the internal carotid artery, the vagus nerve, and jugular vein; the lingual nerve will be observed to hook round it; it is covered in the first place by the sterno-mastoid muscle; then it passes under the trachelo-mastoid, the splenius, and frequently the complexus, and is separated from the occipital bone by the fibres of the obliquus and rectus superior. The artery then changes its direction, and runs upwards, piercing the cranial attachment of the splenius and trapezius, and mounts beneath the integument, freely distributing branches. In its course the following branches are given off:

*Muscular branches.*—Small twigs to the digastricus and stylo-hyoideus, and some of a larger size to the sterno-mastoideus.

An auricular branch to the back part of the concha of the ear, and two or three to the splenius and trachelo-mastoid.

*A long descending branch* (ramus princeps cervicis) is of variable size, being in some cases a small branch, and sometimes nearly as large as the continuation of the artery itself. When this is the case, it descends beneath the complexus, towards the lower part of the neck, and anastomoses freely with the r. cervicalis profundus of the subclavian artery. Some branches of this vessel pass outwards to the transverse processes of the vertebræ, communicating with the r. cervicalis ascendens and the external ramifications of the vertebral artery.

*A Meningeal branch* runs up with the internal jugular vein, enters the skull through the foramen lacerum posterius, and ramifies in the dura mater investing the cerebellum.

The *superficial* or cranial branches of the occipital artery pursue rather a tortuous course, and as they proceed forwards on the skull separate into three divisions, which ramify upon it; these communicate with the branches of the corresponding artery of the opposite side on the one hand, with those of the posterior auris on the other, and with the temporal artery in front. Some of these are given to the fleshy fibres of the occipitalis muscle, others to the skin, and one (*r. mastoideus*) enters the mastoid foramen, and ramifies in the dura mater.

## PLATE XI.

These sketches are intended to show the varieties in the size and place of origin presented by the branches of the brachial artery. The usual distribution of the vessels is given in the preceding Plates, IX. and X.

FIG. 1. A. The brachial artery taking its usual course. b. The sub-scapular artery. c. The posterior circumflex branch. d. The inferior profunda, or ulnar collateral branch, which is seen to arise from the posterior circumflex branch.

FIG. 2. A. The brachial artery. b. The superior profunda. c. The inferior profunda, or ulnar collateral branch, of large size, arising lower down: this is a very frequent mode of distribution.

FIG. 3. Here the radial artery, b, commences in the axilla from the axillary artery, A, and runs down the arm parallel with the brachial artery, c, which finally terminates in the ulnar artery.—(These three drawings are of the right arm.)

FIG. 4. The brachial artery, A, gives off the radial, b, and the ulnar, c, in the middle of the arm; the basilic vein, d, and the cephalic, e, are in their usual situations. The radial artery was punctured in the operation of bleeding in the cephalic vein, and gave rise to an aneurismal tumour, which is marked f.—(This is the left arm.)

FIG. 5. The ulnar artery arises in the middle of the arm from the brachial artery, A, and runs down superficial to the muscles of the fore-arm, and of the process of tendon, d, given off from the biceps muscle. The radial artery, c, is prolonged from the brachial, taking its usual course.—(This is the left arm.)

FIG. 6. The ulnar artery, b, arises very high up, and runs parallel with the brachial, A, with which it is connected at the bend of the elbow by a transverse connecting branch, c; it moreover runs superficial to the flexor muscles. The radial artery, d, takes its usual course; but gives off the interosseous branch.

FIG. 7. The interosseous artery, b, is seen to arise from the brachial, A, high up in the arm: at the bend of the elbow it gets under the pronator and superficial flexor muscles, and comes into its ordinary situation in the fore-arm, where its course is indicated by the letters, b, b. The ulnar artery in this case ran superficial to the muscles of the fore-arm.

FIG. 8. The radial artery here arises from the brachial above the middle of the arm, and runs down superficial to the tendinous process, g, given off by the biceps muscle: the ulnar artery, c, gives off the interosseous artery, d, in the usual situation; but this vessel is seen to divide immediately after its origin into two branches, of which that marked e, occupies the usual situation of the interosseous artery, whilst the other, f, becomes superficial, and runs in front of the anterior annular ligament of the wrist, after which it ends in the superficial palmar arch of arteries.—(Figs. 6, 7, and 8, represent the right arm.)



*Posterior Auricular artery* (plate IV. g)—This is a small vessel, (a. auricularis posterior,) which arises sometimes from the occipital artery, but in most instances from the carotid, a little higher up than the latter. It ascends, under cover of the parotid gland, in the direction of the fold or angle formed by the cartilage of the ear with the side of the head, and finally, after having passed above the mastoid portion of the temporal bone, it divides into two sets of ramusculi, of which one inclines forwards to anastomose with the ramifications of the temporal artery, the other backwards to communicate with the occipital.\* In its course the following branches are given off:

Some small twigs to the parotid gland and digastricus.

A *Stylo-mastoid branch* enters the foramen of that name, and, on reaching the tympanum, divides into delicate ramusculi, which pass, some to the mastoid cells, others to the labyrinth. One branch will constantly be found, in young subjects, to form, by uniting with a twig that enters the fissura Glasseri, a sort of coronary artery round the osseous ring of the meatus auditorius, from which delicate offsets pass inwards, upon the membrana tympani. This sometimes arises from the occipital artery.

One or two branches ramify on the posterior surface of the concha.

Opposite the neck of the condyle of the lower jaw, the external carotid artery divides into two terminating branches, one being superficial, the other deeply seated.

The *Temporal artery* (a. temporalis, plate VI. fig. 2, C, C) is at first imbedded in the substance of the parotid gland, where

## PLATE XII.

The sketches indicate the principal varieties which occur in the arteries of the fore-arm and hand.

- FIG. 1. The radial and ulnar arteries, b, c, occupy their usual positions in the fore-arm. Between them is seen a superficial interosseous branch, a, taking the course of the median nerve. It passes, however, superficial to the annular ligament, and terminates by giving branches to the thumb, the fore-finger, and the middle-finger. The ulnar artery in the palm runs obliquely forwards, instead of making its usual curve, and gives branches to the little-finger, the ring-finger, and one side of the middle-finger.—(This is the left arm.)
- FIG. 2. The radial artery, a, inclines backward in the middle of the fore-arm, and passes superficial to the supinator longus, extensores carpi, and two extensors of the thumb, as well as the posterior annular ligament, instead of passing under them. The superficialis volæ branch, b, occupies the usual position of the radial at the lower part of the fore-arm, and, on reaching the base of the thumb, gives off its first dorsal collateral branch.
- FIG. 3. The ulnar artery, a, runs superficial to the muscles of the fore-arm; the radial artery, b, gives off the interosseous, c.—(Figs. 2 and 3 are of the right arm.)
- FIG. 4. The superficialis volæ branch, b, derived from the radial artery, a, is small, and ramifies merely in the muscles of the thumb, without reaching the palmar arch. The ulnar artery, c, forms by itself the superficial palmar arch, and supplies branches to both sides of the fingers, and also to the thumb.
- FIG. 5. The superficialis volæ branch, b, derived from the radial artery, a, is unusually large, so that it forms by joining with the palmar part of the ulnar artery, c, about half the superficial palmar arch, having previously given branches to both sides of the thumb, and to one side of the fore-finger.
- FIG. 6. The distribution of the arteries in this case is in every particular similar to that in fig. 4, except that the radio-digital branch of the fore-finger is derived from the radial artery.
- FIG. 7. The ulnar artery, c, in this case, instead of forming an arch, inclines obliquely across the palm of the hand. The superficialis volæ branch, b, is large, and gives branches to the thumb and to one side of the fore-finger. There is a connexion between this vessel and the ulnar artery by a transverse slip, d.
- FIG. 8. The superficialis volæ branch, b, from the radial artery, a, is very small, and ceases amongst the muscles of the thumb. The ulnar artery, c, after forming the palmar arch, communicates by a small twig, d, with the palmar digito-radial branch derived from the radial artery.
- FIG. 9. The superficialis volæ branch, b, derived from the radial artery, a, is very large, and supplies branches to the thumb, the fore-finger, and one side of the middle-finger. The ulnar artery, c, waving and tortuous in the palm, gives branches only to the little-finger, the ring-finger, and one side of the middle-finger. There is no branch of connexion between these vessels.
- FIG. 10. The anterior digital branches are here seen to come from the deep palmar arch. The radial artery, a, after giving off its superficialis volæ branch, turns into the palm, and forms its deep arch, c: it gives off a digital branch, which divides for the supply of the fore-finger and middle-finger; then one for the latter and the ring-finger; and finally another, which, after receiving a small twig from the ulnar, is given to the contiguous margins of the ring and little fingers. The ulnar artery, d, gives but one digital branch, e.
- FIG. 11. The only variation here deserving notice is in the branch, a, which is derived from the superficial palmar arch, and gives communicating branches to the digito-radial of the fore-finger, and both digital branches of the thumb.—(Figs. 4, 6, 7, 8, 9, and 11, are of the right hand. Figs. 5 and 10 are of the left.)

\* It was in former times occasionally the practice, in affections of the head, to open this posterior auris artery, for the purpose of detracting blood: a custom which is not yet entirely abandoned. I had recently occasion to cut down and take up this vessel, where an empirical practitioner had performed this operation upon himself, and which had been followed by an aneurismal tumour, that, after a few weeks, burst and flooded him with blood. A single ligature on the cardiac side of the aneurism sufficed to cure it. But apart from this danger, arteriotomy should never be performed in this vessel, for it has running nearly parallel with it some sensitive nervous branches, that might be wounded in the operation.—J. P.

Fig. 1.

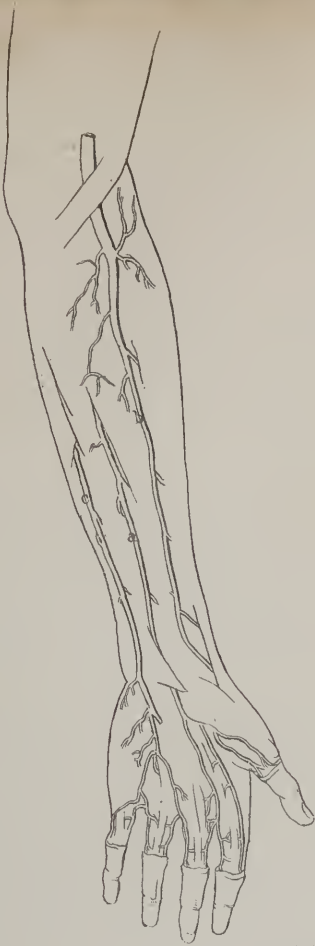

Fig. 2.

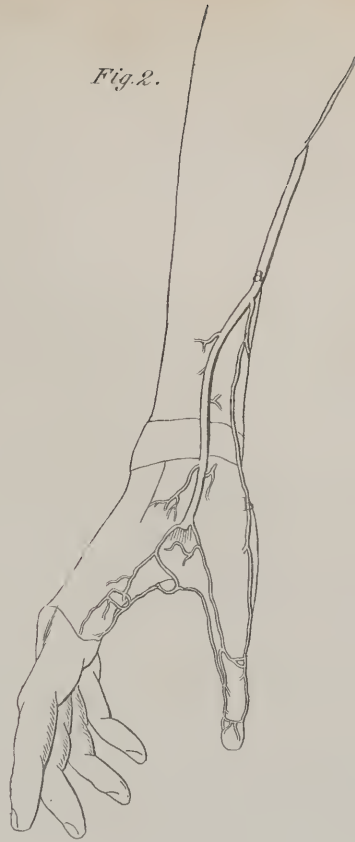

Fig. 3.

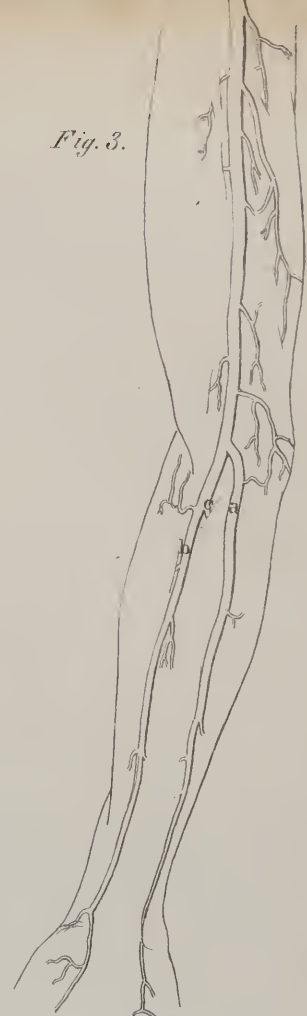


Fig. 4.

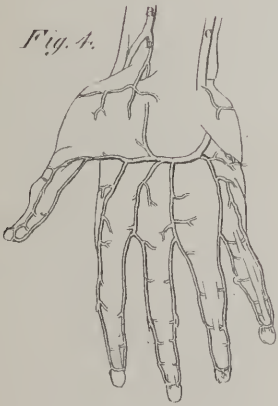


Fig. 5.

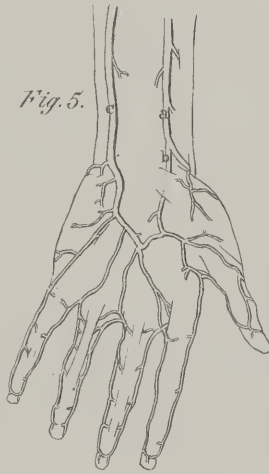


Fig. 6.

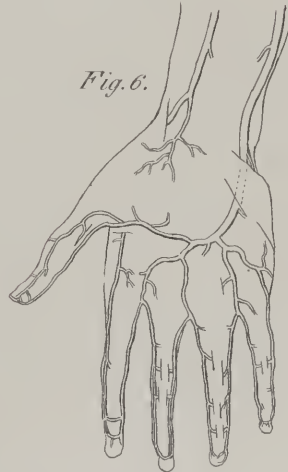

Fig. 7.

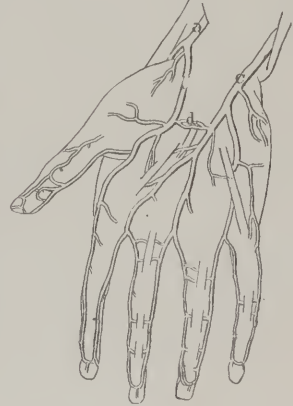

Fig. 8.

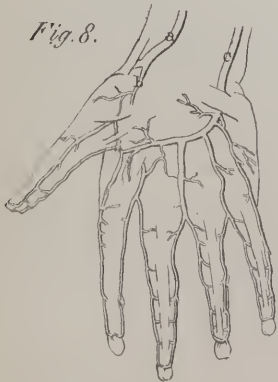


Fig. 9.

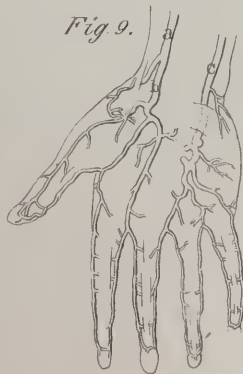

Fig. 10.

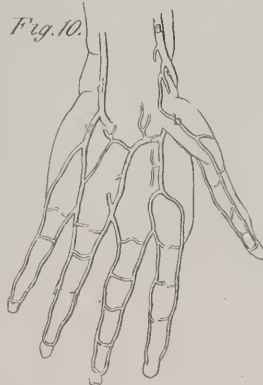
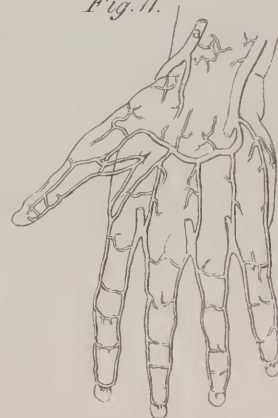

Fig. 11.







it lies in the interval between the tube of the ear and the condyle of the lower jaw. It soon turns forwards to reach the cutaneous surface of the zygoma, on which it may be readily compressed, being merely covered by the integument, the prolonged part of the cervical fascia, and the thin tendon of the *atrahens aurem* muscle. Continuing to ascend, the artery lies beneath the skin, supported by the temporal muscle and its fascia, and divides into two sets of arching branches, which ramify beneath the integument. In its course it gives off:

Some small twigs to the parotid gland.

One or two to the masseter muscle, (*masseterici*.)

*Ramus transversalis faciei* (plate VI. fig. 1, d) arises whilst the artery is deeply seated, and inclines upwards and forwards through the substance of the parotid gland, so as to get between its duct and the zygoma, resting on the masseter muscle, and accompanied by one or two transverse branches of the facial nerve. It sometimes gives off some masseteric branches, and divides into three or four ramusculi, which are distributed to the side of the face, anastomosing with the infra-orbital and facial arteries.

A *middle temporal branch* dips beneath the temporal fascia, and inclines forwards between it and the muscle of the same name, sending branches into the latter, which communicate with the deep temporal branches, whilst others extend to the external angle of the orbit, where they meet some ramifications of the *ramus lachrymalis*. Soon after its origin, this vessel usually gives some twigs to the meatus externus of the ear, (*r. auriculares anteriores*.)

The *Anterior temporal branches* (plate VI. fig. 1, b, b) incline forwards as they ascend, and ramify extensively over the forehead, supplying the orbicularis and occipito-frontalis muscles, and communicating with the frontal branches of the ophthalmic artery.

The *Posterior temporal branch* inclines back on the side of the head, and seems to be the continuation of the original vessel; its branches ramify freely, both upwards to the vertex, where they communicate with those of the corresponding vessel of the opposite side, and backwards, to meet those of the occipital artery.\*

*Internal maxillary artery* (plate VI. fig. 2, B, B.)—This vessel (*a. maxillaris interna*) is larger than the temporal, and follows a serpentine and complex course from its commencement to its termination, changing its direction several times. On leaving the external carotid it inclines downwards and inwards, so as to get under cover of the ramus of the jaw, and, in the next place, proceeds inwards, between the two pterygoid muscles. Opposite the pterygoid process it ascends perpendicularly, passing between the two heads of the pterygoideus externus, and thus reaches the speno-maxillary fossa, where it makes its final turn, forwards and inwards, becoming horizontal. Having assumed this direction, the artery, considerably diminished in size by having given off many branches, passes directly forwards beneath the orbit lodged in the infra-orbital canal, and finally emerges on the face, where it terminates by several small ramusculi. It will thus be observed, that the artery in its course is successively in relation with the ramus of the jaw, the pterygoid muscles, the speno-maxillary fossa, and the floor of the orbit. As at each of these stages of its progress it gives off branches, we may divide them into four sets, corresponding with the points above referred to.

1. Branches of the internal maxillary artery given off near the ramus of the jaw.

*Ramus tympanicus* passes deeply behind the articulation of the lower jaw, and enters the *fissura Glasseri*, supplying the *laxator tympani*, and ramifying in the cavity of that name, as well as on its membrane.

*r. Meningeus parvus* sometimes arises from the succeeding branch, or from one of those given to the pterygoid muscles. It ascends between the pterygoid plate and the circumflexus palati, and enters the skull through the foramen ovale, to supply the dura mater.

*r. Meningeus medius, vel magnus*, (plate VI. fig. 2, 1\*,) is by far the largest of the branches given to the dura mater. It passes directly upwards to the foramen spinale in the sphenoid bone, which transmits it to the interior of the skull, where it will be observed to run in a groove marked on the great wing of the sphenoid bone, the squamous part of the temporal, and the inferior angle of the parietal. From the last point it branches out, its ramifications corresponding with the arborescent lines traced on the cranial bones, but intimately connected with the dura mater; so that, if the latter be detached from the skull, the artery and its branches will be carried with it. (Plate VI. fig. 2, 1\*, 1\*.)

*r. Maxillaris inferior, vel dentalis*, (plate VI. fig. 2, f,) enters the dental canal, accompanied by the nerve of the same name, and runs from behind forwards to the foramen mentale, through which it escapes on the face. In its course, the vessel lies beneath the roots of the teeth, and gives off at intervals small twigs, which ascend and enter the minute apertures in their points, and finally ramify in the pulp of each tooth. Near the foramen mentale a branch passes forwards beneath the incisor teeth, which it supplies, and inosculates, at the symphysis of the chin, with a corresponding artery from the opposite side. Its terminal branches on the face anastomose with the coronary and submental arteries.

2. Branches given off whilst the artery is between the pterygoid muscles:

\* Several cases of traumatic aneurism, of considerable size, following blows, in the larger temporal branches, have come into my hands from the country, in which the more ordinary means of cure had not succeeded. Ligature of the main trunk in front of the ear, or of one of its branches when the tumour seated on it was high up, conjoined with pressure, I have generally found successful.—J. P.

*r. Temporales profundi* are two or three branches which ascend between the temporal muscle and the cranial bones, along which they ramify, freely supplying that muscle. (Plate VI. fig. 2, k, i.)

*r. Pterygoidei*: some small and short ramusculi pass to the pterygoid muscles, which they supply.

*r. Massetericus* is a small but regular branch which passes from within outwards through the sigmoid notch in the lower jaw, and is distributed to the masseter muscle.

3. The branches given by the internal maxillary artery whilst opposite the pterygo-maxillary fissure:

*r. Buccalis* passes obliquely forwards upon the buccinator muscle, to which, and to the other muscles of the cheek, it distributes twigs, and anastomoses with the facial artery. (Plate VI. fig. 2, g.)

*r. Alveolaris vel dentalis superior* turns forwards on the border of the superior maxillary bone, and gives off several small twigs, some of which pierce the bone, and reach the antrum maxillare, where they ramify freely, whilst others penetrate to the alveoli by similar foramina, and enter the roots of the upper teeth to supply their lining membrane. (Plate VI. fig. 2, h.)

*r. Infra-orbitalis* turns horizontally forwards from the artery when it has reached the sphenomaxillary fossa, and enters the infra-orbital canal, when it sends some twigs into the orbit to supply the inferior oblique muscle and the lachrymal gland. It emerges on the face after having traversed the canal, and sends twigs upwards and inwards to the lachrymal sac and angle of the orbit, which communicate with the *r. nasalis lateralis*, whilst others descend, covered by the elevator of the lip, and anastomose with the transversalis faciei and buccal branches.

4. The branches given off in the sphenomaxillary fossa:

*r. Palatinus superior vel descendens* is one of the three branches into which the artery may be said to divide at the point just indicated. It passes perpendicularly downwards through the posterior palatine canal, and so reaches the arch of the palate, along which it ramifies, supplying the gums and soft palate, and anastomosing with the nasal artery by a branch sent up through the foramen incisivum. At its point of origin a reflected branch passes directly backward to enter the Vidian canal with the nerve of the same name. Hence it is termed the *Vidian*, or pterygoid branch. It is distributed to the Eustachian tube and top of the pharynx.

*r. Pterygo-palatinus* is a very small ramusculus, which passes backwards and upwards to reach the pterygo-palatine foramen, by which it reaches the top of the pharynx, where it freely ramifies, after having given some twigs to the Eustachian tube and phenoidal cells.

*r. Nasalis vel sphenopalatinus* artery enters the foramen of that name, by which it reaches the cavity of the nose at the posterior part of the superior meatus. There, lying between the mucous membrane and the bone, it divides into two or three ramusculi; one of these ramifies on the septum narium, the others on the spongy bones, some twigs being sent into the posterior ethmoidal cells as well as the antrum.

The vessels here described as arising from the external carotid, present several varieties in their mode of origin in different instances, and some also as to the relative size of the branches which two or more of them send to the same parts. If the supply from one quarter be greater than usual, that from another will be proportionally diminished, by the operation of a principle of compensation so constantly observable in the distribution of vessels. These arteries are not merely branches issuing from a common trunk, for, if viewed in a general way, it will be found that each of them is intended for a particular organ or system of organs, and therefore should be treated as a trunk in itself, or a special source of supply to the parts to which it is distributed. Thus, the vocal and part of the respiratory apparatus are supplied by the superior thyroid artery ramifying on the exterior, as well as in the interior of the larynx. The upper part of the digestive tube derives its blood from the lingual, the palatine, and pharyngeal arteries. The face, including the organs of expression and mastication, receives supplies from several vessels, the facial and internal maxillary arteries being the chief, whilst the occipital and temporal ramify on the cranium. This arrangement

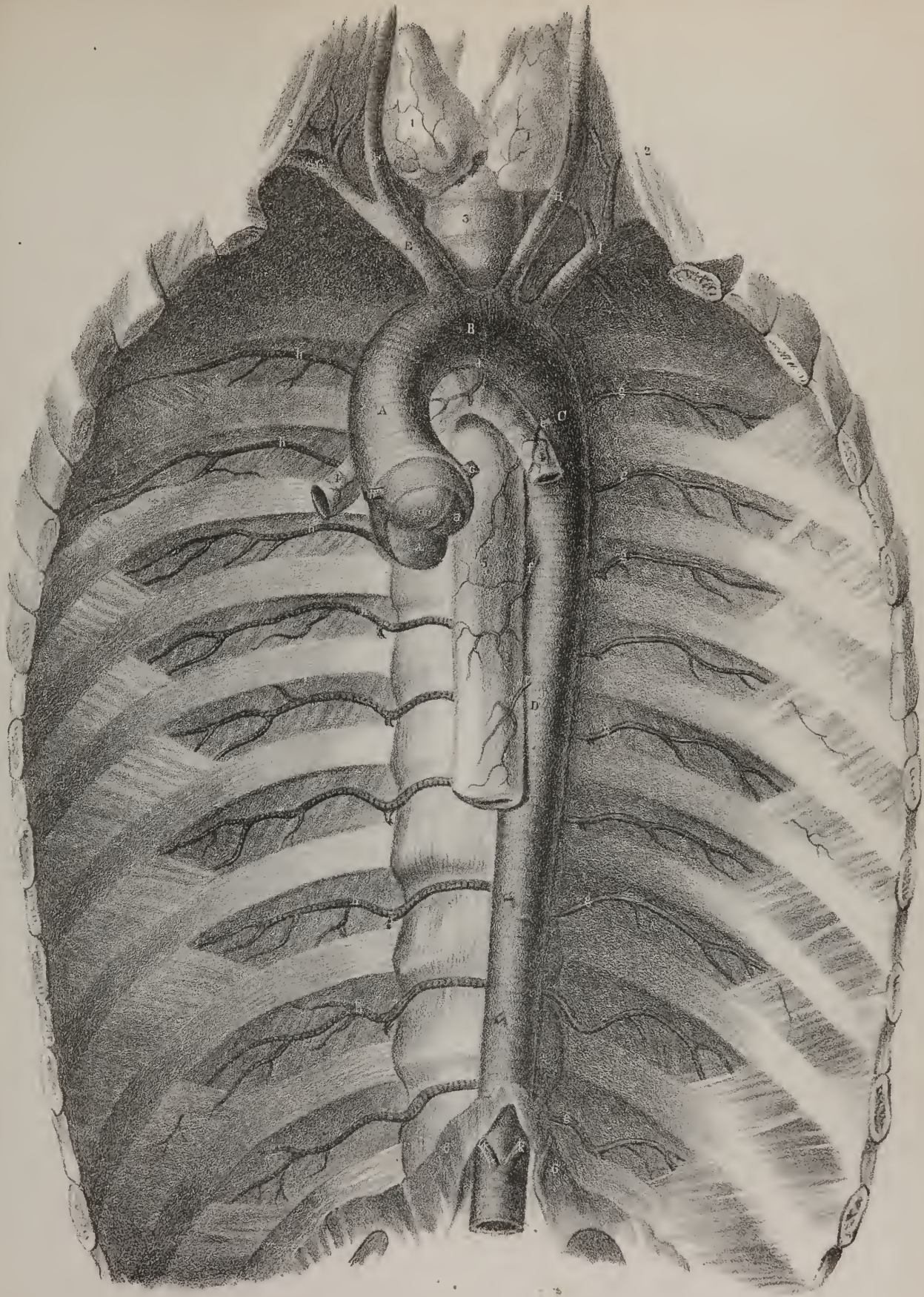
## PLATE XIII.

The curved part, (the arch—*arcus aortæ*,) and the straight part of the aorta, are here shown. The thoracic part of the spine, with part of the ribs and intercostal muscles, remain; all the viscera, with the sternum and anterior extremities of the ribs, having been removed.

Nos. 1, 1. The lateral lobes of the thyroid gland. 2, 2. Part of the anterior scapular muscles. 3. The trachea. 4, 4. The bronchial tubes passing off from the trachea to the lungs. 5. The œsophagus. 6, 6. A few fibres of the diaphragm arching over the aorta as it passes into the abdomen.

A. The ascending part of the arch of the aorta. B. Its transverse part. C. The descending part. D. The straight part, commonly called the thoracic aorta, though that phrase applies to the arched part as well as to this. E. The brachio-cephalic or innominata artery. F. The right carotid artery. G. The right subclavian. H. The left carotid artery. I. The left subclavian artery. a, a, a. The three semi-lunar valves placed at the commencement of the aorta. b. The right coronary artery. c. The left coronary artery. d, e. The bronchial arteries. f, f. The œsophageal arteries. g, g, g. The intercostal arteries of the left side. h, h, h. The intercostal arteries of the right side. i, i, i. The dorsal or posterior branches given off at each side by the intercostal arteries. k, k. The phrenic arteries arising below the diaphragm from the aorta in the abdomen.









was first suggested by Bichât, and is one of the many instances which may be cited of his constant anxiety to make physiology the basis of his classifications.

*Varieties.*—The bifurcation of the common carotid artery may take place lower down or higher up than the margin of the thyroid cartilage. Burns recites a case in which it occurred as low as the fifth or sixth cervical vertebra; and Meckel mentions one in which its division was opposite the styloid process, and another in which the deviation went still farther, no bifurcation having taken place, for the common trunk gave off those branches to the external parts which usually issue from the external carotid, and then continued its course, assuming the direction and destination of the internal carotid.

Varieties frequently occur in the branches of the external carotid. The superior thyroid artery may arise by a branch common to it and the lingual, or may come from the common carotid at its bifurcation. One or two cases have been cited in which it did not exist, at least at one side, its place being supplied by the inferior thyroid.

The lingual artery may arise conjointly with the superior thyroid, but much more frequently with the facial. In the facial artery two varieties very frequently occur, not only in different individuals, but even at opposite sides of the same subject. It has been found very small in some cases, not extending beyond the jaw; but, as if to supply its place, the masseteric and transverse facial branches were unusually large.

The auricular may arise from the occipital, and the latter has in some cases come from the internal carotid.

*Operations.*—The *common carotid artery* may be exposed and tied in the upper part of its course, viz. after it has passed the omo-hyoideus, by proceeding in this way:—The chin being turned to the opposite side, and pushed upwards so as to extend the parts, an incision may be made along the inner border of the sterno-mastoideus, beginning on a level with the cricoid cartilage, and extending upwards for two inches and a half towards the angle of the jaw. The skin being divided, the platysma is to be cut through to the same extent, and afterwards the cervical fascia; in doing which, a portion of the membrane should be pinched up by the forceps, and cut across, so as to make a small opening for the introduction of a director, on which it is to be slit up. This will expose the sheath of the vessels, which may be opened with the same precaution, care being taken to avoid the descendens noni nerve.\* When passing the ligature, it will be found convenient to pinch up the inner margin of the divided sheath with the forceps, and draw it forwards. The point of the needle may then be applied closely to the outer side of the artery, by which means the vagus nerve and jugular vein are excluded, and the instrument will be made to slide smoothly between the artery and its sheath.\*

When proceeding to expose the artery in the lower part of the neck, the incision through the integument should commence on a level with the cricoid cartilage, and extend for fully three inches down towards the sterno-clavicular articulation, along the inner margin of the sterno-mastoid muscle. The skin, platysma, and fascia, being successively divided, the head must be slightly elevated in order to relax the muscles and allow of their being drawn aside. The sterno-mastoid is drawn to the outside, and the sterno-hyoid and sterno-thyroid to the inner side of the wound. Some fibres of the latter may require to be divided in order to bring the sheath of the vessels fully into view. When this is effected, the subsequent steps are the same as in the higher operation.†

*The Internal Carotid artery* (plate IV. C; a. carotis interna) commences at the division of the common carotid, opposite the upper border of the thyroid cartilage, from which point it inclines at first somewhat backwards and outwards, but soon turns forwards and inwards, and ascends to the base of the skull to reach the carotid foramen in the temporal bone. In this course the artery is accompanied by the internal jugular vein, which lies external to it, and by the vagus and sympathetic nerves, to which it is closely united by cellular tissue. The hypo-glossal nerve at first lies behind the artery; but as it descends it inclines to its outer side, and finally passes in front of it as well as of the external carotid artery. The artery is supported by the rectus anticus muscle, and is crossed by the digastricus and stylo-hyoideus muscles, and the lingual nerve. Higher up, the stylo-pharyngeus and stylo-glossus, together with the glosso-pharyngeal nerve, pass also in front of it, interposed between it and the external carotid artery. On reaching the lower margin of the canal appropriated to it in the pars petrosa of the temporal bone, the internal carotid artery ascends perpendicularly a little way, and then inclines forwards and inwards, its direction being influenced by that of the osseous tube which encloses it. It soon, however, ascends somewhat to reach the posterior clinoid process, close by which it pierces the deep lamella of the dura mater, which forms the cavernous sinus, but does not enter the cavity of the latter, as it becomes invested by a reflection of its lining membrane. The artery, in the next place, passes horizontally forwards to the base of the anterior clinoid process, where it curves upwards, and pierces the superficial or cerebral lamella of the cavernous sinus; finally, becoming invested by the arachnoid membrane, it reaches the fissure of Sylvius, in which it divides into its terminal branches. Whilst in the canal, the artery is enclosed in a plexus formed by the sympathetic nerve, and gives off a small branch,

\* It is well to recollect that the descendens noni nerve runs very obliquely down over the sheath of the vessels, traversing some of its cellular layers. It is of very variable size. In one case of operation on the living subject, for ligature of the carotid, it was so large as to be mistaken at first for the par vagum by two of my assistants. However much the cellular tissue and sheath may be injected with blood, the oblique direction and superficial position of the nerve will enable us to distinguish it.—J. P.

† When it is necessary to take up the carotid low in the neck, I prefer to make the incision in the cellular space, between the sternal and clavicular origins of the sterno-cleido-mastoid muscle, immediately behind which, the artery lies. If difficulty occur in reaching the vessel, the sternal portion of the muscle may be divided.—J. P.

which enters the tympanum, and anastomoses with the stylo-mastoid and tympanic arteries. Whilst at the sinus, a small twig is sent to the dura mater (r. meningeus anterior.) The ophthalmic artery is given off close by the anterior clinoid process.

The *Ophthalmic artery* (plate VII. fig. 5, 6, b, b; a. ophthalmica) passes forwards from the internal carotid artery, where it lies by the anterior clinoid process, and enters the orbit by the foramen opticum, placed inferior and external to the optic nerve. It soon changes its direction, passing above and to the inside of the nerve, to reach the inner wall of the orbit, along which it runs, and finally terminates by branches that ramify on the side of the nose.

Its branches are very numerous, being intended to supply the eye and its appendages.

*Ramus lachrymalis* (plate VII. fig. 5, c) is of considerable size, and passes forwards, while the artery lies to the outside of the optic nerve. It runs close by the upper border of the external rectus muscle, which guides it to the lachrymal gland, to which the greater number of its branches are distributed; some, however, pass onwards to the eye-lids, and one or two delicate vessels pierce the malar bone to reach the temporal fossa.

r. *Centralis retinæ* is a very small branch, which pierces the substance of the optic nerve, and runs embedded within it until it arrives on a level with the retina, where it divides into minute branches, which ramify in the anterior or vascular lamella of that membrane; a branch will be observed also to pass through the vitreous humour, and to reach the posterior surface of the capsule of the crystalline lens.

r. *Supra-orbitalis* ascends to get above the muscles, and in its course forwards to the supra-orbital notch lies immediately beneath the roof of the orbit. The artery mounts towards the forehead, and distributes several branches, which communicate with those of the temporal artery.

r. *Ciliares* (plate VII. fig. 6, g) are divisible into three sets; viz. short, long, and anterior ciliary arteries. The short ciliary arteries vary from twelve to fifteen in number, and will be found to enclose the optic nerve as they pass forwards to reach the posterior aspect of the sclerotica, which they pierce about a line or two from the entrance of the optic nerve. These ramify minutely in the choroid membrane. The long ciliary arteries, two in number, lie one at each side of the globe, as they pass forwards between the choroid membrane and the sclerotica. Each of them passes through the ciliary ligament, and divides into two branches which, by anastomosing with one another and with the anterior ciliary arteries, form a vascular zone round the circumference of the iris. From this minute branches pass inwards, again subdividing and anastomosing, the last circle corresponding with the margin of the pupil. The anterior ciliary arteries are derived from some of the muscular branches; they pierce the sclerotica within a line or two of the margin of the cornea, and communicate with the preceding as they ramify in the iris.

r. *Musculares* are subject to many varieties in their course and distribution, like all muscular vessels: they supply the muscles of the orbit.

r. *Ethmoidales* (plate VII. fig. 5, e, e) are two in number; one passes through the posterior foramen in the inner wall of the orbit, and having given some small branches to the posterior ethmoidal cells, enters the skull, and sends minute filaments through the foramina of the cribriform lamella to the nasal fossæ. The other branch passes with the nasal division of the ophthalmic nerve through the anterior foramen, and having given ramusculi to the anterior ethmoidal cells and frontal sinuses, reaches the skull, and, like the preceding, sends its ultimate branches through the cribriform lamella to the nose.

r. *Palpebrales* (superior et inferior; fig. 5, h) arise usually in common, but soon diverge as they pass forwards, one lying above, the other below, the tendon of the orbicularis muscle: they are distributed, as their names imply, to the eye-lids, branches being also sent to the caruncula and lachrymal sac.

r. *Nasalis* (fig. 5, g) passes forwards to the root of the nose, and there ramifies minutely, maintaining a free communication with the termination of the facial artery.\*

r. *Frontalis* runs close to the preceding, but on reaching the margin of the orbit turns upwards on the forehead, where it anastomoses with the supra-orbital artery.

After having pierced the inner lamella of the dura mater, the internal carotid artery gives off the following branches:—

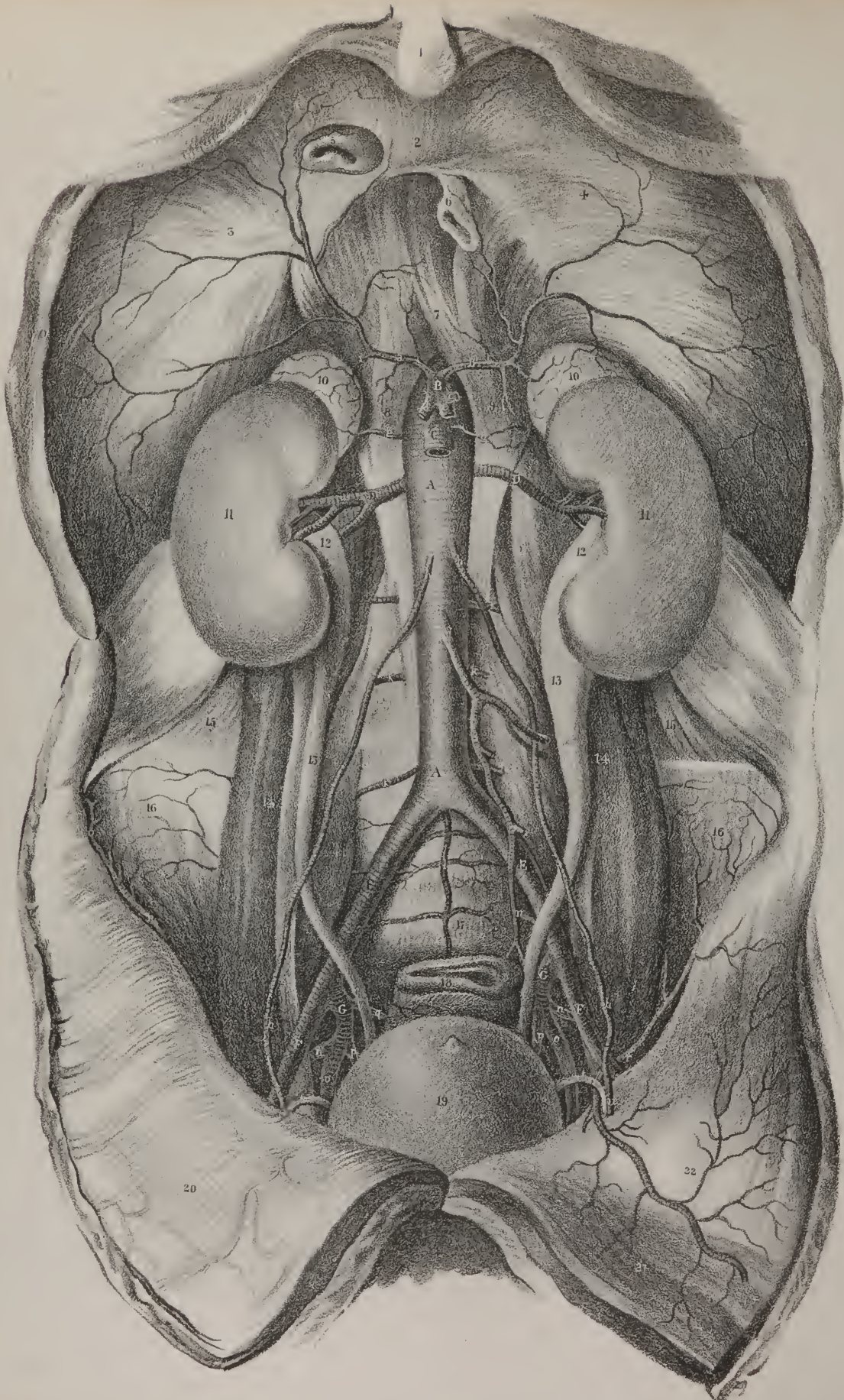
*Ramus communicans posterior* (plate VII. fig. 4, h, h) runs directly backwards, parallel with its fellow of the opposite side so that they enclose within them the infundibulum, with the corpora mammillaria, and both terminate in the posterior cerebral arteries; thus forming the sides of the circle of Willis. In some instances I found two communicating branches, one being very small—about the size of a horse-hair. In one case, there were two at the right side, and one only at the left.

r. *Cerebri anterior* (plate VII. fig. 4, k, k) arises from the division of the internal carotid opposite the inner termination of the fissure of Sylvius. From this point it inclines forwards and inwards to reach the margin of the longitudinal fissure between the cerebral hemispheres, in which it is connected with its fellow of the opposite side by a branch not more than two lines in

\* This termination of the facial artery, which inosculates with the nasal branch of the ophthalmic, is called by surgeons the angular artery. A breadth of five-eighths of an inch across the root of the nose will include the vessel of each side. This fact it is necessary to bear in mind, in restoring a lost nose, with a flap of integuments from the forehead, as it is best, whatever may be said to the contrary, to preserve a fair supply of arterial blood to the flap. I have thrice successfully performed this operation of Rhinoplasty, and in one case with such complete success as nearly to remove every vestige of deformity. The flap did not at the time of the operation lose entirely its natural warmth or colour, and on the fourth day was united throughout by first intention to the groove which was cut for its margin, around the nasal cavity—results which I mainly attribute to the preservation intact of these angular vessels.—J. P.









length, (*r. communicans anterior.*) The two arteries in the next place, lying close together, turn around the anterior border of the corpus callosum, and, on reaching its upper surface, run from before backwards upon it, overlapped by the cerebral hemispheres. In this course numerous branches are given off to the cerebral convolutions.

*r. Cerebri medius* inclines obliquely outwards, taking the course of the fissure of Silvius, within which it divides into several branches, for the supply of the anterior and middle lobes of the brain. Some of these branches, as they ramify in the pia mater, turn forwards to the *substantia perforata antica*; and one or two will also be observed to enter the fissure between the middle lobe and the *crus cerebri*, to reach the descending cornu of the ventricle, where they are distributed to the *plexus choroides* (*rami choroidei.*)

A remarkable inosculation exists between the branches of the vertebral and carotid arteries, by which the circulation in the brain is equalized, and any deficiency that may arise from the obliteration of one, or even two of the vessels, is speedily supplied by the others. This inosculation, which is known as the circle of Willis, results from a direct communication between the following branches. The anterior cerebral arteries, as they converge, are connected by their anterior communicating branch. These, or rather the trunk from which they arise, are united by the reflected communicating branches with the posterior cerebral arteries, and the two latter are united with the basilar artery, at its point of termination. Within the area thus included will be observed the commissure of the optic nerves, the infundibulum and tuber cinereum, the corpora mammillaria, and the origins of the third pair of nerves.

## ARTERIES OF THE UPPER EXTREMITY.

The arterial trunk which supplies the upper extremity continues undivided from its commencement as far as the bend of the elbow; but, like that of the lower extremity, different parts of it have received different names, according to the regions in which they are seated. Whilst in relation with the clavicle, which comprises all that part of the vessel intercepted between its commencement and the lower border of the first rib, it is called *subclavian*; from the point just indicated, to the border of the axilla, it is named *axillary*; and from thence to the bend of the elbow, *brachial*. This mode of division is analogous to that of the inferior arterial trunk into iliac, femoral, and popliteal; and the analogy is completed by the fact, that as the one ultimately divides into the radial and ulnar branches, so does the other into tibial and fibular. As the subclavian artery commences on the left side at the arch of the aorta, and on the right at the division of the brachio-cephalic artery, opposite the sterno-clavicular articulation, the vessels of opposite sides must differ materially in length and relations to contiguous structures in the first part of their course. They both agree, however, in arching upwards and outwards across the lower part of the neck, and in descending beneath the clavicle and subclavius muscle, as far as the lower border of the first rib, where they assume the name of axillary.

*The subclavian artery*, (*arteria subclavia.*)—The two vessels of this name differ in length, relations, and size, in which particulars they may be compared and contrasted as follows:—

*The right Subclavian artery*, (*plate IV. D, E.*) which is usually a little larger than the left, having commenced at the division of the brachio-cephalic artery, behind the sterno-clavicular articulation, arches upwards and outwards to reach the margin of the

## PLATE XIV.

The trunk of the aorta within the abdomen is here shown, together with its different branches.

No. 1. The ensiform cartilage. 2, 3, 4. The divisions of the tendon of the diaphragm. 5. The inferior vena cava as it passes through the opening appropriated to it in the diaphragm. 6. Part of the esophagus as it passes through the diaphragm. 7. The fibres which pass from one crus of the diaphragm to the other, and form the boundary of the aperture which transmits the aorta. 8, 9. The two crura of the diaphragm. 10, 10. The supra-renal capsules. 11, 11. The kidneys. 12, 12. The pelvis of the kidney at each side. 13, 13. The ureters. 14, 14. The *psaos* muscles. 15, 15. The *quadratus lumborum* of each side. 16, 16. The *iliac* muscles. 17. The anterior surface of the sacrum. 18. Part of the rectum. 19. The fundus of the bladder. 20. The parietes of the abdomen everted and thrown down on the thigh. 21. Part of the *rectus abdominis* muscle at the left side exposed by removing the peritoneum and *facia transversalis*. 22. The *transversalis* muscle.

A, A. The trunk of the aorta in the abdomen. B. The *cœliac* artery, or axis arising from the aorta: it gives off three branches, which are marked c, d, e. C. The superior mesenteric artery. D, D. The renal or emulgent artery. E, E. The common trunk of the *iliac* arteries, into which the aorta divides at its termination. F, F. The external *iliac* arteries. G, G. The internal *iliac* arteries.

a, b. The two *phrenic* arteries which are distributed to the diaphragm. c. The coronary artery of the stomach, (*ramus coronarius ventriculi.*) d. The *hepatic* artery, (*r. hepaticus.*) e. The *splenic* artery, (*r. splenicus.*) f, f. Small branches which are given by the *phrenic* arteries to the supra-renal capsules. g, g. The *capsular* arteries. h, h. The *spermatic* arteries. i. The inferior mesenteric artery. k, k, k. The *lumbar* arteries. l. The middle sacral artery. m. The superior *hæmorrhoidal* artery, which is the lower or ternal branch of the inferior mesenteric artery. n. The *gluteal* artery derived from the internal *iliac*. o. The *obturator* artery. p. The *ischiad* artery. q. The lateral sacral artery. r. The *circumflex ilii* artery. s. The *epigastric* artery. t. The *vas deferens*. u. The internal abdominal ring.



scalenus anticus. It there inclines outwards and downwards, beneath the clavicle and subclavius muscle, and becomes continuous with the axillary artery, at the lower border of the first rib. The vessel lies on a plane anterior to that of the left side, inasmuch as the brachio-cephalic artery, from which it arises, is borne forwards by the trachea; in its course it describes a curve, whose convexity looks upwards, approaching the lower nerve of the brachial plexus, whilst its concavity looks downwards, resting on the pleura and first rib. The subclavian vein lies on a plane anterior to the artery, being separated from it by the scalenus anticus muscle, but is somewhat lower down, so as not to obscure or overlap it, except when much distended.

Now, previously to reaching the scalenus, the artery is covered by the skin, the cervical fascia, and by the origin of the sterno-mastoid muscle, and is overlapped by the sterno-hyoideus and sterno-thyroideus muscles; it is also crossed by the nervus vagus, (whose recurrent laryngeal branch passes behind it,) by some branches of the sympathetic nerve, and more externally by the internal jugular vein. In the next part of its course (where it lies behind the scalenus anticus) the artery is still covered by the sterno-mastoid to an extent dependent on the breadth of the clavicular attachment of that muscle: the subclavian vein and the phrenic nerve are here anterior to the artery, but separated from it by the scalenus anticus, on which they rest. But externally to the scalenus, the artery, though still deeply seated, is covered only by the skin, platysma, and fascia, (superficial and deep-seated,) and by some cellular membrane. Here it will be found lodged in a triangular interval, the base of which is formed by the clavicle, and the sides by the scalenus anticus and omo-hyoideus muscles. In the space just indicated, the external jugular vein opens into the subclavian vein. Two arterial branches (posterior scapular and supra-scapular) pass transversely outwards in the same situation—the latter being usually behind the clavicle; the brachial plexus of nerves lies superior and external to the artery, one branch being in close relation to it; the subclavian vein is, as has been above-stated, anterior but at the same time inferior to the artery. This is the situation in which the artery can be most easily compressed or ligatured. (Plate I. Nos. 28, 29, 30; Plate II. A.)

*The left Subclavian artery* arises from the transverse part of the aortic arch at its most depending point, and thence ascends, almost perpendicularly, to get above the level of the first rib, lying close to the vertebræ, and supported by the longus colli muscle. It is overlapped by the upper lobe of the left lung and the reflected part of the pleura, and crossed at its lower part by the nervus vagus, (which had previously been parallel with it,) and above by the left brachio-cephalic vein, and by the sterno-thyroid and sterno-hyoid muscles: all these are interposed between it and the sternum. The artery lies along the left side of, and close to the œsophagus. On reaching the margin of the first rib it turns suddenly outwards, behind the scalenus anticus, and thenceforward follows the same course, and maintains the same relations as the right subclavian. But up to that point it lies so deeply, and changes its course so suddenly when passing outwards behind the scalenus, that it is deemed impossible to apply a ligature upon it previously to reaching that muscle,—an operation which has been performed with success on the corresponding part of the right subclavian artery. (Plate I. Nos. 21, 29, 30.)

Seven branches proceed from the subclavian artery, each to a different destination; three of them, however, in most cases, arise by a common trunk.

The vertebral artery passes up almost in the course of the original vessel, and is conducted by the foramina in the transverse processes of the cervical vertebræ to the base of the brain, the internal mammary artery turns downwards and forwards; the thyroid inclines upwards and inwards to the fore part of the neck: the supra-scapular and the posterior scapular pass outwards across the lower part of the neck, whilst the deep cervical and the superior intercostal pass backwards, and lie deeply, to gain their respective destinations.

*The Vertebral artery* (plate V. fig. 2, g; ramus vertebralis) is a principal branch of the subclavian artery. It enters the foramen in the fifth or sixth cervical vertebra, and ascends vertically along the canal formed by the chain of foramina in the

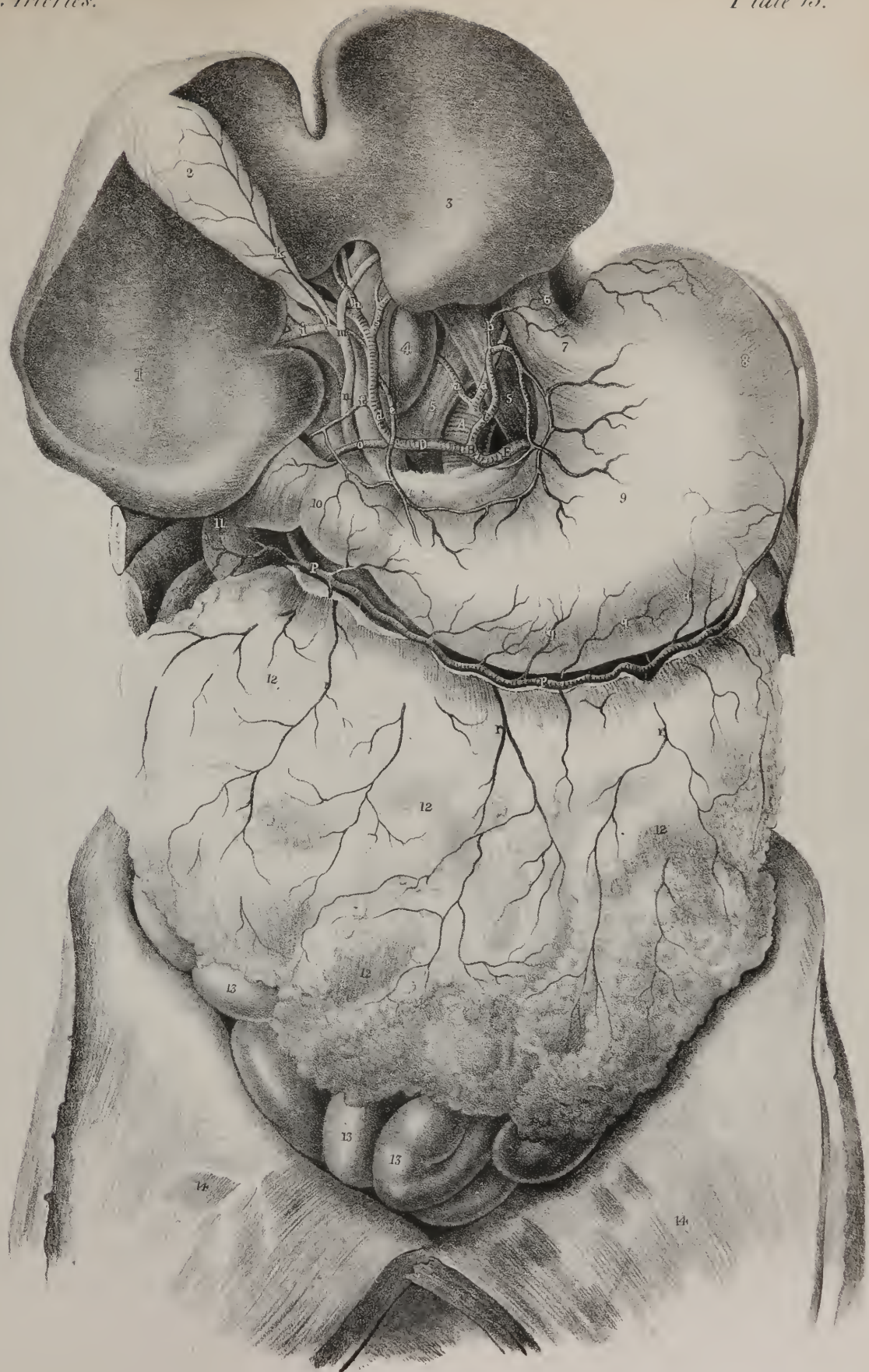
## PLATE XV.

The arteries of the liver and stomach are here shown.

No. 1. The right lobe of the liver. 2. The gall-bladder. 3. The left lobe of the liver. 4. The lobulus Spigelii. 5, 5. The crura of the diaphragm. 6. The œsophagus. 7. Indicates the situation of the cardiac orifice of the stomach. 8. The great cul-de-sac of the stomach. 9. The middle part of the stomach. 10. The pyloric orifice. 11. The duodenum. 12, 12, 12. The great omentum. 13, 13, 13. Some convolutions of the small intestines. 14, 14. The walls of the abdomen everted.

A. The abdominal aorta. B. The cœliac axis where it branches into three vessels, which go to the stomach, the liver, and the spleen. C. The coronary artery of the stomach (arteria coronaria ventriculi.) D. The hepatic artery (arteria hepatica.) E. The splenic artery (arteria splenica.)

a, a. The phrenic arteries (ramusculi phrenici.) b. The ascending œsophageal branch of the coronary artery. c. The continuation of the coronary artery turning back to its anastomosis with the pyloric branch of the hepatic artery. d. The hepatic, or ascending branch of the hepatic artery. e. Its pyloric branch. f. A branch to the duodenum. g. The branch to the left lobe of the liver. h. The middle hepatic branch. i. The right hepatic branch. k. The cystic branch. l. The cystic duct. m. The hepatic duct. n. The common biliary duct (ductus communus choledochus.) o. The gastro-duodenal artery (a. gastro-duodenalis.) p, p. The continuation of the same vessel where it assumes the name of right gastro-epiploic artery (a. gastro-epiploica dextra.) q, q, q. Branch from this vessel to the stomach. r, r, r. Branches to the omentum.









transverse processes, as far as the axis, at which point it inclines outwards, in consequence of the greater width of the atlas. Having passed through the latter, it winds backwards round its articulating process, lying in a shallow groove behind it; and having pierced the dura mater, enters the skull through the foramen magnum. The vessel finally passes forwards, converging to that of the opposite side, and unites with it, their conflux forming the basilar artery.\*

The *Basilar artery* (plate VII. fig. 4, d, d) is so named from its lying on the basilar process of the occipital bone: its length corresponds very nearly with the breadth of the pons Varolii, beneath which it lies, and at whose anterior border it divides into four branches, two for each side. The vertebral artery in its ascent is accompanied by a vein of the same name which commences by branches at the base of the skull, and comes into contact with the artery at the first vertebra. Both vessels lie anterior to the series of cervical nerves, which they cross at right angles. The branches of the vertebral artery in the neck consist of small twigs given off at different points of its course to the dura mater of the spine, and some of variable size to the deep-seated cervical muscles; those within the skull are the following:—

*r. Meningeus posterior*, which is a small branch that arises when the artery is opposite the foramen magnum, and ramifies upon the neighbouring part of the dura mater.

*r. Inferior cerebelli* (plate VII. fig. 4, c) arises at the side of the medulla oblongata, and turns backwards and outwards beneath the corresponding lobe of the cerebellum, to which it distributes numerous ramifications, some of which extend to the inferior vermiform process, and to the fourth ventricle, through the medium of its choroid plexus. There is another of the same name farther forward, e.

*r. Spinalis posterior* inclines backwards round the medulla oblongata, to reach the posterior surface of the medulla spinalis, along which it descends, parallel with its fellow of the opposite side, as far as the second lumbar vertebra, where it terminates in ramifications on the cauda equina. Both these vessels are long and tortuous, and maintain frequent communications by transverse branches.

*r. Spinalis anterior*, (plate VII. fig. 4, b,) smaller than the preceding, descends in front of the medulla oblongata, and unites with the corresponding branch of the opposite side, immediately below the foramen magnum, so as to form one long vessel, which descends in the middle line in front of the medulla spinalis, at the extremity of which it passes through the nervous filaments forming the cauda equina, and terminates at the lower part of the canal in delicate ramifications. This and the preceding branch give numerous ramusculi to the spinal cord and its nerves, and communicate with the branches which enter through the intervertebral foramina.

The branches of the basilar artery are the following:—

Several ramuli are given to the cerebral protuberance and adjacent nerves: one also accompanies the acoustic nerve into the labyrinth of the ear.

*Ramus cerebelli superior* (plate VII. fig. 4, f) turns backwards and outwards round the upper margin of the pons Varolii, to reach the superior surface of the cerebellum, upon which it ramifies freely.

*r. Posterior cerebri* (plate VII. fig. 4, g) is larger than the preceding, and separated from it by the third nerve; it turns round the crus cerebri, and inclines backwards to the posterior lobe of the cerebrum, along which it distributes numerous branches, for the supply of its substance. At the point where this vessel turns backwards, it receives the communicating artery from the internal carotid, and so contributes to form the circle of Willis.

The *inferior Thyroid artery* (plate IV. l; plate V. fig. 2, e; r. thyroideus inferior—ascendens.) The inferior thyroid artery is not unfrequently called *thyroid axis*, because, immediately after its origin, it divides into three branches, which diverge in different directions, viz., the inferior or ascending thyroid, the transversalis colli, and transversalis humeri. It springs from the upper surface of the subclavian artery at a point nearly opposite to that from which the internal mammary artery arises, and to the inner side of the anterior scalenus muscle. At first it presents the appearance of a short stunted trunk; but a line or two from its origin it greatly diminishes in size, owing to its giving off the branches above named. It passes upwards, resting on the longus colli, but soon turns inwards, behind the sheath of the cervical vessels and the sympathetic nerve, directing its course to the thyroid gland, in which its final branches ramify, and where they communicate freely with those of the superior thyroid artery, derived from the carotid.

*Ramulus Cervicalis ascendens* (plate IV. m.) At the point where the inferior thyroid changes its direction, a branch (ascending cervical) usually arises from it, and proceeds upwards, on the line of junction formed by the scalenus anticus and rectus anticus major, ramifying on these muscles, and communicating with the ramusculi sent outwards from the vertebral artery.

*r. Glandulares* are the terminal branches given to the thyroid gland.

\* The vertebral artery, though so deeply lodged, is not exempt from danger in incised and punctured wounds. Two fatal cases have lately been reported. One, that of a female of this city, whose throat was cut with a razor. The carotid escaped, but the instrument, passing through the intervertebral substance between the fourth and fifth cervical vertebræ, opened the vertebral artery. The other was the case of a soldier, in Paris, stabbed by another in the back of the neck with a dagger, who lived for several days. Ligature of the vertebral near its origin, or of the subclavian itself, is the only sure means in such a case of arresting the hemorrhage.—J. P.

*The Supra-scapular artery* (plate IV. n; r. supra-scapularis—transversalis humeri) is smaller than the succeeding branch, (r. scapularis posterior;) it arises almost constantly from the thyroid artery, seldom from the subclavian. It runs from within outwards, lying deeply at the root of the neck, and rests at first upon the scalenus anticus, then crosses the subclavian artery, taking a transverse course under cover of and parallel with the clavicle, to reach the root of the coracoid process of the scapula. At this point it is separated from the corresponding nerve by the ligament stretched across the supra-scapular notch, as the nerve usually passes through the foramen.

*Ramus Supra-spinalis*:—On reaching the supra-spinous fossa, the artery lies close to the bone, and sends outwards a branch (supra-spinal) which ramifies in the supra-spinatus muscle.

*r. Infra-spinalis* (plate VIII. k.) Continuing to descend, the artery in the next place passes through the interval between the glenoid cavity and the spine of the scapula, resting on the neck of that bone, and so reaches the infra-spinous fossa, where it supplies the muscle of that name, and at the same time communicates with the dorsal branch of the sub-scapular artery, and the termination of the scapularis posterior.

*r. Muscularis*:—In its course across the neck some ramuli are given by this vessel to the muscles by which it passes.

*r. Acromialis*:—A small though regular branch will also be found to pass obliquely downwards to reach the cutaneous surface of the acromion, on which it distributes several twigs, which anastomose with those of the thoracico-acromial branch.

*The posterior Scapular artery* (plate IV. o; r. scapularis posterior—transversalis colli) is much more frequently derived from the subclavian itself than from the inferior thyroid; it runs directly outwards across the lower part of the neck, resting on the scaleni muscles and the axillary plexus of nerves, but sometimes passing through the divisions of the latter. On reaching the posterior angle of the scapula it changes its direction, and turns downwards, along the base of that bone, so far as its inferior angle, where it freely anastomoses with the subscapular branch of the axillary artery. It lies deeply in its entire course, and gives off several branches.

*r. Cervicalis superficialis*:—Opposite the anterior border of the trapezius a branch passes upwards, becoming superficial, (hence its name,) and distributes ramusculi in the interval between the trapezius and sterno-mastoid muscles, supplying both, as well as the cervical glands and integuments.

*r. Posterior scapulæ* (plate VIII. b.)—The proper *posterior scapular* branch is in fact the continuation of the vessel, and will be found at the posterior angle of the scapula under cover of the levator anguli muscle, and subsequently under the rhomboidei, to which it gives several branches, as well as to the latissimus dorsi and intercostal muscles, anastomosing at the same time with the intercostal arteries. Towards the inferior angle of the scapula its terminating branches will be found to establish a free anastomosis with the subscapular artery and its dorsal branch.

*The deep Cervical artery* (plate V. fig. 2, k; r. profundus cervicis) is subject to many varieties in its point of origin as well as size. It frequently arises by a short trunk common to it and the superior intercostal artery, or may come even from the thyroid or vertebral. It passes backwards in the interval between the transverse processes of the sixth and seventh cervical vertebræ, and on reaching their dorsal aspect ascends, still deeply seated, between the semi-spinalis colli and the complexus, and sends off several branches to the surrounding muscles. Some of these communicate with ramusculi sent outwards from the vertebral artery, whilst others ascend to anastomose with the descending branch (*princeps servicis*) of the occipital artery.

## PLATE XVI.

FIG. 1. The stomach is here shown as it appears when drawn upwards; thus bringing into view the pancreas, duodenum, and spleen, with their respective arteries.

No. 1. The right lobe of the liver. 2. The gall-bladder. 3. The left lobe of the liver. 4. The middle part of the stomach. 5. Its large or left extremity. 6. The junction of the œsophagus with the stomach. 7. The lower part of the left lobe of the liver. 8, 8. The crura of the diaphragm. 9. The pylorus. 10, 10. The duodenum. 11, 11. The pancreas. 12. The spleen.

A. The abdominal aorta. B. The cœliac artery or axis. C. The coronary artery. D. The hepatic artery. E. The splenic artery. F. The superior mesenteric artery. G. The abdominal aorta.

a, a. The continuation of the coronary artery. b. The place of its anastomosis with the pyloric branch. c, c. Branches to the stomach. d. The pyloric branch of the hepatic artery. e, e. The phrenic arteries. f. The hepatic, or ascending branch of the hepatic artery. g. The gastro-duodenal branch. h. A small pyloric branch. i. The pancreatico-duodenal branch. k, k. The continuation of the gastro-duodenal artery where it assumes the name of right gastro-epiploic artery (arteria gastro-epiploica dextra.) l. The hepatic artery at the transverse fissure of the liver: this and the cystic duct rest on the branches of the vena portæ. m. The cystic branch of the hepatic artery. n, n. The left gastro-epiploic artery derived from the splenic (a. gastro-epiploica sinistra.) o, o. Branches to the stomach (vasa brevia.) p, p. The branches to the spleen. q, q. Small branches to the pancreas (rami pancreatici.) r. The lower pancreatico-duodenal branch derived from the superior mesenteric artery.

FIG. 2. In this drawing we have the arteries at both curvatures, and at the posterior aspect of the stomach.

No. 1. The œsophagus. 2. The cul-de-sac of the stomach. 3. Its middle part. 4. The pylorus.

a. The coronary artery. b. The pyloric branch. c, c, c. Branches descending to the stomach from the arch formed by these vessels. d. Vasa brevia from the splenic artery. e, e. The right gastro-epiploic artery. f, f. Anastomoses between the lower arch of arteries and the upper one. g, g. The left gastro-epiploic artery derived from the splenic.



Fig 1

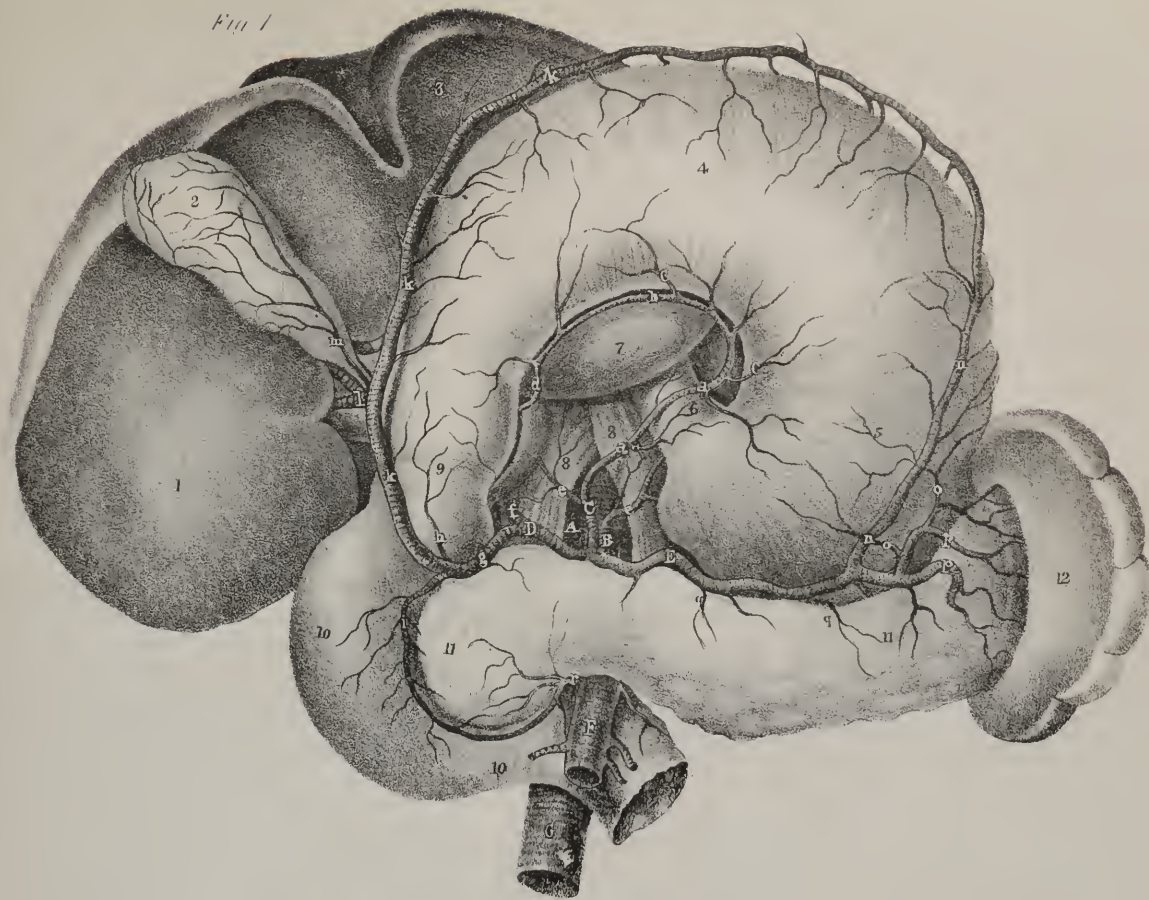
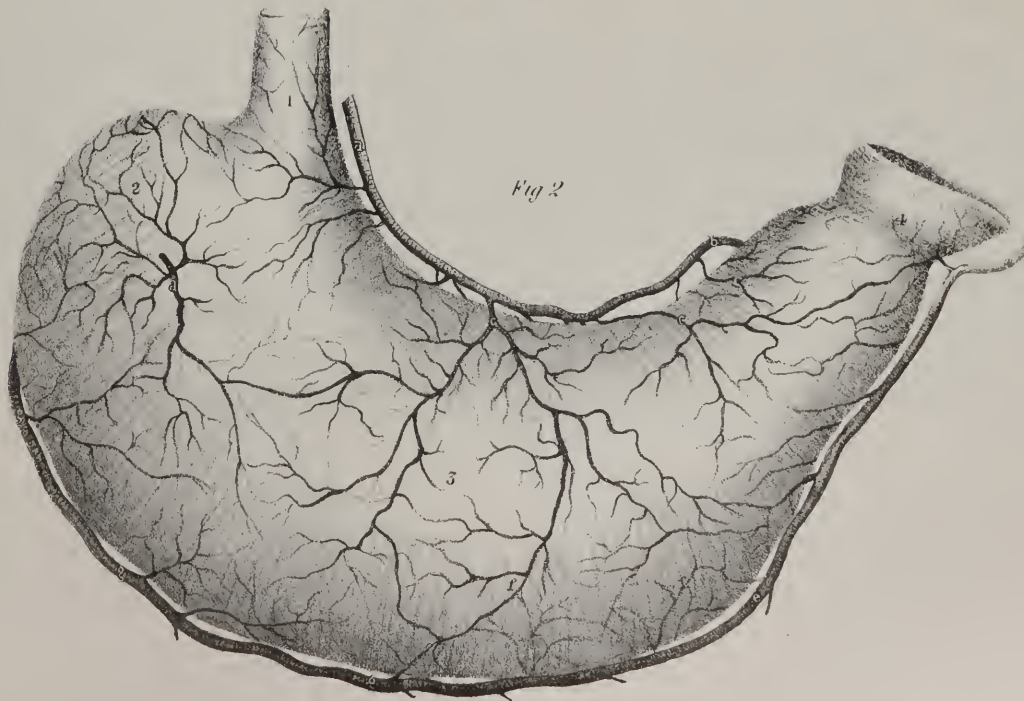
Fig 2







The *internal Mammary artery* (plate VII. fig. 2, n; r. *mammarius internus*) turns forwards from the subclavian to reach the inner surface of the first rib, and then descends between the pleura and the costal cartilages, as far as the cartilage of the seventh rib. At this point it divides into two branches, one of which inclines outwards, along the margin of the thorax, the other continues in the original direction of the vessel, down to the abdomen. Its branches, including the two just alluded to, are the following:—

*Ramus Comae nervi phrenici* is a very small branch, which joins the phrenic nerve where it passes over the mammary artery, or a little lower, and accompanies it to the diaphragm, to which its ramusculi are distributed, anastomosing with the phrenic arteries derived from the abdominal aorta, as well as with the phrenic branches given off by the musculo-phrenic division of the internal mammary.

*Ramuli Mediastini*:—Several small branches pass inwards to the cellular tissue in the anterior mediastinum, and also some to the anterior part of the pericardium.

*r. Thyfici*:—One or more small branches are given off to the thymus gland.

*r. Pericardiacus* is a branch of variable size, which passes backwards into the upper part of the pericardium. Its lowest part receives twigs from r. *musculo-phrenicus*.

*r. Intercostales anteriores* (plate VII. fig. 2, o, p) pass outwards, at each intercostal space, between the pleura and internal intercostal muscles, then between the two layers of the latter, and inosculate with the vessels of the same name, derived from the aorta, maintaining communications at the same time with the thoracic branches of the axillary artery.

*r. Musculo-phrenicus* is the external division of the mammary artery. It inclines outwards, in the direction of the cartilages of the false ribs, sending branches, backwards into the diaphragm, and downwards to the abdominal muscles, whilst others pass outwards, in the intercostal spaces, being disposed in the same way as those which come higher up from the mammary artery itself.

*r. Epigastricus superior* continues in the direction of the mammary artery, passing behind the seventh costal cartilage to reach the parietes of the abdomen. It there lies between the rectus muscle and its sheath: it ramifies freely in the muscles, and anastomoses with the inferior epigastric branch, which comes up from the external iliac artery.

The *superior Intercostal artery* (plate VII. fig. 2, e; r. *intercostalis superior*) turns backwards, immediately after its origin, from the posterior aspect of the subclavian, and reaches the inner surface of the first rib, beneath which it sends outwards an intercostal branch, similar in course and distribution to those derived from the aorta. Opposite the second intercostal space another branch is given off, after which it terminates by a small ramulus that communicates with the first aortic intercostal branch. Some twigs are given to the upper part of the œsophagus, and some also enter the intervertebral foramina, to ramify on the dura mater of the spinal canal.

*Varieties*.—The branches of the subclavian artery present numerous variations in their mode of origin. The thyroid is of considerable size when it gives off the supra-scapular and posterior scapular branches, but is much reduced when it is merely a single vessel for the supply of the thyroid gland. In some cases which have been cited it did not exist; in others it arose from the arch of the aorta, and ascended upon the trachea to its destination. The possibility of such a distribution points out at once how necessary it is to be cautious in performing the operation of tracheotomy.

The posterior scapular branch very frequently comes off singly from the subclavian, in the latter part of its course, where it turns down upon the first rib. The first intercostal and the deep cervical frequently arise by a common trunk. We have already seen that the vertebral has been found arising from the aortic arch. A very singular variety is delineated by Tiedemann, in which the vertebral artery of the left side had two origins, one from the aortic arch, between the left carotid and left subclavian arteries, and the other from the latter vessel, which united and formed the vertebral opposite the fifth cervical vertebra. The mammary artery is very constant; in a few cases it has been known to come from the aortic arch or from the brachio-cephalic.\*

The *Axillary artery* (plate IV. F, G; a. *axillaris*) lies obliquely across the superior and lateral part of the thorax extending from the lower border of the first rib as far as the inferior margin of the tendons of the latissimus dorsi and teres major. In this short course the direction of the vessel is outwards, downwards, and a little backwards, so that when the arm hangs freely by the side, it describes a curve whose convexity looks towards the acromion, and concavity towards the chest. It is accompanied by the axillary vein and brachial plexus of nerves, which lie at different sides of it; hence, in order that we may state precisely the relation of these vessels, as well as of the muscles, to the artery, it becomes necessary to consider it, not as a cylindrical tube, but as if it were compressed so as to present four sides. The acromial side at first corresponds with a small cellular interval that separates it from the plexus of nerves, then with the divisions of the plexus which are in close contact with it, and lower down

\* Variations in regard to the origin of the large vessels from the arch of the aorta, are very frequently met with. In the museum of the Jefferson Medical College are three preparations showing the origin of the right subclavian as a distinct trunk, coming off from the aorta on the left side of the origin of the left subclavian. In each of these cases the ultimate course of the vessel is the same, passing between the lower cervical vertebra and the œsophagus to gain its usual position between the scaleni muscles, where it gives off its customary branches. In two dissections I have seen the right subclavian, having nearly a similar origin, pass between the œsophagus and the trachea. In these cases there is no *arteria innominata*; the right carotid arising either as a distinct trunk, or by a short root common to both carotids. A knowledge of the frequency of these anomalies is important to the surgeon.—J. P.

with the tendon of the subscapular muscle, and finally, at its termination, with the coraco-brachialis, which is interposed between it and the humerus. The thoracic side of the vessel rests on the first intercostal space, then on the first digitation of the serratus magnus muscle. When it passes off the chest into the axillary space, it lies in the cellular interval between the serratus and subscapularis, and becomes supported by the nerves which here surround the vessel. The anterior surface is covered by the pectoralis major and costo-coracoid ligament or membrane in the space between the subclavius and pectoralis minor, then by the latter and the pectoralis major together, and, finally, by the last-named muscle, which covers it to its termination. Its posterior surface is supported by some cellular membrane and the deep divisions of the brachial plexus of nerves. The axillary vein, at first separated from the artery by the insertion of the scalenus anticus muscle, lies inferior and internal to it, that is to say, to its thoracic side: lower down it comes in front of the artery, and conceals it from view when we look into the axillary space.

The space here referred to, when cleared of the cellular tissue and glands which fill it, is of a pyramidal form, the summit being at the interval between the scaleni muscles, and the base at the borders of the pectoralis and latissimus dorsi; its sides are formed as follow, viz. by the pectoral muscles in front, by the latissimus and teres behind, the serratus magnus internally, and the subscapularis and head of the humerus externally. The brachial plexus of nerves is situated above, and to the outer side of the artery at its commencement; at about the middle of its course, the nerves surround it (the vessel being between the two roots of the median nerve;) lastly, the branches proceeding from the plexus are disposed with regard to the artery as follows: the external cutaneous nerve and one root of the median lie at its outer side; the internal cutaneous, the second root of the median, and the ulna, at its inner side; and behind it the circumflex and musculo-spiral.

The axillary artery gives off seven branches, which are named as follows; premising, at the same time, that considerable variety obtains in their mode of origin.

*The upper Thoracic branch* (ramulus thoracicus supremus) is a very small twig which arises just above the border of the pectoralis minor, from the axillary artery itself, or from the thoracico-acromial branch. It inclines forwards and inwards, getting between the pectoral muscles, to which its ramifications are distributed; some of them also go to anastomose with those of the internal mammary and intercostal arteries.

*The Thoracico-acromial branch* (plate IV. p; r. thoracico-acromialis) arises from the fore part of the axillary artery, being rather a large branch. It projects forwards at the upper border of the pectoralis minor, and soon divides into branches which take opposite directions. One set inclines inwards to the thorax, the other outwards to the acromion, whence the vessel derives its name. The thoracic branches are three or four in number, and are distributed to the serratus magnus and pectoral muscles, their extreme terminations communicating with those of the other thoracic branches, as well as with the intercostal branches of the internal mammary artery. The acromial branches incline outwards, and subdivide into a descending and transverse set. The latter proceed towards the acromion, and are distributed partly to the deltoid muscle; whilst others, upon the upper surface of that process, maintain an anastomosis with branches of the supra-scapular and posterior circumflex arteries. The descending branch passes down in the interval between the pectoralis major and deltoid, and ramifies in both.

*Ramulus thoracico-alaris* is very small and variable in size, and altogether unimportant; it is merely distributed to the glands and cellular tissue in the axilla.

*The long Thoracic branch* (plate IV. x; r. thoracicus longus) passes downwards and inwards along the lower border of the pectoralis minor, and is distributed to the mamma, (hence it is often called external mammary,) to the serratus and pectoral muscles, and anastomoses with the external branches of the intercostal arteries.

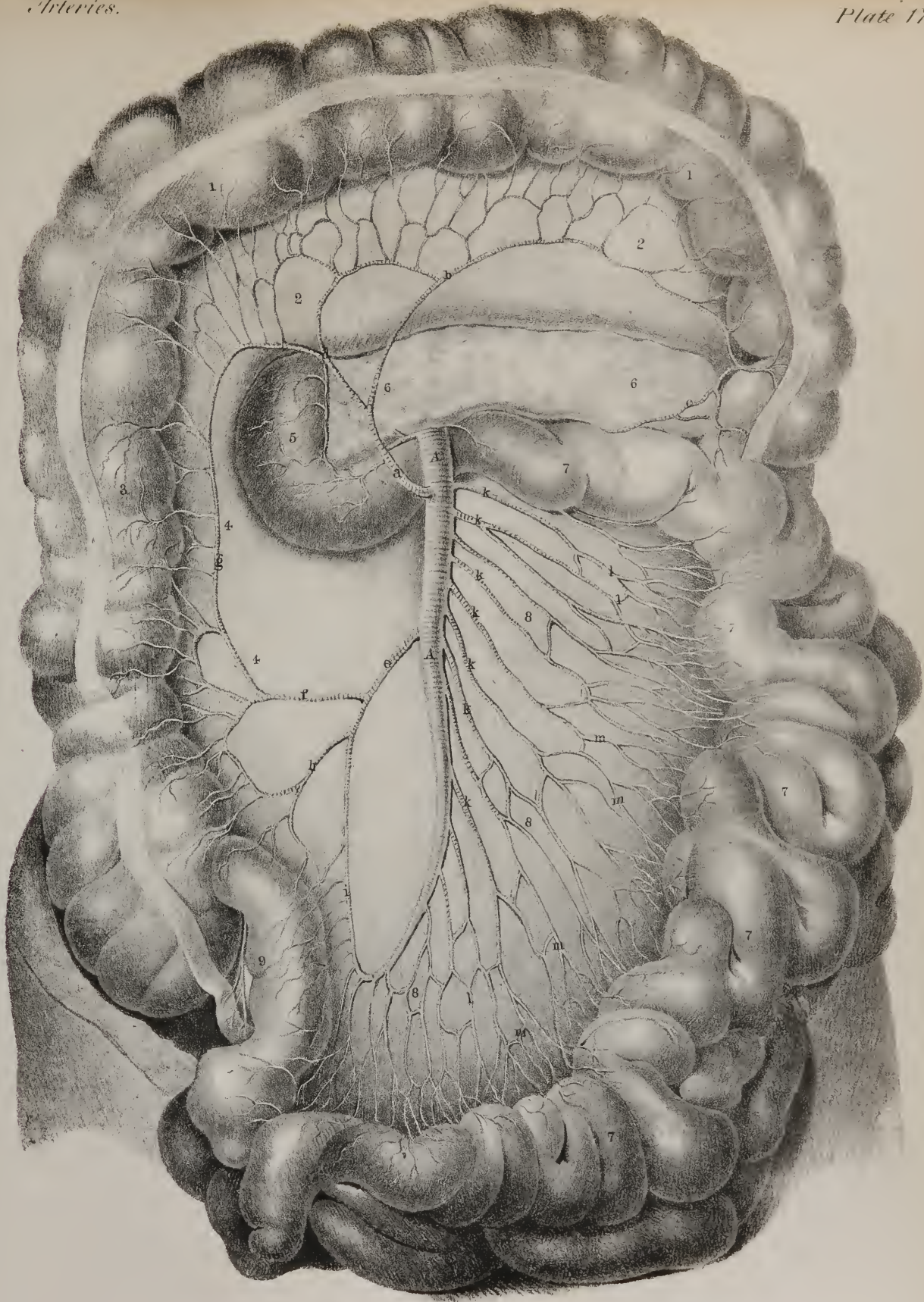
## PLATE XVII.

The superior mesenteric artery, and the branches which it gives to the small and large intestines, are here shown.

Nos. 1, 1. The transverse part of the colon. 2, 2. The layer of peritonæum forming the posterior lamella of the transverse meso-colon, the anterior one being taken away in order to expose the vessels. 3. The ascending part of the colon. 4, 4. The posterior part of the right meso-colon; the anterior one is removed to bring the vessels into view. 5. The descending part of the duodenum. 6, 6. The pancreas. 7, 7, 7. The convolutions of the small intestines. 8, 8, 8. The posterior layer of the mesentery.

A, A. The trunk of the superior mesenteric artery, (arteria mesenterica superior.) a. The middle colic branch, which turns forwards to supply the transverse colon, (arteria colica media, or ramus colicus medius;) it is seen to divide into two branches, of which one goes to the left, and is marked b, by which it communicates with an ascending branch, c, from the inferior mesenteric artery. d. The descending or right branch of the middle colic artery; it turns downwards and communicates with the right colic artery. e. The right colic artery, (arteria colica dextra, or ramus colicus dexter;) it usually comes off as a separate vessel, but in this case the vessel serves as a common trunk, and gives off a branch, f, which occupies the place of the right colic artery, and another, h, the ilio-colic; the right colic anastomoses by an ascending branch, g, with the middle colic artery, whilst another inclines downwards and anastomoses with the ilio-colic. h. The ilio-colic artery (arteria ilio-colica or ramus ilio-colicus) is intermediate in position between the right colic and the termination of the mesenteric artery. i. The termination of the mesenteric artery, where it inclines upwards to anastomose with the ilio-colic. k, k, k, k. Branches derived from the left side of the mesenteric artery for the supply of the small intestines. l, l, l, l. Communicating branches passing from one to the other, forming a net-work. m, m, m, m. Small branches proceeding directly to the intestines.









*The Sub-scapular branch* (plate IV. t; r. sub-scapularis) is the largest branch given off by the axillary artery. It arises from that vessel, close by the lower border of the sub-scapular muscle, along which it proceeds downwards and backwards, soon becoming considerably diminished in size, owing to its giving off a large branch to the dorsum of the scapula. The continuation of the vessel (plate IV. w) proceeds down toward the inferior angle of the scapula, accompanied by the sub-scapular nerve, and lying on the muscle of that name, to which it gives branches, as well as to the serratus magnus and latissimus muscle. Its final ramifications anastomose with those of the posterior scapular artery, and with its own dorsal branch:—the dorsal branch,

*Ramus dorsalis* (plate IV. v.)—The branch just named passes backwards from the sub-scapular artery, about an inch and a half from its origin, and is larger than the continuation of the vessel. Turning round the lower border of the scapula, the dorsal branch passes, first through the interval between the sub-scapularis and latissimus dorsi muscles, and then between the teres major and minor, and may be always found in the fissure between the last-named muscles, immediately behind the long head of the triceps. It gives branches to these muscles, and, on reaching the dorsum of the scapula, ramifies extensively upon it, supplying the infra-spinatus muscle, and anastomosing with the supra-scapular and posterior scapular arteries.

The two following branches are called “circumflex” from the manner in which they pass, one before and the other behind the shaft of the humerus. They come off close to the lower border of the axilla as the axillary artery is about to merge in the brachial. They vary much in their mode of origin; they often arise by a common stem from the axillary artery or from its sub-scapular branch; sometimes the posterior one comes from the upper deep branch of the brachial artery.

*The posterior Circumflex branch* (plate IV. s; r. circumflexus posterior) is not so large as the sub-scapular, near which it arises. It passes backwards immediately after its origin, winds round the shaft of the humerus, lying between the bone and the long head of the triceps, having the teres major muscle below, and the teres minor above it; it terminates by ramifying in the deltoid muscle and on the shoulder-joint, having previously communicated by branches with the anterior circumflex and supra-scapular arteries.

*The anterior Circumflex branch* (plate IV. r; r. circumflexus anterior) is much smaller than the preceding. It passes from within outwards and forwards, under the coraco-brachialis and inner head of the biceps muscle, resting on the fore part of the humerus, until it reaches the bicipital groove. There it divides into two branches, or, in some cases, into two sets of branches; of these, one ascends by the long head of the biceps through the groove in which it runs, and is distributed to the head of the bone and the capsule of the joint; the other continues outwards, in the original direction of the vessel, and, after anastomosing with the posterior circumflex branch, is lost in the deltoid muscle.

*The Brachial artery* (plate IX. figs. 1, 2, A, A; arteria brachialis vel humeraria) is placed along the internal and anterior aspect of the arm, extending from the lower border of the axilla to about a finger's breadth below the bend of the elbow. Its direction is downwards, outwards, and forwards, and may be marked out by a line drawn from midway between the borders of the axilla to the middle point between the condyles of the humerus; so that in the first part of its course the vessel is situated at the inner side of that bone, and inferiorly on its anterior aspect. The artery may be said to be superficial in its whole course, inasmuch as it can be exposed without dividing any muscular fibres, being covered merely by the skin and fascia.

The brachial artery in the upper part of its course rests on the triceps muscle, the spiral nerve however, and the profunda artery intervening; in the middle of the arm it crosses over the insertion of the coraco-brachialis muscle, and lies from thence to its termination on the brachialis anticus. Its external side is in apposition, in the upper half of the arm, with the coraco-brachialis; in the lower with the biceps, the borders of which muscles somewhat overlap it. The venæ comites are in close contact with the artery, short transverse branches of communication passing from one to the other, so as at many points to encircle it: the basilic vein is parallel and superficial to it, sometimes in its entire extent. The median nerve, though its two roots embrace the axillary artery, lies at first to the acromial side of the brachial; but as it descends it inclines in front of the vessel, crossing it about the middle of the arm, so that at the elbow it lies to the inner side of the artery, and on the same plane, both being supported by the brachialis anticus muscle. The nerve usually crosses in front of the artery, but in some instances behind it. The internal cutaneous nerve is superficial to the artery, but it does not lie directly in front of it; for, at the elbow, the nerve is to its inner side, and maintains a similar relation higher up.

At the bend of the arm the artery sinks deeply into an angular interval, enclosed between the pronator teres and supinator radii longus. In this situation the vessel is covered by the fascia of the arm, and crossed by the fibrous process which passes from the tendon of the biceps to that membrane, and separates the artery from the median basilic vein: it rests on the brachialis anticus muscle, having the tendon of the biceps on the radial, the median nerve on the ulnar side, and finally, opposite the insertion of the brachialis anticus, it divides into the radial and ulnar arteries. The position of the artery with regard to the shaft of the humerus deserves particular attention. Superiorly it is parallel with, and to the inner side of the bone, and inferiorly lies directly in front of it. In the former situation, therefore, in order to compress the vessel, the pressure must be directed from within outwards; in the latter, from before backwards; and at the intermediate point the direction of the pressure must also be intermediate, that is to say, backwards and onwards.

The brachial artery in its course gives numerous branches to the muscles by which it passes; none but the following have received names, or require description.



*The superior Collateral artery*, (plate IX. figs. 1, 2, c; arteria profunda superior,) having started from the back part of the artery, just below the border of the teres major, inclines downwards and outwards, to reach the interval between the second and third heads of the triceps. In this course it is accompanied by the musculo-spiral nerve, and both, continuing the same oblique direction, pass between the second head of the triceps and the bone, to reach its external and anterior aspect. In the latter situation, the artery lies deeply in the fissure between the brachialis anticus and supinator longus muscles, considerably diminished in size, by having given off several branches, and descends to the elbow, where it anastomoses with the recurrent branch of the radial artery. The only off-set from this artery that requires a special notice, is one which descends perpendicularly from it, when lying behind the middle of the humerus, and proceeds between the triceps muscle and the bone to the back part of the elbow-joint, where it anastomoses with the interosseous recurrent branch. This vessel is sometimes given off by the sub-scapula artery or by the posterior circumflex.

*Ramus nutritius*.—This is a very small branch given off by the brachial artery about the middle of the arm, or by one of its collateral branches. It inclines downwards and enters the oblique canal in the humerus near the insertion of the coracobrachialis muscle, and is distributed to the medullary membrane.

*The inferior Collateral artery* (plate IX. f; a. profunda inferior) is of small size, and arises from the brachial artery, a little below the middle of the arm. Its direction is downwards and inwards, from the point just indicated, to the back part of the inner condyle of the humerus; to gain which it, in the first place, pierces the intermuscular ligament or septum, and then lies on the inner surface of the triceps, (its third head,) to which it gives branches. In this course the artery lies parallel, and on the same plane, with the ulnar nerve, and enters the interval between the olecranon and inner condyle, where it terminates by anastomosing with the posterior recurrent branch of the ulnar artery.

*The Anastomosing branch*, (plate IX. figs. 1, 2, i; ramulus anastomoticus,) though a very small branch, is almost constant in its occurrence; it arises from the brachial artery, about two inches above the bend of the arm. Resting on the brachialis anticus, this little vessel descends towards the inner condyle, and divides into two sets of ramifications. Of these, one lies in front of the articulation, and after supplying the brachialis anticus and pronator teres muscles, anastomoses with the anterior ulnar recurrent, whilst the other passes backwards, comes into relation with the ulnar nerve, and communicates with the branches of the r. ulnaris recurrens and of the r. profundus inferior.

It must be obvious, that the terms applied to the branches of the brachial artery are rather ill chosen. The r. inferior profundus lies beneath the fascia, and is superficial rather than deep-seated; and the property of anastomosis is common to all, as well as the small branch called anastomoticus magnus or major. The first branch may, with propriety, be named “profundus,” from its situation, or “spiral,” from its direction; and the two others “collateral,” from their relation to the artery itself; so they were named formerly by Winslow, and still by Boyer.

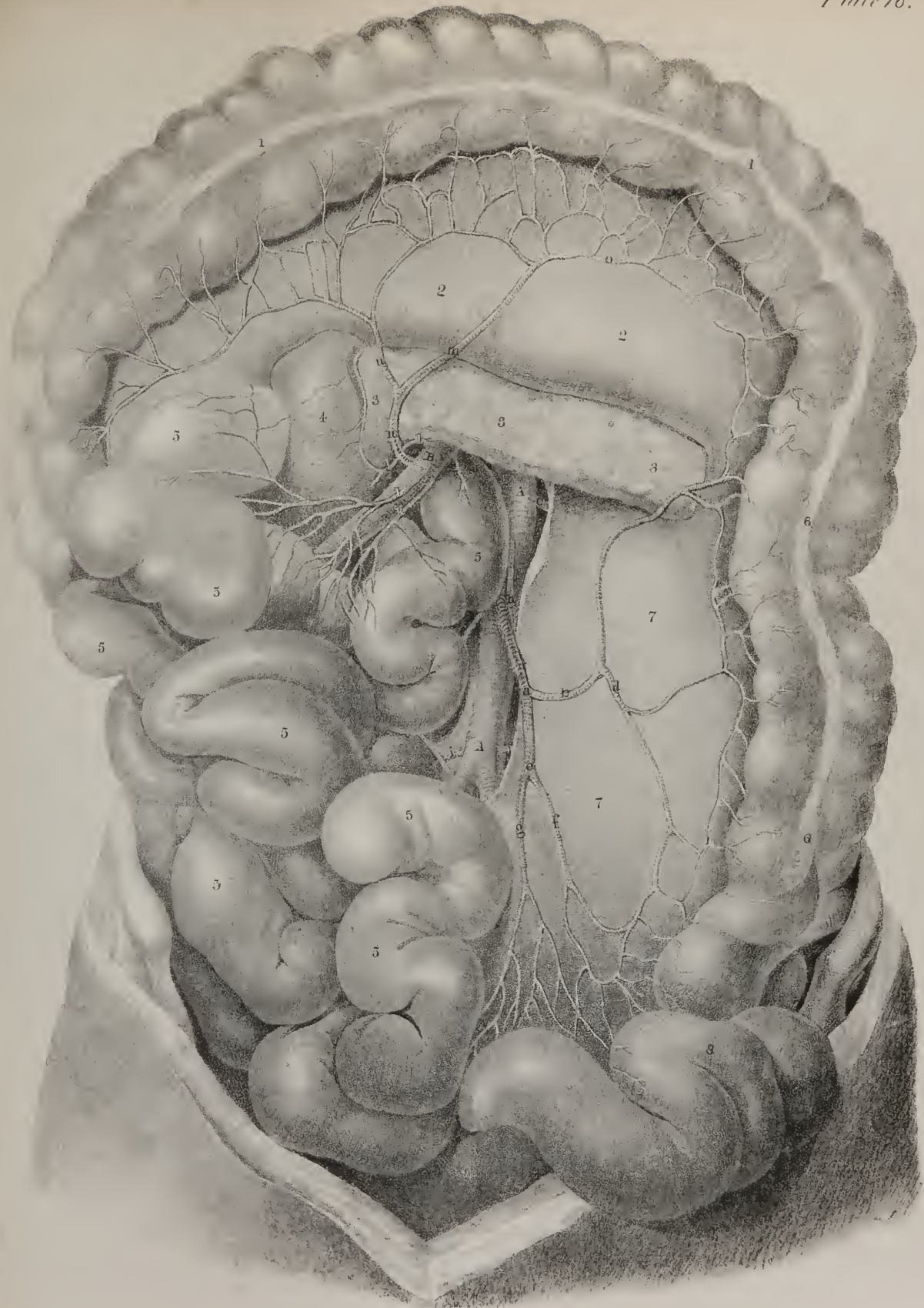
*Varieties*.—The description above given of the course, relations, and mode of division of the brachial artery, is conformable with what obtains in the greatest number of instances. Some varieties, however, occur which deserve notice. The vessel not unfrequently divides as high as the middle of the arm, or even higher, or rather gives off one of its two terminal branches, which most commonly is the radial. On this subject Meckel states, as the result of his observations, that when the radial artery arises in the arm, it usually commences towards the middle point; but that the anomalous division of the ulnar, though less frequent in its occurrence, takes place in most instances higher up, even as high as the point at which the axillary terminates in the brachial. I found in the dissecting-room a few years ago a variety not hitherto noticed. It was at first taken for the ordinary high division of the ulnar artery. The two vessels descended from the point of division at the border of the axilla, and lay parallel with one another in their course through the arm; but instead of diverging, as is usual, at the bend of the elbow, they converged and united so as to form a short trunk, which soon divided again into the radial and ulnar arteries in the regular way. The femoral artery presented a conformation in every particular similar to this in the person of an individual who was the subject of popliteal aneurism, for which an operation was performed by Sir Charles Bell. The pulsation was not stopped when the ligature was applied to the vessel. When the radial arises high up from the brachial artery, it may be situated parallel and

## PLATE XVIII.

The inferior mesenteric artery is here shown.

Nos. 1, 1. The transverse part of the colon drawn upwards on a level with the margin of the ribs; the mesentery with the superior mesenteric artery is drawn over to the right side. 2, 2. The transverse meso-colon. 3, 3, 3. The pancreas. 4. The descending part of the duodenum. 5, 5, 5, 5. Convolutions of the small intestine. 6, 6. The left or descending part of the colon. 7, 7. The left meso-colon. 8. The flexure of the colon. 9. The commencement of the rectum.

A, A. The aorta, lying upon the front of the spine. a. The trunk of the inferior mesenteric artery. b. The left colic artery, (arteria colica sinistra, or ramus colicus sinister.) c. The ascending branch of the left colic artery passing upwards to anastomose with the middle colic artery. d. Its descending branch, which turns down to anastomose with the sigmoid branch. e. The continuation of the inferior mesenteric artery; it gives off, f, the sigmoid branch, (arteria sigmoidea,) which goes to the flexure of the colon, and, g, the superior hæmorrhoidal branch, (arteria hæmorrhoidalis superior,) which passes down behind the rectum. h. The spermatic artery. l. One of the lumbar. B. Superior mesenteric artery, giving off k, l, n branches to the small intestines. m. Colica dextra. n. Descending branch. o. Anastomatic branch. C. Renal artery.







internal to that vessel, or may turn suddenly outwards across it, becoming in a manner superficial to it, but still covered by the fascia. Tiedemann says that in such cases the "radial artery is either enclosed by the aponeurosis of the arm, or, perforating it, runs with the cephalic vein immediately under the skin."\* The latter case must be of rare occurrence. In some instances the radial artery, instead of continuing its course to the lower part of the radius, inclines outwards and backwards a little below the middle of the fore-arm, and so descends along its outer border, superficial to the extensor tendons. When the radial artery arises thus high, and runs superficial, the external or radial recurrent is a branch of the brachial artery, or more rarely of the ulnar.

When the origin of the ulnar artery takes place high in the arm, it lies beneath the fascia as it descends, and runs superficial to the flexor muscles. In one instance of a high division, Tiedemann observed a cross branch connecting the ulnar and brachial. In a few cases an anomalous branch has been observed to pass down from the brachial and end in the radial, or in the brachial itself. This appears to be but a minor degree of that division, and subsequent re-union, instances of which in the brachial and femoral arteries have been above noticed.

The inter-osseous artery, in two or three cases, (at least there are no more recorded,) arose from the brachial about the middle of the arm. Its position was internal, and posterior to the main artery; and on reaching the bend of the elbow, passed deeply between the muscles, and assumed the usual position of the vessel. A superficial anterior inter-osseous artery sometimes exists, which arises a little below the elbow-joint, and takes the course of the median nerve to the palm of the hand, where it terminates by inosculation in the palmar arch.

The brachial artery, when arrived opposite the insertion of the brachialis anticus muscle, divides into its ulnar and radial branches.

*The Ulnar artery* (plate IX. fig. 2, C, C; arteria ulnaris) inclines, in rather a curved direction, downwards and inwards, passing under cover of the superficial muscles which arise from the inner condyle, viz. the pronator teres, flexor carpi radialis, palmaris longus, and flexor sublimis, until it reaches the flexor carpi ulnaris. About the same point, that is, at the junction of the upper with the middle third of the fore-arm, the artery comes into contact with the ulnar nerve, which had previously been separated from it by a considerable interval, having lain behind the inner condyle, but here approaches it, lying to its ulnar side. Thus placed, they both descend towards the inner border of the palm of the hand. In the first part of its course the artery is covered by the muscles above enumerated; in the middle of the arm it is overlapped by the flexor carpi ulnaris; and, in the lower, it runs parallel and in close relation with the outer border of its tendon. In this part of its course the vessel is covered only by the common integuments, the fascia of the arm and a thin layer, by which it is connected to the muscles behind it. For two-thirds of its extent it lies on the flexor profundus muscle; in the rest, on the pronator quadratus and annular ligament. It is accompanied, in its entire extent, by two veins, which lie one on each side. At its origin the artery is in close relation with the median nerve, from which, however, it is soon separated by the origin of the pronator teres from the coronoid process of the ulna; inclining inwards, it approaches the ulnar nerve, and by it is accompanied in the lower two-thirds of its course,—the nerve lying on the ulnar side of the artery.

*Palmar arch* (superficial; plate IX. fig. 1, p, p.)—The ulnar artery, guided as it were by the tendon of the flexor ulnaris muscle, reaches the radial border of the pisiform bone, where, accompanied by the nerve, it passes over the cutaneous surface of the annular ligament of the wrist. At this point the artery begins at once to change its direction, by running outwards and forwards, across the palm of the hand; and on arriving about midway between the flexure formed by the bend of the first joint of the thumb and that of the fore-finger, it terminates by inosculating with a branch (*superficialis volæ*) sent forwards by the radial artery, to unite with it. The vessel thus describes a curve, whose convexity looks forwards. This curved part of the artery is called the *superficial palmar arch*, (*arcus volæ superficialis*), to distinguish it from the deep-seated one formed by the radial artery. It rests on the annular ligament of the wrist at its commencement, and afterwards on the tendons of the flexor sublimis; and is covered, for a short way, by the palmaris brevis, and afterwards by the palmar fascia and integument. The vessel, in the palm, is usually somewhat tortuous; and presents not a few varieties in its course and mode of termination.

The branches of the ulnar artery in the fore-arm are the following:—

*The anterior Recurrent branch* (plate IX. fig. 2, p; ramus recurrens anterior) arches inwards from the ulnar artery, near its origin, running on the brachialis anticus muscle, and covered by the pronator teres, to both of which it sends ramusculi. On reaching the inner condyle, it anastomoses with the ramus profundus inferior and anastomoticus, derived from the brachial artery.

*The posterior Recurrent branch* (plate X. fig. 2, d; r. recurrens posterior) is larger than the preceding, and comes off lower down; but not unfrequently they both arise by a small common trunk. It runs backwards somewhat, and ascends upon the posterior aspect of the inner condyle; and in the interval between that process and the olecranon, anastomoses with the r. pro-

\* It is necessary for bleeders to recollect the anomalous superficial position of one of the arteries at the bend of the arm that is occasionally met with. In two cases of the kind I have had to take up the brachial artery, for aneurism following venesection. Pulsation was stopped in the vessel by the ligature used by the bleeder, and the empty vessel presented to his finger the elastic feeling of a distended vein. In all doubtful cases let the operator, before using his lancet, slacken his ligature and ascertain where the pulsating vessel lies.—J. P.

fundus inferior, some of its branches extending outwards, so as to communicate with those of the *r. profundus superior* and *recurrens inter-osseus*.

The *Inter-osseous branch* (plate IX. fig. 2, D, D; *r. inter-osseus, communis*) is of considerable size, and is sometimes called the common inter-osseous artery, from the circumstance of its dividing into two vessels bearing that name, which lie on the opposite surfaces of the inter-osseous ligament or membrane. This vessel inclines somewhat backwards after its origin, to reach the upper border of the inter-osseous ligament, where its division takes place.

The *anterior Inter-osseous branch* (plate IX. fig. 2, D; plate X. fig. 3, g, h: *r. inter-osseus anterior*) proceeds downwards, lying on the anterior surface of the inter-osseous ligament, and is accompanied by the inter-osseous branch of the median nerve, and overlapped by the contiguous borders of the flexor profundus and flexor longus pollicis. Thus placed, it gives off some muscular branches, and the two nutritious arteries (*r. medullares*) to the radius and ulna. These incline to each side and enter the oblique foramina in the bones just mentioned, to be distributed to the medullary membranes in their interior. The artery continues its course directly downwards until it reaches the upper border of the pronator quadratus muscle, where it gives off some small branches to supply that muscle and ramify upon the carpus, after which it passes from before backwards, through an opening in the inter-osseous ligament; and, on reaching its dorsal surface, proceeds along the back of the carpus, where it maintains communications with the posterior carpal branches of the radial and ulnar arteries.

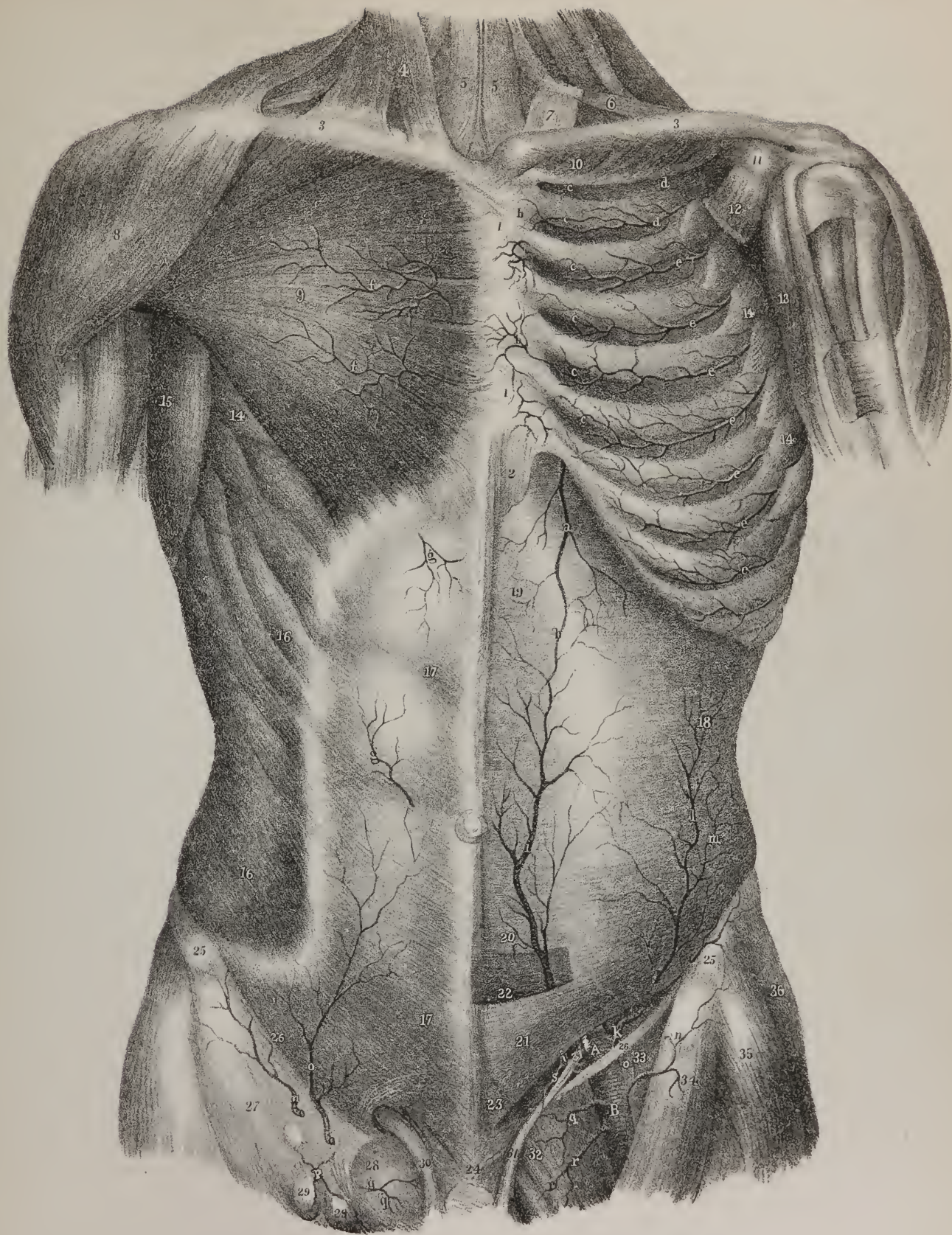
The *posterior Inter-osseous branch* (plate X. figs. 2 and 3, e; *r. inter-osseus posterior*) passes backwards, through the interval left between the oblique ligament and the upper border of the inter-osseous ligament. Continuing its course downwards, along the arm, under cover of the extensor muscles, it gives several branches to them, and reaches the carpus considerably diminished in size, where its terminal branches anastomose with the perforating or terminal branches of the anterior inter-osseous artery, and with the carpal branches of the radial and ulnar arteries. In addition to numerous muscular branches, which require no special notice, this artery, as soon as it reaches the posterior surface of the ligament, gives off a recurrent branch, (*r. recurrens inter-osseus posterior*; plate X. fig. 1, c; fig. 2, f; fig. 3, d,) which is nearly as large as the continuation of the vessel. This branch passes directly upwards, covered by the supinator brevis and anconeus, to reach the interval between the olecranon and external condyle, where it divides into several ramusculi, that anastomose with the terminal branches of the *r. profundus superior* and inferior, as well as of the posterior ulnar recurrens.

## PLATE XIX.

The arteries supplying the anterior parietes of the chest and abdomen, and the superficial blood-vessels in the groin, are here shown.

- No. 1. The sternum covered by the tendinous interlacings of the great pectoral muscle and anterior sterno-costal ligaments. 2. The ensiform cartilage. 3, 3. The clavicles. 4. The sterno-mastoid muscle. 5, 5. The sterno-hyoid muscles. 6. The inferior belly of the omo-hyoid muscle. 7. A process of the deep fascia of the neck, which holds down the tendon of the omo-hyoid muscle, permitting the play of the tendon through it as through a pulley. 8. The deltoid muscle. 9. The great pectoral muscle. 10. The subclavius muscle. 11. The coracoid process. 12. The lesser pectoral muscle divided. 13. The coraco-brachialis muscle. 14, 14. Digitations of the serratus magnus muscle. 15. Latissimus dorsi muscle. 16, 16. The external oblique muscle of the abdomen. 17, 17. The aponeurosis of the external oblique muscle proceeding to its attachment in the linea alba. 18. The transversalis muscle of the abdomen; the external oblique, internal oblique, and rectus muscles having been removed. 19. The aponeurosis of the transversalis muscle forming the posterior layer of the sheath of the rectus muscle. 20. The inferior part of the sheath of the rectus, becoming thin before it is entirely lost. 21. The lower part of the aponeurosis of the transversalis muscle passing in front of the rectus muscle. 22. The rectus muscle cut across to display the epigastric artery. 23. The pyramidalis muscle seen through the aponeurosis of the transversalis muscle. 24. The interlacement of the tendinous fibres of the external oblique muscle, in front of the symphysis of the pubis. 25, 25. The anterior superior spine of the ilium. 26, 26. Poupart's ligament. 27. The form of the sartorius muscle apparent through the fascia lata. 28. The saphenous opening in the fascia lata. 29. Absorbent glands resting on the fascia lata. 30. The spermatic cord, issuing from the external ring in the aponeurosis of the external oblique muscle. 31, 31. The vas deferens crossing the epigastric artery as it curves inwards to the side of the bladder. 32. The pectineus muscle. 33. The iliacus muscle. 34. The sartorius muscle. 35. The anterior border of the glutæus medius muscle. 36. The tensor vaginæ femoris muscle.
- a. The internal mammary artery. b, b. Superficial branches of the internal mammary supplying the front of the sternum. c, c. Intercostal branches of the internal mammary. d, d. Intercostal branches from the superior intercostal artery. e, e. Intercostal arteries from the aorta, inosculating with the anterior intercostal branches of the internal mammary. f, f. External mammary branches from the internal mammary artery.
- A. The external iliac artery, giving off the epigastric and circumflex ilii arteries. B. The femoral artery.
- g, g. Small cutaneous branches from the epigastric artery. h. Inosculation of the internal mammary artery with the epigastric. i, i. The epigastric artery. k. The circumflex ilii artery at its origin from the trunk of the external iliac. l. The continuation of the artery upon the transversalis muscle. m. The branch which follows the curve of the crest of the ilium. n, n. The superficial circumflex ilii artery from the femoral: on the right side it is seen piercing the fascia lata, and running outwards to the crest of the ilium. o, o. The superficial epigastric artery; on the left side it is divided immediately after its origin. p. A small branch to the inguinal glands. q, q. Superficial external pudic arteries. r. Deep external pudic artery. s. The deferential artery from the epigastric, ramifying along the course of the vas deferens.









*Muscular branches* (r. musculares.)—Several branches are distributed to the muscles by the ulnar artery in its course along the arm.

*The dorsal Carpal branch* (plate X. fig. 1, h; fig. 3, p: r. carpi dorsalis) is a branch of variable size, which inclines backwards from the ulnar artery a little before it reaches the pisiform bone. It winds back under the tendon of the flexor carpi ulnaris, and reaches the dorsal surface of the carpus; there it gives some ramuli which anastomose with similar offsets from the metacarpal branch of the radial artery, after which it runs along the metacarpal bone of the little finger, and forms its dorsal branch. From the arch of anastomosis, just referred to, the second and third dorsal inter-osseous branches are derived.

*The palmar Carpal branch* (r. carpi palmaris) is a very small twig, which runs on the anterior surface of the carpus, and anastomoses with a similar offset from the radial artery.

Branches given off by the palmar arch:

*The communicating branch* (plate IX. fig. 2, r; r. communicans) arises a little beyond the pisiform bone, and sinks deeply between the flexor brevis and the abductor of the little finger; it inosculates with the termination of the radial artery, and thereby completes the deep palmar arch.

*Palmar branches* (ramuli palmares.)—From the concavity and dorsal surface of the palmar arch, small branches are given to the parts in the palm of the hand.

*The digital branches*, (plate IX. fig. 1, t, u; r. digitales,) four in number, proceed forwards from the convexity of the palmar arch, to supply the fingers. The *first* branch inclines inwards to the ulnar border of the hand, and after giving ramusculi to the small muscles of the little finger, runs along the inner margin of its phalanges. The *second* runs along the fourth metacarpal space, and at the root of the fingers divides into two ramusculi, which proceed along the contiguous borders of the ring and little fingers. The *third* is similarly disposed of to the ring and middle fingers, and the *fourth* to the latter and the index;—the radial side of the index finger and the thumb are supplied from the radial artery. Each pair of collateral branches, on arriving at about the middle of the last phalanx of the finger, converge and form an arch, from the convexity of which small ramusculi run forwards to its termination.

*The radial artery*, (plate IX. figs. 1 and 2, B; plate X. figs. 1 and 3, i: arteria radialis,) in direction though not in size, appears to be the continuation of the brachial. Its direction is from the point of division above indicated towards the styloid process of the radius, lying obliquely along the anterior aspect of the fore-arm, its course being indicated by a line drawn from the middle of the bend of the elbow to the narrow interval between the trapezium bone and the tendons of the extensors of the thumb. These can be readily felt towards the outer border of the wrist. The artery is covered by the fascia of the arm and integument, and for some way is overlapped by the fleshy part of the supinator longus, which must be drawn aside in order to expose it. It is at first supported by the branches of the musculo-spiral nerve, and some cellular tissue, which separate it from the supinator radii brevis muscle; it then passes over the insertion of the pronator teres and the radial origin of the flexor sublimis; after which, it lies on the flexor pollicis longus and pronator quadratus, until it reaches the end of the radius. To its inner side lies the pronator teres in the upper part of its course, and the flexor carpi radialis in the rest; its outer side being in apposition with the supinator longus all the way down. Two venæ comites run parallel with the artery. The radial branch of the musculo-spiral nerve lies to its radial side during the middle third of its extent; but above that part the nerve is separated from it by a considerable interval, and lower down it turns backwards, to reach the dorsal aspect of the arm, and loses all anatomical relation to it. Opposite the end of the radius the artery inclines outwards, passing between its styloid process and the trapezium, and beneath the two first extensors of the thumb. It then runs forwards for a short way, (lying in the angular interval between the tendons of the two first extensors of the thumb and that of the third,) to gain the angle between the two first metacarpal bones, and makes its final turn into the palm of the hand, by passing between the heads of the abductor indicis muscle.

*Palmar arch* (deep-seated; plate IX. fig. 2, r, r.)—The terminal part of the artery (*arcus volæ profundus*) runs transversely across the palm of the hand, lying on the heads of the inter-osseous muscles (to which it gives branches) and the carpal extremities of the metacarpal bones, and opposite the fourth bone of that name inosculates with the communicating branch from the ulnar artery which completes the deep palmar arch. This differs from the superficial arch, not only in being more deeply seated, (being covered by all the flexor tendons,) but also in retaining its size almost undiminished, and lying near the carpus.

The radial artery gives off the following branches:

*The recurrent branch* (plate IX. 1; plate X. figs. 1, d, 3, b; ramus recurrens) arches upwards from the artery soon after its origin, running between the branches of the spiral nerve. It lies on the supinator brevis, covered by the supinator longus; and opposite the external condyle anastomoses with the terminal branches of the r. profundus superior, having in its course given ramuli to the extensor and supinator muscles.

*Muscular branches* (ramuli musculares.)—Several unnamed branches are given to the muscles on the fore part of the arm.

*The superficial Palmar branch* (plate IX. fig. 1, o; fig. 2, n: r. superficialis volæ) proceeds directly forwards from the artery, where it is about to turn towards the back of the hand, and seems like the proper continuation of that vessel in direction, though not in size, as it is usually small and tapering. In this respect, however, it is subject to many varieties.\* This branch

\* This volar artery is occasionally so large, that when divided it has been found necessary, in order to stop the hemorrhage, to secure it with a ligature.—J. P.

runs over the small muscles of the thumb at their origin, lying upon the annular ligament, to which it is bound down by a thin process of fascia, and terminates by inosculating with the radial extremity of the superficial palmar arch, which it thus completes.

*The posterior Carpal branch* (plate X. figs. 1 and 3, k; r. carpi posterior, r. dorsalis carpi radialis) arises close by the tendons of the radial extensor muscles, beneath which it runs upon the dorsal surface of the carpus, to anastomose with a similar branch, proceeding from the ulnar artery.

*The anterior Carpal branch* (r. carpi anterior.)—A small branch will be found also on the anterior surface of the carpus, arising from the radial artery somewhat higher up. It is usually called *ramus anterior carpi radialis*, to distinguish it from a similar branch of the ulnar artery, with which it anastomoses.

*Metacarpal branch* (plate X. fig. 1, o; figs. 3, s: r. metacarpi.)—When under the extensors of the thumb, a branch goes off obliquely forwards as if to gain the interval between the second and third metacarpal bones. It gives from its ulnar side one or two ramuli, which join with small branches from the posterior carpal branch of the ulnar artery, and form an arch or net-work of vessels upon the carpus. The continuation of the metacarpal branch runs upon the second dorsal inter-osseous muscle; at the cleft between the fingers it gives off ramuli to the dorsal surface of the middle and fore-finger, and communicates with the palmar digital branch at its point of division. This part of the artery is sometimes called the first dorsal inter-osseous branch, the second and third being derived from the arch of arteries above noticed.

*The Dorsal arteries of the thumb* (plate X. fig. 1, l; fig. 3, l, m: r. dorsales pollicis) are two, which sometimes arise separately, at others by a common trunk, which divides into two ramusculi that run along upon the dorsal aspect of the bones of the thumb, one at its radial, the other at its ulnar border.

*The Dorsal branch of the index finger* (r. dorsalis indicis) arises lower down than the preceding, and after sending ramusculi to the abductor indicis, runs along the dorsal surface of the index finger. Its size is very variable.

*The Digito-palmar branch of the thumb* (plate IX. fig. 2, o; plate X. fig. 1, m; fig. 3, n: r. princeps pollicis) commences where the artery is about to turn across the palm of the hand, and after proceeding forwards between the abductor indicis and abductor pollicis, divides, near the extremity of the first metacarpal bone, into two ramusculi, which run along the borders of the phalanges of the thumb at its palmar aspect. These form its collateral branches, and unite by anastomosing upon its second phalanx, in the same way as those of the other fingers, derived from the superficial palmar arch.

*The Digito-radial branch of the fore-finger* (plate IX. fig. 1, r; fig. 2, s; plate X. fig. 1, n; fig. 3, o; r. radialis indicis.)—Close to the preceding, a branch arises, variable in size, but very regular in its course. It runs along the external border of the index finger, and at its last phalanx anastomoses with the corresponding collateral branch derived from the superficial palmar arch.

*Recurrent branches* (ramuli recurrentes.)—From the concavity of the deep palmar arch, ramuli proceed backwards, and communicate with the carpal arteries.

*Inter-osseous branches* (plate IX. fig. 2, t; r. inter-ossei.)—From the convexity of the arch others run forwards along the metacarpal spaces, supplying the inter-osseous muscles, and anastomosing with the digital branches of the ulnar artery.

*Perforating branches* (plate X. fig. 3, r; r. perforantes.)—These are small ramuli, usually three in number, which pass backwards through the metacarpal spaces at their superior extremities, and inosculate with the dorsal inter-osseous branches.

*Varieties.*—The distribution of the arteries in the hand presents, in very many instances, deviations from the arrangement here indicated. We occasionally find the superficial palmar arch formed by the ulnar artery alone, the superficialis volæ branch being too small to extend farther than the muscles of the thumb, upon which it is expended. In such cases the digital branches of the thumb, as well as those of the other fingers, are derived from the ulnar artery, which is necessarily a little larger than usual.

## PLATE XX.

The arteries supplying the uterus, in a woman who died six days after delivery; showing their enlargement and tortuous distribution. Nos. 1, 1. The kidneys. 2, 2. The ureters. 3, 3. The quadratus lumborum muscles. 4, 4. The small psoas muscles. 5, 5. The great psoas muscles. 6, 6. The iliacus muscles. 7, 7. The anterior superior spinous process of the ilium on each side. 8, 8. Poupert's ligament at each side. 9. The prominence of the sacrum. 10. The rectum cut across. 11. The body of the uterus, displaying its enlarged form after recent delivery. 12, 12. The ovaries connected by their ligaments to the upper angles of the uterus. 13, 13. The Fallopian tubes terminating in the fimbriated extremities.

A. The abdominal aorta. B. The divided trunk of the superior mesenteric artery. C, C. The renal arteries. D. The divided inferior mesenteric artery. E, E. The common iliac arteries. F, F. The external iliac arteries. G, G. The internal iliac arteries.

a, a. The spermatic arteries arising from the main trunk of the aorta, enlarged and tortuous in their course through the broad ligaments of the uterus. They are distributed to the ovaries and sides of the uterus, communicating freely with the uterine arteries. b, b. Lumbar arteries. c. The middle sacral artery. d, d. The uterine arteries, arising from the internal iliacs, and ramifying in a tortuous course upon the sides and fundus of the uterus. e, e. The circumflex ilii branches of the external iliac arteries, ramifying round the crest of the ilium, and inosculating with branches from the ilio-lumbar arteries.



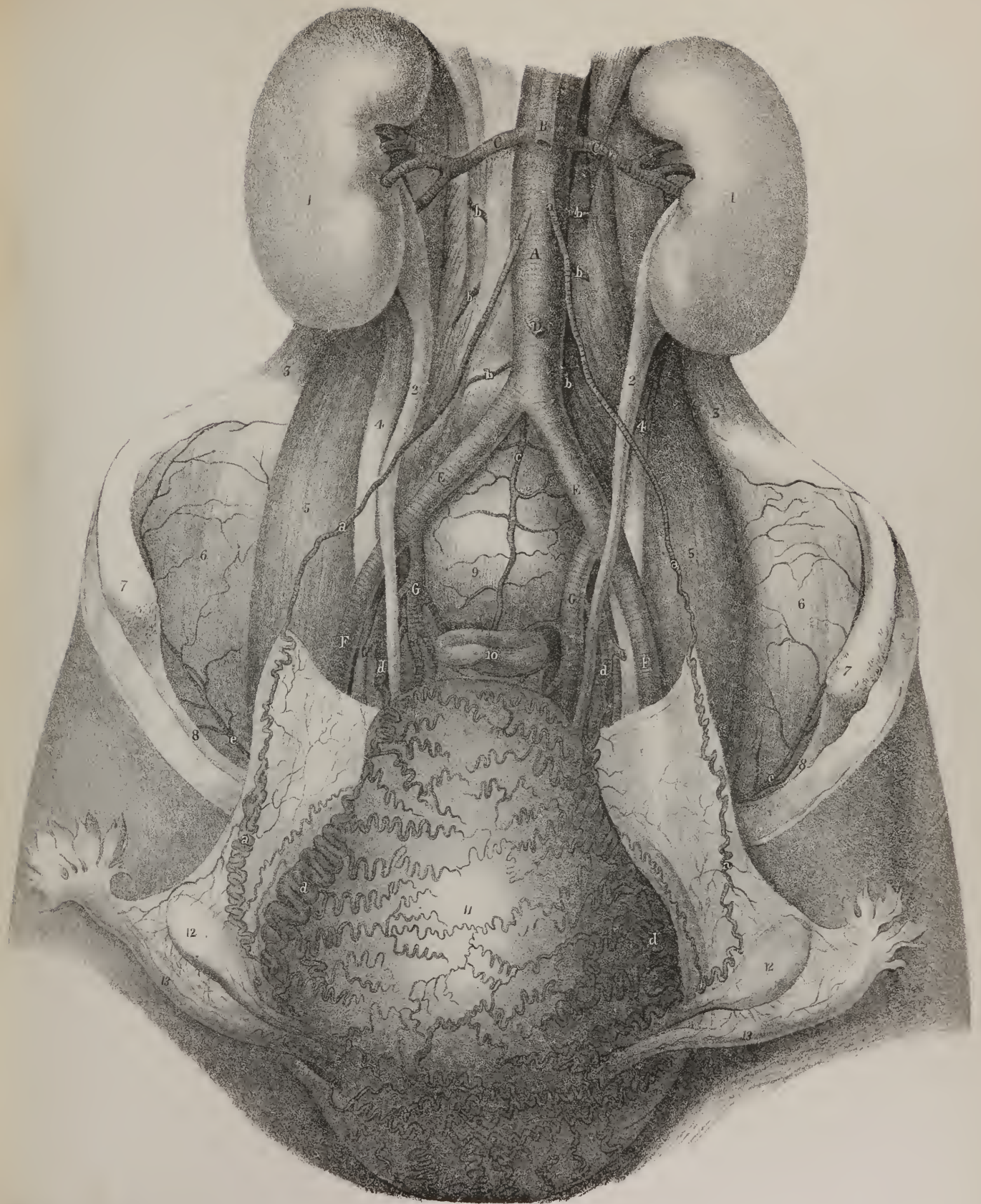








Fig 1

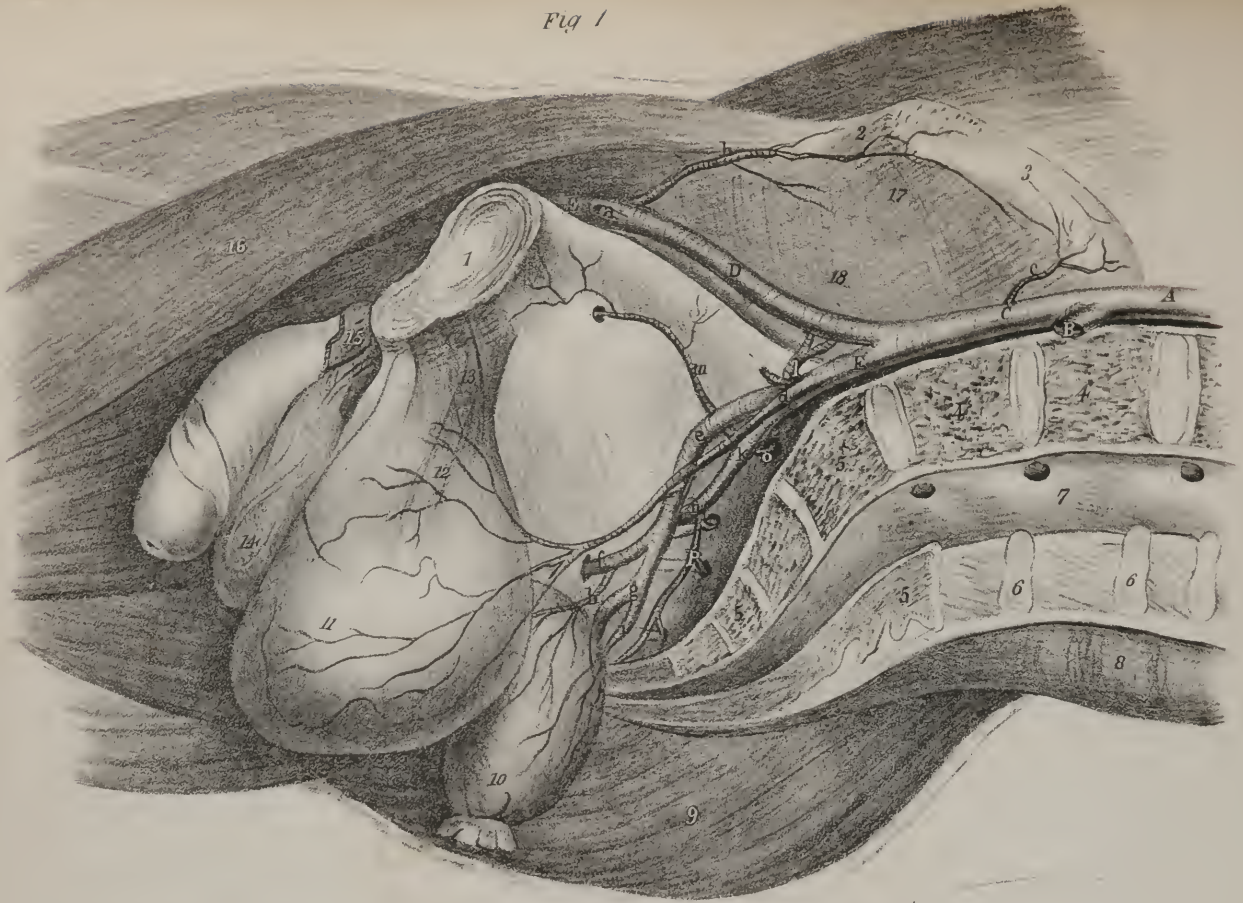
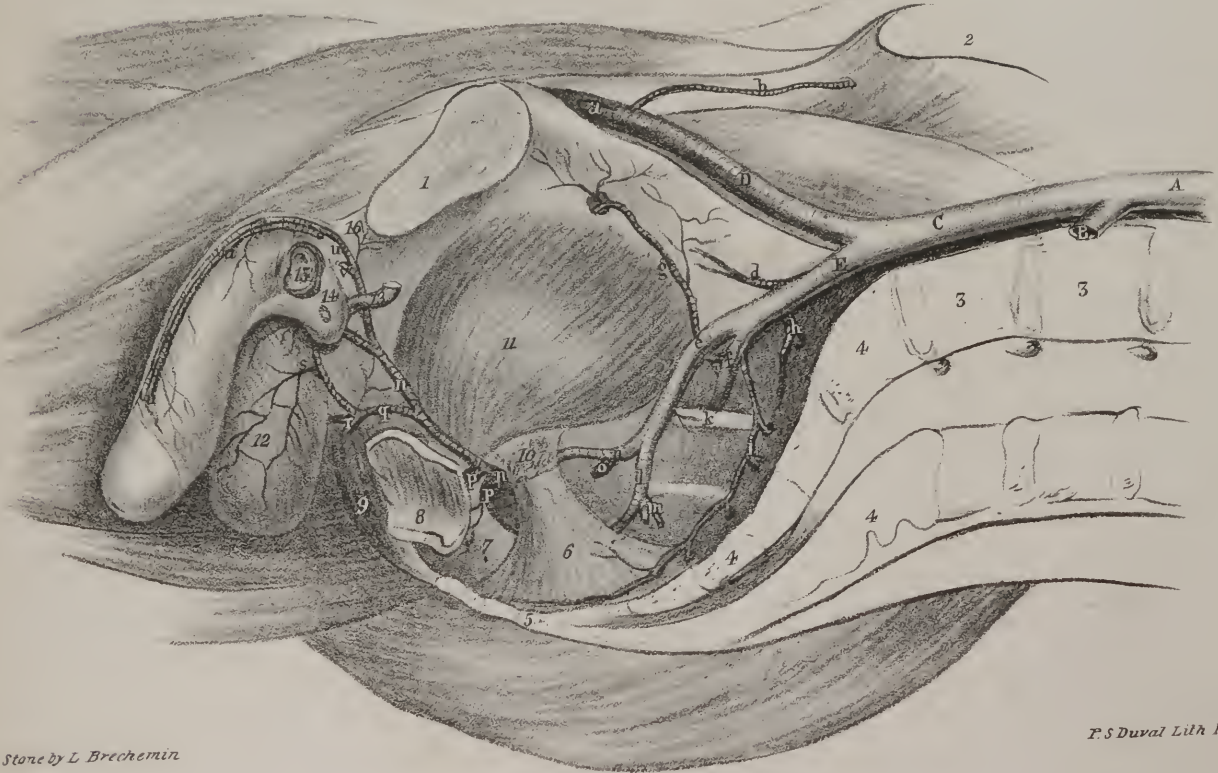


Fig 2



On Stone by L Brechemin

P. S. Duval Lith Phil<sup>a</sup>

Philadelphia, Published by Carey & Hart

In other instances the ulnar artery forms but half the palmar arch. In these the superficialis volæ is larger than usual, and, on reaching the palm, inclines inwards, so as to meet the ulnar artery about the middle line. The digital branches of the fingers are derived from the arch thus formed, and those of the thumb generally from the superficialis volæ by means of a short vessel which it gives off previously to its junction.

The ulnar artery is sometimes found to incline very little towards the radial side of the hand, and to supply no more than the little finger, the ring finger, and one side of the middle finger; the rest of the digital branches being derived from the superficialis volæ; here there is in strictness no palmar arch, and there is no direct connexion between the superficialis volæ and the ulnar artery. The ulnar artery has been observed to incline obliquely across the palm, being directed from the pisiform bone to the root of the fore-finger, supplying the usual number of digital branches. In some of these cases a connexion is formed between it and the superficialis volæ, if the latter be large, by a small transverse branch passing from the one to the other a little before the annular ligament.

The ulnar artery on reaching the palm has been found so diminutive as to terminate in a few offsets upon the muscles of the little finger, being incapable of supplying any digital branches. It may perhaps give one branch to the inner border of the little finger. Here all the collateral branches of the fingers are derived from the deep palmar arch of the radial artery. The inter-osseous branches of the latter, on reaching the cleft of the fingers, divide and run along their margins, occupying the position of the branches ordinarily supplied by the superficial palmar arch.

A superficial inter-osseous artery has been observed to run along the fore-arm in the course of the median nerve, and after passing into the palm of the hand, to join the palmar arch formed in the usual way. But, in some rare instances of this sort, the ulnar artery was found smaller than it generally is, and the thumb, and the fore-finger, and one side of the middle finger, were supplied by the inter-osseous branch.\* The ulnar artery passed obliquely forwards and gave off the remaining digital branches.

The deep palmar arch varies much in its size. The radial artery may in this part be larger than usual, and may give off,

## PLATE XXI.

A lateral view of the arteries of the pelvis in the male subject. The pelvis is divided by a vertical incision carried through the symphysis pubis; the middle of the lumbar vertebræ and sacrum. The viscera are removed from their natural position and drawn downwards.

FIG. 1. No. 1. Symphysis pubis. 2. The anterior superior spine of the ilium. 3. The crest of the ilium. 4, 4. The divided surface of the two last lumbar vertebræ. 5, 5. The divided surface of the sacrum. 6, 6. The divided spinous processes of the two last lumbar vertebræ. 7. The termination of the spinal canal. 8. The erector spinæ muscle of the right side. 9. The glutæus maximus muscle. 10. The rectum, and, 11, the bladder drawn down from the cavity of the pelvis. 12. A slight elevation produced by the prostate gland. 13. The anterior ligaments of the bladder. 14. The scrotum. 15. The corpus cavernosum of the left side, divided. 16. The sartorius muscle. 17, 18. The iliacus and psoas muscles concealed by the iliac fascia.

A. The aorta. B. The left common iliac artery, divided. C. The right common iliac. D. The external iliac. E. The femoral artery. F. The internal iliac.

a. The epigastric artery, cut off. b. The circumflex ilii artery inosculating with, c, the terminal branches of the ilio-lumbar artery. d. The umbilical artery giving branches (superior vesical) to the side of the bladder and prostate gland. e. The anterior branch of the internal iliac artery dividing into, f, the internal pudic, and, g, the sciatic arteries. h. The middle hæmorrhoidal artery, giving off inferior vesical branches. i. An hæmorrhoidal branch from the sciatic artery. k. The posterior branch of the internal iliac artery. l. The ilio-lumbar artery. m. The obturator artery. n. The glutæal artery. o. A small spinal artery, passing into the first sacral foramen. p. The lateral sacral artery.

FIG. 2. The viscera are here removed, and the fascia dissected off from the interior of the pelvis, to show the course and distribution of the internal pudic artery to its termination.

No. 1. The symphysis pubis. 2. Crest of the ilium. 3, 3. Bodies of the fourth and fifth lumbar vertebræ. 4, 4. The sacrum. 5. The coccyx. 6. The anterior sacro-sciatic ligament. 7. The posterior sacro-sciatic ligament. 8. A portion of the extremity of the rectum. 9. The right half of the sphincter ani muscle. 10. The spine of the ischium. 11. The obturator internus muscle. 12. The septum scroti. 13. The membranous part of the urethra. 14. The bulbous portion of the corpus spongiosum. 15. A section of the left corpus cavernosum. 16. The suspensory ligament of the penis.

A. The aorta. B. The left common iliac artery. C. The right common iliac. D. The external iliac. E. The internal iliac.

a. The epigastric artery divided. b. The circumflex ilii artery. d. The umbilical trunk divided. e. The anterior branch of the internal iliac. f. The posterior branch. g. The obturator artery. h. A small sacral artery, sending branches into the first and second sacral foramina. i. The lateral sacral artery. k. The glutæal artery passing out of the pelvis immediately above the first sacral nerve. l. The sciatic artery, giving off, m, a visceral branch. n, n. The internal pudic artery, giving off, o, the middle hæmorrhoidal artery. p, p. External hæmorrhoidal arteries. q. The superficial perinæal artery, giving off, r, the transversus perinæi branch. s. A branch of the superficial artery ramifying upon the septum scroti. t. The artery of the bulb, (r. corporis bulbosi;) that of the left side is seen divided just at its entrance into the bulb. u, u. The dorsalis penis artery. v. The artery of the corpus cavernosum.

\* In anomalies of this description, in which there had occurred a deep wound of the palm, it has been found necessary, before the hæmorrhage could be effectually arrested, to cut down on the front part of the fore-arm, and take up the inter-osseous trunk.—J. P.



as above stated, the collateral branches to the fingers, or it may be smaller, and form only half the deep arch, the rest being made up by the communicating branch of the ulnar artery.

Finally, the greater part of the arch may be formed by the ulnar artery, the radial being so small when it reaches the palm of the hand that it opens into the ulnar at the root of the thumb. Here the size of the vessel which forms the arch diminishes as it runs from the ulnar towards the radial side of the metacarpus.

*The Thoracic aorta* (plate XIII. D ; *its straight portion*.)—The aorta having completed its curve or arch at the lower border of the third dorsal vertebra, descends along the spine to the fourth lumbar vertebra, where it divides into the common iliac arteries. Its direction is not vertically downwards, for as its course is influenced by the spine, upon which it rests, it is necessarily concave forwards in the dorsal region, and convex forwards in the lumbar. Again, its commencement is at the left side of the spine, its termination also inclines a little to the left, whilst about the last dorsal vertebra it is nearly upon the median line. From this arises another curve, the convexity of which is to the right side, and the concavity to the left. Within the thorax it diminishes little in size; in the abdomen the diminution is considerable, in consequence of its giving off large branches soon after its entrance into that cavity.

The thoracic aorta lies in the posterior mediastinum, being before the spine, and behind the root of the left lung and the pericardium; its left side is in contact with the corresponding pleura, the right with the vena azygos major, the thoracic duct, and œsophagus. The latter tube, however, as it descends, inclines in front of the artery, and near the diaphragm gets to its left side.

The branches which it gives are numerous but small.

*The Pericardiac branches* (a. pericardiæ) are some very small and irregular vessels which pass forwards and ramify on the pericardium.

*The Bronchial branches* (plate XIII. d, e ; a. bronchiales) are the proper nutritious arteries of the substance of the lung; they accompany the bronchial tubes in their ramifications through the organ. They vary much in their mode of origin, and also in their number; in some instances there being two, in others three, four, or even five. Thus, two small vessels arise from the aorta, about an inch below the arch, which diverge, inclining forwards and outwards, each being directed to the corresponding bronchus, whose course it takes, dividing and subdividing with the minuter bronchi into the substance of the lung. These are the *superior* bronchial arteries; they occasionally issue from a small common trunk. Lower down, two others (a. bronchiales inferiores) come off, which apply themselves to the bronchi and take a similar course. The right bronchial artery often arises from the first aortic intercostal. The left has been seen to arise from the subclavian, and, in a few rare instances, from the inferior thyroid.

*The Œsophageal branches* (plate XIII. f, f ; a. œsophageales) are also variable in size and number; there are usually four or five, which arise from the fore part or right side of the aorta, and run obliquely downwards upon the œsophagus, freely supplying its substance. The lower branches of these vessels anastomose with the ascending offsets of the coronary artery of the stomach, whilst the upper ones communicate in a similar way with branches of the inferior thyroid.

*The Intercostal arteries* (plate XIII. g, h ; plate XIX. e, e : a. intercostales, inferiores) arise from the posterior part of the aorta, and run at first outwards and upwards upon the bodies of the vertebræ, after which they lie along the intercostal spaces. Their number varies; they are usually eight or nine at the right side, for the two or three first intercostal spaces are supplied by the superior intercostal artery, derived from the subclavian; on the left side there are generally ten. Owing to the position of the aorta with regard to the spine, the right aortic intercostals are a little longer than the left. As these vessels pass outwards, they are covered by the pleura, and crossed by the sympathetic nerve; those of the right side also pass behind the œsophagus, the thoracic duct, and the vena azygos major. When arrived in the intercostal space, the corresponding vein being above it and the nerve below it, the artery gives off its posterior branch, (plate XIII. i, i,) which passes directly backwards, and is ultimately distributed to the muscles of the back which are lodged in the vertebral groove; previously to which, it gives ramusculi to the body of the vertebra upon which it passed, and also one which enters the intervertebral foramen and ramifies upon the membranes of the spinal cord. The continuation of the vessel is placed at first between the pleura and the external intercostal muscle, and then between the two planes of muscles of that name. It divides into two branches, which diverge at an acute angle and then run along parallel to one another, taking the course of the margins of the ribs between which they lie. The inferior or smaller branch inclines downward, and approaches the border of the rib which lies below its intercostal space, and after giving small twigs to the bone and the intercostal muscles, anastomoses with some of the superficial vessels. The superior or larger branch inclines towards the border of the rib which lies above its intercostal space, and, after giving branches to the intercostal muscles and communicating with the preceding branch, anastomoses with the anterior intercostal branches derived from the internal mammary artery, and with the thoracic branches of the axillary artery. The first aortic intercostal artery has an anastomosis with the vessel of that name, which comes from the subclavian artery, and the three last are prolonged amongst the abdominal muscles, where they communicate with the epigastric artery in front, the phrenic internally, and the lumbar branches of the abdominal aorta inferiorly.

*The Abdominal aorta* (plate XIV. A.)—The aorta, after having passed between the crura of the diaphragm, rests on the





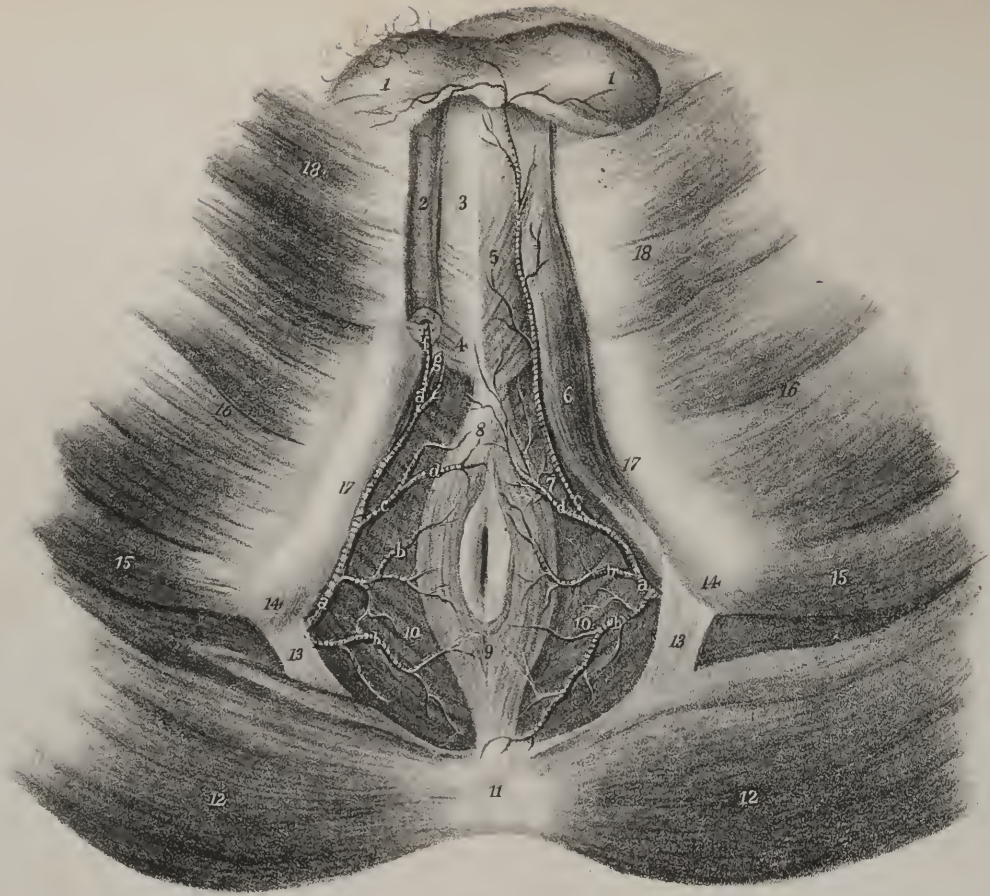
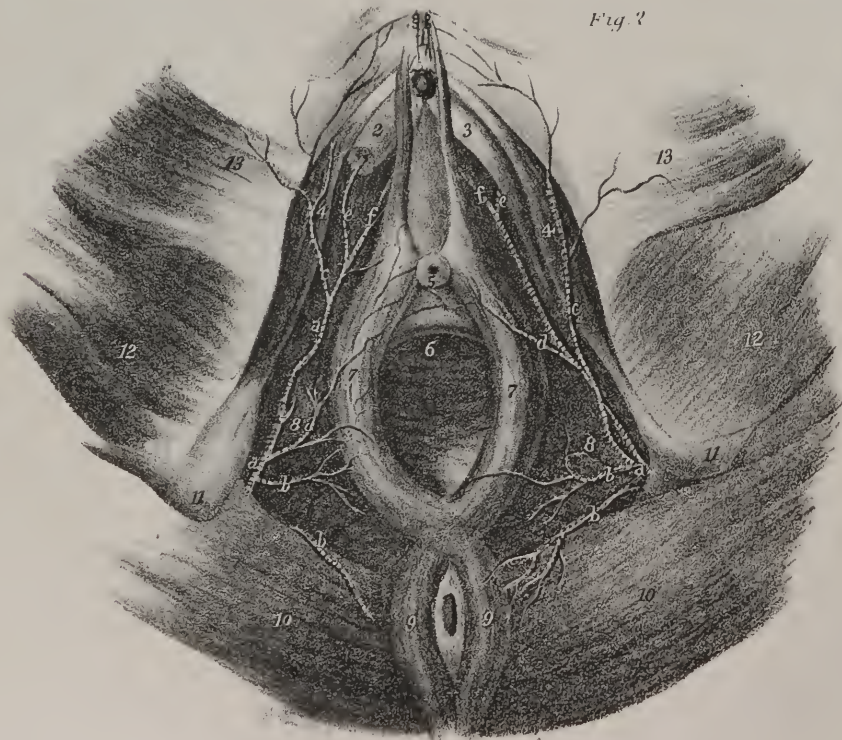


Fig 2



On Stone by L. Brechemin

Philadelphia Published by Carey & Hart

P. S. Duval, Lith. Phil<sup>a</sup>



bodies of the lumbar vertebræ as far as the fourth, where its division takes place. Its anterior surface is successively in apposition with the liver, the pancreas, duodenum, and mesentery. The vena cava accompanies it, lying at its right side, and it is surrounded by a mesh of nerves derived from the sympathetic.

The branches of the abdominal aorta are divided into two sets—1. Those which arise from its fore part and singly, viz. the cœliacæ, and the superior and inferior mesenteric. 2. Those which pass off in pairs, viz. the phrenic, capsular, renal, spermatic, and lumbar.

*The Cœliac artery or Axis* (plates XIV. and XV. B; arteria cœliaca) arises from the aorta whilst between the crura of the diaphragm, and as soon as it becomes apparent in the cavity of the abdomen. In the erect position of the body its direction is nearly horizontally forwards, but it is not more than half an inch long. It is concealed by the small omentum, and lies close to the left side of the lobulus Spigelii, and above the pancreas, the two semi-lunar ganglia being in apposition with it on either side. It gives off three remarkable branches; viz. the coronary artery of the stomach, the hepatic, and splenic.

1. *The Coronary artery of the stomach*, (plate XIV. e; plate XV. C; plate XVI. fig. 1, C. fig. 2, a: a. coronaria ventriculi,) the smallest of the three, inclines upwards, and to the left side, to reach the cardiac orifice of the stomach. At this point some ramuli are sent upwards on the œsophagus, which communicate with the aortic œsophagean branches; others pass before and behind the cardiac extremity of the stomach, which they coil round. The continuation of the vessel inclines from left to right along the upper curvature of the stomach, gives branches to its coats, and inosculates with the pyloric branch of the hepatic artery.

2. *The Hepatic artery*, (plate XIV. d; plates XV. and XVI. D: a. hepatica,) intermediate in size, at least in the adult, between the coronary and the splenic, passes upwards, and to the right side, to reach the transverse fissure of the liver, in which course it lies in front of the vena portæ and to the left of the hepatic duct. Previously to reaching the liver, it gives the following branches:—

*The Pyloric branch* (plate XV. e; plate XVI. d: ramus pyloricus) descends to reach the pyloric end of the stomach, and then turns along its upper curvature, about the middle of which it inosculates with the coronary artery: it is sometimes a branch of the following:—

*The Gastro-duodenal artery* (plate XV. o; plate XVI. fig. 1, g: r. gastro-duodenalis) descends behind the duodenum near the pylorus, and on reaching the lower border of the stomach, changes both its name and direction. It runs from right to left along the great curvature of the stomach, between the lamellæ of the great epiploon, (omentum,) assuming the name of gastro-epiploica dextra, (plate XV. p, p; plate XVI. fig. 1, k, k, fig. 2, e, e,) and inosculates with the gastro-epiploica sinistra derived from the splenic artery. It gives several branches to the duodenum and pancreas; one, larger than the rest, is called pancreatico-duodenalis, (plate XVI. fig. 1, i;) it runs downwards and to the left in forming a curve in its course along the inner margin of the duodenum, distributing branches to it and the pancreas, and communicating with some small branches of the superior mesenteric artery.

Near the transverse fissure of the liver, the hepatic artery divides into its right and left branches, which are intended for the

## PLATE XXII.

The arteries of the male and female perinæum are here shown.

FIG. 1. The male perinæum; the superficial muscles and crus penis of the right side are removed to bring into view the deep vessels.

No. 1. The scrotum drawn upwards towards the abdomen. 2. The corpus cavernosum penis of the right side, divided. 3. The corpus spongiosum penis. 4. The bulb of the urethra. 5. The accelerator urinæ muscle. 6. The erector penis muscle. 7. The transversus perinæi. 8. The tendinous centre of the perinæum. 9. The sphincter ani muscle. 10, 10. The levator ani muscle of either side. 11. The coccyx. 12, 12. The glutæus maximus muscles. 13, 13. The posterior sacro-sciatic ligaments. 14, 14. The tuberosity of the ischium of either side. 15, 15. The semi-membranosus muscles. 16, 16. The adductor magnus muscles. 17, 17. The ramus of the pubis and ischium of each side. 18, 18. The gracilis muscles.

a, a. The internal pudic artery of each side (r. pudicus internus.) b, b. External hæmorrhoidal branches (r. hæmorrhoidales externi.) c, c. The superficial perinæal artery (r. perinæi superficialis.) d. The transversalis perinæi, a branch of the superficial perinæal. e. The artery of the bulb (r. corporis bulbosi.) f. The artery of the corpus cavernosum. g. The dorsalis penis artery.

FIG. 2. The female perinæum.

No. 1. The clitoris. 2. The corpus cavernosum clitoridis of the left side. 3. The corpus cavernosum, divided. 4, 4. The erector clitoridis muscle of either side. 5. The meatus of the urethra. 6. The vagina. 7, 7. The sphincter vaginæ. 8, 8. The levatores ani muscles. 9, 9. The sphincter ani. 10, 10. The glutæus maximus muscles. 11, 11. The tuberosity of the ischium of either side. 12, 12. The adductor magnus muscles. 13, 13. The gracilis muscles.

a, a. The internal pudic arteries. b, b. The external hæmorrhoidal arteries supplying the extremity of the rectum. c, c. The superficial perinæal arteries ramifying in the integument of the vulva. d, d. The transverse branch of the perinæum (r. transversus perinæi) ramifying upon the side of the vagina, and around the meatus urinarius. e, e. The artery of the corpus cavernosum on each side. f, f. The continuation of the internal pudic artery for the supply of the clitoris. g, g. The dorsalis clitoridis branches, ramifying upon the dorsum of the clitoris



supply of the corresponding lobes of that organ. The left, or smaller division, lying in front of the vena portæ, diverges at an acute angle from the other branch, and turns outwards to reach the left extremity of the transverse fissure of the liver, where it enters its substance, divides and subdivides into minute ramusculi, ramifying in the intimate texture of the organ.

The right or larger branch inclines outwards to the right extremity of the transverse fissure. When crossing behind the cystic duct, it gives off a branch, (plate XV. k; plate XVI. fig. 1, m: ramusculus cysticus,) which turns upwards and forwards upon the neck of the gall-bladder, and divides into two ramusculi, of which one ramifies between its coats at its depending surface, the other between it and the liver. The right hepatic artery then divides into two or three branches, which enter the liver by its transverse fissure, and ramify in its substance, accompanying the divisions of the vena portæ and hepatic ducts.

3. *The Splenic artery*, (plate XIV. e; plates XV. and XVI. E: a. splenica,) in the adult, is the largest branch of the cœliac axis, from which it runs outwards, backwards, and to the left side. This artery will be found waving and tortuous in its course, as it passes along the upper border of the pancreas, to which it gives ramuli, and near the spleen divides into several branches. Some of these enter the fissure in that organ, and are distributed to its substance; three or four are reflected towards the bulging end of the stomach, in which they ramify. Its branches are the following:—

*The Pancreatic branches* (plate XVI. fig. 1, q, q; rami pancreatici) are variable in size and number; they are given off whilst the artery is passing along the pancreas, in the substance of which they ramify. One of larger size not unfrequently runs from left to right, in the direction of the pancreatic duct, and is called r. pancreaticus magnus.

*The Splenic branches* (plate XVI. fig. 1, p, p; r. splenici) are the proper terminal branches of the artery; they are five or six in number, and vary in length and size; they enter the spleen by the hilus or fissure in its concave surface, and divide within the organ until they become capillary.

The other branches of the splenic artery are reflected from it, and run a retrograde course.

*The Gastric branches* (plate XVI. fig. 1, o, o, fig. 2, d: r. gastrici; vasa brevia) vary from five to seven in number; they run from left to right, some issuing from the trunk of the splenic artery, others from its terminal branches. Enclosed within the splenic omentum, they reach the left extremity of the stomach, where they divide and spread out between its coats, communicating with the coronary and epiploic arteries.

*The left Gastro-epiploic artery* (plate XVI. fig. 1, n, fig. 2, g; r. gastro-epiploicus sinister) turns forwards and downwards from the splenic, being at the same time reflected from left to right along the great curvature of the stomach, where it anastomoses with the right gastro-epiploic branch. In its course, this vessel lies between the layers of the great omentum, to which it gives

## PLATE XXIII.

This plate shows the relative position of the epigastric artery, to the neck of the sac in oblique and direct inguinal hernia.

FIG. 1 represents the lower part of the abdominal parietes, with two herniæ protruded through the external abdominal rings.

Nos. 1, 1. The external oblique muscle, on each side. 2, 2. The anterior superior spines of the ilium. 3, 3. Poupart's ligament at each side. 4. The linea alba. 5. The symphysis pubis. 6. The suspensory ligament of the penis. 7. The tumor formed by oblique inguinal hernia, passing obliquely between the abdominal parietes before it protrudes at the external abdominal ring. 8. The fascia of the spermatic cord thrown into folds as it quits the hernia to invest the lower part of the cord and testicle. 9. The tumor of a direct inguinal hernia passing directly outwards through the external abdominal ring. 10. The spermatic cord of the left side. 11, 11. The iliacus muscle, at each side. 12, 12. The sartorius muscle, at each side. 13, 13. The recti muscles. 14, 14. The tensor vaginæ femoris muscle, at each side. 15, 15. Part of the glutæus medius.

A, A. The femoral artery, at each side.

a. The course of the epigastric artery represented by dotted lines; it is drawn inwards by the "oblique inguinal hernia," and winds around the inner margin of the neck of the sac. b. The course of the epigastric artery, in relation to the "direct inguinal hernia," ascending upon the outer side of the neck of the sac. c, c. The superficial epigastric artery. d, d. The superficial circumflex ilii arteries. e, e. The superficial external pudic arteries, ramifying upon the intercolumnar fascia (fascia spermatica) of both the hernial tumors.

FIG. 2. The openings formed by the passage of the herniæ, seen from within, for the purpose of displaying more clearly the course of the epigastric artery in relation to the neck of the hernial sac. This view is obtained by sawing vertically through the transverse diameter of the pelvis, and removing its lower part.

Nos. 1, 1. The cut surface of the ilium and pubis. 2, 2. The inner surface of the os pubis. 3, 3. The divided iliac muscles. 4, 4. The psoas muscles divided. 5, 5. The iliac fascia on each side. 6, 6. The anterior superior spinous process of the ilium, at each side. 7, 7. The transversales muscles. 8, 8. Poupart's ligament, at each side. 9, 9. The conjoined tendon of the internal oblique and transversalis muscles, on either side. 10, 10. The crural rings. 11. The opening formed by the distention of the conjoined tendon for the passage of the "direct hernia." 12. The internal ring very much enlarged by the protrusion of "oblique inguinal hernia," opening beneath the lower border of the transversalis muscle. 13, 13. The recti muscles. 14, 14. The termination of the sheath of the recti muscles.

A, A. The external iliac arteries.

a, a. The epigastric artery (a. epigastrica) of the left side, ascending to the outer side of the opening for the "direct hernia." b, b. The epigastric artery of the right side passing upwards upon the inner side of the internal ring. c, c. The circumflex ilii arteries (a. circumflexa ilii) winding along Poupart's ligament on each side of their distribution.



Fig. 1.

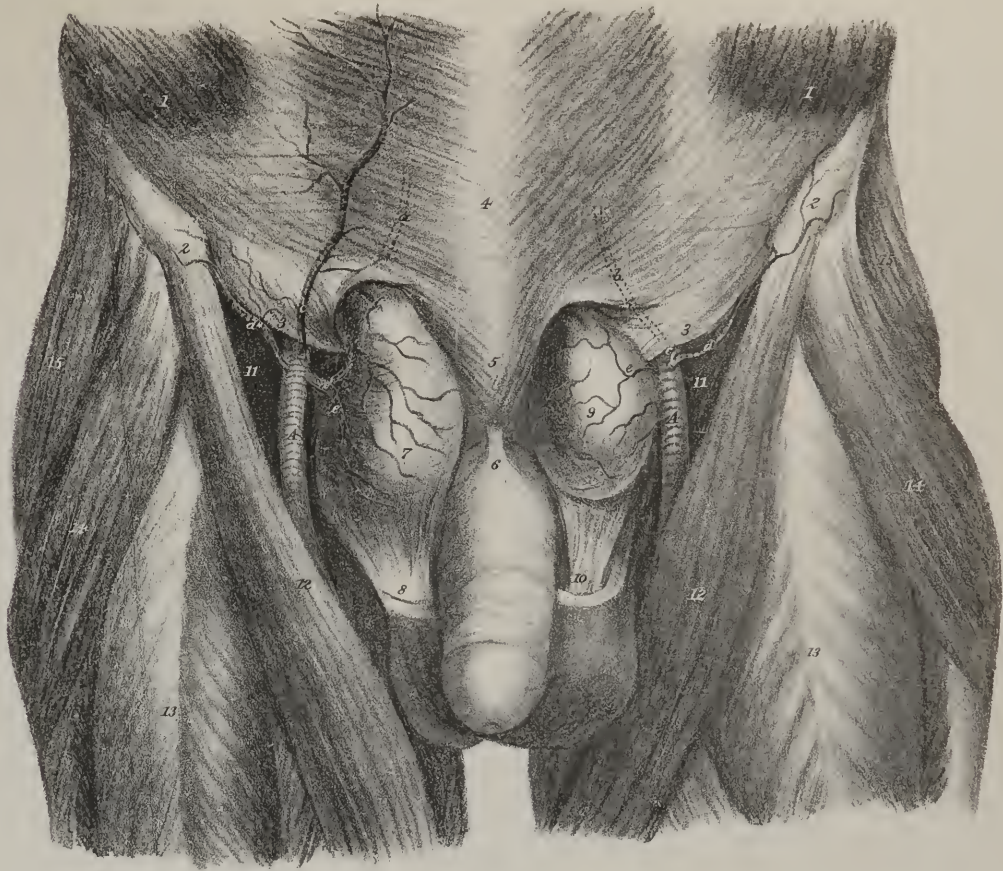
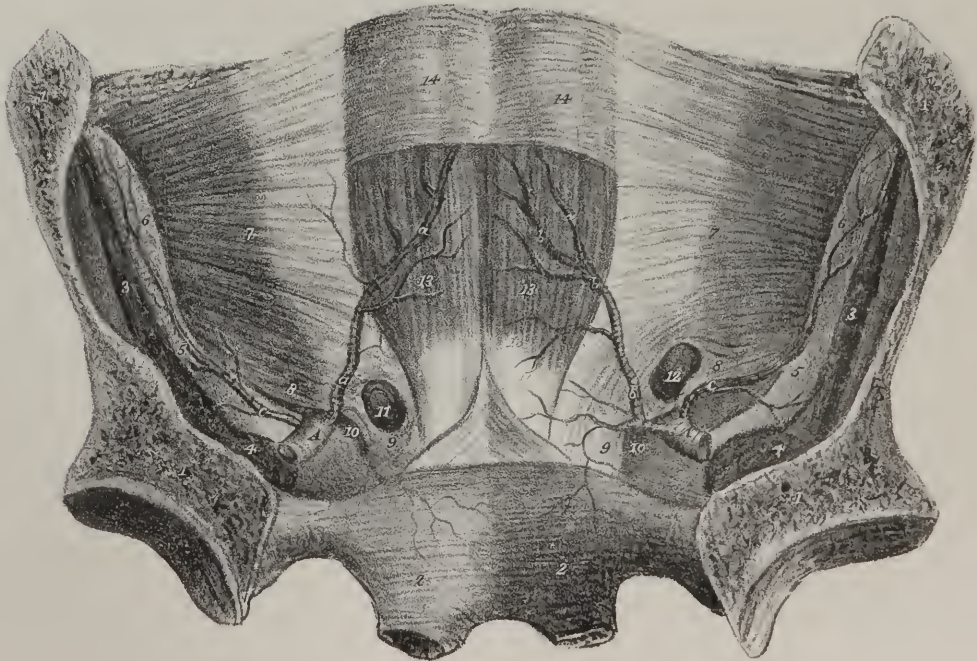


Fig. 2.







several long branches; many also pass upwards from it to both surfaces of the stomach, where they communicate with the other gastric arteries.

*The superior Mesenteric artery* (plate XIV. C; plate XVII. A; plate XVIII. B: a. mesenterica superior) arises from the fore part of the aorta, a little below the cœliac. Its root lies beneath the pancreas, and above the transverse part of the duodenum; and its continuation is enclosed between the lamellæ of the mesentery. This vessel at first inclines downwards, and to the left side, but afterwards changes its direction, running transversely towards the right iliac fossa, opposite to which it inosculates with the ilio-colic branch. It thus describes a curve, whose concavity looks to the right side, so that its branches may be divided into two sets, viz. those which arise from its convexity and those from its concavity. Those which spring from the convex side of the vessel (rami intestini tenuis; plate XVII. k, l, m) are all intended for the supply of the jejunum and ilium. They are usually from sixteen to twenty in number. They run parallel to one another for some way, and then divide into two branches, each of which forms an arch, with a similar offset from the neighbouring branch. From the summit of the first set of arches branches issue, which divide, and re-communicate in the same way, until, finally, after forming four or five such tiers of arches, each smaller than the other, the ultimate ramusculi proceed directly to the intestines, and ramify in their coats. The branches from the right side of the mesenteric artery are given to the large intestine, arteriæ colicæ, or rather rami colici.

*The Ilio-colic branch*, (plate XVII. h; ramus ilio-colicus,) which is the first of these, (taking them in their order from below upwards,) inclines downwards, and to the right side, towards the ilio-colic valve, near which it divides into two branches; of which one arches down, to inosculate with the termination of the mesenteric artery itself, and from the convexity of the arch branches go off towards the junction of the small with the large intestines, particularly to the valve; the other division ascends, and inosculates with the following branch:—

*The right Colic branch* (plate XVII. e, f; r. colicus dexter) passes transversely to the middle of the ascending colon, opposite to which it resolves itself into two branches, of which one descends to communicate with the preceding vessel, whilst the other ascends to join in an arch with the succeeding:—

*The middle Colic branch* (plate XVII. a; plate XVIII. m: r. colicus medius) passes upwards to the transverse colon, and divides in a manner exactly similar to the vessels just noticed. One of its branches inclines to the right, where it inosculates with the preceding vessel; the other descends to the left side, and maintains a similar communication with the left colic branch, derived from the inferior mesenteric artery. From the arches of inosculation thus formed ramusculi pass to the intestine, for the supply of its coats.

*The inferior Mesenteric artery* (plate XIV. i; plate XVIII. a: a. mesenterica inferior) arises from the aorta, about an inch above its termination. It inclines downwards to the left iliac fossa to reach the sigmoid flexure of the colon, from which it descends into the pelvis, and, under the name of superior hæmorrhoidal artery, runs down behind the rectum. Its branches are:—

*The left Colic branch*, (plate XVIII. b; ramus colicus sinister,) which, close by the descending colon, divides into two branches, similar to those of the colic vessels of the opposite side. One of these branches passes upwards along the colon, and inosculates with the descending branch of the middle colic; whilst the descending branch passes along the sigmoid flexure, to which it sends ramusculi. It anastomoses with the sigmoid branch.

*The Sigmoid branch* (plate XVIII. f; r. sigmoideus) runs obliquely outwards to the sigmoid flexure of the colon; it divides into branches, some of which incline upwards and form arches with the preceding vessel, others turn downwards to the top of the rectum. From both, ramuli pass into the coats of the intestine.

*The superior Hæmorrhoidal artery*, (plate XIV. m; plate XVIII. g: r. hæmorrhoidalis superior.)—The continuation of the vessel having assumed the name of the superior hæmorrhoidal artery, lies in the fold of the meso-rectum, and ramifies in the coats of the intestine communicating with the middle and inferior hæmorrhoidal arteries.

We shall find, on even a slight inspection, a continued chain of anastomosis from one end of the alimentary canal to the other. The colic arteries form a vascular circle along the great intestine. The branches from the convex side of the mesenteric artery establish another range of arches along the small intestine, which is connected to the former by the ilio-colic artery. The superior mesenteric again anastomoses by some branches near its root with the pancreatico-duodenalis; the latter, at its commencement, is in a manner continuous with the pyloric artery; and so on, through the coronary and its ascending branches, a similar connection is formed with the œsophageal branches, even up to the pharynx.

The middle sacral artery is the last of the single branches.

*The middle Sacral artery* (plate XIV. l: a. sacra media; r. sacer medius) is a small vessel about the size of a crow-quill, which arises from the extremity of the aorta, just at its bifurcation. From this point the artery proceeds downwards upon the last lumbar vertebra, and over the middle of the sacrum, as far as the coccyx, where it forms small arches of anastomosis with the lateral sacral arteries. From its anterior surface some ramusculi come forwards within the folds of the meso-rectum, and ramify upon the posterior surface of the intestine; and on each side others spread out upon the sacrum, and anastomose with the lateral sacral arteries, occasionally sending small twigs into the anterior sacral foramina.

The branches of the abdominal aorta, which arise in pairs, are, the phrenic, capsular, renal, spermatic, and lumbar.

*The Phrenic arteries* (plate XIV. a, b; a. phrenicæ) are two small vessels which usually arise from the aorta, on a level

with the inferior surface of the diaphragm. They are very close at their origin from the fore part of the aorta, but instantly diverge, cross the crura of the diaphragm, and proceed upwards and outwards upon its central tendon and broad muscle. That of the left side having passed behind the œsophagus, runs up to the left of the œsophageal opening; whilst the right phrenic artery, after having passed behind the liver and the vena cava, lies to the right side of the opening in the diaphragm which transmits the latter. Each of these arteries divides into two branches before it reaches the central tendon of the diaphragm, of which one runs forwards towards the anterior margin of the thorax, distributing branches to the diaphragm, and finally anastomosing with the musculo-phrenic branch of the internal mammary artery. The other pursues a transverse direction towards the lateral margin of the thorax, and communicates with the termination of the intercostal arteries. Each phrenic artery gives small branches to the supra-renal capsule of its own side, and to the crus of the diaphragm; the left sends some to the œsophagus, and the right to the termination of the cava.

*The Capsular or Supra-renal arteries* (plate XIV. g; a. capsulares) are two very small vessels which arise from the aorta, on a level with the superior mesenteric artery, and incline obliquely outwards upon the crura of the diaphragm to the supra-renal capsules to which they are distributed, anastomosing at the same time with the branches derived from the phrenic artery.

*The Renal or Emulgent arteries* (plate XIV. D, D; a. renales) arise from the sides of the aorta, a little below the superior mesenteric artery, that of the right side being somewhat lower down than the left. The direction of each is outwards transversely, so as to form nearly a right angle with the aorta; but it has at the same time an inclination backwards and downwards. In consequence of the position of the aorta upon the spine, the right renal artery has to run a somewhat longer course than the left to reach the kidney; in most cases it crosses behind the vena cava, and is overlapped by its accompanying vein. Previously to reaching the concave border of the kidney, each artery divides into four or five branches, the greater number of which usually lie intermediate between the vein and the pelvis of the kidney, the latter being posterior, the former anterior. These branches, after having passed deeply into the fissure of the kidney, divide into ramusculi, which diverge, and mutually anastomose, forming a vascular interlacement round the conical masses into which the tubuli uriniferi are aggregated; and so, when reduced to the size of capillaries, they constitute, with the ultimate radicles of the renal veins, the proper cortical or secreting structure of the kidney.

*The Spermatic arteries* (plate XIV. h, h; a. spermaticæ) are two very small vessels which arise from the fore part of the aorta, a little below the renal arteries. In the fœtus they are very short, as the testes are placed immediately beneath the kidneys; but the arteries acquire a proportional elongation as these organs remove from the lumbar region down into the scrotum. The direction of each spermatic artery is outwards and downwards, crossing the ureter, resting on the psoas muscle, and, after passing over the external iliac artery, turns forwards to the internal abdominal ring, where it comes into contact with the vas deferens, with which it descends through the canal, forming part of the spermatic cord as far as the testis, to the tubular structure of which it is distributed.

In the female these arteries (plate XX. a, a) do not pass out of the cavity. Their origin, direction, and relations, in the first part of their course conform to what obtains in the male; but at the margin of the pelvis they incline inwards and backwards, so

## PLATE XXIV.

Varieties in the mode of origin and course of arterial branches within the pelvis, in reference to crural hernia, and the operation of lithotomy.

FIG. 1. Shows the obturator artery arising from the external iliac about half an inch above the epigastric.

No. 1. The symphysis pubis. 2. The anterior superior spinous process of the ilium. 3, 3. The two last lumbar vertebræ, divided by a vertical incision. 4. The sacrum. 5, 6. The rectum and bladder drawn down from their natural position in the pelvis.

A. The aorta. B. The left common iliac artery cut off. C. The right common iliac. D. The external iliac. E. The internal iliac artery.

a. The circumflex ilii artery. b. The epigastric artery divided. c. The obturator artery arising from the external iliac. d. The umbilical artery cut off. e. The anterior branch of the internal iliac artery. f. The internal pudic artery. g. The sciatic artery. h. The posterior branch of the internal iliac. i. The glutæal artery. k. The lateral sacral artery.

FIG. 2. The obturator artery arises from a common trunk with the epigastric, and curves downwards to the upper part of the obturator foramen. The artery in this course might have encircled the neck of a hernial sac.

In this figure, and in the following, the references to the secondary parts of the subject are the same as in fig. 1.

a. The circumflex ilii artery. b. The epigastric. c. The obturator artery.

FIG. 3. In this case, the internal pudic artery arose from the anterior branch of the internal iliac, passed forwards by the side of the bladder and prostate gland, and divided into two branches: one, the artery of the corpus cavernosum: and the other, the dorsalis penis.

No. 7. The corpus cavernosum of the left side, divided. 8. The bulb of the urethra. 9. The septum scroti.

l. The obturator artery in its usual position, arising from the posterior branch of the internal iliac. m, m. The internal pudic artery arising from the umbilical trunk. n. The artery of the corpus cavernosum. o, o. The dorsalis penis artery. p. The superior vesical artery. q. An hæmorrhoidal branch from the internal iliac.



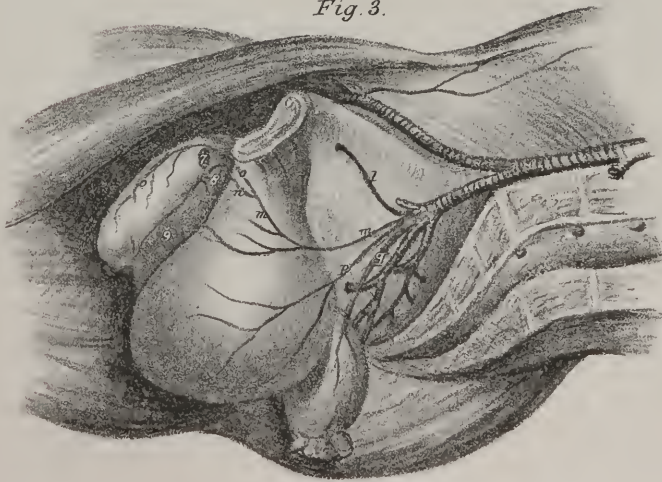
Fig. 1.

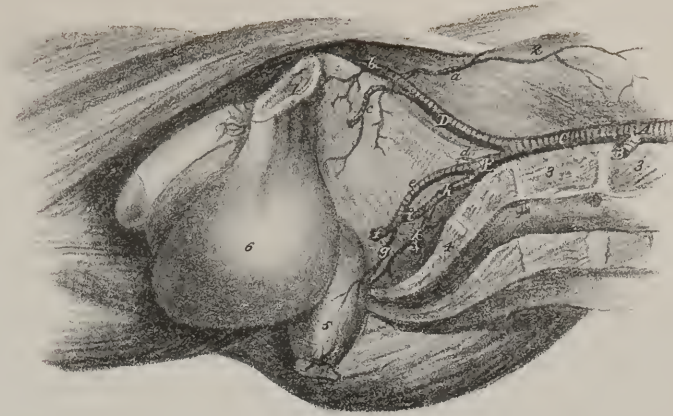

Fig. 2.

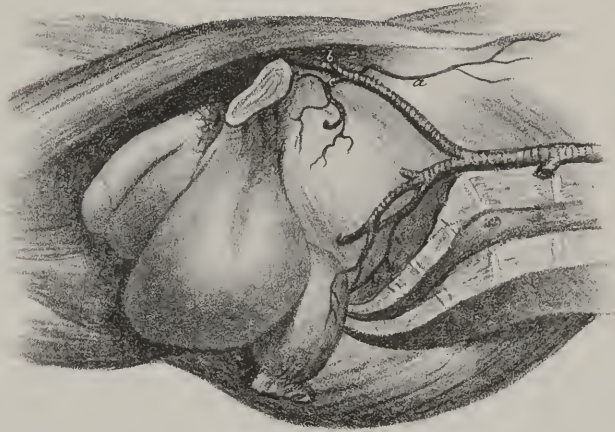

Fig. 3.







as to get between the layers of the broad ligaments of the uterus, by which they are guided to the ovaries, to whose structure they are finally distributed. Some of their ramusculi can also be traced along the round ligament into the inguinal canal, and others as far as the uterus, to which they are conducted by the Fallopian tubes.

*The Lumbar arteries* (plate XIV. k, k; a. lumbales) are analogous to the intercostal arteries, for they are not only similar in their mode of origin, direction, and size, but also, like them, are intended for the supply of the lateral parts of the trunk. Moreover, as the intercostals, by communicating with the internal mammary arteries, form a vascular ring round the thorax, the lumbar arteries, by anastomosing with the epigastric, bear a similar relation to the walls of the abdomen. The lumbar arteries, when they arise singly from the aorta, which is not always the case, are five in number: the first three pass outwards under the crus of the diaphragm, the sympathetic nerve, and the psoas muscle,—the two last under the latter. Those of the right side pass behind the vena cava. In the first part of their course, they rest on the bodies of the vertebræ as they run towards the intervertebral spaces, where they give off two sets of branches, which take different directions; one being posterior, the other internal.

*The Muscular branch*, (r. muscularis.)—The posterior branch of each artery turns directly backwards, between the transverse processes of the vertebræ, and is distributed to the deep-seated lumbar muscles.

*The Spinal branches*, (r. spinales.)—The internal branches, usually two, or one which soon divides into two, enter the intervertebral foramina, and terminate in ramuli, of which some ramify upon the spinal cord and its membranes, communicating with the other spinal arteries; others supply the osseous structure, entering some of the foramina observable upon the surface of the bone, and may be called its nutritious branches (r. nutritii.)

The artery itself, after giving off these branches, runs outwards transversely, maintaining its original direction, and after having passed first between the psoas and quadratus lumborum muscles, it gets between the layers of abdominal muscles and divides into branches, which supply these muscles, and also maintain various anastomoses; for they communicate with the branches of the epigastric and mammary arteries in front, with the terminal branches of the intercostals superiorly, and with those of the ilio-lumbar and circumflex ilii inferiorly.

*Varieties* in the distribution, mode of origin, and relative size of the branches of the abdominal aorta, are of frequent occurrence.

The phrenic arteries, in some instances, arise not separately, but by a common trunk, from the fore part of the aorta; in others, whilst one comes off as usual from that vessel, the other issues from the cœliac, the coronary, the renal, or conjointly with the capsular. These variations, however, seem to exert little influence on their course and distribution.

The hepatic artery, instead of arising from the cœliac, has, in a few instances, been seen to come from the aorta, and in one case from the superior mesenteric. It is much more usual to find two arteries entering the liver in the ordinary way, which, instead of arising by a common trunk, come off separately, one from the coronary, the other from the cœliac or mesenteric. Dr. Green cites a case in which he found three hepatic arteries, “the left from the cœliac, in common with the coronaria ventriculi; another in the middle from the cœliac, also in common with the gastro-epiploica dextra; and a left (qu. right?) hepatic from the superior mesenteric, which gave off the cystic artery.”

We frequently find the kidney at one or both sides receiving more arteries than one, but their size is diminished, from which it would appear that the deviation has gone merely a degree beyond that in which the single artery becomes divided into branches soon after its origin. The additional arteries in these cases come from the lower part of the aorta, or from the common iliac. When a kidney is placed lower than usual, for instance when situated in the pelvis, its artery is derived from the internal iliac or hypogastric. Meckel found in one case the two renal arteries of opposite sides arising by a common trunk from the fore part of the aorta.

The spermatic arteries occasionally arise by a common trunk, somewhat as the phrenics do; not unfrequently one of them is a branch of the renal.

The lumbar arteries of opposite sides, instead of arising separately from the aorta, may occasionally commence by a common trunk, whose branches pass out laterally, and continue their course in the ordinary way. The first lumbar not unfrequently arises conjointly with the last intercostal, and, in some instances, the last is a branch of the common iliac, or of the middle sacral.

The middle sacral artery represents the caudal prolongation of the aorta, but is necessarily diminutive in man, as the coccygeal vertebræ are merely rudimentary or atrophied. It sometimes deviates a little to the side, and proceeds, not from the bifurcation of the aorta, but from one of the common iliac arteries, usually from that of the left side.

The abdominal aorta terminates by dividing into two trunks, called the common iliac arteries, which diverge at an acute angle. This bifurcation usually takes place on the body of the fourth lumbar vertebra, a little to the left of the middle line. The point here indicated will be found on a level with a line drawn from one crista ilii to the other, and may be transixed by another passed horizontally backwards from the left margin of the umbilicus to the vertebral column, in the erect position of the body. It should, however, be observed, that the division not unfrequently takes place higher up or lower down by about the breadth of half a vertebra.

*The common Iliac arteries* (plate XIV. E, E; plate XXI. C; arteriæ iliacæ communes) commence at the bifurcation of the

aorta, and diverge as they pass downwards and outwards to the sacro-iliac symphysis, where each of them divides into two primary branches,—the internal and external iliac arteries; the former being distributed to the viscera of the pelvis, and the soft parts on its external surface, as well as to the perinæum, whilst the latter is prolonged into the lower extremity, after having sent two important branches to the parietes of the abdomen.

The common iliac arteries of opposite sides present some differences in their direction, length, and relations to contiguous parts, which deserve notice. The vessel on the right side passes off more abruptly than the left, and is somewhat longer, as the division of the aorta occurs to the left of the middle line. The right one also lies obliquely on the last lumbar vertebra, from which it is separated by both the common iliac veins, as they terminate in the vena cava. Both these vessels are covered by the peritonæum, and crossed by the ureters just at their point of division; the right being also crossed by the intestine ilium, where it is about to pass into the large intestine; whilst the left lies behind the sigmoid flexure of the colon. To the inner side of the left iliac artery, and supported on the last lumbar vertebra, lies its accompanying vein; on the right side the vein lies nearly behind the artery.

No branch that has received a name or deserves notice is given off by the common iliac trunks; but on reaching the sacro-iliac symphysis, as has been observed, each divides into the internal and external iliac arteries. We shall commence with the description of the internal iliac artery, chiefly because the parts which its branches supply, viz. the pelvic viscera and the perinæum, require to be examined at an early period.

*Dissection.*—In order to trace the branches of the internal iliac artery, it is necessary to obtain a lateral view of the parts within the pelvis. Previously to taking measures for this purpose, the perinæum should be dissected, and the pudic artery examined at the same time. When this has been done, saw through the os pubis a little outside the symphysis, also the sacro-iliac symphysis of the same side; detach the peritonæum and viscera from that side, and push them to the opposite; by these means the whole limb, and the lateral part of the pelvis, can be removed, leaving the contained organs with their vessels, and one side of the cavity, undisturbed. When the parts are sponged, the arteries can be easily traced by commencing with the trunk and proceeding along the branches. In order to expose the branches of the gluteal and ischiadic arteries outside the pelvis, the gluteus maximus muscle must be dissected, detached from its origin, and reflected downwards.

The *internal iliac artery* (plate XIV. G; plate XXI. E; a. iliaca interna, hypogastrica, pelvica,) in the fœtus, both from its direction and size, appears to be the continuation of the common iliac trunk. It is nearly double the size of the external iliac artery, but in the adult the relation in this particular is reversed, the external iliac being larger. As the vessel in the fœtal state differs from that in the adult subject so materially, in length, relations, size, &c., it becomes necessary to describe its condition in the former, previously to considering its course and distribution in the latter.

## PLATE XXV.

A front view of the arteries of the thigh: the right side shows the femoral artery with its superficial branches without any displacement of the muscles. On the left side the knee is turned outwards, and the sartorius and rectus muscles removed so as to expose the femoral artery in its entire course and exhibit its deeper branches.

Nos. 1, 1. The anterior superior spine of the ilium at each side. 2. The aponeurosis of the external oblique muscle. 3. Poupart's ligament. 4. The external abdominal ring. 5. The spermatic cord. 6. The suspensory ligament of the penis. 7, 7. The tensor vaginæ femoris muscle at each side. 8, 8. A part of the gluteus medius muscle at each side. 9, 9. The iliacus muscle at each side. 10, 10. The pectinei muscles. 11, 11. The adductor longus muscle at each side. 12, 12. The gracilis muscles. 13, 13. Part of the adductor magnus muscle. 14. The sartorius muscle. 15. The rectus muscle. 16, 16. The vastus externus muscle at each side. 17, 17. The vastus internus muscle at each side. 18, 18. The patellæ. 19. The ligamentum patellæ of the right side. 20. The head of the fibula. 21. The insertion of the sartorius, semi-tendinosus, and gracilis muscles. 22. The psoas muscle of the left side, the abdominal parietes being removed. 23. The iliacus muscle within the pelvis. 24, 24. The cruræus muscle, the rectus having been removed. 25. The divided tendon of the rectus muscle. 26. The aponeurosis which is sent off from the adductor longus and magnus to become blended with the vastus internus, and beneath which the femoral artery passes into the popliteal region. 27. The semi-membranosus muscle. 28. The expansion of the sartorius tendon. 29. The tendon of the gracilis muscle. 30. The tendon of the semi-tendinosus muscle. 31. The gastrocnemius muscle.

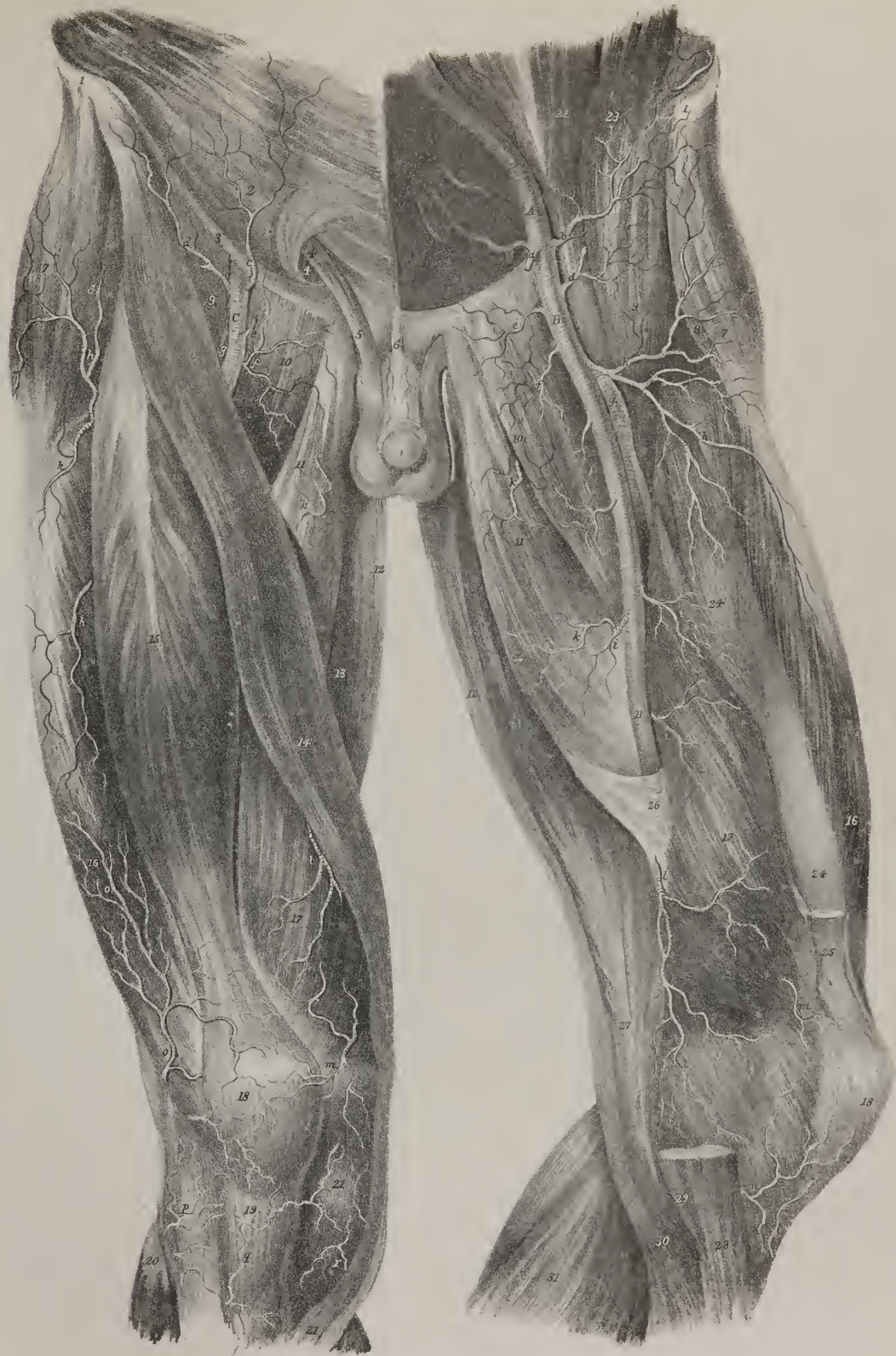A. The external iliac artery.

a. The epigastric artery divided. b. The circumflex ilii artery.

B, B. The femoral artery (a. femoralis) of the left side, shown in its whole course. C. The femoral artery of the right side, seen in the upper triangular space before it is crossed by the sartorius muscle.

c. The superficial epigastric artery (r. epigastricus superficialis.) d, d. The superficial circumflex ilii artery (r. circumflexus ilii superficialis.) e, e. The superior external pudic artery (r. pudendus externus) at each side. f, f. The inferior external pudic artery at each side. g, g. The deep femoral artery (a. profunda femoris) at each side. h, h. The external circumflex artery (r. circumflexus externus) with its branches on either side. i, i. Muscular branches from the femoral artery. k, k. Branches of the obturator artery, piercing the adductor muscles. l, l. The anastomotic artery (r. anastomoticus.) m, m. The superior internal articular artery (r. articularis) at each side. n, n. The inferior internal articular artery at each side. o, o. The superior external articular artery inosculating with descending branches from the external circumflex artery. p. The inferior external articular artery. q. The recurrent branch of the anterior tibial artery (r. recurrens.) These branches form a mesh of arterial interlacements around the knee-joint.









*Internal Iliac artery in the Fœtus.*—When the vessels in the fœtus are injected, (part or the whole of the umbilical cord remaining attached,) it will be found that the internal iliac artery proceeds from the point at which the common trunk divides (sacro-iliac symphysis) forwards and a little downwards, to reach the side of the bladder. In this course the artery descends very little, as the body and fundus of the bladder project into the abdomen in early life. Guided by the side and fundus of the bladder, it reaches the inner surface of the parietes of the abdomen, along which it ascends to the umbilicus, converging to the vessel of the opposite side. When arrived at that aperture, the two arteries come into contact with the umbilical vein, round which they coil in a peculiar manner, until they reach the placenta, in the spongy texture of which their branches ramify until they become capillary. To that part of the vessel which intervenes between the sacro-iliac symphysis and the side of the bladder, the term *hypogastric* can in strictness be applied; the remainder thence onward through the umbilicus to the placenta, being the proper *umbilical* artery, which performs an important part in carrying on the fœtal circulation. In the first part of its course the vessel lies along the margin and side of the pelvis, covered by the peritonæum, then between that membrane and the side of the bladder, to which it gives branches, (*superior vesical*,) and finally, between the peritonæum and the fascia transversalis, which separates it from the rectus muscle and its sheath. After birth, when the placental circulation is no longer carried on, the umbilical arteries gradually contract, become impervious, and reduced to the form of mere ligamentous cords, extending from the side of the bladder to the umbilicus. The remaining part, which still continues pervious, presents a diminution in size proportioned to the decrease in the quantity of blood circulated through it.

The *internal iliac artery in the adult* is a short stunted trunk extending from the sacro-iliac symphysis to the sacro-sciatic notch, opposite to which it may be said to terminate by dividing into branches. The external side of the artery, just at its origin, is in contact with the inner border of the psoas muscle; lower down it rests against part of the sacral plexus. Behind it, is situated the internal iliac vein, and the communicating branch which passes from the lumbar to the sacral plexus; in front it is crossed by the ureter which separates it from the peritonæum. When the depth at which this vessel is situated is duly considered, as well as its close connexion with the different parts here enumerated, we can form some idea of the difficulty of passing a ligature round it in the living subject, without including the nerve, or injuring the vein. Its branches, though constant and regular in their existence and general distribution, still vary much in their origin. Some which are rather small and variable are distributed to the parts or organs within the pelvis, viz., the surface of the sacrum, the rectum, bladder, uterus, and vagina, whilst others of larger size are sent for the most part to the muscles within the cavity of the pelvis, and upon its outside. Viewing the internal iliac artery as we usually do after making a lateral section of the pelvis, it will be observed in most cases to present two primary branches at its point of division, one anterior, the other posterior: the latter gives off the ilio-lumbar, obturator, gluteal, and lateral sacral arteries; whilst from the anterior branch arise the umbilical, (being originally its proper continuation,) the ischiadic, and the pudic, which usually furnishes the vesical, uterine, and middle hæmorrhoidal arteries.

The *Ilio-lumbar artery* (plate XXI. l, c; r. ilio-lumbalis, iliaco-muscularis) resembles the lumbar branches of the aorta in direction and distribution. It passes outwards beneath the psoas muscle and external iliac vessels, to reach the margin of the iliac fossa, where it divides into two sets of branches. Of these, one passes upwards, ramifying into the psoas and quadratus muscles, where some of them communicate with those of the last lumbar arteries, whilst others enter the inter-vertebral foramina, and supply the parts lodged in the vertebral canal. The rest of its branches turn downwards and outwards, either in the substance of the iliacus muscle, or between it and the surface of the ilium. Some of these reach the crista and spine of that bone, where they anastomose with the circumflex ilii, and, if followed with attention, some can be traced forwards through the abdominal muscles, which they supply, and in which they communicate with the external branches of the epigastric artery.

The *Obturator artery* (plate XXI. fig. 1, m, fig. 2, g; plate XXIV. figs. 1, 2, c: r. obturatorius, sub-pubio femoralis) usually arises from the posterior branch of the internal iliac, but not unfrequently from the epigastric. The course and length of the internal or pelvic portion of the vessel will vary materially in these cases; the external or femoral is generally uniform. According to J. Cloquet,\* who noted its distribution in more than two hundred instances, the number in which it arises from the iliac, as compared with that from the epigastric, may be stated as three to one. When the obturator artery arises from the internal iliac, it passes forwards close to the obturator internus muscle, and a little beneath the nerve of the same name, with which it gradually comes into contact. Both pierce the pelvic fascia, pass through a cellular interval between the pubic and ischiatic portions of the obturator muscle, and finally appear at the top of the thigh, after having made their way through the oval aperture in the thyroid or obturator membrane. In this course the nerve lies above the artery, both being placed between the pelvic fascia and peritonæum, as they run along the inner side of the pelvis. But when it arises from the epigastric artery, it has to pass downwards and inwards into the pelvis, in order to reach the thyroid foramen; and in doing so its course must lie along the margin of the crural ring, and must be placed close to some part of the neck of the hernial sac, should a portion of intestine be protruded through that aperture. If the obturator artery arises near the origin of the epigastric, or by a short trunk common to it and that vessel, it will be placed across the external side of the crural ring; but if it starts from a point higher up, as it has to incline inwards whilst descending into the pelvis, it will be found along the superior and internal border of the ring, and therefore

\* Recherches Anatomiques sur les Hernies.



almost surrounding the neck of the sac. This, however, is rather an unusual occurrence; Breschet\* appears to have met only a single instance of it. When the obturator artery has reached the thigh, it is supported on the external obturator muscle, and covered by the pectineus; it soon divides into two branches, one external, the other internal. The *external* branch inclines backwards and outwards, sending off branches, some for the supply of the obturator and quadratus muscles, whilst one or two, in some instances, reach the notch in the acetabulum, through which they pass, and are distributed to the hip-joint. The *internal* branch passes downwards between the abductors, supplies them as well as the pectineus and gracilis, and communicates with branches of the internal circumflex artery.

The *Gluteal artery* (plate XXI. fig. 1, n; plate XXVII. k; r. gluteus, la fessière, Chauss.) is the largest branch of the internal iliac artery; it inclines downwards and outwards, so as to reach the border of the great sciatic notch, beneath which it turns in order to appear on the dorsum of the pelvis. Its trunk will be found, accompanied by the gluteal vein and nerve, in the interval between the contiguous borders of the gluteus medius and pyriformis muscles; but it instantly divides into branches, one of which runs between the gluteus maximus and medius, and is superficial relatively to the other, which is placed between the latter muscle and the gluteus minimus. The first or superficial branch sends off in its course several ramusculi, which are distributed, some inwards, (after piercing the tendinous origin of the gluteus maximus,) to the side of the sacrum, anastomosing with the posterior branches of the sacral arteries; others, of considerable size, pass outwards between the gluteal muscles which they supply. The second or *deep* branch, situated between the gluteus medius and minimus, runs in an arched direction forwards, and may be said to divide into two branches. The superior one, holding the course of the vessel from which it arises, proceeds beneath the gluteus medius and tensor vaginæ femoris, towards the anterior spine of the ilium, and anastomoses with the circumflex ilii and the ascending branches of the external circumflex artery, after having freely supplied the muscles between which it passes. The other branch descends towards the great trochanter, supplies the gluteal muscles, and anastomoses with the external circumflex.

The *Sacral artery*, lateral, (plate XXI. fig. 1, p; fig. 2, h, i; r. sacro-lateralis,) is generally a small single vessel; sometimes there are two, running parallel in the usual direction, which is downwards and inwards, in front of the anterior sacral foramina, resting upon the origin of the pyriformis muscle and the primary branches of the sacral nerves. It lies about an inch outside the middle sacral artery, having between them the sympathetic nerve, and runs as far as the coccyx, where it arches inwards to anastomose with the middle sacral and the lateral sacral of the opposite side. Sometimes it enters the third or fourth sacral foramen, and ramifies in the interior of the canal. Branches pass off anteriorly from this artery to the back part of the rectum and bladder; others, more considerable, incline backwards, and after giving ramusculi to the pyriformis and sacral nerves, enter the foramina, and are distributed to the nerves within the canal, some being prolonged backwards through the posterior sacral foramina, so as to terminate upon the dorsal surface of the sacrum.

## PLATE XXVI.

The deep arteries of the anterior part of the thigh. This view is obtained by removing the sartorius and rectus muscles, and drawing the vastus internus outwards.

No. 1. The crest of the ilium. 2. The anterior superior process of the ilium. 3, 3. The iliacus muscle. 4, 4. The psoas magnus muscle. 5, 5. Poupert's ligament. 6. The crest of the os pubis. 7. The tensor vaginæ femoris muscle. 8. The gluteus medius muscle. 9. The pectineus muscle. 10. The lower border of the adductor brevis muscle. 11. The adductor magnus muscle. 12. The gracilis muscle. 13. Part of the adductor longus. 14. The vastus internus drawn outwards. 15. The cruræus muscle. 16. The vastus externus. 17. The tendon of the rectus muscles. 18. The vastus internus. 19. The patella. 20. The ligament of the patella.

A. The external iliac artery.

a. The circumflex ilii artery, divided. b. The epigastric artery, cut off.

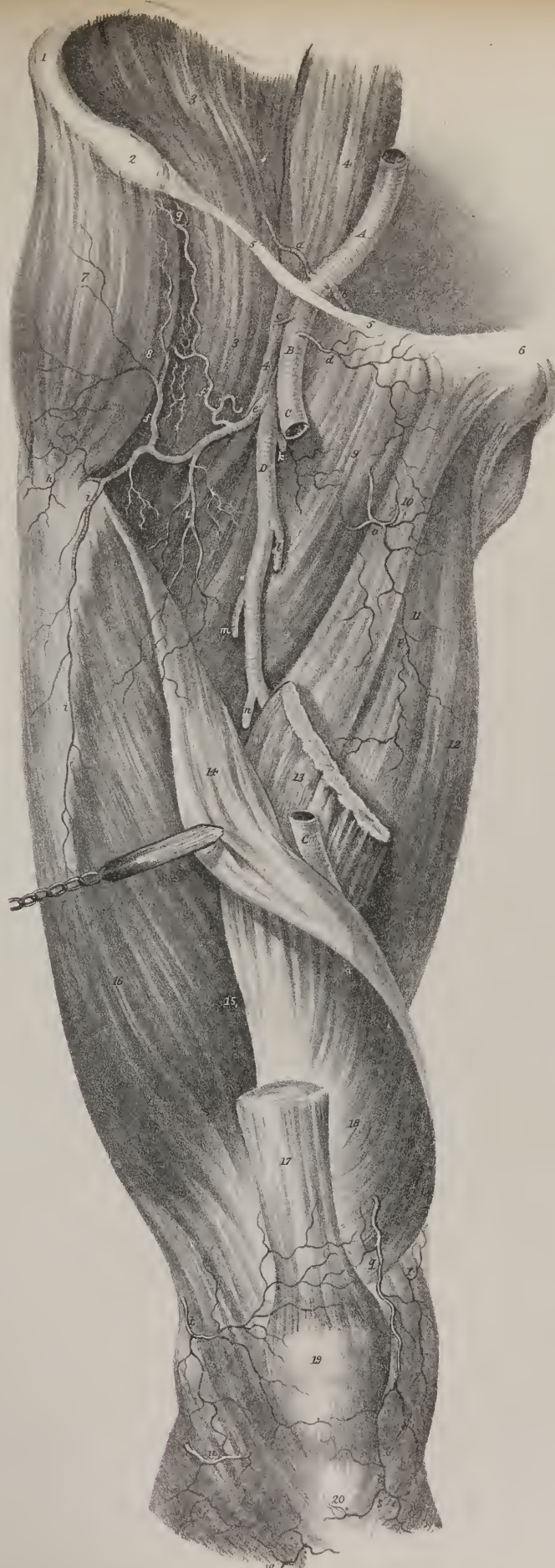B. The common femoral artery. c. The common origin of the superficial circumflex ilii artery and superficial epigastric. d. The deep external pudic artery.

C, C. The divided trunk of the superficial femoral artery. This vessel has been removed to show the course and branches of

D. The deep femoral artery, (a. profunda femoris.)

e. The external circumflex artery, (r. circumflexus externus.) f, f. Ascending branches of the external circumflex artery, inosculating with, g. The terminal branches of the gluteal artery. h, h. Middle branches of the external circumflex, which encircle the thigh, to inosculate with branches of the internal circumflex and sciatic arteries. i, i. Descending branches from the same artery, which communicate with ascending branches from the superior external articular artery. k. The internal circumflex artery (r. circumflexus internus) passing back between the pectineus and psoas muscles. l. The superior perforating artery, (r. perforans superior.) m. The middle perforating artery, (r. perforans medius.) n. The inferior perforating artery, (r. perforans inferior.) o. The termination of the anterior branch of the obturator artery, (r. obturatorius.) p. The posterior branch of the obturator artery. q. One branch of the anastomotic artery (r. anastomoticus) inosculating with the articular branches of the popliteal around the knee-joint. r. The superior internal articular artery. s. The inferior internal articular artery. t. The superior external articular artery. u. The inferior external articular artery. w. The recurrent branch of the anterior tibial artery.

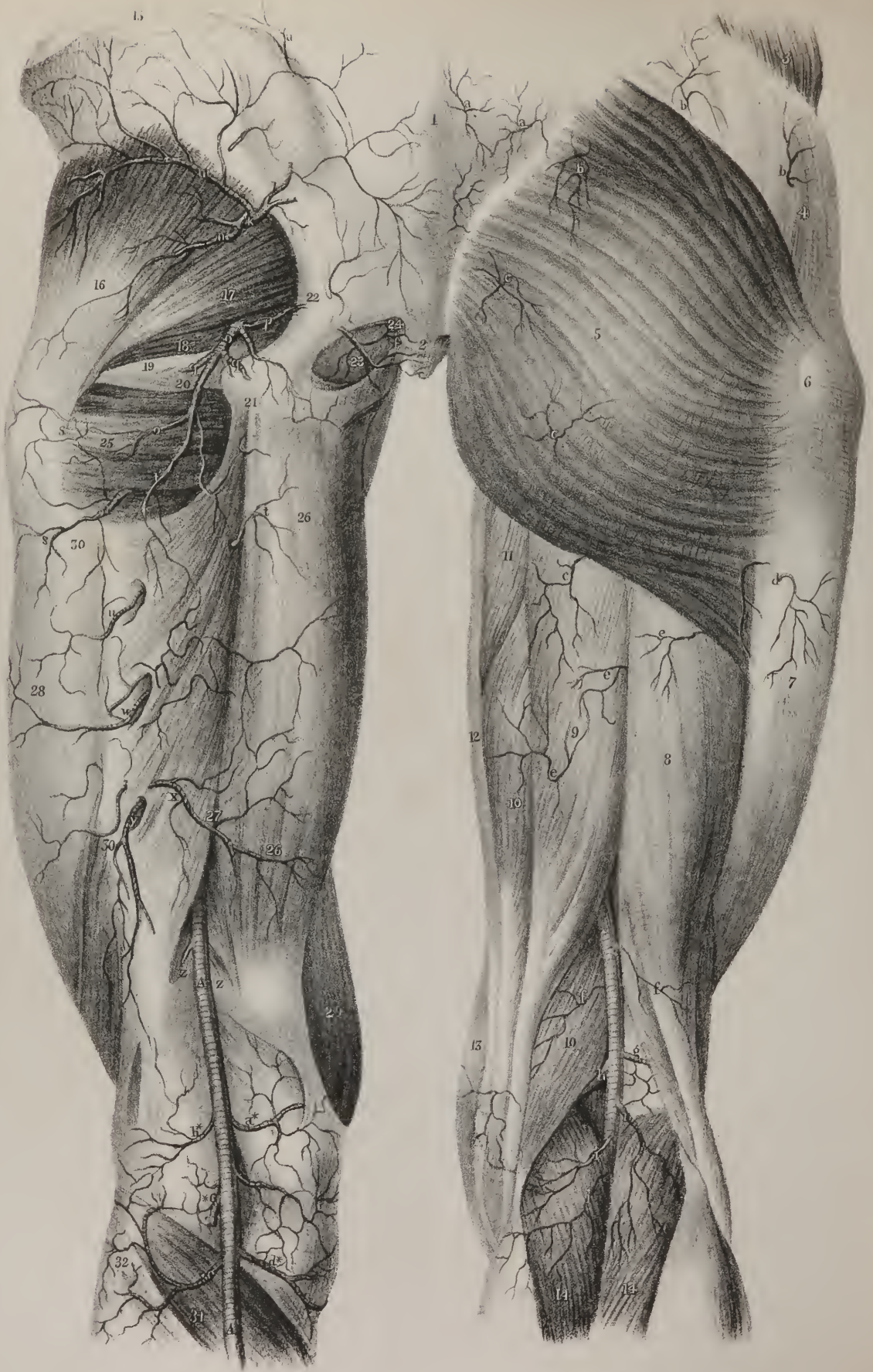\* Thèses présentées et soutenues publiquement devant les Juges du Concours. Paris, 1819.













*The Ischiadic artery* (plate XXI. fig. 1, g; fig. 2, l; plate XXVII, o; r. ischiadicus) is smaller than the gluteal, and arises somewhat lower down. It occasionally forms a common trunk with the pudic artery, in other instances it gives off that vessel when it is about to leave the pelvis. Placed for some way upon the pelvic surface of the pyriformis muscle and the sciatic plexus of nerves, it soon turns backwards beneath the border of that vessel, passing between it and the superior gemellus. In this situation it lies in the interval between the tuber ischii and great trochanter, covered by the gluteus maximus. It gives off several muscular branches, to supply the external rotators on which it lies, as well as the gluteus which conceals it. Two only of its numerous branches have received names, or require a particular notice. An internal branch, the coccygeal, (*ramus coccygeus*, plate XXVII. p, p,) inclines inwards, and pierces the great sacro-sciatic ligament, and so reaches the posterior surface of the coccyx, and supplies the coccygeus and levator ani muscles. A descending branch (*comes nervi ischiadici*, plate XXVII. r; Murray, Harrison) runs downwards, accompanying the sciatic nerve, and sends a long branch into its interior, which passes some way along with it in its course through the thigh. Besides these, some branches, after supplying the upper part of the flexor muscles, anastomose with the gluteal, the circumflex, and superior perforating arteries.

*The Pudic artery*, (plate XXI. fig. 1, f; fig. 2, n, n; plate XXII. a, a; r. pudicus internus, artère honteuse interne.) The parts contained in the perinæum are supplied with blood from the internal pudic artery. This vessel usually arises as a distinct branch from the internal iliac artery, but occasionally is derived from a trunk common to it and the ischiadic. It inclines downwards and outwards to reach the spine of the ischium, lying at first on the sacral plexus, but afterwards passes between the pyriformis and coccygeus muscles, to gain the point just referred to. Having thus passed out of the pelvic cavity, it rests upon the external surface of the spine of the ischium, beneath which it turns inwards through the lesser sciatic notch, and proceeds towards the inner surface of the tuber ischii. In this situation it lies on the obturator internus muscle, to which it is bound down by the obturator fascia, between which structures it lies, in its course forwards and upwards, along the rami of the pubes and ischium, towards the pubic arch. On approaching the latter, the artery pierces the fascia, and becomes placed between the crus penis and the bone, where it divides into its two ultimate branches, viz. ramus dorsalis penis and r. corporis cavernosi. In the first part of its course, whilst within the pelvis, the artery lies behind the bladder and vesiculæ seminales, and is supported by the pyriformis muscle and the sacral nerves; whilst outside the cavity it is placed between the sciatic ligaments, and rests upon the spine of the ischium. With these parts of the vessel we have nothing to do, in a practical point of view; but as soon as it reaches the perinæal space, it enters into new and important relations. Its direction is forwards, upwards, and inwards, taking the direction of the rami of the os pubis and of the ischium. It rests against the obturator internus muscle, which separates it from the bone, being at first about an inch, or somewhat more, higher up than the margin of the tuber ischii, in which situation it is concealed and bound down by the obturator fascia. In the rest of its course, where it corresponds with the rami, it has the bone to its outside, the falciform process of the great sciatic ligament beneath, and the obturator fascia internally. In the course of the artery numerous branches are given off: we may divide them into three sets, viz., the pelvic, the perinæal, and the terminal. The pelvic branches consist, in the first place, of some small unnamed ramusculi given to the coccygeus pyriformis, and obturator

## PLATE XXVII.

The arteries on the back part of the hip and thigh are here shown. On the right side the superficial muscles remain undisturbed; on the left they are removed.

- No. 1. The sacrum concealed by the aponeurosis of the latissimus dorsi muscle. 2. The coccyx. 3. Part of the obliquus externus muscle. 4. The dense fascia which covers in the gluteus medius muscle. 5. The gluteus maximus muscle. 6. The trochanter major. 7. The thick fascia on the outer side of the thigh. 8. The biceps muscle. 9. The semi-tendinosus muscle. 10, 10. The semi-membranosus muscle. 11. Part of the adductor magnus. 12. The gracilis muscle. 13. The sartorius muscle. 14, 14. The gastrocnemius muscle.—Left side; 15. The crest of the ilium. 16. The gluteus minimus muscle. 17. The pyriformis muscle. 18. The gemellus superior. 19. The tendon of the obturator internus. 20. The gemellus inferior. 21. The tuberosity of the ischium, (tuber ischii.) 22. The posterior sacro-sciatic ligament. 23. The obturator internus muscle. 24. The coccygeus muscle. 25. The quadratus femoris muscle. 26, 26. The adductor magnus muscle. 27. The separation in the adductor magnus, through which the femoral artery passes into the popliteal region. 28. The vastus externus muscle. 29. Part of the vastus internus. 30, 30. The linca aspera. 31. The popliteus muscle. 32. The head of the fibula.
- a, a. Superficial branches of the ilio-lumbar artery. b, b. Superficial branches of the gluteal artery. c, c. Superficial branches of the ischiadic artery. d. A superficial branch from the external circumflex artery. e, e. Branches of the perforating arteries. f, f. Muscular branches from the popliteal artery. g. The superior external articular artery. h. The superior internal articular. i, i. Muscular branches (r. musculares, surales) distributed to the muscles of the calf of the leg.—Left side; k. The gluteal artery, (r. gluteus.) l. Its superficial branch. m. The deep branch of the gluteal artery. n. The descending branch. o. The ischiadic artery, (r. ischiadicus.) p, p. Its coccygeal branch, (r. coccygeus.) q, q. Inferior gluteal branches. r. The descending branch, (comes nervi ischiadici.) s, s. Terminal branches of the internal circumflex artery. t. A terminal branch from the obturator artery. u. The termination of the superior perforating artery. w. The middle perforating artery. x. The inferior perforating artery. y. The termination of the profunda artery.
- A. A. The popliteal artery, (a. poplitea.)  
 z, z. Muscular branches (r. musculares) from the popliteal artery. a.\* Superior internal articular artery, (r. articularis.) b.\* Superior external articular artery. c.\* Azygos articular artery, (r. articularis azygos.) d.\* Inferior internal articular artery. e.\* Inferior external articular artery.



muscles; and, secondly, of some which pass inwards to the rectum, prostate, and bladder, and are named from the parts which they supply, viz. vesical, vaginal, uterine, and middle hæmorrhoidal. But as these sometimes come from the ischiadic, or internal iliac arteries, we must notice them separately, and not merely as branches of the pudic. The perinæal branches are the following:—

*The external Hæmorrhoidal*, (plate XXI. fig. 2, p, p; plate XXII. b, b; r. hæmorrhoidales externi,) two or three in number, incline inwards from the pudic artery, when it has reached the tuber ischii, and must necessarily pierce the fascia which binds it down, in order to reach the perinæum. They lie embedded in a quantity of adipose substance, lodged in the interval between the ischium and the sphincter ani, and soon branch out into ramusculi, which are distributed to the parts about the margin of the anus.

*The superficial Perinæal artery* (plate XXI. fig. 2, q; plate XXII. c, c; r. perinæi superficialis) is a long, small, but still regular artery, which supplies the serotum and upper part of the perinæum; it pierces the fascia a little higher up than the preceding, and then turns upwards close by, and parallel with, the rami of the ischium and pubes: it crosses the transversus perinæi muscle, and finally lies in a groove between the erector penis and accelerator urinæ. In this course, it gradually becomes superficial as it ascends, and in the male is distributed to the scrotum, in females to the labium. It not unfrequently gives off the following branch:—

*The transverse artery of the Perinæum* (plate XXI. fig. 2, r; plate XXII. d, d; r. transversus perinæi) arises either from the pudic artery, or from the preceding branch, when on a level with the transversus perinæi muscle. As its name implies, it runs across the perinæum, and terminates in small twigs, which are distributed to the parts between the anus and bulb. Its size is very small.

*The artery of the Bulb* (plate XXI. fig. 2, t; plate XXII. fig. 1, e; r. corporis bulbosi) passes horizontally inwards from the pudic artery when it is on a level with the bulb of the urethra; on reaching which it divides into ramusculi, that soon become capillary, and spread out into the erectile tissue constituting the bulb and corpus spongiosum.

*The artery of the Corpus Caverosum* (plate XXI. fig. 2, v; plate XXII. fig. 1, f; fig. 2, e; r. corporis cavernosi) is one of the terminal branches of the internal pudic. It turns forwards, and enters the body of the corpus cavernosum, in which it ramifies somewhat in the same way as the preceding vessel does in the corpus spongiosum and bulb.

*The dorsal artery of the Penis* (plate XXI. fig. 2, u, u; r. dorsalis penis) passes upwards between the crus penis and the pubic symphysis, and, having pierced the suspensory ligament, runs forward parallel with its fellow of the opposite side, freely supplying the integument in its course. Near the corona glandis, each of these arteries branches out into ramusculi, some of which pierce the glans, whilst others supply the prepuce.

The pudic artery sometimes takes a different course from that here described, plate XXIV. fig. 3, m, m. Instead of passing out by the sciatic notch, it inclines inwards to the side of the bladder, runs along by the prostate gland, and escapes from the pelvis beneath the pubic arch; it thus gains the upper surface of the penis, and in the rest of its course represents the dorsal artery. Tiedemann gives a drawing of this variety: Burns met four cases of it. Mr. Harrison, after alluding to one which he had dissected, observes,\* “should such a variety exist in one who was to become the subject for the lateral operation of lithotomy, I fear this artery must be wounded; and, judging from its size and situation in those cases in which I have seen it take this course, I should apprehend very serious consequences from its division. It is not improbable but that some of those alarming and fatal cases of hæmorrhage which have occurred even to the best operators, may have depended on this variety.”

The dorsal artery of the penis has been observed to arise not from the pudic, but from the a. profunda femoris, from which it passed obliquely upwards and inwards to reach the root of the penis. Tiedemann gives a drawing of this variety.

*The middle Hæmorrhoidal artery* (plate XXI. fig. 1, h, i; r. hæmorrhoidalis medius) is usually a small long vessel derived from the pudic artery; but it may come from the ischiadic or internal iliac. It inclines inwards as it descends, and at the same time comes forwards to gain the side and fore part of the rectum, to which it gives ramusculi, some being prolonged under the peritonæum to the base of the bladder and the vesiculæ seminales. The branches of this vessel form a link of connexion between the external hæmorrhoidal artery derived from the pudic artery, and the superior one, which comes from the inferior mesenteric.

*Vesical arteries*, (r. vesicales,) two or three in number, are derived from the pudic, from the middle hæmorrhoidal, or the ischiadic. They diverge as they pass forwards, one being directed downwards to the base of the bladder, upon which its ramusculi are lost; the other a little upwards to the side of that viscus. The latter may be called middle vesical, to distinguish it from those of the preceding vessel, as well as from some small branches which are situated higher up, and are derived from the internal iliac artery itself, or from the umbilical.

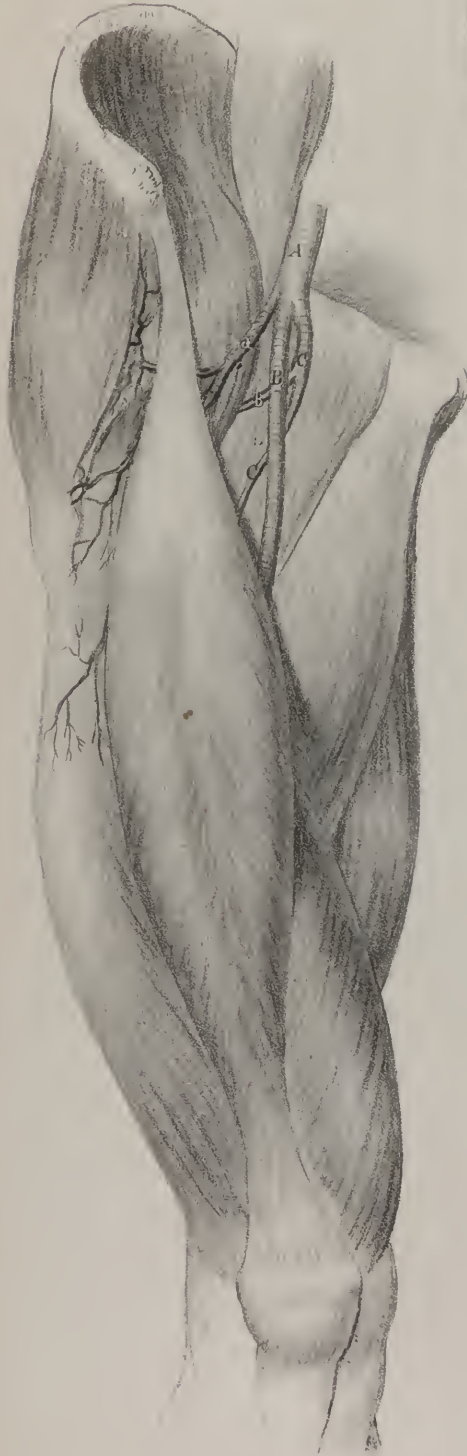*Uterine artery* (r. uterinus) is usually a branch of the pudic, or of the middle hæmorrhoidal, sometimes of the internal iliac. It is very small, and becomes tortuous as it approaches the uterus, to which it is guided by the fold of the broad ligament within which it lies. Its ramusculi ramify in the proper structure of the uterus, some being continued upwards to the ovarium.

*Vaginal artery* (r. vaginalis) arises not unfrequently in common with the uterine, or may come singly from the pudic or

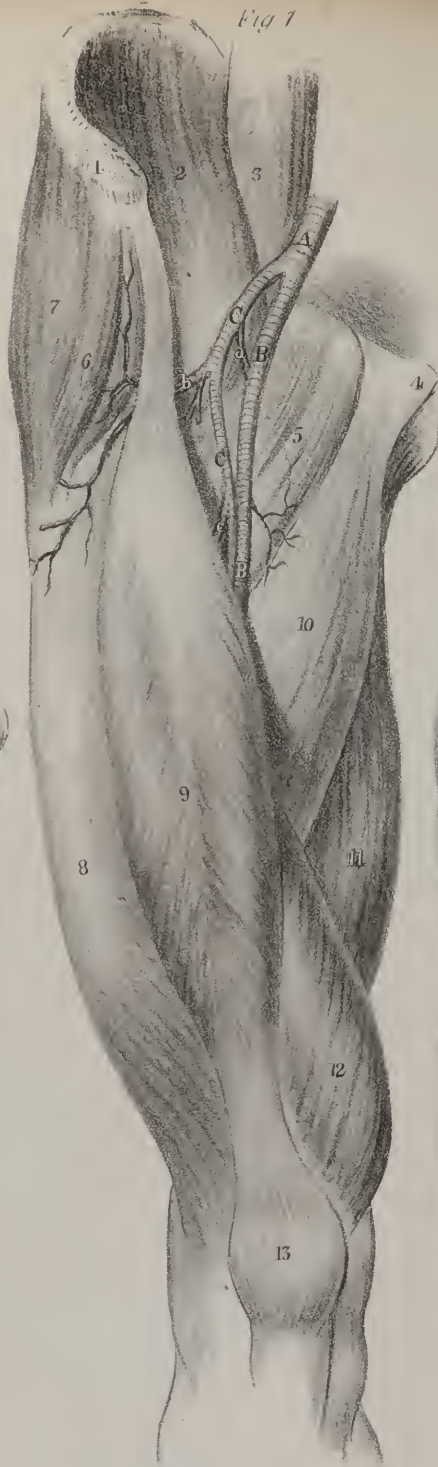\* Surgical Anatomy of Arteries, vol. ii. p. 124.



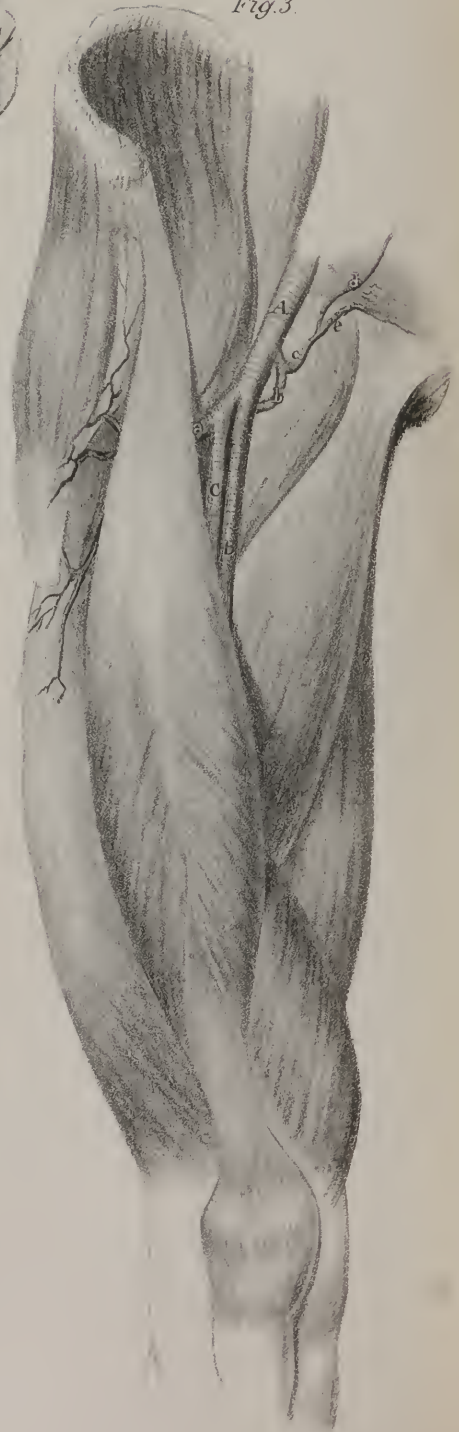*Fig 2*



*Fig 1*



*Fig. 3.*





middle hæmorrhoidal. It runs forwards and inwards to reach the side of the vagina, and then inclines to its upper surface, to which it gives several ramusculi, some extending to the bladder.

*The external Iliac artery* (plate XIV. F; plate XIX. A; plate XXI. D; a. iliaca externa, arteria cruralis in pelvi, Sæmm.) Previously to entering on its description, we may observe, that the vessel whose branches supply the lower extremity continues an undivided trunk from the point already indicated (*sacro-iliac symphysis*) as far as the lower border of the popliteus muscle, where it divides into the anterior and posterior tibial arteries; but though it continues thus undivided, different parts of it have received different names, taken from the anatomical regions through which it passes. Whilst within the pelvis, and running along the iliac region, it is named *iliac*; in the upper two-thirds of the thigh, *femoral*; from thence to the lower boundary of the ham, *popliteal*. Each of these divisions (which are really artificial, being intended merely to facilitate the description of the vessel) is marked by some change in direction, in relation to contiguous parts, and also by a diminution in size, proportioned to the decrease in the quantity of contained fluid consequent on the giving off branches of supply at different intervals.

*Dissection.*—As the external iliac artery and its branches are usually studied immediately after the abdominal viscera have been examined, very little dissection is required to expose them in their entire extent. If the lower part of the parietes of the abdomen be turned down on the thigh, after the viscera have been removed, nothing more is necessary than to gently elevate the peritonæum from the iliac fossa, and draw it inwards towards the pelvis. The trunk of the vessel will then be observed resting on a smooth dense membrane (*fascia iliaca*) which is placed behind it, separating it from the psoas muscle; it is, however, bound down to the fascia by the sub-serous cellular tissue, which adheres firmly to it on each side of the vessel. The epigastric artery, if injected, may also be exposed in the lower and more important part of its course in the same way, namely, by removing the peritonæum from the fascia transversalis, which at once shows its relation to the cord and internal ring; to trace it higher up, the sheath of the rectus must be opened. If the abdomen be not opened, it will be necessary to cut through the three layers of abdominal muscles, in order to reach the epigastric artery. The direction of the vessel may be indicated by drawing a line a little from the pubic side of the middle point, between the superior spine of the ilium and the symphysis pubis, upwards to the side of the ensiform cartilage.

*The external Iliac artery* extends from the sacro-iliac symphysis to Poupart's ligament, its direction being obliquely downwards and outwards, so as to reach the middle point between the anterior and superior spinous process of the ilium and the symphysis pubis. In this course the vessel presents a slight curve, being at first depressed a little backwards into the pelvic cavity; but lower down, where it passes over the brim of the pelvis and is supported by the psoas muscle, it comes a little forwards. It gives no branch of any consequence until it arrives within a few lines of its termination. It at first rests somewhat on the external iliac vein; as it descends it receives some support from the psoas muscle being closely applied to its inner margin, and finally rests upon it for some way, the fascia iliaca interposing. To its external side lies the psoas muscle in its whole course, which separates it from the anterior crural (femoral) nerve; the internal branch of the genito-crural nerve, as it passes inwards to its destination, runs in front of the artery. Anteriorly, the external iliac artery is covered by the peritonæum; internally, it is accompanied by the vein of the same name, which at first is placed rather behind it, but gradually comes forward so as to lie on

## PLATE XXVIII.

This plate represents the principal varieties of arteries occurring in the thigh. The references to the muscles are the same in the three figures.

No. 1. The crest of the ilium. 2. The iliacus internus muscle. 3. The psoas magnus muscle. 4. The spine of the os pubis. 5. The pectineus muscle. 6. The anterior border of the gluteus medius muscle. 7. The tensor vaginae femoris muscle. 8. The vastus externus. 9. The rectus. 10. The adductor longus muscle. 11. Part of the adductor magnus. 12. The vastus internus muscle. 13. The patella.

FIG. 1. The external iliac artery divides at about an inch above Poupart's ligament into two trunks of equal size: the internal one assumes the course and distribution of the superficial femoral artery; the external one gives off the circumflex branches, and represents the profunda femoris artery.

A. The external iliac artery. B, B. The superficial femoral artery. C, C. The profunda femoris.  
a. The internal circumflex artery. b. The external circumflex artery. c. One of the perforating arteries.

FIG. 2. The external iliac artery divides at Poupart's ligament into three branches of nearly equal size: the middle trunk, the proper continuation of the artery, follows the ordinary course of the superficial femoral; the external one is the external circumflex artery; and the internal division winds behind the femoral in the course of the profunda femoris.

A. The external iliac artery. B. The superficial femoral artery. C. The profunda femoris.  
a. The external circumflex artery. b. The internal circumflex artery.

FIG. 3. This figure shows a variety of the internal circumflex artery, which gives off a branch that divides into the epigastric and obturator arteries. In a less rare case a large branch is given off by the common femoral, which divides into three branches of nearly equal size, the epigastric, the obturator, and internal circumflex.

A. The common femoral artery. B. The superficial femoral. C. The profunda femoris.

a. The external circumflex artery. b. The internal circumflex. c. The anomalous branch. d. The epigastric artery. e. The obturator artery.

the same plane when they have reached Poupart's ligament. The artery at this point is supported by the inner side of the psoas muscle, the vein, by the os pubis, where a small part of its upper surface remains uncovered by muscular fibre, between the contiguous borders of the psoas and pectineus; but between the vessels and the bone and muscle just named, the prolonged part of the fascia iliaca is interposed.

Just before its termination the artery gives its two branches, viz. the epigastric and circumflex ilii.

*The Epigastric artery* (plate XIV. s; plate XIX. i, i; r. epigastricus) is situated obliquely at the inferior and anterior part of the abdominal parietes. It arises from the external iliac artery, usually about two or three lines above the margin of Poupart's ligament; in some instances it comes off on a level with it, or even lower down. In the first case, it inclines downwards and inwards, so as to get on a level with the ligament; after which it changes its direction, passing obliquely upwards and inwards, being placed between the fascia transversalis and the peritonæum, until it reaches midway between the umbilicus and pubes, where it enters the sheath of the rectus, in which it ascends above the umbilicus, and terminates in several small branches that anastomose with the terminal branches of the internal mammary and inferior intercostal arteries; in its course it has communica-

## PLATE XXIX.

In this plate the arteries of the front part of the leg and foot are exhibited.

FIG. 1. The muscles and tendons are left in their natural situations; the superficial parts only of the anterior tibial artery and dorsal artery of the foot being seen.

No. 1. The vastus externus muscle inserted into the side of the tendon of, 2, the rectus muscle. 3. The vastus internus muscle. 4. The patella. 5. The ligament of the patella. 6. The tendon of the biceps femoris muscle. 7, 7. The tibia. 8, 8. The tibialis anticus muscle. 9, 9. The extensor proprius pollicis muscle and tendon. 10, 10. The extensor digitorum longus muscle, dividing into its four tendons. 11, 11. The peroneus tertius muscle. 12. The outer ankle, (malleolus externus,) formed by the lower extremity of the fibula. 13. The inner ankle, (malleolus internus.) 14. The anterior annular ligament. 15. The peroneus longus muscle. 16, 16. The external and internal borders of the soleus muscle. 17. The external head of the gastrocnemius muscle. 18. The internal head of the gastrocnemius. 19, 19. The extensor brevis digitorum muscle.

a, b, c, d. The four articular branches (r. articulares) of the popliteal, which form with, e, the recurrent branch (r. recurrens) of the anterior tibial artery, a net-work of anastomoses around the fore-part of the knee-joint. f, f. Superficial branches of the anterior tibial artery perforating the muscles to ramify in the integument of the leg.

A. The anterior tibial artery (a. tibialis antica) in the lower part of its course, lying between the tendons of the extensor communis digitorum, and extensor proprius pollicis. B. The dorsal artery of the foot, (a. dorsalis pedis.)

g. The external malleolar artery (r. malleolaris externus) dividing into an ascending branch, h, which inosculates with, i, the anterior branch of the peroneal artery, (r. peroneus anterior,) and a descending branch, k, which anastomoses with branches of the tarsal artery. l. The internal malleolar artery (r. malleolaris internus) ramifying around the inner ankle. m. The tarsal branch (r. tarsus) of the dorsal artery of the foot. n. A superficial branch of the metatarsal artery. o. An internal branch which supplies the inner border of the foot, and inosculates with branches of the internal plantar artery. p. A small branch of the dorsalis pollicis artery, which ramifies along the inner border of the great toe. q. The dorsal artery of the great toe, (a. dorsalis pollicis,) giving off, r, a collateral branch for the supply of the inner border of the second toe. s, s. Interosseous branches (r. interossei) from the metatarsal artery, which divide into the collateral branches supplying the borders of the toes. t. A collateral branch for the outer side of the little toe.

FIG. 2. The muscles are here drawn aside, and some of the tendons removed, to display the anterior tibial artery in its whole course. The muscles being the same as those described in Fig. 1, particular reference is unnecessary.

No. 1. The tibialis anticus muscle drawn to one side. 2. The extensor digitorum longus muscle. 3. The extensor proprius pollicis muscle. 4, 4. The interosseous membrane. 5. The external malleolus. 6. The internal malleolus. 7. The divided tendons of the extensor digitorum longus muscle. 8. The tendon of the peroneus tertius muscle. 9. The tendon of the extensor proprius pollicis muscle. 10. The tendon of the tibialis anticus muscle. 11, 11. Ligamentous bands passing between the bones of the tarsus. 12, 12. The divided tendons of the extensor digitorum longus muscle.

A, A. The anterior tibial artery. B, B. The dorsal artery of the foot.

a. The recurrent branch of the anterior tibial. b, b. Muscular branches. c. The external malleolar artery. d. Its ascending branch inosculating with, e, the anterior branch of the peroneal artery. f. Its descending branch inosculating with the extremity of the tarsal artery. g. The internal malleolar artery. h. Ascending branches of the internal malleolar anastomosing with branches of the posterior tibial artery. i. Descending branches which inosculate with branches from the internal plantar artery, and internal branches from the dorsalis pedis artery. k, k. Tarsal artery (r. tarsus) inosculating above with the external malleolar artery, beneath with branches from the external plantar artery, and below with the metatarsal branch. l. A deep branch of the tarsal artery which supplies the articulations between the tarsal bones. m. The metatarsal artery (r. metatarsus) giving off, n, n, n, the interosseous branches, (r. interossei,) which divide at the root of the toes into the collateral branches, o, o, supplying the borders of the toes. p, p. Perforating branches (r. perforantes) dipping into the sole of the foot to communicate with the external plantar artery. q. The external collateral branch supplying the outer border of the little toe, generally a branch of the fourth interosseous branch. r, r. Branches from the dorsal artery supplying the inner border of the foot, which anastomose with the internal plantar artery. s. The perforating branch of the dorsal artery passing into the sole of the foot to inosculate with the termination of the external plantar artery. t. The dorsalis pollicis artery, which gives off the collateral branch, u, that runs along the inner border of the great toe. w, w. Collateral branches of the dorsalis pollicis artery supplying the outer border of the great toe and the inner side of the second.



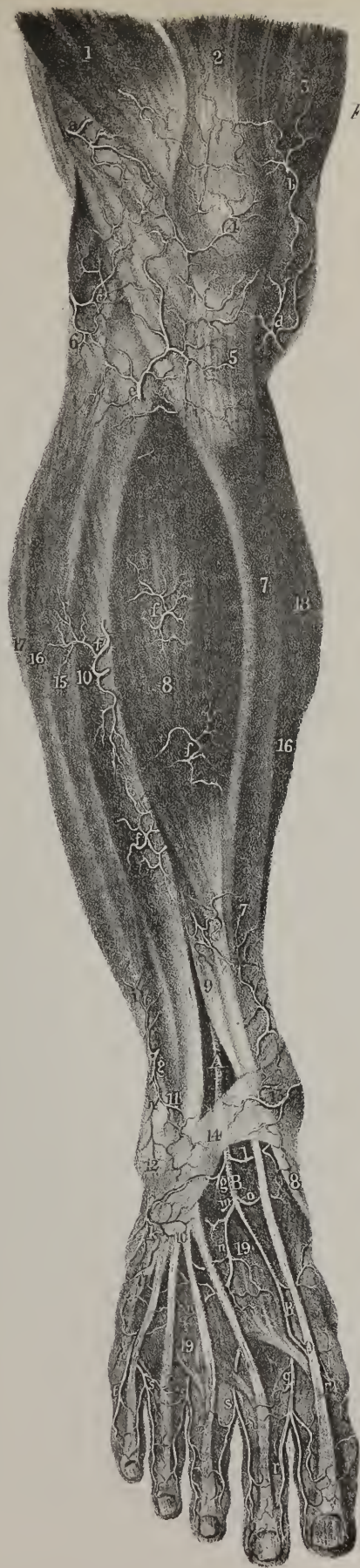

Fig 1.

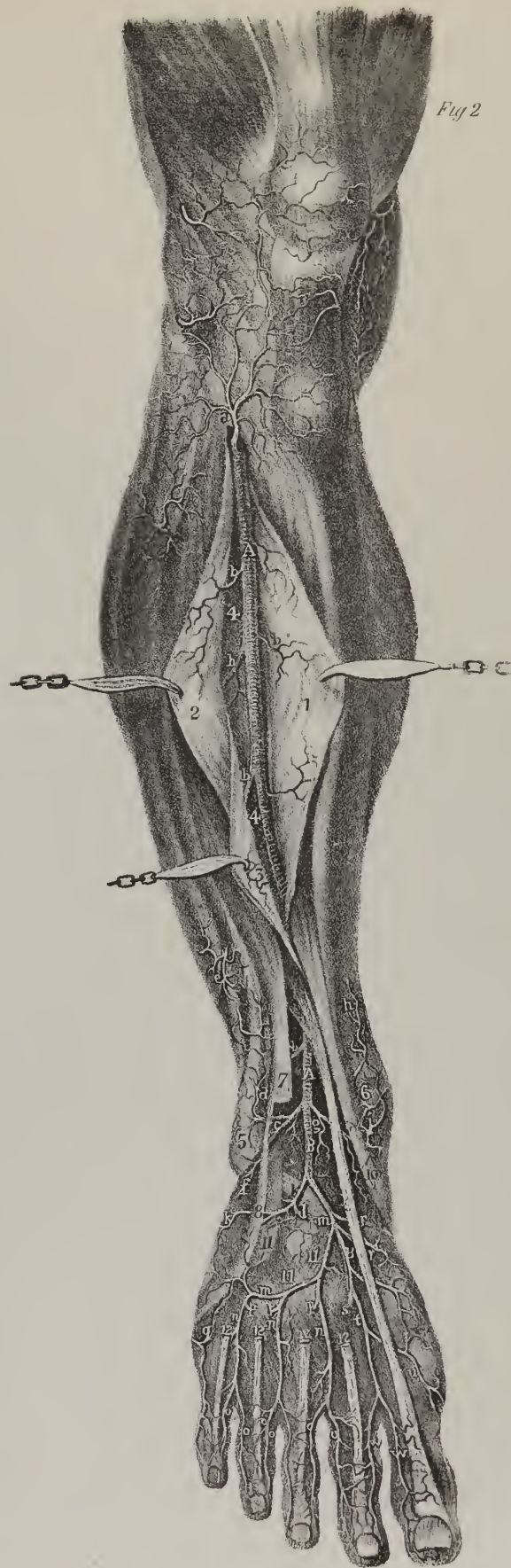


Fig 2.





tion also with some of the lumbar arteries. The epigastric artery is accompanied by one or two veins. In the male it is crossed by the vas deferens, in the female by the round ligament of the uterus. At first the duct lies in front of the artery, then turns round its external side as it descends towards the pelvis. The vessel is therefore placed at the inner side of the internal abdominal ring, through which the spermatic cord passes. Its branches are the following:—

*Cremasteric branch*, (plate XIX. s; r. cremastericus.)—A small branch descends along the spermatic cord beneath the cremaster muscle, passes through the external abdominal ring, and after supplying the parts in the cord, anastomoses with the proper spermatic artery.

*Muscular branches*, (r. musculares.)—Several muscular branches pass from its inner and outer sides to the parts along which it runs; some of the latter communicate with the branches of the lumbar arteries and of the circumflex ilii.

*Anterior branches*, (plate XIX. g, g; r. anteriores.)—Some small ramuli come forwards through the muscle, become subcutaneous, and communicate with the superficial epigastric artery.

*Terminal branches*, (plate XIX. h; r. terminales.)—The terminal branches ascend in the substance of the rectus muscle, and anastomose with the internal mammary and inferior intercostal arteries.

*The Circumflex Ilii artery*, (plate XIV. r; plate XIX. k; plate XXI. fig. 1, b; r. circumflexus ilii,) smaller than the preceding, is placed obliquely along the lower border of the abdomen, lying at first within its parietes, and then between the muscular layers which form them. It arises from the external side of the iliac artery, on a level with Poupart's ligament, whose direction it takes as it runs upwards and outwards to the anterior superior spine of the ilium, where it turns along its crista, and divides into several branches, which are distributed to the abdominal muscles. About an inch after its origin, this artery pierces the fascia iliaca, and runs for some way between it and Poupart's ligament, (corresponding with the line of insertion of that membrane;) but opposite the superior spinous process of the ilium it gets between the transversalis and internal oblique muscles, to which it is finally distributed. It sends off

Some slight twigs, which pierce the muscles, and along the groin anastomose with the superficial circumflex ilii, which comes from the femoral artery, and, farther on, with the branches of the gluteal artery; several smaller branches pass inwards to the iliacus muscle, and anastomose with the ilio-lumbar artery; its terminal branches communicate in the substance of the abdominal muscles with the lumbar arteries on the one hand, and the epigastric on the other.

*Operations.*—In order to expose and tie the external iliac artery in the living subject, it becomes necessary to divide the muscular parietes of the abdomen without injuring the peritonæum, after which this membrane must be pushed upwards from the iliac fossa. For this purpose, Mr. Abernethy made an incision about four inches long over the course of the artery. As the aorta divides on the fourth lumbar vertebra, and as the external iliac artery terminates midway between the anterior spine of the ilium and the pubic symphysis, it would at first sight appear that a line drawn from the umbilicus to the latter point would sufficiently indicate the course of the vessel, which in this, as in all other operations, it is a matter of great consequence to determine accurately. But this line would fall to the inner side of the vessel, more particularly at the right side, in consequence of the transverse direction of the common iliac artery. Hence the sacro-iliac symphysis, being the commencement of the external iliac artery, is the point over which the line must pass, in order that it may coincide with the direction of the vessel. If then, from midway between the anterior superior spine of the ilium and the symphysis pubis, a line be drawn upwards to about an inch to the outside of the umbilicus, it will mark the course of the external iliac artery. The incision through the integuments (the patient being placed in the horizontal position) should begin four inches and a half above Poupart's ligament, and end within half an inch of that line. This exposes the aponeurosis of the obliquus externus, which is to be divided in the same direction and extent. The fore-finger of the left hand should in the next place be insinuated beneath the lower border of the obliquus internus and transversalis muscles, in order to detach them from the peritonæum; but some difficulty will be experienced in effecting this, as it is necessary to tear through the fascia transversalis, which is rather firm in this situation. When the muscles have been elevated for some way, they are to be cautiously divided by a probe-pointed bistoury, carried along the finger. It then only remains, in order to obtain a view of the artery, to push the bag of the peritonæum from below upwards and inwards, towards the margin of the pelvis. It should, however, be recollected, that as the artery is in some measure bound down to the fascia iliaca by the sub-serous cellular tissue, which adheres rather firmly to that membrane, it becomes necessary to free it from this connexion, by carefully scraping, with the extremity of a probe or with the nail, before the needle can be passed round it. As the vein lies close to the artery on its inner side, the needle must be insinuated between them, and passed from within outwards. No nerve, except a small branch of the genito-crural, is implicated in this operation, the anterior crural being separated from the artery by the breadth of the psoas muscle.

The mode of incision here pointed out, by cutting across the fibres of the abdominal muscles, necessarily weakens them where they most require to be strong. Its chief recommendation is, that it enables the operator to place the ligature higher up on the vessel than he could do otherwise, on which account it may be the only operation admissible in certain cases, for instance, where an aneurismal tumour has extended as far as Poupart's ligament, or a little above it. It may be farther observed, that whilst the operation is being performed in this way, much difficulty is experienced in keeping the vessel exposed after the peritonæum and intestines have been pushed up, as they are continually forced down by the descent of the diaphragm; and as the

sides of the wound are held apart by the two retractors, it is difficult to apply a third at its superior angle, so as to bear off the peritonæum and viscera.

Sir Astley Cooper adopts quite a different method of operation; his incision is somewhat transverse with regard to the course of the artery. Commencing about half an inch above, and to the pubic side of the spine of the ilium, he divides the skin in a direction parallel with that of Poupart's ligament, the incision being prolonged somewhat farther than midway between the spine of the ilium and symphysis pubis. The point specified is the inner margin of the abdominal ring; but this is not a good point of reference, as it is not perceptible or tangible before the incision is made. The fibres of the external oblique muscle are in the next place to be divided to the same extent; and when the lunated flap thus formed is elevated, the lower border of the obliquus internus and transversalis is exposed, as well as the spermatic cord, as it passes beneath them. The cord will then serve as a guide to the epigastric artery, in front of which it lies, and this vessel to the iliac artery, which can be detached from its connexions without any further dissection. With this view the finger is passed along the cord, and through the fascia transversalis, or rather through the opening in it, which transmits the cord; the artery is then felt pulsating, and may be secured in the way recommended in the other mode of operation.

*The Femoral artery* (plate XXV. B, C; plate XXVI. B, C; a. femoralis communis; f. superficialis) is placed along the anterior and inner side of the thigh, extending from Poupart's ligament, where it is continuous with the external iliac, as far as the junction of the middle with the inferior third of the thigh, at which point the vessel changes its name and relation to the bone, becoming *popliteal*.

*To expose the artery in the upper third of the Thigh.*—In the first place, let the knee be slightly bent and the limb rotated outwards. And as in this position the course of the femoral artery is indicated by a line extended from midway between the anterior superior spine of the ilium and the pubic symphysis, to the lower border of the patella, the first incision through the skin should be made to the same extent, and in the same direction. In order to reflect the integuments with facility, a second incision may be made transversely at the junction of the upper with the middle third of the thigh; and finally, another in the same direction opposite the termination of the femoral artery. The flaps of skin thus formed are to be dissected back, so as to expose the fascia lata. Whilst doing this, you will observe the superficial epigastric artery running upwards over Poupart's ligament upon the external oblique muscle and the superficial pudic branch, inclining inwards to the pubes. In the next place, the fascia may be divided to the same extent as the skin, so as to expose the muscles, which are to be dissected carefully. A pudic branch will be found running inwards on the pectineus, and the circumflex ilii outwards in the direction of Poupart's ligament. These are all small branches. Lower down you will see a much larger vessel derived from the arteria profunda, viz., the external circumflex, which runs outwards beneath the sartorius and rectus, its trunk affording a clue to its different branches, which can be traced without any difficulty after the vessel has once passed the crural nerves. The dissection of the femoral artery in the upper part of the thigh requires some care, as it is embedded in a quantity of cellular tissue, and gives off its more important branches. The profunda and femoral veins also, which here lie close to it, together with their different branches, pour out blood when divided, which embarrasses the young dissector. Hence it often becomes necessary to divide the veins and remove them, after which the parts may be sponged and the dissection proceeded with. Before this measure is resorted to, the sheath of the vessels should be laid open, and the relative position of the vein and artery considered attentively.

*To expose the artery in the middle third of the Thigh.*—In the middle third of the thigh, little more is necessary in order to exhibit the vessel, after the fascia has been removed, than to turn the sartorius outwards; the course of the artery is then readily perceived, though it is bound down by the firm fascia already noticed, as passing across it from the adductors to the vastus. The relation of the saphenous nerve and vein to the femoral artery should be noted carefully, and its depth from the surface considered, which will at once point out the difficulty of cutting down upon and tying it in this situation, and the comparative facility with which it can be reached in the upper third of the thigh.

*To expose the deep-seated artery, (a. profunda.)*—When the femoral artery has been sufficiently examined, attention should be directed altogether to the deep-seated artery (a. profunda) and its branches. To expedite the dissection, the femoral artery and vein, and also the deep veins, had better be removed; and if, after this, the adductor longus be detached from its origin, and reflected outwards over the vastus, the deep-seated artery will be fully exposed. Little difficulty can occur in tracing the external circumflex branch; but as the internal one sinks deeply between the muscles, it becomes necessary to divide the pectineus at its origin, and turn it outwards on the thigh, after which the artery can be traced as far as the neck of the femur; its terminating branches can be seen only when the posterior part of the thigh has been dissected. In this dissection the crural nerve and its branches should be attended to. They will be observed spreading out into a lash of filaments, which are distributed to the different muscles on the front and inner side of the thigh, whilst a few descend along the course of the artery.

*To expose the perforating branches at the back of the Thigh.*—When the subject is turned on its face, in order to dissect the posterior part of the limb, an incision may be carried through the skin from midway between the tuber ischii and trochanter major to the middle of the popliteal space. This may be met by two transverse incisions, similar to those made on the fore part of the thigh. When the flaps of integument are reflected, and the fascia examined, the latter may be divided to the same extent, which will expose the flexor muscles. These may be easily separated and drawn aside, after which the distribution of the per-





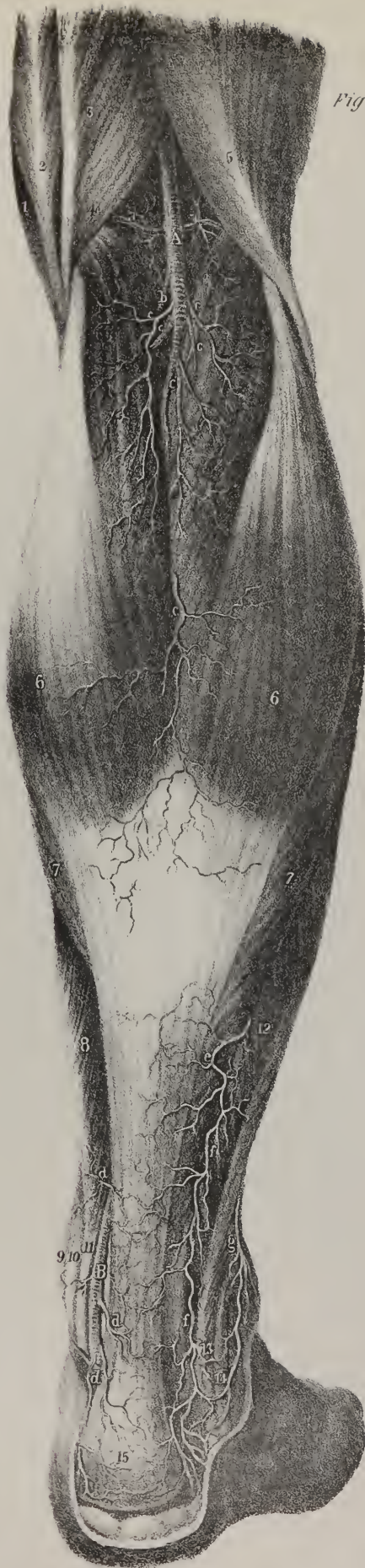

Fig 1

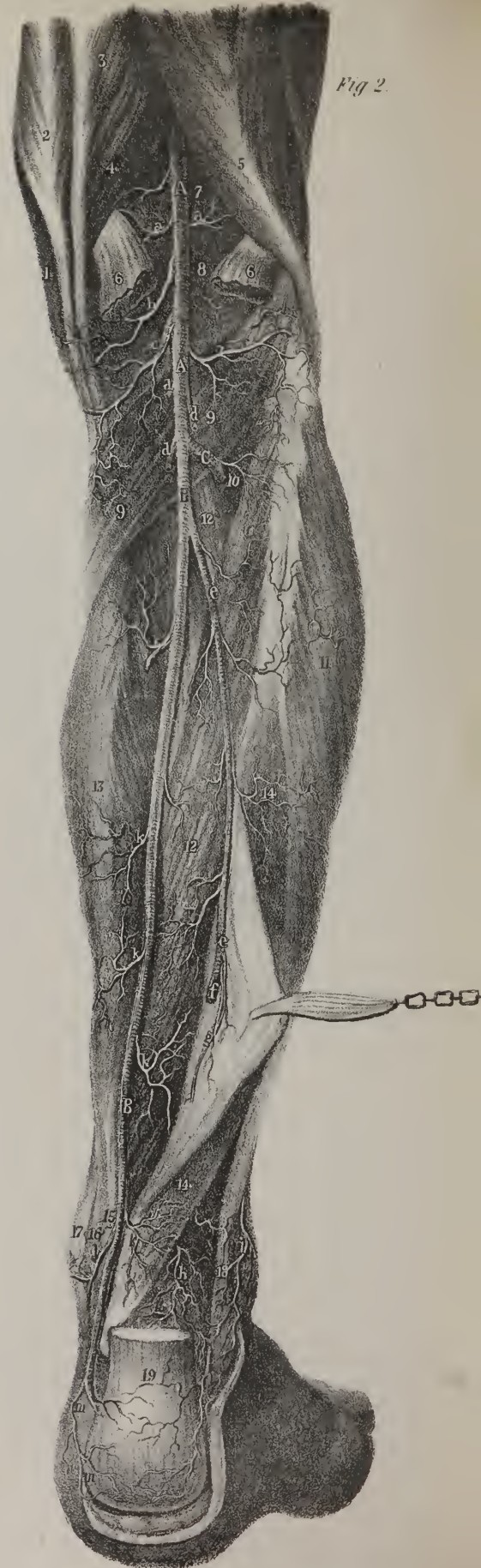


Fig 2



forating branches can be readily examined, as they lie on the adductor magnus, before their final termination. The anastomoses of the circumflex branches shall be considered after we have described the gluteal and sciatic arteries. As the incision through the integument here indicated corresponds with the course of the great sciatic nerve, it may be well to observe its relation and connexions whilst prosecuting the dissection of the arteries.

Resuming our description of the femoral artery, we remark *in limine*, that if the knee be semiflexed, and the limb rotated outwards so as to turn the flat or inner side of the thigh somewhat forwards, the course of the vessel may be marked out by a line drawn, or a cord extended, from midway between the anterior superior spine of the ilium and the symphysis pubis, to the lower border of the patella. In this position of the limb, the vessel cannot be said to incline inwards; but if the subject be laid on the back, and both legs be placed closely together, the arteries of opposite sides will be nearer to one another, and therefore to the median line, in the popliteal space, than when under Poupart's ligament, which indicates a slight inclination inwards. A cursory inspection would, however, lead us to suppose the inclination to be greater than it really is, which is owing to the oblique direction of the femur. This is by no means a matter of indifference in a practical point of view. The superficial vein (*vena saphena*) has been wounded in a few instances during the operation for tying the femoral artery. This accident may happen to any individual who, from supposing that the artery inclines inwards as it descends, makes his first incision oblique, so as to correspond with such a direction of the vessel. It has been said,\* that if a line be drawn from midway between the spine of the ilium and the symphysis pubis, down to the middle of the popliteal space, it will indicate the course of the vessel. This is nearly correct; but as this line runs along the inner surface of the thigh, its course is rendered much more oblique than that of the vessel, which is placed so much nearer the shaft of the femur. In the skeleton, whilst the femur hangs freely, a plummet line suspended from midway between the pubic symphysis and spine of the ilium, will drop exactly between the condyles of the femur, and mark out the general direction of the artery. In the upper third of the thigh it is directly downwards; some slight deviation inwards may occur in the middle third, where the vessel is borne off from the bone by the vastus muscle; but this cannot be so great as to require any obliquity in the direction of an incision made with the view of exposing it.

The direction of the vessel may then be said to be downwards, along the anterior and inner side of the thigh, becoming gradually deeper as it descends; and in its course it lies first on the *psaos* muscle, (supported on its inner border,) which

## PLATE XXX.

The arteries on the posterior part of the leg.

FIG. 1. represents the popliteal artery with its superficial branches; also the posterior tibial artery and branches of the peroneal; the muscles retaining their natural position.

No. 1. The sartorius muscle. 2. The tendon of the gracilis. 3. The semi-tendinosus muscle. 4. The semi-membranosus. 5. The biceps. 6, 6. The gastrocnemius muscle. 7, 7. Part of the soleus projecting beyond the expanded tendon of the gastrocnemius. 8. The flexor longus digitorum muscle. 9. The projection of the inner malleolus. 10. The tendon of the tibialis posticus muscle. 11. The tendon of the flexor longus digitorum. 12. The peroneus brevis muscle. 13. The tendon of the peroneus brevis. 14. The tendon of the peroneus longus. 15. The tendo Achillis inserted into the tuberosity of the os calcis.

A. The popliteal artery (a. poplitea) lying deeply in the popliteal space.

a, a. The superior articular arteries. b. The azygos articular artery. c, c. Muscular branches (r. musculares, surales) supplying the muscles of the calf of the leg.

B. The posterior tibial artery, (a. tibialis postica.)

d, d. Muscular and superficial branches derived from the posterior tibial artery. e. A muscular branch from the peroneal artery. f, f.

The posterior branch of the peroneal artery, (r. peroneus posterior.) g. The anterior branch of the peroneal, (r. peroneus anterior.)

FIG. 2. The superficial muscles are here removed, and the deep layer, with the deep branches of the popliteal and posterior tibial arteries brought into view.

No. 1. The edge of the sartorius muscle. 2. The gracilis muscle. 3. The semi-tendinosus. 4. The semi-membranosus muscle. 5. The biceps muscle. 6, 6. The divided heads of the gastrocnemius muscle. 7. The lower expanded portion of the femur. 8. The posterior ligament of the knee-joint. 9, 9. The popliteal muscle. 10. The opening in the interosseous membrane, through which the anterior tibial artery passes. 11. The peroneus longus muscle. 12, 12. The tibialis posticus muscle. 13. The flexor longus digitorum. 14, 14. The flexor longus pollicis drawn aside with a hook. 15. The tendon of the flexor longus digitorum. 16. Part of the tendon of the flexor longus pollicis. 17. The inner ankle. 18. The tendon of the peroneus longus. 19. The divided tendo Achillis.

A, A. The popliteal artery. B, B. The posterior tibial artery, (a. tibialis postica.) C. The anterior tibial artery, (a. tibialis antica.)

a, a. The superior articular arteries. b. A branch supplying the ligaments of the joint. c, c. The inferior articular arteries. d, d. Muscular branches. e, e. The peroneal artery, (a. peronea.) f. Its anterior branch (r. peroneus anterior) piercing the interosseous membrane, to supply the muscles and integument about the fore part of the outer ankle. g. The posterior branch, (r. peroneus posterior.) h. The terminal branches of the posterior peroneal artery, anastomosing with the terminal branches (i.) of the anterior peroneal. k, k. Muscular branches (r. musculares) of the posterior tibial artery. l. A malleolar branch which anastomoses with the internal malleolar branch of the anterior tibial artery. m, m. Branches which anastomose around the heel with corresponding branches of the peroneal.

\* Boyer, *Traité d'Anatomie*, tom. iii.



separates it successively from the os pubis, the brim of the acetabulum, and the hip-joint. Below this the vessel rests on some branches of the arteria profunda and its accompanying vein, embedded in cellular tissue; these separate it from the pectineus and adductor brevis; it then passes over the adductor longus, and finally over the conjoined tendons of the latter and adductor magnus. Internally, it is in contact with the femoral vein, both vessels lying on the same plane in the first instance, where they are supported by the os pubis; but when the vein sinks behind the artery, the latter comes into contact with the adductor longus and sartorius muscles. Externally, it at first rests against the psoas muscle, which separates it from the anterior crural nerve; but after that muscle has passed backwards to its insertion, it rests against the vastus internus: three or four branches of nerves will here be observed in contact with the sheath of the vessels.

The anterior surface of the artery in the upper third of the thigh is covered only by the common integument, the superficial fascia, the inguinal glands, and the fascia lata; so that it is comparatively superficial, and may be easily compressed against the os pubis or the brim of the acetabulum. In the middle third of the limb the vessel is more deeply seated, as, in addition to the parts already mentioned, it is covered by the sartorius muscle, beneath which may be observed a fascia, composed of oblique fibres, passing from the adductor muscles to the vastus internus. This is thin superiorly, beginning where the sartorius overlaps the vessels, but gradually becomes dense and firm as it approaches the point at which the vessel passes through the opening in the adductor magnus. At Poupart's ligament the femoral vein lies close to the inner side of the artery, and on the same plane with it; it rests on that part of the brim of the pelvis which corresponds with the interval between the contiguous borders of the psoas and pectineus muscles, separated from the bone by the prolonged part of the fascia iliaca, which passes down behind the vessels; when distended, it overlays some of the outer fibres of the pectineus. As the vein descends it gradually inclines backwards, coiling round the artery, so that on reaching the popliteal space it is situated to the outer side and behind that vessel. The anterior crural nerve, at its exit from the abdomen, lies about three quarters of an inch to the outside of the artery, being separated from it by the breadth of the psoas muscle; but when the muscle sinks backwards towards the trochanter minor, two or three branches of the nerve incline towards the artery, and accompany its sheath for some way; of these, the largest, which from its ultimate distribution is called nervus saphenus, is found at the superior and external side of the artery during the middle part of its course, whilst the vein is situated posteriorly and internally for the same extent. This nerve does not accompany the artery and vein as they pass backwards through the adductor magnus; it continues directly downwards to the inner condyle of the femur, and may be found between the tendons of the gracilis and sartorius muscles.

*Branches of the Femoral artery.*—The femoral artery gives off its chief branches in the superior part of its course, whilst it is yet uncovered by muscle. Some of these, small and unimportant, are distributed to the inguinal glands and adjacent muscles; others, though small, have received names, and require a separate notice, viz. the external pudic, (superior and inferior,) the superficial epigastric, the superficial circumflex ilii, and, finally, a branch of considerable size—r. profundus femoris.

*The external Pudic branches* (plate XXIII. e; plate XXV. e, f; rami pudendi externi) arise, either separately or by a

## PLATE XXXI.

Varieties occurring in the distribution of the arteries of the leg.

FIG. 1. The popliteal artery is continued downwards in the course of the peroneal, and divides just above the ankle into two branches, one of them supplying the outer ankle and outer side of the foot; the other, passing behind the inner ankle, becomes the plantar artery. A very small branch is given off from the peroneal at the lower border of the popliteus muscle, which represents the posterior tibial artery in its course, and anastomoses with the plantar branch of the peroneal behind the inner ankle.

No. 1. The border of the sartorius muscle. 2. The tendon of the gracilis muscle. 3. The tendon of the semi-tendinosus muscle. 4. The semi-membranosus muscle. 5. The biceps muscle. 6, 6. The heads of the gastrocnemius muscle. 7, 7. The popliteus muscle. 8. The interosseous membrane. 9, 9. The tibialis posterior muscle. 10, 10. The flexor longus digitorum muscle. 11. The upper part of the flexor longus pollicis arising from the fibula. 12. The peroneus longus muscle. 13. The peroneus brevis muscle. 14. The opening of the tendinous sheath through which the tendon of the flexor longus pollicis passes into the foot. 15. The tendon of the flexor longus digitorum. 16. The tendon of the tibialis posterior muscle. 17. The tendon of the peroneus longus muscle. 18. The divided tendo Achillis.

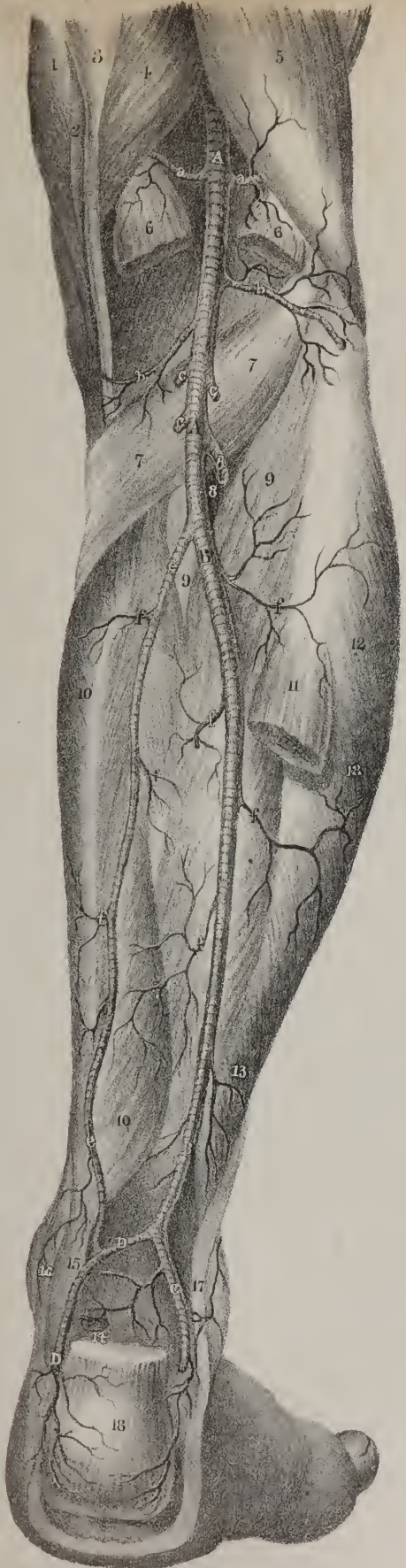
A, A. The popliteal artery. B, B. The continuation of the popliteal artery downwards in the course of the peroneal artery of the regular distribution. C. A large branch passing behind the outer ankle, supplying the outer border of the foot. D, D. Another large branch, passing behind the inner ankle in the ordinary course of the posterior tibial, becomes the plantar artery.

a, a. The superior articular arteries. b, b. The inferior articular arteries. c, c. Muscular branches. d. The anterior tibial artery passing through the opening in the upper part of the interosseous membrane. e, e. A small long branch representing the posterior tibial artery; it anastomoses below with the internal terminal branch of the peroneal. f, f. Muscular branches.

FIG. 2. The popliteal artery, at the lower border of the popliteus muscle, becomes the peroneal, which follows the course of the regular peroneal artery to the ankle, where it divides into three branches of nearly equal size. This variety is more rare than the preceding. The references to this figure are the same as in Fig. 1.

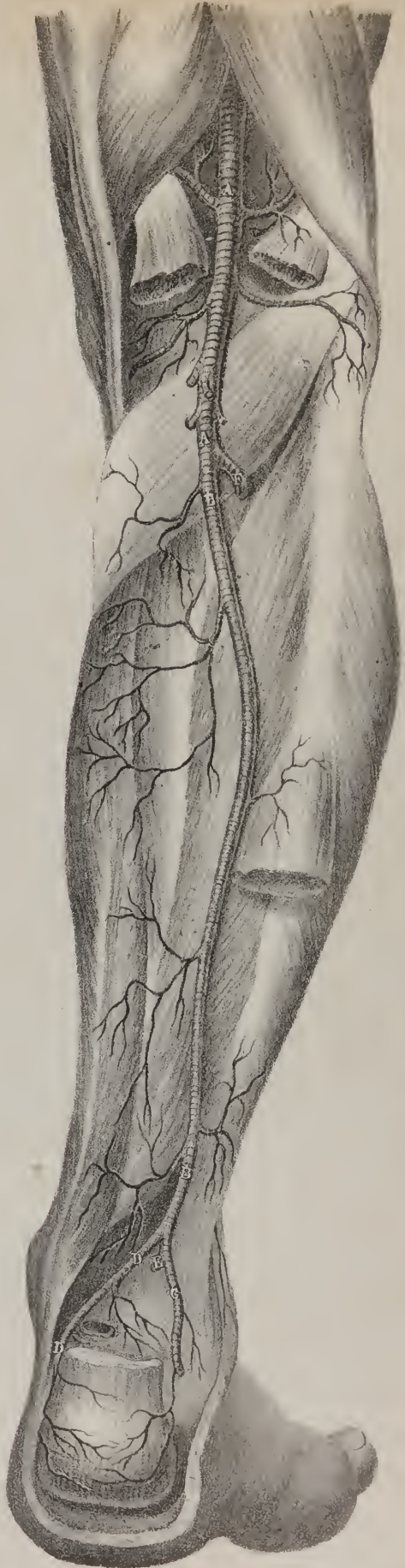
A, A. The popliteal artery. B, B. The anomalous peroneal artery. C. The posterior malleolar branch. D, D. The branch which becomes the plantar artery. E. A large branch which pierces the interosseous membrane, and unites with the termination of the anterior tibial artery to form the dorsal artery of the foot, (a. dorsalis pedis.) F. The anterior tibial artery.

Fig. 1



anatomia

Fig. 2



anatomia







common origin, from the internal side of the femoral artery. The *superior*, or more superficial one, passes upwards and inwards to the spine of the os pubis, crosses the situation of the external abdominal ring, and is distributed to the integuments at the lower part of the abdomen and the external parts of generation. The *inferior* and deeper-seated one passes inwards, resting on the pectineus, and covered by the fascia lata, which it pierces on reaching the ramus of the os pubis, and is distributed to the scrotum in the male, or labium in the female, its branches inosculating with those of the superficial perinæal artery. The superior branch is necessarily cut across whilst the integuments are being divided in the operation for inguinal hernia.

The *superficial Epigastric artery* (plate XXIII. c; plate XXV. c; r. epigastricus superficialis) is larger than the preceding branch; it arises from the femoral artery, about half an inch below Poupart's ligament, passes forwards through the saphenous opening in the fascia lata; after which it changes its direction, and runs perpendicularly upwards on the abdomen, in the superficial fascia covering the obliquus externus. Its terminal branches, ascending as high as the umbilicus, anastomose with those of the proper or deep epigastric and internal mammary arteries. The rest of its branches ramify in the cellular tissue and superficial fascia, on the lower part of the abdomen. This vessel must be divided by the transverse incision made through the integuments in the operation for femoral hernia.

The *superficial Circumflex Ilii artery* (plate XXIII. d. d; plate XXV. d, d; r. circumflexus ilii superficialis) runs outwards and a little upwards, taking the direction of Poupart's ligament, to the spine of the ilium, across the psoas and iliacus muscles, to which it gives some branches. It terminates in several small twigs, which pierce the fascia lata, and anastomose with similar branches from the deep circumflex ilii, the external circumflex, and gluteal arteries.

The *deep-seated Femoral artery* (plate XXV. g, g; plate XXVI. D; r. profundus femoris) may be considered as the proper nutritious vessel of the thigh, its branches being distributed to it exclusively, whereas the femoral artery passes onwards to supply the leg and foot, giving off very few (and these insignificant) branches whilst it corresponds with the femur. In this view of the destination of these vessels, the terms applied to them by Murray seem sufficiently appropriate. The short trunk intervening between Poupart's ligament and the origin of the profunda, he names *a. femoralis communis*; the continuation of the vessel as it passes along the thigh, *a. femoralis superficialis*; and its deep-seated branch, *a. femoralis profunda*. The profunda artery arises from the external and posterior surface of the femoral, usually from an inch and a half to two inches below Poupart's ligament. It at first inclines outwards in front of the iliacus muscle, but soon changes its direction, running downwards and backwards behind the femoral artery. Opposite the junction of the upper with the middle third of the femur, the profunda passes beneath the adductor longus muscle, and inclining outwards to the linea aspera of the femur, soon divides into its terminal branches, which pass between that ridge of bone and the adductor magnus, to reach the posterior part of the thigh, where they are distributed to the long flexor muscles. The trunk of the profunda in this course lies at first on the psoas and iliacus muscles after their junction, then on the pectineus and adductor brevis, finally on the adductor magnus. In the first part of its course it is separated from the femoral artery by the profunda and femoral veins, and by a quantity of cellular tissue, in which all these vessels lie embedded; lower down, the adductor longus is interposed between them. In addition to a number of small and nameless branches, the profunda gives off the following, which deserve particular notice.—

The *external Circumflex artery* (plate XXV. h, h; plate XXVI. e; ramus circumflexus externus) arises from the profunda whilst it rests on the iliacus muscle, and after passing outwards for a short way beneath the sartorius and rectus muscles, and through the divisions of the anterior crural nerve, it gives off branches, which may be divided into three sets, from the directions which they take. The first continue transversely outwards in the course of the vessel, and after passing over the crureus, pierce the vastus externus, so as to get between it and the bone just below the trochanter major, and so reach the posterior side of the thigh, where they anastomose with the internal circumflex branch, also with the gluteal and ischiadic. The ascending branches pass upwards beneath the sartorius and rectus, and finally under the tensor vaginæ femoris, where they communicate with the terminal branches of the gluteal, and with some of the external descending branches of the circumflex ilii. The descending set pass outwards and downwards upon the extensor muscles, covered by the rectus. These are usually three or four in number, some being of a considerable size; most of them are distributed to the muscles on the fore part of the thigh, but one or two can be traced as far as the knee, where they anastomose with the superior articular branches (internal and external) of the popliteal, and with the anastomotic branch of the femoral.

The *internal Circumflex artery* (plate XXVI. k; plate XXVII. s; r. circumflexus internus) arises from the inner and posterior side of the profunda, and turns directly backwards between the pectineus and psoas muscles, so that only a small part of it can be seen without disturbing these muscles. On reaching the tendon of the obturator externus muscle, which in a manner guides it to the posterior part of the thigh, it divides into two branches, or rather sets of branches. One of these ascends, and is distributed partly to the adductor brevis and gracilis, and partly to the external obturator muscle, where it anastomoses with the obturator artery; the other branch passes backwards above the trochanter minor, and appears on the posterior aspect of the limb, between the quadratus femoris and adductor magnus, where it anastomoses with the sciatic and superior perforating branches. When this transverse branch of the internal circumflex arrives opposite the hip-joint, it sends into it, through the notch in the acetabulum, an articular vessel, which passes beneath the transverse ligament, and after supplying the adipose sub-

stance in the depth of the articulation, is guided to the head of the femur by the round ligament. In some instances this vessel is derived from the obturator artery, sometimes the joint receives one from both.

*Perforating branches*, (plate XXVI. l, m, n; plate XXVII. u, w, x; r. perforantes,) so called from piercing the adductor muscles, are three or four in number. The *first* passes backwards between the pectineus and adductor brevis, sometimes through the fibres of the latter, and finally through the adductor magnus, after which it immediately divides into branches, which are distributed to the adductor magnus, the biceps, and gluteus maximus, communicating with the ischiadic and internal circumflex arteries. The *second*, considerably larger than the first, passes through the adductor brevis and magnus, after which it divides into an ascending and descending branch; the former, passing up on the adductor, supplies the posterior muscles, and anastomoses, towards the great trochanter, with the circumflex and ischiadic arteries; the latter descends, and is distributed to the flexor muscles, where it communicates with the terminal branches of the profunda. A branch of this vessel usually enters the medullary foramen of the femur. The *third* perforating artery passes back from the profunda, when it has got under cover of the adductor longus, pierces the adductor magnus, and, like the others, is distributed to the long flexor muscles.

The profunda, (plate XXVII. y,) after having given off these different vessels, becomes considerably diminished in size, and passes backwards close to the linea aspera, where it divides into branches, some of which are distributed to the short head of the biceps, the rest to the other hamstring muscles. These terminal branches do not pass to their destination exactly in the same way as the perforating set do: the latter pierce through the fibres of the adductors about an inch, or a little less, from their insertion; the former pass close to the linea aspera, between it and some tendinous fibres which arch over the vessels, and protect them from compression by the muscle. At these points the muscle is attached, not to the bone, but to the tendinous fibres just referred to. A similar provision will be found in several other parts of the body, for instance, where the r. profundus humeri passes beneath the triceps muscle, &c.

The femoral artery in its course along the thigh gives branches to the contiguous muscles, but none of them merit a particular name or description. Close to its termination a small but regular branch arises from it,—

The *Anastomotic branch* (plate XXV. l, l; plate XXVI. q; ramus anastomoticus) descends from the femoral, as it is about to pass into the popliteal space, in a line continuous with that of the trunk, from which it arises. It pierces the tendinous fascia

## PLATE XXXII.

FIG. 1. The arteries which supply the inner ankle, and side of the foot.

No. 1. The tibia. 2. The internal malleolus. 3. The tibialis anticus muscle. 4. The soleus muscle. 5. The expansion of the gastrocnemius tendon. 6, 6. The flexor digitorum longus muscle. 7. The tendon of the tibialis posticus. 8. The flexor pollicis longus muscle. 9. The tendo Achillis. 10. The internal annular ligament. 11. The anterior annular ligament. 12. The tendon of the tibialis anticus muscle. 13. The tendon of the extensor pollicis proprius. 14, 14. The abductor pollicis muscle. 15. The flexor digitorum brevis.

A. A. The posterior tibial artery, (a. tibialis postica.)

a. a. Muscular and superficial branches from the posterior tibial, inosculating with, b, b, superficial branches of the anterior tibial artery. c, c. Superficial branches from the posterior tibial, inosculating around the heel with, d, branches of the posterior peroneal artery. e, c. Anterior branches of the posterior tibial, inosculating with, f, f, branches of the internal malleolar artery, derived from the anterior tibial. g, g. Superficial branches of the internal plantar artery, supplying the side of the foot, and inosculating with branches from the dorsal artery. h, h. Branches of the internal plantar artery, supplying the integument in the sole of the foot. i. Internal collateral branch from the internal plantar artery.

B. The dorsal artery of the foot (a. dorsalis pedis) lying to the outer side of the tendon of the extensor pollicis proprius.

k. Internal collateral branch of the great toe, from the dorsalis pollicis artery. l, l. Dorsal digital ramuli from the interosseous branches of the metatarsal artery.

FIG. 2. The arteries ramifying around the outer ankle and side of the foot.

No. 1. Tendinous expansion of the gastrocnemius muscle. 2. The soleus muscle. 3. The peroneus longus. 4, 4. The peroneus brevis muscle. 5. The extensor digitorum longus. 6. The tibialis anticus muscle. 7. The peroneus tertius. 8. The lower extremity of the fibula forming the external ankle. 9, 9. The tendon of the peroneus longus. 10. The tendo Achillis. 11. The anterior annular ligament. 12. The external annular ligament. 13, 13. The abductor digiti minimi muscle. 14. The tendon of the peroneus brevis muscle. 15, 15. The extensor digitorum brevis muscle. 16. The tendon of the peroneus tertius. 17. The tendons of the extensor digitorum longus muscle. 18. The tendon of the extensor pollicis proprius. 19, 19. The four tendons of the extensor digitorum brevis.

a. A superficial branch of the posterior tibial artery. b, b. Superficial branches of the posterior peroneal artery. c, c. The posterior peroneal artery, (a. peronea posterior.) d. The anterior peroneal artery, (a. peronea anterior.) e, e. Cutaneous branches of the anterior tibial artery. f, f. Branches of the external malleolar inosculating with terminal branches of the peroneal arteries, also with branches of the tarsal and external plantar arteries.

A. A. The dorsal artery of the foot, (a. dorsalis pedis.)

g. g. Terminal branches of the tarsal artery, (a. tarsea,) inosculating with, h, a branch of the external plantar artery. i. A branch of the metatarsal artery, (a. metatarsea.) k. The dorsalis pollicis artery, dividing into branches for the supply of the inner toes. l, l. Digital ramuli, derived from the interosseous branches of the metatarsea. m. The external collateral branch of the external plantar artery.



Fig. 1.

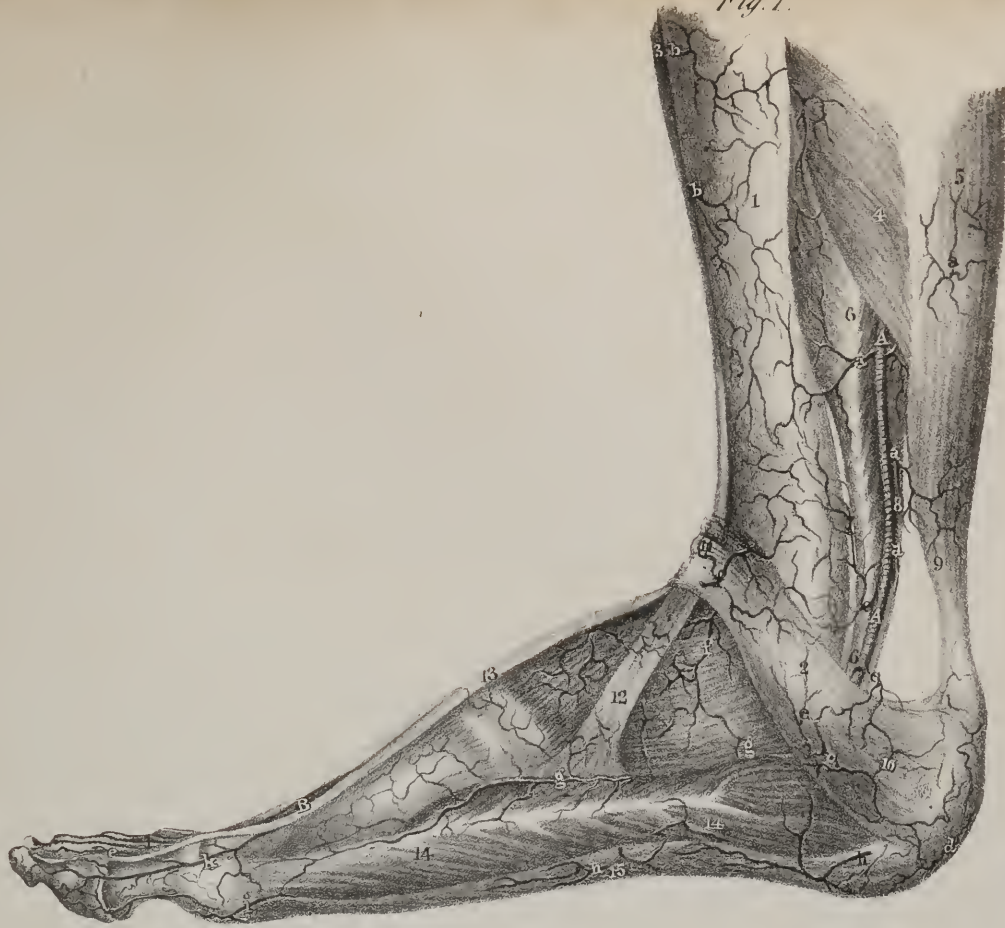
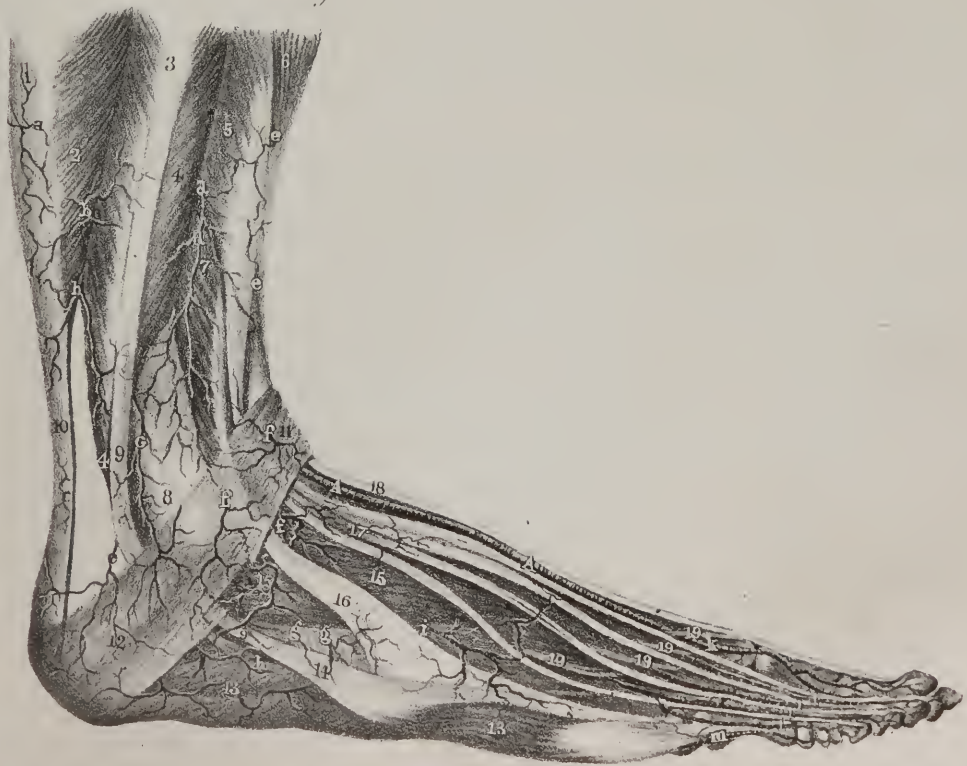
Fig. 2.







which binds down the femoral artery, and gives off two or three branches, whilst the vessel itself passes down to the inner condyle, guided by the prolonged tendon of the adductor magnus, and there anastomoses with the internal articular artery. Its branches pass obliquely outwards through the substance of the vastus internus, and communicate with the long descending branches of the external circumflex artery.

*Varieties.*—It may be observed, that considerable variety obtains in the mode of origin of the branches of arteries here described. Meckel justly observes, that the varieties in the arterial system are not less numerous than those of the venous, which is not generally supposed to be the case. But as these branches are intended to carry on the collateral circulation after the main vessel has been obliterated, their course and distribution are usually regular and uniform. The profunda artery very seldom comes off lower down than two inches from Poupart's ligament. Whenever it deviates from this rule, it, in the great majority of cases, separates from the femoral higher up, either close under the ligament, or even within the pelvis. In an individual who was the subject of popliteal aneurism for which the usual operation was performed, it was found that the ligature when tied did not control the pulsation in the tumour; still a coagulum formed; but the patient died of another disease; and when the limb was dissected, two arteries, of nearly equal size, appeared, occupying the situation of the femoral. A division had taken place high up, and a reunion in the popliteal space just above the tumour. The preparation is preserved in the anatomical museum of the University of London. A similar conformation of the brachial artery has been already indicated. Meckel cites a case in which the femoral artery divided into the anterior and posterior tibial arteries at the top of the thigh at one side, the division being in its regular situation at the other.

*Operations.*—The femoral artery may be tied in the upper or middle third of the thigh; the former situation is now universally preferred, because the operation in the latter is considerably more difficult of execution, without securing any equivalent advantage. The limb being placed in the position pointed out at page 54, an incision is made through the integuments, beginning two inches below the middle point of Poupart's ligament, and carried perpendicularly downwards for three inches, or a little more, in a muscular fat subject. Previously to commencing this incision, it may not be amiss to place a scalpel, or a probe, along Poupart's ligament and mark upon it the middle point; if the external end of the instrument be depressed, so that it should lie horizontally across the thigh, the incision through the integument should be made so as to form with the instrument thus placed a right angle. This suggestion is intended only for those who are about to perform the operation on the dead subject, or who may be planning the execution of it. The fascia lata being exposed, a small part of it should be pinched up with the forceps, and cut across, so as to form a small opening, into which a director is to be passed, in order that the fascia may be safely divided upon it. The sheath of the vessels is thus brought into view, a small part of which should be raised by the forceps and divided, the knife being held in the horizontal position. The vein in this situation will be found behind, and a little to the inner side of the artery; on which account, in carrying the needle round the latter, its point is to be directed from within outwards, and cautiously insinuated between them, its surface being held close to the artery. Some difficulty is generally experienced in effecting this step of the operation. The point of the needle is said to be hitched on some tough cellular membrane, which is pushed onwards, and requires to be divided before the needle can be fairly protruded. This resistance is owing to the sheath of the vessels, now loose after its division, and readily caught into a fold by the point of the instrument. In operating on the dead subject, this impediment is readily removed, by pinching up the external flap of the sheath, and holding it tight with the forceps, whilst the needle is passed round the artery. The nerves, which here lie external to the sheath, will by the same expedient be held out of the way. The ligature of the carotid artery is facilitated by the same means. Would such a measure be advisable in operating on the living? It is not altogether undeserving of attention.

*The Popliteal artery* (plate XXVII. A, A; plate XXX. A, A; a. poplitea) is that part of the arterial trunk which extends from the opening in the adductor magnus to the lower border of the popliteus muscle, being continuous superiorly with the femoral, and inferiorly with the anterior and posterior tibial arteries, into which it divides.

*Dissection.*—The subject being turned on its face, an incision should be made through the skin, along the middle of the popliteal space, extending from the lower third of the thigh as far as the upper fourth of the leg, which corresponds with the length of the popliteal artery. A transverse incision should be made right across this at each extremity; the flaps thus marked out being reflected and the fascia exposed, this membrane is to be divided and reflected in the same manner. By these means the muscles bounding the popliteal space are exposed. The interval which they enclose is of a quadrilateral figure, two sides being formed by the hamstring muscles diverging to their insertions, and two by the heads of the gastrocnemius converging to their point of union. Through the centre of this space, from its superior to its inferior angle, runs the popliteal artery; but to expose it fully, the mass of adipose matter by which it is concealed must be dissected away, in order that its relation to the vein and nerve may be clearly discerned. To follow it up in the superior part of its course nothing more is necessary than to draw aside the flexor, or hamstring muscles, as they are merely connected by some cellular tissue, which retains them in apposition with one another. But as the lower part of the vessel is covered by the gastrocnemius, it will answer all purposes to divide the inner head of that muscle near the condyle, and then reflect and carry it outwards, which will expose it as far as its bifurcation.

The direction of the artery is downwards and a little outwards, running through the centre of the popliteal space. In this course the vessel rests on, or corresponds for some way to, the flat surface of the femur, (a quantity of adipose substance inter-

posing,) then on the posterior surface of the knee-joint, and finally on the popliteus muscle. Its posterior surface is covered for some way by the semimembranosus muscle; in the ham it is covered only by the skin, fascia lata, and a quantity of adipose matter in which it is embedded, but lower down it is concealed by the gastrocnemius. On either side of it lie the hamstring muscles above, and the heads of the gastrocnemius below. The artery is accompanied by the popliteal vein and the sciatic nerve, the vein being posterior and a little external to it, the nerve still more posterior and external, that is to say, lying nearer to the skin and to the head of the fibula. The popliteal artery gives off five articular branches, two above and two below the joint, and one which passes into it,—also some large muscular branches to the gastrocnemius, hamstrings, &c.

*The Muscular branches* (plate XXVII. f, f, i, i, z, z; plate XXX. c, e; rami musculares) are superficial, and come distinctly into view when the fascia is removed. Some of them are small, and are seen passing out at the point of divergence of the hamstring muscles; others, of considerable size, and three or four in number, will be observed between the heads of the gastrocnemius, two or three being distributed to its fleshy substance, and one rather long, and tapering in many cases, descends vertically in the middle line, resting on its posterior surface.

*Articular branches*, (rami articulares.)—Two of these pass away nearly at right angles from the popliteal artery above the flexure of the joint, and two below it; hence they are named internal and external.

Of the *superior pair*:—The *internal* branch (plate XXVII. a\*; plate XXIX. fig. 1, b) turns round the inner side of the femur just above the condyle: and, passing under the tendon of the adductor magnus and vastus internus, divides into branches, of which one, comparatively superficial, enters the substance of the vastus, which it supplies, at the same time anastomosing with

## PLATE XXXIII.

The arteries in the sole of the foot are here shown.

FIG. 1. In this dissection the plantar fascia has been removed with the flexor digitorum brevis muscle, and the deep fascia and cellular tissue which conceal the external plantar artery. The abductor pollicis muscle is drawn aside; the other muscles retain their natural position.

No. 1. The abductor pollicis muscle, the outer head is drawn to one side. 2, 2. The tendon of the flexor pollicis longus muscle. 3. Part of the flexor brevis pollicis muscle. 4. The tendon of the flexor digitorum longus dividing into four, for its attachment to the four lesser toes. 5, 5. The lumbricales muscles. 6, 6. Part of the transversus pedis muscle. 7. Interossei muscles. 8. Part of the flexor brevis digiti minimi. 9, 9. The abductor digiti minimi muscle. 10. The flexor accessorius muscle. 11. The divided origin of the flexor digitorum brevis. 12. The prominence of the internal malleolus of the tibia. 13. The os calcis.

A. The posterior tibial artery (a. tibialis postica) winding around the inner ankle. B. The internal plantar artery, (a. plantaris interna.) C, C. The external plantar artery, (a. plantaris externa.)

a, a. External superficial branches from the posterior tibial artery which anastomose with, b, b, branches of the peroneal and tarsal arteries. c, c. Internal superficial branches which communicate with branches of the internal malleolar artery. d, d. Muscular and superficial branches from the internal plantar artery. e. The termination of the internal plantar artery, forming the inner collateral branch of the great toe. f, f. Muscular and superficial branches from the external plantar artery. g. The fourth digital branch (r. digitalis quartus) of the plantar arch, supplying the outer side of the little toe. h. The third digital branch (r. digitalis tertius) dividing into collateral branches for the supply of the adjacent sides of the little and fourth toes. i. The second digital branch (r. digitalis secundus) distributed in like manner to the third and fourth toes; and, k, k, the first digital branch (r. digitalis primus) to the second and third toes. l. The digital branch which arises from the extremity of the dorsalis pedis artery in the sole of the foot.

FIG. 2. The superficial muscles being removed, the deep course of the plantar arteries is brought into view.

No. 1. The divided tendon of the abductor pollicis muscle. 2. The tendon of the flexor longus pollicis muscle. 3, 3. Tendons of the flexor brevis and longus digitorum muscles. 4, 4. The four dorsal interossei muscles. 5, 5. The three plantar interossei muscles. 6. The flexor brevis digiti minimi muscle. 7, 7. The flexor accessorius divided. 8. Part of the abductor digiti minimi. 9. The origin of the flexor brevis digitorum. 10. The prominence of the inner ankle. 11. The os calcis.

A. The posterior tibial artery. B, B. The internal plantar artery. C, C. The external plantar artery. D. The termination of the external plantar artery, dipping deeply between the two heads of the first dorsal interosseous muscle to inosculate with the communicating branch from the dorsal artery of the foot.

a. The termination of the internal plantar artery forming the first collateral branch of the great toe. b, b. Muscular and superficial branches. c. A small digital branch from the internal plantar artery to the outer side of the great toe. d, d. Muscular and superficial branches from the external plantar artery. e. The fourth digital branch from the plantar arch. f. The third digital branch. g. The second digital branch. h. The first digital branch. i, i. Posterior perforating branches, (r. perforantes,) which inosculate with corresponding branches from the metatarsal artery on the dorsum of the foot. k, k. Anterior perforating branches.

FIG. 3. Anomalous distribution of the arteries in the sole of the foot, in which the order of size and destination of the plantar arteries is nearly reversed; the internal plantar artery being the larger, and supplying two toes and one-half of the third; the external, the smaller branch, ramifying only on the outer side of the little toe: the fourth and adjacent sides of the third and fifth being supplied by the communicating branch from the dorsal artery of the foot, which is so large as to form the plantar arch across the metatarsal bones.

The references are the same as those in Fig. 2.

a. The internal plantar artery. b. The external plantar artery. c. The communicating artery from the dorsalis pedis; immediately upon emerging in the foot it gives off, d, a large branch which unites with the internal plantar artery, and greatly augments its size.



Fig. 1.

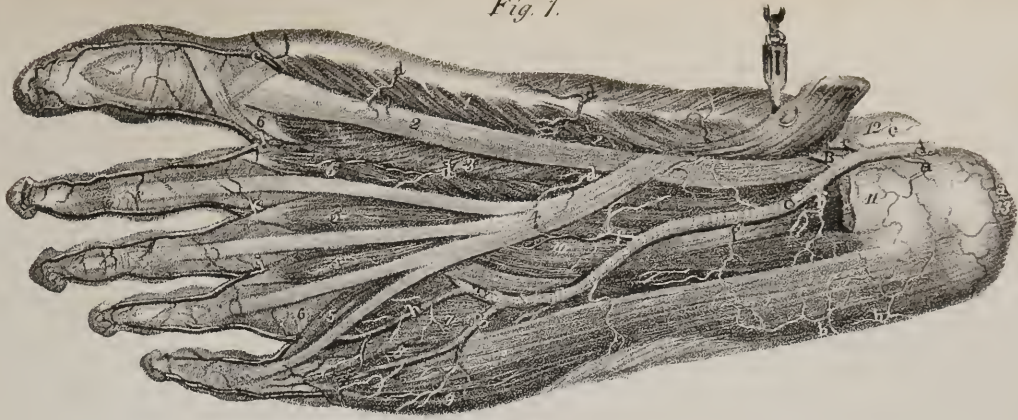


Fig. 3.

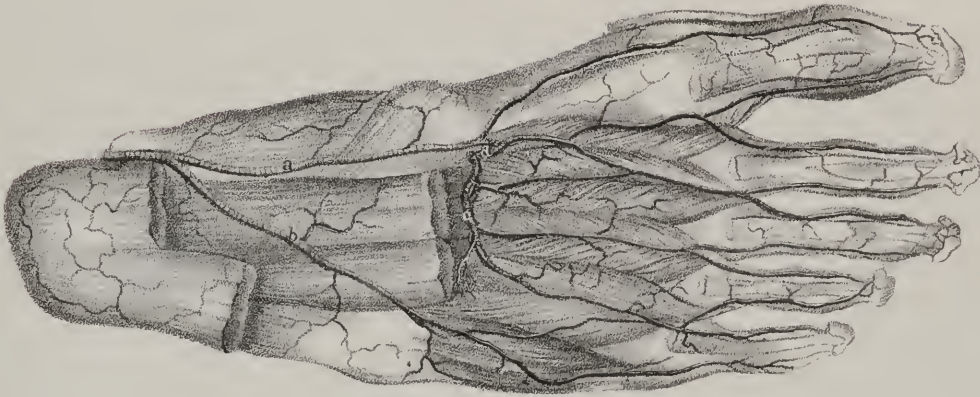
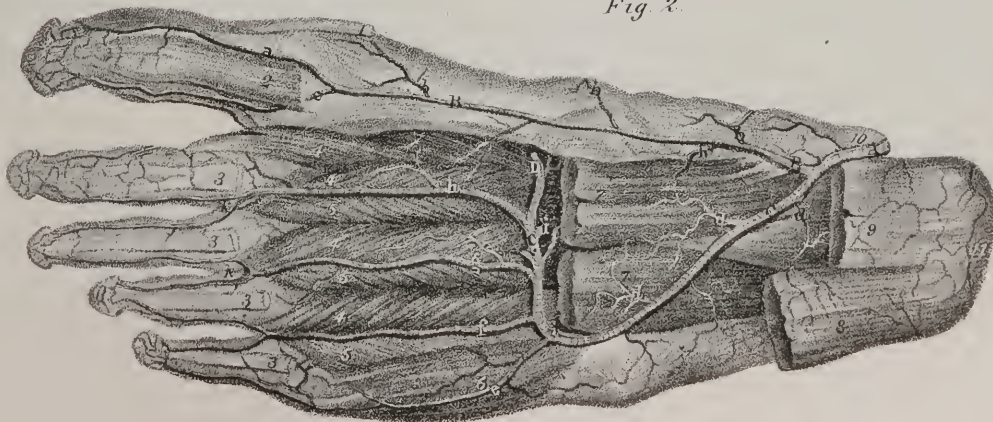


Fig. 2.







the r. anastomoticus, and with the inferior internal articular artery. The other branch runs close to the femur, gives ramusculi to it, also to the structures in the knee-joint, and keeps up a communication with the superior external articular artery. The *external* branch (plate XXVII. b\* ; plate XXIX. fig. 1, a) passes outwards, a little above the external condyle of the femur, crossing under cover of the biceps muscle, and divides into a superficial and deep branch; the latter keeps close to the femur, and, after giving ramusculi to it and to the articulation, anastomoses with the preceding and with the inferior articular branch; the former descends through the vastus to the patella.

Of the *inferior pair*.—The *internal* branch (plate XXVII. d\* ; plate XXIX. fig. 1, d) passes downwards and inwards below the corresponding tuberosity of the tibia, lying between the bone and the internal lateral ligament; its branches ramify on the anterior and inner part of the joint, as far as the patella and its ligament. The *external* one (plate XXVII. e\* ; plate XXIX. fig. 1, c) takes its course outwards under cover of the external head of the gastrocnemius in the first instance, and afterwards under the external lateral ligament of the knee, and the tendon of the biceps muscle; it thus reaches the fore part of the joint, and near the border of the patella divides into branches, of which one descends along the ligament of the patella to communicate with the inferior articular artery of the opposite side, and with the recurrent branch from the anterior tibial; the other ascends, and anastomoses with the superior articular arteries.

In a well-injected limb, the four articular branches form at the front and sides of the joint a complete mesh by their ramifications, all of which freely communicate with one another; and several of them may be traced into the substance of the bones through the foramina on their surface.

The middle or *azygos* branch (plate XXVII. c\*) passes from the anterior surface of the popliteal artery, opposite the flexure of the joint and about midway between the superior and inferior articular arteries; it pierces the posterior ligament of the joint, and divides into minute ramifications for the supply of the crucial ligaments and the other structures within the articulation.

The *posterior Tibial artery* (plate XXX. fig. 2, B, B; a. tibialis postica) is situated along the posterior part of the leg, between the superficial and deep muscles, being firmly bound down to the latter by the deep fascia.

*Dissection*.—When describing the method of exposing the popliteal artery, it was stated that this could be effected by merely dividing the inner head of the gastrocnemius, and turning the corresponding venter of it somewhat outwards. A small part of the posterior tibial artery, which is the continuation of the popliteal, is at the same time brought into view; but as the rest of it lies deeply beneath the soleus, this muscle must be detached wholly or in part, in order to trace the course of the vessel. As the vessels are here bound down to the deep-seated muscles by the deep fascia, and as that membrane exerts an important influence on the progress of operations executed on these arteries, it is advisable to leave it untouched whilst the superficial muscles (those of the calf of the leg) are being removed. This end can only be attained with facility by proceeding with the dissection of the muscles from below upwards. An incision may with this view be made through the strong external fascia of the leg, along the borders of the tendo Achillis. If the tendon be then drawn backwards, and held on the stretch, the deep fascia will be readily exposed, from the ankle, as far as the belly of the soleus muscle. When this is effected, there can be no difficulty in detaching the muscular fibres from the tibia and fibula, as the fascia serves as a guide, indicating the line of separation between the superficial set of muscles which are to be removed, and the vessels and deep-seated muscles that are to be left untouched.\*

The posterior tibial artery extends from the lower border of the popliteus muscle, where it is continuous with the popliteal artery, (of which it may be regarded as the continuation from its direction and course,) as far as the inner border of the calcaneum, where it terminates, by dividing into the plantar arteries. The course of the vessel is obliquely downwards and inwards, being placed above, midway between the bones of the leg, and below, between the inner ankle and the prominence of the heel. Its anterior surface rests successively on the tibialis posticus, the flexor longus digitorum, and inferiorly, for about two inches, on the tibia, separated from it by some cellular tissue; posteriorly, it is covered by the gastrocnemius and soleus, (the deep fascia being interposed,) and, farther down, by the fascia of the leg, as it is stretched from the tendo Achillis to the inner border of the tibia. On each side lie its accompanying veins, and along its external or fibular side runs the posterior tibial nerve. It will be recollected, that in the hollow between the internal malleolus and the calcaneum run three tendons, as well as the posterior tibial vessels. Their relative position may be stated as follows: the tibialis posticus and flexor longus digitorum run close to the inner malleolus; a quarter of an inch behind these is the tibial artery, the nerve being a little posterior to it; and finally, about half an inch further back towards the heel, is the tendon of the flexor longus pollicis. It gives off many branches:—

*Muscular branches*, (plate XXX. fig. 2, k, k; r. musculares).—In its course along the leg, this artery gives several unnamed branches to the contiguous muscles, particularly to the tibialis posticus and the long flexors.

\* The popliteal artery may readily be tied in the living subject by cutting through the skin and fascia lata at the outer margin of the tendon of the semimembranosus muscle, to the extent of three inches. The vein which lies superficial and to the outer margin of the artery, is to be cautiously separated from it, and the ligature passed between them. By extending the incision farther down between the heads of the gastrocnemius externus, and having these held asunder, the patient lying on his abdomen, and his leg partly flexed, it is quite possible to throw a ligature on either one of the separate branches which the popliteal gives off. But in practice I have found it better, when it has been necessary to act upon the vessels so high up as the ham, to tie the femoral artery at the upper part of the middle third of the thigh. The vessel is here more superficial, and we avoid the great risk of producing inflammation in the mass of cellular and fatty matter in the popliteal region, which is apt to lead to burrowing abscesses beneath the hamstring tendons, and ultimately to disease the membranes of the knee-joint.—J. P.



*Nutritious artery*, (ramus nutritius tibiæ.)—In the upper third of its extent, a considerable branch passes forwards to the tibia, and then, by an oblique course through the nutritious foramen in that bone, reaches the medullary membrane, on which its branches ramify.

The chief branch of the posterior tibial is the following:—

*The Peroneal artery* (plate XXX. fig. 2, e, e; a. peronea) is situated deeply along the posterior part of the leg, taking the direction of the fibula; hence it is sometimes called *fibular*. It arises from the posterior tibial, from an inch to two inches below the lower border of the popliteus muscle, and descends almost perpendicularly towards the external ankle. Running for a while parallel and on the same plane with the posterior tibial artery, it lies on the tibialis posticus muscle, and is covered for the same distance by the soleus; as it descends, it inclines outwards to the fibula, and corresponds with the angle of union between it and the interosseous ligament. In this part of its course it is concealed from view by the flexor longus pollicis, to which it gives branches, as well as to the adjacent muscles, and also one to the substance of the fibular, (*ramus nutritius fibulæ*.) On reaching the lower extremity of the interosseous ligament, which is about two inches, or a little more, above the external ankle, the artery usually divides into two branches, named, from their situation, anterior and posterior peroneal.

*Anterior Peroneal branch* (plate XXX. fig. 1, g; fig. 2, i; plate XXXII. fig. 2, d, d; ramus peroneus anterior) passes forwards through the aperture in the interosseous ligament, and so reaches the fore part of the leg; it then descends along the border of the peroneus muscle, and sends branches outwards to the external ankle, which there anastomose with the external malleolar branch of the anterior tibial, and some forwards on the dorsum of the foot, to communicate with the r. dorsalis pedis of the same artery. Some of its ramifications also extend to the outer border of the foot, where they communicate with the external plantar and posterior peroneal arteries.

*The posterior Peroneal branch* (plate XXX. fig. 1, f; fig. 2, g, h; plate XXXII. fig. 2, c, c; r. peroneus posterior) continues in the original course of the artery, running downwards behind the external ankle, to reach the outer surface of the calcaneum. On arriving at the latter situation, it divides into ramusculi, some of which pass backwards to anastomose with the posterior tibial artery, others downwards to the border of the foot, and terminate in the muscles of the little toe, the rest forwards on the tarsus, communicating with the anterior peroneal branch, and with the tarsal branches of the anterior tibial artery.

*Varieties*.—The size and distribution of the fibular artery vary considerably in different instances; in some the posterior tibial is wanting, the popliteal appearing to divide into anterior tibial and fibular, the latter being double its usual size. In such cases, when the vessel reaches the lower part of the leg, it sends inwards a considerable branch, which, taking the course of the posterior tibial artery round the inner ankle, terminates in the plantar branches. In other instances, the anterior tibial artery is very small, and its dorsal branch necessarily too diminutive to carry on the circulation on the foot. The anterior fibular branch is then of considerable size, and supplies its place.

*Operations*.—The posterior tibial artery, in the lower part of its course, where it runs in the depression between the inner ankle and the heel, can be exposed and secured without much difficulty. Towards the middle of this interval, but nearer the prominence of the inner ankle than that of the heel by a finger's breadth, the vessel may be observed to pulsate, if the foot be extended so as to relax the fascia and integuments. An incision should be made about two inches and a half in length, beginning near the inner border of the tendo Achillis, and extended downwards and forwards over the point just indicated. The integuments being thus divided, and the strong fascia of the leg exposed, it is in the next place to be laid open to the same extent, after which a deep fascia comes into view, being a continuation of that above described as binding down the deep muscles and vessels. A small piece of this being pinched up by the points of the forceps, it is cut through so as to allow a director to be inserted beneath it, on which it is to be divided. The vessels are thus laid bare; so that the artery, after having been separated

## PLATE XXXIV.

The arteries of the medulla spinalis.

FIG. 1. represents an anterior view of the medulla oblongata and spinal cord, with its cerebral attachments.

Nos. 1, 1. The crura cerebri. 2, 2. The pons Varolii. 3, 3. The fifth pair of nerves (n. trigemini) at either side. 4, 4. The sixth pair, (n. abducentes.) 5. The medulla oblongata. 6, 6. Filaments of origin of the hypo-glossal and glosso-pharyngeal nerves. 7, 7. Filaments of origin of the pneumo-gastric nerves. 8, 8. The nervus accessorius at each side. 9. The middle (humeral) swelling of the spinal cord. 10. The inferior (lumbar) swelling of the spinal cord. 11. The cauda equina.

A. A. The vertebral arteries, (a. vertebrales.) B. The basilar artery, (a. basilaris.)

a. a. The posterior cerebral arteries, (a. posteriores cerebri.) b, b. The superior cerebellar arteries, (a. cerebelli superiores.) c, c. Transverse branches to the cerebral protuberance. d, d. Inferior cerebellar arteries, (a. inferiores cerebelli.) e, e. Posterior spinal arteries, (a. spinales posteriores.) f, f. The anterior spinal artery, (a. spinalis anterior) formed by the union of a small branch from either side. g, g. Bifurcations in the course of the anterior spinal artery, which afterwards reunite.

FIG. 2. A posterior view of the medulla spinalis, with its arteries.

Nos. 1, 1. The lateral lobes of the cerebellum. 2. The superior vermiform process.

a. a. The posterior spinal arteries, (a. spinales posteriores) winding around the upper part of the medulla spinalis. b, b. Transverse branches of communication between the posterior spinal arteries.

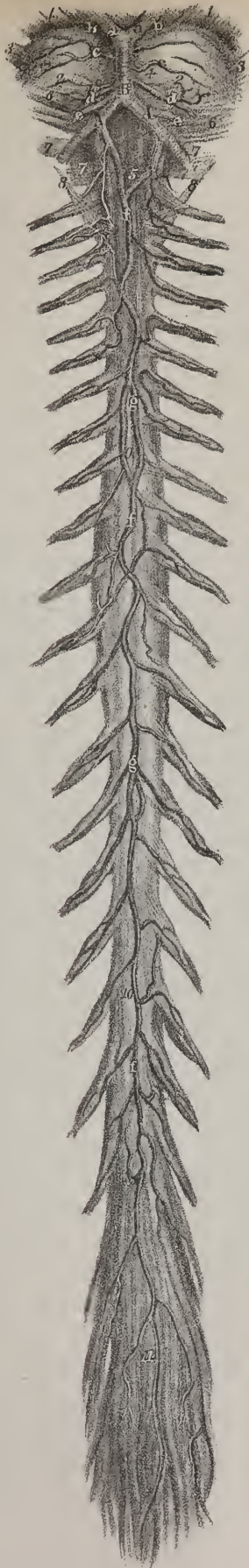


Fig 1



Fig 2





from the nerve and veins with the same precautions as in other situations, may be readily tied, the point of the needle being directed from below upwards and inwards towards the ankle, to avoid the nerve.

In the interval between the lower part of the calf of the leg and the inner ankle, the artery may be exposed in the following way: an incision should be made parallel with the inner border of the tendo Achillis for about the same length, and through the same structures (the skin and two layers of fascia) as in the preceding operation. This will bring the artery into view.

Few operations on arteries, probably none, present more difficulties than that of tying the posterior tibial while it is under cover of the soleus and gastrocnemius. The tibial origin of the former must be detached from the bone; and if, during this step of the operation, the deep fascia be torn, or the muscles rendered in any way confused, there remains no guide to the situation of the artery. In order to relax the muscles as much as possible, the knee must be slightly bent, and the foot extended so as to elevate the heel. If the limb be then placed on its outer side, and the knee supported, the seat of operation will be fairly brought into view. The incision through the skin must be very long, as the vessel lies so deeply; it may vary from four to five inches, according to the thickness of the muscles. It is usually directed to be made along the inner border of the tibia, so as to expose the margin of the gastrocnemius. In doing this the saphena vein can be easily avoided, as its course is quite apparent. When the soleus is exposed, its border is to be detached from the tibia, proceeding from below upwards, so as, if possible, to get a clear view of the deep fascia. If this be once obtained towards the lower part of the incision, a director can, without much difficulty, be insinuated between the membrane and the muscle, preparatory to the division of the fibres of the latter. When, by means of a retractor, the muscles are drawn back, so as to open the wound, its breadth will be found diminished by the posterior border of the incision in the integument; for it will be recollected that its direction coincided, in the first instance, with that of the border of the muscle where it is attached to the bone; but it will no longer do so when the muscle is drawn backwards. In other situations, where deep incisions are required, both margins of the wound can be held aside by the retractors, but here the posterior one only admits of their application, as the other coincides with the tibia. The necessity of some change in the line of the first incision is obviously suggested by these facts; and we believe that M. Lisfranc makes his incision rather obliquely, its direction being from above downwards and backwards, so that when the muscles are retracted, their border may coincide with that of the skin.

*The plantar arteries*, (plate XXXIII.)—When the posterior tibial artery reaches the hollow of the calcaneum, and gets under cover of the internal annular ligament, and of the origin of the abductor pollicis, it divides into the *plantar* arteries, which, from their position, are named internal and external.

The *dissection* of the plantar arteries includes that of the sole of the foot. When the thick skin and cellular texture are removed, and the plantar fascia fully exposed, the external plantar artery may be readily brought into view by cutting through a few fibres of the fascia, along the depression which separates the middle from the external portion of it; for when it has got on a line with the head of the fifth metatarsal bone, the vessel is almost superficial, though in the rest of its extent it is covered deeply by the muscles. The internal plantar artery can be laid bare merely by dividing the thin membrane which covers the abductor pollicis, and turning aside the external border of that muscle. When the plantar fascia and flexor brevis are detached and reflected from the calcaneum, the vessels can be easily traced in the rest of their extent.

*The Internal plantar artery*, (plate XXXIII. figs. 1 and 2, B; a. plantaris interna,) much smaller than the other, turns directly forwards, so as to form, when the body is in the erect position, a right angle with the vessel from which it arises. Placed at first above the abductor pollicis, and afterwards between it and the short flexor, it gives branches to both, and also some which incline towards the inner border of the foot, and communicate with branches of the dorsal arteries. On reaching the extremity of the first metatarsal bone, the internal plantar artery, considerably diminished in size, terminates by running along the inner border of the great toe, anastomosing with its digital branches. The direction of the artery corresponds with that of the line which separates the internal from the middle set of plantar muscles.

*The external Plantar artery*, (plate XXXIII. figs. 1 and 2, C, C; a. plantaris externa,) in size and direction, appears to be the continuation of the posterior tibial. In its course it at first inclines outwards and forwards, to reach the base of the fifth metatarsal bone, where it changes its direction, arching inwards across the foot, to gain the interval between the first and second metatarsal bones, where it receives the communicating branch from the dorsal artery, which completes the plantar arch. The vessel first passes between the calcaneum and the abductor pollicis, then between the flexor brevis digitorum and flexor accessorius; as it turns forwards it lies in the interval between the former muscle and the abductor of the little toe, corresponding with the line separating the middle of the external portion of the plantar fascia; but its transverse part is deeply covered by the flexors of the toes and the lumbricales. The convexity of the arch is directed forwards and outwards, the concavity in the opposite way, and from it are given off numerous branches, varying in size and importance. Of these some pass outwards over the border of the foot, and anastomose with the dorsal arteries; others go back to supply the parts in the hollow of the foot, and several down to the fascia, integument, and subcutaneous cellular substance: these are too irregular to admit of being named or described; but from its superior and anterior surfaces branches are given off which deserve notice:

*Perforating branches*, (plate XXXIII. fig. 2, i, i; rami perforantes,) three in number, pass upwards between the metatarsal

bones, through the posterior extremities of the dorsal interosseous muscles, and, on reaching the dorsum of the foot, inosculate with the metatarsal arteries.

*Digital branches* (plate XXXIII. fig. 1, g, h, i, k; fig. 2, e, f, g, h; rami digitales) are four in number, and from the order in which they arise from the arch, counting from without inwards, they are commonly named first, second, &c.; but we shall name them from their relations to the metatarsal bones. The *fourth* digital branch curves outwards, to gain the external border of the fifth metatarsal bone; for it will be recollected that the most external part of the plantar arch corresponds with the fourth metatarsal space. In its course this vessel crosses under the abductor of the little toe, and then runs along the border of its phalanges, on the last of which it terminates; the *third* digital branch passes forwards along the fourth metatarsal space, and at the cleft between the toes divides into two twigs, which take the contiguous borders of the fifth and fourth toes, and end on the last phalanges: the *second* digital branch is similarly disposed of on the fourth and third toes; and the *first* on the third and second. Near the point of bifurcation, each digital artery sends upwards through the corresponding metatarsal space a small branch, which communicates with the digital branches of the metatarsal artery. These are called the *anterior perforating branches*, (fig. 2, k, k,) to distinguish them from those which come from the arch itself, and pass upwards between the posterior extremities of the metatarsal bones, to inosculate with the dorsal interosseous branches. The digital arteries, which, from their relation to the phalanges, are sometimes called collateral, at their final termination incline towards one another, and form arches by inosculatation, from the convexity of which minute vessels pass forwards to the extremities of the toes. It will be observed, that in this way both sides of the three outer toes, and one side of the second toe, are supplied by branches derived from the plantar arch, in the ordinary distribution of the vessels; whilst both collateral branches of the great toe, and the inner one of the second, are furnished by the dorsal artery.

*The anterior Tibial artery* (plate XXIX. A, A; a. tibialis antica) is placed along the fore part of the leg in the interosseous space, at first deeply seated, but as it descends it gradually becomes comparatively superficial; it extends from the division of the popliteal artery to the bend of the ankle, from which it is prolonged to the interval between the first and second metatarsal bones, under the name of *dorsal* artery.

*Dissection.*—The course of the anterior tibial artery, and that of its continuation, the a. dorsalis pedis, may be marked out by a line drawn from the inner border of the head of the fibula to the middle of the bend of the ankle, and thence continued onwards to the first metatarsal space. To expose the vessel, an incision should be made through the skin, corresponding with this line. Its commencement may, in the next place, be crossed by another, extending from the head of the fibula to the inner tuberosity of the tibia; a similar transverse incision is to be made at the ankle, and, to evert the skin conveniently, a third will be found necessary about midway. The flaps of integument being reflected, the one inwards on the tibia, the other outwards over the fibula, and the fascia exposed, the intervals between the muscles at once become apparent, where their tendons shine through the fascia. This membrane should now be divided in the same extent and direction as the skin, and the artery will be brought into view by separating the muscles, which can be done without the least difficulty by proceeding from below upwards.

The dorsal artery, being placed between the tendon of the extensor proprius pollicis and that of the extensor communis, and uncovered by any structure except the skin and fascia, may be laid bare by an incision carried along the external or fibular border of the tendon of the extensor proprius, for about an inch and a half, or two inches. Above the bend of the ankle the incision must be somewhat longer, say two inches and a half, and the vessel will be found on the tibia, lying under the inner border of the extensor proprius.

The anterior tibial artery, at starting, turns horizontally forwards to reach the anterior surface of the interosseous ligament. In doing so, it necessarily passes between the heads of the tibialis posticus muscle, and through the interval between the bones left unclosed by the ligament. In its course it rests for two-thirds of its extent on the interosseous ligament, and for the rest on the anterior surface of the tibia. In the upper part of its extent it is deeply seated, and is overlapped and concealed by the tibialis anticus and extensor longus digitorum; the former being on its tibial, the latter on its fibular side. Lower down, it lies between the extensor pollicis and tibialis anticus; but as towards the ankle these muscles incline inwards, the one to the tarsus, the other to the first metatarsal bone, whilst the artery continues directly onwards, it necessarily passes beneath the extensor pollicis, and is placed between the tendon of this muscle and that of the extensor communis digitorum. In this situation it is covered only by the skin and fascia of the leg. The anterior tibial artery is accompanied by two veins (*venæ comites*;) the anterior tibial nerve, lies to its fibular side for some way, as being derived from the peroneal nerve, it inclines inwards, so as to get in front of the artery in the middle of the leg, but turns outwards again as it descends lower down. Its branches are the following:

*Muscular branches*, (plate XXIX. fig. 1, f, f; fig. 2, b, b; r. musculares.)—Small muscular branches are given to the tibialis posticus, as it passes between its heads, and as it runs down the leg several branches pass off to the tibialis anticus, extensor communis digitorum, and extensor pollicis.

*The Recurrent branch*, (plate XXIX. fig. 1, e; fig. 2, a; r. recurrens.)—On reaching the front of the leg, it sends upwards a pretty large and regular branch called “recurrent,” because it is reflected up towards the knee from the point where the artery is turning downwards. This branch passes through the fibres of the tibialis anticus, and soon divides into several ramifications,



which on the lateral and fore parts of the knee-joint anastomose with the inferior articular branches of the popliteal artery; and in its progress downwards between the extensor muscles, it gives on each side several muscular branches.

*Malleolar branches*, (plate XXIX. fig. 1, g, l; fig. 2, c, g; r. malleolares.)—Near the ankle-joint two malleolar arteries are given off: the *internal* one, having passed beneath the tendon of the tibialis anticus, reaches the inner ankle, and ramifies upon it, supplying the surrounding textures, and communicating with branches of the posterior tibial artery; the *external* malleolar branch bears a similar relation to the outer ankle; having passed under the tendon of the common extensor, it anastomoses with the posterior peroneal artery, and also with some ascending or reflected branches from the tarsal artery.

*The Dorsal artery of the Foot* (plate XXIX. B, B; a. dorsalis pedis) is the continuation of the anterior tibial artery, extending from its termination at the bend of the ankle to the posterior extremity of the first metatarsal space, where it divides into two branches, of which one proceeds forwards in the first interosseous space, whilst the other dips into the sole of the foot, and terminates by inosculating with the plantar arch. Its course is forwards and inwards, running over the astragalus, the scaphoid, and internal cuneiform bones; it is covered by the skin and fascia, its line of direction corresponding with the interval between the tendons of the extensor proprius pollicis and extensor communis. The principal branches of the dorsal artery are directed outwards and forwards upon the tarsus and metatarsus, and are named accordingly. Some small vessels also run obliquely inwards upon the inner side of the foot, where they terminate in minute ramusculi.

*The Tarsal branch* (plate XXIX. fig. 1, m; fig. 2, k; ramus tarseus) arises from the artery usually where it crosses the scaphoid bone, but its point of origin varies in different instances. It inclines forwards and outwards, describing a slight curve as it runs upon the tarsal bones covered by the extensor brevis muscle, to which it gives ramusculi; some also, of small size, sink deeply into the tarsal articulations, for the nutrition of the different structures which compose them. The artery, having curved backwards to the cuboid bone, divides into branches which take different directions; some forwards, to anastomose with the divisions of the metatarsal artery; others outwards, to communicate at the border of the foot with branches of the external plantar artery; whilst a third set anastomoses with branches of the external malleolar, and with those which the fibular gives to the outside of the calcaneum.

*The Metatarsal branch* (plate XXIX. fig. 2, m, m; r. metatarsus) is usually smaller than the preceding, and comes off farther forward. Its direction is also outwards and forward under the extensor brevis. Sometimes there are two metatarsal arteries, the second being of smaller size, and not unfrequently, when there is but a single vessel of this name, it arises in common with the tarsal artery. Its direction is necessarily influenced by these circumstances, being oblique when it arises far back, and almost transverse when its origin is situated farther forward than usual. Ramusculi pass off in different directions for the supply of the surrounding structures; and some curve backwards, to form anastomoses with those of the tarsal artery; the interossei only deserve notice.

*Interosseous branches* (plate XXIX. fig. 1, s, s; fig. 2, n, n; r. interossei.)—These branches are named “interosseous,” from their position between the metatarsal bones. These are small straight vessels which pass forwards, resting each upon one of the dorsal interosseous muscles, and at the cleft between the toes each divides into two ramusculi which run along the contiguous borders of the toes, forming their dorsal collateral branches, (fig. 2, o, o.) From the external interosseous artery, a small branch is given off, which inclines outwards to gain the external border of the little toe, upon which it lies, forming its first collateral branch. In this way we find that the interosseous branches derived from the metatarsal supply the dorsal surfaces of the three outer toes, and one side of the second. Now each of these vessels at its point of bifurcation communicates with the plantar artery by means of the anterior perforating branches; and again, at the posterior extremity of the interosseous spaces, they receive the posterior perforating branches, (fig. 2, p, p.) These are usually small branches of communication; but sometimes they are of larger size, and, on reaching the upper surface of the foot, form the interosseous arteries, the metatarsal branches being reduced to small ramusculi, which terminate in them.

When the dorsal artery of the foot has reached the posterior extremity of the first metatarsal space, it gives off a branch which runs along the outer surface of the first metatarsal bone, and which, from its analogy to the interosseous branches derived from the metatarsal artery, may be called the first interosseous branch, but is commonly called *r. dorsalis pollicis*, (fig. 1, q; fig. 2, t,) for, on reaching the fissure between the toes, it divides so as to form a collateral branch for the inner side of the second, and for the outer side of the great toe.

The artery, after giving off this branch, dips into the first interosseous space, and divides into its two ultimate branches. One of these, (fig. 2, s,) about two or three lines in length, inclines outwards, and terminates by inosculating with the external plantar artery, so as to complete its arch; the other passes forwards beneath the outer border of the first metatarsal bone, towards the fore part of which it sends inwards a branch which becomes the internal collateral branch of the great toe; after which, on reaching the anterior extremity of the first metatarsal space, it divides into branches which run along the contiguous borders of the first and second toes.

The arteries of the foot are subject to several variations, and none so much so as those of the great toe. When the dorsal artery is small, the digital branches at the plantar surface of the great toe are derived from the vessels in the sole of the foot. When the interosseous branches of the metatarsal artery are small, their place is supplied by the posterior perforating arteries.



*Anastomoses.*—We have made frequent mention of the anastomoses between the different branches of the arteries in the lower extremity. It now becomes necessary to take a general view of them, in order that we may understand the important influence they exert in maintaining the circulation in the limb, when the principal artery is obliterated by an operation, or by disease. It will be recollected, that branches from different directions converge towards the posterior part of the hip-joint. The circumflex arteries (internal and external) turn round the shaft of the femur, one from within, the other from without; the gluteal and ischiadic arteries run from above downwards, and the superior perforating branches from below upwards, towards the same point. So that if the supply from one quarter be diminished or cut off, the loss is speedily made up from some other, the vessels taking on an increase of size and action proportioned to the increased demand upon them. This may be termed the *ilio-femoral anastomosis*. At the anterior and upper part of the limb, a similar mode of connexion occurs, but by no means so extensive, between the ilio-lumbar artery and the circumflex ilii, and again between the latter and the external circumflex on the one hand, and the epigastric on the other.

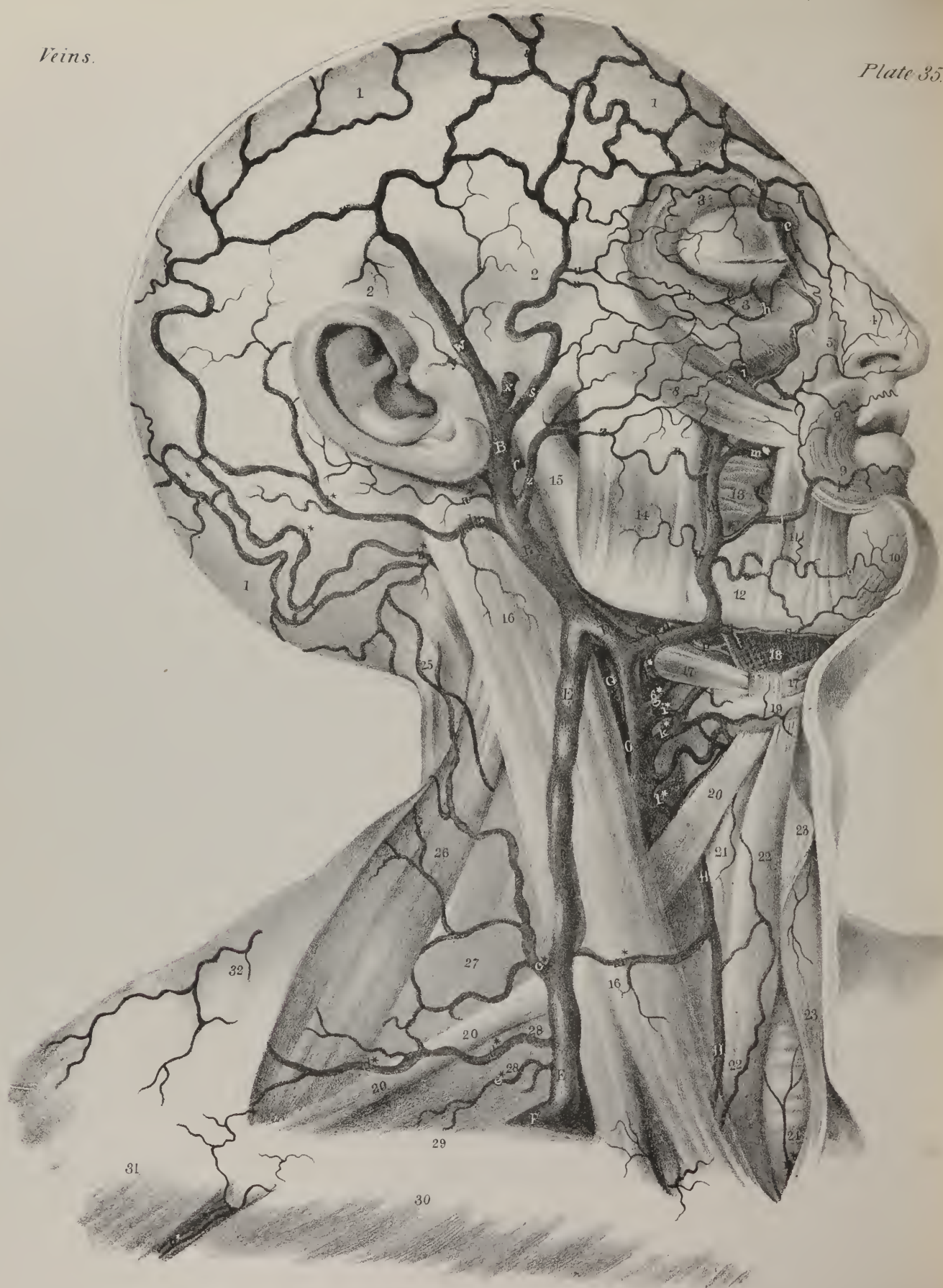
Round the knee-joint a very free communication exists between the four articular arteries (converging to its fore part) and the recurrent tibial from below, and the descending branches of the external circumflex, from the opposite direction. This may be named the *femoro-tibial anastomosis*; and if we examine the condition of the vessels in a well-injected limb, we shall find it connected with the ilio-femoral anastomosis by the descending branches of the external circumflex artery in front, and by the series of perforating branches behind.

The ankle-joint is surrounded by a corresponding distribution of vessels. The posterior tibial artery and the peroneal communicate before they proceed to their final destination. In front of the joint, the anterior peroneal branch anastomoses with the tarsal and external malleolar arteries; the latter communicating again with the posterior fibular, whilst the internal malleolar maintains a similar relation with the posterior tibial, or its branches. This forms the *tibio-tarsal anastomosis*.

This freedom of anastomosis between the capillary terminations of different vessels, may be considered as a provision against the consequences that must otherwise follow the obliteration of any of the main vessels of a limb by an injury or by operation. If the external iliac artery is tied for an aneurism high up in the thigh, an increased quantity of blood is at once thrown on the internal iliac artery and its branches, which thus become distended and enlarged. Whilst this is taking place, the femoral artery and its branches empty themselves of their blood, forcing it on into the veins by their contractile power, at the same time that they receive none in their natural course. But after a while they become filled again, and circulate blood, though in a direction exactly opposite to that in which it had previously flowed in them. The capillary terminations of the circumflex arteries receive from those of the gluteal, sciatic, and obturator, the increased current, which is thrown upon them, and convey it thus into the femoral artery below the tumour for which the operation was performed; and so, in the new order of things, the blood flows from branch to trunk, conducted through the devious route of the collateral vessels, and maintaining the vitality of the limb by what is termed the *collateral circulation*. The anterior and lateral parts of the abdominal parietes, it will be recollected, are supplied by the epigastric and circumflex ilii arteries. When the regular source of their supply is cut off by the obstruction in the iliac artery, gangrene would speedily supervene if the circulation were not restored from some other quarter. A recurrence to the anastomoses of these vessels at once reminds us, that the circumflex ilii artery communicates with the epigastric on the one hand, and the ilio-lumbar on the other, and forms a ready medium of communication between them, when the latter, after the application of the ligature, receives part of the increased current propelled into the internal iliac artery, from which it arises. We need not extend these remarks farther for the present. The anastomoses round the knee and ankle must be sufficiently obvious from what has been already stated. As, however, the subject is one, not only of deep interest, but of great consequence in a practical point of view, we can scarcely refrain from raising this question, What is the condition of the vessels of a limb which has been the subject of an operation for aneurism? We reply in the words of an eminent authority: "In twelve or fourteen months after a ligature has been applied on the femoral artery, it becomes completely obliterated, as far up as the profunda, and down to the origin of the anterior tibial artery, the remnant of the vessel being a mere cord. The circumflex vessels become enlarged, and convey blood to the rectus, sartorius, and vasti, which had previously been supplied by the femoral. The articular arteries round the knee are also enlarged and tortuous; they receive blood, not from the popliteal, but from the common communicating vessels of the profunda." After some general remarks on the effect of ligatures, the description of the limb, which formed the subject of the memoir here referred to, proceeds as follows: "The profunda, which formed the new channel for the blood, was considerably enlarged in diameter, and sent branches larger than usual to the flexor muscles. Just midway on the back part of the thigh, it gave off those branches which became the chief support of the new circulation. The first of the newly established vessels went down to communicate with the superior articular artery, on the inner side of the articulation. Another, guided by the biceps muscle, opened into a muscular branch on the gastrocnemius. Between these, a third vessel, passing along in the course of the sciatic nerve, divided into several branches, communicating with the inferior articular vessels, with the origin of the anterior and posterior tibial arteries, and with some of their muscular branches, in such a way as to form a vascular plexus in the popliteal space. The external circumflex artery was considerably enlarged, and freely supplied the muscles on the fore part of the thigh. The obturator artery did not appear larger than usual, nor could any enlarged communicating branches be traced between the ischiadic and profunda arteries."\*

\* Dissection of an Aneurismal Limb, by Sir Astley Cooper. Med. Chir. Trans. vol. ii.







## CHAPTER II.

## OF THE VEINS.

THOUGH the veins diffused throughout the body form one system, and serve for one especial purpose—that of returning the effete or residual blood to one common recipient (the right auricle) by means of their great trunks, (*venæ cavæ*,) still they admit of a division into compartments, in consideration of certain peculiarities which they present. The veins within the cavity of the cranium and spine form a group, in a manner apart from the others; so does the *vena portarum*, which ramifies in the liver; and perhaps the pulmonary veins may be admitted as a third, from the circumstance of their conveying red blood. Even before the announcement of Harvey's discoveries, anatomists perceived how objectionable it was to classify these vessels with other veins, and sought to mark the distinction between them, by calling them *arteriæ venosæ*; and for the like reason, the pulmonary artery was named *vena arteriosa*.

## PLATE XXXV.

The veins on the external surface of the head and face, with the superficial veins of the neck, are here shown. The arteries are removed lest any ambiguity might arise from the association of the two sets of tubes.

- Nos. 1, 1. The occipito-frontalis muscle. 2, 2. The aponeurosis which conceals the temporal muscle. 3, 3. The orbicularis palpebrarum muscle. 4. The compressor narium. 5. The levator labii superioris alæque nasi. 6. The levator labii superioris proprius. 7. The zygomaticus minor muscle. 8. The zygomaticus major. 9, 9. The orbicularis oris muscle. 10. The depressor labii inferioris. 11. The depressor anguli oris. 12. The body of the inferior maxillary bone. 13. The buccinator muscle. 14, 14. The masseter muscle. 15. The ramus of the inferior maxillary bone. 16, 16. The sterno-mastoid muscle. 17, 17. The digastricus muscle. 18. The mylo-hyoideus muscle. 19. The body of the os hyoides. 20, 20. The omo-hyoideus muscle. 21. Part of the thyro-hyoideus muscle. 22, 22. The sterno-hyoideus muscle, at each side. 23. The projection of the thyroid cartilage. 24. The trachea. 25. The splenius muscle. 26. The levator anguli scapulæ muscle. 27. The posterior scalenus muscle. 28, 28. The lower cervical nerves, descending to form the brachial plexus. 29. The clavicle. 30. Part of the pectoralis major muscle. 31. Part of the deltoid. 32. The trapezius muscle.
- A, A. The facial vein, (*vena facialis*.)  
 a, a. The frontal vein, (*v. frontalis*.) b, b. Transverse branches by means of which this vein communicates with its fellow of the opposite side. c. A branch of the frontal, which dips beneath the orbicularis palpebrarum muscle to communicate with a deep supra-orbital branch. d. The supra-orbital vein, (*v. supra-orbitalis*.) e, e. The angular vein, (*v. angularis*.) f, f. Nasal veins opening into the angular. g. Superior palpebral vein. h, h. Some small veins ramifying around the lower eyelid. i. The inferior palpebral vein, (*v. palpebralis inferior*.) k. The superior coronary vein. l. The inferior coronary vein. m, m. Buccal veins, (*v. buccales*.) n, n. Masseteric veins. o, o. The inferior labial vein. p, p. The ranine vein, (*v. ranina*.) q, q. The submental vein, (*v. submental*is.) r. The inferior palatine vein, (*v. palatina*.)
- B, B. The temporal vein, (*vena temporalis*.)  
 s, s. The anterior temporal vein, (*v. temporalis anterior*.) t. A branch of the temporal vein communicating with the same vein on the opposite side of the head. u, u. External palpebral veins opening into the anterior temporal. w, w. The posterior temporal vein, (*v. temporalis posterior*.) x. The middle temporal vein, (*v. temporalis media*.) y, y. Anterior auricular veins, (*v. auriculares anteriores*.) z, z. The transverse vein of the face, (*v. transversalis faciei*.) a\*. The posterior auricular vein, (*v. auricularis posterior*.)
- C. The internal maxillary vein, (*v. maxillaris interna*.) To expose this vein, the small branches from the parotid gland (*v. parotidæ*) and from the articulation of the lower jaw, (*v. articularis*), have been removed. D. The anterior terminal branch of the temporal vein inclining inwards to join the facial vein. E, E. The external jugular vein, (*v. jugularis externa*.)
- b\*. The mastoid vein, which generally descends to open into the external jugular vein. c\*. A muscular and superficial trunk from the back part of the neck. d\*, d\*. The posterior scapular vein, (*v. posterior scapulæ*.) e\*. The supra-scapular vein, (*v. supra-scapularis*.)
- F. The upper border of the subclavian vein, (*vena subclavia*.) G, G. The internal jugular vein, (*vena jugularis interna*.)
- f\*. The pharyngeal vein, (*v. pharyngea*.) g\*. The lingual vein, (*v. lingualis*.) h\*, h\*. The occipital vein, (*v. occipitalis*.) i\*. The laryngeal vein, (*v. laryngea*.) k\*. The superior thyroid vein, (*v. thyroidea superior*.) l\*. The middle thyroid vein, (*v. thyroidea media*.)
- H, H. The anterior jugular vein, (*vena jugularis anterior*.)
- n\*. A communicating branch passing between the anterior and middle jugular veins, which receives some superficial veins from the fore part of the neck, (*v. cutanæ*.) o\*. An inferior thyroid vein, (*v. thyroidea inferior*.) o\*. The termination of the cephalic vein.

We shall commence our description of the veins with those which form the superior vena cava, or more properly, with those which, commencing by minute ramusculi in the head, neck, the upper extremities, and the walls of the thorax, form so many tributary streams, gradually increasing in size as they diminish in number, until they are finally united into one current, that of the superior vena cava. The cerebro-spinal veins may be considered an offset connected with this part of the venous system, as their contents are, for the most part, poured into it. The venous ramifications, which terminate in the inferior vena cava, come next in order; to this the vena portarum is an adjunct. The veins of the heart open directly into the right auricle itself, and so cannot be said to belong to either venous trunk; the vena azygos (major and minor) is a tributary to the superior vena cava, at the same time that it serves as a substitute for both these vessels within the thorax, and also as a medium of connexion between them.

The veins of the head are divided, like the arteries, into two sets,—those which ramify on its exterior, and those placed in its interior: and a sufficient correspondence exists between the ramifications of both orders of vessels to warrant us in saying generally, that the one returns the residue of the blood circulated by the external carotid artery, the other by the internal. The veins on the exterior of the head converge and unite, so as to form two trunks, the facial and the temporal.

*The Facial vein.*—The facial vein (plate XXXV. A; vena facialis) lies obliquely along the side of the face, extending from the inner margin of the orbit downwards and backwards to the anterior edge of the masseter muscle. Resting on the same plane as the facial artery, but farther back, and less tortuous, it still maintains very nearly the same relations. It may be said to commence at the side of the root of the nose by a vein formed by the conflux of branches from the forehead, the eyebrow, and nose, and to increase by receiving others at each step of its course.

*The Frontal vein* (plate XXXV. a, a; vena frontalis) commences on the roof of the skull by ramusculi, which pass obliquely downwards and forwards upon the forehead, maintaining communications in their course with the anterior branches of the temporal vein. By gradually converging, these branches form a vein of some size, which descends vertically, parallel with the corresponding vessel of the opposite side, with which it is connected by transverse branches. In some instances both unite and form a short trunk, which again divides at the root of the nose, its branches diverging as they descend, so as to become continuous with the angular vein. When descending from the forehead, it receives a branch from the eyebrow, and some, of smaller size, from the nose and upper eyelid.

*The Supra-orbital vein* (plate XXXV. d: vena supra-orbitalis; v. supercili) runs transversely inwards in the direction of the eyebrow, covered by the occipito-frontalis muscle. Its radicles are connected externally with those of the external palpebral and superficial temporal veins; in its course it receives branches from the contiguous muscles and tegument, and at the inner angle of the orbit it inclines downwards, to terminate in the frontal vein. The supra-orbital and frontal veins, by their junction, form the angular vein, (*vena angularis*; plate XXXV. e, e,) which is perceptible beneath the skin as it runs obliquely downwards and outwards by the inner margin of the orbit, resting against the side of the root of the nose. This small vessel receives by its inner side the *nasal veins*, (f, f,) which pass upward obliquely to join it from the side and ridge of the nose; whilst some small palpebral veins open into it from the opposite direction. When arrived on a level with the lower margin of the orbit, the angular vein may be said to terminate by becoming continuous with the facial vein.

The facial vein, commencing as has been just stated, gradually increases, by receiving ramusculi from the lower eyelid, (h,) and from the ala of the nose; also from the upper lip branches arise which, after a short course, open into it. By its outer side it receives a vein, (*v. palpebralis inferior, externa*; i,) which is formed by small branches derived from the lower eyelid, from the external side of the orbit, and the prominence of the cheek. The direction of this vessel is obliquely inwards above the zygomatic muscle, beneath which it turns previously to its termination. When on a level with the angle of the mouth, the facial vein is further increased by branches from the lips, which perhaps may be called coronary veins, (k, l,) and from the cheek, (*venæ buccales*; m, m,) and still lower down from the masseter muscle, (n, n,) on the one hand, and the chin (o) on the other. When arrived at the lower border of the jaw, the vein inclines outwards and backwards, covered by the cervical fascia and the platysma muscle, and soon unites with a large branch of communication derived from the temporal vein, (D,) to form a vessel of considerable size, which opens, at an acute angle, into the trunk of the internal jugular vein.

Previously to its termination, the facial vein receives the following veins:—viz. *vena ranina*, (p, p,) a small vessel which lies along the under surface of the tongue, close by the frænum linguæ, in apposition with the artery of the same name; its course is backwards and outwards, between the mylo-hyoideus and hyo-glossus muscles, to open into the facial vein, or sometimes into the lingual:—*vena submentalis*, (q, q;) this vessel, larger than the preceding, commences by radicles derived from the sublingual gland, from which it passes backwards in the course of the duct; it receives branches from the submaxillary gland, and from the mylo-hyoideus muscles, and, keeping close under cover of the margin of the jaw-bone, it joins the facial vein; but in some instances it pours its contents into the lingual or superior thyroid vein. *Vena palatina* (r) returns the blood from the amygdala and soft palate; it passes downwards, deeply seated by the side of the pharynx, to join one of the preceding veins, or terminate in the facial separately.

*The Temporal vein* (plate XXXV. B; vena temporalis) is a vessel of considerable size, whose trunk passes almost perpendicularly downwards before the external auditory tube, extending from the zygo-ma, upon which it rests, to the angle of the jaw,





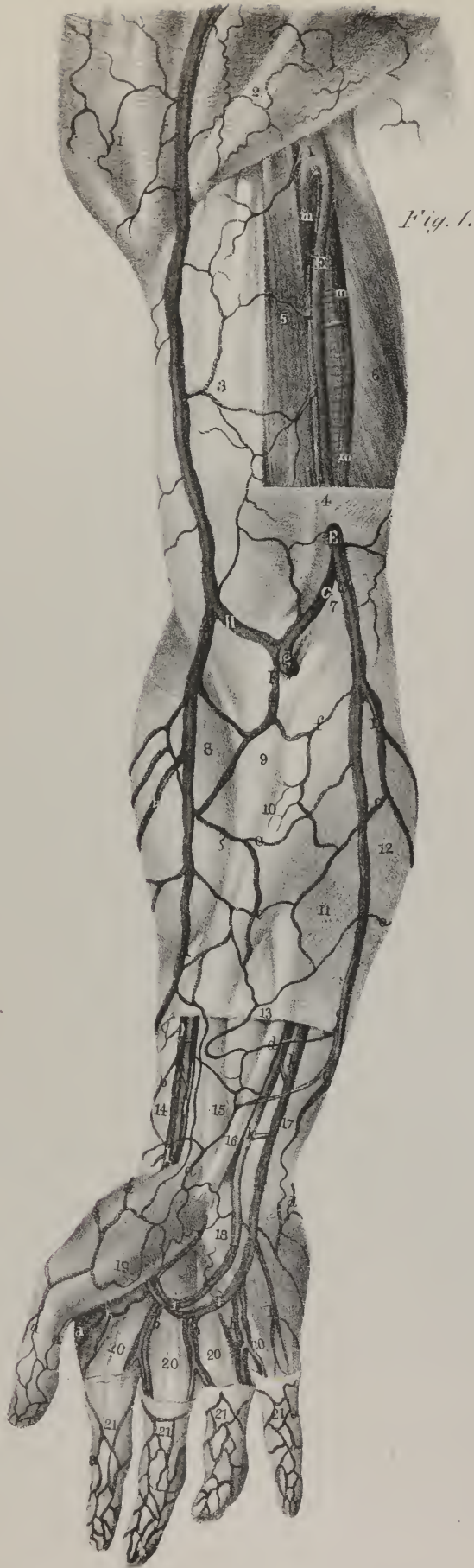

Fig. 1.

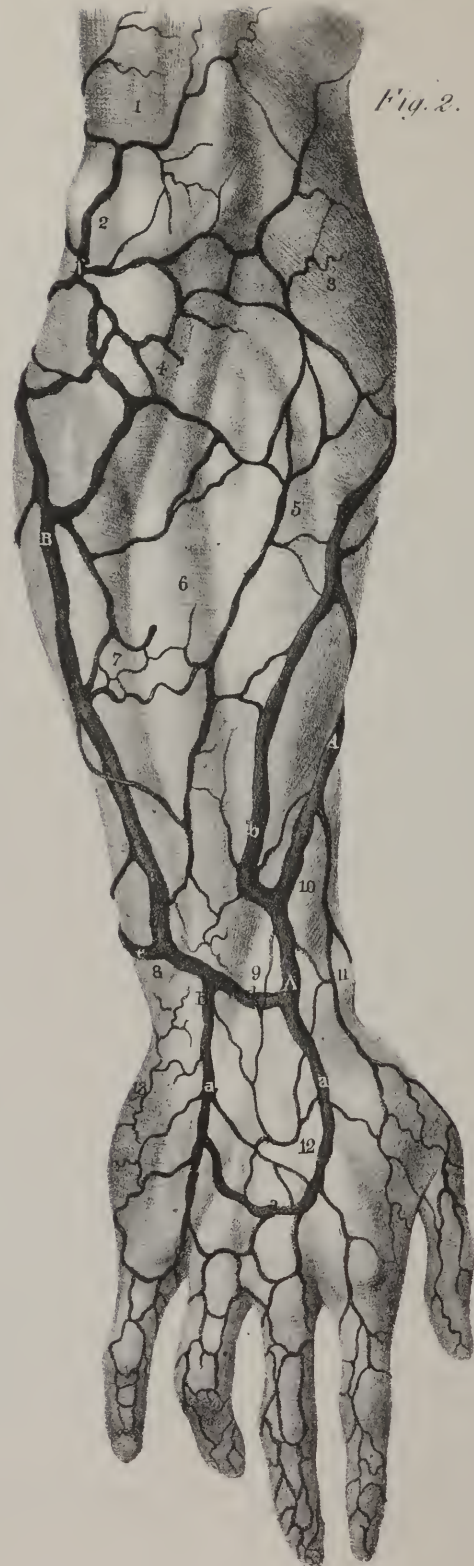

Fig. 2.

whilst its branches spread out upon the side of the head, some being superficial, others deeply seated. The superficial branches commence by minute ramifications upon the arch of the skull, where they communicate with the radicles of the frontal and occipital veins, as well as with those of the corresponding vein of the opposite side. That from the fore part (*v. temporalis anterior*; s, s) inclines downwards and a little backwards, the vein seated posteriorly (*v. temporalis posterior*; w, w) runs forwards over the ear, both being placed between the skin and the temporal fascia. Converging in this way, they unite at an angle above the zygoma, and at their junction commences the trunk of the temporal vein. To this same point also passes a large branch, which may be called the middle temporal vein, (*v. temporalis media*; x,) to distinguish it from those which are still deeper seated, and open into the internal maxillary vein. This vessel arises in the substance of the temporal muscle, from which the branches emerge, and form a vessel of some size upon its surface; the vessel pierces the fascia at the upper border of the zygoma, and opens into the commencement of the common trunk, formed as has been above stated. The temporal vein gradually sinks into the substance of the parotid gland as it descends behind the ramus of the jaw. When under cover of its angle, it divides into two vessels, of which one, ordinarily the larger, inclines inwards to join with the facial vein, whilst the other turns backwards, and becomes continuous with the external jugular vein. The branches which open into the temporal vein in its course are numerous:— from the parotid gland several ramusculi, (*venæ parotidæ*;) from the articulation of the jaw, (*vena articularis*;) from the external ear, (*venæ auriculares*; y, y,) from the side of the face a vein of some size, (*vena transversalis faciei*; z, z.) This vessel

## PLATE XXXVI.

The veins of the upper extremity are here shown.

FIG. 1. Portions of the fascia have been removed from the upper arm, fore-arm, and hand, for the purpose of exhibiting the deep vessels.

No. 1. The deltoid muscle veiled by a thin fascia. 2. The pectoralis muscle seen through the fascia. 3. The fascia covering the biceps muscle. 4. The boundary of the incision made to remove the fascia from over the brachial artery. 5. The inner edge of the biceps and coraco-brachialis muscles. 6. The triceps. 7. The process of fascia sent inwards over the flexor muscles by the tendon of the biceps. 8. The prominence made by the supinator longus muscle. 9. The prominent outline of the pronator radii teres. 10, 11. The outlines of the flexor carpi radialis and palmaris longus muscles. 12. The situation of the flexor carpi ulnaris. 13. The divided edge of the fascia of the fore-arm. 14. The tendon of the supinator longus muscle. 15. The tendons of the flexor muscles surrounded by a cellular sheath. 16. The tendon of the palmaris longus. 17. The tendon of the flexor carpi ulnaris. 18. The annular ligament. 19. The muscles forming the ball of the thumb covered by fascia. 20, 20. The tendons of the superficial flexor muscle. 21, 21. The fascia surrounding the fingers.

A, A. The radial cutaneous vein, (*v. radialis cutanea*.) B, B. The cephalic vein, (*v. cephalica*.)

a, a. Branches ramifying around the back part of the thumb and fore-finger, which unite to form the commencement of the radial cutaneous vein. b, b. Branches from the posterior aspect of the fore-arm. c, c. Branches from the anterior surface of the fore-arm. These last maintain a communication also with the median and ulnar veins.

C, C. The anterior ulnar cutaneous vein, (*v. ulnaris cutanea anterior*.) D. The posterior ulnar cutaneous vein, (*v. ulnaris cutanea posterior*.) E, E. The basilic, piercing the fascia of the upper arm to terminate in the axillary vein.

d, d. Branches of origin of the anterior ulnar cutaneous vein. e, e. Branches of communication with the posterior ulnar cutaneous. f. Branch of communication with the median vein.

F. The median vein, (*v. mediana*.) G. The median basilic vein, (*v. mediana basilica*.) H. The median cephalic vein (*v. mediana-cephalica*.)

g. The deep median branch of communication with the deep brachial veins.

The deep veins:—

h, h. Digital veins formed by the union of the collateral branches from the sides of the fingers. i, i. Accompanying veins (*v. comites*) of the superficial palmar arch. k, k. Accompanying veins of the ulnar artery, (*v. comites arteriæ ulnaris*;) communicating with each other by means of transverse branches. l, l. Accompanying veins of the radial artery, (*v. comites arteriæ radialis*.) m, m. Accompanying veins of the brachial artery, (*v. comites arteriæ brachialis*.)

I. The axillary vein, (*v. axillaris*.)

FIG. 2. The superficial veins on the posterior aspect of the fore-arm and hand.

No. 1. The fascia covering the lower part of the triceps muscle. 2. The prominence of the olecranon. 3. The convexity formed by the supinator longus and extensor carpi radialis longior muscles. 4. The outline of the anconeus muscle seen through the fascia. 5, 6, 7. The outlines formed by the projection of the extensor carpi radialis brevior, extensor communis digitorum, and extensor carpi ulnaris muscles. 8. The prominence of the lower extremity of the ulna. 9. The posterior annular ligament. 10. The swelling of the extensores ossis metacarpi and primi intermodii muscles. 11. The projection of the styloid process of the radius. 12. The fascia covering the back part of the hand. 13. That covering the muscles of the little finger.

A, A. The radial cutaneous vein, (*v. radialis cutanea*.) B, B. The posterior ulnar cutaneous vein, (*v. ulnaris cutanea posterior*.)

a, a. The venous arch on the back of the hand, formed by branches from the fingers and thumb; it pours its blood on the one side into the radial, on the other into the ulnar vein. b, b. A large posterior venous trunk, which collects the blood from the back part of the fore-arm, and unites near the middle of its course with the radial cutaneous vein. c, c. The radial vein of the posterior ulnar cutaneous, (*v. salvatella*.) d. A large communicating branch between the radial and posterior ulnar cutaneous veins. e. A communicating branch which unites with the anterior ulnar cutaneous vein. f. A considerable vein formed by the reunion of the small veins around the elbow, which opens into the same vein near its termination.



corresponds with the artery of the same name, by receiving branches from the parts it supplies. Its direction is transversely outwards from the side of the face to the temporal vein. From the opposite direction is received the *vena auricularis posterior*, (a\*,) which is increased by the stylo-mastoid vein. Besides these, a vein of considerable size joins the temporal whilst embedded in the parotid gland, viz. the internal maxillary vein:—

*The Internal Maxillary vein* (plate XXXV. C; *vena maxillaris interna*) corresponds in direction, position, and relations, with the artery of the same name. Three or four temporal branches descend from the fossa, deeply seated; others come from the pterygoid muscles; some from the surface of the upper jaw; and one, of large size, from the lower one, emerging from the dental foramen, (*vena dentalis inferior*.) All these unite to form a short trunk, which joins nearly at right angles with the temporal vein.

*External Jugular vein*, (plate XXXV. E, E; *vena jugularis externa*; *trachelo-subcutanea*.)—This vein commences on a level with the angle of the jaw by the junction of two branches; one the communicating branch received from the termination of the temporal vein, the other derived from the mastoid region. The latter (b\*, b\*) passes downwards and forwards obliquely to the point above stated, from behind the ear, resting on the mastoid muscle. The external jugular vein assumes at once the perpendicular direction, lying between the platysma and sterno-mastoid. In consequence of the obliquity of the muscle last named, the vein gets to its outer border, close by which it descends to the lower part of the neck, where it inclines inwards behind the muscle, to terminate (either as a single trunk, or by two or three branches) in the subclavian vein (F) near its junction with the internal jugular. In this course it receives one or two large branches from the back of the neck; one of them, (c\*,) lying at first between the splenius and trapezius, passes down at the outside of the jugular vein, and about the middle of the neck opens into it. Some superficial branches also join it from the fore part of the neck, (*venæ cutaneæ*; m\*.) Some of these commence over the submaxillary gland, some under the chin; and converging, they form a vein, often of considerable size, (*v. jugularis anterior*; H,) which lies along the inner border of the sterno-mastoid muscle, receives some eutaneous branches lower down, and then inclines outwards to terminate in the external jugular vein. Previously to its termination two large veins open into it, derived from the region of the scapula, (*vena supra-scapularis*, e\*; et *vena posterior scapulae*, d\*.) Their direction is transverse from without inwards, lying parallel with the arteries of the same.

## PLATE XXXVII.

This plate represents the great venous trunks which unite to form the superior vena cava. The internal jugular veins are brought into view by removing the sterno-hyoid, sterno-thyroid, and the lower portion of the sterno-mastoid muscles. The heart, with the great vessels arising from its base, are exposed by sawing through the clavicles and ribs, and removing the sternum, with the whole anterior wall of the thorax.

Nos. 1, 1. The lower border of the inferior maxilla. 2. The body of the hyoid bone. 3. The thyroid cartilage. 4, 4. The thyro-hyoid muscles. 5. The cricoid cartilage. 6, 6. The thyroid gland. 7. The trachea. 8. The brachio-cephalic artery. 9, 9. The carotid arteries. 10, 10. The cut surface of the sterno-mastoid muscle at each side. 11, 11. The anterior scalenus muscle at each side. 12. The posterior scalenus at the right side. 13, 13. The inferior portion of the omo-hyoid muscle. 14, 14. The subclavian arteries. 15, 15. The trapezius muscle at each side. 16, 16. The divided clavicles. 17, 17. The deltoid muscles. 18. The axillary artery of the right upper extremity. 19, 19. The serratus magnus divided by an incision parallel to the cut extremities of the ribs. 20, 20. The intercostal muscles at each side, divided by the vertical section. 21, 21. The cut extremities of the ribs. 22. The arch of the aorta. 23. The trunk of the pulmonary artery. 24. The left pulmonary artery. 25. The left auricle of the heart. 26. The left ventricle. 27. The right ventricle. 28. The right auricle. 29. The descending aorta.

A, A. The external jugular vein (*v. jugularis externa*) at each side.

a, a. The posterior superficial vein of the neck. b, b. The posterior scapular veins. c, c. The supra-scapular veins.

B, B. The anterior jugular veins, (*v. jugulares anteriores*;) formed by superficial branches from the fore-part of the neck and thyroid gland. The vein of the right side opens into the external jugular, that of the left into the subclavian vein. C, C. The internal jugular veins, (*v. jugulares internæ*.)

d, d. The common trunk formed by the facial and temporal veins. e, e. The lingual veins. f, f. The superior thyroid veins. g, g. The middle thyroid veins.

D, D. The axillary veins, (*v. axillares*.)

h, h. The *venæ comites* of the brachial vein. i, i. The basilic veins at each side. k, k. The cephalic veins. l, l. The trunk formed by the subscapular and posterior circumflex veins at each side. m, m. The anterior circumflex veins. n, n. The axillary thoracic veins. o, o. The inferior thoracic veins. p, p. The superior thoracic veins. q, q. The acromial thoracic veins.

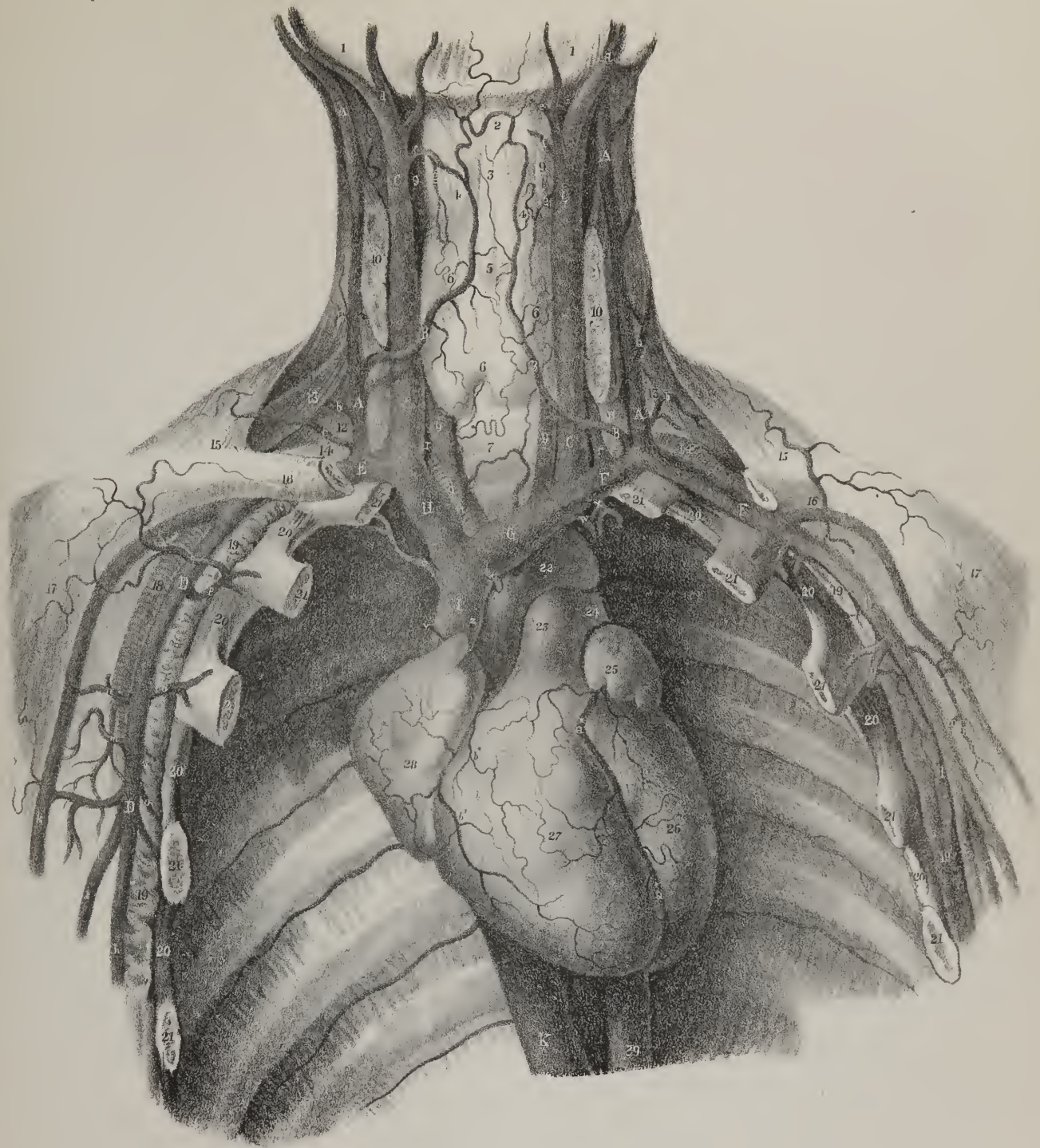
E. The right subclavian vein, (*v. subclavia dextra*.) F, F. The left subclavian vein, (*v. subclavia sinistra*.)

r, r. The vertebral veins, (*v. vertebrales*.)

G. The left brachio-cephalic vein, (*v. brachio-cephalica sinistra, innominata*.) H. The right brachio-cephalic vein, (*v. brachio-cephalica dextra, innominata*.)

s. The left inferior thyroid vein, (*v. thyroidea inferior*.) t. The right inferior thyroid vein. u. The internal mammary vein of the right side, (*v. mammaria interna*.) w. The left internal mammary vein. x. The superior intercostal vein, (*v. intercostalis superior*.) y. A small pericardiac vein. z, z. Small branches from the mediastinum and pericardium. a\*. The large cardiac vein, (*v. cordis maxima*.) b\*, b\*. Small cardiac veins, (*v. cordis parvæ*.)







*Internal Jugular vein*, (plate XXXV. G, G; plate XXXVII. B, B: vena jugularis interna.)—The blood from the brain and cranial cavity is received by the internal jugular veins, which are continuous at their upper extremities with the lateral sinuses; whilst inferiorly, they terminate in the brachio-cephalic veins. The junction of the vein with the sinus is at the broad part of the foramen lacerum, (*fossa jugularis*), beneath which it is supported by the rectus lateralis muscle, and lies close at the outer side of the internal carotid artery, so far as the cornu of the os hyoides. Now, as the part of the vessel which extends from the skull to this point corresponds with the internal carotid artery, and receives its residual blood, it may with much propriety (and also with advantage, as tending to render the nomenclature uniform) be called *vena carotis interna*. Some confusion would arise from calling it “cephalica,” as the external superficial vein of the arm has, without any proper reason, received that name. Again, the short vessel which extends downwards from the junction of the facial and temporal veins and joins the preceding, may, for the like reason, be called *vena carotis externa*; and finally, the trunk which results from the conflux of these vessels, and which extends thence down to the inner end of the clavicle, should be called *vena carotis communis*. At present, the entire length of the vessel included between the point just named and the base of the skull, is known as the internal “jugular” vein, as if it belonged to the throat, and had no correspondence in its divisions and distribution with the artery which it accompanies. However, we must defer to usage, and continue for the present so to name it.

The internal jugular vein having passed down to a level with the os hyoides, receives the common trunk formed by the facial and temporal veins, and then becomes considerably enlarged. It descends parallel with the common carotid artery, lying at its outside enclosed in the same sheath, together with the vagus nerve, and at the root of the neck joins nearly at a right angle with the subclavian vein, and so forms the innominate, or brachio-cephalic. Previously to its junction with the facial vein, the internal jugular receives branches from the tongue, pharynx, and occiput:—*Vena lingualis* (plate XXXV. g\*) commences at the side and upper surface of the tongue, passes backwards, receiving branches from the sublingual gland; occasionally the ranine vein joins it, sometimes also the pharyngeal. In either case it passes backwards between the mylo-hyoideus and hyo-glossus muscles, to open into the jugular vein. *Vena pharyngea* (f\*) commences at the back and sides of the pharynx, and terminates in the lingual, or separately in the jugular vein. *Vena occipitalis* (h,\* h\*) corresponds in its course, and in the distribution of its branches, with the artery of the same name. It communicates with a plexus of veins on the outside of the occiput, and terminates occasionally in the external jugular vein, but more frequently in the internal.

*Vena laryngea* (i\*) is a small vessel whose branches come out of the larynx through the thyro-hyoid membrane; they unite and form one vein, which opens into the internal jugular, (its anterior or facial division:) sometimes it terminates in the superior thyroid vein.

*Vena thyroidea superior* (k\*) arises by ramusculi, which ramify in the thyroid gland, in company with the branches of the superior thyroid artery. These unite and form a single vessel, which runs transversely outwards, and open into the jugular vein, (its common trunk.) Lower down we find another branch coming from the same source, (*vena thyroidea media*; l\*.)

## VEINS OF THE UPPER EXTREMITIES.

The veins of the upper extremity are divisible into two sets, one being superficial, the other deep-seated. The superficial veins are much larger, and lie between the skin and fascia. They commence on the dorsal surface of the fingers, and as they converge and communicate with one another on the back of the hand, they form a sort of venous plexus, from which issue two chief veins, that take, one the radial, the other the ulnar border of the fore-arm.

*The Radial Cutaneous vein* (plate XXXVI. A, A; vena radialis cutanea, v. cephalica) commences by ramusculi placed on the dorsal surface of the thumb and fore-finger. These ascend upon the outer border of the wrist, and form by their union a pretty large vessel, which passes along the radial border of the fore-arm, receiving numerous branches from its anterior and posterior surfaces. At the bend of the arm it receives a division of the median vein, and then continues its course at the outer side of the upper arm, and is named the *cephalic vein*. The cephalic vein (*v. cephalica*, fig. 1, B, B) thus formed ascends along the external border of the biceps muscle, and then in the interval between the pectoralis major and deltoid, and finally terminates in the axillary vein, between the coracoid process and the clavicle.

There are two ulnar cutaneous veins, (plate XXXVI. fig. 1, C, D, fig. 2, B; *vena ulnaris cutanea, anterior et posterior*.) one on the anterior, the other on the posterior surface of the fore-arm. The posterior one begins on the back of the hand by some ramusculi, which unite to form a vein placed over the fourth metacarpal space, and called by some of the older anatomists “salvatella,” (fig. 2, c, c.) This proceeds along the ulnar border of the fore-arm, at its posterior aspect, and somewhat below the bend of the elbow, turns forwards to join with the anterior ulnar cutaneous vein. The vein last named commences upon the anterior surface of the wrist, and thence ascends along the fore-arm, communicating by branches with the median vein on the one hand, and the posterior ulnar cutaneous on the other. At the bend of the elbow it unites with the posterior ulnar cutaneous vein, and assumes the name of “basilic vein.”

*The Basilic vein* (plate XXXVI. fig. 1, E, E; v. basilica) is usually of considerable size; it receives at its origin a division



of the median vein, (median basilic,) and ascending along the inner border of the biceps muscle, in front of the brachial artery, terminates in one of the *venæ comites* of that vessel, or in the axillary vein. The position and relations of the veins here described are sufficiently expressed by calling them radial and ulnar cutaneous whilst in the fore-arm, and internal and external brachial in the upper arm. The terms "basilic" and "cephalic" serve no useful purpose.

*The Median vein*, (plate XXXVI. fig. 1, F; v. mediana.)—The median vein results from the union, on the anterior part of the fore-arm, of several branches. It is a short trunk, which serves as a means of communication between the ulnar and radial veins on each side, as well as between the superficial and deep veins of the arm. Its length is subject to many varieties; it terminates by dividing into two branches, which diverge at an angle; one inclining inwards to join the basilic vein, and thence named *median-basilic*, (G,) passes in front of the brachial artery, from which it is separated by the fibrous offset given by the tendon of the biceps muscle to the fascia covering the flexor muscles; it is crossed by twigs of the internal cutaneous nerve: the other division (*median-cephalic*, H) directed outwards, unites with the cephalic vein; this is crossed by branches of the external cutaneous nerve. The termination of the median vein is also connected with the deep veins by a short branch, (g,) which sinks between the muscles, to the veins accompanying the brachial artery. The nomenclature may be simplified by considering these three as communicating branches, and so naming them internal, external, and middle.

*Of the deep-seated veins*.—The brachial artery, its branches, and their several divisions, are each accompanied by two veins, hence named *venæ comites*.

*The deep Ulnar veins* (plate XXXVI. fig. 1, k, k; *venæ comites arteriæ ulnaris*.)—On the palmar surface of the hand the incipient *ramusculi* disposed along the borders of the digital phalanges become united at the cleft between the fingers into one small vessel, which, with one similarly formed from the contiguous border of the next finger, run along the inter-osseous spaces, and terminate in the superficial palmar arch of veins, from which two branches proceed at each side of the wrist, the external following the course of the *superficialis volæ* artery, whilst those on the inner side accompany the ulnar artery. The deep ulnar veins, commencing thus at the inner side of the superficial palmar arch, pass in front of the wrist, where they communicate with the inter-osseous and the superficial veins; then proceeding upwards along the inner side of the fore-arm, in apposition with the ulnar artery, they receive several branches from the neighbouring muscles; and lastly, being joined by the vessels which accompany the inter-osseous and ulnar recurrent arteries, unite with the deep radial veins to form the *venæ comites* of the brachial artery.

*The Inter-osseous veins* (v. com. art. inter-oss.) consist of two sets, (anterior and posterior,) corresponding to the arteries with which they are associated. The anterior take their rise in front of the wrist-joint, where they communicate freely with the deep radial and ulnar veins. In their course upwards they are joined by several small branches, and are connected at the lower part of the fore-arm with veins situated posteriorly, by means of branches which pass through the inter-osseous membrane near the elbow-joint; after being joined by the posterior inter-osseous veins, they open into the *venæ comites* of the ulnar artery. The veins which accompany the posterior inter-osseous artery, previously to passing from behind to join with the anterior, communicate by their incipient radicles with the ulnar cutaneous veins, and through branches accompanying the recurrent inter-osseous artery, with the cephalic vein.

The small radicles which give rise to the deep radial veins (*venæ comites art. radialis*; plate XXXVI. fig. 1, l, l) run upon the inter-osseous muscles of the hand; they are united in front with the digital veins previously described, and at each end of the space separating the metacarpal bones, are connected by perforating branches with small vessels situated on the back of the hand; by uniting across the carpal end of the metacarpus, they form an arch corresponding with that formed by the radial artery. This deep venous arch communicates on its inner side with the superficial palmar arch, and from its radial side proceed what may be considered properly the *venæ comites* of the radial artery. These vessels, when passing upwards to the fore-arm, receive at the wrist a dorsal branch, and one which passes over the small muscles of the thumb, with the *superficialis volæ* artery; then pursuing the course of the radial artery, they are joined by small veins from the surrounding parts, and end in the *venæ comites* of the upper arm.

The accompanying veins of the brachial artery (*venæ comites arteriæ brachialis*; plate XXXVI. fig. 1, m, m) resulting from the union of the deep ulnar and radial veins just described, follow, like the several vessels of the same class, the course of the artery with which they are associated. They are joined in their progress, from the bend of the elbow upwards on the arm, by the veins which are distributed with the branches of the brachial artery, namely, the anastomotic and the two deep or collateral arteries of the arm. At the lower margin of the axillary muscles, the brachial veins unite to form the axillary; not unfrequently, however, one of them will be found to come forward and unite with the basilic, which soon becomes continuous with the axillary vein.

Between the several veins of the upper extremity hitherto described, numerous connexions exist in their whole course. Thus, those placed immediately under the integument are connected by branches arching in different directions from one to the other over the hand and fore-arm; each pair of *venæ comites* are united by short transverse vessels crossing the artery which they accompany, whilst between those attending the different arteries frequent communications exist; moreover, as has been in many instances specially indicated, the different series of vessels, namely, those situated superficially and more deeply, com-





Fig 1




Fig 2



municate freely, especially in the neighbourhood of joints. This disposition prevents the occurrence of any impediment to the course of the circulation, by reason of muscular action, or the frequent and varied motions of the joints.

*The Axillary vein* (plate XXXVI. fig. 1, I; plate XXXVII. D, D: v. axillaris) arches, like the corresponding artery, from the margin of the axillary muscles to the lower border of the first rib; it is covered by the pectoral muscles and the costo-coracoid membrane, and is placed anterior to the axillary artery. The branches which open into the axillary vein are very numerous. It results, as above stated, from the union of the venæ comites of the brachial artery; it receives the veins of the arm, (the basilic at its commencement, the cephalic towards its termination;) it is also joined by the several veins corresponding with the branches of the axillary artery, viz. the two circumflex (l, m) and the subscapular (l) from the shoulder, the alar (n) from the axilla, and the inferior, (o,) the superior, (p,) and acromial (q) thoracic veins from the side of the chest. The axillary vein, therefore, returns all the blood from the superior extremity; its size is very considerable.

*The Subclavian veins* (plate XXXVII. E, F; v. subclaviæ, dextra et sinistra) are the continuation of the axillary. Each extends from the lower margin of the first rib to the inner end of the clavicle, behind which it is joined by the internal jugular vein, the union forming the vena innominata, or brachio-cephalica. The subclavian vein arches over the first rib; it is covered by the clavicle, the subclavius, and the sterno-mastoid muscles, and lies on a plane anterior to the corresponding artery, from which, while resting on the rib, it is separated by the scalenus anticus muscle and the phrenic nerve. On the outer side of the last-named muscle it receives the external jugular vein, and on its inner side becomes united with the internal jugular: in their course to join it, both these veins pass in front of the subclavian artery, and add to the difficulty of placing a ligature on that vessel. The subclavian vein also receives the following as so many branches:—

*The Vertebral vein* (plate XXXVII. r, r; v. vertebralis) takes its rise from several ramusculi proceeding from the pericranium and the deep muscles lying behind the foramen magnum of the occipital bone; having passed from thence outwards and downwards to reach the foramen in the transverse process of the atlas, it comes into relation with the vertebral artery, with which it descends through the canal formed by the corresponding foramina of the other cervical vertebræ as far as the sixth. Here it emerges and joins the subclavian vein; a small branch or division sometimes passes through the foramen in the seventh vertebra, and opens separately into the same vein. It is joined in its course by several branches proceeding from the neighbouring muscles, also immediately before its termination by a vein corresponding to the ramus profundus of the subclavian artery, and in the same situation by another of considerable size, which runs longitudinally on the vertebræ. It communicates frequently with the vein last indicated, and through it with the lateral sinus, by means of an emissary vein passing through the foramen in the mastoid portion of the temporal bone; a connexion is established between the vertebral vein and the occipital sinus through the condyloid foramen, and through the intervertebral foramina it maintains free communication with the following:—

*The superior Intercostal vein*, (plate XXXVII. x, plate XLII.; vena intercostalis superior.)—It sometimes happens that at the right side the veins corresponding with the superior intercostal artery pass downwards separately, to open into the vena azygos, as that vessel arches forwards to join the superior vena cava. When they unite to form a single vein, its size is much inferior to that on the left side. The left superior intercostal vein varies in length in different individuals, being small when the vena azygos minor is large, and *vice versâ*; usually the fifth intercostal branch turns upwards, and joins with or receives the

## PLATE XXXVIII.

The spinal veins are here shown.

FIG. 1. The dorsi-spinal veins, (v. dorsi-spinales.) This view is obtained by removing all the muscles of the back, together with the soft parts of the head and neck, the ribs and iliac bones.

No. 1, 1. The tubercle of the occipital bone. 2, 2. The mastoid processes. 3, 3. The mastoid foramen at each side, through which passes a vein to communicate with the lateral sinus. 4. The spinous tubercle of the atlas. 5, 5. Its transverse processes. 6. The spinous process of the axis. 7, 7. The bifid spinous processes of the cervical vertebræ. 8. The spinous process of the last cervical vertebra. 9, 9. The first dorsal vertebra. 10, 10. The last dorsal. 11, 11. The first lumbar vertebra. 12, 12. The sacrum. 13, 13. The posterior sacral foramina. 14, 14. The articulating surfaces of the sacrum. 15. The coccyx.

a, a. Venous branches ramifying upon the inferior surface of the occiput; communicating below with the cervical dorsi-spinal veins. b, b. The mastoid vein at each side. c, c. Lateral branches of the cervical dorsi-spinal veins, communicating with the vertebral veins. d, d. The small vein which passes through the foramen in the transverse process of the last cervical vertebra. e, e. Venous branches from the surrounding muscles, which supply the dorsi-spinal veins.

FIG. 2. The spinal veins beneath the vertebral arches, which receive the blood from the dorsi-spinal. To obtain this view, the posterior part of the occipital bone, and the arches of all the vertebræ, and sacrum, are removed.

Nos. 1, 1. The dura mater, covering the lobes of the cerebellum. 2, 2. The dura mater of the spinal cord.

a, a. Veins ramifying upon the exterior of the dura mater. b, b. Veins in the cervical region, so numerous as almost to conceal the dura mater. c, c. Veins passing out from the spinal canal through the intervertebral foramina, and pouring their blood into the vertebral and deep cervical veins. d, d. Communicating veins opening into the superior intercostal vein. e, e. Communicating veins to the vena azygos minor. f, f. Communicating veins to the vena azygos major. g, g. Communicating branches to the lumbar veins.

fourth, third, second, and first, as it passes by the heads of the ribs. At the second vertebra it inclines forwards, and opens into the left brachio-cephalic vein. It receives in its course the left bronchial vein. The sixth intercostal vein generally crosses the spine, and opens separately into the azygos major; it communicates by a small branch with the azygos minor, and also with the left superior intercostal vein.

*The Brachio-cephalic vein, (vena innominata.)*—The blood returned from the superior extremities through the subclavian veins, and from the head and neck by the jugular veins, is poured into two trunks, which may therefore be named brachio-cephalic. These vessels, (*venæ innominatæ, v. brachio-cephalicæ*; plate XXXVII. G, H,) resulting from the union of the subclavian with the internal jugular vein at each side, extend from the inner extremities of both clavicles to beneath the cartilage of the first rib on the right side, where, by uniting, they form the superior vena cava. In consequence of the situation of the point at which they meet, the brachio-cephalic veins differ considerably in direction, length, and relations; that of the right side is very short and nearly vertical in its direction. The vein of the left side, about three times longer than the preceding, is directed transversely to the right, at the same time inclining downwards: it crosses behind the first bone of the sternum, separated from it by the sterno-hyoid and sterno-thyroid muscles, and by the thymus, when it exists, or some cellular tissue; it lies in front of the three primary branches given off from the transverse portion of the arch of the aorta.

*The inferior Thyroid veins* (plate XXXVII. s, t; *venæ thyroideæ inferiores*) emerge from a sort of venous plexus on the thyroid body—those of opposite sides communicate by small branches across the trachea. The vein of the left side descends in front of the trachea, behind the sterno-thyroid muscles, and ends in the left brachio-cephalic or innominata vein; that of the right side inclines outwards in some degree, and opens into the corresponding brachio-cephalic vein, or into the angle of union between it and the vessel of the opposite side.

*The internal Mammary veins* (plate XXXVII. u, w; *venæ mammariæ internæ*) follow exactly the course of the arteries of the same name. They arise by small branches, derived from the fore part of the walls of the abdomen, where they anastomose with the epigastric veins; from thence proceeding upwards behind the cartilages of the ribs between them and the pleura, they receive the veins which correspond with the anterior intercostal branches of the internal mammary artery, (*v. intercostales anteriores*), together with some small diaphragmatic, thymic, and mediastinal ramusculi, and finally terminate—that of the left side in the left brachio-cephalic vein, that of the right side usually in the vena cava.

*The superior Vena Cava* (plate XXXVII. I; *vena cava superior*) conveys to the heart the blood which is returned from the head, the neck, the upper extremities, and the thorax. It extends in nearly a vertical direction from opposite the cartilage of the first rib on the right side of the sternum to the base of the heart, where it opens into the right auricle; at about an inch and a half above its termination, it is invested by the fibrous layer of the pericardium, the serous membrane being reflected over it. The superior cava lies immediately in front of the right pulmonary vessels, and between the right lung and the aorta, which partly overlap it. It receives several small veins from the pericardium and the mediastinum, and lastly is joined from behind by the vena azygos.

*The Azygos vein, (plate XLII. G; vena azygos, v. sine pari.)*—The name given to this vein signifies that it has no fellow or corresponding vessel, (*a priv. ζευγυμεναι*;) but it cannot be applied with propriety, inasmuch as there is a similar vessel on the opposite side, though of smaller size, (azygos minor.) The incipient radicles of the vena azygos issue either from the inferior cava, where that vessel turns forward to reach the opening in the diaphragm, or much more frequently from one of the lumbar veins of the right side, sometimes from the renal vein. The vein passes from the abdomen into the thorax, through the aortic opening in the diaphragm, or more externally through the fibres of that muscle, and ascends on the bodies of the dorsal vertebræ, until it arrives opposite the root of the right lung: here it arches forward above the bronchus, and opens into the superior vena cava, immediately above the point at which that vessel is invested by the pericardium. When passing through the diaphragm, this vein is in company with the thoracic duct, and both are situated on the right side of the aorta: in the thorax, maintaining the

## PLATE XXXIX.

The veins enclosed within the vertebral canal.

FIG. 1. The medullary-spinal veins, (*v. medullary-spinales*.) These veins are displayed by removing the dura mater.

Nos. 1, 1. The lobes of the cerebellum. 2. The superior vermiform process. 3, 3. The spinal cord. 4, 4. The cauda equina.

FIG. 2. The great spinal veins, (*veines meningo-rachidiennes*, Chaussier, Breschet.) To obtain a view of these veins, the arches of the vertebræ are cut deeper than in the former sections, and the spinal cord removed; they are then seen resting upon the posterior surface of the bodies of the vertebræ.

Nos. 1, 1. The line of invertebral substance apparent between some of the bodies of the vertebræ.

a, a. The two great lateral venous trunks. b, b. The points at which the spinal veins receive the blood from the bodies of the vertebræ.

FIG. 3. A lateral section of a lumbar vertebra, to show the proper vertebral vein, (*v. basis vertebræ*.)

a. The venous trunk escaping through the foramen in the middle of the body of the vertebra. b. Some small venous branches observed in the cancellous structure of the spinous process.

FIG. 4. A transverse section of a lumbar vertebra, showing the ramifications of the same vein.



Fig 2.

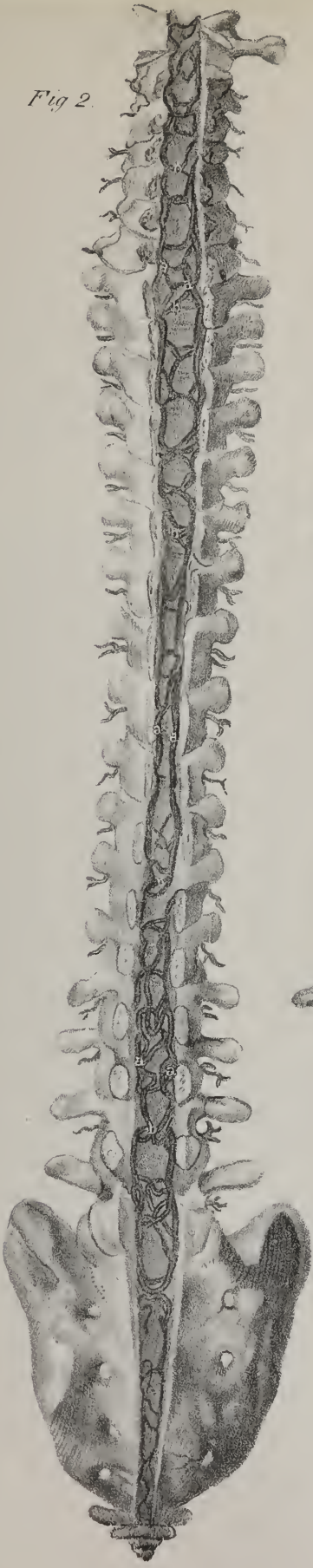

Fig. 1.

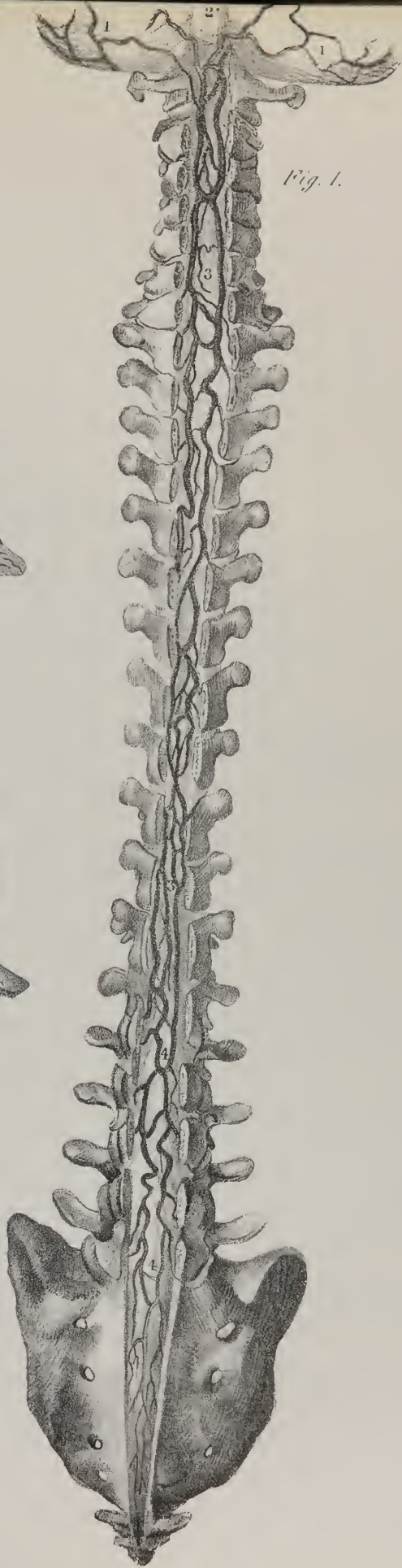

Fig. 3.

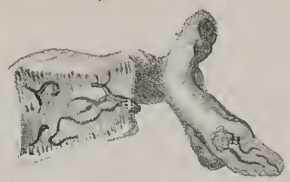
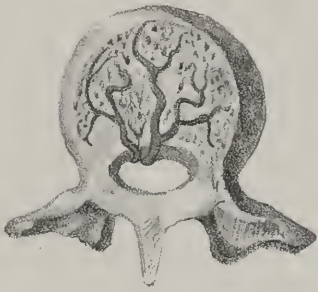
Fig. 4.







same position with respect to the duct and œsophagus, it crosses in front of the intercostal arteries, and is covered by the pleura. It receives the several veins which accompany the aortic intercostal arteries of the right side, (*v. intercostales posteriores*;) and, at about the seventh dorsal vertebra, the *v. azygos minor*: it is also joined by several œsophageal and other small veins, and near its termination by the bronchial vein of the right lung. It is connected with the commencement of the left superior intercostal vein; and as it communicates with the inferior vena cava, while it terminates in the superior, it forms a connexion between both these vessels. Meckel in one instance found the azygos terminating in the subclavian vein.

*The lesser Vena Azygos* (plate XLII. H; *vena azygos minor*) commences from one of the lumbar veins, or from the left renal vein, and having entered the thorax with the aorta, or through the crus of the diaphragm, runs on the spine, and opens into the preceding vein, opposite the sixth or seventh dorsal vertebra. It receives the lower intercostal veins of the left side.

*The Bronchial veins* (plate XLII. d; *venæ bronchiales*) return the residue of the blood employed in the nutrition of the lungs. They commence in the minute texture of these organs by radicles corresponding with those of the bronchial arteries. Their course is determined by that of the bronchi, which in a manner support them, as they pass towards the back part of the lungs. That of the right side opens into the *vena azygos major* near its termination, that of the opposite side ends in the superior intercostal vein.

## VEINS OF THE SPINE AND CRANIUM.

The part of the venous system contained within the skull and spinal canal, presents certain peculiarities deserving especial notice. In the skull we find a series of sinuses, representing at once reservoirs and canals, interposed between the small veins which directly receive the blood from the arteries, and the large trunks (jugular veins) which transmit it towards the heart. The sinuses in the skull are formed within the layers of the *dura mater*, their cavities being lined by a continuation of the inner coat or membrane of the veins: they are very numerous, and vary considerably in form and size. In the spinal canal a chain of venous tubes runs along its whole length, which present some analogy to the cranial sinuses, but still differ in such a way that we may consider them as a transition-link between the veins diffused throughout the body and the sinuses.

The veins within and upon the spinal column may be arranged under the following heads:—viz. 1. Those placed deeply in the vertebral grooves, having close relation to the spines and arches of the vertebræ; 2. The veins of the spinal cord itself; 3. Two long veins, or rather chains of veins, extending the whole length of the canal; 4. Veins lodged within the bodies of the vertebræ; 5. Branches of communication which connect all these together; and, finally, another set, by which they are brought into connexion with the general venous system.

*Preparation and Dissection.*—The long spinal veins were first described by Chaussier; the veins of the cranial and spinal bones, as well as of the osseous system generally, were subsequently examined with great care by Dupuytren, and demonstrated in his lectures on anatomy. Breschet subsequently took up the subject,\* and still continues his researches upon it.† In order to inject these vessels, an old and emaciated subject should be chosen, as the venous system becomes more developed in advanced age; it should be placed in a warm-bath in the usual way, and thoroughly warmed previous to injection. As the vessels cannot be filled from any single vessel, advantage must be taken of their numerous connexions to inject them from different points. With this view, an injecting pipe must be inserted into the superior longitudinal sinus, another into the *vena azygos major*, also into the superior and inferior cava. Through all these vessels the injecting fluid should be conveyed, and through at least two or three of them, if possible, at the same time. The posterior and external veins (if the injection has succeeded) are to be traced through the mass of dorsal muscles; those within the spine are best seen by making a vertical section of it and of the skull, dividing it into two lateral halves; or the arches may be cut out, and the cavity exposed.

*The Dorsi-spinal veins* (plate XXXVIII. fig. 1; *venæ dorsi-spinales*; Dupuytren, Breschet.)—The blood is received and returned from the muscles and tegument placed along the back part of the spine, by a series of short veins, which run horizontally forwards and terminate in some of the larger veins within the spine; hence they are named as above. Commencing by small ramusculi, they gradually increase as they run forwards, close by the spinous processes; and on reaching the interval between the arches of the vertebræ, they pierce the *ligamenta subflava*, to terminate in a venous plexus within the canal. Towards the external part of the intervertebral grooves another set of veins arise, which pass obliquely inwards, through the inter-transverse spaces, in company with the posterior branches of the lumbar and intercostal arteries, and open into the veins which accompany these vessels.

*The Medulli-spinal veins* (plate XXXIX. fig. 1; *v. medulli-spinales*; Breschet.)—These appertain solely to the spinal cord and its nerves, upon which they are placed, enclosed within the tube of the *dura mater*. Though they communicate by branches with the other spinal veins, they are not injected concurrently with them, even when the injecting process above described is most successful. Breschet gives the following as the best method of demonstrating them:—

*Preparation.*—Let the injection consist of a strong solution of isinglass, coloured with indigo or Prussian blue, open the spinal canal in the lumbar region, slit up the *dura mater*, and search for one of the largest of the veins which rest upon the cord;

\* Essai sur les Veines du Rachis. 4to.

† Traité Anatomique sur le Système Veineux. Fol. avec planches.

into this pass the point of a very small syringe—a silver injecting pipe would answer better; then cautiously introduce the injection, for the coats of the veins are exceedingly thin and weak.

The medullary-spinal veins are very small, long, and tortuous; they run upon both surfaces of the cord, where they form a diffused plexus or net-work, by mutually giving and receiving branches. The general direction of these vessels is from below upwards, but still they do not increase as they approach the base of the skull, on the contrary their size is smaller than in the lumbar region. This arises from the fact, that the blood brought into these superficial vessels, by the small veins which open into them from the substance of the cord, is sent outwards directly by the branches which accompany the nerves towards the intervertebral foramina, where they pour it into the great spinal veins. Near the base of the skull the medulla spinalis unites, and form two or three small trunks, which maintain, by transverse branches, communications with the vertebral veins, after which they terminate in the inferior cerebellar veins, or in the petrosal sinuses.

*The proper Vertebral veins*, (plate XXXIX. figs. 3 and 4; v. basis vertebræ.)—The large apertures observable in the bodies of the vertebræ lodge veins of corresponding size: any arterial branches which may enter by them are very small. In the posterior flat surface of these bones, and equidistant from their upper and under margins, we find a large foramen leading into a canal, which, running forwards for two or three lines, divides into two similar tubes of smaller size. Each of the latter turns inwards and unites with its fellow, forming an arch, from the convexity of which small branches pass obliquely forwards. Some of these terminate in the cancelli of the bone, others are prolonged to its convex surface, where they anastomose with some of the superficial veins. Whilst the final ramifications of these venous canals terminate, as has been just stated, or rather (taking it in the course of the current) commence, the trunk of each when it reaches the spinal canal divides into two branches, which diverge and terminate in the large spinal veins.

The blood collected by the different vessels here described is poured by them into two large veins, or rather tortuous venous canals, which extend the whole length of the spine lodged in its interior. These vessels may be named the great spinal veins; Chaussier and Breschet call them *veines meningo-rachidiennes*; but they are not enclosed within, or formed by, the dura mater,

## PLATE XL.

This plate exhibits the cerebral sinuses and veins.

FIG. 1. A vertical section of the head, displaying the cavity of the cranium lined by the dura mater, with the processes formed by the latter membrane; also the septum nasi.

Nos. 1, 1. Section of the frontal bone. 2, 2. Section of the parietal bone. 3. Cut surface of the occipital bone. 4. Foramen magnum. 5. Basilar process of the occipital bone. 6. The sphenoid cells. 7. The posterior clinoid process. 8. The processus olivaris of the sphenoid bone. 9. The cribriform lamella. 10. The crista galli. 11. The frontal sinuses. 12, 12. The falx major. 13. The tentorium cerebelli. 14. The petrous portion of the temporal bone, with the internal auditory foramen. 15. The lesser wing of the sphenoid. 16, 16. The interior of the cranium lined by the dura mater, through which are seen the branches of the arteria meningea media. 17, 17. The septum nasi. 18. Section of the palate processes of the superior maxillary and palate bones. 19. The right posterior naris. 20. The internal pterygoid plate of the sphenoid bone.

A, A. The superior longitudinal sinus, (sinus longitudinalis.) B. The conflux of the sinuses, (torcular Herophilii.) C, C. The right lateral sinus (s. lateralis) winding to its termination at the foramen lacerum posterius.

a, a. Cerebral veins, opening into the superior longitudinal sinus at an acute angle, and opposite to the current of the blood in that vessel. b, b. Small veins which return the blood from the falx cerebri. c, c. The inferior longitudinal sinus, (s. longitudinalis inferior.) d, d. The venæ Galeni returning the blood from the lateral ventricles. e. The straight, or fourth sinus, (s. rectus.) f. The superior petrosal sinus, (s. petrosus superior.) g. The inferior petrosal sinus, (s. petrosus inferior.) h. The occipital sinus, (s. occipitalis posterior.) i. A nasal vein which opens into the superior longitudinal sinus. k, k. A plexus of veins ramifying in the mucous membrane covering the septum. l. The sphenopalatine vein. m. The naso-palatine vein, maintaining a communication between the veins of the nose and palate. n, n. Palatine veins.

FIG. 2. A vertical view of the superior longitudinal sinus, with the cerebral veins opening into it from behind forwards. This view is obtained by removing the calvarium and the dura mater, leaving only a small portion of the latter membrane attached on each side of the sinus.

Nos. 1, 1. The cut surface of the circumference of the skull. 2, 2. The hemispheres of the brain. 3, 3. The cut edges of the dura mater on each side of the superior longitudinal sinus.

A, A. The superior longitudinal sinus.

a, a. Cerebral veins, lying in the depressions between the convolutions of the hemispheres. b, b. The openings of small veins from the diploe of the cranial bones.

FIG. 3. A diagram representing the formation of the superior and inferior longitudinal sinuses between the layers of the dura mater.

Nos. 1, 1. A section of the upper part of the frontal bone. 2, 2. The dura mater lining the bone. 3, 3. The inner layers of the dura mater divided so as to enclose the triangular space, (a.) 4. Vertical section of the falx cerebri.

a. The form of the triangular canal of the superior longitudinal sinus. b. Circular canal in the lower border of the falx, the inferior longitudinal sinus.

FIG. 4. A small portion of the superior longitudinal sinus removed from the skull, and laid open to show—

a, a. The obliquity of the apertures by which, b, b, the cerebral veins open into the canal, and, c, c, chordæ Willisii, which stretch transversely across the sinus. The arrow denotes the course of the current of the blood in the sinus, in opposition to the current poured in by the veins.



Fig. 1.

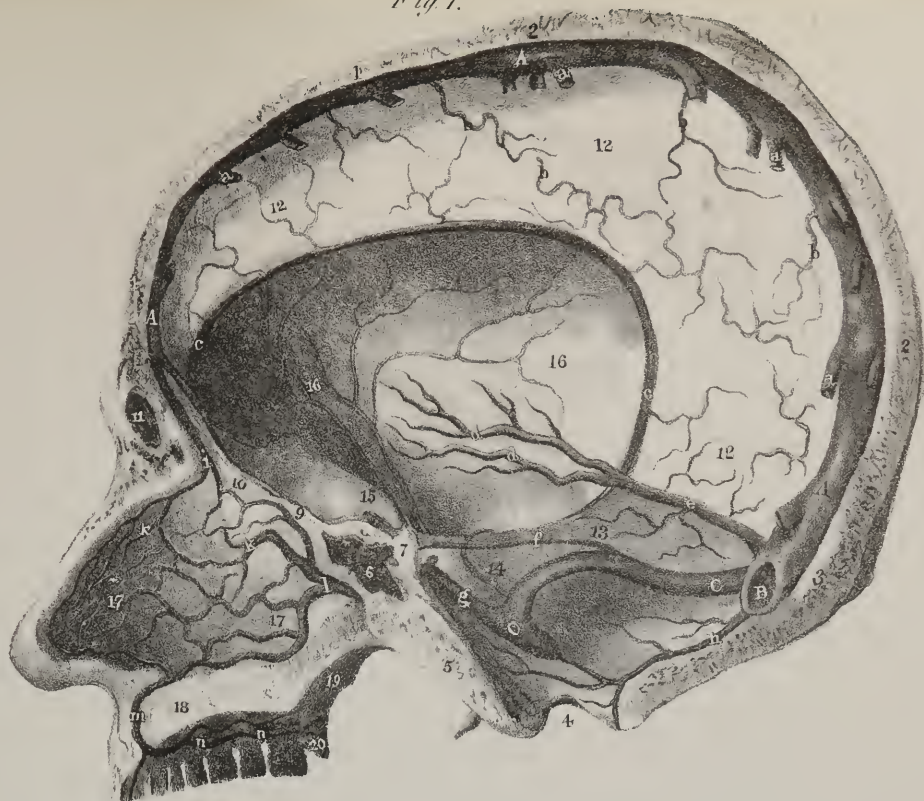


Fig. 2.

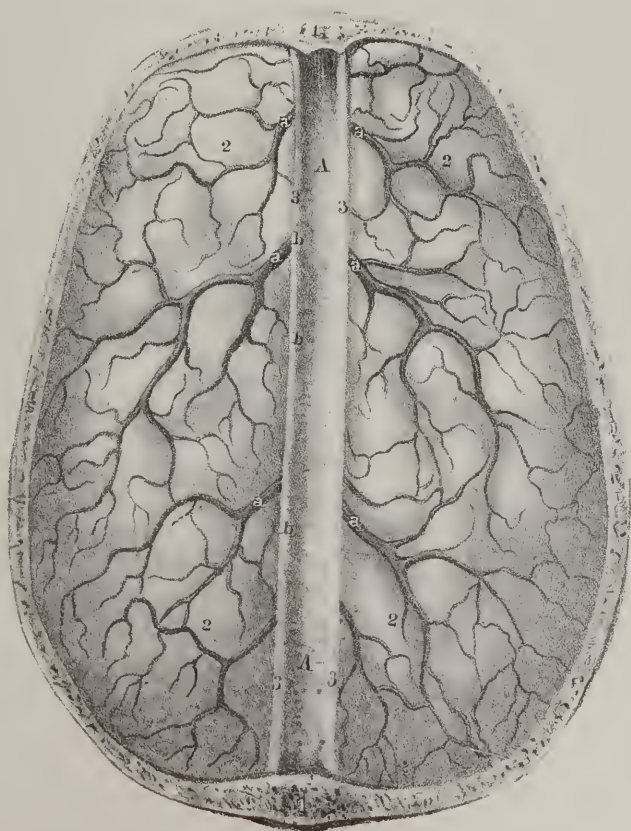

Fig. 3.



Fig. 4.











(μηνύξ,) therefore the name is not well chosen. They do not present the appearance of continuous tubes; for, from space to space, they are alternately constricted and enlarged, so as to resemble a series of links, the constricted points corresponding with the intervertebral foramina, where they are drawn forwards, and in a manner secured by the branches of communication which pass outwards. They lie behind the bodies of the vertebræ, occupying the interval at each side between the intervertebral foramina and those in the centre of the bodies of these bones. In some parts the links of the chain which they form are double, or even triple, and occasionally detached from any connexion with the link above or that below, which shows that each portion is, as it were, a separate trunk by itself, receiving the blood on the one hand, and propelling it into the general circulation on the other, and that the current therefore does not ascend or descend along the column which the series of veins forms. Each of these venous trunks is as long as the interval between two intervertebral foramina. In the thoracic region their communicating branches open into the intercostal veins, in the loins into the lumbar veins, in the neck for the most part into the vertebral.

A complex interlacement of tortuous veins (plate XXXVIII. fig. 2) is established along the inner surface of the arches of the vertebræ. In the lower part of the canal the interlacement is not so close as in the upper portion, where it usually conceals (if the injection has run minutely) the whole surface of the dura mater. These veins also converge to the intervertebral foramina, and open by rather narrow channels into the intercostal veins. From a consideration of the connexion and arrangement of the different parts of this complex apparatus, it would appear that the blood at each stage flows through them from behind forwards horizontally. The dorsi-spinal veins pour their blood into the plexus inside the arches of the vertebræ, from which it is collected by two or three small branches that converge to the intervertebral foramina, and open into some of the prævertebral veins, (lumbar, azygos, or cervical.) Into these also the contents of the great spinal veins are conveyed by the short communicating branches already noticed.

This adjustment of the venous tubes necessarily determines the course of the current; but it will naturally be asked, what is the agency which propels it, seeing how many obstacles tend to retard its flow? The "vis à tergo" could not be sufficient of itself where everything seems to favour stagnation. The chief, if not the sole propelling power, seems to be the physico-mechanical influence exerted by the expansion of the thorax; by means of which the pressure on the venous trunk within the chest is diminished, whilst that on all other parts remains undiminished, and so the current is made to flow towards that point where it meets the least resistance.

*Cerebral veins*, (plate XL. fig. 2, a, a.)—The part of the venous system contained within the skull consists of veins, properly so called, and sinuses, which resemble so many recipients or reservoirs. The veins which return the blood from the cerebral mass are divisible into two sets, one being superficial, the other deeply seated. The superficial veins of the brain branch out upon every part of its surface, their ultimate radicles dipping into its substance, whilst their large extremities terminate in the different sinuses. Upon the upper surface of the hemispheres the veins will be seen lodged in the sulci, between the convolutions, which

## PLATE XLI.

In this plate the sinuses of the base of the cranium and the veins of the diploë are shown.

FIG. 1. The upper hemisphere of the skull is removed, and the dura mater opened along the course of the venous sinuses, for the purpose of displaying their channels more distinctly. The veins of the orbit are brought into view on the right side by removing part of the orbital plate of the frontal bone, with a portion of the lesser wing of the sphenoid.

Nos. 1, 1. The cut surface of the circumference of the cranium. 2, 2. The cut edge of the dura mater. 3. The orbital plate of the frontal bone on the left side, covered by dura mater. 4. The crista galli process of the ethmoid bone, from which the anterior extremity of the falx cerebri is removed. 5, 5. The cribriform foramina for the transmission of the filaments of the olfactory nerves. 6, 6. The cut edge of the roof of the orbit. 7, 7. The lesser wing of the sphenoid. 8. The anterior clinoid process on the left side. 9. The optic foramen of the left side. 10. The olivary process of the sphenoid bone. 11. The sella Turcica. 12, 12. The posterior clinoid processes. 13, 13. Branches of the middle meningeal artery seen through the dura mater. 14, 14. Petrous portion of the temporal bone at each side. 15, 15. The internal auditory foramina. 16. The basilar process of the occipital bone. 17, 17. The inferior occipital fossæ, which lodge the lobes of the cerebellum. 18. The upper eyelid. 19. The globe of the eye. 20. The reflected tendon of the superior oblique muscle. 21. The lachrymal gland. 22. The optic nerve.

a. The commencement of the superior longitudinal sinus. b. The termination of the superior longitudinal sinus in the torcular Herophilii. c, c. The lateral sinuses, (s. laterales.) d, d. The termination of the lateral sinuses at the jugular fossæ. e. The ophthalmic vein, (v. ophthalmica,) formed by the convergence of the orbital veins. f, f. The supra-orbital vein. g, g. Superior palpebral veins. h. The supra-trochlear vein. i, i. The lachrymal vein. k, k. The nasal vein. l, l. Ciliary veins. m, m. The cavernous sinus (s. cavernosus) at each side. n. The anterior semicircle of the circular sinus, (s. circularis.) o. Part of the posterior segment of the sinus; the rest is concealed by the posterior clinoid processes. p, p. The inferior petrosal sinuses, (s. petrosi inferiores.) q. The basilar sinus, (s. occipitalis anterior;—basilaris.) r, r. The superior petrosal sinuses, (s. petrosi superiores.) s. The occipital sinus, (s. occipitalis posterior.)

FIG. 2. represents the veins of the diploë. This view is obtained by removing the outer table of the skull; the venous canals are then exposed. They are extremely irregular in their distribution and dissimilar in different skulls.

a. A venous canal that terminated at the parietal foramen in the veins of the integument. b. Another canal which communicated with the mastoid foramen. This foramen was placed farther back than ordinary, in the occipital bone.



give them a waving direction. They are not, however, confined to the sulci; for some of the branches will be observed to pass over the convexity of the convolutions. On reaching the margin of the great fissure between the hemispheres, (their general direction being for the most part transversely inwards,) they receive the branches which come up from the inner flat surface of the hemisphere, become invested by a tubular sheath of the arachnoid membrane, and turn forwards in such a way as to open obliquely into the superior longitudinal sinus.

The veins at the sides, and under the surface of the brain, are similarly placed; but their direction is outwards, to open into the lateral sinuses at each side.

The deep-seated or internal veins commence within the ventricles of the brain. Upon the surface of the corpus striatum several minute venous branches are seen, after having emerged from its interior. Most of these converge, and form a slender vein, (*vena corporis striati*;) which runs along the groove between the corpus striatum and optic thalamus, to open into one of the veins of the choroid plexus. The minute veins spread out in the choroid plexus pass backwards, and incline towards the middle line from each side, so as form, by their union, two veins, (*venæ Galeni*; plate XL. fig. 1, d, d.) These, lying parallel, run directly backwards, enclosed within the velum interpositum, and escape from the ventricle by passing through the great fissure between the under surface of the corpus callosum and the tubercula quadrigemina. In this way they reach the anterior margin of the tentorium cerebelli, at its angle of union with the falx, where they terminate by opening into the straight sinus.

The veins of the cerebellum (*venæ cerebelli*) are disposed in two sets, not merely from a reference to their position, but also from a consideration of their direction and termination. Those of the upper surface incline inwards and forwards for the most part, and so will be found to run upon the superior vermiform process, over which they ascend a little to reach the straight sinus, in which they terminate: some, farther forward, open into the *venæ Galeni*. Those at the under surface run transversely outwards, and pour their contents into the lateral sinus.

*Cerebral sinuses*, (plate XL. and plate XLI.)—The sinuses placed within the cranial cavity, and which are interposed between the veins above noticed and the internal jugular veins which receive the blood from them, are numerous; and, by reason of a difference in their position, admit of being divided into two sets, viz., those placed in the prominent folds of the dura mater, and those disposed at the base of the skull. The form and size of these reservoirs are various; but all are lined by a continuation of the inner membrane of the veins, the dura mater serving as a substitute for their fibrous coat, which extends no farther than the base of the skull.

The sinuses which are formed in the prominent processes of the dura mater converge to a common point, which corresponds with the internal occipital protuberance, and is called the *conflux of the sinuses*, or *torcular Herophili*, (plate XL. fig. 1, B; plate XLI. fig. 1, b :) its form is very irregular. If a square piece of bone be removed, and the dura mater laid open at the point above referred to, the apertures of the following sinuses will be observed opening into it:

*The superior Longitudinal sinus*, (plate XL. fig. 1, A, A; sinus longitudinalis; s. falciformis superior,) commencing at the crista galli, extends from before backwards, in the upper border of the falx, gradually increasing in size as it proceeds. Across its cavity, which is triangular, several bands (*chordæ Willisii*; fig. 4, c, c) extend obliquely. The veins from the cerebral surface open into this sinus in such a way that the apertures of the greater number of them are directed from behind forwards, (fig. 4, a, a,) contrary to the direction of the current within it; so that though regurgitation may take place into the sinus, it does not follow that it shall extend into the brain, as the blood in the sinus, by its pressure, will close the mouths of the veins, by reason of the peculiar arrangement just noticed.

*The inferior Longitudinal sinus* (plate XL. fig. 1, c, c; s. longitudinalis inferior, s. falciformis inferior) is very small, and circular in its form; its diameter is inconsiderable. Placed in the inferior concave border of the falx, it runs from before backwards, and opens into the straight sinus on reaching the anterior margin of the tentorium.

*The straight sinus* (plate XL. fig. 1, e; s. rectus, s. quartus, s. tentorii) may be considered as the continuation of the inferior longitudinal sinus; it runs backwards in the direction of the base of the falx cerebri, gradually widening as it approaches the conflux, where it terminates. Its form is triangular; some transverse bands cross its interior. Besides the inferior longitudinal sinus, the *venæ Galeni* and the superior veins of the cerebellum open into it.

*The Lateral sinuses* (plate XL. fig. 1, C; plate XLI. fig. 1, c, c; s. laterales, s. transversi) are of considerable capacity. Their direction conforms to that of the groove marked along the interior of the occipital bone, from opposite the internal occipital protuberance to the foramen lacerum posterius. The sinus of the right side is usually larger than that of the left; both commence at the conflux, and terminate at the outlet just noticed, where they are continuous with the jugular veins. In addition to the blood transmitted from both the longitudinal sinuses, from the straight and occipital sinuses, they also receive that of the veins which arise from the sides and base of the brain, and also from the under surface of the cerebellum.

*The posterior Occipital sinus* (plate XL. fig. 1, h; plate XLI. fig. 1, s: s. occipitalis posterior) is sometimes a single canal, not unfrequently double, as if composed of two compartments. It lies along the attached border of the falx cerebelli, extending from the posterior margin of the foramen magnum to the conflux.

The sinuses placed at the base of the skull are as follows, taking them in their order from before backwards:

*The Circular sinus*, (plate XLI. fig. 1, n, o; s. circularis, s. coronoides, s. Ridley.)—The name expresses its form; its



position is round the margin of the pituitary fossa. It is not always a complete ring, as it represents sometimes a semicircle, placed usually before the gland, sometimes behind it. This little reservoir takes up the blood from the pituitary body by minute veins. It communicates at each side with the cavernous sinus.

*The Cavernous sinuses* (plate XLI. fig. 1, m, m; s. cavernosi) are two in number, placed at the sides of the body of the sphenoid bone, and of a very irregular form, but of considerable size. Each receives the ophthalmic vein at its fore part, communicates internally with the circular sinus, and posteriorly with the petrosal sinuses. The name given to this sinus seems to have been adopted from the winding complex appearance which its interior presents. The dura mater at the side of the body of the sphenoid bone divides into two layers; one of these rests on the bone, whilst the other is stretched from the margin of the sphenoidal fissure backwards, to the upper border of the pars petrosa; so that they leave an interval between them, constituting the sinus. The membrane which lines the ophthalmic vein and the circular sinus, when prolonged into the cavity now under consideration, is considerably dilated; it is intimately connected with that layer of the dura mater which forms the inner wall of the sinus, but is separated from the outer one by an interval which lodges the carotid artery, with the third, fourth, ophthalmic division of the fifth, and the sixth nerves.

*The superior Petrosal sinus* (plate XL. fig. 1, f; plate XLI. fig. 1, r: s. petrosus superior) represents a narrow canal, running along the upper angle of the pars petrosa. Commencing at the posterior part of the cavernous sinus, its direction is outwards and backwards in the attached margin of the tentorium cerebelli; it descends a little, and ends in the curved part of the lateral sinus, where it lies upon the temporal bone.

*The inferior Petrosal sinus* (plate XL. fig. 1, g; plate XLI. fig. 1, p: s. petrosus inferior) at its inner extremity is near to the preceding; it passes outwards, and a little downwards, taking the direction of the inferior angle of the pars petrosa, where it is in apposition with the basilar process of the occipital bone; it opens into the lateral sinus near its termination.

*The Occipital sinus*, (plate XLI. fig. 1, q; s. occipitalis anterior, s. basilaris.)—This is placed at the fore part of the basilar process of the occipital bone, extended transversely, so as to establish a communication between the sinuses just described; for its extremities are connected with both the petrosal and the cavernous sinuses of each side.

*The Ophthalmic vein*, (plate XLI. fig. 1, e; v. ophthalmica.)—This vessel may be placed in connexion with those of the cranial cavity, as it opens into the cavernous sinus. Its branches and radicles ramify in the different structures contained within the orbit, in company with the branches of the ophthalmic artery. Minute ramifications arise from the palpebræ, (g, g,) where they communicate with those of the angular vein; those which accompany the supra-orbital artery have similar connexions with the external veins of the forehead. These pass backwards, converging to form others of larger size. The branches arising from the lachrymal gland, from the different muscles, from the ethmoidal cells, those from the globe of the eye itself, all taking the names of the arterial branches which they accompany, join to form a short single trunk, which leaves the orbit by the inner part of the sphenoidal fissure, and terminates in the cavernous sinus.

*Veins of the Diploë*, (plate XLI. fig. 2; venæ ossium cranii.)—In order to demonstrate the position and direction of the veins of the diploë, detach the pericranium, and remove the external table of the skull by carefully filing it away; the vessels thus named will then be brought into view. Lodged in grooves hollowed in the bone, their ramifications form a series of irregular areolæ, from which a few larger vessels issue. These are directed downwards at different parts of the circumference of the cranium, and terminate, partly in the veins on the outer surface of the bones, partly in the lateral sinuses of the dura mater.

## OF THE VEINS WHICH FORM THE INFERIOR VENA CAVA.

These consist of the vessels which return the blood from the lower extremity, from the viscera of the pelvis and of the abdomen. The veins of the lower extremity, as in other parts of the body, are divisible into two sets, of which one is deeply seated, whilst the other runs superficially between the common integument and fascia. Immediately under the integuments on the dorsum of the foot there exists a series of small veins disposed in meshes; from these issue two principal trunks, (saphenous,) which are named, from their relative position, internal and external, or, from their relative length, the greater and smaller.

*The internal Saphenous vein* (plate XLIII. fig. 1, A; v. saphena major, vel interna) extends from the ankle to within an inch and a half of Poupart's ligament; in this course it lies superficially between the integument and fascia. Taking rise from the plexus previously indicated, it passes upwards in front of the inner malleolus, and thence along the corresponding border of the tibia, accompanied by the internal saphenous nerve. At the knee, the vein inclines a little backwards, as it passes by the internal condyle, after which it ascends along the inner and anterior side of the thigh, and terminates in the femoral vein, after passing through an aperture in the fascia lata, which, from this circumstance, has been termed the saphenous opening. It is joined in this long course by numerous cutaneous branches, and near its termination receives the *superficial epigastric*, (fig. 1, a,) *superficial circumflex ilii*, (b,) and *pubic veins*, (c, c;) the former passing down from the abdomen between the lamellæ of the superficial fascia, the latter from the groin and pubes.

*The external Saphenous vein* (plate XLIII. fig. 2, A; v. saphena externa, vel minor) proceeds from the outer side of the dorsum of the foot, and passes behind the outer ankle, gradually inclining backwards to the tendo Achillis. Passing along the

border of the tendon, it gets on the belly of the gastrocnemius muscle, on which it ascends, accompanied by the external saphenous nerve, with which it runs between the heads of the gastrocnemius, and pours its contents into the popliteal vein.

The deep veins of the lower extremity accompany the arteries and their branches, following exactly their distribution. Those below the knee being for the most part disposed in pairs, and presenting the disposition described in the corresponding veins of the upper extremity, are named the *venæ comites* of the vessels with which they are associated. The *venæ comites* of the arteries of the leg, namely, the anterior and posterior tibial veins, (the latter having previously received the peroneal,) unite near the lower border of the popliteus muscle, and form by their junction the popliteal vein.

*The Popliteal vein*, (plate XLIII. fig. 2, B; v. poplitea.)—The popliteal vein, thus formed, receives branches corresponding with the articular vessels; but its chief branch is the external saphenous vein. In its course through the ham, the popliteal vein is placed posterior and exterior to the artery, that is to say, between it and the nerve. Thus situated, it passes up through the aperture in the adductor magnus, and becomes continuous with the femoral vein.

*The Femoral vein* (plate XLII. O; v. femoralis) extends, like the artery which it accompanies, through the upper two-thirds of the thigh. Placed at first behind that vessel, it gradually inclines inwards and forwards, so that on reaching Poupart's ligament (where it terminates in the iliac vein) it lies on the inner side, and on the same plane as the artery, being separated from it only by a slight lamella that passes from before backwards, across the membranous tube which invests them. In the lower part of its course, the vein receives all the venous branches which accompany the ramifications of the arteries. In the upper part, the profunda vein opens into it, which returns the blood from all that part of the muscular structure of the thigh supplied by the profunda artery; and near its termination it is joined by the internal saphenous vein.

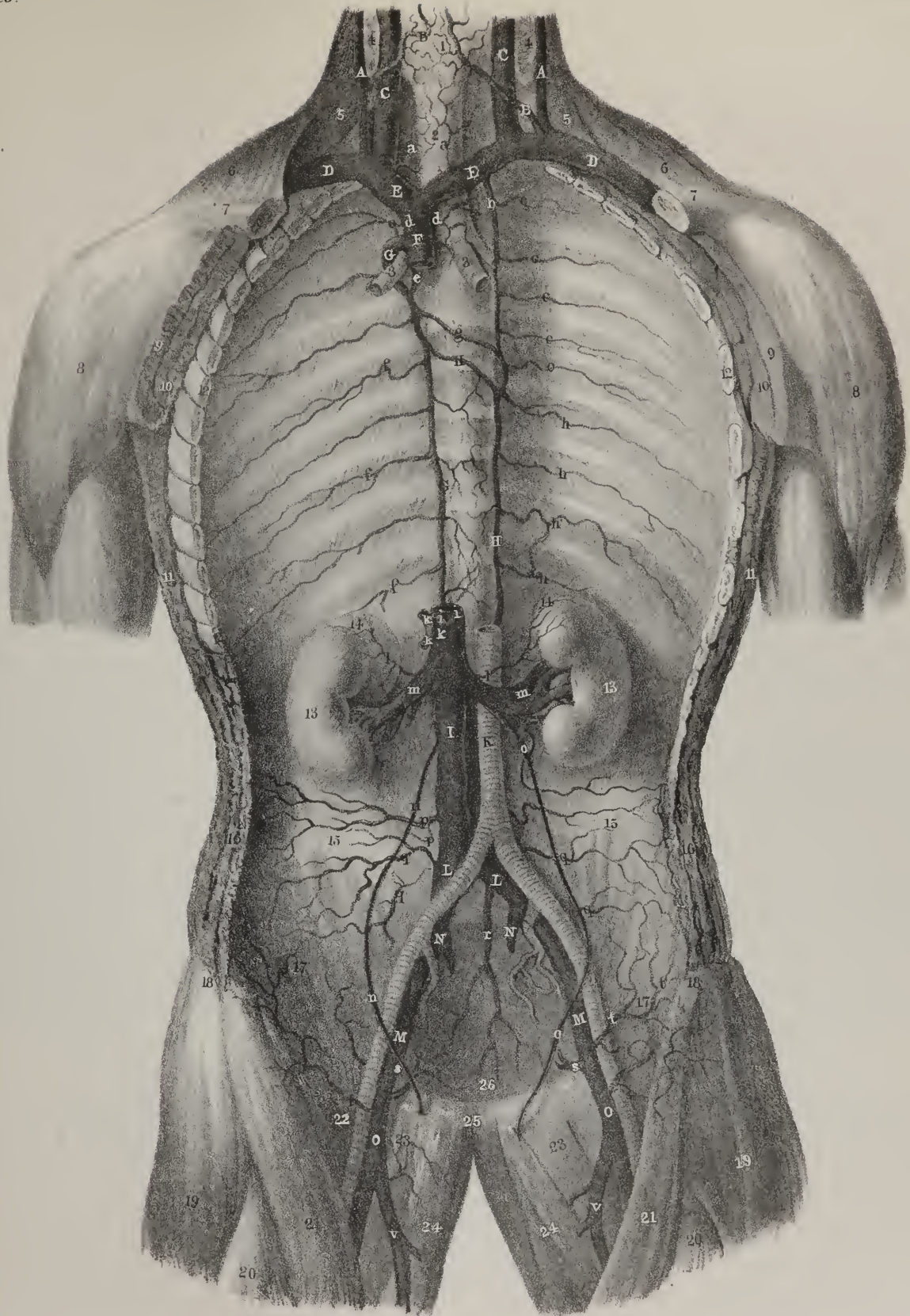
*External Iliac vein*, (plate XLII. M; v. iliaca externa.)—The femoral vein, placed at the inner side of the artery, enters the abdomen through the femoral ring, and assumes the name of *external iliac vein*. This vessel, lying at first on the inner side, and on the same plane with the artery of the same name, gradually inclines somewhat behind it as it approaches the sacro-iliac symphysis, where it joins the internal iliac vein, to form with it the common iliac vein. Near its commencement at Poupart's ligament, the external iliac receives the circumflex ilii and epigastric veins.

*Internal Iliac vein*, (plate XLII. N; v. iliaca interna.)—All the branches of the internal iliac artery are accompanied by veins except the umbilical, whose corresponding vein passes in the fœtus upwards to the liver; these several veins give rise to the internal iliac. The vessel thus formed lies behind the corresponding artery in front of the sacro-iliac symphysis, and, after a very short course upwards to the margin of the pelvis, joins with the external iliac vein. It returns the blood from the organs contained within the pelvis, and from the large mass of muscles which occupy its outer surface. The branches of this vein being remarkable for their size and their frequent interlacings one with the other, they have been described as forming a series of plexuses, severally

## PLATE XLII. .

- The superior and inferior cava and azygos veins are here shown. The dissection required to procure this view consists in removing the whole anterior part of the thorax and abdomen, together with the viscera.
- No. 1. The thyroid gland. 2. The trachea. 3, 3. The bronchi. 4, 4. The divided sterno-mastoid muscles. 5, 5. The lower belly of the omo-hyoid muscles. 6, 6. Part of the trapezius muscle at each side. 7, 7. The divided clavicle at each side. 8, 8. The deltoid muscles. 9, 9. The divided pectoralis major at each side. 10, 10. The divided pectoralis minor. 11, 11. The cut serrations of the serratus magnus muscle. 12, 12. The cut extremities of the ribs. 13, 13. The kidneys. 14, 14. The renal capsules. 15, 15. The crest of the ilium at each side. 16, 16. The divided abdominal muscles. 17, 17. The iliacus internus muscle at each side. 18, 18. The anterior superior spinous processes of the ilium. 19, 19. The tensor vaginæ muscle at each side. 20, 20. The recti muscles. 21, 21. The sartorius muscle at each side. 22. Part of the psoas muscle at the right side; on the left it is entirely removed. 23, 23. The pectinei muscles. 24, 24. The adductor longus muscle at each side. 25. The symphysis pubis. 26. The cavity of the pelvis.
- A, A. The external jugular veins. B, B. The anterior jugulars. C, C. The internal jugular veins. D, D. The subclavian veins. E, E. The *venæ innominatæ*. F. The superior vena cava. G, G. The greater vena azygos, (v. azygos major.) H, H. The lesser vena azygos, (v. azygos minor.)
- a, a. The inferior thyroid veins. b. The superior intercostal vein, (v. intercostalis superior,) formed by, c, c, the five superior intercostal veins of the left side. d, d. The bronchial veins, (v. bronchiales.) e, e. A venous trunk formed by the union of the two upper intercostal veins of the right side. f, f. The posterior intercostal veins of the right side, (v. intercostales posteriores.) g. The sixth intercostal vein crossing the fifth dorsal vertebra to terminate in the vena azygos of the right side. h. Posterior intercostal veins of the left side.
- I. The inferior vena cava, (v. cava inferior.) K. The abdominal aorta. L, L. The common iliac veins, (v. iliacæ communes.) M, M. The external iliac veins, (v. iliacæ externæ.) N, N. The internal iliac vein (v. iliaca interna) of the right side. O, O. The femoral veins, (v. femorales.)
- i, i. The termination of the phrenic veins, (v. phrenicæ inferiores.) k, k. The hepatic veins, (v. hepaticæ.) l, l. The capsular veins, (v. capsulares.) m, m. The renal veins, (v. renales vel emulgentes.) n, n. Spermatic veins (v. spermaticæ) of the right side, opening into the inferior vena cava. o, o. Left spermatic veins terminating in the left renal vein. p, p. Lumbar veins, (v. lumbales.) q, q. Muscular branches distributed to the iliaci interni muscles. r. The middle sacral vein, (v. sacra media.) s, s. Divided trunks of the epigastric veins. t, t. The circumflex ilii veins. v. The internal saphenous veins.









named from the organs on whose surface the interlacement occurs: thus the vesical, hæmorrhoidal, or uterine plexus, are not unfrequently mentioned. The only branch which requires more detailed notice is that named *vena dorsalis penis* in the male. This vessel is of considerable size. Commencing by a series of ramusculi which issue from the glans penis, we find in the first instance one at each side of the median line, in the dorsal groove of the penis: here they communicate with branches which accompany the internal and external pudic arteries. Proceeding backwards, they unite and form a short trunk which passes under the compressor muscle, and enters the pelvis beneath the sub-pubic ligament. Here it divides, its branches from thence passing obliquely downwards and backwards over the prostate and neck of the bladder, where it anastomoses with branches of the vesical veins, forming a sort of plexus, and finally opens into the internal iliac vein.

*The common Iliac vein*, (plate XLII. L; v. iliaca communis,) formed by the confluence of the two iliac veins, passes upwards, converging towards the corresponding vessel of the opposite side, and both unite at the junction of the fourth with the fifth lumbar vertebra, a little to the right of the middle line, where they terminate in the inferior or ascending cava. The right is shorter, and nearly vertical in its direction, and both pass under the right common iliac artery.

*The inferior Vena Cava* (plate XLII. I; v. cava inferior) returns the residue of the blood circulated by the abdominal aorta. It commences at the conflux of the two common iliac veins on the side of the fourth lumbar vertebra, and thence ascends along the right side of the aorta, as far as the posterior border of the liver; it there becomes lodged in a groove in that organ, after which it inclines forwards to reach the opening in the diaphragm appropriated to it, and immediately terminates in the right auricle of the heart. In its course it receives the veins corresponding with the renal, lumbar, and middle sacral arteries; also the inferior phrenic, capsular, and spermatic; and finally, the hepatic veins, which, through the medium of the *vena portæ*, return the blood from the chylopoietic viscera. In a case reported by Meckel,\* the inferior vena cava followed the course usually taken by the *azygos vein*, and terminated in the superior cava. The hepatic veins united into a single trunk, which assumed the ordinary position of the inferior vena cava, passed through its foramen in the diaphragm, and opened into the right auricle.

*The middle Sacral vein*, (plate XLII. r; v. sacra media.)—This vein, taking its course upwards on the anterior surface of the sacrum, opens into the commencement of the vena cava, or sometimes into the left common iliac vein as it crosses that bone.

*The Lumbar veins* (plate XLII. p, p; v. lumbales) commence by small branches in the muscles of the back and abdomen, where they communicate with the epigastric and other veins in the neighbourhood; arrived at the spine, they proceed forward behind the *psaos muscle*, those on the left side passing also behind the aorta, and terminate in the vena cava. Some of these veins are frequently found to unite into one trunk before their termination.

*The Spermatic veins*, (plate XLII. n, o; v. spermaticæ.)—Proceeding upwards from the testis, and forming one of the constituents of the spermatic cord, each spermatic vein enters the abdomen, and ascends on the *psaos muscle* behind the peritonæum. Below the external ring the veins are numerous, branched and convoluted; they have valves, but still may be injected from above downwards. These branches gradually unite, and form a single vessel, which opens on the right side into the vena cava, on the left into the renal vein. The spermatic veins sometimes bifurcate before their termination, each division opening separately; in this case, that of the right side may be found communicating with the vena cava and the renal vein.

*The Renal veins*, (plate XLII. m, m; v. renales, vel emulgentes.)—These veins are short, but of very considerable calibre. That of the left side is longer than the right, and passes generally in front of the aorta. They join the vena cava at nearly a right angle. The renal veins usually receive branches from the supra-renal capsules; the left has also opening into it the spermatic vein of the same side.

*The Capsular veins*, (plate XLII. l, l; v. capsulares.)—The veins of the supra-renal capsules are very small; they usually join on the right side with the vena cava, on the left with the renal veins.

*The inferior Phrenic veins* (v. phrenicæ inferiores) follow exactly the course of the arteries supplied to the diaphragm by the abdominal aorta.

## VEINS OF THE LIVER.

In the adult, as well as in the *fœtus*, the veins of the liver present peculiarities which in a manner mark them off as a separate compartment of the venous system; for here a vein seems to assume the functions of an artery, and to convey the materials from which the peculiar secretion of the organ is elaborated. The *vena portæ*, or vein of the gate, has been so called from its entering the transverse fissure of the liver, which was likened to a gateway, the minor lobes placed before and behind it representing its pillars. This vessel conveys to the liver the residual blood from all the chylopoietic viscera. The veins from these different sources unite into two principal trunks, viz. the splenic and superior mesenteric; from the conflux of these proceeds the *vena portæ*, which again spreads out and ramifies in the liver, so that it may be said to have two sets of branches, viz. the incipient in the intestines, and the terminal in the liver, both being connected by an intermediate trunk.

*The Splenic vein* (plate XLIV. B; v. splenica) is a vessel of very considerable size, for it returns the blood not only from

\* Med. Gaz. 1830.

the spleen, but also from the pancreas, duodenum, the greater part of the stomach and omentum, the left colon, and part of the rectum. It commences by five or six branches which issue separately from the fissure of the spleen, but soon join to form a single vessel. Its direction is then transverse from left to right, embedded in the substance of the pancreas, in company with the splenic artery, beneath which it is placed. On reaching the front of the spine it joins the superior mesenteric vein, nearly at a right angle. It receives branches from the pancreas, (*venæ pancreaticæ*; a, a,) from the duodenum, (*v. duodenales*), from the left extremity of the stomach, some of which, from the arteries they accompany, may be called *v. gastricæ*, or *vasa brevia*, (c, c;) also the two following, which require a more detailed notice:—

*The inferior Mesenteric vein*, (plate XLIV. C, C; v. mesenterica inferior.)—The branches of this vein correspond with the ramifications of the artery of the same name. They commence behind and at the sides of the rectum, from which they ascend and unite to form a single vessel, towards the sigmoid flexure of the colon. From this point it passes upwards and inwards along the lumbar region, behind the peritonæum, and runs between the transverse meso-colon and the spine; sometimes it lies farther to the left, but in either case it passes under the pancreas, so as to reach the splenic vein, in which it terminates.

*The Coronary vein of the stomach*, (plate XLIV. e; v. coronaria ventriculi.)—This vein lies parallel with the artery of the same name. Its size is inconsiderable, and its direction transverse from the cardiac to the pyloric part of the stomach, along the lesser curvature. On reaching the latter point it turns downwards, and opens into the splenic vein, or in some instances into the trunk of the vena portæ.

*The superior Mesenteric vein* (plate XLIV. D, D; v. mesenterica superior) corresponds with the artery of the same name, lying to its right, and somewhat anteriorly, and returns the blood from the same parts, viz. the small intestine, and the ascending and transverse parts of the colon. The trunk formed by the union of these branches inclines upwards and to the right side, passing in front of the transverse part of the duodenum and behind the pancreas, where it joins with the splenic vein.

*The Portal vein*, (plate XLIV. A; v. portæ.)—The trunk of the vena portæ, commencing at the junction of the splenic and mesenteric veins, passes upwards, forwards, and a little to the right, to reach the transverse fissure of the liver, being about three inches in length. It comes into intimate relation with the biliary vessels, being placed closely behind, and in a manner between the hepatic artery and the hepatic ducts. It is surrounded by the filaments of the hepatic plexus of nerves, together with the lymphatics. All these are embedded in loose cellular tissue, and enclosed within the layers of the gastro-hepatic omentum. When near to the right extremity of the transverse fissure, the vena portæ divides into two branches. That of the right side directly enters the substance of the corresponding lobe of the liver, and spreads out into branches, each of which is accompanied by a branch of the hepatic artery and of the hepatic duct. The left branch, which is smaller, but necessarily longer, passes across to gain the left extremity of the fissure, where it enters and ramifies like the preceding branch. The blood conveyed to the liver by this vessel is collected again, and returned into the current of the circulation by the hepatic veins.

*The Hepatic veins* (plate XLII. k, k; v. hepaticæ) commence by radicles, which communicate (as may be shown by injection) with the terminations of the vena portæ. These gradually enlarge as they pass upwards, converging to the point at which the vena cava passes behind the liver, and pour their contents into that vein. There are usually three sets, proceeding to a common point; those from the right and left lobes being oblique in their direction, those from the lobulus Spigelii and middle of the liver occupying an intermediate position.

*The great vein of the Heart* (plate XXXVII. a\* ; v. cordis maxima.)—This vessel is of considerable size, and from the way in which it coils round the left side of the base of the heart, or rather of the ventricle, it may be named “coronary.” Its chief branch runs along the groove at the anterior convex surface of the heart, corresponding with the septum ventriculorum. Commencing at the apex, it gradually increases as it approaches the base of the ventricles, receiving branches from both, particularly

## PLATE XLIII.

The superficial veins of the lower extremity.

FIG. 1. The internal saphenous vein, with its ramifications, seen upon the anterior and inner aspect of the leg and thigh.

No. 1. The anterior superior spine of the ilium. 2. The superficial fascia of the abdomen. 3. Poupart's ligament. 4. The spine of the pubis. 5. The iliac portion of the fascia lata perforated by holes for the passage of superficial vessels and lymphatics. 6. The falciform border of the saphenous opening. 7. The pubic portion of the fascia lata. 8. The projection formed by the sartorius muscle. 9. The projection of the tensor vaginæ femoris muscle. 10. The projection of the vastus externus. 11. The situation of the rectus muscle. 12. The adductor muscles. 13. The bellying of the vastus internus. 14. The patella. 15. The cutaneous surface of the tibia. 16. The inner ankle.

A, A. The internal saphenous vein, (v. saphena interna, vel major.)

a. The superficial epigastric vein, (v. epigastrica superficialis.) b. The superficial circumflex ilii vein, (v. circumflexa ilii superficialis.) c, c. Superficial pudic veins, (v. pudicæ superficiales.)

FIG. 2. The posterior and external aspect of the leg, showing the ramifications of the external saphenous vein.

No. 1. The inner hamstring. 2. The outer hamstring. 3. The popliteal fascia. 4, 4. The heads of the gastrocnemius muscle. 5. The external ankle.

A, A. The external saphenous vein, (v. saphena externa, vel minor.) B. The popliteal vein, (v. poplitea.)



Fig. 1.

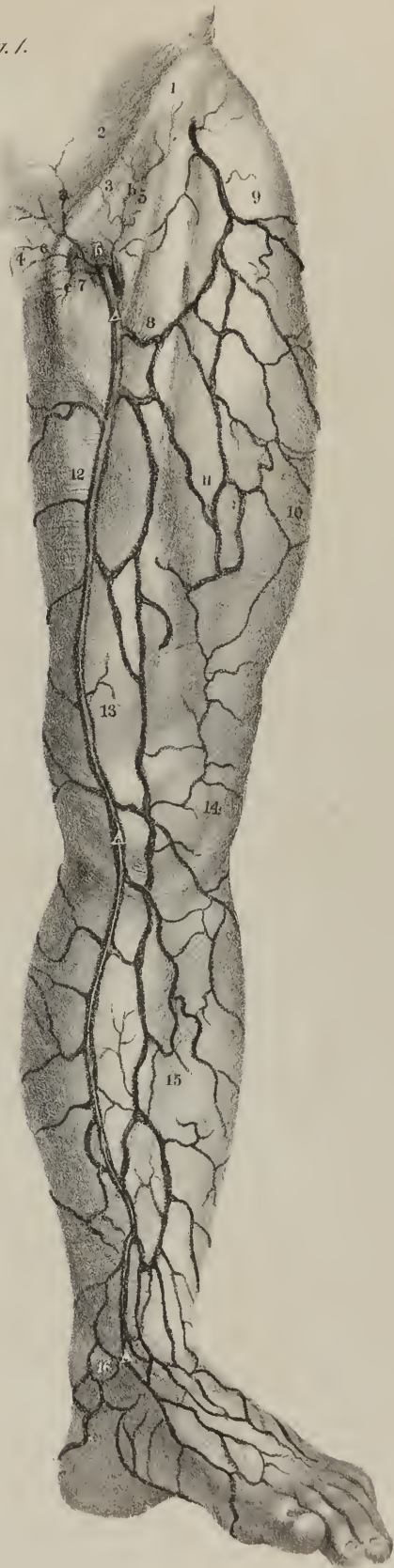
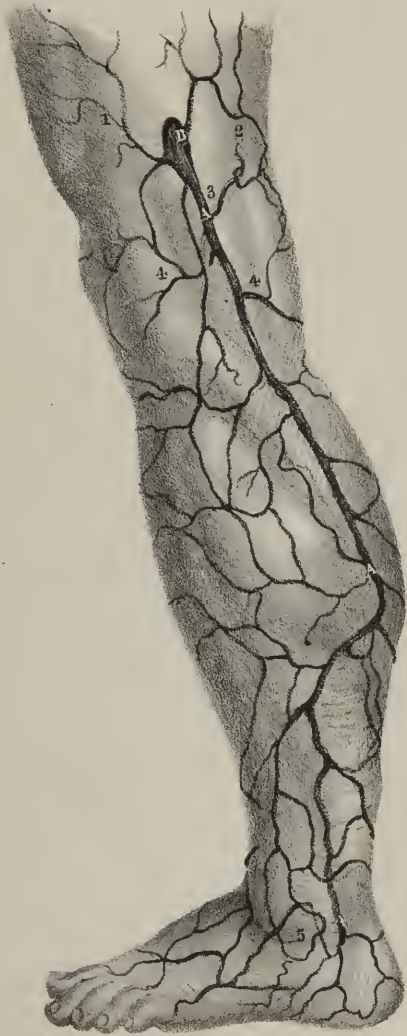
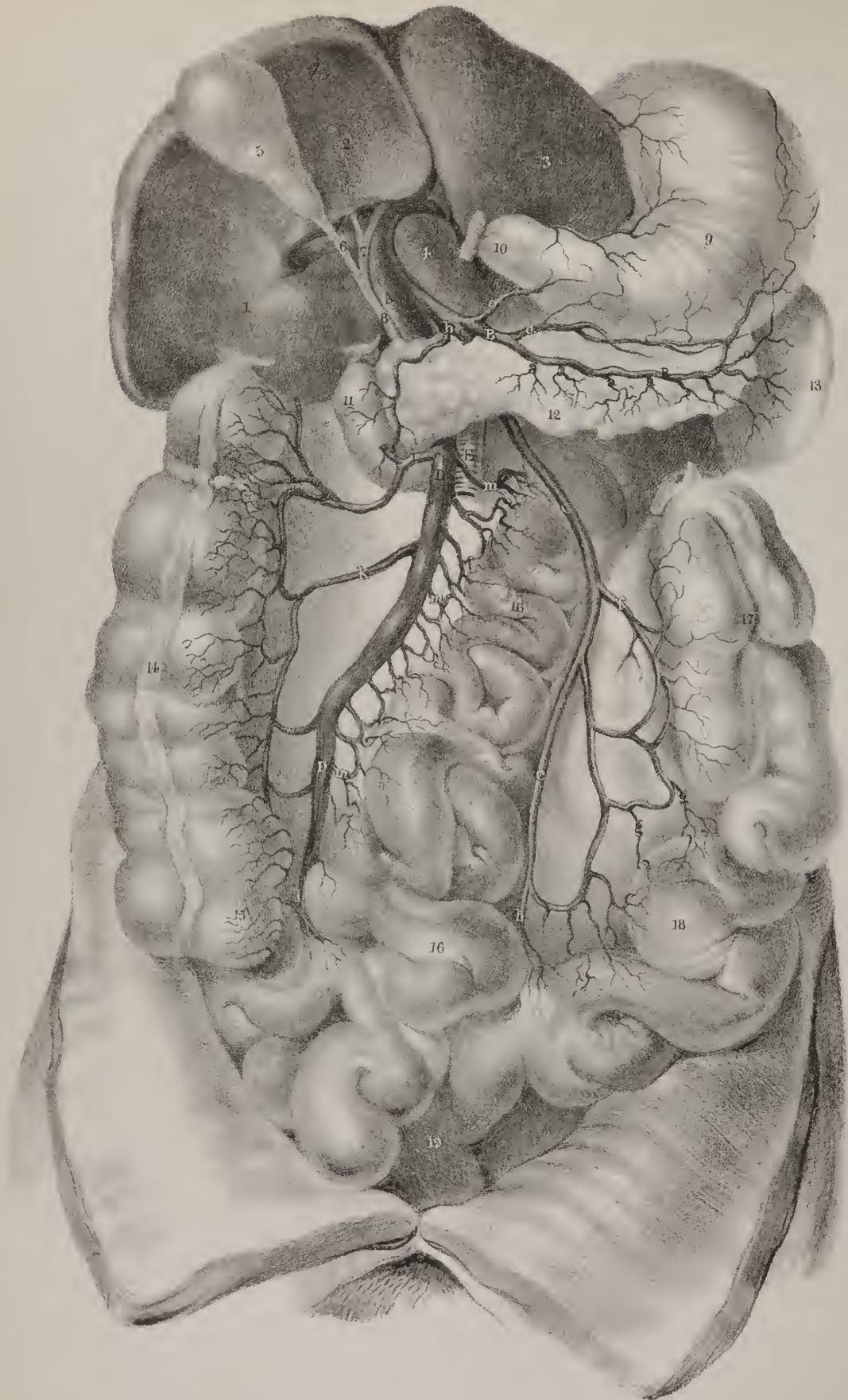
Fig. 2.











from the left. It then inclines backwards, and to the left side, running in the groove between the left auricle and ventricle, but prolongs its course a few lines beyond this to open into the right auricle, close to the septum auricularum. In this course it receives branches from the ventricles, also from the left auricle; and when it passes by the thick margin of the left ventricle, it receives a vein of some size, which ascends to join it.

*The middle Coronary vein*, (v. cordis media.)—The term “coronary” cannot be applied to this vessel with any propriety, as its direction is altogether straight, running along the groove between the ventricles at the posterior surface of the heart. It commences by small branches at the apex, communicating with those of the preceding vein, ascends to the base, receiving ramusculi from the fleshy substance of both cavities, and opens into the vena maxima, near its termination.

*The small Coronary veins*, (plate XXXVII. b\*, b\*; v. cordis parvæ.)—Several small branches arise from the anterior surface of the right ventricle, from which they pass upwards and outwards, to open separately into the right auricle, after having crossed over the groove which separates it from the ventricle.

*Venæ cordis minimæ*.—Under this name are included those minute vessels whose orifices are observable in the interior of the right auricle, which, from having been noticed by an old anatomist, Thebesius, are generally called *foramina Thebesii*.

## PLATE XLIV.

In this plate the portal vein, formed by the venous trunks from the abdominal viscera, is shown.

- No. 1. The right lobe of the liver. 2. The lobulus quadratus. 3. The left lobe. 4. The lobulus Spigelii. 5. The gall-bladder. 6. The cystic duct. 7. The hepatic duct. 8. The ductus communis choledochus. 9. The stomach. 10. Its pyloric extremity; and, 11, the descending portion of the duodenum, the intervening portion having been removed. 12. The pancreas. 13. The spleen. 14. The ascending colon. 15. The cæcum. 16, 16. The small intestine. 17. The descending colon; the transverse portion is removed. 18. The sigmoid flexure. 19. The commencement of the rectum.
- A. The portal vein, (v. portæ.) B. The splenic vein, (v. splenica.)
- a, a. Pancreatic veins, (v. pancreaticæ.) b. The pancreatico-duodenal vein, (v. pancreatico-duodenalis.) c, c. Gastric veins, (v. gastricæ, vel vasa brevia.) d. The gastro-epiploic vein, (v. gastro-epiploica.) e. The coronaria ventriculi vein.
- C, C. The inferior mesenteric vein, (v. mesenterica inferior.)
- f. The left colic vein, (v. colica sinistra.) g, g. Sigmoid veins, (v. sigmoideæ.) h. The superior hæmorrhoidal vein, (v. hæmorrhoidalis superior.)
- D. The superior mesenteric vein, (v. mesenterica superior,) lying to the right of, E, the trunk of the superior mesenteric artery.
- i. The divided trunk of the middle colic vein, (v. colica media.) k. The right colic vein, (v. colica dextra.) l. The ilio-colic vein, (v. ilio-colica.) m, m. The veins from the small intestines, (v. colicæ.)



## CHAPTER III.

## THE ABSORBENTS.

THE absorbing vessels, considered as a system or whole, are divisible into two sets: 1, those which return the chyle from the alimentary canal; and 2, those which take up the lymph or residue of nutrition from all the other parts of the body: both are connected in their course with ganglia or glands. We shall here describe their course and position, and in an outline of the general anatomy of absorbents, indicate their conformation and structure. The chyle vessels, by their union, form a large trunk, (thoracic duct,) which is a common reservoir for receiving their contents, as well as those of the lymphatics, which come—from both the lower extremities,—from the cavity of the abdomen and its viscera, except the right lobe of the liver,—from the walls of the abdomen at both sides, and from the surface of the left side of the thorax,—from the left lung, the left side of the heart, and left side of the diaphragm,—from the left upper extremity, and from the corresponding side of the head and neck. But the lymphatic vessels which arise from the right upper extremity, the right side of the head and neck, from the right lung, and from the corresponding half of the liver and diaphragm, pour their contents, by a short trunk, into the conflux of the right subclavian and internal jugular veins. This vessel may be called the right lymphatic duct; it is commonly named the right thoracic duct, though no part of it lies within that cavity. The duct of the left side is not entirely thoracic; for its commencement is in the abdomen, and its termination in the neck.

*Vasa lactea, vel chyliifera.* The lacteal vessels, plate XLV. l, l.—These vessels commence in the intestinal canal, from which they extend to the thoracic duct, in which they all terminate. They are much more numerous in the small intestine than in the large; hence they exist in greatest number in the mesentery, particularly in that part of it which corresponds with the jejunum and duodenum. We find two sets of these vessels along the tube of the intestine, taking a different direction, and lying on different planes. One runs longitudinally in the course of the canal, lying beneath its peritonæal coat; whilst the other, placed between the muscular and mucous coats, is transverse, being directed from the intestine along with its nutritious vessels, and, like them, enclosed within the folds of the peritonæum. It was at one time supposed that the superficial absorbents here noticed were lymphatics, and that the others were lacteals; the distinction, however, is not tenable: both seem to communicate and anastomose. “The lacteals (says Cruikshank) absorb chyle when it is presented to them; and at other times they absorb other fluids.”\* The deep-seated lacteals, when they enter the mesentery, take the course of the vessels, passing through the lymphatic glands, of which many are placed within its folds. They gradually unite as they proceed, two or three perhaps converging to form one; and so they become diminished in number, until finally, towards the root of the mesenteric artery, two or

## PLATE XLV.

Lymphatic vessels of the abdominal viscera.

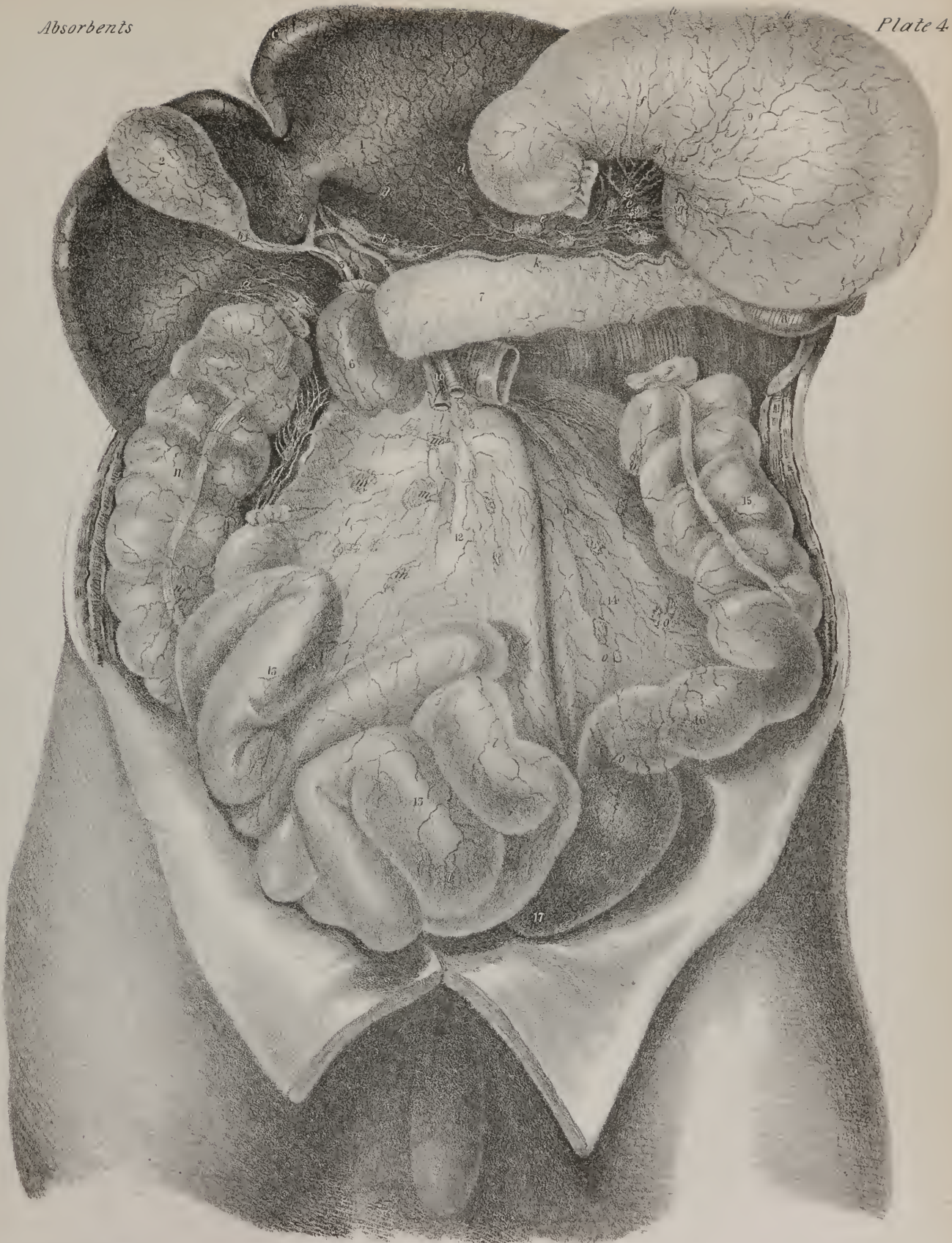
This view is obtained by raising the liver, and drawing the stomach upwards and outwards. Part of the duodenum and small intestine, and the transverse colon, are removed, and the anterior layer of the mesentery dissected away.

Nos. 1, 1. The under surface of the liver. 2. The gall bladder. 3. The ductus communis choledochus. 4. The portal vein. 5. The hepatic artery. 6. The descending portion of the duodenum. 7. The pancreas. 8. The lower part of the spleen projecting below the great end of the stomach. 9. The stomach. 10. The superior mesenteric artery and vein, resting upon the transverse portion of the duodenum. 11. The ascending colon. 12. The mesentery. 13. The small intestines. 14. The layer of peritonæum which connects the descending colon to the posterior wall of the abdomen. 15. The descending colon. 16. The sigmoid flexure. 17. The rectum.

a. A group of lymphatics from the right lobe of the liver, passing to its posterior border to terminate in the commencement of the thoracic duct. b, b. A second group from the gall-bladder and middle portion of the liver, proceeding along the course of the hepatic vessels between the layers of the lesser omentum. c. One or two lymphatic trunks passing to the upper surface of the liver. d, d. Lymphatics from the left lobe passing to the coronary glands, e, e. f, f. Lymphatics from the stomach converging to the group of glands, g, g, placed along the concave border of the organ. h, h. Lymphatics converging to the glands on convex border of the stomach. i. Lymphatics from the great end of the stomach descending to the splenic glands. k, k. Pancreatic lymphatic vessels. l, l. Lacteal vessels originating upon the surface of the small intestine, and converging to the root of the mesentery. m, m. Mesenteric glands. n, n. Lymphatic vessels from the ascending colon, terminating in glands along its fixed border. o, o. Lymphatics and glands from the descending colon, converging towards the vertebral column and root of the mesentery.

\* Anatomy of the Absorbing Vessels, p. 161.









three trunks shall have resulted from the junction of all. Sometimes, however, six or seven of these vessels open separately into the commencement of the thoracic duct. In this way the lacteals, from the whole of the small intestine and from the cæcum, together with the ascending and transverse parts of the colon, terminate; those from the descending colon and its sigmoid flexure usually join some of the lumbar lymphatics, or turn upwards, and open by a single vessel into the lower end of the duct. To the same point we trace, from below upwards, the lymphatic vessels, from the two lower extremities; so that the thoracic duct may be said to commence at the conflux of those just named with the common trunk of the lacteals.

The absorbents are called also lymphatics, *vasa lymphatica*, absorbent system, *système absorbant*.—The term “absorbent” means, literally, sucking up; and is used to denote the property (ascribed to certain vessels found very generally diffused throughout the system) of imbibing substances placed in contact with them, and carrying them into the current of the circulation. Under this head are included two sets of vessels, together with a number of nodular bodies of various forms and sizes, called glands; these are situated in the course of the vessels, and are appended to them. The vessels are transparent, their coats being very thin, and appear white when filled with their fluid contents during life; they are very small, and increase but little in size by the conflux of branches; so that they cannot be said to present an arborescent form, like arteries and veins; they rather resemble a diffused net-work, and when artificially injected look like jointed cords.

*Lymphatics and lacteals.*—From a difference in the nature of the fluid which the absorbent vessels contain, they are divided into two orders, viz. lymphatics and lacteals. The latter are confined to the cavity of the abdomen, and only absorb chyle, the product of digestion; the former are diffused through the body at large, and are engaged in that process of absorption which is constantly going on in the various structures of which it is composed.

*Glands.*—In different parts of the course of the absorbing vessels, rounded or oval bodies are situated, called *glands*, (*lymphatic* or *conglobate*), which in the extremities are found usually at the flexures of joints, but in the cavities are variously disposed. The vessels, as is evident from the results of injection, on arriving at the glands, become intimately connected with them, and in a manner ramify through their interior; for if some quicksilver be introduced into the vessel, it will soon permeate the whole substance of the gland.

*Inferent and efferent vessels.*—The entering vessels are on this account called “*vasa inferentia*.” The vessels which issue from the glands appear to arise from their interior by a number of minute radicles, which unite to form tubes, of about the same size as those which had entered at the opposite side. These pass on in the course of the circulation; and as they convey away whatever fluids had passed through the glands, they are called “*vasa efferentia*.” It should be observed, that anatomists are by no means agreed as to the precise distribution of the minute tubuli which are convoluted in the interior of the glands.

*Thoracic duct.*—All the chyloferous vessels, as well as all the lymphatics, which arise from the lower extremities, from the left side of the thorax, the left upper extremity, and the lateral half of the head and neck of the same side, pour their contents into a common trunk—the “left,” or “great thoracic duct,” (*ductus thoracicus sinister vel major*, Sæmm.) This is a tube similar in structure, but larger than those which open into it, which runs along the spinal column, from the second lumbar vertebra to the lower part of the neck, where it opens into the angle formed by the union of the left subclavian and jugular veins. The rest of the absorbents, consisting of those which return the lymph from the right upper extremity, from the right half of the thorax, and the corresponding side of the head and neck, terminate in a short trunk, the “right,” or “small lymphatic duct,” which opens into the junction of the right subclavian and jugular veins. These, it should be observed, are not the only points at which absorbents open into veins. Lippi has shown some of them terminating in the inferior cava, also in the iliac and renal veins.

Lymphatics for the most part follow the course of veins, and like them are divisible into two sets, one superficial, the other deep-seated. They are said to consist of only two coats, perhaps because the external or cellular one is too thin to be satisfactorily demonstrated. The internal coat, or lining membrane, like that of veins, is smooth, thin, delicate, and formed into folds which constitute valves that allow the contained fluid to pass freely towards the common trunk, but prevent its return. The knotted appearance presented by lymphatics when injected, is owing to the column of the mercury, or other substance employed, being interrupted by the valves. The proper coat, corresponding with that of veins, is dense, firm, and most probably fibrous, though it is not easy to demonstrate the fact, except in the thoracic duct of a horse, or of some large animal. It is slightly elastic, and appears to be irritable; for we observe the lacteals to contract, and force on their contents, when the mesentery is exposed in an animal while the process of digestion is going on.

*Absorbents.—History.* The vessels included under this head appear not to have been known to the ancients: their discovery may fairly be considered of modern date, and different parts of this order of vessels were traced out by different persons at different times. In 1563, Eustachius first saw the thoracic duct in the horse, and called it “*vena alba thoracis*;” he says that a great offset comes from the junction of the left subclavian and jugular vein, (*magna quædam propago germinat*); that it was white, and filled with an aqueous fluid; that soon after its origin it divided into two branches, which soon unite again; that it runs down upon the left side of the vertebra, pierces the diaphragm, embraces the aorta, then widens, and finally terminates in a way which he could not explain,—“*obscurissimum finem mihi adhuc non bene perceptum obtinet*.”

The nature of this vessel was not understood by its discoverer, nor were any of its connexions by branches known until the



year 1622, when Asellius, also an Italian anatomist, whilst looking at the movements of the diaphragm in the dog, saw some white lines running along the mesentery, which at first he took for nerves; but, having punctured them, a white fluid ran out, when they shrunk and became invisible. He thus ascertained that they were a new order of vessels, which were perceptible only when the intestines contained alimentary matter. He named them "vasa lactea," and attributed to them the power of absorbing chyle from the intestinal canal; thus to the three orders of vessels, arteries, veins, and nerves, known to exist in man and animals, Asellius added a fourth, the lacteals. "Aliud est genus, quartum, novum, et ignotum hactenus, à me primo observatum."

Asellius made many dissections and experiments to satisfy a laudable curiosity as to the existence and nature of these vessels in other animals as well as in the dog. He tells us that seldom did a week pass, and never did a month pass, in which he did not perform some experiment; so that, during the progress of his researches, dogs, cats, lambs, hogs, sheep, and cows were offered up on the altar of science. He made one great offering which he commemorates as a great achievement: "Quinetiam equus huic uni rei emptus, et vivus exenteratus."

Human dissection was not at that time practised; he therefore had no opportunity of seeing lacteals in the human subject; so that he gravely informs us, "Hominem vivum, (quod tamen Herophilus et Erasistratus fecere,) nunquam incidi fateor, nec incidam; nam nefas et morte piandum cum Celso existimo præsidem salutis humanæ artem pestem alicui eam atrocissimam inferre."

As Asellius had no opportunity of demonstrating lacteals in the human subject, though he affirmed their existence from analogy, their existence was denied by most anatomists, who still continued to assert that chyle was taken up by the veins. Even Harvey adhered to the old doctrine: he seemed inclined to think that there was no necessity in searching after any new way for the chyle in adults besides that which exists in the egg, and in the chick, where the umbilical veins and arteries suffice.

It was in 1634 that the lacteals were first seen in the human subject by Verlingius, who described and figured them; he saw the lymphatics of the liver, and was the first who, since Eustachius, saw the thoracic duct; for all other anatomists, with Asellius, thought that the chyle vessels went to the liver.

The lymphatics were seen by Rudbeck, a Swede, about twenty-eight years after the discovery of the lacteals: he considered them a fifth set of vessels, and named them *vasa serosa*. About the same time, Bartholin, a Dane, saw the lymphatics; but he must have learned a little of them from having edited the work of Verlingius: in 1653, they were first demonstrated in this country by Dr. Jolliffe.

If the lacteals and lymphatics be considered as parts of one system, all those persons whose names are thus connected with successive discoveries, may be considered as having traced out some additional parts rather than as having made distinct discoveries.

Additions were made from time to time to the discoveries here mentioned, which showed their existence in several of the lower animals. Mr. Hunter showed them in the crocodile and in the goose; Mr. Hewson in the turkey and in fishes; Bartholin also saw them in the globe-fish: still most persons, even up to the time of the Hunters, supposed them to be merely appendages to the veins.

The *thoracic duct* (plate XLVII.) is from eighteen to twenty inches long in the adult, for it extends usually from the second lumbar vertebra to the root of the neck. Its commencement, however, is often opposite the third lumbar vertebra; in some cases as high as the first, or even the last dorsal. Here there is usually a dilatation, which varies considerably in degree, being in some cases scarcely perceptible, in others considerable. This part of the duct is called *receptaculum chyli*: but the term is not well

## PLATE XLVI.

Superficial lymphatics of the lower extremity.

FIG. 1. An anterior view of the leg and thigh; showing the superficial veins and lymphatic vessels resting on the deep fascia.

No. 1. The superficial fascia of the abdomen. 2. The anterior superior spine of the ilium. 3. The saphenous opening. 4. The convexity of the vastus internus muscle. 5. The patella. 6. The inner ankle.

A, A. The internal saphenous vein.

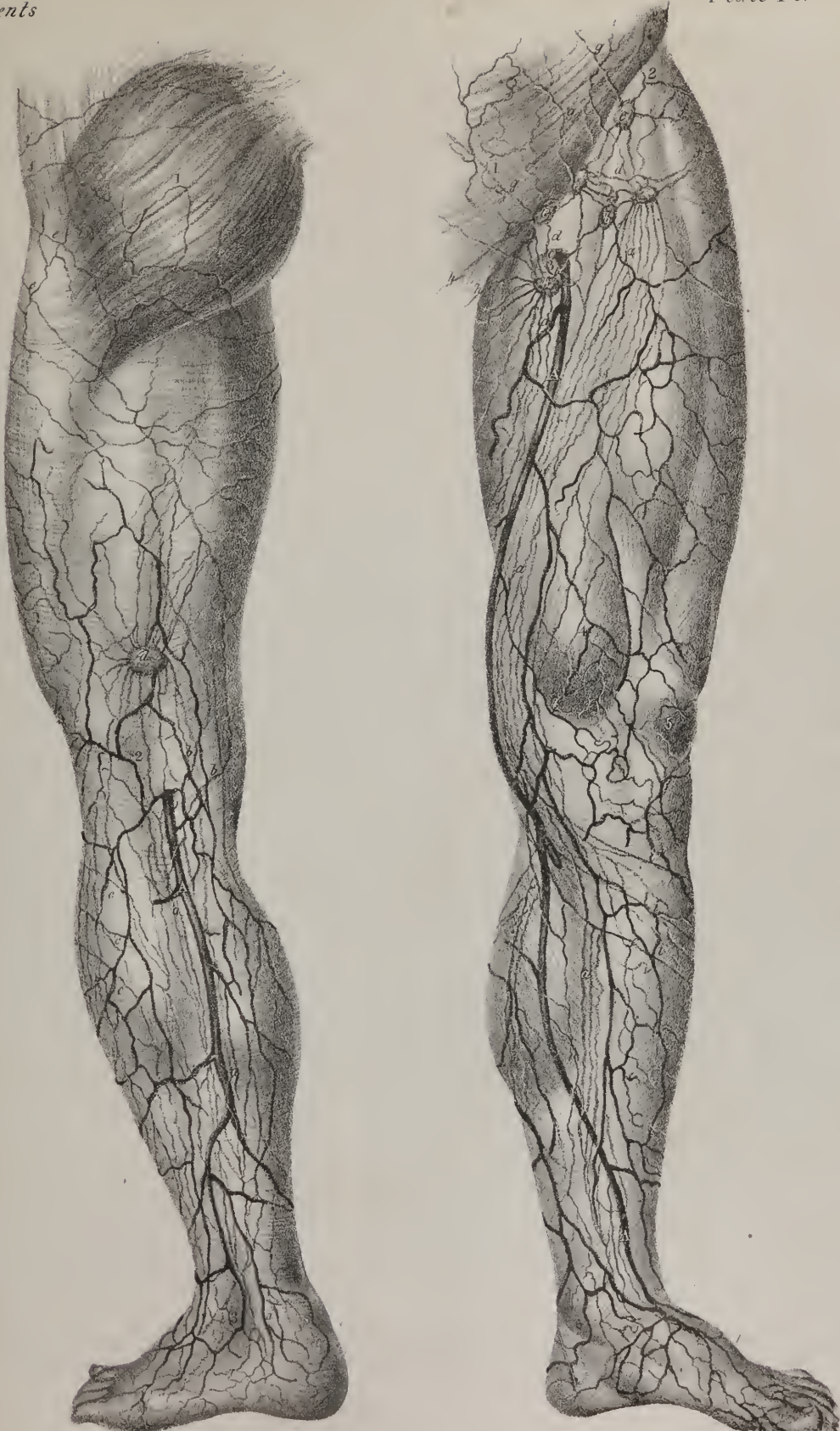a, a. Lymphatic vessels accompanying the internal saphenous vein along the inner side of the leg and thigh. b, b. The lower group of inguinal glands, receiving the lymphatics from below. c. Lymphatic vessels passing through the saphenous opening. d, d. Communicating vessels between the lower, and, e, e, the upper group of inguinal glands. f, f. Superficial lymphatic vessels from the gluteal region. g, g. Superficial abdominal lymphatics. h, h. Lymphatic vessels from the penis and scrotum. i, i. Several vessels that cross the front of the tibia from the outer to the inner side.

FIG. 2. Posterior aspect of the leg and thigh.

No. 1. The gluteus maximus. 2. The popliteal region. 3. The external ankle.

A, A. The external saphenous vein.

a, a. Lymphatic vessels accompanying the external saphenous vein. b, b. Lymphatics winding around the lower border of the thigh to the internal saphenous vein. c, c. Several vessels passing beneath the knee to join the internal saphenous lymphatics at the inner condyle. d. A superficial lymphatic ganglion situated just above the ham. e, e. Lymphatic vessels passing around the hip to the inguinal glands. f, f. Lymphatics from the gluteal region, destined to the inguinal glands.







chosen, as it receives lymph as well as chyle; nor is it always applicable, for there may be no dilatation. It lies to the left side and behind the aorta, and is about three lines in diameter; but as it ascends it passes to the right side of that vessel, getting into contact with the right crus of the diaphragm, and so reaches the thorax, where it is placed at first upon the fore part of the dorsal vertebræ, between the aorta and the vena azygos major, the latter being to its right side. It ascends gradually inclining to the left, at the same time diminishing in size until it reaches the third dorsal vertebra, where, after passing behind the arch of the aorta, it comes into contact with the œsophagus, lying between its left side and the pleura. Continuing its course, it ascends into the neck, supported by the longus colli muscle, until it comes on a level with the upper border of the seventh cervical vertebra, where it changes its direction and comes forwards, at the same time inclining downwards and inwards, so as to describe a curve, previously to its termination at the external angle formed by the union of the subclavian and internal jugular veins. The duct does not always remain single in its whole extent; it frequently divides opposite the seventh or eighth dorsal vertebra into two branches, which unite again; sometimes in its course it separates into two or three branches, which afterwards unite, and enclose between them so many spaces or islets. Mr. Cruikshank in one case found the duct double in its entire length; "in another, triple, or nearly so." When in the neck, it often divides into two or three branches, which in some instances terminate separately, but in others join again previously to their termination. At the junction of the duct with the veins there are two valves so placed as to prevent the entrance of any blood into the duct, and whilst they allow the chyle and lymph freely to pass into the veins, they effectually prevent their return into the duct. The diminution in the size of the duct as it ascends has been noticed; at the fifth dorsal vertebra it is often no more than about two lines in diameter, but above this point it enlarges again. It is generally waving and tortuous in its course.

*Lymphatic vessels*, (vasa lymphatica).—We shall trace up the course of the lymphatic vessels which pour their contents into the thoracic duct, beginning with those of the lower extremities:

The *lymphatics of the lower extremity* (plate XLVI.) present the same disposition as those of the upper. The superficial series, disposed between the integuments and fascia of the limb, are arranged into two sets, of which one accompanies the internal saphenous vein, the other following the course of the external. The vessels composing the first set take rise on the dorsum and inner side of the foot: passing partly in front and in part behind the internal malleolus, they ascend along the inner side of the knee and anterior surface of the thigh, and terminate in the superficial inguinal glands. In their course these vessels are joined by several branches proceeding from the integuments of the leg and thigh. The lymphatics, which constitute the second division of the cutaneous series, are much less numerous than those just described. Commencing from radicles which occupy the outer margin of the foot, they pass behind the external malleolus, and ascend along the posterior part of the leg; here they get under cover of the fascia, and proceed between the heads of the gastrocnemius muscle to terminate in the popliteal glands. This course corresponds to that of the smaller saphenous vein, which these lymphatics accompany.

The deep-seated lymphatics, associated in their whole course with the arteries and their branches, consist in the leg of three divisions, namely, anterior tibial, posterior tibial, and peroneal. In the leg, neither these nor the superficial vessels meet with any lymphatic gland, with the exception of those accompanying the anterior tibial artery, which occasionally pass through one: this gland, when it exists, which is not always the case, is situated on the inter-osseous ligament, about the middle of the leg. The several sets of deep lymphatics here pointed out, after ascending with the blood-vessels, unite in the glands situated in the popliteal space. These (the popliteal lymphatic glands) are usually very small, and four or five in number; they surround the popliteal vessels, and are imbedded in a quantity of loose fat. The popliteal glands receive the deep-seated lymphatics of the leg, and those which accompany the external saphenous vein, and from them proceed vasa efferentia, which ascend with the femoral artery to the glands of the groin.

The inguinal glands, like the lymphatic vessels, are, from their relative position, divisible into a superficial and a deep set; the former being placed immediately under the integuments, the latter under the fascia lata. The superficial glands (plate XLVI. fig. 1. b, b, e, e) are larger than the others; their number varies much, but may be stated to average about eight or ten: they are disposed irregularly about Poupart's ligament and the saphenous opening of the fascia; a few sometimes extend for two or three inches downwards on the saphenous vein. The deep-seated glands (plate XLVII. d, d, f, f) are placed around the femoral artery and vein, immediately behind the preceding. In addition to the lymphatics of the inferior extremity already described, the inguinal glands are joined by some superficial vessels from the external generative organs, from the lower part of the abdominal parietes, and several which proceed from the integuments covering the outer side of the pelvis. The deep lymphatics, which are derived from the mass of the muscles on the pelvis, and many proceeding from the adductor muscles of the thigh, accompanying respectively the gluteal, sciatic, and obturator arteries, enter the cavity of the pelvis with these vessels, and proceed in a series of glands situated in the neighbourhood of the trunk by which the vessels are given off. The vasa efferentia of the superficial inguinal glands perforate the fascia, come into connexion with those situated deeply, pass into the abdomen by the side of the blood-vessels, and terminate in a chain of lymphatics lying along the external iliac artery, and communicating with the lumbar glands.

*Lymphatics of the abdomen and pelvis*, (plate XLVI. fig. 1, g, g.)—The lymphatic vessels of the abdominal parietes consist of several groups, proceeding in different directions, but all referable to the arteries supplied to the different regions. A super-

ficial series, derived from the integuments covering anteriorly the lower part of the abdomen, (from the umbilicus downwards,) descends, converging to the superficial inguinal glands; and those deeply seated in the same situation, pursuing a similar direction, join glands situated on the external iliac artery, both following respectively the superficial and deep epigastric blood-vessels. The other lymphatics, (plate XLVII. k, k,) proceeding from the lateral and posterior part of the parietes of the abdomen, pass inwards between the fibres of the muscles; a small portion then winds round the crista of the ilium, meeting in their course one or two small glands, and proceed along Poupart's ligament with the circumflex ilii artery, to terminate in the external iliac glands; while the greatest number, directed backwards with the lumbar and ilio-lumbar arteries, and being joined by radicles from the large muscles of the back, pass behind the psoas muscle to the vertebral column, where they end in glands surrounding the large blood-vessels.

*Lymphatics of the pelvic viscera.*—The course of these, as of the lymphatic vessels in other parts, is indicated by that of their arteries and veins. The lymphatics of the bladder, taking rise from the entire surface of that organ, join in the glands placed about the internal iliac artery: with these are associated the lymphatics of the prostate gland and of the vesiculae seminales.

Those of the rectum are frequently of considerable size: immediately after leaving the intestine, some pass through small glands which lie contiguous to it; finally, they pass to glands situated in the hollow of the sacrum; some to those in the lumbar region.

In the unimpregnated state of the uterus, its lymphatics are small, but during the period of gestation they become of considerable size. Issuing from the entire substance of the organ, the greatest number descend, unite with those of the vagina, and passing backwards, join the internal iliac glands; thus pursuing the direction of the principal uterine blood-vessels. Others springing from the superior part (fundus) of the uterus, pass outwards in the folds of the peritonæum which constitute its broad ligaments, and join with the lymphatics derived from the ovarium and Fallopian tubes. The united vessels now ascend with the ovarium (in the male, spermatic) arteries, and, at a point where these take their rise, become connected with the lymphatics placed on the aorta and vena cava.

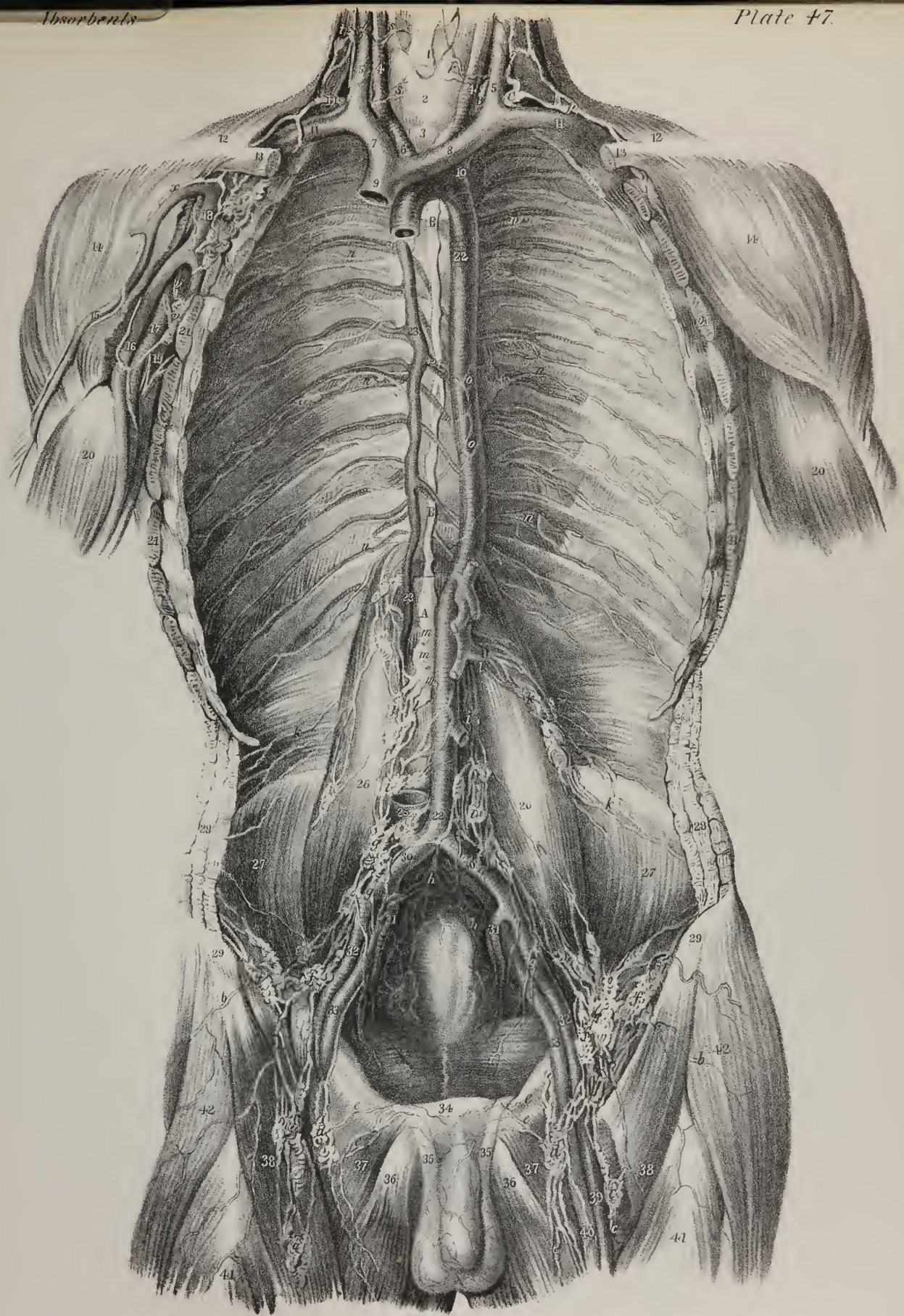
The *lymphatics of the penis* (plate XLVII. e, c) consist of superficial and deep sets, which pursue different courses. Those placed superficially usually form three vessels; two being placed laterally, the other superiorly. Commencing in the prepuce, they pass backwards, and generally unite on the dorsum penis, and again subdividing, send branches on each side to the inguinal glands.

The *lymphatics of the scrotum*, together with those from the integuments of the perinæum, may be associated; for all,

## PLATE XLVII.

- Deep lymphatics of the trunk, with the course and relations of the thoracic duct. To obtain this view, the anterior wall of the thorax and abdomen has been removed, together with the viscera of those cavities.
- No. 1. The larynx. 2. The thyroid gland. 3. The trachea. 4, 4. The common carotid arteries. 5, 5. The internal jugular veins. 6. The arteria innominata. 7. The right vena innominata. 8. The left vena innominata. 9. The superior cava cut short. 10. The left subclavian artery. 11, 11. The subclavian veins. 12, 12. Part of the trapezius muscle at each side. 13, 13. The clavicles, divided. 14, 14. The deltoid muscles. 15. The cephalic vein of the right arm. 16. The basilic vein. 17. The axillary artery. 18. The axillary vein. 19. One of the venæ comites. 20, 20. Part of the biceps muscle at each side. 21, 21. Line of section of the serratus magnus muscles. 22, 22. The aorta. 23, 23. The vena azygos major. 24. The vena azygos minor opening into the preceding. 25. The inferior vena cava, divided. 26, 26. The psoas magnus muscle at each side. 27, 27. The iliacus muscle at each side. 28, 28. The abdominal muscles, divided. 29, 29. The anterior superior spine of the ilium at each side. 30, 30. The common iliac arteries. 31, 31. The internal iliac arteries. 32, 32. The external iliac arteries. 33, 33. The external iliac veins. 34. The symphysis pubis. 35, 35. The spermatic chords. 36, 36. The adductor longus muscle at each side. 37, 37. The pectinei muscles. 38, 38. The sartorius muscle at each side. 39. The femoral artery of the left thigh. 40. The femoral vein. 41, 41. Part of the rectus muscle at each side. 42. The tensor vaginæ femoris muscle at each side.
- A. The receptaculum chyli. B, B. The thoracic duct, (ductus thoracicus.) C. The thoracic duct curving downwards and forwards to terminate at the junction of the left jugular and subclavian veins.
- a, a. Superficial lymphatic vessels and glands following the course of the saphenous vein. b, b. Superficial femoral lymphatics converging to the inguinal group of glands. c, c. Deep femoral lymphatic vessels and glands. d, d. Inguinal glands receiving, e, e, the lymphatic vessels of the penis and testes. f, f. Deep inguinal glands. g, g. Iliac lymphatic vessels and glands. h, h. Pelvic lymphatic vessels and glands. i, i. Lumbar lymphatic vessels and glands. k, k. Lymphatic vessels from the posterior wall of the abdomen converging to the lumbar glands. l, l. Large trunks by which the lumbar lymphatic vessels terminate in the receptaculum chyli. m, m. Divided trunks of the lacteal vessels. n, n. Intercostal lymphatic vessels converging to the chain of glands in the posterior mediastinum. o, o. Aortic lymphatic vessels. p. A large lymphatic trunk formed by the lymphatic vessels of the left upper extremity. q. Cervical lymphatic vessels converging towards the termination of the thoracic duct. r. Lymphatic vessels from the larynx and thyroid gland.
- D. The right lymphatic duct, (ductus lymphaticus dexter,) terminating at the junction of the right jugular with the subclavian vein. s, s. Lymphatic vessels from the right side of the larynx and thyroid gland converging to the right lymphatic duct. t. Cervical lymphatic vessels and glands. v. Axillary lymphatic vessels and glands. x. Lymphatic vessel accompanying the cephalic vein.









guided, as it were, by the superficial pudic vessels, join the inguinal lymphatic glands. The deep-seated lymphatics of the penis accompany the internal pudic vessels, and unite with glands on the internal iliac artery. The lymphatics of the labia, clitoris, &c., in the female, present a disposition entirely similar to that here described in the male organs.

*Lymphatics of the testis* commence by radicles issuing from the substance of the testis, and from the tunica vaginalis. Collected into several trunks of considerable size, they ascend, with the other constituents of the spermatic cord, to the internal abdominal ring, and finally accompany the spermatic vessels to enter the large lumbar lymphatic glands.

*Lymphatics of the kidney*.—Those placed superficially are very indistinct; they become united with the deep-seated set, at the inner margin (hilus) of the kidney, from which they incline inwards to the lumbar glands. The lymphatics of the suprarenal capsules unite with those of the kidney. The lymphatic vessels of the ureter are numerous; they communicate with those of the kidney and the bladder, and for the most part terminate with the former.

*Lymphatics of the stomach*, (plate XLV. f, g, h, i.)—These at first are disposed into two planes, one lying under the peritonæal coat, the other between the muscular coat and the mucous lining; by taking the direction of the vessels they become aggregated into three fasciculi. One set takes the direction of the coronary artery, receiving, as it runs from left to right, branches from both surfaces of the organ, and at the pylorus turns backwards to join some of the larger trunks. Another, from the left extremity of the stomach, follows the vasa brevia, and unites with those of the spleen; whilst the third, guided by the right gastro-epiploic vessels, inclines from left to right along its great curvature, from which they pass backwards, and at the root of the mesentery terminate in one of the principal lacteal vessels.

*Lymphatics of the spleen and pancreas*, (plate XLV. k, k.)—Some of the lymphatics of the spleen lie immediately under its peritonæal covering, others in the substance of the organ. Both converge to the inner side of the spleen, come into relation with the blood-vessels, and accompanying them, pass through a series of small glands, and finally become connected with the lymphatics of the digestive organs.

Lymphatics emerge from the pancreas at different points, and join those last described.

The *lymphatics of the liver* (plates XLV. and XLIX.) are divisible into three principal sets—those upon its upper surface, those on the lower one, the third being diffused throughout its substance with the hepatic vessels. Those upon the upper surface, though spread out pretty equally upon it, incline in their course to different points, and so become distinguishable into groups, of which four are ordinarily enumerated. Thus, from the middle of the great lobe, five or six branches run obliquely upwards to the suspensory ligament, where they form a large trunk, which passes between the fibres of the diaphragm, behind the ensiform cartilage. When in the mediastinum, they pass along the chain of glands which accompany the internal mammary vessels, and so they are conducted to the root of the neck, generally at the right side, where they terminate in the lymphatic trunk of that side. The second group consists of vessels which incline upwards and outwards to the right lateral ligament, opposite to which they unite into one or two of larger size, which pierce the diaphragm, and run upon its convex surface to join the preceding trunk in the mediastinum. In some cases, however, these, instead of passing into the thorax, turn backwards and inwards on reaching the posterior border of the liver, and, running upon the crus of the diaphragm, open into the thoracic duct at its commencement. A similar fasciculus is formed upon the left lobe of the liver, which, after passing through the left lateral ligament, pierces the diaphragm, upon which they ascend to the glands above noticed. Finally, towards the lower sharp border of the liver, at each side, some vessels will be observed also to turn downwards and join those placed upon its under surface.

A diffused plexus is formed by ramifications upon the concave surface of the liver. On the right lobe they will be found running downwards over the surface of the gall-bladder to the transverse fissure, where some join the deep-seated set, and others, after passing through a few glands, are, as it were, guided by the hepatic artery to the right side of the aorta, where they terminate in the thoracic duct. Branches also proceed to the concave border of the stomach, between the folds of the small omentum, to join with the coronary lymphatics of the stomach.

The deep-seated lymphatic vessels of the liver accompany the ramifications of the vena portæ in the interior of the organ, from which they escape by the transverse fissure. After communicating with the superficial vessels, and also with those of the stomach, they pass backwards, and at the side of the cœliac artery, join with one of the lacteal trunks, previously to its termination in the thoracic duct.

*Mesenteric glands* (plate XLV. m, m.)—These bodies vary in number from one hundred and thirty to a hundred and fifty; and in the healthy state are seldom larger than an almond. They are most numerous in that part of the mesentery which corresponds with the jejunum. Through these the lacteals may be said to pass in their course to the thoracic duct; they seldom occur nearer to the attached border of the intestine than two inches. Small glands are also disseminated irregularly between the folds of the peritonæum connected with the large intestine; they are not numerous, and require no special consideration.

*Lymphatic glands of the abdomen*, (plate XLVII.)—The lymphatics of the lower half of the body have been traced into the abdomen, to a series of glands situated in front of the vertebral column and the sacrum. Though these are connected by vessels passing from one to the other, forming a sort of chain in the situation indicated, yet as they are more numerous, or as it were aggregated together at particular points, they are divisible into different series. In the pelvis, some of the glands are placed behind the rectum in the hollow of the sacrum, and are hence named sacral glands; others, situated more externally, sur-

rounding the internal iliac artery, are denominated the internal iliac glands. It does not appear necessary to name them separately; they receive the lymphatics corresponding to the branches of the internal iliac artery, and communicate upwards with the lumbar glands.

The *lumbar lymphatic glands* (plate XLVII. i, i) are very large and numerous; they are placed in front of the lumbar vertebræ, surrounding the aorta and vena cava. To them we have traced the lymphatics which accompany several of the branches of the abdominal aorta, those of the inferior extremity being also connected with them. The vessels passing between the glands here described, progressively increasing in size while their number diminishes, at length form the trunks, which, with those of the lacteals, give rise to the thoracic duct.

The lymphatics of the thorax are divisible into two sets, viz. those of its parietes and those of the contained viscera. The former are arranged in two distinct planes, one lying between the skin and the muscles, the other being deeply seated. The superficial lymphatics at the front of the chest run upon the pectoralis major muscle, for the most part outwards and upwards, to reach the axilla, where they open into the glands. Those on the posterior surface lie upon the trapezius, and latissimus dorsi; some incline downwards, others upwards, some transverse,—all converging to the axilla, where, through the medium of the glands, they join with the lymphatics of the upper extremity. The deep vessels at the fore part of the chest correspond, in their general distribution, with the internal mammary artery; for they commence in the muscles of the abdomen, run upwards through the cellular interval, between the fibres of the diaphragm at their attachment to the ensiform cartilage, and so they ascend behind the costal cartilages to the summit of the thorax. In their course they receive branches from the anterior part of the intercostal spaces, and ultimately terminate, that of the left side in the thoracic duct, whilst the corresponding one ends in the right lymphatic trunk.

The lymphatics placed deeply at the sides and back part of the chest (plate XLVII. n, n) follow the distribution of the aortic intercostal arteries; for they receive branches from the dorsal muscles, which come forwards through the inter-transverse spaces, and others from the sides running along the intercostal spaces. All these incline inwards to the spine, and terminate in the thoracic duct.

The *lymphatics of the lungs*, (plate XLIX. d, d,) as in other organs, are disposed in two planes, one being superficial, the other deep-seated. Those at the surface run beneath the pleura, where they form a diffused net-work by their anastomoses. Their number is considerable, but they cannot be demonstrated with equal facility in all cases. "I have been able," says Cruikshank,\* "at one time to show the whole external surface of the lungs covered with absorbents I had injected; at another time I have not been able to find one." One of the easiest methods of finding them is to inflate the lungs of a still-born child from the trachea; the air passes from the cells into the absorbents, and enables us to see those on the surface: if a puncture be made into one of them with a lancet, the air will partially escape, and then the injecting pipe, containing a column of quicksilver, can be introduced.† Most of these converge to the root of the lungs, and terminate in the bronchial glands.

The deep lymphatics of the lungs run with the vessels along the bronchi, communicating freely with those at the surface,

## PLATE XLVIII.

Superficial lymphatics of the upper extremity.

FIG. 1. The anterior view of the arm. The muscles are retained in their relative position by the fascia. The lymphatic vessels take the course of the superficial veins.

No. 1. The convexity of the deltoid muscle. 2. The anterior border of the axilla formed by the pectoralis major muscle. 3. The posterior border of the axilla formed by the latissimus dorsi. 4. The convexity formed by the biceps muscle. 5. The triceps. 6, 7. The convexity of the pronator teres and flexor muscles of the fore-arm.

A, A. The radial vein. B. The anterior ulnar vein. C. The posterior ulnar vein. D. The median vein. E. The median cephalic vein. F. The median basilic vein. G. The basilic vein passing beneath the fascia of the upper arm. H, H. The cephalic vein.

a, a. Lymphatic vessels following the course of the radial and cephalic veins, and crossing the front of the biceps muscle to join the axillary glands, b, b. c, c. A long lymphatic vessel accompanying the cephalic vein. d, d. Ulnar lymphatic vessels proceeding to the axillary glands. e, e. Median lymphatic vessels also ascending to the axillary glands. f, f. Two lymphatic glands immediately above the inner condyle. g. A small gland in the course of the lymphatic vessels of the inner side of the arm. h. A lymphatic gland receiving vessels from the posterior aspect of the upper arm. i, i. Axillary glands receiving lymphatic vessels from the posterior part of the arm and side of the chest.

FIG. 2. A posterior view of the arm, invested by its fascia.

No. 1. The convexity of the deltoid muscle. 2. The triceps. 3. The convex outline of the biceps. 4. The olecranon.

A, A. The radial vein. B, B. The posterior ulnar vein.

a, a. Digital lymphatic vessels. b, b. Lymphatic vessels following the course of the radial vein. c, c. Lymphatic vessels from the back of the fore-arm turning around the arm immediately above the outer condyle to join the axillary glands. d, d. Other lymphatic vessels passing around the inner side of the arm to the axillary glands. e, e. Posterior ulnar lymphatic vessels. f, f. Lymphatic vessels from the region of the deltoid muscle, passing to the axillary glands.

\* Anatomy of the Absorbents, p. 194.

† Loc. cit.



Fig 2

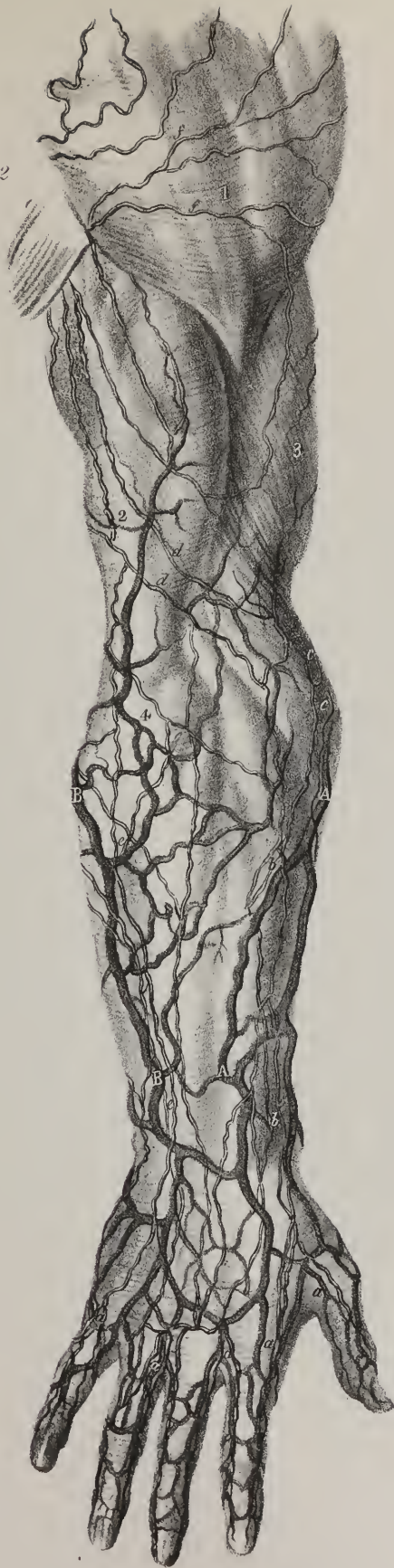
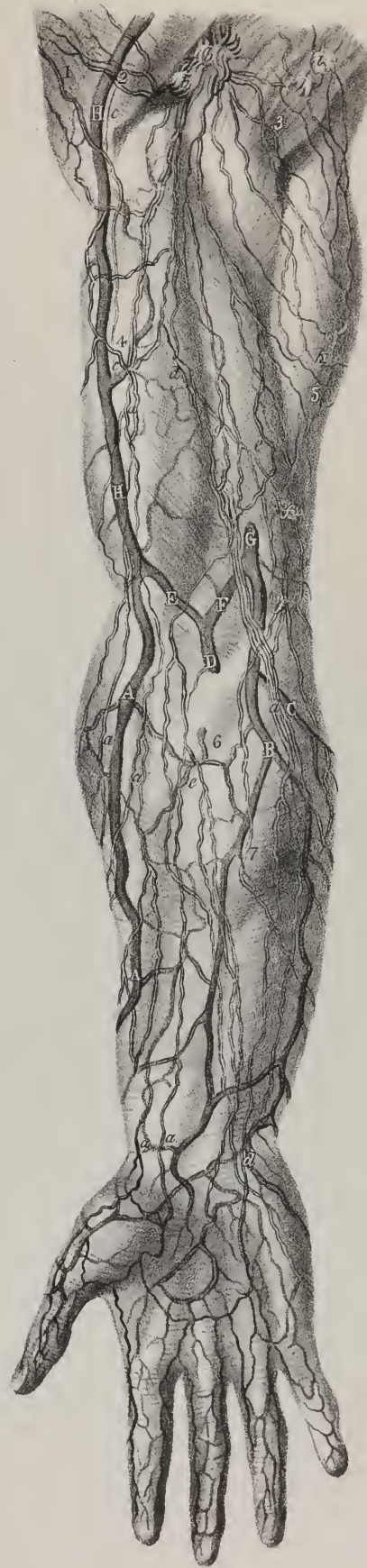
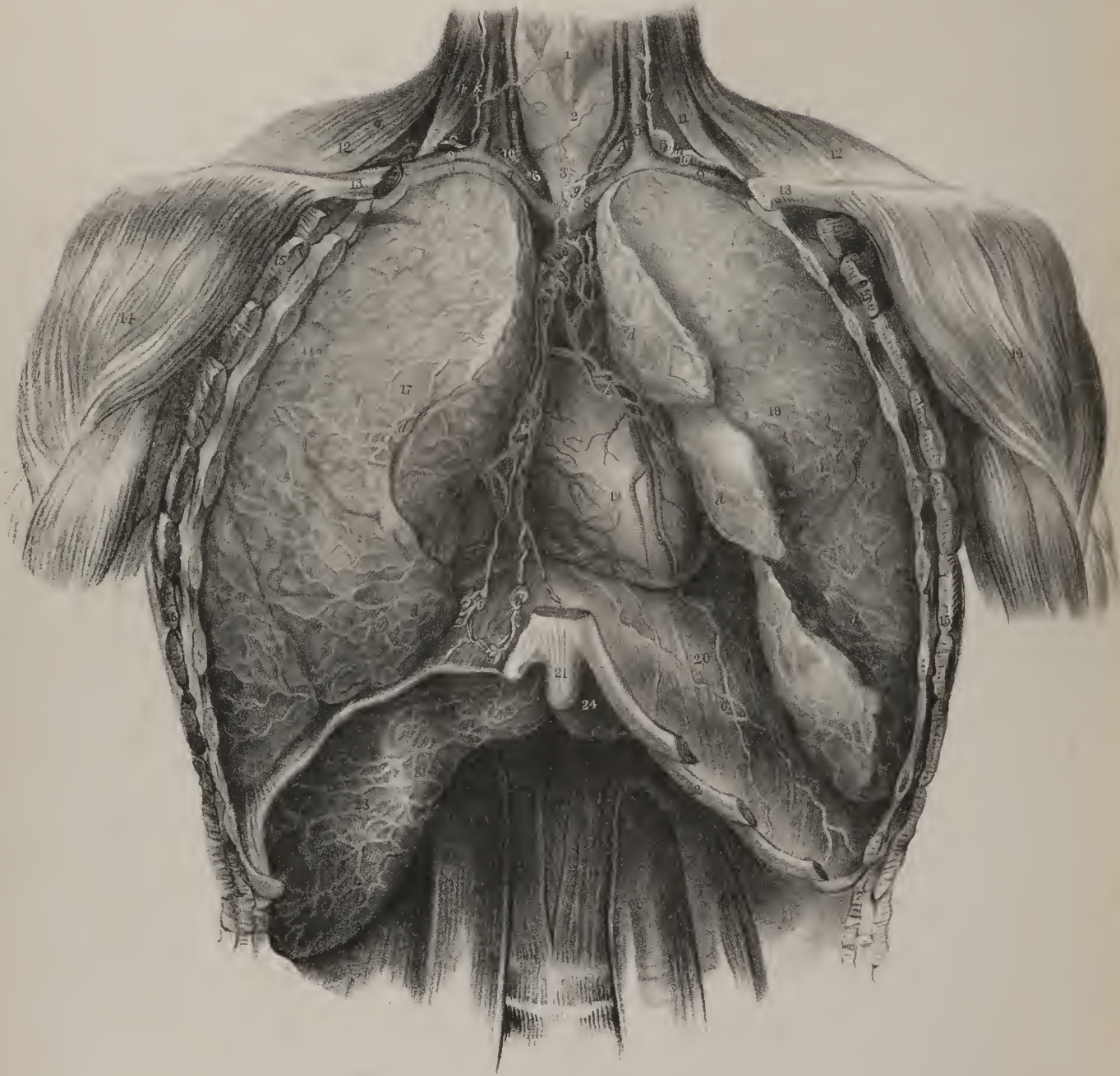
Fig 1











and at the root the lungs open into the bronchial glands. From these, two or three trunks issue, which ascend along the trachea to the root of the neck, and terminate at the left side in the thoracic duct, at the right in the corresponding lymphatic duct.

*Lymphatics of the thymus gland.*—On the spinal surface of the thymus, Sir Astley Cooper\* observes, “numerous absorbent glands are found; and if these be injected, many absorbents are discovered. But upon the posterior surface of the cornua and cervical portion, two large vessels proceed on each cornu, and the side of the trachea, towards the junction of the jugular veins with the superior cava. They are sufficiently large to admit a pipe to throw in coarse injection, and I can readily inject them with wax, dissect and preserve them, so as to make very interesting preparations of them. They pass nearly straight upon the spinal surface of the cornua, converging a little as they proceed towards the sternum, and terminate in the jugular veins by one or more orifices on each side.”

*Lymphatics of the thyroid gland,* (plate XLIX.)—From each lateral lobe of this organ some absorbing vessels arise, which converge and unite to form one short trunk, that opens at the right side into the right lymphatic duct, at the left into the thoracic. They may be demonstrated by inserting the injecting pipe into the substance of the gland, when the mercury, by its weight, will force its way into the lymphatics.

*Lymphatics of the heart,* (plate XLIX. e, f.)—These follow the coronary vessels, from the apex of the organ up to its base. Those of the right side converge to the origin of the aorta; a trunk of some size is thus formed, which runs upwards over the aortic arch, gets between the carotid and brachio-cephalic arteries, where it sinks backwards to the trachea, by which it ascends to the root of the neck, to terminate in the right lymphatic trunk. The left lymphatic branches ascend to the base of the heart; where they also communicate with the preceding, and then proceed, having united into a single vessel, along the pulmonary artery, towards its bifurcation. At this point it gets behind the arch of the aorta, passes through some lymphatic glands, and finally ascends by the trachea to terminate in the thoracic duct.

*Lymphatics of the œsophagus.*—Along this tube a plexus is formed by absorbing vessels, which pass upwards upon it, traversing the glands which lie in their course; and after having communicated by anastomoses with the lymphatics of the lungs, at the root of that organ, and also higher up, finally terminate in the thoracic duct.

*Lymphatic glands of the thorax,* (plate XLIX.)—In the description of the vessels, we have noticed the ovoid bodies with which they are connected. Thus, six or seven small glands are placed in the course of the internal mammary vessels, and through which the lymphatics pass; they may be named the *anterior mediastinal* glands, (b, b.) Three or four lie behind the aortic arch, and one before it, (*cardiac glands*), having a similar relation to the lymphatic vessels; some, also, are found along the œsophagus, varying from fifteen to twenty in number, (*œsophageal glands*.) At the root of the lungs ten or twelve similar bodies are placed of larger size, and usually named *bronchial glands*. The largest of these occupy the interval between the bronchi at their bifurcation, whilst others of smaller size rest upon these tubes for some way within the lungs. In early infancy their colour is pale red; towards puberty, we find them verging to gray, and studded with dark spots; at a more advanced age they are frequently very dark. In chronic diseases of the lungs they become enlarged and indurated, so as to press on the air-tubes, and cause much irritation. They are frequently the seat of tubercular deposits.

*Lymphatics of the superior extremity,* (plate XLVIII.)—These are divisible into two series, one of which is superficial, the other deeply-seated; the former accompanying the cutaneous veins, the latter following the course of the deep vessels.

The *superficial lymphatics* commence by two divisions. Of these, one corresponds with the branches of the ulnar cutaneous

## PLATE XLIX.

Lymphatic vessels of the viscera of the thorax, and convex surface of the liver.

- No. 1. The thyroid cartilage. 2. Thyroid gland. 3. Trachea. 4, 4. Carotid arteries. 5, 5. Internal jugular veins. 6. Arteria innominata. 7. The right innominata vein. 8. The left innominata vein. 9, 9. Subclavian veins. 10, 10. Subclavian arteries. 11, 11. The anterior scalenus muscle at each side. 12, 12. The trapezius muscle at each side. 13, 13. The clavicles sawn through. 14, 14. The deltoid muscles. 15, 15. The serratus magnus muscle at each side, divided. 16. The arch of the aorta. 17. The right lung. 18. The left lung. 19. The heart. 20. The diaphragm; on the right side a portion is removed to bring into view the upper surface of the liver. 21. The ensiform cartilage. 22. Cartilages of the ribs forming the lower border of the thorax. 23. The convex surface of the right lobe of the liver. 24. The left lobe.
- A. The thoracic duct deeply seated at the root of the neck. B. The thoracic duct curving forwards and downwards to terminate at the junction of the left jugular and subclavian veins. C. The right lymphatic duct.
- a, a. Lymphatic vessels from the convex surface of the liver, converging to, b, b, a chain of glands and vessels in the anterior mediastinum. c, c. Lymphatic vessels from the diaphragm. d, d. Lymphatic vessels from the surface of the lungs converging towards the roots of those organs. e. Lymphatic vessels of the right ventricle of the heart. f. Lymphatic vessels of the left ventricle of the heart. g. A lymphatic gland receiving converging vessels from the root of the neck and viscera of the thorax. h. A large lymphatic trunk from the upper extremity. i. A lymphatic trunk accompanying the left jugular vein. k. A lymphatic trunk descending along the right jugular vein to terminate in the right lymphatic duct.

\* Anatomy of the Thymus Gland, p. 14.



vein, which its different ramusculi accompany, from the inner border of the hand, along the anterior and inner surface of the fore-arm as far as the bend of the elbow. In this course they receive numerous branches from the surrounding parts, and join at the point just indicated with a portion of those which constitute the second or external division. Some now enter a lymphatic gland (f) situated in front of the inner condyle of the humerus; continuing their course upwards from thence, they terminate either in glands placed along the brachial artery, or in those of the axilla, where they unite with the deep lymphatics. Those which constitute the second division are less numerous than the preceding. Proceeding from the integuments on the outer margin and back of the hand, they follow the course of the radial cutaneous veins to the bend of the elbow; here the greater number become united to the preceding series, whilst a few accompany the cephalic vein, ascend on the external side of the arm, pass with that vessel between the deltoid and great pectoral muscle, and end in one or more lymphatic glands beneath the clavicle, communicating with those at the lower part of the neck.

The deep lymphatic vessels correspond exactly to the arteries which they accompany. In the fore-arm, the deep lymphatics consist, therefore, of three sets, associated with the radial, the ulnar, and inter-osseous arteries; in their progress upwards they maintain communication with those placed superficially. Some of them pass to the glands which lie near the brachial artery; finally, all end in the glands of the axilla.

The *glands of the axilla* (plate XLVII. v; plate XLVIII. b, b, i, i) are generally ten or twelve in number; in this, however, as well as in their size, they vary considerably in different individuals; they are placed along the axillary vessels, embedded in a quantity of loose cellular tissue. They receive the lymphatic vessels of the arm already described, as well as those proceeding from the integuments of the back, from the anterior surface of the thorax and mamma, and are therefore liable to be influenced by disease affecting any of these parts.

From the glands in the axilla, vessels, fewer in number but larger in size, issue and proceed along with the subclavian artery, in some parts twining round it. From the top of the thorax they ascend into the neck, close to the subclavian vein, and terminate, those of the left side in the thoracic duct, those of the right side in the second or smaller lymphatic duct. These vessels sometimes unite into a single trunk, which opens separately into the subclavian vein near its termination.

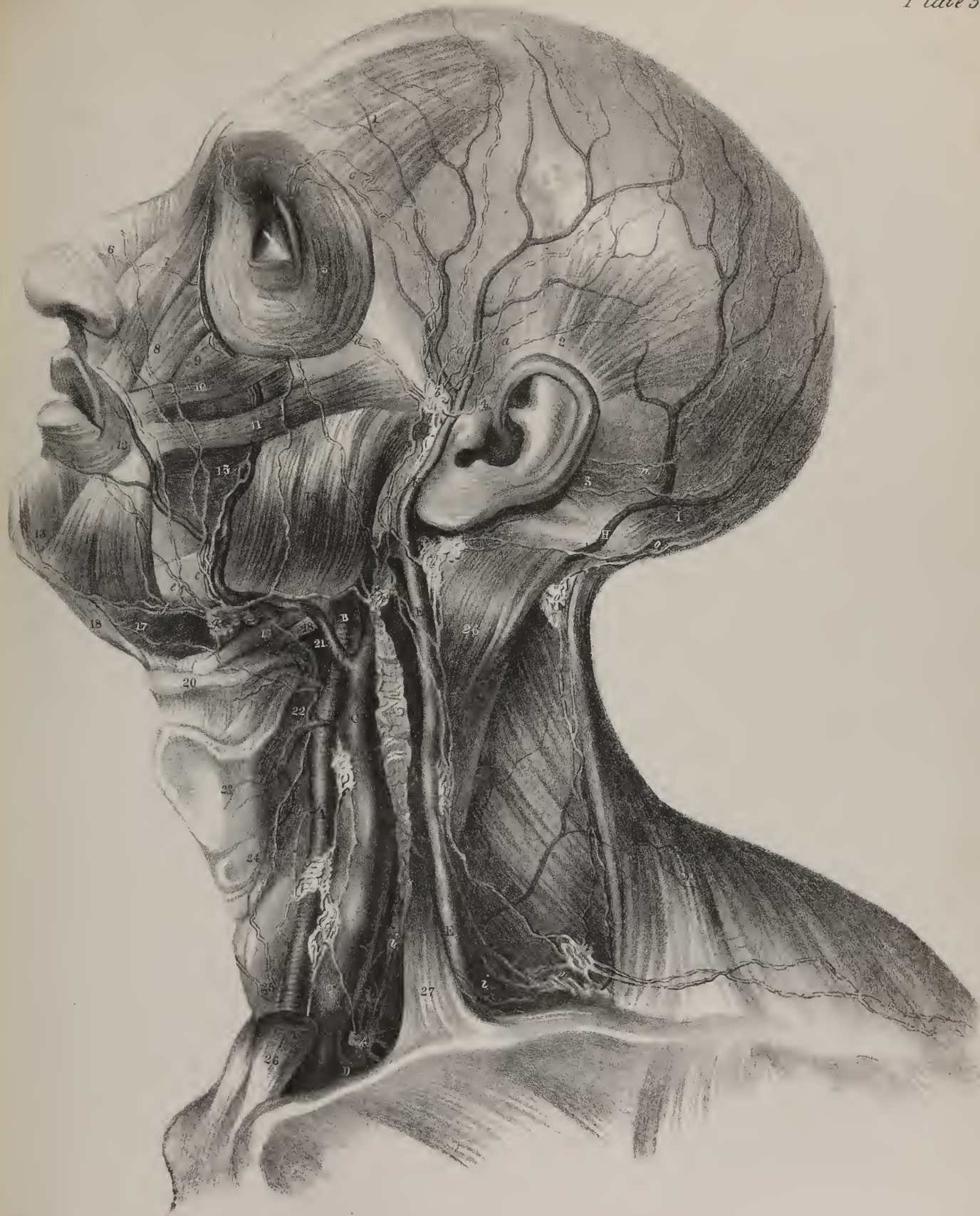
*Lymphatic vessels and glands of the head and neck*, (plate L.)—The lymphatics of the head consist of those of the cranium and the face. The former commence by a series of minute radicles disseminated over the scalp; in their descent they diminish in number, increasing in size, and separate into an anterior and posterior division, which follow respectively the course of the temporal and the occipital arteries. The former pass in front of the ear; some at this point enter one or two glands usually placed in the immediate neighbourhood of the zygoma, while others go to those situated on the parotid gland; finally all end in the lymphatic glands of the neck. The posterior division of the cranial lymphatics accompany the occipital artery, then pass to the glands situated behind the ear, (over the mastoid process of the temporal bone,) and thence join the superficial lymphatics of the neck. The superficial lymphatics of the face, more numerous than those of the cranium, descend obliquely in the course of the fascial vein, and join the glands placed beneath the base of the lower maxillary bone; a few of these in their descent pass through one or two glands situated over the buccinator muscle. The deep-seated lymphatics of the face issue from the cavity of

## PLATE L.

Lymphatic vessels and glands of the head and neck.

- Nos. 1, 1. The occipito-frontalis muscle. 2. The attollens aurem muscle. 3. The retrahens aurem muscle. 4. The attrahens aurem muscle. 5. The orbicularis palpebrarum muscle. 6. The compressor narium. 7. The levator labii superioris alæque nasi. 8. The levator labii superioris proprius muscle. 9. The levator anguli oris. 10. The zygomaticus minor muscle. 11. The zygomaticus major. 12. The orbicularis oris. 13. The depressor labii inferioris muscle. 14. The depressor anguli oris. 15. The buccinator muscle. 16. The masseter muscle. 17. The mylo-hyoideus muscle. 18. The digastricus muscle. 19. The stylo-hyoideus muscle. 20. The hyoid bone. 21. Part of the middle constrictor muscle of the pharynx. 22. The origin of the inferior constrictor muscle. 23. The thyroid cartilage. 24. The cricoid cartilage. 25. The thyroid gland. 26, 26. The sterno-mastoid muscle; its middle portion is removed to bring into view the deep cervical vessels with their accompanying lymphatics. 27. Part of the clavicular origin of the sterno-mastoid. 28. The trapezius muscle.
- A. The common carotid artery. B. The external carotid. C. C. The internal jugular vein. D. The subclavian vein. E, E. The external jugular vein. F. The temporal vein. G, G. The facial vein. H. The occipital vein.
- a, a. Temporal lymphatic vessels converging to, b, b, lymphatic glands situated near the zygoma and parotid gland. c, c. Two lymphatic vessels from the eyebrow and integument of the forehead, passing backwards to the zygomatic glands. d. Lymphatic vessels from the lower eyelid converging to the same glands. e, e. Lymphatic vessels from the forehead, nose, and mouth, following the course of the facial vein, to the submaxillary lymphatic glands. f, f. Submaxillary lymphatic vessels also converging to the submaxillary lymphatic glands. g. h, h. Deep cervical lymphatic glands and vessels, receiving lymphatic branches from the anterior part of the neck and thyroid gland. i, i. Lymphatic trunks converging from the neck and upper extremity to the termination of the thoracic duct. k. l, l. Superficial cervical glands and vessels accompanying the external jugular vein, and terminating in a group of glands, m, which receives the lymphatic vessels from the posterior part of the neck and superficial parts of the shoulder, and communicates with the axillary glands. n. Occipital lymphatic vessels terminating in glands situated behind the ear. o. Other lymphatic vessels communicating with the superficial cervical vessels and glands.







the nose, the mouth, &c., and proceed in the course of the internal maxillary artery; when arrived at the angle of the jaw, they join the glands which occur at this point. The lymphatic glands described as existing on different parts of the head are few and very small; those of the neck, on the contrary, are comparatively large and very numerous.

The *cervical glands* (plate L.) are almost all placed on the sides of the neck, and are divisible into a superficial and deep-seated series. Of the former, some lie along the base of the inferior maxillary bone; (g) the remainder, disposed in the course of the external jugular vein, (l, l,) occur in greatest number in the angular space behind the lower end of the sterno-mastoid muscle, where the external jugular joins the subclavian vein; at the point indicated, they approach and communicate with the axillary glands. The deep-seated cervical glands (h, h) are placed along the carotid artery and internal jugular vein; extending downwards on different sides of these vessels as far as the thorax. The lymphatic vessels of the cranium and face, (already described,) together with those of the pharynx, larynx, and other parts of the neck, being received into these glands, and again issuing from them, progressively diminish in number during their descent, and ultimately, at the bottom of the neck, unite into one trunk. This vessel usually pours its contents at the left side into the thoracic duct, (k,) immediately before its termination, and at the opposite side into the large right lymphatic duct, (plate XLVII. D;) it, however, sometimes terminates separately at the confluence of the subclavian and internal jugular veins, or in one of these vessels immediately beyond their point of junction.

*Right lymphatic duct*, (ductus lymphaticus dexter; plate XLVII. D; plate XLIX. C.) This is a short vessel, about two lines in diameter, and about three quarters of an inch in length, which receives the lymph from the absorbents of the right upper extremity, and corresponding side of the head and chest. It runs obliquely into the angle formed by the union of the right subclavian and internal jugular veins, where its orifice is guarded by two valves.

END OF THE VASCULAR SYSTEM.





# INDEX.

---

- Absorbents, page 84.  
     history of, page 85.
- Absorbent glands, page 85.
- Anastomoses, page 7.  
     femoro-tibial, page 66.  
     ilio-femoral, 66.  
     tibio-tarsal, 66.
- Aorta, page 14. (Pl. III. fig. 1, A, A.)  
     abdominal, page 40. (Pl. XIV. A, A.)  
     arch, page 15. (Pl. I. nos. 17, 18; Pl. XIII. A, B, C.)  
     thoracic, page 40. (Pl. XIII. D.)
- Arch, superficial palmar, page 35. (Pl. IX. fig. 1, p, p.)  
     deep palmar, page 37. (Pl. IX. fig. 2, r, r.)
- Arcus volæ sublimis, *see* Arch, superficial palmar.  
     — profundus, *see* Arch, deep palmar.
- Arter. acromialis, page 32. (Pl. IV. p.)  
     alveolaris, page 24.  
     anastomotica femoralis, page 58. (Pl. XXV. 1, 1; Pl. XXVI. q.)  
         — magna, page 34. (Pl. IX. figs. 1, 2, i.)  
     angularis, page 19.  
     articulares popliteæ inferiores, page 61. (Pl. XXVII. d\*, e\*; Pl. XXIX. fig. 1, c, d.)  
         — superiores, page 60. (Pl. XXVII. a\*, b\*; Pl. XXIX. fig. 1, a, b.)  
     articularis popliteæ azygos, page 61. (Pl. XXVII. c\*.)  
     auriculares anteriores, page 23.  
     auricularis posterior, page 22. (Pl. IV. g.)  
     axillaris, page 31. (Pl. IV. F, G.)  
     axis cœliacus, page 41. (Pl. XIV. & XV. B.)  
     — thyroideus, page 29. (Pl. IV. k; Pl. V. fig. 2, d.)  
     basilaris, page 29. (Pl. VII. fig. 4, d, d.)  
     brachialis, page 33. (Pl. IX. figs. 1, 2, A, A.)  
     brachio-cephalica, page 16. (Pl. I. no. 19; Pl. III. fig. 1, B; Pl. XIII. E.)  
     bronchialis, page 40. (Pl. XIII. d, e.)  
     buccalis, page 24. (Pl. VI. fig. 2, g.)
- Arter. capsulares, page 44. (Pl. XIV. g.)  
     carotis communis, page 16. (Pl. I. nos. 20, 27; Pl. IV. A, A; Pl. XIII. F, H.)  
         — externa, page 18. (Pl. II. C; Pl. IV. B; Pl. V. fig. 1, A, A.)  
         — interna, page 25. (Pl. IV. C.)  
     carpi dorsalis radialis, page 38. (Pl. X. figs. 1, 3, K.)  
         — palmaris radialis, page 37.  
         — dorsalis ulnaris, page 37. (Pl. X. fig. 1, h, fig. 3, p.)  
         — palmaris ulnaris, page 37.  
     centralis retinæ, page 26.  
     cerebelli inferior, page 29. (Pl. VII. fig. 4, c.)  
         — superior, page 29. (Pl. VII. fig. 4, f.)  
     cerebri anterior, page 26. (Pl. VII. fig. 4, k, k.)  
         — media, page 27.  
         — posterior, page 29. (Pl. VII. fig. 3, i, i, fig. 4, g, g.)  
     cervicalis ascendens, page 29. (Pl. IV. m.)  
         — profunda, page 30. (Pl. V. fig. 2, k.)  
         — superficialis, page 30.  
     choroideæ, page 27.  
     ciliares, page 26. (Pl. VII. fig. 6, g.)  
     circumflexa anterior, page 33. (Pl. IV. r.)  
         — externa, page 57. (Pl. XXV. h, h; Pl. XXVI. e.)  
         — ilii, page 53. (Pl. XIV. r; Pl. XIX. k; Pl. XXI. fig. 1, b.)  
         — superficialis, page 57. (Pl. XXIII. d, d; Pl. XXV. d, d.)  
         — interna, page 57. (Pl. XXVI. k; Pl. XXVII. s.)  
         — posterior, page 33. (Pl. IV. s.)  
     coccygea, page 49. (Pl. XXVII. p, p.)  
     cœliaca, page 41. (Pl. XIV. & XV. B.)  
     colica dextra, page 43. (Pl. XVII. e, f.)  
         — media, page 43. (Pl. XVII. a; Pl. XVIII. m.)  
         — sinistra, page 43. (Pl. XVIII. b.)  
     comes nervi ischiadici, page 49. (Pl. XXVII. r.)  
         — phrenici, page 31.  
     communicans cerebri anterior, page 26. (Pl. VII. fig. 4, l.)  
         — posterior, page 26. (Pl. VII. fig. 4, h, h.)

- Arter. communicans palmaris, page 37. (Pl. IX. fig. 2, r.)  
 ————— plantaris, page 65. (Pl. XXIX. fig. 2, s.)  
 coronaria dextra, page 16. (Pl. XIII. b.)  
 ————— labii inferioris, page 19. (Pl. VI. fig. 1, g.)  
 ————— superioris, page 20. (Pl. VI. fig. 1, h.)  
 ————— sinistra, page 16. (Pl. XIII. c.)  
 ————— ventriculi, page 41. (Pl. XIV. c; Pl. XV. C; Pl. XVI. fig. 1, C, fig. 2, a.)  
 corporis bulbosi, page 50. (Pl. XXI. fig. 2, t; Pl. XXII. fig. 1, e.)  
 ————— cavernosi, page 50. (Pl. XXI. fig. 2, v; Pl. XXII. fig. 1, f, fig. 2, e.)  
 cremasterica, page 53. (Pl. XIX. s.)  
 cystica, page 42. (Pl. XV. k; Pl. XVI. fig. 1, m.)  
 dentalis inferior, page 23. (Pl. VI. fig. 2, f.)  
 ————— superior, page 24. (Pl. VI. fig. 2, h.)  
 digitales manûs, page 37. (Pl. IX. fig. 1, t, u.)  
 ————— pedis, page 64. (Pl. XXXIII. fig. 1, g, h, i, k, fig. 2, e, f, g, h.)  
 dorsales linguæ, page 19. (Pl. VII. fig. 1, d.)  
 ————— pollicis, page 38. (Pl. X. fig. 1, l, fig. 3, l, m.)  
 dorsalis carpi radialis, page 38. (Pl. X. figs. 1, 2, k, k.)  
 ————— ulnaris, page 37. (Pl. X. fig. 1, h, fig. 2, p.)  
 ————— indicis, page 38.  
 ————— pedis, page 65. (Pl. XXIX. B, B.)  
 ————— penis, page 50. (Pl. XXI. fig. 2, u, u.)  
 ————— pollicis pedis, page 65. (Pl. XXIX. fig. 1, q, fig. 2, t.)  
 ————— scapulæ, page 33. (Pl. IV. v.)  
 emulgens, page 44. (Pl. XIV. D, D.)  
 epigastrica, page 52. (Pl. XIV. s; Pl. XIX. i, i.)  
 ————— superficialis, page 57. (Pl. XXIII. c; Pl. XXV. c.)  
 ————— superior, page 31. (Pl. XIX. a.)  
 ethmoidales, page 26. (Pl. VII. fig. 5, e, e.)  
 facialis, page 19. (Pl. IV. c; Pl. VI. fig. 1, e, e, fig. 2, D.)  
 femoralis, page 54. (Pl. XXV. B, C; Pl. XXVI. B, C.)  
 frontalis, page 26.  
 gastricæ, page 42. (Pl. XVI. fig. 1, o, o.)  
 gastro-duodenalis, page 41. (Pl. XV. o; Pl. XVI. fig. 1, g.)  
 ————— epiploica dextra, page 41. (Pl. XV. p, p; Pl. XVI. fig. 1, k, k, fig. 2, e, e.)  
 ————— sinistra, page 42. (Pl. XVI. fig. 1, n, fig. 2, g.)  
 glutæa, page 48. (Pl. XXI. fig. 1, n; Pl. XXVII. k.)  
 hæmorrhoidales externæ, page 50. (Pl. XXI. fig. 2, p, p; Pl. XXII. b, b.)  
 hæmorrhoidalis media, page 50. (Pl. XXI. fig. 1, h, i.)  
 ————— superior, page 43. (Pl. XIV. m; Pl. XVIII. g.)  
 hepatica, page 41. (Pl. XIV. d; Pl. XV. & XVI. D.)  
 humeraria, page 33. (Pl. IX. figs. 1, 2, A, A.)  
 hyoidea lingualis, page 19. (Pl. VII. fig. 1, e.)  
 ————— thyroideæ, page 18. (Pl. V. fig. 1.)  
 hypogastrica, page 46. (Pl. XIV. G; Pl. XXI. E.)  
 iliaca communis, page 45. (Pl. XIV. E, E; Pl. XXI. C.)  
 ————— externa, page 51. (Pl. XIV. F; Pl. XIX. A; Pl. XXI. D.)  
 ————— interna, page 46. (Pl. XIV. G; Pl. XXI. E.)  
 ilio-colica, page 43. (Pl. XVII. h.)  
 ————— lumbalis, page 47. (Pl. XXI. l, c.)  
 infra-orbitalis, page 24. (Pl. VI. fig. 2.)
- Arter. infra-spinalis scapulæ, page 30. (Pl. VIII. k.)  
 innominata, page 16. (Pl. I. no. 19; Pl. III. fig. 1, B; Pl. XIII. E.)  
 intercostales, page 40. (Pl. XIII. g, h; Pl. XIX. e, e.)  
 ————— anteriores, page 31. (Pl. VII. fig. 2, o, p.)  
 intercostalis superior, page 31. (Pl. VII. fig. 2, e.)  
 interossea, page 36. (Pl. IX. fig. 2, D, D.)  
 ————— anterior, page 36. (Pl. IX. fig. 2, D; Pl. X. fig. 3, g, h.)  
 ————— posterior, page 36. (Pl. X. figs. 2, 3, e.)  
 interossee digitorum mantis, page 38. (Pl. IX. fig. 2, t.)  
 ————— pedis, page 65. (Pl. XXIX. fig. 1, s, s.)  
 i. testini tenuis, page 43. (Pl. XVII. k, l, m.)  
 ischiadica, page 49. (Pl. XXI. fig. 1, g, fig. 2, l; Pl. XXVII. o.)  
 labialis, page 19. (Pl. IV. c; Pl. VI. fig. 1, e, e, fig. 2, D.)  
 ————— inferior vel superficialis, page 19. (Pl. VI. fig. 2, s.)  
 lachrymalis, page 26. (Pl. VII. fig. 5, c.)  
 laryngealis, page 18. (Pl. II.)  
 lingualis, page 19. (Pl. IV. b; Pl. VII. fig. 1, C, C.)  
 lumbales, page 45. (Pl. XIV. k, k.)  
 malleolaris externæ, page 65. (Pl. XXIX. fig. 1, g, fig. 2, c.)  
 ————— internæ, page 65. (Pl. XXIX. fig. 1, l, fig. 2, g.)  
 mammaria interna, page 31. (Pl. VII. fig. 2, n.)  
 masseterica, page 24.  
 mastoidea, page 22.  
 maxillaris externa, page 19. (Pl. IV. c; Pl. VI. fig. 1, c, c, fig. 2, D.)  
 ————— inferior, page 23. (Pl. VI. fig. 2, f.)  
 ————— interna, page 23. (Pl. VI. fig. 2, B.)  
 mediastinæ, page 31.  
 meningeæ anterior, page 25.  
 ————— inferior, page 21.  
 ————— media vel magna, page 23. (Pl. VI. fig. 2, l.)  
 ————— parva, page 23.  
 ————— posterior, page 29.  
 mesenterica superior, page 43. (Pl. XIV. C; Pl. XVII. A; Pl. XVIII. B.)  
 ————— inferior, page 43. (Pl. XIV. i; XVIII. a.)  
 metatarsea, page 65. (Pl. XXIX. fig. 2, m, m.)  
 musculo-phrenica, page 31.  
 nasalis lateralis, page 20.  
 ————— maxillaris, page 24.  
 ————— ophthalmicæ, page 26. (Pl. VI. o; Pl. VII. fig. 5, g.)  
 ————— septi, page 20.  
 nutritia fibulæ, page 62.  
 ————— humeri, page 33.  
 ————— tibiarum, page 62.  
 obturatoria, page 47. (Pl. XXI. fig. 1, m, fig. 2, g; Pl. XXIV. figs. 1, 2, c.)  
 occipitalis, page 22. (Pl. IV. f; Pl. VIII. a.)  
 œsophageales, page 40. (Pl. XIII. f, f.)  
 ophthalmica, page 26. (Pl. VII. figs. 5, 6, b, b.)  
 palatina inferior, page 19.  
 ————— superior vel descendens, page 24.  
 palpebrales, page 26. (Pl. VII. fig. 5, n.)  
 pancreatica magna, page 42.  
 pancreaticæ parvæ, page 42. (Pl. XVI. fig. 1, q, q.)  
 pancreatico-duodenalis, page 41. (Pl. XIV. c; Pl. XV. C; Pl. XVI. fig. 1, C, fig. 2, e.)



Arter. perforantes femoralis, page 58. (Pl. XXVI. l, m, n; Pl. XXVII. u, w, x.)  
 ——— palmares, page 38. (Pl. X. fig. 3, r.)  
 ——— plantares anteriores, page 64. (Pl. XXXIII. fig. 2, k, k.)  
 ——— posteriores, page 63. (Pl. XXXI. fig. 2, i, i.)  
 pericardiaca, page 40.  
 perinei superficialis, page 50. (Pl. XXI. fig. 2, q; Pl. XXII. c, c.)  
 peronea, page 62. (Pl. XXX. fig. 2, e, e.)  
 ——— anterior, page 62. (Pl. XXX. fig. 1, g, fig. 2, i; Pl. XXXII. fig. 2, d, d.)  
 ——— posterior, page 62. (Pl. XXX. fig. 1, f, fig. 2, g, h; Pl. XXXII. fig. 2, c, c.)  
 pharyngea ascendens, page 20.  
 phrenica, page 43. (Pl. XIV. a, b.)  
 plantaris externa, page 63. (Pl. XXXIII. figs. 1, 2, C, C.)  
 ——— interna, page 63. (Pl. XXXIII. figs. 1, 2, B, B.)  
 poplitea, page 59. (Pl. XXVII. A, A; Pl. XXX. A, A.)  
 princeps cervicis, page 21.  
 ——— pollicis, page 38. (Pl. IX. fig. 2, o; Pl. X. fig. 1, m.)  
 profunda cervicis, page 30. (Pl. V. fig. 2, k.)  
 ——— femoris, page 57. (Pl. XXV. g, g; Pl. XXVI. D; Pl. XXVII. y.)  
 ——— inferior, page 34. (Pl. IX. f.)  
 ——— superior, page 34. (Pl. IX. figs. 1, 2, c.)  
 pterygoidea, page 24. (Pl. VI. fig. 2, e.)  
 pterygo-palatina, page 24.  
 pudenda externa, page 56. (Pl. XXXIII. e; Pl. XXV. e, f.)  
 pudica interna, page 49. (Pl. XXI. fig. 1, f, fig. 2, n, n; Pl. XXII. a, a.)  
 pylorica, page 41. (Pl. XV. e; Pl. XVI. d.)  
 radialis, page 37. (Pl. IX. figs. 1, 2, B; Pl. X. figs. 1, 3, i.)  
 ——— indicis, page 38. (Pl. IX. fig. 1, r, fig. 2, s.)  
 ranina, page 19. (Pl. VII. fig. 1, h.)  
 recurrens interossea, page 36. (Pl. X. fig. 1, c, fig. 2, f, fig. 3, d.)  
 ——— radialis, page 37. (Pl. IX. l; Pl. X. fig. 1, d, fig. 3, b.)  
 ——— tibialis, page 64. (Pl. XXIX. fig. 1, e, fig. 2, e.)  
 ——— ulnaris anterior, page 35. (Pl. IX. fig. 2, p.)  
 ——— posterior, page 35. (Pl. X. fig. 2, d.)  
 recurrentes arcus palmaris, page 38. (Pl. X. fig. 1, n, fig. 3, o.)  
 renalis, page 44. (Pl. XIV. D, D.)  
 sacra lateralis, page 48. (Pl. XXI. fig. 1, p, fig. 2, h, i.)  
 ——— media, page 43. (Pl. XIV. l.)  
 scapularis posterior, page 30. (Pl. XL.)  
 scapulæ posterior, page 30. (Pl. VIII. b.)  
 sigmoidea, page 43. (Pl. XVIII. f.)  
 spermatica, page 44. (Pl. XIV. h, h.)  
 sphæno-palatina, page 24.  
 spinalis anterior, page 29. (Pl. VII. fig. 4, b.)  
 ——— posterior, page 29. (Pl. VII. fig. 4, c.)  
 splenica, page 42. (Pl. XIV. c; Pl. XV. & XVI. E.)  
 stylo-mastoidea, page 22.  
 subclavia dextra, page 27. (Pl. I. no. 23; Pl. II. A; Pl. IV. D, E; Pl. XIII. G.)  
 ——— sinistra, page 28. (Pl. I. no. 21; Pl. XIII. I.)  
 sublingualis, page 19. (Pl. VII. fig. 1, f.)  
 submental, page 19. (Pl. V. fig. 1, c.)

ARTERIES.—13

Arter. subscapularis, page 33. (Pl. IV. t.)  
 superficialis volæ, page 37. (Pl. IX. fig. 1, o, fig. 2, n.)  
 supra-orbitalis, page 26. (Pl. II. n; Pl. VI. fig. 1, a.)  
 ——— scapularis, page 30. (Pl. IV. n.)  
 ——— spinalis, page 30.  
 tarsea, page 65. (Pl. XXIX. fig. 1, m.)  
 temporales profundæ, page 24. (Pl. VI. fig. 2, k, i.)  
 temporalis, page 22. (Pl. VI. fig. 2, c, c.)  
 ——— anterior, page 23. (Pl. II. m; Pl. VI. fig. 1. b. c.)  
 ——— media, page 23.  
 ——— posterior, page 23. (Pl. II. l.)  
 thoracica acromialis, page 32. (Pl. IV. p.)  
 ——— alaris, page 32.  
 ——— longa, page 32. (Pl. IV. x.)  
 ——— suprema, page 32. (Pl. IV. q.)  
 thymica, page 31.  
 thyroidea inferior, page 29. (Pl. IV. l; Pl. V. fig. 2, e.)  
 ——— superior, page 18. (Pl. II. e; Pl. IV. a; Pl. V. fig. 1, a.)  
 tibialis antica, page 64. (Pl. XXIX. A, A.)  
 ——— postica, page 61. (Pl. XXX. fig. 2, B, B.)  
 tonsillaris, page 19.  
 transversa perinei, page 50. (Pl. XXI. fig. 2, r; Pl. XXII. d, d.)  
 transversalis colli, page 30. (Pl. IV. o.)  
 ——— faciei, page 23. (Pl. VI. fig. 1, d.)  
 ——— humeri, page 30. (Pl. IV. n.)  
 tympanica, page 23. (Pl. VI. fig. 2, m.)  
 ulnaris, page 35. (Pl. IX. fig. 2, C, C.)  
 uterina, page 50. (Pl. XX. d, d.)  
 vaginales, page 50.  
 vasa brevia, page 42. (Pl. XVI. fig. 1, o, o.)  
 vertebralis, page 28. (Pl. V. fig. 2, g.)  
 vesicales, page 50. (Pl. XXI. fig. 1, h.)  
 ——— superiores, page 47. (Pl. XXI. fig. 1, d.)  
 vidiana, page 24.  
 Artery, contractility, page 9.  
 structure, page 8.  
 Blood, arterial, page 4.  
 venous, page 4.  
 Chordæ Willisii, page 78. (Pl. XL. fig. 4, c, c.)  
 Circle of Willis, page 27. (Pl. VII. fig. 4.)  
 Circulation, general idea, page 4. (Pl. III. fig. 1.)  
 Ductus lymphaticus dexter, page 93. (Pl. XLVII. D; Pl. XLIX. C.)  
 thoracicus, page 86. (Pl. XLVII. B, B, C.)  
 Glands, (lymphatic,) abdominal, page 89. (Pl. XLVII.)  
 axillary, page 92. (Pl. XLVII. v; Pl. XLVIII. b, b, i, i.)  
 cervical, page 93. (Pl. L.)  
 inguinal, page 87. (Pl. XLVI. fig. 1, b, c; Pl. XLVII. d, f.)  
 lumbar, page 90. (Pl. XLVII. i.)  
 mesenteric, page 89. (Pl. XLV. m, m.)  
 popliteal, page 87.  
 Lacteals, page 84. (Pl. XLV. l, l.)  
 Lymphatic vessels, general idea, page 85.  
 Lymphatics of the abdomen, page 87. (Pl. XLVI. fig. 1, g; Pl. XLVII. k.)

- Lymphatics of the head and neck**, page 92. (Pl. L.)  
 heart, page 91. (Pl. XLIX. e, f.)  
 kidney, page 89.  
 liver, page 89. (Pl. XLV. a, b, c, d; Pl. XLIX. a, a.)  
 lower extremity, page 87. (Pl. XLVI.)  
 lungs, page 90. (Pl. XLIX. d, d.)  
 œsophagus, page 91.  
 pancreas, page 89. (Pl. XLV. K.)  
 peivis, page 88. (Pl. XLVII. h.)  
 penis, page 88. (Pl. XLVII. e.)  
 scrotum, page 88.  
 spleen, page 89. (Pl. XLV. k.)  
 stomach, page 89. (Pl. XLV. f, g, h, i.)  
 testis, page 89.  
 thorax, page 90. (Pls. XLVII. & XLIX.)  
 thymus, page 91.  
 thyroid, page 91. (Pl. XLIX.)  
 upper extremity, page 91. (Pl. XLVIII.)
- Mesenteric glands**, page 89. (Pl. XLV. m, m.)
- Operations on the carotid artery**, page 25.  
 femoral artery, page 59.  
 iliac artery, page 53.  
 peroneal, page 62.  
 posterior tibial, page 63.
- Sinus basilaris**, page 79. (Pl. XLI. fig. 1, q.)  
 cavernosus, page 79. (Pl. XLI. fig. 1, m, m.)  
 circularis, page 78. (Pl. XLI. fig. 1, n, o.)  
 laterales, page 78. (Pl. XL. fig. 1, C; Pl. XLI. fig. 1, c, c.)  
 longitudinalis inferior, page 78. (Pl. XL. fig. 1, c, c.)  
 ——— superior, page 78. (Pl. XL. fig. 1, a, a.)  
 occipitalis anterior, page 79. (Pl. XLI. fig. 1, q.)  
 ——— posterior, page 78. (Pl. XL. fig. 1, h; Pl. XLI. fig. 1, s, s.)  
 petrosus inferior, page 79. (Pl. XL. fig. 1, g; Pl. XLI. fig. 1, p.)  
 ——— superior, page 79. (Pl. XL. fig. 1, f; Pl. XLI. fig. 1, r.)  
 quartus, page 78. (Pl. XL. fig. 1, e.)  
 rectus, page 78. (Pl. XL. fig. 1, e.)
- Sinuses, cerebral**, page 78. (Pls. XL. & XLI.)
- Thoracic duct**, page 86. (Pl. XLVII. B, B, C.)
- Torcular Herophili**, page 78. (Pl. XL. fig. 1, B.)
- Varieties of the abdominal aorta, its branches**, page 45.  
 brachial artery and branches, page 34. (Pl. XI.)  
 carotid artery, page 25.  
 femoral, and branches, page 59. (Pl. XXVIII.)  
 obturator artery, page 47. (Pl. XXIV. figs. 1, 2.)  
 peroneal artery, page 62. (Pl. XXXI.)  
 pudic artery, page 50. (Pl. XXIV. fig. 3.)  
 radial artery in hand, (Pl. XII.)  
 subclavian artery, page 31.  
 tibial, posterior, page 62. (Pl. XXXI.)  
 ulnar, in hand. (Pl. XII.)
- Vasa brevia**, page 42. (Pl. XVI. fig. 1, o, o.)  
 lactea, vel chyliifera, page 84. (Pl. XLV. l, l.)  
 vasorum, page 8.
- Veins, general idea**, page 7.  
**Ven. angularis**, page 68. (Pl. XXXV. e, e.)  
 auriculares anteriores, page 69. (Pl. XXXV. y, y.)  
 auricularis posterior, page 70. (Pl. XXXV. a\*.)  
 axillaris, page 73. (Pl. XXXVI. fig. 1, I.)  
 azygos major, page 74. (Pl. XLII. G.)  
 ——— minor, page 75. (Pl. XLII. H.)  
 basilica, page 71. (Pl. XXXVI. fig. 1, E, E.)  
 basis vertebræ, page 76. (Pl. XXXIX. figs. 3, 4.)  
 brachio-cephalicæ, page 73. (Pl. XXXVII. G, H.)  
 bronchiales, page 75. (Pl. XLII. d.)  
 buccalis, page 68. (Pl. XXXV. m, m.)  
 capsulares, page 81. (Pl. XLII. l, l.)  
 carotis externa, page 70. (Pl. XXXV. E, E.)  
 ——— interna, page 71. (Pl. XXXV. G, G; Pl. XXXVII. B, B.)  
 cava inferior, page 81. (Pl. XLII. I.)  
 ——— superior, page 74. (Pl. XXXVII. I.)  
 cerebelli, page 78.  
 cerebri, page 77. (Pl. XL. fig. 2, a, a.)  
 cephalica, page 71. (Pl. XXXVI. B.)  
 circumflexa ilii superficialis, page 79. (Pl. XLIII. fig. 1, B.)  
 comites brachialis, page 72. (Pl. XXXVI. fig. 1, m.)  
 ——— interosseæ, page 72.  
 ——— radialis, page 72. (Pl. XXXVI. fig. 1, l.)  
 ——— ulnaris, page 72. (Pl. XXXVI. fig. 1, k, k.)  
 cordis maxima, page 82. (Pl. XXXVII. a\*.)  
 ——— media, page 83.  
 ——— minima, page 83.  
 ——— parvæ, page 83. (Pl. XXXVII. b\*, b\*.)  
 coronaria ventriculi, page 82. (Pl. XLIV. e.)  
 coronariæ laborum, page 68. (Pl. XXXV. k, l.)  
 corporis striati, page 78.  
 cutaneæ cervicis, page 70. (Pl. XXXV. c\*, m\*.)  
 dentalis inferior, page 70.  
 dorsi spinales, page 75. (Pl. XXXVIII. fig. 1.)  
 duodenales, page 82.  
 emulgentes, page 81. (Pl. XLII. m, m.)  
 epigastrica superficialis, page 79. (Pl. XLIII. fig. 1, a.)  
 facialis, page 68. (Pl. XXXV. A.)  
 femoralis, page 80. (Pl. XLII. O.)  
 frontalis, page 68. (Pl. XXXV. a, a.)  
 Galeni, page 78. (Pl. XL. fig. 1, d, d.)  
 gastricæ, page 82. (Pl. XLIV. c, c.)  
 hepaticæ, page 82. (Pl. XLII. k, k.)  
 iliaca externa, page 80. (Pl. XLII. M.)  
 ——— interna, page 80. (Pl. XLII. N.)  
 iliaca communes, page 81. (Pl. XLII. L.)  
 innominatæ, page 74. (Pl. XXXVII. G, H.)  
 intercostales, page 75. (Pl. XLII. f, f, h, h.)  
 ——— anteriores, page 74.  
 intercostalis superior, page 73. (Pl. XXXVII. x; Pl. XLII. b.)  
 jugularis anterior, page 70. (Pl. XXXV. H.)  
 ——— externa, page 70. (Pl. XXXV. E, E.)  
 ——— interna, page 71. (Pl. XXXV. G, G; Pl. XXXVII. B, B.)  
 laryngea, page 71. (Pl. XXXV. i\*.)

- Ven. lingualis, page 71. (Pl. XXXV. g\*.)  
 lumbales, page 81. (Pl. XLII. p, p.)  
 mammaria interna, page 74. (Pl. XXXVII. u, w.)  
 massetericæ, page 68. (Pl. XXXV. n, n.)  
 maxillaris interna, page 70. (Pl. XXXV. C.)  
 mediana, page 72. (Pl. XXXVI. fig. 1, F.)  
 ——— basilica, page 71. (Pl. XXXVI. fig. 1, G.)  
 ——— cephalica, page 71. (Pl. XXXVI. fig. 1, H.)  
 medulli-spinales, page 75. (Pl. XXXIX. fig. 1.)  
 meningo-rachidianæ, page 76. (Pl. XXXIX. fig. 2.)  
 mesenterica inferior, page 82. (Pl. XLIV. C, C.)  
 ——— superior, page 82, (Pl. XLIV. D, D.)  
 nasalis, page 68. (Pl. XXXV. f, f.)  
 occipitalis, page 71. (Pl. XXXV. h\*.)  
 ophthalmica, page 79. (Pl. XLI. fig. 1, e.)  
 ossium cranii, page 79. (Pl. XLI. fig. 2.)  
 palatina, page 68. (Pl. XXXV. r.)  
 palpebrales externæ, page 68. (Pl. XXXV. i.)  
 ——— internæ, page 79. (Pl. XLI. fig. 1, g, g.)  
 pancreaticæ, page 82. (Pl. XLIV. a, a.)  
 parotideæ, page 69.  
 pharyngea, page 71. (Pl. XXXV. f\*.)  
 phrenicæ, page 81.  
 poplitea, page 80. (Pl. XLIII. fig. 2, B.)  
 portæ, page 82. (Pl. XXIV. A.)  
 posterior scapulæ, page 70. (Pl. XXXV. d\*.)
- Ven. pudendæ externæ, page 79. (Pl. XLIII. fig. 1, c, c.)  
 radialis cutanea, page 71. (Pl. XXXVI. A.)  
 ranina, page 68. (Pl. XXXV. p, p.)  
 renalis, page 81. (Pl. XLII. m, m.)  
 sacra media, page 81. (Pl. XLII. r.)  
 salvatella, page 71. (Pl. XXXVI. fig. 2, c.)  
 saphena major, v. interna, page 79. (Pl. XLIII. fig. 1, A.)  
 ——— minor, v. externa, page 79. (Pl. XLIII. fig. 2, A.)  
 spermaticæ, page 81. (Pl. XLII. n, o.)  
 splenica, page 81. (Pl. XLIV. B.)  
 subclavia, page 73. (Pl. XXXVII. E, F.)  
 submentalialis, page 68. (Pl. XXXV. q, q.)  
 supra-orbitalis, page 68. (Pl. XXXV. d.)  
 ——— scapularis, page 70. (Pl. XXXV. e\*.)  
 temporalis, page 68. (Pl. XXXV. B.)  
 ——— anterior, page 69. (Pl. XXXV. s, s.)  
 ——— media, page 69. (Pl. XXXV. x.)  
 ——— posterior, page 69. (Pl. XXXV. w, w.)  
 thyroidea media, page 71. (Pl. XXXV. l\*.)  
 ——— superior, page 71. (Pl. XXXV. k\*.)  
 thyroideæ inferiores, page 74. (Pl. XXXVII. s, t.)  
 trachelo-subcutanea, page 70. (Pl. XXXV. E, E.)  
 transversalis faciei, page 69. (Pl. XXXV. z, z.)  
 ulnaris cutanea anterior, page 71. (Pl. XXXVI. fig. 1, C, C.)  
 ——— posterior, page 71. (Pl. XXXVI. fig. 1, D, fig. 2, b, b.)  
 vertebralis, page 73. (Pl. XXXVII. r.)

END OF THE VASCULAR SYSTEM.





THE  
N E R V E S  
OF  
THE HUMAN BODY.







Fig. 1.

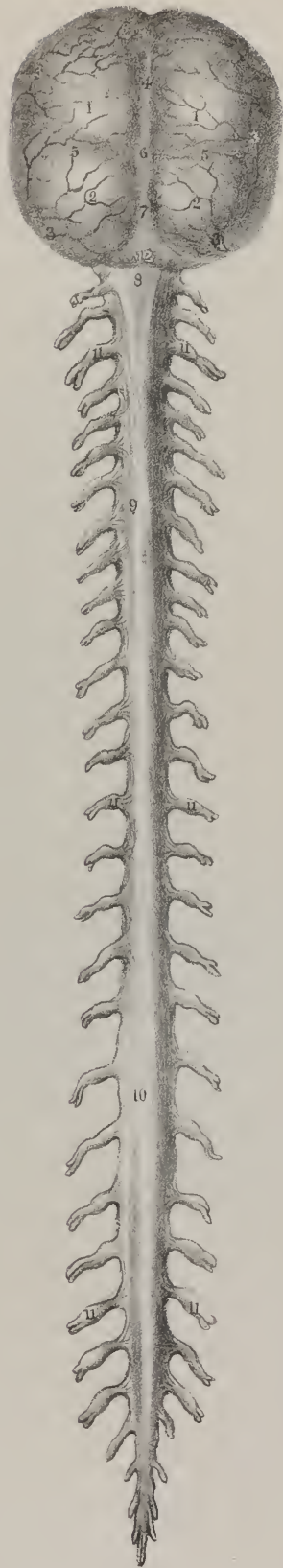
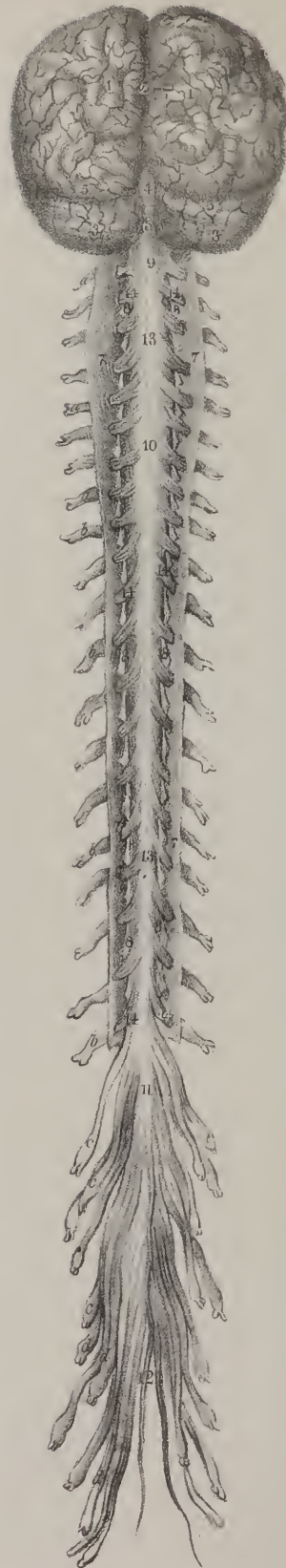


Fig. 2.



# NERVOUS SYSTEM.

---

IN the present division we commence the description of the nervous system. No part of the living economy of man and of animals has occupied more the attention of anatomists and physiologists of all countries, particularly within the present century. The nervous structure exists in various degrees of development in all the great divisions of the animal kingdom, and is recognizable in almost every class,—its conformation presenting a well-marked series of phases as we trace it from above downwards in the series. It is frequently said that as there are multitudes of animals in which no trace of nervous matter has hitherto been demonstrated, we are not warranted in inferring its existence; yet when we observe groups of these in a drop of water under the microscope, and see them make determinate efforts in eluding one another, in seizing their prey, when we note their various movements so like in order and method those of animals higher in the scale, and with which we are better acquainted, we cannot hesitate to admit that they are susceptible of external impressions; that is, are the subjects of sensation, and that they are capable of originating distinct acts of volition. We cannot expect to find nervous filaments in the soft gelatinous matter of which the poriferous animals consist. “Their nervous globules (observes Dr. Grant in his Lectures) are diffused through every part of the homogeneous cellular tissue of the body, which possesses the same properties in every part, and is infinitely divisible without destroying its vitality. Their ciliated gemmules, however, are endowed with remarkable living properties and powers of spontaneous motion. They have an obvious object in their motions; they can accelerate, retard, or cease at pleasure the vibrations of their cilia; they can change the direction of their course in the water, perceive each other’s vicinity, revolve round

## PLATE I.

The brain and spinal cord, or cerebro-spinal axis.

FIG. 1. The posterior aspect of the brain and spinal cord invested by the dura mater.

Nos. 1, 1. Convexities of the dura mater caused by the projection of the posterior lobes of the cerebrum. 2, 2. Convexities formed by the lobes of the cerebellum. 3, 3. Meningeal arteries supplying the dura mater. 4. A depressed line formed by the collapse of the superior longitudinal sinus. 5, 5. Other lines marking the course of the lateral sinuses. 6. The situation of the torcular Herophili, or conflux of the sinuses. 7. The course of the occipital sinus. 8. The superior swelling of the spinal cord, formed by the medulla oblongata. 9. The middle swelling, corresponding with the origin of the nerves forming the brachial plexus. 10. The inferior swelling, from which the lumbar nerves arise. 11, 11. The spinal nerves, surrounded by a sheath of dura mater; the swelling caused by the ganglion on the posterior root is distinctly marked. 12. A rough surface by which the dura mater is connected to the margin of the occipital foramen and atlas.

FIG. 2. The dura mater has been removed from the brain, and is spread open along the spinal cord, so as to display the pia mater, covered by the thin and transparent arachnoid membrane.

Nos. 1, 1. The convolutions of the two hemispheres of the cerebrum covered by their vascular membrane, the pia mater. 2. The median fissure between the hemispheres, which receives the falx major. 3, 3. The lateral lobes of the cerebellum, also invested with pia mater. 4. The superior vermiform process of the cerebellum. 5, 5. The fissure separating the posterior lobes of the cerebrum from the cerebellum, which lodges the tentorium cerebelli. 6. The depression between the two lobes of the cerebellum, lodging the falx minor. 7, 7. The dura mater of the spinal cord laid open: it is entirely removed below. 8, 8. The membrana dentata, or ligamentum denticulatum, connecting the sides of the spinal cord to the inner surface of the dura mater. 9. The superior swelling of the spinal cord. 10. The middle, or brachial swelling. 11. The inferior, or lumbar swelling. 12. The cauda equina. 13. The posterior longitudinal fissure. 14, 14. The posterior roots of the spinal nerves.

a, a. The eight cervical nerves. b, b. The twelve dorsal nerves. c, c. The five lumbar nerves. d, d. The five sacral nerves. e. The two coccygeal nerves.



each other, distinguish the most suitable place for the fixing of each species, or bound forward from a state of rest; yet these gemmules contain no visible fibre.”

The nervous system (*systeme nerveux*,) nervous tissue (*tissu nerveux*,) *nervus nervos*, may, with great propriety, be said to preside over all the leading functions of the economy; for it would be restricting its influence to a very narrow limit, were we to say that it merely receives impressions from without, and transmits volitions from within: its dominion extends much further. When we see a limb deprived of sensation and motion by an apoplectic seizure, we at once admit that these powers are dependent on nervous action; and we cannot but infer that nutrition and animal heat are equally so, when, at a subsequent period, we find it wasted and reduced in temperature. All persons are aware how the secretions may become deranged and vitiated by injuries of the spinal cord: that of the kidneys, for instance, becomes small in quantity, turbid, and ammoniacal; digestion is suspended by the section of the vagus nerves; and the researches of Le Gallois and Wilson Philip have shown how the circulation is affected by and through the nervous influence. Finally, intellect and reason are instantaneously extinguished if a small fragment of bone be depressed upon the surface of the brain.

*Nervous System—general idea of.*—Many persons evince a disposition to compare and contrast objects, rather than formally describe them, perhaps with a view of conveying some general notion of their composition and characters. The nervous system has been dealt with in this way, having been likened to a tree; the brain serving as the root, the spinal cord the trunk, and the nerves as branches: but latterly it has been viewed in a different way; the nerves being considered the roots, as they are known to be formed first, and may, as in acephalous cases, exist, although the central masses are never formed; and lastly, it has been compared to a vast net-work of nerves, interlacing by their ultimate filaments at their peripheral terminations throughout the system, and also becoming united by decussation, or by commissures in the central masses. However vague, and in some respects questionable, such loose generalities as these may be, they serve the purpose of conveying to the mind the idea that the nervous system, though complex and subdivided, forms one whole, all its parts being intimately connected and associated, at the same time that some are placed in subordination to others.

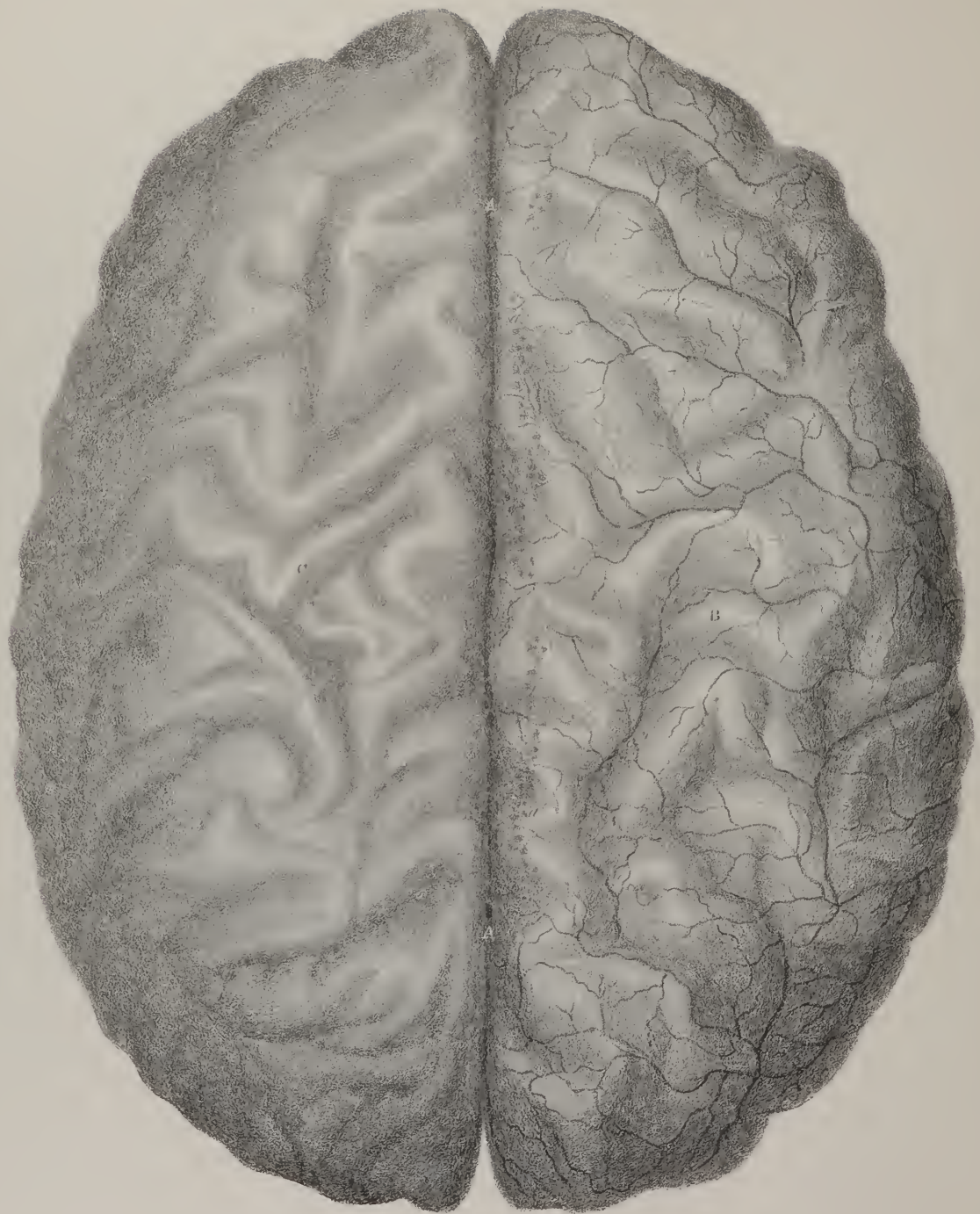
*Nervous System, symmetrical.*—When viewed as a whole, the nervous system is symmetrical in the strictest sense. It consists of two lateral halves, which, being disposed similarly on each side of the central line, resemble one another in every particular. Thus, the brain is divided into two hemispheres, each presenting on its inferior surface three lobes; the cerebellum also is divided into two lobes; and the medulla oblongata into two lateral halves, each consisting of three fasciculi, or bundles of fibres, the division being established by two grooves or sulci, one on its anterior, the other on its posterior aspect, situated exactly in the median line. These sulci, by being continued along the whole length of the medulla spinalis, divide it also into two symmetrical portions. This symmetrical arrangement extends to the nerves, so long as they retain the form of distinct cords; but when, at their peripheral termination, they become expanded into, and blended with, the minute texture of the different organs which they supply, their mode of distribution eludes our research. We can, however, infer that their filaments interlace one with another, so as to form a net-work, by which a complete and free communication is established between them.

*Commissures.*—Again, when we examine the central parts, we find that each lateral half is connected with the other by certain transverse bands, disposed along the middle line, and which are termed commissures. On this union and connexion between the different parts of the nervous system, by which they become intimately blended at their periphery, as well as towards the centre, the individuality of the animal essentially depends.

The central parts of the nervous system are deeply seated, being enclosed within the spinal canal and the cavity of the cranium. The nervous cords, too, are in a great degree withdrawn from the influence of external agencies by the situations in which they are placed during their course. Their final terminations only approach the surface, where, by being expanded on the internal and external teguments, they communicate to these parts their sentient and tactile properties.

*Composition.*—The nervous system is made up of two substances, readily distinguishable by their colour, texture, and consistence. One is greyish, or rather a pale ash colour, and hence named *cineritious*, (*substantia cinerea*;) and as in the brain it forms an investment for the white substance, it is usually termed *cortical*, (*s. corticalis*.) The other substance is of a pure white colour, and from the relation just indicated is called *medullary*, (*substantia medullaris*.) It cannot, however, be said with propriety that the one is external, or the other internal, as their position is reversed in different parts of the system. The grey substance invests the cerebral hemispheres, and forms at the same time several masses disposed in their interior; but in the medulla spinalis it is altogether deeply seated. The white substance, on the contrary, is enclosed by the grey in the brain, but becomes the cortex in the medulla. The cineritious substance is more soft and vascular than the other, and when minutely injected appears as if entirely composed of vessels. Though the white substance in the natural state is not much firmer than jelly, it acquires a great degree of firmness by maceration in spirit, and presents at all times a distinctly fibrous appearance. When these two sorts of nervous matter are attentively examined, they will be found to consist of a peculiar substance called *neurine*, deposited in the areolæ, of a delicate cellular tissue. This anatomical element, in its natural condition, is soft and semi-fluid, and wherever it predominates much, the part will be pulpy and almost diffuent, whilst other portions of the structure are comparatively firm, by reason of the greater quantity of cellular tissue which they contain. The colour of neurine presents some varieties, being white, grey, or yellowish, and in some places of a dusky hue.







When a thin layer of nervous substance is examined with a microscope, it presents the appearance of small granules, placed in lines more or less regularly; but their form and size are liable to vary. These have been taken by some observers for globules, and have formed the basis of many speculations concerning the nature of nervous action: but they resemble much more nearly the delicate flakes observed in coagulated albumen. According to the analysis of Vauquelin, neurine consists of

Water	. . . . .	80.00 parts.
Albumen	. . . . .	7.00
White fatty matter	. . . . .	4.53
Red fatty matter	. . . . .	0.70
Osmazome	. . . . .	1.12
Phosphorus	. . . . .	1.50
Sulphur	. . . . .	5.15

*Nerves.*—The nerves or nervous cords which issue from the central mass consist of a cylinder of neurine, of a perfectly white colour, enclosed in a thin firm sheath of condensed cellular tissue, called neurilema, (*νευρον*, a nerve; *λεμμα*, a husk or rind.) But the cords thus formed are not simple in their structure, for each may be divided into a number of smaller filaments, possessed of the same component parts as the nerve itself. According to the researches of Prevost and Dumas, one of these minor subdivisions is itself an aggregate of four delicate fibres, placed pair and pair—two external and two internal, the former being more easily recognized than the latter; and, in all, they observe a number of globules placed in regular lines, thus identifying their composition with that of the brain: but this does not accord with the researches of other physiologists.

The modes of dividing and arranging the parts of this complex structure, suggested by different writers, appear to have been adopted in the first instance in conformity with the opinions which they entertained of its functions and properties. According to Galen, the brain should be considered as the central or fundamental part; Bartholin assigned that rank to the spinal cord. Most anatomists, in times past, divided the system into two parts, viz. the brain and spinal cord, or the central mass, (axc cerebro-spinal,) and the nerves as prolongations from it. Bichat, guided by his peculiar views of the vital phenomena, contended for the existence of two sorts of nervous influence: one being derived from the apparatus appropriated to animal life, viz. the spinal cord, brain, and cerebellum, and the nerves which are connected with them; the other, from the two knotted cords which lie along the spine, which he called the nerves of organic or vegetative life, but which are generally known as the sympathetic or trisplanchnic nerves. Dr. Gall extends the principle of subdivision much farther than his predecessors had done; his previous inquiry into the nature and manifestations of the mental faculties having led him to observe their different modifications in various tribes of animals, as well as in individuals of the same species, and conceiving them to be so many distinct powers, which necessarily require distinct material instruments,—he concluded that each, when in action, works by a distinct portion of cerebral substance, which may be considered as its seat and its organ. In this view of the subject, the nervous system appears to be divisible into as many parts as there are functions to be performed, and faculties to be exercised, each part constituting a special apparatus or organ, as follows:—1. the spinal cord and the double-rooted nerves connected with it, forming the apparatus of sensation and voluntary motion; 2. the medulla oblongata and its nerves, being the apparatus of the special senses; 3. the cerebral masses, (cerebrum and cerebellum,) divided into the several organs of instincts, sentiments, moral and intellectual faculties.

Willis arranged the nerves under three heads; those arising from the brain, ten in number on each side; those of the spinal cord, thirty-one pairs; and thirdly, the sympathetic nerves. According to this arrangement, nerves differing materially in structure and in function are grouped together, and some which are totally distinct in every particular, are set down as parts of one whole. The seventh pair of nerves, for instance, consist of a hard and a soft part, (portio dura, portio mollis;) and the eighth consists of three parts, the nervus vagus, glosso-pharyngeal, and spinal accessory. Sæmmering has in some measure lessened the confusion arising from this mode of arrangement, by separating the facial nerve from the auditory, and detaching the glosso-pharyngeal and the accessory from the vagus; but the classification still includes a consideration of their position only, without making any reference to structure or function. An arrangement of the nervous system, perfectly free from objection, cannot be expected in the present state of our knowledge; for that pre-supposes a perfect acquaintance with its structure and conformation in all classes of animals, from the highest to the lowest,—of its developement, as tending to show the subordination and dependence of its parts,—and of the functions which each of them performs. The division of the nerves into cerebral and spinal cannot be

## PLATE II.

The brain removed from the cranium, displaying its upper surface. The pia mater on the right side is retained; on the left side it has been removed to show the form and arrangement of the convolutions.

A, A. The median fissure dividing the two cerebral hemispheres. Before the removal of the dura mater it is occupied by the falx. B. The right hemisphere invested by its pia mater. C. The left hemisphere, marked by the furrows which divide the convolutions.

a, a. The small granular bodies, which are termed glandulæ Pacchioni.

adhered to any longer; for the fifth,\* so called, cerebral nerve is strikingly contrasted in its structure and function with those around it, and with which it has hitherto been classed, whilst it is in every respect similar to those attached to the spinal cord. Neither ought we to continue, as heretofore, to enumerate the nerves in the order of their position from before backwards along the basis of the brain; for the first cerebral nerve (olfactory) has no similarity in character or in function with the third (motor), nor is the second (optic) more closely allied to the sixth (abductor), or the seventh (auditory) to the ninth (lingual). The nerves of the special senses form a distinct group. The following arrangement of the different parts of the nervous system will suffice for present purposes, and will be found to conform to the views of the best informed physiologists:—

- |  |   |  |   |  |
|--|---|--|---|--|
| Nervous system of animal life, or life of external relation, (Bichât.)         | } | Cerebro-spinal axis, composed of   | { | 1. The spinal cord, with its cranial prolongation, (medulla oblongata,) which probably should not be restricted to the lower margin of the pons, but be considered as extending up to where the crura cerebri become identified with the hemispheres, thus including the tractus motorius. |
|  |   |  | } | 2. Cerebral masses, (cerebrum and cerebellum.)   |
| Nervous system of organic, or vegetative life; the life of nutrition (Bichât.) | } | Nerves, or chordæ interruptiæ grouped into sets, according to their structure and functions. | { | 1. The spinal nerves, symmetrical, with double roots, a ganglion on the posterior one, thirty-two pairs, including the tri-facial or cranial double-rooted nerve.  |
|  |   |  |   | }  |

The tri-splanchnic nervous system, whose ramifications extend through all the viscera, (*σπλαγγχια*) called by some gangliac. (though ganglia are not peculiar to it), also sympathetic. We may, with De Blainville,† consider it as divisible into two parts: one placed in front of the spine, (præ-vertebral,) composed of plexus and ganglia, (scmi-lunar and cardiac,) whose branches are distributed to the primary organs of digestion and circulation; the other, consisting of two knotted cords, extended along the whole length of the spine, communicating with the præ-vertebral plexus on the one hand, and with the cerebro-spinal nerves on the other.

We shall describe and illustrate the different parts of the nervous system in the following order, (having first treated of the membranes which invest them):—1. The spinal cord; 2. The brain; 3. The cerebral nerves, properly so called, viz. olfactory, optic, auditory; 4. The single-rooted motor nerves, viz. the third, sixth, ninth, and fourth; 5. The respiratory set of nerves, facial, (portio dura,) glosso-pharyngeal, nervus vagus, and accessorius; 6. The spinal nerves with two roots; and, 7. The sympathetic nervous system.

## MEMBRANES OF THE BRAIN AND SPINAL CORD.

The brain and the spinal cord are invested by three membranous lamellæ, namely, the dura mater, the arachnoid membrane, and the pia mater.

*Dura mater*.—The dura mater, (plate I. fig. 1; *μηνινγξ σκληρη*), which is the most external of the three, is thick, firm, and resisting, and belongs to the class of fibrous, or rather fibro-serous membranes, as it is in reality a compound structure; the outer lamella being fibrous, the inner serous and derived from the arachnoid membrane.‡ It is in close apposition with the cranium, which it lines, at the same time that it invests the brain, and sends inwards processes, which are interposed between its different parts, serving to sustain them. It is, moreover, prolonged in a tubular form through the spinal canal, but is separated from the bones by a lamella of adipose tissue and the great spinal veins. It adheres closely to the arch of the skull, particularly along the sutures, but at its base the points of connexion are multiplied by its passing over the inequalities of the surface, and still more so by sending tubular prolongations through the different foramina, serving to enclose and protect the nerves which they transmit.

\* Sir C. Bell on the Nervous System.

† Cours d'Anatomie et de Physiologie Comparée.

‡ It is better, as conveying a clearer idea to the mind of the student, to consider the dura mater as composed of two fibrous layers, which are closely united except at the place of the sinuses, where they separate to form these venous canals. They are connected by short dense cellular tissue, but by maceration or careful dissection, may be separated from either margin of the longitudinal sinus far down on the sides of the cerebrum. The inner one of these layers is closely lined by the outer leaflet of the arachnoid sac, in the same manner as the fibrous coat of the pericardium, and the tunica albuginea testis are faced by their respective serous membranes.—J. P.







Along the spinal column similar prolongations pass out with the nerves through the intervertebral foramina: these constitute its chief connexion with the bones. But towards the lower part of the sacral canal it is fixed by some irregular fibrous bands.

The processes formed by the dura mater are the following:—

The *falx cerebri* is lodged in the longitudinal fissure between the hemispheres of the brain, forming a partition between them. It is narrow before, broad behind, and presents a curved border inferiorly, so that in shape it resembles a sickle: hence its name. It extends from the crista galli of the ethmoid bone, which is inserted between its lamellæ, to the internal occipital protuberance, on a level with which it branches out at each side, becoming blended with the tentorium cerebelli. It seems as if formed in the following manner:—The fibres of the dura mater, on approaching the sagittal suture from each side, divide into two lamellæ, one of which is continued uninterruptedly across, thereby maintaining the continuity of the membræ; but the other dips down, converging to that of the opposite side, by which means they enclose between them an angular interval, viz. the longitudinal sinus. After their union they continue to descend to the margin of the falx, where they separate, and unite again, so as to form the inferior longitudinal sinus. A section of the upper sinus is found to be triangular, of the lower circular. On the surface of the dura mater, in the sinus, or upon the cerebral hemispheres, small albuminous masses occasionally exist, called glandulæ Pacchioni, apparently resulting from morbid action.\*

The *tentorium cerebelli* spreads out from the base of the falx, and serves to support the posterior lobes of the brain; one border of it is attached all around to the lateral grooves on the occipital bone, and to the margin of the pars petrosa; the other, concave and free, encloses an oval interval, which transmits the crura cerebri, processus ad testes, and basilar artery.

The *falx cerebelli* is a narrow fold placed between the lobes of the cerebellum, extending vertically from the under surface of the tentorium to the foramen magnum; its base lodges the occipital sinuses.

*Pia mater*.—The pia mater, (plate II. B, *μηνιγξ λικτερη*.) in its anatomical characters differs considerably from the other membranes. It is made up of a thin lamella of cellular tissue, permeated by a multitude of minute capillary arteries, which ramify in it previously to their entrance into the cerebral substance. It invests the medulla spinalis, as well as the brain, and dips into the sulci between the convolutions of the latter: we also find it enclosed within the ventricles, where it is named “plexus choroides,” (*χορδοειδης*.) Its inner surface is in close contact with the cerebral substance; the external is in apposition with the arachnoid membrane on the surface of the convolutions, but loses all connection with it after passing into the sulci.

*Plexus choroides*.—(Plates IV. P, and V.)—In the fissure observable at the base of the brain, between the inner margin of its middle lobe and the crus cerebri, the pia mater, which invests the external surface, is continuous with that process of it (plexus choroides) which is found in the ventricles; so that, when we trace it, we find it, as it were, entering at the inferior cornu of the ventricle, where it corresponds at first with the interstice between the corpus fimbriatum and the crus cerebri, and afterwards lies along the floor of the ventricle, in which it ascends upon the thalamus nervi optici, and unites at the foramen or fissure of Monro with the plexus of the other side. At its entrance into the ventricle the plexus is drawn together so as to resemble a small vascular bundle, and becomes invested by the arachnoid membrane, which, by its reflection from the sides of the ventricles to the plexus, maintains the integrity of the cavity.

Where the pia mater is prolonged on the medulla oblongata, it forms a small plexus, which enters into the fourth ventricle, and becomes also invested by a duplicature of the arachnoid. As the membrane descends into the spinal canal, it becomes firm, resistant, and much paler in colour. Its inner surface is in close contact with the cord, the exterior is but slightly connected with the arachnoid; but the nerves, at the different points at which they pass outwards, derive from it their immediate investment, or neurilema. The difference of character here pointed out between the spinal and cerebral parts of the pia mater, appears to MM. Jules and Hippolite Cloquet sufficient to induce them to consider it as a distinct structure. But it would be difficult to show

### PLATE III.

This view of the brain is named the centrum ovale majus: it is made by slicing off the hemispheres of the cerebrum to a level with the corpus callosum.

A, A. The corpus callosum, or great commissure of the hemispheres, marked by transverse lines, (lineæ transversus.) B. The raphé, extending along the middle line of the corpus callosum. C, C. The white, or medullary substance of the brain, marked by numerous red points, produced by the division of small arteries. D, D. The grey, or cortical substance of the brain, surrounding the white substance, and passing deeply to the bottom of the sulci, E, E, which are of very unequal extent. F. The posterior border of the cerebellum.

\* Of the nature of the glandulæ Pacchioni nothing is positively known. They are met with before birth, and are most abundant in the latter periods of life. They are so generally met with, that it is difficult to conceive them the product of disease. A striking analogy is, however, observed between them and a collection of small albuminous corpuscles occasionally seen in the plexus choroides of the lateral ventricles, around the pineal gland and at the bottom of the fourth ventricle. Small hydatid vesicles are frequently met with in the plexus choroides, intermixed with these corpuscles, rendering the morbid origin of the latter quite probable.—J. P



where the continuity of the membrane is interrupted; and as to any difference of character and consistence that may appear, they are merely such as may be supposed to arise from the different circumstances in which the membrane is placed. In the spine it is exposed, at least in some degree, to the influence of motion and pressure, which necessarily produce the same effect on it as on cellular textures elsewhere; that is to say, they render it thick and lamellar. Again, in the skull it is in contact with gray substance, in the spine with white; so that we can readily account for the difference of the vascularity in the membrane, by recurring to the relative vascularity of the structures with which it is in contact.

*Arachnoid membrane.*—The serous investment of the brain and spinal cord is called the *arachnoid membrane*, from its tenuity, (αράχνη, a spider's web; εἶδος.) It is smooth and transparent, and, like all the other membranes to which it belongs, forms a shut sac: one part of it invests the cord and the brain, passing over its surface without dipping into the convolutions; the other lines the dura mater, and its different processes, with which it is inseparably connected. Moreover, as the nerves and vessels pass across the intervals between their points of attachment to the cerebral substance, and those by which they escape from the cavity of the cranium, they are enclosed in tubular prolongations of the arachnoid membrane, which are continuous by one extremity with the portion investing the brain and the cord, and by the other with that which lines the dura mater. By this arrangement the continuity of the membrane is maintained, at the same time that the apertures of transmission are closed. The arachnoid membrane is prolonged into the ventricles, lining them in their entire extent, and forming within them a remarkable duplicature, (plate V., *velum interpositum*.) By these means its arrangement is rendered as complex as that of the peritonæum; and were we, with the same view, and on the same principle, to “trace its reflections,” they would be found as follow:

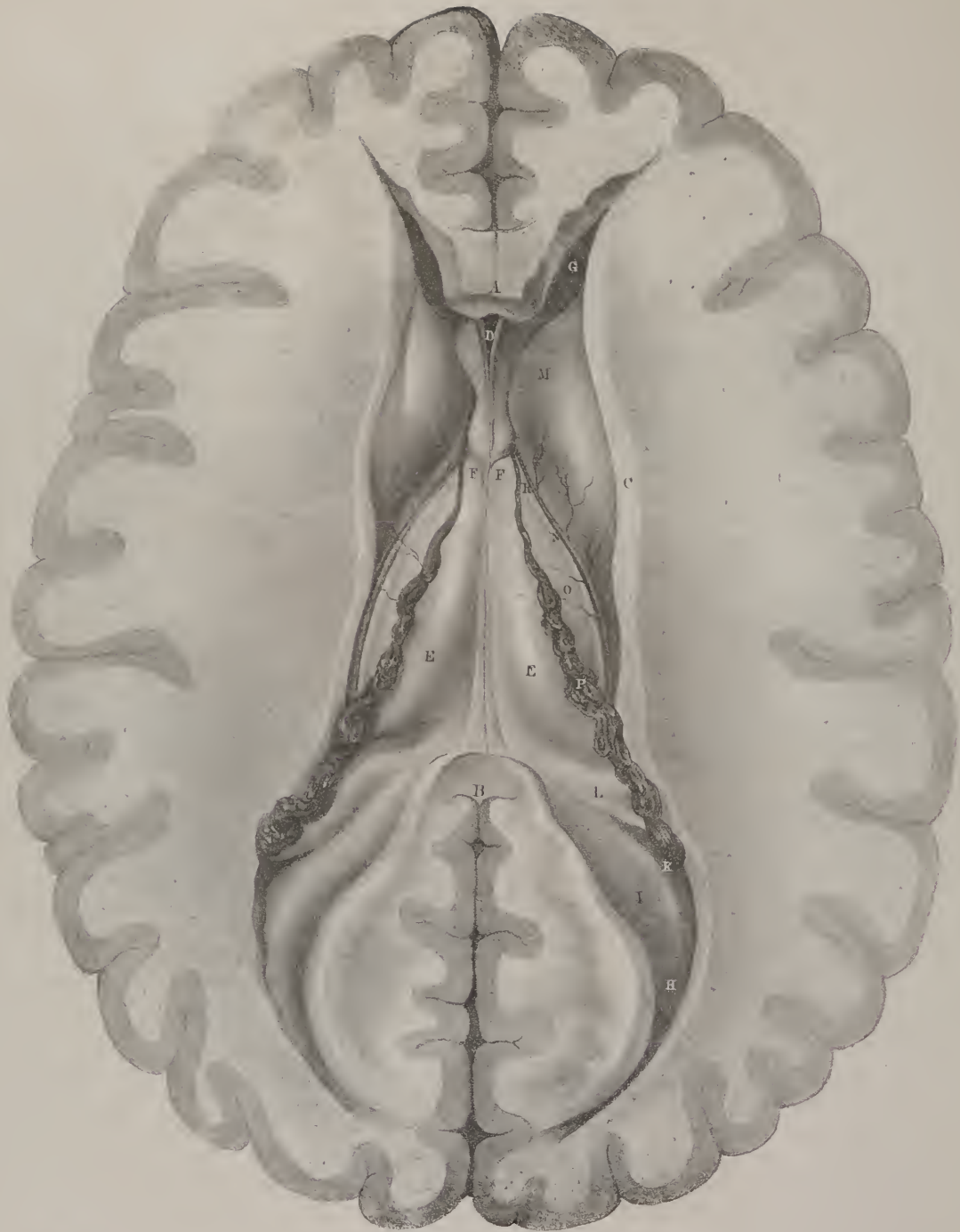
We shall suppose, in the first place, a vertical section of the skull and the spine to be made, so as to lay open their cavities. Commencing then at the vertex, we trace the membrane along the upper and under surface of the anterior lobe of the brain, and thence downwards upon the crus cerebri and pons. We then follow it on the anterior surface of the medulla spinalis down to the extremity of the cauda equina, where it is reflected upon the different nerves which guide it to the contiguous surface of the dura mater, with which it becomes in a manner identified, forming a lining for it as far as the foramen magnum. From the foramen the membrane continues its adhesion to the dura mater, forwards upon the base of the skull, then up along its roof, and thence backwards to the occipital protuberance. At the latter point it is reflected over the tentorium, coating both its surfaces, and is thence prolonged down through the foramen magnum, still bearing the same relation to the fibrous membrane, as far as the extremity of the canal. At this point it is reflected forwards upon the medulla, which it invests in its entire extent. From the medulla oblongata it is, as it were, guided by the corpora restiformia to the cerebellum, and having invested both its surfaces, reaches the processus ad testes, on which it is continued to the under surface of the cerebral hemisphere, and is thence prolonged to the vertex, that is to say, to the point from which we set out.

When the continuity of surface is thus shown at each side, the lateral parts of the membrane will be found continuous, by tracing them over the flat surfaces of the hemispheres, and down to the corpus colosum; so that if a transverse section were made of the cerebral hemispheres, the part of the membrane which is reflected from their flat surfaces over the corpus colosum will represent a cul-de-sac.

But it will be asked, how and where can the external or investing part be shown to be continuous with that which lines the ventricles? The fact can be demonstrated as follows:—If we trace the membrane along the posterior border of the corpus colosum, it will be found to turn beneath it, and to enter the ventricle through the fissure of Bichât. Again, the part of it which lies on the tubercula quadrigemina is also prolonged into the ventricles, lying, like the preceding, close on the cerebral substance, and constituting an investment for it. If the falx and tentorium have been left undisturbed, a tubular process of arachnoid membrane will be observed, (by drawing aside the posterior cerebral lobes,) passing out of the fissure, and directed backwards to the point at which the border of the falx joins with that of the tentorium. This process is prolonged from the velum interpositum, and encloses the venæ Galeni, which are two small veins that return the blood from the plexus choroides, and pass from before backwards, enclosed within the velum, to terminate in the straight sinus. We have then within the ventricles to examine a prolongation of the membrane which lines their surface, and another, which is in a manner free and unattached, (*velum interpositum*,) each being continuous with the other, and both with the more extended serous surface already examined. That the membrane lines the roof of the ventricles, may be proved by cautiously dividing the fibres of the corpus callosum, and pushing them aside. A thin membranous lamella will be thus exposed, which, though diaphanous, is sufficiently firm to confine air or fluid passed into the ventricle. There are then two entering layers, one along the roof, the other on the floor of the ventricle, and a returning or tubular process continued back from these, and terminating as above stated. Their arrangement appears to be as follows:—the arachnoid membrane, after investing the surface of the corpus callosum as far as its posterior border, turns beneath it, passing through the foramen of Bichât. After lining the under surface of the fornix, it is reflected over its borders to the septum lucidum, upon which it is prolonged to the roof of the ventricles, and so to their outer margins. In this way it may be traced into the posterior and descending cornua as far as the points at which the plexus choroides of each side enters, on the upper surface of which it is reflected, to form the commencement of the velum interpositum. Now the part of the membrane that covers the tubercula quadrigemina, on reaching the interior of the ventricle, sends in the middle line a process into the third ventricle, which is prolonged in the form of a cul-de-sac downwards into the fourth ventricle, lining its walls and closing its cavity inferiorly. On







each side the membrane extends along the floor of the ventricles to their outer margins, where it is continuous with the part already traced to these points. It is similarly disposed of in the floor of the posterior and descending cornua; and on reaching the fissures which admit the plexus choroides at each side, it is reflected on the under surface of the latter, the part that lined the roof having been reflected on their upper surface; so that they are enclosed between two lamellæ of the serous membrane, in their entire extent, from the lateral fissures to the foramen Monroi. These lamellæ, from being stretched from side to side, between the fornix and the third ventricle, constitute what is called *velum interpositum*: posteriorly, the velum is narrowed to a funnel-shaped process, which makes its exit through the fissure of Bichât, and, on reaching the point at which the falx spreads into the tentorium, becomes continuous with the part of the membrane which lines these processes.

*Membrana dentata*, (plate I., fig. 2, 8, 8; ligamentum denticulatum, vel serratum.)—At each side of the spinal cord, along its whole length, is placed a shining, thin, but firm membrane, which is attached to the tube of the dura mater by a series of pointed processes, from which circumstance its name is derived. It extends from the border of the foramen magnum, to which its first dentation is attached, down to the first lumbar vertebra, in all which extent it is interposed between the anterior and posterior roots of the nerves, one of its surfaces looking forwards, the other backwards. The external or dentated border being attached (by so many points as there are dentations—about twenty in all,) to the dura mater, the place of their attachment is midway, or very nearly so, between the foramina for the exit of the nerves. Its inner border, corresponding in position and direction with the lateral sulcus of the spinal cord, rests against the pia mater, which encloses the cord, and appears to be connected with it by delicate cellular tissue. Is it a distinct structure? *Adhuc sub judice lis est.*

*The spinal cord.*—The spinal cord, (plate I.; chorda spinalis, medulla spinalis, cerebrum oblongatum,) is that part of the cerebro-spinal mass which is enclosed within the spinal canal. The term “medulla,” commonly given to it, cannot with propriety be retained; as it obviously bears no similitude to the “marrow” of long bones; and it certainly is not a prolongation of the brain, which the name cerebrum oblongatum would imply, for its appearance and development precede that of the brain. We must observe, that though, as the name implies, the greater part of the cord is enclosed within the canal, still a portion of it is prolonged into the skull, and rests on the basilar process of the occipital bone. On this is founded its division into *chorda spinalis* and *chorda oblongata*, (medulla oblongata.)

*Spinal cord, dissection of.*—In order to expose the cord, previously to examining its structure, it is necessary to saw through the broad part of the occipital bone down to the foramen magnum, and then to cut through the arches of the vertebræ at each side, along the whole of the column, with a knife, or chisel and mallet, as it is both tedious and troublesome to saw them. The arches being removed, the dura mater may be laid open in its entire length, and the description of the contained parts referred to. Slit open the tube formed by the dura mater, reflect the borders of it to each side, observe the roots of the nerves, the filaments which collect to compose them, and carefully note the ligamentum dentatum—its relations to the nerves and to the other membranes.

In the adult human subject, the cord extends from the lower border of the pons Varolii as far as the first or second lumbar vertebra. In the early periods of fetal life it extends throughout the whole length of the spinal canal, conforming in this particular with the permanent condition of it in lower animals, in which it reaches even to the caudal prolongation of the column. As the process of growth and development goes on, the relation of the cord to its osseous canal varies, so that ultimately it reaches only to the point above stated. Keuffel, however, saw it in one case end opposite the eleventh dorsal vertebra, and in another reach as far as the third lumbar. Its form, considered in its general outline, is cylindrical: but its transverse diameter is somewhat greater than the antero-posterior, which gives it a flattened appearance in the former direction. The size of the cord is not the same from one extremity to the other; neither does it increase or diminish uniformly. Three distinct swellings are observable in different parts of its extent. Superiorly (fig. 1, No. 8; fig. 2, No. 9,) it is enlarged where it is in apposition with the margin of the pons Varolii, but gradually diminishes as it approaches the foramen magnum. The second swelling, (fig. 1, No. 9; fig. 2, No. 10,) corresponds with the interval between the third and sixth cervical vertebræ; the third, (fig. 1, No. 10; fig. 2, No. 11,) with that between the tenth dorsal and the first lumbar. Its inferior termination is subject to considerable variety in different

## PLATE IV.

The lateral ventricles of the brain.\* These are brought into view by removing the corpus callosum, and dividing the hemispheres in the course of the cornua.

A. The anterior extremity of the corpus callosum. B. Its posterior extremity continuous with the fornix. C. The edge of the hemisphere, from which the corpus callosum has been divided. D. The two lamellæ of the septum lucidum, the intervening space being the fifth ventricle. E, E. The fornix. F, F. The pillars (erura,) of the fornix. G. The anterior cornu of the right lateral ventricle. H. Its posterior cornu (digital cavity,) containing the hippocampus minor. I. K. The entrance of the inferior or descending cornu. L. The commencement of the hippocampus major. M. The corpus striatum of the right lateral ventricle. N. The tænia semieircularis. O. The optic thalamus of the right side. P. The choroid plexus, communicating with that of the opposite side through, R, the foramen of Monro.



cases. It usually becomes fusiform, and terminates in a point a few lines below the lumbar swelling: in other instances it ends in a small bulb, slightly constricted at its centre; but any varieties of conformation presented by this portion deserve little attention, as none of the nerves arise from it.

When detached from its connexions, the cord is found to be divided into two lateral halves, by grooves (sulci) extending along its whole length, one situated on the anterior, the other on the posterior aspect. The white substance which encircles these two lateral parts or fascies dips into the sulci; but it is somewhat remarkable, that, in the anterior one, the fibres are observed to pass from side to side, and intermix along the median line; in the posterior one they all pursue the longitudinal direction. At each side of these grooves, two others (*fissuræ laterales*) may be observed running parallel with them, being, however, but faintly marked. These indicate the lines in which the anterior and posterior roots of the spinal nerves are attached to the cord; and, finally, along the lateral aspect of the cord, a slightly depressed line may be traced down as a continuation of that which separates the corpus restiforme from the olivare, gradually, however, becoming more faint, and ceasing to be perceptible about the upper part of the dorsal region.

*Spinal nerves.*—The spinal cord gives attachment to thirty-one pairs of nerves, which are regular, symmetrical, and double-rooted. One of the roots of each nerve arises from the anterior, the other, (plate I. fig. 2, 14, 14,) from the posterior aspect of the cord. The fibres which form the latter pass outwards, converging towards one another, and in the tubular investment of dura mater, which encloses them, form a ganglion, (fig. 1, 11, 11.) The fibres of the anterior root pass to the same point, and, having united, join with the preceding, immediately external to the ganglion. The trunk thus formed is a compound nerve in structure and in function, sensation being transmitted, according to the researches of Sir C. Bell, by the posterior root, and the power of motion by the anterior. There are eight cervical pairs of nerves, (fig. 2, a, a,) the upper four of which form a plexus at the side of the neck, (cervical plexus;) the lower four, with the first dorsal, constitute the brachial plexus: the dorsal nerves are twelve in number, (fig. 2, b, b;) eleven of them correspond with the intercostal spaces. There are five pairs of lumbar nerves, (fig. 2, c, c,) and six sacral, (fig. 2, d, d,) which form each a plexus, (lumbar and sacral plexus,) but which are joined in such a way as to form one elongated interlacement, (lumbo-sacral,) from which issue the nerves of the lower extremity.

*Medulla oblongata.*—The cranial portion of the cord, (plate VIII. F.; *chorda oblongata, medulla oblongata*), is broad and thick superiorly near the pons Varolii, but tapers gradually towards the occipital foramen. Its anterior aspect is rounded, the posterior is somewhat flattened, and each presents a continuation of the median sulcus (anterior and posterior) by which it is divided into two symmetrical parts. The lateral depressions, which correspond with the points of origin of the spinal nerves, are also continued upwards, into the medulla oblongata. But though inferiorly the divisions established by these lines are so slightly marked as to have escaped notice, until Chaussier directed his attention to the subject, yet in the superior part (*medulla oblongata*) they are so well defined as to have been deemed deserving of particular names. The anterior and posterior pair have been called the anterior and posterior pyramids; the middle, from their shape, the corpora olivaria. These, according to Gall, are made up of the primitive or formative fibres of the cerebrum and cerebellum; for if they be traced upwards, the anterior pyramids and the corpora olivaria will be found continuous with the fibres which are expanded into the cerebral hemispheres, whilst the posterior pyramids (usually called, since Ridley's time, *corpora restiformia*) are evolved into the lobes of the cerebellum. Besides these parts, which have been noticed by all anatomists, Sir C. Bell has described another, which is situated between the corpus olivare and restiforme. This consists of a narrow line of white matter, which may be traced along the medulla oblongata, and from thence downwards between the anterior and posterior roots of the spinal nerves. It is but slightly marked in the lower part of its extent, but becomes more perceptible opposite the corpus olivare; after which it narrows, and ceases altogether at the margin of the pons, "not being continued upwards into the cerebral mass." This may be termed *tractus respiratorius*, as it gives origin to the class of respiratory nerves as established by Sir C. Bell.

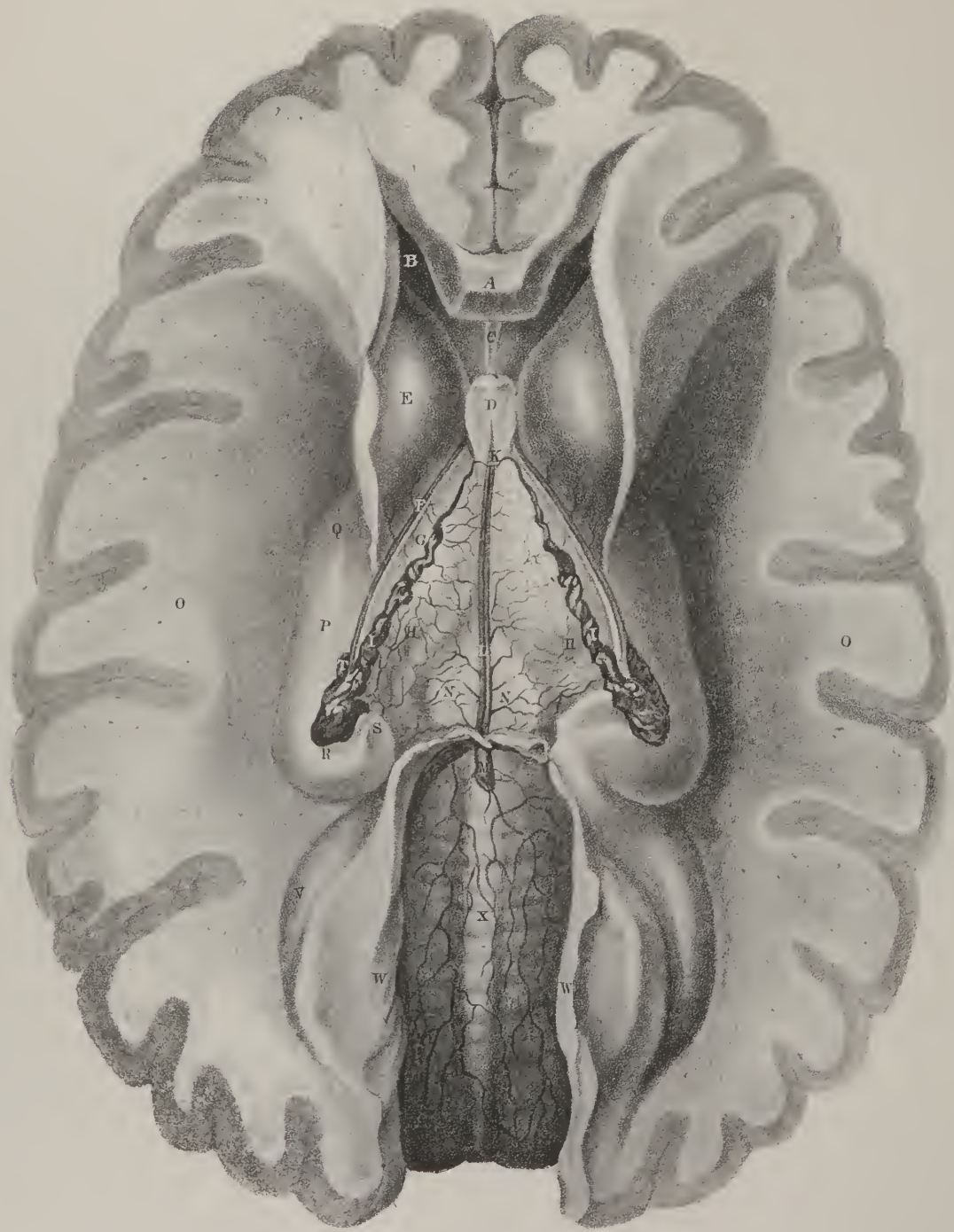
*Structure.*—A transverse section of the medulla shows it to consist of a thin lamella of white matter, enclosing the gray or ceneritious substance. The latter is disposed in a very peculiar way, (plate VIII. G. ;) it presents two lateral portions, each of a crescentic form, their concavities looking outwards; the convex sides of each are turned towards the middle line, and are connected by a short transverse fasciculus of gray matter. The anterior cornua of the lateral masses are rather thick and rounded; the posterior extend as far as the corresponding collateral sulci.

The *anterior pyramids*, (plate VIII. m; corpora pyramidalia,) are close together, being separated only by the anterior sulcus, and extend, enclosed between the corpora olivaria, from the margin of the pons Varolii to the foramen magnum. Some of the fibres of each pyramid which are close to the sulcus pass across it obliquely; and so a decussation (n) is produced between them. The rest continue their course uninterruptedly, so that only a part of the pyramids change place, or decussate.

The *olivary bodies*, (plate VIII. o; corpora olivaria,) when stripped of their medullary lamella, are found to consist each of an oblong mass of gray matter, surrounded by a fringed or scalloped border, and attached towards the middle line by a slight petiole. Owing to this arrangement, it presents, when divided by a transverse section, an arborescent appearance.

The *posterior pyramids*, (plate VII. X., X.; plate VIII. p; corpora restiformia, pyramides postérieures, Gall,) correspond with the posterior and lateral parts of the medulla; they diverge as they ascend towards the lobes of the cerebellum. The posterior aspect of the medulla oblongata is slightly concave, and divided into two lateral parts by the median sulcus, to which two







oblique lines converge, giving it an indented appearance. This has been termed *calamus scriptorius*, (plate VII. W.) One or two elongated cords are also observable on this surface, which have not as yet received names, "but whose offices may one day be discovered."\*

*The Brain.*—The part of the central mass of the nervous system which is lodged within the skull, has been called from this circumstance "encephalum." It presents, even on a superficial inspection, a division into parts, which differ in position, size, and form, as well as in the arrangement of their components; these have been named cerebrum, cerebellum, (or great and little brain,) cerebral protuberance, and lastly, the connecting link between these and the spinal part, viz. the medulla oblongata.

*Dissection of the Brain.*—When proceeding to open the skull, (the muscles having been previously dissected,) it will be found convenient to saw through the external table of the bones all round, from the superciliary ridge to the occipital protuberance. When this has been done, the inner table may be broken through by employing a small mallet and chisel, or a strong knife made for the purpose. After the roof of the skull is removed, the chin should be supported on a block, and the dissection proceeded with. An incision may be made along the middle line, so as to lay open the longitudinal sinus, after which the dura mater may be divided by a horizontal incision carried along the whole length of one of the hemispheres, on a level with the section made in the bone. This portion of the membrane may then be drawn to the opposite side, which will expose the surface of the brain, the falx cerebri, the fissure between the hemispheres, &c. All the parts here named should be examined attentively, the descriptions given of them in the different sections being at the same time read.

In the next place, let the hemisphere which is uncovered be drawn aside so as to expose the corpus callosum; after which its substance may be cut through, by passing down a scalpel to a level with the corpus callosum, and then directing its edge outwards and upwards somewhat, so as to avoid entering the ventricle.

*To open the Ventricle.*—The lateral ventricle may be opened by making an incision through the corpus callosum parallel with its raphé, and everting the external portion of it. The parts within the body and anterior and posterior cornua of the ventricle being examined, the descriptions given of their form, size, and position being read, the descending cornu should in the next place be traced by following the plexus choroides downwards into it: after which it can be fully exposed by making an incision through the substance of the optic thalamus down to the cornu, so as to remove the external two-thirds of it. If the cornu ammonis be drawn outwards, the point at which the plexus enters will distinctly appear, and also the change presented by the pia mater where it enters the ventricle. The greater part of the substance of the hemisphere may now be removed, and the tentorium cerebelli at the same time detached from the pars petrosa, and reflected backwards. This will expose the greater number of the cerebral nerves, and give a side-view of their course and relations within the cranium. Those within the cavernous sinus may be brought into view by following the third, fifth, and sixth through the foramina in the dura mater, and everting it as it is cut up.

The brain, (plate II., *cerebrum*.) forms the largest portion of the central mass of the nervous system, and occupies the principal part of the cranial cavity. It extends from the frontal bone to the occipital fossæ, resting on the orbital processes of the former, on the tentorium cerebelli posteriorly, and in the centre descends into the middle fossæ, at the base of the skull. Its superior surface is convex and arched, corresponding with the vault of the cranium, beneath which it is placed, and presents along the middle line a deep fissure (A), running from before backwards, by which it is divided into two equal parts (*hemispheres*). The surface of the brain is rendered unequal by several depressions and elevations marked upon it. The elevations are called *convolutions* (*gyri*), and are situated between the depressions (*sulci*.) The course of the convolutions is winding and tortuous, as the name

## PLATE V.

In this view of the brain the fornix is removed, and the hemispheres are sliced away nearly to their base, to show the extent of the middle or descending cornu.

- A. The anterior extremity of the corpus callosum. B. The anterior cornu of the lateral ventricle of one side. C. The remains of the septum lucidum and fifth ventricle. D. The anterior pillars of the fornix divided and thrown forwards. E. The corpus striatum of the left ventricle. F. The tenia semicircularis. G. The thalamus opticus. H, H. The velum interpositum, a vascular net-work extending between the choroid plexus. I, I. The choroid plexus. K. The communication between the choroid plexus of each side anteriorly. L. The venæ Galeni terminating posteriorly in, M, the commencement of the straight (fourth) sinus. N, N. The impression of the corpora quadrigemina, seen through the velum interpositum. O, O. The hemispheres of the brain sliced very deeply to display the parts contained in the descending cornu. P. The hippocampus major. Q. The pes hippocampi. R. Part of the corpus fimbriatum. S. The divided extremity of the hippocampus major and corpus fimbriatum. T. The choroid plexus contained within the middle cornu. V. The outline of the posterior cornu. W. The posterior lobes of the cerebrum divided to show the upper surface of the cerebellum invested by pia mater. X. The superior vermiform process of the cerebellum.

\* Sir C. Bell's Exposition of the Nervous System, p. 21.

implies, and their size presents many varieties in different places. It should be observed, that the anterior extremity of the brain, which corresponds with the frontal bone, is narrower than the posterior, which is in apposition with the occipital bone.

*Hemispheres* (plate II. B, C).—The external surface of each hemisphere is convex in its general outline; the internal is flat and compressed, as it rests against its fellow of the opposite side, the falx major being interposed between them. The inferior surface presents several depressions and inequalities, corresponding with those of the base of the skull.

*Lobes* (plate VIII.).—On the inferior surface of each hemisphere is observed its division into three *lobes*. The anterior lobe (A) rests on the orbital process of the frontal bone and the smaller wing of the sphenoid bone; the posterior (C) is supported by the tentorium cerebelli; and the middle (B) is received into the central fossa, at the base of the skull. The anterior is separated from the middle lobe by a deep fissure (*fissura Sylvii*); but there is no precise line of demarcation between the latter and the posterior.

The *Brain—its external surface*.—The relation of size, form, and situation of the different objects seen on the external surface of the brain, should be carefully noted, as illusions are constantly being made to them during the description of the parts deeply seated, and also when tracing the progress of its development in the human subject, or in the animal series, and particularly when, after the manner of Gall and Spurzheim, we follow the course of the nervous fibres through the successive steps of their expansion, as the phrase is, from the medulla upwards into the cerebral hemispheres. Nothing of consequence remains to be noticed on the superior and external surface, in addition to what has been already stated.

To *examine the origin of the nerves and the parts at the base of the brain*, it must be detached from its situation and inverted; but it is not necessary to repeat what has been already stated in our description of the exterior of the brain; note first the parts which lie along the median line, beginning with the anterior sulcus, and proceeding with them from before backwards. Note their size and relations, compare them with the descriptions. Then take the objects which are placed more externally. Observe the relative position, form, direction, and size of the different nerves. You will at once recognize the olfactory running forwards, in a manner embedded in a groove in the anterior lobe, about a finger's breadth outside the median sulcus. In the interval between these, at their roots, you recognize the commissure of the optic nerves, behind which is the tuber cinereum and the infundibulum; behind the tuber are the corpora albicantia, and then a small depressed triangular space, the locus perforatus, on each side of which is the crus cerebri. Attached to the crus, towards its inner side, is the third nerve, and upon its outer side rests the inner convolution of the middle lobe; evert the latter, and you see the fissure through which the pia mater enters the inferior cornu of the lateral ventricle. Whilst doing this, you recognize the optic nerve, rather soft and flat, resting on the crus cerebri, and curving forwards to its commissure.

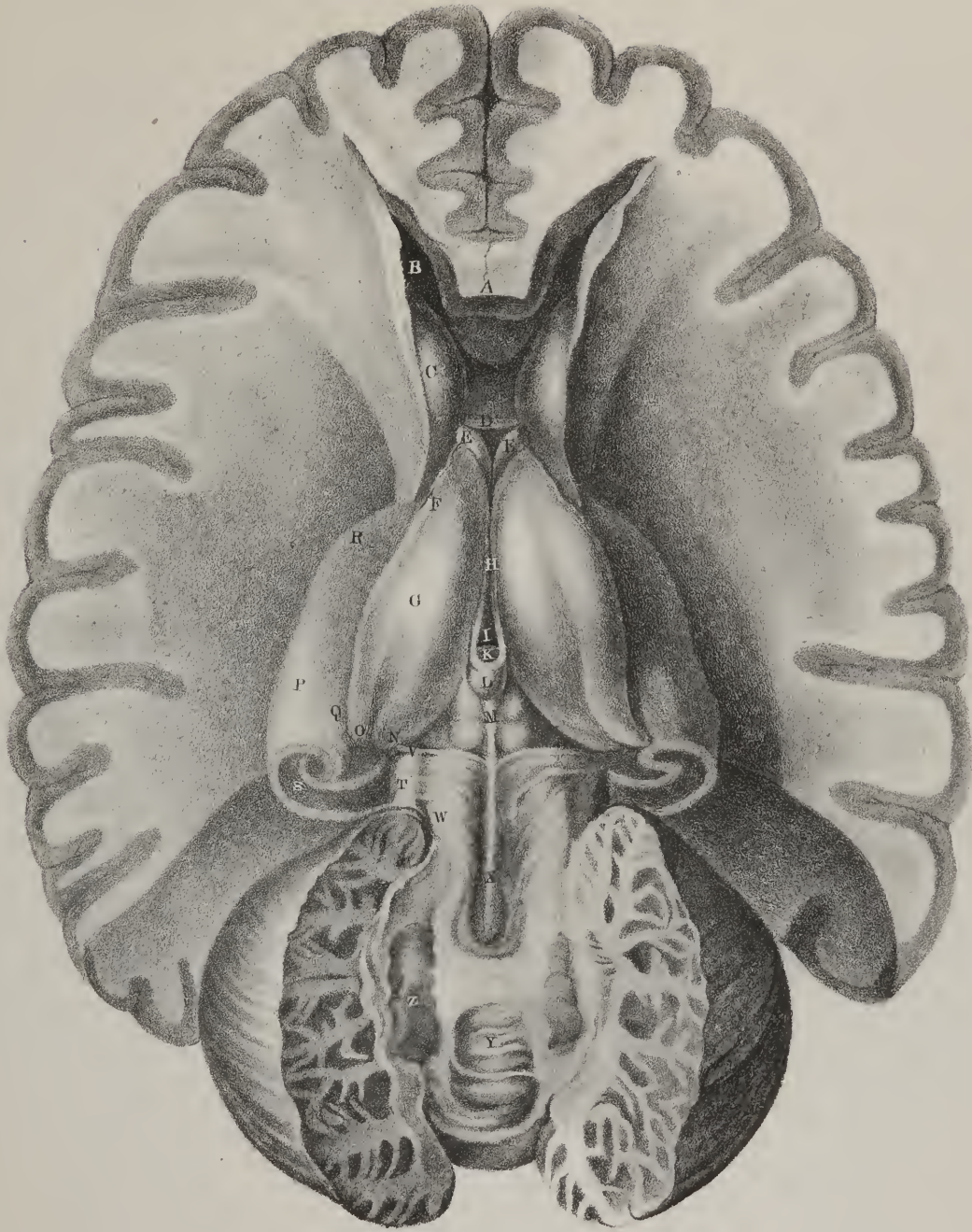
Now, returning again to the middle line, you find behind the crura, and as if overlapping them at their commencement, the broad white lamella—pons Varolii; trace its fibres outwards, and you observe them to be continuous with the crus cerebelli at each side, which is concealed by some minor lobules. And here, at the junction of the pons with the crus, you see the fifth nerve. At the posterior border of the pons is the medulla oblongata, presenting the two pyramids close together, one at each side of the middle line; external to these are the olivary bodies, and still farther out the restiform. At the junction of the pyramid with the pons is the sixth nerve. Along the groove, between the pyramid and the olivary, are several delicate filaments, forming the origin of the ninth or lingual nerve. A little farther out you see a small nerve running parallel with the medulla, as it were, coming up from the foramen magnum—this is the nervus accessorius. Now look at the groove between the olivary and

## PLATE VI.

Upon removing the velum interpositum, shown in the last plate, the third ventricle, the fissure between the thalami optici, is brought into view. The hemispheres on each side have been deeply excavated, and a large part of the corpora striata cut away so as to display the extremities of the middle cornua, and the large bodies, hippocampi majores, which occupy them. Posteriorly, the upper portion of the cerebellum has been removed to show the position and appearance of the fourth ventricle, previously to the rupture of the valve of Vieussens.

A. The anterior extremity of the corpus callosum. B. The anterior cornu of the lateral ventricles. C. Part of the corpus striatum. D. The anterior commissure of the third ventricle. E, E. The crura of the fornix descending through the foramen commune anterius. F. The tonia semicircularis. G. The thalamus opticus. H. The fissure between the thalami optici, which is called the third ventricle. I. The foramen commune posterius. K. The posterior commissure of the third ventricle. L. The pineal gland connected to the thalami optici by its two peduncles. M. The corpora quadrigemina. N. The corpus geniculatum internum of the thalamus opticus. O. Part of the corpus geniculatum externum; the rest has been removed with the hemisphere. P. The hippocampus major. Q. The corpus fimbriatum attached to the concave border of the hippocampus major. R. The pes hippocampi. S. The cut surface of the hippocampus major, showing the convoluted arrangement of the grey and white substance of which it consists. T. The upper surface of the crus cerebri. V. The fourth nerve arising from the valve of Vieussens, close to the corpora quadrigemina, and winding around the crus cerebri. W. The processus e cerebello ad testes. X. The valve of Vieussens. Y. The middle portion of the cerebellum connecting the two lateral lobes. Z. The corpus rhomboideum, in the centre of the white substance of the cerebellum.









restiform bodies, and you will find in the first place, high up and close to the pons, the portio dura, a rounded small cord; immediately beneath it a very small nerve—the glosso-pharyngeal, to which succeeds a flat fasciculus, the nervus vagus. Evert the medulla a little, or draw it forwards—you see the calamus scriptorius—a groove and fissure like the point of a writing-pen; higher up, a few oblique lines faintly traced upon the surface, and then the portio mollis, or auditory nerve. Finally, draw the lobes of the cerebellum forward so as to invert it, you see a white lamella in front of it—the valve of Vieussens, and the fourth nerve attached to it.

*The Brain—its base or inferior surface*, (plate VIII.)—When we turn to the inferior surface, we observe that it presents in the middle line, and in front, a fissure (a), being the continuation of the longitudinal one, which establishes the separation between the hemispheres. It lodges the anterior extremity of the falx cerebri, its depth being limited by the corpus callosum, which passes across from one hemisphere to the other. The inferior surface of each anterior lobe, as it corresponds with the orbital plate on which it rests, is slightly concave.

*Sulcus olfactorius*.—A few lines external to the longitudinal fissure, and parallel with it, is a groove, resembling one of the sulci, which lodges the olfactory nerve (1), and at its posterior extremity is a rounded papilla, from which one root of that nerve is derived.

*Fissure of Sylvius* (b).—Posterior to the groove just noticed is the fissure (fissura Sylvii) which marks the separation between the anterior and middle lobes, and lodges the middle artery of the brain. It inclines from within outwards and upwards, and gradually terminates amongst the convolutions on the exterior of the hemisphere, its direction corresponding with that of the small wing of the sphenoid bone. At its internal termination it forms a right angle with another fissure (c), which extends from before backwards, and which is bounded externally by the middle lobe, internally by the crus cerebri and tractus opticus, and deserves notice because it transmits the pia mater from the external surface into the lateral ventricle.

The angular part of the anterior lobe, which is included between the internal termination of the fissure of Sylvius, the longitudinal fissure, and the commissure of the optic nerves, has been named by Vicq-d'Asy *substantia perforata antea* (d), and by Reil *lamina cribrosa*, because it presents several foramina for the transmission of vessels. It deserves attention, inasmuch as the white lines seen at its inner border are continuous with those of the corpus callosum.

*Optic commissure* (v).—Between the fissuræ Sylvii, and corresponding with the interval between their internal terminations, is situated the *commissure of the optic nerves*. It is flat and quadrilateral in its form: one surface looks upward to the brain, and is connected with the anterior termination of the corpus callosum, which passes upon it in the form of a thin semi-transparent lamella; the other surface rests upon the depressed part of the sphenoid bone, which lies before the pituitary fossa; the lateral and anterior margins are free, but the posterior one is intimately connected with a delicate stratum of grey matter, which is inserted between the nerves as they converge to their commissure.

*Tuber cinereum* (e).—The piece of grey matter just referred to is called by Scemmering *tuber cinereum*: it extends from the posterior margin of the optic commissure to the corpora albicantia, gradually becoming a little thicker and firmer; for in front it is so thin as to be torn by the slightest touch. Its superior surface forms part of the floor of the third ventricle; the inferior one is slightly convex, and gives attachment by its centre to a funnel-shaped process, called *infundibulum* (f; plate IX. fig. 1, c; tige pituitaire.) This is a thin elongated process of reddish grey matter, inclined obliquely downwards and forwards from the tuber cinereum to the pituitary gland: its extremities are slightly expanded, and its centre constricted, which gives it an hour-glass shape.

*Pituitary gland or body*, (plate IX. fig. 1, d.)—The pituitary gland appears to have received its name from its being supposed, in the infancy of anatomy, to communicate with the nose, and to secrete the viscid mucus (pituita) of that cavity; it is lodged in the excavation in the upper surface of the body of the sphenoid bone, and is unequally divided into two portions or lobes: the anterior, which is larger and more firm than the other, is convex in front, and concave behind, so as to receive the other, whose border is round and convex. The situation of the pituitary gland is peculiar: it is interposed between the two lamellæ of the fibro-serous membrane. The dura mater will be found to line the surface of the bone on which the gland rests; but the arachnoid membrane, after having formed a funnel-shaped process round the infundibulum, is reflected off from it at its lower extremity, and stretched across the upper surface of the gland until it reaches the clinoid processes, where it becomes continuous with the inner lamella of the fibro-serous membrane. When cut into thin slices, it appears to consist of two substances, one being reddish grey, the other white.

*Mammillary bodies*, (plate VIII. g.)—Immediately behind the tuber cinereum are placed two small bodies, called corpora mammillaria, (albicantia, pisiformia.) Their size is about that of a pea, but they are not quite round, being slightly compressed on three sides. Placed in apposition with one another, they are connected by a delicate process of grey matter, of which substance the greater part of their mass consists; they are, however, invested by a lamella of white matter, derived from the anterior pillars of the fornix, of which they may be regarded as the termination.

Behind the mammillary bodies is situated a thin lamella of white substance, which is pierced by a number of foramina, for the transmission of vessels, and called *locus perforatus*, (h,) and sometimes *pons Tarini*. Its shape is triangular, the sides being

formed by the crura cerebri, the base by the mammillary bodies, the apex being at the border of the pons Varolii; it forms part of the floor of the third ventricle.

The *crura cerebri* (i) are two thick rounded bodies, about three-fourths of an inch long, and situated towards the centre of the base of the brain, from which they project rather prominently. They are extended from the pons Varolii forwards and upwards to the under surface of the hemispheres, into which they seem as if inserted. They are nearly in contact behind, but diverge as they pass forwards, so as to leave an interval, which is occupied by the locus perforatus. The external surface of the crura consists of white matter, which is about two lines thick, and presents a distinctly fibrous character; within this is enclosed a quantity of grey substance, so dark as to have received the name of *locus niger*. The arrangement of these structures can be readily seen by making a transverse section of the crus: the dark part is found to be convex inferiorly, and concave above, so that the section of it presents a lunated form. The optic nerves rest upon the external surface of the crura as they pass forwards to their commissure.

The *great Commissure—corpus callosum*, (plate III. A, A.)—All the parts of the brain hitherto noticed can be examined without any division of its texture, as they are placed superficially; but several are enclosed within its interior, which cannot be seen without dissection. Between the hemispheres, and extending transversely from one to the other, is placed the *corpus callosum*, (meso-lobe, commissura magna cerebri;) its form is that of a broad layer of white fibres placed horizontally, but nearer to the anterior than to the posterior margin of the brain. Its extent from before backwards is about three inches, but its breadth from side to side cannot be assigned, as it becomes blended with the substance of the hemispheres. Its superior surface is convex in its general outline, and concealed by the hemispheres, which overlap it. When these are removed, a superficial linear impression (B) will be perceived exactly in the middle line, and at each side of it a slight longitudinal elevation. To this the term *raphé*, or suture, is applied, as it indicates the point at which the union of the hemispheres takes place when their development is being completed. The fibres obviously are transverse from without inwards, for they commence at the circumference of the hemispheres, and terminate by their junction along the raphé. The inferior surface of the corpus callosum forms the roof of the lateral ventricles on each side, and towards the middle line it rests on the fornix, with which it is blended posteriorly: in front it gives attachment to the septum lucidum. Its anterior extremity, which, when viewed externally, presents a rounded border, is prolonged downwards and backwards to the base of the brain, where it forms a thin semi-transparent lamella. This reflected part (plate IX. fig. 1, C.) is nearly horizontal in its direction, so that it lies beneath the corpora striata, and above the commissure of the optic nerves, to which it adheres, but still passes backwards, and becomes continuous with the tuber cinereum in the middle line, whilst at each side its margins are blended with the substantia perforata. The posterior border of the corpus callosum (plate IX. fig. 1, D.) is thick and rounded at the middle line, its thickness being greater (as may be seen when it is cut through perpendicularly) than that of the anterior border, owing to its receiving a greater number of converging fibres from the posterior lobes. A little more externally, the border of the corpus callosum gives off at each side two fasciculi of fibres, which can be traced, one into the posterior, the other into the descending cornu of the ventricle; one of these forms the medullary investment of the hippocampus minor, the other that of the hippocampus major.

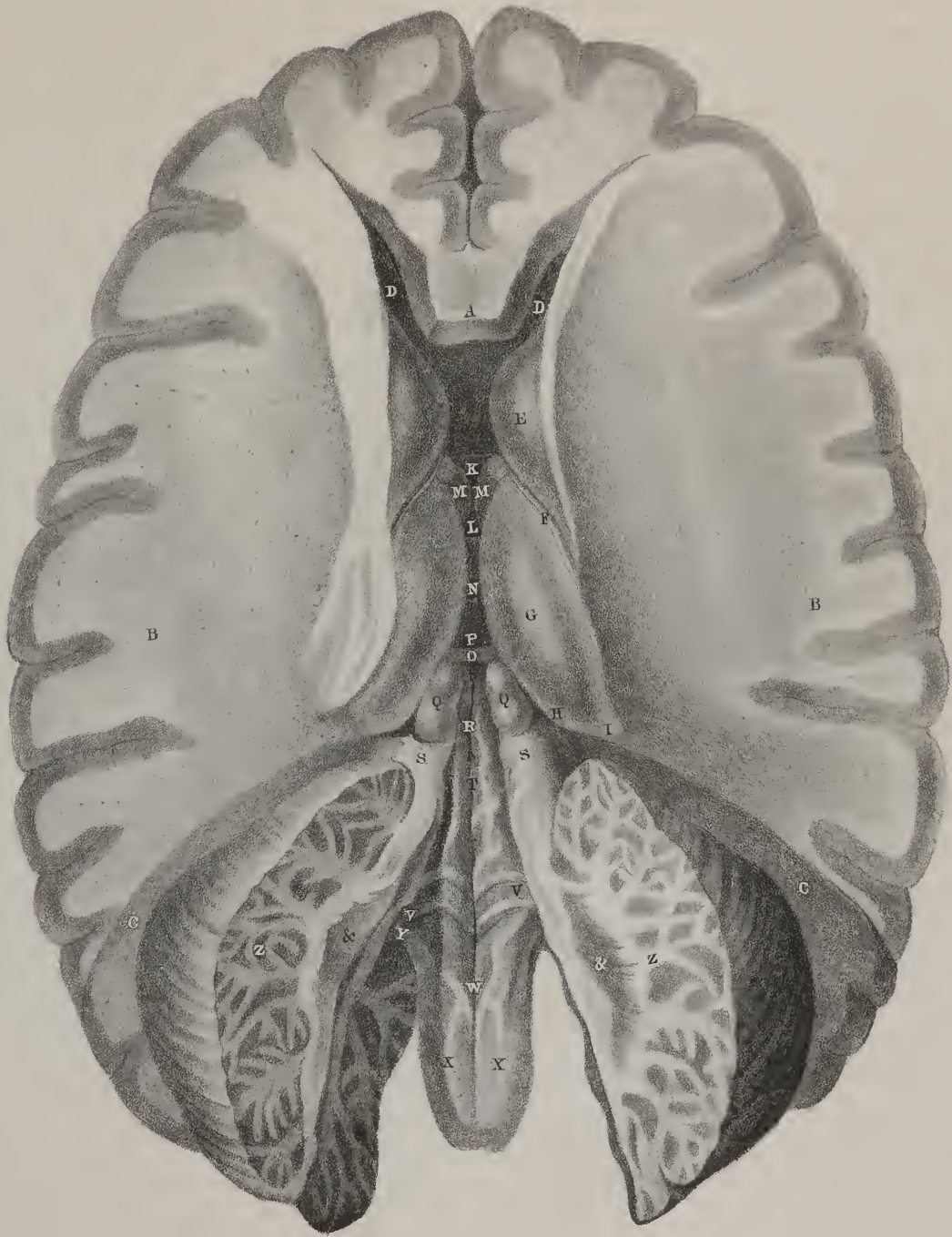
*Lateral ventricles*, (plate IV.; ventriculi tricornes.)—Beneath the corpus callosum are situated the lateral ventricles, occupying the interior of the hemispheres. Their shape is very irregular, and can scarcely be said to bear a resemblance to any

## PLATE VII.

In this view of the brain the hemispheres have been slightly separated from each other, in order to bring more clearly into view the commissures of the third ventricle; the corpora quadrigemina have been divided along the median line to show the canal which is situated beneath them; and the middle third of the cerebellum has been removed, and the valve of Vieussens broken down, to display the fourth ventricle. The plane of the corpus callosum is preserved at the anterior part, to enable the student to compare the depth of the various sections that have been made to expose the different layers.

- A. The anterior part of the corpus callosum. B, B. The middle lobes of the hemispheres, sliced downwards nearly to the base of the brain. C, C. The divided surface of the posterior lobes of the brain, which have been removed to make room for the expansion of the cerebellum. D, D. The anterior cornua of the lateral ventricles. E. The corpus striatum of the right side. F. The *tenia semicircularis* of the same side. G. The right thalamus opticus. H. Its *corpus geniculatum internum*. I. Part of the *corpus geniculatum externum*. K. The anterior commissure connecting the corpora striata of either side. L. The foramen commune anterius occupied by, M, M, the two crura of the fornix passing downwards to the corpora albicantia. N. The soft commissure, (*commissura mollis*.) O. The posterior commissure. P. The foramen commune posterius. Q, Q. The corpora quadrigemina, divided and drawn apart to show the canal, R, named *iter à tertio ad quartum ventriculum*. S, S. The remains of the valve of Vieussens turned aside over the white rounded cords, the *processus e cerebello ad testes*. T. The cavity of the fourth ventricle. V, V. The white transverse lines (*lineæ transversæ*.) of the fourth ventricle, the origins of the auditory nerves. W. The *calamus scriptorius*. X, X. The *corpora restiformia*, or posterior pyramids. Y. The *corpus restiforme* of the left side, seen entering the white substance of the cerebellum. Z, Z. The arborescent structure of the cerebellum, called *arbor vite*. &. The *corpus rhomboideum*, in the centre of the white substance of the cerebellum.







known figure. Each of them may be considered as divisible into a body or central portion, and three cornua or diverticula, which pass away in different directions. The central part lies horizontally: one cornu extends forwards from it into the anterior lobe, another backwards into the posterior, and the third downwards into the middle one; each of these presents certain peculiarities referable to the parts seen within them, which deserve notice. In the central part will be observed the corpus striatum, and thalamus nervi optici, and between them the tænia semicircularis; also the margin of the fornix, and part of the plexus choroides. These objects are for the present merely enumerated; each of them shall be noticed separately.

*Septum inter ventriculos*, (plate IV. B.; plate IX. fig. 1, I.)—Previously to describing the objects just named, it may be observed that the lateral ventricles are separated by a partition, (*septum lucidum*.) which extends from the corpus callosum perpendicularly down to its reflected lamella in front, and to the fornix behind; it is round and broad before, but becomes narrowed to a point posteriorly. It consists of two thin lamellæ of white substance, between which is a fissure, or interval, called the *fifth ventricle*.

*Fornix*, (plate IV. E, E.: plate IX. fig. 1, E.)—Beneath the corpus callosum and septum lucidum is a triangular lamella of white matter, which is extended from behind forwards over the third ventricle, and is thence termed *fornix*. Its upper surface gives attachment to part of the septum lucidum, and posteriorly becomes united with the corpus callosum; the inferior one overlays the third ventricle and the thalami nervorum opticorum, but is separated from them by the velum interpositum. Some oblique lines are traced on this surface, on which account it has been termed *lyra*, or *corpus psalloides*. The anterior extremity of the fornix is narrow, and divides into two fasciculi, (F, F; *pillars of the fornix*.) which curve downwards at the fore part of the third ventricle, immediately behind the anterior commissure, and terminate at the base of the brain by investing the corpora mamillaria. The base or posterior extremity of the fornix gives off at each angle a thin flat process, (plate V. R.) which passes into the descending cornu of the ventricle, and assumes the name of *corpus fimbriatum*.

The *anterior cornu* (plate IV. G.) of each ventricle inclines forwards and outwards, diverging from its fellow of the opposite side; the corpus striatum (M; its fore part,) projects a little into its floor: the remainder of it resembles a groove in the cerebral substance. The *posterior cornu* (H) called the *digital cavity*, converges towards that of the opposite side, and presents in its floor the *hippocampus minor*, (I; calcar, unguis.) This is a slight elevation, composed of a lamella of white matter, (continuous with, or derived from, the corpus callosum,) enclosing some cineritious substance; it gradually tapers to a point, and reaches to within an inch of the posterior extremity of the hemisphere.

The *inferior* or *descending cornu* (plate IV. K; plate V.) passes at first backwards and outwards from the body of the ventricle; but, after descending a little, it changes its direction altogether, and proceeds forwards and inwards, to terminate at the base of the brain, within a few lines of the fissure of Sylvius. This is the largest of the cornua: its convexity looks outwards and backwards, its concavity in the opposite direction: the under surface of the thalamus forms its roof, and the plexus choroides rests loosely on its floor, concealing the hippocampus major and corpus fimbriatum.

The *hippocampus major*, (plate V. P; cornu ammonis,) resembles in shape a cerebral convolution; it is curved so that its convex border looks outwards, and the concave inwards, conforming with the direction of the cavity in which it lies. Its anterior extremity expands somewhat, and presents two or three, and sometimes as many as five small prominences, separated by slight depressions, which make it to resemble somewhat the back of the hand when shut close. Some of the older anatomists called it *pes hippocampi* (Q,) from its resemblance to the clubbed foot of some of the lower animals. External to the part where the cornu makes its curve forwards, a slight elevation is observed, which is called *pes accessorius*.

*Corpus fimbriatum*, (R.)—Along the inner border of the cornu is a narrow falciform process of white substance, (*corpus fimbriatum*.) which is adherent by one edge to the floor of the cornu. It gradually becomes narrow, and ends in a point a little behind the *pes hippocampi*. Near the inner border of the corpus fimbriatum a narrow line of cineritious substance (*fascia dentata*.) is placed; it is not perceptible until the middle lobe, together with the inferior cornu of the ventricle, is drawn outwards, as it is excluded from the cavity of the cornu by the reflection of the arachnoid membrane; its free border is marked by several transverse notches, giving it a dentated appearance, from which its name is derived.

The cornu ammonis consists externally of a lamella of white substance, which, if traced upwards into the body of the ventricle, will be found continuous with the corpus callosum. The corpus fimbriatum, in like manner, will be found continuous with the fornix.

The *corpora striata*, (plate IV. M, plate V. E; ganglions cérébraux supérieurs, Gall.) are two in number, situated one in the body of each lateral ventricle. Each of these bodies is pyriform in its shape, the larger extremity being turned forwards and inwards, the smaller backwards and outwards. The superior surface is smooth and slightly prominent in the cavity, all the rest being imbedded in the substance of the hemisphere. Their position is so oblique, that though in front they are separated by not more than three or four lines, their posterior extremities are from an inch and a half to two inches apart, the interval being occupied by the optic thalami and the third ventricle. Their external surface is composed of grey substance, but internally the grey and white are intermingled, so as to produce a striated appearance, whence the name is derived. The white fibres here found are continuous with those of the anterior pyramids and of the crura cerebri, (plate IX. fig. 2, H; plate X.) They spread out considerably as they pass through the mass of grey matter of which the corpora striata consist, and



appear to be at the same time enlarged and increased. Hence these bodies are considered by Dr. Gall to be ganglia of encrease placed in the course of the fibres which are diverging to form the cerebral hemispheres.

The *optic thalami* (plate IV. O, plate VI. G; thalami nervorum opticorum, ganglions cérébraux postérieurs, Gall) are placed behind and between the corpora striata. The upper surface of each projects into the body of the corresponding ventricle; the inferior one forms the roof of its descending cornu, and the external is blended with the corpus striatum and the substance of the hemisphere. The internal surface of each thalamus, which is contiguous to that of the opposite side, is united to it by a soft lamella of grey substance called the *soft commissure*, (plate VI. H, plate VII. N; commissura mollis.) The union, however, may be called partial, for before and behind the commissure a small interval exists, where the thalami are unconnected, being merely in apposition.

*Corpora geniculata*.—On the posterior border of each thalamus are observed two slightly raised papillæ, (plate VI. N, O; *corpus geniculatum internum et externum*;) which are connected by medullary striæ to the tubercula quadrigemina, the external one being also united to the origin of the optic nerve.

*Tænia semi-circularis*.—The contiguous borders of the optic thalamus and corpus striatum are separated by a thin fasciculus of nervous matter, of a pale straw colour, (plate IV. N; *tænia semi-circularis*;) commencing near the anterior pillar of the fornix; it extends from before backwards between the bodies just named, and can be traced as far as the posterior border of the thalamus, and for a little way into the roof of the descending cornu, where it seems to cease.

*Pineal gland and its peduncles*, (plate VI. L.)—Along the inner margins of the thalami two delicate white fasciculi arise, and pass backwards, converging to the pineal gland, whose *peduncles* they form, and at the same time constitute its only bond of connexion with the substance of the brain. The pineal gland is a small mass of grey substance of a conical shape, and is sometimes called *conarium*, occasionally also *acervulus*. Its base rests on the tubercula quadrigemina; it usually contains in its interior some sabulous matter; at its first formation it consists of two masses, which unite into one.\*

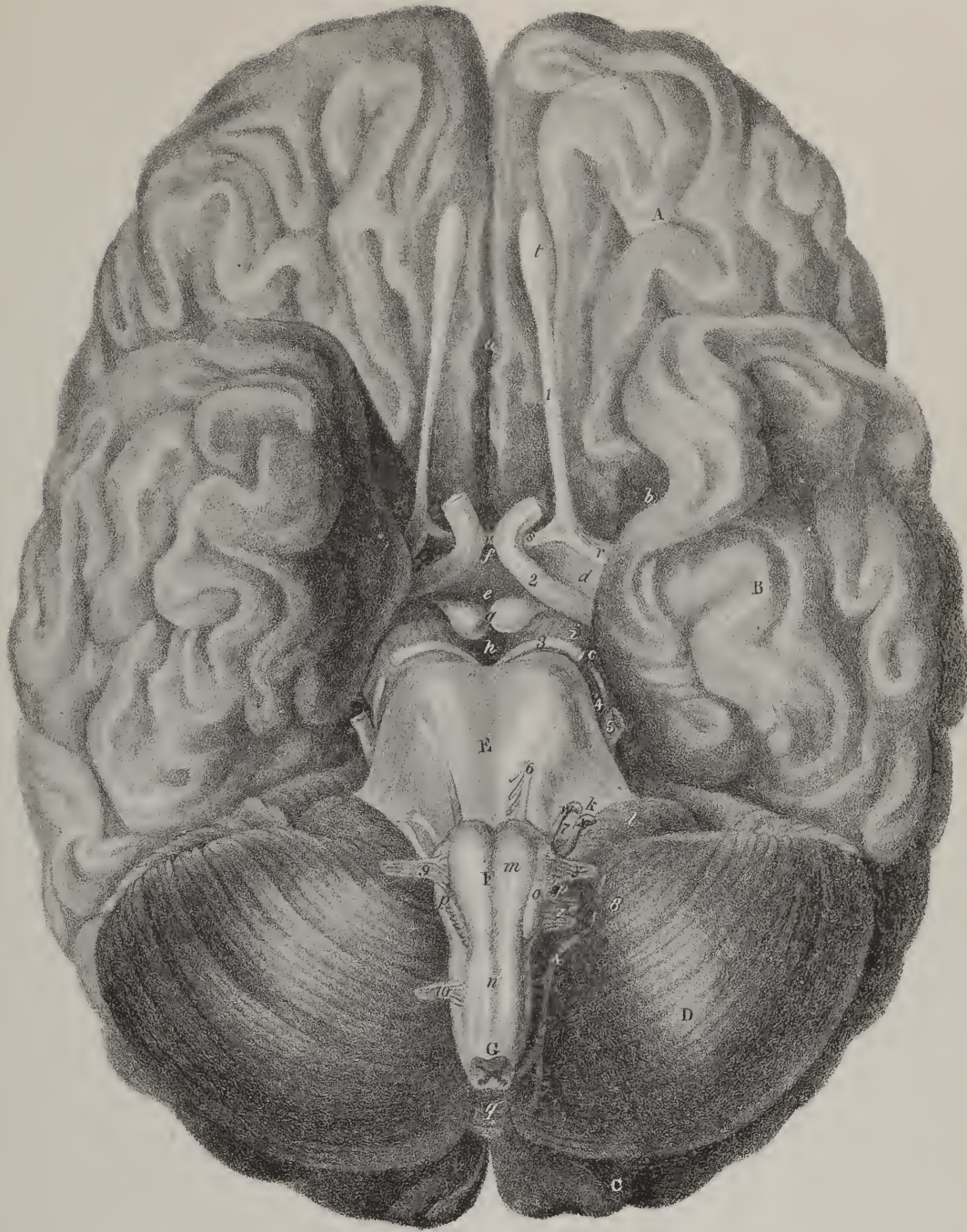
The *third ventricle*, (plates VI. and VII.)—The optic thalami enclose between them a narrow cavity, (*third ventricle*;) which corresponds exactly with the middle line, and resembles a longitudinal fissure. Its sides are formed by the thalami, its floor by the locus perforatus and tuber cinereum; the velum interpositum and fornix cover it in. The anterior commissure, and the pillars of the fornix, bound it in front. Into this cavity leads an aperture (plate VII. L; *foramen commune anterius, foramen Monroi*;) which is a rima between the anterior pillars of the fornix and the thalami, and which establishes a communication between the third and the lateral ventricles; a foramen leads out of it downwards and forwards, (*iter ad infundibulum*.) It may be observed that the infundibulum becomes imperforate at its middle, which appears to be owing to a small cul-de-sac of arachnoid

## PLATE VIII.

The base of the brain, displaying the origins of the cerebral nerves.

- A. The anterior lobe of the brain. B. The middle lobe. C. A small portion of the posterior lobe, seen projecting beyond the cerebellum. D. The right lobe of the cerebellum. E. The cerebral protuberance, or Pons Varolii. F. The medulla oblongata. G. Commencement of the spinal cord, divided by a transverse section which displays its internal structure.
- a. The longitudinal fissure of the brain, separating the two anterior lobes. b. The fissure of Sylvius. c. The fissure through which the pia mater enters the lateral ventricles. d. The substantia perforata antica. e. The tuber cinereum. f. The infundibulum. g. The corpora mammillaria, (albicantia.) h. The locus perforatus, or pons Tarini. i. The crus cerebri of the right side. k. The crus cerebelli of the right side. l. The lobular appendix of the cerebellum, (lobulus nervi vagi; flocculus.) m. The corpus pyramidale of the right side. n. Decussation of the fibres of the corpora pyramidalia in the medulla oblongata. o. Corpus olivare. p. Corpus restiforme. q. The inferior vermiform process of the cerebellum.
1. The first cerebral nerve,—olfactory.  
r. Its external root. s. Its internal root. t. The olfactory bulb, (bulbus olfactorius.)  
2. The second, or optic nerve.  
v. Its commissure.  
3. The third nerve, (motores oculorum.) 4. The fourth nerve, (nervus patheticus, n. trochlearis.) 5. The fifth nerve, (nervus trigeminus; trifacial.) 6. The sixth nerve, (nervus abducens.) 7. The seventh pair.  
w. The facial nerve, (nervus facialis; portio dura.) x. The auditory nerve, (nervus auditorius; portio mollis.)  
8. The eighth pair.  
y. The glosso-pharyngeal nerve, (nervus glosso-pharyngeus.) z. The pneumo-gastric nerve, (nervus vagus; par vagum.) &. The spinal accessory nerve, (nervus accessorius.)  
9. The ninth nerve, (nervus lingualis; hypo-glossus.) 10. The anterior root of the first spinal nerve.

\* The term *acervulus cerebri*, was employed by Sæmmering to denote the minute transparent calcareous concretions, which are found upon the surface or in the substance of the pineal gland, and are collected into a little quadrilateral mass. When a single one is found it is of larger size, and commonly irregular and rough on its exterior. I have several times in my dissections observed a process of medullary neurine, passing from the anterior point of the nates, to be connected with the pineal gland, and with its peduncles as they leave the gland, which appears to have escaped the notice of other observers.—J. P.







membrane which is prolonged into it. From the posterior extremity of the ventricle another foramen, (plate VI. I, plate VII. P, foramen commune posterior,) opens into a canal, (plate VII. R; *iter a tertio ad quartum ventriculum*; *aquæductus Sylvii*;) which leads obliquely downwards and backwards into the fourth ventricle.

*Commissures, anterior and posterior.*—Two cord-like fasciculi are stretched across the extremities of the third ventricle, and prolonged into the hemispheres which they connect, serving as commissures. The *anterior commissure*, (plate VI. D; plate VII. K,) lies just before the pillars of the fornix, and as it extends laterally it will be found imbedded in the substance of the corpora striata at each side, but does not become blended with them; its extremities arch backwards a considerable way, so as to form a curve whose convexity looks forwards. The *posterior commissure* (plate VI. K; plate VII. O) is much shorter than the preceding, and extends but a few lines on each side into the thalami; it lies behind the ventricle, before the tubercula quadrigemina, and above the aqueduct of Sylvius.

*The cerebellum*, (plates V. VI. VII. VIII. and IX. fig. 1.)—The second division of the central mass of the nervous system is the cerebellum, which differs in situation and size, as well as in the arrangement of its component parts, from the cerebrum. It is lodged in the recess formed between the tentorium cerebelli and the inferior occipital fossæ, its weight as compared with that of the brain being as 1 to 16 in the infant, and as 1 to 8 in the adult. Its surface, instead of convolutions, is divided into a number of concentric lamellæ, (*folia cerebelli*;) placed perpendicularly on their edges, and enclosed one within the other. If, however, the sulci between them be opened, several other lamellæ will be found enclosed within them, but smaller, more irregular, and with various degrees of inclination.

*Lobes.*—The cerebellum is divided into two lateral lobes, the division being established behind by a fissure, which receives the falx cerebelli, and in front by a deep excavation, which lodges the medulla oblongata.

*Superior vermiform process*, (plate V. X.)—The superior surface of the cerebellum is slightly depressed on each side where the tentorium rests upon it, but along the middle line a rounded ridge (*processus vermiformis superior*) runs from before backwards, and seems as if produced by the ripping up or admixture of the lamellæ of the lobes as they extend from without inwards. There appear to be from sixty to seventy lamellæ on the upper surface of the cerebellum, which are aggregated into five fasciculi.

*Inferior vermiform process*, (plate VIII. q.)—The inferior surface is convex, and dips down into the occipital fossæ; along the middle line runs the *inferior vermiform process*, interposed between the lateral lobes; it resembles a lobule formed of short transverse plates; its anterior extremity has been compared to a mammillary process.

The mass of medullary matter enclosed within the cerebellum is connected with three pairs of medullary fasciculi; viz. *processus à cerebello ad testes*, *corpora restiformia*, and *crura cerebelli*, which require a detailed notice.

*Processus e cerebello ad testes*, (plate VI. W.; plate VII. S.)—From the interior of the lobes, two fasciculi of white fibres pass forwards and upwards to the lower pair of the tubercula quadrigemina; the name given to them indicates the points between which they lie; they converge in their ascent, and are connected by a semi-transparent medullary lamella, named the valve of Vieussens. The valve (*valvula Vieusseni*; plate VI. X.) presents on its upper surface a slight groove, running from above downwards, and sometimes a linear ridge, like a raphé; it overhangs the fourth ventricle.

*Posterior pyramids*, (plate VII. X, X.: *corpora restiformia*, *pyramides postérieures*.)—Two white rounded processes pass obliquely upwards and outwards from the medulla oblongata into the cerebellum, named by Ridley “restiform” bodies, by Gall “posterior pyramids;” we have already noticed them as part of the medulla oblongata.

*Peduncles of the cerebellum*, (plate VIII. k; *crura cerebelli*.)—These are the largest of the fasciculi here referred to; they are at first concealed within the lobes, and even when about to emerge from their substance, they are overlapped by some minor lobules. They incline forwards and inwards, descending somewhat, and become continuous with the fibres of the pons Varolii, which are thus derived from the *crura cerebelli*. The pons, from its mode of formation, bears the same relation to the cerebellum that the corpus callosum does to the cerebrum, as it is composed of converging fibres, and may therefore be called a commissure.

*Fourth ventricle*, (plate VII. T.)—The cerebellum encloses a cavity called the “fourth ventricle,” the roof of which is formed by the valve of Vieussens and *processus ad testes*, the sides by the lobes of the cerebellum; the dorsal surface of the medulla oblongata forms its floor, and it is completed inferiorly by a reflection of the arachnoid membrane: a process of pia mater projects into it at this situation, called *plexus choroides minor*.

*Corpus dentatum*, (plate IX. fig. 2, R.; plate X. U.)—If a vertical section be made of one of the lobes of the cerebellum, in such a way as that two-thirds of its breadth shall lie external to the incision, an oval nucleus of gray substance (*corpus dentatum*, vel *rhomboideum*) will be exposed: its texture is usually firm, and its border notched, so as to give it a dentated appearance. Gall considers it as a ganglion of increase to the formative fibres of the cerebellum. The surface of the section here indicated presents rather a peculiar appearance: the white substance will be found so disposed as to represent the stalk and branches of a tree, hence called *arbor vitæ*. The branches project into the lamellæ of the cerebellum, which are not unfrequently in figurative phrase termed *folia*, for the gray substance invests them so as to make them resemble pinnatifid leaves. If a horizontal section be made, so as to divide the lobe into two equal parts, the quantity of white substance will appear considerably greater than that of the gray.

*Cerebral protuberance.*—The cerebral protuberance, (plate VIII. E. ; plate IX. fig. 1, h ; fig. 2, D. ; plate X. I, V. : nodus cerebri, pons Varolii, protuberantia annularis,) is much the smallest portion of the central mass ; its relative size being to that of the rest as 1 to 72. It is placed beneath the cerebrum, above the medulla oblongata, and before the cerebellum, having intimate relations with each by continuity of substance ; hence it has been termed *nodus encephali*. It is a square mass, its depth being about equal to its length. Its anterior surface is convex, and rests against the basilar process of the occipital bone, and is composed of the converging fibres of the cerebellum, disposed so as to form a portion of a ring, which encloses the contiguous extremities of the crura cerebri and medulla oblongata ;—it is termed *protuberantia annularis*, or *pons Varolii*. Its upper border is bounded by a transverse line, marking its separation from the crura cerebri, and the lower by another line, which divides it from the medulla oblongata ; along its middle is a shallow groove, running from above downwards, which corresponds with the basilar artery.

*Tubercula quadrigemina*, (plate VI. M.)—Upon the posterior surface of the cerebral protuberance, which is almost entirely concealed by the cerebellum, are placed four white rounded bodies, (tubercula, vel corpora quadrigemina,) disposed in pairs, one above the other, and separated by two decussating lines. The upper pair are the larger, and called *nates*—the lower, *testes* ; they are connected in front with the thalami, inferiorly with the processus ad testes and the valve of Vieussens, and between their upper surface and the corpus callosum is a rima or fissure, (*fissure of Bichât*), through which the arachnoid membrane enters to line the ventricles.

*Communication between the ventricles of the brain.*—The irregular vacuities disposed in the interior of the cerebellum and brain communicate freely with one another by certain constricted portions, or foramina. If, whilst the brain and cerebellum remain *in situ*, the latter be divided by a vertical incision made from the valve of Vieussens downwards through its substance, the fourth ventricle will be exposed. This cavity contracts towards its upper part into a tube, (aqueduct of Sylvius,) which is directed upwards and forwards, under the tubercula quadrigemina and the posterior commissure, into the middle or third ventricle.

## PLATE IX.

FIG. 1. Represents a longitudinal section of the cerebrum and cerebellum, made perpendicularly between the two hemispheres.

A, A. The internal convolutions of the right cerebral hemisphere. B. The corpus callosum. C. The anterior extremity of the corpus callosum turning downwards towards the base of the brain. D. The posterior folded border of the corpus callosum, becoming continuous with, E, the fornix. F. The right crus of the fornix descending to, G, the corpus mamillare, (albicansium.) H. The band of white fibres passing from the corpus mamillare into the thalamus opticus. I. The septum lucidum. K. The foramen of Monro. L. The divided edge of the velum interpositum. M. The central part of the fissure of Bichât, through which the trunk of the vena Galeni, N, is seen escaping from the brain. O. The anterior commissure of the third ventricle. P. The middle commissure, (commissura mollis.) Q. The posterior commissure. R. The right thalamus opticus. S. The right peduncle of the pineal gland. T. The pineal gland. U. The corpora quadrigemina. V. The iter à tertio ad quartum ventriculum. W. The divided edge of the valve of Vieussens. X. The processus è cerebello ad testes. Y. The fourth ventricle. Z. Section of the cerebellum, showing the arrangement of the white and grey substance named arbor vita.

1. The olfactory nerve.  
a. The substantia perforata antica.  
2. The optic nerve of the right side.  
b. The tuber cinereum. c. The infundibulum. d. The pituitary gland. e. The crus cerebri of the right side. f. The locus perforatus.  
3. The third nerve, (n. motorius oculi.)  
g. The middle lobe of the brain of the right side. h. Section of the pons Varolii, through which the ascending fibres of the corpus pyramidale, i, are seen separated by grey matter as they pass onwards to the crus cerebri. k. Section of the inferior transverse or converging fibres of the pons Varolii. l. Section of the superior transverse or converging fibres of the pons Varolii. m. Section of the medulla oblongata.

FIG. 2. In this drawing the development of the brain from the primitive fasciculi of the medulla oblongata, and the formation of the diverging fibres, described by Gall and Spurzheim, are exhibited. A section has been made through the outer third of the medulla oblongata and cerebellum ; the crus cerebelli has been divided, and the outer convolutions of the right hemisphere carefully raised in the direction of the fibres.

A. The medulla oblongata. B. The corpus pyramidale. C. The fibres of the corpus pyramidale expanding in the grey substance of the pons Varolii. D. The pons Varolii. E. The divided edge of the transverse or converging fibres of the pons Varolii. F. The passage of the fibres of the corpus pyramidale through the crus cerebri. G. The course of the fibres through the thalamus opticus, the inferior cerebral ganglion of Gall. H. The corpus striatum, (superior cerebral ganglion, Gall,) from which the fibres diverge to the convolutions of the middle and anterior lobes. I. The lower part of the middle lobe of the cerebrum. K. The anterior lobe. L. The posterior lobe. M. The corpus olivare. N. The ganglion of the corpus olivare. O, O. The course of the fibres of the corpus olivare through the pons Varolii, crus cerebri, thalamus opticus, and corpus striatum, to expand into the upper convolutions of the hemisphere and posterior lobe. P. The corpus restiforme. Q. The fibres of the corpus restiforme entering the substance of the cerebellum. R. The corpus dentatum, (vel rhomboideum,) or ganglion of the cerebellum. S. The processus è cerebello ad testes, or fibres of communication between the cerebellum and cerebrum.



Fig. 1.

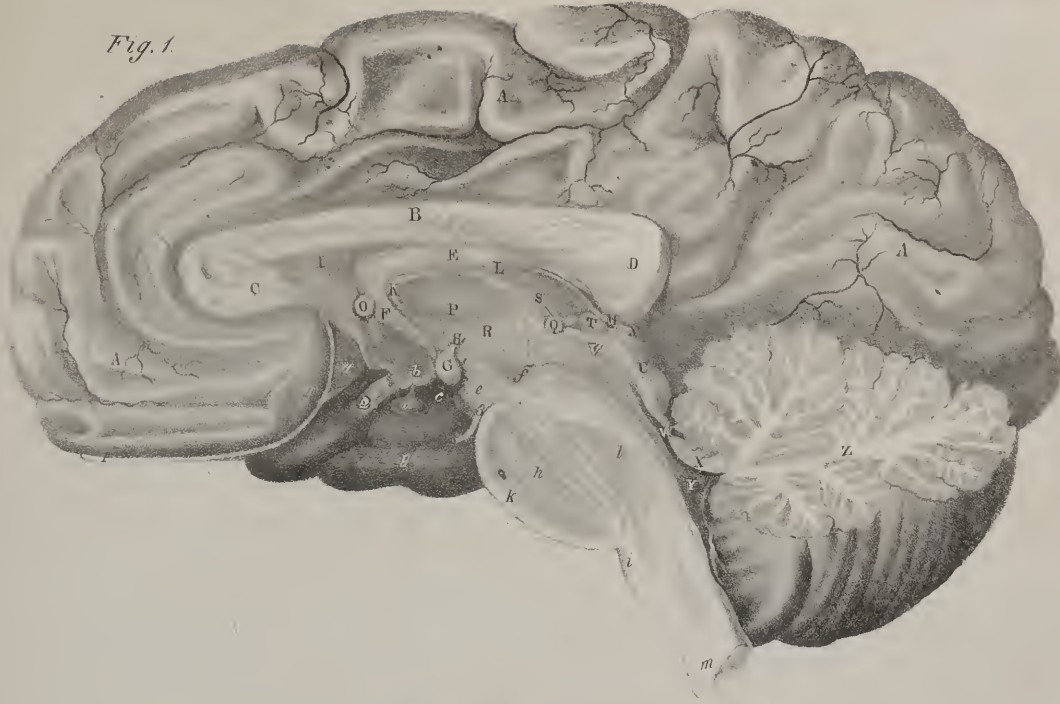
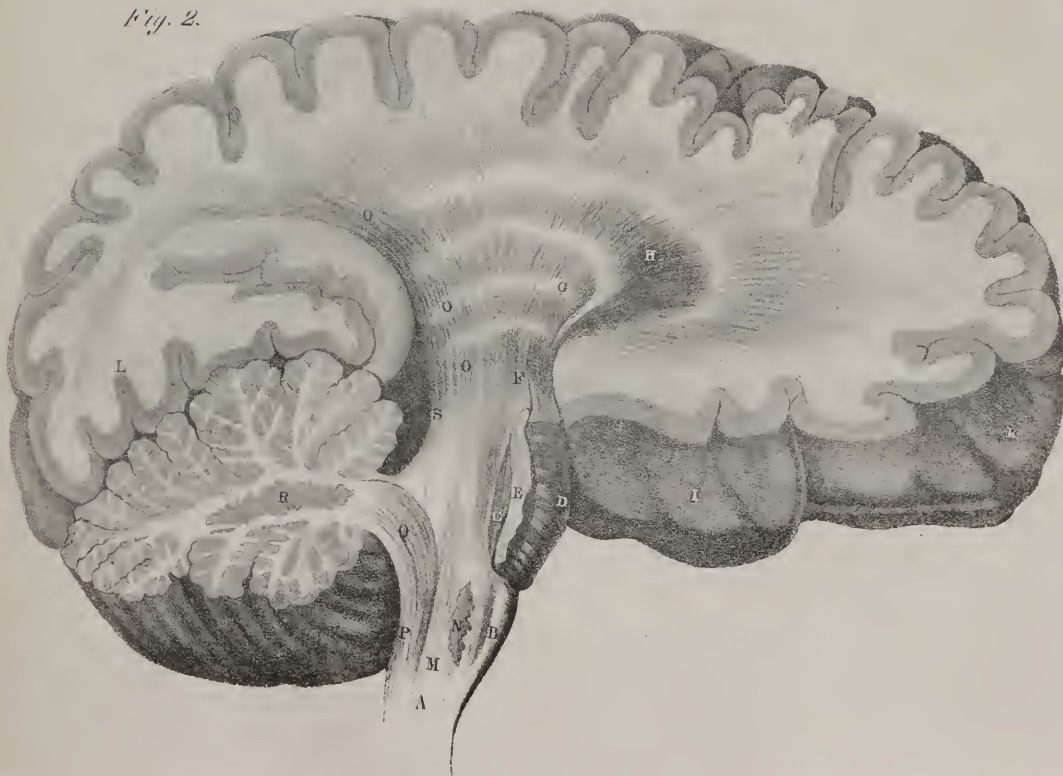


Fig. 2.







The latter again communicates at each side with the lateral ventricles by a rima (*foramen monroi*), situated between the pillars of the fornix and the thalami, on which they rest. When the ventricles have been distended with fluid, this rima assumes a rounded form, and then only represents a foramen. These vacuities, then, should be considered not as so many separate cavities, but as a series of compartments of one cavity contained within the cerebral mass; and this is the appearance they present during the early periods of fetal life. The cavity, however, is not a shut sac, for the membrane which lines it is continuous with that which invests the external surface of the brain and cerebellum. It has been already stated, that the arachnoid membrane passes in through the fissure of Bichât. Two other fissures are situated, one on each side between the corpus fimbriatum and the crus cerebri, through which the pia mater enters, to form the plexus choroides. These may be considered as chinks between the portions of cerebral substance just referred to; but they are closed up by the manner in which the arachnoid membrane is reflected from the sides of the cornua of the ventricles upon the plexus choroides.

*Structure of the brain*, (plate IX. fig. 2; plate X.)—The cerebral hemispheres are considered by Gall as resulting from an expansion or evolution of the fibres of the medulla oblongata, which he therefore terms primitive, or formative fasciculi.

*Diverging fibres* (plate X.)—The fibres of the anterior pyramids may be traced upwards to the margin of the pons, where they become somewhat constricted. From the inner border of each, some fibres pass across the middle sulcus, and mutually change place, or decussate; those of the right side passing to the left, and *vice versa*. If an incision, a line or two in depth, be made through the pons, so that one lateral half of it may be turned outwards, the fibres of the pyramid will be observed to pass into a quantity of grey substance (W) lodged in the interior of the nodus encephali. In this situation the fibres diverge and separate, and are also considerably increased: at the upper margin of the pons they become continuous with the crus cerebri (X). Here an additional increase is derived from their passage through the grey substance lodged in the interior of the crus, after which they proceed through the inferior cerebral ganglion (Y; *thalamus nervi optici*), and in the next place through the superior one (Z; *corpus striatum*), being successively increased and rendered still more divergent, until finally they reach the anterior and middle lobes (a, a), where they are evolved into their inferior, external, and anterior convolutions. The corpus olivare contains within itself a small ganglion (plate IX. fig. 2, N); its fibres pass without any decussation, into the grey substance lodged in the cerebral protuberance, where, like the pyramids, they receive additions, after which they pass into the crus cerebri (O, O), of which they form the posterior and inner part. Continuing their ascent, after being increased in the locus niger, they pass through the optic thalamus, and thence into the corpus striatum, receiving additions as they radiate through each, and finally are continued upwards into the convolutions at the summit of the hemisphere, and backwards into those of the posterior lobe. Previously to entering the optic thalamus, some fibres of the corpus olivare have been observed to turn inwards, so as to give to the tubercula quadrigemina their medullary investment, and also to unite with those of the opposite side, to form the valve of Vieussens. Finally, the diverging fibres traced up, as has been pointed out, through their successive steps of increase, terminate in the grey substance of the cerebral convolutions.

*Converging fibres*—Another order of fibres may be observed quite distinct from those above noticed, and taking a different direction. These are called the “converging fibres,” as they commence at the peripheral terminations of the preceding set, and pass from without inwards to the middle line, so as to connect the lateral parts, and bring them into relation with one another; on which account they are called commissures. The anterior and posterior commissures are formed in this way, as is also the corpus callosum; though the greater number of the fibres which compose the latter are transverse, those towards its extremities are oblique. This is owing to the manner in which the converging fibres of the anterior lobe are constrained to pass from before backwards, and those of the posterior lobe from behind forwards, in order to gain the corresponding borders of the corpus callosum. By this arrangement a greater number of fibres is collected to its extremities, which renders them thicker (particularly the posterior one) than any other part of its extent. Some of the inferior fibres thus traced from without inwards, instead of uniting with the corresponding set along the middle line, become reflected downwards from the under surface of the corpus callosum to the fornix, and so form the septum lucidum. The convolutions of the posterior lobe are brought into relation with those of the middle one by means of the fornix, the fibres of which are stretched from behind forwards, in such a way, that whilst its body is in a manner unattached, the extremities are identified with the parts just referred to.

*Diverging fibres of the cerebellum*, (plate IX. fig. 2, Q; plate X. T.)—The formative fibres of the cerebellum are derived from the posterior pyramids, or corpora restiformia; they pass upwards and outwards, and soon meet the corpus rhomboideum, which is considered as the ganglion of the cerebellum: the fibres are supposed to proceed through the grey substance of which it is composed, though it is difficult to demonstrate the fact; after which they pass outwards, diverging into the lobes of the cerebellum.

*Converging fibres*.—From the peripheral terminations of the diverging fibres in the folia, a new set arise, which incline inwards towards the middle line. These are the converging fibres, which, by their union, form the crura cerebelli; and the fibres of each crus, expanding as they pass downwards and inwards, constitute by their junction the pons Varolii, which brings the lateral lobes of the cerebellum into relation, and becomes thereby their commissure. The processus à cerebello ad testes bring the lobes of the cerebellum into intimate connexion with the cerebral hemispheres.

The weight of the brain in the adult is about three pounds; that of the cerebellum about four ounces and a half, and of the medulla oblongata half an ounce.

*Vessels.*—The brain is supplied with blood by the two internal carotid arteries, and the two vertebral; its residual blood is returned by the two internal jugular veins.

## OF THE CEREBRAL NERVES.

*Olfactory nerve*, (plate VIII. 1; plate XI.; nervus olfactorius, par primum.)—The olfactory, or, as it is frequently called, the first pair of nerves, lies in a longitudinal groove marked on the under surface of the anterior lobe of the brain, about half an inch exterior to the median fissure; when undisturbed it appears flat, but is really triangular in form, the upper angle being lodged in the groove just alluded to. The nerve is soft in its texture, not being invested by a membranous tube or neurilemma; but the arachnoid membrane is stretched across its inferior surface, and so retains it *in situ*. The nerve arises by three roots, two of which are medullary, the third or intermediate one being efferent. The external root (r) is the longest, and may be traced in the form of a white line obliquely outwards along the border of the fissure of Sylvius, where it corresponds with the last convolution of the anterior lobe of the brain. The internal root, (s,) shorter and broader than the preceding, arises, at the inner termination of the fissure of Sylvius, from the substantia perforata, (d.) By turning down the nerve from the groove in which it is lodged, we see the third origin, which is a delicate line of grey matter, derived from a papilla at the posterior extremity of the sulcus, or groove, just referred to. The first and second roots converge to the third, and the nerve thus formed passes forwards by the side of the crista galli, where it expands into an elongated bulb, (plate VIII. b; plate XI. A, A. : *bulbus olfactorius*.) From the under surface of this structure numerous filaments descend through the cribriform lamella of the ethmoid bone, each of which is invested by a tubular prolongation of the dura mater, and also by one from the arachnoid membrane, which latter, after descending a little way, re-ascends, and becomes continuous with the serous lining of the dura mater. The filaments of the olfactory nerve are arranged into three sets—the internal set, (plate XI. fig. 2, C, C.) are lodged for awhile in grooves upon the

## PLATE X.

The development of the cerebrum and cerebellum from the primitive fasciculi of the medulla oblongata, traced from the base of the brain is here shown.

- On the right side, the base of the brain is left nearly entire; on the left side, the converging fibres of the pons Varolii have been removed, and a section made through the crus cerebri towards the circumference of the hemisphere, to display the course and radiation of the diverging fibres.
- A. The anterior lobe of the right hemisphere. B. Its middle lobe. C, C. The posterior lobes of both hemispheres. D. The crus cerebri of the right side. E. A section of the inner border of the middle lobe, showing the expansion of some of the fibres of the crus cerebri. This section was made to bring into view the entire course of the optic nerve, (2,) around the crus cerebri. F. Part of the tuber cinereum. G, G. The corpora albicantia. H. The locus perforatus. I. The right half of the pons Varolii. K. The crus cerebelli of the right side. L. The medulla oblongata. M, M. The corpora pyramidalia. N, N. The corpora olivaria. O, O. The corpora restiformia. P. The right lobe of the cerebellum. Q. The flocculus or pneumogastric lobe of the cerebellum. R. The inferior vermiform process. S. The left lobe of the cerebellum divided by a longitudinal incision through its outer third. T. The ascending fibres of the corpus restiforme expanding into the cerebellum, and surrounding the corpus rhomboideum, U, or ganglion of the cerebellum. V. The superior converging fibres of the pons Varolii, forming the crus cerebelli. W. The diverging fibres of the corpus pyramidale, expanding in the grey substance of the pons Varolii. X. The passage of the diverging fibres through the crus cerebri. Y. The admixture of the diverging fibres with the grey substance of the thalamus opticus, or inferior ganglion of the cerebrum. Z. The admixture of the diverging fibres with the grey substance of the corpus striatum, or superior ganglion of the cerebrum.
- a, a. The expansion of the diverging fibres into the convolutions of the left hemisphere. b, b. The divergence and expansion of the primitive fibres of the corpora olivaria through the ganglia of the cerebrum into the left hemisphere, principally its posterior lobe. c. The anterior commissure of the third ventricle, consisting of converging fibres connecting the corpora striata. d. The band of white fibres reflected from the corpus mammillare into the thalamus opticus.
1. The olfactory nerve, (n. olfactorius.)
  - e. Its inner root. f. The expansion of its external root.
  2. The optic nerve, (n. opticus.)
  3. The third nerve, (n. motorius oculi.)
  4. The fourth nerve, (n. patheticus.)
  - 5, 5. The fifth nerve, (n. trigeminus.) On the left side it is traced to its origin by two roots: one, g, the anterior root, is continuous with the diverging fibres of the corpus pyramidale; the other, h, the posterior root, passes forwards from the corpus restiforme.
  6. The sixth nerve, (n. abducens.)
  7. The seventh pair of nerves.
  - i. The portio dura. k. The portio mollis.



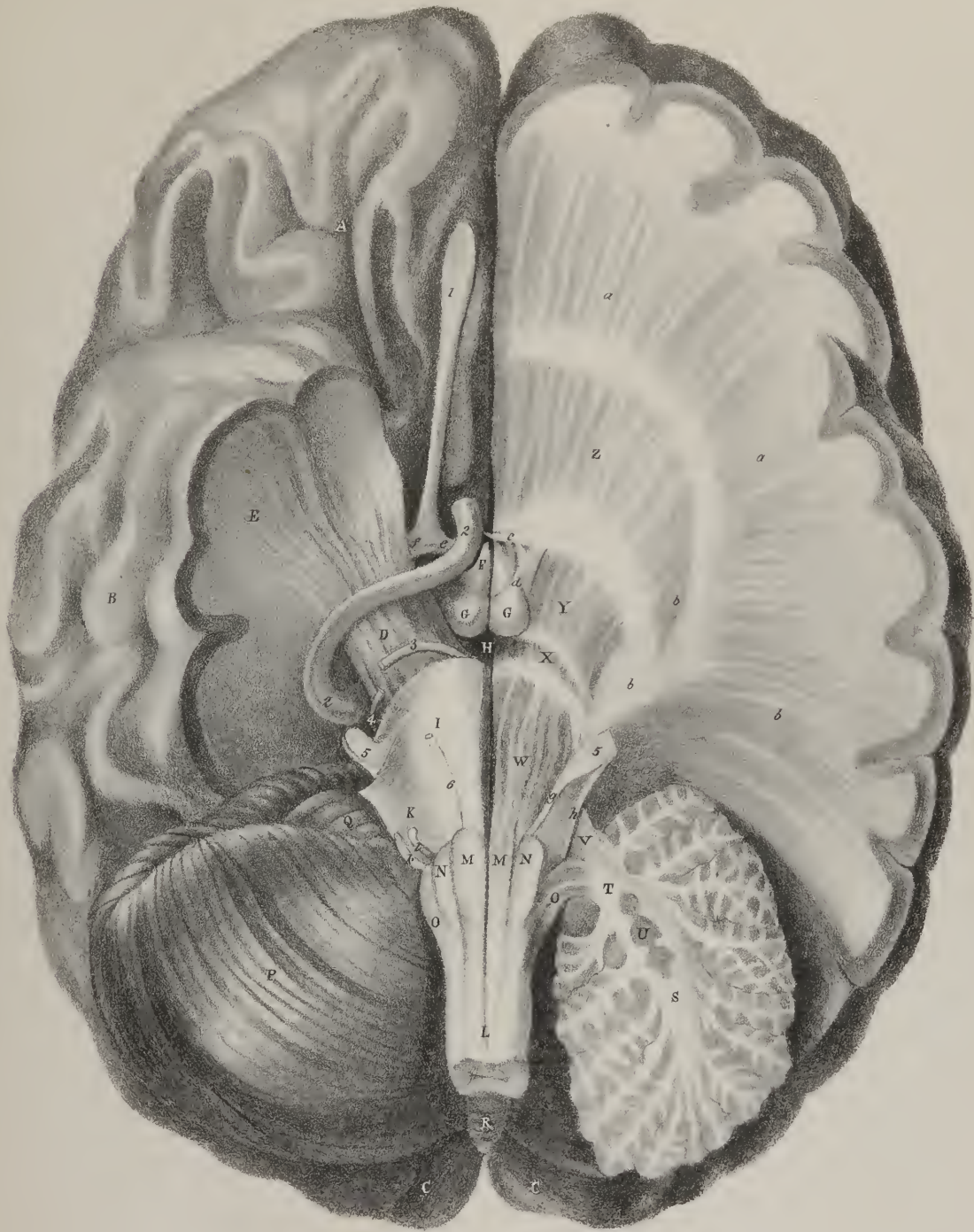


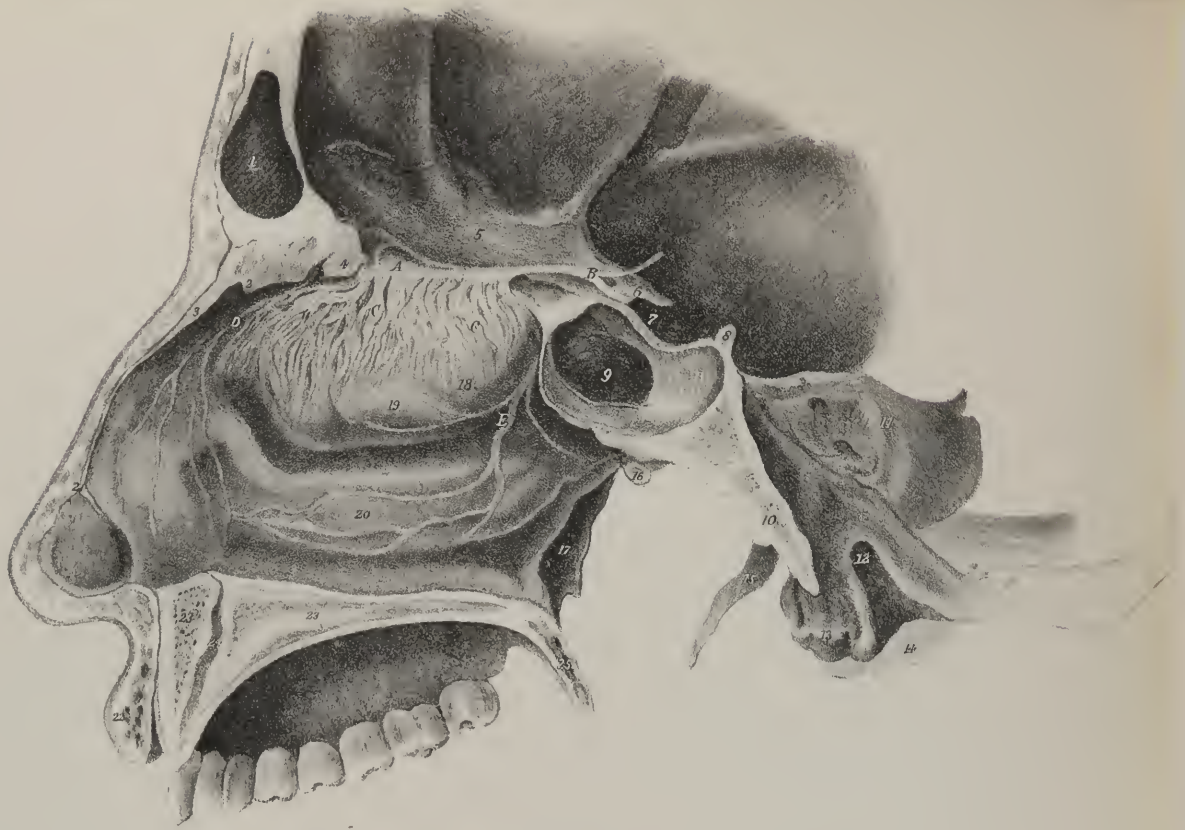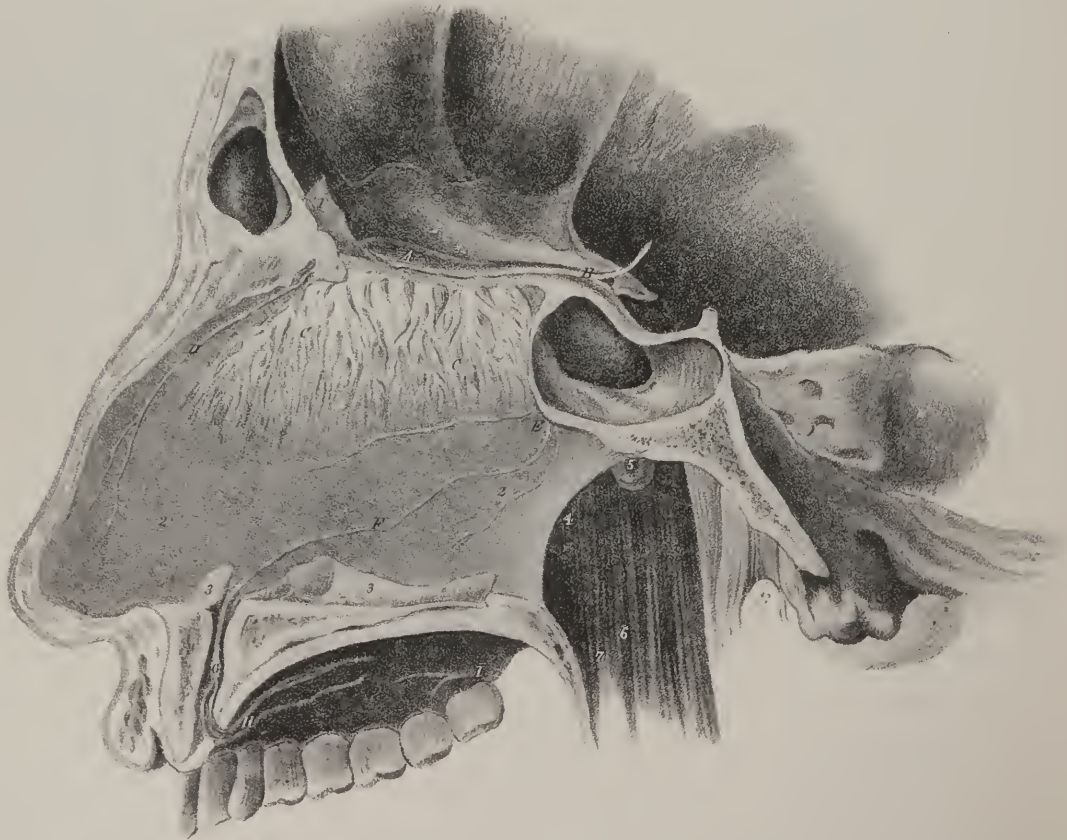








Fig 2



surface of the septum nasi, but soon ramify in the pituitary membrane; the external set, (fig. 1, C, C.) descend upon the two superior turbinated bones, and upon the plain surface before them; but the middle ones are short, and confined to the roof of the nares. We speak of the "origin" of this nerve from the brain, and we indicate its "roots" as if it commenced there and terminated in the nose. But all that we know of its development and of its function shows the reverse to be the fact. As it is a nerve of simple sensation, and as impressions are conveyed by it in one direction only, viz. from without inwards, it would be better to consider the so-called roots as its points of attachment and connexion with the brain.

Though the whole of this tract is considered a nerve, the term in strictness applies only to the filaments which pass down into the nose from the bulb; the rest, or cranial part, appearing to be a prolongation of the cerebral substance itself,—of the grey as well as the white, which does not occur in the nerves. In fishes it obviously is a prolongation from the olfactory lobe—a continuation of its proper substance, and even in some cases the two olfactory nerves are connected by a transverse fasciculus like a commissure. It was usual to say that the external root of the nerve was connected with the under surface of the corpus striatum; but no relation exists between this body and the nerve.\* For though the latter is fairly developed in reptiles, the former is atrophied; and again, the corpus striatum exists in cetaceous mammalia, though, according to Cuvier, the olfactory nerve does not exist in them—or, at all events, is reduced to the minimum of size of which it is capable.

*Optic nerve*, (plate VIII. 2; plate XII. fig. 1, 2, 2: *nervus opticus, par secundum*.)—The optic nerves present several striking peculiarities. They are united by a commissure, are of considerable size, but give off no branches; and their length within the skull is greater than that exterior to it. Each optic nerve arises not from the optic thalamus, but from the corpus geniculatum externum, (plate XII. a, a,) and from a white fasciculus (b, b) sent downwards from the nates; or rather these are the points by which it is attached to the cerebral substance, and to which it conveys its impressions. The nerve, at first soft and flat, rests on the crus cerebri, and passes forwards, converging to its fellow of the opposite side, with which it unites before the pituitary fossa, and between the anterior clinoid processes. From the commissure (c) each of the nerves proceeds forwards and outwards through the foramen opticum, where it is surrounded by the recti muscles; and having reached the posterior surface of the globe of the eye, pierces the sclerotic coat, after which it passes through the choroid, and finally becomes continuous with the retina.

*The Optic commissure: its structure*.—A considerable difference of opinion exists concerning the disposition of the fibrillæ

## PLATE XI.

The distribution of the olfactory, or first pair of cerebral nerves, (*nervus olfactorius*.)

FIG. 1. The distribution of the filaments of the olfactory, sphenopalatine, and fifth nerves, to the mucous lining of the external wall of the right nostril. This view is effected by making a vertical section of the head, parallel with and a little to the side of the septum narium.

No. 1. The cavity of the frontal sinus. 2. The nasal spine of the frontal bone. 3. The right nasal bone. 4. The root of the crista galli. 5. The roof of the right orbit. 6. The anterior clinoid process of the sphenoid bone. 7. The concavity of the sella Turcica. 8. The posterior clinoid process. 9. The sphenoidal sinus. 10. The basilar process of the occipital bone. 11. The petrous portion of the temporal bone. 12. The anterior condyloid foramen of the occipital bone. 13. The right condyle of the occipital bone. 14. The inner aspect of the mastoid process. 15. The styloid process of the temporal bone. 16. The opening of the Eustachian tube. 17. The external pterygoid plate of the sphenoid. 18. The projection of the superior spongy bone, arching over the superior meatus. 19. Projection of the middle spongy bone, arching over the middle meatus. 20. Projection of the inferior spongy bone, arching over the inferior meatus. 21. Section of the soft parts of the nose. 22. Section of the upper lip. 23, 23. Section of the hard palate. 24. The naso-palatine canal. 25. Section of the uvula.

A. The bulb of the olfactory nerve. B. The three roots by which it arises from the brain. C, C. The distribution of its filaments to the mucous membrane covering the superior and middle turbinate bones. D. A twig from the nasal branch of the ophthalmic division of the fifth nerve. E. The sphenopalatine nerves, or nasal branches of Meckel's ganglion, entering the nasal fossa through the sphenopalatine foramen.

FIG. 2. Shows the distribution of the same nerves upon the osseous surface of the mucous membrane lining the septum narium. The section has been made through the left nostril close to the middle line, and the septum has been broken and torn from the membrane, so as to leave it without other support than its attachments to the roof and floor of the nasal fossa.

The points of reference are nearly the same as in the preceding figure; the same numbers, therefore, apply to both, with the few following additions to this figure:

No. 1. The crista galli. 2, 2. The mucous membrane of the right surface of the septum. 3, 3. The broken edge of the septum narium, the remaining portion being removed. 4. The posterior opening of the right nostril. 5. The opening of the right Eustachian tube. 6. The cavity of the pharynx. 7. The right arch of the soft palate.

A. The bulb of the right olfactory nerve. B. Its three roots. C, C. Disposition of its filaments upon the osseous surface of the mucous membrane. D. The nasal nerve; a branch of the ophthalmic division of the fifth pair of nerves. E. Sphenopalatine nerves, distributed to the mucous membrane of the septum. F. The long sphenopalatine nerve, entering the naso-palatine canal to join the naso-palatine ganglion. G, H. Anterior palatine nerves. I. Posterior palatine nerves from Meckel's ganglion.

\* Serres, vol. i. p. 290.



of the optic nerves at their commissure. Some of the earlier anatomists supposed that they were merely applied one to the other without any actual admixture of their substance; this opinion has now no supporters. Several physiologists are of opinion that a decussation between the nerves of opposite sides takes place, the fibres of that on the right side passing to the left, and *vice versa*. Others, on the contrary, contend that the decussation, or crossing, exists only to a certain extent, being confined to the fibres on the inner side of each nerve, the rest passing on uninterruptedly. The anatomical examination of the fibrillæ, after the nerves have been macerated in dilute nitric acid, seems to indicate that those on the external border of each of them proceeds forwards without admixture, but that several pass obliquely inwards through the commissure, and afterwards form a part of the fibres which proceed to the eye of the opposite side: this at least is the result of Caldani's observations. Little account can be made of conclusions deduced from experiments on animals; the quantity of injury inflicted by opening the skull, in order to divide the nerves or their commissure, is sufficient to confound all the sensations of the animal, and render any inferences nugatory that may be drawn from them. Observations on the morbid conditions of the nerves have been adduced in support of both opinions: thus, in a case in which the right eye had been destroyed, the optic nerve was found altered and wasted back to the commissure on that side, and thence to the brain at the opposite side; thus supporting the theory of decussation. Some cases have also occurred in which blindness of one eye was traced to a morbid alteration of the nerve of the opposite side, at its origin from the brain. Some other instances, however, would go to prove that the decussation is only partial. In one instance in which the eye had been destroyed, and its nerve altered in texture for some way, it was found that the external fibres of the diseased nerve could be traced from the commissure directly backwards to the brain at the same side, so could the external fibres of the sound nerve; thus showing that no decussation took place between them; but the internal fibres of the diseased nerve could be traced obliquely through the commissure, and also backwards along the inner side of the opposite nerve to its origin, whilst the inner fibres of the sound nerve seemed, but not so distinctly, to cross also to the opposite side. Each of these opposing opinions, then, is borne out by the observations to a certain extent; so that the advocates of them are not warranted in concluding that either is universally true. Professor Meckel supposes that the anterior or orbital parts of the nerves issue from a common point, (the commissure,) produced by a union of the fibres which are prolonged from the brain, and that the mode of union is not quite identical in all cases, for that in the different other structures which are joined along the middle line, varieties in the manner and degree of their union are constantly observed to occur.

Otto\* remarks, that in cyclopic monsters, and in hemicephalic cases, the optic nerves have been seen to run apart and without a commissure; and that in dropsy of the brain the commissure has been observed torn asunder, and, instead of crossing, only connected by a transverse portion of nerve.

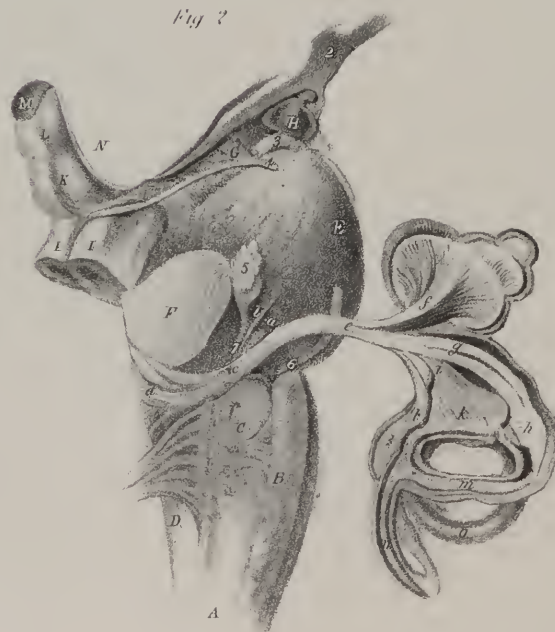
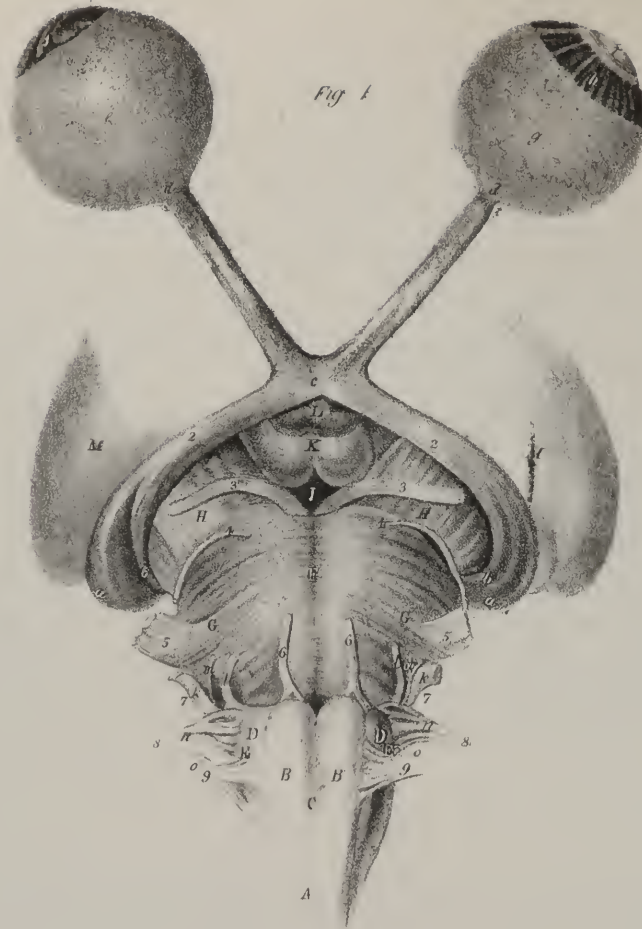
*Auditory nerve* (plate VIII. x; plate XII. fig. 2, c; *nervus auditorius, portio mollis paris septimi*).—The auditory nerve is usually, since the time of Willis, called “the soft portion” of the seventh cerebral nerve. The use of such a name confounds all distinctions of structure, function, place of origin, and mode of termination; in each of which particulars these nerves differ from one another. One of them is subservient to a special sense—that of hearing, and is susceptible of no impression except that of sound; the other is altogether a nerve of motion, and has little, if any, sensibility. The auditory nerve is nearly as soft as the olfactory; the facial is a firm cord, like the motor oculi nerve. Now, as to origin, the facial arises from the groove between the corpus olivare and pyramidale, and forms the first of a series, which are associated at their place of origin, and combine in some remarkable particulars of function; viz. the glosso-pharyngeal, pneumo-gastric, and spinal accessory nerves: with these the auditory nerve obviously has nothing to do; for, to give an abridged expression of its commencement and termination, it extends from the floor of the fourth ventricle to the meatus auditorius internus, through which it is conducted into the internal ear. In this course it is not in connexion, but merely in apposition with the facial nerve, which lies internal and anterior to it, and even compresses its surface so as to mark it by a slight groove. But what is its proper origin? It has been usual for a long time (ever since Piceolomini pointed out a connexion between it and certain white striæ or lines traced upon the posterior surface of the restiform bodies) to say that this nerve arises from the floor (d) of the fourth ventricle, by some white fibres which lie obliquely upon it. This sufficiently indicates the place; but as to the mode of the connexion, that is another question. Wenzel showed that the fibres of the auditory nerve are traceable to the “loculus cœruleus” in the floor of the fourth ventricle. Serres calls it “ruban gris” when much developed; and, as the general result of his researches, says, that in all the mammiferous animals which he has examined, he found the nerve connected with the lateral parts of the medulla by two sets of fibres, of which the posterior one is attached to the side of the fourth ventricle, the “ruban gris” being in intimate connexion with it, whilst the anterior fasciculus is fixed to the extremity of the trapezium. Now the trapezium is a flat, narrow band of white fibres, extended transversely behind the pons, and before the olivary bodies. It is readily distinguishable from the pons, for the latter is continuous with the crura cerebelli, whilst the band here alluded to commences in the fourth ventricle.

It may perhaps appear an unnecessary refinement to say, as M. Serres does, that though the nerve is connected to the points here indicated, it still does not arise from them; for that it is but substituting the word “insertion” for “origin,” leaving the facts to stand as before. It is sufficiently known that this nerve, as well as all others, is produced and grows independently of the brain

\* South's edition, p. 448.







and cord; that they are deposited by their own nutrient vessels, each in its proper place, and that their progress is from without inwards; consequently they do not "arise" from the brain in the same sense as plants arise from their roots. Now, when the auditory nerve grows inwards and comes into contact with the side of the ventricle, it contracts a union with it, which may be called organic, as the two structures are intimately blended. The white striæ are developed subsequently, and so also is the grey matter, the "ruban gris."

As the auditory nerve inclines outwards to gain the meatus internus, it is, as has been above stated, in close contact with the facial nerve, from which it is separated by a small arterial branch derived from the basilar, or anterior cerebelli artery that accompanies it into the meatus. The distribution of the nerve shall be indicated when treating of the anatomy of the ear.

*Third cerebral nerve*, (plate VIII. 3; plate XIII. III: *nervus motorius oculi, motores oculorum, par tertium*).—This nerve, which is the third in order when they are counted from before backwards, arises from the inner border of the crus cerebri, about two lines anterior to the pons Varolii. This is only the point at which the nerve issues from the cerebral substance, and becomes invested by its neurilema and a tubular sheath of arachnoid membrane, for its fibrillæ can be traced backwards into the grey substance within the cerebral protuberance, if the pons Varolii be removed. The nerve passes forwards, and a little outwards, to enter a canal appropriated to it in the dura mater, close by the posterior clinoid process, at which point its serous investment leaves it, and becomes continuous with that which lines the dura mater. As the nerve proceeds forwards, it lies along the external wall of the cavernous sinus, being at first placed superior and internal to the fourth, the ophthalmic branch of the fifth and sixth nerves; as it approaches the sphenoidal fissure, it descends so as to become inferior to the other nerves, and divides into two

## PLATE XII.

The origin and distribution of the optic and auditory nerves.

FIG. 1. The origin of the second pair of cerebral nerves, or optic, (*nervi optici*.) The hemispheres of the cerebrum and cerebellum, and the corpora striata, have been removed, so as to leave only the thalami optici, and their communications with the medulla oblongata.

A. The medulla oblongata. B, B. The corpora pyramidalia. C. Decussation of the corpora pyramidalia. D, D. The corpora olivaria. E, E. The corpora restiformia. F. The pons Varolii. G, G. Division of the transverse fibres of the pons Varolii, to give passage to the fifth nerve. H, H. The cruri cerebri. I. The locus perforatus. K. The corpora mammillaria. L. The tuber cinereum, with part of the infundibulum. M, M. The thalami optici.

No. 2, 2. The optic nerves.

a, a, The origin of the optic nerve from the corpus geniculatum externum. b, b. The fasciculus sent down from the nates. c. The commissure of the optic nerves. d, d. The constriction of the optic nerve, opposite its entrance into the sclerotic coat. e. The sclerotic coat of the eye. f. The cornea. g. The retina of the eye. h. The zonula ciliaris. i. The lens.

3, 3. The third pair of nerves, (*n. motores oculorum*.)

4, 4. The fourth pair, (*n. pathetica*.)

5, 5. The fifth pair, (*n. trigemina; trifacial*.)

6, 6. The sixth pair, (*n. abducentes*.)

7, 7. The seventh pair.

k, The portio mollis, (*n. auditorius*.) l, The portio dura, (*n. facialis*.) m. The portio minor, (*vel intermedia*), of the facial nerve.

8, 8. Part of the eighth pair.

n. The glosso-pharyngeal nerve. o. The pneumo-gastric nerve, (*par vagum*.)

9, 9. The ninth pair, (*n. hypo-glossus*.)

FIG. 2. The origin and distribution of the auditory nerve, (*nervus auditorius; portio mollis septimi paris*.) The preparation of the brain is the same as in the preceding figure, but seen from the side. The labyrinth of the ear, to which this nerve is distributed, is somewhat magnified.

A. The medulla oblongata. B. The right corpus pyramidale. C. The corpus olivare. D. The corpus restiforme. E. The pons Varolii. F. Section of the crus cerebelli of the right side. G. The right crus cerebri. H. Tuber cinereum, with part of the infundibulum.

I, I. Processus è cerebello ad testes. K. The nates. L. The testes. M. The pineal gland. N. Lateral section of the thalamus opticus.

No. 2. The commissure of the optic nerves.

3. The third nerve.

4. The fourth nerve, traced backwards to its origin.

5. The fifth nerve.

6. The sixth nerve.

7. The seventh pair.

a. The portio dura. b. The portio minor of the facial nerve. c. The portio mollis, or auditory nerve. d. The origin of the auditory nerve from the floor of the fourth ventricle. e. The division of the nerve into a branch for the cochlea, and two for the vestibule. f. The expansion of the auditory nerve within the canals of the cochlea. g. The vestibular branch to the ampulla, h, of the superior semicircular canal. i. The third branch of the auditory nerve expanding into the sacculus vestibuli, k. l. The ampulla of the posterior semicircular canal. m. The nervous lining of the superior semicircular canal. n. The nervous lining of the posterior semicircular canal. o. The inferior semicircular canal.



branches, which separately pierce the dura mater, and enter the orbit by passing between the heads of the external rectus muscle. The superior or smaller branch (plate XIII. a) ascends so as to get above the optic nerve, and gives one or two ramusculi to the superior rectus muscle, the other being prolonged to the levator palpebræ: the inferior or larger branch (b) lies beneath, and to the outside of the optic nerve, where it divides into three branches, one of which passes obliquely inwards to the rectus internus muscle; another descends and is distributed to the rectus inferior; whilst the third, longer than either, passes forwards between the inferior and external recti muscles, and terminates in the obliquus inferior: these several nerves enter the muscles at the surface which looks towards the eye-ball. The branch last described gives off a filament (c), which enters the inferior and posterior angle of the lenticular ganglion.

*Fourth nerve*, (plate VIII. 4; plate XII. figs. 1, and 2, 4; plate XIII. IV.: nervus trochlearis, nervus patheticus, par quartum.)—This is called the fourth, though it does not range in line with the others. It is the smallest of the cerebral nerves: it arises by two, and sometimes by three filaments, from the valve of Vieussens, immediately beneath the tubercula quadrigemina. Each nerve (plate XIII. IV.) passes forwards on the side of the cerebral protuberance, on a level with the margin of the tentorium cerebelli, and enters an aperture in the dura mater, a little inferior and external to that of the third pair: by this it is conducted into the cavernous sinus, along whose external wall it runs towards the sphenoidal fissure, through which it enters the orbit, at the same time passing above the third nerve. The nerve finally inclines upwards and inwards, mounting over the superior rectus muscle and the levator palpebræ, and divides into two or three filaments, which enter the superior oblique muscle at its orbital surface. Whilst the nerve lies along the external wall of the cavernous sinus, a small filament passes off from it, and is reflected back in the tentorium cerebelli as far as the lateral sinus.

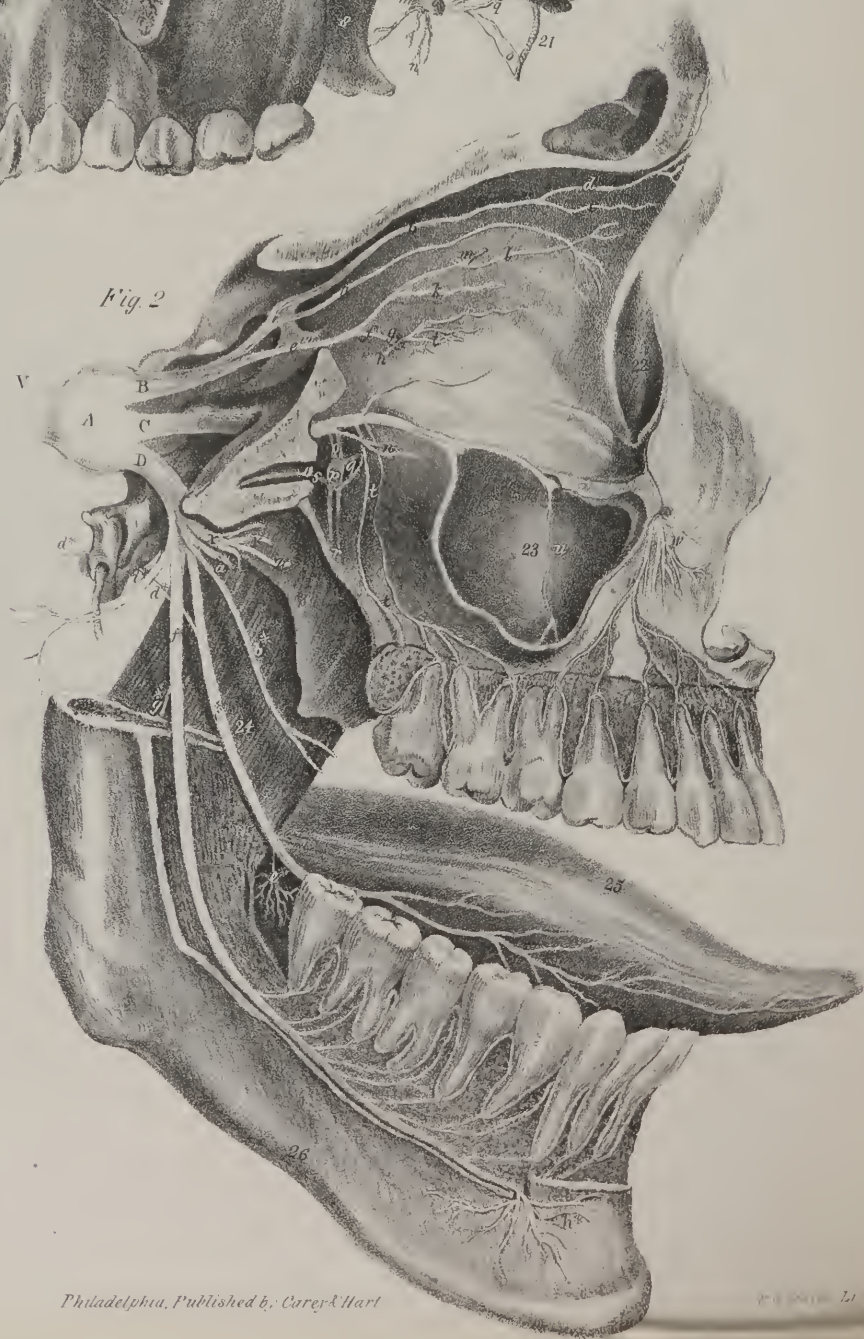
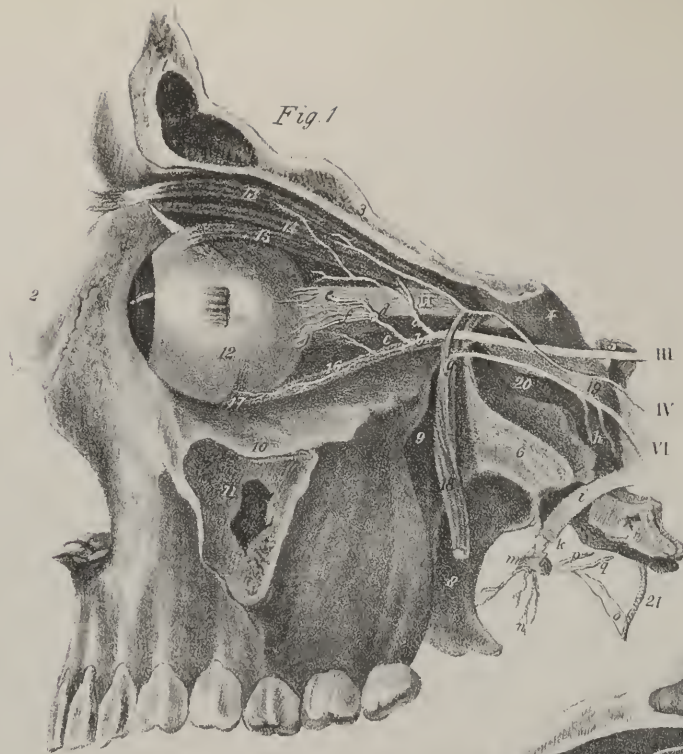
*Sixth nerve*, (plate VIII. 6; plate XII. fig. 1, 6: nervus abducens; par sextum.)—This nerve arises, close by the central line, from the superior extremity of the corpus pyramidale, where it joins with the pons Varolii. From this point the nerve, (plate XIII. fig. 1, VI.) passes forwards and upwards, to enter the cavernous sinus, by a foramen in the dura mater, where it rests against the outer side of the carotid artery, and whilst so placed receives two or three filaments (h) of communication from the superior cervical ganglion, or rather from the carotid plexus. The nerve passes thence forwards to the sphenoidal fissure, separated from the cavity of the cavernous sinus by its lining membrane; and on passing into the orbit runs between the two heads of the external rectus, to which it is distributed by two or three filaments, which pierce the ocular surface of the muscle.

*Ninth nerve*, (plate VIII. 9; plate XII. fig. 1, 9: nervus lingualis, or the ninth pair of nerves; n. hypo-glossus, par nonum.) It arises by several delicate filaments placed in a continued series along the sulcus between the corpus pyramidale and olivare of each side. These filaments converge and unite as they pass forwards to the anterior condyloid foramen, through which the nerve they form makes its exit from the cranium. The nerve (plate XVI.) at first is deeply seated, lying posterior and internal to the sympathetic and vagus nerves, with both of which and the first cervical nerve it communicates; but it gradually comes forwards as it descends, and after passing between the carotid artery and jugular vein, becomes more superficial than either of the nerves just mentioned, and lies a little below the posterior belly of the digastricus muscle. The nerve now inclines forwards and inwards, parallel with the cornu of the os hyoides, gets under cover of the mylo-hyoid muscle, and is separated from the lingual artery by the hyo-glossus muscle, at the inner border of which it ascends somewhat, and divides into several filaments, which are distributed to the genio-hyo-glossus and lingualis muscles.

*Ramus descendens noni*.—At the point where the nerve makes its turn forwards, it will be observed to hook round the occipital artery, and then, where it crosses over the external carotid artery, to give off its chief branch, the *descendens noni*, which inclines downwards and inwards in front of the sheath that encloses the carotid artery and internal jugular vein, and at the middle of the neck curves outwards to form an inverted arch, by joining with two branches from the cervical plexus of the nerves. The convexity of the arch looks downwards, and from it several long delicate filaments are given off, which descend upon the fore part of the neck, and are distributed to the sterno-hyoid and sterno-thyroid muscles, also to the omo-hyoideus. Previously to its ultimate division, the lingual nerve gives some filaments to the hyo-glossus muscle, and others to communicate with the gustatory nerve.

*Facial nerve*, (plate VIII. 7, w: nervus facialis: portio dura paris septimi, sympatheticus minor.)—The facial nerve arises from the sulcus between the corpora restiformia and olivaria, close by the lower margin of the pons Varolii, whence it passes forwards and outwards, closely applied to the portio mollis, which is slightly hollowed to receive it, whilst in the meatus it receives some filaments from the auditory nerve. (Cruveilhier.) Having reached the fundus of the meatus auditorius internus, the portio dura enters an osseous tube, (*aqueduct of Fallopius*), through which it is conducted, in a curved direction, outwards and backwards, to the stylo-mastoid foramen. After having passed about two lines into the tube just named, a small nerve (*Vidian*) becomes applied to its inferior surface, and accompanies it nearly to the point of its exit from the foramen above mentioned. The Vidian nerve there leaves it, and passes obliquely across the cavity of the tympanum, where it assumes the name of chorda tympani; its course and destination shall be particularly considered when treating of the gangliac system of nerves. While within its osseous canal, the facial nerve gives two small filaments, which enter the cavity of the tympanum, and are distributed to the tensor tympani and stapedius muscles; the former being given off at the commencement, the latter near the termination of this portion of its course.







After having issued from the stylo-mastoid foramen, the nerve (plate XIV. A) sends off three small branches previously to its ultimate division.

The *posterior auricular* branch (a; n. auricularis posterior) inclines backwards and upwards in front of the mastoid process, and subdivides into two branches, one of which ramifies in the occipitalis muscle and the integuments, while the other gives twigs to the retrahens aurem muscle, to the pinna, and to the meatus externus. The *stylo-hyoid branch* (b; n. stylo-hyoideus) descends upon the stylo-hyoideus muscle, to which, and to the digastricus, it is partly distributed, the remainder of its filaments maintaining communication with the sympathetic nerve and the ascending branch of the cervical plexus. The *digastric branch* (ramus digastricus) inclines outwards to the posterior belly of the digastric muscle, to which it distributes the greater number of its filaments, the remainder maintaining communications with the nerves emerging from the foramen lacerum, in front of the internal jugular vein.

The facial nerve, after giving off these branches, inclines forwards beneath the external meatus to the ramus of the inferior

## PLATE XIII.

FIG. 1. The nerves of the orbit, with the ophthalmic and otic ganglia, are here shown. This view has been procured by removing the upper and outer wall of the orbit.

No. 4. The section of the frontal bone, showing the cavity of the frontal sinus. 2. Nasal bone of the left side. 3. Section of the upper wall of the orbit. 4. The anterior clinoid process. 5. The posterior clinoid process. 6. Section of the greater ala of the sphenoid bone. 7. The spinous process of the sphenoid bone. 8. The pterygoid process. 9. The pterygo-maxillary fossa. 10. The floor of the orbit. 11. Section of the superior maxillary bone, showing the cavity of the antrum maxillare. 12. The globe of the eye. 13. The levator palpebræ superioris muscle. 14. The superior oblique muscle. 15. The superior rectus muscle. 16. The inferior rectus. 17. Part of the inferior oblique muscle. 18. The external rectus muscle, divided and turned down. 19. The internal carotid artery. 20. The depression for the cavernous sinus. 21. The arteria meningea media, entering the spinous foramen in the sphenoid bone.

II. The optic nerve.

III. The third nerve, (n. motorius oculi.)

a. The superior branch of the third nerve. b. Its inferior branch. c. The branch to the ophthalmic ganglion. d. The ophthalmic or lenticular ganglion. e. The upper fasciculus of ciliary nerves. f. The lower fasciculus.

IV. The fourth nerve, (n. trochlearis patheticus.)

VI. The sixth nerve, (n. abducens.)

g. The passage of the sixth nerve between the two heads of the external rectus muscle. h. Filaments of communication from the superior cervical ganglion of the sympathetic to the sixth nerve. i. The trunk of the inferior maxillary nerve. k. Its motor root. l. The otic ganglion, (ganglion oticum vel auriculare.) m. The internal pterygoid nerve, piercing the otic ganglion. n. Filaments of communication with the auricular nerve. o. Nervi molles to the otic ganglion from the superior cervical ganglion of the sympathetic, accompanying the middle meningeal artery. p. Filament to the tensor tympani muscle. q. Communicating filaments between the otic ganglion and the nervus tympanicus; a branch of the glosso-pharyngeal nerve.

FIG. 2. The fifth nerve, (n. trigeminus,) with its branches. This dissection has been made by dividing the bones nearer to the middle line than in fig. 1. The ramus of the inferior maxillary bone has been sawn across, and the external wall of the bone and alveolar process chiselled away, both in the upper and lower maxilla, to bring into view the branches of the dental nerves, which are distributed to the teeth. The numeral references are the same as in fig. 1.

No. 22. The depression in the lachrymal bone for the lachrymal sac. 23. The inner wall of the antrum maxillare. 24. The internal pterygoid muscle. 25. The tongue. 26. The inferior maxillary bone.

V. The fifth nerve, (n. trigeminus.)

A. The Casserian ganglion. B. The ophthalmic nerve, (n. ophthalmicus.)

a. The lachrymal nerve, (n. lachrymalis.) b. The frontal nerve, (n. frontalis.) c. Its supra-trochlear branch, (n. supra-trochlearis.) d. Its supra-orbital branch, (n. supra-orbitalis.) e. The nasal nerve, (n. oculo-nasalis.) f. Branch to the ophthalmic ganglion, (ramus ad ganglion.) g. The ophthalmic ganglion. h. Its branch to the inferior division of the third nerve. i. Its ciliary branches. k. Ciliary branch of the nasal to the globe of the eye. l. Infra-trochlear branch of the nasal nerve. m. The continuation of the nasal nerve through the anterior ethmoidal foramen into the nose, (n. nasalis internus vel ethmoidalis.)

C. The superior maxillary nerve, (n. maxillaris superior.)

n. Its orbital branch, (n. subcutaneus malæ.) o. Branches of communication from Meckel's ganglion. p. Meckel's ganglion. q. Spheno-palatine branches of Meckel's ganglion. r. Palatine nerves. s. The Vidian nerve: the bone is removed so as to show this nerve in its passage through the Vidian or pterygoid canal. t. Posterior dental branches of the superior maxillary nerve. u. A dental nerve given off from the superior maxillary while in its canal, and passing between the mucous membrane and outer wall of the antrum to supply the teeth. v. Anterior dental branch. w. Terminal branches of the superior maxillary, distributed to the face.

D. The inferior maxillary nerve, (n. infra-maxillaris.)

x. The muscular division of the nerve. y. The deep temporal branches, (n. temporales profundi.) z. The masseteric branch, (n. massetericus.) a\*. The external pterygoid branch, (n. pterygoideus externus.) b\*. The buccal branch, (n. buccalis.) c\*. The gustatory nerve, (n. gustatorius vel lingualis.) d\*. The chorda tympani nerve. e\*. The submaxillary ganglion. f\*. The inferior dental nerve, (n. dentalis.) g\*. Its mylo-hyoidean branch, (n. mylo-hyoideus.) h\*. The mental nerve, (n. mentalis.) i\*. The auricular nerve, (n. temporalis superficialis,) embracing the arteria meningea media.

maxilla, lying deeply embedded in the substance of the parotid gland. Here it divides into two primary branches, which have been named from their destination temporo-facial and cervico-facial; sometimes as many as four, or even five, exist; these communicating one with another form a sort of plexus, (c; plexus parotideus, pes anserinus,) from which numerous branches are distributed to the temples, the face, and neck. The branches from the plexus, formed as above, may be divided into three sets differing in destination and direction.

The first ascend upon the zygoma in front of the ear (d, d; rami temporales,) accompanying the temporal artery and its branches even to the summit of the head, supplying filaments to the integuments, and the several muscles, namely, those of the pinna, the frontal part of the occipito-frontalis, and orbicularis palpebrarum. They communicate with the terminal branches of the occipital nerves (s), and upon the forehead, eyebrow, and upper lid, they interlace with the frontal nerves (g). The second set consists of branches which pass transversely upon the cheek and side of the face (e, e; rami malaris), ramifying upon the lower eye-lid, the side of the nose, and the lips, where filaments are furnished to the muscles, and interlace with those of the superior maxillary branch of the fifth nerve (i): one of these usually runs between the parotid duct and the transversalis faciei artery. These two sets of branches were combined by Chaussier under the denomination temporo-facial. The third or descending branches (f, f; cervico-facial, Chaus.) run obliquely over the masseter muscle, inclining towards the base of the jaw-bone, beneath which some of them ramify in the platysma and the integuments, and communicate with the ascending branches (m) of the cervical nerves; but others higher up are distributed in the depressor muscles of the lip, and maintain a similar connexion with the inferior maxillary branch (k) of the fifth nerve, where it ramifies on the chin. Having stated the general plan, according to which the distribution of the facial nerve takes place, it may be observed, that its filaments enter the substance of the muscle of the temple and eye-lids, those of the cheeks, lips, and nose. Now, it will be recollected that these are all supplied with branches from the different divisions of the fifth nerve also, which suggests the question—Do these parts receive merely an additional quantity of the same influence by their double supply of nerves, or do they derive from these sources an influence differing not in degree, but in kind?\* The question has been decided by direct experiment. If the seventh nerve be divided, the muscles it supplies lose the power of motion, but retain their sensibility; but if the fifth nerve be cut across, motion is retained, though the sensibility is lost.

*Glosso-pharyngeal nerve*, (plate XV.; nervus glosso-pharyngeus,) is a small nerve placed at its origin between the facial and the vagus nerve, its root being implanted by separate filaments into the groove between the corpus olivare and restiforme. The nerve inclines outwards and forwards to the foramen lacerum posterius, where it enters a small canal formed for it by the dura mater, through which it escapes from the skull. In its transit it lies internal and anterior to the jugular vein:—while in the canal it presents a slight gangliform swelling (ganglion petrosum); below the ganglion it descends almost vertically before the internal carotid artery, and between the stylo-glossus and stylo-pharyngeus muscles. It then curves forwards to reach the dorsum of the tongue. It gives several branches as follows:

The *tympanic branch*, (ramus tympanicus, v. Jacobsoni,) arises from the ganglion, and enters a canal in the bone appropriated to it. The orifice of the osseous canal is seen in the jugular fossa, from which it inclines upwards, and penetrates the inner wall of the tympanum. From this, three canals, still more minute, branch off: one inclines downwards to the carotid canal; a second forwards and upwards to the hiatus Fallopii; a third directly upwards behind the fenestra ovalis, to reach the upper surface of the bone, where it terminates in a groove internal to the hiatus Fallopii. Now, the nerve emerging from the ganglion enters the canal, and divides into three branches corresponding with those just indicated as existing in the bone. One descends to join the carotid plexus; of the others, one joins with the Vidian nerve in the hiatus, and the third terminates in the otic ganglion. Arnold, in his seventh plate, figures two other filaments; one going to the foramen rotundum, the other to the foramen ovale.

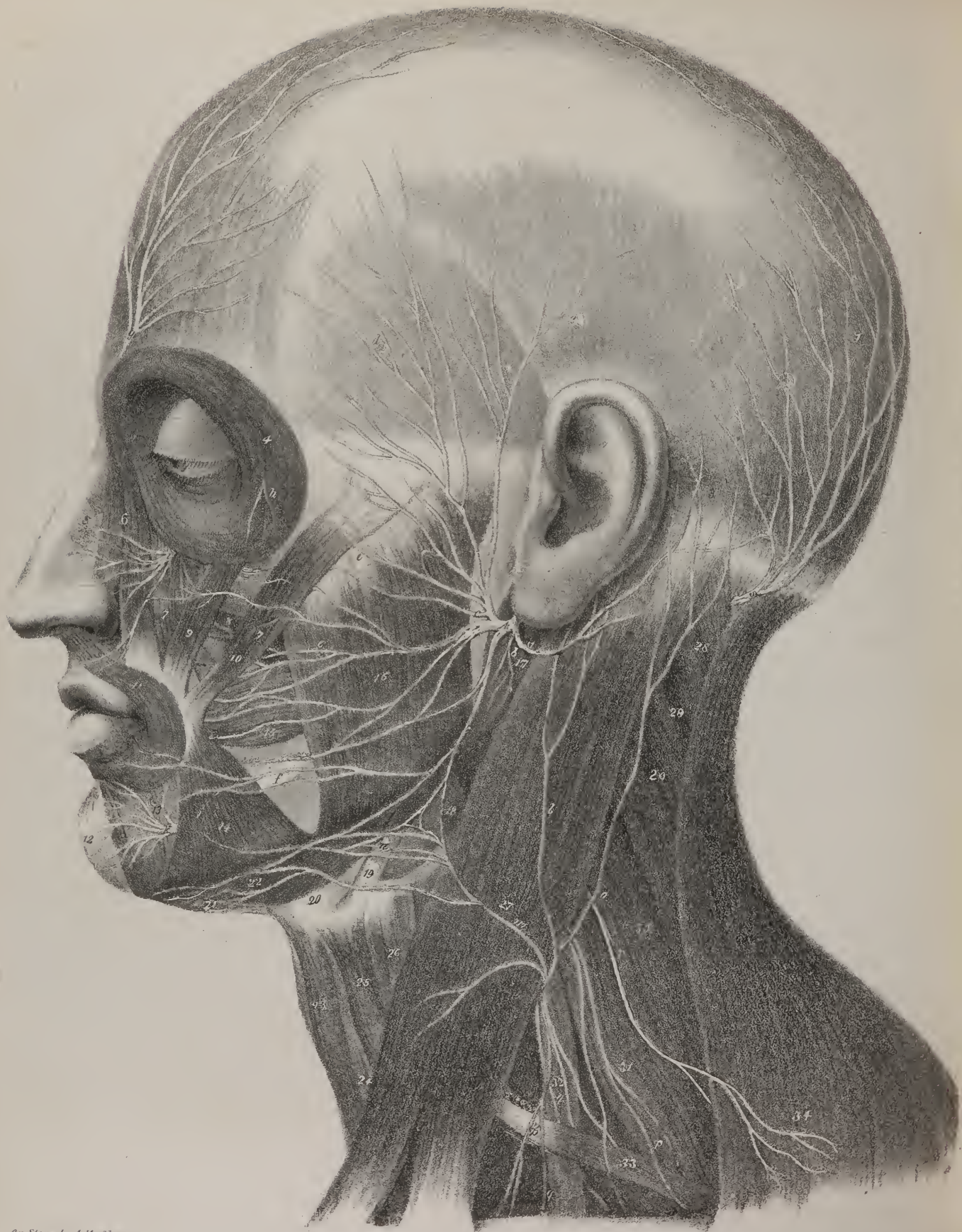
A branch passes off from the ganglion, and inclines downwards and outwards for a little way behind the styloid process; after which it curves up to join the portio dura, or facial nerve, as it issues from the stylo-mastoid foramen. This is the *ramus anastomoticus ad nervum facialem*. Another proceeds to the vagus and spinal accessory. Two or three descend upon the carotid artery, and join the nervous plexus upon it. A muscular branch is given off from the outer side of the nerve, which divides into two: one to the posterior belly of the digastric muscle—*ramus digastricus*, the other to the stylo-hyoid—*ramus stylo-hyoideus*. The pharyngeal branches are two or three which incline inwards, and ramify upon the superior and middle constrictors, contributing to form the pharyngeal plexus. Where the nerve lies close to the tonsil, it gives off some filaments which spread upon it as a plexus—*rami tonsillares*. Finally, on reaching the root of the tongue, the terminal branches of the nerves pass forwards, approaching the mucous membrane, to which and the follicles they seem to be distributed.

*Pneumo-gastric nerve*, (plate XV.: nervus pneumo-gastricus; n. vagus; par vagum, sympatheticus medius, pneumo-gastrique,) arises immediately beneath the preceding, by eight or ten filaments placed closely together, so as to form a flat fasciculus. The nerve inclines outwards and forwards to the foramen lacerum, through which it escapes from the cranium, being in its passage separated from the jugular vein by a process of membrane or of bone, and from the nerves which take a similar course by a tubular prolongation of the dura mater which invests it. The filaments by which the nerve arises become aggregated

\* Exposition of the Nervous System, by C. Bell.







On Stone by A. Koelner.

Philadelphia, Published by Carey & Hart

18 Dural Lith.



together at the foramen, and within it the nerve presents a gangliform enlargement; as it emerges from the foramen, and descends beneath the base of the skull, a close communication by branches is established between it and the glosso-pharyngeal, lingual, and sympathetic nerves. In the same situation, also, it presents an elongated swelling, resembling a ganglion in colour and consistence. Soon after its exit from the skull, the nerve inclines outwards and a little backwards, supported by the rectus capitis anticus major; it assumes a vertical direction, and a fixed position or relation with regard to the cervical vessels; for as it continues its course along the neck, it is enclosed within the sheath of these vessels, lying between the carotid artery and jugular vein, and with them overlaid by the sterno-mastoid muscle. Whilst within the jugular fossa, a branch is given off from the ganglion which lies between the jugular vein and the fore part of the fossa, and passes by a small aperture into a canal that leads to the aqueduct of Fallopius, where it joins the facial nerve. Beneath the base of the skull a branch of communication joins the nerve, derived from the spinal accessory, also from the lingual nerve where the latter is crossing in front of it. Filaments also connect it with the glosso-pharyngeal and the sympathetic. When entering the thorax, the nerve of the right side passes between the subclavian artery and vein, crossing the artery at right angles, and gives off a recurrent branch, which, after turning behind the artery, ascends by the trachea to the larynx. But at the left side the nerve descends parallel with the subclavian artery, to reach the arch of the aorta, round which the recurrent branch takes its course. After having given the recurrent branch, the vagus nerve inclines inwards and backwards, to reach the side of the trachea, where some branches are given off to form a plexus on the anterior aspect of the bronchi, and a considerable number to form another on their posterior surface (*pulmonary plexus, anterior and posterior.*) At the lower extremity of the plexus, four or five fasciculi will be observed to pass backwards to the œsophagus, upon which they are prolonged downwards, forming the continuation of the vagus nerve. The branches of both sides are connected by filaments sent obliquely from one to the other, so as to form a sort of mesh. Resting on the œsophagus, and closely connected with it, each of these sets of branches unite to form a single cord, that of the left side inclining somewhat to the fore part of the œsophagus, whilst the right one lies more posteriorly. Both enter the abdomen through the œsophagean opening, and are distributed by numerous filaments to the surface of the stomach. The term "pneumo-gastric" is sufficiently expressive of its destination; the lungs and the stomach being the chief organs it supplies.

The branches of the vagus nerve, including those by which it terminates, are the following:

The *pharyngeal branch* (plate XV. k) arises from the vagus nerve immediately after its exit from the foramen lacerum, and inclines downwards and inwards to the side of the pharynx, behind which it divides into two or three filaments, which, conjointly with others derived from the glosso-pharyngeal, the superior laryngeal, and sympathetic nerves, form a plexus (l; *pharyngeal*) behind the middle constrictor muscle; several filaments will be observed to pass from this plexus to the other constrictor muscles also.

The *descending or superior laryngeal nerve* (plate XV. m) passes downwards and inwards behind the internal carotid artery, and divides into two branches, both being intended to ramify in the structures of the larynx. The *external branch* (o) passes on the side of the larynx, and gives filaments to the sterno-thyroid, crico-thyroid, and thyro-hyoid muscles, and to the

## PLATE XIV.

In this plate the facial nerve is exhibited, together with the terminal branches of the fifth nerve. In the neck, the branches of the cervical plexus and great occipital nerve are seen.

Nos. 1, 1. The occipito-frontalis muscle. 2. The attollens aurem muscle. 3. The retrahens aurem muscle. 4. The orbicularis palpebrarum. 5. The compressor nasi muscle. 6. The levator labii superioris alæque nasi. 7. The levator labii superioris proprius. 8. Part of the levator anguli oris. 9. Zygomaticus minor muscle. 10. Zygomaticus major. 11. Orbicularis oris muscle. 12. Levator labii inferioris muscle. 13. The depressor labii inferioris. 14. The depressor anguli oris. 15. The buccinator muscle. 16. The masseter muscle. 17. The posterior belly of the digastricus muscle. 18. Part of the hyo-glossus. 19. The stylo-hyoideus muscle. 20. The pulley of the digastricus muscle. 21. The anterior belly of the digastricus muscle. 22. The mylo-hyoideus muscle. 23. The sterno-hyoideus muscle. 24. Part of the sterno-thyroideus muscle. 25. The upper portion of the omo-hyoideus muscle. 26. The thyro-hyoideus muscle. 27. The sterno-mastoid muscle. 28. Part of the splenius capitis muscle. 29. Part of the splenius colli. 30. The levator anguli scapulae muscle. 31. The posterior scalenus muscle. 32. The anterior scalenus. 33. The inferior portion of the omo-hyoideus muscle. 34. The trapezius muscle.

A. The facial nerve, (portio dura paris septimi, sympatheticus minor.)

a, Its posterior auricular branch, (n. auricularis posterior.) b. The stylo-hyoid branch, (n. stylo-hyoideus.) c. The pes anserinus, (plexus parotideus.) d, d. Temporal branches of the facial nerve, (rami temporales.) e, e. Malar branches. f, f. Cervico-facial branches. g. The supra-orbital nerve, a branch of the frontal division of the ophthalmic. h. A twig from the orbital, (n. subcutaneous male,) branch of the superior maxillary nerve. i. The termination of the superior maxillary nerve upon the face. k. The terminal branches of the inferior dental branch of the inferior maxillary nerve. l. The middle branch of the cervical plexus,—the auricularis magnus nerve. m. The internal branch of the cervical plexus,—superficialis colli nerve. n. The plexus formed between the branches of the superficialis colli nerve and the cervico-facial portion of the facial. o. The posterior branch of the cervical plexus,—occipitalis minor. p, p. Descending branches of the cervical plexus. q, q. The phrenic nerve. r. The nervus accessorius of the eighth pair. s. The posterior or great occipital nerve.

thyroid gland. The *internal* one pierces the thyro-hyoid membrane, together with the laryngeal artery, and divides into several small filaments, some of which incline upwards to the root of the epiglottis, and ramify on its upper surface, and in the substance of the epiglottic gland: others proceed downwards;—of these, one or two, of very small size, pass through the ary-tænoid gland, and terminate partly in it, and partly in the mucous membrane; another goes to the ary-tænoid muscle; and a third, after communicating with the inferior laryngeal nerve, runs along the groove between the side of the thyroid cartilage and the cricoid, to terminate in the crico-thyroid muscle,—this is a long slender twig.

Below the middle of the neck two or three filaments, (plate XV. q, r, r; *cardiac branches*;) are given off, which unite with those of the superficialis cordis, (a branch of the great sympathetic,) and from the interlacement formed between them branches are continued down to the arch of the aorta, where they terminate in the cardiac plexus.

The *recurrent* or *inferior laryngeal* nerve runs a very remarkable course; for, as its name implies, after leaving the pneumo-gastric nerve, it turns back into the neck again; but its point of departure, as well as its course and relations, are not the same at both sides. When the pneumo-gastric nerve of the right side is about to descend into the thorax, it passes before the subclavian artery. At that point, the recurrent (plate XVI. r) branch leaves it, and turns round the artery to gain its posterior aspect; after which it inclines obliquely inwards behind the common carotid and inferior thyroid arteries, to reach the side of the larynx. At the left side the nerve descends into the thorax parallel with the subclavian artery, and the recurrent (plate XV. v, v) passes in front of the arch of the aorta and turns behind it, inclining obliquely upwards and inwards, to reach the side of the trachea. Whilst making its turn, the recurrent nerve of each side gives off some filaments (w) to the pulmonary plexus. When arrived at the top of the trachea, the recurrent gives some small filaments to the inferior constrictor of the pharynx, and then enters the cavity of the larynx, where it gives branches to the crico-ary-tænoid and ary-tænoid muscles, communicating (p) at the same time with the superior laryngeal nerve. Both these nerves in their course give small branches to the œsophagus and under surface of the trachea; and some also descend in front of that tube, to join the anterior pulmonary plexus.

*Bronchial branches.*—We may so name several filaments which pass inwards to the bronchus, some anterior to it, but still more behind it. Five or six small branches incline inwards from the nerve, immediately after it has got into the thorax, and, reaching the root of the bronchus, join with the filaments which come down from the recurrent, and form with them the *anterior pulmonary plexus*, (plate XV. x.) Continuing its course, the nerve sinks backwards, and applies itself to the posterior surface of the bronchus, where it appears at the same time to enlarge and assume the pearly tinge peculiar to the divisions of the sympathetic nerves. It gives off a great number of branches, which form a complex interlacement behind the root of the lung, and hence named *posterior pulmonary plexus*, (y.) The plexus is further increased by filaments from the third and fourth thoracic ganglion of the sympathetic nerve. Its ramifications take the course of the bronchi through the lungs, even to the air-cells. Those of the anterior pulmonary plexus are similarly disposed. The anterior one, moreover, sends filaments to join with the cardiac plexus.

*Œsophageal branches.*—The nerve, after giving off the pulmonary branches, applies itself to the œsophagus, not, however, as a distinct trunk, but divided into from three to four or five branches; those of the left being anterior, and those of the right rather posterior to the tube; but they communicate by oblique and transverse branches. This interlacement is usually called the *œsophagean plexus*, (plate XV. z, z.) A little above the diaphragm the branches of the nerve join again, and form at each side of the œsophagus a short single nerve, which enters the abdomen, guided by the tube just named to the stomach.

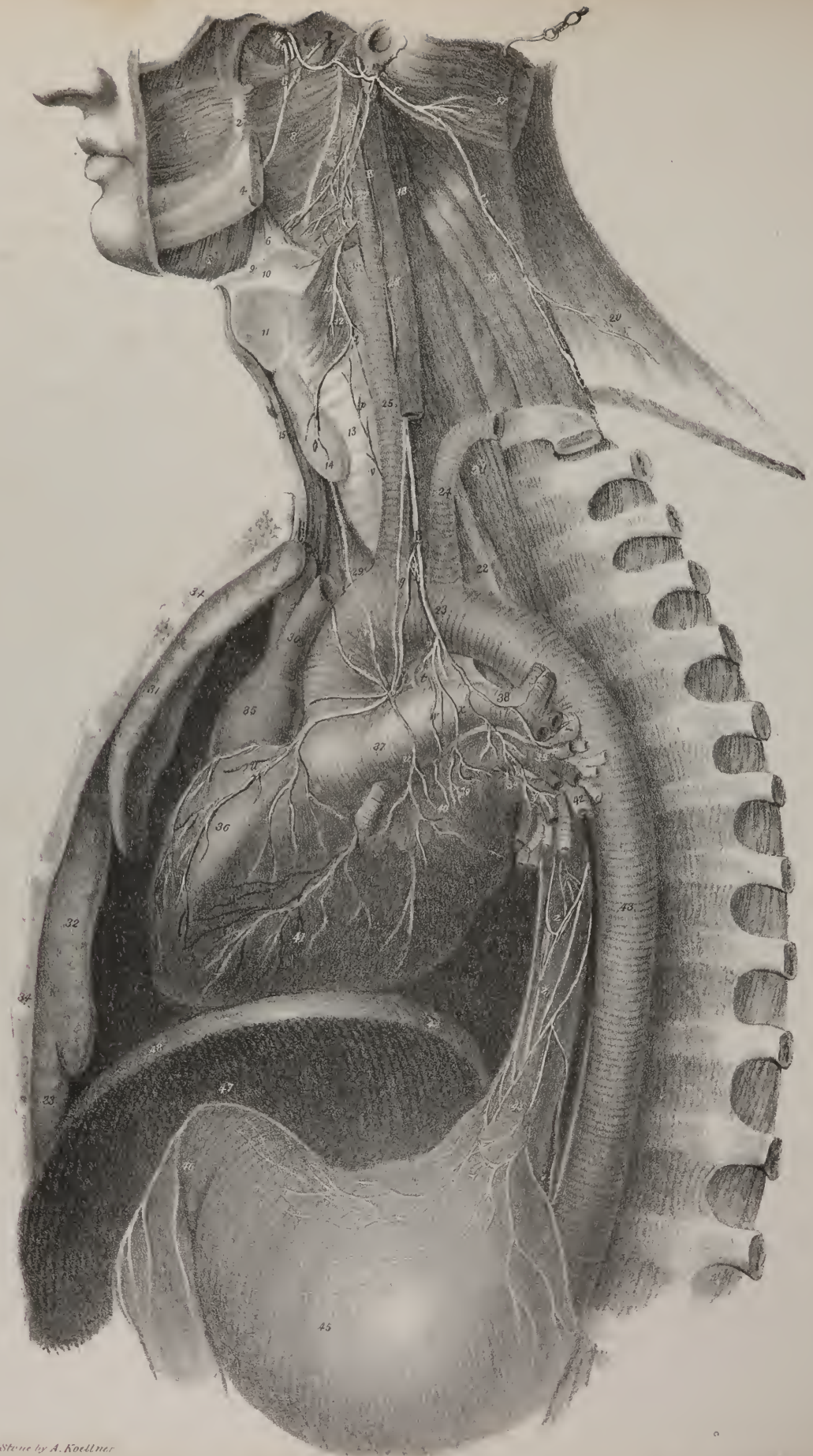
The terminal branches of the vagus nerves ramify on the stomach. The *left*, on reaching the cardia, spreads out into branches on the anterior surface of the viscus; some of these run along the smaller curvature, where they communicate with those of the right vagus nerve, and finally several filaments are prolonged within the folds of the small omentum, to join with the hepatic plexus. The nerve of the right side, after forming a plexus round the cardia, distributes branches to the posterior surface of the stomach as far as the pylorus, where it communicates with the preceding nerve, and with the coronary plexus formed by the splanchnic nerve; and finally one or two branches pass backwards, leaving the stomach altogether, and join the solar plexus.

*Spinal accessory nerve*, (nervus accessorius.)—The *spinal accessory* nerve ascends from the spinal canal into the cranium, and applies itself to the pneumo-gastric nerve—hence its name. It arises by several filaments from the side of the spinal cord, commencing opposite the fourth cervical vertebra. From this point the nerve ascends to the foramen magnum, lying between the ligamentum dentatum and the posterior roots of the spinal nerves; and, having mounted into the cranium, it comes into contact with the pneumo-gastric nerve, close by which it passes through the foramen lacerum, but in a separate sheath of the dura mater. At the base of the skull this nerve is connected by filaments with the two preceding nerves, as well as with the lingual and sympathetic; after which it inclines outwards and downwards (plate XV. C, C) behind the internal jugular vein, and through the substance of the sterno-mastoid muscle, giving off at the same time several branches for its supply. Having emerged from the muscle at its posterior border, the nerve (plate XIV. r) communicates with those which form the cervical plexus, and then continues its course obliquely downwards and outwards across the neck, until it gets under cover of the trapezius muscle, to which it is finally distributed by several filaments.

The *phrenic nerve*, (plate XVI. x.; nervus phrenicus; diaphragmaticus,) arises from the lower part of the cervical plexus;







on Stone by A. Koellner



its principal root comes from the fourth nerve; one higher up, of smaller size, issues from the third and usually another from the upper part of the brachial plexus joins it. At first the nerve inclines inwards, descending between the contiguous terminations of the rectus anticus and scalenus anticus muscles, then gets upon the latter, and, so supported, reaches the top of the thorax, which it enters between the subclavian artery and vein, generally crossing the root of the internal mammary artery. It now inclines inwards and somewhat forwards, runs anterior to the root of the lung, insinuates itself between the pleura and the fibrous pericardium, by which it is guided to the diaphragm. Previously to reaching this muscle, the nerve divides into four or five filaments, which pierce its substance, and spread out within it; some of small size also reach its inferior surface, and guided by the phrenic arteries, join the solar plexus; one or two at the right side pass down with the inferior vena cava.\*

*Fifth cerebral nerve.*—We commence the description of the symmetrical nerves which have double roots with that which is commonly called the fifth cerebral nerve.

*Nervus trigeminus, (nerf trifacial, par quintum.)*—This nerve in its structure and functions is analogous to the regular or symmetrical nerves. It consists of two parts, derived from distinct sources; one communicating sensation, the other the power of motion; and the former, like the posterior roots of the spinal nerves, forms a ganglion, whilst the latter passes beneath the ganglion, and is unconnected with it, but unites with the third division of the nerve soon after its exit from the skull. The fifth nerve, (plate VII. 5; plate XII. 5,) issues from the cerebral substance about the middle of the crus cerebelli, close to its junction with the pons Varolii. The point here indicated marks the emergence of the nerve from the surface; but the filaments of both roots can be traced deeply; those of the sensitive or larger division can be followed downwards and backwards to the posterior columns of the medulla oblongata, whilst the other can be traced to the motor tract. It consists of from eighty to a hundred filaments, each invested by a neurilema. The filaments at the circumference receive their neurilema sooner than those of the centre, so that if the nerve be torn off, a sort of mammillary process remains, which seems as if it had been concealed in the interior of the nerve. The nerve, (plate XIII. fig. 2, V,) thus constituted, passes forwards, and on the summit of the pars petrosa pierces the dura mater, and enters a canal formed for it in that membrane. At this point the portion derived from the posterior root alters its appearance; its fibres diverge as they run forwards, and form a compressed plexus of a semi-lunar shape, named *Casserian ganglion*, (plate XIII. fig. 2, A.) It somewhat resembles a crescent, and from its anterior or convex border three branches are given off, one of which passes into the orbit, another proceeds forwards beneath the orbit to the face, and the third descends through the foramen

## PLATE XV.

The distribution of the eighth pair of nerves.

- No. 1. The buccinator muscle. 2. The pterygo-maxillary ligament. 3. The superior constrictor of the pharynx. 4. The body of the lower jaw divided. 5. The mylo-hyoideus muscle. 6. The hyo-glossus muscle. 7. The stylo-pharyngeus muscle divided. 8. The middle constrictor muscle. 9. The great cornu of the os hyoides. 10. The thyro-hyoidean membrane. 11. The thyroid cartilage. 12. The inferior constrictor muscle. 13. The trachea. 14. The thyroid gland. 15. The border of the sterno-hyoid and sterno-thyroid muscles of the right side. 16. The root of the styloid process; the other portion has been removed. 17. The upper part of the sterno-mastoid muscle drawn aside with a hook. 18. The rectus anticus major muscle. 19. The levator anguli scapulæ. 20. The trapezius muscle. 21. The longus colli muscle. 22. The œsophagus. 23. The arch of the aorta. 24. The left subclavian artery. 25. The right carotid artery. 26. The external carotid. 27. The internal carotid artery. 28. The internal jugular vein. 29. The arteria innominata. 30. The superior cava. 31. The superior lobe of the right lung. 32. Its middle lobe. 33. The inferior lobe. 34. Vertical section of the sternum. 35. The right auricle of the heart. 36. The right ventricle. 37. The pulmonary artery. 38. The left pulmonary artery. 39, 39. The left pulmonary veins. 40. The left auricle. 41. The left ventricle. 42. The extremities of the left bronchia. 43. The thoracic aorta. 44. The œsophagus. 45. The stomach. 46. Its pyloric extremity. 47. The under surface of the diaphragm. 48. Its divided edge.
- a. The inferior maxillary nerve. b. The gustatory nerve. c. The chorda tympani nerve. d. The auricular nerve. e. Its communication with the facial nerve, (portio dura.) f. The facial nerve escaping from the stylo-mastoidean foramen.
- A. The glosso-pharyngeal nerve.
- g. Its communication with the facial nerve. h, h. Branches to the stylo-pharyngeus muscle. i, i. Branches to the pharyngeal plexus.
- B, B. The pneumo-gastric nerve.
- k. The pharyngeal branch, descending to form the pharyngeal plexus. l. The pharyngeal plexus. m. The superior laryngeal branch. n. Branches to the pharyngeal plexus. o. The external branch of the superior laryngeal nerve. p. Its communication with the inferior laryngeal. q. Cardiac branches. r, r. Cardiac branches from the right pneumo-gastric nerve. s. The left cardiac ganglion and plexus. t. The upper extremity of the right cardiac ganglion. u, u. Branches distributed to the heart. v, v. The recurrent or inferior laryngeal nerve. w. Branches sent from the curve of the recurrent nerve to the pulmonary plexus. x. The anterior pulmonary plexus. y. Branches of the posterior pulmonary plexus. z, z. The œsophagean plexus.
- C, C. The spinal accessory nerve, (n. accessorius.)

\* I have frequently observed ganglia on the branches of the phrenic nerve, in instances where it has communicated freely with the plexuses of the abdomen. I have observed them mostly on the right side, which alone sends branches to the hepatic plexus.—J. P.



ovale, to be distributed to the tongue, to the teeth, and to the muscles of the lower-jaw. The two former communicate sensibility only to the structures in which they ramify; but the latter gives the power of motion to certain muscles, and sensibility generally to all the organs to which it is distributed; hence it is a compound nerve, and its component parts can at once be recognised by drawing the plexus or ganglion forwards, which will bring into view a nervous cord that lies beneath it on the bone, and which, if traced backwards, will be observed to be continuous with the anterior root of the nerve, and if followed will be found to pass through the foramen, with the third division of the ganglion, and to unite with it immediately after its exit from the skull; the mode of union being perfectly analogous to that of the anterior and posterior roots of the spinal nerves.

*Ophthalmic nerve.*—The first or ophthalmic branch, (plate XIII. fig. 2, B; *ramus quinti paris primus*, v. *ophthalmicus*.) is the smallest of the divisions of the ganglion: it lies beneath and to the outside of the other orbital nerves, and receives, whilst lying along the outer side of the cavernous sinus, some filaments from the sympathetic. It divides into three branches, which separately pierce the dura mater to enter the orbit through the sphenoidal fissure. These branches, from their destinations, are called lachrymal, frontal, and nasal.

The lachrymal branch, (plate XIII. a; *nervus lachrymalis*.) which is smaller than the others, and also inferior to them, passes forwards between the orbit and the external rectus muscle, to the lachrymal gland, to which it distributes four or five filaments, that enter at its ocular surface; some are also prolonged to the external side of the orbit, and ramify in the orbicular muscle and integument; one or two delicate filaments are also reflected inwards to the upper eye-lid. The lachrymal nerve, near its commencement, receives one or two filaments of communication from the superior maxillary nerve; and, as it proceeds forwards, one or two delicate threads are given off, which pierce the malar bone, and anastomose with the deep temporal branches of the facial nerve.

The frontal branch, (plate XIII. b; *r. frontalis*.) which is the largest offset of the ophthalmic nerve, inclines upwards and inwards, to get between the levator palpebræ and the orbit, being at first closely connected with the fourth nerve. About midway between the summit and base of the orbit, it divides into two branches, one lying internal to the other, but on the same plane; the internal or super-trochlear branch (*c*; *r. supra-trochlearis*) passes forwards to the point at which the trochlea or pulley of the superior oblique muscle is attached to the margin of the orbit, close to which it emerges on the forehead, lying between the muscles and the bone. It soon, however, pierces the occipito-frontalis, to which it distributes filaments, and ascends upon the forehead and arch of the skull, ramifying freely upon them. The external, or supra-orbital branch (*d*.) passes directly forwards to the supra-

## PLATE XVI.

The course and distribution of the ninth or lingual nerve is shown in this figure. The other deep-seated nerves upon the side of the neck are also seen.

No. 1. The mastoid process of the temporal bone. 2. The external auditory process. 3. The styloid process. 4. The glenoid cavity. 5. The zygoma. 6. The external pterygoid plate of the sphenoid bone. 7. The superior maxillary bone. 8. The tongue. 9. Section of the inferior maxillary bone. 10. The divided edge of the mylo-hyoideus muscle. 11. The genio-hyoideus muscle. 12. The genio-hyo-glossus. 13. The sublingual gland. 14. The duct of the submaxillary gland,—Wharton's duct. 15. The hyo-glossus muscle. 16. The stylo-glossus muscle. 17. The stylo-pharyngeus muscle. 18. The middle constrictor muscle of the pharynx. 19. The great cornu of the os hyoides. 20. The thyro-hyoidean membrane. 21. The ascending cornu of the os hyoides. 22. The origin of the inferior constrictor muscle of the pharynx. 23. The thyro-hyoideus muscle. 24. Part of the sterno-thyroideus muscle divided. 25. Part of the omo-hyoideus muscle. 26. The sterno-hyoideus divided at its lower part. 27. The trachea. 28. The arteria innominata. 29, 29. The right subclavian artery. 30. The common carotid artery. 31. The external carotid artery. 32. The superior thyroid artery cut short. 33. The lingual artery. 34. The facial artery. 35. The occipital artery. 36. The internal carotid artery. 37. The internal jugular vein. 38. The subclavian vein. 39. The commencement of the right vena innominata. 40. The left vena innominata. 41. The divided edge of the sternum. 42. The scalenus anticus muscle. 43. The scalenus posticus muscle. 44. The levator anguli scapulæ muscle. 45. The edge of the splenius capitis muscle. 46. The trapezius muscle.

A, A. The ninth or lingual nerve, (n. hypo-glossus.)

a. Branches of communication with the gustatory nerve. b. A branch to the origin of the muscles from the os hyoides. c. The nonus descendens nerve. d. The loop formed with the branch from the cervical nerves. e, e. Muscular branches to the depressors of the larynx, given off by the nonus descendens and the arch of communication. f. A filament from the second cervical nerve, and g, one from the third, uniting to form the communicating branch which forms the loop with the nonus descendens. h. The auricular nerve. i. The inferior dental nerve. k. Its mylo-hyoidean branch. l, l. The gustatory nerve. m. The chorda tympani passing to the gustatory nerve. n. The chorda tympani leaving the gustatory nerve, to join the submaxillary ganglion. o. The submaxillary ganglion. p. Filaments of communication with the lingual nerve.

B. The glosso-pharyngeal nerve.

q. Its branch to the stylo-pharyngeus muscle.

C. The pneumo-gastric or vagus nerve.

r, r. Its recurrent branch. s, s. The second, third, and fourth cervical nerves. t, t. The four inferior cervical nerves. u. The first dorsal nerve. v, v. The brachial plexus of nerves. w, w. The long thoracic nerve, or external respiratory of Bell. x. The phrenic nerve.









orbital notch, through which it escapes on the forehead, its subsequent course and distribution being similar to that of the preceding. These nerves maintain communication with the temporal branches of the facial or portio dura.

The nasal branch, (plate XIII. e; *r. oculo-nasalis*,) is intermediate in size and position between the preceding nerves. Having entered the orbit through a separate foramen in the dura mater, it passes between the two heads of the external rectus muscle, and then inclines inwards and forwards, rising over the optic nerve to reach the inner side of the orbit: whilst passing over the optic nerve, it gives a small branch, (f; *r. ad ganglion*,) which terminates in the posterior and superior angle of the lenticular ganglion, (g,) and two filaments (k,) which pierce the globe of the eye, and are distributed in the same way as the ciliary branch derived from the ganglion. At the inner wall of the orbit the nerve divides into two twigs, one (m) of which passes into the cavity of the nose, (*r. nasalis internus*, *v. ethmoidalis*,) the other (l) issues from the orbit beneath the trochlea, and has on that account been called the infra-trochlear branch. The nasal branch passes inwards to the cavity of the cranium, through the foramen orbitale internum anterius, and, on reaching the side of the crista galli, runs forwards on the cribriform lamella, descending into the nose through its anterior foramen or fissure. In this situation the nerve divides into two filaments, of which one (plate XI. fig. 2, D; *ramus septi*) passes down upon the septum narium, on which it divides into two or three offsets; the other runs in a groove at the inner surface of the os nasi, and, piercing the fibrous structure which connects it with the nasal cartilage, ramifies upon the tegument of the tip and ala of the nose. The infra-trochlear branch, above referred to, emerges from the orbit at the inner side of and beneath the trochlea, where it divides into filaments, which are given to the upper eye-lid, the tensor tarsi muscle, and the root of the nose; some of them also extending to the lachrymal sac and caruncula lachrymalis.

*Superior maxillary nerve.*—The superior maxillary nerve, or second division of the fifth, (plate XIII. fig. 2, C, C; *ramus quinti paris secundus*; *r. maxillaris superior*,) is intermediate in size, as well as in direction and situation, between the ophthalmic and inferior maxillary nerves. It passes forwards, and leaves the skull by the foramen rotundum of the sphenoid bone; after which it crosses the sphenomaxillary fossa, and enters the infra-orbital canal, through which it is conducted beneath the floor of the orbit, and finally ramifies on the cheek and side of the face. Whilst passing across the fossa, it gives two branches of communication, (o,) which pass down to Meckel's ganglion, (p;) immediately after its exit from the foramen rotundum it sends upwards into the orbit a branch (u; *orbital, nervus subcutaneous malaræ*) which passes forwards, and forms an anastomosis with the lachrymal nerve, sending twigs to the lachrymal gland, some of which are continued along the outer margin of the orbit, to be distributed to the orbicular muscle and the integument; and also a filament which passes through the malar bone to the temporal fossa, and communicates with one of the deep temporal branches. The *posterior dental* branches, (t, t,) three or four in number, descend upon the tuberosity of the superior maxillary bone, and enter the foramina observable on its surface: through these the filaments descend to the alveoli of the molar teeth, in the pulp of which they ramify: one filament will be observed to run along the alveolar border of the superior maxilla, supplying the gums. Before it emerges on the face, the superior maxillary nerve sends downwards a branch, (v; *anterior dental*,) which divides into three or four filaments, for the supply of the bicuspid, canine, and incisor teeth. At its exit from the infra-orbital foramen, the nerve (w) is concealed by the orbicularis and levator labii superioris muscles, where it divides into a number of branches, some of which incline inwards to the nose, and communicate with the nasal branch of the ophthalmic nerve; others pass downwards upon the cheek and upper lip; and a third set incline somewhat outwards, forming a complete mesh by their interlacement with the branches of the facial or portio dura nerve.

*Inferior maxillary nerve.*—The inferior maxillary nerve, (plate XIII. fig. 2, D,) the third and largest branch of the fifth pair, (*ramus tertius quinti paris*; *r. infra-maxillaris*,) is made up, as has been said, of two portions, which issue from the cranium by the foramen ovale of the sphenoid bone, and become united immediately after their exit. A few lines beneath the base of the skull, in which situation it is under cover of the pterygoideus externus muscle, the nerve divides into two primary branches. One of these, (x,) which lies superior to the other, and also is smaller than it, soon subdivides into five offsets, which are distributed to the deep-seated muscles as follow:—The deep temporal branches, (y,) two in number, (*r. temporales profundi*, anterior and posterior,) at first pass outwards between the external pterygoid muscle and the bone, one of them at the same time inclining forwards; they then ascend, and become applied to the inner surface of the temporal muscle, to which most of them are distributed; some, however, pierce its fibres and fascia, and, becoming superficial, anastomose with the superficial temporal branches of the facial nerve. The buccal branch (b\*; *r. buccalis*) is longer than any of the others; it inclines downwards and forwards between the pterygoid muscles, and reaches the surface of the buccinator muscle, on which it spreads out into four or five filaments, which communicate with branches of the facial nerve, supplying the muscles of the cheek and lips. In its course it furnishes some twigs to the external pterygoid and temporal muscles. This nerve is sometimes found to arise by a common trunk with, or to give off, one of the preceding (temporal) branches. The pterygoid nerve (*n. pterygoideus*) passes between the pterygoid and circumflexus palati muscles, to ramify in the internal pterygoid; there is frequently more than one pterygoid twig. The masseteric branch (z; *r. massetericus*) is directed transversely outwards in front of the glenoid fossa of the temporal bone, passes between the temporal and external pterygoid muscles, and finally escaping through the sigmoid notch of the lower maxillary bone, supplies the muscle from which its name is derived.

The remaining division of the inferior maxillary nerve subdivides into three branches, viz. the gustatory, auricular, and inferior dental.

*The gustatory nerve*, (plate XIII. fig. 2, c\* ; n. gustatorius v. lingualis,) immediately after its origin, sends a short branch, of considerable thickness, to the dental nerve : lying anteriorly to this, it then descends between the pterygoid muscles for some way, where it is joined at an angle by the chorda tympani nerve, (d,) which accompanies it whilst descending inside the ramus of the lower maxillary bone, but soon parts from it, (e\*,) to be distributed to the submaxillary gland. The gustatory nerve continues its course forwards, under the mucous membrane of the mouth, to reach the side of the tongue, passing between the hyoglossus and mylo-hyoideus muscles, in company with the duct of the submaxillary gland. As it ascends by the side of the tongue, it gets above the sublingual gland, and divides into several minute filaments, which may be traced beneath the mucous membrane, gradually becoming soft and waving, until they reach the papillæ, where they terminate. The nerve, during its course, gives one or two filaments to the internal pterygoid muscle, also some which communicate with the hypoglossal nerve, and others to the sublingual gland.

*The auricular or superficial temporal branch*, (plate XIII. fig. 2, i : r. meatûs auditorii externi, Meckel ; temporalis superficialis,) often commences by two roots ; it inclines outwards, to gain the interval between the condyle of the lower jaw and the meatus auditorius externus, where it divides into two branches, whilst lying deeply in the substance of the parotid gland. One of these branches ascends behind the neck of the condyle of the lower jaw, between the articulation and the meatus externus of the ear ; gradually becoming superficial, it divides into offsets, which mount up in the temporal fossa, taking the course of the temporal artery, its filaments being traced to the tegument upon the side of the head ; at its commencement it gives a branch which joins the facial nerve, and in its course one to the articulation of the lower jaw and the meatus auditorius. The inferior branch divides into offsets, which, passing through the parotid gland, reach the lobule and tegument of the ear, and communicate with the posterior branches of the second cervical nerve.

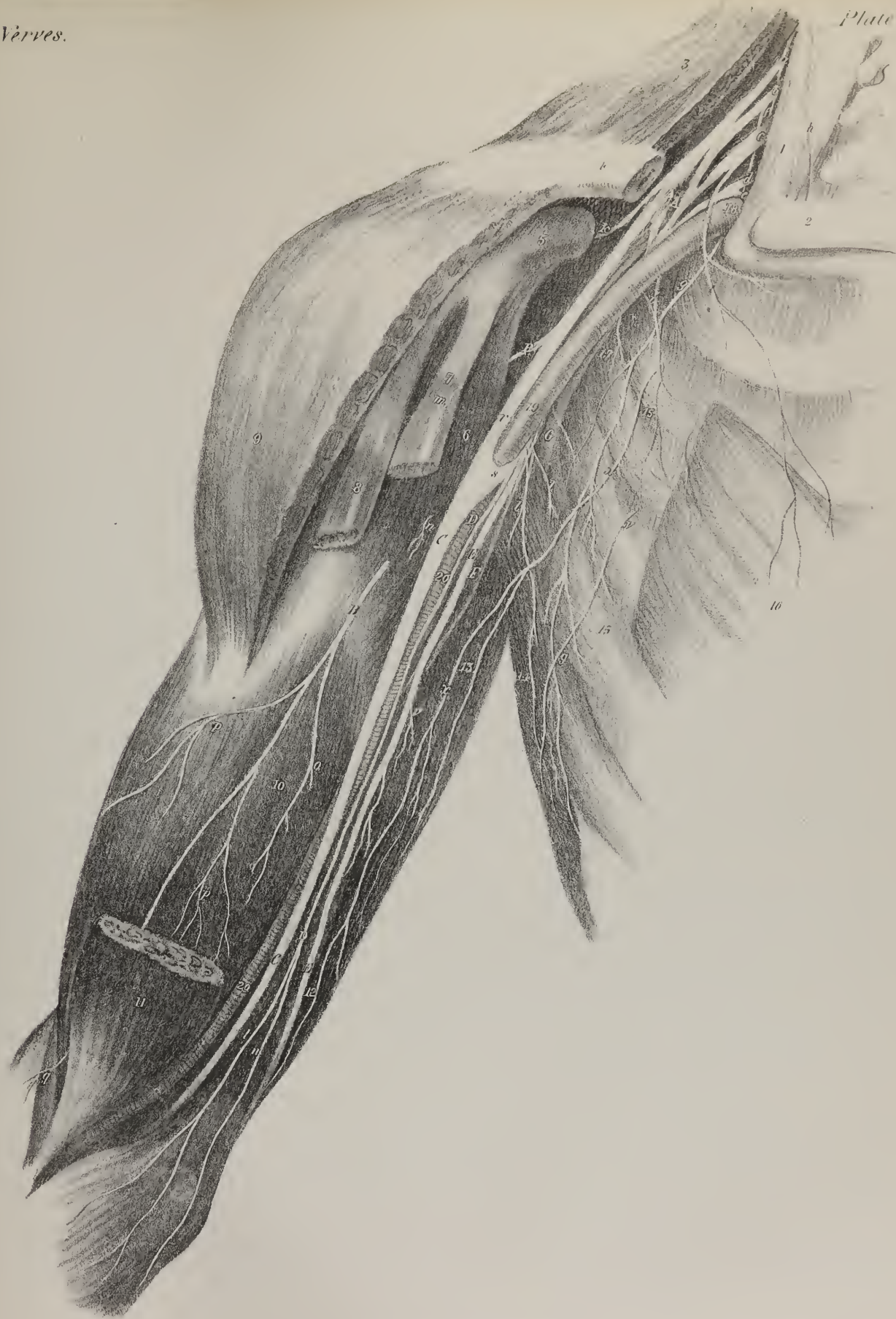
*The inferior dental nerve*, (plate XIII. fig. 2, f\* ; n. dentalis,) usually receiving at its commencement a short thick branch from the gustatory, arises as it were by two roots, (between which the internal maxillary artery passes,) and is the largest of the branches of the inferior maxillary nerve. It descends at first between the two pterygoid muscles close to the gustatory, then passes between the internal pterygoid and the ramus of the inferior maxilla, protected from the action of the former by the internal lateral ligament of the temporo-maxillary articulation, and arrives at the orifice of the dental canal which occupies the inner surface of the ramus of the inferior maxillary bone. At this point a long delicate branch (g\* ; *ramus mylo-hyoideus*) is given off, which inclines downwards and forwards in a groove marked for it on the inside of the ramus of the jaw. This branch rests

## PLATE XVII.

This plate shows the brachial plexus with its branches, the nerves of the upper extremity.

- No. 1. The scalenus anticus muscle crossed by the phrenic nerve. 2. The sternal portion of the clavicle. 3. The trapezius muscle. 4. The scapular portion of the clavicle. 5. The coracoid process. 6. The coraco-brachialis muscle. 7. The short head of the biceps. 8. Its long head. 9. The deltoid muscle. 10. The brachialis anticus muscle. 11. The lower part of the biceps muscle. 12. The internal head of the triceps muscle. 13. The middle or long head of the triceps. 14. The edge of the latissimus dorsi muscle. 15. The serratus magnus muscle. 16. The origin of the pectoralis minor muscle. 17. The subscapularis muscle. 18. The subclavian artery. 19. The axillary artery. 20, 20. The brachial artery.
- a. The anterior division of the fifth cervical nerve. b. The anterior division of the sixth cervical nerve. c. The anterior division of the seventh cervical nerve. d. The anterior division of the eighth cervical nerve. e. The anterior division of the first dorsal nerve. f. The two filaments of origin of the long thoracic nerve, the external respiratory of Sir Charles Bell. g. The long thoracic nerve. h. The phrenic nerve, or internal respiratory nerve.
- A. The brachial plexus.
- i, i. The short thoracic nerves. k. The supra-scapular nerve. l, l. Subscapular nerves.
- B, B. The external cutaneous nerve, (musculo-cutaneous, nervus perforans Casserii.)
- m. A branch to the short head of the biceps muscle. n. A muscular branch piercing the coraco-brachialis muscle. o. A branch to the biceps muscle; its filaments are cut away. p, p. Branches to the brachialis anticus muscle. q. The cutaneous portion of the nerve dividing into two branches to supply the integument of the fore-arm.
- C, C. The median nerve, (nervus medianus.)
- r. Its external head. s. Its internal head.
- D, D. The internal cutaneous nerve, (nervus cutaneus internus.)
- t. Its anterior branch. u. Its posterior branch.
- E, E. The ulnar nerve, (nervus ulnaris.)
- V. Muscular branches to the triceps muscle.
- F. The musculo-spiral nerve, (nervus radialis.) G. Circumflex nerve, (nervus circumflexus brachii vel axillaris.)
- x, x. The intercosto-humeral nerve, (nerve of Wrisberg,) from the second dorsal nerve. y. The intercosto-humeral nerve from the third dorsal nerve.









on the inferior surface of the mylo-hyoidus muscle, to which, as well as to the sub-maxillary gland and anterior belly of the digastricus, it gives filaments. The dental nerve, having entered the canal appropriated to it in the lower jaw, passes horizontally forwards about three lines beneath the roots of the teeth, to each of which it sends filaments, which incline obliquely upwards, and enter the foramina in their apices, to be distributed to their central pulp. When arrived opposite the foramen mentale, the nerve divides into two branches, one of which, smaller than the other, continues in the canal as far as the symphysis of the chin, where it anastomoses with the corresponding nerve of the opposite side; and from the arch thus formed filaments ascend to supply the canine and incisor teeth. The other division of the nerve (h\*; *ramus mentalis*) passes through the foramen, and appears on the face, where it ramifies freely in the muscles and integuments of the chin and lip, its filaments communicating with those of the fascial nerve.

*Spinal nerves.*—The spinal nerves (plate I. fig. 2) are thirty-one pairs in all; and each individual nerve is attached by two sets of filaments, one to the anterior, the other to the posterior surface of the spinal cord. These unite into one short trunk, which, as it passes out of the intervertebral foramina, divides into two branches, one anterior, the other posterior, which are distributed respectively to the parts in front of and behind the vertebral column. The anterior branches are, with one or two exceptions to be noticed in the special description of the nerves, larger than the others, and form the several plexuses found in different situations. These nerves are usually arranged in four groups, from a consideration of the regions in which they are situated, viz. cervical, dorsal, lumbar, and sacral.

The cervical nerves are sometimes described as eight, sometimes as seven, in number; the difference depending on the place assigned to that which emerges from the spinal canal above the first vertebra of the neck.

*First cervical nerve.*—The first cervical nerve (plate I. fig. 2; *nervus sub-occipitalis, decimus cerebri*) is the smallest of the spinal nerves, except the last sacral. Willis and several succeeding anatomists considered it as one of the cerebral nerves; but Sæmmering, Meekel, and Bell, have on just grounds associated it with those that arise from the spinal column, because, like them, it arises by two roots, presents a ganglion on the posterior one, and in its general distribution is analogous to those which succeed it. This nerve passes out between the arch of the atlas and the occipital bone, lying in the groove on the upper surface of the former, and reaches the triangular space bounded by the recti and obliqui muscles, where it divides into an anterior and a posterior branch. The latter resolves itself into four or five filaments, which are distributed to the small muscles just mentioned, and to the complexus. It may be here observed, that the posterior branches of the three upper cervical nerves mutually communicate by a filament sent from one to the other, previously to their final division, so that an interlacement is formed between them, though it does not receive the name of plexus. The *anterior* branch of the first cervical nerve, smaller than the posterior, runs obliquely forwards upon the transverse process of the atlas, and, on reaching the anterior surface of the spinal column, descends and joins with a branch sent up from the second nerve, having previously given some filaments to the muscles by which it passes. At the point of union also some twigs are sent to communicate with the lingual and vagus nerves and the superior cervical ganglion, at the base of the skull; a slender filament descends with the vertebral artery in its canal.

*Second, third, and fourth cervical nerves.*—The second, third, and fourth cervical nerves may in their description be taken together, inasmuch as by their anterior branches they form the cervical plexus. Their posterior branches shall be described in the first instance.

*Posterior branches.*—The posterior branch of the second cervical nerve, (plate XIV. s.) of greater size than the anterior, passes backwards and upwards, covered by the complexus, and resting on the rectus posterior and obliquus inferior. To these, as well as to the splenius, it gives ramusculi, and finally having pierced the fibres of the complexus, becomes subcutaneous, ramifying in the skin of the occiput. It communicates with the corresponding branches of the nerves next to it, namely, the first and third. The posterior branch of the third nerve, less in size than the anterior, passes backwards by the articulation of the second and third vertebra, anastomoses with the preceding branch, and supplies filaments to the muscles in its neighbourhood; finally it pierces the muscles and ascends, becoming subcutaneous, and ramifies on the back part of the head and neck. The posterior branch of the fourth is smaller than either of those above it, except the first. It passes directly backwards between the transverse processes of the third and fourth vertebræ, and having given several filaments to the complexus muscle, pierces the splenius and trapezius, supplying both, and ultimately terminates in the integuments of the neck.

*Anterior branches.*—The anterior branches of the second, third, and fourth nerves communicate by small twigs with the superior cervical ganglion, and will be observed, as soon as they appear on the fore part of the neck, to send filaments mutually one to the other, in order to form the cervical plexus. The *cervical plexus* (plate XVI. s, s.) thus formed, is placed at the upper and lateral part of the neck; it extends from the transverse process of the second to that of the fourth vertebra, resting on the fibres of the posterior scalenus and levator scapulæ muscles, and concealed by the sterno-mastoid. Its branches are divisible into a superficial and a deep set; the latter being placed under cover of the sterno-mastoid, whilst the former lie immediately beneath the fascia, some of them passing up towards the jaw and ear, others down to the clavicle.

1. *Superficial branches, (ascending; plate XIV.)*—These, as they issue from the plexus, are three in number. They turn round the posterior border of the sterno-mastoid muscle, and will be observed to differ in size and direction as they lie upon

its cutaneous surface. The middle or largest branch (l; *nervus auricularis magnus*, Sæmm.; *zigomato-auriculaire*, Chauss.) ascends perpendicularly towards the interval between the lobe of the ear and the angle of the jaw, lying close to the external jugular vein, and, on reaching the parotid gland, divides into branches, one or two of which pass deeply into its substance and join with those of the facial nerve. The rest of the branches remain superficial, and ramify in the integument of the external ear, some at its facial, and one or two at its occipital aspect. The internal branch (m; *r. superficialis colli*) inclines obliquely up towards the submaxillary gland, giving filaments to the platysma and digastricus, also one or two which join with the cervical branches of the facial nerve: it finally divides into delicate filaments, which interlace with those of the chorda tympani and of the gustatory, as they ramify on the submaxillary gland, forming a sort of plexus by their union. The posterior branch (o; *r. occipitalis minor*) runs along the posterior border of the mastoid muscle, lying on the splenius, and terminates by three or four filaments in the integument of the occiput and ear, anastomosing with a branch of the portio dura.

*Superficial branches (descending; plate XIV.)*—These as they come from the plexus will be seen in the interval between the contiguous borders of the sterno-mastoid and trapezius, diverging as they pass down to the lower part of the neck. They are embedded in a considerable quantity of cellular tissue, and as they diverge to their destination, one set passes over the clavicle (p. p; *r. clavieulares*), and supplies the integument on the upper part of the thorax; another on the acromion (*r. aeromiales*), whilst some lie rather deeply behind the clavicle, being distributed to the posterior belly of the omo-hyoideus and to the serratus magnus:

2. *The deep branches.*—A few pass backwards, communicate with the spinal accessory nerve, and ramify in the trapezius and levator anguli scapulæ muscles. The other branches of this series are arranged in two divisions: one of these consists of two filaments (plate XVI., g), derived from the second and third nerves, which incline inwards as they descend in front of the sheath of the cervical vessels, to join the descendens noni (c), and form with it an inverted arch. From the convexity of this arch, which looks downwards, three or four long waving filaments (e, e) proceed towards the front of the neck, where they are distributed to the sterno-hyoideus and sterno-thyroideus, as well as to the omo-hyoideus muscles. The other division consists of two branches which converge and unite on the scalenus anticus to form the *phrenic nerve* (x).

*The phrenic nerve*, (plate XIV. q; plate XVI. x.)—The branches which form it will be observed to come from the third and fourth nerves; but they are further increased by a branch derived from the fifth, as it descends to the axillary plexus. The phrenic nerve thus constituted lies on the scalenus anticus, near its inner border, and passes into the thorax, to be ultimately distributed to the diaphragm.

## PLATE XVIII.

The superficial and deep nerves of the front of the fore-arm are here shown. In fig. 1, the fascia has been left, and the superficial nerves are seen lying on its surface. In fig. 2, the superficial muscles of the fore-arm have been removed so as to show the course and relations of the different nerves.

FIG. 1. No. 1. The tendon of the palmaris longus muscle, continuous with the palmar fascia. 2. The palmar fascia. 3. The palmaris brevis muscle. 4. The abductor pollicis muscle covered by a thin layer of fascia.

A. The internal cutaneous nerve.

a. Its posterior branches. b. Its anterior branches. c. Filaments of communication with the external cutaneous nerve. d. A filament of the ulnar nerve uniting with a branch of the internal cutaneous.

B. The external cutaneous nerve.

e. Its posterior branch. f, f. Its anterior branches. g. A branch of communication from the radial nerve. h. The radial cutaneous nerve. i. The palmar cutaneous nerve, a branch of the median.

FIG. 2. No. 1. The lower part of the biceps muscle. 2. The brachial artery. 3. The inner head of the triceps muscle. 4, 4. The external head of the pronator radii teres muscle cut through. 5. Its internal head. 6. The origin of the flexor carpi radialis muscle divided. 7, 7. The flexor carpi ulnaris muscle. 8, 8. The flexor profundus digitorum muscle. 9, 9. The ulnar artery. 10. The interosseous artery. 11. The flexor longus pollicis muscle. 12, 12. The radial artery. 13. The supinator brevis muscle. 14. The extensor carpi radialis longior. 15. The supinator longus muscle. 16. The pronator quadratus muscle. 17. The tendon of the palmaris longus muscle. 18. The superficialis volæ artery. 19. The abductor pollicis muscle. 20. The flexor brevis pollicis muscle. 21. The adductor pollicis muscle. 22, 22. The tendons of the flexor profundus digitorum muscle. 23. The superficial palmar arch. 24. The adductor minimi digiti muscle. 25. The abductor minimi digiti. 26, 26. The lumbricales muscles.

A. The termination of the musculo-spiral nerve.

a. The radial nerve. b. The posterior interosseous nerve.

B, B. The median nerve.

c. A branch supplying the pronator radii teres muscle and elbow joint. d. Branches to the superficial muscles of the fore-arm. e. The anterior interosseous nerve. f. The superficial palmar nerve. g. A branch to the muscles of the ball of the thumb. h. Collateral branches to the thumb. i. Digital branch of the first finger. k, k. Digital branches of the middle and ring fingers. l, l. Posterior branches of the digital nerves.

C, C. The ulnar nerve.

m, m. Muscular branches. n. Cutaneous branch. o. Dorsal branch. p. Communicating branch with the median. q. Superficial palmar branch. r, r. Deep palmar branch.



Fig 1.

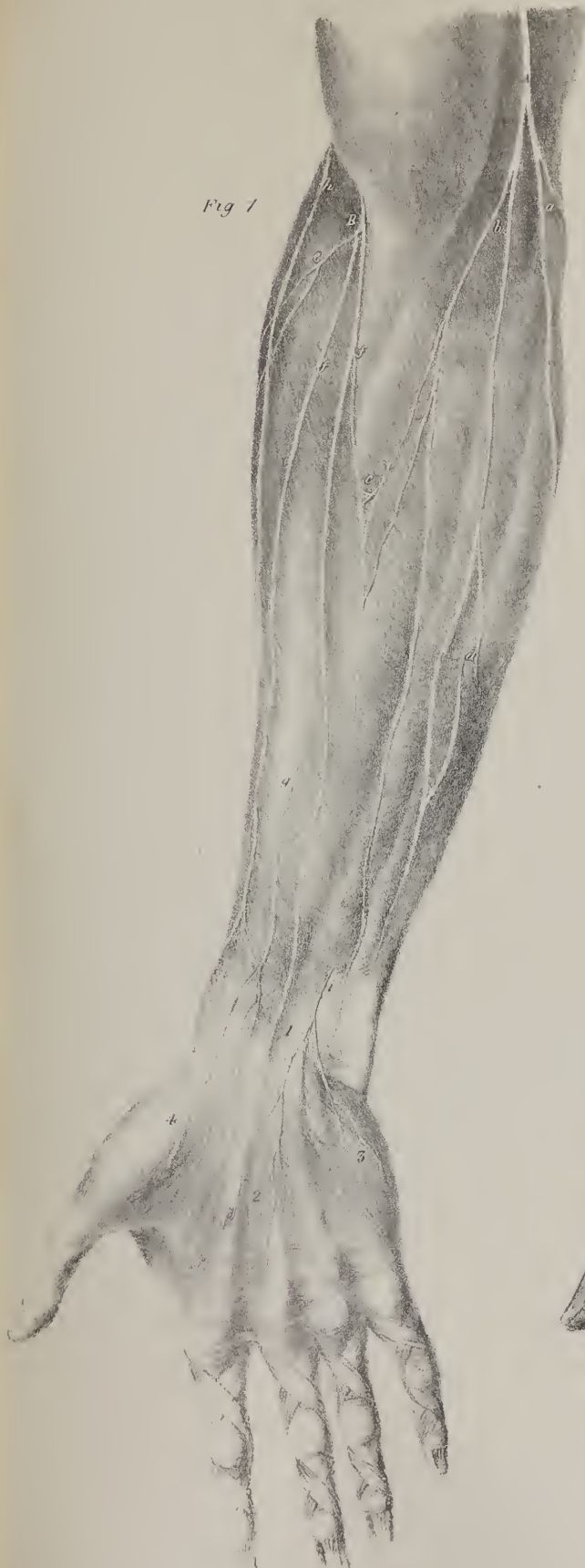
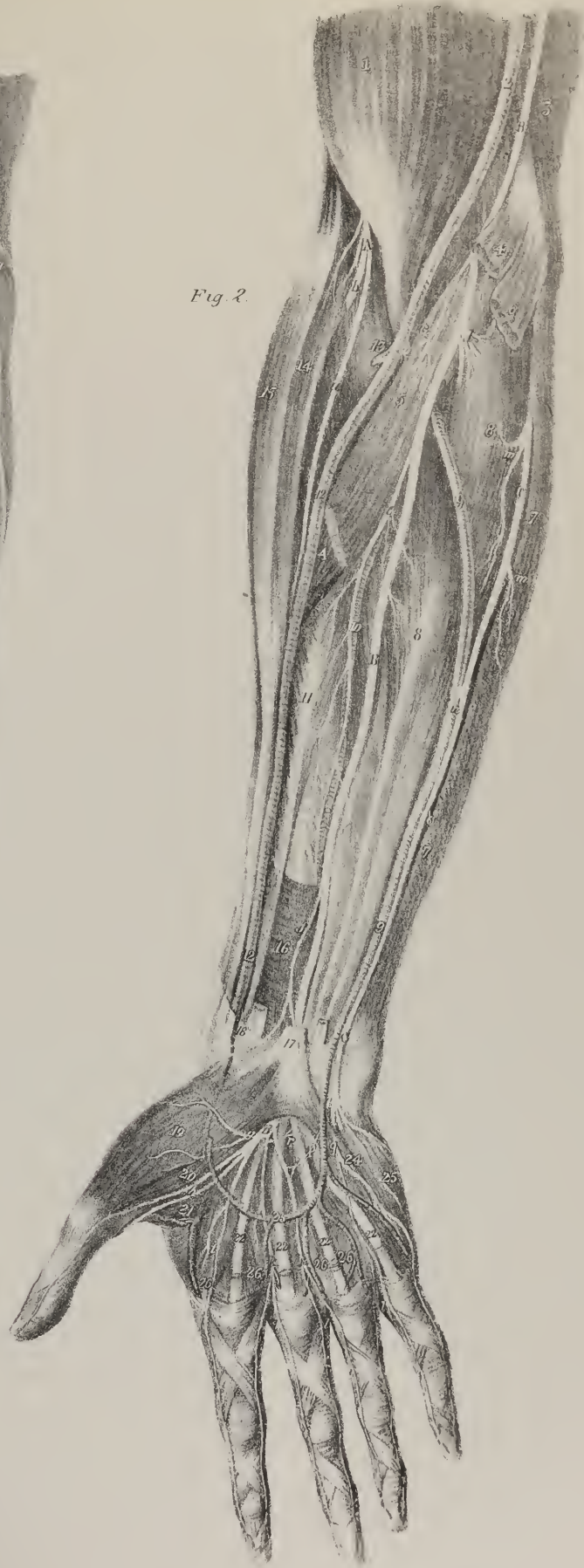

Fig 2.









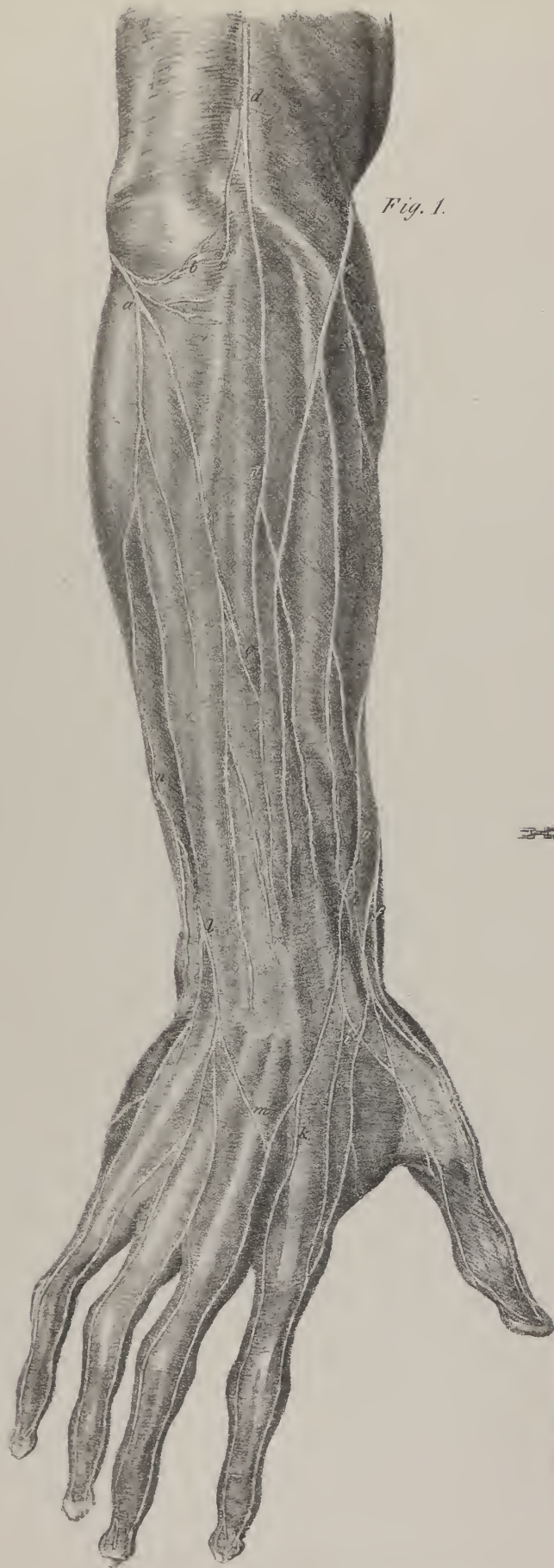

Fig. 1.

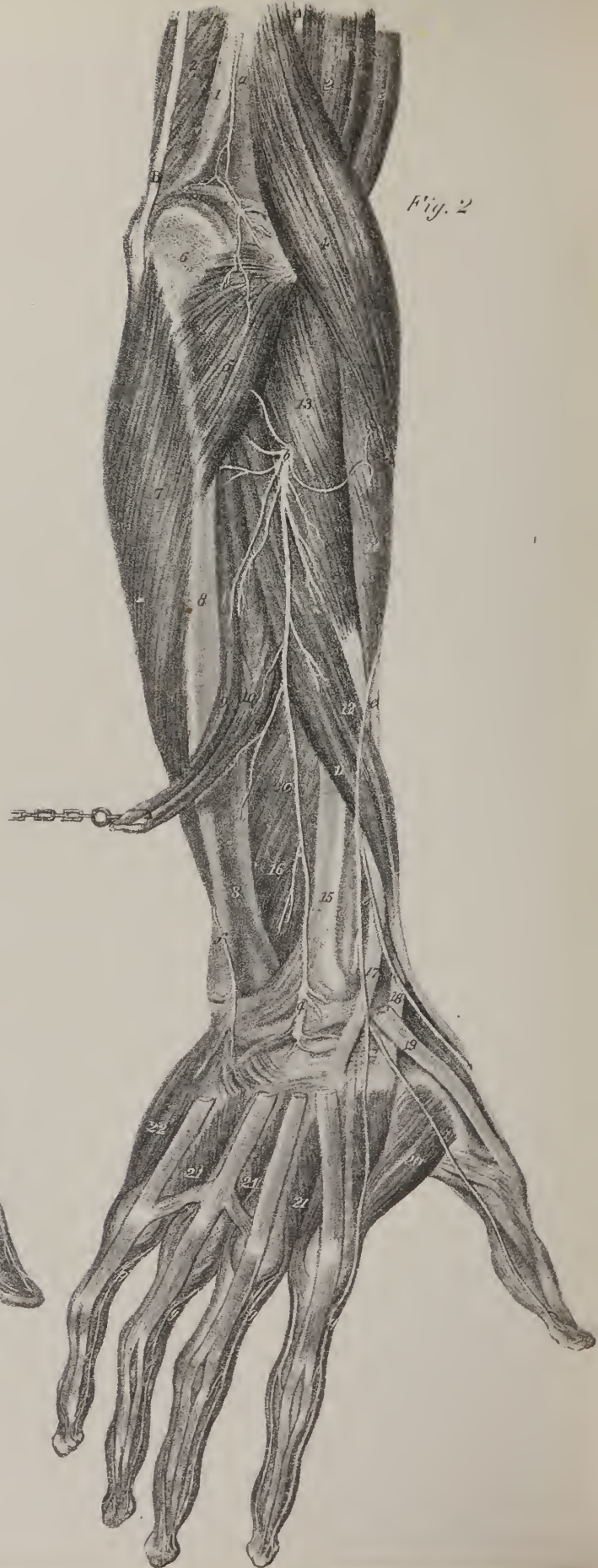

Fig. 2.

*Fifth, sixth, seventh, and eighth cervical nerves.*—The four inferior cervical nerves, namely, the fifth, sixth, seventh and eighth, divide, like the preceding, into anterior and posterior branches. The latter are small; they pass backwards from the intervertebral foramina, and supply the muscles and integuments at the lower part of the neck.

*Brachial plexus.*—The anterior branches of these nerves are of very considerable size, much larger than those which form the cervical plexus. After emerging from the intervertebral foramina, they receive some filaments from the inferior or middle cervical ganglia of the sympathetic; and, being joined by the corresponding branch of the first dorsal nerve, unite in a peculiar way to form an interlacement called the *brachial* or *axillary plexus* (plate XVI. v, v), which extends from opposite the sixth cervical vertebra to the coracoid process. In the neck, the branches which form it lie between the scaleni muscles; closely aggregated together, they pass downwards and outwards into the axillary space, between the subclavius muscle and the first rib, and are placed at the acromial side of the accompanying artery.

The branches which form this plexus are said by Boyer, and other anatomists, to interlace inextricably. An arrangement of them, however, may be made as follows:—a probe may be previously passed across, through the primary divisions of the plexus, so as to divide them into an anterior and posterior set. The anterior branches of the fifth and sixth cervical nerves will be observed, after coming out of the intervertebral foramina, to unite and form a common trunk, which, after giving off the supra-scapular nerve, separates into two divisions. Of these, one, posterior in situation, descends to form the circumflex nerve, and gives a small slip to form the spiral: the anterior division unites with a similar one from the seventh, and the common trunk thus resulting gives at its upper side the external cutaneous nerve; at the lower, the outer head of the median. The first dorsal nerve ascends to join the last cervical, to form a common trunk, which also separates into two divisions. The posterior one unites with a similar offset from the seventh to form the spiral nerve; whilst the anterior, after giving off from its inner side the internal cutaneous nerve, divides ultimately into the ulnar nerve and the inner head of the median.

*Brachial plexus—its branches.*—From this nervous interlacement several nerves proceed, which may be divided into three sets:—1. The first consists of those which pass off rather higher up from the plexus, viz. the supra-scapular, the sub-scapular, and the thoracic, the latter consisting usually of three branches, all, however, going to nearly the same destination. Opposite the coracoid process, the plexus divides into six ultimate branches, for the supply of the limb, which may be resolved into—2, those which reach the hand and fingers, consisting of the ulnar, median, and spiral nerves; and 3, those which do not extend so far, namely, the internal cutaneous, the external cutaneous, and the circumflex nerves.

*Nerves of the superior extremity.*—The first set of these nerves, according to the division above indicated, consists of the supra-scapular, the sub-scapular, and the thoracic nerves or branches.

*Supra-scapular nerve.*—The supra-scapular nerve, (plate XVII. h; *n. supra-scapularis*), passes off from the plexus as high up as opposite the sixth cervical vertebra. Its direction is backwards and outwards, as it descends to the superior border of

## PLATE XIX.

The nerves of the posterior part of the fore-arm are here shown.

FIG. 1. The superficial nerves resting on the deep fascia.

a, The posterior branch of the internal cutaneous nerve. b. Branches distributed to the integument around the olecranon. c. Branch of communication with the radial cutaneous nerve. d. Radial cutaneous nerve, (*nervus cutaneus externus superior*.) e. Posterior branch of the external cutaneous nerve. f. Another branch of the external cutaneous nerve. g. The radial nerve. h. The posterior collateral branch to the thumb. i. The branch of the first metacarpal space. k. The branch of the second metacarpal space. l. The dorsal branch of the ulnar nerve piercing the fascia, and becoming superficial. m. Its communicating branch with the radial. n. A branch of the internal cutaneous nerve.

FIG. 2. A deep view of the nerves supplying the posterior aspect of the fore-arm. The triceps muscle has been removed from its insertion in the upper arm; and the extensor communis digitorum, extensor digiti minimi, and extensor carpi ulnaris have been dissected away from the fore-arm.

No. 1. The lower part of the humerus. 2, 2. The posterior surface of the brachialis anticus muscle. 3. The biceps. 4. The supinator longus muscle. 5. The anconeus muscle. 6. The olecranon process of the ulna. 7. The flexor carpi ulnaris muscle. 8, 8. The ulna. 9, 10. The indicator and extensor secundi internodii pollicis muscles drawn aside with a hook. 11. The extensor primi internodii muscle. 12. The extensor ossis metacarpi pollicis muscle. 13. The supinator brevis muscle. 14. The extensor carpi radialis longior. 15. The lower part of the radius. 16. The interosseous membrane. 17. The tendon of the extensor carpi radialis brevior. 18. The tendon of the extensor carpi radialis longior. 19. The tendon of the extensor secundi internodii pollicis. 20. The abductor indicis muscle. 21, 21. Dorsal interossei muscles. 22. The abductor minimi digiti muscle.

A. The musculo-spiral nerve.

a. A branch of the musculo-spiral nerve distributed to the joint. b. The posterior branch of the musculo-spiral nerve, (*nervus profundus vel muscularis*.) c. The posterior interosseous nerve, (*nervus interosseus posticus*.) d. The ganglion formed upon the posterior interosseous nerve at its distribution to the wrist joint. e. The radial nerve.

B. The ulnar nerve, passing behind the inner condyle of the humerus.

f. Its dorsal branch. g, g. The dorsal collateral branches of the digital nerves.



the scapula. The nerve passes through the supra-scapular notch or foramen, and so reaches the dorsum of the scapula, where it gives branches, first, to the supra-spinatus muscle, and then continues its course upon the neck of that bone, until it arrives in the infra-spinal fossa, where it terminates by ramifying in the muscles.

*Sub-scapular nerves.*—The sub-scapular nerves, (plate XVII. l, l; *n. sub-scapulares*.) pass backwards from the plexus, at first lying deeply in the axillary space; they are usually three in number. One, the smallest of the three, enters the sub-scapular muscle, and is distributed to its substance. The others not unfrequently arise by a common trunk, but sometimes separately; both proceed in the same course as the sub-scapular artery, one supplying the muscle of that name, as well as the teres major and minor; whilst the other, somewhat larger, pierces the teres major, and ramifies in the latissimus dorsi.

*Thoracic nerves.*—The thoracic nerves (plate XVII. i, i; *n. thoracici*) are usually three in number. Of these, two may be observed to pass down on the fore part of the thorax, lying in front of the axillary vessels, and to terminate it by ramifying in the substance of the pectoralis major and minor muscles. Another very long branch (g) commences by two filaments (f), which soon unite to form a thin, flat nerve, that lies behind the plexus and the axillary vessels. It descends along the thoracic side of the axillary space, resting upon the serratus magnus muscle, to which in its course it gives branches, and finally terminates by ramifying in the lower part of that muscle. This nerve, from its situation, is called the posterior thoracic branch. Sir C. Bell classes it amongst the respiratory nerves, as, according to his views, its function is to associate the muscle to which it is distributed with the general respiratory movements. From its situation it is named the *external respiratory nerve*, to distinguish it from the phrenic, which is placed within the thorax.

*Internal cutaneous nerve.*—The internal cutaneous nerve, (plate XVII. D; plate XVIII. fig. 1, A: *n. cutaneus internus*.) commencing at the inferior and internal part of the plexus, descends along the inner side of the arm, being the smallest and most superficial of the nerves derived from the plexus. It lies for some way covered by the fascia of the arm, and divides, at a variable distance above the elbow, into two branches, which separately pierce the fascia. One of these may be observed to cross in front of the median basilic vein, and then to descend along the fore part of the arm, gradually inclining towards its inner side. It distributes several filaments to the skin, and maintains communications with the external cutaneous nerve on the one hand, and with the larger branch, or proper continuation of the internal cutaneous, on the other, and finally ceases at the wrist. The other division of the nerve is larger than the preceding, and lies nearer to the inner condyle of the humerus. At the bend of the elbow it inclines towards the ulnar border of the fore-arm, distributing filaments on each side as it descends, which freely ramify in the integument. Towards the carpus the nerve is necessarily much diminished, after having given off so many branches; its final ramifications may be traced as far as the skin over the inner border of the hand. Previously to reaching the elbow, and before its division, the nerve sends off several small and delicate branches to supply the skin that covers the biceps and triceps muscles.

*External cutaneous nerve.*—The external cutaneous nerve, (plate XVII. B; plate XVIII. fig. 1, B; *museulo-cutaneus, nervus perforans Casserii*.) issues from the superior and external part of the plexus, being intermediate in size between the preceding nerve and the ulnar. Its direction is outwards and downwards, so as to reach the border of the coraco-brachialis muscle, the fibres of which it in most cases pierces, but sometimes passes behind it. In either case, the nerve passes between the biceps and brachialis anticus muscles, where it gives off three or four branches to the muscles between which it lies, the continuation of the nerve being intended for the skin, whence its name, *museulo-cutaneus*. After this the nerve inclines outwards as it descends, reaches the outer border of the arm, and pierces the fascia, so as to come into contact with the median cephalic vein, behind which it lies. The nerve is thus placed between the fascia and integument, at the external or radial border of the fore-arm, along which it continues to descend as far as the wrist, where it terminates by dividing into two sets of filaments, one of which ramifies in the skin covering the anterior, the other in that on the posterior aspect of the carpus.


The branches given off by the nerve in its entire course are divisible into two sets, one muscular, the other cutaneous, whence its name. The muscular branches (plate XVII. m, n, o, p) consist of three or four filaments distributed to the flexor muscles; one may be traced for some way in the interior of the coraco-brachialis, arising from the nerve whilst passing through its substance, or beneath it; the others go to the biceps and brachialis anticus, one communicating with the median nerve. The cutaneous branches (plate XVII. q; plate XVIII. fig. 1, e, f) not only supply the integument of the fore-arm, but also maintain communications with the internal cutaneous nerve on the one hand, and the cutaneous branches of the spiral nerve on the other, by filaments which take a curved direction, and unite with similar offsets from the nerves just mentioned, so as to form arches, whose convexity, for the most part, looks down towards the hand. Finally, on the fore part of the wrist and root of the thumb, its terminal branches unite, in the same way with the cutaneous branches sent by the median nerve, to the integument on the palm of the hand.

*Circumflex nerve.*—The circumflex or axillary nerve, (plate XVII. G; *n. circumflexus brachii v. axillaris*), is deeply seated, and altogether concealed by the plexus. It passes outwards and backwards immediately after its origin, and soon comes into contact with the posterior circumflex artery. The nerve and artery will be observed to run together close behind the shaft of the humerus, in order to reach its external aspect, where they both turn forwards somewhat, so as to lie between the bone and the deltoid muscle, to which the branches of both are finally distributed. The long head of the triceps lies behind the nerve in the first part of its course, and the sub-scapularis above it, the teres major being below it. To each of these, filaments are given;

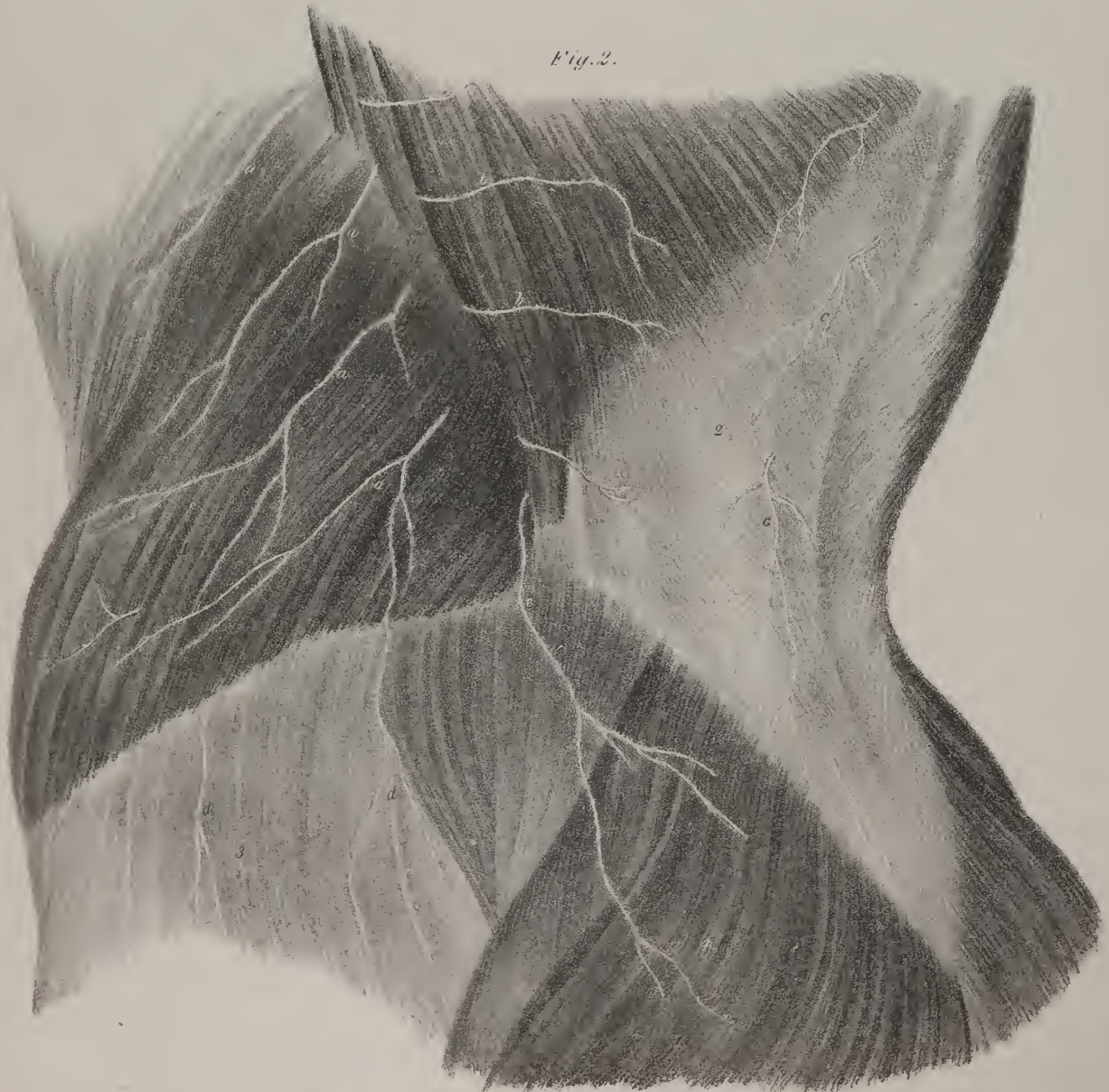




*Fig. 1.*



*Fig. 2.*





and where it turns beneath the deltoid, a considerable branch descends, becoming superficial, and is distributed to the skin, covering that muscle and the triceps extensor.

*Ulnar nerve.*—The ulnar nerve, (plate XVII. E, E; plate XVIII. fig. 2, C, C: *n. ulnaris*), intermediate in size between the external cutaneous and median nerves, is usually detached from the plexus opposite the lower border of the sub-scapular muscle. It inclines a little backwards as it descends along the arm, resting on the short head of the triceps, until it reaches the interval between the inner condyle of the humerus and the olecranon. There the nerve, after passing through the interval between the heads of the flexor carpi ulnaris muscle, reaches the fore-arm, along which it descends close to its ulnar border, resting on the flexor profundus muscle, and covered by the flexor carpi ulnaris. Towards the lower part of the fore-arm the nerve lies close to the radial border of the tendon of the last-named muscle, along which it runs, in company with the ulnar artery, to the pisiform bone and annular ligament of the wrist. Having passed in front of the latter, it divides into two branches, one being superficial, the other deep-seated.

The *superficial* branch, (plate XVIII. fig. 2, q,) the larger of the two, soon gives off, at its inner side, a considerable branch, which inclines towards the ulnar border of the hand, lying upon the short muscles of the little finger, to which it gives filaments. On reaching the head of the metacarpal bone, it proceeds along the inner margin of the digital phalanges to their extremity, forming the internal collateral branch of the little finger. Continuing its course directly forwards, the superficial branch rests on the abductor muscle of the little finger, where it gives an offset (p) from its radial side, which joins with the last digital branch of the median nerve; and, finally, on arriving opposite the heads of the metacarpal bones, (fourth and fifth,) it divides into two ramusculi, which run along the contiguous borders of the ring and little fingers.

The *deep-seated palmar* branch (r, r) of the ulnar nerve becomes concealed from view by passing beneath the adductor of the little finger. It then inclines outwards across the metacarpus, covered by the flexor tendons, resting on the inter-ossei, and terminates by two or three filaments, which ramify in the adductor pollicis. The deep nerve, like the corresponding artery, forms an arch, whose convexity is turned towards the fingers, and, in its course, branches are given off on each side to the inter-ossei muscles, as well as to the small muscles of the little finger.

The ulnar nerve distributes several branches, which, if taken in the order of their occurrence, will be found as follow: 1, at the lower border of the axilla, one or two filaments are given to the teres major and latissimus dorsi; 2, in the arm a few branches pass into the substance of the long and short heads of the triceps muscle, on which the nerve lies; 3, in the fore-arm, numerous branches are given to the contiguous muscles, viz. the flexor carpi ulnaris and flexor profundus, and also some filaments, which maintain communications with the branches of the median nerve; 4, at the union of the middle with the lower third of the fore-arm, a branch of considerable size (plate XVIII. fig. 2, o) inclines backwards from the nerve, and reaches the dorsal aspect of the limb, after having passed beneath the flexor ulnaris muscle. Continuing to descend, it lies superficial to the extensor carpi ulnaris, and so reaches the back of the hand, where it sends a branch along the inner border of the fifth metacarpal bone, which gives filaments to the abductor of the little finger, and finally runs along its ulnar margin as far as the last phalanx. The continuation of the nerve corresponds in its course with the fourth metacarpal space, giving off several small filaments to the skin and parts on the back of the hand, and, on reaching the heads of the metacarpal bones, divides into two branches, which extend upon the contiguous margins of the little and ring fingers, in their entire length, forming their collateral branches. From the radial side of the nerve a branch not unfrequently is sent, which supplies also the external border of the ring finger, and the adjacent one of the middle finger. But it will sometimes be observed that this branch joins with some derived from the termination of the spiral nerve, and that from their union branches proceed to supply the contiguous borders of the ring and middle fingers.

## PLATE XX.

FIG. 1. A section of the thorax, showing the distribution of the intercostal nerves.

Nos. 1, 1. The dorsal portion of the vertebral column. 2, 2. The inner surfaces of the ribs of the left side. 3, 3. The external intercostal muscles. 4, 4. The internal intercostal muscles.

a, a. The intercostal nerves, (*n. intercostales*, vel *dorsales*), emerging from the intervertebral foramina. b, b. The anterior branches, (*rami intercostales*.) c, c. The posterior branches, (*rami dorsales*, vel *postici*.) d, d. The anterior branches, or intercostal nerves, of the left side. e, e. Muscular branches. f, f. The superficial or cutaneous branches piercing the external intercostal muscles.

FIG. 2. A superficial view of the side of the trunk, showing the distribution of the cutaneous nerves.

No. 1. The external oblique muscle. 2. The latissimus dorsi. 3. The fascia covering the gluteus medius muscle. 4. The gluteus maximus.

a, a. Superficial or cutaneous branches of the inferior intercostal nerves. b, b. Cutaneous branches reflected backwards. c, c. Cutaneous branches from the dorsal branches of the intercostal nerves. d, d. Cutaneous branches from the musculo-cutaneous branches of the lumbar plexus. e. Cutaneous branch from one of the lumbar nerves.



*Median nerve.*—The median nerve, (plate XVII. C. C; plate XVIII. fig. 2, B, B: *n. medianus*), is so called from the position which it occupies in the fore-arm. It is of considerable size, and arises from the plexus by two fasciculi, or heads, which embrace the axillary artery. The artery, in this situation, is surrounded on every side by the divisions of the plexus. In front lies the median nerve, behind it are placed the circumflex and spiral, to the outer side one of the heads of the median, together with the external cutaneous nerve, and to the inner, the second head of the median, with the internal cutaneous and ulnar nerves. The median nerve inclines outwards at first, in order to come into contact with the coraco-brachialis muscle. Towards the middle of the arm it crosses the brachial artery, usually in front, occasionally behind it, and becomes placed at its inner side, resting on the brachialis anticus. At the bend of the elbow the nerve sinks deeply into the interval between the pronator teres and the supinator longus muscles, and passes between the two heads of the pronator teres, and beneath the upper border of the flexor sublimis. Continuing its course along the fore-arm, the nerve lies between the muscle last named and the flexor profundus, with which it passes behind the annular ligament of the wrist, and so reaches the palm of the hand, where it divides into five branches.

## PLATE XXI.

In this plate the lumbar plexus is seen, together with its branches. The dissection has been effected by removing the anterior parietes of the abdomen and the viscera. On the right side the psoas muscle is left; on the opposite side it has been taken away to show the manner of formation of the plexus. The sacral plexus is also shown.

Nos. 1, 1. Part of the greater muscle of the diaphragm. 2, 2. The ligamenta arcuata externa. 3, 3. The ligamenta arcuata interna. 4, 4. The openings for the lesser splanchnic nerves. 5. The lesser muscle of the diaphragm. 6. Its long origin. 7. Its short origin. 8. The aortic opening. 9. The fifth lumbar vertebra. 10. The psoas magnus muscle. 11. The quadratus lumborum of the right side. 12. The cut edge of the anterior aponeurotic lamella of the transversalis muscle: the lamella has been removed to show the quadratus muscle. 13. The iliacus internus muscle. 14. The divided edge of the transversalis muscle. 15. The divided edge of the internal oblique muscle. 16. The divided edge of the external oblique muscle. 17. The anterior superior spine of the ilium. 18. Poupart's ligament. 19. The iliacus muscle below Poupart's ligament. 20. The psoas muscle in the thigh. 21. The pectineus muscle. 22. The adductor longus. 23. The gracilis muscle. 24. The sartorius. 25. The upper part of the rectus. 26. The tensor vaginae femoris muscle. 27. The anterior border of the gluteus medius. 28. The quadratus lumborum muscle of the left side. 29, 29. The intertransversales muscles of the lumbar vertebrae. 30. The divided edge of the anterior lamella of the transversalis muscle. 31, 31. The divided edges of the external oblique, internal oblique, and transversalis muscles of the left side. 32. The iliacus internus muscle. 33. The anterior surface of the sacrum. 34, 34. Part of the levator ani muscle at each side. 35. The symphysis pubis. 36, 36. The spermatic cords of the testicles. 37. The lower edge of the aponeurosis of the external oblique muscle turned aside. 38, 38. The fascia lata of the left thigh.

A. The first lumbar nerve.

a. The branch of communication from the last dorsal, dorsi-lumbar nerve. b. The branch of communication to the second lumbar nerve. c, c. The external or superior musculo-cutaneous nerve, (ilio-scrotal, ilio-inguinal:) the same nerve is seen issuing from beneath the psoas magnus muscle on the right side. d. Its muscular branch, divided. e, e. Its scrotal branch. f, f. The internal or inferior musculo-cutaneous nerve. g. Its branch of distribution to the groin and scrotum on the right side.

B. The second lumbar nerve.

h. Filaments which it receives from the second lumbar ganglion of the sympathetic nerve. i. The branch of communication with the third lumbar nerve. k, k. The external cutaneous nerve, (inguino-cutaneous.) l, l. The same nerve on the outer side of the thigh. m, m. The external pudic nerve, (n. spermaticus externus, pudendus externus, genito-cruralis.) n. Its spermatic branch. o. Its crural branch.

C. The third lumbar nerve.

p. Filaments from the second lumbar ganglion of the sympathetic. q. A branch of communication with the fourth lumbar nerve. r. The large trunk formed by the union of branches from the first, second, and third nerves, descending to join the fourth lumbar nerve. s, s. Muscular branches.

D. The fourth lumbar nerve.

t. Filaments of communication with the third lumbar ganglion of the sympathetic. u. A branch of communication with the fifth lumbar nerve. v. A branch which unites with a corresponding branch from the third to form the obturator nerve.

E, E. The obturator nerve, (n. obturatorius.) F, F. The crural nerve, (n. femoralis.)

w, w. Muscular branches to the iliacus and psoas muscles. x, x. Its superficial, or cutaneous branches. y. Its muscular branches. z. Its sphenous branches.

G. The fifth lumbar, or lumbo-sacral nerve, descending to join the sacral plexus.

a\*. Filaments from the communicating branch between the third and fourth lumbar ganglia of the sympathetic.

H. The gluteal nerve, (n. gluteus superior.) I, I. The sacral plexus formed by the union of the lumbo-sacral with the four upper sacral nerves.

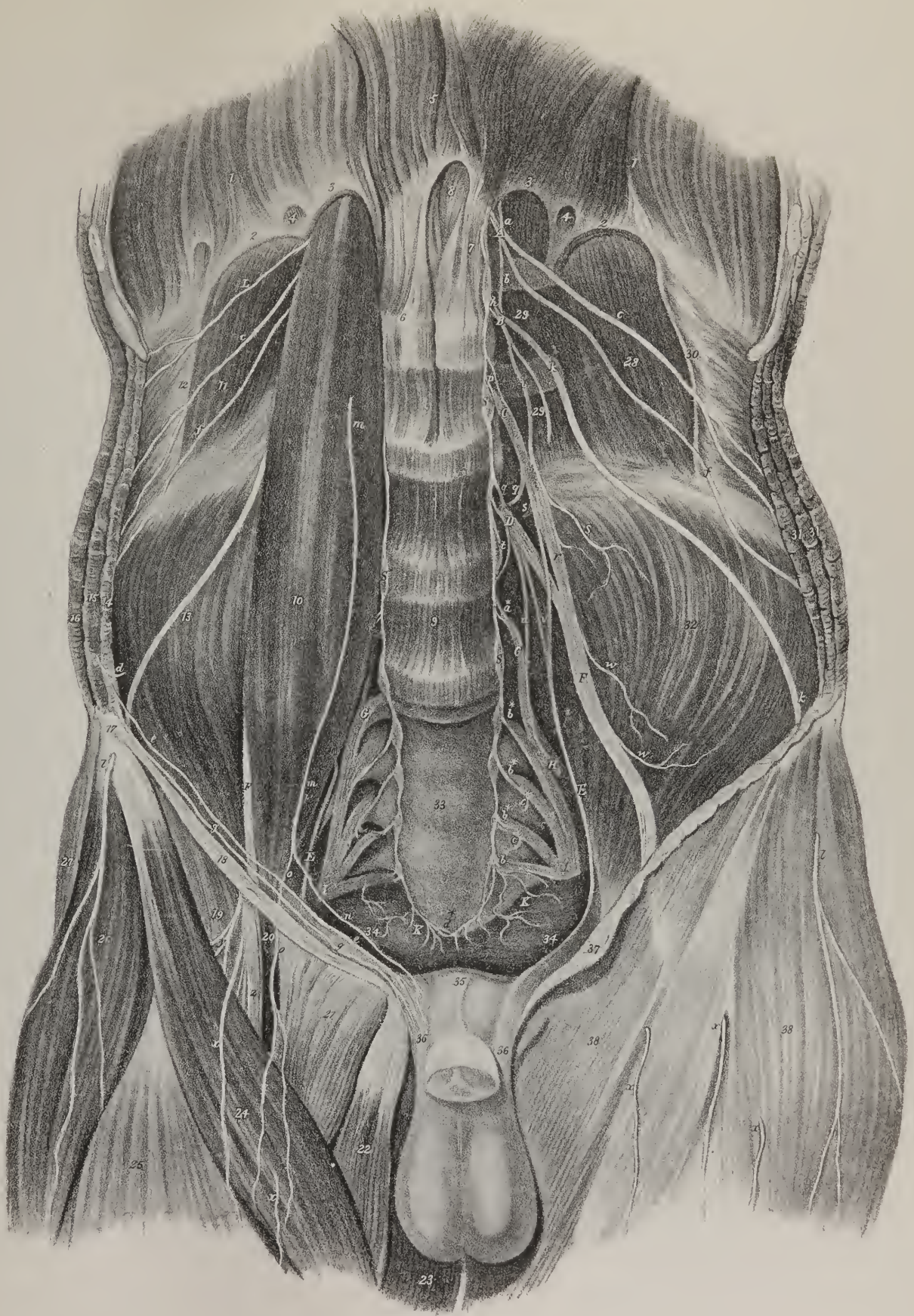
b\*, b\*. Filaments of communication from the sacral ganglia of the sympathetic. c\*, c\*. Visceral branches divided.

K, K. The fifth sacral nerve. S, S. The sympathetic nerve, its lumbar and sacral portions.

d\*. Its terminal ganglion, ganglion impar, (g. azygos.)

L. A muscular branch from the last dorsal nerve.









The *first digital* branch proceeds outwards and forwards, lying upon the abductor and short flexor of the thumb, to both of which it gives filaments. It thus reaches the radial border of the thumb, and passes along its phalanges to their extremity.

The *second* branch is also intended for the thumb, being placed parallel with the preceding at its ulnar margin.

The *third*, larger than the preceding, sometimes forms, at its commencement, a common trunk with them. It proceeds directly forwards, giving some filaments to the abductor indicis, and one to the first lumbricalis muscle, and finally runs along the radial border of the phalanges of that finger.

The *fourth* branch, still larger, corresponds in its course with the second metacarpal space, where it gives a ramusculus to the second lumbricalis muscle, and finally divides into two collateral branches of equal size, which supply the adjacent borders of the fore and middle fingers.

The *fifth* digital branch lies in the third metacarpal space, where it communicates by a transverse slip with the ulnar nerve (its second digital branch). Like the fourth, it divides into two branches, which are placed along the contiguous margins of the middle and ring fingers.

In the arm the median nerve communicates with the musculo-cutaneous, and gives only a very few muscular branches, which are so small as scarcely to deserve notice; they are distributed to the muscles arising from the inner condyle of the humerus, opposite which they are given off. The most remarkable of these is the interosseous nerve (plate XVIII. fig. 2, e; *n. interosseous anticus*.) This is of considerable size; immediately after its origin it passes backwards to reach the anterior surface of the interosseous ligament, where it comes into contact with the artery of the same name. In this situation, the nerve is interposed between the flexor profundus and flexor pollicis longus, and so continues, as far as the upper border of the pronator quadratus muscle. Having passed under cover of the muscle just named, to which it gives some small filaments, the nerve turns backwards through the interosseous ligament, and so gains the dorsal surface of the hand, where it ramifies in several filaments.

At the lower part of the fore-arm, another branch is given off, called, from its ultimate destination, the *cutaneous palmar* branch (plate XVIII. fig. 1, i; fig. 2, f). This descends between the flexor tendons, passes in front of the annular ligament and palmar fascia, and divides into filaments, which supply the skin at the centre of the palm of the hand.

*Musculo-spiral nerve.*—The musculo-spiral nerve (plate XVII. F; plate XVIII. A: *nervus radialis*, Sæmm.; *nerf radio-digital*, Chauss.) is, at first, the largest of those which issue from the plexus. Its direction is downwards, backwards, and outwards, winding in a spiral manner round the bone, whence its name is derived. It lies in the cellular interval between the short and middle heads of the triceps muscle, accompanied by the superior profunda, or spiral artery. But, in order to reach the external and anterior aspect of the humerus, where it finally appears, the nerve passes between the second head of the muscle and the bone, lying in a canal formed for it by some tendinous fibres, which arch obliquely over it. The nerve (plate XVIII. fig. 2, A), in the next place, lies deeply in the interval between the brachialis anticus and supinator longus, which overlap and conceal it, until it reaches the elbow-joint. There it divides into two primary branches, one being placed on the anterior and external part of the fore-arm, the other lying deeply at its posterior aspect.

The *anterior branch* (plate XVIII. fig. 2, a) resembles the continuation of the nerve in direction, though not in size. It proceeds directly downwards, guided by the supinator longus, giving several branches, usually five or six, which are distributed to the extensor and supinator muscles. In the middle third of the arm, the nerve, considerably reduced in size, comes into relation with the radial artery, and lies to its outer side for some way. After a while it inclines outwards, beneath the tendon of the supinator longus, to reach the external border of the fore-arm (plate XIX. fig. 1, g; fig. 2, e), upon which it descends, lying superficial to the extensors of the thumb. Near the carpus it divides into two, or sometimes into three branches. One of these (fig. 1, h) runs along the radial border of the thumb, forming its first posterior collateral branch. Another (fig. 1, i) corresponds with the first metacarpal space, and divides, for the supply of the ulnar border of the thumb and the adjacent border of the fore-finger. The third, after having given a branch from its ulnar side, which supplies the contiguous borders of the ring and middle fingers, proceeds forwards in the second metacarpal space, and divides into two collateral branches for the supply of the index and middle fingers (their adjacent borders). This branch of the spiral nerve will thus supply, besides the thumb, both sides of the index and middle fingers, and one side of the ring finger. In some cases, both sides of the latter receive their nerves from the ulnar, and, occasionally, its radial collateral branch is derived from an interlacement formed by the ramifications of the ulnar and spiral nerves.

The *branches* of the spiral nerve are numerous. Two or three, of considerable size, are given to the triceps, whilst the nerve is in contact with it. One of these ultimately becomes cutaneous, and is sometimes called *nervus cutaneus externus superior*, (plate IX. fig. 1, d.) It ramifies for some way in the integument covering the external and posterior part of the arm, and even of the fore-arm, where it communicates with the branches of the proper external cutaneous nerve. Then it gives the different muscular branches above mentioned to the supinators and extensors on the outer border of the fore-arm, and in the same situation its deep-seated branch. This branch, (plate XVIII. fig. 2, b; plate XIX. fig. 2, b: *ramus profundus*, vel *muscularis*.) is larger than the continuation of the nerve. It inclines outwards as it descends, and after having passed beneath the supinator longus and the two radial extensors, pierces the substance of the supinator brevis, giving it several filaments. On arriving at the

lower border of that muscle, the nerve gives off several branches, some being distributed to the long extensors of the fingers, others to those of the thumb. Finally, one rather remarkable by its size and regularity, (plate XIX. fig. 2, c; *ramus interosseus posticus*), passes along the deep-seated muscles, (the extensors of the thumb and index finger,) distributes branches to them, and extends as far as the carpus, ramifying on its posterior aspect.

*Intercosto-humeral nerves.*—The superior extremity, in addition to the several nerves thus derived from the brachial plexus, receives three long branches, which come from the first, second, and third intercostal nerves. The branch derived from the first intercostal nerve passes out between the first and second ribs, and after giving filaments to the skin at the axilla, runs a little way in the integument of the inner and upper part of the arm.

The branch from the second intercostal nerve (plate XVII. x) passes out from the second intercostal space, gives a filament or two which turn forwards to the skin upon the front of the chest, and after communicating with the first perforating branch just noticed, and the third which lies beneath it, as well as with the internal cutaneous nerve, it gives branches to the skin of the axilla, and terminates along the inner side of the arm. The branch from the third intercostal nerve, (plate XVII. y,) after piercing the muscles, gives filaments to the tegument below the axilla and along the lower border of the scapula. The origin and termination of these nerves are briefly indicated by the name given to them—"intercosto-humeral."

*Dorsal nerves.*—The dorsal nerves (*nervi dorsales*, v. *intercostales*) consist of twelve pairs; the first issues through the intervertebral foramen, between the first and second dorsal vertebræ, the last between the twelfth and first lumbar. The part of the spinal cord with which the cervical nerves are connected being nearly opposite the intervertebral foramen which gives them exit, the roots proceed almost horizontally outwards; those of the dorsal region, on the contrary, proceed obliquely downwards to leave the canal; and the degree of obliquity gradually increases from above downwards, so that the last deviates from the horizontal direction more than any of those above it. In size they are less than the inferior cervical, the lumbar, and the greater number of the sacral: this, doubtless, is owing to the parts to which the dorsal nerves are distributed (the parietes of the thorax and abdomen) being less in extent than the upper and lower extremities, to which the others are given. Immediately after leaving the intervertebral foramina, they divide, as was described in treating of the cervical nerves, into posterior and anterior branches.

The posterior branches (plate XX. fig. 1, c, c; *rami dorsales*, vel *postici*) pass backwards between the transverse processes, and are distributed to the dorsal muscles, some ramifying close to the spine, others near the angles of the ribs. This difference of distribution has given rise to these branches being considered divisible into an internal and an external series; both supply the erector spinæ and superficial muscles, namely, the rhomboidei, trapezius, and latissimus dorsi, and send filaments also to the integuments.

The anterior branches, (plate XX. fig. 1, a, a; *rami intercostales*.) follow the intercostal spaces, lying, in the first instance, near the lower margin of the rib above them, but as they advance they gradually descend, and approach the inferior one, in this respect corresponding with the intercostal arteries which they accompany. Immediately after their commencement, the anterior branches communicate, each by one or two small filaments, with the neighbouring ganglion of the sympathetic nerve. Proceeding outwards, they at first lie between the pleura and external intercostal muscles; towards the angles of the ribs they pass between the two layers of intercostal muscles, furnishing them with several filaments, and at length each gives a large superficial branch, (fig. 1, f, f.) This is given off at about half the length of the intercostal space; or, as this does not apply except in the superior nerves, it will be more correct to state the point to be midway between the spine and the median line in front.

## PLATE XXII.

The branches of the sacral plexus, as they are seen issuing from the openings on the posterior aspect of the pelvis. The gluteus maximus and medius muscles have been removed, as have also the origins of the latissimus dorsi and erector spinæ from the sacrum.

No. 1. That portion of the external surface of the ilium to which the gluteus medius was attached. 2. The posterior superior spinous process of the ilium. 3. Its posterior inferior spinous process. 4, 4. The posterior sacro-iliac ligaments. 5. The posterior surface of the sacrum, upon which the posterior sacral foramina are seen, giving exit to the posterior sacral nerves. 6. The coccyx. 7. The gluteus minimus muscle. 8. The pyriformis muscle. 9. The gemellus superior muscle. 10. The obturator internus muscle. 11. The gemellus inferior muscle. 12. The quadratus femoris muscle. 13. The tuberosity of the ischium. 14. The great or posterior sacro-ischiadic ligament. 15. The spine of the ischium. 16. The fibres of origin of the obturator internus muscle. 17. The ramus of the ischium and pubis. 18. The gracilis muscle. 19. The semi-tendinosus muscle. 20. The long head of the biceps muscle. 21. The upper part of the adductor magnus muscle. 22. The vastus externus muscle. 23. The trochanter major of the femur.

A, A. The posterior branches of the sacral nerves. B. The gluteal nerve, (n. gluteus superior.)

a. Its ascending branch. b. Its descending branch. c. Branches distributed to the gluteus maximus muscle.

C, C. The internal pudic nerve, (n. pudendus.)

d. External hæmorrhoidal branch, (n. hæmorrhoidalis inferior.) e. The perineal branch, (n. pudendus inferior.)

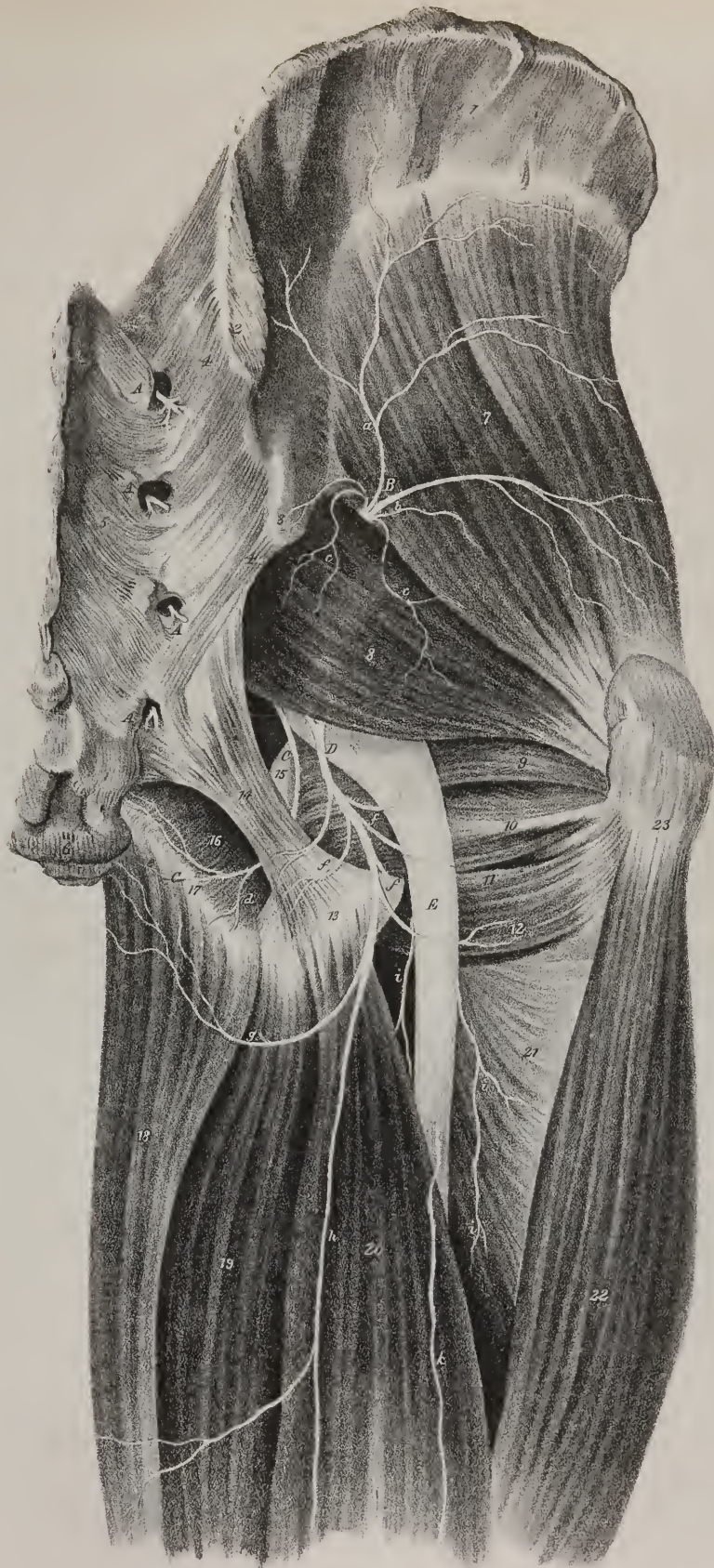
D. The small sciatic nerve, (n. ischiadicus minor, vel gluteus inferior.)

f, f. Inferior gluteal branches. g. The posterior and internal cutaneous nerve. h. The middle posterior cutaneous nerve.

E. The great sciatic nerve, (n. ischiadicus.)

i, i. Muscular branches. k. Cutaneous branch, one of the posterior external cutaneous nerves.









The further distribution of the nerves presenting some peculiarities in several, it is necessary to describe them specially.

The anterior division of the first nerve sends upwards over the head of the first rib a large branch (plate XVII. e) to join with the brachial plexus. The continuation of the intercostal nerves in the first seven spaces, that is to say, those which lie between the true or sternal ribs, after giving off each a superficial branch, pursue their original course forwards to the sternum, furnishing twigs to the intercostal muscles and triangularis sterni; and finally piercing them, they ramify in the pectoralis major and the integuments in the neighbourhood of the sternum. The four following intercostal nerves being those which correspond with the false or asternal ribs, after having furnished their superficial branches, approach the anterior extremity of the intercostal spaces, pass over the costal attachment of the diaphragm, and advance between the transversalis and obliquus internus abdominal muscles; to these they supply numerous twigs, and finally terminate in the substance of the rectus and the integuments covering it.

The superficial or external branches of the first, second, and third nerves pass across the axilla, and ramify in the integuments of the arm on its inner and posterior aspect; the former communicates with the internal cutaneous nerve. These are the *intercosto-humeral* branches, (plate XVII. x, y.) The corresponding branches (plate XX. fig. 1, f, f; fig. 2, a, a) of the dorsal nerves, from the fourth to the eleventh inclusive, pass through the external intercostal muscles, and are distributed to the superficial muscles of the thorax and abdomen; the superior supplying the pectoral muscles and the mamma, those lower down the serratus magnus and the external oblique abdominal muscles; and all send filaments to the integuments.

The anterior branch of the twelfth dorsal nerve, passing below the last rib, cannot be named intercostal. At its commencement it sends a communicating branch to the first lumbar nerve, (plate XXI. a; *dorsi-lumbar*;) it then passes outwards, inclining obliquely down from the last rib, and lies in front of the quadratus lumborum. Near the outer margin of the last-named muscle, this nerve divides into deep and superficial branches, which are disposed in the same manner as those above it: thus the deep-set ramify between the transversalis and internal oblique muscles, and end in the rectus: while the superficial proceed along between the two superficial muscles, in which and the integuments they are expended.

*Lumbar nerves.*—The nerves which communicate the power of sensation and motion to the lower extremity, are derived from the lumbar and sacral plexus, that is, from a net-work or interlacement which the anterior branches of the lumbar and sacral nerves form, after they have passed out of the spinal canal. As the entire of these nerves maintain thus an uninterrupted communication at their origin, and are distributed to similar structures, they have been associated under the general name “lumbo-sacral” plexus. This union resembles that which exists between the cervical and brachial plexus, being perhaps even more intimate.

The lumbar nerves, (*nervi lumbales*), five in number, arise from the medulla spinalis by double roots. These, before uniting at the inner-vertebral foramen, proceed in a very oblique course, the last approaching to the vertical direction. Though exceedingly close, as it were compressed together within the spinal canal, the roots of different pairs have no communication one with the other; they form part of what is named the “cauda equina” of the spinal cord. The trunks formed by the union of each pair of roots pass through the inter-vertebral foramina, the first being transmitted through that between the first lumbar vertebra and the second, the fifth through that between the last and the sacrum. These trunks are very short, being not more than a few lines in length, as they immediately divide into two branches, called, from their direction, anterior and posterior.

The *posterior* branches of the lumbar nerves (*rami postici*, vel *dorsales*) pass backwards, immediately after their division, between the transverse processes of the vertebræ, and are distributed to the deep-seated extensor muscles situated along the spine, some of their branches (plate XX. fig. 2, c, c) extending as far as the skin. It may be observed, that they diminish gradually in size from the first to the last.

The *anterior* branches of the lumbar nerves (*rami lumbales*) increase in size from above downwards, and inclining outwards as they descend, become mutually connected by communicating filaments, sent from one to the other.

*Lumbar plexus*, (plate XXI.)—By the union in the way here indicated of the anterior branches of the first four lumbar nerves, A, B, C, D, (that of the fifth going to join the sacral,) a plexus or interlacement is formed (*plexus lumbalis*) reaching from the second to the fourth lumbar vertebra, resting on the junction of the transverse processes with their bodies, and covered by the psoas muscle. In addition to this mutual communication, each nerve receives one or two small filaments from the lumbar ganglia of the sympathetic nerve, (n, p, t, a\*.) The plexus is moreover brought into relation with the dorsal nerves by a branch (a) which the last dorsal sends down to the first lumbar, and also with the sacral nerves by the fifth lumbar, (G,) which becomes associated with them. As the latter communicating branch, which is of considerable size, has been named *lumbo sacral*, the former, though very small and delicate, may with equal propriety be termed *dorsi lumbar*.

The lumbar plexus thus constituted gives off the following branches, which, if taken in the order of their origin, from above downwards, may be thus arranged: the musculo-cutaneous, external cutaneous, external pudic, the crural and obturator nerves, and lastly the lumbo-sacral or communicating branch.

The *musculo-cutaneous* branches (plate XXI. c, f) are usually two in number, and are derived either from the first lumbar nerve, or in some cases from the filament sent from it to the second. Both pass downwards and outwards through the upper part of the psoas muscle, supported on the quadratus lumborum, to the posterior part of the crista iliï. While in the lumbar region

these branches run parallel, one being placed a little superior and external to the other. 1. The *external* branch (*c*; *ilio-scrotal*, or *ilio-inguinal*), on reaching the posterior part of the crista ilii, gets between the transversalis and internal oblique muscles, and divides into two ramusculi, one of which, (plate XX. fig. 2, e,) after giving some twigs to the transversalis and iliacus, pierces the abdominal muscles, becomes subcutaneous on the posterior part of the ilium, and is distributed to the skin over the gluteus medius and maximus. The other (plate XXI. d, e) proceeds obliquely forwards and inwards, as far as the anterior superior spine of the ilium, and then takes the direction of the crural arch. On reaching the abdominal ring, it passes outwards, together with the spermatic cord, to which it distributes several filaments; some also reach the skin of the scrotum, others that on the pubes and labia in females. The distribution of the branches of this nerve indicates the propriety of the names applied to it, viz. ilio-scrotal, or ilio-inguinal. 2. The second, or more *internal* branch, (plate XXI. f, g,) after descending a little, lies on the fascia iliaca, covered by the peritonæum. After running for a while parallel to, and within half an inch of the crista ilii, it passes through the fibres of the transversalis, and so is placed between that muscle and the internal oblique, and soon after between the latter and the external oblique. To these muscles it gives delicate branches, and terminates by sending two or three which ramify on the integument of the groin and scrotum, communicating with the other cutaneous branches in these structures.

The *external cutaneous* branch, (plate XXI. k, k; inguino-cutané, Chauss.) proceeding from the anterior branch of the second, or from that between it and the third lumbar nerve, passes through the psoas muscle on a level with the crista ilii, runs from thence downwards and a little outwards, lying on the fascia iliaca. On reaching the anterior superior spinous process of the ilium, it emerges from the pelvis, (l,) by passing through the interval between that process of bone and the inferior one; after which the nerve divides into two ramusculi, which separately pierce the fascia lata of the thigh, and proceed to different destinations. 1. One of these inclines backwards, and, becoming subcutaneous, runs over the tensor vaginæ muscle, and along the external part of the thigh, placed between the fascia and the integuments, distributing filaments as it descends, until it ceases to be discernible about the union of the middle with the lower third of the thigh. 2. The *anterior* branch pierces the fascia from an inch and a half to two inches below the anterior superior spine of the ilium, becoming also subcutaneous, and ramifies as far as the external side of the knee, in numerous delicate filaments, which will be found on the fascia covering the vastus externus muscle.

The *external pudic* branch (plate XXI. m, m: nervus spermaticus externus, Scæmm.; pudendus externus; genito-cruralis) arises from the second lumbar nerve, or from the communicating branch between it and the first, pierces through the fibres of the psoas muscle and the fascia that covers it, and then runs vertically downwards, lying on the anterior surface of that muscle. In this course it is covered by the peritonæum, and, on approaching the crural arch, it divides into two ramusculi, one being internal, the other external in its direction. 1. The *internal* ramusculus, (n,) somewhat larger and longer than the other, turns forwards a little, so as to come into contact with the spermatic cord, or round ligament, which it accompanies through the abdominal ring, being distributed to the cremaster muscle and the investments of the testis in the male, some of its filaments extending also to the neighbouring parts of the groin, and in the female to the labia and pubes. 2. The *external* branch (o) inclines outwards in front of the external iliac vessels, just at their termination, passes beneath the crural arch, and divides into several filaments, which ramify in the inguinal region and in front of the thigh, some of them becoming subcutaneous.

## PLATE XXIII.

In this plate are shown the nerves which are distributed on the anterior and inner aspect of the thigh. The sartorius and part of the abductor longus muscle have been removed in order to bring the deep-seated nerves more clearly into view.

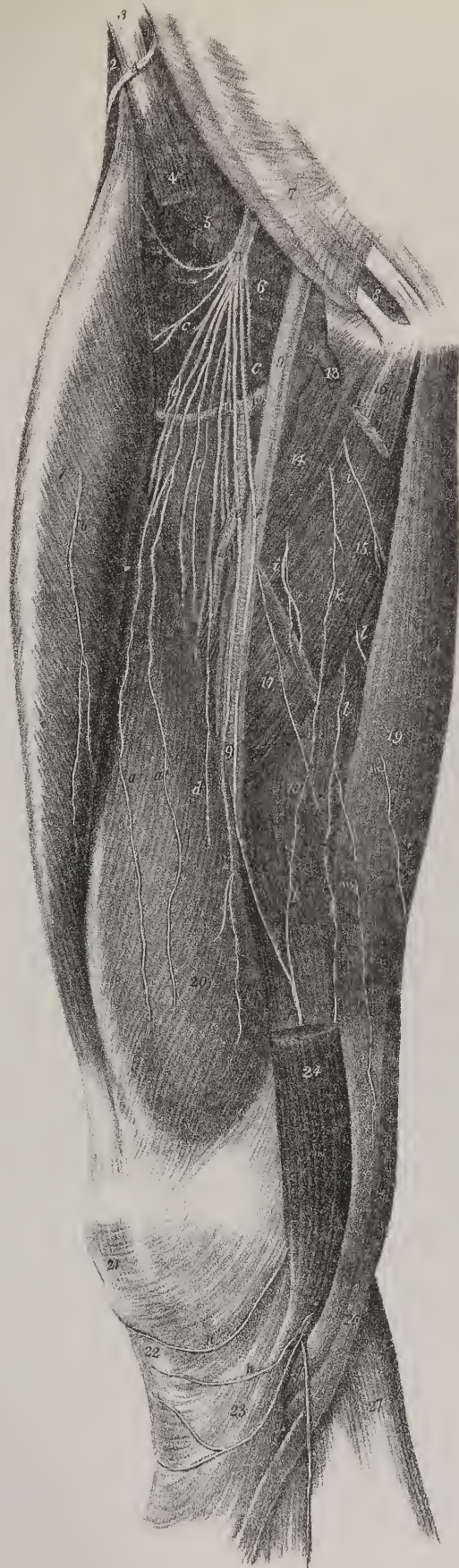No. 1. The rectus muscle. 2. The edge of the tensor vaginæ femoris muscle. 3. The anterior superior spinous process of the ilium. 4. The upper part of the sartorius muscle. 5. The iliacus muscle. 6. The psoas muscle. 7. The aponeurosis of the external oblique muscle of the abdomen. 8. The external abdominal ring. 9, 9. The femoral artery. 10, 10. The profunda artery. 11. Its external circumflex branch. 12. The femoral vein. 13. The termination of the internal saphenous vein in the femoral vein. 14. The pectineus muscle. 15. The adductor brevis muscle. 16. The tendon of origin of the adductor longus muscle. 17. The lower portion of the adductor longus muscle. 18. The adductor magnus muscle. 19. The gracilis muscle. 20. The vastus internus muscle. 21. The patella. 22. The ligamentum patellæ. 23. The expansion of the tendon of the sartorius muscle. 24. The lower part of the sartorius muscle. 25. The tendon of the gracilis muscle. 26. The tendon of the semi-tendinosus muscle. 27. The fascia covering the gastrocnemius muscle.

A. The external cutaneous nerve, escaping from beneath Poupart's ligament to gain the outer side of the thigh.

B. The crural nerve, (nervus femoralis.)

a, a. Its anterior cutaneous branches. b. An anterior cutaneous branch piercing the rectus muscle to reach the integument. c, c. Muscular branches. d. A large muscular branch distributed to the vastus internus muscle. e, e. The short sphenous nerve. f, f. The long or internal saphenous nerve, (nervus saphenus major, vel internus.) g. The internal saphenous nerve passing between the tendons of the sartorius and gracilis. h, h. Branches of the internal saphenous nerve distributed to the knee-joint and to the integument about the knee. i, i. Anterior branches of the obturator nerve distributed to muscles. k. A long descending branch of the obturator nerve communicating with the internal saphenous nerve. l, l. Branches of the obturator nerve descending behind the adductor brevis muscle. m, m. Cutaneous filaments of the obturator nerve.







The *crural nerve* (plate XXI. F, F; plate XXIII, B: *nervus femoro-præ-tibialis*) arises from the second, third, and fourth lumbar nerves, the greater part being derived from the two last; in some instances, also, it receives a small filament from the first, or from the communicating branch that passes between it and the second. The nerve thus formed is of considerable size, and is situated at first deeply in the sulcus between the contiguous margins of the psoas and iliacus muscles. As it descends it comes forwards somewhat, so as to become apparent, though it still remains covered by the fascia iliaca, and is guided to the crural arch by the psoas muscle, (its external border,) which separates it from the iliac artery. In this course the nerve gives from its external side several small filaments to the iliacus muscle; internally, some also pass over the iliac vessels, and others to the psoas muscle. Amongst the latter, one may be observed to take a retrograde course, running from below upwards on the muscle. Close to Poupart's ligament, or immediately after it has passed beneath it, the anterior crural nerve spreads out and divides into a lash of branches, which diverge to their different destinations, and may be divided into a superficial and deep set, the former piercing the fascia, and becoming subcutaneous, forming the cutaneous nerves of the anterior and inner parts of the thigh, the latter remaining covered by that membrane.

The *superficial* branches are very slender, and usually two in number, (plate XXI. x, x; plate XXIII. a, a,) sometimes there are more. They pierce the fascia from half an inch to an inch below Poupart's ligament, one just in front of the femoral artery, the other about midway between that point and the external border of the thigh. These may be called the anterior cutaneous branches, to distinguish them from the external cutaneous nerve and its branches, already described. One of these cutaneous branches passes down beneath the integument, lying on that part of the fascia which covers the rectus muscle, and may be traced as far as the front of the knee. The other runs more internal, distributing filaments as it descends over the sartorius and vastus internus, as far as the inner side of the knee-joint.

The *deep-seated* branches of the anterior crural nerve are very numerous, and admit of being divided into an external, internal, and long or descending set. The long descending branches are two in number (plate XXI. z); they both incline inwards as they descend, and come into contact with the sheath of the femoral vessels, where they are crossed by the sartorius muscle. One of these (plate XXIII. e, e) lies along the external side of the sheath of the vessels for some way, and distributes filaments to the sartorius as it descends; it soon, however, inclines outwards, and ramifies in the vastus internus as far as the knee. The other branch (f, f; *nervus saphenus major, vel internus; tibio-cutans*, Chauss.) is larger and much longer than the preceding. It inclines inwards to get upon the sheath of the vessels; it then runs under cover of the fascia extended from the adductors to the vastus internus, and lies for about the middle third of the thigh towards the superior and external side of the artery. When the artery is about to pass backwards into the popliteal space, the nerve ceases to accompany it, and continues its course directly down to the knee, covered by the sartorius, to which it gives some filaments. Opposite the inner condyle, the saphenous nerve may be found between the tendons of the sartorius and gracilis muscles (plate XXIII. g). In this situation the nerve becomes subcutaneous, and applies itself to the saphenous vein, which it accompanies along the anterior and inner side of the leg, distributing filaments to the integuments as it descends. It passes with the vein in front of the inner ankle, and ramifies by several minute filaments upon the dorsum of the foot. At its origin, this nerve receives a branch of communication from the obturator. In its course along the thigh it is the collateral or satellite nerve of the femoral artery; and in the leg, of the saphena vein.

The rest of the deep-seated branches (plate XXI. y; plate XXIII. c, c) are distributed almost exclusively to the muscles of the thigh, and may, as we have said, be divided (from a consideration of their direction) into an external and an internal set. The *external* branches incline outwards in front of the iliacus and psoas muscles, gradually diverging as they proceed. They get under cover of the sartorius, and give off three or four filaments for its supply, some of which pierce the fibres of the muscle, and ramify on its anterior surface; two of these, after piercing the sheath of the sartorius, become subcutaneous and reach as far as the patella. Other branches, still very numerous, pass beneath the rectus and tensor vaginæ femoris, supplying both; the remainder being distributed to the psoas and iliacus muscles after their junction, and finally to the two vasti and the crureus. The *internal* set of branches, not so large or so numerous, incline inwards beneath the femoral vessels, and supply the pectineus and adductor longus.

The *obturator nerve* (plate XXI. E. E.; *nervus obturatorius, sub-pubio-femoralis*) arises from the third and fourth lumbar nerves, and is smaller than the crural nerve, from which it is separated by the breadth of the psoas muscle, one running along its external border in the iliac fossa, the other placed beneath its inner margin, along the brim of the pelvis. In this course the nerve lies between the peritonæum and the pelvic fascia, being situated about half an inch above the obturator artery, (when it arises from the internal iliac,) but gradually descends, so as to come into contact with it as they approach the obturator foramen, through which they pass out from the pelvis to reach the upper part of the thigh. Whilst within the pelvis, it gives off no branches: as it passes out of the foramen, it gives two offsets to the obturator external muscle, of which one enters its upper border, the other its anterior surface. From this a filament inclines outwards to the cotyloid notch through which it reaches the hip-joint. On reaching the thigh, the nerve lies deeply between the pectineus and obturator externus muscles, and divides into two branches, one lying on a plane anterior to the other, the adductor brevis being in fact interposed between them.

The *posterior*, or deep branch (plate XXI. l, l), passes backwards, descending behind the adductor brevis, and so reaches the anterior surface of the adductor magnus, to which it is distributed. The *anterior* branch (plate XXIII. i, i) will be observed to



incline downwards and inwards between the pectineus and adductor brevis, and there divide into three offsets, which are distributed to the gracilis, and the long and short adductors. The branch to the gracilis inclines inwards, and runs for some way upon its inner surface before it terminates. The branch to the short adductor runs upon its anterior surface, and divides into filaments which penetrate its substance above its middle; from some of these an offset (k) usually passes to join the saphenous nerve. The branch to the adductor longus, after passing behind the muscle and giving it filaments, descends to the inner side of the thigh, gives a connecting branch to the saphenous nerve, and can be traced to the inner side of the knee, arising from the lumbo-sacral nerve as here indicated.

*Lumbo-sacral nerve.*—The lumbo-sacral, or communicating nerve, (plate XXI. G, G; *nervus lumbo-sacralis*,) is the last offset from the lumbar plexus, and in size is larger than either of the preceding nerves. It is made up of the whole of the anterior branch of the fifth pair, and of the connecting branch sent down from the fourth. It passes backwards in front of the sacro-iliac symphysis to reach the pelvis, where it joins the first sacral nerve, and so contributes to form the sacral plexus, at the same time that it forms the connecting link between it and the lumbar plexus. Before its termination it gives off the gluteal branch, which is the only one that arises from it.

The *gluteal* nerve (plate XXI. H; plate XXII. B: *nervus gluteus superior*) turns outwards beneath the border of the sciatic notch, and above the pyriformis muscle. On reaching the exterior of the pelvis, the nerve immediately divides into filaments, which ramify over the dorsum ilii, supplying the two deep-seated gluteal muscles.

*Sacral nerves.*—The sacral nerves, five, and not unfrequently six in number, arise from the extremity of the medulla spinalis, which, it may be observed, ceases in the adult subject opposite the second lumbar vertebra. The fasciculi which compose the roots of these nerves must therefore descend almost vertically in the sacral canal, to reach the foramina through which they are transmitted; and as they are divided into a number of filaments, proceeding from a root or common point of attachment, they assume that peculiar appearance which has given rise to the term *cauda equina*, usually applied to them with the lower lumbar nerves, which present a like disposition, though in a less marked degree. While yet within the sacral canal, the two roots by which each nerve arises unite to form a common trunk, which soon divides into two branches that take quite an opposite course, one being directed backwards, the other forwards.

The *posterior* branches (plate XXII. A, A) of the four superior sacral nerves, like those of the lumbar set, are much smaller than the anterior. They pass backwards through the posterior sacral foramina, penetrate the tendinous origin of the sacro-lumbalis muscle, to which they distribute filaments in their passage, and become subcutaneous. Each of these branches inclines outwards, lying on the fascia that covers the gluteus maximus muscle, and is finally distributed to the skin covering the nates.

## PLATE XXIV.

The nerves of the anterior aspect of the leg are exhibited in this plate. In fig. 1, the superficial nerves distributed to the integument are seen resting on the deep fascia. In fig. 2, the fascia, with some of the muscles, have been removed to show the deep-seated nerves.

FIG. 1. a, a. The middle cutaneous nerves, branches of the anterior crural. b. The termination of one of the branches of the external cutaneous nerve.

A, A. The internal saphenous nerve.

c, c. Branches of the internal saphenous nerve distributed to the integument around the knee. d. The termination of the internal saphenous nerve on the inner side of the foot and great toe.

B. The musculo-cutaneous nerve piercing the deep fascia.

e. Its internal branch, supplying the great toe and the adjoining side of the second. f. The external branch, supplying the three outer toes and half the second. g. A cutaneous branch distributed over the external ankle.

C. The external saphenous nerve, ramifying on the outer border of the foot.

h. Its branch of communication with the external branch of the musculo-cutaneous.

D. The termination of the anterior tibial nerve, distributed upon the adjoining sides of the great and second toes.

FIG. 2. The deep fascia has been removed, together with the tibialis anticus and extensor proprius pollicis muscles from the front of the leg, and the peroneus longus from the outer side.

No. 1. The lower part of the vastus externus muscle. 2. The tendon of the rectus muscle. 3. The lower part of the vastus internus muscle. 4. The internal lateral ligament of the knee-joint. 5. The patella. 6. The ligamentum patellæ. 7. The tendon of the biceps muscle. 8. The origin of the peroneus longus muscle from the head of the fibula; the rest of the muscle has been removed. 9. The soleus muscle. 10. The peroneus brevis muscle. 11. The extensor communis digitorum muscle. 12. The interosseous membrane. 13. The tibia. 14. One belly of the gastrocnemius muscle. 15. A part of the soleus muscle. 16. The tendon of the tibialis anticus muscle. 17. The tendon of the extensor proprius pollicis muscle. 18. The anterior annular ligament. 19. The peroneus tertius muscle. 20. The lower part of the fibula. 21, 21. The extensor brevis digitorum muscle.

A. The peroneal nerve, (*nervus peroneus*.) B. The musculo-cutaneous nerve; a division of the peroneal nerve.

a, a. Muscular branches distributed to the muscles of the calf.

C, C. The anterior tibial nerve, (*interosseous nerve*, *nervus tibialis anticus*.)

b, b. Its muscular branches. c, c. Branches distributed to the joints of the foot. d, d. Branches distributed to the extensor brevis digitorum muscle. e, e. Interosseous branches. f. The termination of the anterior tibial nerve.

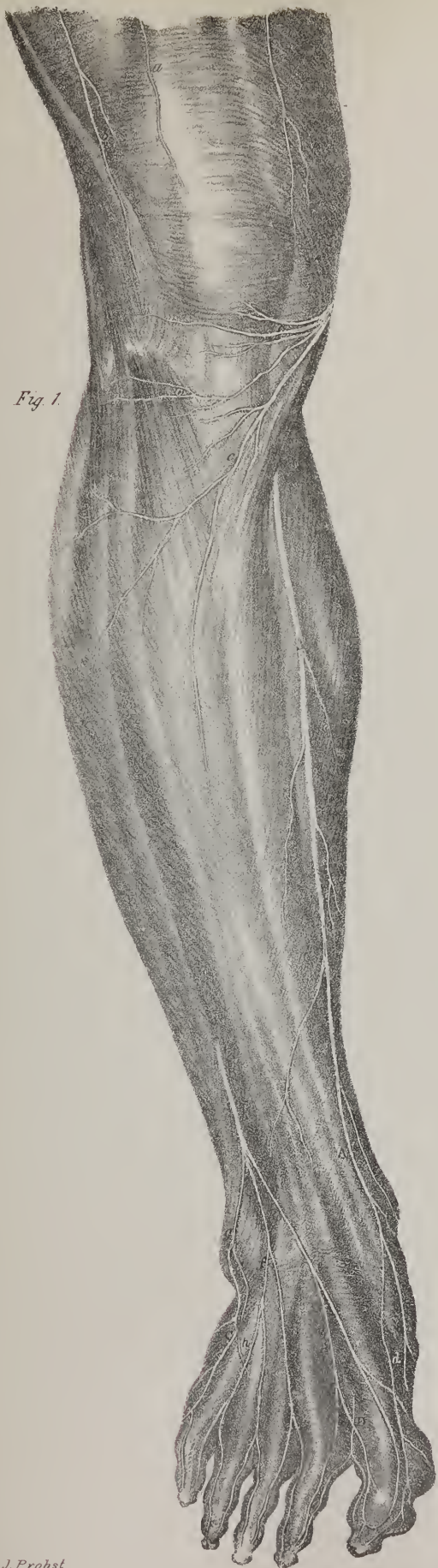


Fig. 1.

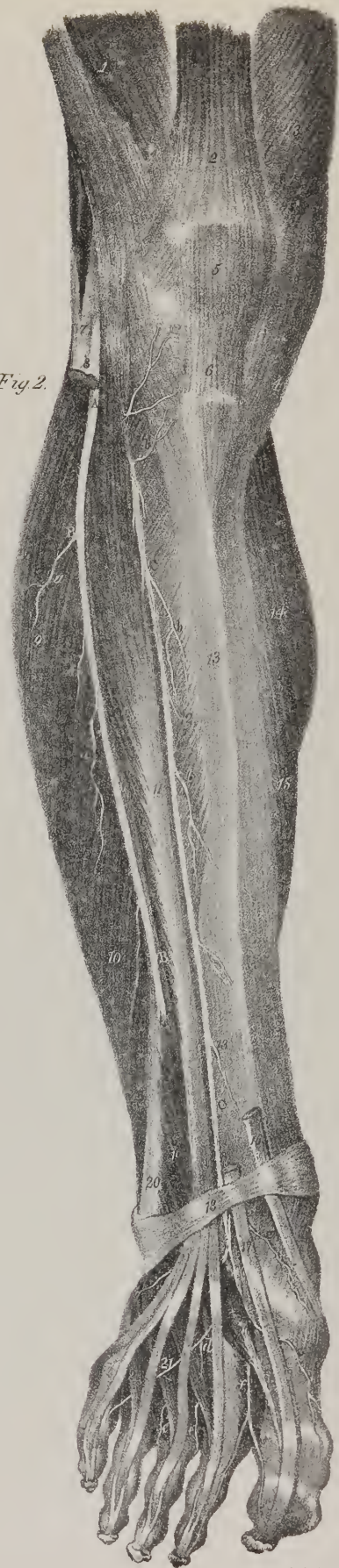

Fig. 2.







Fig. 1.

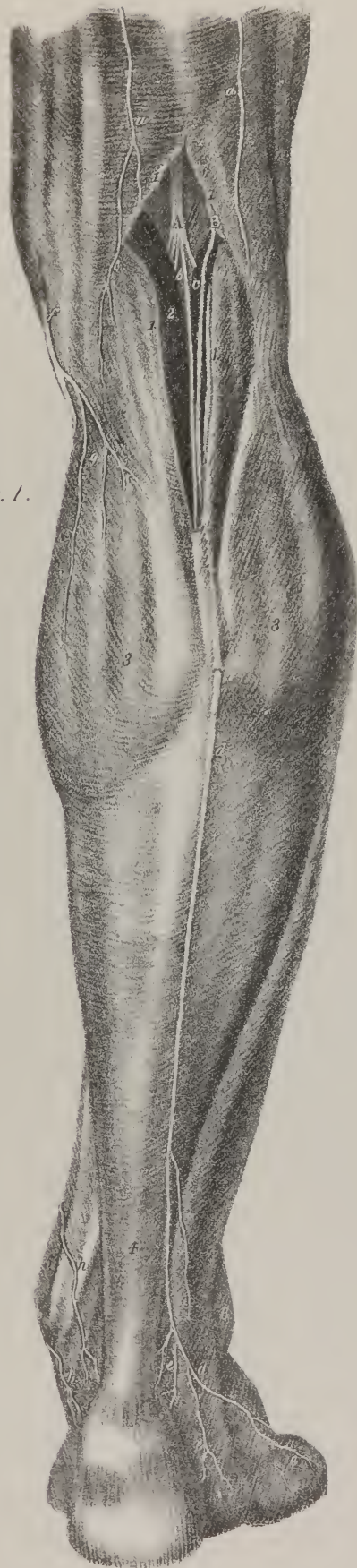
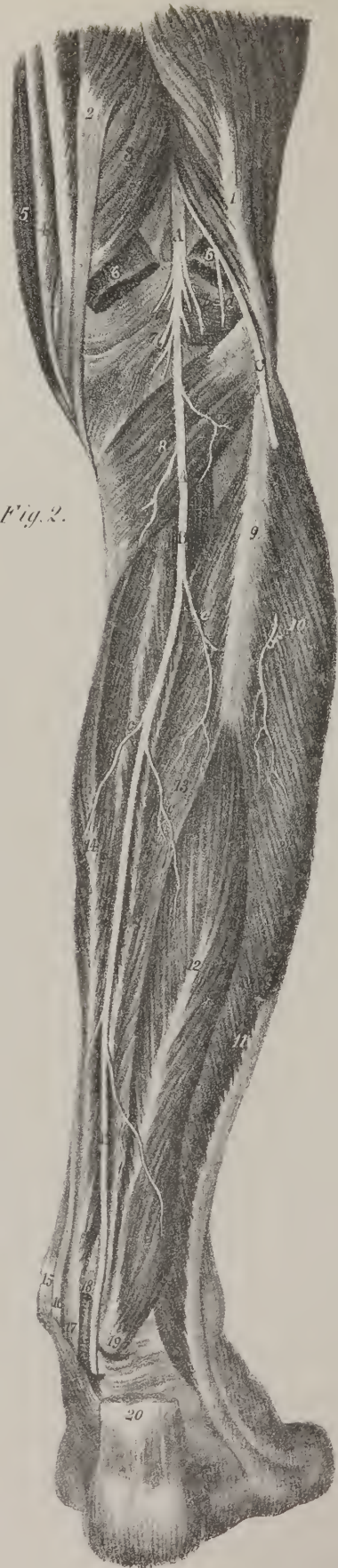
Fig. 2.



The posterior branches of the two last sacral nerves are much smaller than any of the others; they pass downwards and forwards to supply the integuments round the margin of the anus. These several nerves have for the most part a communication from one to the other, each being connected with that which precedes and follows.

The *anterior* branches (plate XXI.; *rami antici*) of the sacral nerves, diminish in size from above downwards. They issue from the spinal canal through the anterior sacral foramina, and immediately each communicates with the neighbouring pelvic ganglion of the sympathetic nerve. The first three sacral nerves passing outwards and uniting with the communicating branch sent down from the fourth and fifth lumbar nerves, and having received some branches from the fourth sacral, form the sacral plexus, not as in other instances, by sending fasciculi from one to the other, so as to constitute an interlacement, but by a union of their fibres, forming a large compressed cord, from which nerves are given off. The anterior branch of the fourth sacral nerve, after passing through the fourth sacral foramen, communicates by a filament with the sympathetic, and gives some offsets, which, with similar branches from the third, go to the hypogastric plexus. It sends some filaments to the levator ani and coccygeus muscles, after which it terminates in the skin about the anus, and in the sphincter ani. The anterior branches of the fifth and sixth sacral nerves are very small, and do not enter into the formation of the plexus: they pass forwards, the first between the sacrum and coccyx, the second in a notch on the side of the latter, and are distributed to the muscles in their immediate neighbourhood, namely, the sphincter ani and coccygeus.

The *sacral plexus*, (plate XXI. I; plexus sacralis, vel ischiadicus,) formed as above stated, is situated deeply at the posterior and lateral part of the pelvis, resting on the surface of the pyriformis muscle, crossed by some of the branches of the internal iliac artery, and covered (particularly at the left side) by the rectum.

The branches of the sacral plexus may be divided into two sets, one internal, the other external; the former (plate XXI. c\*, c\*) consisting of the hæmorrhoidal, vaginal, uterine, vesicle, and pudic, are distributed to the parts in the pelvis and perinæum; the latter, intended for the supply of the lower extremity, are two in number, and are named the small and the great sciatic nerves.

The hæmorrhoidal nerves (*nervi hæmorrhoidales superiores*) pass forward to the lower part of the rectum, and ramify in its muscular coat and mucous lining membrane, from the sphincter upwards to a considerable distance. These nerves interlace with branches of the sympathetic, and communicate with the vesical and vaginal nerves, which occasionally are even given off altogether from them.

*Vaginal and uterine nerves.*—Several slender twigs pass forward by the side of the rectum, and are distributed to the

## PLATE XXV.

In this plate are shown the superficial and deep nerves of the posterior aspect of the leg.

FIG. 1. The deep fascia has been left, covering in the muscles, excepting in the popliteal region, where a small portion has been removed, together with the cellular tissue and fat, in order to bring into view the popliteal nerve.

Nos. 1, 1. The divided edges of the popliteal fascia. 2. Part of the inner head of the gastrocnemius muscle. 3, 3. Convexities formed by the gastrocnemius muscle. 4. The tendo Achillis seen through the fascia. 5. The internal malleolus. 6. The external malleolus, a, a. Posterior cutaneous nerves, branches of the sciatic nerves.

A. The popliteal nerve, (n. popliteus.)

b. A branch of the popliteal nerve; the nervus cutaneus longus posterior, vel communicans tibiæ.

B. The fibular nerve, (n. peroneus.)

c. The communicans fibulæ. d, d. The external saphenous nerve formed by the union of the communicans tibiæ with the communicans fibulæ. e, e. Branches distributed to the outer ankle and outer border of the foot. f. The internal saphenous nerve piercing the fascia and becoming superficial. g. Cutaneous branches to the integument of the calf. h, h. Branches to the inner ankle and side of the heel.

FIG. 2. The superficial layer of muscles has been removed, in order to bring into view the deep layer, and the course and distribution of the posterior tibial nerve.

No. 1. The biceps muscle. 2. The semi-tendinosus. 3. The semi-membranosus muscle. 4. The gracilis muscle. 5. The edge of the sartorius. 6, 6. The divided heads of the gastrocnemius muscle. 7. The ligamentum posticum Winslowii. 8. The popliteus muscle. 9. The upper extremity of the fibula. 10. The peroneus longus muscle. 11. The peroneus brevis. 12. The flexor longus pollicis muscle. 13, 13. The tibialis posticus muscle. 14. The flexor longus digitorum muscle. 15. The inner malleolus. 16. The tendon of the tibialis posticus muscle. 17. The tendon of the flexor longus digitorum. 18. The posterior tibial artery. 19. The tendon of the flexor longus pollicis muscle. 20. The tendo Achillis divided.

A, A. The popliteal nerve, (n. popliteus.)

a, a. Its muscular branches. b. The communicans tibiæ branch cut across.

B, B. The posterior tibial nerve, (n. tibialis posticus.)

c, c. Its muscular branches.

C. The fibular nerve, (n. peroneus.)

d. The communicans fibulæ branch, divided. e. The point at which the fibular nerve passes beneath the head of the peroneus longus muscle. f. A muscular branch from the fibular nerve.



vagina; a few ascending reach the lower part of the uterus, anastomosing with the numerous branches of the sympathetic nerve supplied to that organ.

The vesical nerves, frequently confounded at their commencement with the two preceding series, proceed forwards to the lower part of the bladder, and ramify in its two internal coats. In their course they furnish twigs to the vesiculæ seminales and prostate gland in the male, and the urethra in the female.

The pudic nerve, (plate XXII. C, C; *nervus pudendus*,) is derived principally from the third sacral; it inclines downwards and outwards from the plexus, so as to come into contact with the pudic artery as it is escaping from the pelvis, in the interval between the pyriformis and coeeygeus muscles. Its course and distribution are similar in every respect to that of the artery. In company with it, the nerve returns to the pelvis through the small sciatic foramen, and gives off a superficial branch, (e: perinæal nerve; u. pudendus inferior.) This long branch, ascending on the inner side of the tuber ischii, sends one or frequently more twigs to the sphincter ani and margin of the anus (d: n. hæmorrhoidalis inferior;) then it passes forward along the perinæum, in the interval between the erector penis and accelerator urinæ muscles, and, after furnishing filaments to them and the transversus perinæi, terminates in the dartos and the integuments of the scrotum.

The continuation of the pudic nerve ascends on the rami of the ischium and os pubis, where it gives some filaments to the obturator internus muscle. The nerve in the next place reaches the dorsum of the penis by passing between the corpus cavernosum and the pubic symphysis; after which it passes forwards beneath the skin as far as the glans, where its filaments cease to be discernible; it distributes filaments during its course to the integuments and the urethra.

In the female the pudic nerve presents nearly a like disposition, but the superficial perinæal nerve is larger than the deep-seated one just described, because it is distributed to the labium, whilst the other supplies the clitoris.

The small sciatic nerve, (plate XXII. D; *nervus ischiadicus minor*, v. *gluteus inferior*,) arises from the posterior and lower part of the plexus, from which it inclines backwards and downwards to reach the lower border of the pyriformis muscle, beneath which it escapes from the pelvis. In this situation it will be found on the same plane with the great sciatic nerve, but on its inner side, both resting on the superior gemellus, and covered by the gluteus maximus. Here the nerve receives a short twig from the great sciatic, and may be said to divide into branches, which take different directions; one being directed outwards to the great gluteus, others inwards, and a third set downwards along the thigh. It is, however, more conformable with usage to consider the descending part as the proper continuation of the nerve, and the others as its offsets, or branches. The *inferior gluteal* branches (plate XXII. f, f) may be so called to distinguish them from the superior gluteal nerve, (a branch given from the lumbosacral, or communicating nerve,) from which, at their exit from the pelvis, they are separated by the breadth of the pyriformis muscle. The greater number of these branches are short, as they have merely to turn outwards a little, in order to reach the pelvic surface of the gluteus maximus, to which they are distributed. One of them, however, may be observed to curve round the border of the pyriformis, and proceed obliquely forwards beneath the gluteus, extending as far as its anterior border. 2. A branch (g; *posterior and internal cutaneous*) inclines inwards beneath the tuber ischii, and divides into filaments, some of which are distributed to the gracilis, whilst others pierce the fascia, and become subcutaneous, ramifying in the integument that covers the upper and inner part of the thigh, as well as the perinæum and scrotum or labium. 3. From the posterior surface of the nerve proceeds the *middle cutaneous* branch, (h;) this passes along the anterior surface of the gluteus maximus to its lower border; then, perforating the fascia, it continues to descend, distributing filaments to the skin, as far as the popliteal space, where it terminates. More cutaneous twigs derived from this nerve will frequently be found piercing the fascia at different points, together with others to be presently noticed, which are given off from the great sciatic nerve.

The continuation of the small sciatic nerve, as it descends, inclines inwards, covered by the fascia, and rests on the flexor muscles, to which it distributes branches, in its course towards the inner side of the popliteal space, where it usually ceases.

*Great sciatic nerve.*—The great sciatic nerve, (plate XXII. E: *nervus ischiadicus*, Scemm.; *grand femoro-poplite*, Chauss.) is the largest nerve in the body. From its size and direction it may be considered as the continuation or prolongation of the plexus, it being impossible to determine where the one ceases or the other begins. The fasciculi which enter into its composition are derived from all the nerves which go to form the sacral plexus. Thus formed, the nerve emerges from the pelvis, beneath the lower border of the pyriformis muscle, (a portion sometimes passing through its fibres,) and lies in the interval between the trochanter major and tuber ischii, whence it proceeds almost vertically downwards to the popliteal space. In the upper part of this course it rests against the external rotator muscles, in the rest it is supported by the adductor magnus, and is covered for a short way by the gluteus maximus, and lower down by the flexor muscles of the leg; but in the ham it is placed in the interval between them, embedded in a quantity of adipose substance, and covered only by the fascia and integument. The branches of this nerve are necessarily very numerous:—1. As it emerges from the pelvis it sends a branch to the obturator internus, and another to join the nerve last described. 2. From its posterior surface some filaments pass to the gluteus muscle, whose size and number depend on that of the inferior gluteal branches, derived from the small sciatic nerve, being few and small when the latter are numerous, and *vice versa*; for here, as elsewhere, in the nervous as well as in the vascular system, a principle of compensation obtains, by which, when the supply from one source is considerable, that from another admits of being proportionally diminished. Farther down it gives filaments to the flexor muscles, as they lie over it. From some of these branches, or from the trunk itself,

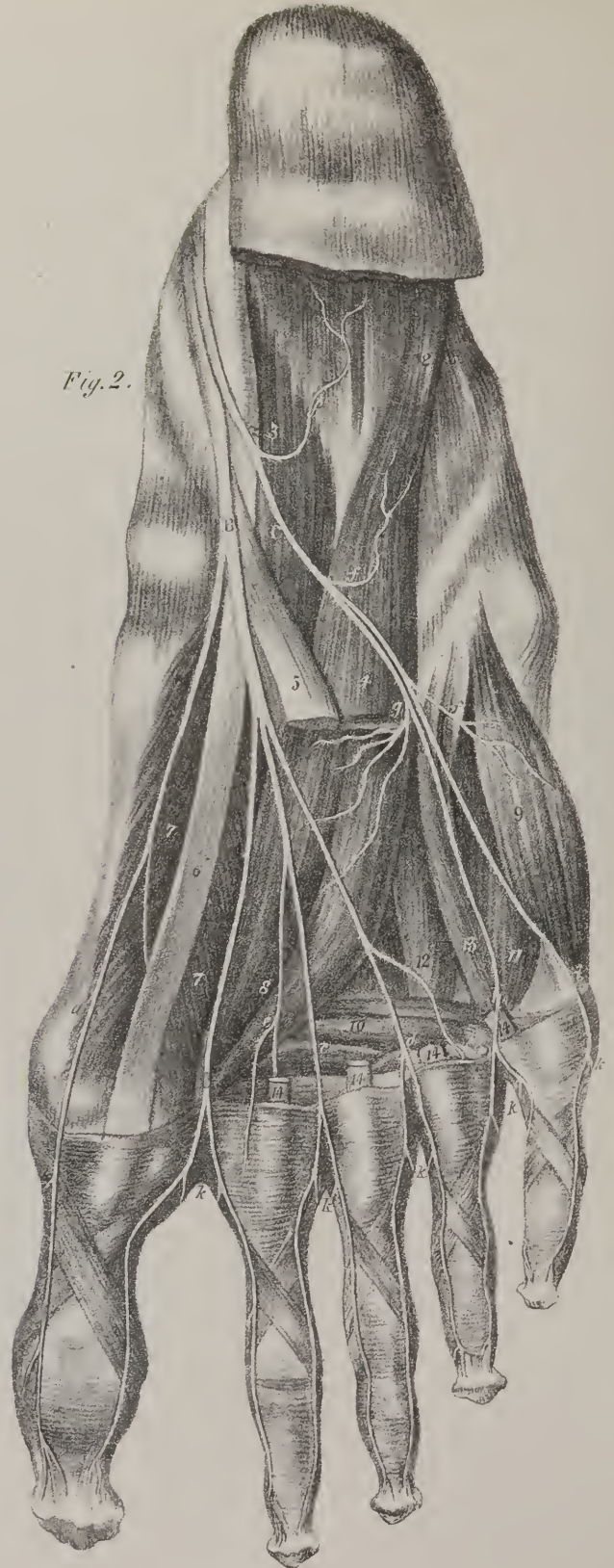




Fig. 1.

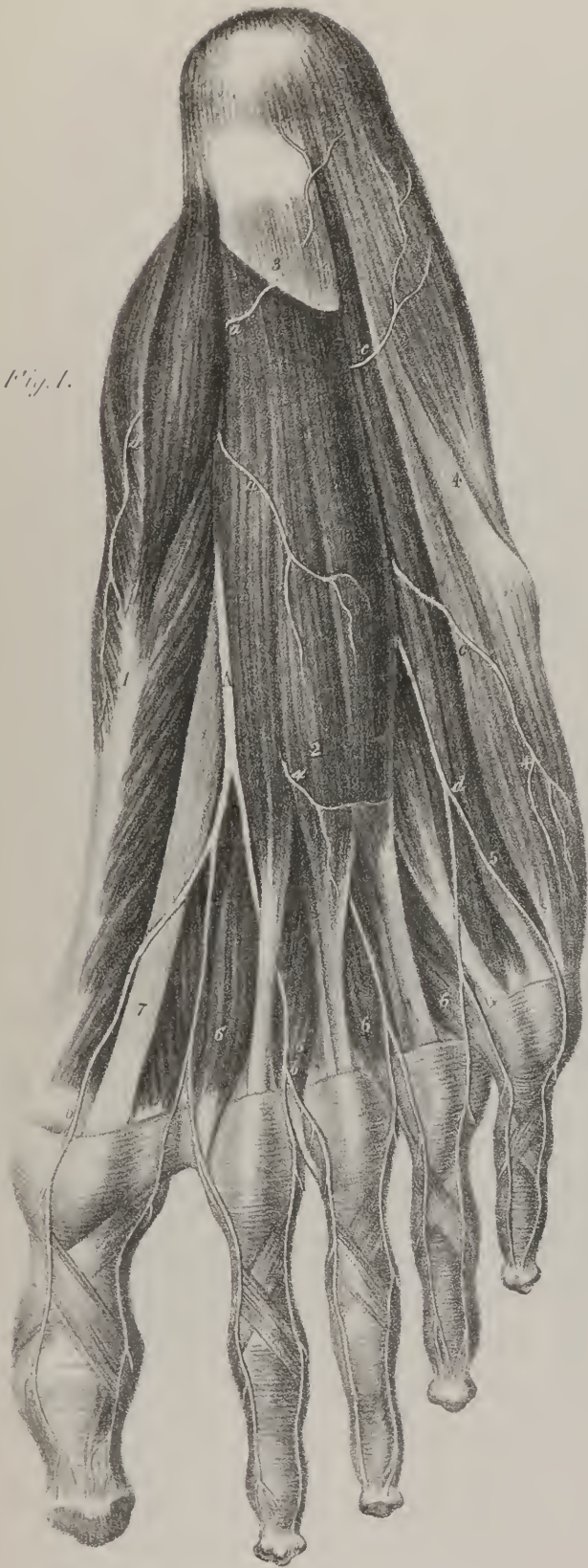

Fig. 2.





one or two others pass backwards, and directly pierce the fascia; after which they proceed down towards the external side of the ham, ramifying in the integuments. These may be termed the posterior and *external cutaneous* branches, (plate XXII. k.) to distinguish them from those that arise from the small sciatic nerve. 3. From its anterior surface branches proceed to supply the external rotators, (plate XXV. fig. 1, a, a, (a filament extending to the capsule of the hip-joint) and the adductor magnus, on which the nerve lies, and some pass outwards to the short head of the biceps muscle.

The sciatic nerve divides, generally about the middle of the thigh, into an external and internal branch,—the latter, in direction and size, being its proper continuation. This division sometimes takes place lower down than the point here indicated, and in many instances much higher,—occasionally even within the pelvis. The internal or larger division lies behind and to the outer side of the popliteal artery, whilst in the popliteal space; hence during that part of its extent it may be called the popliteal nerve. According to the arrangement usually adopted, the nerve is considered as dividing into two branches, viz. the posterior tibial and fibular. But were we to adhere to this division, we should have no popliteal nerve, and it would evidently be a misnomer to speak of the posterior tibial in the popliteal space, and describe its relations to the popliteal artery. When treating of the external division, we cannot avoid this otherwise than by a periphrasis.

The internal or larger division of the sciatic nerve, (plate XXV. figs. 1 and 2, A; *popliteal, nervus popliteus*.) passes directly downwards through the ham, covered by the fascia, and lying posterior and external to the popliteal vessels, from which it is separated by some adipose substance. After having passed below the joint, it rests on the popliteus muscles covered by the gastrocnemius. In this situation it inclines inwards, and, crossing the artery, lies to its inner side. Like the artery, the nerve assumes the name of posterior tibial, (*nervus tibialis posticus*.) when it has passed below the popliteus muscle. In the leg it resumes its original position with regard to the blood-vessels, being again placed externally to them; here it lies on or rather behind the tibialis posticus and flexor communis muscles, covered by the deep fascia which separates it from the soleus. Gradually inclining to the inner side of the leg, the posterior tibial nerve, as it descends, passes through that arched interval which separates the inner ankle from the calcaneum, and like the artery which it accompanies, divides into its two terminal branches, viz. the internal and external plantar.

In this course the nerve gives several branches to supply the muscles along which it passes. A branch of considerable size (plate XXV. fig. 1, b; *nervus cutaneus longus posterior, vel communicans tibiæ*, Sæmm.) runs directly downwards between the heads of the gastrocnemius, and then over the posterior surface of that muscle, gradually inclining outwards to reach the external border of the tendo Achillis. In this course the nerve accompanies the external saphenous vein; and about the middle of the calf of the leg, or sometimes lower down, it joins with a corresponding branch (c) sent from the fibular nerve. The nerve resulting from this union may be called *external saphenous* (d, d); with the vein so named it passes down behind the external ankle, so as to reach the dorsum of the foot, where it divides into two branches, one running on the fourth, the other on the fifth metatarsal bone, and distributing filaments as far as the corresponding digital phalanges. The branch here described lies beneath the fascia in its course down the leg, but at different intervals sends through it filaments which ramify in the integuments, some

## PLATE XXVI.

In this plate the distribution of the plantar nerves to the sole of the foot is exhibited.

FIG. 1. The superficial layer of muscles, the plantar fascia having been removed.

No. 1. The abductor pollicis muscle. 2. The flexor brevis digitorum. 3. Part of the plantar fascia. 4, 4. The abductor minimi digiti muscle. 5. The border of the flexor brevis digiti minimi. 6, 6. The lumbricales muscles. 7. The tendon of the flexor longus pollicis.

A. The internal plantar nerve, (n. plantaris internus.)

a, a. Muscular branches. b, b. Digital branches. c, c. Muscular branches of the external plantar nerve. d. The digital branch of the external plantar nerve.

FIG. 2. A deep view of the sole of the foot; the superficial and part of the middle layer of muscles have been removed.

No. 1. The os calcis, with the attachment of the superficial layer of muscles. 2. The external head of the flexor accessorius muscle. 3. Its internal head. 4. The flexor accessorius cut across. 5. The common tendon of the flexor longus digitorum muscle. 6. The tendon of the flexor longus pollicis. 7, 7. The flexor brevis pollicis muscle. 8. The adductor pollicis. 9. The flexor minimi digiti muscle. 10. The transversus pedis muscle. 11. The third plantar interosseous muscle. 12. The second plantar interosseous. 13. The fourth dorsal interosseous muscle. 14, 14. The divided tendons of the flexor longus digitorum muscle. 15. The projection of the tendon of the peroneus longus muscle in its course across the foot.

A. The posterior tibial nerve, (n. tibialis posticus.) B. The internal plantar nerve, (n. plantaris internus.)

a. The first digital branch supplying the inner side of the great toe. b. The second digital branch supplying the adjoining sides of the great and second toes. c. The third digital branch supplying the adjoining sides of the second and third toes. d. The fourth digital nerve supplying the third and fourth toes. e. A muscular branch.

C. The external plantar nerve, (n. plantaris externus.)

f, f. Its muscular branches. g. Its deep branch. h. A digital branch supplying the adjoining sides of the fourth and fifth toes. i. The external digital branch distributed to the outer side of the little toe. k, k. Digital filaments to the dorsal surface of the toes.

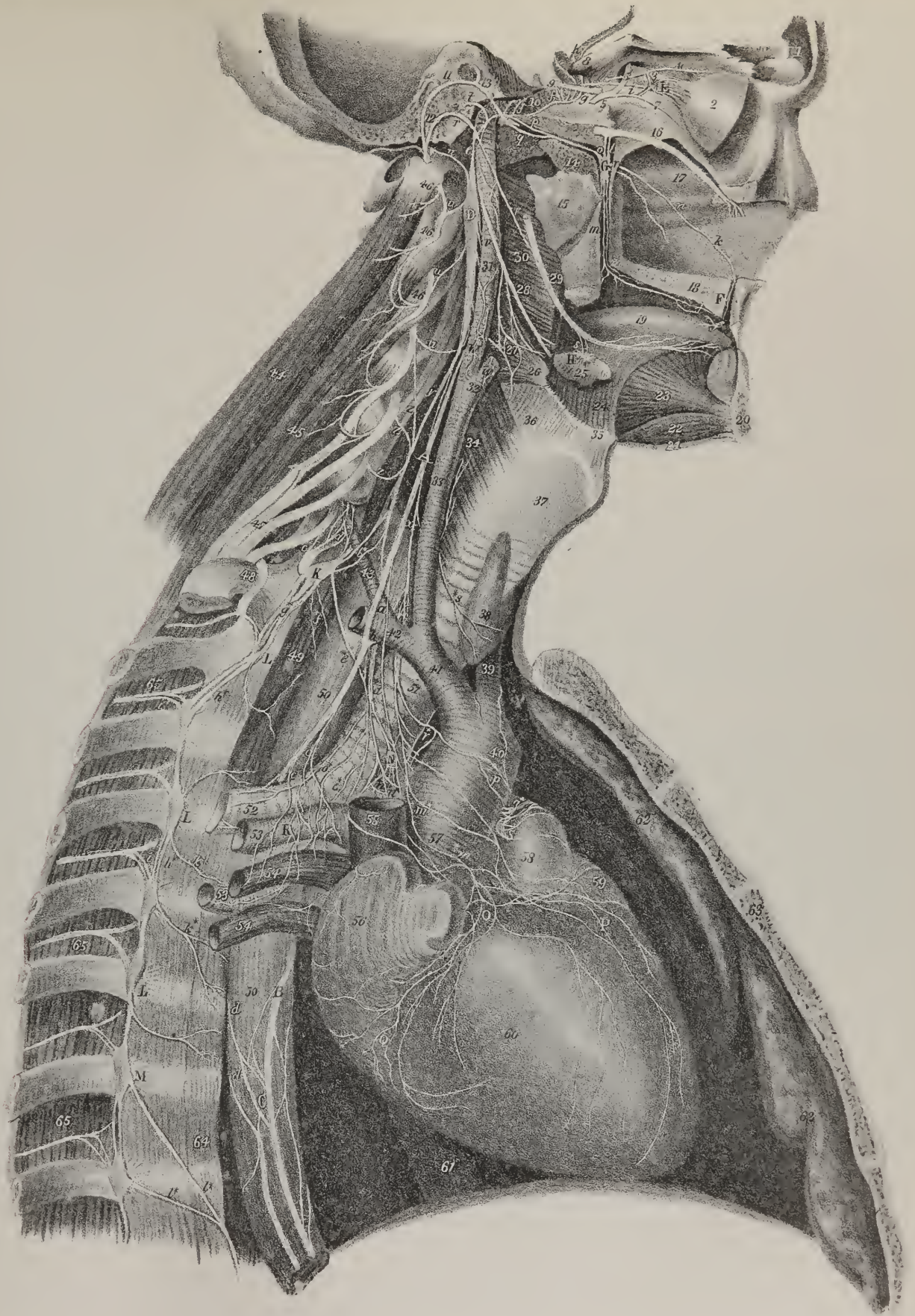
of them descending as far as the bend of the ankle. Several muscular branches proceed from the nerve to the heads of the gastrocnemius, the plantaris, popliteus, and soleus muscles; and in the lower part of its course it supplies the tibialis posticus, and the long flexors, its filaments diverging and uniting again so as in some places to form a mesh round the posterior tibial artery.

## PLATE XXVII.

Sympathetic nerve. The course and distribution of the sympathetic nerve in the upper half of the body. The distribution of the pneumo-gastric nerve on the right side is also shown.

- No. 1. Section of the frontal bone through the frontal sinuses. 2. The posterior half of the globe of the eye. 3. The optic nerve. 4. The nasal branch of the ophthalmic nerve. 5. The trunk of the third nerve, (n. motor oculi.) 6. The ascending branch of the third nerve. 7. Its inferior branch. 8. The anterior clinoid process of the sphenoid bone. 9. Part of the sixth nerve, (n. abducens.) 10. The internal carotid artery lodged in the carotid canal. 11. A section of the petrous portion of the temporal bone. 12. The facial nerve, (portio dura,) descending through the aqueductus Fallopii to the stylo-mastoid foramen. 13. The angular swelling upon the facial nerve at the point where it is joined by the petrosal branch of the Vidian nerve. 14. A section through the root of the pterygoid process of the sphenoid bone, showing the Vidian canal. 15. Part of the external pterygoid plate of the sphenoid bone. 16. The superior maxillary nerve. 17. The septum narium. 18. Section of the hard palate. 19. The tongue. 20. Section through the symphysis of the lower jaw. 21. The cut edge of the mylo-hyoideus muscle. 22. The genio-hyoideus muscle. 23. The genio-hyo-glossus muscle. 24. The hyo-glossus muscle. 25. The submaxillary gland. 26. A part of the middle constrictor. 27. The pharyngeal plexus of nerves. 28. The glosso-pharyngeal nerve. 29. The gustatory branch of the fifth nerve. 30. The superior constrictor muscle. 31. The internal carotid artery. 32. The external carotid artery cut short. 33. The common carotid. 34. The origin of the inferior constrictor muscle, upon which is seen ramifying a branch of the recurrent nerve. 35. The os hyoides. 36. The thyro-hyoidean membrane. 37. The thyroid cartilage. 38. The thyroid gland. 39. The left carotid artery. 40. The arch of the aorta. 41. The arteria innominata. 42. The right subclavian artery. 43. The vertebral artery. 44. The levator anguli scapulae muscle. 45. The scalenus posticus muscle. 46, 46. The second, third, and fourth cervical nerves. 47. The brachial plexus of nerves. 48. The ascending division of the first dorsal nerve, joining the brachial plexus. 49. The lower part of the longus colli muscle. 50, 50. The oesophagus. 51. The trachea. 52. The right bronchus. 53, 53. Branches of the right pulmonary artery. 54, 54. Right pulmonary veins. 55. The trunk of the superior vena cava cut off near the auricle. 56. The right auricle. 57. The ascending aorta. 58. The pulmonary artery. 59. The tip of the appendix of the left auricle. 60. The right ventricle. 61. The inferior vena cava. 62, 62. The two lobes of the left lung. 63. Section of the sternum. 64. The anterior common ligament of the vertebral column. 65, 65. Intercostal nerves.
- A. The right pneumo-gastric nerve.
- a. A cardiac branch from the pneumo-gastric nerve. b. The point at which the recurrent nerve is given off from the pneumo-gastric; the recurrent may be seen quitting the nerve to ascend behind the subclavian artery. c, c. Branches descending to form the anterior pulmonary plexus with the assistance of branches from the great cardiac plexus.
- B. The left pneumo-gastric nerve. C. The oesophageal plexus.
- d, d. Branches of the right pneumo-gastric nerve passing forwards to join the oesophageal plexus.
- D. The superior cervical ganglion of the sympathetic nerve.
- e. Its ascending branch, dividing to embrace the internal carotid artery in the carotid canal. f, f. The carotid plexus. g. Two branches from the carotid plexus to join the sixth nerve. h. Sympathetic filaments ascending from the carotid plexus along the anterior cerebral artery to communicate with the ganglion of Ribes.
- E. The ciliary or lenticular ganglion, giving off ciliary branches to the globe of the eye, 2. It sends a branch of communication to the nasal nerve, 4; and another to the inferior branch of the third nerve, 7.
- i. A branch of communication to the carotid plexus.
- F. The naso-palatine ganglion, (Cloquet's ganglion.)
- j. Anterior palatine branches. k. The filament of communication with Meckel's ganglion.
- G. The sphenopalatine ganglion, (Meckel's.)
- l. Two ascending branches of communication with the superior maxillary nerve, 16. m, m. Descending branches; posterior palatine nerves. n, n. Anterior branches; sphenopalatine, or nasal nerves. o. Posterior branch; the Vidian nerve. p. Its carotid branch. q. Its petrous branch. r, r. The chorda tympani nerve. s. The chorda tympani, with another nervous filament, quitting the gustatory nerve to communicate with the submaxillary ganglion, H.
- t. The nervus petrosus superficialis minor, a filament from the carotid plexus going to unite with the tympanic nerve on the inner wall of the tympanum. u, u. Branches of communication from the superior cervical ganglion to the upper cervical nerves. v, v. Internal branches to communicate with the pneumo-gastric nerve, and to assist in forming the pharyngeal plexus, 27. w, w. Nervi molles, accompanying the internal and external carotids. x, x. The superior cardiac nerve, (n. superficialis cordis.) y. The cord of communication between the superior cervical ganglion, D, and the middle cervical ganglion, I.
- I. The middle cervical ganglion, (thyroid ganglion.)
- z, z. Filaments of communication with the fifth, sixth, and seventh cervical nerves. a\*, a\*. The middle cardiac nerve, (n. cardiacus magnus.) b\*. Cord of communication with the third cervical ganglion.
- K. The third cervical ganglion; brought into view by drawing the vertebral artery, 43, to one side.
- c\*. A filament of communication with the eighth cervical nerve. d\*. Filaments which ascend with the vertebral artery through the foramina in the transverse processes of the cervical vertebrae to accompany its branches. e\*. The inferior cardiac nerve. f\*. Two small filaments distributed to the posterior mediastinum. g\*. Communicating filaments with the first dorsal ganglion.









Some filaments are also distributed on the ligaments at the ankle, and on the bursa and fascia near the insertion of the tendo Achillis.\*

When arrived at the hollow of the calcaneum, and lying under cover of the abductor pollicis muscle, the posterior tibial nerve sends off a filament which ramifies in the integuments of the sole of the foot, previously to its division into the internal and external plantar branches.

*Internal plantar nerve.*—The internal plantar nerve, (plate XXVI. fig. 1, A; fig. 2, B: *n. plantaris internus*), the larger of the two, passes directly forwards beneath the tarsal bones, concealed by the abductor pollicis muscle, to which, as well as to the flexor accessorius and flexor brevis, it gives branches. It soon divides into, or gives off, four branches, intended to supply both sides of the great toe, and of the two next to it, as well as the inner side of the fourth. The first ramusculus (fig. 2, a) is smaller than any of the others; it proceeds forwards and inwards beneath the flexor brevis pollicis, to reach the inner side of the great toe, forming its first collateral branch: the second (b), as it passes forwards, corresponds with the interval between the first and second metatarsal bones, where it gives filaments to the flexor brevis and the first lumbricalis, and, on reaching the fissure between the toes, divides into two offsets, which run along the contiguous borders of the first and second toes: the third (c) lies in the second metatarsal space, supplies the first plantar interosseous muscle, and, like the preceding branch, divides into two parts to supply the external border of the second toe, and the adjacent one of the third: the fourth ramusculus (d) follows a similar course and distribution with regard to the third metatarsal space, and the digital phalanges of the third and fourth toes; it also joins with, or receives a filament from, the superficial branch of the external plantar nerve.

*External plantar nerve.*—The external plantar nerve (plate XXVI. fig. 2; *n. plantaris externus*) proceeds forwards and outwards, lying between the flexor accessorius and flexor brevis digitorum. In this course it gives a branch which passes to the external border of the foot, and is distributed to the abductor minimi digiti; after which it divides into two branches, one being intended to complete the digital branches of the toes, the other to supply the deep-seated muscles in the sole of the foot. 1. The first of these, on reaching the extremity of the fifth metatarsal bone, sends along the outer border of the foot and of the little toe a collateral branch, similar to that which is given to the great toe by the internal plantar nerve. The continuation of the branch may be observed to correspond with the fourth metatarsal space, where it communicates by an oblique filament with the internal plantar nerve; after which it proceeds to the heads of the metatarsal bones, and divides into branches, which supply the external border of the fourth toe, and the adjacent one of the fifth. 2. The deep branch (g) sends outwards a filament to the flexor of the little toe, and then proceeds almost directly forwards into the sole of the foot, where it divides into branches which supply the abductor pollicis, the interossei, and transversus pedis muscles.

*Fibular nerve.*—The external division of the great sciatic nerve (plate XXV. fig. 1, B; fig. 2, C: *nervus peroneus, ramus peroneus nervi femoro-poplitei*) inclines outwards as it descends from the point of division towards the external condyle of the femur, to which it is guided by the border of the biceps muscle. It then proceeds obliquely forwards, lying in the interval between the external head of the gastrocnemius and the biceps, and reaches the posterior surface of the head of the fibula, where it may with propriety be named *fibular* or *peroneal*. The nerve continues to descend for a short way between the external surface of the bone and the peroneus longus muscle, where it is usually said to divide into two branches, one being named anterior tibial, the other the musculo-cutaneous. But as the latter, in size and direction, represents the continuation of the nerve, we shall so consider it, and treat the former as a branch, more especially as from its relations and course it is analogous to the interosseous branch in the fore-arm. The peroneal nerve (plate XXIV. fig. 2, B, B), as it passes downwards, lies between the peroneus longus and the extensor communis, and afterwards between the latter muscle and the peroneus brevis, giving branches to each. Towards the middle of the leg, it (fig. 1, B) escapes from under cover of the muscles, much diminished in size, descends for some

L, L. Dorsal ganglia of the sympathetic.

h\*, h\*. Cords of communication between the ganglia. i\*, i\*. Filaments of communication with the intercostal nerves. k\*, k\*. Internal or aortic branches.

l\*, l\*. The two first branches that go to form the great splanchnic nerve.

N. The great cardiac plexus.

m\*, m\*. Filaments which descend in front of the ascending aorta to assist in forming the anterior cardiac plexus, O.

P. The anterior or left coronary plexus. Q. Filaments which follow the course of the right coronary artery to the posterior aspect of the heart, where they assist in forming the posterior coronary plexus.

n\*. Filaments which descend upon the posterior aspect of the heart, and form the posterior cardiac plexus. o\*, o\*. Filaments which assist in forming the anterior pulmonary plexus, R. p\*. Filaments which descend in front of the arch of the aorta to communicate with branches of the cardiac ganglion, q\*.

S. One extremity of the cardiac ganglion.

r\*. Branches from the cardiac nerves of the left side joining the great cardiac plexus. s\*. A filament from the nervus superficialis cordis to the thyroid gland.

\* Demonstration of the Nerves, by Mr. Swan.

way beneath the fascia, and divides into two branches—one being a little external to the other. The *external* branch (fig. 1, f), lying between the fascia covering the extensor tendons and the skin, passes over the bend of the ankle and dorsum of the foot, and divides into three ramusculi on reaching the latter situation. One of these is directed forwards, corresponding with the fourth metatarsal space, and ramifies in filaments on the dorsum of the little toe and outer border of the foot. In the latter situation its place is not unfrequently supplied by the external saphenous nerve. The next ramusculus passes along the interval between the fourth and third toes, supplying both; whilst the third, or most internal of them, is similarly disposed of on the phalanges of the third and second toes. The *internal* branch (fig. 1, e), is directed towards the base of the first metatarsal bone, on which, after having given some filaments to supply the inner border of the foot, it divides into two ramusculi, which ramify on the upper surface of the first and second toes.

*Branches of the peroneal nerve.*—The peroneal nerve sends, in the popliteal space, a branch which supplies the short head of the biceps muscle, and terminates on the ligaments of the outer side of the knee-joint. Its chief branches, taken in their order from above downwards, are as follows:

1. A considerable branch (plate XXV. fig. 1, c) is given off in the popliteal space, which descends between the external head of the gastrocnemius and the fascia, sending at intervals some branches which pierce the latter to supply the integuments. It finally divides into two or three branches, some of which ramify on the external side of the leg, whilst one joins with the superficial branch of the posterior tibial nerve, to form with it the communication alluded to in the description of the latter.

2. The anterior tibial, or interosseous nerve, (plate XXIV. fig. 2, C, C; *n. tibialis anticus*;) immediately after its origin below the head of the fibula, turns forwards and inwards between the surface of that bone and the peroneus longus and extensor communis muscles, giving branches to both. On reaching the interosseous ligament, it lies to the external side of the anterior tibial artery, but as it descends it inclines somewhat in front of that vessel, and so passes beneath the annular ligament of the ankle-joint to gain the dorsum of the foot. In this course the nerve gives off filaments to the muscles between which it lies, viz. the extensor proprius pollicis and tibialis anticus, and finally terminates in the situation just referred to by dividing into two ramusculi, of which one passes forwards and supplies the extensor digitorum brevis, and some of the interossei a few of its filaments uniting with the terminal branches of the peroneal nerve. The other division proceeds inwards over the first metatarsal bone, and ramifies on the first and second toes.

3. Several muscular branches are given by the peroneal nerve, in the upper part of the leg, to the peronei and extensor muscles; and, finally,

4. Some small cutaneous branches, which pass down towards the external ankle.

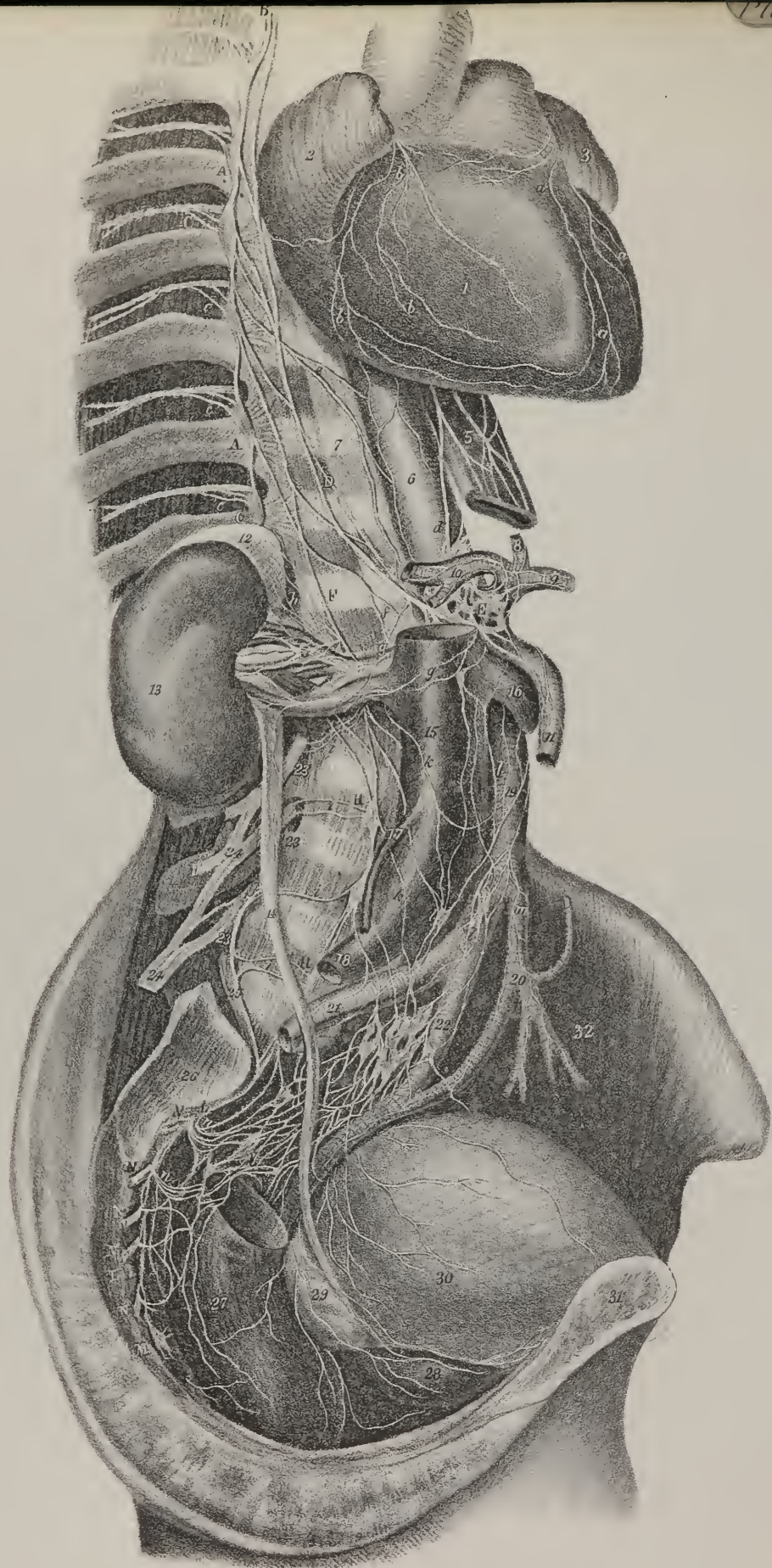
*Sympathetic nerves.*—The sympathetic nerves (*nervi intercostales; nerfs de la vie organique*, Bichât) form a system by themselves, characterised by many peculiarities which distinguish them from those nervous cords which are connected with the brain and the spinal cord. They extend from the cranium to the pelvis, lying along the vertebral column, and present a chain of ganglia connected by nervous filaments. In the infancy of anatomy the term “ganglion” was used to denote a swelling in the sheath of tendons, and even at the present day it is not unfrequently employed in the same sense. It was subsequently applied to the knotted appearance presented by certain nerves; but of late years a considerable latitude has been given to its signification by Gall and Spurzheim, who include within its comprehension the several masses of eideritious substance enclosed within the spinal cord and the brain, and which, according to their theory, are considered “ganglia of increase” to the formative fibres of the cerebral hemispheres.

Nervous ganglia may be divided into two orders: 1. Those observable on the posterior roots of the cerebro-spinal nerves, including that of the fifth nerve, as well as the swelling on the nervus vagus and glosso-pharyngeal. To this group may be added those connected with the branches of the cerebro-spinal nerves, such as the ophthalmic, otic, sphenopalatine, sub-maxillary, and naso-palatine ganglia. 2. The ganglia of the sympathetic nerves.

To the latter we confine our attention in the present section. Previously to Bichât's time, the sympathetic was considered as a nerve derived from the brain, and extended along the spinal column, presenting at stated intervals small knots or enlargements, but without interruption to its continuity. Bichât, however, supposed that the ganglia formed so many separate centres of nervous influence, and that each was connected with those near it by cords of communication. In this view of the matter, the sympathetic nerves may be compared to two chains, each made up of a number of separate links. The question then arises, whether the nervous filaments pass uninterruptedly through the ganglia or not? Lobstein examined a portion of the cord after having subjected it to maceration for a long time, and found that the filaments which issue from the first cervical ganglion passed without any interruption through the second and third, down to the first thoracic ganglion; moreover, that they continue still through the second, third, and fourth of this series, lying towards the inner side of each, mixed somewhat with other filaments, though not in any way interrupted. But what, it will be asked, are the “other” filaments here alluded to as being extraneous to those which pass down through the ganglia? Are they the terminations of the branches derived from the cerebro-spinal nerves, according to the views of some anatomists, or the commencement of those which are given off from the ganglia to these nerves, according to others? This is altogether an open question—no answer can as yet be given to it. Each ganglion is invested by a thin investment of cellular tissue, which connects it with the surrounding structures,









and forms a nidus for the vessels which supply its proper substance; but when this is removed, another lamella is found, forming an envelope for the filaments which enter and depart from the ganglion, as well as for that body itself. After long continued maceration, we find the ganglion composed of delicate filaments, continuous at one extremity with the cord which enters it, and at the other with that which issues from it. The filaments seem as if unravelled, the interstices between them being filled with a greyish, semi-transparent, pulpy substance, which may be considered the peculiar matter of the ganglion. It has been supposed similar, if not identical with the cineritious substance of the brain; but that remains to be determined by future inquirers.

At one time the nervous cord now under consideration was said to arise from the sixth cerebral nerve, by filaments which pass down from it as it crosses the cavernous sinus; so that it would appear to be derived from the brain through the medium of the nerve just named. Some assign it a great number of roots derived from the spinal nerves, inasmuch as each of them is connected with it by filaments which appear to issue from them as they pass out of the intervertebral foramina. Were this opinion tenable, the sympathetic nerve may be likened to a creeping plant, which as it elongates acquires new joints, each of which takes root so as to form a new centre of increase. But we cannot now view the matter in this light. It is not at all correct to say, that this nervous cord arises, or starts from, or begins at, the sixth nerve; and nothing but the imperfection of language can justify the expressions, "the nerve arises from and proceeds to," or "the nerve gives off a branch which goes to form a plexus or a ganglion;" for every nerve, vessel, ganglion, or muscle—every organized part or structure, whether a compound organ or a simple filament—is secreted and deposited in its proper place by its own vessels, and no such elongation of it does or can take place as is implied by the phrase, "it arises above, proceeds down, and terminates in such a manner." Now, as to the sympathetic nerve, so far from being in any way derived from the brain or the spinal cord, it is produced independently of either, and exists notwithstanding the absence of both. It is found perfectly formed in acephalous infants, therefore does not arise mediately or immediately from the brain; neither can it be said to receive roots from the spinal cord, for it is known to exist as early in the foetal state as the cord itself, and to be fully developed even though the latter be altogether wanting.

It appears that whilst the organs of vegetative life are being formed, the sympathetic nerves are produced concurrently with them, and that as the growth of these parts proceeds from the circumference to the centre, and of the whole body from its lateral parts to the median line, the sympathetic nerves also conform to this general law. The two cords which represent them are placed one at each side along the sides of the spine; branches of communication connect them, on the one hand, with the ganglia and plexus along the middle line in front of the spine, and on the other with the nerves of animal life. Thus we see that the

## PLATE XXVIII.

The sympathetic nerve of the right side in the lower half of the body.

No. 1. The right ventricle of the heart. 2. The right auricle. 3. The left auricle.

a, a. Some filaments of the anterior coronary plexus. b, b. Filaments of the right coronary plexus.

A, A. The dorsal portion of the sympathetic nerve. B. The sixth dorsal ganglion. C. The twelfth dorsal ganglion.

c, c. Communicating branches to the intercostal nerves, 4, 4.

D. The greater splanchnic nerve, (nervus splanchnicus major.) E. The right semilunar ganglion.

d. A large branch of communication between the right pneumo-gastric nerve and the semilunar ganglion.

5. The œsophagus, with part of the œsophageal plexus. 6. The thoracic aorta. 7. The anterior common ligament.

e. A small aortic branch from the sympathetic, communicating with other aortic filaments derived from the dorsal ganglia of the left side.

8. Filaments accompanying the coronary artery of the stomach, and forming the coronary plexus. 9. The splenic artery, with a part of the splenic plexus. 10. The hepatic artery, with a part of the hepatic plexus. 11. The superior mesenteric artery, upon which are seen ramifying some filaments of the mesenteric plexus.

F. The lesser splanchnic nerve, (nervus splanchnicus minor.) G. The renal plexus ramifying upon the renal vessels.

f. A branch from the lesser splanchnic nerve to communicate with the semilunar ganglion. g, g. Filaments from the semilunar ganglion to the renal plexus. h. Filaments from the renal plexus to the renal capsule.

12. The renal capsule. 13. The right kidney. 14. The ureter. 15. The inferior vena cava. 16. The left renal vein. 17. The right spermatic vein. 18. The common iliac vein. 19. The abdominal aorta. 20. The inferior mesenteric artery. 21. The right common iliac artery. 22. The left common iliac artery.

H, H. The lumbar portion of the sympathetic.

i, i. Filaments of communication with the anterior branches of the lumbar nerves, 23, 23.

24, 24. The lumbar plexus. 25. The lumbo-sacral nerve.

k, k. Filaments of communication with the aortic plexus. l, l. The aortic plexus. m. The inferior mesenteric plexus.

I. The hypogastric plexus. K, the right lateral portion of the hypogastric plexus, receiving branches from the sacral nerves and sacral ganglia. L, L. The sacral portion of the sympathetic nerve. M. The terminal or azygos ganglion, (ganglion impar.) N, N. Sacral nerves.

n, n. Branches from the sacral nerves communicating with the lateral portion of the hypogastric plexus.

26. The articulating surface of the sacrum. 27. The rectum. 28. The prostate gland. 29. The vesicula seminalis. 30. The urinary bladder. 31. The symphysis pubis. 32. The iliacus internus muscle of the left side.



sympathetic nerves, though forming a system in themselves, present two parts—1. one consisting of the ganglia and plexus in immediate connexion with the different organs, and placed in front of the spine, hence named prævertebral, viz. the semilunar ganglia in the abdomen, (and the plexus in connexion with it, viz. the mesenteric, hepatic, stomaclic, aortic, &c.,) the cardiac ganglion and pulmonary plexus in the thorax, and the pharyngeal plexus in the neck; 2. and another, represented by the two knotted cords extended along the sides of the spine connected with the preceding by numerous branches, and also with the nerves of animal life, being, as it were, interposed between the vegetative and the animal sphere, and most likely constituting the bond of sympathy between both, as well as between the different individual parts of the former.

When we examine these lateral cords, we find that they present each twelve knots or ganglia in the thorax, five in the abdomen, and four along the sacrum, with a single or azygos one at the extremity. So far they appear to correspond with the pieces of the spine. Seeing this in three regions of the body, we should be disposed to expect a similar conformity in the cervical and cranial parts. We should perhaps be prepared to find the chain extended from the thorax along the cervical vertebræ, not in front, but at the sides of the bodies of the vertebræ, and therefore concealed from view by being enclosed within the foramina of the transverse processes. And in the cranial region we should feel disposed to keep up the analogy, by considering what is called the first or great cervical ganglion, as that which corresponds with the first cranial piece (the occipital bone); the spheno-palatine ganglion as being in relation with the second cranial piece; the ophthalmic with the third; and the naso-palatine as the counterpart at the anterior extremity of the osseous structure of the system, with the azygos already stated to exist at the extremity of the coccyx. Such a correspondence as this, however, cannot be fairly established. In the cranial region they approach to it as near as could be expected, considering the difference of form and development between the cranial and dorsal pieces: but in the neck we find but three ganglia, which are thrown forwards and out of line, so as to rank with the prævertebral

## PLATE XXIX.

The anatomy of the appendages of the eye is shown in this plate.

FIG. 1. The eye-brow, (supercilium;) eye-lids, (palpebræ;) eye-lashes, (cilia;) plica semilunaris, and caruncula lachrymalis, are seen in this figure, together with the front surface of the eye-ball. The dark circular hole in the centre of the transparent part of the eye is the pupil, and the surrounding disk the iris.

FIG. 2. The eye-lashes have been removed, to show that they are implanted in a triple row.

No. 1. The three rows of small openings for the passage of the cilia in the upper lid. 2. The three rows of openings for the cilia in the lower lid. The larger openings, placed in a single row near the edge of the lids, are the terminations of the Meibomian follicles. 3. The outer angle, (canthus,) of the eye. 4. The inner canthus. 5, 5. The lachrymal tubercles, upon which are seen the openings, (puncta lachrymalia,) of the lachrymal ducts. 6. The plica semilunaris, a small fold of the conjunctiva. 7. The caruncula lachrymalis.

FIG. 3. An internal view of the eye-lids.—(From Sæmmering.)

Nos. 1, 1. The inner surface of the orbicularis palpebrarum muscle. 2, 2. The conjunctiva lining the inner surface of the eye-lids. 3, 3. Slight elevations upon the inner surface of the lids, formed by the projection of the Meibomian follicles. The semilunar outline of the two lids results from the form of the tarsal cartilages. 4, 4. The lachrymal tubercles, upon which are seen the puncta lachrymalia, the openings of the lachrymal ducts. 5. The lachrymal gland seen upon its under surface. 6. The openings of the seven excretory ducts of the lachrymal gland.

FIG. 4. The lachrymal ducts and lachrymal sac and nasal duct.

Nos. 1, 1. The puncta lachrymalia. 2, 2. The lachrymal ducts. 3. The lachrymal sac. 4. The nasal duct. 5. The caruncula lachrymalis. 6. The plica semilunaris. 7. The lachrymal gland, seen from the anterior surface.

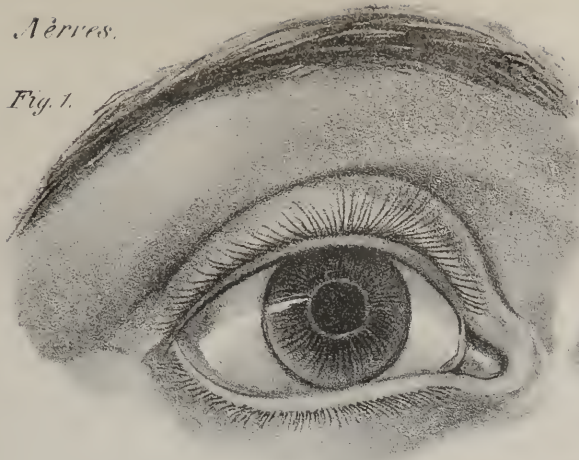
FIG. 5. The lachrymal gland, seen upon its upper surface.

FIG. 6. A vertical section of the orbit and globe of the eye, for the purpose of showing the anatomical composition of the eye-lids, and their relation to the surface of the eye.

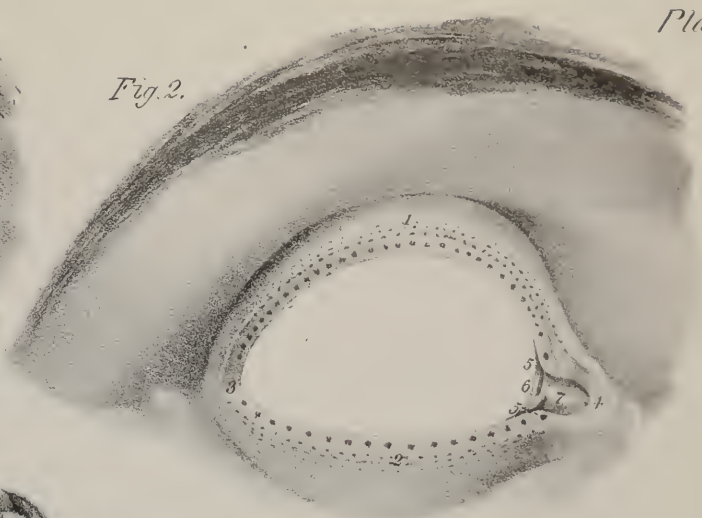
No. 1. The cut edge of the orbital plate of the frontal bone. 2. A part of the left frontal sinus. 3. The periosteum of the roof of the orbit, which is continuous with the pericranium, 4; and with the broad ligament, 5, of the upper eye-lid. 6. The periosteum of the inferior wall of the orbit. 7. The broad ligament of the lower lid. 8, 8. The fat enclosed in loose cellular tissue which fills up all the vacant spaces in the orbit. 9. The levator palpebræ muscle inserted by its tendon into the convex border of the tarsal cartilage of the upper eye-lid. 10. The superior rectus muscle. 11. The inferior rectus muscle. 12. The optic nerve. 13. The sclerotic coat of the eye-ball, thicker posteriorly than in front. 14. The dark line, is the choroid coat. 15. The white line within the choroid, is the retina. 16. The thinner white edge within the retina, is the hyaloid membrane. 17. The cornea. 18. The anterior chamber. 19. The divided edge of the iris, attached by its circumference to the ciliary ligament, 20. 21. The divided edge of the ciliary processes. 22. The lens, surrounded by the canal of Petit, 23. 24. The integument of the forehead. 25. The thin integument of the upper eyelid. 26, 26. The orbicularis palpebrarum muscle. 27. The tarsal cartilage of the upper lid. 28. The tarsal cartilage of the lower lid. 29. The fold of conjunctiva of the upper lid. 30. The fold of conjunctiva of the lower lid. 31. The eye-lashes. 32. The corrugator supercilii muscle cut across.

FIG. 7. The inner surface of the two tarsal cartilages, showing the Meibomian follicles partially embedded in their structure. The upper lid is broad and semilunar, the lower narrow. The ducts are seen opening along the margins of the cartilages. This figure is drawn from nature.

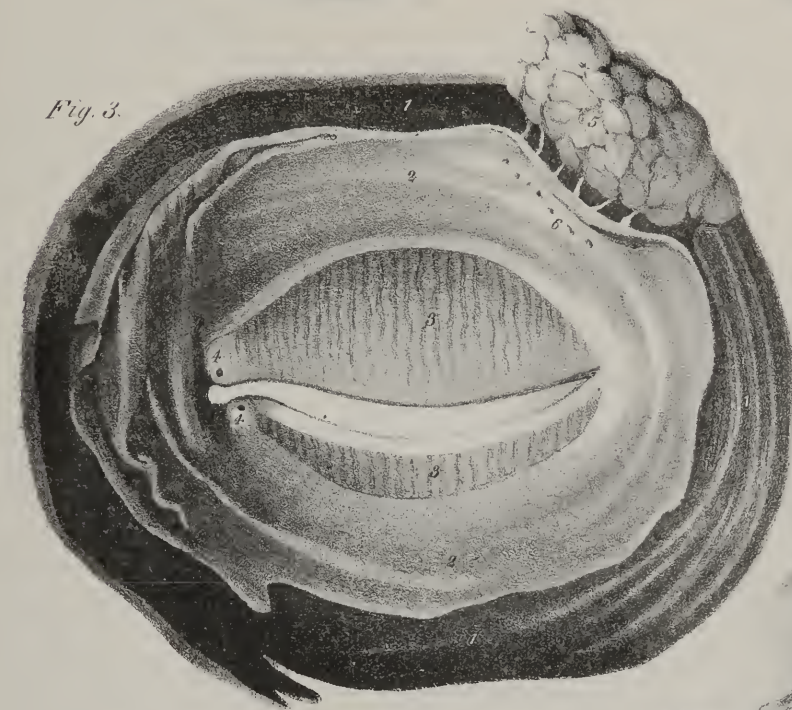
*Fig. 1.*



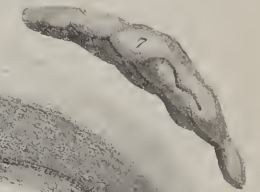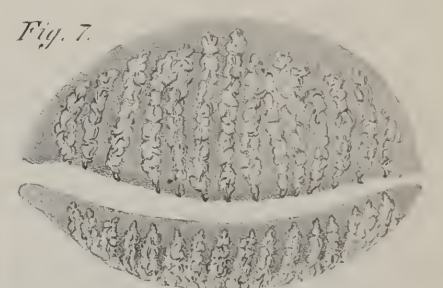
*Fig. 2.*



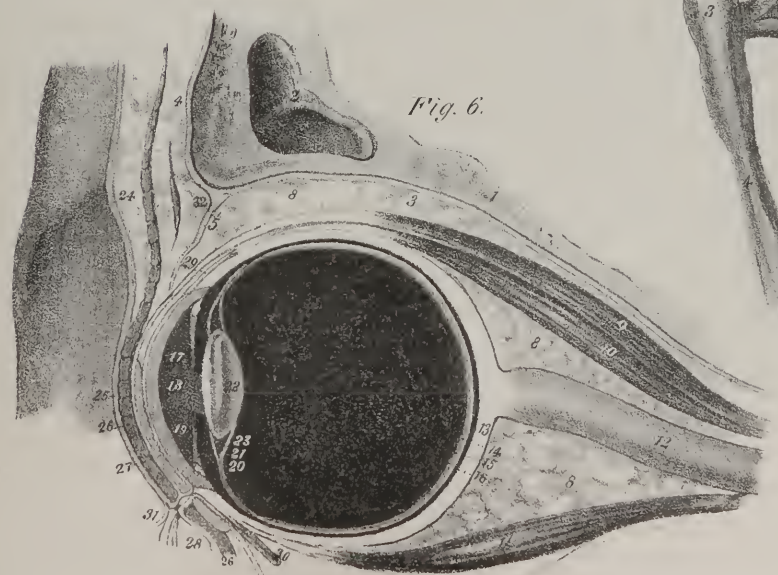
*Fig. 3.*




*Fig. 7.*



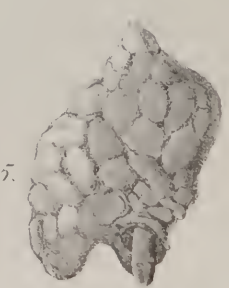
*Fig. 6.*



*Fig. 4.*



*Fig. 5.*









rather than with the lateral part of the sympathetic system. And when we remove the anterior roots of the transverse process in the neck, (which are but appendages to them, being in fact rudimentary ribs,) we find upon the vertebral artery a plexus, but not a chain of ganglia. De Blainville says,\* that in the elephant it has been found; but he does not give a reference to the person on whose authority the statement rests. Perhaps it may not be out of place to observe, that, as the organs of assimilation, secretion, and circulation, are placed in subordination to the sympathetic nerves, (or nerves of vegetative life, as they are frequently called,) the thoracic and abdominal parts of the sympathetic system are highly developed; and that the cervical is much less so, having fewer ganglia and smaller plexuses, whilst the nerves of animal life are numerous and large, inasmuch as the upper part of the alimentary canal and the larynx are strictly voluntary organs, and through the medium of their proper nerves are subjected to the immediate control of the will. Again, the small and large intestines are supplied exclusively by the sympathetic nerves, as far as the rectum; there the nerves of animal life begin to be received, and towards its lower extremity predominate over the others, giving it, through the agency of its sphincters and levator, a strictly voluntary power. Concurrently with this change, as if by a principle of compensation, the sacral ganglia diminish in size, and become uncertain in their number.

The consistence of the sympathetic nerves is very variable, some being rather firm and dense, others so tender as to be easily torn, and so soft as to have received the name of "nervi molles." Their colour, and that of their ganglia, varies. They are not of that clear whiteness which the cerebro-spinal nerves present; their tinge is like that of mother-of-pearl. The thoracic ganglia are of the same aspect, but the semilunar and the first cervical are reddish, particularly the former, which in many cases looks almost fleshy.

In order to facilitate the description of the sympathetic nerves, it becomes necessary to consider them as divisible into superior, middle, and inferior portions, corresponding with the cervical and cranial regions, the thoracic, and the abdominal. As they are symmetrical, the description of one will suffice for both. Each nerve consists, in most instances, of three cervical ganglia, twelve dorsal, five lumbar, and four or five sacral, with their cords of connexion. To these should be added some small ganglia in the cranium; viz. the ophthalmic or lenticular in the orbit, the spheno-palatine or the ganglion of Meckel, the submaxillary, the otic or auricular as described by Arnold, the cavernous, the naso-palatine as indicated by Cloquet, and one described by Ribes as being placed on the branch of communication between the anterior cerebral arteries. We shall commence with the superior cervical ganglion.

*Superior cervical ganglion and its branches.*—The superior, or great cervical ganglion; (plate XXVII. D,) is elongated and fusiform, so as to extend from two or three lines beneath the base of the skull, to the transverse process of the third or fourth cervical vertebra. Its length varies considerably in different cases, being from an inch and a half to two inches, or even more. Lobstein found it in one case to measure thirty lines; its thickness is about two or three lines. It lies on the rectus anticus muscle, concealed by the jugular vein and carotid artery. Branches proceed from it in every possible direction, which may be arranged into sets as follow—ascending, descending, external, internal, and anterior.

The *ascending* branches (e) are two in number; they enter the foramen caroticum, and form round the artery a plexus, (f, f; *plexus caroticus*, v. *cavernosus*.) Upon one of the filaments forming this plexus or interlacement round the artery, a gangliform enlargement sometimes is seen at the first curvature of the vessel, and which has been termed the carotid ganglion, (ganglion caroticum.) From the plexus filaments are traced upwards connecting it with the sixth, fifth, and third nerves, and the ophthalmic ganglion, as follows:—two filaments (g) pass upwards to communicate with the sixth nerve in the cavernous sinus;—one or two may also be traced along the carotid artery as far as the minute ganglion placed on the arteria communicans, and from this point filaments extend upon the coats of the artery throughout its ramifications; another terminates in the pituitary gland and infundibulum; one joins the third pair before it passes into the orbit, and one or two extend to the ophthalmic branch of the fifth. A filament also ascends to the nasal branch of the ophthalmic nerve, and is prolonged to the ophthalmic ganglion; and another communicates with the descending branch of the Vidian nerve. We may, however, consider these last-named branches as being derived, the one from the ophthalmic ganglion, and escorted for a while by the fifth nerve, in order to be ultimately prolonged to the carotid plexus, so as to connect the ganglion here named with the rest of the system; and the other, (p,) viz. the inferior branch of the Vidian, as being continued to the same point, in order to associate Meckel's ganglion, and thereby the naso-palatine ganglion, with the general gangliac system. Finally, from the plexus a filament (t) is derived, which is conducted by a minute aperture from the carotid canal into the tympanum to join the tympanic branch of the glosso-pharyngeal nerve.

The *external* branches (u, u) derived from the first cervical ganglion are short, and pass outwards to the superior cervical nerves, at the points at which they appear in front of the neck.

The *internal* set (v, v) incline obliquely inwards to the parts placed along the middle line, particularly to the pharynx, where they contribute to the formation of the pharyngeal plexus.

The *anterior* branches are very numerous; some of them communicate by anastomosis with the vagus, glosso-pharyngeal, lingual, and facial nerves. Others pass forwards on the external carotid artery, and accompany its different ramifications. These,

\* Cours d'Anatomie et de Physiologie Comparée.

from their appearance, are called *nervi molles*, (w, w;) they may be arranged in five sets of filaments, corresponding with the arteries which they accompany, viz. the superior thyroid, the laryngeal, the lingual, the labial, and ascending pharyngeal.

The *descending* branches are divisible into two sets. The first are two or three which unite to form the superficialis nerve, (x, x;) the other (y) is the cord by which the superior cervical ganglion is connected with the middle or inferior one, forming the continuation of the sympathetic nerve. It is in general a long and thin branch, but in some instances its place is supplied by two filaments running parallel. It descends behind the sheath of the vessels, resting on the rectus anticus and longus colli, and opposite the fifth cervical vertebra it joins the middle ganglion: but as this sometimes does not exist, particularly at the right side, the nerve continues its course to the third ganglion. This branch usually gives filaments which communicate with the second and third cervical nerves, with the par vagum and the cardiac nerves.

*Middle cervical ganglion.*—The middle cervical ganglion, (plate XXVII. I,) when it exists, (which is not always the case,) is small, and very variable in its shape. It will be found on a level with the transverse process of the fifth or sixth cervical vertebra, where it is concealed by the sheath of the great vessels. It is so constantly in relation to the inferior thyroid artery, that Lobstein names it “ganglion thyroideum.” It receives the branch of communication (y) sent down to it from the superior cervical ganglion, and gives one (b\*) which connects it with the inferior. From its external side branches (z, z) pass to the third, fourth, and fifth cervical nerves; some proceed inwards upon the thyroid artery, others to communicate with the recurrent nerve. Finally, from its fore part issues the middle cardiac nerve, (a\*, a\*,) and some filaments which join the plexus on the subclavian artery.

*Inferior cervical ganglion.*—The inferior cervical ganglion (plate XXVII. K) is also variable in its form, being usually single, but sometimes double. It lies in the angle between the transverse process of the last cervical vertebra and the neck of the first

## PLATE XXX.

The anatomy of the globe of the eye.

FIG. 1. The external tunic of the eye.

No. 1. The sclerotic coat. 2, 2. Small openings in the posterior aspect of the sclerotic for the passage of ciliary arteries and nerves. 3. The optic nerve. 4. The constriction of the sheath of the optic nerve at its junction with the sclerotic coat. 5. The insertion of the superior rectus muscle. 6. The insertion of the external rectus muscle. 7. The insertion of the inferior rectus. 8. The tunica albuginea, formed by the expansion of the tendons of the four recti muscles. 9. The cornea, through which is seen the iris and a part of the pupil.

FIG. 2. The second tunic of the eye-ball, seen from its nasal side.—(From Sæmmering.)

No. 1. The posterior part of the sclerotic coat; the rest having been removed to bring the choroid coat into view. 2, 2. The choroid coat, upon which are seen the whirls of the *venæ vorticosaë*. 3. The long internal ciliary artery. 4. The internal ciliary nerve. 5. Ciliary veins returning from the iris between the long ciliary nerve and artery. 6, 6. Ciliary nerves. 7. The ciliary ligament. 8. The iris. 9. The opening of the pupil.

FIG. 3. The second tunic of the eye-ball, seen from its inferior side. If this figure be compared with the preceding, it will be observed that, in consequence of the entrance of the optic nerve into the eye-ball on the nasal side of the globe of the eye, the inferior side is longer than the internal, and therefore the edge of the iris only is seen.—(From Sæmmering.)

No. 1. The posterior part of the sclerotic coat. 2. The optic nerve. 3, 3. The choroid coat. 4. A ciliary nerve formed by the union of two distinct filaments. 5, 5. Ciliary nerves. 6. The whirls of the *venæ vorticosaë*, called by Sæmmering the “inferior venarum vortex.” 7. The ciliary ligament. 8. The edge of the iris.

FIG. 4. The third tunic of the eye-ball, seen from the outer side of the globe of the eye.

No. 1. The retina. 2. The foramen of Sæmmering surrounded by a yellow halo—the *limbus luteus*. 3. The optic nerve stripped of its neurilema. 4, 4. The scolloped anterior margin of the retina. 5. The zonula ciliaris, connected posteriorly with the scolloped border of the retina, and attached anteriorly to the anterior surface of the lens. 6, 6. The anterior fluted boundary of the canal of Petit. 7. The lens.

FIG. 5. A horizontal section of the globe of the eye.

No. 1. The sclerotic coat, thicker posteriorly than in front. 2. The sclerotic coat, continuous with the neurilema of the optic nerve. 3. The bevelled anterior margin of the sclerotic, receiving the edge of the cornea. 4. The cornea. 5. The external or venous layer of the choroid coat, which is continuous anteriorly with the ciliary ligament. 6. 7. The internal or arterial layer of the choroid coat, continuous anteriorly with 8, the ciliary processes. 9. The retina. 10. The zonula ciliaris, continued forwards from the anterior border of the retina to the front surface of the lens. 11. The hyaloid membrane. 12. That portion of the hyaloid membrane which is continued behind the lens. 13. The anterior chamber of the eye. 14. Its lining membrane, which secretes the aqueous humour. 15. The iris, composed of two layers. Three layers are seen in the figure: the most anterior is the membrane of the aqueous humour; the second, thicker than the first, is the fibrous layer; and the third, the dark layer, represents the uvea. 16. The opening of the pupil. 17. The posterior chamber. 18. The lens, showing its concentric structure. 19. The capsule of the lens. 20. The canal of Petit, bounded in front by the zonula ciliaris, behind by the hyaloid membrane, and internally by the edge of the lens. 21. The vitreous humour, contained in a delicate cellular tissue formed by the hyaloid membrane. 22. The canal of hyaloid membrane which traverses the vitreous humour and contains the artery of the lens. 23. The nervous substance of the optic nerve piercing the choroid membrane, and terminating in the retina. 24. The *arteria centralis retinae*, passing through the centre of the optic nerve.



Fig. 1.

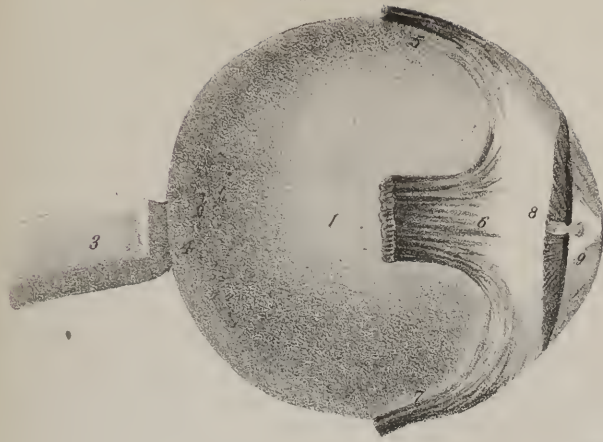

Fig. 2.

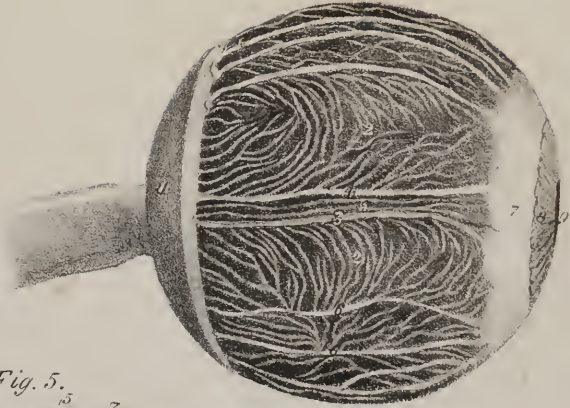


Fig. 5.

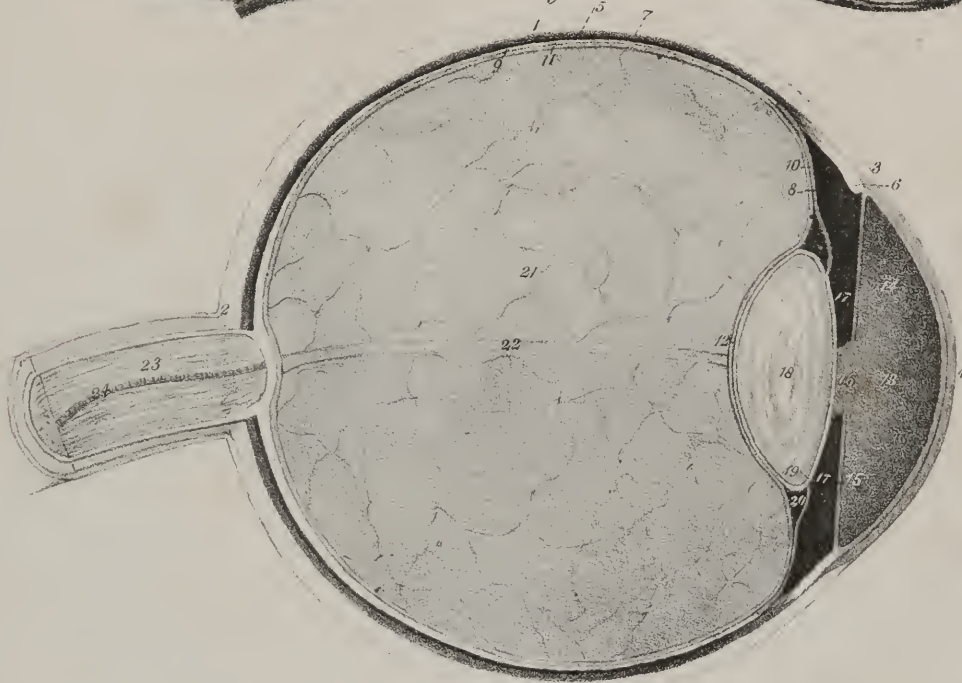


Fig. 3.

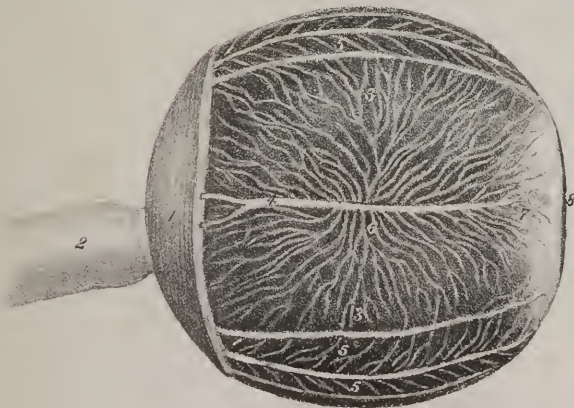
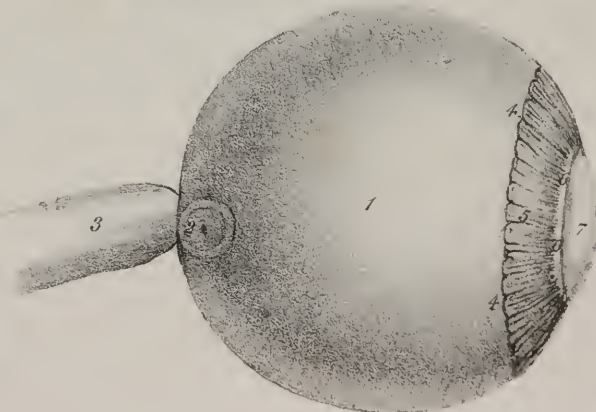


Fig. 4.









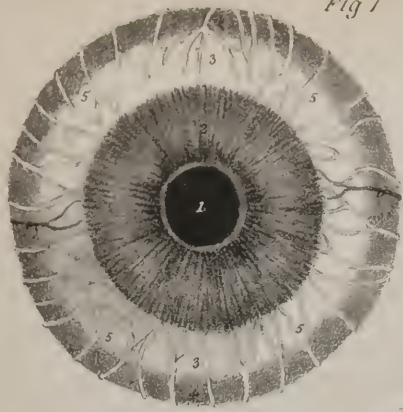


Fig 1

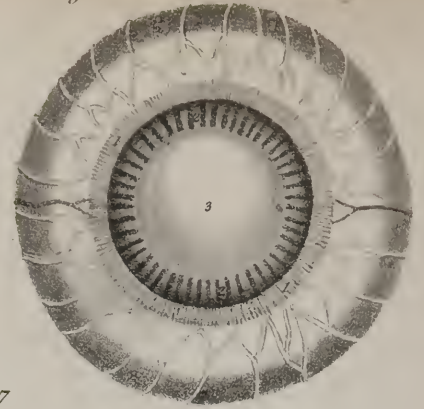


Fig 2




Fig 6

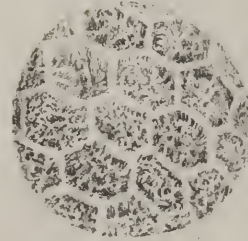


Fig 7

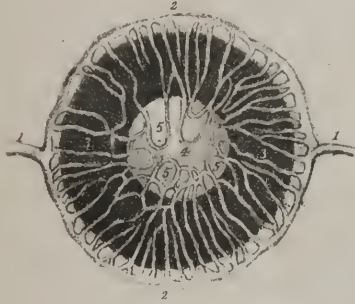

Fig 11

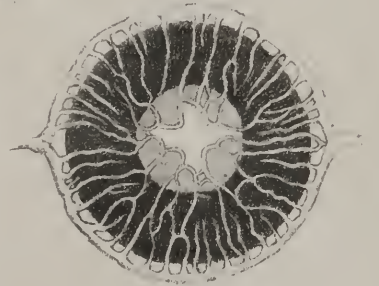

Fig 12



Fig 8

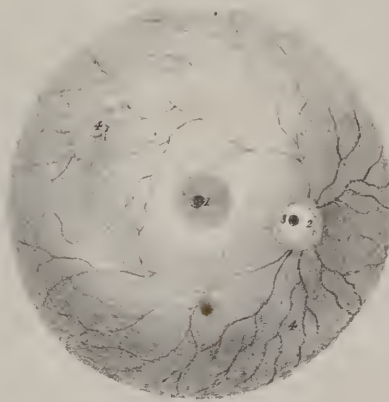


Fig 5



Fig 10

Fig 3



Fig 9

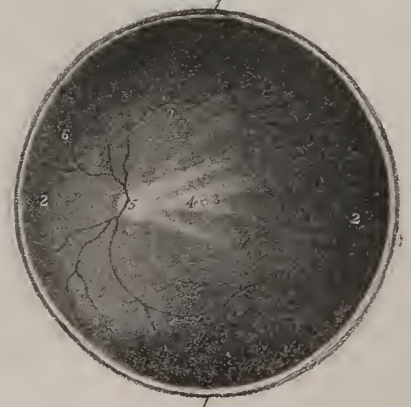

Fig 4



rib, close by the vertebral artery, which almost conceals it from view. It receives the communicating branch (b\*) from the middle ganglion, and sends down four or five, (g\*), which pass, some in front, some behind the subclavian artery, and end in the first thoracic ganglion; in some instances it is placed in such close contact with the latter, that they become united inseparably, as if they were but one nervous mass. Some branches (c\*) pass outwards, which soon join the spinal nerves that form the axillary plexus, particularly the seventh, eighth, and first dorsal; and whilst others pass inwards, to contribute to the formation of the pulmonary plexus. An ascending branch enters the canal formed by the chain of foramina in the transverse processes of the cervical vertebræ, and forms a *plexus* (d\*, *vertebral*) upon the vertebral artery. The filaments of this interlacement can be traced upon the vessel up to the base of the skull, at each step of its ascent maintaining communications with the spinal nerves, from the fifth up to the first. Finally, the inferior cardiac nerve (e\*) may be considered as the anterior branch of the ganglion.

Before we proceed to describe the thoracic portion of the nerve, it may be well to conclude our notice of the cranial part, by describing the ophthalmic ganglion, the spheno-palatine, the naso-palatine, otic, and submaxillary ganglia with their branches.

*Ophthalmic ganglion and its branches.*—The ophthalmic ganglion (plate XXVII. E) is frequently called “lenticular” (lens or lenticula, a lenti-seed,) and “ciliary” (ganglion ciliare) from the nerves which issue from it; it lies within the orbit, about midway between the optic foramen and the globe of the eye, and placed between the external rectus muscle and the optic nerve;

## PLATE XXXI.

The anatomy of the deep tunics of the eye.

FIG. 1. The second tunic of the globe of the eye seen from the front.

Nos. 1, 1. The pupil. 2, 2. The iris. 3, 3. The ciliary ligament. 4, 4. The choroid membrane. 5, 5. The ciliary nerves, which are seen converging from every point of the circumference of the globe towards the margin of the iris. 6, 6. The long ciliary arteries.

FIG. 2. The same view of the globe of the eye. The iris has been carefully divided near to the margin of its circumference and removed, in order to display the ciliary processes from the front, and their relation to the lens. The choroid ciliary ligament, and ciliary nerves and arteries, are the same as in the preceding figure.

Nos. 1, 1. The divided edge of the iris. 2, 2. The ciliary processes surrounding and overlapping the lens. 3. The crystalline lens.

FIG. 3. A posterior view of the iris and ciliary processes. In this preparation the globe of the eye has been divided transversely, and the vitreous humour and lens have then been removed.

Nos. 1, 1. The pupil. 2, 2. The posterior surface of the iris, named from its dark colour, uvea. 3, 3. The ciliary processes. 4, 4. The internal surface of the choroid membrane. 5, 5. The divided edge of the sclerotic and choroid coats.

FIG. 4. A transverse section of the globe of the left eye, showing the internal surface of its posterior half.

Nos. 1, 1. The divided edge of the sclerotic coat, choroid, and retina. 2, 2. The internal surface of the retina. 3. The foramen of Sæmmering; the limbus luteus which surrounds it is rendered imperceptible by the shadow thrown by the side of the segment. 4. The fold of the retina which usually conceals the foramen of Sæmmering. 5. The extremity of the optic nerve, situated to the nasal side of the central axis of the globe of the eye, and pierced by the arteria centralis retinae. 6, 6. Ramifications of the arteria centralis retinae.

FIG. 5. The posterior surface of the retina seen from the exterior. The figure represents the left eye-ball.

Nos. 1, 1. The foramen of Sæmmering surrounded by a yellowish halo, called limbus luteus. 2. The optic nerve, divided at its point of expansion into the retina. 3. The divided trunk of the arteria centralis retinae, occupying the centre of the optic nerve. 4, 4. The ramifications of the arteria centralis retinae upon the inner surface of the retina, forming its vascular layer; it is seen through the two external layers.

FIG. 6. A diagram representing the direction of the fibres in the anterior layer of the iris.

Nos. 1, 1. The pupil. 2. The circular fibres occupying the central margin of the iris, and acting as a sphincter to the pupil. 3, 3. The radiating fibres, proceeding from the external border of the circular fibres to the periphery of the iris.

FIG. 7. A small portion of the membrana pigmenti of the choroid coat highly magnified, and drawn from nature. It is seen to be composed of regular hexagonal plates, having their tissue filled with granules of colouring matter separated by interstices. The membrana pigmenti is formed by several laminæ of these plates, which are largest upon the free surface of the membrane, and smaller towards the choroid.

FIG. 8. Nos. 1, 1. A front view of the crystalline lens. 2. A side view of the crystalline lens. 3. Its anterior and least convex side. 4. Its posterior and most convex surface.

FIG. 9. The crystalline lens, marked by three lines, which become apparent after death, or after immersion in boiling water. These lines denote a tendency in the lens to split into three segments.

FIG. 10. A lens split into three segments after immersion in boiling water. The faces of the segments show the concentric laminæ of which the lens is composed. The nucleus is observed in one of the segments, and the corresponding depressions in the other two.

FIG. 11. The iris and membrana pupillaris of a fœtus six months and a half old, highly magnified. (After Cloquet.)

Nos. 1, 1. The extremities of the two long ciliary arteries. 2, 2. The arterial circle formed around the circumference of the iris. 3. The iris. 4. The membrana pupillaris. 5, 5. The arterial loops formed between the two layers of the membrana pupillaris. The centre of the membrana pupillaris has no appearance of vessels.

FIG. 12. The iris of a fœtus at the eighth month, showing the mode of rupture of the membrana pupillaris, and the retraction of the vascular loops. The references are the same as in the preceding figure.

it is very small, and not easily found, owing to its being embedded in the soft adipose tissue which fills up the interstices between the different parts within the orbit.

Its branches are the following:—From its anterior border from sixteen to twenty delicate filaments issue, which proceed forwards to the surface of the sclerotica, and pierce it through minute foramina: these are the *ciliary nerves*. In their course to the globe of the eye they are accompanied by one or two filaments derived from the nasal nerve, but they do not form a plexus or an interlacement: they become, however, disposed or divided into two fasciculi, one above, the other below the optic nerve, the latter being the more numerous. They pass along between the choroid membrane and the contiguous surface of the sclerotica, lodged in grooves in the latter; and on reaching the ciliary ligament they pierce it, some few of them appearing to be lost in its substance, whilst all the rest pass inwards, and ramify in the iris.

The posterior border of the ganglion, which seems as if terminated by two angles, receives two branches, of which one passes downwards and forwards from the nasal branch (4) of the ophthalmic nerve: the other branch is shorter than the preceding, and is derived from the inferior oblique branch (7) of the motor nerve of the eye: it joins the postero-inferior angle of the ganglion. A third branch (i) reaches the ganglion usually in company with the long or upper root, which appears to be the medium of communication with the rest of the ganglionic system, being derived from the carotid or cavernous plexus.

*Spheno-palatine ganglion and its branches.*—The spheno-palatine, or Meckel's ganglion, (plate XXVII. G,) is very deeply seated, being placed in the pterygo-maxillary fossa, close by the spheno-palatine foramen; its size is small, its colour reddish, and form variable, being sometimes triangular, but still convex upon its outer surface; sometimes it is heart-shaped. Its branches may be divided into the following sets; superior, inferior, internal, and posterior.

The superior branches are two, (plate XXVII, l,) which pass downwards from the superior maxillary nerve as it passes across the pterygo-maxillary fossa previously to its entrance into the infra-orbital canal.

The *inferior or descending* branches (plate XXVII. m) are three: they form the *palatine nerves*, which are so called from their destination.

The *great palatine nerve* passes directly down, to reach the posterior palatine canal. In its descent, whilst in the canal, one or two small filaments are sent off through the nasal plate of the palate bone, and ramify in the pituitary membrane; these lie between the inferior and middle turbinated bones; but lower down a small branch is given off, which, after passing through a similar osseous foramen, enters the velum palati and the amygdala. Finally, after having passed through the canal, the nerve turns forwards beneath the arch of the palate, where it divides into two branches, which ramify in the soft structures of the palate and gums, where they communicate with the terminal filaments of the naso-palatine ganglion.

The *middle palatine nerve* descends parallel with the preceding, but in a separate canal, which opens before the ramulus of the pterygoid process. The nerve on reaching this point divides into three or four filaments, which ramify in the soft palate and tonsil. The *small palatine nerve* runs in a similar direction, but farther back, and is distributed to the same parts.

The *internal or spheno-palatine* branches, (plate XXVII. n,) three or four in number, pass inwards through the foramen from which they take their name, to reach the nasal fossæ. Two or three of these run upon the spongy bones; the other (k) from its destination is named "naso-palatine;" it passes obliquely downwards and forwards along the septum, and reaches the upper orifice of the anterior palatine canal, where it terminates in the *naso-palatine ganglion*, (F.) This ganglion is very small, and placed in the anterior palatine canal; it is a single or azygos ganglion, and receives by its upper border the naso-palatine branch of each side, which converge to it; it gives off two or three small filaments, which descend to the membrane of the palate.

*Vidian nerve.*—The *posterior* branch of Meckel's ganglion is called pterygoid, or Vidian, (plate XXVII. o;) it passes back through the pterygoid or Vidian canal in the base of the process of that name. Having reached the foramen lacerum basis cranii, it divides into two branches, one of which (p) inclines downwards and outwards, and enters the carotid canal, where it terminates in the carotid plexus, and so connects the spheno-palatine ganglion with the first cervical; the other branch (q) enters the cranium, but does not pierce the dura mater. It runs outwards and backwards beneath that membrane, lodged in a groove on the upper surface of the pars petrosa, and having passed through the hiatus Fallopii, reaches the aquæductus Fallopii, where it becomes applied to the inferior surface of the facial or portio dura nerve, (12, 13,) which it accompanies to within two lines or so of its exit from the stylo-mastoid foramen. The Vidian nerve at this point turns forwards into the tympanum, where it runs between the long process of the incus and the handle of the malleus, assuming the name of *chorda tympani*, (r.) In the next place the nerve descends, and escapes through the Glasserian fissure, inclining at the same time forwards and inwards, so as to come into contact with the gustatory nerve, (29,) which it accompanies along the inferior maxilla, until it approaches the submaxillary gland. When near the gland, the chorda tympani (s) separates from the gustatory nerve, and descends upon the gland, and terminates in a small ganglion (H) placed upon that body.

The *submaxillary ganglion* (plate XXVII. H), so called from its position and relations, rests upon the gland just named; it is very small; receives the Vidian nerve at its posterior border, and two filaments from the gustatory nerve at its upper side; also one or two filaments from the sympathetic nerve, accompanying the facial nerve, pass upwards to join it. Two sets of



filaments pass forwards from the ganglion: one joining the gustatory nerve, the other accompanying the duct of the submaxillary gland.

The Vidian nerve is here described as a continued thread extending from Meckel's ganglion to the submaxillary ganglion: this is done merely to give precision to its description and anatomical relations. But it is not to be thence inferred that it has no connexion with the portio dura and gustator nerves, for in most dissections filaments appear to pass from the one to the other; neither has any question been raised as to the function of this nerve, or of the other branches of Meckel's ganglion.

*The Otic ganglion.*—This body (plate XIII. fig. 1, 1; *ganglion oticum*, v. *auriculare*) was discovered by Dr. Arnold of Heidelberg, and is sometimes named after him. It is a small reddish-grey, soft ganglion, situated a little below the foramen ovale, on the inner side of the third division of the fifth nerve, nearly at the point where its motor or smaller root joins the larger or sensitive one. Thus, whilst its outer side is supported by the nerve, the inner is in relation with the cartilaginous part of the Eustachian tube, and the origin of the circumflexus palati muscle; and the middle meningeal artery lies behind it. To the ganglion filaments are traced from three sources, which may be considered as its roots; 1st, from the fifth nerve, particularly its smaller division (k), also from its internal pterygoid branch (m); 2nd, from the sympathetic system a filament (o) joins it, derived from the plexus that surrounds the middle meningeal artery; 3rd, the small petrosal branch (q) prolonged from the tympanic branch of the glosso-pharyngeal nerve, the course of which has been indicated in the description of the last named nerve. From the ganglion, a branch (p) passes backwards and upwards to the tensor tympani muscle, another obliquely forwards to the tensor palati, and two (n) descend to anastomose with the anterior auricular nerve. (Arnold.)

*Thoracic ganglia and plexus.*—The thoracic portion of the sympathetic nerve (plate XXVII. L, L, M; plate XXVIII. A, B, C) comprises, first, a series of ganglia, twelve in number, disposed in a regular series upon the heads of the ribs or in the intercostal space, and connected by short nervous cords passing from one to the other; secondly, of the plexus, formed along the middle line, for the supply of the heart and lungs by the sympathetic and pneumo-gastric nerves, which present this remarkable difference, that the pulmonary plexus is formed for the most part by the latter, and the cardiac by the sympathetic nerves. The latter will be noticed first, from their connexion with the ganglia of the neck, already described.

*Cardiac plexus and ganglion.*—The heart receives its nervous influence by branches derived principally from the cervical ganglia at each side, to which are added others from the vagus nerve and the recurrent. The nerves of each side communicate variously with one another; and all, by interlacing behind and upon the aorta, form a plexus from which filaments descend to the substance of the heart. The plexus, from its situation, may be called "aortic," but from the destination is usually named "cardiac." The interlacement between the nerves is so complex and diffuse that it is considered by Mr. Swan and others as divisible into portions, or separate plexuses, viz. "the right and left lateral cardiac, the ventricular and auricular." By the cardiac nerves of each side an interlacement or plexus is formed behind the aortic arch, above the trunk of the right pulmonary artery—plexus cardiacus magnus, profundus (plate XXVII. N). "Anastomosis illa valdè insignis, quæ inter utriusque lateris cardiacorum nervorum truneosub aortæ curvaturâ paulo supra cor conficitur." Scarpa. At the concavity of the aortic arch, between it and the pulmonary artery, a similar interlacement exists; and in this situation, to the right of the ductus arteriosus, a gangliform enlargement is usually found, named by Wrisberg the cardiac ganglion (plate XXVII. S; *ganglion cardiacum*.) It is rounded and elongated, from half to three quarters of inch long; it appears soft, but is of moderate consistence; its colour is that of mother-of-pearl.

From this plexus three orders of filaments proceed; some ( $o^*$ ,  $o^*$ ) pass backwards, and join the pulmonary plexus, others ( $m^*$ ,  $p^*$ ) turn forwards, to gain the fore part of the aorta; but the descending branches, by far the most numerous, pass to the heart itself, where they are disposed in two sets, which take the course of the coronary arteries, and are thence termed the coronary plexus. The branches of the *right coronary plexus*, (plate XXVII. Q) pass forwards between the aorta and the pulmonary artery, and ramify on the right ventricle and auricle, the greater number of them being directed towards the right border of the heart, where they communicate with the branches of the posterior plexus. The *posterior coronary plexus* will be found to ramify on the inferior and posterior surface of the left ventricle and auricle. These nerves were at one time supposed to be confined to the arteries which they accompany; but the researches of Scarpa have clearly shown that they pass away from the vessels in many places, and enter the muscular structure of the heart.

*Cardiac nerves.*—The cardiac plexus receives at its upper extremity the cardiac nerves of each side derived from the sympathetic, and some branches from the pneumo-gastric and its recurrent.

The superior cardiac nerve, (plate XXVII. x, x; *superficialis cordis*,) commences by three or four filaments from the first cervical ganglion, and usually receives one or two from the trunk of the sympathetic nerve. It is very small and delicate; it descends along the neck behind the sheath of the vessels, taking the direction of the carotid artery; it crosses the inferior thyroid artery, forming a plexus upon it; it enters the thorax, crossing the subclavian artery, and is guided by the innominata to the aortic arch, where it terminates in the plexus. In its course the nerve anastomoses with the middle and inferior cardiac nerves, and with branches of the vagus and recurrent. In some instances the nerve is found to divide at the lower part of the neck into three branches, of which a very small one inclines inwards, and contributes to form a plexus round the inferior thyroid artery; some join the middle, or great cardiac nerve, whilst the remainder form with the recurrent nerve a plexus, from which branches



descend to the great cardiac plexus. The middle cardiac nerve (plate XXVII. a\* ; *cardiacus magnus*) on the right side is the largest of the set ; on the left it is sometimes wanting. It descends from the middle cervical ganglion, or from the trunk of the sympathetic, should the former be wanting ; and after passing in front of the subclavian artery inclines backwards to reach the posterior surface of the aortic arch, where it terminates in the cardiac ganglion. The *inferior* cardiac nerve (e\*) arises from the last cervical ganglion, by several filaments which pass behind the subclavian artery, but afterwards cross in front of the aorta, the greater number of its filaments reaching the anterior coronary plexus, the rest joining with the preceding. On the left side the inferior cardiac nerve is sometimes larger than the others. We have here described the nerves and the ganglia as we ordinarily find them. The names employed, being taken from a general average of cases, will be found not to agree with the distribution in certain cases. Upon this point, Mr. Swan\* has very justly remarked, "If the sympathetic and its ganglia corresponded in different subjects, and gave off similar branches to form the cardiac nerves, it would be in every respect advantageous to have a specific name for each nerve ; but as there is so much uncertainty, particularly as to the extent both of the prolongations of the sympathetic and its ganglia, and consequently as to the situation and number of the branches given off from these, it will be much less perplexing to the student, and quite as conducive to every useful purpose, to call all the nerves arising from the sympathetic and par vagum in the neck, and proceeding to the heart and its large vessels, the right and left lateral cardiac plexus."

The thoracic ganglia, (plate XXVII. L, L, M ; plate XXVIII. A, B, C,) as has been said, lie on the heads of the ribs or in the intercostal spaces, covered by the pleura. Considering each of them as a centre from which branches proceed, we observe a branch of communication passing upwards to the ganglion above it, and downwards to that below it, so as to continue the series. Externally one, or, more commonly, two filaments (i\*, i\*) pass from each to the contiguous intercostal nerve, so as to connect the nerves of organic with those of animal life. The internal branches pass towards the middle line, some reaching the side of the trachea, and ending in the pulmonary plexus ; others, ramifying on the œsophagus and aorta, form what may be called the thoracic plexus.

*Splanchnic nerves.*—Branches from the sixth to the ninth thoracic ganglia, and sometimes to the tenth inclusively, pass obliquely downwards and inwards on the sides of the bodies of the vertebræ, and unite into a single trunk, (plate XXVIII. D ;

## PLATE XXXII.

The anatomy of the external ear is here shown.

FIG. 1. The pinna of the left ear.

FIG. 2. The same ear, the cuticle having been removed to show the numerous openings of the sebaceous follicles in the cutis. These are particularly distinct in the fossa innominata and concha, and at the base of the lobulus.

Nos. 1, 1. The point of connexion of the pinna with the side of the face. 2, 2. The helix. 3. The commencement of the helix in the concha. 4. The anti-helix. 5, 5. The two superior branches of the anti-helix, which inclose the angular shaped fossa, 6, the fossa scaphoides, (f. navicularis.) 7. The fossa innominata. 8. The tragus. 9. The anti-tragus. 10. The concha, divided into two parts by the commencement of the helix. 11. The entrance of the meatus auditorius. 12. The lobulus.

FIG. 3. The arteries distributed upon the pinna. The references to the component parts of the ear are the same as in fig. 2, or fig. 4.

No. 1. The temporal artery. 2, 2. Anterior auricular arteries, branches of the temporal : they supply the anterior border of the pinna. 3, 3. Branches from the posterior auricular artery, which pass through openings in the fibro-cartilage, and are distributed upon its external surface.

FIG. 4. The fibro-cartilage of the left ear.

Nos. 1, 1. The folded border of the fibro-cartilage which forms the helix. 2. The tubercle of the helix, which gives attachment to the superior anterior ligament of the pinna, and to the *atrahens aurem* muscle. 3. The fissure of the helix. 4. The elevation forming the anti-helix. 5. The scaphoid fossa, very deep in the fibro-cartilage. 6. The *processus caudatus* of the helix and anti-helix. It is separated from the anti-tragus, 7, by a lengthened fissure, which is closed in the undissected ear by ligamentous fibres. 8. The commencement of the helix, dividing the cavity of the concha into two parts, 9, 9. 10. The portion of the fibro-cartilage which supports the tragus. 11. The fissure of the tragus. 12. The semilunar notch of the concha. 13. The semilunar ridge of the meatus auditorius. 14. The fissure which separates the upper part of the cartilage of the meatus from the concha ; it is completed in the undissected ear by the fibrous membrane of the meatus. 15. The inferior process of the cartilage of the meatus.

FIG. 5. The posterior surface of the fibro-cartilage.

Nos. 1, 1. The rounded border corresponding with the helix. 2. A depression corresponding with the superior ramus of the anti-helix. 3. A convex surface formed by the depression of the fossa scaphoides. 4. The *processus caudatus* of the helix and anti-helix. 5, 5. The convex surface corresponding with the cavity of the concha. 6, 6. Two tubercles upon the posterior surface of the concha, which give attachment to the posterior ligaments of the pinna, and to the tendons of the *retrahens aurem* muscle. 7. The tubercle of the helix. 8. The fissure between the tragus and concha, closed in the undissected ear by the fibrous membrane of the meatus. 9. The tragus. 10. The fossa of the tragus. 11. The semilunar ridge of the meatus. 12. The cartilage of the meatus auditorius. 13. The inferior process of the cartilage of the meatus.

\* A Demonstration of the Nerves of the Human Body, by Joseph Swan, p. 6.

Fig. 1.

Fig. 2.

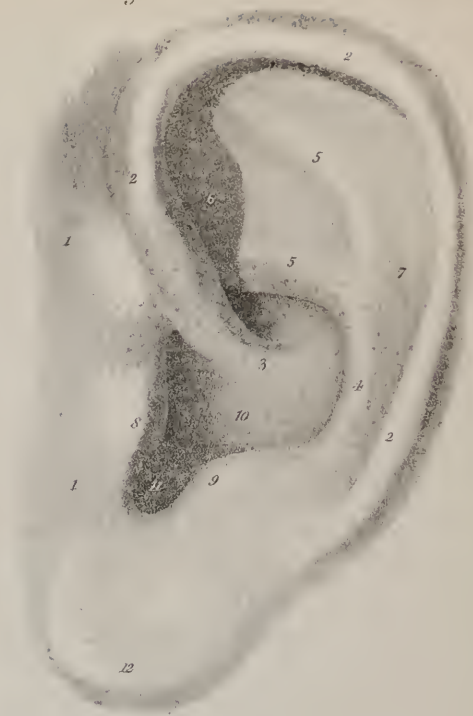
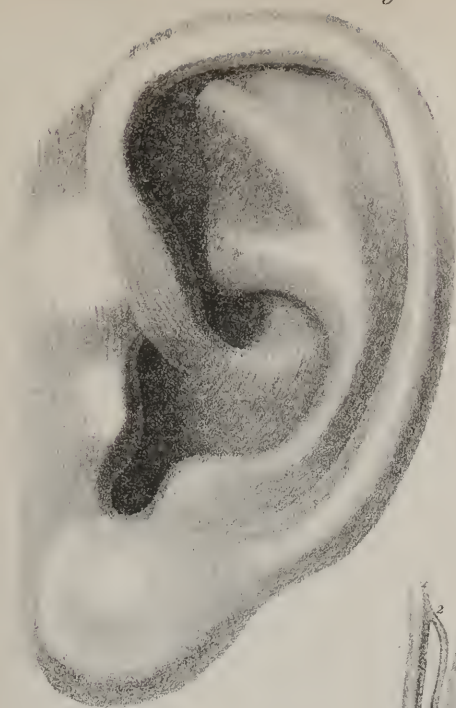


Fig 3

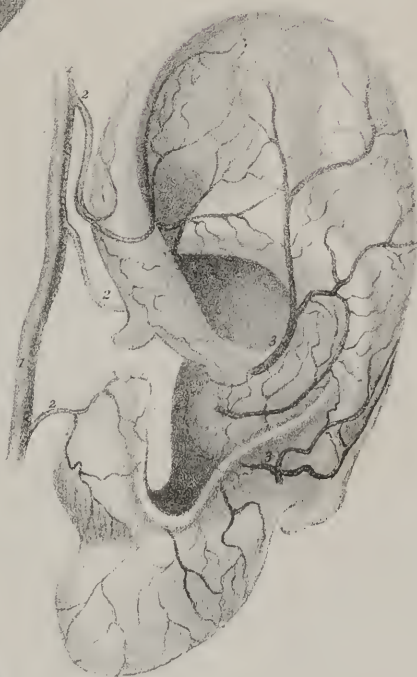
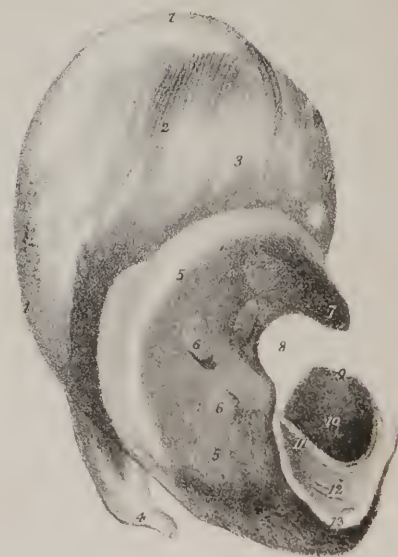
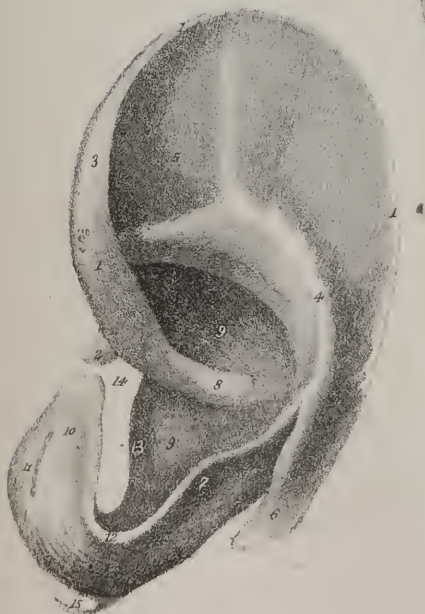

Fig 4

Fig 5









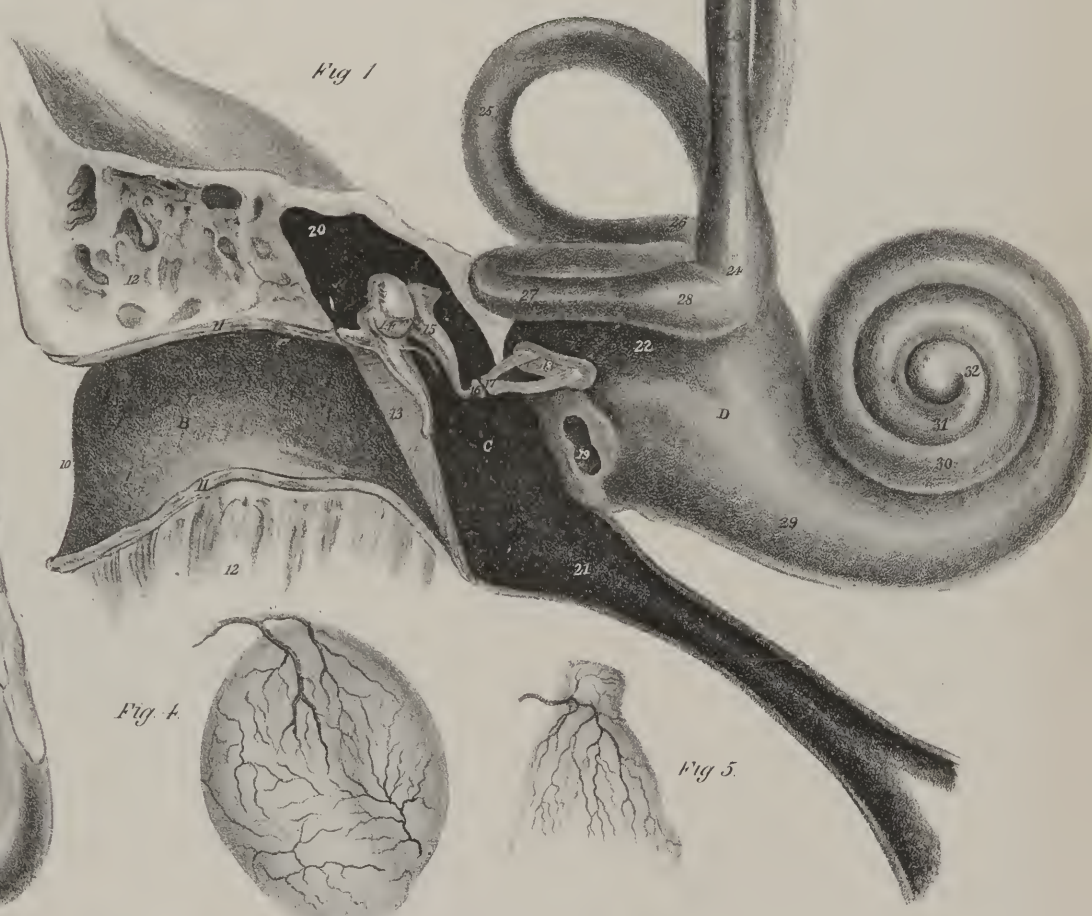
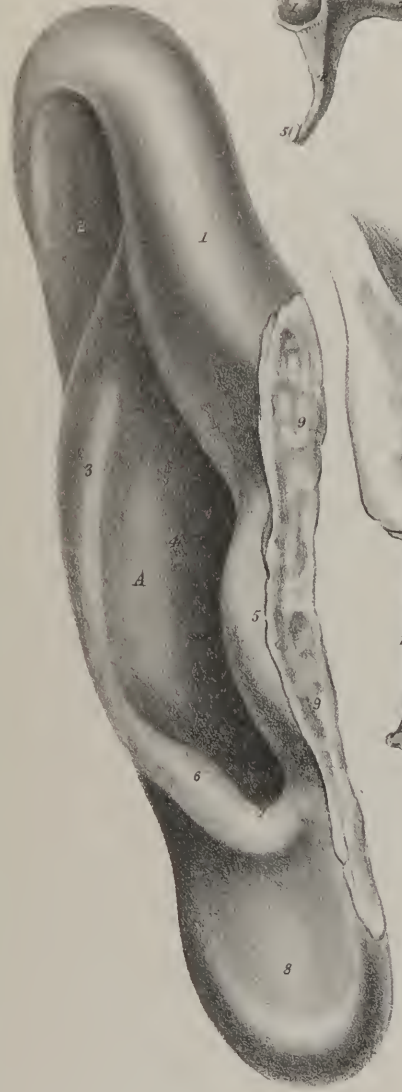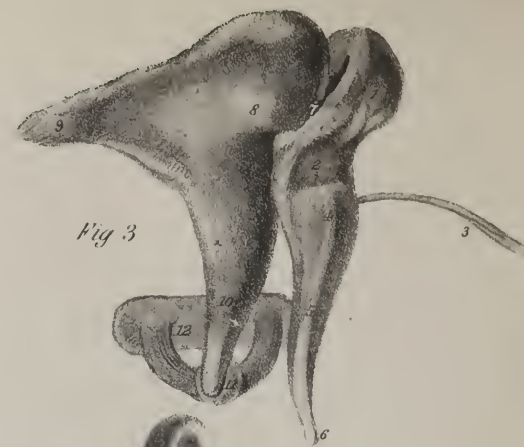
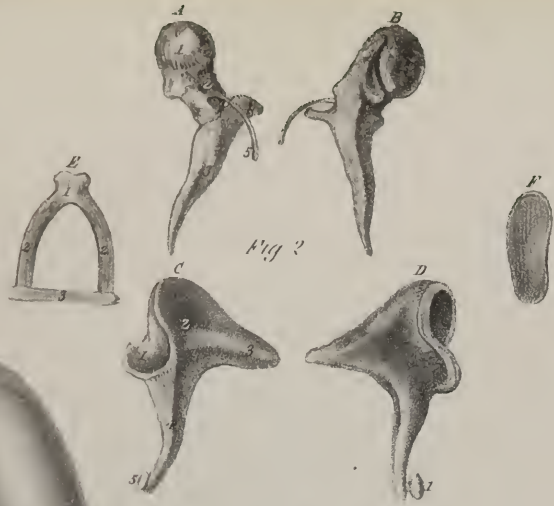


Fig 4

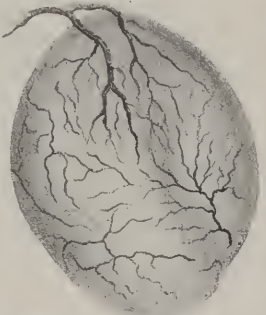


Fig 5

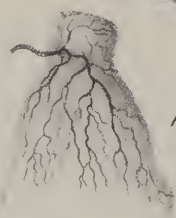
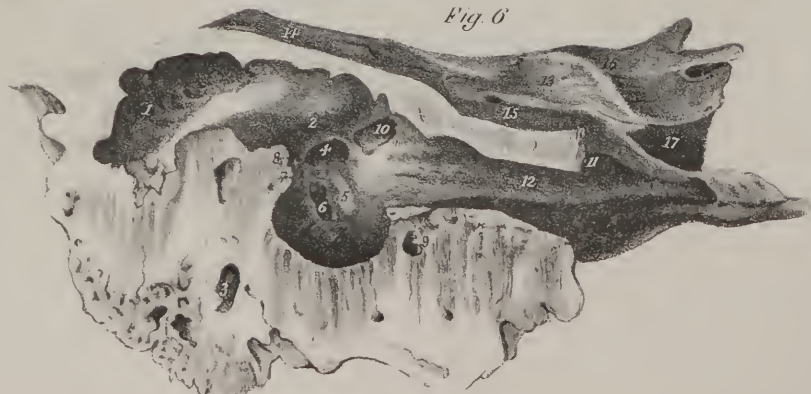
Fig 6



*nervus splanchnicus major*), which passes in a slight longitudinal fissure between the fibres of the crus of the diaphragm, and terminates in the semi-lunar ganglion, (E.) The anterior branches of the tenth and eleventh unite into a small nerve, (F; *splanchnicus minor*), which pierces the crus of the diaphragm external to the larger nerve, with which it communicates by branches, and finally terminates in the renal plexus, (G.)

*Abdominal ganglia*.—The abdominal part of the sympathetic nerve, (plate XXVIII. H,) consists of the semi-lunar ganglia and solar plexus, with the primary and secondary plexus which issue from them; and, secondly, of the direct continuation of the nerve. The former may be called the prævertebral part, from its position before the spine. Its ramifications are extensive and numerous, being diffused throughout the whole of the chylopoietic viscera, all of them being either immediately or remotely con-

## PLATE XXXIII.

Anatomy of the organ of hearing; middle ear, or tympanum.

FIG. 1. A magnified view of the organ of hearing, showing its division into external, middle, and internal ear. The parts of which this drawing is composed are enlarged from nature.

A. The pinna of the right ear. B. The meatus. These two portions constitute the external ear.

No. 1. The anterior border of the helix. 2. The fossa scaphoides. 3. The anti-helix. 4. The concha. 5. The tragus. 6. The anti-tragus. 7. The semilunar notch of the concha. 8. The lobulus. 9, 9. The cut surface by which the pinna was connected with the face. 10. The margin of the meatus auditorius externus. 11, 11. The section of the integument which lines the meatus; the dark spots upon this surface represent sections of the ceruminous follicles. The interior of the meatus, B, will be observed to be studded with hairs, which are directed towards the centre of the canal. 12, 12. The divided surface of the petrous portion of the temporal bone.

C. The cavity of the tympanum cross by the four small bones of the ear, the ossicula auditûs.

13. A section of the membrana tympani, divided through its middle. This membrane is concave externally, and convex within. 14. The malleus. 15. The incus. 16. The os orbiculare. 17. The stapes; the foot of the stapes. 18, closes the fenestra ovalis. 19. The fenestra rotunda leading into the cochlea. 20. The opening into the mastoid cells. 21. The Eustachian tube.

D. The labyrinth, or internal ear.

22. The vestibule. 23. The perpendicular semicircular canal. 24. Its ampulla. 25. The oblique semicircular canal. 26. Its ampulla. 27. The horizontal semicircular canal. 28. Its ampulla. 29. The commencement of the first turn of the bony canal of the cochlea. 30. The point of completion of its first turn. 31. The point of completion of its second turn. 32. The remaining half-turn, forming a slight expansion at its extremity, called the cupola. These two turns and a half constitute the cochlea.

FIG. 2. The small bones of the tympanum; ossicula auditûs, considerably magnified.

A. An anterior view of the malleus.

1. The articulating head of the malleus. 2. Its neck. 3. The manubrium, or handle. 4. The short process; processus brevis. 5. The long process; processus gracilis.

B. A posterior view of the malleus. Its divisions and processes are the same as in the preceding figure. C. A posterior view of the incus.

No. 1. The articulating surface which receives the head of the malleus. 2. The body of the incus. 3. Its short process. 4. Its long process. 5. The os orbiculare.

D. An anterior view of the incus. The points of reference are the same as in the preceding figure. The small rounded process, the os orbiculare, 1, at the extremity of the long process, is more distinctly seen in this view.

E. A side view of the stapes.

No. 1. Its head. The constricted portion immediately beneath the head is the neck. 2, 2. Its two branches. 3. Its foot.

F. The foot of the stapes, seen by that surface which is received into the fenestra ovalis of the vestibule.

FIG. 3. The ossicula auditûs of the right ear, seen in their natural position when examined from the meatus. They are very much magnified.

No. 1. The head of the malleus. 2. Its neck. 3. The processus gracilis, or long process. 4. Its short process. 5. Its manubrium, or handle. 6. The apex of the handle, which is attached to the centre of the membrana tympani. 7. The articulation between the head of the malleus and incus. 8. The body of the incus. 9. The short process of the incus. 10. Its long process. 11. The articulation between the os orbiculare and stapes. 12. The stapes.

FIG. 4. This figure shows the distribution of arteries upon the fibrous layer of the membrana tympani. The drawing was made from the injected membrane in a fœtus.

FIG. 5. The stapes enclosed by the mucous membrane of the tympanum, showing the arterial distribution upon its surface.

FIG. 6. A section of the petrous portion of the temporal bone, showing its inner wall.

No. 1. The irregular cavity forming part of the mastoid cells. 2. An elevated ridge formed by the canal of the aqueductus Fallopii. This canal gives passage to the facial nerve. It has been cut across in making the section, and the opening of the divided canal is seen at 3. 4. The fenestra ovalis. 5. The promontory. 6. The fenestra rotunda. 7. The pyramid, upon the posterior boundary of the tympanum. 8. The opening of entrance for the chorda tympani nerve. 9. Its opening of exit. 10. The termination of the canal for the tensor tympani muscle. 11. The commencement of its canal. 12. The canal of the Eustachian tube. 13. The anterior surface of the petrous portion of the temporal bone. 14. A prominence marking the situation of the superior semicircular canal. 15. A shallow depression leading to a small foramen, the hiatus Fallopii. This foramen gives passage to the petrosal branch of the Vidian nerve. 16. The notch upon which the fifth nerve lies, previously to forming the Casserian ganglion. 17. The termination of the carotid canal.



nected with the semi-lunar ganglia and solar plexus, from which their nervous filaments spread out like rays from a common centre. Their arrangement, however, is very easily understood by any one who recollects the distribution of the arteries to the viscera, inasmuch as these vessels support and conduct the nerves in their passage to the different organs. The nervous filaments interlace in their passage, so as to form a plexus previously to entering the substance of the organ; and the plexus is named from the parts within or upon which its ramifications are spread. The continuation of the nerve itself lies along the lumbar vertebrae at each side, representing those two lateral cords which are placed along the spine within the thorax.

*Semi-lunar ganglia.*—The semi-lunar ganglia (plate XXVIII. E) are two small reddish masses, placed upon the crura of the diaphragm; close beside the cœliac artery. These are in the first place connected at their upper and outer borders with the great splanchnic nerves, (D,) which may be said to terminate in them—the point of junction being readily perceived by a marked difference of colour. The ganglia are connected by a transverse mass of similar structure, or are so close as to appear united at the lower surface of the cœliac artery. The upper border of each ganglion is concave, the lower convex; hence their name “semi-lunar.” But the two bodies so named, and in which the great splanchnic nerves terminate, form only a part of the nervous structure placed in this situation. The anterior border of each will be found connected with eight or ten smaller masses of a structure similar to themselves, which rest upon the crura of the diaphragm and the aorta, each being connected with the other by slips and by filaments, so as to enclose spaces. Now, to the aggregate of these islets of nervous substance the term *solar plexus* is applied, from which, as from a common centre of radiation, proceed filaments, accompanying the different arteries which spring from the aorta, constituting as many secondary plexus as there are organs to be supplied. These we shall arrange in the same order as the arterial branches:—

The *phrenic plexus* (sub-diaphragmatic) consists of filaments which accompany the phrenic artery. They will be found upon the crus of the diaphragm, passing upwards from the upper margin of the plexus; they are usually three or four, and very delicate; they form a slight interlacement with one another by small branches of communication, and with the phrenic nerve by a filament which joins it, or rather the terminal branch of it, which ends in the solar plexus. The phrenic plexus gives branches to the crura and broad part of the diaphragm.

The *cœliac plexus* consists of numerous large and close-set branches, which issue directly from the solar plexus, projecting forwards a little round the cœliac artery. Like the vessel just named, the plexus separates into three divisions, following the coronary, hepatic, and splenic arteries.

The *coronary or stomachic plexus* (plate XXVIII. 8) consists of numerous filaments, which are enclosed within the small omentum, and are guided by the coronary artery to the stomach. They form an interlacement, by branches of communication one with the other, also with the terminal branches of the pneumo-gastric nerves, and finally spread out upon both surfaces of the stomach.

The *hepatic plexus* (plate XXVIII. 10) consists of a great number of branches, which accompany the hepatic and portal vessels, enclosed like them within the small omentum. These branches form a complex interlacement, which is joined by some filaments from the pneumo-gastric nerve. The greater part of the plexus reaches the transverse fissure of the liver, and there enters its substance, into which they can be traced for some way, apparently more connected with the arteries than with the veins. Another part of the plexus takes the course of the pyloric artery, and descends to the right extremity of the stomach. And a third set of filaments, following the gastro-duodenalis, reaches the under surface and the great curvature of the stomach. Some of these incline outwards into the duodenum, and backwards to the pancreas, in company with the ductus choledochus. The cystic artery is also attended by some delicate branches, which ramify in the gall-bladder.

The *splenic plexus* (plate XXVIII. 9) consists of comparatively few branches, and the interlacement which they form is not so close as in the preceding instances. It accompanies the splenic artery, and gives off several filaments to the pancreas. Previously to its entering the spleen, some branches are reflected from it, along the vasa brevia, to the great curvature of the stomach.

The *aortic plexus* (plate XXVIII. 1, 1) is the direct continuation of the solar; its branches form upon the aorta a complex net-work, which can be traced along the iliac vessels; its principal offsets are the following:—The *superior mesenteric plexus* (11) is a broad, expanded, and complex interlacement of nervous filaments, enclosed between the layers of the mesentery, and accompanying the mesenteric artery to the small intestines on the one hand, and on the other to the cœcum and colon, guided by the colic arteries. The *inferior mesenteric plexus* (m) follows the inferior mesenteric artery; at its commencement its branches communicate with those of the preceding plexus, and towards its lower part, where it descends into the pelvis, it receives an increase from the nervous interlacement upon the iliac vessels; and farther down, where it becomes lodged between the layers of the meso-rectum, it is connected with the hypogastric plexus.

The *renal plexus* (plate XXVIII. G) of each side differs from the preceding, inasmuch as it receives, in addition to the branches which follow the renal artery, the small splanchnic nerve, (F.) Its divisions accompany those of the artery to the fissure of the kidney. A minor plexus, similarly formed, passes to the supra-renal capsule.

The *spermatic plexus* consists at each side of some minute filaments, traceable from the renal plexus, and also from the aortic; they accompany the spermatic arteries in their course and distribution.





Fig 1

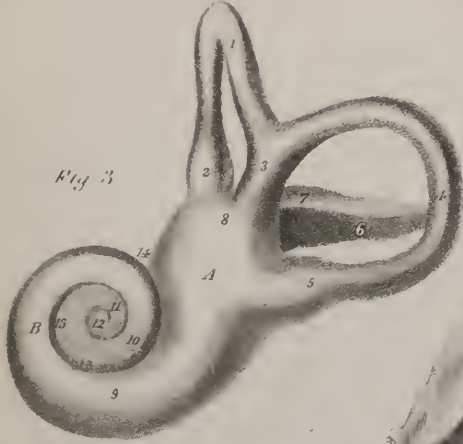
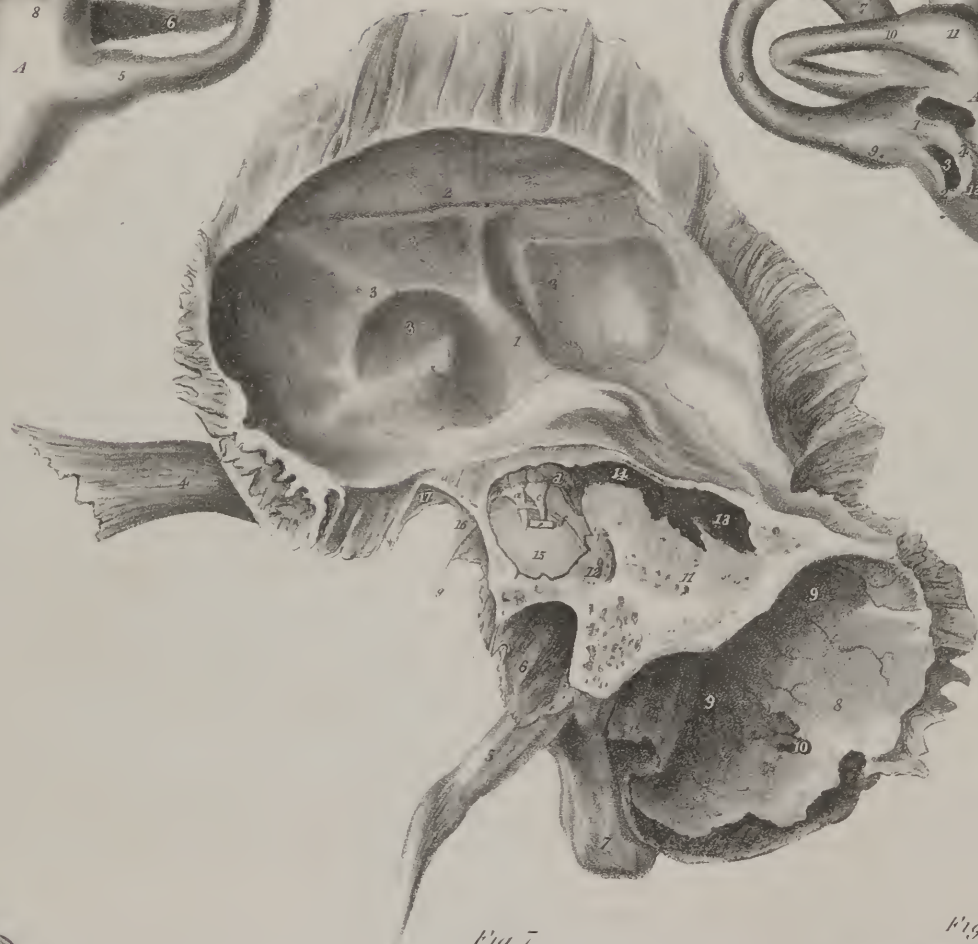


Fig 3

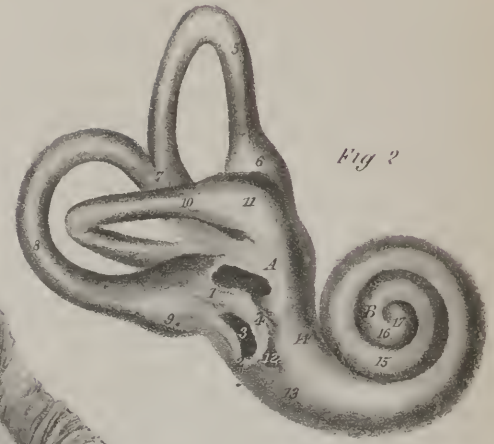

Fig 2

Fig 7



Fig 5

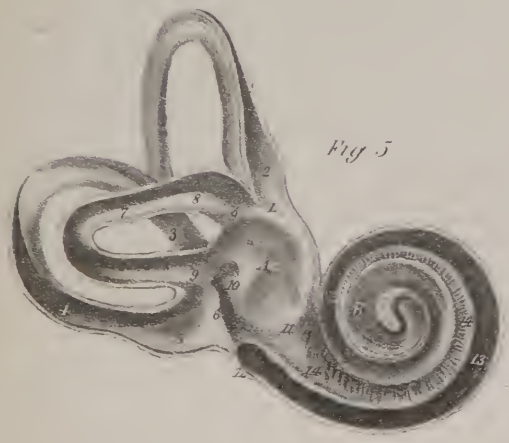


Fig 4





*Lumbar ganglia.* Having traced the various ramifications of the prævertebral ganglia and plexus of the sympathetic nerves in the abdomen, we recur to the lateral cords. In the thorax we find the chain which they present at each side extended in such a way that the ganglia correspond with the heads of the ribs or the intervening spaces. When continued into the abdomen (which they enter by passing beneath the ligamentum arcuatum proprium,) the two nerves incline forwards and inwards, so as to lie each

## PLATE XXXIV.

Organ of hearing: views of the tympanum and labyrinth.

FIG. 1. An internal view of the right temporal bone; the petrous portion has been sawn through its base and removed, in order to show the membrana tympani, with the relative position of the ossicula auditus.

No. 1. The internal surface of the squamous portion of the temporal bone. 2. A groove formed by a branch of the arteria meningea media. 3, 3. Depressions and elevations corresponding with the convolutions of the brain. 4. The zygomatic process. 5. The styloid process; remarkably long in this bone. 6. The vaginal process. 7. The inner surface of the mastoid process. 8. The inner surface of the mastoid portion of the temporal bone. 9, 9. The groove for the lateral sinus. 10. The termination of the mastoid foramen in the groove for the lateral sinus. 11. The divided surface of the petrous portion of the temporal bone. 12. The opening of the aqueductus Fallopii upon the face of the section. 13. Part of the mastoid cells. 14. The opening of the mastoid cells into the tympanum. 15. The membrana tympani.

a. The malleus, in its relative position with regard to the membrana tympani. b. The processus gracilis projecting forwards. c. The long process of the incus. d. The short process of the incus projecting backwards. e. The foot of the stapes. f. The chorda tympani nerve. g. The chorda tympani nerve after its escape through the fissura Glaseri. 16. The fissura Glaseri. 17. Part of the glenoid fossa.

FIG. 2. The labyrinth of the right ear in its natural position; seen upon its anterior aspect.

No. 1. The inner wall of the tympanum. 2. The fenestra ovalis. 3. The fenestra rotunda. 4. The promontory.

A. The vestibule.

5. The superior or perpendicular semicircular canal. 6. Its ampulla. 7. The common tube formed by the union of the superior and middle semicircular canals. 8. The middle or oblique semicircular canal. 9. Its ampulla. 10. The inferior or horizontal semicircular canal. 11. Its ampulla.

B. The cochlea.

12. A slight depression marking the separation of the two canals of the cochlea. 13. The tubulus of the scala tympani. 14. The tubulus of the scala vestibuli. 15. The completion of the first turn of the cochlea. 16. The completion of its second turn. 17. The remaining half-turn, terminating in the rounded expansion called the cupola.

FIG. 3. The labyrinth of the right ear, in its natural position, viewed from behind.

A. The vestibule.

No. 1. The superior or perpendicular semicircular canal. 2. Its ampulla. 3. The common tube of the superior and middle semicircular canals. 4. The middle or oblique semicircular canal. 5. Its ampulla. 6. The inferior or horizontal semicircular canal. 7. Its ampulla. 8. The opening of the aqueductus vestibuli.

B. The cochlea.

9. The first turn of the cochlea. 10. The completion of the first turn. 11. The completion of the second turn. 12. The remaining half turn. 13, 13. Numerous foramina through which the filaments of the auditory nerve enter the cochlea. This part corresponds with the termination of the meatus auditorius internus. 14. A part of the canal of the aqueductus Fallopii.

FIG. 4. The labyrinth of the right ear in its natural position, viewed from the meatus auditorius externus.

No. 1. The inner wall of the tympanum. 2. The fenestra ovalis. 3. The fenestra rotunda. 4. The promontory.

A. The vestibule.

5. The perpendicular semicircular canal. 6. Its ampulla. 7. The common tube of the perpendicular and oblique canals. 8. The oblique semicircular canal. 9. Its ampulla. 10. The horizontal semicircular canal. 11. Its ampulla.

B. The cochlea.

12. The commencement of its first turn. 13. Its first turn. 14. Its second turn. 15. The remaining half-turn, or cupola.

FIG. 5. The labyrinth laid open so as to display its internal cavity.

A. The internal cavity of the vestibule.

No. 1. The opening into the perpendicular semicircular canal. 2. Its ampulla. 3. The common tube of the superior and oblique semicircular canals. 4. The canal of the oblique semicircular canal laid open. 5. Its ampulla. 6. Its opening into the vestibule. 7. The horizontal semicircular canal. 8. Its ampulla. 9, 9. Its two openings into the vestibule. 10. The opening of the common tube of the perpendicular and oblique canals.

B. The cochlea.

11. The opening of the scala vestibuli into the vestibule. 12. A part of the fenestra rotunda. 13, 13. The scala tympani. 14, 14. The lamina spiralis.

FIG. 6. A vertical section of the cochlea in the dried bone.

No. 1. The cul-de-sac of the meatus auditorius internus. 2. The first turn of the cochlea near its commencement. 3, 3. The modiolus. 4, 4. The lamina spiralis.

FIG. 7. A vertical section of the cochlea in the fresh subject. The references are the same as in the preceding figure. It will be observed that the lamina spiralis is completed by the mucous membrane, which covers it so as to divide the canal into its two cavities; the superior, 5, 5, being the scala vestibuli, and the inferior, 6, 6, the scala tympani.

along the inner border of the psoas muscle. The lumbar ganglia (plate XXVIII. H, H) vary much in number: there are usually, however, four or five. They are tapering, and also smaller than those in the thorax, their connecting branches being at the same time longer and more slender. From space to space branches (i, i) pass outwards from the ganglia, and, insinuating themselves under or between the fibres of the psoas muscle, join the anterior branches of the spinal nerves, which form the lumbar plexus. Another set of filaments (k, k) passes inwards in front of the aorta, and joins the aortic plexus, which they in this way contribute to form.

*Sacral ganglia—Hypogastric plexus.*—From the last lumbar ganglion, at each side, nervous branches extend down over the border of the pelvis, inclining inwards as they descend upon the anterior surface of the sacrum. There are usually four, sometimes but three, sacral ganglia (plate XXVIII. L, L) at each side, with a terminal or azygos one (M) at the coccyx. The branches from the sacral ganglia proceed in opposite directions, like those of the preceding sets—some externally, to join with the branches of the sacral plexus; others internally, which are of little importance, as they merely establish a communication with the parallel cord of the opposite side. The anterior filaments are numerous and important, as they contribute to form the *hypogastric plexus*, (L) from which the pelvic viscera receive branches. This is a complex and extended interlacement, placed deeply in the pelvis, part of it being contained within the meso-rectum, where its fibres are continuous with those of the inferior mesenteric plexus, part in the false ligaments of the bladder, or in the broad ligaments of the uterus. In it we find a mixture of branches from nerves of both systems, viz. from the sacral ganglia, the inferior mesenteric, and aortic plexus; and in the next place from the vesical, uterine, and hæmorrhoidal nerves, derived from the spinal nerves (N, N; sacral plexus.) The offsets from the hypogastric plexus follow the arteries in their course to the pelvic viscera, viz. to the rectum, bladder, vesiculæ seminales, uterus, vagina, &c.

## ORGANS OF SENSE.

### APPENDAGES OF THE EYE.

Before we proceed to examine the globe of the eye, we have to notice and describe certain accessory structures which are placed in relation to it, and are called its "appendages." All these are lodged either within the orbit, or in its immediate vicinity.

The appendages of each eye, in addition to the muscles, ophthalmic artery, vein, and nerves, comprise the eye-brow, eye-lids, and the lachrymal apparatus.

*Eye-brows.*—The eye-brows (plate XXIX. fig. 1; *supercilia*) are the arched ridges which surmount the upper border of the orbits, extending from near the root of the nose to the temples. They consist of integument, rather thickened, and studded with short hairs, which are inserted obliquely into it; also of a lamella of adipose tissue, and of the orbicularis and corrugator supercilii muscles. They form the boundary between the forehead and the eye-lids.

*Eye-lids.*—The eye-lids (plate XXIX. figs. 1, 2, 3, 7; *palpebræ*) are two thin moveable curtains placed in front of the eye, and calculated to conceal it, or leave it exposed, as occasion may require. The upper lid, which is larger and more moveable than the other, has a muscle exclusively intended for its elevation, whilst the lower one is raised up only by the action of the inferior half of the orbicular muscle. They are joined at the outer and inner angles of the eye, (fig. 2, Nos. 3, 4; *canthi*;) whilst in the interval they are separated by a transverse slit, (*fissura palpebrarum*.) Externally, the lids are covered by integument, which is thin and delicate; internally, they are lined by the conjunctiva, which is more vascular than where it passes over the ball of the eye. Between these tegumentary membranes are placed the fibres of the orbicular muscle in both lids, and those of the levator palpebræ in the upper one, together with the tarsal cartilages, and along the margins of the lids the eye-lashes. The free margin of the eye-lids is straight, (fig. 2, No. 4,) and rounded towards the inner angle for a distance of about two lines and a half, the caruncula lachrymalis (7) being there interposed between them. At the point just indicated, the borders of the lids become thicker at the same time that their surfaces become arched, the external one being convex, the internal concave, inasmuch as it rests on the convexity of the globe of the eye. Now the borders of the lids in all this part of their extent, which is about four-fifths of their breadth from within outwards, are slightly bevelled off, so that when closed they come into contact only at the outer or cutaneous line. By this conformation a triangular groove is produced, whose sides are formed by the free margins of the lids, and base by the globe of the eye. Along this the tears appear to be conducted towards the inner angle, where the ducts are placed to receive them. At the union of the straight with the arched part of each lid will be seen a very small elevation (fig. 2, Nos. 5, 5) pierced by a minute foramen, (punctum,) which leads into the lachrymal ducts.

*Tarsal cartilages.*—The tarsal cartilages (plate XXIX. fig. 6, Nos. 27, 28; fig. 7; *tarsi*) are two thin lamellæ of fibro-cartilage, placed one in each lid: the lower cartilage is narrow, about two lines in breadth, elongated, and nearly of equal breadth from side to side; that of the upper lid is four or five lines broad at the middle, but narrows to a point at the lateral margins. The ciliary, or contiguous margins of the cartilages, are rather thick, bevelled off as above stated, and covered by the conjunctiva, where it is continuous with the external tegument; but the opposite margins are thin and attached to the orbit through the





Fig 2

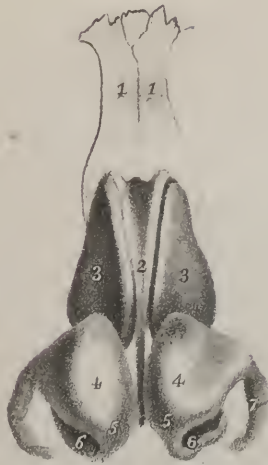

Fig 1



Fig 3



Fig 4

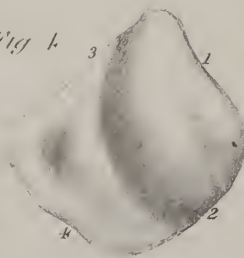


Fig 8

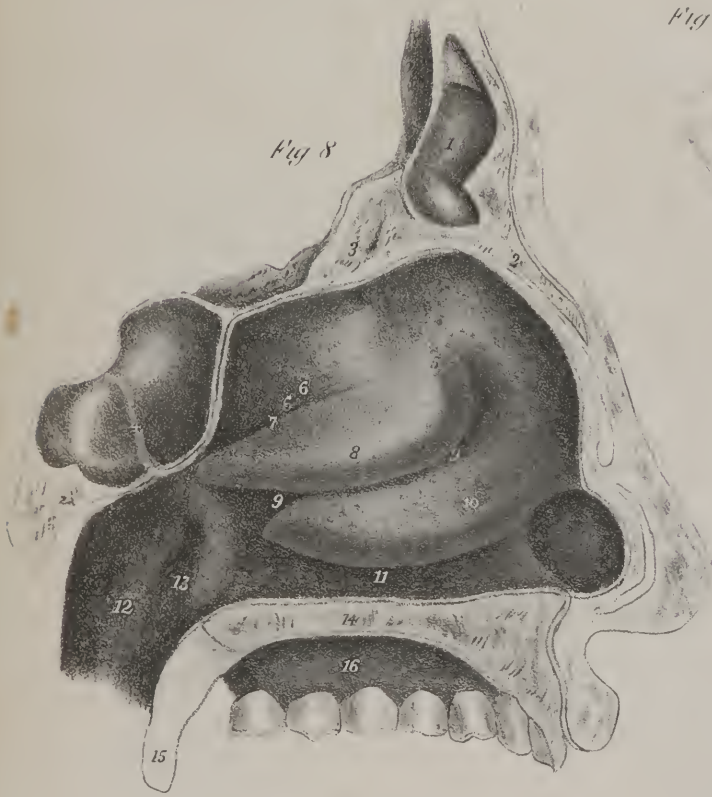


Fig 9

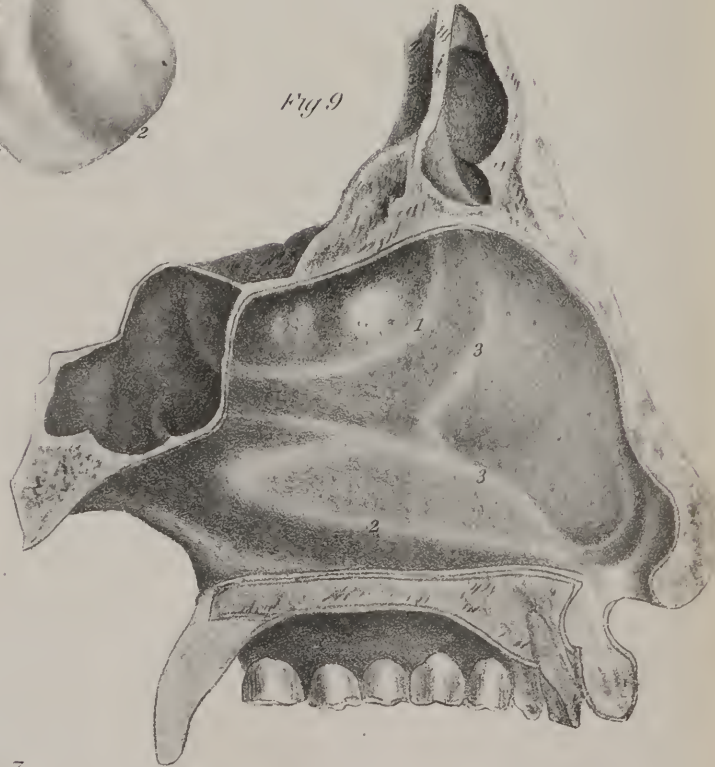


Fig 7

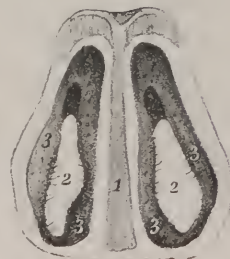



Fig 6



Fig 5



medium of a thin cellulo-fibrous lamella, (fig. 6, Nos. 5, 7,) prolonged obliquely to its border, where it becomes continuous with the periosteum, and is called the broad ligament. The cartilages extend inwards no further than the puncta, and there they become connected with the fibrous lamellæ, into which the tendon of the orbicularis muscle divides; and externally they become gradually thinner, and are connected with a fibrous lamella, which attaches them to the margin of the orbit. These means of connexion are sometimes called ligaments (*ligamentum tarsi, internum et externum.*)

*Eye-lashes.*—Along the margin of each eye-lid, at the line of junction of the skin with the conjunctiva, are placed two or more rows of hairs, called *cilia*, or *eye-lashes*, (plate XXIX. fig. 1; fig. 2, Nos. 1, 2: fig. 6, No. 31.) They are more closely set, and also longer, in the upper than in the lower lid, and at the middle of each than towards their angles; they become thin and scattered in the interval between the puncta and the inner commissure. They are curved in such a way that those of the upper lid present a convexity directed downwards and forwards—those of the lower, upwards and forwards, by which they come into apposition sufficiently for the protection of the eye, even before the lids come into close contact.

*Meibomian glands*, (glandulæ Meibomii.)—These are sebaceous follicles (plate XXIX. fig. 7) placed between the conjunctiva or lining membrane of the lids and the tarsal cartilages. They are very minute; their colour, or rather that of the secreted matter, being yellow, distinguishes them from the other structures. They are small culs-de-sac disposed in rows, running in parallel lines, and vertically from the attached to the free margin of each cartilage, along which they open by minute pores, (fig. 2;) the cartilages present grooves upon their surface corresponding with the rows of the follicles. There are usually from twenty to thirty of them in the upper lid, and about the same number in the lower.

Along the line of the eye-lashes, the external tegument of the lids changes its appearance and characters; it becomes thin and soft, so as to resemble mucous membrane. It is obviously prolonged from the free margin to the inner surface of the lids, and from these it is reflected over the fore part of the globe of the eye. Moreover, through the puncta and lachrymal ducts above alluded to, it is prolonged into the nasal cavity. At the inner angle or commissure of the lids, which is more open than the external one, the conjunctiva forms a fold, which encloses some fine cellular tissue, a delicate plate of fibrous structure, and also some mucous follicles, which, together, may be said to represent a third eye-lid in a rudimentary form. These are known as the *plica semi-lunaris* and *caruncula lachrymalis*.

## PLATE XXXV.

The organ of smell: the nose and nasal fossæ.

FIG. 1. The nose, deprived of its cuticle, in order to show the numerous openings of sebaceous follicles.

FIG. 2. The fibro-cartilages of the nose, seen from the front.

Nos. 1, 1. The nasal bones. 2. The antero-superior border of the cartilage of the septum. 3, 3. The two superior lateral cartilages. 4, 4. The two inferior lateral or alar cartilages. 5, 5. The projecting portions of the alar cartilages, which give form to the lobe of the nose. 6, 6. The internal portions of the alar cartilages. 7, 7. The cartilaginous plates which take the curve of the ala of the nose.

FIG. 3. A side view of the fibro-cartilages of the nose. The references are the same as in the preceding figure.

FIG. 4. The cartilage of the septum, (cartilago septi,) separated from the other cartilages, and viewed from its right side.

No. 1. The antero-superior border, against which the lateral cartilages rest. 2. The antero-inferior border, which is in relation with the columna. 3. The postero-superior border, which unites with the central lamella of the ethmoid bone. 4. The postero-inferior border, which unites with the vomer.

FIG. 5. The alar cartilage of the right side, seen from within.

No. 1. The external portion of the cartilage. 2. Its internal portion. 3. The projection corresponding with the lobe or tip of the nose. 4. The small cartilaginous plates which form the curve of the ala.

FIG. 6. The alar cartilage of the right side seen from the exterior. The references are the same as in the preceding figure.

FIG. 7. A transverse section of the nose at about its middle, showing the openings of the nares from within.

No. 1. The section of the cartilage of the septum. 2, 2. The openings of the nares. 3, 3. The mucous membrane lining the internal surface of the nose, upon which are seen short hairs, (vibrissæ,) and the openings of sebaceous follicles.

FIG. 8. A longitudinal section of the nasal fossa of the left side, showing its external wall.

No. 1. The frontal sinus. 2. The nasal bone. 3. The crista galli process of the ethmoid bone. 4. The sphenoidal cells. 5. The external wall of the nasal fossa covered with mucous membrane. The whole surface of the membrane is studded with the openings of mucous follicles. 6. A convex projection produced by the superior spongy bone. 7. The superior meatus. 8. The projection of the middle spongy bone. 9, 9. The middle meatus. 10. The projection of the inferior spongy bone. 11. The inferior meatus. 12. The upper part of the pharynx. 13. The opening of the Eustachian tube. 14. The section of the bony palate. 15. Section of the velum pendulum palati. 16. The roof of the palate.

FIG. 9. A longitudinal section of the nasal fossæ, made a little to the right of the middle line, in order to show the septum narium covered by its mucous membrane.

The references to the surrounding points are the same as in the preceding figure.

No. 1. That portion of the septum formed by the central lamella of the ethmoid bone. 2. A slight projection produced by the vomer. 3, 3. A slight ridge marking the union between the central lamella of the ethmoid bone and vomer and the cartilage of the septum. The whole surface of the mucous membrane is spotted with openings of mucous follicles.



*Plica semi-lunaris*.—This is a small angular fold (plate XXIX. fig. 1; fig. 2, No. 6; fig. 4, No. 6) of the conjunctiva, seen resting on the globe of the eye, at the inner commissure of the lids; its base, which is concave, looks outwards, the apex inwards. About a line to the inside of its base rises up the *caruncula lachrymalis* (fig. 1; fig. 2, No. 7; fig. 4, No. 5). Its form is conical; its summit corresponds with the inner angle of the lids; it looks red and fleshy. It consists of a cluster of delicate mucous follicles, from which an unctuous matter exudes; upon the surface are seen some minute hairs. The caruncula is not unfrequently included amongst the lachrymal apparatus, from its being supposed to assist in directing the tears into the puncta: such, however, is not the use of the third lid, of which this is a rudiment.

*Lachrymal apparatus*.—The lachrymal apparatus consists of the lachrymal gland, puncta, and ducts, the lachrymal sac and its duct.

*Lachrymal gland*.—The lachrymal gland (plate XXIX. fig. 3, No. 5; fig. 4, No. 7; fig. 5) is placed at the upper and outer part of the orbit, near its anterior border, corresponding with the lachrymal fossa in the orbital plate of the frontal bone. The gland is convex upon its upper surface (fig. 5), where it is in apposition with the wall of the orbit, and with which it is connected by a fibrous lamella, described by Semmerring as a ligament; its under surface (fig. 3, No. 5) is concave, where it rests upon the globe of the eye, the recti muscles (superior and external) interposing. Its length is three quarters of an inch, its breadth half an inch; the inner border is compressed and thin, the external one being a little thicker. The gland is divisible into two lobes, which are so closely connected that the line of separation (which is not complete) is not at first observed. When the cellular tissue which invests it is removed, it is at once perceived to belong to the class of conglomerate glands, being composed of a number of granules, each forming a secreting structure, which produces the tears. From the granules arise excretory ducts, which emerge from the gland at its anterior border, run downwards and inwards close to the conjunctiva, between it and the broad tarsal ligament, and open in a row upon its free surface (fig. 3, No. 6), about three lines above the upper margin of the tarsal cartilage; these ducts are usually seven in number.

*Puncta lachrymalia and lachrymal ducts*.—Where the external margin of the caruncula is in apposition with each lid, a minute foramen will be observed (plate XXIX. fig. 2, No. 5, 5; fig. 3, Nos 4, 4; fig. 4, No. 1, 1; *punctum lachrymale*). The puncta are situated where the curved and straight parts of the lids meet, in the summit of a small papilla; they form the openings of two canals (fig. 4, Nos. 2, 2; *lachrymal ducts, canaliculi lachrymales*) which lead into the sac (3), or reservoir, for the reception of the tears. The superior canal is longer than the other: if a thin bristle be passed into it, it will be found first to ascend a little, and then to turn obliquely downwards and inwards. The inferior one descends a little, and then turns inwards with a very slight ascent: both open into the external and anterior side of the lachrymal sac, generally by two distinct orifices, which are close together, but sometimes by a common duct.

*Lachrymal sac*.—The lachrymal sac (plate XXIX. fig. 4; *saccus lachrymalis*) is a membranous reservoir, placed in a groove formed for it in the os unguis and nasal process of the superior maxillary bone, at the inner canthus of the eye. Its form is oval, terminating superiorly in a cul-de-sac, but inferiorly it is prolonged into a tube (4; the nasal duct); at its superior and external side it receives the lachrymal ducts. The sac is crossed by the tendon of the orbicular muscle, being at the same time covered by its fibres as well as by its reflected tendon. It consists of two layers of membrane, united by cellular tissue, one of which is a mucous lining continuous below with that of the nasal fossæ, and above with the conjunctiva, through the medium of the lachrymal ducts; and the other a thin fibrous membrane, serving at the same time as periosteum for the bone in which it is lodged.\*

*Nasal duct*.—The nasal duct (plate XXIX. fig. 4, No. 4; *ductus ad nasum*) is about six inches in length in the recent state, its direction being downwards, backwards, and a little outwards. Communicating above with the lachrymal sac, it terminates in the inferior meatus of the nose by an oblique slit or orifice, which is surrounded by a small fold of the pituitary membrane. It often appears as if constricted at the middle, at the same time that it presents a slight curve, whose convexity is turned forwards. The osseous structure here consists of the os unguis, the superior maxilla, and the inferior turbinated bone, which together form a complete canal.

## GLOBE OF THE EYE.

The globe of the eye (plate XXX. fig. 1) is situated at the internal and anterior part of the orbital fossa, which lodges it and its appendages: its form is that of a spheroid, slightly compressed at the four opposite points of its circumference, which correspond with the insertion of the recti muscles (5, 6, 7). The direction of the axis of the globe of the eye does not correspond

\* *Tensor Tarsi*. (Horner's muscle.) A small muscle, to which he gave the name of *Tensor Tarsi*, was described by Wm. E. Horner, M. D., Professor of Anatomy of the University of Pennsylvania, in 1824. It is a thin plane of muscular fibres, three lines in breadth and six in length. It arises from the orbital surface of the os unguis, passes over the outer face of the lachrymal sac, and divides into two slips, which are inserted on the lachrymal canals as far as the puncta. Its use appears to be to draw the puncta inwards, to compress the lachrymal sac, and keep the edges of the lids in relation with the surface of the eye-balls.—J. P.



with that of the orbit; the axes of the eyes are parallel with one another, whilst those of the orbits diverge considerably in front, and if prolonged backwards would decussate behind the body of the sphenoid bone; hence as the optic nerves coincide in their direction with that of the axes of the orbits, each of them enters the globe of the corresponding eye to the inner side of its axis, and consequently of the axis of vision. When viewed in profile, the globe appears to be composed of segments of two spheres, of which the anterior (9) is smaller and more prominent; hence, when its different diameters are compared, it will be found that the antero-posterior exceeds the others by about a line. Anteriorly the globe of the eye is in relation with the conjunctiva (plate XXIX. fig. 6, Nos. 29, 30), which is reflected from the eye-lids upon it; posteriorly with the vessels and nerves (optic and ciliary) which enter it, and with a quantity of adipose substance (8, 8) in which it is in some measure embedded; round its circumference, with the six muscles inserted into it; superiorly and towards its outer side, with the lachrymal gland; and internally with the caruncula, tensor tarsi, and lachrymal sac.\*

The globe, or, as it is often called, the ball of the eye, is composed of membranes, placed one within the other, and of humours or fluids which they enclose; the former are not unfrequently called coats or tunics; but as none of them forms a complete investment, the term is not so applicable as that here adopted. The membranes are the conjunctiva, sclerotica, cornea, choroid, retina, and iris, the capsule of the crystalline lens, the hyaloid membrane, and that of the aqueous humour. The humours are the aqueous, vitreous, and the crystalline lens.

*Dissection.*—The eye should be examined whilst fresh, as the humours soon become putrid, and the membranes alter in consistence and other properties. The eyes of animals will answer sufficiently well in the first instance; but the relative proportions of the different parts must be studied in the human eye before operations can be attempted with safety. In order to obtain correct notions of the situation and relation of the various structures, it is necessary to make several sections of the globe. Thus a vertical section, by dividing it into two equal parts, will show the relative extent of the cornea and sclerotica, their mode of connexion, and the varying thickness of the latter in different parts. If it be suspended in water, the relation of the iris to the ciliary processes may be observed, and also the manner in which the latter are continuous with the choroid membrane. If a transverse section be carried through the coats, and the posterior half of them be removed, leaving the vitreous humour resting on the anterior one, that disposition of the ciliary processes may be distinctly seen by which they are aggregated together so as to form a complete circle round the lens. When the ball of the eye is firmly compressed, the fluid within the lamellæ of the cornea is made to ooze out on its surface, and that membrane becomes opaque. The structure of the choroid membrane can be examined with most effect after the vessels have been filled with some fine injection, either from the internal carotid or ophthalmic artery. The size injection will answer sufficiently well for ordinary purposes.

In order to proceed with the examination, the fore part of the eye should be fixed: for this purpose a pin may be passed across the cornea, and the ends of it secured to a small plate of glass by a thread or cord. To keep the eye steady, it will be found useful to affix to the glass a lump of common wax, on the top of which the eye may be secured as above mentioned. Two

\* The ball is retained in the orbit and prevented from protruding, partly by means of the recti muscles and partly by the fascia which embraces it and the vessels and nerves that enter it. It is pressed by the recti muscles against a mass of fatty matter and elastic cellular tissue, the resiliency of which appears to be the cause of its moving forwards again, when the action of the muscles has ceased. For it is well known that when, from general emaciation, the amount of fat is diminished in the orbit, the eye-ball sinks, notwithstanding the oblique muscles are preserved intact.

Of the fascia it seems necessary to give an account, as no good description of it is found in any treatise of anatomy. In the autumn of 1839, I discovered, after some operations for strabismus, that this structure had not been well described, and that the minute arrangements of it which had escaped notice would serve to explain the causes of the failures that had occurred in this operation from the hands of skilful surgeons. I described this fascia in my lectures on surgery the following winter, and published a brief account of it in the Medical Examiner of this city the succeeding spring; since then notices of the same fascia have appeared by several observers. Remove with the saw and hammer the outer part of the upper wall of the orbit. Divide with a pair of scissors the free portion of both lids near their middle, and hold the four corners asunder. It will then be seen by dissection, that, besides the skin and superficial fasciæ (which includes the orbicularis muscle,) and the palpebral ligament, there is a thick band of dense yellow fascia, attached in front to the tarsal cartilages running on the outer face of the conjunctiva and united to the sclerotic coat, where the lining conjunctival membrane is reflected forwards upon the ball of the eye. From this fascia processes are sent off backwards. One runs on the outer side of the mass of fat to the anterior circumference of the orbit, to which it is slightly attached, forms a capsule to the lachrymal gland, a sheath to the levator palpebræ, is adherent to both canthi and to the lachrymal sac, and is finally lost upon the periosteum in the back portion of the orbit. Another process runs on the inside of the mass of fat, is reflected over the tendons and bellies of the muscles, forming a perfect sheath for them with a sort of synovial bursæ, where the tendons traverse it, and is also lost in the back portion of the orbit. This fills up the space between the muscles, forms a dense capsule over the posterior part of the ball, and may be called the muscular fascia. Between this and the above fascia the fat is lodged. Below the muscular, is found a thin fibro-cellular layer, which I have called the sclerotic fascia, covering closely the sclerotic coat, and lost upon the sheath of the optic nerve. This forms a covering to the fasciculi of vessels and nerves, which run forwards to enter the tunica choroides and iris, by traversing the sclerotic coat. Between this and the muscular fascia there is but slight union, and the blunt hook can be readily swept over the ball except at the places of insertion of the tendons of the oblique. In the operation for strabismus the muscular fascia must necessarily be cut with the tendon; and care should be taken to divide it on both surfaces of the tendon. Frequently it appears to share in the shortened or contracted state of the muscle, and requires to be opened freely upwards or downwards as may be required, to allow the eye to take its straight position in the orbit. To the neglect of attending to these facts, an operation which ought uniformly to succeed has failed in the hands of some of the desired success. But this fascia, which it is to be recollected is one of the stays which hold the ball, must not be divided to the least unnecessary extent, for fear of the bulging of the organ, a deformity that the tact and experience of the operator may readily prevent, but which when once produced it is difficult afterwards to remove.

incisions should then be carried over the ball of the eye, decussating with one another at the optic nerve, and thereby dividing the sclerotica into four elliptic segments. These are easily everted, and drawn outwards after a little cautious dissection, by which means the choroid is exposed.

In order to exhibit the retina, the eye should be fixed, and the same incisions made through the sclerotica. The apparatus should then be immersed in a bowl of water, in order that the humours may be supported when the exterior membranes are removed. But, in separating the choroid, two pairs of forceps should be used, one being employed to pinch up and hold a small portion of it, whilst it is torn with the other. This process may be continued until the whole of the vascular membrane is detached and everted, leaving the retina fully exposed.

*The conjunctiva.*—The conjunctiva (*membrana conjunctiva, sive adnata*) is included by some writers amongst the accessory structures of the globe of the eye, and not amongst its proper membranes; as if it were a tegument or means of connexion with adjacent structures, and did not form part of the organ itself, considered as an optical instrument. Be this as it may, the membrane lines the free border and inner surface of the eye-lids, from which it is reflected upon the globe of the eye, so as to cover its anterior third. Along the borders of the lids it is continuous with the skin, and, by lining the *puncta lachrymalia*, forms a continuous surface with the mucous membrane of the lachrymal passages and nasal fossæ. It is red and vascular on the

## PLATE XXXVI.

The anatomy of the organ of taste: the tongue.

FIG. 1. The dorsum of the tongue, showing the papillæ.

No. 1. The epiglottis. 2, 2. The great cornua of the os hyoides. 3, 3. Folds of mucous membrane, called fræna epiglottidis, or glosso-epiglottidean ligaments. 4. The base or root of the tongue. 5, 5. Mucous glands covering the root of the tongue. 6. The raphé. 7. The apex or point of the tongue. 8, 8. The papillæ lenticulares, (calyceiformes, circumvallatæ,) forming two rows upon the base of the tongue, which approach each other on the middle line. 9. The foramen cæcum. 10, 10. Papillæ fungiformes. 11, 11. Papillæ conicæ. 12, 12. Papillæ filiformes.

FIG. 2. Arrangement of the muscular fibres in a superficial dissection of the tongue, made according to the plan described by Gerdy.

No. 1. The epiglottis. 2. The greater cornua of the os hyoides. 3. The lesser cornua of the os hyoides. 4. An expansion of yellow elastic tissue spreading upon the dorsum of the tongue, and containing a number of mucous follicles, 5, 5. 6, 6. Median longitudinal fibres, (superficial lingual muscle of Gerdy,) attached posteriorly to the elastic tissue, and converging anteriorly towards the raphé. 7, 7. Superior fasciuli of the hyo-glossus muscle, (chondro-glossi muscles.) 8, 8. Lateral fasciuli of the hyo-glossus, (æarato-glossi,) passing between the two portions of the stylo-glossus, and spreading out along the border of the tongue. 9, 9. The hyo-glossus muscle. 10, 10. The longitudinal portion of the stylo-glossus muscle. 11, 11. Its transverse portion. The whole surface of the tongue is studded with small points,—the cut extremities of the perpendicular fibres which are inserted into the under surface of the mucous membrane.

FIG. 3. The superficial lingual muscle has been removed in this dissection in order to display the arrangement of the fibres in a deeper layer.

No. 1. The epiglottis. 2. The process of elastic tissue cut through. 3, 3. The great cornua of the os hyoides. 4, 4. The lesser cornua of the os hyoides. 5, 5. The hyo-glossus muscle at each side. 6, 6. The fasciulus of the hyo-glossus muscle which passes between the two portions of the stylo-glossus muscle, and encircles the lateral boundary of the tongue. 7, 7. The longitudinal portion of the stylo-glossus muscle. 8, 8. The transverse portion of the stylo-glossus muscle. 9. The follicular tissue mixed with fat. 10. The fibrous raphé of the tongue. 11, 11. Fibres of the transverse muscle interspersed with points which indicate the transverse division of vertical fibres.

FIG. 4. A view of the muscles upon the under surface of the tongue.

No. 1. The body of the os hyoides. 2, 2. The genio-hyo-glossi muscles divided from their attachment to the lower jaw. 3. The lingualis muscle, (deep lingual of Gerdy,) of the right side seen through its entire extent. 4. The lingualis muscle of the left side partly concealed by the hyo-glossus muscle. 5. The hyo-glossus muscle of the left side; the right has been removed. 6, 6. The longitudinal portion of the stylo-glossus muscle. 7, 7. The transverse portion of the stylo-glossus muscle. 8, 8. The mucous membrane of the tongue covered with papillæ.

FIG. 5. A transverse section of the tongue made near to its base.

Nos. 1, 1. The mucous membrane on the exterior. 2. The elastic tissue. 3, 3. The superficial lingual muscle. 4, 4. The vertical fibres, which are oblique in their direction at the base of the tongue. 5, 5. Fibres of the transverse muscle somewhat curved near the base of the tongue. 6. A fibro-cartilaginous plate developed in the fibrous tissue of the raphé. 7, 7. The divided fibres of the linguales muscles. 8. The two genio-hyo-glossi muscles.

FIG. 6. A transverse section of the tongue made near to its anterior third.

Nos. 1, 1. The mucous membrane. 2, 2. The superficial lingual muscle. 3, 3. The divided fibres of the linguales muscles. 4, 4. Vertical fibres. 5, 5. Transverse fibres. 6. The genio-hyo-glossi muscles. 7. A part of the central cartilaginous plate developed in the fibrous structure of the raphé.

FIG. 7. A papilla fungiformis and several papillæ conicæ highly magnified, showing the disposition of their capillaries; from Sæmmering.

FIG. 8. A. Papillæ filiformes, highly magnified. B. Transverse section of the papilla calyceiformis; loops of capillary vessels are seen upon its surface.

No. 1. The papilla. 2, 2. The fissure of the cup in which it is lodged. Both of these figures are copied from Sæmmering.



Fig 2

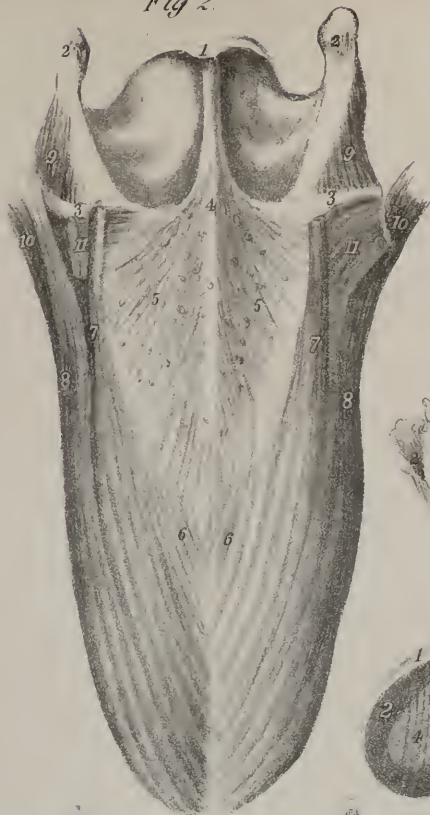

Fig 8

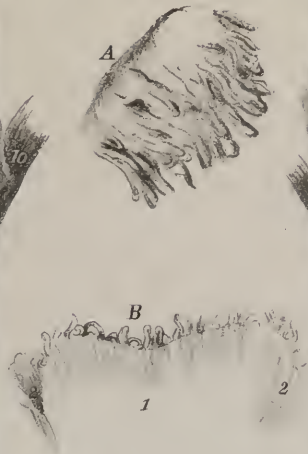

Fig 3




Fig 6



Fig 1

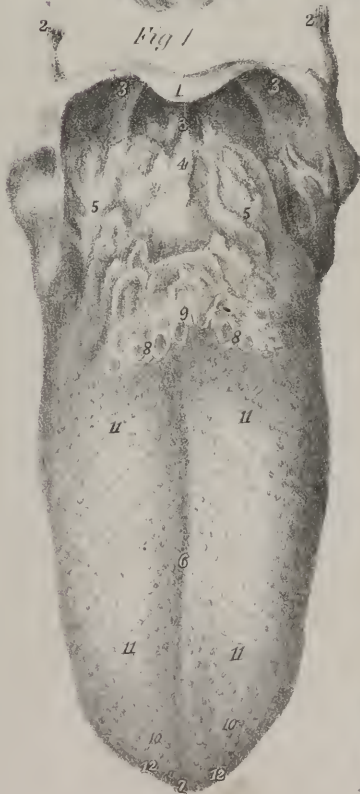

Fig 4



Fig 7

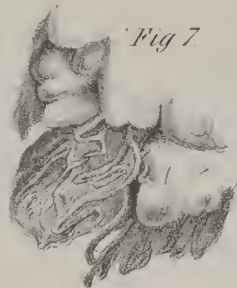


Fig 5









Fig. 1.



Fig. 2.




Fig. 3.




Fig. 4.




Fig. 5.




Fig. 6.




Fig. 8.



Fig. 7.




Fig. 9.





lids, but firm and pale on the sclerotica: it becomes thin and transparent on the cornea, so much so that some anatomists have doubted whether it extends over the entire of its surface. At present very few persons continue sceptical on this point; for even *à priori* we should infer its extension over the cornea, as every structure of the kind is known to require the protection of a tegumentary membrane. Moreover, in reptiles which cast their epidermis at stated times, the covering of the cornea comes away together with the rest; and finally, in the mus typhlus it is covered with hairs.

*The Sclerotica.*—The sclerotic (*σκληρός*, hard; *cornea opaca*: plate XXX. fig. 1, No. 1) belongs to the class of fibrous membranes; it is firm and resistant in its texture, and forms about four-fifths of the external investment of the eye, extending from the entrance of the optic nerve to the border of the cornea. Its external surface is convex, and in relation with the conjunctiva, with the tendinous expansions of the muscles, and the vessels and nerves of the orbit: the internal surface is concave, and in apposition with the choroid membrane, with which it is connected by vascular and nervous filaments, and by some delicate cellular tissue. Posteriorly it is pierced by a small circular aperture for the transmission of the optic nerve, situated a little to the inner side of the axis of the globe; anteriorly it is truncated, so as to leave an aperture about six lines in diameter, but somewhat greater in the transverse than in the vertical direction. The inner edge of this aperture is slightly bevelled off, (plate XXX. fig. 5, No. 3,) so as to allow the cornea to be inserted into it, somewhat as a watch-glass is into its case. The sclerotica being a fibrous membrane, its fibres interlace intimately, but do not assume any assignable direction. It is thicker posteriorly (fig. 5) than towards its anterior part; but in this latter situation it is strengthened by the tendinous expansions of the muscles, which some anatomists have considered as a distinct membrane, and denominated *tunica albuginea*, (fig. 1, No. 8.) At the back part of the globe it is about a line in thickness: at the insertion of the recti muscles it is scarcely half a line; but near the cornea it thickens somewhat. The aperture for the optic nerve is a little nearer to the nasal than to the temporal side of the globe, and is found to be divided by a number of septa, so as to constitute a *cribriform plate*, through which the pulp of the nerve may be made to ooze as if through minute pores. In the middle will be found one of these of larger size than the rest, which is named *porus opticus*, (plate XXXI. fig. 5, No. 3.) It gives passage to the centralis retinæ artery. At its exit from the skull, the nerve receives an investment from the dura mater, which accompanies it to the point at which it pierces the sclerotica, where it separates from the nerve, and becomes blended with the substance of the latter membrane.

*The Cornea.*—The cornea (plate XXX. fig. 1, No. 9; fig. 5, No. 4; *cornea pellucida*) occupies the anterior fifth of the globe

## PLATE XXXVII.

The organ of touch: the skin.

FIG. 1. A square of cuticle from the sole of the foot, highly magnified and seen upon its external surface.

A. Ridges which mark the rows of papillæ of the cutis. B. Interlinear furrows which correspond with the depressions between the papillæ of the cutis. C. The openings of the sudoriferous ducts on the surface of the ridges: the appearance of transverse lines is produced by the depressions surrounding the openings of the sudoriferous ducts.

FIG. 2. A square of cuticle seen upon its internal surface.

A. The sulci which correspond with the ridges of the external surface of the cuticle. B. Ridges which correspond with the interlinear furrows of the external surface. C. Conical processes of the cuticle, into which the terminations of the sudoriferous ducts are received.

FIG. 3. A square of rete mucosum seen upon its external or epidermal surface.

A. Ridges corresponding in size and form with the papillæ of the cutis, and with the ridges of the cuticle. B. Furrows corresponding with the interlinear sulci of the cutis and of the cuticle. C. The transverse depressions mark the divisions between the secondary papillæ, (interpapillary.)

FIG. 4. A square of rete mucosum seen upon its internal or dermal surface.

A. The sulci for the rows of papillæ of the cutis, divided into small fossæ by transverse partitions. The small fossæ receive the secondary papillæ of the cutis. B. The longitudinal ridges correspond with the interlinear sulci between the rows of papillæ. C. Upon the summits of the ridges, at one angle of the square, are seen some of the dark vesicular corpuscles which give colour to the rete in the negro.

FIG. 5. A square of cutis seen upon its external surface.

A. The rows of papillæ separated by interlinear longitudinal furrows. The secondary papillæ, B, are divided from each other by transverse interpapillary depressions. Each of the secondary papillæ consists of a group of primary papillæ which are the true papillæ of the cutis. C. Some of the primary papillæ, longer than the rest, are seen projecting from the secondary papillæ. D. At one angle of the square the secondary papillæ are shown to be composed of a considerable number of primary papillæ.

FIG. 6. A square of cutis seen upon its under surface, showing the fibrous structure of the corium.

A, A. Cells between the fibrous bands of the corium, which receive the adipose lobules of the superficial fascia.

FIG. 7. A portion of cutis, from which the rete mucosum is partly turned back, in order to show the sudoriferous ducts passing between the two layers.

A. The rete mucosum. B, B. The cutis, with its rows of papillæ. C, C. The sudoriferous ducts, issuing from the transverse depressions between the secondary papillæ.

FIG. 8. A thumb, from which the cuticle has been removed, to show the arrangement of the papillæ upon its tactile surface.

FIG. 9. The thumb of the opposite hand, showing a different arrangement of the tactile papillæ.

of the eye, its transverse diameter being about seven lines, the vertical a little less. The anterior surface, which is convex and prominent, is in contact with the conjunctiva; the posterior is concave, and is lined by the membrane of the aqueous humour: its circumference, nearly circular in the human subject, is received within or overlaid by the anterior border of the sclerotica, with which it is so intimately united as not to be separable from it without long-continued maceration. Its degree of convexity varies in different individuals, and at different periods of life. It is composed of five or six concentric lamellæ, united by some connecting medium, probably a fine cellular tissue, the interstices of which contain an aqueous or serous fluid. It is thicker than the sclerotica, which may be readily seen by making a section of both; but it is by no means so dense; its layers will be found to slide almost upon one another when it is pressed between the fingers. The lamellated structure of the cornea is beautifully adapted to the functions of the eye. Were it fibrous, like the sclerotica, even though at the same time translucent, it would cause a dispersion of the rays of light, and thereby resolve them into their primitive or prismatic rays, which would necessarily produce a coloured and confused image. The effect may be readily exemplified by looking at a lighted taper through a feather: the flame will instantly appear surrounded by a halo of coloured images; and were the cornea made up of fibres woven ever so finely, the effect would be similar.

*Ciliary ligament.*—The ciliary ligament, (plate XXX. fig. 2, No. 7; fig. 5, No. 6; plate XXXI. fig. 1, No. 3; *orbiculus ciliaris*, Haller,) is a ring of light gray matter, about a line and a half in breadth, which is attached to the inner surface of the sclerotica, just at its junction with the cornea. Externally it is united, though slightly, with the sclerotica; posteriorly with the choroid membrane; and anteriorly with the iris, which may be said to be inserted into its substance. It adheres more firmly to the choroid than to the other textures; for though it is separated by a slight effort from the latter, it remains securely attached to the former. The ciliary arteries pass through it, and distribute some twigs to it, as do the ciliary nerves in their course to the iris. Its external surface or circumference presents a slight groove which runs around it, so that when in apposition with the sclerotica a minute canal is enclosed between them. Fontana appears to have been the first who noticed this circumstance; hence it has been named the canal of Fontana. Some anatomists have considered the ciliary ligament as a ganglion in which the ciliary nerves terminate, and from which branches proceed to the iris; but no instance can be adduced in which a nervous ganglion forms the medium of union and connexion between parts in the same way that this structure does, as we find it attached to the sclerotica, and giving attachment to the iris, choroid membrane, and ciliary processes.

*The Choroid.*—The choroid membrane (plate XXX. fig. 2, No. 2; fig. 3, No. 3; fig. 5, No. 5; *tunica, vasculosa, choroidea*) lies between the sclerotica and the retina, extending from the entrance of the optic nerve as far as the ciliary ligament. In the greater part of its extent it is connected, though loosely, to the sclerotica by cellular tissue, and by the vessels which pass from without to reach it; but anteriorly the union is established through the medium of the ciliary ligament. The inner surface is in apposition with the retina, or rather with Jacob's membrane. Posteriorly the choroid presents a foramen, with a well-defined margin, for the transmission of the optic nerve: anteriorly, after becoming connected with the ciliary ligament, it is prolonged inwards towards the axis of the eye, and is drawn into a number of delicate folds, the aggregate of which forms a complete circle, resting, like a collar, round the border of the crystalline lens, and the anterior surface of the vitreous humour. In this manner are formed the ciliary processes, the aggregate of which has been variously named by different anatomists (*corpus ciliare, corona ciliaris*.)

The choroid membrane is essentially vascular in its structure, being composed of minute arteries and veins, united by cellular tissue. When the sclerotica is removed so as fully to expose the choroid membrane, we find lying upon its surface, if the dissection has been carefully executed, the ciliary nerves (plate XXX. fig. 2, Nos. 6, 6; fig. 3, Nos. 5, 5) compressed and flat: their destination is the ciliary ligament and iris. Two long arteries will also be found (long ciliary arteries, fig. 2, No. 3; plate XXXI., fig. 1, Nos. 6, 6) passing horizontally forwards, maintaining little, if any, connexion with the choroid; for, after having pierced the sclerotica, they lie between the latter and the choroid, without giving branches to either; and when they reach the ciliary ligament, they turn inwards and divide into branches, which are exclusively distributed to the iris. These vessels are situated at opposite sides of the globe, nearly on a line with its axis; the external one, however, is a little above, the internal a little below it. But there is a set of vessels which are intimately connected with this membrane, being distributed to it exclusively, viz. the *short ciliary arteries*, which pierce the sclerotica nearer to the optic nerve than the long ones, and soon divide into branches: these run at first parallel with one another, and mutually send twigs of communication, so that they all freely anastomose, particularly towards the anterior part of the choroid, where they form a circle, consisting of a most minute interlacement of vessels. The veins are readily distinguishable from the arteries by their greater size, as well as by their peculiar arrangement. They extend from before backwards in a radiated form, describing arches as they converge to the posterior part of the eye, and form by this union three or four small vessels, which pierce the sclerotica, and open into some of the secondary branches of the ophthalmic vein. As the veins of the choroid membrane are disposed in whirls, they are usually denominated *vasa vorticosa*, (plate XXX.; fig. 2, Nos. 2, 2; fig. 3, Nos. 3, 6;) they occupy for the most part the external, and the arteries the internal surface of the membrane. On this distribution of the vessels is founded the division of the choroid into two lamellæ, of which the internal is denominated *tunica Ruyschiana*, in compliment to Ruysch, who was the first that succeeded in demonstrating its structure by injection. The inner surface of the membrane, from its villous or fleecy appearance, has been called *tapetum*; when





Fig. 1.

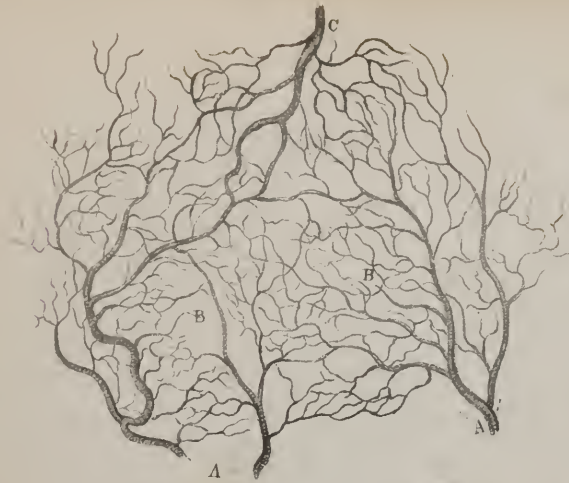


Fig 2.



Fig 5



Fig. 3.

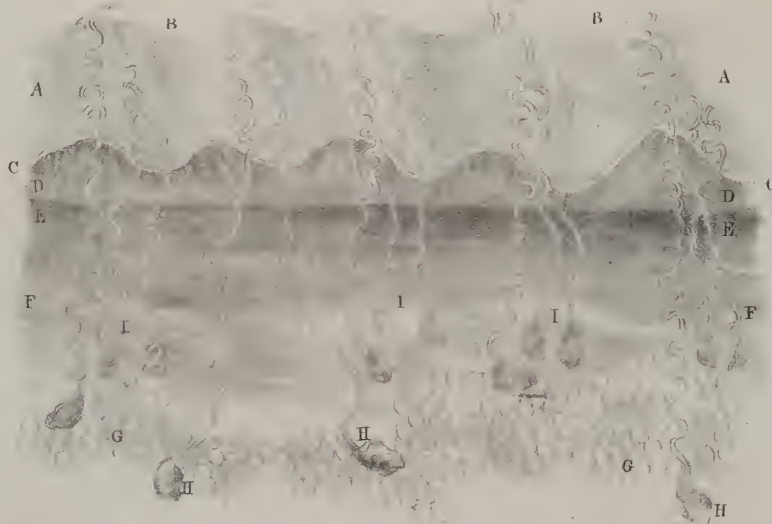


Fig. 6.




Fig. 7.

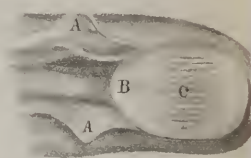


Fig 4.




Fig 8.




Fig. 9.



minutely injected, it is of a deep scarlet colour. It appears to secrete the colouring matter, (*pigmentum nigrum*.) which is a viscid and apparently mucous secretion, deposited upon the internal surface of the membrane. Its quantity varies in different parts, being more abundant anteriorly and in the interstices of the ciliary processes.

*Ciliary processes.*—The ciliary processes, formed, as has been above stated, of the anterior margin of the choroid, are from sixty to eighty in number, (plate XXXI. fig. 2, No. 2; fig. 3, No. 3; plate XXX. fig. 5, No. 8.) The form of each lamella, or process, is triangular; one side looks forward to the iris, the other backward to the vitreous humour, with which it is in contact; the third or internal one, the shortest, is free. The processes are alternately long and short, and in their arrangement resemble the plicæ observable on the under surface of a mushroom. The intervals between the processes are filled by a pigment similar to the *pigmentum nigrum* in every particular, which leaves on the surface of the lens and of the vitreous humour a number of dark striated lines, corresponding not with the processes, but with the intervals between them. When removing the ciliary processes, it will be observed that they are not merely in contact with the anterior part of the hyaloid membrane; minute plicæ of the latter project into the interstices between the processes, and seem to be connected with them. The name ciliary body (*corpus ciliare*) is usually given to the aggregate of the ciliary processes.

*Retina.*—The retina (plate XXX. fig. 4, No. 1; fig. 5, No. 9; *tunica nervea*) is placed between the choroid membrane and the vitreous humour, with which it is merely in apposition. It extends from the bottom of the eye, where it is continuous with the optic nerve, forwards as far as the commencement of the ciliary processes, where it appears to terminate by a defined and rather prominent line. Its structure is soft and pulpy; in the living subject it is transparent, and so continues for some hours after death, but then becomes of a pale white colour. When the ophthalmic artery has been minutely injected, the membrane can be shown to consist of two lamellæ, of which the internal is vascular, and presents several small vessels, which arise from the centralis retinae artery; the external lamella appears to consist of white nervous matter. If the eye be macerated for some days in water,

## PLATE XXXVIII.

The anatomy of the skin.

FIG. 1. Capillary vessels of the skin, considerably magnified, from an injected preparation.

A, A. Arterial branches. B, B. Capillaries. C. A venous trunk collecting the blood from the capillaries.

FIG. 2. Plexus of lymphatic vessels in the skin, considerably magnified, from an injected preparation.

FIG. 3. A thin section of the skin from the palm of the hand, highly magnified.

A, A. The cuticle, showing its laminated structure and the oblique direction of the laminae. B, B. The imbricated arrangement of the surface of the cuticle, giving rise to the appearance of ridges and furrows. C, C. The rete mucosum:—this was seen beneath the microscope, with a transmitted light, as a narrow translucent line; its thickness in relation to the cuticle and papillary layer is carefully preserved. D, D. The papillary layer of the cutis, in which are represented five secondary or larger papillæ: each secondary papilla being seen to be composed of a group of primary papillæ. E, E. The upper part of the corium, darker in colour than the rest of the layers, from its compactness of structure, which prevents the passage of transmitted light, and also from its greater vascularity. F, F. The lower part of the corium, less compact and vascular than its upper surface. G, G. Adipose vesicles. H, H. Sudoriferous follicles, from which the sudoriferous ducts are seen issuing, and traversing the corium, papillary layer, rete mucosum, and cuticle, to reach the pores upon the surface of the skin. In the cuticle the sudoriferous ducts are beautifully spiral; in the papillary layer they are slightly curved; and in the corium they generally lose the regular spiral arrangement and become serpentine, or retain one or two turns only. I, I. Some sudoriferous follicles and ducts, seen dimly in the deeper parts of the section.

FIG. 4. A thin section of the scalp, highly magnified; showing the mode of growth of the hairs, and the form and arrangement of the sebaceous follicles.

A, A. The cuticle. B, B. The thin layer of rete mucosum. C, C. The papillary layer. D, D. The corium. E, E. Adipose vesicles. F, F. The secreting follicle of the hair. G, G. Sebaceous follicles, terminating in ducts which open into the follicle of the hair. Sometimes a sebaceous follicle is situated at each side of the hair, as at H. I. The bulb of the hair. K. The irregular branch-like developed from the cylinder of the hair. L, L. Sudoriferous follicles, from which ducts are seen ascending to the surface of the cuticle.

FIG. 5. A thin section of skin from the extremity of the nose, showing the sebaceous follicles.

A, A. The sebaceous follicles of irregular form, consisting apparently of the convolutions of a single tube. B, B. The small down-like hairs, provided with a secreting follicle, but having no connexion with the sebaceous follicles. C, C. The openings of the ducts of the follicles upon the surface of the skin.

FIG. 6. Section of a thumb, showing the relation of the nail to the soft parts.

A. The last phalanx. B. The cuticle reflected upon the root of the nail. C. The nail. D. The cuticle of the point of the thumb continuous with the inner surface of the nail. E. One of the longitudinal and plicated papillæ, which secretes the nail.

FIG. 7. The upper surface of the thumb, from which the cuticle and nail have been removed.

A, A. Two flaps of skin turned aside from over the insertion of the root of the nail. B. The smooth surface of the secreting structure of the nail which corresponds with the lunula. C. The longitudinal and plicated papillæ which secrete the laminae of the nail.

FIG. 8. The under or dermal surface of the nail.

A. The thin edge by which the nail is inserted beneath the integument of the finger. B. The lunula. C. The laminae of the nail, secreted by the plicated papillæ.

FIG. 9. A magnified representation of the arrangement of the secreting capillaries of one of the plicated papillæ.



the latter part of the retina can be washed away, leaving the vascular lamella in its natural position. About two lines outside the entrance of the optic nerve may be observed in the retina a small hole and a yellow spot, first described by Sæmmering, and named by him, the one *foramen centrale*, the other *limbus luteus*, (plate XXX. fig. 4, No. 2: plate XXXI. fig. 4, No. 4; fig. 5, No. 1.) The yellow spot appears to coincide with the axis of vision; the appearance which has been called a foramen is owing to a transparent point in the retina, and not to a perforation of its substance; the outer or medullary layer is merely deficient.

“Exclusively of the two layers here noticed, the retina is found to be covered on its external surface by a delicate transparent membrane, united to it by cellular substance and vessels. If the sclerotica be removed, and the choroid membrane carefully torn and averted, small portions of the structure here alluded to can be detached, or a globule of air, or even of quicksilver, may be insinuated beneath it, by which means it is raised, and can be seen distinctly if held towards the light.”\* This is now known as *Jacob’s membrane*. It cannot be said to be a part of the retina, or to consist of its medullary lamella detached by the process resorted to in the dissection of the organ; for the yellow spot of Sæmmering is not distinctly seen until Jacob’s membrane is removed; and when this has been effected, we can still show the retina to consist of its two lamellæ.

*The Iris.*—The iris, (plate XXX. fig. 2, No. 3; fig. 5, No. 15: plate XXXI. fig. 1, No. 2,) which presents the coloured circle seen through the transparent cornea, resembles a partition placed vertically so as to divide, but very unequally, the interval between the cornea and the lens into two parts. This interval is filled by the aqueous humour, so that the iris moves freely in the fluid. The space between it and the cornea, which is much the larger, is called the *anterior chamber*, (plate XXX. fig. 5, No. 13;) that behind it is the *posterior chamber*, (17;) both communicate through the pupil. The iris presents two flat surfaces and two circumferences; on the anterior surface, which is differently coloured in different individuals, may be observed two concentric rings, of which the external (plate XXXI. fig. 6, No. 3: annulus major) is broader than the internal, but not so deeply coloured: it is marked by several striated lines, which pass from the great circumference inwards to the pupil, where they seem to bifurcate. The inner ring (fig. 6, No. 2: annulus minor) is more deeply coloured, and surrounds the pupil. The posterior surface contiguous to the ciliary processes is covered by a dark pigment similar to that of the choroid; it is usually called *uvea*, (fig. 3, No. 2.) When this is washed off, a number of fine lines, or fibres, may be observed, with the assistance of a magnifying power, converging from the greater circumference to the pupil; these are distinct from one another in the former situation, but in the latter are blended so as to form a membranous zone.

The great circumference of the iris corresponds with the ciliary ligament, (plate XXXI. fig. 1, Nos. 3, 3,) into which it may be said to be inserted: the smaller forms the border of the aperture called the *pupil*, (fig. 1, No. 1: pupilla.) The pupillary aperture is closed in the fœtus, up to the seventh month, by a delicate transparent membrane, called, from this circumstance, *membrana pupillaris*, (plate XXXI. figs. 11, 12.) If examined after the vessels of the eye have been injected, it will be found distinct from the iris, and appearing as if inserted into its margin, so as to cut off all communication between the two chambers. It becomes reticulated a little after the time referred to, then a few fragments of it only remain, and finally it disappears before birth. According to M. Jules Cloquet’s account, it is a sort of mediastinum formed by the contiguous sides of two small culs-de-sac, one of which is the membrane of the aqueous humour continued across upon the front of the iris, the other the lining membrane of the posterior chamber, both being in apposition at the pupil.

The iris is abundantly supplied with nerves from the ciliary nerves: it receives the two long ciliary arteries which pass along between the choroid and sclerotica, and the smaller, or anterior ones, which pierce the ciliary ligament from without. These vessels approach the iris from four opposite directions, and at its greatest circumference freely anastomose, so as to form the larger vascular circle of the iris. From this circle branches pass inwards, converging, and form at a little distance from the pupil another circle, by a second anastomosis. Finally, from this inner circle minute filaments pass inwards, and seem to terminate at the pupillary margin of the iris. The veins, in general, take the same course as the arteries, but the greater number open into the vasa vorticiosa. The ciliary nerves, after having passed through the ciliary ligament, incline inwards upon the anterior surface of the iris, where they divide into fine filaments, which soon elude our research, even with the aid of a microscope.

*The Humours of the Eye.*—The *aqueous* humour is a thin, pellucid fluid, which fills up the two chambers of the eye, occupying the space between the cornea and crystalline lens. Its specific gravity and chemical composition differ little, if at all, from those of the vitreous humour; it is moreover enclosed in a thin transparent membrane, which secretes it in the first instance, and reproduces it when evacuated by accident, or during operations. This membrane, (plate XXX. fig. 5, No. 14,) usually called the *capsule* of the aqueous humour, lines the cornea and the anterior surface of the iris, but does not seem to extend into the posterior chamber.

*Crystalline lens.*—The crystalline lens (plate XXX. fig. 4, No. 7; fig. 5, No. 18: plate XXXI. fig. 2, No. 3: figs. 8, 9, 10) is situated at the union of the anterior third with the two posterior thirds of the eye, lying behind the iris, surrounded by the ciliary processes, and embedded in the vitreous humour; it is perfectly transparent, soft in the greater part of its extent, but of high refracting power. The lens is doubly convex; but the posterior segment which is received into the vitreous humour is more convex than the anterior; the convexity of both is greater in infancy than in adult age. The greatest thickness of the lens is

\* An Account of a Membrane now first described, by Arthur Jacob, M. D.—*Phil. Trans.* 1819.



about two lines and a half; its circumference measures from twelve to fourteen. It consists externally of a soft and homogeneous substance, presenting no trace of organization; but the central part, more dense and firm, is made up of concentric lamellæ.

The lens is enclosed in a delicate capsule, which invests it all round, but without any distinguishable adherence to it, and is thicker and firmer on the anterior than on the posterior surface. If a puncture be made in the membrane, a small quantity of a pellucid fluid, which is termed *liquor Morgagni*, issues from the incision.\* When macerated in a dilute acid, or suddenly plunged into boiling water, the capsule becomes opaque and corrugated, presenting a pale, milky appearance. The lens, having its posterior segment embedded in vitreous humour, is retained in its situation so firmly that it requires some effort to detach it. This is accounted for by supposing that the lens and its capsule are both enclosed within a duplicature of the hyaloid membrane; or rather, after investing the vitreous humour, this membrane, as it approaches the circumference of the lens, divides into two lamellæ, of which one passes before, the other behind that body. By this arrangement an interstice of a triangular form is left, the apex of which is at the point of division of the membrane, the base at the margin of the lens; and as this is continued all round, it forms a canal, named the *canal of Petit*, (plate XXX. fig. 5, No. 20.) When distended with air, which can be easily done by puncturing it and inserting the point of a blowpipe, the canal presents the appearance of a chain of minute vesicles disposed round the lens, communicating freely, inasmuch as the air passes from one to the other. This is attributable to the existence of filaments or bands connecting the lamella which passes before with that passing behind the lens, so as to stricture the intervening space—the canal, from point to point. The formation of the canal, and the connection of the lens with the vitreous humour, has been accounted for in a different way from that here indicated. The hyaloid membrane, instead of dividing into lamellæ which encase the lens, may be said to pass altogether behind it, simply enclosing the vitreous humour, as in other parts of its extent. The zonula of Zinn (plate XXX. fig. 4, No. 5) is considered a distinct structure, being firmer than the hyaloid upon which it rests. It is a flat, thin, membranous lamella, whose inner circumference surrounds the lens, the outer being connected organically with the anterior edge of the retina; its anterior surface presenting a number of dark lines, being so many markings left by the pigment of the ciliary processes which rest upon it, as well as delicate folds which are received into the interstices between these processes, and form a connection with them. This membrane, supposing it to be a distinct structure from the hyaloid, may be said to retain the lens in its situation, and to form the anterior wall of the canal of Petit.

The capsule of the lens receives a minute branch from the *arteria centralis retinae*, which ramifies on its posterior segment, but none of its branches have been found to extend to the substance of the lens. The lens has been supposed to be muscular in its structure, and thereby to possess the power of altering its form, so as to adapt the eye to the different distances within which distinct vision obtains. This opinion was first promulgated by Dr. Pemberton,† in a thesis written at Leyden. Dr. Young‡ brought it forward again some years ago, and several physiologists have assented to it. Chemical analysis, however, has long since shown that the lens consists of pure albumen, some gelatine, and water, without the slightest admixture of fibrine, the essential constituent of muscle. Moreover, were it muscular, it must consist of fibres of some sort; and were these ever so minute or so fine, the density of the points corresponding with the fibres must be greater than that of the intervals, for intervals there must be where there are striæ, or lines; and to suppose a muscle without lines and intervals, is to suppose what has not yet been seen in nature. Were such a structure as this made a medium for the transmission of light, the rays must be dispersed and resolved into their primitive or prismatic rays, producing of necessity a coloration of the image and indistinctness of vision. The remarks and the experiment above cited, to show that the cornea must be homogeneous, apply with equal force to the structure of the lens.

*Vitreous humour.*—The *vitreous humour* (plate XXX. fig. 5, No. 21; humor vitreus, corpus vitreum) fills up the posterior two-thirds of the globe of the eye. It consists of a thin transparent fluid enclosed in a fine membrane, (*hyaloid membrane*, 11;) this not only invests it externally, but forms a number of processes, projecting inwards, and dividing it into detached masses, which may thus be said to be lodged within the areolar intervals of the membrane. Some anatomists suppose also that it forms a tubular fold (22) which reaches from behind forward, enclosing the branch of the *centralis retinae* artery which passes to the lens. This structure, though thin and transparent, is yet firm, particularly at the fore part. The term *corpus vitreum* is sometimes applied to the fluid and the capsule taken together. Anteriorly, at the central part, is a slight depression which lodges the posterior segment of the crystalline lens, and farther out, where it corresponds with the ciliary processes, is an annulus, or disk, called the zonula of Zinn: we here observe a number of dark lines converging like radii, and disposed in the form of a disk round the lens. But, besides the dark lines, which are merely streaks left by the pigment which had exuded from the intervals between the ciliary processes, there are also some delicate plicæ in the membrane itself; these project so as to be received between the contiguous ciliary processes, and form a connexion with them. This part of the membrane appears to differ somewhat from the rest of it, which induced Zinn to consider it a distinct structure; hence he called it “membranula,” and the coloured disk and plicæ “zonula coronæ ciliaris.”

\* From several examinations, which I have made of the eyes of animals immediately after death, and in criminals shortly after execution, I am disposed to believe that the liquor Morgagni does not exist during life. It is found, however, some hours after death, and is probably an exudation of serum from the substance of the lens.—J. P.

† Haller, *Disputationes Anatomicæ*, tom. vii.

‡ *Phil. Trans.* 1809.

When the eye is examined as an optical instrument, with a view to determine the influence which it can exert upon the rays of light, it becomes necessary to examine the dimensions, form, densities, &c. of its different components. The humours being so many media of transmission, their effects can be calculated only by knowing their density, refracting and dispersive powers. And as the membranes serve to enclose the area within which all the changes take place, the form of the space, its axis, and diameters, require to be subjected to accurate measurement. But these topics do not properly come within the scope of an elementary work on anatomy.

## THE EAR.

The organ of hearing is divisible into three parts, viz. the auricula, or external ear, which receives the impressions of sound; the tympanum, a middle chamber, which transmits them; and the labyrinth, or internal ear, which contains the sentient apparatus.

The *auricula* (including under that term the pinna, or flat part; and the meatus auditorius, or the tube which leads from it to the tympanum) is placed at the side of the head, behind the jaw, and before the mastoid process.

The *pinna*, or flat part, (plate XXXII.,) is of an irregularly oval form, its superior extremity being broad, the inferior somewhat elongated and narrow. Its surfaces are marked by some prominent lines and depressions which have received particular names. The semi-circular prominent line (plate XXXII; fig. 2, Nos. 2, 2) which runs round the border of the pinna, is called the *helix*; it may be said to commence at the centre of the concha, above the meatus externus, and to terminate at the lobule, after having formed the margin of the ear. Within this, and, as it were, enclosed by it, is another curved prominence, the *anti-helix*, (4,) which begins above the concha by two slightly elevated lines (5, 5) that converge and unite to form the line that bounds the concha, and finally terminates at the anti-tragus. The *tragus* (8) is a small triangular prominence, that projects over the anterior and external part of the auditory tube; its margin is covered with hairs; and opposed to it stands another, which is smaller, and called, from its position, *anti-tragus*, (9;) it forms the termination of the anti-helix.

These parts owe their form and consistence to a firm lamella of fibro-cartilage, which constitutes their basis, and upon which the integument is reflected, giving it its exterior investment. The inferior and elongated portion of the pinna is called the lobule, (12, *lobulus*.) It is soft and pendulous, and differs in structure from all the rest, as it contains no cartilage, being composed merely of a thick lamella of condensed cellular and adipose tissue, subjacent to the common integument. Between the prominences above noticed three depressions are observable, differing very much in form and size. The helix and anti-helix are separated by a narrow groove (7) sometimes called *fossa innominata*. The shallow depression (6) between the two ridges presented by the anti-helix superiorly, is termed *fossa navicularis*; whilst the deep excavation, (10,) bounded by the anti-helix, and leading into the meatus auditorius, is called *concha*. This is a deep depression, bounded above and behind by a crescentic prominent margin formed by the anti-helix; it is surmounted in front by the tragus, at the opposite point by the anti-tragus, and divided unequally by the ascending curve of the helix, which, as we have said, may be considered to arise out of it. The inferior, or larger fossa of the concha, leads forwards and inwards to the meatus externus. The concha is necessarily prominent and convex posteriorly, and to this part the term *dorsum* is sometimes applied. When the integuments are removed, it will be found that the cartilage is incomplete at some points, presenting fissures which are filled up by cellular or fibrous membrane. Between the tragus and the commencement of the helix, there is a large interval of this sort, (fig. 4, No. 14,) and another between the inferior termination of the helix and anti-helix, where they surmount the lobule.

The pinna is retained in its situation not only by the integument and by its connexion with the meatus, but also by fibrous bands, which some have described as ligaments: one of these connects the tragus with the root of the zygoma, another passes from the convexity of the concha to the mastoid process, a third extends from the temporal aponeurosis to the upper part of the concha.

We have already described the muscles of the external ear. These may be said to act on the pinna as a whole; there are others, however, which are calculated to move the different parts of which it is composed, but are so rudimentary in man as scarcely to deserve notice. It is usual to enumerate five of these, their names being taken from the parts of the pinna to which they are attached. As to their action, we may omit all mention of it in the human subject.

*Musculus major helicis* arises just above the tragus, runs upwards upon the helix, and terminates where it is about to curve backwards. *m. Minor helicis* commences in the concha close to the commencement of the helix, inclines upwards and forwards, and is lost upon the rim of the helix. *m. Antitragicus* commences at the posterior surface of the anti-tragus, upon which it passes upwards and outwards to terminate upon the helix, crossing the fissure between it and the anti-tragus. *m. Tragicus* consists of some fibres which are placed upon the tragus, extended from its base to its apex. *m. Transversus auriculæ* stretches from the convexity of the concha to that of the fossa innominata. To these Mr. Tod,\* in his publication on the ear, has added two muscles not hitherto named: *musculus obliquus auris*, which extends from the dorsum of the concha to that of the scapha; and *m. contractor meatûs* (*trago-helicis*), which ascends from the tragus obliquely to the anterior extremity of the helix.

\* The Anatomy and Physiology of the Organ of Hearing, by David Tod.



The *auditory tube* (plate XXXIII. fig. 1, B; meatus auditorius externus) leads from the concha towards the cavity of the tympanum, from which it is separated by the membrana tympani: its direction is obliquely forwards and inwards, with a slight inclination at first upwards and then downwards, so that it describes a curve, the concavity of which looks downwards and a little forwards. The length of the tube is about ten or eleven lines, but its lower surface measures more than the upper, in consequence of the obliquity of the membrana tympani; its form is oval, for when a section is made of the tube, its greater diameter will be that from above downwards. Its capacity is not equal throughout its entire extent; it is wider externally where it passes off from the concha than internally at its termination, and about the middle point between these it is a little narrower than elsewhere. The meatus is made up partly of cartilage, and partly of a ring of bone, about six lines long, and placed between the mastoid process and the root of the zygoma, and above the glenoid fossa. In the adult it is identified with the temporal bone; in the fœtus it represents a thin osseous ring, connected with it chiefly by membrane, and somewhat by bone at its upper and outer part. The cartilaginous part (plate XXXII. fig. 5, No. 12) is continuous externally with the concha, from which it is prolonged inwards, to be attached by some short irregular fibres to the rough margin of the osseous ring, with which it thus forms a continuous tube. The cartilaginous and osseous structure occupy each about half the length of the meatus. But the cartilage does not complete the tube in its external half; it may be said to commence from the base of the tragus and the inferior and back part of the concha; proceeding inwards, it becomes curved upon itself so as to form the under and anterior portion of the tube, but it is deficient at its superior and external part, where its place is supplied by dense fibrous membrane. The meatus is lined by a prolongation of the external tegument, which resembles a blind sac, like the finger of a glove, its termination being reflected upon the outer surface of the membrana tympani. The tegument gradually becomes thinner as it recedes from the concha; and when its cuticle is removed, it presents a number of pores or apertures, being the outlets of the glands which secrete the cerumen of the ear.

*Membrana Tympani—the Tympanum.*—The membrana tympani (plate XXXIII. fig. 1, No. 13; plate XXXIV. fig. 1, No. 15) forms the inner boundary of the meatus externus, and separates it from the cavity of the tympanum. The membrane is inserted into the inner margin of the osseous tube, and is placed so obliquely in its situation that its external surface looks outwards, downwards, and forwards; it is, moreover, concave, whilst the internal surface, which looks to the cavity of the tympanum, is convex. The membrane consists of three lamellæ, one being proper to itself, and of a fibrous structure, the others being tegumentary membranes, reflected upon it, and derived, the one from the skin, which is prolonged in the form of a cul-de-sac into the auditory tube, whilst the other is continuous with the mucous lining of the tympanum.

Sir Everard Home advocated the opinion, that the proper or middle membrane of the membrana tympani consisted of muscular fibres, and supported his views by appealing to his dissection of the part in the elephant. No one is disposed to deny its being fibrous; but as to its being muscular, that forms an additional matter of inquiry. The fibres appear to converge from the circumference of the ring of bone towards the central line, and are connected intimately with, if not actually inserted into, the outer surface and apex of the long handle of the malleus, also into its short process. From this arrangement it results, that all that part which corresponds with the former is concave outwards; but the remainder, being about an eighth of the whole, is slightly convex. The form of the membrane is an irregular oval in the fœtus, but in the adult it is nearly circular.

The *cavity of the tympanum* (plate XXXIII. fig. 1, C) is narrow and irregular in its form, and so placed in the pars petrosa that the meatus externus lies to its outside, the labyrinth to the inner side, while the mastoid cells open into it posteriorly, and the Eustachian tube anteriorly. Its external wall is formed almost exclusively by the membrana tympani; the internal is composed of an irregular bony lamella, in which we observe the following elevations, openings, &c. The *promontory*, (fig. 6, No. 5; promontorium,) a rounded bony eminence, corresponds with the middle of the extent of the tympanum, if taken from before backwards. Above the promontory is situated an aperture, the *fenestra ovalis*, (fig. 6, No. 4,) which leads into the vestibule, but is closed by a thin membrane, which prevents any direct communication between the cavities. The greater diameter of the fenestra is directed obliquely backwards and a little downwards. Beneath the promontory, and almost concealed by it, is another aperture, called *fenestra rotunda*, (6,) though its form rather approaches that of a triangle; it corresponds with that part of the cochlea called *scala tympani*, and is also closed by a membrane.

When we examine the circumference of the tympanum, we find, at a point posterior and external to the promontory, and opposite to the inferior extremity of the fenestra ovalis, a small triangular bony process called the *pyramid*, (fig. 6, No. 7,) the summit of which presents a minute opening, leading to a tube (*fistula*) in its interior, that lodges the stapedius muscle. Between the pyramid, the promontory, and fenestra ovalis, is a depression called sinus or sulcus tympani. Behind and at the root of the pyramid is a minute foramen, (*8 apertura chordæ*;) which gives passage to the vidian nerve as it enters the tympanum from the aqueduct of Fallopius, and assumes the name of the chorda tympani. This bony canal is sometimes called iter ab aquæductu ad tympanum. A little above this orifice is a convex ridge, (2,) which runs upwards and forwards over the fenestra ovalis; it marks the course of the aqueduct of Fallopius. At the posterior and superior part of the cavity is situated an aperture, leading into the interior of the mastoid process, (1,) which is hollowed into cells partially separated by bony septa, and lined by mucous membrane prolonged from the tympanum; so that the mastoid cells may be considered as diverticula or prolongations from the latter cavity. In the anterior part of the floor of the cavity is the glenoid fissure, which transmits the chorda tympani nerve, the laxator tympani



muscle, and lodges the processus gracilis of the malleus. Finally, at the inner and anterior part of the cavity are two orifices, with a small bony lamella (*processus cochleariformis*) interposed between them, which separates two canals into which these orifices lead; the superior or smaller one (fig. 6, No. 10) transmits the tensor tympani muscle, the other (12) forms part of the Eustachian tube.

*Eustachian Tube.*—The Eustachian tube, (plate XXXIII. fig. 1, No. 21,) is from an inch and a half to two inches long, its posterior and external part being an osseous canal, the remainder composed of fibro-cartilage and fibrous membrane; its direction, as it leads from the anterior and inner part of the tympanum to the fauces, being forwards, inwards, and a little downwards. The osseous part narrows somewhat as it proceeds forwards; the cartilaginous, on the contrary widens, so that the tube is constricted towards the middle, but is expanded at its extremities, particularly at the guttural one, which will be found thickened and trumpet-shaped. The osseous part of the tube occupies about one-third of its extent, and is placed beneath the canal for the tensor tympani muscle, from which, and from the carotid canal, it is separated by a thin osseous lamella. The cartilage does not surround the tube; it forms the inner and upper side of it, and also part of the external, the remainder being made up of fibrous membrane. The tube thus formed is lined by mucous membrane prolonged into it from the pharynx, which thus becomes continuous with the lining of the tympanum.

*Bones of the Ear.*—The bones of the ear (*ossicula auditûs*) form a chain consisting of three minute pieces, extended across the cavity from the membrana tympani to the fenestra ovalis, each being articulated with the other, so that the whole chain is movable. A fourth is very generally enumerated—the os orbiculare; but Sæmmering and some other anatomists consider it merely as a process of the incus. The bones are arranged in such a way that the malleus or external one is connected with the membrana tympani, whilst the stapes, which is placed internally, rests on the membrane of the fenestra ovalis, the incus being situated between both and articulated with them.

The *malleus*, (plate XXXIII. fig. 2, A, B,) so called from some resemblance to a hammer, is the first or most external of the series, and presents a head, neck, and processes. The head, or superior part (1) is convex and round in the greater part of its extent, but presents at its inner and posterior aspect two slightly irregular surfaces, covered with cartilage, by which it articulates with the incus. The neck (2) is the short constricted part that intervenes between the head and the processes. The handle (3, *manubrium*) is an elongated process, which, when the bone is *in situ*, inclines downwards and forwards, and terminates in a small rounded process, corresponding with the most prominent part of the membrana tympani, with which it is intimately connected. The short process (4) inclines outwards at right angles, from the upper extremity of the handle, and lies in contact with the membrana tympani. The long process (5, *gracilis, anterior*) extends from the cervix obliquely downwards and forwards; it is very thin, and ends in a point which passes into the glenoidal fissure.

The *incus*, (fig. 2, C, D,) is so called from some resemblance in shape to that of an anvil; it has been compared also to a molar tooth; but its similitude to either is very remote. This bone lies a little behind and to the inside of the malleus; it may be considered as divisible into a body and two processes. The body, (2,) compressed and somewhat square in its form, is directed forwards and upwards; and if its anterior border be viewed in profile, it will be found to present two surfaces, which meet at an angle, and are intended to articulate with the head of the malleus. One of the processes (3, *processus brevis*) shorter than the other, and also superior and posterior to, is directed obliquely backwards towards the mastoid cells, where it terminates in a free point; the other process (4, *processus longus*) is longer but thinner than the preceding; it is directed forwards and downwards in the greater part of its extent, but near its termination it suddenly turns inwards, and ends in a small rounded process or nodule, (C, No. 5; D, No. 1,) which articulates with the head of the stapes. This is the part which is considered by some to be a distinct bone, and as such is named *os orbiculare*.

The *stapes*, (fig. 2, E,) or stirrup-bone, is placed horizontally, with its base resting against the fenestra ovalis, and its head articulated with the round nodule at the extremity of the long process of the incus, which it receives in a small shallow cavity. The base of the bone is of the same form as the fenestra ovalis, on which it rests, its upper border being convex, and the lower straight. The anterior process is shorter and straighter than the posterior, and both are slightly grooved along their inner borders, where they give attachment to a membrane that fills the interval between them. The two processes converge and meet at a narrowed part, which is sometimes called the neck, and which is surmounted by a small tubercle or head. The head inclines outwards, and articulates, as above stated, with the incus.

*Internal muscles of the Ear.*—These muscles,\* like the bones above described, are the smallest in the body: only four are usually enumerated, of which three are attached to the malleus. *m. Internus mallei* (tensor tympani) arises from the upper surface of the cartilage of the Eustachian tube, and also from the contiguous border of the pars petrosa; thence it inclines outwards and backwards in the osseous canal that runs parallel with the Eustachian tube, and becomes tendinous on entering the tympanum, where it is inserted into the short process of the malleus. *m. Externus mallei* (laxator tympani major) arises from the spinous process of the sphenoid bone, and, soon becoming tendinous, passes through the glenoid fissure to be inserted into the processus gracilis of the malleus. *m. Laxator tympani minor* is very small, and so indistinct that many anatomists have omitted it altogether; it arises from the upper border of the osseous part of the auditory tube, and descends to be inserted into the manu-

\* Figures of these muscles will be found in plate LI. of the division upon the Muscles.

brium of the malleus, near its short process. *m. Stapedius* is lodged within the tube of the pyramid, from the summit of which a small tendon issues, to be attached to the neck of the stapes.

*The labyrinth.*—The labyrinth is so called from its complexity; it lies internal to the tympanum, and consists of three parts; viz. the vestibule, semicircular canals, and cochlea.

The *vestibule* (plate XXXIII. fig. 1, No. 22; plate XXXIV. figs. 2, 3, 4, 5) is small irregular cavity of an ovoid figure, bounded externally by that bony lamella in which we noticed the fenestra ovalis and promontory, internally by the cribriform lamella at the bottom of the meatus auditorius internus, posteriorly by the semicircular canals, and anteriorly by the cochlea. Along its upper surface runs the aquæductus Fallopii, an osseous tube which leads obliquely outwards and backwards from the meatus internus to the stylo-mastoid foramen, and lodges the facial and vidian nerves. The cavity (plate XXXIV. fig. 5, A) is divided into two slight foveæ, or pits, one being circular, the other oval, and intended to lodge two sacculi, which enclose the expanded part of the auditory nerve. The vestibule is lined by a delicate membrane, which appears to be of the serous class, as it secretes a fine fluid (*liquor Cotunni*) which fills all the intervals left unoccupied by the expansion of the nerve. The following foramina are observable in the interior of the cavity: externally, the fenestra ovalis; internally, four or five minute holes, which transmit the auditory nerve. These are placed in the plate of bone (*lamina cribrosa*) which closes the meatus auditorius internus; at its posterior and external part, five openings, which lead into the semicircular canals, two of them opening by a common foramen; near the common orifice just mentioned is a small foramen (plate XXXIV. fig. 3, No. 8) leading into the aquæductus vestibuli, a small curved canal about four lines long, which leads outwards and backwards to open on the posterior surface of the pars petrosa: it transmits a small vein; at the anterior and inferior part of the cavity is the opening into the cochlea.

*Semicircular canals.*—The semicircular canals (plate XXXIII. fig. 1, Nos. 23, 25, 27) are three small osseous tubes (plate XXXIV. figs. 2, 3, 4, 5) curved so as to form a considerable segment of a circle. They are embedded in the substance of the petrous portion of the temporal bone, and therefore cannot be seen until its external plate is removed, and the reticular texture beneath it is pecked away. They are distinguished, by a consideration of their position, into superior or vertical, (plate XXXIII. fig. 1, No. 23,) external or horizontal, (27,) and posterior or oblique, (25.) They lie behind the vestibule, each being somewhat greater than a semicircle. The contiguous limbi of the posterior and superior canals become united for about two lines before they reach the vestibule. Each of the canals is lined by a fine membrane enclosing the expansion of the nerve, and at their vestibular orifice, or commencement, a slight dilatation (24, 26, 28; ampulla) will be observed, corresponding with a similar enlargement of the nerve.

*Cochlea.*—The cochlea (plate XXXIII. fig. 1, Nos. 30, 31, 32; plate XXXIV. figs. 2, 3, 4, 5, 6, 7) has been so called from some resemblance to the shell of a snail. When insulated from the rest of the bone, it is of a pyramidal form, the base being turned to the meatus internus, the apex outwards and a little downwards, so as to approach the horizontal part of the carotid canal. The cochlea consists of a spiral osseous tube coiled round a central axis, (plate XXXIV. fig. 6, Nos. 3, 3; *modiolus*.) The tube makes two turns and a half from the base of the cochlea to its summit, which is called the *cupola*. From its inner surface projects a thin bony lamella, (fig. 6, Nos. 4, 4,) which extends about half-way across its cavity, and gives attachment to a delicate membranous plate, which completes the separation of the spiral tube into two parts, called *scalæ*, or stairs. The separation between the *scalæ* is complete in the natural condition, except at the cupola, where the osseous part of the septum is deficient, and allows a communication between them. The septum consists partly of a bony plate, partly of membrane. The former is usually named *lamina spiralis*; it commences at the base of the cochlea, and coils round the modiolus nearly to its apex, where it ends in a hook-like process. The membranous part of the septum is a little broader than the lamina spiralis, from the border of which it extends outwards to the wall of the cochlea, to which it becomes attached, and so completes the partition between the two *scalæ*. One of the *scalæ* (fig. 7, Nos. 5, 5; *scala vestibuli*) commences at the vestibule, and, after making its two turns and a half, ends in the cupola; the other (fig. 7, Nos. 6, 6; *scala tympani*) may be said to commence at the cupola, and, after making its turns round the modiolus, to end at the fenestra rotunda. The base of the *modiolus* communicates with the meatus internus, and is pierced by minute foramina, which give admission to the filaments of the nerve, and to some small blood-vessels: its summit opens into the cupola, where it is expanded, and thence termed *infundibulum*. In the *scala tympani*, near its termination at the fenestra rotunda, a minute foramen exists, which leads into a canal, (*aquæductus cochleæ*.) This canal is three or four lines long, and terminates at the posterior border of the pars petrosa, near the jugular fossa; it transmits a small vein.

In our description of the nerves and vessels, we must notice the *osseous canals* which lodge or transmit them. The passages which convey the nerves from the cranium to the internal ear are the hiatus Fallopii, the auditory meatus, and the aquæductus Fallopii. The first of these is a fissure which leads obliquely backwards and outwards upon the anterior surface of the pars petrosa of the temporal bone, and which lodges the vidian nerve. The meatus auditorius internus is an oblique canal in the posterior surface of the bone, from two lines and a half to three lines in diameter, and three lines in depth; its direction is outwards and forwards. It is bounded by a concave lamella of bone, and at first appears like a cul-de-sac, but the plate of bone is perforated by foramina. The meatus contains, in the natural condition, the proper auditory and the facial nerve, with a small vessel, a branch of the posterior cerebral artery. In the bottom of the meatus will be observed a slight ridge of bone, which divides it into two pits, the upper or smaller one being for the facial nerve, whilst the lower receives the auditory. A smaller



foramen transmits the former, but for the latter there are several; hence the osseous plate is sometimes called lamina cribrosa, from its numerous perforations.

The *auditory nerve*, whilst within the meatus, divides into several filaments, which separately pass through the foramina in its bottom; but they admit of being arranged in three sets, from a consideration of the parts of the labyrinth in which they ultimately terminate. One set passes directly into the base of the cochlea, and is lodged in the hollow of its central pillar or modiolus, from which the nerve proceeds by many minute pores to the scalæ, upon the entire surface of which it forms a delicate expansion, supported by the osseous and the membranous part of the septum. The second set of filaments enters the vestibule, and forms an expansion supported by the lining membrane, which is dilated so as to resemble a sac, (*sacculus vestibuli*.) A third set, situated higher up than the preceding, enters the ampulla at the commencement of the superior semicircular canal. Here it loses its fibrous appearance, as if the nervous matter were formed into a tubular lamella prolonged through the canal, assuming its form, and supported by its lining membrane. Similar nervous expansions exist in the posterior and external semicircular canals.

*Membrane of the labyrinth*, (*labyrinthus membranaceus*).—The interior of the labyrinth is lined by a very delicate membrane, which necessarily takes the form of its different parts and recesses; it gives support to the nerves, and also serves to secrete a limpid fluid, (*aqua labyrinthi*), which fills up the intervals left unoccupied by the membrane and the nerves. The fluid is one of the agents employed in conveying impressions from without to the sentient extremities of the auditory nerve. The vibrations of the air, agitated by sounding bodies, act upon the *membrana tympani*; its various changes necessarily influence the chain of ossicula; so that whatever motion is given to the malleus, is conveyed by it through the incus to the stapes, and so to the membrane of the *fenestra ovalis*. By the means of the latter, the fluid of the labyrinth is compressed, and through it the nerves; when this is effected, the merely physical part of the function of hearing is completed. But a new chain of phenomena instantly succeeds. The impression received by the nervous expansions in the labyrinth is conveyed to the sensorium, by which means an internal sensation is produced, the character and intensity of the one being proportioned to that of the other. This, which may be considered the second link in the chain, gives still but a simple sensation. Memory and association, in other words previous experience, must lend their aid to enable us to establish that sort of connexion between the mere impressions received and various external agents, which is necessary in order that they should be made to stand in the relation of sign and thing signified.

The *aqueduct of Fallopius* commences at the upper and inner part of the meatus internus; it is a small osseous tube lodged in the *pars petrosa*, through which it runs from the point just indicated to the stylo-mastoid foramen. At first, for about two lines, it inclines forwards and outwards, then changes, so as to turn outwards and backwards, descending to the foramen above named. It transmits the facial nerve, and also the vidian, which joins the former where the canal changes its direction. In its passage, the nerve gives off some small filaments, which enter the tympanum, and supply its muscles. Mr. Tod observes that the chorda tympani gives branches to all the muscles in the tympanum, and “seems to be the nerve both of motion and perception to these organs.”

The *vessels* of the tympanum, and of the labyrinth.—The stylo-mastoid branch and the ramus tympanicus spread out in minute ramusculi in the tympanum. They are accompanied by veins which take a similar course. The labyrinth is supplied by the internal auditory artery, which enters the meatus internus, together with the nerves, and, after passing through one of the foramina, ramifies upon the lining membrane. The residual blood is returned by two veins, which are lodged in the minute canals called *aquæductus vestibuli et cochleæ*.

## THE NOSE.

Having already described the olfactory nerve and the naso-palatine, it remains to notice the cartilages and the mucous lining membrane.

*Cartilages of the Nose*, (plate XXXV.)—Of these, five are usually enumerated. The *middle* cartilage (fig. 2, No. 2; fig. 4: cartilago septi) is a flat triangular lamella placed vertically; its upper border articulating with the perpendicular plate of the ethmoid bone, the lower resting upon the vomer and maxillary bones, and the anterior supporting the lateral cartilages and the integument. The two *superior lateral* cartilages (fig. 2, Nos. 3, 3) are of a square form, and extend from the nasal bones downwards, between the ascending processes of the superior maxillary bones, with each of which they articulate; and towards the middle line, along the ridge of the nose, they rest against the middle cartilage, which serves to support them. The two *inferior* cartilages (fig. 2, Nos. 4, 4: figs. 5 and 6) form the *alæ nasi*; they unite superiorly with the preceding, externally with the maxillary bones, and in front with the middle cartilage; they are thin and curved, so as to form the arch of the anterior nares.

The mucous membrane (figs. 8 and 9; *membrana Schneideriana, v. pituitaria*) lines and closely adheres to the bones which form the nasal fossæ—extending from the nostrils, where it is continuous with the skin, to the posterior nares, at which point it joins the mucous membrane of the pharynx. It is also continuous with the lining membrane of the several sinuses which open into the meatus narium, and (through the ductus ad nasum) with the conjunctiva. The pituitary membrane is of a red colour, of considerable thickness, soft, and villous on the surface, except towards the anterior nares, where it becomes thinner, and the villi



are less numerous. In the situation just mentioned it is studded with strong hairs, (fig. 7; *vibrissæ*.) which serve to prevent, during inspiration, the entrance of bodies floating in the air.

The membrane that lines the several sinuses differs remarkably from the preceding. It is pale, thin, and adheres very slightly to the surface of the bones.

## THE TONGUE.

The *tongue* (plate XXXVI.; *lingua*) is not only the proper organ of taste, but, by means of its great mobility, assists other parts in deglutition, in speech, in suction, &c. Its upper surface, or *dorsum*, (fig. 1,) is convex in its general outline, and marked along the middle by a slight groove, or *raphé*, (6,) which divides it into two symmetrical parts. About a quarter of an inch from its base will be observed a round hole, (9; *foramen cæcum*.) which forms a sort of reservoir for some of the mucous follicles placed in considerable number in that situation. We speak of its point or anterior narrowed extremity, of its sides, and of its base, which is in intimate connexion with the *os hyoides*. Upon its upper surface we find several projecting points, or *papillæ*, differing so far in size and number as to admit of being arranged as follows:—1. *Papillæ lenticulares*, (8, 8,) which vary in number from ten to fifteen, are disposed in two lines, converging to an angle just before the *foramen cæcum*. They are rounded on their free surface, and resemble so many inverted cones, their summits being imbedded in the substance of the tongue. 2. *Papillæ capitatæ*, vel *fungiformes*, (10, 10,) are more numerous than the preceding, and also smaller. They are placed, for the most part, towards the borders and point of the tongue. They present each a rounded head, supported by a short thin pedicle. 3. *Papillæ conicæ*, vel *pyramidales* (11, 11) are much more numerous than the others, and are diffused over the whole of the *dorsum* of the tongue, from the lenticular *papillæ* to its point. They are minute and tapering. A fourth class has been recognised by some persons, (12, 12; *papillæ filiformes*.) but they are very few, and placed close to the apex of the tongue. The *papillæ* at the point and sides consist of the ultimate terminations of the gustatory nerve, surrounded by a delicate vascular plexus, and supported by cellular tissue.

*Structure*.—Beneath the mucous membrane is placed a thin but firm lamella of condensed cellular tissue, approaching in its characters to elastic tissue. If all the muscles ordinarily described as belonging to the tongue be dissected away, a considerable mass of fleshy substance will still remain, the fibres of which appear interlaced in such a way as to be with great difficulty traced. Upon the upper surface and sides of the tongue a thin stratum of fleshy fibres is placed, extending longitudinally from behind forwards. At the under surface, the fibres of the *linguales* muscles run in the same way, but that they form fasciculi, not a layer. If the *genio-hyo-glossi* be carefully dissected to their insertion, their fibres will be found to turn outwards, or to become blended with others which pass transversely from the *raphé* to the borders on each side. Both the planes of fibres here noticed are placed horizontally, one being at the upper, the other at the under surface; a third set seems to connect them, by passing vertically from one to the other.

## TEGUMENTARY MEMBRANE, (EXTERNAL.)

The tegumentary membranes, as their name implies, (*tegere*, to cover,) encase the whole surface of the body, and are also prolonged into its interior, so as to line all those cavities and passages which are in contact with external agencies. This gives rise to a very natural division of them into external and internal, or, in other words, into skin and mucous membrane.

The *skin*, (*cutis*, *pellis*, common integument, *tissu dermoïd*.) presents the same form and extent as the body which it covers, and follows all its inequalities, whether they be elevations or depressions. It is a compound structure made up of three layers, viz. *corium*, *rete mucosum*, and *cuticle*.

*The Corium*.—The *corium* (plate XXXVIII. fig. 3, D, E, F; fig. 4, C, D: *cutis vera*, *δερμα*) forms the basis or principal part of the skin; it is much thicker than the others, and gives them support, as it is subjacent to them. By maceration, its tissue becomes softened, and in a manner unravelled; it will then appear to be made up of dense filaments, crossing in various directions so as to enclose spaces or *areolæ*. These are of considerable size at the inner or attached surface of the membrane, where granules of *adeps* project into them, but gradually diminish towards the outer surface, where the texture becomes so close and dense as to be considered by some anatomists as a separate layer, which they have named “*textus papillaris*.” But though there are no adequate grounds for such a subdivision, the term employed expresses a fact which deserves attention, viz. that the surface is not quite smooth or homogeneous, but is studded with a number of minute projections called *papillæ*.

The *corium* when examined by itself is pale or dull white, whatever be the tinge which the tegument presents in different races of men or in individuals during life. Any changes of tint which are observed to occur in it, are evidently owing to different degrees of vascularity or of injection, as we see in the state of blushing, and in the rosy hue of health as contrasted with the pallor of disease. Its thickness varies considerably, being in some parts not more than a quarter of a line, in others a line and a half or more. Thus it is very thin in the eyelids, on the *mammæ* and *axillæ*; it is thicker at the back part of the trunk than in

front, and at the outer than at the inner side of the limbs; and acquires its greatest thickness on the palms of the hands and soles of the feet. As the fluids which it contains evaporate after death, it becomes hard, yellow, and elastic. It is extensible, as we see, when tumours become developed under it, or in pregnancy and hydropic affections; when the distending cause is removed, it slowly retracts. It contains a great quantity of gelatine; on this its capability of being tanned depends; and on its great tenacity its usefulness in the arts when brought to the state of leather.

When proceeding to examine the structure of the corium, a small piece may be detached from some part where it is thick, and highly developed; for instance, from the bulb of the thumb, or, still better, from the under surface of the heel. By maceration in water for some while, the cuticle and rete mucosum admit of being easily removed; after which, by immersion in hot water for a few minutes, the papillary projections upon the outer surface are rendered more distinct. The inner surface may, in the next place, be sliced away so as to leave merely the outer stratum rendered so thin as to be translucent. If in this state it be placed under the microscope, its papillary surface will present the appearance indicated in fig. 5, plate XXXVII.; first, a number of minute conical elevations are seen, most of them slightly inclined towards their summits: next, it will be observed, that these are not scattered irregularly; on the contrary, they are disposed in rows or lines (A;) as here drawn, the lines appear to be straight, but in their natural position they represent curves in some parts, as on the bulbs of the fingers; they are more or less oblique in others, as on the palm of the hand; or they are transverse, as on the wrist. "These conical papillæ (observes Prochaska) are disposed in curved lines, so that on each line there is a double row of papillæ, between which minute holes are observed, corresponding with the pores visible in the epidermis, through which, when the hand perspires, we can see the drops of sweat to issue." When looking at a piece of corium so prepared, and placed as here indicated, the summits of the papillæ present an appearance not very unlike that given by the summits of bicuspid or molar teeth, as they are passing through the gums in the infantile state.

The papillæ are thus set in raised lines of the corium, separated from one another by linear depressions or furrows. Each raised line, however, is not a continuous ridge: it is intersected from point to point by transverse lines. Now the latter may be called interpapillary, from their being interposed between the papillæ; and the former, interlinear. Each interpapillary furrow will be observed to be slightly depressed at its middle, and at this point there is a minute pore or aperture which gives passage to a sudoriferous duct.

When about to examine the structure of the papillæ, a small slip, as thin as it can be taken, may be detached from the edge of a piece of skin, selected as already intimated. A cataract knife will be found useful for such purposes. This slice may be laid on a small piece of glass, and viewed with a single lens, say of the tenth of an inch focus. It will present the appearance indicated in fig. 3, plate XXXVIII., where the papillæ (D, D) are seen in a row, corresponding with the ridge or linear elevation in the corium, already noticed; when examined in this way, they do not all appear of the same size. This may be owing to the displacement of the structure from its natural connexions, or to the want of its usual degree of vascular turgescence; investigations of this kind cannot be conducted without such displacement. Now, in each papilla we can recognise as constituents, 1. The corium raised into a minute summit corresponding with the papilla. 2. Capillary vessels which ramify freely in the corium and around the nerve, but reach no farther than its papillary surface; for if a part, say a finger, be minutely injected, the capillaries will be found to curve, form arches, and return into the veins. 3. The nerves of the skin, when traced in the subcutaneous adipose tissue, present the same characters as elsewhere: but as they enter the corium they gradually become softer and present a waving appearance, and this seems to increase as each filament passes into its papilla. It is difficult to say how it terminates, whether it becomes soft and stripped of its neurilema, or whether it curves and forms a loop; be this as it may, the nerve reaches the summit of the papilla, still without piercing it.

*Sudoriferous ducts.*—When noticing the appearance of the papillæ and their arrangement, mention was made of the fact, that in each interpapillary furrow a minute pore existed which transmits a sudoriferous duct. These ducts are easily shown by carefully raising and folding back the epidermis of a piece of skin for some time macerated: as it is slowly drawn back, small filaments will be observed along the line of reflection passing from the corium through the rete and epidermis, as represented, fig. 7, plate XXXVII. C, C. These filaments are the ducts; they are tortuous, they admit of being stretched; when torn, they retract instantly, being highly elastic. They pierce the epidermis obliquely, and terminate by open pores upon its surface, as shown, fig. 1, C. As the sudoriferous ducts eliminate from the system an excrementitious fluid,—the perspiration,—it will be asked, how do they commence, or whence do they receive this fluid? Is it from the capillary net-work of the corium? If so, the perspiration must exist already formed in the blood. Analogy with other fluids, such as the bile and urine, would lead us to infer, *à priori*, that the perspiration is elaborated by a distinct apparatus, not of course accumulated into a mass, like the secreting organs of the fluids just mentioned, but diffused in the form of separate particles or granules, and lodged in, or just under, the tegument. The duct, after piercing the corium, is traced to a small oblong vascular gland-like mass, (plate XXXVIII. fig. 3, H, H,) which lies embedded in the subcutaneous adipose matter, and which appears to be the immediate secreting organ of the perspired fluid.

*Lymphatics.*—Besides the blood-vessels, nerves, and sudoriferous ducts, lymphatic vessels exist abundantly on the skin. Whilst injecting the lymphatics of the lower limb with mercury, the fluid, after filling the glands of the groin, will often pass in-



wards towards the penis and scrotum, creeping for a while under the skin; they then enter its texture, and ramify so freely as to represent a close and intricate net-work. In this way they are injected, contrary to the natural course of the fluids which circulate in them, and consequently in opposition to the valves if there be any. The valves appear to be complete, and to offer resistance to this process in the primary and secondary vessels of this order, but at their peripheral and capillary ramifications the valvular apparatus becomes less and less perfect.

If these vessels be regarded as inhalent or exhalent, how do they commence? Some have said, that they begin with pores, opening on the surface, perhaps from confounding them with the sweat-ducts, or from supposing, according to theoretic views, that there must be openings to admit of the entrance or exit of fluids. The uniform results, however, of injections seem to me to prove that these vessels, like blood-vessels, at their peripheral expansion, which may be regarded as their commencement, form an extensive net-work, and that whatever passage of fluids takes place into or out of them must be by percolation or imbibition, and not by any capillary movement through pores.

*The Rete Mucosum.*—The *rete mucosum* (plate XXXVII. figs. 3 and 4; fig. 7, A) appears at first as a glairy exudation between the corium and cuticle, adhering to both, particularly to the former. Malpighi (after whom it has been called *rete Malpighi*; *corpus mucosum*—*rete glutinosum Malpighianum*) stated it to consist of small fibres, so arranged as to form a net-work. But Henle has shown that it consists of an assemblage of oval vesicular bodies. It is more and more distinct, in proportion as the skin is of a darker hue, so that it is very easily demonstrated in the dark races. When a blister has been applied to the skin of a negro, if it be not very stimulating, the cuticle alone will be raised in about twelve hours. After this is detached, the exposed surface appears covered with a dark coating. But if the blister has been very active, another layer, of a dark colour, comes away with it. This is the *rete mucosum*, which gives to the different races of mankind their various shades of colour; for the other two layers of the tegument are pale and colourless, as we see when their separation is effected by maceration after death, or by vesicating the living surface.

The nature of the stratum which is thus found interposed between corium and cuticle, has given rise to much discussion. Nerves cannot be traced into it, nor has any process of injection shown blood-vessels within it in the healthy state. It appears to be a semi-fluid deposit or secretion, rather than an organized substance: some persons, however, consider it to be a partially organized cellular tissue, containing in its areolæ a dark substance resembling the pigmentum nigrum of the eye; others, as Gautier and Dutrochet, go so far as to resolve it into four layers placed one over the other. In the white races the rete not only loses all colour, but becomes so thin, that it is difficult to demonstrate it; indeed, some eminent anatomists, Bichât, Chaussier, and Dr. Gordon, from these circumstances, denied its existence altogether. But we generally find, on attentive examination, a viscid, semi-fluid stratum occupying the situation of the rete, which, however, is soft and glairy, and, most probably, a secretion produced by the vascular surface of the cutis, or by a special apparatus.

M. Breschet is disposed from various considerations to take the rete and the cuticle together, and to regard them as strata of corneous structure deposited upon the corium. “Nous considérons ici comme épiderme toute l'épaisseur de la couche cornée qui est située au dessus du derme, et qui est traversée par plusieurs organes. Le feuillet le plus externe de cette substance cornée constitue la cuticule ou l'épiderme proprement dit de beaucoup d'auteurs.” [Recherches sur la Structure de la Peau, p. 38, note.] We still, however, shall continue to consider these two lamellæ as sufficiently distinct to retain them as separate structures, and to treat of each separately. Though the rete possesses neither nerves nor blood-vessels, (we have already stated that both these reach no farther than the papillary surface of the corium,) still, vessels of another kind are recognised by M. Breschet himself as existing in it, and which he considers to be analogous to lymphatics, and to constitute an inhalent apparatus. Now, as nothing of this kind exists in the epidermis, we may consider this circumstance, together with its scale-like texture and difference of colour, sufficient to distinguish it from the rete.

When a piece of skin has been sufficiently macerated to allow the cuticle and rete to be detached (having selected a part where the cuticle is thickened,) we can readily see the rete as a distinct layer, particularly if the piece so prepared be placed in spirit, so as to corrugate it a little. The rete, soft and thin, appears as if it had been moulded upon the corium; it takes an exact impression of its lines and ridges and papillæ, as represented in fig. 3. Now when in raising the rete and epidermis, in order to see the sweat-ducts, as shown in fig. 7, we can with the aid of a glass recognise other tubes which are distinguished from the ducts by their smaller size, by anastomosing with one another, so as to form a net-work, (which the ducts never do.) Moreover, they are not tortuous, nor do they pierce the epidermis. Some offsets or efferent vessels issue from this net-work, and pierce the corium close to the pore which transmits the sweat-duct, and appear to terminate in the venous capillaries of the corium. Within the meshes thus formed is deposited that soft, glairy, mucus-like deposit which gives to the tegument its different shades of colour. Is this product exuded by the vessels here noticed, or by the capillary vessels of the corium; or is it secreted by a distinct apparatus? M. Breschet describes and delineates two distinct secreting organs, one for the mucus which he terms *blemmogenous* (*βλέμμα mucus, γέννω I* produce,) and the other, for the colour, *chromatogenous*, (*χρῶμα colour, γεννω.*) Those which produce the mucus he describes as minute red glands (*petites glandes rougeâtres*) placed just under the corium, embedded amongst adipose vesicles. From the summit of each a duct issues which pierces the corium and opens upon its surface. The colour-producing



apparatus Breschet places towards the outer surface of the corium beneath and between the papillary ridges, and in the depth of the interlinear furrows. The secreted product is poured into the grooves by minute ducts.

*The Cuticle.*—The *cuticle* (plate XXXVII. fig. 1 and 2; plate XXXVIII. figs. 3, A; fig. 4, A; cuticula, epidermis, scarf-skin,) is the outer layer of the tegument. Though very thin in most parts, it becomes thick and indurated in the soles of the feet, or wherever it is habitually subjected to pressure. Its inner surface is connected with the rete mucosum and corium by delicate filaments and by the sweat-ducts, but can be readily separated from them by decoction or maceration: the external surface presents a number of narrow lines or ridges, which make it appear, when examined with a glass, rugged and uneven. This observation seems to have led to an opinion entertained by some anatomists, namely, that the cuticle consists of scales, or lamellæ, disposed like those of fishes, or imbricated. The raised lines here noticed (plate XXXVII. fig. 1, A; plate XXXVIII. fig. 3,) correspond with those of the corium; their direction varies, being more or less curved, oblique, or transverse, as may at once be seen by viewing them with a lens upon the ends of the fingers, the palm of the hand, and then at the wrist. These lines are separated by furrows, which are depressed into those of the corium, the rete interposing. These interlinear furrows are intersected by transverse ones, in the middle of each of which we can readily see with the aid of a glass, and often with the unassisted eye, a minute porous depression or infundibulum, (plate XXXVII. fig. 1, C,) where the sweat-duct terminates. As the epidermis is very thin, its inner surface presents, when raised from its connections, the reverse of these elevations and depressions (fig. 2.) This view of it shows that it is so deposited upon the papillary surface of the corium, as to form a mould representing all its elevations and depressions. This is seen more distinctly if the epidermis be slightly corrugated by immersion in spirit or solution of alum. When first exuded, it resembles a thin pellicle of mucus laid upon the surface; and, if examined beneath the microscope, it will be observed to consist of an assemblage of minute oval vesicles like those of the rete mucosum. As it gradually dries and loses its semi-fluid appearance, the vesicles become flattened in oval scales, having a nucleus in the centre of each, and the lines and ridges become apparent. We can easily trace the steps of these changes, if we note what takes place when it is reproduced upon a part that has been blistered. When the cuticle is detached and laid in water, for some while its inner surface appears smooth and uniform. This is owing to its being stretched by the process to which it is subjected. Moreover, even the pores through which the sweat-ducts pass are invisible; hence many anatomists have denied their existence. Béclard says that he charged a shred of epidermis with a column of mercury, about the weight of one atmosphere, and yet could not perceive any proof of its being porous. This is explicable by reference to a fact above stated with regard to the sweat-ducts, viz. that they are so elastic, that when stretched they retract forcibly, and contract their calibre so as effectually to close the porosities. As the epidermis is insensible, and without vessels or nerves, we may liken it to a dry varnish, which protects the sentient surface of the corium from irritation; moreover, it lessens evaporation, and impedes if it does not altogether resist the absorption of injurious substances.

*The Hairs.*—To the skin are attached, as appendages, the hairs and nails.

*Hairs* (plate XXXVIII. fig. 4, K; crines, pili) are slender, conical, horny filaments, which in many animals cover nearly the whole body; but in man are principally developed upon the scalp, pubes, and chin. Each hair consists of a stem and a root. The former is free and unattached, of a different colour in different individuals, and tapering towards its summit, which is usually split, or subdivided into filaments; the root is destitute of colour, and bulbous or irregular in its form. If a hair be plucked out, the part which had been lodged in the skin is found covered by a thin white tubular sheath which still adheres to it. If examined with a glass whilst still in its place, the stem of the hair being at the same time drawn tightly, as if in the act of plucking it out, the sheath here noticed appears at its outer edge to be continuous with the corium at the point where the hair pierces it. By dividing this tube, and drawing it aside with the point of a fine needle, another membrane, softer and thinner, appears within it, and which seems connected with the rete mucosum. In treating of this subject, we constantly employ the terms “bulb, follicle, papilla.” Sometimes the word bulb is used as if it were meant to express the widened and colourless part of the hair, together with its membranous sheath, as they are seen when extracted; this obviously includes two things which are sufficiently distinct. Béclard (*Anat. Gen.* v. 336) takes bulb and follicle as synonymous terms; he says, “The bulb or follicle of the hairs, which Malpighi compared to the vessels in which gardeners plant flowers, is situated in the substance of the dermis, or beneath it.” It seems to me better to restrict the word bulb to the root or point of origin of the hair, where it is colourless, soft, and a little enlarged; follicle will then properly express the tubular canal in which it is lodged whilst within the corium. The follicle is supplied with some minute capillary vessels, and also nervous filaments. Béclard, following out his general views as to the continuity of tissues, views the matter in this way. The outer layer of the sheath is traced down from the corium, the other from the rete; both rise a little at the bottom of the tube to form a secreting papilla: as to the cuticle, it is obviously reflected outwards upon the stem of the hair, and becomes united with its outer surface. The bulbs of the hairs, therefore, observes Béclard, “seem to consist of a small part of the skin, sunk, depressed, or folded upon itself, surmounted by a papilla, which is supplied with vessels and nerves.” The analogy between hairs and nails, and a consideration of the mode of implantation and growth of the latter, support this view of the subject. M. Breschet (*Recherches sur les appareils tegumentaires*, p. 84) observes that he has not as yet determined (the subject being still under examination) whether the hairs arise, as they are commonly said to do, in a duplicature of the skin, or whether they are secreted by glandular organs placed at the inner surface of the corium, (*à la*

*base du derm.*) He inclines to the latter opinion. If it be established, then, we shall have to modify our view of the matter slightly, and the facts will stand thus:—The bulb of the hair is implanted on the papilla, which secretes it in the first instance, and supplies materials for its growth, which are added continually to its base, so as to elongate it and cause its protrusion. The papilla at its base is connected with the surrounding cellular tissue by filaments, and by nerves and vessels; whilst by its summit and sides it gives attachment to the bulb of the hair. The investing sheath, already noticed, continuous with the corium and rete at the point of emergence of the hair, dips down, enclosing it as far as its edge, where it is slightly connected with the papilla. But these are not the only means by which it is fixed in its situation: the cuticle dips into the orifice of the follicle for a little way, and so comes into contact with the surface of the hair, on which it is reflected and prolonged, so as to become in a manner identified with its structure.

The difference of colour in hair seems to depend, according to Vauquelin, on the presence or absence of a coloured oil. He found in black hair a substance resembling mucus, and which appears to be a modified albumen, with two oily matters, one colourless, the other a greenish black tinge, and rather thick. He obtained also in his analysis phosphate and carbonate of lime, oxide of manganese and iron, sulphur and some silex. In red hair the iron and manganese exist in less quantity, and the coloured oil is of a reddish tinge. In fair hair the coloured oil is less; in that which is perfectly white it is altogether colourless. The saline substance appears to be that which imparts the colour to the animal matter or oil: we know that hair admits readily of being dyed whilst still growing, or after it is cut off.

*The Nails.*—The *nails* (plate XXXVIII. figs. 6, 7, 8; unguis) are horny lamellæ, or scales, placed at the extremities of the fingers and toes, on their dorsal surface. The root of the nail, (fig. 8, A,) which is about one-fifth of its length, is thin and white, dentated at its margin, and received into a groove, or sulcus, (fig. 6, B,) in the corium; its external surface is convex, and marked by some slight longitudinal lines running from behind forwards. At the posterior or attached extremity, a small portion will be observed, differing in colour from the rest, and usually called “lunula,” (fig. 8, B,) from its form: the free extremity of a nail is its thickest part, and projects for some way beyond the end of the finger. The mode of connexion established between the nail and the tegument is as follows:—The subjacent part of the corium, thick and red, is surmounted by a number of papillæ, (fig. 7, C,) placed in linear series on every part of it except that beneath the lunula. The under surface of the nail is at the same time soft, and marked by narrow grooves, (fig. 8, C,) intended to lodge the papillæ just noticed, and to become intimately connected with them: again, its posterior extremity is received into a sulcus in the corium, which at this point is stripped of its epidermis; but the latter, at the root of the nail, dips into the sulcus and becomes reflected on its upper surface, forming a smooth, superficial lamella upon it. At the free extremity of the nail, the epidermis, after covering the end of the finger, is reflected on its under surface, becoming identified with it. Finally, the disposition of the epidermis along the sides resembles, for a short way, that which takes place at the root; but further forwards it is reflected in the way that obtains at the free border of the nail.

In fig. 6, by a vertical section of the last phalanx of the thumb, the relation of the cuticle and corium to the nail, and of the latter to the papillæ, is shown. At fig. 9, an enlarged view of the papillæ is given, and of the loops formed by the vessels within them.

Hairs and nails, with the analogous textures, feathers, wool, claws, and hoofs, in different animals, form a section by themselves under the head *Corneous*, or *Horny* tissue. They grow and increase by deposits at their base of a glairy fluid or semi-fluid matter, resembling mucus or modified albumen, which gradually concretes and becomes harder as it is pushed forward and protruded.





# INDEX.

- Accervulus, page 16. (Pl. VI. L.)  
 Albuginea, tunica oculi, page 67. (Pl. XXX. fig. 1, no. 8.)  
 Ampulla, page 75. (Pl. XXXIII. fig. 1, nos. 24, 26, 28.)  
 Antihelix, page 72. (Pl. XXXII. fig. 2, no. 4.)  
 Antitragus, page 72. (Pl. XXXII. fig. 2, no. 9.)  
 Apertura chordæ, page 73. (Pl. XXXIII. fig. 6, no. 8.)  
 Appendages of the eye, page 62.  
 Aquæductus cochleæ, page 75.  
     Fallopii, pages 73, 76. (Pl. XXXIII. fig. 6, no. 2.)  
     Sylvii, page 17. (Pl. VII. R.)  
     vestibuli, page 75. (Pl. XXXIV. fig. 3, no. 8.)  
 Aqueous humour, page 70.  
 Arachnoid membrane, page 8.  
 Arbor vitæ, page 17. (Pl. IX. fig. 1, Z, fig. 2; Pl. X. S.)  
 Auditory tube, page 73. (Pl. XXXIII. fig. 1, B.)  
 Auricula, page 72.  
 Base of the brain, page 13. (Pl. VIII.)  
 Brain, page 11.  
 Bulbus olfactorius, page 20. (Pl. VIII. t; Pl. XI. A.)  
 Calamus scriptorius, page 11. (Pl. VII. W.)  
 Canal of Fontana, page 68.  
     Petit, page 71. (Pl. XXX. fig. 5, no. 20.)  
 Canthi, page 62. (Pl. XXIX. fig. 2, nos. 3, 4.)  
 Cartilages of the nose, page 76. (Pl. XXXV.)  
 Caruncula lachrymalis, page 64. (Pl. XXIX. fig. 1, fig. 2, no. 7, fig. 4,  
     no. 5.)  
 Cerebellum, page 17. (Pls. V. VI. VII. VIII. IX.)  
 Cerebral protuberance, *see* Pons Varolii.  
 Cerebrum, page 11.  
 Chambers of the eye, page 70. (Pl. XXX. fig. 5, nos. 13, 17.)  
 Choroid membrane, page 68. (Pl. XXX. fig. 2, no. 2, fig. 3, no. 3, fig. 5,  
     no. 5.)  
 Cilia, page 63. (Pl. XXIX. fig. 1, fig. 2, nos. 1 & 2, fig. 6, no. 31.)  
 Ciliary ligament, page 68. (Pl. XXX. fig. 2, no. 7, fig. 5, no. 6; Pl. XXXI.  
     fig. 1, no. 3.)  
 Ciliary processes, page 69. (Pl. XXXI. fig. 2, no. 2, fig. 3, no. 3; Pl. XXX.  
     fig. 5, no. 8.)  
 Cochlea, page 75. (Pl. XXXIII. fig. 1; Pl. XXXIV. figs. 2, 3, 4, 5, 6, 7.)  
 Commissures, page 4.  
     anterior, page 17. (Pl. VI. D; Pl. VII. K.)  
     great, page 14. (Pl. III. A, A.)  
     mollis, page 16. (Pl. VI. H; Pl. VII. N.)  
     of the optic nerve, pages 13, 21. (Pl. VIII. v; Pl. XII.  
         fig. 1, c.)  
     posterior, page 17. (Pl. VI. K; Pl. VII. O.)  
 Conarium, *see* Pineal gland.  
 Concha, page 72. (Pl. XXXII. fig. 2, no. 10.)  
 Conjunctiva, page 66.  
 Converging fibres of the cerebellum, page 19.  
     cerebrum, page 19.  
 Convolutions, page 11. (Pl. II.)  
 Corium, page 77. (Pl. XXXVIII. fig. 3, D, E, F, fig. 4, C, D.)  
 Cornea, page 67. (Pl. XXX. fig. 1, no. 9, fig. 5, no. 4.)  
 Cornu anterior, page 15. (Pl. IV. G.)  
     Ammonis, *see* Hippocampus major.  
     inferior or descending, page 15. (Pl. IV. K; Pl. V.)  
     posterior, page 15. (Pl. IV. H.)  
 Corona ciliaris, page 69. *See* Ciliary processes.  
 Corpora albicantia, v. mammillaria, v. pisiformia, page 13. (Pl. VIII. g;  
     Pl. IX. fig. 1, g; Pl. X. g; Pl. XII. fig. 1, K.)  
     olivaria, page 10. (Pl. VIII. o.)  
     pyramidalia, page 10. (Pl. VIII. m.)  
     quadrigemina, page 18. (Pl. VI. M.)  
     restiformia, page 10. (Pl. VII. x; Pl. VIII. p.)  
     striata, page 15. (Pl. IV. M; Pl. V. E.)  
 Corpus callosum, page 14. (Pl. III. A, A.)  
     ciliare, page 69. *See* Ciliary processes.  
     dentatum, vel rhomboideum, page 17. (Pl. IX. fig. 2, R; Pl. X. U.)  
     fimbriatum, page 15. (Pl. V. R.)  
     geniculatum externum, page 16. (Pl. VI. N.)  
     ———— internum, page 16. (Pl. VI. O.)  
     psaloides, page 15.  
     vitreum, *see* Vitreous humour.  
 Cribriform plate, page 67.  
 Crystalline lens, *see* Lens.  
 Crura cerebelli, page 17. (Pl. VIII. K.)

- Crura cerebri, page 14. (Pl. VIII. i; Pl. IX. fig. 1, c, fig. 2, F; Pl. X. d, x; Pl. XII. fig. 1, H, fig. 2, G.)  
of fornix, page 15. Pl. IV. F, F; Pl. IX. fig. 1, F.)
- Cupula, page 75.
- Cuticle, page 80. (Pl. XXXVII. figs. 1 & 2; Pl. XXXVIII. fig. 3, A, fig. 4, A.)
- Cutis, page 77. (Pl. XXXVIII. fig. 3, D, E, F, fig. 4, C, D.)
- Digital cavity, page 15. (Pl. IV. H.)
- Diverging fibres, cerebellum, page 19. (Pl. IX. fig. 2, Q; Pl. X, T.)  
cerebrum, page 19. (Pl. X.)
- Dura mater, page 6. (Pl. I. fig. 1.)
- Ear, page 72.
- Epidermis, page 80. (Pl. XXXVII. figs. 1 & 2; Pl. XXXVIII. fig. 3, A, fig. 4, A.)
- Eustachian tube, page 74. (Pl. XXXIII. fig. 1, no. 21.)
- Eye-brows, page 62. (Pl. XXIX. fig. 1.)
- Eye-lashes, page 63. (Pl. XXIX. fig. 1, fig. 2, nos. 1 & 2, fig. 6, no. 31.)
- Eyelids, page 62. (Pl. XXIX. figs. 1, 2, 3, 7.)
- Falx cerebelli, page 7.  
cerebri, page 7.
- Fascia dentata, page 15.
- Fenestra ovalis, page 73. (Pl. XXXIII. fig. 6, no. 4.)  
rotunda, page 73. (Pl. XXXIII. fig. 6, no. 6.)
- Fissure of Bichât, page 19.  
Sylvius, page 13. (Pl. VIII. b.)
- Flocculus, page 16. (Pl. VIII. i; Pl. X. Q.)
- Folia cerebelli, page 17. (Pl. IX.)
- Foramen cæcum, page 77. (Pl. XXXVI. fig. 1, no. 9.)  
centrale of Sæmmering, page 70. (Pl. XXX. fig. 4, no. 2; Pl. XXXI. fig. 4, no. 4, fig. 5, no. 1.)  
commune anterius, page 16. (Pl. VII. L.)  
—— posterius, page 17. (Pl. VI. I; Pl. VII. P.)  
Monroi, page 16. (Pl. VII. L.)
- Fornix, page 15. (Pl. IV. E; Pl. IX. fig. 1, E.)
- Fossa innominata, page 72. (Pl. XXXII. fig. 2, no. 7.)  
navicularis, v. scaphoides, page 72. (Pl. XXXII. fig. 2, no. 6.)
- Fourth ventricle, page 17. (Pl. VII. T.)
- Ganglia, abdominal, page 59. (Pl. XXVIII. H.)  
lumbar, page 61. (Pl. XXVIII. H.)  
sacral, page 62. (Pl. XXVIII. L.)  
thoracic, pages 57, 58. (Pl. XXVII. L, L, M; Pl. XXVIII. A, B, C.)
- Ganglion azygos, page 62. (Pl. XXVIII. M.)  
cardiac, page 57. (Pl. XXVII. S.)  
Cassarian, page 29. (Pl. XIII. fig. 2, A.)  
cervical inferior, page 54. (Pl. XXVII. K.)  
—— middle, page 54. (Pl. XXVII. S.)  
—— superior, page 53. (Pl. XXVII. D.)  
lenticular, *see* Ophthalmic.  
Meckel's, *see* Spheno-palatine.  
naso-palatine, page 56. (Pl. XI. fig. 2, G; Pl. XXVII. F.)  
ophthalmic, page 56. (Pl. XIII. fig. 1, d, fig. 2, g; Pl. XXVII. E.)  
otic, page 57. (Pl. XIII. fig. 1, l.)  
petrosus, page 26.  
semilunar, page 60. (Pl. XXVIII. E.)  
spheno-palatine, page 56. (Pl. XIII. fig. 2, p; Pl. XXVII. G.)
- Ganglion submaxillary, page 56. (Pl. XIII. fig. 2, e\*; Pl. XXVII. H.)  
thyroid, *see* Middle cervical.
- Globe of the eye, page 64. (Pl. XXX.)
- Gyri, *see* Convolutions.
- Hairs, page 80. (Pl. XXXVIII. fig. 4, K.)
- Helix, page 72. (Pl. XXXII. fig. 2, no. 2.)
- Hemispheres of the brain, page 12. (Pl. II. B, C.)
- Hiatus Fallopii, page 75.
- Hippocampus major, page 15. (Pl. V. P.)  
minor, page 15. (Pl. IV. I.)
- Humours of the eye, page 70.
- Hyaloid membrane, page 71. (Pl. XXX. fig. 5, no. 11.)
- Incus, page 74. (Pl. XXXIII. fig. 2, C, D.)
- Infundibulum, page 13. (Pl. IX. fig. 1, c.)
- Iris, page 70. (Pl. XXX. fig. 2, no. 3, fig. 5, no. 15; Pl. XXXI. fig. 1, no. 2.)
- Iter ad infundibulum, page 16.
- Iter à tertio ad quartum ventriculum, page 16. (Pl. VII. R.)
- Jacob's membrane, page 70.
- Labyrinth, page 75.
- Labyrinthus membranaceus, page 76.
- Lachrymal apparatus, page 64.  
ducts, page 64. (Pl. XXIX. fig. 4, no. 2.)  
gland, page 64. (Pl. XXIX. fig. 3, no. 5, fig. 4, no. 7, fig. 5.)  
sac, page 64. (Pl. XXIX. fig. 4.)
- Lamina cribrosa, pages 13, 75. (Pl. VIII. d.)  
spiralis, page 75. (Pl. XXXIV. fig. 6, no. 4.)
- Lateral ventricles, page 14. (Pl. IV.)
- Lens, page 70. (Pl. XXX. fig. 4, no. 7, fig. 5, no. 18; Pl. XXXI. fig. 2, no. 3, figs. 8, 9, 10.)
- Ligamentum denticulatum, page 9. (Pl. I. fig. 2, no. 8.)
- Limbus luteus, page 70. (Pl. XXX. fig. 4, no. 2; Pl. XXXI. fig. 4, no. 4, fig. 5, no. 1.)
- Liquor Cotunni, page 75.  
Morgagni, page 71.
- Lobes of the brain, page 12. (Pl. VIII.)
- Lobulus, page 72. (Pl. XXXII. fig. 2, no. 12.)
- Locus niger, page 14.  
perforatus, page 13. (Pl. VIII. h; Pl. X. H; Pl. XII. fig. 1, I.)
- Lunula, page 81. (Pl. XXXVIII. fig. 8, B.)
- Lyra, page 15.
- Malleus, page 74. (Pl. XXXIII. fig. 2, A, B.)
- Mammillary bodies, page 13. (Pl. VIII. g; Pl. IX. fig. 1, g; Pl. X. g; Pl. XII. fig. 1, K.)
- Mastoid cells, page 73. (Pl. XXXIII. fig. 6, no. 1.)
- Medulla oblongata, page 10. (Pl. VIII. F.)  
spinalis, page 9. (Pl. I.)
- Meibomian glands, page 63. (Pl. XXIX. fig. 7.)
- Membrana dentata, page 9. (Pl. I. fig. 2, nos. 8, 8.)  
pupillaris, page 70. (Pl. XXXI. figs. 11 & 12.)  
tympani, page 73. (Pl. XXXIII. fig. 1, no. 13; Pl. XXXIV. fig. 1, no. 15.)
- Membranes of the brain and spinal cord, page 6.
- Modiolus, page 75. (Pl. XXXIV. fig. 6, nos. 3, 3.)
- Musculus antitragicus, page 72.  
contractor meatūs, page 72.

- Musculus externus mallei, page 74.  
 internus mallei, page 74.  
 laxator tympani major, page 74.  
 ———— minor, page 74.  
 major helicis, page 72.  
 minor helicis, page 72.  
 obliquus auris, page 72.  
 stapedius, page 75.  
 tensor tympani, page 74.  
 tragicus, page 72.  
 transversus auriculæ, page 72.
- Nails, page 81. (Pl. XXXVIII. figs. 6, 7, 8.)  
 Nasal duct, page 64. (Pl. XXIX. fig. 4, no. 4.)  
 Nates, page 18. (Pl. VI. M.)  
 Nerv. abducens, page 24. (Pl. VIII. no. 6; Pl. XII. fig. 1, no. 6; Pl. XIII. fig. 1, no. 6.)  
 accessorius, page 28. (Pl. VIII. & Pl. XIV. r; Pl. XV. C.)  
 acromiales, page 34.  
 auditory, pages 22, 76. (Pl. VIII. x; Pl. XII. fig. 2, c.)  
 auricular, page 32. (Pl. XIII. fig. 2, i; Pl. XV. d; Pl. XVI. h.)  
 auricularis magnus, page 34. (Pl. XIV. l.)  
 ———— posterior, page 25. (Pl. XIV. a.)  
 bronchial, page 28. (Pl. XV. x, y.)  
 buccal, page 31. (Pl. XIII. fig. 2, b\*.)  
 cardiac, inferior, page 58. (Pl. XXVII. e\*.)  
 ———— middle, page 58. (Pl. XXVII. a\*.)  
 ———— of the pneumo-gastric, page 28. (Pl. XV. q, r.)  
 ———— superior, page 57. (Pl. XXVII. x.)  
 cerebral, page 20.  
 cervical, page 33. (Pl. I. fig. 2.)  
 chorda tympani, page 56. (Pl. XIII. fig. 2, d\*; Pl. XV. c, Pl. XXVII. r.)  
 ciliary, page 56. (Pl. XIII. fig. 1, e, f, fig. 2, i; Pl. XXVII. E.)  
 circumflex, page 36. (Pl. XVII. G.)  
 claviculares, page 34. (Pl. XIV. p, p.)  
 communicans fibularis, pages 47, 49. (Pl. XXV. fig. 1, c.)  
 ———— tibiæ, vel poplitei, page 47. (Pl. XXV. fig. 1, b.)  
 crural, page 43. (Pl. XXI. F; Pl. XXIII. B.)  
 cutaneus, cruralis, page 43. (Pl. XXI. x; Pl. XXXIII. a.)  
 ———— externus, brachialis, page 36. (Pl. XVII. B; Pl. XVIII. fig. 1, B.)  
 ———— lumbalis, page 42. (Pl. XXI. k, l; Pl. XXXIII. A.)  
 ———— superior, v. spiralis, page 39. (Pl. IX. fig. 1, d.)  
 ———— internus brachialis, page 36. (Pl. XVII. D; Pl. XVIII. fig. 1, A.)  
 dental anterior, page 31. (Pl. XIII. fig. 2, v.)  
 ———— inferior, page 33. (Pl. XIII. fig. 2, f\*; Pl. XVI. i.)  
 ———— posterior, page 31. (Pl. XIII. fig. 2, t, t.)  
 descendens noni, page 24. (Pl. XVI. c.)  
 digastric, page 25.  
 digital, page 39.  
 dorsal, page 40. (Pl. XX. fig. 1, a.)  
 dorsi-lumbar, page 41. (Pl. XXI. a.)  
 facial, page 24. (Pl. VIII. nos. 7, w; Pl. XIV. A.)  
 femoral, *see* Crural.
- Nerv. fibular, page 49. (Pl. XXV. fig. 1, B, fig. 2, C; Pl. XXIV. figs. 1 & 2, B.)  
 fifth pair, *see* Trifacial.  
 fourth pair, *see* Patheticus.  
 frontal, page 30. (Pl. XIII. b.)  
 glosso-pharyngeal, page 26. (Pl. XV. A; Pl. XVI. B.)  
 gluteal, page 44. (Pl. XXI. H; Pl. XXII. B.)  
 gustatory, page 32. (Pl. XIII. fig. 2, c\*; Pl. XV. b; Pl. XVI. l.)  
 hæmorrhoidal, page 45.  
 hypoglossal, page 24. (Pl. VIII. no. 9; Pl. XII. fig. 1, no. 9; Pl. XVI. A.)  
 ilio-inguinal, page 42. (Pl. XXI. c, d, e.)  
 ilio-scrotal, page 42.  
 infra-orbital, page 31. (Pl. XIII. fig. 2, w.)  
 inguino-cutaneous, page 42. (Pl. XXI. k, l; Pl. XXIII. A.)  
 intercostal, page 40. (Pl. XX. fig. 1, a.)  
 intercosto-humeral, page 40. (Pl. XVII. x, y.)  
 interosseous anterior, page 39. (Pl. XVIII. fig. 2, e.)  
 ———— posterior, page 40. (Pl. XIX. fig. 2, c.)  
 ischiadic, greater, page 46. (Pl. XXII. E.)  
 ———— lesser, page 46. (Pl. XXII. D.)  
 Jacobson's, page 26.  
 lachrymal, page 30. (Pl. XIII. a.)  
 laryngeal inferior, page 23. (Pl. XV. v, v; Pl. XVI. r.)  
 ———— superior, page 27. (Pl. XV. m.)  
 lingual, page 24. (Pl. VIII. no. 9; Pl. XII. fig. 1, no. 9; Pl. XVI. A.)  
 lumbar, page 41. (Pl. XXII.)  
 lumbo-sacral, pages 41, 44. (Pl. XXI. G.)  
 masseteric, page 31. (Pl. XIII. fig. 2, z.)  
 maxillary inferior, page 31. (Pl. XIII. fig. 2, D.)  
 maxillary superior, page 31. (Pl. XIII. fig. 2, C.)  
 median, page 33. (Pl. XVII. C; Pl. XVIII. fig. 2, B.)  
 mental, page 33. (Pl. XV. n\*.)  
 molles, page 54. (Pl. XXVII. w.)  
 motores oculorum, page 23. (Pl. VIII. no. 3; Pl. XIII. fig. 1, no. 3.)  
 musculo-cutaneous brachial, *see* External cutaneous.  
 ———— lumbar, page 41. (Pl. XXI. c, f.)  
 musculo-spiral, page 39. (Pl. XVII. F; Pl. XVIII. fig. 2, A.)  
 milo-hyoidean, page 33. (Pl. XV. g\*.)  
 nasal, page 31. (Pl. XIII. e.)  
 ninth pair, *see* Lingual.  
 obturator, page 43. (Pl. XXI. E.)  
 occipitalis minor, page 34. (Pl. XIV. o.)  
 oculo-nasal, page 31. (Pl. XIII. e.)  
 cesophageal, page 28. (Pl. XV. z, z.)  
 olfactory, page 20. (Pl. VIII. no. 1; Pl. XI.)  
 ophthalmic, page 30. (Pl. XIII. fig. 2, B.)  
 optic, page 21. (Pl. VIII. no. 2; Pl. XII. fig. 1, nos. 2, 2.)  
 orbital, page 31. (Pl. XIII. fig. 2, n.)  
 palatine, page 56. (Pl. XI. fig. 2, I; Pl. XIII. fig. 2, r; Pl. XXVII. m.)  
 palmaris cutaneus, v. superficialis, page 39. (Pl. XVIII. fig. 1, i, fig. 2, f.)  
 ———— profundus, page 37. (Pl. XVII. r.)  
 patheticus, page 24. (Pl. VIII. no. 4; Pl. XII. figs. 1 & 2, no. 4; Pl. XIII. fig. 1, no. 4.)



Nerv. perforans Casserii, *see* External cutaneous.

peroneal, *see* Fibular.

pharyngeal, page 27. (Pl. XV. k.)

phrenic, pages 28, 34. (Pl. XIV. q; Pl. XVI. x.)

plantar external, page 49. (Pl. XXVI. fig. 2, C.)

—— internal, page 49. (Pl. XXVI. fig. 1, A, fig. 2, B.)

pneumo-gastric, page 26. (Pl. XV. B; Pl. XVI. C.)

popliteal, page 47. (Pl. XXV. figs. 1 & 2, A.)

portio dura, *see* Facial.

—— mollis, *see* Auditory.

pterygoid, page 31.

pubic, page 46. (Pl. XXI. C.)

—— external, page 42. (Pl. XXI. m, n, o.)

radial, page 39. (Pl. XVIII. fig. 2, a; Pl. XIX. fig. 1, g, fig. 2, e.)

recurrent laryngeal, page 28. (Pl. XV. v, v; Pl. XVI. r.)

respiratory, external, page 36. (Pl. XVII. g.)

sacral, page 44. (Pl. XXI. I; Pl. XXII. A.)

saphenus externus, page 47. (Pl. XXV. fig. 1, d.)

—— internus, vel major, page 43. (Pl. XXI. z; Pl. XXIII. f, g.)

sixth pair, page 24. (Pl. VIII. no. 6; Pl. XII. fig. 1, no. 6; Pl. XIII. fig. 1, no. 6.)

spermatic, external, page 42. (Pl. XXI. m, n, o.)

spheno-palatine, page 56. (Pl. XI. figs. 1 & 2, E; Pl. XIII. fig. 2, q; Pl. XXVII. u.)

spinal, page 33. (Pl. I. fig. 2.)

spinal accessory, page 28. (Pl. VIII. & Pl. XIV. r; Pl. XV.)

splanchnic, great, page 59. (Pl. XXVIII. D.)

—— lesser, page 59. (Pl. XXVIII. F.)

stylo-hyoidean, page 25. (Pl. XIV. b.)

subcutaneous malæ, page 31. (Pl. XIII. fig. 2, n.)

sub-occipital, page 33. (Pl. I. fig. 2.)

sub-scapular, page 36. (Pl. XVII. l. l.)

superficialis colli, page 34. (Pl. XIV. m.)

—— cordis, *see* Cardiac, superior.

supra-scapular, page 35. (Pl. XVII. h.)

sympathetic, page 50. (Pls. XXVII. & XXVIII.)

temporal, superficial, *see* Auricular.

temporales profundi, page 31. (Pl. XIII. fig. 2, y.)

third pair, *see* Motores oculorum.

thoracic, page 36. (Pl. XVII. i, i.)

tibial, anterior, page 50. (Pl. XXIV. fig. 2, C.)

—— posterior, page 47. (Pl. XXV. fig. 2, B.)

trochlearis, page 24. (Pl. VIII. no. 4; Pl. XII. figs. 1 & 2, no. 4; Pl. XIII. fig. 1, no. 4.)

tympanic, page 26.

ulnar, page 37. (Pl. XVII. E; Pl. XVIII. fig. 2, C.)

uterine, page 45.

vaginal, page 45.

vagus, *see* Pneumo-gastric.

vesical, page 46.

Vidian, page 56. (Pl. XIII. fig. 2, s; Pl. XXVII. o.)

Nervous system, general idea of, page 4.

symmetrical, page 4.

composition, page 4.

chemical analysis, page 5.

Nodus encephali, *see* Pons Varolii.

Nose, page 76. (Pl. XXXV.)

Optic commissure, pages 13, 21. (Pl. VIII. v; Pl. XII. fig. 1, c.)  
thalami, page 16. (Pl. IV. O; Pl. VI. G.)

Orbiculus ciliaris, *see* Ciliary ligament.

Os orbiculare, page 74. (Pl. XXXIII. fig. 2, C, no. 5, D. no. 1.)

Ossicula auditûs, page 74. (Pl. XXXIII.)

Palpebræ, page 62. (Pl. XXIX. figs. 1, 2, 3, 7.)

Papillæ capitatæ, vel fungiformes, page 77. (Pl. XXXVI. fig. 1.)

conicæ, vel pyramidales, page 77.

filiformes, page 77.

fungiformes, page 77.

lenticulares, page 77.

Peduncles of the cerebellum, *see* Crura cerebelli.

pineal gland, *see* Pineal gland.

Pes accessorius, page 15.

anserinus, page 26. (Pl. XV. l.)

hippocampi, page 15. (Pl. V. Q.)

Pia mater, page 7. (Pl. I. fig. 2; Pl. II.)

Pigmentum nigrum, page 69.

Pillars of the fornix, page 15. (Pl. IV. F, F; Pl. IX. fig. 1, F.)

Pineal gland, page 16. (Pl. VI. L.)

Pinna, page 72. (Pl. XXXII.)

Pituitary gland, page 13. (Pl. IX. fig. 1, d.)

membrane, page 76. (Pl. XXXV. figs. 8, 9.)

Plexus aortic, page 60. (Pl. XXVIII. l.)

axillary, *see* Brachial.

brachial, page 35. (Pl. XVI. v, v.)

cardiac, page 57. (Pl. XXVII. N.)

carotid, page 53. (Pl. XXVII. f.)

cavernous, page 53. (Pl. XXVII. f.)

cervical, page 33. (Pl. XVI. s, s.)

choroid, page 7. (Pl. IV. P; Pl. V. I.)

—— minor, page 17.

cœliac, page 60.

coronary, posterior, page 57.

—— right, page 57. (Pl. XXVII. Q.)

—— stomachic, page 60. (Pl. XXVIII. no. 8.)

hepatic, page 60. (Pl. XXVIII. no. 10.)

hypogastric, page 62. (Pl. XXVIII. I.)

lumbar, page 41. (Pl. XXI.)

mesenteric, inferior, page 60. (Pl. XXVIII. m.)

—— superior, page 60. (Pl. XXVIII. no. 11.)

œsophagean, page 28. (Pl. XV. z, z.)

parotid, page 26. (Pl. XIV. c.)

pharyngeal, page 27. (Pl. XV. l.)

phrenic, page 60.

pulmonary, anterior, page 28. (Pl. XV. x, y.)

—— posterior, page 28. (Pl. XV. x, y.)

renal, page 60. (Pl. XXXVIII. G.)

sacral, page 44. (Pl. XXI. I.)

solar, page 60. (Pl. XXVIII. E.)

spermatic, page 60.

splenic, page 60. (Pl. XXVIII. no. 9.)

vertebral, page 55. (Pl. XXVII. K.)

Plica semilunaris, page 64. (Pl. XXIX. fig. 1, fig. 2, no. 6, fig. 4, no. 6.)

Pons Tarini, *see* Locus perforatus.

- Pons Varolii, page 18. (Pl. VIII. E; Pl. IX. fig. 1, h, fig. 2, D; Pl. X. I. V.)
- Porus opticus, page 67. (Pl. XXXI. fig. 5, no. 3.)
- Processus cochleariformis, page 74.  
e cerebello ad testes, page 17. (Pl. VI. W; Pl. VII. S.)  
vermiformis inferior, *see* Vermiform process.  
——— superior, *see* Vermiform process.
- Promontory, page 73. (Pl. XXXIII. fig. 6, no. 5.)
- Protuberantia annularis, *see* Pons Varolii.
- Puncta lachrymalia, page 64. (Pl. XXIX. fig. 2, no. 5, fig. 3, no. 4, fig. 4, no. 1.)
- Pupil, page 70. (Pl. XXXI. fig. 1, no. 1.)
- Pyramid, page 73. (Pl. XXXIII. fig. 6, no. 7.)
- Pyramids, anterior, *see* Corpora pyramidalia.  
posterior, page 17. (Pl. VII. X.)
- Rete mucosum, page 79. (Pl. XXXVII. figs. 3 & 4, fig. 7, A.)
- Retina, page 69. (Pl. XXX. fig. 4, no. 1, fig. 5, no. 9.)
- Scala tympani, page 75. (Pl. XXXIV. fig. 7, nos. 6, 6.)  
vestibuli page 75. (Pl. XXXIV. fig. 7, nos. 5, 5.)
- Schneiderian membrane, page 76. (Pl. XXXV. figs. 8, 9.)
- Sclerotic coat, page 67. (Pl. XXX. fig. 1, no. 1.)
- Semicircular canals, page 75. (Pl. XXXIII. fig. 1; Pl. XXXIV. figs. 2, 3, 4, 5.)
- Septum lucidum, page 15. (Pl. IV. D; Pl. IX. fig. 1, I.)
- Skin, page 77.
- Spinal cord, page 9. (Pl. I.)  
nerves, page 10. (Pl. I.)
- Stapes, page 74. (Pl. XXXIII. fig. 2, E.)
- Substantia perforata antica, page 13. (Pl. VIII. d.)
- Sudoriferous ducts, page 78. (Pl. XXXVII. fig. 7, C, C.)  
glands, page 78. (Pl. XXXVIII. fig. 3, H, H.)
- Sulci, page 11. (Pl. II.)
- Sulcus olfactorius, page 13
- Sulcus tympani, page 73.
- Supercilia, *see* Eye-brows.
- Tænia semicircularis, page 16. (Pl. IV. N.)
- Tarsal cartilages, page 62. (Pl. XXIX. fig. 6; Pls. XXVII. & XXVIII. fig. 7.)
- Tentorium cerebelli, page 7.
- Testes, page 18. (Pl. VI. M.)
- Thalami optici, page 16. (Pl. IV. O; Pl. VI. G.)
- Third ventricle, page 16. (Pls. VI. & VII.)
- Tongue, page 77. (Pl. XXXVI.)
- Tractus respiratorius, page 10.
- Tragus, page 72. (Pl. XXXII. fig. 2, no. 8.)
- Tuber cinereum, page 13. (Pl. VIII. e; Pl. XII. fig. 1, L.)
- Tubercula quadrigemina, page 18. (Pl. VI. M.)
- Tunica albuginea, page 67. (Pl. XXX. fig. 1, no. 8.)  
Ruyschiana, page 68.
- Tympanum, page 73. (Pl. XXXIII. fig. 1, C.)
- Uvea, page 70. (Pl. XXXI. fig. 3, no. 2.)
- Valve of Vieussens, page 17. (Pl. VI. X.)
- Vasa vorticosa, page 68. (Pl. XXX. fig. 2, nos. 2, 2, fig. 3, nos. 3, 6.)
- Ventricles, communications between, page 18.  
fifth, page 15. (Pl. IV. D.)  
fourth, page 17. (Pl. VII. T.)  
lateral, page 14. (Pl. IV.)  
third, page 16. (Pls. VI. & VII.)
- Vermiform process, inferior, page 17. (Pl. VIII. q.)  
superior, page 17. (Pl. V. X.)
- Vestibule, page 75. (Pl. XXXIII. fig. 1, nos. 2, 2; Pl. XXXIV. figs. 2, 3, 4, 5.)
- Vibrissæ, page 77. (Pl. XXXV. figs. 8, 9.)
- Vitreous humour, page 71. (Pl. XXX. fig. 5, no. 21.)
- Zonula coronæ ciliaris, *see* Zonula of Zinn.
- Zonula of Zinn, page 71. (Pl. XXX. fig. 4, no. 5.)





THE  
VISCERA  
OF  
THE HUMAN BODY.



# VISCERA

OF

## THE HUMAN BODY.

---

THE viscera of the human body include the various organs which are contained in the three great internal cavities, viz. the head, the thorax, and the abdomen. The study of these organs constitutes that part of the science of anatomy which is named Splanchnology, (*σπλαγγχον*, *viscus*.)

The viscera of the head and spinal column are the brain and spinal cord, together with the principal organs of sense. These we have considered in the division upon the Nervous System, to which they more directly belong than to the viscera of the other cavities, which we are now about to examine.

The viscera of the chest are, the central organ of circulation—the heart; the organs of respiration—the lungs, and the thymus gland. The abdominal viscera are divisible into those which properly belong to that cavity, viz. the alimentary canal, the liver, spleen, and pancreas; and those of the pelvis—the bladder, and internal organs of generation.

In the description and delineation of these viscera, we shall pursue a physiological rather than an anatomical order, commencing in the first place with the organs of digestion; taking next those of respiration and the central organ of circulation; then proceeding to the organs for the secretion of urine, and lastly to the organs of generation.

The organs of digestion include the mouth and alimentary canal, consisting of the pharynx, œsophagus, stomach, small intestine, and large intestine—the small intestine being apportioned into the duodenum, jejunum, and ilium,—and the large, into the cæcum, colon, and rectum. To these may be added the various glands which pour their secreted fluids upon the surface of the mucous membrane. The glands which are subservient to digestion are, the salivary and the various mucous follicles and glands opening into the mouth, the tonsils into the fauces, the liver and pancreas into the duodenum, and the proper follicles and glands of the mucous membrane throughout its entire extent.

In the mouth is performed the process of *mastication*, through the agency of the teeth and of the muscles which move the jaws; while the salivary glands, mixing their secretion with the alimentary substances, conform the mass to a proper consistence and effect *insalivation*. *Deglutition* is conducted by the muscles of the fauces, soft palate, tongue, and pharynx, and by the muscular coat of the œsophagus, the surface of the canal being lubricated by the secretion of the mucous follicles and glands, particularly by the tonsils. In the stomach the ingesta are converted into a greyish pulp, constituting *chymification*. The chyme being conveyed into the duodenum and small intestines, is submitted to the action of the bile and pancreatic fluid which separate the chyle. This part of the process is named *chylification*: the chyle is taken up by the lacteals and conveyed by the thoracic duct into the current of the venous blood at the root of the neck, to be thence circulated through the capillaries of the lungs, where it is submitted to the action of the atmospheric air and converted into blood. The rest of the ingesta is passed onwards through the canal, while its nutritive parts are constantly absorbed by the lacteals which occupy every point of the surface of the mucous membrane. Reaching the large intestine, the ingesta undergo another change which is termed *fecification*, and after being collected in the rectum, they are eventually removed entirely from the body by the act of *expulsion*.

Entering into the structure of the alimentary canal is a serous membrane, the peritoneum, the largest membrane of that class in the animal economy, and lining its interior, is a mucous membrane, a part of the general gastro-pulmonary mucous membrane.

*Serous Membranes*.—Serous tissue, or membrane, has several synonyms, viz. *tissu séreux*, *membrana sérosa*, *pellucida*.—The structures included under this head are so named, because their surface is constantly moistened by a thin, albuminous fluid resembling the serum of blood; their form is that of a shut sac, without inlet or other interruption to its continuity. (*Sacculi occlusi*, “*sacs sans ouverture*.”)—Each is a delicate membrane, smooth and homogeneous in its structure, and so thin as to be transparent, were it separated from the organs or parts with which it is in contact.



The recent researches of Henle\* have shown that serous membranes, like mucous surfaces, are invested by an epithelium composed of stratified layers of vesicles and angular flattened plates, the former being situated nearest the membrane and the latter upon the surface. When first secreted, these bodies have the form of vesicles with central nuclei; but as they approach the surface, they gradually flatten and assume the form of thin plates, in the centre of which the nuclei are still perceptible. These bodies have been observed upon the serous membranes of the cavities of the body, on the lining membrane of the ventricles, internal lining of the heart, arteries, veins, and lymphatics, and upon some of the membranes of the eyeball.

A membrane which, if detached and distended, would resemble a bladder or a balloon (and such is the fact with regard to the serous membranes,) necessarily presents two surfaces. Of these the inner one is perfectly smooth in its natural condition, and lubricated by a fine halitus exhaled upon it, which is occasionally accumulated and condensed into the fluid form. The external surface is rendered rough and flocculent by a number of cellular filaments, which pass off from it to the contiguous viscera, and form the means of its connexion with them. In this class we find grouped together several structures which agree in possessing the conformation and character here indicated, and in exhibiting, when diseased, nearly the same forms of organic change, though no direct communication subsists between them, and each of them is perfectly insulated from the others. The arachnoid membrane, which invests the brain, lines its cavities, and is, moreover, prolonged over the spinal cord, belongs to the class of serous membranes; so do the two pleuræ, which invest the lungs, and the proper pericardium, which encloses the heart; likewise the peritonæum, which is reflected over the different viscera of the abdomen, and the two processes which extend from it upon the testes (*tunicæ vaginales*.) The membrane which lines the anterior chamber of the eye and secretes the aqueous humour, is of the same structure; so is that which encloses the vitreous humour, viz. the hyaloid membrane, and also the capsule of the crystalline lens. The inner or lining coat of arteries and veins presents several points of similitude to those here enumerated.

As serous membranes are thus placed within the great cavities of the body, and as they line the inner surface of their walls, and surround, at the same time, to a greater or less extent, the contained parts, anatomists recognise in each of them two portions,—one *investing* the viscera, the other *reflected* upon the walls of the cavity. Thus, in the pericardium, one part of the serous membrane encloses the body of the heart, extends for some way on the great vessels, and then passes off to line the fibrous bag which retains that organ in its situation; so that it forms a single sac, one part of which is doubled within the other. This is strictly true with regard to the pericardium; it is not less so in the case of the peritonæum and arachnoid membrane, though from their extent, and the great complexity of their arrangement, it is not at first sight easily perceived. It is the investing part of serous membranes which gives to different organs their shining appearance; and as it is very thin, their colour, form, and even the minute inequalities of their surface, are distinctly seen through it, as we observe when examining the heart, brain, lungs, &c. Though these structures appear destitute of fibres, or of any assignable internal organisation (being what Haller considered them, merely condensed cellular tissue,) still, if any part of them be inflamed, vessels will be traced into their tissue. It requires some

## PLATE I.

In this plate the salivary glands are exhibited in their natural situations.

A. The parotid gland.

a. The duct of the parotid gland—Stenon's duct. b. The *socia* parotidis.

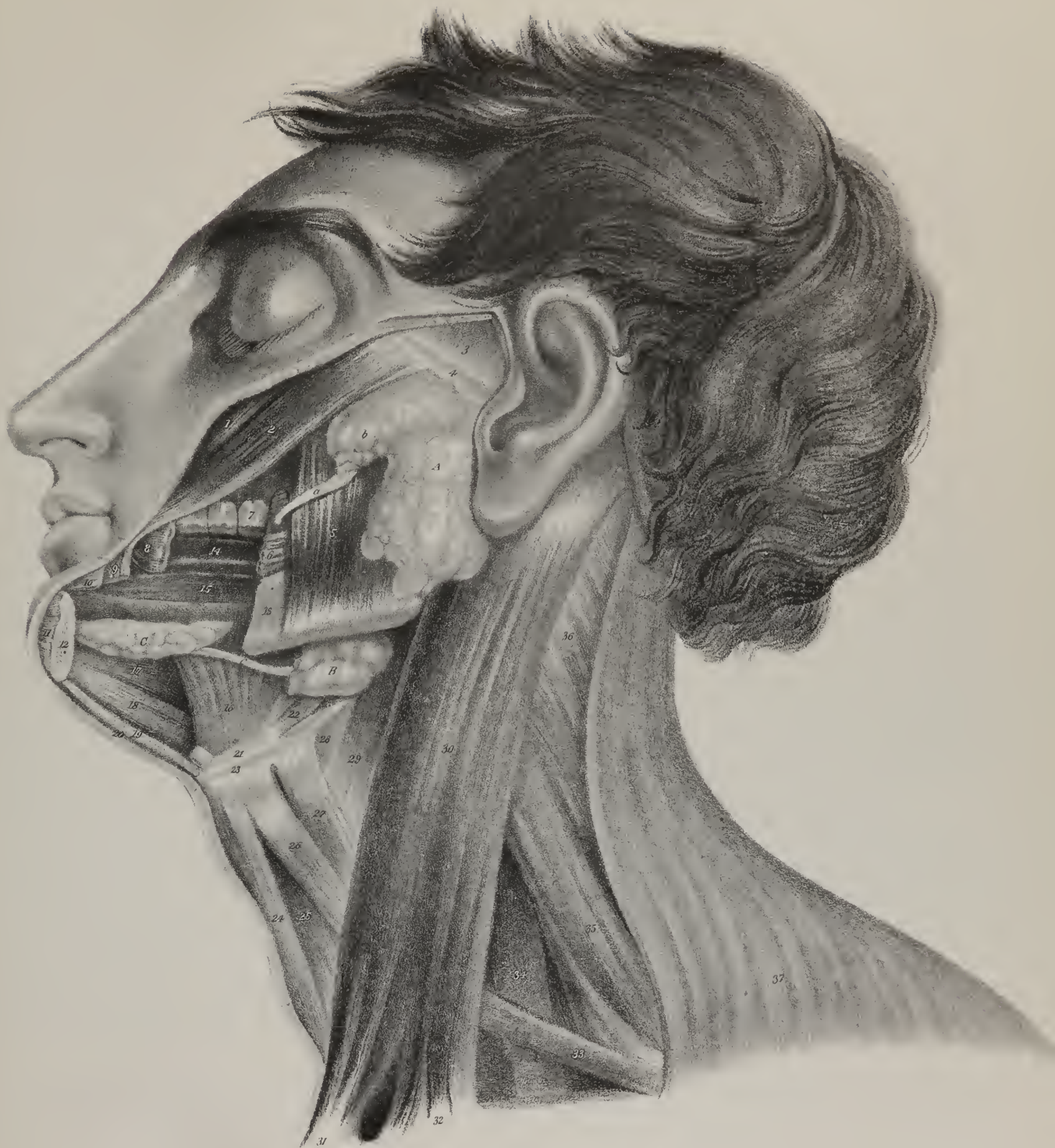
B. The submaxillary gland.

c. Its excretory duct—Wharton's duct.

C. The sublingual gland.

No. 1. The zygomaticus minor muscle seen beneath the divided edge of the integument. 2. The zygomaticus major. 3. The temporal fascia. 4. The zigoma. 5. The masseter muscle, overlapped by the parotid gland, and crossed by Stenon's duct. 6. A part of the buccinator, the rest having been removed with a part of the lower jaw in order to bring into view the cavity of the mouth and the side of the tongue. This portion of the buccinator is pierced by Stenon's duct. 7. The first molar tooth of the upper jaw. 8. A portion of the buccinator muscle at its insertion. 9. A small portion of the depressor anguli oris muscle. 10. The edge of the orbicularis oris muscle. 11. The cut edge of the muscles of the chin. 12. The cut surface of the body of the lower jaw. 13. The body of the lower jaw. The intermediate portion between 12 and 13 has been removed to show the position of the sublingual gland. 14. The dorsum of the tongue. 15. Fibres of the stylo-glossus muscle. 16. The hyo-glossus muscle crossed by Wharton's duct, and brought into view by the removal of the mylo-hyoideus muscle. 17. The genio-hyo-glossus muscle. 18. The genio-hyoideus muscle. 19. The divided edge of the mylo-hyoideus muscle. 20. The cut edge of the platysma myoides. 21. The pulley of the digastric muscle. 22. The posterior belly of the digastric muscle. 23. The os hyoides. 24. The sterno-hyoideus muscle. 25. The sterno-thyroideus muscle. 26. The superior belly of the omo-hyoid muscle. 27. The thyro-hyoideus muscle. 28. The thyro-hyoidean membrane. 29. The inferior constrictor muscle of the pharynx. 30. The sternomastoid muscle. 31. Its sternal origin. 32. Its clavicular origin. 33. The inferior belly of the omo-hyoid muscle. 34. The scalenus anticus muscle. 35. The scalenus posticus. 36. The splenius colli muscle. 37. The trapezius.

\* Müller's Archiv. für Anatomie und Physiologie, &c. No. 1, 1833.







care to determine this point with precision; for the vessels which ramify in the subserous cellular web will often appear to run in the membrane itself, when in reality they are external to it.

Serous membranes allow a considerable degree of distension during life, as we see in cases of dropsy, and in the state of pregnancy, also in herniæ; and they retract slowly when the distending cause is removed. They exhibit no animal sensibility in their natural condition, but acute pain arises when inflammation is excited. They confine to fixed positions some organs, for instance, the large intestine, the liver, and stomach; in others, as the small intestines, they facilitate movement by means of the smoothness of their surface and the fluid which they secrete. By being reflected from one viscus to another, they necessarily, in the intervening spaces, form folds, in which the vessels are conveniently lodged, and by which they are in a manner guided to the organs which they supply. It must be evident that these membranes cannot completely invest at every part any of the organs with which they are in contact; each of them will be left uncovered at the points of reflection, and there the vessels can enter them without piercing the membrane, or interrupting its continuity. The folds or duplicatures of peritonæum, termed omenta, mesentery, mesocola, afford illustrations of what has been here stated. There is but one exception to the general principle above indicated, viz. that serous membranes form shut sacs, without interruption to their continuity or external communication. It occurs at the free, or, as it is technically called, "fimbriated," border of the Fallopian tubes in the female; for there, the serous investing layer is continuous with the mucous lining, and is necessarily open, to give passage to the ovum.

Are serous membranes furnished with exhalent vessels to pour out the fluid which moistens them, and with absorbents to take up the surplus or residue of it? The existence of such vessels cannot be demonstrated; it has been assumed, in order to account for the effusion and absorption of fluids, which, until lately, were conceived to be inexplicable on any other hypothesis. It is now, however, clearly demonstrable, that fluids and gases can pass through organised membranes without being conducted across them by exhalent vessels. If a piece of membrane, or, what will answer better, if the cæcum of a common fowl, containing a few drachms of milk, of a solution of gum Arabic, or of common salt, be suspended in a glass filled with water, it will be found that in a few hours the water has entered the intestine, and ascended within its cavity until it overflows at the top. But if the mode of experimenting be altered,—if, whilst the intestine is filled with pure water, the fluid in which it is suspended be rendered specifically heavier by the addition of any saline substance, the direction of the current will be reversed; it will flow outwards from the interior of the membrane. Thus, in the former case, there is a passing into the interior of an organised structure, which M. Dutrochet calls *endosmosis* (ενδοσ, inward; ωσμος, effort;) in the latter, the tendency is in the opposite direction, therefore called *exosmosis* (εξω, outward; ωσμος.) But though the stream seems thus to run altogether from the rarer to the denser fluid, yet we find that a minor current exists in the opposite direction. If a solution of prussiate of potash be enclosed within the intestine, endosmosis takes place rapidly, and at the same time exosmosis goes on, but in a slight degree, which may be proved by adding a few drops of muriate of iron to the external fluid, when it will be found to have received some of the salt of potash. Gases also percolate membranes, and in a determined direction.\* If a bottle, with a wide mouth, be filled with carbonic acid, and closed at top with a layer of Indian rubber, exosmosis will occur; for the membrane will become depressed into the glass, showing that the carbonic acid escapes out of it, though it has to go contrary to its gravity.† If the experiment be reversed, by placing, under a receiver filled with carbonic acid, a bottle containing atmospheric air, closed in by a membrane, endosmosis will occur; for the cover becomes distended and elevated, showing that the carbonic acid has a tendency to pass in that direction in which the atmospheric air is placed. Mere gravity or density does not determine the direction of the current. The chemical composition of the substances employed appears to exert an influence on the result; so also does the galvanic agent.

*Mucous Membrane.*—The internal tegument, or mucous membrane, is differently named by writers, *tissu muqueux*, Bichât; *membrana mucosa, villosa, mucipara*.—The tegumentary membrane is not confined to the external parts of the body; it is prolonged into their interior, where it serves a corresponding purpose; but in this situation it presents some important modifications in its character; and, from the nature of the fluid which covers and moistens it, receives the name of "mucous membrane." From the lips and nares, it extends along the whole length of the alimentary canal, as well as into the different follicles and excretory ducts which open into it. The larynx, trachea, bronchi, and air-cells of the lungs, are lined in the same way by a mucous membrane; and, as the whole forms a continuous surface, it has been named by Bichât, the "*gastro-pulmonary mucous membrane*." A similar mucous surface may be traced from the orifice of the meatus urinarius, along the urethra, bladder, and ureters, to their termination in the tubuli of the kidney; also into the vasa deferentia, from which it is probably continued into the tubular structure

\* Faust and Mitchell. American Journal of Medical Sciences, No. 13.

† J. K. Mitchell, M. D., Professor of the Practice of Medicine in Jefferson Medical College, has shown in the journal referred to, that the penetrability of membranes by liquids or gases is dependent on the same cause as that which produces capillary attraction in general—and seems to be independent of chemical affinities. He has also demonstrated that the specific gravity and volume of atoms, have no share in the result, since the transmission of liquids or gases is often reversed as to direction by substituting different membranes.

Thus water goes to alcohol through animal membranes—but alcohol to water through gum elastic.—Scattered hints on the transmissibility of gases through membranes, are found in the works of Priestley, Dobereiner, and Graham; but, as Dr. Turner remarks, we are indebted to American philosophy for the discovery of the principles of these phenomena. Dr. Mitchell was the first to detect the error of Dutrochet, who announced the supposed law of the passage of less dense fluids towards more dense ones, by showing that the relative densities have no share in the result.—J. P.

of the testes in males. In the female, it is prolonged from the vagina into the uterus, and thence into the Fallopian tubes to their termination. This continuous tube forms the "*genito-urinary mucous membrane*."

Between the two great divisions of the internal tegument here pointed out, no organic connexion or communication exists. The general form of each may be said to be that of a canal, or tube, of considerable extent, but presenting numerous contractions and dilatations, corresponding with those of the hollow organs which they line. Their external surface is rough and flocculent; for it is attached by cellular tissue (sub-mucous) to the contiguous textures. The strength and closeness of its adherence varies in different parts of its extent. In the stomach it is easily separated; from the pylorus to the ilio-cæcal valve it gradually becomes more firmly attached, at the valve itself it is less so; but in the large intestine it is again very closely adherent, and so continues to the rectum, near the extremity of which it is comparatively loose. The thickness of the membrane also varies; it is greatest in the stomach and duodenum, and thence diminishes gradually towards the lower part of the small intestine; at the ilio-cæcal valve it increases somewhat; it becomes thinner again along the large intestine, (being about half as thick as in the stomach;) but it increases perceptibly towards the extremity of the rectum. Its firmness and power of resistance are greatest in the stomach and duodenum, which seems to depend on its greater thickness in these parts.

The colour of the mucous membrane varies in different parts of its extent; to which circumstance, in a great degree, is owing the discrepancy we find amongst writers upon this point. Bécлар says it is white, with a reddish tinge; Boyer, that it is yellowish grey, becoming red in the stomach, and reddish in the intestine; Gavard states it to be greyish, with an inclination to red. These statements are too general; for we find that the colour of the membrane is influenced by the age of the individual, by the circumstances which preceded his death, the condition of the thoracic viscera, by the time which has elapsed between death and the performance of the examination, and by the position in which the body has been laid. Hence arises the necessity of distinguishing that which is inherent in the membrane, from what is extraneous to it. For this purpose, a small piece must be carefully dissected off, and held up to the light; it will be found homogeneous, translucent, and of a pale white colour, or greyish with a delicate rosy tinge. This is the healthy colour and condition of the membrane, when examined by itself after death; and if we inspect the intestine in a subject that has died without disease or disturbance of the abdominal viscera, we perceive, from the outside, some branching vessels creeping beneath the peritonæum, in a direction from the attached to the free border of the tube: a similar appearance will present itself from within, owing to the vessels lying in the submucous cellular tissue. During life, the vessels being necessarily more or less distended with blood, impart a tinge to the surrounding textures; and so the mucous membrane is rendered of a delicate rosy red, varying in degree according to the quantity of fluids circulating in a given part at any particular time. Hence it deepens in the stomach during the digestive process, and this deeper tinge creeps along the intestine as the alimentary mass passes from stage to stage during its progress; for the afflux of blood thus determined now to one point, now to another, carries with it the colour by a sort of derivation.

*Plicæ, or rugæ*.—The inner surface of the mucous membrane presents several inequalities (elevations and depressions) which deserve notice. In the stomach and in the bladder, when cut open, we observe numerous small ridges running in various directions, giving it an areolar aspect: these are termed *rugæ*; but they are not permanent; they arise from a contraction of the muscular fibres, and consequently disappear when the viscus is distended. In the œsophagus similar folds exist, but all running longitudinally.

*Valvulæ conniventes*.—In the small intestine we find folds which are permanent in their existence and fixed in their direction,

## PLATE II.

Anatomy of the mouth, the mucous glands, and the development of the parotid gland.

FIG. 1. The mouth held widely open.

Nos. 1, 1. The upper lip drawn upwards by a hook. 2. The frænum of the upper lip. 3. The four incisor teeth of the upper jaw. 4, 4. The canine teeth of the upper jaw. 5, 5. The bicuspid teeth of the upper jaw. 6, 6. The two anterior molares of the upper jaw, the third did not exist in this subject. 7, 7. A bristle inserted into the duct (Stenon's) of the parotid gland, which opens into the mouth opposite the second molar tooth of the upper jaw. 8. The palate marked by transverse elevations. 9, 9. The soft palate. 10. The uvula. 11, 11. The anterior arch or pillar of the soft palate. 12, 12. The posterior arch or pillar. 13, 13. The amygdala or tonsil. 14, 14. The pharynx. 15, 15. The dorsum of the tongue. 16. The apex of the tongue. 17. The frænum linguæ. 18, 18. Two bristles inserted into the openings of the ducts (Wharton's) of the submaxillary glands. 19, 19. Small openings of the sublingual ducts. 20, 20. The three molar teeth of the lower jaw. 21, 21. The two bicuspid teeth of the lower jaw. 22, 22. The canine teeth of the lower jaw. 23, 23. The incisor teeth of the lower jaw. 24. The frænum of the lower lip. 25. The lower lip.

FIG. 2. The inner surface of the lips showing the numerous small glandular bodies, labial glands which are situated immediately beneath the mucous membrane.

FIG. 3. A branch of the parotid gland from a fœtal calf highly magnified, and intended to display the structure of the salivary glands. The artery is injected with size and vermilion.

a. The artery. d. The duct. c. The cæcal terminations of the duct.



Fig 1

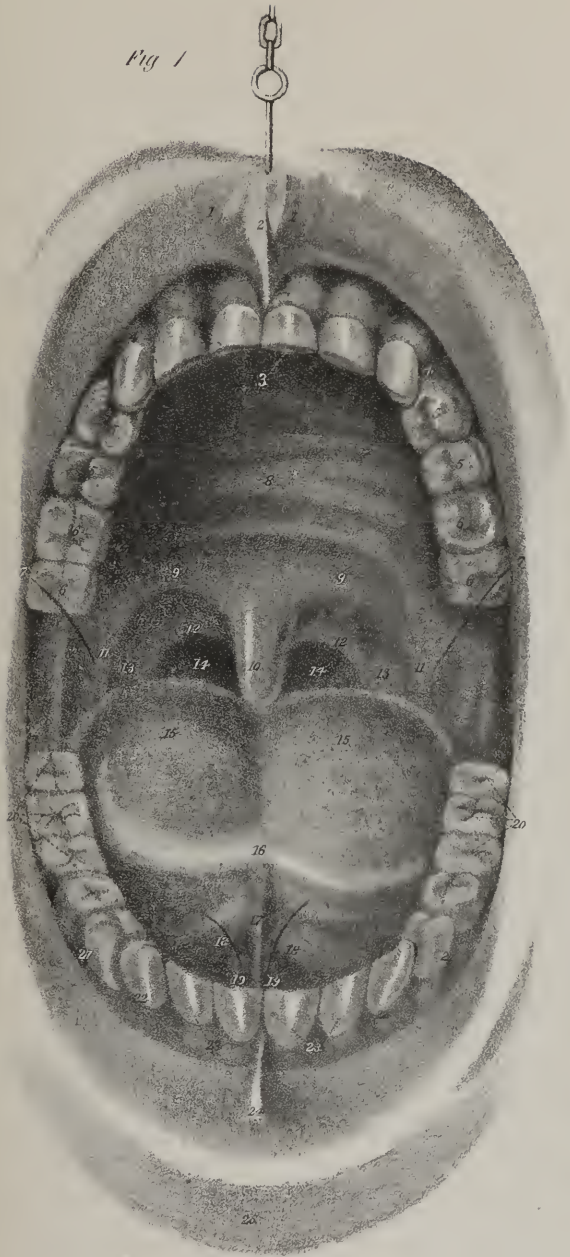
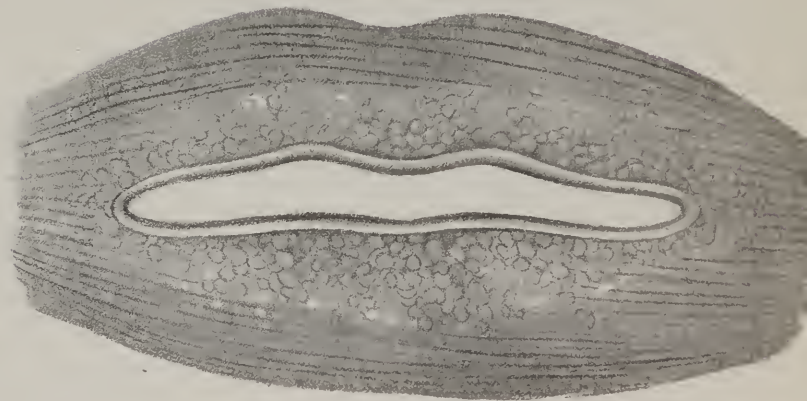

Fig 3



Fig 2





st  
je  
re  
pea  
anc  
WE  
wit  
they  
de  
owe  
of lo  
face  
reca  
ours  
plur  
I  
pace  
mach  
ind li  
resou  
unwe  
atral  
fabric  
ery lay  
unmed  
of a la  
ri fee  
re has  
with a  
are a  
ind  
the. e  
observ  
en of  
a. r. r. r.  
come  
and  
res.  
ours  
dly  
pres  
ind  
sua  
case  
per  
ery  
ery  
pas  
ind  
or

showing that they depend, not on the contraction of the muscular coat, but on the special conformation of the mucous membrane itself. These are termed *valvulæ conniventes*, and are formed of duplicatures, or narrow plaits of the membrane placed transversely with regard to the axis of the canal, and projecting into its interior. None of these extend round the whole circle—few reach farther than one third of its circumference. Some depart a little from the transverse direction, becoming rather oblique; and a few, of minute size, may be observed to run longitudinally, intersecting the spaces enclosed by those which are larger. When the membrane is detached, and stretched a little, the valves are unfolded and disappear, as the sub-mucous cellular tissue which connects them is torn asunder. The point at which the *valvulæ* commence is at about an inch below the pylorus, where they are rather small and but slightly projecting; but they gradually increase in size and breadth from thence down to the middle of the jejunum, where they project inwards about two lines; but they gradually diminish along the ileum, and cease at its lower end, a few oblique or longitudinal lines alone remaining. The term “*plica*” would better express the character and mode of formation of these projections than “*valvula*,” for they are merely folds of the membrane, which enlarge the extent of surface by which it comes into contact with the alimentary mass, and increase its absorbing power. The true valves are the ilio-cæcal and the pylorus; for they are contractile, (muscular fibre entering into their composition,) and exercise an influence on the course of the aliments. The term “*valve*” is also applied to three or four projecting and permanent ridges which exist in the interior of the rectum.\* We shall recur to these when treating of the pelvic viscera.

*Villi*.—All the elevations hitherto noticed are readily perceived, even on a cursory inspection; they are easily shown in a piece of intestine inflated, dried, and then laid open, or, without any preparation, by merely laying it open; there are others which require a little more attention in order to be distinctly seen. If the mucous surface be held up to the light, or allowed to float in water, it will be found covered with a vast number of minute downy processes, giving it a flocculent appearance. Some persons have likened this to the pile, or soft surface of velvet; and hence arose the term “*villi*,” by which the projections are known. Their intimate structure has been made the subject of much minute examination, and of not a little controversy; perhaps arising from the opinion, so very generally entertained, that absorption of chyle was effected by the capillary attraction of lacteal vessels, and that the open mouths of these must be placed in the villi. Lieberkuhn concluded, (*Dissert. Anat. pathol. de fabricâ et actione villorum intestinorum tenuium hominis*.) from his microscopical researches, that each villus consists of a capillary lacteal vessel, and a nerve with a delicate vascular plexus spread upon the lacteal, which becomes expanded into an ampulla immediately after its origin, in the form of a minute pore. Sheldon, Cruickshank, and Hewson, admit generally the existence of a lacteal with vessels and nerves in each villus; but deny the existence of any expansion or ampulla in its interior. We cannot feel surprised at any difference of opinion which may exist concerning the intimate structure of such minute objects, when we find that their outward form is said by some to be round, by others to be conical; whilst a third likens it to a mushroom with a stalk and pileus. All agreed in admitting an absorbing orifice at the extremity of each villus, whatever discrepancy may have existed upon other points. Béclard, (*Anat. Générale*.) however, after repeating the observations previously made by others, found that these projections are neither conical, tubular, nor expanded at the summit; but that they appear as so many plates, folia, or leaflets, set closely together, and forming a tufted pile. This is the true account of the matter: most of the antecedent observations bear evidence of being undertaken and conducted under the influence of a preconceived opinion as to the mechanism of absorption. There no longer remains any necessity for admitting the existence of pores, ampullæ, or capillary attraction, in order to account for the phenomena. Membranes we know to be permeable by fluids, and in a determinate direction; it matters little, then, whether, with Majendie and Fodera, we adopt the term imbibition to express the fact; or, with Dutrochet, name it endosmosis.

*Mucous Follicles*.—Along the alimentary canal we find, in various parts, minute orifices leading into small follicles, or shut sacs, which appear to be merely depressions into, or inversions of, the mucous membrane. They are embedded in the sub-mucous cellular tissue, and can therefore be readily seen upon the external or attached surface of the mucous lining, if it be carefully dissected away. Their capacity is generally small; in some parts they are simple in their structure, detached, and scattered, as we see in the stomach and duodenum, where they are named *glandulæ Brunneri*. Towards the lower part of the ileum, and even higher up along the jejunum, they are clustered together into spots, (*glandulæ aggregatæ*, *glandulæ Peyeri*.) In some situations, several follicles open into a common dilated orifice, as into the lacunæ of the urethra and rectum, or into the foramen cæcum at the back of the tongue: finally, several follicles, by being united into bundles of various forms, constitute a compound secreting organ, with ramified ducts or lacunæ, as we see exemplified in the tonsils, the prostate and Cowper’s glands. All these structures come under the general head “*mucous follicles*,” for they have been supposed to secrete the fluid which moistens the surfaces upon which they open. But it is more probable that mucus, like synovia and the serous halitus, is produced by every part of the membrane, and that the follicles elaborate each a distinct product. The secretion of the prostate gland appears to differ as much from that of the tonsils, as the cerumen of the ear does from the sebaceous matter exuded upon the glans penis, or clitoris.

The *structure* of the internal tegumentary membrane resembles that of the external or true skin, so far as that it consists of

\* Observations on the Mucous Membrane of the Rectum, by Dr. Houston, Dublin Hospital Reports, vol. v.

a corium or dermis, and an epidermis, which is here called epithelium, ( $\varepsilon\pi\iota$ , upon;  $\theta\eta\lambda\eta$ , a nipple or papilla;) for, when traced inwards from the margin of the lips, it is found to cover the papillæ on the surface of the tongue. A rete mucosum cannot be demonstrated in any part of it. The corium is soft, cellular, and spongy, varying in thickness and density in different parts, as we have already stated. The epidermis is prolonged upon its surface for some way, and may be traced as far as the union of the œsophagus with the stomach. The vagina also is similarly coated as far as the neck of the uterus; but the deeper-seated parts appear to be protected, not by an insensible epidermis, but by a softer and more delicate epithelium.\*

The epithelium of mucous membrane is composed of several layers of minute bodies, which have a laminated arrangement upon the surface of the membrane. These are best observed, according to Henle,† upon the conjunctiva, where the layers are clearly distinguishable. The layer immediately in contact with the mucous membrane consists of minute cells or vesicles, having each a central nucleus; but, as we approach the surface, the cells become flattened and assume an angular form. The nucleus is still perceptible, and the minute scales resulting from the flattening of the cells have the appearance of a tessellated pavement. In the mouth the arrangement of these bodies is precisely similar, but the scales are of larger size. In the alimentary canal they are lengthened and conical, and placed perpendicularly to the surface, the apices of the cones being in contact with the mucous membrane, and the bases forming by their juxtaposition the surface of the epithelium; like the preceding, they are provided with a central nucleus. On the surface of the mucous membrane of the nasal passages, of the larynx, trachea, and lungs, and of the vagina and uterus, another kind of scale is observed to compose the epithelium. It is cylindrical in form, like those of the intestine; and possesses, like them, a central nucleus. Upon its obtuse extremity are a number of minute cilia, which probably continue in constant motion during life, and diffuse the secretion equally over the surface of the membrane. According to Henle, the number of cilia upon each of these "ciliary cylinders" varies from three to eight.

*Organs of Digestion.*—The digestive organs consist of a primary or fundamental part, the alimentary canal, and certain accessories, which are in a manner appended to it. Under this head are included the salivary glands, (sublingual and submaxillary, parotid and pancreas,) the liver, and the spleen. Though the canal (*canalis cibarius*) forms one continuous tube, from its commencement at the mouth to its termination at the anus, it presents numerous modifications in its dimensions and form in different parts; moreover, as one portion of it is lodged at the base of the skull, another in the neck and thorax, and a third in the abdomen, it becomes necessary to treat of each separately. To avoid unnecessary subdivision, we shall consider it as composed

### PLATE III.

The anatomy of the pharynx and œsophagus.

FIG. 1. The pharynx laid open from its posterior part, in order to show the foramina which open into it.

No. 1. Basilar process of the occipital bone, which has been divided by a section carried transversely through the base of the skull. 2, 2. The posterior clinoid processes of the sphenoid bone. 3, 3. The anterior clinoid processes. 4, 4. The lesser wings of the sphenoid. 5, 5. The greater wings. 6, 6. A section through the squamous portion of the temporal bone. 7, 7. Divided surface of the petrous portion of the temporal bone. 8, 8. The carotid canal. 9, 9. The condyles of the lower jaw. 10, 10. The rami of the lower jaw. 11, 11. The divided edges of the pharynx drawn outwards. 12, 12. The posterior nares. 13. The posterior border of the vomer covered by mucous membrane, separating the posterior nares. 14, 14. The openings of the Eustachian tubes. 15, 15. The posterior extremities of the inferior spongy bones. 16. The soft palate, upon the middle line of which is seen a slight elevation formed by the projection of the zygus uvulæ muscle beneath the mucous membrane. 17, 17. A slight elevation of the mucous membrane, marking the direction of the levator palati muscle. 18. The uvula. 19, 19. The opening of the fauces. 20, 20. The arches of the soft palate. 21, 21. The anterior arches formed by the projection of the palato-glossus muscle at each side. 22. The posterior arches formed by the palato-pharyngeus muscle at either side. 23, 23. The tonsils. 24. The root of the tongue, marked by numerous elevations corresponding with mucous follicles. 25. The epiglottis. 26. The lateral fræna epiglottidis. 27. The opening into the larynx. 28, 28. The aryteno-epiglottidean folds of mucous membrane. 29. The convexity formed by the larynx. 30, 30. Two slight projections corresponding with the ascending cornua of the thyroid cartilage. 31. The opening into the œsophagus. 32, 32. Longitudinal folds formed by the mucous membrane of the œsophagus. 33. The œsophagus marked by its longitudinal fibres. 34. The trachea divided transversely.

FIG. 2. A portion of œsophagus, showing its muscular fibres.

No. 1. The external, or longitudinal fibres. 2. A part of the layer of longitudinal fibres turned down from the circular layer. 3. The internal, or circular fibres.

FIG. 3. The lower part of the œsophagus, a portion having been cut out for the purpose of showing the lining of mucous membrane.

No. 1. The exterior of the œsophagus, marked by longitudinal fibres. 2, 2. The divided edges of the œsophagus. 3. The mucous lining thrown into longitudinal folds. 4, 4. The terminal margin of the cuticular epithelium of the œsophagus. 5. A part of the stomach.

FIG. 4. A transverse section of the œsophagus, showing it to be closed in the contracted state of the muscular coat.

Nos. 1, 1. The external, or longitudinal layer of muscular fibres. 2, 2. The internal, or circular layer. 3, 3. The lining membrane thrown into folds which close the cylinder of the œsophagus.

\* In the Amer. Jour. of the Med. Sciences, for May, 1835, will be found a very interesting communication on the structure of the mucous membrane of the alimentary canal, by W. E. Horner, M. D., Prof. Anat. University of Pennsylvania. The double vascular layer which he has shown to exist in the mucous membrane, the inner or superficial one consisting almost wholly of a minute cribriform intertexture of veins, the shape and composition of the villi, the size and the immense number of the follicles of Leiberkuhn, which he estimates in the whole alimentary canal to upwards of forty-six millions, the peculiar character of Peyer's Glands, and the developement of a vesicular eruption in cholera, are the subjects of the paper, which will well repay a careful perusal.—J. P.

† Symbolæ ad anatomiam villorum intestinalium, imprimis eorum epithelii et vasorum lacteorum. Berlin, 1837.



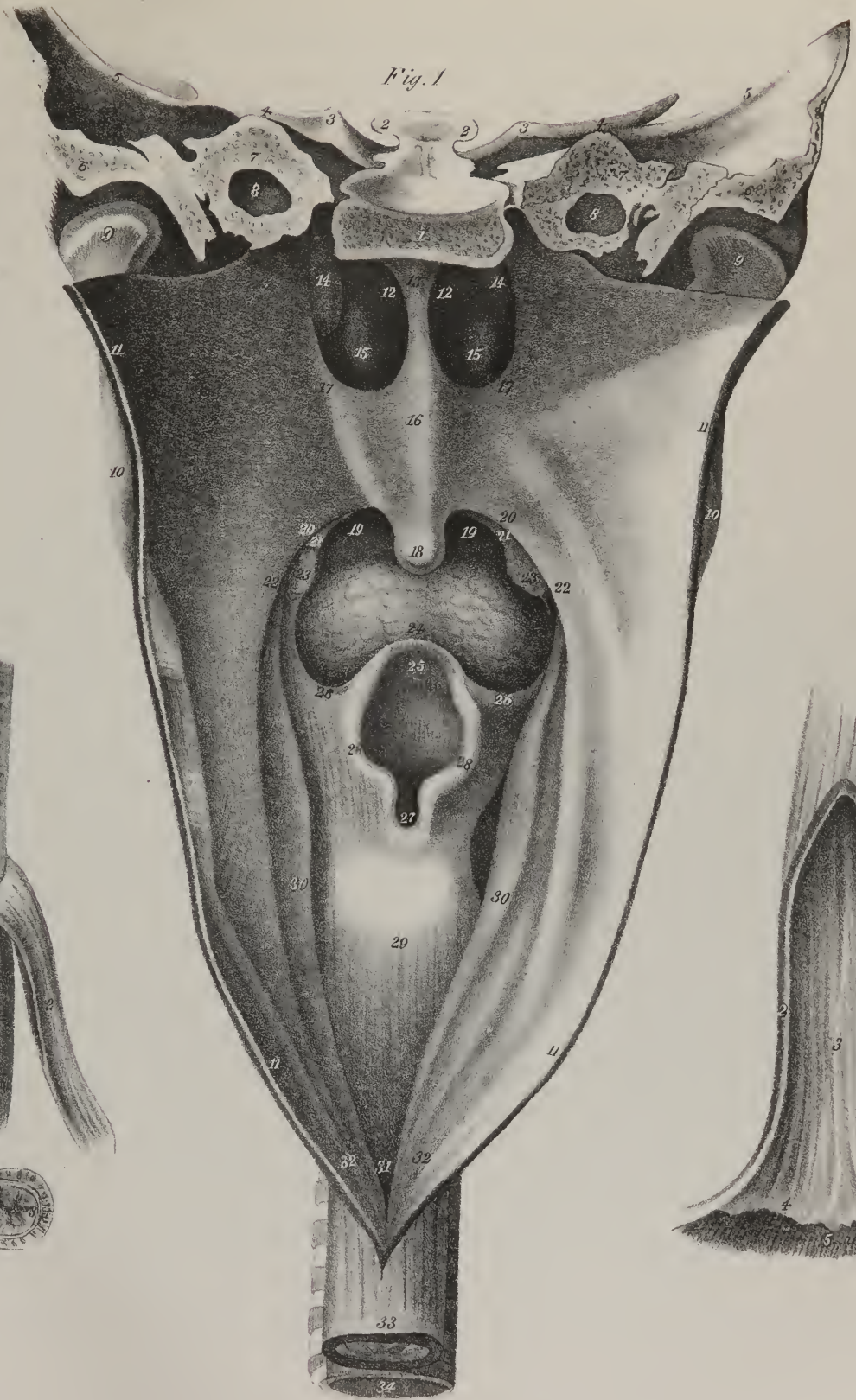


Fig. 2.



Fig. 3.

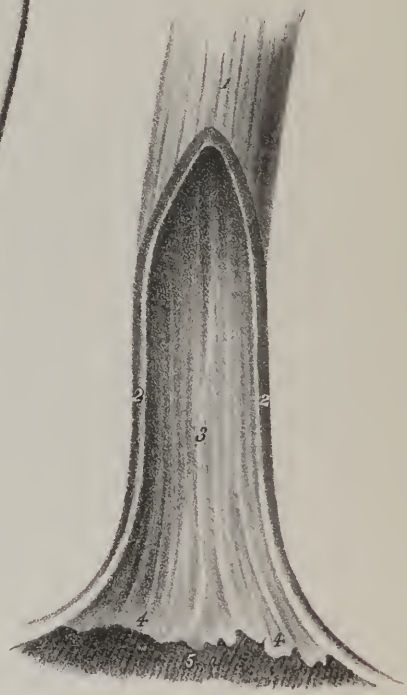



Fig. 4.







of two parts, one above the diaphragm, the other below it. The first division includes the organs of mastication and deglutition; the second, those of digestion properly so called, and of defæcation.

*The Mouth.*—The space included between the lips (*labia*) and the throat (*fauces*) is called mouth, (plate II. : *os* ; *cavum oris*.) Its roof is the palate, its floor the tongue, its sides the cheeks, (*buccæ*.) Immediately within its external aperture (*rima*) are the dental arches. All these parts are coated with a mucous membrane, which has been already described. In the present section, therefore, it remains for us to notice some folds which are formed by its reflections, and which, from some assumed resemblance to check ligaments, have been called *fræna*. Inside each lip, at the middle line corresponding with the symphysis of the jaw-bones, a small vertical fold (fig. 1, Nos. 2, 24) is placed, (*frænum labii superioris et inferioris*.) One of larger size (fig. 1, No. 17) extends from the under surface of the tongue downwards and forwards, (*frænum linguæ*;) when the point of the tongue is raised, the form of this fold is triangular, its base being forwards. At the root of the tongue we observe another, extended backwards from its upper surface upon the epiglottis, (*frænum epiglottidis*.) Most of the constituents of the other parts here enumerated have already been noticed; the muscles of the lips and cheeks, those of the palate, and of the tongue.

*The Tongue.\**—The tongue (plate II. fig. 1, 15, 16; *lingua*) is not only the proper organ of taste, but, by means of its great mobility, assists other parts in deglutition, in speech, in suction, &c. Its upper surface, or dorsum, is convex in its general outline, and marked along the middle by a slight groove, or raphé, which divides it into two symmetrical parts. About a quarter of an inch from its base will be observed a round hole, (*foramen cæcum*;) which forms a sort of reservoir for some of the mucous follicles placed in considerable number in that situation. We speak of its point or anterior narrowed extremity, of its sides, and of its base, which is in intimate connexion with the *os hyoides*. Upon its upper surface we find several projecting points, or *papillæ*, differing so far in size and number as to admit of being arranged as follows:—1. *Papillæ lenticulares*, which vary in number from ten to fifteen, are disposed in two lines, converging to an angle just before the foramen cæcum. They are rounded on their free surface, and resemble so many inverted cones, their summits being embedded in the substance of the tongue. 2. *Papillæ capitatae* vel *fungiformes*, are more numerous than the preceding, and also smaller. They are placed, for the most part, towards the borders and point of the tongue. They present each a rounded head, supported by a short thin pedicle. 3. *Papillæ conicæ*, vel *pyramidales*, are much more numerous than the others, and are diffused over the whole of the dorsum of the tongue, from the lenticular papillæ to its point. They are minute and tapering. A fourth class has been recognised by some persons, (*papillæ filiformes*;) but they are very few, and placed close to the apex of the tongue. The papillæ at the point and sides consist of the ultimate terminations of the gustatory nerve, surrounded by a delicate vascular plexus, and supported by cellular tissue.

*Structure.*—Beneath the mucous membrane is placed a thin but firm lamella of condensed cellular tissue, approaching in its characters to elastic tissue. If all the muscles ordinarily described as belonging to the tongue be dissected away, a considerable mass of fleshy substance will still remain, the fibres of which appear interlaced in such a way as to be with great difficulty traced. Upon the upper surface and sides of the tongue a thin stratum of fleshy fibres is placed, extending longitudinally from behind forwards. At the under surface, the fibres of the linguales muscles run in the same way, but that they form fasciculi, not a layer. If the genio-hyo-glossi be carefully dissected to their insertion, their fibres will be found to turn outwards, or to become blended with others which pass transversely from the raphé to the borders on each side. Both the planes of fibres here noticed are placed horizontally, one being at the upper, the other at the under surface; a third set seems to connect them, by passing vertically from one to the other.

*The Soft Palate.*—The soft palate (plate II. fig. 1, Nos. 9, 9; plate III. fig. 1, No. 16: *velum pendulum palati*) forms a partial and movable curtain between the mouth and the pharynx. Its upper border is straight, and attached to the margin of the palate bones; the lower is divided into two parts by a conical depending process, called *uvula*, (plate II. fig. 1, No. 10; plate III. fig. 1, No. 18.) From this, as from a common point of departure, two curved lines (plate II. fig. 1, Nos. 11, 12) will be observed to extend at each side, one proceeding downwards and forwards to the side of the tongue, the other backwards to the pharynx; both being named, from their form, the arches of the palate. In the angular interval left by their divergence is lodged the tonsil, or amygdala; the anterior arch is also called the *isthmus* of the fauces, as it marks the narrowed interval between the mouth and the throat, or pharynx. The soft palate consists of five pairs of muscles enclosed by the mucous membrane.

*Amygdala*, (plate II. fig. 1, No. 13; plate III. fig. 1, No. 23.)—Between the arches of the soft palate, on each side, is lodged an elongated oval structure, about the size and shape of an almond, from which circumstance it is termed *amygdala*; in common language it is called *tonsil*: it seems to be composed of a great number of mucous follicles aggregated together into a mass. Its internal surface presents several small apertures, which lead into follicles, or cells, that secrete a mucous and viscid fluid. It is of a reddish grey colour, and exceedingly vascular. Before it, is the palato-glossus muscle; behind, the palato-pharyngeus: internally, the mucous membrane; externally, the stylo-glossus.

*Salivary Glands.*—Three secreting organs, belonging to the class of conglomerate glands, are placed at each side in the region now under consideration, viz. the parotid, submaxillary, and sublingual glands. They differ in size and situation, but agree

\* The plates illustrative of the anatomy of the tongue are contained in Division III. upon the Nervous System and Organs of Sense.



in being of a pale ash-colour, also in being composed of minute lobuli aggregated into bundles and lobes, and in secreting the salivary fluid, which is conveyed into the mouth by ducts that arise by radicles from the granular structure of each gland.

*The Parotid Gland.*—The parotid gland, (plate I, A; *παρα, near; οὖς, ωτος, the ear,*) so called from its position with regard to the ear, is the largest of these. Its superficial extent is from the zygoma to a level with the angle of the jaw and mastoid process, and from the meatus externus of the ear and anterior margin of the mastoid process to the ramus of the jaw and masseter muscle, being also prolonged upon the latter by a process which accompanies its duct, and thence named *socia parotidis*, (b.) The external surface of the gland is covered by the skin, and partially by the platysma muscle, and bound down by a prolongation of the cervical fascia. Its substance projects deeply towards the base of the skull, filling up the interval between the ramus of the jaw and the mastoid process, and necessarily maintaining various and complex relations with nerves and vessels therein situated. Thus, one process of it fills up the posterior part of the glenoid cavity, another passes behind and between the styloid muscles; a third, covered by the ramus of the jaw, rests against the pterygoideus internus. Through its substance pass the external carotid artery, with its accompanying vein, also the facial nerve; and close to its internal or deep-seated surface are placed the internal carotid artery, together with the internal jugular vein. Considering the complexity of these relations, is it possible in the living subject to dissect out the body of the gland and its various deep-seated processes? The duct of the gland (a; *ductus Stenonis*) arises by minute radicles in the lobuli, (plate II. fig. 3.) and taking a transverse course passes forwards on the masseter muscle, and pierces the buccinator muscle, and the mucous membrane of the mouth, opposite the second dens molaris of the upper jaw. The duct is accompanied by a process of the gland already noticed: it is composed of two tunics, the external one being thick and fibrous in its structure; the internal one is a mucous lining prolonged into it from that of the mouth, and, though it appears some lines in diameter, its calibre will barely admit a thin wire. Its direction across the face may be indicated by a line drawn from the lower margin of the concha of the ear to midway between the red margin of the lip and the ala of the nose.

*The Submaxillary Gland.*—The submaxillary gland (plate I. B) lies behind and beneath the ramus of the jaw, resting on the mylo-hyoideus muscle, and separated from the parotid gland by the stylo-maxillary membrane, where it is covered by the skin and platysma, and invested by a thin lamella of cellular membrane. The facial artery runs in a groove on its upper surface. A process of the gland turns round the posterior border of the mylo-hyoideus muscle, lying beneath the mucous membrane. Its excretory duct (c) is called *ductus Whartoni*, though it was known before that anatomist's time: in its passage to the mouth, it at first inclines backwards, to reach the posterior border of the mylo-hyoideus muscle; after which it runs forwards and inwards along the side of the hyo-glossus and genio-hyo-glossus muscles, towards the side of the frænum of the tongue, where it terminates.

*The Sublingual Gland.*—The sublingual gland (plate I. C) is much smaller than the others, and of an oval form. As its name implies, it lies beneath the tongue, close to the side of its frænum, resting against the genio-hyo-glossus muscle, supported by the mylo-hyoideus, and in close contact with the duct and deep process of the submaxillary gland. Its secretion is poured into the mouth by several minute orifices (plate II. fig. 1, No. 19) which open beneath the tongue on each side. Sometimes one or two small ducts join with that of the submaxillary gland.

*The Pharynx.*—The pharynx (plate III. fig. 1; fauces, throat) is a musculo-membranous bag, extended from the centre of the base of the skull as far as opposite the fifth cervical vertebra, where it becomes continuous with the œsophagus. Its superior wall or roof consists of the osseous structure just named, (lined by mucous membrane,) and its sides and back part of three pairs

## PLATE IV.

In this plate is seen the alimentary canal, removed from the abdomen, and separated from its connexions.

A. The stomach.

No. 1. The œsophagus. 2. The great, or cardiac extremity of the stomach. 3. Its lesser, or pyloric end. 4. A constriction corresponding with the pylorus. 5. The superior, or lesser curve of the stomach. 6. Its inferior, or greater curve.

B. The duodenum.

No. 7. Its ascending portion. 8. Its descending portion. 9. Its transverse portion. 10. The termination of the pancreatic duct opening into the descending portion of the duodenum near its inferior angle. 11. The termination of the ductus communis choledochus in the duodenum. 12. The ductus communis choledochus. 13. The common hepatic duct formed by the union of the right and left hepatic ducts. 14. The cystic duct. 15. The gall-bladder.

C, C. The small intestine.

No. 16. The upper part of the jejunum where it is continuous with the duodenum. 17, 17. The jejunum. 18, 18. The ileum, of a lighter colour than the jejunum. 19. The termination of the ileum in the large intestine.

D. The cæcum.

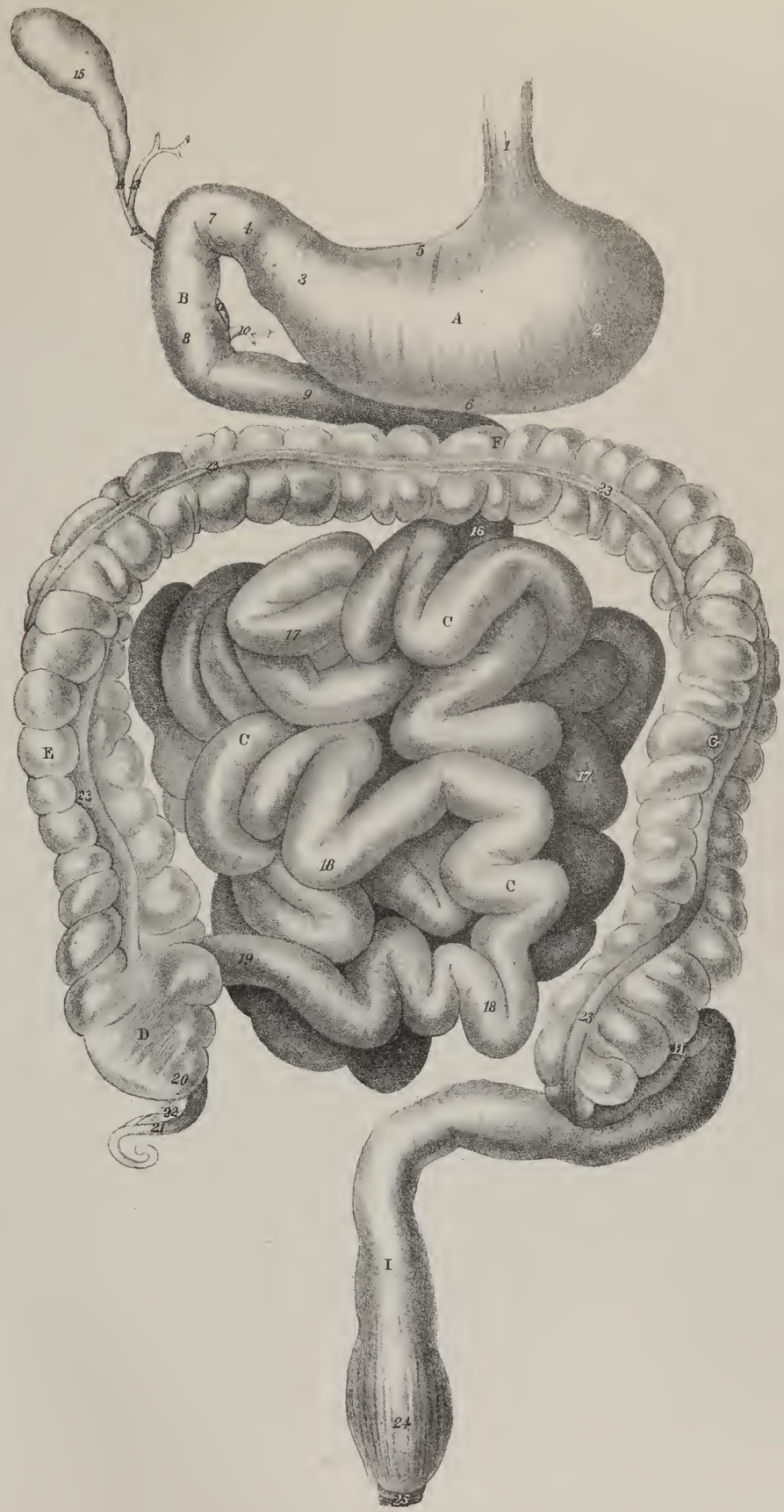
No. 20. The cul-de-sac of the cæcum. 21. The appendix vermiformis, connected with the cæcum by a delicate mesentery, 22.

E. The ascending colon. F. The transverse colon. G. The descending colon.

Nos. 23, 23. The longitudinal bands of muscular fibres which produce the peculiar sacculated character of the colon.

H. The sigmoid flexure of the colon. I. The rectum, in which the sacculated appearance is lost.

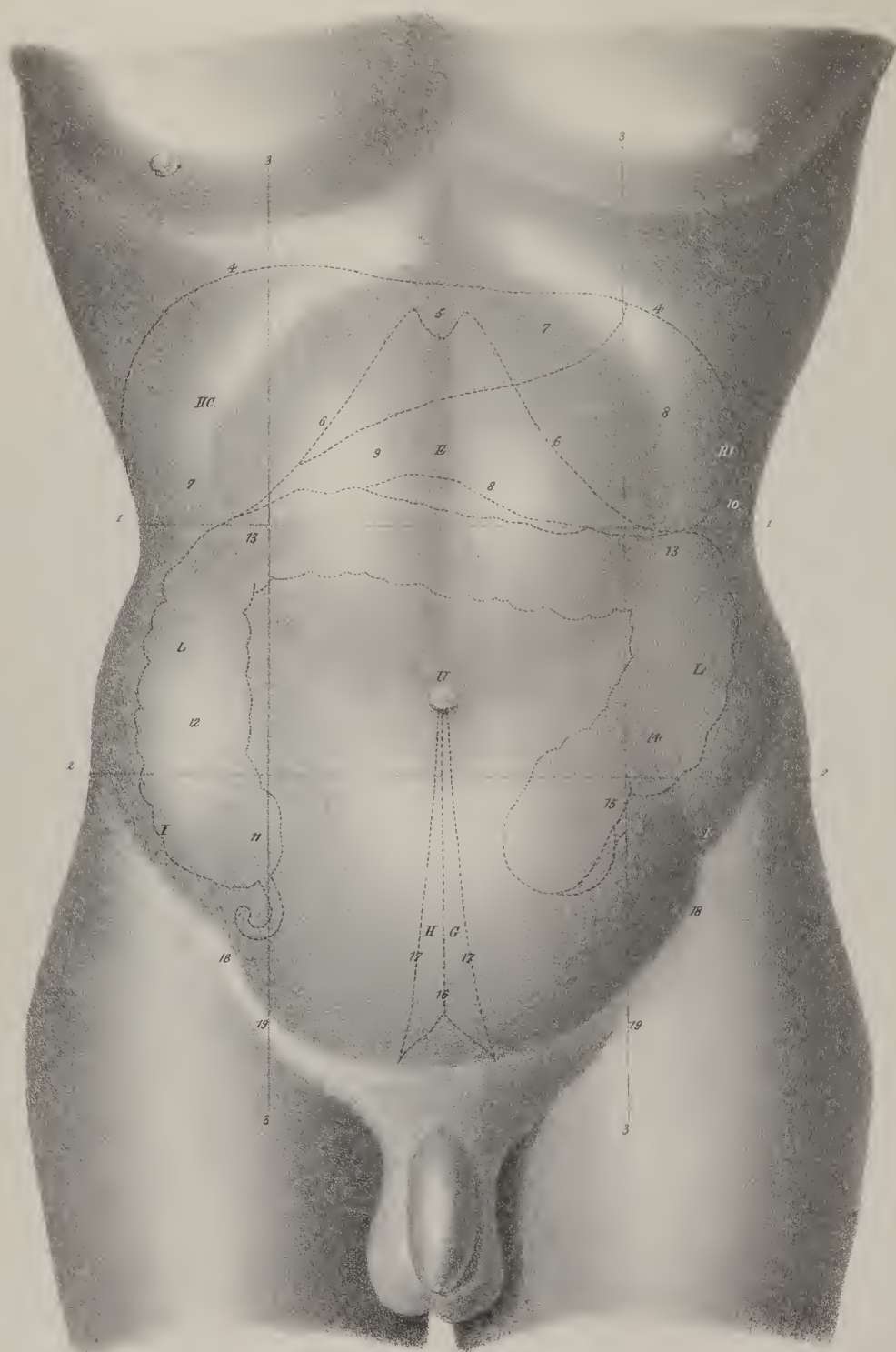
No. 24. Some of the longitudinal muscular fibres seen upon the rectum. 25. The sphincter ani.











of flat muscles, (constrictors,) with two pairs of accessories, stylo-pharyngeus and palato-pharyngeus. It is more expanded in the middle than at its extremities, of which the lower one gradually tapers, so as to represent a funnel, when in connexion with the œsophagus. Its posterior surface rests against the spinal column; its sides are included between the great cervical vessels; anteriorly, it communicates with the nose by two apertures, (12, 12; posterior nares;) with the mouth through the palatal arch, (19, 19; isthmus faucium;) lower down with the larynx, by the glottis, (27;) laterally with the tympanal cavities of the ears, by the Eustachian tubes, (14, 14;) and inferiorly is continued into the œsophagus, (33.)

*The Œsophagus.*—The œsophagus (plate III. fig. 1, No. 33; figs. 2, 3, 4: οἶσος, feram; φαγῶς, edo) is a musculo-membranous tube, extended from the pharynx to the stomach. It is the narrowest part of the alimentary canal, being about an inch in diameter; and, though far less curved than any other, it is not perfectly straight. As it lies along in front of the spine in the neck and thorax, it necessarily presents a slight concavity forwards in the latter region, corresponding with that of the spine. Besides this, it has two slight lateral curves, for its commencement lies upon the median line; further down, towards the root of the neck, it inclines to the left side; but, thence to the fifth dorsal vertebra, it gradually resumes its position in the middle line; finally, when approaching the diaphragm, it deviates again to the left, at the same time coming forward to the foramen œsophageum of the diaphragm. The œsophagus is closely applied to the anterior surface of the vertebral column, being merely separated from it superiorly by the longus colli muscle, lower down by the thoracic duct, and towards its lower extremity by the aorta. In the neck it lies immediately behind the trachea, but, inclining to the left side, comes into relation with the left carotid artery: in the chest it is concealed by the remaining part of the trachea and by the pericardium. The cervical portion has on each side the common carotid arteries; in the thorax, the aorta, except near the diaphragm, lies to its left side, and the vena azygos to the right; here the œsophagus is partially covered by serous membrane lying in the interval between the pleuræ, (posterior mediastinum.)

*Structure.*—The œsophagus consists of a muscular or external coat, and of a mucous lining. While in the thorax it receives its arteries from the aorta, (r. œsophagei,) in the neck from the inferior thyroid artery. The branches of the nervus vagus form a plexus upon it; and superiorly, the recurrent nerve is in close relation to it. Its muscular coat consists of two sets of fibres, forming distinct planes, and taking different directions. Those of the external layer (plate III. fig. 2, No. 1) are well marked, all disposed longitudinally in the direction of its axis, and of considerable thickness; the inner fibres (No. 3) run in the opposite way, so as to form rings or circles round the tube: near its extremities they are quite transverse; in the intervening space they are somewhat oblique. At the commencement of the œsophagus its muscular fibres are blended with those of the pharynx, the circular set being, as it were, a continuation of the lower border of the inferior constrictor. But the longitudinal fibres present a peculiarity which deserves attention: they are disposed in three fasciculi; one at each side, which is blended with the inferior constrictor; and one in front, which is attached to the cricoid cartilage at the prominent ridge, between the crico-arytenoidæi muscles. At the lower extremity of the œsophagus its fibres become blended, or rather continuous, with those of the stomach. The lining membrane is continuous superiorly with that of the mouth and nose, inferiorly with that of the stomach; it is pale, but dense and firm. It presents several slight longitudinal folds, which disappear when the tube is distended. Its inner surface is coated by a prolongation of the epidermis, which can be recognised as far as the cardiac orifice of the stomach.

The part of the alimentary canal which is beneath the diaphragm consists of the stomach and intestines. Previously to describing them, it is necessary to notice the conformation of the cavity in which they are contained, viz. the abdomen.

*The Abdomen.*—The abdomen (*abdere*, to conceal) is the largest cavity in the body.

*Its extent and boundaries.*—It extends from the diaphragm, which forms its upper boundary, to the levatores ani; and from the transversales muscles in front, to the spine, quadrati lumborum, and iliaci, behind. In these structures, which form the walls of the cavity, several apertures exist from the transmission of parts into and out of it. Superiorly, there are three in the diaphragm, for the aorta, œsophagus, and vena cava; inferiorly, there are two at each side, one for the femoral vessels, and one for

## P L A T E V .

The regions of the abdomen.

- Nos. 1, 1. A line drawn from the most prominent point of the cartilages of the ribs of one side to that of the opposite side. 2, 2. A line drawn from the most convex part of the crest of the ilium on one side to the same part on the opposite side. 3, 3. Two lines drawn perpendicularly downwards from the cartilage of the eighth rib to the middle of Poupart's ligament.
- E. The epigastric region. HC, HC. The hypochondriac regions. U. The umbilical region. L, L. The lumbar regions. IIG. The hypogastric region. I, I. The iliac regions.
- 4, 4. The line of the convexity of the diaphragm. 5. The situation of the ensiform cartilage. 6, 6. The line of the inferior margin of the thorax. 7, 7. The situation of the liver, marked by dotted lines. 8, 8. The situation of the stomach. 9. The situation of the pylorus. 10. The situation of the spleen. 11. The cæcum. 12. The ascending colon. 13, 13. The transverse colon. 14. The descending colon. 15. The sigmoid flexure of the colon. 16. A dotted line marking the course of the urachus. 17, 17. The course of the umbilical ligaments. 18, 18. The anterior superior spine of the ilium. 19, 19. The line of Poupart's ligament marking the groin.



the spermatic cord; in front there is one—the umbilicus, which, during fœtal life, transmits the umbilical arteries and vein. To these may be added the several interstices and apertures which give passage to the obturator, sciatic, pudic, and gluteal vessels.

*Its contents.*—The abdomen contains the greater part of the digestive organs, those for the secretion of urine, and part of those of generation. The first class includes the stomach and intestines, the spleen, the liver, and the pancreas, and the lacteal vessels, with their glands; the second comprises the kidneys and supra-renal capsules, with the ureters and bladder; and the third the spermatic vessels and ducts, with the vesiculæ seminales in the male, and the uterus, with the ovaries and Fallopian tubes, together with the vagina, in the female.

*Division into regions.*—The great cavity which extends, as above stated, from the diaphragm to the levatores ani, presents a sufficiently obvious division into two parts, the upper or larger one being the abdomen, properly so called, the lower the pelvis, the crista of the pubic bones and the ilio-pectineal line, which extends backwards to the promontory of the sacrum, marking the boundary between them. Again, the larger or upper compartment is subjected to what may be called a technical subdivision into regions; not that there are any septa or partitions between them, but because of the many and important parts which are contained in it, and which require to be minutely described. Pathologists have also found it necessary in order to give precision to their inquiries, as well as clearness to the communication of the results of them to others, to adopt those subdivisions which anatomists had established for the purpose of facilitating their descriptions of parts.

With these views the cavity of the abdomen has been divided into three primary regions, a superior, an inferior, and a middle, which is intermediate between both. These may be marked out by two transverse lines, drawn round the body as follows: one (plate V. Nos. 1, 1) having commenced at the most prominent point of the cartilages of the ribs at one side, is drawn across to the corresponding point on the opposite, and so continued round the spine to the place at which it began, thus completing the circle. The other line (2, 2) proceeding from the crista of the ilium at one side, extends to that of the other, and so round the body, as in the former instance. The superior division, or zone, is called, from its position, the *epigastric region*, (*επι*, above or upon; *γαστήρ*, the abdomen.) Its lower boundary corresponds with the line above indicated, the upper with the ensiform cartilage and the diaphragm. The inferior division has been named the *hypogastric region*, (*υπο*, under or beneath; *γαστήρ*, the abdomen,) which extends from the lower transverse line to the crista of the os pubis, and to Poupart's ligament on each side. The intermediate, or middle division, is called the *umbilical region*, from the circumstance of the umbilical aperture being placed at its centre. These divisions not having been found sufficient for the purposes above stated, it became necessary to subdivide each of them into three minor regions, which may be done by drawing two lines (3, 3) parallel to one another, from the cartilage of the eighth rib at each side down to the centre of Poupart's ligament. By this expedient each primary region is divided into a central and two lateral ones. The epigastric region is thus resolved to the two *hypochondriac regions*, (*ΗC*: *υπο*, under; *χονδρος*, the cartilage,) and the proper epigastric region, (*E*), which is sometimes called "serobiculus cordis." The middle zone is divided into the proper *umbilical region* in the centre (*U*) and the *lumbar region* at each side, (*L*, *L*), and the inferior zone into the proper *hypogastric* or *pubic region* (*HG*) in the centre, and the *iliac region* at each side, (*I*, *I*).

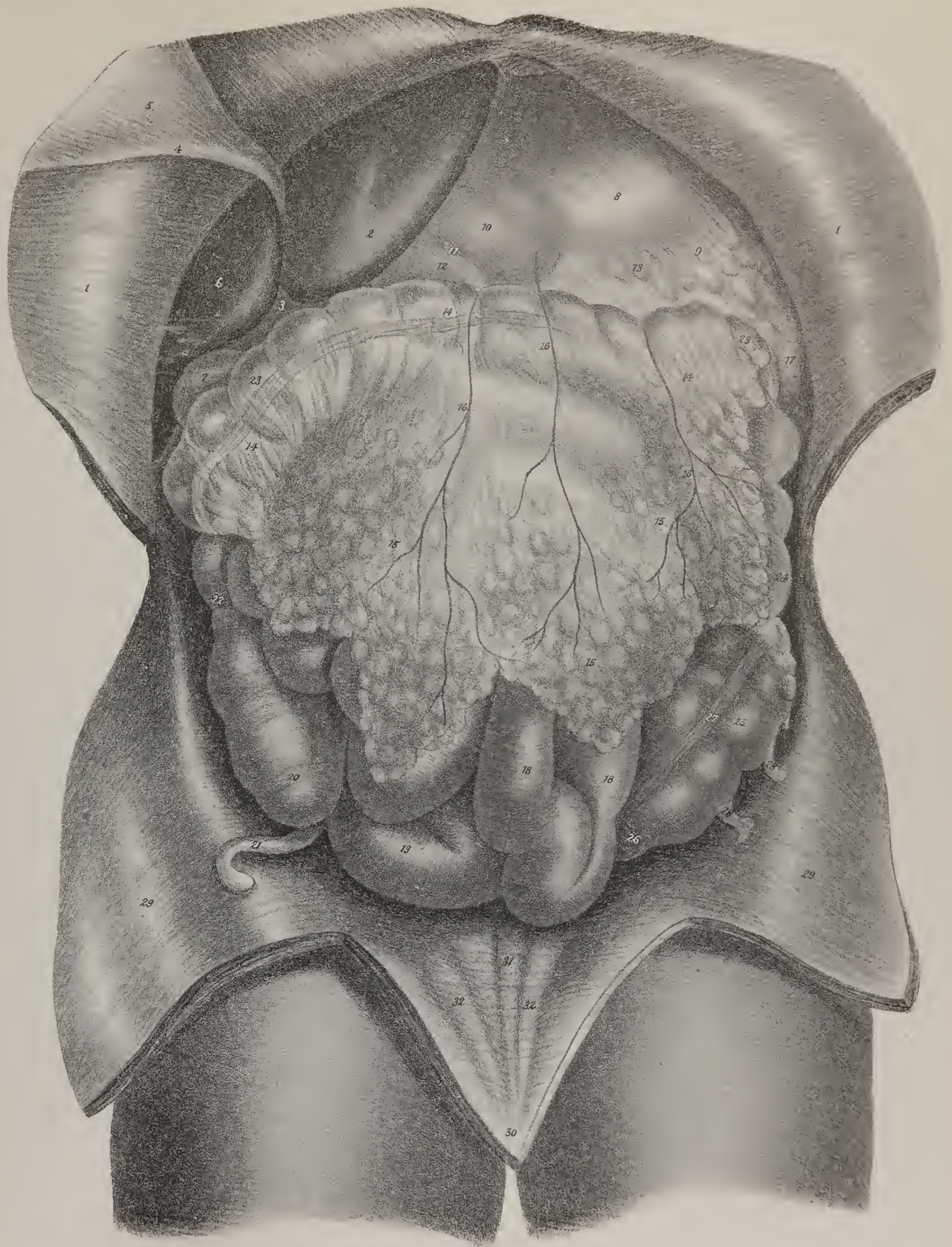
The mode of subdividing the primary regions here suggested, differs from that adopted by others. The vertical lines are usually directed to be drawn from the most prominent point of the costal cartilages to the anterior superior spinous process of the

## PLATE VI.

The viscera of the abdomen in their natural position. This view is obtained by simply dividing the parietes by a crucial incision and turning aside the flaps.

Nos. 1, 1. The two superior flaps of the abdominal parietes turned over the border of the chest. The smooth and shining investment of peritoneum is well expressed in the drawing. 2. The liver,—its left lobe. 3. The cleft on the anterior margin of the liver. 4. The round ligament of the liver. 5. That part of the broad ligament which is attached to the abdominal parietes. 6. The right lobe of the liver. 7. The fundus of the gall-bladder projecting slightly beyond the margin of the right lobe. 8. The stomach. 9. The great curve of the stomach. 10. The lesser end of the stomach. 11. The pylorus. 12. The commencement of the duodenum. 13. The great omentum, given off from the great curve of the stomach. 14, 14. The two anterior layers of the great omentum passing in front of the transverse colon. 15, 15. The great omentum. 16, 16. Omental branches of the gastro-epiploic arteries, passing from the great curve of the stomach, and in front of the transverse colon. 17. The edge of the spleen partly concealed by the border of the great omentum. 18. The small intestines. 19. The ileum near its termination in the cæcum. 20. The cæcum. 21. The appendix vermiformis. 22. The ascending colon. 23, 23. The transverse colon, partly seen through the thin anterior layers of the great omentum. 24. The descending colon. 25. The sigmoid flexure. 26. The commencement of the rectum. 27. One of the longitudinal bands of the large intestine. 29, 28. Appendices epiploicæ. 29, 29. Lateral flaps of the abdominal parietes, displaying the bright and polished surface of the peritoneum. 30. An anterior and inferior flap, upon which are seen some slightly elevated ridges formed by fibrous cords situated beneath the peritoneum. 31. The elevation formed by the fibrous and cord-like remains of the urachus. 32, 32. The ridges formed by the fibrous cords of the umbilical arteries, the umbilical ligaments.









ilium. It must be obvious that the very purpose and intent of marking out these lines show that they are not confined to the surface on which they are drawn. They are, on the contrary, supposed to be projected into so many planes, forming partitions, which divide the cavity into compartments, each containing a certain portion of the abdominal viscera. Now, if lines were drawn from the costal cartilages to the spine of the ilium, they would exert no influence on the hypogastric region, inasmuch as they cease at its upper boundary; and in the next place, if projected backwards, they would leave the lateral parts of the umbilical region far too small. These reasons are obviously sufficient to warrant a departure from usage and precedent.

The epigastric region contains	{	The middle part of the stomach, with its pyloric extremity, the left lobe of the liver, the hepatic vessels, and lobulus Spigelii, the pancreas, the cœliac axis, the semilunar ganglia, part of the vena cava, also of the aorta, together with the vena azygos, and thoracic duct, as they lie between the crura of the diaphragm.
The left hypochondriac . . .	{	The large end of the stomach with the spleen and narrow extremity of the pancreas, part of the colon, the renal capsule, and upper part of the kidney.
Right hypochondriac . . .	{	The right lobe of the liver, with the gall-bladder, part of the duodenum and of the ascending colon, the renal capsule, and part of the kidney.
Umbilical . . . . .	{	Part of the omentum and mesentery, the transverse part of the colon, transverse part of the duodenum, with some convolutions of the jejunum.
Right lumbar . . . . .		Ascending colon, lower half of the kidney, and part of the jejunum.
Left lumbar . . . . .		Similar parts at the opposite side.
Hypogastric region . . . .	{	The convolutions of the ileum, the bladder in children, and in adults if distended, the uterus under like circumstances.
Right iliac fossa . . . . .		The cæcum, ilio-cæcal valve, the ureter and spermatic vessels.
Left iliac fossa . . . . .		Sigmoid flexure of the colon, the ureter, and spermatic vessels.

As it is the usual practice to examine the serous membrane which invests the different organs here enumerated, and also lines the abdomen, we shall describe it in this place.

The *Peritonæum*; its general conformation.—The name applied to this membrane has been taken from its relation to the abdominal viscera, (*περιτείνω*, to extend around.) It is the most extensive serous sac in the body, as it not only lines the parietes of the abdomen, but is also reflected over each of the organs it contains, at the same time that it forms several folds of considerable extent.

*Preparation.*—After the abdominal muscles have been dissected, the transversalis muscle should be carefully separated from the peritonæum, and removed altogether from it, commencing over the iliac region, and so proceeding up to the costal cartilages, and backwards, deeply into the lumbar region. The same should be done at the opposite side; but, along the middle line, part of the aponeurosis must be allowed to remain, in consequence of its firm adhesion to the membrane. This at once gives a general view of the membrane: it appears like a loose bag placed within the walls of the abdomen, forming a lining for them. The more usual mode however is, after dissecting the muscles, to divide whatever remains of the parieties by a perpendicular and transverse incision, and reflect the flaps thus formed.

The student will find his progress facilitated if he will first make himself familiar with the names, position, and extent of the different folds of the membrane which have received names, and then proceed to trace their connexion and continuity as parts of a whole.

The drawing (plate VII. fig. 1) will serve for both purposes; it is a diagram which represents the parts as they would be seen if a vertical section were made through the abdomen and its contents, so that they may be seen in a side view. L, is the liver; S, the stomach; C, the transverse colon; D, the transverse part of the duodenum; P, the pancreas; I, the small intestines; B, the bladder; R, the rectum; o, o, n, mark the great omentum; e, h, the small omentum; s, t, the mesentery; p, the transverse meso-colon.

The folds or duplicatures, above alluded to, are as follows:

The *Great Omentum* (plate VI. Nos. 15, 15; plate VII. fig. 1, o, o: epiploon majus: epiploon gastro-colicum; *επιπλω*, to float upon) is the broad floating process of peritonæum which lies loosely over the fore part of the small intestines. Its upper extremity is attached to the great curvature of the stomach, to the left of which it is continuous with the gastro-splenic omentum; at the right side it extends as far as the duodenum; it is intimately connected with the transverse colon, below which it floats loosely over the small intestines. It consists, at the lower part, that is to say, below the transverse colon, of four lamellæ.

The *Small Omentum* (plate VII. fig. 1, e, h: o. minus; epiploon gastro-hepaticum) extends from the transverse fissure of the liver to the concave border of the stomach, enclosing the hepatic vessels. At its right margin, the membrane is folded so that both layers are continuous, whilst the left extends over to the œsophagus. Behind this is a canal, i, which leads down behind the stomach into the bag of the great omentum. Through this, which is called *foramen Winslowi*, the great cavity of the peritonæum becomes continuous with that enclosed within the layers of the great omentum.

The *Mesentery* (plate VII. fig. 1, s, t: mesenterium, *μεσος*, εντερον, intestine) is the large duplicature which corresponds by

its greater circumference with the whole length of the jejunum and ileum, to which it is conducted by the mesenteric vessels, which it encloses, together with the lacteal absorbents and their glands, whilst its base or point of reflection extends obliquely across the spine from the left side of the second lumbar vertebra down to the right sacro-iliac symphysis. Its upper and left border is continuous with the transverse meso-colon, whilst at the lower and right side it gradually spreads into the ascending meso-colon.

*Meso-cola.*—The lateral parts of the colon are bound down by duplicatures, which are named from their position *meso-colon ascendens, et descendens*, (plate VII. fig. 2, b, i.) The transverse portion of that intestine is connected with a broader one, (plate VII. fig. 1, p; *meso-colon transversum*,) continuous with the posterior layers of the great omentum; for these, after enclosing the transverse colon, are continued backwards to the spine, at the same time diverging so as to leave an angular interval, across which runs the terminal or third portion of the duodenum.

*Meso-rectum.*—This is a narrow fold which connects the back part of the rectum with the sacrum.

*Appendices Epiploicæ.*—Along the great intestine some processes (plate VI. Nos. 28, 28) are attached, varying in form and size, some fringed, others pediculated. They are diverticula or sacculi formed by the peritonæal coat of the gut, filled with adeps.

We find the following duplicatures connected with the liver, (plate X.) It may be here observed that these as well as other folds which are situated in the pelvis, are called “ligaments,” from their effect in retaining the organs in their situations. There are four folds of this sort attached to the liver; one upon its upper surface, connecting it with the diaphragm, from which circumstance it is called its “suspensory ligament,” (*ligamentum suspensorium*,) but from its shape it is named “falciform process,” or falk. It indicates the line of division between the left and right lobes of the liver; its lower border or base encloses the umbilical vein, or the ligament into which it is converted. The folds which connect the lateral lobes of the liver at each side to the diaphragm, are called “lateral or triangular ligaments,” (*ligamentum laterale dextrum, et sinistrum*,) between these lies another towards the middle line, the “coronary ligament,” (*ligamentum coronarium*, plate VII. fig. 1, b, g; plate X.)

In the pelvis there are some folds connected with the bladder, the rectum, and the uterus, which deserve notice.

From the summit of the bladder three long but very narrow folds extend upwards to the umbilicus, (plate VI. Nos. 31, 32;)

## PLATE VII.

Sections of the abdomen, showing the reflections of its serous membrane, the peritonæum.

FIG. 1. A vertical section of the abdominal cavity.

- A. The diaphragm. L. The liver. 1. The free margin of the liver. 2. The posterior or rounded border of the liver, which lies in contact with the diaphragm. S. The stomach. 3. Its cardiac orifice. 4. The œsophagus seen indistinctly as it passes through the diaphragm. C. The transverse colon divided transversely. D. The transverse portion of the duodenum. P. The pancreas. 5. The abdominal aorta. 6. The right common iliac artery. 7. The fifth lumbar vertebra. 8. The first lumbar vertebra. I. The tube of the small intestine divided transversely. 9, 9. The mass of the small intestines enclosed by peritonæum. 10. The divided cylinder of the rectum. R. The rectum. 11. The sacrum. 12. The coccyx. B. The urinary bladder. 13. The ureter of the right side. 14. The vesicula seminalis of the same side. 15. The prostate gland enclosed by the pelvic fascia. 16. The symphysis pubis. 17, 17. The abdominal parietes.
- a, a. An anterior layer of the peritonæum, which lines the abdominal parietes and the under surface of the diaphragm. b. The reflection of this layer from the diaphragm to the convex surface of the liver. c. The same layer investing the convex surface of the liver. d. Its reflection upon the concave surface of this organ. e. Its reflection from the under or concave surface of the liver to the lesser curvature of the stomach. f. A posterior layer of the peritonæum lining the posterior wall of the cavity of the abdomen. g. Its point of reflection upon the posterior and rounded border of the liver. The layers b and g constitute the coronary ligament of the liver. h. The reflection of the posterior layer from the liver to the lesser curvature of the stomach. The two layers e and h constitute the lesser omentum. i. The situation of the foramen of Winslow, marked inferiorly by a dotted line. k. The anterior layer of peritonæum, passing in front of the stomach. l. The posterior layer, passing behind the stomach. m. The approximation of the two layers at the greater curvature of the stomach. n. The reflection of these two layers upwards to the colon. The four layers formed by this reflection constitute, o, o, the great omentum. p. The two ascending layers continued backwards towards the vertebral column, after having surrounded the transverse colon: they constitute the transverse meso-colon. q. The superior layer of the transverse meso-colon continued upwards in front of the pancreas, and shown to be continuous with the posterior layer, f. The cavity, r, r, has been very inappropriately named the lesser cavity of the peritonæum: it communicates with the general cavity through the foramen of Winslow. s, s. The inferior layer of the transverse meso-colon reflected downwards upon the small intestines, and returning upon itself, t, t, forms the duplicature, s, t, the mesentery, which retains the small intestines in connexion with the posterior wall of the abdomen. v, v. The inferior layer of the mesentery continued downwards over the rectum, and reflected at x upon the posterior surface of the urinary bladder. The duplicature at x is the recto-vesical fold of peritonæum. The layer is then traced upwards, z, z, upon the anterior wall of the abdomen, and shown to be continuous with the anterior layer, a, a.

FIG. 2. A transverse section of the cavity of the abdomen, showing the reflections of the peritonæum.

- Nos. 1, 1. The integument surrounding the abdomen. 2, 2. The rectus muscle enclosed in its sheath. 3. The linea alba. 4, 4. The linea semilunaris at each side. 5, 5. The three planes of abdominal muscles,—obliquus externus, obliquus internus, and transversalis. 6, 6. The erector spinæ. 7, 7. The quadratus lumborum enclosed in its sheath. 8, 8. The psoas muscle on each side. 9.



Fig. 2.

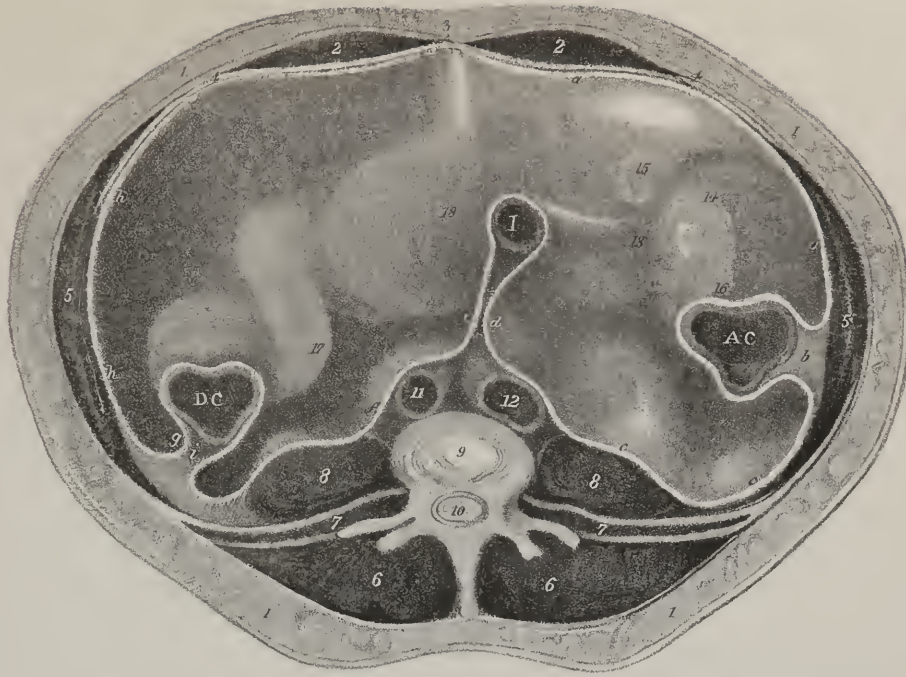
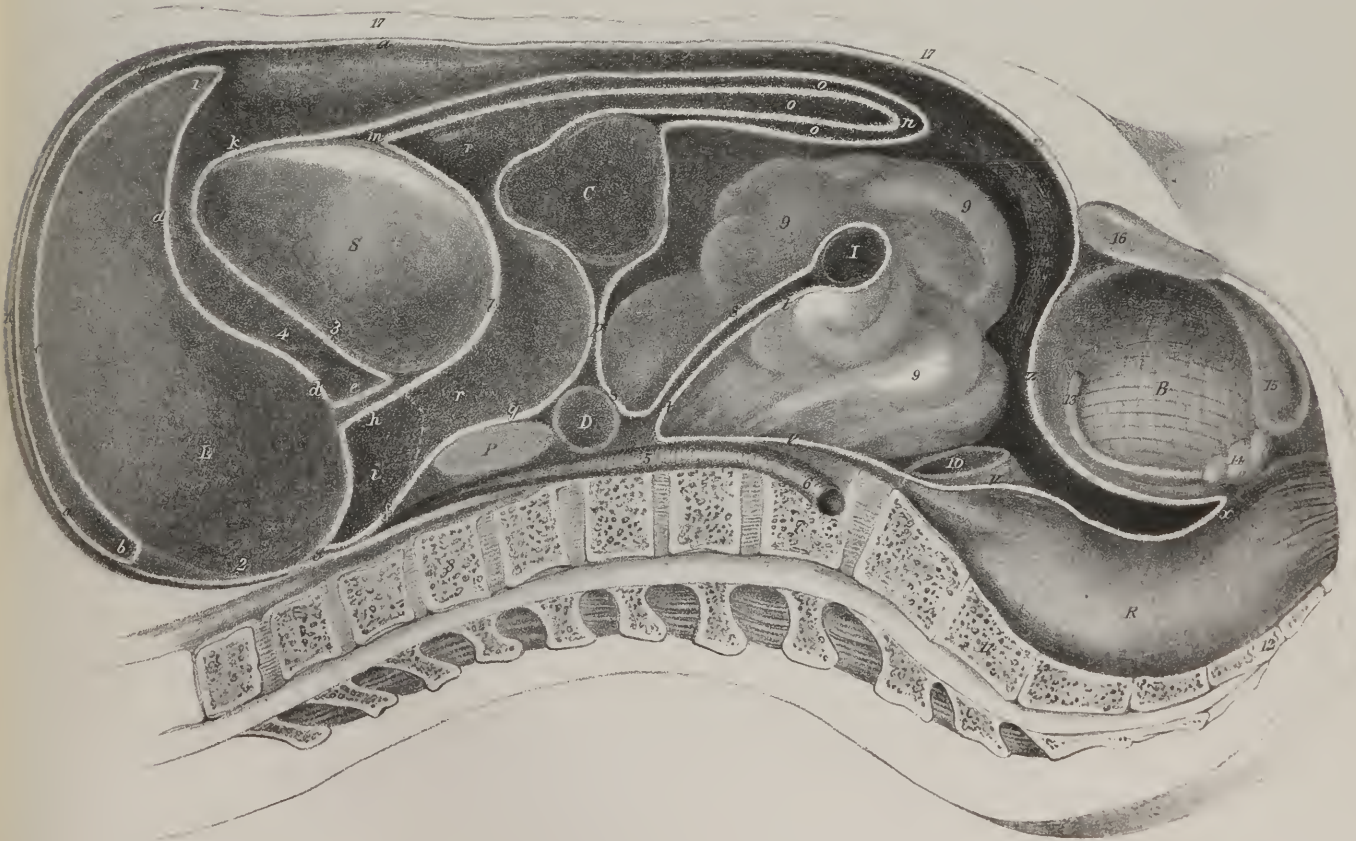
Fig. 1





one  
error  
P  
none  
or  
T  
sh  
mist  
is fa  
er b  
art of  
act of  
oming  
es w  
e b  
ers i  
ppe  
se li  
piat  
and  
pa. L  
o. o  
mine  
a sud  
ange  
ize c  
maie  
In  
rag  
mae  
a thi  
erit  
ed ca  
esse  
at oib  
mal c  
zath  
ing  
est  
is pit  
were  
with  
at os  
T

one in the middle line, corresponding with the urachus, and one on each side with the umbilical arteries. Where the peritonæum is reflected from the base of the bladder backwards upon the rectum, it presents two lunated folds, usually called the "posterior ligaments" of the bladder.

From the sides of the uterus two broad folds of peritonæum extend outwards to the wall of the pelvis, with which they connect it; hence they are called the "broad ligaments" of the uterus. They enclose the uterine vessels, the round ligaments, the ovaria, and the Fallopian tubes.

The student may now proceed to note the way in which the peritonæum is reflected from one organ to another, and how it is thrown into the folds here indicated. Begin at the small omentum, (plate VII. fig. 1, e, h,) as a starting point: you find it to consist of two layers; take the upper one, c, trace it to the small curvature of the stomach, S, and then over its anterior surface, k, as far as the great curvature, m; from this it reaches down, forming the upper layer of the great omentum, o, o, at whose lower border, n, it becomes reflected, and returns up as far as the transverse colon, C; having invested the under surface of this part of the intestine, it passes backward, forming the under layer of the transverse meso-colon, p, and then beneath the transverse part of the duodenum, D; at this point it is again prolonged forwards to the small intestine, I, and returns after investing it, thus forming the upper and under layers of the mesentery, s, t. From the mesentery it reaches down in front of the spine at v, and then upon the rectum, R, and the bladder, B, forming a fold at the point of reflection, x, from one to the other. From the summit of the bladder it is prolonged to the parietes of the abdomen at z, and so upwards as far as the costal cartilages at a, where it comes into contact with the diaphragm, D, whose under surface it lines. From this it is reflected upon the liver at b, forming the upper layer of its coronary and lateral ligaments. It invests the upper and under surface of the liver, L, as far as the transverse fissure, where it is reflected down upon the portal vessels, forming the upper or anterior layer of the small omentum, to the point at which we commenced to trace its reflections and relations to the viscera. Now, beginning again at the small omentum, and taking its under layer, h, you trace it to the small curvature of the stomach, and thence along the under surface of this organ, l, as far as its great curvature, m; from this point the membrane reaches down, forming the inner layer of the great omentum, o, o, at whose lower border it is reflected up to the transverse colon, C; after investing the upper surface of this part of the intestine, it is reflected back towards the spine, forming the upper layer of the transverse meso-colon, p; it is thence prolonged at q, successively in front of the transverse part of the duodenum, D, the pancreas, P, and the crura of the diaphragm: from the diaphragm it is reflected to the liver at g, where it forms the under layer of its coronary and lateral ligaments: it invests the surface of the liver as far as the transverse fissure, where it is reflected down, forming the under layer of the small omentum, whence we set out in tracing its reflections.

It may here be observed, that it is difficult at first sight to conceive how the different vessels can reach the viscera without piercing the peritonæum, inasmuch as the trunks from which they proceed lie behind it. The aorta lies on the spine, behind the peritonæum; the kidneys, placed at the sides, are also behind that membrane; there can, therefore, be no difficulty in perceiving how their vessels reach them. The mesentery, consisting of two lamellæ, is reflected from the spine close to the origin of the superior mesenteric artery, which is thus placed between its layers. The inferior mesenteric artery, after running behind the peritonæum to the pelvis, lies between the sacrum and rectum, in the fold of the meso-rectum; the colic vessels are enclosed in the meso-cola. It remains for us first to consider how the cœliac axis and its vessels lie with regard to the membrane; which can only be done with effect by examining the formation of what is called Winslow's foramen, which, properly speaking, is a canal or tube, not a perforation, as the term foramen would imply. If the finger be passed close by the neck of the gall-bladder, beneath the free border of the small omentum, the two lamellæ of the omentum, with the hepatic vessels enclosed, will lie upon the finger, and the ascending layer of the transverse meso-colon behind it. If an effort be made to pass the finger down behind the stomach, it is at once checked by the manner in which the membrane is there reflected backwards and upwards. Just below the point of reflection stands the cœliac axis, so that its hepatic and coronary branches, by passing over this reflected part, can get between the layers of the small omentum, and thus reach their destinations. Now, the splenic artery runs along the pancreas, which has been shown to be posterior to the ascending layer of the transverse meso-colon, but on reaching the spleen it insinuates itself between the layers of its epiploon, (gastro-splenicum.)

*The Stomach.*—The stomach (plate IV. A; plate VI. No. 8; plate VIII. fig. 1; plate IX. fig. 1: γαστήρ, ventriculus) is a

- The upper surface of a lumbar vertebra. 10. The divided cauda equina. 11. The aorta. 12. The inferior vena cava. I. The ileum near to its termination. 13. The termination of the ileum in the colon is dimly seen in the lower part of the cavity. 14. The cæcum. 15. The appendix vermiformis. 16. The ascending colon. A, C. Section of the ascending colon. D, C. Section of the descending colon. 17. Sigmoid flexure. 18. The convex outline of the urinary bladder.
- a, a. The peritonæum traced from the linea alba upon the inner surface of the abdominal parietes to its reflection around the ascending colon. b. The ascending meso-colon. c. The layer continued onwards over the psoas muscle and inferior vena cava, and reflected forwards at d, so as to encircle the small intestine. e. The peritonæal layer returning towards the vertebral column. These two layers, d and e together, constitute the mesentery. f. The returning layer, continued into the left lumbar region, surrounds the descending colon, and returning upon itself, g, is thence traced upwards, h, h, to the linea alba, where it is seen to be continuous with a, a. The duplicature, i, is the descending meso-colon.

hollow, musculo-membranous viscus, occupying part of the left hypochondriac and epigastric regions. It is the largest or most distended part of the alimentary canal, being continuous, by one extremity, with the œsophagus, (plate IV. 1.) which opens into it from above, and by the other with the duodenum, (7,) which forms the first part of the intestines properly so called. Its form is somewhat conical, being also curved, so as to incline downwards and forwards; but its form and direction vary remarkably in different ages of life: in the fœtus it does not extend so transversely from left to right as is the case in the adult; the pylorus is, on the contrary, placed with rather a slight obliquity beneath the cardia, the line of its axis being from above downwards.

The stomach is in intimate relation with many important organs; it lies beneath the diaphragm and liver, above the transverse colon, having the spleen on its left, and the duodenum on its right, whilst its anterior surface is in contact with the wall of the abdomen, and the posterior rests on the pancreas and great vessels,—the ascending layer of the transverse meso-colon interposing. It is usual to consider successively its surfaces, borders, and extremities. When empty, one surface looks forwards, and the other backwards; but when distended its body changes its position, so that the former inclines somewhat upwards, the latter obliquely downwards, by which means the great curvature comes towards the anterior parietes of the abdomen, whilst the smaller looks towards the spine and large vessels. The lower border of the stomach is of considerable extent, and is named its *great curvature*, (plate IV. No. 6;) along it run the gastro-epiploic vessels; opposite the spleen it expands very much, bulging out into a sort of diverticulum, which is called the *great cul-de-sac* of the stomach, and sometimes its left or *splenic* extremity, (2.) A fold of peritonæum (*splenic omentum*) connects this part of the stomach with the spleen; the rest of the curvature gives attachment to the great omentum.

The upper border is concave, and forms the *small curvature*, (5,) which extends from the œsophagus to the pylorus, being not more than three inches in length; it is connected by the small omentum to the inferior surface of the liver, the vascular arch formed by the coronary and pyloric arteries being parallel with it.

The *left* or *splenic* extremity of the stomach comprises the expanded or dilated part above noticed; at its upper part, where it touches the diaphragm, it becomes, as it were, constricted rather abruptly, and unites with the termination of the œsophagus,

## PLATE VIII.

Disposition and structure of the mucous membrane of the alimentary canal.

FIG. 1. A longitudinal section of the stomach and duodenum, showing their internal surface, with the arrangement of the mucous membrane.

No. 1. The lower part of the œsophagus. 2. The cardiac orifice of the stomach. 3, 3. The abrupt border formed by the termination of the cuticular epithelium of the œsophagus at the cardiac opening of the stomach. 4, 4. The rugæ of the mucous membrane. 5. The great end of the stomach, in which the rugæ of the mucous membrane are less marked than in the middle of the organ. 6. The lesser curve of the stomach. 7, 7. The greater curve. 8. The pylorus. 9, 9. Two segments of a spiral fold of mucous membrane situated in the pyloric opening. 10. The ascending portion of the duodenum. 11. The descending portion of the duodenum. 12. The transverse portion of the duodenum. 13. The commencement of the jejunum. 14, 14. The first valvulæ conniventes, which are of small size. 15, 15. Larger valvulæ conniventes. 16. The papilla upon which the ductus communis choledochus and pancreatic duct terminate. 17. A part of the ductus communis choledochus. 18. The pancreatic duct near to its termination.

FIG. 2. A section of the cæcum and part of the colon, with the lower termination of the ileum, showing the ileo-cæcal valve.

No. 1. The ileum near to its termination. 2. The cul-de-sac of the cæcum. 3, 3. The appendix vermiformis. 4. The entrance of the appendix vermiformis. 5, 5. The two semilunar segments forming the ileo-cæcal valve. 6. The opening of the ileum into the cæcum. 7. The colon. 8, 8. Valvular projections of the mucous membrane forming the boundaries of the sacculi of the large intestine. 9, 9. The surface of the mucous membrane raised into minute folds.

FIG. 3. A section of the cæcum through the ileo-cæcal valve.

No. 1. The ileum. 2. The cæcum. 3. The appendix vermiformis. 4. A small mesentery attached to the appendix vermiformis, and producing its curve. 5, 5. The two segments of the ileo-cæcal valve, each formed by three layers, the middle dark layer representing an extension of the muscular coat. 6. The colon. 7, 7. The folds which form the boundaries of the sacculi of the large intestine.

FIG. 4. Scales of epithelium from the surface of the mucous membrane of the mouth, each presenting a central nucleus.

FIG. 5. Cylinders of epithelium from the mucous membrane of the cardiac extremity of the stomach.—From Henle's "Symbolæ ad anatomiam villorum intestinalium, imprimis eorum epithelii et vasorum lacteorum."

FIG. 6. Cylinders of epithelium from the jejunum.—After Henle.

a. The central nucleus. b. The small end, which is in contact with the mucous membrane. c. The broad end or free extremity of the cylinder. d. A cylinder placed obliquely in order to show the surface of the free extremity.

FIG. 7. A group of cylinders of epithelium from the small intestine, agglutinated together, and seen by their free extremities. The nuclei are slightly seen through the centre of the broad end of each cylinder.—After Henle.

FIG. 8. An ideal diagram of a single villus of the small intestine covered with columnar cylinders of epithelium. Fig. 7 represents a small group of these cylinders more highly magnified.—After Henle.

FIG. 9. A transverse section of a circular villus, showing the radiated and columnar disposition of the cylinders of epithelium.—After Henle.



Fig 5

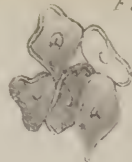
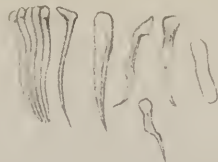
Fig 9

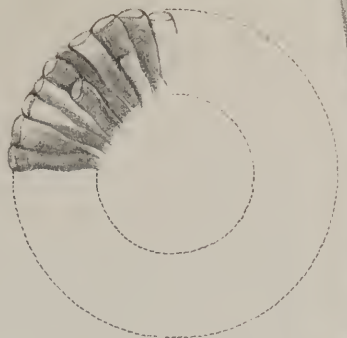


Fig 6

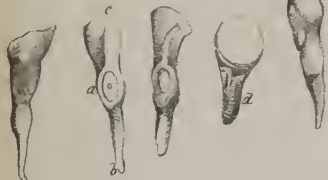

Fig 1

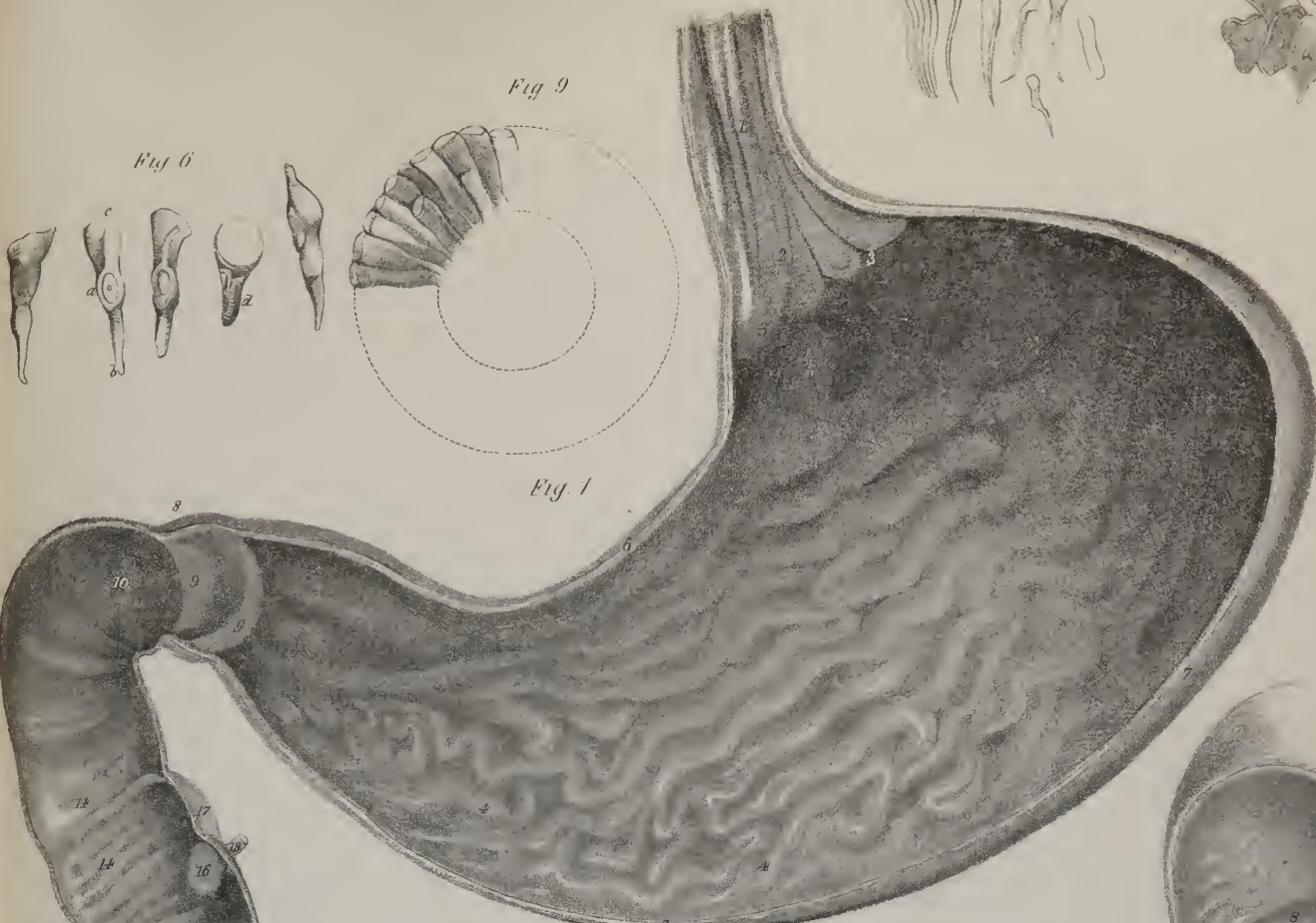


Fig 3

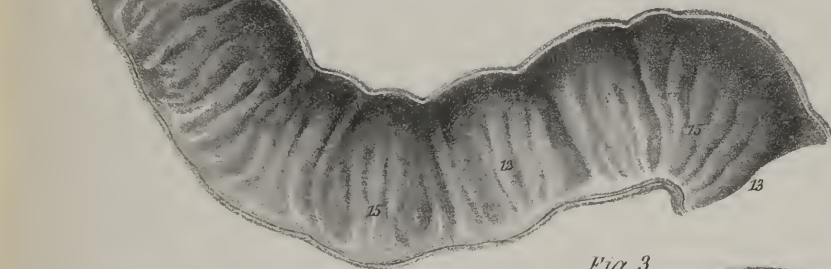


Fig 2

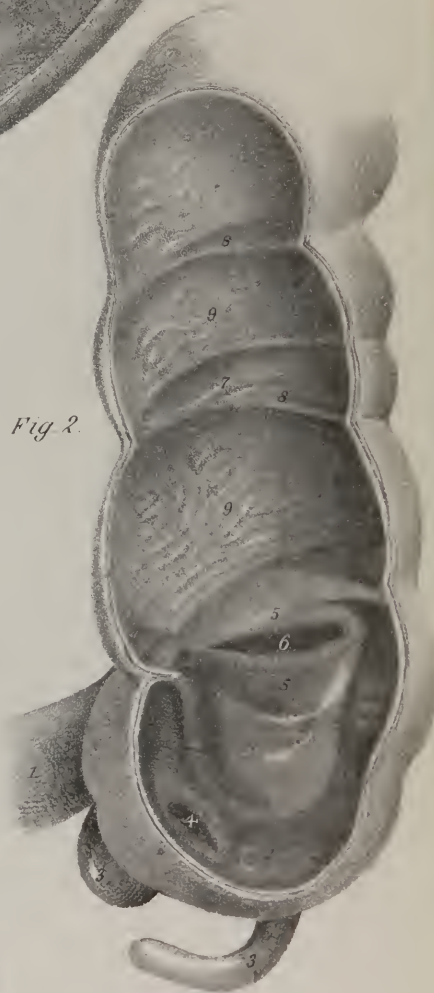


Fig 7

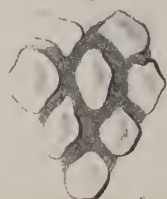
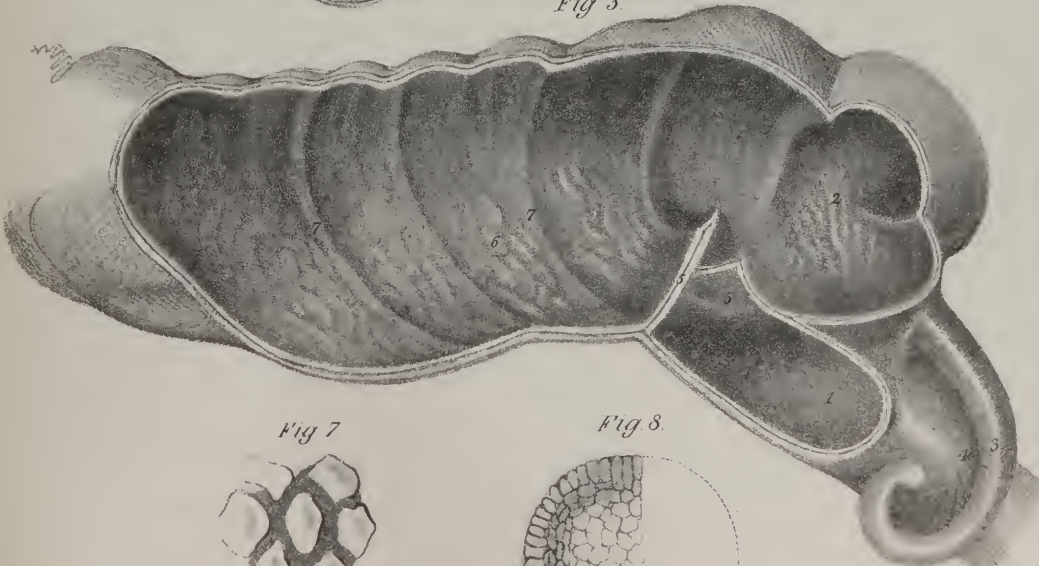
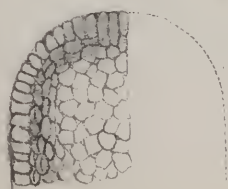


Fig 8



wh  
app  
and  
No.  
sum.  
under  
perce  
are in  
cates  
which  
be for  
contra  
Su  
merly  
being s  
derive  
every a  
ple file  
posed le  
radial  
erend  
rectre.  
hand o  
rather le  
us deli  
as bee  
Fe  
upper o  
branche  
terva  
st of t  
Th  
n diff  
weary  
stadio  
which  
valve j  
investi  
ru. the  
betwe  
L  
equal  
is ow  
be pp  
trans  
sone  
ry th  
dine  
pau  
ry d  
the  
sion  
et  
ine



which here opens into it. The junction here indicated takes place in such a way, that two-thirds of the length of the stomach appear to its right, and one-third to the left. This narrowed part corresponds with the upper aperture or inlet of the stomach, and is called *cardia*, or the *cardiac* orifice, (plate VIII. fig. 1, No. 2.) The *right*, or *pyloric* extremity of the stomach, (plate IV. No. 3,) is elongated so as to represent the summit of a cone, to which this organ has been likened; it commences at a slight angular turn, marked by a crease or fold, where the great curve of the stomach ends at the right side, from which it ascends towards the under surface of the liver, at the same time inclining backwards, and ends at a circular constricted line (4) which can readily be perceived at the exterior, and which, when compressed between the fingers, gives the sensation as if a cord-like ring surrounded the interior of the tube. The point here indicated corresponds with the inferior opening of the stomach, by which it communicates with the duodenum; it is called the *pyloric* aperture, for it is surrounded by a ring of muscular fibres above alluded to, and which is termed *pylorus*, (*πύλη*, a gate; *οὐρός*, a guardian,) from some resemblance to a sphincter muscle. When examined, it will be found so placed, that, whilst its circumference is identified with the wall of the stomach, its free border projects towards the central line of the canal, as if for the purpose of retaining the food until it is digested.

*Structure.*—The stomach is composed of three coats, connected together by two lamellæ of cellular tissue, which were formerly enumerated also,—particularly the one between the middle and inner coats,—and which was called the nervous tunic, from being supposed to consist of the ultimate ramification of the nerves. The external, or *serous* coat, (plate IX. fig. 1, Nos. 2, 2,) is derived from the peritonæum, and forms but a partial investment for this, as for other organs, inasmuch as, by being reflected away at its curvatures, it leaves two linear intervals there uncovered. The second, or *muscular* coat, (fig. 1.) consists of thin and pale fibres, placed on different planes, and pursuing different directions. The fibres subjacent to the serous membrane are disposed longitudinally, (3,) being continuous with those of the œsophagus, from which they spread out, as they proceed from the cardiac towards the pyloric orifice; the second layer of fibres is circular, (4, 4;) but though no individual fibre can be found to extend farther than from a third to a half of the circumference of the viscus, yet they can sometimes constrict it towards the centre, so as to give it a sort of hour-glass contraction.\* The fibres of the third order (6, 6) are scattered and irregular; being found only towards the splenic end of the stomach, where they in a manner decussate with the circular fibres, which in that part are rather few in number. The internal coat, called *mucous*, (plate VIII.) from its peculiar secretion, and *villous*, from the numerous delicate papillæ, like the pile of velvet, that project upon it, forms part of the lining membrane of the alimentary canal. It has been already described in the section on the general anatomy of mucous membranes, (page 4 et seq.)

*Vessels and nerves.*—The stomach derives its blood from two arterial arches, which correspond with its two curvatures; the upper one being formed by the coronary artery and the pyloric branch of the hepatic, the lower by the two gastro-epiploic branches; one being derived from the hepatic, the other from the splenic artery. Besides these, its splenic end receives the vasa brevia from the splenic artery. Its residual blood is conveyed by corresponding veins into the splenic vein; whilst its nerves consist of the terminal branches of the two vagus nerves, and of the stomachic plexus, which is derived from the great solar plexus.

*The Intestinal Canal.*—The intestinal canal (plate IV.) extends from the pylorus to the anus, and in the human subject varies in different individuals; hence it has been variously stated as being from fifteen to twenty-seven feet by Meckel, and from ten to twenty-five by Cruveilhier. It is coiled on itself, so as to form folds or convolutions, and presents two parts, differing in size and situation, as well as in external conformation. Moreover, the division between them is marked by a peculiar valvular structure, which prevents a reflux of the ingesta after they have passed beyond it. The part of the canal between the pylorus and the valve just referred to is called the small intestine, (*intestinum tenue*; B, C;) the remainder thence onward to the anus, the large intestine, (*intestinum crassum*; D to L.) Anatomists have agreed to consider the small intestines as divisible into three parts, viz. the *duodenum*, *jejunum*, and *ileum*; premising, however, that they are but portions of a continuous tube, the lines of division between them being altogether arbitrary.

*Duodenum.*—The duodenum (plate IV. B; plate VIII. fig. 1, Nos. 10, 11, 12) has been so called from being in its length equal to about twelve fingers' breadth. Its diameter is greater than that of the jejunum or ileum; it is also more distensible. In its course it will be observed to curve on itself, so as to describe a considerable portion of a circle; for, having commenced at the pylorus, it ends at the left side of the second lumbar vertebra, and is divisible into three portions, each presenting some circumstances deserving of notice. The first, which is the shortest, being about two inches in length, ascends a little, at the same time inclining backwards and to the right side so as to touch the gall-bladder: hence, soon after death, it becomes tinged yellow by the bile. Opposite the neck of the gall-bladder the intestine turns on itself, and descends perpendicularly in front of the right kidney as far as the third lumbar vertebra, where it again alters its direction, passing across the spine, ascending a little, so as to end at the left side of the second lumbar vertebra, where it is continuous with the jejunum. The concavity of the curve formed by the duodenum is turned to the left side, so as to enclose within it the head of the pancreas. Its transverse part is crossed by the mesenteric vessels, which necessarily separate it from the lower border of the pancreas. The ascending portion is not only shorter than the others, but is also of smaller diameter; it is covered in the greater part of its extent by peritonæum. The descending part is covered by it only on its anterior surface, whilst the transverse part has no immediate serous investment, as it merely lies in the divergence of the two layers of the transverse meso-colon. Its muscular coat is thick, the circular fibres being

\* Sir E. Home, Phil. Trans.—Wilson, Philip, On the Vital Functions.



more strongly marked than the longitudinal. The internal surface presents a great number of transverse folds, called *valvule conniventes*. At the angle of union formed by the descending and transverse parts of the intestine, will be observed a small papilla, marking the orifice of the biliary and pancreatic ducts, which open at that point.

*Jejunum and Ileum.*—The jejunum and ileum (plate IV. C, C) are so called, the former from being usually found empty after death, the latter from its position in the fossæ of that name. They occupy the interval from the duodenum to the ilio-colic valve, two-fifths of the whole length being assigned to the jejunum, (17, 17,) and three-fifths to the ileum, (18, 18.) The diameter of the tube diminishes gradually as it approaches the latter point. This part of the intestinal canal presents numerous coils or convolutions, which, taken together, are found in the umbilical region, at the same time extending laterally into the lumbar regions, and downwards into the hypogastric and iliac. Thus situated, the small intestine is in a manner enclosed within the curve formed by the colon. The outer surface is smooth, and free in its entire extent, except along its posterior border, where it is connected with the mesentery.

*Structure.*—The coats of the jejunum are thicker than those of the ileum, but they are similar in every other respect; the serous coat is derived from the mesentery, to the circumference of which these portions of the canal are attached; and the muscular coat presents some longitudinal and superficial fibres, the rest forming arches of circles, but not extending round the tube. The *valvulæ conniventes*, which are numerous at the commencement of the jejunum, diminish in number and size gradually towards the ileum, and cease in the lower part of the latter.

*Vessels and nerves.*—The duodenum receives its arteries from the pancreatico-duodenalis, from the pyloric and superior mesenteric arteries; its veins open into the coronary and superior mesenteric; its nerves are offsets from the mesenteric and solar plexus. The jejunum and ileum are supplied by the superior mesenteric vessels.

## PLATE IX.

The muscular coat of the alimentary canal, with the structure of the mucous membrane

FIG. 1. The muscular coat of the stomach.

NO. 1. The œsophagus, upon which are seen the longitudinal fibres. 2, 2. The peritonæal coat turned back from the surface of the stomach. 3. The longitudinal fibres of the stomach, most apparent along its lesser curve. 4, 4. The circular fibres, most developed towards the lesser end. 5. The annular aggregation of the circular fibres forming the constriction of the pylorus. 6, 6. The oblique fibres at the great end of the stomach. 7. The commencement of the duodenum.

FIG. 2. A portion of small intestine from which the serous coat has been stripped off.

NO. 1. The longitudinal fibres. A portion of the longitudinal fibres has been removed in order to bring into view the deeper layer, which is composed of circular fibres.

FIG. 3. The rectum.

NO. 1. The termination of the colon. 2, 2, 2. The three longitudinal bands of muscular fibres. 3, 3. The longitudinal muscular fibres of the rectum. 4. A portion of the layer of longitudinal fibres, turned down in order to show the circular fibres, 5. 6. The internal sphincter.

FIG. 4. A small portion of the mucous membrane of the œsophagus near its lower extremity, exhibiting an arborescent conglomerate gland (œsophageal gland) opening upon the surface by a somewhat lengthened oblique duct. The small circles scattered over the surface are the openings of mucous follicles. This preparation is magnified fifteen times.—From Dr. T. L. W. Bischoff's paper, "Ueber den Bau der Magenschleimhaut," in Müller's Archiv. for 1838.

FIG. 5. Cells of the human stomach; open mouths of tubes seen at the bottom of each: magnified thirty-two diameters.—From Dr. Sprott Boyd's "Essay on the Structure of the Mucous Membrane of the Stomach," in the Edinburgh Medical and Surgical Journal for 1836, vol. xlvi.

FIG. 6. The inner surface of the stomach of a woman, magnified twenty-five times. The openings of the gastric follicles are disposed in groups.—From Dr. T. L. W. Bischoff's paper.

FIG. 7. A perpendicular section of the mucous membrane of the stomach from the cardiac extremity. The gastric follicles are seen to terminate in simple cæcal extremities; they are filled with a granular-looking secretion.—From Dr. T. L. W. Bischoff's paper.

FIG. 8. A perpendicular section of the mucous membrane of the stomach from the pyloric extremity; the cæcal terminations of the gastric follicles are clustered.—From Dr. T. L. W. Bischoff's paper.

FIG. 9. A portion of the mucous membrane of the duodenum, seen upon its under surface, and showing the duodenal or Brunner's glands. This preparation is magnified fifteen times.—From Dr. T. L. W. Bischoff's paper.

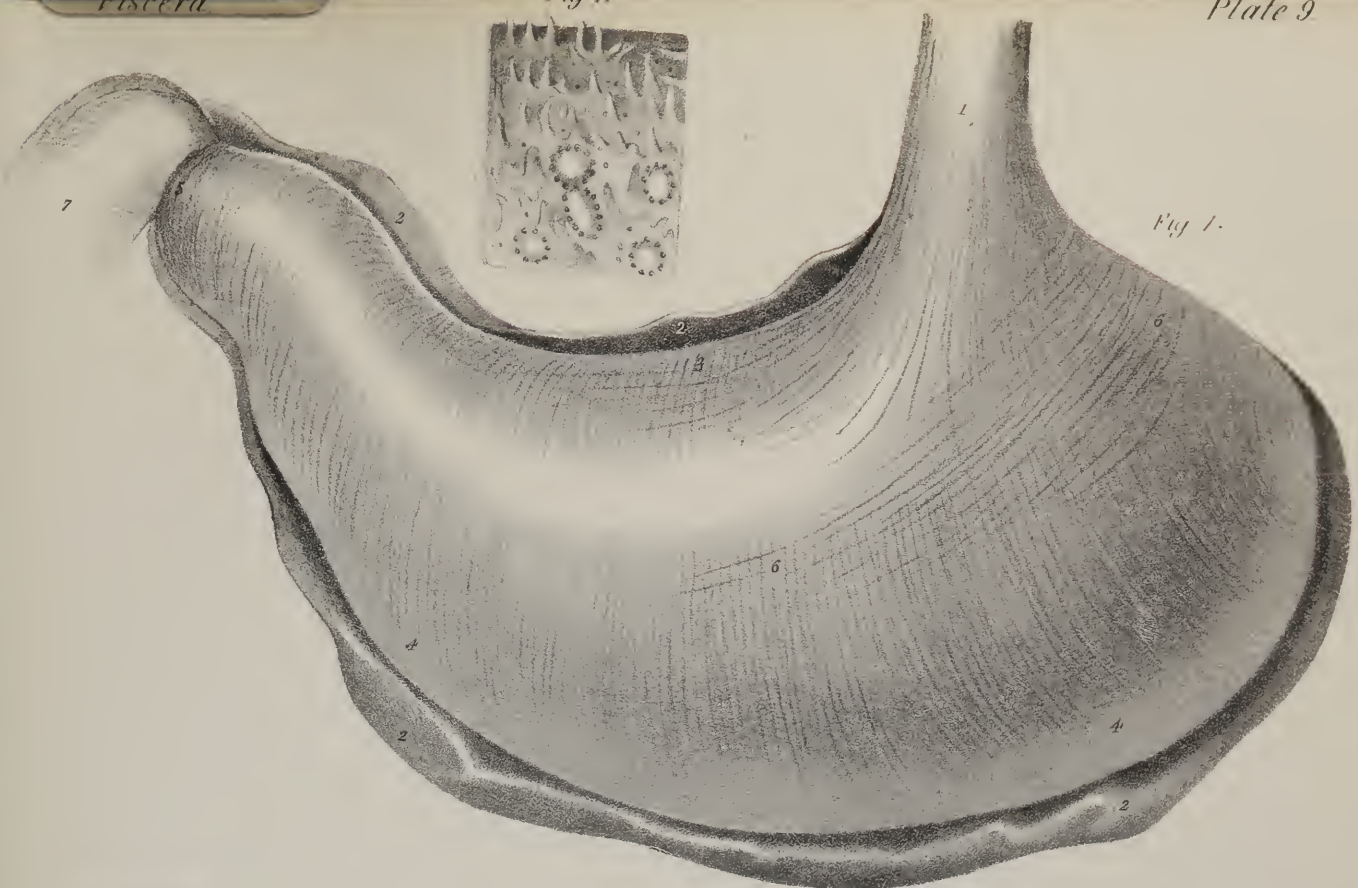
FIG. 10. A small portion of the mucous surface of the lower extremity of the ileum, showing a cluster of Peyer's glands, natural size. The villi are seen upon one side of the preparation.

NO. 1. A solitary gland forming a projection of the mucous membrane.

FIG. 11. A small portion of one extremity of a cluster of Peyer's glands highly magnified. The white patches of the glands are each surrounded by a zone of openings resembling those of the follicles of Lieberkuhn, which are seen to be scattered irregularly between the villi in the upper part of the figure. A number of conical villi are also seen.—From Müller's Physiology, translated by Dr. Baly: after the illustrations to Dr. Boehm's paper "De Glandulorum Intestinalium Structurâ Penitiori," Berlin, 1835.

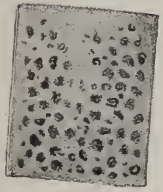
FIG. 12. a. A solitary gland from the large intestine, somewhat enlarged, and delineated from nature. b. A section of one of these follicles.—After Dr. Boehm.

*Fig 11*




*Fig 1.*

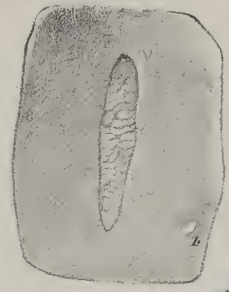*Fig 6*




*Fig 5*



*Fig 10.*



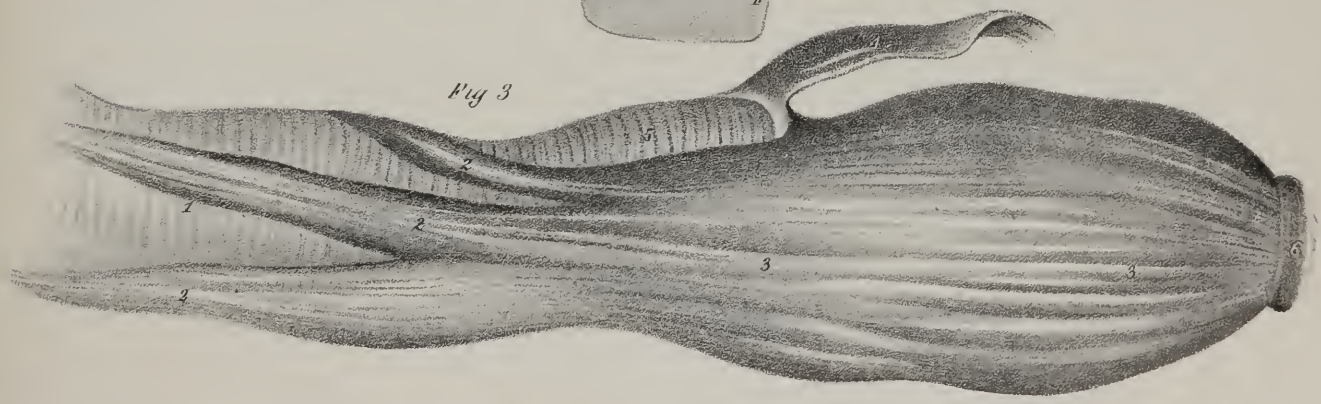
*Fig 9*




*Fig 4*




*Fig 3*



*Fig 8*



*Fig 2*



*Fig 7*



*Fig 12*












Fig 1

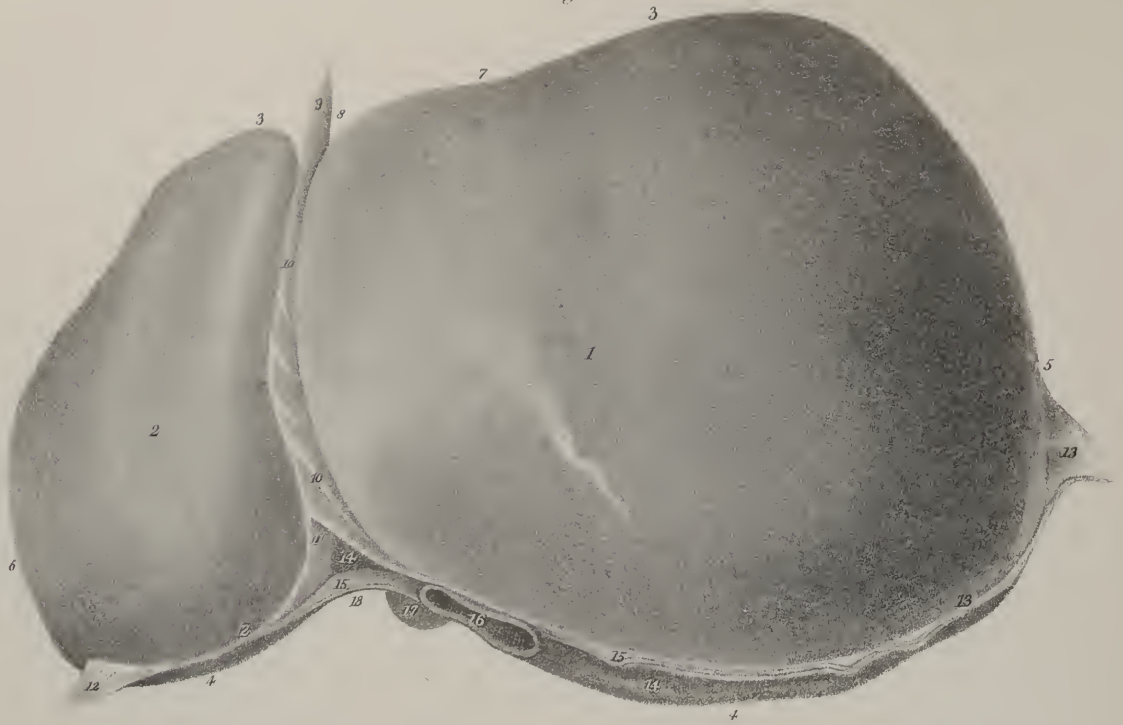
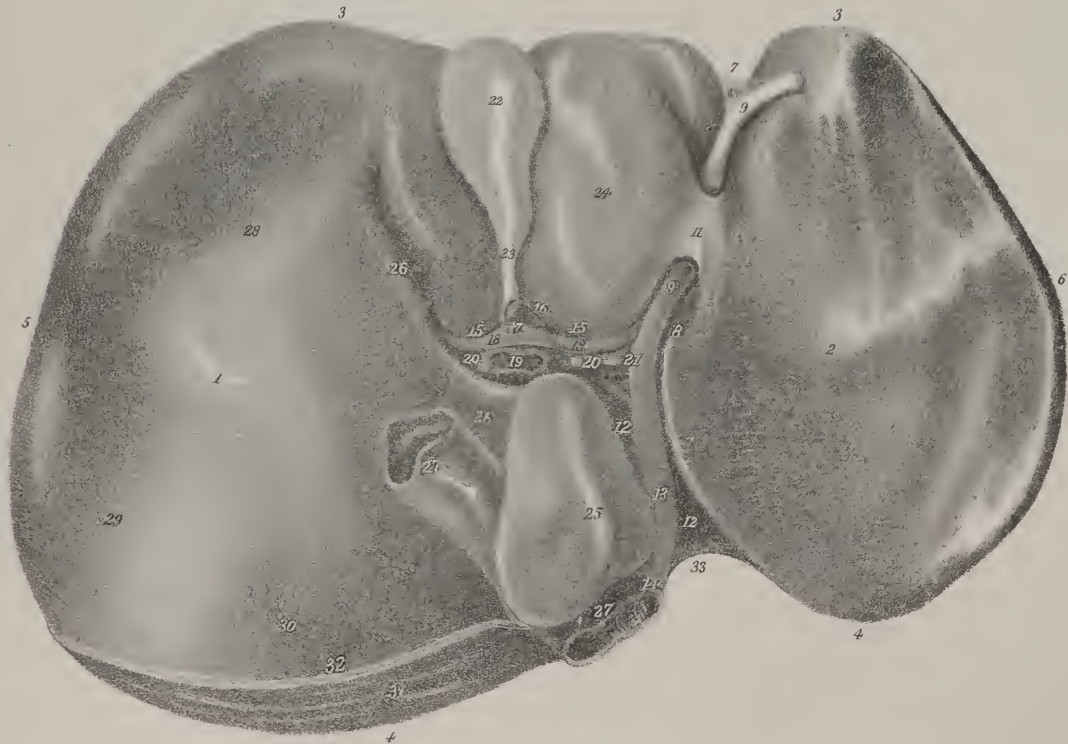


Fig 2



The *large intestine* (plate IV. D—I) presents on its exterior surface a sacculated appearance, and is fixed in its situation by folds of the peritonæum. Its length is to that of the rest of the canal as one to five, and is disposed so as to describe, whilst in the abdomen, an arch, the extremities of which are fixed in the iliac fossæ, the upper part or curve extending as high as the liver and stomach; whilst the terminal part descends into the pelvis, and describes another curve, corresponding with that of the sacrum. The large intestine consists of three portions, differing in length and situation, viz. the cæcum, colon, and rectum.

*Cæcum.*—The cæcum (plate IV. D; plate VIII. figs. 2, 3, No. 2) is fixed in the right iliac fossa, where it forms a sort of cul-de-sac, being a short rounded pouch, extended down from the colon, with which it is continuous, and receiving at its left side the ileum, which opens into it at an angle, being directed from left to right, and from below upwards. It is sometimes called *caput coli*. It is covered by the peritonæum in front and at the sides, but posteriorly it is left uncovered, where the membrane is reflected away from it. To its lower and inner part is attached a round tapering process, (*appendix cæci*), which, from its resemblance to an earth-worm, is also called *appendix vermiformis*. This is about three inches long, and slightly convoluted, a small fold of peritonæum serving to retain it in that condition. Its coats are as thick as those of the cæcum, with which they are continuous, for both are lined with mucous membrane, and the muscular fibres of the one are prolonged to the other. In the early periods of fetal life no distinction is perceptible between them; they form a long tube, projecting below the small intestine, and continuous above with the colon. But towards the time of parturition, this part of the canal becomes constricted for about two-thirds of its length, the rest retaining its natural size; and so that peculiar conformation is established which we find in after life, at least in man, and one of the higher species of the quadrumana, in whom it may be regarded as a rudiment of the tubular diverticulum which is found in the rest of the mammalia.

*Colon.*—The colon, (plate IV. E—H,) by reason of the curve it describes, presents three parts: of these one, the right or ascending part, passes up from the right iliac fossa, where it is continuous with the cæcum, as far as the inferior surface of the liver, supported on the quadratus lumborum muscle and the right kidney, its external border being in contact with the wall of the abdomen, the internal with the convolutions of the small intestines. Another part (middle or transverse) passes across from right to left, beneath the liver and stomach, concealed by the great omentum, and supported by the ascending layer of the transverse meso-colon. And the third portion (left or descending) extends from the spleen to the left iliac fossa, where it makes a double curve, so as to resemble the letter S, placed horizontally. Hence it is termed the *sigmoid flexure* of the colon. From the point just indicated, the intestine inclines inwards, passing over the border of the pelvis, and assumes the name of “rectum.” This we shall describe separately, in consequence of the peculiarities of its structure and the importance of its relations.

## PLATE X.

The anatomy of the liver.

FIG. 1. The liver seen upon its superior or convex surface, showing its general form and the attachments of its ligaments.

No. 1. The right or greater lobe. 2. The left or lesser lobe. 3, 3. The anterior or free margin of the liver. 4, 4. Its posterior or attached border. 5. Its greater or right extremity. 6. The lesser or left extremity. 7. A slight indentation upon the free margin of the right lobe, corresponding with the situation of the fundus of the gall-bladder. 8. The deep notch upon the anterior margin, which distinguishes the right from the left lobe. 9. The round ligament. 10, 10. The ligamentum suspensorium, or falciform ligament, (broad,) formed by two layers of peritonæum. 11. The point at which the two layers of peritonæum forming the falciform ligament separate from each other to become continuous with the lateral ligaments. 12. The left lateral ligament. 13, 13. The right lateral ligament. 14, 14. The large space upon the posterior border of the liver left uncovered by peritonæum; the surface is roughened by cellular tissue which connects the capsule of the organ at this point with the diaphragm. The peritonæum, 15, 15, surrounding this space, is the coronary ligament. 16. The inferior vena cava emerging from its fissure in the posterior border of the liver previously to piercing the diaphragm. 17. A part of the lobulus Spigelii. 18. An indentation corresponding with the convexity of the vertebral column.

FIG. 2. The inferior or concave surface of the liver, showing its subdivisions into lobes.

No. 1. The right lobe. 2. The left lobe. 3, 3. The anterior or free margin. 4, 4. The posterior or attached border. 5. The greater or right extremity. 6. The lesser or left extremity. 7. The notch upon the anterior margin of the liver. 8, 8. The umbilical or longitudinal fissure. 9, 9. The round ligament, the fibrous cord resulting from the obliteration of the umbilical vein. 10. A portion of the falciform ligament connected to the round ligament. 11. The pons hepatis, a band formed by the substance of the liver, and extending from the right to the left lobe across the umbilical fissure. 12, 12. The posterior part of the longitudinal fissure, which is called the fissure for the ductus venosus. 13. The fibrous cord resulting from the obliteration of the ductus venosus, attached posteriorly, 14, to the cellular coat of the inferior vena cava. 15, 15. The transverse fissure. 16. The trunk of the hepatic duct cut across. 17. The hepatic artery, dividing into, 18, 18, the right and left hepatic arteries. 19. The portal vein, dividing into two large branches, 20, 20, for the two lateral lobes. 21. A fibrous connexion between the portal vein and the remains of the umbilical vein, an indication of the communication subsisting between these vessels in the fetus. 22. The fundus of the gall-bladder. 23. The neck. 24. The lobulus quadratus. 25. The lobulus Spigelii. 26, 26. The lobulus caudatus. 27, 27. The inferior vena cava lodged in a deep fissure upon the posterior part of the liver. 28. A depression corresponding with the curve of the ascending colon. 29. A depression produced by the contact of the right kidney. 30. A depression against which the right supra-renal capsule rests. 31. The rough surface of the posterior border of the liver. 32. The inferior layer of the coronary ligament. 33. The concavity corresponding with the convexity of the vertebral column.



*Structure.*—The large intestine is composed of three tunics, like the rest of the canal. The serous coat (plate VII. figs. 1, 2) invests the ascending and descending portions of the colon only at the front and sides, as the posterior and inner border corresponds with the interval between the lamellæ of the meso-cola; and, as its transverse arch gives attachment to the great omentum and the transverse meso-colon, it is uncovered along these points. The external surface of the cæcum and colon is marked by three narrow lines (plate IV. No. 23; plate IX. fig. 3) running their entire length, composed of the external or longitudinal fibres of the muscular coat clustered together, and which, by being somewhat shorter than the intestine, draw it into folds or sacculi, commencing at the cæcum, and extending to the sigmoid flexure of the colon, the rectum not being marked by any such appearance; at different points are also placed appendices epiploicæ, (plate VI. Nos. 28, 28,) noticed already in the description of the peritonæum. The inner surface of the large intestine presents prominent lines and sacculi, corresponding with those seen on the exterior; and at the junction of the ileum with the cæcum there is a valve, which deserves particular notice.

## PLATE XI.

The minute anatomy and structure of the liver, after Kiernan. The drawings are copied, with Mr. Kiernan's permission, from the illustrations to his paper entitled "The Anatomy and Physiology of the Liver," published by the Royal Society in the Philosophical Transactions for 1833.

FIG. 1. A group of lobules as they appear upon the external surface of the liver: they are angular in form from compression, and from the presence of a smaller quantity of Glisson's capsule than usual. They were delineated from a liver in the state of anæmia.

a. The inter-lobular spaces, which contain the larger inter-lobular branches of the hepatic duct, portal vein, and hepatic artery. b. The inter-lobular fissures, in which the smaller inter-lobular branches of the hepatic duct, portal vein, and hepatic artery ramify. c, c. Intra-lobular veins, occupying the centres of the lobules. d, d. Smaller veins, converging to form the intra-lobular veins.

FIG. 2. A group of lobules as they appear on the external surface of the liver; they are rounded in their form, from the presence of a greater quantity of Glisson's capsule, and exhibit the first stage of hepatic-venous congestion.

The references, a, b, c, are the same as in the preceding figure. The inter-lobular spaces and fissures are larger than those represented in fig. 1, and contain more of the capsule of Glisson. d, d. The central portion of the lobule, or that immediately encircling the intra-lobular vein, is of a dark colour, from congestion of that vein and of the central portion of the lobular venous plexus. This congested part of the lobule constitutes "the medullary substance of Ferrein, the cortical substance of Autenrieth, the red substance of MM. Boulland, Andral, and other anatomists, and the cellulo-vascular substance of Mappes." e, e. "The non-congested marginal portion of the lobules, constituting the cortical substance of Ferrein, the medullary substance of Autenrieth, the yellow substance of MM. Boulland and Andral, and the granular substance of Mappes."

FIG. 3. Lobules in the second stage of hepatic-venous congestion, as they appear on the external surface of the liver.

a, b. The inter-lobular spaces and fissures. c. The congested intra-lobular veins. d, d. "Appearances produced by more extensive congestion of the lobular venous plexuses. It will be remarked that in this, as in the preceding figure, the intra-lobular veins and the central portions of the lobules are congested, but that in this figure the congestion is not confined to the centres of the lobules; that it extends to their margins, and to those branches of the portal vein which ramify in the inter-lobular fissures; the congested substance is consequently continuous, and the non-congested substance is in isolated patches. As the congestion extends from the hepatic to the portal vein, and as those branches of the portal vein contained in the fissures are smaller than those contained in the spaces, those in the fissures are congested before those in the spaces; the fissures are therefore in many parts rendered obscure, in consequence of the congested state of the smaller inter-lobular portal veins contained in them, and of the corresponding marginal portions of the lobules: the congestion not having extended to the veins in the spaces (a.) those portions of the lobules immediately surrounding them are not congested. The congested portion in this figure is the red or medullary substance of Ferrein, now appearing cortical; in the preceding figure it appeared medullary: in this it is continuous throughout the liver; in the preceding figure it was in isolated patches."

e, e. "Non-congested portions of the lobules, much resembling in some parts transverse sections, and in other parts longitudinal sections of single lobules. These apparently whole bodies are composed of the non-congested, opposite, marginal portions of three or four contiguous lobules; the congestion not having extended to the portal veins ramifying in the spaces and fissures, which are seen between the different portions of which they are formed. They are of a yellowish-white or yellow colour, according to the quantity and quality of the bile they contain. These are the bodies represented by Müller, by M. Boulland, and by Dr. Hope; they are the non-congested or yellow substance, now appearing medullary and in isolated patches; in the preceding figure it appeared cortical and continuous. This is the nutmeg liver of pathologists, the hypertrophy of the red substance of M. Andral."

FIG. 4. The lobules in a state of portal venous congestion, as they appear upon the surface of the liver. This pathological appearance is of very rare occurrence, and was seen by Mr. Kiernan only in children.

The references, a, b, and c, are the same as in the preceding figures. d. "The central portion of the lobules in a state of anæmia. This is the yellow or non-congested substance appearing medullary, and arising from non-congestion of the intra-lobular veins, and of the central portions of the lobular venous plexuses. e. The marginal portion of the lobules in a congested state."

FIG. 5. A longitudinal section of a sub-lobular hepatic vein.

a. Two superficial lobules terminating by truncated extremities upon the surface of the liver. b. The capsular surface of the lobule, which is invested by Glisson's capsule. c. The base of the lobule resting upon the external coat of a sub-lobular vein, and having no covering of Glisson's capsule. d. The intra-lobular vein in the centre of the lobule. e, e. The openings of intra-

Fig. 1.

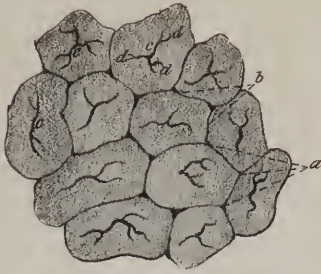

Fig. 6.

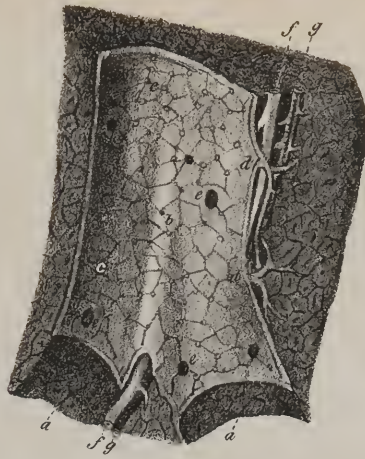


Fig. 2.

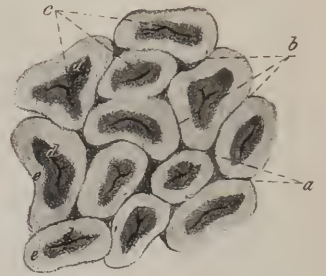


Fig. 8.

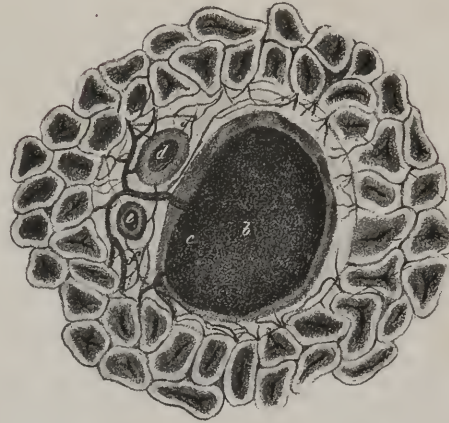


Fig. 5.

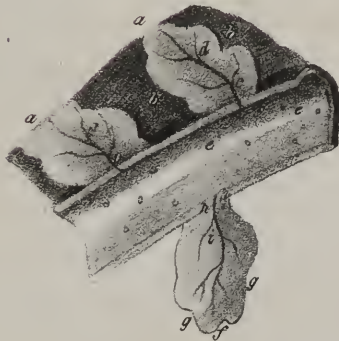

Fig. 9.

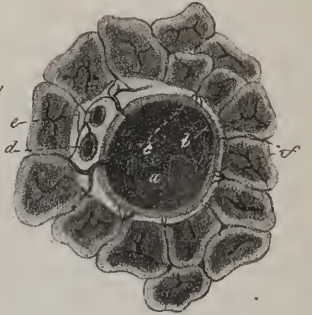


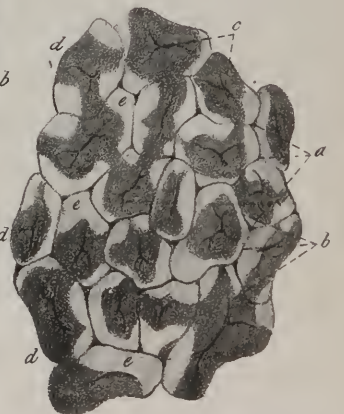
Fig. 7.

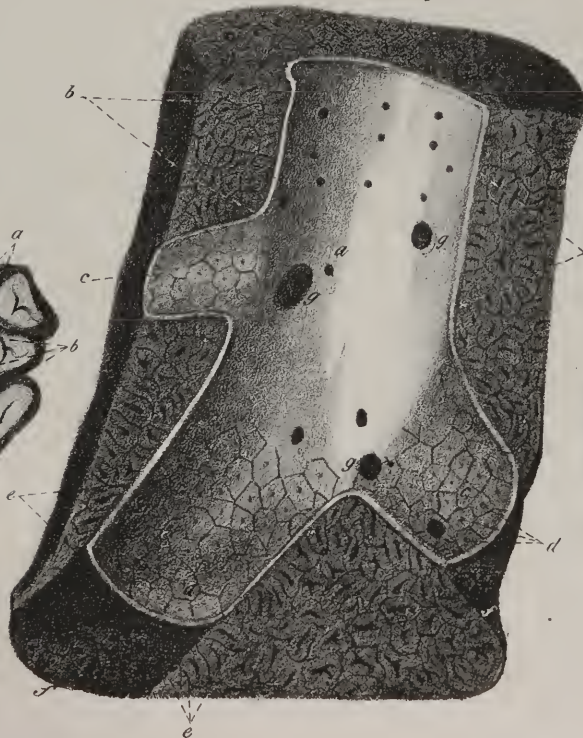

Fig. 4.

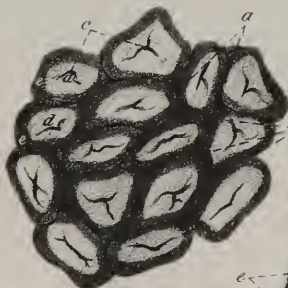

Fig. 3.





par  
the  
terri  
leant  
of be  
mace  
long  
round  
shape  
P  
quest  
just n  
T  
where  
n desc  
front o  
or the  
as to be  
limatio  
Lelios  
re rec  
the sign  
connect



*Valvula coli*; *v. ilio-colica*; *v. Bauhini*, (plate VIII. figs. 2, 3).—When the large intestine is laid open along the right side, particularly if it has been partially dried, a narrow aperture, of an elliptic form, will be observed leading from the ileum into the cæcum and colon at their junction. This narrowing of the canal is caused by two lunated folds which project into its interior, and form the valve. The lower fold is the larger of the two; its convex border is attached to the line of union of the ileum with the cæcum, that of the upper or smaller fold corresponds with its junction with the colon; whilst the straight margins of both project inwards, and are in apposition one with the other. Each of these is made up of the mucous membrane, the sub-mucous cellular tissue, and the circular fibres of the ileum and large intestine projected into the interior of the canal, whilst the longitudinal fibres and the serous coat are continued uninterruptedly from one to the other. If the two latter be divided all round externally at the angle of union, and the ileum drawn outwards, the valve will be effaced, and present a rounded or funnel-shaped opening.

*Vessels and nerves*.—The colon receives its arteries from the right side, or concavity of the arch formed by the superior mesenteric artery, and one also from the inferior mesenteric. Its veins terminate in those which accompany the two arteries just named. Its nerves are offsets from the mesenteric plexus, (superior and inferior.)

The *Rectum*, (plate IV. No. 1; plate VII. fig. 1,) or terminal part of the great intestine, extends from the left sacro-iliac symphysis (where it is continuous with the sigmoid flexure of the colon) to the anus, its direction being at first obliquely from left to right, as it descends to gain the middle line of the sacrum. When deep in the pelvis, it changes its direction, in order to pass forwards in front of the lower part of the sacrum and the coccyx, and behind the bladder, prostate gland, and vesiculæ seminales in the male, or the uterus and vagina in the female. When opposite the prostate, it makes its final turn, inclining downwards somewhat, so as to leave an angular interval between its upper surface and the neck of the bladder. Thus the intestine presents a lateral inclination at its upper part from left to right, and also two curves, from which it is evident that the name (rectum) given to it is ill-chosen, and calculated to convey erroneous impressions. The curves here referred to may be said to indicate a division of the rectum into three parts, differing in situation and relation to contiguous organs. That part of the intestine included between the sigmoid flexure and the first turn, which is about half its length, is covered by peritonæum in front and at the sides, and also connected by its fold, (meso-rectum,) though loosely, to the sacrum. The middle portion, or that between the curves, is about

lobular veins into the sub-lobular vein. f. One of the internal lobules divided by the longitudinal incision through the centre of its axis, showing its foliated appearance. g. The capsular surface of the lobule. h. Its base resting upon the sub-lobular vein. i. The intra-lobular vein.

FIG. 6. A longitudinal section of a small portal vein and canal; the lobules are in a state of anæmia.

a, a. Portions of the portal canals from which the vein has been removed. The parietes are composed of lobules similar to those of the external surface of the liver, separated from each other by fissures and spaces. b. The portal vein, the outline of the fissures and spaces are seen through its coats. c. The mouths of inter-lobular veins, which enter the inter-lobular spaces against which they are placed, and ramify directly in the inter-lobular fissures. d, d. Two vaginal veins, which form a plexus within the portal canal, and give off inter-lobular branches to the inter-lobular spaces and fissures. e, e. The orifices of small portal veins, which enter smaller canals. f. The hepatic duct, giving off vaginal branches. g. The hepatic artery, giving off vaginal branches.

FIG. 7. A longitudinal section of an hepatic vein; the lobules are in the first stage of hepatic-venous congestion.

a. An hepatic trunk; its coats are thick and opaque, and the hepatic-venous canal in which it lies is lined by a prolongation of the proper capsule of the liver. This canal is formed by the capsular surfaces of its parietal lobules, b, b. c. c. Sub-lobular veins terminating in the hepatic trunk. The coats of these veins are thin and transparent, so that the outline of the lobules with their spaces and fissures may be seen through them. d. The mouths of intra-lobular veins opening through the centres of the bases of the lobules. e, e. Longitudinal sections of the lobules, showing the intra-lobular vein opening directly into the sub-lobular vein. f, f. Portions of the sub-lobular canals from which the vein is removed; the form of the bases of the lobules, with the intra-lobular veins opening through the centre of each, is seen. These canals are formed wholly by the bases of the lobules, g, g. The openings of other sub-lobular veins.

FIG. 8. A transverse section of a large portal canal and its vessels. The lobules are in a state of general congestion, their central portions being more congested than their marginal portions.

a. Superficial lobules forming the parietes of the canal. They are similar to those of the external surface, fig. 5, a; being perforated by their intra-lobular veins. b. Section of a portal vein. c. Vaginal branches forming a vaginal plexus, from which the inter-lobular branches are given off. d. Section of an hepatic duct, from which vaginal branches are given off to form a vaginal plexus. e. Section of a branch of the hepatic artery, also giving off vaginal branches. f, f. The vaginal plexus, formed by the vaginal branches of the portal vein, hepatic duct, and artery. The white substance in which the plexus ramifies is Glisson's capsule, which completely surrounds the vessels in the large canals, but is most abundant on the side corresponding with the artery and duct.

FIG. 9. Transverse section of a small portal canal. The lobules are in a state of general congestion.

a. The portal vein, a great portion of which is in apposition with the inter-lobular spaces on the parietes of the canal. b. The inter-lobular veins arising from the portal trunk, and entering the inter-lobular spaces with the inter-lobular duct and artery, without forming a plexus in the canal. c. Two vaginal branches, forming a plexus in the canal, from which the inter-lobular branches are given off. On this side the vein resembles a large portal vein in being separated from the walls of the canal by a vaginal plexus enveloped in Glisson's capsule. d. The hepatic duct giving off vaginal branches. e. The hepatic artery giving off vaginal branches. f. Three vessels,—a vein, a duct, and an artery entering each inter-lobular space on the surface of the canal.

three inches long, its direction being forwards and a little downwards; it rests on the lower part of the sacrum, on the coccyx, and the coccygei muscles, whilst its upper surface lies immediately beneath the base of the bladder and the prostate gland, being separated from the former on either side by the vesiculæ seminales, and between them merely by some loose cellular tissue. This part is stripped altogether of the peritonæal coat at the side as well as posteriorly, and it remains only for a very little way upon its upper surface, for it becomes reflected off it opposite the points at which the ureters impinge on the base of the bladder. Now, in the situation here indicated, the peritonæum forms a small cul-de-sac as it is being reflected, the base of which projects forwards somewhat beyond the level of the ureters, forming a lunated fold, (if the parts be viewed laterally,) whose concavity looks forwards. The third portion of the intestine extends from opposite the prostate gland to the anus, its length being from an inch to an inch and a half, its direction downwards and backwards. At its commencement it is close to the under surface of the prostate gland; it soon becomes invested by the internal sphincter muscle, and embraced by the levatores ani, at the same time contracting its diameter towards its termination, where it is surrounded by the external sphincter muscle.

*Structure*, (plate IX. fig. 3.)—The relation of the peritonæal coat to the intestine having been already sufficiently indicated, we may observe, with regard to the muscular tunic, that the longitudinal fibres, which are considerably developed, are not aggregated into fasciculi as in the colon, but disposed equally all round the tube of the intestine, just as they are in the œsophagus, so that in this particular not a little similitude exists between these two parts of the alimentary canal. At the lower portion of the gut the longitudinal fibres cease, whilst the circular set becomes proportionally developed, so as to form what is termed the internal sphincter muscle. The mucous membrane is thicker and much more vascular than it is in the colon, and presents three prominent folds at different points. One projects backwards from the upper and fore part of the tube, where it corresponds with the prostate gland, the second from its side at the second curve, the third higher. The position, and the degree of projection of these folds, should be attentively considered; they must necessarily exert a material influence on the introduction of instruments.\*

## PLATE XII.

The minute structure of the liver, and the anatomy of the gall-bladder.

FIG. 1. Three of the lobules of the liver, showing the distribution of the portal and hepatic vein within the lobule.—From Mr. Kiernan's paper.

a, a. The inter-lobular (portal) veins entering the inter-lobular spaces. b, b. The inter-lobular veins contained in the inter-lobular fissures, and forming venous circles around the lobules. "This is the appearance which the venous circles present when examined with a common magnifying glass: they are, however, formed by numerous, and not by single branches, as represented in the figure." c, c. "The lobular venous plexuses, the branches of which, communicating with each other by intermediate vessels, terminate in the intra-lobular veins. The circular and ovoid spaces seen between the branches of the plexuses are occupied by portions of the biliary plexuses, constituting the acini of Malpighi." d, d. Intra-lobular veins, the commencement of the hepatic veins; formed by the union of branches from the plexuses.

FIG. 2. "represents the inter-lobular ducts entering the lobules, and forming the lobular biliary plexuses."—After Kiernan.

"a. Two lobules. b, b. Inter-lobular ducts. c, c. Inter-lobular cellular tissue; *i. e.* Glisson's capsule. d, d. The external portions of the lobular biliary plexuses injected. e, e. The intra-lobular branches of the hepatic vein. f, f. The uninjected central portions of the lobules." "No such view of the ducts as that represented in this figure can be obtained in the liver. The inter-lobular ducts are in the figure seen anastomosing with each other: I have never seen these anastomoses, but I have seen the anastomoses of the ducts in the left lateral ligament, and, from the results of experiments related in this paper, I believe the inter-lobular ducts anastomose. I have never injected the lobular biliary plexuses to the extent represented in the figure."

FIG. 3. "represents the biliary ducts ramifying in the left lateral ligament of the liver."—After Kiernan.

a, a. The posterior edge of the left lobe of the liver. b. The free edge of the ligament. c. The edge which is attached to the diaphragm. d, d. "Biliary ducts emerging from the liver, and ascending to ramify in the ligament. e. Arches formed by the ducts towards the upper part of the ligament. f. The plexuses formed by the minute ducts."

FIG. 4. A small hepatic duct laid open in order to show the two rows of follicles; discovered by Kiernan.

a, a. The rows of muciparous follicles.

FIG. 5. The gall-bladder removed from its connection with the liver.

a. The body of the gall-bladder. b. The fundus. c. The neck, from which the anterior segment has been removed in order to show the arrangement of the spiral valve contained within it, and formed by the mucous membrane. d. The cystic duct. e. The hepatic ducts of the right and left lobes of the liver. f. The common hepatic duct. g. The ductus communis choledochus. h. The constriction upon the extremity of this duct where it is passing between the muscular and mucous coats of the duodenum. i. The trunk of the pancreatic duct opening into the ductus communis choledochus at its termination.

FIG. 6. A small portion of the internal surface of the gall-bladder, showing the reticulated rugæ upon its mucous membrane. In the fossæ between the rugæ the muciparous follicles (a, a) are distinctly seen.

FIG. 7. Portions of the columnar epithelium of the mucous membrane of the gall-bladder.—After Henle.

a. Lateral view of a group of these columns. b. A group of columns seen by their free extremities, exemplifying the mode in which they are compacted to produce the smooth surface of the membrane. c. Isolated columns.

\* Mr. Houston's Dublin Hospital Reports, vol. v.



Fig. 2.

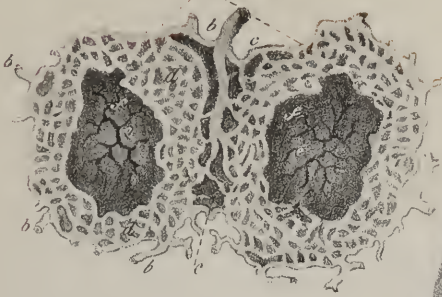


Fig. 1.

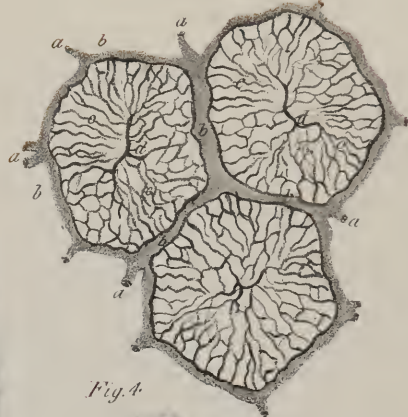

Fig. 5.

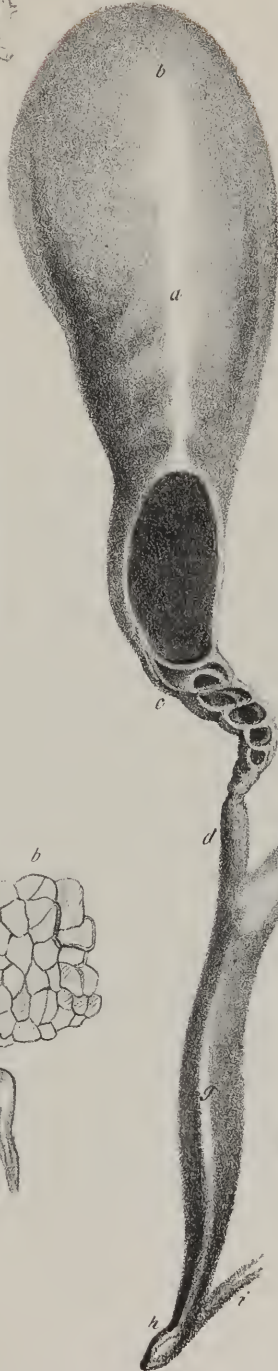

Fig. 4.




Fig. 6.




Fig. 7.

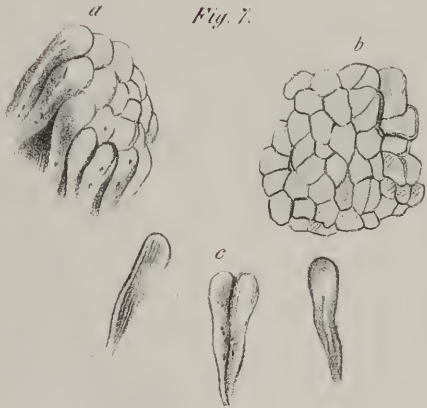
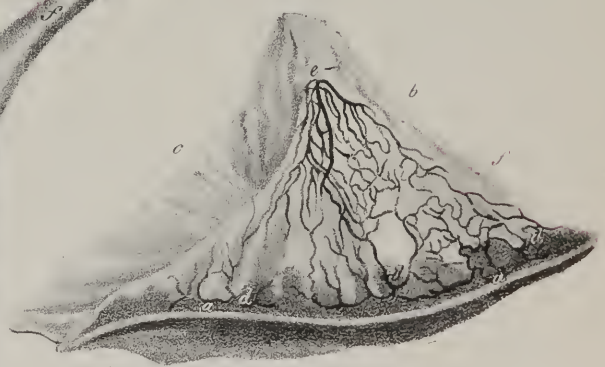


Fig. 3.





No  
niti

choi  
de e  
cum  
reser  
time  
re de  
T

regist  
re so  
f the  
r blic  
spost

WI

The  
vied  
a larg  
The  
me.

1. 1  
r lth  
weiro  
gan, w  
form

2. 1  
has m  
ra the  
both  
stanc

3. 1  
A. N  
meria  
the p

4. 1  
around  
en by  
5. 1  
remat

6. 1  
entire  
7. 1  
wire

8. 1  
the fe  
on th  
S  
extra  
p. con

9. 1  
10. 1  
11. 1

No doubt they have been often taken for strictures. In reference to this matter, also, the lateral deviation and the curves above noticed should likewise be studied.\*

*Vessels and nerves.*—The rectum receives arteries from three sources: from the inferior mesenteric, its superior hæmorrhoidal branches; from the internal iliac, or from one of its principal branches, the middle hæmorrhoidal; and from the pudic, the external hæmorrhoidal. The veins are very numerous, and form a complex interlacement, (hæmorrhoidal plexus,) which communicates with the internal iliac vein by branches accompanying the middle hæmorrhoidal artery, and with the inferior mesenteric vein. The nerves are also numerous, and derived from two sources; from the cerebro-spinal system it receives several filaments, which come from the sciatic plexus, also from the pudic nerve. From the sympathetic system numerous branches also are derived, which come from the inferior mesenteric plexus, and also from the hypogastric plexus.

*The Liver.*—The liver (plate X; *hepar jecur*) is of considerable size; it occupies the right hypochondriac, and part of the epigastric region, extending also somewhat into the left hypochondriac, and so will be found placed beneath the diaphragm, above the stomach and arch of the colon, behind the cartilages of the ribs, and before the spine,—the aorta, the vena cava, and crura of the diaphragm being interposed. In this situation it is retained by four folds of peritonæum, called *ligaments*, viz. the falx, or falciform fold, (fig. 1, Nos. 10, 10,) on its upper surface; and the coronary, (15, 15,) and two lateral ones, (12, 13,) placed at its posterior border. These have been already described with the other processes of the peritonæum.

When examining the form of the liver, it is necessary to consider separately each of its surfaces, borders, and extremities.

The *superior* surface, (fig. 1,) smooth and convex in its general outline, corresponds with the arch of the diaphragm, and is divided by the falx into two parts or lobes, named, from their position, the *right* and *left* lobes, the former being considerably the larger.

The *inferior* surface (fig. 2) is irregularly concave, and presents certain fissures, eminences, and depressions, deserving of notice.

1. *Right and left lobes.*—The division of the liver into right and left lobes, which is indicated upon the upper surface by the falx or suspensory ligament, is here marked by a fissure (fig. 2, Nos. 8, 8; 12, 12) which extends from the anterior to the posterior border. The right lobe (figs. 1 and 2, No. 1) is considerably larger than the left; it occupies the right hypochondriac region, whilst the other (figs. 1 and 2, No. 2) is placed in the epigastric and left hypochondriac; the proportion as to size between the former and latter is about five or six to one.

2. The *umbilical fissure.*—Extending from before backwards, a deep groove or fissure will be observed, (fig. 2, Nos. 8, 8; sulcus umbilicalis—longitudinalis, horizontalis,) which in fetal life lodges the umbilical vein in that part of its extent which reaches from the anterior border to the transverse fissure, whilst the remaining portion (12, 12) transmits the ductus venosus. In after life both these degenerate into ligamentous cords. This fissure is in some instances converted into a canal, by a portion of the substance of the liver (fig. 2, No. 11; *pons hepatis*) being extended across it.

3. The *transverse fissure.*—Running transversely with regard to the preceding, and at right angles with it, is a second fissure, (fig. 2, No. 15; sulcus transversus; s. *venæ portæ*.) It occupies the middle third of the transverse diameter of the liver, being somewhat nearer the posterior than the anterior border. The older anatomists likened it to a gateway, which gave transmission to the portal vessels, as it lodges the vena portæ, the hepatic artery, and biliary ducts, with the nerves and lymphatics.

4. The *square lobe.*—In front of the transverse fissure a square piece is marked off, (fig. 2, No. 24; lobulus quadratus,) which is bounded behind by the fissure just named, before by the margin of the liver, on the left by the longitudinal fissure, and on the right by the gall-bladder.

5. The *pyramidal* or *Spigelian lobe.*—Behind the transverse fissure, and concealed by the hepatic vessels and small omentum, is situated another lobe, (fig. 2, No. 25; lobulus Spigelii;) it projects in the form of a pyramidal mass, forming a sort of promontory between the three great veins, or rather the fissures which lodge them, viz. the vena portæ, vena cava, and the umbilical vein. Its base is connected with the right lobe by a process, which is named *lobulus caudatus*, (fig. 2, No. 26.) This lobule has before it the transverse fissure, and behind it another which lodges the inferior vena cava. The square and pyramidal lobes were formerly likened to the *pillars* of a gate, and the transverse fissure to a gateway (*porta*) for the entrance of the vessels; from this the great vein, *vena portæ*, took its name.

Some confusion arises from applying the term “lobulus” to the portions of the liver here described, viz. lobulus Spigelii—quadratus—caudatus, at the same time that we speak of the “lobuli” or “lobules” of which these and all other parts of the liver are composed, and in which its secretion is elaborated. It would be better to restrict the term to the minute lobules, and call the masses above noticed minor lobes, which will sufficiently distinguish them from the great lobes (right and left) into which the liver is divided.

The depressions on the lower surface of the liver are very slight; they merely correspond with the position of the contigu-

\* The longitudinal fibres of the rectum, as first noticed by Prof. Horner, turn from without inwards between the internal and external sphincter muscles, and then ascend upwards for an inch or two in contact with the mucous coat, into which they are finally inserted by fasciculi which form the base of the columns of the rectum. Many of these fibres terminate also between the fasciculi of the circular fibres.—J. P.

ous viscera. In the left lobe a depression will be observed corresponding with the upper surface of the stomach; on the right, one for the gall-bladder, and two others, very faintly marked, indicating the points of contact of the colon and the right kidney.

The *anterior border* (figs. 1 and 2, Nos. 3, 3) of the liver, which lies beneath the margin of the chest, is sharp and thin, and presents a notch, indicating the commencement of the longitudinal fissure; and sometimes another, which lodges the fundus of the gall-bladder. The *posterior and superior border* (figs. 1 and 2, Nos. 4, 4) is thick and rounded; it is marked by two grooves, of which one, broad and superficial, indicates where it rests on the spine, the other transmits the vena cava. The right extremity (5, 5) is rounded and thick; the left, (6, 6,) on the contrary, is thin and oblique, being directed towards the cardiac orifice of the stomach, and the spleen.

*Structure.*—The liver is invested by the peritonæum, except at the points of reflection of the falx and of the lateral and coronary ligaments. Its surface is throughout smooth and shining, which is owing to its serous covering. Subjacent to this is a very thin lamella of cellular tissue, which invests the organ in its entire extent; on the surface it is not more developed than the sub-serous cellular tissue in many other parts. Opposite the transverse fissure, however, it becomes considerably increased in quantity, encases the hepatic vessels, and accompanies them throughout their ramifications, supporting them in their course, and constituting a nidus for them when they become capillary. The liver is dense and heavy, of a deep red colour, or a brownish red, with very frequently a slight purple tinge along its sharp margin. Its weight is about four pounds; its transverse diameter is from twelve to thirteen inches, its thickness about five or six. When torn or divided, the surface exposed by the fracture presents a granular appearance, as if it were made up of minute granules or lobules, from which circumstance the liver has been classed amongst the conglomerate glands. Its colour in some points is of a yellowish tinge, in others of a dusky red; the former being caused by the bile of the ducts exuding through their coats, the latter is obviously owing to the blood retained in greater or less quantity in the hepatic and portal veins.

At the outset of any inquiry into the intimate structure of this or of any other organ, it is necessary to ascertain the vessels which enter into it, their mode of distribution, and mutual relations. Those of the liver may be stated as follows: 1. The *vena portæ*, (fig. 2, Nos. 19, 20, 20) conveys into it the residual blood from all the chylo-poietic viscera. Its branches (right and left) spread out like arteries in the corresponding sides of the liver, until they become capillary in its granular structure. 2. The *hepatic veins* commence by radicles continuous (as may be shown by injection) with the terminations of the vena portæ. These gradually enlarge as they pass upwards, converging to the point at which the vena cava passes behind the liver, and pour their contents into that vein, (fig. 2, Nos. 27, 27.) They are usually three in number; their direction is upwards and inwards, converging towards the sulcus which lodges the vena cava; and most of them have also an inclination from before backwards, inasmuch as they have to pass from the anterior surface to the posterior border. These veins are, moreover, so intimately connected with the substance of the liver, that they do not collapse when cut across; and finally, they proceed to their destination unaccompanied by any other vessel. From this it must be obvious that the hepatic veins cross those of the vena portæ, which not only diverge towards the lateral masses of the liver, but also have to come forwards to its anterior surface. 3. The *hepatic artery*, (fig. 2, Nos. 17, 18, 18,) arising from the cœliac, ascends to the transverse fissure, where it divides into two branches, which accompany those of the vena portæ to their terminations. 4. The *nerves*, forming a plexus (*hepatic*) round the artery and veins, are derived from the great solar plexus. 5. The *lymphatics* are exceedingly numerous; some being extended upon its surfaces, others arising from its interior, the latter following the course of the blood-vessels. 6. The *hepatic or biliary duct* (fig. 2, No. 16; ductus hepaticus—

## PLATE XIII.

The anatomy of the pancreas and spleen.

FIG. 1. The pancreas viewed upon its anterior surface with its relation to the duodenum.

No. 1. The body of the pancreas. 2. The head of the pancreas. 3. Its small extremity. 4. The splenic artery, lying along the upper border of the pancreas, and making several curves in its course. 5. The pyloric extremity of the stomach. 6. The pylorus. 7. The ascending portion of the duodenum. 8. The descending portion. 9. The third, or horizontal portion. 10. The trunk of the superior mesenteric artery. 11. The superior mesenteric vein.

FIG. 2. A dissection of the pancreas, showing the excretory duct with its branches; the duodenum is laid open by a longitudinal incision.

Nos. 1, 1. The pancreatic duct. 2. Two branches from the small extremity of the gland uniting at an acute angle. 3. The papilla upon which the pancreatic duct opens into the duodenum. 4. The ductus communis choledochus, advancing from behind the duodenum to open upon the same papilla. 5, 5. A section of the spiral fold of mucous membrane situated at the pylorus. 6, 6. Valvulæ conniventes, of small size in the duodenum.

FIG. 3. The spleen, seen in the position which it occupies in the abdomen.

No. 1. Its convex surface. 2, 2. The concave surface. 3, 3. The hilus lienis, or groove through which the vessels pass to supply the organ. 4. The splenic artery, dividing into branches.

FIG. 4. The convex surface of the same spleen.

No. 1. Its anterior border, upon which is seen one of the clefts generally found in this part of the organ. 2. Another cleft upon its upper extremity.



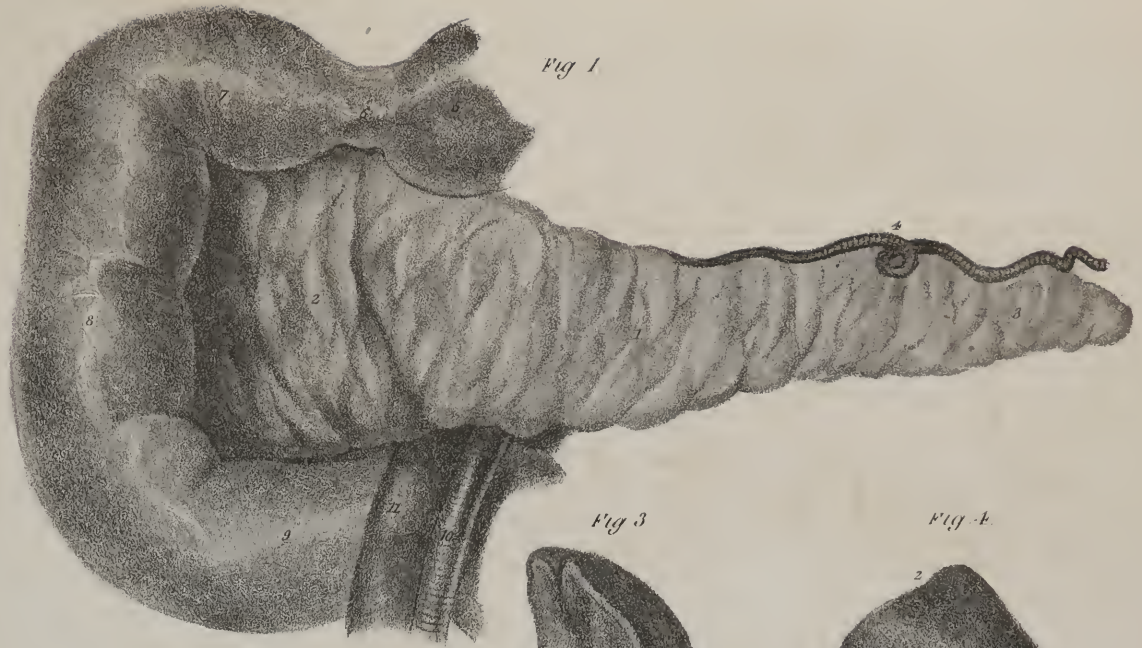

Fig 1

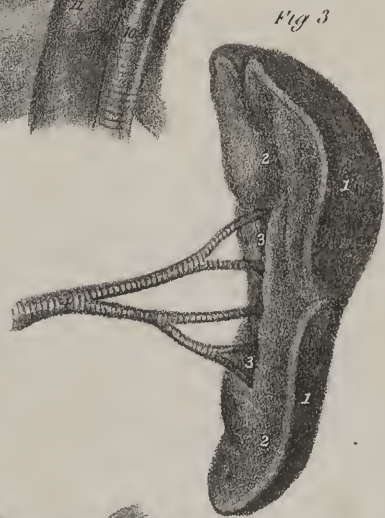

Fig 3



Fig 4

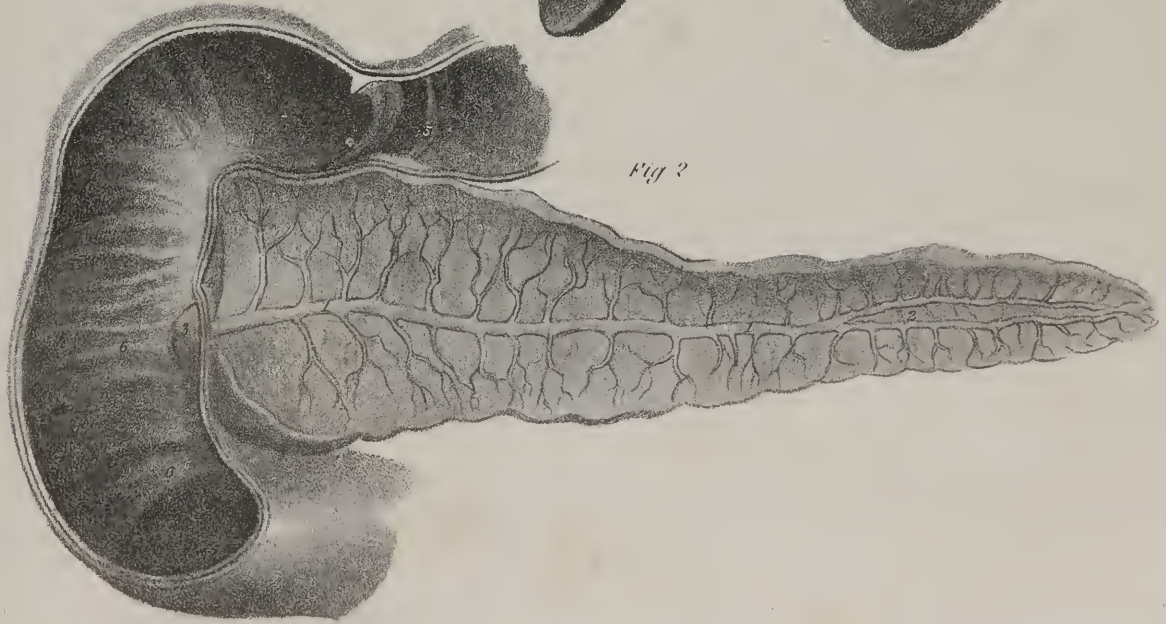

Fig 2

billar  
branc  
the ot  
extern  
the due  
the sub  
cular p  
Su  
above  
the cap  
is inval  
on the  
results  
brough  
the out  
own flut  
which t  
Th  
on the li  
no set  
unres  
trude  
rim. t  
ad fou  
ry cap  
biary  
cauf  
T  
distr  
The h  
uninc  
esse  
cont  
of m  
c' b  
net  
re



biliarius) arises by minute ramusculi in the lobules, where they are intimately connected with those of the vena portæ, whose branches they accompany as they converge towards the transverse fissure, out of which issue two branches, one for the left lobe, the other for the right; these soon unite, and by their union they form the duct. It consists of two coats or tunics, of which the external is fibrous and the internal mucous. 7. A lamella of cellular membrane encloses the vena portæ, the hepatic artery, and the duct, previously to their entrance into the fissure, and accompanies them to their final termination, loosely connecting them to the substance of the organ. This has been called the *capsule of Glisson*, who supposed it to possess a contractile, and even a muscular power, and on this hypothesis sought to explain the portal circulation.\*

Such are the anatomical elements of which the liver is composed, its proximate constituents being the granules or lobules above noticed. These were supposed by Malpighi to be hollow in the interior, and to form follicles, or *acini*, interposed between the capillary terminations of the vena portæ and of the artery, and the incipient radicles of the hepatic duct;—a conjecture which is invalidated by the fact, that injections passed into the vein return by the duct without appearing to suffer extravasation. Ruysch, on the contrary, supposed them to be solid, and to consist of an interlacement formed by the capillaries of the different orders of vessels. Now, when we consider the course of the vessels, and of the fluids they contain, we perceive that two sorts of blood are brought to each lobule by the portal vein and hepatic artery, the former conveying materials for the secretion of bile, the latter for the nutrition of the organ: and that a different sort of blood is conveyed away by the hepatic vein, whilst at the same moment a new fluid (the bile) is received and carried down by the duct; so that each lobule forms the centre of a minute eddy within which the fluids turn; and where they not only change their direction, but also receive a total alteration of character.

The recent researches of Mr. Kiernan give a very clear view of several points connected with the distribution of the vessels in the liver, and particularly of the structure of the lobuli. It is obvious that the interior of the organ is channeled or hollowed into two sets of canals; the one giving lodgment to the hepatic veins; the other to the portal vein, its branches, and the accompanying arteries and ducts. At the transverse fissure, the vein, duct, and artery divide into branches which enter the portal canals. These divide and subdivide into smaller branches, which enter the smaller canals; and every canal, however small, contains an offset from the portal vein, the hepatic artery, and the duct. These are enclosed by Glisson's capsule, which lines the portal canals, and forms sheaths for the larger vessels, and a web in which the smaller vessels ramify; it enters the inter-lobular fissures, forming capsules for the lobules, and finally extends into their interior, and with the blood-vessels expands itself over the secreting biliary ducts. "The capsule thus presents three portions—a vaginal—inter-lobular—and lobular portion; and as the vessels ramify in the capsule, their branches admit of a similar division."

The hepatic ducts can be traced along the canals, in the fissures between the lobules, and into the lobules where they form plexuses. "These may be called the lobular biliary or secreting plexuses, as being the immediate agents in the secretion of bile." The branches of the portal vein and the hepatic arteries also enter the lobules. The venous branches form a plexus which communicates with the incipient radicles of the hepatic vein; and the arteries, which are very few and very minute, are the nutrient vessels of the lobules, and probably terminate in the plexus of the portal vein. The branches of the artery ramify freely upon the coats of the portal vein, and on the hepatic ducts, furnishing materials for the nutrition of both, and to the latter for the secretion of mucus which lubricates their interior.

The trunks of the hepatic veins are lodged in the "hepatic venous canals." Their incipient radicles commence in the interior of the lobules, so that each lobule may be said to be "sessile" upon a minute venous branch. Hence when an hepatic vein is laid open, the orifice of each minute branch which terminates in it is seen to come out of the middle of a lobule; but the branches of the portal vein, when viewed in the same way, correspond with the interstices between the lobules.

*Structure of the lobules.*—Each lobule is found to consist of a reticulated plexus formed by the minute radicles of the biliary ducts; for these, when examined with a high magnifying power, are seen to divide and subdivide so as to form a mesh in its interior, which is supported by a nidus of cellular tissue furnished by Glisson's capsule. Upon this mesh or plexus is disposed another, formed by the terminal branches of the portal vein. This is the "lobular venous plexus," from which that formed by the ducts can be distinguished, as the latter presents somewhat the appearance of cells. The branches of the venous plexus converge from the circumference of the lobule towards its centre, and communicate with the incipient radicles of the hepatic vein.

It is difficult to inject the ducts, owing to their being filled with bile. Mr. Kiernan succeeds by first tying the portal vein and hepatic artery in a living animal after feeding it. By this expedient the secretion of bile is suspended, and that which the ducts contain is discharged. The ducts cannot be injected directly from the hepatic vein, for no branches of this vessel ramify on their coats. Whenever it does reach the ducts, it is only through the branches of the portal vein which spread upon them. And even when the ducts are injected from the portal vein or the hepatic artery, the fluid gets into their interior by rupturing their lining membrane.

The residue of the blood conveyed by the hepatic artery to the lobules, to the different vessels, and the ducts for their nutrition, is taken up by minute veins and conveyed into the portal vein, so that part of the blood from which bile is secreted is derived from the liver itself.—(See Mr. Kiernan's paper. †)

\* Glisson, de Anatomia Hepatis.

† Philosophical Transactions, 1833, part ii.



The *gall-bladder* (plate XII; *vesicula fellea*) is a membranous sac, of a pyriform shape, lodged in a slight depression at the inferior surface of the right lobe of the liver. Its position is oblique, so that its fundus inclines downwards, and to the right side, being on a level with the lower margin of the liver, whilst its body and neck are directed backwards, upwards, and to the left. Its neck tapers gradually, and is prolonged into a small tube, (*ductus cysticus*, *κυστικὴ*, vesica,) which at first inclines inwards and backwards, then descends and joins at an angle with the hepatic duct to form a common canal, (*ductus communis choledochus*, *χολη*, bile, *δέχομαι*, to receive,) which lies on a level with the hepatic artery, and on the same plane, the vena portæ being behind and between both. The common duct is about three inches long, it descends behind the pylorus, insinuates itself between the descending part of the duodenum and the head of the pancreas, with whose duct it comes into contact, and both together pierce the coats of the duodenum, running for three quarters of an inch between them, previously to terminating on the inner surface of that intestine. The gall-bladder is composed of two coats, united by a lamella of cellular membrane: the external one is but a partial covering, being derived from the peritonæum; the internal is a mucous lining, continuous with that in the ducts. In the neck of the sac the mucous membrane projects inwards, so as to form folds, disposed spirally, and calculated not only to favour the ascent of the bile into its reservoir, but also to graduate its flow as it descends. If the pipe of a syringe be inserted into the hepatic duct, the duodenum being at the same time laid open, and the fundus of the gall-bladder cut off, water forced along it will be found to ascend into the latter almost as soon as it appears in the intestine. This would indicate a resistance to its course at the mouth of the common duct, which is produced by a small valvular fold of membrane, placed within the orifice. The effect of the spiral lamella in the gall-bladder can be readily perceived by the manner in which the fluid ascends contrary to its gravity.

*The Spleen.*—The spleen (*lien*, *splen*) is a soft, spongy, and exceedingly vascular organ, placed in the left hypochondriac region, between the diaphragm and the stomach, and beneath the cartilages of the ribs. Its colour is deeply red, with a tinge of blue, particularly round its margin. Its form is somewhat oval, being smooth and convex on the exterior, where it is in apposition with the diaphragm, and irregularly concave on the opposite side, which is divided into two parts, but unequally, by a longitudinal slit (*hilus lienis*) for the transmission of its vessels. The spleen has a peritonæal investment prolonged to it from the stomach, by which, as well as by vessels, it is connected to that organ; but it has also a smooth and fibrous tunic proper to itself. Its size is very variable, not only in different individuals, but also in the same person. Taking a general average, its greatest diameter measures about four inches, its breadth three, and its thickness from two to two and a half; its weight from eight to ten ounces. Its consistence is so slight that it is easily torn, and in many cases it is found soon after death so soft as to be readily broken down by a slight pressure, when it appears a grumous, dark, confused mass.

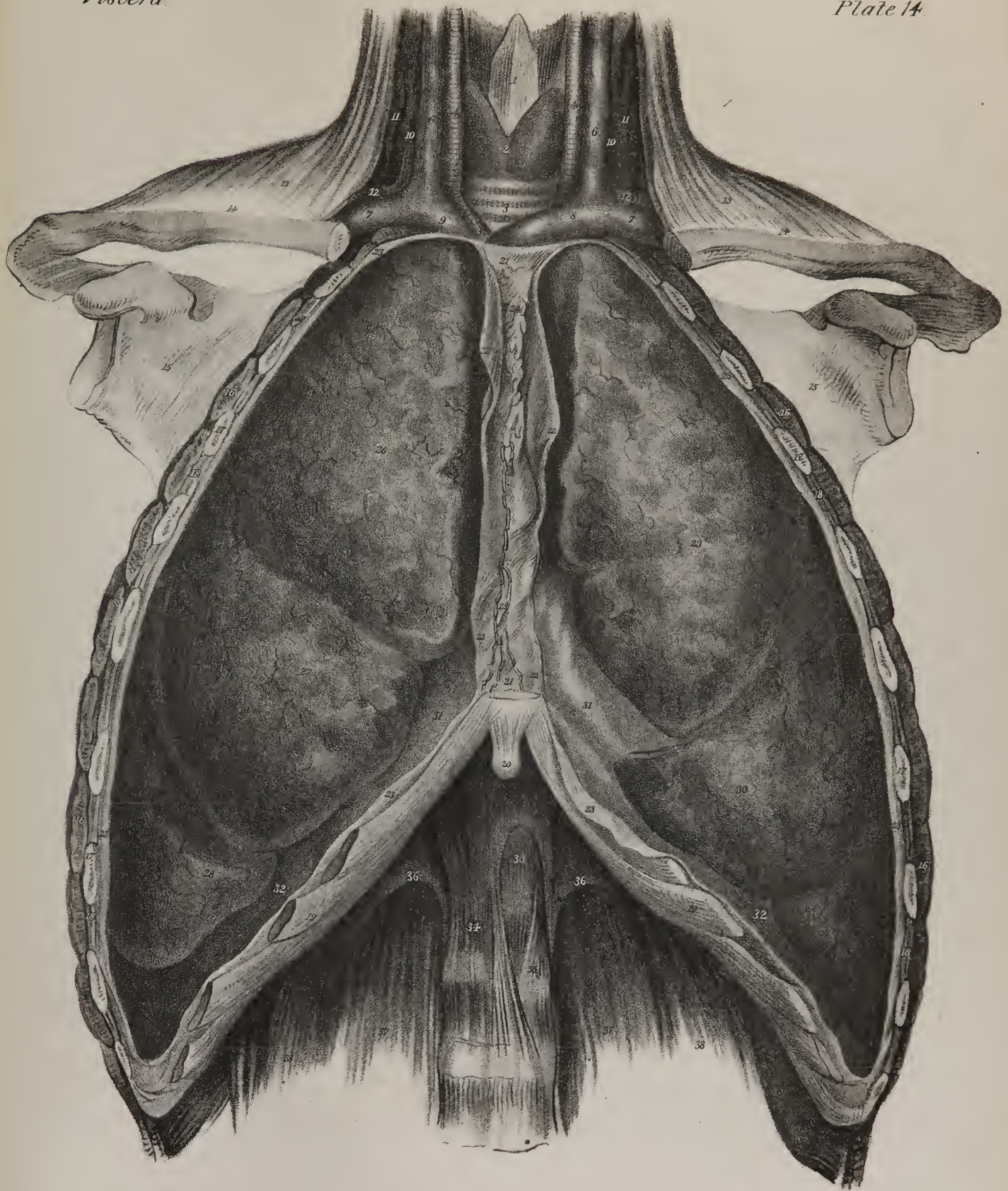
*Structure.*—The fibrous or proper coat of the spleen is so firmly adherent to the serous investment, that they cannot be separated, except at its concave surface. From its interior, a multitude of cellular bands and fibres project, which form, by their intersections, cells of various forms and sizes. The splenic artery and vein are both of very large size compared with the bulk of the organ. They ramify minutely in its interior, and freely communicate, which is proved by the facility with which injections pass from one to the other. Its nerves are derived from the solar plexus forming an interlacement (*splenic plexus*) previously to their entrance into it; its lymphatic vessels are very numerous; but as there is no appreciable product elaborated by this apparatus, it has no excretory duct; and as no necessary dependence or connexion has hitherto been established between it and any other organ, (for it has been extirpated from dogs without causing death, or even, in some cases, any very material dis-


## PLATE XIV.

The anatomy of the organs of respiration—the lungs. In this plate the lungs are seen to occupy their natural position in the chest; the view has been obtained by removing the anterior wall of the thorax, after dividing the ribs on each side, and the costal cartilages below.

No. 1. The prominence of the thyroid cartilage. 2. The thyroid gland. 3. The trachea. 4, 4. The common carotid arteries. 5. The upper border of the arteria innominata. 6, 6. The internal jugular veins. 7, 7. The subclavian veins. 8. The left vena innominata. 9. The right vena innominata. 10, 10. The anterior scaleni muscles. 11, 11. The sterno-mastoid muscles, divided by a vertical section. 12, 12. The subclavian arteries in the third part of their course. 13, 13. The trapezius muscle at each side, in outline. 14, 14. A part of the clavicle at each side. 15, 15. The scapula at each side, in outline. 16, 16. The divided serrations of the serratus magnus muscle. 17, 17. The divided extremities of the ribs. 18, 18. The intercostal muscles. 19, 19. The costal cartilages, forming the lower boundary of the chest. 20. The ensiform cartilage. 21, 21. The anterior mediastinum, separating the two sides of the chest. 22, 22. The two layers of the reflected pleura, forming the lateral boundaries of the anterior mediastinum. 23, 23. The pleura costalis, lining the internal surface of the chest. 24. The remains of the thymus gland. 25. Some lymphatic vessels from the liver passing upwards to the lymphatic glands at the root of the neck; the number is placed near to a lymphatic gland. 26. The superior lobe of the right lung. 27. The middle lobe of the right lung. 28. The inferior lobe of the right lung. 29. The superior lobe of the left lung. 30. The inferior lobe of the left lung. 31, 31. The pericardium concealing the heart. 32, 32. The upper surface of the diaphragm lined by the pleura parietalis. 33. The aortic opening of the diaphragm, formed by its two crura. 34. The right crus of the lesser muscle. 35. The left crus. 36, 36. The ligamentum arcuatum internum at each side, beneath which is seen passing the psoas muscle, 37, 37. 38, 38. The quadratus lumborum at each side.







I  
 the  
 w  
 de  
 in  
 sta  
 app  
 be  
 and  
 the  
 due  
 pro  
 is e  
 C  
 the  
 is se  
  
 ma  
 long  
 feel  
 cut  
 erre  
 no  
  
 dut  
 com  
  
  
 are  
 lang  
 pers  
 ce  
 wh  
 ce  
 list  
 left  
 of  
 rad  
 dom  
 are  
 into  
 base  
 pla  
 wa  
  
 re  
 (



turbance of their functions,) the purpose which it serves in the animal economy remains altogether unknown. Besides the cellular structure and vascular arrangement above indicated, several minute granular bodies are scattered through the substance of the spleen, of a whitish colour, but variable in size and form.

*The Pancreas.*—The pancreas is a conglomerate gland, being composed of a number of granules aggregated together; in which respect, as well as in its function, it resembles the salivary glands, with which it is classed. The greater part of it lies deeply in the epigastric region, resting on the spine, the great vessels interposing, and concealed by the stomach, one end being in contact with the spleen, and therefore lying in the left hypochondrium, the other surrounded by the curve of the duodenum, so that its direction is obliquely downwards, and to the right side. The gland is compressed and flat, and, after the stomach is drawn upwards, it will be found still covered by the ascending layer of the transverse meso-colon. The superior mesenteric artery will be observed interposed between its lower surface and border and the transverse part of the duodenum, and along its superior and posterior margin run the splenic vessels. The left, or splenic extremity, is narrow and thin; the right is broader, and called the *head* of the pancreas; a small part of it is also detached somewhat from the rest, and called the *lesser pancreas*. Its excretory duct (*ductus pancreaticus*) commences by filaments which issue from the different granules, and gradually increases in size as it proceeds from left to right through the substance of the gland, and will be found nearer the lower than the upper border; near its extremity it is joined by the duct of the smaller pancreas. When arrived at the right border of the gland, the duct comes into close apposition with the ductus communis choledochus, with which it pierces obliquely the coats of the duodenum, and becomes identified with it, so that both terminate by a single orifice which opens on the inner surface of the duodenum at the junction of its second and third portions.

*Structure.*—The globules of which this gland is composed are aggregated into bundles, and these connected so as to form a mass by cellular tissue, which, however, does not constitute a proper capsule for it. It is of a pale ash-colour, about six inches long, one and a half in breadth, and from half an inch to three quarters in thickness. Each granule seems to contain within itself all the elements of a secreting organ; in its interior is a minute cell or cul-de-sac, being the ultimate radicle of the excretory duct; around which is a minute vascular plexus—all supported and connected by cellular tissue, in which also run filaments of nerves. The arteries of the pancreas come from the splenic, pancreatico-duodenalis, and root of the mesenteric; the veins open into the splenic; the nerves are offsets from the solar plexus.

After the organs of digestion, those of absorption follow, when taken in their physiological order, as they take up the product of digestion and convey it into the current of the circulation. We have already described the absorbing vessels and their common trunk, (thoracic duct,) so that we may now continue our route, and proceed to the circulating system.

We shall premise a few remarks on the thorax, previously to describing the organs which it contains.

## THE THORAX.

The thorax is somewhat conical in its form, and intended to lodge the central organs of circulation and respiration. It is intermediate not only in size and situation, but also in the structure of its walls, between the abdomen and the cranium; the one being composed almost entirely of soft parts, and the other an osseous case, whilst the thorax consists of muscular and osseous parts in nearly equal proportions. The spaces between the ribs are filled by the intercostal muscles. The base is formed by the diaphragm. In the natural condition, when the scapulæ and arms are attached to the trunk, the top of the chest is wider than the bottom; but when these parts are detached, and nothing remains but the walls of the cavity, the proportions are reversed, for it appears a truncated cone, the summit being above. The upper aperture is bounded at each side by the first rib, before by the top of the sternum, behind by the spine. Its breadth from side to side is greater than its depth from before backwards. Its plane, or line of direction, is backwards and upwards; through it pass the great arteries and veins of the head and upper extremities, the trachea, œsophagus, vagus and sympathetic nerves, the thoracic duct, sterno-hyoid and sterno-thyroid muscles anteriorly, and the longi colli posteriorly. The base of the thorax is also oblique: its inclination, however, being from before backwards and downwards; hence the depth of the cavity is greater behind than before. The breadth of the base from side to side is greater than its depth. The thorax, in the natural condition, is divided into two lateral chambers by a partition (mediastinum) formed by the reflection of the pleuræ; it extends from the summit to the base of the cavity, and from the sternum back to the spine. It may be likened to a hollow partition, composed of two parallel planes, leaving an interval between them which lodges the vessels, nerves, and tubes above enumerated, and transmits those which pass down to the abdomen.

## ORGANS OF CIRCULATION.

When treating of the general anatomy of the vascular system, we have given an outline of the apparatus of circulation. It remains for us in the present section to describe the central organ of the circulation, (the heart,) with its investing membrane, (pericardium.)

*Pericardium.*—The pericardium, or “heart-purse,” ( $\pi\epsilon\pi\tau\iota$  and  $\kappa\eta\zeta$ , the heart,) is a membranous sac which invests the heart, and the commencement of the large arterial and venous trunks which are connected with it. It is composed of two layers, the external being fibrous, the internal serous: it is situated above the central aponeurosis of the diaphragm, behind the sternum and the cartilages of the third, fourth, and fifth ribs of the left side, before the bronchi, œsophagus, and descending aorta, and between the reflected layers of the pleuræ, which separate it from the lungs. Though the two membranes of which the pericardium is composed are intimately united, still their general conformation, as well as their structure and properties, are so different that it is impossible to describe them together; we must, then, notice each separately.

The *fibrous* membrane, dense, thick, and unyielding, consists of fibres which interlace in every direction. Most of them are attached to the central aponeurosis of the diaphragm, and superiorly, where they embrace the large vessels, they form tubular prolongations, which, after passing for some way upon them, become blended with their external coats; of these, eight are usually enumerated, viz. one for the superior vena cava, four for the pulmonary veins, one for the aorta, and two for the right and left branches of the pulmonary artery. As the inferior vena cava opens into the right auricle as soon as it penetrates the diaphragm, it cannot be said to receive an investment in the same way as the other vessels.

The internal or *serous* lamella of the pericardium represents a shut sac partially inverted on itself, and so disposed as that the internal or inverted part embraces the heart, whilst the other lines the inner surface of the fibrous lamella. It was the great simplicity of arrangement observable in the serous pericardium, as contrasted with that of other membranes of the same class, that suggested to Bichât the idea of comparing it to a double night-cap; for if the heart could be drawn out of it without injury to its continuity, it would resemble an elongated sac closed on all sides, and we should then have demonstrative proof, that, though that organ is invested by the membrane, it is still without its proper cavity.

*The Heart.*—The heart, ( $\text{cor}$ ,  $\kappa\eta\zeta$ ), the central organ of the circulation, is a hollow muscle, irregularly pyramidal in its shape, which lies between the lungs, enclosed in its proper investment, the pericardium. It is placed so obliquely, that if a line corresponding with its axis were passed through it at the moment of its pulsation, its direction, taken from base to apex, would be down-

## PLATE XV.

The organs of respiration and circulation,—the lungs and heart.

FIG. 1. An anterior view of the lungs and heart, with their great vessels.

No. 1. The right auricle of the heart. 2. The appendix auriculæ. 3. The superior vena cava. 4. The right vena innominata. 5. The right internal jugular vein. 6. The right subclavian vein. 7. The left vena innominata. 8. The left internal jugular vein. 9. The left subclavian vein. 10. The right ventricle. 11. Branches of the left coronary artery and great cardiac vein ramifying along the anterior ventricular groove. 12, 12. Branches of the right coronary artery and anterior cardiac veins. 13. The pulmonary artery. 14. The left pulmonary artery, passing into the root of the left lung. 15. The right pulmonary artery, entering the right lung. 16. The appendix of the left auricle. 17. One of the left pulmonary veins. 18. One of the right pulmonary veins. 19. The left ventricle. 20. The ascending aorta. 21. The arch of the aorta. 22. The arteria innominata, dividing into, 23, the right common carotid artery, and, 24, the right subclavian artery, of which the commencement only is seen. 25. The left common carotid artery. 26, 26. The left subclavian artery. 27. The trachea. 28. The right bronchus. 29. The left bronchus. The bronchus, with the large vessels, 15 and 18, on the right side, and 14 and 17, on the left side, constitutes the root of the corresponding lung. Their relative situation to each other from before backwards is the same on both sides; the pulmonary veins, 17, 18, being the most anterior; next, the pulmonary arteries, 14, 15; and then the bronchi, 28, 29. From above downwards, on the right side, the bronchus, 28, is the highest; next, the pulmonary artery, 15; and then the pulmonary veins, 18. And on the left side, first the pulmonary artery, 14; then the bronchus, 29; and then the pulmonary veins, 17. 30. The superior lobe of the right lung; its internal or concave surface. 31. Its external and convex surface. 32. The concave surface of the middle lobe of the right lung. 33. Its convex surface. 34. The inferior lobe. 35. The inferior surface of the inferior lobe of the right lung. 36. The internal surface of the superior lobe of the left lung. 37, 37. Its external surface. 38. The inferior lobe of the left lung.

FIG. 2. A posterior view of the lungs and heart, showing the relation of the great vessels.

No. 1. The membranous part of the trachea: the granulations upon its surface are the tracheal glands. 2. The right bronchus. 3. The left bronchus. 4. The left auricle. 5. One of the right pulmonary veins. 6. One of the left pulmonary veins. 7. The root of the other left pulmonary vein. 8. The posterior aspect of the left ventricle. 9. The inferior vena cava, cut short near its connection with the right auricle. 10. The right pulmonary artery, entering the root of the right lung. 11. The left pulmonary artery. 12. The superior vena cava. 13. The vena azygos, cut short just as it is about to arch over the right bronchus and terminate in the superior vena cava. 14. The right vena innominata. 15. The right subclavian vein. 16. The right internal jugular vein. 17. The trunk of the arteria innominata. 18. The right subclavian artery. 19. The right common carotid artery. 20. The left vena innominata. 21. The left subclavian vein. 22. The left internal jugular vein. 23. The left common carotid artery. 24. The left subclavian artery. 25. The trunk of the aorta, cut through just as it is about to arch over the root of the left lung. 26. The superior lobe of the left lung. 27. The inferior lobe. 28. Its inferior surface. 29. The internal or cardiac surface. 30, 30. The superior lobe of the right lung. 31. The posterior part of the middle lobe. 32. The inferior lobe of the right lung. 33. A part of its inferior surface, which rests on the diaphragm. 34. Its internal or cardiac surface.



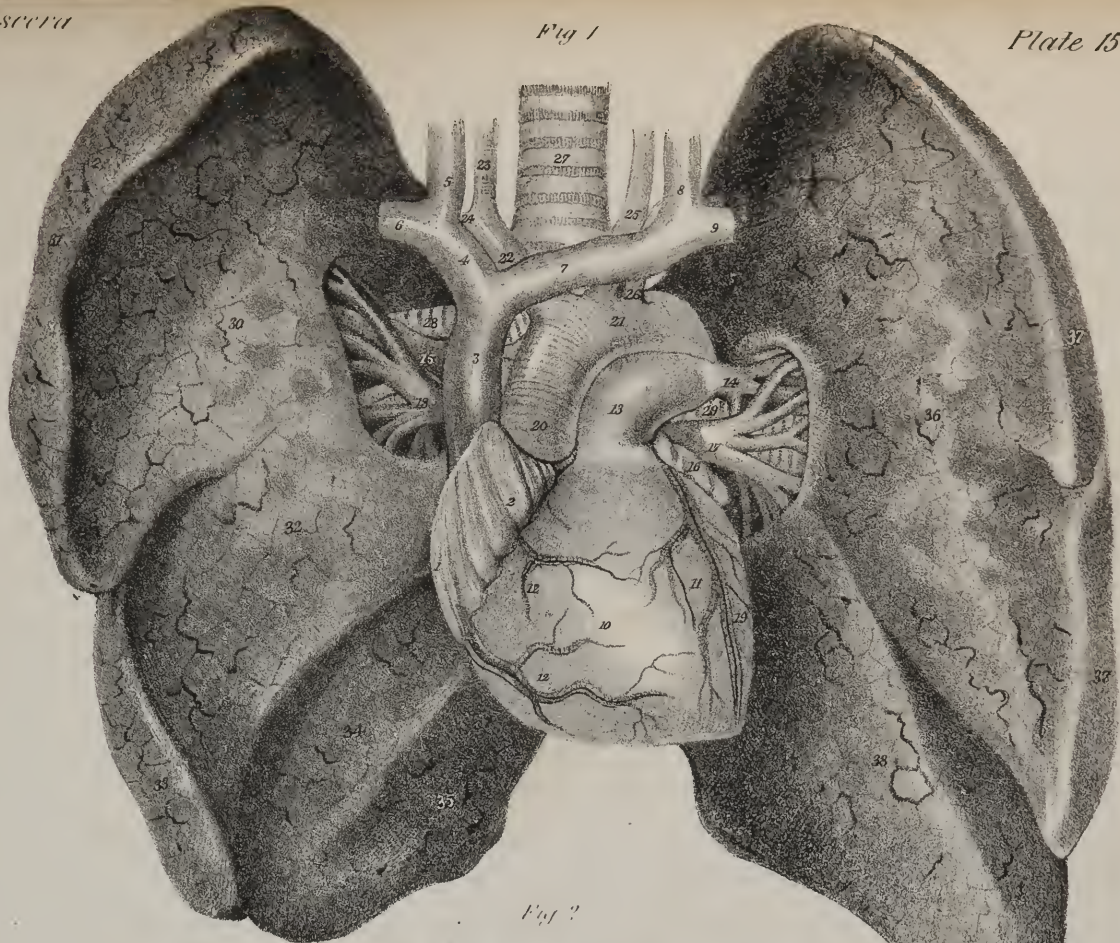
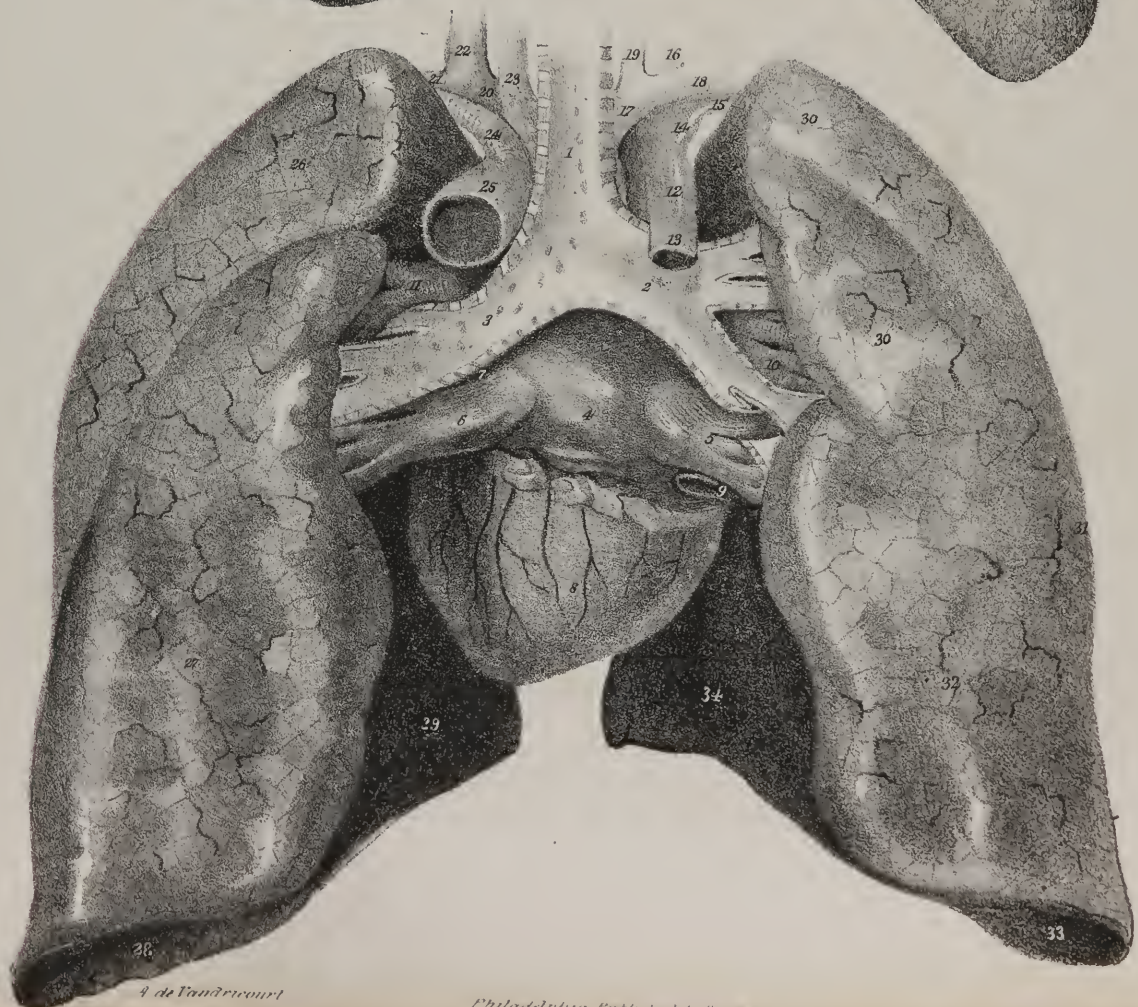


Fig 2





wa  
and  
sur  
was  
wa  
set  
se  
th  
wa  
V  
app  
incl  
The p  
cont  
T  
ars. v  
sp  
word  
read  
reabl  
lay t  
T  
in is  
remi  
In  
fr  
arwa  
led L  
er  
with  
s fa  
are  
ma  
app  
are  
thi  
se  
an  
i f  
the  
A g  
ap  
an

wards, forwards, and to the left side. The anterior surface of the heart is convex in its general outline; the posterior is flat, and rests on the diaphragm: the lower, or right border, is rather thin, and longer than the upper, which is rounded. The heart's surface is marked on its anterior and posterior aspect by two lines, of which one runs transversely, the other from above downwards; their position indicates the division of the organ into four different compartments, or cavities. The base of the heart (which is comparatively thin and flaccid in its structure) consists of that part which is in immediate connexion with the veins, (*pars cordis venosa*), and is divided into two cavities, called auricles, from the fact that each is surmounted by an appendage resembling an ear, (*auricula*.) It is separated from the lower or pyramidal part by a deep transverse groove, (*sulcus auriculo-ventricularis*.) These circumstances are most distinctly observable when the heart is distended. The portion between the transverse sulcus and the summit is thick and muscular, and connected with the arterial trunks; it consists of two cavities, (ventricles,) the division between which is indicated by two slight grooves extending from the base to the apex, and lodging the descending branches of the coronary vessels.

When we consider the heart in its physiological relations, we adopt a different mode of division; for we find it to be a double organ, made up of two hearts, one for the pulmonary circulation, (cor pulmonale,) occupying the right side, and consisting of an auricle and a ventricle; the other for the system at large, (cor systemicum,) also consisting of two cavities of the same denomination. The pulmonic heart is the agent for the circulation of black blood, the systemic circulates red blood. Now, as no two of these cavities agree in form or in the arrangement of their components, it becomes necessary to describe each separately.

The *right auricle* rests on the diaphragm, and forms the right and anterior part of the base of the heart. It presents two parts, which, though not marked off by any precise line of division, yet differ in size and form. One of these, large and flaccid, occupies the interval between the venæ cavæ so as to receive directly the blood which they convey, and is hence named *sinus venarum cavarum*. The other projects forwards and inwards, between the right ventricle and the root of the aorta, like an appendage to the general cavity; and so it is sometimes named "auricular appendage," but more frequently *auricula*, from some resemblance to a dog's ear. It is triangular in form, compressed, and slightly dentated at its border. It is thicker and more fleshy than the sinus.

The external surface of the auricle, unattached in the greater part of its extent, is prolonged upwards, and to the left side, into its auricular appendage; inferiorly, it is connected with the right ventricle, internally with the left auricle: into its upper extremity opens the vena cava superior; and into the lower, the inferior vena cava.

In order to examine the interior of the auricle, an incision may be made from the junction of the cavæ across to the auricula, from the middle of which another may be carried upwards into the superior cava. If the lower border of this incision be drawn forwards, the cavæ will be observed to incline inwards at an angle, their conflux being marked by a slight elevation, called *Lower's tubercle*, (*tuberculum Loweri*.) The greater part of the cavity forms a pouch, (*sinus*), which is smooth, and but slightly muscular in its structure. The inner surface of the auricula is distinguished from the rest by several fleshy fasciculi, which run transversely upon it, called *musculi pectinati*. The inner side of the auricle is thin and smooth; it corresponds with or is formed by the partition (*septum auricularum*) which separates it from the left auricle. At its lower part, and just above the orifice of the inferior vena cava, is situated an oval depression, (*fossa ovalis*, *vestigium foraminis ovalis*), indicating the original communication between the auricles: it is bounded superiorly by a prominent convex border of a lunated form, its concavity looking downwards, and named *annulus fossæ ovalis*. Though the development of the septum be carried to the full extent, that lamella of it which closes the foramen ovale having extended up to a level with the annulus, we often find its upper border merely in apposition, but not united by adhesion to the corresponding part of the septum, so that an oblique or valvular aperture remains between the auricles; still, during the action of the organ, there is sufficient provision against any communication between these cavities. At the line of union between the inferior cava and the auricle is situated a crescentic fold of the lining membrane, called *valvula Eustachii*. This in the fetal state is large; in the adult it is comparatively diminutive, and often even perforated by several foramina. One border of the valve rests upon the wall of the auricle, with which it is continuous. Another is free and unattached, being of a crescentic form; its upper extremity blends itself with the inner border of the annulus ovalis, and the inferior with the corresponding part of the orifice of the vena cava inferior. Between this valve (its left side) and the ventricular opening is situated the orifice of the coronary vein, protected by a valve. Several minute foramina may also be observed in different parts of the auricle, resembling the orifices of small veins, and called *foramina Thebesii*. Placed obliquely between the appendix and the inferior cava, we observe the *auriculo-ventricular opening*, of an elliptic form, and about an inch in diameter; round its circumference is attached the base of the tricuspid valve, the rest of which lies in the cavity of the ventricle.

The *right ventricle* (*ventriculus pulmonalis*) extends from the base of the right auricle to the apex of the heart. Its form is somewhat triangular: to see its interior it will be found convenient to make an angular or V-shaped flap, by dissecting up its anterior wall. When this is done, we observe that the interior surface presents a number of rounded fleshy fasciculi, which are called *columnæ carneæ*, and are divisible into three orders. The first, adherent by both extremities, are free in the rest of their extent; others are but slightly prominent, being attached by their extremities, and also by the greater part of their circumference; the third set form three or four fasciculi, which are directed from the summit towards the base of the ventricle, where they are connected with the borders and apices of the tricuspid valves, through the medium of several tendinous processes, called *chordæ*

*tendineæ*. The base of the ventricle is prolonged upwards : its surface becoming at the same time quite smooth, somewhat in the form of a funnel, where it gives attachment to the pulmonary artery ; so that the mouth of this vessel is placed higher up, and to the left of the auricular opening. At its orifice three membranous folds are placed, called *sigmoid valves*. One border of these is attached at the line of union of the ventricle with the artery ; the other is free in the cavity of the latter, and presents in its middle a small granule, called *nodulus* or *corpus Arantii*. The *tricuspid valve* is so called from its being divided into three points or processes, formed by the lining membrane of the auricle and ventricle. Each is triangular in its form ; their bases, which are continuous and undivided from one another, being attached all round the circumference of the opening, whilst in the rest of their extent they lie within the cavity of the ventricle. One of them rests upon the septum, or corresponds with it ; another with the anterior wall of the cavity ; whilst the third or larger is inclined obliquely upwards, and, as it were, interposed between the auricular and pulmonary apertures. The free margin of each is a little thickened, and gives attachment to the chordæ tendineæ.

The *left auricle* (sinus pulmonalis) is situated at the posterior part of the base of the heart, where the greater portion of it is concealed by the pulmonary artery and the aorta, which overlap it, the auricula alone being visible, without detaching these vessels, or inverting the position of the heart. When distended, it is of a square form, and into its angles open the pulmonary veins, those of the left lung being very close together. From its upper and left extremity projects the auricula, which is narrower, but longer and more tapering than that of the right side. Its margins are more deeply dentated, and present some angular inflections or zigzags. Its point rests on the root of the pulmonary artery. The interior of the left auricula presents muscoli pectinati similar to those in the right, but the general cavity of the auricle is smooth. A slight depression may be observed in the septum auricularum, corresponding with the fossa ovalis. In the inferior part of the cavity is situated the *auriculo-ventricular opening*, the circumference of which gives attachment to the mitral valve.

The *left ventricle* (ventriculus aorticus) occupies the left border of the heart, about one-third of its extent appearing on the anterior surface, the rest being placed posteriorly, owing to the obliquity of the septum ventriculorum. Its cavity can be conveniently exposed by making two incisions through its wall parallel with the septum, and uniting at an angle near the apex. When the flap thus formed is drawn upwards, the great thickness of the walls of the cavity, as compared with those of the right ven-

## PLATE XVI.

### Anatomy of the lungs and pleura.

FIG. 1. A section of the chest, showing the relative position of its viscera and large vessels, with the reflections of the pleuræ.

No. 1. The divided surface of the sternum. 2, 2. Divided extremities of two costal cartilages. 3, 3. The upper borders of two ribs, forming the boundaries of the section. 4. The upper surface of a dorsal vertebra. 5. Section of the spinal cord. 6. Section of the right lung : its superior lobe. 7. Section of the middle lobe. 8. Section of the superior lobe of the left lung. 9. Section of its inferior lobe. The structure of the lung is seen upon the surface of these sections. 10, 10. The pleura pulmonalis of the two lungs. 11, 11. The point of reflection of the pleura from the surface of the lung upon its root, and thence upon the mediastinum. 12, 12. The pleura lining the external surface of the pericardium at each side. 13, 13. The two layers of the pleura reflexa, leaving between them the space, 14, which is called the anterior mediastinum. 15, 15. The pleura costalis. 16, 16. The pleura at each side, forming the lateral boundaries of the posterior mediastinum. 17, 17. The sympathetic nerve at each side, lying between the pleura costalis and the necks of the ribs. 18, 18. The cavity of the pleura at each side. 19. The heart, occupying its natural position in the chest ; in the middle mediastinum. 20, 20. The pericardium : the figures are situated in the cavity of the pericardium. 21, 21. The phrenic nerve on each side of the pericardium, situated between that layer and the pleura. 22. The left ventricle ; the figure 19 is placed upon the right ventricle. 23. The left appendix auriculæ. 24. The right appendix auriculæ. 25. The sinus of the right auricle. 26. The superior vena cava, divided near its entrance into the right auricle. 27. Part of the ascending aorta. 28. The trunk of the pulmonary artery. 29. The right pulmonary artery. 30. The left pulmonary artery. 31. Part of the ligamentous cord of the ductus arteriosus. 32, 32. Pulmonary veins. 33. The right bronchus, cut short just as it is entering the lung above and rather behind the right pulmonary artery. 34. The left bronchus, descending behind the left pulmonary artery to enter the lung beneath that trunk. The vessels 29, 32, 33, on the right side, constitute the root of the right lung ; and 30, 32, and 34, the root of the left lung. 35. The trunk of the descending aorta, divided across. 36. The thoracic duct. 37. The section of the œsophagus. 38. Divisions of the left pneumogastric nerve. 39. The right pneumogastric nerve. 40. The divided cylinder of the vena azygos. The structures from No. 35 to 40 are situated within the posterior mediastinum.

FIG. 2. A minute portion of the human lung, magnified fifty diameters ; copied from Bourger's plates. This figure shows the capillary net-work formed by the ultimate ramifications of the pulmonary artery and veins.

Nos. 1, 1. The arterial side of the figure. 2. A large branch of the pulmonary artery supplying the plexus with blood. 3. A venous trunk conveying the blood from the capillary plexus.

FIG. 3. A portion of the lung ; showing the distribution of the nervous filaments of the pulmonary plexuses around the vessels and bronchial tubes.—After Reisseisen.

No. 1. The pulmonary vein. 2. The pulmonary artery. 3, 3. The bronchial tube. The nervous filaments are seen ramifying upon these vessels.



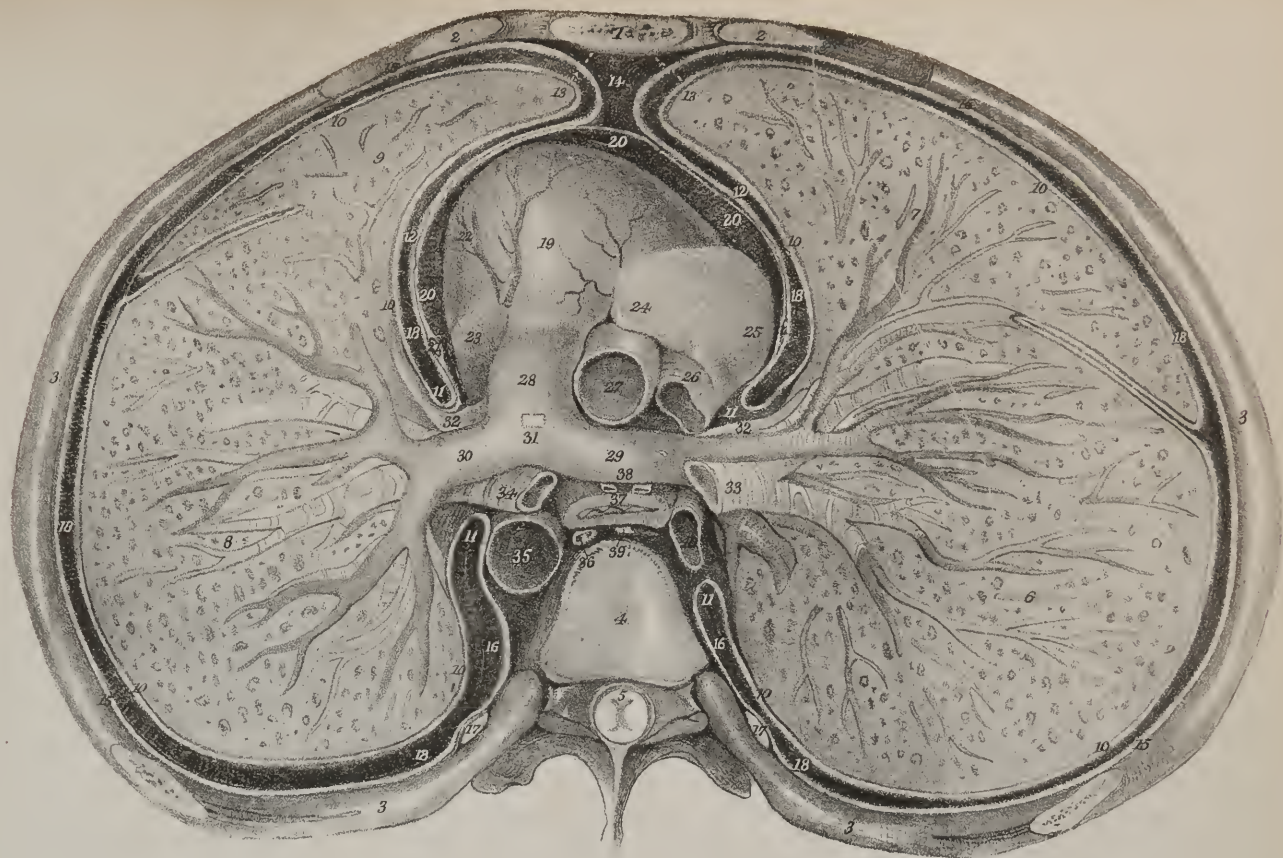


Fig 3

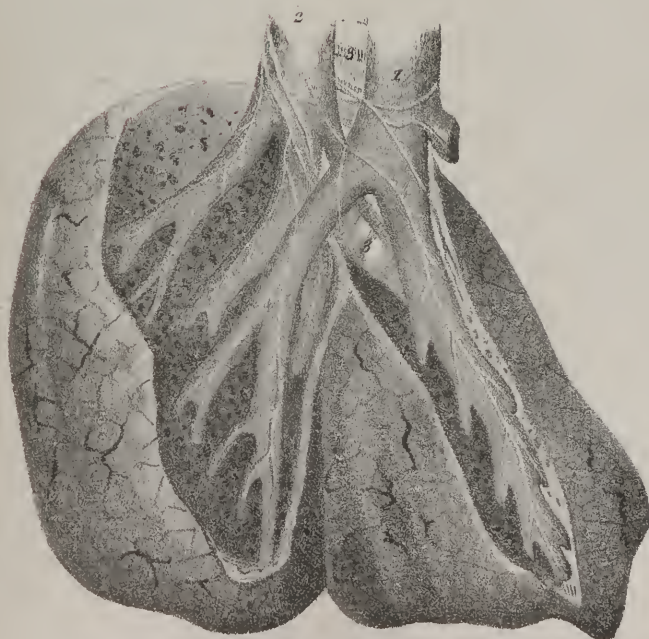
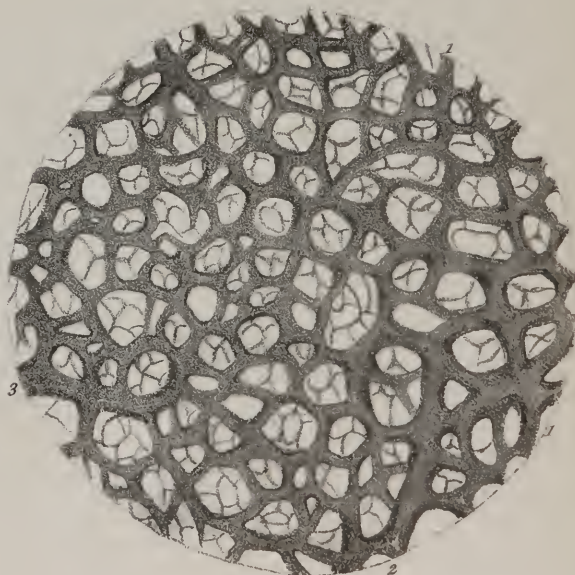


Fig 2



tride  
part 1  
along  
size, co  
each 1  
cube.  
in pl  
of 1 bo  
which  
from to  
ures. I  
Str  
a me  
raive  
nd the  
the mu  
ories.  
with 1  
res an  
pment  
on sho  
as sho  
paces  
be bend  
nd acc  
cour  
sh ven  
at, ho  
as to  
only  
possible  
Bu  
had had  
them  
se ser  
mind and  
stant  
trav  
sued  
water  
per a  
erby  
in, a  
the  
is if  
man  
step  
me  
the  
me



tricle, is rendered manifest. The columnæ carneæ resemble those of the right side, but are thicker, and directed for the most part from the base to the apex of the heart. Their intersections are exceedingly numerous at the summit of the cavity, and along its posterior wall, but the upper part of the anterior one is comparatively smooth. Two fleshy fasciculi of considerable size, commencing by smaller bundles, one from the anterior, the other from the posterior surface, pass upwards and terminate each in a blunted extremity, from which numerous chordæ tendineæ branch off to be inserted into the edges of the mitral valve. The auriculo-ventricular opening is guarded by a valve, similar in structure to that of the right side, but differing from it in presenting but two pointed processes; hence it has been termed the *mitral valve*, (*valvula mitralis*.) The larger division of it looks towards the aortic opening. To the right side of and before the large opening just noticed, is situated a smaller one, which communicates with the aorta, and is guarded by three valvular folds of the lining membrane, similar in structure and form to those of the pulmonary artery, and also called *sigmoid* or *semi-lunar valves*. In one instance we saw four semi-lunar valves, in another there were but two.

*Structure.*—The heart is covered by the serous layer of the pericardium, which is reflected upon it, and lined in its interior by a membrane of apparently similar structure, which not only serves as a coating for its proper substance, but also forms folds or valves at the auriculo-ventricular openings at each side, as well as the semi-lunar valves, where it is prolonged into the aorta and the pulmonary artery. Between the investing and the lining membrane is placed the proper muscular tissue of the organ. The muscular fibres of which the parietes of the heart are made up, differ not only in their quantity and number in each of its cavities, but also in their mode of arrangement. The smoothness of the heart's surface is obviously owing to the membrane which invests it. Within the cavities of the ventricles, and in the auricular appendages, we can readily see how the muscular fibres are disposed and interlaced, without disturbing the lining membrane; but to expose those on the outer surface, the investing membrane must be taken off. When this is carefully done, it will be found that the fibres of the ventricles run obliquely from above downwards to the left, and backwards, which disposition of them can be demonstrated even to the apex. M. Gerdy has shown that the fibres also form curves, whose convexity is turned forwards towards the apex; for if any given fibre commences at the surface, it will be found to dip in so as to become deeply seated at its termination, and *vice versâ*, by which means the bend of their curves will be turned as above stated. Owing to this disposition, the fibres of one ventricle are not all continued across into the other; many of them are seen to turn inwards at the septum, and mix with its substance. By following the course of these, we can separate the septum into two planes; but the greater part of its substance appears to belong to the left ventricle. The external stratum of fibres extends over the whole surface of the ventricles; within these is another plane, (not, however, so extensive, as it does not reach much more than halfway to the apex,) whose fibres take a different direction, so as to decussate with those of the outer layer; and, lastly, a third plane at the inner surface of the ventricles runs longitudinally from below upwards to the base, being continuous with the columnæ carneæ; but towards the apex they run in every possible direction, rendering the surface minutely reticulated.

But, it will be asked, have these fibres any common point of departure—an origin, as it is usually called? They will be found to commence at the base of each ventricle, deeply in the groove which separates it from the auricle. The examination of them is facilitated by filling all the cavities with plaster of Paris, and immersing the heart in boiling water for an hour or two; the serous pericardium can then be easily removed, and the muscular fibres traced deeply into the groove, where they will be found attached to a white tendinous, or rather cellulo-fibrous band of fibres. A fasciculus of this sort occupies the grooves at the anterior and posterior aspect, corresponding with the auriculo-ventricular openings; but it does not reach round their circumference; it seldom extends more than halfway. The two pair of fasciculi thus disposed are connected with a fibrous structure placed at the aortic aperture, at each side of which are two tendinous points, connected by a transverse band passing round the posterior segment of the aperture. To this band the fibrous fasciculi in the posterior grooves are attached, whilst the anterior pair are connected with the tendinous points. Taken altogether, this structure may be called *apparatus tendinosus cordis*. M. Gerdy\* names it “*tissu albuginé cardiaque*,” and Wolff “*textus cartilagineus cordis*.” The muscular fibres of the auricles are thin, and in a manner scattered; most of those in the sinuses are transverse, but posteriorly, at the junction of the venæ cavæ in the right auricle, some run longitudinally; and higher up, at the orifice of the superior cava, they become circular, and seem as if prolonged a little way upon it.

During the progress of *post-mortem* examinations, it often becomes a question whether the heart of the subject is of its natural size—its walls of their proper thickness—its cavities of their normal capacity—or, in other words, does simple hypertrophy exist, or hypertrophy with dilatation, or the concentric hypertrophy described by Bertin?† Laennec has stated,‡ as the result of his observations, that the heart in its natural condition is about the same size as the closed hand of the individual. This cannot be considered a good standard of comparison, for no part of the body is so liable to be influenced by accidental circumstances as the hand. We must then resort to weight and measure to determine the point. Its weight is about ten ounces,§ its length from the apex to the middle of the auricles averages five inches and a half, of which four appertain to the

\* Mémoire sur l'Organisation du Cœur.—*Journal Comp. du Dict. des Sciences Médicales*.

† Traité des Maladies du Cœur.

‡ Traité de l'Auscultation Médiate, vol. ii.

§ Meckel, vol. ii. p. 252 et seq.



ventricles; the breadth of the ventricles is three inches at their base, and that of the auricles three and a half. The thickness of the walls of the left ventricle is a little more than double that of the right. Now, the anterior wall of the left ventricle is five or six lines in thickness at the base, but scarcely three towards the apex. The thickness of the septum at its middle is about four lines. The results of measurement made by different persons to determine the capacity of these cavities are so various, that nothing positive can be stated upon it.

*Vessels and nerves.*—The heart receives its blood by the two coronary arteries; its veins terminate in the right auricle; its nerves come from the cardiac plexus, and appear very small as compared with the bulk and quantity of matter of the organ; a circumstance which was much insisted on in the discussion of the long-litigated question—Do the fibres of the heart possess their susceptibility to impression (irritability) *per se*, or do they derive it from the nerves?

We may, in concluding these remarks, observe, that those deviations from the normal condition of the heart which are congenital, and are ordinarily termed malformations, are referable to the general law which we indicated when treating of varieties in the distribution of arteries; for in many instances they are found to be but repetitions of some of the fixed modes of conformation in inferior animals, most commonly that of reptiles. The degrees of deviation in different instances are various. In some the organ is altogether rudimentary, being “a mere expanded vascular trunk. To these follow the heart, with a very imperfect muscular structure, containing a single valveless cavity, with a very imperfect trace of an auricle; then such hearts as are occasionally formed with but a single ventricle and auricle, with a corresponding vascular trunk; succeeded by those which, having merely a single ventricle, are furnished with an auricle more or less perfectly divided by a partition into two cavities, whence the venous and arterial trunks simultaneously arise, either confounded together or distinctly divided. More perfect and more common are those formations of the heart in which, either by the increased capacity of the ventricles, or by the gradual developement of the partition, merely open at a single point, the division into two ventricles is effected, of which sometimes the right, sometimes the left, is imperfect. Lastly, we meet with hearts which depart from the normal structure merely so far as that the fetal blood-passages remain open, the oval hole, or the ductus arteriosus, (one or both,) remaining unclosed.”\* †

## PLATE XVII.

The anatomy of the trachea and bronchial tubes.

FIG. 1. The posterior part of the trachea at the point of its bifurcation into the two bronchi.

Nos. 1, 1. The extremities of the semi-lunar fibro-cartilages of the trachea. 2. The right bronchus, larger than the left, and passing off from the extremity of the trachea at a right angle. 3. The subdivision of the right bronchus into bronchial tubes. 4. The left bronchus, longer and narrower than the right, and more oblique in its direction. 5, 5. The bronchial tubes into which the bronchus is dividing. 6, 6. Bronchial tubes upon which the irregular plates and patches of fibro-cartilage are seen surrounding the entire cylinder. 7, 7. Bronchial glands, situated in considerable number upon the trunks of the two bronchi, and upon the lower extremity of the trachea. 8. The fibro-cellular membrane which completes the posterior part of the trachea and bronchi; the granulations situated upon this membrane are the tracheal glands. 9. The muscular layer of the trachea; this layer is brought into view by turning down the cellulo-fibrous membrane.

FIG. 2. The larynx and trachea, with the ramifications of the bronchial tubes.

No. 1. The thyroid cartilage. 2. The projection called pomum Adami. 3, 3. The *alæ* of the thyroid cartilage. 4, 4. The oblique line upon each *ala*. 5, 5. The superior cornua of the cartilage. 6, 6. Its inferior cornua. 7. The crico-thyroidean membrane. 8. The cricoid cartilage. 9, 9. The fibro-cartilaginous rings of the trachea. 10. One of these rings, having a peculiar form, and several communications with adjoining rings. 11. A communicating band passing obliquely between two rings. 12. A bifurcating ring. 13. A double bifurcating ring. 14. The last tracheal ring, which always presents an angular pointed process inferiorly. 15. The elastic tissue connecting the cricoid cartilage with the first tracheal ring. 16, 16. The elastic tissue connecting the other tracheal rings together. 17. The right bronchus. 18, 18. Bifurcations of the right bronchus, upon which the fibro-cartilage is distributed in irregular plates. 19. The left bronchus. 20, 20. Bronchial tubes given off from the left bronchus, and exhibiting the same irregular patches of fibro-cartilage which are seen on the right side.

FIG. 3. Minute subdivisions of a bronchial tube.—After Ruysch.

FIG. 4. A small portion of lung considerably magnified; the terminal bronchial tubes are filled with mercury, and are seen to end in small vesicular dilatations, the air-cells.—After Cloquet.

FIG. 5. Horizontal section of a single ring of the trachea, showing its curve, and the extent of the membranous layer which connects the extremities of the fibro-cartilage posteriorly.

\* Otto's Compendium of Pathological Anatomy, translated by J. F. South.

† In cases where the foramen ovale remains open, individuals will, notwithstanding, occasionally attain to adult life. I have met with two subjects in the dissecting room, one of twenty and the other about twenty-five years of age, fat and well developed, in which the foramen was largely open. In one the opening was rather larger than in the other, being of equal size of the auriculo-ventricular passage, and without the vestige of a valve. Both individuals had apparently died suddenly. Both the right cavities had their walls of equal thickness with the left, and their capacity was greater. The valves on the left side were healthy; but the tricuspid valves and the semi-lunar valves of the pulmonary artery on the right side (a fact of unusual occurrence) were thickened and studded with ossific concretions. I have recently examined a child of eight years, in which the foramen ovale was open, and a congenital

Fig 3

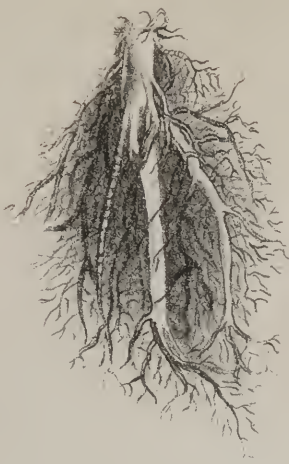

Fig 1

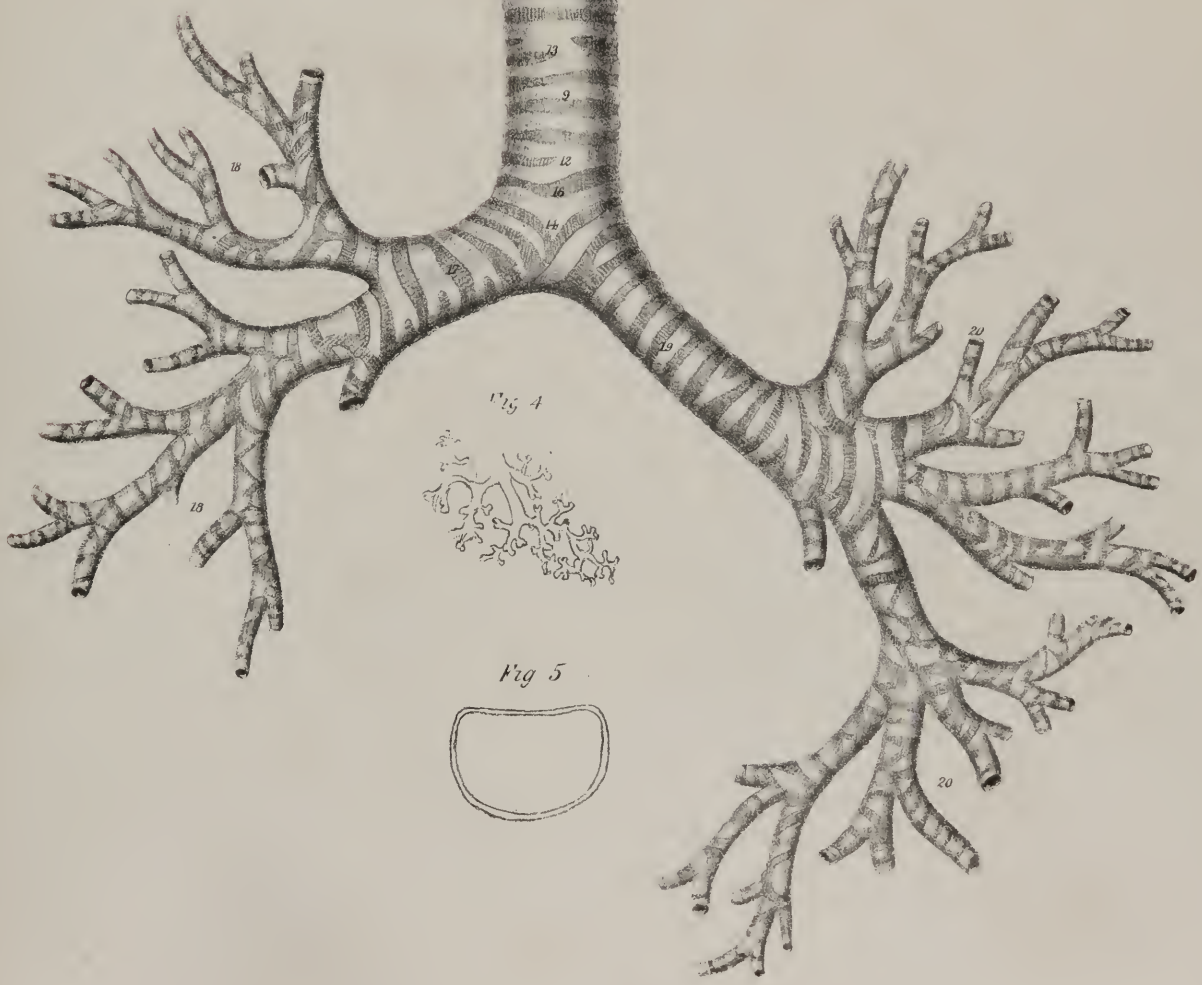
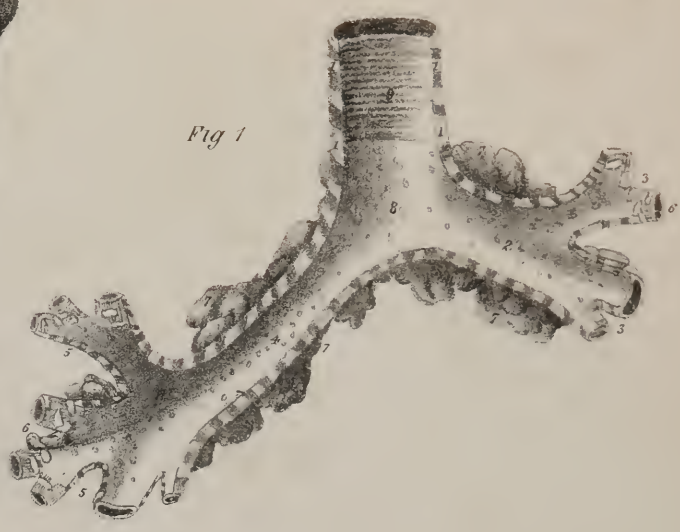
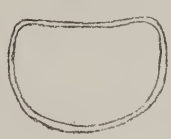

Fig 4




Fig 5









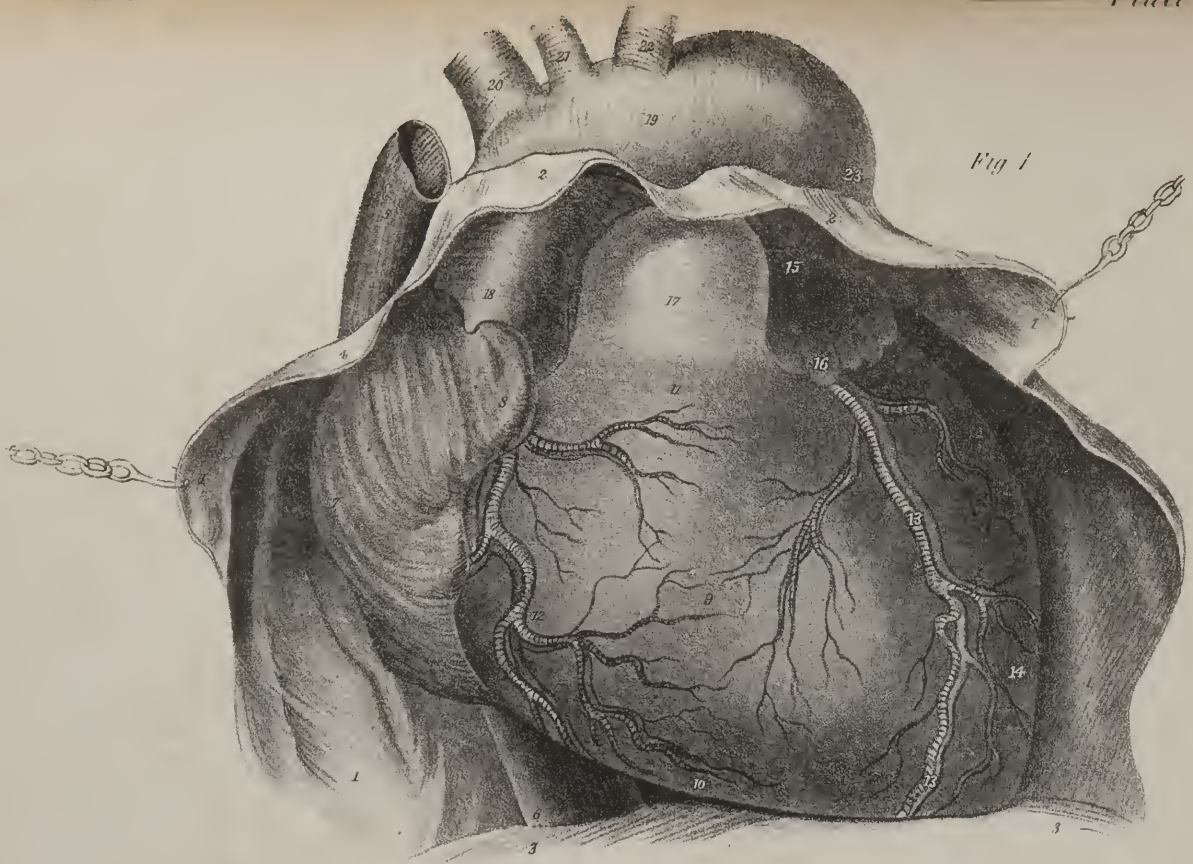


Fig 1

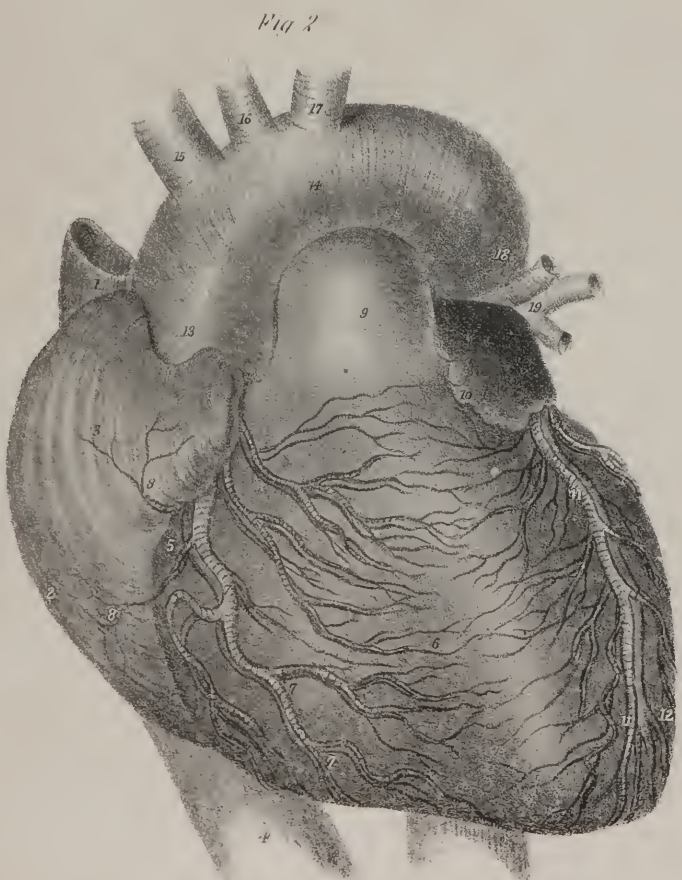


Fig 2

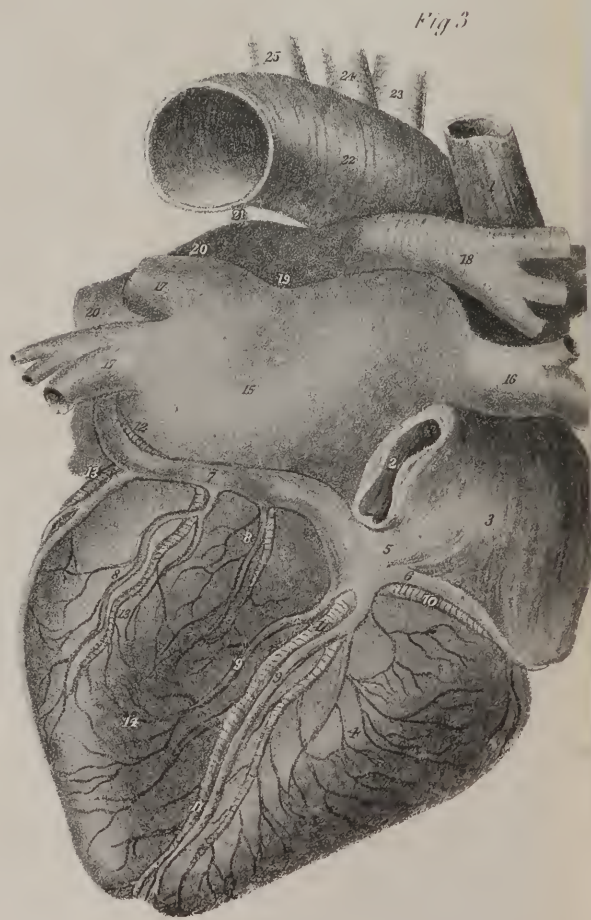


Fig 3



*The Lungs.*—The lungs (plates XIV. XV. XVI. ; *pulmones*) constitute the organ of respiration, and are two in number; they occupy the lateral parts of the cavity of the thorax, which they completely fill. Each lung is of a conical figure, and rests upon the diaphragm, whilst its summit extends a little above the first rib. The external surface of the lung, smooth and convex in its general outline, corresponds with the arch of the ribs; the internal is compressed, and rests against the mediastinum, and at its middle third the bronchi and vessels enter its substance, forming, by their aggregate, what is called the *root* of the lung. The anterior border is thin and sharp, whilst the posterior is rounded and prominent, being received into the groove formed between the vertebral column and the ribs. The base, surrounded by a sharp border, is concave, and rests on the arch of the diaphragm; whilst the summit is tapering and rounded, where it ascends between the *scaleni* muscles. Each lung is divided into lobes by a deep fissure, whose direction is from above downwards, and from behind forwards; the lower lobe of each is thus quadrilateral in its figure, the upper conical. The perpendicular depth of the left lung is greater than that of the right, as the corresponding part of the diaphragm does not ascend so high; its inner border is also excavated to receive the pericardium and heart. The left lung has two lobes, divided, as has been above stated; the right presents three, the third being intermediate in size and situation between the two others. It appears like an angular piece, detached by a groove from the anterior and inferior part of the upper lobe.

Each lung is invested by a serous lamella, derived from the pleura; its interior is lined by a prolongation of mucous membrane, and the intervening structures form, by their aggregate, what is called the *parenchyma* of the organ.

## PLATE XVIII.

The anatomy of the heart.

FIG. 1. The anterior surface of the heart brought into view by dividing and drawing aside the pericardium. It occupies its natural position in the chest, resting, by its under side, upon the central tendon of the diaphragm.

Nos. 1, 1. The pericardium, drawn to either side by hooks. 2, 2. The attachment of the fibrous layer of the pericardium to the external coat of the aorta and the great vessels of the root of the heart. 3, 3. The diaphragm, to which the fibrous layer of the pericardium is attached inferiorly. 4, 4. The fibrous surface of the pericardium; the figures 1, 1 are situated upon the serous surface. 5. The trunk of the superior vena cava. 6. The inferior vena cava, emerging from the opening in the diaphragm to enter the right auricle. 7. The sinus of the right auricle. 8. Its appendix. 9. The right ventricle. 10. Its sharp border. 11. The infundibuliform portion, which corresponds with the sinus of the pulmonary artery. 12. Branches of the right coronary artery and anterior cardiac vein. 13. The left coronary artery and great cardiac vein with their ramifications, in the anterior ventricular groove. 14. The left ventricle, forming the apex of the heart. 15. The left auricle. 16. Its auricular appendage. 17. The pulmonary artery. 18. The ascending aorta. 19. The arch of the aorta. 20. The trunk of the *arteria innominata*. 21. The left carotid artery. 22. The left subclavian artery. 23. The descending aorta.

FIG. 2. The anterior surface of the heart; showing the distribution of the coronary vessels, the pericardium having been removed.

No. 1. The trunk of the superior vena cava. 2. The sinus of the right auricle. 3. The appendix auriculæ. 4. The inferior vena cava. 5. The right auriculo-ventricular groove, in which the right coronary vessels are situated. 6. The right ventricle. 7. A large branch of the right coronary artery, accompanied by the ramifications of the anterior cardiac vein. 8, 8. Two small branches distributed to the right auricle. 9. The pulmonary artery. 10. The left appendix auriculæ. 11. The left coronary artery, descending along the anterior ventricular groove to the apex of the heart, and accompanied by the ramifications of the great cardiac vein. 12. The left ventricle. 13. The ascending aorta. 14. The arch of the aorta. 15. The trunk of the *arteria innominata*. 16. The left carotid artery. 17. The left subclavian artery. 18. The commencement of the descending aorta. 19. One of the left pulmonary veins.

FIG. 3. The posterior surface of the same heart; showing the distribution of vessels upon this aspect.

No. 1. The trunk of the superior vena cava. 2. The opening of the inferior vena cava. 3. The posterior aspect of the right auricle. 4. The right ventricle. 5. The opening of the coronary vein into the right auricle. 6. A large trunk receiving the blood from the anterior cardiac veins. 7. The trunk of the great cardiac vein. 8, 8. The left cardiac veins. 9, 9. The posterior cardiac veins, joining the great cardiac vein. 10. The right coronary artery, winding around the right auriculo-ventricular groove. 11. The same artery, descending the posterior ventricular groove. 12. A small portion of the posterior branch of the left coronary artery, winding along the left auriculo-ventricular groove to join the right coronary; the rest of the artery is concealed by the trunk of the great coronary vein. 13, 13. Small twigs from this portion of the left coronary artery. 14. The left ventricle. 15. The left auricle. 16, 16. The right pulmonary veins. 17, 17. The left pulmonary veins; the superior one is cut off close to the auricle. 18. The right pulmonary artery. 19. The trunk of the pulmonary artery at its bifurcation. 20, 20. The left pulmonary artery. 21. The fibrous cord resulting from the obliteration of the *ductus arteriosus* of the fetus. 22. The arch of the aorta. 23. The trunk of the *arteria innominata*. 24. The left carotid artery. 25. The left subclavian artery.

defect found in the pulmonary artery,—that vessel being about one third of its usual size, and having its valves so closely adherent to the inner surface of the artery, as to be incapable of closing in the least the opening into the ventricle. The right cavities were much larger than the left, and the wall of the right ventricle was nearly half an inch in thickness. The *ductus arteriosus* was closed. The *ductus venosus* was pervious. The liver was large in size, and of the bluish aspect common to the amphibia. The thymus gland was unusually large. One kidney was undeveloped, it not being larger than a horse-chestnut. The lungs were almost entirely filled with tubercular matter, and several large cavities existed in the upper lobes.—J. P.



*The Pleura.*—There are two membranes named *pleura*, (plates XIV. XVI.) each being thin, semi-transparent, and so disposed as to form a shut sac, thus conforming to the general law of serous membranes. Each membrane will thus be found to line the inner surface of the thoracic parietes, and to be reflected over the corresponding lung, giving it a smooth investment, the point of reflection corresponding with the root of the organ. Inferiorly, the membrane covers the convex surface of the diaphragm, and superiorly forms a small cul-de-sac at the bottom of the neck, over the summit of the lung. The part of the membrane which invests the lung is called *pleura pulmonalis*—that which lines the thorax, *pleura costalis*; it would be more correct to say, “*pars pulmonalis*,” and “*pars costalis*.” These two membranous sacs, by their apposition along the middle line, form a partition (*mediastinum*) which divides the thorax into its two lateral chambers; it extends from the top of the thorax to the diaphragm, and from the spine to the sternum, with some inclination to the left side, (inferiorly,) owing to the position of the pericardium and heart. The interval between the two membranes in this situation gives lodgement, immediately behind the sternum, to the thymus gland and some cellular tissue; and lower down to the pericardium and heart. Along the spine we find, similarly situated with regard to the membranes, the œsophagus, the vagus nerves, the descending aorta, thoracic duct, vena azygos, and splanchnic nerves, with some lymphatic glands and cellular tissue. Now the bronchi and root of the lungs, by their transverse position, sepa-

## PLATE XIX.

The internal cavities of the heart, with the peculiarities of the fetal heart.

FIG. 1. The right side of the heart; the parietes of the right auricle and ventricle have been removed in order to show their interior.

No. 1. The sinus of the right auricle. 2. The superior vena cava. 3. The inferior vena cava. 4. The appendix auriculæ. 5. The muscoli pectinati, seen in the appendix. 6. The opening of the superior vena cava. 7. The septum auricularum. 8, 8. The annulus ovalis. 9. The fossa ovalis. 10. The opening of entrance of the inferior vena cava. 11. The opening of the coronary vein. 12. The coronary valve. 13. The auriculo-ventricular groove. 14. The cavity of the right ventricle. 15. The right segment, or “curtain” of the tricuspid valve. 16. Chordæ tendinæ of the right valve, inserted into, 17, the right columnæ papillaris, (columnæ carneæ.) 18. A small moderator band. 19. Chordæ tendinæ of the right valve, inserted into the third and smallest columnæ papillaris, 20. 21. The long columnæ papillaris, attached by its base to the right wall of the ventricle. 22. The “long moderator band.”\* 23. Chordæ tendinæ of the right segment of the tricuspid valve, inserted into the apex of the long columnæ papillaris. 24. The anterior segment, or “curtain,” of the tricuspid valve, situated between the auriculo-ventricular opening and that of the pulmonary artery. 25. Chordæ tendinæ of this valve, inserted into the apex of the long columnæ papillaris. 26. Other chordæ tendinæ of the anterior valve, inserted into the septum ventriculorum. 27, 27. Chordæ tendinæ of the third segment or valve, the “fixed curtain.” 28. Columnæ carneæ. 29, 29. The cut edge of the section of the right ventricle. 30, 30. The three semi-lunar valves of the pulmonary artery. 31. The pulmonary artery. 32. The ascending aorta. 33. The left appendix auriculæ. 34. The anterior coronary vessels, taking their course along the anterior ventricular groove. 35. The external surface of the right ventricle. 36. The left ventricle.

FIG. 2. The left side of the heart: the cavities are exhibited by removing a part of their external wall.

No. 1. The cavity of the left auricle. 2. The entrance of the two right pulmonary veins, 3, 3. 4. The entrance of the two left pulmonary veins, 5. 6. The external surface of the sinus of the auricle. 7. The appendix auriculæ. 8. Muscoli pectinati in the appendix auriculæ. 9. The auriculo-ventricular opening. 10. The auriculo-ventricular groove. 11. The great cardiac vein. 12, 12. The cut edge of the section of the outer wall of the ventricle. 13. One segment of the mitral valve, attached by chordæ tendinæ to three columnæ papillares, (columnæ carneæ,) 14, 14. 15. Chordæ tendinæ of the opposite valve attached to other columnæ papillares, (columnæ carneæ.) 16. The sinus of the ventricle, leading upwards to the opening of the aorta: some carneæ columnæ are seen upon this wall of the ventricle below the figures. 17, 17. The cut edges of a section of the apex of the left ventricle. 18. Columnæ carneæ. 19. The anterior coronary vessels, ramifying in the anterior coronary groove. 20. The right ventricle. 21. The pulmonary artery. 22. The appendix of the right ventricle. 23. The commencement of the arch of the aorta.

FIG. 3. A horizontal section made through the ventricles of the heart near to their base, showing the relative dimensions of the walls of the two cavities.

Nos. 1, 1. The wall of the right ventricle. 2. The area of its cavity. 3, 3. The septum ventriculorum. 4, 4. The wall of the left ventricle. 5, 5. The area of its cavity. 6, 6. Part of the mitral valve; the free segment of the valve appears to divide the area into two nearly equal portions.

FIG. 4. The fetal heart at about the eighth month, showing the foramen ovale, widely distended.—From a dried specimen in the collection of the Editors, prepared by inflation.

No. 1. The foramen ovale. 2. The incipient septum ovale, forming a thin falciform projection upon the posterior wall of the auricles. 3. The entrance of the superior vena cava into the right auricle. 4. The opening of the coronary vein. 5. The auriculo-ventricular opening. 6. The right ventricle. 7. The appendix of the right auricle. 8. The aorta.

FIG. 5. A front view of the same heart.

No. 1. The right auricle. 2. The right ventricle. 3. The left ventricle. 4. The left auricle. 5. The pulmonary artery. 6, 6. Its right branch. 7. Its left branch. 8. The ductus arteriosus. 9. The ascending aorta. 10. The arch of the aorta giving off its three branches.

\* Essay on the Safety-valve function in the Right Ventricle of the Human Heart, by T. W. King.—*Guy's Hospital Reports*, vol. ii.

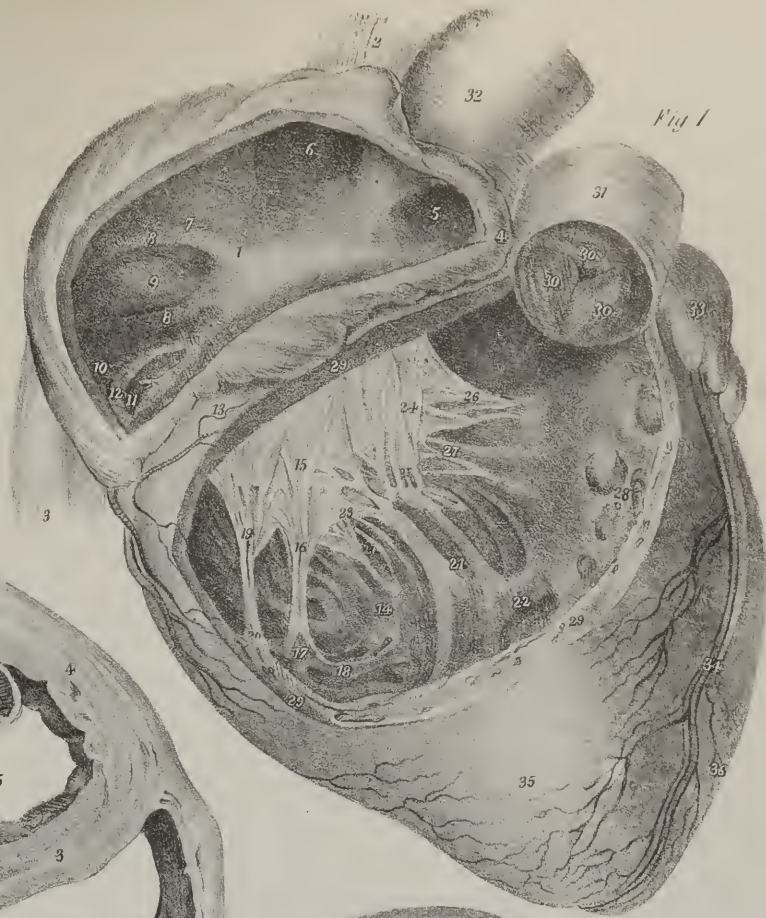


Fig 1

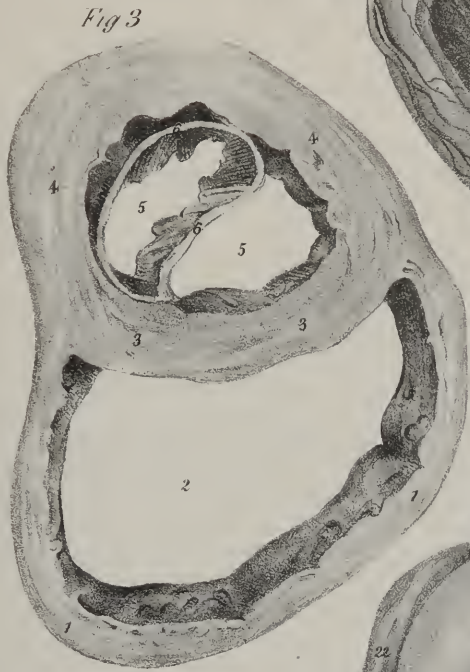

Fig 3



Fig 4

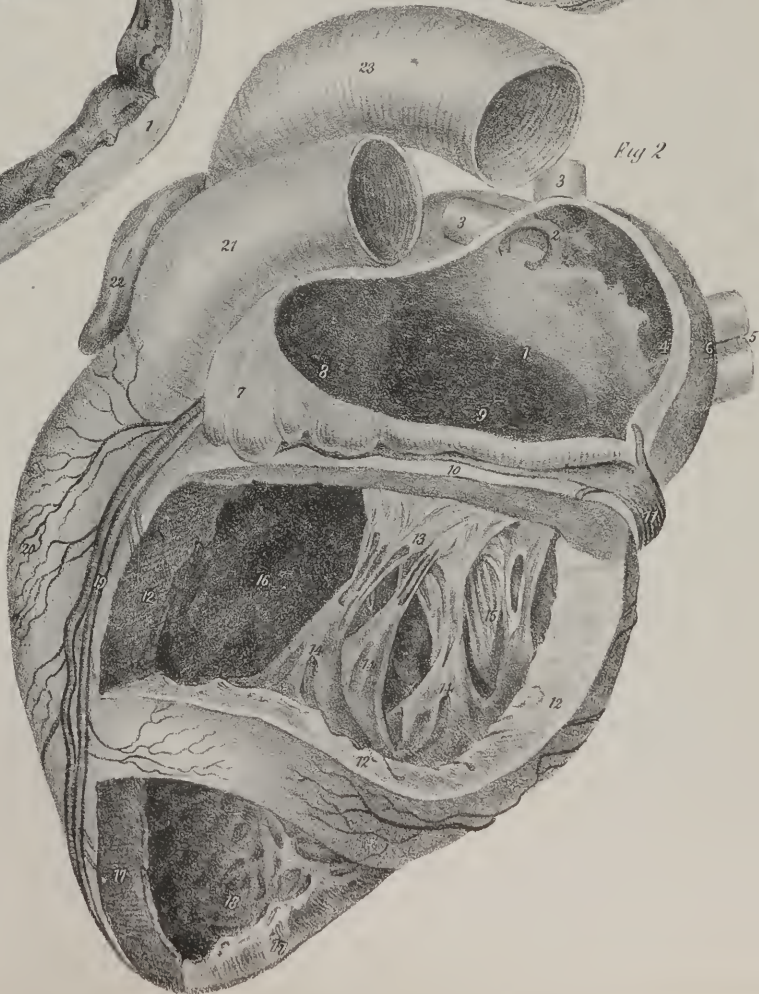


Fig 2

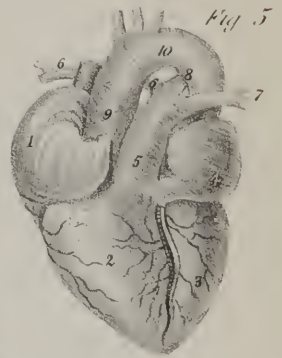


Fig 5



rate  
medic

and p  
enclos

T

trache

T

to the

somew

reins, a

rein, at

the rig

fourth c

right pu

to react

Each br

the rig

ubes of

a series

minute

Str

and of

deficien

n us rig

laterior

whole o

ongitue

Aspose

The

radual

ference

open.

require

by our

creates

the wit

ries fo

that th

lungs

them

seated

great

virtual

.

palm

some

app

org

inf

wi

sk

Sp



rate the mediastinal interstice into two parts, of which one is termed, ordinarily, the *anterior*, and the other the *posterior mediastinum*.

*Structure*.—The anatomical constituents of each lung are: 1. The bronchus and its ramifications. 2. The pulmonary artery and pulmonary veins. 3. Bronchial arteries and veins. 4. Lymphatics. 5. Nerves of the pulmonary plexus. These are enclosed in a quantity of cellular tissue, which forms a connecting medium between them.

*The Trachea and Bronchi*.—The description of the bronchus considered as a constituent of the lung, includes that of the trachea, or rather presupposes a knowledge of it.

The *Trachea* (plate XVII. fig. 2; *τραχεία ασπρηια*, aspera arteria) is a cylindrical tube, which extends from the cricoid cartilage to the third dorsal vertebra, where its division into the bronchi takes place. It rests on the œsophagus, which, however, inclines somewhat to its left side. It is enclosed between the great vessels of the neck, and covered partly by the thyroid gland and its veins, also by the sterno-hyoid and sterno-thyroid muscles, and crossed by the brachio-cephalic artery, the left brachio-cephalic vein, and the arch of the aorta. The bronchi, commencing at the bifurcation of the trachea, incline laterally towards the lungs; the right one, larger but shorter than the other, inclines outwards, almost horizontally, and enters the lung on a level with the fourth dorsal vertebra; it is enclosed by the termination of the vena azygos, which hooks round it, and by the arch formed by the right pulmonary artery. The left bronchus, less in diameter, but longer than the right, inclines obliquely downwards and outwards to reach the lung. The arch of the aorta hooks round it, and the left pulmonary artery lies upon its superior and anterior border. Each bronchus, at its entrance into the lung, divides into two branches, one being intended for each lobe. The lower branch of the right lobe also subdivides, or rather gives off a branch to its middle lobe. Each bronchial ramification in its course gives off tubes of smaller size; and so, by a process of division and subdivision continued through five or six successive stages of decrease, a series of tubes is formed, increasing in number as they decrease in size, until, finally, each becoming capillary, terminates in a minute cul-de-sac or air-vesicle, the aggregate of which constitutes the proper cellular structure of the lungs.

*Structure of the Trachea*.—This tube is composed of fibro-cartilaginous rings, varying from sixteen to twenty in number, and of membranes which connect them. The rings do not extend all round the tube; they exist at the front and sides, but are deficient posteriorly. A thin, yet elastic, fibrous lamella forms the circumference of the tubes, serving to connect the cartilaginous rings, which seem as if developed in its interior, and also to complete the circuit posteriorly where these rings are deficient. Interiorly to these is situated the mucous lining, continuous superiorly with that of the larynx, and prolonged throughout the whole of the bronchial ramifications. Where the cartilaginous rings are deficient, the mucous membrane is supported by some longitudinal fibres, and beneath it we also find a series of muscular fibres resembling those of the intestinal canal. These are disposed transversely, so as to connect the extremities of the cartilaginous rings.\*

The bronchi and their primary ramifications are made up of the same constituents as the trachea; but the rings are found gradually to lose their annular form, and to degenerate into lamellæ of irregular shape, placed in different parts of the circumference of the canal. At the several points of subdivision, however, they are still somewhat annular, so as to keep their orifices open. The rings thus gradually disappear, so that at the ultimate divisions of the bronchi they no longer exist, nor are they required, for the air which distends the vesicles is never altogether excluded from them. So far as the bronchi are cognizable by our senses, they appear to consist of materials analogous to those found in the larger tubes, but gradually reduced to the greatest degree of tenuity. If they be injected with quicksilver, the globular form of the vesicles, and the cylindrical form of the ultimate ramusculi which terminate in them, are rendered manifest; and as the mucous membrane is prolonged into the vesicles forming their lining, it is a legitimate matter of inference; from the various facts disclosed by the general anatomy of tissues, that the fibrous lamellæ and muscular structure extend to them also. In support of this inference it may be urged, that if the lungs were simply passive, and therefore incapable of contributing to the expulsion of the air, the subsidence of the thorax upon them would only press the air out of the parts near their surface, but could exert little influence over those which are deeper seated. Besides, if one side of the thorax of a living animal be opened, the degree in which the lung becomes diminished is greater than that which is ordinarily produced by the weight of the atmosphere. This indicates a contractile, and even an irritable power in the organ.†

*Pulmonary artery*.—The pulmonary artery (plate XV. fig. 1, Nos. 13, 14, 15; plate XVI. fig. 1, Nos. 28, 29, 30: *arteria pulmonalis, vena arteriosa*) arises from the base of the right ventricle of the heart, from which it proceeds upwards and a little towards the left side for the space of about two inches, having a slight inclination, at the same time, from before backwards; opposite the concavity of the aortic arch, it bifurcates into its right and left branches. It partially conceals the aorta at its origin, and is connected with it by the serous lamella of the pericardium. At its point of bifurcation it is also connected to the

\* At the orifices of the bronchial ramifications, the existence of a semi-lunar cartilage has been pointed out by Dr. Horner, forming rather more than half of their circumference, and having its concave edge upwards. These cartilages appear to be intended to keep the orifices open.—J. P.

† From some researches into the structure of the air-vesicles, made by distending them with tallow, drying the lung, and then removing the tallow with spirits of turpentine, Dr. Horner is led to conclude, that the cells of the individual lobules communicate freely together, but not those of different lobules. The researches of the microscopical anatomists have not confirmed this opinion. Gerber, (General and Minute Anatomy. Lond. 1542) figures them as distinct cells, like Reisseissen, Wagner, and Rathkø.—J. P.

cavity, of the arch by the ductus arteriosus in foetal life, and subsequently by the ligamentous remains of that vessel. The *right* branch, larger and longer than the left, inclines almost transversely towards the corresponding lung, which it reaches after passing behind the ascending aorta and the superior vena cava: it lies upon the right bronchus, but soon makes a turn so as to embrace it; after which it separates into three divisions. The *left* branch passes in front of the descending aorta, immediately beneath its arch, and, after reaching the upper border of the corresponding bronchus, divides into two branches. The primary and each succeeding division of the pulmonary arteries correspond with those of the bronchial tubes, whose course they follow to their final terminations in the air-vesicles, where they become capillary.

*Pulmonary veins.*—The pulmonary veins, (plate XV. fig. 1, Nos. 17, 18; fig. 2, Nos. 5, 6, 7; *venæ pulmonales, arteriæ venosæ*.) two in number at each side, commence by minute radicles, which are continuous with the capillary terminations of the arteries. They are found to converge to the root of the lung from different parts of its structure, and in their course increase in size as

## PLATE XX.

This plate shows the arrangement of the fibres entering into the structure of the heart, according to the researches of Mr. Searle. The drawings have been made from dissections made by Mr. Searle, and most liberally placed at the disposal of the Editors of this work.

FIG. 1. An anterior view of the ventricles of the heart, showing the oblique course and arrangement of the superficial fibres of these cavities.

No. 1. The fasciculus derived from the deep fibres of the left ventricle, emerging from that cavity at its apex. 2. This fasciculus now becomes superficial, winding around the apex of the left ventricle. 3, 3. The fibres of this fasciculus, very much spread out, and taking an oblique course over the front surface of both ventricles. 4, 4. Small accessory fasciculi of fibres derived from the right surface of the septum ventriculorum, and constituting part of the superficial layer of fibres. 5. The left ventricle. 6. The right ventricle. 7. The convexity corresponding with the ventricular sinus of the pulmonary artery.

FIG. 2. The base of the heart, showing the attachment of the superficial fibres of the ventricles to the fibrous rings of the auriculo-ventricular openings, and of the pulmonary artery and aorta.

No. 1. The opening of the pulmonary artery. 2. The opening of the aorta. 3. The right auriculo-ventricular opening. 4. The left auriculo-ventricular opening. The superficial fibres near their insertion assume almost a vertical direction.

FIG. 3. A dissection of the anterior aspect of the heart, showing the superficial fibres raised and turned back in three flaps, in order to bring into view the middle layer of fibres.

No. 1. The flap raised from off the right ventricle. 2. The flap reflected from off the upper part of the left ventricle. 3. The superficial fibres turned down from the lower third of the left ventricle. 4. These fibres are seen to form a fasciculus, which enters the left ventricle through its apex, and is continuous with the deep fibres of that cavity. 5. The broad and thick band of fibres derived from the left surface of the septum ventriculorum at the posterior ventricular groove, and from the columnæ papillares of the left wall of the ventricle. 6, 6. The anterior ventricular groove; at this groove the band, 5, divides into two bands, short and long. 7, 7. The short band, winding obliquely around the lower third of the anterior surface of the right ventricle to the posterior surface of the heart. 8. The short band, near to its termination, appearing from the posterior surface of the base of the ventricles; its fibres are inserted into the anterior border of the left auriculo-ventricular ring, and into the anterior part of the root of the aorta and pulmonary artery. The long band, given off from the deep surface of the band, 5, at the anterior ventricular groove, passes directly backwards, forming the middle layer of the septum ventriculorum, and emerging at the posterior ventricular groove, winds from right to left around the middle third of the posterior aspect of the left ventricle. 9, 9. The long band appearing on the anterior aspect of the left ventricle. 10, 10. Its continuation upon the anterior surface of the upper half of the right ventricle to the posterior surface of the base of both ventricles.

FIG. 4. The middle layer of the fibres of the ventricles, seen upon the posterior surface of the heart.

No. 1. The right ventricle. 2. The right auriculo-ventricular opening. 3. The left ventricle. 4. The opening of the aorta. 5. The fasciculus of superficial fibres of the heart, escaping from the apex of the left ventricle, and seen to be derived from the deep fibres. 6. The thick layer of fibres which gives origin to the short and long bands; this layer is seen on the anterior aspect of the left ventricle in fig. 3, No. 5. 7, 7. The posterior ventricular groove. 8, 8. The short band of the middle layer of the heart; this band is proceeding from right to left. Its commencement is seen in fig. 3, Nos. 7, 7, and its termination at No. 8. 9, 9. The long band winding from right to left around the base of the ventricles. 10, 10. Its fibres, beginning to twist upon themselves to form the rope which surrounds the brim of the left auriculo-ventricular opening.

FIG. 5. An anterior view of the heart; the middle layer of fibres divided over the right ventricle to show the internal fibres of that cavity.

No. 1. The spiral arrangement of the fibres at the apex of the left ventricle. 2, 2. The short band, divided and turned aside. 3, 3. The continuation of the short band, from the section to the posterior aspect of the heart. 4, 4. The long band, divided and turned aside. 5, 5. The continuation of the long band, from the section, in its course towards the posterior surface of the base of the ventricles. 6, 6. The right surface of the septum ventriculorum. 7, 7. The fibres of the right surface of the septum ventriculorum, seen to be continuous with the internal surface of the short band, while some of the fibres pierce the band to constitute the accessory fibres of the superficial layer.—See fig. 1, Nos. 4, 4. 8, 8. The fibres of the upper part of this surface of the septum are continuous with the internal surface of the long band. These fibres are derived from the right segment of the root of the aorta. 9. 10. The pulmonary artery. 11, 11. A layer of fibres derived from the margin of the root of the pulmonary artery, taking a spiral course around the internal surface of the right ventricle, and constituting its internal layer. This layer is augmented by fibres from the columnæ papillares of the right ventricle, and is continuous at the posterior ventricular groove with the long band directly that it has passed through the septum. 12. The left ventricle.



Fig 1



Fig 2

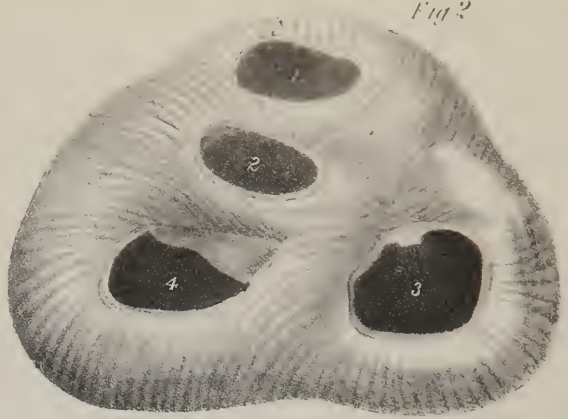

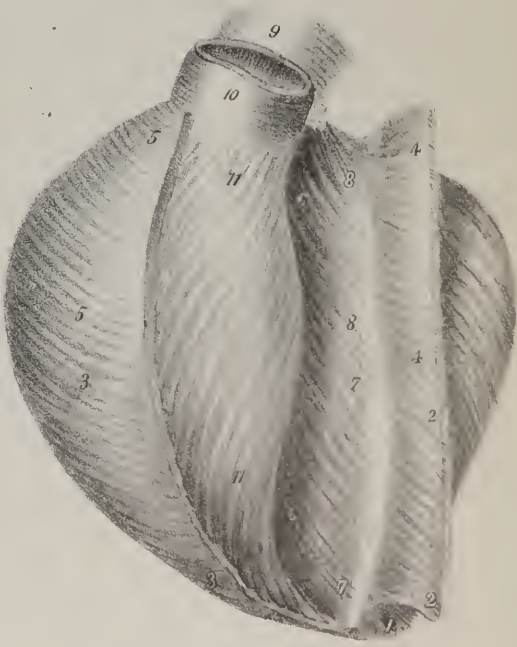
Fig 3



Fig 4



Fig 5





the  
ha  
sm  
  
the  
at l  
nuc  
the l  
cate  
not t  
quest  
  
the ge  
inter  
that t  
Beise  
of the  
and ra  
Th  
can be  
ing-  
they pe  
the cor  
Th  
The re  
are th  
of the l  
me, is  
thin  
is un  
is is  
is the  
incre  
or cha  
Th  
an ex  
the sur  
aris, t  
ructed  
and  
ing s  
trem  
own a  
if the  
the ne  
was a  
was a  
whilst  
can. a  
Th  
the le  
sing

they diminish in number. The veins of the right lung pass behind the right auricle and the superior vena cava; those of the left have a shorter course to run in order to reach the left auricle, which is their common destination; thus, the pulmonary, or smaller circulation, which commences at the right ventricle, and ends at the left ventricle, is completed.

The *bronchial arteries* arise from the aorta; on reaching the root of the lungs each divides into small branches, which follow the divisions of the bronchi until they become capillary. The veins which return the blood of the bronchial arteries terminate at the right side in the vena azygos, at the left in the superior intercostal. Some of them, also, in their course appear to communicate with branches of the pulmonary veins. Some anatomists have been led to conclude, from a consideration of the size of the lungs, that they could not be dependent on the bronchial arteries alone for their nutrition. A similar idea seems to have been entertained concerning the nerves by Haller, who says, "neque multos nec magnos pulmonis nervos esse." But if we compare not the size, but the quantity of matter of the lungs, with that of any other organ, even of the liver, we shall find no reason to question the sufficiency of the bronchial arteries, or to doubt whether they are as well supplied with nerves as other parts.

The *nerves* of the lung are derived from the pulmonary plexus, (anterior and posterior.) The nervus vagus contributes much the greater share to the formation of the plexus, assisted by the sympathetic nerve. The branches of both form an inextricable interlacement exterior to the lungs, but are not found to anastomose within their substance. An opinion for some time prevailed, that the gangliac nerves were distributed exclusively to the vessels of the lung, and those of the nervus vagus to the bronchi. But Reisseissen,\* after a most minute examination of this, and almost every other question that can be raised concerning the structure of the lungs, has come to the conclusion, that the branches derived from the nerves belong alike to the vessels as to the bronchi, and ramify indiscriminately on both.

The *lymphatics* of the lungs are divisible into two sets; one being superficial, the other deep-seated. The superficial vessels run beneath the pleura, and after ramifying, so as to enclose areolar spaces, terminate in the bronchial glands at the root of the lung. The deep-set take the course of the veins; they enter the bronchial glands, and after having emerged from them again, they pass along the trachea; those of the left side terminating in the thoracic duct, those of the right in the lymphatic trunk of the corresponding side.

*The Thymus gland.*—The structure of this organ (plates XXII. XXIII.) has been hitherto little known, (thymus, à θυμος.) The recent researches of Sir Astley Cooper have, however, exhibited every part of it in a perfectly clear point of view, and have thrown much light on the purposes which it appears to serve in the economy. "Perhaps," observes Sir Astley,† "no part of the body is more difficult of investigation than the thymus gland in the human subject. Its small size, the delicacy of its texture, its soft and pulpy nature, which renders it liable to tear under the slightest force, and the numerous small lobes which are combined to form it—all conspire to produce this difficulty, and to render it necessary to call in the aids which injection, hardening, unravelling, and the most careful and repeated dissecting, can furnish." A leading peculiarity of this organ is, that its existence is temporary; it can be distinguished as early as the third month of fœtal life; it increases until birth, but its increase is not equable, being much more rapid during the seventh month than in the fifth or sixth. At birth, its weight is about half an ounce; it increases a little to the end of the first year, when it begins to decrease to the time of puberty, and is not only atrophied, but so far changes, as, "in after-age, to cease to have cavities, becoming a body of very small dimensions."‡

The thymus is narrow and elongated, part being lodged in the thorax, (in the mediastinum,) close behind the sternum, and part extended upwards into the neck. Its colour is greyish, or rather ash-colour, with a reddish tinge; its consistence very soft; its surface uneven and distinctly lobulated. It is not a single organ; for though it presents two lateral and nearly symmetrical parts, the only difference between them being, that the left is often larger than the right; still, as these parts "are generally separated from each other as regards glandular substance, they may properly be called a right and left thymus gland."§ Sometimes a third thoracic lobe exists, which appears to join together those that are placed laterally, but by careful dissection they admit of being separated. Each lateral part may be said to present a base, a summit, two surfaces, and two borders. The base or broad extremity rests on the upper part of the pericardium, to which it is connected by cellular tissue; for at birth it reaches as low down as opposite the fourth rib. The summit extends as high as the thyroid gland; the anterior surface lies behind the first bone of the sternum and the upper part of the second, the origins of the sterno-hyoidei and sterno-thyroidei muscles interposing; in the neck, the latter muscles cover it. The posterior surface rests, while in the thorax, on the left brachio-cephalic vein, on the convexity of the aortic arch, and the origins of the large vessels, (a thin layer of cellular tissue interposing;) in the neck, it rests upon the front and sides of the trachea as far up as the thyroid gland. The inner borders are in apposition one with the other, whilst the external margins are enclosed within the interval between the internal mammary vessels and the layers of the mediastinum, and higher up between the great cervical vessels.

The thymus is surrounded by a layer of cellular tissue, which not only connects it with surrounding parts, but binds together the lateral masses that compose it. When this is removed, "the substance of the gland is exposed, which is found to be of the conglomerate kind, being formed of numerous lobes, connected together by a second covering of reticular tissue, uniting the

\* De structurâ Pulmonum.

† Op. cit. p. 19.

‡ The Anatomy of the Thymus Gland, by Sir A. Cooper.

§ Op. cit. p. 26.

lobes to each other.\* Now, the size of the lobes varies considerably, some being as small as a pin's head, whilst others are as large as a pea. If a section of the gland be made, an elongated cavity will be found in its interior, containing an albuminous fluid, and round this the lobes are disposed in a peculiar way. In order to understand the relation which subsists between the cavity and the lobes, and the structure and mode of connexion of the latter, it becomes necessary to unravel one of the lateral masses. In order to effect this, Sir Astley observes:† "to unravel it satisfactorily, it is necessary to dissect it, in part, in water, and then harden it in alcohol, when the dissection may be minutely pursued." After this is effected, it will be found that the lobes are connected by a strong fasciculus—a rope, in fact, round which they are attached like knots, and that "these ropes are disposed spirally around a central, or nearly central cavity." In this position they are retained by the cellular envelope externally, and the mucous lining of the cavity internally, as well as by the different vessels. Every lobe, or rather lobule, contains several small cavities, each of which resembles a small cul-de-sac, being "a secretory cell for producing the fluid" above alluded to. The cells of each lobule open into a small pouch at its base, and this, in turn, communicates with the large central cavity of the gland. "If a pipe be introduced into the gland, and alcohol be injected, and the organ then be immersed in strong spirit, or a solution of alum, a large cavity (that just referred to) will be filled, which I shall call the reservoir of the thymus."‡ The reservoir extends through the thoracic and cervical portions of the gland, being larger in the former. It is lined by a vascular mucous membrane, which is evidently prolonged through the pouches into the cells.

The reservoir, pouches, and cells contain a white fluid "like chyle," or "like cream, but with a small admixture of red globules." In the human foetus this fluid has been found by Sir Astley in too small proportion to be submitted to chemical analysis. But the thymic fluid of the foetal calf, which exists in great abundance, gave the following analytical§ results:—one hundred parts of the fluid contained sixteen parts of solid matter, which consisted of,

Incipient fibrine,	Muriate and phosphate of potash,
Albumen,	Phosphate of soda,
Mucus, and muco-extractive matter,	Phosphoric acid, a trace.

Sir Astley Cooper concludes his anatomical description of this gland with the following interesting physiological observation: "As the thymus secretes all the parts of the blood, viz. albumen, fibrine, and particles, is it not probable that the gland is

## PLATE XXI.

The anatomy of the fibres of the heart, according to the researches of Searle. The figures (with the exception of fig. 3) are drawn from dissections made by Mr. Searle, and very liberally placed at the disposal of the Editors of this work.

FIG. 1. The fibres of the heart unwound, so as to show the mode of connection of the fibres forming the two ventricles.

NO. 1. The left ventricle. 2. The right ventricle. 3. The cavity of the left ventricle. 4. The rope divided just as it is about to spread out upon the internal surface of the septum ventriculorum. 5. The corresponding section of the rope, forming a part of the brim of the left auriculo-ventricular opening. 6, 6. The carneæ columnæ of the left ventricle. 7, 7. Radiated expansions of the fibres of the carneæ columnæ. 8. Some of the fibres of the rope, (No. 1,) proceeding from its radiated expansion. 9, 9. A band of fibres derived from the carneæ columnæ and rope, winding spirally around the apex of the heart, closing the left ventricle, and then forming the superficial layer of fibres of the heart. 10. Fibres derived from the carneæ columnæ and radiated expansion of the rope, forming in the natural state of the heart the thick band of the apex of the left ventricle, represented in plate XX. fig. 3, No. 5. 11, 11. The fibres derived from the carneæ columnæ and rope, which in the direction of a line drawn between these two figures, corresponding with the anterior coronary track, divides into the short and long bands. 12. Fibres passing onwards to assist in forming the rope, No. 5. 13. The pulmonary artery. 14. The fibres proceeding from the pulmonary artery to form the inner layer of the right ventricle. 15. The left section of the aorta. 16. Fibres proceeding from the margin of the aorta, and assisting to form the right layer of the septum ventriculorum. 17. Fibres proceeding from the aorta to assist in forming the rope.

FIG. 2. The heart, viewed upon its anterior surface, and showing the internal layer of fibres of the left ventricle.

NO. 1. The right ventricle, in which the layers of fibres have been irregularly divided. 2. The rope, forming the brim of the left auriculo-ventricular opening, and showing the twisted disposition of its fibres. 3, 3. The fibres of the rope, expanding so as to form a radiated band, which constitutes the left surface of the septum ventriculorum. 4. The heads of the carneæ columnæ of the left ventricle. 5, 5. A band formed by fibres from the two preceding sources, after winding around the anterior surface of the left ventricle; the divided edge, 6, 6, becomes continuous with the middle layer of the septum, 7, 7. 8, 8. Another portion of this broad and thick band, which is wound around the apex of the left ventricle, and forms the short band of the heart. 9. The aorta.

FIG. 3. A diagram, showing the direction of the bands of fibres forming the layers of the ventricles of the heart.

NOS. 1, 1. The left layer of the septum ventriculorum, formed by fibres from the rope. 2, 2. Carneæ columnæ. 3, 3. A band formed, conjointly by fibres from the two preceding sources. 4, 4. This band winding around the apex of the left ventricle to the septum, 5, where it divides into the short and the long band. 6, 6. The short band, receiving an accession of fibres at the septum, winds

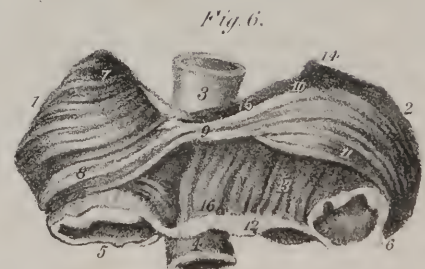
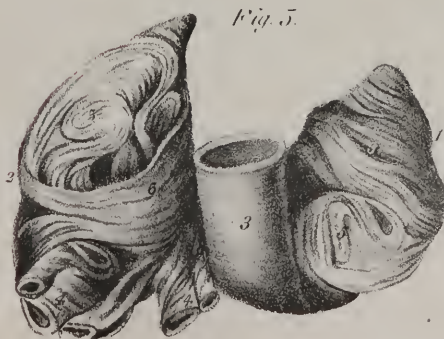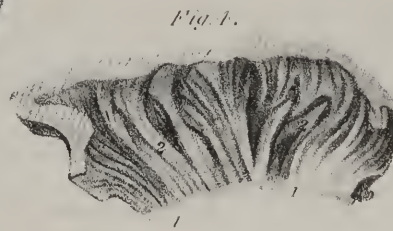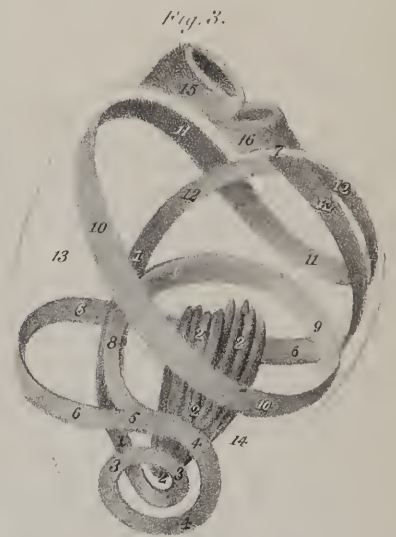
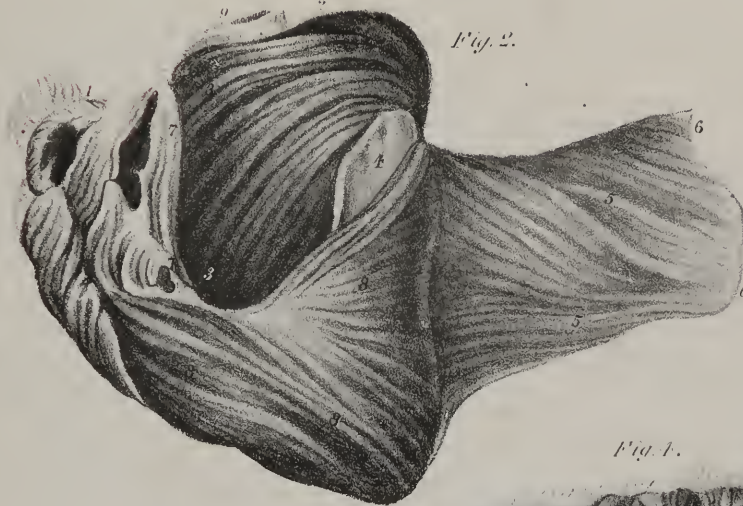
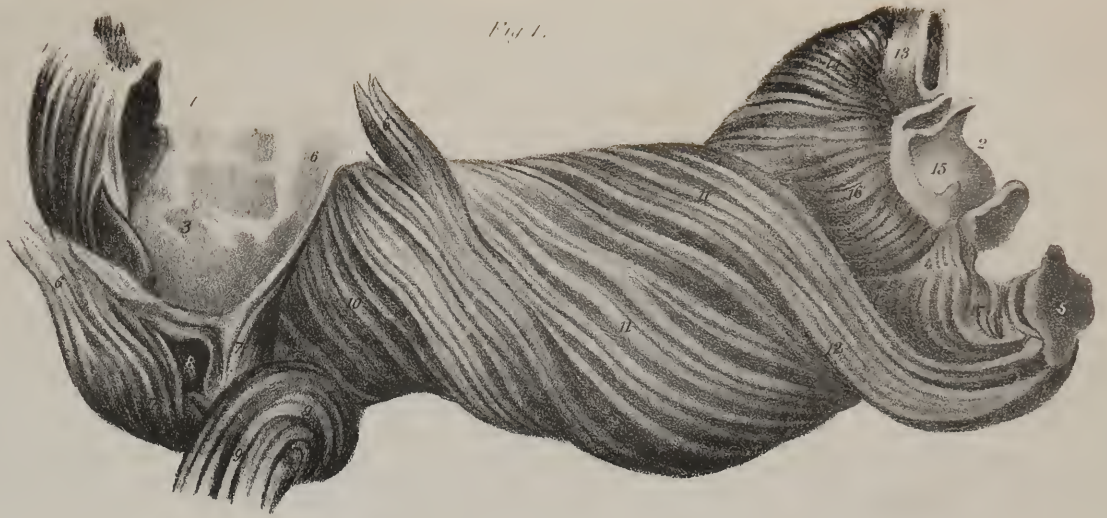\* Op. cit. p. 27.

† Op. cit. p. 28.

‡ Op. cit. p. 29.

§ This analysis was conducted by Dr. Dowler of Richmond.





desi  
the l  
ity  
super  
the m  
St. A  
even t  
branch  
array,  
and syn  
them o  
and ter  
jection  
they are  
No  
trous

The  
as the  
The  
use hav  
the bla  
ermon  
of right  
custome  
wealth  
The  
asidin  
orted p  
arms n



designed to prepare a fluid well fitted for the fœtal growth and nourishment from the blood of the mother, before the birth of the fœtus, and consequently before chyle is formed for food?—and this process continues for a short time after birth, the quantity of fluid secreted from the thymus gradually declining as that of chylication becomes perfectly established.”

*Vessels and Nerves.*—The thoracic part receives its arteries from the internal mammary artery; the cervical from the superior thyroid, and sometimes from the inferior thyroid. The veins run a different course from the arteries, and open, for the most part, into the vena innominata. The nerves are very minute; Haller thought they were derived from the phrenic; Sir A. Cooper says that he could not trace any branch from that nerve going to the gland; some evidently pass along it, and even through its cellular envelope, but they proceed on to the pericardium. He further observes, that a plexus is formed by branches from the sympathetic upon the internal mammary artery, and that filaments from this plexus pass along upon the thymic artery, which in a manner guides them to the gland. Besides this, “he has seen a filament from the junction of the par vagum and sympathetic pass on the side of the thyroid gland to the thymus.” As to absorbents, Sir Astley has succeeded in injecting them only once in the human subject; but in the fœtal calf they pass nearly straight along the posterior surface of the gland, and terminate in the vena innominata. They are sufficiently large to admit an injecting pipe, and to receive ordinary coarse injection. The remarks upon them thus conclude: “These vessels, I consider, and shall name, the *absorbent ducts* of the gland; they are the carriers of the fluid from the thymus into the veins, at the lower part of the neck.”

Not content with stating the result of his researches, the distinguished author details his methods of conducting them, obviously to abridge the labour of those who are not as well versed as himself (and few are) in anatomical pursuits.

### THE URINARY ORGANS.

These consist of the organs by which the urine is secreted, (kidneys,) and those by which it is excreted, namely, the ureters, the bladder, and the urethra.

*The Kidneys.*—The kidneys (plate XXIV. *renes*, νεφροί) are two in number; but this is not invariable, as in some rare cases three have been found, while in others but one existed. They communicate each by a separate duct, (ureter,) with a reservoir, (the bladder,) which receives the secretion of both. They are placed deeply at the posterior part of the abdomen behind the peritonæum, lying one on each side of the vertebral column, on a level with the two last dorsal and two first lumbar vertebræ; the right is, however, a little lower down than the left. The kidneys are covered by a quantity of loose cellular tissue, which sometimes contains much dense fat. They are of a deep red colour. Each measures about four inches in length and two in breadth; the form is peculiar,—being compressed and ovoid, the kidney presents for examination two surfaces and two borders.

The anterior surface, convex, lies behind the peritonæum, which separates it on the right side from the duodenum and ascending colon, and on the left from the descending portion of the latter; the posterior is embedded in cellular tissue, and supported partly on the broad part of the diaphragm, partly on the quadratus lumborum, or rather on the anterior lamina of the fibrous membrane by which the transversalis abdominis muscle is connected to the spine; the external border is convex in its

around the posterior part of the two ventricles, and terminates at 7, by being inserted into the anterior border of the auriculo-ventricular ring, and into the root of the aorta and pulmonary artery. 8. The long band, passing directly backwards through the septum, of which it forms the middle layer. 9, 9. The long band, after it has emerged from the septum, and is pursuing its course around the posterior part of the left ventricle, having received an accession of fibres from the internal layer of the right ventricle. 10, 10. The continuation of the long band across the anterior aspect of the two ventricles. 11, 11. The prolongation of the long band around the posterior part of the base of the heart. 12, 12. Its continuation, under the name of “the rope,” to the point *L*, where it becomes the left layer of the septum ventriculorum. 13. The right ventricle. 14. The left ventricle. 15. The pulmonary artery. 16. The aorta.

FIG. 4. An internal view of a section of the right auricle, showing the mode of distribution of its fibres. This preparation is made from the heart of a horse.

Nos. 1, 1. The fibrous margin of the right auriculo-ventricular ring. 2, 2. The fibres proceeding from this ring forming columns as they ascend, from which branches are given off, which sub-ramify.

FIG. 5. A posterior view of the auricles of the heart, with the mode of distribution of the muscular fibres upon their external surface.

No. 1. The right auricle. 2. The left auricle. 3. The superior vena cava. 4, 4. Openings of the pulmonary veins. 5, 5. The fibres of the two auricles disposed in a convoluted manner. 6. The posterior band of the fasciculus of fibres, fig. 6, No. 8, passing from the anterior aspect of the auricles, and encircling the openings of the pulmonary veins.

FIG. 6. An anterior view of the two auricles, showing the arrangement of their fibres.

No. 1. The right auricle. 2. The left auricle. 3. The superior vena cava. 4. The inferior vena cava. 5. The fibrous ring of the right auriculo-ventricular opening. 6. The fibrous ring of the left auriculo-ventricular opening. 7. The fibres winding in a spiral direction around the appendix of the right auricle. 8. A band formed by these fibres, continued across the septum, at 9, to the anterior surface of the left auricle. 10. The prolongation of these fibres, forming a superior band, which encircles the apex of the auricle. 11. An anterior band, which passes completely around the auricle, and, returning in its circle, is partly attached to the margin of the aorta, 12, and partly continued onwards, 13, to the appendix auriculæ, 14. 15. A posterior band of fibres, which is prolonged backwards to the posterior surface of the left auricle. 16. A band of fibres proceeding from the margin of the aorta to the superior vena cava, and entering into the formation of the septum auriculorum.



general outline, the internal concave, and excavated at the middle, where it presents a fissure for the transmission of the vessels. The superior extremity, which is thick, rounded, and inclined inwards, supports the supra-renal capsule: the inferior is smaller, somewhat flat, and diverges from the spine.

*Structure.*—The surface of the kidney is invested by a thin, yet firm membrane, which turns over the concave border, and comes into contact with its pelvis, on which it is reflected, gradually degenerating into cellular tissue. If a section be made of the organ from the convex to the concave border, it is seen to be formed of two substances, differing materially one from the other; these, from their relative position, are usually named cortical and medullary.

The *cortical substance*, (*substantia corticalis*), placed immediately under the investing membrane, occupies the entire circumference of the organ, being about two lines in thickness, and sends inwards prolongations, between which the medullary portion is placed. It is of a deep red colour, easily torn, and is formed almost entirely by the capillary terminations of blood-vessels. The *medullary part* consists of a series of pyramidal or conical masses, the bases of which are directed towards the surface of the kidney, and the small extremities towards its fissure; the cones are invested, except at their apices, by the cortical substance. The medullary substance is more dense than the preceding, and the colour is much less dark. From being made up of a series of minute tubes, it is also named *tubular substance*; a term preferable to medullary, which is altogether objectionable.

## PLATE XXII.

- The anatomy of the thymus gland. The figures of this plate, and of the succeeding, have been copied, with the kind and liberal permission of Sir Astley Cooper, from that distinguished author's beautiful monograph, "The Anatomy of the Thymus Gland."
- FIG. 1. The thymus gland of the human embryo at rather more than two months.  
 No. 1. The larynx and trachea. 2. The gland, presenting a bilobate form. 3. The heart.
- FIG. 2. The thymus gland in an embryo at the third month.  
 No. 1. The thyroid gland, resting upon the upper part of the trachea, and concealing the larynx. 2. The trachea, bounded on each side by the common carotid artery. 3. The thymus gland. 4. The heart.
- FIG. 3. The thymus gland in a fœtus at the fourth month.  
 No. 1. The larynx, partly concealed by the thyroid gland. 2. The trachea, bounded laterally by the common carotid arteries. 3. The thymus gland; the median division into two lateral portions is distinctly perceived. 4. The heart.
- FIG. 4. The thymus gland in the fœtus at the fifth month.  
 No. 1. The larynx and trachea, partly concealed by the thyroid gland. 2. The right lateral portion of the gland, extending upwards by the side of the trachea and larynx to the ala of the thyroid cartilage. 3. The left lateral portion. 4. The heart.
- FIG. 5. The thymus gland in a fœtus at the sixth month.  
 No. 1. The larynx and trachea. 2. The thymus gland; its lateral portions extending upwards on either side of the trachea, and resting inferiorly on the heart. 3. The heart.
- FIG. 6. The thymus gland of a fœtus at the seventh month. The position and extent of the gland are well exhibited in this figure.  
 No. 1. The larynx. 2. The right lateral portion of the gland. 3. Its left lateral portion. 4. The heart.
- FIG. 7. The thymus gland from an anencephalous fœtus at the eighth month; "the organ is broader than usual," and the cervical portions appear deficient.  
 No. 1. The thyroid cartilage. 2. The thyroid gland. 3. The trachea. 4. The right lateral portion of the thymus gland. 5. Its left lateral portion. 6. The heart.
- FIG. 8. The thymus gland at the ninth month.  
 No. 1. The thyroid gland, lying upon the upper part of the trachea; the ramified vessels upon this gland are chiefly thyroid veins. 2. The right lateral portion of the thymus gland. 3. Its left lateral portion. 4. The right auricle of the heart. 5. The right ventricle. 6. The appendix of the left auricle. 7. The left ventricle.
- FIG. 9. One of the lateral portions of the thymus gland, hardened in alcohol, and freed from surrounding cellular tissue. It "shows the serpentine course of the lobes of which the gland is composed."
- FIG. 10. "The glands injected with wax, and partially unravelled." This figure, adds Sir Astley Cooper, in a note, "is drawn from one of my best preparations."
- No. 1. The cervical portion of the left gland. 2. The thoracic portion. 3. The isthmus of communication between these two portions. 4. The cervical portion of the right gland. 5. Its thoracic portion. 6. The isthmus of communication between the two. The lobes,—with their smaller component structures, the cells,—are beautifully seen in this preparation; and, in consequence of the unravelling, the rope is also well exhibited in the right gland.
- FIG. 11. "The spiral course of the lobes, shown by unravelling the rope of which each gland is composed."
- FIG. 12. "The rope still farther unravelled, and portions of the reservoir opened where the lobes coalesce."
- Nos. 1, 1. Portions of the reservoir laid open.
- FIG. 13. "The thymus gland of a full-grown fœtus, filled with alcohol, and hardened in it; shows the form, course, and size of the reservoirs, the mouths of the pouches proceeding from them, and the secretory cells in the walls of the gland."
- No. 1. The cervical portion of the gland. 2, 2. Its thoracic portion. 3, 3. The reservoir of the cervical portion. 4, 4. The reservoir of the thoracic portion. 5, 5. Secretory cells and pouches seen in the walls of the gland. 6, 6. The pores, or openings of the secretory cells and pouches, upon the internal surface of the reservoir.
- FIG. 14. "Portions of the lobes sliced off after they have been distended with alcohol, to show the secretory cells and pouches."

Fig. 1.



Fig. 2.



Fig. 3.



Fig. 4.



Fig. 8.

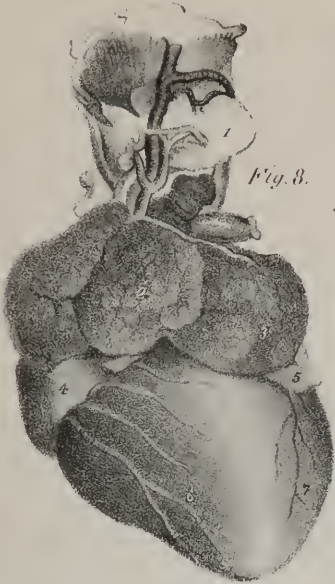

Fig. 7.



Fig. 6.



Fig. 5.

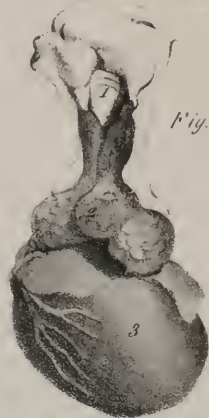

Fig. 9.



Fig. 10.

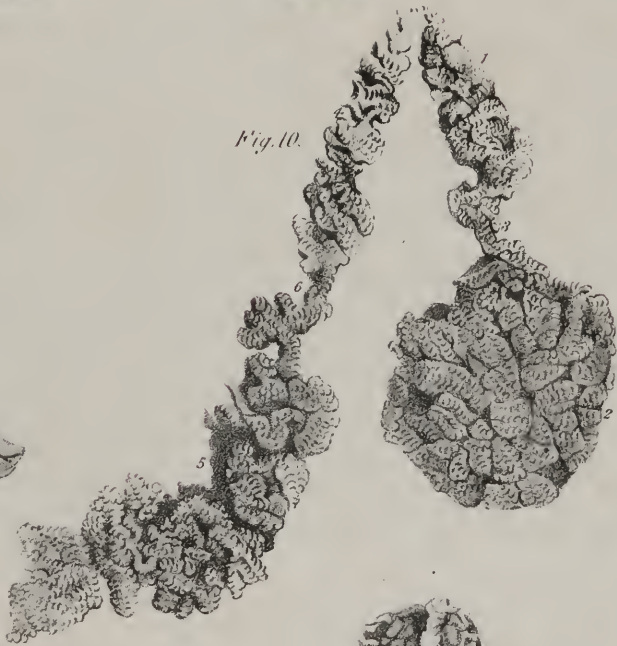

Fig. 11.



Fig. 12.

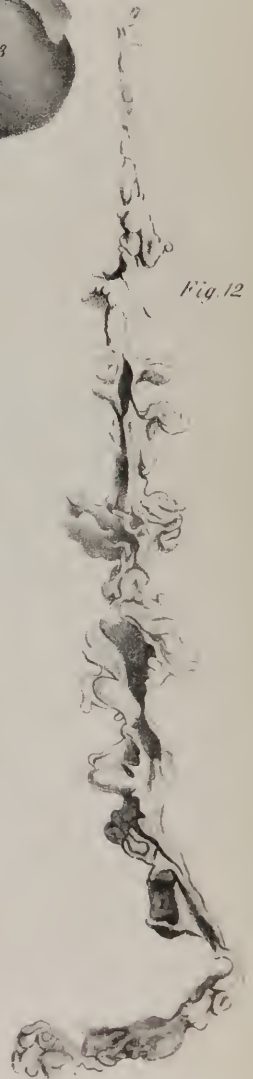

Fig. 13.

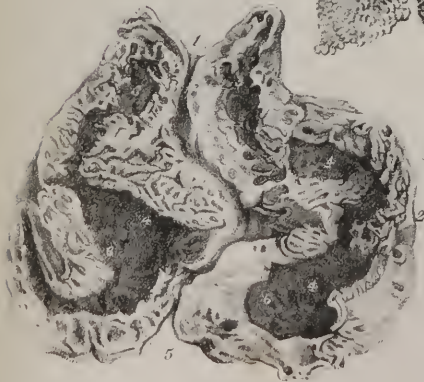

Fig. 14.







In the kidney we follow, as in the liver, its component parts into the interior, with a view to ascertain their mode of arrangement, as on this its structure depends. The fissure of the kidney lodges the renal artery and vein, the nerves and lymphatics, together with the commencement of the excretory duct. This last (the ureter) expands opposite the fissure of the kidney into an irregularly oval and compressed ampulla, called the *pelvis*, which is partly concealed by the vessels. If the ureter and pelvis be inflated, or, what is better, if they be distended with soft injection, it will be found, on dissecting off the anterior wall of the kidney, that on entering its substance the pelvis gives off three tubes, one corresponding with each extremity, and another with the middle of the organ; these again subdivide into from seven to thirteen smaller tubes, (*infundibula*), and the infundibula terminate in cup-like cavities, (*calices*), formed by their extremities being depressed, or, as it were, slightly inverted on themselves.

Each calyx embraces the extremity of one, sometimes of more rounded processes, (*papillæ mammillæ*), and each papilla is the summit of a conical mass, whose base looks towards the circumference of the kidney, and is, together with the sides, embedded, as it were, in the cortical part of the kidney. The conical masses are usually more numerous than the calices, in which they terminate: each is composed of minute tubes, (*tubuli uriniferi*), of which one extremity opens on the surface of the papilla, and therefore pours its contents into the investing calyx; whilst the other, prolonged to the base of the cone, ramifies through the cortical substance of the kidney, forming an intricate plexus with neighbouring tubuli, and terminates by a cæcal extremity. These tubuli communicate frequently with each other, and are surrounded by a fine net-work of capillary vessels, by which the urine is secreted. After its elaboration, it is received by the tubuli, and is thence passed on successively by the calices, infundibula, and pelvis, whose structure is similar to that of the ureter, being but so many prolongations of it. Though the mucous membrane of each calyx appears to cease where it is reflected over the surface of the papilla, yet we can scarcely avoid coming to the conclusion that it is prolonged into the tubuli uriniferi, as there is no part of the economy in which an excrementitious fluid is allowed to rest on the structure of an organ unprotected by a tegumentary membrane. Again, though the fibrous investment of each infundibulum and calyx seems also to cease at the margin of the papilla, it is more than probable that it also is prolonged, so as to become continuous with the fibres which constitute the tubuli.

*Vessels and nerves of the Kidney.*—The renal artery is derived from the aorta, and divides into five or six branches previously to entering the fissure of the kidney; its branches pass between the papillæ, and so continue until they reach the bases of the conical masses, where they divide and ramify, so as to form a complete vascular net-work, encasing the inner or tubular structure, and so forming a cortex, or exterior investment for it. The minute ramifications of the artery form in the cortical structure of the organ a multitude of extremely small bodies, called glomeruli, (*corpora Malpighiana*.) These glomeruli are about  $\frac{1}{13}$  of an inch in diameter, and are composed of an aggregated plexus of capillary vessels, enclosing a small central cavity, the use of which is unknown. The radicles of the renal vein, commencing from the capillary vessels, convey the effete blood into the course of the circulation, and open into the inferior vena cava. The lymphatics of the kidney are very numerous. The nerves (which are derived from the renal plexus of the sympathetic system) are, on the contrary, comparatively few; their distribution has not been followed to any considerable depth in the substance of the organ.

During fetal life, the surface of the kidney is marked by deep fissures, which indicate its division at that period into several lobules. These contain each the elements of a distinct organ; they gradually become united, and at length the kidney assumes the uniform appearance seen in the adult. The lobulated condition of the kidney is permanent in many of the lower animals.

*Supra-renal capsules.*—The *supra-renal capsules* are so named from surmounting the kidneys; other names have been given them from hypotheses concerning their use (atrabiliary capsules, *renes succenturiati*.) Each of these bodies is compressed, and rather flat; the upper border is convex, the lower is excavated, and rests on the superior extremity and partly on the inner border of the kidney, to which it is united by cellular tissue. They are formed of two substances: an external, which is dark yellow in colour, somewhat dense and striated; and an internal, which is deep brown, soft, and pulpy. The interior is hollowed into a small triangular cavity, containing a viscid fluid. Some anatomists, however, believe that this cavity is produced by the decomposition of the pulpy substance in which it is found.

In early fetal life the supra-renal capsules are granular in structure, and exceed the kidneys in size; the latter, however, rapidly increasing, become much the larger towards the end of that period. After birth, the supra-renal capsules even become diminished, and apparently shrivelled.

In structure it is composed of two substances, cortical and medullary. The cortical substance is of a yellowish colour, and consists of straight parallel fibres placed perpendicularly side by side. The medullary substance is generally of a dark brown colour, double the quantity of the yellow substance, soft in texture, and contains within its centre the trunk of a large vein—the vena supra-renal. It is the large size of this vein that gives to the fresh supra-renal capsule the appearance of a central cavity; the dark-coloured pulpy or fluid contents of the capsule, at a certain period after death, are produced by softening of the medullary substance. Dr. Nagel\* has shown, by his injections and microscopic examinations, that the appearance of straight fibres in the cortical substance is caused by the direction of a plexus of capillary vessels. Of the numerous minute arteries supplying the supra-renal capsule, he says, the greater number enter the cortical substance at every point of its surface, and, after proceeding

\* Müller's Archiv. 1836.

for scarcely half a line in its substance, divide into a plexus of straight capillary vessels. Some few of the small arteries pierce the cortical layer and give off several branches in the medullary substance, which proceed in different directions, and re-enter the cortical layer to divide into a capillary plexus in a similar manner with the preceding. From the capillary plexus composing the cortical layer the blood is received by numerous small veins, which form a venous plexus in the medullary substance and terminate at acute angles in the large central vein.

*Vessels and Nerves.*—The supra-renal arteries are derived from the aorta, from the renal, and from the phrenic arteries; they are remarkable for the innumerable minute arteries into which they divide previously to entering the capsule. The *supra-renal vein*, collecting the blood from the medullary venous plexus, and receiving several branches which pierce the cortical layer, opens directly into the vena cava on the right side, and into the renal vein on the left.

The *lymphatics* are large and very numerous; they terminate in the lumbar glands. The *nerves* are derived from the renal and from the phrenic plexus:

The description of these bodies is placed in the present section in consequence of their connexion with the kidneys, and not from any consideration of their function, about which there has hitherto been nothing more than conjecture.

*Ureters.*—The pelvis, (renalis,) which has been previously described as receiving all the urine from the calices, gradually becomes narrowed, and, opposite the lower border of the kidney, assumes the name of ureter. This duct extends from the point here indicated to the posterior and inferior part of the bladder, into which the canals from both kidneys open. Each thus averages about eighteen inches in length; its calibre is usually compared to that of a quill.

The ureter, in its whole course, lies behind the peritonæum; superiorly, it rests against the psoas muscle, and is crossed by the spermatic blood-vessels, (these being in front;) lower down it passes over the common iliac vessels; lastly, in the male, the vas deferens crosses to its inner side immediately before it terminates.

In opening into the bladder, the ureters pass obliquely between its muscular and mucous coats, before they end on its inner surface; this arrangement has a valvular effect, preventing the fluid from passing back towards the kidney. The structure is the same as that of the pelvis, and consists of an external fibrous tunic, lined by a thin mucous membrane.

*Urinary bladder.*—The bladder (vesica urinaria) is a musculo-membranous reservoir, placed deeply in the pelvis, behind the

## PLATE XXIII.

The anatomy of the thymus gland. The figures in this plate, with those in the preceding, have been copied, with the kind and liberal permission of Sir Astley Cooper, from that distinguished author's beautiful monograph, "The Anatomy of the Thymus Gland."

FIG. 1. The arteries of the thymus gland.

No. 1. The cervical portion of the gland. 2. Its thoracic portion. 3. A branch of the internal mammary artery. 4. A branch of the inferior thyroid artery. 5, 5. A venous branch.

FIG. 2. The veins of the thymus gland.

No. 1. A venous trunk collecting the returning blood from the thoracic portion of the gland, and terminating in the vena innominata. 2, 2. A vein proceeding along the cervical portion of the gland to open into the inferior thyroid veins. 3. The branch from the inferior thyroid artery.

FIG. 3. Two sections of the thymus gland, its cavities having been distended with alcohol.

No. 1. Shows a part of the reservoir, with the pores upon its internal surface; and the pouches and secretory cells in the parietes of the gland. 2. Shows the cavities of the pouches and the secretory cells in a section made near the surface of the gland.

FIG. 4. A diagram, which is intended to convey a general idea of the structure of the thymus gland.

No. 1. The reservoir. 2, 2. The openings of pouches upon the internal surface of the reservoir. 3, 3. Pouches laid open by a section. 4, 4. Lobes; the lobes being made up of small granular lobules, which are the secretory cavities or cells.

FIG. 5. The arteries and veins of the thymus gland: the gland itself is injected with wax.

No. 1. The larynx. 2. The thyroid gland. 3. The trachea. 4, 4. The common carotid arteries. 5, 5. The internal jugular veins. 6. The left vena innominata. 7, 7. The cervical portion of the gland. 8, 8. Its thoracic portion. 9, 9. Arteries supplying the gland, proceeding from the inferior thyroid arteries. 10. A vein which opens into the upper part of the left vena innominata. 11. Another thymic vein opening into the lower part of the left vena innominata. 12. The heart, upon which the coronary vessels are seen to be distributed. 13. The right auricle. 14. The left auricle. 15. The root of the pulmonary artery.

FIG. 6. The thymus gland at the ninth month, injected with wax to show its lobes and cells.

No. 1. The larynx. 2. The trachea. 3, 3. The common carotid arteries. 4, 4. The cervical portion of the gland. 5, 5. Its thoracic portion. 6. The heart. 7. The root of the pulmonary artery. 8. The right auricle. 9. The left auricle.

FIG. 7. A posterior view of the thymus gland in the fœtal calf, intended to show the large lymphatic vessels (thymic ducts) which proceed from the upper extremity of the cervical portion of the gland, and terminate in the large vessels at the root of the neck.

No. 1. The larynx. 2. The trachea. 3, 3. The cervical portion of the gland. 4. Its thoracic portion. 5, 5. The internal jugular veins. 6. The superior vena cava. 7, 7. The thymic ducts. 8. The point of termination of these ducts in the superior part of the superior vena cava.



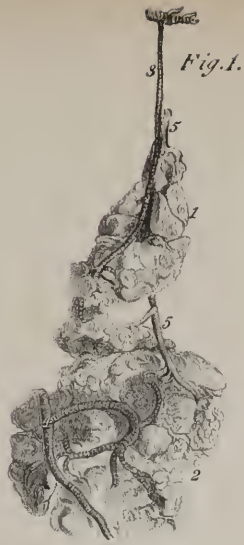

Fig. 1.

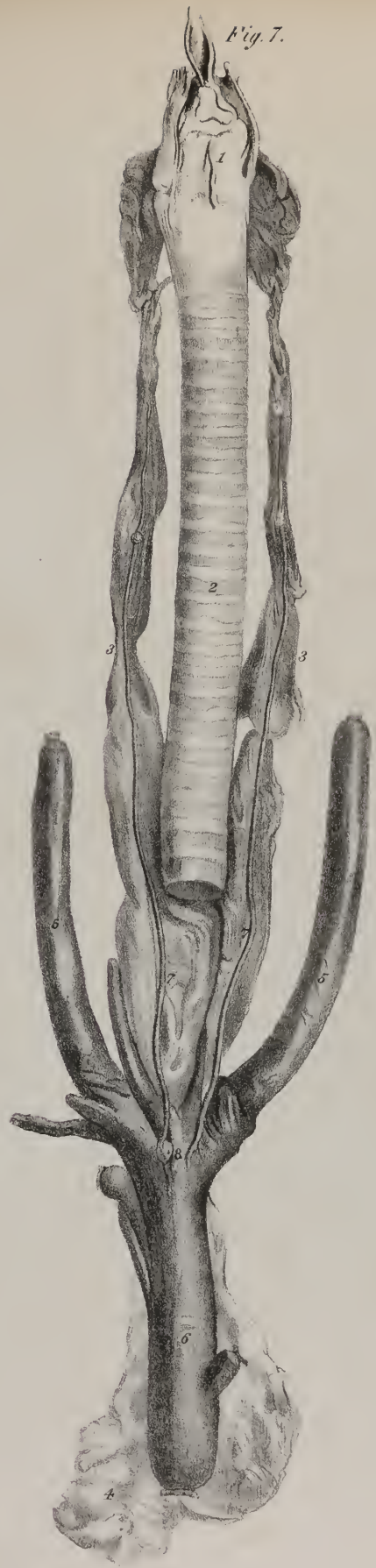

Fig. 7.

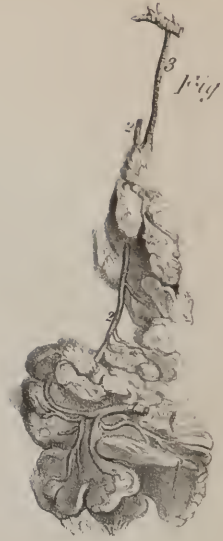

Fig. 2.

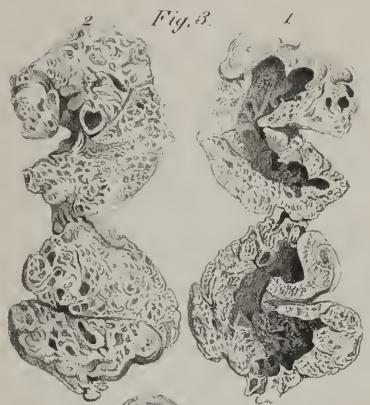

Fig. 3.




Fig. 4.

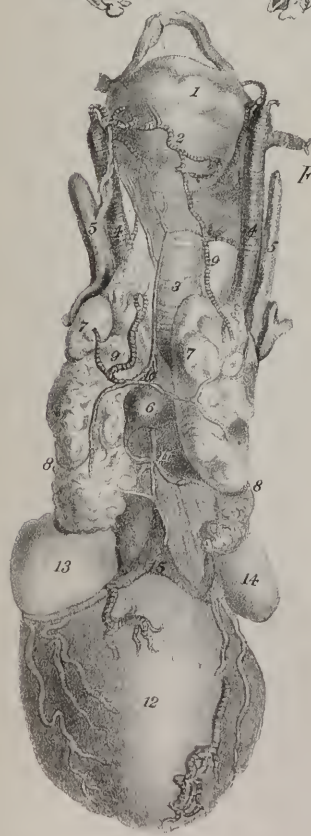


Fig. 5.

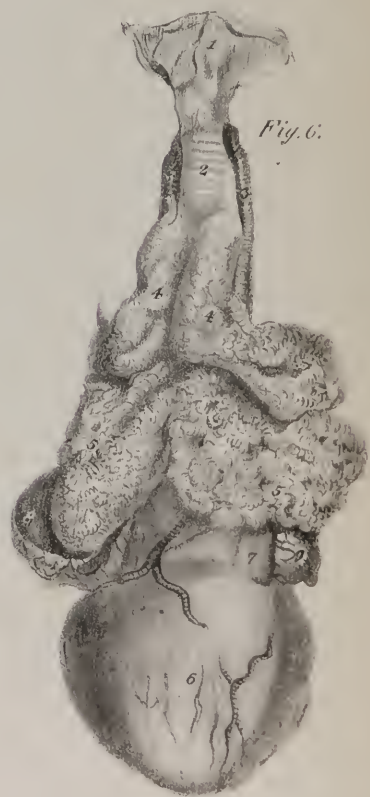

Fig. 6.



public  
the se  
I  
may b  
narrow  
into it,  
chang  
the we  
to the  
heighte  
differen  
greatly  
T  
being g  
and up  
the uni  
is base  
part of  
being u  
overin  
and is  
the sid  
T  
which  
tem a  
form.  
the ur  
water  
a bein  
inter  
to a  
ward  
const  
betw  
the n  
the  
tra  
his  
Th  
re  
:  
re  
w  
t

pubic symphysis, and before the rectum in the male, but separated from it by the uterus and vagina in the female. It receives the secretion of the kidneys by the ureters, and discharges it by the urethra.

In infancy, the bladder is elongated and pyriform in its shape, and contained altogether in the abdomen. At this period it may be considered as divisible into three portions; the rounded or upper extremity being with propriety called its *fundus*, the narrow tapering part the *neck*, the intermediate portion being the *body*. As the pelvis expands, the bladder gradually subsides into it, so as not to rise above its margin (at least in the adult) unless when distended, and at the same time assumes a remarkable change of form. It becomes a compressed oval, for the lower part of its body expands and subsides on the rectum, probably by the weight of the fluid it habitually sustains, and to this part is applied the term *base* or "*bas-fond*." Thus we are obliged to recur to the original application of the terms, in order to explain an apparent inconsistency in those employed; and the inconsistency is heightened by making the term "*fundus*" and "*summit*" synonymous, at the same time that "*fundus*" and "*base*" are applied to different parts of the same viscus. Yet, so the nomenclature runs; that which was the *fundus* in the fetal bladder is not unfrequently called "*summit*," because it is the highest part.

The direction of the bladder is oblique, being inclined somewhat forwards and upwards, from base to summit; and, as it is being gradually distended, it comes forwards more and more, the neck being fixed, whilst the *fundus* and body curve forwards and upwards with the distension. If examined in this condition, three agamentous cords (*viz.* the urachus, and the remains of the umbilical arteries) will be observed to pass from its summit obliquely upwards behind the recti muscles to the umbilicus. Into its base two tubes are inserted, *viz.* the ureters; and at the sides the vasa deferentia pass obliquely backwards. Now all that part of the posterior surface and sides of the bladder included between these lines is covered by peritonæum, the remainder being uncovered. Thus, at the fore part, from the point of attachment of the urachus down to the neck of the bladder, no serous covering exists. In the collapsed condition all this lies behind the pubes; but, when distended, part of it rises above its margin, and is in contact with the recti muscles; inferiorly, from the entrance of the ureters to the urethra it is also uncovered, and on the sides from the vasa deferentia forwards to the surface of the pelvis.

The base and neck are the parts which deserve the greater share of attention. The *base* is that depending part of the viscus which rests on the rectum. Attached to it we find the vesiculæ seminales and vasa deferentia, so disposed as to leave between them an interval, in which the bladder is separated from the rectum only by some cellular tissue. This space is triangular in its form, the sides being formed by the vesiculæ converging to the prostate, whilst the base corresponds with the interval between the ureters. It is by no means so extensive when the parts are *in situ*, as may be inferred from viewing them after they are disturbed. The vesiculæ are in close contact for some lines before they reach the base of the prostate; and as the peritonæum is being reflected off the bladder at the entrance of the ureters, it forms a curved fold, whose convexity inclines forwards in the interval between them. The *neck*, or constricted part at which the bladder is continuous with the urethra, is usually compared to a truncated cone, longer below and at the sides than above. In infancy it is oblique, its direction being downwards and forwards, but in the adult it becomes almost horizontal. The posterior part of it rests on the rectum, the rest being encircled by the prostate gland. In the female, the parts of the bladder last described are in close relation with the vagina, which is interposed between them and the rectum. Moreover, there are no organs appended to them, the vesiculæ and prostate being peculiar to the male.

The *inner surface* of the bladder is lined by mucous membrane, continuous with that which is prolonged upwards along the ureters, and downwards through the urethra. When collapsed, it presents throughout the body and *fundus* slight rugæ, or waving lines, which exist no longer in the distended condition. But towards the lower part, and corresponding with what we described, externally, as the base, a smooth and slightly raised surface appears, in which no rugæ occur under any circumstances. The shape of this part is that of a triangle, its two posterior angles being indicated by the openings of the ureters, and the anterior or apex by the commencement of the urethra: this part of the bladder is endowed with peculiar sensibility. It is the "*trigone vesical*" of Lieutaud and Camper;\* its apex or anterior angle, from being slightly elevated, has also been named "*luette vesicale*," (*uvula vesicæ*.) This corresponds to the third or transverse lobe of the prostate, which is placed beneath. Along the sides of the trigone, and under cover of the mucous membrane, muscular fibres extend from the prostate, diverging to the internal orifice of the ureters, and are fixed to both these points. The orifice of the ureters is not protected from the reflux of the urine by any valve; but the obliquity of their course through the substance of the bladder serves the purpose. Sir C. Bell supposes, that, as in contraction of the bladder, the point at which its outer coat is penetrated by the ureter is drawn towards the neck of the organ, (its fixed point,) and therefore opposite the internal orifice, the longitudinal fibres are intended to act on the latter at the same time; so that, drawing it proportionally forward towards the prostate, they may thus maintain the required obliquity.

*Structure.*—The bladder, like the other hollow viscera, is composed of three coats, or layers, united by cellular tissue. The peritonæal, or exterior coat, we have already noticed as forming a partial investment.

The *muscular* layer consists of pale fibres disposed in different directions, all of which are sometimes mentioned under the general name *detrusor urinæ*. The external fibres on the fore part may be seen to pass upwards from the neck to the summit.

\* Camper, Fascic. Anat. Pathol.

and thence downwards and backwards to the base of the prostate gland. On the sides they follow an oblique course. The internal set are for the most part transverse, and towards the neck so nearly assume a circular direction, that some anatomists have considered them as a sphincter muscle, (*sphincter vesicæ*.\*) These are disposed immediately behind the prostate, and therefore behind the opening of the seminal vessels: they are most apparent inferiorly. When the bladder is distended, intervals occur between the bundles of muscular fibres in which the inner tunic is seen. The protrusion of the latter in these inter-spaces forming a species of hernia of the mucous membrane, will constitute what is called the sacculated bladder. The muscular fibres sometimes become much thickened (hypertrophied) by over-action, or in consequence of inflammation, and form considerable projections on the internal surface of the bladder, giving to it the peculiar appearance expressed among the French by the term "vessie à colonnès."

The *mucous* coat is smooth when distended, but corrugated when the bladder is contracted; its colour is pale, with a slight rose tint. The portion covering the "trigone" is smooth in all conditions of the organ, and paler than in any other part. The muscular and mucous membranes are united by a well-marked layer of cellular tissue, frequently mentioned as a separate coat, under the name vascular or nervous tunic.

*Vessels and nerves of the Bladder.*—In early life the bladder receives its arteries from the hypogastric; in the adult it is supplied by the proper vesical arteries, and by twigs derived from the hæmorrhoidal and internal pudic vessels, the greater number being towards the neck and base. Its veins form a plexus at the same situation, and open into those of the internal iliac. The lymphatics follow a similar course. The nerves come from the sacral plexus of the cerebro-spinal system and the hypogastric plexus of the sympathetic.

*Ligaments of the Bladder.*—The bladder is retained *in situ* by certain membranous reflections called ligaments. The fascia iliaca, it will be recollected, descends into the pelvis, becoming adherent to its margin; thence it is prolonged downwards, under the name fascia pelvica, to a level with an oblique line extended from the pubic symphysis to the spine of the ischium. At that point it contracts a close connexion with the obturator fascia, after which it is continued on the inner surface of the levator ani, to the side of the bladder and prostate gland, with whose structure it becomes in a manner indented; from its destination, this last portion is sometimes called vesical fascia. A similar arrangement of the membrane takes place at the opposite side, and both are termed the *lateral ligaments* of the bladder. The fascia transversalis, it will be also recollected, is continued down behind the pubic symphysis, and on reaching the fore part of the neck of the bladder is reflected over the prostate on its upper surface. From the point of reflection two dense fasciculi of fibres (one at each side of the median line, with a slight cellular interval between them) pass also upon the upper surface of the bladder; these are the *anterior ligaments*. They are considered by some anatomists as tendons of attachment for the muscular fibres of the bladder to the symphysis pubis.

## PLATE XXIV.

The anatomy of the kidney and supra-renal capsule.

FIG. 1. The left kidney, surmounted by the supra-renal capsule, and showing the relative position of its vessels.

Nos. 1, 1. Swellings upon the surface of the kidney, marking its original composition of distinct lobes. 2. The supra-renal capsule. 3, 3. Two branches of the renal artery. 4. The renal vein. 5. The supra-renal vein. 6. The pelvis of the kidney. 7. The ureter.

FIG. 2. A section of the kidney.

Nos. 1, 1. The cortical or vascular structure. 2, 2. The medullary or tubular structure, disposed in cones. 3, 3. The papillæ, or apices of the cones. 4, 4. Other papillæ, seen terminating by their apices in the infundibula of the organ. 5, 5. The calices. 6, 6, 6. The three infundibula. 7, 7. The pelvis of the kidney. 8. Its ureter.

FIG. 3. The microscopic structure of the kidney, according to Krause of Hanover.—From Müller's Archiv. for 1837.

Nos. 1, 1. Conical lobules, composed of the convolutions of the terminal uriniferous tubuli; tubuli uriniferi corticales. The tubuli, 2, 2, from these conical lobules, terminate in the bases of the cones of the tubular structure of the kidney, fig. 2, Nos. 2, 2. 3. A small artery, giving off branches to the glomeruli, (4, 4,) or Malpighian bodies. These are the globular bodies seen amongst the tubuli.

FIG. 4. The arrangement and dichotomous mode of division of the tubuli uriniferi in the tubular portion of the kidney.—After Schumlansky.

No. 1. The papilla of the cone.

FIG. 5. A supra-renal capsule, seen upon its posterior surface.

Nos. 1, 1. Cellular tissue, in which are seen a multitude of small thread-like vessels, principally arteries, converging to the surface of the organ.

FIG. 6. A section of the supra-renal capsule.

Nos. 1, 1. The light-coloured cortical portion of the organ. 2, 2. Its medullary portion, which is dark-coloured, and soft in texture. 3. The trunk of a large vein, found in the centre of the capsule,—vena suprarenalis.

\* For a fuller account of the structure of the neck of the bladder, the American student is referred to Pancoast's Wistar, or Horner's Anatomy.—J. P.



Fig. 4.




Fig. 1.

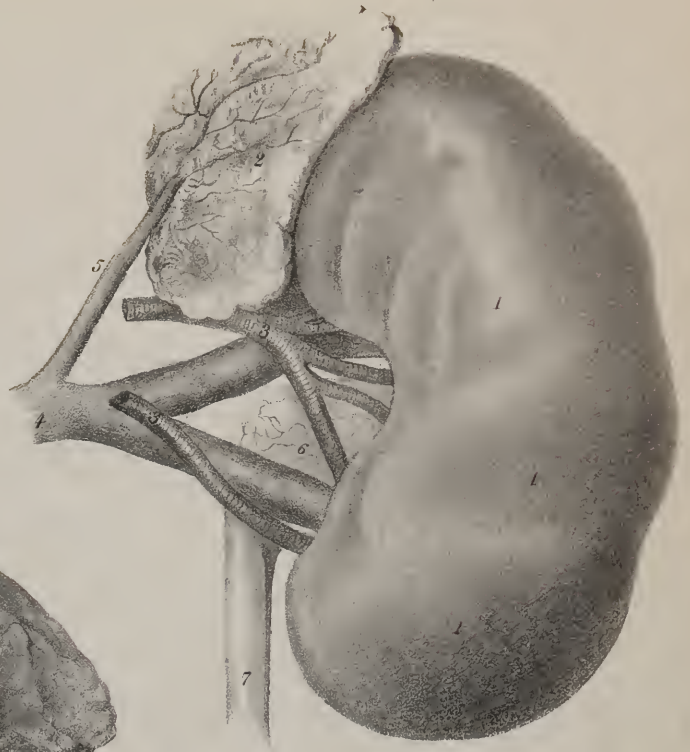


Fig. 6.

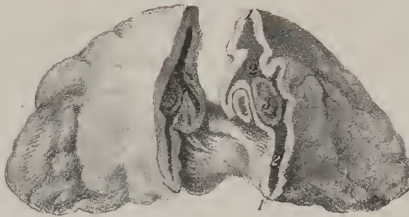


Fig. 5.


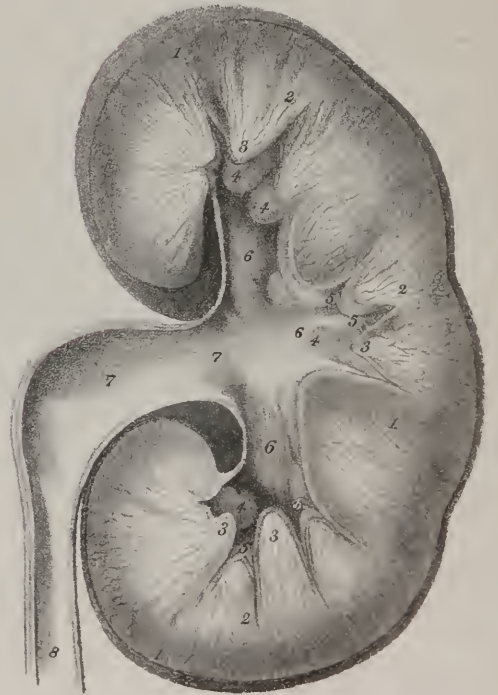


Fig. 3.

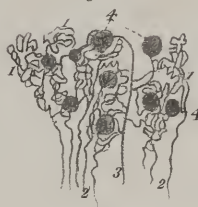

Fig. 2.



be  
part  
of  
the  
with  
prev  
pube  
simp  
T  
cedde  
uniaz  
is str  
ozae  
P  
s mit  
T  
the pet  
cony  
pland  
In  
part of  
exam  
T  
press  
are t  
stand  
hale  
stace  
long  
It  
s mit  
neral  
rase  
The p  
stford  
I  
body  
resol  
write  
erac  
calm  
a wil  
mon  
erec  
pas  
mo  
on

As the peritonæum is being reflected to and from the bladder, it necessarily forms certain folds or duplicatures, which have been termed ligaments. Two of these will be observed extending from its sides to the iliac fossæ, and two posteriorly, corresponding with the course of the umbilical arteries; but, instead of checking its motions, they serve rather as provisions to admit of the changes consequent on distension, and therefore should not be called ligaments.

*Urachus.*—The urachus is a fibro-cellular cord, extending from the apex of the bladder upwards towards the umbilicus, lying behind the linea alba, and in front of the peritonæum. Inferiorly, it is connected with the muscular fibres of the bladder: the superior extremity, prolonged upwards to the umbilicus, becomes united with the fibrous tissue of the linea alba. In man, the urachus appears to be merely the rudiment of a tube which, in his embryonic condition, as in inferior animals, communicates with the allantois. It perhaps serves to maintain the proper position of the upper part of the bladder, and, during its distension, prevents the peritonæum from being insinuated between it and the abdominal parietes.

*Urethra.*—The urethra is a membranous tube directed in the median line from behind forwards, beneath the arch of the pubes; by one extremity it is continuous with the neck of the bladder, by the other it opens externally. In the female, it serves simply for the excretion of urine; in the male, it is the outlet also for the seminal fluid.

The *female urethra* is about an inch and a half in length, and is slightly curved, the concavity looking forward. It lies embedded in the upper wall of the vagina, under cover of the anterior ligaments of the bladder. The external orifice (meatus urinarius) opens beneath the symphysis pubis, about an inch behind the clitoris, and immediately above the inlet to the vagina. Its *structure* consists of a mucous lining membrane, covered by a layer of cellular tissue; these being unconnected with any dense or unyielding parts, the female urethra admits of considerable dilatation.

From the function and connexions of the *male urethra*, it may be associated with the organs of generation; moreover, as it is united to other parts, (the prostate and penis,) its description will be more conveniently placed after theirs.

*The Male Organs of Generation.*—The male organs of generation are situated for the most part on the anterior surface of the pelvis, differing in this respect from the corresponding parts in the female, the greater number of which are lodged in its cavity. They consist of, 1, the testes and their excretory ducts, the prostate and Cowper's glands, (considered as accessory glands,) the urethra; 2, the penis.

In pursuing the physiological order, the organs should be examined as they are here enumerated; but as the urethra forms part of the urinary apparatus just treated of, we shall commence with it, premising the description of those parts of the generative system with which it is united, namely, the prostate and the penis.

*The Prostate Gland,* (plates XXV. XXVI.)—The prostate gland (prostata) has been compared to a truncated cone, compressed from above downwards; but it more nearly resembles a chestnut both in shape and size. It usually measures a little more than an inch from side to side, an inch from before backwards, and half an inch in thickness. Situated deeply in the pelvis, behind the deep perinæal fascia and beneath the arch of the pubes, the prostate will be found to enclose part of the neck of the bladder and the commencement of the urethra at their junction; the tube, however, being so placed as that two-thirds of the substance of the gland lie beneath it. The prostate is also traversed by the common seminal ducts, which pass from behind forward through its substance and open into the urethra.

It lies immediately beneath the anterior ligaments of the bladder, and rests on the middle portion of the rectum, to which it is united by means of dense cellular membrane. The posterior border is notched in the middle, and of considerable thickness; laterally it gives attachment to, or is, as it were, slung by, the anterior part of the levator ani. In consequence of their intimate connexion with the rectum, the inferior surface and posterior border are readily felt by the finger introduced into the intcstine. The prostate is enclosed in a fibrous cover derived from the deep perinæal fascia; this membrane is frequently very dense, and affords considerable resistance in section of the gland during the operation of lithotomy.

*Lobes—structure.*—It consists of three lobes, two of which, placed laterally, are of equal size; the third (a small rounded body) is connected intimately with the others, lying behind and between them. The third lobe is exposed by turning down the vesiculæ and seminal ducts, being placed between the latter and the bladder, and corresponds to the elevation described as the *luette vesicale*. If enlarged, the third lobe forms a projection into the neck of the bladder, which would afford impediment to the evacuation of urine or the introduction of an instrument. The term *luette vesicale*, or *uvula vesicæ*, which has the same significance, would be more fitly applied to the diseased condition indicated than to the healthy state of the part.

The tissue of the gland is resistant, of a grayish colour, and consists of a series of follicles aggregated together. These secrete a whitish ropy mucus, (liquor prostaticus,) which is poured from ten or twelve orifices into the urethra on each side of the *veru montanum*.

*The Penis,* (plates XXVI. XXVII.)—The penis, which supports the greater part of the urethra, is composed of vascular or erectile substance, occupying, as it were, three compartments, or forming three bodies, as they are termed. Of these, two are placed superiorly, one at each side of the median line, (*corpora cavernosa penis*;) the other is situated beneath the preceding, and more especially connected with the urethra, whence it is named *corpus spongiosum urethræ*. The entire, intimately connected one with another, are invested by integument, the peculiar disposition of which renders a special description necessary.

*The integument—prepuce.*—The skin on the pubes is supported by a thick cushion of yellow adipose matter, and studded



with hairs after puberty. It is prolonged (but much altered in character, inasmuch as here it is very thin, and fat is never deposited under it) on the body of the penis, forming a complete and close investment for it, as far as the extremity of the corpora cavernosa; at this point it is continued forwards, forming a loose and unattached fold called *prepuce*, which is intended to protect the glans. The margin of the prepuce terminates in a red line, where it becomes continuous with the mucous membrane. The latter may be traced down to the corona glandis, forming a lining for the prepuce, and thence over the glans to the orifice of the urethra, with whose lining membrane it becomes continuous. From beneath the opening of the urethra to the base of the glans, the membrane is thrown into a fold, called *frænum præputiî*. These integuments derive their blood-vessels from the superficial pudic branches of the crural arteries, and from the dorsalis penis branches of the internal pudic. Their lymphatics terminate in the inguinal glands.

The *corpora cavernosa* form the principal part of the body of the penis, and necessarily determine its form and consistence. They represent longitudinal sections of two cylindrical tubes, placed laterally with regard to one another, and intimately blended along the middle line for three parts of their length, whilst at the lower part they branch out into two processes, (*crura*.) so that the whole resembles the letter Y reversed. The *crura* are attached to the rami of the ischia and ossa pubis, and thence ascend, converging to the fore part of the pubic symphysis, where they become united. Along the middle line a vertical septum exists, which, however, forms but a partial separation, as it presents, more particularly towards the anterior extremity, many large foramina or fissures which admit of a free communication from side to side,—from this circumstance it is named *septum pectiniforme*.\*

The inferior surface of the penis presents, along the middle line, a groove, which partly lodges the canal of the urethra; the anterior extremity is rounded and supports the glans, with whose base it is firmly united. The upper surface, or dorsum, is

## PLATE XXV.

The viscera of the pelvis.

FIG. 1. A side view of the viscera of the pelvis in their relative position.

No. 1. Part of the cavity of the abdomen. 2. The abdominal parietes. 3. The body of the os pubis sawn through somewhat to the left of the symphysis. 4. A fold of integument turned back from over the pubic region. 5. The body of the urinary bladder. 6. Its fundus. 7. The point of connexion of the urachus. 8. The vas deferens, passing downwards to the vesicula seminalis. 9. The ureter of the left side, entering between the coats of the bladder. 10. The base of the bladder. 11. The vesicula seminalis of the left side. 12. The cervix of the bladder. 13, 13. The pelvic fascia, reflected from the internal surface of the pubis and side of the pelvis upon the bladder and rectum. 14. The prostate gland. 15. A space, which is occupied by cellular tissue and a plexus of veins. 16. The deep perinæal fascia, consisting of two layers; the posterior layer is seen to be reflected backwards upon the prostate gland; the anterior layer is divided farther from the middle line, so that its reflection forwards cannot be perceived. 17. The membranous portion of the urethra, unusually short in this subject. 18. The two layers of deep perinæal fascia below the membranous portion of the urethra. 19. Cowper's gland of the left side. 20. The perinæum. 21. The superficial perinæal fascia, which is continuous with the deep fascia. 22. The anal layer of fascia, continued downwards upon the levator ani. 23. The levator ani muscle. 24. The superficial sphincter ani. 25. The prolongation of the superficial sphincter ani forwards upon the common superficial fascia. 26. The bulbous portion of the corpus spongiosum. 27. The body of the corpus spongiosum. 28. The left crus of the corpus cavernosum, divided. 29. A space in the perinæum, from which the accelerator urinæ muscle has been removed in order to see the bulb more distinctly: this space is occupied by the muscles and vessels of the perinæum. 30. The third portion of the rectum, covered by a layer of fascia derived from the pelvic fascia. 31. The second, or middle portion of the rectum: its muscular coat shown. 32. The first portion of the rectum. 33. The peritonæum, reflected from the anterior surface of the rectum upon the posterior part of the bladder. 34. The recto-vesical fold of peritonæum. 35. The reflection of the peritonæum from the fundus of the bladder, upon the internal surface of the parietes of the abdomen. 36, 36. Section of the sacrum. 37. Section of the coccyx. 38, 38. Section of the integument over the posterior surface of the sacrum.

FIG. 2. An anterior view of the urinary bladder, showing the distribution of its muscular coat.

No. 1. The prostate gland. 2. A portion of the membranous part of the urethra. 3, 3. Tendons of the bladder, or of the detrusor urinæ muscle. 4, 4. That process of the expanded tendon which is inserted into the os pubis near the symphysis. 5, 5. The inferior portion, attached to the ramus of the pubis and ischium. 6, 6. The longitudinal fibres of the detrusor urinæ, expanding laterally as they ascend the anterior surface of the bladder. 7, 7. Fibres disposed in an oblique direction. 8. The urachus, upon which some of the longitudinal fibres may be followed. 9. Decussation of the longitudinal fibres upon the neck of the bladder.

FIG. 3. A posterior view of the same urinary bladder.

No. 1. The urachus. 2, 2. The longitudinal fibres passing over the summit of the bladder to descend vertically along its posterior surface. 3, 3. Some of the longitudinal fibres thrown into an oblique position upon the sides of the bladder. 4, 4. The vesiculæ seminales. 5, 5. The vasa deferentia. 6. The triangular interval at the base of the bladder, through which the recto-vesical operation for puncturing the bladder is performed. 7, 7. The ureters, upon which some of the longitudinal fibres are traced from the bladder.

\* The septum pectiniforme, at its margins, is continued into a layer of circular fibres, constituting the external coat of the corpus cavernosum penis.—Vide Horner's Anat., vol. 2, p. 87, 5th edit.—J. P.

Fig 1

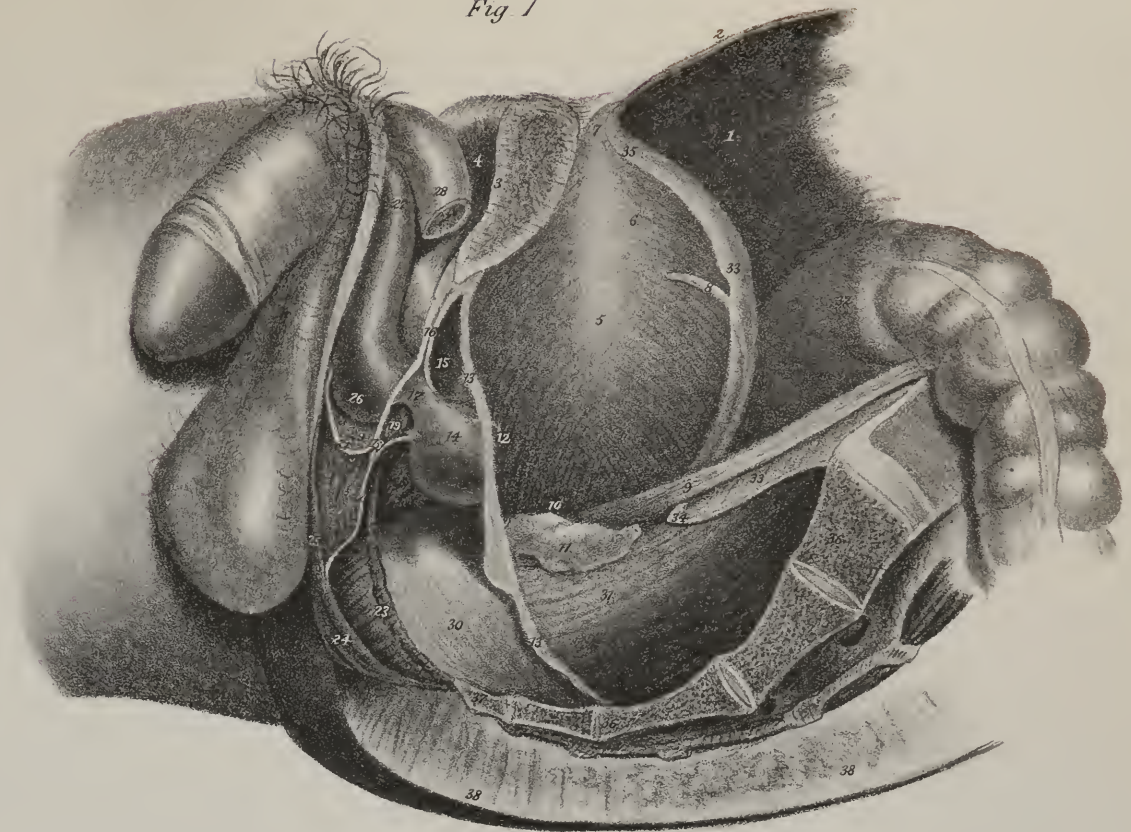


Fig 2



Fig 3







also marked, but slightly, for the dorsal vein, and is attached to the symphysis pubis by a triangular *suspensory ligament*. This is a dense lamella of fibres, so placed, that whilst the cutaneous border is free, the superior one is attached to the pubes, and the inferior to the body of the penis, where its fibres spread out, becoming identified with its structure.

*Structure*.—The corpora cavernosa are composed of a fibrous sheath, enclosing a quantity of erectile tissue. The exterior investment is dense, elastic, and resisting, though composed for the most part of longitudinal fibres. From the inside of its circumference thin lamellæ project, forming partial septa, by means of which the shape of the part is maintained, more than a certain degree of distension is prevented, and the cavity is divided into several small cells. Within these is enclosed the intricate vascular interlacement just alluded to, which consists of numerous ramifications of blood-vessels, chiefly veins, forming complicated anastomoses.

A transverse section of the body of the penis will show the relation and connexion of its component parts. On the sides are two cylindrical tubes, formed by a fibrous membrane, enclosing a vascular mass in the interior, and divided along the middle line by a vertical septum; beneath and between these runs the urethra, surrounded by its vascular investment. The vessels and nerves of the corpora cavernosa are derived from the internal pudic.

About an inch, or a little less, from the anterior margin of the prostate, the urethra comes into contact with what is called the bulb, which is succeeded by a prolongation, similar in structure, named corpus spongiosum, and the latter finally expands into the glans penis; so that the canal is invested for three-fourths of its length by a vascular net-work, which, by being differently disposed in different parts, has received the names just mentioned. It consists of a minute interlacement of capillary vessels, connected together by cellular membrane, capable of receiving a considerable quantity of blood, and thereby assuming that state of tension which attends the venereal orgasm. Hence it has been termed erectile tissue.

The *bulb* is thick, and pendent from the under surface of the canal: it is placed externally to the pelvis, being in front of the deep perinæal fascia, which sends forwards on it a tubular investment. It rests on and is supported by the acceleratores urinæ, and lies immediately beneath the angle formed by the junction of the corpora cavernosa. The bulb receives a large artery from the internal pudic.

The *corpus spongiosum*, extending between the bulb and glans, surrounds the urethra, but exists in greater quantity along its lower aspect; this is partly covered by the same muscles as the preceding.

The *glans* (glans penis) forms the extremity of the penis; it is a conical prominence, slightly compressed from before backwards, presenting at its summit a vertical fissure, marking the termination of the urethra; its base is supported by the extremity of the corpora cavernosa, and presents a circular ridge, (corona glandis.) Behind the last-named part exists a circular constriction, (cervix,) in which are several follicles, (glandulæ Tysoni,) that secrete a substance of peculiar odour. The glans is covered by a thin dry mucous membrane, which is intimately adherent to the structure beneath it, and is continuous at the cervix with the inner layer of the prepuce, as well as with the lining membrane of the urethra at the orifice of that canal. It is also protected by the prepuce.

*Urethra*.—The urethra is extended from the neck of the bladder to the extremity of the penis; its length has been very differently stated by different persons. It is usually set down as being from nine to twelve inches; but an examination of a considerable number of cases made to determine this point, gave, as the greatest length, nine inches and a half, and the least seven inches and a half.\* Its diameter varies in different parts, being about four lines wide in the greater part of its extent, and from two and a half to three at its orifice.† The tube consists of two structures: one being the mucous lining, continuous with that of the bladder; the other a lamella of cellular membrane, resembling the sub-mucous tissue elsewhere, and which serves to connect it with the contiguous structures found along its course.

The urethra is considered as being divisible into three portions, which are named according to the structures that surround them, each presenting some peculiarities deserving notice.

1. The *prostatic portion* (pars prostatica) is from twelve to fifteen lines in length; it is the widest part of the canal, being, however, larger in the middle than at its extremities. In the middle of its floor, or lower surface, projects a narrow ridge, of some lines in length, formed by an elevation of the lining membrane and subjacent cellular tissue. From its shape it has received the name of *caput gallinaginis*, or *veru montanum*.‡ In the middle of its anterior part is a depression, (sinus peculiaris,) close beside the margins of which are placed the openings of the two common seminal ducts, (ductus ejaculatorii,) one at each side. External to this ridge the surface is depressed a little into a groove, (sinus prostaticus,) and is pierced by several minute foramina, communicating with the cells in the substance of the prostate, and through which a viscid fluid is made to ooze if it be pressed.

2. The *membranous part* (pars membranosa) comprises the interval between the margin of the prostate and the bulb, being from ten to twelve lines in length. It is the narrowest part of the canal, and composed of the proper membranes only of the

\* Whately on the Treatment of Strictures.

† Sir E. Home's Practical Observations on the Treatment of Strictures in the Urethra.

‡ The caput gallinaginis, according to Mr. Harrison, of Dublin, is composed in part of erectile tissue. Observations of this structure in its healthy and morbid states, seem in a measure confirmatory of this opinion.—J. P.

urethra,—hence its name; but it is encased by an offset from the deep perinæal fascia, which is continued backwards around it and the prostrate, and is supported by the terminal expansions of Wilson's muscles. The membranous part is in close relation with Cowper's glands, and at its extremity passes through an aperture in the deep perinæal fascia, which, from this circumstance and its shape, is sometimes named the triangular ligament of the urethra.

3. The *bulbous* part of the urethra (*pars bulbosa*) dilates somewhat at its lower surface, but the diameter of the canal at this point does not exceed that of the following part by more than a line, under ordinary circumstances.

4. *Pars spongiosa* is from six to seven inches in length, and continues uniform in its size, being intermediate in diameter between the membranous and bulbous part, whilst in the glans another dilatation appears to take place, called *fossa navicularis*, previously to its narrowing into the orifice of the urethra. It has been contended by M. Amussat, that this dilatation is rather apparent than real, and that it is owing to the fact that the glans, by its greater firmness of texture, draws the lining membrane outwards with it when the urethra is laid open, thereby making it appear wider than it is in reality.\*

## PLATE XXVI.

The anatomy of the urinary bladder and urethra, and of the male organs of generation.

FIG. 1. The urinary bladder, laid open from the front in order to show the anatomy of its interior. The urethra is also exhibited throughout its entire course; the prostatic portion being opened from above, and the spongy portion from the under part of the corpus spongiosum.

No. 1. The mucous lining of the interior of the bladder. 2, 2. The divided coats of the bladder turned aside. 3, 3. The openings of the termination of the ureters. 4. The triangular smooth surface at the base of the bladder, which is called the trigone vesicæ, or trigonum vesicæ. 5. The projection of the mucous membrane at the commencement of the urethra, which is called the uvula vesicæ. 6, 6. The neck of the bladder. 7, 7. The prostate gland. 8, 8. The divided surfaces of the prostate, resulting from the incision which has been made to show the prostatic portion of the urethra. 9, 9. The prostatic portion of the urethra. 10. The veru montanum, or caput gallinaginis. 11, 11. The openings of the ejaculatory ducts; an aperture between these openings leads into the sinus pocularis. 12, 12. The prostatic sinuses, in which are seen the numerous openings of the prostatic ducts. 13, 13. The membranous portion of the urethra; it has been divided across in order to show the rest of the urethra from the under part of the corpus spongiosum. A small part of this portion of the urethra has been removed. 14, 14. Cowper's glands. 15, 15. The ducts of these glands traced for some distance between the corpus spongiosum and the coats of the urethra previously to opening into that canal. 16, 16. The bulb of the urethra, divided by a longitudinal incision; the erectile tissue shown. 17, 17. The body of the corpus spongiosum divided. 18, 18. The corpus cavernosum. 19, 19. The glans penis. 20. The bulbous portion of the urethra. 21. The dilatation called the fossa navicularis. 22, 22. The openings of small mucous lacunæ upon the upper wall of the urethra. 23. The opening of the lacuna magna.

FIG. 2. The interior of the urinary bladder and urethra, shown by means of a vertical incision in the longitudinal direction.

No. 1. The interior of the body of the bladder. 2. Its fundus. 3. Its base. 4, 4. The neck. 5. The recto-vesical fold of the peritonæum. 6. The urachus, the point of reflection of the peritonæum upon the internal surface of the abdominal parietes. 7. The trigonum vesicæ. 8. The opening of entrance of the ureter of the right side. 9. The uvula vesicæ. 10, 10. The prostate gland. 11. The third lobe, or isthmus of the left prostate gland. 12. The vesicula seminalis of the left side. 13. The ejaculatory duct passing beneath the isthmus, or third lobe of the prostate, to open into the prostatic portion of the urethra. 14. The veru montanum, or caput gallinaginis. 15. The prostatic portion of the urethra. 16. The membranous portion. 17. One of Cowper's glands, with its excretory duct. 18, 18. The corpus cavernosum, divided a little to the left of the middle line. 19. A part of the septum pectiniforme. 20. The bulb of the corpus spongiosum. 21. The body of the corpus spongiosum. 22, 22. The glans penis. 23. The bulbous portion of the urethra. 24. The fossa navicularis of the urethra. 25. The meatus urinarius. 26, 26. The openings of mucous lacunæ. 27. The line of junction between the corpus cavernosum and glans penis.

FIG. 3. The under surface of the base of the bladder, with the vesiculæ seminales in their relative position.

No. 1. The recto-vesical fold of peritonæum removed from the anterior surface of the rectum and sacrum, and raised for a short distance from the base of the bladder, and folded back upon that organ. 2, 2. The vasa deferentia. 3, 3. The vesiculæ seminales. 4. The triangular space upon the exterior of the base of the bladder, through which the recto-vesical operation for puncture of the bladder is performed. 5, 5. The ureters. 6. The prostate gland. 7. The commencement of the membranous part of the urethra.

FIG. 4. The vesiculæ seminales turned back from the base of the bladder, in order to show the passage of the ejaculatory ducts beneath the isthmus of the prostate gland.

No. 1. A portion of the bladder turned up from the prostate gland. 2, 2. The lateral lobes of the prostate. 3. Its third lobe or isthmus. 4, 4. The vesiculæ seminales. 5, 5. The vasa deferentia. 6. The ejaculatory ducts.

\* A very extraordinary discrepancy exists among surgical writers, in regard to the length of the urethral canal. According to Sabatier it is from ten to twelve inches long; Cloquet and Lisfranc, nine to twelve; Amusat, seven to eight; Civiale and Malgaigne, about six. Much of this difference may be accounted for by the modes of admeasurement,—whether the urethra be measured on the living subject, with the aid of the catheter, which gives us the natural length of the organ in its unexcited state, or after its removal from the body, and having been stretched out on a board.—The former measurement,



Fig 1.

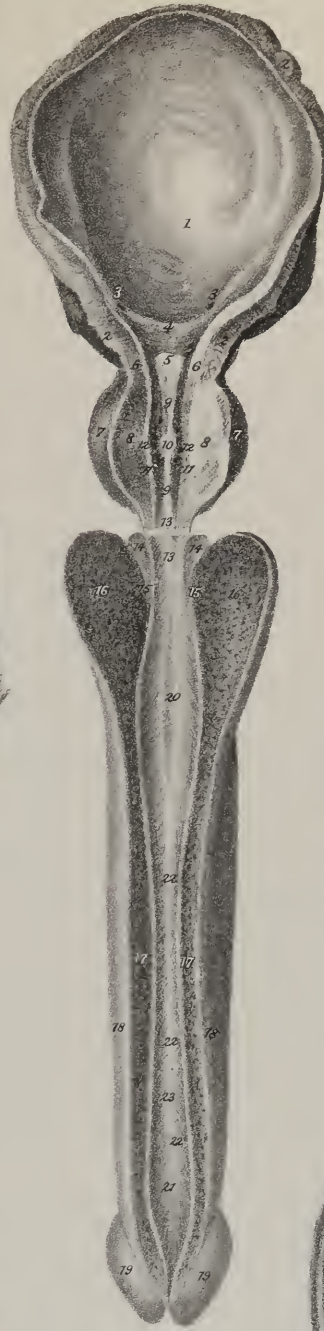

Fig 3.

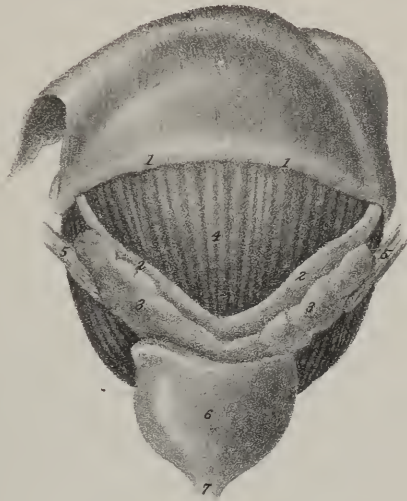

Fig 4.

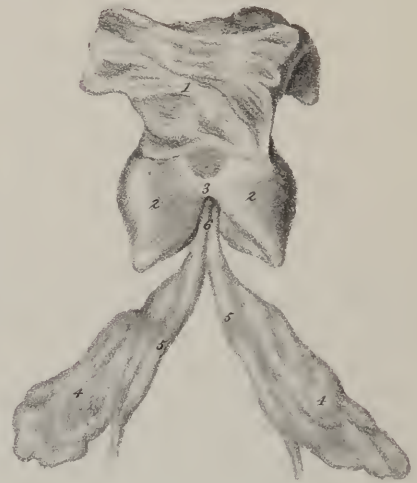
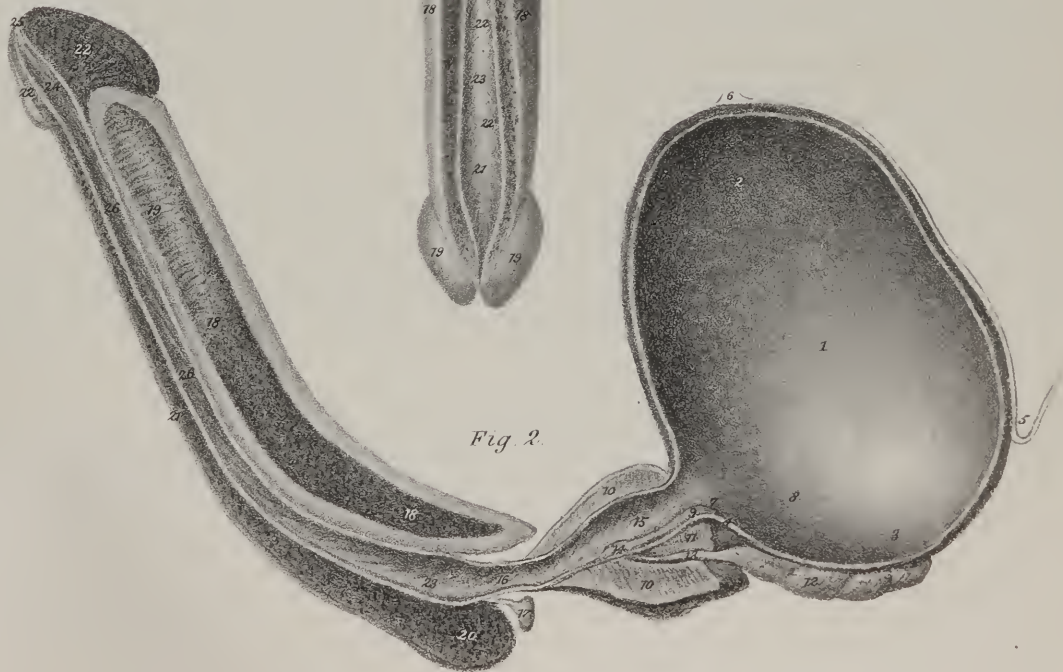


Fig 2.





t  
b  
no  
de  
pe  
is c  
lie,  
by  
as t  
close  
lowe  
men  
by M  
place  
the c  
secret  
the a  
time  
to dis  
cal-d  
and n  
row  
with  
this c  
almo  
ing f  
tunic  
from  
sider  
weat  
being  
line  
It is  
sere  
wh  
ope  
m

*Lining membrane.*—*Lacunæ.*—The lining membrane is smooth and lubricated, as mucous surfaces usually are. Several minute foramina will be found to open into it, being the orifices of mucous follicles, or cryptæ, placed exterior to the mucous membrane, but lined by delicate processes prolonged from it into their interior. These are named *lacunæ*; they are inclined from behind forward, so that urine, when being evacuated, does not find ingress to them.

*Cowper's Glands.*—These are two small masses, about the size and shape of peas, placed immediately beneath the membranous part of the urethra, and behind the bulb. They consist of several small lobules, united by a membranous investment. Two ducts, from three quarters of an inch to an inch long, issue from them, and proceed forwards, to open into the urethra a little before the bulb. They are retained *in situ*, and supported by a tubular prolongation sent forwards on the urethra from the deep perinæal fascia. The existence of Cowper's glands is not constant. In front of them a single small granule or glandular body is occasionally found.

*The Testes;—their change of situation,—descent (?)*—The testicles, (*διδυμοι, testes*), the secreting organs of the seminal fluid, lie, in the earlier months of fetal life, on the psoas muscles, near the lower extremities of the kidneys. Each of them is invested by a proper capsule, or fibrous tunic, and receives, moreover, a partial covering from the peritonæum, to about the same extent as the kidney does, as both are similarly circumstanced with regard to that membrane. It receives its artery from the aorta, close to which it lies, whilst the vein opens into the vena cava on the right side, and into the renal vein on the left. From the lower extremity its duct (vast deferens) will be observed to descend towards the neck of the bladder.

*Gubernaculum testis.*—From the lower end of the testis a cellulo-fibrous cord, of a very different character from that just mentioned, is extended down through the inguinal canal, to the external surface of the pubic symphysis. This has been called by Mr. Hunter gubernaculum testis; it appears a little broader above than below, and also to contain a minute canal.

In the seventh month of pregnancy the length of the gubernaculum is considerably diminished, as the testis has changed its place, having removed from the lumbar region to the iliac fossa. This in strictness cannot be considered a "descent:" for, in the ordinary position of the fœtus, the change is the reverse of that in which its gravity would draw it, and therefore it is rather an ascent. In the eighth month, the testis enters the internal ring, lying behind a process of peritonæum, which makes its exit from the abdomen by the inguinal canal; and at the ninth month it will be found at the bottom of the scrotum, bearing the same relation to its peritonæal investment that it had originally done to the whole membrane, that is to say, lying behind and exterior to its cavity, but still partially covered by it.

The process of peritonæum that accompanies the testis in its course from the lumbar region to the scrotum, is an elongated cul-de-sac, somewhat like the finger of a glove, communicating at the inguinal ring with the general cavity of that membrane, and resting on the fore part of the testis and its cord, but closely adherent to both. By degrees its aperture is closed by the narrowing of the ring, and all communication with the abdomen is cut off; after which the part of the process which corresponds with the cord degenerates into cellular tissue, whilst that over the testis remains still a serous cavity. The position and relation of this organ to its serous investment may be illustrated by taking a small bladder, and pressing some elongated body, such as an almond, against its side, so as partially to invest it, the invested portion being made to serve as an immediate though partial covering for the substance so placed, as a part must remain unconcealed along the lines of reflection. This is the way in which the *tunica vaginalis* is derived from the peritonæum, and the position in which the testis is placed with regard to it.

*Coverings of the Testis and Cord.*—Whilst passing through the inguinal canal, the testis and cord become covered by offsets from the abdominal muscles; exterior to which lie the superficial fascia and the integument. These structures we shall now consider as they are found in the adult.

*Scrotum.*—The testes are contained in a cul-de-sac, or purse-like investment, (*scrotum*), which is short and corrugated in cold weather and in robust persons, but becomes elongated and flaccid in the opposite circumstances. The covering of the testes being composed of several strata, differing in structure, each requires separate examination.

The skin is of a darker colour than elsewhere; it is also thrown into several rugæ or folds, and marked along the middle line by a slightly elevated ridge or raphé, extending from the penis along the centre of the perinæum to the margin of the anus. It is furnished with several sebaceous follicles and some scattered hairs, the bulbs of which are distinctly perceptible when the scrotum is elongated.

which gives the shorter length, is the only one of value in practice. In the opinion of most American anatomists, the genital organs are more fully developed in the black than in the white. The following is the measure, during life, of the length of the urethra in four blacks and two mulattoes, which I recently made in the Philadelphia Hospital:

Negro,	6 feet 4 inches in height,	length of urethra, moderately stretched on the catheter,	8 $\frac{3}{4}$ inches,	unstretched,	7 $\frac{1}{4}$ inches.
do.	5 " 5 "	"	8 $\frac{3}{4}$ "	"	7 $\frac{1}{4}$ "
do.	5 " 6 "	"	8 $\frac{3}{4}$ "	"	7 "
Mulatto,	6 " 1 "	"	8 "	"	6 $\frac{3}{4}$ "
do.	6 "	"	8 $\frac{3}{4}$ "	"	7 $\frac{1}{4}$ "
A small negro boy aged nine,			4 "	"	3 $\frac{1}{2}$ "

The *dartos* is a thin lamella of a peculiar texture, placed beneath the skin, and so disposed as to form two sacs, each containing the testis of the corresponding side, and both united along the median line,—thus forming a partition between them, (*septum scroti*.) This structure is vascular, and striated so as to resemble in some degree muscular fibre. It is confessedly contractile, and serves the purpose of drawing up and sustaining the testes, at the same time that it corrugates the skin; but when macerated, or tried by the usual tests, no trace of fibrine can be discovered in it. When examined with attention, it will be found that its texture gradually becomes assimilated to the superficial fascia which descends from the abdomen round the cord, and again, below the scrotum, it in the same way passes into the superficial fascia of that region. We may now call to our aid a few facts, which will assist in throwing some light upon, if they do not actually determine, a litigated question. That lamella which lies between the skin and abdominal muscles in the human subject is merely cellular membrane; in the larger quadrupeds a layer of elastic tissue (*tissu jaune*) is substituted, in order to support the weight of the viscera. In the human subject such a support is not wanted for the abdomen, but the pendulous testes require something of the kind. When emaciation occurs, indicating a general diminution in the subcutaneous cellular deposit, the testes hang lower than they had previously done, owing to the absorption of the elastic tissue of the *dartos*, and its consequent conversion into mere cellular membrane; but when the *embonpoint* is restored, the testes rise to their usual level, by the restoration of the sustaining agent. In this view of the subject the *dartos* constitutes a transition structure between cellular membrane and elastic tissue.

*Fascia of the Cord, Cremaster, &c.*—Beneath the *dartos* lies the thin fibrous expansion derived from the external abdominal ring; it is connected with that next in order. The *cremaster*, named also from its colour *tunica erythroides*, (*ερυθρος*, red; *ειδος*,) consists of muscular fibres arching downwards in front of the cord and testes, some being also placed behind. The fibres of the

## PLATE XXVII.

Anatomy of the male organs of generation.

FIG. 1. A longitudinal section of the penis, near to the middle line of the *corpus cavernosum*, in order to show the *septum pectiniforme*.

Nos. 1, 1. The fibrous sheath that invests the *corpora cavernosa*. 2, 2. The posterior part of the *septum pectiniforme*, in which the fibrous bands are very closely aggregated together so as to form a complete division. 3. The anterior part of the *septum pectiniforme*; the bands are placed wider apart, and permit of a communication of the proper texture of the two *corpora cavernosa*. 4, 4. The cut extremities of some of the oblique fibrous cords or trabeculae. 5, 5. Cut surface of the *glans penis*. 6. The *meatus urinarius*. 7, 7. The *corpus spongiosum*. 8. The *fossa navicularis* of the urethra. 9. The canal of the urethra: the small depressions upon its surface are the openings of the *lacunae*. 10. The bulbous portion of the urethra. 11. The bulb of the *corpus spongiosum*.

FIG. 2. A section of the *corpus cavernosum*, showing the cellular structure, and the distribution of the artery. The figure is copied from one of the beautiful plates accompanying Sir Everard Home's "Observations on the Human Urethra," &c. published in the *Transactions of the Royal Society for 1820*. Sir E. Home gives the following account of the preparation from which this figure was drawn:—"The *corpora cavernosa* were injected with mercury through the arteries, and the mercury was retained there by plugging up the trunks with common injection. The parts were then dried, and a longitudinal section made so as to let the mercury escape, and leave the trellis-work empty." This section is magnified two diameters.

Nos. 1, 1. The fibrous envelope of the *corpus cavernosum*. 2, 2. Branches of the artery of the *corpus cavernosum*. 3, 3. One of the *dorsales penis* arteries.

FIG. 3. A transverse section of the penis, made at about its middle. "The *corpora cavernosa* and *corpus spongiosum* had been injected by the arteries with spirit, and then allowed to harden in spirit. The urethra had also been injected with spirit, and kept distended."—From Sir Everard Home's figure in the *Philosophical Transactions*.

Nos. 1, 1. The fibrous sheath of the *corpora cavernosa*. 2. The *septum pectiniforme*. 3, 3. The cellular structure of the *corpora cavernosa*: some small branches of an artery are seen ramifying amongst the cells. 4, 4. The *corpus spongiosum*. 5. The urethra; its lining membrane is thrown into longitudinal folds. 6, 6. The cellular envelope of the penis. 7, 7. The cellular tissue connecting the *corpus spongiosum* to the under part of the *corpora cavernosa*. 8, 8. The vessels and nerves of the *dorsum penis*.

FIG. 4. A small portion of the cellular structure of the *corpus cavernosum* of the last section, magnified fifteen diameters.—From Sir E. Home's paper.

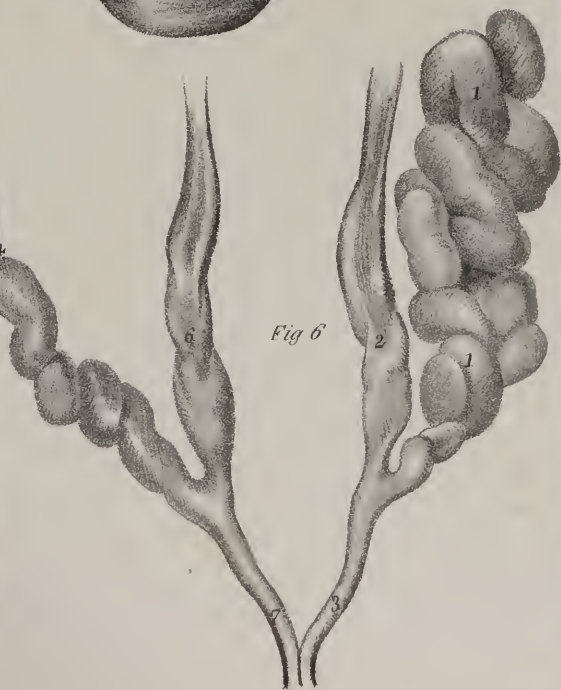
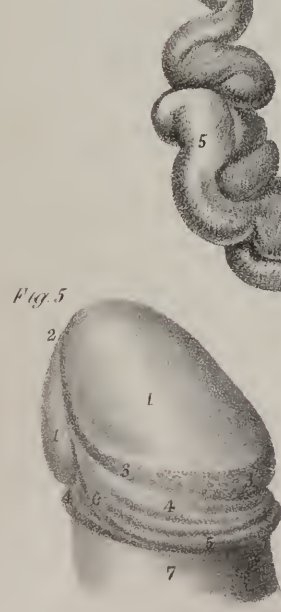
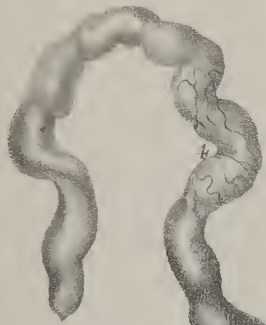
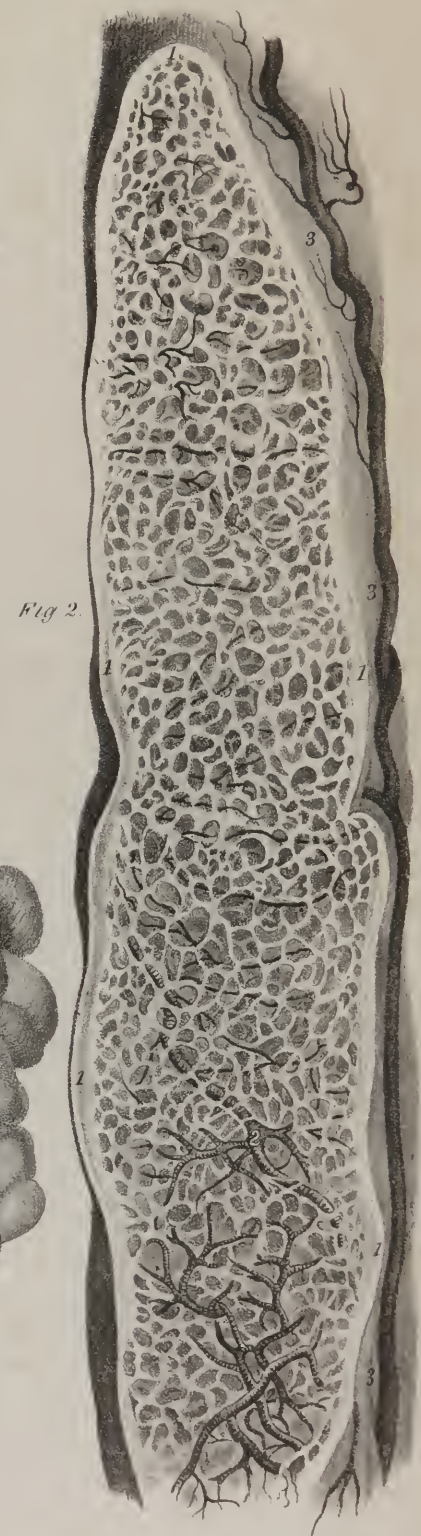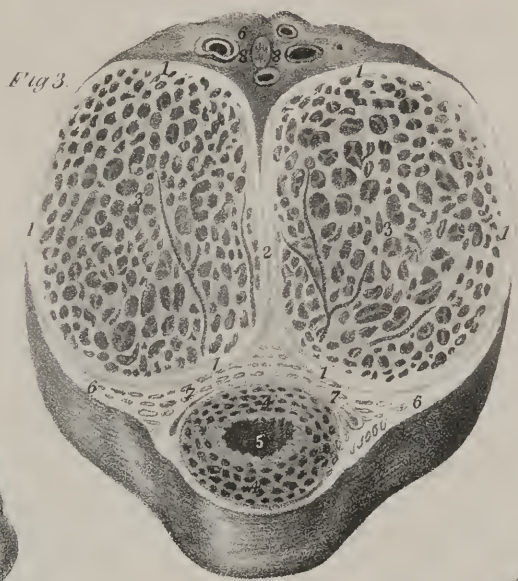
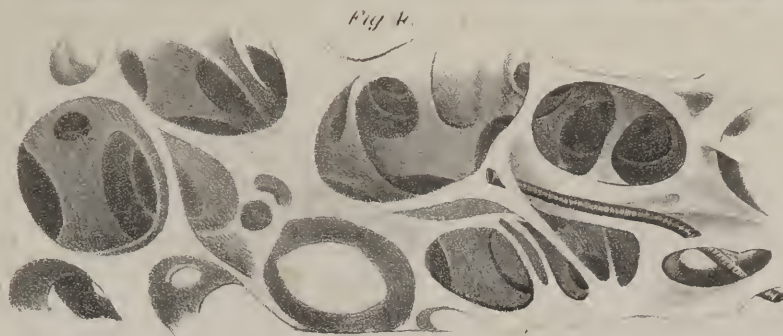

FIG. 5. The extremity of the penis, showing the *glans*.

Nos. 1, 1. The *glans penis*. 2. The *meatus urinarius*. 3, 3. The *corona glandis*, upon which are seen the small granulations formed by the *glandulae odoriferae*. 4, 4. The sinus which surrounds the base of the *glans penis*. 5, 5. The fold of integument and mucous membrane,—the *prepuce*. 6. The *frænum præputii*. 7. The integument of the penis.

FIG. 6. The *vesiculæ seminales*, with their efferent ducts.

No. 1. The left *vesicula seminalis*, distended with air and dried; its cellulo-fibrous capsule has been removed in order to show the numerous convolutions of which the *vesicula* is composed. 2. The *vas deferens*, forming convolutions previously to its termination. 3. The *ejaculatory duct*, formed by the union of the *vas deferens* with the duct of the *vesicula seminalis*. 4, 4. The right *vesicula seminalis* unravelled, showing its constitution of a single duct. 5. A *cæcal pouch* developed from the principal duct of the *vesicula*. 6. The right *vas deferens*. 7. The right *ejaculatory duct*.

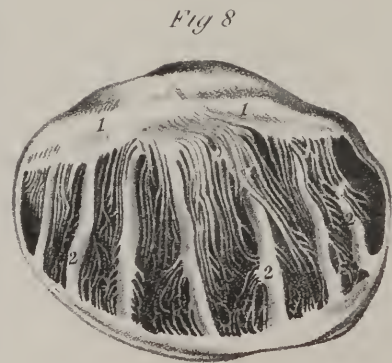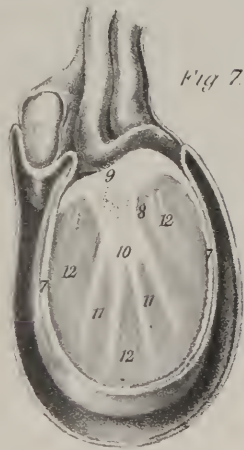
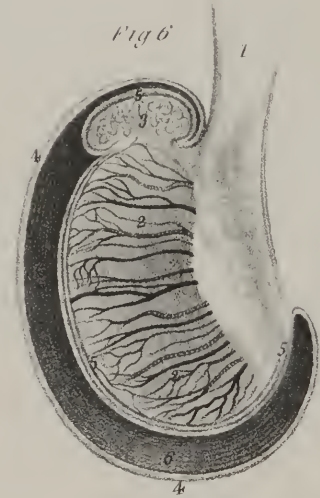
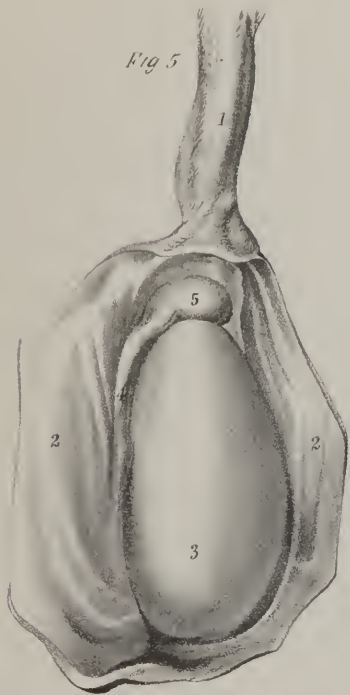
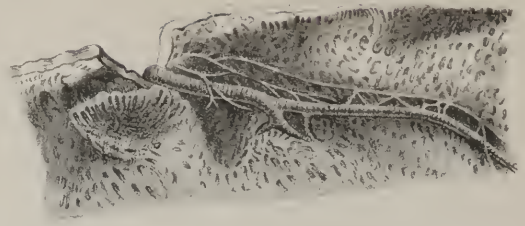
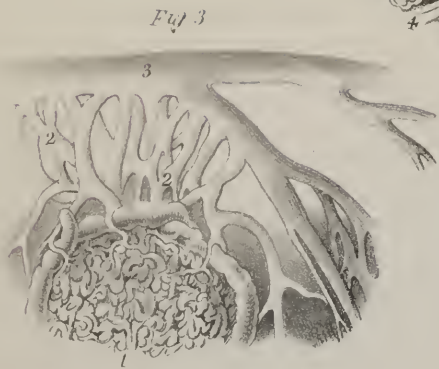












cremaster, where they are distinct one from the other, (intervals existing between them,) are connected by cellular tissue. Under the preceding is found a thin cellular investment, which is continued from the fascia transversalis at the internal abdominal ring. The three laminæ here described, namely, that given from the margin of the external ring, the cremaster, and the process derived from the fascia transversalis, are common to the spermatic cord and the testis; on the latter they are closely united one to the other, and to its serous tunic.

*Vessels and nerves.*—The investments of the cord and testes are supplied with blood from three sources. 1. The external pudic artery passes inwards from the femoral, and crossing the cord, distributes branches to the anterior and lateral parts of the scrotum, as well as to the integuments of the penis and pubes. 2. More deeply seated than the preceding is situated a branch given from the epigastric artery. This supplies the cremaster, from which it is named *ramus cremastericus*, and sends ramifications to the integument of the scrotum and pubes. 3. The perinæal branch of the internal pudic proceeds along the perinæum, from behind forwards to the scrotum, in which it is distributed, especially towards the septum.

The *veins*, owing to the thinness of the skin of the scrotum, are apparent on the surface; they follow the course of the arteries. The lymphatics for the most part open into the inguinal lymphatic glands.

The *nerves*, like the arteries, are three in number. One, the ilio-scrotal, proceeding from the musculo-cutaneous branch of the lumbar plexus, passes out of the external abdominal ring, and divides into filaments, which supply the integument of the scrotum. In some cases two small branches are found to follow the course here pointed out. 2. The genito-crural proceeds also from the lumbar plexus. As its name implies, this nerve, dividing, sends one part to the integuments of the thigh, the other comes into contact with the spermatic cord at the internal abdominal ring. This latter, passing through the inguinal canal,

## PLATE XXVIII.

Anatomy of the male organs of generation.

FIG. 1. The peculiar distribution of the arteries of the penis, supposed by Müller to produce the erection of the organ. This figure exhibits the arteriæ helicinæ in a magnified portion of the corpus cavernosum penis.—From Müller's Archiv. for 1835.

Nos. 1, 1. The cellular structure of the corpus cavernosum. 2, 2. Branches of the artery of the corpus cavernosum, taking their course in the substance of the walls of the cells. 3, 3. Nutritious twigs of the artery of the corpus cavernosum, which terminate in capillaries continuous with the veins. 4, 4. Helicine arteries, terminating in a tuft (Quast) of club-shaped and tendril-like twigs, curved like horns at their extremities. This tuft is inclosed in an elastic membrane, and projects into one of the venous cells of the erectile tissue. 5, 5. Helicine arteries, terminating in a single twig.

FIG. 2. A single tuft of a helicine artery, projecting into one of the venous cells.

FIG. 3. A magnified view of a portion of injected corpus cavernosum penis, showing the communication of the venous cells with the dorsalis penis vein.

No. 1. The venous cells of the periphery of the corpus cavernosum. 2, 2. Small veins, collecting the returning blood from the venous cells. 3. The dorsalis penis vein.

FIG. 4. Distribution of nervous filaments to the cellular texture of the corpus cavernosum, in company with a branch of the artery of the corpus cavernosum.—The four preceding figures are copied from Müller's Archiv. for 1835.

FIG. 5. A testis, with a portion of the spermatic cord; the tunica vaginalis is laid open in order to show the body of the gland and the epididymis.

No. 1. The spermatic cord. 2, 2. The tunica vaginalis reflexa. 3. The testis, invested by the tunica vaginalis propria. 4. The epididymis. 5. The globus major of the epididymis.

FIG. 6. A diagram representing a longitudinal section of the testis, and showing the mode of reflection of the tunica vaginalis.

No. 1. The spermatic cord. 2, 2. A section of the substance of the testis, showing its internal texture. 3. Section of the epididymis. 4, 4. The tunica vaginalis reflexa. 5, 5. The tunica vaginalis propria, investing the testis and epididymis. 6. The cavity of the tunica vaginalis.

FIG. 7. A transverse section of the testis, showing the reflection of the tunica vaginalis. The references are the same as in the preceding figure.

Nos. 7, 7. The tunica albuginea. 8. The inflection of the tunica albuginea, forming the mediastinum testis. 9. The vessels of the testis, situated in the posterior part of the mediastinum. 10. The divided tubes of the rete testis. 11. The fibrous cords or ligaments of the tunica albuginea. 12, 12. The lobular structure of the testis.

FIG. 8. The "tunica albuginea, cut perpendicularly through its centre."—The two last figures are copied from Sir Astley Cooper's beautiful monograph "On the Structure and Diseases of the Testis."

Nos. 1, 1. The mediastinum testis. 2, 2. The fibrous cords or "ligaments which connect the sides of the tunica albuginea, and which form strong bands of union between them, to prevent the injurious effects of violence. Between these pillars are seen ligaments, which are shorter and more delicate, some of which proceed from the mediastinum, and a few from the opposite edge of the testis, from which membranes are extended to envelope the lobes of the tubuli."—Sir Astley Cooper's description, Op. cit.

FIG. 9. The spermatic cord, in which the vessels are successfully injected.

No. 1. The spermatic artery. 2. The deferential artery, accompanying the vas deferens. 3, 3. The vas deferens. 4. The globus minor of the epididymis. 5. The globus major of the epididymis. 6. The body of the testis. 7. The cremasteric artery. 8, 8. Spermatic veins. 9, 9. Small convoluted ramuscules of the spermatic veins, called "vasa pampiniformia."



sends many filaments to the cremaster, while others are given generally to the covers of the cord and testis. The third is the perinæal nerve. It accompanies the artery of the same name, and ramifies in the inferior and lateral parts of the scrotum.

*Tunica vaginalis.*—Under the parts described as forming investments common to the cord and the testis, lies the proper serous covering (*tunica vaginalis*) of the latter, (plate XXVIII.) The manner in which this membrane is derived from the peritonæum, and the changes which occur subsequently to its being drawn from the abdomen into the scrotum, have been already described. In the adult it forms a shut sac, inverted on itself in such a way as that one part of it covers the body of the testis, as well as the epididymis, except where the vessels enter its posterior border; at which point the other part is reflected outwards, and becomes a lining to the preceding investments, to which it is closely adherent. From the difference in the disposition or relations of both these parts of the membrane, they generally receive different names. One (that adherent to the testis) is called *tunica vaginalis testis*, the other is named *tunica vaginalis reflexa*.

*The Testes,—their disposition and structure.*—Having considered their change of position, and examined the various structures by which they are invested, we now proceed to the description of the organs themselves.

The testes (plates XXVIII. and XXIX.) are suspended at unequal heights, that of the right side being higher than the opposite; this disposition prevents the inconvenience or injury that might result from one being pressed against the other in certain positions of the thighs. They are of an oval form, somewhat compressed laterally, and so placed by the manner in which they are suspended by the spermatic cords, that their upper extremities are turned obliquely forwards, and the lower in a corresponding degree backwards. The long diameter of each varies from an inch and a half to two inches; that from side to side is about an inch or a little more. Along the posterior border is placed an elongated appendage, called epididymis. The secretory structure of the testis is enclosed in a firm capsule named the tunica albuginea.

*Tunica albuginea.*—This membrane immediately invests the substance of the testicle, and at the same time determines its

## PLATE XXIX.

Anatomy of the testis, with its descent in the fœtus.

FIG. 1. A transverse section of the testis, showing the membranous septa which inclose and separate the lobules of the testis.—From Sir Astley Cooper's beautiful monograph.

Nos. 1, 1. The tunica albuginea. 2. A thin membranous layer derived from the tunica albuginea, and investing the epididymis and vessels of the testis. 3. The vessels of the testis. 4. The mediastinum testis. 5, 5. Fibrous bands given off from the mediastinum, and attached by their extremity to the internal surface of the tunica albuginea. 6, 6. Niches formed by membranous septa, serving to lodge the lobules of the testis. 7, 7. Two of the lobules invested with the tunica vasculosa testis.

FIG. 2. The testis viewed from the side: a part of the tunica albuginea has been removed in order to show the lobules, inclosed in the thin expansion of the tunica vasculosa.—After Sir Astley Cooper.

Nos. 1, 1. The tunica vaginalis. 2, 2. The tunica albuginea. 3. A part of the mediastinum testis. 4, 4. The lobuli testis invested by the tunica vasculosa, in which the peculiar arrangement of the vessels will be observed.

FIG. 3. A longitudinal section of the testis, showing the disposition of the lobules, with their connexion to the mediastinum.—After Sir Astley Cooper.

No. 1. The lower part of the spermatic cord. 2. The globus major of the epididymis. 3. The globus minor of the epididymis; the body of the epididymis is concealed by the testis. 4, 4. The tunica albuginea. 5, 5. The mediastinum testis. 6, 6. Lobules of the testis, invested by the tunica vasculosa.

FIG. 4. A transverse section of the testis, showing the tubuli composing the lobules injected with mercury.—From one of Sir Astley Cooper's beautiful preparations.

Nos. 1, 1. The tunica albuginea. 2. The mediastinum: the dark points upon the surface represent the extremities of the rete testis by which the tubuli have been filled with the injection. 3, 3. The lobuli testis, seen to be composed of the convolutions of minute tubes, the tubuli seminiferi. 4, 4. The vasa recta.

FIG. 5. A very beautiful preparation, made by Sir Astley Cooper, in which the tubuli are filled with size injection, and unravelled.

FIG. 6. The substance of the testis, as seen upon the removal of the tunica albuginea and tunica vasculosa.—After Sir Astley Cooper.

Nos. 1, 1. The flattened extremities of the lobuli testis.

FIG. 7. The secreting and excreting structure of the testis.—From a preparation injected with mercury and dried.

Nos. 1, 1. The tunica albuginea. 2, 2. The mediastinum testis. 3, 3. Lobules of the testis, composed of the convolutions of the tubuli seminiferi. 4, 4. Vasa recta. 5, 5. The rete testis. 6, 6. Vasa efferentia. 7, 7. Cones of tubuli formed by the vasa efferentia, and called coni vasculosi. 8. The mass of tubuli at the upper extremity of the organ constitutes the globus major of the epididymis. 9, 9. The body of the epididymis. 10. The globus minor of the epididymis. 11, 11. The convoluted commencement of the vas deferens. 12. The vasculum aberrans, terminating in the commencement of the vas deferens. 13. The vas deferens.

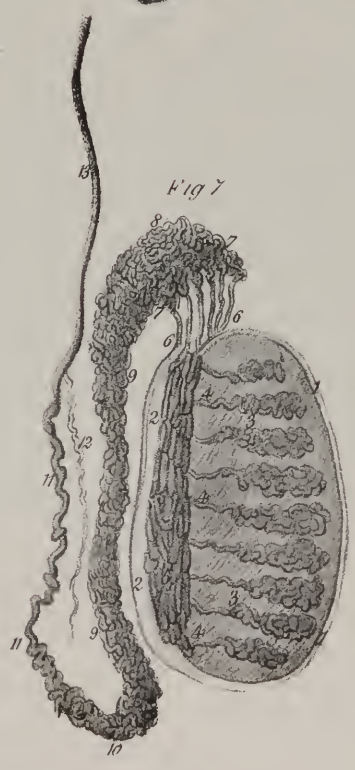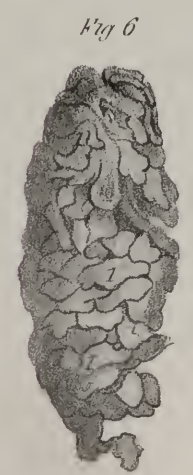
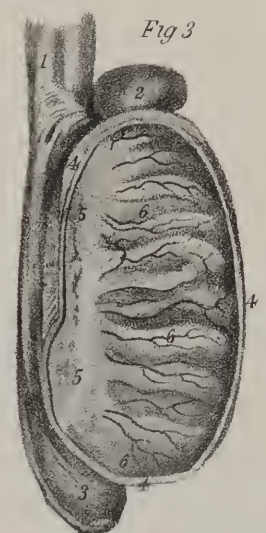
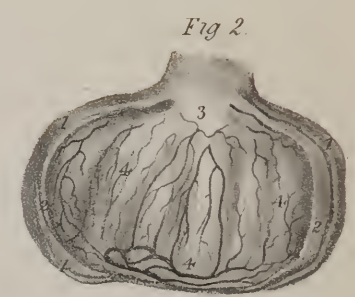
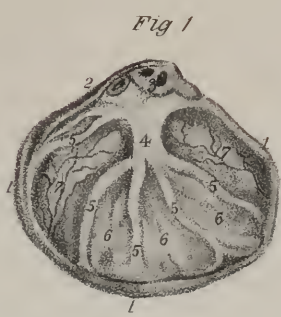FIG. 8. A diagram section of the scrotum of a fœtus, representing the descent of the testis.

No. 1. The gubernaculum testis. 2. The testis. 3, 3. The peritonæum, being carried down into the scrotum by the testis.

FIG. 9. A more advanced stage in the descent of the testis, after it has completely descended, but previously to the closure of the tunica vaginalis.

No. 1. The testis. 2. The spermatic cord. 3, 3. The peritonæum. 4, 4. The cavity of the tunica vaginalis communicating with the cavity of the peritonæum: this is the condition of parts previously to the occurrence of congenital inguinal hernia.





for  
the  
to the  
direct  
form  
Thus  
the h  
vessel  
fibrous  
which  
the for  
T  
cations  
vascula  
sacule  
T  
papyl  
trabec  
others  
circumf  
from th  
Th  
number  
sets con  
maintain  
approac  
Va  
fibres of  
the bloo  
vessels  
The vas  
other has  
Va  
nity ca  
sequence  
epidym  
extremie  
T  
anica  
and the  
being u  
effluent  
Va  
so well  
deferret  
abdom  
deferret  
blood  
from t  
Arrive  
desce  
of the

form. It is of a clear white colour, dense and fibrous,—its fibres interlacing in every direction. Its outer surface is covered by the tunica vaginalis, except posteriorly, where the spermatic vessels pass through it, at which point that membrane is reflected off.

At the posterior border of the testis the tunica albuginea separates into two laminae; one of which, the external, is continued to the vas deferens, (the excretory duct of the testis;) the other, joining with a corresponding layer from the opposite side, is directed for the space of a few lines into the substance of the gland. This last part, known by the name *corpus Highmorianum*, forms an incomplete septum in the cavity of the tunica albuginea, and is thence named by Sir A. Cooper\* “mediastinum testis.” Thus projecting from behind forwards, it is broader superiorly than at its lower extremity, and extends from the upper nearly to the lower end of the testis. Between the fibres of the mediastinum small intervals exist, which lodge seminal canals and blood-vessels, to be afterwards described. From its surface (which looks towards the cavity of the tunica albuginea) are given off fibrous processes that admit of being distinguished into two series. One of these consists of several slender cords or filaments, which, being also connected to the tunica albuginea at different points, serve to maintain the shape of the testis. The others, in the form of delicate laminae, separate and support the several lobules into which the seminal vessels are divided.

*Tunica vasculosa*.—The inner surface of the tunica albuginea is lined by a delicate membrane formed of the ultimate ramifications of the spermatic blood-vessels, united by a minute portion of cellular tissue, and hence named tunica vasculosa.† This vascular membrane is also expanded over the fibrous processes already pointed out, and is thus brought into relation with each lobule of the testis.

The tunica albuginea being removed, the *glandular structure* of the testis lies exposed. It has the appearance of a soft, pulpy, dark yellow mass, divided into lobes. This substance is, by injection, found to consist of vast numbers of minute tubes (tubuli seminiferi) which do not communicate one with the other. The lobes (*lobuli testis*) differ in size, some containing one, others a greater number of the seminal tubes. Their shape is somewhat conical; the large end of each is directed towards the circumference of the testis, the small one towards the mediastinum. They are supported by the fibrous expansions extended from the mediastinum to the tunica albuginea.

The *tubuli seminiferi* (vascula serpentina) are the vessels in which the seminal fluid is secreted. According to Monro, their number is about three hundred, the length of each about sixteen feet, and the diameter  $\frac{1}{200}$  of an inch. Each of these small vessels commences by a closed extremity towards the inner surface of the fibrous covering of the testis, and from this point proceeds, inclining from side to side in a serpentine or zig-zag course, towards the mediastinum. It loses the convoluted disposition as it approaches that process, and, passing through its fibres, opens into the next order of vessels.

*Vasa recta*.—The second order of seminal vessels are situated in the substance of the tunica albuginea, or rather amid the fibres of that process of it which has been termed mediastinum; of this they occupy but the anterior part, the posterior lodging the blood-vessels. The aggregate of them is named *rete testis*. Being less convoluted than the tubuli, though not straight, these vessels are named *vasa recta*. Their direction is backwards and upwards, to reach the posterior and upper part of the testis. The vasa recta are fewer in number, and larger than the tubuli seminiferi, from which they receive the secretion; and, on the other hand, are more numerous and smaller than the vessels into which they discharge it.

*Vasa efferentia*.—The two preceding series of canals form, with the membrane in which they are contained, what is properly called the body of the testis; they next transmit the seminal fluid from it, (to its appendage, the epididymis,) and are in consequence named *vasa efferentia*: they are from twelve to fifteen in number, and open separately into a single vessel, of which the epididymis is formed. Being straight at the point at which they leave the testis, and very much convoluted towards their other extremity, they present a conical disposition, from which the name *coni vasculosi* has been applied to them.

The *epididymis* (επι, upon; διδυμος, testis) is placed along the posterior border of the testis, and is partially invested by the tunica vaginalis. Its upper or larger extremity is called the head or globus major; the lower is named its cauda or globus minor; and the narrow intervening part, the body. The epididymis consists of a single tube much convoluted, the several convolutions being united one to the other by small fibrous bands; the larger size of the upper part is owing to its connexion with the vasa efferentia. The seminal canal at the globus minor assumes the name of vas deferens.

*Vas deferens*.—This is the excretory duct of the testis; there are therefore two, one on each side. The tortuous condition, so well marked in the epididymis, gradually diminishes, and is entirely lost at a short distance from the commencement of the vas deferens. Each extends from the lower border of the epididymis to the prostatic part of the urethra, passing through the abdominal parietes; its length is very considerable, and its course necessarily complicated. Ascending behind the testes, the vas deferens comes into relation with the spermatic artery, veins, and nerves, constituting with them the cord. It lies behind the blood-vessels, and is readily distinguishable from them by its hard, cord-like feel. The direction of the spermatic cord is vertical from the testes upwards to the external abdominal ring; here it inclines obliquely outwards in the course of the inguinal canal. Arrived at the internal ring, the vas deferens turns away from the other vessels, and passes downwards into the pelvis. In descending, it runs along the side of the bladder, and passing anteriorly to the termination of the ureter, reaches the inner border of the vesicula seminalis, with whose duct it unites to form the common seminal or ejaculatory duct. The vas deferens is formed

\* Observations on the Structure and Diseases of the Testis.

† Sir A. Cooper, loc. cit.



of an external peculiarly thick and dense substance, and an internal mucous lining membrane; the calibre of its canal is very minute, especially towards its commencement.

*Vesiculæ Seminales.*—The vesiculæ seminales (plates XXVI. XXVII.) are two narrow, membranous sacs, placed along the base of the bladder, and extended obliquely from the ureters to the base of the prostate gland. Their breadth is not more than three or four lines, their length two inches and a half. They converge anteriorly, and diverge behind, so as to include between them an angular space, in which the bladder rests immediately on the rectum. Each vesicula is convoluted, so as to appear much shorter than it really is, and consists of two lamellæ, the exterior one being dense and firm, whilst the internal is in every respect similar to mucous membrane, and thrown into folds, so as to divide the cavity into cells. The anterior extremity of the vesicula ends in a narrow tube, which unites with the vas deferens, forming a common duct.

The common seminal ducts (*ductus ejaculatorii*) result from the union of the vas deferens and the tube from the vesicula on each side. Each is about an inch in length. They run forward parallel one to the other, lying between the middle and two lateral lobes of the prostate, then between the latter and the mucous membrane,—piercing which, they open into the urethra, beside the margins of the sinus which exists at the anterior part of the veru montanum.

*Vessels and nerves of the Testis.*—The vessels and nerves of the parts which cover the spermatic cord and testis have been already described; it remains to point out those which are furnished to the organ itself.

*Artery of the Vas Deferens.*—A long, slender branch, given off by a vesical artery, accompanies each vas deferens, ramifying in its coats, and hence named deferential.\* It extends as far as the testis, and communicates with the vessel to be next noticed.

The *spermatic artery* is slender and remarkably long. In early fœtal life, the length is, however, no greater than ordinary, as at that period the testis is situated near the parts of the aorta from which the artery springs. The spermatic artery, as it approaches the testis, gives off small branches to the epididymis, then perforates the tunica albuginea, and ramifies in the vascular membrane to supply the tubuli seminiferi.

The *spermatic veins* commence by radicles from the different parts of the epididymis and testis; these unite into two or three vessels, which freely communicate one with the other, forming a sort of plexus. Following the course of the arteries,

## PLATE XXX.

Female organs of generation, external and internal, with a side view of the viscera of the female pelvis.

FIG. 1. The external organs of generation of the adult female.

Nos. 1, 1. The mons Veneris. 2, 2. The labia majora. 3. The anterior commissure of the vulva. 4. The posterior commissure of the vulva. The elliptical area included within these limits is the vulva. 5. The perinæum. 6. The margin of the anus. 7. The fossa navicularis. 8. The clitoris. 9, 9. The præputium clitoridis. 10. The glans clitoridis. 11, 11. The labia minora, or nymphæ, losing themselves gradually upon the walls of the vulva. 12. The vestibule. 13. The tubercle of mucous membrane, which marks the situation of the orifice of the urethra. 14. The meatus urinarius. 15. The opening of the vagina. 16, 16. Carunculæ myrtiformes, bordering the entrance of the vagina.

FIGS. 2, 3, 4, 5, represent various forms of the hymen.

FIG. 2. Nos. 1, 1. The hymen, consisting of a membranous septum perforated through its centre. 2. The vestibule.

FIG. 3. No. 1. The semi-lunar form of the hymen,—a membranous septum, incomplete in front, and having the concavity directed forwards. 2. The opening of the vagina. 3. The vestibule, perforated at its lower part by the meatus urinarius.

FIG. 4. No. 1. A vertical septum dividing the entrance of the vagina into two lateral openings. 2. The vestibule, with the meatus urinarius.

FIG. 5. No. 1. A transverse membranous septum, dividing the entrance of the vagina into an anterior and posterior opening; the latter being large and well defined, the former narrow and valvular. 2. The vestibule.

FIG. 6. A side view of the female pelvis, showing the position of the viscera.

No. 1. The prominence of fat which produces the elevation of the mons Veneris. 2. The cartilaginous surface of the symphysis pubis. 3. The rectus muscle attached to the upper part of the body of the os pubis. 4. The bladder, distended with fluid; the figure marks its body. 5. The fundus of the bladder, from which the peritonæum is reflected upon the internal surface of the abdominal parietes. 6, 6. The ureter of the left side. 7. The base of the bladder. 8. Its cervix. 9. The urethra. 10. The meatus urinarius. 11. The clitoris; the left crus is divided across. 12. The labium pudendi majus of the right side. 13. The entrance of the vagina. 14, 14. Carunculæ myrtiformes. 15, 15. The transverse rugæ of the vagina. 16. The os uteri projecting into the upper part of the vagina. 17. Its anterior lip. 18. Its posterior or longer lip. 19. The divided edge of the vagina, at its attachment to the cervix uteri. 20. The cervix, or neck of the uterus. 21. The body of the uterus. 22. The fundus of the uterus. 23. The left broad ligament of the uterus. 24, 24. The left Fallopian tube. 25. Its fimbriated extremity. 26. The convex surface of the left ovary, seen projecting below the cut border of the broad ligament. 27. The round ligament. 28. The duplicature formed by the passage of the peritonæum from the anterior surface of the vagina to the base of the bladder. 29. The posterior duplicature, formed by the peritonæum in passing from the anterior surface of the rectum to the posterior surface of the vagina. 30. The cavity of the peritonæum. 31. The upper portion of the rectum. 32. The middle portion of the rectum. 33. The inferior and terminal portion of the rectum. 34. The superficial spincter ani muscle. 35. The anus. 36. Section of the last lumbar vertebra. 37, 37. Divided surface of a vertical section of the sacrum. 38. The coccyx.

\* Sir A. Cooper, loc. cit.

Fig 2



Fig 3

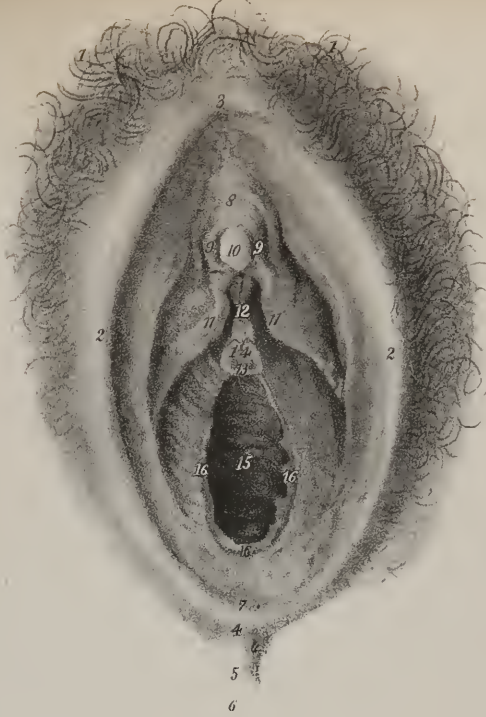

Fig 4


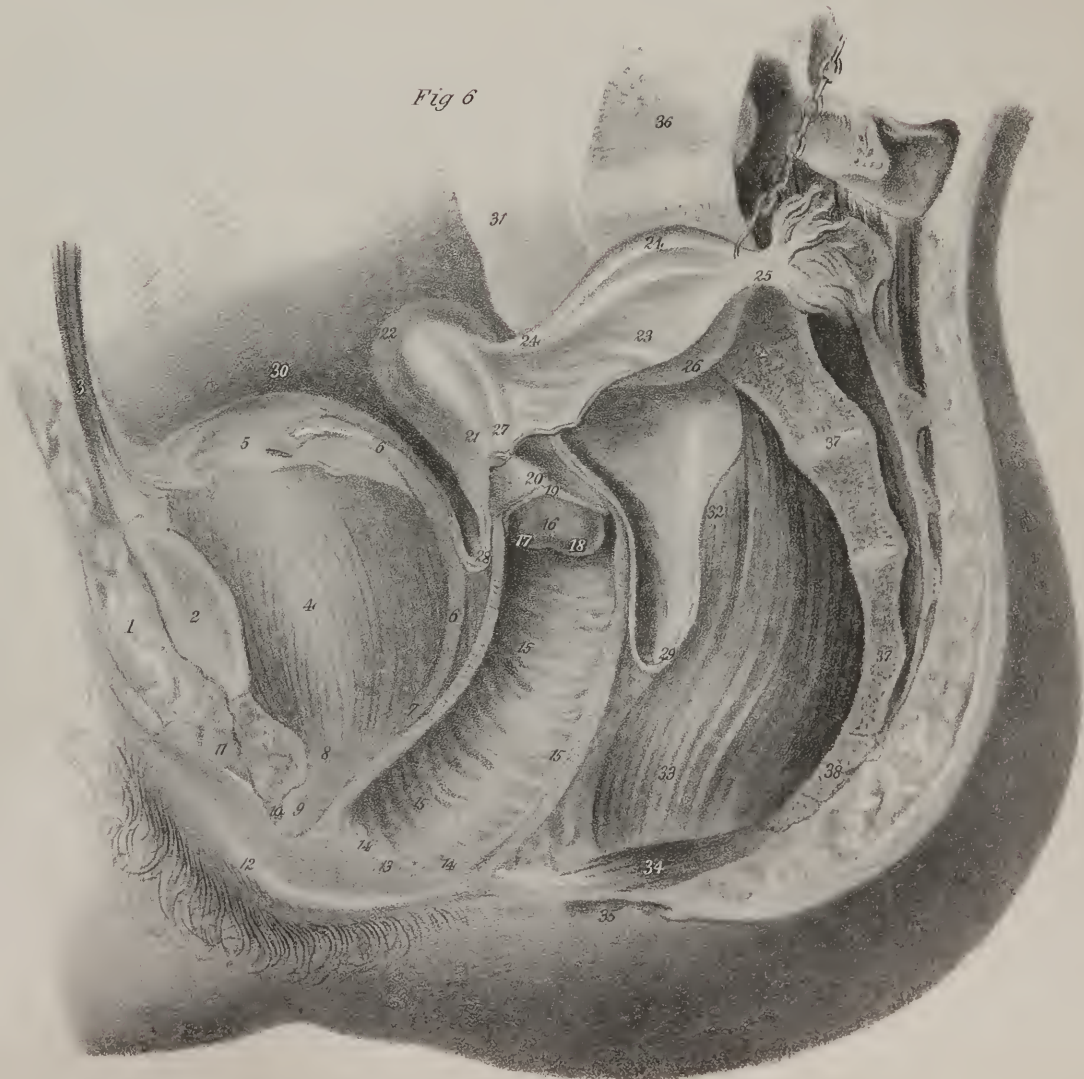


Fig 5.

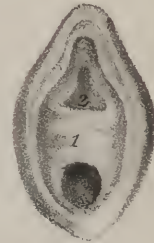

Fig 6







they unite in the abdomen into one trunk, which opens on the right side into the vena cava, and on the left side into the renal vein. The *lymphatics* consist at first of three or four vessels, which decrease in number as they ascend. They accompany the spermatic veins, and terminate in lymphatic glands, lying about the large vessels in front of the vertebral column.

The *nerves* are derived from the sympathetic system. The spermatic plexus follows the course of the spermatic artery to the testis. It receives some additional filaments, which accompany the artery of the vas deferens, from the hypogastric plexus.

*Female Organs of Generation.*—The genital organs in the female are divisible, as are those of the male, into two classes: 1, those of formation, (*organa generationis, vel formationis,*) consisting of the ovaries, uterus, and Fallopian tubes; and 2, those of copulation, viz. the vagina and vulva. We commence with the latter, as they are usually first examined.

*Vulva, or Pudendum,* is a general term, which is considered as including all the parts perceptible externally; they are also sometimes called external genital organs, and consist of the mons Veneris, the labia, the hymen or carunculæ, the clitoris, and the nymphæ. The orifice of the urethra is also noticed in connexion with them, but solely from its situation.

*Mons Veneris.*—The integument on the fore part of the pubic symphysis is elevated by a quantity of cellular and adipose substance deposited beneath it, and is studded with hair. This part, from its surmounting the labia, has been called mons Veneris. The *labia pudendi* (labia externa v. majora) extend downwards from the mons, gradually becoming thinner as they descend. They form two folds, so placed as to leave an elliptic interval (*rima*) between them, the external part of each being continuous with the skin of the thigh, and covered with scattered hairs, whilst the inner is lined by mucous membrane, forming the commencement of the genito-urinary mucous system. The labia unite both beneath the mons and before the perinæum, the points of union being called commissures; the inferior one has also received the name of *fourchette*. This is about an inch distant from the margin of the anus,—the interval being named the perinæum. Immediately above and on the inner side of the lower commissure, the labia are connected by a slight transverse fold, (*frænulum pudendi*;) the space between it and the entrance of the vagina has been called *fossa navicularis*.

The *hymen* is a thin duplicature of the mucous membrane, placed at the lateral and inferior parts of the entrance of the vagina; its form varies very considerably in different persons, but is most frequently semi-lunar, the concave margin looking obliquely upwards. In the same situation are found, after the rupture of the membrane, some small rounded masses called *carunculæ myrtiformes*.

*Clitoris.*—Beneath the upper commissure, and within the labia, is the *clitoris*, a small elongated body, resembling in conformation and structure the diminutive of the penis: thus, it is sustained by two corpora cavernosa separated by an incomplete septum, and attached by crura to the rami of the ossa pubis. It is also surmounted by a glans, though imperforate, from which depends a fold of membrane analogous to the prepuce, and acted on by a muscle.

*Nymphæ—labia interna v. minora.*—From the clitoris two folds of mucous membrane, in form not unlike a cock's comb, descend obliquely outwards, one on each side. These are the nymphæ. Their inner surface is continuous with that of the vagina, the external insensibly passes into that of the labia. They contain, between the laminæ of mucous membrane, a small quantity of erectile tissue, which appears continuous with that of the glans clitoridis.

*The Vestibule.*—Between the nymphæ, and beneath the clitoris, is an angular interval called vestibule, at the centre of whose base is situated a circular orifice leading to the meatus urinarius. The membranous fold which surrounds the orifice of the urethra is rather prominent in some instances, so as readily to indicate its situation. The urethra has been already described.

The *mucous membrane* may be traced inwards from the external labia, where it is continuous with the skin: it forms the nymphæ by being folded on itself, and is prolonged into the urethra and vagina. It is reddish in colour, is covered by epidermis, and beneath it lie a considerable number of mucous follicles.

*Vessels and nerves.*—The parts here described are abundantly furnished with vessels and nerves. The arteries are the internal and external pudic. The veins and lymphatics correspond in their course with the arteries. The nerves proceed from the lumbar and the sacral plexus.

*The Vagina.*—The *vagina* is a membranous and dilatable tube extended from the vulva to the neck of the uterus, which it embraces; it rests on the rectum, supports the bladder and urethra in front, and is enclosed between the levatores ani. Thus placed, it is oblique from below upwards and backwards, its axis corresponding with that of the outlet of the pelvis. It is also slightly curved, the concavity of the curve looking upwards. Hence its length will be found greater if measured on the lower than on the upper surface, being in the latter direction about four inches and a half, while in the former it amounts to six and a half or seven. The extremities of the vagina are somewhat narrower than the middle part: the inferior is surrounded by a constrictor muscle: the superior embraces the uterus at a greater height behind than in front, and is covered by peritonæum.\*

\* Plate XXX. fig. 6, exhibits the manner in which the vagina sustains the womb at its top, or upper extremity. Prolapsus uteri, which is so common a malady, is mostly an affection of the vagina; its real nature is a loss of tone or tension in that tube, which sinking downwards, lets the uterus fall to the lower part of the excavation of the pelvis. The cure consists in restoring to the vagina its normal length.—“To cure a prolapsus,” says Professor Meigs, “means to restore the tone of the vagina. This is done by keeping it extended for several months with a proper pessary and by increasing and fortifying the general health of the patient.”—J. P.

On the *inner surface* of the vagina, along the superior, as well as the inferior wall, a slightly elevated line extends from before backwards, similar to the raphé in the middle line in other situations. Several transverse lines (*rugæ*) will also be observed, particularly in persons who have not borne children, running at right angles with those just mentioned. The *rugæ* are but folds of the mucous membrane, and are calculated to admit of the elongation of the vagina that occurs during the ascent of the uterus in pregnancy.

The exterior layer of which the vagina is composed is cellulo-fibrous in its structure, and contracts a close connexion superiorly with the fibrous structure of the uterus. It is thin, firm, and of a pale red colour. Round the lower part of the tube a lamella of erectile tissue is placed, which diminishes gradually in quantity from thence upwards, so that near the uterus little or none can be discovered. The arteries of the vagina arise from the internal iliac. It is furnished with nerves from the cerebro-spinal and the sympathetic systems.

*Uterus.*—The uterus (the womb; matrix) is the largest of the genital organs, and is fitted to contain and support the new being during the period of fœtal life. It lies between the bladder and rectum, above the vagina, with which it is intimately connected, and enclosed in a fold of peritonæum, which, being extended laterally, connects it to the sides of the pelvis. In the ordinary condition, the uterus does not extend upwards beyond the margin of the pelvis. The superior part inclines forwards, the inferior backwards; its direction thus corresponds to the upper axis of the pelvis, and forms an angle with that of the vagina. The average dimensions of the uterus may be stated to be about three inches in length, two in breadth superiorly, and one inch in thickness. The shape is somewhat triangular or pyriform, but compressed from before backwards, and is considered as presenting a fundus, a body, and a neck, with the enclosed cavity.

## PLATE XXXI.

The internal organs of generation of the female.

FIG. 1. An anterior view of the uterus and its appendages: on the left side the peritonæal layers constituting the broad ligament have been removed in order to show the parts included between them.

Nos. 1. The body of the uterus. 2. The fundus of the uterus. 3, 3. Its superior angles, with each of which the Fallopian tube, the round ligament, and the ligament of the ovary, are connected. 4. The cervix of the uterus. 5. The os uteri bounded by the anterior and posterior lips, of which the posterior, 6, is the most protuberant. 7, 7. The attachment of the vagina to the cervix uteri. 8, 8. The transverse *rugæ* of the mucous membrane of the vagina. 9, 9. The inferior column of the vagina, to which the transverse *rugæ* proceed. 10, 10. The right broad ligament of the uterus, formed by two layers of the peritonæum. 11, 11. The cut edge of the broad ligament. 12. The cut edge of the anterior layer of the peritonæum, just before it passes forwards to the posterior surface of the bladder. 13, 13. The divided edge of the peritonæum covering the anterior surface of the uterus. The continuation of this layer outwards would have formed the anterior fold of the broad ligament of the left side, which has been removed. 14, 14. The Fallopian tube of the right side, situated in the upper and rounded border of the broad ligament. 15. The enlargement of the Fallopian tube near its terminal extremity. 16. The fimbriæ of the extremity of the Fallopian tube. 17. The round ligament of the right side, raising the anterior layer of the broad ligament into a convex ridge. 18. The round ligament separated from the duplicature of the broad ligament. 19. The Fallopian tube of the left side. 20. Its smaller extremity, connected with the superior angle of the uterus. 21. Its larger and more expanded extremity. 22. Its fimbriated extremity. 23. The opening (orificium abdominale) of the Fallopian tube seen by separating the fimbriæ. 24. One of the fimbriæ attached to the ovary. 25. The ovary of the left side. 26. The ligament of the ovary, attached to the upper angle of the uterus. 27. The round ligament of the left side.

FIG. 2. A vertical and lateral section of the uterus, showing the form of its internal cavity.

Nos. 1, 1. The substance of the uterus. 2, 2. The peritonæal covering of the uterus. 3. The cavity of the uterus. 4, 4. The openings leading into the Fallopian tubes. 5. The orificium internum of the uterus. 6. The dilated part of the cavity of the uterus corresponding with the cervix: this part of the organ is seen to be marked by ridges which have somewhat of an arborescent form, the *arbor vitæ uterina*. 7. The orificium externum, or os uteri. 8. The upper part of the vagina.

FIG. 3. A vertical section of the uterus made in the antero-posterior direction.

Nos. 1, 1. The substance of the uterus. 2, 2. Its peritonæal layer. 3. The cavity of the uterus. 4. The constriction corresponding with the orificium internum uteri. 5. The dilated portion of the cavity corresponding with the cervix. 6. The orificium externum, or os uteri. 7. Section of the anterior lip of the os uteri. 8. Section of the posterior lip. 9. The upper part of the vagina.

FIG. 4. An uterus at the ninth month of pregnancy, turned inside out, so as to show its internal surface.—From Dr. Hunter's admirable work.

Nos. 1, 1. The ostium uterinum of each Fallopian tube, around which the enlarged fibres of the uterus are seen arranged in concentric circles. 2, 2. That portion of the uterus to which the placenta was attached: the enlarged muscular bands have a reticulated arrangement. 3, 3. The lower part of the body of the uterus, in which the muscular fibres are disposed in a circular direction. 4. A trace of the *arbor vitæ uterina*, nearly obliterated by the distension of the organ. 5. The os uteri.

FIGS. 5 and 6. The ovary of a woman who died at the third month of pregnancy. On the surface of fig. 5 the cicatrix left by the rupture through which the ovum escaped, is seen. In the section of the same ovary, the corpus luteum, and the cavity originally occupied by the ovum, are perceived.





Fig 2

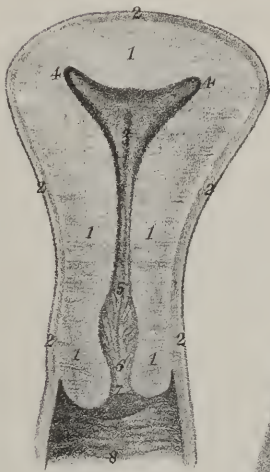


Fig 3

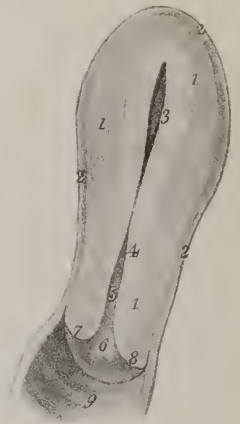

Fig 4

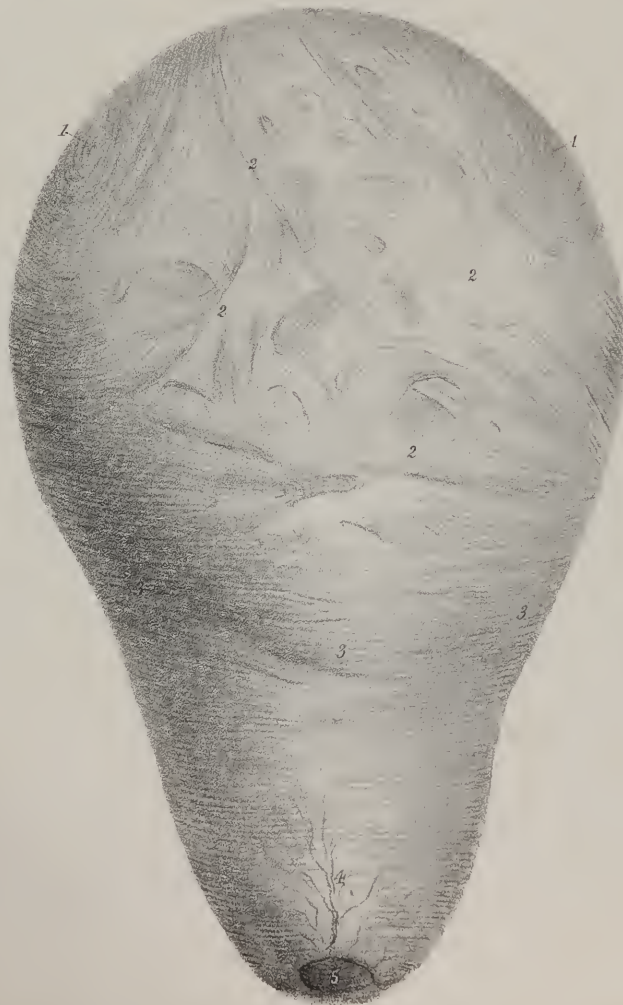
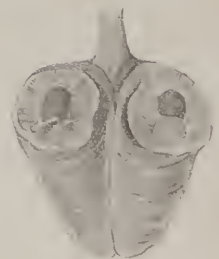


Fig 5

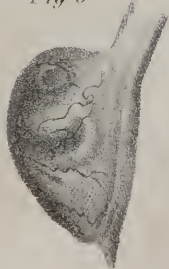

Fig 6







The *fundus* is the broad part which projects above the attachments of the Fallopian tubes, surmounting the body; it presents a convex border, and is covered by peritonæum in its entire extent. The *body* tapers gradually as it extends from the fundus to the neck, its two sides being straight; its surfaces, however, are both convex. At the union of the sides with the rounded superior border or base are two projecting angles, into which the Fallopian tubes are inserted, the round ligaments being a little before, and the ligaments of the ovaria behind and beneath them. The *neck* (*cervix uteri*) is continuous with the body, narrowing gradually to the extremity; it is from six to eight lines long, and projects into the cavity of the vagina, which is attached around, by its line of union with the body of the organ, but extends upwards to a greater distance behind than in front. This part is sometimes named vaginal, (*pars uteri vaginalis*.) Its extremity presents a transverse fissure, by which the cavity of the uterus communicates with the vagina; this is named variously—*os uteri*, *os uteri externum*, and (from some supposed likeness of the part to the mouth of the tench fish) *os tinæ*. It is bounded by two lips, (*labia*), which are distinguished by their relative position into anterior and posterior, the latter being the thinner and longer.

The *cavity* is very small, in proportion to the size of the uterus. The part contained in the body of the organ is triangular, the base being directed upwards: at its two superior angles will be observed two minute foramina, which lead into the Fallopian tubes. Where the neck is continuous with the body, the cavity is slightly constricted: this point is, in consequence, sometimes named the internal orifice, (*os uteri internum*.) The portion which corresponds to the neck is more properly a canal; it is slightly dilated in the middle, and opens inferiorly into the vagina at the *os tinæ*. The inner surface is marked by two slightly raised longitudinal lines, which run, one on the anterior, the other on the posterior wall; in the neck are also seen some slight rugæ directed obliquely from the former, and thus presenting an appearance not unfrequently named *arbor vitæ uterinus*.

The *mucous membrane* which lines the uterus is so closely adherent to the proper substance of the organ, that its existence has been doubted by some anatomists; it is continued from the vagina, and into the Fallopian tubes. In the cervix, especially towards its lower part, there are several mucous follicles. There are also occasionally found in the same situation some small vesicular bodies which, from an erroneous opinion as to their nature, have been named *ova*, (*ovula*, *Naboth*.) They appear to be mucous follicles altered by diseased action.

*Proper tissue* of the uterus.—Though much difference heretofore existed concerning the nature of the proper tissue of this organ, it is now generally admitted to be muscular. The fibres are rendered distinct in cases in which the organ is enlarged, as during gestation, or when it contains a tumour. From the intricacy with which they interlace one with the other, it is difficult, if not impossible, to describe them more particularly than by assigning their general course. The muscular substance is most abundant towards the fundus of the uterus; the fibres are disposed in a longitudinal, a circular or transverse, and an oblique direction. The first appear to be the most numerous; those directed transversely are connected on each side with the Fallopian tubes and the round ligaments. The *outer surface* of the uterus has been already stated to be closely invested by the peritonæum.

*Ligaments of the Uterus*.—The *broad ligaments*.—The peritonæum, which covers the uterus on its anterior and posterior surfaces, is directed outwards to be connected to the sides of the pelvis. The part intervening between the uterus and the pelvis, on each side, is called the broad ligament, (*ligamentum uteri latum*.) Each consists of a fold of serous membrane, between the laminae of which are situated the ovary, the Fallopian tube, the round ligament, and some blood-vessels.

The peritonæum, where it is reflected off from the uterus, in front to the bladder and behind to the rectum, is sometimes also regarded as constituting anterior and posterior ligaments.

The *round ligaments* are cord-like fasciculi of fibres, attached to the angle of the uterus one on each side, immediately before the Fallopian tube. From this point the ligament passes upwards and outwards to reach the internal inguinal ring, and, after having passed through the canal of the same name, reaches the fore part of the pubic symphysis, where its fibres become expanded, and united with the substance of the labium and mons Veneris.\*

The *arteries of the uterus* are very tortuous, and are four in number, viz. the two ovarian (which correspond to the spermatic of the male) and the uterine. The former pass in between the folds which constitute the broad ligaments, give branches to the Fallopian tubes, the ovaria, and uterus, and anastomose with the other uterine vessels. The uterine arteries are derived from the internal iliac. They become insinuated beneath the peritonæum, supply vessels to the vagina, and ramify in the uterus. The *veins* and *absorbents* follow the course of the arteries.

*Development*.—The uterus presents very considerable changes at different periods of life. In the fœtus it extends upwards into the abdomen, and is nearly vertical in direction. The situation and direction gradually altering, it assumes the position and inclination previously described. At the earliest period of development it is divided superiorly into two distinct parts. The cornua, as they may be termed, gradually become united, and form an undivided organ with a single cavity. Such is the ordinary course;

\* It is evident, from an inspection of the *broad ligaments* in situ, that they serve merely as stays to the uterus, preventing it from vibrating to the right or left, according to the side on which the female lies. They have no influence in causing or preventing prolapsus of the organ. The *round ligaments* are also stays to the womb, but act in a different direction. The bladder, when filled with urine, presses the uterus backwards, and would always retrovert it, but for the action of these ligaments. There are many women subject to a retroversion every time that the bladder is very much distended, and some in whom retroversion is a chronic condition. In all such, much of the fault is attributable to a great relaxation of these fibrous organs.—Vide Philadelphia Practice of Midwifery, by C. D. Meigs, M. D., Prof. Mid. and Dis. of Women and Children, in Jefferson Medical College.—J. P.

but cases occur in which the cornua remain permanently separate, constituting what is generally termed the double uterms. The state here referred to results from the non-union of the lateral halves, of which the upper part of the uterus originally consists. It is worthy of remark, that this condition is permanent in some inferior animals.

Subsequently to the period first mentioned, (after the lateral parts become united,) the uterus is nearly cylindrical, being of equal dimensions at its upper and lower extremities. The fundus, however, gradually increasing in breadth, the uterus assumes the pyriform shape, which is not completed till about the age of puberty. In old age the organ loses the triangular form, and becomes irregularly cylindrical, at the same time that it increases much in density.

During gestation, besides the remarkable increase of size and consequent change of situation, the muscular fibres become more perceptible; the arteries, veins, and lymphatics are greatly enlarged; the nerves, too, become more apparent. The substance of the organ is increased in thickness (to an inconsiderable degree) in the first instance, but, as the time of parturition approaches, it is somewhat thinner than in the unimpregnated condition.

*Ovaries.*—The ovaries (*ovaria*) are two compressed and irregularly oval bodies, somewhat granulated on the surface, and enclosed between the folds of the broad ligaments. From the internal extremity of each descends a fibrous cord (the *ligament of the ovary*.) which attaches it to the angle of the uterus, behind the insertion of the Fallopian tube,—by one of the fimbriæ of which the outer extremity is supported. The ovarium is enclosed in a proper capsule, which is a thin cellulo-fibrous membrane; its proper structure presents, when divided, the appearance of a firm yet vascular mass giving lodgment to some small vesicles, (*ovula Graafiana*.) These, in females who have not had children, vary in number from about eight to fifteen or twenty.\*

The *Fallopian tubes* may be considered as the excretory ducts of the ovaria, before and a little beneath which they are situated; they are about three inches in length. The attached extremity of each tube is narrow and cord-like; the unattached

## PLATE XXXII.

The anatomy of the mammary gland.

FIG. 1. The virgin mamma of the left side: from a young woman twenty years of age.

FIG. 2. The right mamma of a pregnant woman thirty-eight weeks after conception.—From Dr. Montgomery's work, entitled "An Exposition of the Signs and Symptoms of Pregnancy, the Period of Human Gestation, and the Signs of Delivery."

In this mamma the larger size of the organ, as contrasted with the virgin mamma, will be remarked; the larger size, wrinkled and papillous appearance of the nipple; the greater circle, and deeper colour of the areola; and the large size and tuberculous aspect of the sebaceous follicles dispersed upon the areola. The enlarged veins meandering over the mamma, and rendered visible by their bluish tracks through the integument, are also characteristic of the period.

FIG. 3. The right mamma of a woman twenty-eight years of age, at the period of three weeks after delivery. The nipple, with the areola, are copied from the Atlas of Sir Astley Cooper's splendid work "On the Anatomy of the Breast;" the rest of the mamma was drawn from nature.

In explanation of the nipple and areola of this figure, Sir Astley Cooper writes, "Lactation three weeks after delivery, nipple extremely papillous, areola much extended, measuring two inches, tubercles appear upon various parts of the areola. Milk could not be pressed from the tubercles when the orifices of the nipple were closed and the breast compressed." The more tumid appearance of the breast, and the greater transparency of the integument, will be remarked. The veins are larger in size, and more distinctly perceived through the skin.

FIG. 4. From Sir Astley Cooper's splendid work, "The papillæ of the nipple, (magnified to double their natural dimensions;) showing their foliated appearance towards their summits, and the circles which they form towards the areola."

FIG. 5. From Sir Astley Cooper's splendid work.—"The nipple and the straight ducts, twenty-one in number."

FIG. 6. From Sir Astley Cooper's splendid work.—"Lactiferous tubes, or ducts, injected with red wax; showing their radiated direction, and, in some places, their inter-ramification."

FIG. 7. From Sir Astley Cooper's splendid work.—"A section of the breast at twenty years of age; showing the skin, the fascia, the ligamenta suspensoria, and the fat between them."

No. 1. The nipple. 2, 2. The integument. 3, 3. The ligamenta suspensoria: the interspaces of these ligamentous bands are occupied by adipose tissue. "It is," writes Sir Astley Cooper, "by these processes that the breast is suspended in its situation, and I shall therefore call them the *ligamenta suspensoria*."

"By these processes the breast is slung upon the fore-part of the chest, for they form a moveable but very firm connexion with the skin, so that the breast has sufficient motion to elude violence; yet by this fibrous tissue it is, excepting under age, lactation, or relaxation, prevented from much change of place."

4. The mammary gland. 5. The cellular tissue interposed between the mammary gland and the surface of the muscles of the chest. 6, 6. The pectoralis major muscle.

FIG. 8. From Sir Astley Cooper's splendid work.—Shows the origin of the lactiferous ducts from the milk-cells: the cells with their ducts are magnified four times.

\* The ovula Graafiana have been seen in the ovaries of very young children. Two very large ones were found by Professor Meigs, in the ovaries of a child of four years, which died suddenly with convulsions. Dr. Martin Barry (Lond. Philos. Trans.) supposes that these bodies, which he calls ovisacs, are innumerable.—J. P.



Fig 1




Fig 2




Fig 3




Fig 4




Fig 5





Fig 6

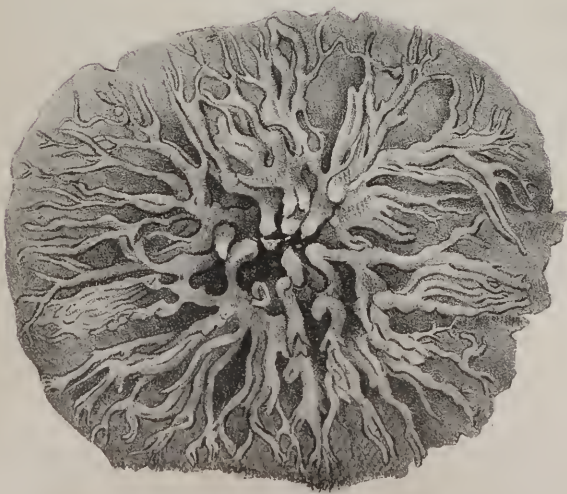

Fig 8



Fig 7





or free extremity is broad, and divided into a number of irregular processes, (*fimbriae*), one of which is longer than the rest, and attached to the corresponding ovarium. The fimbriated border presents a fissure or opening, (*ostium abdominale*), into which the impregnated ovum is received at the moment of its liberation from the ovarium, and thence conveyed along the tube, which opens into the uterus by another aperture, (*ostium uterinum*.) At this point it may be observed, that the serous membrane is in a manner continuous with the mucous, and consequently must be considered as interrupted, inasmuch as there is a real hilus along the fissured edge of the tube. Between the external serous covering and the lining membrane the tubes are composed of a thin layer of erectile tissue. The contained canal is very minute, particularly near the point at which it communicates with the uterus.

*Mammary Glands.*—The mammary glands (*mammæ*) are accessory organs to the genital system, and, when fully developed after puberty, present the appearance of two rounded eminences placed one at each side on the front of the thorax, resting on the pectoral muscles. The base of the mamma is not exactly circular: it is rather ovoid or elliptical, the long diameter being directed obliquely upwards and outwards. A little below the centre of each projects a small conical body called the nipple, on which open several foramina that lead from the lacteal ducts. A coloured circle, or areola, surrounds the nipple, within which the skin is of a darker tinge than elsewhere. Beneath the skin is deposited, in most cases, a considerable quantity of adipose substance, which surrounds the proper substance of the gland.

*Structure.*—The mamma is a conglomerate gland, for it is found to consist of several small lobes, each being an aggregate of a number of lobules, (*acini*.) Each lobule is about the size of a millet seed, oblong in its form, and hollow; its elements or components may be said to be a mucous lining, and an envelope of cellular tissue, in which the secreting vessels ramify. From the lobules thus formed arise the minute radicles of the lactiferous tubes, (*tubuli lactiferi*), which receive the secretion when elaborated. The tubes converge towards the nipple, so as to become collected into a fasciculus beneath it, in which situation they are supported by some firm cellular tissue:—the number varies from twelve to fifteen, and each is found to belong to a particular lobe of the gland; its incipient radicles or branches commencing from the interior of the lobules which form it. In this way four, six, or eight minute ducts unite to form one lactiferous tube, which inclines towards the areola, where it dilates somewhat, particularly during the period of lactation; but at the base of the nipple it narrows again, and runs in a straight course from its base to its summit, where it terminates. The tubes are lined throughout by a tegumentary membrane, (*mucous*), which extends inwards from the minute orifices in the nipple, and permeates their entire extent, even to the lobules; and this inner lining appears to be enclosed in another tunic, formed of condensed cellular tissue.

Upon the surface of the areola and nipple several minute orifices open, which lead into sebaceous follicles, the secretion of which exudes upon the skin, to protect it from irritation.





# INDEX.

---

- Abdomen, page 11.  
    contents of the, 12.  
    extent and boundaries, 11.  
    regions of the, 12. (Pl. V.)
- Abdominal viscera. (Pl. VI.)
- Acini of the liver, page 25.
- Aggregate glands, page 7.
- Air-cells, page 35. (Pl. XXVII.)
- Alimentary canal, page 8. (Pls. IV. VIII. IX.)
- Amygdalæ, *see* Tonsils.
- Annulus ovalis, page 29. (Pl. XIX.)
- Aorta. (Pls. XV. XVIII.)
- Appendices epiploicæ, page 14. (Pl. VI.)
- Appendix auriculæ, page 29.  
    vermiformis cæci, page 19. (Pls. III. IV. VI.)
- Arches of the palate. (Pls. II. III.)
- Areola, page 59. (Pl. XXXII.)
- Auricle, left, page 30.  
    right, page 29.
- Auricles and ventricles. (Pls. XVIII. XIX.)
- Auriculo-ventricular openings, pages 29, 30.
- Biliary ducts, page 25. (Pls. IV. XII.)
- Bladder, urinary, page 42. (Pls. XXV. XXVI.)  
    ligaments of the, page 44.  
    structure of the, page 43.  
    vessels and nerves of the, page 44.
- Bronchi, page 35. (Pls. XV. XVII.)
- Bronchial glands, page 37. (Pl. XVII.)  
    tubes, page 35. (Pls. XVI. XVII.)
- Brunner's glands, page 7. (Pl. IX.)
- Buccæ, page 9.
- Bulb of the urethra, page 47. (Pl. XXVI.)
- Cæcum, page 19. (Pls. IV. VIII.)
- Calices of the kidney, page 41. (Pl. XXIV.)
- Canalis cibarius, page 8.
- Capillaries of the lungs. (Pl. XVI.)
- Capsule of Glisson, page 25.
- Capsules, supra-renal, page 41. (Pl. XXIV.)
- Caput coli, page 19.  
    gallinæ, page 47. (Pl. XXVI.)
- Cardia, or cardiac orifice of the stomach, page 17. (Pl. VIII.)
- Carunculæ myrtiformes, page 55. (Pl. XXX.)
- Cheeks, page 9.
- Chordæ tendineæ, page 29. (Pl. XIX.)
- Chylification, page 3.
- Chymification, *ib.*
- Circulation, organs of, page 27.
- Clitoris, page 55. (Pl. XXX.)
- Colon, page 19. (Pls. IV. VI. VIII.)
- Columnæ carneæ, page 29. (Pl. XIX.)
- Columnar epithelium. (Pl. VIII.)
- Coni vasculosi, page 53. (Pl. XXIX.)
- Corona glandis, page 47. (Pl. XXVII.)
- Coronary valve, page 29. (Pl. XIX.)
- Coronary vessels, page 32. (Pl. XVIII.)
- Corpora cavernosa, page 47. (Pls. XXVI. XXVII.)  
    Malpighiana, page 41. (Pl. XXIV.)
- Corpus Arantii, page 30.  
    cavernosum, page 46. (Pls. XXVI. XXVII.)  
    Highmorianum, page 53. (Pls. XXVIII. XXIX.)  
    luteum. (Pl. XXXI.)  
    spongiosum, page 47. (Pls. XXV. XXVI. XXXI.)
- Coverings of the spermatic cord, page 51.
- Cowper's glands, page 49. (Pl. XXVI.)
- Cremaster, page 50.
- Cystic duct, page 26. (Pls. IV. XII.)
- Dartos, page 50.
- Deglutition, page 3.
- Detrusor urinæ, page 43. (Pl. XXV.)
- Digestion, organs of, pages 3, 8.
- Duct, Stenon's, page 10. (Pls. I. II.)  
    Wharton's, page *ib.* (Pl. I.)
- Ducts, biliary, page 26.  
    ejaculatory, page 54. (Pls. XXVI. XXVII.)  
    sub-lingual, page 10. (Pl. I.)  
    thymic, page 33. (Pl. XXIII.)
- Ductus arteriosus. (Pl. XIX.)  
    communis choledochus, page 26. (Pls. IV. VIII. XII. XIII.)
- Ductus ejaculatorii, page 54. (Pls. XXVI. XXVII.)
- Duodenum, page 17. (Pls. IV. VIII. XIII.)
- Ejaculatory ducts, page 51. (Pls. XXVI. XXVII.)
- Endosmosis, page 5.

- Epididymis, page 53. (Pls. XXVIII. XXIX.)
- Epigastric region, page 12. (Pl. V.)
- Epiglottis, page 9.
- Epithelium of the alimentary canal. (Pl. VIII.)  
of the gall-bladder. (Pl. XII.)  
of mucous membranes, page 8.  
of the œsophagus, page 11. (Pls. III. VIII.)  
of serous membranes, page 1.
- Erectile tissue, page 47. (Pls. XXVII. XXVIII.)
- Eustachian tubes, page 11. (Pl. III.)  
valve, page 29.
- Exosmosis, page 5.
- Expulsion, page 3.
- Fœcification, *ib.*
- Fallopian tubes, page 53. (Pls. XXX. XXXI.)
- Fascia, pelvic. (Pl. XXV.)  
perinæal. (Pl. XXV.)
- Fauces, page 9. (Pls. II. III.)
- Female organs of generation, page 55. (Pls. XXX. XXXI.)
- Fimbriæ of the Fallopian tube, page 59. (Pl. XXX.)
- Fissure, longitudinal, page 23.  
transverse, *ib.*  
umbilical, *ib.*
- Fissures of the liver, *ib.*
- Fœtal heart. (Pl. XIX.)
- Follicles, mucous, page 7.
- Foramen cœcum, page 9.  
ovale. (Pl. XIX.)  
of Winslow, page 15. (Pl. VII.)
- Foramina Thebesii, page 29.
- Fossa ovalis, *ib.*  
navicularis urethræ, page 43. (Pl. XXVI.)  
————— vulvæ, page 55. (Pl. XXX.)
- Fourchette, *ib.* (Pl. XXX.)
- Fræna epiglottidis, page 9. (Pl. III.)  
labiorum, *ib.* (Pl. II.)
- Frænulum pudendi, page 55. (Pl. XXX.)
- Frænulum linguæ, page 9. (Pl. II.)  
præputii, page 46.
- Gall-bladder, page 26. (Pls. IV. VI. X. XII.)
- Gastric follicles, or glands. (Pl. IX.)
- Gastro-pulmonary mucous membrane, page 5.
- Gastro-splenic omentum, page 15.
- Generation, female organs of, page 55. (Pls. XXX. XXXI.)  
male organs of, page 45. (Pls. XXV. XXVI. XXVII.  
XXVIII. XXIX.)
- Genito-urinary mucous membrane, page 6.
- Gland, parotid, page 10. (Pl. I.)
- Gland, prostate, page 45. (Pl. XXV.)  
sub-lingual, page 10. (Pl. I.)  
sub-maxillary, *ib.* (Pl. I.)  
thymus, page 37. (Pls. XXII. XXIII.)
- Glands of the alimentary canal. (Pl. IX.)  
bronchial, page 37. (Pl. XVII.)  
Brunner's, page 7. (Pl. IX.)  
Cowper's, page 49. (Pl. XXVI.)  
labial. (Pl. II.)
- Glands, Peyer's, page 7. (Pl. IX.)  
salivary, page 9. (Pl. I.)  
tracheal. (Pl. XVII.)  
of Tyson, page 47. (Pl. XXVII.)
- Glandulæ odorifæræ, v. Tysoni, page 47. (Pl. XXVII.)
- Glans penis, page 47. (Pls. XXVI. XXVII.)
- Glisson's capsule, page 25.
- Globus major epididymis, page 53. (Pls. XXVIII. XXIX.)  
minor epididymis, *ib.*
- Gubernaculum testis, page 49. (Pl. XXIX.)
- Heart, page 23. (Pls. XV. XVI. XVIII. XIX. XX. XXI.)  
arrangement of the fibres of the. (Pls. XX. XXI.)  
cavities of the, page 29. (Pl. XIX.)  
M. Gerdy's views, page 31.  
Mr. Searle's researches, page 36.
- Helicine arteries. (Pl. XXVIII.)
- Hepatic ducts, page 24. (Pls. IV. XII.)
- Hepatic-venous canals, page 25.
- Hilus lienis, page 26. (Pl. XIII.)
- Hymen, page 55. (Pl. XXX.)
- Ileo-cæcal valve, page 20. (Pl. VIII.)
- Ileo-colic valve, page 21. (Pl. VIII.)
- Ileum, page 18. (Pl. IV.)
- Iliac regions, page 12. (Pl. V.)
- Infundibula of the kidney, page 41. (Pl. XXIV.)
- Insalivation, page 3.
- Inter-lobular veins. (Pl. XI.)
- Intestinal canal, structure of the, page 17. (Pl. IX.)
- Intestines, *ib.* (Pls. IV. VI. IX.)
- Intra-lobular veins, page 25. (Pl. XI.)
- Isthmus of the fauces, page 9. (Pl. II.)
- Jejunum, page 18. (Pl. IV.)
- Kidneys, anatomy of the, page 39. (Pl. XXIV.)  
structure of the, 40. (Pl. XXIV.)  
vessels and nerves of the, page 41.
- Kiernan's researches on the anatomy of the liver, page 25. (Pls. XI. XII.)
- Labia pudendi, page 55. (Pl. XXX.)
- Labial glands. (Pl. II.)
- Lactiferous ducts, page 59. (Pl. XXXII.)
- Lacunæ of the urethra, page 49. (Pl. XXVI.)
- Larynx. (Pls. XIV. XVII.)
- Ligamenta suspensoria of the mamma. (Pl. XXXII.)
- Ligaments of the bladder, page 46.  
of the liver, pages 14. 23. (Pls. VII. X.)  
of the uterus, page 57. (Pl. XXX.)
- Lips, anatomy of the, page 9. (Pl. II.)
- Liquor prostaticus, page 45.
- Liver, page 23. (Pls. VI. X.)  
borders of the, 24.  
structure of the, *ib.*
- Lobes of the liver, page 23.
- Lobular biliary plexus. (Pl. XII.)  
venous plexus, page 25. (Pl. XII.)
- Lobules of the liver. (Pl. XI.)  
of the thymus gland. (Pl. XXII.)
- Lobuli testis, page 53. (Pl. XXIX.)
- Lobulus caudatus, page 23. (Pl. X.)



- Lobulus, quadratus, 23. (Pl. X.)  
     Spigellii, *ib.* (Pl. X.)  
 Lobus caudatus, *ib.* (Pl. X.)  
     quadratus, *ib.* (Pl. X.)  
     Spigellii, *ib.* (Pl. X.)  
 Luette vesicale, page 43. (Pl. XXVI.)  
 Lumbar regions, page 12. (Pl. V.)  
 Lungs, page 33. (Pls. XIV. XV. XVI.)  
 Lungs, structure of the, page 35. (Pl. XVI.)  
 Malpighian bodies, page 41. (Pl. XXIV.)  
 Manimæ, page 59. (Pl. XXXII.)  
 Mammary glands, *ib.* (Pl. XXXII.)  
 Mastication, page 3.  
 Meatus urinarius, page 45.  
     — feminae, pages 45. 55. (Pl. XXX.)  
 Mediastinum, page 35.  
     anterior, *ib.* (Pls. XIV. XVI.)  
     posterior, *ib.* (Pl. XVI.)  
     testis, page 53. (Pls. XXVIII. XXIX.)  
 Mesentery, page 13. (Pl. VII.)  
 Meso-cola, page 14. (Pl. VII.)  
 Meso-rectum, pages 14. 21.  
 Milk-cells. (Pl. XXXII.)  
 Mitral valve, page 31. (Pl. XIX.)  
 Mons Veneris, page 55. (Pl. XXX.)  
 Mouth, page 9. (Pl. II.)  
 Muciparous follicles. (Pl. XII.)  
 Mucous follicles, page 7.  
     membrane, pages 5—8.  
 Muscles of the ureters, page 43.  
 Musculi pectinati, page 29.  
 Nares, posterior, page 11. (Pl. III.)  
 Nipple, page 59. (Pl. XXXII.)  
 Nymphæ, page 55. (Pl. XXX.)  
 Oesophageal glands. (Pl. IX.)  
 Oesophagus, page 11. (Pl. III.)  
 Omentum, greater, page 13. (Pls. VI. VII.)  
     lesser, *ib.* (Pl. VII.)  
 Organs of digestion, page 8.  
     of generation, female, page 55. (Pls. XXX. XXXI.)  
     — male, page 45. (Pls. XXV. XXVI. XXVII.  
         XXVIII. XXIX.)  
     — male and female, analogy between, page 55.  
     urinary, page 39.  
 Os uteri, page 57. (Pl. XXX.)  
 Ovaries, anatomy of the, page 58.  
     ligament of the, *ib.*  
 Ovula Graafiana, *ib.*  
     of Naboth, page 57.  
 Palate, soft, page 9. (Pls. II. III.)  
 Pancreas, anatomy of the, page 27. (Pl. XIII.)  
     structure of the, *ib.*  
 Pancreatic duct, *ib.* (Pls. VIII. XIII.)  
 Papillæ capitatæ, page 9.  
     conicæ, vel pyramidales, *ib.*  
     filiformes, *ib.*  
     fungiformes, *ib.*  
 Papillæ of the kidney, page 41. (Pl. XXIV.)  
     lenticulares, page 9.  
     of the nipple. (Pl. XXXII.)  
 Parotid gland, page 10. (Pl. I.)  
     development of the. (Pl. II.)  
 Pelvic fascia. (Pl. XXV.)  
     viscera, page 42. (Pls. XXV. XXX.)  
 Pelvis of the kidney, page 41. (Pl. XXIV.)  
     viscera of the, page 42. (Pls. XXV. XXX.)  
 Penis, page 45. (Pls. XXVI. XXVII.)  
 Pericardium, page 23. (Pls. XIV. XVI. XVIII.)  
 Perinæal fascia. (Pl. XXV.)  
 Perinæum. (Pl. XXV.)  
 Peritonæum, page 13. (Pls. VI. VII. XXV.)  
     reflections of the, page 15.  
 Peyer's glands, page 7. (Pl. IX.)  
 Pharynx, anatomy of the, page 10. (Pl. III.)  
 Pleura costalis, page 34.  
     pulmonalis, *ib.*  
 Pleuræ, *ib.* (Pls. XIV. XVI.)  
 Plicæ of the mucous membrane, page 6. (Pl. III.)  
 Portal vein. (Pl. X.)  
 Prepuce, page 45.  
 Prostate gland, *ib.* (Pls. XXV. XXVI.)  
 Prostatic sinuses, page 47. (Pl. XXVI.)  
 Prostatic portion of the urethra, *ib.*  
 Pudendum, page 55. (Pl. XXX.)  
 Pulmonary artery, page 35. (Pls. XV. XVI. XVIII.)  
     veins, 36. (Pls. XV. XVI.)  
 Pyloric valve, page 17. (Pls. VIII. XIII.)  
 Pylorus, *ib.* (Pls. VIII. XIII.)  
 Rectum, anatomy of the, page 21. (Pls. IV. XXV.)  
     structure of the, page 22.  
     vessels and nerves of the, page 23.  
 Reservoir of the thymus gland, page 38. (Pls. XXII. XXIII.)  
 Respiration, organs of the, page 33. (Pls. XIV. XV.)  
 Rete testis, page 53. (Pl. XXIX.)  
 Rope of the thymus gland. (Pl. XXII.)  
 Rugæ of the mucous membrane, page 6.  
     of the stomach, page 17. (Pl. VIII.)  
     of the vagina, page 56.  
 Salivary glands, page 9. (Pl. I.)  
 Scrobiculus cordis, page 12.  
 Scrotum, page 49.  
 Septum auricularum, page 29.  
     pectiniforme, page 46. (Pl. XXVII.)  
     scroti, page 50.  
 Serous membranes, general anatomy, page 3.  
 Sigmoid valves, pages 30, 31. (Pl. XIX.)  
 Sinus pocularis, page 47.  
     prostaticus, *ib.* (Pl. XXVI.)  
 Socia parotidis, page 10. (Pl. I.)  
 Soft palate, page 9. (Pl. II.)  
 Solitary glands. (Pl. IX.)  
 Spermatic cord, coverings of the, page 51.  
     vessels of the, *ib.* (Pl. XXVIII.)  
 Sphincter vesicæ, page 44.

- Spleen, page 26. (Pls. VI. XIII.)  
 structure of the, *ib.*
- Stenon's duct, page 10. (Pls. I. II.)
- Stomach, page 15. (Pls. IV. VI. VII. VIII.)  
 coats of the, page 17. (Pl. IX.)  
 structure of the, *ib.* (Pl. IX.)
- Sub-lingual gland, page 10. (Pl. I.)
- Sub-lobular veins. (Pl. XI.)
- Sub-maxillary gland, page 10. (Pl. I.)
- Supra-renal capsules, page 41. (Pl. XXIV.)  
 structure of the, *ib.* (Pl. XXIV.)  
 vessels and nerves of the, page 42.
- Suspensory ligament, page 47.
- Tendons of the bladder, page 44. (Pl. XXV.)
- Testicles, descent of the, page 49. (Pl. XXIX.)
- Testes, anatomy of the, page 52. (Pls. XXVIII. XXIX.)  
 change of situation of the, page 49. (Pl. XXIX.)  
 vessels and nerves of the, page 54.
- Thorax, anatomy of the, page 27.
- Thymic ducts, page 38. (Pl. XXIII.)  
 secretion, analysis of the, *ib.*
- Thymus gland, page 37. (Pls. XXII. XXIII.)  
 remains of the. (Pl. XIV.)  
 structure of the, page 38.  
 vessels of the, page 39. (Pl. XXIII.)
- Thyroid gland. (Pl. XIV.)
- Tongue, anatomy and structure, page 9.
- Tonsils, *ib.* (Pls. II. III.)
- Trabeculae testis. (Pls. XXVIII. XXIX.)
- Trachea, page 35. (Pls. XIV. XV. XVII.)  
 structure of the, *ib.*
- Tracheal glands. (Pl. XVII.)
- Tricuspid valve, page 30. (Pl. XIX.)
- Trigone vesicale, page 43. (Pl. XXVI.)
- Tubercles of the areola. (Pl. XXXII.)
- Tuberculum Loweri, page 29.
- Tubuli lactiferi, page 59. (Pl. XXXII.)  
 seminiferi, page 53. (Pl. XXIX.)  
 uriniferi, page 41. (Pl. XXIV.)
- Tunica albuginea, page 52. (Pls. XXVIII. XXIX.)  
 vaginalis, *ib.* (Pl. XXXVIII.)  
 vasculosa, page 53. (Pl. XXIX.)
- Tyson's glands, page 47.
- Umbilical ligaments, page 47. (Pl. VI.)  
 region, page 12. (Pl. V.)  
 vein, remains of the. (Pl. X.)
- Urachus, pages 15. 45. (Pls. VI. XXXV.)
- Ureters, page 42. (Pl. XXV.)
- Ureters, muscles of the, page 42.
- Urethra, female, page 45.  
 male, page 47. (Pl. XXVI.)  
 — bulbous portion of the, page 48.  
 — membranous portion of the, page 47.  
 — prostatic portion of the, *ib.*  
 — spongy portion of the, page 48.
- Urinary bladder, page 42.  
 organs, page 39.
- Uriniferous tubuli, page 41. (Pl. XXIV.)
- Uterus, page 56. (Pl. XXX.)  
 developement of the, page 57.  
 ligaments of the, *ib.*  
 structure of the, *ib.*  
 vessels of the, *ib.*
- Uvula, page 9. (Pls. II. III.)  
 vesicae, page 43. (Pl. XXVI.)
- Vagina, page 55. (Pl. XXX.)
- Valve, coronary, page 29. (Pl. XIX.)  
 Eustachian, page 29.  
 ileo-colic, page 21. (Pl. VIII.)  
 pyloric, page 17. (Pls. VIII. XIII.)  
 tricuspid, page 30. (Pl. XIX.)
- Valvula Bauhini, page 21. (Pl. VIII.)
- Valvulae conniventes, page 18. (Pls. V. VIII.)
- Vasa deferens, page 53. (Pls. XXV. XXVI. XXVII. XXVIII. XXIX.)
- Vasa deferentia, *ib.* (Pls. XXV. XXVI. XXVII.)  
 efferentia, *ib.* (Pl. XXIX.)  
 pampiniformia. (Pl. XXVIII.)  
 recta, page 53. (Pl. XXIX.)
- Vasculum aberrans. (Pl. XXIX.)
- Veins, hepatic, page 24. (Pl. XI.)  
 inter-lobular, page 25. (Pl. XI.)  
 intra-lobular, *ib.* (Pl. XI.)  
 portal, *ib.* (Pls. XI. XII.)  
 sub-lobular, *ib.* (Pl. XI.)
- Velum pendulum palati, page 9. (Pl. II.)
- Ventricle, left, page 30.  
 right, page 29.
- Veru montanum, page 47. (Pl. XXVI.)
- Vesiculae seminales, page 54. (Pls. XXV. XXVI. XXVII.)
- Vestibule of the vulva, page 55. (Pl. XXX.)
- Villi, anatomy of the, page 7.
- Viscera of the abdomen. (Pl. VI.)  
 of the body, page 3.  
 of the pelvis, page 42. (Pls. XXV. XXX.)
- Vulva, page 55. (Pl. XXX.)
- Wharton's duct, page 10. (Pl. I.)













★ ★ ARMY ★ ★

