


HOLT (L.E.)

A REPORT OF FIVE CASES  
OF ABSCESS OF THE BRAIN IN INFANTS, TO-  
GETHER WITH A SUMMARY OF TWENTY-  
SEVEN COLLECTED CASES, IN INFANTS AND  
VERY YOUNG CHILDREN.

BY

L. EMMETT HOLT, M.D.

*New York.*





A REPORT OF FIVE CASES OF ABSCESS OF THE BRAIN  
IN INFANTS, TOGETHER WITH A SUMMARY OF  
TWENTY-SEVEN COLLECTED CASES, IN INFANTS  
AND VERY YOUNG CHILDREN.\*

BY L. EMMETT HOLT, M.D.,

New York.

The literature of cerebral abscess in infancy and early childhood is very meagre. How rare this condition is may be judged from the fact that in a collection of ninety cases of abscess of the brain in 1867, Meyer found only three under ten years of age; in a collection of seventeen cases in children under fifteen, by Wyss in 1871, only four were under five years, two of these being in infants under one year. This is quite remarkable, since the two most potent causes of abscess, traumatism and otitis, are both so frequent during the first five years of life.

The cases reported thus far have many of them been with very imperfect clinical histories, so imperfect, in fact, as often to throw little light upon the course of the disease at this early age. After five years, cases of brain abscess are not infrequent, and as a rule, the course resembles that seen in older children and early adult life. Four of the cases here reported came under observation in the Babies' Hospital in a single year, and two of them were under observation long enough to give an opportunity for careful study and record. It is the purpose of the present paper to furnish, together with a report of the cases mentioned, a collection of all that could be found in literature in children under five years; not, however, including any of five or over.

CASE I.—*An abscess in the left parietal lobe containing two ounces of pus, with latent symptoms.*

A female child, six weeks old, was admitted to the Hospital, March 17, 1897. The history given was that the child was

\* Read before the American Pediatric Society, Washington, May 3, 1897.

LIBRARY  
SURGEON GENERAL'S OFFICE

NOV. -2--1898

618.

born after an easy, uncomplicated labor; that there had been no ophthalmia; no umbilical inflammation, and no traumatism. The infant was said always to have been well and healthy, and nothing abnormal had been noticed until four days previously, when swelling at the lower part of the left thigh was observed. The parents were not very intelligent, and no other facts could be ascertained.

The child was admitted at night and no careful record was made of her general symptoms. She was well nourished, but very pale and greatly prostrated; pulse very feeble; temperature 99.5°; there was no coma. The only thing about the patient which attracted particular attention was, in addition to the great prostration, a swelling at the lower portion of the left thigh. This was quite prominent, and at its inner surface was an area of fluctuation. An erysipelatous blush surrounded the knee and extended up the thigh to the groin.

The child was seen shortly after by Dr. A. L. Fisk, Surgeon to the Hospital, who laid open the thigh. He found no pus, but only a mass of disorganized blood and lacerated tissues. The thigh was thoroughly irrigated, and the wound drained and closed. No improvement followed the operation; the temperature remained slightly elevated, and the blush extended rapidly upward until it reached the navel. The child grew gradually worse and died the following morning, eighteen hours after admission.

AUTOPSY.—*Brain*: The convolutions of the left side were much flattened. The brain generally was firm, but quite pale, except over the medulla and pons, which were congested. No adhesions between the dura and skull, or between the dura and pia. There was a localized meningitis over the left hemisphere in the parietal region, extending somewhat on to the occipital and temporo-sphenoidal lobes. The pia was infiltrated with pus and fibrin in places, but the exudation was nowhere abundant. Occupying chiefly the left parietal lobe was an abscess cavity (Fig. 1) measuring 7 c.m. by 5 c.m., and containing two ounces of thick, yellow, odorless pus. Its external wall was very thin, being scarcely two millimetres in thickness. In front the abscess was bounded by the ascending frontal, and behind by the anterior occipital convolution. The abscess wall was sharply limited, but showed no well-defined lining membrane.

The sac communicated with the left lateral ventricle, which, however, was not filled with pus.

The temporal bone on both sides was opened, and thin, yellow pus was found in both middle ears, but much more upon the left side. (No discharge during life.)

On laying open the left thigh there was found a transverse laceration of the quadriceps muscle, just above the knee joint, with very extensive extravasation. The articular surfaces of the femur, fibula and tibia were reddened, and the cartilages slightly softened. There was some bloody effusion into the knee joint.

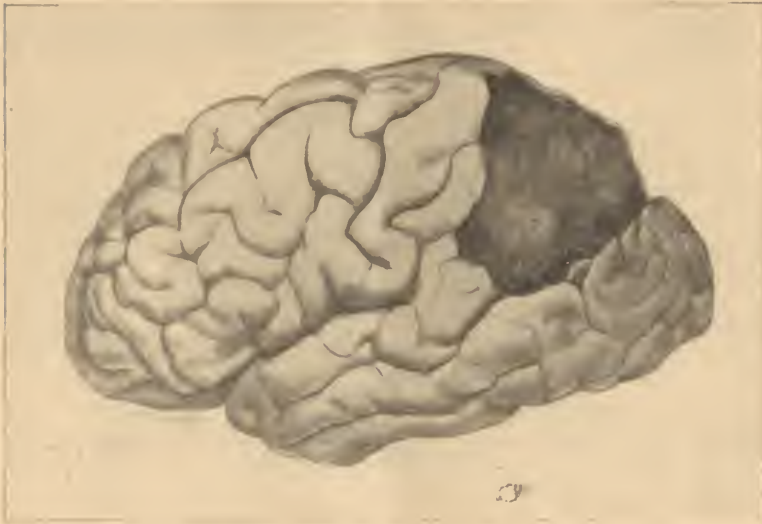

Fig. 1. ABSCESS OF PARIETAL LOBE IN A CHILD SIX WEEKS OLD. (Case I.)

There was no fracture and the epiphysis was not separated. The other organs showed nothing of importance.

A bacteriological examination was made with the following result:

The heart's blood, liver, left knee, thigh wound and abscess cavity of the brain all contained the streptococcus and staphylococcus pyogenes. The spleen and kidneys contained the streptococcus in pure culture. The culture from the right ear was contaminated; that from the left ear contained the streptococcus.

The finding of an abscess in this case was entirely unexpected, for there was nothing in the history or the symptoms to point to

any serious brain lesion. Although carefully questioned, the parents positively stated that the child had appeared well until four days before admission. The condition found in the left thigh could only have resulted from traumatism, although no history of it could be obtained. It is not easy to state what the order of development of the different lesions was, but it seems most probable that the brain became infected from the ear, and that the thigh was a later condition infected from the brain or from the ear. The absence of pus from the lacerated thigh tissues, and the large collection in the brain, make it highly improbable that the thigh lesion was the primary one.

CASE II.—*Abscess of both parieto-occipital lobes and the cerebellum; pus in all the ventricles of the brain.*

L. K., a female child, three months old, was admitted to the Hospital, November 19, 1896. The family history was negative. One child had died at eight months of some brain disease after two days' illness; one, of measles, and one of pneumonia. The patient was the only child living and had always been breast-fed. The mother was a Russian, and very little that was definite could be learned regarding the present illness, except that the child had been apparently well until three days before, since which time fever had been present.

The examination on admission showed a plump, well-nourished infant; length, 23 inches; weight, 10 pounds, 1½ ounces; sutures still open; eyes, ears, nose and throat normal; scalp covered with seborrhœic eczema; tongue slightly coated; respirations shallow and irregular, almost Cheyne-Stokes; abdomen retracted; no rigidity of the extremities; no strabismus, drowsiness, paralysis, or stupor; liver, spleen, lungs, heart, normal. The temperature was 99° F., but rose the same afternoon to 102° F.

November 24th. The child has not done well; there has been continued fever and a loss of half a pound in weight. The child has vomited once or twice; takes food poorly. The pulse is strong and regular; there is slight cervical opisthotonos; fontanel not bulging. Unless disturbed, the child lies quietly all the time. No new nervous symptoms have developed since admission.

December 8th. There have been very few changes during the last week. The fever has continued, ranging from 99° to

101° F. She has lost ground steadily, the weight having dropped to eight pounds and a half. The bowels move regularly and the stools are well digested. Once in two or three days there has been vomiting. The lungs are still negative. There is now present quite a marked degree of opisthotonos, and the abdomen is retracted. The pulse is rapid but regular. The child is quiet, but there is no stupor.

December 10th. The opisthotonos is constant and is becoming more marked. There is a convergent strabismus which is not constant. The pupils are regular and respond normally; a slight nystagmus noticed to-day for the first time. The abdomen is still retracted; hands quite firmly clinched; no general rigidity; many rales in the right lung behind.

December 12th. There is now distinct bulging of the fon-

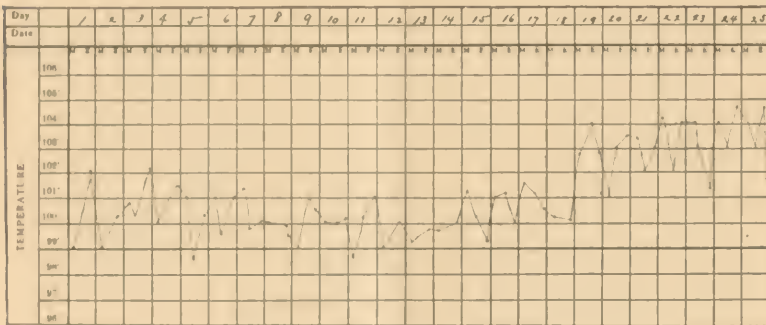


Fig. 2. TEMPERATURE RANGE IN CASE II.

tanel; pupils are still normal; the mental symptoms have not increased; there is no stupor.

December 13th. There is marked rigidity of the arms and hands, and moderate rigidity of the legs; also very marked nystagmus; general convulsive movements occurred to-day. The pulse is rapid, slightly irregular, at times intermittent. Respiration continues very irregular, almost typically Cheyne-Stokes. The abdomen is not now retracted; there is drowsiness, but no coma. The child vomited three times during the day and died quietly of exhaustion at 10 P.M., having been under observation exactly twenty-five days.

The marked symptoms were the constant fever (see chart) which, during the last week, was high; continued irregularity of respiration and cervical opisthotonos, but with no other con-

stant nervous symptoms; nystagmus, rigidity, retraction of the abdomen and vomiting,—all being only slightly marked and not constant. The case appeared like an irregular type of meningitis.

AUTOPSY.—On removing the brain from the cranium, 100 c.c. of bloody cerebro-spinal fluid escaped. There was observed a distinct bulging of the right parietal lobe, on opening which there was found a considerable quantity of green, viscid pus. This abscess cavity was found to communicate freely with the right lateral ventricle; and both lateral ventricles, as well as the third and fourth, were dilated and filled with pus. The abscess had broken across the mid-brain, and all parts about were considerably softened. On the inner side of the left hemisphere (Fig 3) a similar collection of pus was seen to that upon the right side, but it was more deeply situated. The cerebellum was softened, especially on its inferior surface, and was infiltrated with pus cells, as the microscope showed. There were nowhere any marked evidences of meningitis, although the pia over the parietal and occipital lobes was much congested.

The sinuses were normal; a recent non-adherent thrombus of a dark red color was found in the lateral sinus.

The petrous portion of the temporal bone was opened on both sides, the right being found normal; but on the left side a collection of pale green pus was found in the internal auditory canal. (No discharge noticed during life.)

The spinal cord was not examined. There was a moderate amount of hypostatic pneumonia, and an extremely fatty liver, but nothing of importance in any of the other organs.

Cultures were made from the pus on the surface of the cerebellum, from the lateral ventricles, from the middle ear; and all showed a growth of a diplococcus, and a short, plump, motile bacillus. The former was identified as the pneumococcus, and the latter as the bacillus coli commune. The same was found in the lung.

The long period of observation made it possible for many examinations of this child to be made, and she was seen by several members of the Hospital staff. The case was regarded during life as one of meningitis of an irregular type, and in the absence of definite focal symptoms, it does not seem possible for a differential diagnosis to have been made. The source of infection seems pretty clearly to have been the ears.



CASE III.—*Superficial abscess of the cerebellum ; diffuse purulent meningitis.*

P. F., male, five months, admitted to the hospital, October 5, 1896, thirty-six hours before death. The family history was negative; the child was reported to have been well and strong until seven weeks before when it was said he fell from the bed to the floor. How he struck could not be ascertained as not much attention was paid to this, and nothing of importance was observed until three days later when he was suddenly taken with sharp piercing cries and vomited several times. From that time he had not been well; had steadily lost flesh;

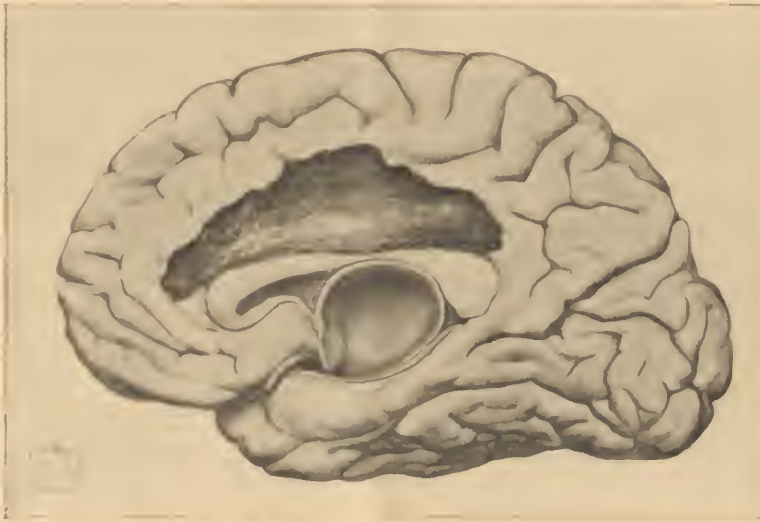

Fig. 3. ABSCESS ON INNER SURFACE OF RIGHT HEMISPHERE. (Case II.)

there had been frequent attacks of trembling and muscular twitching, but no general convulsions. No other details that were reliable could be obtained.

On admission the child was much emaciated and was in quite a deep stupor. There was no apparent paralysis, but a general spastic condition of the muscles of all the extremities; the neck was stiff, the head drawn back in opisthotonos; the hands were tightly clenched; the abdomen retracted; the pupils responded very sluggishly to light and, by tests, there appeared to be no vision. The pulse was 200 and weak. The temperature was 100.6° F. and rose later in the day to 101.6° F.

On the following day the child vomited several times a bloody fluid, and had several tarry stools; bleeding also occurred from the left ear. There were general convulsions lasting two hours. The temperature fluctuated during the day between 98° and 104.2° F.; the child lost steadily and died at eleven P.M.

AUTOPSY.—There were evidences of a diffuse purulent meningitis over both hemispheres with an abundant exudation which was most marked at the convexity along the superior longitudinal sinus; the convolutions were flattened. Four ounces of turbid cerebro-spinal fluid were collected and measured. On removing the brain from the skull an abscess was opened about 2 c.m. in diameter on the inferior surface of the cerebellum. This contained green viscid pus and broken down brain tissue, and was surrounded by quite a dense membrane. It extended inward into the vermiform process. Both the lateral ventricles and third ventricle contained the same thick pus. Only the upper part of the spinal cord was examined; this was normal. The central canal was not dilated.

Pus from the abscess cavity was stained with gentian violet and acetic acid, and an organism resembling the meningococcus was found.

This case was almost moribund at the time of admission and was under observation so short a time that there was no opportunity to study it carefully. Unfortunately the middle ear was not examined at autopsy but there was no history of a discharge, except the bloody one mentioned. The symptoms during the period of observation were regarded as due to meningitis.

CASE IV. *One large and two small abscesses of the cerebellum.*

F. L., female, nine months old; was admitted to the Hospital, December 7, 1896. There were four other children in the family; all reported healthy. The patient had never been strong; had measles three months ago, and was said to have been failing since that time. Reports regarding the duration of present illness were somewhat conflicting, but it appeared certain that the child had been ailing at least six weeks. Not much that was reliable could be learned regarding the early symptoms. There had been no vomiting, no diarrhœa.

On admission the child was fairly nourished, weighed four-

teen pounds and five ounces, and had six teeth. The fontanel was rather large and slightly bulging. The eyes, ears, throat and nose were normal. There was internal strabismus; the pupils were dilated and responded feebly to light; knee-jerk, increased on both sides. The child was quiet but did not seem at all stupid; no paralysis, arms and legs being freely moved. Considerable cerebral irritability was manifested by grinding of the teeth and throwing the arms wildly about. The head was drawn back, but the post-cervical muscles were not rigid; pulse slightly irregular; respiration shallow and very irregular; temperature normal.

During the first few days of observation there was no special change in the symptoms. Marked irritability alternated with periods of drowsiness. The pulse at times was decidedly irregular and at times intermittent. The abdomen was not retracted; there was no vomiting; no constipation.

December 11. It was noted that the child had been part of the time very restless and in the intervals more drowsy than before; had vomited twice.

December 16. The bulging of the fontanel was increasing; pupils moderately dilated and did not respond to light; there was a loss of sympathetic reflexes; there was then a very marked general hyperæsthesia.

December 18. The condition was about stationary; vomited about once each day; on account of the great restlessness required bromide, two or three doses daily. Lumbar puncture made and about 10 c. c. of clear fluid drawn, cultures from which showed the staphylococcus pyogenes aureus, and another organism resembling the pneumococcus.

December 20. A very marked intermittent flush was noted which covered the face and neck and upper part of the chest. This came out rapidly and disappeared in a few minutes. When fully out it resembled closely the eruption of scarlet fever. It occurred several times a day, lasting from five to twenty minutes. Ankle clonus on the left side was noted.

December 25th. The history states that the child's general condition has improved in a most surprising way since her admission, and she has gained one pound in weight; the appetite is good, and the stools are digested. The temperature has been normal nearly all the time. Both the pulse and respiration have now become regular, but the drowsiness has rather in-

creased and opisthotonos is still present. The knee reflexes are still much exaggerated, and there is slight rigidity of the feet and legs.

December 28. The pulse is more rapid, 160 to-day, but quite regular. The flushing of the face and neck is still repeated several times a day.

December 29. A marked tremor of the right hand is noticed for the first time, and continued for the greater part of the day. The left hand is somewhat rigid, and when touched the rigidity is followed by a rhythmical tremor which lasts several minutes. The rigidity of the lower extremities is now marked; the feet in extreme extension. The child is considerably weaker.

December 30. The rigidity of both feet and hands has increased; pulse 132, regular and strong; respiration 40 to 60 and very irregular; occasionally a slight tremor of the hands; right pupil is smaller than the left but both respond better than a few days ago; fontanel still tense and markedly bulging; opisthotonos less marked. The mental condition is about the same; when undisturbed the child is drowsy and quiet but very irritable when touched, and cries out in a fretful way. The abdomen is still normal. Her general condition is not so good; she has lost a pound in weight.

January 2. A second lumbar puncture made and 18 c. c. of clear fluid withdrawn, a bacteriological examination of which showed the staphylococcus in pure culture.

January 3. The withdrawal of the fluid has not been followed by any depression of the fontanel or any other change in the symptoms. The reflexes are all greatly exaggerated. Slight convulsive movements of the hands occurred to-day, followed by tremor lasting for some time. For the past two weeks the child has taken large doses of iodide of potassium but without any apparent improvement and it is now discontinued.

January 4. Frequent convulsive movements occur affecting the right hand and arm. There is paralysis now of the left side of the face; the mouth is drawn to one side; the naso-labial fold is deepened and the left eye very imperfectly closed. (This paralysis did not continue.)

January 7. The general condition has improved decidedly during the past week and she has more than regained her lost weight. In other respects there is little change. She is very restless much of the time but sleeps quietly at night. A puru-

lent discharge from the ear noticed to-day, which is regarded as a possible explanation of the higher temperature of the last few days.

Cultures from the pus of the ear showed staphylococcus, streptococcus and another organism which resembles the meningococcus.

January 13. The discharge from the ear continues quite freely and has become offensive in spite of the frequent syringing. The pulse is weaker, quite irregular, and vasomotor symptoms continue. The child is more quiet than formerly.

January 14. Is growing steadily worse so far as the nervous symptoms are concerned. There is more dulness and less irritability. A careful test to-day shows that vision is present; pupils are still dilated and respond feebly to light; pulse irregular but not intermittent. Respiration irregular. The rigidity of the extremities is constant and now marked.

January 16. Swallowing has become so difficult that it has become necessary to give all food by stomach tube. Pulse is weaker and slightly irregular; stupor is more pronounced and opisthotonos less marked. There a few rales at the right apex behind.

January 21. Has failed rapidly in the last few days, having lost a pound in weight. Pulse is rapid and regular; pupils not so widely dilated; vomits occasionally for a day or two but not in any characteristic way. Still very irritable when disturbed but otherwise is quiet.

January 24. An examination of the eyes made by Dr. W. A. Holden, who reports a pallor of both optic discs, which, however, are sharply outlined; the vessels are of fairly normal calibre; no changes in the macula. He makes a diagnosis of simple optic nerve atrophy.

January 25. Rales on both sides of the chest behind. The bowels have been regular since admission and the stools are still well digested, although in general condition the child is losing rapidly.

January 28. Patient moribund, but not comatose. Pupils smaller than a few days ago; fontanel now depressed; rigidity of the extremities continues; pulse very rapid but regular. Died quietly from exhaustion on the morning of the 29th, having been under observation fifty-four days.

The symptoms which this long case showed may be grouped as follows:

*Motor.*—Opisthotonos nearly constant and generally marked; rigidity of all four extremities during the last four weeks only; tremor of the hands, especially the right, frequent during the last few weeks; no paralysis except a slight temporary one of the face; no general convulsions; ankle clonus for a time, especially upon the left side; knee-jerk always much exaggerated upon both sides.

*Sensory.*—Moderate hyperæsthesia early in the illness, no evidence at any time of headache or other pain.

*Vaso-motor.*—*Tache cérébrale* nearly constant; very marked and irregular flushing of the face and neck during the third, fourth and fifth weeks.

*Mental.*—General irritability alternating with dulness; no deep stupor or coma.

*Special Senses.*—Slight internal strabismus early; pupils dilated throughout the attack and responded feebly to light; optic nerve atrophy discovered in the sixth week; purulent discharge from the left ear developed in the fourth week.

*General.*—Pulse usually rapid and regular, occasionally irregular but never slow or intermittent; respiration very irregular nearly all the time, and much of the time on the Cheyne-Stokes order; temperature (see Fig. 4), practically normal for the first two weeks, the marked rise in the fourth week, apparently from otitis; constant elevation only during the last eight days; vomiting occasional and never characteristic of brain disease; the bowels always regular; abdomen never retracted; fontanel constantly tense and bulging. The progress was very irregular both as regards the nervous symptoms and the general condition, the child alternately losing and gaining in weight, and the nervous symptoms showing no steady advance for the first month of observation. Another factor in the diagnosis was the presence of pus organisms in the fluid drawn by lumbar puncture in the second and third weeks.

To summarize briefly, the symptoms which were practically always present were cervical opisthotonos, a tense bulging fontanel, moderate equal dilatation of the pupils, irregular respiration, a condition of mental irritability alternating with dulness, and increased knee-jerk. Late in the disease there were added

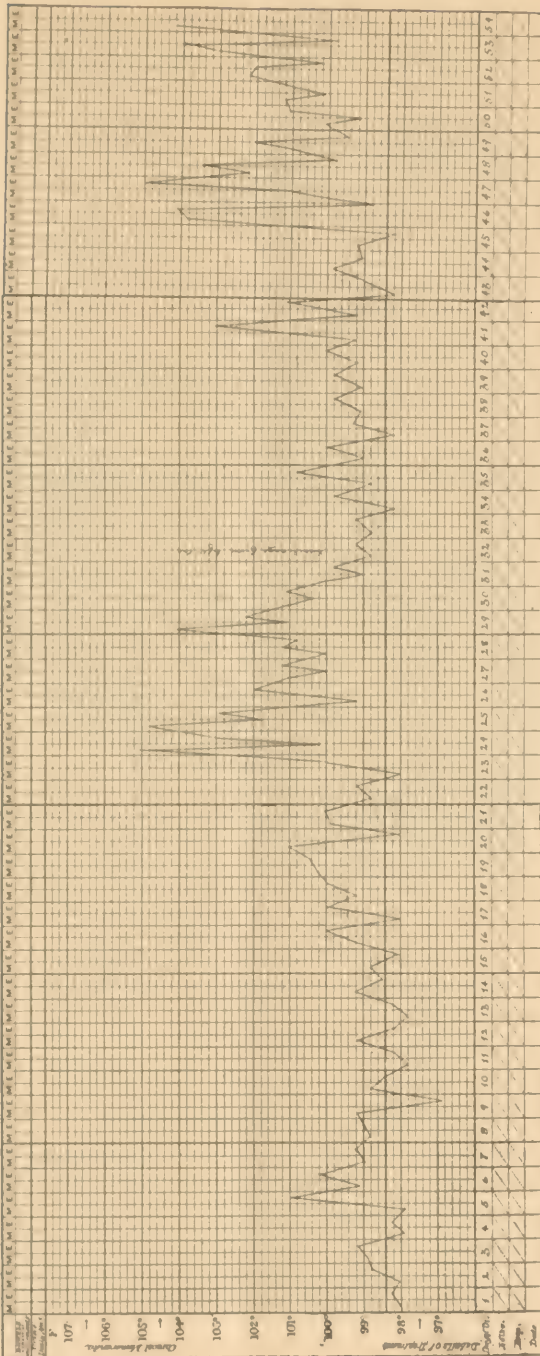


Fig. 4. TEMPERATURE RANGE IN CASE OF ABSCESSSES OF THE CEREBELLUM. (CASE IV.)

irregular temperature, a discharging ear, rigidity of all the four extremities, marked vaso-motor symptoms, and optic-nerve atrophy.

The case was seen by nearly all the physicians connected with the Hospital and by many others. At the end of the second week one only was willing to put himself on record as in favor of tubercular meningitis, the others present at this consultation regarding the case as one of basilar tumor. The latter diagnosis was concurred in by a prominent nerve specialist who saw the case late in the fourth week. However, only two weeks before death another prominent specialist made a diagnosis of "arrested cerebral development, an atrophic cortex and latent hydrocephalus." After the result of the lumbar puncture was known the diagnosis was thought by those watching the case closely to lie between meningitis and abscess, and during the last week the latter diagnosis was regarded as altogether the more probable one.

AUTOPSY.—The pia mater was adherent to the dura over the right temporo-sphenoidal lobe and over the cerebellum; at the base there was a moderate amount of meningitis with purulent exudation; the cerebro-spinal fluid was increased in quantity, and the amount of fluid in the ventricles was greater than normal although they were not distended and the fluid was not purulent.

The right lobe of the cerebellum was considerably larger than the left, measuring 1 cm. more in both diameters; the middle lobe appeared compressed. In the right lobe of the cerebellum (Fig. 5), there was a large abscess which occupied nearly the whole lobe; this was surrounded by a sac wall which was dense and firm and about 1 mm. in thickness; the abscess contained a viscid greenish pus. A little to one side of this large abscess was a smaller one about 4 cm. in diameter; this was superficial, and though the walls of the two sacs were upon one side in contact, they did not appear to communicate. A third abscess about 2 cm. in diameter was superficially situated in the left lobe of the cerebellum, and like the other two was surrounded by a dense fibrous wall. There were no collections of pus in the cerebrum and no meningitis of the convexity. The medulla was compressed and displaced to the left.



There was no pus in the internal auditory canal. Nothing of importance was discovered in any of the other organs.

Smears from all the abscesses showed the staphylococcus, and plate cultures showed the same organism, pure. A microscopical examination of the wall of the large abscess showed a dense fibrous structure lined with stratified epithelium, and in places, some pigmentation. It appeared to have been an old cyst which had become infected.

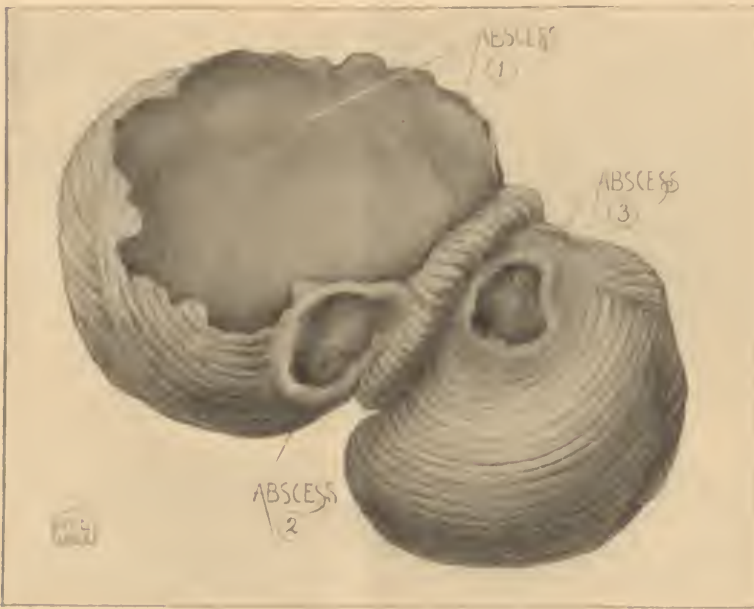

Fig. 5. ABSCESSES OF CEREBELLUM. (Case IV.)

CASE V.—*Acute pyocephalus, or suppurative ependymitis with pus filling both lateral ventricles, complicating a spinal meningitis which followed the infection of a spina-bifida sac.*

This case has already been published by Dr. Ira Van Gieson and myself (*Journal of Nervous and Mental Disease*, December, 1890.) and a brief abstract of that report will be here sufficient.

The patient was a female infant dying at the age of three weeks, having been under my observation in the Hospital since it was three days old. It was admitted for a lumbo-sacral spina bifida complicated by double talipes equino-varus and para-

plegia. The spina bifida was covered with a granulating surface and had a very thin translucent wall. During the first two days the temperature was taken and found normal; it was not subsequently recorded but it did not appear elevated at any time. For the first two weeks the child was very quiet and slept most of the time, giving no sign of any cerebral disorder. During the last four or five days she failed rapidly and died apparently of innutrition, there having been no fever, vomiting, opisthotonos or convulsions. There was no enlargement of the head.

At autopsy the ventricles were found greatly enlarged and contained five ounces of thin yellow pus. They were surrounded by a mere shell of brain tissue which had an average thickness of less than 1 cm. There was no corresponding increase in the size of the brain as a whole. There was suppurative inflammation of the sac of the spina bifida, which contained half an ounce of pus, and purulent spinal meningitis extending throughout the cord and evidences of inflammation throughout the central canal. Under the microscope the same micrococci could be traced from the wall of the spina-bifida sac along the surface and central canal of the cord to the lateral ventricles. The symptoms were, therefore, entirely latent, there being no evidence of anything except a rapidly failing nutrition.

While this case should not strictly be classed as an abscess of the brain, it still has certain features in common with such abscesses, and illustrates a mode, although a rare one, of intracranial infection. Evidently the primary condition was a patent central canal of the cord with hydrocephalus, not accompanied by any enlargement of the head, and the origin of the pus was the access of pus germs to a previously serous fluid. That such an active and wide-spread infection of the central nervous system should occur without convulsions, fever, or any of the usual symptoms of brain or cord inflammation, seems most astonishing and serves to emphasize the fact illustrated by the other cases reported, that the ordinary rules of diagnosis do not apply in the case of young infants.

#### COLLECTED CASES.

CASE VI.—*Cerebral abscess following trauma (?) ; no symptoms until a few hours before death.* (Youl, *Lancet*, 1847. i., 71.)

A child eight months old, no evidence of previous disease, received a wound in the temporal region by some sharp body,

which healed properly; no cerebral symptoms observed until two weeks after the injury, when child vomited and shortly after was seized with general convulsions and died in an hour. Autopsy showed abscess containing two ounces of pus in the hemisphere situated [in frontal lobe?] at a point opposite to the scar of the external wound: surrounding brain tissue much disorganized; no meningitis. Abscess communicated with lateral ventricle.

CASE VII.—*Abscess of unknown origin in the cerebellum; pus in both lateral ventricles.* (Hughes-Willshire, *Lancet*, October, 1853.)

Female child three months old with cerebral symptoms for twenty days; under observation for two weeks. Sudden onset with a sort of convulsive attack, very restless, nursed with difficulty; repeated convulsions during the period of observation, also vomiting, irregular respiration and extreme restlessness; temperature not mentioned. Autopsy showed brain congested, softened patches of meningitis over convexity; abscess cavity in the cerebellum which appeared to be lined by a thin membrane, medulla softened. about three ounces of pus in each ventricle, ependyma thickened and vascular, spinal cord so far as examined was normal.

CASE VIII.—*Abscess involving the entire frontal lobe.* (Wyss. *Jahrbuch für Kinderheilkunde.* iv., 129-139.)

Boy ten and one-half months old, who fell several feet striking the head four days before the first symptoms. Sudden onset with crying and severe pain in the night, followed ten hours later by twitching of right arm and leg. Eight days after onset, paralysis of right arm and leg. Five weeks after onset, twitching of left arm and leg, fever present; circumference of head increased. On week later measles developed; child became unconscious; pupils equally dilated; right arm flexed; contracture at elbow and knee. Six to eight convulsions daily, during one of which the child died, on the ninth day after onset of measles and seven weeks after beginning of illness. Autopsy showed left hemisphere of brain larger than right, owing to an enormous abscess involving almost the entire frontal lobe. Abscess cavity separated from surrounding brain substance by a membrane having smooth surface; no communication with ventricles, which were distended with clear serum.

CASE IX.—*Abscess of occipital lobe of left hemisphere following a punctured wound.* (Wyss. *loc. cit.*)

Boy eighteen months old. Eight days before death he fell striking head against a frame containing nails, two or three of which penetrated the skull. Except for restlessness the

child was well, until one day before death. He then began to vomit and during the following night twitching of arm and leg occurred; respiration became noisy and death occurred in about twenty-four hours. Autopsy revealed two wounds in occipital region around which there was slight infiltration but no suppuration.

Abscess in posterior lobe of left hemisphere, the latter being broken down and softened as far as the roof of the left lateral ventricle; ventricle contained blood stained serum but no pus; area of softening not sharply defined.

CASE X.—*Abscess of the entire left cerebral hemisphere.* (*Bednar. Wiener Med. Wochenschrift.* 1871.)

An infant of six weeks in whom the first symptom appeared on seventh day after vaccination; no traumatism. No motor disturbances, but the head rapidly enlarged in all directions; pupils contracted, and the eyes were turned inward and upward. Death on the third day. Autopsy.—Entire left hemisphere hollowed out and filled with pus; cavity separated from cortical surface in the frontal region by a very thin wall of softened brain matter. In parietal region, wall somewhat thicker; cavity communicated with left ventricle; inner wall roughened and fatty. Pus in the right and in the third and fourth ventricles, also in the spinal cord in the space between the dura and pia. Meningitis present.

CASE XI.—*Encysted abscess of the right ventricle.* (*Warner. British Medical Journal.* 1873. Vol. ii., p. 460.)

The patient was fourteen months old and had indefinite symptoms for several months; first definite symptom was a convulsion lasting for three hours, followed two days later by another and this two days later by a convulsion in which the right arm and left leg only were involved. Eight days after the onset two more convulsions occurred during the last of which the child died. Head generally enlarged; anterior fontanel open and pulsated strongly; pupils dilated equally, disc in each eye normal. The autopsy revealed an apparently encysted abscess containing four ounces of pus in the front part of the right ventricle bulging into the anterior lobe. Abscess limited by a thick, tough and vascular membrane apparently of some duration. A slight amount of meningitis at the base of the brain; no tubercles.

CASE XII.—*Abscess of parietal lobe, following punctured wound: operation; recovery.* (*Courvoisier. Correspondenzblatt. für Schweizer Aerzte. Basel.* 1879. Vol. lx., No. 14.)

Girl, two and a-half years old, who had received a penetrating wound with a pair of shears in left parietal region. Seven days later the first symptoms developed, consisting of vomiting,

insomnia, headache, paralysis of right leg and arm, ptosis, and strabismus of left side. Later, fever and paralysis of left face, with paralysis of right arm and leg. Operation four days after onset of symptoms. Depressed fracture found and piece of bone removed, when thick, yellow pus escaped; incision of dura released a tumblerful of pus. Five hours after the operation consciousness returned and paralysis disappeared. Two months later the child was perfectly well, except for some paresis of right arm and leg.

CASE XIII.—*Abscess of frontal lobe following traumatism.* (Koehler. *Irrenfreund. Heilbrunn.* 1879. Vol. xxi., 33-44.)

Boy, eighteen months old, who fell, striking forehead against a file, which penetrated the frontal bone. Four weeks later the scar inflamed and a piece of file one inch long was removed. Subsequently the child began to vomit and passed into coma. A small swelling appeared at the aperture in the frontal bone, which pulsated and was easily reduced. Pus was removed by aspiration, and the patient improved. Coma again developed and the swelling again appeared, but upon aspiration, no pus was obtained. Tremor of left half of body. Death in coma, after an illness of a few days. Autopsy.—Abscess the size of an egg in left hemisphere; cavity communicated with opening in the frontal bone and with left ventricle. Pus had penetrated through the foramen of Munro into the right ventricle; third and fourth ventricles also contained pus. The author believes that the abscess had existed for several weeks without definite symptoms, and that death was due to rupture into the ventricles.

CASE XIV.—*Pyocephalus in a child of five months.* (*Transactions of the Pathological Society of London.* 1881. xxxii., 6.)

Child of five months had been in good health until one week previous to admission to the Hospital, when it had a convulsion. On admission, slight opisthotonos; thirteen days later, opisthotonos had increased, and child in a convulsion. During the last three days the temperature ranged from 101° to 103.4° F. Duration of symptoms, twenty days. Autopsy.—Walls of ventricles injected and their cavities much distended with pus. The central canal of the cord, and also the subarachnoid space, contained pus. Signs of meningitis from the optic chiasm to the medulla; no tubercle in brain or other organs.

CASE XV.—*Multiple abscesses of the brain of pyæmic origin.* (Etlinger. *Jahrbuch für Kinderheilkunde.* 1881. xvii., 110.)

A child of seven weeks, which died after being under observation twenty-four hours. Temperature 39° C.; frequent clonic spasms; pupils dilated; right divergent strabismus and left facial

paralysis. Autopsy revealed diffuse purulent meningitis of the convexity and base of both hemispheres. Where the gray and white matter met, about thirty encapsulated abscesses were found, varying in size from a pea to a hazelnut. Phlebitis of the umbilical vein and of vena porta. The abscesses probably originated from embolism of capillaries. Meningitis was probably caused by the bursting of some of the abscesses into the meninges.

CASE XVI.—*Cerebellar abscess of traumatic (?) origin without fracture of the skull* (Hadden. *St. Thomas' Hospital Reports, London. 1884-86. xiv., 279.*)

A girl, seven months old, had received an injury to the head three months before the appearance of the first symptoms. Initial symptoms, fever and vomiting, ten days after which convulsions occurred. When first seen, the child was unconscious; neck and extremities rigid; respirations 60; temperature 101.2°. Convulsions continued, and before death the pupils became dilated and fixed; there was nystagmus and strabismus. Death four weeks after the first symptoms. Autopsy revealed a superficial abscess involving the under surface of left lobe of cerebellum. Pus in the mastoid cells on both sides; acute meningitis of the base and spinal cord. [In this case it appears probable, from the presence of pus in the mastoid cells, that this may have been the origin of the abscess, rather than the injury to which it is ascribed. REF.]

CASE XVII.—*Abscess of the temporo-sphenoidal lobe secondary to ear disease.* (Randall. *Proceedings of Philadelphia Pathological Society. University Medical Magazine. 1888-89. i., 373.*)

A girl of four years, suffering from suppuration of the mastoids and the left elbow joint and thumb. Caries of both temporal bones from which sequestra were at various times removed; thumb amputated, elbow joint excised. Though these operations were well borne, the child gradually sank and died without cerebral symptoms. At autopsy a large abscess was found in the left temporo-sphenoidal lobe above the opening in the root of the tympanum, which had evidently burst and evacuated itself through the ear causing a gush of pus which had preceded death. No meningitis; lungs filled with cheesy tubercular nodules.

CASE XVIII.—*Abscess of the temporo-sphenoid lobe following otitis and mastoid abscess.* (Dench, *American Gynecological and Obstetrical Journal, October, 1897, also New York Eye and Ear Infirmary Reports, 1897, page 121.*)

The child, two months old, brought to the Infirmary Clinic with a history of the symptoms of acute suppurative otitis of

two weeks' duration, and a swelling behind the left ear which had lasted nearly as long. Patient was admitted to the hospital, the soft fluctuating swelling over the mastoid was incised, and half an ounce of thick pus evacuated. A portion of the temporal bone, above and behind, was coated with unhealthy granulations. The dura was exposed but appeared healthy and no exploration of the brain was made. During the next two weeks the patient was in excellent condition but had fever— $102.5^{\circ}$  to  $103.5^{\circ}$ . On the fourth day was dull; had a slight paralysis of left face, refused to nurse; temperature rose to  $104.5^{\circ}$ . Probe pushed through the dura and half a drachm of thick pus escaped; probe passed two inches into the brain, opening enlarged; no further pus found. Child brightened after operation but the next day developed irregular respiration, general convulsions, died; no autopsy.

CASE XIX.—*Traumatic abscess of the right frontal lobe, operation, recovery.* (Borelius. *Jahrbuch für Kinderheilkunde.* Vol. xxxii., p. 189.)

A boy four years old, who fell upon a splinter of wood which punctured the upper eyelid. One week later, the lid became swollen and epileptiform seizures and other cerebral symptoms occurred; no paralysis, but twitching was more marked in left arm and leg. After an exploratory puncture, deep incision was made in the upper eyelid and a large amount of pus evacuated. A probe would pass through roof of orbit into frontal lobe. Drainage tube inserted and patient recovered without cerebral symptoms; discharged one month after operation.

CASE XX.—*Abscess of left lobe of cerebellum following otitis.* (Clarkson, *Edinburgh Medical Journal.* 1892. Nov., p. 475.)

A boy two and one-half years old who had suffered from otorrhœa left side for eighteen months before death. First grave symptoms five weeks before death when left facial paralysis was observed, followed by drowsiness and vomiting of a cerebral type. No paralysis or contraction of any muscles of the limbs. Temperature normal until shortly before death, when it reached  $103^{\circ}$ . Operation performed by trephining over temporo-sphenoidal region; but abscess was not reached. Condition so bad that further operation deemed unwise. Child gradually lapsed into coma and died the next day; no localizing symptoms. Autopsy showed abscess in left lobe of cerebellum the size of a small egg and a localized meningitis. No other lesion of the brain. Middle ear was filled with unhealthy granulations which extended into the internal ear, the bony walls of which were carious.

CASE XXI.—*Abscess of temporo-sphenoidal lobe secondary to otitis and mastoid disease. Operation, recovery.* (McEwen. *Pyogenic Diseases of the Brain and Spinal Cord.* 1893. Chap. II., p. 79.)

Patient twenty-two months old when admitted to hospital with symptoms of cerebral disturbance and a discharge from the ear. For four months discharge had been profuse and very offensive. Paralysis of seventh nerve occurred six weeks prior to admission; constant pain; temperature 103°. Operation five days after admission, necrosed portions of mastoid and a considerable portion of petrous bone being extracted. Abscess in temporo-sphenoidal lobe from which two drachms of pus were removed; surface of brain eroded and softened. Abscess cavity washed with boracic solution and drainage tube inserted. Temperature fell and continued normal; tube removed on sixth day and the wound closed at the end of a month; child known to be well six months later.

CASE XXII.—*Abscess of temporo-sphenoidal lobe secondary to otitis and mastoid disease. Operation and recovery.* (McEwen, *loc. cit.* 1893. Chap. II., p. 79.)

Patient two years old. Profuse, foul smelling, purulent discharge from left ear for four months; facial paralysis. Operation on the following day; necrosed mass removed from mastoid together with portion of the petrous bone, which gave vent to several ounces of pus. Eroded aperture found in dura mater leading into an abscess cavity in temporo-sphenoidal lobe. Cavity washed but no drainage tube inserted as the opening was large. Surface of the brain shaggy and softened. Complete recovery.

CASE XXIII.—*Abscess of temporo-sphenoidal lobe, following otitis.* (McEwen, *loc. cit.* 1893. Chap. ii., p. 181.)

A boy of three years had a purulent discharge from left ear for more than two years. A year later he had an illness lasting a month, probably a cerebral abscess, which discharged suddenly through the ear, after which he rapidly recovered. Some discharge continuing from the ear, however, a solution of nitrate of silver was injected, which was retained and caused excruciating pain, followed in two hours by delirium, and finally by coma, which persisted until death occurred, four days after. Examination after death showed that the membrana tympani had disappeared, and that a probe could be passed freely into an old abscess cavity with firm walls in temporo-sphenoidal lobe. The silver solution had probably entered this cavity, causing encephalitis, which resulted in death. The abscess was probably of more than a year's duration.



CASE XXIV.—*Cerebellar abscess following otitis.* (McEwen, *loc. cit.*, p. 79.)

A girl four years old had contracted scarlet fever. On twenty-first day of illness, left otorrhœa; on thirty-first day, nervous symptoms, with amaurosis and mydriasis; on thirty-eighth day an abscess behind the left ear burst and fœtid pus escaped; on sixty-ninth day, child could see and was well for three months, except for a fœtid discharge from the sinus. Seven months after onset of first illness she was seized with headache, followed by retraction of the head and other grave nervous symptoms, including convulsions. During the last days of life she became blind; death on the fifteenth day of the second illness. Autopsy.—Abscess was in left lobe of cerebellum extending into the pons; abscess in pons had firm walls. Pia mater over cerebrum involved and all the ventricles enormously distended with chronic serous effusion. The cord showed marked lepto-meningitis with a large amount of serum within the membrane, but no pus. Petrous portion of temporal bone extensively eroded and necrosed. The author believes that erosion of this bone first occurred, and through it the cerebellar fossa was invaded. The sinus was thrombosed and an extra dural abscess was formed, followed by one in the cerebellar hemisphere. The cerebellar abscess probably formed after the scarlet fever.

CASE XXV.—*Cerebellar abscess following otitis.* (McEwen, *loc. cit.*, p. 216.)

A boy three years old. When one year old, he had measles followed by pertussis, during which a discharge occurred from the right ear; one month later abscess behind the ear. This was opened but for two years pus had flowed from the opening and from the meatus. First cerebral symptoms two weeks before admission. Ophthalmoscopic examination showed congested fundi but no distinct optic neuritis; subsequently, congestion of the fundi became greater; when the child attempted to sit up he fell to the right; marked cerebellar ataxia; the temperature which had for some time been sub-normal or normal rose suddenly to 102°; death twenty-two days after onset of brain symptoms. Autopsy.—Abscess involving middle lobe of the cerebellum projecting into the ventricle; anterior wall had disappeared: posterior wall remained and was firm and yellow; right lateral cerebellar lobe softened; dura thickened particularly over the temporal bone. Marked lepto-meningitis with miliary tubercles scattered freely in the sylvian fissure, acute basal and cerebellar lepto-meningitis; cerebral ventricles greatly distended with fluid; tubercle in other organs, especially lungs. The author believes that it is possible that the whole disease originated from tubercle of the petrous bone spreading thence to the membranes of brain.

CASE XXVI.—*Traumatic abscess of the frontal lobe; operation; recovery.* (Zdekauer. *Jahrbuch für Kinderheilkunde.* 1893. xxxv., 297.)

A boy two and three-fourth years old, who fell upon a nail which penetrated left side of head. Five days later, fever; complete right hemiplegia and left side ptosis; temperature 39°C., pulse 45. Over left temporal bone, there was a wound from which pus discharged. Operation performed in which the dura was found to be fluctuating. Puncture of dura released two ounces of green malodorous pus. Drainage tube inserted and pulse soon rose to 95 and temperature fell to 37°C. An uneventful recovery followed, the paralysis having entirely disappeared, with the exception of paresis of left hand.

CASE XXVII.—*Abscess of the temporo-sphenoidal lobe following otitis.* (Ashby and Wright. *The Diseases of Children.* Ed. 1893. p. 430.)

A girl two years old who had a discharge from the left ear for three months. Fourteen days before admission she had a right-sided convulsion, and four days later a second convulsion. Almost complete motor and sensory paralysis of right arm and leg with loss of sensation on left side of face and left ptosis. Death eighteen days after the first convulsion. Abscess cavity found in left temporo-sphenoidal lobe extending into occipital lobe and reaching internal capsule.

CASE XXVIII. *Abscess in the left middle lobe of the cerebrum following otitis.* (Reimer. *Jahrbuch für Kinderheilk.* xi., p. 58.)

Male, four years old, admitted with general tuberculosis; no previous history except that he had been ill for two months. Was under observation seven days. On admission, a foul discharge from left ear; left facial paralysis; ptosis and external strabismus left side, both pupils dilated; partial anæsthesia of left face; complained of severe pain in left side of head; mind clear; contracture of right hand; temperature 39° C.; irregular pulse. Three days later became stupid; had a chill, temperature 40° C.; general convulsions followed by paralysis of right side; died quietly with subnormal temperature. Autopsy showed large abscess in the left middle lobe filling two-thirds of the lobe; purulent meningitis at the base; dura greatly thickened and adherent over middle fossa; ventricles dilated with serum; caries of the petrous bone; ossicles destroyed; pus in mastoid cells; general tuberculosis.

CASE XXIX. *Abscess in the left frontal lobe following necrosis of the frontal bone.* (Reimer, *loc. cit.*, p. 60.)

Male, three years old, delicate, rachitic; under observation seven and a half weeks; cerebral symptoms of six weeks dura-

tion. Bone disease existed for two and one-half months and had gone on to suppuration when brain symptoms, vomiting, fever and convulsions, developed. The local symptoms were headache of left side and later anæsthesia of left face; diminished hearing of left side and paralysis of left sixth nerve. Ten days before death, convulsions and high fever, followed by loss of speech and loss of consciousness; cornea ulcerated and perforated; death in convulsions. Fever during last two weeks constantly high, but pneumonia present. Autopsy showed large abscess occupying nearly the whole of left frontal lobe, containing foul pus; turbid serum in the ventricles; purulent meningitis at the convexity and on the left side at the base also; extensive necrosis of frontal bone; dura was adherent here and greatly thickened.

CASE XXX. *Abscess in the right middle lobe of the cerebrum following otitis.* (*Reimer, loc. cit.*, p. 67.)

Male child, four years old; delicate, rachitic; otitis of right side for one year; under observation for five days. Admitted with paralysis of right face, deafness in the right ear and a foul aural discharge; irregular pupils, the left being large, and severe pain in the head referred to the forehead, right side; very restless and irritable. Signs of tuberculosis in the lungs. Temperature during period of observation from 40° to 41° C. (probably from tuberculosis) and paralysis of right arm developed. Died from pulmonary hemorrhage with a slight convulsion at the close. Autopsy showed general tuberculosis; tubercular meningitis, particularly at the base; caries of petrous bone and ossicles, and abscess in the right middle lobe, size of walnut, containing foul pus. [Cerebral symptoms in this case were certainly in the main due to meningitis. Ref.]

CASE XXXI.—*Two abscesses in the middle and one in the posterior lobe of the cerebrum.* (*Lloyd. Med. Times and Gazette.* 1861. i., p. 199.)

Boy four years old who received wound in right side of neck, which bled freely. Twenty-five days later had a convulsion after which he was paralyzed on left side. He had no further marked symptoms and died ten days later. Right hemisphere softened with two circumscribed abscesses in the middle and one in the posterior lobe. Lesions supposed by author to be due to diminished blood supply.

CASE XXXII.—*A large abscess of parietal lobe following traumatism.* (*Unpublished case of C. T. Poore, M.D., referred to in Starr's "Brain Surgery,"* p. 185.)

Male, three years old, in August fell down stairs striking head against heel of mother's shoe, and causing scalp wound in left parietal region. One hour later convulsions, which were

repeated in three hours. Admitted to hospital October 10, with history that he had lately dragged right foot and not used right hand; was nauseated and cried out nights. On October 20, first careful examination made showing complete paralysis of right arm and leg, partial of right face; right pupil larger than left, both respond to light; mental dulness. A scar at site of injury and skull felt to be depressed, no fever. Five days later was trephined at this point; dura found normal; incised, brain found normal; considerable shock and further exploration decided against. After operation paralysis improved, especially in arm. November 3, had convulsions, which were repeated frequently the next ten days, sometimes beginning on right side, some during times more marked on left side. Pupils contracted; died in convulsions November 17th, twenty-four days after operation and about three months after the injury. For two weeks after operation temperature not above 100.4°; during next week, normal most of the time; on the day before death, rose to 105.5° F.; no deep coma, pulse 90 to 110, sometimes irregular; respiration 16 to 20. Autopsy showed general adhesions of pia, but no acute meningitis. Large abscess in left parietal lobe containing eight ounces of pus; no communication with ventricle.

ETIOLOGY.—Of the 32 cases, 13 were under one year of age, 9 of these being under six months and 5 under three months; 3 occurred during the second year, and 5 in each the third, fourth and sixth years, no case being included which was five years old or over.

Of the 13 first-year cases, 2 were distinctly traumatic and 1 probably so; 1 was positively an ear case and 4 others probably so; 1 complicated pyæmia; 1 spina-bifida, and in 3 the origin was uncertain. Of the cases over one year old, 10 were positively sequelæ of otitis; 7 positively traumatic, and 1 doubtfully so; 1 was secondary to necrosis of the skull. The two most important factors in the etiology of cerebral abscess in young children, as at all ages, are, therefore, otitis and traumatism.

In three of the cases (I., II., IV.), no discharge from the ear had preceded the cerebral symptoms; however, in 1 there was an ear discharge during the course of the brain abscess, and in 2 others pus was found in the middle ear at autopsy although no discharge was present during life. These last cases deserve more than passing notice; the frequency with which pus is found in the middle ear in very young children, particularly infants, who have died from various forms of disease, has only recently been appreciated. Kossel (*Jahrb. f. Kinderb.* xxxvii.,

445) found it in 85 out of 108 consecutive cases examined; Rasch (*Jahrb. f. Kinderb.* xxxvii., 319), in 45 out of 60 cases; Hartmann (*Jahrb. f. Kinderb.* xl., 285), in 35 out of 47 autopsies, in 28 of which it was double. The majority of the above patients were infants, and in a large percentage of them no symptoms of otitis had existed during life. In this condition, it seems to me, is to be found an explanation of the origin, not only of brain abscess which develops without exciting cause, but also of very many of the cases of acute meningitis for which no etiology can be found. It is highly probable that in the 4 cases in infants of three, five, six, and fourteen months respectively, in which no cause could be traced, light might have been thrown upon the etiology had the middle ear been examined at autopsy, which unfortunately is not recorded.

There were 11 cases in which an aural discharge preceded the brain symptoms, and in 6 of these there had been a mastoid abscess. The discharge from the ear had lasted two or three weeks in 1 case; from three to four months in 3 cases; seven months, fourteen months, and two years each in 1 case. In 8 of the 11 cases, it is positively stated that caries of the petrous bone existed, and in 2 others this condition seems probable from the history; the remaining one had a mastoid abscess. It is, therefore, the old and usually the neglected cases of otitis which are likely to be complicated by brain abscess, and nearly always it is secondary to caries of the temporal bone.

Traumatism was assigned as a cause in 10 cases; in 7 of these (VI., IX., XII., XIII., XIX., XXVI., XXXII.) the abscess followed a wound with fracture of the skull; in 3 there was history of injury but no fracture; in 1 of these the injury was three months before the symptoms, but as pus was found at autopsy in the mastoid, this should probably be ranked as a case due to ear disease. In 7 of the traumatic cases decided cerebral symptoms developed within a week after the injury; in 4 of these there was fracture, and in 3 none. In 1 case the first symptoms were at the end of two weeks; in 1 case at the end of four weeks, and in 1 case without fracture, at the end of three months, this being a doubtful case.

Of the remaining cases, 1 (V.) was due to infection of the brain previously the seat of hydrocephalus, from a spina-bifida sac, and one (XV.) was due to pyæmia following omphalitis in the newly-born; case XXI. was possibly pyæmic also. Necro-

sis of the frontal bone was responsible for 1 case, and although syphilis is probable in this, the full history makes no mention of it.

*SYMPTOMS.—The mode of onset.*—This is of considerable interest as it is one of the points which may be of value in differential diagnosis. In 7 cases the onset was gradual with indefinite symptoms; in 2, gradual with facial paralysis; in 1 with hemiplegia and fever; in another with hemiplegia only, and in 1 with fever only, making in all 11 cases with a gradual onset. In 15 cases the development of the cerebral symptoms was abrupt; with general convulsions in 7 cases; with localized convulsions in 3; with intense headache in 3, vomiting in 7, and fever with vomiting and convulsions or paralysis in only 3. In the remainder the mode of onset is not reported.

In 3 cases the disease was entirely latent, and in 2 others no symptoms were noticed until the last twenty-four hours, so that in 5 the abscess practically ran its course without symptoms. In 27 cases constitutional and cerebral symptoms were present, varying much in degree and duration.

*Focal symptoms.*—These depend upon the position, not the size of the abscess; they are very often wanting for the reason that parts in which the great proportion of abscesses are found (temporo-sphenoidal lobe, cerebellum, or frontal lobe), are not those which usually give rise to definite focal symptoms from any form of lesion.

In only 12 cases (VIII., XII., XV., XVIII., and cases XXV to XXXII) were there distinct focal symptoms; in 7 of these there was hemiplegia, and it is interesting to note that 5 were traumatic cases, 2 being instances of very large abscesses secondary to otitis. Of the remaining 5 cases with focal symptoms, there was one (XXV) of cerebellar abscess which presented quite typical cerebellar ataxia, but in the others they were not sufficiently definite to localize the disease.

It is of interest to group the cranial-nerve symptoms recorded and see to what degree they aided in the diagnosis. There were 20 cases in which some such symptoms were present. In 3 cases there were only dilated pupils; in one, only contracted pupils; in one, only internal strabismus; in one, strabismus and dilated pupils.

Facial paralysis was observed in 10 cases; but in 6, as it followed old ear disease, it was probably peripheral, in 4 of these

being the only nerve symptom. In the remaining cases with facial paralysis (IV, XII, XV, XXXII), reference to the table presented below will show the value of the symptom.

Anæsthesia of the face was noted in three cases (XXVII, XXVIII, XXIX).

Ptosis was noted in four cases (XII, XXVII, XXVIII, XXIX).

External strabismus was noted but twice (XV, XXVIII).

Optic-nerve atrophy was noted but once (IV).

In going over these cranial-nerve symptoms it will be seen that in the six cases first mentioned the symptoms have no localizing value, and that in those of facial paralysis following ear disease it has none, this being in all probability peripheral, although this point is not definitely stated. Such a paralysis, in which the whole side of the face is involved, must be carefully distinguished from one in which it is of central origin where only the lower half of the face is affected.

There are several reasons why these cranial-nerve symptoms were of so little value in the diagnosis; one being that in these patients they were often temporary and not constant, and another that they were in several instances due to meningitis and not to the cerebral abscess. It is quite probable that many focal symptoms were overlooked on account of the age of the patients and the difficulties in the way of careful examination.

It is hardly necessary to say in this connection that opisthotonus and nystagmus are not focal symptoms, and that, particularly in infants, even localized convulsions often are not so, although they may continue for a considerable time. That the reader may see the exact relation of the symptoms to the situation of the abscess, they have been grouped in parallel columns.

I. No cerebral symptoms. (6 weeks old, ear case ?)	Large abscess in L. parietal lobe.
II. Fever, irregular respiration, opisthotonus, nystagmus, retracted abdomen, no focal symptoms. (3 months old, ear case ?)	Abscess in both parieto-occipital lobes and cerebellum, pus in ventricles.
III. Fever, opisthotonus, general rigidity of extremities, stupor, retracted abdomen, no focal symptoms. (5 months old, traumatic.)	Small abscess of cerebellum, pus in ventricles, meningitis.

IV. Fever, bulging fontanel, opisthotonus, dilated pupils, increased knee-jerk, vaso-motor paralysis, irregular respiration, general rigidity of extremities, mental dulness, no coma, optic nerve atrophy. (9 months old, ear case ?)	Cerebellar abscesses; large and small one in R. hemisphere, small one in L.
V. No cerebral symptoms. (3 weeks old, infection from spina bifida.)	Both ventricles filled with pus, meningitis.
VI. Vomiting, general convulsions, no focal symptoms. (8 months old, traumatic.)	Abscess in frontal lobe communicating with ventricle.
VII. Vomiting, convulsions, irregular respiration, no focal symptoms. (3 months old; cause ?)	Cerebellar abscess communicating with ventricle.
VIII. Convulsive movements of R. arm and leg followed by paralysis, blindness, equal dilatation of pupils, stupor, enlargement of the head. (10½ months old, traumatic.)	Enormous abscess of L. frontal lobe.
IX. Vomiting and convulsions, no focal symptoms. (18 months old, traumatic.)	Abscess in occipital lobe.
X. Enlargement of the head, contracted pupils, internal strabismus. (6 months old; cause ?)	Abscess involving nearly whole of hemisphere communicating with L. ventricle.
XI. Repeated general convulsions, once R. side only, enlargement of the head, pupils equal and dilated. (14 months old; cause ?)	Large encysted abscess of the R. ventricle.
XII. Paralysis of the L. face, R. arm and leg, ptosis and internal strabismus of the L. side. Recovered after operation. (2½ years old, traumatic.)	Large abscess in parietal lobe L. side.
XIII. Vomiting, coma, no focal symptoms. (18 months old, traumatic.)	Large abscess in frontal lobe.
XIV. Convulsions, opisthotonus, fever, no focal symptoms. (5 months old; cause ?)	Both ventricles filled with pus, meningitis, pus in central canal of cord.
XV. Fever, convulsions, dilated pupils, R. external strabismus, L. facial paralysis. (7 weeks old, pyæmic.)	Multiple abscesses, meningitis.



<p>XVI. Convulsions, coma, opisthotonus, rigidity of extremities, fever, nystagmus, dilatation of pupils, strabismus. (7 months old, traumatic.)</p>	<p>Cerebellar abscess of under surface of L. lobe, meningitis.</p>
<p>XVII. No cerebral symptoms. (4 years old, ear case.)</p>	<p>Large abscess in L. temporo-sphenoidal lobe.</p>
<p>XVIII. Fever, paralysis L. face, stupor, terminal convulsions, cerebral symptoms of few hours only. (2 mos. old, ear case, unsuccessful operation)</p>	<p>Small abscess in L. temporo-sphenoidal lobe.</p>
<p>XIX. Convulsions especially of L. side and "other cerebral symptoms," but no paralysis. (4 years old, traumatic case; recovered after operation.)</p>	<p>Large abscess in frontal lobe.</p>
<p>XX. Facial paralysis, terminal fever and coma (2½ years old, ear case; unsuccessful operation.)</p>	<p>Abscess of the left lobe of cerebellum.</p>
<p>XXI. Pain, fever, facial paralysis, and "symptoms of cerebral disturbance" (22 months old, ear case; recovered after operation.)</p>	<p>Small abscess in temporo-sphenoidal lobe.</p>
<p>XXII. L. facial paralysis. (2 years old, ear case; recovered after operation.)</p>	<p>Abscess in L. temporo-sphenoidal lobe.</p>
<p>XXIII. Large discharge of pus from abscess through ear; severe pain, terminal coma. (3 years old, ear case.)</p>	<p>Abscess in L. temporo-sphenoidal lobe.</p>
<p>XXIV. Headache, opisthotonus, convulsions, blindness. (4 years old, ear case.)</p>	<p>Abscess in L. lobe of cerebellum extending into the pons; meningitis.</p>
<p>XXV. Congested optic discs, cerebellar ataxia, fever. (3 years old, ear case)</p>	<p>Abscess of middle lobe of cerebellum; meningitis.</p>
<p>XXVI. Fever, R. hemiplegia, L. ptosis, wound discharging pus in L. temporal region. (2½ years old, traumatic case; operation, recovery.)</p>	<p>Abscess in posterior part of L. frontal lobe.</p>
<p>XXVII. Convulsions of R. side followed by paralysis and anaesthesia of R. arm and leg, L. ptosis and anaesthesia of L. face. (2 years old, ear case.)</p>	<p>Abscess in temporo-sphenoidal lobe extending into occipital and reaching the internal capsule.</p>

XXVIII. Paralysis and partial anæsthesia of L. face, ptosis and external strabismus L. side, both pupils dilated, pain in L. side of head, chill, fever and general convulsions followed by R. hemiplegia. (4 years old, ear case.)	Large abscess of L. middle lobe; basilar meningitis.
XXIX. Fever, vomiting, convulsions, localized headache L. side, anæsthesia L. face, L. internal strabismus; later aphasia. (3 years old, necrosis of frontal bone.)	Large abscess of L. frontal lobe, meningitis, embolism of Sylvian artery.
XXX. Paralysis R. face, irregular pupils, L. being large, localized headache; fever, paralysis of R. arm. (4 years old, ear case.)	Abscess in R. middle lobe, tubercular meningitis.
XXXI. Convulsions, L. hemiplegia. (4 years old, traumatic case.)	Two abscesses in R. middle lobe and one in posterior lobe.
XXXII. Early convulsions, drowsiness, and later R. hemiplegia, ptosis R. side, slight fever, irregular pupils, intermittent pulse, convulsions. (3 years old, traumatic case; unsuccessful operation).	Large abscess in L. parietal lobe containing six ounces of pus.

*General symptoms* were thus much more constant than focal ones, but hardly more definite, and frequently they bore no relation whatever to the size of the abscess,—for example, in case X, with an abscess filling a large part of one hemisphere, definite symptoms were of but three days' duration; and in XVII, a large abscess existed without any cerebral symptoms.

Of general symptoms, records regarding temperature are most meagre; in 3 uncomplicated cases (II, IV, XXXI,) where full temperature records were kept for a long period, the temperature was normal much of the time, and in several the others constant fever existed only in the terminal stage. Two of these charts are given in full. In most of the remaining cases where the temperature is mentioned, such complications were present as to make it impossible to draw any inference.

Rigors were noted in but a single case.

Convulsions were present in 20 of the cases, usually marking the onset of the brain symptoms, or frequently the final stage.

Deep coma was rare, being noted but four times, the usual

mental condition being dulness or apathy, alternating with irritability even after the development of definite cerebral symptoms.

Enlargement of the head and bulging of the anterior fontanel were noted each in 2 cases.

Pain in the head was recorded six times, but in the majority it was not localized on account of the age of the patients.

The other symptoms recorded were of most variable character, and such as might be met with in any case of acute brain disease of whatever nature.

*Duration of Symptoms.*—In 5 cases the symptoms were either entirely latent or of less than twenty-four hours' duration; in the remaining cases in which the course was not influenced by an operation, the symptoms lasted from one to seven days in 3; from one to four weeks in 5; from four to eight weeks in 7; for three months in 2, and for seven months and one year each in one case. In two-thirds of the non-operative cases, therefore, the duration was four weeks or less.

*The Progress of the Disease.*—Of 26 cases, the course of which was not influenced by operation, there were 20 in which there were no symptoms until the terminal ones, these being of less than three weeks' duration in 15, and over three weeks in 5 cases. In 4 cases only was there a period of early acute symptoms following otitis or injury, and then an interval of latent symptoms with a terminal acute stage. In 2, the course was prolonged and irregular, but without any interval of cessation.

*Spontaneous Opening.*—In 3 cases (XVII, XXIII, XXIV) a cerebral abscess is reported to have discharged during life through the ear. In two the discharge of pus was followed by great improvement in the cerebral symptoms; in the third a gush of pus took place from the ear just before death.

*DIAGNOSIS.*—One has only to glance over the reports of the cases here collected to see how extremely difficult, in a very large number of the cases, is the diagnosis of cerebral abscess in very young children. Many of our most valuable symptoms in older patients, such as headache, tenderness of the skull, visual disturbances, deafness on one side, and various other sensory manifestations, are of no value in young children. In cases presenting only the acute terminal symptoms a diagnosis is impossible. However, with a scar on the scalp or a history of an injury by some sharp instrument, or of a mastoid abscess, or of a long standing aural discharge, followed by hemiplegia, which

develops either slowly without fever, or more rapidly with vomiting, fever, convulsions and other symptoms of acute intracranial inflammation, one can be reasonably sure of the existence of a brain abscess. In the group of cases intermediate between the two just mentioned, where the previous history is uncertain or altogether wanting, where the course is prolonged and irregular, the fever absent or only slightly marked, and paralysis wanting, one must always be in great doubt, sometimes even though he has watched the case for a long time. On account of the position of most of these abscesses their symptoms are general rather than focal, and often only general brain symptoms are present, unless the motor centre of the arm or leg is invaded. Paralysis of the whole side of the face counts for nothing in the ear cases.

In little children it is with meningitis rather than tumor that abscess is usually confounded, the difficulty in diagnosis being much increased by the fact that so often meningitis is also present. It is impossible to distinguish between these two conditions in the cases of abscess where definite brain symptoms are present only for the last week or two of the disease, whether they have developed without assignable cause, or have been immediately preceded by injury or by an old ear discharge. However, if there is an interval after an injury of a few days or weeks before brain symptoms begin, whether the latter come on abruptly with headache, vomiting, convulsions and fever, or gradually with paralysis and very little fever, abscess is altogether probable. In the slower and less acute cases, the progress is apt to be more irregular than in meningitis, and if paralysis of the arm, leg or lower half of the face is present, it is apt to be more complete and constant than in meningitis. Bulging of the fontanel and enlargement of the head are more likely to be great in abscess than in meningitis, unless the latter is basilar, in which situation it usually gives other definite symptoms. Chronic meningitis is distinguished by the absence of exciting causes such as provoke abscess, by its very slow and insidious beginning and prolonged course.

To distinguish between abscess and tumor at this period of life is not usually so difficult. In tumor the cranial nerve symptoms are more frequent and more prominent; irritative symptoms such as localized convulsions are more marked, and pressure symptoms usually less so, unless the tumor is so situated as to

cause distension of the ventricles. Tumors are generally smaller than abscesses, and all focal symptoms are apt to be more definite than abscess. Valuable assistance may sometimes be obtained by lumbar puncture. The discovery of pyogenic organisms in this fluid makes abscess or meningitis practically certain, although it does not tell us which one. Case IV. shows that optic-nerve atrophy cannot be depended upon as a differential symptom in a doubtful case, although it is much more frequent in tumor than in abscess. After all, it is the definite cause, the shorter duration and more rapid progress, which chiefly distinguish abscess from tumor, very few of the abscess cases giving symptoms for a longer time than eight weeks.

LESIONS.—The abscesses in this series of cases varied greatly in size, from very small multiple ones (XV.) to those containing as much as eight ounces of pus (XXXII.), and occupying a large part of one cerebral hemisphere.

In 25 of the 32 cases the abscess was single; in 3, three abscesses were present; in one case there were many small abscesses; in three the pus was in the ventricle only.

The situation of the abscess was as follows:

Temporo-sphenoidal lobe, 6 cases, all secondary to otitis.

“Middle” lobe (probably temporo-sphenoidal), 2 cases, secondary to otitis.

Cerebellum, 7 cases: 4, secondary to otitis; 1 and possibly 2, traumatic; 1, cause unknown.

Frontal lobe, 6 cases: 5, traumatic; 1, secondary to necrosis.

Parietal lobe, 4 cases: 2, traumatic; 2, probably from otitis.

Left hemisphere, 2 cases: 1, cause unknown; 1, traumatic.

Multiple of cortex, 1 case, pyæmic.

Pus in ventricles only, 3 cases: 1, infection from spina-bifida sac; 2, cause unknown.

In 7 cases the abscess is stated to have communicated with the ventricles, and in most of these the amount of pus in the ventricles was large.

In 15 cases meningitis was present; in 5 of these it was localized, and in one it was tubercular.

There were at least two cases (IV., VII.), in which the structure of the abscess wall makes it probable that the abscess arose as an infection of an old cerebellar cyst. There was another case in which there appears to have been a cyst of the ventricle, and two more where there was infection of a previously simple

hydrocephalus. This is a feature in the development of brain abscess in very early life which merits further study.

THE RESULTS OF OPERATION.—Operative interference was resorted to in 9 cases, 5 of which recovered. The youngest case operated on (XVIII.) was two months old; the youngest successful case (XXI.) was twenty-two months old. Two of the successful cases were for traumatic abscesses, one in the frontal and one in the parietal lobe; the remaining 3 were temporo-sphenoidal abscesses following otitis.

One of the unsuccessful operations (XXXII.) was for a traumatic abscess in the parietal lobe; nothing was found on opening the dura. Another case (XX.), complicating otitis, was trephined over the temporo-sphenoidal lobe, the autopsy showing the abscess to be cerebellar. Another case (XVIII.) was operated on for mastoid disease, and skull opened with negative result; later a probe pushed through the dura was followed by a discharge of a quantity of pus. The fourth case (XIII.) was aspirated through a wound with no benefit. In cases XVIII., XX., XXXII., further exploration of the cranial cavity was deemed unwise, because of the child's collapsed condition at that stage in the operation. Nearly all surgeons agree in the great shock which attends surgery of the brain in young children, and this should make one hesitate strongly in advising surgical interference in cases under three years old, unless there are very definite focal symptoms.

#### CONCLUSIONS.

- (1) Abscess of the brain in children under five years is rare.
- (2) The principal causes are otitis and traumatism.
- (3) It rarely follows acute otitis, but most often neglected cases, and is usually secondary to disease of the petrous bone.
- (4) In the cases occurring in infancy without evident cause, the source of infection is probably the ears, even though there is no discharge.
- (5) The development of abscess after injury to the head without fracture of the skull is extremely rare. In nearly all of the traumatic cases, definite cerebral symptoms show themselves within the first two weeks after the injury. In cases with falls, as remote as several months, there is probably some other cause, such as a latent otitis.
- (6) In a large proportion of the cases only general symptoms are present, and these in very great variety.

(7) Focal symptoms may be misleading unless they are constant, and even then they may depend upon associated lesions, such as meningitis. Motor symptoms only can be trusted since the sensory symptoms are difficult or impossible to determine in infants or young children.

(8) Rapid progress, fever, and a history of injury or otitis generally make a diagnosis from tumor easy. In the slower cases with little or no fever, valuable assistance may be obtained from lumbar puncture.

(9) From acute meningitis the diagnosis is more difficult, and in the cases in which there are only terminal symptoms the diagnosis is impossible. In the more protracted cases, the distinctive points with reference to abscess are the slower and more irregular course and, as a rule, a lower temperature.

(10) On account of the great amount of shock attending brain surgery in very young children, operation should not be urged unless definite localizing symptoms are present, the principal one being hemiplegia.

---

I wish to express my indebtedness to Dr. Martha Wollstein for the bacteriological work done upon these cases, and to Dr. Louise Cordes for drawings of the pathological specimens.

14 WEST FIFTY-FIFTH STREET.





FROM  
ARCHIVES  
OF  
PEDIATRICS

A MONTHLY JOURNAL DEVOTED TO DISEASES OF  
INFANTS AND CHILDREN.

EDITED BY

FLOYD M. CRANDALL, M.D.

“Pediatrics is the specialty of the  
general practitioner.”

Volume begins with January. Sub-  
scriptions may begin at any time.  
\$3.00 a year in advance.

**E. B. TREAT & CO., Publishers,**  
241-243 West 23d Street, New York.

