

Kelly (H.H.) 91

[Reprinted from THE MEDICAL NEWS, September 6, 1890.]

CEPHALHÆMATOMA.

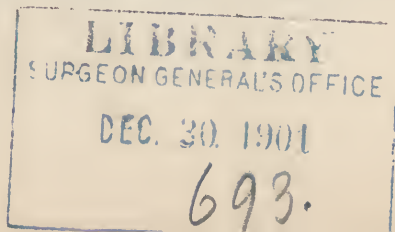
A Case of Sub-pericranial Blood-tumor in the Newborn Child

By HOWARD A. KELLY, M.D.,
GYNECOLOGIST AND OBSTETRICIAN TO THE JOHNS HOPKINS HOSPITAL,
BALTIMORE.

My desire in reporting a case of this interesting disease is not so much to place on record another example of a rare affection, but rather to call the attention of the profession to one of the most important, and as yet but rarely recognized diseases of very early childhood, as well as to prepare the way for a discussion of this subject at the meeting of the American Gynecological Society, to be held on September 16th of this year. Few men outside of the ranks of the pure specialists are aware that such a disease as cephalhæmatoma (cephalohæmatoma) exists. Cases which occur in the practice of the general practitioner are diagnosed and treated by him upon "general principles."

The information which he possesses upon this subject is fairly comparable to that of a physician practising early in the last century.

A well-defined disease appearing soon after birth, running a brief, definite course, tending, as a rule, to resolution, but capable of seriously affecting the health, or even of implicating the life of the child,



must be a matter of interest to every medical man ; and the interest is heightened by the relative frequency of the disease (probably one in 250 obstetric cases), with the certainty that even a moderate obstetrical experience will sometime surely bring one or more cases under observation, and demand decision as to their nature and the course to be pursued.

Our curiosity is still further aroused, and our interest enhanced, when we learn that we have here also one of those curious examples of the tendency, felt even in scientific matters, of an important discovery to remain for a long time in the almost exclusive possession of its original promulgators, while, in the face of the clearest demonstrations and the most numerous writings, surrounding nations long seem to ignore its existence.

Thus the discovery of cephalhæmatoma dates from the close of the last century, when Dr. Michaelis, of Harburg, wrote in the second volume of *Loder's Journal*, "upon a peculiar kind of blood tumor,"¹ giving a full, clear account of the affection. This able article provoked within the succeeding thirty years a host of other writings, and abundant records of cases, in various German journals, and since that time cephalhæmatoma has been regularly registered among the more important diseases to which the newborn are liable.

In the following brief description of the disease, before illustrating my subject with the report of a case, I will make free use of the language of Michaelis.

¹ "Ueber eine eigene art von Blutgeschwülsten."

Cephalhæmatoma (the name given to the disease by Nægele¹) is a circumscribed effusion of blood between the periosteum and one of the flat cranial bones, appearing usually the day after birth, and gradually increasing in size until it forms a tense, prominent, rounded, or ovoid swelling. Its commonest seat is over one or both parietal bones. It is always lateral, never crossing a suture. The skin over the tumor remains movable and unaltered in appearance. The tumor is not painful, and does not decrease in size upon pressure. After two or three weeks, as a rule, it gradually disappears by absorption.

One of the most important diagnostic signs of the disease is the existence of a bony wall, one or two millimetres in height, which surrounds the whole outer circumference of the tumor. This can be distinctly felt through the skin, and gives at once the impression of a depressed fracture.

Injury usually has no apparent connection with the origin of this tumor, which often appears after natural, easy, and short labors, and upon a part of the head which was not prominent in the birth. Instead of being absorbed the collection of blood may undergo suppuration, perforating the cranial cavity, or rupturing externally.

The earlier observers frequently incised the tumor, cleaned out the blood, and put on a compress. The best treatment to-day is to wait for two or three weeks for resolution by absorption, and, if

¹ V. Zeller: *De Cephalhæmatomate seu sanguineo cranii tumore recensatorum.* Heidelberg, 1822.

this should not take place, to incise and empty the sac under strict antiseptic precautions, and apply an antiseptic dressing. Whenever signs of suppuration arise the tumor should be freely opened at once, well washed out, and drained.

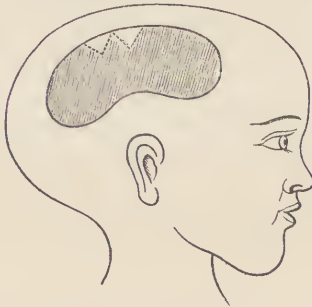This, in brief, is the outline of the disease to which I desire to call attention by this preliminary note, in advance of a more formal, elaborate article upon the same subject, prepared for the meeting of the American Gynecological Society. The following case recently came under my observation :

I was called early one morning last June to attend Mrs. A., primipara, forty-one years old. She was of medium height, had a normal pelvis, and the uterus contained a living child.

She had had pains with great regularity during the preceding night, with the effect of bringing the head well into the pelvis, with the occiput to the left and anterior. The waters had already discharged through the os, which was dilated to about 2 centimetres. By noon the strong, regular pains had brought the head to within an inch of the floor of the pelvis—well flexed, and the flat bones extensively overlapping. At this point the head became firmly wedged. From 1.38 to 7.25 o'clock in the evening she had 106 pains, without bringing the head a half inch nearer the pelvic floor. The child was in good condition, but the mother seemed so exhausted that I then gave her benumbing doses of chloroform by inhalation, and applied Naegele's forceps. By assisting each pain I delivered her after an hour, with a slight tear, entirely within the vagina and in the left sulcus. The child was a female, weighing about 3000 grammes. At the outer angle of its right eye

was a slight indentation in the skin from the pressure of the forceps, which disappeared in two days.

A large caput succedaneum covered the occipital region. No other deformity or evidence of injury was visible. On the second day I observed a reniform swelling over the most prominent portion of the right parietal bone, 6 cm. in length by 2.5 in breadth, lying entirely within the border of the bone, which could be felt on all sides around the swelling. The concavity of its circumference looked downward toward the right ear, while its convexity was more or less parallel with the sagittal suture.



Showing the position of the cephalhæmatoma. Its relative size is greater than natural. The dotted triangles represent the bony plates which formed in the pericranium as the tumor disappeared.

At first slightly elevated, the tumor distended in two or three days, until it formed a prominent, rounded, tense sac. Its circumference did not appear to increase. Elasticity and fluctuation were distinct. There was no pulsation.

Pressure was painful only upon being prolonged when the child became restless. It did not reduce the size of the tumor. The scalp over the tumor was movable and unchanged in appearance. Sur-

rounding the whole margin of the tumor a distinct sharp ridge could be felt, and within this craterous orifice palpation at first conveyed the sensation that the bone was wanting. Deeper palpation, however, touched the bony floor, removing the deception.

The tumor thus formed resembled in shape a potato cut in half lengthwise and laid flat on the head. It thus made a very conspicuous deformity, giving the head an extraordinary lop-sided appearance. The treatment was a policy of inactivity.

I did absolutely nothing to the tumor. In about ten days it began to diminish in size, and in three weeks and a half it had almost entirely disappeared. At this time there was still a slight elevation, and on pressure the fluid seemed to shoot under a parchment-like membrane. The borders felt rough, and from the upper margin two triangular plates projected over the denuded bone, apparently lying in the periosteum. Later no trace of the tumor could be detected.

