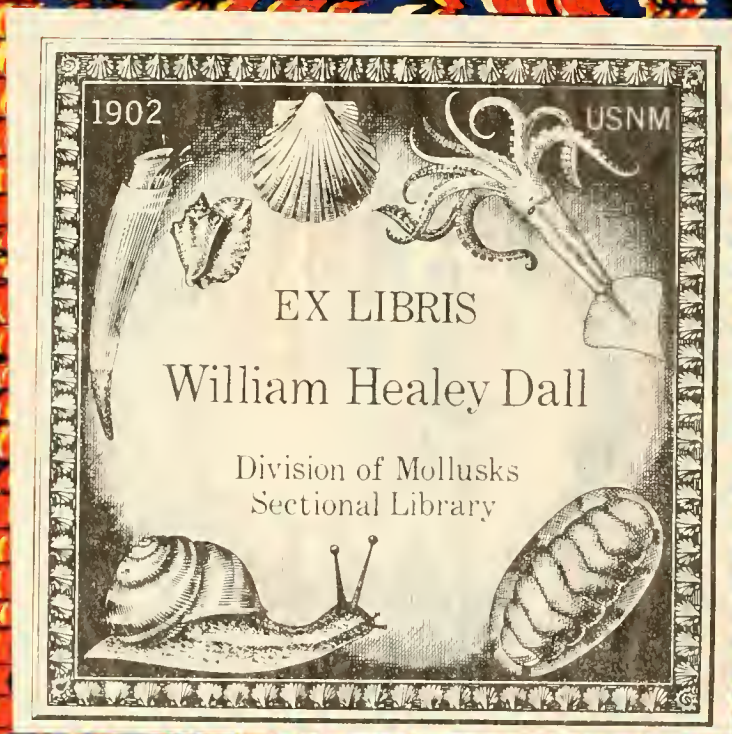


qQL
430.3
N4G8
MOLL





J. GIFF

Division of Mollusks
Sectional Library

J GRIFF

Division of Mollusks
Sectional Library

MEMOIRS

OF THE

NATIONAL ACADEMY OF SCIENCES.

Volume VIII.

WASHINGTON:
GOVERNMENT PRINTING OFFICE
1898.

MEMOIRS

OF THE

NATIONAL ACADEMY OF SCIENCES.

Volume VIII.
FIFTH MEMOIR.

N. M. C.
274234

Griffiths

WASHINGTON:
GOVERNMENT PRINTING OFFICE,
1900.

NATIONAL ACADEMY OF SCIENCES.

Volume VIII.

FIFTH MEMOIR.

ANATOMY OF NAUTILUS POMPILIUS.

L. E. Griffin

Division of Mollusks
Section of Librarian

THE ANATOMY OF NAUTILUS POMPILIUS

BY LAWRENCE EDMONDS GRIFFIN.

Bruce Fellow of Johns Hopkins University.

[Communicated by Prof. WILLIAM KEITH BROOKS.]

INTRODUCTION.

In the year 1890 Mr. LOUIS F. MENAGE, of Minneapolis, Minnesota, generously enabled the Minnesota Academy of Sciences, of the same city, to make scientific collections in the Philippine Islands. Prof. DEAN C. WORCESTER and Dr. FRANK S. BOURNES made the expedition to the islands for the Academy, gathering in the course of their three years stay a large collection of scientific material.

Certain anatomical material was comprised in the collection. This the Academy placed at the disposal of the Department of Animal Biology of the University of Minnesota.

In the collection of anatomical material were sixty-six specimens of *Nautilus pompilius*. It is these specimens which Professor NACHTRIEB allowed me the privilege of studying after I came to him as a student of zoology, and upon which the following paper is based.

While the specimens were not sufficiently well preserved to allow of histological study throughout, they were, for the most part, excellently preserved for anatomical study, Professor WORCESTER having taken care that they should not be contracted, and that they should be as well preserved as the circumstances permitted. Some of the external parts, however, were found to be in good order for the study of their microscopical anatomy, if not for cytological study.

My studies upon the Pearly Nautilus were commenced at the University of Minnesota, under the guidance of Professor NACHTRIEB. I wish to express my indebtedness to him for the rare privilege of studying this material, in which I have found great pleasure as well as profit, and to thank him for much kindness and many helps in the course of my work.

The work has been completed since I came to Johns Hopkins University, and I wish to express my gratitude to Professor BROOKS for his interest in my work and for advice and assistance which have enabled me, I hope, to correct or to avoid some of the faults to which my inexperience lays me liable.

Professor WORCESTER has also been very kind to me in furnishing me with what information he possessed in regard to the occurrence, habits, and mode of capture of the Nautilus.

The soft parts of the Nautilus remained unknown until the year 1832. It is true that long before this RUMPH had published a figure of the animal, accompanied by a description of its habits and portions of its anatomy, but the figure is not remarkable for its clearness, and the description was unintelligible until elucidated by the figures and accounts of later observers. At a later date than RUMPH, QUOY and GAIMARD published a notice regarding what they supposed to be a portion of the body of a Nautilus.

In the year mentioned OWEN published his famous Memoir on the Pearly Nautilus. This still remains the best work which we have upon the anatomy of Nautilus.

that OWEN had but a single specimen for dissection and no guides in his work, we can not but recognize the patient genius which enabled him to produce so complete, clear, accurate, and enduring a work.

The work of VALENCIENNES (1841) added to our knowledge minor facts which OWEN had not described, beside correcting OWEN in a few slight errors.

Both these anatomists had female specimens. VAN DER HOEVEN (1848, 1856) was the first to dissect and describe a male Nautilus.

Between then and now numerous papers have appeared treating of various points in the anatomy of Nautilus. But still its development is entirely unknown. Only recently WILLEY has spent a considerable time in New Guinea in the endeavor to obtain its embryology. He has published a number of interesting papers upon details of its anatomy and its habits, and has succeeded in obtaining fertilized eggs, but has so far kept silence regarding their development.

Such a paper as my own may seem superfluous to many in view of the numerous papers which have already been published upon the same subject. But I hope that it will have a useful place since I have endeavored to gather together the various disconnected accounts of Nautilus anatomy and, adding to them what new facts I have been able to discover, to publish an account of the gross anatomy of Nautilus which shall be as complete as possible. Few persons have the opportunity, and still fewer the time to examine all the various papers on this subject, so I hope that, beside adding to our knowledge of Nautilus, this paper may be found convenient by the student of comparative anatomy.

Although the shell of the animal might properly be considered in an anatomical description, in this case it is so well known that another description of it by me would serve no good purpose.

The Nautili of the Menage collection were captured in water of 1,800 feet depth off the southern coast of Negros, Philippine Islands. An extract from a letter of Professor WORCESTER to the Minnesota Academy of Natural Sciences tells of the mode of capturing the animals.

"Their (the natives') method is to lower a large bamboo basket, baited with meat, in six or eight hundred feet of water. This basket is made on the principle of the old-fashioned rat trap, allowing the animal to enter easily but preventing its escape. Every morning these traps are drawn up for inspection, and a single one sometimes contains four or five live Pearly Nautili; which are sold for food, bringing about 4 cents apiece."

This was written after a preliminary examination of the ground, but several months before the capture of the specimens which were sent to this country. The specimens taken by the expedition were caught in deeper water than that mentioned in the letter.

The natives ordinarily set their traps for a deep-sea food fish, the capture of the Nautili being in a measure accidental, at most, incidental.

Nautilus is not confined to deep water. It has generally been found there, but WILLEY has also obtained it in water only 2 or 3 fathoms in depth.

Nautilus is carnivorous, and apparently predatory, the crop and stomach of captured specimens being usually filled with fragments of crustacea, or the chicken, or fish, or whatever other meat is used for baiting the trap. The appearances indicate that it feeds mostly upon a species of decapod crustacea. These are devoured shell and all. The jaws appear strong enough to crush any moderately thick-shelled mollusk upon which the Nautilus might happen.

WILLEY (1897, 1) says: "One of the surest ways of obtaining Nautilus, and in fact, the method by which I have obtained most of my specimens at Lifu, is to bait the fish basket with the cooked and bruised exoskeleton of *Palinurus*, or an allied form. The strongly scented 'potage' so produced is then wrapped up in cocoanut fibre like a small parcel, and then placed in the fish trap overnight. There is therefore nothing to be seen, but on the other hand there is something to be smelt, and by this means I have obtained as many as ten Nautili at one time."

While this observation points to the probability of Nautilus being chiefly guided by its sense of smell in the capture of its prey, it is not by any means proof that the eyes are not also useful in this action. We would rather expect that smell would be the guiding sense from the fact that the Nautilus is usually found at great depths where darkness must prevail, and from the simple character of the eyes.

GENERAL SKETCH OF ANATOMY.

The Nautilus occupies a light gracefully formed shell, which is beautifully marked with alternating bands of reddish brown and white, except near the mouth, where the dark bands do not interrupt the white ground. (Fig. 11). The shell is coiled dorsally (exogastrically) so that the older parts are completely hidden by the younger. An adult shell has about two and a half whorls. As the Nautilus increases in size it grows forward in its shell, leaving an unoccupied space behind itself. At frequent intervals it forms septa which completely separate the unoccupied portion from the living chamber of the shell, except at the centers of the septa, where they inclose a tubular process of the body wall, which extends to the oldest chamber of the shell. (Fig. 1.) The unoccupied chambers of the shell are filled with a gas which resembles air in its composition, but having a slightly greater proportion of nitrogen than the latter.

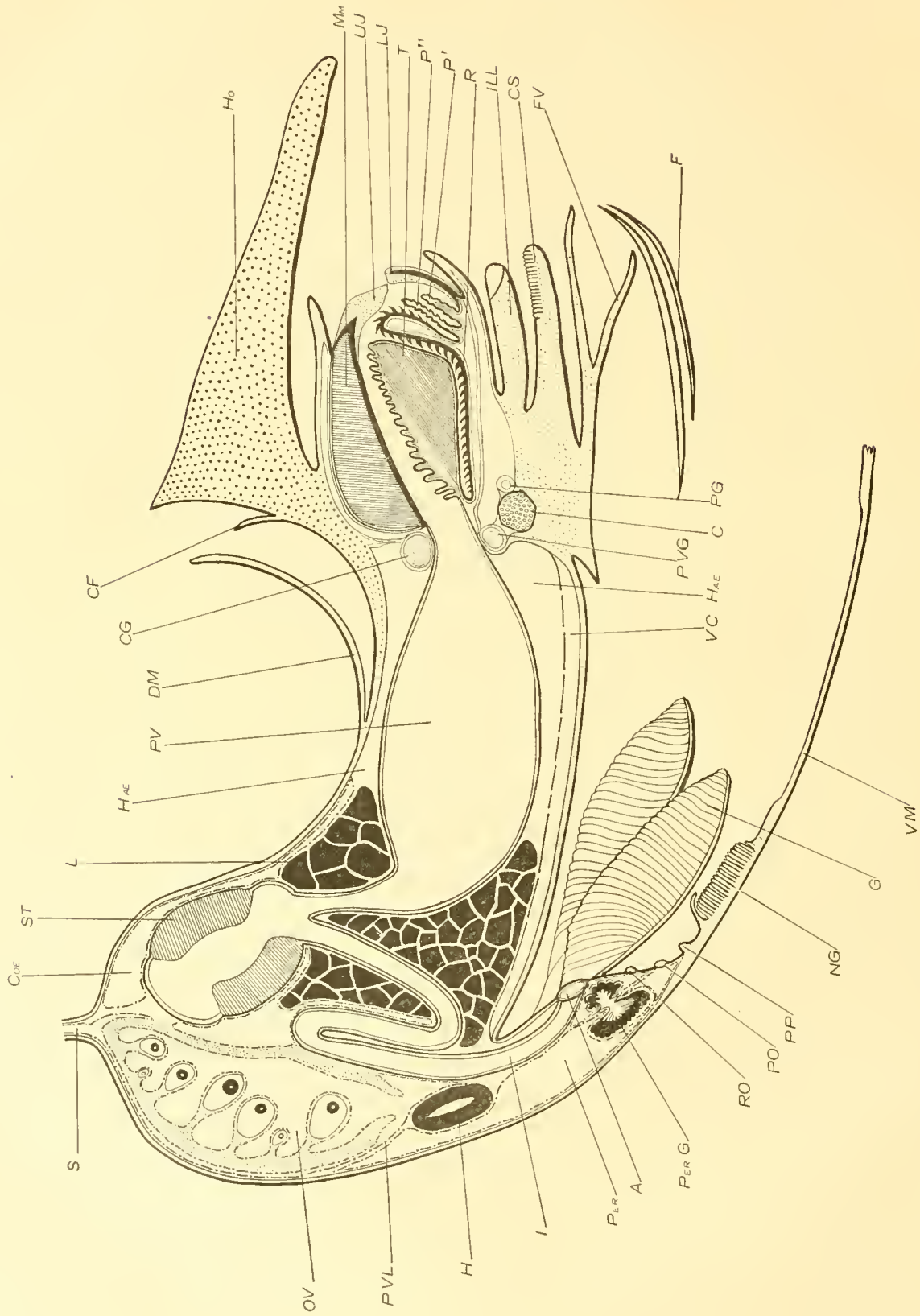
When the Nautilus is in its natural position the involution of the shell is uppermost, while the mouth of the shell is below and turned forward. (Fig. 1.) The body is now nearly horizontal; the head, surrounded by tentacles, is anterior; the siphuncle is near the posterior end of the body; the funnel is upon the ventral side, and the depression which receives the involution of the shell marks the dorsal side of the body. (Fig. 2.) The orientation of the body and the description of the anatomy are made more difficult by the upward curve of the posterior part of the body. Thus, the siphuncle springs from the dorsal surface near the posterior end, and not from the extreme posterior end of the body. (Fig. 2.)

The body of Nautilus is roughly oblong, and between 6 and 7 inches in length. The anterior portion of the animal which projects from the shell, comprising the cephalic and nuchal regions, with the jaws, organs of sense, motion, and adhesion, is tough and muscular. The posterior portion of the body is covered and protected by the shell, and consequently the body wall is here so thin that the viscera can easily be distinguished through it.

The part of the body contained within the shell conforms exactly to the latter. In the middle dorsal region the body is deeply hollowed to receive the involution of the shell. All other portions of the body within the shell are smoothly and evenly convex. The anterior part of the body is covered by the large triangular hood. At the sides and ventrally are the numerous digital tentacles, the sheaths of which, fused to each other and the hood, form a solid wall around the mouth parts, to which the name cephalic sheath has been given. Within the cephalic sheath are the projecting parrot-like mandibles, surrounded by several groups of smaller tentacles. Beneath is the large muscular funnel, the crura of which pass upward upon the sides of the body just back of the bases of the tentacles to the upper edges of the body, where they are joined by the crescentic ridge extending across the back of the hood. (Fig. 2, CR.) In the angle between the projecting posterior corners of the hood, the back of the cephalic sheath and the crura of the funnel, are the large round eyes (E). Two tentacles, the pre- and post-oculars (Fig. 1, O', O''), spring from close to the base of each eye, while just beneath each eye is a small projecting pyramidal organ supposed to have an olfactory function.

The mantle fold projects freely entirely around the body. The edge of the mantle is attached along the edge of the shell, but from the umbilicus of the shell upward it extends as a convex fold covering the dark portion of the involution of the shell. The mantle cavity is shallow dorsally, while very deep and capacious ventrally. The organs of the pallial complex are all within the ventral portion of the mantle cavity. (Fig. 3.) The four gills, the renal, pericardial, and anal orifices, and certain papillae sometimes spoken of as osphradia, are borne by the mantle. In adult females the inner side of the mantle also bears a large bilateral nidamental gland. (Fig. 4, N.) The reproductive orifices are situated upon the body wall near the origin of the mantle. The mantle is continuous posteriorly with the thin and transparent wall of the visceral portion of the body.

The body wall is produced from the end of the body as a slender tube, the siphuncle, which extends within the siphon of the shell to its very end. (Fig. 1, fig. 2.) At the sides and above the middle of the body are seen the crescentic areas of attachment of the strong shell muscles by which the body is held to the shell. (Fig. 1, SM.) Beside these areas of attachment, the wall of



TEXT-FIG. 1.—DIAGRAMMATIC LONGITUDINAL SECTION OF NAUTILUS.

- A, anus.
 C, cartilage.
 CF, crescentic fold on back of hood.
 CG, cerebral ganglion.
 CG₂, genital division of coelom; the coelomic epithelium is indicated by the dotted line.
 CS, ventral portion of cephalic sheath bearing the folds which receive the spermatophore.
 DM, dorsal portion of mantle.
 F, overlapping edges of funnel.
 FV, valve of funnel.
 G, gill; the bases of the gills lie to the sides of the plane of section.
 H, heart.
 HAE, haemocoel.
 HO, hood.
 I, intestine; brought into the plane of the diagram.
 ILL₂, inferior labial lobe.
 L, liver.
 L₂, lower jaw.
 MM, mandibular muscle.
 NG, nodular gland.
 OV, ovary.
- P', anterior prelingual process.
 P'', posterior prelingual process.
 PER, pericardial division of coelom.
 PG, anterior pericardial gland; opposite is the renal appendage in the renal sac. These parts have been moved slightly medial to be in the plane of section.
 PG, pedal commissure.
 PO, pericardial pore.
 PP, preanal papilla.
 PV, proventriculus.
 PVG, pleuro-visceral ganglion.
 PVL, pallio-visceral ligament.
 R, radula; the radular sac extends backward under the tongue as far as the commencement of the oesophagus.
 RO, renal pore.
 S, siphuncle.
 ST, stomach, suspended from the ovary by the gastric ligament.
 T, tongue.
 UJ, upper jaw.
 VC, vena cava.
 VM, ventral portion of mantle.

the body is attached to the shell along three aponeurotic bands, two ventral and one dorsal, which extend between the ends of the areas of attachment of the shell muscles. (Fig. 1.)

The division of the body of the Nautilus into cephalic, nuchal, and visceral regions is not as distinct as it is in many dibranchiates. At times it proves convenient to recognize such divisions, although they are entirely without morphological importance. For this reason we may consider the cephalic region to be that which bears the tentacles, buccal mass, and eyes. A section through the body just back of the eyes would also pass just back of the central nervous system. The nuchal region is that of less girth, which extends between the posterior edges of the cephalic sheath and the attachment of the mantle. Accordingly, this bears the funnel and its crura, the reproductive orifices, and the mantle. The visceral region comprises the remaining posterior portion of the body, the wall of which we have already noted as thin and semitransparent.

THE TENTACLES.

A.—DIGITAL TENTACLES.

For the purposes of description each tentacle will be considered to consist of two parts—a cirrus, which is the active part of the organ, and a sheath which forms a protection for the cirrus. The sheath of certain tentacles is lacking (or undifferentiated), the cirrus, never normally. In this application of the terms we need not take into account the probable morphological importance of the sheath.

The digital tentacles include those tentacles which form the cephalic sheath and hood. Each is composed of two parts—a retractile (or extensible) adhesive cirrus, and a tough, thick-walled, more or less rigid sheath into which the cirrus may be entirely withdrawn. (Fig. 1, C; Fig. 49; Fig. 50.) This is the essential structure of not alone the digital tentacles, but all the tentacles with which a Nautilus is so generously supplied. Whatever differences there are, they are modifications of this plan.

The digital tentacles are symmetrically arranged upon each side of the head, according to the diagram presented in text-figure 2, CS, p. 116. A careful examination of more than fifty specimens has led me to make this statement in the face of other statements denying any regularity of arrangement of these tentacles. Whether each individual tentacle, as determined by the innervation, always occupies the same identical position is more than I can assert, because of the extreme difficulty of satisfactorily following the nerve to each tentacle. However this may be, the arrangement of the tentacles follows a definite plan from which variations were found in only five specimens out of fifty-one examined at one time.* Except in one case the variation occurred upon one side only. I see no especial morphological importance to be attached to this arrangement; nevertheless, the fact is interesting and its knowledge may sometime be helpful when the development of Nautilus comes to be studied.

As has already been mentioned, the cephalic sheath is formed by the fusion of the sheaths of the individual digital tentacles. The hood, which forms the entire dorsal part of the cephalic sheath, is itself composed of the enormously developed sheaths of two tentacles. (Fig. 1, Ho; Fig. 2, Ho.A.) The hood is roughly triangular in shape. It is thickest in its middle posterior part, sloping from here to thin edges anteriorly and laterally. It presents three superficial fasciæ (Fig. 2); a dorsal about an inch in width sloping downward and forward to the anterior edge, and two lateral which slope from the middle fascia to the lateral edges. The dorsal fascia maintains an equal width throughout its length—this varying in different specimens between 18 and 25 millimeters. Accordingly the anterior edge of the hood is approximately straight and not pointed. The lateral fasciæ, however, are widest opposite the posterior end of the middle fascia, gradually narrowing to a point anteriorly, and to a blunt rounded extremity posteriorly which overlies the umbilicus of the shell. The posterior surface of the hood is pressed closely against the involution of the shell, and following its shape is deeply concave. The postero-

*The tentacles of a dozen other specimens since examined have conformed to the same plan.

lateral corners lying against the umbilici of the shell are sometimes spoken of as the auricles of the hood. (Fig. 2, Ho.A.) In most specimens a slight groove runs along the middle of the dorsal fascia of the hood, although it is frequently absent.

Scattered more or less evenly over the surface of the hood are numerous small papillæ. The possibility of these possessing a tactile function is immediately suggested, but my material shows no structure to confirm it. The papillæ are differently distributed upon different Nautili, in some being most thickly placed upon the median portion of the hood, in others upon the lateral parts. But comparing one specimen with another, the papillæ may be said to be evenly distributed over the entire surface.

In the anterior edge of the hood are two small openings leading into deep cavities, in each of which is a cirrus exactly similar to the cirri of the neighboring tentacles. (Fig. 2, Ho.C.) The presence of the cirri, the innervation and the anatomical relations of the hood, and the fact that the neighboring tentacles are sometimes closely fused with it leave no doubt that the hood is composed of two tentacles, the sheaths of which have become much enlarged and closely fused. It seems probable that the hood of the Nautilus, aside from its other uses, serves to protect the animal when withdrawn into its shell in much the same way as the operculum of a Gastropod protects its owner. It is noticeable how closely the hood of a strongly contracted Nautilus fits the opening of the shell.

A cleft of varying depth existed in the middle of the anterior edge of the hood of several specimens in line with the median groove before mentioned. This may be an indication of an originally less completely fused condition of the hood tentacles.

Below the hood are eighteen digital tentacles upon each side. Including the tentacles forming the hood there are thus nineteen upon each side, a number from which I found no variations in any of sixty-six specimens. But that variations in the number do occur is proved by the fact that RUMPH and OWEN each counted twenty tentacles upon a side, while VALENCIENNES found only eighteen upon a side in his specimen. In another specimen OWEN found only seventeen tentacles upon one side, while the number was normal upon the opposite side.

The sheaths of the digital tentacles are fused to each other except for a distance of about half an inch at their tips. The exterior of the cephalic sheath is made rough by the projecting angles of the tentacle sheaths, and by this means the course of the individual sheaths can be followed to a certain degree. The internal surface, on the other hand, is perfectly smooth except at one point. The exception is possessed by the female only. Upon the outside of the cephalic sheath are seen four tentacles which are so much smaller than the others that they do not begin to reach the anterior edge of the sheath.

The tentacle next the hood on each side possesses a much larger sheath than the remaining lateral tentacles, the increase in size being especially expressed in breadth. The sheath is considerably flattened and overlaps the next lower tentacle sheath as it is itself overlapped by the edge of the hood. It is usually fused along nearly its entire length to the ventral side of the hood, leaving a crease where the edge of the hood projects. (Fig. 1; Fig. 2, DT.) Its outer surface bears papillæ like those upon the hood. Normally the tip of the sheath is entirely free, but occasionally its sheath and the hood are so closely fused that no line of demarcation can be observed, the tips of the sheaths being included in the fusion. Rarely other more lateral tentacles may be included in this close fusion, so that the area of the hood may be considerably increased.

The remaining tentacles present no differences beyond those of size and shape which we may expect to find. The tips of the sheaths where their shape is unaffected by fusion are roughly triangular or quadrangular. Usually one of the angles is turned outward, and this may be continued as a distinct ridge nearly or quite to the posterior edge of the cephalic sheath.

At the sides of the head the posterior part of the cephalic sheath falls away abruptly to the level of the nuchal region. (Fig. 1.) These posterior faces are quite smooth. From the hood they slope first down and back, then, from the level of the lower edge of the eye, they slope down and forward. The faces become narrower as they pass downward and gradually disappear upon

the ventral surface of the cephalic sheath. The eyes are situated partly within the angles between the auricles of the hood and the upper portions of the just described posterior faces of the cephalic sheath.

In the ventral surface of the cephalic sheath is a broad and deep channel, into which fits the dorsal part of the funnel. (Text-fig. 2; Pl. 3, Fig. 3.) The anterior edge of the sheath, in line with the channel, is deeply notched, so that ventrally the tentacles of the two sides are widely separated. (Figs. 24 and 25.) Partly surrounding and extending back from the edges of the ventral notch in the cephalic sheath of the female is the exception previously noted to the complete smoothness of the inner surface of the cephalic sheath. (Figs. 24 and 25.) We see here a large number of low, narrow, glandular lamellæ extending parallel to each other from side to side of the area. The lamellæ of the anterior half of the organ frequently radiate from centers at each side of the notch in the sheath. Consequently, while their median portions extend transversely to the axis of the body, the lateral portions turn more or less sharply forward. The posterior lamellæ do not reach the centers referred to, and so the forward bend at the sides becomes less and less pronounced as the back of the area is approached. Finally the most posterior lamellæ are almost straight.

Considerable differences exist in the shape of this area in different specimens. The one which I have described and figured in Fig. 24 seems to be quite rare, although for a considerable time I thought it to be the normal shape. Instead, the lamellæ rarely meet at such centers as I have figured. The differences in the descriptions of various authors suggest that practically the only constant feature may be the presence of numerous lamellæ, while their arrangement is capable of a high degree of variability. Frequently the area is nearly or quite separated into two portions by a median furrow. VALENCIENNES and LANKESTER refer to the organ as a paired structure. OWEN describes it as consisting of "two clusters of soft conical papillæ, and on each side of these a group of laminae disposed longitudinally".

As noted, the organ, as it may fairly be called, exists in the female only. Slight folds of the skin are often found in the same region of the male, but they are evidently adventitious, resulting from contraction, and do not in any way represent a structure similar to the one possessed by the female.

The lamellæ of the female form an organ for the retention of the spermatophore. In the case figured (Fig. 25) the spermatophore is arranged with unusual symmetry. In no other instance was it so nicely coiled as in this, though it was always spread out upon the surface of the lamellæ so that few coils overlapped. The coils of the spermatophore were in all cases so firmly glued to the lamellæ that it was impossible to remove them without breaking either lamellæ or spermatophore. KERR mentions that in his specimen the spermatophore was partly embedded in the coagulated secretion of the lamellæ. The secretion has not been so noticeable in my own specimens, being only sufficient to hold the spermatophores, but that very tightly.

Having considered the digital tentacles as a complex, the cephalic sheath, let us now consider their individual structure. It has been noticed that each tentacle comprises two parts, namely, a slender retractile cirrus and a tough sheath within which the cirrus may be entirely withdrawn.

The completely extended cirri are often fully twice the length of the sheaths. They are supple and slender, tapering slightly to a bluntly rounded point. Average dimensions of the larger cirri would be 10 centimeters in length by 4 millimeters in diameter. Each cirrus presents throughout its length, except the basal portion, a series of narrow annular grooves and ridges. (Fig. 50.) These vary in number according to the length of the cirrus. Upon a cirrus of ordinary length there are 50 to 60 ridges. The cirri are ordinarily three sided in the portion which is commonly extended outside the sheath, the broadest and flattest side being turned inward toward the mouth. Exceptional cirri which are round are quite common, and in any case the outer angle of the cirrus is much rounded, and the portion which remains inside the sheath is always nearly round, being flattened only slightly upon the inner side. WILLEY states that the outer sides are deep brown in color, while the inner side is of a pale neutral tint. A

usual, but not a constant, feature is a shallow longitudinal groove occupying the middle of the inner face of the cirrus. (Fig. 49.)

The annular grooves are much deeper upon the inner side than upon the outer sides, and as a consequence the alternating ridges are also much more prominent upon the inner side. (Fig. 50.) To use a comparison, the cirri are somewhat like high piles of thin, flat disks, fastened together through their centers. This comparison, however, applies closely to the terminal third or half of the cirrus only. Upon the proximal part, which is always retained within the sheath, the annular grooves quickly disappear on the outer surfaces. The grooves persist on the inner side, gradually becoming fainter and fainter, until within a couple of centimeters of the proximal end of the cirrus. The proximal end of the cirrus is usually perfectly round and perfectly smooth; it tapers slightly to the base, which has about half the greatest diameter of the cirrus. The terminal disks are broken off with great ease; the query arises if regeneration of some sort does not take place. The inner projecting part of each disk forms an adhesive organ, the structure of which will presently be described in detail.

The tissues of the cirrus are continuous at its base with the tissues of its sheath. The sheaths of the larger tentacles have a depth of about 6 centimeters. The epithelium extends from the surface of the cirrus upon the inner surface of its sheath, and over the margin of the latter upon the surface of the body. The free portion of each sheath is usually angular and slightly tapering. At its blunt extremity is a round, oval, or slit-like opening, through which the cirrus projects. The cavity of the sheath frequently extends to near the cephalic ganglia—much farther, therefore, than there is any external indication of the individual sheath. With the exception of those two which form the hood, one sheath is very much like another. The reasons for believing the hood to be composed of the greatly enlarged and closely fused sheaths of two ordinary tentacles have already been given.

The tentacle sheaths are composed of a dense felt of large, branched elastic fibres; its interstices are occupied by white fibrous connective tissue fibres and nuclei. Small scattering bundles of longitudinal and transverse muscle fibres traverse the sheaths. In places the longitudinal muscles approach a regular arrangement. The amount of muscular tissue is, however, so small that there can be but very little movement of the individual sheaths. The external surface of the sheath is covered by a columnar epithelium, the cells of which measure 52μ by 4μ – 8μ ; the cells lining the cavity of the sheath are much lower, being only 24μ by 3μ – 6μ in their dimensions. Both inner and outer epithelia contain very numerous glandular cells. The oval nuclei are situated in the lower half of the cells, but do not all lie in one plane. Large capillaries with endothelial walls are surprisingly numerous in the tissues of the sheath, and here, as elsewhere, the capillaries do not collapse when empty. But the vascular system is not completely closed. The tissues of the sheaths are like a fine mesh work, in the spaces of which the blood flows freely. There is no dermis.

The hood presents some modifications of this plan. The cells of the epithelium measure 36μ by 4μ – 6μ . Immediately beneath the epithelium is a dermis formed by a layer of particularly closely woven elastic fibres which, on account of its density, is easily distinguished by the naked eye from the underlying tissue, although it can not be readily dissected away. The dermis is almost entirely destitute of muscular fibres and is penetrated in every direction by great numbers of vascular lacunæ. But even in the hood the dermis is not an absolutely constant character. Throughout the hood numbers of capillaries with endothelial walls can be seen. The capillaries are of large caliber and, curiously enough, remain open when empty, so that their cross sections are circular. In the posterior part of the hood many large muscles run in various directions just beneath the dermis. They form a layer which seems to have much to do with the contraction of the posterior portion of the hood. The muscles become smaller and less numerous toward the outer side and the deeper portions of the hood.

Posteriorly the hood is concave and fits snugly around the involution of the shell. The epithelial cells of this are smaller than those of the upper surface of the hood and of the remainder of the cephalic sheath, their dimensions being 28μ by 3μ – 6μ . The epithelial cells of this surface as well as those of the upper surface of the hood are loaded with fine granules of a

brown pigment. In sections the pigment appears as a dark band near the outer ends of the cells, a narrow unpigmented band being outside this, while the pigment granules gradually disappear toward the bases of the cells, leaving this region also uncolored. These surfaces of the hood bear numerous small pits lined with the pigmented epithelium. Granular cells are exceedingly numerous, especially upon the concave posterior face of the hood. It seems probable that the dark brown, sometimes black, layer of organic matter found upon the involution of the shell is deposited by these cells. The thin crescentic ridge which projects from the posterior face of the hood does not possess a pigmented epithelium and may not play any prominent part in the deposition of the dark layer.

The great density of the elastic tissue makes the cephalic sheath exceedingly firm and difficult to penetrate. It must afford a very considerable protection to the Nautilus.

A cross section of a cirrus shows a highly muscular organ, usually of triangular outline in its terminal third. (Fig. 49.) Near the center is a large nerve which extends the entire length of the cirrus. (Fig. 50, N.) The nerve is situated toward the inner side of the cirrus, i. e., toward the flattened side turned toward the mouth of the animal. Close to the nerve and upon its inner side is a small strong walled artery (A), and still closer to the inner side of the cirrus is a somewhat larger vein (V). The nerve is surrounded by a sheath of connective tissue and muscle fibres (T), while outside this is a mass of longitudinal muscles forming the greater part of the cirrus (LM). The connective tissue and muscle fibres surrounding the nerve are mostly transverse to the axis of the cirrus, and they pass outward in such a way as to divide the longitudinal muscles into radiating bundles which appear in cross section like the spokes of a wheel. The radial arrangement is almost lost upon the inner side of the nerve, where the muscle bundles become small and irregularly arranged. The radial longitudinal muscles do not extend to the periphery of the cirrus. They are bounded by a narrow band of oblique muscles (Fig. 51, OM). Outside this is a layer of small bundles of longitudinal muscle fibres (LM); while outside the latter is a thin layer of circular muscle fibres (CM). The outer muscular layers lose their identity upon the inner side of the cirrus, where transverse muscles predominate. A thin layer of connective tissue frequently separates the external circular muscles and the epithelium. The peculiar arrangement of the longitudinal muscles persists for a time after they enter the body wall at the base of the cirrus, but it is then lost as the muscles separate.

If, now, we examine the radially arranged longitudinal muscles more carefully we find that each muscle is composed of a large number of small fasciculi, held in a mesh work of connective tissue into which penetrates an occasional transverse muscle fibre. The fasciculi of the longitudinal muscles do not extend straight up and down the cirrus, but have a slightly oblique course upward and inward; i. e., as the muscles pass toward the tip of the cirrus the fasciculi pass from the outer to the inner side of the muscle. (Fig. 50, LM.) The fibres of the fasciculi, however, take a course parallel to the axis of the cirrus and are only rarely oblique to it.

The transverse muscle fibres radiate in all directions from about the nerve, passing between the longitudinal muscles and penetrating the outer circular layer. (Fig. 51.) The fibres are gathered into strands, few of which, however, radiate directly outward from the nerve, though at first sight they may seem to do so. Most pass in an hyperbolic curve from between two longitudinal muscles to between two others about 90 degrees away. Under this arrangement, when the transverse muscles contract, the outer portions of the cirrus alone are compressed and the nerve is not disturbed. After repeated examinations I am convinced that these are actually muscle fibres and not some form of connective tissue which, in the invertebrates, is often so hard to distinguish from muscle tissue. There is also considerable connective tissue in the transverse strands of the cirrus.

The fibres of the longitudinal muscles of the cirri are unstriated, smooth, slender, and exceedingly long (400 μ to 600 μ), and tapering gradually to pointed ends. An oval nucleus lies at the side of the cell near its middle. There is very little elastic connective tissue in the cirrus.

The retraction of the cirrus is accomplished by the longitudinal muscles; the elongation by

the circular, oblique, and transverse muscles. Their peculiar arrangement enables the cirrus to elongate or shorten without any undue pressure upon the central nerve. The arrangement of the cirrus muscles is very similar to that in the arms of the Octopoda and Decapoda. In these also there is a large, nearly central nerve, surrounded by a mass of connective tissue and transverse muscle fibres. Around this are the longitudinal muscles, which are also arranged radially. But instead of forming a complete circle, as in the cirri of *Nautilus*, the longitudinal muscles form two to four separate masses. In its essential features, however, the arrangement is remarkably similar in both the Di- and Tetra-branchiata.

It has been mentioned that between the annular grooves of the cirrus are comparatively wide projecting ridges, which show well in a longitudinal section of a cirrus. (Fig. 50.) The ridges are annular, extending completely around the cirrus. The inner portion of each annular ridge projects considerably more than the outer portions and forms an organ of adhesion. Into this projecting portion great numbers of muscle fibres extend nearly perpendicular to the inner surface. (Figs. 50 and 51.) The arrangement of the muscles in this region is very peculiar. Naturally there are almost no longitudinal fibres present. As the transverse muscles issue from between the inner longitudinal muscles they seem to branch to form an extensive brush, the outer ends of which are applied to the basement membrane. The muscle fibres are not branched, but are so attached to one another (like the straws of a broom to the handle) as to form a central strand which passes between the longitudinal muscles. (Fig. 51, RM.) This strand can be traced in an arc, as has been described for other transverse muscle fibres, across a portion of the cirrus till it passes outward between longitudinal muscles. Apparently the central strand serves as a sort of tendon to the radiating fibres of the inner portion of the annular ridge. These radiating fibres are short and thick, and quite unlike those in the other portions of the cirrus.

As each strand forming the so-called tendon runs to an opposite portion of the cirrus the contraction of all these can scarcely take place without causing some contraction of the cirrus in a transverse direction, i. e., a lengthening of the cirrus. Possibly many of the arcuate transverse fibres share in this action.

As the contraction of the radiating fibres within the inner portion of the ridge would pull the inner face of this latter inward, a sucker is thus formed. If these suckers were applied to any object the effect of the contraction of the transverse fibres in the body of the cirrus would be not to lengthen the latter, but to increase its rigidity, and thus increase the mechanical efficiency of the suckers along it. Any one such sucker would possess but little holding power, but thirty or more suckers upon each of thirty or more cirri must be able to hold very strongly.

WILLEY says that "most of the tentacular appendages of *nautilus* have essentially an adhesive function, to which is related a prehensile function. They are employed for seizing hold of food and for attachment to surfaces. Attachment is effected by the definite suctorial ridges upon their lower and inner surfaces. When attached by its tentacles, *nautilus* holds on with considerable tenacity, and sometimes in forcibly detaching it some of the tentacles break off and remain fixed to the surface of attachment." In Fig. 1, pl. II, Q. J. M. S. 40, WILLEY represents a *Nautilus* holding to a glass vessel.

In considering the remarkable holding power of cephalopod suckers we must remember that attachment is effected under water, so that a perfect vacuum is possible. Another condition must affect the deep-sea forms like *Nautilus* much more, namely, that they are under a pressure of 20 to 80 atmospheres, where any vacuum attachment would be immensely more powerful than at the surface.

The nerve of the cirrus extends throughout its length, remaining of the same size nearly to the end. It tapers slightly here and ends abruptly immediately beneath the epithelium of the tip of the cirrus. (Fig. 50.) Ganglion cells are found at the periphery of the nerve as far as it runs in the cirrus. (Fig. 71.) But in regions corresponding to the annular ridges aggregations of ganglion cells are found which form annular enlargements or ganglia upon the nerve. There is a ganglion for each and every annulus. Numerous small nerves arise from these ganglia and pass to the external parts of the cirrus. Branches to the inner portions are especially numerous.

The nerves to the digital tentacles arise singly, as a rule, from the outer edges and lower side of the pedal ganglia. (Fig. 41, 9.) Only the nerves to a few of the more dorsal tentacles arise from a common nerve. (Fig. 41, 10.) The hood receives branches from several nerves.

A small artery with thick elastic walls is found close to the inner side of the nerve. (Fig. 51, A.) Just outside this is a much larger vein. (Fig. 51, V.) Both vessels are elliptical in cross section. This position of the artery and vein is so characteristic that even in extremely modified cirri, such as those of the spadix, the inner side of the cirrus can be determined at once in sections by the position of the vessels.

Between the epithelium of the cirrus and the circular muscle are numerous, very large, capillaries with endothelial walls. Closed capillaries are occasionally, but rarely, found in the muscular and nervous tissue. Here the circulation takes place through minute fissures in the tissues.

Immediately behind the cerebral ganglion the dorsal aorta divides into two branches—the innominate arteries, from which arise branches to the eyes, buccal mass, labial tentacles, funnel, shell muscles, and cephalic sheath (Text-fig. 10). The posterior portion of the hood is supplied by small arteries arising directly from the innominates (10). The main branches of the innominates run forward and downward upon each side, giving off branches to the individual digital tentacles (5, 4).

The veins of the cephalic sheath unite in common veins which penetrate the cartilage and enter the anterior end of the vena cava.

The epithelium of the cirri forms a feature of exceeding interest. It consists of a single layer of slender columnar cells. The epithelium upon the outer sides is of the ordinary type and contains great numbers of goblet cells. These cells are 40μ in height by 4μ in diameter. In the bottoms of the annular grooves the cells are very much shorter, often almost cubical.

But the epithelium of the inner surface of the ridges is very peculiar. A longitudinal section of a cirrus (Figs. 50 and 72) shows that the upper surface of the projecting portion of each ridge is horizontal and makes a sharp angle with the inner surface, while there is a gradual bend from the inner to the lower surface. The epithelial cells of the vertical inner surface are exceedingly slender, having a height of 108μ and a width of $2-4\mu$. Their width has been exaggerated in the figures of the single cells shown at the left of Fig. 72, as well as in the main portion of Fig. 72, for convenience in representation. The epithelial cells of the upper surface of the projecting portion of the ridge are only about one-eighth as high and much wider, beside being of a totally different character. The change from one kind of cells to the other takes place quite abruptly at the sharp angle of the ridge. The change in length and character of cells is much more gradual where the epithelium passes from the inner to the lower surface. The relations and characters of these cells are shown as well as my limited ability as an artist allows in Fig. 72, which was drawn from a section stained with borax carmine and Lyons blue; the colors of the stain have been copied faithfully.

The epithelium of the upper surface contains many mucous cells the secretion of which remained unstained with either stain, excepting the portion extruded from the cells and certain small granules which stained red. Mucous cells are occasionally found in the depth of the groove, but none, of this character at least, are found upon the inner surface of the ridge.

The nuclei of the slender cells upon the inner face of the ridge are situated very close to the bases of the cells. From the nucleus out almost every cell contains a large number of granules which stain a brilliant red. Sometimes the granules are arranged in a single row extending from the nucleus to the free end of the cell. Sometimes they form a dense accumulation almost filling the body of the cell. A very few scattered granules were sometimes found in the base of the cell beneath the nucleus, but never in any numbers or regularly arranged as they usually were upon the outer side of the nucleus. The granules seem to be some sort of a secretory product, but this is evidently of a different chemical nature, as well as physical, from that formed by the cells of the upper surface of the ridge or of the entire outer sides of the cirrus. Possibly its formation is connected with the function of adhesion belonging to these portions of the cirrus.

Beneath the epithelium just described is a thick basement membrane. This is exceedingly uneven, being full of small pits. The unevennesses of the basement membrane, however, are not copied by the surface of the epithelium. Over the remainder of the cirrus the basement membrane is very thin. The transition from thick to thin basement membrane is as sudden and marked as the transition from high to low epithelial cells, and occurs at the same place. (Fig. 72.)

Many of the slender cells of the inner surface of the ridge taper to a fine thread-like base, which often seems to penetrate the basement membrane and to be continued a short distance toward the center of the cirrus as a slender fibre, but it is not possible to be sure of this because of the unevennesses of the basement membrane. What appears to be a fibre penetrating the membrane may be only the slender basal portion of a cell entering one of the pits of the membrane. We can not help but suspect from their shape, position, and structure that these cells are sensory as well as secretory, but the determination of this question will require specially prepared material. Here, as in other places where the histology of *Nautilus* is described, descriptions of the tissues are given as they have been found under certain (rather unfavorable) conditions, and no attempt is made to insist upon any doubtful interpretations.

Variations in the shape and structure of the tentacles are quite common and take place in four directions, as far as my observation extends.

1. The free ends of the sheaths may be more or less fused; fusion may occur between any two sheaths, but is most usual among those nearest the hood.

2. The free portion of the sheath is sometimes split into two halves, leaving the cirrus projecting between them. This may be the result of injuries received by the animal early in life, but no trace of any injury is shown by any other part and the innermost digital tentacles are always the ones to be affected; from their position we should expect these tentacles to be rather less exposed to injuries than any others.

3. The opening through which the cirrus projects from the sheath may be displaced. Usually the displacement is toward the inner side and the opening is found a few millimeters below the tip of the sheath. But it may be at the very base of the sheath, which then projects in the usual manner, but with closed tip, while the greater portion of the cirrus lies outside the sheath.

Less frequently, and only among the dorsal tentacles, the openings are upon the outer side of the sheath. In one specimen one of the cirri of the hood extended from its sheath 10 millimeters back from the edge of the hood. The hood-cirrus of the other side was normal, while the cirri of the two neighboring tentacles both projected from the sides of their sheaths several millimeters back from their tips.

4. The cirrus may be entirely absent and the sheath closed. This occurred in but one specimen. Where the cirrus of the left side of the hood should have projected, only a nipple-like projection of the integument was seen. Upon slitting the hood back of this projection the cavity of the sheath was found empty, without the least trace of a cirrus, and not extending the usual distance into the hood.

The more common variations of the tentacles were those of fusion of the sheaths with one another. The general tendency, in fact, seems to be toward more complete fusion and increasing solidity of the cephalic sheath.

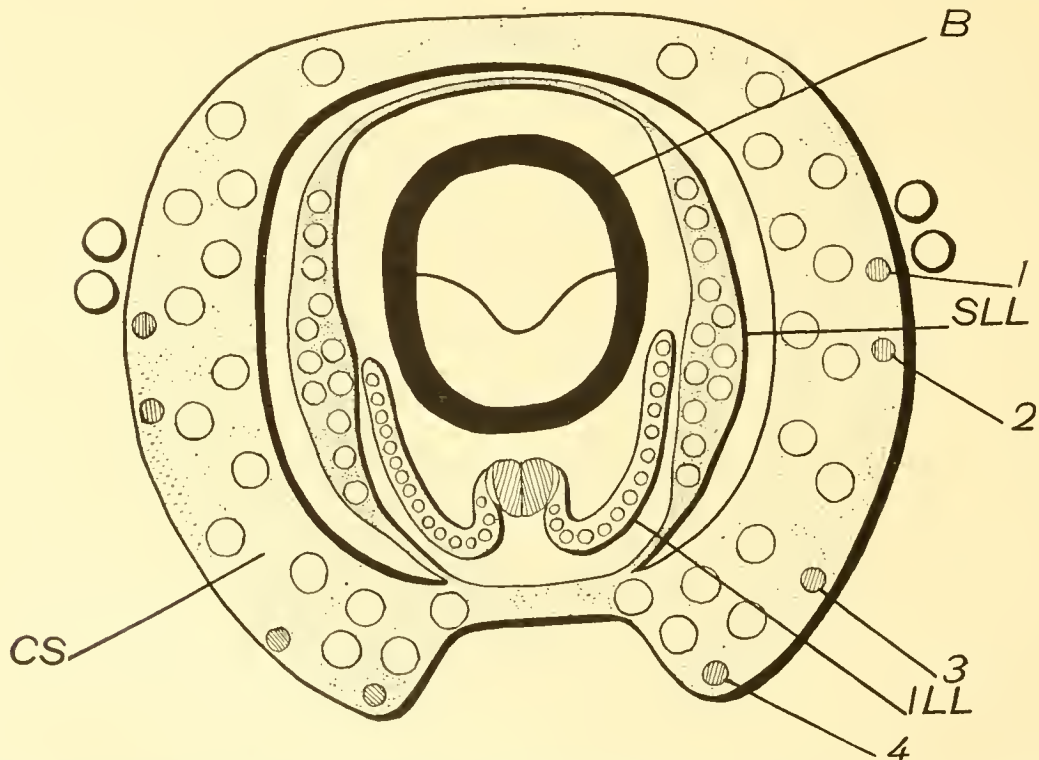
B.—INNER TENTACLES OF THE FEMALE.

If now we open the cephalic sheath or cut it away we see that the mouth parts of both male and female *Nautili* are surrounded by still other groups of tentacles. We see, further, that these groups are evidently more specialized than the digital tentacles, and that the groups are not alike in male and female, either in number, shape, or position, while their specialization is of a higher degree in the male than in the female. It is therefore impracticable to attempt a parallel description of the inner tentacles of the two sexes. The conditions are more simple in the female, so I shall attempt their description first.

The tentacles about the mouth parts are designated by the general name "labial tentacles."

Two groups situated upon either side of the buccal cone, and nearly meeting dorsally, are the superior labial tentacles. (Fig. 5, SLL; Text-fig. 2, SLL.) Two other groups, situated below the buccal cone but wrapping around it laterally, are the inferior labial tentacles. (Fig. 5, L; Text-fig. 2, ILL.)

The superior labial tentacles project from two broad, flat, thin lobes which arise from the base of the inner side of the cephalic sheath. The lobes are about 3 centimeters broad and 2 centimeters high. From the ends of the lobes low ridges are continued; dorsally to unite the two, ventrally to end above the funnel near the innermost digital tentacle of each side. (Text-fig. 2.) One might say that these two lobes are only local elevations of a single ridge which nearly surrounds the mouth parts. The upper edge of each lobe is subdivided into a number of more or less separate processes. The tip of each process is free for from 6 to 10 millimeters, while grooves upon both surfaces of the lobe indicate a division for some distance farther back. At the tip of each process is an opening leading into a cavity $1\frac{1}{2}$ to 2 centimeters



TEXT-FIG. 2.—Diagram of the arrangement of the tentacles of the female nautilus, viewing them from the front.

B, buccal mass. CS, cephalic sheath, composed of the fused sheaths of the digital tentacles. ILL, inferior labial lobe. SLL, superior labial lobe. 1, 2, 3, 4, a series of four small digital tentacles upon the outer side of the cephalic sheath.

deep; each projection is the free end of the sheath of the cirrus which projects through its opening. Thus the superior labial tentacles have the same principal structures as the digital tentacles.

The number of tentacles in the superior labial group is very variable within certain limits. The most ordinary number is twelve in each group; as few as ten, or as many as fourteen are quite common. RUMPH (1805) counted sixteen in each group. The number is usually, but not necessarily, the same in both groups of one individual. I have not, however, found a difference of more than one.

The arrangement of the tentacles seems to be constant. As is shown in the diagram (Text-fig. 2) there is an inner row of nine, and, at about the middle of this, an outer row of three. The variable tentacles seem to be at the ends of the longer row, the shorter row having always been found to be normal.

The cirri of the labial tentacles are, of course, shorter and more slender, but their structure and shape are the same as of the digital tentacles.

The structure of the inferior labial lobe is more complicated. I have retained OWEN's designations of superior and inferior instead of the ones suggested by VAN DER HOEVEN, external and internal, for these lobes because the former names indicate better their actual positions. I have already spoken of two inferior groups of labial tentacles. Two groups there are, but they are borne upon a single lobe, the inferior labial lobe.

The inferior labial lobe (Fig. 5, L; fig. 26) arises immediately below the buccal cone as a process about $2\frac{1}{2}$ centimeters broad and 8 millimeters thick. About $2\frac{1}{2}$ centimeters from its base the process is split into two symmetrical portions. Each portion widens out like a fan and bears a single row of tentacles along its edge. (Text-fig. 2, ILL.) Each of these parts wraps itself about the buccal cone internal to the superior labial lobes. The inner surface of each is concave, the outer surface convex. Sheaths and cirri of the inferior labial groups are like those already described for the superior labial tentacles, except that the sheaths do not project freely. The middle tentacles of each inferior group are the longest; those at the outer end of the row are only slightly shorter, but the inner tentacles decrease rapidly and greatly in size. A progressive reduction in the development of the sheaths is also noticeable among the innermost tentacles. The innermost tentacle is frequently a mere papilla 2 or 3 millimeters in height.

The number of tentacles in each inferior labial group usually varies between ten and fourteen. The number upon the opposite divisions of the same lobe frequently differs by one or two. VAN DER HOEVEN reports fourteen upon the left and sixteen upon the right side.

At the junction of the outer portions of the lobe, upon its inner side, is an oval or polygonal organ composed of sixteen to twenty closely folded thin triangular lamellæ, the widest portion or base of the organ being directed posteriorly. (Fig. 5, L; Fig. 20; Text-fig. 2, ILL.) Usually sixteen lamellæ compose the organ, which OWEN supposed to be the olfactory organ of Nautilus.

The lamellæ are symmetrically disposed with respect to the median line of the body. Occasionally there is a difference of one in the number of lamellæ of the two halves of the organ. The organ represented in Fig. 20 was more expanded than most, so shows the relative arrangement and form of the lamellæ better than is usually the case. This organ measured 12 millimeters in breadth and 9 in length. The triangular lamellæ are attached to the labial lobe by one edge, the point opposite then projecting upward and inward. The line of attachment of each of the median lamellæ is parallel to the axis of the body, while the outer lamellæ are attached at acute angles to the axis. The outer lamella of each side usually lies somewhat above the others, overlapping them and lying in the continuation of the rows of tentacles upon the outer parts of the labial lobe. A ridge across the open back of the organ connects the two outer lamellæ.

Each lamella is distinctly and closely grooved upon its outer side, the grooves reminding one of those upon the cirri. Less numerous, distinct, and regular grooves are seen upon the inner sides of the lamellæ. A large nerve runs through the center of each lamella to its tip. The nerve possesses an outer layer of ganglion cells which are evenly distributed upon its surface and not grouped in ganglionic masses as they are upon the nerve of a cirrus.

Both surfaces of the lamellæ are deeply pitted, and all portions are covered with a highly glandular epithelium.

The musculature of a lamella has essentially the same arrangement as that of a cirrus. In consequence of the flattened form of the lamellæ their longitudinal muscles extend outward to the edges upon either side of the nerve. The transverse fibers, which are radially arranged about the nerve in the cirri, here, therefore, pass directly across the thin lamellæ between the bundles of longitudinal fibres. External to the latter are circular muscle fibres.

In the farthest depths of the fissure between each two lamellæ is a small opening leading into a sunken organ which I do not hesitate to call sensory. These organs ordinarily consist of two parts: 1, a tubular neck opening outwardly as has just been mentioned, and opening inwardly into 2, a (comparatively) large cavity which extends in the solid tissue of the labial lobe at right angles to the surfaces of the lamellæ. (Text-fig. 3, G.)

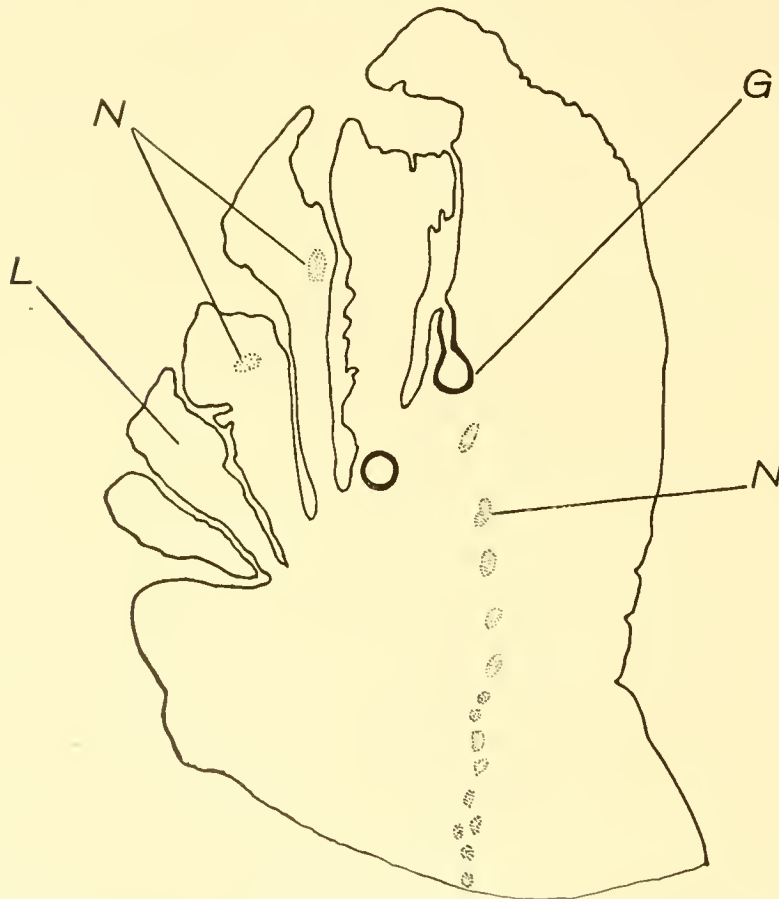
The whole structure reminds one strongly of a diminutive tunnel driven in both directions

from its shaft. The tunnel is round in cross section, and as a rule the shaft is near its center. A section of the organ through the middle of its shaft therefore is flask-shaped, the neck (shaft) being slightly bulged at its center. The shaft may, however, be at one end of the tunnel. Shaft and tunnel are lined throughout with a peculiar epithelium. The cells are extraordinarily slender, almost like threads in their proportions, and the free end of each is prolonged into a sensory spike, the multitude of which causes the surface of the tunnel and shaft to appear ciliated. A very slender nucleus is situated in the basal third of each cell. None of the cells lining the cavity are glandular. The length of the cells varies greatly in different cavities, as well as in different regions of the same cavity. This peculiar epithelium may extend outward from the mouth of the shaft for a little distance into the fissure between the lamellæ. I have not observed any

special nerves going to these organs, but as they lie close to the large nerves of the lamellæ better material may reveal the innervation.

There seems to me to be but little doubt that these cavities are sensory organs of a simple type, and but little more doubt that their function is olfactory as was assumed by OWEN and others for for the group of lamellæ as a whole. I find, however, no sensory structures upon the lamellæ, nor any indication of these latter possessing any special sensory function.

The sensory organs situated between the outer three or four lamellæ may be less developed than those between the inner lamellæ. The shaft may be shorter; the tunnel short, or little more than a spherical pocket. In two cases the only indications of the sense organs were small hemispherical projections between the bases of the lamellæ covered by the sensory epithelium. These were the two



TEXT-FIG. 3.—Camera lucida outline of a section of the lamellated organ of the inferior labial lobe of the female; \cdot 13.
G, sensory pit; L, lamella; N, N, nerves of lamellæ.

outer organs of one side. But there was no gradual transition from this to the more complicated and apparently more typical form of organ.

The muscles of the tentacles pass into the labial lobe as in other cases already described, interlacing here with the numerous intrinsic muscles. The inferior labial lobe is a strongly muscular and evidently contractile organ in both its divided and undivided portions. A rather complicated system of muscles extends from its base to the surrounding regions of the cephalic sheath, providing for the motion of the lobe in all directions.

The inner side of the cephalic sheath and all the organs within it, labial lobes and buccal cone, are covered with what may fairly be called a skin. This may easily be removed from their surfaces, leaving the muscular bases of the organs bare. It consists of a single layer of columnar epithelial cells similar to those upon the outer surface of the cephalic sheath, resting upon a thick connective tissue dermis. The dermis tissue is somewhat fibrous, but reminds one strongly of

embryonic gelatinous tissue. Probably better preserved material would show more structure than I have been able to discover. When the skin has been removed from the labial lobes their muscles come into view.

The muscle fibres of the superior labial lobes pass into the tissues of the cephalic sheath without forming any distinct muscles. But in regard to the inferior labial lobe the case is very different.

A longitudinal median muscle, the dorsal median retractor (Fig. 26, 5), extends over the dorsal face of the lobe from just back of the lamellated organ to the base of the lobe, where it enters the ventral portion of the cephalic sheath immediately above the funnel. A similar, but much smaller, longitudinal muscle follows a similar median course upon the ventral face of the lobe.

There remain three pairs of muscles arranged symmetrically at the sides of the lobe. 1 and 1' (Fig. 26) extend out and back from the sides of the lobe to insertions in the lateral regions of the cephalic sheath immediately below the bases of the superior labial lobes. These appear to be the muscles used in raising the lobe and its tentacles.

2 and 2' (Fig. 26) originate near the base of the lobe and pass outward from the median line over the base. The outer ends of these muscles are expanded and flattened, and are inserted over the inner faces of the superior labial lobes. This arrangement evidently serves for the approximation of the superior and inferior lobes and their tentacles. The posterior portions of the inner ends of 2 and 2' separate from the remainder of the muscles and unite with each other above the median muscle 5.

The muscles 3, 4, and 3', 4', (Fig. 26), the lateral retractor muscles, have their origins in the posterior region of the lobe beneath the inner parts of the muscles 2 and 2'. They pass beneath these latter backward and slightly toward the median line. Arising as single muscles, they separate into two distinct portions. The smaller outer portions pass into the base of the buccal mass behind the inferior buccal retractors, as is shown for similar muscles in the figure of VAN DER HOEVEN'S organ. (Fig. 29.) The larger inner portions pass back to insertions upon the median processes of the cartilage.

The base of the lobe is thick and muscular and its tissues extend directly into the ventral portion of the cephalic sheath.

The inferior labial lobes are supplied with blood by a branch from each tentacular artery. (Text-fig. 10, pp. 182, 3.)

A large nerve leaves each pedal ganglion near the infundibular nerve (Fig. 41, 7), which runs forward and enters the side of the inferior labial lobe. Within the lobe it enlarges into a ganglion, from which the separate nerves of the tentacles and the lamellæ arise. (Fig. 41, 35.)

It must be noted that while the inferior labial lobe is bilaterally symmetrical it is not paired as are the superior labial lobes. Young specimens seem to indicate that it is unpaired in its origin.

We have still to consider what the relation is between the lamellæ upon the median part of the lobe and the tentacles upon either side of the lamellæ. Can the two sorts of structures be homologous, or must they be considered as developed separately—one for adhesion and the other for smelling, tasting, or some other function?

It has already been noted that as we approach the lamellæ the inner cirri of each side, i. e., those nearest the lamellæ, rapidly decrease in length. Hand in hand with the decrease in length of the cirri goes a decrease in the depth of their sheaths. Moreover, we often find that the tentacle next to the lamellæ is a small, scarcely noticeable papilla. In some cases such a papilla is partly or wholly surrounded by a shallow groove. Further development of papilla and groove would lead to the formation of a cirrus and a sheath, and tentacles sometimes actually illustrate steps in this process. The minute papillæ, annularly grooved, are supplied with a nerve similar in all respects but length to the nerve of fully developed cirri.

On the other hand, the outer lamellæ are sometimes small and not much different from the rudimentary tentacles just described. So, if we consider shape alone, it is not at all difficult to imagine that lamellæ and tentacles are but differently developed individuals of a single series.

There are, however, other facts which favor this view. The transverse furrows upon the outer sides of the lamellæ are obviously comparable with the grooves upon the cirri. We also note that each lamella possesses a nerve extending throughout its length which has essentially the same structure as the nerve of a cirrus; it has a like complete investment of ganglion cells, although these are not collected into ganglia; beside this, the nerves of the lamellæ arise from the same ganglion as the nerves of the cirri, and it is impossible to distinguish the nerves of cirri and lamellæ before they arrive at their respective terminations. The nerves of the lamellæ are simply the innermost of the series arising from the ganglia.

The arrangement of the muscles of the lamellæ is according to the same plan as is that of the cirri. We have also noted that the sensory organs at the bases of the outer lamellæ have a tendency to be simpler or less developed than those between the inner lamellæ.

The number of both lamellæ and cirri is quite variable, but the number of lamellæ does not seem to bear any constant relation to that of the cirri. The entire number of lamellæ and cirri borne by the inferior labial lobe is about forty.

The facts stated seem to indicate that the lamellated organ is composed of a number of slightly modified labial tentacles, and is not a structure developed upon the labial lobe separately from the tentacles. Furthermore, there are indications that the outer members of the series of lamellæ and the inner members of the series of tentacles graduate into each other, possibly being developed in one direction in some individuals and in the opposite direction in other individuals.

The inferior labial lobe of a half-grown female showed an interesting condition in the development of the lobe. The superior labial lobes were as well developed, proportionally, as in a mature specimen. The inferior labial lobe, on the contrary, was in a rudimentary condition. It reached only about to the middle of the buccal mass. Each side of the anterior edge of the lobe was produced in a curve; in the center were a number of fine lamellæ. The tentacles at the edges of the lobe were very rudimentary, in many cases apparently not yet being differentiated into cirrus and sheath.

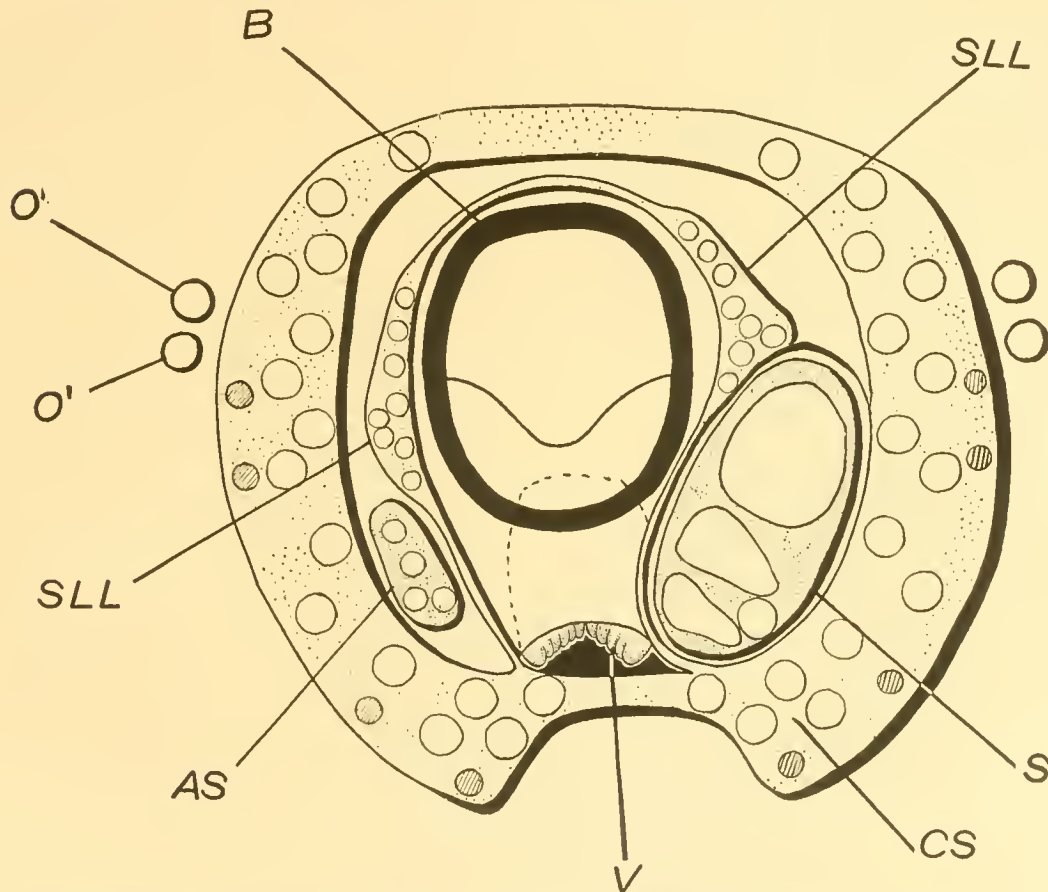
HASWELL makes the following statement: "One of the six or eight female specimens examined by me presents a condition of the median minor tentaculiferous lobe which may, perhaps, have a bearing on the functions of the part. In this specimen, which was a good-sized one and fully developed in other respects, the lobe in question (the group of lamellæ) was represented by a rudiment, in which, however, all the parts of the perfected structure were distinctly and symmetrically represented."

C.—INNER TENTACLES OF THE MALE.

The arrangement which we see when we open the cephalic sheath of the male is quite different from that which we have observed in the female. The buccal cone occupies the same relative position in both sexes. At each side of and dorsal to the buccal cone of the male is a group of tentacles closely resembling the superior labial tentacles of the female. (Fig. 7; Text-fig. 4.) They are borne upon two lobes which are elevations of a ridge of the base of the cephalic sheath nearly encircling the buccal cone. The ridge is very low dorsally and ventrally to the tentacle lobes, which latter rise to a height of from $1\frac{1}{2}$ to 3 centimeters. Ventrally the ends of the ridge approach each other like the tips of a horseshoe and end upon the cephalic sheath near the innermost digital tentacle. This ridge obviously corresponds to the similar ridge of the female which bears the superior labial lobes, and we shall also term these tentacle-bearing lobes of the male superior labial lobes.

Outside the ventral ends of the ridge bearing the superior labial lobes are two groups of tentacles, one at each side of the head, which do not appear in the female. There are four tentacles in each group. (Fig. 7, Sp. ASp; Text-fig. 4, S, AS.) The tentacles of the right-hand group do not differ markedly from the tentacles of the superior labial group. The tentacles of the left-hand group, however, are enormously developed and form a conspicuous organ known as the spadix. The smaller corresponding group of the right side is called the antispadix.

Immediately beneath the buccal cone is still another organ which is peculiar to the male. It was discovered by VAN DER HOEVEN, and has since been known as VAN DER HOEVEN'S organ. It lies in a pocket formed by the ventral portion of the cephalic sheath ventrally, and dorsally by a fold connecting the ends of the horseshoe-shaped ridge which bears the superior labial lobes. (Text-fig. 4, V.) The organ can not be seen until the cephalic sheath has been opened, so closely does it lie under the buccal mass. Even then the observer can only notice that its anterior end appears to be formed of small lobes and is bilaterally symmetrical. In the diagram (Text-fig. 4, V) it is represented, for the sake of convenience in drawing merely, as projecting at some dis-



TEXT-FIG. 4.—Diagram of the arrangement of the tentacles of the male nautilus, viewing them from in front.

AS, antispadix; B, buccal mass; CS, cephalic sheath, composed of the fused sheaths of the digital tentacles; O', preocular tentacle; O'', postocular tentacle; S, spadix; SLL, superior labial lobe; V, Van der Hoeven's organ.

tance from the buccal mass, which it does not actually do. Its shape is roughly outlined by the dotted line. I hope to present sufficient evidence to be convincing that VAN DER HOEVEN'S organ is the homologue of the inferior labial lobes of the female.

SUPERIOR LABIAL LOBES.

The only considerable difference between the superior labial tentacles of the male and those of the female is in their number. Eight tentacles are usually borne upon each superior labial lobe of the male, while twelve is the usual number upon each of these lobes of the female. Less than eight tentacles may occur upon each lobe of the male, although I have never found more than this number. Two of my specimens presented only six tentacles upon each lobe; one specimen had six upon one lobe and seven upon the other.

The superior labial tentacles of the male are slightly more robust than those of the female; their sheaths are more completely separated in the male than in the female. Two of the tenta-

cles are more or less crowded to the outside of the row formed by the other six, as is shown in Text-fig. 4, and in Fig. 7, SLL. Aside from these there are no differences between the superior labial lobes and tentacles of the two sexes.

Each cirrus possesses a nerve, which springs directly from the pedal ganglion. These nerves leave the edge of the ganglion just dorsally to the nerves of the digital tentacles; being of only about half the size of the latter they are easily distinguished from them, although not so readily traced to their respective cirri.

SPADIX AND ANTISPADIX.

The spadix and the antispadix are morphologically equivalent organs, although the antispadix is simple in all its parts, while the parts of the spadix are highly developed and modified, and several structures are there developed which are not represented in the antispadix. A previous study of the antispadix will probably aid in the understanding of the spadix.

Before proceeding, we must notice the position of the two organs. The spadix is usually upon the left side of the head and the antispadix upon the right side, but this arrangement may be reversed. Out of forty-seven male Nautili, nine, or 19 per cent, had the spadix upon the right and the antispadix upon the left side. WILLEY found an even greater proportion of reversals. "Out of thirty-seven males which were examined ad hoc, twenty-three had the spadix upon the left side and fourteen had it upon the right side" (1896, 1). This is 37 per cent of the total.

One of my specimens possessed a well-developed spadix upon one side and an abnormally developed spadix upon the opposite side.

The antispadix is composed of four tentacles similar to those of the superior labial groups, except as they are somewhat larger and longer than the latter. (Fig. 7, A. Sp; Fig. 12.) The tentacles are arranged in a row, which in the natural position of the animal is dorso-ventral. To distinguish the tentacles I shall number them 1, 2, 3, 4, from above downward, and shall speak of them as the first, second, third, or fourth tentacles. The sheaths of the first, second, and third tentacles are fused as far as their tips, thus forming a narrow, flattened process. It is convenient to speak of the fused sheaths as the sheath of the antispadix. The fourth tentacle is united to the process at the base only. (Fig. 12.) It is situated a little externally to the other tentacles, extending past the third, so that its dorsal edge comes to lie in a groove formed by a projection of the sheath of the antispadix.

At the bases of the cirri the muscular tissues of the cirri and their sheaths unite to form a strong, flat sheet of muscle, which lies against the inner side of the cephalic sheath, but entirely separate from it until near the cartilage. Here it unites with the tissues of the cephalic sheath. The muscular base of the antispadix is entirely separate from the muscular base of the superior labial lobe, although close to it. It is easily seen when the skin between the antispadix and the buccal mass has been cut.

Upon the outer surface of the sheath of the antispadix, near its tip and between the first and second cirri, is a small glandular area. (Fig. 12, G.) Its structure will be described with that of a similar area upon the sheath of the spadix.

The antispadix projects from a pocket between the cephalic sheath and the ridge of the labial lobe and at the ventral end of the lobe. (Fig. 7; Text-fig. 4.) The lobe of the antispadix is about two centimeters in length from the base of the pocket to the tip of the sheath. As a consequence of the shortening of the rows, the superior labial tentacles are further removed from the ventral side of the cephalic sheath in the male than in the female. (Text-figs. 2 and 4.) The low ventral portions of the labial ridge are therefore considerably increased in length in the male. As the spadix increases in size it crowds the superior labial tentacles of this side still farther toward the dorsal side of the head and stretches the ventral portion of the labial ridge.

The spadix presents a very different appearance from the antispadix upon the opposite side of the head. (Fig. 7, Sp.; Figs. 13 and 14; Text-fig. 4, S.) It forms a large, very solid organ, five to seven centimeters in length, two to three centimeters in dorsi-ventral measurement, and one

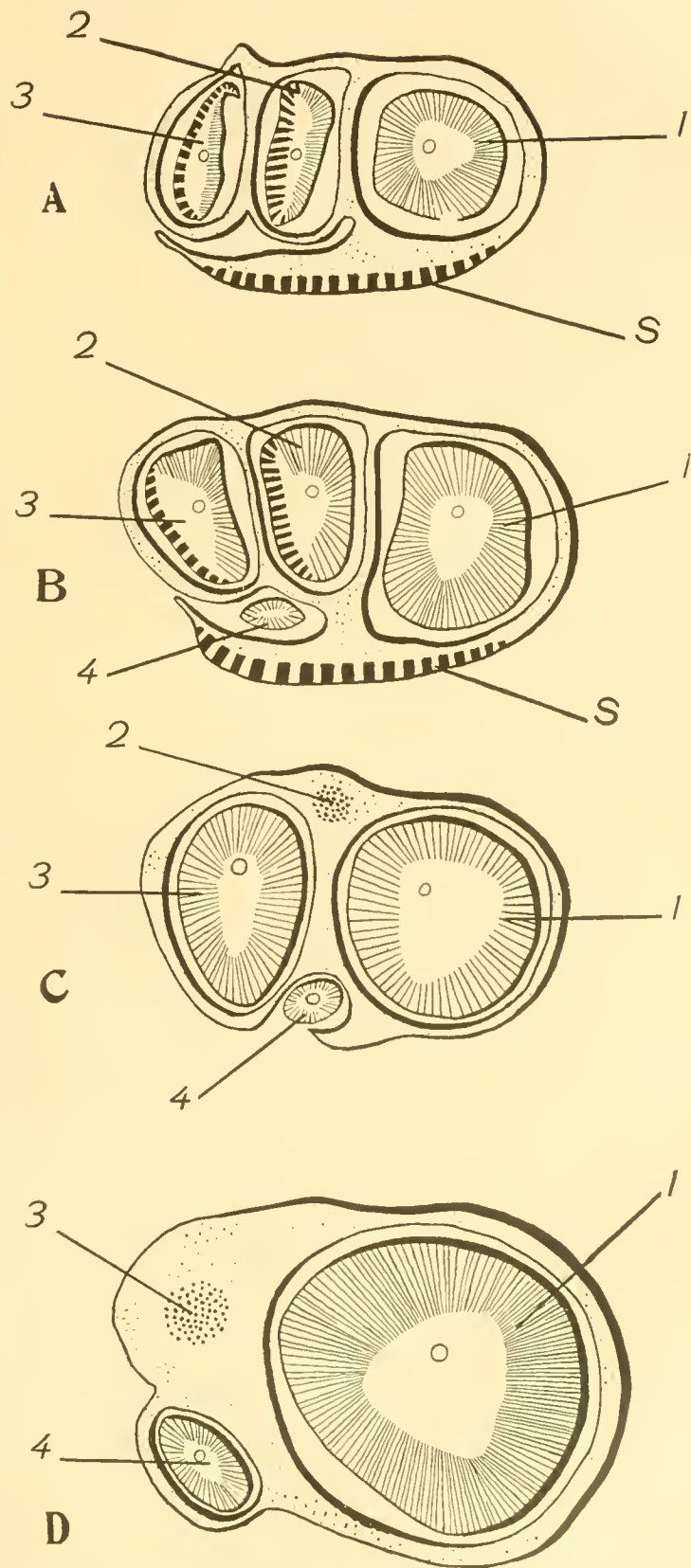
and a half centimeters in thickness. It remains of about the same width and thickness nearly to the irregularly conical end. The tentacles of the spadix have the same relative arrangement as those of the antispadix. Each is greatly increased in size, with the exception of the fourth tentacle, which is but little larger than its representative in the antispadix.

The cirrus of the first tentacle has become an enormous conical, fleshy organ. (Fig. 15.) The cirrus of the second has become flattened as well as enlarged, and bears numerous rows of small glands upon one surface. (Fig. 16.) The cirrus of the third is also flattened at its tip, and shows upon its ventral side many rows of fine pores. (Figs. 17 and 18.)

The sheaths of the first, second, and third tentacles are completely fused and have developed in accordance with the cirri, and now form a structure which Vayssiere has proposed to call the sheath of the spadix. (Figs. 13 and 14.)

There is a groove in the outer side of the sheath of the spadix, between the second and third cirri, into which the tip of the fourth cirrus is pressed. (Fig. 14.) The tip of this cirrus is overlapped by a broad flap, which corresponds to the smaller flap noticed upon the outer side of the antispadix. The base of the fourth tentacle lies within a notch in the sheath of the spadix and is not covered. Its own sheath is short and is free from the sheath of the spadix for a short distance only. In this respect the fourth tentacle of the spadix differs quite noticeably from the corresponding tentacle of the antispadix.

Upon the outer side of the sheath of the spadix, and near its tip, is a large circular glandular area, slightly raised above the general surface. (Fig. 14, G.) The glandular area extends out



TEXT-FIG 5.—Transverse sections of the spadix at successive levels.

A, nearest the tip; D, nearest the base of the organ; 1, first cirrus; 2, second cirrus; 3, third cirrus; 4, fourth cirrus; S, slime gland of spadix sheath.

upon the flap covering the tip of the fourth tentacle. Upon its surface numerous pores, the openings of tubular glands, are easily seen.

The bulk of the spadix is composed of the cirri of the first, second, and third tentacles. The fourth tentacle may almost be said not to enter into the formation of the spadix, so small is it compared with the mass formed by the other tentacles. (Fig. 19.)

The cirri of the spadix are not of equal length, like those of the antispadix. Neither their bases nor their tips are at the same level. Text-figure 5 is intended to show the relative length and position of the cirri of the spadix by means of diagrammatic sections of four regions of the organ. In A, a section through the tip of the spadix, the fourth cirrus does not appear. In section B, taken a quarter of its length from the tip of the spadix, the tip of the fourth cirrus is cut through. In section C, taken just below the middle of the spadix, the second cirrus has ended, and in the position it occupied we see only bundles of muscle fibres passing from its base in the sheath of the spadix. The fourth cirrus is no longer completely shut in by the flap of the spadix sheath. In section D, taken through the base of the spadix, the third cirrus has disappeared in like manner as the second. In spite of the disappearance of two cirri the spadix has increased in size continually as we have approached its base. This is accounted for almost entirely by the great increase in the size of the first cirrus alone. But the fourth cirrus has also increased in size and is, at the base, included within the sheath of the spadix. Strands of muscle from the bases of the second and third cirri also form a portion of the organ. The fourth cirrus is still free from the sheath of the spadix back of where the tissues of the first cirrus and the sheath unite. Finally, the tissues of all the tentacles are united to form a solid base for the spadix, which is firmly attached to the posterior region of the cephalic sheath and the cartilage.

Let us now turn to more detailed descriptions of the separate portions of the spadix.

THE SHEATH OF THE SPADIX.

This somewhat indefinite name is nevertheless convenient, and for this reason it seems appropriate and worth retaining. From the previous description and diagrams it will be noticed that in the anterior region of the sheath it is composed of the sheaths of the tentacles alone, but in its posterior or basal part it includes the muscle tissue extending from the bases of the second and third tentacles.

Sometimes slight longitudinal grooves upon the outside of the sheath indicate the position and boundaries of the cirri within. (Fig. 13.) Upon the outer side of the spadix, i. e., the side turned away from the mouth, is a deeper groove which receives the fourth cirrus. The anterior end of this groove is hidden by the large flap developed on this side from the sheath of the spadix. This flap, extending along the entire length of the spadix, is widest near the tip of the organ, while it becomes a mere ridge near the base. The free edge of the flap is thin and evenly curved. It is about twelve millimetres in width at its broadest part.

Examination of the sheath with a lens reveals minute pits upon the surfaces near its tip, numerous upon the outer surface and less so upon the inner surface. Except for these and the glandular area upon the outer side the sheath is quite smooth.

The sheath is composed of an external layer of longitudinal muscle fibres, and of inner circular fibres ringing each cirrus cavity. It is covered by a single-layered epithelium, composed of slender columnar cells, the basal halves of which are occupied by elongate, oval nuclei. Goblet cells, filled with granular secretion, are found in exceedingly great numbers in the epithelium of the external surface of the anterior portion of the sheath, but in small numbers upon the basal portion. The pits and short grooves upon the anterior portion of the sheath, noticed under the lens, are lined mostly by mucus-secreting cells and serve the purpose of increasing the secretory surface. The epithelium upon the inner surface of the sheath is very similar to that upon the outer surface, except that the cells are shorter, the nuclei nearly round, and the goblet cells very rare. Indeed, the latter are only present near the edges of the cavities occupied by the cirri.

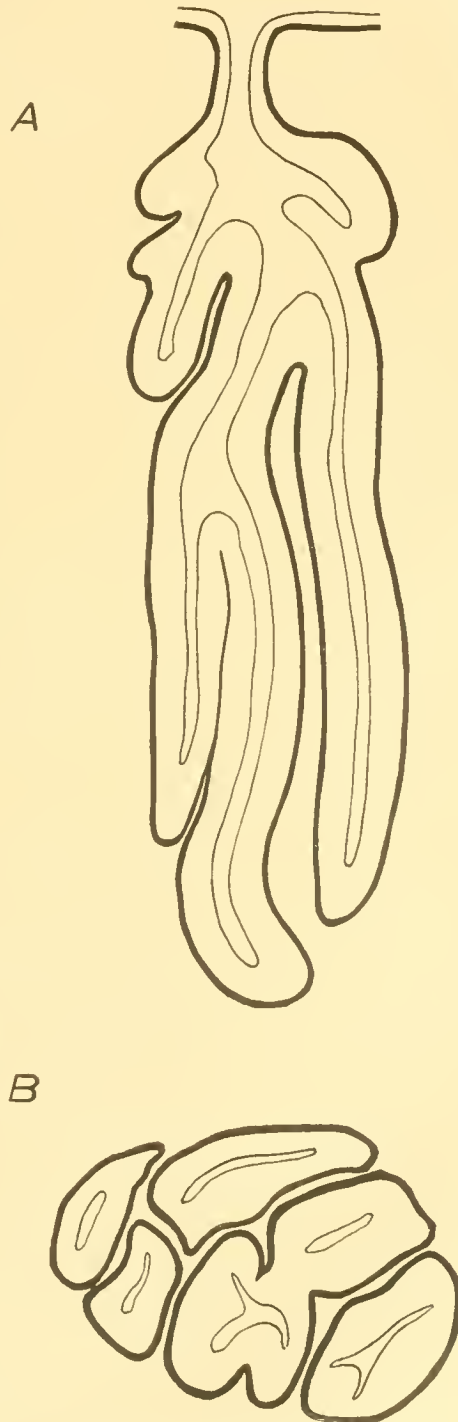
Immediately under the epithelium is a dermis of felted fibrous and elastic connective tissue. In the thinnest portions this, containing a few muscle fibres, forms the entire substance of the

sheath. In the thicker portions the amount of muscle tissue within the dermis is very considerable, and is roughly arranged in the longitudinal and circular layers already mentioned. It must not be forgotten that a quite considerable portion of the sheath is derived from the tissues of the second and third tentacles after these have become continuous with the tissues of the former. The spaces between the muscles are occupied by fibrous and elastic connective tissue. The sheath is penetrated by a perfect network of vascular lacunae.

Until we have some idea of the function of the glandular area upon the outer side of the spadix sheath the term "slime gland" will do very well to designate it. It is surprising that this structure should not have been mentioned by VAYSSIERE in his excellent paper upon *Nautilus*. The slime gland forms a nearly circular area upon the outer side of the spadix sheath, from 25 to 30 millimeters in diameter, and is considerably raised above the surrounding surface, besides being of a much darker color, all in all being a quite conspicuous organ. (Fig. 14.) Numerous pores, the openings of the glands within, open upon its surface. The glands are formed of long, branching tubes, which are packed closely together, and occupy three-quarters of the thickness of the sheath at this point. (Fig. 57.) The sheath contains but little muscle tissue in this region, being composed almost entirely of fibrous connective tissue which, below the slime gland, is reduced to a network inclosing great numbers of vascular lacunae of all sizes. The larger spaces have endothelial walls. The lacunae are much more numerous than they are represented in Fig. 57, by far the greater number being too small to be shown in such a figure.

The structure of the glands is quite simple. From a short, narrow neck arise several tubular outgrowths. (Fig. 57; Text-fig. 6, A.) Most of these are long and slender and extend into the sheath nearly at right angles to its surface. Around the outer part of the neck are often grouped short tubules or mere outpocketings of the wall. The main tubules may themselves be branched. The tubules of each gland lie parallel and close to each other, separated by only a small amount of submucous tissue. (Text-fig. 6, A and B.) The tubules are packed together so that they form a package of almost equal transverse diameters from end to end.

The tubules are lined by a single layer of tall, columnar secretory cells. The lumen of the tubules are extremely narrow, being rarely of greater width than half the height of the cells lining them. (Fig. 57.) The epithelial cells are extremely slender, averaging about 100μ in length and 4μ to 8μ in their transverse diameters. (Fig. 57, A.) The epithelium rests upon a thin basement membrane. At the very base of each cell is a small oval nucleus, 3μ by 8μ in its dimensions. From just above the nucleus to its free end each cell is packed with deeply staining granules of



TEXT-FIG. 6.—Slightly diagrammatic sections of a single gland of the slime gland of the spadix sheath. A, longitudinal section; B, transverse section.

secretion. The region of the cell immediately about the nucleus is entirely free from any secretion, so that the outer edge of the tubule shows a clear border in sections. Figure 57 A shows a single cell of the secretory epithelium drawn with the aid of a camera lucida. It was taken from a place where the epithelium was lower than ordinary, but otherwise is characteristic. The single row of deeply staining granules almost completely fills the body of the cell. The bent base of the cell is a very characteristic feature, although not found universally. The short basal portion of the cell is directed upward and inward, and the longer outer portion of the cell is perpendicular to the axis of the tubule. As the neck of the gland is approached a change takes place in the character of the epithelial cells. The epithelium becomes lower and the cells contain fewer and smaller granules. Finally the epithelium is only of about half the height of that in the tubules; the granule secreting cells disappear, and ordinary goblet mucous cells are found scattered in the epithelium, which is of the same character as that clothing the surface of the slime gland between the pores of the glands.

At the edge of the slime gland are all stages between fully developed tubular glands and the merest invaginations of the surface epithelium. One might almost say that there is here an ontogenetic series in the development of the glands. The smallest invaginations are lined with epithelium entirely similar to that upon the surface of the slime gland. Farther from the edge the invaginations become deeper, and from the inner parts outgrowths occur which become the glandular tubules of fully developed glands. The young tubules possess an epithelium like that of the adult in its essential characters, but at first only a few cells appear to be glandular. These are typical goblet cells filled with finely granular secretion. In more developed glands the secreting cells become more numerous, the granules of secretion are larger, and finally all the cells below the neck of the gland are filled with coarse granules.

The description of the glands upon the outer side of the antispadix was referred to this place. They are of the same character as those of the slime gland of the spadix, but are less developed. The glandular epithelium and the secretion are apparently alike in both organs. The glands upon the sheath of the antispadix are proportionately shallower and are less branched than those of the spadix, but otherwise the structure seems to be the same.

FIRST CIRRUS OF THE SPADIX. (FIG. 15.)

The first cirrus is much the largest of the four forming the spadix. It is nearly circular in section, gradually diminishing in size from the base to near the tip. The latter diminishes in size very rapidly, causing the cirrus to end in a point like the tip of a low cone. The tip is frequently excentric and is sometimes produced like a nipple. The surface of the cirrus is smooth except near the tip, where very faint annular grooves may be noticed. The base of the cirrus, its largest part, measures 32 millimeters dorso-ventrally and 17 millimeters from side to side. It is 6 centimeters in length.

From the ventral side of the base a strong muscle passes ventrally and across the body, to become lost in the tissues of the opposite side of the cephalic sheath. The main mass of the tissue of the cirrus passes immediately into the tissues of the posterior portion of the cephalic sheath on its own side. The development of a special muscle for this cirrus, as well as the remarkable muscular development of the cirrus itself, indicates that the cirrus is very actively employed at some time or other in the animal's existence, and it may also indicate that the cirrus is extended or retracted as a whole from its base and is not extensile in the same manner as the cirri of other tentacles; but all statements of how this and the other cirri of the spadix are used are as yet guesses, pure and simple.

Transverse and longitudinal sections explain the rest of the structure of this cirrus. (Figs. 52 and 53.) Near the center of the cirrus, but still to the inner side of it (i. e., the side nearest the buccal mass), is the large nerve N. This is surrounded by the transverse musculature of the cirrus. Around the core of transverse muscles is a thick ring of longitudinal muscles, which are divided by radial septa of transverse muscles. Outside this follow three thin layers of muscle—a circular, an outer longitudinal, and an outer circular layer. The essential features of the arrangement of the musculature are therefore the same as those of the digital or labial cirri.

A longitudinal section of the cirrus shows that the central transverse musculature consists of alternating layers of crossing fibres. (Fig. 52.) The section figured in Fig. 53 has been cut a trifle obliquely so that it passes through several of these alternating layers. The layers of muscles are arranged like the crossing boards of a double floor.

The surface of the cirrus is covered by a fine columnar epithelium in which are scattered great numbers of goblet cells. The epithelial surface is increased by numerous pits the lining epithelium of which is especially supplied with secreting cells.

The nerve of the cirrus is enlarged at regular and frequent intervals, like the nerves of the digital cirri. Each enlargement corresponds in position to a pair of the alternating layers of the transverse musculature. In a young *Nautilus* the first cirrus of the as-yet-undeveloped spadix is like one of the labial cirri, slender and marked with annular grooves. The corresponding segmentation of the cirrus and its nerve in the digital and labial tentacles has already been noticed. Probably there is a similar correspondence here, while the transverse musculature is also segmentally arranged. As the cirrus under discussion increases in size the external segmentation becomes obliterated. The branches of the nerve pass outward in the layers of the transverse muscle. The nerve ends abruptly near the tip of the cirrus. An artery runs along the inner side of the nerve A. The vein divides and its branches come to lie at a considerable distance from the nerve, V, V', Fig. 53.

Between the outer layer of muscles and the epithelium is a layer of connective tissue which is curiously developed in one region. (Fig. 52.) Over most of the cirrus the layer is thin and the tissue firm and close, containing a few muscle fibres; but just below the tip it is much thickened and great numbers of vascular lacunæ, large and small, make their appearance in it. The larger lacunæ have endothelial walls. Fig. 52 only represents the larger lacunæ, and not the far greater number of small ones. It may be possible that this forms a kind of erectile tissue.

SECOND CIRRUS OF SPADIX. (FIG. 16.)

The second cirrus of the spadix is much more modified than the first, for that is modified in shape and size mainly, while this has undergone modification of structure also. It is slender, and instead of becoming larger at its base it narrows. Its muscles are continued into the sheath of the spadix between the first and the third cirri. (Text-fig. 5, C, 2.) Its length is about 4 centimeters. Its basal portion, to within about 15 millimeters of the tip, is round and smooth. Exceedingly indistinct annular grooves can sometimes be seen in this portion of the cirrus. At the point referred to the cirrus begins to be flattened upon both dorsal and ventral surfaces. It ends in a flat, thin-edged, lancet-like tip. A little distance from the tip one edge remains thick while the other is thin, giving the cirrus a triangular shape. Concurrently with the flattening the cirrus becomes more and more distinctly annulated, the grooves appearing a little more strongly marked upon the ventral than upon the dorsal surface.

In general this cirrus adheres to the plan of structure already described for other cirri. The nerve, extending through the cirrus near its center, does not possess any unusual characters. It is of good size, showing ganglionic enlargements at regular intervals which correspond with the annulations upon the surface of the cirrus, and extends to the very tip of the cirrus. (Fig. 61, N.) Upon the inner side of the nerve is an artery, and still farther toward the inner edge of the cirrus a large vein. (Fig. 56, A and V.) The nerve and the artery are surrounded by transverse muscle fibres, but the radial arrangement of the musculature has been lost to a large extent and is replaced by an arrangement of the longitudinal muscles in lines extending across the cirrus in the direction of the shorter transverse axis, the dorso-ventral axis. In the round basal portion of the cirrus the arrangement of the muscles is similar to that in the digital cirri.

The dorsal side of the cirrus, amounting to from one-half to one-third of its entire thickness, from the point where the annulations first show plainly, is occupied by glands and not by muscles. (Figs. 56 and 61, G.) The glands open by very minute pores in the annular grooves, a single row of closely placed pores occupying each groove. The pores of the glands are upon the slopes of the grooves and not in the bottoms. They are so small that they are only to be seen in sections.

The circular and outer longitudinal rings of muscles have been greatly reduced in this cirrus, the longitudinal having almost completely disappeared. Immediately underneath the glands is a thin layer of the circular muscles. With the development of the glands the dermis tissue has become greatly increased, so that now the glands are surrounded by fibrous tissue, traversed here and there by muscle fibres. Each gland has a thin tunic of muscle fibres. A few vascular lacunae are found in the dermis.

The glands have the shape of thick, round-bodied flasks with very short and narrow necks. (Fig. 55.) Owing to their mutual pressure the glands are usually polygonal. They are 0.8 to 1 millimeter in length and 0.4 to 0.6 millimeter in diameter. The exterior of the cirrus is covered by an epithelium of very slender columnar cells, none of which are secretory. At the mouths of the glands a transition occurs to shorter or even cubical cells which line the duct and upper part of the body of the gland. The sides and the base of the gland are lined with exceedingly long, slender, secretory cells, whose oval nuclei lie in the very bases of the cells. There is considerable variation in the length of the cells of the upper side of the gland. Sometimes they are scarcely longer than those of the duct; sometimes, again, as long as any in the gland. Mucous cells are sometimes scattered among the cells of the upper sides and the duct of the gland, the other cells of these regions not appearing to be secretory; again, all are secretory. The portion of the secretory cell above the nucleus is closely packed with fine granules. The large lumens of the glands were in most cases filled with a finely granular secretion. Glands near the tip of the cirrus may be more or less distinctly divided into two portions, which are partially separated by a constriction—a basal thick-walled secretory portion and an outer thin-walled portion, which may be a collecting or storing chamber, from which the duct leads to the exterior.

The ridges upon the surface of the cirrus are almost entirely occupied by large vascular lacunae. A network of connective tissue extends between the lacunae of the ventral ridges, but there is almost no connective tissue in the ridges of the dorsal side.

THIRD CIRRUS OF SPADIX. (FIGS. 17 AND 18.)

The third cirrus is the most highly modified and remarkable of the group. It is longer and larger than the second, being intermediate in size between this and the first. As has already been noted, its base lies posterior to that of the second. It is oval in cross section at the base instead of round, as is the case with all the other cirri of the spadix. It is narrowed at the base, however, like the second cirrus. For about half its length it is oval and perfectly smooth. At its middle it begins to be still more flattened dorso-ventrally, until near its tip it is almost perfectly flat upon both sides. The dorsal side is apt to be somewhat concave and the ventral side convex. A longitudinal ridge may be present along the median line of the dorsal side near the tip, caused by the tissues passing over the nerve lying directly underneath.

At the same time that the cirrus becomes flattened it loses its smooth surface. The dorsal surface becomes marked by transverse ridges, which are at first very faint, but become distinct as the tip of the cirrus is approached. At the very tip, however, the ridges become crowded and less distinct. They also disappear at the edges of the cirrus, leaving a smooth, unmarked margin. Close examination with the naked eye discovers many smaller ridges extending longitudinally between the transverse.

It is upon the opposite (the ventral) side of the cirrus that we find a most peculiar structure. (Fig. 18.) Arranged across the cirrus in rows which seem to correspond closely to the ridges of the opposite side are great numbers of fine pits extending into the tissue of the cirrus. The largest of these may be a little more than a half a millimeter in diameter. Examination with a hand lens shows the openings to be nearly square, the sides being parallel to the main axis of the cirrus, and to be set as closely to each other in both directions as is possible. The openings are often so regularly spaced that they form longitudinal as well as transverse rows. Only a thin wall remains between the pits. At the posterior end of the pitted surface the pits become small, imperfectly formed, and finally disappear. Similarly the pits are not well developed at the tip of the cirrus. When the fingers are passed over the pitted surface it feels like shagreen, and

suggests that it is covered by a rough cuticle. This, however, is not the case, as we shall presently see.

The middle part of the cirrus, where the transition from the oval to the flattened shape takes place, is triangular in section for a distance. (Fig. 59.) The inner side of the cirrus forms the short side of the triangle. The dorsal and ventral surfaces of this region bear their characteristic structures. The inner surface is smooth and muscular.

In general the structure of this cirrus is so like that of the second that no detailed description is necessary of any part except the pits. In Fig. 59 we have a transverse, slightly oblique section of the third cirrus, and in Fig. 60 a longitudinal section of the same cirrus, both drawn with the aid of the camera lucida. Fig. 62 shows a longitudinal section through the center of a pit magnified to 34 diameters. The pits are simple cavities 1 millimeter in depth, into which a fleshy tongue projects from the posterior side as the animal is in its swimming position. Supposing the cirrus to be placed tip upward, the tongue projects from the floor of the cavity. The cavity of the crypt forms only a narrow fissure about three sides and the edges of the fourth side of the tongue. This is thus attached to the wall of the crypt along a narrow median region. (Figs. 59 and 60.) The tongue is strongly muscular, the muscle fibres mostly extending from the base toward the tip. The tissue between the crypts is largely muscular; all the muscle fibres, both of the tongues and of the intermediate tissues, are much finer than those making up the body of the cirrus. Many connective tissue nuclei are scattered among the muscle fibres.

Beneath the epithelium of the sides of the crypts and their tongues is a clear layer of a peculiar structure. (Fig. 62.) This layer does not extend quite to the bottoms of the crypts, but commencing near here, becomes gradually thicker and thicker as the openings of the crypts are approached. The clear layer is especially thick upon the anterior edge of the crypt, i. e., upon the edge toward the tip of the cirrus. Under low powers the layer appears homogeneous and structureless, but high powers of the microscope reveal numerous and exceedingly fine fibres in it. No nuclei whatever are found in the layer. At the extreme outer edge of the layer, immediately under the epithelium, no fibres at all, nor any other structural element can be distinguished. Passing inward, the fibres are progressively more and more distinct. Along the inner edge of the layer, next to the muscle, is a distinct layer of small nuclei which appear like connective tissue nuclei. It is this clear layer which gives the surface of this portion of the cirrus its hard character. It seems to form a supporting tissue or sort of exoskeleton for the other tissues of the crypts, or perhaps for the cirrus as a whole.

The surface of the cirrus is covered with a single layered epithelium. Those portions of the cirrus not occupied by crypts are covered by an epithelium similar to that of the second cirrus. In the region of the crypts it is considerably modified. In the deepest parts of the crypts the cells are of about the same proportions as those upon the dorsal side of the cirrus—slender columnar cells, among which are numerous goblet cells. The number of secretory cells in these regions is not at all remarkable.

As the cells extend outward upon the sides of the crypts and their tongues, they gradually decrease in length and increase in breadth, until a veritable pavement epithelium is formed. The outer portions of the sides of the crypts and all the area between their openings is covered by an epithelium of this character.

The function of the crypts is entirely unknown, and I do not see that we have facts of any kind upon which to base even guesses as to the nature of their uses in the economy of *Nautilus*. The number of glandular cells in the crypts is so small that, as VAYSSIERE says, the latter can scarcely have been developed for the purpose of increasing glandular area. The development of muscle tissue about the crypts, and especially in their tongues, together with the development of a firm, hard layer upon their surfaces, indicates a considerable and important activity for these structures and for the cirrus as a whole as well.

FOURTH CIRRUS OF SPADIX. (FIG. 19.)

As has been said, this cirrus is almost unmodified. It is the smallest of the group and is nearly hidden by the flap upon the outer side of the spadix. It is scarcely longer than the

corresponding cirrus of the antispadix, but is of considerably greater diameter. The tip is flattened. Elsewhere the cirrus is nearly round. Its lower portion is smooth, while the distal half is more or less distinctly grooved. This cirrus has its origin at the very base of the spadix, and is free for almost its entire length from the main portion of this organ. It possesses a very short separate sheath which is not nearly as long as the sheath of the corresponding cirrus of the antispadix. (Figs. 12 and 14.) This sheath is united to the base of the spadix sheath. The base of the fourth cirrus passes under the base of the first cirrus to its outer side. Aside from the reduction of the annular ridges, the appearance of this cirrus is not markedly different from that of the digital cirri.

The essential features in the structure of this cirrus are also almost the same as those described for the digital cirri. (Figs. 54 and 58.) The arrangement of the muscles is somewhat modified by the great development of the transverse musculature, the strands of which are sometimes as large as those of the longitudinal muscles. The regular radial arrangement of the latter is largely lost. The epithelium of the annular ridges is not especially developed at any point, although distinctly higher upon the ridges than between them. Large blood spaces run within the ridges upon the inner side of the cirrus. They extend only a portion, one-half or less, of the distance across the inner face of the cirrus. These spaces are lined with flat endothelial cells, and communicate with veins lying deeper in the cirrus. They lie almost directly beneath the epithelium. They are not present in the small ridges near the tip of the cirrus, appearing in the tenth to the fifteenth from the tip, and increasing in size as the ridges increase in breadth and height.

The nerves of the spadix come off from the left pedal ganglion; those of the antispadix from the right pedal ganglion. It is very difficult to trace the nerves into the individual tentacles, although I have succeeded in doing this in a few instances. The four nerves to the cirri of the spadix or the antispadix spring from the edge of the ganglion. They appear to belong to the superior labial series, but being a little larger. A few special nerves pass from the ganglion into the base of the spadix. One of these (Figs. 41, 30) forms an enlargement in the base of the spadix, from which several small nerves pass into the surrounding tissues.

In a less than half-grown male the spadix formed a very small, flat organ, resembling the antispadix, which scarcely reached as far as the tips of the jaws. VAYSSIÈRE has already shown that the cirri of the spadix are at first like those of the antispadix, and that they undergo modification quite late in the life of the Nautilus.

VAN DER HOEVEN'S ORGAN.

Directly beneath the buccal mass of the male Nautilus is a peculiar organ discovered by VAN DER HOEVEN and since known by the name used at the beginning of this paragraph. (Figs. 8, 9, 10, 66, 67, 68, and 73.) To this organ an olfactory function has been ascribed, without any evidence, to be sure, but apparently in accordance with a common custom of describing any organ of Nautilus, the function of which is unknown, as an olfactory organ. The organ opens into a pocket formed laterally by the labial ridges, ventrally by the cephalic sheath, and dorsally by a ridge connecting the labial ridges. Into this pocket the anterior end of the organ projects freely. (Fig. 8.) The walls of the pocket soon attach themselves to the organ and, being continued upon its surface, form a tunic. This attachment takes place near the anterior end of the organ dorsally, but near the middle ventrally. (Fig. 9.) The organ is oval, the long axis lying parallel to the long axis of the body, and is flattened dorso-ventrally. It is 25 millimeters in length, 15 millimeters in width, and 10 millimeters in thickness.

If the pocket, or atrium, into which the organ projects be opened as far back as the attachment of its walls to the organ, we see that the anterior part of the latter is divided by a median longitudinal fissure which extends from the ventral side nearly through to the dorsal side of the organ. (Fig. 8, VF; Fig. 10.) The fissure does not extend on the surface quite as far back as the attachment of the integument to the organ. Transverse and longitudinal sections reveal the fact that the fissure just mentioned does, however, extend within the organ for some distance

into its posterior half, and that it communicates dorsally with a broad transverse fissure near the dorsal side of the organ. (Figs. 9 and 10, H.) The transverse horizontal fissure extends almost to the posterior end of the organ.

The anterior free portion of the organ is firm in texture and is seen to be partly divided into lobes by fissures extending from the edges of the vertical fissure. In longitudinal and cross sections of the organ the deeper parts of the longitudinal fissure are seen to be bordered by thin, shelf-like laminae, which extend about halfway to the lateral edges of the organ. (Figs. 10 and 66.) The laminae do not reach the posterior part of the organ, extending only as far as the posterior end of the vertical fissure, which ends in a line directed upward and backward.

The regions posterior to the laminae and dorsal and lateral to the horizontal fissure are glandular. The openings of the glands can be seen with the naked eye or a hand lens upon the walls of the horizontal fissure. The glandular part of the organ is quite distinctly different from the remainder in appearance and texture, but still is firm and hard.

Both the lobules of the anterior region and the horizontal laminae radiate from a small region of firmer tissue near the anterior end and on each side of the vertical fissure. (Fig. 9.) The lobules noticed at the sides of the anterior portion of the vertical fissure are thick and fleshy and often have their edges rounded. Posteriorly they are seen to graduate into the horizontal laminae; as a matter of fact, lobules and laminae are differently developed members of a single series. Counting all as laminae, there are from 20 to 24 laminae upon each side of the vertical fissure.

Several muscles are attached along the lateral edges of the anterior part of the organ. At their attachment they usually form a distinct muscular ridge from which two principal muscles separate themselves on each side. One pair of muscles extends backward along the sides of the organ to penetrate the muscular base of the buccal mass above and outside the ventral buccal retractors. (Fig. 8.) The other pair of muscles extends outward and each soon divides into two branches. The anterior branches are spread out upon the bases of the superior labial lobes. The posterior branches go to the sides of the cephalic sheath below the anterior. This arrangement of the muscles shows distinct resemblances to that of the muscles of the inferior labial lobe of the female. (Fig. 26.)

A large nerve arises from the pedal ganglion just outside the infundibular nerve. (Fig. 41, 7 and 35.) The two nerves pass along the sides of the organ of VAN DER HOEVEN, entering it a little anterior to its middle.

A branch from the tentacular artery of each side supplies VAN DER HOEVEN'S organ with blood. These are the same branches which, in the female, supply the inferior labial lobe. (Text-fig. 10, p. 182, 1 and 3.)

The firm tissue forming so large a proportion of the anterior part of the organ is composed of a thick-meshed reticulum of elastic tissue fibres, in the interspaces of which run bundles of muscle fibres. The tunic is composed of a layer of muscle very distinct from the underlying tissues. The bodies of the lobules and the laminae are almost entirely composed of elastic tissue. The bodies of the thin horizontal laminae which lie hidden within the organ are not thicker, and frequently not as thick as the epithelium of either surface.

The epithelium of the lobules and the laminae is of exactly the same character. It averages 80μ in height, and is composed of a single cell layer comprising two entirely different sorts of cells. The more evident, and at first sight the only sort, are slender columnar cells from 5μ to 8μ in transverse diameter. Oval nuclei situated in the very bases of the cells make a distinct row along the laminae. All these cells appear to be able to form a secretion, which is contained in the cells in the shape of granules, which stain with remarkable intensity. But while all the cells appear to possess the power of secretion, not all in my preparations were exercising it. Next to areas in which all the cells were choked with secretion are areas the cells of which contained no secretion whatever. And as a rule, there is no gradual transition from one area to the other. The boundaries of the areas are distinct; upon one side all the cells are crowded with secretion, upon the other side not a single cell contains any secretion. In only a few places are secreting cells mixed with others not secreting along the edges of the areas. As a rule, the areas free from secretion are near the edges of the laminae turned toward the fissure (the

inner), while the outer parts of the laminae are covered by cells full of secretion. Occasionally, however, non-secreting areas may be found near the outer attached edges of the laminae as well. No secretion has been found in the cavity of the organ. The sum and substance of these facts probably amounts to this, that the secretory function of the epithelium of the laminae is exercised periodically only, and that my material was collected during the period of preparation, but before the entire secretory area had assumed its function.

The epithelium of the laminae appears to be ciliated, and this appearance is connected with the presence of a second sort of cells in the epithelium. I have stained a number of preparations with borax carmine, and then with Lyons blue. Such preparations show a second line of nuclei at the level of the middle of the epithelium of the laminae. These nuclei are exceedingly slender, being 6μ to 8μ in length by 1μ to $1\frac{1}{2}\mu$ in width. They belong to and are situated near the center of long thread-like sensory cells, which stand thickly around the secretory cells. (Fig. 73.) The ends of the former project beyond the latter, forming sensory spikes, which are so numerous that they give the appearance of a thick coating of strong cilia belonging to the secretory cells. The cell bodies of the sensory cells are so slender and absolutely thread-like that they are not clearly visible without special stains, and then only in places where the other epithelial cells have been accidentally separated. Fig. 73 is an accurate drawing of such a place under a magnification of nearly 500 diameters, but taken from the glandular portion of the organ and not from the laminae. The sensory cells, however, are alike in both regions. Favorable cross sections of the epithelia show the nuclei of the sensory cells thickly clustered around and between the secretory cells. The bases of the sensory cells pass into the subepithelial tissue as fine fibres, and are there lost; but it seems only reasonable to suppose that they are directly continuous with nerves, and that the cells are true sensory elements. We have now a better ground than before for supposing this organ to have a sensory function, which may very possibly be olfactory.

The epithelium of the surface of the anterior parts of the organ and of the skin forming the walls of the atrium is of the same form as that of the laminae, though apparently not at all glandular.

The glandular portion of the organ is composed almost entirely of long branched glandular tubules with narrow lumens. (Figs. 66, 67, and 68.) The tubules are parallel to each other, while the submucous tissue separating them is so slight in amount as to form little more than a separating lamella. (Fig. 68.) The tubules are lined by a single-layered epithelium, composed, like that of the laminae, of secretory and sensory cells.

The secretory cells are of a very different character from those of the laminae and probably produce a different secretion. The regular arrangement of their brilliantly staining nuclei in the bases of the cells causes stained sections to appear almost diagrammatic. I do not think that the histological condition of my material is good enough to warrant my making a detailed comparison between these cells and the secretory cells of the laminae. The regular arrangement of the tubules make the glandular region a striking feature of sections. The clearness of its secreting cells compared with those of the laminae, their slightly greater width, and the larger intensely staining nuclei are features which quite clearly distinguish the secreting cells of the glands from those of the laminae.

The gland cells average 90μ in length and are from 7μ to 10μ in width. The secretion collects in the shape of numerous droplets or granules in the portion of the cell above the nucleus. No secretion was found in the lumens of the glands.

Around and between the secretory cells are sensory cells exactly similar to those described in the epithelium of the laminae (Fig. 73). The slender nuclei of the sensory cells form a quite distinct row at the middle of the epithelium. The sensory cells are not so numerous in the glands as upon the laminae, but still their number is surprising. Fig. 73 is drawn from a section in which the secretory cells had separated from the submucosa and each other, leaving the sensory cells revealed. The section was cut somewhat obliquely, and so does not show the free ends of the cells. The sensory cells are perhaps a little more numerous here than in most portions of

the glands, although the portion to be drawn was chosen at random. In a few places in my sections of the glandular portion of the organ I have seen the ends of the sensory cells projecting beyond the surface of the epithelium as sensory spikes, but in most places the projecting parts were not present. Whether this is the normal condition or is due to poor preservation of the material I can not say.

The nerves (Fig. 8, N) which enter each side of VAN DER HOEVEN'S organ end in ganglia at the sides and near the posterior ends of the laminae (Fig. 41, 35; Fig. 66, Gn). From the ganglia a small nerve extends into each lamina (Fig. 66, N), and two or three nerves on each side pass into the posterior glandular region. Each nerve to the laminae is accompanied by a small artery. The laminar nerves possess an outer layer of ganglion cells as well as ganglion cells scattered throughout them. Each of the small lobular divisions of the anterior part of the organ receives a single nerve as well as the thin laminae.

The facts described seem to me to constitute good and sufficient evidence for considering the inferior labial lobe of the female and VAN DER HOEVEN'S organ to be homologous. The position in the body is the same; the principal muscles are very nearly alike; the innervation is the same; the course of their blood vessels is the same.

It also seems probable that each lamina corresponds to one of the cirri or lamellae borne upon the inferior labial lobe of the female. The main evidence for this rests upon the innervation of the laminae, which is exactly similar to that of the cirri and lamellae of the inferior labial lobe. The structure of the nerves themselves is also the same in the two organs. The presence of a small blood vessel running close to each laminar nerve also constitutes a bit of evidence in favor of this view. The number of laminae in VAN DER HOEVEN'S organ is the same as the number of cirri and lamellae combined of the inferior labial lobe, and the reasons for considering the cirri and lamellae of the latter to be homologous have already been brought forward.

Finally the sensory cells add support to the view. It will be remembered that between the lamellae of the inferior labial lobe are pits lined by a peculiar epithelium. The cells of this epithelium appear to be exactly similar to the sensory cells scattered over the surfaces of VAN DER HOEVEN'S organ, and I think it not improbable, taking into consideration the other evidence for the homology of these organs, that during the course of the metamorphosis of the inferior labial lobe of the male, the sensory cells, which in the female are confined to limited areas occupied by them alone, have become distributed over the entire surface of the organ.

The glandular part of VAN DER HOEVEN'S organ, which forms so large a proportion of the whole, does not seem to correspond to any portion of the inferior labial lobe of the female. The gland is probably a new formation developed in accordance with the changed and special functions of the lobe.

The inferior labial lobe of the female is evidently in much more nearly the primitive condition, its parts being but little modified from the type of structure of the many simple tentacles around it.

Here, too, the question constantly arises. What are the functions of this organ?

When any organ differs so much in the two sexes it seems only reasonable to consider that it is a sexual organ of some sort. We have, then, at least reasonable grounds for saying that VAN DER HOEVEN'S organ, and possibly the inferior labial lobe, is an accessory sexual organ; but we know nothing whatever of its chief functions. Apparently its secretory functions are only periodically and not constantly active. To what use the secretion is put is impossible to guess, even if guesses happened to be desirable. The organ may be a sensory organ all the time and a secretory organ only part of the time, or both functions may be active only periodically. In the latter case, again, the sensory function may be active only when the organ is not secreting, or this may be the time when the sensory function is most active, or the only time when it is active. It seems probable that the sensory function is either that of tasting or smelling. Possibly the activity of the secretory cells, or at least the flow of secretion, depends upon the perception of certain substances in the water by the sensory cells, or the sensory function may have a much closer relation to the everyday life of the animal.

OCULAR TENTACLES.

There are four of these tentacles, two springing from near the base of the stalk of each eye. The eyes, it will be remembered, are attached to the sides of the head in the angle formed by the posterior edge of the lateral portion of the cephalic sheath and the projecting auricles of the hood. The ocular tentacles arise above the level of attachment of the eyes, one in front of, and the other behind, each eye (Fig. 1, *O'* and *O''*; Fig. 2, *O'*; Fig. 3, *O''*). Accordingly, they are distinguished as the preocular and the postocular tentacles.

The preocular is situated upon the base of the cephalic sheath, immediately back of the posterior corner of the sheath of the second digital tentacle, and in the angle formed by the projecting sides of the hood and the lateral walls of the head. Its sheath forms a portion of the posterior part of the cephalic sheath, only a few millimeters of its tip being free.

The postocular arises above the posterior edge of the eye in the angle made by the hood and the sides of the head. It stands straight out from the sides of the head, having a free sheath 6 to 10 millimeters long. The preocular is directed outward and forward, the postocular outward and slightly backward. Both tentacles are well protected by the projecting sides of the hood.

The cirri of the ocular tentacles are in their general features like those of the digital tentacles, but under the general similarity are most important differences of structure as well as of function. They are oval, lacking the angles of the digitals (Fig. 65). The annular grooves are very deep upon the anterior sides, and this is especially noticeable near the tips of the cirri (Figs. 64 and 63). OWEN (1832, p. 14) well describes these cirri as "in reality composed of a number of flattened circular disks appended to a lateral stem." The closely pressed ridges project from the base to the tip of the cirrus like the lateral plates of a cephalopod gill.

Observations made by WILLEY and published in the fortieth volume of the Quarterly Journal of Microscopical Science are well worth quoting in this connection:

"The occurrence of a special tentacle in front of the eye and another behind the eye in *Nautilus* is well known. These tentacles resemble the large number of remaining tentacular appendages in being ringed and also in being retractile within sheaths, but differ from them in almost every other respect. In the first place, most of the tentacular appendages of *Nautilus* have essentially an adhesive function, to which is related a prehensile function. They are employed for seizing hold of food and for attachment to surfaces. . . .

"It will not be surprising to learn that the adhesive tentacles are not ciliated; but it is necessary to mention this negative fact, because the preocular and postocular tentacles are ciliated. On the side corresponding to the suctorial ridges of the adhesive tentacles the annulations of the preocular and postocular tentacles form deep grooves, between which the ridges project as prominent lamellæ. The upper and lower surfaces of the lamellæ and the bases of the grooves are covered with vibratile cilia. There can be but little doubt that the preocular and postocular tentacles of *Nautilus* represent tentacular processes, homologous with the adhesive tentacles, which have been modified to serve an accessory olfactory function. We will therefore speak of them as the olfactory tentacles, in contrast to the adhesive tentacles. . . .

"The olfactory tentacles . . . when extended stand out from the body nearly at a right angle, the preocular tentacle being directed slightly forward and the postocular tentacle usually tending backward. The ciliated olfactory lamellæ are directed strictly forward.

"In the living *Nautilus* the olfactory tentacles otherwise offer a strong contrast to the adhesive tentacles by their almost uniform white color. When examined under the microscope there is found to be a little brown pigment in the annulations and at the edges of the lamellæ, but when viewed in toto under water the general color effect is white.

"Moreover, the adhesive tentacles can be touched without necessarily being retracted, but at the slightest contact with a foreign body the olfactory tentacles are instantly retracted within their sheaths. The presence of accessory olfactory tentacles in *Nautilus* can, I think, be related to an essential bionomical difference between the existing Tetrabranchiata and the Dibbranchiata.

"*Nautilus* finds its food chiefly by the sense of smell, while it is a matter of more or less

common observation that the Dibranchiata, with their remarkably perfect eyes, pursue their quarry by the sense of sight."

The structure of the preocular and postocular cirri seems to be the same in all respects. The annular grooves, which are so deep upon the anterior side, are frequently no more than grooves in the epithelium upon the opposite side; i. e., the groove is formed by certain of the epithelial cells being shorter than those of the remaining surface of the cirrus, the bases of all being at the same level. In other portions of the cirri the grooves affect the subepithelial tissues of the posterior side as well. The ridges upon the anterior face of the lower part of the cirrus are very thin and flat, are closely pressed together, and lie in a plane perpendicular to the axis of the cirrus. The ridges of the tip of the cirrus are not flat, nor of even thickness, are more separated from each other, and turn upward around the cirrus like portions of the rim of a saucer. They form little cups, open toward the tip of the cirrus.

The epithelial cells of the cirri are all slender columnar cells. The cells of the bottoms of the grooves are taller than those upon the outer portions of the ridges. The former are about 60μ in height and 4μ in width. They are ciliated, the fine cilia being about 14μ in length. The latter cells are only 44μ in height. All possess oval nuclei irregularly located in the basal halves of the cells. Occasionally a goblet mucus cell is found among the ciliated cells. Goblet cells are frequent upon the posterior surfaces of the cirri and upon the unciliated portions of the ridges. The basement membrane upon which the epithelium rests is remarkable for its sharp outline and irregular surface. One can scarcely imagine a surface more wrinkled and pitted in a minute way. The outer surface of the epithelium, however, does not repeat this irregularity.

The subepithelial tissue of the ridges is very scant, what little there is consisting of fibrous and elastic connective tissues, and containing few muscle fibres.

From the structure of the cirrus, the side bearing the high ridges evidently corresponds to the inner side of the cirri of the other groups, although it is turned forward. As a matter of fact, if the ocular cirri were pulled forward until they were parallel to the digital cirri, the now anterior sides would then be inner. For the sake of convenience in description and the comparison thus introduced, I shall speak of the anatomically anterior side, when needful, as the inner side.

The arrangement of musculature is practically that which has been described as typical of the digital tentacles, except that it is even more regular in the ocular tentacles. As portions of the ridges are not constructed for adhesion there is no interruption of the arrangement of the muscles upon the inner side of the cirrus. Radially arranged longitudinal muscles surround the nerve, although this is, as in the former case, nearer the inner side of the cirrus than the outer. The two layers of circular muscle fibres and the outer longitudinal muscles pass uninterruptedly around the cirrus.

The ocular cirri are especially well supplied with rather large blood vessels. It would be interesting to know if the arteries described by WILLEY as going to the eye do not also give off branches to the ocular tentacles, or if the latter are supplied from the tentacular artery. Upon the inner side of the nerve is an artery which corresponds in position to the artery of a digital cirrus. Several other arteries, perhaps branches of this, lie near the nerve. A large vein lies between the artery and the inner side of the cirrus.

The structure of the nerves of the ocular tentacles is notable. (Fig. 64 and 65, N.) The nerves of the preocular and postocular tentacles arise as branches of a nerve which springs from the side of the pedal ganglion, the remainder of it being distributed to several of the digital tentacles. (Fig. 41, 11.) A cross section of the ocular tentacles shows that their nerves are of unusual size. Near the tip of the cirrus the nerve has the same character as the nerves of the cirri already described. It has an outer layer of ganglion cells, thickened in each segment into ganglia. Shortly, farther from the tip of the cirrus, numerous bundles of nerve fibres join themselves to the inner side of the nerve trunk. As these pass toward the base of the tentacle they seem to gradually enter the nerve trunk, their places being taken by other nerve bundles from the outer parts of the cirrus. Thus a kind of accessory nerve is formed which extends from near the tip of the cirrus to its base along the inner side of the primary nerve trunk. (Fig. 65, N'.) These

nerve bundles are not surrounded by ganglion cells like the nerve trunk, so it is easy to distinguish the boundaries of the latter in both longitudinal and cross sections. Nevertheless, they contain numerous nerve cells lying singly or in groups, some of the groups forming what one might call strands of nerve cells, parallel to the nerve bundles. At the base of the cirrus all the lateral bundles have entered the nerve trunk, which is here of the ordinary size. The nerve, as a whole, is enlarged in each segment of the cirrus by aggregations of nerve cells, the primary nerve trunk being the part most affected. From each ganglion twelve to sixteen nerves pass radially to different parts of the segment, especially to the lamella-like ridge of the inner side. These nerves are very large and distinct. The nerves passing to the ridges can be traced to directly beneath the basement membrane of the epithelium. I could not determine any direct connection of the nerves with cells of the epithelium, although, in view of the peculiar character of the tentacles and the epithelium of the grooves, and the very liberal and conspicuous innervation of these regions, it seems probable that future research will reveal special nervous elements in the epithelium.

The most curious feature of the ocular tentacles is yet to be described. The tips of the cirri, consisting of several segments, or of a single terminal segment, break very readily. The ease with which the segments break off is explained by the presence in the cirrus of breaking planes, as I have called them. In longitudinal sections lines are seen stretching across the cirrus from groove to groove, along which the connective tissues are weak or discontinuous. (Fig. 64, X.) The planes correspond to the grooves between each two segments. The longitudinal muscles and the nerve cord are not broken, but the muscles at least break very easily along the planes. Occasionally connective tissue nuclei are gathered along the breaking planes, though this may be a coincidence rather than a structural character.

At all events, there seems to be here a provision for the amputation of segments of the preocular and postocular cirri with considerable ease. It would seem as if the retraction of the cirri within their sheaths at the slightest touch, as already quoted from WILLEY'S published observations, would protect them from injury. And especially so, as they are situated in a nook under the auricle of the hood, back of the cephalic sheath, and above the eye, so that it seems as if they need be only partly retracted within their sheaths to be completely sheltered. I feel quite sure, from the constancy of these structures between all the segments of my sections, that they are not artifacts, although I do not by any means deny such a possibility. If they are natural structures they appear to be a mechanism providing for the common and easy loss of (but not self-amputation, necessarily) terminal segments of the ocular tentacles, and they also point to the possibility of rapid regeneration of the lost portion, as is the case in other animals in which provision is made for the easy loss of certain parts of their bodies. But it is also very strange that *Nautilus* should possess such a mechanism in the ocular tentacles when it also has the ability to retract them quickly upon a slight stimulus.

The innervation of the ocular tentacles, as well as their position and structure, leaves no doubt but that they are members of the digital series which have become modified for sensory functions.

To summarize:

The *digital tentacles* of both sexes are exactly alike in number, distribution, and structure. Their fused sheaths form the cephalic sheath, a fleshy wall surrounding the anterior portion of the head. Upon the inner side of the cephalic sheath of the female, above the funnel, is a lamellated region for receiving the spermatophore.

The *superior labial tentacles* are alike in position and structure in both sexes, but are less in number in the male than in the female.

The *inferior labial lobes* and tentacles are present in both sexes, but are quite different in each. In the female the lobe is large and muscular. Upon its anterior edge are numerous tentacles, some of which develop cirri, while others form lamellae, at the bases of which are certain sensory pits. In the male the lobe and its tentacles are represented by VAN DER HOEVEN'S organ. The laminae of this correspond to the cirri plus the lamellae of the inferior labial lobe of the female, while the gland is not represented in the latter organ.

The *spadix* and *antispadix* do not correspond to any group of tentacles in the female, as far as our present knowledge goes. It has been suggested that they have been formed by the separation of the four ventral tentacles of the superior labial group. It is true that the number of tentacles comprised by the *spadix* or the *antispadix* added to that of the superior labial group equals the number of tentacles in a superior labial group of the female, and that in young animals they are like these in size and structure. The innervation of the *spadix* and *antispadix* also seems to be like that of the superior labial tentacles. Yet the two organs are so completely separated from the labial tentacles, even standing entirely outside the labial ridge, that we must consider it still an open question if they are represented in the female until embryological evidence can be obtained.

The *ocular tentacles* are members of the digital series which have become modified for sensory functions.

This seems the best place to consider another secondary sexual character, which after all is closely connected with the tentacles. Both VAYSSIERE and WILLEY point out that a difference exists in the shape of the opening of the male and female shells. In general the shell of the male is larger than that of the female, and the breadth of the opening of the shell is greater in proportion to its height in the male than in the female shell. But these characters are so variable that in examining a large number of empty shells I was unable to determine which had belonged to males and which to females. WILLEY himself emphasizes the variability of this character. The hood of the male exceeds that of the female in size in the same manner as has just been mentioned for the opening of the shell.

The generally larger hood and shell opening of the male seems to be largely the result of the growth of the *spadix*.

PALLIAL COMPLEX.

MANTLE.

The mantle cavity of *Nautilus* extends completely around the body; it is shallow dorsally, but ventrally a deep, capacious cavity, which contains the various organs spoken of as the pallial complex.

The mantle itself is a thin and only slightly muscular fold, which fits closely against the walls of the inhabited chamber of the shell. I wish to make a sharp distinction between the mantle and the body wall, especially between it and the thin, membranous portion of the body wall covering the visceral hump and so frequently spoken of as the mantle. I shall limit the term "mantle" in this description to the projecting fold around the middle of the body, extending forward from its junction with the body wall and elsewhere free from the body, surrounding it like a cape. The name can not properly be applied to any other portion of the body wall.

The ventral and lateral edges of the mantle follow the edge of the shell and are attached to it (Fig. 1, V M). From umbilicus to umbilicus, dorsally, the mantle forms a free fold, which lies against the involution of the shell (Figs. 1, 2, and 5, D M). The most shallow parts of the mantle cavity are just beneath the umbilici of the shell, dorsal to each shell muscle. The edge of the mantle following the edge of the shell slopes rapidly upward and backward to the umbilici. The posterior limit of the mantle cavity also slopes upward and somewhat forward to the same point. Thus the depth of the mantle cavity or the width of the mantle, 10 centimeters in the mid-ventral line, is reduced to 1 centimeter over the shell muscles. The dorsal portion of the mantle is produced upward and forward and is closely pressed against the lower portion of the involution of the shell. In the mid-dorsal line, therefore, the mantle has a width, or the mantle cavity a depth, of about 4 centimeters. The dorsal part of the mantle cavity contains no organs, and is nearly closed off from the ventral part by the narrowness of the lateral portions, which are still more nearly closed by the upper ends of the crura of the funnel. The dorsal part of the mantle cavity must be nearly minimal in volume, since the hood and body wall forming its floor fit closely around the involution of the shell. The dorsal portion of the mantle is probably strongly contracted in alcoholic specimens, since it does not extend nearly as high up on the

involutions of the shell as the posterior face of the hood. It has been suggested that the black layer seen upon the lower portion of the involution of the shell is deposited by the dorsal portion of the mantle. The epithelium of the posterior surface of the hood is pigmented and glandular, and probably plays the principal part in the deposition of the black material.

The mantle is for the most part a very thin, almost membranous, fold and is only slightly muscular. The contrast between it and the mantle of most of the Dibranchiata is very striking in this respect. The anterior border of the part of the mantle which is attached to the edge of the shell is slightly thickened and is comparatively quite muscular, forming a band along the edge of the mantle 1 centimeter to 1.5 centimeters in breadth. The median ventral portion of the mantle is also frequently especially muscular, and forms a strip which joins the muscular border like the stem of a T. The edge of the mantle is marked by two parallel grooves separated by a sharp ridge. The mantle seems to be attached to the edge of the shell, not only by its own edge, but also along a narrow band extending back from the edge on the outer side, along which the epithelium is peculiarly modified. Probably this attachment is not very strong.

The dorsal portion of the mantle is of uniform thickness, and, while very thin, is still much more muscular than the ventral portion.

The ventral portion of the mantle frequently presents a peculiar appearance. The tissues on either side of the middle line seem to have become chitinized; the mantle in these spots appears thin, transparent, and structureless, and has the appearance of a thin sheet of chitin. Sometimes the chitinized areas (if we may so call them) are small, like oval windows set in the sides of the mantle; sometimes they extend over the greater part of the ventral portion of the mantle, and sometimes even across the mid-ventral line. In any case the thickened border of the mantle is not affected. This change in the tissues of the mantle appears to begin on each side of the middle line ventrally and then to spread in all directions from the two starting points until nearly the whole of the ventral part of the mantle is affected. The question, Is this an accompaniment of senility? can not help but be suggested.

Speaking more exactly, the preceding description applies to the greater part of the ventral portion of the mantle, but not to all of it. There is a narrow posterior region which is thickened and which has hitherto been described as being part of the body wall. I wish to call especial attention to the fact that the posterior portion of the mantle of *Nautilus* is a true outfolding of the body wall, and that the renal sacs and the rectum are situated within this portion of the mantle and not inside the general body, as in the Dibranchiata. The pallial complex of *Nautilus* is entirely different from that of the Dibranchiata, not alone in its parts, but also in the relation of these parts to the body and to each other. This will be brought out as we proceed with the description of the separate parts of the complex.

As the renal sacs lie in the posterior part of the mantle, this is consequently thickened and entirely different in its appearance from the anterior part. The renal sacs occupy only the central or most ventral region of the posterior portion of the mantle. They lie entirely between the posterior pair of gills. When the mantle is turned back and the animal turned ventral side up, as is usually done in examining these parts (Figs. 3 and 4), the renal organs sink more or less into the body, and the inner side of the mantle above them sinks down until flush with the surface of the body, so that the real relation of the parts is obscured. I presume that it is owing to this fact that the true position of the renal organs has been overlooked for so long by most observers. I can not understand from his words whether WILLEY (1895) recognizes the same relations between the parts of the pallial complex as I do or not. However, if one cuts the mantle of a well-preserved specimen in the mid-ventral line while the animal is held in its natural position, there is no doubt whatever about the extent of the mantle nor of the positions of the renal sacs, rectum, anus, and gills, as well. The inner and outer walls of the posterior portion of the mantle fold are very thin and soft. KEFERSTEIN described the thickened portion of the mantle as a projecting part of the body wall forming a posterior wall to the mantle cavity, upon which were located the anus, gills, and nephridial and pericardial pores. OWEN describes the gills as situated upon the mantle. JOURNIN, however, certainly recognizes the real extent of the mantle and the position of the various parts of the pallial complex.

The discovery of the pallial arterial system is due to WILLEY, who by means of injections was enabled to describe this peculiar system. The lesser aorta divides into two branches almost immediately after leaving the heart. One branch, the septal, goes backward and supplies blood to the siphuncle and the septal region of the body wall. The other branch, the pallial artery, bends downward to the middle line of the body wall and then runs straight forward below the skin on the surface of the renal sacs, and then in the median line of the ventral portion of the mantle nearly to its anterior edge. From its posterior part the pallial artery gives off branches to the intestine and the rectum. In front of the anus, at the posterior limit of the thin portion of the mantle, it gives off a large branch upon each side, the branchio-osphradial arteries. These supply the posterior portion of the mantle and "send up branches to the tips of the branchiæ, supplying the integument of the latter, and also a small branch into each of the osphradia. . . . In the female they also supply the nidamental gland." As the pallial artery passes forward it gives off several small branches to the lateral portions of the mantle. Arriving near the edge of the mantle it divides into two branches, which turn to either side and follow the posterior edge of the muscular margin of the mantle, the marginal pallial arteries. Very numerous and regularly arranged short branches, the radial pallial arteries, spring from the anterior side of the marginal pallial arteries, while longer and more irregular branches pass from the marginal pallial arteries backward into the middle parts of the mantle.

The marginal pallial arteries do not finally end in capillaries or blood sinuses, but unite with the pallio-nuchal branches of the dorsal aorta, thus forming a complete arterial circle, discovered by WILLEY, which he has named the *circulus pallialis*. The union takes place at the dorsal sides of the shell muscles.

In addition to forming a union with the marginal pallial arteries, the pallio-nuchal arteries give off branches to the dorsal portion of the mantle, and to the dorsal nuchal region of the body wall (the region which is hollowed out to receive the involution of the shell), and to the crura of the funnel.

In regard to the pallial veins WILLEY says the following:

"When a *Nautilus* becomes moribund it usually rises to the surface, owing to an abundant production of gas in the interior of the body. If it is allowed to die and is then removed from the shell the veins are found to be injected with gas of some sort, and the finest ramifications of the veins, in the mantle at least, are displayed with a clearness which could hardly be attained by artificial injection.

"The mantle is simply riddled by these veins in a manner which defies one's powers of draftmanship. The veins are collected into two main trunks, which lie on either side of the anterior pallial artery, and proceed backward to open into the afferent branchial vessels. At the sides of the mantle there are also a number of lateral pallial veins, which open into a large sinus situated over the shell muscles."

The mantle of the specimen OWEN described possessed a peculiar abnormality. Its opposite sides had grown together above the funnel so that OWEN describes and figures it as "perforated by a large aperture through which the funnel passes."

BODY WALL.

The inner side of the mantle cavity is formed by the body wall, to which I wish to devote a few words so as to lay a foundation for a point to be brought forward later.

Laterally—i. e., at the sides of the body—the inner wall of the mantle cavity is formed by the sides of the great shell muscles alone (Figs. 3 and 4). These muscles pass from the cephalic cartilage outward and backward, forming the sides and part of the floor of the middle region of the body wall, to be attached one to each side of the shell just anterior to the edge of the last septum. Perhaps we might say that they end immediately back of the lateral portions of the mantle cavity, for these parts of the mantle cavity are limited posteriorly by the outer ends of the shell muscles. The muscles are only about 5 centimeters in length, but 2.5 centimeters in breadth by 1.75 centimeters in thickness. These dimensions convey an idea of what the power

of these muscles must be. The outer sides of the muscles are convex, the inner sides concave. The shape of the muscles in cross section is about the same as the shape of the area of attachment of the muscles to the shell.

The muscles meet anteriorly, but as they pass outward and backward a considerable triangular space is left between their ventral edges. This portion of the body wall is composed of quite a strong layer of transverse muscle fibres, which are continued, in part at least, outward over the shell muscles. The actual thickness of this region of the body wall is very little, but it is considerable when compared with that of the body wall covering the visceral region. The vena cava lies in the middle of the triangular space between the shell muscles.

Between the dorsal edges of the shell muscles is another thin portion of the body wall, which forms the floor of the dorsal portion of the mantle cavity. This is also supplied with a quite strong musculature. This dorsal region of the body wall is concave, like a mold of the involution of the shell. It passes into the hood anteriorly and laterally, becoming gradually thicker and firmer.

The shell muscles have a very copious supply of blood received through a number of arteries.

The posterior columellar arteries are the largest and most important of those supplying the muscles. The left posterior columellar artery arises with the hepatic artery from a short common branch of the dorsal aorta—the hepatico-columellar artery. (Text-fig. 10, p. 182.) The columellar artery takes a diagonal course upward, outward, and forward to the upper edge of the left shell muscle, immediately anterior to its attachment to the shell. Then, bending downward and backward upon the inner surface of the muscle, it gives off numerous branches which penetrate the muscle. The right posterior columellar muscle arises from the right side of the dorsal aorta about 7 millimeters anterior to the origin of the hepatico-columellar muscle. As the posterior portion of the dorsal aorta lies upon the left side of the body, the right posterior columellar artery has a longer course to run to reach the right shell muscle than the left posterior columellar artery has to reach the left shell muscle. Otherwise the course of the two arteries is the same upon their respective sides.

From the point where each posterior columellar artery bends downward a branch is given off to the region of the mantle in front of the shell muscles and to the portion of the body wall dorsal to it.

The anterior portions of the shell muscles are supplied with blood by a branch of each innominate artery. These (the anterior columellar arteries) pass backward, downward, and outward to the muscles. (Text-fig. 10, p. 182.)

In addition to these special arteries to the shell muscles, the nuchal arteries, or their branches pass along the inner dorsal edges of the muscles and appear to send small branches into them.

The shell muscles are innervated from the visceral ganglia. Exceedingly numerous flattened band-like nerves pass from the posterior side of each ganglion into the muscles. (Figs. 11, 14.)

GILLS.

The two pairs of gills are situated upon the mantle at the sides of the ventral mantle chamber. (Figs. 3 and 4). They are arranged as an anterior and a posterior pair, one gill of each pair lying upon each side of the mantle, close to each other. The gills of *Nautilus* differ from those of the *Dibranchiata*, not only in number, but also in that they are situated upon the mantle instead of upon the body wall, and in that they are attached by their bases only, otherwise lying freely in the mantle chamber. They have much the same shape and structure as the gills of the *Dibranchiata*. The gills are situated upon the thin and muscular part of the mantle just below the convex anterior angle of the outer end of the shell muscle, the base of the anterior gill lying about 8 millimeters in front of the base of the posterior gill. The bases of the gills are sometimes placed so closely to each other that they seem, as OWEN said, "each pair arising by a common peduncle from the inner surface of the mantle," though I have never found this to be literally true. Examination always has shown that the bases of the gills were separate from each other.

Though there is rarely any considerable difference in the size of the gills, it will usually be found that the gills of the anterior pair are thicker than those of the posterior pair, while the latter may be a trifle the longest. Average measurements for the anterior gills are 18 millimeters in width and 11 millimeters in thickness. The posterior gills are 15 millimeters in width and 9 millimeters in thickness. Both pairs of gills are about 5 centimeters in length. Each gill is composed of two rows of flat, crescentic leaflets attached alternately to the sides of an oval stem. Although the posterior gills possess somewhat the smallest bulks, they bear more leaflets than the anterior gills, having about sixty-five pairs, while the latter have only about fifty-five. Owing to the arrangement and shape of the leaflets the gills are flattened dorso-ventrally. The number of leaflets varies considerably in different specimens, being as low as thirty in some. The leaflets are attached upon the stem obliquely to the base of the gill. The leaflets of the tip of the gill are rudimentary; they become more complex toward the base of the gill, being completely formed at about the tenth from the tip.

It will be noticed that in this description I have apparently reversed the position of the gills as given by previous observers. This is explained by the fact that others have described the gills in the position they occupy after the mantle has been reverted, and as though they were attached to the body wall. OWEN recognized the pallial position of the gills, but later observers, with the exception of JOUBIN, seem to have assumed that the gills are upon the body wall, and this makes the posterior and anterior gills of their descriptions correspond to the anterior and posterior gills of my description.

The stems of the gills are flattened at their bases in the plane of the greatest width of the gills to form thin plates. (Fig. 4, at the end of the index line B V.) The lines of attachment of the stems of the gills to the inner side of the mantle are directed upward, forward, and slightly outward. The anterior gills lie a little to the outside of the posterior gills. The branchial vein runs along the ventral side of each gill as a projecting ridge. The branchial veins of the anterior gills run inward from the bases of the gills toward the median line, suspended by a thin ligamentous band, which may be considered as an inward extension of the base of the stem of the gills. (Fig. 4, B V.) At the outer borders of the inner renal sacs the veins pass inward through the mantle toward the heart. The lower leaflets of the anterior gills extend inward for some distance upon the ligamentous support of the branchial veins.

Each leaflet is composed of two parts, a central or basal supporting portion of the same tissues as the stem of the gill and an outer folded respiratory portion. (Fig. 23.) A branch of the branchial vein passes along the outer edge of each leaflet. Between the smooth basal part of the leaflet and the collecting vein the leaflet appears to be ridged. In reality it is not ridged, but folded or tucked, and the folds of the tucks alternating upon one side with those of the other side form the apparent ridges. The sides of the folds, however, have fine folds nearly at right angles to the edges of the primary folds. Along both edges of the folds are small blood vessels running at right angles to the marginal vessels of the leaflet.

The branchial vein lies upon the surface of the gill, forming a projecting ridge. Above the branchial vein the leaflets of the opposite sides of the gill are united to each other in such a way as to form a longitudinal septum extending between the vein and the stem of the gill. There is no branchial canal in the gill of *Nautilus*. Upon the dorsal side the leaflets project considerably beyond the stem of the gill, which is thus hidden in a groove between them. The stem is considerably wider upon its dorsal than upon its ventral edge, and thus the leaflets come to be quite widely separated dorsally. As the tip of the gill is approached the stem narrows. Toward the base of the gill the dorsal side of the stem is produced into a sharp ridge. From the distal end of the ridge to the tip of the gill the stem is marked by transverse grooves, extending from side to side between successive pairs of leaflets.

The branchial arteries pass outward from the vena cava through the posterior walls of the nephridial chambers. Here they form outpocketings into the glandular appendages upon both sides of the walls. From here the arteries pass into the mantle and run in it along the bases of the gills until they reach the middle of the attachment of the gills to the body. At this point they turn and run along the ventral side of the stem of the gill to its tip. I have never been

able to find the valves mentioned by OWEN as existing in the branchial arteries at the bases of the gills. The minute structure of the gills of *Nautilus pompilius* and *macromphalus* has been studied by JOUBIN. He considers that the thickened stem of the gill of *Nautilus* forms a structure which is comparable with the glands he has described in the gills of other Cephalopods, which are organs in which the blood corpuscles are formed.

The stem is covered externally by a layer of muscle fibres which also pass outward along the concave edge of each leaflet. The stem is composed almost entirely of connective tissue, in which the glandular elements are disposed at several points.

Near the outer surface of the stem is a layer of quite large vascular lacunæ, incompletely lined with flattened endothelial cells. The lacunæ are separated only by thin lamellæ of connective tissue. The lacunæ also extend outward into the supporting portion of each leaflet. Only very small lacunæ are found in the center of the stem. In the middle of the outer side of the stem a large vein is constantly present, extending from the tip of the stem to near its base, where it opens into the branchial artery.

In the central portion of the stem, but still near the median vein, are a number of lacunæ which, instead of being empty, like those at the surface of the stem, are filled with large granular cells, each possessing a large nucleus. These may be found throughout the remainder of the gland (or stem), scattered here and there in the connective tissue. JOUBIN considers that the central region is the only portion presenting an aspect comparable to that observed throughout the whole of the glands of other Cephalopods.

The remainder of the stem (gland, JOUBIN terms it) is formed of connective tissue, in which large numbers of muscle fibres are scattered.

The concave border of each leaflet is thickened, the thickening being due to a lateral extension of the tissues of the stem of the gill into each leaflet. (Fig. 23.) It forms the supporting part of the leaflet, as well as containing portions of the branchial gland. It contains very numerous vascular lacunæ, which differ in their arrangement from those of the stem in that the larger lacunæ are in the central portion, while the smaller lacunæ are external. The lacunæ receive blood from the afferent vessel of the leaflet. Here and there are free cells in the lacunæ similar to those observed in the principal part of the gland. All this region of the leaflet is covered with tall, columnar, epithelial cells. The outer ends of the cells bear a distinct border.

The thin respiratory membrane is covered with large, flattened, epithelial cells. A great number of lacunæ penetrate the inner part of the membrane, scarcely separated by a network of connective tissue cells.

A band of muscle continued from the surface of the stem passes outward along the side of the afferent vessel turned toward the respiratory membrane. In places the muscle projects into the afferent vessel and is bathed by the blood flowing in it.

The blood reaches the gill through the branchial artery which runs along the inner side of the stem from the base to the tip of the gill. (Fig. 23. 2.) Two sets of vessels are given off from the branchial artery. Upon opening the artery two rows of large alternating openings are seen in the wall turned toward the leaflets. These lead into the afferent vessels of the leaflets, which run along the concave side of each, close to the edge of the respiratory membrane. Two other rows of alternating openings, smaller than and median to the first, lead into vessels which pass into the stem of the gill.

From the afferent vessels of the leaflets smaller vessels arise which pass at right angles to the first along the entire length of the upper edges of the primary folds of the respiratory membrane. Opposite each secondary fold is an opening in the wall of the vessel of the primary fold through which the venous blood passes into the lacunæ of the secondary fold, where the interchange of gases between the blood and the water takes place.

In a similar but inverse manner the arterial blood is collected from the secondary folds into efferent vessels lying along the lower edge of each primary fold. These unite in a vein following the outer or convex border of each leaflet, which vessels themselves unite with the branchial vein.

From the afferent vessels of each leaflet the blood escapes through several openings into the

lacunæ of the supporting portion of the leaflet. These are in communication with the lacunæ of the stem of the gill, and so the blood passes from the leaflets into the stem. From the lacunæ of the stem it is gathered into the median longitudinal vessel lying near the surface of the stem. During its passage through the stem and its lateral extensions the blood has caught up many of the free cells of the branchial glands, which now form new blood corpuscles. They are carried by the longitudinal vessel into the branchial artery at the base of the gill, and thus into the circulation. It will be noticed that all the blood passing through the stem of the gill is venous, and that, having made this short circuit, it passes again into the branchial vein, the greater part then passing through the branchial leaflets into the systemic circulation.

An observation made by WILLEY on a young *Nautilus* is significant. Describing it, WILLEY says:

"The youngest individual I have as yet obtained was a male with the following dimensions:

	Millimeters.
Length from root of siphuncle to mid-anterior point of hood (measured along the dorsum).....	25
Length of hood in middle line.....	10.5
Breadth of body across middle of eyes.....	15

"The surface of the hood was perfectly white and unpigmented. The branchiæ of opposite sides were in close apposition in the median line, and, curiously enough, the larger posterior pair extended forward far into the interior of the funnel.

"The shell was perforated at the umbilicus, as it is throughout life in *N. umbilicatus*."

If this specimen was a typical one of the young *Nautilus* it is evident that the gills are moved outward toward the sides of the body as the animal approaches maturity, a fact which possesses still more interest when we remember that the rudiments of the gills of the Dibranchiata arise close to the median line of the body, on either side of the anus, and that they move to the sides of the body late in development only.

The branchial nerves are two large, flattened, band-like nerves, one of which arises from the posterior side and near the inner end of each visceral ganglion. (Fig. 41, 22.) They run directly backward, along the ventral body wall, to the posterior limit of the mantle cavity. Here they turn outward and forward in the inner wall of the mantle fold. After giving off a couple of small branches which apparently supply the walls of the renal sacs, the nerves fork near the bases of the gills, and a branch passes into each gill. (Fig. 41, 19 and 20.)

The later shifting of the gills to the sides of the body may account for the peculiarly exposed course of the branchial veins of the anterior gills. (Fig. 4, BV.)

INTERBRANCHIAL AND PREANAL PAPILLÆ.

Just in front of the base of each posterior gill is a small papilla upon the inner surface of the mantle. (Fig. 3, IP.) The papillæ are about 2 millimeters in height and width. It is to these papillæ, situated between the bases of the anterior and posterior gills, that I apply the name interbranchial papillæ.

In the median line of the ventral part, just in front of the line limiting the thin portion of the mantle, two papillæ project from the inner surface of the mantle. (Figs. 3 and 4, PA.) Each papilla has the shape of a bilobed transverse ridge, and usually the two are fused, forming a distinct ridge across the median line of the mantle. It is only rarely that the papillæ are separate, and even then the separation is so slight as to be scarcely noticeable. WILLEY describes a case in which the interval between the papillæ was 2.5 millimeters. The sometimes total separation and nearly constant partial separation of the two parts of the ridge leads me to describe it as two papillæ fused rather than as a single papilla.

The united papillæ have usually passed, heretofore, by the name of postanal or supra-anal papillæ. As it is readily demonstrated that they are situated upon the inner surface of the mantle and not upon the body wall, they can not be postanal except when the mantle is turned back and the natural position of the parts of the pallial complex is reversed. To avoid this difficulty I suggest that they be called the preanal papillæ.

In 1883 LANKESTER and BOURNE first called particular attention to the interbranchial

papillæ, calling them osphradia, and suggesting that they correspond to the osphradia found so widely distributed among the Mollusca. Their specimens were not sufficiently well preserved to allow an histological examination of the papillæ, so the hypothesis depended entirely upon the evidence of their innervation. LANKESTER and BOURNE describe a small nerve as arising from the nerve to the anterior gill near the fork of the branchial nerve and running into the papilla. This innervation corresponds to the innervation of the osphradia of other Mollusca.

WILLEY (1895) describes a small nerve proceeding to the osphradium of LANKESTER and BOURNE from the point of bifurcation of the branchial nerve. He also suggests that the preanal papillæ represent a pair of osphradia, "corresponding metamERICALLY with the pair described by LANKESTER and BOURNE between the bases of the gill plumes." This suggestion is based upon the form, and variations in form, and upon the innervation of the papillæ. It has already been stated that the halves of the preanal ridge may be entirely separated, and that they are always distinctly marked.

WILLEY finds that a small nerve arises beside (inside of) each visceral nerve and runs backward close to it. Arriving at the point at which the visceral nerves bend outward, the inner nerves continue near the median line, passing into the mantle; they were traced through the nidamental gland of the female. In regard to the relation of this nerve to the preanal papilla WILLEY says: "The inner and smaller visceral nerve passes over the region of the renal sacs on each side to the base of what I may call the posterior osphradia, to which it undoubtedly sends nerve fibres, although I can not say positively that I have definitely traced these."

In another place in the same article he says: "As to the innervation, I will say at once that it is very difficult to see the actual nerves or nerve fibres (because the nerves are often not compact trunks, but broken up into loose strands) which pass into the osphradia; but the anatomical relations of the visceral nerves to the osphradia, which, I think, have never been fully described, are such as to leave no doubt as to the source from which the osphradia derive their innervation."

WILLEY called attention to the fact that these two papillæ have essentially the same topographical relations to the anterior gills which the osphradia of LANKESTER and BOURNE have to the posterior gills. "Their greater proximity to the middle line is shared in common with the posterior (anterior) renal sacs and apertures and even the posterior (anterior) branchial veins, as compared with the corresponding anterior (posterior) structures. That they are bifid, and therefore more highly developed than the anterior (posterior) osphradia, is in keeping with their position in the living Nautilus in the anterior region of the mantle cavity, and also with the fact that the posterior (anterior) branchiæ, with which they would be associated in the metameric system, are considerably larger than the anterior (posterior) branchiæ." The words in parentheses indicate the relative natural position of the organs, WILLEY having described them as they appear after the mantle has been turned back.

WILLEY'S argument for the metameric relation of the anterior gills and the preanal papillæ appears to be strengthened by the fact that in the young specimen already mentioned he found the gills closely approximated in the middle line, and in that case the preanal papillæ could not have been far from the bases of the anterior gills.

In a later article WILLEY gives more interesting facts in regard to the structure of the osphradia. "By means of macroscopic sections of fresh material the presence of vibratile cilia on the sensory epithelium of both the inner and outer osphradia can be demonstrated, and this I regard as the final proof of the osphradial character of the so-called postanal papillæ. The sensory epithelium of both osphradia is distinguished from the surrounding ectoderm both by the presence of the cilia and by the general absence of goblet cells.

"The olfactory lamellæ of the accessory olfactory tentacles (the pre- and post oculars) and the sensory epithelium of the osphradia are the only places where I have observed vibrating cilia in Nautilus hitherto."

A set of serial sections of the preanal papillæ of a male brought to light an interesting structure in this. In the base of each papilla is a gland composed of a number of irregular branching tubules. (Fig. 69, G.) Each opens separately to the exterior through a very minute pore. The

tubules increase in size toward the ultimate branches. They are lined by a single layer of not very tall columnar cells, the nuclei of which stained deeply while the body of the cells remained unstained and clear. That the cells are secretory is proved by the fact that the cavities of the glands were filled by a secretion, the granules of which were so fine that it appeared homogeneous under ordinary high powers.

These glands may be the homologues of the glands Kerr described as being scattered over the area between the preanal papillæ and the nidamental gland in the female. I find the same area continuously glandular and much thickened. (See p. 147.)

The epithelium had been entirely rubbed off from the surface of the interbranchial papillæ and the preanal papillæ, of which I made series of sections. Therefore, I have no personal knowledge of its character. As regards the innervation of the papillæ, serial sections do not reveal any such abundance of nerves as we should expect, were they sensory organs of importance. The edge of the ventral part of the mantle possesses a remarkable number of nerves, many of considerable size. This being the fact, we have a right to expect that the innervation of sense organs of the importance of osphradia will have an at least equally plentiful supply of nerves. Instead of this being the case, serial sections do not show any nerves whatever passing into the interbranchial or preanal papillæ. The large nerve of the posterior gill is seen running by the base of the interbranchial papilla, but neither in dissections nor in serial sections have I seen any nerve pass from this into the papilla.

I do not wish to be understood to deny that the interbranchial and preanal papillæ are osphradia, but I do wish to call attention to the fact that they are not yet proven to be osphradia. WILLEY admits, and calls attention to the fact, that he has not been able to absolutely trace any nerves into these papillæ. He goes very much farther than the known facts warrant when he regards the presence of vibratile cilia "as the final proof of the osphradial character of the postanal papillæ." While it is true that sensory organs are frequently covered by a ciliated epithelium, among the cells of which the special sensory elements are nestled, the fact that certain portions of the body of an animal are ciliated does not in and of itself constitute proof that these portions of the body are sensory organs. The final proof as to whether or not these papillæ of *Nautilus* are osphradia must be, besides the presence of special sensory cells, their innervation; and at present both these points are very much in doubt. The nature of the nerves of *Nautilus*, to which WILLEY has called attention, and the position of these papillæ with respect to the course of the nerves, render an investigation of their innervation quite difficult.

The morphological importance of osphradia is too great to permit of any assumption of their presence in *Nautilus* without complete proof. It is because I do not consider that the osphradial nature of the papillæ under discussion has been proved beyond any doubt that I have used the name "interbranchial papillæ" for the papillæ which have been called the osphradia of *Nautilus* ever since the publication of the paper by LANKESTER and BOURNE. This is suggested as a provisional name until such time as the true nature of these papillæ shall have been proven.

RENAL AND PERICARDIAL PORES.

The renal organs are situated in the posterior portion of the mantle fold, their presence causing the considerable thickness of this portion of the mantle. The glands situated upon the anterior branchial arteries are shoved together in the median line below or anterior to the rectum. The glands situated upon the posterior branchial arteries are just outside and behind those already mentioned. So that we can with justice speak of anterior and posterior renal organs (Fig. 36). The anterior renal sacs lie beside each other on either side of the middle line; the posterior renal sacs are separated by the two anterior renal sacs. Each renal sac communicates with the exterior by a slit-like opening situated upon the inner side of the mantle. The openings of the posterior renal sacs are at the inner ends of the bases of the posterior gills (Fig. 3, R P). The openings of the anterior renal sacs are located at the inner ends of the bases of the anterior gills, or near where the anterior branchial veins pass through the mantle into the body (Fig. 3, R A). Upon the inner side of each anterior renal pore is another opening, the pericardial pore (Fig. 3, P P).

Each renal or pericardial pore is surrounded by a lip, a raised thickened portion of the mantle. The pericardial pores are the largest of the six, being 3 millimeters in length. The renal pores are each 2 millimeters in length. The lips of the latter are divided into inner and outer parts, forming tight valves. The main axes of the pores are all directed obliquely backward and outward.

ANUS.

In the median line of the mantle, just posterior to and above the anterior renal sacs, is the anus (Fig. 3, A). Its edges are plaited and project slightly from the surface of the mantle. The anus is situated upon the thickened posterior portion of the mantle, about 8 millimeters from the line along which the mantle joins the body wall. The anus of VALENCIENNES'S specimen was situated upon the body wall between and at the middle of the shell muscles. VALENCIENNES has shown himself too good an observer for us to consider that he made a mistake in this description and figure. It was simply a very peculiar and rare abnormality.

REPRODUCTIVE APERTURES.

The reproductive apertures of both male and female Nautili are paired. The two differ from each other in the same sex, and the right apertures are differently formed in the two sexes. The apertures of the female present the simplest conditions. The aperture of the functional oviduct is upon the right side of the body, at the tip of a projection from the body wall (Fig. 4, O V), immediately anterior to the crease formed by the junction of the mantle with the body wall and about halfway between the right shell muscle and the median line of the body. The transverse slit-like aperture is borne upon a dorso-ventrally flattened plaited projection of the body wall. This projection, which forms the tip of the oviduct, is, in preserved specimens, of a dark-brown color. The color is the same as that of the nidamental gland, which WILLEY tells us is a bright yellow in the fresh condition; so the tip of the oviduct may also be of a very different color in the living than in the preserved specimens. It forms a projection 12 millimeters in width, 5 millimeters in thickness (dorso-ventral measurement), and 10 millimeters in length. The length of the dorsal side is not quite so great as that of the ventral side. The walls are thick and transversely folded, and are evidently glandular. In spite of its comparatively large size the tip of the oviduct is not a conspicuous part of the pallial complex, being situated so low in the crease formed by the mantle and the ventral body wall.

The aperture of the left reproductive duct is an exceedingly minute pore on the left side of the body, in the crease formed by the union of mantle and body wall, and located immediately posterior to or above the base of the posterior (the smaller) gill. The position and form of this aperture are the same in both male and female Nautili. The aperture leads into the organ commonly called the pyriform sac, which there seems to be good reason to consider as the vestige of the left reproductive duct of Nautilus. It has the same structure in both sexes.

The functional male efferent duct opens at the tip of the penis, a tubular organ lying in the median line of the ventral body wall. (Fig. 3, P.) The tip of the penis only is free from the body wall. The cavity of the penis is divided a little back of the tip of the organ by a longitudinal partition into two portions, which are parallel for a certain distance. They then fork, the left branch turning outward and backward toward the minute left reproductive aperture, and soon ending blindly. The right branch continues to the right to that region of the crease between the mantle and the body wall where the tip of the oviduct is located in the female. It here penetrates the body wall and becomes continuous with the vas deferens. Just back of the penis, which term refers to that median structure within which the efferent ducts are parallel to each other and finally unite, and are contained within a common wall, the right duct is swollen to form a considerable sac, the spermatophore sac. This forms a protrusion of the body wall which is quite noticeable. The structure of these parts will be described in more detail in the section treating of the reproductive organs.

NIDAMENTAL GLAND.

Immediately in front of the preanal papillæ of the female a large pleated gland is situated upon the inner side of the mantle. (Fig. 4, N.) This has been called the nidamental gland. In the fresh condition it is of a light yellow color, but when preserved its color is a dark brown.

The nidamental gland extends across the mantle nearly the entire distance between the bases of the anterior gills. It has been called kidney-shaped. It is shaped as a number of thin, closely pressed, parallel folds would be if their ends were bent around close to their middle portions until the opposite ends nearly meet each other. Most of the folds of the gland are thus continuous around the curved ends of the organ. The infolding has taken place toward the anterior side of the main portion of the gland. The gland is about 60 millimeters in width, and 25 millimeters to 32 millimeters in length. At its edges the mantle is raised, forming a border entirely around the gland. On the posterior side and between the anterior and posterior portions of the gland the border thus formed is only a low ridge. Upon the ends and the anterior side of the gland the raised mantle forms a fold which overlaps more than half of the inturned portions of the gland. The outer surface of the ridge of the mantle is smooth, and the inner surface as well of the overlapping anterior parts. The inner surface of the other parts of the border is ridged perpendicularly and is apparently covered by an extension of the glandular tissue of the gland.

By means of the raised border of the gland a canal is formed which enters the anterior side of the gland and branching, extends to each side between the anterior and posterior portions of the gland. OWEN suggests that the divisions of the nidamental gland serve "both to conduct the secretion nearer the orifice of the oviduct, and also to prevent its being drawn within the respiratory currents of water, and so washed away as soon as formed." If the channel between the different portions of the gland serves to conduct the secretions of the gland, it is difficult to see how it conducts them near the orifice of the oviduct with its open end directed away from the oviduct and its lateral branches ending under the overlapping border of the gland.

The parallel glandular folds of which the organ is composed are quite separate in the anterior portions, but are grown together closely in the posterior portion.

Medianly, between the ends of the anterior portions of the gland, is a thickened, apparently glandular, projecting portion of the mantle. In the center of this is a low, longitudinal ridge. (Fig. 4, Y.)

The gland is supplied with blood through branches of the branchial arteries. A large blood lacuna lies in the median line in the mantle below the nidamental gland. This breaks up into numerous smaller lacunæ in the thickened portion of the mantle between the ends of the gland.

In a half-grown female the nidamental gland was just forming. The mantle was scarcely thickened, but the outlines of the different portions of the gland were already marked out by the border formed by the raised fold of the mantle. The glandular area was covered by very fine parallel ridges, scarcely visible to the naked eye. The gland was of the same color as the surrounding portions of the mantle.

KERR has described a series of glands between the preanal papillæ and the posterior side of the nidamental gland. The apertures, "to the number of about 150, form a band about 0.5 millimeter in width, curving gently forward on either side of the postanal papilla, tapering off and terminating close to the advehent vessel of the posterior gill. In section these openings are seen to be the apertures of tubular ducts which pass inwards perpendicular to the surface for some little distance and then break up into several blindly ending branches. These are lined by involution of the surface epithelium, which, in the neighborhood of each aperture, increases to about twice its thickness elsewhere, its cilia at the same time becoming long and powerful (0.03 millimeter in length). Once within the narrow aperture the lumen of the tube expands to about 0.05 millimeter in diameter, and the lining epithelium becomes shorter, the remainder of the lumen being lined by comparatively short columnar cells, each with a round ellipsoidal nucleus." In some females this area is greatly swollen, forming a single elongate gland. It is not possible, then, to distinguish the separate apertures of the glands upon the surface. I have not yet been able to determine if the glands in the bases of the preanal papillæ of the male are homologous

with the just mentioned glands upon the mantle of the female. Their structure is certainly very much like that of the glands described by KERR. As the epithelium of the inner surface of the mantle had been rubbed off in my specimens, I can not say anything about its structure. It is strange that WILLEY should have overlooked the ciliated surfaces described by KERR. KERR's observation certainly weakens WILLEY's "final proof" regarding the osphradial nature of certain papillæ, for this is proof that other regions of the body, aside from the surfaces of the grooves of the ocular tentacles and the interbranchial papillæ and the preanal papillæ, are ciliated. The glandular area is differently developed in different females of various ages, and this I take to be an indication that it forms an accessory part of the female reproductive apparatus.

Let us now sum up the observations on the pallial complex. The mantle is continuous around the body, forming a broad ventral fold fastened along its edge to the edge of the shell, and a small free dorsal fold, connected by very narrow lateral portions. In conformity with this structure there is a capacious ventral mantle cavity containing all the organs collectively forming the pallial complex, and a small dorsal mantle cavity; the two are connected by shallow lateral cavities.

The pallial complex consists of the following parts: The anus; two pairs of gills; two pairs of nephridial pores; one pair of pericardial pores; two interbranchial and two preanal papillæ, which may be osphradia, corresponding metamERICALLY to the gills; one pair of reproductive apertures; in the female, the nidamental gland.

All these parts of the pallial complex, except the reproductive apertures, are situated upon the inner side of the mantle. The latter are situated upon the body wall. The renal sacs also might be considered as forming parts of the pallial complex, for they are situated *within* the base of the mantle.

This arrangement of the parts of the pallial complex of *Nautilus* is very interesting when compared with the *Dibranchiata*, in which all the organs mentioned are located upon the body wall. The arrangement of the organs of the pallial complex of *Nautilus* is the same as in many *Gastropoda*.

FUNNEL.

The funnel is an organ of great size, not to be overlooked in the most casual glance at the animal. While showing a general similarity to the funnel of the *Dibranchiata*, it also presents differences of the utmost interest to the student of comparative anatomy. Lying closely pressed against the ventral side of the head and nuchal regions, it has a length of about 8 centimeters and a breadth of 4 centimeters. (Figs. 3, 4, and 6.) The width of the funnel varies greatly in preserved specimens, depending largely upon the state of contraction of the organ. It forms an extremely solid mass of tissue. Its posterior end extends well into the mantle cavity. The anterior end lies partly in the ventral groove of the cephalic sheath, and its tip extends a very little beyond the posterior border of the ventral notch of the cephalic sheath. (Figs. 7, 24, and 25.) The funnel forms a long cylinder, but instead of being closed, like the funnel of the *Dibranchiata*, it is open upon the ventral side, where its edges merely overlap each other. It is as if the edges of a flat, oblong piece of tissue had been inrolled about the longitudinal axis until their edges slightly overlapped. A better illustration, and one which expresses the commonly accepted morphological idea, is to suppose the edges of the foot of a gastropod to be inrolled toward the ventral side, and about the longitudinal axis.

The partly closed funnel of *Nautilus* presents, therefore, in the adult condition a form which is found in the embryonic stages only of the *Dibranchiata*.

At the posterior end of the funnel the sides separate and pass upward over the sides of the nuchal region of the body, just behind the auricles of the hood, forming the crura of the funnel, to the dorsal edges of the shell muscles. (Fig. 6, CR.) The dorsal ends of the crura are united by a thin crescentic ridge running around the posterior excavated side of the hood. (Figs. 5 and 7, CR.)

Only the posterior portion of the funnel is attached to the body. The anterior five-eighths projects completely free from the body, able to move in any direction. If we examine the inside of the funnel, we shall get a logical means of separating the anterior and posterior portions of

the funnel, which are really fundamentally different parts of the organ. In the first place, we notice the valve of the funnel projecting from the dorsal wall near the tip. (Fig. 6, V.) This is a thin, tough, tongue-shaped structure precisely like the valve of the funnel of *Loligo*. The line of attachment of the valve is exactly transverse to the axis of the funnel and is about 3 centimeters from the tip of the funnel. The valve itself is 2.25 centimeters in length by 1.5 centimeters in breadth at the base. In preserved specimens the valve is directed forward and lies closely pressed against the roof of the funnel. Halfway between the base of the valve and the posterior end of the funnel are two white lines in the roof of the funnel which approach each other like the sides of a V. (Fig. 6, C.) The point of the V (which is directed backward) is not complete, as the posterior and inner ends of the lines remain separated by a distance of about 5 millimeters. The lines are 3 millimeters in width and 2 centimeters in length. They are caused by the superficial position of the ventral limbs of the cartilage, which here lie almost immediately beneath the epithelium of the funnel, allowing the white cartilage to show plainly through the thin overlying tissues. There is a marked difference in the appearance and structure of the funnel anterior to these lines and posterior to them. The anterior portion is smooth, and light in color. It is composed mostly of elastic tissues; small bundles of muscles form a quite definite layer upon the outer side just under the epithelium, while there are only scattered muscles upon the inner side of this portion. The part of the funnel in front of the arms of the cartilage is that which has already been referred to as free from the body. It is freely movable, but evidently only slightly contractile. The attachment of the funnel to the body begins anteriorly on a line passing through the middle of the white lines on the internal surface of the funnel.

The part of the funnel back of the processes of the cartilage is composed entirely of muscle, and is often in a state of extreme contraction in preserved specimens. The darker color of this part readily distinguishes it from the anterior part. The roof of the posterior part of the funnel is attached to the body along a median strip 7 millimeters in width and extending to the back edge of the roof of the funnel. The crura, being attached to the nuchal surface by their anterior and inner edges, meet the anterior end of the attachment of the funnel and form the outer sides of two deep pockets lying between them and the roof of the funnel and the median attachment of the latter to the body. These lateral pockets are very similar to the pockets, or valves, beside the funnel of *Loligo*. The attachment of the roof of the funnel to the body forks posteriorly, often leaving quite a pocket above the median portion of the roof of the funnel. From the ends of the fork two ribbons of skin, each attached by one edge, run back along the ventral surfaces of the shell muscles for a distance of 30 to 35 millimeters. They may be 2 or 3 millimeters in height at their anterior ends, but gradually diminish in height until they disappear.

The posterior portion of the funnel possesses an internal layer of longitudinal muscles extending from the posterior sides of the limbs of the cartilage to the posterior edge of the funnel. The external layer of oblique and transverse muscles is continuous with the muscles of the crura, which seem to branch on the sides of the funnel, part of their muscles passing on to the sides and ventral part of the funnel and part passing into the roof of the funnel. The roof of the funnel might almost be described as a shelf extending between the crura. If the funnel is formed in the same way in *Nautilus* as in the *Dibranchiata* whose development has been observed, the roof of the funnel really consists, in large part, of a portion of the ventral surface of the body folded in between lateral ridges.

The crura are composed of the same dark muscle as the posterior part of the funnel. They form strong muscular bands, which, attached to the sides of the nuchal region by their anterior and inner edges, extend upward and backward close to the stalks of the eyes and immediately back of and under the auricles of the hood. (Fig. 1. CR.) Their upper ends are attached along the dorsal edges of the shell muscles and extend back to the posterior limit of the mantle cavity at these points. It will be remembered that the mantle cavity is most shallow above the shell muscles, being scarcely more than 10 millimeters in depth. The sides of the crura turn outward and backward. They thin out gradually from the attached borders to the free edges, so that the latter are thin, sharp, and pliable. Similarly, the overlapping edges of the funnel, with which the free edges of the crura are continuous, are thin and fit so closely against one another that

the funnel is, to all intents and purposes, a tightly closed tube. Apparently it makes no difference which edge is outermost, though in most cases the right side of the funnel overlaps the left. There is no structural difference between the two sides.

The crescentic ridge running in an almost horizontal line around the concave posterior side of the hood is so closely related anatomically to the crura as to almost seem to be a continuation of them. Its similar shape and relation to the surface of the body point to a similarity of function, at the least. The ends of the crescentic ridge arise upon the dorsal or inner sides of the ends of the crura (Figs. 5 and 7); these surfaces correspond to the anterior surfaces of the lower parts of the crura. In this way the crescentic ridge unites the upper ends of the crura.

Aside from the great mass of muscle forming the posterior portion of the funnel and its crura, which can not be separated into separate muscles, the funnel possesses two distinct and independent muscles. These (the *Levatores infundibuli* Owen) pass from the central part of the cephalic cartilage outward and forward in the lateral parts of the roof of the funnel to near its tip. They are slender round muscles, 2 millimeters in diameter and 35 millimeters in length. They lie in smooth-walled cavities or tunnels in the tissue of the funnel, so that they are attached only at the two ends. The anterior ends spread out in the tissues of the roof of the funnel a few millimeters in front of the base of its valve. They seem to have no connection with the valve. On account of their being attached at the ends only, the contraction of these muscles probably affects only the tip of the funnel, pulling or bending it upward. The tip would be straightened or bent downward by the intrinsic muscles of this part of the funnel. The length of the levatores must allow a considerable contraction, and consequently they are able to cause a considerable motion of the tip of the funnel. Their position and course is indicated externally by slight ridges upon the surface of the funnel where it touches the edges of the ventral groove of the cephalic sheath. Blood lacunæ open into the sheaths of the levatores.

The funnel receives its blood through two arteries which spring from the tentacular arteries near their origins, and which, according to WILLEY (1896, p. 178), "pass through the cartilage into the funnel." (Text-fig. 10, p. 182.)

The infundibular nerves are two in number, each of considerable size. They are the innermost nerves springing from each pedal ganglion. (Fig. 41, 8.)

VISCERAL BODY WALL.

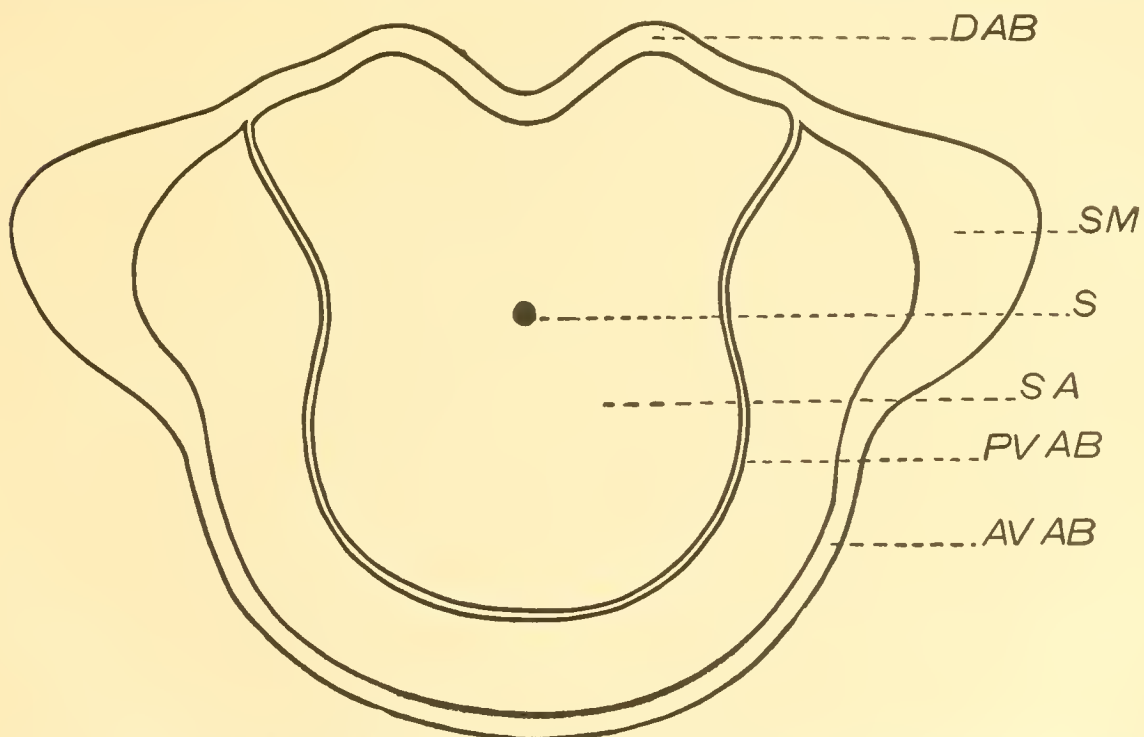
The body wall of the posterior end of the body of Nautilus is very thin, soft, and delicate. In some cases semitransparent, the outlines of several of the viscera can be distinguished through it. The greater part of this portion of the body wall is applied to the last septum of the shell, and the septa are formed by its epithelium. The thin body wall extends out upon the outer side of the mantle fold, so that there is no external sign of the posterior limit of the mantle fold. The thin body wall of the visceral region is composed of fibrous tissue in which are numerous fine branching blood vessels and a very noticeable nervous plexus. Externally it is covered by a layer of short columnar epithelial cells. Internally—that is, upon the celomic side—it is covered by comparatively large flat polygonal pavement cells. At the posterior end of the body (dorsally as the animal is curved) the body wall is produced into a long slender tube, the siphuncle, which passes through the siphon to the last chamber of the shell, where it probably ends blindly, like the siphon. The body wall is firmly attached to the shell over the end of each shell muscle and along three aponeurotic bands extending between the ends of the attachments of the shell muscles. (Text fig. 7.) Everywhere over these aponeurotic areas, a thin plate or ribbon of chitinous material is found between the body wall and the shell. This is secreted by the epithelial cells of the aponeurotic areas and seems to form a kind of cementing substance by means of which the body wall is firmly attached to the smooth surface of the shell.

The attachments of the body wall to the shell over the ends of the shell muscles form areas of the same shape as the ends of the muscles. (Fig. 1, S M.) They are roughly crescentic, or perhaps better, approach in shape spherical right-angled triangles, the right angles being directed forward and downward.

The dorsal aponeurotic band (Figs. 1 and 2, DA) extends between the dorsal ends of these areas over the dorsal side of the animal. Passing over the excavated dorsal region of the body it bends quite sharply backward as the middle line is approached. At the middle line there is a pointed backward projection of the aponeurotic band. The band is about 3 millimeters in width.

Some of the older septa show a minute cup-like backward projection at the middle of their inner edge. (Fig. 1.) These depressions in the faces of the septa can be traced, constantly less developed, to the newest septum. In this it is only a notch in the extreme edge of the septum, into which the projection of the dorsal aponeurotic band just mentioned fits. From this it would seem that in young specimens there is a projection of the mantle corresponding to the depression in the septum, which has been gradually reduced until in the adult it remains only as a point at the middle of the dorsal aponeurotic band.

The ventral ends of the columellar aponeurotic areas are connected by the anterior ventral aponeurotic band, which extends over the ventral surface of the body. (Fig. 1, AV.) This is also



TEXT-FIG. 7.—Outlines of the areas of attachment of the shell muscles and aponeurotic bands to the shell spread out flat. The outline of the septal area has been drawn from a wax model.

AVAB, anterior ventral aponeurotic band. PVAB, posterior ventral aponeurotic band. DAB, dorsal aponeurotic band. SA, septal area. S, siphon. SM, shell muscle.

about 3 millimeters in width. A third aponeurotic band, the posterior ventral aponeurotic band, connects the dorsal ends of the columellar aponeurotic areas, extending also around the ventral surface of the body. (Fig. 1, PV.) As the body is curved the actual position of the ventral surface is posterior. The last band is only one-third as wide as the others. It is drawn somewhat too wide in Fig. 1.

The posterior ventral aponeurotic band first passes directly backward from the end of the columellar aponeurotic area parallel to the dorsal edges of the body. It then makes a smooth curve downward and somewhat forward over the sides of the body; its median ventral portion is parallel to the anterior ventral aponeurotic band.

The posterior ventral aponeurotic band and the dorsal aponeurotic band have a peculiar relation to the septal region of the body wall, since this is bounded by these two bands. In most shells the aponeurotic bands and areas leave slight scars upon the inside of the shell, and

by these one can observe that the two bands just mentioned always lie exactly at the edge of the septum.¹

This portion of the body wall is marked off from the rest by its arterial vessels also. (Text-fig. 11, p. 186.) The septal artery runs backward from the heart, and entering the body wall below and a little to the left of the base of the siphuncle divides into two branches which are distributed exclusively to the septal region of the body wall and to the siphuncle. The siphuncular artery is a branch of sometimes the left, sometimes the right, septal artery. A variable number of smaller branches of the septal arteries may also pass into the walls of the siphuncle. The branches of the posterior columellar arteries to the dorsal body wall seem also to enter the septal area, but I can not be sure of their distribution without injected specimens. WILLEY states that "the septum-producing area of the mantle" is distinguished in fresh specimens "from the surrounding portions of the mantle by its greater thickness and opacity." Such a distinction can not be observed in alcoholic specimens.

MOVEMENTS OF SWIMMING AND RESPIRATION.

Nautilus swims in a manner very much like that of the *Dibranchiata*, backward (or with the posterior end of the body pointed in the direction of motion), propelling itself by means of jets of water squirted through the funnel. On account of the presence and the position of the air chambers of the shell the involution of the latter is always dorsal. WILLEY has already clearly stated that on this account it would be impossible for the animal to turn over in the water.

In the figure (a photograph) which WILLEY gives of a living *Nautilus* in the swimming position the anterior end of the body is raised so that the eyes are above the edges of the shell, and the back of the hood nearly covers the dark portion of the involution of the shell, apparently projecting higher upon this than the dorsal portion of the mantle.

When we are told that the manner of progression of *Nautilus* is like that of the *Dibranchiata* we involuntarily imagine that the water is expelled from the mantle cavity by the contraction of the mantle.

Possibly this is the case, but the scantiness of the musculature of the mantle seems to afford good ground for doubt. It has been pointed out in some cases that a chitinization of portions of the mantle takes place, which would surely interfere with its contraction.

Apparently also the mantle is attached to the edge of the shell. If this is true it is impossible that the mantle by its contraction should drive the water from the mantle cavity.

How, then, can the expulsion of water take place? There are two conceivable ways, one of which has been observed.

We have noticed that the crura of the funnel extend upward along the sides of the body from the posterior end of the funnel. They are attached to the body by one edge; in expanded specimens the crura are seen to gradually thin out from the attached edge to a very thin, pliable free edge.

If the crura should be set so that their surfaces form a large angle with the body, the outer free edges would be in contact with the inner surface of the mantle, and thus the mantle cavity would be completely closed except for the passage through the funnel. The dorsal ends of the crura turn along the upper sides of the shell muscles toward the posterior limit of the, here very narrow, mantle cavity. These ends would serve to close the communication between the dorsal and ventral portions of the mantle cavity.

¹In Part VIII, Vol. IX, of the Proceedings of the Cambridge Philosophical Society, p. 398, Willey claims that a previous account of these aponeurotic bands published by me does not give him proper credit for the description of the "septal contour." I read Willey's previous paper carefully before writing my first description, and have read it several times since. He does not in any way describe the manner of limitation of the septal area. It seems, therefore, that my description completes his without in any way intruding upon his priority, a thing I have not the least desire to do. It may be well to state that in gathering the accounts of many authors into one and incorporating them with my own work to form as complete an account of the anatomy of nautilus as possible, I have purposely refrained in most cases from referring in the text to the original descriptions of the various parts. Those who are familiar with Cephalopod literature will give credit where credit is due. References in the text are, for the purposes of this work, needless.

If the crura should now be swept inward like fans, touching the inner surface of the mantle as long as is possible, the volume of the mantle cavity would be slightly reduced and some of its contained water would be expelled. If this fan-like motion were repeated continuously, a current of water sufficient for the purposes of respiration would be kept flowing into and out of the mantle cavity.

That such a motion of the crura does actually take place is proven by a passage which I shall quote from WILLEY.

"There is a slight error in MOSELEY's account of the movements of the Nautilus, which may as well be corrected. He says, 'On either side of the base of the membranous operculum-like headfold . . . the fold of the mantle closing the gill cavity was to be seen rising and falling, with a regular pulsating motion, as the animal in breathing took in the water, to be expelled by the siphon.' It is not a fold of the mantle which is thus seen to pulsate, but the posterior free membrane-like expansion of the funnel on either side."

The current of water caused by the movement of the crura scarcely seems capable of propelling the Nautilus during vigorous swimming. In view of the fact that WILLEY and MOSELEY, who have seen the living Nautilus swim, say nothing of the manner in which this movement is effected, it would be presumptuous for one like myself, who has only seen the preserved animals in a laboratory far distant from their native haunts, to form theories as to the swimming movements. I should like to point out, however, that the water in the mantle cavity could be forced out by the withdrawal of the head end of the animal into its shell, caused by the contraction of the shell muscles.

If at the same time the crura of the funnel be set so as to close the lateral portions of the mantle cavity, the expelled water must pass through the funnel and might propel the animal. The thinness of the mantle and its relation to the shell suggests, at least, that its contraction is not a factor in the propulsion of the animal.

MOSELEY says that in swimming the various sets of tentacles are extended radially from the head. WILLEY corroborates this account.

In regard to the Nautilus's power of moving up or down in the water, WILLEY says: "I have never found any necessity for framing an elaborate theory as to the rising and sinking of the shell. A remarkably small weight is sufficient to sink such an empty shell, and when the living animal retracts itself and ceases all muscular action, thereby converting itself, as it were, into a dead weight, it is heavy enough to sink several shells in addition to its own."

The air chambers of the shell seem to support the shell itself, relieving the animal of the hindrance which the weight of the shell would otherwise be. That the living Nautilus would float or sink according as it moved or remained quiet was suggested as the result of careful computations by MEIGEN thirty years ago.

ALIMENTARY SYSTEM.

It may be well to give a short general description of the alimentary system before passing to a detailed description of its various parts.

The buccal mass forms a large, bluntly conical mass, situated within the various groups of tentacles. (Fig. 7, B.) It is armed with an enormous pair of jaws, which are looked upon still more respectfully when one dissects their strong musculature. The upper jaw fits snugly within the projecting lower jaw, while the tips of both jaws are beaked and are reinforced by a considerable deposition of extremely hard calcareous material. Upon the floor of the buccal cavity is the large tongue, bearing a long-toothed radula. (Fig. 32, Tn.) Two fleshy folds arise from the floor of the buccal cavity in front of the tongue. (Fig. 32, AP, PP.) The salivary glands are contained in two larger folds which are situated upon either side of the tongue. (Fig. 32, SP, SO.) The œsophageal opening is immediately behind the tongue. The œsophagus is long and extremely distensible; when full it forms a large pear-shaped crop, with thin, smooth walls; empty and contracted it is a narrow, folded tube. (Figs. 7 and 27, Oe.) The œsophagus passes straight back through the body, finally entering a small chamber which acts as a common vestibule to the stomach and the intestine. (Fig. 32, V.) The muscular stomach (Fig. 27, St) lies

posterior to the vestibule, while the intestine passes from its right side. (Fig. 27, I¹, I², I³.) Communicating with the intestine near its beginning is the caecum (Fig. 27, Coe), into which the duct of the liver opens. The large lobes of the liver lie under and partially surround the alimentary canal. (Fig. 27, L, L¹.) The intestine passes around the posterior and right sides of the caecum, then turns downward and backward beneath the caecum and the stomach. It turns forward again and passes above the heart to the anus. The branches of this loop run parallelly, close beside each other, and are connected by a mesentery. The terminal portion of the gut is slightly constricted and is more muscular than the preceding parts, and has been termed the rectum.

Since the jaws serve as points of attachment for the fleshy portions of the buccal mass, it is necessary to describe their form before describing the soft parts.

The jaws of *Nautilus* are like those of other Cephalopoda, in being large and hooked (much like the beak of a parrot), in the upper fitting inside the lower jaw, in being formed for the most part of chitin, and in each jaw dividing into two flanges a little distance back of the cutting edge. (Figs. 30 and 31.) Unlike other cephalopod jaws, those of the *Nautilus* are coated with a hard calcareous deposit for some distance back from the biting edges. Nor are they so sharply pointed as the jaws of other cephalopods. The calcareous deposit thickens toward the edge of the jaw, so that this, instead of being sharp, is broad and flat except for a few irregularities of the surface. The heaviest deposit is usually upon the upper jaw, the entire point of which is calcareous. Aside from this deposit the jaws are of hard, black chitin, extremely strong and light. In Figs. 30 and 31 the two jaws are shown; the lower jaw has been split through the middle to show its inner flange.

The lower jaw is 30 millimeters in length by 28 millimeters in width; the upper jaw is 32 millimeters in length by 17 millimeters in width. The flanges of both jaws are unequal in size, the inner flange of the lower and the outer flange of the upper jaw being much smaller than the other flange of each jaw. It is as though the edge of the lower jaw had been turned inward while the edge of the upper jaw had been turned outward upon itself. The larger flanges of each jaw extend nearly to the back of the buccal mass, that of the lower jaw upon the outside, while that of the upper jaw is deeply buried under muscles and forms the roof and sides of the mouth. The smaller flanges of the jaws are broadest anteriorly, gradually narrowing as they pass to the sides.

The chitinous portion of the lower jaw is pointed in front, the contour of the jaw being unchanged after the calcareous matter has been removed. The chitinous part of the upper jaw, on the other hand, is blunt or even notched anteriorly, the sharp point of the jaw being entirely formed by the calcareous deposit.

The buccal mass projects from the body in the midst of the tentacles. The enormous jaws with their muscles form the bulk of the organ; within is a comparatively small cavity well filled by the tongue and several projecting fleshy folds. Back of the cutting edges each jaw divides into two thin flanges, an inner and an outer, to which the jaw muscles are attached. The external flanges lie upon the surface of the buccal mass and may be seen by merely turning back the buccal membrane. The internal flanges lie deep and are not seen until the buccal mass is nearly dissected.

The skin of the head is carried forward upon the buccal mass, forming a mantle or collar around the jaws, the buccal membrane. (Fig. 28, BM.) Upon and just within the edge of the buccal membrane are a large number of more or less slender papillae. Those upon the edge are frequently quite like small tentacles. The buccal membrane is attached to the buccal mass along the posterior edges of the external flanges of the upper and lower jaws. It is readily seen, therefore, that the anterior portion of the membrane is in reality a double fold. Except near the edge of the fold the outer and inner portions are actually separated by a space which is part of the haemocoel. Near the edge the two parts are tightly bound together by muscle fibres and connective tissue. The inner part of the fold—i. e., that part which is attached to the jaws and immediately surrounds them—is extremely thin and delicate except along the anterior edge. Between the jaws and the buccal membrane is a space which, at the sides, where the external

flanges of the lower jaws extend far back, forms two deep pockets. The buccal membrane fits closely around the jaws and reduces the space between itself and them to a minimum.

The inner fold of the buccal membrane is somewhat thickened dorsally, and here it bears, a few millimeters back of the papillæ, two parallel transverse folds extending across the middle line. The folds are very thin, about 18 millimeters in length by 2 millimeters to 3 millimeters in height, and are close together.

When we slit open the cephalic sheath and buccal membrane dorsally we expose the base of the buccal mass, the œsophagus, and cephalic commissure crossing the œsophagus. (Figs. 7 and 28.) The hæmocœlic space existing between the buccal membrane and the base of the buccal mass has been mentioned. This is in communication with a labyrinth of similar spaces extending between the muscles and membranes of the buccal mass and cephalic sheath. These are further in communication with the main part of the hæmocœl which surrounds the œsophagus and liver. Many of the membranes and small muscles found around the base of the buccal mass are very inconstant in their occurrence and extent.

Strong muscles attach the buccal mass to the cephalic cartilage and body wall and govern its motions as a whole. Six muscles, arranged in pairs, seem to be retractors of the buccal mass. Four of these are dorsal and two are ventral. It seems convenient to distinguish the two pairs of dorsal muscles as the dorsal retractors and the dorso-lateral retractors. The dorsal retractors arise near the center of the cartilage and run inward and forward upon the buccal mass to their insertions dorsally between the flanges of the upper jaw. (Fig. 28, DR.) The dorso-lateral retractors have their origins immediately beneath those of the dorsal retractors (in contact with them, in fact). They run under the dorsal retractors to the buccal mass, where they spread out fanwise over the sides of the buccal mass and are inserted at the edge of the external flange of the lower jaw. (Fig. 28, DLR.) The development of the dorso-lateral retractors seems to be more or less variable; when best developed they are fully as distinct and as strong muscles as the dorsal retractors. The cerebral ganglia lie just back of the buccal mass and directly under these muscles (Fig. 28, CG); from them a number of fine nerves pass upward between the retractors to the dorsal parts of the buccal mass and the edge of the buccal membrane. (Fig. 28, N.)

The ventral buccal retractors have their origins upon the body of the cartilage and run forward and outward upon the under surface of the buccal mass to be inserted along the lower edge of the external flange of the lower jaw. These muscles are sometimes divided into more or less distinct parts. The retractors of VAN DER HOEVEN'S organ, which are partly attached to the base of the buccal mass, may pass above the ventral retractors or between the muscle bundles in case the muscles divide. (Fig. 29.)

A narrow band of muscle fibres extends along the median line of the inner surface of the outer fold of the buccal membrane into the body wall, the median muscle of the buccal membrane. From either side of the median muscle a broad bandlike muscle passes outward and downward to the ventral side of the buccal mass, where its fibres mingle with those of the ventral retractors and are attached to the edge of the lower jaw. (Figs. 28 and 33, LM.) These muscles are evidently levators of the buccal mass, as they hold it suspended in a sort of sling. It will be noticed that the six retractors and the two levators spread out considerably over the surface of the buccal mass and that their fibres commingle to a certain extent. The muscles are connected by a muscular membrane and thus, by the union of the distal portions of the muscles and this membrane, a complete covering is formed to the posterior part of the buccal mass, extending from the edges of the jaws to the circum-œsophageal nerve ring and firmly united to the tough covering of the nerve ring. (Figs. 28, 33, and 34, MM.) A second, more ventral membrane is stretched between the ventral retractors near their origins, thus forming an apparently closed chamber. (Fig. 33, OM.) Another membrane may extend between the levator muscles and the outer fold of the buccal membrane. Ventrally this membrane may be continued by the edges of VAN DER HOEVEN'S organ, as in Fig. 29, though it is rarely anything like as complete as it was in this specimen.

Upon laying open the muscular membrane, which has been described as covering the buccal mass back of the jaws, a very intricate system of intrinsic buccal muscles is exposed. Observing

the dorsal aspect of the buccal mass (Fig. 34) we see posteriorly a dark semicircle, the posterior edge of the inner flange of the upper jaw covered by only a thin membrane. From the entire outer surface of the inner flange of the upper jaw muscle bundles extend to the inner surface of the outer flange and out between the flanges of the lower jaw, the mandibular muscle. This powerful muscle, which occupies the entire space between these flanges of the two jaws, forms the closing muscle of the jaws. When we see this we are no longer surprised at the Nautilus's ability to nip off the leg of a chicken as if with a pair of shears. A groove along the mid-dorsal line indicates the line of nearly complete separation of the muscle bundles of the right and left sides. The separation is not complete, for many bundles cross from each side to the other. An artery runs immediately above this groove, but outside the muscular membrane, the branches of which are distributed to the mandibular muscles.

Upon the ventral side of the buccal mass a much more complicated arrangement holds. (Fig. 33.) Centrally the radular sac may be seen extending more than half the length of the buccal mass. At the sides are muscles which control some of the mouth parts, and portions of the buccal nervous system. I find, by comparing my notes and figures, that these muscles are slightly variable, therefore I shall describe only such as seem to be fairly constant.

By reference to Fig. 33 it will be seen that several muscles on each side have their origins in the muscular membrane already described as covering the posterior part of the buccal mass. Two pairs of these muscles (1 and 2) pass into the cavity of the anterior of the two folds in front of the tongue (the anterior prelingual process) and are attached to its walls, evidently being retractors of the organ. The median pair (2) unite as they enter the fold, but after their union give off several small branches.

A third pair of muscles (4) arise near the side of the buccal mass and run upward and inward to within the fold immediately in front of the tongue (the posterior prelingual process), but mostly to the fold which bears the anterior free part of the radula. A peculiar muscle (figured in Fig. 33, 3) arises with a double head from the muscular membrane closing the front of the space between the ventral buccal retractors and runs forward, at first above and then beneath the radular sac, to be attached to the fold in front of the tongue. Two pairs of slender muscles (5 and 6) arise from the posterior part of the muscular membrane. The longer pair (5) extend forward under the muscles already described to the surface of the tongue bearing the free part of the radula. The shorter pair of muscles extend only to the membrane covering the slight downward projection of the upper jaw.

With muscles 1 and 2 arises a third quite strong muscle (7), which passes upward and directly inward to be attached to the dorsal surface of the radular sac. From its position I should think that this muscle may function either as protractor or retractor of the radular sac, always tending to pull it back to its resting position.

From each ventral posterior corner of the inner flange of the upper jaw a strong muscle (8) runs forward and outward to be attached to the ventral edge of the outer flange of the lower jaw. The contraction of these muscles probably acts to open the jaws. The central part of the buccal nervous system lies beneath these muscles; the pharyngeal commissure, however, runs above them, between them and the lateral parts of the mandibular muscles.

Immediately above the posterior portion of the radular sac is a muscular membrane, containing both transverse and longitudinal fibres, which forms the ventral wall of the space containing the lingual and radular muscles. Quite a number of small muscles extend between this membrane and the dorsal wall of the radular sac, while the membrane itself is attached anteriorly to the radular sac. From the dorsal side of the membrane and the posterior side of the anterior upwardly directed portion of the radular sac a median septum extends to the dorsal integument of the tongue. (Fig. 35, S.) This septum, thin ventrally, becomes thicker and muscular dorsally, and is split into two parts, which are attached to the bottoms of the V-shaped folds extending back from the opening of the radula. (Fig. 35, X.)

Upon each side of the septum are three muscles which form the mass of the tongue, and are chief in controlling the movements of the tongue and radula. Next to the septum is a broad, flat muscle (the internal lingual, IL), which runs parallel to the septum, to be inserted

into the base of the depression running back from the radular opening. Outside of this is another flat muscle, the radular (R), having its origin just in front of the internal lingual. It runs forward and inward, and, uniting with its fellow on the opposite side, is attached to the anterior side of the ascending portion of the radular sac. Above the two muscles just described is a very much larger muscle which forms the bulk of the tongue. To this I have given the name external lingual (EL). Its origin lies above the origins of the other two muscles. From this it runs forward and upward and inward, partly to join its fellow of the opposite side in forming a sling which covers the whole of the ascending portion of the radular sac anteriorly, and partly to be inserted dorsally along the ridge of the tongue. The sling formed by the external linguals in front of the radular sac is not attached to the latter in any way. These three muscles do not have their origins upon any hard part, such as the jaws, but in a sort of tendinous mass (T), which is firmly attached to the floor of the mouth and the muscular membrane described a short time ago. From this tendon a short, strong muscle, the lingual protractor (LP), runs forward and outward under the edge of the opening muscle of the jaws (Fig. 33, 8) to the projecting point of the inner flange of the upper jaw. It would seem as if the only effect of the contraction of this muscle must be to pull the origin of the lingual muscles forward, possibly permitting a greater extension of the tongue; the combined effect of the contraction of the internal and external lingual and the radular muscles would be to pull the tongue and the radula up and back; a simultaneous contraction of the lingual protractor would possibly keep the radula tightly pressed against the object it was rasping. The sling formed by the external lingual is not attached to the radular sac in any place. The integument which supports the free portion of the radula is strongly supplied with muscle fibres running outward and downward to the sides of the jaw; the distinct muscles going to these parts have been mentioned. While these muscles are comparatively weak, they probably are protractors of the tongue. For the structure of the radula indicates that its rasping or pulling effect is produced only when the tongue is thrust upward and backward, and only in this motion would great resistance be encountered. Consequently the muscles which pull the tongue back are large and strong. As no great resistance would be encountered in pulling the tongue forward, the small muscles attached to the integument seem to be sufficient. The integument of the tongue is supplied with a weak longitudinal musculature.

Small muscles extend into the salivary lobes from near the origins of the lingual muscles.

The walls of the mouth cavity are formed by the inner flange of the upper jaw, except ventrally. From the floor of the mouth the tongue, bearing the radula, and four fleshy processes, project into the cavity. In front of the tongue are two processes (Fig. 32, PP and AP), one behind the other, which are really upfoldings of the floor of the mouth. The anterior process is 8 millimeters in height and 12 millimeters in width, covered with papillæ upon both sides, the papillæ upon the anterior side being much smaller than those upon the posterior side. The posterior of the two processes is slightly higher and considerably wider than the anterior. Its base is carried up a short distance on each side of the tongue. This process bears papillæ only upon the edge and the posterior side; the anterior surface is covered with fine transverse ridges.

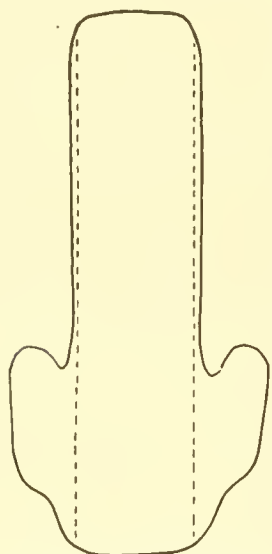
The tongue is a large organ which occupies most of the space within the mouth. (Fig. 32, Tn.) It is about 22 millimeters in length, 10 millimeters in width, and 15 millimeters in height. Anteriorly the tongue rises abruptly and with somewhat of an overhang to its full height. For nearly half its length it maintains this height, then slopes gradually to the floor of the mouth, immediately in front of the œsophageal opening. The shape of the tongue may vary, e. g., it may slope downward and forward to the opening of radular sac, and then sloping down and back. The sides of the tongue are nearly vertical and are entirely free from papillæ. The dorsal surface of the tongue, on the other hand, is thickly covered with large papillæ. Just in front of the œsophageal opening are a number of peculiarly long and slender papillæ.

The anterior surface of the tongue is covered by the radula. (Fig. 32, R.) The radula passes up over the tip of the tongue and then almost immediately bends downward again and is lost to view in the radular sac. The radular sac passes downward and a little backward under the integument of the point of the tongue till it reaches the under side of the tongue, where it abruptly

bends backward and so passes beneath the tongue to near the œsophagus. (Fig. 33, RS). Grooves run inward from each side of the tongue to the opening of the radular sac, giving it a V shape.

The radular sac (Fig. 33) is about 25 millimeters in length and has an average width of 8 millimeters. Its ventral and lateral walls are thin and transparent and allow the brown color of the radula to show through. The extreme posterior portion of the sac, however, is colorless, since the teeth are formed here and have not yet taken on their color. This part of the sac also is somewhat wider than the rest, for the radula, at first spread out flat, becomes more and more inrolled at the edges as it grows forward. From each posterior corner of the radular sac a ligament of elastic fibres runs back to the muscular membrane near the œsophagus, evidently tending to hold the radular sac in place (RL). The dorsal wall of the radular sac is quite thick, and fits closely upon the teeth. In the anterior portion, where the radula is inrolled, the dorsal wall of the sac projects to occupy the groove. As the radula passes out of its sac a plain chitinous border, 3 to 4 millimeters wide, is added upon each side. (Text fig. 8.) This border appears to be formed at the bottoms of the grooves running back from the opening of the radular sac.

Let us now examine the separate teeth of the radula. The teeth are arranged in rows running across the chitinous, ribbon-like base of the radula; there are in all about fifty of these rows. In each row are thirteen teeth symmetrically arranged with regard to the central tooth. Each of the six lateral teeth is exactly like the corresponding tooth of the opposite side in shape and position. It scarcely seems necessary to give a detailed description of each tooth after the careful descriptions and figures of Vayssiere and with the figures accompanying this paper. I should not have drawn new figures of the teeth if Vayssiere had not used the shape of the lingual teeth as a character to distinguish between the two species of NAUTILUS, *N. pompilius* and *N. macromphalus*. But when I found as great differences in shape between his figures of the teeth of *N. pompilius* and my specimens of the teeth of the same species as he shows between the teeth of the two species it seemed to me to be wise to make new figures for the sake of comparison. All the teeth are very firmly attached to the chitinous ribbon by large bases. The bases of the central seven teeth are approximately square, while the bases of the other teeth are much longer than wide. The projecting tip of the central tooth is directed straight backward; the other teeth while projecting backward are also directed more or less inward toward the central tooth. Let us number the teeth from the central tooth outward, distinguishing them as first lateral, second lateral, and so on.



TEXT-FIG. 8.—Outline of the radular ribbon. The dotted lines indicate the position of the outer rows of teeth.

Immediately outside the central tooth (Fig. 42) is a tooth very much like the central one but smaller and having a shorter and a much less slender point. (Fig. 43.) The second lateral tooth has a broader base and a much shorter, blunter point, which is directed toward the central tooth. (Fig. 44.) The third lateral tooth (Fig. 45) is long and slender and curved. Attached by a base which makes an obtuse angle with the body of the tooth, it projects backward and inward so as to cover the first and second lateral teeth of more posterior rows. The outer (anterior) face of the tooth is gonged so as to form a sharp edge running nearly parallel to the inner outline of the tooth. The fourth lateral tooth (Fig. 46) is rod-like and attached to the ribbon along its entire length. Its dorsal surface is sharply ridged for nearly the length of the tooth; for part of its length the ridge is produced into a thin, sharp, transparent blade of chitin which also projects backward. The fifth lateral tooth (Fig. 47) is very much like the third, but longer, more slender, slightly less curved, and often more sharply pointed. It is similarly gonged out upon the outer surface, but the sharp edge is not so close to the inner edge of the tooth as on the third lateral tooth. This tooth overlaps the fourth lateral tooth and the base of the third lateral tooth in more posterior rows. The outermost tooth of all is also rod-like, attached to the ribbon along its entire length, and bears a slight

backwardly pointing projection upon its inner end. (Fig. 48.) The bases of the teeth form various angles with the axis of the radula. The outer tooth makes an angle of about 45 degrees with this axis, while the bases of the third and fifth lateral teeth make angles of 30 degrees with it. The bases of the other teeth are transverse to the axis of the radula.

The formation of the radula takes place in the extreme posterior part of the radula sac. The first 8 or 10 rows of teeth are colorless and soft; from here on the teeth gradually turn to dark brown, become hard, and assume their full size.

From the floor of the mouth a broad, flat process, 12 millimeters in length and 10 millimeters in height, arises at each side of the posterior part of the tongue. The inner sides of these processes bear papillæ to a varying extent in different individuals. They may be entirely covered except for a small space in the center, or only the upper half may be covered. A small, slightly elevated area in the center of the inner side of the process is always free from papillæ, and here is a minute pore, the opening of the salivary gland. The salivary glands are ovoid bodies, indistinctly divided into lobules, 5 millimeters by 4 millimeters by $2\frac{1}{2}$ millimeters, situated within these processes, with their longest axes directed downward and backward. The duct is near the anterior end of the gland; the duct, however, is so short that it scarcely deserves the name, for the glands lie close against the integument of the processes. (Fig. 70.)

The jaws of the Nautilus are admirably adapted for crushing and biting hard objects. The calcareous layer which covers the inner and outer surfaces of the chitinous parts of both jaws forms a thick, square edge which is practicably unbreakable; slight projecting roughnesses of the edges prevent their slipping upon large and smooth objects. After the jaws have become thoroughly dry the calcareous substance is very brittle and readily peels off the chitinous base, so that in a few days, even without handling, the calcareous matter may have fallen away completely. But while the calcareous matter of the jaws contains any moisture it is extremely tough and hard to remove. This it must always be when the Nautilus is under natural conditions, so there is no doubt but that the calcareous material of the jaws means added strength in no small degree.

Without the addition of the calcareous matter the chitinous parts of the jaws would be unable to handle the food they do now. In other words, the addition of calcareous material to the jaws is a modification of the type of structure observable in the jaws of other cephalopoda which enables the Nautilus to subsist upon animals possessing shells heavy enough to protect them from most other predatory animals.

The upper jaw fits snugly inside the lower, so that its outer edge just passes the inner edge of the lower jaw in closing. Consequently when the animal is biting any substance the action of the jaws is not that of a pair of nippers, in which the two jaws meet each other, pinching the substance in two between them, but instead like that of a steel shear, where two heavy blades having broad flat faces and sharp square corners move past each other. By this construction and motion the maximum cutting power is attained with the least exertion and the least risk of breaking the edges of the jaws.

The traps in which the Nautili were caught were baited with chicken, so I often have found the crop filled with large pieces of chicken flesh. Feathers and flesh and bones, even the leg bones, are cut as cleanly as with a pair of shears; everything attests the power of the jaws and their muscles. Apparently also the Nautilus does not pluck its chickens. The remains of some crustacean found in the stomach and intestine are evidence of the ability of the Nautilus to handle any food of this nature. It also seems scarcely doubtful that the Nautilus could eat many of the thinner shelled mollusca, although there is no evidence of such a diet.

For an animal provided with such powerful jaws a radula seems much like a superfluity. Certainly it can not, as in many of the gastropoda, be the chief organ for seizing and tearing food. The slender and almost delicate form of many of the radular teeth precludes the idea that the radula may be used to rasp away objects which are too hard to be broken by the jaws. It seems possible that the radula may be used to scrape the flesh out of shells, crustacean or molluscan, which have been broken by the jaws. But the contents of the digestive tract

indicate that the Nautilus does not trouble itself in this way, but swallows shells and all, leaving the separation of food from refuse to the operations of digestion. Nevertheless, if the radula is excluded from any part in gathering food, it may be of extreme importance in the swallowing of the food. The sides and roof of the mouth are formed by the inner flange of the upper jaw, and consequently the activity of the organs of the floor of the mouth alone must carry the food to the opening of the œsophagus. The radula may seize fleshy food and hold it while it is being bitten; it would also prevent partly bitten food from escaping while the jaws take a new hold. After the food had been bitten off the radula would certainly pull it back upon the surface of the tongue, which, with possibly some aid from the salivary processes, would press the food back into the opening of the œsophagus.

It is probable that when the radula is in use and consequently under tension the long, lateral teeth are erected so that they no longer cover more central teeth, and are in better position for holding any substance firmly.

The function of the processes in front of and at the sides of the tongue is also problematical, if we do not use a still stronger term. It is reasonable to suppose that at least one of their functions is to aid in the swallowing of the food. While we do not suppose that the processes at the sides of the tongue have been developed for the sake of bearing the salivary glands, these glands are now much more advantageously situated on account of the high tongue, to aid in the deglutition of food than they would be were they in the floor of the mouth.

STEINMANN'S paper on the formation of calcareous matter by the mollusca suggests another possible function of the processes in front of the tongue (especially the anterior one) and the buccal membrane. The decaying secretions of these parts combining with calcium salts of the sea water may form the calcareous matter which covers the tips of both jaws. This is the only explanation I have found which seems to be at all adequate to account for the formation of so much calcareous matter at this point. For there is here no closely applied epidermis, as at the edge of the shell, which could be supposed to take an active part in the formation of this material.

The œsophagus leaves the buccal mass at its posterior end and so low down as to be almost ventral. It immediately passes through the nerve ring as a small, round tube 5 millimeters in diameter. The lengthy œsophagus runs straight back through the hæmocœl to the stomach. (Fig. 27.) The portion of the œsophagus between the nerve ring and the stomach is extremely distensible and forms a crop in which a large amount of food can be stored and gradually passed to the stomach to undergo trituration. When completely filled the crop forms a large pear-shaped sac with smooth, thin walls. But when it is only partly filled or is empty the crop shrinks in size and the walls thicken, becoming folded internally with close, longitudinal folds. In the specimen figured (Fig. 32) the posterior part of the crop contained a little food while the remaining portion was empty, so both conditions of the wall have been shown. The folds of the anterior portion of the œsophagus are more permanent, probably disappearing more or less only when large pieces of food are being swallowed. The opening in the nerve ring through which the œsophagus passes is so small that it is difficult to imagine how some of the large pieces of food found in the crop could have passed through without exerting a considerable pressure upon the ganglia. At the posterior end of the crop are several longitudinal folds which end abruptly within the opening into the vestibule of the stomach and seem to be more permanent than the other folds mentioned above. (Fig. 32, X.)

The stomach, into which the œsophagus opens, is an oval, laterally flattened organ 27 millimeters by 27 millimeters by 15 millimeters in dimensions. At first sight it appears to lie in the genital portion of the cœlom, but in reality it lies in the hæmocœl, closely covered by a backwardly projecting pocket of the membrane which separates cœlom from hæmocœl. The posterior end of the stomach is supported by a thin ligament extending between it and the gonad. (Fig. 27, GL.) The stomach lies in front of, below, and to the left of the gonad. At the center of each flattened side is an irregularly oval, white, tendinous area about 8 millimeters long, from which the muscles radiate which surround the stomach by a thick wall except at the anterior and posterior ends. At the former, where the œsophagus enters and the intestine leaves, a thin-walled chamber is formed, elsewhere spoken of as the vestibule. The muscles pass from one tendon to

the other, forming a very thick wall upon the dorsal and ventral sides of the stomach. The posterior wall of the stomach is thin, like the anterior. Within the muscular layer is a white layer of what seems to be elastic tissue, at least as thick everywhere as the muscle layer. Under the thickest part of the muscular layer, i. e., between the tendons of the stomach dorsally and ventrally, the elastic tissue layer is so thickened as to form thick pads which project into the cavity of the stomach. (Fig. 32.) Except upon the anterior and posterior walls, the inner surface of the stomach is thrown into fine, parallel, longitudinal ridges. Inside the walls of the stomach, covering only the ridged portions, is a thick, chitinous lining, which in life must lie closely upon the epithelium of the stomach and be formed by it, since it copies accurately all the ridges and folds of the walls of the stomach. In my preserved specimens the lining has always been entirely free from the walls, probably as the result of shrinkage. Compared with external chitinous parts this lining is quite soft, but nevertheless it must be a great protection to the fleshy walls of the stomach while the food, often mixed with hard, sharp pieces of shell, is being triturated.

From the anterior edge of the rigid pad of the ventral side of the stomach springs a row of small, slender tentacles. (Fig. 32, T.) I have found fine processes upon the corresponding part of the chitinous lining, which may possibly lie upon and protect the tentacles. What the function of these tentacles can be is hard to imagine. Perhaps they are sensory and have something to do with the passage of the food into or out of the stomach. In view of the character of the debris found in the intestine it does not seem probable that they are used to sift out the finely divided particles of food. Besides extremely small particles of food one finds in the intestine large pieces of crustacean shells and even entire pleopods. *A priori*, any sifting apparatus would therefore seem superfluous. It is unfortunate that the condition of my material prevents any histological examination of these organs.

The position of these tentacles clearly marks a line of separation between the anterior portion of the stomach into which the œsophagus and intestine open and the posterior portion where the food is ground, and makes the term *vestibule* seem reasonable in speaking of this portion. (Fig. 32, V.)

The opening into the intestine is upon the right side of the vestibule. I have been unable to find the valve guarding the entrance to the intestine mentioned by OWEN. From the vestibule the intestine passes to the right around the back of the cœcum and then forward upon the right side of the latter organ. (Fig. 27, 1¹.) Then, bending downward and backward around the part of the liver connecting the right and left lobes, the intestine forms a backwardly directed loop. (Fig. 27, 1² and 1³.) The two legs of the loop lie parallel and close to one another, connected by a delicate mesentery in which runs an artery giving off branches to each part of the intestine. (Fig. 27, 1A.) The second loop of the intestine is directed upward as well as backward, so that its end lies beneath the siphuncle. A ligament from the right anterior face of the gonad extends to the left leg of the loop and slings the loop of the intestine in position. (Fig. 27, 1L; Fig. 38, 1.1.) The left and larger leg of the loop runs straight forward under the stomach, crop, and liver in the mesentery above the heart and between the anterior renal sacs to the plicated anus upon the inner side of the mantle. The last part of the intestine is thickened and folded longitudinally and is called the rectum.

The cœcum is a blind sac opening into the intestine 10 to 12 millimeters from its origin and lying within the first loop of the intestine. (Fig. 27, Coe.) In and about the cœcum is the most complicated part of the entire digestive tract. The cœcum itself is a thin walled, oval, laterally flattened organ, 18 millimeters in length and 11 millimeters in width. The duct of the liver enters the cœcum opposite the intestinal opening; usually the minor ducts of the separate lobes of the liver unite into a common duct before entering the cœcum, but they may open separately. (Fig. 32, HD.) The intestinal and hepatic openings are both near the lower side of the cœcum. From the dorsal and posterior walls transverse, shelf-like lamellæ extend into the cavity of the cœcum, leaving its lower portion only unobstructed. The surfaces of the lamellæ are folded and pitted, so that their appearance lends support to the *a priori* judgment from their position that the lamellæ must be glandular, adding their secretion

to that of the liver as this flows through the cœcum. The lamellæ are about thirteen in number. The cœcum opens into the intestine, not directly, but through a short neck of about the same diameter as the intestine. The mouth of the cœcum is surrounded by a muscular thickening of the walls which is evidently a sphincter; ventrally the thickening extends from the opposite sides toward the intestine as a V-shaped ridge. From the opening of the neck of the cœcum into the intestine a thin, wide, projecting fold extends about 30 millimeters along the intestine toward the anus. (Fig. 32, 1.) The fold is widest at the beginning, where it evidently forms a valve guarding the cœcum against the entrance of food from the intestine. As it passes along the intestine the fold crosses over the ventral to the posterior side, at the same time becoming lower and lower until it can scarcely be seen. The middle part of the fold is of considerable thickness and is evidently glandular. From the point of the V formed by the sphincter of the cœcum a low ridge extends into the center of the pocket-like valve guarding the intestinal opening. From the point of the V also a second fold (Fig. 32, 2) extends along the right side of the intestine nearly parallel to the first fold. It is, however, not so prominent as the other. It gradually becomes lower until it disappears. A number of oblique, apparently glandular, foldings of the ventral side of the intestine connect the two folds.

In some specimens, perhaps usually, a low, longitudinal ridge occupies the base of the channel formed by the parallel folds. To this the oblique folds run and meet like the sides of a V, the apex being directed toward the rectum.

The first or posterior fold does not entirely disappear like the second, but is continued as a low, scarcely perceptible ridge to the rectum. Close beside this, anteriorly we may term it, another ridge runs exactly parallel for its entire length. (Fig. 32, 3, 3.) This third fold commences near the end of the anterior fold of the first part of the intestine, but seems to have no connection whatever with it. The two parallel folds commence upon the posterior side of the intestine; as they run back along the second loop of the intestine they pass to the opposite side, upon which they continue until the rectum is reached, when they become ventral and are lost among the longitudinal foldings of this part of the intestine. As they make the sharp turn at the back of the second loop the folds become much thickened; another thickening of the folds is observable at the beginning of the second loop. Upon the posterior side of the turn of the second loop is a thick, foliaceous ridge 20 millimeters in length. (Fig. 32, 4.) This is connected with the posterior of the two parallel ridges by a number of fine, transverse folds running across the ventral side of the intestine.

The intestine is extremely thin walled and plentifully supplied with blood vessels. In a number of instances the diagonal ridges of the intestines were immediately above small arteries; whether there is an intimate connection between ridges and blood vessels in all cases can be determined only after an histological examination which my material did not permit.

The structure of the cœcum seems to indicate that it may serve as a collecting place for the secretions of the liver with which its own secretions are mixed. When the proper time arrives the sphincter relaxes and the accumulated secretions are guided along the channel between the parallel ridges of the intestine. As has already been described, the posterior and larger of the two ridges of this part of the intestine serves as a valve to prevent food entering the cœcum; the disposition of the folds also renders it probable that the mixing of the food with the secretions of the liver and cœcum does not take place until some distance beyond the point where the latter enter the intestine. There is no use in making any further conjectures as to the functions of these ridges which, endostyle-like, extend along the intestine, until we know their histological structure.

The liver is a large, dark-brown, lobed mass which lies underneath the posterior part of the crop and the stomach and cœcum, and surrounds parts of the intestine. (Fig. 27, L, L; L¹, L¹.) It is generally divided into five parts, two right and two left lobes, and a median portion which may or may not assume the form of a lobe. The left lobes are very considerably larger than the right. The main ducts of the right and left lobes unite in pairs, the ducts thus formed uniting to make a common duct a short distance from the cœcum. The large ducts are covered by small lobules, which empty their secretion directly into the ducts. The hepatic artery and its

branches run along the dorsal sides of the hepatic ducts giving off a branch to each lobule. The duct of the right lobes of the liver passes under the first loop of the intestine as this runs forward around the cœcum. The intestine passes backward under the median part of the liver, nearly enclosing it in a loop.

VALENCIENNES has figured an exceedingly interesting abnormality in his specimen. The anus is shown situated upon the body wall between the shell muscles. This is the only record of any such misplacement of the anus. VALENCIENNES's specimen seems to be perfectly normal in every other particular.

We have no knowledge regarding the innervation of the portions of the alimentary system back of the buccal mass. It has so far been impossible to trace any nerves to these organs.

RENAL ORGANS.

It has already been mentioned several times that the renal organs of *Nautilus* are situated in the posterior region of the ventral portion of the mantle. Like the gills, they are four in number, the renal glands being situated upon the branchial arteries.

From the posterior side of each branchial artery, at about one-third the distance from its origin to the base of the gill, hangs a large bunch of finger-like follicles. (Fig. 36, a. p. g. and p. p. g.) These hang into the pericardial cavity. On account of their resemblance in many ways to the pericardial glands of the *Dibranchiata* the four follicular appendages from the posterior sides of the branchial arteries are also generally called pericardial glands.

From the anterior side of each branchial artery, immediately opposite the follicular appendage, hang two appendages subdivided by narrow fissures into small, polygonal lobes, pressed closely together so that they appear to form a single hemispherical mass of about the same size as the follicular appendage on the posterior side of the artery. (Fig. 37.) These have been called the renal appendages. Each pair of renal appendages hangs into a chamber, the renal sac, which is completely closed off from the cœlom, and has but a single opening to the exterior, situated upon the inner surface of the mantle. (Fig. 36, r. s; Fig. 3, RA, RP.)

The renal sacs are arranged in pairs; an inner (anterior) pair which lie side by side medianly, possessing a common dividing wall, and an outer (posterior) pair, which lie at either side of and slightly posterior to the inner pair, nowhere touching each other.

The dorsal or outer walls of the anterior sacs are formed by the integument of the mantle. The ventral or inner wall is formed by the visceropericardial ligament (Fig. 36, p. v. l.), which is continued forward to unite with the integument of the mantle. A common, thin, vertical partition separates the two sacs medianly.

The posterior walls are formed by a narrow septum, extending between the visceropericardial ligament and the inner wall of the mantle. A section of either sac parallel to the longitudinal axis of the body is triangular—the base of the triangle being posterior and formed by the last-mentioned wall of the sac, while the apex is directed anteriorly and is formed by the union of the edge of the visceropericardial ligament to the inner wall of the mantle fold.

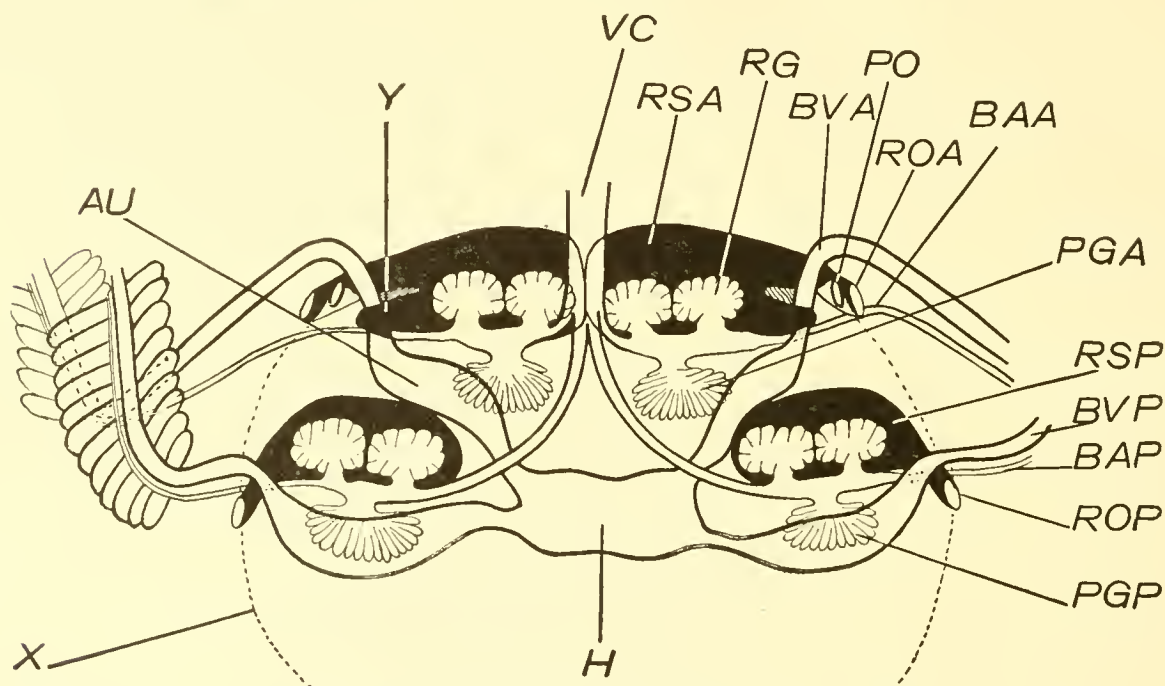
The longest diameter of the chambers is transverse to the long axis of the body. Passing toward the sides the chambers gradually decrease in size; finally, near the outer ends, forming a canal only, which leads to the external opening.

To the outer sides of the lobular appendages the branchial vein, passing through the mantle to the heart, pushes the walls of the sac inward from the posterior edge. (Text-fig. 9, BVA, Y.) A short, blind pocket is formed upon the posterior side of the branchial vein. The narrow portion of the renal sac anterior to the vein forms the canal leading to the exterior. This passes the anterior side of the vein, then turns backward below the vein and opens outward just posterior to it, through the outer of the two pores lying side by side upon the inner surface of the mantle. (Fig. 3, RA.)

The anterior branchial arteries pass outwardly from the vena cava in the posterior walls of the anterior renal sacs. Each passes below the canal of the sac leading to the exterior, and on in the mantle to the gill along the ligament-like base of the anterior gills. It thus lies immediately below the branchial vein.

The other two renal sacs, the posterior sacs, lie at the sides of the body, widely separated from each other. A little posterior to the inner sacs, they are considerably outside them, to close the ventral sides of the shell muscles.

The dorsal wall of each sac is formed by the inner wall of the mantle fold, and is that portion of the inner wall of the mantle fold lying between the anterior renal pores and the base of the posterior gill. The posterior and anterior walls of the sac are formed by septa extending backward and downward from the inner wall of the mantle. They unite around the lobular appendages to form a closed sac, from the posterior edge of which a thin ligament extends backward and somewhat inward, attached along one edge to the visceral body wall. (Fig. 36, L.) The outer end of the sac is narrowed to form a canal which, running in the substance of the mantle



TEXT-FIG. 9.—DIAGRAM OF THE RENAL SACS AND NEIGHBORING ORGANS OF NAUTILUS, AS VIEWED FROM THE DORSAL SIDE.

AU, auricular expansion of left anterior branchial vein.
 BAA, anterior branchial artery.
 BAP, posterior branchial artery.
 BVA, anterior branchial vein.
 BVP, posterior branchial vein.
 H, heart.
 PGA, anterior pericardial appendage.
 PGP, posterior pericardial appendage.
 PO, pericardial pore.

RG, anterior renal appendage.
 ROA, anterior renal pore.
 ROP, posterior renal pore.
 RSA, anterior renal sac.
 RSP, posterior renal sac.
 VC, vena cava.
 X, outline of pericardial division of coelom.
 Y, cul de sac of anterior renal sac.

close to the ventral surface of the shell muscle outside and ventral to the branchial artery, opens to the exterior through one of the posterior renal pores. (Fig. 3, RP.) The posterior branchial arteries run through the posterior walls of the outer renal sacs. (Text-fig. 9, BAP.)

Between the inner and outer renal sacs is left a narrow offset of the pericardial cavity extending into the mantle fold. The auricular enlargements of the anterior branchial veins lie in this space. From the outer end of the enlarged auricular portion of the vein where it turns upward to pass through the inner wall of the mantle fold, a triangular septum stretched between the outer and inner walls of the mantle fold extends outward to the lateral edge of the pericardial space. By this means a narrow passage is formed between the anterior side of the outer renal sac and the septum. This passage, passing along the outer side of the anterior branchial vein, opens to the exterior through the pericardial pore. (Fig. 3, PP.)

Within the lips of each of the pericardial and renal apertures are folds from each side; they are especially well developed upon the lips of the renal apertures, and lapping past each other form valves which are difficult to push aside with a probe, and which must be effectual in preventing ingress or egress of any substance except under the control of the animal.

The histology of the pericardial glands and the renal appendages has been investigated to a limited extent by VIGELIUS, but our knowledge of the microscopic structure of these organs is still most elementary.

The branchial arteries run outward from the vena cava through the posterior walls of the renal sacs. At about the middle of these the arteries form sinus-like enlargements, in the walls of which are usually three openings—one on the posterior wall leading into the central blood space of the pericardial gland, and two in the anterior wall leading into the central cavities of the lobular renal appendages.

The pericardial glands are made up of a large number of finger-like follicles radiating from the central cavity, which is in communication with the branchial artery. The glands are not stalked, but are attached to a quite considerable area of the wall of each renal sac around the fissure leading into the central cavity of the gland. The follicles of the glands are sometimes slightly constricted at their bases or may be enlarged a little distally. Blood spaces extending outward in the follicles from the central cavity form a closed finely branching system. The external or pericardial surface of each follicle is covered by minute pores, leading into tubules which everywhere penetrate between and separate the branching blood vessels. The blood vessels possess a very thin endothelial wall, which lies close to the inner side of the columnar epithelium of the tubules. The structure of the pericardial glands is very similar to that of the venous appendages of the Dibranchiata.

GROBBEN¹ remarks upon the resemblance in essential structure of the pericardial glands of *Nautilus* to those of *Eledone moschata*. The glands are much further subdivided in *Nautilus* than in *Eledone*.

The renal appendages have much the same structure as the pericardial glands. They hang in pairs from the anterior sides of the branchial arteries, pressed closely against each other so as at first sight to appear like a single structure, but in reality connected only by the wall of the branchial artery.

The renal appendages are divided by narrow, not very deep, fissures into large, flattened, polygonal lobes, and so present an appearance quite different from that of the pericardial glands. Like the pericardial glands, the renal appendages are sessile upon the branchial arteries.

The openings in the anterior walls of the arteries lead into a sinus-like central blood space in each renal appendage. From the central blood space the branches to the lobes pass outward, breaking up into numerous closed vessels. These are separated by invaginations of the columnar surface epithelium, which comes into close contact with the thin endothelial walls of the blood vessels. The outer ends of the tubules pushed inward from the surfaces of the lobes are radial; the inner ends run irregularly.

The renal sacs are often completely filled with a gritty substance, like fine sand. Sometimes it is white, sometimes a faint rose-pink in color. This constitutes the excretory product of the renal appendages. It is composed of rounded grains, formed by numerous concentric layers, reminding one strongly of starch grains by their appearance. The grains are single or compound, often being joined so as to form short varicose rods. Rarely irregular masses are formed. When the deposit in the renal sacs is of a pink color most of the granules have a slight pink tinge. Some are deep red, while others contain a deep red center and a light peripheral portion. The granules are frequently found in the tubules of the appendages.

According to KEFERSTEIN, the excreted substance found in the renal sacs contains a slight amount of fat. The greater proportion is, however, made up of inorganic substances. The principal of these is calcium phosphate. Lesser amounts are found of calcium sulphate, calcium

¹ Morphologische Studien über den Harn, und Geschlechtsapparat sowie die Leibeshöhle des Cephalopoden. Arb. a. d. Zool. Inst. d. Univ. Wien. T. V., 1884.

carbonate, ferric phosphate, and magnesium ammonium phosphate. The excretion contains no uric acid.

The amount of the excreted products in the renal sac may be quite considerable. In one case the deposit obtained from the four sacs amounted to 3.28 grams.

The secretion of the pericardial glands is often quite large in amount, being sufficient to glue the viscera together and cause considerable trouble to the dissector. Of course there is a probability that the glands have been stimulated to abnormal activity by the handling of the animal. The coagulated secretion appears much like mucus. KEFERSTEIN found no traces of uric acid in either the pericardial glands or their secretion.

BODY CAVITY.

The body cavity of *Nautilus* is very extensive, and consists of two distinctly separated portions—an anterior hæmocœl and a posterior and ventral cœlom. The principal portion of the hæmocœl forms a space around the œsophagus with its crop-like distensible portion, and the liver, occupying the entire space between these organs and the body wall. (Fig. 7.) The hæmocœl is continued anteriorly in the form of many splits and spaces between the muscles and membranes around the buccal mass. These cavities and others which communicate with the main portion of the hæmocœl are in free communication with blood sinuses in the various organs.

The hæmocœl is traversed by many fine shreds of connective tissue, which pass from one to another portion of the body wall or from the walls of the body to the viscera lying within the cavity. All these connections are exceedingly delicate, and are so easily ruptured or dissected that for all purposes of dissection the organs in the hæmocœl lie freely in the cavity. The vena cava lies along the ventral wall of the body and through its dorsal wall are numerous openings, from twenty to seventy-five, allowing free passage to the blood from the hæmocœl into the vena cava. At least, as the blood in the vena cava moves toward the gills and through them to the heart, it is more justifiable to presume that the blood which enters the hæmocœl through numerous sinuses is drawn into the vena cava than that the flow occurs in the opposite direction. Some of the openings in the walls of the vena cava are large enough to admit the end of a probe 1 millimeter or more in diameter; others are so small as to be scarcely visible.

The cœlom is situated posteriorly to the hæmocœl, and is completely separated from it by a thin membranous wall. (Fig. 7.) This wall, which I have called the hæmocœlic membrane, is attached to the body wall dorsally along the line of the dorsal aponeurotic band. (Fig. 7, X.) At the sides of the body its edges are fastened to the inner surfaces of the shell muscles, passing downward and slightly backward. The ventral edge is attached to the ventral body wall along the line of junction of the body wall and the inner wall of the mantle fold.

The anterior face of the hæmocœlic membrane is rough, and is attached to the organs within the hæmocœl by a few strands of connective tissue. The posterior, cœlomic face of the membrane is smooth and covered by the cœlomic epithelium.

The attachments of the hæmocœlic membrane to the body walls are considerably in front of the posterior ends of the organs contained within the hæmocœl. Consequently it is pushed backward by the lobes of the liver, forming sack-like coverings for these. (Fig. 7, L, L.) It covers other organs in a manner to be described presently.

There is a considerable mechanical advantage in the dorsal attachment of the membrane, on account of the membrane forming sac-like coverings for the backwardly projecting viscera; it also serves to support these viscera. The support is rendered much more effectual by the attachment of the membrane to the body wall along the dorsal aponeurotic band, where the latter is itself attached to and supported by the shell, than it could be if the membrane were attached to the loose wall of the body back of the aponeurotic band.

The cœlom also is a cavity of very considerable extent. It occupies the entire posterior portion of the body, extending forward dorsally above the lobes of the liver and ventrally into the mantle fold. (Figs. 7 and 36.)

The cœlom is divided by an almost complete membranous partition into two chambers, the ventral of which contains the heart and its auricles and the pericardial glands, and is therefore called the pericardial chamber (Fig. 36), while the much larger dorsal and posterior chamber contains the gonad and stomach and second loop of the intestine, and is called the genital chamber. (Fig. 7.)

The membrane separating the two divisions of the cœlom was named by HUXLEY the pallio-visceral ligament. (Fig. 36, p. v. l.) It is attached posteriorly to the ventral body wall between the anterior and posterior ventral aponeurotic bands. It extends forward from here in a nearly horizontal plane, attached by its edges to the lateral walls of the body, and finally is attached anteriorly to the inner wall of the mantle fold, the anterior portion of the ligament forming the ventral or posterior walls of the anterior renal sacs.

When the pericardial chamber is opened the ventral body wall and the posterior portion of the pallio-visceral ligament will be found to be very closely applied to each other.

As a matter of fact the heart is within the pallio-visceral ligament, and not far from its center. The heart projects from the under side of the ligament, while the branchial veins, expanding near the heart to form the auricles, extend freely through the pericardial chamber to the points where they enter the wall of the mantle. Necessarily the branchial veins are also surrounded by extensions of the pallio-visceral ligament and covered by the cœlomic epithelium.

It has already been intimated that the pallio-visceral ligament is not quite complete. There are, in fact, three openings in it by which the pericardial and genital divisions of the cœlom are put into communication with each other. The smallest of these, and for a long time considered to be the only one, lies just back of the left side of the heart. (Fig. 36, p. v-p. ap.) It is an oval opening, the longer axis of which is directed posteriorly, and when undisturbed the edges of the opening lie against each other. The common septal artery passes through this opening into the genital division of the cœlom.

The other two openings through the pallio-visceral ligament lie at either side of and mostly anterior to the heart (Figs. 36, 38, and 39). These were first described by HUXLEY. They generally extend nearly to the middle line in front of the heart, leaving the heart suspended by a narrow ligament anteriorly. But their size and position is subject to considerable variation. In the specimen from which Fig. 36 was drawn the openings were widely separated anterior to the heart, and the left opening was at least twice as large as the right. In Figs. 38 and 39 the openings are seen to be much closer to each other in front of the heart, those shown in Fig. 39 being even less separated than those in Fig. 38. In Fig. 39, too, the left opening is very much larger than the right, while in Fig. 38 the left opening is only slightly larger than the right. The edges of both openings are attached to the dorsal and anterior side of the heart.

The dorsal aorta passes through the left opening, and following the posterior side of the hæmocœlic membrane for a short distance, penetrates this and runs forward in the hæmocœl above the œsophagus. (Fig. 7, Ao.)

From the posterior wall of each renal sac glandular appendages hang into the pericardial cavity. The secretory epithelium of these appendages is a portion of the cœlomic epithelium.

The genital division of the cœlom is much more extensive than the pericardial division. It is traversed by several ligaments which support and inclose viscera.

Principal of these is the genital ligament, within which the gonad is inclosed. This extends from the posterior wall of the cœlom, just above the origin of the siphuncle, to the pallio-visceral ligament just back of the heart. (Figs. 7, 38, and 39.) At its upper end this ligament forms a band a couple of centimeters in breadth, attached to the body wall obliquely, in a line directed downward from the right to the left side.

The gonad, being contained within this ligament, causes a great enlargement of its lower portion, and finally projects into the pallio-visceral ligament, causing the latter to appear to be attached to the ventral surface of the gonad. The posterior opening through the pallio-visceral ligament is just to the left of this attachment, the ligament being continued on the right side of the opening up over the surface of the gonad. In this way the common septal artery comes

to pass through the opening directly upon the surface of the gonad without at any point passing freely across the cœlom. The area of attachment of the gonad to the pallio-visceral ligament is quite wide.

At the aperture of the gonad the cœlomic epithelium is continued inside the cavity of the gonad. Thus the cavity of the ovary or of the testis is a nearly inclosed portion of the cœlom. The ova and follicle cells are developed from the cœlomic epithelium.

The genital ligament is raised from the upper or anterior surface of the gonad along two lines. (Figs. 38 and 39.) The right elevation forms a fold which incloses and suspends the second loop of the intestine. As the sides of the fold come together between the two parts of the loop a mesentery is formed binding these together. The anteriorly directed portion of the loop lies next the gonad. As this passes beyond the gonad anteriorly into the rectum it remains inclosed by the fold, which is here produced directly from the portion of the pallio-visceral ligament between the two anterior visceropericardial openings.

The second elevation of the genital ligament runs to the left side of the gonad and is produced from here to the posterior portion of the stomach as a distinct ligament.

The upper end of the genital ligament is sometimes found to be thickened and shrunken, appearing as if it contained muscular tissue and had contracted strongly.

Although the second loop of the intestine and the stomach appear to lie in the cœlom, they are in reality outside of it. They lie in pockets of the hæmocœlic membrane, which is only more closely applied to these organs than to the lobes of the liver. In the case of the stomach this is quite evident. With the intestine it is less so, but examination shows that the ligament surrounding the second loop of the intestine is continuous with the hæmocœlic membrane around and between the two branches of the loop.

In fact, these ligaments are composed of double lamellæ containing the viscera inside them, and covered outside by the cœlomic epithelium. They have something the same relation to the cœlom as the mesenteries of a vertebrate. The blood sinuses contained by them may be considered as portions of the hæmocœl. The ligament of the stomach is sometimes plainly hollow, and filled with coagulated blood.

The right, functional genital duct, and the left, non-functional genital duct, are both contained in the pallio-visceral ligament, their inner borders following closely the right and left anterior visceropericardial openings, respectively.

The pallio-visceral and genital ligaments are, like the intestinal and gastric ligaments, composed of double lamellæ, containing the organs within them. The ova and their follicle cells and the pericardial glands are the only organs literally lying in the cœlom.

The cœlom is lined with an epithelium composed of flattened polygonal cells. Upon the anterior wall of the cœlom some of the cells, according to HALLER, can be distinguished by their taking a more intense stain from the ordinary cœlomic epithelial cells.

The renal sacs should also be considered as portions of the cœlom, or secondary body cavity. Their complete separation from the main portion of the cœlom is explained by some as a result of the displacement of the reno-pericardial openings from the inside of the anterior renal sacs to the surface of the body at one side of the external openings of the renal sacs. According to this view, *Nautilus* originally possessed but one pair of renal sacs—the anterior, beside the apertures of which the pericardial pores are found—while the posterior sacs have been derived by a division of the anterior sacs, and a separation of the two pairs of sacs thus formed. In somewhat the same manner and at the same time the anterior gills and their vessels have divided to form the posterior gills and their vessels.

The explanation is certainly far-fetched, and can not be received with too much caution. Other explanations are possible, and it is quite probable that some other will be found in future years which will show that this one is entirely erroneous in its conceptions.

It is at least as easy to suppose that the posterior gills and renal sacs have been developed independently of the corresponding anterior organs and that similarity of function has brought about similarity of structure, just as it has in several instances in adult and embryonic organs of widely separated groups.

We have still a portion of the *cœlom* to consider—that portion which stretches out in the siphuncle. Upon the right side of the attachment of the genital ligament to the body wall is an opening which leads into a cavity continued to the end of the siphuncle. The structure of the siphuncle has been described in some detail by HALLER, and its consideration seems to occur most logically at this point.

The genital ligament lies directly over the opening from the *cœlom* into the siphuncle, and makes the opening quite difficult to find sometimes. However, it is always single and upon the right side of the ligament. The cavity of the siphuncle is divided into three tubular portions, one of which is dorsal and two ventral. The cavities are lined by a continuation of the *cœlomic* epithelium, which is here composed of low cubical cells. The siphuncle is narrowed where it passes through each septum. At these points the siphuncular cavities also are narrowed, but not occluded.

The common septal artery passes along the genital ligament to the posterior portion of the body wall near the base of the siphuncle. It here divides into a right and a left branch, from one of which, sometimes the right and sometimes the left, the siphuncular artery is given off. (Text-fig. 11, p. 186.) This extends through the entire length of the siphuncle, finally ending openly.

The spaces intervening between the cavities of the siphuncle and the siphuncular artery are filled by a loose reticular connective tissue, the spaces of which contain venous blood, and are in communication through the walls of the body and the various ligaments crossing the *cœlom* with the cavity of the *hamocœl*.

HALLER describes a very curious structure of the epithelium covering the siphuncle externally. According to his description, the basement membrane is thrown into fine longitudinal folds. The epithelium does not cover the edges of the folds, these being in direct contact with the inner wall of the siphon. The epithelium covering the grooves between the edges of the folds forms a continuous protoplasmic layer, in which cell boundaries are not distinguishable. This layer shows striations perpendicular to its surface. It stains intensely with hamatoxylin. The widely separated nuclei are disk-shaped and lie in the upper or outer portion of the layer.

The tissues of the base of the siphon seem always to be continued into the genital ligament, forming a small rounded nodular eminence close to its attachment. In one case, shown in Fig. 38, a cord of tissue extends from this eminence along the ligament of the stomach. What this is I have not yet been able to determine.

There have been several theories advanced as to the function of the siphuncle. Most consider that it is in some way connected with hydrostatic properties of the shell and attempt to explain the rising and sinking of the animal as in some way dependent upon the action of the siphuncle. Reeve's theory of its action is very interesting, and a paragraph from him is worth quoting.

"The following appears to us to be the manner in which the *Nautilus* constructs its shell. The animal in its embryo formation deposits a simple hollow shell, out of which it necessarily advances as it increases in bulk; and in order to assist its specific gravity at the bottom of the ocean the vacated portion of the shell is chambered in by the secretion of transverse septa, the animal having first taken the precaution to secure a strong tubiform membrane to the inner wall in order to adjust its position (a consideration of the habits of this pelagic mollusk will show the necessity for this membrane). As the soft parts increase in bulk, the muscular girdle which binds them to the shell would naturally be forced from any adhesion, but from its being furnished with a certain degree of elasticity it advances by a series of periodical slips, the suddenness of which is undoubtedly counteracted by the attachment of the central membrane. The growth of the shell then proceeds in a circular direction, and serves to buoy up its inhabitant in the water by having the vacated portion chambered in to meet its specific gravity. The geometrical increase of it arises simply thus: The natural position of the *Nautilus*, like other cephalopods, is with its head downward, the shell being consequently above; and the periodical slip of the belt of adhesion most probably takes place when the animal is in this supine position. It lets itself down, and round and round, as it were, upon its axis by the limited extension of

this membranous pulley: the operation ceases when it arrives at maturity, and the membrane, being no longer wanted, probably decays. Such is the manner in which our observations lead us to suppose the Nautilus grows: the chambers have certainly no communication with the surrounding fluid. The camberated portion of the shell of Nautilus is evidently a simple, mechanical construction (though planned by the wisest intelligence) to assist the specific gravity of its inhabitant whilst under the different mutations of pressure that it is liable to at different periods of growth in its passage through the element: and it is, moreover, a contrivance that could only be effected by the aid of this adjusting membrane upon the simple geometry of motion above described."

The siphuncle is, therefore, according to this theory, a mechanical contrivance regulating the form of the shell and partially supporting the body during the formation of new septa.

These theories as to the function of the siphuncle have been gradually discarded as study revealed more of the structure of fossil cephalopod shells and as our morphological conceptions matured. Our present knowledge indicates that the siphuncle is a vestigial structure, having no immediate connection with the ability of the Nautilus to rise or sink. This has been proven by WILLEY in a series of direct experiments.

In a communication from New Guinea, in September, 1895, WILLEY (1896, 1) gives an account of his experiments, as follows:

"Being desirous of obtaining, if possible, experimental evidence as to the physiological significance of the siphuncle in the Pearly Nautilus, I have made several successful attempts to cut the siphuncle without otherwise injuring the animal. The evidence supplied by the experiment can not be regarded as conclusive, on account of the altered conditions of depth and temperature to which the Nautilus is exposed by being brought up to the surface, but it may be well to consider what the results indicate.

"At first I sawed through the shell into one of the chambers, and then cut the siphuncle. This method has the disadvantages of injuriously affecting the efficiency of the chambers and of causing a more or less considerable loss of blood to the animal. The latter will, however, live in confinement about as long as untouched individuals.

"A young Nautilus operated upon in this way on June 26 was placed in the sea in shallow water for its movements to be watched. It sank slowly to the bottom, and then for a long time made active revolving motions about the vertical axis, but scarcely made any progressive movements.

"On another occasion (July 10), after several trials, I found that the best way of performing the operation is to saw through the shell in the neighborhood of the posterior portion of the body of the animal, over the cardiac region, and not to tamper with the chambers. If the shell be held mouth downward this point lies approximately in the same vertical and transverse plane with the points where the free margin of the mouth of the shell merges into the umbilicus. When a large enough hole has been made in the shell to admit the scissors, the shell being still held upside down, the ventral visceral portion of the body usually detaches itself from the shell, or can be readily caused to do so, and, sinking inward, exposes the root of the siphuncle, which can then be severed. On returning the shell to its normal position the body immediately resumes its normal intimate contact with the wall of the cavity in which it lives, and the pressure so exerted prevents any extensive loss of blood. Under these conditions the operation does not, as a rule, appear to affect the vitality of the animal in any degree.

"A Nautilus¹ which was treated in this way on July 10, on being placed in the sea, swam about very vigorously for some time in the middle stratum of water, but most of the time at a little distance from the bottom. On September 13 I operated on four more individuals taken in Talli Bay, on the north coast of the Gazelle peninsula. One of them showed a tendency to sink to the bottom, which it always performed very gradually. In this one I had accidentally punctured the mantle over the heart. The others remained floating and swimming about on the

¹ It should perhaps be mentioned that in this particular individual I accidentally cut into the last chamber and plugged the opening with wax.

surface during the whole time of observation. They did not go far in one steady direction, but tended to go in circles, as in fact did another one whose siphuncle was uncut. If one of the individuals floating at the surface was forced down to the bottom with a hand net, it would slowly rise to the surface again. This also often happens with a *Nautilus* that has not been operated on.

"The results indicated by the above experiments, which, it may be added, are worth repeating, may be summarized as follows:

"The cutting of the siphuncle (α) does not temporarily affect the vitality of the animal; (β) does not prevent it from making movements of translation;¹ (γ) does not prevent it from floating at the surface; (δ) does not prevent it from sinking to the bottom.

"It still remains to be ascertained whether a *Nautilus* whose siphuncle has been cut, having sunk to the bottom of the sea in shallow water, will undertake a journey to the surface. My experiment of July 10 would seem to indicate that this might be expected to occur.

"The above experiments do not appear to oppose the view which I expressed in a former communication—that the siphuncle of *Nautilus pompilius* is, in some measure, of the nature of a vestigial structure.

"It might, indeed, be legitimate to suppose, on the principle of the correlation of organs, that in the Nautiloidea the course of evolution has led to a reduction of the siphuncle *pari passu* with an increase in the efficiency of the chambers as hydrostatic organs."

REPRODUCTIVE SYSTEM.

The first specimens of *Nautilus* to be obtained were females. After VAN DER HOEVEN had received a male specimen for many years again only females were obtained by naturalists, until the opinion came to be held that the females of *Nautilus* must greatly exceed the males in number. In recent years, however, especially in the collections made by WILLEY and in the MENAGE COLLECTION, the ratio has been inverted, the males being about three times as numerous as the females.

WILLEY states, in *Natural Science* for June, 1895, that out of sixty-seven individuals, fifty-one were male and sixteen female. In the MENAGE COLLECTION out of sixty-six specimens fifty were males and sixteen females. These numbers do not justify us in yet stating that there is a difference in the numbers of the sexes. The males may be much the more active in their habits at all times; the females may also retire into hiding during oviposition, and may possibly remain watching over their eggs until the young hatch, so that during a large portion of the year they are less liable to capture than are the males.

REPRODUCTIVE ORGANS OF THE MALE. (FIG. 38.)

The testis is a large oval organ situated in the extreme posterior and upper part of the cœlom, directly beneath the origin of the siphuncle (Figs. 7 and 38). Its posterior face is smoothly convex, fitting the concavity of the septum. The anterior surface, however, is flattened and shows irregular facets caused by pressure against other viscera, the stomach and liver upon the left, the intestine and the accessory reproductive gland upon the right.

The testis is covered by an extremely thin, delicate tunic, through which may be seen the indistinctly demarcated lobes of the organ. Over the posterior surface the tunic is closely attached to the tissues within, connective tissue strands extending from the tunic between the lobes. Anteriorly the tunic is entirely free from the mass of inclosed tissue, forming a sac which opens through a slit at the end of a short funnel-shaped production of the tunic (Fig. 38, T. ap.).

The testis does not lie free within the cœlom, but is attached to its walls by several ligaments. The case is summed up shortly by saying that the testis is contained within a ligament which has been invaginated into itself at one point to form the cavity of the testis. The point of invagination corresponds to the opening of the testis. This genital ligament (Fig. 38, g. l.), as

¹ In speaking above of progressive movements I mean, of course, in the usual backward direction.

we may term it, extends from the anterior portion of the pallio-visceral ligament upward and backward to the body wall just above the origin of the siphon. Thus the testis, a specialized portion of the wall of the genital ligament, comes to be slung by its upper and lower ends.

The upper attachment of the testis is effected by a membranous ligament about 2 centimeters broad extending from the anterior face of the testis, 1 centimeter below the upper end of the organ, to the body wall just above the origin of the siphuncle. The attachment of the ligament to the body wall is diagonal, passing across the body from right to left, and also somewhat downward. In this way the opening of the siphuncle into the cœlom comes to lie upon the right side of the genital ligament. Tissues of the base of the siphuncle seem to extend into the genital ligament, so that there is always a bulge in the ligament at this point.

Being continued on the testis the ligament separates into two portions which run downward over the anterior surface of the organ. These are merely elevations of the tunic of the testis. One passes over the surface of the testis to the left, leaving it at its edge and forming the suspensory ligament of the stomach (gas. l.). The other passes downward, first to the right, then slightly to the left until it reaches the anterior edge of the testis, where it is continued as a dorsal fold of the pallio-visceral ligament over the heart. This forms the suspensory ligament of the intestine and rectum (I. l.). It is attached first to the portion of the intestine leading forward to the rectum; enveloping this it forms the mesentery between the branches of the intestine, and then envelops the backwardly directed branch of the intestine. It must be remembered that all these ligaments are double folds, in some of which the walls covered externally by the cœlomic epithelium are closely pressed together, while in others organs or portions of organs, such as the intestine, stomach, etc., are pushed between the walls.

The posterior side of the anterior end of the testis is broadly attached to the pallio-visceral ligament. This attachment is immediately posterior to the heart. As the heart is surrounded and slung by the same ligament, the ventral surface of the testis and the dorsal surface of the heart come into very close contact.

The funnel-shaped tube through which the cavity of the testis is placed in communication with the vas deferens is formed by a thickened portion of its tunic about 4 millimeters in length and 3 millimeters in breadth at the tip. The tip is sometimes slightly expanded. The opening in it is slit-like.

The surface of the testis inside the tunic appears somewhat granular. KERR, describing the structure of the testis of an immature individual, says that "the aperture of the organ is seen to lead into a vestibule, into which open several ducts. Each of these, traced inward, divides up into numerous tubules which end blindly and are aggregated into distinct lobes and lobules. Vestibule and tubes are lined by epithelium continuous with that of the general cœlom."

The measurements of the testis of one specimen were: Length, 41 millimeters; breadth, 36 millimeters; thickness, 24 millimeters. At the right of the testis, and extending anterior to it, is a large accessory gland, which is formed around the convoluted vas deferens (ac. gl.). The accessory gland lies within the pallio-visceral ligament upon the right of the right anterior viscero-pericardial aperture. Posteriorly it projects freely, carrying the dorsal wall of the ligament over its surface. Lying in the pallio-visceral ligament in this way, the accessory gland is very closely attached by the ligament to the anterior portion of the testis. On account of the elevation of the posterior portion of the accessory gland above the pallio-visceral ligament, the portion of the ligament uniting this portion of the gland and the testis appears at first sight like a separate ligament, but is in reality only a fold of the pallio-visceral ligament (*y*).

The accessory gland projects entirely dorsally from the pallio-visceral ligament. It forms an oval organ, smaller anteriorly than posteriorly, the measurements of which are: Length, 27 millimeters; breadth, 20 millimeters; thickness, 15 millimeters. Its tissues are much firmer than those of the testis.

When in its natural position the accessory gland lies against the right anterior face of the testis, the loop of the intestine being held between the upper portion of the gland and the testis. In Fig. 38 the gland is turned outward so as to show the face which is ordinarily pressed against

the testis. Near the lower edge of this face is a funicular depression leading into the vas deferens (v. d.). The funnel of the testis fits snugly within this opening, so that, as KERR remarks, "though the cavities of the testis and of the vas deferens open quite independently into the coelom, they are at least during sexual maturity functionally continuous with one another."

The vas deferens winds about through the accessory gland, finally passing into a tough-walled sac which occupies most of the anterior end of the gland. The accessory gland "is composed of numerous caecal tubular outgrowths from the duct itself" (KERR). The proximal end of the vas deferens is exceedingly thin walled and small, being on this account very difficult to trace (v. d¹). It is rather less than a millimeter in diameter in this portion, but from the point v. d² its walls are very thick, the whole tube being about three times its former thickness, while the lumen remains about the same size as before. The thickened portion of the vas deferens opens into the right side of the tough-walled sac (S. V.), 12 millimeters long, occupying the anterior portion of the gland, which we may call the seminal vesicle. The seminal vesicle is easily distinguished without dissection of the gland.

The opening of the seminal vesicle is just in front of the junction of the mantle with the body wall. The remaining parts of the genital duct can be traced from the mantle cavity. They cause projections of the body wall so that their shape and course can be followed without dissection, but they are easily dissected by removing the integument.

The seminal vesicle opens by a very small orifice into a thick-walled tube which turns obliquely to the left, toward the center of the body. It quickly enlarges into a good-sized sac, 11 millimeters long, the spermatophore sac (Sp. s.). This is incompletely divided into two parts by a longitudinal septum extending into it from the posterior wall, upon the left side of the opening into the sac, nearly to the anterior end (Sep.). Coiled spermatophores are frequently found in the sac, bent around the anterior edge of the septum into a U-shaped mass. The anterior edge of the septum is frequently arcuate, so that the opening from one side to the other of the spermatophore sac is 3 or 4 millimeters in diameter and nearly round.

From the spermatophore sac a short thick-walled tube leads forward to the penis.

The penis is a tubular organ 4 to 5 millimeters in diameter, lying in the middle of the ventral surface of the body, its axis corresponding with the longitudinal axis of the body (Fig. 3, P.).

The walls of the penis are thick and muscular. Its tip usually projects freely from the body wall, and bears a small aperture (P. ap.). This leads into a cavity which divides almost immediately into a right and left portion. The right portion connects with the cavity of the spermatophore sac (P. r.). The wall of the cavity is thrown into longitudinal folds, which, however, are only found in the contracted condition of the organ. When a spermatophore is in the tube the walls are smooth.

A fleshy tube is prolonged posteriorly from the left side of the penis obliquely outward and backward for 8 to 15 millimeters (P. l.). This ends blindly with a slight enlargement. The left-hand cavity of the penis is continued into this tube. Its walls are folded like those of the right cavity of the penis, but not so strongly. In the enlarged portion the cavity also is larger. Near the end of the tube I have found a very minute, yet distinct opening upon the right side, leading into a short narrow sac parallel to the posterior portion of the larger tube. This sac evidently corresponds to the spermatophore sac of the opposite side. In one of the specimens examined the left portion of the penis was entirely lacking. There seems to be considerable variability in the extent of its development.

It is in the vas deferens that the spermatophores are formed. Each spermatophore consists of a thick-walled tube of chitin, one millimeter in diameter and five to ten centimeters in length. The lumen of the tube is very small and is filled with spermatozoa. I have several times found a spermatophore irregularly coiled in the seminal vesicle, or rather one end of it was coiled up here. The other end extended back in the vas deferens as far as the end or a trifle beyond the end of the thick-walled portion. The wall of the spermatophore seemed to be fully formed until near the posterior end. For the last centimeter the wall became gradually thinner and paler, finally disappearing.

In a less than half-grown male, the testis formed an elongate organ situated in the genital ligament immediately back of the heart. It measured 13 millimeters in length by 3 millimeters in breadth.

In this specimen the two halves of the penis were exactly alike; the right half could not be traced into any communication with the vas deferens. It seemed to end blindly in the body wall. I was not able to find any external opening of the vas deferens. The spermatophore sac existed as a small tubular diverticulum of the right half of the penis, just as I have found it in the left half of the penis of the adult.

Upon the left side of the lower end of the testis, within the pallio-visceral ligament, is a curious sac-like organ (pyr. s.). The blind enlarged end of the sac is close to the left side of the heart. Its position varies somewhat in different individuals, being in some close—even dorsal—to the heart, in others quite to the left of the heart, depending upon the shape and extent of the left anterior visceropericardial aperture. The neck of the sac is elongated, forming a narrow tube which opens into the mantle cavity through the pore already noticed upon the left side of the body at the line of junction of the mantle fold with the body wall (pyr. ap.). The sac is much flattened, causing a scarcely noticeable thickening of the pallio-visceral ligament. Its walls are thin and soft and are folded upon the inner side.

REPRODUCTIVE ORGANS OF THE FEMALE. (FIG. 39.)

The ovary (Ov.) occupies the same position as the testis, but is somewhat smaller than the fully developed testis and more rounded, forming a body 35 millimeters in length and 25 millimeters in breadth. It is suspended by ligaments in the same manner as the testis, the course of the ligament of the stomach, however, being slightly different. The fold of which the gastric ligament is a continuation extends from the upper end to the left side of the testis; it extends to the lower end of the ovary and the gastric ligament arises from its middle (gas. l.).

The aperture of the ovary is upon a small protuberance of the wall upon the right side of the lower end of the ovary (Ov. ap.). Anatomically the ovary opens into the cœlom; actually the aperture of the ovary is closely applied to the inner opening of the genital duct, so that the duct is functionally continuous from the ovary.

The posterior portion of the inside of the ovary is entirely covered by egg-follicles in various stages of development. The mature follicles are about 15 millimeters in length by 10 to 12 millimeters in diameter, each containing a single yolk-laden ovum. The older follicles are suspended from the wall of the ovary by slender, membranous stalks, which are usually simple, but, according to KERR, occasionally branch. The epithelium of the inner surface of the follicle, which is applied to the ovum, is continuous over the outside of the follicle with the cœlomic epithelium lining the ovary. The older follicles at least possess a three-lipped aperture at the end opposite the stalk, through which the ovum escapes. Follicles from which the ova have been shed are ruptured half way to their bases. KERR finds that between the bases of the follicles the lining epithelium of the ovary "thickens up into syncytial masses of protoplasm containing large round nuclei, each with a large deeply staining nucleolus, around which the protoplasm tends to segregate off more or less distinctly. The primitive ovum develops within such a heap, the nucleus increasing in size and assuming more and more the character of a 'germinal vesicle,' and the protoplasm first becoming more distinctly aggregated round the nucleus and marked off from the surrounding protoplasm and then increasing rapidly in size. As the ovum increases in size, the substance of the ovarian wall grows up round it to form the follicle, while the syncytium accompanying the ovum apparently gives rise to the lining cells of the follicle." In the young follicle the surface next the ovum is smooth, but as the ovum and follicle increase in size the inner surface of the latter becomes raised into anastomosing ridges, which penetrate deeply into the ovum. WILLEY found that the meshes formed by the ridges are much wider in submature than in the less mature ova, and would presumably be found to flatten out in completely ripe ova.

At the end of the ovum next the opening of the follicle is an area of protoplasm free from

yolk, in which the large nucleus is located. Over this region of the ovum the ridges are absent, while those which lie at the margin of the area form incomplete meshes open on the side toward the egg nucleus.

The clear polar area of the ovum is approximately triangular, "and from each of the corners of the triangle what may be called a line of weakness occurs in the follicular wall, bound on either side by incomplete meshes." (WILLEY.)

"The yolk is viscous and glutinous, and possesses a translucent brownish tinge. The nearly ripe ova rupture with the utmost facility." (WILLEY.)

"In the female the ramifications of the genital artery pass up on to the surface of the individual ova, and form a kind of capillary system, the finer branches following, but not always confined to, the reticular markings formed by the ridges of the follicular membrane which project into the yolk. The arteries which traverse the surface of the ova give off minute branches which pass inward, as it were, into the depths of the follicular ridges; and these deep-lying vessels anastomose with one another, while the superficial branches appear, as a rule, not to form anastomoses. It may be added that the impression of anastomoses is much more readily conveyed by examination with a hand-lens than it is by the use of the compound microscope." (WILLEY.)

The epithelium about the mouth of the ovary is composed of columnar cells bearing long cilia; farther within the ovary the epithelium gradually passes from columnar to cubical cells.

KEFERSTEIN¹ and LANKESTER and BOURNE have figured a large albumen gland attached to the ovary near its mouth. This has the shape of a large sac, of about the same volume as the ovary, lying upon the right side of the latter. BOURNE'S diagram may be simply a copy of KEFERSTEIN'S figure; nothing in the text gives any information as to whether the authors had seen the albuminous gland in their own dissections or not.

No other authors describe such a structure. I have myself been unable to find any traces of it in several female Nautili I have dissected. In several cases I have found the ovary filled with a hard, solid, brown coagulum, probably secreted by the walls of the ovary. As in one of the specimens dissected all the large ova had just been shed, this specimen was certainly sexually mature. If the gland is only formed periodically, we should certainly expect to find it in such a specimen. It is probable that the ovary of KEFERSTEIN'S specimen was abnormal and possessed a hernia-like protrusion.

HALLER has previously noted the absence of such a structure as KEFERSTEIN figures and has come to the conclusion that the ovary of KEFERSTEIN'S specimen was in a pathological condition. Some of HALLER'S specimens also had the ovary filled with the secretion already mentioned, of which he speaks as follows: "It has the same appearance as the egg-yolk, staining similarly with certain stains (carmin) or remaining unstained with others (hæmatoxylin). This yolk is the same as that in the eggs, from which I distinguish it by the name of the free yolk, and is used by being taken into the eggs. At first I thought that it might possibly be composed of an accumulation of yolk cells, but nuclei could not be discovered in it by means of the various nuclear stains used, it being a homogeneous mass—a secretion from cells. I then sought for a glandular differentiation, which, as processes of the ovarial wall, might project inward and function in the secretion of the free yolk. However, there was no such structure present, and nothing remains but to hold the portions of the wall of the ovary which are free from eggs responsible for the production of this yolk. It is probably the right lateral side of the ovary, upon which I have never found eggs, which performs this secretion.

"The cells of this portion of the ovarial wall would not, then, function as germinal epithelium, but would furnish a sort of nutrient material, not by giving off cells, but instead, pure yolk-stuff. The histological structure of that portion of the ovarial wall seems to me to indicate this. I found there a layer of cells, the elements of which were in all things very much like the follicle cells; it is composed of high cylindrical elements, which are completely filled with yolk granules. In places, where the cells had been separated from each other by shrinkage caused by alcohol, one could observe numerous protoplasmic connections between them. The cell nuclei are, like

¹BRONN'S *Classen und Ordnungen*.

those of the follicle cells, very irregular, and indistinctly bounded. It is characteristic that the chromatin is gathered in a coil in the center of the nucleus."

The mouth of the ovary is usually pressed closely against the inner opening of the oviduct, so that the two are functionally continuous. The oviduct lies between the walls of the pallio-visceral ligament and is thus closely attached to the ovary.

HALLER mentions that in several cases the mouth of the ovary was not in contact with the inner opening of the oviduct, and so opened into the cœlom.

The posterior half of the oviduct is thin-walled and broad, much like a flattened sac. Its walls seem to be glandular, and are quite smooth. The internal opening of the oviduct is often much larger than I have shown it in figure 39, which, however, is an accurate representation of the condition of the specimen from which it was drawn.

The oviduct leads forward and to the right side of the body. About 20 millimeters from its beginning it becomes much narrower, and its walls become thick and raised internally into annular ridges. The width of the posterior portion of the oviduct is 17 millimeters, while that of the anterior portion is 12 millimeters. Shortly anterior to the commencement of the thickening the oviduct reaches the surface of the body at the line of junction of the mantle and body wall, from which it projects as a large rounded eminence from 7 to 12 millimeters. The projecting portion of the oviduct is ridged externally and presents an appearance which suggests that a portion of the oviduct has been evaginated. The external aperture of the oviduct forms a transverse slit at the end of the projecting portion. The distal portion of the oviduct is evidently glandular and suggests strongly the glandular distal portion of the oviduct of several Dibranchiata.

Upon the left side of the heart, in the female as well as in the male Nautilus, is a pyriform sac lying within the pallio-visceral ligament, and in all respects like the pyriform sac of the male. The position of its aperture, upon the left side of the body, corresponds to that of the functional oviduct upon the right side.

The nidamental gland has been described in the section devoted to the pallial complex. We have as yet no proof of the function of this gland. Analogy, however, guides us in giving it this designation.

The ovary of a half-grown female was a small elongated body, 18 millimeters in length by 6 millimeters in width. It was situated within the genital ligament close to the heart, extending along about one-third of the genital ligament. The intestine and stomach were attached directly to the genital ligament above the ovary. The ovary evidently grows backward and upward in the ligament so that when it is mature the ligaments of the intestine and stomach are attached to its surface.

The ovary opened into the cœlom just back of the heart, and so at a considerable distance from the inner opening of the oviduct. The functional oviduct was scarcely different from the pyriform sac at this time. The walls of the portion near the external aperture, which later became rugose and greatly thickened, were in this case only slightly ridged and scarcely thickened at all. The oviduct papilla projected very little into the mantle cavity, and was not at all pleated.

The genital arteries were discovered by means of injections by WILLEY; since then I have been able to trace the arteries in uninjected specimens. They are three in number and arise directly from the heart. They arise close together in a row from the posterior portion of the dorsal surface of the heart. (Text-fig. 10, p. 182.)

The genital artery is the middle one of the three, and its main trunk passes over the dorsal surface of the gonad.

The right-hand artery forms the gonadual artery and goes to the functional genital duct. The left-hand artery is that of pyriform sac, being distributed mainly to this. Upon morphological grounds it should be considered to be the left gonadual artery.

Both the gonadual artery and the artery of the pyriform sac "give off a branch which passes into the perigonadial membrane." (WILLEY.)

The further ramifications of the genital artery of the female have already been mentioned.

The pyriform sac was first described by OWEN in a female specimen, and given this name by him. OWEN did not discover the opening of the sac to the exterior, and was led by its position

to believe that the pyriform sac was a vestige of an organ which, at some former period in the history of the species, had formed a communication between the venous sinus and systemic ventricle, independent of the branchial circulation.

KEFERSTEIN discovered the opening of the sac to the exterior.

Many years after LANKESTER and BOURNE first discovered the presence of the organ in the male Nautilus, and showed that it has the same structure and position in both sexes. These authors called attention to the exactly similar position of the genital duct upon the right side of the body and the pyriform sac and its duct upon the left side, and suggested that the latter is the left genital duct in a vestigial condition. The similarity of the functional and non-functional genital ducts is evident in the female, in which the aperture of the oviduct occupies a position upon the right side of the body corresponding closely to the position of the aperture of the pyriform sac upon the left side.

Later observers have added still further evidence in favor of the homology of the pyriform sac with the functional genital duct. KERR finds that in a very young female the inner part of the genital duct has exactly the appearance of the pyriform sac in the adult, the rudiment of the gonad being quite distinct and apparently median and unpaired.

The first part of the statement adds great strength to the view which considers the pyriform sac to be a left genital duct. The latter part of the statement answers the question left open by LANKESTER and BOURNE—whether the pyriform sac represented only the left genital duct, or the genital duct and the gonad of the same side.

KERR also remarks that "in the young animal, the NEEDHAM's sac (spermatophore sac) being not yet expanded, the form and size of the right portion of the apparatus (penis) are in almost exactly the same condition as is the left in the adult."

The discovery by WILLEY of the symmetrical arrangement of the arteries of the gonad and genital duct and the pyriform sac entirely justifies the conclusion that the latter two are homologues. The fact that from both the gonaducal artery and the artery of the pyriform sac a branch is sent to the ovarian membrane forms a strong piece of evidence that these are equivalent arteries, and also indicates that the pyriform sac corresponds to the genital duct alone, and not to an entire left reproductive apparatus.

It is then about as well established as anatomical evidence alone can establish such facts, that Nautilus possesses a single unpaired, median gonad, and a pair of gonaducts: one of these, the right, is functional and highly developed; the other, the left, exists in the condition of a sac opening to the exterior, and no longer functions as a gonaduct.

The spermatophore is formed in the vas deferens. Apparently the formation takes place in the thickened portion of the vas deferens, as in the specimens I have dissected the spermatophore ended at about the commencement of this portion of the tube—either a little distal or proximal to this point. As the spermatophore is formed it is moved forward and finally it debouches in the seminal vesicle, where it is irregularly and loosely coiled. From here it passes into the spermatophore sac where I have always found the coil occupying the two sacs, bent around the longitudinal septum in the form of a U. I have next found the spermatophore occupying the tip of the penis, causing a great distention of this organ. The spermatophore is now tightly coiled into an ovoid mass, about 8 millimeters in length by 5 millimeters in diameter.

From the penis the spermatophore is in some way passed to the superior labial tentacles. I have several times found a single spermatophore tightly held by the upper tentacles of either the right or left superior labial group. But when among the labial tentacles the spermatophore is always surrounded by a closed, tough sac of a chitinous material. The sac with the spermatophore inside it forms a roughly spherical mass, averaging 13 millimeters in diameter. The spermatophore is loosely coiled and lies free inside the sac.

We find here two questions to be answered. The first is, How and where is the sac formed around spermatophore? One would naturally expect such a structure to be formed either in the spermatophore sac or the penis. But I have never found a sac around a spermatophore contained in the spermatophore sac or in the penis—only around those held among the labial tentacles; but around each of these. Possibly the secretion of VAN DER HOEVEN's organ forms the sac

The second question is, How are the spermatophores conveyed from the penis to the labial tentacles? The latter are widely removed from the penis, beside being inside the cephalic sheath. One course has suggested itself as possible. The spermatophore being discharged from the penis may be carried through the funnel to its tip. It will be remembered that the tip of the funnel lies in a groove on the ventral side of the cephalic sheath, and that the cephalic sheath is deeply notched just above the tip of the funnel, so that the latter projects slightly beyond the posterior edge of the notch. It may be that when the spermatophore reaches the tip of the funnel it is grasped by some of the tentacles, either digital or labial, and conveyed by them to its final position among the dorsal tentacles of the superior labial group. VAN DER HOEVEN'S organ lies just back of the ventral notch, and if it plays any part in the formation of the sac of the spermatophore, the spermatophore may remain for a time in the depression into which the organ opens. Possibly the tip of the funnel may be turned upward and the spermatophore forced inside the cephalic sheath by a jet of water. I do not wish this suggestion to be interpreted as my theory of how the spermatophore travels to the labial tentacles from the penis. It is only a suggestion, which may be far from the truth, but which, arising from the anatomical relations of the various parts concerned, I think it can do no harm to publish. Such a transfer would, however, involve an active coordination of different parts which is quite unique among Mollusca in processes accessory to fertilization.

It is noticeable that the spermatophores are not found in any connection with the spadix, which has been frequently considered analogous to the hectocotyized arm of the Dibranchiata. What the rôle of this organ is, is as much a mystery as ever. Its large size and complicated structure indicate that its function is important, and that there may be several minor processes which cooperate to perform the function for which the structure has been developed.

It has been suggested that the spadix is thrust into the mantle cavity of the female during copulation. Evidently this is the idea of VAYSSIÈRE, who suggests that the function of the large, firm, and pointed first cirrus of the spadix is to facilitate the introduction of the spadix into the mantle chamber of the female. The fourth cirrus on account of its small size and position may have little share in the functions of the spadix. VAYSSIÈRE considers that the active parts in transferring the spermatophore to the female are the second and third cirri. The latter is especially fitted for this, and he suggests that the spermatozoa are carried in the crypts after the destruction of their protective envelopes, and being ejected from these by a momentary turgescence of the tongues are deposited at the orifice of the oviduct.

The second and third cirri of the spadix are evidently capable of considerable extension, and are probably very active portions of the organ in doing whatever work for which it is designed, but there is scarcely any reason to suppose that the spadix, and especially the third cirrus thereof, act as VAYSSIÈRE has suggested. For we have already noticed that the female frequently carries a spermatophore coiled upon the surface of the lamellated region inside the edges of the ventral notch of the cephalic sheath. It seems probable that the spermatophore is transferred from the male direct to this place. It is quite remarkable that the sac which surrounds the spermatophore when among the tentacles of the male has already been lost, the spermatophore lying naked, coiled upon the surface of the receiving apparatus of the female.

As the spermatophore is still intact, the third cirrus of the spadix certainly has no such use as VAYSSIÈRE suggests. Indeed, it seems strange that so complicated an organ as the spadix should have been required for so simple an operation as placing the spermatophore inside the cephalic sheath, of the female. The female *Loligo* carries spermatophores upon the buccal membrane, but in the case of *Loligo pealii* there is not the slightest trace of a hectocotyized arm or other specialized apparatus for depositing the spermatophores upon the buccal membrane of the female. It seems quite possible that the spadix of *Nautilus* may not function at all in the transfer, it being entirely accomplished by the superior labial tentacles. Or possibly the spadix serves to push aside the tentacles of the female and allow of the deposition of the spermatophore within them.

The development of the spadix in the adult male alone indicates that it is an accessory reproductive organ, but of its function we are absolutely ignorant.

How is the protective envelope of the spermatophore destroyed? There is no evidence as yet to indicate whether this is done by the male, or if the envelope is intact when the female receives the spermatophore. In the latter case the envelope may be destroyed by the action of the secretion of the receiving lamellae, or more actively, by the tentacles after being received, or by the handling it may undergo during the transfer from the male to the female.

I do not know of anyone who has ever found spermatophores upon any other region of the body of the female *Nautilus* than the one described.

Another question arises. How long is the spermatophore retained among the tentacles of the male or upon the receiving apparatus of the female? I am inclined to think that the spermatophore may be retained for a variable but not usually long time among the tentacles of the male. I have several times found a spermatophore in the process of formation within the vas deferens, and another coiled up in the spermatophore sac. In another case the spermatophore sac contained one spermatophore while another occupied the tip of the penis. The comparatively immense size of the fully developed testis indicates that it can produce an enormous number of spermatozoa in a very short time. The accessory gland, too, is of a size which shows that it can very quickly produce the secretion required for the tubular walls of a spermatophore. Spermatophore after spermatophore is probably produced in rapid succession throughout the breeding season; or if this is continuous, the year round, as WILLEY suggests, throughout the period of sexual activity. It seems probable that the males carry a spermatophore among the tentacles only till it can be transferred to a female. Then another spermatophore takes the place of the first, and so on. The female may carry the spermatophore for a longer time. Apparently a single one is carried at any time.

THE CIRCULATION.

ARTERIAL CIRCULATION.

The figures of the arterial circulation have been made partly from my own dissections and partly from the published figures and descriptions of WILLEY. In some instances I had obtained the same results as WILLEY before he published his figures, in others I have merely verified his work, and in places I rely entirely upon his figures and descriptions in order that my own descriptions may be as complete as possible. Some facts are, I think, published for the first time.

In the case of the branches of the lesser aorta and the arteries of the reproductive apparatus the completeness of the account is entirely due to the researches of WILLEY.

In both figures of the arterial system the arteries are viewed from the dorsal side. As the vessels represented in text-fig. 11 lie almost entirely ventral to those of text-fig. 10, I believe that they are shown with less danger of confusion in separate figures.

The heart is situated immediately back of the mantle fold in the portion of the coelom known as the pericardium. It is an oblong muscular organ of quite considerable size, being 2 centimeters in width, 1 centimeter in length (antero-posterior measurement), and 6 to 8 millimeters in thickness. The long axis of the heart is exactly transverse to the long axis of the body. The right side of the heart is slightly longer than the left side, so the symmetry of the heart is not quite perfect.

A branchial vein enters each corner of the heart. The portion of each branchial vein near the heart is capable of considerable distension, and these portions have been called the auricles of the heart. But very frequently one or all these vessels show no increase in diameter near the heart. This fact indicates that the so-called auricles of *Nautilus*, while physiologically similar, have not the same morphological importance and should not be considered as organs of the same nature as the auricles of the heart of the *Gastropoda* and the *Lamellibranchiata*. In these classes the auricle forms a distinct chamber, which even in its development is distinct from both the ventricle and the branchial veins, which the auricles of *Nautilus* are not. The term is a convenient one anatomically, indicating the portion of the branchial vein inside the pericardium

which is evidently pulsatile, but it should not be used in the same morphological sense as in other groups.

Five vessels arise from the dorsal side of the heart, the courses of which will be described presently.

The heart has thick muscular walls, and in the contracted state consequent upon death a very small fissure-like cavity. The inner surface of the heart is pitted, and by its appearance reminds one strongly of the inner surface of a mammalian heart, though by no means distinctly trabeculated. I have not been able to find any valves at the openings of the vessels leading into or from the heart, except possibly the dorsal aorta. The openings are, however, tightly closed, and it is possible that at the commencement of systole the walls of the heart contract first around the openings of the branchial veins, and thus the regurgitation of blood is prevented.

Until otherwise indicated all references will be to text-fig. 10.

The largest vessel proceeding from the heart is the dorsal aorta. This arises from the dorsal surface of the heart, on the left side and near the posterior edge. The base of the aorta is conical and possesses thick muscular walls, and could probably be properly spoken of as a conus arteriosus. At the end of the muscular portion of the base of the aorta is an elevation of the inner wall, which may be a valve. In some specimens this is quite distinct and much like a semi-lunar valve; in others it is barely noticeable. Possibly the conical base of the aorta should be considered morphologically as a portion of the heart itself.

Along the median part of the posterior edge of the heart, dorsally also, arise three small arteries. They lie in the portion of the pallio-visceral ligament attached to the posterior side of the heart. The artery at the left is the artery of the pyriform sac; the middle one is the genital artery, while the one on the right is the gonadual artery.

Also from the dorsal side of the heart, but near the anterior edge, arises the fifth artery, the lesser aorta.

Let us now follow the course of the dorsal aorta and its branches. From its origin on the dorsal side of the heart the aorta extends upward and backward and to the left along the posterior side of the hæmocœlic membrane. Turning forward it penetrates the membrane and enters the hæmocœl, in which it lies free, running forward over the liver and the œsophagus. In the posterior portion of the hæmocœl the aorta lies well to the left of the cavity, but as it extends forward it approaches the median line until, near the œsophageal nerve ring, it lies in the median line. Immediately back of the nerve ring the aorta divides into a left and a right branch, the innominate arteries, from which lesser branches are given off to the cephalic region and the funnel.

Commencing from the posterior end of the aorta, the first branch leaves it just after the aorta enters the hæmocœl. Coming off from the right side of the aorta, it runs directly toward the right side of the body, giving off first a branch anteriorly which passes to the posterior portion of the proventriculus, the posterior proventricular artery; next, a branch posteriorly which immediately bends forward and passes around the anterior side of the stomach to the cœcum, the cœcal artery; finally, the end of the artery passes to the stomach, forming the gastric artery, which breaks up into numerous fine vessels in the walls of the stomach.

Five or 6 millimeters anterior to the origin of this artery a much larger artery leaves the left side of the aorta. After a course of about 5 millimeters this artery divides into two branches, the anterior of which goes to the left shell muscle (the left posterior columellar artery), while the posterior branch proceeds to the liver (hepatic artery). I have called the branch of the aorta from which both these arteries arise the hepatico-columellar artery.

The hepatic artery goes to the junction of the two left lobes of the liver. It divides here into three branches. The left and middle branches enter the left lobes of the liver in which they break up into the fine lobular branches. The right-hand branch of the hepatic artery follows the median connecting portion of the liver to the junction of the two right lobes of the liver. Here it divides into a branch for each lobe. In its course it gives off a considerable branch to the median portion of the liver.

The left posterior columellar artery runs forward and upward to the dorsal edge of the left shell muscle near its attachment. After giving off a branch to the dorsal portion of the body wall it bends downward along the inner surface of the shell muscle, giving off numerous branches which enter the muscle.

The right posterior columellar artery arises from the right side of the aorta about 5 millimeters anterior to the origin of the hepatico-columellar artery. Since the posterior portion of the aorta is upon the left side of the body cavity, the right posterior columellar artery is considerably longer than the corresponding left artery. The course of the right posterior columellar artery is the same, only inverted, as that of the left.

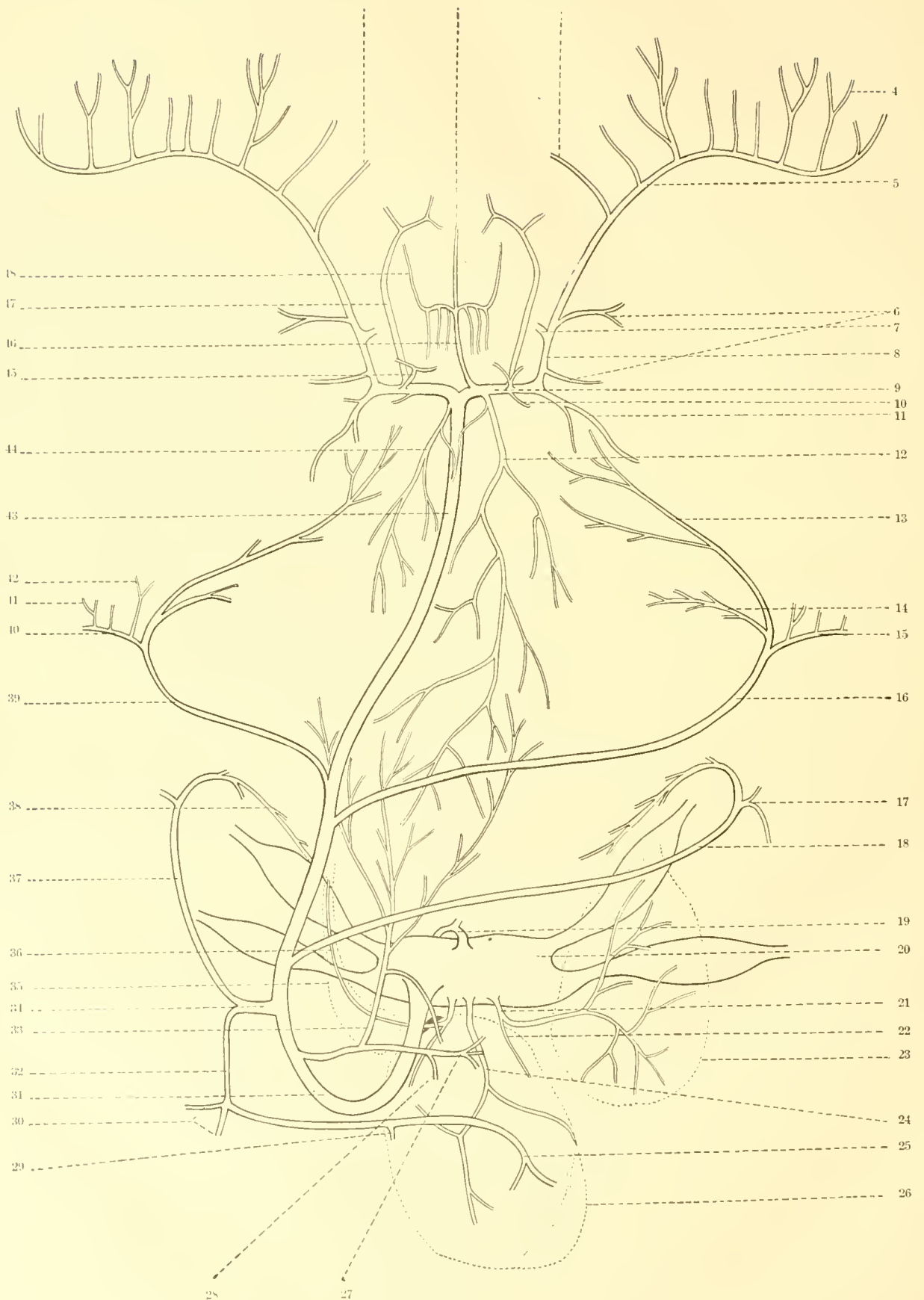
About 20 millimeters anterior to the origin of the last artery the right pallio-nuchal artery arises as a branch of the aorta. The left pallio-nuchal artery arises from the aorta 4 or 5 millimeters anterior to the right pallio-nuchal. These arteries pass upward and outward to the dorsal side of the body, entering the body wall at the base of the mantle fold where the latter crosses the dorsal edges of the shell muscles. Several branches leave the pallio-nuchal arteries at this point. Some of these pass into the dorsal portion of the mantle lying against the involution of the shell. The main portion of each artery is continued in the thin wall of the dorsal nuchal region, supplying especially the crescentic fold upon the posterior face of the hood. As it passes along the edge of the shell muscle it appears to send some small branches into the tissues of the muscle. A considerable branch extends into the crus of the funnel. From the outer side of the pallio-nuchal artery a branch enters the mantle, which becomes continuous with the marginal pallial branch of the anterior pallial artery.

Usually no other vessels arise from the aorta until it divides into the innominate arteries.

The anterior proventricular arteries, supplying blood to rather more than the anterior half of the proventriculus, frequently arise from the junction of the aorta with the innominate arteries. These arteries are, however, extremely variable in their position, a fact to which WILLEY has called attention. One or both may arise from the innominates, or one may be entirely absent. In WILLEY'S Fig. 23 (1896, 1), the left anterior proventricular artery arises from the aorta a considerable distance below its division into the innominate arteries. Two small arterioles going from the anterior proventricular arteries to the walls of the aorta show also considerable variation in their points of origin. Ordinarily one arises from the base of each proventricular artery. In the case figured by WILLEY both arterioles arise from the right anterior proventricular artery, the left proventricular artery being absent in this case.

The buccal artery usually springs from the right innominate close to its separation from the left. It passes forward upon the dorsal side of the buccal mass, presently dividing into three branches. The median branch, the superior mandibular artery, runs straight forward in the median line of the buccal mass, giving off branches to the superior mandibular muscles. The lateral branches first pass outward to the sides of the buccal mass, giving off on the way several small branches posteriorly to the mandibular muscles, then turn forward and pass into the buccal membrane and its papillæ. Of the origin of the buccal artery WILLEY says: "It is a singular fact that the great median buccal artery always springs from the right innominate artery. The constancy of this origin would seem to indicate that it is potentially a paired structure." I have dissected specimens in which the buccal artery sprung from the junction of the innominate arteries; in other words, was median. Either position, lateral or median, may be secondary, resulting from a displacement of the base of the artery during growth, and it is difficult to decide which is primitive without the evidence of embryology.

Five or six millimeters from their junction a branch arises from the anterior side of each innominate (the inferior mandibular artery), which runs forward on the under side of the buccal mass to the muscles and organs of the floor of the pharynx. These arteries are closely bound to the buccal nervous system, careful dissection being required to separate the nervous from the arterial elements. The inferior mandibular arteries supply not only the lower parts of the mandibular muscles but also the tongue and the radular sac, the processes anterior to the tongue, and the salivary processes.



TEXT-FIG. 10.—THE DORSAL AORTA, THE GENITAL AND GONADUCAL ARTERIES, AND THE ARTERY OF THE PYRIFORM SAC VIEWED FROM THE DORSAL SIDE.

This figure and the one following are combinations of the results of my own dissections, and the figures of various parts of the vascular system published by WILLEY.

- | | |
|---|--|
| 1, left artery of VAN DER HOEVEN'S organ in the male; of inferior labial lobe in the female. | 25, artery of right lobes of liver. |
| 2, superior mandibular artery. | 26, outline of gonad. |
| 3, right artery of VAN DER HOEVEN'S organ in the male; of inferior labial lobe in the female. | 27, gastric artery. |
| 4, arteries to individual digital tentacles. | 28, cecal artery. |
| 5, right tentacular artery. | 29, artery to middle portion of liver. |
| 6, arteries of eye. | 30, arteries to left lobes of liver. |
| 7, infundibular artery. | 31, dorsal aorta. |
| 8, pedal artery. | 32, hepatic artery. |
| 9, innominate artery. | 33, posterior proventricular artery. |
| 10, artery entering posterior part of hood. | 34, hepatico-columellar artery. |
| 11, right anterior columellar artery. | 35, outline of pyriform sac. |
| 12, right anterior proventricular artery. | 36, artery of pyriform sac. |
| 13, nuchal artery. | 37, left posterior columellar artery. |
| 14, crural artery. | 38, descending portion of columellar artery giving off branches to musele. |
| 15, marginal pallial artery. | 39, left pallio-nuchal artery. |
| 16, right pallio-nuchal artery. | 40, marginal pallial artery. |
| 17, branch to dorsal body-wall. | 41, radial pallial artery. |
| 18, right posterior columellar artery. | 42, artery to dorsal portion of mantle. |
| 19, lesser aorta. | 43, dorsal aorta. |
| 20, heart. | 44, left anterior proventricular artery. |
| 21, gonaducal artery. | 45, cerebral artery. |
| 22, branch to wall of gonad. | 46, buccal artery. |
| 23, outline of genital duct. | 47, inferior mandibular artery. |
| 24, genital artery. | 48, labial artery. |

From the dorsal side of the innominates, near the origins of the inferior mandibular arteries, arise arterioles which pass into the cerebral ganglia. From the posterior side of the innominates other small vessels pass into the posterior portion of the hood.

Finally, each innominate divides, one branch passing backward into the shell muscles and forming the anterior columellar artery, the other branch passing forward and downward along the bases of the tentacles, forming the pedal artery. Near the base of the pedal artery two arterioles pass outward to the eye. Between these a large branch arises from the pedal artery which passes to the funnel, the infundibular artery. The remainder of the pedal artery, which gives off branches to the individual tentacles, WILLEY has very conveniently named the tentacular artery. The first of the branches of the tentacular artery passes into the inferior labial lobe in the female, and into VAN DER HOEVEN'S organ in the male.

The origin of the genital and gonaductal arteries and the artery of the pyriform sac has already been mentioned.

The genital artery passes from the heart directly back upon the gonad, in which it breaks up into capillary branches.

The gonaductal artery passes to the right from the heart and is distributed to the walls of the functional genital duct.

The artery of the pyriform sac, or the non-functional genital duct, passes to the left from the heart and extends along this organ.

WILLEY shows that both the gonaductal artery and the artery of the pyriform sac give off a branch which passes into the perigonadial membrane, and he says: "This apparently trifling fact, combined with the subsymmetrical relations of the gonaduct and the pear-shaped gland, may indicate that the latter is the metamorphosed genital duct of the left side, and not, as I believe has been suggested, the morphological equivalent of an entire left genital apparatus."

Almost immediately after its origin from the anterior side of the heart, the lesser aorta divides into two branches.¹ One, the pallial artery, runs straight forward in the median line of the mantle and is distributed to the intestine, rectum, and mantle. The other, the common septal artery, runs almost straight backward and is distributed entirely to the septal portion of the body wall and the siphuncle.

The pallial artery is inclosed by the pallio-visceral ligament. A few millimeters anterior to the heart it gives off a slender branch (the intestinal artery), which runs back in the membrane uniting the two portions of the second loop of the intestine. Small arterioles pass from either side into the intestinal tissues.

In front of the intestinal artery several small rectal arteries arise directly from the pallial artery and pass to the walls of the rectum.

At the point where the two walls of the mantle fold unite and the mantle becomes thin, a pair of vessels arise from the pallial artery and pass outward to the right and the left in the substance of the mantle. These arteries, discovered by WILLEY, were called by him the branchio-osphradial arteries, "since among their minor ramifications they send up branches to the tips of the branchiæ, supplying the integument of the latter, and also a small branch into each of the osphradia." In the female the nidamental glands are supplied by branches of the branchio-osphradial arteries. I retain the name "branchio-osphradial" for these arteries because, although the osphradial character of the papillæ referred to is not yet well proven, there is still a considerable probability of it, and it does not seem worth while to burden the literature of the subject with a new name which might in time prove more correct, but for the present would be no more intelligible or convenient.

The pallial artery now passes forward nearly to the mantle edge. It here divides into a right and a left branch (the marginal pallial arteries), which run parallel to the edge of the mantle till they unite dorsally with the pallio-muchal branches of the dorsal aorta. In this way a remarkable arterial circuit is formed, to which WILLEY has given the name "circulus pallialis."

¹The arteries described after this are represented in text-fig. 11

From the anterior side of the marginal pallial artery a regular series of small arteries pass into the portion of the mantle in front of the marginal artery, which we have noticed to be especially muscular and slightly thicker than the middle portions of the mantle.

From the posterior side of the marginal artery and from the anterior portion of the pallial artery numerous vessels pass into the middle portions of the mantle.

The common septal artery bends around the anterior side of the heart immediately after its origin and then passes backward along the ventral surface of the heart. It is here covered by the portion of the pallio-visceral ligament which incloses the heart and hangs suspended in a mesentery-like fold of the ligament. Running backward under the left side of the heart, the artery arrives at the posterior viscero-pericardial opening, through which it passes by following the right edge. This edge being attached to the gonad, the artery passes directly upon the surface of the ovary or testis, as the case may be. Passing over the lower edge onto the anterior face of the gonad, the artery reaches the gastric ligament, along the edge of which it passes to the posterior wall of the body near the base of the siphuncle. The common septal artery does not appear to give off any branches to the gonad.

Arrived at the posterior wall of the body, the artery divides into a right and a left septal artery. These ramify over the portion of the body wall which faces the septum. It will be remembered that this portion of the body wall is bounded by the dorsal and the posterior ventral aponeurotic bands. The branches of the septal arteries are rigidly confined to the septal area of the body wall (WILLEY).

The siphuncular artery arises as a branch of one of the septal arteries, sometimes of one, sometimes of the other. Entering the base of the siphuncle, the artery extends through it to the end. Other smaller branches of the septal arteries may also enter the base of the siphuncle.

VENOUS CIRCULATION.

Only a portion of the venous system appears to be closed. The blood passes from the arterial capillaries into sinuses, which in one way or another are placed in communication with the vena cava. In the mantle there seems to be a quite extensive closed circulation.

The vena cava lies in the ventral wall of the body, extending from the cephalic cartilage to the posterior limit of the mantle cavity. It possesses thin muscular walls of its own, which appear to be innervated by two nerves springing from the pleuro-visceral ganglia. In its anterior portion the vena cava is bounded laterally by the inner faces of the shell muscles, which, touching each other ventrally, are separated dorsally. A triangular space is thus formed, which is occupied by the vena cava.

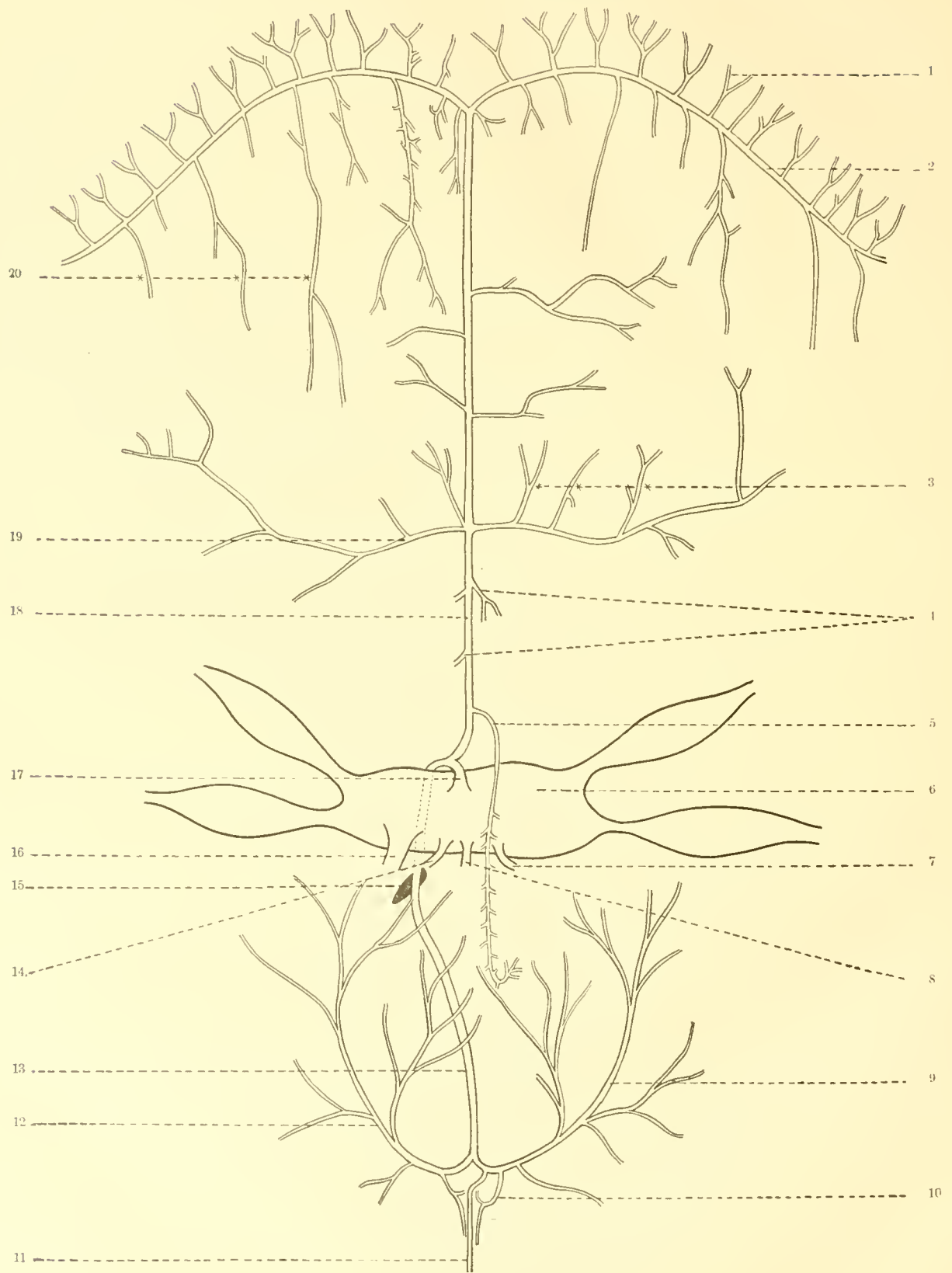
The dorsal wall of the vena cava, which is flush with the inner surface of the body wall, is perforated by numerous holes of varying size.

The vena cava is in communication anteriorly with numerous extensive blood spaces in the tissues surrounding the buccal mass and at the bases of the tentacles. Some of these spaces appear much like definite branches of the vena cava. The vena cava also receives several large veins from the shell muscles and the body wall, but these vessels are not constant in either number or position. Two veins on each side of the cephalic region pass through the body of the cartilage into the anterior end of the vena cava.

Through the openings in its dorsal wall by which the vena cava is in communication with the hæmocel blood enters the vena cava through the latter cavity from the sinuses of the body wall, and probably from the viscera contained in the hæmocel and its extensions.

At the posterior limit of the mantle cavity the vena cava divides into a right and a left branch, which branches almost immediately subdivide into two branches passing to the anterior and posterior gills of either side, the branchial arteries. Each of the branchial arteries, on its way to the gill, passes through the posterior wall of a renal sac, where it sends branches into the renal and pericardial appendages. (Text-fig. 9, p. 164.)

WILLEY says that the veins of the mantle "are collected into two main trunks, which lie on



TEXT-FIG. 11.—THE LESSER AORTA AND ITS BRANCHES, VIEWED FROM THE DORSAL SIDE.

- | | |
|-----------------------------------|--|
| 1, radial pallial artery. | 11, siphuncular artery. |
| 2, marginal pallial artery. | 12, left septal artery. |
| 3, arteries of nidamental gland. | 13, common septal artery. |
| 4, rectal arteries. | 14, artery of pyriform sac. |
| 5, intestinal artery. | 15, posterior visceropericardial aperture. |
| 6, heart. | 16, dorsal aorta. |
| 7, gonaducal artery. | 17, lesser aorta. |
| 8, genital artery. | 18, pallial artery. |
| 9, right septal artery. | 19, branchio-osphradial artery. |
| 10, accessory siphuncular artery. | 20, median pallial arteries. |

either side of the anterior pallial artery, and proceed backward to open into the different branchial vessels. At the sides of the mantle there are also a number of lateral pallial veins, which open into a large sinus situated over the shell muscle."

The peculiar perforated structure of the vena cava, together with the large size of the hæmocoel, may have an important bearing upon the ability of the Nautilus to endure being suddenly hauled to the surface without suffering apparent ill results. The specimens which I have had the privilege of studying were captured at a depth of from twelve hundred to eighteen hundred feet. At the latter depth they would be under a pressure of eighty atmospheres. Professor WORCESTER has told me that while the Nautili came to the surface uninjured, other animals brought up with them, as fish and crustacea, were always dead upon reaching the surface.

It is evident that something in its structure must account for the ability of the Nautilus to withstand such sudden and tremendous changes of pressure, though this function may be, and probably is, only a concomitant of the structure and not its principal function.

In order that a change of pressure should not prove injurious to an animal it is only necessary that the internal pressure of the tissues should remain equal to the external pressure. It seems to me that this result would be easily accomplished in Nautilus in the following manner. The pressure of the surrounding water upon the body would be transferred immediately to the blood contained in the hæmocoel. The cavity of the hæmocoel is in direct communication with that of the vena cava, and consequently with all the vascular spaces of the body, through the holes in the dorsal wall of the vena cava. By this means the pressure of the blood in the hæmocoel is directly transmitted to the blood of the entire body, and thus the pressure within and without the body is equalized. No change in the volume of the body would occur because the volume of the hæmocoel and coelom is minimal, and because of the incompressibility of the fluid.

The hæmocoel is completely closed from the exterior, so no water enters it, or anywhere comes in direct communication with the blood. It seems entirely improbable that water ever enters the coelom through the pericardial pores, as has been suggested.

NERVOUS SYSTEM. (FIG. 41.)

The central nervous system of Nautilus consists of three ganglionic bands which unite so as to form a ring around the œsophagus, two passing ventrally to the œsophagus and one dorsally.

The dorsal band represents the cerebral ganglia plus their commissure (12). The ends of the band are sometimes slightly larger than the central portion, but there is never any such separation of the parts as to allow us to say, these are the cerebral ganglia, or this is the cerebral commissure.

The posterior of the ventral bands represents the pleuro-visceral ganglia (13); this also is not separated into a pair of ganglia and a commissure, although the ends of the band are sometimes larger than the central portion. The anterior ventral band is composed of two distinct ganglia united by a slender commissure, the pedal ganglia (28) and the pedal commissure (29). The pedal ganglia are flat and crescentic in outline.

The cerebral, pedal, and pleuro-visceral ganglia form a junction at the sides of the œsophagus. The pleuro-visceral ganglia seem almost to join the pedal ganglia rather than the cerebral, but closer examination proves that they unite with the cerebral ganglia to as great an extent at least as with the pedal ganglia.

I shall speak of the cerebral and pleuro-visceral ganglia as if each band were in reality a single ganglion.

From each outer side of the cerebral ganglion an enormous optic nerve passes outward into the stalk of the eye (24 and 25). The base of the optic nerve is swollen and may form an optic ganglion, a point which the study of sections alone will settle. The optic nerve is almost immediately divided into numerous parallel small nerves which in passing outward twist slightly about the axis of the nerve. They are much more closely pressed in the stalk of the eye than nearer the cerebral ganglion. At the back of the retina the nerves separate and form a mesh about this bowl-shaped organ.

Near each end two nerves pass from the anterior side of the cerebral ganglion forward to

the ventral side of the buccal mass, where they enter the buccal nervous system (5 and 6). These are the outer and inner cerebro-buccal connectives of each side. The buccal connectives are of considerable length. In preserved and contracted specimens they are found to make numerous loops, which provide the extra length required when the buccal mass is thrust forward.

The buccal nervous system consists of two pairs of ganglia united by connectives and two commissures passing anterior to the œsophagus. The cerebro-buccal connectives pass through the muscular membrane which covers the ventral surface of the buccal mass and unite with the pharyngeal ganglia—slender ganglia lying at the sides of the ventral surface of the buccal mass, immediately upon the lower edge of the mandibular muscles (4). The pharyngeal ganglia are united by the long pharyngeal commissure passing anteriorly along the edge of the lower jaw (2). From the posterior ends of the pharyngeal ganglia strong connectives extend backward and inward to the buccal ganglia at the sides of the œsophagus as it issues from the buccal mass (32). The buccal ganglia are quite small. They are connected by a commissure passing around the anterior side of the œsophagus (33).

Numerous nerves are given off by the pharyngeal ganglia to the mandibular muscles. A nerve arising on the posterior side of the buccal ganglion bends over the dorsal side of the latter and passes to the salivary gland (34). A small nerve passes from the buccal ganglion to the œsophagus (31). Other nerves seem to pass into the tongue, but could not be accurately traced.

A number of small nerves (more than a dozen) leave the anterior side of the cerebral ganglion between the bases of the inner cerebro-buccal connectives and pass forward upon the dorsal surface of the buccal mass (27). Some of these nerves or their branches enter the mandibular muscles. The majority of them pass into the space between the folds of the buccal membrane and are distributed to the papillæ along the edge of the membrane.

A few small nerves (23) leave the posterior sides of the outer ends of the cerebral ganglion and pass to the posterior portion of the dorsal buccal retractors close to their attachment to the cartilage. These seem to be the same nerves which VALENCIENNES describes as proceeding to the cavity of the cartilage which he mistook for the otocyst.

In one specimen I have been able to trace the otocystic nerves. They are small, of about the same size as the nerve figured as going to the post-ocular tentacle. Each arises from the dorsal surface of the cerebral ganglion, just above the base of the optic nerve. As the otocyst is pressed between the posterior surface of the pedal ganglion and the cartilage, the otocystic nerve passes into the angle between the cerebral and pedal ganglia and then runs along the posterior surface of the pedal ganglion. The tunie of the nerve is so closely attached to that of the pedal ganglion that the nerve seems at first sight to spring from this ganglion. The nerve spreads out fan-wise upon the surface of the otocyst.

The nerve of the rhinophore seems to leave the cerebral ganglion close to the base of the optic nerve, but I am not entirely sure of its course.

No nerves are given off from the inner edges of the pedal ganglia, but from the outer edges arise exceedingly numerous closely set nerves. These nerves are distributed entirely to the funnel, the labial tentacles, and the digital tentacles and the cephalic sheath. In other words, they pass only to those parts which some consider to be homologous with the foot of other mollusca.

The infundibular nerves are a pair of large nerves leaving the inner end of each ganglion, passing forward and downward into the tissues of the funnel (8). They are situated at either end of the pedal commissure, from which no nerves arise. For the first part of their course the infundibular nerves lie in a cavity slightly larger than themselves, probably a blood space.

Just outside the infundibular nerves two conspicuous but smaller nerves (7) pass forward from the pedal ganglia to the inferior labial lobes in the female or to their homologue in the male, VAN DER HOEVEN'S organ. The nerves enter the base of the inferior labial lobe; they enter VAN DER HOEVEN'S organ at about the middle of each side. In each case after the nerves have entered they expand into small ganglia (35), from which nerves are given off to the separate tentacles of the organs. Fig. 41 is drawn from a male specimen in which the nerves pass inward from the ganglion instead of forward as in the female.

The outer edge of each pedal ganglion is fringed with numerous fine nerves. These nerves may be separated into two groups. The first of these are small, very slender nerves, which spring from the anterior or upper side of the edge of the ganglion. These nerves go to the tentacles of the superior labial groups; in the male, the nerves of the spadix and antispadix also are included in this series. The nerves of the tentacles of the spadix are, however, much larger than the nerves of the superior labial tentacles, or of the tentacles of the antispadix. In one dissection I found a quite peculiar nerve (30); it passes from the left pedal ganglion into the base of the first cirrus of the spadix, where it ends in an enlargement from which a number of small branches proceed into the surrounding tissues.

The apparently similar innervation of the superior labial tentacles and the tentacles of the spadix and the antispadix points to the latter being separated portions of the superior labial groups. But it is not safe to rely overmuch upon the, at present very slight, evidence of the innervation. The nerves arising from the pedal ganglia are too little separated for us to distinguish accurately between one group and another.

The second series of nerves are much larger than the first and arise from the lower or posterior portion of the edge of the ganglion, or even from the side pressed against the cartilage. They proceed to the individual digital tentacles (9).

Several large nerves leave the upper (or outer) ends of the pedal ganglia, near the junction with the cerebral and pleuro-visceral ganglia. From these nerves (10) branches proceed to some of the digital tentacles and to the hood.

Finally, a large nerve leaves the pedal ganglion very close to its junction with the other ganglia. The two main branches into which this divides become the nerves of the preocular and postocular tentacles. Finer branches proceed to the posterior portion of the hood, and sometimes to cirri of digital tentacles.

Numerous nerves, large and small, arise from the posterior edge of the pleuro-visceral ganglion. The nerves of the two sides are separated by a narrow median interval free from nerves. On either side of the interval a large visceral nerve (22) leaves the ganglion and runs straight backward, lying upon the inner surface of the body wall at the side of and parallel to the vena cava. At the posterior limit of the mantle cavity the visceral nerve turns outward and forward in the mantle, finally dividing into two branches which extend into the gills (19 and 20).

Before the visceral nerve divides to form the branchial nerves I have found it to give off two branches, which seemed to pass into the posterior walls of the renal sacs (17 and 18).

Just before the visceral nerve bends into the mantle it gives off small nerves to the spermatophore sac and genital duct (16).

Frequently connected with the visceral nerves are a pair of slender nerves which pass to the dorsal wall of the vena cava (15 and 21). These are, however, very variable in their origin. Always present, they sometimes both arise from the visceral nerves at about the middle of their course in the body. Sometimes both arise directly from the pleuro-visceral ganglion just inside the origins of the visceral nerves, as is figured by WILLEY; or one may arise from the pleuro-visceral ganglion, while the other springs from some portion of the visceral nerve, as is shown in Fig. 41.

WILLEY is quite sure that these nerves innervate the preanal papillæ, and partly for this reason considers the papillæ as the anterior pair of osphradia. I have not been able to trace the nerves anywhere but to the walls of the vena cava; although this does not constitute proof that they end there.

LANKASTER and BOURNE state absolutely, WILLEY with confidence, that they have traced a small nerve from the bifurcation of the branchial nerves into the interbranchial papillæ. This branch also I have been unable to find, either in several dissections or in a series of sections of the papilla.

Outside the visceral nerves a number of nerves of various sizes leave the pleuro-visceral ganglion and extend into the shell muscles and the body wall (14). The number of these is much larger than is represented in Fig. 41, only the larger ones being drawn.

From the extreme ends of the pleuro-visceral ganglion a few very small nerves extend into

the posterior portion of the hood. From its innervation, which is derived from the cerebral, pedal, and pleuro-visceral ganglia, the posterior portion of the hood seems to be fairly comparable with the dorsal portion of the nuchal region of the Gastropoda.

EYE.

The eye of the Nautilus is bowl-shaped, to use a rough comparison, the top of the bowl being closed by a thin membrane which is perforated centrally by a small round hole, while the base of the bowl projects as a short stalk which is attached to the side of the head (Fig. 1, E). The top of the bowl is turned outward. The eye does not seem to be round, but somewhat triangular, the rounded apex being directed ventrally. It is 22 millimeters in length (antero-posteriorly), 15 millimeters high (dorso-ventrally), and 12 millimeters from the base to the outer side. The stalk of the eye is 9 millimeters in diameter, but only 2 or 3 millimeters long.

The edge of the eye is produced into a flange ventrally and laterally, but not dorsally. The round aperture in the outer face of the eye is usually spoken of as the pupil and leads into the cavity of the eye lined by the retina, there being no lens or any medium of refraction in the eye. The sea water has free ingress to or egress from the cavity of the eye. The pupil is about 2 millimeters in diameter. From the ventral side of the pupil a groove leads across the face of the eye to its ventral edge. The posterior edge of the groove projects over the groove to the opposite side, transforming this into a tubular channel.

Usually the edges and the center of the face of the eye are slightly raised, leaving a depression between them. Except for a few almost microscopic depressions of the surface, the face and sides of the eye are quite smooth. The outer epithelium of the eye is composed of long, slender ciliated cells. The groove on the face of the eye is lined with a similar epithelium. VOX HENSEN suggests that a constant stream of water may be driven through it, keeping the pupil clean, and preventing the entrance of foreign bodies into the eye.

The membrane forming the outer face of the eye is quite thin; 1 millimeter thick at the edges, it gradually becomes thinner until the pupil is reached, where it is scarcely thicker than writing paper.

The sides of the eye are much thicker than the outer face, and they increase in thickness as they approach the stalk. The dorsal side is about 1.5 millimeters in thickness; the ventral side is double this thickness. The capsule of the eye is composed for the most part of connective tissues; a little muscular tissue is also present.

In longitudinal section the cavity of the eye is oval with a blunt outer and somewhat pointed inner pole. The wall of the outer portion of the cavity is of an intense black color. This black area is approximately circular. The side and back walls are of a light gray color, the line of demarkation between the black and gray portions of the wall being very sharp. The difference in color is caused by the fact that in the posterior portion of the cavity the retina bears rods which hide the pigment, while the rods are absent on the anterior portion of the retina.

I follow HALLER's account of the structure of the retina. The retina is about 1 millimeter in thickness at the posterior side of the cavity, gradually becoming thinner as it passes anteriorly. The branches of the optic nerve spread out in a thin fibre layer immediately beneath the retinal epithelium.

The epithelial layer of the retina is composed of two kinds of cells. The first are columnar cells, having a width equal to about one-eighth of their height. The nucleus lies in the upper end of the lower third of the cell. Fine pigment granules lie in the cell above the nucleus, but rarely below it.

The second kind of retinal cells are much more slender than the first, almost thread-like in shape. The nucleus usually lies at the beginning of the upper third of the cell. The pigment granules are larger than in the broader cells, and often are so large compared with the width of the cell body as to be arranged like a string of beads. They also frequently extend below the nucleus. The broad and fine cells alternate regularly. The pigment does not extend quite to the upper end of the cell, nor often into the lower third of the cell. Thus the pigment forms a dark band which is very noticeable in sections of the eye.

The rod layer which covers the gray portion of the retina is composed of slender rods of equal size. The rods are about three times as long as the retinal cells. Each rod is composed of an axial cord which stains deeply in carmine, and of a lightly staining cortex.

The epithelium of the retina is separated from the nerve-fibre layer by a thick basement membrane, through which the nerve fibres penetrate and enter the retinal cells. The nerve fibres enter the broad retinal cells just above the nucleus. The bases of the fine retinal cells are continuous with nerve fibres.

RHINOPHORE. (Figs. 21 and 22.)

Between the stalk of the eye and the projecting posterior edge of the cephalic sheath is an organ, probably olfactory, which has lately been compared with the rhinophore of certain Gastropoda, and to which this name is applied. It is a small pyramidal protuberance of the side of the head, located on a horizontal line with the lower edge of the stalk of the eye. The body of the eye projects over the rhinophore, completely hiding it when the Nautilus is not viewed from below. The posterior side of the rhinophore is produced into a finger-like process of about the same height as the pyramidal base; the whole is 8 or 10 millimeters in height. The process is not annulated and is "not retractile" (WILLEY, 1897, 1), and bears no resemblance nor relation to the digital tentacles. It may be well to speak of this as the tentacle of the rhinophore. Just dorsal to the tentacle is a pit 6 millimeters in depth and 2 millimeters in diameter (the dorsal pit). On the anterior side of the base of the tentacle is the opening of another pit, narrower but much deeper than the dorsal pit. This is the fossa of the rhinophore. It is 10 or 12 millimeters in depth, extending into the tissues of the head in a line directed inward and downward, except as the last 2 or 3 millimeters of the tube turns sharply forward. The base of the fossa is near the otocyst, and KEFFERSTEIN thinks that this is what MACDONALD mistook for the otocystic canal. From just within the external opening the fossa is continued upward in the center of the tentacle nearly to its tip.

The walls of the fossa are much folded longitudinally and are lined by a single-layered ciliated epithelium of slender columnar cells. Among these are many cells which remind one strongly of the olfactory cells in some of the vertebrata.

The middle portion of these cells is swollen, forming a large, spherical, clear body which is distinguishable in sections viewed under low powers. The proximal and distal ends of the cells seem to be exceedingly slender and thread-like. These cells are limited to the walls of the fossa. The epithelium of the dorsal pit is like that of the outer surface of the rhinophore.

A large nerve appears to leave the anterior side of the cerebral ganglion just under the point of union of the cerebral and optic ganglia, and, lying close to the fossa, extend to the tip of the tentacle of the rhinophore.

The body of the rhinophore is composed for the most part of dense elastic connective tissue, though in the base of the organ are some muscles.

KEFFERSTEIN describes the tentacle of the rhinophore as "ein zungenförmiger Lappen . . . der wie eine Klappe die Mündung seines Axenkanals schliessen kann." In preserved specimens the tentacle frequently is folded down over the mouth of the fossa, but this is apparently due to its being pressed upon the eye, so that the tentacle is probably in an unnatural position.

OTOCYSTS.

The otocysts of *Nautilus pompilius* lie upon the front side of the cartilage immediately back of the pedal ganglia, and near the junction of the latter with the cerebral and pleurovisceral ganglia. They are ovate in form, measuring about 3.5 millimeters in the direction of their long diameter. The end of the auditory nerve spreads out over the surface of the otocyst.

The otocyst is a thin walled sac almost completely filled by an immense number of elliptical crystals packed closely together. The crystals vary in thickness between 0.0011 and 0.0066 millimeter, and in length from 0.0033 to 0.014 millimeter. The crystals are composed of calcium carbonate, giving characteristic chemical and light reactions. They all have the shape which would be assumed by a perfect crystal of dog-tooth spar if all its angles were rounded. Very

frequently cases of the twinning of two or more crystals are seen. In instances where two crystals are twinned the angle between their axis is usually 78° , any divergence from this angle being quite small, so far as observed. When twinned the ends of each crystal are as perfect as in single crystals. The union of two or several crystals forms the cross and star-shaped bodies, "etc." mentioned by MACDONALD.

CARTILAGE. (Fig. 40.)

In the region of the bases of the digital tentacles is a large and strong cartilage which affords a firm place of attachment for the major muscles of the body. It is composed of a central portion which OWEN has termed the body, from each side of which a pair of processes project dorsally (the cephalic processes) and ventrally (the infundibular processes). The cartilage slants from above downward and forward, the ends of the cephalic processes reaching dorsally to the body wall of the nuchal region immediately back of the hood and in front of the crura of the funnel, while the infundibular processes extend into the funnel through the inner wall of which they show as white lines.

The greatest width of the cartilage is 3 centimeters, the length between the tips of the processes is 4.75 centimeters. The infundibular processes have a length of 2.5 centimeters, the cephalic processes a length of 1 centimeter.

The cephalic processes are round and end squarely. The muscles of the digital tentacles, the labial tentacles, and the spadix are attached to their anterior faces. The shell muscles find an attachment upon their posterior faces.

The infundibular processes are much broader than the cephalic as well as thinner and nearly flat. Their broad anterior faces are turned somewhat inward as well as upward. These faces are slightly concave, while the outer and posterior faces are slightly convex. The tissues of the anterior portion of the funnel are attached to the lower portion of the anterior faces, while the muscles of the posterior portion and of the crura of the funnel are attached to the posterior faces of the infundibular processes. The pedal ganglia lie against the upper portions of the anterior faces of the infundibular processes, while the pleurovisceral ganglia are supported by the median processes of the body of the cartilage. The body of the cartilage is bent downward and backward in the middle, forming a sharp reentrant angle anteriorly and a projecting point posteriorly. From the upper portions of the anterior side of the body of the cartilage a pair of small processes project toward the median line, the median processes (m. p.). The muscles of the buccal mass, the inferior labial lobe or VAN DER HOEVEN'S organ, and the levator muscles of the funnel, are attached to the body of the cartilage. The points of attachment of the latter muscles are marked by the dotted lines at l. i. in Fig. 40.

The body of the cartilage is penetrated by two veins on each side. These enter widely separated upon the anterior side, but leave the cartilage close together upon the posterior side, the cavities of the cartilage containing the veins opening here into a common depression. The upper veins (v) come from the region of the base of the tentacles; the lower veins (v') come from the anterior portion of the funnel. In the central part of the cephalic process is a small cavity which extends nearly to its tip and communicates with the cavity containing the vein from the cephalic region.

SUMMARY.

It may be a convenience if the additions to our knowledge of the anatomy of *Nautilus pompilius* presented in the foregoing pages are briefly summarized. The principal result aimed at has been to unite the numerous isolated observations on *Nautilus* in a coherent account which will at least have the advantage of accessibility.

It has been found that the digital tentacles have a regular arrangement, few variations from which exist.

The nerve of each tentacle possesses accumulations of ganglion cells about its periphery corresponding to each of the annulations of the outer portion of the tentacle. The inner projecting side of each segment of the digital tentacles is covered by a peculiar epithelium, which

there is some reason to consider as sensory. This portion of the segment is also provided with a peculiar musculature which enables it to act as an adhesive organ of considerable power.

The evidence renders it probable that the lamellated organ upon the inferior labial lobe of the female is composed of a number of modified cirri. Between the lamellae are peculiar pits, lined by an epithelium which seems to be sensory.

VAN DER HOEVEN'S organ of the male is shown to be the homologue of the inferior labial lobe of the female. Its lamellae correspond to the lamellae and cirri of the inferior labial lobe. VAN DER HOEVEN'S organ is largely glandular; its activity may be periodic. Among the gland cells in all parts of the organ are scattered great numbers of sensory cells of a peculiar character. These seem to correspond to the sensory cells observed upon the inferior labial lobe of the female. It is to be noted, however, that in the latter organ the sensory cells are concentrated, but in the former scattered. The inferior labial lobe is provided with a quite complex special musculature. A similar musculature is possessed by VAN DER HOEVEN'S organ.

The second cirrus of the spadix bears a set of glands hitherto undescribed. The structure of the large slime gland upon the outer surface of the spadix sheath is described. A similar gland is found in a less developed condition upon the outer side of the sheath of the antispadix. The spadix possesses a powerful muscle, extending from its base across the cephalic sheath.

The ocular tentacles are proven by their innervation to be members of the digital series, modified for a sensory function. Upon the inner side of the nerve, within the ocular tentacles, is an accessory nerve composed of many bundles of nerve fibers, which enter the primary nerve as they pass toward the central nervous system. The ocular tentacles possess "breaking planes," i. e., planes where the tissues are somewhat discontinuous, and along which the tentacles break with great ease.

Attention is called to the fact that the position of the organs of the pallial complex of *Nautilus* has been incorrectly figured and described by all authors except Joubin. The arrangement of these organs differs from that found in the Dibranchiata, and approaches that found in many Gastropoda. The gills, anus, preanal and interbranchial papillae, pericardial and renal pores, and the nidamental gland are situated upon the inner surface of the mantle. The paired reproductive orifices are situated upon the body wall within the mantle cavity.

There does not yet seem to be sufficient evidence to warrant our calling certain papillae near the bases of the gills *osphradia*. Both dissections and serial sections of the papillae in question have failed to show the special innervation required; other observers also seem to be a little less than sure of the presence of special nerves to these papillae.

The funnel is composed of two essentially different portions, the anterior part being fibrous, the posterior portion muscular. The crura of the funnel are so formed that they can, by a fanning motion, cause respiratory currents through the mantle chamber, and possibly currents strong enough for the progression of the animal.

The visceral portion of the body wall is thin and non-muscular. It contains a nervous plexus. It is attached to the shell by three aponeurotic bands proceeding from the ends of the shell muscles. The dorsal and posterior ventral bands limit the septum-forming portion of the body wall. A sharp backward projection of the dorsal aponeurotic band corresponds to a depression in the face of each septum in the younger half or two-thirds of the shell.

Aside from minor additions in the description of the anatomy of the digestive tract as a whole, the muscles of the buccal mass are described and figured. They are found to form a quite highly developed system.

The renal organs are found within the mantle and in the reverse position from that described by earlier authors.

Wiley's sketches and my own dissections have been combined to form a nearly complete account of the arterial circulation.

Some previously undescribed nerves have been followed to their terminations, especially the nerves of the ocular tentacles, of VAN DER HOEVEN'S organ, and of the spadix and antispadix.

The ocular nerves are branches of a nerve supplying digital tentacles as well. The nerves of VAN DER HOEVEN'S organ correspond to the nerves of the inferior labial lobe in all particulars. The otocystic nerve arises from the cerebral ganglion.

BIBLIOGRAPHY.

1894. APPELLÖF, A. Die Schalen von Sepia, Spirula und Nautilus. Studien über den Bau und das Wachstum. *Svenska Akad. Handl.* Bd. xxv, No. 7, 106 pp. 3 figures. 12 plates.
1887. BATHER, F. A. The Growth of Cephalopod Shells. *Geol. Mag.* Dec. 3. Vol. iv, pp. 446-449. 3 figures.
1888. BATHER, F. A. Professor Blake and Shell-growth in Cephalopoda. *Ann. Mag. Nat. Hist.* Vol. i, pp. 421-427.
1831. BENNETT, GEORGE. The Inhabitant of the Pearly Nautilus. *London Medical Gazette.* viii, p. 729. Figs.
1859. BENNETT, G. Notes on the Range of some Species of Nautilus, on the Mode of Capture, and on the Use made of them as an Article of Food. *Proc. Zool. Soc. London.* Pt. 27, pp. 226-229.
1877. BENNETT, G. Notes on the Pearly Nautilus. *Ann. Mag. Nat. Hist.* Ser. 4. Vol. xx, pp. 331-334.
1878. BENNETT, G. On the Habits of the Pearly Nautilus (*Nautilus pompilius*). *Report 47th Meet. Brit. Ass. Adv. Sc.* (1877). p. 101.
1825. BLAINVILLE, H. D. DE. Art. "Nautilé" in *Diction. des Sciences natur.* Tome 34. Paris. pp. 285-296.
1834. BLAINVILLE, H. D. DE. Anatomie des Coquilles polythalamées siphonnées récentes, pour éclaircir la structure des espèces fossiles (Anatomie du Nautilé flamboyé, du Nautilé ombiliqué et de la Spirule). 2 plates. *Nouvelles Ann. de Mus.* Tome 3, pp. 1-27.
1879. BLAKE, J. F. On the Homologies of the Cephalopoda. *Ann. Mag. Nat. Hist.* Vol. iv, No. 22, pp. 303-312.
1888. BLAKE, J. F. Remarks on Shell-growth in Cephalopoda. *Ann. Mag. Nat. Hist.* Vol. i, pp. 376-380.
1856. BOOGAARD, J. A. Recherches microscopiques sur les spermophores du Nautilé. *Ann. Sci. Nat.* 4^e sér., Zoöl. Tome 6, pp. 314-318.
1856. BOOGAARD, J. A. Bericht omtrent mikroskopische onderzoekingen van de spermophoren van *Nautilus pompilius*. Published with VAN DER HOEVEN, 1856.
1883. BOURNE, A. G. The Differences between the Males and Females of the Pearly Nautilus. *Nature.* Vol. xxviii, p. 580.
1888. BROOKS, HENRY. Preliminary Remarks on the Structure of the Siphon and Funnel of *Nautilus pompilius*. 2 plates. *Proc. Bost. Soc. Nat. Hist.* Vol. xxiii, pp. 380-382.
1891. BRUHL, C. B. Cephalopoden-Anatomie. i. Wien. 8 plates.
1837. BUCKLAND, WILLIAM. Geology and Mineralogy considered with reference to Natural Theology. *The Bridgewater Treatises.* vi. 2 vol. 8vo. Philadelphia. (Carey, Lea & Blanchard.
[observations on and theories concerning *Nautilus* are found in Volume 1, pages 238-251.]
1839. CHARLESWORTH, EDW. On a Young Shell of *Nautilus pompilius*. *Proc. Zool. Soc. London.* vii, p. 123.
1850. GRAY, J. E. On the Animal of *Nautilus*. *Ann. Nat. Hist.* Second series, vol. vi, pp. 268-270.
1897. GRIFFIN, LAWRENCE E. Notes on the Anatomy of *Nautilus pompilius*. 5 figures. *Zool. Bot.* Vol. i, pp. 147-155 (161).
1898. GRIFFIN, LAWRENCE E. Notes on the Tentacles of *Nautilus pompilius*. *Johns Hopkins University Circulars.* Vol. xviii, pp. 11, 12.
1900. GRIFFIN, LAWRENCE EDMONDS. The Arterial Circulation of *Nautilus pompilius*. 2 figures. *Johns Hopkins University Circulars.* No. 145, pp. 42-45.
1895. HALLER, B. Beiträge zur Kenntniss der Morphologie von *Nautilus pompilius*. *Deutsche. Med. Nat. Gesellsch. Jena.* Bd. viii. Z. Forschungen von R. Semon. Bd. v, pp. 189-204. 2 figs. Plates XI, XII.
1896. HASWELL, W. A. Note on Certain Points in the Arrangement and Structure of the Tentaculiferous lobes in *Nautilus pompilius*. 1 plate. Jottings from the Biol. Lab. of Sidney University, No. 18. *Proc. Linnæan Soc. New South Wales.* Vol. x, pp. 544-548.
1865. V. HENSEN. Ueber das Auge einiger Cephalopoden. 10 plates. *Zeits. wiss. Zoöl.*, Bd. xv, pp. 155-231 (242). [On the eye of *Nautilus*, pages 203-211; figures 71-84].
1847. HOEVEN, J. VAN DER. Ueber die Structur des *Nautilus pompilius*. *Fror. Not.* 3. Reihe. Bd. iv, No. 69, pp. 33-35.
1847. HOEVEN, J. VAN DER. On the Structure of *Nautilus pompilius*. *Rep. Brit. Assoc. Adv. Sci., 17th Meet. Trans. Sect.* pp. 77, 78.
1848. HOEVEN, J. VAN DER. Eenige afwijkingen in de vorm van het hoofd waargenomen by een mannelijk voorwerp van *Nautilus pompilius*. 1 plate. *Tijdschr. voor de wis- en natuurk. Wetensch.* D. 1, pp. 67-73.

1848. HOEVEN, J. VAN DER. Sur la structure du Nautilus pompilius. *L'Institut*. xvi, No. 739, pp. 74, 75.
1850. HOEVEN, J. VAN DER. Contributions to the Knowledge of the Animal of Nautilus pompilius. 4 plates. *Trans. Zool. Soc. London*. Vol. iv, pt. 1, pp. 21-29. Abstract in *Proc. Zool. Soc.* xviii, 1850, pp. 1-9.
1856. HOEVEN, J. VAN DER. Bijdragen tot de ontleedkundige kennis aangaande Nautilus pompilius L., vooral met betrekking tot het mannelijke dier. *Uitgegeven door de koninglijke Akademie van Wetenschappen, Amsterdam*. C. G. r. d. Post. 4to, 29 pp., 5 plates.
1856. HOEVEN, J. VAN DER. Recherches anatomiques sur le Nautilus pompilius, et particulièrement sur le male. Traduit du hollandais par M. Brullé. 1 plate. *Ann. Sci. Nat.* 4^e sér., Zoöl. Tome 6, pp. 290-314.
1857. HOEVEN, J. VAN DER. Beitrag zur Anatomie von Nautilus pompilius L., besonders des männlichen Thieres. Aus dem Holländischen übersetzt von F. H. Troschel. *Archiv f. Naturg.* 23. Jahrg. Bd. i, pp. 77-103.
1857. HOEVEN, J. VAN DER. Contributions to the Knowledge of the Anatomy of Nautilus pompilius L., especially with Reference to the Male Animal. 2 plates. *Ann. Nat. Hist.* Second Series, vol. xix, pp. 58-73.
1872. HOFFMANN, C. K. Ueber die Stäbchen in der Retina des Nautilus. 1 plate. *Niederl. Arch. f. Zoologie*. Bd. i, pp. 180-183.
1858. HUXLEY, T. H. On some Points in the Anatomy of Nautilus pompilius. 2 woodcuts. *Journ. Proc. Linn. Soc. London*. Vol. iii, pp. 36-44.
1870. Hydrostatische toestel van Nautilus. *Album der Natur*. pp. 331-334.
1877. JHERING, H. VON. Vergleichende Anatomie des Nervensystems und Phylogenie der Mollusken. Leipzig.
1890. JOUBIN, L. Recherches sur la morphologie comparée des glandes salivaires. *Arch. Zoöl. Expér.* Tome 5. Mém. No. 3, 66 pp., 3 figures, 3 plates.
1890. JOUBIN, L. Recherches sur l'appareil respiratoire des Nautilus. *Revue Biol. Lille*. 2^e année. pp. 409-428. Figs. Pl. VII.
1892. JOUBIN, L. Recherches sur la coloration du tegument chez les Céphalopodes. *Arch. Zoöl. Expér.* Tome 10, pp. 277-330. 2 figures. Pls. X-XII.
1865. KEFERSTEIN, W. Beiträge zur Anatomie des Nautilus pompilius. *Götting. Nachricht.* pp. 356-376.
1866. KEFERSTEIN, W. Cephalopoda, in Bronn's *Klassen und Ordnungen*.
1866. KEFERSTEIN, W. Reprint of 1865, in *Malakozool. Blätt. f. 1866*. Bd. xiii, pp. 21-38.
1895. KERR, GRAHAM J. On some points in the Anatomy of Nautilus pompilius. 2 plates. 6 text figures. *Proc. Zool. Soc. London*. pp. 664-686.
1883. LANKESTER, E. RAY, and A. G. BOURNE. On the Existence of Spengel's Olfactory Organ and of Paired Genital Pockets in the Pearly Nautilus. *Quart. Journ. Micr. Sci.* Vol. xxiii, pp. 340-348. 4 figures.
1897. LANKESTER, E. RAY. The Eggs of the Nautilus. (An extract from a letter to the Times on Willey's work.) *Nat. Sci.* Vol. x, p. 160.
1855. MACDONALD, JOHN DENIS. On the Anatomy of Nautilus umbilicatus, compared with that of Nautilus pompilius. 2 plates. *Phil. Trans.* pp. 277-288. Abstract in *Ann. Nat. Hist.* Second series, vol. xv, 1855, pp. 361-363. Abstract in *Proc. Roy. Soc. London*. Vol. vii, 1856, pp. 311-314.
1857. MACDONALD, J. D. Further observations on the Anatomy and Physiology of Nautilus. *Proc. Roy. Soc. London*. Vol. viii, pp. 380-383. Abstract in *Ann. Nat. Hist.* Second series, vol. xix, pp. 397, 398.
1869. MEIGEN, WILHELM. Ueber den hydrostatischen Apparat des Nautilus pompilius. 1 plate. *Jahresbericht d. Gymnas. u. höhere Bürgerschule Wesl.* (1868-1869). 4to, pp. 1-18. 1870. *Arch. f. Naturgesch.* 36. Jahrg., Bd. i, pp. 1-34.
1848. NAUMANN, K. FRDR. Ueber die logarithmische Spirale von Nautilus pompilius und Ammonites galeatus. *Berichte über d. Verhandl. d. k. Sächs. Gesellsch. d. Wiss.* Bd. ii, pp. 26-34.
1832. OWEN, RICHARD. Memoir on the Pearly Nautilus (Nautilus pompilius, Linn.) with illustrations of its external form and internal structure. 8 plates. *Published by the Royal College of Surgeons in London*.
1833. OWEN, RICHARD. Mémoire sur l'animal du Nautilus pompilius. 4 plates. *Ann. Sci. Nat.* Tome 28, pp. 87-158.
1833. OWEN, RICHARD. Der Nautilus pompilius. Figs. *For. Nat.* Bd. xxxviii, No. 815, pp. 1-8.
1835. OWEN, RICHARD. Abhandlungen über das Perlboot (Nautilus pompilius) mit Betrachtungen seiner äussern Gestalt, etc. 4 plates. *Isis*, pp. 1-56.
1842. OWEN, RICHARD. On a Specimen of Nautilus pompilius. *Proc. Zool. Soc. London*. Vol. x, p. 143. *Ann. Nat. Hist.* Vol. xii, p. 132.
1843. OWEN, RICHARD. On the Structure and Homologies of the Cephalic Tentacles in the Pearly Nautilus. *Ann. Nat. Hist.* Vol. xii, pp. 305-312.
1855. PROSCH, V. Om fangsten af levende Nautiler ved Hvalfangerskibe. *Fordhåndlgr. skand. Naturforsk.* 6 Møte, pp. 243, 244.
1830. QUOY ET GAIMARD. Description d'un fragment de Mollusque inconnu, présumé être celui du Nautille flambeé (Nautilus pompilius Linn.). Illustrated. *Ann. Sci. Nat.* Tome 20, pp. 470, 471.
1831. QUOY ET GAIMARD. Stück eines unbekanntes Weichthieres, wahrscheinlich von Nautilus pompilius. *Illust. Isis*, pp. 1146, 1147.
1843. REEVE, LOVELL. History and Observations on the Pearly Nautilus, involving a new theory to account for the caemented construction of its shell by the aid of the siphonic membrane. *Ann. Mag. Nat. Hist.* Vol. xi, pp. 119-125.

1705. RUMPH, G. E. "Nautilus major sive crassus" in his "Amboinsche Rariteitkamer." Amsterdam. Fol., pp. 59-62. Pl. XVII.
1766. G. E. RUMPH's Amboinsche Raritäten-Kammer von Schnecken und Muscheln aus dem Holländischen übersetzt von P. L. St. Müller, vermehrt von J. H. Chemnitz. Auf Kosten, Johann Paul Kraus in Wienn.
1859. SANDBERGER, G. Kurze Betrachtungen über Siphon und Siphonaldute, sowie über Eizelle und andere äussere und innere Merkmale der Schaale des gemeinen Schiffbootes (*Nautilus pompilius* L.); nebst einigen Vergleichen mit analogen Stücken der Gattungen: *Clymenia*, *Goniatites* u. *Ammonites*. 1 plate. 7. *Bericht d. Oberhess. Ges. f. Natur. u. Heilk.* pp. 75-80.
1887. SMITH, EDGAR A. Note on the Pearly Nautilus. *Journ. Conch. London.* Vol. v, pp. 226, 227.
1898. STURANY. Ueber ein Massengeschenk von *Nautilus* Exemplaren durch Dr. Zdekauer. *Annalen des K. K. Naturhistorischen Hofmuseums.* Bd. xiii, H. 4.
1843. Ueber *Nautilus pompilius*. (Abbildung mit Erklärung.) *Fror. N. Not.* Bd. xxvi, No. 572, pp. 344, 345.
1841. VALENCIENNES, A. Nouvelles recherches sur le Nautille flambé. 4 plates. *Archives du Muséum.* Tome 2, pp. 257-314.
1841. VALENCIENNES, A. Nouvelles recherches anatomiques sur le Nautille (*Nautilus pompilius*). *Compt. Rend. Acad. Sc. Paris.* Tome 12, pp. 174-179.
1841. VALENCIENNES, A. On the Anatomy of *Nautilus*. *Ann. Nat. Hist.* Vol. vii, pp. 241-245.
1841. VALENCIENNES, A. Ueber *Nautilus pompilius*. *Fror. N. Not.* Bd. xvii, No. 369, pp. 265, 266.
1841. VALENCIENNES, A. Untersuchungen des Thieres von *Nautilus pompilius*. *Berlin. Monatsber.* pp. 55-58. MÜLLER, JOH. Bemerkungen hierzu. *Ibid.* pp. 58, 59.
1895. VAYSSIÈRE, A. Sur le dimorphisme sexuel des Nautilles. *Compt. Rend.* Tome 120, pp. 1431-1434.
1896. VAYSSIÈRE, A. Etude sur l'organisation du Nautille (caractères zoologiques, dimorphisme sexuel, tentacules et spadice). 4 plates. *Ann. Sci. Nat.* 62^e année. 8^e sér., tome ii, pp. 137-183 (186).
1879. VIGELIUS, W. J. Bijdrage tot de Kennis van het excretorisch System der Cephalopoden. 2 plates. *Academisch Proefschrift. Leiden.* Svo. 175 pp.
1879. VIGELIUS, W. J. Over den bouw der nieren bij Cephalopoden. *Tijdschr. Nederl. Dierk. Vereen.* D. 4. 2. Afl. Versl. pp. lix-lxiii.
1880. VIGELIUS, W. J. Über das Excretionssystem der Cephalopoden. 3 plates. *Niederländisches Arch. f. Zool.* Bd. v, pp. 115-184.
1843. VROLIK, W. Sur l'anatomie du *Nautilus pompilius*. *L'Institut*, xi, No. 518, p. 414.
1843. VROLIK, W. On the Anatomy of the Pearly *Nautilus*. *Ann. Nat. Hist.* Vol. xii, pp. 173-175.
1848. VROLIK, W. Over het maaksel van den *Nautilus pompilius*. *Aanteek. Utrecht. Genootsch.* pp. 34, 35.
1849. VROLIK, W. Brief aan—J. J. Rochussen—over het ontleedkundig zamenstel van den *Nautilus Pompilius*. 2 plates. *Tijdschr. voor de wis- en natuurk. Wetensch.* D. 2, pp. 307-327.
1855. VROLIK, W. Lettre sur quelques points de l'organisation de l'animal du Nautille flambé, adressée à M. Eudes-Deslongschamps. 1 plate. Caën. Hurdel. 4to. 20 pp. *Extrait du X^e volume des mémoires de la Société Linnéenne de Normandie.*
1895. WILLEY, ARTHUR. In the Home of the *Nautilus*. 2 figures. *Nat. Sc. London.* Vol. vi, pp. 405-414.
1896. WILLEY, ARTHUR. Letters from New Guinea on *Nautilus* and some other Organisms. *Quart. Journ. Micr. Sci.* Vol. xxxix, pp. 145-180. 24 figures.
1896. WILLEY, ARTHUR. On some Variations in the Shell of *Nautilus*, with Description of a new Variety (*N. pompilius*, var. *Moretoni*, nov. var.). 3 figures. *Quart. Journ. Micr. Sci.* Vol. xxxix, pp. 227-231.
1897. WILLEY, ARTHUR. The Preocular and Postocular Tentacles and Osphradia of *Nautilus*. 1 plate. *Quart. Journ. Micr. Sci.* Vol. xl, pp. 197-201.
1897. WILLEY, ARTHUR. The Adhesive Tentacles of *Nautilus*, with some Notes on its Pericardium and Spermatophores. 1 plate. *Quart. Journ. Micr. Sci.* Vol. xl, pp. 207, 208 (209).
1897. WILLEY, ARTHUR. Oviposition of the *Nautilus*. 6 figures. *Proc. Roy. Soc., London.* Vol. lx, pp. 467-471.
1897. WILLEY, ARTHUR. The Embryology of the *Nautilus*. 6 figures. (A reprint of the preceding article.) *Nature.* Vol. lv, pp. 402, 403.
1898. WILLEY, ARTHUR. Some Zoological Results of a Voyage to Melanesia during the years 1894-1897. *Proc. Cambridge Philosophical Society.* Vol. ix. Part viii. pp. 398-401.
1870. WOODWARD, HENRY. The Pearly *Nautilus* (*pompilius*). Cuttlefish and their Allies. *Student and Intell. Obs.* Vol. iv. Pt. 1. 2 plates. pp. 1-14. Pt. 2. 2 plates. pp. 241-249.
1871. WOODWARD, HENRY. On the Structure of the Shell in the Pearly *Nautilus*. *Report 40th Meet. Brit. Ass. Adv. Sci.* (1869). pp. 125-129.
1838. WRIGHT, THOMAS. Observations on Dr. Buckland's Theory of the Action of the Siphuncle in the Pearly *Nautilus*. *London and Edinb. Philos. Mag.* n. s., vol. xii, pp. 503-508.

PLATE I.

FIG. 1. A Nautilus seen from the right side, the right half of the shell having been cut away.

AV, anterior ventral aponeurotic band.

C, cirrus of a digital tentacle.

Csh, cephalic sheath, composed of the fused sheaths of digital tentacles.

CR, crus of funnel.

DM, dorsal portion of mantle.

E, eye.

F, funnel.

Ho, hood.

I, involution of shell.

O', preocular tentacle.

O'', postocular tentacle.

PV, posterior ventral aponeurotic band.

S, living chamber of shell.

Si, siphon of shell.

Sl, siphuncle of body.

SM, area of attachment of shell muscle.

Sp, last-formed septum.

VM, ventral portion of mantle. This is free from the body from the edge as far back as the anterior ventral aponeurotic band.

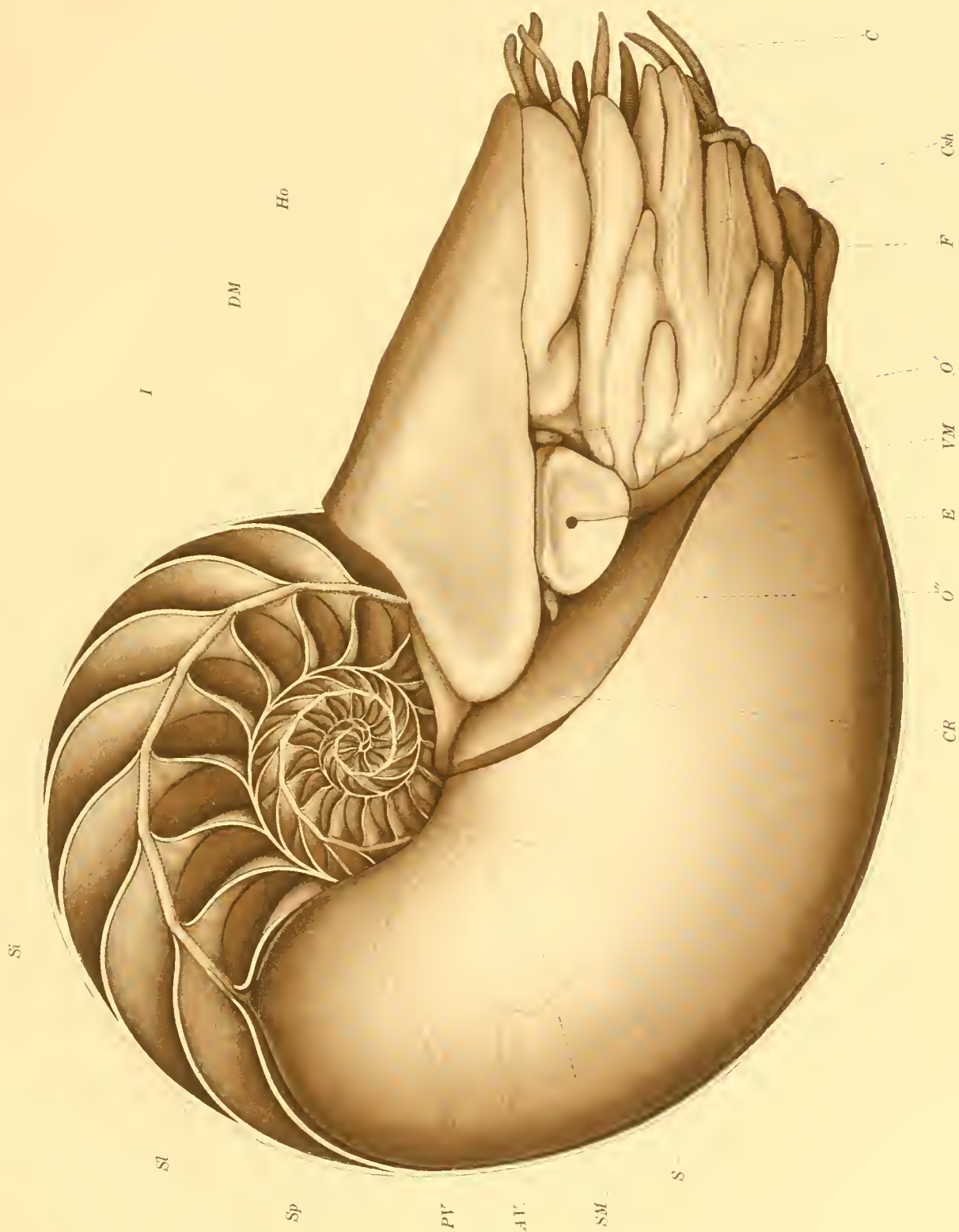


Fig. 1.

PLATE II.

FIG. 2.—View of the dorsal side of a *Nautilus* removed from its shell.

CR, crescentic ridge on the posterior face of the hood.

DA, dorsal aponeurotic band.

DM, dorsal portion of mantle. The index line points to a depression in the dorsal side of the body into which fits the involution of the shell.

DT², second digital tentacle.

E, eye.

HoA, auricle of hood.

HoC, HoC', cirri of tentacles composing the hood.

O', preocular tentacle.

Si, base of siphuncle.

X, backwardly projecting point of dorsal aponeurotic band, which is evidently the cause of the small backward projections near the dorsal edges of the septa, shown in Fig. 1.

y, constriction of the siphuncle where it passes through a septum.

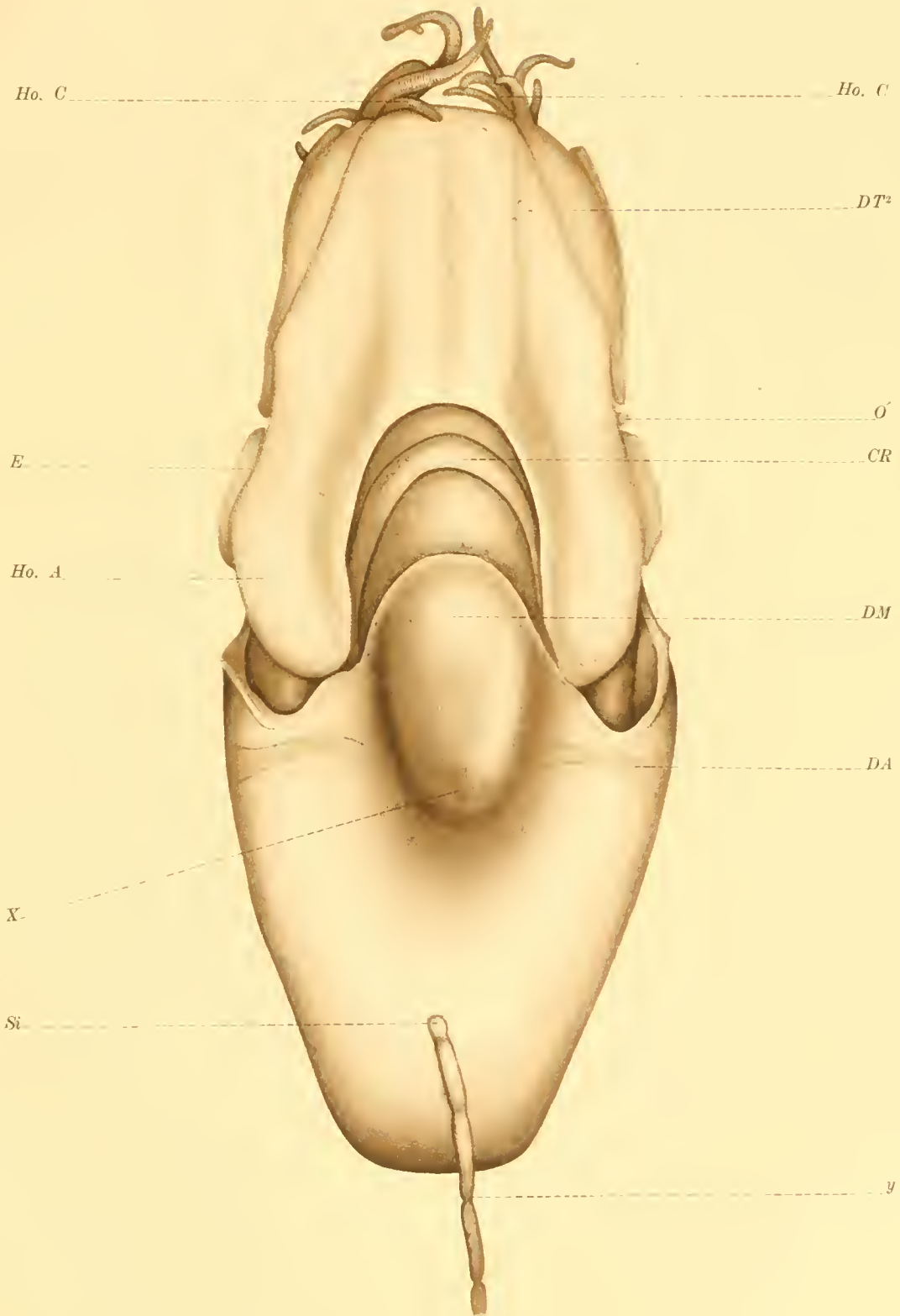


Fig. 2.

PLATE III.

FIG. 3.—Male viewed from the ventral surface: the mantle has been turned back over the posterior end of the body, exposing its inner surface and the organs contained in the mantle chamber.

A, anus.

DT, digital tentacles, composing the cephalic sheath.

E, eye.

F, funnel.

IP, interbranchial papilla.

O', postocular tentacle.

P, penis.

PA, preanal papilla.

PP, pericardial pore.

RA, anterior renal pore.

RP, posterior renal pore.

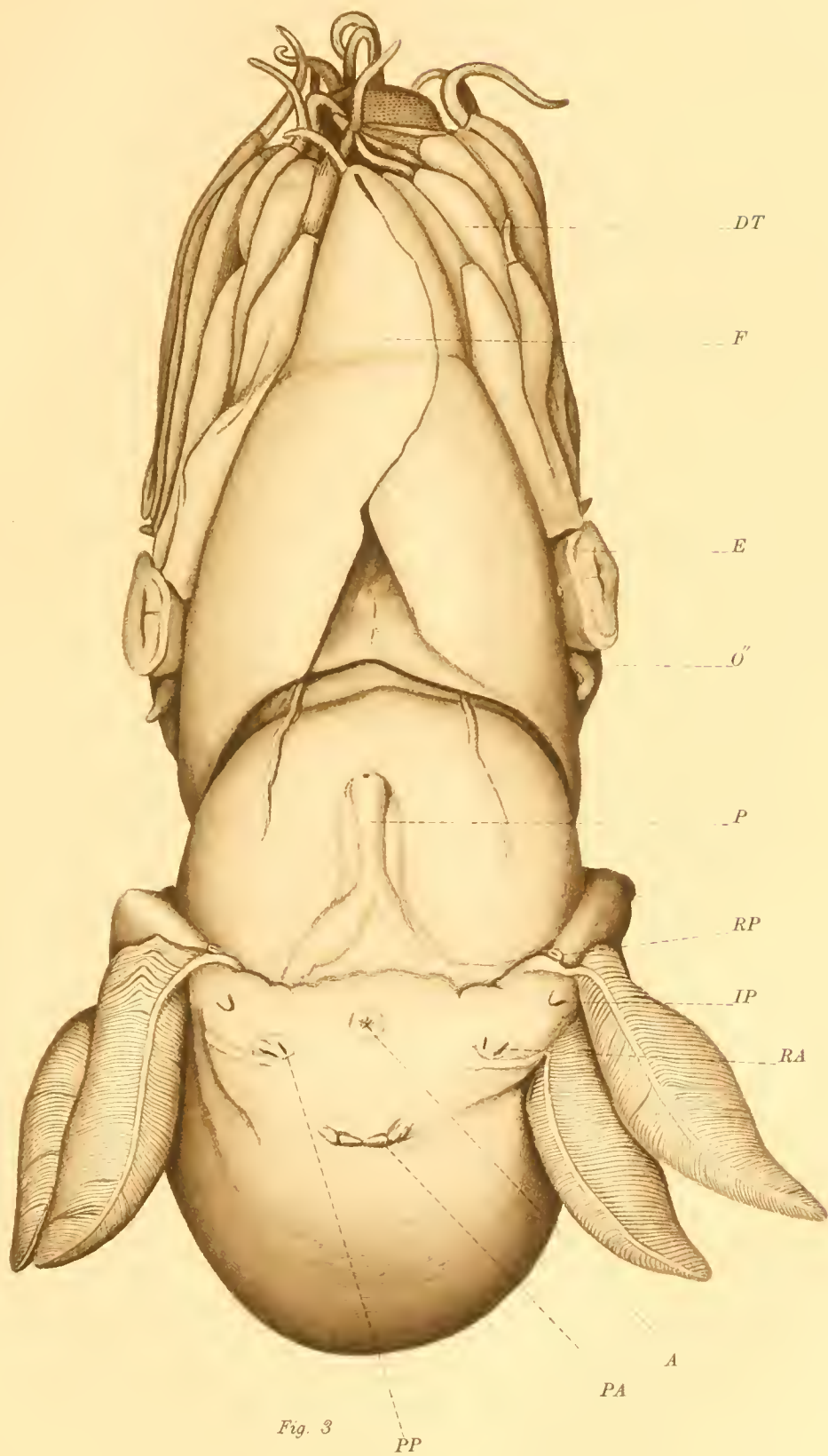


Fig. 3

PLATE IV.

FIG. 4.—Mantle chamber of female viewed from the ventral side. The mantle has been turned back over the posterior end of the body.

B, raised and overlapping border of the nidamental gland.

BV, branchial vein of the anterior gill.

F, base of funnel.

GA, anterior gill.

GP, posterior gill.

LM, lateral portion of mantle.

N, nidamental gland.

OV, protruding end of oviduct; oviducal papilla.

PA, preanal papillae.

SM, shell muscle.

VM, ventral portion of mantle.

Y, thickened portion of mantle between the inturned ends of the nidamental gland.

FIG. 5.—Cephalic region of female viewed from the dorsal side. The hood has been slit open along the median line to show the arrangement of the labial lobes and tentacles.

B, buccal mass.

CR, crescentic ridge upon the posterior face of the hood.

DM, dorsal portion of the mantle.

Ho, hood.

L, lamellated organ upon the center of the inferior labial lobe. The fan-like cirrus-bearing portions of the lobe are seen at the sides of the lamellated organ.

SLL, superior labial lobe.

FIG. 6.—Funnel, opened and viewed from the ventral side.

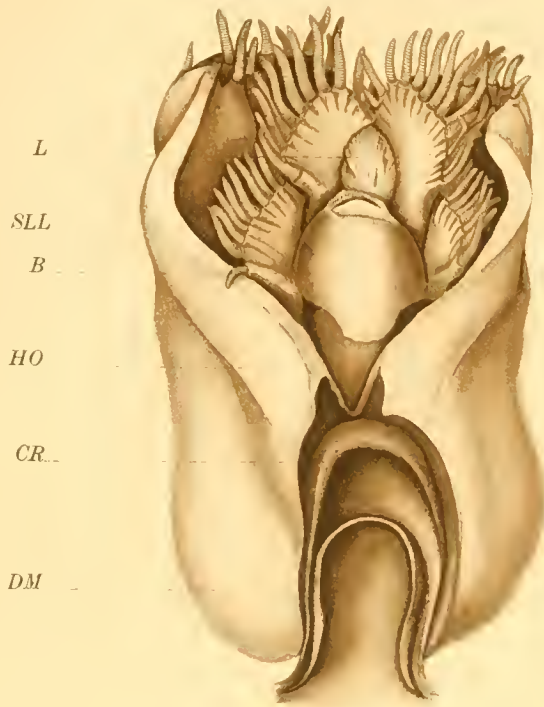
C, infundibular portions of the cartilage showing through the integument of the dorsal wall of the funnel.

CR, crus of funnel.

L, ligamentous band of the integument extending from the posterior edge of the funnel backward over the surface of the shell muscle.

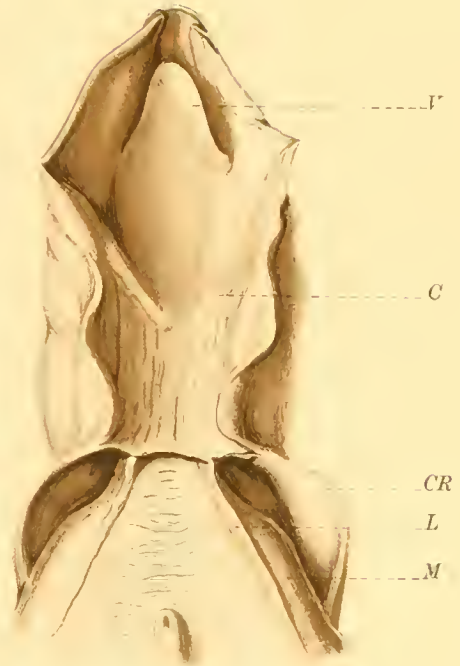
M, shell muscle,

V, valve of funnel



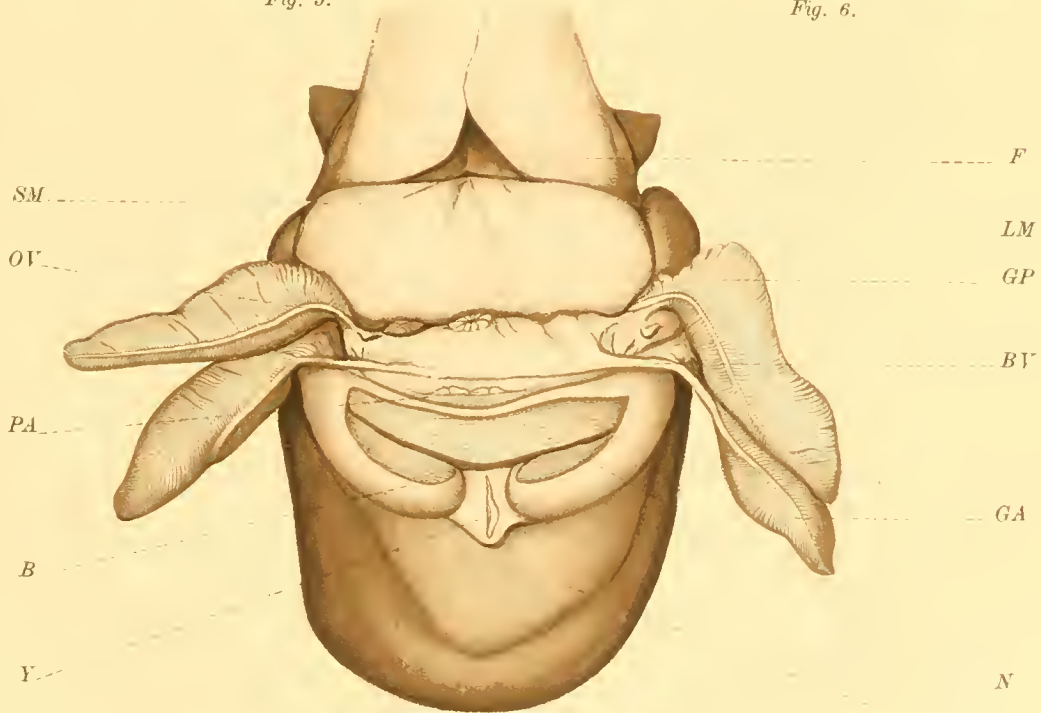
L
SLL
B
HO
CR
DM

Fig. 5.



F
C
CR
L
M

Fig. 6.



SM
OV
PA
B
Y

F
LM
GP
BV
GA
N
VM

Fig. 4.

PLATE V.

FIG. 7.—Male, viewed from the dorsal surface. The hood, mantle, and body wall have been cut open in the median line in order to show the mouth parts, the hæmocæl, and the celom, with their contained organs.

Ao, aorta.

ASp, antispadix.

B, buccal mass.

BM, buccal membrane, cut open dorsally to show the tips of the jaws.

BW, wall of the posterior portion of the body.

CR, crescentic ridge upon the posterior face of the hood.

DBR, dorsal buccal retractor muscle.

DM, dorsal portion of the mantle cut open and folded down.

DT, digital tentacles.

GL, genital ligament.

Ho, hood.

L, L, lobes of the liver, covered by the hæmocælic membrane.

Oe, oesophagus, lying in the hæmocæl.

S, siphuncle.

SL, superior labial lobe.

Sp, spadix.

St, stomach.

T, testis.

UJ, upper jaw.

VM, ventral portion of mantle.

X, junction of the hæmocælic membrane and body wall along the line of the dorsal aponeurotic band.

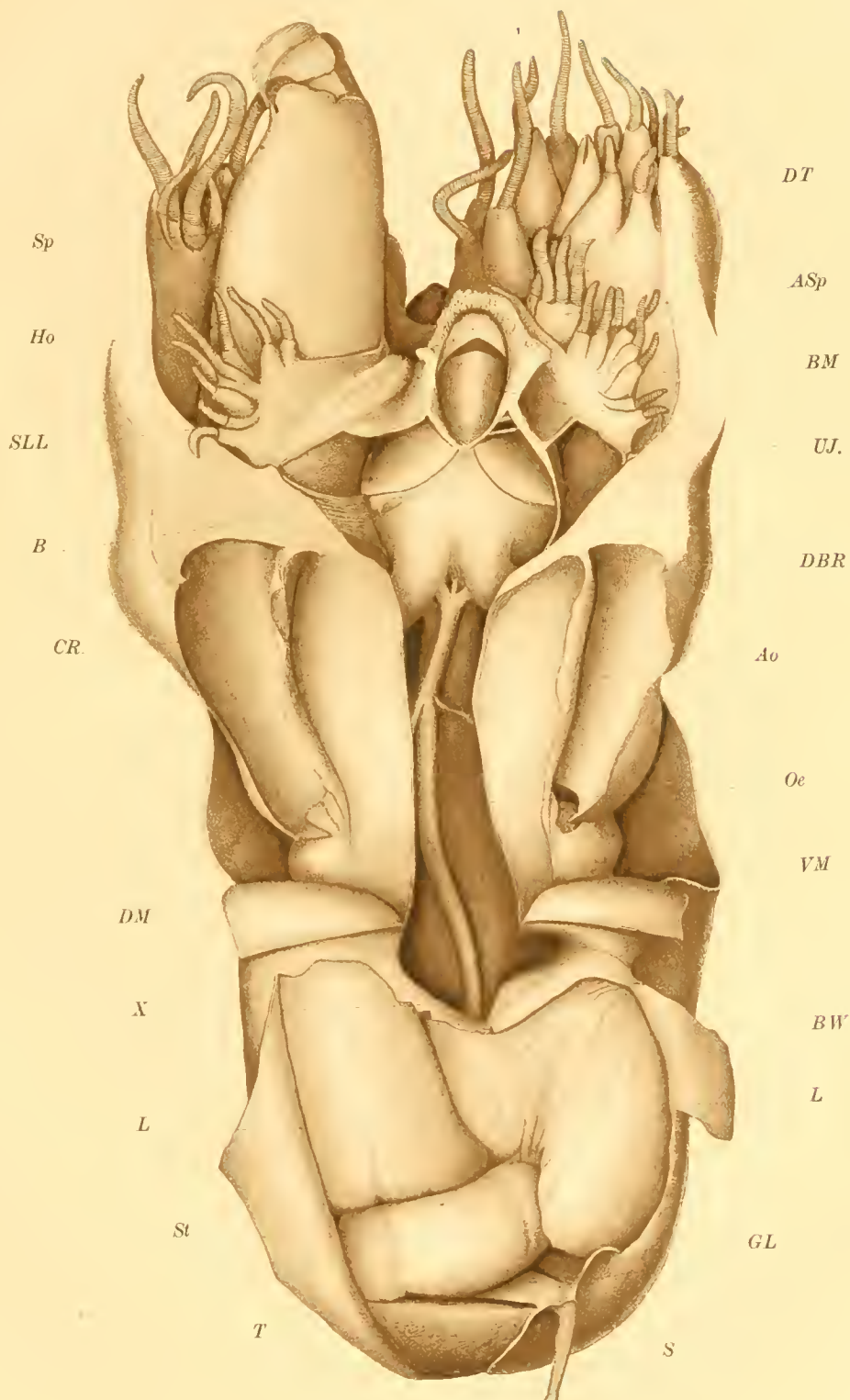


Fig. 7.

PLATE VI.

FIG. 8.—Ventral view of Van der Hoeven's organ. $\times 2$.

L, vertical laminae.

N, nerve.

VF, vertical fissure.

W, wall of the pocket, or atrium, into which the anterior end of the organ projects cut from its attachment to the organ and folded to one side.

1, 2, 3, muscles of the organ.

FIG. 9.—Longitudinal section of Van der Hoeven's organ, taken through the median vertical fissure. (The ventral side is uppermost.) $\times 2$.

G, G, glandular portion of the organ.

HF, horizontal fissure.

L, horizontal laminae.

FIG. 10.—Cross section of Van der Hoeven's organ taken just back of the middle of the organ. (The ventral side is uppermost.) $\times 2$.

FIG. 11.—Shell of *Nautilus pompilius*. $\frac{1}{4}$ natural size.

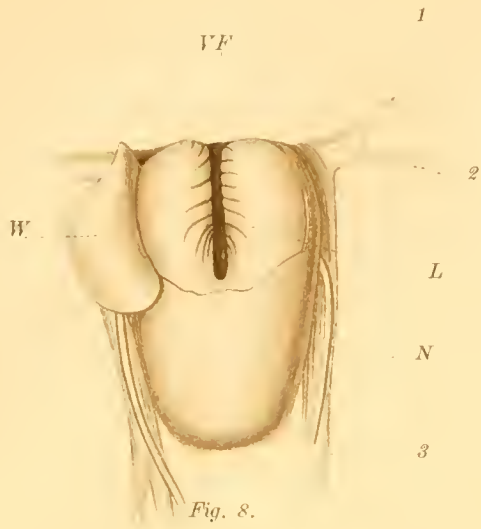


Fig. 8.

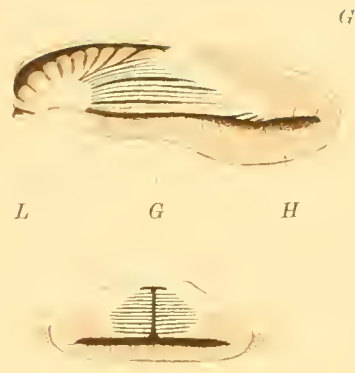

Fig. 10.

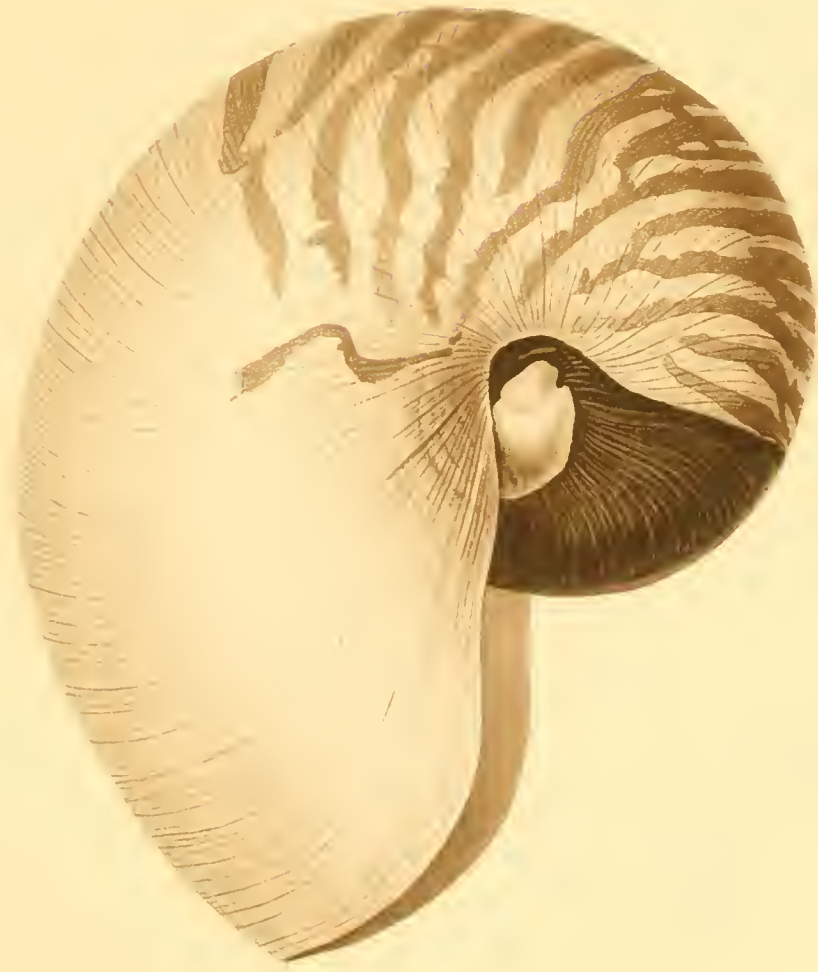

Fig. 11.
Shell.

PLATE VII.

- FIG. 12.—Antispadix, viewed from the outer side. Nearly twice natural size.
G, slime gland upon the sheath of the antispadix.
F, projecting flap of the sheath, partly covering the fourth tentacle.
4, fourth tentacle.
- FIG. 13.—Spadix, viewed from the inner side. The loose integument covering its base has been cut away.
Natural size.
1, first cirrus.
2, second cirrus.
3, third cirrus.
- FIG. 14.—Spadix, viewed from the outer side. Natural size.
G, slime gland of the sheath.
SH, line along which the integument has been cut away to expose the base of the spadix.
1, first cirrus.
2, second cirrus.
3, third cirrus.
4, fourth cirrus, nearly covered by the projecting flap of the spadix sheath.
- FIG. 15.—First cirrus of the spadix. Nearly natural size.
- FIG. 16.—Second cirrus of the spadix, viewed from the ventral side. Natural size.
- FIG. 17.—Third cirrus of the spadix, viewed from the dorsal side. Natural size.
- FIG. 18.—Third cirrus of the spadix, viewed from the ventral side. Natural size.
- FIG. 19.—Fourth cirrus of the spadix. Natural size.
- FIG. 20.—Lamellated organ upon the median portion of the inferior labial lobe of the female, viewed from the dorsal side. Twice natural size.
- FIG. 21.—Rhinophore, viewed from the anterior side. $\times 3$.
DP, aperture of the dorsal pit.
F, aperture of the fossa.
- FIG. 22.—Longitudinal section of the rhinophore passing through the fossa and the tentacle.
a, nerve.
b, c, portions of the fossa. c is near the opening of the fossa to the exterior. The section does not extend to the closed central end of the fossa. The heavy outer line indicates the extent of the external epithelium. Only as much of the rhinophore as is bounded by this line extends beyond the surface of the body.
- FIG. 23.—Cross section through the middle of a gill. $\times 2$.
1, branchial vein.
2, branchial artery.
3, stem of gill.
4, respiratory membrane of leaflet.
5, supporting portion of leaflet.
- FIG. 24.—Lamellated region upon the inner surface of the cephalic sheath of the female, just back of the ventral notch, which forms an organ for receiving the spermatophore. Below the lamellated region the tip of the funnel is seen; at the sides, some of the most ventral digital tentacles. Twice natural size.
- FIG. 25.—Spermatophore *in situ* upon the lamellated receiving region. Natural size.
- FIG. 26.—Base of the inferior labial lobe of the female, seen from the dorsal side. $\times 2$.
1, 1', levator muscles.
2, 2', approximator muscles.
3, 4, 3', 4', lateral retractor muscles.
5, dorsal median retractor muscle.

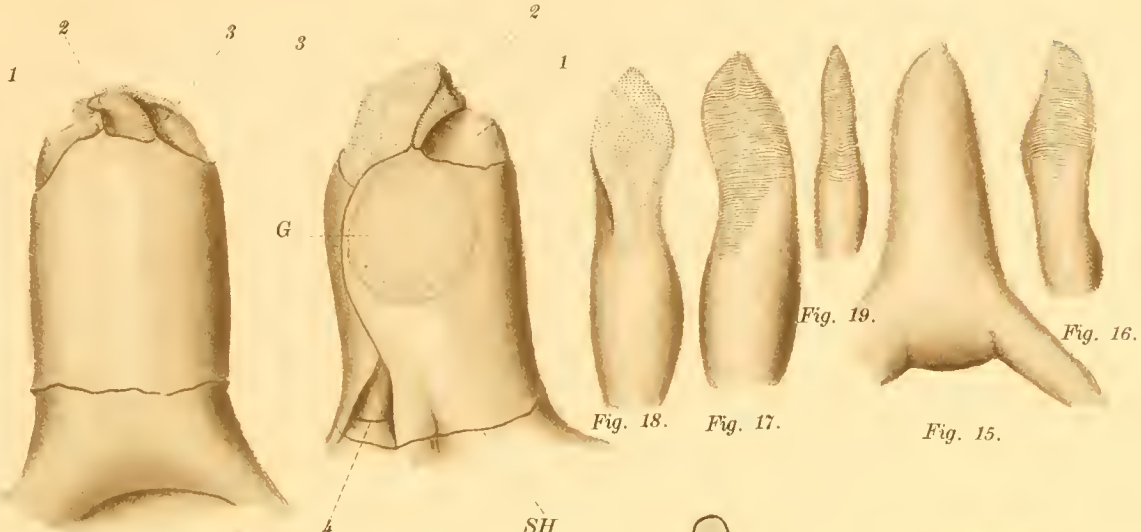


Fig. 13.

Fig. 14.

Fig. 19.

Fig. 16.

Fig. 18.

Fig. 17.

Fig. 15.

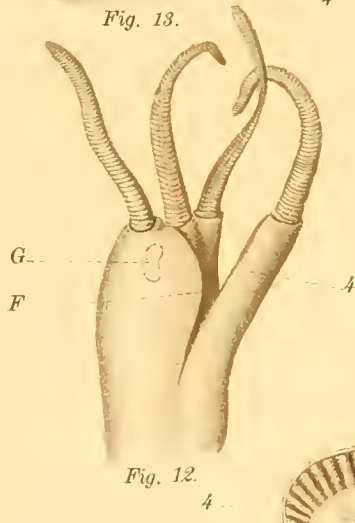


Fig. 12.



Fig. 21.

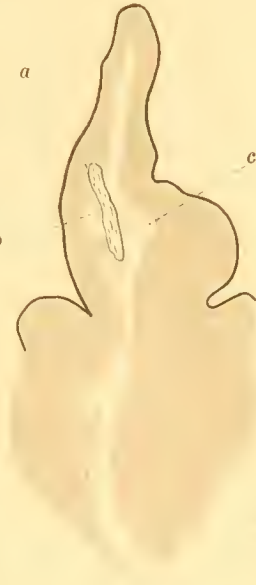

Fig. 22.

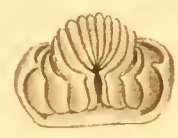

Fig. 20.



Fig. 23.

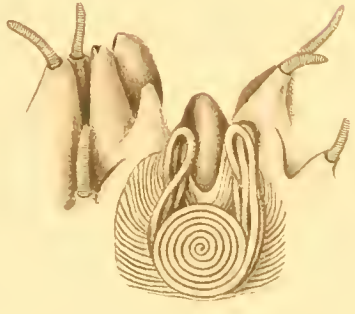


Fig. 25.

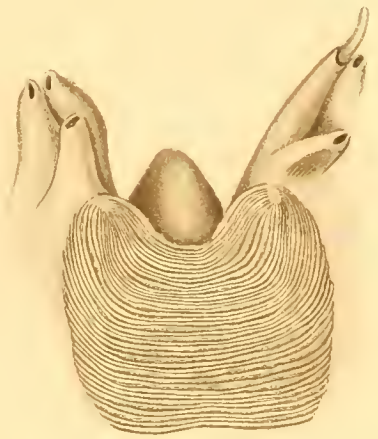


Fig. 24.



Fig. 26.

PLATE VIII.

FIG. 27.—Dorsal view of the digestive organs. Natural size.

- Ao, dorsal aorta, dividing into innominate and buccal arteries.
- B, buccal mass.
- C, C, posterior columellar arteries.
- Coe, coecum.
- GL, gastric ligament.
- H, hepatic artery.
- P, first loop of the intestine around the coecum.
- F, posteriorly directed portion of the second loop of the intestine.
- F', anteriorly directed portion of the second loop of the intestine.
- IA, intestinal artery.
- IL, intestinal ligament.
- L, L, left lobes of the liver.
- L', L', right lobes of the liver.
- Oe, oesophagus (proventriculus).
- PA, anterior proventricular artery.
- PX, PX, pallio-nuchal arteries.
- PP, posterior proventricular artery.
- St, stomach.

FIG. 28.—Dorsal view of the buccal mass, the buccal membrane and enveloping muscular membrane being cut in the median dorsal line and opened. $\times 2$.

- Ao, aorta, dividing into innominate and buccal arteries.
- BM, buccal membrane.
- CG, cerebral ganglion, giving off nerves to the buccal mass.
- DLR, dorso-lateral buccal retractor muscles.
- DR, dorsal buccal retractor muscle.
- LJ, tip of lower jaw.
- LJ', posterior portion of the outer flange of the lower jaw.
- LM, levator muscle of the buccal mass.
- M, mandibular muscle.
- MM, enveloping muscular membrane.
- N, nerves to the buccal membrane.
- Oe, oesophagus.
- UJ, upper jaw.
- X, buccal membrane, passing onto the base of the superior labial lobe.

FIG. 29.—The buccal mass turned upward and backward so as to show its ventral surface and the dorsal surface of Van der Hoeven's organ. Natural size.

FIG. 30.—Side view of the upper jaw. $\times 2$.

FIG. 31.—View of the inner surface of half of the lower jaw, cut in order to show the small inner flange. $\times 2$.

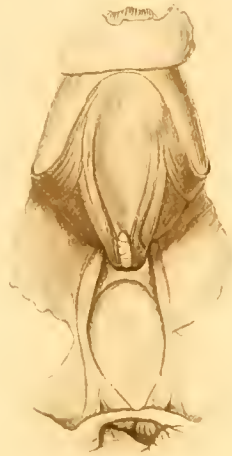

Fig. 29.

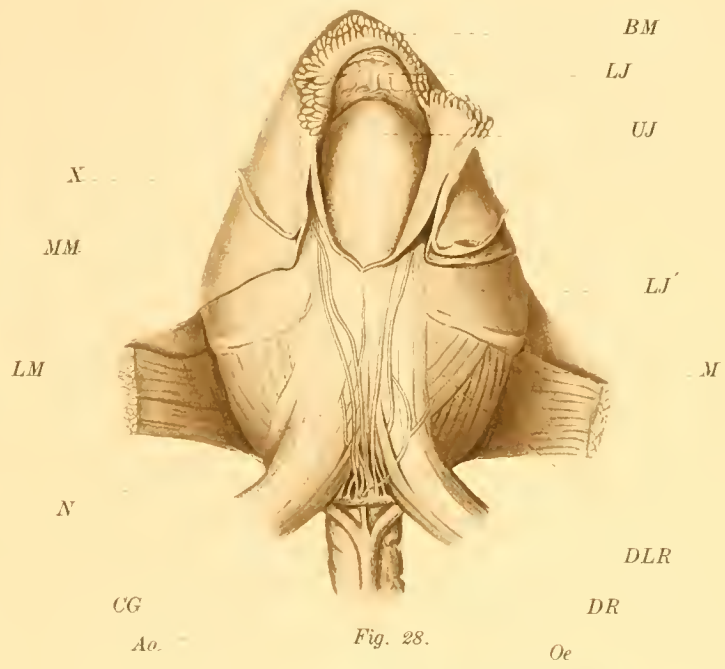
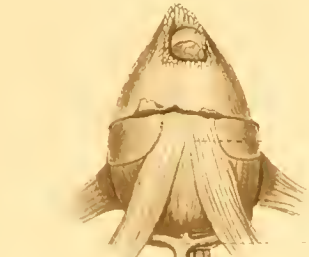


Fig. 28.



PN
L
C

B
Ao
PA
Oe
PN
C
PP

L



Fig. 30.
upper jaw.

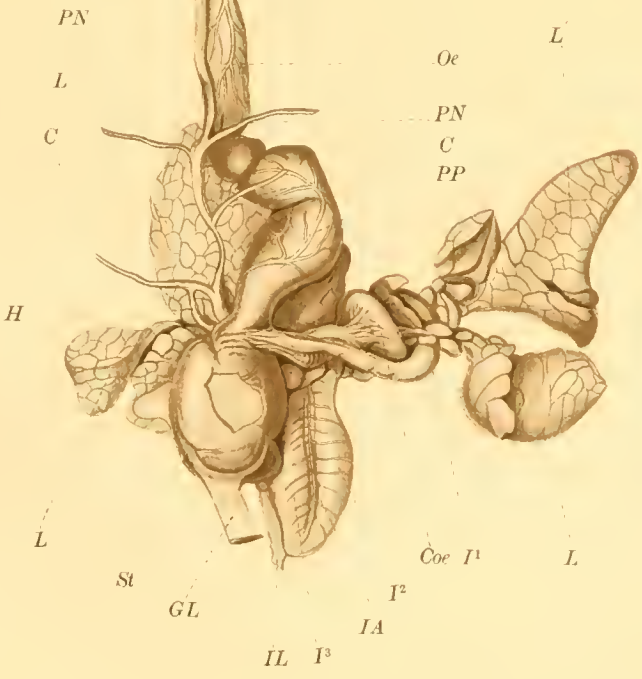


Fig. 27.

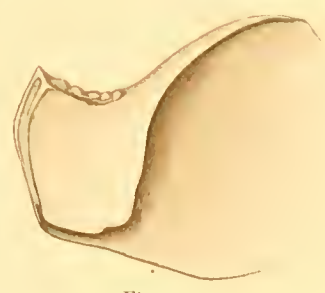

Fig. 31.

L
St
GL
IA
IL P
Coe I

PLATE IX.

FIG. 2. Alimentary canal, opened along the dorsal side. Natural size.

- AP, anterior prelingual process.
- BM, buccal membrane.
- C, caecum, showing its projecting lamelle.
- HD, openings of the hepatic ducts into the caecum.
- LJ, lower jaw.
- MM, mandibular muscle.
- Os, oesophagus.
- PP, posterior prelingual process.
- Pr, proventriculus.
- R, radula.
- Re, rectum.
- S, sacular posterior portion of the stomach.
- SO, salivary pore.
- SP, salivary process.
- T, tentacles of the stomach.
- Tn, tongue.
- UJ, upper jaw.
- V, vestibule.
- X, apparently prominent ridges of the oesophagus.
 - 1, 1, intestinal ridge.
 - 2, intestinal ridge.
 - 3, 3, intestinal ridge.
 - 4, foliaceous ridge.

FIG. 3. Ventral view of the buccal mass, a portion of its muscular membrane having been folded back. $\times 2$.

- BG, buccal ganglion.
- BM, buccal membrane, cut and turned forward over the tip of the jaw.
- LJ, outer flange of the lower jaw.
- LM, layer of muscle of the buccal mass.
- M, mandibular muscle; this ends ventrally along the edge of the upper jaw.
- MM, muscular membrane of the buccal mass.
- N, outer cerebro-buccal connective.
- N', inner cerebro-buccal connective.
- Os, Membrane surrounding the base of the oesophagus and connecting with the membrane surrounding the central nervous system.
- OM, part of the membrane stretched between the ventral buccal retractors.
- Ph. G., pharyngeal ganglion.
- RL, ligament of the radular sac.
- RS, radular sac.
- VBR, ventral buccal retractor muscle.
 - 1, retractor of the anterior prelingual process.
 - 2, 3, retractor of the posterior prelingual process.
 - 2, 3, unpaired muscle, forked posteriorly, going to the posterior prelingual process, and also to the portion of the tongue anterior to the upwardly directed part of the radular sac.
 - 4, muscle to the anterior portion of the tongue.
 - 5, muscle to the membrane covering the projection of the upper jaw.
 - 6, the sclerite of the dorsal surface of the radular sac.
 - 8, Muscle which probably plays a share, at least, in the opening of the jaws.
 - 9, 10, 11, 12, 13, 14, 15, 16, 17, 18, 19, 20, 21, 22, 23, 24, 25, 26, 27, 28, 29, 30, 31, 32, 33, 34, 35, 36, 37, 38, 39, 40, 41, 42, 43, 44, 45, 46, 47, 48, 49, 50, 51, 52, 53, 54, 55, 56, 57, 58, 59, 60, 61, 62, 63, 64, 65, 66, 67, 68, 69, 70, 71, 72, 73, 74, 75, 76, 77, 78, 79, 80, 81, 82, 83, 84, 85, 86, 87, 88, 89, 90, 91, 92, 93, 94, 95, 96, 97, 98, 99, 100, 101, 102, 103, 104, 105, 106, 107, 108, 109, 110, 111, 112, 113, 114, 115, 116, 117, 118, 119, 120, 121, 122, 123, 124, 125, 126, 127, 128, 129, 130, 131, 132, 133, 134, 135, 136, 137, 138, 139, 140, 141, 142, 143, 144, 145, 146, 147, 148, 149, 150, 151, 152, 153, 154, 155, 156, 157, 158, 159, 160, 161, 162, 163, 164, 165, 166, 167, 168, 169, 170, 171, 172, 173, 174, 175, 176, 177, 178, 179, 180, 181, 182, 183, 184, 185, 186, 187, 188, 189, 190, 191, 192, 193, 194, 195, 196, 197, 198, 199, 200, 201, 202, 203, 204, 205, 206, 207, 208, 209, 210, 211, 212, 213, 214, 215, 216, 217, 218, 219, 220, 221, 222, 223, 224, 225, 226, 227, 228, 229, 230, 231, 232, 233, 234, 235, 236, 237, 238, 239, 240, 241, 242, 243, 244, 245, 246, 247, 248, 249, 250, 251, 252, 253, 254, 255, 256, 257, 258, 259, 260, 261, 262, 263, 264, 265, 266, 267, 268, 269, 270, 271, 272, 273, 274, 275, 276, 277, 278, 279, 280, 281, 282, 283, 284, 285, 286, 287, 288, 289, 290, 291, 292, 293, 294, 295, 296, 297, 298, 299, 300, 301, 302, 303, 304, 305, 306, 307, 308, 309, 310, 311, 312, 313, 314, 315, 316, 317, 318, 319, 320, 321, 322, 323, 324, 325, 326, 327, 328, 329, 330, 331, 332, 333, 334, 335, 336, 337, 338, 339, 340, 341, 342, 343, 344, 345, 346, 347, 348, 349, 350, 351, 352, 353, 354, 355, 356, 357, 358, 359, 360, 361, 362, 363, 364, 365, 366, 367, 368, 369, 370, 371, 372, 373, 374, 375, 376, 377, 378, 379, 380, 381, 382, 383, 384, 385, 386, 387, 388, 389, 390, 391, 392, 393, 394, 395, 396, 397, 398, 399, 400, 401, 402, 403, 404, 405, 406, 407, 408, 409, 410, 411, 412, 413, 414, 415, 416, 417, 418, 419, 420, 421, 422, 423, 424, 425, 426, 427, 428, 429, 430, 431, 432, 433, 434, 435, 436, 437, 438, 439, 440, 441, 442, 443, 444, 445, 446, 447, 448, 449, 450, 451, 452, 453, 454, 455, 456, 457, 458, 459, 460, 461, 462, 463, 464, 465, 466, 467, 468, 469, 470, 471, 472, 473, 474, 475, 476, 477, 478, 479, 480, 481, 482, 483, 484, 485, 486, 487, 488, 489, 490, 491, 492, 493, 494, 495, 496, 497, 498, 499, 500, 501, 502, 503, 504, 505, 506, 507, 508, 509, 510, 511, 512, 513, 514, 515, 516, 517, 518, 519, 520, 521, 522, 523, 524, 525, 526, 527, 528, 529, 530, 531, 532, 533, 534, 535, 536, 537, 538, 539, 540, 541, 542, 543, 544, 545, 546, 547, 548, 549, 550, 551, 552, 553, 554, 555, 556, 557, 558, 559, 560, 561, 562, 563, 564, 565, 566, 567, 568, 569, 570, 571, 572, 573, 574, 575, 576, 577, 578, 579, 580, 581, 582, 583, 584, 585, 586, 587, 588, 589, 590, 591, 592, 593, 594, 595, 596, 597, 598, 599, 600, 601, 602, 603, 604, 605, 606, 607, 608, 609, 610, 611, 612, 613, 614, 615, 616, 617, 618, 619, 620, 621, 622, 623, 624, 625, 626, 627, 628, 629, 630, 631, 632, 633, 634, 635, 636, 637, 638, 639, 640, 641, 642, 643, 644, 645, 646, 647, 648, 649, 650, 651, 652, 653, 654, 655, 656, 657, 658, 659, 660, 661, 662, 663, 664, 665, 666, 667, 668, 669, 670, 671, 672, 673, 674, 675, 676, 677, 678, 679, 680, 681, 682, 683, 684, 685, 686, 687, 688, 689, 690, 691, 692, 693, 694, 695, 696, 697, 698, 699, 700, 701, 702, 703, 704, 705, 706, 707, 708, 709, 710, 711, 712, 713, 714, 715, 716, 717, 718, 719, 720, 721, 722, 723, 724, 725, 726, 727, 728, 729, 730, 731, 732, 733, 734, 735, 736, 737, 738, 739, 740, 741, 742, 743, 744, 745, 746, 747, 748, 749, 750, 751, 752, 753, 754, 755, 756, 757, 758, 759, 760, 761, 762, 763, 764, 765, 766, 767, 768, 769, 770, 771, 772, 773, 774, 775, 776, 777, 778, 779, 780, 781, 782, 783, 784, 785, 786, 787, 788, 789, 790, 791, 792, 793, 794, 795, 796, 797, 798, 799, 800, 801, 802, 803, 804, 805, 806, 807, 808, 809, 810, 811, 812, 813, 814, 815, 816, 817, 818, 819, 820, 821, 822, 823, 824, 825, 826, 827, 828, 829, 830, 831, 832, 833, 834, 835, 836, 837, 838, 839, 840, 841, 842, 843, 844, 845, 846, 847, 848, 849, 850, 851, 852, 853, 854, 855, 856, 857, 858, 859, 860, 861, 862, 863, 864, 865, 866, 867, 868, 869, 870, 871, 872, 873, 874, 875, 876, 877, 878, 879, 880, 881, 882, 883, 884, 885, 886, 887, 888, 889, 890, 891, 892, 893, 894, 895, 896, 897, 898, 899, 900, 901, 902, 903, 904, 905, 906, 907, 908, 909, 910, 911, 912, 913, 914, 915, 916, 917, 918, 919, 920, 921, 922, 923, 924, 925, 926, 927, 928, 929, 930, 931, 932, 933, 934, 935, 936, 937, 938, 939, 940, 941, 942, 943, 944, 945, 946, 947, 948, 949, 950, 951, 952, 953, 954, 955, 956, 957, 958, 959, 960, 961, 962, 963, 964, 965, 966, 967, 968, 969, 970, 971, 972, 973, 974, 975, 976, 977, 978, 979, 980, 981, 982, 983, 984, 985, 986, 987, 988, 989, 990, 991, 992, 993, 994, 995, 996, 997, 998, 999, 1000.

FIG. 4. Dorsal view of the buccal mass, the enveloping muscular membrane having been cut along the median line. The vessel is also somewhat from behind. $\times 2$.

- A, branches of the superior mandibular artery penetrating the mandibular muscles.
- BM, buccal membrane, also slit open dorsally.
- LJ, tip of lower jaw.
- M, mandibular muscle.
- MM, muscular membrane of the buccal mass.
- Os, oesophagus, swollen at one place by food which remained in it when the animal died.
- UJ, tip of the upper jaw.
- UJ', posterior edge of the inner flange of the upper jaw.

FIG. 5. The radular sac and the lingual muscles of one side exposed and viewed from the ventral side. $\times 2$.

- EL, external lingual muscle.
- EL', cut end of the external lingual muscle.
- IL, internal lingual muscle.
- LP, lingual protractor muscle.
- R, radular muscle.
- R', cut end of the radular muscle.
- Ro, radula.
- RS, radular sac.
- S, septum extending from the dorsal median line of the tongue to the muscular membrane just above the radular sac, which has been cut away from the exposed side of the preparation.
- T, region on area where the lingual muscles join.
- X, division of the septum.
- Y, point of the upper jaw to which the lingual protractor is attached.

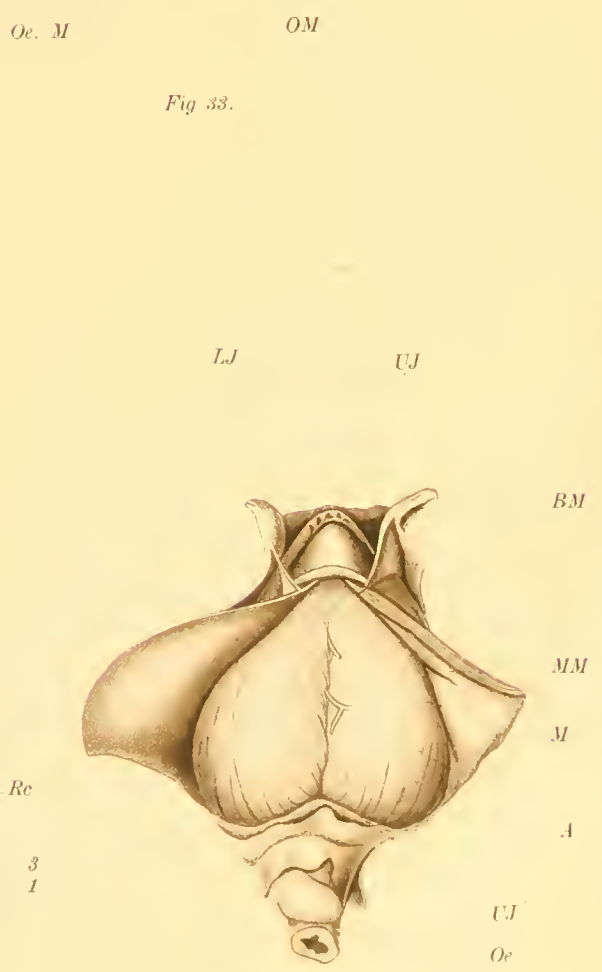
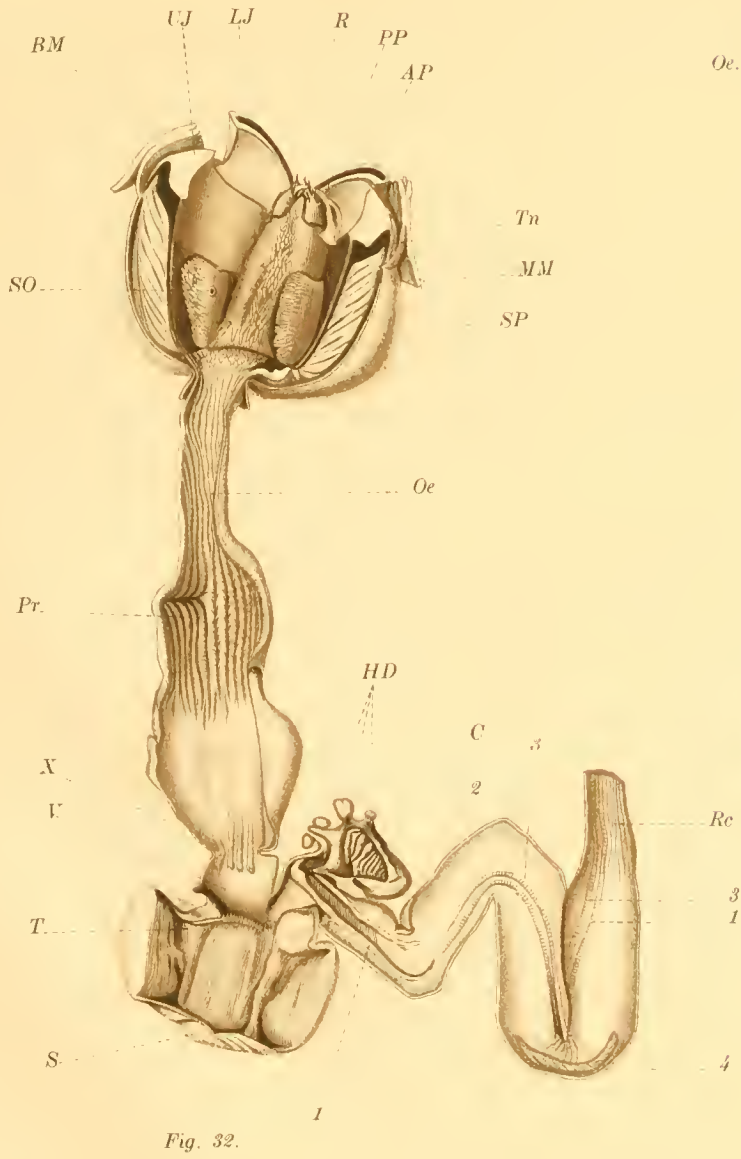
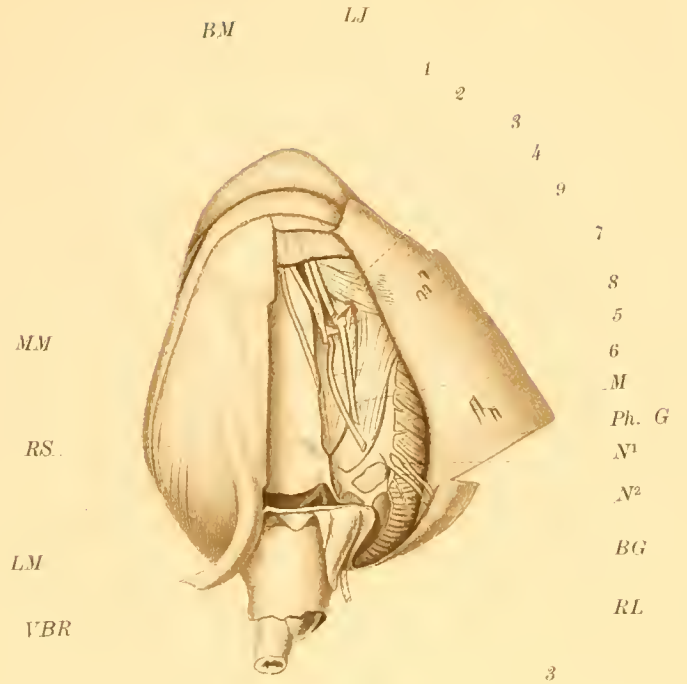
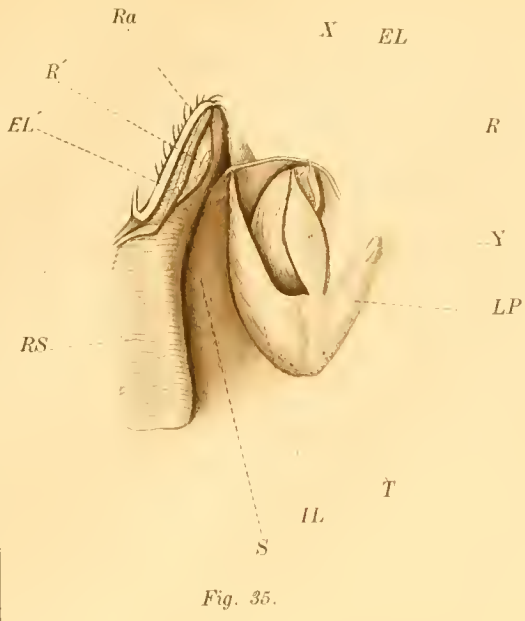


PLATE X.

FIG. 36.—The ventral portion of the body wall is cut open and reflected to show the pericardial chamber. Natural size.

- a. br. v., anterior branchial vein; in this case collapsed and not forming an auricular expansion.
- a. p. g., anterior pericardial gland. The one to the left lies naturally; the one on the right has been turned upward to show the anterior branchial vein.
- H, heart, enfolded by the pallio-visceral ligament. The septal artery runs over its ventral surface, suspended by a mesentery-like fold of the pallio-visceral ligament, and through the posterior viscero-pericardial aperture.
- j, junction of the body wall and the pallio-visceral ligament posteriorly.
- l, ligament from the ventral edge of the posterior renal sac extending along the body wall.
- p. a., pallial artery.
- p. br. v., posterior branchial vein, partly expanded.
- p. p. g., posterior pericardial gland.
- p. v. a. b., posterior ventral aponurotic band.
- p. v. l., pallio-visceral ligament. The three apertures through it by which the pericardial and genital divisions of the coelom are put in communication are at either side of and behind the heart.
- p. v-p. ap., posterior viscero-pericardial aperture.
- pyr. s., pyriform sac.
- r. s., anterior wall of the right posterior renal sac.

FIG. 37.—Renal appendages from the posterior wall of one of the renal sacs. $\times 2$.

FIG. 38.—Male genital organs viewed from above and in front. The anterior portion is represented as dissected from the body wall. Natural size.

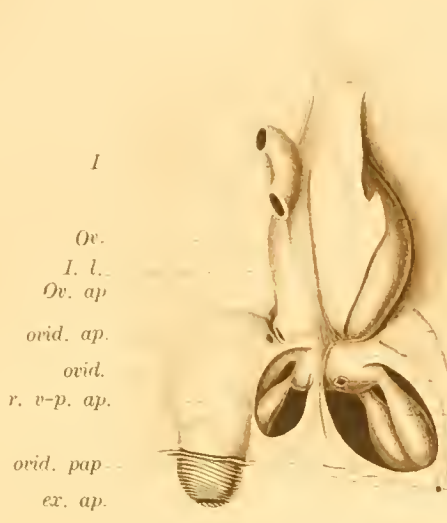
- ac. gl., accessory gland surrounding the vas deferens.
- ao, aorta, passing upward from the heart at the back of the haemocoelic membrane.
- g. l., genital ligament.
- gas. l., gastric ligament.
- I, intestine, cut at the middle of the second loop.
- Il., intestinal ligament.
- P. ap., external opening of the penis.
- P. l., left tube of the penis.
- P. r., right tube of the penis.
- p-v. l., pallio-visceral ligament at its attachment to the posterior side of the heart.
- pyr. ap., external aperture of the pyriform sac.
- pyr. s., pyriform sac.
- r., rectum.
- sep., septum dividing the spermatophore sac.
- sp. s., spermatophore sac.
- S. V., seminal vesicle.
- T. ap., aperture of testis.
- T. g., face of the testis which is pressed against the stomach.
- T. l., face of the testis which is pressed against the liver.
- v. d.¹, proximal thin-walled portion of the vas deferens.
- v. d.², commencement of the thick-walled portion of the vas deferens, which extends from this point to the seminal vesicle.
- s., thickening of the tissues of the genital ligament extending from the root of the siphuncle.
- y, tunic of the accessory gland carried upon the back of the testis.

FIG. 39.—Female genital organs viewed from in front and above. The anterior portion of the ovary rests upon the pallio-visceral ligament. The heart and auricles show through the viscero-pericardial apertures. Natural size.

- ao, aorta.
- ex. ap., external aperture of the oviduct.
- g. l., attachment of the genital ligament to the posterior body wall.
- gas. l., gastric ligament.
- I, intestine.
- Il., intestinal ligament.
- l. a., line along which the haemocoelic membrane is attached ventrally.
- l. v-p. ap., left anterior viscero-pericardial aperture.
- Ov., ovary.
- Ov. ap., aperture of the ovary slightly pulled away from the inner aperture of the oviduct.
- ovid., thin-walled portion of the oviduct.
- ovid. ap., inner aperture of the oviduct.
- ovid. pap., plaited, freely projecting tip of the oviduct: the oviducal papilla.
- p. au., posterior auricle.
- pyr. ap., opening of the pyriform sac into the mantle cavity.
- pyr. s., pyriform sac.
- r. l., ligament attaching the rectum to the pallio-visceral ligament.
- r. v-p. ap., right anterior viscero-pericardial aperture.
- s, nodule in the genital ligament at the root of the siphuncle.

FIG. 40.—Cartilage viewed from the anterior side. Natural size.

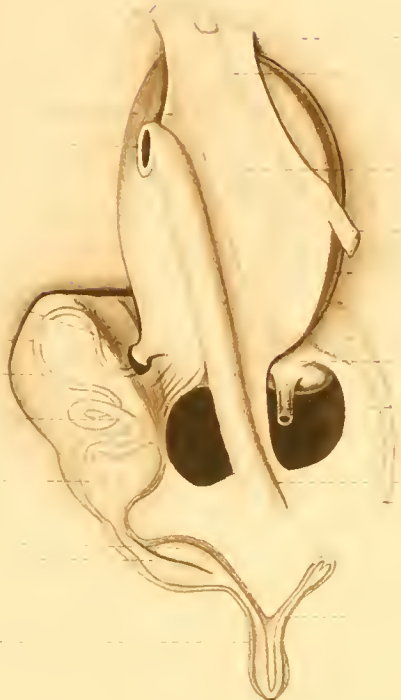- c., cephalic process.
- i., infundibular process.
- l. l., point of attachment of the levator of the funnel.
- m. p., median process of the body of the cartilage.
- v. v., holes through the cartilage occupied by veins.



I
Ov.
I. l.
Ov. ap.
ovid. ap.
ovid.
r. v-p. ap.
ovid. pap.
ex. ap.

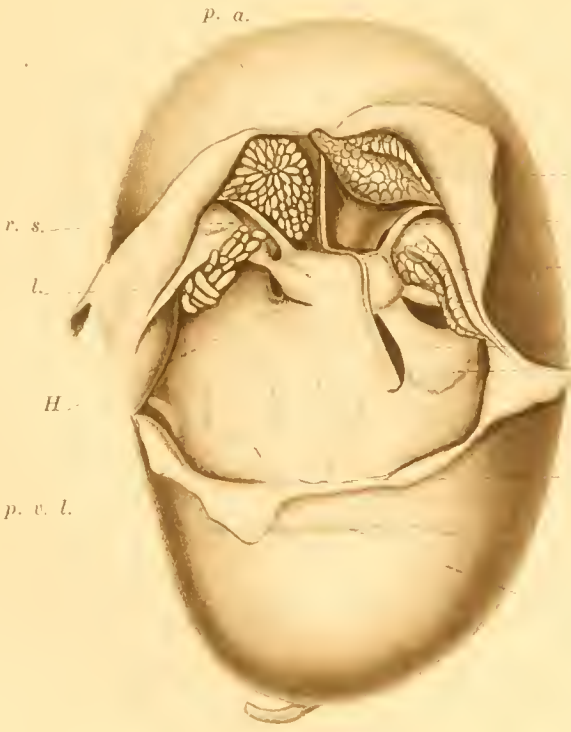
gl
s
I. l.
I.
gas. l.
y
T. ap.
pyr. s
rl
ao
p. au
l. v-p. ap.
pyr. ap.
la.
ac. gl.
v. d. 2
v. d. 2
S. V.

Fig. 39.



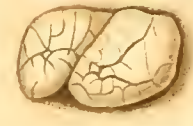g. l.
x
T. g.
gas. l.
T. L.
pyr. s.
p-v. l.
ao
r.
pyr. ap.
P. l.
P. ap.

Fig. 38.



r. s.
l.
H.
p. v. l.

Fig. 36.



a. p. g.
a. br. v.
p. p. g.
p. br. v.
p. v-p. ap.
pyr. s.

Fig. 37.



j.
v.
v.
p. v. a. b.

c
m. p.
l. i.
i.

Fig. 40.

PLATE XI.

- Fig. 41. —Nervous system, dissected and viewed from the dorsal side. $\times 2$.
- 1, nerve to mandibular muscle.
 - 2, pharyngeal commissure.
 - 3, nerves to mandibular muscle.
 - 4, pharyngeal ganglion.
 - 5, outer cerebro-buccal connective.
 - 6, inner cerebro-buccal connective.
 - 7, right nerve of the inferior labial lobe.
 - 8, infundibular nerve.
 - 9, nerves to digital and superior labial tentacles.
 - 10, large nerve innervating hood and digital tentacles.
 - 11, nerve of postocular tentacle; the other branch of this nerve innervates the proocular tentacle and the posterior portion of the hood, and sometimes digital tentacles.
 - 12, cerebral ganglion.
 - 13, pleuro-visceral ganglion.
 - 14, nerves to shell muscle and the body wall.
 - 15, nerve to the walls of the vena cava, in this case springing from the visceral nerve, 22.
 - 16, Nerves to the spermatophore sac and the genital duct.
 - 17, nerve seeming to go to the posterior wall of the anterior renal sac.
 - 18, nerve seeming to go to the posterior wall of the posterior renal sac.
 - 19, posterior branchial nerve.
 - 20, anterior branchial nerve.
 - 21, nerve to the wall of the vena cava, in this case arising directly from the pleuro-visceral ganglion.
 - 22, visceral nerve.
 - 23, nerves from the outer end of the cerebral ganglion to the posterior portion of the hood.
 - 24, base of the optic nerve, which may be a ganglion.
 - 25, portion of the optic nerve in the stalk of the eye.
 - 26, branches of the optic nerve in the capsule of the eye.
 - 27, nerves proceeding from the cerebral ganglion to the dorsal side of the buccal mass, some being distributed to the mandibular muscles, but most passing to the papillae on the edge of the buccal membrane.
 - 28, pedal ganglion.
 - 29, pedal commissure.
 - 30, nerve proceeding to the base of the spadix, and there ending in an enlargement from which several fine nerves go to the tissues of the spadix.
 - 31, nerve to oesophagus.
 - 32, buccal ganglion.
 - 33, buccal commissure.
 - 34, nerve to salivary gland.
 - 35, ganglion of inferior labial lobe (or Van der Hoeven's organ)

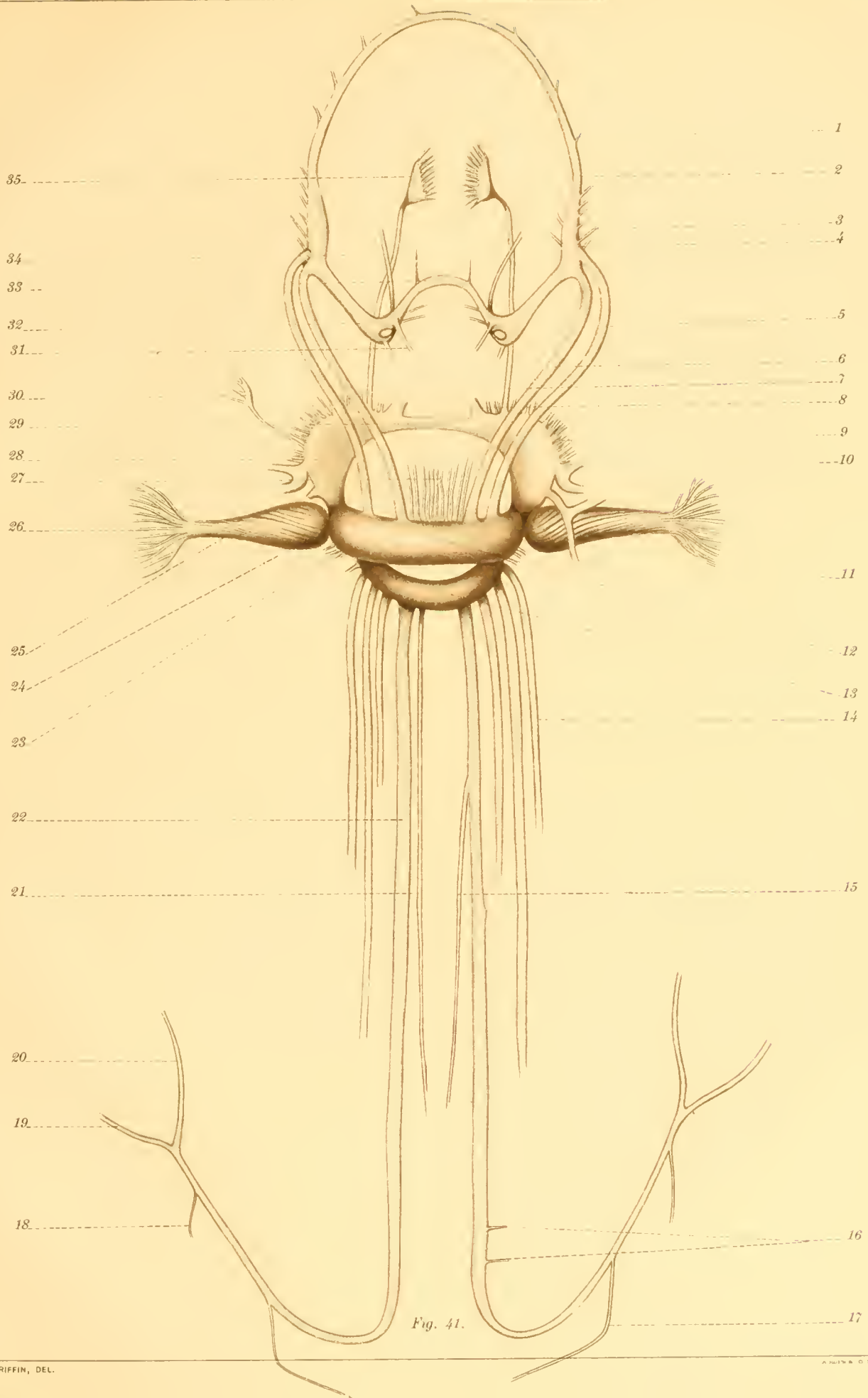


Fig. 41.

PLATE XII.

FIG. 42.—Central tooth of the radula.

FIG. 43.—First lateral tooth of the radula.

FIG. 44.—Second lateral tooth of the radula.

FIG. 45.—Third lateral tooth of the radula.

FIG. 46.—Fourth lateral tooth of the radula.

FIG. 47.—Fifth lateral tooth of the radula.

FIG. 48.—Sixth lateral tooth of the radula.

FIG. 49.—Cross section of a digital tentacle. C. L. $\times 15$.

C, cirrus.

SH, sheath.

FIG. 50.—Longitudinal section of the tip of a digital tentacle. C. L. $\times 20$.

A, artery.

G, G, annular grooves between ridges.

LM, fasciculi of longitudinal muscles.

N, nerve.

R, suctorial ridge.

SH, tip of sheath of cirrus.

T, transverse muscle layer.

V, vein.



Fig. 44.



Fig. 46.

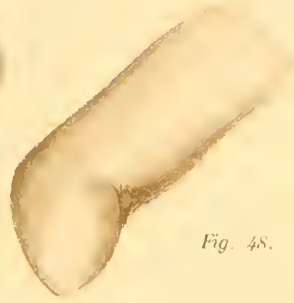

Fig. 48.



Fig. 45.

Fig. 47.



Fig. 42.



Fig. 43.

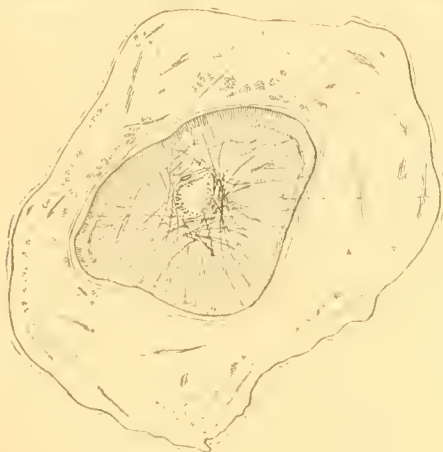


Fig. 49.

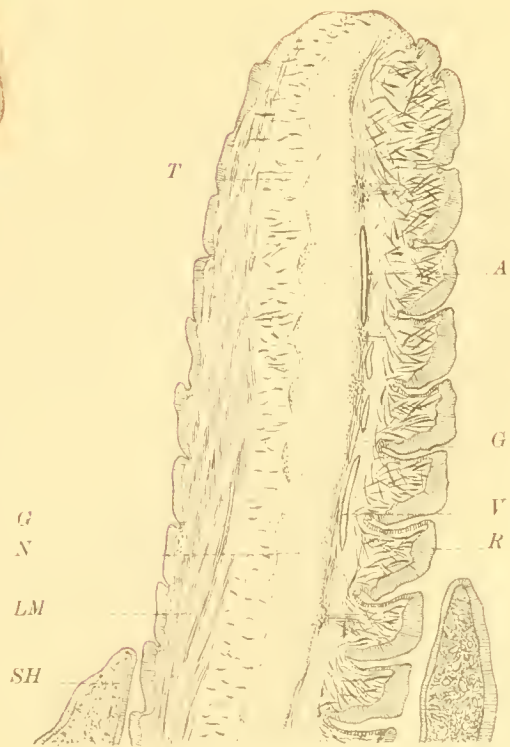


Fig. 50.

PLATE XIII.

FIG. 51.—Cross section of a cirrus of the superior labial group of a male. (C. L. $\times 20$.)

A, artery.

CM, circular muscle layer.

E, thickened epithelium of the inner (suctorial) surface of the annular ridge.

LM, radially arranged longitudinal muscles.

LM', outer layer of longitudinal muscles.

N, nerve.

OM, oblique muscle layer.

RM, radiating transverse muscle fibres inside the projecting portion of the annular ridge.

TM, transverse muscle fibres surrounding the nerve and radiating outward between the longitudinal muscles.

V, vein.

FIG. 52.—Longitudinal section of the tip of the first cirrus of the spadix. (C. L. $\times 14$.)

N, nerve.

TM, alternating layers of transverse muscle fibres.

V, vascular corium of the tip of the cirrus.

FIG. 53.—Cross section of the first cirrus of the spadix. (C. L. $\times 7$.)

A, artery.

N, nerve.

V, V, veins.

FIG. 54.—Cross section of the fourth cirrus of the spadix. (C. L. $\times 14$.)

FIG. 55.—Longitudinal section of a gland of the second cirrus of the spadix. (C. L. $\times 60$.)

E, epithelium of the dorsal surface of the cirrus.

G, secretory epithelium.

L, lumen of gland.

N, neck of gland.

Fig. 52

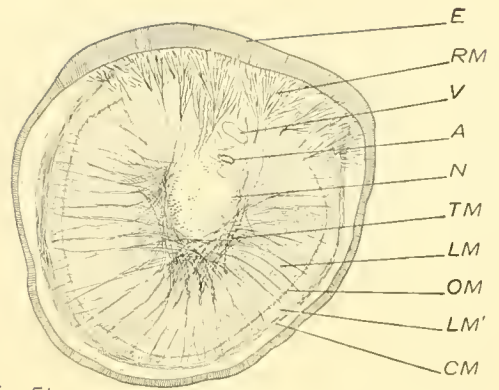
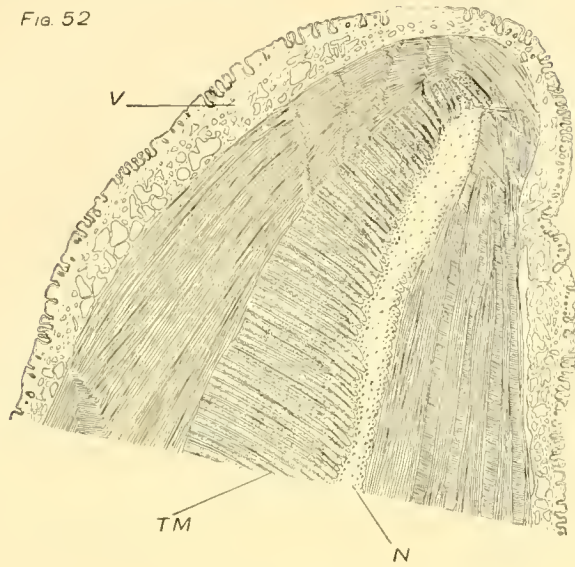


Fig 51

Fig 54

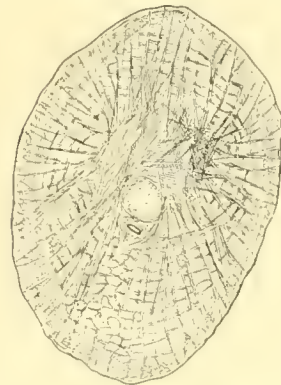

Fig 53

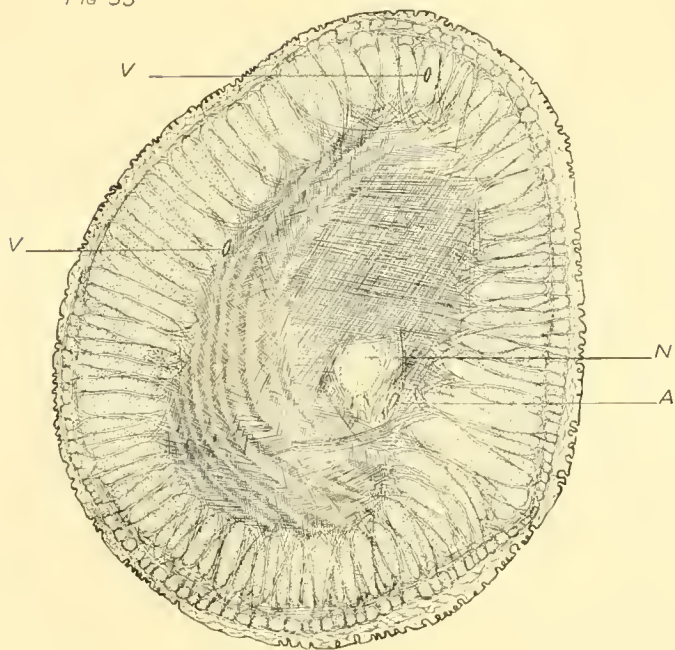


Fig 55

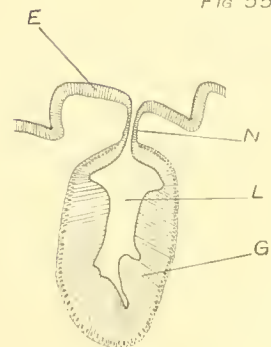


PLATE XIV.

FIG. 56.—Slightly oblique cross section of the second cirrus of the spadix. C. L. $\times 12$.

A, artery.
G, gland.
GL, layer of glands.
N, nerve.
V, vein.

FIG. 57.—Section through the slime gland on the sheath of the spadix perpendicular to the surface. C. L. $\times 20$.

A, a single cell of the glandular epithelium highly magnified. Camera lucida outline. Magnification about 400 diameters.

FIG. 58.—Longitudinal section of the tip of the fourth cirrus of the spadix. C. L. $\times 10$.

N, nerve.
V, vascular sinuses of the body of the cirrus.
V', vascular sinuses in the ridges upon the outer side of the cirrus.

FIG. 59.—Slightly oblique cross section of the third cirrus of the spadix. C. L. $\times 14$.

A, artery.
Cr, crypt, with projecting tongue. By following the series of sections shown by each row of crypts the manner in which the tongue projects from the wall of the crypt may be made out.
CrL, layer of crypts.
V, vein.

FIG. 60.—Longitudinal section of the tip of the third cirrus of the spadix. C. L. $\times 8$.

Cr, crypt.
N, nerve.

FIG. 56

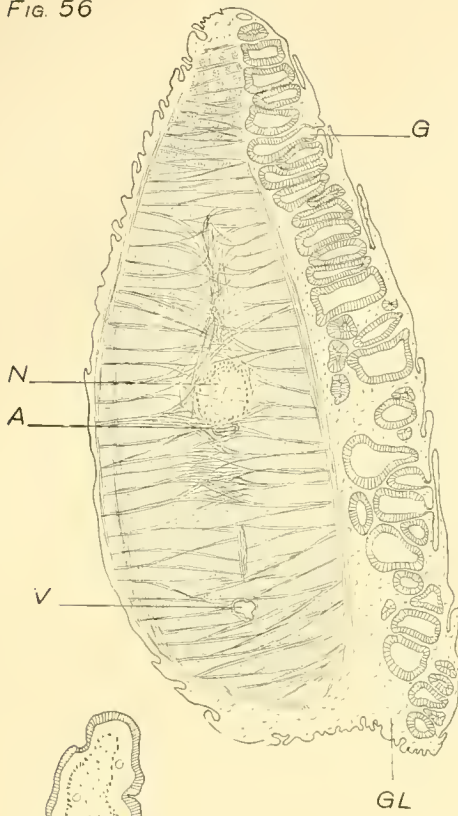


FIG. 57

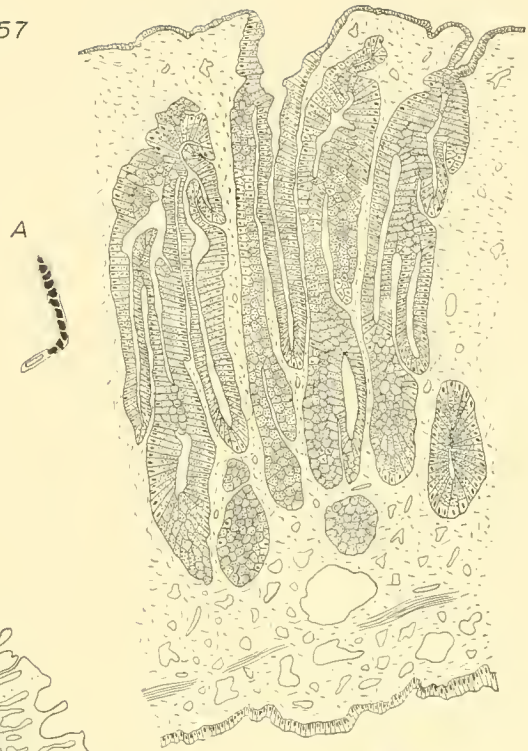


FIG. 58

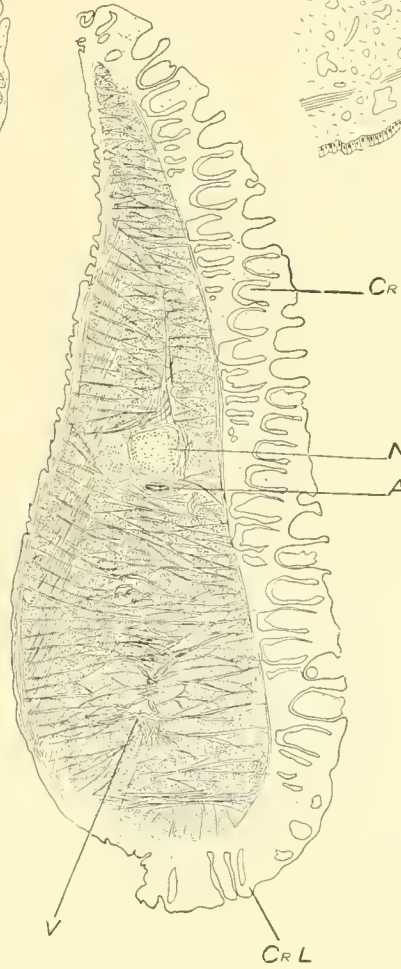
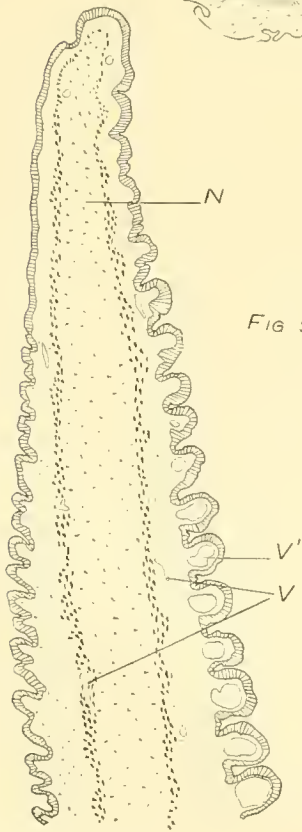


FIG. 59

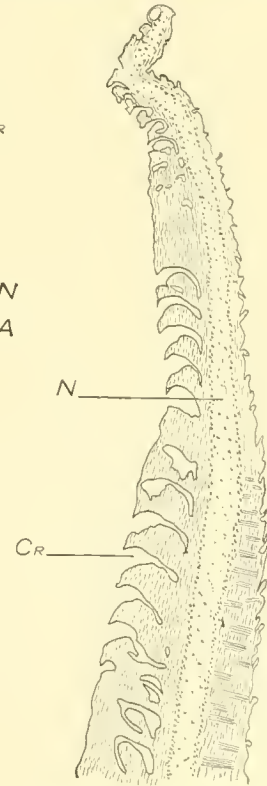


FIG. 60

L. E. Griffin, Del.

PLATE XV.

- FIG. 61.—Longitudinal section of the tip of the second cirrus of the spadix. (C. L. $\times 14$.)
G, gland.
N, nerve.
- FIG. 62.—Longitudinal section through a crypt and its tongue of the third cirrus of the spadix. (C. L. $\times 35$.)
- FIG. 63.—Longitudinal section of the base of the preocular tentacle. (C. L. $\times 20$.)
N, nerve trunk.
N', nerve bundles running along the anterior side of the nerve trunk.
- FIG. 64.—Longitudinal section of the tip of the preocular tentacle. (C. L. $\times 20$.)
A, artery.
CG, ciliated groove on anterior side.
G, groove on posterior side.
N, nerve.
n, branch nerve to the peripheral portion of the tentacle.
R, ridge on anterior side of tentacle.
V, vein.
X, breaking plane.
- FIG. 65.—Slightly oblique cross section of the preocular tentacle about 6 millimeters from its tip. (C. L. $\times 35$.)
CG, ciliated groove between the upper and lower projecting ridges, R and R'.
N, nerve.
N', nerve bundles running along anterior side of nerve.
R, base of projecting ridge.
R', upwardly projecting portion of the next lower ridge.

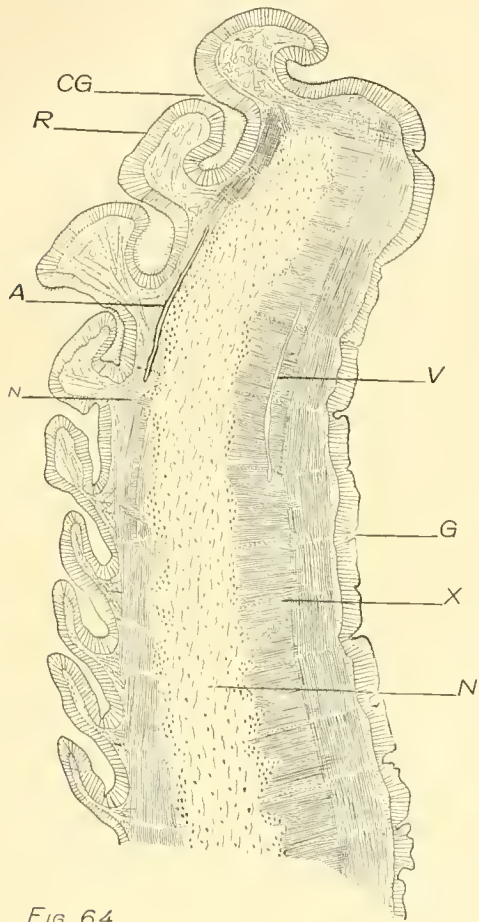


FIG. 64

FIG. 65


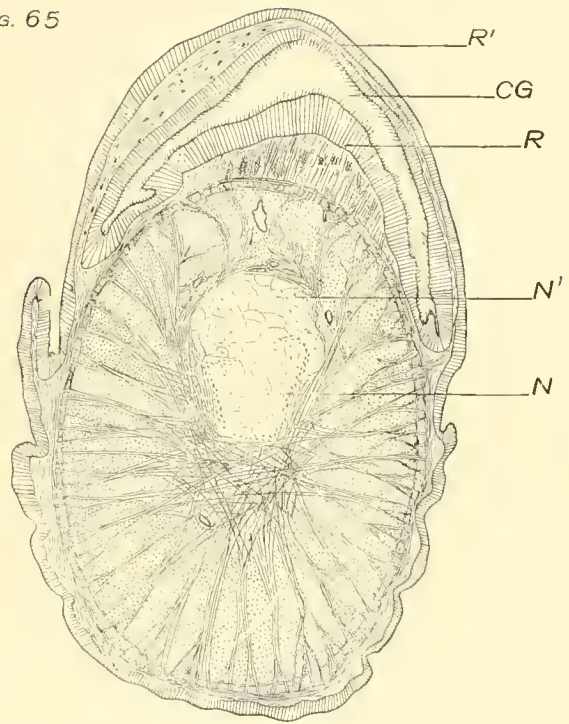


FIG. 63

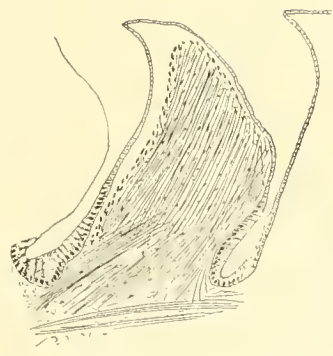


FIG. 62

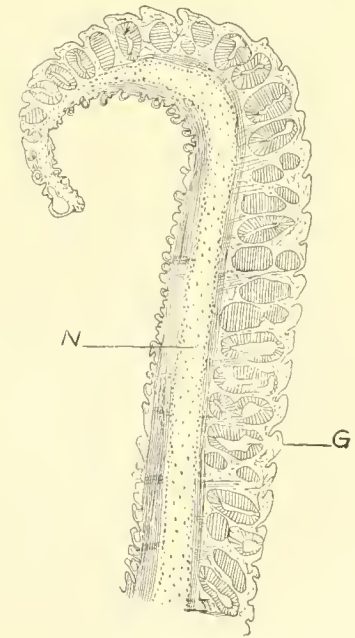


FIG. 61

PLATE XVI.

FIG. 66.—Cross section through the middle of Van der Hoeven's organ. (C. L. $\times 8$.)

D, dorsal surface.

A, atrium.

G, G, G, glandular portions of the organ.

Gn, ganglion.

HF, horizontal fissure.

L, laminae.

N, nerves to the laminae.

SH, wall of the atrium.

VF, vertical fissure.

FIG. 67.—Longitudinal section of a gland of Van der Hoeven's organ. (C. L. $\times 35$.)

FIG. 68.—Cross section of gland tubules of Van der Hoeven's organ. (C. L. $\times 35$.)

FIG. 69.—Section of the mantle through the bases of the preanal papillae. (C. L. $\times 12$.)

G, G, glands.

IM, inner surface of mantle.

O, opening of gland.

OM, outer surface of mantle.

P, P, bases of the preanal papillae.

FIG. 70.—Cross section of the salivary gland. (C. L. $\times 20$.)

A, artery.

BS, blood sinus of salivary process.

N, nerve.

O, opening from the central cavity of the gland to the pharyngeal cavity.

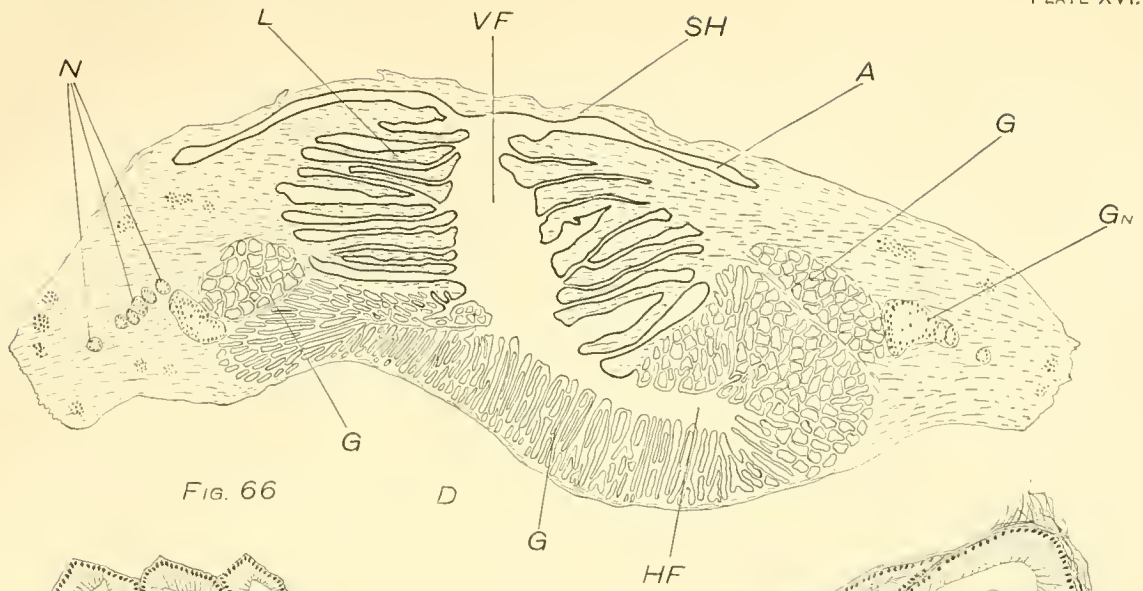


FIG. 66

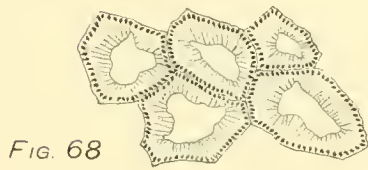


FIG. 68

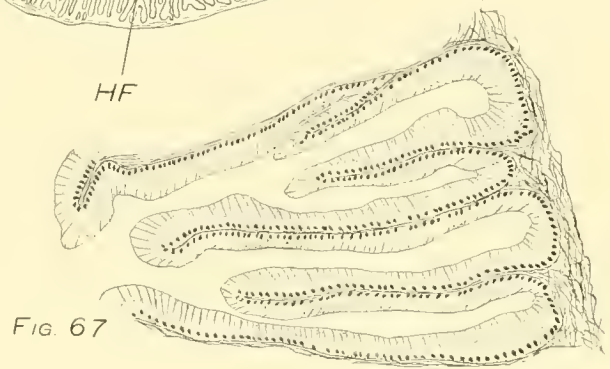


FIG. 67

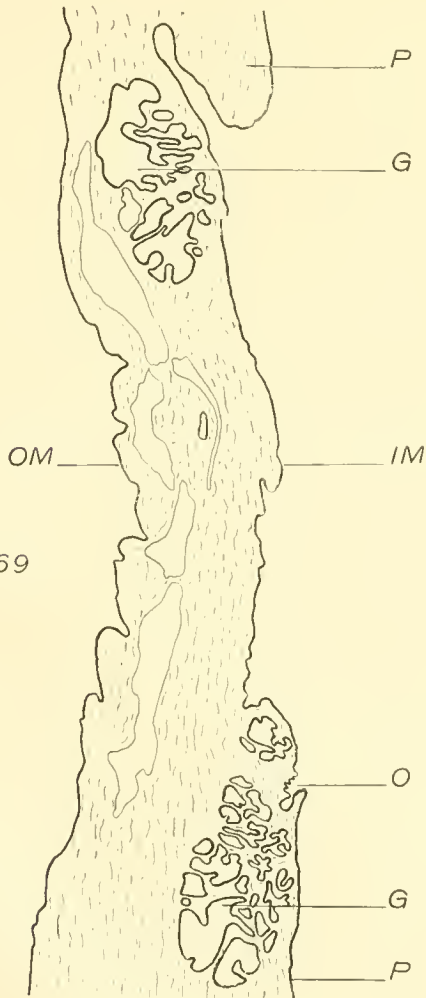


FIG. 69

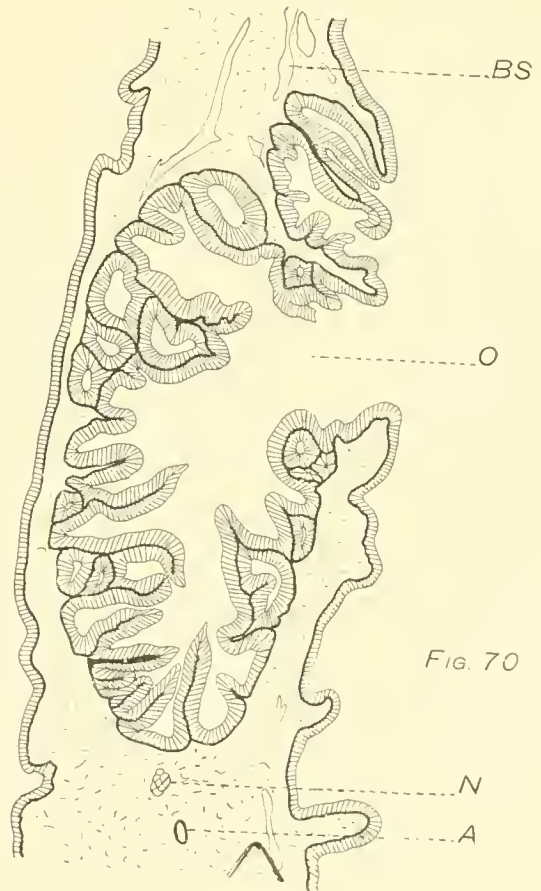


FIG. 70

PLATE XVII.

- FIG. 71.—Cross section of the nerve of a digital tentacle. Borax carmine and Lyons blue stain. The ganglion cells in red.
- FIG. 72.—Epithelium of the inner side of an annular ridge of a digital tentacle. Also two isolated epithelial cells from the inner surface of the ridge.
- FIG. 73.—Section of the secretory epithelium from a gland of Van der Hoeven's organ. The secretory cells had separated from the submucosa, revealing the sensory cells which lie between them. As the section was somewhat oblique, the outer ends of the cells are not shown.

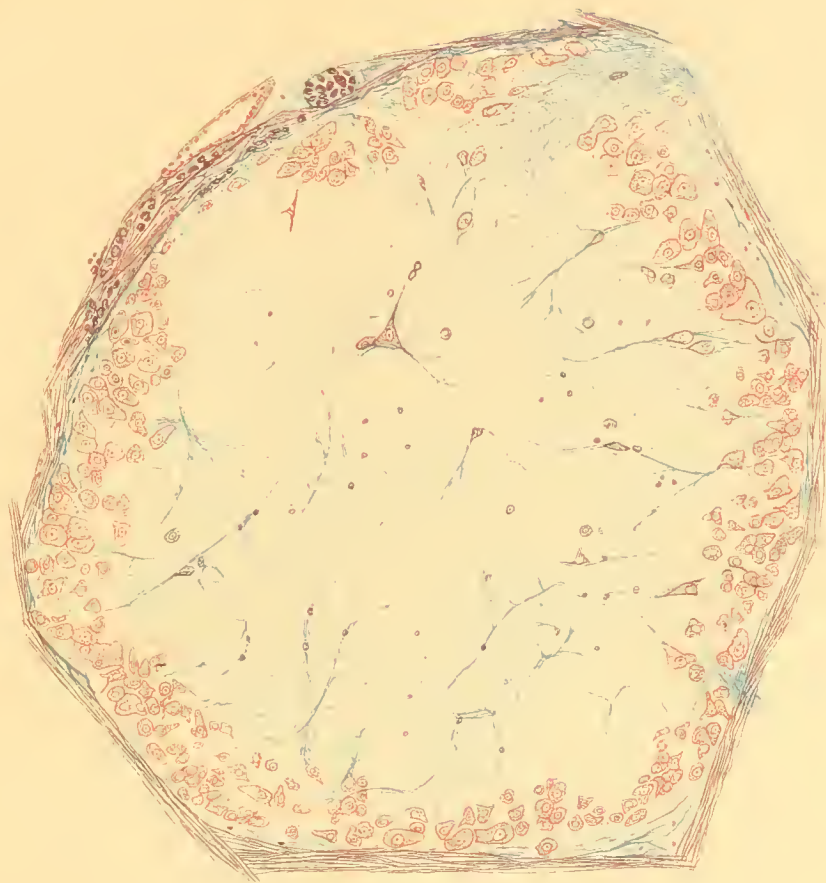


Fig. 71.

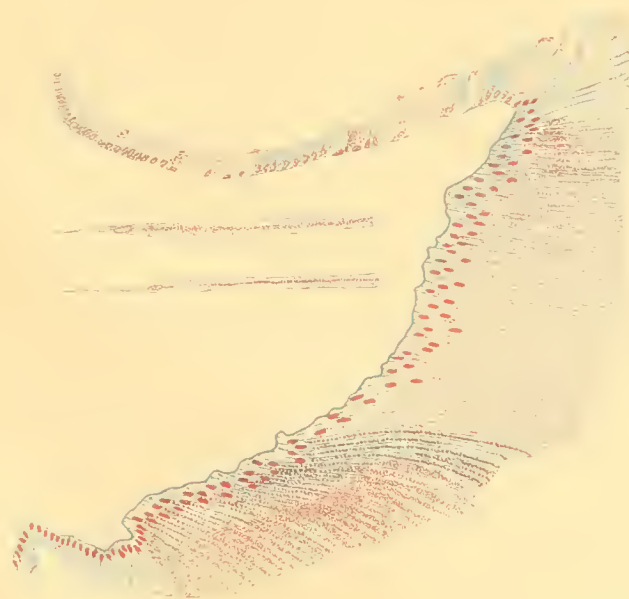


Fig. 72.

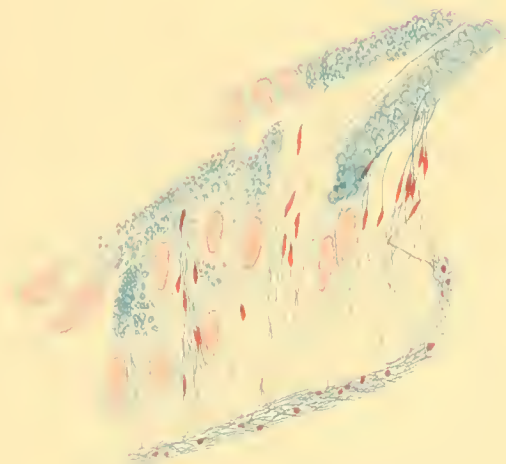


Fig. 73.





