

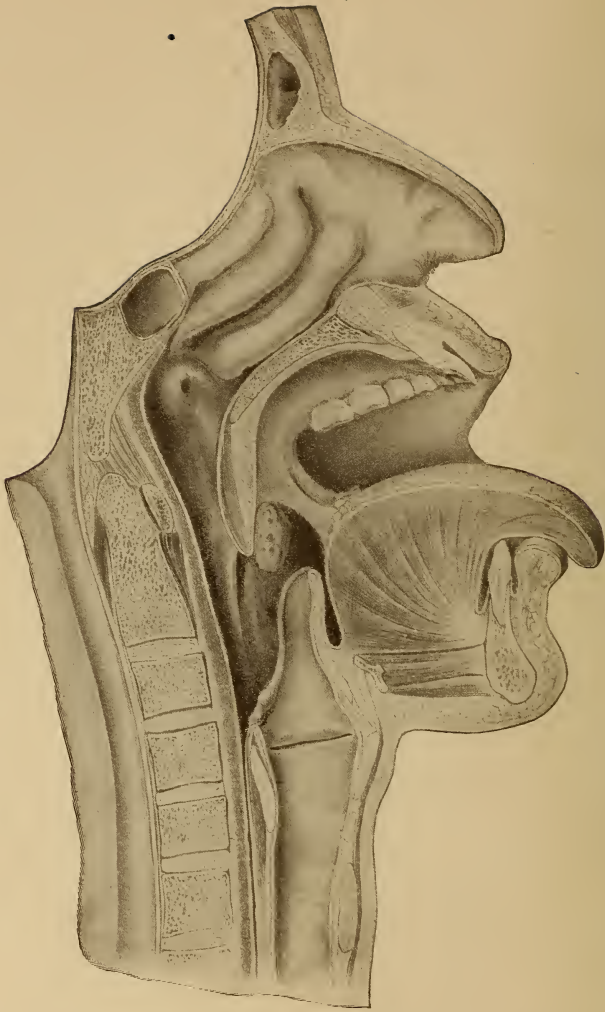


Class RF46

Book F67

Copyright N^o _____

COPYRIGHT DEPOSIT.



VERTICAL ANTEROPOSTERIOR SECTION OF
UPPER RESPIRATORY TRACT.

DISEASES
OF THE
Nose, Throat and Ear.

FOR STUDENTS AND PRACTITIONERS IN WHICH
PARTICULAR ATTENTION IS GIVEN THE
TREATMENT OF DISEASES BY
ECLECTIC MEDICATION

BY
KENT O. FOLTZ, M. D.

Professor of Ophthalmology, Otology, Rhinology and Laryngology in the
Eclectic Medical Institute, Cincinnati; Assistant Editor the Eclectic
Medical Journal; Author of a Manual on Diseases of the Eye.

ILLUSTRATED.



CINCINNATI:
THE SCUDDER BROTHERS COMPANY.

1906.

RFA6
F67

LIBRARY of CONGRESS
Two Copies Received
JUL 16 1906
Copyright Entry
Feb 28, 1906
CLASS *a*, XXc. No.
140717
COPY B.

COPYRIGHTED, 1906, BY
THE SCUDDER BROTHERS COMPANY.

U
S
C
O
P
Y

Dedicated
TO THE
MEMORY OF MY FATHER,
William K. Holtz, M. D.

INTRODUCTION.

I HAVE no apology to offer for this book. For some unaccountable reason there has been a tendency among writers on these subjects to ignore practically everything but local measures in treating the conditions which are so prevalent in the upper respiratory tract and the structures more or less directly dependent upon this region for their proper functional action. Why, with a few notable exceptions, internal medication has been ignored, is impossible to say. In the majority of inflammatory conditions of the upper respiratory tract and the ears, if proper systemic measures are instituted during the second stage, a cure will result. Later, relief is in many cases all that can be expected, but this can not be obtained by the use of sprays, gargles, douches, etc., excepting a very transitory amelioration of the condition. Proper constitutional measures will give more or less permanent relief in practically all but malignant cases.

My experience has been that the selection and administration of drugs from the Eclectic standpoint of specific medication will give more satisfactory results than the generally-accepted method of local treatment only. However, to follow the precepts of specific medication, specific diagnosis is of the utmost importance, and it has been my aim to emphasize these features in this volume. The indications for the use of drugs have been as explicit as seemed necessary.

It must not be inferred that no other drugs are required in treating these diseases, but the ones mentioned are the basis of treatment, and it is presumed the practitioner will use such other remedies as may be indicated, common sense being a requisite in handling specialties as well as in general practice. A knowledge of embryology will be an aid to a more comprehensive study of morbid changes in these structures, and I can not too strongly insist upon this important branch of biology being given more attention.

The liquid drugs employed are the product of the laboratory of Lloyd Brothers, viz., *specific medicines*, unless otherwise stated. The preference is given these on account of the uniformity of strength and because I have been able to get results from these preparations that I could not always obtain from other tinctures.

I wish to thank W. B. Saunders & Company for permission to reproduce several plates; also Max Wocher & Sons Company for the use of cuts of instruments. I also wish especially to thank Miss Margaret Stewart for assistance in proofreading, and Miss Tillie K. Hannah for work on the manuscript. I have endeavored to give credit to the different authors throughout the body of the work, but some of the investigations referred to were in journal articles where the name had inadvertently been lost or overlooked.

As for the style of the book, the author has endeavored to state the subject clearly and concisely, often at the expense of smoothness, but with a desire to impress the important points in making the diagnosis and prescribing the proper remedies.

THE UPPER RESPIRATORY TRACT.

CHAPTER I.

THE NOSE.

ANATOMY.

THE nose is divided into the external and internal portions. The nasal organ possesses several functions. The external portion being necessary only for the adornment of the face, while the internal is for the distribution of the olfactory nerve, and also constitutes the upper portion of the respiratory tract. The peculiar anatomical structure not only prepares the inspired air for entrance into the lungs, but supplies the necessary moisture, regulates the temperature, and also removes the coarser foreign material usually floating in the atmosphere. From the arrangement of not only the olfactory, but also the other nerves in the nasal cavity, a warning of the presence of injurious substances is often given. What is also of especial importance, is the power to determine the properties and character of food and drink, as the nasal region is actually the seat of what is usually called the sense of taste.

The embryological development of the nose in detail is not perfectly understood, but the structures derived from the ectoderm are, the integument; vibrissæ; sebaceous and sweat glands; the nasal mucous membrane, including the glands and mucous membranes of the accessory nasal cavities. The nervous tissues are also derived from this layer, as well as the sensory epithelia of the special sense organs.

The mesoderm supplies the muscular and adipose tissue, cartilages and bony structures.

Besides the division into the external and internal portions, another division of this tract is made, "posterior or postnasal space, sometimes called the vault of the pharynx. In front of this portion is the anterior region, which is divided into two fossæ by the septum. These fossæ extend from the postnasal space forward to the nostrils. Each fossa is bounded internally by the septum, which is formed by the perpendicular plate of the ethmoid and spine of the

DIVISION OF NOSTRILS. (*Septum Narium.*)

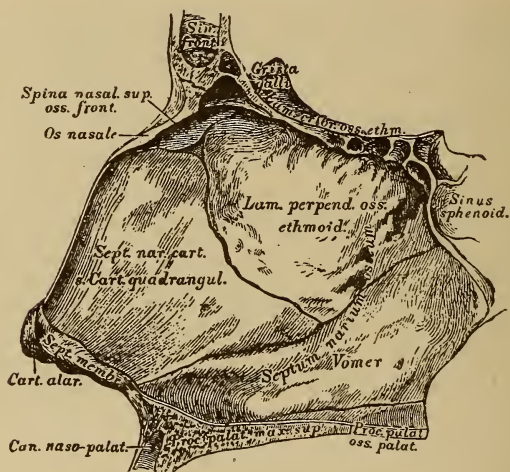


FIG. 2.

frontal bone above, posteriorly by the vomer, and anteriorly by cartilage. The septum is generally perpendicular until about the seventh year; after this age deviation often occurs and generally to the left. The anterior and posterior portions of the roof slope downward, the central portion being nearly horizontal. The roof consists of the nasal process of the frontal and nasal bone in front, the central

portion by the cribriform plate of the ethmoid and the posterior part by the inferior surface of the sphenoid and the sphenoidal turbinates.

The anterior three-fourths of the floor consists of the palate process of the superior maxillary; the posterior portion of the horizontal plate of the palate bone.

The outer anterior wall is formed by the nasal process of the superior maxillary and lacrimal bones, the middle portion by the ethmoid and inner surface of the superior

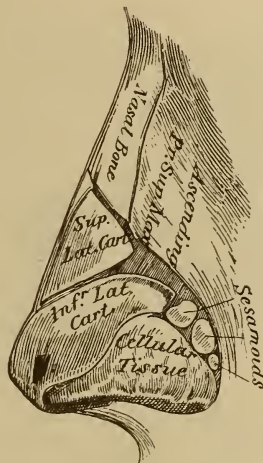


FIG. 3.

maxillary and inferior turbinates, and posteriorly by the vertical plate of the palate and internal pterygoid plate of the sphenoid bone. Extending from the bony walls to the nostrils, the fossæ are called the vestibules, the outer wall of each vestibule is formed by an upper and lower lateral cartilage, and two or three smaller plates of cartilage, the inner wall being formed by the triangular cartilage of the septum. Each fossa contains three, and sometimes four, thin, somewhat triangular bony structures, which extend from the outer wall toward the median line, but do not come

in contact with the septum. These bony processes are the turbinated bodies, and are more or less curved, the convex surface being upward, inward, and somewhat forward. The line of attachment of each is approximately horizontal and are nearly equidistant from each other.

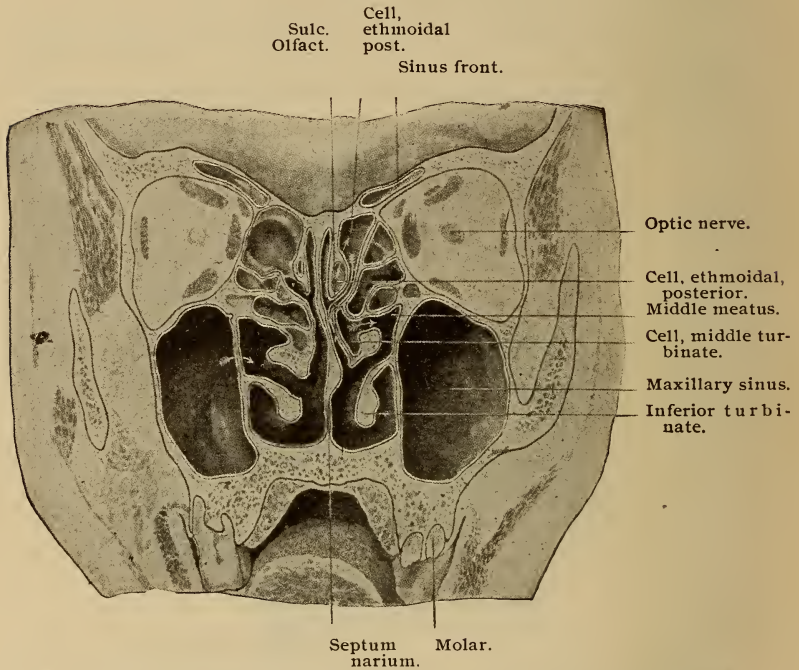


FIG. 4. This section is made vertically through the nasal cavities and maxillary antra on a plane with the first molars. The arrow on the right side indicates an accessory maxillary opening. On the left side are seen the posterior ethmoidal cells opening into the olfactory cleft, and a middle turbinate cell into the middle meatus. The frontal sinuses are shown extending backwards along the orbital roof.

The superior turbinate, which is the smallest, is often divided horizontally, thus forming the fourth turbinate, or

“concha Santoriniana.” The superior turbinate originates from the lateral mass of the ethmoid, and projects downward nearly perpendicularly. The anterior margin is coalescent with the middle turbinate, the posterior being free.

The middle turbinate is from the lateral mass of the ethmoid, is of larger size, more rolled at the center and projects horizontally. The anterior free margin presents the “agger nasi,” a slight elevation projecting downward, and is opposite a corresponding septal elevation. These are important, marking the boundary between the olfactory region above and the respiratory tract below.

The inferior turbinate, as the name indicates, is the lowest, and also the largest. Its structure is more compact, and it is a separate bone. It articulates with the ethmoid, superior maxillary, palate, and lacrimal bones.

The space comprised between each pair of turbinates, and between the inferior turbinate and floor of the nose, is called a meatus, and according to location are designated as superior, middle, and inferior. If through division of the superior turbinate a fourth meatus is formed, it is disregarded, as it is of no particular importance.

Communicating with the meatuses are the accessory sinuses, and as a result of this communication any of these sinuses may become affected in morbid conditions of the nasal fossæ through the continuity of tissue. These sinuses form four groups: the sphenoidal, ethmoidal, frontal, and maxillary, or antra of Highmore.

The sphenoidal sinuses, or cells, are two irregular cavities in the body of the sphenoid, separated from each other by a thin bony septum. They vary in size and are not developed in infancy, but at about the age of three years begin forming, and increase in size with advancing age. In front and below they are partially closed by two thin plates of bone, the sphenoidal turbinated bones, round openings being left at their upper parts, which are located in the upper

and posterior portion of each superior meatus. The roof of the sinuses, which separates them from the brain, is about 1-12 of an inch thick at the thinnest part.

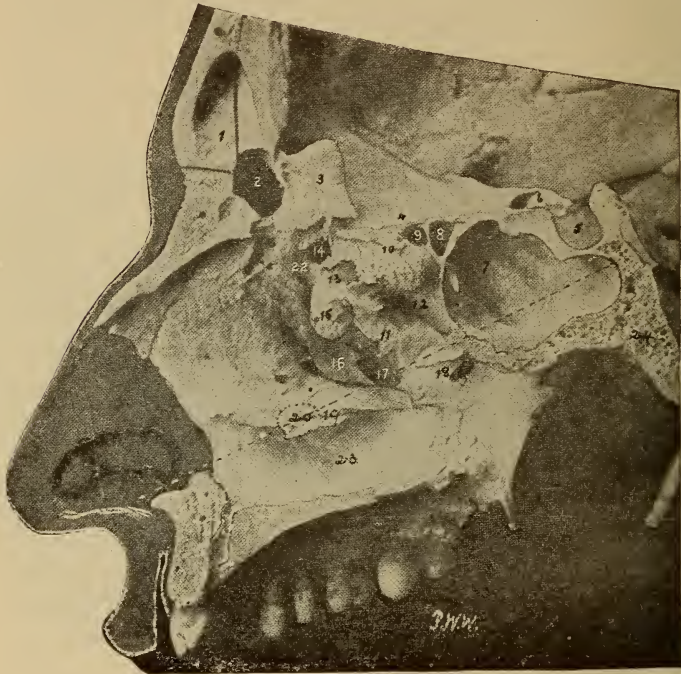


FIG. 5. Vertical section of skull, showing the right accessory sinuses, about two-thirds natural size. (1) Left frontal sinus, separated from right frontal sinus (2) by bony septum; (3) Crista galli; (4) Cribriform plate; (5) Sella turcica; (6) Optic foramen; (7) Sphenoidal sinus; (8, 9) Posterior ethmoidal cells; (10) Portion superior turbinate; (11) Portion middle turbinate; (12) Superior meatus; (13, 14) Anterior ethmoidal cells; (15) Bulla ethmoidalis; (16) Processus unciniformis; (17) Ostium maxillare; (18) Spheno-palatine foramen; (19) Portion inferior turbinate; (20) Location of nasal orifice of nasal duct in inferior meatus; (22) Fronto-nasal duct; (23) Inferior meatus; (24) Sphenoid bone. The dotted line extends from the nasal orifice to the posterior wall of the sphenoidal sinus.

The ethmoidal sinuses, or cells, are located in the lateral mass of the ethmoid, and consist of a number of thin walled cellular cavities, which are enclosed between two vertical plates of bone, the external of which forms part of the orbit, and the internal part of the nasal fossa of the corresponding side. These cells are divided anatomically into the anterior, middle, and posterior. The anterior cells, which are the most numerous, open into the infundibulum, or canal, from the frontal sinus, by means of small openings, ostia ethmoidalia, reaching the middle meatus at the hiatus semilunaris in its extreme anterior part. The posterior cells open into the superior meatus and sometimes connect with the sphenoidal sinus. In some instances the anterior cells may open into the frontal sinuses or even into the orbit.

The frontal sinuses are two irregular cavities, and are larger than the sphenoidal; they are situated in the frontal bone over the anterior portion of the nasal cavity, and extend laterally over the orbits, forming the prominences over the supraorbital arches, the superciliary ridges and also form the prominences over the root of the nose. These sinuses, like the sphenoidal, are usually absent in children, but develop with advancing years. They are larger in men than in women, and the right is usually the largest. The sinuses are separated by a bony lamina, which is often deflected, usually to the opposite side from the septal deviation.

The maxillary sinuses, or antra of Highmore, are situated one in each superior maxillary bone, and are somewhat pyramidal in form. The apex of each is directed outwards and is formed by the malar process; the base by the outer wall of the nose; the roof by the orbital floor, and the floor by the alveolar process. The external wall is the facial surface, and the posterior wall the zygomatic surface of the maxillary. Each maxillary sinus connects by a circular opening with the middle meatus near the posterior part of

the hiatus semilunaris. The opening is called the ostium maxillare. A secondary opening, situated behind this, is sometimes present and is called the ostium maxillare acces-

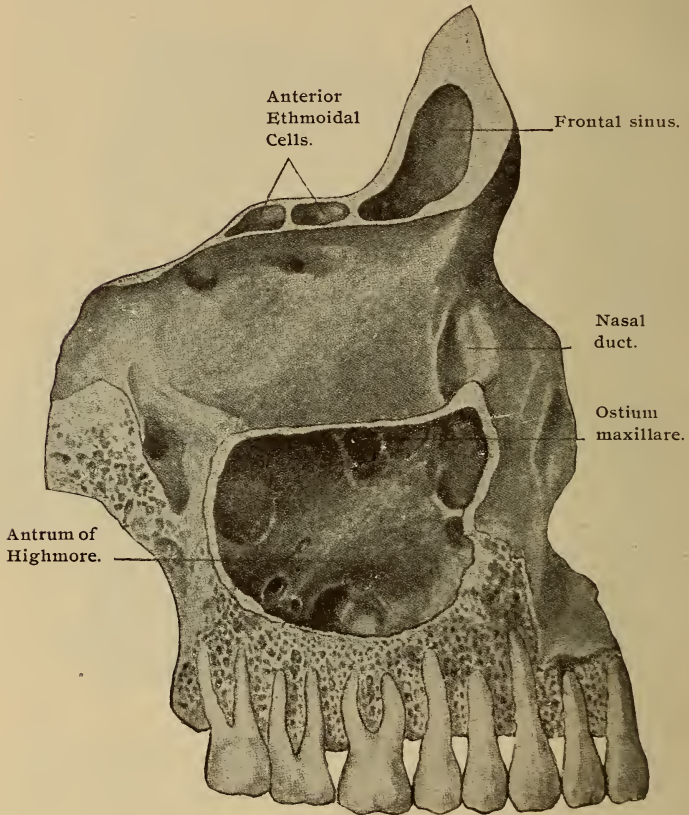


FIG. 6. The external bony wall is removed to show the relation of the roots of the teeth to the antral floor.

sorius. Racial as well as individual differences are found to influence the size of these cavities. Thin laminæ of bone frequently cross these sinuses. The nerves of the teeth and

posterior dental vessels are contained in canals situated in the posterior wall, while the floor is frequently irregular through encroachment of the first and second molars.

The anterior portion of the inferior meatus contains the opening of the nasal duct, which is more or less closed by the valve of Hasner. This duct represents the lower portion of the lacrimal drainage apparatus, being a downward continuation of the lacrimal sac.

The mucous membrane of the accessory cavities varies somewhat from that of the nasal fossæ. The epithelial lining is composed of a single layer of pavement epithelium. The basement membrane and submucosa are thinner than in the exposed regions, while the glands are more numerous at the openings into the nasal fossæ. As all portions of the body, which communicate with the atmosphere are lined with mucous membrane, differentiated according to the character of the work required, it becomes necessary to study each region separately.

The variation in the character of the epithelium is a bar to the ready extension of inflammatory action, although through continuity of tissue, one would suppose that no hindrance would be interposed. The walls of the nasal fossæ are lined with mucous membrane continuous in front at the nostrils with the skin, posteriorly with the pharyngeal mucous membrane. The nasal mucous membrane is variously designated as the pituitary, nasal mucosa, or Schneiderian membrane, and varies in its characteristics according to location, and also changes the lumen of the nasal fossæ, the accessory cavities and their openings as compared with the denuded skull. The membrane is thickest on the convex surface of the turbinates, and quite thin on the floor of the nose and accessory sinuses.

The membrane varies in color according to location. It is a yellowish pink in the olfactory, or upper portion, which includes the roof and superior turbinates, superior meatus,

upper third of the convex surface of the middle turbinates, and the corresponding part of the septum. The lower, or respiratory portion, presents a light pink color, the posterior ends of the turbinates being whitish. The color of the membrane in the accessory cavities is a pale pink. These tints vary in different individuals, as well as in various systemic conditions, and the character of the light used in the examination will also cause a difference in the appearance.

The respiratory, exposed, or epithelial portion, ectodermic in origin, consists of the stratified ciliated columnar type, goblet cells being distributed throughout the superficial layer. The second layer, mucosa or tunica propria, consists of fibrous connective tissue. Lymphoid tissue nodules are found in this portion. The surface of the tunica propria is smooth through lack of sub-epithelial papillæ. Small racemose glands opening on the free surfaces of the membrane are numerous and may be detected by macroscopic inspection. These are mucous glands, some secreting serous fluid and some mucous secretion. The glandular elements are most freely distributed over the inferior turbinates, but the external walls and lower portion of the septum are also freely supplied.

The third, or inner layer, as usually designated, consists of the veins of the mucosa, which are so numerous and wide that this region is often spoken of as cavernous, or erectile tissue, and when the veins become engorged with blood, the fossæ may be nearly or entirely occluded.

The olfactory surfaces differ from the respiratory, not only in color as already mentioned, but in the character of the epithelial cells, which are sustentacular or support cells, and olfactory elements, and also the tunica propria. The sustentacular cells consist of an outer cylindrical division. Near the inner end of each cell there is an oval nucleus. In the same location yellowish pigment, and numerous granules are arranged, forming more or less distinct rows. The

round nuclei of the olfactory cells forms a broad zone adjoining the band of oval nuclei.

The olfactory cells are inconspicuous, elongated, attenuated bodies, surrounded by the supporting elements. The nuclei of the olfactory cells are at different levels. The deepest part consists of small nucleated cells forming the inner boundary of the epithelial layer, and rests upon the tunica propria. The tunica propria in this region consists of fibrous connective tissue, in bundles, as well as delicate elastic fibers. The mucosa contains numerous branched tubular or Bowman's glands.

The veins of the nasal mucous membrane are numerous and of large size, especially over the posterior part of the inferior turbinates. The arterial system is in the deeper layers of the tunica propria, sending branches to the superficial layers, where the sub-epithelial capillary network is formed.

The lymphatic circulation is maintained by a net work of numerous vessels around the lymphoid nodules and in the deeper portion of the tunica propria. In the olfactory region perineurial lymph channels form a net work in the mucosa.

The nerve supply of the nasal mucous membrane consists of the nerves of common sensation and the special, or olfactory sense. The larger filaments of the olfactory nerve lie in grooves in the bony walls, and give off smaller bundles which pass toward the epithelial surface. Perineurial sheaths, prolongations from the intercranial investment of the olfactory nerve, are often found in the mucosa surrounding the nerve twigs. When the epithelium is reached, the nerve fibers divide into their component fibrillæ and pass as naked, often varicosed axis-cylinders between the elements of the neuro-epithelium. The fibrillæ probably are in close contact or continuous with the inner ends of the olfactory cells. The trifacial nerve also supplies some

medullated fibers to the olfactory region, but these probably do not come into direct relation with the olfactory cells. The membrane lining the vestibule is cutaneous in character, the epithelium being squamous.

Blood Supply.—Each fossa receives its blood from the sphenopalatine branch of the internal maxillary, and a small vessel from the small meningeal branch of the internal maxillary, and the anterior and posterior ethmoidal branches of the ophthalmic. The artery of the septum from the superior coronary and the alveolar branch of the internal maxillary which supplies the membrane lining the maxillary antrum. The sphenopalatine enters the fossa just back of the superior meatus, through a foramen of the same name, and divides into an internal and external branch, the first, the naso-palatine, or superior artery of the septum, passes downwards and forwards along the septum, supplying the membrane. The external sub-divides into several branches and supplies the lateral mucous membrane, the antrum, sphenoidal, and ethmoidal sinuses. The anterior and posterior ethmoidal arteries enter the corresponding ethmoidal cells, and are distributed throughout the cavities, they then enter the cranium, dividing into smaller nasal branches, and pass through the cribriform plate of the ethmoid and down the walls of the fossa a short distance. The frontal sinuses are also supplied by the anterior branches. The anterior portion of the septum receives its supply from the septal artery, a branch of the superior coronary of the facial which enters the nose at the junction of the nostril and lip. The free anastomosis and profuse arterial supply renders most operative procedures in this region very annoying, on account of the excessive hemorrhage.

Nerves.—The olfactory nerves proceed from the under surface of the olfactory bulb, and passing through the foramina in the cribriform plate, divide into three more or less distinct sets, the inner distributed to the upper third of

the septum; the outer supplying the superior turbinate, the olfactory portion of the middle turbinate, and the ethmoidal surface anterior to them; the middle division supplying the roof between the distribution of the other two. The sphenopalatine ganglion of the sympathetic supplies branches which are distributed to the upper, middle, and posterior parts of the septum, the lower edges of the superior and the surfaces of the middle inferior turbinates.

General sensation results from the distribution to the upper and anterior part of the septum, the nasal floor, outer walls and anterior surfaces of the inferior turbinates of the nasal branches of the fifth pair. The inferior turbinate and inferior meatus by filaments from the anterior dental branch of the superior maxillary; the upper and back part of the septum and superior turbinate by the Vidian nerve.

The Naso-Pharynx, or Post-Nasal Space.

This comprises the portion of the upper respiratory tract between the plane of the superior nares and the plane extending horizontally backward at the level of the free margin of the soft palate. In front it is continuous with the nasal fossæ, below with the oropharynx, and on the sides with the tympanic cavities through the Eustachian tubes. The roof slopes from the upper borders of the nasal fossæ in front to the posterior and lateral walls, forming a dome-shaped cavity, the dome or vault of the pharynx. The bony borders are, above the vault of the pharynx, the body of the sphenoid and basilar process of the occipital bone with the so-called basilar fibro-cartilage. Behind is located the first cervical vertebra, and laterally the internal pterygoid plates of the sphenoid and petrous portions of the temporal. Anteriorly by the posterior bony margins of the nasal cavities.

The tissues of this region are divided into mucous, fibrous, and muscular. The epithelium of this region is stratified ciliated columnar, with goblet cells interspersed,

but the portion below the level of the soft palate is stratified squamous cells, similar to those found in the oral cavity. The tunica propria consists of fibrous bundles with a variable amount of elastic tissue, sometimes called the pharyngeal aponeurosis. Numerous small papillæ are contained in the sub-epithelial surface of the mucosa, which is covered by the squamous cells, but they are absent beneath the ciliated epithelium. Small mucous pharyngeal glands are found in many places, being especially numerous in the deeper layers of the mucosa surrounding the mouths of the Eustachian tubes. In the upper part of the cavity, arranged as lymph follicles, is a quantity of adenoid tissue, which is especially prominent in the posterior pharyngeal wall between the orifices of the Eustachian tubes. This is called the pharyngeal, or Luschka's tonsil, on account of the similarity of structure to the faucial tonsils. This structure extends in both directions from the median line to a marked depression, Rosenmuller's fossa, or recessus pharyngeus, which separates it from the orifice of the Eustachian tube. The fossa is important in locating the mouth of the tube. The surface of the mass is more or less irregular on account of the depressions formed by the lacunæ or crypts and the minute elevations representing the glandular openings. A slit-like orifice in the lower part leading to a small sac beneath, which Luschka calls the pharyngeal bursa, is found in the majority of cases. The mucous membrane is connected with the fibrous coat by sub-mucous tissue. The posterior part of the fibrous coat is thickened, forming a raphe, which serves as an attachment for the constrictor muscles.

The muscular coat, consisting of striped fibers, comprises the constrictor and other muscles of this region. External to this, areolar tissue of varying thickness forms the attachment for the surrounding structures. The color of the mucous surface in the vault is a deeper pink than that of the nasal fossæ. Around the Eustachian eminences it

is a lighter color, shading to a yellowish tint surrounding the orifices.

Blood Vessels.—The arteries supplying this region are derived from the external carotid. Branches of the ascending pharyngeal being distributed to the greater part. The anterior portion is supplied by the terminal branches of the descending palatine, and sphenopalatine from the internal maxillary. The soft palate and the palatine glands are supplied by the ascending palatine branch of the facial. The venous return is through sub-divisions of the internal jugular vein.

Nerve Supply.—Branches of the second division of the fifth nerve supply the greater portion. Branches from the glosso-pharyngeal, spinal accessory, and the superior cervical ganglion of the sympathetic through the pharyngeal plexus.

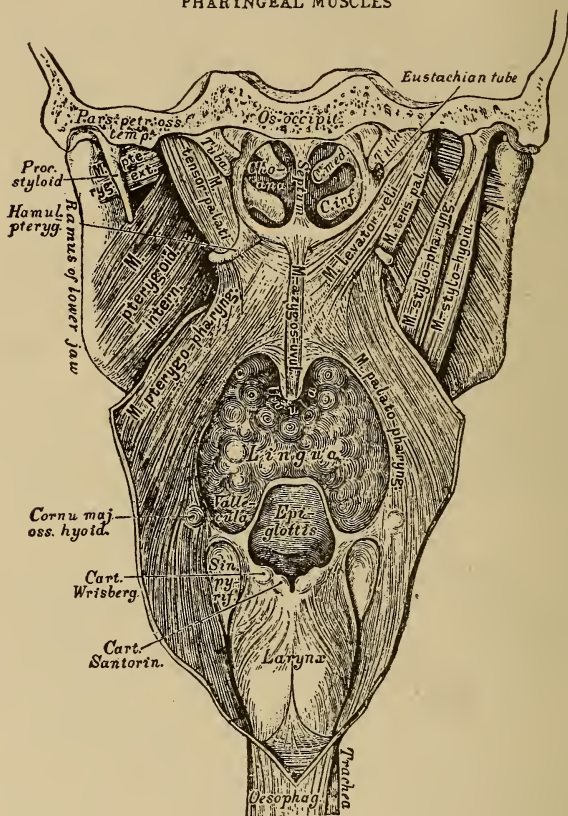
The lymphatics are very numerous in the vicinity of the lymph follicles, forming net works which are continuous with those of the nasal fossæ, esophagus and larynx.

Fauces and Oropharynx.

The roof of the oral cavity is formed by the hard palate anteriorly and the soft palate posteriorly. The hard palate is confined in front and on the sides by the alveolar processes, behind being continuous with the soft palate. The mucous membrane of the hard palate is thin and closely adherent to the periosteum, forming a firm resisting membrane. Corresponding to the suture of the palatal bones is a ridge, which terminates anteriorly in a small papilla corresponding to the orifice of the anterior palatine fossa. On each side of the median line, the mucous membrane presents a corrugated or rugose appearance, and is covered by squamous epithelium. Glands in this region are limited in number. The soft palate, or velum, is a pendulous body and consists of muscular tissue enclosed in

mucous membrane, it is attached to the posterior portion of the hard palate and partially separates the mouth from the pharynx. The sides merge with the faucial pillars, but the

PHARYNGEAL MUSCLES



Posterior view. (Pharynx opened)

FIG. 7.

lower border is free. As a rule, the raphe of the soft palate is not as marked as that of the hard palate.

The muscles consist of five pairs: the levator palati, tensores palati vel dilator tubæ; the palato-glossi, which not

only form the anterior pillars of the fauces, but also act as constrictors of the fauces; the palato-pharyngei, which form the posterior pillars and the azygos uvulæ, consisting of a pair of cylinder-like bundles placed side by side and parallel to the median line of the velum. This pair of muscles with the connective and glandular tissue forms the elongated portion called the uvula. The functions of the palatal muscles are aids in deglutition and vocalization, while the tensor and levator influence the opening of the Eustachian tube allowing free ventilation of the tympanic cavities, and for this reason play an important part in normal hearing.

The action of the uvula has been a matter of much speculation, it undoubtedly acts as a drag or anchor in the act of swallowing, preventing the velum from passing upward into the post-nasal space which would allow food and fluids to enter the nasal fossæ. It also, probably, in connection with the rest of the palatine tissues and epiglottis, partially occludes the oral cavity from the respiratory region in normal breathing. Another function may be that of directing the nasal secretions to the glosso-epiglottic fossæ. (Dobell). When much relaxed or absent, either through ulceration or a faulty operation, phonation is not distinct, and swallowing is liable to be followed by the passage of food into the nasal space. Paresis of the palatal muscles is generally present when the uvula is much elongated or absent.

Tonsils.

The tonsils represent compound lymphatic glands. The size and shape varies, although they approximate an obovate form, and consist of from ten to eighteen lymph follicles contained within a diffuse adenoid tissue. A fibrous capsule not only envelops the mass, but serves to separate it from the surrounding tissues. The oral epithelium is continuous on the mucous surface. Lymphoid cells are distributed throughout the epithelium covering the folds and

depressions of the gland. Mucous glands are numerous in the vicinity of the tonsils, which are situated in the faucial ring and occupy a portion of the triangular space formed by the anterior and posterior pillars of the fauces. The free surface projects into the faucial isthmus. The supra-tonsillar fossa is a variable depression lying behind the anterior pillar.

The tonsil is usually separated from the pharyngeal portion of the tongue by a deep sulcus which may be obliterated, giving then a continuous appearance to the lingual and faucial tonsils. Externally the location of the faucial tonsil is determined by having the head in the normal position, then a spot corresponding to the interval between the angle of the inferior maxillary and the sterno-cleido-mastoid muscle, and the tip of the great cornu of the hyoid bone will be over the gland. Inward pressure on the neck at this point with the finger will press the tonsil towards the median line, thus facilitating tonsillotomy. External to the tonsil is a strong fibrous membrane, a portion of the amygdalo-epiglottic fold, which here lines the fossa of the tonsil. Next to this membrane lies the superior constrictor muscle. These two structures are all that separate the tonsil from the sheath of the internal carotid artery. As a result of this thin barrier, motion is often imparted to hypertrophied or inflamed tonsils by the pulsation of the artery.

Arteries.—The arterial circulation is derived from the facial by the ascending palatine and its tonsillar branches; the lingual; and the ascending pharyngeal. In some cases also there are twigs from the descending palatine, a branch of the internal maxillary. The proximity of the carotid, ascending pharyngeal, and ascending palatine, should be remembered in operative measures. The lingual artery also passes forward close to the lower end of the tonsil, and compression may easily be made at this point.

The veins correspond to the arteries, but form a net

work on the external or carotid side before accompanying their respective arteries. Large branches from this net work also pass to the pterygoid and post-pharyngeal veins.

Lymphatics are numerous and are divided into superficial and deep, they perforate the pharyngeal wall and connect with the upper carotid cervical glands.

The nerves are derived from the glosso-pharyngeal, the fifth, and the sympathetic. A plexus formed by these nerves surrounds the tonsil and also give off branches.

The Pharynx

As usually designated, is the portion seen at the back of the mouth, but really includes the vault of the pharynx, and extends downward until opposite the fifth cervical vertebra and on a level with the cricoid cartilage, where it is continued as the esophagus. The pharynx may be considered as a musculo-membranous structure, four or five inches in length, and capable of more or less contraction or expansion. The boundaries are, behind by the cervical vertebræ and coverings; laterally the internal and external carotid arteries, internal jugular veins; vagus, glosso-pharyngeal, pneumogastric, and hypoglossal nerves. Anteriorly the boundary is interrupted by the structures which have already been described and also the larynx (the laryngo-pharynx), this portion being separated by the epiglottis.

Marked morbid changes in any part of the pharynx may change the quality of the voice, as well as interfere with normal deglutition, and may affect the hearing either through faulty action of the Eustachian tubes or by extension of the morbid state through the tubes to the tympanic cavities.

The pharyngeal aponeurosis investing the pharyngeal structures consists of strong fibrous tissue. This aponeurosis is covered with mucous membrane which is continuous

with the nasal fossæ, Eustachian tubes, mouth, larynx, and esophagus. In the upper portion the epithelium consists of the columnar ciliated form to the level of the nasal floor, below this it is squamous. Acinous glands are numerous throughout the membrane, while the lymphoid glands are grouped, especially in the upper part (pharyngeal tonsils), and surrounding the orifices of the Eustachian tubes. In

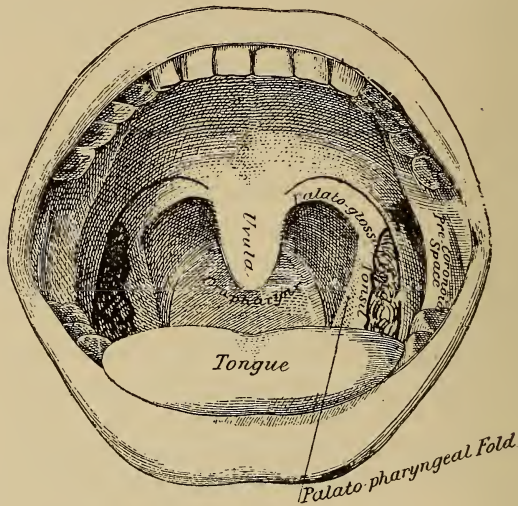


FIG. 8.

the latter location they are sometimes called Eustachian tonsils.

Rosenmuller's fossa is opposite the tip of the petrous bone, one on each side of the pharyngeal wall, extending as a cul-de-sac. Each fossa is in relation behind with the recti muscles, in front with the Eustachian tubes, above with the sphenoid and petrous bones, and externally with the middle meningeal artery and otic ganglion. A thick, soft mucous membrane lines these fossæ, which are supplied with glands and considerable lymphoid tissue. This tissue, as

already mentioned, constitutes the Eustachian tonsil. The character and function of this tissue is similar to that of the other tonsils.

One of the principal functions of the pharynx in the existence of the individual, is its action in the deglutition of food after mastication. The pharynx is raised by the stylo-pharyngei to meet the descending bolus, which is then grasped and carried downward by the action of the three constrictor muscles of the pharynx, the inferior, middle, and superior constrictors. The inferior, or laryngo-pharyngeus is the thickest of the three, and arises from the sides of the cricoid and thyroid cartilages, and then spreads backwards and inwards, being inserted into the fibrous raphe on the posterior pharyngeal wall. The fibers of the inferior portion are horizontal in direction and are continuous with the fibers of the esophagus. The middle, or oropharyngeus, is smaller and fan shaped, and the origin is from the hyoid bone and stylo-hyoid ligament. The fibers diverge from their origin and are also inserted into the fibrous raphe. The superior, or naso-pharyngeus, constitutes the upper, or superior, and is quadrilateral, thinner, and paler in color. Its origin is from the sphenoid and palate bones, and ligamentous and tendinous tissue in this location. The insertion is also into the fibrous raphe, and also by a fibrous aponeurosis to the pharyngeal spine on the basilar process of the occipital bone.

Larynx.

This structure is located at the upper and fore part of the neck, being more or less prominent in the median line, and is easily palpated as it is comparatively close to the cutaneous surface. It is suspended from the hyoid bone, and is behind and below the base of the tongue. The mucous membrane is continuous with that of the pharynx and mouth, and passing downward, forms the tracheal and bronchial mucous membrane.

Surface Landmarks.—The hyoid bone, the central prominence of the thyroid, pomum Adami, and the cricoid can always be discerned. At the level of the lower jaw and just below the mid-line, the body of the hyoid bone can be felt, and traced backward, ending in the greater cornua.

Lower down in the median line there is a distinct de-

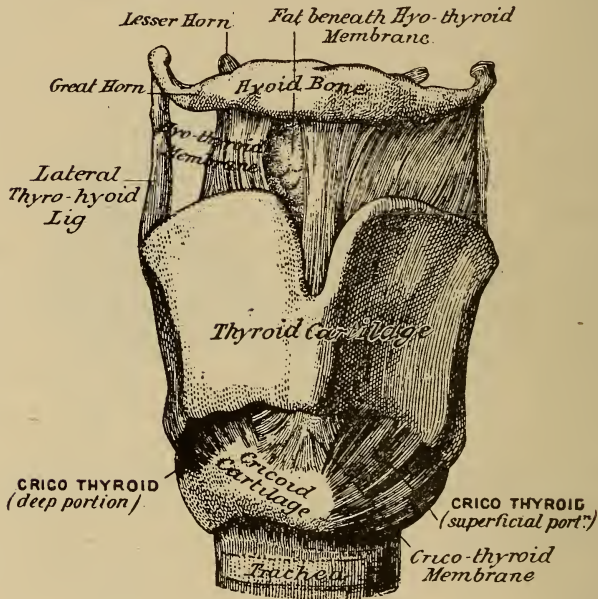


FIG. 9.

pression, corresponding to the central thyro-hyoid ligaments. This point usually designates the apex of the epiglottis.

Below this is the prominence of the thyroid cartilage, varying in size and more marked in males, youth, and thin people. A large bursa is located in the subcutaneous cellular tissue immediately in front of the anterior thyro-hyoid ligament and pomum Adami, which permits freedom of motion of the larynx. Below the pomum the median ridge of

the thyroid cartilage can be distinctly determined. Still lower in the median line the depression corresponding to the crico-thyroid membrane and prominence of the cricoid cartilage can be felt. This is one of the most valuable landmarks.

The upper border of the crico-thyroid membrane is on the level of the rima glottidis, the most narrow portion of the respiratory tract. The cricoid cartilage corresponds with the fifth cervical vertebra, when the head is in a normal position. It also marks the point of crossing the common carotid by the omo-hyoid, the lowest border of the larynx, and narrowest portion of the esophagus. The inferior laryngeal vessels and nerves have their entrance to the larynx at a point corresponding to the upper border.

The lateral lobes of the thyroid gland can be detected at the sides of the thyroid and cricoid cartilages. The gland, adherent to the laryngeal structures and trachea, moves with the larynx in swallowing.

In the median line and below the cricoid cartilage, one can feel the upper portion of the trachea. The upper two rings are close to the cutaneous surface, but those on a plane with the upper border of the sternum are one and one-half to two inches from the surface. Extreme extension of the head and neck will practically add another inch of trachea within reach, as well as making it more prominent. The second, third, and fourth tracheal rings are more or less curved by the thyroid isthmus. A large plexus of veins is always present in this region.

The larynx is composed of nine distinct parts, viz. ; four cartilages, the thyroid, cricoid, and two arytenoid ; one large fibro-cartilage, the epiglottis, and four smaller fibro-cartilages, two of Wrisberg and two of Santorini. The latter are practically supplementary to the arytenoids. Luschka describes an inter-arytenoid cartilage as sometimes occurring, and oftener two pairs of small cartilages, anterior and posterior sesamoid. The thyroid, cricoid, and arytenoid

cartilages frequently undergo ossification in the aged or in some diseases, but the fibro-cartilages are not thus affected. All the cartilages are connected by ligaments and articulations which permit of the various movements required of this organ.

Thyroid Cartilage.—This is the largest of the cartilages, and the name means a shield. The thyroid contains and protects the vocal cords. C. Ludwig terms it the stretching cartilage, as the lever-like movements of the structure control the tension of the cords. It consists of two alæ, or wings, united in front at a sharp angle by the lamina mediana cartilaginis thyroideæ. The vocal cords and the thyro-arytenoidei interni muscles are attached to this median lamina. The wings of the thyroid extending outwards and backwards forms the lateral laryngeal walls. Their superior cornua, or horns, are connected with the hyoid bone by the thyro-hyoid ligaments. The thyro-hyoid membrane, which extends from the cornua to the hyoid bone, unites these structures still more closely.

The epiglottis is attached by its stalk to the inner surface of the thyroid cartilage in the receding angle and just below the median notch. From above the lower border posteriorly, and on each side of the median line, is the cricothyroid membrane which joins the thyroid to the cricoid cartilage. The two inferior cornua of the thyroid articulate with the cricoid by capsular ligaments lined with synovial membrane. The vocal cords and the thyro-arytenoid muscles connect the thyroid and arytenoid cartilages.

Cricoid Cartilage (a ring).—Ludwig terms this the foundation cartilage, as practically it sustains the laryngeal structure. The thyroid rests upon it through the articulations of the inferior cornua, and the arytenoid cartilages rotate upon it. The cricoid is smaller, but thicker and stronger than the thyroid, and is connected with the upper ring of the trachea by fibrous tissue. The anterior portion is

narrow vertically, but posteriorly is broad and deep. The inferior rim is nearly horizontal, while the superior inclines upwards and backwards. The posterior portion, the lamina cartilaginosa cricoidæ is hexagonal in outline. In the median line at the back and internally an elevated ridge separates

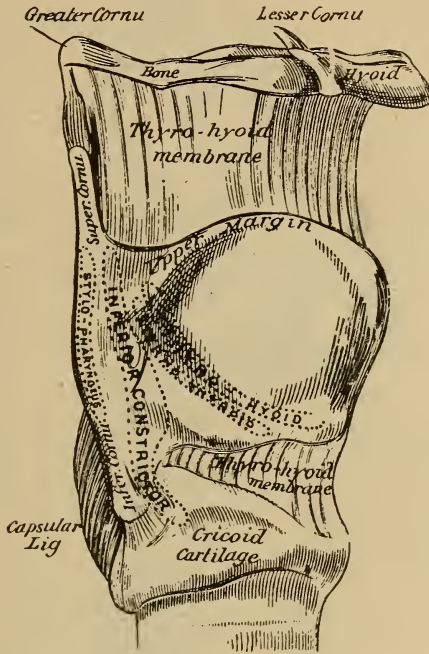


FIG. 10.

two slight depressions which receive the insertion of the posterior crico-arytenoid muscles, and serves for the attachment of the esophageal aponeurosis. Anteriorly the crico-thyroid membrane closes the space between the two cartilages. Two broad saddle-shaped articular surfaces for the bases of the arytenoid cartilages, are on the posterior and superior border.

Arytenoid Cartilages.—There are two of these. They are pyramidal in form, and each has three surfaces, a base and an apex. The posterior surface is triangular, smooth, and concave. The arytenoid muscle is attached to this sur-

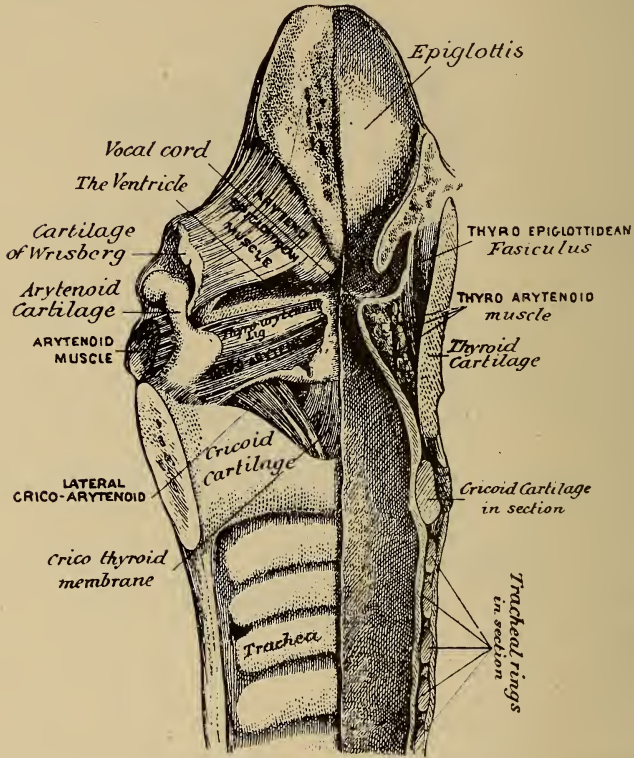


FIG. II.

face. The antero-external surface is rough and convex. The thyro-arytenoid muscle, and also the false vocal cords, are attached to this surface; the latter just above a depression, the fossa triangularis. The internal surface is smooth,

narrow, and flattened, covered with mucous membrane, and almost touches its fellow cartilage.

The base is broad, concave antero-posteriorly, and smooth for articulation with the cricoid. Two processes project from the base; one postero-externally, the muscular process, which is short, rounded, and prominent, and to which the posterior and lateral crico-arytenoid muscles are attached. The second-vocal-process projects anteriorly, it is prominent, but more pointed and flattened. The true vocal cord is attached to this process. Between the two processes is the base of the antero-external surface. The apex of each is pointed and curved upwards and inwards.

Cornicula Laryngis (cartilages of Santorini).—These are above the upper pointed ends of the arytenoids and located in the substance of the ary-epiglottic folds. They are conical, small, and flexile, being composed of yellow fibro-cartilage. They probably prevent pressure of the epiglottis against the apices of the arytenoid cartilages during deglutition.

Cuneiform Cartilages (Cartilages of Wrisberg).—These are two small wedge-shaped cartilages contained within the ary-epiglottic fold and in front of the arytenoids.

Posterior Sesamoid Cartilages.—These are not always present. Luschka describes them as very small, oblong bodies, attached by delicate ligaments to the Santorini cartilages above and the arytenoids below. They are located near the lateral margin of the arytenoids.

Anterior Sesamoid Cartilages.—These are frequently present. Each is about the size of a pin-head, and embedded in the anterior part of the vocal cords. A tough tissue unites them to the thyroid.

Inter-arytenoid Cartilage.—This is very infrequent, but when it does occur it will be found as a small body between the arytenoids.

Epiglottis.—This is a thin leaf-like lamella of yellow

fibro-cartilage, located between the base of the tongue and the superior opening of the larynx. The upper free extremity is broad and rounded; its stalk, or attached end, is long and narrow, and is firmly connected to the thyroid

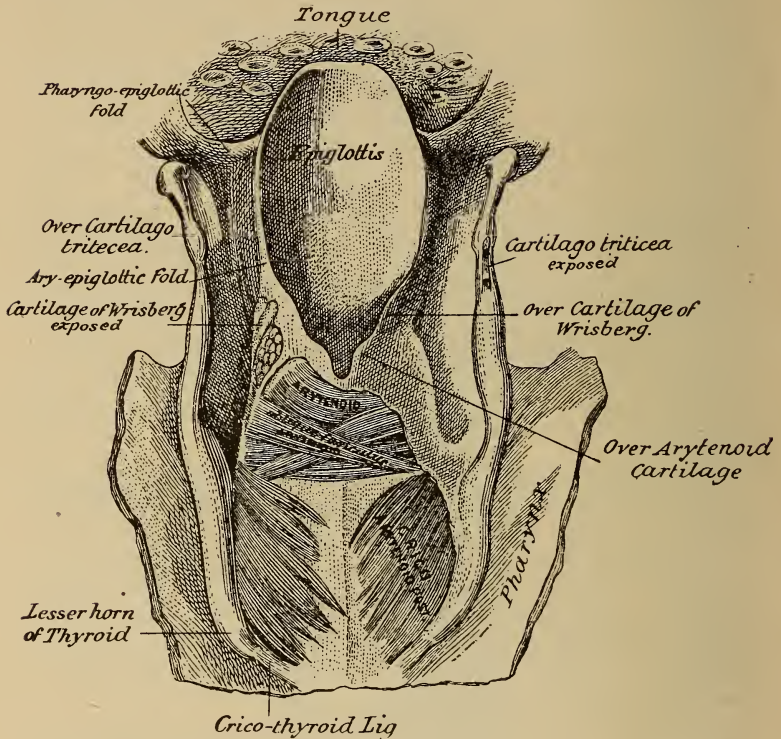


FIG. 12.

cartilage at the receding angle and just below the median notch by the thyro-epiglottic ligament. It is also attached to the posterior surface of the hyoid bone by the hyo-epiglottic ligament which forms part of the central thyro-hyoid ligament.

The body of the epiglottis is retained in position by five

bands, three of which pass forwards to the base of the tongue, and two backwards to the arytenoid cartilages. The central ligament in front consists of a fold of mucous membrane reinforced by fibro-elastic tissue, extending from the center of the body to the base of the tongue, where it expands and merges into the lingual fibrous covering.

The central glosso-epiglottic ligament unites with a strong white fibrous membrane which covers the entire front surface of the epiglottis. The membrane is attached to the entire length of the hyoid bone, and extends from the sides of the epiglottis in two conspicuous folds, spreads laterally and lines the tonsillar fossæ. Lennox Browne designates the membrane as the epiglottic membrane, and the lateral folds as amygdalo-epiglottic ligaments.

The so-called lateral glosso-epiglottic ligaments exist only when the mouth is open and the tongue considerably extended. They consist simply of two folds of mucous membrane extending from the sides of the tongue to the epiglottis.

The posterior, or aryteno-epiglottidean folds are two thick bands consisting of muscle and mucous membrane, extending backwards from the recurved sides of the epiglottis to the arytenoid cartilages. They separate the cavity of the larynx from the hyoid fossæ.

The hyo-epiglottic ligament unites the epiglottis with the basi-hyal.

The epiglottis as a body is curved upon itself from above downwards as well as from side to side. The lingual surface is concave from above downwards and convex from side to side. The superior margin is curved forward over the base of the tongue. The laryngeal surface is concave from side to side, and concavo-convex from above downwards. The degree of curvature varies considerably. A more or less well marked eminence is found on the laryngeal surface at the junction of the stalk and blade.

The interior of the larynx is divided into three divisions ; the supraglottic is the upper and largest, and is the space above the ventricular bands. It is heart-shaped, the broadest part being in front, corresponding with the line of the epiglottis. The lateral walls are formed by the folds connecting the epiglottis with the arytenoid cartilages.

The glottic, or second space, includes the ventricular bands, vocal cords, and ventricles of Morgagni.

Ventricular bands, sometimes called the false vocal cords, are two folds of mucous tissue containing a little fibrous tissue, the superior thyro-arytenoid ligaments. In front they are attached to the thyroid cartilage, and behind to the anterior surface of the arytenoids. They may be closely approximated. The closure occurs in the act of swallowing, as well as some other muscular efforts, as coughing, straining, etc.

Vocal Cords.—These consist of bands of pure yellow, elastic tissue, the inferior thyro-arytenoid ligaments. The cords are attached to and continuous with the upper free margin of the crico-thyroid membrane. As the cords and crico-thyroid membrane are practically continuous structures, it will be necessary to describe the latter first.

Crico-thyroid Membrane.—This is a thin fibro-elastic tissue attached to the upper and inner margin of the anterior two-thirds of the circoïd cartilage. It passes upwards, and converging behind the thyroid cartilage, is attached to the angle of the thyroid cartilage on its inner surface about a quarter of an inch from the inferior border ; behind it is attached to the vocal processes of the arytenoid cartilages, and part of the external border of their base. The upper free margin of the membrane, reinforced by antero-posterior bands of yellow elastic tissue, and placed as a movable band, comprises the inferior thyro-arytenoid ligaments or true vocal cords.

The inner surface of the membrane is smooth and cov-

ered by an adherent mucous membrane. The thyro-arytenoid muscles also cover this surface. Fibers of muscular tissue pass to, and are attached to the vocal cords and upper portion of the thyro-hyoid membrane. These fibers are important in influencing the vibration and position of the vocal cords.

The length of each cord when at rest is approximately three-fourths of an inch in the adult male, and half an inch in the female. A section of the cord shows a triangular form, the acute angle or apex being directed toward the median line. The upper and lower surfaces are not perfectly free, only the edges being so. The vocal cords are really a fold of the crico-thyroid membrane. In color the cords are white, this being most pronounced in the female. The yellow elastic tissue of the cords is necessary for preserving tension without muscular effort, and wrinkling when relaxation occurs.

Ventricles of Morgagni.—These are the two spaces between the ventricular bands and vocal cords, and constitute the inferior openings of the saccules. The ventricles are elliptical in form, and vary considerably in size.

Sacculus Laryngis.—In man this is a comparatively unimportant structure. The sacculi are lined with muciparous glands and a considerable amount of lymphoid tissue, and extend down to the lateral attachments of the vocal cords.

The third, or infra-glottic space, comprises the portion of the larynx from the inferior surface of the vocal cords to the inferior border of the cricoid cartilage.

Physiologically and clinically the second, or middle division, is the most important. Not only phonation is represented at this point, but the vocal cords perform a special action in respiration. This opening is termed the glottis or rima glottidis. In repose the shape is more or less elliptical, being nearly an inch long in the male, and two or three lines less in the female. The shape of the rima glottidis varies

according to requirements; in full inspiration it is irregularly triangular, the apex forward at the thyroid angle, at the origin of the vocal cords—anterior commissure of the vocal cords—the two posterior angles being at the arytenoid cartilages, the insertion of the cords; the base is more or less curved, and is formed by the space between the cartilages—inter-arytenoid space, or posterior commissure of the vocal cords. In the production of high notes, as the upper register in singing the cords are almost closed. All variations are found between these two extremes.

The vocal cords are controlled by certain muscles, the intrinsic are usually grouped as follows :

ACTION.

1. Narrowing the vestibule.

Thyro-ary-epiglottidei	$\left\{ \begin{array}{l} \text{Ary-epiglottici} \\ \text{Thyro-epiglottidei} \end{array} \right\}$	Respiratory.
Arytenoideus		

2. Governing the shape of the Rima Glottidis.

Thyro-arytenoidei	$\left. \begin{array}{l} \left. \begin{array}{l} \text{ex- and interni} \\ \text{Crico-arytenoidei} \\ \text{laterales} \end{array} \right\} \text{Close true glottis} \right\}$	$\left. \begin{array}{l} \text{Vocal and} \\ \text{respiratory.} \end{array} \right\}$
Arytenoideus closes cartilaginous		
glottis		

Crico-arytenoidei postici—open glottis—Respiratory.

3. Governing the pitch of the voice.

Crico-thyroidei Tense the vocal cords.

Thyro-arytenoidei interni	$\left\{ \begin{array}{l} \text{Shorten, relax and bring in} \\ \text{apposition various sections} \\ \text{of the vocal cords and act} \\ \text{as local extensors.} \end{array} \right\}$

(BROWNE.)

Crico-arytenoidei Postici.—These are the abductors of the vocal cords, being active on inspiration. They consist of two triangular muscles, the bases having their origin on

the posterior surface of the cricoid cartilage, they converge upwards and outwards until they reach the processus musculares of the arytenoids. The action of drawing these backwards and inwards causes the processus vocales to move outwards, opening the rima glottidis. This motion varies according to individual needs.

Crico-arytenoidei Laterales.—These muscles have their origin along the upper border and outer surface of the sides of the cricoid cartilage. They pass obliquely upwards and backwards, and are attached to the outer angles of the bases of the arytenoid cartilages and adjacent parts of the anterior surfaces in front of the posterior crico-arytenoid. The upper fibers are occasionally mingled with the fibers of the thyro-arytenoids.

Arytenoideus.—This muscle is square and is attached to the posterior concave surface of the arytenoid cartilages. The action is that of an aid to the crico-arytenoidei laterales in closing the glottis. The opinion now held by many is that this muscle is a continuation of the thyro-arytenoideus. When the arytenoideus acts first, the rima glottidis assumes momentarily a rhomboid shape; when the crico-arytenoidei laterales act first, the vocal cords are approximated and the space between the arytenoid cartilages remains open.

Thyro-arytenoidei.—These two muscles are broad, flat, and fan-shaped, parallel with but external to the vocal cords, being partially inserted into them. The anterior attachment of the muscles is to the internal surface of the thyroid cartilage, the inferior fibers lying close to the angle of the thyroid. Each muscle is composed of two distinct divisions.

The upper is thin, inserted high up on the anterior surface and outer border of the arytenoid cartilage, partially encircling the laryngeal pouch, some of the fibers pass round the outer border of the arytenoid cartilage, and intermingle

with the transverse fibers of the arytenoideus, and underneath the oblique fibers of the ary-epiglottideus.

The lower division is a thick, well defined fleshy bundle, and is reinforced by a few fibers from the outer surface of of the crico-thyroid membrane. It extends backwards and is inserted into the anterior projection, or vocal process of the arytenoid cartilage, external and close to the vocal cord, also to the adjacent surface and close to the insertion of the corresponding lateral crico-arytenoid muscle.

Occasionally there is a small third division—the thyro-arytenoideus of Soemmering—having its origin from behind the thyroid notch, close to the median line and passing internally to the pouch, to be inserted into the antero-external surface of the arytenoid cartilage near its base.

Ary-epiglottici.—These are two thin, flat muscles, having their origin from the outer and posterior border of the apex of the corresponding arytenoid cartilage, and pass upwards and over to the opposite side through the ary-epiglottic folds to the epiglottis. These muscles are called the constrictores vestibuli laryngis. Their action is to approximate the tips of the arytenoid cartilages and to cause the edges of the epiglottis to turn inwards during the act of swallowing, and probably also in phonation.

Crico-thyroidei.—Each muscle presents a fan-like shape and consists of two divisions. The lower ends of each section are pointed and have their origin from the antero-lateral portions of the cricoid cartilage. The fibers diverge as they pass obliquely upwards and backwards, and are inserted into the inferior border of the thyroid cartilage, the anterior borders of the lower cornua and into the internal and external surfaces near the margin. The function of these muscles is to draw the thyroid forwards and downwards, tilt the cricoid and arytenoid cartilages backwards, thus producing tension on the vocal cords.

Arteries.—The laryngeal blood supply is through

branches from the superior and inferior thyroid, the former being a branch of the external carotid, the latter of the thyroid axis from the subclavian. Small branches are derived from the lingual and ascending pharyngeal.

The superior laryngeal artery from the upper thyroid passes upwards, inwards, and downwards, accompanying the superior laryngeal nerve penetrating the thyro-hyoid membrane to the interior of the larynx. Inside the larynx the artery lies between the thyroid cartilage and thyro-arytenoid muscles, and distributes branches to the intralaryngeal structures, uniting above with twigs from the lingual and tonsillar, and below with twigs from the superior laryngeal, a branch of the inferior thyroid. The inferior laryngeal artery varies in size and ascends along the back of the trachea and larynx, being distributed to the small muscles and mucous membrane in the region of the arytenoid cartilages connecting with the superior laryngeal.

Veins.—The laryngeal veins correspond with the arteries. The upper laryngeal veins, penetrating the thyro-hyoid membrane, empty into the internal jugular, lower facial, or the superior thyroid.

Lymphatics.—The laryngeal lymphatics join the cervical glands.

Nerves.—The superior, and recurrent or inferior laryngeal, are branches from the pneumogastric, the motor being of spinal accessory origin. Filaments from the sympathetic accompany the arteries. Plexuses are formed by the junction of quite large branches. Prominent anastomoses occur at the back of the arytenoid cartilages beneath the pharyngeal mucous membrane, also at the sides of the larynx between the wings of the thyroid cartilages and the thyro-arytenoidei.

The superior laryngeal supplies the laryngeal mucous membrane and the crico-thyroid muscles. The recurrent

laryngeal supplies the rest of the muscles. The arytenoideus is supplied by both nerves.

Minute Anatomy.

The laryngeal mucous membrane is similar to the pharyngeal in being composed of epithelium, tunica propria, and submucosa. Stratified squamous epithelium covers the epiglottis and the inner surface of the larynx as far as the lower edge of the false vocal cords. Below this the epithelium is of the stratified ciliated columnar variety, excepting over the true vocal cords where it is again of the stratified squamous type. The tunica propria of the larynx consists of fibrous connective tissue with a network of elastic fibers. Longitudinal bundles of elastic tissue, with some fibrous tissue, constitute the true vocal cords, which are covered with stratified squamous epithelium, reinforced externally by fasciculi from the thyro-arytenoideus muscle. The thyroid, cricoid, and greater part of the arytenoid cartilages are composed mostly of hyaline cartilage. The epiglottis, apex of the processus vocales of the arytenoid cartilages, the cartilages of Wrisberg and Santorini are of the yellow elastic variety. The fibrous connective tissue of the external surface of the larynx connects the perichondrium with the surrounding tissues, muscular attachment being by tendinous tissue continuous with the cartilaginous investment.

CHAPTER II.

EAR.

Physiologically the ear may be divided into two parts, the conducting and receptive portions, but anatomically three divisions are made. (1) External (auricle or pinna, and external auditory canal). (2) Middle (tympanic cavity, membrana tympani, ossicles, Eustachian tube, and mas-

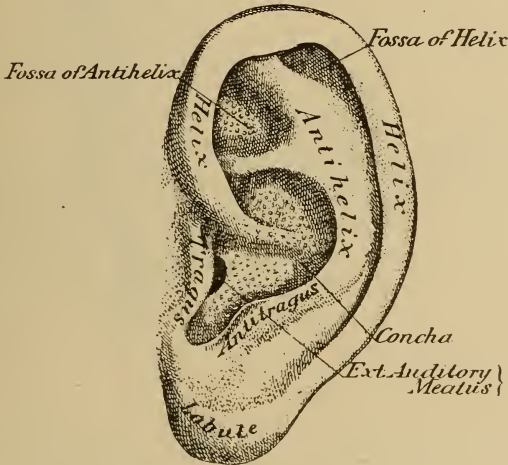


FIG. 13.

toid process). These two anatomical divisions constitute the physiological first or conducting apparatus. (3) The inner or internal (labyrinth) consisting of the vestibulum, the three semi-circular canals and cochlea, the latter being the receptacle for the expansion of the auditory nerve. This constitutes the second physiological division, or receptive portion.

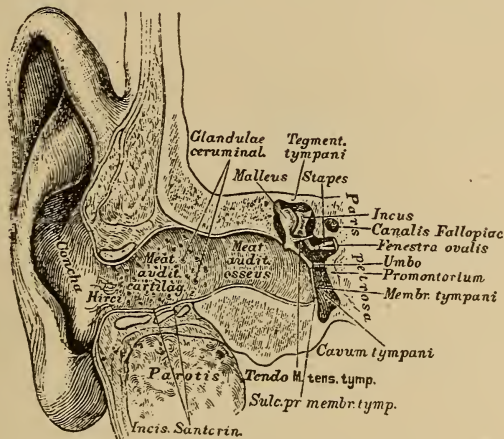
The auricle, or pinna, is ovoid or pyriform, the larger end being above. The external surface is irregularly concave, and directed a little forward. A number of irregularities, the effect of the foldings of the fibro-cartilaginous frame-work are noticeable. The outer rim is the helix. Parallel and in front of the helix is another curve, the antihelix. The latter divides above and encloses a triangular depression, the fossa of the antihelix. The narrow depression between the helix and antihelix is the fossa of the helix. The antihelix curves round a deep depression, the concha, which is partially divided by the beginning of the helix. In front of the concha, and extending backwards over the meatus, is a prominent structure, the tragus. A little below and posteriorly from the tragus, and separated from it by a deep notch (*incisura intertragica*), is a small prominence, the antitragus. Below is the lobule.

The cartilage of the auricle is one piece, but is not continuous throughout. It is lacking in the lobule and practically so between the tragus and helix, the space being filled by dense fibrous tissue. At the front part of the auricle where the helix curves upward, the cartilage forms a small projection, the process of the helix. Several fissures are also present in various parts of the cartilage. The walls of the auricle gradually converge and form the cartilaginous meatus.

Cartilaginous Meatus.—The shape of the canal is oval. The inner extremity of the cartilaginous portion is united to the bony canal by firm bands of connective tissue. Superiorly and posteriorly the cartilaginous structure is lacking, and becomes more marked until at the junction with the bony portion, the inferior wall only contains cartilage, this extending a short distance along the floor of the bony canal.

Firm connective tissue fills the space in the cartilaginous portion where cartilage is lacking. This tissue is continuous with the periosteum of the corresponding part of the

bony canal. Two verticle fissures are present in the anterior cartilaginous wall. These fissures, incisures of Santorini, are filled with connective tissue. The larger is at the base of the tragus, the second deeper in the canal. Sometimes a third fissure, still deeper, is present. These fissures permit of some mobility of the cartilaginous portion, and also on account of less resistance at these points, sometimes allow of spontaneous rupture into the auditory canal in deep abscesses of the parotid gland. Surgically they are important,



Transverse vertical section through Right Ear.

FIG. 14.

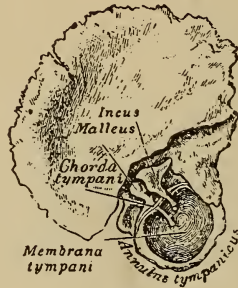
as they allow the turning forward of the auricle and fibro-cartilaginous canal after the posterior, inferior, and superior attachments have been loosened.

Bony Canal.—A consideration of the development of the temporal bone is necessary. This part of the skull is developed from four centers; the squamous, petro-mastoid, auditory or tympanic and stylo-mastoid.

At birth the osseous canal is lacking, fibrous tissue taking its place. At the inner end this terminates in the auditory

process, or tympanic ring. This consists of a thin bony strip, annulus tympanicus, oval in shape and about an eighth of its circumference being lacking. The concave margin of the ring is grooved, sulcus tympani, for the insertion of the membrana tympani.

The squamous portion of the temporal bone is developed from a single center. In early fetal life it presents a flat, bony scale, with a ridge upon the outer surface, which later forms the zygomatic process. Below the root of the zygoma is a shallow depression, the glenoid fossa. Behind this the



Membrana Tympani and Ossicula of new born child from
inner side

FIG. 15.

Bony plate divides into two lamellæ, the inner projecting almost horizontally inward, later forms the roof of the tympanum and mastoid antrum. The outer lamella extends downward and a little inward and presents a deep notch upon the inferior border. The annulus tympanicus joins the latter lamella at this notch, which by the manner of attachment completes the circle. This completed circle gives attachment to the inner end of the fibrous canal. As the fetus develops, this fibrous tissue is replaced by bony tissue, and the annulus tympanicus becomes a bony groove through ossification outwards.

In the adult the deep groove formed by the outward growth of the tympanic ring is called the auditory process. In front it is separated from the squamous portion of the temporal bone by the Glaserian fissure. Posteriorly the auditory process helps in forming the mastoid squamous suture, its postero-superior point being the spinum supra-meatum. The outer plate of the squama, which completes the outline of the bony meatus, grows almost directly outward horizontally, and almost at right angles to the part of the temporal bone above the zygomatic process during development.

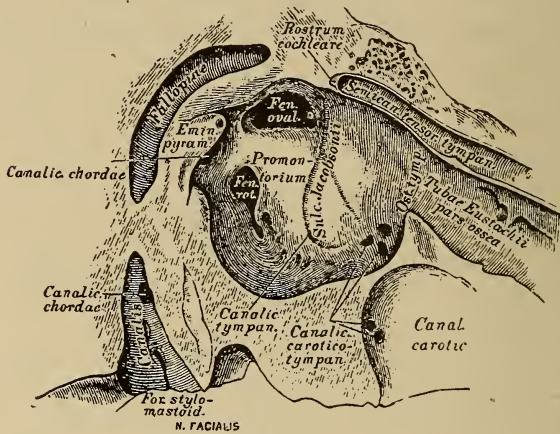
The third portion of the temporal bone, the petro-mastoid, is an oblique triangular pyramid, the apex forward and inward, the base closing the space between the free margin of the squamous plate of the temporal bone and the posterior crus of the annulus tympanicus.

The junction of the mastoid portion to the external squamous lamella forms the mastoid squamous suture. The petrous portion uniting with the inner lamella, forms the petro-squamous suture.

Tympanic Cavity.—This is a chamber more or less surrounded by bony walls. The inner wall is formed by the external surface of the petrous portion of the temporal bone. It is marked by a rounded elevation, the promontory, covering the first turn of the cochlea. Behind and a little below the promontory, is the niche of the round window, into which the fenestra rotunda opens. Above, in the upper and posterior part of the inner wall, is an oval fossa, the pelvis ovalis, at the bottom of which is the oval window. The posterior wall of the pelvis ovalis is abrupt, but the anterior wall gradually slopes forwards, merging into the surface of the promontory. The inferior wall is longer and steeper than the superior. Above the oval window a distinct bony arch is formed by the prominent outer wall of the aqueductus Fallopii protruding into the tympanic cavity. This canal transmits the facial nerve. The outer wall of this canal is

sometimes defective and the facial nerve is then uncovered at this point. It is important to remember this in treating suppurative diseases of the middle ear, as often paralysis results from too energetic measures.

Just above the aqueductus Fallopii is a smaller ridge, caused by the horizontal semi-circular canal. Posteriorly to the pelvis ovalis, and where the inner and posterior walls of the tympanum join, is a small bony pyramid. The tendon



Inner Wall of Tympanum. x 3.

FIG. 16.

of the stapedius muscle passes through its apex. The inner wall of the tympanum is more nearly in the median antero-posterior vertical plane of the body than the plane of the tympanic ring; for this reason the cavity is broader above and behind than below and in front. In front of the promontory the inner wall is smooth and merges into the tympanic orifice of the Eustachian tube.

The Anterior Wall.—The Eustachian tube opens at about the center of the anterior wall. The canal for the tendon of the tensor tympani muscle is above the Eustachian

opening, being separated by a thin, bony plate, the processus cochleariformis. A thin plate of bone separates the anterior wall from the internal carotid artery.

The floor of the cavity is bony, the structure sometimes being fairly compact bone, but often cancellus. The floor is considerably below the lower border of the tympanic ring, and is close to the jugular fossa. Openings sometimes exist between the floor and the fossa, and the bulb of the internal jugular vein may be injured by instrumental manipulation.

The posterior wall presents, besides the pyramid, the

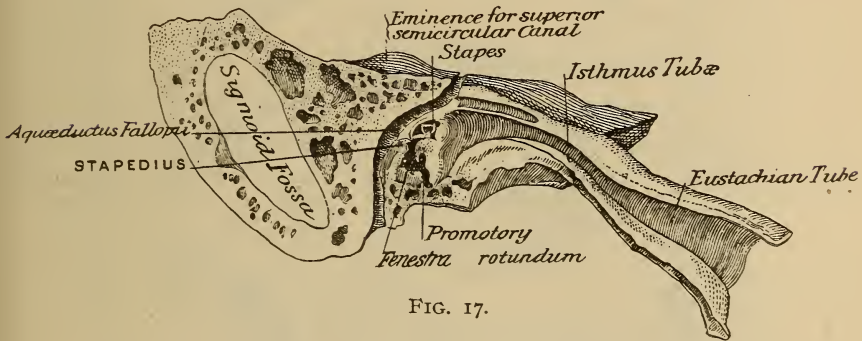


FIG. 17.

opening into the mastoid antrum. This opening is directly above the pyramid.

The external wall is formed principally by the membrana tympani, the inner surface of the tympanic ring, and above, the inner margin of the external plate of the squama and the angle formed by the inner and outer plates also enter into the formation.

The vault of the tympanic cavity, or epitympanic space, is considerably above the plane of the superior wall of the external auditory canal. The portion below this plane is the atrium.

Vault of the Tympanum.—This is more or less pyramidal in shape, the apex being at the angle between the plates

of the squama. These, with the adjoining parts of the petrous bone and petro-squamous suture, form two bony surfaces of the pyramid. The remaining surfaces and base are incomplete, the openings into the mastoid behind and the tympanum below corresponding to these two portions. Normally the base is partially filled in by the ossicles and their ligaments, as well as by reduplications of the tympanic

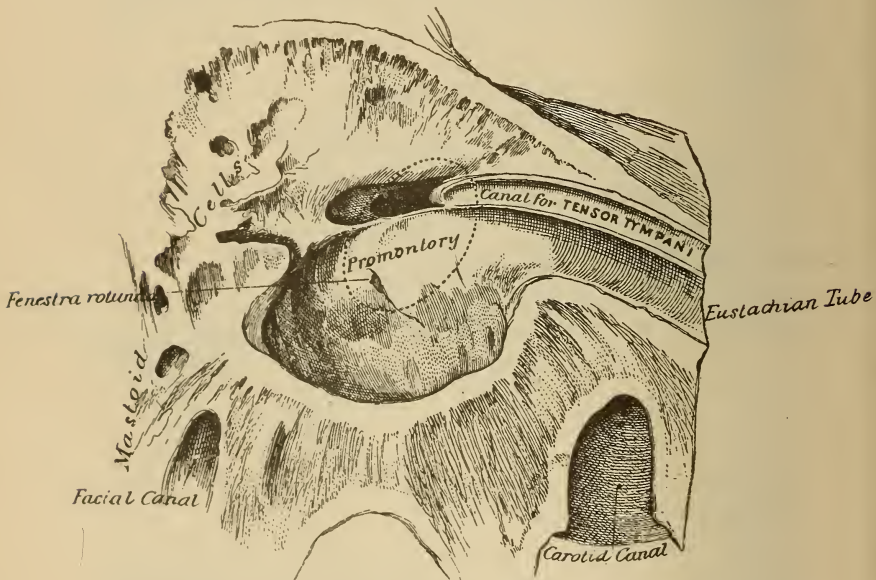


FIG. 18. Vertical section through tympanum. The dotted oval shows the relation of the membrana tympani to the tympanum.

mucous membrane, partially dividing the tympanum into two parts.

OSSICLES.—These are three in number; malleus, incus, and stapes. These bones aid in transmitting and modifying the vibrations of sound by imparting to the labyrinthine fluid increased intensity, but the waves are diminished in amplitude.

The Malleus.—This is the largest of the three bones, and consists of a head, neck, and shaft, or manubrium. The manubrium is classed by some as a process, the same as the processus gracilis and processus brevis.

The head is irregularly oval, presenting posteriorly the surface for articulation with the incus, and anteriorly a groove for the attachment of the anterior ligament.

The neck is a narrow constricted part joining the head and handle at an obtuse angle.

The manubrium, also called the handle, shaft, or long process, is flattened from within outward, and gradually tapers from about the neck to the tip, which occasionally projects slightly forwards, forming a hook. From the junction of the handle with the neck, is the short process, processus brevis, a conical bony projection, directed forward and outward and in contact with the membrana tympani. The external border of the handle furnishes attachment to the tympanic membrane, while the inner border is toward the inner wall. The anterior and posterior surfaces are comparatively broad. Projecting from the anterior surface just below the short process and passing forward and outward to the Glaserian fissure, is the long delicate processus gracilis or folianus, which is often embedded in the fibers of the anterior ligament in adults.

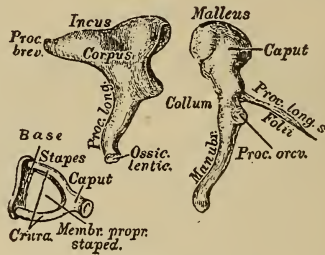
The external surface of the neck of the malleus is roughened, giving attachment for the external ligament. The anterior surface of the neck and contiguous portion of the head are grooved for the insertion of the anterior ligament.

The Incus.—This bone consists of a body and two processes. The body is somewhat quadrilateral, but the height is nearly double the width. The anterior surface presents a concavo-convex facet for articulation with the malleus. This surface is covered with cartilage and lined with synovial membrane.

The two processes form nearly a right angle with each other.

The short, or horizontal, process, conical in form, is really a continuation of the body, and extends backwards, the apex resting in a depression—sella incudis—in the posterior tympanic wall immediately below the opening into the mastoid, having a ligamentous attachment.

The long or descending process is a tapering, slender bone, passing nearly vertically downward from the antero-inferior angle of the body. The lower portion bends inward, the rounded tip being toward the internal wall. This



Ossicula. $\times 3$.

FIG. 19.

tip is the lenticular process and articulates with the head of the stapes.

The Stapes.—This, the third of the series, is a stirrup-shaped bone, consisting of a head, two branches—crura—and base. The head is rounded and presents on the external surface a depression for articulation with the lenticular process of the incus. Just below the head is a constricted part of the bone—the neck—the crura diverging from it. The posterior crus is the most curved and longest. The crura terminate in a flattened, oval-shaped bone, the base or foot-plate, which is fixed to the margin of the fenestra ovalis by ligaments.

The stapes lies almost entirely within the pevis ovalis, so is well shielded from injury when instruments are used through the external auditory canal. The position of the bone is oblique, and is nearer the inferior and posterior walls of the fossa than the anterior and superior. As the posterior wall is nearly vertical, the posterior crus of the stapes is in close relation to it, and adhesions between these two structures are common.

LIGAMENTS OF THE OSSICLES.

Ligaments of the Malleus.—These consist of the anterior, external, posterior, and superior or suspensory.

The anterior is the strongest. Its origin is from the spina tympanica major and walls of the Glaserian fissure. The ligament passes outward, upward, and backward, to be inserted into the anterior surface of the neck and depression on the anterior surface of the head of the malleus.

The External Ligament.—This is rather fan-shaped. Its origin is from the external roughened surface of the neck of the bone, the fibers diverging and being inserted into the free margin of the inner extremity of the superior wall formed by the external plate of the squama. Helmholtz describes the posterior fibers as a distinct band, the posterior ligament.

This band, with the anterior ligament comprises the axis band of the malleus.

The Superior Ligament.—This is a rounded delicate band of fibrous tissue passing from the tegmen tympani downward to the head of the malleus.

Ligaments of the Incus.—The incus is attached to the tympanic wall by a single fibrous band, the posterior ligament. At its origin from near the tip of the lateral surfaces of the short process, it is a dense structure, but the fibers rapidly diverge, and divide into two bundles, which are inserted into a broad area on the posterior tympanic wall.

Ligaments of the Stapes.—The base of the ossicle is held in position in the oval window by means of the annular or stapedio-vestibular ligament. The borders and vestibular surface of the base and periphery of the oval window are covered with hyaline cartilage. The annular ligament is developed from the perichondrium.

Interossicular Ligaments.—The articular surfaces of the ossicles are covered with cartilage. The malleus and incus are united by a loose capsular ligament.

THE EUSTACHIAN TUBE.—This might be called an accessory portion of the middle ear. The function of this tube is for ventilation of the middle ear and to equalize the pressure between the tympanic cavity and the external atmosphere. The tube consists of two portions, the bony or tympanic, and cartilaginous or pharyngeal. The junction of these two is called the isthmus.

The bony portion is about half an inch in length, extending from a comparatively wide opening just above the middle of the internal tympanic wall, and rapidly narrowing as it passes downward, forward, and inward through the petrous portion of the temporal bone to the isthmus, where the diameter is from one-twenty-fifth to one-twelfth of an inch. The bony portion of the canal is somewhat triangular in shape, the vertical line being about double the horizontal. Fibrous tissue joins the bony and cartilaginous portions of the tube at an obtuse angle.

The cartilaginous portion of the tube is about an inch in length. From the isthmus it extends downward to the pharynx increasing in width until at the orifice it is from one-eighth to one-fifth inch in diameter, the vertical still being the greatest. This portion of the canal is fibrocartilaginous. A plate of cartilage, the upper portion of which is curved forward and then downward, forms the posterior wall. A transverse section is hook-shaped. The space between the end of the hook and the lower edge of the cartilag-

inous plate is filled with fibrous and muscular tissue. The lumen of the cartilaginous portion is slitlike. The membranous tube is connected to the inner end of the bony canal the posterior plate of cartilage uniting with an extension of the corresponding bony wall.

MEMBRANA TYMPANI.—Principally for the protection of

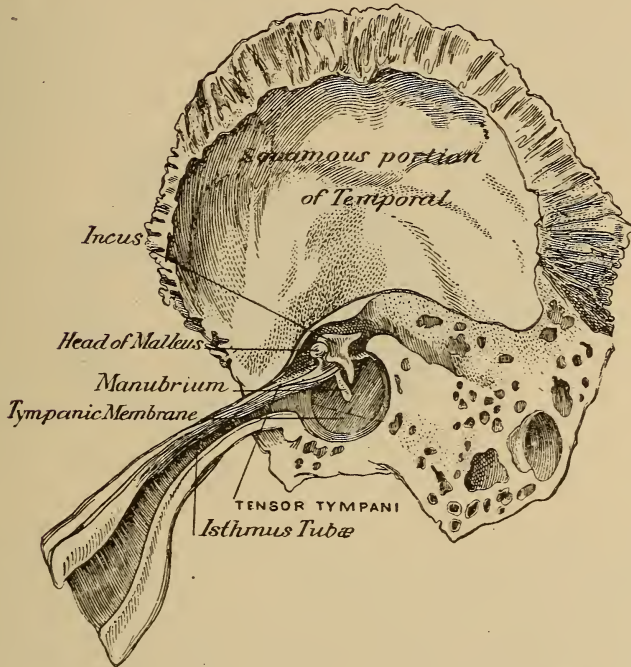


FIG. 20. Eustachian Tube and Tympanum. (Right Ear.)

the intra-tympanic structures, and secondarily for the purpose of assisting in the transmission of sound waves, a partition is placed, dividing the external auditory parts from the middle ear. This is the membrana tympani.

This is a fibrous membrane and forms the greater part of the outer wall of the tympanic cavity. It is located at

the inner extremity of the bony portion of the auditory canal, and at birth is nearly horizontal, gradually assuming a more perpendicular position until adult life. The normal position of the membrane in the adult is obliquely with the long axis of the bony canal, thus making the anterior and inferior auditory canal walls the longest.

The membrana tympani is attached at its margin to a groove, sulcus tympanicus, in the bony canal. The fibrous tissue is somewhat thickened at the point of attachment, the annulus tendinosus, or cartilaginous ring. From this ring some fibers pass outward to the periosteum of the bony

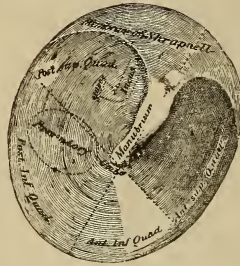


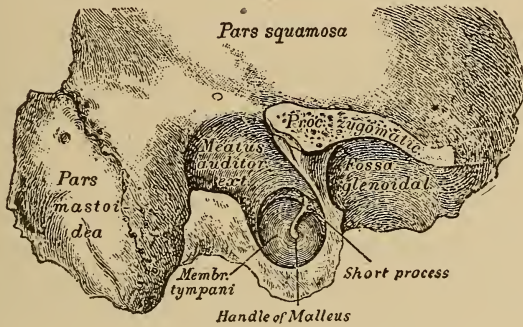
FIG. 21. External Surface of Right Membrana Tympani. $\times 3\frac{1}{2}$.

canal and others go in the opposite direction, mingling with the periosteum of the tympanum.

The manubrium is attached to the substantia propria by means of a thin cartilaginous lamella, which passes along its outer border from the processus brevis to the umbo, the fibers of the membrane being continuous with the perichondrium of the cartilaginous lamella. The circular and radiating fibers are attached directly to the tip of the manubrium. The superior border of the lamina propria joins the anterior and posterior extremities of the annulus tympanicus, forming a tense fibrous band, which is divided into two parts by the short process of the malleus. The pos-

terior fold is the sharply defined superior margin of the membrane extending from the short process to the posterior extremity of the annulus. Shorter and less distinct is the anterior fold.

The fibrous septum is lacking where the curved outline of the annulus is completed by the auditory plate of the temporal bone. This space constitutes the Rivinian segment, and is closed by the cutaneous lining of the external auditory canal. As compared with the rest of the membrana tympani, this portion is loose, and is called the membrana



Right Membrana Tympani. External view.

FIG. 22.

flaccida, or Shrapnell's membrane. The fibrous layer is especially well developed along the anterior and posterior borders, which cause it to be somewhat triangular in shape. These distinct fibrous bands are the fibers of Prussak, and pass from the two extremities of the Rivinian segment to the base of the short process and continuing along the manubrium are merged into the external layer of the membrana propria.

The normal membrane is somewhat oval in outline, and is drawn inward, the most concave point being at the umbo, where the tip of the manubrium is attached directly to the

membrana propria. The anterior and inferior segments bulge outward somewhat, so that although the membrane in its entirety is concave, it is convex from the center to the periphery.

THE MUSCLES.—The muscular structures of the conducting portion are the extrinsic, connecting the auricle to the skull; intrinsic, comprising those of the auricle and canal; the intratympanic, and those of the Eustachian tube.

Posteriorly the auricle is connected to the skull by the mastoid fascia, and anteriorly by the temporal fascia.

Extrinsic Muscles.—There are three, which in man are usually rudimentary so far as action is concerned. The *retrahens aurem*, *attollens aurem*, and *attrahens aurem*.

The *retrahens* has its origin from the mastoid region by short aponeurotic fibers, and is inserted into the auricular cartilage at the posterior and inferior portion.

The *attrahens* has its origin from the lower edge of the epicranial aponeurosis and converges to be inserted into the cranial surface of the spine of the helix.

The *attollens* has its origin from the aponeurosis of the occipito-frontalis, and converges to the insertion at the upper part of the cranial surface of the auricle.

The Intrinsic Muscles.—These are practically rudimentary muscles in man, consisting of incompletely developed muscular fiber bundles arranged between the cartilaginous processes of the auricle.

The Intratympanic Muscles.—Two muscles comprise this group, the *tensor tympani* and *stapedius*.

The Tensor Tympani.—The origin of this muscle is from the upper wall of the cartilaginous Eustachian tube and also the bony walls. It enters the tympanum through a bony canal just above the tympanic opening of the Eustachian tube, being separated from the latter by the *processus cochleariformis*. This process in the tympanum is pyramidal and is sometimes called the anterior pyramid. The

tendon twists almost at a right angle around this process, passes across the tympanum and is inserted along the inner border of the shaft of the malleus just below the neck, some of the fibers pass down for some distance along the handle and extend somewhat upon the anterior surface.

The Stapedius.—The origin of this muscle is from the interior of the pyramid upon the postero-internal wall in front of and below the aqueductus Fallopii. The fibers converge to form a tendon which passes through the pyramidal apex and is inserted into the neck of the stapes at its junction with the posterior crus.

The muscles of the Eustachian tube are two, the tensor palati and levator palati.

The tensor palati controls in a measure the lumen of the Eustachian tube. Its origin is from the scaphoid fossa and spine of the sphenoid anteriorly to the membranous portion of the tube, some fibers coming from the inferior border of the cartilaginous hook. The muscle passes downward in front of the membranous portion and converges into a tendon which encircles the hamular process of the sphenoid, then expands into a broad aponeurosis to be inserted into the anterior surface of the soft palate and the posterior bony edge of the hard palate. The union of the fibers of the two muscles form the median raphe.

The levator palati has its origin from the under surface and near the apex of the petrous portion of the temporal bone, and passes downward, forward, and inward to be inserted in the posterior and superior surface of the soft palate. The body of the muscle is situated along and loosely attached to the inferior edge of the cartilaginous plate which constitutes the posterior tubal wall. It also is in contact with the fibrous inferior wall.

The Arteries.—The arterial supply is principally from the branches of the external carotid, as well as a few branches from the internal carotid. The external carotid

branches supplying the auricle, canal, and tympanum, are the posterior auricular, superficial, temporal, occipital, internal maxillary and ascending pharyngeal.

The posterior auricular supplies the posterior portion of the auricle and canal. The stylomastoid branch passes through the stylomastoid foramen, supplying the mastoid cells and a special branch passes to the stapedius muscle and stapes.

The superficial temporal supplies the anterior portion of the auricle and canal by means of the superior and inferior anterior auricular branches. Anastomoses of these branches with those of the posterior auricular practically complete the arterial supply of the auricle and canal. A small branch from the superficial temporal passes through the Glaserian fissure to the tympanum.

The Occipital Artery.—Branches from this artery pass to the concha, entering from the cranial surface.

The Internal Maxillary.—The most important blood supply, especially in early life, is through the middle meningeal and tympanic branches. A few twigs are distributed to the Eustachian tube before entering the cranium. Inside the skull is the superficial, petrosal branch, which passes through the petro-squamous suture to the tympanum, to be distributed to the tympanic roof, malleus, incus, and part of the internal tympanic wall, anastomosing with the labyrinthine vessels. (Politzer.) Within the Fallopian canal it connects with the stylomastoid.

The Tympanic Branch of the Internal Maxillary.—This branch passes through the Glaserian fissure and is distributed to the anterior portion of the tympanum, anastomosing with the stylomastoid upon the periphery of the membrana tympani.

The internal tympanic wall is supplied by anastomoses of the tympanic artery with the tympanic branches of the internal carotid and the Vidian branch of the internal maxil-

lary. Additional branches are from the internal maxillary, the Vidian, descending palatine, and pterygo-palatine, which send small branches to the Eustachian tube and its muscles.

Veins.—As a rule they accompany the arteries. The majority of the veins of the deeper structures form a plexus upon the superior and upper portion of the posterior wall of the external auditory canal. Those of the posterior wall and auricle empty into the external jugular and mastoid veins, the anterior branches joining the temporal and facial veins. A few of the deeper veins enter the pterygoid plexus. The veins of the Eustachian tube accompany the arteries and empty directly into the internal jugular vein, or sometimes join the facial, lingual, or superior thyroid veins. There is a comparatively large venous trunk between the internal pterygoid muscle and adjacent wall of the tube, which passes to the cavernous sinus.

Lymphatics.—The lymphatic canals are plentifully distributed and anastomose with the superficial lymphatic glands and also those of the submucous system of the pharynx. The lymphatic channels of the canal and tympanum are intimately associated with the superficial lymphatics over the mastoid, the lymph nodules in front of the auricle and those in the cervical region between the platysma and sterno-mastoid muscles. There is also free lymphatic anastomoses through the glands of the lateral pharyngeal walls. The membrana tympani possesses three systems, one for each layer, which connect with each other and with the lymphatic system of the external canal.

Nerves.—The nerve supply to the muscles of the conducting portion of the ear are from branches of the trigeminus, facial, and cervical plexus. The attollens aurem is supplied through the occipitalis minor branch of the cervical plexus. The tensor tympani and tensor palati muscles are supplied by the trigeminus through the otic ganglion,

and the rest of the muscles are supplied directly by the facial or through its ganglionic communications.

The sensory nerves are from the cervical plexus, trigemini, pneumo-gastric, and glosso-pharyngeal. The auricle, superior portion of the meatus and tympanic membrane are supplied by the ariculo-temporal, a branch of the trigemini. The posterior portion of the auricle and meatus are supplied principally by the auricularis magnus derived from the cervical plexus, this branch anastomosing with the auricular branch of the pneumogastric upon the posterior wall of the canal.

The auricular branch of the vagus supplies both the cartilaginous portion of the canal and part of the posterior surface of the auricle.

The tympanic branch of the glosso-pharyngeal reaches the tympanum through a foramen in the tympanic floor, and supplies the mucous membrane and Eustachian tube. It divides upon the internal wall, one branch anastomosing with the twigs of the carotid plexus from the sympathetic system, and forming the tympanic plexus. The second branch, the small, deep petrosal, passes through a foramen in the tegmen tympani to the small superficial petrosal nerve, which is the facial branch to the otic ganglion. The third branch passes from the tympanum and unites with the great superficial petrosal, the facial root of the Vidian nerve, the posterior branch of Meckel's ganglion. This branch is the great deep petrosal.

The chorda tympani passes from the aqueductus Fallopii above the pyramid, crosses the tympanum from behind forward, and passes between the long process of the incus and the handle of the malleus. It passes from the tympanum through a separate canal close to the Glaserian fissure, and joins the lingual branch of the trigemini.

Histology.—The structures giving form to the external ear consist of bony and cartilaginous tissue, excepting the

lobule, which is composed of dense fibrous tissue and fat. Subcutaneous tissue covers these structures and the whole is covered by integument. The cartilage is the yellow elastic variety, forming a thin, tough plate, the irregularities of which give the characteristic form to the ear.

The skin covering the auricle is similar to the contiguous integument, but within the auditory canal some changes occur. The skin over the cartilaginous portion and part of the roof of the bony portion is quite thick as is the subcutaneous tissue. Fine hairs, sebaceous and ceruminous glands are distributed in this portion of the canal. The skin covering the most of the bony portion of the canal, however, is thin and closely connected with the periosteum. Glands and hairs are absent in this portion, as well as in the integument reflected over the external surface of the *membrana tympani*.

The *membrana tympani* consists of three layers; (1) outer or reflected cutaneous layer, (2) middle or lamina propria, consisting of fibrous connective tissue; (3) inner or mucous layer, consisting of a portion of the lining of the tympanic cavity. The outer layer is composed of the epidermis and connective tissue corium, the latter being about one-half as thick as the epithelial layer. The lamina propria composes the fibrous structure of the membrane and represents its mesodermic portion. It consists of two strata of finely felted fibrous tissue bundles. In the radial or outer, the tendency is for the bundles to radiate from the tip of the malleus toward the periphery, while the circular, or inner, are concentrically arranged bundles, the greatest development being at the periphery near the annular attachment of the *membrana tympani*. The mucous layer, a continuation of the tympanic mucous membrane, comprises a thin connective tissue ground work of delicate fibro-elastic tissue bundles, covered by a single layer of low cuboidal polyhedral celled epithelium destitute of cilia.

The blood supply is from two sources; the external from the branches supplying the external auditory canal, the capillaries being distributed within the cutaneous layer, while the internal is derived from the vessels of the tympanic cavity, which are distributed to the mucous layer.

The lymphatic system corresponds to the principal strata.

The nerve supply is similar to that of the blood, being external and internal; the external, or cutaneous, being more or less from the tympanic branch of the auriculo-temporal, which passes beneath the manubrium and divides at the lower third of the process into two terminal twigs. Besides these central nerves, filaments enter the periphery of the membrane at different points, and uniting with the others form a wide meshed plexus, which sends filaments to and surrounds the blood vessels. A sub-epithelial plexus is also formed from this net work. The tympanic plexus sends nerves to the mucous layer, being distributed to the lymphatic and blood systems, as well as a sub-epithelial plexus, and a few twigs into the lamina propria.

THE MIDDLE EAR.—This constitutes the entodermic division of the ear, and comprises the tympanic cavity with the communicating mastoid cells, the ossicles and Eustachian tube. The tympanic cavity is enclosed within bony structures covered with periosteum, over which is the mucous membrane which is indirectly continuous with the pharyngeal mucous membrane. The mucous membrane is closely adherent to the periosteum, but also covers the ossicles and their ligaments, as well as the nerves and blood-vessels crossing the middle ear. The mucosa is composed of a thin fibrous tissue resembling in some places the reticulum of adenoid tissue; the mucous layer is closely connected with the fibrous structure of the periosteum.

The epithelial surface of the tympanic cavity varies in structure; that covering the ossicles, *membrana tympani*, promontory and the mastoid cells, is a single layer of low

cuboidal, polygonal non-ciliated cells, the rest of the surface consisting of the ciliated columnar type. Where nerve trunks or blood vessels are located, the mucosa is much thickened, forming ridges over them. Small tubular glands are sparsely located in the mucous membrane of the anterior portion of the cavity. The mucous membrane covering the antrum and mastoid cells is very thin and delicate.

The structure of the secondary tympanic membrane which closes the fenestra rotunda is; externally the tympanic mucous membrane, composed of a layer of flattened non-ciliated polyhedral cells, and a thin fibrous tunica propria; the lamina propria consists of radially placed bundles of fibrous tissue passing from the indurated point of the base towards the periphery; the inner consists of a thin layer of sub-endothelial fibrous tissue covered by a layer of endothelial plates.

The blood vessels of the tympanic mucous membrane are situated in the deeper periosteal layer of the mucosa, sending branches to the membrane.

Lymphatics.—Within the deep periosteal layer are situated the lymphatics. In the reticular connective tissue of the mucosa are found groups of lymphoid cells giving the appearance of lymphatic nodules.

Nerves.—The principal nerves of this region are derived from the tympanic plexus, and consist almost entirely of medullated fibers lying within the periosteal layer of the mucosa. A sub-epithelial net work of pale non-medullated fibers is derived from a plexus formed by the deeper trunks. Ganglion cells are sometimes found along the course of the larger trunks and their branches.

The ossicles are compact bone, the thicker parts containing Haversian canals and concentric lamellæ. Hyaline cartilage invests all surfaces of contact. A minute intra-articular plate of fibrous cartilage is interposed in the cavity of the ambo-malleal articulation. The malleus throughout

its entire attachment with the membrana tympani is covered by an investment of cartilage, the perichondrium and fibrous tissue of the lamina propria becoming firmly united. A plate of cartilage also covers the base of the stapes which connects with the fenestra ovalis. The annular ligament, consisting of fibrous tissue, occupies the remainder of the fenestra ovalis.

THE EUSTACHIAN TUBE.—This consists of two parts, bone and cartilage composing the frame work, and the mucous membrane. Complete walls are not formed, the completion of the tube being by means of fibrous and other tissues. Mucous membrane lines the entire tube, the portion below the firm structure having a layer of sub-mucous tissue, but in the upper part it is intimately united with the periosteum of the bony walls. The epithelium of the tube is of the ciliated stratified columnar type, that of the pharyngeal portion being of the tall columnar, and that of the tympanic portion the low cuboidal type. The tunica propria is composed of loose connective tissue.

Lymphoid cells in many places are distributed in the reticular connective tissue constituting an adenoid structure. This distribution varies with age, being most generally distributed in childhood, but in adolescence being confined almost entirely to the lower third. At the pharyngeal end small mucous glands are constant, but they may occur throughout the entire tube.

Sub-mucous Layer.—In the cartilaginous portion of the tube the sub-mucous layer is well developed and is composed of fibro-elastic tissue.

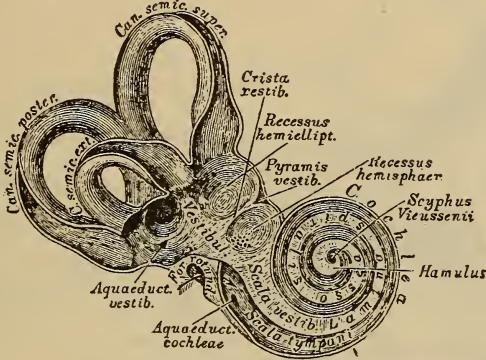
Blood Vessels.—The blood supply to the mucous membrane is from the tympanic and pharyngeal vessels.

Nerves.—These are derived from the tympanic and pharyngeal plexuses, and are situated in the deeper mucosa layers, filaments reaching the epithelial surface.

The Inner Ear, or Receptive Portion.

Under this heading the inner ear, auditory nerve and its origin are necessarily included.

The internal ear proper consists of the bony and membranous labyrinth. The bony portion consists of a series of communicating cavities in the petrous portion of the temporal bone, filled with fluid, the perilymph, in which the membranous labyrinth is suspended. This latter portion is composed of a series of membranous tubes which corre-



The bony Labyrinth.

FIG. 23.

spond in general contour to the bony portion, and these tubes are also filled with fluid, the endolymph.

The Bony Labyrinth.—This may be considered as a central cavity, the vestibule, from which tortuous canals diverge. This central cavity is ovoid in shape, the vertical diameter being the longest, measuring about a quarter of an inch. The short diameter is about one-fifth of an inch. The outer wall presents the foramen ovale, which normally is closed by the foot-plate of the stapes.

The inner wall contains two fossæ, separated by a bony spine, the crista vestibuli. The anterior fossa, the recessus

sphericus, lodges the sacculæ. The posterior fossa, the recessus ellipticus, lodges the utricle.

The posterior wall contains the openings of the three semi-circular canals. There are five openings, as the superior and posterior canals enter the vestibule by one opening. The cochlear canal entrance occupies the place of the anterior wall of the vestibule. Near the border of the recessus ellipticus is a small opening, the orifice of the aqueductus vestibuli, through which the cavities of the membranous labyrinth communicate with the subdural space.

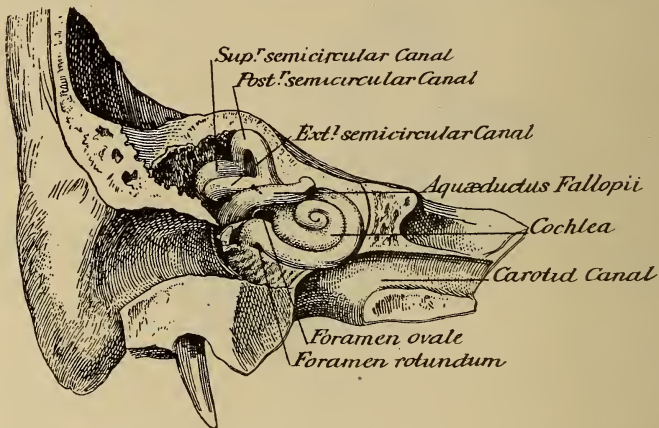


FIG. 24. Bony labyrinth as seen from behind.

The Semi-Circular Canals.—These are so placed that the plane of each is perpendicular to that of the other two. These canals are the superior, posterior, and external. The posterior lies in the vertical plane of the long axis of the petrous portion of the temporal bone. The superior is at right angles to the posterior, and is also vertical. The external is in the horizontal plane. The point of origin and termination of each is the vestibule. The extremities of the canals, with the exception of the common opening, are dilated, forming an ampulla for each.

The Cochlea.—The opening of this is at the anterior and inferior surface of the vestibule. It is a bony tube coiled two and one-half times about a bony axis, the modiolus. Extending from this axis into the cavity of the tube, and partially dividing it, is a thin septum of bone, the lamina spiralis, composed of two thin plates. This bony lamina

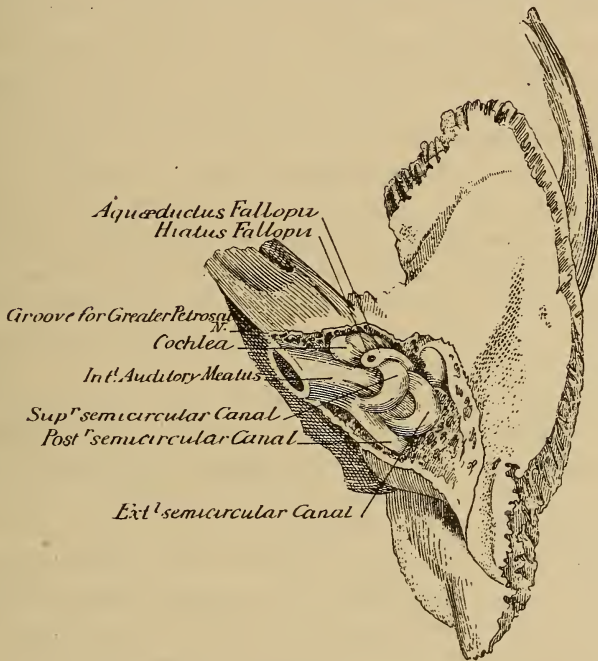


FIG. 25. Bony labyrinth as seen from above.

does not extend quite to the outer wall, a membranous septum completing the division of the cochlear tube. This portion is called the lamina spiralis membranacea. The bony lamina commences at the fenestra rotunda and extends to the cupola, where it ends in a somewhat hook-shaped process, the hamular process. The superior division of the canal is called the scala vestibuli, and the inferior the scala

tympani. A second membrane divides a portion of the scala vestibuli, forming the scala media or ductus cochleæ, this really belongs to the membranous labyrinth.

The terminal half turn of the cochlea forms the cupola. At the apex of the cochlea there is a foramen between the scalæ tympani and vestibuli, the helicotrema.

There are numerous canals traversing the modiolus, the largest passing through the center from the base to the cupola is the canalis centralis modioli, and contains a small nerve and artery. A small opening, the aqueductus cochleæ, leads to a canal inclosing a small vein, and opens on the basilar surface of the temporal bone. A swelling of the cochlear nerve, the ganglion spirale, is contained in a small canal, the canalis spiralis modioli, which twists around the modiolus and lies at the point where the bony lamina is attached to the modiolus. Ganglion cells are found in the ganglion spirale, which give off branches that pass through the bony lamina to the organ of Corti.

The termination of the lamina spiralis is curved, and is called the sulcus spiralis internus, the upper lip the labium vestibulare, the lower lip the labium tympanicum. The crista spiralis is between the labium vestibulare and the origin of Reissner's membrane.

The scala tympani is completed by the membrana basilaris, a delicate membrane which extends from the labium tympanicum to the ligamentum spirale, which appears as an expansion of the basilar membrane attached to the outer bony wall of the cochlea.

The stria vascularis is a thin layer of cells resting on that portion of the ligamentum spirale between the attachment of Reissner's membrane and the prominentia spiralis. The sulcus spiralis externus is between the prominentia spiralis and the attachment of the membrana basilaris, the point of attachment of the membrane being the crista basilaris. The membrane of Reissner reaches from the vestibular

surface of the periosteum of the bony lamina to the ligamentum spirale, forming the upper limit of the scala media, the lower limit being the membrana basilaris. The membrane of Corti, or membrana tectoria, is a delicate structure extending from the attachment of Reissner's membrane and the labium vestibulare to the outer row of hair cells.

The Organ of Corti.—This consists of numerous rods or cells resting on the basilar membrane and covered by the membrana tectoria. The two central rows of cells are rod-like and are the inner and outer rods of Corti, which rest upon the basilar membrane. They are separated at the base, but lean towards each other, forming a small canal, the zona arcuata, which extends throughout the cochlea in a spiral direction. Within the zona arcuata are two rows of cells, one in each angle formed by the rods of Corti with the basilar membrane, and called the floor cells. Nerve fibers cross the zona arcuata to the outer hair cells.

The outer hair cells are usually described as consisting of three to five rows. They are situated externally to the outer rods of Corti, their broad ends directed upwards. The cells of Deiter are between these rows, the broad ends of which are directed downwards. A single row of inner hair cells, smaller than the outer, are situated to the inner side of the inner rods of Corti. A layer of supporting cells continuous with the epithelial lining of the sulcus spiralis internus, is on the inner side of these hair cells. A thin reticulated membrane, membrana reticulata, or Kolliker's membrane, covers and is in contact with the upper ends of the rods of Corti and outer hair cells. Openings through this membrane allow the passage of the cilia of the outer cells. This membrane appears to bind the cells together.

On the outer side of the organ of Corti, probably for its support, is a cell structure, the cells of the upper portion being the supporting cells of Hensen, while those of the lower outer portion, resting on the basilar membrane to the

crista basilaris, are the cells of Claudius, these have a large number of small nuclei.

The membranous labyrinth comprises the membranous semicircular canals, the utricle, and the saccule.

The membranous canals correspond in number, arrangement, and general form to the bony canals, but are about one-third the size of the bony canals. They have five openings into the utricle corresponding to the bony orifices. The ampullæ are the thickest portions of the canals. Three layers compose the membranous canals, the inner being of polygonal nucleated epithelial cells which secrete the fluid endolymph contained within the membranous canals. The middle layer is a compact, nearly homogeneous layer, corresponding to a highly developed basement membrane. The outer layer is of felted connective tissue bundles containing many cells. Inclosed within the bony canals, and surrounding the membranous canals is a fluid perilymph quite similar to the endolymph. The vestibular nerve sends filaments to the ampullæ.

The Utricle.—This is oblong and is in contact with the recessus ellipticus. On the anterior and lateral walls of the utricle, corresponding to their attachment to the bony wall, there is a thickening, caused by a grouping of the lining cells, which projects somewhat into the cavity of the utricle. This ridge is the macula acustica, and is covered by specialized epithelium, consisting of ciliated, or hair cells, between which are situated supporting cells. A clear, transparent semifluid material covers the specialized epithelium of the macula acustica, which contains crystals of carbonate of lime, the otoliths.

The Saccule.—This is spherical and located in the recessus sphericus. There is no apparent communication between the cavities of the saccule and utricle. There is a macula acustica, and also otoliths as in the utricle. A small canal, canalis reuniens, connects the saccule with the ductus

cochlearis of the membranous labyrinth. Stiff cilia, auditory hairs, project from the macula in both the saccule and utricle, which are connected with nerve filaments from the auditory nerve.

The Arteries.—The arterial supply of the labyrinth is from (1) the internal auditory, a branch of the basilar, and the principle source of supply; (2) branches from the occipital; (3) the stylomastoid, from the posterior auricular.

The internal auditory divides at the bottom of the internal auditory meatus into the cochlear and vestibular branches. By means of numerous small branches from the cochlear, which pass through the canals in the modiolus and enter the substance of the lamina spiralis, a capillary network is formed. The membranous labyrinth is supplied by a capillary network from the vestibular division.

Veins.—The veins from the different divisions unite with the superior petrosal sinus.

THE AUDITORY NERVE.—The auditory nerve, nerve of hearing (*portio mollis*), has its superficial origin at the lower border of the pons from a groove between the olivary and restiform bodies. Two deep origins are from the fourth ventricle. The nerve winds around the restiform body, and accompanies the facial nerve across the posterior border of the middle peduncle of the cerebellum to enter the internal auditory meatus. At the bottom of the meatus the facial nerve enters the aqueductus Fallopii.

The auditory nerve divides at the bottom of the meatus into the cochlear and vestibular branches. The vestibular subdivides into the superior, middle, and inferior portions, which are distributed to the *cristæ acusticæ* of the semi-circular canals, and the *maculæ acusticæ* of the utricle and saccule. The cochlear subdivides into numerous small branches, and entering the base of the modiolus, passes between the plates of the bony lamina spiralis where a plexus

is formed, the ganglion spirale. Nerve filaments are distributed from this plexus to the sulcus spiralis and organ of Corti.

The inner ear in its development represents ectodermic and mesodermic tissue, while the middle and external ear contain ectodermic, mesodermic, and entodermic layers.

CHAPTER III.

EXAMINATION.

Success in treating diseases of the ear, nose, or throat does not depend alone upon a knowledge of the anatomy and physiology of these structures, but an inspection of the parts must be made; this means, not only an anatomical but also a positive knowledge of the structures examined. Variations in individual cases must also be taken into consideration, as otherwise a normal might be mistaken for a morbid condition.




FIG. 26. Adjustable swinging gas bracket.

The character of the light used will also make a difference. A light with a yellowish tinge intensifies the color of tissue. The ideal light is a diffuse, clear day light, but unfortunately this is seldom obtainable, artificial illumination having to be resorted to in the majority of instances. My preference is the argand gas burner for office work, as being most easily controlled, and giving less variation in the appearance of tissues than when other means of illumination are employed. If a diffuse electric light were obtainable, it would prove still better, and would compare favorably with

daylight. A portable battery with diagnostic lamps, may in many instances be employed.

Head Mirror.—The head mirror is almost an indispensable article, and as it can be used under any and all conditions, is especially important. The size varies from three inches to four and one-half inches, but the most comfortable to wear, and one also which gives a good illumination, is the three and one-half inch. Larger than this they are cumbersome. These mirrors are concave, with an aperture in the center. The focal distance varies from eight inches to fifteen inches, but a choice of focal distance should be such

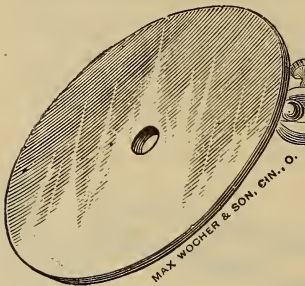


FIG. 27. Head mirror.

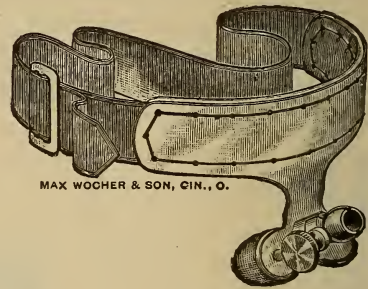


FIG. 28. Schroetter head band.

as will allow the wearer the best illumination and use of the eyes with comfort. The mirror should be attached by a ball and socket joint to some form of head band, and the Schroetter band with nose rest is the most comfortable, although some prefer the metal band with an occipital pad. This is simply a matter of individual preference.

The method of wearing the mirror may be either by bringing the central opening opposite one eye, or with the mirror over the forehead. Both methods should be practiced, as each possesses advantages, but for general purposes, better results are obtained by the forehead position, as this allows binocular single vision.

An electric head lamp may be used instead of a mirror, and in some operative measures is best.

Rhinoscopic and *laryngoscopic mirrors* with an universal handle are necessary. Different sizes of these should be obtained, and the rod on which the mirror is fastened should be flexible, as often it is necessary to change the angle in order to obtain a good view of the parts. The sizes are 0 to 5, No. 4 laryngoscopic being the most generally useful for laryngoscopic, and No. 1 rhinoscopic for nasal work, but as the size used will depend upon the case, an assort-

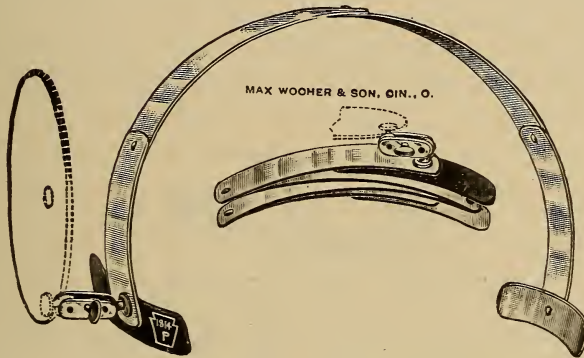


FIG. 29. Worrall's folding spring head band.

ment is preferable. A tongue depressor, the style of which will depend upon individual preference. A nasal speculum, the wire speculum being in most respects desirable, as if properly made it will in the majority of cases be practically self-retaining. A probe is also necessary. Ear speculums, either of hard rubber or metal, of the Gruber pattern. For general work the hard rubber are best. This list comprises the essential instruments for general use.

EXAMINATION OF THE NOSE AND THROAT.

Revolving chairs or stools which can be raised or lowered, are the most useful, as in this way the position of

examiner and patient can be regulated. The light, when it can be arranged, should be on a swinging bracket which can also be raised or lowered, or a floor stand. The light should be to the right of the patient, a little above the ear, and not so close as to inconvenience the patient by the heat. Practice in the use of the head mirror will enable the examiner to keep the parts illuminated. It is better to adopt a routine method of examination, as in this way one is less liable to overlook some of the structures. Excepting in rare instances, it is better to commence with the nose.

Anterior rhinoscopy is the term employed for examining the nasal fossæ through the nostrils. The nostril may be dilated with a speculum, or by pressing the tip of the



FIG. 30. Author's wire speculum.

nose upwards and backwards with the thumb. The latter method is not satisfactory in many cases, and recourse to the speculum is necessary. The usual method of using the speculum is to place the blades against the outer and inner walls of the nostril, but as a rule this is painful, and for an examination the blades resting against the anterior and posterior surfaces of the nostril will be sufficient to give a good view of the nasal cavity, and the patient will seldom complain of any discomfort. Before introducing the speculum, the tip of the nose should be raised to obtain a view of the fossæ, as at times there may be so much deflection of the septum that it will be impossible to introduce a speculum, and at times small pustules are located just within the nostril, and the pressure of the speculum will cause an unnecessary amount of pain.

The position of the head is important. For examining the floor of the nose, the head should be held forward and slightly downward, on account of the anatomical formation. For the middle turbinate the head should be in the natural position, and for the superior portion of the nasal cavity the head should be tipped backward. In this way the anterior portion of the nasal cavities can be examined.

Posterior Rhinoscopy.—Excepting in young children this can usually be accomplished without much difficulty, provided attention is given to a few rules. The rhinoscopic mirror should be slightly warmed, which is readily accomplished by passing it over the top of the gas or lamp chimney. The degree of heat can be determined by pressing the back of the mirror, preferably, on the back of the hand. It should not be too warm, neither so cool that the moisture from the breath condenses on the surface of the mirror, as then a clear image will not be obtained. The patient should be instructed to breathe naturally and through the nose. Then have the patient open the mouth gradually, still breathing through the nose, as in this way the soft palate remains relaxed. The mirror is held loosely in the same position as a pen, the shank resting upon the tip of the middle finger and steadied by the thumb and tip of the index finger, the thumb also serving to rotate the mirror. The arm and forearm should be held in an easy position, otherwise it will be difficult to manipulate the mirror. It is always better for the operator to be ambidextrous in handling instruments; as thus operative procedures can be better performed. The mirror should be introduced into the mouth, keeping to the side corresponding to the hand the mirror is held in, passing diagonally backward, through the faucial space and back of the uvula, care being taken not to touch the surrounding structures. When free in the pharyngeal space, the handle of the mirror is rotated to bring the reflecting surface upward and forward. The position of the

mirror is easily changed, either as regards the angle of the reflecting surface or rotated as required without wrist motion, which would in all probability cause the tissues to be touched, causing the patient to gag.

In examinations of the nose and throat, the best results are obtained when the period of examination is limited to a few seconds, if patients are sensitive, as the dread of an examination with the majority amounts to positive dread, and only as confidence is established, will a prolonged examination be tolerated. It is advisable to make several attempts




FIG. 31. Kyle's tongue controller.

the first or second sitting, rather than weary the patient. In many cases, unless they have taken vocal lessons, it is necessary to use a tongue depressor for posterior rhinoscopic examinations.

Hinged depressors should be avoided, as it is almost impossible to keep them clean. In using the depressor, the patient should be instructed to open the mouth, allowing the tongue to assume a position with the tip against the lower teeth. The depressor being slightly warmed should be introduced, not too far back, as the base of the tongue is extremely sensitive, and considerable resistance will be made, interfering with the use of the mirror. The pressure

should be steady, and directed downward and forward, when the most space will usually be obtained. The largest mirror that the space will allow should be used, as the illumination and size of the image will both be increased. In some cases it is impossible to obtain a view on account of the patient's inability to control the muscles of the pharynx and soft palate. In such cases, a solution of cocaine may be used to allay sensitiveness, or better the auto-spray of 2 per cent cocaine in Kelene. This should be a last resort.

The various instruments devised for retracting the soft palate are of little use.

In some cases a small incandescent electric light in the post nasal space may be advantageously employed. The introduction of the lamp is readily made by following the rules for the rhinoscopic mirror. When the lamp is in position, the patient closes the teeth upon the shank, which holds the lamp in position. The lamp is protected by a perforated cap which allows transmission of the light and also protects the tissues from the heat naturally generated. The cap is movable, so the direction of the rays of light can be controlled. A good view of the anterior nares can be had in this way, and also considerable of the posterior portion. The condition of the accessory cavities can also be fairly well determined, but an anomalous condition must be considered, as otherwise the interrupted transmission of light might lead to a diagnosis of fluids or tumors when they are absent.

In order to determine whether a normal or abnormal condition is present, it is necessary to keep a mental picture of normal structures well in mind.

In the anterior examination, the head positions already described will allow inspection of the various structures, the turbinates on the outer portion of each nasal cavity, and the septum in the median line. By having the patient

incline the head to the right or left, a more extensive view will be obtained, and as the head is thrown backward, the structures, and in some cases, even the superior turbinates and roof of the nasal cavity can be inspected.

The color of the normal mucous membrane is, on the septum a bright pink, a little darker at the junction with the floor of the nose. The anterior portion of the middle turbinate is dark pink, the superior turbinate pink with a yellowish tinge, the roof a more marked yellowish pink, but of lighter shade, and the balance of the structures show a grayish pink color.

The rhinoscopic mirror will show, as the mirror is manipulated to bring the different portions into view, the oval-shaped openings of the choanæ or posterior nares. It must always be remembered that in these views the position of the parts as seen in the mirror are reversed. Usually the septum will be first distinguished broader above and tapering as it approaches the floor of the nose. On each side may be seen, as in a slight shadow, the openings of the nasal passages. By slightly turning the mirror, the inferior turbinate may be seen, resembling a pinkish gray, elongated mass, and apparently resting upon the floor of the nose. Above this the middle meatus will be seen. Above the middle meatus the middle turbinate appears, as a somewhat elongated and slightly fusiform projection, the edges yellowish red, the color becoming deeper towards the base.

The superior meatus appears as a dark line above the posterior portion of the middle turbinate, separating the middle and superior turbinates. The superior turbinate is indistinctly seen as a light reddish band and can not be clearly defined excepting by the post nasal lamp. The color is the same as the middle turbinate and the edge slants upward and forward, appearing as though suspended from the roof.

It is seldom that a satisfactory view of the inferior meatus and floor of the nose can be obtained by the use of the mirror, but a very fair idea of the parts can often be obtained by an anterior examination.

The opening of the Eustachian tube generally appears as a grayish; funnel-shaped depression, the eminence surrounding it and Rosenmuller's fossa separating the Eustachian eminence from the posterior pharyngeal wall, may be inspected by turning the face of the mirror to one side.

To inspect the vault of the pharynx, the handle of the

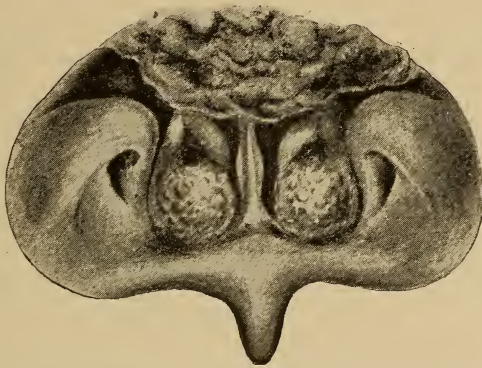


FIG. 32. Posterior view of the nose, showing adenoids in the vault of the pharynx, and hypertrophies of the inferior turbinates.

mirror should be elevated, thus bringing the mirror nearer the horizontal, which will bring the half dome-shaped vault of the pharynx into the field:

The outline is somewhat irregular owing to the glandular tissue present. The age of the patient usually determines the amount of this tissue, in the adult it generally has atrophied more or less. This tissue, the pharyngeal or Luschka's tonsil is always present in children, and may be normal or very much enlarged. The enlargement may be a swelling or an actual proliferation of tissue. The color of

the pharyngeal tonsil varies, in the young often being a deep red color, and in the adult a pinkish gray. The surface becomes smoother toward the pharynx, where a smooth dark red color is present. A view of the pharyngeal vault is not only usually difficult to obtain in children, but often impossible, but a fair idea of the condition may be obtained by introducing the index finger back of the soft palate, and pressing it over the tissues. This procedure, however, is not advisable, as a rule, unless the child has been given an anesthetic sufficient to prevent struggling, as the fright produced will make it very difficult afterwards to do anything with the child.

In prolonged examinations the color of the tissues




FIG. 33G. DeVilbiss Atomizer.

changes, probably through both the influence of the reflected light as well as the action of the muscles.

Office Requisites.—Some instruments are required for office treatment. For cleansing the mucous membranes, numerous appliances have been devised. Cotton applicators, atomizers, douches, and syringes, all have their advantages and disadvantages. Atomizers of numerous kinds are to be obtained, but the simplest in construction is most desirable, and the hand atomizer will prove as satisfactory, in fact, more so usually than the complicated and cumbersome compressed air apparatus, as the force often employed in the latter will aggravate many conditions. With a straight tube atomizer, not only the nasal passages, but also the naso-

pharynx can usually be thoroughly cleansed, but the tube should be of metal and not exceed one-eighth inch in diameter. In nearly all cases the spray can be directed so the entire anterior portion can be reached, and with but few exceptions the tube can be passed through the nasal cavity far enough to reach the post nasal space. The curved tips often furnish with atomizers for spraying the pharyngeal vault are practically worthless as a rule, for few persons can use them, and at times spasmodic contraction of the velum on the tip holds it so firmly that it is difficult to remove without lacerating the tissues.

An objection to atomizers is that when the secretion is very tenacious, it is almost impossible to cleanse the tissues thoroughly.

Douches of various kinds are used, but the objection to them is, that if the fluid enters the nasal cavities with much force, it will produce congestion of the tissues, often increasing a rhinitis. Besides, unless carefully used, there is danger of forcing some of the secretion or fluid into the Eustachian tubes, or possibly into the maxillary sinus. The fluid also seldom reaches any portion but the respiratory tract, and if there is an abundant secretion, it will only partially do the work.

Syringes have also been employed, the post nasal syringe especially. In this method the secretions are swept forward through the nasal cavities and theoretically it is the proper method, but it is not easily used, especially in children, and there is danger of forcing fluid into the Eustachian tube. The instrument I have found most useful and with the fewest objections, is the "Success Nasal Syringe." Much or little force can be employed in emptying the bulb, and the danger of forcing fluids into either the accessory cavities or Eustachian tubes is reduced to a minimum. The parts can be cleansed more thoroughly than by an atomizer, and there is less liability of producing

congestion than with the douche. The tubing being soft rubber, there is little danger of injuring the tissues. Whatever form of cleansing apparatus is used, the fluid employed should be practically at blood heat, and what is also important, is that the specific gravity of the fluid should approximate that of the blood, otherwise the osmosis produced renders the patient uncomfortable.

In the use of any fluid, it must be remembered that an

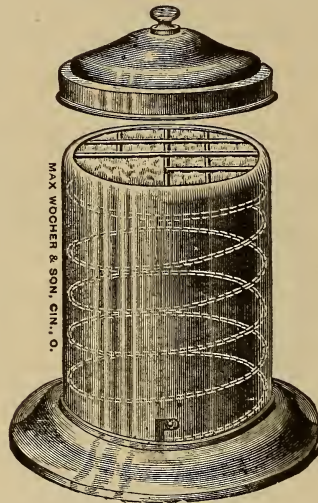


FIG. 34. Cotton holder.

arbitrary rule can not be followed, but that each individual case must be studied, and the preparation modified to suit the condition present, also that as improvement takes place, changes must be made.

The use of cotton applicators is frequently necessary, as by no other method can the surfaces be perfectly cleansed, but care in their use is imperative, as otherwise injury of the tissues results. All manipulations should be carefully performed.

After the structures are thoroughly cleansed, a more accurate idea of the condition of the tissues can be obtained than is otherwise possible.

In some few cases it is necessary to use powders in the nose, and of the various instruments those which will distribute the powder in a fine cloud, are to be preferred to those which throw them in a mass. The DeVilbiss is a favorite, although there are several other good instruments in the market.

Nebulizers and *inhalers* are of value in some cases, although too much reliance must not be placed upon local measures, as constitutional treatment is of the utmost importance if satisfactory results are to be obtained. As re-

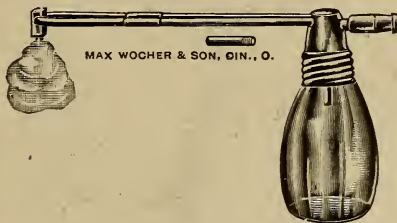


FIG. 35. DeVilbiss powder blower.

gards nebulizers, their long continued use will cause absorption of the oily base, and produce a chronic thickening which is very annoying. It is true that after the use of aqueous solutions, especially in cold weather, the oily preparation afterward is a protection to the mucous membranes, but patients are prone to abuse their use, and will provide themselves with a small oil atomizer, and use it too frequently.

The use of a hot air, or vapor, apparatus is often beneficial, more especially in middle ear affections, but in the accessory sinuses the relief is only temporary, as a rule, still this is often of considerable importance. Inhalers for using steam or medicated vapors may be extemporized by using a

pitcher or small double boiler, such as is used for cooking, filling the outer boiler with hot water, and placing the medicine needed in the inner vessel over which a cone, made by folding a towel or paper, may be used to inhale the vapor.




FIG. 36. Office cabinet with atomizers and nebulizers.

PHARYNGEAL EXAMINATION.—Inspect the condition of the teeth, whether carious or not, the shape of the hard palate, whether symmetrical or not, also as to the palatal arch, which if very high may cause stenosis of the nasal cavities.

The appearance of the velum, whether thickened, thinned, or relaxed, also its color and symmetry, a slight asymmetry may be normal. The uvula should also be inspected, as to size and length. If long enough to rest upon the base of the tongue, it will probably cause a constant irritation, producing an irritative characteristic cough. The shape and size of the tongue should be noted, as this often eliminates systemic conditions. A coated tongue, when not dependent upon an acute disease or alimentary disturbance, may usually be referred to mouth breathing.

The tonsils are normally nearly hidden by the faucial




FIG. 37. Spray bottle holder for warming solutions.

pillars, but may be exposed to view by "gagging" the patient, or drawing the anterior pillar to one side by some instrument. If the tonsil presents a roughened surface, or prominent points, there is an abnormal condition. The color of the normal tonsil is the same as of the surrounding tissues, and any departure from this indicates disease. Adhesion of the tonsil to the faucial pillars is usually the result of ulceration. The tonsils are connected by an adenoid tissue formation extending along the base or root of the tongue and in front of the epiglottis. This is termed the lingual, or fourth tonsil, and consists of a row of small

papules. Normally this structure is not readily seen, excepting by the use of the laryngoscopic mirror. This tissue is subject to the same changes through inflammatory action as the other pharyngeal tissues. The normal color of the pharyngeal surface is a pale pink, and there is the appearance of the mucous membrane resting on a resilient cushion. Changes in color, apparent thinning, thickening, or roughening of the surface indicates morbid changes which may be acute or chronic. While in a normal state the mucous membrane appears moist, there is no excess of secretion, but in morbid changes there is either an excess

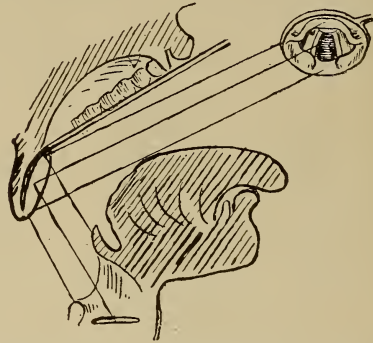


FIG. 38. Proper position of patient's head and the mirror to obtain the laryngeal image.

or deficiency. By having the patient say *ah!* the velum will be retracted, not only showing whether symmetrical action of the muscles exists, but also exposing the posterior pharyngeal wall to about the level of the palatal arch. By causing the patient to gag, the action of the pharyngeal muscles will expose the lateral walls which otherwise are hidden by the posterior faucial pillars, and the condition of the tissues in these regions can be determined.

LARYNGOSCOPY.—The mirror should be warmed as directed for the rhinoscopic mirror. The patient should sit erect or with the body slightly inclined forward. With

the mirror in readiness the patient should be instructed to breathe naturally, and while breathing in this manner, open the mouth and protrude the tongue. In the physician's left hand should be a small napkin, pushed between the index and middle fingers, forming a sac in which the tip of the tongue can rest. Grasping the tongue gently, but firmly, in this manner will allow of some manipulation, and the ring and little fingers resting against the chin will permit greater steadiness, and the tongue can be drawn forward without causing excessive resistance on the part of the patient. The mirror is held in a similar manner as for

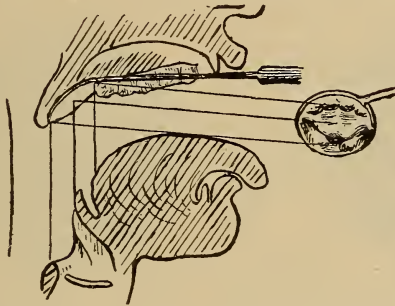


FIG. 39. Faulty position of patient's head and of the mirror. No laryngeal image obtained.

rhinoscopic examinations, but with the reflecting surface facing downwards and forwards. The mirror is passed into the mouth and backwards until the uvula rests upon the back of the mirror, but care should be exercised not to touch the posterior pharyngeal wall. If the positions of the head and mirror are incorrect the probability is that only the dorsum of the tongue and lingual surface of the epiglottis will be seen, but with the disengaged fingers of the left hand, the head can be tilted backwards a little more, and depressing the handle of the mirror slightly, or pushing the mirror back a trifle, will bring the laryngeal structures

into view. If the patient will sound *eh!* several times it will aid by raising the larynx. The vocal cords can be seen, and in the act of phonation and inspiration can be seen approximating and receding from the median line.

It must be remembered in these examinations that the image is inverted.

Clinically the larynx may be divided into three parts, the upper or supraglottic, or that portion above the ventricular bands; the glottic, which lies between the ventricular bands and vocal cords, including the ventricles, and the infraglottic which comprises the portion between the vocal cords and lower border of the cricoid cartilage. The

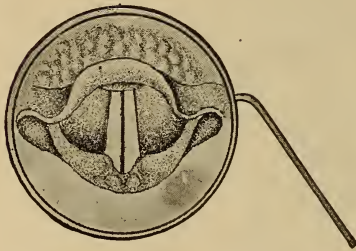


FIG. 40. Position of vocal cords in phonation.

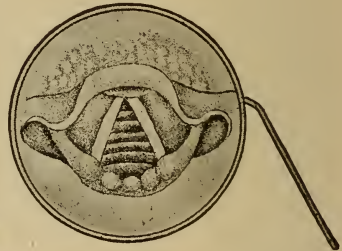


FIG. 41. Position of vocal cords in inspiration.

most conspicuous object seen in the examination is the epiglottis, which on account of its form shows parts of both surfaces. The shape and position varies so much in different individuals that considerable experience is necessary to determine a normal from an abnormal cartilage.

Behind the epiglottis and lower down, the diverging pearly white vocal cords are distinguished, passing backwards to their attachment to the arytenoid cartilages. The Wrisberg and Santorini cartilages are seen as rounded swellings in the lower part of the image, forming in part the posterior boundary of the larynx, and between the arytenoid cartilages is the inter-arytenoid space. The ary-

epiglottic folds of mucous membrane pass from the arytenoid cartilages, on either side, forward to the epiglottis (Williams).

The laryngeal examination should include normal and deep respiration and the movement of the cords during phonation which should reveal any abnormal movement or position. The color of the mucous membrane and the form of the various structures should be noted. The color of the epiglottis is slightly yellowish, the remainder of the laryngeal tissues are a pale pink, excepting the vocal cords. It must be remembered that under the influence of the light, and possibly also the unusual muscular tension or vaso-motor changes during the examination, the color may

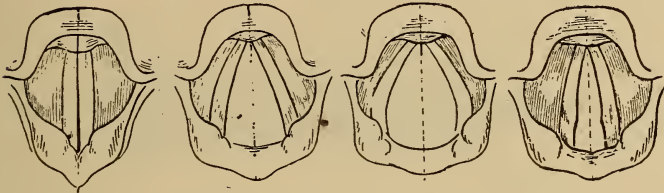


FIG. 42.
Adduction.

FIG. 43.
Respiration.

FIG. 44.
Abduction.

FIG. 45. Cada-
veric position.

change rapidly from the pale anemic membrane to a positive hyperemia. The vocal cords are pearly white or slightly tinged with pink. Persons who use the voice constantly or those with a bass voice, according to Williams, have the cords persistently reddened, and yet they are not abnormal.

In some instances the sensibility of the larynx may have to be determined. This can be done by the use of a bent probe. If anesthesia of the larynx is present no especial reflex will be obtained, while in the normal larynx a violent paroxysm of coughing will result.

Many difficulties are encountered in making a laryngoscopic examination, but they can usually be overcome by

patience, it being well to remember that it is not always the fault of the patient. In some cases more satisfactory results can be obtained by having the patient hold the tongue, which should be grasped between the fingers in such a manner as to keep the hand out of the way. This is important, as otherwise the patient's hand may interfere with the use of the mirror or any instrument used. In some persons there is such a hyperesthetic state that it is nearly impossible to make a satisfactory examination. A few swallows of cold water may relieve this, or as a last resort, the surfaces can be sprayed with a solution of cocaine; or the auto-spray.

Where for purposes of treatment repeated examinations



FIG. 46. Pomeroy's Ear Syringe.

are required, and the patient is not tractable, I have found by having them stand before a mirror, open the mouth and depress the tongue with a tongue depressor, or the handle of a spoon, the sensitiveness usually soon passes off. The same rule will work in rhinoscopy.

Otoscopy.—*Instruments Required in Addition to Those Already Described.*—A syringe is the most generally useful, and also the least liable to do mischief. Different styles are used, but where one does much ear work the capacity of the syringe should be not less than two ounces, and four ounces is more convenient in many respects. The soft rubber pus, or ear syringe will answer the purpose, however, in the majority of cases. Probes and cotton carriers should be light and some of them flexible. Ear specula of assorted sizes. For-

ceps and cures, in the hands of an expert, are necessary, but the novice should not attempt their use, and the expert only with good illumination.

The anatomical relation of the ear to the upper respiratory tract is conducive to extension of morbid conditions from the nasopharyngeal portion through the Eustachian tube to the middle ear, and as a result of this extension, it is absolutely necessary in treating the ear to have a definite knowledge of the morbid condition existing in the upper respiratory tract. This will in many instances determine the character of the changes which have taken place in the Eustachian tube and tympanum.

After obtaining as complete a history of the patient's condition as possible, the examination should begin with an inspection of the auricle and adjacent parts. Abnormal or anomalous conditions should be noted. Inflammation of these structures, or redness over the mastoid. Pressure over the mastoid will often show tenderness, but a comparison of both sides should be made, as hysterical patients will sometimes complain of pain when pressure over the mastoid apex is made, which is not the result of a diseased condition. The position of the auricles, whether symmetrical or not. Redness and tenderness over the mastoid may be due to furuncles of the external meatus, or may be symptomatic of mastoid disease. With the head mirror in position, and by means of an ear speculum the external auditory canal and membrana tympani should be inspected. When the membrane is ruptured, the middle ear may also be inspected. For minute inspection of the membrane, the view obtained by looking through the aperture of the mirror is preferable, but in the majority of cases the mirror over the forehead will be satisfactory. The light should be on a level with the ear, and back of the patient far enough so no discomfort from the heat is noticed. The style of speculum used is largely a matter of choice, but the Gruber pattern

is most generally satisfactory. These may be either of metal or hard rubber. When a metal speculum is used it should be warmed.

In introducing the speculum it should not be pushed forcibly into the canal, but held lightly by the thumb and index finger, and with a gentle rotary motion introduced

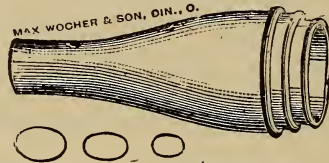


FIG. 47. Gruber's Ear Specula.

into the meatus, not passing back far enough to reach the bony portion, which would cause pain. The speculum may be held in the left hand, the auricle grasped between the index and middle fingers and drawn outward, upward, and backward. When the physician is ambidextrous, the right hand would be used for holding the speculum for the left ear. The hairs in the meatus may be so numerous as to obstruct the view, but usually may be pushed aside with the speculum. Cerumen, scaly material, or any secretion which obstructs the view, must be removed, preferably by syringing. Care is necessary in properly introducing the speculum, as otherwise a view of the walls of the auditory canal are mistaken for the tympanic membrane, leading to a wrong diagnosis. There are a number of diagnostic specula, electrically lighted, etc., but very few of them are of practical use, excepting for obtaining a view of the membrane, as in all mechanical interference, resort to either the electric headlight or the mirror must be made.

The appearance of the canal should be observed. The bony portion is, as a rule, of a pinkish tint, smooth, and glistening. In the examination there is often an annoying

reflex cough, due to irritation of the auricular branch of the pneumogastric nerve.

Membrana Tympani.—The color of the normal membrane varies somewhat and the color described depends upon the color perception of the examiner, a translucent bluish white, or pearly tint, being the usual description. The color varies according to the light used, having a decidedly reddish yellow color when gas light of a yellow color is employed. In the normal ear the long handle of the malleus will be seen projecting downward and backward to the umbo or central concavity of the membrane. From the tip of the process extending downward and for-

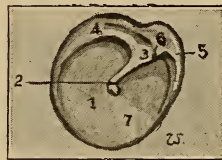

FIG. 48. Normal membrana tympani, right ear. (1) Membrane; (2) handle of the malleus; (3) short process; (4) posterior fold; (5) anterior fold; (6) membrana flaccida; (7) triangular light spot.

ward is a cone of light, the triangular light spot, extending nearly to the periphery of the membrane, the apex toward the tip of the handle. At the upper portion of the manubrium will be seen the short process extending backward. Two folds of the membrane can be distinguished, the anterior and posterior. The membrane above these is called Shrapnell's membrane, or membrana flaccida, and that below, the membrana vibrans. The color of the membrane is to be observed, whether normal, reddened, opaque, thickened, or atrophic, and as to opacities or cicatricial areas. The surface of the drumhead, retracted or bulging. If a collection of fluid is in the tympanum the membrane will be bulging, and the color changed according to the character

of the fluid, which will impart its tint to the membrane. If retracted, the handle of the malleus will appear shortened, the short process and the anterior and posterior folds more prominent, while the cone, or window of light, will be displaced, distorted, or only a portion of it visible. The mobility of the membrane may be determined by the Valsalvan method, by the use of a probe or by Siegle's pneumatic speculum, where either rarification or condensation of the air in the canal can be obtained. The tip of the speculum should be covered with a piece of rubber tubing so as to fit the canal more accurately. This principle is one of the methods used of applying massage to the ear, but never should be employed without a full view of the membrane.

Examination of the Eustachian Tube and Middle Ear.—To determine whether the Eustachian tube is open or not, it is necessary to use Politzer's inflation, the Eustachian catheter, or the Valsalvan method. The latter is not to be recommended under ordinary circumstances, as the patient will in all probability employ it too frequently. The catheter in some instances is the best method for determining the perviousness of the tube, but is not as generally employed as formerly. In fact, inflation is no longer a routine measure, as where any inner ear disease is present, it almost invariably increases the difficulty.

The diagnostic tube is an aid in determining the condition of the Eustachian tube. This tube is of rubber and from two and one-half to three feet long. Two tips are provided, one white and the other black. In this way the examiner always uses the same tip for himself. The one tip is placed in the patient's ear and the other in the surgeon's ear. When the ear is inflated, if normal, a distinct click is heard; if fluid is present in the tympanum, a bubbling sound will be noticed, and a perforation of the membrane will produce a hissing or blowing sound, de-

pending upon the size of the perforation. If no air passes through the Eustachian tube nothing is heard.

The Politzer Method.—The patient is seated in a chair and directed to take some water and hold it in the mouth until directed to swallow. The physician, standing in front of the patient, or a little to one side, introduces the tip of

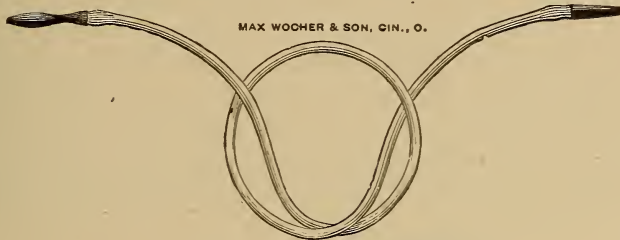


FIG. 49. Diagnostic Tube.

the Politzer bag into one nostril, and with the thumb and index finger closes the *alæ* of the nose by pressing the engaged side against the tip, and the opposite side against the septum. The patient being directed to swallow, the air bag is compressed during the act of deglutition. The sud-

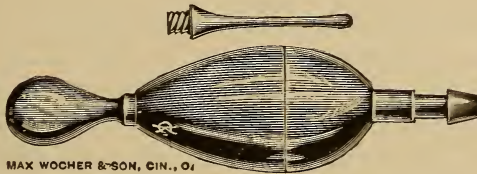


FIG. 50. Roosa's Tip for Air Bag.

den condensation of air in the nasopharynx will force some air into the middle ear. The soft palate is also forced downward and a dull gurgling sound is heard, thus indicating that the various acts have been simultaneously performed, but not necessarily that air has passed into the tympanum. Having the patient close the mouth and make a

moderately forcible expiratory effort, keeping the lips tightly closed, however, will be found less objectionable to many, and besides there is less liability of swallowing air which is not always pleasant to the patient. Politzer has changed the water method by having the patient inspire either through a small rubber tube or the nearly closed lips. In the use of the catheter this inspiratory method will be found useful. The nasopharynx is closed, and through the action of the pharyngei and palati muscles, the Eustachian tube is more open. When secretion is present in the middle ear, the patient should incline the head forward and sideways to facilitate the escape of the fluid to the pharyngeal opening of the tube. If there is a perforation of the mem-

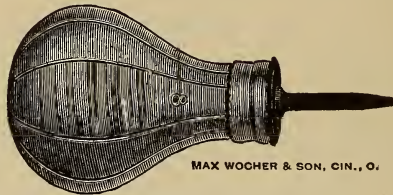


FIG. 51. Politzer's Air Bag.

brane, any fluid present in the tympanum may be forced into the external auditory canal, but when no perforation is present, there is a possibility of forcing some of the secretion into the mastoid, thus producing mastoiditis. In young children, when the mouth is closed, it usually is not necessary to use any of these methods, and if the child cries, it renders the operation still more effective.

Catheterization.—Catheters are made of hard rubber or silver, and several sizes should be obtained. The metal should be malleable as the curve often will have to be modified to suit the individual case: The hard rubber may be modified by carefully heating the part desired to change over the top of a gas or lamp chimney and moulding as

desired. When cold the curve will remain. The tips of these instruments should be probe-pointed, and the double curved catheter of Blake is the most satisfactory. The guide ring or pin at the base of the catheter should be immovable and may be on either the same or opposite side of the tip, but in line with it, so that the direction of the tip is always known by the physician.

The two usual methods of using the catheter vary only in the latter part of the manipulation. With the patient seated and having the catheter warm and lubricated with a bland unirritating substance, the ring and little fingers are placed on the patient's forehead and the tip of the nose gently elevated with the thumb. Holding the catheter in the right hand, as a pen is held, introduce the tip of the



FIG. 52. Eustachian Catheter.

instrument into the nostril and pass carefully along the floor of the nose until the posterior wall of the pharynx is touched, then turn the tip about a quarter turn outward, where it will engage in Rosenmuller's fossa. Then drawing the catheter slightly forward, and slightly elevating the tip, it will be felt gliding over the posterior eminence of the tube. A slight manipulation, raising and turning the tip a little more outward will usually engage the mouth of the Eustachian tube, and the guide will practically be in a line with the external canthus of the corresponding eye. The base of the catheter can now be grasped between the thumb and index finger of the left hand and the catheter tip of the air bag slipped into place, and the air forced through the catheter and Eustachian tube to the middle ear, but care must be exercised not to use too much force in compressing the bag, for if the membrana tympani is thinned, it

may be ruptured by this method. The other method is practically the same until the posterior edge of the hard palate is reached, which is known by the curved portion and tip dropping down, or it may be pushed back until it touches the posterior wall, as in the first method. Then

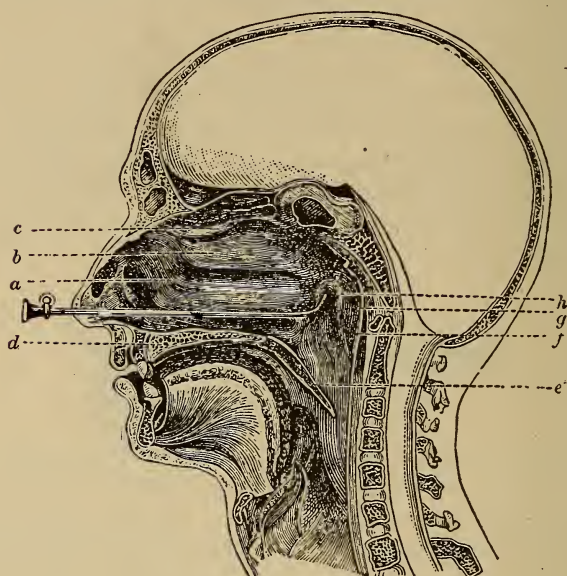


FIG. 53. Vertical section of head showing Eustachian Catheter in position. (a) Inferior turbinate; (b) middle turbinate; (c) superior turbinate; (d) hard palate; (e) soft palate; (f) posterior pharyngeal wall; (g) Rosenmüller's fossa; (h) posterior lip of orifice of the Eustachian tube.

turn the tip inward, bringing it to the horizontal, which the guide will determine, draw the catheter forward until the curved portion engages the posterior edge of the septum, then by rotating the point downward and outward completing a little more than a semi-circle, the point should engage in the mouth of the Eustachian tube. The inflation is com-

pleted as in the first instance. The air bag and Eustachian tip should be connected by a piece of rubber tubing, as otherwise more or less motion will be imparted to the distal end of the catheter and cause the patient pain, if not an actual tearing of tissue.

The direction sometimes given to connect the catheter and air bag before introduction, renders the task more difficult. In some cases there is difficulty in introducing the catheter on account of obstruction in the nasal cavity, one side only may be free enough to allow the instrument to pass without undue discomfort to the patient. In such cases, I have experienced little difficulty in inflating the opposite ear, and in nervous persons nearly always catheterize both ears without withdrawing the catheter. This requires considerable experience, but it is simply a reversal of the position of the tip, and giving a slight inclination of the base of the catheter outward. The distance necessary to reach the opposite opening is not very great, and practice will soon enable one to inflate either or both ears without withdrawing the catheter.

Prior to inflation, the membrana tympani should be inspected to determine both the color and texture. As stated, but little force should be employed, as if the membrana tympani is atrophic, rupture may occur. After inflation the color of the membrana tympani will be changed. If it was white before, it will have a pinkish tint, especially along the handle of the malleus, and if the membrane was reddened, the color will be intensified. Even in using the diagnostic tube it is best to examine the membrana tympani after inflation. In the Valsalvan method, or auto-inflation, the patient holds the nostrils closed, and closing the mouth firmly makes a strong expiratory effort, not allowing air to escape from either the nose or mouth. This forces the air in the nasopharynx through the Eustachian tubes into the tympanum. Inspection of the membrana tympani during

this procedure may determine the mobility of the drum-head. Patients, however, are liable to practice the method with considerable frequency, thus producing relaxation of the membrana tympani. Congestion of the brain sometimes follows this method temporarily, and in persons with a weak or faulty heart action, alarming symptoms are sometimes produced. Relaxation of the membrana tympani will also follow either catheterization, or the use of the Politzer bag, if continued for a considerable period, and although they have their place in aural practice, should not be used as a routine measure.

Hearing Tests.—To determine the acuity of hearing is most important. In the different tests the seat of the lesion is usually determined, whether in the external, middle, or inner ear. Sound vibrations are recognized both through the air and the bones of the head, hence the necessity for different tests. The watch test is the one most frequently employed and also probably the most unsatisfactory. The loudness of tick varies with different watches, but the watch employed should be tried with different persons whose hearing is supposed to be normal. This distance will be the denominator and will usually be twenty-five inches to sixty inches. When the patient hears a sixty-inch watch at ten inches, it is expressed H. D. 10/60. The ear not under test should be closed, which may be done by having the patient moisten the tip of the index finger, press it against the external meatus with force enough to close it. Having the patient close the eyes, hold the watch first so the ticking can be heard, as at times they do not readily understand what is required. Then hold the watch at the normal distance, if not heard, move the watch slowly toward the ear until it is heard. The distance can easily be read on a tape measure, but if it is metal it should not be held against the bones of the head until the tick has been recognized. If the watch is held against the ear first and then moved away,

it will be heard at a greater distance; however, I generally use both methods and compare results. If the watch is not heard until in contact with the ear, it is written C/60, C.= contact, and if it must be pressed firmly against the auricle P/60. P= pressure, if not heard even then the record would show o/60. Of course the ear examined is designated as R. or L. D. or S., according to the individual preference.

Acoumeter.—Politzer devised an acoumeter which al-

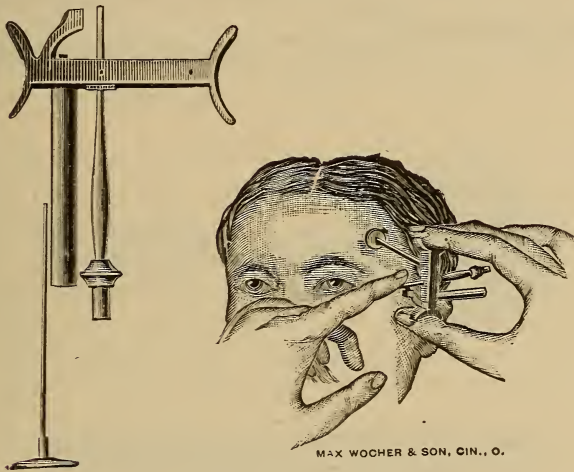


FIG. 54. Politzer's Acoumeter.

ways gives a sound of the same intensity, thus having an instrument of more precision than the watch. The short lever can be depressed only a certain distance, so the hammer in striking the metal bar always falls with the same force. An attachment for testing the mastoid conduction, the temple, etc., consists of a metal rod with a round plate which rests against the bony portion to be tested. The hearing distance by air conduction is measured by the tape as with the watch. Another instrument sometimes em-

ployed, but of no value excepting for aerial hearing, is the metronome. The intensity of this is such that it is difficult to determine the amount of impairment, unless very marked. The hearing acuity should always be tested for speech, both whispered and ordinary conversational tones. The examiner should stand on the side, as otherwise the motion of the lips will furnish a clew to many people, and the test will not be accurate. The distance from the patient should



FIG. 55. Tuning Fork, Middle C.

also be noted in these tests. Whispers, especially when the vowels are accented, can be ordinarily heard by the normal ear at fifty feet in a room that is perfectly quiet, but this is a condition not often obtainable in city practice.

Tuning Forks.—For simple diagnostic purposes, a middle C fork is all that is required, although the specialist should be provided with at least three, C. 128, C²-512, C⁴-2048 vibrations per second. The Blake fork, in which the



FIG. 56. Blake's Tuning Fork.

vibrations are produced by pressing the ends together with the thumb and index finger, will be most desirable where but one is employed. This fork always gives the same intensity, while in using the ordinary form it is difficult to strike the fork with the same force. It should be struck on the knee, and not on a hard substance, on account of the excessive overtones produced. Clamps are also provided for controlling overtones. A fork with a percussion

hammer is made which will allow of a uniform stroke. A Galton whistle is also useful, as the intensity of the note can be regulated. Koenig's rods are used, but excepting for the specialist, are not necessary. Low toned forks are heard better in labyrinthine disease, than high ones, when held close to the ear. When middle ear disease is present and hearing for speech is impaired, the same fork is faintly heard.

In a normal ear, the tuning fork is heard most distinctly when held close to the ear, A. C. best, but is quite indistinct when placed against the mastoid or bones of the cranium. In external and middle ear disease, the tuning fork is heard more plainly when placed against the bone.

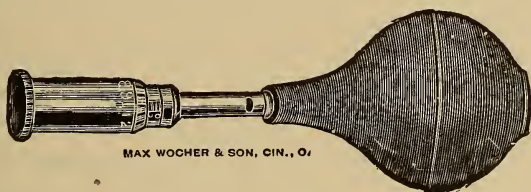


FIG. 57. Galton's Whistle.

So the record would read, B. C. best; that is, bone conduction best, always indicating the ear tested. In inner ear disease the fork is heard better through the air, but the hearing is impaired, and again the formula would read A. C. best; that is, aerial conduction best. The time the fork is heard through the air should be carefully noted, as in many cases where the defect is slight, or inner ear disease is just beginning, this will be the only positive method of determining the lesion.

By inserting the finger tip in the external meatus, the sound is intensified in the abnormal ear, in middle ear and external ear disease when the test is made by bone conduction, whether on the vertex, forehead, or the teeth. In

inner ear disease, bone conduction is nearly or completely destroyed. As a rule aerial conduction is better for the high note tuning fork in middle ear disease.

Galton's whistle is of value in testing with high notes, the range is from about 3,000 to 50,000 vibrations per second.

Koenig's rods, consisting of steel rods, produce vibrations from 10,000 to 40,000 per second, the intervals being 2,500 vibrations.

In old age bone conduction is diminished, Politzer claiming that it is seldom that a low ticking watch is heard through the cranial bones after the age of sixty.

Rinne's Test.—Place the base or handle of the vibrating tuning fork against the side of the skull or on the mastoid. As soon as the patient ceases to hear the vibrations, hold the blades of the fork close to the external auditory meatus, being careful, however, not to touch the ear. If the fork is again heard, it constitutes the positive Rinne test. The negative Rinne test is a reversal of this.

Unless there is disease of the inner ear, these tests are especially valuable in otitis media when marked.

Weber's Test.—This is a better test where the deafness is slight. Using the 512 V. S. tuning fork on the median line of the bones of the head, teeth, or lower jaw, it is usually not difficult to determine which side is most affected, as the fork is heard plainer in the side most affected. In rare cases there will be a difference of tone in the two ears. This may be the result of increased tension of the fluids in the inner ear through congestion or effusion, or by increased inward pressure of the stapes.

CHAPTER IV.

NOSE.

Besides the primary functional relation of the nose to respiration, olfaction, and phonation, a secondary action is performed. In the respiratory act, it is not often that the unmodified external air would not be an irritant to the mucous surfaces of the lower respiratory tract, hence in passing through the normal nasal cavities it is prepared for entrance into the laryngeal and lower structures by modified temperature, moisture, and more or less freedom from suspended foreign matter. After the inspired air has passed through the nasal cavities, the temperature will be found approximately blood heat when it reaches the larynx. This occurs whether the atmospheric temperature is warmer or colder than the body.

The change in the nasal cavities is due, not only to the temperature of the nasal area, but also to the glandular secretion and the vapor exhaled from the lungs deposited upon the nasal tissue and maintained at the body temperature by the vascular supply, especially in the erectile tissue. The larger floating foreign particles are arrested by the vibrissæ, or short stiff hairs in the anterior portion of the vestibule, and the smaller particles are deposited and retained on the moistened mucous membranes by the tenacious mucus. This mucus, with its accumulation of foreign material, is gradually moved forwards toward the nostrils by the movements of the ciliated epithelium, thus tending to keep the nasal surfaces free from detritus.

The various theories of olfaction can be studied in the numerous works on physiology.

In vocalization, the condition of the nasal cavities exerts a marked influence on the quality of tone. When the nasal and post nasal spaces are clear, the full sonorous tones are present, but when there is obstruction in either or both of these cavities, the so-called "nasal twang" is disagreeably present. Another factor in clear sonorous tones is the free movement of the velum.

As accessory functions, free nasal cavities are important in hearing and tasting. In hearing it is necessary that the Eustachian tubes and their mouths be patulous. This permits of equalization of atmospheric pressure between the tympanum and the outer air, and also for the exit of the tympanic secretion. The naso-pharyngeal region, which is largely responsible for the condition of the tubes, is dependent upon the freedom of the nasal cavities.

As regards the sense of taste, every one is familiar with the difficulty of distinguishing different foods when the nasal cavities are occluded, either by a severe cold or by holding the nostrils tightly and endeavoring to determine the character of what is placed in the mouth. This does not apply to bitter, sweet, salt, or sour substances.

The nose is also a sentinel in many cases, as it gives warning of poisonous or irritating vapors. It is also claimed by many that the mucus secreted by the nasal membranes possess a bactericidal influence. Many other attributes are supposed to be possessed by this organ, but they are simply theoretical, being as yet in the evolutionary stage.

Mucous Membranes and Their Pathological Changes.

The popular term "catarrh" is applied to all morbid changes in the throat and nose, and possess no significance as regards the pathological condition. The meaning of the word catarrh is, an exaggerated flow of secretion from the mucous membranes, especially applied to those of the nose

and throat. The name should, for the sake of conciseness, be discarded, unless used in its proper sense as a catarrhal inflammation, meaning increased secretion from mucous surfaces.

There are many systemic diseases which will increase nasal secretion. Circulatory wrongs, vasomotor disturbances, or alteration of the character of the blood. Interference of eliminative action of the kidneys, when the skin and mucous membranes may become vicarious eliminators. Congestion of the nasal and pharyngeal membranes often result from congestion of the thoracic or abdominal viscera. Chronic constipation and intestinal irritation frequently produce thickened and congested mucous membranes of the upper respiratory tract, and not infrequently the veins will present a varicose appearance. Structural changes may result from long continued diseases of any of the viscera.

As unrecognized systemic lesions may be the primary cause of disease in the upper respiratory tract, the importance of an examination of the urine, as well as a careful examination of other organs should be considered.

In many cases a nasal lesion is simply a manifestation of a primary disease of some of the accessory cavities, and will, unless care is taken in the examination, lead to a wrong diagnosis.

A thin, watery, slightly albuminous secretion from the respiratory membrane is often found in marked cases of anemia. In children a similar exudate is often produced by intestinal irritation, resulting from the ingestion of indigestible material, or of intestinal parasites.

The anatomical conformation of the nose also has a marked influence in rendering individuals susceptible to nasal lesions. Those persons who have narrow, slit-like nasal cavities, usually hereditary, are much more liable to nasal disease than those with well developed nasal cavities.

In the former class, the lumen or space between the turbinal and septal tissues is so slight that but little irritation or congestion is required to entirely close the nasal cavity, thus interfering not only with the respiratory function, but also preventing the free escape of secretion, which still more irritates the mucous membranes and ultimately produces a chronic type of rhinitis.

The prevalent idea among the laity that a "catarrh will run into consumption" is untrue, but unquestionably neglected cases of long standing rhinal catarrhal inflammation, on account of the accumulation of secretion in the post-nasal space and posterior portion of the nasal cavities at night, and the unconscious swallowing of this secretion by the patient while asleep will produce a general catarrhal condition of the mucous membranes of the pharynx, larynx, as well as of the esophagus and stomach. This will lower the vitality, not only of these tissues, but of the general system as well, and when there is a tubercular tendency present, it may develop a true case of tuberculosis, but no disease, not tubercular, will develop a tubercular lesion.

Mouth breathing not only causes a physiognomical defect, but eventually impairs the general health. This is especially true of children, as the nasal structures do not develop; the child not only has a stupid look, but is actually stupid in mental work, and listless in play. Digestive disturbances soon appear, and the general health is much below normal. In children otherwise normal, mouth breathing indicates some obstruction to free nasal respiration, and should call for prompt relief. When neglected, not only the appearance of the face is changed, but the hard palate is often distorted, having a high irregular arch instead of the usual dome shape.

According to Kyle, if the nasal floor or superior maxillary bone is thin from defective nasal respiration in early childhood or other causes, the terminal nerve filaments to

the teeth run superficially along the floor of the nose, and if a septal deflection is low down, and with redundant tissue, the inflammatory process injures the nerve roots and causes devitalized teeth, or may ulcerate, producing a sinus discharging around the tooth, simulating pyorrhœa alveolaris.

The shape of the bones of the nose, especially of the floor and turbinates, will markedly influence the drainage of the secretions either forwards or backwards, also the tendency to accumulation of solid foreign substances from the air. If the direction is backward instead of forward there is more tendency to rhinitic inflammation.

Frontal headache and neuralgia and also facial neuralgia may result from either nasal disease or affections of the accessory cavities.

Some occupations appear to cause mouth breathers, as trainmen, motomen, and engineers. In bicycle riders the tendency is also to keep the mouth slightly open, and the irritation caused by particles of dust coming in direct contact with the membranes of the pharynx and larynx often produces marked changes in the appearance of the structures.

Structure of Mucous Membranes.

Nearly all diseases of the mucous membrane are inflammatory, and the structure of this tissue should be well understood to intelligently understand the changes that occur, as well as for the treatment.

Mucous membrane is composed practically of three layers: *a*, external, or epithelial cells; *b*, basement membrane, which supports the epithelial cells; *c*, submucous connective tissue containing the blood vessels, lymphatics, and nerves.

The epithelial portion varies in the character of the cells and the number of layers, according to location and func-

tion. In open cavities it is necessary that it should be soft, moist, and pliable. This is of the utmost importance in the nasal cavities, as the surfaces are constantly exposed to the drying action of the inspired air. As the character of the epithelial structure in this region is also protective, several layers are found, while in such places as require secretion only there is generally a single layer. The ciliated type of epithelium is found in all places where a protective or propulsive force is required, as in the anterior nares and bronchi.

Epithelial cells are miniature laboratories, in which the nutrition supplied is converted into mucus principally, and also according to location, chemical products. This being the case, it can readily be understood how morbid changes in the membrane will modify the product of the cells, and pervert the physiological action of the tissues, changing not only the chemical products, but also the character of the mucus, and retaining material that is both useless and detrimental. The character of perversion induced largely determines the classification in diseases of the mucous membranes.

The subepithelial layer, or basement membrane, furnishing nutrition to the epithelial cells, causes a change in the functions of the cells whenever any local or constitutional lesion affects it. This membrane is usually composed of two layers, although both may not always be distinguished. The external portion furnishes the material from which the epithelial cells reproduce themselves, and is called the genetic layer. In some cases this layer is absent, and if the epithelium is denuded, the surface is covered by growth from the margins. The lower layer of the basement membrane is constant, and consists of fibrous tissue, and possibly may contain some unstriped muscle cells. The thickness of the basement membrane varies according to locality, in the nose and mouth being very thick, while in the alveoli

of the lung it is almost invisible. The nerve fibers do not penetrate the membrane, but the lymphatics open by stomata immediately below or into the genetic epithelial layer.

The submucous connective layer, or submucosa, is the important vascular portion, and varies considerably according to location. In the anterior part of the nasal fossæ it constitutes the erectile tissue. Engorgement of this tissue, whether transitory or permanent, will diminish the lumen of the nasal cavities, causing much discomfort. In the female, engorgement of the erectile tissue is not infrequent during the menstrual period, and in both sexes this engorgement is not infrequent during sexual excitement. In an acute rhinitis (cold) this engorgement causes much discomfort to the patient.

Mucous membrane is not only a protective covering, a secreting membrane for mucus and other products, but it also possesses in a marked degree the property of absorption when in a normal condition. This absorptive action depends usually upon the number of layers of epithelial cells. The health of the individual thus depends upon keeping the mucous membranes of the entire body in a healthy condition, as of necessity nutrition can not be maintained unless the mucous surfaces are kept moist, soft, and pliable. This can not be done unless these same tissues are performing their normal functions of secretion.

INFLAMMATION.—A general consideration of inflammation will assist in understanding the special changes which occur in mucous membranes. "Inflammation is the aggregate of those changes which take place in any tissue as the result of an injurious action to which it has been exposed, providing the injury is not sufficient to devitalize the part."

It must not be inferred that the term injury always means trauma. It may be a direct or indirect irritation, (toxins)—local, constitutional, mechanical, thermal, or

chemical. Acute inflammation always presents definite changes, which may be classified as clinical or macroscopical, and microscopical.

Clinical symptoms are subjective and objective, and divided into five clinical divisions—pain, heat, swelling, discoloration, and perversion of function.

The microscopic changes, as the name implies, are found only by the aid of the microscope. These changes are usually described as: (1). Dilatation of the blood vessels with increased flow and accumulation of blood in the parts, followed by retardation of the current, as a result of the diminished caliber of the vessels through adhesion of the white corpuscles to the vessel walls, and paresis or paralysis of the vessels. As this condition increases, oscillation of the current results, followed by complete stasis (Kyle).

Exudation into the perivascular tissue results before stasis occurs. After stasis the exudate is more marked and also there is migration of the white corpuscles through ameboid movement.

In a sudden and severe inflammation, there is migration of the red corpuscles. Absorption of the exudate or proliferation of the fixed connective tissue cells and migrated corpuscles follows this process. If proliferation and nutrition is good, capillary budding results, and through the process of canalization, the tissue becomes vascularized; but if nutrition fails, simple liquefaction-necrosis and absorption may follow, provided no infection is present; but when infection is present suppuration occurs. The constant clinical stages are: (1) Change in the blood vessels, in the blood and its current—the intravascular, or clinically; the dry stage; (2) second or extravascular stage, exudate of liquor sanguinis and migration of white cells; clinically, wet stage, properly exudative, as the exudate may be plastic (dry); (3) terminative, which depends upon nutrition and infection.

These are the uniformly constant inflammatory manifestations.

By special inflammatory manifestations is understood those appearances which are found in different tissues, organs, parts, or of a special disease or group of diseases.

CLINICAL.	MICROSCOPICAL.
(1) HEAT	
(2) SWELLING.	FIRST STAGE {
	{ (1) <i>Contraction</i> (?)
	{ (2) <i>Dilatation.</i>
	{ (3) <i>Acceleration.</i>
	{ (4) <i>Accumulation.</i>
	{ (5) <i>Retardation.</i>
	{ (6) <i>Oscillation.</i>
	{ (7) <i>Occlusion.</i>
(3) PAIN.	
(4) DISCOLORATION.	SECOND STAGE {
	{ (8) <i>Exudation (of</i>
	{ <i>liquor sanguinis).</i>
	{ (9) <i>Migration (of</i>
	{ <i>corpuscles).</i>
(5) DISORDERED FUNCTION.	THIRD STAGE {
	{ (10) <i>Termination:</i>
	{ (a) <i>By resolution;</i>
	{ (b) <i>By new formation;</i>
	{ (c) <i>By suppuration.</i>

The second stage usually determines the variety of inflammation. (Kyle.)

The types of inflammation of the mucous membranes pathologically considered as special forms are: (a) Catarrhal. (b) Membranous—divided into croupous or pseudomembranous, fibrinoplastic, and diphtheritic. (c) Hemorrhagic. (d) Gangrenous. (e) Suppurative. (f) Chronic infectious.

The varieties of rhinitis and pharyngitis nearly all originate from these types. Constitutional diseases, infectious fevers, etc., causing lesions of the mucous membranes, properly come under one of the above varieties.

CATARRHAL INFLAMMATION.—Clinically an acute and chronic stage is recognized. Pathologically the resulting change is more or less due to acute processes merging by continuation of one of the stages into the chronic, or by repeated acute attacks.

Acute Catarrhal Inflammation of the upper respiratory tract may result from a variety of causes, but the lesion is produced either by direct external irritation of the membrane, or is the result of disturbance of the circulation. Infection is the most common factor in this condition. Catarrhal inflammation of the upper respiratory tract is either concomitant or a sequel of acute infections as scarlet fever, measles, diphtheria, typhus, and typhoid fever. In the early stages of chronic diseases, as syphilis and tuberculosis, a similar condition is found.

Under the classification of irritants a variety of causes may be named, exposure to cold, foreign bodies, hot air or steam, irritating chemical gases, ptomaines, etc., sudden changes in temperature, excessive humidity, rapid changes in atmospheric pressure (caisson disease). The disturbance in circulation and secretion through these causes, produces an inflammatory condition, lessening the resistance to exciting agents. This is true of nearly all irritants. Organic changes in the lungs, liver, and kidneys; intestinal irritation with circulatory disturbances; rheumatism, gout; and allied conditions may be either predisposing factors or actual causes of inflammatory states. Age also has an influence, as in the adult the power of resistance is greatest, while in the young or the aged it is much lessened.

A catarrhal stage is always present in inflammation of the mucous membranes.

In the first stage of inflammation the surface is dry, and usually covered with a thin layer of tenacious mucus. This results from the engorgement of the submucous vessels obstructing the glands. Edema soon follows, caused by exu-

dation in the submucosa, and the tissues become swollen, presenting a more or less dusky red color.

Infiltration of serum and leukocytes into the submucosa soon occurs after the engorgement of the vessels. Interruption of nutrition to the epithelium causes this structure to become cloudy and swollen, desquamation following. There is huskiness of the voice, or even inability to articulate above a whisper, as a result of the congestion of the submucous vessels. Nasal respiration is more or less impeded through engorgement of the erectile tissue, the voice having the characteristic "nasal twang."

The primary stage is generally of short duration, as an excessive amount of secretion soon appears. Rapid desquamation of the epithelial cells ensues and the surface is covered with exudation consisting of degenerated cells, leukocytes, serum, and depending upon the cause and severity of the lesion, fibrin, and albumin. This exudative stage and also by the action of the lymphatics, usually diminishes the infiltration in the submucosa, and if the primary cause is removed, a normal circulation soon returns. Restoration of the epithelial layer results from the genetic layer.

Ulceration is infrequent in this type of inflammation as the basement membrane is seldom affected. If it does, it is usually due to arterial thrombosis which causes localized superficial death by coagulation- and liquefaction-necrosis.

Chronic Catarrhal Inflammation.—This is often the result of neglected or repeated acute attacks. In many cases these acute attacks may be local manifestations of a constitutional disease, as syphilis, the impaired circulation of chronic heart disease, Bright's disease, rheumatism, gout, or so-called "malaria." Persistent local irritation may also be a cause. Organization of inflammatory exudate in the submucosa with proliferation of the fixed connective tissue cells will impair the nutritive functional activity of the mucous glands, producing the hypertrophic type of lesion. Contraction

tion of this adventitious tissue will lessen the blood supply to the epithelial layer and impair the function of the membrane.

As contraction continues the lumen of the nasal passages is increased, and an apparent hypertrophy results in atrophy, or as usually called "dry catarrh," as the secretion is much diminished. If the secretion is dry and tenacious, rendering removal difficult, decomposition often takes place and a marked fetor results; as in ozena.

Membranous Inflammations.—Pathologically this type may be divided into; (a) *croupous* or *pseudomembranous* inflammation, the lowest grade of membranous exudate, consisting of a highly coagulable albuminoid material forming on the surface of the mucous membrane, without ulcerating or organizing. This may result from irritants as chlorine, ammonia, or escharotics, which do not devitalize the basement membrane. It may be found in infectious fevers, pyemia, and kindred conditions.

(b) *Fibrinoplastic Inflammation* is that form where a plastic exudation exists, and the tendency is to organization in layers or masses. This type is seldom found except in the nares.

(c) *Diphtheritic Inflammation.*—This begins as a catarrhal inflammation, and is generally ascribed to the Klebs-Löffler bacillus, or bacillus diphtheria. There is death of the superficial epithelial elements, and changes in the deeper cells of the mucosa. Coagulation-necrosis, or hyaline transformation of the diseased cells is the secondary change, transforming nearly all the dead cellular elements into hyaline material. The foci of degeneration and death starting on the epithelial surfaces and penetrating the tissue is characteristic of diphtheria.

Removal of the membrane exposes a bleeding surface, due to ulceration or destruction of tissue, involving the basement membrane, or, as a result of interference of nutrition

in the submucosa, infective coagulation-necrosis or sloughing occurs. Fibrous tissue formation and contraction follows, and if healing takes place only a partial or else no reformation of epithelial surface results.

Hemorrhagic Inflammation.—This variety of inflammation seldom affects mucous membranes, but when it does it generally is in virulently infectious conditions, as anthrax, pyemia, septicemia, and diphtheria. It has also been known to follow the application of a counter-irritant, as carbolic acid. The inflammation of the mucous surface in this type is rapid and there is interstitial hemorrhage. There is obstruction of the capillaries supplying the area, and blood may ooze onto the surface of the epithelium. Gangrene is liable to occur if the area is small. In hemorrhagic inflammation there is destruction of tissue with resulting cicatrization, while in simple purpuric interstitial hemorrhage, absorption occurs without destruction of mucous membrane.

Gangrenous Inflammation.—Most frequently seen in debilitated children following an acute infectious disease, usually measles. Burns, scalds, or trauma of the mucous surface may also cause this type of inflammation. An embolus depriving a limited area of its blood supply may be a factor. Toxic doses of mercury, arsenic, or antimony may prove exciting causes. Diphtheria is a common cause. No matter what the cause of this form of inflammation, there is a cutting off of the blood supply to the part, and coagulation-necrosis and gangrene is the result. The tissue breaks down through infection, whether primary, secondary, or multiple. As more or less involvement of the submucosa is present, the lymphatics are distended and absorption of toxic material results, eventually producing a general septic condition. Hemorrhage, as a result of the breaking down and infection of the thrombi, may result. Enlargement or suppuration of adjacent lymphatic glands may oc-

cur, or septicemia result from general infection of the blood supply. Gangrenous inflammation is frequent in the tonsils, mouth, and pharynx, but infrequent in the nose.

Suppurative and Pustular Inflammation.—This may be seen during septicemia, pyemia, chicken-pox, small-pox, or erysipelas of the mucous membrane, but seldom in other infectious diseases. In diphtheria, mixed infection may produce pus in the submucosa. Infection of the submucosa may follow an abrasion or destruction of the epithelial surface. The pouring out of infected material into the submucosa produces distension and pus formation. Suppurative tonsillitis is a familiar type of this condition. Pus, now conceded as a product of connective tissue, forms in the submucosa, and escapes by rupturing the basement membrane by a gangrenous or ulcerative process. Dissemination of the material by the lymphatics may occur, when a gangrenous type of inflammation will result.

SPECIFIC INFLAMMATIONS.

Synonyms.—Chronic infectious inflammations: Specific granulomata; Chronic specific inflammatory processes; Infectious granulomata.

There are six varieties of specific inflammatory processes: (1) syphilis; (2) tuberculosis; (3) actinomycosis; (4) glanders; (5) leprosy; (6) rhino-scleroma.

(1) *SYPHILIS.*—Usually the initial lesion of syphilis is the mucous membrane. At the point of infection infiltration of the mucosa with small, round epithelioid and giant cells occurs. Through obliterative changes in the arteries, the superficial blood supply is destroyed, causing ulceration. The tongue, gums, cheeks, tonsils, palate, or pharynx may show these diseased spots. In the tertiary stage gummata may develop, and pass through the same ulcerative process in the mucosa as any of the infectious granuloma. The

amount of fibrous tissue developed in the healing process produces considerable contraction.

(2) TUBERCULOSIS.—Primary tuberculosis of the upper respiratory passages may occur, but usually it is secondary to pulmonary lesions. The tubercle bacillus is considered the cause of tuberculosis, and by gaining an entrance to some portion of the mucous membrane, miliary tubercles develop around the vessels of the submucosa. The morbid process extending from these points, necrosis and ulceration of the tissues follow. Through the ulcer thus formed, the tubercular caseous material is exuded. New fibrous material may form around the ulceration, which in contracting will cause stenosis.

(3) ACTINOMYCOSIS.—This is a common lesion in the mouth, caused usually by an abrasion of the mucous surface affording a nidus for the ray fungus, or actinomyces. Generally introduced into the system with the food. The developed granulation tumor is similar in structure to tubercule. The surrounding zone of proliferating tissue generally resembles sarcoma. Suppuration through mixed infection results. The presence of the ray fungus in the secretion or tissue determines the disease.

(4) GLANDERS.—The *Bacillus Mallei* is the factor in this disease, which makes its appearance usually in the form of ulcers in the nose. The ulcerative process is similar to the forms of inflammation already described. When acute, gangrenous and septic conditions may result. When chronic, the ulcers do not differ in appearance from those of tubercular, syphilitic, or of long-continued catarrhal conditions.

A differential diagnosis is made by the presence or absence of the bacillus mallei in the discharge. It may be mistaken for sarcoma.

(5) LEPROSY.—Infrequently seen in the upper respiratory tract, but may attack the nose or larynx. Generally of

the tubercular variety. Ulceration does not always occur. *Bacillus Lepræ* is the cause of this disease.

(6) RHINOSCLEROMA.—This infrequent inflammatory type is characterized by a thickening and tumefaction of the nasal mucous membrane. The larynx may be the point of attack. The microscopic appearance seems allied to the round-celled sarcoma, but small, highly refracting hyaline bodies are present which are a characteristic element of the growth. The areas of tumefaction present first a pink or red color and are quite sensitive. Later the tissue becomes white. Seldom seen in this country. The cause of the disease is obscure. The condition is chronic.

NASAL BACTERIA.

The question of whether the majority of bacteria are primary or secondary to nasal lesions, is a disputed point. When through faulty anatomical formation of the nasal cavities, there is a condition present which favors the accumulation of dust or secretion; lowered vitality, with the consequent lessened power of resistance through systemic diseases or organic lesions; and the changed character of the secretion, forms a better culture medium for these germs, is still a question for the future to decide. Some claim the normal nasal secretions are inimical to the life of these organisms. What constitutes a normal nasal mucous membrane? Normal functional activity may be present, but through faulty anatomical construction, this normal secretion may accumulate in one or both nasal passages, forming an obstruction which will retain dust and other irritating material, causing local changes in the tissue, perverting the secretion of the area, and forming good culture media for the bacteria which are constantly inhaled.

The normal secretions do not form a suitable media for the cultivation of these organisms, and although they are generally, if not always, present in the secretions, they do

not multiply rapidly and are not considered of any special pathogenomic importance. The bacteria found may be the so-called pathogenetic variety, but non-virulent, and as long as the mucous membrane retains its normal characteristics, they are practically benign. The vocation and environment of a person has a marked influence on the kind of micro-organisms found.

Among many of the most conservative investigators these bacteria are believed to be secondary to the disease, infection of the mucous membrane being brought about by external or internal irritants which have lowered the vitality of the individual epithelial cells. Varieties of blastomycetes are also present and may be factors of irritation, without being in themselves pathogenic.

In rhinitis when there is an accumulation of secretion, which is difficult to dislodge, there will be found such a variety of bacteria that no special variety can be designated as an etiological factor. The bacteria of decomposition are always present, saprophytic bacteria. The products of these scavengers are being constantly absorbed by the mucous membranes, and often may account for some of the symptoms observable as regards the general health in advanced stages of rhinitis. The unconscious swallowing of the infected secretions of the naso-pharynx and pharynx during sleep often causes gastric lesions, diseases of the upper respiratory tract and the stomach being frequently associated. Neither of these lesions in all probability would have developed had the epithelial structures been in a normal condition.

The bacteria found on the mucous membrane of the nose and in the secretion includes many pathogenic cocci and bacilli, as well as numerous unclassified non-pathogenic germs. Staphylococci, or micrococci, are most generally found, especially staphylococcus pyogenes aureus, citreus, and albus. Micrococcus pneumoniae (Fränkel). Bacillus

tuberculosis, Friedländer's pneumococcus, Klebs-Löffler bacillus, Von Hoffman's bacillus (bacillus of pseudodiphtheria), Bacillus foetidus, Loewenberg's ozena diplococcus and different forms of sarcina. Any of these may be found at times, even when not associated with inflammatory conditions, and are nonvirulent, as shown by the escape of the individual from any illness.

CHAPTER V.

ANOMALIES AND THE RELATION OF GENERAL DISEASES TO THE UPPER RESPIRATORY TRACT AND EARS.

ANOMALIES OF THE UPPER RESPIRATORY TRACT.

Nose.—Absence of.—As a congenital condition this is rare. Maisonneuve reports a case where a plane surface, perforated by two small openings, occupied the site of the usual nose. Exaggeration of size is not infrequent, the most noted of which we have a record, being a nose seven and one-half inches long.

Congenital Division of the Nose.—A few cases have been recorded of double noses.

Congenital occlusion of the anterior nares, as well as of the posterior nares have been reported. A central depression of the tip of the nose is sometimes seen, and is analogous to hair lip.

Of the palate, fissures, which may be unilateral, bilateral, median, etc., are usually associated with hair lip.

Uvula.—The uvula may be bifid, double, and is sometimes absent.

Epiglottis.—A few cases are recorded of absence of the epiglottis, and one case of bifurcated epiglottis is reported. Duplication of the epiglottis is reported in several cases.

Congenital web of the vocal cords has been found in a few cases.

General Symptomatology.

Not only a thorough knowledge of special manifestations and general diseases is necessary in studying special branches of medicine, but plenty of good sense and judgment are requisites, for without the latter qualifications irreparable damage may result from bigoted views regarding local symptoms or abnormal conditions. It is always better to discover that a seemingly local manifestation is reflex before resorting to heroic measures, than to find later that what has been done is not only useless, but positively harmful. Fads in operative work should have no place in treating diseases of the ear, nose, or throat, and the tendency now is to conservatism in this line of work. Systemic treatment is being more and more insisted upon and less reliance placed on local measures only. The fact that the use of sprays, etc., are only of value for cleansing purposes and are of no value as curative agents, marks an advance in treating these parts, that is satisfactory to both physician and patient.

Disturbances of the upper respiratory tract and often of the ears, are frequently seen as a result of constitutional lesions, so a brief résumé may be helpful. Chronic pulmonary diseases are sooner or later followed by chronic laryngeal and pharyngeal lesions. Croupous pneumonia is frequently followed by laryngeal complications, and in some instances even ulceration of the cords. Paralysis of the larynx is a not infrequent complication of diseases of the lungs and pleura, through the recurrent laryngeal nerve. Mediastinal tumors most frequently affect the left inferior laryngeal nerve. In enlargement of the thyroid, paralysis of the vocal cords may result, depending more upon the position of the hypertrophy than its size. Circulatory disturbances often affect the upper respiratory tract, producing hemorrhages, hyperemia or congestive conditions. Edema

of the larynx is not infrequent in cardiac lesions which produce general edema. Paralysis also occurs in cardiac disease. Aneurysm of the aorta may produce laryngeal complications.

THE DIGESTIVE TRACT.—Caries of the teeth may produce antral disease and also rhinitis. Intestinal irritation and cirrhosis of the liver often are accompanied by nasal and pharyngeal symptoms. Gout and rheumatism affect the pharynx and larynx. The symptoms may precede the attack, be coincident with it, follow, or especially the rheumatic type, may be the only manifestation of the disease. It is often difficult to make a diagnosis by the appearance of the tissues alone, but the character of the symptoms complained of should usually lead to a correct diagnosis.

In acute and chronic infectious diseases, the implication of the upper air passages is so frequently seen and looked for, that they will not be considered excepting under the proper headings.

KIDNEY DISEASES.—Edema, hemorrhage, and general nutritive changes in the mucous membrane, are the usual complications. Edema of the uvula, posterior pillars of the fauces and lateral pharyngeal walls is most frequent. It is quite constant in the ary-epiglottic folds, and may be unilateral or bilateral. The edema is passive, resulting from venous stasis. An apparent laryngeal stenosis may occur in uremic conditions, but may be recognized by the fact that it appears periodically in persons with normal respiration. Hemorrhages in chronic interstitial nephritis are of frequent occurrence, and may occur in the nose as well as in the larynx.

SEXUAL CONDITIONS.—Turgescence of the erectile tissue of the nose occurs during sexual excitement, and at the period of puberty. The same condition, more or less marked, often occurs in the female at the menopause, during menstruation and pregnancy. In diseases of the repro-

ductive organs, the vascular system is usually the medium through which the phenomena are manifested, there may be hyperemia, swelling, exudation or hemorrhages in the mucous membrane. According to Fliess, certain points on the anterior extremity of the middle and inferior turbinates and the septal tubercle are genital areas, and a beneficial influence over morbid conditions in the female can be exerted by treating these areas. It is claimed that cocainizing the genital areas will relieve the pains of menstruation; minimize labor pains, and that cauterizing these areas will cure dysmenorrhea. The "change of voice," especially in boys, which occurs at puberty is well known. Congestion of the mucous membrane is frequent and the voice "tires" easily. Similar conditions occur during menstruation, pregnancy, and some uterine affections. The change in the character of the voice at puberty is the result of the physiological change in the increased size of the larynx.

Paresthesia and *hyperesthesia* as a result of sexual influences manifest themselves by dryness of the throat, a sensation as of a foreign body or desire to cough. This may result from hyperemia, but is more probably induced by the irritable condition of the nervous system at these times.

Syphilitic phenomena are common, and will be described in full under their appropriate headings.

NERVOUS DISEASES.—In *tabes dorsalis* the olfactory nerve may be affected, and unilateral anosmia, parosmia, and olfactory hallucinations may exist. Laryngeal symptoms may be present, the most frequent being motor palsies of the laryngeal muscles. The typical palsy being of the crico-arytenoideus posticus, one or both sides may be affected. The symptoms in the various forms of paralysis may be very marked or so slight that they are not noticed by the examiner, unless a careful laryngoscopic examination of the patient is made, especially in unilateral paralysis of the

posticus. Complete paralysis of the recurrent nerve is infrequent in tabes dorsalis. Laryngeal palsies are frequently seen in the earlier stages of tabes dorsalis and occasionally are the earliest symptoms.

MULTIPLE SCLEROSIS.—Multiple cerebro-spinal sclerosis produces a number of motor disturbances of the larynx. One peculiarity of the tremulousness of the vocal cords is that it occurs only during phonation, thus differentiating from other diseases, when the tremulousness is seen in phonation and respiration.

The important symptoms in multiple sclerosis are: Retardation of muscular movements, and tremulousness of the cords. Fatigue of the muscles in speaking. Inability to sustain one tone for any length of time, as the irregularity of movement of the cords will produce high-pitched explosive sounds. Incomplete tension and adduction of the cords, giving a rough, hoarse quality of tone. Muscular palsies are infrequent, the adductors are more often affected than the abductors.

Medulla Oblongata.

SYRINGOMYELIA.—Either in the initial or later stages, motor disturbances of the larynx and diminished reflex irritability of the posterior pharyngeal wall may be found.

Neuroses.

PARALYSIS AGITANS.—Motor disturbances of the cords occur, which affect the quality of the voice and of speech. Twitching movements of the cords in phonation and usually in respiration are present. The epiglottis and uvula may also be tremulous.

EPILEPSY.—Göttstein gives as a constant accompaniment of the epileptic seizures, anesthesia of the laryngeal mucous membrane, which may persist for sometime after

the attack. Disagreeable olfactory sensations often constitute an epileptic aura.

HYSTERIA.—In this disease, the effects produced on the mucous membrane and functions of the upper air passages are about as varied as are the manifestations of the general symptoms.

CHAPTER VI.

DISEASES OF THE ANTERIOR NASAL CAVITIES.

ACUTE INFLAMMATORY DISEASES.

Acute Rhinitis.—(a) Simple acute rhinitis. (aa) In children. (aaa) Acute rhinitis in systemic diseases. (1) Measles. (2) Pertussis. (3) Scarlet fever. (4) Small-pox. (5) Typhoid fever. (6) Rheumatism. (7) Diabetes Mellitus. (8) Diphtheria. (9) Erysipelas. (10) Scorbutic Rhinitis. (11) Anemic Rhinitis. (12) Scrofulous Rhinitis. (13) Caseous Rhinitis. (14) Epidemic Influenza.

(b) *Membranous Rhinitis.*—(1) Croupous or Pseudo-membranous. (2) Fibrinoplastic. (3) Diphtheritic.

(c) *Occupation Rhinitis (Traumatic).* (d) *Hyperesthetic Rhinitis (Hay Fever)* See *Neuroses.* (e) *Ulcerative Rhinitis.* (f) *Edematous Rhinitis (Acute Edema).* (g) *Phlegmonous Rhinitis.*

SIMPLE ACUTE RHINITIS.

Synonyms.—Acute Coryza; Acute idiopathic rhinitis; Acute nasal blennorrhœa; Acute nasal catarrh; Acute rhinorrhœa; Catarrhal rhinitis; Cold, or cold in the head; Common sporadic catarrh; Rhinitis catarrhalis; Simple catarrh; Snuffles.

In temperate climates this is the commonest of all diseases.

Etiology.—Predisposing Causes.—The most prominent of predisposing causes is impaired vitality of the entire sys-

tem. This condition is found principally among those who are most of the time indoors, the rooms being overheated, or subjected to variable temperatures. Prolonged mental strain by enfeebling the nervous system will also prove an important factor. Abnormal development of the nasal cavities, as deflections of the septum or narrow cavities. Heredity may be a factor in predisposing to this disease.

Among chronic lesions which may have an influence, may be mentioned syphilis, rheumatism, tuberculosis, asthma, or hay fever. In women of a nervous constitution it sometimes is present at the menstrual period. Improper clothing may be a cause. That temperature and climatic conditions have an influence is certain, as this disease is much more frequent in those localities where extremes in temperature and moisture are common. Sexual excess is also a predisposing factor. In some instances the only explanation is an idiosyncrasy. In old age the disease is comparatively infrequent.

Exciting Causes.—Chilling of the body, either from exposure to draughts, damp or wet feet, or sitting in damp clothing. Going from either overheated rooms into cold rooms or from cold into overheated rooms, or excessive exercise may be factors. In many of the infectious diseases, as measles, scarlet fever, influenza, etc., it is nearly always present. It sometimes accompanies gastric, or intestinal irritation, or may follow a sudden cessation of the discharge in suppurating middle ear disease, or gonorrhoea. It may also be a result of laryngeal, pharyngeal, conjunctival, or accessory sinus inflammation, or be associated with eczema or impetigo.

At times it appears to be epidemic, through climatic conditions. Insufficient sleep is also a factor.

Occupation has a marked influence in many cases. Persons working in places where they are inhaling irritating dust or vapors, which includes persons handling irritating

drugs and chemicals, stone-cutters, cement workers, bronze workers, millers, weavers, and threshers. These forms of inflammation might be classed as traumatic or occupation rhinitis.

Tumors in the nasal cavities or the introduction of foreign bodies will also produce an acute rhinitis. The ingestion of some drugs will have an irritant effect on the mucous membrane as the iodides, arsenic, etc.

Pathology.—The pathology is practically that of a simple catarrhal inflammation. If the attack is the result of a cold, the temperature of the exposed surface is suddenly brought below normal. The irritation of the peripheral nerves of the portion of the body chilled causes, by transmission, a corresponding influence on the sympathetic, reaching the vasomotors of the nasal mucous membrane. The first result is contraction of the vessels, rapidly followed by dilatation. It is usually supposed that rhinal inflammation invariably begins on the superior surface of the middle turbinates, extending in all directions from these foci. The membrane is tumid, dark red in color and the vessels injected. In the initial stage there is little or no secretion, the surface being dry or covered with a thin coating of tenacious mucus. When dilatation of the vessels occurs through vasomotor paresis, there is an exudate of serum into the submucous tissue, migration of white cells and more or less escape of red corpuscles. At the same time there is an exudation of an irritating, saline-laden, clear limpid serum on the surface. The epithelial cells being more or less deprived of their nutrition, become cloudy, swollen, die, and are carried off with the secretions. This material and the leukocytes mixing with the mucus and serum soon forms a profuse, cloudy, thick, more or less puriform secretion depending upon the proportion of the cellular elements. If the inflammation is very severe, there may be small ecchymoses, or even minute abrasions or erosions.

When there are no complications, the vessels gradually resume their tonicity, absorption of extravasated elements occurs, the exudation upon the surface diminishes, thickens, and eventually ceases, new epithelial cells are developed from the genetic layer, and the tissues resume their normal functions.

If the disease is the result of direct irritation by mechanical or chemical irritants, the glandular elements are probably affected first, and, becoming engorged, act as foci for the pathological process.

Symptoms.—The attack is usually sudden, and often is preceded by a feeling of general lassitude and discomfort. There may be an initial chill, especially when the attack is severe. A tingling or tickling sensation in the nose appears early in the attack, and generally causes more or less sneezing. Often there is a dry, burning, or full feeling in the nose or head; a cold sensation in the region of the frontal cells; dull, throbbing frontal or occipital headache; coldness or stiffness of the back of the neck; malaise; burning of the eyes, and fever. In a short time the sensation of stuffiness in the nose becomes aggravated, and the nasal respiration is obstructed. Impairment of the senses of smell and taste, and often, through implication of the Eustachian tubes, of hearing, is noticed. A “nasal twang” is imparted to the voice through the nasal obstruction. There may be considerable disturbance of the general system, but this is the exception.

Inspection of the anterior nares in the first stage reveals a swollen, dry, or glazed mucous membrane, varying in color from a slight to a dark red, depending upon the severity of the attack. The nasal cavity may be occluded by the turgescence of the tissues. As the disease progresses the skin becomes dry and hot; thirst, anorexia and a furred tongue may follow. The nasal secretions may remain clear, or become puriform, and are often very irritating or exco-

riating. The alæ of the nose and upper lip are swollen, reddened, or excoriated. The eyelids become swollen and there is increased lacrimation, and occasionally photophobia. As the severity of the symptoms subsides, there is a tendency for the secretion to fill the respiratory portion of the nasal cavities, leaving the upper spaces clear. The secretion becomes thicker and more opaque during the progress of the second stage. Constipation and high colored urine usually follows in severe cases.

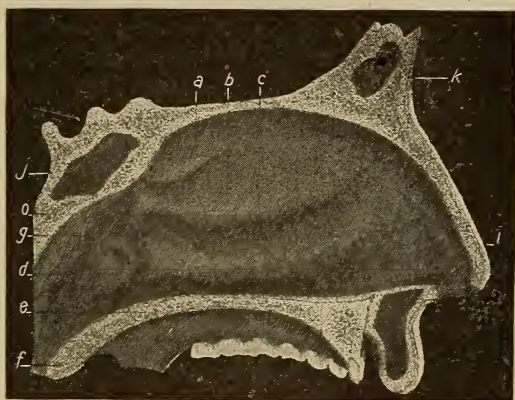


FIG. 58. Normal left nasal cavity. (a) Superior turbinate; (b) middle turbinate; (c) inferior turbinate; (d) Eustachian opening; (e) velum; (f) uvula; (g) post-nasal space; (i) vestibule; (j) sphenoid sinus; (k) frontal sinus; (o) Rosenmüller's fossa.

Inspection during the second stage reveals the tissues swollen, deep red and bathed with the mucus or mucopurulent secretion. The second stage gradually merges into the third or last stage, the symptoms disappear and there is restoration of the tissues to approximately their normal state, if recovery is the termination. The attack, if allowed to pursue its course, lasts for a week or ten days.

The acute rhinitis due to irritants, etc., usually runs a

shorter course, and is devoid of the constitutional disturbances, removal of the exciting cause usually resulting in a speedy cure.

Course.—The length of time required to effect a cure will depend upon the severity of the attack and the time that has elapsed between the initial stage and the time the case is seen. When seen early the disease can usually be aborted,

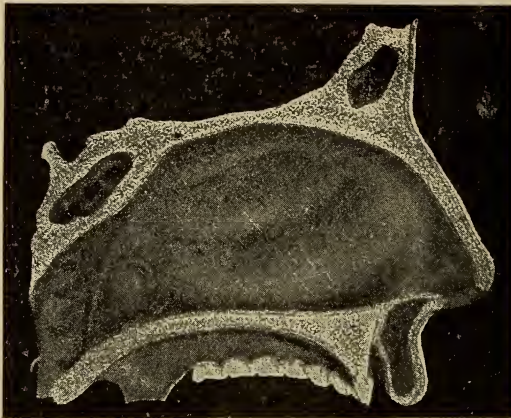


FIG. 59. Appearance of nasal cavity in an acute rhinitis.

but if in the second stage, more time will be required to effect a cure.

Diagnosis.—Generally not difficult, but care should be exercised, as an acute rhinitis is often a symptom of more severe systemic disorders.

Prognosis.—Generally favorable in uncomplicated cases. In the aged, or in debilitated subjects, the liability of complications must be remembered. A chronic condition may result, especially in those who are subject to repeated attacks.

Complications.—These, as a rule, are not serious, but

implication of the accessory cavities, nasal ducts, or Eustachian tubes, or extension of the morbid process to the pharynx and larynx, may cause some chronic lesion.

Treatment.—For controlling the morbid condition, the employment of constitutional remedies will give far better results than local measures. The use of cocaine, or the suprarenal derivatives, while in many instances affording temporary relief, will in the reaction, produce not only more engorgement of the tissues, but also in many cases permanent relaxation. The danger of inducing the cocaine habit must also be remembered, and if used, the patient should be kept in ignorance of the drug employed. In my experience better results are obtained by systemic medication. For relief of the sneezing, stearate of zinc with europhin has sometimes been a useful local application. The employment of various medicaments in oily solutions has been disappointing, excepting for temporarily lubricating the tissues.

If the patient is seen in the early stages, especially when the weather is warm and depressing, aconite and gelsemium. An acrid, watery secretion with erysipelatous redness of the alæ and tip of the nose, and chilly sensations, belladonna. With a thin watery secretion, non-excoriating, dist. hamamelis. If the discharge is thin, watery, and excoriating, liquor potassii arsenitis. The discharge moderately profuse and thick, hydrastis. If the secretion is tough, tenacious, and stringy, potassium bichromate. When the nasal passages are alternately open and closed, especially if the pharyngeal structures appear relaxed, nux vomica. In those cases where there is pain passing from the throat to the ear on swallowing, bryonia. When the pharyngei muscles have a bruised feeling, cimicifuga. With a tendency to soreness of the tonsils, or glandular enlargement, phytoacca. With a thick, yellowish-green secretion, pulsatilla is recommended, but have been disappointed in its use, unless

there was the typical apprehensive condition present. With a sensation of stuffiness at the root of the nose, with a more or less constant desire to blow the nose, and little or no secretion present, sticta.

ACUTE RHINITIS IN CHILDREN.—This does not materially differ from the same condition in the adult, only as the development of the nasal structure modifies the type. The inability in the very young to nurse freely, on account of nasal obstruction, renders the case more distressing. It is of the utmost importance in these cases to differentiate between an acute rhinitis and that of hereditary syphilis.

Another differentiation must be made between acute simple rhinitis and the purulent form resulting from infection in the parturient canal.

Treatment.—This does not vary materially from that already described, excepting local cleansing is required so the child may breathe more freely. The nasal cavities may often be cleansed by the use of small rolls of blotting paper, or twisting absorbent cotton into a tight roll, which will remove the secretion quite thoroughly. The use of the nasal syringe may be beneficial in these cases and is usually well tolerated. On account of the sensitiveness of the mucous surfaces, the utmost care must be exercised to avoid injury to the membrane. Complications are more infrequent than in adults, but they may be the same.

SIMPLE ACUTE RHINITIS IN SOME OF THE CONSTITUTIONAL DISEASES.

Simple acute rhinitis is of more or less clinical importance in a number of diseases.

Measles.—Acute coryza is one of the prominent symptoms in the initial stage. Associated with this will be injection of the conjunctiva, excessive lachrimation, photophobia, and the characteristic cough. It is claimed that at times, following a severe coryza, ulceration of the septum occurs.

DIFFERENTIAL DIAGNOSIS.

SIMPLE ACUTE RHINITIS.	SYPHILITIC RHINITIS.
No specific disease of parents.	Specific disease of one or both parents.
Normal development.	Imperfect development; shrivelled, senile appearance.
Normal skin.	Abnormal skin; hue sallow; rash present.
No systemic lesions.	Specific lesions, condylomata, mucous patches, copper colored blotches, onychia, osseous enlargements, alopecia, or lusterless brittle hair, lips ulcerated, rhagades, and infrequently subcutaneous hemorrhages.
Normal.	Liver and spleen enlarged.
Normal.	Child seldom smiles; a peculiar plaintive feeble voice and cry.
Normal Nutrition.	Impaired nutrition during nasal attacks.
Occasionally swelling of maxillary glands, and painful.	Enlargement of cervical, cervico-maxillary, axillary and inguinal glands, painless.
Fever more or less marked.	Fever absent.
No flattening of nose. Ulceration absent.	Disposition to ulceration of membranes and cartilages. Flattening of nose.
Discharge not offensive, seldom streaked with blood, and never truly purulent.	Discharge offensive, often streaked with blood and purulent with necrotic tissue intermingled.
No formation of crusts.	Formation of crusts, which when detached leave a bleeding surface.
Fissures and ulcers of alæ absent.	Fissures and ulcers of alæ present.

Pertussis (Whooping-cough).—Catarrhal inflammation of all the exposed mucous surfaces is found as an initial symptom of this disease, the patient presenting all the symptoms of having contracted a severe cold. The associated symptoms may make it difficult to differentiate from measles, until a few days have elapsed.

Scarlet Fever.—Excepting in very mild cases, there is an acute catarrhal inflammation of the nasal mucous membranes, the discharge being thin, acrid, watery, or corpuscular.

Variola (Small-pox).—Decided involvement of the nasal mucous tissues, and pronounced coryza with associated eye complications, as in measles, are present.

Typhoid Fever (Enteric Fever).—Congestion of the nasal tissues is frequent during the course of the disease. Epistaxis may be an early symptom. Unless there is necrosis of the cartilage coryza is infrequent.

RHEUMATISM.—*Acute Articular*.—In articular rheumatism an acute rhinitis often accompanies the commencement of the attack, probably the result of the excess of uric acid, which irritates the mucous membrane which is a factor in the process of elimination.

Diabetes Mellitus.—Kyle reports two cases of acute coryza apparently dependent upon the constitutional condition, the severity of the attacks being apparently controlled by the amount of sugar in the urine.

Epidemic Influenza (La Grippe).—A typical coryza is present in the thoracic form of influenza accompanied by a severe paroxysmal cough.

Diphtheria.—Acute simple rhinitis is very frequent in this disease. It may be the initial stage of invasion of the disease from the pharynx, or it may result from primary infection of the nasal cavities. Membrane is not always formed in the nasal fossæ, a catarrhal process being maintained.

Erysipelas.—Acute rhinitis sometimes accompanies primary erysipalalous infection of the nasal cavities. The inflammation is severe, the tissues much swollen, and there is a decided tendency to extension to the nasal duct and cutaneous surfaces.

Scorbutic Rhinitis.—In infantile scurvy, there is often inflammation of the nasal tissues and excoriation about the nasal openings.

Anemic Rhinitis.—This is a non-inflammatory state of the nasal tissues, in which there is engorgement of the submucosa vessels and a clear exudate. Symptoms of an acute rhinitis are absent. Age is not a factor.

Etiology.—The mucous membrane of all the functioning organs present practically the same condition in anemic persons. Local irritation is absent, but with the general malnutrition and muscular relaxation, there is also a relaxed condition of the vessels of the submucosa with the consequent escape of fluid. This effusion is not from the arterioles only, but on account of the lack of tonicity of the vessels and walls, the circulation is impeded, and more or less venous stasis results. This is true of the mucous membrane of the kidneys and alimentary canal in anemia.

Pathology.—The surface of the nasal mucous membrane is pale, watery, and at the junction with the skin, a drawn or puckered appearance is noted. The vessels lacking the support of muscular tissue, readily fill with blood, but as the submucosa is relaxed through lack of nutrition, there is a decided tendency to both venous and arterial stasis. Exudation into the tissue follows, and as the nutrition is impaired and there is absorption of the exudate by the epithelial cells, destruction through hydropic degeneration follows.

Symptoms.—The general systemic line of symptoms are present. The nasal tissues are covered with a thin secretion, which may be irritating. It is seldom there is any tendency for the secretion to dry or form crusts on the mucous

surface, and there is no odor. The interference to normal respiration is usually not excessive, but in one case under treatment the relaxation was so marked that the inferior turbinal tissues moved backward and forward with each respiratory effort, and the noise, which might be called moist, could be distinctly heard in an adjoining room. The discharge is continuous, compelling the patient to use a handkerchief incessantly. The nasopharyngeal and pharyngeal mucosa may also present the anemic condition, but to a lesser degree, as in these regions the erectile tissue is scanty or lacking.

Treatment.—Local treatment alone is of little value. The application of an ointment of salicylic acid on a pledget of cotton, allowing it to remain in contact with the relaxed tissue an hour, if possible, will often markedly relieve the edematous condition. This application should not be made on the same side oftener than every three or four days, as it may produce considerable discomfort or soreness. The salicylic acid wash, as a cleansing agent, and also to aid in removing the infiltrated fluid, has given the best results in my experience. This should be used twice a day. If an atomizer is preferred, the solution should be diluted with water, using equal parts of each, but the solution should always be warmed. In constitutional treatment, the remedies given under acute rhinitis will usually be indicated, but the cause of the disease must be determined and treated to get results. If faulty heart action is partly responsible, cratægus has given good results in several cases. The causative factor must be found and relieved.

Scrofulous Rhinitis.

Synonyms.—Tubercular rhinitis; strumous rhinitis; scrofulous ozena.

Tubercular rhinitis is a term often used for this form of nasal disease.

Etiology.—This is a local manifestation of a systemic condition, and is found most frequently in ill-nourished children with an inherited predisposition to tuberculosis. It is usually accredited as being one of the initial stages of tuberculosis, or it may be secondary to tubercular disease of some other portion of the body. An ulcerative process with a scab formation in a person afflicted with pulmonary tuberculosis renders them more liable to rhinitis.

Pathology.—Two forms of the process are found. In the first type there is a tubercular infiltration which produces a well defined tumor, most frequently on the inferior turbinates, the nasal floor, and occasionally on the septum. The second type is an ulcerative process attacking the anterior portion of the septum, nasal floor, or the turbinal tissues.

In the first form round cell infiltration and giant cell formation occur. The surface of the tumor may be lobulated and papillomatous in appearance. In the second form the ulcer is usually shallow, edges irregular, and with no zone of inflammatory swelling. The secretion is white or yellowish in color, and tubercular bacilli are sometimes present. Necrosis of the turbinal bones may occur if the ulcerative process involves the turbinates.

In these cases there is a sluggish lymphatic and circulatory condition. The glands retain much of the detritus which should be eliminated, and frequently produces an ulcerative process in the adjacent structures. The ulcerative process is generally indolent in character.

Diagnosis.—Usually there is enlargement of the cervical, submaxillary and sublingual glands, or there may be scars of a previous lymphadenitis, the characteristic anemia, pinched expression of the face, excoriation of the orifices of the nostrils, and tendency to crust formation in the nasal fossæ.

If any odor is present it usually is offensive.

Pain is infrequent unless the deeper structures or accessory sinuses are affected. When crusts form it usually is on account of the rapid evaporation of the watery elements of the secretion. When perforation of the septum occurs it generally is multiple, thus differing from syphilitic perforation.

Implication of the pharynx, soft palate, larynx, and ears may follow, and more or less destruction of tissue in these regions results.

Prognosis.—Always guarded. In favorable cases and where seen early, very good results may be obtained, but in the later stages it is always unfavorable. In children as they approach the age of puberty, the most annoying symptoms subside or disappear as a rule.

Treatment.—Constitutional measures are the most important, although local treatment for the purpose of cleanliness is necessary. The following will be found especially useful: ℞—Acid salicylic (Lloyd's), ʒss; sodii boras, ʒiiss; Lloyd's hydrastis, f.ʒj; aqua, q. s. f.ʒiv. Mix. Sig. A teaspoonful in sufficient warm water to fill a nasal syringe twice. In some instances a stronger alkaline solution is necessary, as: ℞—Sodii boras, sodii bicarbonas, sodii chloras, aa. ʒij; aqua, ʒxvj. This is to be used full strength, but must be warmed.

Constitutional Treatment.—When there is a tough, stringy, tenacious secretion, or with a crust formation, which when dislodged is streaked with blood, potassium bichromate. When the secretion is thick and yellow, but not purulent, arsenic iodide. If a passive epistaxis occurs, carboveg. or dist. hamamelis. With a distinctly purulent secretion, lime in some form. A moderately profuse and moderately thick secretion, hydrastis. With a tendency to ulceration of the bony or cartilaginous structures, the patient having light hair, eyes and complexion, gold and sodium chloride. Phytolacca is nearly always required in these

cases on account of glandular enlargement, and lime also is indicated even without ulcerative processes.

Hygienic measures are of the utmost importance. Plenty of outdoor exercise, not carried to the point of fatigue, however. Nutritious food, properly ventilated sleeping rooms and freedom from both mechanical and chemical irritants. The excretory functions should be kept in as nearly a normal condition as possible.

Caseous Rhinitis.

Synonyms.—Coryza caseosa; cholesteatomatous rhinitis; rhinitis caseosa.

This disease is infrequently seen, and does not seem to implicate the mucosa, but rather is the result of some associated condition. There is an accumulation of a cheesy, gelatinous substance in the nasal fossæ, which may be so abundant as to produce displacement of the structures and facial deformity. The odor accompanying this disease is very fetid. The material is composed of cholesterine crystals, granular leukocytes, fatty cells and stearin. A tuberculous, or syphilitic, taint appears to favor the disease. In the report of one case, the cause was ascribed to degeneration of a myxomatous growth.

Treatment.—Removal of the material by curettement, cleansing with an alkaline solution, followed by the salicylic acid solution.

Epidemic Influenza.

Synonym.—La Grippe.

Coryza is usually very severe, and nearly always a painful, paroxysmal cough accompanies it. The systemic symptoms usually appear so early that a mistake in diagnosis is practically inexcusable. The effects of this disease on the mucous membrane of the upper respiratory tract and accessory sinuses, as well as the sequelæ, are important.

Pfeiffer's bacillus is now supposed to be the causative factor of this disease, but its method of attacking and penetrating tissues, is certainly erratic. Acute otitis media, which rapidly becomes a suppurative process is frequent, as well as acute mastoid disease. Either or both of these may be associated with or follow la grippe.

The frontal sinuses are usually affected in the early stages of the disease. The ethmoid cells are affected either early or during the most severe stage, and often becomes a chronic suppurative ethmoiditis, in which it differs from an ethmoiditis resulting from ordinary coryza, or that resulting from the infectious fevers. The antra of Highmore are the most frequently affected, suppuration rapidly occurring.

Tonsillar and peritonsillar inflammation is frequent, and usually ends in suppuration.

The effects of epidemic influenza on the mucous membrane are variable, and seemingly not in proportion to the severity of the attack. A mild attack may cause a persistent irritated and thickened condition. The pain and discomfort during such an attack may be much more severe than the macroscopic appearances would indicate. Occasionally blood clots will form on the membrane of the upper respiratory tract, without a true hemorrhage, and the membrane will be sensitive, dry and painful, and with very little swelling. The removal of the clots will not be followed by bleeding, but in two or three hours there will be new clots. The usual location is in the pharynx and nasopharynx, although it may occur in the nares. The expectoration of blood-stained mucus will have, in conjunction with the disease depression, a decidedly depressing effect.

After the subsidence of the disease, there is often both a subjective and objective thickening of the mucous membrane. The tissue presents a tough and infiltrated appearance, and the entire mucous structure is usually affected.

Membranous Rhinitis.

This classification includes: (a) Croupous or pseudomembranous rhinitis; (b) fibrinoplastic rhinitis; (c) diphtheritic rhinitis—usually conceded to be due to the Klebs-Löffler bacillus.

Croupous or Pseudomembranous Rhinitis.

Synonyms.—Membranous rhinitis; primary pseudomembranous rhinitis.

An acute inflammation of the mucous membranes. Age offers no immunity, although it is neither so severe nor of as long duration in the adult as in children. The false membrane which forms upon the epithelial surface is albuminous in character, does not show a tendency to organize, nor are the deeper structures involved.

Etiology.—Croupous rhinitis in many cases is supposed to be due to irritation resulting from micro-organisms on the mucous surfaces, when there is diminished cell resistance; or as a result of subnormal resistance through systemic conditions. There is no one specific bacterial form which causes the disease. The streptococcus pyogenes is supposed to be the most frequent factor, but there may be associated with them other forms of staphylococci, and the attenuated form of diphtheria bacillus (Von Hoffman's bacillus). Croupous rhinitis has been observed following the use of the galvanocautery or other operations in the nasal cavities. Cases have also been reported as sequelæ of measles, tonsillitis and also in hereditary syphilis.

Poor hygienic conditions, or any cause which diminishes the resisting power of the mucous surfaces may be a factor.

Pathology.—Primarily the pathology is that of acute catarrhal rhinitis. Swollen, turgid, and congested mucosa, followed by an excessive exudate of serum and cellular ele-

ments upon the membrane. The secretion is mildly purulent, and excoriation of the nasal openings and upper lip occurs. The discharge is seldom fetid. When fully developed, the membrane will usually be found on the surface of the lower and middle turbinates and the anterior part of the septum. It may be slight, or involve the entire nasal cavity. Recurrence is usual upon removal of the membrane. In adults the membrane is thin and gelatinous, but tenacious and of a pearly tint. In children it is liable to be thicker and may be friable. The membrane is composed of a network of fibrin with leukocytes, red blood cells, desquamated epithelium, and bacteria.

Symptoms.—The initial stage is the same as in acute rhinitis. Mouth breathing soon follows as a result of occlusion of the nasal fossæ through swelling of the tissues. The dry stage is short, there soon being an excessive secretion, at first clear, but soon becoming opaque and thicker. Although the fever subsides, malaise continues. Frontal headache, more or less loss of smell, and neuralgia of the nasal nerve may occur. When the secretion thickens, shreds or small pieces of false membrane are formed, which generally is the first distinctive feature of the disease. Inspection of the nasal cavities will reveal the membrane, unless occlusion has resulted from excessive swelling of the tissues. In adults this condition lasts from eight to fourteen days, and in children from ten days to five weeks.

Diagnosis.—The shreds of membrane in the discharge, and the presence of membrane in the nasal cavities differentiate it from acute rhinitis. The table will give the differential diagnosis between croupous and diphtheritic rhinitis.

Prognosis.—Favorable, but the possibility of subsequent attacks must be remembered.

Treatment.—*Locally.*—The use of the alkaline solution, followed with the salicylic acid solution. If any of the membrane remains, it may be removed by the use of cotton

with the cotton carrier, but care must be used to avoid injuring the sensitive mucous membrane. The insufflation of the following powder will be found beneficial. ℞—Acid salicylic, gr. xx; Acid Boric ʒvj; used with a Devilbiss powder blower.

DIFFERENTIAL DIAGNOSIS.

CROUPOUS RHINITIS.	DIPHThERITIC RHINITIS.
Systemic symptoms not severe.	Systemic symptoms usually severe.
Sporadic.	Epidemic usually.
Primary. Membrane seldom extends beyond the nasal cavities.	Generally secondary, it may be by auto-infection or extension, faucial or pharyngeal false membrane preceding or accompanying the nasal membrane.
Albuminuria absent.	Albuminuria present.
Lymphatic glands not enlarged.	Cervical lymphatics enlarged.
Membrane brighter colored and pearly.	Membrane dirty or grayish white; rough.
Superficial.	Deeper layer of mucous membrane.
Easily removed.	Difficult to remove.
On removal no bleeding surface, possibly slight capillary oozing.	On removal bleeding more or less profuse.
Neither ulcer nor scar follows removal.	Ulceration and subsequent scar may follow removal.
Discharge slightly if at all fetid.	Discharge fetid.
May be found at any age.	Usually in children.
Paralysis of velum absent.	Paralysis of velum may be present.

Internal.—During the fever, aconite. Potassium bichromate will aid in preventing the formation of the membrane. If the disease is confined exclusively to the nasal cavities, potassium iodide or jaborandi. The bowels should

be moved with a saline cathartic, and for children the solution citrate of magnesia is usually preferable.

Fibrinoplastic Rhinitis.

The exudate is similar to that of the croupous form, but is more fibrinous, with a tendency to organization. The general health is not usually affected in this disease, although there is often a previous lowered vitality, the result of poor hygienic conditions. The disease is most frequent in youth.

Fibrinoplastic rhinitis commences similarly to any catarrhal inflammation, and is quickly followed by a coagulable, albuminoid fibrinous secretion. The pharynx and tonsils may be implicated through extension. The membrane may be fairly adherent to the mucous membrane, and if forcibly detached, leaves a bleeding surface. There have been no specific germs discovered in the exudate, except staphylococci. The disease is sporadic, neither infection nor contagion being found. The disease assumes a chronic type.

Treatment.—The alkaline wash followed by the salicylic acid solution. The advisability of forcibly removing the membrane will depend upon the condition of the nasal passages. If occluded, the membrane may be removed with forceps, but usually it is preferable not to do so. The insufflation of salicylic acid and boric acid often aids in causing detachment, and preventing the membrane reforming. The internal administration of potassium bichromate, phyto-lacca, or jaborandi will usually be indicated.

Diphtheritic Rhinitis.

Synonym.—Nasal diphtheria.

This is an acute inflammation of the nasal mucous membrane, and may be primary, but usually is secondary to pharyngeal diphtheria.

Occupation Rhinitis.

Synonym.—Traumatic rhinitis.

Etiology.—The acute inflammation of this form, may result from irritating vapors, as ammonia, bromine, iodine, chlorine, etc., or the inhalation of floating irritating material in the air, as found in flour mills, or among coal miners, wood carvers, weavers, hat makers, etc. Steam and smoke also come under the list of causes, but the nasal membranes are not affected as much as the pharyngeal. Foreign bodies or direct injury are often factors. The fumes of many volatile drugs will not only cause the condition, but will also prevent any especial relief, until the exciting cause is removed.

Pathology.—The morbid changes do not vary from those of simple acute rhinitis, unless the result of the irritating fumes of potassium bichromate, arsenious acid, or mercury, the effect being only local. Subsequent to the acute inflammation, local areas of degeneration may be found, which implicate the submucosa, forming ulcers, at first small and round, gradually becoming larger and oval. This generally occurs on the cartilaginous portion of the septum and sometimes causes perforation.

Symptoms.—The general symptoms are tickling sensations in the nose, followed by paroxysms of sneezing, accompanied or followed by a profuse secretion. This secretion is watery in character at first, but later assumes a greenish tinge, is thicker and more tenacious. When superficial necrosis begins, the secretion forms in crusts, and as the process goes on to ulceration, hemorrhage occurs. There is seldom any fetor. The upper and posterior portion of the cartilaginous septum is most frequently affected by the ulcerative process, although the turbinates may be ulcerated. The lower anterior portion of the cartilage is not affected, and falling in of the nose does not occur.

Prognosis.—Usually good if the exciting cause is removed. It is supposed that those who recover from this form of rhinitis are less likely to have catarrhal inflammation of the nasal tissues.

Treatment.—Removal of the cause is essential. If the patient's vocation is such that avoidance of the irritating material is impossible, the nasal tissues should be protected from the irritant, preferably by the use of a mask or inhaler, but the use of moistened plugs of cotton or wool may be used, changing them frequently, especially when exposed to acrid or acid fumes.

Locally the alkaline wash or salicylic acid wash. Internally when there is a tendency to ulceration, or if ulceration has commenced, the administration of potassium bichromate. Local cleanliness, however, is of the utmost importance.

Acute Edematous Rhinitis.

This is not to be mistaken for rhinitis edematosa or cyanotic rhinitis. The acute phenomena are the same as in edema of other regions. It is especially liable to occur in this region as there is no muscular support to the mucous membrane.

This form of rhinitis may result from any sudden change in the vascular tissue, which, becoming overdistended, a watery infiltration occurs of the connective tissue spaces of the submucosa connective tissue cells, and possibly of the surface epithelial cells. If this distention continues until nutrition is impaired, hydropic degeneration will result. Inflammatory processes follow instead of precede in this type. It may result from the inhalation of steam, very irritating vapors, injuries of the membrane, or of the bony cartilaginous or connective tissue of the nose.

Treatment.—If there is complete occlusion of the nasal cavities, it will usually be necessary to puncture the dependent portions. The use of pledgets of cotton saturated

with glycerine or covered with the salicylic acid ointment will usually afford prompt relief. Internally, apis or apocynum. The acute symptoms usually subside in one or two days without any treatment.

Phlegmonous Rhinitis.

This is either an acute abscess of the septum, or of the submucosa. The position and severity of the lesion is almost the only difference from a nasal furuncle.

Diagnosis.—A distinct circumscribed swelling on one or both sides of the septum. The appearance and course are similar to an acute abscess elsewhere. The disease differs from ordinary furunculosis in not usually appearing in crops. If possible to abort the suppurative process, it should be done, but on account of the location this is not often accomplished. An alcoholic saturated solution of boric acid or tr. iodine may be applied. Internally the administration of lime. After suppuration has occurred, a free incision should be made, and the cavity frequently cleansed with an alkaline wash. Empyema of the antrum of Highmore, or an alveolar abscess, the result of carious teeth may be present at the same time.

CHAPTER VII.

DISEASES OF THE ANTERIOR NASAL CAVITIES.

CHRONIC INFLAMMATORY DISEASES.

Chronic Rhinitis. (1) Simple Chronic Rhinitis; (2) Intumescent Rhinitis; (3) Hyperplastic Rhinitis; (4) Ozena as a Symptom; (5) Atrophic Rhinitis; (6) Purulent Rhinitis; (7) Nasal Hydrorrhea; (8) Edematous Rhinitis (Cyanotic); (9) Specific Inflammations (Granulomata); (a) Syphilis. (1) Acquired. (2) Congenital. (b) Tuberculosis; (c) Glanders; (d) Leprosy; (e) Actinomycosis; (f) Rhinoscleroma.

Simple Chronic Rhinitis.

Synonyms.—Catarrhus longus; simple chronic nasal catarrh; chronic rhinitis; chronic nasal catarrh; chronic coryza; chronic blennorrhœa; chronic rhinorrhœa; rhinitis chronica; rhinitis simplex; fluxus nasalis.

This is a chronic inflammatory action of the nasal mucous membrane, resulting from prolonged irritation or repeated attacks of the acute type, especially when neglected. It is intermediate between acute and commencing atrophic rhinitis.

Etiology.—Chronic rhinitis may be the result of repeated acute attacks, the continuation of a neglected severe attack, and occasionally no cause can be assigned. Debilitated conditions of the muscular or nervous systems are conducive to the development of this disease. Predisposing causes are the same as those producing acute rhinitis. The

disease is especially liable to follow the simple acute rhinitis which occurs in infectious diseases, or the acute rhinitis of the new-born. The disease is often seen between the ages of sixteen and thirty-five.

Pathology.—Relaxation of the membrane and erectile tissue. The characteristic appearance of atony of the vascular system will be present. The tissues being flabby and readily distended with blood. The contractile power of the vessels is more or less diminished. There is venous engorgement of the erectile tissue. The walls of the blood vessels become more permeable to the inclosed fluid and there is escape, especially of the white corpuscles of the blood, into the surrounding tissue. These elements proliferate and in connection with the proliferation of the fixed connective cells, new tissue of inflammatory origin is formed. The continuation of the chronic inflammatory stage after the newly formed tissue is organized, marks the intermediate stage, which eventually leads to atrophic rhinitis. This intermediate stage is frequently mistaken for hypertrophic rhinitis. There is more or less exudation on the surface, intermingled with migrated cells and degenerated epithelium. Glandular atrophy results from the pressure, both of vascular distention and increase of connective tissue.

Symptoms.—Usually the first symptoms are irritation of the nose, or increased nasal or postnasal discharge. Slight exposure will increase the secretion, and there will be a slight sense of discomfort in the nose. During the early stages the secretion is usually thin and watery; later it generally becomes thicker, more tenacious, mucopurulent or purulent. Occasionally there may form dry, greenish crusts, or thin strings of secretion extending across the nasal passages. If the crusts remain for any length of time, they may become infected, and emit an annoying odor. If the patient continually “picks the nose” to remove the crusts, the irritation produced may result in ulceration of the vestibular

and septal tissue with perforation. The discharge in the debilitated may be profuse, non-irritating, clear, and watery. An intermittent partial or complete occlusion of the nose may occur, but a "stuffy" sensation is nearly always present, with a dull heavy pain over the bridge or at the root of the nose; dull frontal headache, the result of closure of the infundibuli, and occasionally hebetude and indisposition to work will be present. The neuroses which often accompany this disease are itching or tickling in the nose; sneezing; spasmodic cough, usually dry; vomiting, or asthma. There is a slight "nasal twang" to the voice.

In the later stages the sense of smell is usually impaired. Disturbances of the digestive apparatus, probably due to swallowing the secretion, will often produce a general debility of the system. Attacks of acute rhinitis are frequent on slight exposure, especially in damp weather. Redness of the tip and alæ of the nose is often present in cases of long standing, and may be accompanied with more or less swelling of the tissues. Inspection of the nasal cavities will reveal a diffuse, more or less swollen membrane, especially on the middle and inferior turbinates and the septum, red, soft and cushion like, with some portions covered with secretion. Hyperesthetic areas are usually found.

Pressure with a probe will cause the tissue to pit easily, the indentation disappearing slowly. The application of a solution of cocaine, or preparations of the suprarenal gland will cause a contraction of the swollen tissues. These methods differentiate a chronic rhinitis from a hypertrophic, as in the latter the tissues do not pit readily, and the indentation quickly disappears, and with the constricting agents there is only a partial subsidence of the swollen tissue. In persons much debilitated, or the aged, the membranes may be pale, and bathed with a watery secretion. The secretion varies, but may be thin, thick, scanty, copious, bland, exoriating, white, discolored, or bloody. The disease is most

annoying in spring, autumn, and winter, but usually causes little annoyance in the summer, unless the vocation requires the patient to be exposed to irritating dust or vapors.

Diagnosis.—The history of the case, careful inspection, and palpation of the tissues with a probe, or the use of contractile agents.

Prognosis.—The occupation of the patient and hygienic surroundings will have much to do with the prognosis.

Complications.—There may be more or less loss of the sense of smell, and necessarily a corresponding loss of the sense of taste. Implication of the Eustachian tubes will cause aural complications. The accessory sinuses and lacrimal drainage system may be affected. Granulation tissue or polypi may also be unpleasant complications, and digestive disturbances are frequent.

Treatment.—Constitutional treatment is of the utmost importance in this as in the majority of catarrhal affections. In chronic rhinitis the cause of the disease and its elimination is necessary. Such measures as will relieve the annoying symptoms resulting from the changes in the mucous structures, are also necessary, as these changes otherwise remain after the removal of the exciting cause. Hygienic measures are a necessity, as the general health must be maintained.

Local measures will consist of cleansing the mucous surfaces, and the salicylic acid solution will be the most generally useful. For relieving the swollen condition of the mucous tissues, the introduction of a pledget of cotton covered with the salicylic acid ointment, will quickly relieve, giving more respiratory space. The amount of secretion is usually much increased on removal of the cotton, as exosmosis results from the application, decreasing the amount of infiltration. The mechanical pressure of the cotton and stimulating action of the acid, soon produces enough retraction to give relief. The application should not be made

to the same side oftener than twice a week, and should be persisted in for from three to six weeks.

Constitutional.—Where there is anemia and malnutrition, a relaxed condition of the mucous membranes and the secretion a thin mucus, iodide of iron. If the secretion is purulent, lime in some form. A moderately profuse discharge from both the anterior and posterior nares, hydrastis. In nervous women, with a relaxed condition of the tissues, but no apprehensiveness, ignatia. With relaxed tissues and gastric complications, atonic in character, nuxvomica. Hydrastis is also usually indicated in this condition. When there is a persistent, stuffed sensation near the root of the nose, with a desire to blow the nose and little or no secretion obtained, sticta. When the secretion is tough, tenacious, and stringy, potassium bichromate. With lymphatic glands or glandular tissue swollen, phytolacca. A thin, watery, nonexcoriating secretion, hamamelis. Thin, watery, excoriating discharge, liquor potassii arsenitis. In strumous cases, arsenic iodide.

Operative.—If polypi are present, their removal is imperative, as no treatment will be beneficial as long as these growths remain as irritants. When possible to do so they should be removed with the cold wire snare. When through deformity of the structures, this is impossible, the use of scissors should take precedence, but some cases will present in which the forceps will have to be employed.

In many cases there will be found a hanging turbinate, usually the middle. This condition causes an irritation and thickening of the mucous tissue, and if the turbinate is large and spongy it may be necessary to operate, removing a portion of the bone. Generally the thickening is confined to the mucous tissues, and the use of the tampons of cotton with the salicylic acid ointment, or graduated pressure with malleable nasal tubes should be tried before radical measures are resorted to. In the use of the tubes, they should

be fitted to the cavity and gradually enlarged. The time they are worn at first is only one or two hours, increasing the time as the irritability of the tissues diminishes. Another method is to scrape the bony structure with a sharp pointed probe. Cocainizing the tissue and making a puncture, pass the probe to the periosteum, and gently scrape the tissue. Inflammatory action will result and the contraction following will relieve the turgescence. The use of a Graefe cataract knife introduced in a similar manner to the probe, will also be followed by reduction of the turgescence without destruction of the epithelial surface.

The indiscriminate removal of turbinal tissue is to be deplored, and the operation should never be performed excepting as a last resort. When it is necessary to remove a portion of the bone, the mucous tissue should be dissected from the bone and the edge only of the bone removed, as a rule. In many of these cases, much benefit can be obtained by electrolysis or kataphoresis, especially when the result of local lesions. The employment of the actual or galvano cautery in these cases is seldom beneficial, as the difficulty of controlling the destruction of tissue is extremely difficult.

Intumescent Rhinitis.

This is really not a distinct form, but a modification of chronic rhinitis. One or both nasal passages may show a sudden turgescence with a permanent boggy state of the mucous membrane. Changes in the structure of the submucosa are not marked, as the membrane will often become almost normal. In recurrence there is an excessive secretion, sometimes clear and watery, or tenacious and mucopurulent. Accompanying or preceding the exacerbation there may be excessive itching, due to the irritation caused by the vascular change. Frequently there is engorgement of the cutaneous vessels, the skin being reddened and somewhat sensitive.

Symptoms.—A characteristic of this lesion is the rapidity of the swelling of the turbinal and septal mucous membrane. The exudate causes the swelling, and differentiates it from cyanotic rhinitis which is produced by engorgement of the vessels. Both cavities may be affected at the same time, or they may be alternately swollen. In lying on the side, the lower nasal cavity will usually be occluded. The liability to colds, especially in the fall, winter, and spring, is much increased in persons having this disease. Hoarseness on arising is often complained of, and there is more or less difficulty in expectorating the mucus which clings to the tissues, especially of the soft palate. Occasionally the efforts to dislodge the material will cause vomiting. A hacking cough may annoy the patient, as well as an irritating hoarseness on prolonged use of the voice for speaking or singing. Dull frontal headache; tired sensation in the eyes; dryness and tickling in the throat; coated tongue and gastric disturbances and offensive breath are symptoms sometimes found.

Prognosis.—Usually favorable.

Treatment.—Essentially the same as for simple chronic rhinitis. The itching sensation can usually be quickly relieved by stearate of zinc with euphphen.

Hyperplastic Rhinitis.

Synonyms.—Obstructive rhinitis; Hypertrophic nasal catarrh; Hypertrophic ozena; Hypertrophy of the turbinated bones; Chronic hypertrophic rhinitis; Hypertrophic rhinitis.

This is a chronic disease affecting the entire structure of the mucous tissue.

Etiology.—The etiology and pathology of so-called hypertrophic rhinitis is a vexed question, as there is considerable diversity of opinion regarding the disease, and also a great deal of confusion as to the diagnosis. It is fre-

quently difficult to distinguish between a chronic rhinitis, intumescent rhinitis, and the hypertrophic form so-called, as during some of the stages of each the symptoms are essentially the same, but the final stage is very different. In the hyperplastic, or hypertrophic form, the increase of connective tissue elements of the submucosa is similar to that of a benign tumor, and remains practically the same, not contracting as does the tissue resulting from inflammatory processes. The disease may result from repeated or continued attacks of chronic rhinitis. Climate seems to have but little to do with the condition.

Pathology.—There is increased connective tissue formation, as a result of constant irritation causing hyperemia, but not producing a true congestion. New gland tissue may also be formed as a result of this increased tissue, but there is not a normal function of the new gland tissue. Increased fibrous structure is found in the submucosa, the vessels being abnormally separated by the thickening of the connective tissue support. There is an increase in the capillary supply, but the basement membrane is but little if any changed. The epithelial portion is thickened and there is an increase of cell layers. The external layer may be ciliated and the inner layer of the columnar type. Folds and furrows are present in the epithelial structure.

Symptoms.—There are no specially characteristic symptoms differentiating this from several other forms of rhinitis. One or both sides may be involved, and the morbid process may be located in either the anterior or posterior portion of the turbinal tissue, or cover the entire surface. The progress of the disease is essentially chronic. The color of the membrane varies according to the stage and amount of thickening. The character and quantity of the discharge varies. There may be an increase in the turbinated bony structure. Often there will be found deflection of the septum, exostosis or enchondrosis. Not infrequently the diag-

nosis of a fibrous polypus is made on account of the appearance of the thickened mucous tissues. Nasal respiration is impaired, and slight irritation will produce a marked engorgement of the tissues. Any position which facilitates gravitation, will increase the distention of tissue. The constant impairment of nasal respiration, especially during sleeping hours, promotes the habit of mouth breathing.

The secretion is tough, tenacious, and thick, even when

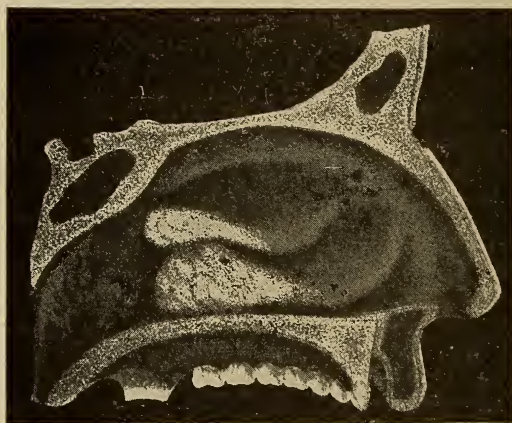


FIG. 60. Hyperplastic rhinitis, all the tissues of the middle and inferior turbinates affected. The nasopharynx showing fimbriated adenoid growths.

scanty, and is difficult of removal. The sense of smell is impaired or lost entirely. The tissues of the anterior region of the nose may be nearly normal in color or reddened. The anterior portions of the inferior and middle turbinates may be much swollen, smooth, or lobulated, and that of the inferior may project sufficiently to touch the septum. The septal tissues present irregular areas of swollen tissue, especially the lower portion. In many cases the changes in the anterior portion of the nasal cavities are not marked, but

the posterior portion, especially of the inferior turbinate will be much affected. The rhinoscopic mirror will reveal a rounded whitish mass, which may be lobulated. The middle turbinate may present the same appearance to a lesser degree. These masses may partially or completely fill the choanæ, and sometimes may project into the vault of the pharynx, encroaching on the orifices of the Eustachian tubes. The so-called mulberry form is regarded by some as an early stage of the disease. The color is dark red or purplish, and the mass may bleed on slight irritation. The posterior portion of the septum may also present either of these conditions. The middle portion of the turbinates may present the same appearance as either the anterior or posterior parts. Frequently pedunculated masses, and papillomatous like growths may be found projecting from the turbinates. Longitudinal grooves may be found on the septum, the result of pressure from the impinging turbinates. The superior turbinates and roofs of the fossæ are seldom implicated in the morbid process.

Eye complications are frequently present when the superior portion of the nasal cavities are affected.

The quality of the voice is changed, there being a nasal twang to the voice, as a result of interference with nasal resonance. Conjunctival irritation and epiphora as a result of occlusion of the nasal duct is frequently present when the middle turbinate is affected. Impaired hearing will result when the posterior portions of the middle and inferior turbinates are involved, through interference with the Eustachian orifices. Frontal headache of a dull, intermittent character is often present. Retention of secretion in the nasal cavities may result from both the irregular surfaces and change in the consistency of the secretion. The secretion may become offensive. Cough may result from the secretion passing into the nasopharynx. If mucoid degeneration takes place, the tissues appear whitish or gray-

ish. A sensation of fullness and pressure over the bridge of the nose is not uncommon. Nasal polypi are not infrequent complications.

Diagnosis.—The differential diagnosis between hyperplastic rhinitis and chronic, intumescent or cyanotic, as well as the engorgement of mucous tissue found in plethoric persons, is important. There should be preservation of all the mucous membrane possible in the hyperplastic form, as there can be no return to normal function of the membrane, while in the other types there may be. The application of cocaine does not produce much shrinking of the tissues, and the use of a probe will not produce pitting unless considerable pressure is made, and the depression disappears slowly.

Prognosis.—Usually favorable as regards relief.

Complications.—Naso-pharyngitis, pharyngitis, laryngitis, tracheitis or bronchitis, are pretty certain to follow, and in persons predisposed to pulmonary phthisis, it may be the starting point of this disease. Dyspepsia is also frequently a complication. As reflex conditions, epilepsy, asthma, chorea, spasms of the glottis, optic neuritis, scotoma, hyperemia of the fundus, orbital neuralgia, and even glaucoma may occur. Ear complications are frequent. Polypi and adenoid growths are often present.

Treatment.—Local treatment should be carefully employed for the purpose of cleanliness, but if carelessly used it will do harm by needlessly irritating the tissues. Operative measures are necessary in all but the mildest cases. The removal of excess of tissue is imperative. The use of caustic preparations is not generally advisable as the destruction of tissue is not always readily controlled. The damage which may result from the use of the actual cautery, except in experienced hands, must be remembered. By the use of a proper knife, a wedge-shaped incision may be made and the redundant tissue removed with a scissors or snare.

When the turbinated bone is thickened or hanging, the mucous membrane should be dissected from the bony structure and the edge of the bone removed by the saw or forceps. The portion of tissue removed should be that which is most prominent or is producing the most irritation or obstruction. For cleansing the nasal cavity after an operation either the saline wash or salicylic acid wash should be used with the nasal syringe. If the tissue is sessile, the use of the cold wire snare is preferable. Plenty of time should be taken in using the snare, as the operation will be less painful and there will also be less hemorrhage. In some cases it will be better to cauterize the traumatic surface with chromic acid fused on an applicator or probe. The use of the galvano-cautery is attended with too much danger excepting in the hands of an expert. Electrolysis has given good results in many cases, using the bipolar method, and using a double needle. The current should be gradually increased from five to ten milliamperes, and as gradually diminished, two to five minutes time will be sufficient.

Ozena.

The term ozena has, like malaria, been used to cover a multitude of sins, as it has been applied indifferently to various diseases of the nose. The true significance of the term is a "stench," and is simply a symptom, the same as a cough, and should not be classed as a distinct disease. Ozena may be present in atrophic rhinitis, syphilis, suppurative diseases of the accessory sinuses, coryza caseosa, glanders, malformation of the nasal structures, neoplasms, or a foreign body in the nasal space. The odor may be slight or extremely offensive. The patient may or may not be conscious of it. It may be intermittent or constant and is not always modified by the use of disinfectant methods. Various theories regarding the cause of the odor have been advanced, but the most rational appears to be that it is the

result of putrefaction changes in the secretion and tissues involved. Ozena is in no sense of the word a disease, but a symptom.

Atrophic Rhinitis.

Synonyms.—Atrophic catarrh; Atrophic nasal catarrh; Chronic atrophic rhinitis; Chronic fetid rhinitis; Cirrhotic rhinitis; Dry catarrh; Dry nasal catarrh; Dysodia; Fetid atrophic rhinitis; Fetid catarrh; Fetid Coryza; Fetid rhinitis; Idiopathic or constitutional ozena; Ozena; Rhinitis atrophica; Rhinitis atrophica simplex; Rhinitis fœtida atrophica; Rhinitis sicca; Sclerotic rhinitis; Simple ozena; Atrophic endorhinitis.

Atrophic rhinitis may be generally classified as primary or secondary, although it is neither a true distinct process nor an inflammatory condition, but follows some previous affection.

Primary, when a direct lesion as simple atrophy or a trophic process.

Secondary, when the result of a pre-existing local lesion which causes the atrophy, or when the result of a morbid process in some other region.

The causes of atrophy may be subdivided as follows:

Atrophy, the result of an inflammatory process which is followed by contraction, thus lessening the blood supply. This may produce atrophy and by pressure will probably diminish the function of the glandular elements.

Interference of the general circulation may cause over-distention of the vessels of the submucosa, thus producing pressure which will be followed by connective tissue and glandular atrophy.

The primary cause of the atrophy will determine the treatment of these cases, if seen before the final atrophic changes have taken place.

General Considerations.—Atrophy and degeneration are

separate changes. In simple atrophy the nutrition is lessened and function impaired, although there may be no wasting of the tissue, but rather an increase through fluid distention, although there are lessened structural elements. The size and probably the number of cellular elements are diminished, but the individual cell is present, which may, through proper treatment be restored to approximately its normal state.

In degeneration there is complete loss of function, and the cell undergoes a complete change so that a return to normal action is impossible. If the case is seen during the atrophic stage proper and the exciting cause can be removed, a return to normal conditions may be obtained, but after degenerative changes have occurred, this is impossible. Degeneration of tissue is usually secondary to atrophy, but sometimes occurs without previous atrophy.

In pressure atrophy resulting from inflammatory contraction, the process can not be controlled by any known method, no matter whether primary or secondary, but although the change is similar, if the atrophy is the result of impaired nutrition, the functions may be improved, provided nutrition can be restored. Ozena is sometimes a prominent symptom, with but slight change in the mucous membrane of the nose, still the offensive odor is present, and it will often be found that some of the accessory sinuses are affected.

Atrophy from a Pre-existing Local Lesion.

Etiology.—The atrophy is the result of inflammatory conditions which may be simple or infective. It may be from a rhinitis due to traumatism, a chronic or membranous type, or malformations of the structures of the nasal cavities. The hereditary tendency, frequently referred to, is usually due to the hereditary nasal structure, which favors inflammatory action. Inflammatory action caused by, or following

infectious inflammatory processes, implicating the submucosa, and producing permanent changes in the epithelial layer should be classed as exciting causes.

Any systemic disease, as measles, scarlet fever, diphtheria, and sometimes enteric fever, may also be a cause. It may also be a sequelæ of chronic catarrhal conditions of the accessory sinuses, or of a chronic purulent rhinitis. Age does not seem to be a factor, but it is most generally found under the age of thirty. The simple dry rhinitis of the aged is probably due more to senile than to true pathological changes. No micro-organisms which can be definitely ascribed as factors have been discovered, although several have been described as supposed causes. They probably are only adventitious.

Pathology.—There is an excess of connective tissue elements of inflammatory origin which, following the rule of this structure, contracts. Prior to contraction, there is a chronic inflammatory process with organization. But when contraction commences, the circulation of the entire tissue is interfered with, the pressure involving the gland elements as well as impairing nutrition, and atrophy results. In some cases there is thinning of the bony structure of the turbinates, especially of the middle and inferior, but this appears to be the result of constitutional rather than local causes. In the later stages of the disease the mucous membrane resembles cutaneous structure rather than mucous. The epithelium is scanty and cuboidal or flat in shape, and more or less granular débris is present as a result of desquamation and cell destruction. The basement membrane is not so much involved, but the submucosa is decidedly thinned and changed in structure. In the external portions, the glandular formations are partially or completely destroyed, the blood vessels lessened in quantity, or those present have decidedly thickened walls. There is more or less round-celled infiltration and granular débris. The deeper

structures are fibrous, but not so decidedly contracted. Generally the venous sinuses are obliterated.

In infectious inflammatory processes, the pathology is similar, only there is primary involvement of the epithelial surface. The changes are more rapid. There is usually also implication of the glands of the posterior pharyngeal wall, as well as of the pharyngeal and faucial tonsils.

Symptoms.—Usually a history of previous catarrhal symptoms, which, if complicated by nasal irregularities, will

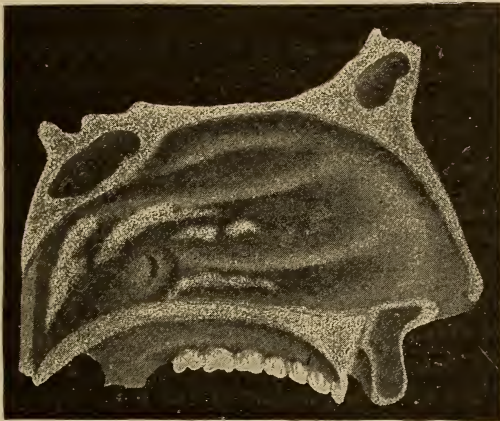


FIG. 61. View of left nasal cavity in atrophic rhinitis.

increase the discomfort of the patient. As the atrophy progresses, the secretion will vary in quantity, and there is a tendency to form crusts.

In the earlier atrophic stages the crusts are readily dislodged, but later they become more adherent, and are only removed by the use of considerable force. The annoyance caused by the crusts will often cause the patient to pick the nose, and the irritation thus produced is probably the cause of ulceration of the septum. The surface of the mucous membrane is irregular and the color varies. The areas in-

volved in the process of atrophy are grayish or white, while the intervening tissue is boggy or edematous. The tissues generally affected are those of the anterior and middle portions of the middle turbinates and anterior portion of the inferior turbinates.

An offensive odor is not always present, especially if the patient can keep the nasal cavities comparatively free from the accumulations, which will adhere to all portions of the tissue. More or less hemorrhage, generally the result of attempts to remove the crusts, may occur. The irritation in these cases will usually produce a constant desire to free the nasal cavity, and there is often a sensation of an accumulated secretion in the naso-pharynx, which is a reflex from the nasal condition.

If of the infectious type, the secretion is profuse, mucopurulent, irritating and offensive. Not infrequently in these cases the post nasal space is involved through the excessive secretion. When complicated with any accessory sinus disease, especially of the sphenoid, the odor is marked, and persists after thorough cleansing of the nasal cavities. The patient complains of dryness and irritation of the nasal cavities and naso-pharynx. Sometimes there is persistent itching of the anterior portion of the nasal cavities. The sensation of a foreign body in the nose is often complained of. The efforts to dislodge this will often loosen some of the incrustation, and it will be expelled, either through the anterior nares, or be drawn into the naso-pharynx and expectorated. These dislodged masses vary in consistency, shape, and size, and usually are extremely offensive. At times the amount of secretion may be sufficient to occlude the nasal passages, usually being situated at the posterior portion.

Pain, as a rule, is not present, although there may be a dull pain over the bridge of the nose, back of the eyeballs or in the frontal region. A dislike for mental activity is present

and the patient often becomes pessimistic from worry over the condition producing the offensive odor. A hacking, persistent cough and hoarseness is often present. Disturbances of the alimentary canal are frequent, and a subnormal condition of the general system, as a result of the dyspeptic state. The special senses of hearing, smelling, and tasting are often impaired.

In typical cases a peculiar facial expression is developed. The nostrils are widely expanded, alæ thin and flat, and the sulci separating them from the cheek obliterated. A strumous appearance, with dull, expressionless face, thick lips, glands enlarged and some form of reflex rash on the face or nose may be present.

Anterior inspection shows an enlarged nasal space, and not infrequently the roofs of the nasal fossæ and also the naso-pharyngeal walls may be inspected in this way. The tissue of the turbinates is reduced, and presents a shrivelled, shrunken, dry, glazed appearance. The color is pale, and the normal soft velvety sensation with a probe is lost. Pressure with the probe reveals a resisting surface which does not pit. Strings of inspissated secretion may be seen crossing from the turbinates to the septum, or the secretion may be in masses or crusts located in the affected areas. These may be offensive and closely adherent to the surfaces. When removed there is generally found an abraided surface, and some oozing of blood. The under surface of the crusts when removed will often show streaks of blood. In some cases the entire membrane may be covered with the dried secretion. When this condition occurs, the necessary manipulation for cleansing the cavities will cause the membrane to be darker in color, but this is only temporary, the characteristic pale appearance soon returning.

Although a true ulcerative condition is infrequent, slight abrasions or superficial desquamation may show the location of dislodged crusts or mechanical interference on the

part of the patient. The naso-pharyngeal mucous membrane partakes of the same characteristics and often the pharyngeal tonsil is more or less atrophied.

Diagnosis.—The history of the case, and attention to the symptoms and appearances already mentioned.

Prognosis.—Relief from the most unpleasant symptoms and odor can usually be given, but it is practically impossible to restore the normal functions of the tissues.

Complications.—Accumulation of secretion in the vault of the pharynx, and atrophic changes of the naso-pharyngeal tissues. Impairment of hearing through involvement of the Eustachian tubes, the morbid process extending through continuity of tissue. The accessory sinuses are often affected. Gastric disturbances and frequently reflex conditions may be present.

Treatment.—Cleanliness is of the utmost importance. No unnecessary force should be employed in removing the crusts, as more surface may be denuded and the chances of ulceration increased. For cleansing the nasal cavities, the use of a warm alkaline solution, or the salicylic acid solution. If the crusts are very tenacious, the employment of cotton tampons saturated with glycerine, allowed to remain in contact with the tissues from ten to twenty minutes, will usually facilitate their removal, and the glycerine also appears to have a stimulating influence on the tissues and remaining glandular elements. If erosions of the surface present after the removal of the crusts, insufflations of boric acid or aristol should be used. It is a question whether decidedly astringent preparations should ever be employed in these cases. The offensive odor may be controlled in a measure by the use of potassium chlorate, or potassium permanganate. If anomalous conditions of the nasal structures are present they should be corrected.

Internally.—When the discharge is profuse, yellow, and thick, tonsils enlarged, naso-pharyngeal membrane thick-

ened, arsenic iodide. With a chlorotic condition, especially with pain in the frontal region, aggravated by motion and loss of smell, cuprum. A thick, offensive, tenacious discharge, often streaked with blood, or when the crusts leave an eroded surface when dislodged, potassium bichromate. If the patients have been loaded with mercury, potassium iodide. Marked and persistent excoriation of the nostrils and upper lip, particularly with a specific history, and enlargement of the lymphatics, phytolacca. The secretion purulent in character, lime. With an ulcerative tendency of the submucosa or periosteum, silicea. Thick, tenacious, hard crusts, forming especially in the olfactory region, thuja. The secretion moderately profuse, hydrastis.

Secondary Atrophy Resulting from Other Lesions.

Secondary atrophy is a result of lesions of other organs, and is produced by cyanotic congestion.

Etiology.—Abnormal conditions of the nasal structures may in some cases be associated with the atrophy, but the primary cause is a diseased condition of some remote organ, as the heart, lungs, liver, or kidneys, which will produce venous stasis through interference of the venous circulation. The retardation is most marked in those structures which are lax, hence the mucous membranes are especially liable to be affected. Another important factor is the imperfect elimination of waste products from the system in lesions of the urinary, alimentary, or respiratory organs; the retained excrementitious material acting as an irritant, will manifest itself by inflammatory action.

Pathology.—The submucosa is first affected. Nutrition is impaired, although there is an excess of blood to the parts. The excessive distention of the vessels causes atrophy of the perivascular structures through pressure, as well as through lack of nutrition. This necessarily produces atrophy and degeneration of the epithelium.

The tissues in this form of atrophy do not present the shrunken appearance found in typical atrophic rhinitis, but there is lessened functional activity, though not always diminished size of the tissues.

The apparent enlargement is due to engorgement, while there is actually a diminution of the structural elements.

Symptoms.—The mucous membrane of the septum, middle and inferior turbinates, and occasionally of the superior turbinate, will be injected, tense and sodden. The characteristic symptoms of an acute inflammation may be present. The external tissues of the tip of the nose are often reddened. Nasal respiration is usually markedly impeded, and generally there is an excessive exudation as a result of the over distention of the blood vessels. The voice has a nasal twang. Frontal headache is not infrequent, and a sensation of fullness over the bridge of the nose, is often complained of. The ocular conjunctiva may be congested, and excessive lacrimation annoy the patient. The senses of smell and taste are impaired. A slight odor may be present but is not constant.

Prognosis.—This will depend upon the causative lesion.

Diagnosis.—A differential diagnosis must be made between this type and intumescent, acute, and occasionally a chronic rhinitis. Palpation with a probe, careful inspection of the tissues, and the history, will all have to be considered.

Complications.—The accessory sinuses are at times implicated. The nasopharynx and rarely the larynx may present the same morbid appearance. When the nasopharyngeal tissues are affected there is usually involvement of the Eustachian tubes with a consequent disturbance of hearing.

Treatment.—Internal treatment in these cases must be for alleviating the morbid condition which is the cause of the local manifestation.

Local treatment will be for keeping the nasal tissues free

from accumulated secretion, and also for relieving the obstructed respiration. As a cleansing solution the following will be found desirable: ℞—Acid salicylic (Lloyd's), ℥ss; sodii boras, ℥jss; Lloyd's hydrastis fl ℥i; dist; hamamelis q. s. fl ℥jv. Sig. Teaspoonful in enough warm water to fill nasal syringe twice. For reducing the swollen, turgid tissue, tampons of cotton smeared with the salicylic acid ointment will be efficacious. The ointment is: ℞—Acid salicylic (Lloyd's), gr. xx; glycerine, q. s.; white vaseline, ℥j. The acid is rubbed to a smooth creamy paste with the glycerine before the vaseline is added. This will make an ointment free from lumps. In using this ointment, the tampon of cotton should be allowed to remain an hour and then removed. The application should not be made to the same side of the nose oftener than twice a week.

Purulent Rhinitis.

Synonym.—Purulent nasal catarrh.

This is an infrequent type. The nasal mucous membrane, through infection, secretes a purulent material. This does not include strumous rhinitis, or that resulting from injury or foreign bodies in the nose. It is usually a chronic condition.

It may be the result of introducing the finger into the nose, after being in contact with an infected discharge.

In the New-Born.—The condition may result from infection while passing through the parturient canal, or the introduction of irritative substances by careless washing of the child. In some cases, a purulent rhinitis may develop that can not be ascribed to any of these causes.

Pathology.—Liquefaction-necrosis of the tissues results from the irritation of the infectious material similar to that found in abscess walls of other structures. The mucous membrane becomes practically pyogenic.

Symptoms.—In this form of rhinitis there is a contin-

uous discharge of a thick, tenacious, mucopurulent, usually bright yellow secretion, and generally from both nostrils. Slight febrile symptoms may precede the attack. The discharge is irritating and frequently excoriating, causing excoriation and ulceration of the upper lip. The infected area is confined to the anterior portion of the nasal passages. Respiration is but little if any interfered with. In severe cases the discharge may be through the naso-pharynx. There is very little odor unless the discharge becomes quite thick and remains for some time in the nasal cavities.

Prognosis.—Even when recovery occurs, there is diminished functional activity of the mucous membrane.

Treatment.—Thorough cleanliness must be insisted upon, and the alkaline wash followed by the salicylic acid wash will prove efficacious. If there is any odor, potassium chlorate or potassium permanganate should be used. After the tissues are clean, they should be carefully dried with cotton pledgets, and compound stearate of zinc with salicylic acid (mild), or the compound stearate of zinc with eucalypti insufflated.

Internal medication should consist in the administration of lime. When the lymphatics or tonsils are enlarged, phytolacca. In anemic individuals, arsenic iodide. In babies the use of inunctions of cod liver oil may be required, especially where there is a tendency to marasmus. Lime water should be given, and can be given with milk.

Nasal Hydrorrhea.

Synonyms.—Hydrorrhea nasalis; Rhinorrhea.

Etiology.—This obscure affection of the nasal tissues has as a characteristic symptom, a profuse, thin, watery discharge from the anterior nares. The idea that it is the escape of cerebro-spinal fluid is held by some, while polypi or chronic catarrh of the antrum is the supposed cause by

others. It may result as a reflex condition, but usually appears to be the result of some systemic lesion in which the venous return is impeded. This produces a cyanotic state of the nasal tissue, which allows an escape of serum into the perivascular tissue, producing distention or edema. The escape of this infiltrated fluid by exosmosis, relieves the tissues temporarily.

Pathology.—In three cases which the author has had under observation, the mucous membranes were edematous, and with an appearance as though a puncture would be followed by an escape of fluid. The color of the tissues was pale pink. On pressure with a probe the pitting slowly disappeared. A dull bluish-red or pale pink is the color usually found, similar to that seen in chronic congestion. Microscopic examinations of the tissue in these cases reveals small round celled infiltration into the submucosa, and relaxed, thinned vessel walls. The fluid contains simply an excess of inorganic salts.

Symptoms.—During the paroxysm there is a constant dropping from the nose of a clear, transparent, colorless watery fluid. This may come without any warning, or be gradual, and will last from a few minutes to half an hour, excepting in very aggravated cases. There is usually sneezing preceding the escape of fluid, and at times headache. The attacks may or may not show a marked periodicity, or be nearly continuous. One case had the attack as soon as she arose in the morning, and the recurrence was about every half or three-quarters of an hour. She would use anywhere from ten to twenty handkerchiefs every day, but this was an aggravated case. Pain may be present, but is not a constant symptom. The discharge may be bland or irritating. The maximum of the attacks is usually during the waking hours, although cases which are worse at night are reported. Coughing spells or spasm of the glottis may result from escape of the fluid into the nasopharynx. The

sneezing spells may be very severe. Constitutional symptoms vary and should be carefully studied.

Diagnosis.—The history, character of the discharge, inspection, and palpation with a probe will make the diagnosis comparatively easy.

Prognosis.—If the exciting cause can be determined and corrected, a cure will result.

Treatment.—The local treatment that I have employed with good results in many cases, is the salicylic acid wash, used two or three times a day and the cotton tampons of salicylic acid ointment every second day. Internally, if no systemic lesions are present, distillate hamamelis and hydrastis. In one case where the discharge was acrid and excoiating, liquor potassii arsenitis was used. In the cases I have treated a cure was effected in from three to five months.

Chronic Edematous Rhinitis.

Synonyms.—Cyanotic rhinitis; Rhinitis œdematosa chronica.

Etiology.—In nearly every case there is some morbid condition of the liver, and the concensus of opinion is that it is usually of hepatic origin. Morbid changes of the liver, kidneys, heart, or lungs which impede the circulation, and cause cyanotic congestion in remote tissues, are the probable causes of edema. Chronic edematous rhinitis may occasionally accompany asthma. It has also been classed as a neurosis.

Pathology.—Infiltration of serum into the connective tissue causes swelling of the turbinates. The swelling may be migratory, local, or general. Obstruction of the vascular structures, either through engorgement or passive congestion, causes the swelling and not tissue proliferation.

Symptoms.—The middle and inferior turbinates are affected with either intermittent or constant swelling, and interference of nasal respiration is commensurate with the

swelling. The location of the swelling varies. It may resemble a cyst, causing pain, lachrimation, and an excretion of thin serum. If punctured, a thin serum escapes. Cocaine has but little contractile power on the enlargement. Ulceration may occur in the later stages.

Diagnosis.—The symptoms given will determine.

Prognosis.—This will depend upon the systemic cause.

Treatment.—Compresses of cotton coated with salicylic acid ointment or glycerine may relieve the condition until constitutional remedies correct the cause. In some cases scarification may be necessary. Internally the use of chionanthus or chelidonium for hepatic engorgement. Apocynum, apis, or the two combined, in renal affections. Strophanthus, cactus, glonoin, digitalis, or cratægus in cardiac lesions. Bryonia or asclepias in pulmonary diseases. In fact, the indicated remedy should be used.

Specific Inflammations (Granulomata).

(1) Syphilis. (a) Acquired; (b) Hereditary. (2) Tuberculosis. (a) Lupus. (3) Glanders. (4) Leprosy. (5) Actinomycosis. (6) Rhinoscleroïma.

Nasal Syphilis.

Synonyms.—Specific catarrh; specific rhinitis; syphilitic ozena; syphilitic rhinitis.

This is a local nasal manifestation of the constitutional disease. The disease may be acquired or hereditary. In the acquired form three stages are generally recognized, and it is infrequent for one to merge uninterruptedly into another, there being a stage of quiescence separating them.

Acquired Syphilis.—In some instances syphilis may be contracted at birth or in utero, but as a rule a later period of life marks the initial lesion, especially after the age of puberty.

Etiology.—Whether or not this disease is due to a special micro-organism, the bacillus of Lustgarten, is a question, but that there is infection through an abrasion of the skin or mucous membrane is unquestioned. The disease is transmitted only by inoculation, and usually the initial lesion is located on the genitalia. The disease may be transmitted by kissing, as in one case under observation, a baby was inoculated on the lower eye-lid of the right eye by being kissed by a woman who had mucous patches in the mouth. Infected surgical instruments, household utensils, or the passing “growler” or dipper used for drinking purposes by gangs of workmen, may be the cause of infection. In some cases the initial lesion has occurred in the nose, usually by means of an infected finger. The Eustachian catheter has been responsible for a few cases of infection.

As a rule specific manifestations of the nose are secondary or tertiary lesions, the result of an initial sore on some other portion of the body. In persons of a strumous diathesis, or lowered vitality, the local symptoms are usually more pronounced and severe.

PATHOLOGY.—*Primary Stage.*—An initial syphilitic lesion of the mucous membrane of the nose presents similar appearances as in other localities. Varying from ten days to six weeks after infection, a comparatively small, hard, elevated, roundish, circumscribed papule, reddish or grayish-red in color, appears at the point of infection. As a rule this enlarges, a central necrosis soon follows; and a rather shallow ulcer forms, the floor and sides of which are fairly smooth. The ulcerative surface is covered by a thin glairy secretion. There is small round celled infiltration into the mucosa and upper portion of the submucosa. Infiltration of the vessel walls and sclerotic changes are present. In the later stages the usual degenerative pressure changes are observed.

Secondary Stage.—The pathological changes of the

coryza stage are similar to that of a simple catarrhal inflammation, only the condition lasts longer, and resolution usually follows, so that there are slight, if any, evidences remaining of a catarrhal condition. The mucous patches appear as small oval or roundish papules, of a bluish-red color. They may be single, or multiple when they may coalesce and vary in size. Ulceration usually soon follows, forming a shallow ulcer, the edges slightly raised and surrounded by a more or less dark red zone. A grayish or creamy yellow pus bathes the surface. The pus, which is easily removed, will leave a raw-looking surface, which does not bleed easily. When the ulcerative surface is superficial, which is the rule, it will gradually heal, leaving slight evidences of an ulcer. When the ulcerative process has extended deeper into the tissues, a dense glistening cicatrix remains.

The microscopic examination shows fluid infiltration and also small, round cells into the mucosa and outer portions of the submucosa. The epithelial cells are swollen, and there is an excess of fluid and small round cells. There is slight, if any evidence of organization, a partial gelatinous character of the cellular elements being found. A later stage will show desquamation of the epithelium, fatty degeneration, disintegration, and liquefaction of the cellular elements, forming a more or less deep ulcer. At the margin, the epithelium shows a disposition to extend inward by proliferation, and the adjacent tissues show an inflammatory condition. There is not much tendency to organization. At a still later period the healing process through cell proliferation and reformation of epithelium is found, unless the ulcer is deep, when new tissue is formed and a fibrous cicatrix results.

Tertiary Stage.—In the tertiary period the lesions are usually very destructive to tissue, the bony and cartilaginous structures being involved as well as the mucous tissues overlying them. The submucosa is the first affected, gumma-

tous nodules or a diffuse inflammatory process developing. A diffuse thickening, or circumscribed areas of elevated, hard or soft, according to the stage, rounded ulcerations are formed. If uninfluenced by treatment, a fatty degeneration of the gumma occurs, with necrosis of the overlying tissue forming a deep, spreading, erosive ulcer, discharging a foul secretion, the result of vascular involvement. With proper treatment, a characteristic stellate cicatrix remains.

Microscopically the gummata will be found composed of small round and epithelioid cells in masses, and near the margins, giant cells. Fibrous bands passing through the cell-masses may be found at an early stage. Inflammatory proliferation and fibrous formation will be found in the surrounding tissue. Thickening of the blood vessel walls soon occurs. Eventually fatty degeneration of the center of the gumma results, and the entire mass may present a deep suppurating ulcer, or if infection is absent, organization of fibrous tissue may occur. Necrotic changes in the cartilages or bones may take place previous to, or at the time, or subsequent to the gummata, and may be extensive. These processes may start either from inflammation immediately external to, or develop in the bony structure itself.

SYMPTOMS.—*Primary*.—The initial lesion may be on any portion of the mucous surface reached by an infected finger or instrument, the alæ or septum being usually reported. The lesion itself is painless, but a neuralgic pain as a result of its influence may occur. There is little or no difference between the lesion and a non-specific ulcerative papule in the same location. The symptoms being similar; more or less occlusion of the nasal space affecting respiration, olfaction, and phonation proportionately. Fever is occasionally present, and reflex disturbances may be noticed. The papule is circumscribed, firm and hard to probe palpation. Ulceration soon follows. The size varies. If it is on the anterior part of the septum, it may entirely fill the vestibule, pre-

venting inspection of the nasal cavity. The submaxillary glands are often implicated. They are somewhat enlarged and freely movable, but the enlargement is slow, they seldom attain much size, and are painless with but little tendency to suppuration, and specific treatment soon causes them to disappear.

Secondary.—In a certain number of cases secondary manifestations occur in the nose, usually within six months of the initial lesion. In typical cases there will often be fever until the eruption appears, insomnia, restlessness and more or less shifting bodily pains. There is often anorexia. Symptoms of coryza, sneezing, lachrimation, photophobia, dull headache, impeded respiration, and disturbed olfaction and phonation may present. The secretion from the nose is profuse, being watery and thin in the earlier stages.

Inspection reveals a red, swollen, and congested mucous membrane, sometimes edematous, especially of the middle turbinate. The coryza becomes more severe, with a thicker secretion which gradually becomes more or less fetid, and eventually is nearly or entirely purulent, with not infrequently a slight amount of blood. The pituitary membrane, which is early covered with a thin secretion, shows areas that are disposed to spread and coalesce, and are covered with a greenish-yellow exudate. As the disease progresses, mucous patches may appear within the vestibule, or at the margins of the alæ or septum. When they are found in the posterior nares, they appear as slight elevations of a purplish-red or ashy hue, ulcerated and generally covered by a yellowish exudate. These elevations are surrounded by inflammatory areas. The coryza is usually persistent unless specific systemic treatment is used. A valuable diagnostic aid in these cases is the cutaneous eruption and rash.

TERTIARY.—When the disease has been neglected, or improperly treated, and reaches the so-called tertiary stage,

the symptoms usually develop after the lapse of five or more years, even as late as twenty years. The mucous membrane slowly swells as a result of cellular infiltration and proliferation. This swelling may be diffuse and cover a considerable surface, or may be circumscribed in nodules or gumma, occupying the respiratory region as a rule. The color at first is a reddish or purplish red, but finally becomes pale. In the early stages the swellings are firm and hard, and on pressure with a probe do not pit readily, but later they become softer. Pain is not a constant symptom, but when present is generally neuralgic in form, and is the result of the irritation caused by the presence of the growth. Impeded respiration results, as in any other type of obstructive rhinitis.

The course of the disease varies. Occasionally a condition simulating atrophic rhinitis follows. There being necrosis and absorption of the bony and cartilaginous tissues, but with no surface lesions or secondary infection, scar tissue followed by contraction increases the space of the nasal cavities. The quantity of secretion is lessened, and becoming inspissated forms crusts, and the odor is marked. The sense of smell is lost, and the increased nasal space permits of free inspiration, but the inspired air is practically unmodified. As a rule ulceration ensues, the inflammatory tissues soften and ulcerate. The discharge becomes abundant, being frequently dark colored, and possessing a peculiarly persistent foul odor, which it is almost impossible to modify. Dark yellowish or yellowish-green crusts, of inspissated secretion cover the membrane and ulcerations. The destructive process slowly progresses and forms large suppurative foci, covered more or less by the crusts. Bone necrosis either occurs at this period or may have preceded it, and in the discharge will be found small, discolored, and offensive sequestra. Palpation with a probe will reveal the roughened surface, and often small fragments of necrosed

bone will be dislodged. If the process continues until extensive destruction of bony tissue occurs, there will be marked changes in the appearance of the face through the loss of support to the nasal bridge, the tip of the nose and the bridge both falling in and flattening, when the cartilage and vomer have been destroyed. There may be partial or complete destruction of the turbinates. Perforation of the hard palate may also occur. Complete destruction of the nasal tissues may follow in severe cases, leaving simply two openings in the face where the nose should be. Perforation into the cranial cavity may also result.

DIAGNOSIS.—Primary.—The initial lesion in the nasal fossæ being so seldom found, renders a diagnosis difficult. Often its character is not positively known until secondary manifestations appear, although a careful inspection may reveal the peculiar characteristics of a true chancre.

Secondary.—The nasal manifestations of this stage may be very slight. The history, general symptoms and cutaneous eruption, together with the general improvement under specific treatment, will prove the character of the disease.

Tertiary.—In so-called tertiary lesions the characteristics are so pronounced that there is seldom any mistake in diagnosis, the necrosis and foul, disgusting odor being pathognomonic.

Prognosis.—In the secondary stage, prompt effective treatment usually results in a good recovery. Good results may follow in the tertiary stage, provided the destruction of tissue is not too extensive, and the recuperative powers are fairly good. The prognosis is less favorable when the necrosis is considerable, and the tendency to rapid ulcerative destruction of tissue is enhanced by feeble reparative powers. The length of time which elapses between the commencement of the necrosis and the commencement of treatment is also an important factor.

COMPLICATIONS.—There may be necrosis into the cranial cavity, or the necrosis may invade the ethmoid, superior maxillary, sphenoid or even the occipital bone.

TREATMENT.—*Primary*.—When the initial lesion is in the nose, it is necessary to keep the nasal surfaces as clean as possible. The use of the alkaline wash or salicylic acid wash will be effective. After the cleansing, an application of R̄—Thuja, Lloyd's hydrastis $\bar{a}\bar{a}$ q. s., should be made with a brush of cotton.

Neither cauterants of any kind should be used, nor excision of the chancre. If there is enlargement of the lymphatics, the internal administration of phytolacca is indicated.

Secondary.—Local treatment is of little value for the coryza of secondary syphilis. Mucous patches should be treated with thuja, after cleansing the surfaces. In many instances the application of thuja alone has caused more rapid healing than the combination with hydrastis. It is seldom necessary to use silver nitrate in these cases, but occasionally it gives more prompt relief. The application is best made by fusing the silver salt on a roughened probe.

Constitutional Treatment.—With swelling of the glands, phytolacca is indicated. Iris may be combined with the phytolacca when the lymphatic swellings are rather soft, but when firm the phytolacca alone is better. Hydrastis is indicated whenever the mucous patches are present, or with a moderately profuse secretion. When the discharge is tough, tenacious, and stringy, and ulceration appears, give potassium bichromate. Potassium iodide in full doses should be given, but the effect should be kept just within the limit of iodism: In administering potassium iodide care must be exercised to avoid gastric irritation. The drug should be given after meals and at bed time, and in plenty of water. The patient is directed to take not less than a glass of water with each dose. The various preparations

on the market for preventing gastric irritation are inferior to copious draughts of water. The same rule holds with other drugs. The more effort made to disguise the drug, the more the patient eventually rebels against medicine. The water possesses valuable medical properties in increasing the amount of urine excreted, and as the syphilitic poison is eliminated largely by the excretory organs, it is of the utmost importance that these organs be kept in the best possible condition. Corrosive mercuric chloride or red mercuric iodide in small doses can be combined with the potassium iodide, or given separately as desired. It is not usually necessary to push these drugs to the limit, but simply to get the medicinal effect.

Tertiary.—In the ulcerative process of this stage, the salicylic acid wash is a favorite, but the application of thuja afterwards should be thoroughly made. Care must be exercised in all manipulations, as a fresh nidus for infection may otherwise be produced. In some cases the points of ulceration may require the solid silver nitrate, but not often. The cautery is seldom required, and the damage which may result in careless hands, is as bad as the original disease. When the deeper structures are involved, curettement and removal of loose bone is necessary. The odor may be partially modified by the use of potassium permanganate, grs. j-ij; Aqua, 98° Fah. ʒj. Cleansing the nasal cavities every two to four hours, as necessary. The use of thuja should not be forgotten in the ulcerative condition.

Constitutional.—Potassium iodide, corrosive mercuric chloride, red mercuric iodide, phytolacca, hydrastis, potassium bichromate, Donovan's Solution, gold and sodium chloride are the drugs usually indicated.

Alcoholic liquors and tobacco must be interdicted. Prescribe plenty of out-door exercise, good food, and copious draughts of water. The excretory organs must not be allowed to become sluggish. If the cartilaginous support is

destroyed, producing deformity, some mechanical appliance for restoring the contour of the nose will be required as soon as the destructive process is controlled, or the paraffin method may be used.

In cases where there is not too much destruction of the soft tissues, the paraffin method is giving the most satisfactory results. The successful operation requires rigid aseptic precautions, the injection of a small amount of paraffin at a sitting, and the proper melting point of the material. Bad results can usually be traced to neglect of one of these essentials. There is danger, however, of embolism, even with the most rigid precautions, and embolism in the lung has been reported following this treatment, which should not be employed unless the tissue is in a fairly healthy condition. Much cicatricial tissue is a positive contraindication, as well as an ulcerative state.

The best syringe for the injection is Quinlan's, a constant flow of water at the proper temperature, 118° - 125° Fah. keeping the paraffin at the proper temperature. The paraffin must be thoroughly sterilized, and the skin at the point of puncture carefully cleansed, taking the same precautions as for any surgical procedure.

It is better to introduce only a small quantity at a time, repeating the operation, than to overdistend the tissues, as this may cause pressure necrosis. The paraffin can be moulded into the desired shape by manipulation with the fingers. Heat should be applied over the area to prevent the too sudden cooling of the material, gradually diminishing the temperature to the body temperature.

Encapsulation by the formation of connective tissue around the paraffin mass results.

Kyle gives the salient points of this method to be (1) Asepsis. (2) Paraffin, melting point of 38° or 39° C. (3) Do not use too hot. (4) Introduce needle as far from depression as possible, carrying the needle subcutaneously to

the required spot. (5) Do not use too much paraffin; repeated injections can be made.

Hereditary Syphilis.

Synonyms.—Congenital syphilis of the nose; inherited syphilis of the nose.

This term is applied to syphilitic infection in utero. The disease may manifest itself before the third month, or it may not appear until near the age of puberty. The former is usually classified as secondary and the latter as tertiary. The term snuffles is applied to the early form, and *syphilis tarda* to the latter form.

Etiology.—Transmission through the parents. If the father, sperm-inheritance, and if the mother, germ-inheritance. Not infrequently there is a combination of the two. In those cases where inoculation occurs during the passage through the parturient canal, it is acquired syphilis, not hereditary.

PATHOLOGY.—*Early.*—The pathological conditions are similar to the secondary acquired form, but are liable to be intensified, and as the nasal chambers are small, more marked destruction of tissue may result. There may be necrosis and absorption of bone and cartilage as a result of deep inflammation. The flattened nasal bridge usually resulting from this form is probably due to lack of development, depending upon the reaction following the inflammatory condition.

Late.—Identical with the so-called tertiary lesions of the acquired disease.

SYMPTOMS.—*Early.*—Seldom earlier than the second or third week, and infrequently later than three months, a severe rhinitis is noticed. The nasal mucous membrane is reddened and swollen. There is a copious, clear, watery discharge, irritating and excoriating. As the process con-

tinues the character of the discharge changes, becoming muco-purulent, thicker and with a tendency to crust formation. In severe cases, ulceration and necrosis may occur, and the discharge becomes purulent, mixed with blood and shreds of necrosed tissue. The characteristic odor is noticed. At the angles of the alæ and nasal margins, fissures appear. The breathing becomes noisy on account of the interference of nasal respiration, hence the common name "snuffles," and the child commences to breathe through the mouth. As a result of the impeded respiration the child has difficulty in nursing, and during sleep "suffocative spasms" are not infrequent. Mucous patches at the angles of the nostrils and on the nasal membrane are often present, and occasionally necrosis of the bony or cartilaginous nasal structures follows. The flattening of the nasal bridge is pathognomonic and is evidently due to non-development, through inflammatory interference with tissue growth.

The constitutional disturbances are marked, either at birth or soon after. The child is ill-nourished and weazened. This condition becomes more marked through the inability to nurse properly, and the inhalation of the foul odors and swallowing of the fetid secretions still further impair vitality. The skin has a sallow, muddy, unhealthy hue, and various lesions may be present. Mucous patches are frequent, especially at the muco-cutaneous junctions. The hair and nails are also included in the general degeneracy. Restlessness, yawning, fitful sleep, and a gradually acquired shrill pitch of the voice are also important symptoms.

Late.—The usual conditions of the hereditary form which appears between the third month and puberty, do not differ materially from the tertiary acquired form, so will not be repeated.

DIAGNOSIS.—*Early.*—The symptoms of this form are usually pathognomonic. The coryza, appearance, and expression of the face, parental history when obtainable, and

unyielding to treatment excepting specific, will make the diagnosis certain.

Late.—Easy as a rule. The history of the case, progressive destruction of nasal tissues, peculiar horrid odor, and the amelioration of the conditions under specific treatment all point to the character of the disease. In some instances lupus may be confounded with syphilis, but lupus is seldom a primary disease of the nasal cavities, but extends usually from the face. Lupus is also slower in its destructive process, attacks cartilaginous structures and not bony, so does not affect the hard palate, and the odor is not so offensive.

PROGNOSIS.—*Early.*—As a rule, the sooner after birth the disease manifests itself, the less favorable the prognosis. The general severity, and the vitality of the child are also important factors. When nutrition is fairly good, and the child has an average amount of vitality, yielding quickly to proper treatment, the prognosis is fair in the milder cases. In those cases where these conditions are reversed, the chances are against recovery. The transmission also appears to be an important factor also, as it seems the death rate in sperm transmission is a little over 25 per cent; germ transmission nearly 60 per cent; and 70 per cent when both parents are infected.

Late.—The strength of the patient, the severity of the manifestations as regards necrotic changes and the time of commencing treatment, largely determine the results. The earlier treatment is begun, especially before there is much destruction of tissue, the better.

TREATMENT.—*Local.*—Cleanliness of the nasal surfaces is absolutely necessary, but in very young children is difficult to obtain. Small rolls of blotting paper may be employed to remove the excessive amount of secretion, or the child may be made to sneeze, which will often cause expulsion of considerable secretion. The nasal syringe can

be used in many cases, using the salicylic acid wash, or an alkaline solution, especially when there is formation of crusts. After the surfaces are clean, any ulcerative points should be touched with thuja and hydrastis. This may be done with cotton wrapped on a probe or the solution may be warmed and dropped into the nose with a medicine dropper. The same care must be exercised as in adult cases not to abrade unaffected tissue, as this will give a fresh nidus for infection. For the offensive odor the potassium permanganate solution should be employed. In some cases the atomizer can be used better than any other method. The douche in these cases should never be employed.

Constitutional.—Potassium iodide, gold and sodium chloride, potassium bichromate, etc., and such other remedies as are indicated.

Nasal Tuberculosis.

Synonyms.—Nasal phthisis; Tuberculosis nasalis; Phthisis nasalis.

This is fortunately an infrequent disease. It is a chronic infectious inflammation. There are either the characteristic tubercular ulcers of the mucosa, or tubercles forming tumors which eventually break down and ulcerate. Both of these conditions may be present at the same time.

The nasal secretion is increased and fetid. The disease is essentially chronic, and is modified little, if any, by treatment.

Etiology.—Predisposing causes: in the majority of cases there is a tubercular diathesis. Most frequently the disease is a secondary infection from tubercular lesions in other parts of the body. Abrasions of the nasal mucous membrane and lowered vitality are important predisposing factors. Malformations of the nasal cavities from any cause have also been ascribed as factors in causing this disease, as, through retention of secretion, the resistance of the parts

is diminished, and the liability of infection increased. Whether the disease is contagious has not been definitely decided.

Exciting Causes.—The bacillus tuberculosis is now quite generally conceded to be the direct cause of the disease. In a very few instances has primary infection of the nose occurred, as actual contact of the infection upon an abraded surface appears necessary.

The action of the nasal secretion is to carry away all deleterious material, thus lessening the liability to primary infection, unless there is an open lesion of the mucous surface.

Secondary infection may occur through the blood circulation, lymph channels, continuity or contiguity of structures. As a rule it results from infection of the lower respiratory tract, the infected material coming in contact with abraded nasal surfaces during violent paroxysms of coughing.

Pathology.—The macroscopic appearance may be that of a diffuse swelling from a general tubercular infiltration; or miliary nodules may be present, which sometimes coalesce, forming a single growth. In either form the nutrition is eventually interfered with, and liquefaction-necrosis results, then ulceration and mixed infection, which is followed by typical tubercular ulcers.

The ulceration spreads slowly, and often the floor and margins present small miliary tubercles: these softening and breaking down increase the ulcerated area. As a rule, there is more or less inflammatory action surrounding the ulcerated areas.

Microscopic.—Small round lymphoid cells are numerous, as well as many epithelial cells and some giant cells. The tubercle bacilli are not usually numerous. The tendency of the cells is to form masses, which, through proliferation, increase in size and cause considerable pressure

which mechanically interferes with the blood supply, eventually obliterating it entirely; liquefaction-necrosis, and ulceration follow. The glandular structures are involved through the pressure of the infiltrate; distortion, obliteration, or desquamation of the secretory epithelium being found. The collection of the infiltrate acting as a foreign body, causes the surrounding tissue to show inflammatory conditions. The size of the tubercular tumor varies from the size of a pin-head to that of a large pea. The growth is slow, and the appearance depends upon whether in the progressive or retrogressive stage. In the early stage the growth is firm to touch with considerable hyperemia, but later becomes softer and paler. The base of the tubercle is usually broad, and there is a zone of redness surrounding it.

The pathological process is similar to that of other regions, modified somewhat by its location. Partial absorption of the infiltrate may follow when caseation results. Generally the overlying tissue breaks down, and discharge of the cheesy contents, together with pyogenic infection, produces the typical tubercular ulcer. In some instances an attempt at healing is made, and proliferation and organization of inflammatory tissue into fibrous cicatrices results. This formation is very liable, however, to tubercular degeneration at a later stage. As a rule, fibrous thickening in the tissue surrounding the tubercle occurs.

Symptoms.—As the disease is usually secondary, there will be found more or less systemic disturbances, according to the extent and severity of the primary disease. On this account a varied range of symptoms may present themselves, from slight evidences of hereditary tendency, to emaciation, hectic flushes, racking cough, and extreme exhaustion. The rhinitis is insidious in its onset. In the ulcerative form, a small ulcer, usually on the anterior portion of the septum, will be seen. This spreads slowly and gradually over the septal surface to the floor of the fossa, but

seldom to the turbinates. Occasionally it may extend to the upper lip. The ulceration is round or ovoid, the edges irregular and uneven, sometimes slightly raised. The floor is rough, and contains grayish or yellowish broken-down tissue. Caseating tubercles may also be present, either on the floor or margin of the ulcer. Perforation of the septum may occur. Secretion is increased, and is mucoid or mucopurulent, and more or less offensive. Occasionally there is crust formation, and the forcible removal of the crust is followed by slight hemorrhage. Pain is almost entirely absent in this disease. There is but slight, if any, disposition to heal, and if healing does occur, it is only temporary.

In those cases where the tubercular neoplasms are characteristic, the rule is for the turbinates to be affected. The tumors varying in size cause more or less obstruction to respiration. The shape also varies, but generally is irregularly rounded; the surface may be smooth, granular or nodular. The base may be broad, and the color vary from a gray or pale pink to dark red, or in the later stages, yellowish or whitish. Occasionally there is pallor of the mucous membrane. Hemorrhage may result from very slight irritation, or from no apparent cause. The tumors are firm and hard to touch in the early stages, but later there is often softening in the center with the periphery hard, and at last the entire nodule softens, ruptures, and discharges, forming a tubercular ulcer, similar to that of the first form. The nasal secretion is moderately increased, assuming after ulceration the characteristics already described.

There is absence of pain, and the only annoyance usually complained of, is the impeded nasal respiration, which may be complete. The same stubbornness to healing is present as in the first type. Removal of the tumor will leave a traumatism, which heals very slowly, and with a tendency to recurrence. Granulations filling the nasal cavities have been

reported in a few cases. Both forms may occur at the same time, and one or both sides may be involved.

Diagnosis.—The only positive proof is the finding of the tubercular bacilli in the secretion or growth. Tubercular manifestations in the oropharynx, larynx, or lungs, and a history of hereditary predisposition, are also important. Syphilitic lesions are eliminated by the history, general symptoms and reaction to antisyphilitic treatment. In some cases both conditions may be present at the same time. Malignant growths are usually more rapid in growth, and generally painful, and the age of the patient is of diagnostic value.

Prognosis.—Not favorable as regards a cure. The disease usually is extremely chronic, extending over a period of years, but is the least fatal of any of the tubercular manifestations. As a complication of tuberculosis in other respiratory regions, it may hasten death. As a predisposing factor in many infectious and systemic diseases, it plays an important part.

Complications.—As a result of impaired resistance through both local and systemic infection, the tissues are especially liable to other pathologic changes.

Treatment.—Cleanliness of the nasal tissues is important. The use of both an alkaline wash and the salicylic acid solution is beneficial. Tubercular formations should be removed by means of the snare or scissors, and their bases touched with chromic or salicylic acid. Ulcerative areas should be curetted, and usually a 50 per cent lactic acid is used over the entire traumatism. When operative measures are employed they should be radical, as otherwise there will be a rapid dissemination of the disease. Pain is not often present, but when it is, it may be relieved by the use of the chloretone inhalant. The general systemic condition must be brought to as near normal as possible. Out-door life is of the utmost importance. When there is

increased temperature and pulse, veratrum and liquor potassii arsenitis should be employed. Fatty foods, plenty of rich milk and good butter are pleasanter than cod-liver oil, and much less liable to disturb the stomach.

Lupus.

Lupus of the nasal mucous membrane is seldom primary, but usually secondary to that of the face. Small elevated nodules, with a disposition to coalesce and later ulcerate, characterize this disease. In some cases absorption may occur, which is later followed by atrophy.

Etiology.—The generally accepted view that lupus is essentially a tubercular disease, seems plausible on account of the course and character manifested. The victims of this disease nearly always present a tubercular history. Fortunately the disease is not prevalent. The claim is made by some that females are more frequently affected than males, and that it is oftener seen in inhabitants of the country than of cities. The time of the first manifestation is usually before middle age, but may occur at any period of life. Abrasions or atonic conditions of the mucous membrane are probably predisposing factors. There does not seem to be any hereditary transmission of lupus.

Pathology.—When the disease is primarily of the nasal mucous membranes, the anterior portion of the septum just within the nostrils is the usual site of invasion, spreading as a rule across the nasal floor to the turbinates. If the disease extends from the face, the lateral cartilages are involved. The bony structures are seldom, if ever, implicated. Hamilton claims the lymphatic system is sometimes affected, but there is not often implication of distant tissue. Small nodes, either single or multiple, mark the onset of the disease. These increase in number, with coalescence, finally producing slightly elevated, nodular surfaces. The nodules are small, hard, and circumscribed, and the over-

lying tissue hyperemic, traversed by tortuous and congested blood vessels. The nodules may finally become paler in color, and when ulceration occurs, light brownish flakes of inspissated secretion may cover the surface. As a result of obliterated blood-supply, degenerative changes take place in the nodules, causing ulceration and discharge of necrosed and liquefied tissue, forming an oval or round ulcer, the margins of which are indurated, presenting a shallow, cup-shaped depression. Perforation of the cartilaginous septum may follow. The necrosis in these cases is usually serpiginous in character. The nasal floor and turbinates may be involved, especially the middle turbinate, but the bony structure is not affected as is the cartilage.

Histologically, a differentiation from tubercular disease can not be made. In the fully developed nodule will be the central giant cell, numerous small cells and peripheral epithelioid cells. Tubercule bacilli are usually found in this disease. The adjoining tissue shows more or less inflammatory action. Mucoïd change and fatty degeneration appear later, but preceding ulceration. The lower parts of the mass generally show marked cellular fatty-degeneration absorption. Occasionally the disease does not follow the ulcerative course, but on reaching the nodular development stage undergoes degenerative changes, the nodule eventually being absorbed and leaving a fibrous tissue cicatrix, which finally is followed by atrophic changes.

Symptoms.—One or both nasal cavities may be affected. Occlusion of one or both sides by the nodular growths may occur. Frequently it is impossible to examine the deeper portions of the nasal cavities, and the middle turbinates may be entirely concealed. The secretion is slight, at first clear, becoming thicker as ulceration progresses, and if retained for some time in the nasal cavity, putrefactive changes occur, causing the secretion to be somewhat fetid. Grayish or dark colored scales or scabs usually form over the lesion,

which are more or less tenacious. Detachment of these crusts is often followed by oozing of blood.

When inspection of the nares is possible, the characteristic small nodules may be seen, usually on the septum. These nodules are more irregular in outline than in the cutaneous form. In the early stages of development the nodules are firm and hard to the probe, but later, when they soften, the probe readily penetrates the mass, and may even pass through the cartilage, producing a slight hemorrhage. While the growths are generally painful to touch, their presence and growth seldom cause much pain. When the ulcerative type presents, the serpiginous form of spreading is seen. The ulcerative process is essentially chronic, and may cause perforation of the septum. The external appearance of the nose is changed, being pale, rigid, and later pinched and shrunken looking, as cicatrization progresses. When there is a simultaneous destruction of the integument, extensive ulcerations and erosions present, leading to extreme deformity, or sometimes even stenosis, from the resulting cicatrization. There is in some cases considerable itching. *Lupus exedens* is usually applied to the ulcerative form, and *non-exedens* when ulceration does not occur. In the latter form there is not the extension of the disease that occurs in the former.

Diagnosis.—Generally easy, if the symptoms described are remembered. Syphilis is differentiated by the history, intermittent periods, bone involvement, and amelioration by specific treatment. Malignant growths usually develop more rapidly, are painful and generally appear later in life. Fibroma are usually firmer and not easily torn. Mucous polypi are smooth, soft, glistening, and generally pedunculated. Nasal tuberculosis nodules are not irritable to touch, and the extension is different, while reparative tendencies are rare.

Prognosis.—Unfavorable regarding a cure or prevention

of deformity, but it is seldom fatal. The disease is essentially chronic in its course, and may sometimes be checked. Spontaneous recoveries have been reported.

COMPLICATIONS.—Erysipelas has been reported, and any of the infectious conditions may be contracted through the denuded surfaces.

TREATMENT.—*Local*.—Thorough extirpation of the lesions. After anesthetizing the mucous surface, the crusts should be removed, and by curettage, the morbid tissue, invading also some of the surrounding healthy tissue, then using 60 per cent lactic acid or strong carbohc acid over the traumatic surface. Cleanliness of the nasal surfaces can be obtained by the use of the salicylic acid solution, followed by the application of stearate of zinc with salicylic acid.

Internally.—Phytolacca, liquor potassii arsenitis, syrup of calcium lactophosphate, hydrastis, nux, etc., should be given.

Glanders.

Synonyms.—Equinia; Maliasmus; Malleus; Malleus humidus.

An exceedingly contagious disease of horses, not often transmitted to man. When it is, there are severe constitutional symptoms, and formation in the submucosa of the infected mucous membrane of granulation-tumors, which soon ulcerate, and are accompanied by an offensive discharge. As a rule, the nasal mucosa is first affected. The progress of the disease is rapid, and usually fatal. Either acute or chronic conditions may occur. The manifestation of the disease in the respiratory tract only is considered.

Etiology.—In 1882 Loeffler found the bacillus mallei, which is recognized as the cause of glanders. The disease is most frequently found among horses, but is sometimes transmitted to man. Cases have been reported where the disease has been communicated from one person to another.

The disease is most frequently found among people who are employed about horses. The invasion of the disease seems to depend upon an abrasion of the skin or mucous membrane, although cases have developed where this does not seem to have occurred. It is at times difficult to obtain a satisfactory history.

Pathology.—In this disease numerous scattered or closely grouped granulation tumors are found on the nasal submucosa. The lymph structures are invaded, and their location is determined by the new formation. Whether the irritation is caused by the presence of the bacilli, or by the products of the germs, has not been definitely settled; but there is a proliferation of leukocytes forming lymphoid cells, and an ever-increasing number of the bacilli. Nutrition is arrested, and commencing at the center of the mass, liquefaction necrosis results. When this occurs, rupture of the tissues follows and there is a discharge of puruloid secretion over the surface of the mucous membrane. Small abscesses, or ulcers, result, which vary in size. Microscopical sections will show the tumor to consist mostly of epithelioid and lymphoid cells, numbers of bacilli, and some fibrous structure. Two forms exist, the acute and chronic.

Symptoms.—The chronic form is neither as frequent nor as rapid as the acute, but the chronic usually terminates in an acute type. In the chronic form the membrane becomes swollen and often painful, and is covered with dirty, crusty scabs. There is more or less viscid, mucopurulent fetid discharge, which becomes serous as the ulceration progresses. The cutaneous surface is implicated, and there is either the development, maturation, and discharge of subcutaneous nodules, or the superficial formation of bullæ. Extensive lymphadenitis and lymphangitis result, and the extent of the suppuration will produce an irregular fever. The deeper structures are destroyed, there is also necrosis of the bone and cartilage, with escape of necrosed material and

gangrene of the surrounding structures. When the acute form does not terminate the attack rapidly, the patient becomes emaciated, profuse sweating occurs, colliquative diarrhea with exhaustion follows, and finally, death from collapse.

In the acute form, the symptoms are those of an acute infection; lassitude, rigors, rheumatic-like pains in the trunk, back, extremities and joints, besides headache, dyspnea, irritation of the stomach with nausea and vomiting, and finally diarrhea. The infected site becomes hot, red, and swollen, lymphangitis soon occurs and the surrounding structures swell and redden. Small nodules form in the submucosa, which, from a translucent appearance, become darker, then yellowish, eventually rupturing. A thick, semi-fluid deep yellow, frequently blood streaked, offensive discharge follows. The ulcerative process shows little tendency to heal. The cutaneous surfaces become involved in a similar manner. Enlargement of the lymphatics, especially of the neck, rapidly follows. Constitutional disturbances are marked, temperature increased, pulse rapid, tongue dry and coated with a whitish fur. A typhoidal condition soon occurs, emaciation and exhaustion from the profuse sweating, nausea, vomiting, and frequent diarrhea, until death results.

Diagnosis.—The positive diagnostic test is the recognition of the bacilli mallei, or by inoculation of susceptible animals, as the guinea pig, rabbit, or mice. The occupation of the patient will often aid in the diagnosis, as stablemen run greater risks of infection than others. The disease may simulate typhoid, but lacks the rose spots. Pyemia or malignant growths may be difficult to distinguish from this disease. The diagnosis should always be by exclusion.

Prognosis.—Always guarded. Some cases are reported as having recovered from the acute form, but death usually results, generally within a few days. In the chronic form

with skin complications, the result is usually fatal. Although some recoveries occur, death results usually in from six to eight months.

COMPLICATIONS.—In man, as in the horse, a subacute pneumonia may result.

Treatment.—For the nasal condition, opening and curetting the nodules, abscesses or ulcers, and cauterization of infected parts, and the removal of all suspicious growths. The cauterization may be made with carbolic acid, carefully applied to the affected area after curettage. A solution of potassium permanganate, or the salicylic acid wash, may be employed to keep the nasal surfaces as clean as possible. The constitutional symptoms should be met with aconite or veratrum, for the fever; phytolacca or iris, or both combined, for the lymphatic disturbance; baptisia, echinacea, or potassium chlorate, for the evident septic state; potassium bichromate for the ulcerative condition and tenacious secretion. Potassium iodide has been reported curative in some cases; giving the drug in large doses.

Leprosy.

Synonyms.—Elephantiasis Græcorum; Lepra.

In this country, leprosy is seldom seen. The nasal, pharyngeal, or laryngeal invasion occurs as complications of the systemic infection. Two forms are recognized, the anesthetic and tubercular.

In the first variety, there are anesthetic areas caused by neuritis of the connected nerve supply, followed by tropho-neurotic changes.

In the tubercular variety there are local granulation-tissue masses in the submucosa, which undergo liquefaction-necrosis and ulceration, the ulcers showing a variable tendency to cicatricial healing.

Etiology.—This disease is supposed to be caused by the bacillus lepræ. Leprosy is most frequently seen in the Sand-

wich Islands, China, and India, the majority of cases being between fifteen and thirty years of age. The disease is but slightly contagious, and the exact method of inoculation is not understood. It appears to be as varied in the manner of transmission as syphilis. Heredity is probably an important factor.

Pathology.—Both the anesthetic and tubercular varieties may co-exist in the same patient. In the first form, there are changes in the nerves supplying the affected areas. The nerves show, by microscopical examination, a chronic interstitial neuritis. When the nerve influence is destroyed, atrophic changes occur, the anesthetic areas ulcerate, muscle and glands atrophy, and necrotic bone is discharged. In the tubercular form the lesion is characteristic, and certainly places the disease among the infectious granulomata. At the point of infection, there is an inflammation which is followed by infiltration and proliferation of the cellular elements, and the formation of a granulation tumor.

Symptoms.—As a rule, the disease of the respiratory tract is secondary to the cutaneous and constitutional condition. The anesthetic form is reported not to manifest itself under five years from the time of the onset of the disease. Complete anesthetic areas are found in the nose and pharynx; the soft palate is not sensitive, and motor paralysis of the larynx sometimes occurs. Ulceration, and later absorption of the nasal bones follows. The nodules in the tubercular form follow the same course of development as those of the skin. First, the erythematous stage, in which the mucous membrane reddens, is hyperemic, and often there is epistaxis. Eventually the membrane pales and thickens. There is the appearance of a thin transparent coating over the mucous surface, and the sensibility to odors and touch is lessened. Respiration may be interfered with through the thickening, and in those cases where the pharynx and larynx are also affected, the effort to talk will

quickly produce fatigue and dryness of the throat, the voice gradually assuming a nasal character, then shrill, and finally aphonía. In the second stage there develops in the inflamed areas numerous small nodular masses, which may continue discrete, or coalesce. These producing pressure atrophy of the glandular elements in the overlying tissue, the surface will present a smooth, tense, and glistening appearance. The respiration is still impaired. The duration of this stage is variable, extending from a few weeks to several months, or it may be final. In the third stage, the nodules soften, open, and form small ulcers. Pyogenic infection results, the discharge thickens, is yellowish or brownish, is nearly always offensive, and there is a disposition to crust formation. The ulcers increase in size and produce facial changes, similar to those seen in tertiary syphilis. Atrophy and disintegration of the turbinates results, perforation of the septum, and often of the hard palate. The entire framework of the nose is weakened, and flattening or collapse of the nose follows. The soft palate is frequently destroyed. When cicatricial bands form, they, by their contraction, produce still more distortion of the structures.

Diagnosis.—Usually easy, as the cutaneous condition will eliminate other diseases. Tertiary syphilis is differentiated by the history and amelioration by specific treatment.

Prognosis.—The same as for the general disease. The anesthetic form runs its course in from fifteen to twenty years, and the tubercular in from eight to ten years. Spontaneous recoveries sometimes occur, and cures are not infrequently reported.

Treatment.—So far, any one line of treatment has proven unsatisfactory. Ingals claims some cases were improved by the use of chaulmugra oil, 5 to 60 drops a day, taken internally, and inunctions of the same, one part to five or six parts of lard.

Nasal Actinomycosis.

This disease may occur in the nasal mucous membrane, but so far, no cases are known. The probabilities are that it has not been recognized, as even the pharyngeal form is often unrecognized. The description of the pharyngeal disease will suffice for such cases as may occur.

Rhinoscleroma.

Rhinoscleroma is seldom seen. Firm, hard, nodular tissue, with a tendency to lateral extension, is formed in the submucosa or deeper layer of the cutaneous structure. There is no pain, no discharge, and seldom, if ever, ulceration. Systemic symptoms are absent, and the growth is very slow in development. The cause is not positively known.

Etiology.—At the present time a bacillus is credited with being the cause, the bacillus of rhinoscleroma. There seems to be no predisposing factor. The disease appears to be most frequent in Southeastern Europe, and the ages range from fourteen to forty-five.

Pathology.—There is a round celled infiltrate into the corium and papillæ if the formation is in the skin, or in the submucosa if in the mucous membrane. Histologically the lesion shows fibrous tissue and small round cells, large spherical, hyaline cells with a protoplasmic reticulum containing one or more nuclei, smaller translucent hyaline particles, and the bacilli. Sometimes the smaller hyaline granules and bacilli are found in the interstitial lymph channels in the fibrous structure. Through the increase of the infiltrate, more or less pressure atrophy of the glandular elements results. The round cell becomes spindle-shaped, and finally forms fibrous tissue. Fatty or granular degeneration does not occur, and there are no evidences of breaking down.

Symptoms.—The slow development and absence of sys-

temic disturbances are characteristic. The disease usually commences at the margin of the nostrils and contiguous part of the upper lip, as small nodules, either discrete or confluent. They are firm, sharply defined, slightly elevated, hard and smooth to touch, traversed by dilated blood vessels, are hairless, and sometimes somewhat glossy. The tissue covering the masses may be natural in color or slightly darkened. With the exception of a slight tenderness on pressure, there is no pain. The tendency is to follow the mucous rather than the cutaneous surface, and the disease spreads by lateral infiltration, or coalescence. Occasionally it assumes the form of a general diffuse infiltration instead of forming nodules. The morbid process gradually extends through the nasal mucous membrane, and may invade the pharyngeal, laryngeal, and even tracheal tissues, obstructing respiration and phonation.

Diagnosis.—May be overlooked on account of its rarity, but by remembering the characteristic symptoms, it is comparatively easy.

Prognosis.—As far as a cure is concerned, it is unfavorable, but there appears to be no effect upon the general health, excepting through mechanical interference with respiration when the larynx and trachea are involved.

Treatment.—Purely empirical.

Furunculosis.

Synonyms.—Phlegmonous rhinitis; boils.

Furunculosis is applied to abscess formation of any part of the nose, but phlegmonous rhinitis is used only to indicate abscess of the nasal mucous membrane, which is seldom seen.

Etiology.—As a rule follows an injury, and occurs most frequently on the septum near the nasal orifice. It may be single or multiple. A hair follicle may be the site of the inflammation. In many persons furuncles occur fre-

quently, and involve the cartilage. Seen oftenest in the young or middle aged. Chronic constipation appears to be a factor in some cases. The infectious fevers also appear to favor their development.

Pathology.—Same as any abscess formation.

Symptoms.—The swelling, throbbing, and sense of tension is characteristic, as well as the appearance on inspection.

Treatment.—When pus has formed the abscess should be freely opened and the contents well washed out with some cleansing solution. The advisability of using a compress must depend upon the extent of the lesion. In some cases the pus is within the septum, separating the cartilage, and a sharp knife is required to puncture the cartilage. Internally, the administration of calcium sulphide, or lime water should be persisted in for some time, as this has a tendency to prevent a recurrence.

CHAPTER VIII.

INFLAMMATORY DISEASES OF THE ANTERIOR NASAL CAVITIES.

ULCERS OF THE ANTERIOR NASAL CAVITIES.

These may be divided into non-infected and infected. The non-infected are divided into simple, and compound-malignant.

The simple comprise eight classes: 1, Catarrhal; 2, Herpetic; 3, Eczematous; 4, Result of foreign bodies; 5, Neuro-paralytic; 6, Scorbutic; 7, Diabetic; 8, Varicose.

COMPOUND-MALIGNANT.

The infected are divided into: 1, Tubercular (lupoid). 2, Syphilitic. 3, Leprous. 4, Glanders. 5, Diphtheritic. 6, In measles. 7, In rheumatism. 8, In scarlet fever. 9, In small-pox. 10, In typhoid fever. 11, In typhus fever. (Kyle).

For convenience, the different forms of nasal mucous membrane ulceration will be considered collectively.

A superficial necrosis extending through the basement membrane, whether involving the submucosa or not, is an ulcer.

Whenever there is ulceration or fetid discharge, a careful inspection of the parts should always be made before cleansing, as this will aid in making a diagnosis.

Non-Infected Ulcers.

SIMPLE ULCERS.

CATARRHAL.—In those cases where a profuse discharge is manifest, there are sometimes found ulcerated areas on prominent points near the nasal orifices. These points may be septal exostoses or contact surfaces between enlarged turbinates and the septum, or any location where secretion may be retained. The ulcerated areas are sensitive and painful, as a rule, and always cause the patient considerable annoyance.

Treatment.—Careful cleansing of the ulcers with an alkaline solution, followed by the salicylic acid wash. The application of stearate of zinc with salicylic acid will protect and stimulate the ulcer. Aristol will also be found beneficial in many of these cases. Internally, the administration of potassium bichromate will nearly always cause a rapid improvement.

HERPETIC.—Herpes of the mucous membrane is sometimes seen. The vesicles are in groups, each about the size of a millet seed or split pea. There is local irritation and rise of temperature, accelerated pulse and often considerable thirst. In a few days the vesicles dry, and thin scabs or crusts remain, which may unite, and usually without a surrounding inflammatory zone.

Treatment.—Thorough cleansing of the area with an alkaline solution, followed by the salicylic acid ointment. The bowels should be thoroughly evacuated.

ECZEMATOUS.—This form is oftenest found in young children who also have eczema on the upper lip and face. It sometimes follows the exanthemata, particularly measles. In adults it is occasionally found associated with eczema of other portions of the body.

In children, an improper diet, or irritation of the lower bowel from ascarides or undigested material, may act as an

exciting cause of this disease. The discharge seldom has an offensive odor. The amount of the secretion varies, but there is a formation of tough, firmly adherent crusts at different points. The itching which is often excessive, leads the patient to pick the nose more or less continually, which increases the irritation, and usually prolongs the disease.

In adults, the urine often shows an excess of urates. The individual is inclined to avoid exercise, and there is often a torpid state of both mind and body.

Treatment.—An alkaline solution will best soften and cleanse. The application of the salicylic acid ointment should be made after all the crusts have been removed. In some cases beneficial results follow the application of a two per cent solution of silver nitrate. In children, the administration of santonine often removes irritation of the bowels, even when worms are not present. If *ascaris vermicularis* are present, an infusion of quassia is a useful remedy. The diet should be nutritious, and avoidance of overfeeding is essential. The general health always needs attention.

ULCERS DUE TO FOREIGN BODIES.—A foreign body in the nasal cavity may be the cause of an ulcer. The characteristics are usually the same as in the simple catarrhal type. The removal of the foreign body nearly always results in a cure, but if not, the treatment already suggested should be employed.

NEUROPARALYTIC.—Paresis or paralysis of the fifth pair of nerves may cause ulceration of the nasal mucous membrane. Excoriations varying in size, dry, sluggish, and without a tendency to heal, are characteristic. Hemorrhage, as well as loss of smell on the affected side, is sometimes present.

Treatment.—This should be directed to the cause of the nerve affection, restoring proper nerve stimulation. Locally, the use of cleansing solutions and stimulation of the ulcers are necessary.

SCORBUTIC.—This is an extremely rare condition, but is sometimes seen in cases of scurvy when there has been irritation of the nasal mucous membrane. It may also occur as a part of a general facial scorbutic ulceration. The discharge is fetid and extremely offensive. The edges of the ulcers are thick, hard, and present a shiny appearance, while the surface is covered with clots of blood, and has a fungoid appearance. The ulcer usually spreads rapidly, and there is more or less bleeding.

Treatment.—The administration of lemon juice, and a vegetable diet seems to influence this disease more favorably than anything else. The ulcerative lesion should be kept clean with a solution of lemon juice or dilute hydrochloric acid, 10 drops to half an ounce of water. The fungoid masses should be removed with scissors and forceps, and a powder of salicylic acid one part, boric acid six parts, applied to the surface.

DIABETIC.—These ulcers are due to the general impaired condition of the entire system, which often causes a low grade inflammation of the upper respiratory tract. As a rule the ulcers are near the nasal orifices, being the result of picking or rubbing the nose to relieve the intense itching usually present in diabetic cases. There appears to be a direct relationship between the ulcerative process and the amount of sugar in the urine. These ulcers do not present any especial characteristics, but in connection with diabetes should be treated as local manifestations of a systemic infection.

VARICOSE.—The venous plexuses of the turbinal nasal region may become so engorged as to cause excessive distension, even to the point of rupture and ulceration. The posterior border of the velum may also be affected. There is often a cyanotic condition of the mucous membrane in these cases. The ulcers are sluggish, forming slowly and healing equally as slowly. They present a bluish-red color,

are indolent, irregular in outline, shallow, and covered with a sanious, crusty discharge, and have a tendency to bleed freely.

Treatment.—Locally the surface should be cleansed with the salicylic acid solution and distilled hamamelis. Internally, the use of distilled hamamelis and collinsonia soon afford relief from the engorgement of the venous sinuses.

Compound-Malignant Ulcers.

An ulcerative process may occur when any malignant growth is present in the nose, but there is no especial difference in the appearance from an ulceration in other parts of the body from the same cause, so the descriptions will be given under tumors.

Infected Ulcers.

TUBERCULAR ULCERS (LUPOID).—In the nasal tissues, tuberculosis is uncommon. When it does occur, any of the structures may be the site of the lesion, but the septum appears to be the preference. The simple tubercular ulcer is whitish gray, shallow, with irregular outline, and at times it is difficult to determine where the infection stops, and healthy membrane commences. In the early stages the miliary tubercles which have not broken down can often be seen near the periphery of the ulcer. There is a tendency to hemorrhage. The surface of the ulcer is often crusted with discolored mucus.

Treatment.—When possible the infected area should be removed, either by the knife or by cautery. The traumatism is generally treated with 50 per cent lactic acid, and then covered with compound stearate of zinc with salicylic acid, mild. Aristol may also be used. Iodoform is employed, but on account of the odor is usually objected to by the patient. Internally, the treatment should be the same as employed for general tuberculosis.

SYPHILITIC ULCERS.—In the nasal fossæ we may have the initial sore, or any of the manifestations, even to necrosis. Chancre of the nose is not often seen. It may present a granular appearance, or be hard and cartilaginous with an ulcerating surface. The symptoms are hemorrhage, stenosis, and when located on the alæ, deformity.

The mucous patch in the nose is not liable to produce any subjective symptoms. The lesion is similar to the patches in the mouth.

Superficial ulcer is infrequently seen. It is usually on the septum, but may be located on the turbinates, or floor of the nose. The edges of the ulcer are quite well defined, while the mucous membrane surrounding the lesion is normal in appearance. There is a slight depression in the center of the ulcer. A thick, stringy, yellowish-gray mucus covers the surface of the ulcer. When this is removed, the surface presents a grayish pink color. The ulcerative area is but slightly sensitive to touch, but bleeds easily. There is but little tendency to extension.

The deep ulcer with bony necrosis is the result of a gummy deposit, and as a rule does not appear until ten or fifteen years after the initial sore. The septum is most frequently affected, and the process is more amenable to treatment than when affecting the turbinates, where it assumes a more chronic type, with more extensive destruction of tissue through extension into the subjacent tissues. These ulcers seldom extend beyond the posterior nares.

Treatment.—See nasal syphilis.

LEPROUS ULCERS.—Generally caused by extension of the disease from the alæ. When ulceration of the nodules occurs, the odor of the sanious, watery discharge is very offensive. Perforation of the triangular cartilage, and total destruction of the same, as well as of the alæ, may occur in aggravated cases. The appearances have been described:

GLANDERS.—In a few days after the onset of systemic

symptoms, there is a glairy, thick, fetid, deep yellow discharge, which is streaked with blood. The nodules, singly or in groups, are at first small, but rapidly increase in size. They are colorless in the early stages, then red, and finally yellowish, resembling pustules. Ulcerative tendencies are marked and with but slight disposition to heal. The accessory sinuses may be affected. The diagnosis can be determined only by the systemic condition and history.

DIPHThERITIC ULCERS.—Nasal diphtheria may be primary, or secondary by extension. The peculiar grayish membrane, and acrid, irritating, brown ichorous discharge are characteristic of the nasal lesion. The ulceration is similar to that found elsewhere in this disease.

CROUPOUS, OR FIBRINOUS ULCERATION.—*Chronic*.—In persons where there is defective nutrition, a chronic membranous condition may affect the nasal tissues. The cause is obscure. Ulceration may occur, probably as the result of combined local infection and impaired nutrition. The treatment outlined under *Fibrino-plastic Rhinitis* is required.

ULCERS IN MEASLES, RHEUMATISM, SCARLET FEVER, SMALL-POX, TYPHOID FEVER, AND TYPHUS FEVER.—The mucous tissue, and sometimes the bones and cartilages may be involved in ulceration, the result of the above named diseases. Perforation of the septum may occur, and obliteration of the nostrils has been reported in small-pox. There are no characteristic peculiarities about the ulcers occurring in these diseases, but nasal manifestations should be noted. In typhoid fever, on account^o of the sub-normal state of the system, the ulcerative process may be so extensive, that the cartilage and bony structures may all be destroyed, causing considerable deformity of the nose.

CHAPTER IX.

NASAL NEUROSES.

NEUROSES OF OLFACTION.—(1) Parosmia; (2) Hyperosmia; (3) Anosmia.

REFLEX NASAL NEUROSES.—(a) Respiratory Neuroses. (1) Sneezing; (2) Hydrorrhea; (3) Hyperesthetic rhinitis (Hay fever); (4) Cough; (5) Pharynx and mouth; (6) Larynx; (7) Asthma.

(b) REFLEXES OUTSIDE OF THE RESPIRATORY TRACT.—(1) Ear; (2) Eye; (3) Migraine, Congestive Headache, Neuralgia; (4) Chorea, Epilepsy, Vertigo, and Aprosexia; (5) Stomach; (6) Heart; (7) Sexual Organs.

The general term neuroses includes changes in olfaction as well as reflex phenomena.

NEUROSES OF OLFACTION.—When the olfactory nerve terminals, the mucous membrane of the superior turbinates, the upper half of the middle turbinates, and upper three-fourths of the posterior portion of the septum are normal, allowing free circulation of air, the sense of smell is normal, provided the remainder of the olfactory tract is healthy.

Any alteration of one or more of these factors may produce loss of, or perversion of the sense of smell.

PAROSMIA.—This is a perversion of the sense of smell, causing the perception of imaginary odors. Morbid conditions of the olfactory nerve or bulb, altered secretion, overstimulation of the nerve terminals, or brain lesions, may be the causes of this condition.

Sensory illusions of smell have been observed among insane people, and also in those affected with other nervous diseases.

Treatment.—This may be an early symptom of some brain lesion, and a careful examination should be made. Potassium iodide, potassium bichromate, pulsatilla, bryonia, or phosphorus, are most generally indicated.

HYPEROSMIA.—A hypersensitiveness to olfactory stimulation. Odors hardly perceptible to the ordinarily normal nose may be so marked as to be positively nauseating, and unpleasant odors may persist for several hours after the stimulus has been removed. Hypersensitiveness of the sense of smell, as well as exaggeration of all impressions, may result from the exhaustion of nerve force through exhausting or wasting diseases. This condition is also sometimes found in hysteria, neurasthenia, or hypochondria.

In women, hyperosmia may be present with sexual or uterine disturbances, especially during the menstrual period.

Treatment.—The treatment must be directed to restoring the nervous system to as near normal as possible. In hyperosmia, ignatia and physostigma should be added to the list.

ANOSMIA.—Impairment of the sense of smell may be partial or complete. When partial it is termed dysosphresia.

Anosmia may be a congenital or an acquired defect. Changes in the upper nasal passages which prevent the free circulation of air may produce this condition. A "cold in the head" is a frequent cause of temporary loss of sense of smell. H. Zwaardsmaker divides anosmia into two general classes: First, as to obstruction, which prevents stimuli from reaching the olfactory region; this may be in the anterior cavities, preventing ingress to external odors, or by occlusion of the post nasal space or choanæ, which prevents the odors accompanying the acts of eating or drinking from gaining access to the sensory region.

Any malformations or morbid conditions of the nasal cavities, post-nasal growths, paralysis of the alæ nasi, or

absence of the external parts of the nose, may cause unilateral or bilateral loss of smell.

Second, anosmia essentialis and anosmia intracranialis, depending on whether the nerve endings of the olfactory cells, the nerves themselves, or the central olfactory region of the brain is affected.

Essential anosmia may be unilateral, bilateral, temporary or permanent. It may result primarily from direct irritation of gases, strong, pungent, or disagreeable odors, or constantly inhaled tobacco smoke. Traumatism of the olfactory nerves, diseases or trauma of the ethmoid bone may produce anosmia. The application of cocaine or the supranal preparations have also caused temporary anosmia.

Adenoids, polypi, increased or diminished nasal secretion, the extension of chronic inflammation from the nasal respiratory tract, ascending neuritis of the olfactory nerve, morphine, atropine, or mercurial poisoning may be causes of anosmia.

Anosmia intracranialis may be caused primarily by an injury of the olfactory bulb or nerve tract, by tumors in close proximity, degenerative changes, congenital defects of the conducting nerves or receptive areas, and through senile degeneration. Secondary causes of anosmia may be hemorrhage, abscess, tumors, necrotic or atrophic intracranial conditions.

Prognosis.—This will depend very much upon the cause. The length of time anosmia has been present does not have much influence, as cures have been reported where the defect had existed for over thirty years.

Treatment.—When not due to some central lesion, improvement can sometimes be obtained by both local and internal treatment. Vibratory massage or the galvanic current has given good results in some cases, where stimulation of the olfactory region was required. Internally, nux, phosphorus, ignatia, or hyoscyamus may be needed.

Reflex Nasal Neuroses.

This term is applied to symptoms originating in nasal excitability or nervous instability. The term reflex, although generally applied, is hardly appropriate, as physiologically it means the reaction of a nerve center to an impulse transmitted to it by a sensory nerve, the response being in the form of activity of some centrifugal nerve. The terms sensory, motor, trophic, and vasomotor neuroses of peripheral origin are better. Two general divisions are most convenient; neuroses of the respiratory tract, and neuroses affecting other portions of the body.

RESPIRATORY NEUROSES.

This includes the reflex phenomena occurring in the nose, nasopharynx, pharynx, mouth, larynx, and bronchi.

SNEEZING.—Paroxysmal sneezing often occurs where no alteration of the nasal tissues can be discovered. It may be the result of an exceedingly irritable condition of the membranes, with a corresponding irritability of the vasomotor centers depending upon a lowered vitality. In the majority of cases, however, there is unilateral or bilateral vascular occlusion with excessive secretion. This condition varies with the state of the nervous system, and depends upon the direct cause, as drafts, irritating fumes, dust, etc. In some instances, an exciting lesion is found in the nasal fossæ, as polypi, septal spurs, or an excessive chronic distention of the cavernous tissue.

Treatment.—When possible to locate the exciting cause, its removal will suffice. When due to overdistention of the cavernous tissue, contraction by means of submucous puncture, the galvano cautery, or similar measures should be employed. When no exciting cause can be found, the general health should be improved.

Hyperesthetic Rhinitis.

Synonyms.—Autumnal catarrh; Catarrhus æstivus; Coryza vasomotoria periodica; Hay asthma; Hay fever; Idiosyncratic coryza; June cold; Peach cold; Periodical hyperesthetic rhinitis; Pollen catarrh; Pruritic rhinitis; Rag-weed fever; Rhinitis hyperesthetica; Rose catarrh; Rose cold; Rose fever; Summer catarrh.

This disease, if it is a disease, is a periodical inflammatory state of the nasal tissues, usually with the lapse of a year between the attacks. It is most prevalent during the warmer seasons of the year, although well marked cases occur during the winter months. Seldom seen before the age of ten years, and the primary attack is infrequent after twenty-five. After forty the condition is seldom seen.

Various theories have been advanced regarding the cause of this condition. The theory of a local irritant, due either to some substance in the atmosphere, as pollen, or to a local manifestation from some systemic wrong, as uric acid,—is most generally accepted. The most plausible theories, however, are that it is either a disease of the nasal tissues, giving rise to various reflexes, or that it is a neurosis. The condition is found most frequently among persons having a highly developed nervous organization. How much of a factor the psychological condition plays is a question.

ETIOLOGY.—*Predisposing Causes.*—Either neurosthenia or neurasthenia may be predisposing factors. There may be a hereditary tendency, as found in neurotic families, or it may be the sequence of a prolonged nervous strain. It is a well-known fact that the condition is more prevalent among the highly educated than the illiterate; among those whose vocation requires mental effort, rather than physical, and also among urban rather than country people.

It is evident that no one cause can be ascribed as an etiological factor, but various causes may, and do, produce

the same general line of symptoms, which are grouped as hay fever or hyperesthetic rhinitis. Sensitive areas of the nasal mucous tissue, or malformations of the nasal fossæ may be ascribed as factors in some cases, although such conditions are probably more sensitive to an irritant. Kyle believes that in many cases the cause of the local irritant is due to some chemical change in the secretion of the mucous glands. The conjunctiva, stomach, and frequently the bladder are affected in this disease, and the uric acid theory does not explain all the cases. As the arterial supply of the nasal and nasopharyngeal mucous membrane comes mostly through the bony structures, which also support the membrane, it is easy to see why these regions should be more susceptible to congestion, infiltration, and deposit, than where there is a muscular foundation.

Males are oftener affected than females, and usually prior to the age of forty. Occasional cases are found when the initial attack is subsequent to this age, and one case has been reported in a child of two years. The disease is most prevalent in the United States and England. High altitudes seem to be practically free from the condition, although this is not an invariable rule. Americans and English are the races most affected.

Exciting Causes.—Blackley has demonstrated that pollen is the exciting cause in the majority of cases. Some individuals are susceptible to ammoniacal fumes, while others may be influenced by apparently innocuous substances.

Pathology.—During an attack, all the evidences of a catarrhal inflammation are present, but there are no characteristic structural changes. Hypersensitive areas are present during the attack, usually located at the extremities of the inferior turbinates, and at a corresponding point on the posterior portion of the septum. On the anterior part of the septum, or nasal wall, within the angle defining the vestibule, there is also, often, a sensitive area. The mid-

surface of the middle turbinate may also occasionally have an area of hypersensitiveness. These areas are necessary for the attack, as mechanical irritation of these surfaces causes an acute manifestation of the condition.

Symptoms.—These vary in different individuals, and even in the same person during different attacks. The usual premonitory symptoms can be summed up in the words "spring fever," the drowsiness, lassitude, and weariness being extreme. Sneezing soon follows, and the paroxysms

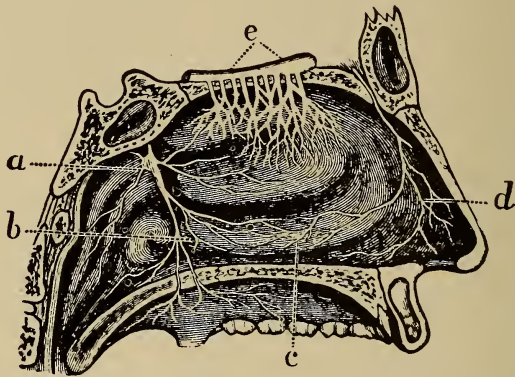


FIG. 62. Nerve supply of nasal mucosa. *a.* Sphenopalatine ganglion; *b.* posterior area; *c.* middle area; *d.* anterior area; *e.* olfactory bulb.

are sometimes of long duration. Itching and burning of the nose, eyes, and roof of the mouth are part, or all, present. Lacrimation and a thin ichorous discharge from the nose soon follows. The burning sensation of the eyes is often marked, and the conjunctiva becomes congested, the flow of tears becoming more marked. Frequently nasal respiration is impossible owing to the congestion of the turbinates. Headache follows, and as a result of mouth breathing, the pharyngeal mucous membrane becomes dry and irritated, and the larynx irritable. Cough soon makes its appearance,

and the asthmatic conditions are so pronounced in some cases that bronchial catarrh with asthma is the diagnosis. The asthmatic symptoms become more marked with repeated attacks.

Diagnosis.—This is not difficult, as acute nasal catarrh is about the only affliction that could be mistaken for this disease.

Treatment.—The main reliance has been on local treatment, and as a result has not been very successful. Internal treatment for the relief and diminution of the severity of the attacks must be borne in mind.

The local application of cocaine has held for a number of years, but the effects are so transient that it keeps the patient busy alternating the cocaine and handkerchief. I have used the unguent-salicylic acid in those cases having the full turbinal tissues, and a few applications seemed to give very marked relief. The engorged conditions passed off, not as rapidly as under cocaine, but more permanently.

In the early stages, especially with anemic, delicate persons, the arsenic iodide, 1-100 gr., given three or four times a day, will give relief and mitigate the attack as a rule. Euphrasia has been recommended, when the lachrimation is profuse and a burning sensation was present. Gelsemium seems to find a place where there is fullness in the frontal region, dryness of the nasal fossæ, and mild nasal obstruction. Naphthaline has been much extolled. The indications given are marked asthmatic symptoms, the discharges from the nose and eyes excoriating. The 1-100 gr. is given internally, and $\frac{1}{5}$ per cent solution may be used locally. I have had no experience with this drug.

Taking the theory that uric acid is the prime cause, the treatment resolves itself into anti-uric acid treatment. The administration of dilute phosphoric acid in these cases has been tried, and favorable results reported. I have had no experience with this form of treatment, but would rely more

on such remedies as I have found efficacious in similar forms of rhinitis, sticta when the secretion is scanty, but a desire to blow the nose, potassium bichromate with thick tenacious discharge, distilled hamamelis with thin, watery, non-excoriating discharge, liquor potassii arsenitis with thin, watery, excoriating discharge. In fact, whatever is the indicated remedy should be employed.

COUGH.—Nasal cough may result from a simple coryza, chronic or hyperplastic rhinitis, septal irregularities, polypi, hypertrophic conditions of the nasal structures or from vasomotor changes. Mackenzie, as the result of experiments, describes a "well defined sensitive area situated near the posterior extremity of the inferior turbinated bone and contiguous portion of the septum." When this region is irritated, through any cause, reflex cough results. A careful investigation will often reveal this locality as the origin of a cough for which no other cause can be found.

PHARYNX AND MOUTH.—Nasal disease has been credited with producing in this region, hyperesthesia, parasthesia or the sensation of a foreign body, neuralgia, palatal paresis, dysphagia, hiccough, and salivation.

LARYNX.—Aphonia, has been reported cured by nasal medication. There is no question but that the presence of abnormal nasal or nasopharyngeal conditions may produce laryngeal spasm or spasmodic croup.

ASTHMA.—Intranasal irritation is in some cases the cause of asthma, hence after the elimination of other causes, the nose should be carefully examined. In cases of nasal asthma, the rales are dry just preceding and following the attack.

Treatment.—This resolves itself into restoring as nearly as possible the normal condition of the nose as well as of the general system.

Reflexes Outside of the Respiratory Tract.

EAR.—Reflex conditions ascribed to nasal irritation are sometimes found in the ear. A persistent cough may result from reflex irritation produced by impacted cerumen, foreign bodies in the external auditory canal, or, as I have found in two cases, moist eczema of the canal when the exudation was allowed to remain for some time. In one case under observation, severe asthmatic attacks were cured by the removal of a ceruminous mass from the right ear. Ear-ache, tinnitus aurium, and other aural manifestations have been credited as reflex from nasal diseases.

EYE.—Lacrimation is of frequent occurrence when applications are made to the nasal tissues, or when nasal irritation is due to nasal lesions. Among the numerous reflexes may be mentioned asthenopia, retinal hyperesthesia, photophobia, scintillating scotomata, phlyctenular conjunctivitis, blepharitis, edema, glaucoma, and pain in the eyeballs. Operative measures on the nasal tissues may also produce some of the same conditions.

MIGRAINE, CONGESTIVE HEADACHE, NEURALGIA (SUPRA-ORBITAL, TIC DOULOUREUX).—A cure or relief has followed treatment of the nasal fossæ in many cases of migraine or sick headache, the so-called congestive headaches, and neuralgia of the various branches of the trigeminus nerve. In the headaches frequently seen at the age of puberty, the nasal mucous membrane seems to be peculiarly irritable. Neuralgia may be a reflex phenomenon of adenoids, lesions of the middle and posterior parts of the inferior turbinates, septal spurs, and synechiæ. In one especially marked case of supraorbital neuralgia, I found a large polypus, the removal of which gave immediate relief.

CHOREA, EPILEPSY, VERTIGO, APROSEXIA.—In chorea and epilepsy, whether the reported cures following the correction of nasal lesions and removal of adenoids, were due

to the removal of these obstructions, or on account of the improvement of the general health which usually rapidly follows unobstructed breathing, is a question.

VERTIGO.—In this condition there is also an element of doubt, as the attacks may have been aural in type, through the extension of the nasal disease, producing morbid changes in the Eustachian tube or middle ear.

APROSEXIA (inability to fix the mind on any subject.)—This is a nasal reflex which is supposed to depend upon the communication between the nose and brain.

STOMACH.—Gastric disturbances have been supposed to be reflex from nasal lesions, but they are more likely to be the result of extension through continuity of tissue, or the ingestion of the nasal secretions. The swallowing of air, which is not uncommon when the nose is occluded, may also be a cause of nausea, etc.

HEART.—Cardiac disturbances have been credited to nasal lesions. Some cases of exophthalmic goitre have been reported cured by treatment of the nose.

ERYTHEMA, URTICARIA AND ACNE OF THE NOSE AND FACE have been referred to intranasal diseases.

SEXUAL ORGANS.—Overindulgence of the physiological sexual function, the changes at the time of puberty, pregnancy, menopause, and menstrual derangements, or chronic diseases of the uterus and ovaries, may produce reflex nasal symptoms, as sneezing, dyspnea, or epistaxis.

Treatment.—In all of these cases, both local and constitutional measures should be employed.

Local.—Polypi, adenoids, or other growths should be removed by surgical means, deflections of the septum corrected, septal spurs removed, and enlarged turbinates, or redundancy of tissue, reduced by such means as seem best fitted to the case. But in all these procedures care must be exercised that an aggravation of the condition does not follow. Some disturbance is to be expected for a few days fol-

lowing mechanical interference, but it should soon disappear.

Constitutional.—A careful examination of each case must be made, and any systemic wrong treated from a rational standpoint, endeavoring to restore both the physical and the nervous systems to their normal conditions.

CHAPTER X.

NON-INFLAMMATORY DISEASES OF THE ANTERIOR NASAL CAVITIES.

Epistaxis.

Varieties.—1, traumatic; 2, local nasal lesions; 3, systemic; 4, vicarious.

Synonyms.—Nose-bleed; hemorrhagia narium; rhinorrhagia.

Etiology.—The statement is made that epistaxis may be a symptom, a disease, or a physiological process. It is most prevalent in males, and occurs more frequently between the ages of two years and puberty. At no period of life, however, is there an immunity from this condition.

The four divisions given are the most convenient for classification.

(1) *Traumatic.*—Blows upon the nose, occurring in various ways, are probably the most frequent cause. Abrasions of the mucous membrane may be the result either of accident or operative measures, or the careless handling of instruments in making an examination or local applications, the introduction of foreign bodies, so frequent among children; picking the nose, a not uncommon habit even among adults; or the occupation, in which one is exposed to the inhalation of irritating dust or acrid fumes. In this class come steel grinders, stone cutters, chemical and medical drug workers.

(2) *Local Nasal Lesions.*—The hyperemia present in the different nasal diseases, predisposes to hemorrhage. In-

creased heart action through severe manual exercise, as well as in the physical changes occurring at puberty, produces hyperemia of the nasal tissue, which often results in epistaxis. In these conditions the hemorrhage may be regarded as a natural means of relief. Sexual abuse has been ascribed as a factor by some, but other abnormalities may really be the exciting cause. In ulcerative lesions a bloody discharge is frequent, especially in malignant growths. Foreign bodies, when present for some time, may act as exciting factors in causing hemorrhage. Polypi and adenoid growths are often causes of bloody or blood-streaked discharges. In hay fever the nasal secretions are often tinged with blood. Malformations of the septum may also be a cause. In simple, chronic, or atrophic rhinitis, hemorrhage often follows slight mechanical interference.

(3) *Systemic*.—This division comprises a long list, and the nasal hemorrhage may be of little consequence, or it may be a serious matter. The hemorrhagic diathesis, hemophilia or bleeder, is probably the most intractable. Often the first intimation of this condition is a profuse, persistent nasal hemorrhage which may come on without any appreciable cause, by some agency so slight as to be overlooked.

Epistaxis may appear at the onset of typhoid fever, and at any time during the eruptive fevers, and also may occur in diphtheria, pneumonia, relapsing fever, influenza, gout, scurvy, purpura, the anemias, bronchitis, emphysema, specific inflammations, as syphilis, tuberculosis, and leprosy.

Cardiac lesions may also cause congestion of the nasal mucous membrane, resulting in hemorrhage. In arteriosclerosis hemorrhage seldom occurs, although ecchymotic spots are not infrequent in the post-nasal space. In cirrhosis and acute yellow atrophy of the liver, or in pressure caused by neighboring tumors or enlarged organs, there may be some nasal hemorrhage. Albuminuria, bronchocele, or other tumors of the neck, which cause pressure, retarding

the return flow of blood, ill-fitting or tight neckwear may be exciting causes. Plethoric persons are often troubled with nasal hemorrhage. Chronic alcoholism and the atheroma of the aged are predisposing factors. A slight hemorrhage may precede or accompany apoplexy.

Congestion of the cerebral vessels during continued or severe mental effort, is occasionally relieved by a nasal hemorrhage. Atmospheric conditions are in some cases a factor, through the disturbance of the intra- and extra-vascular pressure. This accounts for the frequency of epistaxis in making rapid ascents to higher altitudes, or among workers in deep mines or in caissons, who are affected on reaching the normal atmospheric pressure. The toxic doses of some drugs occasionally produce epistaxis, as phosphorus, chloramid, and the compounds of the salicyl group.

(4) *Vicarious*.—Vicarious menstruation is usually from the nasal tissues. Epistaxis may occur when there is a sudden cessation of the flow of blood from hemorrhoids. A severe sneeze, cough, or energetic blowing of the nose may also start a hemorrhage.

Pathology.—On account of the anatomical construction in this region, there is neither muscular structure in which the tissues are imbedded, nor muscular contraction to assist in closing a wound, or retraction of the severed ends of blood vessels. Hemorrhage may be from any part of the nasal membrane. Certain areas are more likely to be the site, especially at a point in the anterior inferior part of the septum, called the locus Kieselbachii, where the vascular plexus is the most intricate.

On inspection the membrane may be red and swollen; it may present varicosities, erosions, or a sharp cut. In some cases the margins of a perforation of the septum, or the edges of a ruptured cyst may be the site. The hemorrhage may be a slow, steady, capillary oozing, a more rapid flow, or a rapid pulsating arterial flow. Usually the hemorrhage ceases spontaneously, as a rule, through the formation of

thrombi. After a copious hemorrhage the membrane is often pale and anemic, but soon regains its normal appearance. In plethora, severe renal and cardiac conditions, epistaxis appears to be nature's method of relief, and in these cases it does not constitute a pathological epistaxis.

Symptoms.—The prominent symptom is the escape of blood through the anterior nares; if in the posterior part, or the patient is in the recumbent position, the blood passes through the choanæ into the pharynx, and if swallowed or it enters the bronchial and pulmonary tracts the appearance when ejected may simulate hematemesis or hemoptysis.

The quantity of blood lost varies from an amount so slight as to scarcely tinge the nasal secretions, to a profuse, persistent flow. The attacks may be infrequent, or may occur daily, and may last from a few minutes to several hours. As a rule, the blood coagulates readily, excepting in hemophilia. Often there are no preliminary symptoms, the first intimation being a bubbling of the inspired air through the blood in the respiratory tract, the discoloration of the handkerchief in trying to relieve the sensation of fullness, or the blood dropping from the nose. In other cases there may be, prior to the attack, congestive headache, sensation of fullness of the head, tinnitus aurium, vertigo, or visual disturbances.

The sequelæ vary considerably, depending upon the amount of the hemorrhage. In cases of plethora, or congestive renal, hepatic, or cardiac states, there is usually a sense of general relief. In many cases where the amount of blood lost is inconsiderable, little or no after effects are noticed. When the amount is considerable, headache, or the symptoms of exsanguination and syncope may soon appear. The hemorrhage may be unilateral or bilateral. As a rule, when depending upon local affections or a traumatism, it is from one side. Systemic or vicarious epistaxis is usually from both sides. The site of the hemorrhage can usually

be located by anterior or posterior rhinoscopy. It is claimed by some that a brownish stain reveals the site, during the intervals between periodical attacks.

Diagnosis.—The diagnosis is usually easy, but both anterior and posterior rhinoscopy may be necessary for a positive diagnosis. The hemorrhages from local lesions are usually unilateral, but those from the stomach, pharynx, lungs, tongue, or fractures of the base of the skull, when the exit is through the nose, are generally bilateral, unless there is occlusion of one side. In the latter condition, there is usually a clinical history which will establish the diagnosis. A hemorrhage from the posterior and inferior part of the septum may be deceptive. Hemorrhage from the accessory sinuses are often difficult to locate, but if the bleeding is at or near the openings of the sinuses, care should be taken in making the diagnosis.

Prognosis.—Generally favorable, unless the hemorrhage is the result of malignant growths in the nose. When due to systemic lesions the prognosis will depend upon the character of the disease. In hemophilia or in chronic heart disease the outlook is unfavorable.

Complications.—Syncope sometimes occurs, not only on account of the loss of blood, but also through psychological effects produced by the sight of blood.

Treatment.—When dependent upon systemic diseases, the treatment must be directed to the exciting cause. If due to foreign bodies, their removal is necessary. In the majority of cases no treatment is required. When the hemorrhage is moderately severe, pressure on the *alæ*, if from this portion, or on the upper lip so that the superior coronary artery is compressed, when from the septum, may control the bleeding. The use of mineral astringents, as a rule, should be avoided, as the resulting mass is often difficult of removal, and when removed is frequently followed by another hemorrhage. Tannic acid in powder, or a 10 per cent solution is sometimes effective. The use of cocaine, while

it may check the hemorrhage, is dangerous on account of the danger of absorption. The use of the suprarenal products, while often temporarily useful, is not advisable, as secondary hemorrhage is not unlikely.

The recumbent position, with the arms extended above the head, sometimes suffices. The use of cauterants, as a rule, should be avoided. In some cases the plugging of the nares by the use of Bellocq's canula, or the nasal gauze packer, may be necessary. The cotton or gauze should be covered with some oily substance in order to prevent shrinking, and also to facilitate removal. When cotton tampons are used, a thread should be fastened around each one, so they may be readily removed. The use of small rubber bags introduced into the nares, then inflated with air, or filled with water, has also been recommended. Kyle reports a case in which the posterior nares was occluded with pledgets of cotton, then the anterior nares plugged with the same material, leaving the intervening space to be filled with blood, the pressure eventually causing the hemorrhage to cease. The objection to this method is the possibility of the blood entering the maxillary sinus and producing inflammatory action. When the nasal cavities have been tamponed, the tampons should not be allowed to remain over forty-eight hours, and usually a shorter time is sufficient. If left too long, either pyemia or the pressure of the packing may devitalize the tissues. A careful cleansing of the nasal cavities should follow the removal of the tampons, and the patient should be cautioned against over-exertion for several days.

Internally, the use of ergot when the hemorrhage is arterial in character; hamamelis in hemorrhoidal cases, or where there is simply a venous oozing. Carbo veg. is also indicated in the oozing form. Belladonna in some cases. Cactus in functional heart disease. Glonoin in organic cardiac lesions. In cases of anemia, with lowered arterial pressure, nux, or veratrum may be indicated.

CHAPTER XI.

FOREIGN BODIES IN THE ANTERIOR NASAL CAVITIES.

(1) INANIMATE; (a) RHINOLITHS, (b) MISCELLANEOUS. (2) ANIMATE, (a) PARASITES.

Inanimate.

RHINOLITHS.

Synonyms.—Nasal calculi; Nasal concretions.

A rhinolith is a foreign body in the nasal cavity formed by the deposit of mineral salts; in nearly every case there is a nucleus of some kind forming a nidus.

Etiology.—These formations are usually the result of either a modification of the nasal secretions, or some condition causing its retention. Females appear most liable to this condition, and the gouty diathesis has found favor with some as a factor. They are seldom found in children.

Location.—Usually in the inferior meatus, but may occur in any portion of the nasal cavity.

These formations are single, as a rule, although occasionally two are found joined together. The shape varies, as also the weight, from a grain or two, to a quite large mass, 720 grains being reported in one case. The surface may be comparatively smooth, or rough. The color varies from a dirty white to almost black. They may be compact or friable. In some cases the outer portion is hard while the center is soft or crumbling. The composition is usually the carbonates and phosphates of calcium and magnesium, with traces of chloride and carbonate of sodium, and or-

ganic material. The typical structure of a calculus is usually shown and with some sort of a nucleus.

Symptoms.—Usually none, until the rhinolith is of sufficient size to cause the usual line of symptoms caused by a foreign body.

Diagnosis.—An inspection of the nasal cavity after thorough cleansing, the use of a probe, and the history, will suffice.

Prognosis.—The same as any foreign body in this region.

Treatment.—When not encysted, the removal is usually easily accomplished in the same manner as any foreign body. When encysted, it should be freed from its surroundings and removed. When of considerable size, and soft enough to be crushed, the removal is easy. The subsequent treatment is cleansing the nasal cavity two or three times a day with an alkaline wash, until there is no longer any irritation.

MISCELLANEOUS.

The inanimate objects which may be found in the nasal cavities are limited only by the inability of entrance to the spaces.

Etiology.—There are three methods of entrance. Direct insertion anteriorly by the patient, which is more often observed in children, the mentally unbalanced and malingerers. Also through the choanæ, the result of vomiting, or choking during the act of swallowing, when the material may be forced behind the soft palate. In paralysis of the faucial tissues, this is often an annoying feature during the act of deglutition. Penetration of the nasal structures has in a few instances been observed, and comprises the third method.

Pathology.—This necessarily varies according to the character of the foreign substance. It may be so small, and so located, that no attention is given to its presence. The opposite extreme is also found, and variations between the

two are quite frequent. In some cases an acute inflammation is caused almost at once, or may appear only after the lapse of considerable time. The membrane becomes swollen, the submucosa infiltrated as in any inflammatory process, and there is increased activity of the glandular elements in the immediate vicinity of the offending object. As the swelling continues there is increased pressure, and in such substances as absorb moisture with consequent increase of size, the nutrition to the affected area is destroyed, and necrotic changes occur in the epithelium. Through this change infection results, and irregular ulcerations are formed. In cases where the neighboring vessels can supply sufficient nutriment to cause budding, granulation tissue may form, more or less embedding the foreign body. When the pressure is considerable and is continued for some time, the necrosis will extend to the deeper structures, and there may result a perforation of the septum, the nasal floor, or even the lateral wall. It is not often, however, that such results occur, as medical assistance is usually sought before the ulcerative stage is reached. As a result of the inflammatory action, there is a retention of secretion through nasal obstruction, and decomposition rapidly following, the odor becomes intolerable. The retention of this putrefactive material maintains or increases the inflammatory process. Epistaxis is often present.

Symptoms.—These vary according to the size, character, and location of the body. In an ordinarily severe case the membrane is swollen, reddened, and painful; there is an increased discharge, glairy at first, then mucoid, and later purulent and frequently offensive. Unless there is perforation of the septum, the discharge is unilateral, and may be streaked with blood. When acrid, there is excoriation of the nostril and upper lip. Respiration on the affected side is impaired and a nasal twang imparted to the voice. The ala is often reddened and swollen. Neuralgic pain in the nose, cheek, or frontal region may be present, and the eye

or ear be implicated. Paroxysms of sneezing, vertigo, nausea, and vomiting may result.

Inspection of the nasal cavity will usually reveal the foreign body, although in some cases a thorough cleansing of the cavity may first be necessary. When the foreign body has been pushed far back in the meatus by unsuccessful attempts at removal, a probe may be necessary to definitely locate the object. As a rule the location is in the anterior portion, between the inferior turbinate and the septum.

Diagnosis.—Not difficult as a rule.

Prognosis.—Good, as the removal of the foreign body is usually followed by a rapid amelioration of the annoying symptoms.

Treatment.—But few objects can successfully be removed by the use of forceps, which will only push back still further into the nasal fossa an object that is smooth and hard. Quier's foreign body extractor is useful in many cases, while a probe bent to form a hook may often be all that is required. An aneurism needle has frequently been a useful instrument in these cases, and the Gross curette, especially when the object is a bean or something which can be penetrated by the sharp point, may remove the body. If a shoe button, and the eye is forward, it can be grasped with forceps. If an organic body and it has swollen, it may be necessary to break or crush it before it can be removed. The post nasal syringe has been successfully used, and the tip of a Politzer air bag placed in the free nostril, so as to close it, then compressing the bulb forcibly, may expel the body. After the removal of a foreign body the nose may be cleansed two or three times a day with some soothing wash.

Animate.

In some parts of the country, reports are not infrequent of the larvæ of flies being found in the nasal cavities. In northern latitudes this seldom happens. The invasion of the

nasal cavities by any animate object causes more or less pain, as well as increased secretion. When due to larvæ it is the result of ova deposited in the nasal cavity. These hatch and the maggots develop.

Course.—If allowed to remain, the mucous membranes and underlying tissues are soon destroyed, and bony necrosis follows. Suppuration is extensive, and the larvæ may burrow through the nasal walls, or into the accessory sinuses, and even into the cranial cavity. Meningeal inflammation frequently occurs where the bony structures are affected, resulting fatally.

Symptoms.—The symptoms are very pronounced. The discomfort and pain rapidly increase. The pain may be referred to any portion of the head, but the frontal region is most affected, the pain being persistent. The secretion soon becomes purulent, and frequent hemorrhage is present. Edema of the face often occurs. Severe septic poisoning is shown by the systemic disturbance.

Diagnosis.—This is positively made by the discovery of the larvæ in the discharges, or in the nasal cavities.

Prognosis.—This depends upon the progress the destructive process has made as well as upon the condition of the general health.

Treatment.—When possible to get any air through the nasal cavities, the vapor of chloroform or gasoline will kill the larvæ. The procedure of injecting chloroform and water, equal parts, into the nasal cavities is not to be recommended. The vapor should be forcibly blown into the cavities, either by means of a Devilbiss powder blower, or some instrument where sufficient pressure can be used to get penetration of the vapor. The larvæ can then usually be easily removed by syringing, but may have to be picked out with a forceps. A cleansing solution should be used after the removal of the larvæ, and following this, the salicylic acid wash. If the accessory sinuses are invaded, operative measures are imperative.

CHAPTER XII.

NEOPLASMS OF THE RESPIRATORY TRACT.

DIVISIONS.

Non-Malignant.

Origin.—Blastodermic layer—hypoblastic, epiblastic. Epithelial-tissue type—adult variety (typical, benign). (1) Papilloma. (2) Adenoma.

Origin.—Blastodermic layer—mesoblastic. Connective-tissue type—adult variety (typical, benign). (1) Angioma. (2) Chondroma (enchondroma). (3) Exostosis. (4) Fibroma. (5) Lipoma. (6) Osteoma. (a) Eburnated; (b) Cancellated. (7) Myxoma (polyp). (a) Myxofibroma; (b) Mucocele; (c) Cystic.

Malignant.

Origin.—Blastodermic layer—hypoblastic, epiblastic. Epithelial-tissue type—embryonic variety (atypical, malignant). (1) Carcinoma. (a) Epithelioma. 1, Squamous-celled. 2, Cylindrical-celled. 3, Tubulated. (b) Glandular. 1, Scirrhus. 2, Encephaloid.

Origin.—Blastodermic layer—mesoblastic. Connective-tissue type—embryonic variety (atypical, malignant). (1) Sarcoma. (a) Round-celled, small and large. (b) Spindle-celled, small and large. (c) Mixed-celled. (d) Giant or myeloid. (e) Alveolar.

Mixed Tumors.

1, Adenocarcinoma. 2, Myxocarcinoma. 3, Myxosarcoma. 4, Myxofibroma. 5, Teratoma.

Cysts.

1, Simple or Retention-cysts. 2, Cystoma. 3, Dermoid cysts.

All neoplasms of the upper air passages will be considered under this chapter heading.

Papilloma.

NARES.—When the growth is situated at the junction of the skin and mucous membrane, it is usually the hard type, resembling microscopically an ordinary cutaneous wart. Not often multiple. Generally lobulated and on account of its usual location is constantly irritated, hence is supposed to be the starting point of a malignant change. One orifice only is affected, as a rule.

Treatment.—Removal by surgical measures is usually preferable.

NASAL CAVITY.—Papilloma is probably of infrequent occurrence in the nasal cavity. When present, the favorite location seems to be the inferior turbinate, lower and anterior portion of the septum and the membrane of the vestibule. Usually of the hard form, resembling in microscopic structure the cutaneous wart. It is very vascular and has a tendency to ulcerate. It is not often multiple, and is usually small.

Symptoms.—Sensation of irritation, and frequently a copious discharge. Some pain may be present at times. If the growth obtains sufficient size, obstruction of the nasal cavity may result. Slight hemorrhage may also occur at times. As a reflex, asthmatic cough has been noted. When

there is much ulceration and hemorrhage, a malignant change may be possible.

Treatment.—Complete removal of the growth by surgical means. Reduction of the size, and even complete disappearance of the growth, has occurred by the repeated applications of a saturated solution of salicylic acid in thuja.

NASOPHARYNX.—But few cases have been reported. The location is the posterior inferior border of the inferior turbinate. It resembles villous papillomata.

Symptoms.—Practically the same as a foreign body in this location, causing a rhinopharyngitis. If of considerable size there is impeded nasal respiration, and possibly occlusion of the Eustachian orifice. A persistent hacking cough, and the sensation of a foreign body in the nasopharynx. Nasal polypi are reported as being present in these cases.

Treatment.—Removal of the growth.

PHARYNX.—The most frequent location for papillomata is the free border of the faucial pillars, the uvula or the tonsils, although they may occur on any portion of the pharyngeal membrane. The growth may be single or multiple, and as a rule it is of the hard type, usually following or associated with inflammatory conditions.

Symptoms.—Such as would naturally follow.

Treatment.—Removal by cutting forceps, care being taken not to injure any more tissue than necessary for complete excision.

LARYNX.—Here papillomata are the most frequent of benign tumors. On account of the location or through irritating applications, the site of this growth may become malignant. The varieties of papilloma described depend upon the amount of fibrous tissue and the implication of the subepithelial structures. The tumors may occur at any age, they may be congenital, multiple or single, pedunculated or sessile, and vary in shape. Usually they are situated at the

anterior angle or portion of the vocal cords, although the ventricular bands or epiglottis may be the site. The variation in size depends usually upon the length of time of growth. In adults the tumors are slow in growth, and, as a rule, are in the supraglottic region. In children the growth is rapid, and any portion of the larynx may be invaded.

Symptoms.—Interference with natural phonation is the most marked symptom. This depends upon the location and size. When located in the aryepiglottic folds, epiglottic folds, or the ventricular bands, no distinct change in the voice may result. Respiration may be unimpaired. Spasmodic contraction of the laryngeal muscles may occur in children. Usually the size of the tumor influences the respiratory action. When pedunculated and resting on the vocal cords, dyspnea may occur. When above the cords, dyspnea is most marked on inspiration; when below the cords, on expiration, but spasm of the glottis may result in either case. Inflammation of the larynx usually accompanies the presence of a tumor. Hemorrhage is an infrequent symptom, unless the tumor is malignant. Pain is seldom present.

Diagnosis.—Papilloma might be mistaken for the early stages of an epithelioma. Papilloma may occur at any age, and is a prominent, grayish white elevation with an irregular surface, but an unbroken epithelial covering, little or no disposition to bleed, and located at the anterior portion of the vocal cords. Epithelioma seldom occurs in the young, is not lobulated, and involves surrounding tissues. There is a disposition to bleed, and also to ulceration. It may be located in any part of the larynx, but the posterior portion of the vocal cords is the favorite location.

Prognosis.—Unless the growth is of considerable size, or its location produces dangerous spasms or dyspnea, there is no immediate danger. Tracheotomy will relieve, even

when such a condition presents. The removal of the growth is always to be advised.

Treatment.—Operative measures are usually to be recommended. When the growth is small, touching it with a saturated solution of salicylic acid in thuja, and also giving thuja internally, may be curative. In operative procedures, the instrument required will depend upon the location and size of the mass. Whatever method is used, care should be exercised to remove the entire growth, with the slightest possible disturbance of the surrounding healthy tissue. Chemical caustics should not be employed.

Adenoma.

ANTERIOR NARES.—Simple adenoma, excepting at the nasal orifice is practically a histological impossibility.

NASOPHARYNX.—Simple adenoma of this region is very infrequent.

FAUCES.—A cystic adenoma may occur in this region, but usually the growth is an adenofibroma. The growth is similar to that of any benign mass, and is not often seen in adult life, even to the age of sixty. Most often found in females.

Etiology.—It partakes of the characteristics of all benign growths in being slow in development.

Symptoms.—Usually none excepting a sensation of fullness. Occasionally, if occurring in the nasopharynx, there is some interference with nasal respiration. If in the faucial region, a desire to swallow, sometimes interference with deglutition, and very infrequently some pain. Hemorrhage, when it does occur, is slight.

Pathology.—An adenoma consists simply of a hyperplasia of gland structure elements, its type being found in the acinous or tubular gland structures. By obstruction of the duct, it may become cystic and undergo mucoid degeneration. Usually sessile.

DIFFERENTIAL DIAGNOSIS.

FIBROMA.	ADENOMA.
Rapid development.	Slow development.
Pain rather marked.	Pain slight.
More interference with function.	Slight interference with function.
Infrequent.	Frequent.
Earlier life.	Middle life to sixty years.

Treatment.—Surgical measures are necessary when the growth is of such proportions as to interfere with the normal functions of the part. The growth should be dissected from its surroundings when encapsulated. If multiple, each individual mass should be removed.

LARYNX.—It is a question whether a true adenoma occurs here. Clinically, however, a growth within the vestibule of the larynx should be removed as soon as possible.

Angioma.

NASAL CAVITY.—Infrequently found, but appears to prefer the septum. It is formed by the distention of vessels already present, rather than by a new vessel growth. The distention is produced by changes in the walls of the vessels. The condition is most frequently seen in those of a lymphatic temperament.

Symptoms.—Obstruction of the nasal cavity is the principal symptom. Pain is seldom present. When the growth is of considerable size, a mucopurulent discharge is present. Hemorrhage may occur, and occasionally is excessive, this being determined by the location of the angioma. Deformity of the nose seldom results. The varieties usually seen are the simple and cavernous. The simple are often congenital, and are generally small, with a comparatively

smooth surface. The cavernous variety has larger vessels and the surface is rather irregular. Either variety is found most frequently in early life; seldom, if ever, in old age.

Diagnosis.—Pressure will markedly diminish the size of the growth. Pulsation is usually present, marked when it communicates with an artery; slight with a vein. Slight manipulation will cause hemorrhage. The color varies from a light red to a bluish red, the usual color being a dark red, on account of the growth communicating with both an artery and vein. The color also varies according to the position of the tumor in the tissues.

Prognosis.—Good, when properly removed. There is no tendency to recurrence.

Treatment.—The cold wire snare is best in the majority of cases, but the work must be slowly done, on account of the tendency to hemorrhage. If the tumor is sessile, the loop can be held in position by transfixing the mass with a needle before tightening the loop. Ligation by means of strong silk ligatures, transfixing with several sutures, may also be employed. The stump should be cauterized with chromic acid, 20 per cent; trichloroacetic acid 1:2000; or salicylic acid ointment. In some few cases bipolar electrolysis has given good results.

FAUCES.—In the faucial region angiomata are seldom of the simple form, a mixed variety being generally found. The lateral walls are most frequently affected. As there is so much vascularity of this region, the vessels of the tumor are usually of considerable size, and there is a decided tendency to hemorrhage.

Symptoms.—The principal symptoms are a sense of obstruction in the throat, pain on deglutition, and the liability of hemorrhage.

Treatment.—Either electrolysis or the galvano-cautery, but in the removal of the growth care is necessary, as the liability of an excessive hemorrhage is to be remembered.

PHARYNX AND UVULA.—“Cruveilhier's plexus” is often the site of a varicose tumor, and the hyoid fossa is also a favorite location for angioma. Angioma of the uvula is seldom seen.

Symptoms.—When the tumor is of considerable size, there is a constant sense of discomfort or fullness in the throat, and usually an irritating cough.

Treatment.—Electrolysis or the galvano-cautery.

TONSIL.—Only a few cases have been reported.

Treatment.—The cold wire snare, cutting slowly on account of the profuse hemorrhage.

LARYNX.—Seldom found, but has been reported implicating the ventricular bands, epiglottis and the lingual sinus. The tumor is nearly always small, and of a bright red color, racemose and unilateral.

Chondroma (Enchondroma).

NASAL CAVITIES.—The term should be applied to cartilaginous tissue formations having their site in any portion of the nasal cavities or accessory sinuses, with the exception of the triangular cartilage of the septum. Chondroma, if of any considerable size, may cause deformity of the nose, and through pressure, absorption of the contiguous bony structures may result, invading even the orbit and cranium.

True chondroma are infrequently seen; the favorite location is at the junction of the cartilaginous septum and an alar cartilage. The tumor is usually round and nodular, and occurs in early youth; generally unilateral.

Symptoms.—Impairment of nasal respiration depends upon the size of the tumor. When of considerable size it will cause an accumulation of secretion, which soon becomes muco-purulent and offensive. Pain is seldom present, unless the location and size produce pressure. Being non-vascular there is no tendency to bleed. It grows very slowly.

Diagnosis.—Palpation with a probe will demonstrate a hard but slightly elastic mass. The texture of the tumor is hard and dense, immovable, usually of a pink or yellowish-white color. It may be round or irregular and nodulated. Puncture with a needle will differentiate from an osteoma.

Prognosis.—This depends upon early recognition and removal, before deformity or bony absorption occurs.

Treatment.—Complete removal by means of the knife, nasal drill, or saw. If of considerable size, an external operation may be required. This is true also when the growth originates in the accessory cavities. The hemorrhage is slight.

NASO-PHARYNX.—Two cases only have been reported, both occurring in young adults.

LARYNX.—The favorite location is the cricoid cartilage, although the thyroid, epiglottis, and arytenoid cartilages may be affected. The tumor is sessile, immovable, and usually extends inward. It may be of sufficient size to produce symptoms of dyspnea. A slightly hyperemic membrane usually covers the tumor, and hemorrhage, when it occurs, is from this membrane.

Diagnosis.—The tumor is hard, dense, slightly lobulated, and slow of growth.

DIFFERENTIAL DIAGNOSIS.

PERICHONDRITIS.	CARCINOMA.	CHONDROMA.
A determinable cause, usually.	No cause.....	No cause.....
Age not a factor.....	Advanced age.....	Early life, usually.....
Onset sudden.....	Slow.....	Slow.....
Acute local inflammation.	Inflammation late.....	Inflammation absent, unless the result of obstruction.
Edematous tendency early.	Seldom, if present late..	Seldom, if present late..
Any of the cartilages....	Seldom below the glottis.	Usually the cricoid cartilage.
Localized	Disposition to spread, and glandular involvement.	Localized.....

Prognosis.—Good if removed early.

Treatment.—If small the growths may be cauterized with chromic acid, or removed with cutting forceps. When large a thyrotomy may be necessary.

Exostosis.

Ziegler applies this term to either bony or cartilaginous growths. The variety arising from either bone or cartilage, and either partly cartilaginous or entirely bony, is termed connective-tissue exostosis. The variety which forms from cartilage only, is called cartilaginous exostosis or ecchondrosis. The growths may be from the septum or turbinated bones, and are usually called crests, ridges, spurs, excrescences, or redundancies. The connective tissue type may be located anteriorly on the triangular cartilage, or posteriorly on the vomer. At times the floor of the nose is the location, or the turbinates, especially the middle. When located on the turbinates, the growth is usually in the shape of a spur, or may extend entirely across the nasal cavity. It may have its site either in the bone or the periosteum, and is always covered with mucous membrane. Such growths are always more or less sessile, no matter from which portion of the nasal structures they have their origin. They may be congenital, or the result of malformations, or of traumatism. On the septum, the cartilaginous spur usually presents the appearance of a short ridge close to the nasal floor. In the early stages it may be entirely cartilaginous, but later may become a compact bony structure, so that its removal with the ordinary nasal saw will be difficult. When the ridge extends to the posterior portion of the cartilage or invades the vomer, it may resemble a fold, the anterior portion being cartilaginous, the posterior portion bony, and always covered with mucous membrane. A corresponding depression is usually found on the opposite side, and this must be taken into consideration in operative measures.

Symptoms.—As a rule impeded nasal respiration is the most prominent, although in several cases the patients have complained of neuralgic pains in the frontal, orbital, or supraorbital regions, pressure on the exostosis starting or increasing the pain.

Treatment.—Unless there is obstruction to nasal respiration, or a tendency to accumulation of secretion, or some reflex irritation caused by its presence, removal is not necessary. When operative measures are required, the mucous membrane should be carefully dissected up from the lower margin of the growth, and the projection removed by means of a saw, cutting forceps, or whatever instrument is applicable to the case. Local anesthesia should be induced prior to the operation. After the removal of the growth, the flap of mucous membrane should be made to cover the traumatic surface. Excepting in cases of severe hemorrhage no packing of the cavity is required. The necessity for douching the nose repeatedly after the operation depends upon the case, but, as a rule, I consider it better surgery to interfere as little as possible, as healing is more likely to progress favorably without the use of solutions, which simply macerate the tissues and encourage ulceration or sloughing of tissue. As a rule, the healing process will be completed in from ten days to two weeks, but some systemic conditions may retard the process. When ulceration does occur, the surface may be touched with a saturated solution of Lloyd's salicylic acid and thuja, or thuja and Lloyd's hydrastis. Internally, the use of potassium bichromate will check the ulcerative process.

Fibroma.

NASAL CAVITIES.—In the nasal cavity a true fibroma may occur, but it is usually a mixed type of tumor. The structure is the same as of this growth in other regions. The site is the submucosa. Histologically the growth differs from mucous polypi in the small amount of matrix;

clinically, they are distinguished by the deep red color, lack of translucency, firmer resistance to the probe, lobulated and irregular appearance, and in usually being sessile. Fibromata usually have their site from the posterior and inferior margin of the middle turbinate. If located in the anterior space, they may arise from the lower margin of the middle turbinate, or from the anterior portion of the superior turbinate. Very seldom do they have their origin from the septal tissue, and only a few cases have been reported as having the floor of the nose for the origin. The shape varies according to location. In the posterior portion it may extend backwards into the post nasal space, and be pedunculated. In the anterior portion of the nasal cavity the growth is usually smaller, more elongated, and possibly more irregular in outline. If degenerative processes take place, or much irritation of the mass occurs, a malignant growth may occur. Males are most frequently affected, and between the ages of fifteen and thirty.

In the early stages there is little, if any, pain, but when the tumor attains considerable size, the pressure on adjacent structures causes pain. A muco-purulent discharge is usually present, and hemorrhage, which may be frequent or severe, may occur. The obstruction to nasal respiration depends upon the size of the tumor. More or less complete loss of smell usually results, as well as a nasal twang to the voice. When the tumor attains considerable size nasal deformity occurs, the so-called "frog-face" resulting from the pressure upon the nasal bones. Fibroma are often associated with mucous polypi.

Diagnosis.—The sense of touch by the use of a probe, and the appearance of the tumor by anterior or posterior rhinoscopy, are the principal methods of diagnosis.

Prognosis.—This depends upon the early recognition of the growth. If deformity of the nose has occurred, or much change in the structures has resulted, the prognosis is more unfavorable.

Treatment.—Removal by the cold wire snare is best when it can be used. The work should be by slow contraction of the loop, to prevent hemorrhage. If hemorrhage does follow, the usual methods of controlling it should be employed. The use of cocaine or suprarenal products is to be decried, as the danger of secondary hemorrhage is increased.

NASOPHARYNX.—True fibroma may have their origin in the post-nasal space, the basilar process of the occipital bone being the favorite location. It may extend upward, causing displacement of bony tissue, or downward filling the nasopharyngeal space and even the pharynx.

Symptoms.—The size of the growth and its direction frequently causes a variation of the symptoms. When upward, they do not vary particularly from those where the growth is in the posterior portion of the nasal cavity, excepting there may be more of a sensation of pressure over the bridge of the nose, and a more continuous headache. When the growth is downward, there is an early change in the character of the voice, a sensation of some foreign body in the pharynx producing a constant desire to swallow, sensitiveness of the pharyngeal tissues, and often a slight hemorrhage. Pressure paralysis will cause some impairment of the action of the soft palate and uvula.

Diagnosis.—Palpation with the finger, and posterior rhinoscopy.

Prognosis.—The early recognition is important, as in this location the danger to the patient is greater than when occurring in the nasal cavities.

Treatment.—When possible to do so, the complete removal of the growth by the cold wire snare is best.

TONSIL.—A few cases have been reported, and usually are of the fibroplastic variety. They are slow in developing, and the symptoms are similar to those of enlarged tonsils.

Treatment.—When not very vascular, the mass may be

removed with a tonsillotome, or better, by the cold wire snare, as this will usually not be followed by excessive hemorrhage. If adhesions are present between the tonsil and faucial pillars, they should be divided before operating.

LARYNX.—Fibroma of the larynx usually occur from the tissue of the vocal cords. Usually, on account of the location, the growth is not large.

Symptoms.—As a rule, the first symptom is interference with phonation. This may vary from slight hoarseness to complete aphonia. Occasionally diplophonia, or double voice, occurs, but this is only when the growths are small. The respiration is interfered with in nearly one-third of the cases, and often there is dyspnea. The presence of the growth frequently causes cough. Pain is not often present. Very infrequently is there any effect produced on the act of swallowing. Hemorrhage does not often occur, unless ulceration takes place, which is infrequent. Found usually in youth or early adult life, seldom in the adult or aged. Nearly always single and sessile.

Diagnosis.—The smooth vascular surface. Sometimes a microscopical examination is necessary to differentiate from papilloma.

Prognosis.—Favorable as regards removal, but a change in the voice may be permanent.

Treatment.—As a rule, tracheotomy must first be performed, after which the growth may be removed by biting forceps and curette, but these operations should not be undertaken by the novice.

Lipoma.

NARES.—This form of tumor is infrequent in the anterior nasal cavity. On the external nasal surface it is not uncommon.

NASOPHARYNX, PHARYNX, AND LARYNX.—This form of growth is seldom found.

Treatment.—Removal is not difficult if a biting forceps or curette is used.

Osteoma.

NARES.—Osteomata of the nasal cavities may occur primarily from the bony or cartilaginous walls, or from some of the accessory sinuses, and project into the nasal space. Generally the site of the tumor is in the upper portion of the nasal cavity. The shape depends largely upon the pressure exerted by the surrounding structures. Two varieties are recognized, viz., eburnated and cancellous. Proliferation of the osteoblast generally commences in the periosteum. The cause is unknown.

Pathology.—Although the two divisions, eburnated and cancellous, are recognized, they are generally found together, one form predominating. When an osteoma has its origin in an accessory sinus, the ethmoid is the favorite cavity. The growth is usually single and irregular in shape, but the conformation is influenced by its location.

Symptoms.—The size and location of the growth determines the degree of nasal obstruction. Headache is often severe, and many of the early symptoms may be mistaken for sinus lesions. Epistaxis often occurs and a muco-purulent discharge, usually offensive, is found in many cases. Pain is frequently present. Deformity of the upper part of the nose is often found. Invasion of the orbit may occur when the growth extends upward through the ethmoid cells.

Diagnosis.—Ordinarily there is little difficulty in recognizing the tumor, and by the use of a probe or needle its bony character can be determined. The growth of a simple osteoma is usually slow. If there is a disposition to rapid growth, a sarcomatous element must be thought of. A sarcomatous change usually occurs at the base of the tumor.

Prognosis.—Usually favorable, especially if removed before invasion of the accessory sinuses, or before facial deformity has resulted.

Treatment.—When seen early, or if confined to the nasal space, bone cutting forceps, saw, or gouge, according to the character of the growth. As a rule, in the growth by extension, or if its origin is in an accessory sinus, an external operation will be necessary.

Myxoma (Nasal Polypus).

Myxoma is a low grade of adult connective tissue tumor. Considerable confusion has occurred regarding these growths in the nasal cavities, as a result of not differentiating between mucoid and myxomatous degeneration of tissue, and an actual neoplasm. Myxomatous degeneration, especially of the lower portion of the middle turbinated mucous membrane, often occurs. That a passive congestion, followed by watery infiltration into the connective tissue, and eventually absorption of connective tissue cells may result in hydropic degeneration of some cells and myxomatous or gelatinous change in others, producing a polypoid appearing growth, is considered unquestioned. Simple chronic inflammation may produce the same result.

Etiology.—Myxomata, simple or mixed, are the most frequently seen of nasal tumors. The cause of these growths is obscure, but, as a rule, they are most frequently found in persons having tortuous or narrow nasal cavities. Sex does not appear to be a factor. The ages in which they are oftenest found is between fifteen and thirty. They may be single, but most frequently are multiple. Usually they are pedunculated. Both nasal cavities are usually affected. Damp weather will increase the size of the tumors. Thermometric changes do not seem to have any influence. The general systemic condition does not appear to be a factor, although the impaired nasal respiration leaves its usual effect upon the health of the patient. The usual origin of myxomata is the middle turbinate, although they may have their site from any portion of the nasal tissue. The shape

and size of the growth are largely influenced by the location, without reference to its being pedunculated or sessile. In some cases the tumor is so large as to project from the anterior naris when the pedicle is generally found to be long and slender. Myxoma usually present a glistening, whitish gray, translucent appearance. Palpation with a probe will cause disappearance of the glistening spot, the growth being easily indented having an elastic sensation. Generally the surface is smooth, and blood vessels are distinctly visible.

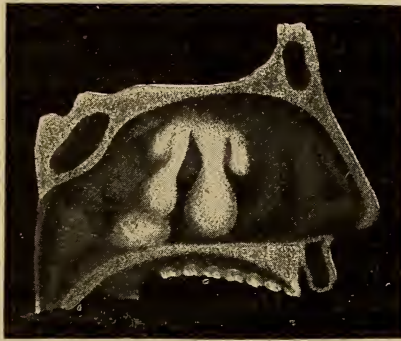


FIG. 63. Myxomata having their origin from the superior turbinate, and one from the inferior turbinate.

The size is variable, being from the size of a pin head to sufficient to fill the entire nasal cavity. When the origin is from the floor of the nose or septum, usually but one is found. If from the middle or superior turbinates, or the roof of the nose, they are generally multiple. If from the septum, they are usually a mixed form, angiofibromyxoma.

Pathology.—A true myxoma consists of a thin cover or sac of connective tissue, enclosing a mucoïd substance with spindle-shaped cells and fine connective tissue trabeculæ. These growths generally partake of the mixed type, and fibrous connective tissue stroma is found (myxofibroma).

Symptoms.—These vary according to size, number, and location of the growths. A nasal twang is often present, with impeded nasal respiration and increased secretion, which may be offensive. When there is much nasal obstruction, the various pharyngeal and laryngeal phenomena are present which characterize mouth breathers. If located in the upper portion of the nasal cavity, pressure may be made on the lacrimal duct, interfering with the free exit of secretion. In some cases deformity of the nose may result. If the tumor occludes the opening of the antrum of Highmore, complications of this region may follow. Reflex symptoms may result from the pressure of these tumors, as asthma, laryngeal or pharyngeal, etc. The sense of smell is usually impaired or destroyed.

Diagnosis.—Inspection or palpation with a probe is usually sufficient, although in some cases, when the growth is located well back in the nasal cavity, posterior rhinoscopy is necessary. Often a polypoid hypertrophy of the border of the superior turbinate, when the body is long and projecting, may be found. This myxomatous, or mucoid degeneration, is generally associated with, or follows, simple chronic or hyperplastic rhinitis. It is easily differentiated from true myxoma.

Prognosis.—Good, only for a marked tendency in some cases for recurrence of other tumors near the original location, especially when there are bony projections, as are often found in the upper portion of the nasal cavity.

Treatment.—Removal by means of the cold wire snare is preferable, but in those cases where it can not be used, a biting forceps may be employed. As little disturbance of the surrounding tissue as possible should be made, as this may form a site for a new growth. The use of cauterant preparations is to be condemned. The application of salicylic acid ointment to the site of the growth after removal is beneficial.

Fibrous Polypi; Myxofibroma.

This form differs only from myxoma in having a fibrous connective tissue framework.

Etiology.—Essentially the same as true myxoma. Usually occurs between the ages of twenty and thirty, seldom found in the aged or in children. The tumor is quite vascular, generally sessile, involves deeper structures, and there is usually more hemorrhage when removed than in myxoma. There appears to be a type where there is a disposition to reformation from adjacent tissue, with a tendency to sarcomatous development (myxosarcoma). The growth probably does not degenerate into a sarcoma, but furnishes a favorable nidus for its development. Fibromyxoma seldom have their origin from the septum or floor of the nose. They may be single or multiple, and vary in shape and size.

Pathology.—The microscopic appearance varies from myxoma according to the amount of fibrous connective tissue stroma present.

Symptoms.—Practically the same as myxoma.

Diagnosis.—By inspection and probe.

Prognosis.—Usually favorable, if thoroughly removed early. The tendency is to recurrence.

Treatment.—The cold wire snare or alligator jaw forceps, disturbing the normal mucous membrane as little as possible, is the most satisfactory method. With the snare, the wire should be tightened slowly, as this procedure decreases the amount of hemorrhage. Healing is usually complete in from five to seven days. The introduction of a cotton tampon coated with salicylic acid ointment is usually all the after treatment required. In only exceptional cases have I found it necessary to use washes.

Mucocele.

Synonyms.—Gelatinous or Mucous Polypi.

Etiology.—These growths are practically retention cysts, the origin being the mucous glands. They are usually found in cases having abnormal conditions of the nasal cavities, as septal deflection, cartilaginous or bony growths, etc.

Pathology.—That of a retention cyst. The contents of the cyst are very gelatinous, contain albumin and mucin, and are either fluid or semi-fluid.

Symptoms.—Similar to nasal myxoma. As the tumors are usually sessile, the circulation is more obstructed. As a result, the external surface of the nose is liable to be swollen, slightly edematous and often with partial or complete obliteration of the labionasal fold.

Diagnosis.—The growths are usually in the superior portion of the nasal cavity. Cocaine has no contractile influence.

Prognosis.—Good.

Treatment.—Open and curette, so as to destroy the sac. Apply to the surface either thuja and hydrastis $\bar{a}\bar{a}$. or salicylic acid ointment.

NASOPHARYNX.—In this region the tumors are usually associated with mucocele of the anterior nares. The cause and pathology are the same as of the anterior nares.

Symptoms.—These are similar, excepting the probability of affecting the Eustachian tubes, producing middle ear disease. Irritation of the pharynx, larynx, or bronchi often result. The location is most frequently on either the posterior inferior margin of the middle turbinate, or the same location on the inferior turbinate.

Treatment.—Removal by means of the cold wire snare, either with the curved canula, passing it through the mouth and back of the soft palate, or if possible, passing the straight canula through the nasal chamber. It is sometimes possible to use the alligator-jawed forceps through the

nasal cavity, locating the tumor with the rhinoscopic mirror.

LARYNX.—The two forms, myxofibroma and fibromyxoma, are clinically identical, although differing somewhat in their microscopic aspect. The tumors are variable in size, generally single, and may be pedunculated, but usually sessile. Their origin may be from any portion of the larynx, but is generally from the upper portion. They present a semi-translucent, pinkish gray appearance, with blood vessels clearly discernible. These growths are most frequent in middle life, and are found oftener among those who over-use the voice. Seldom recur after removal. When there is considerable fibrous tissue present, the appearance is that of papilloma.

Pathology.—Histologically the appearance is that of nasal fibromyxoma, only the capsule is more fibrous.

Symptoms.—Identically the same as a movable foreign body. Changes in the tone and character of the voice result. When the tumor is movable and located below the vocal cords, spasmodic interruption in phonation often results on account of the tumor being forced upward between the vocal cords. Depending upon the size and location of the growth, there may be difficult respiration. Tracheotomy may be necessary in some cases. Pain or hemorrhage are infrequent.

Diagnosis.—It is often difficult to obtain a laryngoscopic view, even with cocaine anesthesia, on account of the hypersensitive condition of the parts. The attachment and appearance will aid, and the microscopic examination will determine its benign character.

Prognosis.—The early recognition and removal of the growth will be favorable. The location and size must also be considered. The most distressing symptoms, however, can usually be relieved.

Treatment.—The removal of these growths should not be attempted excepting by a skilled operator, as the opera-

tion is a difficult one to perform. The damage which may result through incompetent manipulation may be more serious than the original disease. When possible to perform an intralaryngeal operation, a local anesthetic is preferable. The laryngeal mirror to guide the forceps should always be used. The forceps employed will depend upon the location of the tumor, and should never be employed excepting under full illumination with the laryngoscopic mirror.

Embryonic Epithelial Tumors.

CARCINOMA.

NASAL CAVITIES.—Carcinoma in this region is generally the squamous-celled variety of epithelioma. It is infrequently found, but when it is, it is usually primary, and invades the contiguous tissues. The origin may be the mucocutaneous junctures, extending into both surfaces. As a rule, the tumor commences as a small nodular area of infiltration, extending rather rapidly, and with a tendency to early ulceration.

Etiology.—The cause is largely conjectural. The varieties of carcinoma all belong to the epithelial type and are embryonic. Predisposition to the disease may be inherited. Constant irritation is recognized as a factor, while traumatism often leads to sarcoma. Carcinoma of the nasal cavities is usually located in the anterior portion.

Pathology.—The microscopic appearance depends largely upon the development of the tumor. In some cases there is a large preponderance of normal tissue, as a result of the tendency to increase through the lymphatics. The development of the growth eventually resembles scirrhus carcinoma. The growth is practically characteristic of all carcinomatous tumors.

Symptoms.—An early symptom is the pain which usually is not constant, but when present is lancinating. The color and odor of the mucopurulent secretion is almost character-

istic. Hemorrhage is not as free as in sarcoma. Nasal respiration is not much impaired in the early stages, but later may be considerable. The ethmoid and sphenoid cells are sometimes implicated. If this occurs, vision is usually affected, and in some cases the growth may cause an exophthalmos. Enlargement of the lymphatics is inconsiderable in primary carcinoma of the nose, but when secondary, or if there is a general carcinomatous condition, the glands are often affected. The ulceration is deep and ragged, and there is a thin grayish brown, offensive discharge. The characteristic cachexia increases with the advance of the disease.

Diagnosis.—Not always easy even by microscopic examination, unless the section is taken before ulceration commences. When taken from an ulcerated surface, it is practically impossible to differentiate from sarcoma, or an ulceration from a simple inflammatory process. The secretion in carcinoma is not adherent to the surface, but in tubercular lesions it is tenacious, stringy, and adherent.

Prognosis.—Always guarded. If complete extirpation is impossible, it is better left alone. The action of the X-rays, or the Finsen rays seems to promise more than any other procedure.

Treatment.—As stated, operative measures, unless resorted to early, are ineffective. Such measures as will conduce to the comfort of the patient should be employed.

NASOPHARYNX.—In this region primary carcinoma is infrequent. If it does occur, the soft palate is usually implicated.

Symptoms.—The growth is slow, and the interference with nasal respiration is gradual. Pain in the early stages is slight, but gradually increases in severity. Secretion is increased, and after ulceration occurs is mucopurulent and stained with blood. The glands of the nasopharynx, pharynx, and cervical region are finally involved.

Diagnosis.—Certain only by microscopic examination.

Prognosis.—Unfavorable. Death usually results in from one to three years.

Treatment.—Usually only palliative. In some instances a radical operation may be more or less successful.

SOFT PALATE.—In this structure, carcinoma usually presents the appearance of epithelioma, and may be cylindrical, squamous-celled, or tubulated. Usually occurs after middle age. Is found most frequently in males. The origin of the growth is in the muciparous glands, and for this reason the tubulated variety is most common. Carcinoma of the velum is generally primary, and is often confined to this tissue, but in the later stages of the disease it sometimes invades the adjacent tissues.

SYMPTOMS.—The first symptom is usually a diminished movement of the velum. As the growth increases the motion is still more lessened, and food often regurgitates into the nasopharynx. Phonation is impaired. The adjacent mucous tissue is often slightly inflamed and some edema may be present. If the adjacent tissues are affected, and the growth is of considerable size, often severe laryngeal obstruction may result, causing sufficient dyspnea to make tracheotomy necessary. Pain is neither severe nor constant, excepting in the later stages, and where there is implication of adjacent tissue. Ulceration is usually absent in primary carcinoma of this structure.

Diagnosis.—Microscopic examination is the only sure differentiation between carcinoma, papilloma, and adenofibroma.

Prognosis.—Usually fatal, as recurrence is almost sure, although it may not recur within a year.

Treatment.—Palliative, so far as now known.

PHARYNX.—In this region the growth usually begins on the posterior wall, follows the lymphatics, invading the lateral and anterior walls, and generally the tonsils, velum, and nasopharynx. Is often associated with carcinoma of the esophagus.

As a rule the growth is the squamous-celled, epithelial type, but occasionally it is scirrhus.

Symptoms.—Pain is infrequent in the early stages, but after ulceration, which occurs early in this region, the pain is quite constant. The act of deglutition increases the pain, which is lancinating and radiating. There is impairment of phonation. The secretions are very profuse, white and fetid after ulceration begins. If the growth is of the epithelial type, it is soft and spongy. When of the scirrhus form, it is first a hard, irregular tumor. In the early stages the mucous membrane covering either form is about normal in appearance, but after ulceration begins it is entirely lost. In the scirrhus form especially, the cervical glands are enlarged early. When the tumor is in the lower pharyngeal region and restricted to the posterior surface, it is usually fungoid. The outline is irregular, and the surrounding tissues swollen. The cervical glands are not involved as much when the growth is in the lower portion of the pharynx.

DIFFERENTIAL DIAGNOSIS.

CARCINOMA.	FIBROMA.	SYPHILIS.
Tissues adjacent to pharynx usually involved.	Confined to pharynx.	Probably other manifestations; ulceration may be single or multiple.
Sessile.	Pedunculated.	Indurated.
Irregularly firm.	Dense and firm.	Somewhat firm. Inflammatory areas surrounding lesion.
Ulceration.	None.	Ulceration.
No tendency of ulcer to heal.		Tendency to heal.
Remedies produce no effect.	Remedies produce no effect.	Yield to proper remedies.
Pain severe.	Pain absent.	Pain on irritation.

Prognosis.—Fatal.

Treatment.—Palliative.

TONSIL.—Carcinoma of the tonsil is very seldom seen. It is usually the squamous or cylindrical-celled epithelioma. In nearly all cases it is secondary, extending from the pillars of the fauces or the tongue. Early in epithelioma there is ulceration of the tonsil and enlargement of the cervical glands. Seldom occurs under the age of forty. The tumor is usually small, and invasion of surrounding structures is rapid if primary. The fetor from the ulceration is characteristic. The cachexia of wasting diseases and malnutrition is present. The secretion is excessive, and becomes more or less purulent and very irritating as ulceration progresses. Pain, increased by swallowing, is marked. When the deeper tissues are involved, a severe or even fatal hemorrhage may occur. As the disease progresses the cachexia increases, and there is a tendency to edema of the glottis. The voice is much changed.

Treatment.—Same as for sarcoma.

PHARYNX.—There is a diversity of opinion regarding primary malignant tumors of this structure, microscopic examinations not always positively determining their character. Carcinoma of the laryngeal tissues may have a nodular, papillary appearance. Later the true character of the tumor may be apparent. The difficulty experienced in making a microscopic examination is accounted for because of these growths often having a papillomatous surface, and the portion removed simply includes these nodules. There appears to be a hereditary disposition to laryngeal carcinoma in about twenty-five per cent of cases.

Pathology.—Usually epithelial in variety, squamous-celled or the tubulated type most frequently. The latter is really an adenocarcinoma. Any portion of the larynx may be involved, but the primary site is usually in the ventricular bands, vocal cords, or epiglottis. When the tumor

is intrinsic, it does not often involve the surrounding tissue, and the glands of the neck are not affected. This is probably because death results comparatively early in the disease. When the tumor is extrinsic, or in the epiglottis, the surrounding structures are affected, and also the glands of the neck.

Symptoms.—In the early stages, the symptoms do not vary essentially from those of a benign growth. The site of the tumor will determine early changes in the voice. When of the vocal cords or ventricular bands, the vocal change will be early. The change is more of power than of register or tone, and is rather characteristic. Pronounced dyspnea may occur as the growth increases. When intrinsic, dysphagia may be present, which accounts for the accumulation of secretion in the mouth. The glands may be affected. In the extrinsic form this occurs early, but in the intrinsic, when it occurs, it is a late development. Usually ulceration occurs in from three to six months. Hemorrhage occurs with the ulcerative process, gradually increasing with the progress of the disease. It is seldom that the ulceration involves the deeper structures, but when it does, interstitial necrosis follows. Prior to ulceration the secretion is excessive, but otherwise not abnormal. When ulceration takes place the secretion becomes mucopurulent and tenacious. It may be streaked with blood, greenish or grayish-brown in color, and may contain necrotic tissue and pus cells. The breath has an offensive, musty odor. Pain is usually a constant symptom, although when the growth is intrinsic it does not develop as early, and is not as pronounced. The cancerous cachexia is more marked in the extrinsic variety.

Diagnosis.—The diagnosis is usually difficult, as it is often almost impossible to make a satisfactory laryngoscopic examination, even of a healthy larynx. The location of the tumor, the ulcer, and glandular enlargement are aids.

Occasionally a specimen can be obtained for microscopic examination, but this piece should not be taken from the ulcerative portion. Usually the secretion is not adherent to the tumor, while it is tenacious, stringy, and adherent in tubercular lesions.

Prognosis.—Unfavorable, as there is a recurrence in the majority of cases.

TREATMENT.—Radical operative measures, when made early, may in some cases prove effective. When the disease has progressed to the ulcerative stage, palliative means may give relief from the most painful symptoms. Keeping the parts as clean as possible by the use of disinfecting and alkaline solutions will diminish the discomfort of the patient, and may partially lessen the disagreeable odor.

Embryonic Connective-tissue Tumors.

SARCOMA.

NASAL CAVITIES.—Sarcoma in this region is usually secondary. Sarcoma of the nasal cavities may appear at any age, usually before forty. The development is rather slow.

Pathology.—The origin is in the deep connective tissue, spreading to the mucous surface. When the growth is rapid, it is generally of the small round-celled variety. Nasal sarcomata are most frequently of the large-celled type, and grow slowly. The growth originating usually in the deeper structures, the mucous membrane covering the tumor is normal until the mass nears the surface, when the mucous membrane becomes thinner, with flattening of the epithelial cells. Fibrous tissue is not often found in the tumor, the cells being supported by a fibrinoplastic intercellular material. The growth is nodulated, generally soft and almost semifluctuating, the firmness of the growth depending upon its location. It presents a fungoid appearance.

Symptoms.—Obstruction of the nasal cavity is the first

symptom. Prior to ulceration the catarrhal discharge does not vary from that found in any case of impeded nasal respiration. After ulceration begins, which is usually late, and is coincident with increased vascularity, the secretion assumes a mucopurulent character, is stained with blood, and very offensive. Profuse hemorrhages frequently accompany this stage. Nasal deformity and pain depend upon the location. The pain is slight when the soft tissues only are affected, but when there is bony structure supporting the infected tissues, the pain is severe. This is very marked when the accessory cavities are involved.

Diagnosis.—A positive diagnosis is possible only by a microscopic examination of some of the tumor, in conjunction with the clinical history. Any of the nasal tissues may be affected.

Prognosis.—Unfavorable. If recognized early an operation which will completely remove the tumor may give fair results, as in this location the prognosis is better than when sarcoma is located elsewhere in the body.

Treatment.—Complete destruction of the tumor in the early stage is the best procedure. Curretage or the galvano-cautery are preferable. None of the morbid tissue should be left, or the operation will increase the destructive process. Owing to the vascular structure, excessive hemorrhage may occur. This should be controlled by plugging the nasal cavity with gauze. When the tumor involves surrounding structures, an external operation will be required.

NASOPHARYNX.—Sarcoma in this region is rather infrequent. Males are more often affected than females. The usual age is between forty and fifty, although no period of life seems exempt. The origin is in the submucosa over the basilar process of the occipital bone. The tendency of the growth is usually downward, and presents a lobulated irregular surface. The sarcoma is nearly always of the small, round-celled variety, which grows rapidly and in a short

time invades the pharynx. The bony tissues are not often involved. The tumor is soft and fungoid. In some instances it has extended upward, invading the sphenoid or sphenomaxillary sinuses.

Symptoms.—The early symptoms do not differ essentially from those of any impediment to nasal respiration, but in a short time the secretion becomes bloody and offensive. Ulceration and hemorrhage rapidly develop. There is impaired general health, the result of both the impeded nasal respiration and the difficulty in swallowing. As a result of extension to the Eustachian orifices, the hearing is impaired. Until the tumor is of considerable size, the pain is usually not severe.

Diagnosis.—Sometimes difficult, but the rapidity of the growth, lobulated appearance, soft sensation on palpation, and exceeding vascularity will assist in the diagnosis. A microscopic examination of a portion is also an aid. In early life the development is usually rapid, as it is nearly always the small round-celled variety. When of the large-celled type, the development is slower. The tendency to recurrence after operative measures is marked.

Treatment.—Practically, palliative measures are all that can be employed, as radical operations usually prove unavailing. In some cases an excessive hemorrhage may result from the ulceration, requiring the employment of styptics or the galvano-cautery. Such measures as will sustain and improve the general condition should be employed.

FAUCES, PILLARS, AND SOFT PALATE.—Sarcoma of these structures is generally of the mixed-celled variety, and is irregular in growth. Development is slow, and with a tendency to localization. If involvement of surrounding tissue occurs, it appears late and progresses slowly. Owing to the anatomical structure of the parts, ulceration is not always present. The deeper structures are very seldom involved. External manifestations of the disease are lacking.

Symptoms.—The symptoms do not vary materially from those of sarcoma of the nasopharynx, but the pain is less severe. Ulceration and hemorrhage are slight. Edema of the adjacent tissues is frequent.

Diagnosis.—The clinical history and a microscopic examination.

Prognosis.—Guarded. Recovery is said to occur in thirty to fifty per cent of cases. There is a liability to recurrence.

Treatment.—When possible, complete extirpation of the growth. Hemorrhage is sometimes so excessive that ligation of some of the larger arteries may be necessary.

PHARYNX.—Primary sarcoma in the pharynx is seldom seen, but when it does occur it is usually between the ages of thirty-five and fifty.

Pathology.—The pathology of the growth here is similar to that occurring in other regions, excepting that it may, through invasion of the lymph spaces by sarcomatous cells, assume what is called lymphosarcoma.

Symptoms.—These are of mechanical obstruction, and a constant sensation of a foreign body in the affected region. Difficulty in swallowing and when the tumor is large, some dyspnea, more pronounced in the recumbent position. Prior to ulceration, there is increased secretion. When ulceration takes place, the secretion is tenacious, stained with blood, and has an offensive odor. Pain is not severe, excepting on irritation produced by pressure or the implication of surrounding tissues. Hemorrhage is usually not severe. Nasal respiration is impeded and there is marked change of voice. Congestion and edema of adjacent tissue results. The cachexia is probably produced as much by the inability to take nourishment, as by the disease.

Diagnosis.—Clinical history in conjunction with a microscopic examination of the growth. The portion excised should never be taken from the ulcerating surface.

Prognosis.—Unfavorable. It is only a question of time until the disease results fatally.

Treatment.—Occasionally the tumor may be surrounded by a pseudo-capsule, and in such cases complete enucleation may be possible. Usually the surrounding tissues are affected, and the operation will be followed by a rapid recurrence of the disease. If there is considerable dyspnea, a tracheotomy may give temporary relief. The treatment, however, is palliative in the majority of cases. The parts should be kept as free from secretion as possible. The juice of pineapple seems to relieve much of the pain and irritation caused by the raw surfaces.

TONSIL.—Of malignant growths of the tonsil, primary sarcoma is the most frequent. It is generally of the lymphosarcoma type. The tumor is prominent, projecting into the faucial region, and interferes with nasal respiration through obstruction of the nasopharynx. When of considerable size there is difficulty in swallowing, and clearness of articulate speech is lost. The growth is usually very vascular, with marked disposition to ulcerate, and hemorrhage may be excessive or even fatal. The deeper structures are also liable to invasion. The cell formation may be of any variety, but when of rapid growth it is usually of the small round-celled type.

Symptoms.—There are no special early symptoms peculiar to sarcoma differentiating it from other growths. Secretion is usually increased, and there is a peculiar fetid odor which is more pronounced after ulceration. A radiating pain extending to the ear, angle of the jaw, or to the tongue or teeth, is often present, and increased on swallowing. The pain usually begins quite early and is a valuable diagnostic symptom. As the growth continues there is aggravation of the symptoms. Sarcoma of the tonsil is generally nodular and rather firm.

DIFFERENTIAL DIAGNOSIS.

SARCOMA.	CARCINOMA.
Generally over fifteen.	Generally over forty.
Frequently primary.	Seldom primary.
Very vascular; ulcerates early; hemorrhage profuse.	Ulcerates late; hemorrhage slight.
Late involvement of cervical glands.	Early involvement of cervical glands.
Sometimes encapsulated.	Not encapsulated.
Sex not a factor.	Most frequent in males.

Prognosis.—Unfavorable.

Treatment.—Operative, if recognized early. When late, palliative.

LARYNX.—Seldom seen in the very young. The tumor originates in the deeper structures, and although it may be nodular the surface is smooth. It is usually primary in the vocal cords, eventually implicating the other laryngeal structures. The growth may involve all or part of the larynx, but seldom invades contiguous tissue.

Symptoms.—Phonation is defective, and the respiratory action is interfered with early in the disease. Both symptoms rapidly grow worse as the tumor increases in size. An irritating, hacking, spasmodic cough increases the discomfort of the patient. Before ulceration begins the character of the secretion is practically normal, but there is an apparent increase due to the pain induced on swallowing. With the ulceration, the cough increases, and the secretion becomes mucopurulent, tenacious, and offensive. There is often hemorrhage, but it is more continuous than profuse. The growth usually does not get very large, as the distressing symptoms generally lead to an early diagnosis. The

pain is generally intermittent and irregular, sometimes severe, but is usually more a sensation of discomfort.

Diagnosis.—Difficult. The attempt at removal of a portion of the growth for microscopic examination is a questionable proceeding.

Prognosis.—Fatal.

Treatment.—Complete resection or extirpation of the larynx is the only measure which promises any relief.

Mixed Tumors.

ADENOCARCINOMA.—This is really a tubulated epithelioma, a carcinoma originating in gland tissue.

MYXOCARCINOMA.—A mucoïd or myxomatous degeneration of any carcinoma. The term denotes the variety of change.

TERATOMA.—This is a congenital growth, consisting of the three embryonic layers.

Cysts.

The classification of cysts is by no means clear, as there is a diversity of opinion regarding their cause and pathology.

SIMPLE OR RETENTION CYST.—This results from an inflammatory action either within a gland duct or in the surrounding structure, which eventually lessens the caliber of the duct, thus interfering with the escape of the secretion, and gradually causes a saccular dilatation at some part of the duct. When complete occlusion occurs, the continued secretion increases the size of the cyst. After a time the pressure will cause degeneration and desquamation of the epithelial cells of the duct, and the walls are thinned by the same cause. Usually found after the age of twenty. This form is often called mucocele and is common in the nose, nasopharynx, and upper portion of the larynx. In the nasopharynx the origin is in the adenoid tissue of the vault.

Seldom multiple. The symptoms are the same as myxoma.

Treatment.—Puncture and curettement. The snare if pedunculated.

CYSTOMA, (*Hygroma, Hydroma*).—This cyst may be found in the nose, nasopharynx, pharynx, or larynx, and is a dilatation of lymph vessels normally present. Most frequently seen after the age of twenty-five. Recurrence is frequent on account of the difficulty usually found in completely removing it.

DERMOID.—This develops either from inclusion of a portion of the epiblastic layer within the mesoblast, or the distention of the cavity of some persistent fetal structure which normally should have been obliterated. The walls of the cyst contain hair follicles and sebaceous glands, the secretions from the latter forming the contents of the cyst. Dermoid cysts are seldom found in the respiratory tract excepting in the nose. When they interfere with respiration, they should be removed.

CHAPTER XIII.

DISEASES OF THE ANTERIOR NASAL CAVITIES.

SEPTUM.—(1) Malformations. (2) Deformities. (a) Deviation or Deflection. (1) Disease. (2) Traumatic. (3) Congenital. (b) Synechia. (1) Congenital. (2) Acquired. (3) Collapse of Alæ Nasi. (4) Ulceration and Perforation. (Caries and Necrosis.) (5) Edema. (sub-mucous infiltration). (6) Abscess. (a) Acute. (b) Chronic. (7) Depression of Nasal Cartilage. (8) Tumors. (a) Exostoses, Eëchondroses, Spurs, etc. (See Tumors, page —.) (b) Blood cyst or Hematoma.

SEPTUM.

Kyle's modification of Walsam's table of causes of nasal obstruction is given as being comprehensive and simple.

Tabular View of Conditions Causing Nasal Obstruction.

(a) Intranasal.

1st. LOCAL.—(a) *Septal*.—(1) Spur and erection of tubercle. (2) Deviation and deflection, or split septum. (3) Dislocation of Columnar cartilage. (4) Hematoma. (5) Enchondroma and osteoma. (6) Papilloma. (7) Vascular and erectile tumors. (8) Myxoma (polypus). (9) Sarcoma and carcinoma. (10) Inflammation and abscess. (11) Necrosis. (12) Local contagious ulcers (soft chancre). (13) Primary syphilitic sore (hard chancre). (14) Gumma and periostitis. (15) Tubercle. (16) Lupus. (17) Rhinoscleroma. (17) Glanders. (19) Actinomycosis.

(b) *Turbinal*.—(1) Erection of turgescence. (2) Hypertrophy (local and general). (3) Necrosis. (4) Varix. (5) Vascular and erectile tumors. (6) Myxoma (polypus). (7) Papilloma. (8) Sarcoma and carcinoma. (9) Tubercle. (10) Gumma. (11) Lupus. (12) Rhinoscleroma. (13) Actinomycosis.

(c) *Accidental*.—(1) Foreign body. (2) Rhinolith. (3) Adhesion of turbinate to septum. (4) Larvæ, etc.

2d. General.—(1) So-called hypertrophic rhinitis. (2) Syphilis. (3) Tubercle. (4) Lupus. (5) Rhinoscleroma. (6) Actinomycosis. (7) Glanders. (8) Diphtheria. (9) Congenital smallness.

(b) Extranasal.

(I) OCCLUSION OF ANTERIOR NARES.—(1) Congenital malformation. (2) Cicatricial contraction, due to—(a) Injury and burns; (b) Syphilis; (c) Tubercle; (d) Lupus.

II. OCCLUSION OF POSTERIOR NARES.—(1) Congenital malformation. (2) Cicatricial contraction, due to—(a) Syphilis; (b) Tubercle; (c) Lupus.

III. OBSTRUCTION IN THE NASOPHARYNX.—(1) Adenoid vegetations. (2) Hypertrophy of pharyngeal tonsil. (3) Growths from the vault (nasopharyngeal polypus). (4) Retropharyngeal abscess. (5) Adhesion of soft palate to pharyngeal wall. (6) Retropharyngeal adenoma. (7) Retropharyngeal sarcoma. (8) Enlargement of the tonsils (adenoma). (9) Tumors of the soft palate. (10) Meningocele and encephalocele. (11) Growth from sphenoid sinuses. (12) Enchondroma of Eustachian tube.

(IV) OBSTRUCTION DUE TO EXTENSION OF GROWTHS FROM NEIGHBORING CAVITIES.—(1) Fibrous, osseous, sarcomatous, and carcinomatous tumors of the antrum. (2) Growths from the ethmoidal, sphenoidal, and frontal sinuses.

SYMPTOMS, SIGNS, AND EFFECTS OF NASAL OBSTRUCTION.—The most prominent symptoms of nasal obstruction are: (a) Inability to breathe freely through the nose; (b) Alteration in the voice; (c) Characteristic facial expression; (d) The presence of a discharge from the nose, or at the back of the throat.

(1) Swelling or redness of the external nose. (2) Intolerable itching in the nostril. (3) Headache. (4) Vertigo. (5) Aproxia. (6) Impaired general health. (7) Defective development. (8) Deformity of the chest. (9) Hypochondriasis and melancholia. (10) Shallow breathing. (11) Elongation of uvula. (12) Spasmodic cough and asthma. (13) Aphonia. (14) Night sweats. (15) Nightmare and distressing dreams. (16) Snoring. (17) Constant and oft-recurring catarrh of the pharynx, larynx, trachea, and bronchi. (18) Restlessness, twitching, and even convulsions in young patients. (19) Sneezing. (20) Perversion of the senses of smell and taste. (21) Sensation as of a movable body in the nose. (22) Deafness. (23) Salivation. (24) Eye-affections. (25) Hernia. (26) Stammering and stuttering, nocturnal enuresis, epilepsy, chorea, dyspepsia, gastralgia, palpitation of the heart, and muscular rheumatism.

The causes of nasal obstruction may be conveniently classified under the following heads:

1. The *intranasal*, or those depending on some primary condition in the nose itself.
2. The *extranasal*, or those depending on some condition external to the nose.

The *intranasal* may be subdivided into local and general.

1. The local causes are due to lesions limited to the septum, turbinates, or other parts of the nasal chambers; to accidental conditions, as the presence of a foreign body or rhinolith; and to adhesions between the turbinates and septum.

2. The general intranasal causes are such as depend on a general swelling of the mucous membrane, due to catarrh or to such affections as syphilis, tuberculosis, rhinoscleroma, etc.

The *extranasal* causes may be subdivided into the following classes:

1. Occlusion of the anterior nares, due to congenital malformation, or cicatricial contraction following an injury or such diseases as syphilis or lupus.

2. Occlusion of the posterior nares, which may also be the result of congenital malformation or of cicatricial contraction.

3. Obstruction in the nasopharynx, due to adenoid vegetations; polypi, or growths; enlargement of the faucial tonsils; adhesion of the soft palate to the postpharyngeal wall; tumors of the soft palate; meningocele and encephalocele.

4. Obstruction caused by extension of growths from neighboring cavities, such as the antrum or the ethmoidal or frontal sinuses.

1. Malformations of the Septum.

Under this heading all congenital conditions are included. It may be a deflection, deviation, or deformity. As a rule the cartilaginous portion only is affected. When there is only a partial development of this portion there may be an opening between the two nasal cavities, which resembles a perforation from disease. Any of the dimensions of the cartilage may be deficient. Congenital anomalies of the septum are associated with irregular development of the palatal or facial bones.

2. Deformities of the Septum.

In the ideal nose the septum is perpendicular to the nasal floor, and divides the space into two equal cavities. This

condition is seldom if ever found, the nasal passages being asymmetrical, usually through variation of the septum. In adult life this may be more marked than in childhood. Inflammatory changes also have a tendency to increase the deviation. Each case presents its characteristic changes. The septal curvature may be horizontal or perpendicular.

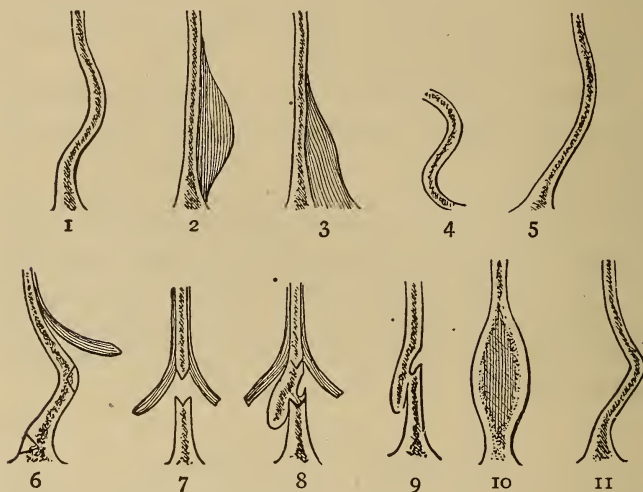


FIG. 64. Deflections of the septum: 1. Redundant tissue, concave; 2. redundant tissue or spur; 3. redundant tissue at floor; 4. S deflection; 5. simple deflection to the left; 6. lines of cuts for correcting 1 and 11; 7 and 8, method of correcting 9; 10. split cartilaginous septum. (After Kyle.)

The different curvatures will usually come under the classification shown in Fig. No. 64.

I. DEVIATION OR DEFLECTION FROM DISEASE.—This may be a primary or secondary condition. Any inflammatory action of the septal mucous membrane or perichondrium may result in deviation or deformity. Superficial ulceration of the mucous membrane of the septum, the result of abrasions or of eruptive disease, may be followed by devi-

ation of this structure. Hypertrophied turbinates, or tumors in the nasal cavity, may, through pressure, be an exciting cause. The unrecognized presence of a foreign body may also be a factor in producing this condition. Syphilis, lupus, or tuberculosis may also cause deflection.

2. TRAUMATIC DEFLECTION.—This condition occurs most frequently in childhood, although often not recognized until later in life. Children when quite young are especially liable to injuries involving the nose, but usually no attention is paid to the condition, which later often results in a marked deformity of the septum. The bony portion is nearly always affected in these cases. The deformity may not be perceptible externally, but as a rule it shows, and the direction of the blow, as well as its force, will be apparent by the amount of deflection. In some instances, the resulting deformity of a traumatism may require extensive surgical measures, especially when the bony framework is injured. Often a traumatic deflection occurs just within the nasal orifices. This is due to dislocation of the anterior end of the septum from the columnar cartilage. In these cases there is usually considerable obstruction to nasal respiration. Inspection will show the cartilage just within one of the anterior nares, extending to the muco-cutaneous surface. It is prominent, smooth, and covered with thin mucous membrane, usually slightly inflamed. The opposite nostril will show a slight depression corresponding to the prominence. Usually the result of an injury, but may be due to disease or irregular development. The tip of the nose is usually somewhat deformed. A slight dislocation is very frequent, and seldom requires surgical treatment, unless there is also considerable deviation of the cartilaginous or bony portions of the septum to interfere with normal respiration. When the cartilage is split and with but slight depression on the opposite side, the obstructing portion should be removed. When the opposite side is intact, there

will be no danger of the tip of the nose drooping. The mucous membrane should be dissected from the prominent surface, the cartilage removed with knife or gouge, and the flap allowed to drop into position. Healing rapidly ensues.

3. CONGENITAL DEFLECTION.—It is probably true that many of the cases of so-called congenital deformity of the nasal structures are the result of pressure during parturition. The body structures are soft, almost cartilaginous, and it is an acknowledged fact that manipulation of the nose in early infancy will modify its shape. Unimpeded nasal respiration also has a marked influence on the regular development of the nasal fossæ, the superior arch and the symmetry of the facial bones. When there is a deficiency of respiratory nasal space prior to the age of seven, the bony and cartilaginous structures become so firm that comparatively little can be done to remedy the defect.

Treatment.—No set rules can be laid down for treatment in these cases. Practically all operations are modifications of Adam's method. Each case must be studied according to its individual merits. A general line only of procedure can be given. When only the cartilage is deflected, and it is thin and flexible so that it can be readily pushed to the normal position by inserting the finger into the nostril, the desired result can be obtained by using a malleable tube or splint. This is molded to fit the deflected surface, and by gradually expanding the tube the desired amount of pressure can be obtained. This pressure induces a slow inflammatory process which eventually strengthens the cartilage and retains it in its normal position. The tube should be worn for four to twelve hours each day for two or three weeks. Care should always be exercised that too much pressure is not produced, on account of the danger of starting an ulcerative process.

In deflection of the septum, where it is not sufficient to interfere with free respiration, operative measures are

usually unnecessary. In surgical cases, if the deflection is confined to the cartilage, the curvature being comparatively regular, and no especial thickening of tissue, it is not necessary to remove any of the tissue. If the curvature extends close to the floor of the nose, an incision should be made on the concaved surface close to the lower portion dividing the mucous membrane and perichondrium. Then with the nasal saw cut nearly two-thirds through the cartilage. It is not necessary to make this incision when the curvature does not reach the nasal floor, the cartilaginous septum being fractured by a rolling motion of the forceps, so the septum may be restored to the desired position. By the use of the nasal tubes, the septum is retained in place. Should there be much swelling of the tissues within twenty-four or forty-eight hours, the tubes should be removed until the swelling subsides. When there is but little swelling and edema, the tubes may be left in position. The pressure can easily be regulated. During the time the tubes are worn, the nostrils should be flushed occasionally to get rid of excess of secretion. A solution of 10 gr. boric acid to an ounce of warm water is best. The tube may be removed daily for the purpose of cleansing if the tissues are much swollen, and be left out for several hours. As a rule I have not found this necessary. When the bony portion of the septum is also deviated, it is necessary to extend the field of operation, sawing through the bony portion to about the same depth as the cartilaginous septum, making two cuts, in order to control the line of fracture, then the septum is crushed with the forceps. The cut should always be deep enough to make it comparatively easy to fracture the bony partition. The tissue is kept in position by the means already described. When the deflection is vertical or V-shaped, two vertical incisions two-thirds of the perpendicular length and dividing the deflection into equal parts, are necessary before crushing. The

same after treatment should be used as in the other varieties. Enlarged turbinates are often present in the nasal cavity corresponding to the concave surface; and their reduction or partial removal will be necessary.

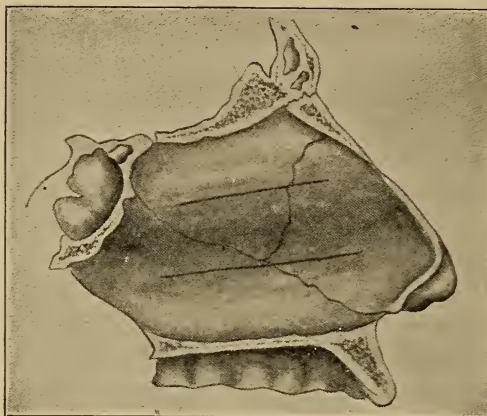
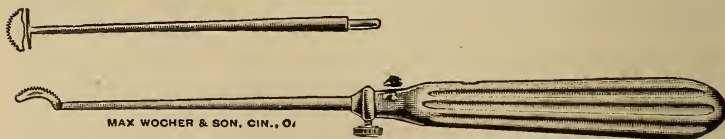


FIG. 65. Lateral deflection involving both bony and cartilaginous septum, showing lines for saw cuts to control the fracture in straightening. (About $\frac{2}{3}$ natural size. *After Kyle.*)



FIG. 66. Sharp bulging of septum on one side only.

In some cases of deflection, there appears to have been a splitting of the two halves (Fig. 66), one side only bulging, the other side being almost perpendicular. The bulging is acute, and there is considerable thickening of the



Kyle's Saws.

apex. In such cases a semi-circular incision is made on the under side, the mucous membrane dissected upward, and the projection sawed off. The operation should be made in such a way that no injury is done to the mucous

membrane on the unaffected side, as this will increase the danger of ulceration or perforation. When there is redundant tissue as well as deviation of the septum, the excess of tissue must be removed to make the operation successful. When the defect is of the cartilaginous portion, the mucous membrane should be dissected upward from the lower portion of the curvature, and a sufficient amount of cartilage removed, the section being V-shaped. This

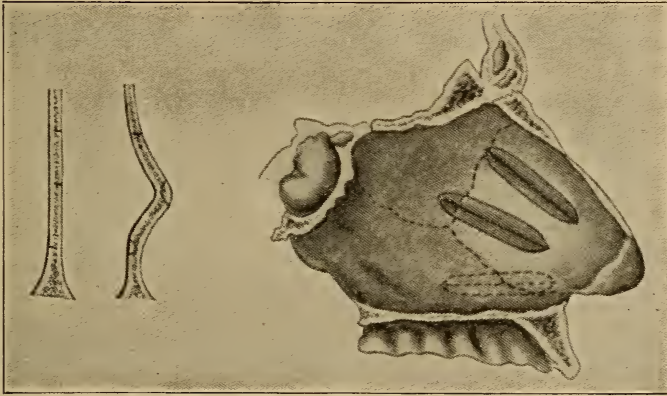


FIG. 67. The V-shaped cuts are diagrammatic. The position and direction vary according to the case. The dotted line indicates the position of cut on opposite side. (*After Kyle.*)

may be done with a saw or knife. The incisions should be made so as not to injure the mucous membrane on the opposite side. The V-shaped incisions, the number depending upon the amount of deflection, will give the best results, as when the septum is pushed to the normal position there will not be the tendency to a return to the abnormal position, through pressure. This operation of Kyle's has given the best results of any so far devised. When properly performed no support is required, and usually the less washing of the cavity, the better the results.

There are numerous operations devised for correcting deviations, and all have their good points, but the operator must use his own judgment in each case. The Asch operation is probably used in the greatest number of cases. The cuts made with the Asch forceps are as nearly at right angles to each other as possible, and through the point of greatest deviation, then the crushing forceps are used to destroy the resiliency of the deflected portion. The parts are held in position by the nasal tubes.

SYNECHIA.—This is generally a bony, cartilaginous, or

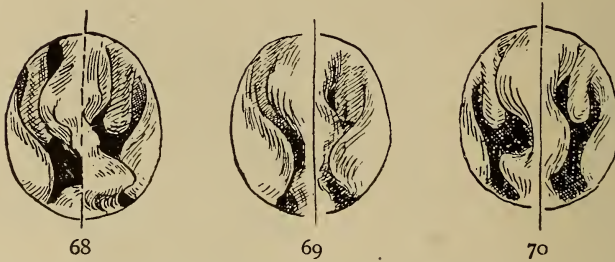


FIG. 68. Septal deviation and prominent spur in a case of hypertrophic rhinitis. FIG. 69. Deflection of septum with osseous enlargement associated with enlargement of the turbinate tissue. FIG. 70. Same as 69, after the application of cocaine, which constricts the soft tissue.

fibrous band extending from the septum to the lateral nasal wall. A synechia may extend from one turbinate to another. The condition may be either acquired or congenital.

Acquired.—In this form there must be erosion of the mucous surfaces. The two surfaces are usually in contact with each other, but occasionally a fibrous band may be found through the uniting of the plastic material from the ulcerated surfaces, building up until they meet. The conditions requisite to form a synechia may be brought about in various ways, such as the irritation of foreign bodies, simple chronic or hyperplastic rhinitis producing ulceration

through pressure of the surfaces, or by surgical measures, or the use of escharotics. The interference to nasal respiration will produce a line of symptoms not differing from any other obstruction in the nasal cavities.

Congenital.—The usual location is between the middle turbinate and the septum. The synechia is usually cartilaginous or bony.

Treatment.—Removal of the band should be insisted upon. The operation should be so done that there will be as little injury of the surrounding tissues as possible. Usually the less interference with the nasal cavity after the operation, the better. If exuberant granulations occur, the use of salicylic acid ointment is generally all that is necessary.

3. Collapse of the Alæ.

Collapse of the alæ or narrowing of the nostrils may result from non-development of the lateral cartilages or by lack of development through interference with nasal respiration in infancy. When there is obstruction of nasal respiration, the dilator muscles of the alæ become weakened through lack of use, and collapse. In long, pointed noses, having narrow, slit-like nasal orifices, the constrictor muscles may increase the narrowing. Whenever there is collapse or excessive narrowing of the nostrils, mouth breathing follows, and various affections of the pharynx and larynx result.

Treatment.—In some cases, especially when the narrowing is due to the action of the constrictor muscles, a short, perforated silver tube, made especially for the case, and fitted within the nostril, not extending to the bony portion of the septum, may improve the condition. The tube should be worn at night, or not over fifteen hours at a time. The tube can be easily changed in contour as required, and by persisting in its use for a number of months many cases are benefited. When the narrowing is due to faulty devel-

opment of the lateral cartilages, little can be done. In some cases, however, the use of the tubes will improve the condition.

4. Ulceration and Perforation (Caries and Necrosis).

ULCERATION.—Ulceration and perforation of the nasal septum are often associated. Ulceration may exist without perforation, but perforation seldom occurs without a preceding ulceration, the exceptions being the result of traumatism, or congenital.

Ulceration may be caused by external conditions, as dust or irritating vapors acting as mechanical irritants. Vascular changes from any cause may result in ulceration. As a result of vascular changes, there may be an itching or irritation, which will induce the patient to pick the septal region, thus producing an area for ulceration. In deflections of the septum, particularly where it is an acute angular deviation, ulceration is liable to occur on the concave surface. This results from the vascular changes as well as from irritation due to accumulation of foreign material. Intestinal obstruction or irritation, menstrual derangements, and in several cases under observation prostatic irritation, produced a tendency to engorgement of the nasal mucosa, causing a desire to pick the nose.

A foreign body or a growth in the nose may cause ulceration, either through irritation or pressure against the mucosa. Lesions of the cartilage, or perichondritis from an acute infectious fever or specific inflammatory condition affecting the mucous tissue, may be a cause. In these cases the lesion is secondary, the destructive process commencing in the deeper tissues and progressing toward the surface, being a reversal of the usual ulcerative process. Ulceration of the mucous membrane may follow in any systemic disease when there is lowered vitality.

In syphilitic ulceration there is nearly always bony ne-

crisis also. Irritating vapors, the use of the actual or galvano-cautery, or of escharotics, may cause ulceration. While ulceration may occur at any period of life, it is less frequent in the very young or aged. When found in infants or the very young, inherited syphilis should be suspected.

Location.—Usually on the mucous membrane covering the cartilaginous septum, but when due to specific or infectious disease, the membrane covering the bony portion may also be affected. The ulceration is usually located in the upper two-thirds of the septum, but the position is also dependent upon the cause. The size varies from a pin-head to almost the entire mucous surface. One side of the septum only is usually affected, and when occurring on both sides it is not necessarily opposite. The character of the discharge varies. In specific ulcers, or those resulting from foreign bodies, there is an offensive odor. In other ulcers the odor is slight, if any. The amount of the discharge depends largely upon the extent of the ulcerative surface.

Treatment.—In ulceration of the septum, if seen early, the destructive process can usually be arrested without perforation. The difficulty in too many cases is over-anxiety to do something, and the ulcerative surface is irritated and made worse by frequent local applications. The policy of letting the surfaces severely alone, excepting when some unirritating wash is necessary for cleansing purposes, will result in more cures than the diligent application of ointments, powders, etc. The internal administration of potassium bichromate 1/100 gr. will effect a cure in the majority of cases. If the ulceration is specific, the application of thuja in glycerine or Lloyd's hydrastis will aid the healing process, but systemic treatment must be used. Potassium iodide in full doses in acquired syphilis; in the hereditary form, gold and sodium chloride. Potassium bichromate may be used in connection with the above treatment. When there is an edematous condition of the tissue surrounding the ulcer, the salicylic acid wash will be beneficial, but must

not be used too frequently. The mucous membrane of the nasal cavities is not intended for any form of heroic local treatment.

PERFORATION OF THE SEPTUM.—Perforation of the cartilage occurs in about one-half of one per cent of cases. Congenital defects are rare. Occupation appears to be a prominent factor. When the vocation is such as exposes the person to irritants, the cases of perforation are more frequent. Usually the perforation is the result of picking the nose to relieve the irritation caused by the vapors or dust in which one is working. Necrosis of the cartilage is often found in syphilitic and tubercular inflammatory processes. It sometimes also follows eruptive or infectious fevers. Injuries also may be factors in perforation, through the employment of escharotics or cauteries. In many cases the patient is unaware of an existing perforation until an examination by a physician reveals the fact. The shape and size of the perforation is influenced largely by the cause and location. When in the cartilaginous portion, it is usually round or oval, but is usually irregular if in the bony portion, when it generally is of syphilitic origin. Usually the perforation is single, but may be multiple. In congenital perforation there is usually asymmetry of some of the facial bones, and an absence of inflammatory action. A septal abscess when it ruptures spontaneously, frequently causes necrosis of the cartilage, and perforation. Perforation may also result from a malignant growth, as carcinoma. Perforations may be divided into four general classes:

(1) FAULTY DEVELOPMENT. (2) LOCALIZED INFLAMMATORY CONDITIONS. (3) INJURY. (4) A LOCAL MANIFESTATION OF SOME CONSTITUTIONAL CONDITION.

Sex.—This does not seem to be a factor. Vocation, nasal deformities, and constitutional disorders are the principal causes.

Age.—Usually between twenty and forty, although they

may occur at any age. The ulceration leading to a perforation is generally unilateral. When the necrosis is on both sides, the perforation usually results from a systemic infection.

Pathology.—Practically the same as necrosis of tissue in other regions.

Symptoms.—There are no symptoms peculiar to this condition, the discovery being made either accidentally or during an examination. When a perforation has occurred, it is very seldom anything can be done to close it, treatment being directed to preventing more destruction of tissue.

Treatment.—When due to occupation, and it is impracticable for the patient to abandon the work, the use of a mask would in many cases prevent an increase of the ulceration, but there are few who will use such appliances. Plugging the nostrils with a small piece of sponge or cotton wool will often be of use. The advice often given to cleanse the nasal cavities frequently with an alkaline solution is of doubtful utility, excepting among those working in acid fumes. In some cases it may be necessary to touch the edges of the perforation at bleeding or ulcerative points with some strongly astringent preparation, or a 50 per cent solution of silver nitrate. When of syphilitic origin, potassium iodide should be given until the physiological effects are obtained. When the bony structures are also affected, the gold and sodium chloride will be found valuable. This drug should also be pushed to its full effects. Perforation, the result of tubercular disease, shows a disposition to invade the surrounding tissues. In these cases Fowler's solution and phytolacca should be given, as there is a probability of spreading by lymphatic invasion.

5. Edema (Submucous infiltration.)

Edema of the septal mucous membrane may occur at any stage. External irritants coming in contact with the

mucous surface; injuries of not enough force to fracture the bones or cartilage, or associated with a perichondritis may cause it; edema may be found in specific inflammatory conditions, or involvement of the cartilage following typhoid or infectious fevers. Edema may be unilateral or bilateral, more often the latter. Edema is not infrequent after operative procedures, especially the cautery or escharotics. It may also result from affections of the teeth.

Treatment.—Often absorption occurs without any treatment. When it is sufficient to cause obstruction of nasal respiration, puncture may be required. The local application of a cotton tampon saturated with glycerin will often cause a rapid reduction of the swelling. The use of salicylic acid ointment on cotton tampons will also afford relief. Internally the use of apis and apocynum will usually rapidly relieve the condition.

6. Abscess.

ACUTE ABSCESS.

Etiology.—An acute abscess of the septum may follow a traumatism, either direct or through effusion of blood into the tissue, the result of a blow. It may also follow the infectious fevers, and has been noticed in erysipelas and the so-called uric acid diathesis. An acute abscess may result from an acute coryza, or may be associated with purulent rhinitis in children, or in scrofulous or rachitic persons. In dental disease it is sometimes present, especially when the superior maxillary bones are malformed.

Pathology.—Similar to abscess formation elsewhere.

Symptoms.—When the result of traumatism, there are signs of external injury, as well as the history. Swollen and edematous mucous membrane, often occluding both nostrils, will be found. The external surface of the nose is swollen and reddened. Frontal headache; conjunctiva of the eyeballs congested and the lids more or less edema-

tous. Severe throbbing, lancinating pain in nose. General malaise, and often increased temperature. In from twenty-four to forty-eight hours a distinct pointing can usually be observed; the discoloration is more pronounced, and the pain less severe. The swelling may involve the entire face, or only the upper lip. The nose is extremely sensitive to pressure. As the abscess progresses, fluctuation will be found on palpation.

Diagnosis.—Usually easy; but an acute edema may be mistaken for this condition; however the symptoms are less marked, with the exception of the swelling.

Prognosis.—Favorable, if recognized early and a free incision is made. When allowed to rupture spontaneously there may result either deformity or perforation.

Treatment.—A free incision through one side of the cartilage, at a point low enough to insure drainage, should be made as soon as the disease is recognized. As there is a tendency to early closure of the incision, free drainage may be maintained by introducing a strip of gauze in the opening, or by making the incision obliquely through the cartilage. After opening the abscess, the cavity should be thoroughly cleansed. Internally the administration of gold and sodium chloride, silicea, or calcium sulphide. If a rheumatic or gouty diathesis is present, the use of rhus tox., bryonia, cimicifuga, or rhamnus Californica may be required. Colchium is of value in the gouty form, but care should be observed not to give it in doses that will derange the bowels, a result often following the use of this drug.

CHRONIC ABSCESS.—Seldom seen. It sometimes follows typhoid or other fevers, where the cartilage becomes involved, or as the result of syphilitic or tubercular necrosis. Perforation, however, usually follows the latter affections. As a rule chronic abscess invades the anterior portion of the cartilaginous septum, the development is slow, and the symptoms not marked. Examination reveals a fluctuating

tumor of the septum, which partly obstructs the fossæ. When of syphilitic or tubercular origin, the history will aid in the diagnosis.

Treatment.—A free incision should be made on one side, the limiting membrane thoroughly curetted, and the cavity well washed. In some cases it will be best to pack the cavity with gauze after the flushing. There is in these cases a tendency to perforation. Internally the use of lime, gold and sodium chloride, etc. Hygienic and medicinal measures to improve the general nutrition should be employed.

7. Depression of Nasal Cartilage.

When there is depression of the cartilage, various external deformities of the nose result. Trauma or abscess of the septum may be the cause of the depression. Ulceration and perforation of the septum may be associated with this condition. Depression of the cartilage may take place without destruction of tissue, or there may be more or less loss of structure. A depression, the result of septal perforation, will usually be flat, the soft structures appearing to be spread out on the face. The nasal orifice is increased laterally and diminished perpendicularly. Depression, the result of an injury or septal abscess has a sunken appearance on the top of the nose, and tip tilted up.

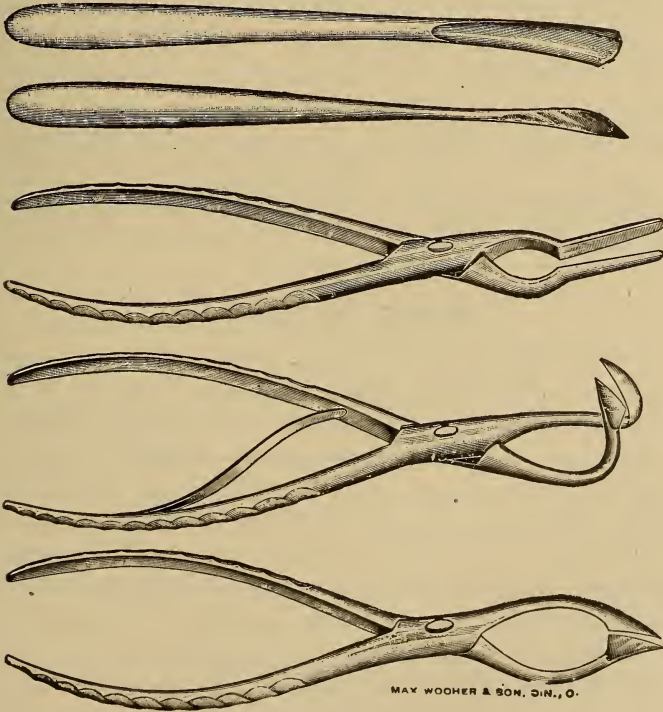
Treatment.—Each case must be treated according to the character of the deformity.

TUMORS.—Bony growths have been considered.

Hematoma of the Septum (Blood-cyst).

Hematoma is a sudden effusion of blood into the submucosa caused by an injury. The effusion may be bilateral or unilateral, involving part or all of the septum. Fracture of the bone or cartilage may also be present. There is a history of injury, sudden appearance and secondary in-

flammation. The effused blood may become encysted or may break down and suppurate through secondary inflammation. Small hematoma may result from the rupture of a blood vessel, as sometimes happens in the exanthemata, or on violent exertion. These cysts are usually soon absorbed and treatment is not required. In extensive effusion it is nearly always necessary to incise. After evacuation of the blood, the nasal cavity should be packed with gauze, so that pressure over the location of the hematoma is exerted. The gauze should be changed every twenty-four hours, and should not be packed so tightly as to cause ulceration



Asch Nasal Set.

CHAPTER XIV.

DISEASES OF THE ANTERIOR NASAL CAVITIES.

DISEASES OF THE ACCESSORY SINUSES.

DISEASES OF THE MAXILLARY SINUS.—(a) Catarrhal Inflammations. (1) Acute. (2) Chronic. (b) Ozena. (c) Empyema. (1) Acute Purulent Inflammation. (2) Chronic Purulent Inflammation. (3) Confined Suppuration. (d) Specific Inflammations. (e) Acute Infectious Diseases. (f) Emphysema. (g) Foreign Bodies. (h) Mucocele. (i) Tumors. (j) Phlegmonous Inflammation.

Very little is known of the functions of the accessory sinuses, and the majority of diseases affecting these cavities are not well understood.

Catarrhal Inflammations.

ACUTE CATARRHAL INFLAMMATION.—This may occur with any acute rhinitis, being simply an extension of the inflammatory process. The cause of the rhinitis will have considerable influence on the antral condition. Carious teeth or disease of the alveolar process may in some instances cause antral disease through continuity of tissue. It has also been found following intranasal operations, especially cauterization; the insufflation of powder or considerable pressure in the use of the douche. The method of plugging both the anterior and posterior nares in epistaxis; the employment of hydrogen dioxide in the nasal cavity may, by causing extraneous material to be forced

into the antrum, excite an acute inflammatory process. It has also been traced to the entrance of secretions from the frontal or ethmoidal sinuses through the antral opening. The disease is sometimes found following a traumatism, or coexistent with nasal manifestations of the exanthemata, or a part of a general manifestation of cardiac or renal disease. Tumors, teeth, etc., in the cavity have been found to be causes of the disease. Systemic poisoning has also produced it.

Symptoms.—As a rule the pain is not severe, but is deep-seated. Pressure against the upper teeth on the affected side may cause a sensation of tenderness. There may also be more or less constant dull pain along the teeth of the affected side, and also infraorbital or intraorbital pain. Edema of the mucosa on the antral side may be present.

Diagnosis.—Not always easy, excepting in typical cases.

Prognosis.—Usually favorable.

Treatment.—The inflammatory process is identically the same as of mucous membrane elsewhere. The majority of writers insist that treatment is not of the same value here as in more open cavities, but this has not been true in the majority of cases. In some instances it is true the antral opening will become closed, so that an artificial opening into the antrum will be required. In such cases the point which will afford the best drainage should be selected. The contour of the antrum must be considered. The canine fossa may be the point of selection, or the opening may be made through the nasal cavity, using a curved trocar and canula.

Local.—Douches should be avoided as a rule. In many cases where there is edema of the tissues the use of either cotton tampons saturated with glycerin, or covered with salicylic acid ointment will relieve the occlusion, free drainage resulting.

Internally in the early stage, aconite. Gelsemium, by rendering the secretion more fluid will usually be indicated. Phytolacca, potassium bichromate, lime, silicea, or hamamelis may be required. After the acute symptoms subside, hydrastis in combination with phytolacca is nearly always indicated.

The use of powerful constricting solutions, while giving relief temporarily, will cause relaxation of the tissues and complications later on.

CHRONIC CATARRHAL INFLAMMATION.—This condition is frequently the result of repeated acute attacks, or from an acute inflammation where the exciting cause is constant. As a rule, suppuration occurs in these cases, but at times the disease is simply that of a chronic catarrhal inflammation. If the disease is unchecked the antral opening may become closed, and the secretions being retained, the term *hydrops antri* might be used.

In some cases there may be a low-grade cell proliferation from the mucous membrane, forming myxomatous masses and filling the cavity with a soft, translucent material, which is the condition termed mucocoele. The pathological changes are similar to inflammatory changes of any mucous membrane.

Symptoms.—These vary considerably, but are influenced very much by the patency of the ostium maxillare. Usually there is a sense of slight irritation or a dull ache in the sinus. At intervals there will be a discharge of secretion into the nasal cavity of the affected side. This secretion may be a clear, glairy, tenacious, mucous material, or may partake of any of the characteristics of mucous membrane secretion. After the escape of this secretion there is a sense of relief on the affected side.

On inspection the secretion can often be seen oozing from the antral opening, filling the middle meatus. This may be more marked if the excess is wiped away, and the

head inclined sideways to assist gravity in emptying the antrum.

When the antral opening is closed, preventing the escape of the secretion, there will ensue a severe line of symptoms: gradual distention of the antrum results, the thin walls allowing swelling in all directions; the eyes become congested and prominent; the cheek swollen and teeth sore. The pain gradually increases until relieved by the exit of the secretion either by natural or operative methods.

Diagnosis.—Often difficult on account of nasal conditions which mask the antral disease.

Prognosis.—Guarded, as a cure depends upon so many influences.

Treatment.—The infected form of this disease is most often seen, although occasionally a non-infected case presents. In these cases an opening into the antrum is required, and curettement of the antral surface whenever pressure symptoms are prominent. Systemic measures will frequently obviate the necessity for surgical treatment. Internally, calcium, silicea, gold and sodium chloride, potassium iodide. The same general line of treatment given under acute catarrhal inflammation will be required.

OZENA OF THE ANTRUM.—This may be independent of, or accompany, ozena of the nasal cavities. The causes and pathology are probably identical with the nasal form. There are no characteristic symptoms of the disease in this location, but this condition may possibly account for the foul odor where no nasal manifestations are present.

Diagnosis.—Difficult.

Prognosis.—Guarded.

Treatment.—If the cause can be determined, the removal of the exciting factor will be necessary. As a rule, the treatment will not vary essentially from the chronic catarrhal type. The use of potassium bichromate in these cases will have a tendency to relieve the crust formation.

Empyema of the Antrum.

ACUTE PURULENT INFLAMMATION.—Empyema is usually the result of a catarrhal inflammation, which becomes purulent in character. A general debilitated condition of the system is often present. The claim is made by some that the abuse of certain drugs, especially mercury, is a factor in some instances. Disease or division of the fifth nerve has been given as an incidental factor. The infectious diseases, la grippe, traumatism, and diseases of the teeth or alveolar process, the latter especially, are important causes of this disease. Children are usually exempt on account of the lack of development of the antrum prior to puberty.

Symptoms.—Usually marked. A profuse discharge of pus from the nostril of the affected side; this may be constant but usually appears suddenly, with marked intervals of freedom from the discharge. The material, as a rule, is yellowish, sometimes streaked with blood, and may have a slight, or very offensive odor. The exit of pus is often facilitated by inclining the head sideways, downward, and forward. Pain will depend upon the ease with which the secretion escapes from the antrum. When present, is usually described as dull and heavy, and there is nearly always inability to locate the site definitely. Percussion of the teeth or cheek may reveal tenderness. At times there may be a small fistula at the point where a tooth has been extracted, and pus may be found in the opening. Occasionally there are systemic disturbances, as a chill, headache, etc.

Diagnosis.—Anterior rhinoscopy may reveal pus in the middle meatus of the affected side. This should be carefully wiped away, and the head then inclined obliquely downward and forward, the affected side upward, when if pus is again found in this location, it will be good evidence

of antral disease. The possibility of empyema of the other accessory sinuses must be remembered. The more or less constant return of pus and the sensation of discomfort or pain in the antral region tend to confirm the diagnosis. The use of the diagnostic lamp for transillumination of the structures, while of value in some cases, is not positive evidence of pus in the antrum, as there are many conditions which may obstruct the passage of light, as asymmetry of the antra, external swelling, or discoloration.

Prognosis.—Guarded. The disease may rapidly subside, or may merge into a stubborn chronic condition.

Treatment.—Similar to that for the catarrhal form.

CHRONIC PURULENT INFLAMMATION.—The causes of this form are practically the same as of the acute type, or it may result from the acute type. The pathology is similar to chronic suppuration of the mucous membrane generally.

Symptoms.—These depend upon whether there is a free exit for the pus, or whether it is retained within the antrum. In the former case, the symptoms are similar to those of the acute type. There is, however, usually more discharge from the affected side, the secretion often being bright yellow and with more or less fetor. During sleep the purulent material may pass back through the posterior nares into the pharynx. A hacking cough is often present, resulting from the dripping of the discharge from the posterior nares. Mental depression is often present, the patient imagining those around can detect the offensive odor. This is unusual, as the odor is not often marked. There may be an acrid, bitter, or mawkish sweet taste resulting from the discharge, and gastric disturbances are not infrequent as a result of swallowing some of the purulent material. The general health is often affected.

Diagnosis.—The symptoms given, and a careful examination similar to that of the acute type.

Prognosis.—Time and steady treatment are necessary for a cure, but the disease is a difficult one to treat, although it is seldom, if ever, fatal.

CONFINED SUPPURATION.—In this type the pus is retained within the antrum, not finding a natural means of egress. This condition usually results from an occlusion of the antral opening, which may be closed prior to the acute suppurative process, or be occluded by the inflammatory or other morbid conditions. In some few cases the occlusion may be congenital. A turgescient condition of the nasal mucosa through an acute catarrhal condition, or coexistent with the exanthemata, may be a cause. Polypi or the presence of a foreign body may also be a cause. As a rule, the disease is slow in development. The antral region becomes tender on pressure, especially pressure on the teeth. A dull headache may be present and also a sensation of fullness and heaviness of the superior maxillary. The pain becomes aggravated, and there may be throbbing and beating, with supra-orbital, infra-orbital, or root of the nose, aching. Swelling of the antral walls may become excessive. There may be stenosis of the nasal space on the affected side, the hard palate bulging, and sometimes spontaneous rupture through this structure. Swelling of the cheek, exophthalmos, conjunctival congestion, impaired vision, and excessive lacrimation may occur. The tissues over the antrum are hot to touch, reddened, and edematous; constant and severe pain is present, and the teeth seem to be too long. It is difficult to masticate food. Speech is abnormal and sleep practically impossible. The symptoms of septic infection may present, as sweats, chills, and rigors, increased temperature and high-colored urine. Sometimes the antral walls may be so thinned and tense as to give crepitus on pressure. Dullness on percussion, and fluctuation may be found. Eventually the point of least resistance gives way, allowing the exit of accumulated pus

and the establishment of a more or less permanent fistula. This may be through any portion of the antral walls.

Diagnosis.—When fully developed the diagnosis is easy. Prior to this, however, it is sometimes difficult.

Prognosis.—Guarded, as complications may arise, and a chronic suppurative inflammation is quite likely to follow. Intracranial lesions may result regardless of any treatment.

Transillumination.—While in typical forms of the antrum this method is of undoubted aid, atypical types are unfortunately so common that little reliance can be placed upon this method, although it will assist in making a diagnosis in a sufficient number of cases to be of value to the physician. The age and sex must be considered, as in chil-



FIG. 71. Antrum Illuminator.

dren and women the antra are often higher than the floor of the nose, and the walls usually thicker. In the aged the walls are thinner. The best position for the lamp is in the nasopharynx. The examination should be made in a darkened room. In typical normal antra the cavities will be seen as clear areas on either side of the nose, but, as already stated, so many persons present atypical antral cavities that failure to get equal illumination does not positively indicate a morbid condition.

Treatment.—This should consist of remedial, and in many cases surgical measures. If the antral opening is closed through swollen nasal tissues, especially when they present a soggy appearance, the introduction of a pledget of cotton saturated with glycerin will frequently deplete

the tissues sufficiently to allow drainage of the retained material. In some cases the ointment of salicylic acid answers better, as the results are more permanent. Internally, aconite and gelsemium or pulsatilla will often prove effective, provided there is no necrosis of the bone. If the discharge is purulent, calcium or silicea, or the two alternated, will give marked relief. When necrosis of the bony structures has occurred, gold and sodium chloride will be the best treatment.

Operative measures are frequently necessary to provide free drainage, the site for operative procedures depending upon the individual case. Drainage from below is undoubtedly the best, and should be obtained when possible, although the general rule is to treat through the nasal cavities when the disease is of nasal origin, and through the alveolar process when dental. No arbitrary rules can be laid down in these cases. If an artificial opening is to be made through the nasal cavity, the usual method is to use a spear-shaped knife. This is introduced into the inferior meatus with the point toward the floor until just below the antral opening, then turning the point toward the antrum and giving a sharp thrust, it will penetrate the wall. This opening will allow cleansing as well as free drainage. A curved trocar and canula, or a drill may also be used, but in cases of narrow nasal cavities these methods are often impracticable. In operating through the alveolar process, the canine fossa is the easiest of access. If the teeth are all perfect, the opening may be made between the first and second molars, or between the second bicuspid and first molar. If either of the bicuspids or the first molar is absent, the opening should be through the socket (Jame-son). After opening into the antrum, if no granulations or other morbid growths are present, thorough irrigation should be made with a warm, saturated solution of boric acid, followed by 1/1000 solution pyoctanin. In the major-

ity of cases packing the antrum with gauze, which should be replaced twice the first twenty-four hours, and afterwards usually once a day, is the best procedure. This should be continued as long as any morbid material is present. When the healing process is delayed through granulation tissue areas, the opening may be enlarged and the antrum curetted.

Tuberculosis, Syphilis, Glanders, Actinomycosis.

These affections are infrequent, and when present are usually the result of similar nasal diseases.

Acute Infectious Diseases.

Occasionally the antra are affected during nasal diphtheria, small-pox, erysipelas, etc. When this occurs it simply increases the symptoms already present. The general line of treatment is usually sufficient.

Emphysema of the Antrum of Highmore.

This is where there is an accumulation of gas in the antrum. As a rule, it is the result of the accumulation of gases from a decayed tooth communicating with the antrum. The gases may be confined to the cavity by occlusion of the ostium maxillare. When a free escape of the gas occurs, a diagnosis of some nasal lesion is often made.

Symptoms.—These depend upon the condition of the antral orifice. When partially or completely closed, there may be a sensation of intranasal pressure, dull in character, and a heavy, aggravating headache, increased on leaning forward. The functions of the eye, nose, or mouth may be disturbed.

Diagnosis.—Frequently difficult, and must usually be made by exclusion. Caries of the teeth may aid in the diagnosis. Dental irritation of this region, with later an

abatement of pain, and again pressure symptoms in the cheek, and a constant or intermittent ozenous odor should be viewed with suspicion.

Prognosis.—Good, as the removal of the exciting cause usually results in a cure.

Treatment.—The free exit of the gas, and referring the case to a good dentist.

FOREIGN BODIES IN THE ANTRUM.—These may be animate or inanimate. The former are seldom found, although insects and maggots have sometimes been found, having made their entrance from the nasal cavities through the antral opening.

Inanimate Objects.—These may be the ends of dental or surgical instruments broken during operations upon the superior maxilla, or cotton, drainage tubes, etc. In a few cases foreign bodies find entrance through penetrating wounds of the cheek. Sometimes an intra-antral tooth, or a tumor, may cause the distress.

Symptoms.—Identical with those of a catarrhal or suppurative process.

Diagnosis.—Conjectural as a rule, unless a history of trauma can be elicited.

An exploratory opening is usually the only certain diagnostic method.

Treatment.—The ingenuity of the operator will often be severely tested in these cases. Sometimes the foreign body can be grasped with delicate forceps, or a small probe bent to form a hook. A steel crochet needle may be useful in some cases, but care must be exercised not to entangle and injure the tissues. Occasionally free injections of tepid saline solution will bring the offending substance into a position where it can be easily removed. In the majority of cases it is necessary to open into the antrum, preferably through the canine fossa. Animate objects seldom make their way into the antrum, although such cases are re-

corded. The symptoms are then aggravated, especially if the object is alive, its motion producing an almost intolerable pain. The treatment is similar to that for inanimate bodies.

MUCOCELE OF THE ANTRUM.—This may result during or following a chronic inflammation of the antral membrane. The pathology is practically the same as found in the development of myxomatous masses in the nasal cavities.

Symptoms.—About the same as in confined suppuration, only the course is slower, and there is not the systemic disturbance. In some cases the mass may occlude the antral opening, and cause an empyema. Usually there are no marked symptoms until the antrum becomes nearly filled, when there is a sensation of uneasiness and heaviness, and an aching pain which increases with the size of the growth. Facial deformity may become marked. The antral walls become thinned, and crepitus may be detected on palpation of certain areas. The symptoms are similar to those of empyema, but without the acute, rapid, and systemic manifestations.

Diagnosis.—In the early stages, often impossible. In the later stages it is frequently difficult. Aspiration through the nasal walls will show whether the pressure is due to fluid or not.

Prognosis.—Guarded, as it is usually difficult to cure.

Treatment.—In some cases simply draining and washing out the antrum will suffice. In many cases it is necessary to enter the antrum, either through the outer or nasal wall, and curette the antrum. The cavity is then packed with borated gauze, and this treatment continued until healing results.

TUMORS.—Tumors of the antrum are infrequent. Myxoma and osteoma are the most frequent, but fibroma, enchondroma, and angioma have been reported. Carci-

noma and sarcoma may be either primary or secondary, but will always invade adjacent structures. Cysts and cystic degeneration within the antrum are rather frequent. They may be retention cysts, caused by dilatation of the mucous follicles. Cystic degeneration may result from inflammatory conditions of the mucous membrane. A dentigerous cyst may develop as the result of an inflammatory process extending from the root of a tooth which penetrates the antrum, and is covered by the mucous membrane.

Diagnosis.—Usually must be made by an exploratory opening.

Treatment.—Practically the same as in mucocele.

PHLEGMONOUS INFLAMMATION.—Usually found associated with a similar condition of the upper respiratory tract. The symptoms are those of a very severe catarrhal inflammation. This disease seldom occurs. Is rapidly fatal.

Diseases of the Ethmoidal Cells.

- (1) Catarrhal inflammation. (a) Acute. (b) Chronic.
- (2) Suppurating Ethmoiditis. (a) Acute. (b) Chronic.
- (3) Mucocele and non-infected Fluid retention. (4) Specific inflammations. (5) Tumors.

The anatomical, location and construction of the ethmoidal cells must be considered in both recognizing the diseases affecting them, and in making a diagnosis. In many cases a diseased condition is not recognized here, on account of other symptoms predominating. The nasal openings of the anterior cells are so situated as to be covered by morbid discharges from either the frontal or maxillary sinuses. The posterior set are in a similar relation to the sphenoidal sinus, and there may be extension of inflammatory action, or occlusion from various causes in the nasal cavities affecting these outlets, or there may be pri-

mary involvement of the cells, which later will affect the nasal tissues.

Catarrhal Inflammation.

Usually results from an acute rhinitis. The inflammation may be either acute or chronic, the latter often becoming suppurative.

Symptoms.—It is very difficult to differentiate, as the symptoms are frequently entirely masked by the nasal manifestations. Pain may be more deep-seated and persistent than in a rhinitis.

Diagnosis.—Very difficult, but at times the location and character of the pain will aid.

Prognosis.—Favorable, unless suppuration follows.

Treatment.—The same treatment given under acute rhinitis.

Suppurating Ethmoiditis.

Synonyms.—Purulent Ethmoiditis; Ethmoidal Suppuration.

Suppuration may be an acute process, but usually is chronic. It may result from simple catarrhal inflammation, especially when the tissues near the cell openings are affected. Generally one side only is affected, but may be bilateral. Very often other of the accessory sinuses are similarly diseased. Any obstruction of the drainage of the cells causing an accumulation of secretion may be a factor. Often seen in scrofulous or tuberculosis cases, and not infrequently in the tertiary forms of syphilis. Erysipelas and acute infectious diseases may also be causes. Traumatism, or fracture of the base of the skull, or even intranasal operations, especially if much pressure is exerted on the septum, may lead to suppuration. Foreign bodies, either animate or inanimate, have also been reported as factors.

Pathology.—The membrane is thickened and rough.

The bony partitions become necrotic and are embedded in the purulent mass. Small sequestræ are sometimes found in the later stages.

Symptoms.—Infrequently there are no symptoms, excepting the discharge of pus. Some cases may run an acute or chronic course, showing slight characteristic symptoms. The majority, however, are chronic and have characteristic, and usually, present severe symptoms, without any disposition to spontaneous recovery. Besides the usual symptoms of rhinitis, there is a deep-seated pain, referred to the back part of the orbit or the eyeball. As the disease progresses, the pain may extend to the temporal region. Pus escapes from the nostril of the affected side, and there may be a slight, or quite offensive odor. Sometimes the flow of pus may be increased or induced by pressure upon the eyeball. Inspection sometimes reveals the discharge from the anterior cells as it oozes out under the middle turbinate, and occasionally that from the posterior and middle cells, high up in the posterior part of the superior meatus. When the patient is in the recumbent position, the discharge passes backward into the nasopharynx, and eventually into the stomach, causing gastric disturbances. Usually, as the disease continues, small pieces of necrotic tissue and crumbling bits of carious bone will be found in the discharge. The quantity of discharge varies from a small amount to a profuse and nearly continuous flow. Occasionally there may be a certain amount of material retained, only partial evacuation occurring. When this happens there will be some symptoms of internal pressure, but not so decided as in complete retention. In retention there will be more or less severe disturbances of the eye, which becomes more or less prominent and congested, with increased lachrymation and edema of the lids. The mobility of the eyeballs is diminished, and may be immobile in severe cases. Diplopia or even blindness may occur. Ol-

faction is impaired or destroyed. As a result of pus absorption, chills, irregular fever and night sweats may occur, as well as a general depression of both the mental and physical systems. There may be symptoms of meningitis. If the pressure continues there will be increased distention, and frequently at the inner canthus of the affected side there will be a small, smooth tumor, which may rapidly increase in size, increasing the symptoms of inflammation. When the distention is extreme, the consequent thinning of tissue will be followed by rupture and the escape of pus. This may occur in a few weeks, or only after the lapse of years after the suppurative process has started. The direction in which the rupture occurs varies; it may be at the inner canthus, and an intractable, fistulous opening result. It may be the cause of an orbital abscess followed by panophthalmitis. The maxillary sinus, frontal sinus, or the nasal chamber may be the point of selection. Often it opens into the anterior cranial fossa, producing a quickly fatal suppurative meningitis. After the escape of the pus, there is an amelioration of the most severe symptoms, but a persistent fistula remains.

Diagnosis.—In a typical, uncomplicated case not very difficult. If suppurating disease of the other sinuses is present, it is difficult. The location of the pain, ocular disturbances, character of the nasal discharge, etc., will aid. Transillumination may aid in some instances, and in the later stages a probe passed over the affected area may give a grating or crumbling sensation.

Prognosis.—Unfavorable. In some few instances the disease may spontaneously disappear. Usually it is very intractable, and is always a menace to life.

Treatment.—In either the acute or chronic forms relief from the turgescence of the nasal tissues is important, but in the acute form the pus usually soon finds an exit. In either form, however, amelioration of the symptoms may

be obtained by the use of pledgets of cotton saturated with glycerin or covered with salicylic acid ointment, and placed well up toward the roof of the nasal cavity. The ointment should not be used too frequently, as it will cause excessive irritation. Solutions which cause depletion of the nasal tissues may be employed, provided they can be carried up toward the roof of the nose. Any deformities of the nasal cavities should be corrected, so that free drainage can be obtained. Nasal polypi are often found in this condition, and should be removed. When the anterior portion of the middle turbinate is enlarged, impeding free exit from the anterior cells, the morbid portion should be excised. Granulations and necrosed bone should be thoroughly curetted. Either Myles' or Bryan's curettes are preferable. Usually local anesthesia is all that is necessary for operating on the ethmoid cells, but in some cases general anesthesia is required. After curettement, a careful cleansing of the area should be made with the salicylic acid wash, and a packing of borated gauze should be used for two or three days. A solution of asepsin is useful as an injection into the diseased areas. Powders are always to be avoided. The systemic treatment is the same as in antral disease.

MUCOCELE AND NON-INFECTED FLUID-RETENTION.—This is of infrequent occurrence, and presents the same etiological and pathological conditions as present in the other accessory sinuses.

Symptoms.—Not well defined, and usually are not recognized. The usual line of symptoms of chronic inflammatory processes are present. In the later stages pressure symptoms are sometimes fairly well developed. Occasionally external deformity and eye symptoms may occur.

Diagnosis.—Quite difficult, and often made only after a long observation of the case.

Prognosis.—Fairly good.

Treatment.—Curettement and complete evacuation of

the morbid material and daily cleansing of the cavity until healing occurs.

SPECIFIC INFLAMMATIONS.—Comprising the specific inflammations may be syphilis, tuberculosis, glanders, actinomycosis, and the acute infectious diseases. Implication of the ethmoid cells is always an unfavorable and sometimes a fatal complication.

Symptoms.—These may be localized, but are often unrecognizable on account of the general symptoms.

Diagnosis.—Difficult.

Prognosis.—Usually unfavorable.

Treatment.—Must be directed to the primary cause.

Tumors.

Infrequently found. Myxomata are probably the most frequently found. Osteomata may also occur, and the tendency is to encroach upon or involve the orbit. Fibroma is very infrequent in this region. Carcinoma and sarcoma sometimes invade these sinuses, but usually are secondary.

Treatment.—Surgical. In the malignant type the morbid growth has usually progressed to a stage that renders operations impracticable.

Diseases of the Sphenoidal Sinuses.

- (1) Catarrhal inflammation. (a) Acute. (b) Chronic.
- (2) Empyema. (a) Acute. (b) Chronic. (c) Confined.
- (3) Tumors. (4) Syphilis, Tuberculosis, and Acute Infections.
- (5) Mucocele.

Pathological changes of the sphenoidal sinuses are usually difficult to diagnose. The probabilities are that these cavities are seldom affected unless there is a preceding or accompanying affection of the nasal cavities or the other sinuses. The symptoms are obscure in the majority of cases. Excepting in rare instances it is practically impos-

sible to get a view of the outlets of these sinuses. Usually unilateral.

CATARRHAL INFLAMMATION.—This may result through extension of inflammatory conditions from the nasal cavities or nasopharynx, or even from inflammatory action of adjacent structures. The disease may be acute or chronic. There may be retention of the material which will result in degenerative changes or suppuration.

Symptoms.—These are neither marked nor characteristic. A sensation of weight and fullness deep in the middle region of the head may be complained of, and discomfort in the occipital region, a dull headache, or pain along a portion or the entire distribution of the trifacial nerve. There may be dull pain in the posterior portion of the orbit of the affected side, and sometimes ocular disturbances. More or less mucus exudes, either intermittently or continuously, and usually is discharged into the nasopharynx. At times the discharge may become inspissated, the masses occurring in the upper and posterior part of the nasal space.

Diagnosis.—Difficult. Often entirely overlooked.

Prognosis.—Good in uncomplicated cases of the acute catarrhal type. If complicated, and particularly in the chronic type, degenerative or suppurative changes may prove fatal.

Treatment.—This should be along the line of treatment of other sinus lesions.

EMPHYEMA OF THE SPHENOIDAL SINUS.—The causes of this condition are similar to those producing catarrhal inflammation. It may result from direct infection through the sphenoidal openings. Compound fractures, operative measures, or occasionally other traumatisms may be a cause. Syphilis, tuberculosis, and the acute infectious diseases may precede or be coincident. It may be found in necrosis of the bony structures, and may accompany or complicate tubercular meningitis. One or both sides may

be affected. It may be either acute or chronic, and a confined suppuration may result from either, and is always a menace to life. A small proportion of cases result from infection of a seromucous accumulation in the sphenoidal space.

Symptoms.—Vary in severity. The character and location of pain is not constant. Headache may be dull and diffuse, or localized, sharp, and neuralgic. The pain may involve either or both the supraorbital and infraorbital nerves, or if the material is confined, the neuralgic pain may follow the entire distribution of the fifth nerve on the affected side. This pain may or may not be constant. There is always more or less purulent discharge, which may be thin or comparatively thick, the odor of which is slightly or markedly fetid, and in the later stages it often contains small particles of bone. In some cases the discharge may be seen at the upper and posterior part of the nasal space, as the openings are located just above the posterior ends of the middle turbinates. Naturally the discharge is inclined to flow into the nasopharynx. It is often increased by pus from the ethmoidal cells. When the patient is in the recumbent position it may accumulate in the vault of the pharynx causing nausea, or passing into the stomach produce gastric complications. Tinnitus aurium and vertigo may also be very annoying. In the acute type these symptoms may continue for a variable period, and then gradually diminish, but the chronic form is more likely to follow. The symptoms are always more severe when there is a confined suppuration. In the chronic type the symptoms are practically the same, only the pain is less severe, or the patient becomes more tolerant of the pain. Exacerbations are more or less frequent. The greatest change noticed in the discharge is that it is more fetid. Crumbling bone will also be found in the later stages. Hebetude is usually marked, the eyes heavy and dull, and

a general physical depression. Sleep is disturbed, gastric disturbances are marked, the tongue heavily coated, and the breath sour. The patient shows the depression of suppurative drain. When the escape of the discharge is interfered with, the symptoms are all increased in severity. The causes of obstruction are similar to those found in the other sinuses. Systemic manifestations peculiar to pus formation are noted. Cerebral disturbances may result from extension through contiguity of structures. As the internal pressure increases, disturbances of the eye become marked, there is photophobia, increased lacrimation, congestion of the lids and conjunctiva. If the distention continues, pressure against the optic nerve will cause diminution of the visual field. Scotoma and even total blindness may follow. The choked disk of optic neuritis will be seen with the ophthalmoscope. Continuation of the swelling will result in restricted motion, or even immobility of the eyeball. Exophthalmos may be a feature. There will be an aggravation of ear symptoms, dizziness being almost continuous when in the upright position, also nausea and vomiting. The recumbent position will often have to be maintained in these cases. The swelling may be sufficient to close the nasal cavities. At this stage the pain may be so severe as to cause delirium. Thinning of the sinus walls will follow, unless relief is given, and rupture of the structure at the weakened point will relieve the most distressing symptoms. The rupture may take place into any of the adjacent cavities, as the orbit, skull above, or ethmoidal cells.

Diagnosis.—In the early stages very difficult. Occasionally the sphenoidal symptoms are so prominent that a diagnosis can be made by exclusion.

Prognosis.—Always guarded. The acute form may subside spontaneously, but as a rule it becomes chronic or confined. The danger of cerebral or orbital complications must be remembered. If an early recognition of the process is possible, surgical interference may relieve the condition.

Treatment.—The nasal cavities should be cleansed, preferably with the salicylic acid wash. Irregularities of the nasal structures should be corrected. The cells may be opened by the use of a sharp gouge. In cases where the septum is comparatively straight and the posterior portion of the middle turbinate has been removed, the pus can often be seen oozing from the natural openings high up and near the septum. In using the gouge it should be passed through the nasal cavity along the upper border of the middle turbinate. The point of the instrument is directed backward and upward, thus entering the cells at the lowest point. Care must be taken in this manipulation for fear of passing through the cells into the cranial cavity. Posterior rhinoscopy is especially valuable in performing this operation. After the escape of the pus, the anterior wall and floor of the cavity should be carefully curetted, but the upper and external walls should not be subjected to this procedure. Sometimes the sudden exit of the confined material will be followed by dangerous syncope. The cavity should be carefully cleansed with a wash of calendulated boric acid, gr. viij to water fl. ʒj.

Internally.—The same treatment as recommended under antral disease.

TUMORS.—Myxomata and osteomata sometimes occur. They are usually small, but may increase slowly and steadily, invading surrounding structures. Symptoms may or may not be present. When of considerable size, pressure symptoms may be present, especially affections of the eyeball or optic nerve. When possible, the growth should be removed. Carcinoma and sarcoma are usually secondary. In these cases death soon results.

SYPHILIS, TUBERCULOSIS, AND ACUTE INFECTIONS.—Any of these may affect the sphenoid cells, and always constitute a dangerous complication.

MUCOCELE.—The conditions causing mucocele in this

location are identically the same as in the other accessory sinuses. Usually can not be diagnosed.

Diseases of the Frontal Sinus.

(1) Acute Catarrhal Inflammation. (2) Chronic Catarrhal Inflammation. (3) Empyema. (a) Acute Purulent Inflammation. (b) Chronic Purulent Inflammation. (c) Confined Suppuration. (4) Mucocele. (5) Foreign Bodies. (6) Infectious Conditions. (7) Tumors.

Acute Catarrhal Inflammation.

This is not an infrequent complication of inflammatory diseases of the nasal tissues. As the development of the frontal sinuses is not complete under the age of twenty, it is seldom any morbid process is found in this location prior to this age. Catarrhal affections are more frequent than suppurative, as ordinarily drainage is more free than from the other cavities. The inflammatory process is usually secondary to nasal diseases. Any condition which will close the sinus outlet has a decided etiological bearing. The disease may be a complication of, or follow, la grippe. Traumatism, scrofulous or specific taints, improper use of the nasal douche, nasal tumors, foreign bodies, as well as some gastro-intestinal lesions, may have a causative influence. The acute inflammation may be the initial stage of a chronic type, or precede suppuration. The pathology is practically that of any acute catarrhal inflammation of mucous membrane.

Symptoms.—These may be very slight, and not noticeable on account of the primary condition, or they may be so severe as to mask the original disease. Usually pain is the most prominent feature, and may occur before, during, or following the nasal disease. One or both sinuses may be affected. The pain may be severe, dull, or sharp and neu-

ralgic, and is confined to the frontal region. Coughing, blowing the nose, inclining the head downward, or the use of cardiac stimulants increase the pain. A sensation of fullness and weight in the forehead is marked; this may increase in severity or be partially relieved by the escape of mucus into the nasal cavity. Tenderness along the course of the supra-orbital nerve is usually marked. Reflex eye symptoms are usually very pronounced. Nausea and vomiting frequently occur.

Diagnosis.—Usually easy, the localized character of the symptoms determining the site of the lesion.

Prognosis.—Good, as a rule, but may become chronic or suppurative.

TREATMENT.—*Local.*—The use of tampons, saturated with glycerin, placed well up in the nasal cavity of the affected side often give relief by lessening the turgescence of the tissues, and allowing the escape of the accumulated material. The ointment of salicylic acid also can be used, but as it will cause excessive tenderness if used frequently, it is not as good a remedy as the glycerin.

Internally.—Gelsemium will form the basis of treatment. Bryonia, pulsatilla, phytolacca, hydrastis, or hamamelis may also be indicated. The use of cocaine or suprarenal products in these cases is usually to be deprecated, as the relaxation which follows their more or less persistent use renders the patient more liable to succeeding attacks. A saline cathartic will usually afford some relief, and the bowels should be kept open; codeine or morphine may have to be given for the relief of pain.

Chronic Catarrhal Inflammation.

This may result from a continuation of an acute attack, or follow repeated acute attacks, and will result from the presence of the irritative cause, the most frequent cause be-

ing some obstruction to the exit of the frontal canal through a nasal lesion in the location of the opening.

Pathology.—The membrane presents an irregular thickening and roughening. It may be granular, or in the later stages give evidences of myxomatous proliferation.

Symptoms.—Nearly the same as in the acute attacks, but the pain is usually more severe and constant. There usually occurs at irregular periods a discharge of a clear mucoserous fluid, which is followed by relief of the aggravated symptoms.

Diagnosis.—Usually easy, if the symptoms are observed.

Prognosis.—Generally good. Suppuration may follow, and if distention results, it will modify the prognosis, as cerebral complications may follow, or there may be a fistulous opening.

Treatment.—The treatment will not vary particularly from that of the acute form.

Empyema of the Frontal Sinus.

ACUTE PURULENT INFLAMMATION.

This may appear at any time during an acute or chronic catarrhal attack, or even be an original inflammation of the frontal sinus. Suppuration is not very frequently found, probably on account of the facility of drainage from the sinuses. The causes are essentially the same as in the catarrhal conditions, but with an element favoring the formation of pus.

Symptoms.—Practically as in catarrhal forms, only more severe. The pain is more of a throbbing character. The discharge is a bright yellow pus, which escapes from the nostril of the affected side. There may be an offensive odor. At times it is difficult to differentiate from disease of the other sinuses, but usually the local symptoms will predominate. Transillumination is of doubtful value.

Prognosis.—Guarded. Many cases terminate spontane-

ously, while others result in a persistent chronic suppuration. In some cases there may be occlusion of the exit causing a constantly increasing amount of pus in the cavity, which may result in cerebral complications.

CHRONIC SUPPURATIVE INFLAMMATION (*Chronic Purulent Inflammation*).

This may follow an acute attack, or be the result of repeated attacks. The continuance will depend upon the exciting cause, as well as upon the condition of the outlets of the sinus. Any cause interfering with free drainage will prolong the disease.

Pathology.—A thickened, rough, pyogenic membrane bathed with yellow and sometimes fetid pus.

Symptoms.—Simply modifications of those already given.



FIG. 72. Frontal Sinus Illuminator.

Diagnosis.—Usually easy, but sometimes the case must be under observation for some time.

Prognosis.—Guarded.

CONFINED SUPPURATION.—This is the most dangerous of the suppurative types. It may occur at any time during an acute or chronic attack. The causes of occlusion may be any morbid condition of either the sinus or nasal cavity.

Symptoms.—Similar to those found in abscess formation of any closed cavity. The pain is constant, throbbing, and boring in character, and confined to the frontal region. There is a persistent and severe headache, sleep is practically impossible. The tissues over the sinuses are swollen, edematous, and reddened. The eyes are suffused. Pressure either over the sinuses or at the inner angle of the eye is extremely painful. Systemic symptoms of pus formation are present.

If not relieved, the pressure will produce bulging over the affected cavity, and especially at the inner angle of the orbit. Diplopia, the result of displacement of the eyeball, follows, or the optic nerve may be subjected to pressure, causing more or less blindness. Olfaction may be destroyed, and cerebral complications are likely to occur. After a time the walls become so thinned that a sense of fluctuation or crackling may occur on palpation. When allowed to run its course, rupture will follow in the line of least resistance, and the abscess will empty. This may be in any direction, the inner orbital angle, into the orbit, into the space between the dura mater and inner table of the skull, into the nasal cavity, or it may open in through the external tables of the frontal bone. When rupture occurs, giving free exit to the purulent material, the relief is immediate.

Diagnosis.—Usually easy after the local swelling and systemic symptoms have occurred. Transillumination may be of confirmatory value.

Prognosis.—Always guarded. As a result of the disease, meningitis may follow. Sometimes panophthalmitis occurs, necessitating the removal of the affected eye. An obstinate fistulous tract may also be formed.

TREATMENT.—*Local.*—Same as given under catarrhal inflammation.

Internally.—The use of calcium sulphide or silicea, but dependence must be placed upon surgical measures as a rule. Bryan's operation is preferable in the majority of cases, as the resulting scar is not seen. This operation should not be attempted until all nasal obstructions to the sinus openings have been removed, as in some cases this will allow drainage. The ethmoidal cells should also be examined, and if carious, curetted. When the external operation is necessary, the eyebrow is shaved, and the integument of the forehead prepared as in any surgical operation. The skin is then drawn upward, and the incision commenced

just at the median side of the supra-orbital notch, carried down to the bone and continued to the inner angle of the orbit, following along the lower border of the supra-orbital ridge. This flap of skin and periosteum is raised. If there is not space enough to apply the trephine, the incision should be carried across the root of the nose to the corresponding inner angle. A small crown trephine about 1 cm. in diameter is placed about two lines outside the median line and the same distance above the supra-orbital ridge. When the button of bone has been removed, all carious and granulation tissue should be removed, the frontonasal duct enlarged and a self-retaining drainage tube introduced. The parts should be thoroughly irrigated with an antiseptic solution, and the lining membrane touched with a solution of salicylic acid, gr. x, Lloyd's thuja, Lloyd's hydrastis, āā ʒij, aqua ʒss. The wound is then closed. If the fronto-ethmoidal cells and ethmoidal cells proper are carious, the diseased tissue should be curetted, working within the sinus and using the little finger of the other hand in the nose as a guide. In these cases a large opening is made from the sinus into the nasal cavity, and instead of a drainage tube, borated or iodoform gauze is packed in the cavity and brought down through the nose. The wound is closed as in the preceding operation. After the gauze is removed the cavity may have to be irrigated, when a curved canula can be used. Any mild, unirritating antiseptic solution may be used.

Mucocele of the Frontal Sinus.

This results from a long continued catarrhal inflammation, where there is either the formation of myxomatous masses, mucoid degeneration or proliferation of mucous cysts. The growth of these elements develops a mass, held by a thin membrane, consisting mostly or entirely of the elements constituting normal mucus.

Symptoms.—Practically the same as in free mucoserous

fluid. There may be symptoms of internal pressure, but the external phenomena are absent, as well as the systemic symptoms of pus. The pain is less severe. The sinus walls may become thinned, and sometimes there is escape of the sinus contents. Degenerative changes, even pus, may result.

Diagnosis.—Difficult. The pressure symptoms with absence of pus poisoning and history may lead to a diagnosis. It is practically impossible to differentiate from any tumor in this location.

Prognosis.—Fairly favorable. Empyema may occur. There may also be cerebral or ocular complications.

Treatment.—Sometimes spontaneous rupture and discharge occurs. Usually surgical measures are required. In most cases this can most easily be done with Palmer's frontal sinus drill, perforating through the frontonasal duct from the nose. Curettement of the sinus should then be done. When successfully performed free drainage at least will result, even if a cure is not accomplished. When a cure does not follow the operation, the external operation must be performed.

Foreign Bodies.

These may be animate or inanimate. Animate foreign bodies may be worms or larvæ. This condition is infrequently seen. The symptoms are those of most intense pain, suppuration, and fetid discharge. Ulceration and necrosis soon follow. The diagnosis is made by the presence of the bodies in the nasal discharge as well as the localized symptoms. Cases of this character are more often found in tropical climates than in the temperate zones. The prognosis is guarded.

Inanimate objects may be bullets, shot, pieces of metal, etc., the history of a traumatism usually being sufficient for determination. Symptoms may be entirely absent, or they may be those of a chronic catarrhal or suppurative action. These cases are infrequent.

Treatment.—Either surgical, or if animate bodies the use of an ethereal solution, chloroform vapor or emulsion, followed by flushing with an antiseptic solution.

INFECTIOUS CONDITIONS OF THE FRONTAL SINUS.—These may be erysipelas, diphtheria, tuberculosis, la grippe, syphilis, etc., but are usually secondary to nasal involvement.

TUMORS.—These may be primary, or associated with similar growths of adjacent structures. Those most frequently found are fibroma, myxoma, and osteoma. Cystic tumors may occur at any age, or may be congenital. In character they are either that of mucocele or steatomatous. Malignant tumors are usually secondary, and are fatal. Tumors of the frontal sinus are always dangerous. When benign and recognized early, an external operation may prove curative.

CHAPTER XV.

DISEASES OF THE NASOPHARYNX.

(a) Acute and Chronic Inflammatory Diseases. — (1) Acute Nasopharyngitis. (2) Simple Chronic Nasopharyngitis. (3) Atrophic Nasopharyngitis. (4) Hyperplastic Nasopharyngitis. (5) Specific Inflammations. (a) Syphilis. (b) Tuberculosis. (c) Lupus. (d) Glanders. (e) Actinomycosis. (6) Neuroses.

Acute Rhinopharyngitis.

Synonyms.—Acute catarrh of the nasopharynx; acute postnasal catarrh; acute nasopharyngitis; acute retronasal catarrh.

This is an acute catarrhal inflammation of the nasopharyngeal mucous membrane.

Etiology.—Predisposing causes: The most active cause is climatic changes, especially in the spring and fall. The patient's powers of resistance to these changes are also factors. A hypersensitive condition of these tissues is not infrequently found in neurasthenic patients. The disease is infrequently seen in children; but a scrofulous diathesis is a predisposing condition.

Exciting Causes.—It may accompany either an acute pharyngitis or rhinitis, or may be an exacerbation of a chronic catarrhal inflammation of this region. It may also result from extension of an inflammatory process in either the nose or pharynx through continuity of tissue. Local irritation caused by the inhalation of dust or chemical fumes may be a cause. Any of the conditions which might pro-

voke an acute rhinitis, may involve the nasopharynx. Among the infectious diseases, scarlet fever, diphtheria, and measles are quite likely to be followed or complicated by acute rhinopharyngitis.

Pathology.—Practically the same as in acute catarrhal inflammation of any mucous membrane.

Symptoms.—These vary according to the severity of the case. When the disease accompanies an acute rhinitis or pharyngitis, it may not be recognized. When occurring independently, however, the symptoms are quite well defined. The attack is sudden, usually with a slight rise in temperature, not often reaching 101° F., malaise, disturbance of the stomach and bowels, and tongue coated. A dryness of the postnasal space is present, which is very uncomfortable, as well as a sensation of tightness, which is increased on swallowing.

A neuralgic pain is usually complained of, and is referred to the pharyngeal vault, roof of the mouth, angles of the jaws, or the vertex, and is generally persistent during the attack. Slight hemorrhages may occur. The dryness continues for one or two days, or until secretion commences. The secretion at first is quite clear, but thick and tenacious; then it changes to a white color, and finally becomes purulent. The secretion is adherent to the mucous membrane, and on account of the irritation produced, a more or less constant "hawking" and spitting result. Sometimes the secretion is expelled through the nose, but as a rule through the mouth. Some of the secretion is unavoidably swallowed, and this increases the gastric disturbance.

The secretion may produce an acute rhinitis through irritation. If an aggravated case, catarrhal ulcers may form, the hearing may be impaired, and the voice become hoarse through impeded circulation. Cough is not often present. After ten days or two weeks the symptoms gradually disappear, and the tissues regain approximately their normal

condition. Very infrequently there is bronchial or tracheal involvement.

Inspection of the nasopharynx during the early stage reveals a reddened, swollen condition, with dry, glazed surface, and tortuous, congested vessels. In the later stages the secretion will be seen clinging to or hanging from the walls, filling the crypts of Luschka's tonsil, as well as Rosenmüller's fossæ.

Diagnosis.—The history of the case, but especially by posterior rhinoscopic examination.

Prognosis.—Favorable.

Treatment.—Local treatment is of no especial value, excepting to cleanse the surfaces, and for this purpose any of the alkaline washes will do. Internally, during the initial stages, jaborandi. If there is much burning, as sometimes occurs, rhus tox. should be added. For the pain, aggravated on swallowing, bryonia. When the mucous follicles are engorged, phytolacca. The remedy generally indicated after secretion is established is potassium bichromate, 1/100 gr., giving it every three hours. When the secretion becomes purulent, lime, either as lime water or the sulphide of lime. After the subsidence of the disease, hydrastis and phytolacca should be administered for several weeks, or until the tissues regain their normal activity.

Simple Chronic Rhinopharyngitis.

Synonyms.—American catarrh; chronic catarrh of the nasopharynx; chronic postnasal catarrh; chronic retronasal catarrh; simple chronic nasopharyngitis; chronic rhinopharyngitis; catarrh of the pharyngeal bursa; chronic adenoiditis.

This is a simple chronic catarrhal inflammation of the nasopharynx, characterized by a constant secretion of tough, tenacious mucus, which may be purulent, or in cases of long standing may form firm crusts. The nasopharyngeal

wall is more or less covered with this tenacious secretion, which gradually passes down to the pharynx, and causes the patient to make more or less constant efforts to clear the throat by "hawking." Acute attacks are frequent without any apparent cause. Rhinitis or pharyngitis may also be present.

Etiology.—Usually the result of repeated acute attacks, the cause being practically the same as in acute attacks of rhinitis or pharyngitis. It may also follow a stubborn attack of acute rhinopharyngitis, where the exciting cause is continuous. It often accompanies either a chronic pharyngitis or rhinitis, and may be an extension of either or both to this region.

Predisposing Causes.—It is more frequently found in youth than in adult life. Heredity may have an influence, through peculiarities of the nasal structure, or a low resisting power. Among the latter can be classed the neurotic, rheumatic, gouty, scrofulous, anemic, etc., diatheses. Alimentary wrongs undoubtedly are predisposing factors. The exanthemata are also exciting causes. The improper use of the voice in public speaking and singing; abnormal conditions of the nasal, faucial, or pharyngeal region may also cause such a condition.

Exciting Causes.—Besides the predisposing causes, the same conditions as produce a rhinitis or pharyngitis will be equally as active in nasopharyngeal disease. The position of the nasopharynx must also be considered, as irritating material frequently lodges here, and it is very difficult for the patient to cleanse this space.

Pathology.—The same general characteristics of simple inflammation of mucous membranes is observed. It usually is paler than normal, somewhat edematous, and the mucous glands are reddened and prominent.

Symptoms.—Usually an illy defined sensation of uneasiness. A dryness and sensation of a foreign body in the naso-

pharynx. In some cases the effort to dislodge this will cause vomiting. This discomfort is usually most marked in the morning. In severe cases the patient is almost continually trying to clear the throat, on account of the more or less constant "dropping." This material in conjunction with the repeated efforts to clear the throat, will cause irritation of the lower pharynx, which often produces an annoying spasmodic cough. The character of the discharge varies according to the stage of the disease. In the early stages it is thick, usually clear, and tenacious or gelatinous. As the disease progresses it becomes mucopurulent or purulent, varying in color from a light yellow to a dirty greenish color. After a time there is a tendency to the formation of crusts or scabs, or possibly thick, semi-solid masses. If saprophytic infection occurs, there will be a disagreeable odor, which is frequently augmented by the fetid breath found with gastric disorders. The expectoration is often streaked with blood. As a rule the Eustachian tubes and tympani are implicated, an annoying tinnitus aurium and impaired hearing being complained of. The voice is weak and muffled, clearing in a measure after expectoration. Depending upon the individual as well as the severity of the case, there may be dull frontal or occipital headache, pain in the upper cervical region, dull, heavy, tired feeling in the head, disinclination or incapacity for work of any kind, and occasionally there may be temporary loss of memory. Disturbances of the digestive tract are usually present, most frequently of the atonic type. A chronic rhinitis, pharyngitis, or laryngitis often augment the discomfort of the patient. Exacerbations are frequent. Inspection of the vault of the pharynx, prior to cleansing, will reveal swollen tissues, the tubal openings filled with secretion, the walls of the postnasal space covered more or less completely with the characteristic secretion. This is especially marked over the pharyngeal tonsil. In cases of long standing the soft palate and uvula may be swollen and relaxed.

Diagnosis.—Usually easy. The history, efforts to clear the throat, and a rhinoscopic examination will readily determine the condition.

Prognosis.—Guarded. While not a fatal disease, the complications which may arise, as well as the liability of atrophic changes occurring, must be remembered. Also the chronic course, and the disinclination of most persons to continue treatment for a sufficient time to effect a cure will have to be considered. In some cases the disease disappears when middle age occurs.

Complications.—A chronic inflammatory condition appears to render the patient more susceptible to infectious diseases, particularly in early life. The unconscious swallowing of the accumulated discharge often causes severe gastric disturbances. The irritation caused by the tenacious material in the nasopharynx may also cause irritation of the pharynx and larynx, rendering these structures more liable to inflammatory lesions, which may also extend to the bronchial and pulmonary tissues. Aural lesions are not infrequent.

TREATMENT.—*Local.*—The necessity of cleansing the postnasal space is acknowledged, but the long continued and repeated use of any solution will probably aggravate the condition. The use of a saline solution, or preferably the salicylic acid wash, often enough to keep the surfaces free from the secretion, will be all that is required. The main reliance must be upon internal medication. Potassium bichromate, jaborandi, phytolacca, hydrastis, potassium iodide, lime, apis, apocynum, nux, ignatia, are usually required in this condition.

Atrophic Nasopharyngitis.

In the nasopharynx an atrophic condition is generally found with an atrophic rhinitis, but it may be independent of such a nasal lesion. The change of character of the

mucous membrane epithelium acts as a bar to the extension of inflammatory processes, even though there is continuity of tissue.

Atrophic changes in the vault of the pharynx are identical with the same condition in the anterior nares. The contour of the nasopharyngeal space may influence the condition.

In many persons the nasopharyngeal space is very narrow, the posterior wall curving forward at the point where the soft palate normally comes in contact with the nasopharyngeal wall. When this occurs the attachment of the faucial arch to the lateral walls of the pharynx causes the formation of a pocket on each side. As there is a tendency in atrophic conditions for the accumulation of secretion, these pocket formations are liable to increase the collection of secretion. The irritation produced by this retained material, I have found, will usually cause an increase of the size of the pockets through increasing the amount of adhesions.

When the pockets are present, the patient has the sensation of a foreign body in the pharynx, and there is more or less constant hawking in the effort to clear the throat. The secretion is particularly tenacious and may adhere to any portion of the pharyngeal walls.

The most important complication of this form of nasopharyngitis is the involvement of the Eustachian tubes. The disease may invade the mucous tissues of the tubes, or the ventilation of the tympanum may be obstructed through the accumulation of secretion in or about the tubal openings.

The pathology is the same as in atrophic rhinitis.

Diagnosis.—The associated conditions will make diagnosis comparatively easy as a rule.

Prognosis.—This will depend upon the changes which have taken place.

Treatment.—Local treatment in these cases is of secondary importance, although in many cases an alkaline wash will materially aid in cleansing the tissues. Internally, potassium bichromate, phytolacca, jaborandi, or hydrastis will be necessary.

Various methods of getting rid of the lateral pockets have been tried, the majority being to cauterize by some means, so the pockets would become closed through inflammatory processes. These measures are to be condemned, as the space between the oropharynx and vault of the pharynx is still more reduced. In all these cases of narrowed space, even without decided pockets, I have loosened, stretched, or divided the posterior faucial pillars from the lateroposterior wall. In nearly every case there has been a marked improvement in a very short time, the irritation and cough rapidly disappearing.

Hyperplastic Rhinopharyngitis. (Hyperplastic Nasopharyngitis.)

The causes of this condition are the same as produce the same state in the nasal cavities. There is an excessive growth of the submucosa connective tissue, which is not followed by contraction. The nasopharyngeal tissues usually involved are the posterior and inferior ends of the turbinates, especially the middle and inferior. It may be associated with the same disease of the anterior nasal cavities. The appearance of the structures on rhinoscopic examination does not vary much from a simple chronic rhinitis. The tissues, however, are smoother, although they may be lobulated.

Symptoms.—The postnasal obstruction is the most prominent.

Treatment.—This is surgical in the majority of cases.

Neuroses of the Rhinopharynx.

Reflex disturbances are not uncommon, the most frequent being laryngismus stridulus, stammering, and general convulsive attacks. Alimentary disturbances, as vomiting, eructation, etc., may be reflex, but usually are the result of ingestion of secretion from the nasopharynx. Aural complications are usually due to extension of the inflammatory process through the Eustachian tubes, and not reflex.

CHAPTER XVI.

DISEASES OF THE UVULA AND SOFT PALATE.

(1) Malformations. (a) Bifid. Rudimentary. (b) Elongation. (2) Inflammatory Diseases. (a) Acute uvulitis. (b) Chronic uvulitis. (c) Ulceration. (3) Non-inflammatory Diseases. (a) Adhesions. (b) Neuroses. (1) Hyperesthesia. (2) Anesthesia. (3) Paresthesia. (4) Neuralgia. (5) Spasmodic Contraction. (6) Paralysis. (7) Acute Bulbar Paralysis. (8) Chronic Bulbar Paralysis. (9) Apoplectiform. Bulbar Paralysis. (10) Herpes of the Fauces.

Bifid and Rudimentary Malformations.

A bifid uvula is the most common anomaly of the uvula, although congenital absence or imperfect developments have been noted. Bifurcation may be simply at the tip of the uvula, or may divide the entire structure. Unless it proves a source of irritation, it is not necessary to do anything with it. When a morbid condition results, however, as a result of the malformation, the median sides of the uvula should be denuded of the mucous membrane. One or two stitches may be necessary, passing through the body of the uvula. Healing is rapid, and the cicatrization resulting will shorten the uvula. The operation can be done under cocaine anesthesia, or the cocaine autospray.

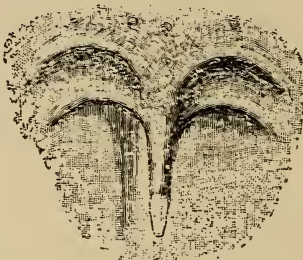Elongation of the Uvula.

No fixed rule for the normal length of the uvula can be given. In the adult, however, it is seldom longer than

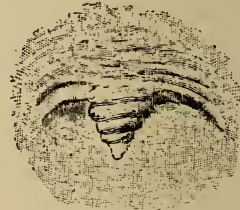$\frac{3}{8}$ inch, if longer some indications of irritation may be present. When the organ drags upon the base of the tongue, it may be considered abnormally long.

Etiology.—Congenital fullness of tissue, general relaxation of the faucial tissues, due to the general physical condition, partial paralysis following infectious diseases. Chronic catarrhal inflammations of the nasopharynx, growths or structural changes in the pharyngeal vault, are the most frequent causes.

Pathology.—The diameter of the uvula is not often increased, excepting in chronic catarrhal inflammation. The



73



74

FIG. 73. Elongation of the uvula. FIG. 74. The same, on attempting a high note, showing the wrinkling of the relaxed tissues.

length is increased either by an increase of white fibrous and yellow elastic tissue, similar to that of the normal uvula, or by a relaxation of the submucous structures, allowing what appears to be a slipping of the mucous membrane over the azygos muscle. The cause of the elongation contributes to the appearance of the uvula.

Symptoms.—There is a tickling or irritating sensation, causing frequent attempts to clear the throat, either by expectoration or swallowing; more or less constant irritative cough, increased on lying down, as the uvula then rests against the pharyngeal wall. Damp, "muggy" weather also increases this cough, as there is then more relaxation of the

tissues than in dry weather with a high barometric pressure. In aggravated cases, asthmatic or choking attacks, spasm of the glottis, chronic laryngitis, and faulty phonation may result.

Diagnosis.—Inspection will usually reveal the condition.

Prognosis.—Good.

Treatment.—When the relaxation is temporary or simply the result of an acute inflammatory condition, the removal of the cause is all that is required. In the chronic types,

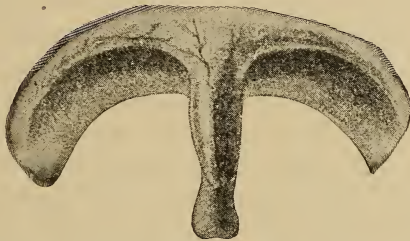

FIG. 75. An apparent slipping of the mucous membrane over the muscular tissue.

however, the use of local measures is simply temporizing, the removal of a small portion of the tip being necessary. Sajou's uvula scissors are the easiest managed, care being taken not to remove too much tissue. Kyle has employed the method of removing a Λ shaped portion by grasping the tip of the uvula with forceps, simply steadying the struc-

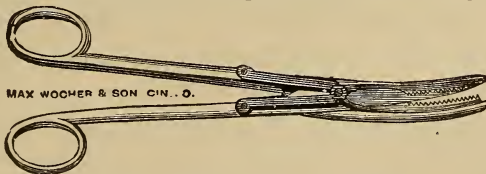


FIG. 76. Sajou's Uvula Scissors.

ture, then transfixing with a small sharp-pointed bistoury, making the wedge-shaped incision. The raw surfaces may be held in apposition by the use of sutures.

Inflammatory Diseases.**ACUTE UVULITIS.**

Synonyms.—Edema of the uvula; Acute infiltration.

Etiology.—An elongated uvula is more liable to an acute inflammation or an injury than a normal one. Acute uvulitis is frequently seen in rachitic persons and in digestive wrongs. Extension of inflammation from adjacent structures is frequent. A swollen edematous uvula is often found during an attack of acute pharyngitis or quinsy. The swallowing of irritants produces an acute inflammation with edema. Frequently the primary cause is obscure.

Pathology.—The inflammatory stages are more rapid than ordinary, as there is lack of both muscular and bony support.

Symptoms.—Usually the first symptom is that of a foreign body, which gives a sensation of irritation and tickling of the fauces and pharynx. There is an effort to swallow or expectorate the supposedly foreign body. Cough is usually also an accompaniment. Sometimes there is difficulty and pain on swallowing, and dyspneic symptoms may be present.

Diagnosis.—Easily made on inspection.

Treatment.—In aggravated cases it may be necessary to puncture the uvula with a small bistoury, but this is seldom necessary. Internally apis or apocynum, alternated or combined, will reduce the edema quite rapidly. The treatment of the exciting cause, when of an acute inflammatory nature, will effect a cure.

CHRONIC UVULITIS.

The acute process may become chronic. This form is usually found with a chronic rhinopharyngitis or chronic pharyngitis.

Symptoms.—Usually so slight as to be disregarded. The treatment of the associated disease usually affords relief.

ABSCESSSES, either acute or chronic, may occur in the uvula or soft palate, but are infrequent.

ULCERATION.

Infrequently there may be ulceration of the uvula without implication of adjacent structures. Tubercular or syphilitic ulceration may attack the uvula either primarily or secondarily, the characteristic appearances of the lesion being the same as seen in other locations.

Treatment.—In the simple form of ulcers, touching with solid stick of silver nitrate is all that is necessary. If syphilitic, the surfaces should be carefully cleansed, and the areas touched with Lloyd's thuja. Internally, the use of the remedies given under nasal rhinitis should be followed.

MYCOSIS.—This disease when involving the uvula is usually an extension from the pharynx, the characteristic small whitish masses projecting from the surface. The treatment is given under mycosis of the pharynx.

EMPHYSEMA.—The uvula and soft palate may be the site of emphysema, as the result of careless manipulation of the Eustachian catheter.

Treatment.—Numerous punctures.

Non-Inflammatory Diseases.

ADHESIONS.

These usually result from syphilitic lesions on the posterior portion of the uvula or velum, with corresponding ulceration on the posterior pharyngeal wall. This deformity depends upon the union of the adjacent surfaces. When due to syphilis the characteristic stellate cicatrices are seen. Extensive burns or lupus may present similar pictures, but are easily eliminated as a rule. The adherence may be partial or complete. It may result either from acquired or hereditary syphilis, which can usually be readily determined by the appearance of the nasal tissues and teeth. Perforation of the velum, half arches, and even the hard palate may occur. Any of these abnormalities usually change the character of the voice.

Treatment.—If in the active stage, prompt measures may afford partial relief. In perforation of the hard palate, ordinary chewing gum may be used to close the perforation. This is readily replaced. When extensive adhesions between the velum and posterior pharyngeal wall are present, operative measures may benefit, provided proper internal medication is employed, otherwise it is useless. The patient should usually be put on preparatory treatment. Several cases operated upon successfully were treated with anti-syphilitic remedies before and after the operation.

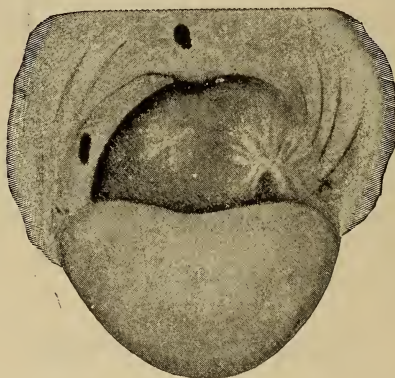


FIG. 77. Syphilitic perforations of velum. Characteristic stellate cicatrix of left side of pharyngeal wall and adhesion of the faucial tissue to the posterior pharyngeal wall.

Neuroses.

ANESTHESIA, HYPERESTHESIA, and PARESTHESIA of the velum and its appendages may occur. These probably depend upon some anomalous condition of adjacent structure, or some systemic wrongs. The treatment will necessarily be directed to such conditions.

NEURALGIA.—In hysterical persons this may be found as a local manifestation. It may be associated with follicular or lateral pharyngitis or some abnormal state of the tonsillar

structures. Remedies that will improve general nutrition are indicated.

SPASMODIC CONTRACTION.—This is usually of the levator palati, but is not often seen. No definite cause is known.

PARALYSIS.—The muscles of the velum or uvula may become paralyzed as a result of inflammatory action of the fauces, especially in diphtheria. It may be central, local, or the result of general blood depravation.

Symptoms.—Deglutition is impaired and there is a tendency for fluids to enter the nasal cavities. The voice is thick and there is a nasal twang. Articulate speech is impaired or at times impossible. As there is difficulty in expectorating, the mouth becomes filled with saliva, which may escape from the corners of the mouth. One or both sides may be affected. When but one side, the tissues will be dragged toward the healthy side.

Diagnosis.—Generally easy.

Prognosis.—Depends upon the cause. If due to diphtheria, a cure usually results, although it may take several months. Nux, strychnine, or ignatia usually forms the basis of treatment. Electricity is also advocated in these cases.

ACUTE BULBAR PARALYSIS.—Very seldom occurs. The onset is sudden, the progress of paralytic development rapid, and death soon follows. There is at first headache, giddiness, possibly vomiting, soon followed by difficulty in walking. While the patient retains consciousness, there is difficulty in swallowing and articulating, which rapidly increases in severity. Death from cardiac involvement usually occurs in from four to ten days. Treatment has been ineffectual.

CHRONIC BULBAR PARALYSIS.—Duchenne describes as labioglossopharyngeal paralysis a condition usually resulting from degenerative changes in the bulbar nuclei of the medulla, which is an insidious disease. There is gradual involvement of the larynx, pharynx, tongue, etc. Death may

rapidly result, or the patient may linger for several years, finally dying from starvation.

APOPLECTIFORM BULBAR PARALYSIS.—A hemorrhage, embolism, endarteritis, or softening implicating the ganglia in the floor of the fourth ventricle, may cause a sudden apoplectiform paralysis of the velum, contiguous structures, and pharynx, which usually is temporary, but may terminate fatally. A positive localization of the origin is usually difficult.

Symptoms.—Usually come on suddenly during sleep. There will be on awakening, malaise, a disposition to keep quiet, dizziness, and sometimes headache with vomiting. Occasionally the extremities are somewhat affected. Paralysis of the velum may be bilateral or unilateral, the usual line of symptoms being present. The prognosis is not particularly serious. Treatment should be directed to the relief of the exciting cause.

Tumors, meningitis, cysts, or abscesses—tubercular or syphilitic—attacking the medulla, are usually slow in developing, involve other structures whose centers are in proximity to the palatal, and produce a complicated line of symptoms. The symptoms given under these headings describe only those of this region, and do not describe all that may arise.

HERPES OF THE FAUCES.—Fortunately this is not often encountered, but it usually attacks the uvula and velum. There is more or less discomfort, occasionally actual pain and an annoying itching ascribed to the fauces. Inspection shows small purplish papules distinctly differentiated from the pink normal mucosa. Usually unilateral, either irregularly placed, or in circular form. The disease may disappear after five or ten days, reappearing after a variable time of weeks or months. The treatment should be to improve the general health, and locally some sedative application, as chloretone inhalant, used to relieve the most aggravating symptoms.

CHAPTER XVII.

DISEASES OF THE TONSILS.

(1) PHARYNGEAL. (2) FAUCIAL. (3) LINGUAL. (4) LARYNGEAL.

PHARYNGEAL TONSIL.—*Luschka's Tonsil*.—This is situated at the posterior wall of the pharyngeal vault, and is normally present in children. It usually atrophies between the ages of twelve and twenty, but when abnormal this may not occur. The surface is often lobulated. This structure comprises lymphatic or adenoid tissue held together by fine trabeculæ of connective tissue elements. It is practically a conglomerate gland, and is covered with a thin mucous membrane having a single layer of columniated epithelium, which occasionally is ciliated. Numerous follicles are contained in the gland and the vascular supply is abundant. In many cases this tissue involves the openings of the Eustachian tubes, and then we have the tubal tonsil.

FAUCIAL TONSILS.—These are two, contained in the spaces between the pillars of the fauces. They are lymphoid in character, and contain follicles and crypts. They are very vascular, and the mucous membrane covering is lined with squamous epithelium.

LINGUAL TONSILS.—These comprise a series of lymphoid masses situated at the posterior one-fourth of the tongue.

LARYNGEAL TONSILS.—These are small lymphoid masses or nodules located within the ventricle of the larynx, and are seen on inspection only when diseased.

Inside the nasal openings, beneath the mucous membrane, diffuse adenoid tissue is present, but in some locations is in masses of lymph-follicles, designated as nasal tonsils.

Luschka's bursa consists of a crypt or depression located in the lower portion of the pharyngeal tonsil.

Pharyngeal Tonsil.

Synonyms.—Luschka's tonsil; adenoids; adenoid vegetations; discrete tonsils.

The pharyngeal tonsil is a normal gland from the average age of three years to about fifteen or sixteen years, when atrophy usually occurs. No inconvenience is noticed unless the tissue becomes hypertrophied, when there is impeded nasal respiration. In some few cases the hypertrophy seemed to be congenital or occurred soon after birth. An early recognition of enlargement of Luschka's tonsil is important, as the normal development of the nasal structures and the palatal portion of the superior maxillary depends upon normal respiration. Not only is the bony portion influenced, but the *alæ nasi* and their muscles as well.

If the disease is not recognized before the bony structures are firmly united, operative measures will give only partial relief, and the patient may remain a confirmed mouth breather. The superior maxillary arch is usually abnormal, being highly arched, and the upper teeth are decidedly deformed. The "inherited tendency" to adenoids is usually the family nose with its narrow openings and narrow nasal cavities. Unilateral obstruction may sometimes occur.

Adenoids comprise not only hypertrophy of the pharyngeal tonsil, but the closed follicles of the posterior and postero-lateral walls of the nasopharynx.

Etiology.—As a rule the morbid condition is not present before the age of three years, and it may become pronounced at any time before twelve years. Usually physiological atrophy should take place between the age of ten years and sixteen years. Sex is not a factor. Hereditary taints, general debility of the system, as well as the family nose may be factors. Climatic conditions, such as sudden changes of

temperature or an excessively damp atmosphere, are especially favorable factors. Probably on account of irritating vapors the children in cities are more often affected than those living in the country. Purulent rhinitis or the infectious diseases may also be exciting factors. The uric acid diathesis is also accredited with being a cause. Disturbances of the alimentary canal, either disease or the irritation caused by intestinal parasites or undigested material will cause turgescence of the nasal and nasopharyngeal tissue. Renal or pulmonary affections have been supposed to be exciting causes.

Pathology.—Histologically the normal gland shows the same characteristic structure as other glands of the same type. The pathology varies, as there are practically four types.

The soft variety is that of a smooth, semifluctuating mass, distributed over nearly the entire nasopharynx. Atmospheric changes and the general health of the patient influence the condition. The growth is composed mostly of lymphoid tissue, covered with a thin layer of epithelium, having an illy formed basement membrane and submucosa. This type is friable, being easily broken down with the finger.

The edematous or cyanotic type is practically due to venous stasis and edema, without much increase of gland structure. This form is associated with either intestinal irritation or systemic circulatory wrongs. Children having intestinal worms are most frequently affected with this type. The growth is smooth and tense, but readily compressible.

The hyperplastic or hard type has an increased amount of connective tissue elements, as well as an increase of lymphoid material. The mucous membrane usually consists of several layers of epithelial cells. The surface is lobulated, but smooth to touch.

There is another hard form which results from inflammatory conditions of the lymphoid and connective tissue

structures, followed by slight contraction. This form may be secondary to inflammatory action in the nose or nasopharynx, or from the use of the thermo- or galvano-cautery.

The appearance of these lesions varies according to the stage. In children it is usually impossible to get a view of the tissues by posterior rhinoscopy on account of the small nasopharynx. Examination with the finger is the only sure method in these cases. Frequently the gland tissue just back of the posterior faucial pillars is enlarged, and usually it is secondary to the hypertrophied pharyngeal tonsil. This lat-

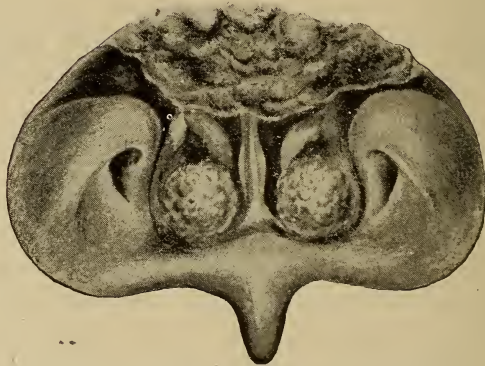


FIG. 78. Posterior rhinoscopic view in an adult showing hyperplastic adenoid tissue and hypertrophy of the inferior turbinates.

eral tissue nearly always disappears after the adenoid operation.

The so-called recurrent cases, after an operation, are generally the result of hypertrophy of tissue not removed, rather than a reformation at the original location.

When hyperplastic or inflammatory changes have occurred in the pharyngeal tonsil, atrophy seldom takes place, so the tissue remains enlarged after the age for physiological atrophy, and may continue to adult life or even old age.

Symptoms.—The clinical features do not vary particu-

larly from those found in any nasal obstruction, only they are more pronounced, and permanent alteration of adjacent structures is more frequently seen. The expressionless face is quite characteristic. The prominent upper lip, chin receding, bridge of the nose broadened, and the mouth usually

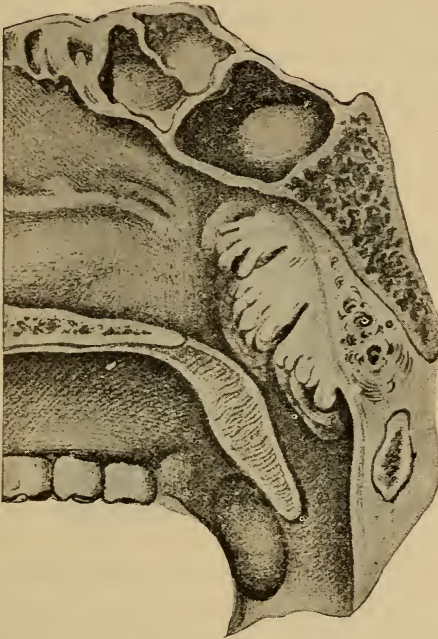


FIG. 79. Vertical antero-posterior section through the post-nasal region in adolescence, showing enlargement of the pharyngeal tonsil. (*Zuckerkindl.*)

open, all imparting a stupid look to the patient which is almost always present. The child is usually unable to concentrate its mind for any length of time. The hearing is generally impaired. There is an aversion to active sports, an irritable temper, sleep disturbed, and after a variable time a debilitated condition of the system.

Allen and Cohen attribute the mental inactivity as possibly being due to lymphatic or circulatory changes between the brain and nasopharynx. Another explanation for this condition is the lack of ventilation to the frontal lobes of the brain through obstructed nasal respiration. If the postnasal obstruction is slight, there may be nasal respiration during waking hours, and mouth breathing only at night, the child simply complaining during the day of irritation in the throat, the exciting cause frequently being undetected. The usual



FIG. 80. Typical facies in adenoids.

symptoms of pharyngeal and laryngeal irritation will be noticed. The development of the physical system will also be retarded.

The character of the voice is changed, the so-called "nasal twang" becoming more and more marked, the letters *m*, *u*, and *ng* being especially difficult to pronounce. Ear-ache and deafness are common symptoms. Epistaxis, most frequently at night, often occurs, but is not often profuse. If the growth extends well down in the nasopharynx, and the gland tissue of the lateral walls is enlarged, there is often difficulty in swallowing fluids, causing choking.

The faucial tonsils often become enlarged, the velum and uvula relaxed, and the glands at the angle of the jaw enlarged. Gastric complications are common. Frontal headache, eyes dull, and the conjunctiva often congested are frequent symptoms, the sense of smell and taste are usually impaired. It is not often all of these symptoms are present in one case, but more or less of them will be noted.

Diagnosis.—Usually not difficult, remembering the facies, irregularity of the teeth, and associated lesions of the ears, pharynx, and larynx. A digital examination will confirm the diagnosis.

Prognosis.—This depends largely upon the time of recognition of the disease.

Treatment.—This depends largely upon the type of the obstruction, but prompt relief should always be given. If the enlargement is of the edematous form, the result of intestinal or gastric irritation, the removal of the irritation will generally give quick relief to the nasal symptoms. If there are cardiac wrongs, the proper remedies will also relieve the edematous condition.

The soft variety can easily be crushed with the finger, and whether advisable to lacerate the tissue to any extent must be determined in each individual case. I believe it best to give enough general anesthesia to keep the child quiet. The operation in itself is not painful, but the child will be frightened more by the gagging produced than by the actual operation. Partial anesthesia is all that is required. There is not much hemorrhage in these cases, and the slight inflammatory action following will soon subside with absorption of the mass. The hands of the operator should, of course, be thoroughly cleansed before operating.

In the hard varieties, operative measures only will give relief. The question of anesthesia must always be considered. Individually, general anesthesia with chloroform is preferred, the extent depending upon the amount of time likely

to be required. If the faucial tonsils are enlarged and require removal, this should be done before the adenoid operation.

After the patient is anesthetized, the mouth gag should be placed in position, and the patient placed so the head will

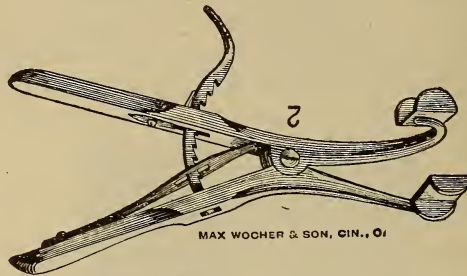


FIG. 81. Denhardt's Mouth Gag.

hang over the edge of the table, or if on an operating table, a modified Trendelenburg position may be used. The post-nasal space should be carefully examined with the index finger before attempting to operate. The curette is then introduced, using the index finger of the unoccupied hand as a guide. The curette at first should be carried into the nasopharynx well forward toward the choanæ, until far enough



FIG. 82. Gottstein's Curette.

up to engage the mass, then with a sweep of the blade bring away the tissue in the median line. The operation is repeated on each side, always guiding the instrument and being careful not to injure the tissues about the openings of the Eustachian tubes. In some cases where the amount of tissue is small and high in the pharyngeal vault, the small

curette recommended by Kyle, using it through the nose and guiding as with the Gottstein curette, can be used to advantage.

There is little danger of secondary hemorrhage, excepting where there are anomalous vessels, or the patient is a bleeder. If a persistent hemorrhage does occur, the nasopharynx may be packed with gauze or cotton tampons until the bleeding stops.

In the majority of cases no local after treatment is employed. The patient is usually kept quiet for a few days, and usually hydrastis and phytolacca are given internally. If local measures are necessary, an alkaline wash is used.

Faucial Tonsils.

INFLAMMATORY DISEASES.

(1) *Acute.* (a) Acute Superficial. (b) Cryptic. (c) Rheumatic or Gouty. (d) Herpetic. (e) Tonsillar and Peritonsillar Abscess. (f) Membranous Inflammation.

(2) *Chronic.* (a) Enlargement or Hypertrophy. (b) Caseous. (c) Chronic Abscess. (d) Atrophy. (e) Mycosis.

(3) *Foreign Bodies.*

The faucial tonsils are practically lymphatic glands. On account of the structure and exposed position, the pathological changes are important. The glands may be involved either from local conditions, or secondarily through systemic lesions. Superficial ulceration of the tonsil may be a cause of systemic infection. Primary infection may be associated with pharyngeal or laryngeal lesions, as in the infective fevers or exanthemata. In rheumatic or gouty conditions, or intestinal wrongs where autointoxication results, local manifestations in the tonsils may occur. Anemic conditions are liable to cause changes in the lymphoid structure of the tonsil. Ulceration often results in any inflammation of the gland.

Acute Superficial Tonsillitis.

Synonyms.—Acute catarrhal tonsillitis; Tonsillitis; Acute catarrhal angina.

This is an acute inflammation of the tonsillar mucous membrane, and may invade the crypts and parenchyma. It may extend to, or be caused by, inflammatory action of contiguous structures.

Etiology.—This condition is most often seen in children and young persons. This is probably because the lymphoid tissue is most highly developed at this period, as later in life atrophy usually occurs. Sudden changes in the temperature or exposure are frequent causes. Injury of the tonsils or adjacent tissues may also be a cause, also irritation from acrid fumes or vapors, scalds, or inhalation of steam. Mouth breathing may be a predisposing factor. Lowered vitality from any cause may be an important factor.

Pathology.—Practically that of any catarrhal inflammation of mucous tissue surfaces.

Symptoms.—These vary in intensity. Usually there is a feeling of malaise, some headache, stiffness of the muscles of the neck, and a slight chill followed by fever. Slight pain on swallowing and a sensation of fullness is also present; later the pain may be continuous, but is always increased on swallowing. If neglected, motion of the head and neck will be painful, or even torticollis may occur. Inspection shows a deep red color, with an edematous appearance. The soft palate, uvula, and faucial pillars are also implicated. As the process continues, the crypts are filled with serum and fibrin resembling patches of membrane. Tinnitus and pain in the ear may be complained of. There may be hoarseness due to change in the circulation of the epiglottic region or vestibule of the larynx. Nasal resonance is also often faulty through the swelling of the uvula and velum. In young children the symptoms are often more

marked, and the attack rapid in development. Recurrence is the rule, and as a result there is a decided enlargement of the tonsil. Glandular involvement is the exception.

Diagnosis.—The disease is often bilateral. The rapid progress and absence of adherent membrane on the tonsil or surrounding structures will aid in the diagnosis.

Prognosis.—Good. Recurrence may be prevented in the majority of cases by proper measures.

Complications.—In some cases owing to congestion of the laryngeal structures, there may be relaxation of the vocal cords. The loss of voice may occur after the acute attack. Catarrhal or purulent otitis media may follow. Elongation of the uvula may result from the relaxation of the velum.

Treatment.—These cases usually recover rapidly if proper medication is employed. Local measures are not of much use. Unless contraindicated, a saline cathartic is beneficial in the majority of cases. Internal medication. When the pain on swallowing is very severe, the drugs may be used either with an atomizer or in concentrated solution, thus relieving the necessity for swallowing. Aconite combined with phytolacca will usually afford prompt relief. Eating ice-cream often relieves much of the congestion, and is not only a food, but a medicine as well. In some cases hot drinks will be desired. The direction usually given, to use a gargle, is cruel. It not only increases the congestion, but, what is most important is the fluid seldom comes in contact with the inflamed structures. The atomizer is more useful and does not increase the congestion. Steam is sometimes beneficial, and can be medicated.

Cryptic Tonsillitis.

Synonyms.—Lacunar Tonsillitis. Follicular Tonsillitis.

This type differs from the superficial only in the amount of tissue affected. There may be only a few of the crypts, or the entire tonsil may be implicated. When the deeper

structures are involved, affecting the entire gland, it is termed parenchymatous tonsillitis.

Etiology.—The liability to this type is much increased by the anatomical structure. The deep crypts with small openings favor the accumulation and retention of the secretions sufficiently to cause irritation of the crypt walls; this, with decomposition of the material, forms a nidus for infection. A vitality lowered from any cause is also a predisposing factor. Climatic changes are important in producing the disease. The disease is found most frequently between the ages of ten and thirty years.

Pathology.—The tonsillar enlargement is the result of vascular engorgement, accumulated secretion, and inflammatory exudate within the crypts, as well as into the parenchyma itself. This exudate being serous, accounts both for the edematous condition and the infiltration of the migrated leukocytes. The exudate on the surface separates as fibrin and serum. The most of the fibrin may be deposited in the crypts, giving the impression of membrane formation, while it is only the retained inflammatory exudate. Infection through the crypts and also from the impeded blood-supply to the inflamed area may cause the tissue to undergo liquefaction-necrosis and abscess-formation.

Symptoms.—Pain is a constant, characteristic symptom. Motion, either on opening the mouth or on swallowing, increases the pain. Sharp neuralgic pain, passing to the ear and to the cervical region, is often complained of. The quality of the voice is changed. Normal respiration is not often impeded, unless the postpharyngeal tissues are involved. An irritating cough, reflex in character, through inflammatory pressure on the phrenic and recurrent laryngeal nerves, may be present. The effort to clear the throat is almost constant. The disease is usually unilateral. The increase of pain on swallowing is due to muscular spasm and diminished size of the faucial opening. The pain is

usually referred to the temporomaxillary articulation. In many cases it is almost impossible to swallow either liquids or solids, and often when the effort is made there will be regurgitation of the material. Through extension of the inflammation to the vault of the pharynx, the Eustachian tubes may become affected, thus causing middle ear disease.

Inspection of the tonsil is often difficult on account of the patient not being able to open the mouth. When possible to get a good view, the surface of the tonsil appears deeply reddened and edematous, with whitish or yellowish

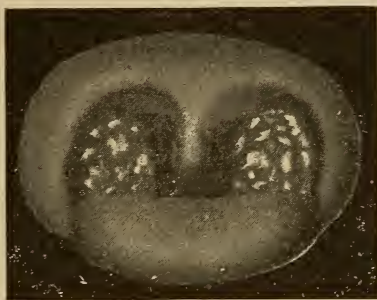

FIG. 83. Cryptic or Follicular Tonsillitis.

points indicating the orifices of the crypts. When there is a profuse inflammatory exudate, there is a serofibrinous material, more or less covering the surface, which has a resemblance to membranous inflammation. The febrile symptoms vary considerably. As a rule there is increased temperature, skin dry and warm, and more or less nausea. As the disease progresses, and if suppuration occurs, there will be chills, the skin clammy, mental dullness, face pallid and with an anxious expression. The tongue is heavily coated, usually a pasty or dirty colored coating, and the breath is peculiarly offensive. Thirst is a constant and annoying feature. The usual clinical symptoms of inflammatory action are noted

in this form of tonsillitis. Constipation, scanty, high-colored urine, with an excess of urea and urates, and occasionally a small amount of albumin. The glands at the angle of the jaw may be enlarged, but usually not in the early stages.

Diagnosis.—The severity of the symptoms as well as the appearance of the tonsil, will differentiate from the superficial variety.

Prognosis.—Good. When seen early it is seldom that suppuration occurs.

Treatment.—Will not vary from that already given under acute superficial tonsillitis, excepting more attention to the activity of the excretory functions is required. The use of the atomizer or concentrated medicines will be appreciated by the patient. The medicine should be given frequently until there is an improvement in the condition. In some cases it will be necessary to evacuate the crypts, but often the case is seen too late to do this, and it is better to wait until the acute symptoms have subsided, rather than torture the patient by forcing the mouth open.

Rheumatic or Gouty Tonsillitis.

Whether the uric acid diathesis is a factor in producing this form of tonsillitis is a question, but that infectious material in the system, from any cause, is liable to infect the lymphatic system, and especially the faucial tonsils, is unquestionably true. Any portion of the tonsil may be involved. Usually there is a history of repeated attacks of acute tonsillitis, varying in severity. Rheumatic constitutional symptoms may or may not coexist. Acute exacerbations occur, but the irritation is constant and the inflammatory process is usually slow. Both tonsils are often affected and are enlarged and irregular, almost meeting in the median line. This condition interferes with normal respiration and nasal resonance. The voice is thick and muffled, there is an annoying accumulation of secretion in

the throat, and the breath is offensive through the retention of decomposing material in the tonsillar crypts. There is often regurgitation of fluids and food into the nasopharynx on attempting to swallow. The symptoms and pathology do not vary particularly from the other varieties of tonsillitis. Connective tissue changes in the tonsils usually follow repeated attacks, and the tonsil will be firm and hard to touch.

Diagnosis.—It is difficult to differentiate on inspection, although usually there is a peculiar appearance of the blood stasis, which is not often found in the other varieties, but this is difficult to describe. There is also a more or less bruised sensation of the pharyngeal tissues, independent of the soreness, which is lacking in the other varieties. The history of a rheumatic or gouty tendency will also be an aid. Whether or not future experience will substantiate the uric acid diathesis as the principal factor remains to be seen.

Prognosis.—Favorable.

Treatment.—The eliminative functions must be kept active. For the constipation which usually is present, rhamnus Californica. With an edematous condition of the tissues, apis or apocynum. In some cases when the tongue is pallid and coated with a light pasty fur, or the coating is dirty, urine scanty, and with a dull headache, potassium acetate will be indicated. When there is a bruised sensation of the pharyngeal tissues, cimicifuga. Besides these remedies, those given under acute superficial tonsillitis are often indicated during an acute attack. For the chronic condition, in addition to the hygienic and eliminative measures, phytolacca should be given for its influence on the glandular system, and iris should be combined with it if the lymphatic circulation is sluggish.

Herpetic Tonsillitis.

In this variety herpetic vesicles on the tonsil are associated with an acute pharyngitis.

Etiology.—As a rule this condition occurs in persons whose power of resistance is weakened. Anemic conditions also seem to favor its development. Cold or exposure are the most frequent exciting causes.

Pathology.—The vesicle has a bleb-like appearance, and is filled with a fluid or semi-fluid material. The outer wall of the vesicle consists of a thin layer of mucous membrane. Sometimes a false membrane is formed over the mucous surface, the result of fibrinous exudate and coagulation necrosis of the epithelium.

Symptoms.—The condition develops rapidly, temperature generally high, marked chills, aching pains referred to the bones, anorexia, severe headache, tongue heavily coated, and nausea. The pharyngeal and faucial regions are painful, and present a decidedly red color on inspection. The minute vesicles repeatedly occur on both the pharyngeal and tonsillar surfaces. In the early stages they are discrete, but after twenty-four hours may become confluent, forming large blebs. After twenty-four or forty-eight hours the vesicles usually open, leaving whitish ulcers. The glands are not often affected. After three or four days the lesions generally entirely disappear.

Diagnosis.—Inspection and the history of the case will determine the character of the disease.

Prognosis.—Good. There is a tendency to recurrence, however.

Treatment.—The use of rhus will usually relieve the burning sensation. Local applications are of little benefit. Systemic improvement must be relied upon to effect a cure.

Tonsillar and Peritonsillar Abscess.

Synonyms.—Peritonsillar Phlegmon; Phlegmonous Tonsillitis; Quinsy.

It is not often that a suppurative inflammation is limited to the faucial tonsil, the peritonsillar tissue usually being the

structure involved. The disease may result from infection through the tonsil, following or accompanying some inflammatory action of the tonsil or its contiguous structure. In many cases the lesion is the result of, or associated with some constitutional septic condition, or to infected emboli. The infectious fevers often have peritonsillar abscess as an accompaniment.

Etiology.—Infection may be present from the inception of the disease, or it may be secondary to any of the varieties of inflammation of this region. Lessened physiological resistance of the mucous membrane will increase the liability to infection. The exact relation of the buccal bacteria to the process is undetermined, but probably they are simply subordinate factors.

Pathology.—The morbid changes are the same as found in inflammatory action of mucous membrane surfaces. The gland is held and nourished only at the external side, and for this reason rapid engorgement is favored. The lymphatic channels afford an easy and rapid spread of inflammatory products, which accounts for the usual implication of the cervical and sublingual lymphatics. The contiguous connective tissue is early infiltrated with embryonal cells. There is considerable edema both internally and externally, as a result of the impeded lymphatic circulation. As a result of lack of nutrition, coagulation-necrosis follows at a point remote from the blood supply, which is in the tonsillar or peritonsillar tissue, an abscess forming. The process is the same as in any abscess formation. There is more tendency to extension of the abscess when the point is back of the tonsil or in the peritonsillar structure, than when in the tonsil itself. When in the latter tissue a spontaneous rupture will generally be at the lowest part of the gland, opening directly into the pharynx. When the abscess is in the peritonsillar tissue, the line of least resistance is usually followed, which may be anterior or posterior, following along

the muscles toward the larynx. These cases may require an incision penetrating the entire tonsillar structure.

Symptoms.—The symptoms of tonsillar and peritonsillar abscess are similar, but vary somewhat in intensity. Before pus is formed, the symptoms are practically those of acute catarrhal or lacunar tonsillitis. This may continue two or four days. Sometimes there is an apparent improvement, when suddenly a recurrence of the symptoms occurs. There is restlessness and fever, abnormal secretion, mouth dry, appetite impaired, constipation, and scanty urine. Pain in the tonsillar region is continuous, and radiates to the ear and

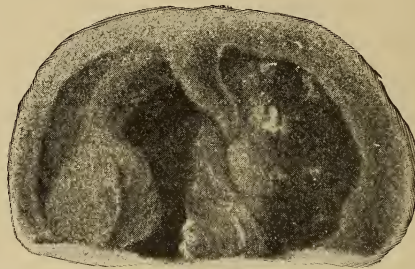

FIG. 84. Tonsillar abscess of left tonsil.

larynx. Motion of the head or swallowing increases the pain. The pillars of the fauces, and often the velum and uvula, as well as the pharyngeal and laryngeal tissues, are red and edematous. Edema of the glottis sometimes results. If suppuration ensues, the symptoms are all aggravated, the swelling of the tissues increased, and swallowing is a positive torture. It is almost impossible for the patient to open the mouth, somewhat simulating lockjaw. External pressure at the angle of the jaw causes intense pain, while tenderness is constantly present. Sometimes at the commencement of the attack there is rigor, followed by several chills. The breath is offensive, and the tongue coated with

a brownish, dirty fur. The severity of the symptoms do not always depend upon the amount of pus formed. Spontaneous rupture may take place at the lower portion of the gland, or in severe and infected cases necrosis and partial sloughing of the tonsil may follow. Usually operative measures are instituted before such a result occurs. In some cases ulceration may follow the suppuration, but not often. The symptoms are less severe in tonsillar than in peritonsillar abscess. Glandular implication and external swelling is less. Often there are numerous small abscesses instead of one. The abscesses may be deep-seated or close to the surface, and may require opening, or may rupture spontaneously. It is often impossible to detect fluctuation. If the disease occurs as a complication of measles, scarlet fever, typhoid fever, or influenza, the progress is slower and generally more serious. The disease is most often unilateral.

Complications.—Serious complications seldom arise, but the abscess may spread, following the line of least resistance, into the deeper cervical tissues, and pointing externally. Edema of the glottis is to be feared when there is much watery exudate into the intercellular spaces. Middle ear disease may result by extension of the inflammatory process into the nasopharynx, affecting the Eustachian tubes. When there is extensive necrosis in a deep-seated abscess, there is a possibility of involvement of the internal carotid, or thrombosis of the jugular veins. Thickening of some portions of the tonsil and contraction at the site of the abscess, may form a lobulated irregular gland. Adhesions between the tonsil and faucial pillars usually result.

Diagnosis.—The clinical symptoms, previous history, inspection when possible, and the peculiarly offensive breath should make a diagnosis comparatively easy.

Prognosis.—Usually favorable.

Treatment.—The treatment already given will prove successful in the majority of cases, if seen before suppuration

has commenced. After the formation of an abscess, however, incision is necessary. When possible to locate the abscess, there is but little difficulty in obtaining drainage. A curved bistoury may be used or a tenotomy knife. When the former, the blade should be protected with adhesive plaster, excepting the actual cutting portion. When the incision is made, the direction of the cut should be toward the pharynx, to avoid anomalous vessels.

Membranous Inflammation of the Tonsil.

Synonyms.—Membranous tonsillitis; Fibrinous tonsillitis.

Different conditions of infection may occur in which membrane closely resembling diphtheritic membrane will form, either on the surface or within the crypts. In many cases the caseous material in the crypts and extending to the orifices will be seen as localized membranous inflammation. In streptococcal infection, membrane is often found on the faucial pillars, tonsil, and wall of pharynx. In disturbances of the alimentary canal the pharyngeal and faucial membrane is frequently reddened, inflamed, and small membranous patches are seen. After the use of the cautery, escharotics, or tonsillotomy, membrane may form.

Pathology.—This is practically the same as is found in infection with the Klebs-Löffler bacillus. The bacteria present are really of secondary importance. The exciting factors of the disease have been given. Localized ulcers may form, giving the so-called ulcerative tonsillitis, which is quite noticeable when the crypts are invaded.

Symptoms.—Seldom very intense. The glands of the neck may be enlarged through infection of the lymphatics. Pain in the tonsil is constant, and is increased on swallowing, the breath is offensive, the voice more or less impaired through extension of the inflammatory action. Pharyngeal inflammation and occasionally an abscess may form through

infection, although when the case is seen early, complications are infrequent.

Treatment.—Besides what has already been given, potassium bichromate internally will be useful. A three per cent solution of this drug may also be beneficial used as a spray.

Enlargement or Hypertrophy of the Tonsil.

Synonyms.—Hyperplastic Tonsillitis; Hypertrophic Tonsillitis.

Two varieties of enlarged tonsils occur. In one type the structure is soft, the increase in size being due largely to glandular material. In the second type the structure is hard, there being more connective tissue increase, although glandular tissue may also be increased. It is necessary to remember that simply an enlarged tonsil does not always mean a hypertrophied condition, as the enlargement may be the result of vascular conditions, venous stasis, or an edematous state of the tonsil. In children the tonsils are normally large, and there is also gland tissue outside the faucial pillars, and the condition does not necessarily denote a morbid condition. Hypertrophy is often applied in cases which are only inflammatory or hyperplastic.

Etiology.—Increase in size of the tonsils may be due to a variety of causes. Inherited taints seem to predispose or actually cause such changes. A chronic inflammatory condition as in gouty, rheumatic, or the so-called uric acid diathesis, is a common factor. Sex does not seem to have any influence. Lesions of the throat are prolific causes. Climate also influences changes of the tonsils and throat. Lowered vitality, the result of specific inflammation, as well as the acute infectious diseases of children, often cause permanent enlargement. Cardiac, pulmonary, hepatic, renal, or intestinal lesions, when causing obstruction to the venous flow, may cause enlargement of the gland. In these cases there

is cyanosis of the mucous membranes. The tonsil is soft and boggy, as a result of watery or serous infiltration into the tissues and a slow chronic inflammatory change. In repeated tonsillar or peritonsillar abscess, the enlargement is an inflammatory increase in the connective tissue.

Pathology.—In the soft variety, the glandular element predominates, fine trabeculæ of connective tissue supporting the clusters of glands. The structures are the same as in the normal tonsil, unless there has been a decided chronic inflammatory condition, when there may be considerable increase of connective tissue. The fibrous character in these cases is probably due to the organization of inflammatory material. Where the tonsil is decidedly lobulated, the connective tissue is fibrous, the crypts are deeper, more irregular, and their openings contracted. When the connective tissue is largely hyperplastic, the gland is less irregular, there is less contraction, and the crypts less saccular and not so liable to retain caseous material. When the tonsil is enlarged through a chronic irritation, the thickening is more regular in all the gland structure. If the result of repeated inflammatory lesions, it is irregularly fibrous, and after contraction is lobulated. Climatic conditions and derangements of the vascular system influence the soft variety. The soft and hyperplastic forms usually atrophy in adult life. When the enlargement is the result of inflammatory action, atrophy less often occurs, although some diminution in size may take place. This form is frequently associated with inflammatory lesions in adjacent structures, the most frequent being adhesions between the tonsils and pillars of the fauces, especially the anterior. These adhesions often provoke as annoying symptoms as the enlarged tonsil. This condition usually reveals the tonsil as a hard fibrous mass, and with the adhesions there is a constant irritation, causing symptoms similar to chronic pharyngitis. Glandular enlargement in the velum and faucial pillars will be present.

Symptoms.—The glands may be so enlarged as to almost touch, and some cases have been reported where they have actually met and become adherent from ulceration. Normal respiration is impeded, the mobility of the uvula impaired, and regurgitation of fluids and food often occurs on swallowing. The openings of the Eustachian tubes may be affected, either by pressure or extension of the inflammatory process. Laryngeal and pharyngeal irritation results, in the majority of cases, through mouth breathing. The facies is similar, but not so marked, as in adenoid hypertrophy. Restlessness at night, and a hacking, rasping cough is often present. Adenoid hypertrophy is often associated with tonsillar enlargement, when all the symptoms are accentuated. Systemic derangements are usually very noticeable; anemia, languor, and subnormal mental and physical states. There is the nasal twang to the voice, and imperfect phonation. Middle ear lesions are frequently present. In children especially, deglutition is faulty. Adhesions of the tonsils to the faucial pillars is nearly always a complication. These adhesions being of inflammatory origin, and contraction following, the gross appearance of the tonsils will be changed. More discomfort often results than in an actual inflammatory state. The sensation of a foreign body in the throat, frequently associated with gastric disturbances and nausea, are often complained of. Bronchial and asthmatic cough may be present as reflex conditions. The recumbent position often increases the annoyance.

Diagnosis.—Easy, inspection revealing the condition. Digital examination will determine the character of the enlargement.

Prognosis.—Good.

Treatment.—The treatment will depend upon the character of the glands, and resolves itself into medical or surgical. In children and young adults the tonsils are usually large, and unless there are irritative symptoms, or

interference with phonation or swallowing, no radical treatment is necessary. In advanced years the same rule holds good. When the tonsils are soft in character, internal medication will usually have an influence in reducing their size. If due to circulatory wrongs, the treatment must be directed to this lesion. When the enlargement is lymphoid in character, phytolacca or iris is most generally indicated, but the drugs must be used for some time to get results. In the fibroid types medication, either local or internal, is of little use. When the tonsil is enlarged, smooth, and regular, a small portion removed by the tonsillotome will usually suffice, on account of the contraction following. When irregular, nodular, and pedunculated, the irregular portion may be removed by the tonsillotome or Kyle's curved scissors, or any of the instruments devised for this purpose. Local



MAX WOCHER & SON, CINCINNATI, O.

FIG. 85. Douglas' Tonsil Knife.

applications of drugs are of little use. The cold wire snare or galvano-cautery snare are not as generally applicable as the tonsillotome. Before using a tonsillotome the presence of adhesions should be determined by a careful examination, using a curved probe or blunt hook for the purpose. When adhesions are present, they should be divided before attempting to use the tonsillotome. The tonsillotome should not be too sharp, but sharp enough to cut through the tissues without dragging on the gland. When the edge of the instrument is right, there is but little annoyance from hemorrhage, excepting in the case of bleeders. With such, or where anomalous vessels are present, it is not advisable to operate. Cutting too deeply into the structures, especially when a bistoury is used, might be followed by severe hemorrhage. In such cases the stump may have to be ligated, or a tonsil clamp may be required. In children the danger of hemor-

rhage is less than in adults, although as a rule there will be profuse bleeding for a few minutes after the operation. In cases of persistent oozing, Lloyd's ergot or carbo veg. IX may be given. Secondary hemorrhage sometimes occurs, but the danger is materially lessened when no constricting drugs have been employed. The use of cocaine or the suprarenal products is to be condemned in these cases, as they unquestionably increase the danger of secondary hemorrhage. In many cases the adhesions resulting from inflammatory action not only cause a sensation of constriction, but a distinct discomfort on swallowing, and also a change in the character of the voice. Not infrequently these adhesions cause the tonsil to be unduly prominent. The division of the bands will often afford relief without removal of the gland.

Caseous Tonsillitis.

This is practically an inflammation due to mechanical irritation. It may result from repeated inflammatory attacks, or from an enlarged tonsil with increased depth of the crypts which have been changed by the morbid process, and pockets resulting scattered through the tonsil, most frequently in the lower portion. At times pockets may be found in the upper portion of the gland. Food and secretions accumulate in these pockets, and acting as foreign bodies, as well as through decomposition, produce inflammatory action in the surrounding tissue. The history given in these cases is usually of repeated attacks of sore throat, a pricking sensation in the tonsil, and occasionally the escape of small particles of offensive smelling caseous material. Sometimes the patient is able to express this material, but frequently the material is retained by constriction or occlusion of the mouths of the pockets. In some cases the orifice closes, retaining the mass, which is noticed on inspection as a grayish-white nodule. Puncture of this nodule will allow the escape of an offensive semi-fluid material. An

excess of lime salts may also form a calculus in these pockets. This is termed a tonsillolith or amygdalolith. A pocket may be formed at the base of the tonsil by adhesion with the anterior pillar.

Treatment.—A free incision of the pocket from base to orifice. The use of a solution of Lloyd's Salicylic acid, gr. xx to Alcohol ℥j. should be made to each pocket, or 95 per cent carbolic acid. The internal use of phytolacca will aid in many cases through its action on the gland tissue.

CHRONIC ABSCESS OF THE TONSIL.—But few cases have been reported. Kyle is inclined to believe from cases he has seen that the condition is the result of a caseous crypt, and not pyogenic.

Treatment.—Incision, curettement, and cauterization of the surface.

ATROPHY OF THE TONSIL.—Neither physiological nor pathological atrophy lead, as a rule, to any discomfort. In one case, however, through adhesions and diminished blood supply following morbid atrophy, it was necessary to remove the atrophied glands to give relief from annoying reflex symptoms.

Mycosis of the Tonsil.

This is frequently caused by the *Leptothrix buccalis* affecting the outer layer of epithelium, occasionally within the crypts, but oftener about their orifices. Yellowish or yellowish-white spots indicate the affected areas. The affection is in reality a coagulation or liquefaction necrosis of the outer layer of epithelium. The pillars of the fauces, the pharyngeal membrane, and the base of the tongue are often similarly affected through extension.

Disturbances of the alimentary canal, especially the stomach, may be a factor.

Symptoms.—Usually the condition is discovered accidentally, but in some cases there is a pricking sensation.

Diagnosis.—The appearance and microscopic examination.

Prognosis.—Good, but persistency in treatment is necessary, as it is likely to recur.

Treatment.—Carious teeth should receive attention, as well as any alimentary disturbances. The use of the salicylic acid wash locally will be found beneficial, and internally the administration of phytolacca or iris, but treatment must be continued for a long time.

Foreign Bodies.

Any sharp-pointed foreign body may become entangled or imbedded in the tonsil, especially if it is enlarged.

Symptoms.—The same as a foreign body in the pharynx or at the base of the tongue.

Inspection will usually reveal the foreign body, but care must be used in the examination, or gagging may cause the offending body to be concealed by the faucial pillars. In some cases the object may be so deeply imbedded that only by digital examination can it be found.

Lingual Tonsil.

(1) Acute Inflammation (Preglottic Tonsillitis). (2) Acute Phlegmonous Inflammation (Abscess). (3) Hypertrophy. (4) Mycosis. (5) Varices. (a) Regular Dilatation. (b) Saccular Dilatation. (c) Idiopathic Hemorrhage.

Synonyms.—Buccal Tonsil; Fourth Tonsil.

Back of the circumvallate papillæ and above the epiglottic attachment, a number of rounded elevations are located. These masses are adenoid tissue, the lingual tonsil. In the center of each mass is a small orifice leading into a central crypt lined with stratified pavement epithelium, and surrounded by adenoid tissue supported by the connective tissue elements of the part. At the bottom of each crypt is the opening of a duct of a mucous gland.

The lingual tonsil is important both physiologically and pathologically. Owing to its location, it has a close vascular and lymphatic connection with the tongue, upper portion of the larynx, pillars of the fauces, and lateral pharyngeal walls. As a rule, there are from ten to twenty of these modified racemose masses. The location renders the tonsil peculiarly liable to irritation in swallowing, and also there




FIG. 86. Hypertrophied adenoid tissue in the glossoepiglottic fossæ.

is the same tendency to morbid changes as is found in other gland tissue.

Acute Inflammation.

Synonym.—Pre-glottic Tonsillitis.

Etiology.—An acute or chronic inflammatory process is the most frequent in this gland, being secondary to a systemic condition. It may accompany or follow the infectious fevers, tubercular or syphilitic conditions. In influenza, especially when the upper air passages are most affected, an inflammatory state often continues. Wrongs of the alimentary canal and autointoxication are often factors. Irritating smells or vapors may also have an influence.

Pathology.—The changes are practically those of simple acute or chronic inflammation. The mass is swollen, edematous, and is readily seen either by direct inspection or by means of the laryngoscope. The gland may sometimes be

affected by inflammatory action of adjacent or surrounding tissues.

Symptoms.—The secretion is excessive, and there is a constant desire to clear the throat. Even after the membrane is cleared of secretion, there is a sensation of a foreign body remaining. The patient frequently complains of the sensation of "swallowing over something." The use of the voice often causes aching of the throat and a roughness or hoarseness which is due to excessive secretion and the associated inflammatory action about the larynx. A persistent hacking cough may also be present. The sense of taste may be impaired or entirely lost. The sublingual glands and those at the angle of the jaw may be slightly enlarged.

When the nasopharyngeal tissues are involved in a general catarrhal condition and the uvula relaxed or elongated, the latter structure may come in contact with the epiglottis or lingual tonsil, and be the cause of constant irritation and a hacking cough.

Diagnosis.—The laryngoscopic mirror will show the prominent masses and retained secretion.

Prognosis.—Good.

Treatment.—The primary cause must be corrected. For the local lesion, phytolacca and hydrastis or potassium bichromate are indicated. Locally, the use of the salicylic acid wash will be found beneficial in clearing away the secretion, and also in stimulating the glands to normal activity.

Acute Phlegmonous Inflammation.

This may be a primary condition, either associated with phlegmonous lesions of contiguous structures, or resulting from a mechanical injury. Usually the entire tonsil is implicated.

Symptoms.—General febrile symptoms are present. There is pain localized in the region of the hyoid bone, and on one or both sides. There is considerable pain on attempt-

ing to swallow, and also much difficulty in swallowing. The pain usually extends to the ear. There is little if any difficulty in opening the mouth, but protrusion of the tongue increases the pain. Hypersecretion is usually marked. Edema of the glottis may be threatened in severe cases.

Diagnosis.—By digital examination and the laryngoscope.

Treatment.—If recognized early, an incision should be made, but the abscess usually ruptures spontaneously.

Hyperplasia.

Infrequently seen, but may accompany chronic inflammatory conditions of the pharynx.

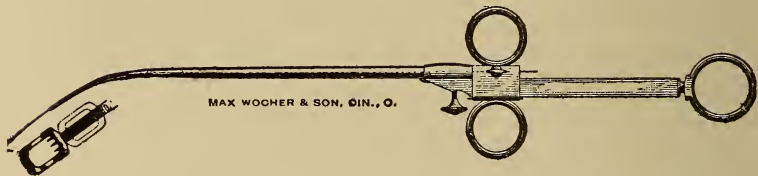


FIG. 87. Lingual Tonsillotome.

Symptoms.—Similar to those of acute inflammation, but with freedom from pain. There is often a sensation of a foreign body which may be on either side of or at the center of the hyoid bone. Eating or drinking causes disappearance of the symptoms, but use of the voice increases them.

Diagnosis.—The laryngoscopic or digital examination will determine the condition.

Treatment.—Very light cauterization with the galvano-cautery is the best method for this condition. The knife must be used cautiously. Twenty per cent chromic acid may be used every fourth or fifty day, being careful not to use an excess of the solution.

Mycosis of the Lingual Tonsil.

This is an inflammatory condition, the result of local infection with the *Leptothrix buccalis*. Small yellowish projections are seen under the tonsil which resemble mold. Ulceration seldom occurs.

Treatment.—The salicylic acid solution used as a mouth wash, or a solution of aseptin. The alimentary canal will usually have to be treated, as digestive wrongs aggravate the condition. Locally the use of iodine, touching the affected areas will be required. Occasionally the galvanocautery may be needed.

Varices.

The veins at the base of the tongue may be regularly or irregularly dilated. In the former condition they will appear as bluish, sinuous cords, while in the latter there will be a nodular appearance. These may rupture, and occasionally a severe hemorrhage will result. In females it may be especially marked at the menstrual period, during pregnancy or the menopause. Alcoholism may also be a cause. In males there appears to be a tendency for this hemorrhagic condition during the cycle which corresponds in a measure with the menstrual function in the female. This is as yet an undetermined factor in the male, but according to Havelock Ellis it undoubtedly is a factor, not only in this but also in rhinitic and pharyngeal diseases.

Etiology.—As a rule is dependent upon impeded venous circulation, the primary cause of which may be intestinal, cardiac, hepatic, or renal lesions.

Symptoms.—Generally subjective. Usually a sensation of a moving substance in the throat. In some cases there is the sensation of a soft foreign body at the base of the tongue.

Treatment.—This should be directed to the primary

cause. We know of two remedies which have a direct influence upon varicosed conditions; collinsonia and hamamelis, and excepting in aggravated cases either of them, combined or alternated with the remedies directed to the primary cause, will prove effective. When persistent hemorrhage occurs, either the hamamelis or carbo-veg. should be given. Occasionally the galvano-cautery may be required.

Laryngeal Tonsil.

Located within the ventricle of the larynx small areas of adenoid tissue are found, which are properly lymph-follicles. It is only when inflammatory conditions of the larynx are present that they can be discerned as minute elevations.

Treatment.—The same as directed for laryngeal inflammation.

CHAPTER XIII.

DISEASES OF THE PHARYNX.

MALFORMATIONS AND DEFORMITIES; Stenosis.—I. Dilatation (Pharyngocele). Diverticulum.

Acute Inflammatory Diseases. (1) Simple Acute Pharyngitis. (2) Infective Pharyngitis. (3) Membranous Pharyngitis. (a) Croupous; Simple Membranous. (b) Diphtheritic. (4) Gangrenous Pharyngitis. (5) Traumatic Pharyngitis. (6) Hemorrhagic Pharyngitis. (7) The Pharynx in Exanthemata and other Febrile Affections. (a) Scarlet Fever. (b) Small-pox. (c) Measles. (d) Erysipelas. (e) Intermittent Fever. (f) Gout. (g) Typhus Fever. (h) Typhoid Fever. (i) Influenza. (j) Varioloid. (k) Chicken-pox. (8) Ludwig's Angina.

Chronic Inflammatory Diseases. (1) Simple Chronic Pharyngitis. (2) Subacute Pharyngitis. (3) Follicular Pharyngitis. (4) Hyperplastic Change in the Pharyngeal Structure. (5) Atrophic Pharyngitis. (6) Rheumatic Pharyngitis. (a) Acute. (b) Chronic. (7) Infectious Granulomata of the Pharynx and Nasopharynx. (a) Tuberculosis. (1) Lupus. (b) Syphilis. (c) Glanders. (d) Actinomycosis.

Abscess, Retropharyngeal. Urticaria. Herpes. Pharyngomycosis.

Non-inflammatory Diseases.—(1) Pulsating arteries. (2) Anemia of the Pharynx. (3) Neuroses of the Pharynx. (a) Anesthesia. (b) Hyperesthesia. (c) Pares-

thesia. (d) Neuralgia. (e) Neuroses of Motion. (1) Spasms. (2) Paralysis.

Foreign Bodies in the Pharynx. (Kyle.)

Malformations and Deformities of the Pharynx.

Stenosis is one of the most important malformations, and may be congenital, occur early in life, or be secondary to inflammatory or traumatic conditions.

Congenital atresia, complete or partial, seldom occurs.

Secondary stenosis may result from cicatricial contraction, either following specific inflammation or a traumatism. Syphilis is the most frequent of the former. Specific lesions of the pharyngeal tissues causing adhesions to the contiguous structures, or contraction, is often found. This condition may exist either low in the nasopharyngeal or in the laryngopharyngeal space, and the peculiar stellate characteristic of a syphilitic scar is present. The treatment usually is unsatisfactory, as time is an important factor, and the patient will not remain long enough under treatment. The stricture should be divided and dilated for a considerable time, and active antisyphilitic measures adopted.

Tubercular constrictions are practically unknown, as the tendency in these cases is to continue ulcerating. The infective diseases which are most liable to have adhesions and contractions as sequelæ, are scarlet fever, diphtheria, small-pox, and erysipelas.

Traumatic stenosis may occur at any period, and usually follows scalding by hot liquids or erosions of caustic liquids, taken accidentally or intentionally. Usually this traumatic lesion is rapidly fatal, not only on account of the extent of the lesion, but also because severe edema of the glottis is usually associated with the resulting inflammation.

Treatment.—In these cases emollient remedies should be employed, usually those of an oily nature are preferable. A five per cent carbolyzed vaseline will often give relief.

Spasmodic contraction is usually the result of swallowing food before it is properly masticated.

EXTRINSIC STENOSIS.—Disease of the cervical vertebrae is the most frequent cause. Any lesion of the spine which causes a constriction of the pharyngeal space may produce this condition.

Retropharyngeal abscess may cause a diminution of the pharyngeal cavity. Increased size of the apices of the lateral lobes of the thyroid gland may, through pressure, produce inflammation and cause choking sensations.

When the cervical glands are affected in Hodgkin's disease, the pharyngeal space may be diminished.

DIVERTICULA, OR DILATATIONS OF THE PHARYNX.—This may occur through arrested development in fetal life, or result from imperfect growth or mechanical distention. Congenital pouches are usually associated with total atresia of the pharynx, or absence of the esophagus. The cause of this condition is not definitely known.

Pouches or dilatations of the pharynx (pharyngocele) are oftenest found in old age, although they may be overlooked earlier in life. The most frequent cause is the ingestion of improperly masticated food. Usually the first manifestation of a morbid state, is the inability to swallow, or pain on attempting to do so. Masses of undigested food may be ejected, without the effort to vomit, and may occur at any time after eating. Occasionally the pouch may be so large that the contained food will produce a visible distention on that side of the neck, and the patient may be able to cause the food to enter the esophagus by making pressure against the distention.

Treatment.—Usually unsatisfactory. When the pouch is large, causing a visible swelling of the neck, a properly adjusted pad may relieve the condition. The galvano-cautery, or freshening the edges of the pouch and suturing have been advised, but the results are usually unsatisfactory.

Simple Acute Pharyngitis.

Synonym.—Acute catarrhal pharyngitis.

This corresponds to an acute catarrhal inflammation of mucous tissue in general.

Etiology.—This may be the result of a simple "cold," exposure, or by extension from contiguous structures. A rhinitis or nasopharyngitis may be the direct cause. Disturbances of the alimentary canal may also cause it, through impaired vitality of the general system, producing a lessened resistance of the pharyngeal structures.

Influenza, systemic diseases, poor hygienic surroundings, sedentary habits, any of these may more or less be factors in causing an acute pharyngitis. Inflammatory affections of the lingual tonsil often cause symptoms simulating acute pharyngitis. Alcoholism, or the excessive use of tobacco, may predispose through their influence on the general system. It probably is oftenest found in youth and middle age. In children intestinal irritation is frequently the cause. Occupation is a factor, as those who are exposed to irritating fumes, dust, hot dry air, or sudden changes of temperature, are more liable to acute pharyngitis than when the surroundings are more favorable.

Pathology.—This is the same as in an acute catarrhal inflammation of any mucous tissue.

Symptoms.—The attack is usually sudden, and the severity depends upon the rapidity of onset. The membrane varies in color from a bright pink to a deep red. The pharyngeal vessels are usually distinctly congested. There is always a distinct band extending along the pillars of the fauces and the edge of the soft palate, including the uvula. The width and intensity of color of this band will determine not only the severity of the attack, but also the stage. The broader and deeper the color, the more severe the inflammatory action. If in the early stages, the band is sharply defined, while later the outer edge of the band merges in color

into that of the continuous tissue. Some edema of the edges of these structures may be present, giving a translucent appearance.

In the early stage the membrane is smooth and shining, becoming roughened in the second stage. In the first stage the throat is dry, with small masses of mucous scattered over the surface.

The second stage is characterized by profuse secretion and exudate. At first this is watery, becoming tenacious and mucopurulent as the process progresses. When the exudate is fibrinous, it will coagulate on the mucous membrane. The constant effort to clear the throat increases the irritation. There is usually severe pain and irritation, which is augmented on swallowing. There is a sensation of fullness or constriction of the throat, with a constant desire to swallow. The pain often extends to the ear, even without the presence of a nasopharyngitis, and is usually increased by the act of deglutition.

The larynx may be affected by extension of the inflammation through continuity of tissue. Whether or not the hearing is impaired will depend upon the involvement of the nasopharynx. The act of swallowing increases the pain, and the sense of taste is usually impaired. The desire to clear the throat will cause more or less constant hawking or coughing, and in those cases where there is laryngeal or bronchial irritation the cough will be more spasmodic. Quite often the sputum will be streaked with blood, as the result of rupture of some of the congested blood-vessels.

The respiration is free, unless there is laryngeal or nasal complications. The voice is changed in character, and in laryngeal involvement may be lost.

The systemic manifestations depend largely upon the severity of the case, as well as whether it is associated with an epidemic condition. There will be increased temperature, gastric disturbances, constipation, and scanty, high-colored

urine. The tongue will be coated and the breath offensive. Headache and pain in the muscles of the neck are usually severe when epidemic conditions are present.

Diagnosis.—This is not difficult, in the majority of cases. In children a hasty diagnosis should not be made, as the pharyngeal symptoms may precede some systemic disease.

Prognosis.—Good. Under proper treatment an uncomplicated case should recover in three to five days.

Treatment.—This should consist of constitutional measures, as local means are practically worthless, excepting to amuse the patient. During the early stages, aconite, dist. hamamelis, nux, belladonna, gelsemium, apis, apocynum, hydrastis, potassium bichromate, phytolacca, rhus tox., or cimicifuga, are usually indicated.

When the pharyngeal lesion is the result of systemic disease, the latter should be treated, but the treatment given above will reach the majority of cases. In cases of hepatic engorgement, chionanthus gtt. jv. should be given. This drug will do better work if it is given in concentrated form, with directions to drop it in water when taken. If put into a watery menstruum, it appears to lose its medicinal properties very rapidly.

The use of opiates is seldom required, and should be avoided if possible, as their action is to retard recovery.

Infective Pharyngitis.

Symptoms.—Ulcerative sore throat; Hospital sore throat; Phlegmonous pharyngitis; Suppurative pharyngitis.

This is an infective condition, in which there is superficial ulceration of the pharyngeal mucous membrane.

Etiology.—Persons exposed to septic influences, when the vitality is lessened, are liable to infective pharyngitis. Physicians not infrequently have this disease during epidemics of diphtheria or scarlet fever. In hospitals the at-

tendants are often affected. It is also a not infrequent condition among those working in dissecting rooms. The bacteria usually found are the streptococci and staphylococci. The pseudobacillus of diphtheria may be present, but is not a factor.

Pathology.—Ulceration of the pharyngeal mucous membrane may occur in nearly any inflammatory action of these tissues, but is usually the result of an infection. Liquefaction necrosis is characteristic, small ulcers often extending through the basement membrane, resulting. In some cases the process is not decidedly ulcerative, being desquamative, the basement membrane not being implicated. Sometimes the infection localizes under the mucous membrane, forming an abscess, or the superficial tissue may secrete pus through the infection, a granular appearance resulting, which causes the suppurative form. If there are small abscesses in the submucosa, a diffuse suppurative pharyngitis—peripharyngeal phlegmon—results. Excepting in diphtheritic infection, the different varieties differ only in degree.

Symptoms.—The first symptom is sensitiveness of the throat, increased on swallowing. This is soon followed by dryness and a swollen and rigid sensation. Pain extending from the throat to the ears, and muscles of the neck and pharyngei muscles sore. The temperature is increased. Restlessness and depression is complained of. The secretions are scanty, the tongue coated with a heavy fur, and the breath offensive. There is often dull frontal headache and mental dullness.

The ulcers are usually on the lateral walls of the pharynx, often behind the faucial pillars, when they are frequently overlooked. The tonsils and velum are often affected. The ulcer is generally small, and has a shaggy membrane covering it. This is the result of liquefaction—and coagulation—necrosis. After this substance has sloughed the ulcer will be clear.

Diagnosis.—The history, rapid development, and microscopic examination will determine the character of the lesion.

Prognosis.—Usually favorable. Septicemia may occur.

Treatment.—The nature of this disease requires placing the patient under good hygienic surroundings. The bowels should be freely evacuated, a saline cathartic being preferable. For the suppurative tendency, the use of lime, either lime water or calcium sulphide, every hour. For the septic condition, especially with dusky, leaden-colored ulcerations, baptisia. When the surfaces of the ulcers are dirty looking, the mucous membrane bluish or purplish in color, and an asthenic type of ulceration, echinacea.

Besides these remedies, the drugs given under acute simple pharyngitis will usually be sufficient.

Membranous Pharyngitis.

Varieties.—Croupous; Simple membranous; Diphtheria.

CROUPOUS.

Not infrequently there is seen an inflammatory condition which is of an infectious character, but is not diphtheritic. While the streptococcus pyogenes are found in abundance, giving rise to the term streptococcal infection, yet they are not the cause of the disease. Some writers describe this as erysipelas of the throat. Clinically it is difficult to distinguish from diphtheria, but it runs its course more rapidly, and is not as severe.

Among laboratory workers, or persons exposed to infectious conditions, the disease is most frequent.

There is neither ulceration nor implication of the basement membrane, as there is in ulcerative pharyngitis. The mucous membrane is covered with a very coagulable albuminoid substance, which forms a false membrane and is coincident with desquamation of the surface epithelium. On

removal of the membrane no ulceration will be found, and should there be any bleeding it will be simply a capillary oozing. Whether this condition is contagious or infectious has not been determined, but until the diagnosis is positively made due care should be taken, as the earlier diphtheritic symptoms are almost identical.

Diagnosis.—This is made from the clinical symptoms and also by microscopic examination.

Treatment.—The surfaces should be kept as clean as possible, and for this purpose the salicylic acid wash will be found especially useful. A two per cent solution of potassium bichromate is also a remedy that is indicated in many cases. Swabbing of the tissues or any rough manipulation is to be avoided. Internally the treatment should be along the indicated line given under simple pharyngitis.

DIPHTHERIA.

As this disease is fully described and the methods of treatment given in works on Theory and Practice, it will not be described. The only thing in these cases is to avoid the barbarous methods in vogue of swabbing the throat.

Gangrenous Pharyngitis.

Synonym.—Putrid sore throat.

This infrequent affection is the result of an antecedent disease, infectious in character. It is generally associated with the infectious febrile diseases, or as a sequelæ of trauma, either accidental or operative. It is caused by the localization of an infectious process in the submucosa. An infected embolus may lodge in the submucosa and be followed by abscess formation. As the nutrition of the basement membrane is obtained from the submucosa, if this supply is interfered with by an infectious process, necrosis follows. On the surface of the mucous membrane, over the

affected portion, there is an accumulation of inflammatory fibrinous material, the removal of which also removes a slough. Practically the condition is a localized superficial necrosis, affecting the basement membrane as well, thus resulting in a true ulcer.

This gangrenous condition may be the result of local infection, liquefaction necrosis of the epithelium following, and the affection of the deeper tissues through the lymph channels. This forms a severe phlegmonous inflammation with sloughing of the infected area.

Symptoms.—The onset is sudden, and the disease runs a rapid course. Usually there is a rapid increase of temperature, as a result of toxic poisoning. If actual necrosis results, there may be a sudden decrease of temperature to subnormal. Pain, as a rule, is severe and lancinating in character. The cervical and submaxillary glands are often enlarged. With the advent of necrosis, the breath becomes extremely fetid, the characteristic odor of gangrenous tissue. Prostration and mental depression are present as in other septic diseases. Sepsis results not only from the local area, but also through the alimentary tract, the result of the patient swallowing the infected material.

Prognosis.—Unfavorable, it being often impossible to check the disease, and the patient dies from syncope.

Treatment.—Internal medication is the only hope. Echinacea, baptisia, potassium chlorate, calcium sulphide. The eliminative functions should be kept active, and so-called stimulating remedies employed. Locally, a spray or wash of potassium permanganate or potassium chlorate may aid in relieving the odor. The surfaces may also be cleansed with some solution, so that a less quantity of the secretion is swallowed.

Occupation Pharyngitis.

Synonym.—Traumatic pharyngitis.

This is an acute inflammation, the result of wounds, for-

eign bodies, inhalation of irritative dusts or vapors, or of caustic substances.

Etiology.—Young children or feeble-minded persons are most frequently the class in which this condition is observed, as they are more liable to drink corrosive solutions or boiling liquids. It is also frequently seen in adults whose vocation keeps them more or less constantly exposed to irritating dust, as sweepers, miners, weavers, threshers, etc. Those who work in chemical laboratories are also often affected. The lodging of sharp foreign bodies of any kind in the pharyngeal tissue is often a cause. In the latter cases the inflammation spreads from the point of irritation to the surrounding tissue. If the submucous connective tissue is injured, suppuration and abscess formation is liable to result.

When the inflammation is caused by vapors, chemical fumes, dust, or fluids, the tissues are more regularly affected, no focus of inflammation being found. The membrane of adjacent structures is also involved. If the exciting cause is a caustic solution, a scald or burn, edema of the glottis, as well as of the pharyngeal tissue, is liable quickly to follow the injury. The inflammatory action is very severe and rapid in its progress.

Treatment.—If due to a foreign body, this should be removed as soon as possible. Often the offending substance has been removed, and there is simply the infected traumatism when the patient is seen. If there is edema, numerous punctures should be made in the tissue. In burns, caustics, etc., the parts should be thoroughly covered with a five per cent carbolized vaseline, which will allay the pain. Any oily substance may be used, however. In some cases the edema is so severe and sudden as to require intubation or tracheotomy, and in some cases it may extend so low in the trachea that neither method will do any good. It is impossible to state here the antidotes for the various es-

charotics. Such local means should be employed as will relieve the pronounced pain.

Hemorrhagic Pharyngitis.

Etiology.—In hemorrhagic pharyngitis there are single or multiple small areas of extravasated blood, the result of ruptured blood-vessels, the inflammatory action being secondary to the hemorrhage. It is often found after the eruptive fevers, or any condition causing relaxation of the walls of the vessels and perivascular tissue. The hemorrhagic nidus appears like small, dull red, slightly edematous spots. If seen within twenty-four hours, inflammatory action may be absent, but after this period there is usually an active inflammation.

The rule is for the areas to be located on either side of the median line, but any portion of the pharyngeal surface may be affected. Usually the condition shows as multiple spots, but there may be but one. If the hemorrhage is slight, the appearance will be similar to the petechiæ of eruptive fevers.

In specific processes, as syphilis or tuberculosis, hemorrhagic areas may be found in the mucous membrane of the uvula and soft palate.

Symptoms.—These are about the same as in acute pharyngitis, but are generally of longer duration. Blood stained or streaked mucus may at times be expectorated. Pain is not severe, but as a rule is localized. In some cases necrotic changes occur in the hemorrhagic spot, ulceration following, which is termed hemorrhagic ulceration of the pharynx.

Treatment.—The inhalation of steam may afford relief, but the main treatment must be directed to the systemic lesion. The bowels should be kept in good condition. The treatment given under acute pharyngitis should be followed.

The Pharynx in the Exanthemata and Other Febrile Diseases.

CHICKEN POX.—In severe cases, when the eruption is considerable, there are often pharyngeal complications, although the hard and soft palate are most affected. Flaccid vesicles which have a surrounding area of hyperemia are usually found. The epithelial surface of the vesicles rapidly desquamate, leaving excoriations. The lymphatics of the neck may be swollen and tender, and there is usually considerable pain in the throat.

ERYSIPELAS.—This may be primary or secondary. The tissues swollen, livid, red, and shining, with the formation of vesicles varying in size from a pinhead to one-half inch in diameter, leaving a gangrenous area, comprise the pharyngeal phenomena. In epidemic erysipelatous fever, usually called "black tongue," not only the pharynx, but also the larynx, may become involved. If the pharyngeal lesion is secondary, it may be by extension from the cuticle through the mouth, nose, or even the ears, or by metastasis from the integument to the mucous tissues. The systemic disturbances are most persistent.

Symptoms.—Difficulty in swallowing and a sharp pain in the throat are usually the first symptoms. After efflorescence occurs the fever often decreases, again increasing with another crop of vesicles. The vesicles may contain serum, pus, or blood. Gangrenous spots may form. The disease may extend to the accessory sinuses, tonsils, and middle ear. Erysipelas of the pharynx may be a complication of smallpox or almost any febrile disease.

Prognosis.—Guarded, as by extension it may terminate fatally.

GOUT.—Pharyngeal and laryngeal inflammatory phenomena, the result of the systemic disease, may occur. The throat symptoms may precede or follow the actual attack. There are no distinctive appearances, the diagnosis depend-

ing largely upon the previous history. The pain usually is sharp and more or less constant.

INFLUENZA (La Grippe).—An acute catarrhal condition of the pharyngeal tissue is usually present. The nasal and nasopharyngeal tissues are almost always affected. There is a decided tendency to a chronic type. Ulcerative processes may occur, and a croupous exudate on the tonsils and posterior pharyngeal wall has been seen. The pain may be severe.

INTERMITTENT FEVER.—The entire respiratory tract may have, as a result of changes in the blood, an irritative inflammation. There may be coryza, and paralysis of the muscles of deglutition has been observed. In the pharynx a burning pain is sometimes complained of. A subacute pharyngitis or enlargement of the tonsils may occur.

MEASLES.—The catarrhal inflammation of measles is most marked on the laryngeal and bronchial tissues, but there is a characteristic appearance of the mucous membrane of the fauces, palate, uvula, and pharynx. There may be diffuse redness, or a blotchy or punctate rash, which may appear with, or precede, the cutaneous manifestation. The middle ear may be involved through extension of the inflammatory process through the Eustachian tube.

SCARLET FEVER.—In this disease throat symptoms are probably always present, the severity depending on the variety of the disease.

According to Dr. R. L. Thomas, the throat lesions are of three types. In the simple form there is redness of the fauces, tonsils, tonsillar follicles, velum, and pharynx, and a sensation of obstruction in the throat. In the anginosa form all the tissues are a vivid red, and there is considerable swelling of the structures, the sensation of an obstructive condition of the throat being marked. There is considerable induration and often follicular tonsillitis. Soreness is present from the onset of the disease, and deglutition is painful and difficult. The secretion from the mucous

follicles and salivary glands is excessively viscid and tenacious. Occasionally ulceration may begin on the fifth or sixth day, the secretion being difficult of removal and very offensive. The ulcers may become phagedenic in character, the disease then being rapidly fatal. The cervical glands may be enlarged, and if neglected inflame and suppurate.

In scarlatina maligna the third form is found, which is sometimes called membranous angina. The throat at first is dry and tumid, soon showing a dirty moist exudate; the deeper tissues become infiltrated, and the inflammation is extreme. The submaxillary glands are swollen as well as the cervical. Foul phagedenic ulcers are found in the pharynx. Suppuration of the cervical glands ensues, and a disgusting pultaceous abscess results.

The latter form, when it occurs early, or even later than the fifth or sixth day, is ascribed to the Klebs-Löffler bacillus, a true diphtheritic type, or to streptococci, or different forms of micrococci. The general appearance is suggestive of diphtheria.

Any of these types may by extension involve the Eustachian tubes and middle ear, causing a suppurative otitis media. Deafness from inner ear complications is not infrequent, although in what manner the infection causes labyrinthine disease is unknown.

SMALL-POX.—Pharyngeal manifestations may be observed during either the stage of infection, or occasionally the incubation period. It may be a dusky appearance of the mucous membrane, or a catarrhal inflammation with swelling of contiguous tissues. Occasionally there is lymphatic involvement. Ecchymoses and membranous exudation in the pharynx may appear before the cutaneous eruption in hemorrhagic small-pox. Usually the eruption in the throat appears after the cutaneous eruption. If a pseudomembrane forms in the throat, there will be intense pain and difficult deglutition.

Complications and sequelæ: Infectious inflammation of the parotid and other glandular structures, abscess of the larynx, and often purulent otitis media.

TYPHOID FEVER.—As is to be expected, pharyngeal and laryngeal affections are comparatively frequent in this disease, especially laryngeal. It may be a catarrhal, croupous, follicular, ulcerative, or diphtheritic and aphthous pharyngeal inflammation. In the early stages there is often dryness of the throat, making the effort to swallow more or less difficult. Later the difficulty in swallowing may be simply a nervous condition, especially in children. The pharyngeal, faucial, lingual, and tonsillar follicles may be affected coincidentally with the intestinal glandular involvement. Infrequently there may be so much infection that the terms tonsillo-typhoid or pharyngo-typhoid may be used.

Bone and cartilage necrosis or abscess formation, as a result of the lowered vitality, is most to be expected, and the most serious lesions are oftener laryngeal than pharyngeal.

TYPHUS FEVER.—The pharyngeal mucous membrane and buccal mucosa are usually involved. The color is a dusky red, injected, and the mucous follicles enlarged, containing puriform material, or puriform areas may occur in the areolar tissue of the posterior pharyngeal wall. A viscid mucus or flakes of pseudo-membranous exudate may cover the mucous membrane. There may be difficulty in swallowing. Unless infection occurs, suppuration or ulceration is infrequent.

VARIOLOID.—Usually not much involvement of the pharynx. In some cases, however, there may be hoarseness, and difficulty in swallowing.

Ludwig's Angina.

Synonyms.—Angina Ludovici; Cellulitis of the neck.

This is really an acute cellulitis of the neck, and generally is secondary to septic fevers, as diphtheria and scarlet

fever, but may result from traumatisms. It is supposed to be of bacterial origin. The pharyngeal symptoms, which are severe and come on rapidly, are soon followed by infection of the parotid or submaxillary glands, and suppuration rapidly supervenes.

Prompt remedial measures may give relief. If not, surgical means must be employed. This must not be delayed, on account of the danger of constitutional infection.

Simple Chronic Pharyngitis.

Synonyms.—Clergymen's sore throat; voice users' sore throat; exudative pharyngitis.

This form of pharyngitis is a chronic inflammatory condition of the mucous membrane, permanent changes resulting in the glands or submucosa.

Etiology.—The disease may be caused by a long continued acute or subacute pharyngitis. The prolonged use of the voice by public speakers, especially those who have not acquired the proper method of controlling the muscles, will produce as a reaction muscular contraction of the larynx and pharynx, with anemia of the tissues. After relaxation of the muscular tissues occurs, dilatation of the vessels results, and there is stasis. Frequent repetitions of this condition will produce changes in the perivascular tissue nearly identical with those of chronic inflammation. The morbid change is very similar to that of cyanotic congestion. The pathological changes are always the same in this disease, although the causes and symptoms may differ.

Systemic diseases in which modification of the nutrition occurs as a result of venous stasis or cyanotic congestion, due to liver, lung, kidney, or cardiac lesions, may be an exciting cause. Some nervous states, especially peripheral, may have a causative influence in these cases. Digestive wrongs, through lowering of the general resisting power, will often prove an exciting cause. The abuse of stimulants

or narcotics will cause a chronic pharyngitis. Sexual excesses are also credited as favoring the condition. The excessive use of tobacco will cause local irritation, which is acutely only a symptom of systemic conditions, the result of the absorption of the tobacco alkaloids.

Gouty or rheumatic persons, those suffering from auto-intoxication, or from any impairment of the excretory or secretory organs, are especially liable to this disease. Malformations of the pharynx will also have a causative influence. The different types of rhinitis will also be factors, either through extension of the inflammatory state, or by the passing of the nasal discharge over the pharyngeal tissue. The latter condition may be the cause, as a result of the irritation produced, or through the efforts to clear the throat. Mouth breathers are often affected, even when not speakers.

Pathology.—The pathological changes found in the tissues in chronic pharyngitis vary, and many of the so-called diseases are simply definite stages of the inflammatory action. In simple chronic pharyngitis the inflammatory change in the submucosa is slow. There may be only a slight exudate from the blood-vessels on account of but little irritation; a few leukocytes will be found in the exudate, and proliferation slowly occurs in the connective tissue spaces. This, in connection with slow proliferation of the fixed connective tissue cells, gradually causes a permanent thickening of the mucosa. This increase of the connective tissue elements causes more or less irritation of the glandular elements, and there is an increase of secretion. As organization of this inflammatory material occurs, the glandular elements of the submucosa are subjected to pressure, through the increased amount of organized material.

Eventually this organized inflammatory material will commence contracting, and there is necessarily a change in the condition, the inflammatory stage having subsided, and

pressure atrophy resulting. These pathological changes vary in rapidity and according to the cause, still the change is practically the same in all cases of chronic pharyngitis.

A condition is found in which there is an actual increase in connective tissue elements, which is more like a hyperplasia. This is not a true hypertrophy, as there is a decrease in function of the membrane. When this is the case, atrophy does not take place; the mucous membranes do not become dry, and accumulations of changed secretion on the surface are not found.

Symptoms.—The mucous membrane is irregularly hyperemic or congested. The variation in color is marked, the border of the pharyngeal structure being bright colored, and the balance of the tissue showing more the color of congestion. The palatine folds and the lower and anterior margin of the velum are light red. The posterior pharyngeal wall often shows congested capillaries and small veins; the surface is irregular, but not so marked as in true follicular pharyngitis. At the base of the tongue varicose vessels are often found; this is more prominent after contraction has occurred.

The depressions in the pharyngeal tissue will be filled with a tenacious secretion, which, unless carefully noticed, will be taken for membranous inflammation. If the disease is the result of any of the forms of pneumoconiosis, the secretion will be colored according to the material which causes the inflammatory action.

The secretions are changed as a result of the morbid processes; they are more tenacious as the changes become more marked, and there is a tendency to crust formation. The character of the voice is changed, hoarseness and lack of control being most marked; the voice is weak, lacking carrying power, and the muscles of the throat ache when a prolonged effort to use the voice is made. This sensation is wholly or partly relieved by making a slight pressure on

the neck with the fingers. In singing, the range is lessened, and there is not full control of the tone and pitch. Unless some complications exist, nasal respiration is fairly free.

An irritating, hacking cough is present, with a constant desire to clear the throat. Occasionally there are streaks of blood in the expectoration, the result of rupture of some of the congested blood-vessels. There is a continual desire to swallow; this results from the enlarged lingual tonsil and accumulation of secretion in the pharynx. There is often a sensation of a foreign body in the throat, similar to the condition of globus hystericus. Pain on swallowing is variable, depending upon the amount of inflammation and the stage of the process. Usually there is not much pain, unless warm fluids or highly seasoned foods are taken.

The sense of taste is not much impaired, unless the anterior pharynx and nasal cavities are affected, when both the senses of taste and smell will be markedly lessened. If the Eustachian tubes are involved the hearing will be impaired.

The secretions are always increased after eating, causing paroxysms of coughing and hacking, which may be severe enough to result in vomiting. The inhalation of dust or irritating vapors, or sudden changes of temperature, as going from a warm room into a cold, will also cause a coughing paroxysm. Gastric wrongs are usually present, and may be either primary or secondary. Laryngitis is often associated with the pharyngeal lesion.

Diagnosis.—Easily made.

Prognosis.—This will depend upon the causative factor. If this can be removed, the prognosis is good; otherwise not.

Treatment.—The general health must be considered in this disease. The alimentary tract must be kept in an active condition, and the remedies employed for this purpose should be carefully selected.

Local.—Often it will be necessary to use the atomizer for cleansing the mucous surfaces. Either the alkaline

wash or the salicylic acid solution will be all that is necessary.

Internal.—Besides what has been said regarding the alimentary tract, the remedies most frequently required are phytolacca, iris, potassium bichromate, potassium iodide, bryonia, hydrastis, jaborandi, liquor potassii arsenitis, nux vomica, podophyllum, ignatia, penthorum sedoides, hamamelis, collinsonia, or arsenious acid.

Should there be any malformation of the bony framework of the pharynx, a complete cure is impossible.

Subacute Pharyngitis.

This is really a late stage of an acute condition, either where the treatment has been unavailing or neglected.

Symptoms.—The same as in the later stages of an acute attack, or the early stage of the chronic. It is an intermediate form.

Treatment.—The same as in simple chronic pharyngitis.

Follicular Pharyngitis.

Synonyms.—Clergymen's sore throat; dysphonia clericorum; folliculous pharyngitis; granular pharyngitis.

In this disease the glands of the mucous membrane are especially affected. The secretion is changed in character, and in the advanced stages of the disease is very scanty, tenacious, and irritative. Irritation of the pharynx, often a sharp, hacking cough, and always a change in the voice, which varies from a slight hoarseness to complete aphonia. The appearance of the pharyngeal tissue is characteristic; there is a varying amount of congestion, and numerous elevations of a reddish or yellowish color. These vary in size from a pinhead to a split pea, and may be discrete or coalesce. This uneven condition is caused by the inflamed and distended glands. When the secretion has been exuded,

whitish or yellowish flakes of thick, whitish, or yellowish material will be found adhering to the elevations.

ETIOLOGY.—Predisposing Causes.—Any condition which may cause a chronic inflammation of the respiratory mucous membrane may be a factor. The disease is seen more frequently in the young and middle-aged than in old age, and in men more than in women. Any diathesis or condition which lowers the resisting powers of the individual may have a predisposing influence. Climatic conditions are important, as those subjected to a smoke-laden atmosphere will be more susceptible than those living in a clear atmosphere. Whether the use of tobacco is a prophylactic or not is a question, but it certainly is not a remedial agent in this disease.

Occupation is an undoubted predisposing factor, as those who use the voice considerably are more liable to the disease; clergymen, auctioneers, lawyers, etc., are especially liable to follicular pharyngitis. Actors and singers who have had proper vocal instructions are not often afflicted, but otherwise the disease is not infrequent.

Follicular pharyngitis is really only a type of simple chronic pharyngitis, and besides the causes already given, it may follow frequent attacks of acute pharyngitis, or a neglected, severe, prolonged attack.

Exciting Causes.—Improper use of the voice in any way, especially in the effort of loud or high-keyed notes. Faulty vocalization is probably one of the most frequent causes. This defect, when associated with impure air, either as a result of suspended material or lack of the proper amount of oxygen, unquestionably has an influence in causing the disease. It is supposed that the ingestion of pungent condiments, through their influence on the glands, may also be an exciting cause. Many cases, however, are seen where no cause can be ascribed, and some, at least, are those having a marked tendency to glandular involvement.

Pathology.—As regards the mucous membrane, the pathology is similar to that of a simple chronic catarrhal inflammation. The glandular structures, however, are affected particularly. Through overstimulation the function of the glands is exhausted, and the glands and surrounding tissue become inflamed. This practically results in encysted foreign bodies in the membrane, which are a source of constant annoyance. Inspection will reveal the morbid membrane studded with more or less reddish or yellowish elevations. The swelling may be partly due to inflammation of the tissue surrounding the glands, and partly to disten-



FIG. 88. Follicular Pharyngitis.

tion of the glands themselves through obstruction of their orifices. If rupture of the glands has occurred, there will be found a thick, pasty, cheesy, foul, light-colored material covering the site of the glands. This is termed the exudative form. The microscopic appearances in the periglandular tissue are the same as present in ordinary inflammation. The openings of the glands are closed by inflammatory swelling, impacted cell masses, or inspissated secretion. The lumen of the glands or their ducts are enlarged, the lining epithelium swollen, and the cells show fatty degeneration. Calcareous deposits are sometimes present in the retained glandular secretion. Adhesion of the pillars of the fauces to the tonsils is a frequent complication.

Symptoms.—Usually there are repeated attacks of acute pharyngitis or a chronic inflammatory condition. The disease is usually insidious. A not infrequent premonitory symptom is the excessive secretion of mucus or mucoid fluid on attempting to use the voice, the mouth being filled with the secretion. This action of the glands soon disappears, and the glandular involvement becomes apparent. The glands become inflamed, and the secretion is diminished in quantity. A dry or parched feeling is complained of, and there is a sensation of irritation in the throat, particularly after trying to use the voice. This is usually transient at first, but becomes more severe and of longer duration with each recurrence.

The discomfort in the throat finally becomes permanent. The voice becomes hoarse, muffled, or even only a whisper, and sometimes even complete aphonia occurs, depending upon the severity of the disease and the effort made to use the voice. The pharyngeal tissues become "tired," and occasionally painful in trying to talk, even in ordinary conversation. If there is much soreness of the tissue, speech may be hesitating and slow. The pain is usually of a burning, pricking, or stinging character. It may be a dull aching or bruised sensation, and deglutition often increases any of the symptoms.

The secretion is not unlike that of a simple chronic pharyngitis. Cough is usually a troublesome symptom, and is generally sharp and metallic, and may be constant or in paroxysms. This causes increased soreness of the pharyngeal tissues. The uvula is often relaxed and increases the discomfort of the patient, as well as increases the cough. Through extension of the disease, the olfactory and auditory senses may be impaired. Disturbances of the alimentary canal are not infrequent, and this complication aids in the general depression sometimes found.

Inspection reveals the characteristic appearance of the

pharyngeal tissues, the elevations of a reddish or yellowish color and varying in size. These may be few or numerous, discrete or coalescing. A very frequent condition associated with this disease is a band-like thickening behind the posterior pillars of the fauces, or even adherent to the pillars, interfering with the action of these muscles. This constitutes the condition called *pharyngitis hypertrophica lateralis*. Depending upon the stage of the disease will be found irregular masses of cheesy material covering the follicles. Between the follicles will be dilated blood-vessels. More or less congestion of the entire pharyngeal membrane is usually present. In advanced cases the tissues may all present a relaxed appearance, the uvula and velum often being flabby looking, and even the base of the tongue expressionless.

Diagnosis.—Usually easy.

Prognosis.—Good, in the majority of cases, provided the tissues are not overworked, and the patient will persist in the treatment.

Treatment.—The general health should be considered, and, when possible, complete rest of the throat be given. The treatment given under simple chronic pharyngitis will usually suffice. In cases of long standing, where the glands and surrounding tissues have become permanently affected, the careful use of the galvano-cautery may be an important aid. It is important to remember that too much operative interference may result in a worse condition than the original disease.

Hyperplastic Change in the Pharyngeal Structure.

The mucous membrane and supporting tissue of the lateral pharyngeal walls may present a thickened condition. Contraction seldom occurs, as it is really a hyperplasia. It is usually termed *pharyngitis hypertrophica lateralis*, as the posterior surface is infrequently affected. It seems to be

an extension or association of chronic inflammatory action from contiguous tissue. It is practically found only with a chronic inflammatory nasopharyngitis.

Atrophic Pharyngitis.

Synonyms.—Dry pharyngitis; pharyngitis sicca.

This condition is the result of inflammatory processes, the changes being more or less permanent.

Etiology.—The causes which lead to an atrophic pharyngitis are varied, but the morbid change which is produced is practically the same in all cases. Any exciting cause, as local irritants, may produce a chronic inflammation. Under this may be classed occupation irritation, where dust or irritating vapors are constantly inhaled. The pharynx becomes implicated through extension of inflammatory action from contiguous structures, causing first a thickening of the submucosa, followed by contraction.

The contraction of inflammatory organized tissue affects the glands of the mucous membrane, changing the secretion, or even destroying the glands. The secretion which is present is so changed that it is a source of irritation.

Systemic disturbances interfering with the circulatory system, especially where venous stasis results, may be a cause of atrophic degeneration. In these cases the general appearance of the membrane varies somewhat from that resulting from inflammatory atrophy, but the results are practically the same.

Some nerve lesion, the cause of which is difficult to trace, may also cause atrophy with similar results to those found following inflammatory processes.

A dry pharyngitis, not atrophic, is often seen, which is the result of some systemic condition, changing the general nutrition and causing solidification of the glandular secretion. In this form of pharyngitis the secretion from the pharyngeal glands adheres to the mucous surface, and gives

a glazed or vanished appearance to the mucous membrane. These cases are not truly atrophic, but the result of perverted secretion. It is found in diabetes mellitus, as well as in some forms of stomach and intestinal wrongs.

The claim is made by some that atrophic pharyngitis is the result of atrophic rhinitis, but it is more likely that both are caused by the same factor. In some cases extension through continuity of tissue may occur, but they are probably the exception. Impeded nasal respiration is undoubtedly an important causative factor in producing some types

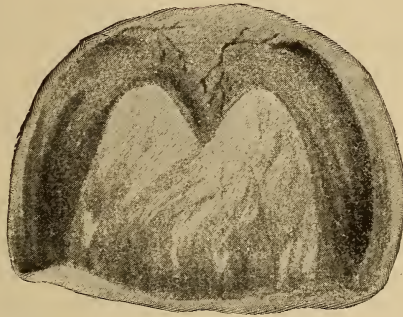

FIG. 89. Atrophic Pharyngitis. The thinning of the tissues shows fairly well.

of dry pharyngitis, as mouth breathers, as a rule, are afflicted with this condition, atrophic changes eventually resulting.

Pathology.—In the simple dry form, where the secretion simply dries and hardens on the pharyngeal surface, morbid changes in the membrane are very slight. The changed secretion may, through constant irritation, cause a chronic inflammation, which will eventually lead to contraction of the inflammatory tissue, producing a true atrophic process. This necessarily produces changes in the vascular supply, and through pressure, changes or destroys the secreting action of the mucous glands.

The morbid changes resulting from vascular wrongs, as often found in heart, lung, liver, kidney, or alimentary diseases, are due to lack of nutrition, as well as pressure on the perivascular structure by the overdilation of the blood-vessels, the glands also being affected. If this pressure continues for some time, pressure atrophy may follow, although occasionally slight inflammatory changes may have occurred early. The result is permanent, as in the true inflammatory type.

Symptoms.—The most pronounced symptoms are the burning, itching sensation and annoying dryness. As a result of this dryness it is difficult to swallow solids without first moistening the mucous surfaces. A sensation of stiffness and rigidity of the throat is present. In some cases the secretions are so dry and firm that a grating sound can be heard when a probe or the end of a tongue depressor is passed over it.

The character of the secretion varies according to the degree of change and its cause. In the simple form, where the submucous tissue is little affected, the membrane is thin, translucent, and smooth. As the pathologic changes increase in the submucosa and glands, the secretion becomes thicker, is irregularly massed, and is of a brown or green color. There is the sensation of a foreign body in the throat, which aids in increasing the hacking cough.

The nasal cavities often, and the nasopharynx nearly always, present a similar condition, and the Eustachian tubes are usually affected.

In the early stage of atrophy, or in the simple dry type, the removal of the secretion will leave the mucous membrane reddened and extremely sensitive. Later, when there is crust formation, their removal will leave the surface with irregularly colored patches, some having an inflamed appearance, and some being pale and colorless. The membrane appears thinner than usual, excepting in those cases

of atrophy due to venous stasis and pressure atrophy. In this class the surface is more nodular, the blood-vessels appear to be more on the surface, and, excepting in the latter stages, there is not the tendency for the secretion to form in masses. The breath is usually offensive.

Diagnosis.—Easy, as a simple inspection of the pharynx will reveal the condition.

Prognosis.—Favorable in all forms in the early stages. Unfavorable after permanent atrophic changes have occurred.

Treatment.—After the contraction of the mucosa has advanced to such an extent as to destroy the glandular elements of the tissues, only palliative measures will be of use. Prior to this, however, a partial or complete cure can be obtained. The condition of the nasal and postnasal tissues must also be considered in these cases.

Local Treatment.—This has but little effect, only as it removes a source of irritation by the removal of the tenacious or dried secretions. This secretion can be removed in many cases by the use of an alkaline wash. Sometimes the use of pledgets of cotton on a curved probe will be necessary. The salicylic acid wash has been found to be one of the best local applications in these cases, as it has the property of stimulating glandular activity. Irritating measures are to be avoided.

The same general line of treatment should be followed as in atrophic nasopharyngitis.

Acute Rheumatic Pharyngitis.

Synonyms.—Rheumatic sore throat; Rheumatic angina; Gouty sore throat.

This is an acute inflammation resulting from some constitutional irritant. The uric acid diathesis is at present credited as the cause.

Etiology.—The uric acid diathesis may manifest itself in different ways. The secreting or glandular tissues may be unduly irritated through an excessive amount of work being required of them. This applies to the pharyngeal tissues, as well as the renal. The membranes of the nasal, laryngeal, or alimentary tract may be the point of local manifestation.

Pathology.—The morbid changes in an acute attack are identical with those of a catarrhal inflammation. It must be remembered that in this condition we have merely a local manifestation of a systemic disorder, the result being an overworking of the glandular structures of the mucous membrane. Ulceration of the pharyngeal tissues occurs, but usually is confined to small areas.

Symptoms.—The attack is usually sudden, the first symptom being a sensation of fullness in the throat, and pain, increased on swallowing. The desire to swallow becomes constant and difficult, the throat feeling rigid and stiff. There may be a sensation of heat, dryness, and irritation, or a suddenly increased flow of mucus. There is always a tendency to clear the throat, which if continued becomes a source of irritation. The act of swallowing appears to reveal a new area of soreness, and the head assumes a different position during each deglutition, which is characteristic of rheumatic pharyngitis. The attack may continue a few hours or several days. Acute exacerbations are frequent. General rheumatic symptoms may be present. The contiguous mucous membranes may be affected, but not to the same extent. The symptoms often pass away as quickly as they came. The pain is superficial. Slight febrile symptoms may be present.

Diagnosis.—An examination of the urine makes the diagnosis positive, but the sudden onset and a rheumatic tendency will suffice.

Prognosis.—Favorable.

Treatment.—The general health of the patient must be considered. Hygienic measures must be instituted, and the eliminative functions improved. The employment of sodium salicylate, bryonia, phytolacca, cimicifuga, rhus tox., rhamnus Californica, etc., according to indications, will give relief. The kidneys should be required to perform their functions, and potassium acetate, apis, apocynum, or similar remedies employed.

Chronic Rheumatic Pharyngitis.

Synonym.—Gouty sore throat.

A chronic inflammatory condition, permanent changes resulting from the continued irritation of the uric acid diathesis.

Etiology.—Simply the result of, or the continuation of, repeated acute attacks.

Pathology.—A permanent thickening of the connective-tissue elements of the submucosa.

Symptoms.—In the acute attacks the symptoms are the same as of a rheumatic pharyngitis. There is always present a sensitive condition of the tissues, a hacking cough, and a continuous effort to clear the throat, as a result of the accumulated mucus, or irritation resulting from the chronic condition. Sudden changes of temperature or barometric pressure will aggravate the symptoms. Laryngeal complications are usually present.

Diagnosis.—The history, and by urinalysis.

Prognosis.—Fairly favorable, unless extensive morbid changes in the tissues have taken place.

Treatment.—Practically the same as in the acute type, only more time will be required.

INFECTIOUS GRANULOMATA OF THE PHARYNX, NASOPHARYNX, AND TONSILS.

Tuberculosis.

Synonyms.—Tuberculosis of the pharynx; Consumption of the pharynx.

This is usually secondary, or may accompany pulmonary tuberculosis, but is very infrequent.

Symptoms.—Unless a known pulmonary lesion exists, the early symptoms may be regarded as an acute or sub-acute pharyngitis. Later, local swellings resulting from the inflammatory exudate occur, and may involve the velum, uvula, faucial pillars, or any portion of the pharyngeal tissues. The tonsils may be affected, either primarily or secondarily. The disease usually extends downwards more rapidly than upwards. Infiltration and thickening of the tissues produces a variety of symptoms. The thickened soft palate, by not properly closing the nasopharynx during the act of swallowing, may permit food or fluids to enter the nasal cavities. There is also a tendency for the mucus or mucopurulent material to accumulate and become inspissated. When the uvula is thickened, it may cause a short, hacking, irritative cough. Usually coincident with the swelling there will be seen miliary tubercles as small yellowish spots beneath the surface of the membrane. After a variable period these soften, rupture, and form minute ulcers, often scarcely noticeable. Their outline is irregularly rounded, the ulcers shallow, the floor covered with a grayish secretion. There is no well defined areola of inflammation, and there is a general pallor of the membrane.

The ulcerative process rapidly increases, each focus extending in depth as well as laterally. These areas coalescing, soon cause extensive ulcerative tracts. In some cases there will be spaces of unaffected tissue between the ulcerative areas, presenting the "moth-eaten" appearance. Oc-

asionally miliary tubercles may be seen in the floor of the ulcers, or masses of granulations at their edges. Irritation of these surfaces may cause bleeding.

As the disease progresses, the secretion becomes more profuse, tenacious, and slimy, and may interfere with respiration, or it may be wheezy. The ulceration rapidly progresses, and may result in complete destruction of the palatal soft tissues. The larynx or buccal cavity may be affected simultaneously, and aggravates the condition. In a few cases partial cicatrization may occur. A variable amount of pain is always present, its location depending upon the situation of the lesion.

In the early stages the pain is described as a dry, parched, burning ache; this becomes later sharp and lancinating in character. The ear may be involved, especially if the lateral pharyngeal wall or faucial pillars be the seat of the active disease. Motion increases the pain, and the act of swallowing becomes more painful as the morbid process increases. The voice is muffled, and there is difficulty in clearing the throat. Cough is present and may be pulmonary, or the result of the pharyngeal lesion. In the latter case it is the dry, hacking, irritative form. The breath is fetid. The other symptoms are those caused by the pulmonary lesions which accompany or soon follow in this disease.

Diagnosis.—Usually easy, but occasionally, prior to ulceration, it may be difficult. The chances of a mixed infection must be remembered.

Prognosis.—Unfavorable, as death usually follows within six months.

Treatment.—Pharyngeal tuberculosis is seldom primary, but is usually secondary to laryngeal or pulmonary tuberculosis. Local measures are for the alleviation of the pain resulting from the ulceration. Cocaine has been employed, but on account of its influence on the general system should

be resorted to only in aggravated cases. Chloretone inhalant has afforded relief in some cases, and so far as noted without injurious effects. The salicylic acid wash will cleanse the tissues, and if three per cent carbolic acid is added, will cause some anesthesia of the tissues. The juice of the pineapple, as a spray, has given relief in some cases. Internally, the use of the remedies already given will be found most advantageous.

Lupus.

The generally accepted theory is that lupus is simply a local manifestation of tuberculosis. The scrofulous diathesis appears to favor its appearance. It is seldom a primary affection of the pharynx, being usually secondary to nasal or buccal invasion, which in turn results from extension of the disease from the facial integument. Any portion of the pharyngeal tissues, tonsils, or faucial pillars may be affected. The progress is slow, but the loss of tissue excessive. Men are most often affected. The disease appears usually under the age of thirty, and frequently is preceded by recurring attacks of pharyngitis.

Pathology.—There is a cellular infiltrate into the deeper layers of the mucous membrane and underlying tissues. The infiltrate is in masses between the trabeculæ of connective tissue and glandular structure, and closely associated with a blood-vessel. Microscopically the characteristic appearance of granulation-tissue, with numerous giant cells among the cellular elements, and a few tubercular bacilli. The later appearances are those of ulceration and extensive and rapid cicatrization, or infrequently absorption. Any portion of the pharynx, tonsils, or faucial pillars may be affected.

Symptoms.—Usually there is not enough discomfort to cause the patient to seek aid until the disease has progressed for some time. There is little if any pain, and the pharynx

geal functions are not materially interfered with unless the epiglottis is considerably involved, or there is much implication of the tissues in the immediate vicinity of the Eustachian orifices. In the early stages the mucous membrane at the site of infection is livid, smooth, dry, or may be granular. Small, lighter colored points may be seen designating the location of typical lupus nodules. These soon show as miliary nodules varying from a millet seed to half a pea in size, and plentifully distributed over the affected surface, giving the appearance of a mamillated membrane. Their color is that of the surrounding membrane, they are smooth and soft to touch, easily penetrated, and painless. Occasionally there will be no external ulceration, but absorption of the inflammatory infiltrate may result in considerable loss of tissue. External ulceration is the rule, the nodules softening and breaking down, forming necrotic, slightly elevated foci. They present thickened, inflamed borders, and are covered with a grayish, glairy, tenacious secretion. These nodules may remain discrete, or coalesce.

The ulceration is not as deep as in tertiary syphilitic lesions. The characteristic tendency to cicatrization after ulceration, is present. The changes in the pharyngeal structures are usually extensive, and depend upon the location of the lesions and severity of the ulceration. The general health is not usually impaired.

Diagnosis.—Generally easy. The slowness of the morbid process, shallow ulcers, and rapid cicatrization distinguish it from syphilis. The lack of improvement under anti-syphilitic treatment will be an aid.

Prognosis.—Unfavorable, as many cases will grow gradually worse, no matter what measures are adopted.

Treatment.—Complete removal of diseased tissue by curettement or the galvano-cautery. Caustic drugs should not be employed, as their action is difficult to control. The salicylic acid wash is valuable in these cases. Internally

the use of *phytolacca*, *jaborandi*, or *hydrastis* may be indicated. In severe cases, where the laryngeal structures are involved, tracheotomy may be required.

Syphilis.

Syphilis of the pharynx may be either acquired or congenital. The former is found more often after puberty, while the congenital may manifest itself during the first few months after birth (secondary), or usually not until after the age of fifteen (tertiary), the late hereditary syphilis. The pharynx generally is markedly affected in syphilis, and the symptoms are characteristic.

PRIMARY.—After the genitalia, the lips, tonsils, and pharynx are the most frequently affected regions of the primary lesions. The infection may result from kissing, infected drinking cups, especially in public places, surgical instruments, pipes, etc. Infection from syphilitic nurses have been reported, and among sexual perverts is not infrequently found. The primary sore in these regions is more often found in females. The tonsils seem to be the favorite location. One only may be affected, but both may be. Faulty diagnosis is probably responsible for more cases not being reported.

Symptoms.—Usually not severe, nor long continued. The character of the primary lesion is practically the same as on the mucous membrane of the female genitalia. When the pharyngeal surfaces are the location of other morbid conditions, the diagnosis is difficult. The infection may be at any point of abrasion. The tonsil is the usual location, and palpation with a probe may determine the hard base. There may be a slight inflammation of the tonsil; or considerable ulceration instead of the typical lesion. Infrequently the typical sore may be covered with a false membrane, which is easily removed and reveals the chancre. The entire gland is inflamed, hardened, and enlarged. Dur-

ing the continuance of the sore, pain is variable, but there is more or less difficulty in swallowing, local tenderness, and the usual annoying symptoms of sore throat.

When the initial lesion is on the posterior pillars, there is usually pain referred to the ear, and if there is occlusion of the openings of the Eustachian tubes ear symptoms will develop. There will also be the characteristic indolent swelling of the lymphatics at the angle of the jaw and sternocleido-mastoid muscles, either of one or both sides depending upon the site of the sore. The skin covering the glands is not discolored; the glands can be felt as hard, movable bodies, and without a tendency to suppurate.

SECONDARY LESIONS.—These may be of either the acquired or hereditary disease. If acquired, they appear with other systemic manifestations, usually six or eight weeks after the infection. When hereditary, the appearance is usually within two months after birth.

Symptoms.—The most prominent are erythema, mucous patch, or occasionally superficial ulceration. Erythema usually is the first noticed, and may be confined to a limited area, or cover the entire visible pharyngeal wall. None of the pharyngeal and tonsillar surfaces are immune, but it is infrequently found above the level of the hard palate. There may be a diffuse, dusky, dirty reddening, but more often there are small, sharply defined, dusky red areas with practically normal tissue separating them, giving a mottled appearance which is pathognomonic. Accompanying the erythema, cough, a dry or tickling sensation, and dull pain may be present. The usual symptoms of a catarrhal pharyngitis may be noted. The erythema generally persists during the cutaneous eruption, but readily yields to specific medication.

Mucous patches follow the erythematous condition, the time of their appearance varying. These may be located on any portion of the pharyngeal, tonsillar, or faucial surfaces, the anterior portions of the latter being most frequently

affected. The patches commence as dark, dusky-red rounded elevations, clearly defined, and soon soften, superficial necrosis following, forming rounded areas with well defined borders slightly elevated above the surrounding membrane, and covered with a grayish and poisonous secretion. Surrounding each ulcer is a zone of inflamed tissue. The ulcers are usually not deep, and there is little tendency to spread, cicatrization following with a fibrous scar. A fetid breath is often present, but there is slight discomfort resulting from the lesions. Occasionally there is a disposition to superficial erosion of the membrane, which follows



FIG. 90. Syphilitic perforating ulcers of velum.

a whitening or cloudiness of the upper layers, but is not severe. A recurrence is liable to occur if treatment is too early discontinued.

TERTIARY.—These lesions in the acquired form may be found at about seven years, but usually not until twenty or more years after the infection. In congenital syphilis they seldom appear before the age of fifteen. The pathognomonic feature is the gumma, with its attendant destruction of tissue and marked changes in the structures. Infrequently there will be extensive malignant ulceration of the entire pharynx, which soon proves fatal. Any of the pharyngeal and contiguous structures may be affected,

Symptoms.—The gumma are smooth, sharply defined, and there is no marked discoloration of the membrane covering the mass. After a variable period ulceration occurs. This is deep and extensive, the destruction of tissue being considerable, destroying not only the pharyngeal, but the tonsillar, faucial, and even the velum tissue, the latter either sloughing, or being extensively perforated. Some cases have been seen in which the process has extended to the deep vessels of the neck, fatal hemorrhage occurring. The bony tissues of the posterior pharyngeal wall and vault are often affected. The intervertebral discs and bodies of the ver-



FIG. 91. Hereditary tertiary ulceration of velum.

tebræ may necrose, exposing the spinal cord. The base of the skull may be exposed, and through necrosis, the brain be exposed. When such a condition exists, the fetor is very marked. The discharge consists of a disgusting, dirty, purulent material, containing particles of necrosed bone. Sequestra may be formed, and palpation with a probe will give the characteristic sensation. Healing may occur, even without specific treatment, of thick fibrous and contracting cicatrices. As a result of this destructive process, the entire pharynx may be deformed, the nasopharynx practically destroyed, as well as the soft palate. Adhesions may result, partially or completely occluding the pharyngeal spaces.

This necessarily impairs the pharyngeal functions. The discomfort of the patient is not in proportion to the amount of the destructive process.

Diagnosis.—In the secondary and tertiary forms it is comparatively easy, as the lesions are characteristic, and systemic conditions will be an aid, even without a specific history, which is not always easily obtained. The ready response to specific treatment will soon clear all doubts. The primary lesion is more difficult to diagnosticate, and sometimes may not be made until secondary manifestations present.

Prognosis.—This will depend considerably upon the general health. Proper treatment will usually result in a cure if employed early, but after severe structural changes have occurred the prognosis is more unfavorable. The tertiary form is the most intractable.

Treatment.—Practically the same as in syphilitic rhinitis.

Glanders.

Synonyms.—Equinia; Malleus humidus.

The etiology, pathology, symptoms, etc., are practically the same as in the nasal cavities.

Actinomycosis.

Etiology.—The ray-fungus is credited as the cause of this condition. This fungus is only found in the small yellowish masses mixed with the purulent discharge. Within the morbid tissue the appearance of the fungus is that of small clusters of irregularly sized cells, which if cultivated on artificial media, appear as tangled masses of threads. Any of these forms are virulent. The disease is similar to glanders, in being primarily one affecting the higher animals, the bovine race most frequently, but is easily communicated to man. Actinomycosis is infrequently seen in

the pharynx and tonsils, but it may occur either primarily or secondarily.

Pathology.—The invasion of the fungus results in the development of a granulation tumor, the appearance of which is similar to the local manifestation of tuberculosis. There will be found small, round cells, together with giant and epithelioid cells. Later there will be inflammatory reaction, resulting in proliferation of the tissue-elements and the formation of morbid tissue, which is readily mistaken for sarcomatous material. Suppuration follows, which is extremely stubborn. Infection is transmitted by the lymphatic and vascular systems, usually the latter. The disease is chronic in character.

Symptoms.—Two types are to be considered—those in which there is local swelling and ulceration, and the cases where there is a general systemic disturbance from the suppurative products, or a metastatic action similar to any chronic suppuration. The local symptoms develop slowly, and are similar to any gradual interference of the functions of the pharynx. At the point of infection a small, round, and reddened elevation is seen. The surrounding tissues will be swollen, and in a short time the permanent characteristics of a chronic condition result. The swelling is clearly defined, irregular, firm to probe-palpation, not hypersensitive, and slowly increases in size.

Suppuration and sinus formation follow. The discharge from the sinuses is steady, more or less purulent, and contains small yellowish masses made up principally of the ray-fungus. The sinuses are deep, and implicate considerable tissue. The disease does not often extend beyond the points of infection. Pain is dependent mostly upon the location and extent of the swelling. It is usually a constant, heavy, local aching, but may be variable. The breath may be fetid and gastric complications may occur. Metastatic development in the lungs, alimentary tract, or in any part of the

body may occur. The systemic manifestations will depend upon the severity of the invasion, but a fatal termination from exhaustion or complications usually follows.

Diagnosis.—Can only be made, so far as now known, by a microscopic examination revealing the ray-fungus, and confirmation by inoculating some animal.

Prognosis.—Unfavorable, as the disease is seldom recognized until too late.

Treatment.—No constitutional treatment is efficacious, although large doses of potassium iodide have been reported as curative. When possible, the extirpation of diseased tissue offers the most satisfactory results.

Retro-Pharyngeal Abscess.

This results from the formation of pus, and may be located high up behind the velum, or by burrowing may invade the cervical or mediastinal regions. In infancy or early childhood the lymphatic system is usually at fault, or may be the cause. In adults the pus is in the cellular tissues. As the disease differs according to the age, it is most convenient to divide it into two classes, infancy and adults.

Abscess During Infancy.—In these cases it is usually at the side, seldom being in the center of the pharynx. The disease is most frequently found in the children of syphilitic or tubercular parents. The probability is that it is secondary to infection of the lymphatic glands. The loose structure of the pharyngeal tissues favors the accumulation and easy burrowing of pus in nearly any direction. The disease is usually insidious in its course, often no symptoms being noticed until dyspnea or attacks of choking on attempting to swallow are present; the condition being more like that of a chronic abscess. Occasionally there are clinical symptoms calling attention to the pharynx, even in the early

stages, depending upon the location of the abscess. Cough and change in the voice may be present.

Abscess in Adults.—The onset is usually marked, probably on account of the involvement of the cellular tissue. Pain referred to the fauces and increased on swallowing is usually first complained of, the pain being out of proportion to the evident amount of inflammation. Fever is usually present and may become hectic in character. The location of the abscess will largely determine the symptoms. A deep-seated, constant pain is present, and increases until rupture or surgical interference occurs. Dyspnea is not often present.

Diagnosis.—Inspection will reveal an asymmetry of the tissue, the bulging portion being bright red and somewhat glazed. Palpation will determine fluctuation, and probe palpation will cause a bleaching of the tissues, the color returning slowly. In children there may be but slight evidences of inflammation surrounding the abscess, the diagnosis depending upon the recognition of the swelling lessening the pharyngeal space. In children, croup, bronchitis, or edema of the larynx may be mistaken for this disease. In adults the possibility of an aneurism in this region must be remembered.

Prognosis.—When acute, the abscess usually ruptures in from five to ten days, unless recognized and opened previously. Spontaneous rupture during sleep, with some of the pus entering the larynx, may cause broncho-pneumonia or asphyxiation. In children an early recognition of the disease will usually be favorable. Complications caused by, or as a sequence of the abscess, may result fatally. Abscess resulting from, or as a symptom of vertebral disease, is insidious, and usually fatal. When healing takes place the inflammatory tissue may appear as a nodular mass on the pharyngeal wall, and later produce a constant irritation.

Treatment.—Evacuation of the abscess should always be

done as soon as recognized. If pus has not formed when the swelling is discovered, scarification or multiple puncture will often afford relief. In opening the abscess, the patient's head should be lowered to prevent the pus entering the air passages. The use of the autospray of cocaine two per cent will be useful. When the lymphatic glands are the site of abscess formation, the incision should be made externally along the anterior border of the sterno-cleido-mastoid muscle, care being taken not to injure the blood-vessels of this region; general anesthesia is preferable.

Internal Medication.—Lime in some form, phytolacca, iris, arsenic iodide, and when the bony structures of the spine are involved, gold and sodium chloride, silicea, or potassium iodide.

Urticaria.

Urticaria may cause edema of the glottis in connection with the pharyngeal manifestation. The disease is seldom seen.

Ecthyma, pemphigus, erythema multiformum and exudative have been reported.

Herpes.

Synonyms.—Pharyngitis herpetica; common membranous sore throat; aphthous sore throat; benign croupous angina; simple membranous sore throat.

In this disease there are numerous small, discrete, eruptive points distributed over the fauces and pharynx. These disappear after a variable period of a few days or weeks, then recur. This may last an indefinite time.

Etiology.—Obscure, but evidently the result of an irritation or inflammation affecting the terminal nerve filaments. The primary cause may be disturbances of the alimentary tract, systemic diatheses, or diminished eliminative action. It may accompany or follow febrile states, and infrequently has been noted as coincident with uterine affec-

tions. The implication of the trifacial nerve is usually given as a cause.

Symptoms.—Usually sudden in onset, with sometimes a slight fever, discomfort, or pain. A general feeling of a subnormal condition and gastric wrongs prior to the eruption may be present. One or both sides may be affected. Usually one of the first symptoms is a sensation of dryness, soon followed by pain radiating to the ears, and sometimes to the nasal chambers or larynx. Herpetic eruption of the lips will often be found. The pain may cause difficulty in swallowing, but this will depend largely upon the location of the lesions. On inspection there will be found round or oval discrete areas on the uvula, velum, faucial pillars, or pharynx. Usually vesicular and in groups, or scattered over the surfaces. These soon become excoriated, and covered by a thin, yellowish-white, easily removed false membrane. The exposed surface bleeds easily. Sometimes there will be little, if any, change in the mucous membrane. There may be at the same time an involvement of any mucocutaneous surface.

Diagnosis.—Usually easy, if the symptoms are carefully noted.

Prognosis.—The tendency to recur must be remembered, as well as that it renders the patient more susceptible to infectious diseases.

Treatment.—Saline cathartics to empty the bowels thoroughly. Rhus tox., apis, or bryonia are usually indicated. The use of fresh chocolate creams will be found useful in allaying the irritation. Locally the chloretone inhalant, or a sedative spray, may help relieve.

Pharyngomycosis.

The development of *Leptothrix* spores in the follicles of the pharynx, tonsils, etc., produce the condition called mycosis.

Etiology.—The primary cause is the *Leptothrix* in the secretions of the mouth, which find in an acid state or an acute inflammation of the pharyngeal mucous membrane or tonsillar crypts, a favorable nidus for development. A sub-normal systemic state, or local inflammatory condition, is usually present.

Pathology.—*Leptothrix* belongs to the schizomycetes class of fungi, and is present in nearly all locations containing decomposing vegetable material. The changes in the affected membrane are generally superficial, consisting in thickening of the upper epithelial cells, coagulation-necrosis with desquamation following. The crypts are distended with the fungoid growth. Infrequently the submucosa and connective tissues are affected. The patches are white, and look like mould.

Symptoms.—These are due more to mechanical irritation than to inflammatory action. A slight cough, and stiffness of the parts, more marked on swallowing, may be noted.

Diagnosis.—The primary location is usually the faucial or lingual tonsil, and may invade the pharynx, nasopharynx, velum and uvula, and the tongue. It may be differentiated from the cheesy lacunar masses, by leaving a bleeding surface when removed. The material is very similar to that of keratosis, but in the latter the masses are firmer and more difficult to remove. Some hemorrhage occurs in either case. A microscopical examination will establish the diagnosis.

Prognosis.—Chronic course.

Treatment.—Curettement and the use of a saturated solution of salicylic acid in thuja; tr. iodine or a 20 per cent chromic acid. Keep the mouth well cleansed by the use of a saturated solution of boric acid. In extreme cases the galvano-cautery or removal of the tonsils.

Keratosis.

Synonym.—Hyperkeratosis.

In this disease horn-like whitish tufts are formed, the usual location being in and around the tonsils, lateral pharyngeal walls, and base of the tongue. Infrequently may occur on the pharyngeal vault. Constitutional disturbances do not appear to have an influence. Gray, of Glasgow, reports a rare case affecting the larynx, in which the appearances were those of tuberculosis, but clinical symptoms were absent.

Etiology.—The disease is usually seen between the ages of twelve and thirty-five. Sex does not seem to be a factor. Neither climatic nor social conditions appear to have an influence. Occupation and hygienic surroundings are also eliminated as factors. Some inflammatory state of the nasal or nasopharyngeal tissues will often be found. The condition, according to Siebenmann and Kyle, is that it is subepithelial.

Pathology.—From microscopic examinations the morbid process appears to extend from below towards the surface. The keratosis, whatever its cause, seems to be dependent upon the subepithelial structure and the accompanying degenerative processes. The fibrous bands extending from the subepithelial tissue, penetrating and obliterating the basement membrane, and extending to the epithelial surface, are probably organized connective-tissue papillæ crowded upward through the epithelial layer, and become horn-like on the surface. The degenerative changes seem to be largely hyaline.

Symptoms.—These are variable, depending largely upon the site of the growth. When located in the tonsil, symptoms are usually absent, the presence of the tufts usually being discovered accidentally. If in the faucial region, a sensation of stiffness and scratching may be complained of,

which is usually aggravated on swallowing and after eating. When the faucial pillars are the location, the sensation of a foreign body is usually complained of. When located on the base of the tongue, there will be more or less cough and hawking to clear the throat.

Several forms occur, probably not distinct types, but varying according to the location and duration of the process. There are the minute, distinctly white spots, not elevated above the mucous membrane; the broad, white masses elevated above the mucous membrane, usually found upon the pillars and lateral pharyngeal walls; and the conical or triangular horny projections. The latter are the most frequent. The growths are small, hard, and adherent to the mucosa, being removed only by considerable effort, and do not disintegrate when removed. The most dense are from the base of the tongue and tonsillar crypts. Those about the faucial isthmus are often surrounded by a pultaceous material. The usual location of what is termed keratosis pharyngei is Waldeyer's lymphatic chain.

Diagnosis.—Febrile symptoms are absent. Spontaneous resolution often occurs, the time being variable. The tufts are usually a pearly, waxy white, and firm, and microscopic sections can be made. Sometimes the disease presents wedge-like, triangular projections, extending into the parenchymatous coats. These are of a yellowish, glassy appearance. The tufts are larger, and entangled with epithelial plates and granular debris.

Treatment.—The actual cautery or thorough curettement are the most satisfactory. This should be followed by the use of salicylic acid wash or 20 to 40 per cent chromic acid.

Pulsating Arteries of the Pharynx.

Anomalous configuration of the posterior lateral pharyngeal walls may be attended by anomalous vascular conditions. The branches of the ascending pharyngeal may be

enlarged, or even the ascending pharyngeal artery may be distinctly seen in the pharyngeal wall. As muscular support is missing, a pulsating artery results. Another factor is the superficial location, and the frequent tendency to inflammation of the mucous membrane. Aneurism of the vessel is frequently found. Pulsating arteries are infrequent, but when present there is usually the sensation of a movable foreign body in the pharynx, and a constant desire to remove it by efforts to clear the throat. Rupture of the aneurism may cause an excessive hemorrhage. Treatment is not of much value.

Anemia of the Pharynx.

In general anemia there is a subnormal systemic condition, and through the lack of tonicity, connective-tissue relaxation occurs. In tissue lacking support, as is the case practically when located on bony structure, there is exosmosis from the arterial system, and retardation of the venous circulation from the same cause, as well as some from the veins. As the vascular supply to the pharynx is considerable, it is to be expected that this region will have some exhibition of the systemic disturbance. The tissues may be somewhat edematous, but pale and flabby looking. Dilated, tortuous vessels will be seen on the surface and within the tissue. Relaxation of the velum, palate, and elongation of the uvula result from the morbid condition. This causes an additional irritation through mechanical means. The secretion is profuse, and usually watery. The symptoms are very much like those of the early stages of simple chronic pharyngitis. No decided pathological changes occur. Anemia is most frequently seen in females.

Symptoms.—A sensation similar to that of a foreign body in the throat, and a constant desire to swallow.

Treatment.—Must be constitutional.

Neuroses of the Pharynx.

1. Anesthesia. 2. Hyperesthesia. 3. Paresthesia. 4. Neuralgia. 5. Neuroses of Motion. (a) Spasm. (b) Paralysis.

ANESTHESIA.—This is infrequent. A bolus of food is not felt, and particles of the food remain in the pharynx, or may enter the larynx and lower respiratory tract.

Etiology.—Morphine, large doses of bromides, or local anesthetics produce a temporary anesthesia. A nervous anesthesia is usually the result of ulceration, fibrous-tissue formation destroying the nerve terminals. It may occur from a progressive bulbar paralysis. In hysteria, occasionally in general paralysis of the insane, epilepsy, typhus fever and cholera, it may be found.

Prognosis.—The cause will determine the prognosis, which is unfavorable in extensive cicatrization or progressive bulbar paralysis.

Treatment.—Nux, strychnine, ignatia, pulsatilla, or the galvanic current. Sometimes nourishment must be administered by the stomach-tube.

HYPERESTHESIA.—This is quite frequently found. In acute inflammation, among excessive users of tobacco or alcoholics, it is also often present. Elongation of the uvula, hysteria, and neurasthenia may cause it. In some cases no factor can be discovered.

Treatment.—Pulsatilla, passiflora, ignatia, or bromides may be required.

PARESTHESIA.—Abnormal pharyngeal sensations may simulate cold, heat, a foreign body, or a swelling.

Very often after the removal of a foreign body from the pharynx, the patient will insist that something remains. This is due to irritation of the nerve terminals, which continues for some time. In hysterical persons abnormal sensations are frequent. Abnormal states of the follicles of the

pharyngeal, faucial; or lingual mucous membranes may be a factor in this condition.

Prognosis.—Guarded.

Treatment.—Enlarged follicles should be punctured and the contents expressed. When of neurotic origin, the treatment must be directed to the systemic condition.

NEURALGIA.—This results from the same causes as paresthesia, but actual pain is present. The actual cause of neuralgia elsewhere may produce pharyngeal neuralgia. In anemic or chlorotic persons it may be bilateral or unilateral.

Treatment.—Locally sedative applications. Systemically, removal of the exciting cause if it can be determined.

Neuroses of Motion.

Synonyms.—Clonic spasm of the pharynx; Pharyngeal nystagmus.

(a) *Spasm.*—Acute faucial inflammation, hydrophobia, lissophobia, cerebral lesions, chronic pharyngitis, hysteria, or epilepsy may be factors.

Spasmodic ejection of food in deglutition may occur.

A differential diagnosis must be made from stricture or paralysis of the esophagus, or paralysis of the pharynx. The use of an esophageal bougie will aid in the diagnosis. The spasm may be intermittent, and continue for a variable period, even months, necessitating rectal feeding.

Treatment.—No general line of treatment can be followed. A careful investigation as to the cause, and the treatment of this is necessary.

(b) *Paralysis.*—This may be of one or both sides, and one or all of the constrictors affected.

Etiology.—Myelitis, either acute or chronic, embolism, hemorrhage, tumors, basilar meningitis, cerebrospinal meningitis, syphilis, sunstroke, tuberculosis; or any condition which implicates the governing nervous areas of the pharynx, may cause or simulate this condition. It may be asso-

ciated with facial paralysis, and is not infrequently found following diphtheria. When it occurs during the course of acute febrile diseases the prognosis is bad. It may be an early symptom of what Duchenne terms Glossolabiolaryngeal paralysis or progressive bulbar paralysis. The exciting cause may affect the central point, along the course of the nerve, or its periphery.

Symptoms. — Difficulty on swallowing is the most marked. This causes an accumulation of saliva which dribbles from the mouth. The effort to swallow is accompanied by contortions of the facial muscles and also those of the neck. Fluids often enter the trachea, causing cough or spasm of the glottis, even though deglutition is apparently successful. The expression of the face in attempted deglutition is that of pain and sorrow. When the velum palati is affected, food may be forced into the postnasal space.

In acute bulbar paralysis the pharyngeal symptoms are often unnoticed, on account of the disturbances elsewhere. Dizziness, headache, erratic walking, faulty phonation, and impaired respiration follow rapidly to a fatal ending, as a rule. In progressive bulbar paralysis the symptoms usually begin with disturbances of the tongue, lips, pharyngeal, and laryngeal constrictors in rapid succession. Difficulty in speech finally becomes a mumbling sound. Atrophy of the tongue occurs, which renders mastication and deglutition difficult. There will be an accumulation of food between the cheeks and gums. It will be impossible to produce dental or labial sounds. Saliva runs from the corners of the mouth or may pass into the larynx, causing violent spasmodic gagging and coughing, or even a septic pneumonia. Diphtheritic pharyngeal paralysis may result from central toxemia or peripheral nerve-necrosis, and may be bilateral or unilateral. Dysphagia, regurgitation of food through the nose, impairment of the sense of smell and taste, food pass-

ing into the larynx, and inability to eject the accumulated mucus, are the prominent symptoms.

Diagnosis.—The history and symptoms will determine the condition.

Prognosis.—When caused by diphtheria, or accompanied with facial paralysis, the prognosis is fairly good. When it occurs late in febrile diseases, or from acute bulbar or progressive bulbar paralysis, it is usually fatal.

Treatment.—This will depend upon the exciting cause, discrimination in determining this being essential.

Foreign Bodies in the Pharynx.

Various objects may become lodged in the pharyngeal or surrounding tissues, and sometimes are very difficult to locate and remove. The form of the object has more to do with its retention in this region than the size. The introduction of a foreign body may be either accidental or with food. Pins, fishbones, fragments of bone from steak or roasts, in fact almost any object may be found lodged in the pharyngeal region. Sharp or pointed objects frequently penetrate the spongy tissue of the faucial or lingual tonsils. Small objects, especially irregular in outline, may become lodged in the pyriform sinus, the posterior pharyngeal wall or at the esophageal entrance. Smooth objects may stop at the cricoid eminence.

Sharply pointed bodies, when allowed to remain, may induce inflammation and suppuration. In some cases they may pierce the tissues and become encysted, or even migrate to some other location.

Symptoms.—Usually pain in the invaded region, but this may be referred to some other point. Cough and retching are sometimes present. The symptoms produced by the larger bodies will depend upon their location. If low in the pharynx, near or within the esophageal entrance, there will be pain on swallowing. When there is pressure against

the larynx, the voice will be affected. In children convulsions may occur, and in adults convulsive action of the fauces.

To locate the foreign body, the patient should be instructed to open the mouth naturally, and an inspection made. Then the tongue depressor should be used, and if failure to locate the body results, the mirror may be used. The use of the autospray of two per cent cocaine will often be necessary, especially when the object can not be discovered by the methods described. After anesthesia, the index finger should be introduced and passed carefully around all the structures within reach. In some cases cotton loosely wrapped on a probe may engage the body. Curved forceps may be required for the removal of the offending substance. Considerable ingenuity is sometimes necessary to dislodge the foreign body. After its removal there is often a persistent sensation of irritation. A sedative solution will often aid in allaying this sensation.

CHAPTER XIX.

DISEASES OF THE LARYNX.

MALFORMATIONS AND DEFORMITIES.—(1) *Congenital*. (a) Stenosis. (b) Dilatation or Pouch (Laryngocele). (c) Hypertrophies. (2) *Acquired*. (a) Stenosis. (1) Tubercular. (2) Syphilitic. (3) Lupus. (4) Traumatic.

ACUTE INFLAMMATORY DISEASES.—(1) *Acute Catarrhal Laryngitis*. (2) *Acute Catarrhal Laryngitis in Systemic Diseases*. (a) Erysipelas. (b) Measles. (c) Scarlet Fever. (d) Typhoid. (e) Typhus. (f) Influenza. (g) Miasmatic Epiglottitis. (h) Rheumatism. (3) *Acute Laryngitis in Children*. (4) *Laryngismus Stridulus*. (a) Spasm in Children. (b) Spasm in Adults. (c) Spasmodic Laryngitis. (5) Acute Epiglottitis. (6) Traumatic Laryngitis. (7) Suppurative Laryngitis. (8) Rheumatic Laryngitis. (9) *Edematous Laryngitis*. (a) Chronic Edema. (10) *Membranous Laryngitis*. (a) Croupous. (b) Fibrinoplastic. (11) Hemorrhagic Laryngitis. Chondritis and Perichondritis.

SIMPLE CHRONIC INFLAMMATIONS.—(1) Simple Chronic Laryngitis. (2) Follicular Laryngitis. (3) Dry Laryngitis. (4) Cyanotic Laryngitis. (5) Hyperplastic Laryngitis. Anemia. Hyperemia. Singers' Nodules.

SPECIFIC INFLAMMATIONS.—(1) Syphilis. (2) Tuberculosis. Laryngeal Hemorrhage. Foreign Bodies. Pro- lapse of Laryngeal Ventricles. Neuroses.

Malformations and Deformities.

The form of the larynx varies, but when much deviation from the standard occurs it is called abnormal. The vari-

ations from congenital conditions are usually due to hereditary taints. In some instances an extremely small larynx may occur.

Congenital Stenosis.—Defective development of the larynx is frequently present when there are malformations of the genital apparatus, lungs, trachea, or bronchi. Bands or webs of tissue extending across the glottis are most often found, and are most frequent in the anterior commissure. In the interarytenoid region a cleft may be present, affecting the cricoid cartilage, epiglottis, and also the palate. Occasionally there may be an incomplete separation of the vocal cords at the anterior portion, and not interfere with phonation.

Treatment.—Enlarged tonsils, nasal polypi, adenoids, or septal deviations impairing respiration, should be corrected. In some the use of an intubation tube, which may be worn for a variable period, will suffice, but in some cases the web must be divided. The tube is either worn constantly or introduced at times after this procedure. Tracheotomy may be necessary in some cases.

DILATATIONS OR POUCHES.—Laryngocele of the laryngeal lining may be the result of congenital anomalies, or may appear after necrotic action of the cartilage, the pouches resulting from exterior communication.

HYPERTROPHIES.—In the anterior commissure, or projecting from the vocal cords, projections of normal tissue are sometimes found. They may be acquired or congenital, and are really hyperplasias. The cause is unknown.

Symptoms.—Impaired phonation, and often a persistent metallic cough, or spasm of the glottis may be present.

Treatment.—Abnormalities of the upper respiratory tract interfering with free respiration should be removed. Operative measures, unless contraindicated, should be insisted upon. Local applications are usually harmful.

ACQUIRED STENOSIS.—A constant contraction of the

laryngeal aperture may result from traumatism or systemic diseases. (a) Cicatricial narrowing or exuberant granulation, resulting from injury by foreign bodies, attempted suicide by cutting the throat, the swallowing of caustic or hot liquids, or inhalation of steam, may cause stenosis. The prognosis is unfavorable, as loss of phonative action, as well as extensive cicatrization or edema, may prove fatal. Tracheotomy is necessary when the stenosis endangers life. The operative measures will vary with the severity of the case. (b) Laryngeal syphilis may cause stenosis. Chronic edema during any stage of the disease may cause the contraction.

Sudden acute marked dyspnea in children is frequently a syphilitic edema. The usual syphilitic stenosis results from cicatricial bands or webs connecting the vocal cords, ventricular bands, or different parts of the larynx.

Symptoms.—Hoarseness or limitation of the register of the voice. Sometimes impaired respiration. According to Lennox Browne, intermittent attacks of dyspnea for many years is characteristic of syphilis. There is a spasmodic cough, scanty expectoration, and often pain and difficulty in swallowing.

Treatment.—Usually mechanical.

TUBERCULOUS STENOSIS is not often cicatricial, healing seldom occurring. Edema is to be feared.

LUPUS.—Contraction of the laryngeal aperture from lupus lesions is usually a matting together of the parts, which may be so extensive as to leave only a pinhole opening. The tissues usually are anemic, excepting where reddish nodules show an acute inflammation.

Symptoms.—Usually the symptoms are not in proportion to the appearance of the lesion. There is not often much difficulty in respiration and deglutition, or much change in the voice. A lupus web is usually supraglottic, while in syphilis or tuberculosis the tissues are usually af-

fectured at the level of or below the aperture. Laryngeal lupus is usually secondary.

Prognosis.—Not as unfavorable as in syphilitic or tubercular lesions, as slow, spontaneous absorption may occur. Later tuberculosis may be a complication.

Treatment.—Operative.

INFLAMMATORY DISEASES OF THE LARYNX.

Acute Catarrhal Laryngitis.

Synonyms.—Acute catarrh of the larynx; Laryngorrhœa; Spurious Croup.

In this disease there is an acute catarrhal inflammation of the laryngeal mucous membrane, which produces a slight dyspnea and hoarseness. These symptoms are more pronounced in children than in adults, although seldom endangering life. The inflammatory action may be either superficial or interstitial; when the latter, the disease may result in a chronic condition with permanent alteration of the tissue.

Acute catarrhal inflammation of the larynx results from the same causes as produce similar affections of any mucous membrane, but laryngeal disturbances are less frequently found than of any other portion of the respiratory tract. Sedentary habits appear to favor the development of laryngeal lesions. Persons with lowered vitality are also the victims of laryngeal diseases, as mucous membranes also partake of the general subnormal condition. Gastro-intestinal disturbances, through the same derangement of resisting power, will increase the liability. Cold and exposure, especially wet or cold feet, or remaining inactive when the clothing is damp, will predispose to this affection. Obstruction of nasal respiration, or vitiated air from any cause, will also prove a factor for the development of this condition.

Extension of the inflammatory process to the trachea and bronchial tubes often occurs. Sex and age are not

really factors, but the general condition of the patient, the habits of life and environment are of the utmost importance in producing the condition. Persons living an active, outdoor life, provided their vocation will permit of not unnecessarily exposing themselves to unfavorable conditions, are seldom affected with this disease. In some cases a laryngeal catarrh is simply an accompaniment of the eruptive fevers, influenza, hay fever, or occurs with an asthmatic tendency. The local application of drugs to the pharyngeal mucous membrane in pharyngitis has frequently produced laryngeal complications. The presence of foreign bodies around the larynx, or external pressure of any kind, may be factors.

Pathology.—The pathology is identical with that of acute catarrhal inflammation of any portion of the upper respiratory tract, excepting that on account of the deficiency of glandular elements in the larynx, the exudate is that of inflammation, lacking the hypersecretion of the glands so freely distributed in the other portions of the tract. If the exciting cause is removed, there is a rapid return to the normal, but when the excitant is not removed, a chronic condition will follow, with permanent structural changes.

Symptoms.—Often the first symptom noticed will be a desire to cough. This results from the lack of secretion. Change in the voice, coming on suddenly, and soon followed by soreness or a sensation of roughness and thickening in the throat and a constricted feeling, are complained of. Attempts to use the voice aggravate the symptoms, and in some instances the hoarseness will continue throughout the attack, or the patient may be unable to speak above a whisper. As a rule, the cough is shrill and metallic, and in the early stages dry and rasping.

In children the respiration is more impeded than in adults, but as a rule is not specially distressing unless there is considerable edema, such as sometimes occurs in traumatic cases.

As the disease progresses and the second stage is reached the secretion will relieve the dryness, and the cough is less irritating and rasping. In children there is usually slightly increased temperature, and often some in adults. During the second or third stage in young people there may be suffocative attacks during sleep. These are probably the result of either accumulations of secretion, or of dried secretion within the larynx. The inflammation usually passes off rapidly, unless the exciting cause remains.

Diagnosis.—Generally not difficult. In young persons, however, the possibility of the symptoms being those of some of the eruptive fevers, or diphtheria, should be remembered.

Prognosis.—Good. The majority of uncomplicated cases will recover in a few days with good hygienic treatment.

Treatment.—If there is increased temperature, and even when there is not, if the case is seen during the first or second stage, aconite in small doses every hour. Ipecac may be used in combination with the aconite, but the dose should not exceed $\frac{1}{3}$ drop. After the second stage, collinsonia will relieve the hoarseness and cough. When the secretion is tough, tenacious, and stringy, potassium bichromate will give the most relief; the secretions soon become less tenacious, and the hoarseness and cough found with this form of secretion is rapidly relieved.

It is important to remember that no more effort should be made to use the voice than is absolutely necessary.

Acute Laryngitis in Constitutional Diseases.

ERYSIPELAS.—Laryngeal involvement may be primary or secondary. Not infrequently facial erysipelas of a supposedly idiopathic character is secondary to a faucial origin. The severity of the attack varies as in any other location. The disease is often endemic or epidemic.

Symptoms.—Often ushered in with a chill, then fever, and rapidly followed by vomiting, delirium, and general prostration. The local symptoms are pain, dyspnea, or odynophagia. During the early stages the larynx appears as in a simple acute laryngitis, but the disposition to extension, systemic symptoms, and lymphatic involvement should make the diagnosis easy as a rule.

Prognosis.—Guarded, as usually it is fatal.

Treatment.—Same as in erysipelas of other regions.

MEASLES.—A catarrhal inflammation of the upper respiratory tract is characteristic of measles. This may precede or accompany the cutaneous phenomena. Usually the laryngeal involvement is confined to the catarrhal type, but in some instances ulceration or gangrene may result from the mechanical irritation of excessive coughing. A pseudo-membranous form is sometimes seen. In a severe laryngeal complication there will be a dry, hard, painful, and recurring cough; loud, whistling respiration, and occasionally a spasmodic cough which is suffocative, and followed by expectoration of a dry, inspissated mucus. The larynx is deep red in color, and the vocal cords yellowish-red and somewhat injected.

Prognosis.—Usually good, but a sudden edema may be an unpleasant complication. If a membranous or ulcerative condition arises, the prognosis is unfavorable.

Treatment.—Locally the use of sprays that will relieve the pain, and internally the indicated remedy.

SCARLET FEVER.—Usually the pharyngeal manifestations are only those of hyperemia, or a mild catarrhal inflammation. In some cases, however, there may be severe laryngeal complications, as edema, ulceration, or gangrene, which may cause a fatal termination.

SMALL-POX.—In this disease there may be any grade of involvement, from a slight catarrhal stage to that of ulcer-

ation, and possibly perforation. Asphyxia may occur in the malignant type.

TYPHOID FEVER.—Occasionally a simple catarrhal inflammation may occur. Ulceration is infrequent, but may be a complication. Usually these complications occur in the later stages of typhoid.

TYPHUS FEVER.—In this disease laryngeal complications are usually dangerous. The tissues are swollen, bright red, or of a dusky hue, and bathed with a tenacious mucus or pus. Infrequently a destructive process will denude the cartilages, leaving a blackish-gray surface.

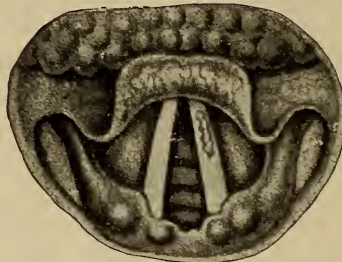


FIG. 92. Catarrhal ulcer of left cord in an acute laryngitis resulting from typhoid fever.

INFLUENZA.—An acute inflammatory action is usually present in this disease. The mucous membrane is swollen, shining, and reddened. Sometimes grayish-white spots may be seen, resembling a superficial necrosis. Local or general edema may occur, and prompt action will be required. Paralysis, spasm, or a chronic inflammatory action may follow in these cases.

MIASMATIC EPIGLOTTITIS.—An acute inflammatory action, implicating the epiglottis, may occur. Edema is the marked condition, and may require a tracheotomy. Croupal symptoms often present in so-called malarial poisoning, but the diagnosis should be easily made by the general manifestations.

Treatment.—Puncture or scarification of the epiglottis. Apis or apocynum internally, and the proper treatment for the periodicity.

RHEUMATISM.—That rheumatism may cause an acute affection of the larynx is unquestioned. The action is probably that of a rheumatic arthritis. There is pain on speaking, the articulations are swollen and tender, and the vocal cords may be immobile, swollen, and reddened.

Treatment.—Sedative local measures, and internally rhus, bryonia, cimicifuga, salicylic acid, or the salicylates, colchicum, and rhamnus Californica.

Acute Laryngitis in Children.

Synonyms.—Spasmodic croup; False croup.

The etiology and pathology of an acute catarrhal inflammation in children are the same as in adults; but as the laryngeal structures are smaller in the former, the mucous tissues more relaxed, and a more rapid engorgement occurs, it is a more serious condition, and the symptoms are more pronounced. The membrane affected may be above or below the glottis, or both may be affected. The terms supraglottic, subglottic, and acute laryngitis are used to designate the tissue implicated. The age most often affected is between two and five, but it may occur earlier, and as late as fifteen. Any slight catarrhal inflammation of the upper respiratory tract may be a factor, or an inflammatory state of the faucial, lingual, or pharyngeal tonsil. Exposure to cold, alimentary disturbance, or some systemic condition may cause or be associated with the condition.

Symptoms.—Hoarseness or even aphonia, sometimes cough, febrile symptoms, and dyspnea, especially in the subglottic form. When supraglottic, dyspnea is slight, as is the spasm of the glottis. The tendency to extension must be remembered, particularly if the contiguous structures are involved. The fact that supraglottic inflammation may be

an early symptom of diphtheria or scarlet fever, should be remembered. It is usually difficult to make a laryngoscopic examination in children, and not infrequently impossible, but patience and careful manipulation will often prove successful.

Treatment.—Usually, the less local treatment, the better. Swabbing the larynx is brutal. Internally, aconite and ipecac, in small doses frequently repeated, are all that is required. Emesis is seldom if ever necessary in these cases.

Prophylaxis.—Much can be accomplished by using cold sponge baths to the neck, chest, and back, followed by brisk rubbing with a coarse towel. This should be sufficient to redden the skin. Free ventilation of the sleeping apartments at all seasons should be insisted upon. The wearing of chest-protectors, mufflers, etc., should be condemned, as they render the patient more susceptible to colds. Warm clothing, but not an excessive amount, should be worn. These precautions will diminish catarrhal diseases in children and adults.

Laryngismus Stridulus.

Synonyms.—Asthma rachiticum; Cerebral croup; Child crouching; False croup; Miller's asthma; Laryngeal spasm; Spasmodic croup; Spasmodic laryngitis; Spasm of the larynx; Spasm of the glottis; Spasm of the abductors of the vocal cords; Spasmus glottidis; Thymic asthma.

In this condition there is laryngeal spasm and stridor, and it is an unpleasant symptom which may accompany any laryngeal or tracheal disease. It may be present in any form of croup, in whooping-cough, alimentary wrongs, dentition, rachitis or neurotic children, or caused by mechanical irritation of the fauces or nasopharynx. In adults it may be a reflex from the generative organs; pressure resulting from carious cervical vertebræ or an enlarged thymus gland (thymic asthma); abscesses, either acute or chronic; or pressure on any portion of the pneumogastric or spinal ac-

cessory nerve may be a cause. A bilateral or unilateral paralysis of the posterior crico-arytenoid muscle may be present. Cerebral irritation or lingual lesions may be a cause. In fact, it is to be considered as a local manifestation of some constitutional or local disturbance, a symptom and not a disease.

Treatment.—This must be directed to the immediate cause, but in some cases radical measures are required. Tracheotomy may be necessary. Traction on the tongue, holding it firmly and making rhythmical traction sixteen or eighteen times a minute, may afford relief. Firm pressure with traction at the angle of the jaw will also often relieve the condition. Cold water applied to the face or neck, or hot water at the back of the neck, may give relief.

Spasm of the Larynx in Children.

Synonym.—Spasm of the glottis in children.

A subnormal child under unfavorable environment, or through any agency which will produce irritation of the nervous system, or the entrance of foreign bodies in the esophagus or larynx, may be subject to laryngeal spasm.

Symptoms.—Children under two years of age are most frequently affected. The attack is usually sudden, respiration is labored, and sometimes for a number of seconds is impossible. If the attack comes on during sleep, the facial expression is that of terror. The patient may become cyanotic, the neck turgid, convergent strabismus occur, and convulsive movements of the extremities, or even a general convulsive attack; with relaxation of the laryngeal spasm there is a subsidence of the alarming symptoms, and the child falls back exhausted. A rapid recurrence of the symptoms may follow, or there may be an interval of months between the attacks. The nutrition is still more impaired through the disturbance of the nervous system.

Diagnosis.—The sudden attack is usually conclusive.

In morbid growths causing dyspnea, there is usually a progressive action. Intralaryngeal tumors generally cause hoarseness or loss of voice. Edema, general infectious diseases, or laryngitis, as a rule, show fever or some characteristic symptoms. Very seldom is bilateral abductor paralysis found in infancy.

Prognosis.—The frequency of the attacks and the general condition of the patient will govern the prognosis.

Treatment.—During the attack the child should be in a semi-recumbent position, the clothing loosened, and plenty of fresh air admitted to the room. The administration of lobelia or gelsemium, dropping the concentrated preparation on the tongue, will usually give relief. In some cases, intubation or tracheotomy may be necessary. Rhythmical traction of the tongue may afford relief, but the use of lobelia will usually relax and give relief quicker than any other measure. During the intervals of recurrence, the treatment should be directed to the causative factor.

Spasm of the Larynx in Adults.

Synonym.—Spasm of the glottis in adults.

Etiology.—Abnormal states of the nervous system are predisposing causes. A reflex from some lesion of the respiratory tract is often a factor, as in some instances a systemic disease may be productive of laryngeal manifestations. Hysteria may also be a cause.

Symptoms.—The dyspnea usually occurs at night, and varies both in intensity and duration. A struggle for breath, a limited number of crowing, noisy respirations and cyanosis. The spasm usually lasts not to exceed twenty seconds, when it gradually subsides. The attacks are more irregular in recurrence than in children. If they occur during the daytime, they are usually the result of some central nervous lesion, the result of pressure, or a systemic disease.

Diagnosis.—To determine the actual cause is the greatest

difficulty. The diagnosis must be made by exclusion. In bilateral abductor paralysis the laryngoscopic examination will show the lack of abduction.

Prognosis.—Unless the result of systemic disease, the prognosis is usually favorable.

Treatment.—Correction of any abnormalities of the upper air passages. If due to some systemic disease, this should be looked after. For the relief of the attacks, the treatment is essentially the same as in spasm of the larynx in children.

Spasmodic Laryngitis.

Synonyms.—Catarrhal croup; Catarrhal laryngitis; Laryngitis stridulosa; Mucous croup; False croup; Pseudo-croup; Stridulous angina; Stridulous laryngitis; Spasm of the larynx; Spasmodic croup; Spurious croup.

There is always an inflammation of the laryngeal and tracheal mucous membrane, with an associated spasmodic contraction of the laryngeal muscles. This causes cough, difficult respiration, stridor, and sometimes dyspnea. The spasm is not dependent upon the amount of inflammatory action. When supraglottic there is often spasm, while if subglottic a true or membranous croup is the condition, but both forms may exist. A neurosis may cause laryngeal stridulus without inflammatory action.

Etiology.—An inherited tendency is often present, and any state of the system causing a lowered vitality predisposes to this condition. Colds are the most frequent exciting factor. It is not infrequently found as a precursor of children's diseases.

Symptoms.—The attacks may occur at any age, from a few months to ten or twelve years. Usually there is some cough and symptoms of coryza preceding the attack, but often there are no premonitory symptoms. The attack is most frequently between ten and two o'clock at night. After a natural sleep varying in duration, the child awakes

with a loud, rasping, wheezing, asthmatic cough, the respiration is very labored, and on inspiration there is a peculiar whistling sound. The face is markedly flushed, and there is an anxious and terrified expression. The child will usually cling to the attendant as if in terror. The pulse, on account of increased vascular tension, the result of the impaired respiration, will be rapid and hard. The duration of the attack varies from half an hour to two or three hours. Infrequently there may be two or more attacks the same night, but usually they are repeated on successive nights. As a result of the coughing and forced respiration, there is usually a decided inflammatory action following the paroxysm. A hoarse, croupy cough, with an excessive catarrhal secretion, often lasts for several days, and if a decided cold has been contracted, a catarrhal pneumonia may result.

Diagnosis.—Not infrequently this is mistaken for pseudo-membranous croup, but in the latter the disease is insidious, the cough which is present increasing gradually, and does not abate during the day. In spasmodic laryngitis the paroxysm is sudden and rapidly reaches the climax, and invariably occurs at night. The cough is loud, wheezy, and dry, and change in the voice is simply the result of impaired respiration, and is sudden. There is slight or no inflammatory action of the faucial structures. In true croup, on account of the membrane, the cough is harsh and rough, and increases in severity. The voice is changed, owing to the presence of the membrane, but the change is gradual.

Prognosis.—Usually favorable, as rational treatment will generally effect a cure. Fatal results may follow in some cases, so the general condition of the patient must be considered.

Treatment.—The relief of the spasmodic action of the laryngeal muscles, and alleviation of laryngeal inflammation are important. Placing the child in a bath I consider barbarous. The treatment I have found most beneficial

was employed by my father in over forty-five years of active practice, a large proportion of his work being among children. The child should be allowed to remain in its crib or bed. No extra clothing should be placed over it. Plenty of fresh air should be admitted to the room, but the temperature should not be allowed to drop below 60° Fah. Emesis is seldom, if ever, required. The following is given: ℞ Aconite, gtt. iij-v; ipecac, gtt. viij-xv; aqua, qs. ʒjv. Mix. Teaspoonful every fifteen minutes for an hour, then every half-hour or hour. In the majority of cases the child will be sleeping quietly before an hour has passed. The medicine can be continued during the waking hours, giving it every two hours, and it will relieve the irritation of the mucous tissues, preventing a recurrence of the attack in many cases. The production of emesis simply takes the strength of the little patient, and renders it more susceptible to subsequent attacks, and often with a fatal termination. During the intervals of the paroxysms, or following a single attack, such hygienic and medicinal measures should be instituted as will lessen the susceptibility of the patient to climatic changes.

Acute Epiglottitis.

This is not really a distinct condition, as it is always associated with an inflammation of contiguous structures, but the epiglottis appears to be the most affected. It is often found accompanying lesions of the lingual tonsil.

Symptoms.—There is a sensation as of a foreign body in the throat, and a disposition to gag or vomit, some difficulty in swallowing, but practically no pain. Edema is usually present, and there is profuse secretion, especially after eating. Tenderness on pressure is seldom present, but occasionally there may be slight tenderness over the hyoid bone.

Treatment.—This is the same as for acute laryngitis.

Traumatic Laryngitis.

This form of inflammation is similar to that of an acute pharyngitis, but the severity depends upon the direct cause. The inflammatory process is severe, and the mucous tissues of the larynx and contiguous structures are involved. If the result of direct injuries or foreign bodies, the inflammation may not extend beyond the larynx. When the result of inhalation of vapors, or corrosive substances, the tissues of the fauces, tongue, and pharynx are implicated. Gangrene often follows from corrosive poisons, burns, or scalds. Edema is usually present. If the laryngeal trouble is due to a foreign body, tracheotomy may be required. If the condition is the result of scalds or corrosive substances, emollient preparations are required. The chloretone inhalant will be found useful. Puncture of the tissue may be necessary, but usually the prompt use of apis or apocynum will be all that is required. Tracheotomy may be necessary in some cases.

Suppurative Laryngitis.

Synonyms.—Phlegmonous laryngitis; Purulent laryngitis; Suppuration of the larynx.

These terms are really misnomers, as suppuration of the laryngeal mucous membrane is secondary to bony, cartilaginous, or submucosa infection from the laryngeal structure. A chondritis or perichondritis, usually due to syphilis or typhoidal conditions, is the usual cause. Edema of the larynx is always a complication which may result in suppuration. The superior portion of the larynx is most often affected, but by extension the cords and inferior portion may be involved. The pathological changes are those of abscess formation elsewhere.

Symptoms.—There may be external swelling, and there is an external localized point of tenderness. While the pain

is continuous, it is not severe. Pressure increases the pain, and deglutition is difficult. The voice and respiration are irregularly affected. There are cyanotic periods, and a constant disposition to clear the throat. Choking paroxysms are frequent, and are usually relieved after a violent coughing spell. The inflammation of the tissue is so severe that inspection of the larynx is practically impossible.

Diagnosis.—The symptoms described, and the gradual progress of the disease will differentiate from diphtheria, membranous or spasmodic croup.

Prognosis.—Unfavorable. Suffocation or a constitutional infection usually results.

Treatment.—Internally, the use of calcium sulphide, silicea, gold and sodium chloride, apis or apocynum. Scarification may be required, and often tracheotomy.

Rheumatic Laryngitis.

Synonyms.—Gouty throat; Gouty sore throat; Laryngeal rheumatism.

This differs from an acute laryngitis in being a local manifestation of a systemic wrong. The pain is intense, and there is in addition a bruised sensation. It may precede, accompany, or follow a general rheumatic condition, or it may be the only manifestation of the disease. Deglutition or external pressure may increase the pain, or the reverse may be true. Slight laryngeal hemorrhage may occur in severe cases. The pharyngeal tissues and tonsils are often involved. The voice is usually changed, and aphonia may be present. Hebetude may be marked, as well as a general debilitated condition. The neck and throat muscles usually feel sore and bruised. If the result of a true gouty condition, there may be deposits at the crico-arytenoid articulations.

Treatment.—The same as in rheumatic pharyngitis.

Edematous Laryngitis.

Synonyms.—Acute cellulitis of the larynx; Edema glottidis; Edema of the glottis; Phlegmonous laryngitis; Purulent suppurative laryngitis.

In this there is a watery infiltration into the submucosa, resulting from sudden hyperemia, or hyperemia and congestion from inflammation, or in cyanotic conditions (angioneurotic). The edematous process is virtually always the same, although the exciting cause varies. When infectious, the process is usually rapid.

Etiology.—It may follow injuries, inhalation of steam or irritating vapors, or the use of escharotics. Edema may result from inflammation of surrounding or adjacent tissues; enlarged or suppurating lymphatics of the neck causing pressure; injuries or foreign bodies at the base of the tongue; tumors of adjoining structures which impede venous return; foreign bodies lodged in the esophagus behind the larynx or trachea, or a chondritis or perichondritis. Edema is often associated with specific inflammations, and may be a complication of typhoid fever. Edema may be primary, but usually is secondary. A chronic type may result from cardiac lesions. In fibroid changes of the kidneys, liver, or lungs, causing interference with the vascular system, especially the venous flow, a cyanotic condition of the mucous membrane is produced similar to that in cardiac disease. In specific inflammation, the result of local ulceration, with following fibroid tissue formation and cicatrization, the venous system may be implicated sufficiently to cause local edema. Major surgical operations about the throat or lower jaw may also be a cause, through excessive cicatrization. Infectious conditions of the mucous surface, as in diphtheria, scarlet fever, and streptococcal infection, may cause an acute edema.

Pathology.—The vascular arrangement of the larynx,

and lack of support of the mucous membrane vessels, allows rapid congestion and exudation into the perivascular structure. This serum distends the intercellular spaces and lymph channels, and some is taken up by the connective tissue or epithelium. Hydropic degeneration results if prompt relief is not obtained in the chronic type; in the acute type this result seldom occurs. The edema may be most marked in the ventricular bands, the epiglottis, or the aryepiglottic folds. The entire larynx may be affected, the trachea and the muscles of the neck may be involved. This is most marked when due to the inhalation of irritating vapors, the use of escharotics, or of foreign bodies.

Symptoms.—In the acute type the edema is sudden, and if associated with inflammation of contiguous structures a chill may be a precursor. The voice is rapidly affected, and stridulous respiration is marked. Dyspnea is an early symptom, and rapidly becomes more labored. The face is flushed, and the entire circulatory system gives evidence of impaired respiratory function. An apprehensive and restless state is noted. The symptoms rapidly increase, and in some cases death results, unless prompt surgical relief is rendered. Usually the course of the attack is not so serious. Pain is felt on swallowing, a sensation as of a foreign body, a disposition to clear the throat, with but little expectoration, and a wheezy cough. The patient is inclined to keep in an upright position, leaning a little forward.

Examination will reveal the epiglottis swollen, so much so that a laryngeal image can not be obtained. A rapid digital examination, as well as the symptoms of laryngeal obstruction, will confirm the diagnosis. Usually the entire laryngeal tissue is affected, as well as the surrounding tissues. In the chronic form the symptoms are less severe and slower in developing, and the respiration not so markedly impeded. This state may continue for a number of weeks without any serious complications. The cyanotic

condition is often relieved by the collateral circulation. When the edema results from cicatrization or local causes, as tumors, the symptoms may require tracheotomy.

Diagnosis.—Acute edema is determined by examination and the subjective symptoms. In chronic edema by the history and laryngoscopic examination.

Prognosis.—Usually good in the acute type, if promptly treated. When much of the structure is involved, and it extends too low to be relieved by tracheotomy, the prognosis is unfavorable.

Treatment.—For the relief of the edema, apis, or apocynum will usually give prompt relief. Scarification or puncture may be required as a preliminary measure. If the edema is dependent upon cardiac, hepatic, or renal disease, free catharsis with salines or elaterium should be continued until the condition is relieved. A careful examination should be made to determine the exciting cause, and the treatment directed to this. In edema associated with syphilis, the administration of potassium iodide frequently increases the condition, and should be discontinued.

Chronic Edema of the Larynx.

This may result from an acute edema, but usually is a local manifestation of some constitutional disease, as syphilis, tuberculosis, or malignant growths. The morbid changes are those of hydropic degeneration and pressure atrophy.

Prognosis.—Very unfavorable.

Treatment.—Depends upon the cause.

Membranous Laryngitis.

Synonyms.—Croupous laryngitis; Cyanche trachealis; Diphtheritic croup; Fibrinous croup; Fibrinous laryngitis; Idiopathic membranous croup; Laryngeal diphtheria; Lar-

yngotracheitis; Membranous croup; Pseudo-membranous croup; Pseudo-membranous laryngitis; True croup.

Membranous laryngitis is divided into three varieties corresponding to membranous inflammation of the nose and pharynx. These are croupous, diphtheritic, and fibrinoplastic. The croupous and fibrinoplastic will be considered, as the diphtheritic properly belongs under diphtheria.

Etiology.—Membranous inflammation of the mucous membrane depends upon the systemic condition and some irritant of the mucous membrane. It may follow the employment, accidental or otherwise, of corrosive chemicals, burns, scalds, inhalation of irritating vapors, thermo-cautery, wounds, and also by the action of some pathogenic bacteria. The Klebs-Löffler bacillus, in its true virulent form, is not an etiological factor. Membranous inflammation may occur at any season, and is most frequently seen in children between the ages of one year and six years. It is comparatively infrequent later in life. Boys are most often affected. It is often found in children as a complication in the exanthemata, or it may be secondary to membranous inflammation of the pharynx or tonsils. As a rule, membranous inflammation of the larynx is diphtheritic, but it is impossible in many cases to make a positive diagnosis excepting by a close watching of the case. There is no doubt that many cases of the fibrinous variety of membranous inflammation are neither contagious nor infectious, although often there is little clinical difference between this and true diphtheria. The morbid differences are also often very similar, excepting that in the non-diphtheritic form the false membrane is on the surface of the mucous membrane, and on removal neither necrotic changes nor ulceration are found. In diphtheritic inflammation, ulceration, perforating the basement membrane is present, the exudate and acute inflammatory action being confined mostly to the laryngeal structure. Systemic infection is more pronounced in diphtheritic in-

flammation, as well as the clinical symptoms. While isolation of a case is advisable, a too hasty diagnosis of diphtheria should not be made. In the latter disease the symptoms increase in intensity, but in the non-diphtheritic type there will be an amelioration in twenty-four or forty-eight hours, and a cure in three or four days as a rule. Remember that membranous laryngitis is not always diphtheria.

Pathology.—The changes are those of an acute inflammatory process.

Symptoms.—The most pronounced and alarming symptoms are the peculiar brazen cough, usually stridulous respiration, hoarseness of the voice, and often dyspnea. Fever usually increases gradually. Prior to the attack there is often some cough or catarrhal inflammation. This may continue for three or four days, when the symptoms may disappear. A slight membrane may form without any marked systemic symptoms, or the symptoms may rapidly grow worse, the cough becoming harsh and ringing, the voice rapidly changing, and the respiration labored. High fever and general depression appear later. Remissions of the condition will be marked. The eliminative functions are deranged, there being scanty, high-colored urine, bowels constipated, skin dry, and the patient very thirsty. Restlessness is marked, the patient keeping the head well back, the respiration is difficult, and the croupal sound more or less constant. Shreds or masses of membrane are often coughed up or vomited. Deglutition is seldom affected. Occasionally the cough entirely disappears. Dyspnea may be constant, instead of paroxysmal. The skin is livid and partially anesthetic, and the extremities become cold. Death is pretty sure to follow unless prompt relief is obtained. Bronchitis or pneumonia may be a complication if the attack continues for several days. When a laryngoscopic view can be obtained, it will reveal the membrane, immobility of the vocal cords, and apparently a binding together of the aryte-

noid cartilages and the interarytenoid space by the false membrane.

Diagnosis.—The disease may be mistaken for spasmodic laryngitis, acute laryngitis, edema of the larynx, diphtheria, retrolaryngeal or retropharyngeal abscess, tonsillitis, whooping cough, capillary bronchitis, or foreign bodies in the larynx or throat.

Prognosis.—In severe cases always doubtful. The mortality is always high. Extension of the disease to the trachea or bronchial tubes is a serious complication.

Treatment.—The salicylic acid wash used in an atomizer is often beneficial. The air of the room should be made moist by the use of steam. Emesis is usually to be avoided, as the strength of the child should be conserved. Internally aconite, gelsemium, ipecac, lobelia in small doses, jaborandi, phytolacca, collinsonia, potassium bichromate, apis, apocynum. For sustaining the patient's strength, whisky or brandy.

Surgical Measures.—If remedies fail to relieve the condition, and there is a steady increase of the stenosis and constant dyspnea, intubation or tracheotomy should be performed, preferably the former, as more cures result than in tracheotomy.

Hemorrhagic Laryngitis.

Synonym.—Hemorrhagic inflammation of the larynx.

This is a distinct condition from laryngeal hemorrhage. The latter may result from syphilitic or tubercular ulceration, from malignant disease or from a traumatism. It may be the result of a rapid acute inflammation, or of a lesion of the walls of the arteries. In these the hemorrhage is secondary. Hemorrhagic laryngitis is infrequent.

Pathology.—If the hemorrhage is in the tissue, and is from a ruptured vessel, a small hemorrhagic infarction occurs. When this is in the submucosa, absorption may occur without any material change resulting. If the area is

sufficient to interfere with the blood supply and produce local non-infected necrosis, provided the surrounding inflammatory area has good nutrition, the necrotic space will be filled with connective-tissue cells or granulation tissue, leaving some cicatricial changes.

Symptoms.—Inspection will determine whether the site of the hemorrhage is above the larynx or not. If it is from below the vocal cords, the blood will be mixed with mucus. If from the larynx, rales in the lungs will be absent, and the mucus and blood are not thoroughly mixed. The laryngoscopic image may reveal the hemorrhagic site.

Prognosis.—Seldom fatal, and not often profuse. In advanced cases of pulmonary tuberculosis, laryngeal hemorrhage may occur. In such cases the prognosis will be governed by the condition of the patient.

Treatment.—Practically as in hemorrhagic conditions of the mucous membranes elsewhere. If hematoma is formed, it should be opened and the clot removed. The use of intralaryngeal applications usually do more harm than good.

Chondritis and Perichondritis.

The two conditions are so closely allied that they will be grouped under one heading.

Etiology.—A traumatism of any kind, either direct or indirect, may cause an inflammation of the cartilage or perichondrium. Infected emboli or infective material absorbed by or passing through the mucous membrane may also cause this condition. Foreign bodies lodged in the esophagus back of the larynx may also be factors. Gout or rheumatism may be an etiological factor. Specific inflammations as syphilis, tuberculosis, actinomycosis, and glanders, may have an incidental relation to the affection. The disease may result either by direct involvement or by pyemic metastasis in diphtheria, smallpox, and typhoid fever. Benign or malignant tumors of the larynx or parts contiguous may be a factor.

Pressure of the plates of the cricoid against the vertebræ in the aged, or in persons compelled to lie in bed for a considerable period, has been credited as a cause of perichondritis. Exposure to cold or damp, chilling of the body, overuse of the voice when there is an inflammatory state of the larynx, may produce a painful inflammatory action in part or all of the laryngeal cartilages or their perichondrium.

PATHOLOGY.—Syphilis.—The morbid changes here are similar to those in other cartilages from this disease.

Tuberculosis.—The laryngeal lesion may be primary or secondary. Considerable edema is usually present in perichondrial infection, impeding laryngeal movement and markedly changing the voice. Ulceration is slight in the early stage, but later the edema diminishes, and a gray ulceration, usually beginning behind, slowly advances toward the front. Some edema nearly always remains. The secretions are adherent and tenacious. In the later stages, necrotic or gangrenous conditions of the cartilages may occur. Fungus formations may be seen growing from the edges of the ulcerated surface. These are termed tuberculous granulomata or papillomata.

Typhoid Fever.—First there is hyperemia and congestion, soon followed by an inflammatory edema, with exudation into the surrounding or contiguous soft tissue. The edematous stage and the ulcerative stage, which has progressed to necrosis of the cartilages, differ in degree only, but not in kind. The arterial supply of the laryngeal cartilages is poor at all times, so these are quite susceptible to necrotic changes. During an attack of typhoid fever there is a general subnormal nutrition, and the circulation to this location, depending as it does largely upon the surrounding tissue, is very much diminished. Necrosis of the tissue rapidly follows, which may slough out in small pieces, or altogether. The probability is that in the majority of cases of chondritis or perichondritis resulting from typhoid fever,

the infection and inflammatory process simulate those of abscess formation and follow the line of least resistance, opening on the mucous membrane as an ulcer. The typhoid bacillus is generally found in the necrosed material. Ulceration is usually located posteriorly, and the cartilaginous lesion is on the side and toward the posterior portion of the larynx. When the perichondrium remains, and only a portion of the cartilage is destroyed, new cartilage may be formed.

TRAUMATISM; RHEUMATISM.—In chondritis or perichondritis, the result of either of these causes, there may be absorption and resolution of the exudation and swelling. Usually prompt treatment and complete removal of the affected tissues is necessary on account of the severity of the symptoms. The condition usually commences as a perichondritis.

Order of Implication.—The cricoid cartilage is generally most affected, and also the most frequently. The inner surface is usually markedly tumefied. The arytenoid is next, generally unilateral, and affects both the air and esophageal tracts. Necrosis usually occurs earlier in this than in the cricoid. The thyroid cartilage may have one or both surfaces affected, and one or both wings, but the rule is one, and on the inner side. The blood supply to this cartilage is fairly good, so extensive necrosis is less liable to occur. The epiglottis is not often primarily involved, but may be secondarily. The tracheal rings sometimes are affected. Occasionally in any of these, organization may follow after necrosis, resulting in a collapse of the necrotic portion, and finally scar-tissue.

Symptoms.—These are almost the same as in chondritis and perichondritis, and a differential diagnosis is not important, the treatment being similar in each.

SYPHILIS AND TUBERCULOSIS.—In chondritis or perichondritis the symptoms resulting from either of these dis-

eases are very similar. They are not unlike those found in chronic laryngitis, but in the tubercular form there is more pain. An increase of temperature is usually present in either syphilitic or tubercular forms. In the latter, edema may be so pronounced as to require tracheotomy. The act of swallowing is also painful, as the posterior portion of the larynx is usually affected. Complete or partial aphonia, due to destruction of the laryngeal cartilages, may occur later in the disease. If spontaneous rupture occurs, it may be into the larynx or pharynx. The epiglottis may be affected, and is an unpleasant complication. In syphilis there

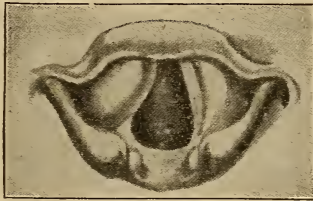

FIG. 93. Syphilitic perichondritis of the right wing of the thyroid cartilage, causing a swelling beneath the right ventricular band.

may be the characteristic odor of the secretions. Pain on swallowing is increased in both forms.

TYPHOID FEVER.—When chondritis or perichondritis are present as a complication of typhoid fever, it may not be discovered for several days. Hoarseness and difficulty in swallowing are common complications. They may continue for some time, when suddenly, from a slight cold, exposure, or without any known factor, deglutition becomes more painful and there is an increase of hoarseness. Usually there will follow in a few hours difficult breathing, and often suffocative paroxysms. Laryngeal stenosis results, with stridor, inspiratory depressions of the neck and chest-walls, and the respiration becomes labored and noisy. Dyspnea

increases, and swallowing is almost impossible. There is not much increase of expectoration. The suffocative attacks become more frequent and alarming. The face is livid, and the expression that of anguish. Tracheotomy may be necessary.

In some cases a discharge of pus and necrosed cartilage may afford relief. Recurrence is not infrequent, or a permanent fistula may result. The temperature is not often as high as in an acute abscess. The process may last for days or weeks. In the early stage, when the disease is confined to the perichondrium, the symptoms are most severe. In the acute stage the action is rapid. Emphysema of the tissues of the neck may result from a perforating ulcer in the posterior wall of the larynx. Occasionally suppuration may extend downward into the mediastina. Fortunately neither of these complications is frequent, but occurs oftener in adults than in children. Necrosis of the cartilage is frequent and also dangerous, increasing the mortality to about 95 per cent of the cases so affected.

The laryngoscopic examination will show the posterior plate of the cricoid cartilage involved, as a rule. Wherever located, there will be an irregular, nodular and unilateral, sharply-defined swelling. Ulcers may occasionally be seen on the posterior wall of the larynx or the vocal cords. Congestion and swelling of all the surrounding tissues may be present. Paralysis of the muscles may occur, more frequently in males.

RHEUMATISM, TRAUMATISM, EXPOSURE TO COLDS, ETC.
—Characteristic symptoms are usually absent in the earlier stages, although some hoarseness and localized pain may be present. The latter is more marked on movement or external pressure. Deglutition or use of the voice may cause discomfort or pain. Eventually hoarseness and sometimes cough may develop. Difficult deglutition, and later difficult breathing, with sometimes paroxysmal, suffocative attacks,

and eventually stenosis may occur. Evacuation of the abscess by any means will relieve the symptoms.

CRICOID CARTILAGE.—When this cartilage is the site of the disease, the posterior surface is most liable to be affected, as a result of irritation. The inflammatory process generally extends from the upper articular surface toward the arytenoid cartilage. Both inspiratory and expiratory dyspnea results. Aphonia and dysphagia always occur, which may be temporary or permanent. Cough is usually present.

ARYTENOID CARTILAGE.—Perichondritis of these structures is frequent. Swelling over the cuneiform cartilage, and an abnormal sluggish movement of the vocal cords will present. When the crico-arytenoid articulation is affected, ankylosis or necrosis may occur, which may produce a permanent change, or even loss of the voice.

THYROID CARTILAGE.—When the site is external, the swelling can be felt and seen. The pain is localized, whether on the inner or outer surface of the larynx. A bulging inward at the anterior angle between the vocal cords may occur. Change of voice will be noticed, and interference with respiration and deglutition, depending upon the severity of the attack. When the entire cartilage is affected, death usually follows.

Perichondritis of the small cartilages can not be determined clinically. Ossification of the laryngeal cartilages usually results in the aged.

Fibrous degeneration, while possible, has never been authoritatively reported.

DIAGNOSIS. — *Syphilitic Perichondritis.* — The history, when obtainable, and a careful search for previous syphilitic lesions. Swelling is usually more pronounced in syphilitic than in tubercular infection. A disposition to heal is also more marked in the former than in the latter, or in a carcinomatous condition. The secretions are fairly profuse, and in syphilis have a decided odor.

Tuberculosis.—In the early stages the mucous membrane is pallid, and circumscribed, nodular, tumefied areas are seen, most frequently about the supra-arytenoid extremity of the aryepiglottic fold, and usually more prominent posteriorly. They are not always on the same side as the affected lung. The family history is important, and a bacteriological examination is often an aid. The edema is usually more chronic than in syphilis. When ulceration occurs, it presents a more worm-eaten appearance than in syphilis, the surface being covered with a greenish, tenacious pus and surrounded with papillomatous proliferation. The ulceration usually extends from below upwards, while in syphilis the reverse is the rule.

Typhoid Fever.—There should be no difficulty, as a rule, in this form.

Rheumatism, Traumatism, Exposure to Cold, Etc.—In rheumatism or gout there are usually other diagnostic symptoms. An examination of the urine will aid in obscure cases.

In traumatism, the history will usually reveal the cause. The laryngoscopic image is similar in all these cases.

PROGNOSIS. — *Tubercular.* — Unfavorable, although the progress of the disease is slow; when the larynx is seriously affected, a cure is impossible.

Syphilitic.—While unfavorable, it is better than tubercular. The time it is seen, and the promptness of treatment, will largely determine the outcome.

Typhoid Fever.—Unfavorable. The general condition will, however, have an influence.

In the other types the prognosis is fairly favorable.

TREATMENT.—*Tubercular.*—Improvement of the general debility is essential. Life in the open air and exercise within the point of fatigue. Plenty of fatty foods, especially such as are composed largely of the liquid fats, either animal or vegetable. Especial attention must be given to the

digestive tract. The use of veratrum, liquor potassii arsenitis, and lactophosphate of lime will usually be indicated. When suppuration occurs, lime or silicea. When the disease has continued for some time, and there is extensive implication of the structures, but little can be accomplished.

Syphilis.—The treatment given under syphilitic rhinitis should be followed. The edematous engorgement of tissue may require either intubation or tracheotomy.

Typhoid Fever.—Scarification and puncture may be necessary in the early stages. Intubation or tracheotomy may be required. Apis or apocynum, or the two combined, will often relieve the edema. For the suppurative condition the treatment does not vary materially from that already given for cartilaginous affections.

Traumatism, Rheumatism, Exposure to Cold, Etc.—The use of aconite, apis, apocynum, saline cathartics, etc., should be used as indicated, also anti-rheumatic remedies, when rheumatism is the factor.

Simple Chronic Laryngitis.

Synonym.—Chronic catarrh of the larynx.

Definition.—This is a chronic inflammation resulting in structural changes, either superficial or deep, of the laryngeal tissues. What is usually called the sub-acute form is really only the commencement of the chronic inflammation, the structural changes not being pronounced. Hoarseness, or loss of voice, is characteristic. Ulceration is sometimes found.

Etiology.—Simple chronic laryngitis may result from, or be coincident with, repeated catarrhal inflammation of the larynx or pharynx and, in some instances, of the nose. Invasion of the larynx through continuity of tissue is probably more infrequent than is usually supposed, as the causes producing morbid conditions of the nasal or pharyngeal tissues would also affect the laryngeal.

In cases where there is an accumulation of secretion in contact with the larynx, the irritation so produced may be an exciting cause, and the efforts of the patient to clear the throat will increase the inflammatory action. Inflammation of the contiguous esophagus may be a factor in laryngeal catarrh. As a sequel of la grippe, a chronic catarrh is often a persistent feature, the infiltrated material apparently differing from the usual exudate. Continuous exposure to an atmosphere charged with irritating material will eventually produce a catarrhal state. Constitutional disturbances in which there is lowered resistance or circulatory wrongs may predispose to chronic catarrh. Where there is faulty nasal respiration, either through obstruction of the nasal cavities, resulting in mouth breathing, or through excessive atrophy or destruction of nasal structures from any cause, so that the air is not properly prepared for entering the larynx, chronic laryngitis is quite frequent.

Excessive or faulty use of the voice is also a cause. The abuse of alcohol and tobacco may also produce the disease. Abnormal conditions in the pharynx, or an elongated uvula, hypertrophied faucial or lingual tonsils may be exciting factors. Atmospheric changes, when the other portions of the respiratory tract are healthy, will produce no effect; but otherwise, such changes are frequently exciting factors.

Pathology.—The changes vary according to the exciting cause. If the irritation is constant, with slow inflammatory action, allowing proliferation of the exudate and fixed connective tissue cells, the submucosa will be affected. Engorgement of the blood-vessels, causing permanent dilatation, may also cause thickening, through secondary changes. The epithelial layer will be affected in either case, and the changes may be either in the mucous membrane or in the deeper muscular tissues. When the deeper tissues are affected the symptoms are more pronounced, and the structural changes more permanent.

If the mucous membrane of the ventricular bands become permanently thickened, there will be a change in the vocal cords, either by the inflammatory action, or on account of the implication of the intrinsic muscles and abnormal circulation. The change in voice is marked when permanent connective-tissue changes have occurred.

Symptoms.—These are both objective and subjective. The quality of the voice is irregular, and conversation inclined to spasmodic pronunciation. The patient complains of the throat aching or feeling fatigued. When not trying to talk, there may be no particular indication of wrong, or there may be a sensation of dryness or irritation. After sleeping and also after eating the secretions are profuse and there is more or less hawking or coughing until the excess of secretion is removed.

A tickling sensation is usually present, interfering with the articulation of words on account of the attendant cough. Complete loss of voice at times, even while talking, is not uncommon, the voice returning as suddenly as it was lost. A rough or rasping feeling is often spoken of by the patient. In some cases the voice will be husky when the patient begins to talk, and after a few minutes it will become clear, and, if the conversational effort is prolonged, the voice will sink to a whisper.

In uncomplicated cases the secretion is not usually profuse, but is tenacious, varying in color from a frothy white to a yellowish or even pus-like secretion. At times the secretion may be tinged with blood.

On inspection, the laryngeal membrane presents a peculiar reddened, boggy, or edematous appearance. Blood-vessels may often be distinctly seen on the epiglottis or within the larynx. At the base of the cords the tissue will be swollen, as well as within the ventricular bands. The vocal cords are usually involved secondarily. Superficial ulceration sometimes occurs, but more frequently localized

areas of desquamation are formed, and usually between the arytenoid cartilages.

Diagnosis.—This disease may be mistaken for edema, paralysis, malignant growths, tuberculosis, or syphilis.

Edema.—The swelling comes on rapidly, and is more marked.

Paralysis.—Swelling slight, if any. The odor of retained secretion, continuous hoarseness, and lack of movement of the larynx.

Chronic Laryngitis.—Hoarseness variable, and most marked mornings and after eating. Mobility of the larynx lessened. The effort to use the voice may temporarily clear it, but the symptoms usually return with increased severity, differing in this from edema, paralysis, syphilis, or tuberculosis. The history is most important.

Tubercular Laryngitis.—The history and general condition of the patient.

Syphilitic Laryngitis.—History when obtainable. Amelioration of the symptoms with antisyphilitic remedies. Healing usually results in a stellate scar well up in the larynx. Edema not localized and produces dyspnea. In the so-called tertiary stage localization may occur, the result of chondritis or perichondritis.

Malignant Disease.—The age and history must be considered. Glandular affection occurs late in carcinoma. Edema is slight until characteristic symptoms are present. Changes in the voice occur early, and a catarrhal condition is always present. With the increase of growth, swelling and edema result, and later ulceration. The odor is very similar to that noticed in paralysis. Severe hemorrhage often occurs after ulceration commences. Pain is severe and lancinating.

Prognosis.—When seen before much structural change occurs, many cases can be cured. After structural changes have occurred, the permanent restoration of the natural voice is impossible.

Treatment.—Any nasal anomalies should be corrected. The nasopharynx and pharynx should be kept as free from accumulated secretion as possible, and for this purpose the salicylic acid wash is one of the best preparations. Internally collinsonia, phytolacca, hydrastis, apis, apocynum, potassium bichromate, jaborandi, bryonia, rhus, lime in some form, and potassium iodide.

The general health should receive attention, but usually when the proper remedies are employed for the catarrhal state, the general condition will improve. Rest of the laryngeal structures is imperative for satisfactory results.

Follicular Laryngitis.

Synonyms.—Granular laryngitis; Glandular laryngitis.

This is an inflammatory condition usually starting in and affecting primarily the entire mucous membrane, and localizes in the small racemose gland-structure. Follicular pharyngitis may be associated with it. Minute elevations caused by the retained secretion will be seen. Ulceration of these elevations may allow the escape of the secretion.

Etiology.—The mucous follicles are not numerous, and are mostly situated on the lateral and posterior surfaces. They are most frequently associated with systemic wrongs, or following fevers or wasting diseases where glandular secretion is abnormal. In persons who use the voice considerably, vascular engorgement of the mucous membrane temporarily obstructs the glandular secretion. In gouty patients, and in the so-called uric acid diathesis, it is also sometimes seen.

Pathology.—Practically the same as in follicular pharyngitis.

Diagnosis.—The laryngoscopic image will usually determine the condition.

Prognosis.—If seen early, it is good. If permanent

changes have taken place in the tissues, relief from the most annoying symptoms may be all that can be accomplished.

Symptoms.—Usually referred to the larynx. A tickling sensation and frequent effort or desire to clear the throat is generally present. Cough may be present, but is voluntary, unless complicated by tracheal or bronchial inflammation. The cough is often dry and expectoration scanty; if profuse, it results from associated inflammatory conditions. Changes in the voice vary, and are not characteristic. Some hoarseness results from the adherent mucus, hyperemia, or congestion. The symptoms do not differ materially in uncomplicated cases from simple chronic laryngitis.

Treatment.—The causative factor should be determined. If due to the patient's vocation, this should be changed if possible. When the result of systemic derangement, relief will follow its elimination. For the laryngeal condition, the remedies given under simple chronic laryngitis will be required.

Dry Laryngitis.

Synonyms. — Atrophic laryngitis; Laryngitis sicca; Ozena laryngis.

In this affection the secretion is retained upon the mucous surface and forms crusts.

Etiology.—This condition is usually associated with atrophic pharyngitis, and sometimes the same condition of the nasopharynx and nares. The causative factor, whether local or constitutional, which affects the latter structures, may affect the larynx, but not so frequently. Whatever the cause, there is a change in the submucosa and impaired glandular action. The character of the secretion varies, according to the tissue and glandular changes. The respiration of over-heated, gas-laden air is an especially important factor.

Pathology.—The accumulated secretion is composed of inspissated mucus, holding desquamated epithelium and

leukocytes. The secretion contains an excess of fibrin, and a deficient amount of serum. The bacillus foetidus often invades this exudate, causing an offensive breath—the so-called laryngotracheal ozena. The crusts are most frequently below the vocal cords. In many cases there is slight crust formation, the surface being dry and glazed. This is the case usually when the disease is due to a systemic lesion, the laryngeal affection being secondary. A true atrophic state of the laryngeal tissues is infrequent, the condition partaking more of the character of dry laryngitis, through perversion of secretion. The changes in the tissue are not so decided as in the nasal and pharyngeal region.

Symptoms.—These vary considerably. The symptoms during the day are not so marked as during sleep. In the latter, the recumbent position favors the accumulation of mucus and formation of crusts, which will produce paroxysms of coughing, weakening the patient. Difficult respiration and change in the voice may occur. As a result of the laryngeal accumulation considerable irritation is produced, causing violent paroxysms of coughing, during which some of the secretion may be expelled, affording temporary relief. When there is not the tendency to crust formation, and the tissues are dry and glazed, there is not the day and night difference in symptoms. The cough is more continuous and sudden changes in tone are frequent, but respiration is slightly, if at all impeded. When the accumulated material is expelled it resembles that found in atrophic pharyngitis or rhinitis. Occasionally the secretion is slightly stained with blood, the result of capillary hemorrhage, and this will often alarm the patient.

Diagnosis.—This is made by the subjective symptoms and a laryngeal examination. The crusts may be mistaken for ulcerative areas. The affection is usually subglottic.

Prognosis.—As the condition is essentially chronic, and the structural changes depend upon the time the disease is

recognized, the prognosis is necessarily guarded. More or less relief, however, can usually be promised.

Treatment.—The general health should be improved, and if the disease is due to some systemic condition, this should be corrected. Drugs influencing glandular structures are necessary. The use internally of jaborandi, phytolacca, iris, collinsonia, hydrastis, potassium bichromate, potassium iodide in small doses or ammonium iodide in fractional grain doses will increase glandular activity. The use of local applications is liable to do more harm than good.

Cyanotic Laryngitis.

Synonyms.—Angio-neurotic edema; Chronic edema; Symptomatic laryngitis.

This condition has already been described in the anterior nares and nasopharynx. The lesion in the larynx is very similar to that in either of the two mentioned.

Symptoms.—Practically those of chronic pharyngitis. Mackenzie describes under the heading *phlebectasis laryngea* practically this condition, it being a varicosed state of the veins, of the epiglottis, arytenoids, and ventricular bands.

Prognosis.—This depends upon the cause, and whether it is amenable to treatment.

Treatment.—This must be directed to the causative factor. Cardiac and renal remedies are most frequently required, as cactus, glonoin, strophanthus, cratægus oxy-cantha, apis, apocynum, digitalis, elaterium.

Hyperplastic Laryngitis.

Synonyms.—Hypertrophic laryngitis; Hypertrophy of the laryngeal tissue.

This is infrequently seen. It is the result of proliferation of fixed connective tissue cells, rather from a slight irritation than an inflammation. If from the latter, complete organization and contraction does not occur. The thicken-

ing is permanent, and there is some obstruction and interference with the mobility of the larynx. The cause is not understood, and treatment gives no relief.

Anemia of the Larynx.

This is a local manifestation of a systemic condition. The blood supply is deficient, and vascular tonicity subnormal. The tissues are lax and boggy. Venous stasis and seepage from the relaxed vessels is the cause of the boggy condition of the tissues. Change in the tone and power of the voice may result, or the edema may be so marked as to cause aphonia. Change in the tissues is slight, unless associated with other lesions.

Diagnosis, prognosis, and treatment depend upon the causative factor.

Hyperemia of the Larynx.

This condition is found in persons where there is simply irritation enough to cause a localized increase of blood to the part, but not sufficient to produce inflammation. Vocation is a factor. Excessive use of alcoholics or tobacco may produce a very similar condition.

Pathology.—The hyperemia may be diffuse or irregularly distributed. It may be either sub- or supra-glottic, or both. Changes in the tissues are slight.

Symptoms.—In plethoric persons with overstimulation of the circulation, a slight hemorrhage may occur, the voice is somewhat changed, being irregular and imperfect in tone, and a more or less constant desire to clear the throat, with sometimes a hypersecretion. Pain is absent in uncomplicated cases.

Treatment.—Removal of the exciting cause is most important. Internally the remedies already recommended for laryngeal affections.

Pemphigus of the Larynx.

This infrequent inflammatory condition is characterized by an eruption of vesicles very similar in appearance to herpes of the skin. The vesicles are most frequently on the ventricular bands and arytenoid surfaces, their formation being preceded by mild systemic symptoms, rigor, and some increase of temperature. The throat is sore, and there is a sharp, cutting pain increased on deglutition, also change in the voice. Inspection will reveal a similar condition of the faucial and pharyngeal tissues. Some edema may surround the vesicles. The eruption may accompany alimentary wrongs, or may follow typhoidal or suppurative conditions. Usually the vesicles rupture in a few hours, leaving small, superficial ulcers.

Treatment.—Intestinal lesions should be corrected, and such remedies employed as will restore the secretions to normal.

Singer's Nodules.

Synonyms.—Chorditis tuberosa; Trachoma; Trachoma of the larynx; Trachoma of the vocal cords; Pachydermia laryngis.

This is a new growth resulting from inflammatory action, and is located within the vocal cord, affecting the margin, and most frequently between the anterior and middle thirds. The growth is a small ovoid nodule, located at the edge of the cord. The growth may be single or multiple, both cords may be affected simultaneously, or one later on, and are usually opposite each other.

Etiology.—This is an inflammatory condition with inflammatory organization, resulting in continued interference of phonation after the active action has subsided. The supposition is that the improper use of the vocal organs, and the frequent and sustained efforts required for certain tones, is an important factor. In the middle or upper middle reg-

ister the vocal cords are practically retained in the same position, and the extrinsic and intrinsic muscles sustain a relatively continuous tension. Singers, or those using the voice a great deal, are most liable to this condition. Other factors to be considered are, the use of the voice when the surrounding tissue of the vocal cords is congested directly or indirectly with inflammation of the laryngeal structure; excessive use of the voice when the cords are hyperemic from violent exercise. Circumscribed hemorrhagic areas, with localized inflammation, occurring during or following la grippe in which laryngeal complications were present, have been noted. A tubercular tendency appears to be a predisposing cause. A subnormal vascular tonicity may be an indirect causative factor.

Pathology.—This appears to be practically like the results from an inflammatory change. The fact that there is no tendency to increase in size, shows it is truly an inflammatory process. Some consider the swellings to be of glandular origin, but this is hardly tenable, as gland element is absent in the vocal cord structure.

Symptoms.—Principally the change in the voice, which varies according to the stage of the disease and implication of the cords. It may be simply a slight hoarseness, or complete loss of voice. The patient is apprehensive, which increases the irregularity of vocalization. Paresis of the tensor muscles and a chronic laryngitis are usually present in complete aphonia. As the nodule becomes more fibrous and affects the surrounding tissue in contracting, the voice changes more markedly.

Diagnosis.—By the history and the laryngoscopic mirror. During the early stage the nodule is reddened; later, whitish or grayish white. The size is variable, from about the size of a millet-seed up. When only one cord is affected, the fellow cord may have a corresponding depression. If multiple and on one cord only, an undulating edge results.

The chance of an early stage of a malignant growth must be considered.

Prognosis.—Fairly favorable in the early stage, and when but one nodule is present. If of long standing, and fibrous tissue formation and contraction have occurred, restoration of the voice is unusual.

Treatment.—Although some benefit has been obtained by careful exercise of the muscles, especially the intrinsic, other measures are usually required. Operative procedures will depend upon the location and size of the nodule, also whether single or multiple, pedunculated or sessile. If pedunculated, the laryngeal cutting forceps will readily remove the growth. If sessile, and seen early, crushing the nodule with blunt forceps may give fairly good results. Local applications of a three per cent solution of zinc chloride, or ferrum perchloride to aqua \mathfrak{z} j, is recommended by some operators.

Chronic Inflammations of the Larynx.

SYPHILIS OF THE LARYNX.

Synonyms.—Specific laryngitis; Laryngitis specifica.

This is a syphilitic inflammation which may show secondary or tertiary lesions similar to those occurring in other parts of the body. In the secondary lesions there may be erythema, superficial ulceration, mucous patches, and small condylomata. In the tertiary form there are gummata, deep and extensive ulceration, and later cicatrization. The disease may be acquired or hereditary, and may appear at any age.

Etiology.—Primary infection is practically unknown, but is a possibility. Both secondary and tertiary manifestations may occur in acquired syphilis, but the tertiary form is by far the most frequent in the hereditary disease. In the acquired form the tertiary type is most frequent, and may

develop years after the initial lesion. Males are most often affected, and the winter season appears to develop the condition most frequently. Age is not a factor.

Pathology.—This is the same as in nasal syphilis.

Symptoms.—No characteristic symptoms of the disease are present. Usually subjective symptoms are slight, and the condition is supposed to be merely a cold, but occasionally there is severe pain, and between these extremes all conditions may exist. In the secondary lesions the general symptoms are very like those of the tertiary type, only differing in degree. The most pronounced is the change in the quality of the voice. Phonation may be difficult and painful, or even aphonia may occur. Paralysis of the vocal cords sometimes occurs early, and is generally unilateral. A short, hacking cough is frequently an annoying feature. The expectorated material varies from a thin serous material, through the different grades, to the offensive necrotic discharge of the later stages. The amount of discharge from the larynx is slight, and is best observed from the larynx with the laryngoscopic mirror. The pain usually depends upon the amount of ulceration and irritation, and is less severe than in tubercular laryngitis. Dysphagia may occur, and dyspnea in the later stages of gummata, or cicatricial contraction may become marked. Localized pain and tenderness may be considerable. Hemorrhage may occur, but is infrequent. In secondary syphilis the usual conditions are erythema, superficial ulceration, mucous patch, and condyloma.

ERYTHEMA.—This may follow the primary lesion within a few weeks, but usually occurs four or five months later, often following the disappearance of the cutaneous eruption. The laryngoscopic image will reveal, either areas or the entire surface of the posterior portion of the epiglottis, the aryepiglottic folds, false cords, and occasionally the vocal cords, with an inflammatory turgescence. The con-

gestion may be uniform, and appear like a simple catarrhal condition. In typical cases a mottled appearance is noticed. Sometimes the vocal cords are infiltrated and swollen. There is neither pain nor difficulty in swallowing, but there may be some cough. Hoarseness or complete aphonia may result when the vocal cords are affected. Proper treatment rapidly relieves the condition, and makes the diagnosis certain.

SUPERFICIAL ULCER.—This lesion is located practically the same as the erythema, and results from necrosis of the syphilitic inflammatory material in the upper layers of the membrane, or from disintegration of a mucous patch. The shape is irregularly rounded, having an inflammatory areola surrounding it. The ulcer is shallow and covered by a yellowish, sanious material. One ulcer may heal and another form elsewhere, the condition being chronic. This disposition to recur has been termed recurrent ulcerative laryngitis. When upon the vocal cords the lesions are so minute that they are often overlooked. The characteristic stellate scar usually is seen after healing occurs. The symptoms are usually slight. There is not much pain as a rule, but it is proportionate to the extent of the lesion. Expectoration is slight, and there is not much cough or vocal impairment. Usually occurs between two and seven years after the initial lesion.

MUCOUS PATCH.—This condition is seldom seen, some denying its existence upon the laryngeal surface. Patches may occur simultaneously with the same condition of the pharynx or tongue, or alone, usually on the supper surface and free margins of the epiglottis, the arytenoid structures, and vocal bands. They have never been observed below the vocal cords. The patches have a regularly rounded appearance, the margins slightly elevated, and the surrounding tissue reddened and inflamed. The area is whitish, or covered with a yellowish, pultaceous material, which may be

stained with blood. The floor of the lesion may be the site of rapid, persistent granulations. The areas may be painful to probe palpation. Multiple or single areas may be present, and a well defined cicatrix usually follows healing. The virulent character of the secretion in this condition should be remembered. Recurrence is infrequent.

CONDYLOMATA.—Occasionally these occur as small, yellowish papules with an elevated base. They are not often annoying, and generally disappear spontaneously.

TERTIARY MANIFESTATIONS.—This type is usually that of hereditary syphilis, but when not the manifestations seldom appear before five years after the initial lesion.

GUMMA.—Most frequent in the epiglottis, upon the arytenoids, or the interarytenoid commissure, but no portion of the laryngeal structure is immune. The gumma may be single or multiple. They appear first in the deeper layers of the membrane, and are small, smooth prominences, the same color as the surrounding membrane. The growth is slow, and when fully developed they vary from the size of a pinhead to a small marble. Inflammatory symptoms seldom precede the condition. When fully developed, softening follows, a yellow spot appears in the center, rupture of the overlying tissue and escape of the morbid material occurs, a deep and destructive ulcer forming. Usually the destructive process is rapid, but sometimes it may be slow, or even absent. The symptoms depend upon the size and location. When there is pain, it usually is a dull, deep-seated aching. Palpation may reveal tenderness. Discomfort on swallowing and change in the voice may follow. Cough is seldom present, but impaired respiration through occlusion of the respiratory tract may occur. Unilateral, and sometimes bilateral, paralytic phenomena may occur, a peculiar stridor of the voice resulting.

TERTIARY ULCERATION.—This results from gummatous degeneration, and is especially severe and destructive.

After the gumma ruptures, a deep, foul, rapidly destructive ulceration follows. The site is usually on the free margins of the epiglottis, and nearly always unsymmetrical. The edges are sharply defined, but ragged, and the ulcer is filled with an offensive, greenish or yellowish, purulent, tenacious material, while the membrane surrounding the lesion is inflamed and elevated. Coalescence of adjacent ulcers occurs, and the destructive process extends rapidly in depth and area. In the later stages the perichondrium is affected, and the laryngeal cartilages ulcerate and necrose. Any portion of the larynx may be involved in the destructive process, and the resulting condition is dangerous. The thyroid is usually the last to be affected, and in the latest stage of the disease. Pain is often constant and intense, dull and deep-seated. Pain on swallowing is often excruciating. Severe dyspnea may present.

Dysphonia or *aphonia* may occur, while change in the voice is practically always present. The expectoration is mucopurulent in character, and dark, offensive particles of necrosed tissue, occasionally stained with blood, will be found. Hemorrhage seldom occurs. Small portions of the laryngeal structure may be expectorated or swallowed. In the later stages of the disease difficulty in swallowing is often present, and in eating, particles of food or fluids may enter the larynx, causing choking and strangling paroxysms. Following the perichondrial lesion, pain and tenderness may be intense. External swelling sometimes occurs. Recurrent attacks are frequent.

CICATRIZATION.—After the tertiary ulcerative stage, rapid cicatrization may follow with the resulting contraction and stenosis. The form of the larynx is permanently changed and also its functions. The subjective symptoms of the ulcerative stage are increased, and asphyxia may become imminent. This condition is more likely to follow recurrent attacks.

Diagnosis.—The history when obtainable; the general condition; the result of specific treatment; and the local phenomena. The possibility of tubercular or carcinoma as a complicating condition must be remembered. In tubercular laryngitis, the membranes are pale, the ulceration shallow, and the inflammatory zone absent. There is more pain and but slight tendency to heal, besides there is usually a pulmonary lesion. In carcinoma prior to ulceration, there is a distinct, well defined tumor, and after ulceration the pain is sharp and lancinating. In lupus, ulceration may be absent, and cicatrization is not marked.

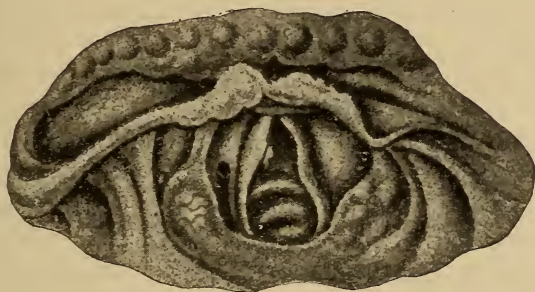

FIG. 94. Cicatrization and deformity resulting from syphilitic ulceration.

Prognosis.—Usually favorable so far as life is concerned, although it may be extremely chronic in character. Impairment of function results in cases where there has been much destruction of tissue. The secondary lesions are more amenable to treatment than the tertiary, where surgical interference may be required in the later stages.

TREATMENT.—*Local.*—In superficial ulceration, after thorough cleansing of the surface, touching the area with a solution of silver nitrate gr. xx to xl, aqua ʒj, or thuja and Lloyd's Hydrastis āā will be required. The latter is preferable in the majority of cases. In secondary and tertiary

lesions local treatment is important, but systemic measures are necessary for good results. The internal medication is the same as in syphilitic rhinitis or pharyngitis.

Tuberculosis of the Larynx.

Synonyms.—Consumption of the larynx; Consumption of the throat; Laryngeal phthisis; Tubercular laryngitis.

This condition may precede, but usually follows or occurs simultaneously with pulmonary lesions. There is swelling of the laryngeal mucosa and development of miliary tubercles. Small spreading ulcers that become confluent and cause extensive ulceration follows the breaking down of these tubercles, resulting in changes in the structure of the larynx.

Etiology.—The generally accepted theory is that it is caused by the Bacillus tuberculosis, or Bacillus of Koch. Primary infection of the larynx may occur, but it is usually secondary to pulmonary tuberculosis. A predisposing factor is undoubtedly heredity, but a subnormal condition of the system will furnish nearly as many cases. The disease is found most often between the ages of twenty and thirty-five, and most frequently in males.

Pathology.—Practically the same as in any other region.

Symptoms.—These vary according to the individual, the location, extent, and progress. The usual location of invasion is upon the posterior region, this being due to the anatomical relations of the larynx. Usually the disease commences insidiously, and is variable in duration. One of the first symptoms the patient complains of is a dry, burning sensation in the throat. Hoarseness and lack of vocal power soon follows. Often these symptoms have been present for some time, as an acute, subacute, or chronic laryngitis often precedes the tubercular lesion. Pain is usually absent in the earlier stages, but the sensation as if a foreign body was irritating or scratching the throat is often present.

After ulceration begins, the pain is usually marked. Tenderness and pain on pressure may be severe. The change in voice is influenced by the location of the lesion. As a rule, there is hoarseness and lowered pitch, and sometimes aphonia. The effort to talk may be extremely painful. Cough is nearly always present, but is not always annoying. Especially in the later stages, the cough may cause intense pain during a paroxysm. Swallowing becomes progressively more painful, as a rule, while choking and strangling spells cause dread of attempting deglutition. In the late stage, regurgitation of food, and the entrance of particles of food or of fluids into the larynx during inspiration, frequently occurs. There is not much secretion from the laryngeal tissues, but it is quite tenacious. In cases where there is apparently an excessive secretion, it is from the lungs. Particles of disintegrated cartilage may sometimes be ejected in the later stages.

Dyspnea may occur at any time during the course of the disease, and may necessitate tracheotomy. Infrequently a condition of stenosis from partial cicatrization of an ulcerative area may occur which will also demand operative interference. Besides the local symptoms, there will be the general manifestations of the systemic lesion.

The laryngoscopic image is as varied as the clinical symptoms. In the rapid type there is usually a hyperemic appearance, while in the slow or chronic type an anemic condition is usually found. After the initial stage, localized swellings may be found, hyperemic in the acute type, but anemic in the chronic. These elevations increase in size, and may become so large that dyspnea results, especially when near the laryngeal entrance. The epiglottis is a frequent location for infiltration, and may assume a variety of forms. The arytenoid regions are often affected, and a certain rounded turgescence of the prominences has been termed "club-shaped" arytenoids.

The membranes become more and more anemic and paler, and numerous bodies resembling small, yellowish seeds can be seen beneath the surface. The number increases, and degenerative changes occur, leaving small ulcers from the softening and escape of their contents. The formation of these necrotic spots introduces the final stage. Coalescence and extension of the process occurs. The appearance of the larynx is changed according to the stage. The lesions may be small, shallow, and separate, with a tendency to spread; the floor irregular and bathed with a grayish, tenacious secretion, and the edges of the ulcer well

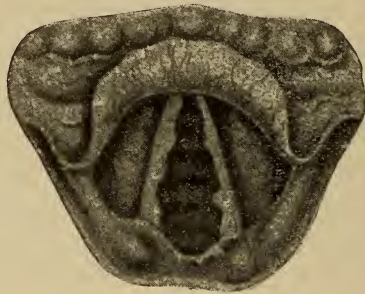

FIG. 95. Tubercular ulceration of both cords.

defined; or there may be a large, roughened, irregular lesion. Implication of the cords may occur at any stage of the disease. The appearance and conditions are about as varied as the individuals affected.

Diagnosis.—Usually not difficult, particularly when pulmonary lesions are coincident with the laryngeal affection. In laryngeal tuberculosis the expectorated secretion from the larynx seldom contains the bacilli. Clinical symptoms, history, and amelioration of the condition by treatment, differentiate syphilis. The table of differential diagnosis by Joseph S. Gibb is valuable in distinguishing between the lesions likely to be mistaken for tuberculosis.

SYPHILIS.	CARCINOMA.	TUBERCULOSIS.	LEUPUS.
<p>Pain usually slight.</p> <p>Attacks any portion of the larynx, and ulcerates rapidly.</p> <p>Seldom seen in the stage of induration, the first evidence being a clear-cut, deep ulcer.</p> <p>Some induration around the ulcer, but usually very little edema.</p> <p>Ulcer extends deeply, often involving cartilage.</p> <p>Surface of ulcer covered by mucopurulent secretion and necrosed tissue.</p> <p>Mucous membrane hyperemic and injected.</p> <p>Laryngeal stenosis not common until cicatrization occurs.</p> <p>General health unimpaired.</p> <p>Frequent evidences of syphilitic disease in other tissues.</p> <p>Rapidly improves under the iodides.</p>	<p>Pain constant, lancinating.</p> <p>Attacks any portion of the larynx, and ulcerates more slowly than syphilis.</p> <p>The first appearance is that of a new growth occupying the laryngeal cavity; no clear-cut ulcer.</p> <p>The growth fills or encroaches on the laryngeal cavity.</p> <p>Growth extends in all directions, involving all tissues in its course.</p> <p>Surface of growth covered by discharge.</p> <p>Mucous membrane hyperemic.</p> <p>Laryngeal stenosis quite common.</p> <p>Early in disease no impairment of general health; later on marked cachexia.</p> <p>In primary laryngeal carcinoma, no other involvement until later in the disease.</p> <p>Iodides have no influence on the course of the disease.</p>	<p>Pain severe on deglutition.</p> <p>The favorite site is in the interarytenoid space or the base of the arytenoid cartilage; ulcerates slowly.</p> <p>Usually the first appearance is small spots of induration, which is rapidly followed by great edema.</p> <p>Great edema of arytenoids.</p> <p>Ulcer extends laterally, but not deeply.</p> <p>Surface of ulcer covered by thick mucopurulent secretion and agglutinated mucus.</p> <p>Mucous membrane pale.</p> <p>Laryngeal stenosis rarely occurs.</p> <p>Health impaired previous to laryngeal involvement.</p> <p>Previous and coincident pulmonary trouble common.</p> <p>Iodides have no influence.</p>	<p>No pain.</p> <p>Attacks any portion; ulcerates very slowly.</p> <p>Nodular masses.</p> <p>Little or no edema.</p> <p>Very slow in progress; ulcer seldom observed.</p> <p>Little or no discharge.</p> <p>Mucous membrane injected.</p> <p>Slight stenosis.</p> <p>Very slight impairment of general health.</p> <p>Frequently cutaneous manifestations.</p> <p>Iodides have no influence.</p>

Prognosis.—Usually unfavorable.

Treatment.—The local treatment is the same whether the laryngeal lesions are primary or secondary. The surfaces should be cleansed as thoroughly as possible, using the salicylic acid wash with hamamelis. After this process, the surface should be dried and very carefully touched with dilute nitric or dilute hydrochloric acid. No excess of the acid should be on the applicator. If the ulcer is deep, thorough curettement under local anesthesia should be done. Laryngectomy in primary cases will often effect a cure. The advice to seek another climate, while necessary in some cases, is usually a doubtful measure. For the relief of the pain, pineapple juice, used as a spray or with an applicator, will relieve many cases. Cocaine is very evanescent in its action. Chloretone used with an oily base often affords relief, but various remedies will have to be employed. The cough can often be controlled by the use of hydrastis and ergot, in dose of from gtt. v-xx of each in plenty of water. Other internal remedies for the disease are rhus tox, bryonia, collinsonia, phytolacca, liquor potassii arsenitis, potassium bichromate, veratrum. Cataphoresis is recommended by Scheppegegrell. The food should consist of fatty substances, especially those containing a large amount of the fluid fats. Plenty of fresh air should be insisted upon, as well as exercise short of fatigue.

Laryngeal Hemorrhage.

Laryngeal hemorrhage comprises rupture of a blood-vessel, with escape of blood into the submucous tissue, forming hematoma, and also an escape of blood from the surface of the mucous membrane. The interstitial and slight hemorrhage causing inflammation has been given under hemorrhagic laryngitis.

Etiology.—Probably is usually the result of some systemic lesion. Occasional cases will be seen where the pa-

tient seemingly is in good health. Any condition which may cause superficial congestion may produce laryngeal hemorrhage.

Symptoms.—When the hemorrhage is confined to the submucous tissue, the symptoms usually are those of laryngeal irritation, a disposition to cough, alteration of the voice, and if a hematoma of much size occurs, difficulty in breathing. A slight effort will cause the ejection of blood in streaks or masses, without being mixed with mucus or saliva; or the blood may be clotted by retention in the larynx, then expelled as small, dark colored masses, and

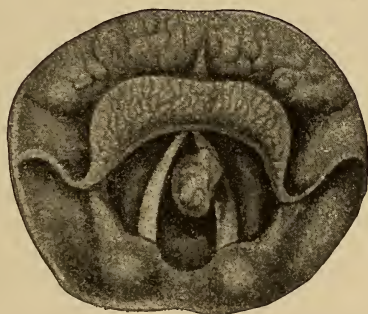


FIG. 96. Fibroid polypus on the left vocal cord.

without much change in the amount for several days, is a characteristic symptom.

Prognosis.—Usually favorable as concerns life.

Treatment.—When the hemorrhage is in the form of a hematoma encroaching upon the lumen of the larynx, and causing difficulty in breathing, the tumor should be incised and the clot removed. If the hemorrhage is from the surface, the internal use of ergot, hamamelis, carbo veg. IX. or belladonna is required. Systemic wrongs should be looked for and corrected so far as possible. For the irritation from small hemorrhagic areas, causing a cough, collinsonia,

sanguinaria nitrate, or morphine sulphate in 1-1000 gr. doses will usually relieve. Avoidance of active exercise and use of the voice should be insisted upon.

Foreign Bodies in the Larynx.

Usually the entrance of foreign bodies into the larynx or the respiratory tract below, is a serious matter. The material may enter during mastication, deglutition, inspiration, or speaking. The severity of the symptoms depend largely upon the size, location, and character of the body.

Two divisions may be made, fluid and solid. Fluids may be liquid food, the purulent material from tonsillar or retro-pharyngeal abscesses, blood during operative procedures or severe nasal hemorrhage, and vomited material. Solids may be classed as animate and inanimate, and comprise anything that can find entrance into the structure. Anomalous or morbid conditions of the throat or larynx inducing anesthesia; fistulas, connecting the respiratory and alimentary tracts, or stricture of the esophagus, causing regurgitation of food, may be predisposing factors.

Symptoms.—Usually when a foreign body has entered the respiratory tract, there will be choking or gasping for breath, dyspnea being most pronounced on inspiratory effort. The facial expression is that of anxiety and often of suffering. Exophthalmos, and in severe cases, congestion of the face and neck may occur. A fatal termination may result, or the symptoms may gradually subside, with practically normal respiration, but when the foreign body is not removed, there are usually recurrences of the attacks, caused either by a change in the position of the patient or of the foreign body. If the foreign body is angular or sharp, the distress is usually greater than when it is smooth. Emphysema of the neck and upper portion of the chest may follow when there is rupture of some portion of the respiratory tract. Hemorrhage may follow erosion of the mem-

brane. A paroxysmal hoarse cough and loss of voice often result. The cough may partake of the characteristics of whooping-cough. Inflammation and ulceration may follow.

Diagnosis.—Usually not difficult, as the history and inspection will be sufficient. Palpation of the larynx may reveal the presence of a foreign body, when a laryngoscopic view is impossible. In doubtful cases the X-ray is of value in determining the presence of a foreign body.

Prognosis.—Guarded.

Treatment.—The use of sternutatories and emetics should be avoided. Inversion of the patient may cause dislodgement of the body, if smooth. If the offending substance can be located in the larynx, it can usually be removed with laryngeal forceps. If all other methods fail, operative measures will be required.

CHAPTER XX.

NEUROSES OF THE LARYNX.

Nervous cough. Mogiphonia. Anesthesia. Paresthesia. Hyperesthesia. Neuralgia. Hysterical Aphonia. Chorea of the Larynx. Dysphonia Spastica. Laryngeal Vertigo.

Paralysis of the Vocal Cords. (a) Paralysis of the Superior Laryngeal Nerves. (b) Recurrent Laryngeal Paralysis. (c) Bilateral Abductor Paralysis. (d) Unilateral Paralysis of Abductors.

Paralysis of Individual Muscles. (a) Paralysis of Central Adductors (Arytenoids). (b) Paralysis of Internal Tensors (Thyro-arytenoids). (c) Bilateral Paralysis of Adductors (Lateral crico-arytenoids). (d) Unilateral Adductor Paralysis (Lateral crico-arytenoid) (Kyle).

Nervous Cough.

In neurotic individuals there may be a croupy, spasmodic, even musical cough, which is truly of nervous origin. In the majority of cases the cough is most annoying during the waking hours, and may be either almost incessant or paroxysmal, but usually it is a short barking cough increased by excitement, when choreic facial twitching may be present. During sleep it may be absent, but is sometimes worse during sleep, and comparatively absent during the day. Again it may be practically continuous, no cessation during the day or night. Sex is not so much a factor as a neurotic condition.

Diagnosis.—This must be by exclusion. The thorax, nose, ears, nasopharynx, pharynx, fauces, larynx, alimentary, and generative systems should be examined for some

condition which may cause a reflex cough. When no definite lesion or condition can be found, the cough is probably strictly nervous in character.

Treatment.—The general health should be improved when possible. For the cough the following has proven efficacious in the majority of cases. ℞ Rhus tox., gtt. iij; Morphine sulphate, gr. 1-8; Aqua ꝑviii. Teaspoonful every five minutes until the cough is less annoying, then every half hour or hour. Gelsemium, pulsatilla, or ipecac may be indicated, but the dosage must be very small. Other remedies may be indicated.

Mogiphonia.

This term is used to designate a lack of tension of the vocal cords, where an extra effort in phonation is required. In ordinary conversation the voice may be normal, but when an extra exertion is necessary, the voice fails.

Treatment.—Massage, friction, and rest of the vocal organs is necessary. Internally collinsonia, coca, hydrastis, nux, or ignatia will aid in recovery.

Anesthesia.

Etiology.—Induced anesthesia will not be considered. Subjective causes may be hysteria, epileptic attacks, catalepsy, the later stages of cholera, paralysis of the insane, bulbar paralysis, diphtheria, erysipelatous or variolous affections of the larynx, cerebral lesions of any character, posterior spinal sclerosis, progressive muscular atrophy, railway spine, lesions of the superior laryngeal nerve or of certain fibers of the pneumogastric, may produce anesthesia of the larynx.

Symptoms.—Choking or coughing, through food or liquids entering the trachea, is the most marked symptom. Septic pneumonia often results in this condition. The laryngoscopic examination may show an erect epiglottis

owing to paresis of the thyro- and ary-epiglottic muscles. Mackenzie has noted a waviness of the outline of the glottis in this condition.

Diagnosis.—The lack of sensitiveness when the larynx is touched with a probe, and also absence of any reflex action.

Prognosis.—Most favorable when it follows or is dependent upon diphtheria. When due to intracranial or spinal lesions, it is unfavorable.

Treatment.—This must be directed to the cause. The use of electricity has been recommended, as well as massage.

Paresthesia.

Under this title are grouped the perverted sensations as of constriction, feeling as of a foreign body, heat, prickling or tickling. Any of these may result from morbid conditions outside of the laryngeal structure. Hypertrophy of the faucial tonsils or cryptic concretions of the same; morbid changes of the lingual tonsils; follicular pharyngitis, elongated uvula, varicosed veins at the base of the tongue, adenoids, etc. In some systemic diseases and neurasthenics, any of these sensations may be present. Before classing the condition as purely nervous, a careful examination of the entire respiratory tract should be made.

Treatment.—This will depend upon the cause. When of neurotic origin, suggestion will usually be most beneficial.

Hyperesthesia.

The normal sensitiveness of the laryngeal membrane varies in different persons, but when it is very marked, it may be called hypersensitive. Acute or chronic laryngitis is a common cause of this condition. Systemic diseases as incipient phthisis, gouty or rheumatic conditions, erosions, or ulcerations, tumors, etc., may be factors.

Symptoms.—A markedly aggravating cough, which may be convulsive and cause gagging whenever any slight irritation is present, or the deglutition of certain substances, are the usual symptoms.

Treatment.—When due to systemic wrongs, these should be treated. Anomalous conditions of the surrounding structures should be corrected. Abrasions, ulcerations or fissures should be cleansed and treated with a strong solution of silver nitrate or even the fused stick.

Neuralgia.

A true neuralgic pain in the larynx seldom occurs, but when it does, it usually is due to some lesion of the larynx or surrounding tissue.

Treatment.—The causative factor must be looked for. For the neuralgic pain, gelsemium, aconite, rhus tox, bryonia.

Hysterical Aphonia.

Synonym.—Functional aphonia.

This consists of a sudden loss of voice, or complete aphonia, and most frequently occurs in neurotic, hysterical persons, especially in females between puberty and the menopause. Shocks, fright, intense emotion of any kind, or anxiety, may produce this disturbance. It is not the result of a morbid lesion, but from some cause there is a temporary loss of control of the adductor nervous supply, probably through some transient cerebral excitement. It may come on gradually or suddenly. Sometimes on retiring with full possession of the faculty of phonation, on awakening partial or complete aphonia will be present. This condition may continue but a few hours, or may last for days, when the voice will return in full force as quickly as it was lost. This condition may recur frequently or only at long intervals of time.

Diagnosis.—This is made by both the general condition and by the laryngoscopic mirror. With the latter, the cords will be seen more toward the median line on attempted phonation, but they do not approximate, but return after a few seconds to the inspiratory position. Cough is present in hysterical aphonia, but is absent in true adductor paralysis. The employment of a general anesthetic to the excitement stage will show, by the return of the voice, that it is not a paralytic condition.

Treatment.—This must be directed to the causative factor of the hysteria, and is often difficult to find. Pulsatilla, ignatia, nux, gelsemium. Electricity has been employed, but has not been successful except in a limited number of cases.

Chorea of the Larynx.

Synonym.—Laryngeal nystagmus.

This condition is characterized by recurrence during the waking hours of a sharp, dry, noisy cough, caused by a violent involuntary spasm of the vocal cords, occurring at varying intervals. It is found most often in girls at about the age of puberty. The sound differs from a true cough, as there is not the preliminary inspiration, the act being an expiratory bark or yelp diminishing in intensity. Choreic symptoms of other parts of the body may be present. Sometimes the articulation is spasmodic but the tone is not changed. When the attack begins, the vocal cords may be seen to suddenly come together, and after a very short interval retreat close to the sides of the larynx. Expulsive effort of the thoracic muscles result from this spasm, and the glottis is forcibly opened with the characteristic sound.

Treatment.—The correction of any abnormal condition of the respiratory tract. The affection is essentially chronic, and not easily relieved. The internal administration of pulsatilla, ignatia, cimicifuga, viburnum, senecio, bryonia, jaborandi, sepia, rhus tox., or gelsemium may relieve. The

faradic or galvanic currents may afford relief. Nux and strychnine are usually contra-indicated.

Dysphonia Spastica.

Synonym.—Spastic paraplegia of the larynx.

This is a spasm of the glottis occurring only during attempted phonation. It occurs in adults, and most often in females. Impairment of the voice, or even aphonia, precedes the condition. The glottis is tightly closed, and continues so during the effort to speak, and opens when the attempt to talk ceases. Excessive use of the voice appears to bring on an attack at times, and if the effort is continued, some cyanosis may occur. The laryngoscopic picture is normal until the cords approximate in phonation, when a tonic spasm results, and the cords may overlap. The laryngeal muscles are not affected in respiration. It is a chronic condition.

Treatment.—Often unsatisfactory. Rest of the vocal organs is most important. Any abnormal condition of the respiratory tract should be corrected, or if of reflex origin, the exciting cause should be removed. Hygienic measures are important. The constant current is recommended, but often the results are unsatisfactory. Internally the use of gelsemium, rhus tox., collinsonia, jaborandi in full doses, pulsatilla, or ignatia may be indicated.

Laryngeal Vertigo.

Synonym.—Spasmodic laryngeal occlusion.

This is a very infrequent affection, and usually without premonitory symptoms, unless it be a slight cough caused by a tickling sensation in the larynx. Spasm of the larynx may occur in a person in apparently good health, causing giddiness, blurring of vision and even unconsciousness. This lasts but a few seconds, but spasmodic twitching of the face or extremities may occur, and the only feeling will

be that of a momentary sense of confusion. Usually no cause can be assigned, although an acute or chronic laryngeal inflammation, aggravated by over-exertion or nervous excitement may be exciting causes. The attacks are usually irregular, even months intervening between seizures. At the onset there is a deep sucking in of air, which being confined by the glottic spasm, increases the pressure in the chest, diminishes heart action, and causes syncope. A continuation of these attacks impairs the entire system. The outcome is favorable under proper treatment, which is similar to that of dysphonia spastica.

Paralysis of the Vocal Cords.

Paralysis of the Superior Laryngeal Nerves.—Sensation of the laryngeal mucous membrane; the action of the cricothyroid muscles, and also in part of the arytenoideus, is supplied by the superior laryngeal nerves.

Paralysis of the superior laryngeal causes loss of sensation in the laryngeal membrane, and impaired or complete loss of the voice. One or both sides of the larynx may be affected.

Etiology.—It may follow diphtheria, overuse of the voice during an attack of acute or subacute laryngitis, or by an injury or section of the nerve. The paralysis is seldom complete unless the result of the later causes.

Symptoms.—The most marked are hoarseness, inability to reach the higher notes, or a peculiar “sliding rise in the pitch of the voice during ordinary conversation, which is beyond the control of the patient.”

Diagnosis.—In a typical case of bilateral paralysis, the laryngoscopic picture is characteristic. The vocal cords approximate in such a way as to divide the glottic aperture into two unequal parts. The lack of action of the cricothyroid muscle and anesthesia of the larynx determines the diagnosis. In unilateral paralysis relaxation of the portion

of the implicated cord between the vocal process and the thyroid cartilage occurs.

Prognosis.—Usually favorable, the time of recovery depending upon the cause.

Treatment.—Attention to the respiratory tract is necessary, as also is rest of the vocal organs. Massage, the faradic or galvanic current should be tried. Internally nux or ignatia is usually indicated.

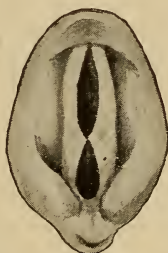


FIG. 97. Bilateral paralysis of the superior laryngeal viscera. Phonation.

Recurrent Laryngeal Paralysis.

With the exception of the cricothyroid and arytenoideus, all the laryngeal muscles are controlled by the recurrent laryngeal nerve. Paralysis of this nerve results in loss of motion of the affected side, as the cricothyroid produces no appreciable motion.

Etiology.—Pressure on the nerve at some point is the most frequent cause. This is especially true on the left side on account of the anatomical relations. Enlarged lymphatics, mediastinal tumors, esophageal cancer, pleuritic adhesions in the early stages of phthisis (usually on the right side); pleural effusion or pericardial sacs, may cause the paralysis. A central lesion from any cause may be an exciting factor, and also toxemia, by producing a toxic neuritis. Laryngeal inflammations may also have an influence in producing this condition.

Symptoms.—When unilateral, it is feeble vocalization rather than hoarseness, but eventually the voice becomes stronger as the unaffected cord is finally approximated to the affected cord. If bilateral, complete aphonia usually results, the patient having difficulty even in whispering.

Cough, dyspnea, etc., are usually accidental.

Diagnosis.—In bilateral paralysis the laryngoscopic image shows the cords relaxed, occupying a position midway between adduction and pronounced abduction—the so-called cadaveric position. In unilateral paralysis the affected cord passes its normal position in the attempt to meet

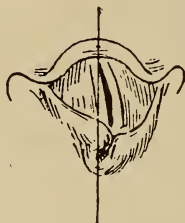

FIG. 98. Paralysis of left vocal cord during phonation.

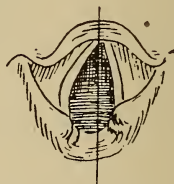

FIG. 99. The same on deep inspiration.

the other, the arytenoid cartilage passing slightly in front and beyond that of the affected side. When the diagnosis is made, the nervous system, cervical region and thorax should be examined to find the exciting factor.

Prognosis.—This will depend upon the cause. When resulting from diphtheria or similar affections, recovery usually occurs in one or two months. It is unfavorable in cases due to severe chronic diseases, or an abnormal factor, and unless relief is obtained fairly early, atrophic changes in the muscles will preclude much improvement.

Treatment.—This must be directed to the underlying cause.

Bilateral Abductor Paralysis.

The action of the posterior crico-arytenoid muscles is to separate the vocal cords during inspiration, and the nerve center controlling this action is located in the medulla.

Etiology.—The most frequent cause of bilateral abductor paralysis is some lesion affecting the central nervous system, and extending to the medullary centers. Syphilis, posterior spinal sclerosis or neoplasms, constitute this group.

More infrequent causes are aneurism, mediastinal tumor, goiter, and cancer of the esophagus or thyroid gland, which affect the recurrent nerve.

Peripheral causes, as laryngeal inflammation, may possibly be a factor, and also hysteria.

Symptoms.—Gradually there is increased difficulty on inspiration, the attacks of "inspiratory dyspnea" increasing in severity and frequency. An inspiratory stridor results, and the entrance of air to the lungs becomes labored. Increased excitement or exertion causes extreme shortness of breath. The expiratory function is quietly performed, and with the exception of some weakening of the voice, no change occurs. Cough and expectoration are difficult.

Diagnosis.—With the exception of ankylosis of the crico-arytenoid articulations, which may result from esophageal cancer or tubercular laryngitis, the laryngoscopic picture is not liable to be mistaken for bilateral abductor paralysis. On inspiration, the cords approach the median line and are motionless. On expiration the cords are separated by the exit of the air. In phonation there is no abnormal movement.

Prognosis.—This depends upon the cause. The slower the development, the less favorable. When the paralysis has continued for ten or twelve months, a return of muscle action is usually impossible.

Treatment.—This must be directed to the cause. As

asphyxiation may occur, the necessity for tracheotomy may be imperative. This is usually a better procedure than intubation. Section of both recurrent laryngeal nerves has been suggested, but according to Bosworth, while it would relieve the attacks of dyspnea, it would cause loss of voice.

Unilateral Paralysis of the Abductors.

Paralysis of one of the muscles of abduction (cricothyroid) may result from (a) some central lesion, (b) pressure on the nerve in its course by an intra-thoracic aneurism, malignant disease, or thickening of the pleura, (c) acute inflammation or other intralaryngeal affections implicating the periphery of the nerve, or (d) gout, rheumatism, diphtheria, plumbism, enteric fever, and the acute infectious diseases.

Symptoms.—Usually not severe. Exertion may cause some shortness of breath, which is most probably due to the causative disease, and is not paroxysmal in character. The voice is unaffected. The laryngoscopic image shows no abnormality during phonation, but during inspiration the cord on the affected side is motionless in the median line, the fellow cord being drawn aside normally.

Prognosis.—Guarded, as both sides may become affected, and the cause may not be amenable to treatment.

Treatment.—This must be directed to the causative factor, and is similar to that given under bilateral paralysis of the abductors. Tracheotomy is never necessary.

Paralysis of Individual Muscles.

Under this grouping will be considered paralysees of the other laryngeal muscles, the result of myopathic causes. Most of these are infrequent, and usually are caused by local inflammation. If associated with constitutional affections as gout, rheumatism, plumbism, etc., they are

usually induced by overuse of the voice or exposure, aggravating the local manifestation of the systemic condition.

PARALYSIS OF THE CENTRAL ADDUCTORS (ARYTENOIDS).—The arytenoids only may be affected, or the cricothyroids may also be implicated when the superior laryngeal nerve is involved. Paralysis of the central adductors may result from any chronic laryngeal inflammation, diphtheria, hysteria, incipient phthisis, or any severe illness. Hoarseness and a rapidly tired sensation on the use of the voice, or aphonia, are the symptoms resulting from the partial closure of the glottis. The laryngoscopic picture is characteristic, showing accurate closure of the anterior two-thirds of the cords, and a triangular space from this point to the vocal processes at the apex, in attempts at phonation.

PARALYSIS OF THE INTERNAL TENSORS (THYROARYTENOIDS).—This is the most frequent form of paralysis of the cords, on account of the anatomical relations. It may be bilateral or unilateral. Excessive use of the voice when there is laryngeal inflammation, fatigue, or strain of the muscles, diphtheria, or hysteria, are the most frequent causes. Change of voice consists of diminished range and less strength. In severe cases, whispering only may be possible. The laryngoscopic image reveals an elliptical space extending the entire length of the cords, through the bulging upward before the air current.

BILATERAL PARALYSIS OF ADDUCTORS (LATERAL CRICOARYTENOIDS).—Hysterical aphonia is usually described under this title, but is really a paresis. Bosworth says a genuine myopathic paralysis of these muscles may result from any of the exanthemata, diphtheria, exposure to cold or plumbism. The laryngoscopic picture is practically impossible to differentiate from bilateral paralysis of the recurrent laryngeal nerve.

UNILATERAL ADDUCTOR PARALYSIS (LATERAL CRICOARYTENOID).—This is very infrequent, and extremely diffi-

TABLE OF PARALYSIS.

	SYMPTOMS.	CAUSE.	MUSCLES.	FUNCTION.	NERVE-SUPPLY.
Cause. { Pressure on nerve-trunk. Central and peripheral lesions.	{ Impaired sensation of laryngeal mem- brane. Tension of cords impaired. Hoarseness.	Diphtheria. Over- use of inflamed larynx.	Crycothyroids.	Phonation, Exter- nal tensors.	Superior Laryn- geal.
{ Weakness of tone or com- plete apho- nia.	{ Voice usually nor- mal. Stridor, es- pecially during sleep.	Central lesion Syphilis, severe cold, wasting disease.	Posterior crico- arytenoids. Ke- ratocricoid.	Inspiration. Ab- ductors of vocal cords, Glottis openers.	Recurrent Laryn- geal.
{ Higher registra- tion. Labored, whispering voice.	{ Difficult or impos- sible phonation. Odor.	Hysteria. Overuse of voice. Anæ- mia. Chlorosis.	Lateral crico-ary- tenoids.	Phonation. Later- nal adductors.	Recurrent Laryn- geal.
{ Hoarseness and fatigue on talk- ing, or aphonia.	{ Chronic inflamma- tion. Severe ex- posure. Hys- teria. Incipient pthisis.	Arytenoids.	Arytenoids.	Phonation, Cen- tral adductors.	Recurrent Laryn- geal. Superior Laryngeal.
{ Position. { Cadaveric.	{ Higher registra- tion. Labored, whispering voice.	Overstrain of in- flamed muscles.	Thyro-arytenoids.	Phonation. Inter- nal tensors. Shortens and re- laxes vocal cords.	Recurrent Laryn- geal.
{ Position. { Cadaveric.	{ Higher registra- tion. Labored, whispering voice.	Overstrain of in- flamed muscles.	Superior Thyro- arytenoids.	Reinforces thyro- arytenoid.	Recurrent Laryn- geal.
{ Position. { Cadaveric.	{ Higher registra- tion. Labored, whispering voice.	Overstrain of in- flamed muscles.	Aryteno-epiglottic.	Constrictor of lar- ynx. Compress- or sacculus lar- yngis.	Recurrent Laryn- geal.

Recurrent Laryngeal.

cult to diagnosticate. It may result from the same causes as already mentioned, and is characterized by impaired action or complete inability to phonate. During the attempt to phonate, the affected cord is firmly drawn in complete abduction, the other cord passing the median line by an extra effort.

Prognosis.—The prognosis of any of this classification depends upon the cause and length of time between the onset and the examination. When resulting from an acute infectious disease or exposure, proper treatment will soon effect a cure, but as near complete rest of the laryngeal muscles as possible, is necessary. If not observed in the early stages, the prognosis is less favorable, especially when the thyro-arytenoids are implicated.

Treatment.—Removal of the cause when possible. Rest of the muscles, electricity, hygiene and such measures as tend to restore the general tonicity of the system.

CHAPTER XXI.

INTUBATION OF THE LARYNX.

This procedure consists in introducing within the larynx a tube for relieving alarming dyspnea.

Indications.—These may be classified as any obstructive dyspnea which threaten life, and results from occlusion of the larynx, excepting glottic spasm. Membranous occlusions, localized within the larynx, or invading this structure from above. Edema, resulting from inhalation of irritating vapors, or the swallowing of caustic or scalding fluids; the localized edema from renal or other organic lesions may be an indication for intubation rather than tracheotomy. Some slow, progressive stenoses, as in specific cicatrization, may be benefited by this procedure. It is best adapted to the years of childhood, and with similar indications is preferable to tracheotomy if the patient has a short, fat, chubby neck.

Contraindications.—When the larynx is invaded by benign or malignant growths, especially the latter, where a laryngectomy is contemplated, or when a morbid process requires absolute rest of functional activity. Also in cases where the obstruction is reasonably certain to be below the lower end of the tube. During spasm of the glottis, excepting when remissions occur which will allow of the introduction of the tubes. When undue force is necessary to introduce the tube.

Instruments.—O'Dwyer's set is most generally used, and consists of the introducing instrument, extractor, assorted tubes, gauge and mouth gag. There should be car-

ried in addition to this strong fine braided ligature silk. A description of the instruments is unnecessary.

Position of the Patient and Physician.—Usually the patient is held in an upright position by an assistant, the arms being confined by wrapping a sheet around the little one. In this way the child is held steadily by the assistant's grasp around the body and arms, the lower extremities being held between the knees. Another assistant stands behind the patient and steadies the head and makes vertical extension of the neck. The gag is placed in position between the molars on the left side, the physician introducing

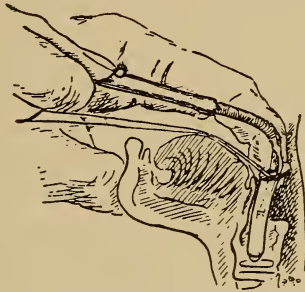


FIG. 100. Showing position of tube and finger in intubation.

the index finger of the left hand into the mouth, following the median line to the epiglottis, which is then raised and steadied by a slight lateral pressure. The tube in position on the introducer is passed back in the median line, using both the index finger and the eye as guides, and keeping the handle of the introducer depressed, until the end of the tube reaches the finger tip, then raising the handle, carefully introduce the tip of the tube into the larynx, guiding its passage with the index finger. When the tube is in place, release the obturator and withdraw the instrument, keeping the tube in place with the finger. After the tube is released,

the silk loop is fastened around the patient's ear or around the neck.

Kyle's method is to wrap the patient tightly in a sheet, confining the arms to the body, and placing the patient on its back on a table, allowing the head to hang over the edge which causes extension of the anterior structures of the neck. An assistant stands on one side and by leaning over holds the patient firmly by the pressure of the shoulders, and prevents lateral movements by extending the arms at the sides, steadying at the same time the patient's head with the hands. The physician sits opposite the patient's face and introduces the gag with the handle turned away from him, and opens the jaws to their full extent. A second assistant, using a soft cloth, grasps the tongue and draws it forward. The index finger of the left hand is then introduced and the epiglottis lifted and steadied. The tube is then introduced, the same positions being observed as in the upright position, the right arm is extended and curved, and the tube readily carried along the median line to the larynx. The rest of the manipulation is identically the same as already described. Before attempting to introduce the tube, the easy movement of the silk loop should be determined, as well as freedom of release of the tube from the obturator.

Accidents, Complications, and Dangers.—It must be remembered that operative procedures involving the respiratory tract are more difficult of performance than a description would indicate. The struggles and gagging of the patient, no matter how firmly held, will make the handling of instruments difficult. The gag may become disarranged, and unless the operator's finger is protected by a metal guard, it may be severely lacerated by the patient's teeth. Secretion may be forcibly expelled during a coughing paroxysm, and strike the physician in the eye, nose, or mouth, thus causing infection. The tube may not be the proper size, if too large it can not be introduced, and if

too small it may pass between the vocal cords into the trachea. The direction of the tube in introducing it, may be faulty, and it will pass into the esophagus. The tube may push membrane before it, occluding the tube and trachea, necessitating immediate tracheotomy. Sometimes the tube will become filled with shredded membrane or tough secretions, necessitating removal and cleansing. Glottic spasm may be so severe that it is impossible to introduce the tube. There should be considerable relief after the tube is introduced, if there is not, a careful examination as to the cause should be made. An undue amount of force should not be made in trying to introduce the tube, and not infrequently several attempts will be necessary. It is essential that the thread be not forgotten, as the tube can usually be quickly removed, and if it has been wrongly placed, there is not the danger of the patient swallowing it.

Post-operative Care.—From the time of the introduction of the tube until its removal, the case must be carefully watched. In membranous conditions the lumen of the tube may be suddenly closed. Closure of the tube may also occur in cases having an excessive amount of tough, tenacious secretion. In either case the tube must be immediately removed and cleansed. It is important that the nurse be instructed regarding the symptoms necessitating the removal of the tube, and also how to remove it by means of the thread. If necessary to remove, and the tube seems to be held firmly in position, the patient should be inverted, and the back and chest sharply slapped, this method will usually dislodge the tube. Occasionally the tube may be displaced during a paroxysm of coughing, when often it will be found unnecessary to replace it. Sometimes the thread will break, and the tube be dislodged and swallowed, but no untoward results follow this accident.

The feeding of the patient is often a difficult problem. Some, after a few efforts, will be able to take liquids, and

others semi-fluids. In some cases with the head lower than the body, fluids can be taken from a nursing bottle. The stomach tube may be required, and even rectal feeding. If nutrition is much impaired, it may necessitate tracheotomy.

In the removal of the tube, if the thread has become detached, the method of procedure is practically the same as for intubation, but the extractor is used instead of the intubator.

Sequelæ.—After the tube has been worn for a time, a paresis of the vocal cords usually occurs, but passes off after a time. Erosion of the cartilages has been reported in a few cases.

CHAPTER XXII.

TRACHEOTOMY, ETC.

This means an incision of the trachea, and the maintenance of an artificial opening more or less permanent, by artificial means.

Similar operations involving the larynx are designated, according to location, laryngotomy, thyrotomy, thyroidotomy, etc.

Indications.—Occlusion of the larynx by membranous formation in croup or diphtheria, especially when the soft tissues of the chest recede in inspiration, unless intubation affords considerable relief, tracheotomy is required. In edema of the glottis and periglottic tissues, and also in some cases of injury at the base of the tongue the pharynx, or laryngeal fractures, a tracheotomy may be necessary. Severe dyspnea resulting from protracted spasmodic action of the laryngeal structures may also be an indication. The operation may also be indicated in some cases of tubercular laryngitis, in the progressive stenosis of syphilis or obstructive gummata. Laryngeal growths, the pressure exerted by inoperable malignant disease, or foreign bodies in the air passages, which can not be removed through the pharynx, may necessitate this operation.

Contra-indications.—Whenever the chances are that intubation will afford relief, tracheotomy should not be performed.

Operative Procedures.—The patient should be lying flat on the back, with a pad under the neck which causes full extension of the head, and the structures of the anterior structures of the neck be made prominent, tense, and firm.

Unless contra-indicated, general anesthesia is preferable, but when not advisable to use general anesthesia, the use of ethyl chloride will suffice, as there is little pain after the integument is divided. When local anesthesia is employed, an assistant must steady the head. The hypodermatic use of cocaine, etc., is not advisable. The skin of the neck should be properly cleansed before making the incision.

The physician should have a small scalpel, grooved director, small retractors, blunt hooks or aneurism needles, tenaculum, hemostats, dissecting forceps, a sharp pointed bistoury for opening the trachea, and a probe pointed bistoury for enlarging the incision if required; tracheotomy tubes, tape, tracheal dilator, tracheal forceps, and such other appliances as are usually required in surgical procedures. An assortment of tracheotomy tubes should be at hand, and the largest that can be worn comfortably is usually the best.

The isthmus of the thyroid gland determines the anatomical division for the various operations. High tracheotomy is understood as being above the level of the middle of the thyroid isthmus, and is most easily performed. If the incision extends upward, dividing the cricoid cartilage, it is called laryngotracheotomy. Low tracheotomy is where the incision opens the trachea below the middle of the thyroid isthmus, and is preferable in some cases of foreign bodies, or if a permanent opening is necessary.

HIGH TRACHEOTOMY.—With the patient in the proper position, the operator locates the landmarks, and ascertains if possible, the course of the anterior jugular veins. The tissues being steadied with one hand, the initial incision is made through the skin, from about the level of the cricoid downward in the median line an inch and a half to two inches. If any veins present, they should be pushed to one side or ligated and divided. The grooved director is pushed under the superficial fascia which is then divided, and the deep fascia exposed. The same procedure is employed in

dividing the fascia and the incision of both must be the same as the initial cut. If any veins are encountered in this deep layer, they should also be pushed aside or ligated and cut. The intermuscular space between the sternohyoids and sternothyroids is determined and opened with a blunt dissector. The blunt retractors should be used to keep the cut surfaces separated, and an equal amount of force used on each, avoiding downward pressure, either of which might cause a displacement of the trachea. The bottom of the opening should be a layer of the deep cervical fascia, which divides in this region to surround the thyroid isthmus, and some of this latter structure may be outlined, or be bulging into the wound. The grooved director should be used, as on the other fascias, and after the incision is made, the isthmus of the thyroid is drawn downward by a blunt hook. If the isthmus occupies too much of the wound, a transverse incision, not over half an inch, may be made over the cricoid, and the fascia and isthmus together be stripped up and drawn downward. The loose connective tissue overlying the trachea must be carefully cleared from the operative field to expose the rings of the trachea. A tenaculum is fastened to the cricoid cartilage, steadying the larynx and trachea, and guarding the knife with the forefinger, to prevent cutting too deeply, the blade is introduced into the trachea in the median line above the isthmus and cutting upward, divide two or three of the tracheal rings. When there is membrane in the trachea, it should be incised, as otherwise it may be pushed downward by the knife. After the trachea is opened, there is often coughing and ejection of bloody mucus, etc. Not infrequently there is an alarming collapse of the patient after the trachea is opened. The trachea should be cleared as much as possible of morbid material, the traumatic surfaces cleansed, and the tube inserted and retained in position by tapes passed around the neck. Sutures may be used below the tube. If tubes are

not used, the opening may be preserved by the use of blunt retractors held in position by tape or elastic bands.

LOW TRACHEOTOMY.—This operation is performed practically the same as the high. The initial incision extends from just below the cricoid cartilage nearly to the manubrium. The fascia are divided as in the high operation, but the thyroid isthmus is drawn upward. In this operation the thyroidea ima artery must be remembered as well as an occasional unusual height of the innominate artery as far as the eighth or seventh ring of the trachea. The size of the thymus gland should also be remembered, it being in inverse ratio to the age of the patient. The rest of the operation is similar to that of a high tracheotomy.

LARYNGOTOMY.—This is probably the easiest and quickest operation in an emergency case on account of the superficial position of the cricothyroid membrane and the lack of important vascular structures, but should not be performed on a patient under thirteen years old on account of the small size of the cricothyroid space. The membranous space between the cricoid and thyroid is determined and a median incision through the skin and fascia is made. The sternohyoid and sternothyroid muscles are separated and a transverse cut is made through the cricothyroid membrane close to the border of the cricoid. The small cricothyroid artery is to be avoided. The knife is to be guarded with the finger as in tracheotomy. A short tube may be inserted or retractors used to keep the wound open. If the operation has been performed as an emergency measure, and it is unnecessary to keep the wound open, it may be allowed to heal by granulation.

Operative Complications and Dangers.—Opening into the larynx is not normally a difficult operation, but when the necessity for operative measures are present, an abnormal condition exists, which complicates the work. Undue haste is usually unnecessary, but in some instances a

prompt thrust with the knife may be required, simply locating the prominent points by a rapid examination, in order to preserve life. The rapid movements of the larynx and trachea in labored inspiratory efforts, makes the work difficult. In these cases there is nearly always considerable engorgement of the veins, and profuse hemorrhage is liable to occur, but this often rapidly diminishes after respiration is restored. An accidental cut of the thyroid isthmus may be followed by a sudden and profuse hemorrhage, requiring an immediate use of hemostatic forceps. A faulty position of the retractors or a deviation from position, may result in a dangerous lateral incision reaching even to the vertebræ. Excessive pressure of the retractors against the trachea may contuse the structures. If membrane is present in the trachea, the knife may push it backward instead of penetrating it, thus giving no relief from the dyspnea, or even aggravating it by crowding the membrane into a compact mass in the trachea. In the latter complication the use of tracheal forceps, scissors, or knife may be promptly required. Occasionally the knife may injure or penetrate the posterior tracheal wall and even incise the esophagus. The trachea may be obstructed with blood, blood and mucus, or mucus, which will have to be removed. In these cases the Trendelenburg position, or partial inversion will aid in expelling the material, keeping the wound open to aid in its expulsion. A flexible catheter may be used to aspirate the material and to force air into the trachea, introducing it far enough so the air enters the lungs. The respiration may suddenly cease, either prior to or following the complete incision. If the former, the operation must be immediately completed and efforts made to restore respiration, the usual methods being employed. As a rule the collapse is transitory.

Post-operative Care, Dangers, and Complications.—The after attention is equally as important as the skill in per-

forming the operation. If the measure is simply for the removal of a foreign body, a thorough cleansing of the wound with an antiseptic solution and covering with a sterile dressing will be all that is required, the wound healing by granulation. If an edematous condition is feared, or for any other reason it is desirable to wait a short time before allowing the closure of the wound, a tube or retractors may be used. Verat. um or aconite is usually required, and cough should be controlled by the indicated remedy. The patient should be kept in the recumbent position, the air in the room warm, and kept moist by boiling water, or moist gauze may be placed over the tube or opening. It is not often necessary to resort to artificial methods of feeding. Careful attention to the usual body functions is necessary and as much rest and sleep as possible insisted upon. When a tube is to be retained, the patient will require close attention, especially while recovering from the anesthetic, and also later on in young children. The moistened gauze should be used, as it clears the inspired air of dust. It is essential that the tube should be kept free of accumulations of mucus, etc., and this will necessitate considerable care in many cases. In conditions where there is a rapid accumulation of secretion, it may be necessary to cleanse the tube every half hour, a feather or brush being used for the purpose. The inner tube may have to be removed on account of becoming occluded with membrane. The canula must also be cleansed with an alkaline solution, but the inner tube should not be left out too long. In membranous cases, the occlusion may require the removal of the canula, and the tracheal dilator and forceps be needed for removing the material. Directions for the removal of the canula the membrane, and for keeping the wound patent until the physician arrives, should be given, as until sufficient healing has occurred to form a canal, the reintroduction of the tube is often difficult. The canula should be removed

every two or three days, and if any discoloration from sloughing areas is observed, such areas should be touched with nitrate of silver, the surfaces cleansed and after cleansing the tube it should be replaced. In membranous cases the tube is required for from eight to fifteen days, but the time varies according to the case. When the tube is permanently removed, the wound heals by granulation.

CHAPTER XXIII.

EAR.

Malformations.

Congenital malformations may be divided into four classes: (1) Deformity of some portion of the auricle, but the general contour of the external ear not changed. (2) Change in contour or a malposition of the auricle. (3) An anomalous condition as supernumerary appendages, fistulæ, etc. (4) Asymmetry of the auricles.

(1) *Helix*.—The so-called Darwinian and satyr ears are not uncommon. The absence of the upper portion of the helix has been reported, as well as an abnormal development of this part.

Antihelix.—This may be developed so as to project beyond the line of the helix. This condition seems to be found more frequently in the criminal classes or the insane. Infrequently there is such a development of the superior crus of the antihelix as to crowd the helix upward and forward, producing the so-called pointed ear.

Lobule.—In the colored race the lobule is often excessively developed. The lobule may be absent or rudimentary. Cleft lobule is probably oftenest found.

Tragus.—This may extend so far backward as to actually interfere with sound waves entering the meatus.

Antitragus.—Very seldom found. In one case reported, two cartilaginous spurs projected from the antitragus into the canal.

(2) CHANGE IN CONTOUR OR A MALPOSITION OF THE AURICLE.—The most notable form is termed microtia, and

results from an arrested or perverted development, the distinctive parts of the auricle being illy defined. One or both sides may be affected, and often there is some deformity of the deeper portion of the ear. As a rule the external auditory meatus is lacking or rudimentary. The ossicles may be absent or non-developed, and the labyrinth is also often defective. To relieve the external appearance a plastic operation may be beneficial when the deformity is not very extensive, but trying to form an artificial meatus is usually an unsatisfactory procedure.

Another anomaly is where the auricle stands out from the head at considerable of an angle. In early childhood an improvement may be obtained in some cases by such measures as will draw the auricle closer to the head and retain it in the desired position. Collodion or adhesive plaster may be employed for the purpose. Strips of gauze may also be employed to press the auricle to its normal position. The mechanical treatment must be continued for some time. In adults, operative measures are necessary.

(3). ANOMALOUS CONDITIONS AS SUPERNUMERARY APPENDAGES, FISTULÆ, ETC.

Auricular Appendages, the General Contour of the Auricle Normal.—The usual location is the region of the tragus, and sometimes these appendages are quite large. The removal of these anomalous growths is usually easy.

Included under this division is "fistula congenita auris." This is the result of defective development and is not very often seen. The defect may or may not be bilateral. The fistula may be located immediately above the tragus, or considerably higher. A slight discharge may come from this tract. Unless a retention cyst forms, no treatment is required. If a cyst forms occluding the opening of the sinus, an incision and removal of the contents, then curetting the walls of the cyst is necessary.

POLYOTIA.—This means, besides microtia, supernumer-

ary growths in the neighborhood of, but distinct from the auricle, and may be only on one side. These growths sometimes are present with a normal auricle. They vary in shape and size, but usually are wart-like. These growths are usually readily removed, although a plastic operation may be required.

CHAPTER XXIV.

WOUNDS, INJURIES, CUTANEOUS AND INFLAMMATORY DISEASES OF THE AURICLE.

Wounds of this structure are infrequent, but more or less severe injury from burns are not uncommon. In lacerated wounds, if seen early, the approximation of the surfaces by adhesive strips, collodion or sutures, which should be introduced on the posterior surface, will usually give satisfactory results. If the injury is of long standing, plastic work is necessary. On account of the large proportion of cartilage in the auricle, perichondritis is liable to follow much bruising of this structure.

Contusion is a not infrequent condition, and hematoma or perichondritis may result, and it is not always easy to differentiate between them in the early stages. There is a spherical tumefaction, which on palpation reveals fluid. The color of the swelling varies, depending upon the character of the injury, and somewhat upon the nature of the fluid. If blood, the appearance is usually a dull deep-red color, but in perichondritis with an effusion of serum, the color may be much lighter, or even no change from the normal. Either condition may remain passive for some time; or it may disappear spontaneously leaving more or less deformity; or suppuration and evacuation of the material may result.

When extravasation of blood has occurred from an injury, the cartilaginous tissue has usually been injured, necrosis and exfoliation nearly always following, resulting in

deformity. In simple perichondritis deformity is less liable to occur.

In burns, not only the integument, but often the deeper structures are injured, and sloughing of the parts may occur. A perichondritis or chondritis is not infrequent in these cases, and the resulting deformity may be considerable, sometimes nearly the entire auricle being destroyed.

Treatment.—In perichondritis from contusion, if seen early, the application of cold by the use of an ice-bag or Leiter's coil, or better still, a cold dressing of aconite and veratrum āā ḡj , to aqua ḡiv , will often prevent much effusion. Evaporating lotions may be used for the same purpose. When effusion has occurred, the most satisfactory results are obtained by a free incision, then curetting the sac walls and packing with gauze, endeavoring to have the space fill by granulation. Often healing will occur in these cases without much deformity. If necrotic changes have occurred, the same procedure is required, all softened areas being curetted, and the after treatment as designated above.

In burns or scalds, the treatment will not vary materially from that already given, only such measures should be employed as will relieve the pain, and for this purpose a 10 per cent aristol ointment has been of value.

When the ears have been frozen, the usual application of snow, or pounded ice, followed by cold water is the best first aid. The after treatment will not vary materially from what has already been given.

Internally aconite, veratrum, and lime in some form are usually required.

In any of these conditions the blood supply must be considered, and the strapping or binding of the auricles to the head, or any undue pressure upon them, or at their attachment, is to be avoided. Extensive loss of tissue or considerable deformity is liable to follow unless free circulation is maintained.

Intertrigo.

This condition is most frequently found in young children, especially among those who are compelled to wear the "cute" caps which press the auricles close to the sides of the head. When this is continued for some time, the action of the body temperature and moisture causes desquamation of the superficial epithelium, exposing the deeper layer of the integument to the air. Hypersecretion from the denuded areas increases the condition, and the intense itching causes the child to still further irritate the parts. The posterior surface of the auricle and the corresponding area of the side of the head, presents a reddened appearance, and an abundance of serum covers the denuded parts. The tissue of the affected area is not thickened, which differentiates the condition from eczema, but the latter soon follows if relief is not promptly given. Illy nourished children appear most susceptible, and hereditary predisposition to skin affections also seems to have an influence in producing this condition. Lack of cleanliness is also an undoubted factor.

Treatment.—Separation of the denuded surfaces, and a covering by some of the dusting or toilet powders is all that is required as a rule. Cleansing of the parts with an un-irritating soap, and in some cases the use of an ointment of Eucalyptus, will also be necessary.

Eczema.

This may be either acute or chronic in character.

Etiology.—The causes are not well understood. Hereditary predisposition, as a gouty or rheumatic tendency, or scrofula, may have an influence, while disturbances of the alimentary canal, improper food, etc., are often followed by this condition.

Local causes are important factors, as the discharge

from a suppurating otitis media, if long continued, is very liable to cause eczema. Lack of cleanliness may also produce this condition, especially where there is a predisposition to skin affections.

Symptoms.—In acute attacks there is often a sensation of burning or discomfort at some part of the auricle. In children, this is usually at or near the junction of the ear with the side of the head, but it may affect any portion of the auricle. An intense pruritus soon follows, and the scratching of the parts increases the irritation. The surface is reddened and desquamation of the superficial epithelial layer soon occurs; a moist serum exudate covering the surface, or later crusts, which on their removal reveal bright red surfaces. A vesicular form may be present, the vesicles soon becoming pustular and rupture, covering the surface with thick, dirty, yellowish crusts, a slight hemorrhage often following their removal.

In the chronic type a part of, or the entire auricle may be affected. It is characterized by either a dull pinkish color, the surface being glossy as though the skin was thin and tense, or as though the superficial epithelium was exfoliated too rapidly, the surface being irregularly covered with fine, whitish scales or crusts. The intense itching causes the patient to pick off these scales, and often abrasion of the skin follows these efforts, which augments the condition. The unabraded surface has a smooth feel to the touch.

Pathology.—In both forms there are true inflammatory changes in the deeper layers of the integument, which do not vary particularly from those of mucous membranes. Palpation reveals the thickened condition of the parts, showing that an infiltration has occurred.

Diagnosis.—Attention to the symptoms usually renders the diagnosis easy.

Treatment.—This necessarily is directed to the exciting

cause, whether local or systemic. The administration of arsenic in some form in chronic conditions, is usually beneficial. Saline cathartics are also often required. Podophyllum, chionanthus, nux, rhus tox., or hydrastis may be indicated. The local use of salicylic acid ointment in the dry, scaly form, will usually afford relief and hasten a cure. In the moist form the ointment of eucalyptus, or the stearate of zinc comp. with euophen or tar will often be most grateful to the patient. Liquid preparations, and frequent bathing of the parts usually increase the trouble. Protection from the air is especially important in the moist forms.

Pemphigus.

This is an infrequent condition, but resembles the same lesion upon other parts of the body. The etiology is unknown. The affection appears in the form of bullæ which are filled with a clear serous fluid, and the blebs are usually located on the margin of the helix and lobule. The fluid may become turbid but seldom is purulent. After a few days spontaneous rupture occurs, the surface eventually showing simply a slight redness, or an eroded condition depending upon whether the sac walls are destroyed or not. When the surface is eroded, there will soon followed a dryness of the area, and a reddened condition will persist for some time. Pain is absent, but recurrence is the rule.

Treatment.—Puncture the blebs, and cover the surface with flexible collodion. Internally such remedies as are indicated.

Herpes.

Infrequently seen. It resembles herpes zoster, modified only by its location. Found most frequently in neurotic subjects.

Etiology.—Faulty nutrition and improper food are often considered factors. As an exciting cause, exposure to cold is often credited, as having a direct influence.

Pathology.—Not understood, but is probably a neuritis of the trophic nerves.

Symptoms.—Usually ushered in by severe systemic symptoms. The pulse is rapid, temperature increased, varying from 100° to 103° Fah., headache and general malaise. Neuralgic pain, confined to the ear, or over the entire side of the face supplied by the affected nerve. The pain may precede the eruption. When the eruption occurs, vesicles filled with serum cover the affected area, the bases being reddened. If coalescence occurs, a bullous type results. The outer surface of the auricle is usually affected, and it usually is unilateral. The affection may invade the external auditory canal. The vesicles rupture in a few days, and the secretion dries and forms small scales which loosen and leave a reddened or brownish colored surface. In cachectic patients, a superficial ulceration may continue for some time. After the eruption the systemic symptoms usually subside. Frequently there are recurrent attacks.

Diagnosis.—Easy after the appearance of the vesicles, but prior to this, it is often difficult.

Treatment.—The constitutional treatment should be directed to cleansing the alimentary tract, and the saline cathartics are usually indicated. The food should be such as produces the least amount of waste products, being nutritious and easily assimilated. For the febrile symptoms, aconite or veratrum. Rhus tox. is often indicated in these cases. Phytolacca is frequently required on account of its action on the glands.

Locally.—Cold applications are often useful before the eruption appears, but after the vesicles form, some unirritating dusting powder should be used.

Syphilis.

Any form of syphilis may appear on the auricle, but is infrequently seen. The appearances are similar to those found elsewhere, and the treatment is the same.

Lupus Erythematosus.

Usually secondary, as the condition spreads from some other portion of the face.

Etiology.—All forms of lupus are now considered tubercular.

Symptoms.—In the early stages, circumscribed, slightly elevated areas are noticed, which soon extend in all directions. The skin over these areas is thickened, injected and separated from the normal cutis by a decided line of demarcation. A glazed appearance is noticed, owing to the retarded blood supply. The general progress is similar to that on the face. Very infrequently both sides are affected.

Treatment.—The same as for this condition on the face.

Lupus Vulgaris.

Very seldom seen as a primary condition. It should be treated the same as when occurring upon the face.

Inflammatory Conditions.

PERICHONDRITIS.

This sometimes occurs as an idiopathic condition, or as a complication of acute inflammatory action of the external auditory canal.

Symptoms.—A sensation of heat, which is soon followed by pain. The auricle swells, and the skin over the affected area becomes a bright red. The swelling may increase until the outline of the auricle is lost, as a result of the effusion of serum between the cartilage and perichondrium. This fluid soon becomes purulent. The portion and extent of the tissue involved determines the amount of deformity. Unless relief is obtained by proper treatment, spontaneous rupture will occur, leaving sinuses which are difficult to heal, and usually considerable deformity remains.

Treatment.—Practically the same as in perichondritis from injuries, excepting that aspiration is not beneficial. Gruening advises incisions passing from before backward; penetrating the entire structure and keeping the incisions open by means of gauze. If the tragus is the part affected, Dench recommends a free incision and curetting of the cavity. The internal treatment should be as indicated.

ERYSIPELAS.

This is practically always secondary to facial erysipelas, and the treatment is the same.

ABSCESS.

Usually an abscess is the result of a perichondritis, but occasionally a circumscribed collection of pus may occur in the portion of the auricle composed of fatty and fibrous tissue. It nearly always is due to local infection, the lobule being usually the site, through irritation from an earring or piercing the ears. Infrequently a superficial abscess is located elsewhere in the auricle without implicating the cartilaginous structure. This condition is a retention cyst, caused by the closure of the orifice of a sebaceous gland.

Treatment.—Evacuation of the abscess and curetting the sac walls is usually all that is required.

HEMATOMA AURIS.

Synonym.—Othematoma.

This consists of an effusion or transudation of blood beneath the perichondrium, separating this tissue from the cartilage.

Etiology.—Often the result of an injury, but among the insane it is of comparatively frequent occurrence. It not infrequently is found occurring without any known cause, and age is not a factor.

Diagnosis.—The swelling is usually sudden, and without any premonitory symptoms, but occasionally there may be an initial burning or itching. The skin covering the swelling may be normal in color, or pale, this depending upon the amount of pressure exerted. The swelling usually involves more or less of the anterior surface. When the result of an injury, the history will aid in making the diagnosis. When not from a traumatism, the suddenness of the swelling will decide its character.

Treatment.—If the swelling is small and of recent occurrence, a firm compress may promote absorption, but as a rule evacuation is the best procedure. Aspiration followed by compression when the tumor is small, or a free incision and curettage if of considerable size, especially if a purulent condition exists. More or less deformity is liable to occur in severe cases.

THICKENING OF THE LOBULE.

This results from a chronic inflammatory action in which both the connective tissue elements and the glandular structures are hypertrophied. It is usually the result of mechanical irritation, most frequently from wearing earrings of cheap material.

Treatment.—Removal of exciting cause. If the deformity is considerable, a plastic operation may be necessary.

OSSIFICATION.

This is of very infrequent occurrence, and but few cases have been reported.

GANGRENE.

Necrosis of the auricular tissues sometimes occurs independent of traumatic lesions. In cases of extreme debility, such as follow the typhoid type of disease; or where a

continued suppurative process with necrosis of the bony structures of the temporal bone have occurred, a gangrenous state may occur, especially if pressure of the auricle against the head is continued for some time.

Treatment.—Practically as in gangrene of other structures.

CHAPTER XXV.

BENIGN AND MALIGNANT TUMORS OF THE AURICLE.

Benign. (1) Angioma, (2) Atheroma, (3) Cystoma,
(4) Fibroma, (5) Lipoma, (6) Papilloma.

Malignant. (1) Epithelioma, (2) Sarcoma.

ANGIOMA.

Infrequently seen, and vary considerably in size. The condition may be single or multiple, and usually the growth is slow. Kipp reports a case in which freezing of the auricle was a cause, but usually it is congenital. The auricle may be changed in contour or position and present a purplish-red color.

Treatment.—This will depend upon the size, character, and location. If small, electrolysis or the galvano-cautery will usually be sufficient. If large, extirpation may be required.

ATHEROMA.

This is caused by a filling up of obstructed sebaceous follicles, the secretion being retained through closure of the orifices, and more or less swelling occurs through continued secretion, and if the gland is active the pressure may be sufficient to cause spontaneous rupture, or some of the secretion may escape through the duct and partially relieve the condition. This may recur repeatedly, the patient complaining of intermittent discharge from the growth. Sometimes the pressure may be severe enough to cause an inflammation within the follicle, when a purulent discharge will result.

Location.—The lobule or the junction of the lobule with the neck is the favorite site, although other parts of the auricle may be affected.

Treatment.—Operative. The tumor should be removed through a free incision, care being taken not to rupture the sac. If the sac is adherent, or ruptures, it should be dissected from the surrounding tissue. Curettement is usually necessary, and salicylic acid ointment, or thuja applied to the cavity.

CYSTOMA.

The term is properly applied to a swelling upon the auricle, the result of a circumscribed collection of fluid independent of traumatism. Usually upon the anterior surface. The skin covering the tumefaction is normal in color and not sensitive to touch. The swelling occurs suddenly and seldom shows a tendency to increase in size. The cause is obscure.

Treatment.—The most certain method of treatment is by an incision, so made as to leave the least possible amount of deformity. This is best done by cleansing the sac thoroughly, closing the incision, and obtaining drainage by puncturing the cartilage, opening upon the posterior surface of the auricle.

FIBROMA.

This is the most frequently found benign growth of the auricle. It is quite common among colored people, and often is of considerable size. The irritation caused by earrings is the usual cause. The lobule is affected more than any other part of the auricle. The tumor is hard, and usually smooth, and is composed of dense, white, fibrous connective tissue. There is often a tendency to recurrence after removal, the new growths sometimes being of a malignant type.

Treatment.—Complete extirpation.

LIPOMA.

These growths sometimes occur just below the lobule. Seldom if ever are they found on the auricle. They should be removed the same as lipoma of other regions.

PAPILLOMA.

These in the simple form appear only as warts, and are easily removed.

Malignant Growths.

Malignant growths of the external ear are seldom primary. They may attack any portion of the auricle or the external auditory canal.

EPITHELIOMA.

Epithelioma of the auricle is probably due to the same cause as in other regions. Seldom occurs under the age of fifty, and the growth is usually slower than when it occurs elsewhere. The cervical glands are not often affected, hence systemic infection is infrequent. The characteristics of the growth are similar to those found in other regions.

Treatment.—Radical treatment, removing the entire mass is the proper measure. If thoroughly performed, there is seldom a recurrence.

SARCOMA.

Sarcoma is comparatively infrequent, and may be either primary or secondary, any portion of the auricle may be affected, and the morbid process may extend to the external auditory canal. The appearance of the growth varies according to its location. It is less firm, and ulceration occurs later than in epithelioma.

Treatment.—Extirpation of the growth by surgical measures. Recurrence is infrequent.

CHAPTER XXVI.

AFFECTIONS OF THE EXTERNAL AUDITORY CANAL.

(1) Acute Circumscribed External Otitis. (2) Chronic Circumscribed External Otitis. (3) Chronic Diffuse External Otitis. (4) Acute Diffuse External Otitis. (5) Croupous and Diphtheritic External Otitis. (6) Hemorrhagic External Otitis. (7) Impacted Cerumen.

Acute Circumscribed External Otitis.

Circumscribed External Otitis; Otitis Externa Circumscripta acuta; Furuncle; Boils.

Etiology.—This condition may result from mechanical irritation, as introducing aurilaves, hairpins, etc., to relieve an itching sensation; to inoculation by the same means; denudation of the epithelium from mechanical causes or cutaneous disease; or from the irritation caused by a suppurative disease of the middle ear. In some cases no cause can be determined.

Pathology.—The fibrocartilaginous portion of the canal is most frequently affected, the favorite location being the inferior, posterior, or superior walls. The swelling is usually near the external opening, but may be in any portion of the canal. The disposition to occur in crops is very marked. Whether a specific germ is responsible is a question, but that the suppurative process is often of a reflex character is very probable. The inflammatory process may extend to the perichondrium, and even the auricle, tym-

panum, or mastoid cells may be implicated. The suppurative process is similar to furuncles in other regions.

Symptoms.—Generally the first indication is a sense of fullness, discomfort, or itching. In a short time tenderness or pain becomes marked. The hearing is impaired, and tinnitus is often very annoying. The pain rapidly increases in severity, often producing hysteria in nervous patients. Pressure in front of the tragus increases the pain, and motion of the lower maxillary may be so painful that mastication of food, or talking may be almost impossible. The pain is often worse at night, but is more or less constant. If the furuncle is on the posterior wall, the auricle may be more prominent than usual, and pressure on any portion of the auricle causes intense pain. The tissues back of the ear are also often edematous when the furuncle is in this location. When the abscess is in the tissues of the anterior wall, the tissues in front of the ear often seem swollen.

The cervical and preauricular lymphatics are often swollen, and occasionally the parotid. Systemic symptoms are not always present. There may be a feeling of malaise, slight headache, and loss of appetite, but it is caused more by the pain and loss of sleep than an actual systemic infection. After forty-eight or ninety-six hours the distressing symptoms usually subside quite suddenly, the furuncle having opened spontaneously and the contents escaping from the meatus as a purulent discharge, may lead to a diagnosis of middle ear suppuration, unless a careful inspection is made. Recurrence of the condition is the rule. If the tympanum or mastoid cells are implicated, the pain will be more intense, and systemic disturbances are more or less marked.

Diagnosis.—Not always easy. In the early stages the pain is not localized, and an inspection of the canal may not reveal any disturbance. Palpation with a probe may reveal a sensitive area, and the examination should be made without using a speculum if possible, as the sensitive spot may

otherwise be covered by the speculum. When the furuncle is in the deeper portion of the canal, the speculum will usually be required. A slight redness of the affected spot may sometimes be detected. After swelling occurs, it is usually easy to determine the character of the condition, unless the tumefaction is sufficient to occlude the canal, when a positive diagnosis can not always be made. Pressure in front of the tragus will increase the pain, and aid in differentiating furunculosis from tympanic or mastoid inflammation. Movement of the auricle in different directions will also increase the pain when the inflammatory action is in the canal.

Edema over the mastoid may occur, and lead to a diagnosis of mastoid disease, but if firm pressure is made over the mastoid and care exercised not to impart motion to the canal, which can be done by making the pressure rather backward and inward, when the inflammatory process is confined to the canal, there is no increased tenderness. Suppuration of the parotid gland may lead to an error in diagnosis. The gland is often affected secondarily when the furuncle is located on the anteroinferior wall of the canal.

Prognosis.—In uncomplicated cases the condition usually lasts from four to eight days, the severity of the attack being about the third day. The tendency for recurring attacks must be remembered. If uncomplicated there is not often any impairment of hearing.

Treatment.—When the condition is recognized early, a saturated alcoholic solution of boric acid has been claimed to be efficacious in aborting the boils. The method often employed of blood-letting is a relic of barbarism. For relief of the pain after swelling commences; the use of dry heat will sometimes be beneficial, Japanese pocket-stoves being especially useful. The introduction of pledgets of cotton saturated with tincture of opium will probably relieve more cases than any other drug. A ten or twenty per cent

solution of menthol in albolene will sometimes give relief. The oil used should always be one that will not oxidize, as a rancid fat in the canal may cause a chronic eczematous affection that is difficult to cure. Poultices in the ear are also to be avoided, as they are likely to increase the liability of successive crops of boils. The use of white vaseline alone, or an ointment of boric acid in white vaseline will soften the integument and hasten rupture of the boil. It is the best practice in these cases to freely open the boil as soon as it is plainly discernible, and not to wait until pus has formed. This can be done with but little pain to the patient if the furuncle is in the external portion of the meatus, by packing the canal below the tumefaction with cotton, then freeze the part with ethyl chloride. If the furuncle is in the deeper portion of the canal, cocaine in absolute alcohol and aniline oil $\bar{a}\bar{a}$, to make a twenty per cent solution, and used a few minutes before making the incision, will diminish the sensibility of the parts. The incision must be extensive enough to relieve the tension, a slight puncture simply increases the pain. The relief from tension and the hemorrhage following an incision will afford considerable relief. After an incision has been made, the canal may be douched with a solution of boric acid, or simply tepid water, but the stream of fluid should be continuous, for ten or twenty minutes. A fountain syringe, or rubber tubing acting as a siphon, may be employed. Care should be taken that the receptacle for the fluid is only high enough so the water will flow into the canal without producing undue pressure on the membrana tympani. Even after a free incision, there will be a discharge of blood-stained purulent material for several days, although the parts will return to their normal contour usually within twenty-four hours. Exuberant granulations may occur, but are readily removed by a sharp curette, or the application of

saturated Lloyd's salicylic acid in thuja, nitrate of silver or chromic acid. The former solution is preferable.

Internal treatment is valuable to prevent a recurrence. The bowels should be kept in an active condition, and calcium sulphide given to the point of saturation. Lime water is usually better for babies, as it can be given in milk or added to the drinking water. In anemic persons arsenic iodide should be employed.

Chronic Circumscribed External Otitis.

This is usually the result of an affection of the cartilaginous or bony structures. If of the cartilage; it may be due to a severe type of acute furunculosis, and if of the bone, it usually is the result of some mastoid affection. These tumefactions are essentially chronic in character, and the only measure of relief is a free incision and removal or destruction of the sac by the use of the curette.

Diffuse External Otitis.

Either an acute or chronic type may occur, and it may affect the entire canal, or only a major portion. The line between the normal and affected parts is not clearly defined.

Acute Diffuse External Otitis.

Etiology.—Injury of the canal by mechanical means is a frequent cause. The use of aurilaves, hairpins, or similar implements for "cleaning the ear," are often the exciting factor. The use of escharotics may also be a cause. Sometimes a furuncle may cause the condition. It may develop from exposure to cold, or may be a complication of influenza, the exanthemata, or typhoidal types of disease. The most frequent cause is a purulent otitis media, in which the tissues of the canal become infected through the surface being bathed with secretion. It frequently is an exacerbation

tion of a former chronic condition. It may also be caused by instillation of various "ear-drops."

Pathology.—The cellular tissue is the site of a diffuse inflammatory action. Severe congestion of the parts is soon followed by a profuse exosmosis causing an edema. Infrequently the formation of pus may follow, if the process is not controlled.

Symptoms.—The initial symptom is a sensation of fullness or discomfort, which rapidly becomes an intense pain. The systemic phenomena are, increased temperature of two or three degrees; rapid pulse; marked prostration; headache; loss of appetite, etc. The canal is closed by the edematous state, and the hearing impaired. Subjective noises are usually present. Pressure on the auricle increases the pain. The post-auricular and sub-auricular lymphatics are often affected, and occasionally the pre-auricular, and movement of the jaws intensifies the pain. Occasionally it is very difficult to open the mouth.

Diagnosis.—Differentiated from furunculosis by the more marked systemic disturbances and more rapid development. The external third of the canal is often normal in size, and the introduction of a speculum does not cause much pain. The deeper portions of the canal are usually diminished in size, the swelling being most frequently from the supero-posterior wall, and the membrana tympani is more or less hidden from inspection. In severe cases complete occlusion of the canal may occur. A dead white color, the result of necrosis of the superficial epithelium, will be seen, and some moisture will cover the swelling. On removal of this covering, a reddened, moist looking surface is present. Probe palpation; pressure in front of the tragus, or an upward and forward motion imparted to the canal is very painful. Edema back of the auricle may be present, and also some enlargement of the lymphatics along the anterior border of the sternomastoid muscle. When this con-

dition occurs, it is often difficult to differentiate between the external otitis and perforation at the tip of the mastoid, excepting by the use of the speculum. Sometimes a diffuse inflammation may result from an acute purulent otitis media, and it is necessary to obtain a view of the membrana tympani to determine positively the condition. Patience in making the examination will usually give the physician a fairly satisfactory view of the drum membrane.

Prognosis.—This depends considerably upon the exciting cause, but usually is of comparatively short duration, unless it is an exacerbation of a chronic lesion.

Treatment.—Continuous irrigation with hot water, or if seen early, the introduction of pledgets of cotton saturated with aconite, veratrum \AA 5j, aqua q. s. \AA ij-jv, will afford relief. In some cases the Leiter coil or ice bag will be most grateful. If relief does not follow within twenty-four hours, a free incision along the postero-superior or posterior wall is advisable, the incision being from one-half to three-fourths of an inch in length, and carried down to the bone. This should only be attempted under good illumination. After the operation, the canal should be freely irrigated every three or four hours until the discharge subsides, after which irrigation is injurious. When syringing is no longer necessary, the use of boric acid is most beneficial.

Internal.—Thorough evacuation of the bowels by a saline cathartic, and the administration of apis, apocynum, or gelsemium are usually indicated. Aconite may be required if febrile symptoms are very marked. The food should be such as is easily assimilated. Opiates are seldom required.

Chronic Diffuse External Otitis.

This term is applied to any diffuse chronic inflammatory condition, whether of the superficial epithelial layer only, or when the entire canal, including bony and cartilaginous tissue is involved.

Etiology.—Traumatism of the canal is a common cause of this condition. The pernicious habit of “digging” into the external auditory canal with wash rags, towels, aural-laves, hair pins, etc., is a very prolific cause of a slight, persistent inflammation. The advice of Prof. Pomeroy “not to go into the canal of the ear with anything smaller than your elbow” was good. The tip of the little finger will go as deeply into the canal as is necessary for cleansing the ear. Injuries of the walls of the canal from any cause may produce the condition. The use of ear drops, especially such as contain an oily base which oxidizes easily; the introduction of foreign bodies into the external auditory canal, and especially the existence of a chronic purulent discharge from the middle ear, are also causes of this condition. The growth of vegetable parasites in the canal is occasionally a factor. Eczema of the canal is often a cause, and is specially intractable, as it is a symptom of some systemic disturbance.

Pathology.—This varies according to the exciting cause. In the mild forms, there is increased glandular activity. When the interglandular tissue is affected, there follows some infiltration of the deeper layers of the integument. The amount of serum exuded depends upon the severity of the process. When profuse, the surface after cleansing, reveals a glistening, smooth red surface. If the exudate is scanty, it dries and with the desquamated epithelial scales, forms yellowish crusts, which more or less occlude the canal. If not checked, an actual hypertrophy of the basement membrane results, narrowing the canal. If the inflammatory process is in the bony portion of the canal, the bony tissue may be implicated, and even the tympanum. In this location it is often difficult to differentiate from mastoid disease.

When the inflammatory action is the result of foreign bodies, traumatism, or the development of vegetable parasites, the character of the changes are similar to those al-

ready described, but vary in intensity. Occasionally there is a rapid proliferation of the epithelial layer, the cells rapidly forming a compact mass which fills the deeper portion of the canal.

In some cases the deeper portions may be the starting point, and later affect the canal walls. This occurs most frequently when the process is located in the bony walls.

If the condition is due to vegetable fungi, a microscopic examination alone will determine the exciting cause.

Symptoms.—These will depend upon the exciting factor as well as the intensity of the inflammatory process. In mild cases there is a sensation of irritation or itching. If due to increased glandular activity, eczema, otomycosis, or fungi, which occlude the canal, impaired hearing or a tinnitus may be the most prominent subjective symptoms. In some there are reflex manifestations, as headache, pain along the branches of the fifth nerve, occasionally epileptiform attacks, and not infrequently sneezing or a paroxysmal cough. Autophony may be an annoying feature when the canal is nearly closed. A scanty secretion, drying in crusts around the opening of the canal, or a comparatively profuse watery discharge may be present. Not infrequently the lymphatics around the auricle are enlarged.

Diagnosis.—When the inflammation is confined to the canal, pressure directed backward and inward behind the auricle, will not reveal any tenderness, but if the pressure is directed forward, moving the fibrocartilaginous portion of the canal, tenderness or pain will be complained of. Palpation above, below, or in front of the canal, will cause more pain than when made over the mastoid. Inspection of the canal will show varying conditions depending upon the severity of the attack as well as the cause. In the milder types, which include seborrhea, eczema, or aspergillus, the walls are more or less covered by some incrustation. In seborrhea it is usually limited to the cartilaginous portion,

and appears as small, thin, yellowish crusts or scales which are easily removed, and have an oily feel. The removal of the crusts shows a reddened surface which is not moist. In eczema, the crusts are larger, more firmly adherent, and the morbid process extends from the external opening to the membrana tympani. The removal of the yellowish brown crusts reveals a reddened, moist surface, upon which a thin serum soon forms when the surface has been dried with cotton. The walls of the canal appear thickened, and probe palpation shows this condition is present.

When due to fungi, in the mild type the walls of the canal are more or less covered by a whitish or yellowish-white coating, which appears to be closely adherent to the canal walls. The cotton used in wiping the canal will remove either scales or even an almost perfect cast of the canal, leaving a denuded appearance of the walls. A microscopic examination will be necessary to determine the character of the fungi. Macroscopic appearances will often aid in determining the character of the variety of fungus. When white, it is usually *aspergillus glaucus*. Occasionally the canal walls and surface of the membrane may be dotted with small dark or black spots, which are the sporangia of *aspergillus niger*.

In desquamative inflammation, there will be found a compact, whitish mass, in the deeper portion of the canal. This is easily penetrated with a probe or curette, but is rather difficult to remove. The canal walls are usually moist, and have a macerated appearance. The superficial epithelium is easily wiped off with cotton.

If the process is a manifestation of mastoid inflammatory action, the superior and posterior walls close to the membrana tympani are usually most affected. The distinct outline between the drum head and the canal wall is more or less obliterated as a result of the bulging of the canal walls.

Prognosis.—This will depend upon the exciting cause as

well as the length of time the morbid process has been present. More or less impairment of hearing may result, and in some cases recurrence of the condition may be expected, no matter what the treatment.

TREATMENT.—*Locally.*—The salicylic acid ointment will often prove beneficial in eczematous or glandular types. In some cases the eucalyptus ointment will be effective. The compound stearate of zinc and tar is useful for relieving the itching. If the condition is the result of fungi, the use of salicylic acid ointment, stearate of zinc with salicylic acid medium, oxide of zinc, or boracic acid twenty parts, salicylic acid one part, will afford relief. Fluids usually aggravate the condition and should seldom be used.

Internally.—Liquor potassii arsenitis, arsenous acid, arsenic iodide, phytolacca, hydrastis, or jaborandi are usually indicated.

Croupous and Diphtheritic External Otitis.

These are infrequent forms of diffuse external otitis, and the croupous is seldom seen. In either type the exudate partakes of the characteristics of the same condition in the throat or nose, modified in a measure by its location. The treatment will be similar to the same affections on the mucous surfaces.

Hemorrhagic External Otitis.

This may be either primary or secondary. The anterior and inferior walls of the canal are most frequently affected. Vesicles filled with a bloody fluid form, and if undisturbed, disappear in a few days, leaving at their site excoriated spots. There is severe pain, sometimes neuralgic in character; elevation of temperature; considerable general prostration, and infrequently delirium. The condition is sometimes present in epidemic influenza. When idiopathic,

Dench considers it a tropho-neurosis, or a complication of a simple diffuse otitis.

Treatment.—Usually systemic.

Impacted Cerumen.

Etiology.—Impacted cerumen may result from an over-activity of the ceruminous glands, or from some anatomical or mechanical interference with the free exit of the secretion from the canal. The occupation has an influence, as those who work in a dusty atmosphere are often affected on account of the floating material mingling with the secretion, causing it to become less fluid. After a variable length of time, when there is an obstructive condition, there will be formed a ceruminous plug, varying in size and consistency.

Pathology.—In simple cases of impacted cerumen, the mass when removed, will be found to be composed of the natural oily material, often vegetable spores, dust, and not infrequently in the center a foreign body which forms a nucleus for the cerumen. The plug is often covered with desquamated epithelium. If the mass is of considerable size, the morbid process is more complete, and a chronic desquamative inflammation of the deeper portion of the canal is present as a result of the presence of the impaction which acts as a foreign body. This impaction probably tends to increase the activity of the glands. When desquamative inflammation complicates the presence of a ceruminous mass, either the deeper portion of the canal may be much enlarged, or the bony walls may be partially destroyed. The posterior wall is most frequently affected, and the pneumatic mastoid spaces may be destroyed. Occasionally a chronic osteitis results from the pressure, and the mastoid cells are not only destroyed, but sclerosis of the entire process with ivory-like material follows. Perforation of the membrana tympani may occur from the pressure, and serious morbid changes result in the tympanum.

Symptoms.—These vary according to the size of the impaction, its location, and the amount of inflammatory action induced by its presence. There may be impaired hearing, tinnitus, autophony, a sensation of fullness, or a dull aching. In many cases there will be no subjective symptoms until the patient has taken a plunge bath, or in swimming or washing, water has entered the canal, which causes swelling of the hardened mass, closing the canal and producing some of the symptoms spoken of. Not infrequently a person will complain of getting water in the ear and not being able to get it out. In some cases there is a gradual diminution of hearing, and finally tinnitus or autophony. The pressure exerted may cause a severe neuralgic pain which may extend to the temporal and supraorbital regions, or affect the entire trigeminal branches. A sensation of numbness is not infrequently complained of, affecting not only the ear but also the entire side of the face.

Reflex phenomena are frequently present. Cough is most often complained of. The cough is spasmodic and often very severe. One case of asthma was relieved of the attacks by the removal of a ceruminous plug from the right ear. Hebetude is sometimes a prominent feature. The fellow ear is occasionally affected by the presence of an impaction in the canal of one ear. Epileptiform attacks or spells of vertigo may result from an impaction.

Diagnosis.—The only positive method of making a diagnosis is by inspection of the canal.

Prognosis.—Favorable so far as the removal of the mass is concerned, but guarded as to a recurrence of the condition, or as regards restoration of hearing. If of long standing, the probabilities are that impaired audition will remain after the ceruminous material has been removed. Not infrequently after the removal of a mass of cerumen there follows an acute diffuse inflammation of the canal, or furuncles may appear. If no special changes have occurred in

the tissues of the canal, there is usually a return of comparatively normal function.

Treatment.—Syringing is the best method for removing the mass, in the majority of cases being all that is required. In exceptional cases a probe or curette may be needed, but considerable skill is necessary in their use, as much damage may result from clumsy handling of the instruments. In the use of the syringe, it is important that the stream of warm water should be properly directed. The canal should be straightened by pulling the auricle upward and backward, the water being directed along the superior wall of the canal, unless there is more space along one of the lateral walls. The removal of the plug results from the force of the fluid back of it, causing it to be swept toward the external opening. If the entire canal appears blocked by the mass, a blunt curette or blunt spud may be used to loosen or remove some of the material. The force of the stream must be graduated to the sensations of the patient. If dizziness occurs, the force should be diminished. It is always preferable to first throw some of the fluid around the opening of the canal. The water should be comfortably warm to the patient. Infrequently a case is found in which the syringe will not remove the mass, and the blunt curette must be employed. In such a case the curette should be used along the posterior wall, making traction outward. After part of the material has been removed, the syringe will usually bring the balance away without much difficulty. In very exceptional cases, forceps will be required, but skill in their use is necessary. After the removal of the plug, the canal should be wiped with cotton, and in cold weather it is best to place a pledget of cotton in the canal and allow it to remain until bedtime. An inspection of the ear should be made within forty-eight hours, as a definite idea of the condition can not be obtained after syringing on account of the maceration of the tissues.

CHAPTER XXVII.

FOREIGN BODIES IN THE CANAL.

Under this heading may be included anything small enough to enter the canal. In children, or the feeble-minded, the introduction of various inanimate foreign bodies is not uncommon. Insects may enter the canal, and in suppurating conditions, maggots may be found. Among inanimate bodies introduced into the external auditory canal, the division must be made of inorganic and organic, as in the latter case swelling of the object may occur, which will cause severe pain.

Symptoms.—The symptoms, when inorganic, do not vary particularly from those given under impacted cerumen. The location will have an influence, for if the body is small and hard and rests against the drum membrane, more or less pain is liable to occur. If organic, and dry when introduced, the absorption of moisture often causes increasing pain, and may swell sufficiently to render it difficult to remove. If the foreign body is an insect or larvæ, the pain is usually so intense as to cause the patient to seek immediate relief.

Diagnosis.—If seen early, and unavailing attempts at removal have not been made, there usually is little difficulty in recognizing a foreign body, but when unskillful efforts at removal have been made, the swollen condition of the canal and often coagulated or dried blood render a diagnosis difficult, excepting from the history.

Prognosis.—Usually favorable, but where unsuccessful attempts at removal have been made, the tissues lacerated, and, as occasionally occurs, the foreign body has been pushed

through the membrana tympani into the tympanum, the prognosis may be unfavorable. The presence of the foreign




FIG. 101. Quier's Foreign Body Instrument.

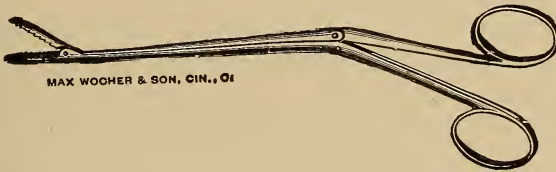


FIG. 102. Alligator Jaw Forceps.

body is often less injurious than the bungling efforts made for its removal.

Treatment.—In practically every case the simplest and safest instrument is the syringe. It is very seldom an object can not be removed from the external auditory canal by this means. If the stream of water is thrown along the




FIG. 103. Wilde's Ear Forceps.

superior wall of the canal, the return flow will usually carry the offending substance with it. In some cases a curette, Quier's foreign body instrument, or a blunt hook may be advantageously used. Forceps are seldom required, and usually simply force the body deeper into the canal. If the object is soft or friable, it may be necessary to break it into small fragments before it can be removed. In some cases general anesthesia is necessary.

Infrequently cases are encountered where it is impossible to remove the foreign body through the external meatus on account of the swollen condition, and resort to radical measures are necessary, but the novice should never attempt such a procedure.

CHAPTER XXVIII.

EXOSTOSES OF THE EXTERNAL AUDITORY CANAL.

Etiology.—Long continued irritation of the canal, especially in chronic purulent otitis media, appears to be a common factor. The condition is not as often seen among Americans as Europeans. There appears to be an hereditary predisposition in some cases to these growths.

Pathology.—Exostoses usually occur either at the junction of the bony and cartilaginous portion of the canal or deeper in the bony portion. One of two forms will be found, either having a broad base or as pedunculated masses. They may be cancellous or the so-called ivory exostoses. They are usually multiple. If but one, and it is of considerable size, the protrusion of the growth may cause the canal to have a slit-like appearance.

Symptoms.—If small, there are often no subjective symptoms, but if of sufficient size to occlude the canal, impaired hearing may result. In these latter cases, there is often a sensation of fullness or stuffiness in the ear, autophony and usually tinnitus. Collection of the normal secretion behind the growths causes a constantly increasing pressure upon the drum membrane as well as the walls of the canal, and a constant irritation will result, if it is not removed. An acute otitis media, or an acute external otitis may result from this accumulation, especially if water enters the canal causing swelling of the material.

Diagnosis.—Usually an inspection of the canal will determine the condition. If the growths are covered by ceru-

men or epithelial scales, syringing the canal will remove the covering material, or the use of a probe will determine the character of the growth.

Prognosis.—Guarded, so far as restoration of normal function is concerned, but usually favorable as regards life. The chance of an exostosis degenerating into a malignant growth should be remembered, especially if it is located near the orifice of the canal. Recurrence after removal is infrequent.

Treatment.—Operative. If the growth is pedunculated and situated well forward in the canal, a chisel will suffice. If the base is broad, it is usually necessary to use small drills in a dental engine, or a radical operation may be required. It is not advisable for the general practitioner to attempt these operations.

CHAPTER XXIX.

INJURIES AND DISEASES OF THE MEMBRANA TYMPANI AND TYMPANUM.

Etiology.—Injuries of the drum head may result either from direct or indirect means. Direct may be from the use of instruments, or through the introduction of foreign bodies into the canal. Indirect means may be through sudden condensation of the air in the canal by a “box” on the ear, the concussion following the discharge of heavy ordnance or a heavy explosion. Severe traction of the auricle, especially in children, may cause rupture of the membrana tympani. In intense inflammatory action in the canal, there may occur necrosis of the membrane, a perforation resulting.

Pathology.—If the injury is from the introduction of instruments, or implements for cleansing the canal or relieving irritation, it is usually located in the upper and posterior quadrant. If the result of concussion, the posterior superior quadrant is usually the location. If from traction upon the auricle, the membrana flaccida is oftenest ruptured. Ruptures due to traumatism usually are single, and their form varies considerably.

Symptoms.—Severe pain is the first symptom of rupture of the membrane from either instrumental manipulation or concussion. The hearing is impaired and tinnitus is decidedly marked. Vertigo usually follows a blow upon the ear, but is more the result of sudden increase of tension in the inner ear than the rupture of the membrane. In a short time the pain decreases and there is a thin watery discharge

in the canal. Blowing the nose will usually produce a whistling sound in the ear. Not infrequently a tedious suppurative process follows the injury, although if there is no injury of the tympanum, healing soon occurs.

Diagnosis.—An otoscopic examination will verify the history of an injury. In the membrana flaccida, ruptures are not so readily recognized as when in the membrana vibrans.

Prognosis.—Favorable in the majority of cases, unless injury of the middle ear structures or of the labyrinth has resulted from the injury.

Treatment.—If the perforation is the result of surgical manipulation, the drying of the canal and membrane with cotton, a slight dusting of the surface with boric acid and introducing a pledget of cotton in the canal, will be all that is required. If there should be sufficient serous discharge to saturate the cotton, the patient should be instructed to replace the moistened cotton with a dry pledget as often as is necessary. Usually healing occurs in twenty-four hours. In other cases the same general line of treatment should be followed, and only in extreme conditions should fluids be used in the ear, as the maceration of the tissues is liable to produce a suppurative condition.

Myringitis.

It is a question whether an independent inflammation of the membrana tympani can occur. Some aurists claim such a condition may be found and recognize an acute and chronic form. In the acute type, part or all of the membrane may be congested. In the later stages of the acute, or occasionally in the chronic form, there may be an effusion of serum in the dermal layer and also slight effusions of blood. Vesicles filled with serum frequently develop.

Symptoms.—Pain, varying in intensity, is present. Tinnitus and a pulsating noise is often complained of. Impair-

ment of hearing is less than in acute otitis media. In four or five days the condition usually is cured.

Treatment.—The use of boric acid insufflations is sufficient.

Inflammation of the Middle Ear.

The lining membrane of the entire middle ear is mucous membrane, and this membrane is subject to the same pathological changes as mucous membranes in other regions of the body. These have already been considered and will not be repeated, only to emphasize the fact that more or less occlusion of the Eustachian tube may result from tubal inflammation; ankylosis of the ossicles follow some exudative forms of inflammation in the tympanum; or by extension from the tympanum there may be a mastoiditis with its attending menace to life.

Tubal Congestion.

Synonyms.—Tubal Catarrh; Acute Salpingitis; Eustachian Catarrh.

Etiology.—Usually results from an acute rhinitis or an acute nasopharyngitis. In young adults it sometimes is a complication of the exanthemata. The use of the nasal douche, post-nasal syringe, or even the atomizer, may cause the condition by some of the fluid entering the tube. Adenoids are frequent factors in this affection.

Pathology.—This may be divided into (1) The changes in the Eustachian mucous membrane. (2) The changes in the tympanum through lack of patency of the tubes.

The tubal change is usually that of a venous hyperemia, but an inflammatory condition may be present. The mucous membrane is swollen and relaxed, the opposite walls being in contact with each other and adhesion resulting through the character of the secretion. Exudation of the blood elements results from the venous hyperemia, and when the

process is fully developed, the exudate is thick, tenacious, white and glairy, and often completely closes the tube. The cartilaginous portion of the tube is usually the most affected.

In closure of the tube, the air confined within the tympanum is rapidly absorbed, the membrana tympani, as a result of the diminished atmospheric pressure in the cavity, being pressed inward by the external pressure. In cases of long continued closure of the tubes, the membrane at the tip of the manubrium, may actually be in contact with the inner wall.

Symptoms.—When the condition is the result of a rhinitis or rhinopharyngitis, the symptoms usually appear suddenly. There is a sensation of stiffness or heaviness in the ear, and the patient places the tip of the finger against the orifice of the auditory canal in order to improve the hearing or relieve the sensation. Sometimes there is pain in the tonsillar region or the vault of the pharynx. The hearing is impaired, and subjective noises may be extremely annoying. The pitch of these sounds is usually high, and in persons who are plethoric, there may be an intensity of the sound with each systole. In some cases as a result of the sudden increase of pressure in the labyrinth, vertigo may be present. A feeling of mental dullness may be noticed, and apprehensiveness is not uncommon.

In some persons any exposure to cold will cause tubal congestion, and while not affecting the hearing, there will be subjective symptoms which are very annoying. These may be the sensation of a foreign body in the pharynx, or an acute pain at the base of the tongue.

Diagnosis.—Inspection will show a retracted membrana tympani, the manubrium more or less obscure while the short process is more prominent. The appearance of the membrane is normal, but the light reflex may be absent, broken, displaced or multiple. Inflation of the middle ear is difficult. Inspection of the nasal cavities and naso-

pharynx will usually reveal congestion or inflammation in one of these regions, besides more or less turgescence of the tissue surrounding the tubal orifice.

Functional tests will show diminished audition. This is probably due to some disturbance in the equilibrium of the labyrinthine fluid. The sudden obstruction of the Eustachian tube may cause a traumatic condition of the labyrinth similar to that produced by the concussion of an explosive or a blow upon the ear. An examination of the ear in the early stage may show the hearing is fairly good for low tones, the upper tone limit lessened, and bone conduction diminished. This condition shows a secondary implication of the labyrinth, and is amenable to treatment. The clinical history, an inspection of the membrane, nose and post-nasal space, will establish the diagnosis.

Prognosis.—Good, but the liability of recurring attacks should be remembered. The normal hearing usually is not recovered for several weeks.

Treatment.—I consider the method usually employed of inflating the ear as pernicious. It is true that temporary relief follows this procedure, but experience has shown that recovery is slow, and recurrence more frequent. There is a congestion or inflammation present, and the forcible dilatation of the tube by the air current will necessarily increase the morbid process. There is also danger of forcing the tubal secretion into the tympanum.

Internal medication promises the best and quickest results. The remedies most frequently required are aconite, gelsemium, phytolacca, bryonia, pulsatilla, jaborandi, liquor potassii arsenitis, belladonna, hamamelis, potassium bichromate, potassium iodide.

Hygienic measures should be insisted upon the same as in catarrhal conditions of the nose or throat. Abnormalities of the nasal or nasopharyngeal tissues should be corrected, provided they are of such a character as to be

either a secondary exciting factor or cause a continuation of the process when once established.

Acute Tubo-Tympanitis.

Synonyms.—Tubo-tympanic catarrh; Tubo-tympanic congestion.

Etiology.—This condition is produced by the same causes as tubal catarrh, but the tympanic mucous membrane is implicated as a sequence of the tubal occlusion.

Pathology.—Hyperemia of the inner wall of the tympanum and also slight hyperemia of the membrana tympani




FIG. 104. Effusion into the Tympanum. (After Politzer.)

as a result of engorgement of the vessels, is present. The congestion may result in hypersecretion and accumulation of mucus in the tympanum, or a simple serous exudate. This occurs most frequently in persons of a gouty diathesis, or in chronic cardiac, hepatic or renal affections. In the membrana tympani the venous congestion will show in the upper and posterior portions near the periphery and also along the handle of the malleus. Occasionally there will be sufficient exudation into the tympanum to cause bulging of, and even threaten rupture of the membrane.

Symptoms.—There is often pain in the ear, and tinnitus may be very marked, especially when the patient is in the recumbent position. Vertigo is a frequent symptom, es-

pecially when the head is suddenly moved backward or to either side. There is often a bubbling or snapping sound in blowing the nose, and also at times on swallowing. Autophony is often an annoying symptom, and some notes produce a sensation of pain. Auto-inflation often improves the hearing, but sudden impairment may follow the act of swallowing.

Diagnosis.—Inspection of the membrane will show some retraction and a pinkish tinge or a dull white color. At the periphery and along the handle of the malleus a marked change in color will be found. The change in the position of the membrane is not so marked as in simple tubal occlusion. If an exudate is present in the tympanum, the lower portion of the membrana tympani will have a slight yellowish tinge, while the portion above the fluid will have a more natural appearance. Aerial conduction is lessened for all sounds. Usually bone conduction is increased, and if the fork is held on the forehead or vertex, the vibrations are heard more distinctly in the ear most affected.

Prognosis.—In children complete restoration of hearing usually results, but in adults there is often some diminution of hearing.

Treatment.—This does not differ materially from that of simple tubal catarrh.

Acute Catarrhal Otitis Media.

Synonyms.—Otitis Media Catarrhalis Acuta; Earache.

This is a true inflammatory condition of the tympanic mucous membrane.

Etiology.—This condition may be a complication in acute infectious diseases, especially the exanthemata, or it may result from a rhinitis or pharyngitis. The use of the nasal douche, or violent efforts to clear the nasal cavities, may be a cause. In teething children earache is not uncommon. Abnormal conditions in the nasopharynx pre-

disposes to this condition. Exposure to cold or wet often causes an acute catarrh of the middle ear.

Pathology.—Similar to that of mucous membrane generally.

Symptoms.—As the symptoms vary according to the age of the patient, a division is made for convenience.

In young children the attack may be so severe that a diagnosis of meningeal or cerebral disease is often made. The attack usually comes on at night, and the first indications of illness will be restlessness, the arms being raised above the head, and often to the affected side. The child soon awakens, usually with a sharp cry of pain. The temperature as a rule varies from 102° to 104° . The child usually, on being lifted from its bed, presses the affected ear against the breast of the party carrying it, and its screams are symptomatic of agony. It is not the fretful cry of cerebral irritation, nor the peculiar moaning cry of meningitis. Excepting in the infrequent condition of both ears being affected at the same time, there is not the disposition to throw the head backward. Spasms or vomiting may occur prior to or during the height of the attack; if this occurs, the differential diagnosis between an acute catarrh of the middle ear and meningitis is often difficult, unless an examination of the ear is made. After a variable period the membrane ruptures, and a sero-mucous discharge will be found in the canal. When rupture occurs, there is usually a diminution of the pain, the temperature is reduced, and the child soon goes to sleep; but as the inflammatory action is liable to continue for several days, a normal temperature is not to be expected at once.

The first few days the discharge is profuse, turbid from the admixture of epithelial cells, and as there is usually considerable mucin present, the secretion is rather viscid. On account of this viscosity free escape of the discharge is impossible unless the opening in the drumhead is of consid-

erable size, and obstructive symptoms may result. After a few days the discharge becomes thin and watery, and often entirely ceases. If properly treated, the discharge does not become purulent, but in neglected cases a purulent discharge will often follow in a short time, and finally result in a chronic purulent otitis media. If the perforation in the membrana tympani becomes closed through any cause before the catarrhal process has subsided, there will be a return of the constitutional phenomena.

In adults the early symptoms may be so slight as to be ignored. Later there is a sensation of fullness in the ear, soon followed by pain, which steadily increases in intensity, and makes it practically impossible to sleep. Usually the pain is localized, and intensified on lying down. Subjective noises of a high pitch are usually present. The acuity of hearing is generally impaired, and almost total deafness in the affected ear may temporarily occur. The pain gradually diminishes after profuse secretion occurs, but there is a sensation of fullness or heaviness in that side of the head. On swallowing there is usually a sharp pain, often extending from the pharynx to the ear, and air passing into the tympanum and through its fluid contents produces a bubbling sound. There is seldom any febrile symptoms, but considerable prostration may result from the severe pain. Rupture of the tympanic membrane may take place within forty-eight hours, but in many cases this does not occur, and the sero-mucus in the tympanum produces the characteristic symptoms of an intratympanic effusion. When rupture occurs, there is usually an abrupt diminution of pain, and the presence of a sero-mucous discharge in the canal. When rupture of the drum membrane does not occur, the vault of the tympanum may be implicated, and at times the mastoid region is invaded by the morbid process. There is intense pain back of the auricle, which gradually involves almost the entire side of the head. In this condi-

tion there is usually increased temperature, as well as more severe local symptoms. If rupture of the drum membrane occurs, there may be a spontaneous cessation of the condition, or it may become a chronic purulent otitis media.

Diagnosis.—This must be made both from the history, symptoms, and an inspection of the membrana tympani. In the early stages there is a marked hyperemia of the membrana tympani, especially along the handle of the malleus. The membrana flaccida is also hyperemic, and often the drum membrane is depressed. In the later stages the membrane is uniformly reddened, the landmarks obliterated, and a bulging may be seen. After the discharge has commenced, the canal of the ear will be found filled with sero-mucus. After this is removed the membrana tympani will show a white, dull coating, the result of necrosis of the superficial epithelium. On the removal of this coating with cotton, the membrane will appear red and swollen. The location of the rupture is usually easy, unless the canal is swollen. Rupture may occur in any part of the membrane, but is usually located in the inferior half.

Prognosis.—Usually favorable, even without treatment, but a chronic purulent otitis media, or even a mastoiditis, may follow. If perforation does not occur, complete resolution may not take place, and infrequently inspissated material remains in the tympanum, which may be a source of annoyance to the patient. One case that I had under treatment for this condition, the removal of this mass of inspissated material by incising the membrane and removing the mass with forceps gave immediate and complete relief.

Treatment.—The most imperative indication is for the relief of the pain, and in the majority of cases the use of chloroform vapor will be most satisfactory. The method usually employed is to pour about half a dram of chloroform into a DeVilbiss powder blower, and by the use of the bulb force the vapor into the external auditory canal. Care must

be exercised, so none of the liquid is thrown into the canal, as it will increase the pain and blister the integument. The use of the chloroform vapor has relieved ninety per cent of the cases in my practice. If this does not afford relief, either blowing warm tobacco smoke into the ear, using a common clay pipe, in the bowl of which is placed a live coal, and placing some tobacco over the coal, then placing the end of the stem at the opening of the canal, blowing through the bowl, will cause the hot air and tobacco smoke to enter the canal. Hot water used with a fountain syringe, having the bag just high enough so the water will flow gently into the canal, and increasing the temperature of the water gradually, as the patient can bear it, is also a measure that will often afford relief, but should not be employed excepting as a last resort.

The use of leeches around the ear, or of oily instillations into the canal is reprehensible.

Internally the use of *pulsatilla* and *gelsemium* will usually materially aid the local measures in relieving the pain. A saline cathartic can often be given to advantage. The use of opiates is infrequently necessary if the above measures have been employed.

Operative procedures are sometimes required, paracentesis of the membrane, especially when there is bulging from an accumulation of secretion in the tympanum. In young children it is better to use general anesthesia, but in adults the use of a fifteen per cent solution of cocaine in equal parts of absolute alcohol and analine pure, will be sufficient. The incision should be made at the most prominent point, or in the posterior-inferior quadrant, and close to the periphery of the membrane.

Acute Purulent Otitis Media.

Synonyms.—Otitis Media Purulenta. Acute Purulent Discharge from the Middle Ear.

The presence of pus is always significant of necrosis of the deeper tissues of the affected region, and in the tympanum the superior portion is most often implicated in this type of inflammation. A primary purulent otitis media is characteristic in this region.

Etiology.—The acute infectious diseases are the most common causes of this condition. The entrance of fluids into the tympanum through the Eustachian tube is also a frequent factor. Extension of an external otitis, by passing through the Rivinian segment may also be a cause. Rupture of the membrana tympani from any cause may be followed by a purulent discharge.

Pathology.—This does not vary particularly from a purulent inflammation of mucous tissue elsewhere, excepting as it is in a confined space, and the liability of extension of the morbid process to the brain or mastoid must be considered.

Symptoms.—The most prominent symptom is the sudden and intense pain in the ear. There is also increased temperature, headache, systemic depression, and usually constipation. Impaired hearing, an annoying tinnitus and occasionally vertigo are usually complained of. In children the symptoms are intensified, convulsions often ushering in the attack. In adults there may be delirium in severe cases. The temperature is much higher than in an acute catarrhal inflammation, and the systemic disturbances are also more marked. Unless relieved, the pain is continuous, until thorough evacuation of the inflammatory products occurs, and if the rupture in the membrane is not of considerable size, and occasionally when it is, there is only partial abatement of the pain. The mastoid may become implicated at any time during the progress of the disease, when there will be an increase of all the symptoms. Sometimes the intracranial structures are affected, and the usual line of symptoms of cerebral lesions will be noted. These symptoms depend upon the region and area involved.

The labyrinth may be affected, and then sudden attacks of dizziness, nausea, and more or less deafness results. It is not often that the labyrinth is involved, but as it sometimes occurs, the symptoms and seriousness of the condition should be remembered.

Diagnosis.—As there is danger of serious impairment of hearing, as well as of life itself, in this disease, an early recognition of the condition is important. A careful examination of the membrane should be made, especially of the upper portion, as in the early stages this is frequently the only part showing any abnormal change. Congestion of a deep, dull-red color will be observed, and does not extend below and often not as far as the posterior fold. As the process continues, there will be a decided engorgement of the tissues, the *membrana flaccida* being pushed outward and a little downward. Occasionally the swelling and edema may be sufficient to overhang the short process. Eventually the hyperemia involves the entire *membrana tympani*, and the outline of the *manubrium* usually can not be discerned.

When it is a complication of scarlet fever or any sudden acute infectious condition, the true character may be obscured by the dead white color of the membrane, caused by the necrosis of the superficial epithelium. This necrosed layer is readily removed with cotton, and the reddened membrane revealed. If the secretions have gravitated into the lower portion of the tympanum, the entire drum membrane may present a bulging into the canal. Occasionally the secretion may be retained by the mucous folds and form several tumefactions in the upper segment of the membrane. Spontaneous rupture usually occurs in the posterior portion of the membrane, above the center and near the periphery, but may occur in the *membrana flaccida*.

Functional examination of the ear gives practically the same results as in an acute catarrhal otitis media. If the

labyrinth is invaded by the process there is lessened bone conduction and the upper notes of the scale are not heard.

Prognosis.—Prior to the formation of pus, spontaneous recovery may result, but later some loss of tissue always occurs, and usually with more or less permanent diminution of the acuity of hearing. A chronic purulent otitis media may follow, or even death as a result of cerebral involvement, either directly or through mastoid inflammation.

Treatment.—The local treatment is the same as in acute catarrhal otitis media, but if relief from the pain is not obtained, paracentesis of the membrana tympani is usually performed. The use of the cocaine in absolute alcohol and aniline will diminish the pain of this procedure, but in children or very nervous persons, general anesthesia may be necessary. The point of incision should be above and posterior to the short process of the malleus, and of such an extent as to freely divide the tissues of the inner wall as well as of the tympanic membrane. The free hemorrhage should be aided by douching with warm water. A free catharsis should be induced, preferably with some of the salines, before attempting paracentesis.

Internally, aconite, gelsemium, jaborandi, phytolacca, pulsatilla, and in addition, calcium sulphide to saturation should be given.

If the mastoid is involved, Leiter's coil or the aural ice bag may be used continuously for a short period, but if relief is not obtained within twenty-four hours, it should be discontinued. If the mastoid tenderness continues, an operation is usually necessary.

After discharge from the tympanum commences, either through an artificial incision, or a spontaneous rupture, the canal should be kept clean by the use of cotton, drying the canal thoroughly, and insufflating boric acid by means of a DeVilbiss powder blower. Care must be exercised, as if much powder is blown into the ear, it may occlude the open-

ing in the membrane and through the pressure exerted, cause serious complications. Simply a light dusting of the powder is required. If the secretion is purulent, the calcined boric acid is preferable. When granulations of recent formation are present, the combination with salicylic acid, or thuja should be employed. When the secretion is scanty, the mucous membrane of the tympanum pallid, the iodoform preparation is indicated.

In but few cases should watery preparations be employed, as there is already an excessive amount of moisture, and it is practically impossible to thoroughly dry the middle ear after irrigation.

Chronic Purulent Otitis Media.

Synonyms.—Otitis Media Purulenta Chronica. Chronic Suppurative Inflammation of the Middle Ear.

Etiology.—This condition may follow an acute catarrhal or an acute purulent inflammation of the tympanum, and in some cases, especially tubercular, it may appear without any premonitory symptoms, being chronic in character from the beginning. When the result of a pre-existing middle ear affection, and the discharge has continued for three months, the term chronic is usually rightly given.

Pathology.—In all of these cases there is more or less necrosis of tissue. It begins usually in the mucous or connective tissue, and in a short time attacks the bony structures. The incus is most often first affected when the bony necrosis begins with the ossicles. The inner tympanic wall is infrequently affected unless the suppurative process is of tubercular origin, or a complication of an acute infectious disease. There is more or less destruction of the membrana tympani, but it is seldom that the entire membrane is destroyed, sometimes there may be only the rim of the membrana vibrans left. Perforation may occur in any portion

of the membrane, but is most frequently found in the posterior or postero-inferior quadrant.

The labyrinth is not often affected in chronic suppuration, but it is sometimes present as a result of the acute stage. Infrequently the entire labyrinth is destroyed by the suppurative process, and when it is, there is nearly always an extension of the inflammatory condition to the cranial cavity.

The most serious complication in chronic suppuration is the liability of extension of the process to the mastoid. This does not often occur if there is free drainage through the external canal, but obstruction, through any cause, of a free exit for the purulent material, may force it backward into the mastoid cells, resulting in an osteitis with more or less destruction of the bony structure.

A chronic inflammatory action of the mastoid is practically always present in chronic suppurative middle ear disease, and consists in a chronic proliferation of the bony tissue, eventually obliterating the pneumatic spaces, the entire process becoming a dense eburnated bone. In these cases an acute inflammatory condition of the tympanum is much more liable to extend to the cranial cavity than where the mastoid spaces are open.

Cholesteatoma may develop from a chronic suppuration of the middle ear, provided the inflammatory action assumes a type of rapidly formed and rapidly desquamated, superficial mucous epithelium, with very little or no fluid inflammatory products. If not removed the masses gradually increase in size, dilating and causing absorption of the surrounding tissue.

Symptoms.—Often the only symptom is the constant purulent discharge from the ear, but the amount may be so slight as to be found only on inspection. The hearing is more or less impaired, but is not proportionate to the extent of the morbid condition. Tinnitus is more infrequent

than in chronic otitis media. Vertigo may occasionally be complained of, and vary in severity. The discharge from the ear is not necessarily continuous, as it may be lacking for weeks, or even months, depending upon the character of the morbid process. In some cases the discharge appears only during or following an acute rhinitis or nasopharyngitis.

Necrosis of the bony structures is usually present in those cases showing granulation tissue in the tympanum, especially where the ear has been kept comparatively free from discharge. The odor in bony necrosis is characteristic. In some cases the amount of the discharge is so slight that it simply remains within the canal, where it dries, forming crusts upon the posterior or superior walls, and may spread downward close to the membrana tympani, concealing it more or less. Implication of the labyrinth is nearly always present in cases of long standing.

Diagnosis.—This is made by inspection of the ear, the history, and also by a functional examination. The use of a probe and also Siegel's otoscope will give much information regarding the condition of the membrana tympani and the mucous lining of the tympanum.

Prognosis.—This will depend upon the cause, the extent of the morbid process and the general condition of the patient. Regarding improvement in hearing, this should be guarded, as in many cases there is but little change in the acuity of hearing. In some cases the hearing may apparently reach the normal, but they are the exception.

Treatment.—This is necessarily local and constitutional.

Local.—Cleanliness is of the utmost importance, and this is best secured by the use of cotton on a cotton carrier. The use of fluids is to be condemned in the majority of cases. There is always an excess of moisture and it is practically impossible to thoroughly dry the ear after syringing. With cotton the ear can be cleansed of such secretion as is

within reach, then an insufflation of powder will be preferable to the pernicious habit of syringing. Only infrequently will the air bag be required. Polypi should be removed with the snare or curette. Exuberant granulations may be present, and must be destroyed by the use of some agent. If the corrosive acids are employed they can be readily




FIG. 105. Wilde's Polypus Snare.

applied by means of a broom splint, cut squarely across the end and dipped into the acid. After a few moments there will be sufficient material in the pith of the splint to do the work, and by wiping the splint with cotton, any excess of acid is removed.

The powders most frequently employed are boric acid, calendulated boric acid, carbolized boric acid 5 per cent,




FIG. 106. DeVilbiss Powder Blower.

ergotized boric acid, boric acid and thuja, boric acid and salicylic acid, boric acid and iodoform, but in some cases other combinations may be required. Powders should be more or less soluble, and should never be packed in the canal. The favorite blower is the DeVilbiss, which throws the powder in a fine cloud, and does not pack it in masses.

In some cases it is necessary to use a liquid preparation to reach the attic or tympanic portion of the Eustachian tube, and thuja, or Lloyd's hydrastis is most frequently employed. The use of hydrogen peroxide is seldom beneficial and there is always danger of its forcing some of the morbid material into the mastoid spaces.

Internally the drugs most frequently employed are calcium sulphide, silicea, gold and sodium chloride, potassium bichromate, phytolacca, hydrastis, pulsatilla and hamamelis.

Otitis Media Purulenta Residua.

Under this title is included the sequelæ of a purulent otitis media, where permanent changes or destruction of tissue occurs. Two classes of cases are found, the acute or sub-acute, and the chronic.

ACUTE OR SUBACUTE.

Etiology.—In this class the exciting cause of the symptoms is usually an acute rhinitis or nasopharyngitis. Epidemic influenza may also be a factor. The employment of artificial aids to hearing, improper methods of cleansing the external auditory canal or the development of aspergillus in the canal may also be exciting causes.

Pathology.—This varies according to the course of the original lesion, but often there is a similar condition to that found in acute catarrhal otitis media, or tubo-tympanic congestion. There may be a serous discharge passing through a perforation in the membrane into the canal, but if the membrane is intact, this secretion collects in the tympanic cavity and may be retained for some time, or may escape through the Eustachian tube. If infection occurs, a chronic purulent otitis media results.

Symptoms.—When much of the membrane is destroyed, there is often some impairment of hearing and tinnitus. The presence of secretion in the canal is the most marked symp-

tom. Pain is infrequent, and the condition is found oftener in children than in adults. Facial paralysis frequently occurs.

Diagnosis.—On inspection, if the membrane is perforated, the mucous tissue of the tympanum appears red and velvety, and covered with a clear, watery or opaque secretion. The existing membrane is thickened, turgescient and edematous. The upper wall of the canal may be pendulous, almost obstructing the lumen of the canal, and making it difficult to inspect the tympanum. Pressure with a probe may crowd this protruding mass aside. It presents some of the characteristics of granulation tissue, but is too dense and firm for true granulation tissue. Pressure produces considerable pain, but there is not much bleeding under probe manipulation.

Prognosis.—Favorable if the discharge is the only symptom, as this frequently ceases spontaneously. Occasionally infection occurs and a chronic purulent condition results. If there is much pain, a cellulitis is present and this is always an unpleasant complication.

Treatment.—This is practically the same as in acute suppurative otitis media.

CHRONIC TYPE.

Etiology.—In this class the changes are the result of chronic inflammatory action, and the insidious character of the condition usually is not such as to direct the patient's attention to the ears until very marked symptoms are manifested. Sclerotic changes in the tympanum, especially of the ossicles, is usually a feature of this type.

Pathology.—The perception of aerial vibrations is much reduced, and may be due to any one of five conditions. (1) Edema of the mucous membrane. (2) Circumscribed hypertrophy. (3) Adhesions of the articulations of the ossicles or of the malleus or incus to the inner wall of the tym-

panum. (4) Bands of cicatricial tissue in the membrane. (5) Adhesions confined to the stapes or its immediate region. One or more of these conditions may be present.

Symptoms.—More or less impairment of the hearing is usually present, and is more marked when it follows the nonsuppurative form than in the purulent suppurative type. Vertigo may occur, especially following some manipulation about the ear, either in examination or syringing. The acuity of hearing is usually not variable. Cholesteatoma may develop.

Diagnosis.—This must be made practically by the functional examination, as inspection does not reveal the changes which have occurred. Bone conduction is increased, the lower tone limit for musical sounds is raised, and the upper tone limit reduced. Conversational tones are less distinct than sharp metallic sounds. If the labyrinth is affected, the upper tone limit is usually much diminished.

Prognosis.—Usually more favorable than any other form of chronic inflammation of the middle ear.

Treatment.—Hygienic measures are necessary, and any abnormal conditions existing in the upper respiratory tract should be corrected. The local and internal medication is practically the same as given under suppurative otitis media. Operative measures are sometimes required, but should only be attempted by a specialist.

Chronic Catarrhal Otitis Media.

Synonyms.—Otitis Media Catarrhalis Chronica. Chronic Non-Suppurative Otitis Media. Chronic Non-Suppurative Catarrh of the Middle Ear.

It is unfortunate that the term catarrh is applied to this form of ear disease, as it is a misnomer. There are two types of this condition, the hypertrophic and the hyperplastic, and the changes which occur in the tympanic tissues are very different in the two forms.

CHRONIC HYPERTROPHIC OTITIS MEDIA.

Etiology.—This may result from an acute catarrhal process in the tympanum; from an acute congestion of the Eustachian tube, and sometimes, so far as a history is concerned, as an idiopathic condition. Frequent attacks of rhinitis or rhino-pharyngitis are common factors, and a moderate amount of adenoid growth, although not sufficient to cause obstruction of nasal respiration, may produce venous engorgement, which interferes with the tympanic circulation and eventually produces hypertrophy of the tissue. Exposure to climatic changes renders one more liable to this condition. Between the ages of fifteen and thirty-five, the process is most frequent. A subnormal condition of the system from any cause may be a factor.

Pathology.—There is the usual change found in mucous membrane where tissue hypertrophy occurs. In the membrana tympani the mucosa is thickened, the fibrous layer swollen, a true hypertrophy resulting. In the later stages there is a deposit of lime salts in the membrane. The membrane varies in appearance, some portions seeming thicker, while other parts appear thinner than normal. The tissue of the Eustachian tube is thickened and free ventilation of the ear does not occur. Retraction of the membrana tympani results, and increases the local inflammatory condition. The changes which take place in the intratympanic structures are usually sufficient to cause more or less permanent impairment of hearing. The hypertrophic process may change to a hyperplastic condition and a dense fibrous tissue result.

Inner ear complications are infrequent in the hypertrophic type.

Symptoms.—Both ears are usually affected, but infrequently to the same extent. The hearing is impaired, and is intermittent in the early stages, but the diminution gradually becomes permanent. Tinnitus is an annoying symp-

tom, and is increased by fatigue, mental exertion, indiscretions in eating or drinking, and by sudden climatic changes. The recumbent position may increase the subjective noises, and they may be synchronous with the heart's action. The noises are described differently by different individuals, and often are unnoticed when external sounds are present, but may become painfully noticeable when in a quiet place. The acuity of hearing is often better in a noisy location. Vertigo may be present, and usually is not severe, but is often increased by blowing the nose. Pain is infrequent, but when present it usually radiates from the pharynx to the ear.

DIAGNOSIS.—*Inspection.*—The appearance of the parts varies. In the early stages the membrane may not show any abnormal condition, or there may be a slight amount of retraction. According to Schwartze, hyperemia along the manubrium and the supero-posterior border, and especially with a reddish reflex from the inner wall of the tympanum, indicates an activity of the inflammatory process. The membrane seems somewhat thickened and the luster is diminished. There is usually a marked change in the appearance of the handle of the malleus as a result of the rotation of the entire ossicle.

In the later stages the retraction is usually very marked, and the membrane has an opaque appearance, the light spot being displaced, broken or lost. If either auto-inflation or Politization has been followed for some time, there may be relaxation of the membrane in the upper and posterior quadrant.

The use of Seigel's otoscope reveals the presence of adhesions or of a relaxed membrane.

Functional Examination.—There is diminished activity of hearing for conversational tones, but whispers are often heard better than ordinary tones. The upper tone limit may be normal or diminished. In the early stages, bone

conduction is increased, and the tuning fork is heard best in the ear most affected, but the reverse is often true in the later stages.

Prognosis.—This depends upon the cause and also the stage of the condition. In early stages, if dependent upon nasal or nasopharyngeal lesions, the prognosis is favorable, provided these are corrected. In atrophic conditions of the nasal or pharyngeal tissues, provided the process has not gone too far, relief may be obtained. The treatment must extend over a considerable period of time, however. Proper

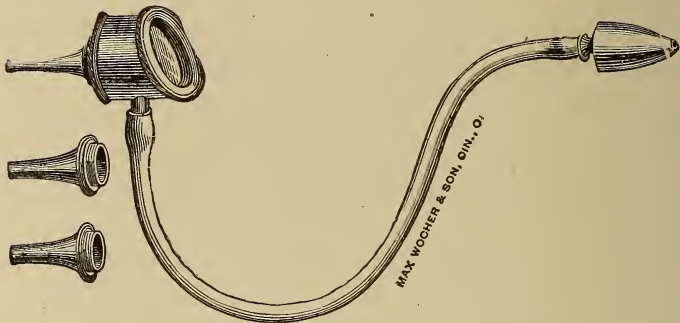


FIG. 107. Siegel's Otoscope.

hygienic measures must be insisted upon, and this includes dietary regulation. In cases of long standing, the condition of the labyrinth must be considered in giving a prognosis.

Treatment.—The upper respiratory tract should be placed in as nearly a normal state as possible. If operative procedures are required, it should be done at once. Local treatment is usually of little avail, the use of proper internal medication being of most value. The drugs usually indicated are phytolacca, iris, jaborandi, cimicifuga, bryonia, pulsatilla, gelsemium, potassium bichromate, po-

tassium iodide, acid hydrobromic dil, and occasionally col-linsonia.

CHRONIC HYPERPLASTIC OTITIS MEDIA.

Etiology.—This condition may result from the hypertrophic form; follow a purulent otitis media; or be idiopathic. In the latter type it may result from a severe illness or a subnormal condition of the system. Females seem to be most often subject to this form of chronic otitis media. The condition may be bilateral, and heredity appears to be a factor, especially in neurotic individuals. Hyperplastic inflammation is most often found between the ages of forty and fifty, but may occur prior to this, but seldom is found after fifty years of age.

Pathology.—This is very similar to the hyperplastic changes occurring in mucous membrane in other regions. The changes are usually more pronounced near the oval or round windows. The bony structures are often involved, as well as the connective tissue. The labyrinth is frequently affected, and often in the early stages. The tissues of the Eustachian tube are affected, and in the later stages, an excessive opening of the canal is usually present, and atrophy of the muscles controlling the tube occurs.

Otosclerosis, Rarefying Osteitis of the Labyrinthine Capsule.

Besides the secondary changes in the labyrinth due to middle ear conditions, bony tissue may develop in the immediate vicinity of the oval or round windows. The growth may be in the vestibule, the stapedio-vestibular ligament, the foot plate of the stapes, the ligament or oval window.

Symptoms.—In the early stages the symptoms are so slight as to be ordinarily ignored. Tinnitus is usually present, and is more noticed than the impairment of hearing. Dizziness may be complained of, and intermittent neuralgic

pain may be present. Headache and hebetude sometimes result from the condition. In the later stages the impairment of hearing is much increased, and is especially noticeable when the acuity of hearing is being tested. Later the tinnitus often becomes less annoying, or may entirely disappear.

Diagnosis.—Inspection does not always show a change in the appearance of the membrane, especially when the condition has been sclerotic from the start. If there is considerable retraction of the membrane the hypertrophic type has usually preceded the hyperplastic changes. In some cases there is a thinning of the membrane and in the later stages the membrane is often of a dead white color, due to atrophic changes in the fibrous layer. The membrana flaccida is not often changed in appearance when the process starts as a hyperplastic condition, but it usually presents a crumpled appearance if hypertrophic changes preceded the hyperplastic.

Functional Examination.—The acuity of hearing is impaired for both conversational and whispered tones. For the acoumeter or watch the diminution varies according to the extent of involvement of the labyrinth. Bone conduction is increased if the tympanum only is affected.

Prognosis.—In this form the prognosis is unfavorable, although the condition may remain passive for a considerable time, as there is a decided tendency to increased impairment of hearing under any form of treatment now known.

Treatment.—The various forms of massage and inflation have not met with the success expected, and in many instances have apparently hastened the morbid process. In some cases forcible inflation may break recent adhesions, but if the process is of long standing, this is hardly to be expected. If more or less absorption of the tissue can be obtained, there may be an improvement of the hearing, but

unfortunately this can seldom be obtained. Occasionally the use of jaborandi, pilocarpine, gelsemium, hydrastis, phytolacca, potassium iodide or physostigma, has appeared to improve the condition. Surgical measures will sometimes improve the condition, but should only be attempted by the specialist.

CHAPTER XXX.

ANATOMY OF THE MASTOID.

The anatomical relations of the mastoid vary with the age and also to a certain degree, with the sex of the patient.

External Contour.—The mastoid process is located at the inferior and external surface of the temporal bone and behind the auricle. The usual form is conoidal. The size of the mastoid usually is dependent upon the strength of the muscles attached to its tip, but there is a more or less uniform development until the age of maturity.

The squamous above and in front, and the petrous behind and below, practically are the portions of the temporal bone that form the mastoid process. The union of these forms the squamo-mastoid suture. The squamous portion of the mastoid forms a triangle, bounded by the suture, the meatus, and the supra-mastoid ridge, which extends behind the posterior root of the zygomatic process, and is always more or less prominent. This important landmark is usually located a little below the floor of the middle cranial fossa, and very seldom above it. Another and an important landmark is the spine of the Henle, which is usually present. This is a more or less rugose prominence, located back of and above the postero-superior quadrant of the meatus and below the origin of the supra-mastoid ridge. According to O. Lenoir, this spine does not spring from the tympanic bone. Prior to four years of age this spine is often absent.

Structure.—The external portion is composed of dense bony tissue and the surface is rough, giving attachment to

various muscles. Numerous foramina are found. The thickness of this outer wall varies, being comparatively thin in children, but increasing in thickness until adult life, when the density and thickness varies considerably. A very dense cortex may lead the operator to believe an eburnated process is encountered. The cavities in the mastoid are divided into the antrum, a constant pneumatic space, and nearly so in

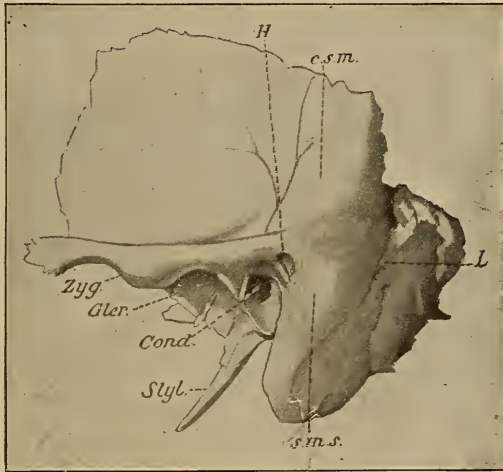


FIG. 108. The field of operation. H, the spine of Henle; c. s. m., the supra-mastoid ridge; s. m. s., the mastoido-squamous ridge; L, the lateral sinus; Cond., the bony meatus; Zyg., Zygoma, and Glen., the glenoid fossa. Styl., styloid process.

its location; and the cells, which vary in different individuals. These cells are divided into the mastoid, petrous, and squamous, according to their situation. Zuckerkandl has made the division of mastoids into pneumatic, mixed, and diploic or sclerosed, according to the prevalence or comparative absence of these cells. In cases of suppurative otitis media, a progressive eburnation almost amounting to

sclerosis of the mastoid spaces may occur. The true mastoid cells are below an imaginary horizontal line a little lower than the junction of the upper third and lower two-thirds of the meatus. When well developed these are the easiest cells reached in operative procedures, and also distinguish between pneumatic, mixed, and diploic mastoids, it being impossible to determine this by any external appearance.

The squamous cells are located in the squamous portion of the process forming the posterior wall of the external auditory meatus. The petrous cells are in the base of the process above the line of the junction of the upper and lower two-thirds of the meatus and extend behind toward the lateral sinus.

The antrum being the most constant, its study is important as regards (a) depth; (b) relation to external landmarks; (c) its relation to adjacent structures which it is necessary to avoid in operative measures.

(a) *Depth*.—This varies according to the age, as well as in individuals. Under one year it is from two to four millimeters. Later the depth is increased but not in a regular ratio. (b) *Position*.—In young children the spongy spot, located above and behind the meatus covers the antrum, which is easily opened by a curette or bistoury. The supra-mastoid ridge, squamoso-mastoid suture, and spine of Henle when present, are the landmarks to remember. The antrum is practically always below the supra-mastoid ridge, above and in front of the squamoso-mastoid suture (Broca). The spine of Henle, or if this is absent, the supra-meatal fossa which may be only a slight depression, are constant guides.

A canal, the *aditus ad antrum*, connects the antrum and tympanum. In the adult this is approximately three to five millimeters long, three millimeters high, and three or four millimeters deep.

(c) *Deep Relations of the Antrum and Aditum.*—Across the roof of the tympanum the aditus is in close relation with the cranial temporal fossa and temporal lobe of the brain.

In operating, the horizontal semi-circular canal, facial nerve, and lateral sinus must be remembered.

The *horizontal semi-circular canal* is located just behind the inner wall of the aditus. The protector should be against this wall to prevent injury. The rest of the canal wall is composed of eburnated bone, and is not liable to injury.

The *facial nerve* leaving by the hiatus Fallopii, passes outward about ten millimeters parallel to the axis of the petrous bone, then passes vertically downward, leaving the cranium at the level of the stylo-mastoid foramen. The horizontal portion and the sharp curve of the facial canal is protected by a lamella of bone which is occasionally very thin. The vertical portion of the canal descends in the anterior region of the mastoid, behind the posterior limb of the tympanic ring. It passes through compact bony tissue. In the vertical part the nerve is separated from the foramen for the jugular vein by a band of tissue which is usually fragile.

The *lateral sinus* is the most important, as it is most frequently injured in mastoid operations. As a rule this sinus is so far removed from the site of operation as to be free from injury, but through mal-position or careless manipulation of the instruments, such an accident may occur.

CHAPTER XXXI.

INFLAMMATION OF THE MASTOID PROCESS AND COMPLICATIONS OF TYMPANIC INFLAMMA- TION.

Etiology.—The usual cause of an acute mastoid inflammation is an extension from the tympanum of an inflammatory process. The causative factor may be either acute or chronic, but a simple catarrhal inflammation is seldom, if ever, a cause.

Inflammation of the Mastoid.

Synonym.—Mastoiditis.

A primary inflammation is infrequent, but sometimes follows a cold, a traumatism, or it may result from a specific or tubercular diathesis. In specific infection the usual cause is probably the breaking down of a gummatous deposit. Inflammatory action in the external auditory canal may implicate the mastoid through contiguity of tissue, especially if the posterior wall is affected. Chronic suppurative otitis media is the most frequent factor of an acute mastoiditis. The exanthemata, diphtheria, typhoid, and typhus fevers, as well as some pulmonary conditions, may be exciting causes. Influenza appears to be a frequent cause, probably on account of its affecting the mucous membranes in nearly all cases.

Pathology.—In chronic purulent otitis media the lining membrane of the mastoid cells is thickened, the vascularity

is increased, and eventually there may be a slight deposit of osseous tissue which in some cases, entirely destroys the cells, the mastoid presenting an ivory-like hardness. Necrotic changes may occur instead of hypertrophic, and if free drainage through the tympanum and external auditory canal is lacking, symptoms of pus retention will be present. This may manifest itself by an increased purulent discharge in the external auditory canal; or if this is obstructed, through the mastoid cortex, either behind the auricle or into the external auditory canal. The pus may find an exit through the mastoid in the digastric fossa, or it may escape through the roof of the antrum, or the tympanic vault into the middle cranial fossa. Occasionally it may pass into the posterior cranial fossa by penetrating into the groove of the lateral sinus.

If the pus enters the cranial cavity, a circumscribed or diffuse meningitis results, and an epidural abscess is formed in the former condition. Thrombosis of the lateral sinus, or a cerebral abscess may also result from this complication.

Symptoms.—Severe pain over the mastoid, especially over the antrum and at the tip, and the pain radiating to different parts of the head and face is complained of. The pain is most severe at night, and is deep-seated and persistent. The pulse and temperature are not always indications of the severity of the process. Edema of the tissue covering the mastoid is more characteristic of an inflammation within the canal, than of mastoid complications. Tumor behind the auricle is infrequent except in childhood. Fluctuation of these tissues is an evidence of spontaneous rupture of the mastoid purulent material.

When intracranial complications occur, the symptoms depend upon the region affected. If an infectious thrombosis is located in one of the larger venous sinuses there is a sudden elevation of temperature, sometimes reaching 105° Fahr. This lasts but a few hours, the temperature dropping

to normal or even subnormal. These changes are intermittent, but may follow in such rapid succession as to be unrecognized, or there may be quite an interval between the changes. After the onset of fever, there is profuse perspiration and later septic conditions are usually present. The patient is weak; the skin a dull, ashy hue; pulse weak, and a decided mental dullness, or even coma, showing a general septic condition.

If a diffuse meningitis develops from intracranial implications, there is severe headache, photophobia, nausea, and vomiting, and a constant high temperature. The base of the brain is usually involved in these cases, and the pulse is rapid. Paralysis of the muscles controlled by the third and sixth nerves soon follows as a rule, and rigidity of the muscles of the neck is an early and characteristic symptom.

Diagnosis.—The most positive symptoms of mastoid development are tenderness on deep pressure over the mastoid, and a bulging of the supero-posterior canal wall close to the tympanic ring. The directions already given for determining whether the tenderness or pain is in the external auditory canal, tympanum or mastoid, must be remembered. Pressure over the tip of the mastoid will cause a sensation of tenderness even in normal individuals, hence great care is necessary in forming an opinion from this manipulation.

Prognosis.—Always guarded, but the exciting cause, age of the patient, and the general condition must be considered. In children, when mastoid complications follow the acute infectious diseases, the prognosis is usually unfavorable. In adults the prognosis is usually good, unless it is a complication of a chronic suppurative otitis media of long standing.

Treatment.—If in the early stages, and unless there are urgent symptoms presenting, an effort should be made to abort the condition. Absolute rest, a light diet, and a saline cathartic are important aids. If a suppurative otitis media

is present, free drainage is necessary, and the opening in the membrana tympani may have to be enlarged, this should be done by means of a probe pointed knife. The canal and tympanum should be kept as free from discharge as possible, but syringing or the use of hydrogen dioxide is to be condemned. Leiter's coil for the application of cold is often beneficial and may be used for twenty-four hours, but should not be employed for a longed period.

Internally.—The use of the remedies advised in acute

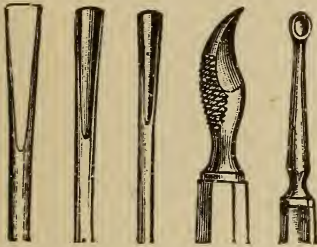


FIG. 109. Mastoid Instruments.



FIG. 110. Mastoid Retractor.



FIG. 111. Mastoid Curettes.

catarrhal otitis media or in the suppurative form should be employed.

In the acute condition where relief is not obtained within seventy-two hours, operative measures are required. In the chronic type it is not usually necessary to resort to radical measures so soon, as proper internal medication will often relieve the condition, and calcium sulphide or silicea are usually indicated.

Operative.—The complete operation is the most efficacious, but should not be attempted excepting by a surgeon

of experience. The instruments required for the operation, besides a razor for shaving the head, are scalpels, artery clamps, periosteotome, scissors straight and curved on the flat, retractors, chisels and gouges, mallet of wood or lead,

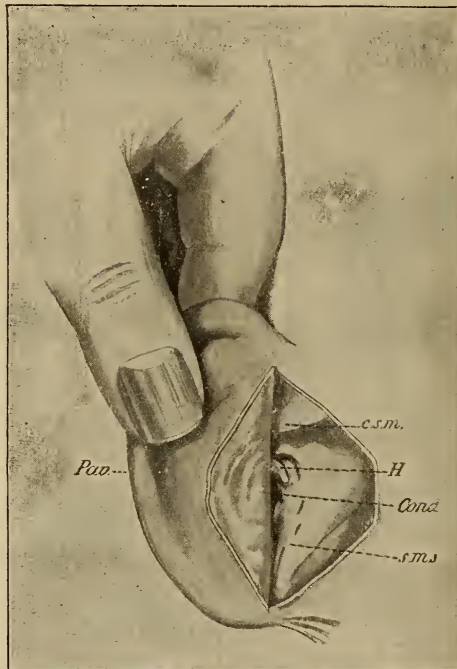


FIG. 112. Visible landmarks after the incision and turning forward of the auricle (*Pav.*) Lettering as in Fig. 108.

dressing forceps, probes, rongeurs, curettes, ear syringe, needles, etc.

The Operation.—The incision of the skin should begin about half an inch below the tip of the mastoid and be carried upward, following the curve of the auricular attach-

ment and about one-fourth inch behind it to a point over the superior portion of the auricle. A transverse incision passing backward, commencing at the base of the mastoid will give additional room. The incision should divide the tissues and periosteum. This will divide the posterior auricular artery and its branches, but the hemorrhage is of little consequence. The periosteum should be raised so the

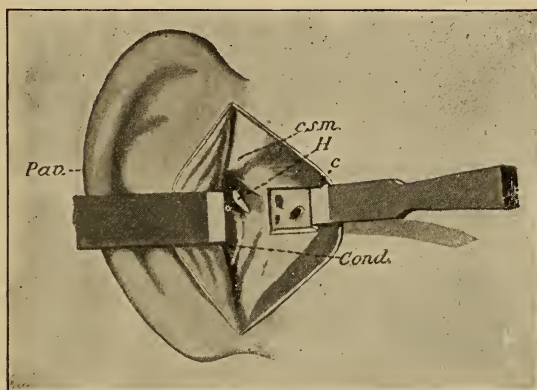


FIG. 113. Showing oblique position of chisel in completing and removing the square of cortex. Lettering as in the previous figures.

landmarks are revealed. The artery forceps can now be applied, and are also aids in retracting the tissues.

In the adult the field of operation is about three-eighths of an inch square. A chisel of this width is held perpendicularly to the bone three-sixteenths of an inch behind the meatus, marked by the spine of Henle, parallel to the circumference of the meatus. Two or three sharp strokes of the mallet should cause the chisel to penetrate a little over one-sixteenth of an inch into the bone. The upper border should be just under the supra-mastoid ridge, and the lower

border at the lower end of the initial cut. The posterior side of the square is the dangerous portion and the chisel should be held at an angle of about forty-five degrees. The use of the mallet will now remove the square of bone.

In rarefying osteitis, the antrum will be readily reached, but frequently it is necessary to go deeper. This should be

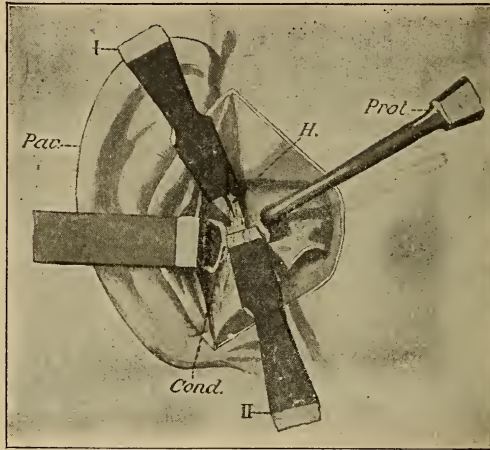


FIG. 114. Showing position of protector (Prot.) and of chisel (I) perpendicular to the bone, chisel (II) obliquely for the removal of the outer attic wall and to make the complete operation. Same lettering as in previous cuts.

done carefully, and in those cases where eburnation has occurred, the work must be cautiously performed.

In children under the age of ten, the curette and hand gouge are usually all that are required, as the bone is soft and spongy.

In nearly all cases after the antrum is located and the mastoid excavated, the bony wall separating the antrum and

external auditory canal should be removed, making but one cavity of the mastoid and tympanum. This may be removed by the rongeur forceps or by the chisel. A Stacke protector should be employed to guard the semicircular canal and facial nerve. After all the structures are exposed, the cavities should be smoothed, necrosed tissue removed, granulations curetted and fistulous tracts excised.

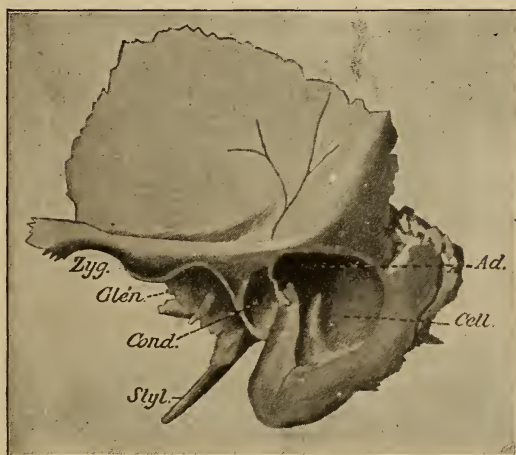


FIG. 115. Complete opening of the mastoid cells (Cell.), the aditus (Ad.), and of the tympanum. The other lettering as in figure 108.

After the morbid tissue has been cleared away, the hemorrhage controlled, and the cavities thoroughly cleansed with some solution, the cavity should be dried with gauze sponges. After the tissues are partially sutured, a packing of gauze should be used to fill the cavity, and also some placed in the external auditory canal. The traumatism should be covered with a gauze pad, and held in position

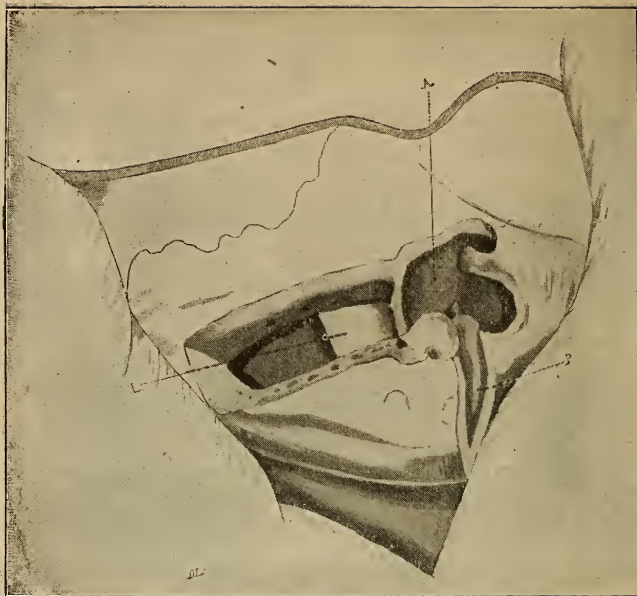

FIG. 116. Sclerosed mastoid (right). Lateral sinus (L) in close proximity to field of operation.

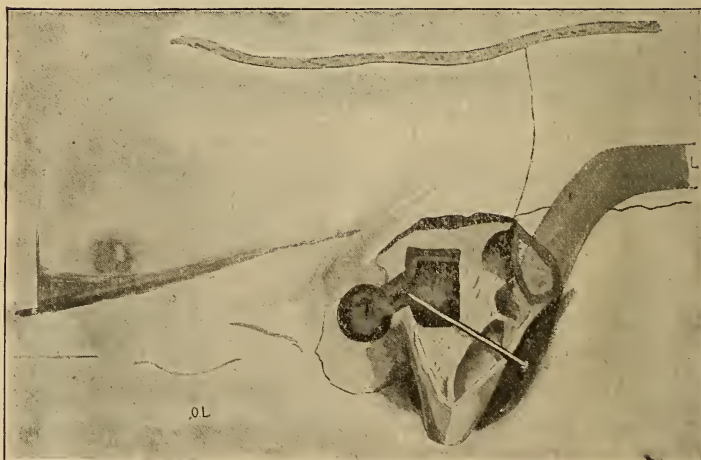


FIG. 117. Mastoid, left side. The antrum opened at a depth of 25 millimeters following the direction of the pin. The lateral sinus (L) 8 millimeters back of field. Wall of aditus removed.

by a bandage which does not compress the auricle against the side of the head.

The after treatment does not vary especially from that of any operative procedure of a similar character.

In some cases it will be necessary to open into the cranial cavity, but the methods required are usually fully described in works on surgery.

CHAPTER XXXII.

INTRACRANIAL COMPLICATIONS OF TYMPANIC INFLAMMATIONS.

Otitic Meningitis.

Either directly from a suppurative process in the tympanum, or by involvement of the mastoid, the meninges may be implicated. This may result by the extension of bony caries, thinness of the bony walls which are perforated by numerous foramina, or by infection through the vessels communicating with the cranial fossa.

Symptoms.—There is usually a constant, high temperature ranging from 101 degrees to 105 degrees Fah. Intense headache, nausea, and vomiting, photophobia and localized or general convulsive symptoms. In children, general convulsions often occur with the high temperature. If the basilar meninges are affected, the Cheyne-Stokes respiration soon occurs. Delirium is frequently present in children, but in adults this is not so often present, and may not be present at all, the patient gradually passing into a comatose state before death results.

In serous meningitis, paralytic and convulsive symptoms are seldom prominent. The temperature is less than in the purulent form, infrequently being more than 103 degrees. A diffuse or localized headache is the most marked symptom. Delirium is usually slight, but it is difficult for the patient to concentrate the mind for any length of time. Divergent strabismus is sometimes pres-

ent as a result of local paresis. Choked disk or a slight swelling of the optic papilla is usually found.

Diagnosis.—Should be by exclusion. The symptoms described should be carefully considered. In children the exclusion of an acute infectious condition or gastro-intestinal wrongs are necessary, as they often produce the same line of symptoms. The cessation of a discharge from the middle ear coincident with the described symptoms; tonic spasm of certain muscles controlled by the third, fourth, and sixth nerves; choked disk; photophobia; respiratory disturbance and later coma, should confirm the diagnosis.

Prognosis.—Usually fatal, although Macewen and Dench have operated with successful results in a few cases.

Treatment.—Early surgical measures.

Sinus Thrombosis.

In acute or chronic otitis media, an infectious thrombosis of one of the large intracranial venous sinuses may occur as a complication. The peculiar relation of the tympanum and mastoid to the cranial cavity and the easy access to the cranial structures through the mastoid vein, makes it comparatively easy for septic material to be carried to the lateral sinus. When such a condition occurs, secondary purulent areas may be found in other viscera, the lungs especially appear to be a favorite site, septic pneumonia resulting.

Symptoms.—Frequently no symptoms are noticed until the later stages. A characteristic symptom is a sudden elevation of temperature, sometimes to 106 degrees, followed by a return to the normal or nearly so. After a time general septic conditions are noted. In uncomplicated cases cerebral symptoms are usually absent. If cerebral symptoms are present in connection with suspected sinus thrombosis, the probability of cerebral lesions, or an extensive secondary meningitis is to be suspected.

Diagnosis.—The extreme variations in temperature, which should be frequently taken, are usually diagnostic of implication of the lateral sinus. Choked disk is confirmatory evidence in cases of suspected sinus thrombosis. The development of asthenic conditions without sufficient tympanic or mastoid disturbance to account for this state of affairs, is also a symptom.

Prognosis.—Guarded, although spontaneous recovery occasionally takes place.

Treatment.—Operative measures give the best results. The internal medication should be such as will best overcome the asthenic condition.

Extradural Abscess.

This is really a circumscribed purulent meningitis. The meninges are adherent to the inner table of the skull, the purulent material being confined to a limited area by the adhesion of the membrane to the bone. An abscess between the dura mater and inner table is usually a complication of a chronic suppurative otitis media or mastoiditis. The thin bone separating the middle ear and mastoid from the cranial cavity becomes necrotic, and a localized low grade of meningitis results. Such a condition does not occur when the process is acute in character.

Symptoms.—Pathognomonic symptoms are few. An intense, constant, localized headache, and elevation of temperature, seldom if ever 102 degrees, are practically the only symptoms which point to the character of the lesion. If the process is in the cerebellar fossa, there may be vertigo and vomiting. In the latter stages, no matter where the lesion is located, there is hebetude, probably from effusion into the ventricles.

Prognosis.—Eventually fatal, unless recognized early and operative measures are promptly employed.

Cerebral Abscess.

A circumscribed purulent area within the brain substance may be either acute or chronic in development. The former are infrequent. The usual factor in chronic cerebral abscess is probably a purulent otitis media. The lesions may be single or multiple, and may involve the cortex or the deeper portions of the brain, and may be bilateral or unilateral. The temporo-sphenoidal lobe is oftenest affected, and the cerebellum is next in frequency. Infrequently a similar process occurs in the medulla. Cerebral abscesses are usually comparatively deep in the brain substance, and if not interfered with, often rupture into the lateral ventricles. The material in these abscesses is often non-infected.

Symptoms.—These depend upon the location. If the process is acute, and the abscess is located so that pressure is produced upon the motor tract or the motor area of the cortex, localized symptoms occur, these being convulsive in character. In chronic cases convulsive attacks are seldom present, paralysis occurring without premonitory symptoms. As a result of the usual location of the lesion, sensory or motor aphasia occurs in many cases, but may not be recognized unless a careful examination is made. Agraphia is sometimes present. Localized symptoms are occasionally absent, particularly if the lesion is in the right hemisphere. The asthenic condition is most important. The mental condition is important, as irritability at times, and again inattention or even somnolence may be noted. Eventually coma supervenes. The temperature seldom goes above 99 degrees, and the pulse may be normal or intermittent. In cases of long standing, a dull diffuse headache is often present. Insomnia may be present.

Diagnosis.—Usually difficult. The symptoms described, and sometimes the presence of choked disk may be an aid,

but the ophthalmoscopic picture is not characteristic of this lesion.

Prognosis.—Unfavorable, although surgical measures may prove curative if the diagnosis can be made sufficiently early.

Cerebellar Abscess.

Abscesses in this region are not infrequent, the source of infection being either through the labyrinth or the posterior wall of the lateral sinus.

Pathology.—There is a breaking down of the infiltrated tissue, pus formation, and an accumulation of fluid in the lateral ventricles. The latter condition is important, as the symptoms presenting may be due entirely to the dilatation of the ventricles.

Symptoms.—Not always readily recognized. If deeply located, the abscess may cause persistent vomiting. Vertigo and unsteadiness in walking may be present. Usually the most prominent symptom is that of intracranial pressure. Hebetude, apathy, and sometimes headache may be present. The temperature is slightly elevated, but seldom reaches 101 degrees. Nystagmus may occur.

Diagnosis.—Difficult.

Prognosis.—Unfavorable unless an early diagnosis and operative measures are instituted in the early stages.

CHAPTER XXXIII.

DISEASES OF THE PERCEPTIVE APPARATUS.

General Considerations.

So many factors may cause disturbance of hearing, and the actual lesions of the perceptive mechanism are so obscure that many of the supposed inner ear conditions are simply a matter of speculation. It is a well known fact that atmospheric conditions, as well as the general physical or nervous condition of the patient, influence audition, and also must have some bearing upon the labyrinth and cerebral centers. When cerebral lesions have been present, either through infection from middle ear disease or from other causes, and the areas of audition have been affected, it is not so difficult to make a diagnosis in known cases or where an accurate history can be obtained. In the majority of cases it is largely a matter of conjecture as to the exact morbid state, so far as our present knowledge is concerned.

Anemia of the Labyrinth.

Etiology.—This may result from a profuse general hemorrhage, caused by a traumatism, an aneurismal rupture, a uterine hemorrhage following partuition, or of a simple or pernicious anæmia.

Symptoms.—In this condition the hearing is impaired

for sharp sounds and high pitched musical tones. There is a lack of nutrition to the labyrinth and the patient has to make a special effort to hear. When a number are talking it is difficult to follow the conversation. Tinnitus is annoying, and is usually increased upon lying down. The sounds are generally dull, low pitched, and synchronous with the heart's action. Vertigo may result from any sudden shock to the nervous system, and sometimes there may be syncope. The facial expression is sometimes characteristic, being dull, abstracted, and listless. The general symptoms of anemia are also present.

Diagnosis.—The pallor of the skin, and especially of the mucous membranes, is usually marked. An inspection of the middle ear seldom reveals any characteristic appearance. A functional examination reveals a normal lower tone perception, and the upper tone limit may be either normal or diminished. Bone conduction is usually considerably reduced. Audition for conversational or whispered tones is usually somewhat deficient. The patient usually repeats the words slowly and hesitatingly, as though not thoroughly comprehending what has been said. The conditions upon which a diagnosis is made are absence of an otitis media; normal tone perception, unless of the upper tone limit; much diminished bone conduction, and the anemic state of the patient.

Prognosis.—Favorable in acute cases the result of hemorrhage, or a simple anemia. Guarded in pernicious anemia, as permanent structural changes often occur through extravasations within the nerve tissue.

Treatment.—The drugs most frequently indicated are: arsenic in some form, cuprum, hydrastis, jaborandi in small doses, physostigma, cactus, cratægus, strophanthus, glonoin, and sometimes the soluble forms of iron. Nux, strychnine, or ignatia may be indicated, and pulsatilla is often required. Attention to the diet and general hygiene is important.

Hyperemia of the Labyrinth.

Etiology.—This condition may result either from venous stasis, or an increased arterial supply. In gouty or rheumatic constitutions such a condition may occur. When the vocation requires excessive exertion, exposure to all kinds of weather, or through the excessive use of alcoholic stimulants, changes in the vascular current may result. Sudden changes in atmospheric pressure, as passing from a caisson to a normal atmospheric condition, or the rapid ascent in an elevator or balloon, causes vascular changes. Sudden condensation of air in the external auditory canal, either by a blow on the ear or concussion, may also be a cause.

Pathology.—Overdistention of the blood vessels for some time will cause localized dilatation, changing the regularity of the blood supply. Rupture of the vessels may occur through a sudden increase of pressure, apoplectic changes resulting. The effusion may be absorbed, or disintegration follow.

Symptoms.—When the blood supply to the labyrinth is excessive, a sensation of fullness and distention in the head is present. Giddiness or sometimes vertigo, and tinnitus, usually high-pitched, is noticed. The impairment of hearing is usually slight. If the walls of the vessels are much affected, the hearing may be considerably impaired, and all the symptoms aggravated. In chronic cases, especially in plethoric persons, sudden emotional excitement, overexertion, indigestion, or even indulgence in alcoholics, will increase these symptoms.

Diagnosis.—Inspection of the membrana tympani may show an increased vascularity. The functional examination shows some lowering of the upper tone limit and a diminution of bone conduction. Conversational tones may be slightly indistinct. Sharp or shrill sounds may be painful. A positive diagnosis is difficult.

Prognosis.—In recent cases, and where the hearing is but slightly impaired, if rapid absorption of the effusion can be obtained, the prognosis is favorable. In cases of long standing some relief may follow a persistent course of treatment.

Treatment.—Improvement of the general condition and good hygienic measures are important. The drugs most frequently required are jaborandi, gelsemium, bryonia, hydrastis, physostigma, potassium iodide, the bromides, acid hydrobromic dil, pulsatilla, cimicifuga, rhus tox, and occasionally the saline laxatives, but not often to the point of catharsis.

Labyrinthine Hemorrhage.

Etiology.—Extravasation of blood from the vessels of the labyrinth may result from external causes, as a fall, blow upon the head, or the concussion from an explosion. Forcible inflation of the middle ear by any method, or severe paroxysms of coughing or sneezing may cause hemorrhage. It may occur in hemophilia, leukemia, arterial sclerosis, or pernicious anemia. Any effort which may produce venous congestion may also be a cause. In cerebral hyperemia it may also be a complication.

Pathology.—Extravasation of blood in the labyrinth produces the same changes as occur with a similar lesion elsewhere. The amount of the effusion and the resulting condition determines whether there will be any improvement or not in the functional activity of the structure.

Symptoms.—These vary according to the severity of the hemorrhage. Vertigo is usually marked, the patient often falling prostrate. Nausea, tinnitus, and a sudden diminution of hearing, are the characteristic symptoms. A functional examination is the only method. The impaired hearing for any sound, and the reduction of bone conduction are important symptoms. The lower portion of the labyrinth is most frequently affected, and the lower tone limit may not be much reduced.

Prognosis.—If but a limited area is affected, spontaneous recovery may follow. Some improvement in the hearing usually follows in all cases.

Treatment.—The patient should be kept as free from excitement as possible, and any exertion should be prohibited. Free catharsis is usually of value in the early stages of the condition. Loud noises should be avoided. Internally the use of jaborandi, gelsemium, bryonia, asclepias, pulsatilla, or potassium iodide are most generally indicated.

Labyrinthine Embolism and Thrombosis.

Etiology.—Either condition is infrequently met with. Thrombosis may result from a severe otitis media, especially following the exanthemata.

Pathology.—The occlusion of a small arterial branch causes an anemia of the affected area. Disintegration follows if a collateral circulation does not occur, or the circulation is not re-established. A venous thrombosis, unless infected, is unimportant.

Symptoms.—These are practically those of labyrinthine hemorrhage, only less marked. The abrupt development of tinnitus is probably the most constant symptom. The hearing may be practically normal.

Prognosis.—Guarded.

Treatment.—Jaborandi, potassium iodide, hydrobromic acid dil., nux vomica, and pulsatilla are most frequently indicated.

Specific Inflammation of the Labyrinth.

Etiology.—The labyrinth is not infrequently affected in either acquired or hereditary syphilis. In the former class the affection is usually a late manifestation, seldom occurring during the secondary stage. In the hereditary form interstitial keratitis is often associated with the aural condition.

Pathology.—The changes which occur are those of a chronic inflammatory action. Specific lesions of the vessels are obliterating endarteritis, as well as those found in the blood vessels of other regions. There is often the formation of new bony tissue, which narrows the lumen of the semicircular canals. In hypertrophic conditions within the vestibule there may be a deposit of bone about the oval window, causing a thickening of the foot plate of the stapes, or synostosis of the stapedio-vestibular articulation.

Symptoms.—There is usually a sudden and marked impairment of hearing, and an annoying tinnitus in the acquired form. In the hereditary type the hearing is usually progressively diminished and associated with interstitial keratitis.

Diagnosis.—In the adult the sudden attack is characteristic. In the hereditary form the general appearance of the patient should direct attention to the probable cause. A functional examination usually reveals only a slight change in the lower tone limit. The upper tone limit is much reduced, especially for sharp metallic sounds. Bone conduction is much diminished or entirely lacking.

Prognosis.—Usually unfavorable, but treatment should be continued for a considerable period.

Treatment.—This should consist of internal remedies. Jaborandi, bryonia, phytolacca, iris, hydrastis, potassium iodide, and mercury in small doses are the most frequently indicated drugs. Occasionally nux or strychnine may be of value.

Secondary Inflammation of the Labyrinth from a Chronic Suppurative or Non-Suppurative Otitis Media.

A long continued morbid process in the tympanum is very liable to cause changes in the labyrinth, either from

the pressure exerted against the exposed structures of the inner ear; through disuse of the auditory nerve filaments, or by extension through contiguity of structure.

Symptoms.—It is difficult to determine positively between tympanic and labyrinthine changes. All the symptoms are such as should be ascribed to the perceptive portion of the ear, and it is practically impossible to determine the exact condition. Tinnitus is practically always present in these cases, but it is intermittent as a rule, and usually is most annoying when in the recumbent position. In neurotics any form of exertion increases the noises. If the labyrinth immediately related to the semicircular canals is affected, or the canals themselves are invaded, vertigo is a frequent symptom.

Diagnosis.—Inspection of the ear shows but little variation from what is ordinarily found in the same class of cases where the inner ear is not affected. The primary lesion not giving a different picture as a result of the labyrinthine lesions. The functional examination shows impaired audition for practically all sounds. The lower tone limit is raised and the upper tone limit reduced, depending upon the involvement of the labyrinth.

Prognosis.—Usually unfavorable, although in some cases considerable improvement may follow a protracted course of treatment.

Treatment.—Morbid tympanic conditions must be remedied, and for these changes either operative or medicinal measures may be required. If the former, the work should only be attempted by a surgeon familiar with the anatomy of the parts. Medicinal treatment must be continued for a protracted period, and the drugs usually required are jaborandi, hydrastis, bryonia, cimicifuga, pulsatilla, hydrobromic acid dil., potassium iodide, or mercurials.

Acute Labyrinthine Inflammation Secondary to Acute Purulent Otitis Media.

Etiology.—This condition is usually the result of a middle ear affection following the exanthemata. It is most often found in children, and usually only in severe types of these diseases.

Pathology.—Panotitis is the term often employed for this condition. There is usually a rapid breaking down of the softer tissues and a caries of the bony structures of the tympanum. The labyrinth is affected either directly through the bony wall or through the oval or round windows. The morbid changes in the labyrinth are similar to those of the tympanum.

Symptoms.—There is usually considerable systemic infection, and in those old enough to intelligently answer questions, vertigo and an intense tinnitus as well as considerable impairment of hearing, or even complete loss of audition are complained of. When the inner wall is affected in this manner, facial paralysis frequently occurs. Sometimes the petrous portion of the temporal bone is more or less affected, and a sequestrum of considerable size may be found. In these cases there may be a profuse hemorrhage from the ear, and if either the internal carotid artery or internal jugular vein are eroded, the hemorrhage is usually fatal. Meningitis is a frequent complication in these cases.

Diagnosis.—An inspection of the ear gives little information, excepting the presence of a severe suppurative otitis media. In the later stages exuberant granulations may be present in the tympanum, and careful manipulation with a probe may reveal denuded areas of the inner tympanic wall. The characteristic odor of bony necrosis is usually present, but an offensive odor is not always positive evidence of bony necrosis. A functional examination in very young patients is impossible, but when old enough to answer intel-

ligerly it will be found that bone conduction is much impaired or destroyed. The upper tone limit is reduced to not over two thousand vibrations per second, while low tones are fairly well heard.

Prognosis.—Unfavorable in the majority of cases, both as to restoration of function and also as regards life.

Treatment.—As thorough cleansing of the ear as possible is important. Internally the use of silicea, lime in some form, gold and sodium chloride, potassium bichromate, or hydrobromic acid dil., are most often required during the acute stages. Later jaborandi, physostigma, nux, or strychnine should be employed.

CHAPTER XXXIV.

THE PERCEPTIVE APPARATUS IN ACUTE INFECTIOUS DISEASES.

Either during or as a sequelæ of diphtheria, influenza, measles, mumps, scarlet fever, typhus or typhoid fever, variola, etc., the ear is often affected. Often the tympanum is first implicated, the labyrinth being secondarily involved, but in many cases, especially in scarlatina, the labyrinth is primarily affected by the specific poison, and the tympanum remains normal.

Pathology.—The inflammatory action induced may cause disintegration of a considerable portion of the auditory nerve terminals, or may simply result in an effusion into the labyrinthine space, increasing the tension of the structures.

Symptoms.—The variation of audition is considerable, and the tinnitus not very annoying. Conversational tones are less readily understood than usual, and loud tones, when uttered close to the ear, may be distinctly understood.

Diagnosis.—Must be made practically by the functional examination, as an inspection of the ear seldom reveals the condition. In the upper portion of the musical scale, gaps are often found.

Prognosis.—In children, and recent cases in adults, considerable improvement usually follows proper internal medication.

Treatment.—Jaborandi is probably the most important remedy in these cases, the dosage rapidly being increased until the physiological action of the drug is obtained. Nux,

ignatia, hydrastis, bryonia, cimicifuga, or physostigma are also often indicated.

Mumps.

In epidemics of this disease there is often implication of the labyrinth. In young children this is a not uncommon cause of deafmutism. When seen early, and proper treatment is instituted, considerable improvement usually follows.

Treatment.—Phytolacca, iris, or potassium iodide are usually needed. Jaborandi, bryonia, and cimicifuga less frequently.

Typhus and Typhoid Fever.

In either of these fevers, the changes produced are probably due more to changes in the cerebrum than in the labyrinth. Proper treatment for the exciting cause is usually all that is required.

Epidemic Influenza; Diphtheria.

In either of these diseases the auditory nerve may be affected practically the same as the optic nerve, a neuritis affecting the nerve trunk, resulting. Sclerotic changes and atrophy of the nerve fibers follow in many cases.

Treatment.—This must be directed to improving the general condition. Mental and physical rest are necessary for good results. The drugs most frequently required are pulsatilla, nux, and ignatia.

Epidemic Cerebro-Spinal Meningitis.

Pathology.—In this condition the inflammatory process seems to follow the lymph channels of the vestibular and cochlear aqueducts, and affects the structures within the bony labyrinth. In the early stages the quantity of the endolymph and perilymph is increased and there is also a change in the character of the fluids. Finally the bony

walls are affected by the inflammatory process. Dilatation of all the blood vessels occurs, and there is migration of the white blood corpuscles into the surrounding tissues, a true hypertrophy resulting. As a result of these changes, hemorrhages are frequently found. The newly formed tissue becomes more dense, and a bony formation may follow, at times even obliterating the semicircular canals or cochlea. In some cases necrosis of the tissues occurs, filling the labyrinth with pus. Secondary involvement of the tympanum may occur through rupture of the membrane of the oval or round windows.

Symptoms.—Besides the meningeal symptoms there is vertigo, sudden loss of audition, and distressing tinnitus.

Diagnosis.—Inspection of the ear gives negative results, but is of value in making the diagnosis by exclusion. Functional examination shows either marked diminution of hearing or complete deafness.

Prognosis.—Unfavorable. If the patient lives there is seldom little, if any, improvement in the hearing.

Treatment.—Internally the use of jaborandi, gelsemium, bryonia, or pulsatilla may slightly improve the hearing, and nux or strychnine are sometimes beneficial.

The Labyrinth in Acute Meningitis.

Pathology.—In non-epidemic meningitis there may be similar secondary labyrinthine changes as occur in the epidemic form. A traumatic meningitis is generally localized, and the affection of the labyrinth is usually of one side. Besides the changes in the labyrinth, the hearing may be affected by direct pressure of inflammatory products upon the trunk of the auditory nerve, involvement of the sheath of the nerve, or by a circumscribed meningitis over the auditory center. The changes which occur in the non-epidemic form are usually not as extensive as in the epidemic type.

Symptoms.—These necessarily vary with the location and severity of the lesion. The vertigo, tinnitus, and reduction of the audition also depend upon the structures invaded.

Diagnosis.—The history of the case is of the utmost importance. Inspection often fails to reveal any morbid condition, unless the tympanum has been affected. The functional tests usually show the lower tone limit normal in labyrinthine lesions, the upper tone limit much reduced, bone conduction slight or none, and conversational tones heard relatively less readily than high-pitched tones. Artificial aids to hearing do not improve audition. If the nerve trunk is subjected to pressure, the notes of the middle register are not well heard, while the upper and lower tone limits are not much affected. Bone conduction is considerably diminished, or lost. If the cortical center is affected, the characteristic tone symptom is the gaps which occur. Word deafness, however, is the best evidence of cortical involvement. The patient may hear words, but can not repeat or define them. In these cases the lesion is bilateral, but the defect is most marked upon the side opposite the affected area. Bone conduction is reduced, and tone gaps may occur in any portion of the scale.

Prognosis.—Excepting in meningitis, the result of abscess and intracranial tumors, the process is not progressive, and the hearing often gradually improves.

Treatment.—Such drugs as will hasten or aid absorption are indicated and include jaborandi, bryonia, gelsemium, and potassium iodide. Other remedies which may be indicated are pulsatilla, hydrastis, phytolacca, nux, phytostigma, and strychnine.

CHAPTER XXXV.

INFLUENCE OF DISEASES OF THE NERVOUS SYSTEM AND OF GEN- ERAL DISEASES UPON THE PERCEPTIVE APPARATUS.

Besides the meningeal inflammation, the hearing power may be impaired or destroyed by affections of a degenerative character in the brain or cord. These may be classed as cerebral congestion, apoplexy, cerebral embolism, endarteritis, cerebral tumors, disseminated sclerosis, tabes dorsalis. It is not often that a cerebral hemorrhage or embolism causes much impairment of hearing.

Word deafness is the most characteristic symptom of a cortical lesion. An important subjective symptom is the presence of complicated auditory hallucinations, as of voices, music, etc. These symptoms may be present in congestion, hemorrhage, degeneration, sclerosis, or neoplasms. If the symptoms are only temporary, the cause is probably either congestion or anemia. Associated phenomena must be considered in making a diagnosis as well as locating the lesion.

In tabes dorsalis the nerve or the auditory centers may be involved in the sclerotic process.

When the cerebellum is affected, vertigo and nausea are predominating symptoms, and the hearing may remain practically normal.

The diagnosis is made more by the general manifestations than by the ear symptoms. The treatment must be along the line of improvement of the exciting cause.

Acute Infectious Diseases with Aural Complications.

Tympanic inflammation is usually present in the acute infectious diseases, if aural complications are present. Usually the degree of inflammation is proportionate to the severity of the general attack. In measles, varicella, mumps, and mild cases of influenza, the tympanum is not often seriously affected, the condition being either a tubal catarrh or an acute catarrhal otitis media. The more active infectious diseases as diphtheria, scarlet fever, typhus fever, variola, and in severe cases of rubeola, the inflammation often affects the connective tissue, being practically a cellulitis. The condition is the same as when occurring in other portions of the body, necrosis resulting and pus forming, with later implications of the bony structures. Suppurative otitis media is the natural sequence of such an infection.

The diagnosis and treatment are practically the same as already given.

Nephritis.

In renal affections the changes found in the ear depend upon the general venous obstruction and also upon what is called arterio-capillary fibrosis. The tissues are poorly supplied with blood as a result of the changes within the walls of the vessels, and a subnormal condition results. Impoverishment of the blood also occurs. Within the tympanum, as a result of these changes, an exosmosis of serum follows. This is similar to the pleural effusion found in nephritis, and the term *otitis media serosa* is often used. The condition is mechanical and not inflammatory. The labyrinth may also be affected, and hemorrhagic lesions in the sheath of the auditory nerve may result from this condition.

Metastasis

A severe suppurative process in any region of the body may be the origin of an infective embolus which may be

carried to the tympanum or labyrinth through the circulatory system. The symptoms will depend upon the occlusion of the circulation or a secondary infection. Chronic suppuration in the accessory nasal cavities may often be a factor for the obscure ear symptoms sometimes observed. In ulcerative endocarditis any of the anatomical divisions of the ear may be affected. In acute pulmonary conditions the tympanum is often affected.

Tuberculosis.

Usually the first intimation of a tympanic lesion is the presence of a discharge in the external auditory canal. Inspection will often reveal a complete destruction of the drum membrane, and also involvement of the ossicles in many cases. If the perforation is small, it is usually round and the edges thickened and everted. Frequently in tuberculosis the perforations are multiple. If the ossicles are affected, the contiguous bony tissue is soon involved and the mastoid is also often implicated in the destructive process.

The diagnosis is usually made through the general condition and the treatment is that employed for the systemic lesion.

Leukemia.

Deafness results in this condition as a sequence of the passage of minute cells or lymph corpuscles into the channels of the labyrinth, diminishing their size and sometimes obliterating them entirely. The aural infection is recognized by the sudden impairment of hearing, which gradually increases; vertigo, nausea, and tinnitus are also present.

Diabetes.

Furunculosis of the external auditory canal is very characteristic in severe cases. Eczema of the canal and auricle

is frequent in this condition. Disturbances in audition are probably the result of hemorrhagic conditions within the labyrinth or effusion into the cortical or medullary centers.

Gout and Rheumatism.

It is probable that either of these conditions frequently affect the ear. A comparatively mild, but persistent eczema of the external auditory canal is often found in gouty subjects. Inflammatory conditions of the tympanum in rheumatic subjects is usually more painful than when uncomplicated. The treatment in these cases is necessarily modified by the rheumatic or gouty condition.

Drug Influences.

Some drugs exert a markedly deleterious influence upon the ear. Quinine is especially pernicious in its effects, when administered for any considerable period. Salicin, salicylic acid and its salts are also drugs which must be cautiously employed in tympanic and labyrinthine congestions or inflammations. Glonoin, amyl nitrite, nux, and strychnine are also to be used with caution in many cases. Any drug which increases the flow of blood to the brain may have a harmful influence on the ear, especially when there is a congestive or inflammatory condition present, and the drugs are employed for some time. This applies more particularly to the physiological drug action rather than the medicinal action. A very common practice is the administration of large doses of quinine for "breaking up a cold in the head." This habit should be condemned. Tobacco has been credited with impairing the hearing, but the probability is its influence is exerted through the effects produced upon the general nervous system.

The Influence of Functional Nervous Conditions upon the Hearing.

The functional nervous conditions most often found are neurasthenia and hysteria. It is often difficult to determine whether there is a co-existing lesion of the ear or not, but in many cases there probably is, and the nervous manifestation is simply more prominent in this region through this morbid condition.

Neurasthenia.

These cases usually present a condition of the nervous system in which any extra exertion produces an exaggerated degree of impairment of any organ affected. In the ear the term "auditory strain" is often used for the auditory manifestations. Following the sleeping hours, the hearing may be fairly good, but later the impairment of hearing is often very marked. Sensitiveness regarding the ability to understand increases the condition, and often the patient becomes a hypochondriac, or in extreme cases, acute melancholia may result. The patient usually hears better in a quiet place. An annoying tinnitus is always present, and is increased when tired. There may be a sense of formication or of occlusion of the external auditory canal. The hearing often varies during an examination.

Diagnosis.—Either inspection or a functional examination often reveals but little, excepting as the general condition is considered. All tests may be negative, unless continued for some time, when the variations of, or diminished acuity of hearing may be observed.

Prognosis.—Unless there are marked changes, the prognosis will depend upon the ability to improve the general nervous condition.

Treatment.—Care in the selection of drugs is necessary. Pulsatilla, ignatia in small doses, rhus tox., gelsemium, hydrobromic acid dil., the bromides, and occasionally physostigma are the drugs most frequently required.

Freedom from any over-exertion is also an important aid in these cases, and often a complete change of scene and associations will be beneficial. Nux, strychnine, or ignatia in large doses, as well as quinine or any drug which increases nervous excitability should be avoided.

Hysteria.

In this condition, which is often present in neurasthenia, the symptoms are practically the same.

Symptoms.—As a rule the deafness appears suddenly, and may be considerable or absolute. It often follows a mental shock, and usually is permanent. An abrupt restoration of hearing may occur without any apparent cause. The condition may be unilateral, and suddenly shift to the opposite side, or both ears may be affected at the same time. Pain in the region of the ear or of the mastoid is not infrequent. Vertigo and tinnitus are usually absent.

Diagnosis.—This must be made by the general condition of the patient as a rule, as all tests are usually negative as regards any characteristic condition.

Prognosis.—This will depend upon the ability to relieve the hysterical condition.

Treatment.—The remedies indicated in hysteria are to be employed.

Reflex Aural Disturbances.

Morbid conditions in any region of the body may induce either functional or structural changes in the ears. The most logical explanation for the changes is that circulatory disturbances are responsible for the disturbance. In the conducting portion of the ear, visual changes may be noted, but in the perceptive region a functional examination only will show an abnormal deviation. The recognition of the case is often difficult, and the outcome will depend upon the ability to relieve the exciting cause.

CHAPTER XXXVI.

DEAF-MUTISM.

Either congenital deafness or the loss of hearing in early childhood is a cause of mutism. In many cases it is impossible to decide the exact condition.

Etiology.—Heredity is often a factor, and degeneration or a hereditary specific condition may be a cause. Injuries to the head during parturition, or attacks of acute infectious diseases during infancy, may result in deaf-mutism. Acute or chronic inflammatory intracranial affections, or adenoids in early childhood may be factors.

Pathology.—A congenital defect in some portion of the auditory mechanism, or an acquired lesion may account for this condition. The changes are varied, and any part of the conducting or perceptive apparatus may be affected.

Symptoms.—Lack of attention to conversation or loud noises often first attracts attention to an aural defect.

Diagnosis.—The variation in the age of children in commencing to articulate, and also in infancy in noticing sounds, varies, and it is often difficult to determine whether it is a case of deafness or of delayed perception of sound. A history of hereditary deafness, of intracranial affections, or of any abnormality of the ear should be considered in making a diagnosis.

Prognosis.—Always guarded, especially in cases under the age of eighteen months.

Treatment.—This must be governed entirely by the cause. In some cases operative measures are required, as where there is much impairment of nasal respiration, either

through nasal malformations or adenoid vegetations. Medicinal measures are of no value in these cases. When free nasal respiration is present, therapeutic measures may benefit the patient in some instances. The use of some appliance for stimulating the auditory tract is also of occasional value, but a careful study of each case must be made.

Artificial Aids to Hearing.

Various appliances have been brought to the notice of a confiding public for the improvement of the hearing, but none have been universally successful. Ear drums, conversation tubes and ear trumpets of different designs, are on the market. The only way to determine positively whether any of these instruments will be beneficial is by a trial. Ear drums are of no benefit unless the membrana tympani has been destroyed, and in many cases a thin layer of cotton will be equally as effective as the expensive ear drum. The instruments which are beneficial when the membrana tympani is not destroyed, can be tried at any instrument makers, and such as appear to give the best results may be employed.

CHAPTER XXXVII.

MATERIA MEDICA AND THERAPEUTICS.

The drugs mentioned under this heading are those which have been found most efficacious. The variation in dosage depends upon the condition, whether destructive or not, and also whether acute or chronic. In chronic cases the doses are smaller than in acute types, and the dose is always for adults unless otherwise stated.*

Acidum Arsenosum.—In the chronic dry scaly form of eczema of the auricle or external auditory canal. Gr. 1-100.

Acidum Boricum, Boric Acid.—This is used either alone or in combination in suppurative otitis media, dusting the powder lightly with the DeVilbiss powder blower. In an acute suppurative otitis media, the plain boric acid is all that is usually required. In chronic cases I generally employ combinations, the names employed for these being more for the sake of convenience than anything else.

Carbolized Boric Acid.—Boric acid to which is added five per cent carbolic acid and thoroughly triturated. *Indications:* Hypersensitive mucous surface; moderately profuse discharge, fetid, not purulent.

Calendulated Boric Acid.—℞ Sp. med. calendula, boric acid āā q. s. Triturate until a dry powder results. *Indications:* Moderately profuse, thin, acrid pus.

Ergotized Boric Acid.—℞ Squibb's ergot ʒss, boric acid

*Many drugs employed are not mentioned in this list as the indications for their use is the same as is mentioned in all Eclectic text-books, and so are not repeated here.

ʒj. Triturate the same as the calendulated product. *Indications:* Membranes turgid and reddened; slight discharge.

Borated Iodoform.—Iodoform ʒj boric acid ʒij. *Indications:* Pallid mucous membrane; discharge scanty.

Salicylated Boric Acid.—Lloyd's Salicylic acid ʒj; boric acid ʒvj. *Indications:* Polypoid granulations, or a soggy condition of the mucous tissue.

Thuja Boric Acid.—Sp. med. thuja ʒj, boric acid ʒij-iv. Triturate. *Indications:* Papillomatous granulations of the mucous membrane.

These combinations are most frequently employed. It is necessary in their preparation that no glycerin is present in the liquid drugs used, and considerable time is necessary to properly triturate the mixture, as the finished article should be free from any lumps.

Acid Hydrobromicum Dilutum. Diluted Hydrobromic Acid.—In tinnitus resulting from the use of quinine, or the tinnitus of nervous persons. Dose, gtt. ss-j.

Acidum Phosphoricum Dilutum. Diluted Phosphoric Acid.—Atony of the nervous system and functional deafness. Dose, gtt. j.

Acidum Salicylicum. Salicylic Acid.—Lloyd's preparation is the one employed. Internally in some of the rheumatic or gouty conditions. The indications are a full, moist, purplish, or leaden-colored tongue. Locally the use with boric acid has been given.

Salicylic Acid Ointment.—Lloyd's salicylic acid gr. xx, white vaselin ʒj. *Indications:* Dry scaly eczema of the external auditory canal. Boggy, edematous state of the turbinal tissues. In the latter condition the ointment should be applied on a pledget of cotton that fills the space between the turbinate and septum, and should be left in position an hour. Do not repeat the application to the same side oftener than every fourth day.

Salicylic Acid Wash.—℞ Lloyd's salicylic acid ʒss, sodium borate ʒjss, Lloyd's hydrastis ʒj, aqua q. s. ʒiv. Use in atomizer. *Indications:* As a cleansing and depleting solution. Also appears to possess a stimulating action on the mucous glands. If there is a profuse, thin watery, non-excoriating discharge, distilled hamamelis should be substituted for the water.

Aconitum. Aconite.—In acute fibrile conditions following the usual indications. In tonsillitis the dosage and frequency should be increased until the tingling sensation of the tongue is marked, then repeated often enough to keep a slight sensation of tingling.

Alkaline Wash.—℞ Sodium bicarbonate. Sodium borate. Sodium chloride āā gr. xxxij, aqua ʒiv. This is used for removing excessive secretion or for softening crust formation.

Ammonii Bromidum. Ammonium Bromide.—In nervous deafness, and also tinnitus from the use of quinine. Dose, gr. ij-v.

Apis.—Edema of the tissues and scanty urine. Dose, gtt. i-10—i-6.

Apocynum.—Excessive edema of the tissues and scanty urine. It may be combined with apis. Dose, gtt. 1-3—j.

Aqua Hamamelidis. Distilled Hamamelis.—*Indications:* Internal.—Profuse thin, watery, non-excoriating discharge from the nose. In passive epistaxis it is a valuable remedy. In pharyngeal conditions, where a varicosed venous appearance is present, or where there is a venous stasis with a hemorrhoidal condition, the drug is indicated. Dose, gtt. ij-v. Locally, as already stated under salicylic acid wash.

Arseni Iodidum. Arsenic Iodide. Iodide of Arsenic.—In scrofulous and anemic cases, also when there is the combination of scrofula and hereditary syphilis. Dose, gr. i-200—i-50.

Asclepias.—When the pulse is strong and vibratile; skin moist; inflammation of serous tissues. Dose, gtt. 1-3—ss.

Auri et Sodii Chloridum. Gold and Sodium Chloride.—In syphilitic cases, either the later stages of acquired, or in the hereditary form, especially when there is necrosis of the bony tissue. Dose, gr. 1-100 in solution.

Baptisia.—In faucial or pharyngeal inflammation when the mucous membrane presents a dusky, leaden-colored hue, and there is a disposition to septic ulceration. The breath is offensive. Dose, gtt. ss—2-3.

Bryonia.—Pain increased by motion. Pain extending from the throat to the ear on swallowing. Dose, gtt. 1-3—ss.

Calx Sulphurata. Calcium Sulphide.—In suppurative conditions of the sinuses, tympanum and mastoid. Also in purulent secretion from the nasal cavities or naso-pharynx. Dose, gr. 1-100—1-10, increasing to saturation in acute tympanic and mastoid suppurative types.

Cannabis Indica.—In migraine, some forms of nervous headache, and facial neuralgia in women during the menstrual period or at the menopause. In cerebral anemia and a subnormal mental state it is useful. Dose, gtt. 1-6—j.

Carbo Ligni. Carbo Vegetabilis.—In epistaxis, especially if passive in character. Preparation, IX trituration. Dose, gr. v—x.

Chloroformum. Chloroform.—In acute catarrhal otitis media, chloroform vapor will relieve the pain quicker and oftener than any other means. Care must be exercised that none of the liquid enters the canal, as it will vesicate and increase the pain. Preferably used in a De Vilbiss powder blower.

Cimicifuga. Macrotys.—Where the tissues have a bruised feeling. In rheumatic pharyngitis with the bruised sensation. Dose, gtt. ss—j.

Coca.—In extreme hoarseness where it is imperative the voice should be used. Especially in those cases where there is an apparent relaxation of the vocal cords. Dose, gtt. iij—x.

Collinsonia.—In laryngitis and also in pharyngitis where the tendency is to irritation of the larynx. The aromatic collinsonia, which is made from the fresh herb, is the preparation employed. Dose, gtt. iij—xv.

Cuprum.—Anemic and chlorotic conditions, with the mucous tissues pallid. Dose, gtt. 1-5.

Echinacea. *Echafolta*.—Mucous membranes dusky, ulcerated, and a general debility. The breath is fetid. There is a condition of sepsis. Dose, gtt. j—v.

Ergota. *Ergot*.—In epistaxis, active in character. Dose, gtt. v—xv.

Gelsemium.—In acute catarrhal otitis media, and in sinus affections, gelsemium will afford relief by increasing the fluidity of the secretion. In neuralgia of the supra-orbital nerve, this drug in combination with bryonia will usually afford prompt relief. Dose, gtt. ss—ij.

Glycerinum. *Glycerin*.—A large pledget of cotton saturated with glycerin and allowed to remain in position for half an hour will deplete edematous nasal tissues, and often relieve the pressure in the accessory sinuses by relieving the swelling around their openings, in a short time. It is seldom more than two applications are necessary.

Grindelia.—Asthmatic conditions and a harsh, dry cough. Dose, gtt. x—xxx.

Hydrastis.—In catarrhal conditions where the secretion is moderately profuse, moderately thick, and not purulent. In atony of the mucous tissues it is also indicated. Dose, gtt. j—ij.

Ignatia.—Especially indicated in nervous females who suffer from uterine disturbances, but are not apprehensive. The hearing is often impaired and tinnitus is frequently

present. There is general atony of all tissues. Dose, gtt. 1-6—1-5.

Ipecacuanha. Ipecac.—Especially valuable in croupous conditions, but should not be carried to the point of emesis. Dose, gtt. 1-6—ss.

Iris.—In enlargement of the lymphatics with a sluggish lymphatic circulation this drug is indicated. The glands are soft. Dose, gtt. ss—v.

Liquor Arseni et Hydrargyri Iodidi. Donovan's Solution.—In secondary syphilis with an elongated, contracted, pointed tongue. Papillæ prominent and reddened. Dose, gtt. ss—j.

Liquor Potassii Arsenitis. Fowler's Solution.—In chronic eczema of the auricle and canal. The dry scaly form especially. In excessive, thin, watery, excoriating discharge from the mucous membranes. Dose, gtt. ss—j.

Lobelia.—In laryngeal spasms the drug should be given in nauseant doses, but not to the point of emesis. Dose, gtt. ss—ij.

Nux Vomica.—In catarrhal conditions where the mucous tissues have a relaxed appearance.

Contraindicated in neurotic persons, or where there is an irritable condition of the central nervous system. Dose, gtt. 1-5—1-3.

Physostigma.—In inflammatory conditions of the meninges, and congestive states of the brain or of the labyrinth, the drug is often indicated. Mental dullness in cerebrospinal meningitis is an indication. Dose, gtt. 1-10—1-5.

Phytolacca.—Indicated in enlargement of the lymphatics especially when they are hard. Also when the mucous follicles are distended with secretion. Its action on the mucous glands is such that the tendency to the formation of a false membrane is lessened. In tonsillar affections, especially acute, this drug in combination with aconite is nearly a specific. In chronic enlargement of the tonsils,

unless hyperplastic in character, phytolacca continued for some time will often diminish their size. In chronic rhinitis, and often in atrophic rhinitis, this remedy through its action on the mucous glands will afford relief. The same is true of follicular and atrophic pharyngitis. Dose, gtt. j—v. This varies according to the amount of inflammation present. In acute cases the maximum dose is often required, and in chronic conditions the minimum dose.

Pilocarpus. Jaborandi.—Especially indicated in atrophic conditions of the mucous tissues of the nose, pharynx, and larynx. The surfaces present a dry, parched appearance. In labyrinthine diseases, particularly where there is effusion, the drug relieves by promoting absorption. Dose, gtt. iiij—viiij.

Piscidia. Jamaica Dogwood.—Frequently required in neuralgic affections of the trifacial nerve, especially when opium or its derivatives are contraindicated. Dose, fl. ext. gtt. v—xv.

Potassii Bichromas. Potassium Bichromate.—Indicated when there is a tough, tenacious, stringy mucus. Also with crust or scab formation in the nose, and when the crusts are dislodged they are streaked with blood, and a slight hemorrhage follows. Also in superficial ulceration of the septum. Locally. A two per cent solution. Internally, gr. i-100, preferably in tablet form.

Potassii Iodidum. Potassium Iodide.—In small doses in atrophic states of the mucous membrane and labyrinthine diseases. Large doses whenever a destructive process appears, due to specific disease. Dose, gr. j—xxx. Always give plenty of water with each dose.

Pulsatilla.—Whenever an apprehensive condition is present, this drug affords relief. In acute catarrhal otitis media, this drug combined with gelsemium usually gives prompt relief. Dose, gtt. j.

Quinina. Quinine.—Contraindicated in practically all ear affections.

Rhus Toxicodendron.—The indications for this drug are: pain diminished or relieved by motion; elevated papillæ at the tip of the tongue, the tongue being pointed and the edges reddened. Dose, gtt. 1-10—1-6.

Sticta.—When there is a feeling of fullness at the root of the nose, and with a disposition to blow the nose without any secretion being dislodged. Dose, gtt. 1-6—1-5.

Strophanthus.—In cardiac insufficiency or muscular debility. Dose, gtt. ss—iij.

Strychninæ Sulphas. Strychnine Sulphate.—The indications and contraindications are practically the same as for nux. Dose, gr. 1-100—1-30.

Syrupus Ferri Iodidi. Syrup of Iodide of Iron.—In some cases of specific disease this is better tolerated than any other iodide. Dose, gtt. x—xx.

Thuja.—In syphilitic erosions and ulcerations in the nose, mouth, or pharynx, the local application of thuja will usually be followed by rapid healing. As a mouth wash in these cases, the use of thuja, Lloyd's hydrastis aa ʒij, glycerin, ʒjv, a teaspoonful of this added to enough water to rinse the mouth thoroughly, will also aid in the recovery from specific buccal lesions.

Veratrum Viride.—In sthenic conditions and traumatism, with the pulse rapid, full, and bounding. Dose, gtt. 1-6—j.

BIBLIOGRAPHY.

- Accessory Sinuses of the Nose.....Turner.
American Dispensary.....Felter-Lloyd.
American Text Book, Eye, Ear, Nose, and Throat.
Anatomy Gray.
Anatomy Holden.
Anatomy and Diseases of Eye and Ear.....Roosa and Davis.
Anomalies and Curiosities of Medicine.....Gould and Pyle.
Atlas of Diseases of the Larynx.....Grünwald and Grayson.
Atlas of Diseases of the Mouth, Pharynx and Nose.....
Grünwald and Newcomb.
Atlas of Nervous System.....Jakob and Fisher.
Atlas of Otology.....Bruhl and Politzer.
Comparative Anatomy and Physiology.....Bell.
Cyclopedia of Medicine.....Sajous.
Deafness, etc.....Woakes.
Diseases of the Brain and Cord.....Macewan.
Diseases of Children.....Mundy.
Diseases of the Ear.....Dench.
Diseases of the Ear.....Poltzer.
Diseases of the Nervous System.....Hammond.
Diseases of the Nose and Throat.....Bosworth.
Diseases of the Nose and Throat.....Coakley.
Diseases of the Nose, Throat, and Ear.....Friedrich and Curtis.
Diseases of the Nose, Throat, and Ear.....Gradle.
Diseases of the Nose and Throat.....Kyle.
Diseases of the Nose and Throat.....Knight.
Diseases of the Nose and Throat.....Price-Brown.
Diseases of the Nose and Throat.....Sajous.
Diseases of the Nose and Throat.....Shurly.
Diseases of the Upper Respiratory Tract.....Williams.
Dynamical Therapeutics.....Webster.
Electricity in Diseases of the Ear, Nose, and Throat... Scheppegrell.
Essential Diseases of Nose and Throat.....Gleason.
Handy Guide in Materia Medica.....Niederkoru.

INDEX.

- Abscess, acute, of septum, 294
acute of uvula, 340
chronic of septum, 295
chronic of tonsil, 370
of auricle, 522
cerebellar, 592
cerebral, 591
retropharyngeal, 418
tonsillar or peritonsillar, 360
- Accessory cavities, 13
- Accessory sinus mucous membrane, 17
- sinuses, 13
sinuses, diseases of, 298
- Acidum boricum, 614
calendulated, 614
carbolized, 614
ergotized, 614
salicylated, 153, 615
and iodoform or borated iodoform, 615
and thuja, 615
- carbolic, 204
chromic, 200
hydrobromicum dilutum, 615
lactic, 200
phosphoricum dilutum, 227, 615
salicylicum, 200, 615
salicylic, ointment, 146, 615
wash, 146, 148, 616
tannic, 236
- Acne of nose, 230
- Aconite, 141, 616
- Actinomycosis of maxillary sinus, 307
- nasal, 210
of pharynx, 416
- Acute bulbar paralysis, 343
catarrh of the larynx, 434
catarrh of the nasopharynx, 328
- Acute catarrhal angina, 354
laryngitis, 434
otitis media, 553
pharyngitis, 380
tonsillitis, 354
cellulitis of the larynx, 448
circumscribed external otitis, 528
coryza, 135
diffuse external otitis, 532
edematous rhinitis, 156
epiglottitis, 445
idiopathic rhinitis, 135
infectious diseases, aural complications in, 607
involvement of inner ear in, 602
of perceptive mechanism, in, 602
inflammation of labyrinth, secondary to acute purulent otitis media, 600
laryngitis in children, 439
in constitutional diseases, 436
- nasal blenorrrhea, 135
catarrh, 135
nasopharyngitis, 328
post-nasal catarrh, 328
purulent discharge from middle ear, 557
purulent otitis media, 557
retronasal catarrh, 328
rheumatic pharyngitis, 405
rhinitis, 135
in children, 142
rhinopharyngitis, 328
rhinorrhoea, 135
salpingitis, 549
tubo-tympanitis, 552
uvulitis, 339
- Adenocarcinoma, 276
Adenoid vegetations, 346

- Adenoiditis, chronic, 330
 Adenoids, 346
 Adenoma of anterior nares, 247
 of fauces, 247
 of larynx, 248
 of nasopharynx, 247
 Aids to hearing, artificial, 613
 Alæ, nasal, collapse of, 289
 Alkaline solution or wash, 143, 616
 American catarrh, 330
 Ammonii bromidum, 616
 Anatomy of anterior nasal cavities, 10
 of ear, 45
 of ethmoidal cells, 15
 of fauces and oropharynx, 23
 of faucial tonsils, 25
 of frontal sinus, 15
 of inferior turbinate, 13
 of larynx, 29
 of lingual tonsil, 345
 of Luschka's tonsils, 28
 of mastoid, 574
 of mucous membrane of accessory sinuses, 17
 of mucous membrane of nasal cavities, 17
 of nasal tonsil, 345
 of nose, 9
 of pharyngeal tonsil, 28
 of pharynx, 27
 of postnasal space, 10, 21
 of septum, 10
 of sinuses, 15
 of antrum of Highmore, 15, 16
 of ethmoidal sinus, 15
 of frontal sinus, 15
 of maxillary sinus, 15, 16
 of sphenoidal sinuses, 13
 of tonsils, 25
 Anemia of labyrinth, 593
 of larynx, 469
 of pharynx, 425
 Anemic rhinitis, 145
 Anesthesia of larynx, 487
 of pharynx, 426
 Angina, acute catarrhal, 354
 benign croupous, 420
 diphtheritic, Ludovici, 392
 Ludwig's, 392
 Angioma of nasal cavity, 248
 of auricle, 525
 of fauces, 249
 of larynx, 250
 of pharynx and uvula, 250
 of tonsil, 250
 Angioneurotic edema of larynx, 468
 Anomalies of upper respiratory tract, 129
 Anosmia, 220, 221
 Anterior nasal cavities, angioma of, 248
 ulcers of, 213
 Anterior nares, adenoma of, 247
 Antihelix, anomalies or malformations of, 512
 Antitragus, anomalies or malformations of, 512
 Antrum of Highmore, 15, 16
 Aphonia, hysterical, 489
 Aphthous throat, 420
 Apis, 157, 616
 Apocynum, 157, 616
 Apoplectiform, bulbar paralysis of soft palate, 344
 Aproxesia, 229, 230
 Aqua hamamelidis, 616
 Arsenic iodide, 148, 176, 177, 227, 616
 Arteries of the ear, 61
 Artificial aids to hearing, 613
 Asclepias, 617
 Asthma, reflex nasal, 220, 228
 rachiticum, 440
 Atheroma of the auricle, 525
 Atrophic catarrh, 170
 endorhinitis, 170
 laryngitis, 466
 nasal catarrh, 170
 nasopharyngitis, 333
 pharyngitis, 402
 rhinitis, 170
 Atrophy due to local manifestation of systemic lesion, 177
 from a pre-existing local lesion, 171
 of tonsil, 370
 Auditory nerve, 75
 Aural complications in acute infectious diseases, 607
 in diabetes, 608

- Aural disturbances. reflex, 229,
 611
 through drug influences, 609
 involvement in gout and rheu-
 matism, 609
 in hysteria, 611
 in leukemia, 608
 in metastasis, 607
 in nephritis, 607
 in neurasthenia, 610
 in syphilis, 597
 in tuberculosis, 608
 reflexes, 611
- Auricle, 45, 46, 512
 abscess of, 522
 angioma of, 525
 atheroma of, 525
 benign tumors of, 525
 cutaneous diseases of, 515
 cystoma of, 526
 diseases of, 515
 eczema of, 517
 epithelioma of, 527
 erysipelas of, 522
 fibroma of, 526
 gangrene of, 523
 hematoma of, 522
 herpes of, 519
 inflammatory affections of, 515
 injuries of, 515
 intertrigo of, 517
 lipoma of, 527
 lupus of, 521
 malignant tumors of, 527
 ossification of, 523
 papilloma of, 527
 pemphigus of, 519
 perichondritis of, 521
 sarcoma of, 527
 syphilis of, 520
 wounds of, 515
- Autumnal catarrh, 224
- Bacilli found in normal nose,
 126
- Bacillus lepræ, 207
 mallei, 204
- Baptisia, 384, 617
- Belladonna, 141
- Benign croupous angina, 420
- Blenorrhœa, acute nasal, 135
 chronic, 158
- Blood-cyst of septum, 296
- Boils in external auditory canal,
 528
 in nose, 211
- Bony canal, 47
 labyrinth, 69
- Bryonia, 141, 617
- Buccal tonsil, 371
- Cactus, 237
- Calcium sulphide, 212, 617
- Calx sulphurata, 212, 617
- Canal bony, 47
 cartilaginous, 46
 external auditory, 528
- Cannabis indica, 617
- Capsule labyrinthine, rarefying
 osteitis of in otosclero-
 sis, 571
- Carbo veg., 148, 237, 617
- Carcinoma of nasal cavities, 264
 of nasopharynx, 265
 of pharynx, 266, 268
 of soft palate, 266
 of tonsil, 268
- Cartilages of nose, depression
 of, 296
- Cartilaginous meatus, 46
- Caseous rhinitis, 149
 tonsillitis, 369
- Catarrh, acute of larynx, 434
 acute nasal, 135
 acute nasopharyngeal, 328
 acute postnasal, 328
 acute retranasal, 328
 American, 330
 atrophic, 170
 autumnal, 224
 chronic, of larynx, 461
 chronic, nasal, 158
 dry, 170
 Eustachian, 549
 hypertrophic nasal, 164
 of pharyngeal bursa, 330
 pollen, 224
 postnasal, chronic, 330
 purulent nasal, 179
 retranasal, chronic, 330
 rose, 224
 specific, 183
 summer, 224
 tubo-tympanic, 552

- Catarrhal croup, 443
 Catarrhal inflammation, 120
 acute, 120
 chronic, 121
 of ethmoid cells, 311
 of frontal sinus, 320
 of maxillary sinus acute, 298
 of maxillary sinus chronic, 300
 of middle ear, acute, 553
 of sphenoidal sinus, 316
 laryngitis, 443
 acute, 434
 pharyngitis, acute 380
 rhinitis, 135
 Catarrhus æstivus, 224
 Catarrhus longus, 158
 Catheterization of Eustachian tube, 102
 Cavity, tympanic, 49
 Cellulitis of larynx, acute, 448
 of neck, 392
 Cerebellar abscess, 592
 Cerebral abscess, 591
 croup, 440
 Cerumen, impacted, 539
 Child crowing, 440
 Chloretone, inhalant, 200
 Chloroform, 242, 556, 617
 Cholesteatomatous rhinitis, 149
 Chondritis of larynx, 454
 Chondroma of nasal cavities, 250
 of larynx, 251
 of nasopharynx, 251
 Chorditis tuberosa, 470
 Chorea of larynx, 490
 neurosis, reflex nasal, 229
 Chronic abscess of septum, 295
 of tonsil, 370
 adenoiditis, 330
 atrophic rhinitis, 170
 blenorrrhea, 158
 bulbar paralysis, 343
 catarrh of the larynx, 461
 of the nasopharynx, 330
 catarrhal otitis media, 567
 circumscribed external otitis, 532
 coryza, 158
 diffuse external otitis, 534
 edema of larynx, 450, 468
 edematous rhinitis, 182
 fetid rhinitis, 170
 Chronic hyperplastic otitis media, 571
 hypertrophic otitis media, 568
 rhinitis, 164
 infectious (specific) inflammations, 124
 nasal catarrh, 158
 nasopharyngitis, 330
 non-suppurative catarrh of middle ear, 567
 otitis media, 568
 postnasal catarrh, 330
 purulent otitis media, 561
 retro-nasal catarrh, 330
 rheumatic pharyngitis, 407
 rhinitis, 158
 rhinopharyngitis, 330
 rhinorrhœa, 158
 specific inflammatory processes, 124
 suppurative inflammation of middle ear, 561
 uvulitis, 340
 Cimicifuga, 141, 617.
 Circumscribed external otitis, 528
 Cirrhotic rhinitis, 170
 Clergyman's sore throat, 393, 397
 Clinical phenomena of inflammation, 118
 Clonic spasm of pharynx, 427
 Coca, 618
 Cocaine, 141
 Cochlea, 71
 Cod liver oil, 180
 Colchicum, 295
 Cold, or cold in the head, 135
 Collapse of nasal alæ, 289
 Collinsonia, 618
 Common membranous sore throat, 420
 Common sporadic catarrh, 135
 Congenital syphilis of nose, 193
 Congestion, tubal, 549
 tubo-tympanic, 552
 Congestive headache, 220, 229
 Consumption of the larynx, 478
 of the pharynx, 408
 of the throat, 478
 Corrosive mercuric chloride, 191

- Corti, organ of, 37
 rods of, 73
 Coryza, acute, 135
 caseosa, 149
 chronic, 158
 fetid, 170
 idiosyncratic (vasomotoria
 periodica), 224
 vasomotoria-periodica, 224
 Cough, 228
 Cratægus, 146
 Croup, catarrhal, 443
 cerebral, 440
 diphtheritic, 450
 false, 439, 440, 443
 fibrinous, 450
 idiopathic membranous, 450
 membranous, 451
 mucous, 443
 pseudomembranous, 451
 spasmodic, 439, 440, 443
 spurious, 434, 443
 true, 451
 Croupous external otitis, 538
 laryngitis, 450
 pharyngitis, 384
 Cryptic tonsillitis, 355
 Cuprum, 177, 618
 Cutaneous diseases of the auri-
 cle, 515
 Cyanotic laryngitis, 468
 rhinitis, 182
 Cynanche trachealis, 450
 Cystoma of auricle, 526
 Cysts, 276
 classification of, 276
 cystoma, 277
 dermoid, 277
 simple or retention, 276

 Deaf-mutism, 612
 Deflections of septum, 281
 Deformities of septum, 281
 Dentigenous cyst, 310
 Depression of nasal cartilages,
 296
 Dermoid cysts, 277
 Diabetes mellitus, aural compli-
 cations in, 608
 acute rhinitis in, 144
 Diabetic nasal ulcers, 213, 216
 Diffuse external otitis, 532

 Diphtheria, acute rhinitis in, 144
 involvement of internal ear
 in, 603
 Diphtheritic croup, 450
 external otitis, 538
 rhinitis, 154
 Discrete tonsil, 346
 Diseases of the accessory sin-
 uses, 298
 of the perceptive apparatus,
 593
 Distilled hamamelis, 616
 Diverticula or dilatation of
 pharynx, 379
 Dome of pharynx, 10
 Donovan's solution, 191, 619
 Drugs affecting the ear, 609
 Dry catarrh, 170
 laryngitis, 466
 nasal catarrh, 170
 pharyngitis, 402
 Dysodia, 170
 Dysphonia clericorum, 397
 spastica, 491

 Ear, anatomy of, 45
 blood supply of, 61
 Ear affections, neuroses, reflex
 nasal, 229
 histology of, 64
 internal, 45, 69
 involvement of in acute infec-
 tious diseases, 607
 in diabetes, 608
 in gout and rheumatism, 609
 in leukemia, 608
 in nephritis, 607
 in syphilis, 597
 in tuberculosis, 608
 lymphatics of, 63
 malformations of, 512
 muscles of, 60
 nerves of, 63
 physical examination of, 96
 Earache, 553
 Echafolta, 618
 Echinacea, 384, 618
 Ecthyma of pharynx, 420
 Eczema of auricle, 517
 Edema, chronic of larynx, 450,
 468
 glottidis, 448

- Edema, chronic of glottis, 448
 of larynx, 448, 450, 468
 of septum, 293
 of uvula, 339
- Edematous laryngitis, 448
 rhinitis, acute, 156
 rhinitis, chronic, 182
- Elongation of uvula, 337
- Elephantiasis Græcorum, 207
- Embolism, labyrinthine, 597
- Empysema of antrum of High
 more, 307
 of uvula, 341
- Empyema of frontal sinus, 322
 of maxillary sinus, 302
 of sphenoidal sinus, 316
- Endorhinitis atrophic, 170
- Enlargement of the tonsil, 365
- Epidemic cerebro-spinal meningitis, 603
 influenza, 144, 149
 influenza, involvement of internal ear in, 603
- Epiglottis, 35
- Epiglottitis, acute, 445
 miasmatic, 438
- Epilepsy, neurosis, reflex nasal, 229
- Epistaxis, 232
 constitutional conditions favoring, 232
 local causative agents, 232
 traumatic, 232
 vicarious, 232, 234
 systemic, 232, 233
- Epithelioma of auricle, 527
- Equinia, 204, 416
- Ergot, 237, 618
- Erysipelas, acute rhinitis in, 145
 of auricle, 522
 of larynx, 436
- Erythema of nose, 230
- Ethmoid cells, diseases of, 310
- Ethmoidal suppuration, 311
- Ethmoiditis, suppurating, 311
- Euphrasia, 227
- Eustachian canal, 56
 catarrh, 549
 tonsils, 28
 tube, 56
- Eustachian tube, catheterization of, 102
 muscles of, 61
 tympanic opening of, 50
- Examination, requisites for, 77, 86, 96
- Examination of ear, physical, 96
 of larynx, 92
 of nose, 80
 of pharynx, 90
- Exostoses of external auditory canal, 545
- Exostoses, nasal, 252
- External auditory canal or meatus, 528
 diseases of, 528
 examination of, 96
- ear, 45
 otitis, acute circumscribed, 528
 chronic circumscribed, 532
 chronic diffuse, 534
 hemorrhagic, 538
- Extradural abscess, 590
- Exudative pharyngitis, 393
- Eye, affections of as reflex nasal neurosis, 229
- False croup, 439, 440, 443
- Fauces and oropharynx, 23
- Fauces, adenoma of, 247
 angioma of, 249
 herpes of, 344
 sarcoma of, 272
- Faucial tonsil, 25, 26, 345, 353
- Fetid coryza, 170
 rhinitis, 170
- Fibrinoplastic rhinitis, 154
- Fibrinous croup, 450
 laryngitis, 450
 tonsillitis, 364
- Fibroma of auricle, 526
 of larynx, 256
 of nasal cavities, 253
 of nasopharynx, 255
 of tonsil, 255
- Fibrous polypi, 261
- Fluxus nasalis, 158
- Follicular laryngitis, 465
 pharyngitis, 397
 tonsillitis, 355
- Folliculous pharyngitis, 397

- Foreign bodies in anterior nasal cavities, 238
animate, 238, 241
inanimate, 238
rhinoliths, 238
miscellaneous, 238, 239
in external auditory canal, 542
in faucial tonsil, 371
in larynx, 484
in pharynx, 429
Fourth tonsil, 371
Fossa, Rosenmüller's, 28
Frontal sinus, 15
diseases of, 320
Functional aphonia, 489
nervous disorders, auditory disturbances in, 610
Furuncle in external auditory canal, 528
Furnuculosis nasal, 211
- Gangrene of auricle, 523
Gangrenous inflammation, 119, 123
pharyngitis, 385
Gasoline, 242
Gelatinous polypi, 262
Gelsemium, 141, 227, 618
General symptomatology, 130
Glanders of maxillary sinus, 307
nasal, 204
ulcers in, 218
of pharynx, 416
Glycerin, 157, 176, 618
Gold and sodium chloride, 148, 293, 617
Gout, aural complications in, 609
Gouty sore throat, 405, 407, 447
throat, 447
tonsillitis, 358
Granular laryngitis, 465
pharyngitis, 397
Grindelia, 618
- Hamamelis, 141, 148, 237
Hay asthma, 224
fever, 224
Headache, congestive, 220, 229
Hearing, artificial aids to, 613
tests, 106
- Heart, affections of as neuroses, reflex nasal, 230
Helix, anomalies of or malformations of, 512
Hematoma, auris, 522
of auricle, 522
of septum, 296
Hemorrhage, laryngeal, 482
Hemorrhagia narium, 232
Hemorrhagic external otitis, 538
inflammation, 119, 123
of larynx, 453
laryngitis, 453
pharyngitis, 388
Hereditary syphilis, 193
Herpes of auricle, 519
of fauces, 344
of pharynx, 420
Herpetic tonsillitis, 359
Hospital sore throat, 382
Hydrargyri chloridum corrosivum, 191
iodidum rubrum, 191
Hydrastis, 141, 190, 618
Hydroma, 277
Hydrorrhea, nasalis, 180
Hygroma, 277
Hyperemia of labyrinth, 595
Hyperemia of larynx, 469
Hyperesthesia of larynx, 488
of pharynx, 426
Hyperesthetic rhinitis, 220, 224
Hyperkeratosis, 423
Hyperosmia, 220, 221
Hyperplastic change in the pharyngeal structure, 401
laryngitis, 468
nasopharyngitis, 335
rhinitis, 164
rhinopharyngitis, 335
tonsillitis, 365
Hypertrophic laryngitis, 468
nasal catarrh, 164
ozena, 164
rhinitis, 164
tonsillitis, 365
Hypertrophy of laryngeal tissue, 468
of turbinated bones, 164
of the tonsil, 365

- Hysteria, disturbance of audition in, 611
 Hysterical aphonia, 489
- Idiopathic or constitutional ozena, 170
 membranous croup, 450
- Idiosyncratic coryza, 224
- Ignatia, 162, 618
- Impacted cerumen, 539
- Incisures of Santorini, 47
- Incus, 53
- Infectious diseases, acute, aural, complications in, 607
 granulomata, 124
 of pharynx, nasopharynx, and tonsils, 408
- Infective pharyngitis, 382
- Inflammation, 117
 actinomycosis, 124, 125
 catarrhal, 119, 120
 acute, causes of, 120
 chronic, causes of, 121
 tissue-change in, 120, 121
 chronic infections, 119
 clinical phenomena of, 118
 definition of, 117
 diphtheritic, 119
 gangrenous, 119, 123
 hemorrhagic, 119, 123
 of labyrinth, secondary, 598
 membranous, 119, 122
 croupous or pseudomembranous, 119, 122
 diphtheritic, 119, 122
 fibrinoplastic, 119, 122
 of middle ear, 549
 microscopical phenomena of, 119
 of floor of the nose affecting the teeth, 114
 of mucous membrane, 117
 specific, 124, 183
 glanders, 124, 125
 leprosy, 124, 125
 rhinoscleroma, 124, 126
 syphilis, 124
 tuberculosis, 124, 125
 stages of, 118
 suppurative and pustular, 119, 124
 varieties of, 119
- Inflammatory affections of the auricle, 515
- Inflammations, specific, 124
- Inflation of middle ear, methods of, 100
- Influence of disease of the nervous system and general diseases upon the perceptive apparatus, 606
- Influenza, epidemic, 144, 149
 acute laryngitis in, 438
- Inherited syphilis of the nose, 193
- Internal ear, involvement of in acute infectious diseases, 602
 syphilis of, 597
- Intertrigo of auricle, 517
- Intubation of larynx, 500
- Intumescent rhinitis, 163
- Iodide of iron, 162
- Ipecac, 436, 445, 619
- Iris, 190, 619
- Jaborandi, 620
- Jamaica dogwood, 620
- June cold, 224
- Keratoses, 423
- Labyrinth, 69
 acute inflammation of secondary to acute purulent otitis media, 600
 anemia of, 593
 anatomy of, 45, 69
 hyperemia, 595
 in acute meningitis, 604
 secondary inflammation of, following chronic middle ear inflammation, 598
 specific inflammation of, 597
 syphilis of, 597
 the bony, 69
 the membranous, 69, 74
- Labyrinthine embolism and thrombosis, 597
 hemorrhage, 596
- Lacunar tonsillitis, 355
- La Grippe, 144, 149

- Laryngeal diphtheria, 450
 hemorrhage, 482
 nystagmus, 490
 occlusion, spasmodic, 491
 phthisis, 478
 rheumatism, 447
 spasm, 440, 443
 tissue, hypertrophy of, 468
 tonsil, 345, 376
 vertigo, 491
- Laryngismus stridulus, 440
- Laryngitis, acute catarrhal, 434
 acute, in children, 439
 acute, in constitutional diseases, 436
 in erysipelas, 436
 in influenza, epidemic (la grippe), 438
 in measles, 437
 in miasmatic epiglottitis, 438
 in rheumatism, 439
 in scarlet fever, 437
 in small-pox, 437
 in typhoid and typhus fever, 438
- atrophic, 466
 catarrhal, 443
 croupous, 450
 cyanotic, 468
 dry, 466
 edematous, 448
 fibrinous, 450
 follicular, 465
 glandular, 465
 granular, 465
 hemorrhagic, 453
 hyperplastic, 468
 hypertrophic, 468
 membranous, 450
 phlegmonous, 446, 448
 pseudomembranous, 451
 purulent, 446
 purulent suppurative, 448
 rheumatic, 447
 sicca, 466
 simple chronic, 461
 spasmodic, 440, 443
 spastic, 472
 suppurative, 446
 symptomatic, 468
 stridulosa, 443
- Laryngitis, syphilitic, 472
 traumatic, 446
 tubercular, 478
- Laryngorrhea, 434
- Laryngotracheitis, 450
- Larynx, 29
 acute catarrh of, 434
 cellulitis of, 448
 adenoma of, 248
 anatomy of, 29
 anemia of, 469
 anesthesia of, 487
 angioma of, 250
 carcinoma of, 264
 catarrh, simple chronic, 461
 chondritis, 454
 chondroma of, 251
 chorea of, 490
 dilatations or pouches, 432
 diseases of, 431
 edema, chronic, 450, 468
 examination of, 92
 fibroma of, 256
 foreign bodies in, 484
 hemorrhage of, 482
 hyperemia of, 469
 hypertrophies of 432
 intubation of, 500
 laryngismus stridulus, 443
 lipoma of, 256
 lupus of, 433
 malformations and deformities of, 431
 mucocele of, 263
 neuralgia of, 489
 papilloma of, 245
 pemphigus, 470
 perichondritis, 454
 sarcoma of, 275
 spasm of in adults, 442
 of in children, 441
 spastic paraplegia, 491
 suppuration of, 446
 surface landmarks of, 30
 syphilis of, 472
 tuberculosis of, 478
 trachoma of, 470
- Leprosy, 207
- Leprosy, nasal, 207
- Leukemia, aural involvement in, 608
- Lime, 148

- Lingual tonsil, 345, 371
 Lipoma of auricle, 527
 of larynx, 256
 of nares, 256
 of nasopharynx, 256
 of pharynx, 256
 Liquor arseni et hydrargyri iodidi, 619
 Liquor potassii arsenitis, 141, 619
 Lobelia, 619
 Lobule, anomalies or malformations of, 512
 thickening of, 523
 Ludwig's angina, 392
 Lupus of auricle, 521
 nasal, 201
 of pharynx, 410
 stenosis of larynx in, 432
 Luschka's bursa, 346
 tonsil, 345, 346
- Malformations and deformities
 of larynx, 431
 of pharynx, 378
 of nasal spaces, congenital, 281
 of septum, 281
 of uvula, 337
 Maliasmus, 204
 Malignant tumors of auricle, 527
 Malleus, 204
 humidus, 204, 416
 of ear, 53
 Mastoid, 574
 inflammation of, 578
 operation, 582
 process, anatomy of, 574
 Mastoiditis, 578
 Materia medica and therapeutics, 614
 Maxillary sinus, diseases of, 298
 Measles, acute rhinitis concomitant with onset, 142
 laryngitis, acute in, 437
 nasal ulcers in, 219
 Membrana flaccida, 59, 99
 tympani, 57, 65
 characteristics of, 99
 color of, 99
 diseases of, 547
 folds of, 58
- Membrana tympani, function of, 57
 injuries of, 547
 vibrans, 99
 Membrane, Shrapnell's, 59
 Membranous croup, 451
 labrinth, 69
 laryngitis, 450
 inflammation of faucial tonsil, 364
 pharyngitis, 384
 rhinitis, 151
 sore throat simple, 420
 tonsillitis, 364
 Menstruation, epistaxis as vicarious, 232, 234
 Metastatic aural involvement, 607
 Miasmatic epiglottitis, 438
 Microtia, 512
 Middle ear, acute catarrhal inflammation of 553
 acute purulent inflammation of, 561
 chronic catarrhal inflammation of, 567
 chronic purulent inflammation of, 561
 diseases of, 547
 inflammation of, 549
 Migraine, neuroses, reflex nasal, 229
 Miller's asthma, 440
 Mogiphonia, 487
 Mucocele of ethmoid cells, 314
 of larynx, 263
 of nasal cavities, anterior, 262
 or nasopharynx, 262
 Mucous croup, 443
 Mucous membrane of accessory sinuses, 17
 of anterior nasal cavities, 17
 inflammation of, 117
 varieties of, 119
 membranes and their pathological changes, 112
 structure of, 115
 polypi, 262
 Mumps, aural complications in, 603
 Muscles of the ear, 60
 of the Eustachian tube, 61
 intratympanic, 60

- Mycosis of faucial tonsil, 370
 of lingual tonsil, 375
 of uvula, 341
 Myringitis, 548
 Myxocarcinoma, 276
 Myxofibroma, 261
 Myxoma of nasal cavity, 258
 of sphenoid cells, 319

 Naphthaline, 227
 Nasal actinomycosis, 210
 alæ, collapse of, 289
 bacteria, 126
 blenorrhæa, acute, 135
 breathing, importance of, 111
 calculi, 238
 cartilages, depression of, 296
 catarrh, acute, 135
 atrophic, 170
 chronic, 158
 cavities, anterior, adenoma of,
 247
 anatomy of, 10
 angioma of, 248
 carcinoma of, 264
 chondroma of, 250
 cysts, 276
 examination of, 80
 exostosis of, 252
 fibroma of, 253
 fibrous polypi, 261
 foreign bodies in, 238
 gelatinous polypi, 262
 hematoma of septum, 296
 histology of mucous mem-
 brane, 17
 lipoma of, 256
 mucocele, 262
 mucous polypi, 262
 myxofibroma, 261
 myxoma, 258
 osteoma, 257
 polypus, 258
 sarcoma, 270
 septum, diseases of, 278
 edema, 293
 perforation of, 292
 ulceration of, 290
 malformation of, 281
 olfactory region, 17, 18
 papilloma of, 244
 ulcers of, 213
 vestibule a part of, 11

 Nasal concretions, 238
 deformities, correction of, 284
 diphtheria, 154
 fossæ, 10
 glanders, 204
 hydrorrhæa, 180
 leprosy, 207
 lupus, 201
 neuroses, 220
 phthisis, 196
 polypus, 258
 syphilis, 183
 tonsil, 345
 tuberculosis, 196
 Nasopharyngitis, acute, 328
 atrophic, 333
 hyperplastic, 335
 simple chronic, 330
 Nasopharynx, adenoma of, 247
 anatomy of, 21, 22
 boundaries, 21
 carcinoma of, 265
 chondroma of, 251
 fibroma of, 255
 lipoma of, 256
 mucocele of, 262
 papilloma of, 245
 sarcoma of, 271
 Neoplasms, 243
 adenocarcinoma, 276
 adenoma of anterior nares, 247
 of fauces, 247
 of larynx, 248
 of nasopharynx, 247
 angioma, of fauces, 249
 of larynx, 250
 of nasal cavities, 248
 of pharynx and uvula, 250
 of tonsil, 250
 carcinoma of nasal cavity, 264
 of nasopharynx, 265
 of pharynx, 266, 268
 of soft palate and uvula, 266
 of tonsil, 268
 chondroma (enchondroma) of
 larynx, 251
 of nasal cavities, 250
 of nasopharynx, 251
 classification of, 243
 cysts, cystoma, 277
 dermoid, 277
 simple or retention (muco-
 cele), 276

- Neoplasms, exostoses, 252
 fibroma of larynx, 256
 of nasal cavities, 253
 of nasopharynx, 255
 of tonsil, 255
 fibrous polypi (myxofibroma),
 261
 lipoma of larynx, 256
 of nares, 256
 of nasopharynx, 256
 of pharynx, 256
 mucocele, 262
 myxocarcinoma, 276
 myxoma (nasal polypus), 258
 of upper respiratory tract, 243
 osteoma of nares, 257
 papilloma of larynx, 245
 of nares, 244
 of nasal cavity, 244
 or nasopharynx, 245
 of pharynx, 245
 polyp. fibrous nasal, 261
 sarcoma of fauces, pillars, and
 soft palate, 272
 of larynx, 275
 of nasal cavities, 270
 of nasopharynx, 271
 of pharynx, 273
 of tonsil, 274
 teratoma, 276
 Nephritis, aural affections in,
 607
 Nerve, auditory, 75
 Nervous cough, 486
 Neuralgia of larynx, 489
 of pharynx, 427
 supraorbital, 229
 Neurasthenia, impairment of
 hearing in, 610
 Neuroses of larynx, 486
 anesthesia, 487
 chorea, 490
 hyperesthesia, 488
 mogophonia, 487
 paresthesia, 488
 Neuroses, nasal, 220
 of olfaction, 220
 anosmia, 220, 221
 hyperosmia, 220, 221
 parosmia, 220
 of nasopharynx, 336
 of pharynx, 426
 Neuroses, reflex nasal, 220
 hyrorrhea as, 220
 non respiratory, ear, 220
 aprosexia, 229
 chorea, 220, 229
 epilepsy, 220, 229
 eye, 220
 headache, congestive, 220,
 229
 migraine, 220, 229
 neuralgia, 220, 229
 neuralgia, supraorbital, 229
 of heart, 220
 of sexual organs, 220
 of stomach, 220
 tic douloureux, 229
 vertigo, 229
 respiratory, asthma, 220, 228
 cough nasal, 220
 hyrorrhea, 220
 of larynx, 220, 228
 aphonia, 228
 spasm, 228
 of pharynx and mouth, 220,
 228
 rhinitis, hyperesthetic, 220,
 224
 of rhinopharynx, 336
 sneezing, 220, 223
 Nose-bleed, 232
 Nux vomica, 141, 162, 237, 619
 Obstruction of nasal cavities.
 causes of, 278
 Obstructive rhinitis, 164
 Occupation pharyngitis, 386
 rhinitis, 155
 Ointment of salicylic acid, 146,
 161
 Olfactory nerves, 20, 21
 Oropharynx and fauces, 23, 24,
 25
 Osseus meatus, 47
 Ossicles, the, 52
 Ossification of the auricle, 523
 Osteoma of nasal cavities, 257
 of sphenoid cells, 319
 Ostium maxillare, 15, 16
 Othematoma of auricle, 522
 Otitic meningitis, 588
 Otitis, acute circumscribed, 528
 acute diffuse external, 532

- Otitis, chronic circumscribed external, 532
 diffuse external, 534
 externa circumscripta acuta, 528
 external, croupous and diphtheritica, 538
 media, catarrhalis, acute, 553
 acute purulent, 557
 catarrhalis chronica, 567
 purulenta, 557
 purulenta residua, 565
 chronic catarrhal, 567
 hyperplastic, 571
 hypertrophic, 568
 chronic purulent, 561
 chronica, 561
- Otosclerosis, 571
- Ozena, 169, 170
 laryngis, 466
- Pachydermia laryngis, 470
- Papilloma of auricle, 527
 of nares, 244
 of nasal cavity, 244
 of nasopharynx, 245
 of larynx, 245
 of pharynx, 245
- Paraffin injections for nasal deformities, 192
- Paralysis, acute bulbar of soft palate, 343
 apoplectiform bulbar of soft palate, 344
 chronic bulbar of soft palate, 343
 soft palate, 343
 uvula, 343
 of vocal cords, 492
 table of, 498
- Paresthesia, larynx, 488
 of pharynx, 426
- Parosmia, 220
- Peach cold, 224
- Pemphigus of auricle, 519
 of larynx, 470
- Perceptive mechanism of ear, diseases of, 593
 effect of diseases of general nervous system upon, 606
- Perceptive mechanism of ear, involvement of in acute infectious diseases, 602
- Perforation of septum, 292
- Perichondritis of auricle, 521
 of larynx, 454
- Periodical hyperesthetic rhinitis, 224
- Peritonsillar or tonsillar abscess, 360
 phlegmon, 360
- Pertussis, 144
- Pharyngeal bursa, catarrh of, 330
 nystagmus, 427
 tonsil, 28, 345, 346
- Pharyngitis, acute rheumatic, 405
 atrophic, 402
 catarrhal, 380
 chronic rheumatic, 407
 croupous, 384
 exudative, 393
 follicular, 397
 gangrenous, 385
 granular, 397
 hemorrhagic, 388
 herpetica, 420
 hypertrophica lateralis, 401
 infective, 382
 membranous, 384
 occupation, 386
 phlegmonous, 382
 sicca, 402
 simple acute, 380
 membranous, 384
 chronic, 393
 subacute, 397
 suppurative, 382
 traumatic, 386
- Pharyngomycosis, 421
- Pharynx, abscess, retropharyngeal, 418
 actinomycosis of, 416
 anatomy of, 27
 anemia of, 425
 anesthesia of, 426
 angioma of, 250
 carcinoma of, 266, 268
 diseases of, 377
 diverticula or dilatation, 379
 dome or vault of, 10, 27

- Pharynx, ecthyma of, 420
 erythema of in exanthemata
 and other fibrile condi-
 tions, 389
- Pharynx, foreign bodies in, 429
 glanders in, 416
 herpes of, 420
 hyperesthesia of, 426
 hyperplastic change in, 401
 infectious granulomata, 408
 lipoma of, 256
 Ludwig's angina, 392
 lupus of, 410
 malformations and deforma-
 tions, 378
 neuralgia of, 427
 neuroses of, 426
 of motion, 426, 427
 papilloma of, 245
 paresthesia of, 426
 pharyngomycosis, 421
 pulsating arteries of, 424
 sarcoma of, 273
 spasm of, 427
 syphilis of, 412
 tuberculosis of, 408
 urticaria of, 420
 vault of, 10
- Phlegmonous rhinitis, 157, 211
 laryngitis, 446, 448
 pharyngitis, 382
 tonsillitis, 360
- Phthisis nasalis, 196
- Phytolacca, 141, 148, 619
- Physostigma, 619
- Pituitary membrane, 17
- Pollen catarrh, 224
- Polyp fibrous nasal, 261
- Postnasal catarrh, acute, 328
 chronic, 330
 cavity, or space, 10, 21
- Potassium bichromate, 141, 148,
 620
 iodide, 190, 620
 permanganate, 191
- Preglottic tonsillitis, 372
- Primary pseudomembranous
 rhinitis, 151
- Pruritic rhinitis, 224
- Pseudocroup, 443
- Pseudomembranous croup, 451
 laryngitis, 451
- Pulsatilla, 141, 620
- Pulsating arteries of the
 pharynx, 424
- Purulent ethmoiditis, 311
 inflammation of middle ear,
 acute, 557
 chronic, 561
 laryngitis, 446
 nasal catarrh, 179
 rhinitis, 179
 suppurative laryngitis, 448
- Putrid sore throat, 385
- Quinine, 620
- Quinsy, 360
- Rag-weed fever, 224
- Recurrent laryngeal paralysis,
 493
- Red mercuric iodide, 191
- Reflex aural disturbances, 229,
 611
 nasal neuroses, 220, 223, 229
- Relation of general diseases to
 the upper respiratory
 tract, 130
- Respiratory neuroses, 223
- Retronasal catarrh, acute, 328
 chronic, 330
- Retro-pharyngeal abscess, 418
- Rheumatic angina, 405
 laryngitis, 447
 pharyngitis, 407
 sore throat, 405
 tonsillitis, 358
- Rheumatism, 144
 acute laryngitis in, 439
 aural complications in, 609
 chondritis and perichondritis
 of larynx in, 455, 458
 nasal ulcers in, 219
- Rhinitis, acute, 135
 simple edematous, 156
 anemic, 145
 atrophica, 170
 simplex, 170
 caseosa, 149
 catarrhalis, 135
 chronica, 158
 croupous, 151
 cyanotic, 182
 diphtheritic, 154


- Rhinitis, edematosa chronica, 182
 edematous, acute, 156
 chronic, 182
 fetid, 170
 fibrinoplastic, 154
 foetida atrophica, 170
 hyperaesthetica, 220, 224
 hyperplastic, 164
 hypertrophic, 164
 idiopathic acute, 135
 intumescent, 163
 membranous, 151
 obstructive, 164
 occupation, 155
 phlegmonous, 211
 pseudomembranous, 151
 purulent, 179
 sclerotic, 170
 scrofulous, 146
 sicca, 170
 simplex, 158
 simple chronic, 158
 strumous, 146
 syphilitic, 183
 traumatic, 155
- Rhinoliths, 238
- Rhinopharyngitis, acute, 328
 atrophic, 333
 chronic, 330
 hyperplastic, 335
- Rhinorrhagia, 232
- Rhinorrhoea, acute, 135
- Rhinorrhoea, 180
 chronic, 158
- Rhinoscleroma, 210
- Rhus tox, 621
- Rose catarrh, 224
 cold, 224
 fever, 224
- Rosenmuller, fossa of, 28
- Sacculæ, the, 74
- Salicylated boric acid, 153
- Salicylic acid ointment, 146, 615,
 wash, 146, 148, 616
- Salpingitis, acute, 549
- Santonine, 215
- Sarcoma of auricle, 527
 of fauces and soft palate, 272
 of larynx, 275
 of nasal cavities, 270
- Sarcoma of nasopharynx, 271
 of pharynx, 273
 of sphenoid cells, 319
 of tonsil, 274
- Scarlet fever, acute rhinitis in,
 144
 laryngitis acute in, 437
 nasal ulcers in, 219
- Schneiderian membrane, 17
- Sclerotic rhinitis, 170
- Scorbutic rhinitis, 145
- Scrofulous ozena, 146
 rhinitis, 146
- Secondary atrophy resulting
 from other lesions, 177
- Secondary inflammation of
 labyrinth, 598
- Semicircular canals, 70
- Septum, abscess of, acute, 294
 chronic, 295
 anatomy of, 10
 deflection and deviation, treat-
 ment, 284
 edema of, 293
 hematoma of, 296
 malformations of, 281
 perforation of, 292
 submucous infiltration, 293
 ulceration of, 290
- Sexual disorders, organs, affec-
 tions of, as reflex nasal
 neuroses, 230
- Shrapnell's membrane, 59
- Silicea, 177
- Silver nitrate, 190
- Simple acute pharyngitis, 380
 rhinitis, 135
 in some of the constitu-
 tional diseases, 142
- catarrh, 135
 chronic laryngitis, 461
 nasal catarrh, 158
 nasopharyngitis, 330
 pharyngitis, 393
 rhinitis, 158
 rhinopharyngitis, 330
 membranous pharyngitis, 384
 or retention cyst, 276
 ozena, 170
 rhinitis, 170
 sore throat, 420
- Singer's nodules, 470

- Sinus thrombosis, 589
 Sinuses accessory, 13
 Sinuses, accessory, diseases of, 298
 ethmoid, anatomy of, 15
 catarrhal inflammation of, 310, 311
 diseases of, 310
 mucocele, 314
 and non-infected fluid-retention, 314
 specific inflammations, 315
 suppurating ethmoiditis, 311
 tumors, 315
 frontal, anatomy of, 15
 catarrhal inflammation, acute, 320
 chronic, 321
 diseases of, 320
 empyema of, 322
 acute purulent inflammation, 322
 chronic purulent inflammation, 323
 chronic suppurative inflammation, 323
 confined suppuration, 323
 foreign bodies, 326
 infectious conditions, 327
 mucous membrane of, 17
 mucocele, 325
 tumors, 327
 maxillary, actinomycosis of, 307
 acute infectious diseases, 307
 anatomy of, 15, 16
 catarrhal inflammation, acute, 298
 inflammation, chronic, 300
 cysts, 310
 diseases of, 298
 emphysema, 307
 empyema of, 302
 acute purulent inflammation, 302
 chronic purulent inflammation, 303
 confined suppuration, 304
 foreign bodies, 308
 glanders of, 307
- Sinuses, maxillary, mucocele of, 309
 ozena of, 301
 phlegmonous inflammation, 310
 syphilis of, 307
 tuberculosis of, 307
 tumors of, 309
 sphenoidal, acute infections, 319
 anatomy of, 13
 catarrhal inflammation, 316
 diseases of, 315
 empyema, 316
 mucocele, 319
 syphilis, 319
 tuberculosis, 319
 tumors, 319
- Small-pox, 144
 acute laryngitis in, 437
 nasal ulcers in, 219
- Sneezing, 220, 223
- Snuffles, 135
- Soft palate, adhesions, 341
 carcinoma of, 266
 diseases of, 337
 herpes, 344
 neuroses, 342
 neuralgia, 342
 paralysis, 343
 acute bulbar, 343
 apoplectiform bulbar, 344
 chronic bulbar, 343
 spasmodic contraction, 343
 sarcoma of, 272
- Solution, alkaline, 148
- Spasm of abductors of vocal cords, 440
 of glottis, 440
 of glottis in adults, 442
 in children, 441
 of larynx, 440, 443
 in adults, 442
 in children, 441
 of pharynx, 427
- Spasmodic croup, 439, 440, 443
 laryngeal occlusion, 491
 laryngitis, 440, 443
- Spasmus glottidis, 440
- Spastic paraplegia of the larynx, 491

- Specific catarrh, 183
 granulomata, 124
 inflammation of labyrinth, 597
 inflammations, 124, 183
 inflammatory processes, 124.
 183
 laryngitis, 472
 rhinitis, 183
 Sphenoidal sinuses, 13
 Spurious croup, 434, 443
 Staphylococci found in normal
 nose, 127
 Stearate of zinc with europheo,
 141
 with salicylic acid, 204
 Stenosis of larynx, 432
 Sticta, 142, 228, 621
 Stomach, affections of as reflex
 nasal neuroses, 230
 Stridulous angina, 443
 laryngitis, 443
 Stropanthus, 621
 Strumous rhinitis, 146
 Strychnine sulphate, 621
 Subacute pharyngitis, 397
 Submucous infiltration of sep-
 tum, 293
 Summer catarrh, 224
 Suppuration of larynx, 446
 Suppuration of middle ear,
 acute, 557
 chronic, 561
 Suppurative otitis media, 561
 laryngitis, 446
 pharyngitis, 382
 or pustular inflammation, 119,
 124
 Suprarenal derivatives, 141
 Surface landmarks of larynx, 30
 Symptomatic laryngitis, 468
 Syphilis, cause of chondritis of
 larynx, 455, 456
 larynx, 472
 nasal, acquired, 183
 hereditary, 183, 193
 pharynx, primary, 412
 secondary, 413
 tertiary, 414
 of auricle, 520
 of labyrinth, 597
 tarda, 193
 Syphilitic ozena, 183
 rhinitis, 183
 Syrup iodide of iron, 621
 Teratoma, 276
 Third tonsil, 28
 Thrombosis, labyrinthine, 597
 Thuja, 177, 190, 621
 Thymic asthma, 440
 Tic douloureux, 229
 Tonsil buccal, 371
 Tonsils, anatomy of, 25, 26
 angioma of, 250
 buccal, 371
 carcinoma of, 268
 chronic abscess of, 370
 classification of, 345
 discrete, 346
 Eustachian tonsils, 28
 faucial, 345
 abscess, chronic, 370
 tonsillar or peritonsillar,
 360
 atrophy, 370
 cryptic tonsillitis, 355
 diseases of, 353
 hypertrophy of, 365
 foreign bodies in, 371
 membranous inflamma-
 tion of, 364
 mycosis, 370
 tonsillolith, 370
 fibroma of, 255
 infectious granuloma of, 408
 fourth, 371
 laryngeal, 345, 376
 anatomy of, 28
 lingual, 345
 acute inflammation, 372
 acute phlegmonous inflam-
 mation of, 373
 classification of diseases of,
 371
 hyperplasia of, 374
 mycosis of, 375
 varices of, 375
 Luschka's tonsil, 346
 nasal, 345
 pharyngeal, 28, 345, 346
 sarcoma of, 274
 tubal, 345

- Tonsillitis, acute catarrhal, 354
 superficial, 354
 caseous, 369
 cryptic, 355
 fibrinous, 364
 follicular, 355
 gouty or rheumatic, 358
 herpetic, 359
 hyperplastic, 365
 hypertrophic, 365
 lacunar, 355
 membranous, 364
 parenchymatous, 366
 phlegmonous, 360
 preglottic, 372
 superficial acute, 354
 suppurative, 124
 ulcerative, 364
 Tracheotomy, 505
 Trachoma, 470
 Trachoma of vocal cords, 470
 Tragus, anomalies or malformations of, 512
 Traumatic laryngitis, 446
 pharyngitis, 386
 rhinitis, 155
 Traumatism, causing chondritis and perichondritis of larynx, 456, 458
 True croup, 451
 Tubal catarrh, 549
 congestion, 549
 tonsil, 345
 Tube, Eustachian, 56
 congestion of, 549
 Tubercular laryngitis, 478
 Tubercular rhinitis, 146
 Tuberculosis, aural involvement in, 608
 Tuberculosis as cause of chondritis of larynx, 455, 456
 of larynx, 478
 of nasopharynx, 408
 nasalis, 196
 of pharynx, 408
 Tubercular laryngitis, 478
 Tubo-tympanic catarrh, 552
 congestion, 552
 Tubotympanitis, 552
 Tumors of auricle, benign, 525
 malignant, 525, 527
 Turbinates, 11
 Tympanic cavity, 49
 membrane, 57
 muscles, 60
 opening of Eustachian tube, 50
 Typhoid fever, acute laryngitis in, 438
 chondritis and perichondritis in, 455, 457
 involvement of internal ear in, 603
 nasal ulcers in, 219
 Typhus fever, acute laryngitis in, 438
 involvement of internal ear in, 603
 nasal ulcers in, 219
 Ulceration, nasal, 213
 of septum, 290
 of uvula, 340
 Ulcerative sore throat, 382
 tonsillitis, 364
 Ulcers, nasal, 213
 compound malignant, 213, 217
 croupous or fibrinous, 219
 diabetic, 213, 216
 diphtheritic, 219
 due to foreign bodies, 213, 215
 glanders, 218
 eczematous, 213, 214
 herpetic, 213, 214
 infected, 213, 217
 leprous, 213, 218
 measles, 219
 neuromyolytic, 213, 215
 scrobutic, 213, 216
 simple, 214
 simple catarrhal, 213, 214
 syphilitic, 213, 218
 tubercular (lupoid), 213, 217
 varicose, 213, 216
 Urticaria of nose, 230
 Urticaria of pharynx, 420
 Uvula, acute abscess of, 340
 infiltration, 339
 adhesion of, 341
 angioma of, 250
 diseases of, 337
 edema of, 339
 elongation of, 337
 emphysema of, 341

- Uvula, malformations of, 337
 mycosis of, 341
 paralysis of, 343
 ulceration of, 340
 uvulitis, acute, 339
 chronic, 340
- Varices of lingual tonsil, 375
- Variola, 144
- Vault of pharynx, 10
- Velum, neuroses of, 342
- Veratrum, 237, 621
- Vertigo, neuroses, reflex nasal,
 229, 230
- Vestibule of ear, 69
- Vestibule of nose, 11
- Vicarious epistaxis, 232, 234
- Vocal cords, 38
 paralysis of, 492
- Voice user's sore throat, 393
- Wash, alkaline, 148
 salicylic acid, 146, 148, 616
- Whooping cough, 144
- Wounds of auricle, 515





DESCRIPTIVE CATALOGUE

AND

PRICE LIST

OF

Eclectic Text-Books

FOR SALE BY

THE SCUDDER BROS. CO.

MEDICAL PUBLISHERS,

1009 Plum Street,

CINCINNATI, O.

AS a school of medicine we profess to have a distinctive practice unlike either our old school or homœopathic neighbors. We claim to use different remedies, or in different form and dose, and for different effects. We boldly claim a more successful practice than either of our competitors, and this claim can only be based upon different principles, a different therapeutics, and a different materia medica.

We must, therefore, have distinctive books which clearly state *our* methods of practice. Old-school works will not serve this purpose, neither will homœopathic. With the pretensions we make, if we can not show that we have such works, and depend on them, we are frauds of the first magnitude.

Now we have a full list of text-books, or books of reference, and by frequent revision they are kept fully up to our practice of to-day. They have been very successful, more so than any American books in the market, and this is the best evidence of their value. They are bought by all schools of medicine, and when bought they are brought into active use.

SPECIAL NOTE.—The prices as given in this catalogue are absolutely net, no discount will be allowed retail purchasers under any consideration. This rule has been established in order that every one will be treated alike, a general reduction in former prices having been made to meet previous retail discounts offered by some dealers. Upon the receipt of the advertised price any book will be forwarded by mail or express, all charges prepaid.

COOPER, WM. COLBY, M. D.

† Tethered Truants.

12mo, 199 pages, Price, cloth, \$1.00
Being Essays, Sketches and Poems.

† Immortality.

12mo, 173 pages, Price, cloth, \$1.00

† Preventive Medicine.

12mo, 147 pages, Price, cloth, \$1.00

ELLINGWOOD, FINLEY, M. D.

Professor of Materia Medica in the Bennett College of Eclectic Medicine, and editor of the Chicago Medical Times.

† Eclectic Materia Medica and Therapeutics,

Royal octavo, 811 pages. (Revised 1905), . Price, cloth, \$5.00; sheep, \$6.00

About 450 remedies. Every subject of interest before the profession to-day in Therapeutics considered. The Department of Pharmacy and Pharmacognosy, by PROF. JOHN URI LLOYD, Ph. M., Ph. G. Five other prominent eclectic writers. PROF. FINLEY ELLINGWOOD, editor of the Times, has been quietly at work on this book for five years and has it now ready for distribution.

FARNUM, EDWARD J., M. D.

Professor of Surgery in the Bennett Medical College of Chicago.

† Deformities.

Royal octavo, 554 pages, 208 illustrations, enameled paper, cloth binding. (Issued 1898), Price, \$5.00 net, postpaid

A text-book on Orthopedic Surgery. Contributors: EDWIN FREEMAN, M. D., Cincinnati; EDWIN YOUNKIN, M. D., St. Louis.

FELTER, HARVEY W., M. D.,

—AND—

LLOYD, JOHN URI, Phr. M.

† American Dispensatory (King.)

(Revised in 1900.) Entirely rewritten and enlarged by HARVEY W. FELTER, M. D., Professor of Anatomy in the Eclectic Medical Institute, Cincinnati, O.; editor Locke's Materia Medica and Therapeutics; President Ohio State Eclectic Medical Association, etc., and JOHN URI LLOYD, Phr. M., Professor of Chemistry and Pharmacy in the Eclectic Medical Institute, Cincinnati, O., formerly Professor of Pharmacy in the Cincinnati College of Pharmacy; ex-President of the American Pharmaceutical Association; author of the Chemistry of Medicines, Drugs and Medicines of North America, Etidorhpa, etc.

Two-volume edition, Royal octavo, each volume containing over 950 pages, with complete indices.

Price, cloth, \$4.50 per volume; sheep, \$5.00 per volume, postpaid

FYFE, JOHN WILLIAM, M. D.

* *The Essentials of Modern Materia Medica and Therapeutics.*

With Formulary by G. W. BOSKOWITZ, M. D., 12mo, 344 pages.
(Issued in 1903), Cloth, \$2.00

The introduction is at once complete, compact and comprehensive. While nothing superfluous is presented, nothing important has been omitted. The action of medicines, strength, dose, prescription writing, dispensing, incompatibility, etc., are each and all carefully and wisely treated. We like the tone of this book; it is decidedly refreshing, refreshingly decided, conservative without being narrow, liberal without lapsing into promiscuous carelessness and wholesale commendation. For the working practitioner, the busy, every-day doctor, the man of few spare moments and fewer idle ones, we think the general verdict will be Eureka.—*Georgia Eclectic Medical Journal.*

FOLTZ, KENT O., M. D.

Professor of Ophthalmology, Otology, Rhinology, and Laryngology,
in the Eclectic Medical Institute, Cincinnati.

* *Diseases of the Eye.*

12mo, 566 pages, fully illustrated. (Issued in 1900), . Price, cloth, \$2.50

A complete manual on the subject for the use of students and Practitioners. This is the first work on this subject which gives particular attention to the treatment of diseases of the eye by Eclectic medication.

* *Diseases of the Nose, Throat, and Ear.*

12mo, over 700 pages, fully illustrated. (Issued 1906), . Price, cloth, \$3.50

This is a companion work to "Diseases of the Eye," but somewhat larger and more comprehensive.

GOSS, I. J. M., M. D.

Late Professor of Practice of Medicine in the Ga. College of Eclectic
Medicine and Surgery.

† *The Practice of Medicine; or the Specific Art of Healing.*

8vo, 569 pages. (Revised 1897), Price, cloth, \$1.50

HOWE, A. JACKSON, M. D.

Late Professor of Surgery in the Eclectic Medical Institute, Cincinnati.
"Prof. Howe was recognized as one of the ablest teachers in this country,
and an operating surgeon with but few peers in the West."

* *Diagnosis and Treatment of Dislocations and Fractures.*

Fourth edition, 8vo, 426 pages, Price, cloth, \$1.50; sheep, \$2.00

† *Operative Gynaecology.*

8vo, 360 pages, Price, sheep, \$4.00

NOTE.—Neither of these works revised since the author's death in 1892.

KING, JOHN, M. D.

Late Professor of Obstetrics in the Eclectic Medical Institute, Cincinnati. "Prof. John King, who was a teacher for more than half a century, is too well known to require more than a catalogue of his books." They are as follows :

† **The American Dispensatory.**

See revised edition, under head of Felter-Lloyd.

† **The American Eclectic Obstetrics.**

Ninth edition, 8vo, 757 pages, Price, sheep, \$5.50
Revised, rewritten and enlarged, by R. C. WINTERMUTE, M. D.

* **Diagnosis and Treatment of Chronic Diseases.**

8vo, 1,700 pages, Price, sheep, \$8.50

† **The New American Family Physician.**

8vo, 1,042 pages, Price, morocco, \$6.50

* **Woman, Her Diseases and Their Treatment.**

Fourth edition, 8vo, 366 pages, Price, cloth, \$1.50; sheep, \$2.00

NOTE.—The last three works not revised since author's death in 1893.

LLOYD, JOHN URL.

Professor of Pharmacy in the Eclectic Medical Institute, Cincinnati; Vice-President of the American Chemical Society; Associate Author of the revised edition of the American Dispensatory; Author of the Pharmacy and Chemistry of the Student's Pocket Medical Lexicon.

† **Red Head.**

A Story of Feud Life in Kentucky. Edition de luxe, cloth, . . . \$1.72

† **Etidorhpa; or The End of Earth.**

12mo, Illustrated. 375 pages. Eleventh edition. Price, cloth, \$1.50

B. O. Fowler, editor of "The Arena," Boston, says: "A most remarkable book. * * Surpasses, in my judgment, anything that has been written by the elder Dumas or Jules Verne, while in moral purpose it is equal to Hugo at his best. * * It appeals to the thoughtful scientist no less than to the lover of fascinating romance."

† **Stringtown on the Pike.**

Price, by mail, \$1.50

A character study of the people of Northern Kentucky. It embraces the superstitions, methods and acts of these people, and is most reliable in its study of human emotions and methods. Fully illustrated with engravings of the people of "Stringtown on the Pike." Judge T. Soule Smith, of Lexington, the best writer in the State, remarks: "No such vivid landscape painting of Kentucky seasons and Kentucky scenery is to be found in any book. The book is a drama of real life under conditions which necessarily make it dramatic.

The editor of "The New Idea," says: "The story is a masterpiece of dialect study."

† **Warwick of the Knobs.**

12mo, 305 pages, Cloth, \$1.50

† **Scroggins.**

12mo, 119 pages, Price, cloth, \$1.50

LOCKE, FREDERICK J., M. D.

Late Dean and Professor of *Materia Medica* and *Therapeutics* in the Eclectic Medical Institute, Cincinnati, Ohio.

FELTER, HARVEY W., M. D., Collaborator.
Professor of *Anatomy* in same.

* *Syllabus of Eclectic Materia Medica and Therapeutics.*

Second edition. (Revised in 1901.) 12mo, 501 pages. Price, cloth, \$2.50

"We have examined this work with great care, and find it fully up to the standard of the works of the Eclectic School. We do not propose to take this as an opportunity to give a lecture on the advisability of continuing self-limited sectarianism in medicine—our views on this subject are already well known to our readers. We have, however, never read a medical book, even a sectarian one, without receiving benefit from it. Every practitioner should study the therapeutic principles of every school of medicine. He should make the best from each one—the everlasting truth—his own. This book before us contains much that is of value. The Eclectic practitioners deserve lasting credit for having developed the therapeutic virtues of many of our common American plants. This is honor enough for one sect in one country."—*Medical World.*

MUNDY, WILLIAM NELSON, M. D.

Formerly Professor of *Physical Diagnosis, Hygiene and Diseases of Children* in the Eclectic Medical Institute.

* *The Eclectic Practice in the Diseases of Children.*

For students and practitioners. 12mo, 631 pages. (Issued in 1902), Cloth, \$2.50

MUNK, J. A., M. D.

Dean of Los Angeles Eclectic Polyclinic. Editor *Los Angeles Journal of Eclectic Medicine.*

† *Arizona Sketches.*

Octavo, 230 pages, fully illustrated, Price, Cloth, \$2.00

NIEDERKORN, JOSEPH S., M. D., Versailles, O.

† *A Handy Reference Book to Specific Medication.*

16mo, pocket size, 151 pages. (New edition, 1905), . Price, flexible leather, \$1.25

PETERSEN, F. J., M. D., Lompo, Cal.

Materia Medica and Clinical Therapeutics.

12mo, 400 pages. (Issued in 1905), Price, cloth, \$3.00

SCUDDER, JOHN M., M. D.

Late Professor of the *Practice of Medicine* in the Eclectic Medical Institute, Cincinnati.

NOTE.—None of Professor Scudder's eight works have been revised since his death in 1894.

* *The Eclectic Practice of Medicine.*

Fourteenth edition revised. 8vo 816 pages.
Price, cloth, \$4.50 ; sheep, \$5.00

SCUDDER, JOHN M., M. D.—*Continued.*

* **The Principles of Medicine.**

Sixth edition. 8vo, 350 pages, Price, cloth, \$1.50; sheep, \$2.00

This is a study of the elements of disease and the principles of cure. It is the basis of our practice, and as we think, the practice of the future. It gives a rational basis for medical practice.

* **The Eclectic Practice in Diseases of Children.**

Seventh edition. 8vo, 486 pages, . . . Price, cloth, \$2.50; sheep, \$3.00

If there is one thing more than another that we take pride in, it is our success in the treatment of children. The teaching of pleasant remedies, in small doses, for direct effect has relieved thousands of children from the horrors of "regular" medicine.

* **A Practical Treatise on the Diseases of Women.**

Illustrated by colored plates and numerous wood engravings, with a paper on Diseases of the Breasts. Fifteenth edition, revised. 8vo, 534 pages, Price, cloth, \$2.75; sheep, \$3.50

This work has stood the test of thirty years, and, as revised, gives our treatment of to-day.

* **Specific Medication and Specific Medicines.**

Fourteenth edition, fourth revision. 12mo, 432 pp., . Price, cloth, \$2.00

* **Specific Diagnosis.**

Ninth edition. 12mo, 388 pages, Price, cloth, \$1.50

These companion volumes have had a larger sale than any other medical works in this country. They appeal to the feeling every thinking physician cherishes, that there must be something certain in medicine, if it can be discovered. They have had a very marked influence upon medical practice, not only of our own school, but also on regular medicine and homœopathy.

* **The American Eclectic Materia Medica and Therapeutics.**

Twelfth edition. 8vo, 748 pages, . . . Price, cloth, \$4.00; sheep, \$4.50

* **The Eclectic Practice of Medicine for Families.**

Twenty-first edition, . . Price, \$3.00; sheep, \$4.00; half morocco, \$5.00

This work contains all of medicine that a family should know. It is Anatomy, Physiology, Hygiene, Practice, Materia Medica, Surgery and Obstetrics. It is concise, plain and correct, and will not lead to household drugging. Liberal offers to Agents. Write for terms.

* **Medicated Inhalations.**

Fourth edition, revised, with new Appendix, by Wm. Byrd Scudder, M. D. 8vo, 159 pages, Price, cloth, \$0.75

"The inhalation of volatile medical substances is a rational method of treating diseases that have heretofore been monopolized by the quacks, and those who degrade the profession of medicine to a commercial level by newspaper advertising. The above book is an endeavor to raise the method to its proper level and field, and to study it scientifically."—*Medical Visitor, Chicago.*

SCUDDER, JOHN K., M. D.

* *Eclectic Medical Journal.*

JOHN K. SCUDDER, M. D., Managing Editor, assisted by the Faculty of the Eclectic Medical Institute.

48 to 64 pages, monthly, \$2.00 per year, in advance

The acknowledged organ of liberal medicine, and a strong advocate of the doctrines of Specific Medication.

THOMAS, ROLLA L., M. D.

Professor of the Practice of Medicine in the Eclectic Medical Institute, Cincinnati.

(Issued 1906.) * *The Eclectic Practice of Medicine.*

8vo, 1,033 pages, fully illustrated, . . . Price, cloth, \$6.00; sheep, \$7.00

Thomas' Practice is a monumental work. Its size and *practical* value make it this. No other work will be so nearly indispensable to the busy practitioner as a refresher, and wholly indispensable to the medical student. The old and experienced doctor *could* exist without it—the medical student *can not* do so and be just to himself. I confidently predict a phenomenal sale of this modern classic, and especially do I expect it to force its way into the eager hands of medical students. They can not finish their medical education without it.

The Doctor's literary style is plain and simple, but strong and compelling. He has indulged in no dictional scollops, no dizzy subtleties, and no vain theorizing—it is all straight, hard common sense. It throws a volume of light on Specific Medication that makes the work in a sense revelational. Dr. Thomas has put the medical world under a mountain of obligation to him.

WILLIAM COLBY COOPER, M. D., Cleves, O.

The mechanical part is fine. The grouping of diseases under their appropriate heads and arrangement of the subject matter enables the busy physician to find just what he wants without delay.

Professor Thomas gives the history, etiology and pathology of diseases in so complete a manner that we have no need now (as heretofore) to consult the works of other schools on these points. Specific Medication, the Eclecticism of the present, is made prominent, while old and tried remedies are not discarded. Eclectics should be proud of this work.

S. M. SHERMAN, M. D., Columbus, O.

WATKINS, LYMAN, M. D.

Professor of Pathology and Physiology in the Eclectic Medical Institute.

* *A Compendium of the Practice of Medicine.*

Second edition. (Issued 1901.) 12mo, 460 pages, . Price, cloth, \$2.50 net

"The Compendium, in clear and concise language, gives a very excellent and suggestive repertory of the specific remedies indicated in the treatment of disease."—*N. Y. Medical Times.*

"The Compendium or hand-book supplies an actual need, which please do not interpret as a perfunctory platitude. Without the pretension of more elaborate works on Theory and Practice, it is the practical elbow of the hurried every-day practitioner."—*Eclectic Medical Gleaner.*

"A misconception of the whole idea of Specific Medication, which is rife in some directions, and which leads to its discredit and condemnation, is, that Eclectics claim to have specifics for diseases, according to the popular nomenclature, when in fact no such pretension has ever been made; and it has never been attempted to adapt the theory to certain combinations of symptoms which have received distinctive names as diseases."—*Medical Brief.*

WEBSTER, HERBERT T., M. D.

Professor of the Principles of Medicine and Pathology in the California Eclectic Medical College, San Francisco, Cal.

† **The Principles of Medicine.**

8vo, 168 pages, Price, cloth, \$1.50

† **The Eclectic Practice of Medicine.**

8vo, 1,233 pages.

New edition in 1902. Two volumes bound in one.

Cloth, \$6.50; sheep, \$7.50

WILDER, ALEXANDER, M. D.† **History of Medicine.**

Nearly 1,000 pages, 8vo, Price, cloth, \$3.00

An authentic history of the healing art from antiquity down to the present time. An exhaustive history of Eclectic Medicine. Intensely interesting. No physician's library complete without it.

WINTERMUTE, ROBERT C., M. D.

Late Professor of Obstetrics and Diseases of Women and Children in the Eclectic Medical Institute, Cincinnati.


† **American Eclectic Obstetrics.**


8vo, 757 pages, Price, sheep, \$5.50


A new edition of the standard edition of King's. Thoroughly revised and rewritten in 1890.


WOODWARD, CHARLES, M. D.† **Intra-Uterine Medication.**

12mo, 208 pages. (Issued 1905), Price, cloth, \$2.50









LIBRARY OF CONGRESS



0 021 067 773 2