

(11)

Struthers

CONTENTS.

I. Definition of the more usual anatomy of these parts. (a.) *Appendix Vermiformis*:—origin, p. 1; direction and length, p. 2; so called valve, p. 3. (b.) *Cæcum*:—definition, p. 4; relation to the peritoneum, p. 4; the fully-formed cæcum, bands and saccules, p. 5; vestigial fossa, p. 6; changes from foetal to adult condition, p. 6. (c.) *Ileo-Colic Valve*:—evolution, p. 7; determining conditions, p. 8; contrast with pyloric valve, p. 8; typical form, p. 9; lower flap, p. 10; upper flap, p. 11; fræna, p. 12; ileo-colic orifice, form, p. 12; direction and size, p. 13; competency of the valve, p. 14. *Table of measurements* of 23 specimens of appendix, cæcum, and valve, pp. 16, 17. *Plate* with 16 figures, and explanation, p. 18.

II. Notes of 23 specimens of appendix, cæcum, and valve, p. 19 to p. 32.

III. The *Appendix Vermiformis* morphologically considered. Theories of supposed function, p. 32; interpretation through comparative anatomy, p. 34; vestigial nature, p. 35; liability to disease, p. 35. Note on the cæcum and valve in various animals.

ON

VARIETIES OF THE APPENDIX VERMIFORMIS, CÆCUM, AND ILEO-COLIC VALVE IN MAN.

By JOHN STRUTHERS, M.D.

(Reprinted from the *Edinburgh Medical Journal* for October, November, and
December 1893.)

ALTHOUGH the more immediate cause of this paper appearing now was the recent discussion of the pathology and surgery of the appendix vermiformis at our Medico-Chirurgical Society, reported in the August number of *this Journal*, I desire to mention that the giving an account of my series of specimens, with remarks on the anatomy of these parts, is an intention of old standing, impeded by the pressure of college duties. When, of the little vestigial tube attached to the cæcum, a physician of experience and standing is able now to say that "probably no portion of the intestinal canal is more frequently the site of acute, severe, and fatal disease than the appendix vermiformis," no apology need be made for any endeavour to add to our knowledge of the various conditions that body may present. The subject, besides, is one of morphological interest. The condition of the cæcum has at the same time to be observed as partly determining that of the appendix. The question of the competency of the ileo-colic valve is also an interesting one clinically as well as anatomically, and that has to be looked into in connexion with the conditions presented by the cæcum.

I. DEFINITION OF THE MORE USUAL ANATOMY OF THESE PARTS.

It will greatly facilitate if the figures and their explanation are looked at first (page 18).

(a.) *Appendix Vermiformis.*

The appendix, like other vestigial structures, frequently presents variation. It varies in its place of origin, mode of origin, direction, length and width, but most frequently has the following characters. It *arises* at about mid-height of the back of the cæcum, generally to the inside of the middle; the *orifice*, situated at the upper or inner side of a special triangular fossa, to be described below as the

“vestigial fossa,” has, at its upper side, a sharp crescentic edge suggesting a valve. The *direction* is at first upwards (ascending stage) to about the level of the top of the cæcum proper, as indicated by the posterior frænal furrow, bound to the cæcum by the peritoneal covering of the back of the cæcum, and then downwards and inwards (second stage), showing itself (as in figs. 3 and 4) below the ileum. There it is usually pendulous and free in the abdominal cavity, surrounded by peritoneum except behind or externally where it is attached by its narrow triangular mesentery, carrying bloodvessels and adapted to the bendings of this stage, but leaving the appendix freely movable there.

The direction of the second stage is liable to very frequent variation. Instead of being directed downwards, giving a pendulous free part, visible in the undissected abdomen, this stage of the appendix may, with cæca of the usual form, have almost any direction; such as straight up, obliquely upwards and outwards, obliquely upwards and inwards (fig. 11), or turned upon itself in a circle (fig. 12), in either case the entire appendix hidden behind the great intestine. When arising from the bottom of a blunt cæcum (figs. 9 and 10), the first stage of the appendix may not be directed upwards; when arising from the end of a tapering cæcum (figs. 5, 6, 7, and 8), the appendix may have any direction, and is not likely to be hidden.

In *length*, in my specimens, the appendix varies from $\frac{3}{4}$ inch (fig. 14) to 6 inches. The length of the appendix proper, shown in fig. 13, was $4\frac{3}{4}$ inches. From 3 to 4 inches may be given as the prevalent length of the appendix, but variation is frequent. It is said to have been found to reach a length of 8 inches. The *width* is commonly compared to that of a goose-quill. In the Table, the diameter is seen to go beyond that in some, to $\frac{1}{3}$ inch (cases 3, fig. 5; 6, fig. 8; 13; and 18, fig. 14), and in some not to exceed $\frac{1}{8}$ inch (cases 16, fig. 13; and 17). In case 20, fig. 15, it is $\frac{1}{10}$ inch; less on the first stage. About $\frac{1}{4}$ inch may be given as a fair average diameter, taken at the middle. In dried specimens, though well inflated, there is, perhaps, some little shrinkage in the width.¹ The diameter usually diminishes a little distally, but not always; the end usually blunt pointed, sometimes quite blunt, sometimes but not often sharp pointed.

¹ As to the influence of age, or sex, on the size of the appendix, my record is scanty. Nos. 1 and 2 were from the fœtus, lengths 1 and $1\frac{3}{4}$ inch, widths $\frac{1}{10}$ and $\frac{1}{8}$ inch. The other specimens were from adults, and of these the age and sex are noted in Nos. 4, 5, 6, 10, 16, and 18. No. 4, fig. 6, was a male æt. 43, appendix fully 2 inches, blocked and now shrivelled; No. 5, fig. 7, a male æt. 79, appendix $3\frac{1}{2}$, blocked and now shrivelled; No. 6, fig. 8, was an aged male, appendix 4 inches long, $\frac{1}{3}$ inch wide. All of these three were terminal from tapering cæca. No. 10, a male æt. 49, appendix $3\frac{1}{2}$ and $\frac{1}{3}$ inch wide; No. 18, fig. 14, a male æt. 45, appendix $\frac{3}{4}$ inch long and $\frac{1}{3}$ inch wide; No. 16, fig. 13, was a female æt. 64, appendix $4\frac{3}{4}$ inches long, $\frac{1}{8}$ inch wide. There is here no definite evidence as to atrophy with age; No. 16, fig. 13, is for it as regards width; No. 6, fig. 8, is against it in regard both to width and length.

At the *origin*, there are to be noted the so-called valve, the orifice, and a short slightly funnel-shaped stage. The "valve" is not a valve proper, not a pouch within the orifice, resisting reflux like a valve in a vein, but merely one of those crescentic edges, or folds, that always occur when a tube passes off from another tube or cavity at an acute angle. If the two tubes are in contact with each other for some distance, fusion of their walls takes place, and there is then, not merely a sharp concave edge, but a common septum having the appearance of a semilunar valve of greater or less depth. When the appendix is continued from the end of a tapering cæcum, there is no valve. Ordinarily, as the appendix goes off at an angle to the axis of the cæcum, there is at least a sharp concave edge or, more usually, more or less of a semilunar membrane, situated always on the side corresponding to the first stage of the appendix. This valve-like fold, or common septum, is well seen in dried specimens, translucent, bounded above by the line of junction of the cæcum and appendix, or, more correctly expressed, by the line where their walls have ceased to be fused. The valvular fold, thus defined, is sometimes large, may, with a good-sized appendix, be $\frac{1}{3}$ to $\frac{1}{2}$ inch across by $\frac{1}{4}$ to $\frac{3}{8}$ inch in height; the free margin not necessarily very concave, the sides of attachment either concave, or straight, or even a little convex towards each other, in the latter cases giving the fold a triangular rather than a semilunar outline.

Any impediment which this valve may offer to the entrance of cæcal contents into the appendix is on the principle of obliquity of perforation, as in the case of the entrance of the ureters into the bladder, but in the latter the opposition is much more effectual from the ureter lying for some distance between the mucous and thick muscular coats of the bladder. In both cases, the obstacle is called into play by the pressure of the contents of the cæcum or bladder, and in both cases is undone by distention. When the fundus of the cæcum is full, or when the body lies on the back or on the left side, there is nothing to prevent semifluid cæcal contents raising the valve and passing into the appendix. That is rendered easier by the depression of the vestigial fossa within which the orifice is placed, giving the appearance of the orifice beginning before the valve begins.

At the ending of ducts the orifice is smaller than the duct, but this does not seem to apply to the appendix. In some of the specimens the orifice does look small for the width of the appendix, but in dried specimens the orifice is apt to suffer contraction. Being transversely oval and looked at from before, the orifice at first glance looks smaller than it really is, but when fairly examined it seems to be of size corresponding to the part of the canal immediately succeeding. As the occurrence of ulceration, or some kind of obstruction, near the orifice is referred to in the account of some of the cases of death from disease of the appendix,

it may be of interest to note that, putting aside specimens in which the appendix begins from a wide funnel of the cæcum, the appendix itself has a short slightly funnel-like stage, for the first $\frac{1}{4}$ to $\frac{1}{2}$ inch, but without sudden or much bend or special point of contraction. Hardened matter making its way up may meet with a slightly diminished calibre $\frac{1}{4}$ to $\frac{1}{2}$ inch after entering, but one would rather expect that the most natural place of arrest would be, not at the end of the orifice stage, but about the middle, where the second stage of the body generally bends away from the ascending stage, or at the very end, from final inpaction or hardening.

(b.) *Cæcum.*

Although the cæcum is always defined as the part below the junction of the small and great intestine, the term is often loosely applied so as to include the neighbouring part of the colon, which is generally somewhat wider than the part of the colon next above. From this vague use of the term may have arisen the serious error of describing the cæcum as usually not covered by peritoneum behind, with the consequent pathological error in speaking, by whatever name, of inflammation and abscess in the supposed loose areolar tissue behind the cæcum.¹

¹ *Note on the relation of the peritoneum to the cæcum.* The following quotation from the article "Stomach and Intestines" in Todd's *Cyclopædia of Anatomy and Physiology* shows the elaborate definiteness with which this error has been committed:—

"The serous covering of the cæcum is chiefly remarkable from the closeness with which it generally attaches the bowel to the fascia over the iliacus muscle. When the tube is but moderately distended, it covers only its anterior surface. Extreme contraction can, however, render it a more complete covering; and may even produce it into a kind of meso-cæcum behind the bowel. While conversely, great distention of the tube reduces the peritoneum to a partial investment; which occupies but a third, or even less, of the intestinal surface."

That passage is marked in my copy of the *Cyclopædia* with the marginal annotation "all wrong." If it be said, in palliation, that the article was written 34 years ago, there is the following in the latest completed edition of our leading text-book in Anatomy (Quain's *Elements of Anatomy*, 1882, vol. ii. p. 614), after a correct definition of the cæcum as "that part of the large intestine which is situated below the entrance of the ileum":—

"It is covered by the peritoneum in front, below, and at the sides: but behind it is usually destitute of peritoneal covering, and is attached by areolar tissue to the fascia covering the right iliacus muscle. In this case the cæcum is comparatively fixed; but in other instances the peritoneum surrounds it almost entirely and forms a duplicature behind it, called meso-cæcum."

And so physicians, misled by such anatomical descriptions, have located inflammation and abscess (variously under the names of perityphlitis, paratyphlitis, and post-cæcal cellulitis) in this supposed bed of areolar tissue behind the cæcum. And I can recollect being taught that the cæcum might be down in a hernia without a sac, because it is not covered by peritoneum behind. As I have long been in the habit in my teaching of commenting on the error in question, and have specially asked the attention of various anatomists to it, the criticism may be recorded here. Such, one is tempted to remark, would seem to be the influence of authority even in our anatomical schools, the little reference to the Book of Nature, for any one who will

In taking the length of the cæcum, the ileum is not a reliable guide; if taken from the lower edge of the ileum the measurement falls short, especially when, as often happens, the last stage of the ileum is directed very obliquely upwards. The upper edge of the end of the ileum would be a less variable point than the lower edge, but it goes about $\frac{1}{2}$ inch above the level of the orifice. The measurements should be taken from the middle of the constrictions defined below as the anterior and posterior frænal furrows (*a, f, f*, fig. 10, seen also in fig. 9; *p, f, f*, figs. 3 and 12, seen also in figs. 11, 15, and 16). There is not generally a constriction marking off the limit of the cæcum on the outer side (seen at *p, f, f*, in fig. 9, but the constriction marked *c, f*, in fig. 10, is below the true limit), as the posterior frænum does not generally pass beyond the postero-external band sufficiently to cause a constriction externally. If within the cavity, the point to measure from is the narrow end of the orifice. With frequent variation in both directions, the more usual length of the cæcum may be given as $2\frac{1}{4}$ to $2\frac{1}{2}$ inches.

The fully-formed Cæcum.—The form and parts of the developed cæcum cannot be interpreted without reference to the stages of transformation from the foetal condition, but the usual characters of the adult cæcum may first be defined. The position of the three longitudinal muscular *bands* of the colon is seen in figs. 3 and 4 (anterior band, *a, b*; postero-internal band, *p, i, b*; postero-external band, *p, e, b*; the same in the other figures), as they traverse the cæcum towards or from the root of the appendix. The *postero-internal* band goes straight down at the meeting of the two flaps of the valve to reach the appendix; the *postero-external* band curves inwards and finally a little upwards to the appendix; and the *anterior* band, having gone down the front (as seen in figs. 9 and 10), passes backwards on the inner side of the fundus, notching the cæcum there, and is continued upwards and outwards on the back of the cæcum, towards the appendix.

The cæcum is thus subdivided into three more or less bulging *saccules* (*s, s, s*, in figs. 3 and 4), a *posterior*, below the posterior frænum of the valve, usually smallest and least bulging of the three, serial with the posterior row of saccules of the colon; an *internal*, below the valve and its anterior frænum, serial with the internal row of saccules of the colon; and an *inferior*, bulging down between the anterior and the postero-external bands, forming the fundus of the adult cæcum, and in series with the external row of saccules of the

take the trouble to lift up the cæca in the daily opportunities of the dissecting room and pathological theatre, may see that ordinarily the cæcum is wholly peritoneal behind as well as in front and on the sides. That cases of exception to some extent may occur need not be doubted, but, if so, they must be rare, and such an occurrence cannot be allowed to excuse the serious error of describing the cæcum as usually uncovered by peritoneum behind. My impression is that variation occurs rather in the opposite direction, the peritoneum extending some way above the cæcum proper upon the back of the colon.

colon. The anterior longitudinal band is the broadest and most marked, having most resistance to sustain; it may lie to either side of the middle line of the cæcum (as in figs. 9 and 10), thereby determining the relative breadth of the internal and external sacculcs; it may notch the fundus at the middle, giving a deeply and nearly equally bifid fundus (as in fig. 16); but generally passes somewhat to the inner side (as in fig. 12), greatly constricting the cæcum there, leaving the external sacculc as the fundus proper of the adult cæcum.

Vestigial. Fossa.—The three longitudinal muscular bands are described as continued from the uniform longitudinal layer of the appendix, but in the main the arrangement at the origin of the appendix is otherwise. As shown in figs. 3 and 4, and seen also in figs. 12, 14, 15, and 16, the three bands do not run upon the appendix, but bifurcate and join each other near it, enclosing a triangular area within which the appendix arises. This area may be termed the vestigial fossa, as it is the remains of what was the end of the foetal cæcum.

This arrangement is seen on examination of a series of dried translucent specimens, in which the disposition of the muscular bundles is clearly seen. The three bands bifurcate in bulk, the bifurcations of each continued into those of the two other bands, the sides of the triangular area from $\frac{3}{4}$ to 1 inch in length, the angles rounded off by the internal bundles turning inwards; and these most internal bundles are seen to send in on the wall of the depressed area, towards the orifice of the appendix, a thin layer of fibres assuming a circular arrangement. The most prominent boundary of this shallow triangular fossa is usually the inferior, owing to the greater bulging of the inferior sacculc, the least prominent the external. The orifice of the appendix is generally towards the upper angle, but may be at the inner side.

Changes from the Foetal to the Adult Condition.—The account usually given of the earlier stages of the intestine is, that there is for a time no cæcum, that a diverticulum grows out and elongates, at first without distinction between cæcum and appendix, and then, that the upper part widens with the great intestine, leaving the appendix as a narrow part. It will suffice here to take the advanced foetal condition, as represented in fig. 1, from a specimen noted below (No. 1) in which the great intestine has not yet attained its full width in comparison with the small intestine. The cæcum is tapering or funnel-shaped, and is continued into a relatively long appendix. The appendix begins by a funnel-shaped stage, and the part to be afterwards relatively narrowed as the orifice is indicated (at *a, p, x*) on the under side.

The transformation from this foetal form to the developed form is shown in the diagram, fig. 2. The diagram is that of an antero-posterior section of the cæcum and appendix, but the end of the ileum, which naturally lies more to the inner side, is introduced in

order to show a section of the ileo-colic valve. The change has consisted in the great growth downwards of the lower and anterior part of the funnel-shaped foetal cæcum, forming the fundus of the developed cæcum. The now relatively narrow appendix is thus left behind, attached abruptly at some part of the back of the developed cæcum. It is found generally about the middle and a little to the inner side, but may be higher or lower, and if the usual transformation does not take place, it remains at the end of a tapering cæcum. Figs. 5, 6, 7, and 8 show examples of the tapering cæcum, with continued appendix; the remaining figures show varieties of the bulbous or bluntly ovoid form of the developed cæcum.

(c.) *Ileo-Colic Valve. Evolution, Normal Characters, and Varieties.*

The valve may be studied with the cæcum suspended in fluid, but its characters are well seen in a series of moderately distended dried specimens, opened in front. My object in this paper is to examine the conditions of this valve in the human body, in which it appears to attain its full development as an arrangement capable, normally, of preventing reflux to the small intestine, perhaps as an adaptation to the erect posture. But it is a composite structure, on the nature of which light is thrown by examining its more simple conditions in other species. The comparative anatomy of this valve cannot be said to have been fully investigated; the inquiry would be a wide and troublesome one, and could be accomplished satisfactorily only with a previous appreciation of the points to be ascertained.

From the specimens I have been able to examine in various mammals, the following conditions seem to indicate the *stages in the evolution of the valve*. The condition is influenced by the direction of the last stage of the ileum. When it is parallel to the cæcum, there may be merely a septum common to the ileum and cæcum, terminating in a sharp crescentic edge. Looking down from the colon, the two apertures are seen like the mouth of a double-barrelled gun, more or less equal, separated by this ileo-cæcal septum. The term "junction" is merely one of convenience, as the two intestines were originally a simple tube, until the great intestine became enlarged, or until a cæcum diverged from it, and spread upon the wall of the ileum. All valvular projections of mucous membrane are originally double; they may remain so, as in the case of the pyloric curtain and the crescentic folds of the colon, or they may fuse, as in the case of this ileo-cæcal septum or the so-called valve of the appendix. When the ileum is parallel to the cæcum, or meets it obliquely, the common septum is more or less longitudinal, not necessarily having a valve-like position, but towards the free edge it may be deflected and send out horns so as to form a commencing valve.

In the next stage, there is, in addition to the common septum,

more or less of a crescentic projection at the opposite side of the mouth of the ileum, confined to it, not going across the colon. In further stages, the horns of the two approach and unite, and, when united, form a more or less circular curtain, like a diaphragm, surrounding the iliac orifice; the latter generally ovoid, the ends at the confluence of the horns. The curtain goes round and round, like the human pyloric curtain, without fræna, and cannot be efficient in preventing reflux unless with the aid of a sphincter muscle at its attached circumference, as occurs at the pylorus. The pyloric "valve" is not a valve but is essentially a sphincter muscle, the variable soft curtain within assisting merely by lessening the size of the aperture to be closed. Nor is the curtain essential. If a series of human pyloric valves be examined, it will be seen that the curtain varies much, often narrower at one side, sometimes reduced to a crescent with a narrow ridge on the rest of the circumference. The sphincter muscle is the essential structure, and the use of the whole "valve" is to prevent premature onward passage, not to prevent reflux, to which it appears to be ready at all times to offer no objection. But the utility of the ileo-cæcal valve is precisely the opposite; in its fully developed condition it is a mechanical valve, proved to be so by its efficiency in the dead body. The presence of an ileo-colic valve to the extent of the curtain stage is, therefore, not to be inferred as constituting an efficient valve. There is want of evidence as to how far, or whether at all, in animals possessing an ileo-colic curtain, there is a sphincter muscle, or any muscular structure beyond the few fibres of the circular coat of the intestine seen in the flaps of the human ileo-colic valve.

In a higher formation of the ileo-colic valve, the upper crescentic fold runs across the colon, the horns of the ileo-cæcal fold running up to near it, but still not constituting an efficient valve; and finally, as in man, when the valve is normal, the horns run up and join the ileo-colic fold; not only is a curtain formed by the junction of the horns of the two crescentic folds, but the continuation of the ileo-colic fold across the colon forms fræna, serving to prevent the flaps from being driven through to the ileum, and the valve is complete.¹

¹ For examples of these various stages of development of the valve, see *Note A*, at the end.

In regard to the *conditions that determine the arrangements of the ileo-colic valve in man*, supposing an efficient valve to be useful, the following considerations may be noted. In an intestine of uniform calibre, an efficient valve would require to resemble those of the veins,—a semilunar pouch with a bulging sinus, the two flaps more than broad enough to meet. But here there are three disturbing conditions requiring a different adaptation :

(1.) *The abrupt change from small tube to large tube.* Had this been the only change, a sufficient projection of the lips of the orifice of the smaller tube, with fræna on the side of the greater tube, would have effected the result; the fræna extending in the direction of the axis of the larger tube. The

The typical form of the valve in the human body is shown in figure 4,—the orifice, the lower flap (*l, v*), the upper flap (*u, v*), the posterior frænum (*p, f*), and part of the anterior frænum. The figure is diagrammatic, as the full breadth of both flaps cannot be seen in one view. In full-face views of the valve and orifice, what appears as the inner half of the back of the cavity belongs to the inner wall, and the end of the ileum should not be seen in such a view. The ileum usually enters at the posterior half of the inner surface of the great bowel, the forward enlargement of the latter in development leaving it there; and the orifice, directed backwards and a little to the right, looks outwards more than forwards. It is most convenient to term the ends of the orifice, and the fræna, anterior and posterior, and the measurement of the flaps from attached to free margin their breadth.

expansion of the greater tube over the lips of the smaller would become a substitute for a sinus for effecting the closure of the valves.

(2.) The *bend on the tube*, nearly rectangular, at the junction. Although the ileum generally approaches the great intestine with more or less obliquity upwards, the plane of the area of junction forms nearly a right angle with the great intestine. As a result of this rectangular setting, the fræna of the valve are not in the direction of the great intestine, as they must have been but for the bend, but run transversely to the axis of the great intestine. As above noted, in connexion with the stages of the valve among mammals, the ileum, cæcum, and colon may all be in the same direction, and nothing more is implied in this arrangement than an ileo-cæcal septum. This relation of the two intestines is in no way incompatible with the further development of an ileo-colic valve were it, so to speak, to be functionally useful, as it appears to be in man and in mammals approaching man. When the cæcum and neighbouring part of the colon have passed across to the right and descended to their permanent locality in the right iliac and lumbar region, the bend becomes a fixed rectangular change of direction, to which a fully developed ileo-colic valve may be regarded as an adaptation, possibly having relation to the erect posture.

(3.) The *divergence of the cæcum*. Simply, an abrupt general enlargement from a small to a great intestine would have enabled the contents of the latter to close the valve, but with the bend up of the colon a short cæcum becomes necessary to effect that result upon the lower flap of the valve. In nearly all of the few mammals in which there is no cæcum, there is the absence of abrupt change from a small to a great intestine, and in all of them there appears to be the absence of any definite bend, and of valve. The cæcum, however, when present at all, goes further than enough to effect the above result, and appears to be a functional organ in connexion with further digestion or absorption; and its divergence affects the lower flap of the valve. The direction of that part of the valve may be regarded as determined by its being, as it were, dragged down by the downward extension of the cæcum; and its occasionally great breadth as resulting from the fusion of the walls of the ileum and cæcum, seen to a large extent in mammals in which the ileum and cæcum are close together.

These three conditions—the abrupt enlargement, the rectangular bend, and the downward growth of the cæcum—may, therefore, be considered as determining the peculiarities of the ileo-colic valve in man. While the two flaps of the fræna and lips of the orifice of the smaller tube entering the greater one, adapted to the function of preventing reflux into the small intestine, they are also serial with the numerous crescentic folds of the great intestine, present in man and in mammals in which the colon is sacculated.

The area enclosed by the outline of the junction of the great and small intestine is easily seen in translucent specimens. When the ileum is directed obliquely upwards, the form of the end is changed to an oval, directed upwards and backwards, $1\frac{1}{2}$ to 2 inches in height, with an average width of 1 inch, but wider at the orifice. The lower half of the area is occupied by the lower flap; and opposite the upper half are the more or less slanting upper flap and the orifice. When the ileum is transverse or descending, the area is reduced to 1 inch in height, or less, and has the usual rounded form of the small intestine, or may be a little compressed vertically. When the ileum passes round to the back, the area is very oblique upwards and backwards and curved, with the concavity towards the great intestine.

The requirements for a fully-formed valve are, sufficient breadth of the lower flap, with outward inclination of the upper part towards the orifice; sufficient breadth of the upper flap, with downward slope to the orifice; the completion of the circle of the curtain by the union of the horns of the flaps at the ends of the orifice; and fræna of fair size, the posterior frænium especially.

The lower flap (ileo-cæcal). The breadth and direction of the lower flap are regulated largely by the direction of the ileum near its ending. The ileum generally approaches the junction with moderate obliquity upwards, with early junction below, or it may be without early junction (case 14, fig. 12); sometimes with great obliquity and earlier junction below (cases 3, fig. 5; 8, fig. 10; 12; 20, fig. 15); sometimes almost vertically at its lower border, with very early junction below (cases 17; 22, fig. 16); sometimes the direction is nearly transverse (cases 5 and 7); sometimes the direction is downwards (cases 4, fig. 6; 7; 9, fig. 9; 16, fig. 13); and sometimes the ileum not only ascends but curves round to the inner part of the back of the great intestine (cases 10 and 17).

Thus, when the ileum passes very obliquely upwards, the lower flap is elongated vertically (broad), is nearly in the direction of that side of the ileum, and is flush with the wall of the cæcum till near the orifice. But when the ileum descends, the lower flap rises towards the orifice at an obtuse angle with both ileum and cæcum, and, although of less breadth, has the appearance of a valve proper. As seen in the Table, the lower flap is generally broader than the upper; in fully-formed valves the two flaps may be of equal breadth (as in cases 11, 12, and 15); with a descending or transverse ileum, the lower is generally narrower than the upper (as in cases 5, 9, and 16). It is seen, therefore, from the above, that great breadth of the lower flap does not necessarily imply corresponding perfection of the valve, but only great obliquity of the ileum.

As to outline, the lower flap is unsymmetrical; anteriorly, it has the form of the lower half of a broad ovoid, carried down by the cæcum; posteriorly, it is prolonged and gradually narrowed to

join the posterior frænum. The attached margin is generally entirely convex in front, generally concave posteriorly on the upper half. When the ileum passes far back, the lower flap is long and much bent, the whole of the attached margin concave towards the great intestine. In case 9, in which the ileum descends, both flaps are uniformly convex at their attached margin, the posterior horn of the lower flap going almost straight up to join in the frænum.

The horns of the lower flap both run up to join the upper, so as to complete the circle of the curtain. The free margin of the anterior horn turns backwards, rounding the broad anterior end of the orifice, forming the narrowest part of the curtain, $\frac{1}{6}$ to $\frac{1}{4}$ inch broad, adhering to the sharp anterior frænum on its surface. The completeness of the circular curtain is accomplished posteriorly by the horn of the lower flap joining the upper flap broadly where the frænum begins. The line of junction may be for $\frac{1}{2}$ inch forwards and outwards to the sharp posterior end of the orifice, the free edge of the horn passing a little under the general concave edge formed by the continuity of the upper flap and the frænum. The prolongation of the lower flap backwards enables it to lay hold of the broad posterior frænum, and renders the frænum much more efficient. This, at the same time, implies a narrow end to the orifice posteriorly. One or both of the horns of the lower flap may fail to reach up to join the upper flap. In case No. 18, fig. 14, the posterior horns do not meet by $\frac{1}{4}$ inch, the posterior frænum wanting, the competency of the valve doubtful. In case 19, the posterior horns do not meet by $\frac{1}{2}$ inch, both the fræna wanting, the valve evidently incompetent; in case 16, fig. 13, both horns of the lower flap fail to reach the upper by $\frac{1}{4}$ inch, the fræna undersized, but the valve looks efficient. In the latter, the ileum descends.

The upper flap (ileo-colic) need not be regarded otherwise than as one of the crescentic folds of the colon, its adaptation as part of the valve consisting in its increased breadth, and in its extending across to the next longitudinal band to form a posterior frænum. The ordinary crescentic folds of the colon are known not to pass round and round, but usually only between neighbouring longitudinal bands, where their horns cease. Sometimes a valvule passes, more or less narrowed, some way beyond a band; and when two occur in the same plane, they are either distinct, or become narrowed where they cross the band. But this greatly developed crescentic fold, including the upper flap of the valve and both fræna, extends from the anterior band to the postero-external band, crossing and attached to the postero-internal band at the posterior end of the orifice. This great fold has an uninterruptedly concave free edge, but a special increase in breadth is seen at the attached margin opposite the orifice, the attached margin showing a notch at each side where the uniformly and deeply convex

margin of the valve-like part descends to meet the attached margin of the fræna, as seen in fig. 4.

The angle at which the upper flap meets the wall of the colon varies; sometimes it is almost a right angle, but the plane of the flap generally slopes downwards towards the free margin. This slope contributes to the perfection of the valve. The amount of the fall is usually about $\frac{1}{4}$ inch but may be $\frac{1}{2}$ inch. It is generally greater than usual when the posterior frænium slopes much downwards in its outward course across the colon. The upper surface of the flap is generally a little concave vertically, varying in that respect, but the concavity is less than the vertical concavity of the lower flap.

The *posterior frænium* is usually much broader and longer than the anterior. It may have the usual crescentic form of other valvulæ coli, but is generally broadest internally from its direct continuity with the upper flap of the valve, giving the continuously concave free margin. The descent of this frænium in its course outwards varies, sometimes there is little if any, sometimes the fall may be as much as an inch, giving a corresponding obliquity to the frænal furrow seen on the surface behind. It often bifurcates before reaching the postero-external band, and may pass a little beyond the band, in that case marking off the limit of the cæcum on the outer side.

The *anterior frænium* extends from the anterior end of the upper flap forwards to the anterior longitudinal band, the corresponding furrow, seen on the surface, marking off the limit of the cæcum on the inner part of the front. It is generally narrow, less than half the breadth of the posterior frænium, but may be as broad. It occasionally gains in breadth at the middle, and may, like the posterior, bifurcate before terminating at the band. In some of the cases noted below, an accessory fold descends obliquely on the walls of the colon, to the upper flap of the valve, or to the broad posterior frænium, or to both. As the measurements of the breadth of the fræna, given in the Table, are taken at the middle, they do not show the greatest breadth. The breadth of the posterior varies generally, but not always, with that of the upper flap of the valve; the anterior gains in breadth at the middle more frequently than the posterior.

Ileo-colic Orifice.—I give the form and sizes as seen in my series of dried specimens. This method preserves the relation of the parts well, but perhaps some little shrinkage may have slightly increased the breadth of the orifice. As to *form*, the orifice usually has the shape of a narrow ovoid, as seen in fig. 4, rounded at the anterior end, sharp-pointed at the posterior end, the lower edge more concave than the upper. With a large upper flap and very descending posterior frænium, the posterior part of the upper edge of the orifice may be convex downwards. The more pointed form at the posterior end is primarily owing to the direction of the ileum and

to the junction being well to the back, rendering a large posterior frænum more effective than a large anterior frænum would be. The relation of the postero-internal band to this end of the orifice is an interesting point in the adaptations here. In all my translucent specimens this band, as seen in fig. 4, passes up entire at or close to the posterior end of the orifice, giving a firm parietal attachment to the flaps of the valve at their meeting. No longitudinal muscular fibres are visible at the more abrupt anterior end of the orifice. In one case (No. 14, fig. 12) in which the ileum has very little direction upwards and no previous contact with the cæcum, the posterior band is seen to pass up on the back of the last half inch of the ileum.

As to *direction*, the axis of the orifice is usually horizontal, or nearly so; with a very descending posterior frænum, the axis inclines downwards and backwards. When the cæcum is held fairly, the orifice looks outwards, but in cases in which the ileum curves more round to the back, the orifice may look as much forwards as outwards. The orifice looks also a little downwards, owing to the projection of the upper flap beyond the lower. This overlapping is normal, is usually for about $\frac{1}{4}$ inch, but may be more. Thus, in cases Nos. 7, 8, 9, 11, 15, 16, 18, 20, the overlapping was for $\frac{1}{4}$ inch; in No. 6, for $\frac{5}{12}$; in No. 12, $\frac{1}{2}$; in No. 17, $\frac{2}{3}$; in No. 13, $\frac{1}{3}$; in No. 14, $\frac{1}{6}$; in No. 21, $\frac{1}{8}$ inch; in Nos. 10 and 22, the two lips of the valve projected equally, but were diseased.

As to the *size* of the orifice, the Table shows considerable variation in what may be called fully-formed valves, but the size of intestine has to be taken into account. The largest orifice in these specimens (No. 7) has length 2 inches, breadth $\frac{3}{4}$ inch, but the intestines are very large; the smallest (No. 21) has length $\frac{3}{4}$, breadth $\frac{1}{6}$ inch; a fair average may be given as length $1\frac{1}{4}$ to $1\frac{1}{2}$ inches, breadth $\frac{1}{2}$ inch. That is in healthy adult specimens. As the result of disease, the orifice may be found much contracted, from cicatrization after ulceration, or from thickening probably following on typhlitis. In case No. 17, in which the margins are thickened by disease, the orifice is $\frac{7}{8}$ by $\frac{5}{8}$ inch; but in the other cases more or less diseased (Nos. 10, 13, 14, and 22) the size of the orifice had not yet been reduced.¹

It is not easy to estimate exactly the *relative size of the ilco-colic and pyloric orifices*, although that is interesting in relation to the getting through of foreign bodies that have passed the pylorus. The aperture of the pyloric curtain is generally oval vertically, varying in size from enough to admit a large finger to enough to admit the point of the forefinger. The largest coin that can be

¹ Among the cases of stenosis of the valve referred to by Mr Treves in his valuable work on intestinal obstruction:—"In two of the cases the valve just admitted the point of the finger, in another it would only give passage to a No. 9 catheter."—*On Intestinal Obstruction: Its Varieties, with their Pathology, Diagnosis, and Treatment*, by Frederick Treves, F.R.C.S., London, 1884, p. 262.

sent by moderate pressure along the œsophagus, can be easily slipped through the moist pylorus. The ileo-colic orifice has a more definite shape, maintained by its fræna, but would admit of some change of shape under pressure. An average diameter of $1\frac{1}{4}$ to $1\frac{1}{2}$ by $\frac{1}{2}$ inch would seem to give a larger capacity to the ileo-colic orifice than that of the pylorus. Putting aside the foreign-body point of view, as not admissible, and although the bulk of the ordinary intestinal contents is usually lessened in the course of the small intestine, it would seem an unnatural arrangement were undigested masses, taken as food and allowed to pass the pylorus, liable to be imprisoned in the small intestine.¹

Competency of the Ileo-colic Valve. It is not to be inferred from the number of cases of incompetent valve, proved or inferred, noted below and in the Table, that that condition is frequent. On the contrary, I believe it to be a rare condition,—that competency, the prevention by the valve of reflux of the contents of the great into the small intestine, is the normal condition. The exceptions occur in cases of abnormal cæcum, such as those here noted, which have been collected during many years because they are exceptional; and in cases where disease has in part destroyed the valve, without having produced stenosis. There seems, however, to be a vague general impression that enemata can pass to the small intestine, and I have met even with the impression that the so-called “stercoraceous” vomit, in cases of strangulated hernia, is from the great intestine, in forgetfulness that the seat of strangulation is above the valve.

My opinion that the valve is normally competent is not founded merely on its anatomy, but on experiment by inflation. Before removal from the body, inflate the parts through an opening made in the ileum some inches from the colon, and tie the ascending colon or constrict it with the hand. On withdrawing the inflation tube the ileum collapses, and it will be found that air cannot be made to pass back from the great intestine, under either gentle or severe pressure with the hand. This demonstration has long been a familiar one in my lecture-room and dissecting-rooms, and I can recall very few instances in which my prediction of the result was not verified. In two such failures the valve was afterwards found to be diseased (cases Nos. 10 and 13). When the parts are out of the body on the dissecting table, the result is less complete, the injury to the peritoneum binding the commencement of the colon and binding the ileum to the great intestine has slackened the attachments of the valve, but even then the regurgitation is very partial, if at all.

It has been replied to me that that was only in the dead

¹ Mr Treves (*loc. cit.*, p. 320) mentions a specimen, in the London College of Surgeons Museum, “showing a dessert-spoon seven inches long and with a bowl $1\frac{1}{2}$ inches wide lying fixed in the cæcum.” A normal ileo-colic orifice would just pass such a bowl.

body; but does that affect the result? Any little action the few circular muscular fibres in the valve can exert in the living body will be rather in the direction of tightening the valve. A muscular action more likely to assist the valve in preventing reflux would be the severe contraction of an empty ileum opposite the area of junction. The idea of being able to relax the valve, so as to allow enemata to pass, by narcotizing the patient, or by narcotizing the valve locally by carbonic acid injected per rectum, or formed from chemicals introduced into the rectum, seems far-fetched; and all such views are met by the fact that the valve is competent in the dead body.

It need not be doubted that, in trying large tepid water enemata, a small quantity of water may at first get past the valve. Supposing, in the semi-erect posture, the cæcum to be nearly filled, for which about a teacupful would suffice, the water might fall over the edge of the lower flap of the valve; or with the body lying on the left side, the same might happen with even a less quantity of water. But that could not accomplish what is wanted; some amount of force is wanted to overcome the supposed obstruction in the small intestine, and as soon as the current of the necessary volume of water sets in, the flaps of the valve could not but be pressed together, and backward passage prevented. In the case of the valves of the veins, I found¹ that the first double valve could be passed by forcible injection with water, the force, however, being too much weakened to overcome the succeeding valve; but the fact remains, as shown by the experimental inflation in the dead body, above described, that, even in great distention and under great pressure, the ileo-colic valve, normally, does not allow of backward passage. I heard once of a case in which turpentine contained in an enema was said to have appeared in the vomit, but on making careful inquiry the case broke down into one of hearsay. The argument for the trial of large enemata of water, or air, or carbonic acid gas, appears to amount to this, that they will likely be useful in any obstruction in the colon, or if the case is one of ileo-colic intussusception; but, in regard to the small intestine, that they can be of avail only on the chance of the patient having an abnormal ileo-colic valve.

¹ "On Jugular Venesection in Asphyxia, Anatomically and Experimentally considered, including the Demonstration of Valves in the Veins of the Neck."—*This Journal*, 1856.

TABLE GIVING THE MEASUREMENTS, IN INCHES AND PARTS OF AN INCH,

Case.	Fig.	Appendix.			Cæcum.			Diam. of Colon.	Diam. of Ileum.
		Place of Origin.	Length	Diam.	Form.	Length	Diam.		
1	1	Fœtus. At end.	1	$\frac{1}{10}$	Fœtus. Funnel.	$\frac{1}{2}$	$\frac{1}{4}$	$\frac{1}{4}$	$\frac{1}{4}$
2	.	Fœtus. At end.	$1\frac{3}{4}$	$\frac{1}{8}$	Fœtus. Cone bent back.	$\frac{3}{4}$	$\frac{1}{2}$	$\frac{1}{2}$	$\frac{3}{8}$
3	5	At end, below.	3	$\frac{1}{3}$	Funnel.	$1\frac{1}{4}$	1	2	$1\frac{1}{2}$
4	6	At end, below. Blocked.	2	○	Funnel.	$4\frac{1}{2}$	3	2	$1\frac{1}{4}$
5	7	At end, below. Blocked.	$3\frac{1}{2}$	○	Funnel.	$4\frac{1}{2}$	3	3	$1\frac{1}{2}$
6	8	At end, internally.	4	$\frac{1}{3}$	Funnel, turned in.	5	$3\frac{1}{4}$	3	$1\frac{1}{2}$
7	.	At end, above. Blocked.	$4\frac{1}{2}$	$\frac{1}{4}$	Bent cone, curved in and up.	8	$4\frac{1}{2}$	5	$1\frac{1}{2}$
8	10	Below.	$3\frac{1}{2}$	$\frac{1}{4}$	Fundus blunt.	$3\frac{1}{4}$	$2\frac{3}{4}$	3	$1\frac{1}{4}$
9	9	Below, partly blocked.	$1\frac{1}{2}$	$\frac{1}{8}$	Fundus blunt.	3	3	3	1
10	.	Below.	$3\frac{1}{2}$	$\frac{1}{8}$	Fundus blunt and bifid.	$2\frac{1}{2}$	$2\frac{1}{2}$	$2\frac{1}{2}$	$\frac{7}{8}$
11	11	Nearly below.	5	$\frac{1}{4}$	Broad, bilobed behind.	$2\frac{1}{4}$	3	3	$1\frac{1}{4}$
12	.	Back, at middle	3	$\frac{1}{4}$	Blunt cone, notched on inner side.	$2\frac{1}{4}$	$2\frac{1}{2}$	$2\frac{1}{2}$	1
13	.	Back, near middle.	$2\frac{1}{2}$	$\frac{1}{3}$	Same as last.	$3\frac{1}{4}$	$2\frac{1}{2}$	3	$1\frac{1}{2}$
14	12	Back, below middle.	4	$\frac{1}{4}$	Same as last.	$2\frac{3}{4}$	$3\frac{1}{4}$	3	1
15	.	Inner side, high up.	2	$\frac{1}{2}$	Blunt cone.	2	2	$1\frac{3}{4}$	1
16	13	Inner side, from funnel.	$4\frac{3}{4}$	$\frac{1}{8}$	Bent cone. Also a funnel.	3	$2\frac{1}{2}$	$2\frac{1}{2}$	1
17	.	Back, high up, from funnel.	4	$\frac{1}{8}$	Blunt cone.	$3\frac{1}{2}$	$2\frac{3}{4}$	2	1
18	14	Inner side.	$\frac{3}{4}$	$\frac{1}{3}$	Blunt cone.	3	3	$3\frac{1}{2}$	$1\frac{1}{2}$
19	.	Back, high up.	$\frac{3}{4}$	$\frac{1}{6}$	Blunt cone.	$1\frac{1}{2}$	2	$1\frac{3}{4}$	1
20	15	Back, at middle.	.	$\frac{1}{10}$	Blunt cone.	$3\frac{1}{2}$	$3\frac{1}{2}$	$3\frac{1}{4}$	1
21	.	Back, at middle. Blocked.	2	○	Broad. Bilobed below.	$2\frac{1}{4}$	$2\frac{3}{4}$	$2\frac{3}{4}$	$1\frac{1}{4}$
22	16	Back, below middle. Disappeared.	○	○	Broad. Bilobed below.	$2\frac{1}{4}$	$3\frac{1}{4}$	$3\frac{1}{4}$	1
23	.	.	6	$\frac{1}{8}$

Note in regard to some of the measurements and definitions in the Table.—1. *Appendix*: Diameters taken at middle; in dried specimens probably a little less than in natural condition. 2. *Cæcum*: Lengths are the mean from limits before, behind, and within cavity. 3. Diameters of cæcum and colon are the mean of the transverse and antero-posterior. 4. *Direction of Ileum*: whether the obliquity upwards is medium or great. This and diameter of ileum to be looked to as bearing on height of area of junction.

AND THE CONDITION OF THE PARTS IN THE CASES OF VARIATION DESCRIBED.

Direction of Ileum.	Height of Area of Junction.	Ileo-colic Valve. Breadth of flaps.		Ileo-colic Orifice.		Frena of the Valve.				Condition of Ileo-colic Valve.
		Lower.	Upper.	Length.	Breadth.	Posterior.		Anterior.		
						Length.	Breadth.	Length.	Breadth.	
Medium up.	Average.	Average.	Average.	Average.	Average.	Long.	Good.	Short.	.	Fully formed.
Greatly up.	1 $\frac{3}{4}$	1	$\frac{1}{2}$	$\frac{3}{4}$	$\frac{1}{2}$	$\frac{1}{2}$	$\frac{1}{2}$	○	○	Quite incompetent.
Descends a little.	1 $\frac{1}{4}$	$\frac{1}{2}$	$\frac{1}{2}$	1 $\frac{1}{2}$	$\frac{1}{2}$	○	○	○	○	Quite incompetent.
Nearly transverse	1 $\frac{1}{2}$	$\frac{1}{2}$	$\frac{1}{2}$	1 $\frac{1}{2}$	1 $\frac{1}{2}$	○	○	○	○	Quite incompetent.
Very little up.	1 $\frac{3}{4}$	1	1 $\frac{1}{2}$	1 $\frac{3}{4}$	$\frac{1}{2}$	1	$\frac{1}{4}$	$\frac{1}{2}$	$\frac{1}{4}$	Fully formed.
Descends a little.	1 $\frac{3}{4}$	1 $\frac{3}{4}$	2	2	$\frac{3}{4}$	3	$\frac{3}{4}$	2	$\frac{1}{2}$	Very fully formed.
Greatly up.	2	1 $\frac{1}{2}$	1	1 $\frac{1}{2}$	$\frac{1}{2}$	1 $\frac{1}{2}$	$\frac{1}{4}$	1 $\frac{1}{2}$	$\frac{1}{4}$	Fully formed.
Descends a little.	1	$\frac{1}{2}$	$\frac{1}{2}$	1 $\frac{1}{2}$	$\frac{1}{2}$	1 $\frac{3}{4}$	$\frac{1}{4}$	1 $\frac{1}{2}$	$\frac{1}{2}$	Undersized. Comp.?
Medium up. Much back.	1 $\frac{3}{4}$	$\frac{3}{4}$	$\frac{1}{2}$	1 $\frac{1}{2}$	$\frac{1}{2}$	○	○	Full.	$\frac{1}{2}$	Incomp. Diseased.
Medium up.	1 $\frac{3}{4}$	1 $\frac{1}{2}$	1 $\frac{1}{2}$	1 $\frac{1}{2}$	$\frac{1}{2}$	2	1	1 $\frac{1}{2}$	$\frac{1}{2}$	Very fully formed.
Very much up.	1 $\frac{1}{2}$	1 $\frac{1}{2}$	1 $\frac{1}{2}$	1 $\frac{1}{2}$	$\frac{1}{2}$	1 $\frac{1}{2}$	$\frac{3}{4}$.	$\frac{1}{2}$	Very fully formed.
Very little up.	1 $\frac{1}{4}$	$\frac{2}{3}$	1	1 $\frac{1}{2}$	$\frac{1}{2}$.	$\frac{1}{2}$.	$\frac{1}{4}$	Incomp. Diseased.
Very little up.	1 $\frac{1}{4}$	$\frac{1}{2}$	$\frac{3}{4}$	1 $\frac{1}{2}$	$\frac{5}{12}$	2	$\frac{1}{2}$	2	$\frac{1}{2}$	Comp.? Some disease.
Very little up.	1 $\frac{1}{2}$	$\frac{3}{4}$	$\frac{3}{4}$	1	$\frac{1}{4}$.	$\frac{1}{4}$	$\frac{3}{4}$	$\frac{1}{2}$	Fully formed.
Descends.	$\frac{7}{8}$	$\frac{1}{2}$	$\frac{3}{4}$	1 $\frac{1}{2}$	$\frac{1}{2}$	1	$\frac{1}{2}$	$\frac{3}{4}$	$\frac{1}{2}$	Medium. Seems competent.
Very much up. Also back.	2	1 $\frac{1}{2}$	1	$\frac{7}{8}$	$\frac{3}{8}$	2	$\frac{1}{2}$	1 $\frac{1}{2}$	$\frac{1}{2}$	Fully formed. Some disease.
Medium up. Ileum large.	2	1 $\frac{1}{4}$	$\frac{1}{2}$	1 $\frac{1}{2}$	$\frac{5}{8}$	○	○	.	$\frac{1}{4}$	Probably incomp.
Medium up.	1 $\frac{1}{4}$	$\frac{3}{4}$	$\frac{1}{2}$	$\frac{7}{8}$	$\frac{5}{8}$	○	○	○	○	Imperfect. Incomp.
Very much up.	1 $\frac{3}{4}$	1	$\frac{7}{8}$	1 $\frac{1}{2}$	$\frac{3}{8}$	2	$\frac{1}{2}$	2	$\frac{1}{2}$	Fully formed.
Medium up.	1 $\frac{1}{4}$	$\frac{5}{8}$	$\frac{5}{8}$	$\frac{3}{4}$	$\frac{1}{2}$	1 $\frac{1}{4}$	$\frac{1}{2}$	1 $\frac{1}{2}$	$\frac{1}{2}$	Fully formed.
Very greatly up.	2 $\frac{1}{4}$	1 $\frac{1}{4}$	$\frac{1}{2}$	1 $\frac{1}{2}$	$\frac{1}{2}$	2	$\frac{1}{2}$	○	○	Medium. Discased. Probably incomp.

5. *Breadth of flaps of Ileo-colic valve* : is the greatest breadth. 6. *Ileo-colic orifice* : probably slightly less in moist condition. 7. *Frena of the valve* : breadths taken at middle, which is usually considerably less than where they join the flaps. 8. *Condition of Ileo-colic valve* : Incompetency was either ascertained or is manifest. Observe that the cases of incompetency were either cases of very abnormal caecum, or cases of diseased valve. ○ signifies that the part was absent ; • that the observation could not be made.

EXPLANATION OF THE PLATE.

All the figures belong to human anatomy. The first four are designs, the remaining twelve are from Nature, selected from among my collection of specimens showing variation of the cæcum and appendix. All the figures reduced to $\frac{1}{2}$ except fig 1.

FIG. 1.—From foetus near full time, about natural size, but cæcum may be more elongated. Appendix seen to be, relatively, long and wide. Colon and cæcum have not attained full size in proportion to small intestine. *a, p, x*, indication of point of distinction between future cæcum and appendix.

FIG. 2.—Diagram of supposed antero-posterior section, mainly to show how downward and forward growth of cæcum gives acquired fundus of usual adult cæcum, and leaves original apex and appendix at back of cæcum. Ileum should not be seen in this section, but is introduced to show limit of cæcum and section of the two flaps of ileo-colic valve; $\frac{3}{4}$ inch allowed for breadth of upper flap, *u, v*, 1 inch for lower, *l, v*; upper flap seen to project beyond lower; both flaps a little concave towards great intestine; vestigial fossa indicated below mouth of appendix.

FIGS. 3 and 4.—Posterior and anterior views of typical adult cæcum and appendix; in fig. 4, anterior wall removed. The three longitudinal bands, anterior, postero-external, and postero-internal, marked respectively, *a, b, p, e, b*,—and *p, i, b; s, s, s*, the three sacculæ of cæcum, internal, inferior, and posterior; *v, f*, vestigial fossa, seen to be bounded by union of bifurcations of the three bands, appendix arising from the fossa. In fig. 3, *p, f, f*, posterior frænal furrow, marking limit of cæcum; ordinary place of origin and position of ascending stage of appendix seen, and most frequent position of second stage, showing itself pendulous and free from behind ileum. In fig. 4, *u, v*, upper flap, *l, v*, lower flap of valve, both flaps represented diagrammatically, upper as seen from above, lower as seen from below; neither quite of full breadth; form of orifice and convexities of horns of lower flap seen; only beginning of anterior frænum seen; *p, f*, posterior frænum, marked off from upper flap at attached margin, but continuous at free margin; posterior horn of both flaps seen to be attached at postero-internal band; most of two ordinary valvulæ coli seen at upper part of figure, attached at narrow end at longitudinal band. Inner half of this view belongs properly to inner side of cavity.

FIGS. 5, 6, 7, and 8 show cæca of the tapering or funnel shape, with appendix continued, being retention more or less of the foetal form.

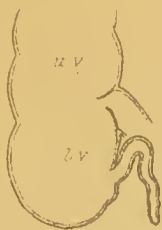The remaining figures, 9 to 16, show cæca of the acquired bluntly-ovoid or bulbous form; fig. 16, the fundus bifid, being deeply notched below at anterior band; fig. 12, the most usual form, gently notched towards inner side at anterior band.

These figures show various conditions of the *appendix*, as to place of origin, direction, length, width, obstruction, and disappearance. In figs. 9, 10, and 11, arising at or very close to lowest part of fundus; in figs. 13 and 14, at inner side; in fig. 13, from a funnel-like remainder of original apex of cæcum, not yet flattened into a vestigial fossa. Figs. 13 and 14 show contrast in length of appendix; figs. 11 and 15 show contrast in its width; figs. 12 and 15 show it entirely hidden behind cæcum; in fig. 12, rolled up at end; in fig. 11, concealed also behind colon; figs. 6, 7, and 9 show partial blocking; and fig. 16 shows its entire disappearance.

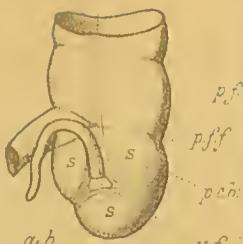
Other points shown in these figures, 9 to 16, are, in fig. 9, *p, f, f*, posterior frænal furrow continued so as to be seen on outer side, and there marking off limit of cæcum, unusual; in fig. 10, *c, f*, furrow of an incidental crescentic fold, liable to be mistaken for the frænal furrow; in fig. 10, *a, f, f*, anterior frænal furrow, marking limit of cæcum; same in fig. 9, but shorter from different position of anterior band; posterior frænal furrow seen in figs. 11, 12, 15, and 16; figs. 12, 15, and 16 show arrangement of the three longitudinal bands surrounding the small bulging vestigial fossa from which appendix arises; the \times on fig. 16 shows where there is a trace of the vanished appendix.



Fig. 1.



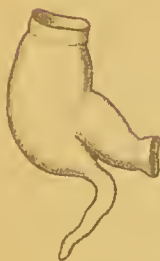2.



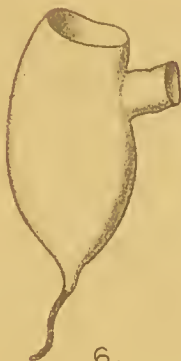3.



4.



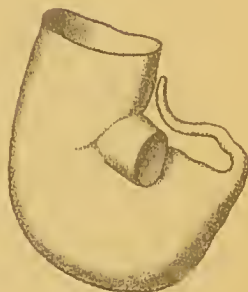5.



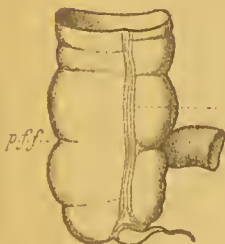
6.



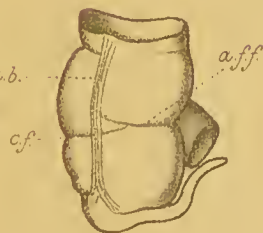
7.



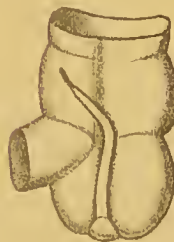8.



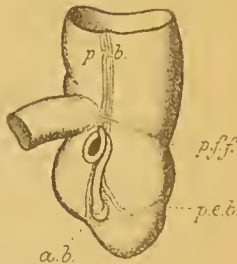
9.



10.



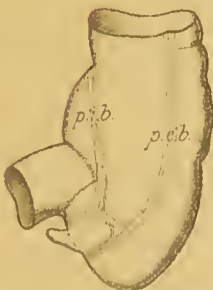11.



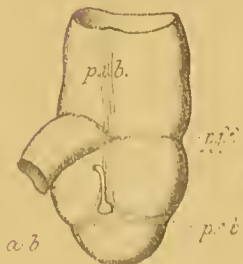12.



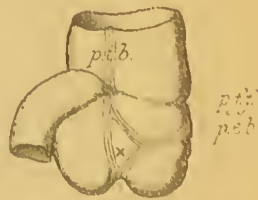13.



14.



15.



16.

John Struther del.

All reduced to $\frac{1}{2}$ except Fig. 1, and size.

F. Ruth latr. F. Anst.

VARIETIES OF THE APPENDIX VERMIFORMIS, CÆCUM, AND ILEO-COLIC VALVE, IN MAN.

II. SPECIMENS SHOWING VARIATION OF THE APPENDIX, CÆCUM, AND ILEO-COLIC VALVE.

These specimens were fairly distended before being dried, and are opened as far as necessary to show the ileo-colic valve, mouth of the appendix, and other characters of the interior. The explanation of the Plate may be referred to in connexion with the description of each of the specimens here mentioned as figured. In the specimens figured, and, indeed, in the whole of my specimens, the cæca are referable to the two forms, the tapering or funnel-shaped form, and the bluntly conical or bulbous form. With each of these forms of cæcum the appendix may be in various conditions. As the last stage of the appendix is generally loosely movable, it has to be kept in mind that, in preparations, the direction of this stage is sometimes determined by the exigencies of space. The Table may be referred to for a general indication of the chief characters of the specimens, and for some comparisons. The descriptions may seem too detailed, but it is when critically studied that such specimens become really interesting.

(a.) *Fœtal Specimens.*

No. 1. From fœtus supposed to be near the full time. Cæcum tapering. Appendix long.

The representation of the fœtal cæcum and appendix given in fig. 1 is mainly from this specimen, but these parts no doubt vary at this period. In this specimen, placing the colon vertically, the tapering cæcum bends downwards and inwards, so that the anterior wall of the upper part (base) of the cæcum, when viewed sideways, is seen to have already begun to form a future fundus. But on all aspects the cæcum presents an elongated tapering form, its general direction inwards and downwards. It is more elongated than in the figure; length over $\frac{1}{2}$ inch and equal to about twice the diameter of the base or that of the colon. Although the cæcum is very tapering, the point of commencement of the appendix is recognisable. As now placed, the appendix first bends with concavity upwards for about $\frac{1}{3}$ of its length, then sharply downwards with the remains of its mesentery, and shows finally two more gentle curves. Total length 1 inch; diameter, at the middle, about $\frac{1}{16}$ inch. Diameter of colon and of base of cæcum about $\frac{1}{4}$ inch; that of end of ileum nearly the same. Ileocolic valve not exposed.

No. 2. From fœtus known to be of the full time. Cæcum transitional. Appendix long.

Translucent preparation showing all the parts well. Diameters, of ileum, $\frac{3}{8}$ inch; of colon and of base of cæcum, $\frac{1}{2}$ inch; of appendix, at middle, $\frac{1}{8}$ inch. Cæcum, as seen from the side, a wide bent cone, turned backwards and inwards, the apex finally tilted a little up, so that the apex is behind the middle of the ileum. Cæcum about $\frac{3}{4}$ inch in length; not nearly so tapering as in last specimen; is rather a moderately bent wide cone turned backwards and inwards. Appendix about $1\frac{3}{4}$ inch in length, begins abruptly from the rapidly contracting apex of the cæcum and turns sharply upwards. As now placed, this long appendix is directed entirely upwards, at first behind the end of the ileum, then

upwards and outwards behind the colon for a length equal to fully twice the diameter of the colon. But the part now placed behind the colon has probably been the pendulous part laid up there for convenience owing to its great length. On the whole the appendix diminishes a little and gradually in diameter; on the proximal third the diameter averages more than $\frac{1}{2}$ inch, on the distal third less than $\frac{1}{6}$ inch. Ileum of medium obliquity upwards; area of junction ovoid. *Ileo-colic valve* well-formed; lower flap the broadest; upper flap slopes downwards considerably; posterior frænum long and with moderate obliquity downwards and outwards; anterior frænum short; orifice as usual in adult, direction a little upwards and outwards, lower edge the most concave. What appears as the opening of the appendix is a wide aperture, about $\frac{2}{3}$ the size of the ileo-colic orifice, external to the lower half of the ileo-cæcal flap, bounded by a sharp crescentic edge above and internally. This opening is into what appears externally as the curved apex of the cæcum, not into the appendix proper. In some of the adult specimens this condition remains, represented by an intermediate vestibule. Looking at the cæcum from the front, the appendix springs from the inner and upper part of the back of what appears as a bluntly conical cæcum. The fundus is already fully formed by the bulging forwards and downwards of the anterior wall of the cæcum. The anterior longitudinal band is visible on the colon, but there is no sacculation on the cæcum and very little on the $1\frac{1}{2}$ inch of colon present.

This specimen shows, in a fœtus, the usual adult form of cæcum nearly attained. It required, further, only the flattening of the original apex at the back, represented in the adult by the vestigial fossa enclosing the orifice of the abruptly arising appendix.

(b.) *Adult Cæca of the Tapering or Funnel form.*

No. 3. (Fig. 5.) Cæcum retaining the fœtal form, with wide Appendix. Ileo-cæcal valve imperfect.

This cæcum is, relatively, even narrower and shorter than in the usual fœtal condition as represented in fig. 1. Sex and age not noted, only that it was adult. Greatest diameter of colon, 2 inches; of cæcum, at base 1, at apex $\frac{1}{2}$ inch. Length of cæcum proper, $1\frac{1}{4}$. *Appendix*, length 3 inches; direction, first inch continues the inward and downward course of the cæcum, then abruptly turned backwards by its mesentery, which crosses here in front. From this crossing being in front, it might be inferred that the turn backwards here was artificial, and that the pendulous stage had been forwards; but the surface behind has no appearance of having been twisted. Appendix wide, diameter about $\frac{1}{2}$ inch at middle, more at first stage, tapering a little towards the bluntly pointed end. Oval-shaped mouth of appendix marked by a narrow valvule at the upper end, but mouth nearly $\frac{1}{2}$ inch wide on its long axis, and in direct continuation with axis of cæcum. The contents of the cæcum could not but pass into the appendix, especially in the erect posture.

Ileo-colic valve unusual. Ileum very oblique upwards. Height of area of junction $1\frac{3}{4}$. Ileo-colic flap nearly normal, breadth $\frac{1}{2}$ inch, much inclined downwards; ileo-cæcal flap appears only as the upper straight edge of a septum between the orifice and the mouth of the cæcum, the septum antero-posterior and directed upwards and outwards; height 1 inch, antero-posteriorly $\frac{1}{2}$ inch. Looking down on them, two large apertures are seen, the external the rounded mouth of the cæcum, about 1 inch in diameter, marked off behind by the short and very little projecting posterior frænum (length $\frac{1}{2}$ inch, breadth $\frac{1}{12}$); the internal the irregularly oval ileo-colic orifice, fully $\frac{3}{4}$ by $\frac{1}{2}$ inch, looking outwards and upwards. The two boundaries of the ileo-colic orifice do not meet by $\frac{1}{2}$ inch, the interval completed by anterior wall of cæcum. It appears that this valve could not be efficient in preventing regurgitation, the ileo-cæcal flap virtually wanting as a

valve, represented only by a fixed septum, while the slanting $\frac{1}{2}$ inch-broad ileo-colic flap is attached to the colon over an inch higher up. Towards its end the *ileum* is enlarged to an average diameter of $1\frac{1}{4}$ inch. At about 2 inches from the end it presents a marked constriction externally and a well-marked valvule internally, $\frac{1}{4}$ inch broad at the middle and going round $\frac{2}{3}$ of the circumference. The same occurrence is noted with No. 12, and with No. 13.

It is rare to find *valvulæ conniventes* so low down in the ileum. According to my observation ("On Diverticula from the Small Intestine," *Edin. Med. and Surg. Journal*, 1854) these folds become slight and scanty at the beginning of the lower third, and are usually absent in the lower fourth of the small intestine. Variations in regard to this are probably not much noted in the dissecting-rooms, but it becomes an interesting point in view of the fact, as far as known, that, except in the ornithorhynchus, the occurrence of *valvulæ conniventes* in the small intestine is peculiar to man, as among the adaptations of the abdomen to the erect posture. The *valvulæ conniventes* are said not to appear till late in uterine life, and to be but rudimentary at birth; the ileo-colic valve at the third month of uterine life; sacculation of the large intestine not till the latter half of uterine life.

No. 4. (Fig. 6.) Large conical and tapering vertically-directed Cæcum, with continued Appendix blocked. Ileo-colic valve imperfect.

From a male subject aged 43. Length of cæcum $4\frac{1}{2}$ inches. Greatest diameter of cæcum, at middle, 3; of colon, 2; of ileum, $1\frac{1}{8}$ inch. The wide conical cæcum diminishes on its lower half uniformly to a diameter of about $\frac{1}{2}$ inch, and then, on its last half inch, tapers rapidly to the pointed apex. The longitudinal bands are not seen on the thin translucent walls of this cæcum. *Appendix* begins without constriction externally and without appearance of valve internally, is fully 2 inches in length and appears to have been pendulous; is now shrivelled and narrow, blocked by matter that has prevented inflation. The contents of the cæcum could hardly fail to pass into this appendix. *Ileo-colic valve*: Ileum directed a little downwards; height of area of junction $1\frac{1}{8}$; valve resembles a pyloric curtain and orifice much more than the normal valve. Orifice vertically oval, $\frac{1}{2}$ by $\frac{5}{12}$ inch, and looks almost directly outwards. Breadth of posterior valvular fold (ileo-colic) $\frac{1}{4}$ inch, of anterior less. The two run into each other below without frænum, and meet above at the sharp end of the ovoid orifice. Curtain nearly at right angles to wall of ileum, its inner surface in line with wall of great intestine. It is not evident how such a valve could be competent to prevent regurgitation, without a sphincter muscle like that of the pylorus.

No. 5. (Fig. 7.) Full-sized conical and tapering Cæcum, curved inwards, with continued Appendix blocked. Ileo-colic valve imperfect.

From a male aged 79. Diameters, ileum $1\frac{1}{4}$ inch; colon 3; cæcum, to middle, about same as colon, on distal half, tapers gradually to a narrow apex. Length of cæcum, along inner margin, 3, along convex outer margin, 6 inches. Direction, first half, downwards; last half, curved inwards and a little downwards. Apex, 1 inch internal to end of ileum, and 3 inches below that. *Appendix* $3\frac{1}{2}$ inches in length, appears to have been pendulous; is now shrivelled, blocked by matter that has prevented inflation. *Ileo-colic valve*: Direction of ileum nearly transverse; height of area of junction $1\frac{1}{2}$; valve very little formed, represented by only a narrow crescentic fold above and below the wide orifice. Breadth of ileo-cæcal fold $\frac{1}{8}$, ileo-colic $\frac{1}{12}$ inch; rounded orifice $1\frac{1}{2}$ inch diameter; the two folds do not meet posteriorly by $\frac{1}{2}$ inch, no posterior frænum, and just meet at their anterior end. This valve cannot have been competent. A crescentic fold begins near the upper part of anterior end of orifice and passes

obliquely upwards across front to outer side of colon. This fold would have formed an anterior frænum had the ileo-colic flap been formed. The longitudinal bands are not seen on the cæcum or on the 2 inches of colon present in this thin-walled translucent specimen.

No. 6. (Fig. 8.) Large conical tapering Cæcum, curved inwards and upwards, with continued Appendix.

From an aged male. This cæcum resembles the last, but there is more inward direction and curving, giving an upturned apex. Diameters, ileum $1\frac{1}{4}$ inches; colon about 3; *cæcum* at first same as colon, at middle has increased to about $3\frac{1}{2}$; along distal third, tapers gradually to a $\frac{1}{2}$ inch-wide apex. In direction, the cæcum soon turns inwards to the horizontal, the axis of the distal third turned inwards and upwards. Length of cæcum, along upper edge 3 inches, along very convex lower edge about 8 inches, the curved axis about 5 inches. *Appendix* proceeds from apex without constriction externally. Orifice, would admit little finger, is marked off above by a sharp edge resulting from the upward direction of the appendix. Length, 4 inches; diameter, at middle, $\frac{1}{2}$ inch, with good capacity throughout. There is some little tapering, evidently on the first fourth, and, again, but less marked, on distal fourth. Appendix now entirely directed upwards and outwards, placed above upper edge of cæcum; but, from position of mesentery on the distal $\frac{2}{3}$, that stage of appendix may be inferred to have been pendulous behind inner end of cæcum.

Ileo-colic valve: Ileum very little direction upwards; height of area of junction $1\frac{3}{4}$; valve fully formed, but fræna short; posterior frænum, length 1 inch, breadth $\frac{1}{4}$; anterior frænum, length $\frac{1}{2}$ inch, breadth $\frac{1}{2}$. Breadth of upper flap $1\frac{1}{4}$, of lower flap 1; projection of free edge of upper flap beyond that of lower, $\frac{5}{12}$. Orifice crescentic, convexity downwards, length $1\frac{1}{4}$, breadth $\frac{5}{12}$ inch. Of the longitudinal bands the postero-internal alone is visible, and that only as far down as to the posterior frænum. There is no sacculation on the cæcum or on the 2 inches of colon present.

No. 7. Cæcum and Colon very large; Cæcum curved inwards and upwards; Appendix blocked.

This enormously large cæcum resembles the last in form, but more turned inwards and apex turned upwards behind ileum. Diameter of colon near cæcum, 5 inches, at six inches higher up, 4; of ileum, $1\frac{1}{4}$; of *cæcum*, at middle, $4\frac{1}{2}$. Length of cæcum, straight along middle, not including upturned apex, 6; upturned part, a blunt cone, 2 inches. *Appendix* from apex of cæcum, length $4\frac{1}{2}$; direction, at first outwards along upper margin of cæcum, behind ileum, for $1\frac{1}{2}$ inch, then backwards along inner side of colon for 2 inches, still naturally adherent, and finally pendulous for 1 inch. Diameter, on first $\frac{3}{4}$ inch, $\frac{1}{4}$ inch, then shrivelled and narrow, blocked by matter that has prevented further inflation.

Ileo-colic valve: Ileum directed a little downwards; height of area of junction $1\frac{3}{4}$; valve fully formed and large, in no way undone by the enormous enlargement of colon and cæcum. Fræna also of full size, each reaching to next band. Upper flap, breadth 2 inches, slopes moderately towards orifice; lower flap, breadth $1\frac{3}{4}$, nearly horizontal, concave towards cæcum. Posterior frænum, breadth at middle $\frac{3}{4}$ inch, length 3, considerable obliquity downwards, bifurcates before reaching postero-external band; anterior frænum, length 2, breadth at middle about $\frac{1}{3}$ inch. Orifice elliptical, directed a little downwards and backwards, length 2, breadth $\frac{3}{4}$ inch, the gape diminished in dried state by great breadth of flaps. Upper flap projects $\frac{1}{4}$ inch beyond lower. No backward current could take place past such a valve. *Other folds and constrictions*: Both colon and cæcum well sacculated; external series on dilated part of colon the narrowest and most bulging. Anterior and postero-external bands become

indistinct about middle of cæcum, but three series of sacculi recognisable on cæcum also; three in each series, the inferior continuous with external series of colon. Only slight ridges within, but at a handsbreadth above ileum, colon has three well-marked valvulæ at intervals of an inch, between anterior and postero-external bands. The great dilatation of colon begins below the lowest of these valvulæ.

(c.) *Adult Cæca of the Bluntly-Conical or Bulbous Form.*

No. 8. (Fig. 10.) Appendix arising from lowest part of cæcum.

This blunt cæcum is undivided; anterior and postero-external longitudinal bands, situated at junction of outer and middle thirds of front and back, well enough seen, but do not indent cæcum either below or on the surfaces. Length of cæcum, in front 3 inches, behind $3\frac{1}{2}$; from level of lower edge of end of ileum, or lowest part of ileo-cæcal flap of valve, $1\frac{1}{2}$. Diameter of cæcum $2\frac{3}{4}$, of colon 3, of ileum $1\frac{1}{2}$. Appendix from lowest part of blunt apex of cæcum, orifice, directly inwards from this, would nearly admit point of little finger. What might be taken for a long "valve" here is but the translucent conjoined walls of the appendix and cæcum; $\frac{3}{4}$ inch in length, in the direction of the appendix; $\frac{1}{2}$ inch in breadth at its slightly concave free margin. Contents of cæcum could not but pass into appendix. Length of appendix $3\frac{1}{2}$. Direction, first half, close below inner part of fundus, adhering to it, and then a narrow mesentery begins; second half, now upwards and outwards behind ileum, but may have been pendulous. Appendix funnel-shaped for $\frac{3}{4}$ inch, then uniform diameter of fully $\frac{1}{4}$ inch to bluntly pointed end.

Ileo-colic valve: Ileum directed very obliquely upwards; height of area of junction 2 inches; valve fully formed; lower flap much the broadest, $1\frac{1}{2}$, upper flap 1 inch. Fræna about equal, length $1\frac{1}{2}$, breadth at middle about $\frac{1}{4}$ inch; reach to anterior and postero-internal bands respectively. Upper flap has moderate slope to orifice, but fræna rather ascend as they pass outwards. Orifice horizontal, length $1\frac{1}{2}$, breadth $\frac{1}{2}$ inch. Upper margin projects $\frac{1}{4}$ inch beyond lower. Lower flap in line with cæcum, not nearly in line with ileum; vertical concavity, towards cæcum, more marked at beginning of upper fourth. *Other folds and constrictions*: furrow shown on outer side in the figure, not frænal, but owing to a broad fold, $\frac{3}{4}$ inch lower, passing between postero-external and anterior bands, with narrow prolongations beyond them, inwards as far as to the postero-internal band, forwards as far as to run obliquely up to join the anterior frænum near the orifice. Constriction seen near end of cæcum, and ridge within, just above appendix, mark off what would have been the vestigial fossa had the cæcum bulged downwards in front of the original apex.

No. 9. (Fig. 9.) Appendix arising from lowest part of cæcum, and blocked.

Length of cæcum, before and behind, 3 inches; diameter nearly 3, of colon 3, of ileum 1. This cæcum is slightly notched below by the anterior longitudinal band external to origin of appendix. Anterior band considerably to inside of middle, postero-external band at junction of middle and outer thirds of back; postero-internal band seen to cross at posterior junction of flaps of valve. In this translucent specimen the course of these bands is well seen. Traced down, they bifurcate and unite around the vestigial fossa, which bulges internal to the notch at the fundus and gives off the appendix. The constriction shown in the figure across the anterior sacculæ of the cæcum corresponds to a well-marked fold within between the anterior and postero-external bands. This fold receives a contribution from the fibres of both bands, and at least one fold on the inner sacculæ of the cæcum receives the same from the postero-internal band. Two slight constrictions shown above the latter correspond to

slight ridges within. *Appendix* arises from inner side of the bulging vestibular fossa; length $1\frac{1}{4}$, first $\frac{1}{8}$ inch funnel-shaped, diameter tapering from $\frac{3}{8}$ to $\frac{1}{2}$ inch, after $\frac{1}{2}$ inch with latter diameter appendix shrivelled, having been blocked by some matter preventing distention. Orifice wide, being mouth of vertically flattened funnel, bounded above by sharp concave edge. Triangular quasi-valve $\frac{1}{8}$ inch long, $\frac{1}{2}$ inch broad at free concave edge.

Ileo-colic valve:—Ileum directed a little downwards, height of area of junction 1 inch. In this specimen we have a good example of the effect of absence of the obliquely upward direction of the ileum on the formation of the valve. The upper flap continues the direction of the curve of the upper border of the ileum, and the lower flap is set at an obtuse angle, upwards, to the lower border of the ileum. Both flaps, simply, are directed obliquely towards the orifice. In this specimen, further, the flaps are rather narrow, but in No. 7 they were seen to be of full breadth. The attached margin of both flaps is uniformly convex, except that the posterior horn of the lower is straight as it ascends to join in the common frænum. Both flaps are undersized, especially the lower; breadth of upper $\frac{5}{16}$ inch, of lower $\frac{1}{4}$. *Fræna* moderate; breadth of posterior at middle, $\frac{1}{4}$ inch, of anterior $\frac{1}{8}$; posterior gains breadth at middle; both extend to the next longitudinal band, the posterior somewhat further, so as to cause a furrow on the outer side, marking off the limit of the cæcum externally and on part of the front, as shown in the figure. Before reaching their respective bands, each frænum bifurcates, the anterior one so early that the upper division might be regarded as a valvula coli accessory to the upper flap of the valve. *Orifice*, horizontal, length $1\frac{1}{8}$, breadth $\frac{1}{2}$ inch; lower edge much the most concave, lower flap being undersized. Lower flap more inclined to orifice than upper; latter moderately so. Upper flap projects $\frac{1}{4}$ inch beyond lower. In regard to possible competency, looking to the breadth and position of the flaps, it does not seem that they could meet efficiently. *Constrictions on the colon* well-developed, one, $2\frac{1}{2}$ inches up, crosses in front from postero-internal to postero-external band, narrowed at anterior band; $\frac{1}{2}$ inch higher, a broader fold is present between anterior and postero-external bands; and $\frac{1}{2}$ inch higher a moderate crescent goes between postero-external and postero-internal bands. With also the crescentic fold above noted crossing anterior saccule of cæcum, it cannot be said that the deficient breadth of the two flaps of the valve is part of any deficiency in the general valvular development of the intestine.

No. 10. Appendix arising from lowest part of a bifurcated cæcum, and directed upwards behind cæcum. Ileo-colic valve thickened and incompetent.

From a male æt. 49. Length of cæcum, before and behind, $2\frac{1}{2}$ inches, from ileum $1\frac{3}{4}$; diameter of cæcum and colon $2\frac{1}{2}$, of ileum $\frac{3}{8}$. *Cæcum* as seen in external lateral view, strongly notched by postero-external longitudinal band. Anterior band faintly marked, with almost no constriction, so that anterior and internal saccules form one wide saccule; but postero-external and postero-internal bands project in, and strongly mark off posterior saccule, which bulges so much as to give bifurcated form to fundus. The two pouches project equally downwards. *Appendix* arises from lowest part of anterior and wider pouch, close to division between them. Orifice towards outer side of small vestigial fossa, oval antero-posteriorly, $\frac{1}{3}$ by $\frac{1}{8}$ inch, sharp crescentic border posteriorly. Length of appendix $3\frac{1}{2}$; direction, curves back below cæcum, lodged between the two sacculi, then up in groove on back as high as middle of extreme end of ileum. Diameter, begins by slightly funnel form, on first inch diminishes from $\frac{1}{4}$ to $\frac{1}{8}$ inch, retains that width till last $\frac{3}{4}$ inch on which it appears rather to increase, end bluntly pointed.

Ileo-colic valve: Specimen marked as one of "Incompetent ileo-colic valve; allowed air to regurgitate freely from great to small intestine, cæcum out of body." Ileum directed upwards and then very much backwards. We have

here an example of the variety in which the ileum curves round to enter at the back. Orifice situated at nearly middle of back of great intestine and looks almost directly forwards. Area of junction nearly horizontal, long axis $1\frac{3}{4}$ inch. Upper flap of valve narrow, $\frac{1}{2}$ inch; lower flap $\frac{3}{4}$ inch anteriorly, but narrows unusually on its posterior half. No posterior frænum, only a thickening in the wall; anterior frænum of good length but narrow, $\frac{1}{2}$ inch. Upper flap slopes considerably to the orifice. Orifice broadly ovoid, $1\frac{1}{2}$ by $\frac{5}{8}$ inch. Upper margin does not project beyond lower. Upper flap thickened and not translucent, as if from disease, especially at margin; edge of lower flap also thickened. The appearances above noted would lead to the inference that this valve could not have been competent, irrespective of the fact that it was found not to be. This may have been in part owing to disease. There are no transverse folds of any kind in the cæcum or the 3 inches of colon present, except those of this imperfect ileo-colic valve.

No. 11. (Fig. 11.) Appendix arising near lowest part of cæcum, and directed upwards and inwards behind colon.

Length of cæcum behind, $2\frac{1}{2}$ inches, from ileum $1\frac{1}{4}$, interior, from posterior end of ileo-colic orifice, 2. Diameter 3, of colon 3, of ileum $1\frac{1}{4}$. Seen behind, as in the figure, fundus bilobed; between the lobes, below, is seen bulging wall of vestigial fossa. Appendix, arising from latter, 5 inches in length; direction, first straight up in deep fossa between bulging sacculi of cæcum to nearly level of upper edge of ileum, then distal half upwards and inwards on back of colon. Diameter $\frac{1}{4}$ inch, till distal inch, which is shrivelled, inflation abruptly stopped by some blocking matter. Orifice, about $\frac{3}{4}$ inch up from bottom of cæcum, rather small, seen at upper angle of vestigial fossa, crescentic edge above. Postero-internal band forms prominent median ridge above orifice, corresponding to groove seen behind between internal and external saccule.

Ileo-colic valve: Ileum directed moderately upwards; height of area of junction $1\frac{3}{4}$ inch; valve large, upper flap and posterior frænum especially. Breadth of flaps, each $1\frac{1}{4}$ inch, upper considerably inclined towards orifice, lower still more so. Both fræna long and very oblique downwards and outwards. Breadth of posterior at middle, 1 inch, of anterior $\frac{1}{2}$. Strong accessory folds from above join upper flap and posterior frænum, former towards anterior and outer part of flap, latter near inner part of attached edge. *Orifice* horizontal, length $1\frac{1}{2}$, breadth $\frac{1}{2}$ inch; upper edge projects $\frac{1}{4}$ inch beyond lower. When specimen held fairly, orifice looks much less outwards than usual, about midway between outwards and forwards.

It is evident that in an operation in a case in which such a variety was present, the appendix would be found very unusually placed, in the deep fossa behind cæcum, bound into the fossa by the peritoneum, and then away up behind colon; or, again, that in an operation on the right colon, the distal part of the appendix might be in the way.

No. 12. Appendix arising from back of a partially bifid cæcum, distal half directed outwards between cæcum and colon.

Length of cavity of cæcum, to inner side 3 inches, at outer side $1\frac{1}{2}$, this owing to great obliquity of upper flap and posterior frænum; same behind from frænal furrow. Diameter of cæcum $2\frac{1}{2}$, of first part of colon $2\frac{1}{2}$, of ileum 1 inch. Cæcum moderately notched (notch $\frac{1}{4}$ inch deep) to inside of middle, by anterior band; fundus descending $\frac{1}{2}$ inch lower, as blunt apex of cæcum, formed by anterior saccule. Appendix arises about middle of back, length 3 inches; direction, first half straight up, then turns, at rounded-off right angle, outwards and then downwards, lodged in frænal furrow between cæcum and colon; about distal $\frac{1}{2}$ inch appears to have been free. After short and slight funnel-shaped beginning, diameter on middle third $\frac{1}{4}$ inch, on first and last

thirds, less than that. Orifice at middle of vestigial fossa seems small for such an appendix, but this cannot now be accurately observed; bounded by crescentic edge above. Vestigial fossa, a rounded depression, receiving end of little finger; surrounded by junction of the bifurcations of the three well-marked bands.

Ileo-colic valve: Ileum directed very obliquely upwards; height of area of junction $1\frac{1}{2}$ inch; valve fully formed; flaps of equal breadth, $1\frac{1}{2}$ inch; fræna large, anterior eut short, breadth $\frac{1}{2}$, length of posterior frænium $1\frac{1}{2}$, breadth at middle $\frac{3}{4}$ inch. Upper flap and posterior frænium together, as in last specimen, form a great crescentic membrane, projecting broadly into the cavity, in this specimen crossing it very obliquely downwards and outwards with a fall of $1\frac{1}{2}$ inch. About an inch above it a great fold, parallel to it, crosses back and outer side of colon, $\frac{3}{4}$ broad to left side, diminishing outwards to $\frac{1}{2}$ inch. *Orifice*, elliptical, and slanting downwards and backwards, $1\frac{3}{8}$ by $\frac{1}{4}$ inch, but compressed from artificial bend up of lower flap; should be reckoned $\frac{1}{2}$ inch. Upper margin projects $\frac{1}{2}$ inch beyond lower; this not owing to any displacement of lower margin. The ileum, $1\frac{1}{2}$ inch from its end, has a valvule, going half round, $\frac{1}{4}$ inch broad at middle.

No. 13. Appendix arising from back of a partially bifid cæcum, and directed upwards. Ileo-colic valve incompetent from disease.

This cæcum is notched on inner side, at anterior band, notch $\frac{1}{2}$ inch deep; anterior sacule goes $1\frac{1}{4}$ inch below notch and forms rounded acquired apex of cæcum. Length, before and behind, $3\frac{1}{4}$, to ileum 3 inches; diameter $2\frac{1}{2}$, of colon, at first sacules, 3, at second sacules, $2\frac{1}{4}$; of ileum $1\frac{1}{2}$. *Appendix* arises a little above and to inner side of middle of back of cæcum; length, $2\frac{1}{2}$; direction, curves like a bow inwards and upwards to behind middle of end of ileum; diameter, at middle $\frac{1}{2}$ inch, less on first and distal fourths; distal $\frac{1}{2}$ inch blocked by matter that has prevented inflation; a very short funnel at beginning is the bulging of vestigial fossa. Latter, seen within, is a rounded depression receiving end of little finger; orifice seems small, but this observation cannot now be accurately made. The three bands project within cæcum, marking off the three sacules, and form equilateral triangular area, of 1 inch, as their bifurcations unite around vestibular fossa.

Ileo-colic valve: This valve allowed of free regurgitation of air from great to small intestine, before removal from the body. Upper flap found to be diseased. Ileum directed moderately upwards; height of area of junction $1\frac{1}{4}$ inch. Lower flap, breadth $\frac{3}{8}$ inch, being less than usual; thickened at orifice. Upper flap of good breadth, 1 inch, but diseased; a semilunar erosion 1 inch broad and $\frac{1}{4}$ inch deep on anterior $\frac{2}{3}$ of its margin, with thickening at and below the margin. Upper flap much inclined towards orifice. *Fræna* horizontal, of good breadth, but now eut short; breadths near orifice, posterior $\frac{1}{2}$ inch, anterior $\frac{1}{4}$ inch. *Orifice*, horizontal, crescentic, upper edge concave upwards, length $1\frac{1}{2}$, breadth $\frac{1}{2}$ inch, upper edge still projects $\frac{1}{2}$ beyond lower. *Other folds*: A crescentic fold, $\frac{1}{2}$ inch broad, subdividing inner sacule of cæcum, passes from anterior band upwards and backwards to lower flap of valve near posterior end of latter. First fold in colon, 2 inches above valve, passes between postero-internal and anterior bands, and a little beyond them. Within end of ileum are two narrow folds like valvulæ conniventes; one behind, runs down to join lower flap of valve above the middle; the other in front, runs up to join the upper flap near the middle of its attached margin.

No. 14. (Fig. 12.) Appendix arising from back of cæcum; distal part coiled up behind cæcum.

This cæcum is gently bilobed on inner side by anterior band; anterior sacule forms blunt acquired apex of cæcum. Length, behind and interior, 3, in front and to ileum $2\frac{1}{2}$ inches; diameter $3\frac{1}{4}$, of colon 3, of ileum 1 inch.

Appendix arises below middle of back ; length 4 inches ; direction, of first half, upwards, distal half coiled circularly below end of ileum, coil more than a circle, tip passing behind ; ascending stage in contact with cæcum, coiled stage nearly so, retained by short mesentery. Begins for $\frac{1}{4}$ inch with moderate funnel shape, from upper part of bulging vestigial fossa ; diameter diminishes a little along first third, average about $\frac{1}{4}$ inch ; then uniform diameter of $\frac{1}{8}$ inch to bluntly pointed end. Orifice at upper part of vestigial fossa ; triangular quasi-valve $\frac{1}{2}$ inch in height, $\frac{1}{4}$ inch in breadth at deeply concave free edge, seen to be the fused walls of cæcum and appendix. This orifice, well seen here, is somewhat less in diameter than the appendix just beyond it. Arrangement at vestigial fossa well seen in this translucent specimen ; bifurcations of each of the three bands join and enclose a triangular area of about 1 inch ; internal fasciculi of each turning in, like circular fibres, and rounding off the angles ; the area, a shallow depression, deepening towards orifice of appendix ; the whole being the flattened remains of the funnel-shaped original apex of the foetal cæcum.

Ileo-colic valve : Ileum very little direction upwards and no previous contact with cæcum ; height of area of junction $1\frac{1}{4}$ inch, and oblique upwards and a little outwards ; valve rather undersized ; upper flap the broadest, upper $\frac{3}{4}$, lower $\frac{1}{2}$ inch, upper slants greatly to orifice ; lower inclined uniformly towards orifice. Attached edge of lower flap convex throughout ; attached edge of upper flap a little concave on both sides. *Fræna* well formed, descend moderately to next longitudinal band ; posterior frænum, length 2 inches, bifurcating before ending at postero-external band, breadth $\frac{1}{2}$; anterior frænum, length 2, breadth $\frac{1}{4}$. *Orifice* nearly horizontal, length $1\frac{1}{2}$, breadth $\frac{5}{8}$; upper edge projects $\frac{1}{2}$ inch beyond lower. Both edges thickened from disease. This valve does not look as if it could be quite competent.

No. 15. Appendix arising high up on inner side of cæcum, and first half directed inwards below ileum.

Great intestine rather small. *Cæcum*, length, at middle, 2 inches, at inner part $2\frac{1}{4}$, at outer part $1\frac{1}{2}$; this from great obliquity of posterior frænum and upper flap of valve. Diameter 2, of colon $1\frac{3}{4}$, of ileum 1 inch. *Appendix* arises high on inner side, only $\frac{1}{4}$ inch below valve. Length 2 inches ; direction, first half transversely inwards, distal half has been pendulous, now turned forwards and then downwards. Narrow mesentery binds first stage to ileum, and continued along concavity of second stage to within $\frac{1}{2}$ inch of end. Diameter $\frac{1}{2}$ inch, uniform to bluntly conical end, the first $\frac{1}{4}$ inch at origin a little wider. Vestigial fossa exceptional, is a transversely elongated boat-shaped recess, $\frac{1}{4}$ inch below and parallel to lower flap, $\frac{2}{3}$ long, $\frac{1}{3}$ broad, and about $\frac{1}{8}$ inch deep towards left end ; appendix proper begins at latter by abrupt rounded orifice with sharp crescentic edge in front. Bluntly conical cæcal cavity formed almost entirely by anterior saccule, narrow space between vestigial fossa and lower flap representing internal saccule.

Ileo-colic valve : Ileum directed very little upwards ; height of area of junction $1\frac{1}{2}$ inch ; valve fully formed ; flaps of equal breadth, $\frac{3}{4}$ inch. *Fræna* well formed, breadth of posterior about middle $\frac{1}{4}$ inch, of anterior $\frac{1}{8}$, length of anterior $\frac{3}{4}$, of posterior 1 inch and then cut short. As above referred to, upper flap and posterior frænum slope very obliquely downwards and outwards, falling $\frac{3}{4}$ inch ; upper flap slopes also very much to orifice, falling $\frac{1}{2}$ inch. Lower flap slopes much and uniformly to orifice. *Orifice*, directed downwards and backwards, crescentic, length 1 inch, breadth $\frac{1}{4}$, upper margin projects $\frac{1}{4}$ inch beyond lower. *Other folds* : Colon well sacculated. A narrow fold, accessory to upper flap, descends on inner side of colon, and ends at about middle of upper flap.

No. 16. (Fig. 13.) Long and narrow Appendix arising from a funnel at inner and back part of cæcum.

From a female æt. 64. Length of cæcum 3 inches ; diameter $2\frac{1}{2}$, of colon

2½, of ileum 1 inch. *Cæcum*, bluntly conical fundus formed by anterior saccule; posterior saccule moderately bulging; internal saccule more bulging. The three bands indistinct at colon but well-marked on cæcum, dividing and surrounding mouth of wide funnel-shaped vestigial fossa; lower boundary rising as crescentic fold from bulging of anterior saccule below it. Funnel 1 inch wide at its nearly round mouth, length $\frac{3}{4}$ inch, proceeds from about middle of inner and posterior aspect of cæcum, appears as if from inner side in the figure, specimen being viewed from inner side to show funnel. Orifice of *Appendix* has no sharp edge or valve, being continued from apex of funnel; length of appendix $4\frac{3}{4}$ inches; tapers a little for first half inch, then diameter about $\frac{1}{2}$ inch. Is now shrunken in parts, but appears to have been open to near if not quite to end. Is now directed as in figure, curving upwards; no note kept as to natural position, but there is no twist or sharp bend of the tube.

Ileo-colic valve: End of ileum directed downwards, and connected to colon earlier than to cæcum; height of area of junction $\frac{3}{4}$ inch. Valve medium size; flaps incline about equally to the orifice; upper flap broadest, $\frac{3}{4}$ inch, lower $\frac{1}{2}$ inch. *Fræna* undersized and have no slope downwards; posterior, length 1 inch, breadth at middle $\frac{1}{2}$; anterior length $\frac{3}{4}$, breadth $\frac{1}{4}$. *Orifice* elliptical, very little slope downwards and backwards; length $1\frac{1}{2}$, breadth $\frac{1}{2}$ inch; upper margin projects $\frac{1}{4}$ inch beyond lower. Horns of lower flap do not join upper by $\frac{1}{4}$ inch, so that fræna belong entirely to upper flap. Margin of upper flap thickened, and that of lower flap slightly so. Nevertheless, this valve looks capable of being efficient.

No. 17. Long and narrow *Appendix* arising from a funnel at upper part of back of cæcum. *Ileo-colic* orifice small.

Length of cæcum $3\frac{1}{2}$ inches; diameter $2\frac{3}{4}$, of colon $2\frac{1}{2}$, of ileum 1 inch. This *cæcum* resembles last in simple bulbous form, anterior band, though well seen, not causing constriction, but funnel-shaped vestigial fossa placed higher, at $\frac{1}{2}$ inch below lower flap of valve. Mouth of funnel, $1\frac{1}{2}$ by $\frac{3}{4}$ inch, surrounded by divisions of the three bands; has large semilunar valve-like fold at upper and inner side, $\frac{1}{3}$ inch broad, containing fibres passing between anterior and postero-external bands. Length of funnel $\frac{1}{2}$ inch. *Appendix* arises from apex of funnel, but passes off at acute angle; small ($\frac{1}{2}$ inch) orifice of appendix proper, shows sharp crescentic edge above, the free edge of a small semi-oval quasi-valve. Length of appendix 4 inches; diameter, after slightly tapering commencement, $\frac{1}{2}$ inch, a little wider on last $\frac{1}{2}$ inch. Direction, now upwards and outwards to behind outer side of first 3 inches of colon. No twist or bend of tube to indicate that this was not the natural position, and appendix appears to have been adherent on to the end.

Ileo-colic valve: Ileum curves very obliquely upwards, joining cæcum $1\frac{1}{2}$ inch below the orifice, and passes more to the back than usual. Area of junction very long, 2 inches, directed upwards and backwards, and curved with concavity outwards. Lower flap of valve therefore long, and its outline curved. *Fræna* and valve together have great obliquity downwards and outwards, giving a fall of 1 inch on upper flap and posterior frænum, and altogether of 2 inches if anterior frænum included; cavity of cæcum thus much longer at inner side—5 inches—than at outer side, 3 inches. Upper flap, breadth 1 inch, not inclined towards orifice, but rather turned up owing to great obliquity of anterior frænum, so that upper surface of the flap is concave to a depth of $\frac{1}{4}$ inch. Lower flap, breadth (height) $1\frac{1}{2}$ inch; in its lower $\frac{2}{3}$, before it inclines towards the orifice, appearing as if part of the wall of the cæcum. *Fræna*, posterior, length to postero-external band 2 inches, bifurcated on last inch, breadth at middle $\frac{1}{2}$ inch; anterior frænum, length to anterior band $1\frac{1}{2}$, breadth $\frac{1}{2}$ inch. *Orifice*, looks more forwards than inwards, partakes of general slant downwards and outwards, elliptical, length $\frac{3}{4}$ inch, breadth $\frac{3}{8}$; upper margin projects $\frac{3}{8}$ inch beyond lower. Upper margin thickened to breadth of $\frac{1}{2}$ inch, as seen below; lower margin only a little thickened. There can be no

doubt as to the competency of this valve, irrespective of the unusually small orifice, and notwithstanding the pathological thickening mentioned.

No. 18. (Fig. 14.) Very short and wide Appendix arising at inner side of cæcum. Ileo-colic valve exceptional and probably incompetent.

From a male, æt. 45. Bluntly pointed fundus of this rather large *cæcum* formed, as usual, by enlarged anterior saccule; internal saccule moderately bulging, marked off in front by depression at anterior band; posterior saccule scarcely bulging. No frænal furrow before or behind; length of cavity 3 inches; length to ileum, vertically $1\frac{1}{2}$, along the side $2\frac{3}{4}$. Diameter of cæcum 3, of colon $3\frac{1}{2}$, of ileum $1\frac{1}{2}$. *Appendix*, length, upper edge $\frac{1}{2}$, lower edge $\frac{3}{4}$ inch. First third tapering, diameter of remainder $\frac{1}{3}$ inch on to blunt end. Arises above middle of inner side, below and rather behind ileum; directed inwards and upwards, with $\frac{1}{3}$ inch-broad mesentery between it and ileum. Seen from within, vestigial fossa is a triangular recess $1\frac{1}{2}$ by $\frac{3}{4}$ inch, bounded by the bifurcations of the three bands. Orifice of appendix a wide oval, nearly admitting point of little finger, bounded on side from which appendix goes by sharp crescentic edge.

Ileo-colic valve: Ileum moderate obliquity upwards; height of area of junction 2 inches. No posterior frænum; posterior horns of flaps do not meet by $\frac{1}{4}$ inch; at anterior end of orifice flaps join in a common membrane $\frac{1}{4}$ inch broad, and a very narrow $\frac{1}{24}$ inch frænal ridge passes from margin of upper flap to anterior band. Breadth of lower flap $1\frac{1}{4}$, of upper $\frac{1}{2}$ inch. *Orifice* a broad oval, slanting a little upwards and backwards, length $1\frac{1}{2}$, breadth $\frac{5}{8}$; lower edge projects $\frac{1}{4}$ inch beyond upper. This valve does not look as if it could prevent regurgitation completely. *Other folds*: The first decided fold in colon occurs 4 inches above valve, passing between postero-external and anterior bands. The constriction, seen on inner side in the figure, about 2 inches above ileum, has not even a ridge within, but lodges a considerable artery. On the outer side of dilated part of colon and of cæcum, several slight constrictions are seen in the figure, corresponding to only narrow ridges within, but mainly lodging the arteries. It may be noted that, on a level with where a prolonged posterior frænum would have been, there is a crescentic fold, $\frac{1}{12}$ inch in breadth, crossing between the postero-external and anterior bands.

No. 19. Short and narrow Appendix from upper part of back of a short cæcum. Ileo-colic valve very exceptional and probably incompetent.

Cæcum of simple bulbous form, length $1\frac{1}{2}$; diameter 2, of colon $1\frac{3}{4}$, of ileum 1 inch. *Appendix* arises quite at upper part of back, oval orifice, $\frac{1}{4}$ inch, close below ileo-cæcal flap, with sharp crescentic edge below. Appendix $\frac{3}{4}$ inch in length, on first half tapers from $\frac{1}{4}$ to $\frac{1}{8}$ inch, last half blocked and shrivelled. Direction now downwards and inwards behind lower part of ileum. *Ileo-colic valve*: Ileum moderate obliquity upwards; height of area of junction $1\frac{1}{2}$ inch. No fræna; posterior horns do not meet by $\frac{1}{2}$ inch; the two flaps form one crescentic curtain-like membrane, broad below, narrow above, passing round $\frac{2}{3}$ of a broadly oval orifice. Breadth of lower part, corresponding to lower flap, $\frac{3}{4}$ inch; at anterior end of orifice $\frac{1}{4}$; above, corresponding to upper flap, $\frac{1}{8}$ inch. Orifice oval, downwards and a little backwards, length $\frac{5}{8}$, breadth $\frac{3}{8}$; admits pulp of forefinger. Valve in its now dried condition projects into great intestine like base of truncated cone, but pressure from great intestine would float it the other way. This valve could not of itself prevent regurgitation, though it might assist a severely contracted ileum to do so. No folds in cæcum or in the 3 inches of colon present. This condition of the valve is interesting, as corresponding to the curtain stage in the evolution of the valve among mammals, referred to in Note A.

No. 20. (Fig. 15.) Very narrow Appendix arising from back of a large cæcum. Ileo-colic valve typical.

Length of *cæcum*, from frænal furrows, $3\frac{1}{2}$ inches, from ileum $2\frac{3}{4}$. Diameter $3\frac{1}{2}$, of colon $3\frac{1}{4}$, of ileum 1 inch. The three saccules of cæcum well marked off by the three bands, within and on the surface; bluntly rounded fundus formed by anterior saccule, dipping $1\frac{1}{2}$ inch below level of vestigial fossa. The fossa is an oval depression, receiving end of little finger, at upper part of equilateral triangular area, of 1 inch, formed by junction of bifurcations of the three bands. Orifice of *appendix*, at upper part of fossa, about $\frac{1}{2}$ inch, bounded above by crescentic free border of $\frac{1}{8}$ inch-long so-called valve. Seen behind, as in the figure, there is first the bulging of the vestibular fossa, and arising from it abruptly the very narrow appendix. Diameter of first $\frac{3}{4}$ inch is only $\frac{1}{7\frac{1}{2}}$ inch, enlarging at bend to $\frac{1}{2}$ inch. Direction at first, for nearly an inch, straight up on back of cæcum, then bends abruptly inwards and downwards. Remainder cut off, shows oval lumen of $\frac{1}{2}$ inch.

Ileo-colic valve: Ileum directed very obliquely up; height of area of junction $1\frac{3}{4}$ inch. Formation of valve what may be called typical. Breadth of lower flap 1 inch, of upper flap $\frac{2}{3}$. *Fræna*, posterior, length to postero-external band 2, breadth at middle $\frac{1}{2}$ inch; anterior frænum, length to anterior band 2, breadth $\frac{1}{2}$ inch. *Orifice*, a narrow ovoid, rounded at anterior end, pointed at posterior end; direction horizontal, length $1\frac{1}{2}$, breadth $\frac{3}{8}$, a little longer and narrower than usual. Upper margin projects $\frac{1}{4}$ inch beyond lower.

No. 21. Narrow Appendix arising from back of deeply bifid cæcum, and blocked. Ileo-colic orifice small.

Length of *cæcum*, from posterior frænal furrow $2\frac{1}{2}$ inches, from ileum $1\frac{1}{4}$, within from valve 2; diameter $2\frac{3}{4}$, of colon same, of ileum $1\frac{1}{2}$ inch. This cæcum is deeply constricted longitudinally, in front and below at anterior band, behind at postero-external band. Seen from cavity, there is a high antero-posterior septum, between the two sacs of the bifid fundus, where the anterior and postero-external bands pass along. Of these two bulging pouches the external, belonging to the anterior saccule, is the broadest, and goes furthest down, projecting $\frac{3}{4}$ inch below notch, the internal about half that distance. Postero-external band well seen, as an elevation within and a groove on the exterior, but posterior saccule of cæcum does not bulge so much as the other two. *Appendix*: Position of closed orifice seen by transfixing with pin from behind, close to outside of elevated septum, at inner part of recognisable triangular vestigial area. Seen behind, appendix arises above middle of back of cæcum, coming out of groove between the two saccules. It is now entirely shrivelled, air having been unable to gain entrance in inflation. It has been about 2 inches in length, appears to have been pendulous, lies a little behind ileum, with narrow mesentery between them; mesentery seen to run along the tortuous shrivelled appendix for $\frac{2}{3}$ of its length. Mesentery seen to carry an artery, size of good pin, from which it may be inferred that the blocking of the appendix is not of old standing.

Ileo-colic valve: Ileum has medium upward direction; height of area of junction $1\frac{1}{2}$ inch; valve remarkable; fræna and upper flap together form one long crescentic symmetrical fold, passing two-thirds round the intestine, reaching between the postero-external and anterior bands, and with great inclination downwards, giving a fall of $\frac{3}{4}$ inch. Here it appears that the upper flap of the valve and the fræna are but one of the *valvulæ coli* more developed. Breadth at upper flap $\frac{5}{8}$, of lower flap $\frac{5}{8}$; fræna nearly symmetrical; length $1\frac{1}{2}$, breadth at middle $\frac{1}{2}$ inch. *Orifice* the smallest I have seen, but no appearance of disease; crescentic, horizontal, length $\frac{3}{4}$, breadth $\frac{1}{2}$ inch. Upper margin projects about $\frac{1}{2}$ inch beyond lower. This valve would be fully efficient.

Other folds: The two fræna, as noted above, cease at the postero-external

and anterior bands respectively, but commencing at these bands there is a crescentic fold, attaining breadth of $\frac{1}{2}$ inch, crossing the anterior saccular series, virtually continuing the slanting plane of the valve and fræna. In this we have an instance of the valvulæ going round and round on the same plane; the one just noted extending only between two neighbouring bands, the other, including the upper flap and its fræna, crossing an intermediate band, and having a continuous free concave edge. A shorter but broader fold crosses between the anterior and postero-external bands about an inch further down. In this much sacculated specimen, the first large fold occurs 2 inches above the valve, connecting the postero-external and postero-internal bands. In the intervening space occur several minor folds, and on the opposite internal saccules two minor ridges. All of these lodge large arteries coming forward from the main trunks at the back, some of the ridges not projecting more than enough for that adaptation.

Blood-supply of the valve, as seen in this well-injected specimen. Posterior part of upper flap and posterior frænium receive supply from main artery in posterior frænal furrow; anterior part of upper flap and anterior frænium from main artery in angle between cæcum and top of ileum; lower flap receives supply, in front, from continuation of latter artery between cæcum and front of ileum, behind, from artery descending between cæcum and back of ileum, and below, from branches ascending from those distributed on cæcum, all branching and anastomosing freely on the flap. The fold noted above as on same oblique plane with fræna, and the crescentic fold an inch below it, are seen to carry each a good-sized arterial arch, distributing and anastomosing across middle line, in accordance with the general system of vascular supply to the anterior series of saccules.

No. 22. (Fig. 16.) Appendix entirely disappeared from its former point of origin at back of deeply bifid cæcum. Ileo-colic valve diseased.

Length of cæcum, behind $2\frac{1}{2}$ inches, to ileum only $\frac{1}{2}$ inch, cavity 2; diameter $3\frac{1}{2}$, of colon $3\frac{1}{4}$, of ileum 1 inch. Fundus divided at unusually strong anterior band, by wide $\frac{1}{2}$ inch-deep notch; the two lobes formed by internal and anterior saccules, of equal breadth and projection downwards. Posterior saccule small and not much bulged, seen in the figure as the upper area between postero-external band and posterior frænal furrow. Seen within, anterior band $\frac{1}{2}$ inch broad in front, now forms at fundus a high and narrow median septum between the two bulging sacculi, which bifurcates upwards, joining bifurcations of the other bands, enclosing well-marked triangular vestigial area, $1\frac{1}{2}$ long by 1 inch in breadth. Orifice of *appendix*, now entirely closed, has been near middle of inner boundary of vestigial triangle, as ascertained by puncturing from behind. Seen behind, there is, where the mark is placed in the figure, below middle of back of cæcum, a small thickening like a stump, indicating where the now absorbed appendix had arisen. There is no trace of an opening either within or without, nor any appearance of disease. The triangular vestigial area, slightly bulging behind, is also shown in the figure.

Ileo-colic valve: Ileum directed almost vertically up and passes further to the back than usual; height of area of junction $2\frac{1}{4}$ inches. Hence, lower flap of valve broad (high) and line of attachment bent with concavity to the right; line of attachment of upper flap uniformly convex. Breadth of lower flap $1\frac{1}{4}$ inch, of upper flap now only $\frac{1}{2}$ inch. Posterior *frænium* large, descends very little, length to postero-external band 2 inches, breadth at middle $\frac{1}{2}$ inch; no anterior frænium. *Orifice* ovoid, sharp at posterior end, horizontal, length $1\frac{3}{8}$ inch, breadth $\frac{5}{8}$; margins equally projecting. Margins of orifice thickened to about $\frac{1}{2}$ inch all round; margin of upper flap shows irregular shallow notch towards outer side as if from former ulceration, and the flap generally towards margin is thickened and wants the usual translucency. This valve looks as if it might have been competent but for the diseased condition of the

upper flap, but the narrowness of the upper flap and the absence of an anterior frænum renders that somewhat doubtful.

Other folds: On outer side, two well-marked folds cross between anterior and postero-external bands, one $\frac{1}{2}$ inch below, the other $\frac{3}{4}$ inch above end of posterior frænum. Constriction caused by upper might be mistaken for limit of cæcum. They are continued as ridges a little way beyond postero-external band, lower one running up to frænum. Between these two large folds is a narrow one in line with lower part of bifurcated end of frænum. Accessory to upper flap of valve, on inner side of colon, a narrow fold descends obliquely backwards to near fore part of middle of flap, which might do a little as substitute for anterior frænum.

No. 23. Four specimens showing variable length of Appendix Vermiformis, one six inches in length.

These four specimens are detached from the cæcum, and laid together to show comparative length. (1.) The longest is 6 inches, diameter about $\frac{1}{8}$ inch, wider on distal inch. (2.) One, $4\frac{1}{2}$ inches in length, diameter about $\frac{1}{8}$ inch, not inflated on distal inch. (3.) One, $3\frac{3}{4}$ inches, well inflated throughout and shows considerable tapering; on first half inch, tapers from $\frac{1}{8}$ to $\frac{1}{4}$ inch; rather before middle, it has diminished to $\frac{1}{8}$ inch, and retains that diameter to the blunt end. These three specimens have still attached to them a short funnel of the cæcum. (4.) One, $2\frac{1}{4}$ inches in length, has arisen abruptly; diameter, on first half inch, $\frac{1}{4}$ inch; at middle, diminished to $\frac{1}{8}$ inch; last quarter inch tapers to a pointed end. In all dried specimens the diameter of the appendix is probably somewhat less than natural. The shortest appendix in all my specimens is that of No. 18, the length $\frac{3}{4}$ inch.

III. THE APPENDIX VERMIFORMIS MORPHOLOGICALLY CONSIDERED.

In my student-days here the following was the view inculcated:—Not doubting an important function, that care had been taken to prevent the entrance of the cæcal contents and to avert the danger of the entrance of foreign bodies, by the following provisions:—(1.) Avoiding the dependent part of the cæcum as the place of origin; (2.) Placing it behind the cæcum, so as to be out of the way of injury, and to avoid the risk of causing strangulation of the intestines; (3.) Placing a valve at the orifice; (4.) Making it go off obliquely, giving a further valvular effect; (5.) Giving it an upward direction. That was the teaching of the science and the natural theology of the day; every species regarded as of independent origin, every structure regarded as designed for use in the organism within which it occurs.

Whether the appendix has or has not an important function, its point of origin and position behind the cæcum are the natural result of the forward and downward enlargement of the cæcum in the process of development. At first a diverticulum of the same width as the colon, the latter and the upper part of the diverticulum have grown wide, and the lower part has remained as the narrow appendix. It does enlarge after birth, growing in length actually though shortening relatively, and in width from that of a crow-quill to that of a goose-quill. Meckel's diverticulum grows still more in width, and is thereby less dangerous than if it had

remained narrow. That diverticulum is actively functional, provided with villi that absorb, open follicles that excrete, and closed follicles that elaborate lymph, like the neighbouring small intestine from which it projects; but it cannot be said to be present from the point of view of utility to the organism within which it may exist, or to be a safe structure. A few inches more to the intestine would give the functional result without the risk. The appendix vermiformis is freely provided with follicles, open and closed, like those of the cæcum. Just half an inch more of cæcum would give the same amount of glandular surface as that of an average appendix, and without the risk.

If it be suggested that the function may be in connexion with the open follicles, the furnishing a special secretion to be added to the cæcal contents, the reply occurs that the method of supplying special secretions elsewhere in the alimentary canal is by ramified glands, such as the salivary glands, pancreas, or the glands of Brunner; a method not attended by risk. If it be suggested that there may be some reason for obtaining this hypothetically important secretion rather by a diverticulum of some kind, there is the consideration that a wider and shorter appendix would have given the desired result with much less risk. If it be suggested that there may be some reason for the narrowness of the appendix—as that the secretion may require to undergo some change before being discharged among the cæcal contents, or that the cæcal contents may not enter the appendix and cause danger, or if not causing danger receiving exclusively the benefit of the special secretion—there is the fact that some chance part of these contents do enter the appendix, appropriating the supposed benefit, with the further result that these stray contents not unfrequently become hardened there, owing to the narrowness of the tube, and produce serious or even fatal results.

If it be suggested that the function of the appendix vermiformis lies rather with the closed glands, with which it is numerous, set, there is the general consideration that lymphoid follicles find lodgement in the walls of mucous passages without reference to the special function performed within the passage, and there is the local consideration that, if the cæcal contents in any way specially furnish material from which lymphoid follicles elaborate their lymph, there was room for those of the appendix in the walls of the cæcum, or at least by the addition of half an inch to the length of the cæcum. The abundance of these follicles in the walls of the appendix vermiformis may, however, play an important part in the pathological conditions to which the appendix now appears to be specially liable, and may to some extent account for these pathological conditions showing themselves during the periods of growth and activity of the system much more frequently than in old age, when lymphoid follicles in the walls of the intestinal canal become atrophied. Thus it would appear that the location of lymphoid

follicles in the walls of the appendix brings with it an additional risk, in combination with that arising from the narrowness of the tube.

Although to the morphologist the discussion of suggestions of special function such as the above may seem frivolous, they are not uncalled for in view of the recent crop of such suggestions since the appendix vermiformis attained so great prominence in medicine and surgery. It is not easy for those whose studies have not extended beyond one species to realize that there are structures the presence of which cannot be accounted for by the observation merely of the organism within which they occur.

Looking for a factor irrespective of special function, we are led into the wide field of the comparative anatomy of the cæcum. That organ varies greatly in different species; in some it is of great length and capacity, evidently in the full play of important function in relation to further digestion or absorption; in some it is as short as in man, or shorter; in some it is altogether absent.¹ An appendix vermiformis strictly comparable to that of man, that is, a very narrow tube beginning abruptly from a wide cæcum, is found only in the anthropoid apes—gorilla, chimpanzee, orang, and the gibbons—in them, as far as observations have yet gone, apparently longer and tending to begin less abruptly than in man.²

¹ Examples of these conditions are mentioned incidentally in Note A, below. For a comprehensive and appreciative view of the anatomy of this and other parts of the digestive organs, may be consulted Sir W. H. Flower's "Lectures on the Comparative Anatomy of the Organs of Digestion of the Mammalia," *Medical Times and Gazette*, 1872.

² Among mammals below these the ending of the cæcum is various; in some, of full width to the end; in some, gradually diminishing distally; in some, the tapering more marked towards the end, but without abruptness and as a continuation of the cæcum. The end of the long and capacious cæcum of the *Rabbit*, about as long as the animal and ten times the capacity of its stomach, has been compared to an appendix vermiformis. In the one before me the cæcum is 20 inches in length; the diameter diminishes gradually along the spirally sacculated part from $1\frac{1}{2}$ inch to $\frac{3}{4}$ inch. The distal part that has been compared to an appendix vermiformis is $2\frac{1}{2}$ inches in length, about $\frac{1}{2}$ part of the whole, has at first a diameter of $\frac{1}{2}$ inch, diminishing to $\frac{3}{8}$ inch at the blunt end; is not sacculated, is thicker walled, and is described as closely set with lymphoid follicles. It is to be borne in mind that this so-called appendix vermiformis is not a narrow tube, in so far that it is wider than the small intestine, the diameter of which is about $\frac{1}{4}$ inch. The last $\frac{3}{4}$ inch of the ileum undergoes an ovoid dilatation to over $\frac{1}{2}$ inch in diameter, the walls thickened with closely set lymphoid follicles. The distal fourth of the long tapering cæcum of the vegetable-feeding marsupial *Koala*, the cæcum of which is over three times the length of the animal, might be called an appendix vermiformis as well as that of the rabbit. In the marsupial *Wombat*, the short narrow tube alongside of the end of the ileum, and opening by the side of the ileum into the colon, has been considered as comparable to an appendix vermiformis. The comparison is not certain in view of the fact of the presence of two cæca not only in birds but in some few of the lower mammalia, and in view of the position of the opening of this tube in the wombat in relation to the short part of the great intestine occupying the position of a cæcum.

The frequent and extreme variation the appendix vermiformis is known to present in man accords with the view that it falls to be classed among the vestigial structures occurring in the human body. It may be regarded in man and in the anthropoid apes simply as the rudimentary representative of the cæcum; the upper part we call cæcum a portion widened with the colon, in adaptation to the play of the ileo-cæcal valve and to the gathering and solidification of intestinal contents preparatory to their being forwarded along the colon. And the walls of both parts are among the numerous localities in which lymphoid follicles are distributed throughout the intestinal canal.

That a part in such a reduced condition should be so frequently the seat of serious trouble to the life of the organism, is a striking fact for consideration in its bearing on the older hypotheses employed to account for the origin and adaptations of animal structures. The difficulty presented is not lessened by the fact that these troubles, arising in the appendix vermiformis, occur mostly during the active periods of life, and with much the greatest frequency in the stronger and more active sex.

Note A.—*Examples of various stages of development of the Ileo-colic valve, referred to above, page 8.*

The condition and adaptations of these parts in the following specimens that I have been able to examine may be shortly noted here.

BIRDS. (1.) A *Wild Swan*. No valve or fold of any kind across the intestine where the two cæca are attached. Small orifice of each cæcum points to great intestine. Cæcal valve: the ileo-cæcal part is very like the lower flap in man when the ileum is oblique, viz., a deep semilunar common septum. At opposite side of cæcal orifice there is a narrow crescentic fold. Closure of cæcal orifice could be effected only by great distention of the intestine. (2.) An *Emeu*. Where the two cæca are attached, there is a circular curtain in the intestinal canal, very like the human pyloric curtain, broadest at the side next the cæca; closure of the intestinal canal not possible unless by a sphincter muscle. Cæcal orifices guarded as follows: are hidden in a narrow gutter between the circular curtain of the intestine and a narrow crescentic fold on the side of the small intestine where the cæca enter. Behind the crescentic fold is a long common parietal ileo-cæcal septum. The arrangement is somewhat like that of the two flaps of the ileo-colic valve in man, the circular curtain like the ileo-colic flap, the crescentic fold and parietal septum like the ileo-cæcal flap; but it has reference to the orifices of the cæca, not to the preventing of reflux from the great to the small intestine; nor will it prevent reflux from the cæca to the small intestine. The circular curtain will prevent the contents of the great intestine from going back directly into the cæca, and the cæcal orifices could be closed by the approximation of the sides of the gutter against entrance from either the great or the small intestine.

MAMMALS. (1.) *Otter, Hedgehog, and Bat*. No cæcum present; no abrupt distinction externally between small and great intestine; in the bat (European), intestine of uniform calibre throughout.

(2.) *Whalebone-Whale*; a *Balænoptera rostrata*, 14½ feet long. Intestines a little wider than average human intestines; cæcum about twice the length. Arrangement at ileo-colic orifice instructive. Area of junction of ileum to cæcum 6 inches in length, with correspondingly long ileo-cæcal common septum. Mouth of ileum projects as a free edge into great intestine, the projection narrow on the fourth of the circumference furthest from the cæcum,

considerable on the side next the cæcum ; there the projecting rim is the upper part of the common septum and is deflected, or admits of being deflected, towards the cæcum. This is as if the lower flap of the human ilco-colic valve sent its horns round the orifice instead of an upper flap. Part of this projecting iliac orifice is close to the lowest crescentic fold of the colon, but does not join it. Crescentic folds in colon numerous and of moderate breadth ; two narrow crescents in cæcum seen to cross upon the ilco-cæcal septum. The arrangement here could not prevent reflux from the great to the small intestine ; great distention of the cæcum could alone close the ileum. We have here an example of the simplest form of circular curtain, formed by the projection of the smaller into the greater tube, but, in the absence of fræna, not capable of resisting reflux.

(3.) *Leopard, Civet Cat, and Mangusta.* Cæcum of medium length and parallel to ileum. Representing the valve, there is only, besides the longitudinal ilco-cæcal septum, a very narrow crescentic fold on the opposite side of the iliac orifice. Scarcely any impediment to reflux into ileum. Cæcum of civet cat is contracted to narrow cone on distal $\frac{1}{4}$ inch ; in mangusta, cæcum much narrowed on distal third, but gradually. (5.) *Kitten.* Ileum adherent to curved cæcum. Besides ilco-cæcal septum, very like the lower flap of the valve in man, there is, at upper side of iliac orifice, a medium-sized crescentic fold, its horns just joining those of lower flap (ileo-cæcal septum). No prolongation to form fræna. The large transversely ovoid orifice could not be closed without a sphincter muscle. Cæcum proportionately rather longer than in man, and diminishes to bluntly pointed end. No sacculation of cæcum, nor of part of colon present, in any of the carnivora mentioned in these notes.

(4.) *Dog ; a large retriever.* Cæcum 8 inches long and coiled ; contact with ileum short. Ileo-colic valve well seen. The fold above the orifice has now united with the horns of the short ilco-cæcal septum, so as to form a circular curtain, like the human pyloric curtain. A very narrow crescent runs across the lower part of the curtain outwards and inwards on the colon, suggesting a commencing frænum, but it is near the attached margin and not of that nature. This large transversely oval iliac orifice could not be closed without a sphincter muscle.

(5.) *Calf ; at birth.* Cæcum about 6 inches in length and curved, twice the diameter of the colon, and enlarging towards its blunt end. Ileum meets great intestine abruptly, area of junction oval in direction of great intestine. Valve much as in dog ; a curtain surrounding a transversely ovoid orifice. On side next cæcum, curtain is formed by upper part of the short ilco-cæcal septum. The appearance of the valve and opening is like that of the cyclids opened. No fold crosses the colon ; valve restricted to iliac orifice. Closure not possible without a sphincter muscle.

(6.) *Rabbit.* The valve is in the form of a curtain, surrounding a transversely oval orifice. Curtain prolonged on the side towards the ileum, as a triangular ilco-cæcal septum, narrow at the other end of the orifice ; attached edges of ilco-cæcal septum are strengthened by narrow crescentic folds, serial with the neighbouring valvules of colon and cæcum, at first suggesting incipient fræna, but they are at the attached edges of the curtain. The enlarged end of the ileum lies across the great intestine at nearly a right angle. Orifice would admit point of little finger ; most of curtain narrow compared with size of orifice ; closure not possible without a sphincter muscle. Here, it may be remarked, notwithstanding the enormous capacity of this long cæcum, in which the intestinal contents must undergo some important change, the ileo-colic valve is not such as to prevent reflux to the small intestine.

(7.) *Small Monkey ; species not noted, but long tailed ; from Edinburgh Zoological Gardens in 1852.* Ileum, colon, and cæcum about half the size of these parts in man, cæcum closely resembles usual adult human cæcum, end bluntly conical ; the three longitudinal bands approach the end, and appear to divide at their last half inch and surround the end. No trace of an appendix. Upward obliquity of ileum moderate. Ileo-colic orifice $\frac{7}{8}$ by $1\frac{1}{8}$ inch, admits

end of forefinger. At first glance the *ileo-colic valve* looks like a well-formed one in man, but is incomplete. Lower flap closely resembles the human, anterior horn joins upper flap, but far back on it near the wall of the colon; but posterior horn does not run quite up, a shortcoming sometimes seen in man, as in case No. 18. Upper part of "valve" is simply a broad crescentic fold of colon, thrice as broad as the numerous valvulæ above it, projecting from the wall of the colon at nearly right angles. It extends between the postero-external and anterior longitudinal bands, across the postero-internal band, broadest ($\frac{1}{2}$ inch broad) opposite the orifice. The four tiers of valvulæ above it, on the 2 inches of colon present, extend only between neighbouring bands.

This valve would not prevent reflux into the small intestine. The lower flap would delay escape from ileum to cæcum, and, reversely, give cæcal contents an upward direction, partly impeding their reflux to the ileum. The upper flap would prevent contents of colon from falling down directly on orifice of ileum, but would equally impede passage of contents onwards from cæcum to colon, and thereby tend to send them back into the ileum. The condition presented by this specimen offers an instructive analysis of the valve in man; the upper flap only a broader than usual crescentic fold of the colon; the lower flap the prolonged ileo-cæcal septum, deflected a little towards the orifice; a more complete carrying up of the lower flap, and junction with the upper at both ends of the orifice, necessary before the two can meet and prevent reflux into the ileum. The lower flap also a crescentic fold of the great intestine, but carried downwards by the downward elongation of the cæcum.

EDINBURGH, *September* 1893.

