



8
28 D 229
No.

28. D. 229
~~28. B. 27.~~

**BOSTON
MEDICAL LIBRARY
ASSOCIATION,
19 BOYLSTON PLACE.**

Received.....

Loaned by *G. C. Shattuck M.D.*





Traverses on the Diseases of the Eye
A
SYNOPSIS

OF THE

DISEASES OF THE EYE,

AND THEIR TREATMENT:

TO WHICH ARE PREFIXED

A SHORT ANATOMICAL DESCRIPTION

AND

A SKETCH OF THE PHYSIOLOGY

OF THAT ORGAN.

BY BENJAMIN TRAVERS, F.R.S.

SURGEON TO ST. THOMAS'S HOSPITAL.

SECOND EDITION.

“Vel me monere hoc, vel percontari puta:
Rectum est, ego ut faciam; non, ut deterream.”

TERENCE.

London:

Printed for

LONGMAN, HURST, REES, ORME, AND BROWN,
PATERNOSTER ROW.

1821.

TO
JOHN RICHARD FARRE, M.D.

THE AUTHOR

DEDICATES

THIS VOLUME

AS A

MEMORIAL

OF

ESTEEM FOR HIS CHARACTER,

ADMIRATION OF HIS TALENTS,

AND

GRATITUDE FOR HIS FRIENDSHIP.

PREFACE.

THE Volume which I now present to the Public, is the result of a more ample opportunity of observing the diseases of the important organ of which it treats, than commonly falls to the lot of Hospital Surgeons. This opportunity, originally derived from my situation during a period of seven years, as Surgeon to the London Infirmary for Diseases of the Eye, has been considerably augmented by private practice in the same branch of the Profession, contingent to that appointment.

I have always thought that the advantages obtained by the subdivision of professional talent and labor, are infinitely overbalanced by those which arise from the general and undivided application of these instruments of knowledge. No fact

more strikingly illustrates the truth of the doctrine, that the confinement of any branch of the Profession to the hands of a few, operates prejudicially to science, than the state of information in this Country, concerning the Diseases of the Eye. Mr. Samuel Cooper has spoken so precisely as I think, upon this subject, that I cannot do better than quote his words.

“The disorders of the eye and its appendages are far more numerous and diversified than those of any other individual part of the body, and some of the requisite operations for their relief ought to be done with the nicest combination of skill and delicacy. These circumstances, strangely enough, have had the effect of inducing an erroneous supposition, that such cases do not properly enter into the department of ordinary surgery; but ought to be consigned to the care of a man, who makes them exclusively the object of his attention, and disregards disease in every other form. The morbid affections of the eye, it is true, like all other surgical cases, must be studied, in order to be understood.

They have no peculiarity, however, except what depends upon their number, and the tenderness and functions of the organ affected. In their nature they are swayed by the same laws which influence all common diseases, for which the practice of surgery is instituted; and their treatment is regulated by general principles, which prevail throughout the whole of this indispensable art.

No one, except the thorough surgeon, can make the complete oculist; by which last term is not meant any body who can merely manage to extract the cataract better than the generality of surgeons, but a man whose science leads him to recognise the analogy betwixt the diseases of the eye and those of other parts, and whose knowledge of the latter, while it qualifies him in a great measure for the treatment of the former, gives him a decided superiority over the bare oculist."

“ On a cru fausement (says the intelligent M. Louis, in adverting to the diseases of the eye,) que le sçavoir nécessaire pour discerner le caractère de ces diverses af-

fections contre-nature, et pour y remédier, faisoit en quelque sorte un art particulier. Mais quels fruits pourroit porter cette branche, étant séparée du tronc? Il est bien prouvé, par les faits, que les progrès de cette partie de la chirurgie ne sont dûs qu'aux grands Maîtres qui ont pratiqué l'art dans toute sa plénitude, et dont l'expérience, relative aux maladies des yeux, a été éclairée par les lumières que leur avoient données les principes qui constituent indivisiblement la science, sans laquelle on ne peut exercer aucune partie avec connoissance de cause."—First Lines of the Practice of Surgery, Vol. I. p. 433. 4th edit.

In this country, I believe no one before myself, who designed to practise general surgery, ventured to give more than a cursory attention to the diseases of the eye. A fear of being disqualified in public opinion, by a reputation acquired in these, for the treatment of other diseases, was a motive, however groundless, sufficient to deter surgeons from the cultivation of a large and legitimate field of observation and practice.

It was with a public avowal of the sentiments so well expressed by the writers just quoted, that I accepted the situation of Surgeon to the Eye Infirmary, in the year 1810; and from these I have never swerved.

At the commencement of the following year, the students of surgery were first invited to attend the practice of the Infirmary; an opportunity eagerly embraced, and which many hundreds have since enjoyed.

Among the gentlemen who with ardor and diligence entered upon this new and interesting study, during my connection with the Infirmary, I have the pleasure of including many of the best educated and most rising men in the Profession; and, if they will permit me to say so, some of my most estimable friends.

Upon occasion of electing a second surgeon to that Establishment in 1814, my friend, Mr. Lawrence, became my colleague. I consider it to be no ordinary sanction of my views, that they were thus

seconded by the co-operation of a gentleman, so highly distinguished as the present senior surgeon of the Infirmary.

But whether my example or my services have been in any degree instrumental in promoting so desirable an object as that of recalling to the notice of the profession at large the neglected subject of these diseases, is a matter of no public interest, and which I am content to leave to the candor of the Profession.

In offering these observations, I entreat it may be understood, that it is far from my meaning to insinuate the slightest derogation from the merits of some truly respectable Members of the Profession, who confine their attention to this class of diseases. We take a different view of the subject; but no man of ingenuous feelings will arrogate to himself that he alone walks in the right path.

In this country, the want of a comprehensive treatise on the diseases of the eye has long been felt and acknowledged. The work of Professor Scarpa was the only

book of reference for English students before the publication of Mr. Saunders's Treatise, which, from its intrinsic evidence of a strong and original talent for observation, leaves us to regret as a national calamity, the premature termination of his labors. Mr. Wardrop's ingenious Essays on the Morbid Anatomy of the Eye, have since contributed to instruct and gratify the Profession. But the object is yet unaccomplished, and I can only flatter myself with having advanced a step or two nearer to its completion.

In Germany a merited share of attention has long been devoted to the diseases of the eye. The elaborate work of Professor Beer of Vienna, who has devoted a life to the subject, is said by those of our countrymen who read the German language, and are competent to appreciate its merit, to evince a familiarity with these diseases—a comprehensiveness of arrangement—a depth and minuteness of observation—a promptitude and fidelity of diagnosis—unattained in any other department of Pathology. Walther of Landshut, Schmidt of Vienna, Himly and Langenbeck of Got-

tingen, and others, have distinguished themselves in the same field of research.

I ardently hope that the example of German industry may operate as an incentive to our exertions, and should it prove so—without meaning to question the extent or value of their researches in ophthalmology—I may be permitted to express my belief, that they can lay us under no deeper obligation.

Nations, like individuals, are distinguished by a peculiar character of mind, to whatever causes attributable, evinced in their respective modes of observing, reflecting and acting; and the sentiment of Phædrus is as strictly applicable to the one as to the other:

“ Sua cuique quum sit animi cogitatio
Colorque privus ————— * ”

I should be sorry to see the sober sense of my countrymen perverted by a taste for fastidious distinctions. Simplicity is the characteristic feature of English Surgery, which is neither more nor less than

the application of the principles of inflammation, as illustrated by the genius of JOHN HUNTER.

I cannot but fear that the condensed and compendious plan of this Volume may occasion disappointment to persons advanced in the study of eye diseases. But I must remind them that it makes no pretension to the character of an elaborate systematic treatise, and is designed more particularly for the information of surgeons and students of surgery. It is the result of personal observation, not a compilation from the works of others. Neither is it in any degree critical. I have not time enough at my command to be an historian, nor ambition to be a controversialist. Facts, whether new or old, derive a value of authenticity from personal observation, which is not enhanced by the custom of collating materials from other sources. Such a custom is likewise inconsistent with another valuable quality, in practical matters especially—I mean conciseness.

It was at the suggestion of a friend that I prefixed the sketches of anatomy and

physiology, for the purpose of bringing the entire subject before the reader in the compass of a volume. In these short pieces, I have aimed at a simple and perspicuous exposition of all that appears essential to a right understanding of the principal diseases of the organ. For the more subtile anatomical points, or rather questions, which I have purposely avoided, I refer my reader to the Appendix.

Against an over-weening spirit of anatomical discovery, the pathologist should be jealously upon his guard, if he would observe honestly and reason accurately on the phenomena of disease. Some ingenious disquisitions have occasionally been given to the Public on the morbid affections of textures, of which the existence is problematical. I would by no means speak with disrespect of the pursuit of minute anatomy, nor presume to question its utility when conducted after the manner of Harvey and Ruysch; but I must be allowed to remark that such points as are too subtile to admit of demonstration, are not to be cleared by the helps of analogy and conjecture, and indeed are never satisfactorily

proved but by the anatomy of disease, from which they derive their importance.

The second part of the work, containing the Pathology, was drawn up and intended for publication in the last Volume of the Surgical Essays, published jointly by Mr. Astley Cooper and myself. It is unnecessary to state the reasons of its postponement; a principal motive was the belief that it would be more useful and acceptable to the junior part of the Profession, as it now stands, connected with the remaining contents of this volume. I am induced to mention this circumstance, by way of apology, for what might appear to be occasional infringements upon the plan of considering the diseases and their treatment distinctly. To a certain extent the blending of these subjects is unavoidable, but the Pathology having been designed for a separate and distinct Essay without any direct view to the subject of treatment, the latter is introduced more freely in the way of illustration, than it would otherwise have been; and, consequently, anticipations and repetitions are more frequent. I do think, however, that this fault is mainly in the plan. I should not therefore *a priori* have

adopted it, but I was unwilling to disturb the arrangement of the piece first written, and to some readers it is probable that the division may not be unacceptable.

Some highly important topics, in the third division of the volume, my experience, as the reader may conclude, would have enabled me to treat much more in detail, than the plan of this work permitted. It is difficult to speak in so small a compass upon subjects like those of cataract and artificial pupil, either of which is sufficient, from its extent and importance, to furnish materials for a distinct volume. I have endeavoured, how successfully I know not, to guard against material omissions, in studying to preserve conciseness.

As I have made little reference to the writings of others, the omission of the *synonima* forming the crabbed vocabulary of Ophthalmologists, ancient and modern, will, I hope, need no apology. The nomenclating mania appears to me an evil of increasing magnitude.

New Broad Street,
Oct. 28, 1820.

PREFACE
TO
THE SECOND EDITION.

THE reception with which this Work has been honored affords me a very sincere gratification. Although it presents only, as its title imports, a general and cursory view of the subject, if that view is a correct one, it fulfils the intention with which it was published. A work of minute detail and elaborate research, though more agreeable to a few readers, would probably be less useful to the professional community.

I have scarcely altered the text of the first edition, but have added a few notes at the end of the volume. I am sorry that I have no better apology to offer for the long interval which has elapsed since the sale of the first edition.

B. T.

*New Broad Street,
Sept. 1st, 1821.*

CONTENTS.

PART I.

	Page
Anatomical Description of the Eye and its Appendages	1
Sketch of the Physiology of the Eye and its Appendages	45

PART II.

CHAPTER I.

PATHOLOGY OF THE MEMBRANES.

SECTION I. Conjunctiva	87
II. Cornea	106
III. Sclerotica.....	126
IV. Choroid and Iris	131
V. Retina	138

CHAPTER II.

PATHOLOGY OF THE HUMORS.

SECTION I. Aqueous Humor	199
II. Vitreous Humor	202
III. Crystalline Humor	211
IV. Diseases affecting the Eyeball	219

CHAPTER III.

PATHOLOGY OF THE APPENDAGES.

	Page
SECTION I. Orbital Appendages	229
II. Facial Appendages	235

PART III.

CHAPTER I.

TREATMENT OF THE DISEASES OF THE EYE.

SECTION I. Simple Inflammation of the Conjunctiva	252
II. Inflammation modified by Struma	262
III. Acute suppurative Inflammation of the Conjunctiva	269
IV. Secondary Diseases of the Conjunctiva...	277

CHAPTER II.

SECTION I. Diseases of the Cornea.....	283
II. Scleratitis, Choroiditis, and Iritis.....	294
III. Amaurosis.....	299
IV. Diseases affecting the Eyeball.....	313

CHAPTER III.

SECTION I. On the Operations for the Cataract.....	318
II. Of the Operations for artificial Pupil	341

CHAPTER IV.

DISEASES OF THE APPENDAGES.

	Page
SECTION I. Diseases of the Eyelids	357
II. Obstruction of the Lacrymal Passages.....	366

APPENDIX	389
EXPLANATION OF THE PLATES	399
NOTES.....	435

A
SYNOPSIS
OF THE
DISEASES OF THE EYE,
AND THEIR TREATMENT,
&c. &c. &c.

PART I.

ANATOMICAL DESCRIPTION

OF

THE EYE

AND ITS APPENDAGES.

THE ORBITS are two funnel-shaped cavities situated under the arch of the forehead, on either side of the root of the nose. The roof of the orbit is formed by the frontal and sphenoid bones; the floor is contributed by the superior maxillary and malar bones; the malar and sphenoid bones make up the temporal side; the lacrymal, æthmoid, sphenoid, and palate bones compose the nasal. The nasal sides are plane, and nearly parallel; the temporal are considerably divergent, so that the axis of the orbit is an oblique line. A line drawn horizontally across the base of the cavity is also oblique; the nasal being more advanced than the temporal angle. This configuration of the orbits prevents us from commanding the parietes of both cavities in a front view of the cranium, and greatly extends the field of vision. The globe of the eye is considerably smaller than the receptacle in which it is con-

Orbits.

tained, to allow of its free motion on all sides. The capaciousness of the orbit provides for the lodgment of the adipose substance upon which the eyeball is cushioned; the muscles which move and adapt it to vision in all directions; the vessels which nourish its membranes and secrete its humors; the nerves which supply these several parts with energy; and the gland for preparing the lubricating fluid which is essential to its economy. These being situated posterior to that membrane which shuts up the cell of the orbit, may be termed, for the convenience of description, the orbitar appendages, in contradistinction to those which the organ presents on its facial aspect, viz. the supercilium or eyebrow, palpebræ or eyelids, and the lacrymal passages; which parts, together with the tunica conjunctiva, I shall call the facial appendages of the globe.

Their holes
and depres-
sions.

The foramina and depressions of the orbit, as of all the bony cavities, form a natural introduction to the anatomy of the parts contained. The nasal and superior sides, for example, are terminated by the optic hole for the introduction into the orbit of the optic nerve. The temporal and superior sides are bounded by an irregular slit or fissure, denominated foramen lacerum orbitale superius; the temporal and inferior are separated by a similar fissure, termed foramen lacerum orbitale inferius vel speno-maxillare. The numerous nerves, the

optic nerve excepted, and the principal vein of the eye and its appendages pass through the foramen lacerum. Two minute foramina left in the suture, connecting the frontal and æthmoid bones, by which a direct vascular and nervous communication is maintained between the nares and the orbit, are termed foramina orbitalia interna, anterius et posterius. A small hole in the orbitar portion of the malar bone establishes a similar communication with the cheek. A depression in the orbitar plate of the os frontis, next its external angular process, receives the lacrymal gland, which is fastened to it by a particular ligament. A minute pit behind and above the internal angular process of the same bone, gives attachment to a ligament and cartilaginous trochlea, in which the tendon of a muscle plays in its passage to the globe. A notch or foramen is observed in the orbitar ridge of the os frontis, which permits vessels and nerves to pass from the orbit to the eyebrow, glabella, and forehead. The infra-orbital canal, which opens obliquely at the back of the orbital floor, is continued under it to the cheek, transmits vessels freely communicating with the ophthalmic, and a nerve from which the inferior palpebra derives its chief supply.

THE GLOBE OR BALL OF THE EYE IS not exactly ^{Eyeball.} spherical, the line forming the visual axis ex-

ceeding its transverse diameter. This line is parallel in the two eyes.

The figure of the orbit demonstrates that a part only of the ball is contained within it. A needle placed upon the temporal angle of the orbit, and pushed horizontally across the globe, perforates the orbital plate of the æthmoid bone, and measures its greatest transverse diameter.

The difference in the degree of projection of the eye in different individuals is determined by the relative volume of the ball and its socket; but the figure and the ordinary interspace of the eyelids are subject to variations, which convey a delusive idea of the magnitude of the globe. When a paralysis affects the palpebral muscle of one eye, the organ, compared with its fellow, has the appearance of being diminished in bulk.

The eye of the female is commonly smaller than that of the male; and the fissure of the eyelids, which are rounder, broader, and more delicate in texture, is generally less.

Humors
and mem-
branes.

The eyeball is composed of the following parts :—

- | | |
|---------------------------|------------------------------------|
| 1. The vitreous humor, | } united by their
common tunic. |
| 2. The crystalline humor, | |

3. The aqueous humor.
4. The retina.
5. The choroides and its appendages, the annulus and processus ciliares.
6. The iris.
7. The sclerotic.
8. The cornea.

The humors give shape to the eyeball, and support to its tunics.

The crystalline is set in the vitreous humor, and washed in front by the aqueous.

The retina is the membranous expansion of the optic nerve, upon which the images of external objects are painted.

The choroid is the bed of the vessels of the eye, and the dark screen which confines and condenses the rays of light in their passage to the retina. Its appendages are auxiliary to this purpose, and to other parts of the economy of vision.

The iris is the colored membrane in which the aperture termed the pupil is formed.

The sclerotic is the external opaque investiture of the choroid.

The cornea is the anterior transparent membrane which first converges the rays of light.

Nearly in the order in which these several parts have been named, I proceed to describe them.

Vitreous
humor.

THE VITREOUS HUMOR is the basis upon which the larger tunics are expanded, and fills a space somewhat exceeding three quarters of the volume of the globe. Upon its anterior surface it is somewhat abruptly flattened, and presents a central cup-like depression; the dimensions of which exactly correspond to the posterior segment of the crystalline humor, which is imbedded therein. Its substance is a glairy fluid heavier than water, perfectly pellucid, and contained within cells formed by processes of its tunic, arranged in horizontal planes. Towards the back and sides of the humor these cells are larger than in the interior, adjacent to the crystalline fossula; the septa are likewise thicker and stronger towards the circumference of the humor. After a careful section of the frozen humor, its substance may be picked out in solid wedge-like flakes from the interstices of the septa. The continuous covering, though of great tenuity and perfect transparency, is of much strength, and resists, owing to the support it receives from the numerous septiform productions of its internal surface, a considerable pressure. When lacerated or wounded, the humor of the corresponding cell or interstice is instantly evacuated; but if the wound is superficial, the humor does not escape in quantity, while supported by the other parts of the globe, or if removed from the globe, while suspended

Hyaloid
tunic.

in a fluid. But if in any way compressed after a wound, a dribbling of the humor goes slowly on, until the cells, which communicate with each other, are emptied.

The tunica hyaloidea is covered by the retina in the whole extent of that membrane, but is connected with it only at the entrance of the optic nerve. The substance of the humor is penetrated by a branch of the arteria centralis retinæ, which contributes a few very delicate vessels to its containing membrane. In the foetus they have been displayed ramifying on the capsule, at the back of the lens.

THE CRYSTALLINE HUMOR is a double convex lens, its breadth about four lines, its thickness about two. The posterior and most convex face of the lens is exactly fitted to the cup in the fore-part of the vitreous humor; the anterior is opposed to the iris, and the circumference to the canal of Petit. The axis of the lens is that of the pupil, a little to the inner side of the axis of the eye. This humor is of perfect transparency in its healthy state. In the foetus and new-born infant, it is spherical, semi-fluid, and has a slightly reddish tint. In the adult, it is gelatinous in consistency, its external lamellæ easily broken down between the fingers, but a nucleus of greater firmness is found in the centre, which in some degree resists this pressure.

Crystalline humor.

In advanced age, the lens becomes more close and compact in texture, and the nucleus acquires a yellow or topaz color.

The texture of the lens is lamellated; the lamellæ concentric and connected by a very delicate fibrous tissue. After maceration, the crystalline breaks into triangular pieces composed of concentric scales, of which the apices meet in the centre. The anterior may sometimes be separated from the posterior part of the lens, at the line of its circumference, as if it were composed of two segments of spheres of unequal size, applied face to face. The crystalline discovers no vascular organization.

Canal of
Petit.

The tunic of the vitreous humor, called tunica hyaloidea, has also, upon its exterior surface, a process or duplicature, membranula coronæ ciliaris of Zinn, who considered it a distinct texture. It is produced at the distance of a line's breadth from the circumference of the cup which receives the crystalline humor. At the verge of the cup the duplicatures coalesce, and thus an annular space is included between them, which has been named, after its describer, canalis Petitionus. Inflation of the canal shews that it is not of uniform dimensions; like the intestine colon, it is tacked up into cells or pouches by short transverse septa, whence the name given by Petit, canal gauderonné, or

godronné. In the grooves corresponding to these septa, the posterior edges of the ciliary processes are inserted. The intervening looser portions of the membrane correspond to the interstices of the processes; and the black radiated lines, which appear upon the membrane of the canal, are stains left by the pigment which fills them. Like the corpus ciliare, the canal is broader on the temporal than on the nasal side.

After the condensation of the lamellæ at the margin of the crystalline, the proper tunic is continued over the concave face of the vitreous humor, posterior to the crystalline lens; and a continuous transparent membrane, produced anteriorly, passes before the crystalline, so as to retain it in its place. This portion of the membrane covering the crystalline is termed capsule of the crystalline, or tunica aranea, and is considerably more dense and elastic than the proper tunic of the vitreous humor. Independent of the membranous enclosure now described, the existence of a distinct and proper capsule of the crystalline is generally assumed; but I have never seen it demonstrated to my satisfaction. A small quantity of aqueous fluid, contained in the capsule enclosing the crystalline humor, is called, after its discoverer, humor Morgagnii.

Capsule of
the crystal-
line.

THE RETINA. The optic nerve having per- Retina.

forated the sclerotic and choroid coats at the internal and posterior part of the globe, terminates abruptly in a little white conical eminence or papilla. From the base of this papilla proceeds the very delicate membranous expansion termed retina. It encompasses the vitreous humor, the front part only excepted. Its anterior termination is also abruptly defined, and corresponds to that of the choroid tunic which lies exterior to it. It is of exceeding delicacy, and, on dissection, resembles, in semi-transparency and in color, the ground glass of which ornamental lamps are constructed. During life it is of perfect transparency. Without caution it cannot be preserved entire in dissection; and if, when the sclerotic and choroid are divided, the parts of the globe are separated by their weight, by its strict adhesion to the other coats at its origin, it is drawn off the vitreous tunic in the form of a fine medullary rope, which expands and reassumes its proper form in water. The arteria centralis, emerging from the axis of the optic nerve, distributes a few delicate branches upon it, which do not in the healthy adult convey red blood.

Its central
foramen.

A minute foramen in the retina is seen on the temporal side of the optic nerve, having a yellow border, around which the arteria and vena centralis, after a delicate injection, display a vascular corona. This appearance first described by Soëmmering, "foramen centrale cum limbo

luteo," is seen only in the recent state of the eye. Its situation corresponds to the extremity of the visual axis. The membranous surface of the retina is opposed to the tunica hyaloidea, the medullary to the choroid. Its attachment, at its insertion into the ciliary body, is very slight, as it commonly yields at that part, if recent and uninjured, rather than tears by the force exerted to separate it entire. The retina is uniformly expanded over the tunica hyaloidea, but has no demonstrable connexion with that membrane.

THE TUNICA CHOROIDES extends from the circumference of the optic nerve to the margin of the exterior or flattened surface of the vitreous humor; there it terminates, together with the retina, in a greyish colored substance, termed ganglion or ligamentum ciliare, or, better, annulus ciliaris, and which is the common centre of union for the interior membranes of the eye.

Choroid
tunic.

The choroid is of a dusky brown color in the adult, reddish in infants, and adhering by an abundant and lax cellular tissue, which may be readily inflated, to the sclerotic coat, and by the numerous ciliary vessels and nerves, which perforate the latter to take their course upon the choroid. This cellular substance is more plentiful in the infant than in the adult, and is most abundant in the track of the principal vessels and nerves. The vessels terminating upon it

Its pig-
ment.

are extremely numerous, and secrete a dark pigment, or varnish, which stains the contiguous adhering surface of the sclerotic; it likewise communicates its stain to the finger, or a piece of white paper, but the texture of the membrane is permanently dark, and is not bleached by maceration.

The interior surface of the choroid is also covered with a black varnish, thicker and deeper colored in the infant than in the adult; but, having no connexion by texture with the retina, its stain is not communicated to this tunic. Around the insertion of the optic nerve, the choroid is destitute of this dye. Residence for some time in alcohol discovers a fine white flocculent substance coating the interior of the choroid, formerly described by Ruysch as a distinct tunic, (*tunica Ruyschiana*,) but not regarded in this light by modern anatomists. The pigment, there can be no doubt, is secreted into a fine cellulous tissue, flakes of which are detached, in some diseased states of the organ, from the ciliary processes and back of the iris, forming to all appearance a real *membrana nigra*.

Its nerves
and vessels.

The ciliary nerves run in parallel lines, at equal distances, upon the choroid; and from their size and whiteness are particularly conspicuous. The long ciliary arteries appear, one on either side of the globe, in their course to the *annulus ciliaris*. Beneath these the membrane

presents, on its opposite sides, vessels arranged in form of trees with weeping branches, or of the figure of a jet d'eau; these, which have been named vasa vorticosa, are veins returning the blood distributed to the ciliary processes, and are collected into three or four distinct venous trunks. The short posterior ciliary arteries pass under the ciliary veins, in the intervals of the trunks, to the interior of the choroid; and uniting with the anterior at the fore part of the globe, their extremities form a very intricate and beautiful net-work upon its interior surface. The adhesion of the choroid to the sclerotic is most strict, adjoining the optic nerve behind, and the ciliary ring before, owing to the introduction of the ciliary vessels at these parts.

THE ANNULUS CILIARIS is an elastic ring composed of a short and dense pulpy texture, closely adherent to the inner border of the sclerotic, at the distance of a line and a half from the external circumference of the cornea. It is of greater breadth on the temporal than on the nasal side. The choroid and retina adjoin its greater, the cornea and iris its lesser circumference. Anteriorly it adheres firmly to the sclerotic, as before observed, and the ciliary processes are attached to its posterior surface, so that it forms a common centre of union for these tunics. Its color is observed to correspond to that of the iris.

Ciliary
ring.

Ciliary
plaits or
processes.

THE PROCESSUS CILIARES. On the internal surface of the choroid, at the root of the annulus ciliaris, the plicæ or processus ciliares arise in delicate striæ, and, advancing a little anterior to the circumference of the crystalline lens, terminate in a circle of fine grey points at the base of the iris. They appear to be radiated folds of the choroid tunic, from sixty to seventy in number, long and short alternately, and gathered at their origin like the plaits of a shirt at the wristband. Viewed collectively through the vitreous humor they have some resemblance to a radiated flower; a small white circle appears within a large dark one. The white lines represent the edges of the plicæ; the black, their interstices coated with pigment. These edges of the plicæ are engrooved in the duplicature of the vitreous capsule, which assists in forming the canal of Petit.

The extremities of the processes projecting from the interior border of the annulus ciliaris interdigitate with the radical fibres of the iris. To obtain a view of them, let the cornea be accurately removed at its junction with the sclerotic, and the iris be torn away, entire, from its ciliary attachment. The points of the processes will then appear, projecting like the teeth of a comb from behind the annulus ciliaris, and the ciliary border of the iris, upon floating it in water, will be found to present a corresponding arrangement.

The processes having their edges thus inlaid in the tunica hyaloidea at the margin of the crystalline fossula, and their points or anterior extremities interlaced with the radical fibres of the iris, form a posterior iris, the aperture of which is exactly occupied by the crystalline lens and its capsule. From their origin to their insertion, they are supported exteriorly by the annulus ciliaris, with which substance they are in fact incorporated. The figure of each plica ciliaris is triangular, the internal obtuse angle being opposed to the circumference of the crystalline lens; the posterior, elongated, loses itself in the choroid; the anterior is inserted into the iris. The anterior edge is attached to the annulus ciliaris and root of the iris, the posterior to the tunica hyaloidea, and the internal and shorter of the three measures the space between the verge of the crystalline lens and the basis of the iris; or, in other words, forms the outer boundary of the posterior chamber.

THE IRIS. This is the colored membrane Iris. which presents a plane surface traversing the globe horizontally, and dividing the corneal from the sclerotic segment. It is rendered imperfect as a septum by the pupilla or round hole in its centre. The pupil is not, however, quite central in relation to the iris, the breadth of the iris being always somewhat less on the nasal than on the temporal side. It is

divided into a ciliary and a pupillary portion. Its attachment is, as already observed, by indenture with the extremities of the plicæ choroideæ, at the inner margin of the annulus ciliaris, from which it originates. The ciliary portion of the iris is the larger one, and is composed of a delicate fibrous and vascular tissue, in which grey serpentine lines or striæ are seen proceeding like radii from the annulus ciliaris: from this the smaller pupillary portion is distinguished by a darker shade of color, and a gently elevated circular line, most conspicuous on the posterior surface of the membrane. The fibres of this portion have a similar tortuous direction, and are convergent towards the pupillar aperture. The pupillary margin is thin and defined, and presents the appearance of a dark circular line when placed upon a white ground, as e. g. the opaque capsule of the crystalline lens. The iris diminishes in thickness from its base to the margin of the pupil. Its anterior surface is richly colored of different hues in different individuals. It is thickly coated on its posterior surface by the pigmentum nigrum.

Its vessels
and nerves.

The ciliary vessels, entering the anterior part of the globe, unite with the other detachments, and form arches at the basis of the iris and processes. From the zone thus produced (zona major) the branches run in straight lines upon the iris. In the dilated state of the pupil these

radiated vessels are tortuous ; by its contraction they become straight. At the distance of rather less than half its diameter from the pupil, another zone is formed by their anastomosis, from which branches are detached to the margin of the pupil. The zona minor gives the appearance of the undulating circular line, distinguishing the pupillary from the ciliary portion of the membrane. The two long ciliary arteries chiefly contribute to the formation of these zones and the supply of the iris. The short ciliaries, seen upon the interior of the choroid, detach numerous fasciculi to each ciliary process, which pursue a serpentine course along the fixed edge of the fold, and are inverted to form concentric arches upon its opposite free margin.

The *membrana pupillaris*, a delicate membrane occupying the pupil of the fœtus, and which is supplied by the vessels of the iris, disappears before birth.

Membrane
of the pu-
pil.

Of the proper structure of the *corpus ciliare* nothing is with certainty known. The notion that it is wholly constituted of vascular and nervous tissue, having no proper fibrous texture for its base, which has also been conceived of the iris, is absurdly contrary to observation and analogy. The *annulus* appears to be a gangliform or bulbous termination of the choroid coat, and the processes resemble plaits or

doublings of this membrane laid back to back, to accommodate it to the area of the posterior chamber. Similar uncertainty prevails as to the structure of the iris, the different opinions of its texture being founded rather upon inference from its functions than upon demonstration. If the former species of evidence be regarded, it is in part unquestionably a muscular texture; the phenomena of its action can be best explained upon the supposition that it is both muscular and elastic, and that these forces act alternately.

Sclerotic
tunic.

THE TUNICA SCLEROTICA is the external covering of the ball, with the exception of one-fifth part, bearing a proportion to the cornea somewhat similar to that which the vitreous bears to the aqueous humor. It is a dense compact fibrous membrane, of a blueish white color; its fibres appear reticulated on maceration. It has few nutrient vessels and no traceable nerves; its texture is both extensile and elastic. In the fœtus and infant it admits of separation into two plates, but these are inseparably connected in the adult. For the entrance of the optic nerve, with the sheath of which it is intimately connected, it is cribrated or perforated with many small holes, by which the fibres of the nerve enter and terminate in the conical protuberance before described. The choroid and retina adhere firmly to the margin of this cribriform plate. In other parts the connection between the sclerotic and choroid is by the medium of blood-

vessels and cellular tissue. The sclerotic around the entrance of the nerve, and likewise around the margin of the cornea, has many small oblique passages, of which the apertures on its internal surface are conspicuous, when separated from the choroid, for the entrance and exit of the ciliary vessels and nerves. Adjoining the cornea, the choroid and conjunctival vessels communicate through the foraminula of the sclerotic, at this part. On its inner surface it has furrows in right lines, in which the long ciliary vessels and nerves are lodged. The sclerotic is of greatest density in the vicinity of the nerve; it gradually diminishes in thickness towards the middle of the globe, where it is fortified by the tendons of the several muscles. The opening in front of the sclerotic is nearly circular, having its inner edge sloped for the broad insertion of the cornea between its anterior and posterior margins.

THE CORNEA is of a horny texture, less ex- Cornea.
tensile than the sclerotic, and perfectly transpa-
rent. It is, onion-like, composed of concentric
lamellæ or pellicles, connected by a delicate
cellular tissue containing a transparent fluid, in
which exhalant and absorbent vessels are abun-
dantly distributed. This tissue is more lax or
copious between the anterior than between the
posterior lamellæ. The transparent conjunctiva
upon the cornea gives a polish and brilliancy to
the surface, which the lamellæ of the cornea do
not possess, and which is lost in, or rather at

the approach of death, by the transudation of the aqueous humor. They are scabrous from the adhesion of the cellular membrane connecting them, and void of lustre. The cornea is externally rather elliptical than circular, being of greater length in the transverse than the vertical diameter.

The cornea is of greater thickness than the sclerotic, in infants especially, in whom its posterior surface is contiguous to the iris. The internal surface is likewise half a line broader than the outer, the margin being obliquely extended from without inwards, to correspond with the sloped edge of the sclerotic. After maceration it may be detached from the sclerotic, to which it is connected by cellular substance: this separation is most readily effected by plunging the macerated eye into boiling water. A fine transparent humor is secreted by colorless exhalant vessels in the areolæ of the cellular membrane between the lamellæ of the cornea. The interstitial substance of the cornea receives no colored vessels. Numerous lines have been observed to form figures of many sides between the plates of the cornea in the eye of the negro, and supposed, from a reddish tinge, to be blood vessels. The existence of nerves has never been demonstrated, and it is much to be doubted if it possess any. On its interior surface the cornea is smooth, and washed by the aqueous humor. According to modern anatomists, it is lined

by a tunic proper to the humor, which is reflected from it upon the face of the iris, and advances even to the margin of the pupil. Its tenuity, if it exist, is such as very rarely to admit of demonstration, at least in the human eye. The convexity of the cornea is greater than that of the sclerotic, being the segment of a sphere seven lines and a half in diameter.

aqueous
humor.

THE AQUEOUS HUMOR. The name of anterior chamber is given to that space comprized between the cornea and the iris, ordinarily about one line and a half in depth. The posterior chamber, not exceeding a quarter of a line, is the space between the iris and the crystalline lens. They communicate by the aperture of the pupil, and both are occupied by the aqueous humor. This is a transparent fluid, evaporates on exposure to heat, and is uncoagulable by heat, acids, or alkalies; it is in quantity about five grains; in quality, viscous and slightly saline. It gives figure and tension to the cornea, keeps the pupil properly dilated, and supports the parts forming the parietes of both chambers. When discharged by the puncture of the cornea, the pupil contracts, and the chambers are obliterated by the collapse of their parietes: it is however reproduced in a few hours. The aqueous humor in fœtuses and new born infants is turbid, and sometimes of a reddish tint.

Aqueous
humor,
and cham-
bers of the
eye.

Veins of
the globe.

The ciliary veins and vasa vorticosa of the choroid jointly return the blood distributed by the ciliary arteries.

They perforate in like manner the sclerotic coat, and terminate in the infra-orbital branch and trunk of the ophthalmic vein, which also receives the vena centralis retinæ.

ORBITAR APPENDAGES.

Periosteum
and fat.

THE PERIOSTEUM AND ADEPS OF THE ORBIT.
The dura mater, which is the internal periosteum of the cranium, lines the orbit, and is continuous at all its openings with the periosteum of the head and face; hence the extensive sympathetic pains in the inflammatory affections of the bones of the face and cranium, and their common membrane. Hence also probably, the suppurative inflammation of the dura mater after extensive fractures and injuries of the orbit.

The fat, which in health is secreted abundantly in the orbit, surrounds the optic nerve, and invests the posterior surface and sides of the globe, forming for it a soft bed, and defending the vessels and nerves from compression in its motions. In emaciating diseases its diminution by absorption produces that characteristic sinking of the globe in its socket, and loss of convexity in the eyelid, which is familiarly expressed by the term "hollow eyed." On the

other hand, its secretion in excess, as in morbid obesity, protrudes, compresses, and thus induces congestion in the vessels of the eye.

I proceed to describe the muscles, vessels, and nerves contained in the orbit.

THE MUSCLES are seven in number; *viz.* the levator palpebræ; the rectus superior, inferior, internus, and externus; obliquus superior and inferior. Muscles.

The levator palpebræ has an acute origin from the periosteum above the foramen opticum; its fibres spread in their course, giving it a fan-like shape, and they are inserted by a broad aponeurosis in a condensed cellular substance, which connects the upper tarsus to the orbital ridge, between the conjunctiva and the fibres of the orbicularis palpebrarum. From the nature and extent of its connection with the eyelid, it results that the partial division of the tarsal ligament, or even the removal of the cartilage, does not take away the power of elevating the lid as the paralysis of this muscle does; the elevation, however, under these circumstances, is imperfectly performed. Elevator of the upper eyelid.

The rectus *superior* lies beneath this muscle, arising from the border of the foramen opticum, and the partition between it and the foramen lacerum. Superior straight muscle.

Internal
and infe-
rior.

The rectus *internus* and rectus *inferior* arise in common from a ligament which in part surrounds the optic foramen, and fills up the foramen lacerum.

External.

The rectus *externus* arises by two distinct heads: the inferior having a common origin with the last named muscles, from the ligament which occupies the inferior angle of the foramen lacerum; the superior from an arch of ligament crossing the foramen above. It is important to note this bicipital origin of the rectus externus, as some of the nerves of the orbit pass through the interspace between its heads, and others through the top of the foramen. The ligament of the foramen sphenomaxillare forks into three intermuscular slips which give origin and support to the external, inferior, and internal recti muscles, in the manner of the intermuscular ligaments of the extremities. The four recti muscles, varying in length and direction as the sides of the orbit to which they are adjacent, pass over the great circumference of the bulb, between which and the cornea they are inserted, at equal distances, by straight tendinous fibres, into the substance of the sclerotic coat.

Superior
oblique.

The superior *oblique* muscle rising from the periosteum between, and a little anterior to the origins of the superior and internal recti, passes its slender rope of tendon through a half ring of

cartilage which is affixed by a ligament to the os frontis, a little above and behind its internal angular process. The trochlea is provided with a sacculus mucosus, and the tendon emerging from it is inclosed in a ligamentous sheath to its insertion in the sclerotic coat, at the posterior and upper surface of the globe, beneath the superior rectus muscle.

The inferior *oblique* rises from the orbitar plate of the superior maxillary bone, behind the lacrymal fossa, and takes an oblique direction between the globe and rectus inferior, to its posterior and outer surface, where it is likewise inserted into the sclerotic.

Inferior
oblique.

The single actions of the recti are expressed by the terms, levator, depressor, adductor, and abductor. Their co-operation retracts the globe in its socket. The oblique muscles, acting singly, roll or rotate the eye in contrary directions. Their co-operation antagonises that of the recti, which power is demonstrated by the course of the superior oblique, the origin of the inferior, and their posterior insertions.

Their ac-
tions.

THE ARTERIES of the eye are principally derived from the ophthalmic artery, which has a short but sharp curve at its origin from the internal carotid, before it enters the orbit. This it does through the foramen opticum, upon the temporal side of the nerve.

Arteries.

The *arteria centralis retinae* which runs in the centre of the optic nerve, and the *long ciliary* arteries which pass upon either side of it, are its first branches; next the *lacrymal* artery, which contributes a ciliary branch, a branch to the rectus externus, and another which runs beneath the globe to the obliquus inferior muscle, and reaches the inferior palpebra. The lacrymal branch then divides into two: one, a branch of communication with the deep temporal branch of the internal maxillary artery at the outer margin of the orbit; another, which is dispersed in the substance of the lacrymal gland and superior palpebra.

The trunk of the ophthalmic artery then crosses obliquely beneath the optic nerve, and on the nasal side of the nerve sends branches to the superior oblique and levator palpebrae, rectus superior and inferior muscles, and commonly a ciliary artery. The remaining branches of the ophthalmic artery, which is here tortuous, are the *frontal*, through the supra-orbital foramen; one or two to the rectus internus, the *nasal* branch which passes by the anterior æthmoid foramen into the nose, and the *infra-trochlear* branch. The ophthalmic artery at length emerges upon the inner canthus, furnishing the *superciliary* and *palpebral* branches, and anastomoses with the nasal branch of the facial artery from the external carotid. The muscular branches penetrate between the fibres, and run-

ning in the same direction, appear beneath the conjunctiva on the sclerotic coat. Here they subdivide and ramify upon the conjunctiva; the fasciculi inosculating so as to form a faint circulus arteriosus around the cornea, when filled with colored blood. Those of the rectus internus are most numerous.

THE VEINS. The ophthalmic and nasal Veins. branches of the anterior division of the facial vein, freely communicate at the inner angle of the orbit with the *ophthalmic vein*; and the anterior and posterior *æthmoidal* or *nasal*, the *lacrymal*, all the *ciliary veins* from the globe, the *vena centralis retinae*, the *infra-orbital*, the several muscular, periosteal, and adipose branches are all collected into this trunk in its passage through the orbit. It takes a serpentine course over the optic nerve, through the foramen lacerum, to terminate in the anterior part of the cavernous sinus of the dura mater.

THE NERVES of the orbit, exclusive of the Nerves. optic, are the third pair, or *motores*; the fourth, or *pathetici*; the first division of the fifth, or *trigemini*; and the sixth, or *abducentes*.

The third pair enter the orbit between the heads of the rectus externus muscle, in company with the nasal branch of the fifth and the sixth pair. Its lesser and superior branch rising

before its entry into the orbit, joins a twig of the fifth pair, to assist in forming the *ophthalmic* or *lenticular ganglion*, and then divides to supply the rectus superior and levator palpebræ muscles. Its larger and inferior branch passes under the optic nerve towards the nasal side of the orbit; and while covered by that nerve, is divided into a branch to the rectus internus, a short thick stalk to the *ophthalmic ganglion*, and a long slender filament to the inferior oblique muscle.

From the *ophthalmic ganglion* lying concealed in fat, on the temporal side of the optic nerve, a superior and inferior fasciculus of *ciliary* nerves arise, and creep along its sides in a serpentine direction to the bulb.

The fourth pair of nerves, with the lacrymal and frontal branch of the fifth, pass through the upper part of the foramen lacerum. It sometimes receives a branch of augmentation from the fifth pair, and always increases in size towards its termination in the central fibres of the superior oblique muscle.

The first or *ophthalmic* division of the fifth pair gives off,

1st. The *supra-orbital*, which is subdivided into the supra and infra trochlear ramuli, and

the proper frontal nerve; which last, running in an external and internal branch upon the levator palpebræ, is distributed upon the forehead.

2ndly. The *lacrymal* nerve, which, taking a direction to the outer canthus, splits into an external and internal branch. The internal supplies with filaments the glomera of the lacrymal gland; twigs from the external likewise enter the gland, and together they are dispersed upon the superior palpebra.

3rd. The *nasal* nerve, which gives a branch to unite with the short stalk of the third pair to form the ophthalmic ganglion, and contributes two *long ciliary* nerves to the globe, then passes obliquely under the superior oblique muscle to the æthmoid foramen, by which it enters the nose, furnishing an infra-trochlear filament to the nasal region of the orbit.

The sixth pair, having parted with the filaments supposed to be the roots of the great sympathetic upon the canalis caroticus, enters the orbit with the nasal of the fifth and the third pair, to be spent upon the rectus externus muscle.

THE LACRYMAL GLAND is of the conglomerate kind, of a flattened oval form, divided by a cleft into two lobes, of which the superior and internal is the smaller and thinner, the inferior and exter-

Lacrymal
gland.

nal the large extremity of the gland. Its position is oblique; the inferior and internal surface hollowed to suit the convexity of the globe; the superior convex to fit the corresponding surface of the orbit to which the gland is attached, by a ligament passing transversely beneath it. It measures, in length, about ten lines; in breadth, five or six. The structure of the gland resembles that of the salivary, its lobules connected by a dense cellular tissue, upon which its vessels and nerves subdivide, to supply the granules of which they are composed. The vessels enter the gland at its posterior margin; and from the anterior, its ducts, five or six in number, pass out in straight lines, and pierce the conjunctiva at the orbitar edge of the superior tarsus.

We have now briefly described the orbitar appendages, or those parts situated behind the tunica conjunctiva, and proceed to the

FACIAL APPENDAGES.

Eyebrows.

THE SUPERCILIUM, OR EYEBROW. The arch of the eyebrow corresponds to that of the superciliary ridge upon which it is planted. It extends from the tuberosity of the frontal sinus to the external angle of the orbit. It consists of a thick row of strong short hairs, which have a disposition almost erect at the commencement of the brow, and are then arched obliquely outward, and gradually reduced in number so as to

terminate the arch acutely. The few erect hairs correspond to the fibres of the corrugator supercilii muscle, the crescentic to the fibres of the orbicularis palpebrarum.

The extent and fulness of the brows vary greatly in different persons. In some, especially persons of dark complexion and black hair, they have little if any interspace at their origin, and are long, prominent, and bushy in the centre of the arch. Among the ancients these were esteemed points of female beauty. The fibres of the occipito-frontalis, or epicranial muscle, terminate beneath the skin of the supercilium, blending with those of the orbicular muscle of the palpebra. The former elevates the brow, wrinkling the integument of the forehead horizontally; the latter depresses it, and closes the eyelids, being the sphincter palpebrarum.

The corrugatores approximate the heads of the supercilia, drawing the integuments over the root of the nose into deep longitudinal rugæ: they co-operate with the orbicularis in the act of frowning. The action of the subjacent muscles renders the brow an important feature in regulating the quantity of light, contracting the field of vision, and in assisting the expression of the sterner passions. It would not be a useless ornament if it were insusceptible of motion, the hair being advantageously

placed upon the projecting ridge of the orbit to entangle and arrest particles, solid and fluid, which might otherwise fall or trickle upon the eye. The habitual depression of the brow is usually a concomitant of a weak or morbid retina; it is characteristic of strumous inflammation, and is observable in all cases where light is offensive, and in those central circumscribed opacities of the cornea and lens, in which the dilated state of the pupil is necessary to vision.

Eyelids.

THE PALPEBRÆ, OR EYELIDS, are those semi-oval curtains which cover the great aperture of the orbit, and graduate the light falling upon the eye by the degree of their separation, or exclude it by their apposition. The skin covering the palpebræ is thin, and loosely connected to the subjacent parts by a fine lax cellular texture, which abounds at the orbitar margins of the palpebræ. The frequent œdema of the eyelids, so disfiguring to the countenance, is owing to the abundance of this tissue void of fat, and subject therefore to serous infiltration.

The superior is broader than the inferior palpebra, covering two thirds of the surface of the globe by its descent. It is also more moveable, the inferior palpebra being inconsiderably elevated to meet it in shutting the eye. The superior palpebra, when drawn up, makes a doubling or deep crescent-shaped fold in the skin

under the orbitar arch, which is effaced when the palpebra falls. Upon the skin of the lower eyelid narrow and gently curved rugæ are seen; these, which are signs of the unequal contractility of the skin and the muscular fibres beneath it, are more strongly marked in persons of advanced years, in whom the muscles have been longer and more vigorously employed, and whose skin is likewise looser, or redundant from the absorption of the adeps beneath it.

When the eyelids are forcibly closed by the sphincter fibres of the orbicularis palpebrarum, the tendon of this muscle starts forward, and the rugæ are extensively radiated from the nasal angle over the skin of the cheek. On removing the skin and the subjacent cellular tissue of the palpebræ, the thinly spread fibres of the orbicularis muscle are seen. The tendon with which these fibres are connected is a little round cord, distinctly seen and felt beneath the tegument, implanted in the nasal process of the maxillary bone, in the great transverse diameter of the orbit. The fibres which lie upon the palpebræ are the interior fibres of the muscle, the fissure of the lids being the axis of the oval formed by it. The inferior external fibres, from the round tendon and contiguous parts of the maxillary bone, take an extensive sweep over the orbitar ridge upon the cheek, towards the temple, where they become thin and scattered.

Orbicular
muscle of
the eyelids.

The superior, from the round tendon and contiguous part of the frontal bone, take the direction of the superciliary arch; being at their commencement connected with the fibres of the corrugator, and in their course blended with those of the frontal muscle. The integument of the palpebræ is adherent to the tendon of the orbicularis, which has been described as the ligament of the palpebræ or tarsi, and the angle of union between them is larger in consequence of this adhesion, than the external. The inner canthus, formed wholly of the doubling of the integument, is that notch or triangular sinus formed between the tarsi and the tendon of the orbicularis.

Tarsal cartilages.

THE TARSI are two elliptical cartilages which give figure and firmness to the palpebræ, and afford a basis for the attachment of their several parts. The superior is broader than the inferior. Their opposite edges are broad and sloped from without inward; their orbital edges are thin and continuous with a condensed cellular membrane, which is ligamentous where it is inserted into the orbital circumference, and especially at the temporal side. Their temporal extremities are angular, the nasal rounded. The former terminate the fissure of the palpebræ at the temporal angle; the latter, which are opposed to each other, and brought into contact when the

lids are closed, are situated at the distance of two lines from the nasal angle, to which they are connected by the doublings of integument forming the borders of the inner canthus. The convex surface of the tarsi is covered by the fibres of the orbicularis and the cellular membrane connecting them with the integument; the concave, which is exactly moulded to the face of the globe, is covered by the membrana conjunctiva.

THE CILIA, OR EYELASHES. Eyelashes The exterior borders of the sloped edges of the tarsi, which are opposed to each other, are furnished with cilia or eyelashes, disposed in three or four rows: these we may therefore call the ciliary borders of the tarsi. The apertures, in which their bulbs are contained, are seen in the integument when the cilia are extracted: they are more numerous and longer upon the centre than the extremities of the tarsal arch, and fewer and shorter on the lower than the upper tarsus. Their direction is curved, those from the upper being arched upwards, from the lower downwards. The length and fulness of the eyelashes vary in different individuals. They are commonly of the same color as the eyebrows.

THE MEIBOMIAN FOLLICLES. Follicles of Meibomius. Upon the interior border of the tarsus the mouths of a row of follicles, seated vertically on the concave surface of the tarsus, form a slightly eminent line.

These follicles, when magnified by a glass, appear to be small knotted tubes, resembling studs of the smallest pearls, arranged for the most part in parallel lines, and communicating with each other at their origin from the orbital edges of the tarsi, but terminating by distinct orifices upon their interior borders, which we may distinguish from the ciliary as the meibomian borders of the tarsi. In their length, connection, and arrangement, they present considerable variety. The fluid, which they secrete, may be expressed in a condensed form in diseased states of the follicles, or, after death, in the shape of small white worms. It is an unctuous fluid lubricating the tarsal edges, preventing the effects of attrition from their frequent contact, and facilitating their motions over the contiguous surface of the globe.

Lacrymal
conduits.

THE PUNCTA LACRYMALIA, SACCULUS, AND DUCTUS LACRYMALIS. The obliquity of the tarsal edges, which are opposed to each other, leaves a groove or sulcus between the meibomian borders and the surface of the globe, when the ciliary borders are in contact. This increases in breadth toward the nasal angles of the tarsi, where the puncta or orifices of the lacrymal excretories are placed upon two small conical eminences accurately opposed, and terminating the meibomian borders: they are two pinholes formed in the cartilaginous substance, and thus preserved permanently open. Their

course is at first perpendicular to the tarsi, in which direction they form a short *cul de sac*; then they are turned at right angles towards the nose, and lie in the doubling of the skin, forming the borders of the inner canthus. They are, if we except their orifices, purely membranous canals leading to the oblong membranous sac situated in the lacrymal fossa; they terminate side by side, or more frequently, in a common duct, in the upper and anterior part of this sac, under the tendon of the orbicularis.

The position and direction of the lacrymal sac correspond to the fossa formed by the anterior concave portion of the os unguis, and the nasal process of the superior maxillary bone, upon which it is seated; it rises a little higher than the termination of the lacrymal duct or ducts, and the transverse tendon of the orbicularis crosses the upper part of it. Below it contracts into a duct, which occupies the canal formed by the nasal process of the maxillary bone, and the spoon-shaped process of the os spongiosum applied to it. The course of this duct is downward, outward, and gently slanting backward; it opens by an oblique fissure under the convex scroll of the spongy bone, in the side and near the floor of the nostril. A probe, introduced from the nostril into the nasal duct, must have a sharp curvature to enter it with facility. The

membrane of the sac and duct is intimately adherent to the bony parietes. The anterior and exposed surface of the sac is defended by a fibrous or ligamentous expansion, derived from the circumference of the lacrymal fossa. The orbital is distinguished from the nasal portion of the duct by a fold or duplicature of its lining membrane, and another similar fold sometimes occurs in the nasal part of the duct. The membrane of the lacrymal canals and nasal duct is abundantly furnished with mucous follicles or lacunæ. The fulness of the membrane, where it is reflected from the nasal extremity of the duct, greatly diminishes the diameter of the bony aperture, and gives it a valve-like form. The diameter of the lacrymal and nasal canals exceeds that of their orifices. The puncta absorb the tears, which have been conducted from the lacrymal ducts by the tarsi, and convey them into the sac to pass off by the nasal duct.

Conjunctive
membrane.

THE TUNICA CONJUNCTIVA. The integument of the eyelids is inflected at the edges of the tarsi, and lines the whole of the concave surfaces of the palpebræ; is reflected upon the visible face of the globe, enters into the puncta, lines the lacrymal sac, and at the nasal extremity of the duct is continuous with the common mucous membrane of the nostrils, fauces, and alimentary canal.

The conjunctiva, having lined the interior surfaces of the tarsi, is connected to the ligaments of the tarsi and palpebral muscles, and thence reflected upon the globe, so as to form an oblong sac or pouch. Its attachment to the sclerotic is such as to prevent its forming folds in the motions of the globe, to the freedom of which it offers no impediment. As it approaches the cornea, its attachment becomes more strict, and at the margin of that membrane it is inseparable from it. Its continuity is ascertained by dissection, but its tenuity and transparency are increased, and when held to the light it has a nearer resemblance to a very delicate lamella of the cornea than to the conjunctiva of the sclerotic. After maceration, the separation is more readily effected.

The character of this membrane is so materially modified by its several relations with the integument, the tarsi, the sclerotic, and the cornea, that its continuity alone establishes its identity. The fact of continuity is, however, corroborated by some pathological phenomena, which so often illustrate problematical points in anatomy and physiology. For example, the conjunctiva furnishes the matrix for the adventitious vessels, which are created to repair breaches of the corneal texture. These vessels, whether formed by the healing process, or

Its continuity demonstrated by disease.

opened by long continued diseased action, as in chronic ophthalmia, are obviously superficial. The circumstances by which they are produced, are characterised by different appearances, as I shall hereafter point out. Again, when a small portion of conjunctiva is abraded by an extraneous particle, the scabrous surface of the cornea is exposed, and ulceration of this surface ensues. The deficiency of the conjunctiva is exactly depicted by the margin of the abrasure, and the contrast of the surfaces. This is very dissimilar to the interstitial ulcer of the cornea. The pterygium, a rare disease, exhibits the continuity in a very striking manner. It has a full broad base next the canthus, where the conjunctiva lies loose, and is gradually flattened and drawn to a point, so as to have a wedge-like form as it approaches the cornea. But although the deposition is beneath the conjunctiva, it does not stop at the cornea, but slowly travels across it. The strictness of the adhesion alters its appearance; the lymph shed between the conjunctiva and cornea, presenting only a progressive dense opacity, instead of the fleshy elevation which it exhibits upon the sclerotic. The continuity of the superjacent texture is demonstrable.

Upon the tarsi, the membrane is closely adherent, and although transparent, appears of a pale red tint; upon the sclerotic and cornea it

is colorless. The sclerotic conjunctiva, however destitute of red vessels in the tranquil state of the organ, becomes conspicuously vascular and acquires a deep red color by inflammation, its minutest capillaries appearing to convey red blood, in the vehement acute ophthalmia. Those of the corneal conjunctiva are only to be seen when, by continued distension, the connection is loosened between the conjunctiva and cornea. In this case, the cornea exhibits red vessels freely inosculating from its opposite sides, and anastomosing with each other. The increase in number and extent of these vessels is a gradual process, demonstrable to observation, and the inflammatory action which precedes this state, is ordinarily of considerable duration. The incapacity of the vessels of the corneal conjunctiva to receive red blood, seems to depend upon the strictness of its adhesion.

THE VALVULA SEMILUNARIS, AND CARUNCULA LACRYMALIS. The conjunctiva is attached to the canthi of the eyelids, and at the internal canthus, forms a semilunar duplicature in shape of a valve. The horns of this crescentic fold are lost in the sinus palpebralis, or angular fold of the conjunctiva.

Semilunar fold and lacrymal caruncle.

On the fore-part of this valve, a small red glandular body, caruncula lacrymalis, is seen, occupying the hollow of the canthus. The

caruncula is a granulated substance, of a conical form and a deep red color. The base of the cone is next the orbit, the apex towards the eye. A few fine hairs are scattered over its surface. It is made up of a congeries of minute follicles, secreting that mucus which accumulates during sleep in the form of a gummy matter, at the inner corner of the eye; and appears to perform a similar office to that of the meibomian glands, which are confined to the tarsi.

From the above description it will be understood, that the palpebra, the anterior hemisphere of the eyeball, and the lacrymal passages, are every where covered by the reflected integument, modified in its disposition and qualities as its economy requires, which invests the organs of sense, the hollow viscera, and forms the external covering of the body. It is by the continuity of this membrane that the sympathy is established between these surfaces, healthy and morbid, remote and contiguous, and that the diseases with which they are affected have for the most part a common character. It remains only that I should point out the origin and disposition of the superficial vessels and nerves, by which the palpebræ are supplied.

Vessels and
nerves of
the eyelids.

THE ARTERIES, VEINS, AND NERVES OF THE
PALPEBRÆ. A superior and inferior branch, de-

rived from the ophthalmic artery, at its egress from the orbit, course along the orbital edges of the tarsi, and form, by inosculation at the external angle, a complete arcus palpebralis. A superciliary arch is also formed by the union of the superciliary artery, from the ophthalmic, with the temporal. The nasal branch of the facial artery assists in forming these arches, and freely communicates with the frontal branch of the ophthalmic. The superior coronary, transverse facial, infra orbital and temporal artery, participate in the supply of the palpebræ.

THE VEINS, beginning by small radicles from the opposite margins of the tarsi, form an intricate plexus beneath the skin of the palpebræ, and are collected into the facial, supra-orbital, and deep temporal vein. The arteries pass in the direction of the orbicular fibres, the veins cross them at right angles; their direction according to the breadth of the palpebræ.

THE NERVES take a direction similar to the veins, the frontal branch of the fifth pair supplies the superciliary and superior palpebral branches; and the infra orbital, or first branch of the superior maxillary nerve, gives off three principal branches, which turn round the trunk of the facial vein to be dispersed upon the lower eyelid.

For the simple and general view which I have taken of the subject of the foregoing description, if any apology be necessary, I know of none more appropriate than that contained in the following paragraph.

“The study of anatomy, as it leads to the knowledge of nature and the art of healing, needs not many descriptions nor minute dissections; what is most worth knowing is soonest learned, and least the subject of dispute; while, dividing and describing the parts, more than the knowledge of their uses requires, perplexes the learner, and makes the science tedious, dry, and difficult.” *Cheselden's Preface to his Anatomy.*

SKETCH
OF THE
PHYSIOLOGY OF THE EYE,
AND ITS APPENDAGES.

It is not my intention to enter into an abstract discourse on the phenomena of vision, a subject more allied to philosophy than medicine, but the preceding sketch would be incomplete without some account of the functions of the organ, and the history of its diseases would want the illustration which a competent knowledge of its œconomy conveys.

I shall suppose the reader acquainted with the prevailing opinions concerning the origin and nature of light; the velocity of its movement; the meaning of the terms direct, reflected, and refracted rays; the equality between the angle of reflection and the angle of incidence; and the facts, that refraction is in-

Preliminary positions.

creased according to the relative density of bodies, and that the convergence of rays after refraction is proportionate to the curvature of the surface through which they pass. Further, the decomposition of light by the prism into seven elementary colors, which differ in their refrangibility ; the reflection of all the rays together producing the appearance of white ; while their partial reflection occasions the various diversities of color, and their total absorption the sensation of black, which is in fact but the absence of color. Lastly, the emission of the rays of light from every visible point of the surface of a luminous body, and their divergence thence so as to form a cone, of which the apex corresponds to the point from which they emanate, and the base to the surface upon which they impinge.

Influence
of the several
textures upon
the rays of
light.

The operation of the cornea upon the rays of light is to render them convergent towards the retina, by reason of the sphericity of its surface, and its greater density compared with the atmospheric medium through which they pass. The rays which fall within an angle of 48° , or thereabouts, measured on the surface of the cornea, pass through it, and are refracted in their passage. Those which are not included within this angle are reflected by the verge of the cornea and the sclerotic coat. The aqueous humor, being of inferior density to the cornea,

diminishes in some degree the convergence of the rays which proceed through it, so that the total effect is nearly the same as that which would result from the refractive power of the aqueous humor alone, if the cornea had not existed. The rays which lie remote from the visual axis, are not transmitted through the pupillar aperture, but are reflected by the iris, and in part absorbed by the pigment coating its posterior surface, without which pigment it would be diaphanous, as in the albino. The superior density of the crystalline co-operates with its curvature to increase the convergence of the rays which are admitted within the pupil; and by their passage through its posterior surface, this convergence is increased, because they arrive at the vitreous humor, which is a medium of inferior density. By the operation of all these causes the rays are collected into foci upon the retina, and that part of the object from which the rays proceed is painted upon this membrane.

The result then, it appears, of a series of refractions of the rays of light in passing through the humors of the eye is their collection into foci upon the retina, so as to form a complete picture of the external scene.

From this account it will be perceived that each pencil will consist of a double cone of rays,

Inversion
of the
image on
the retina.

the axes of which are right lines, their bases meeting in the crystalline and their apices being situated in the object and the retina respectively. The rays from the top of the object are deflected to the bottom of the eye, and those from the side of the object to the right of the observer, are deflected to the left side of the eye, and *vice versâ* hence the inversion of the picture upon the retina. The following simple experiment, demonstrating this fact, is well known. A portion of the coats being removed from the back of the eye, and their place supplied by a piece of oiled or tracing paper, the flame of a candle placed before the cornea is exhibited of diminished size and inverted. We infer that this image excites the perception of the object, because distinct vision is enjoyed only in such confirmations and conditions of the eye, as allow of its being accurately formed and impressed.

Correction
of aberration
from
unequal re-
fraction.

The necessary effect of the spherical figure of the cornea is to occasion an unequal refraction of the rays which permeate it, and hence to create a degree of aberration which would confuse vision. This is corrected in two ways: first, by the gradually increasing density of the lens from the circumference to the centre, and its consequently refracting with less power those rays which arrive at it with a considerable

obliquity; and secondly, by the mobility of the iris, which adapting the size of the pupil to the circumstances of the case, excludes more or less those rays which would produce aberration.

I have stated that the iris serves to arrest those rays which are denied admission through the pupil: they would be unequally refracted by those points of the lens through which, if uninterrupted, they must pass, or would fall so obliquely on the cornea as to be subjected to too great a refraction. This is its passive function; but by its power of dilatation and contraction, in obedience to the stimulus of light upon the retina, it determines the quantity necessary for the purpose of distinct vision. In regulating the quantity of light the iris assists materially in accommodating the eye to different distances: in viewing a distant object the pupil dilates, and in viewing a near one it contracts. It is true that viewing the sun occasions a contraction of the pupil, and the stedfast vision of a near object in deficient light, its dilatation. These are confirmations of the statement that its motions are in obedience to the impression of light upon the retina, because the direct emanation of light from its source in the one case, and the insufficient light in the other, render these objects analogous in this respect to the nearest and the remotest visible objects. But under ordinary

Office of
the iris.

circumstances, the illumination of objects being conformable to the distance, the pupil, in viewing a distant object, is dilated so as to admit as many rays of the enfeebled light as is necessary to the distinct perception of the object, and on the other hand contracts to exclude the superfluous rays, which coming from a near object, would otherwise create confusion. Let a person survey the sun whilst the pupil is fully dilated by belladonna, or under the same circumstances, the flame of a candle brought near to the eye, and in either case he will find his vision confused to dimness. But the fullest permanent dilatation of the pupil will not injure the clearness of his vision of any other remote object, though that of all near objects will be in a degree confused, and the confusion be increased in proportion to the degree of their illumination. Where the iris is from any cause motionless, the power of adapting the eye to distances is lost. I conclude, therefore, that the adaptation of the eye to light co-operates with its adaptation to distance.

Corrective
power of
the lens,

By the peculiar constitution of the crystalline lens, before adverted to, its refractive power is so adjusted to that of the contiguous aqueous and vitreous humors, as to correct the aberrations which the figure of the cornea would occasion, and to throw the most oblique pencils of rays with sufficient accuracy upon the concave face of the retina.

Notwithstanding man, compared with animals, requires the largest quantity of light for vision, the images of objects on his retina are undisturbed by reflection, owing to the absorbing quality of the dark pigment, which being spread over the whole interior of the globe, renders the eye a most perfect camera obscura. Animals, in whom this pigment is a brilliant reflecting surface, have the advantage of seeing in feebler light, and this power is in proportion to the whiteness of the pigment; but the accuracy of their vision, it may be presumed, is in the same proportion defective.

and use of
the pig-
ment.

Not only is the clearness of the image undisturbed by superfluous light, but it is also destitute of color, the decomposition of light by irregular refraction being in ordinary vision prevented or corrected by the structure and curvature of the crystalline lens. Light, artificially separated, either by refraction, reflection, or inflection, produces color; but the light which arrives at the eye in its natural combination of elementary rays, undergoes no such decomposition in its passage through the humors.

Achromatic
power of
the lens.

The retina is equally expanded over the vitreous humor, but the field of vision is limited. This is not, however, confined to the axis of vision; for in certain positions of the eye, ar-

Field of
vision.

tificially induced, we have a clear perception of an object from which the rays pass so obliquely as to fall upon the retina not in the axis of vision. It has been long observed, that if an image fall upon a certain spot of the retina, the perception of it is obscured. This spot, about one thirtieth of an inch in diameter, corresponds to the entrance of the optic nerve.

Magnitude
of the
image.

The magnitude of the image formed upon the retina, is proportional to the angle which the two extremities of the object viewed subtend with the centre of the eye. Hence, the more remote the object the smaller the image.

Duration of
the impres-
sion.

The duration of the impression made upon the retina is in proportion to the strength of the impression; this is illustrated by the appearance of a fiery circle produced by the rapid revolution of a lighted stick. The principal phenomena of ocular spectra admit of an explanation in some degree similar, as for example, the appearance of a luminous halo after looking intently at a colored object, remaining even after the eyelids are closed.

Distance,
size, and
position of
objects.

The eye possesses no absolute power of determining the actual distance, magnitude, and position of objects. Such knowledge is relative, and results from the experience derived

from the combined agency of the senses of sight and touch.

It remains that I should advert to what may be termed the problems of vision ; but as I have little from my own observation to offer upon these subjects, and as their investigation is in a considerable degree connected with the department of physical optics, or of metaphysical speculation, I shall be excused for touching them lightly.

The images of objects are inverted upon the retina, yet we see them, as they are in nature, erect.

Inversion of the image.

If we look in a concave mirror, objects appear inverted. The image formed upon the retina is in this case erect, and we see the object in the same relative position to the image, as all other objects. Of this fact any one may convince himself, by preparing an eye, as before mentioned, and placing beside and a little behind the flame of the candle a spoon, the hollow of which reflects it inverted, when he will observe on the opposite side of the oiled paper the images of the real and the reflected object, the first inverted, the second erect.

It has been generally supposed that we actually see objects inverted, and that this error of the sight is corrected by experience. Some, on the

Common theories.

contrary, have supposed that the mind acquires the perception of objects, not from the picture upon the retina, but from the object itself, by retracing the direction of the pencils to their points of radiation. Others assert, that a decussation of the fibres of the optic nerve corrects the erroneous impression before it is presented to the sensorium.

Berkley's
theory.

The celebrated explanation of Berkley, in so far as it admits of an abridged exposition, is as follows. Visible and tangible ideas occupy distinct provinces, and have originally no affinity to each other. It is only by experience that they become connected. The impressions on the organ of sight suggest by association the ideas of objects acquired by the sense of touch, just in the same way as the word used to denote an object immediately suggests the idea of that object, to a person who is familiar with the language. The image on the retina is merely the instrument, not the object of vision. Its position has originally no influence on the ideas we form of the situation of external objects; and the supposed difficulty in the case of the inverted images arises from confounding ideas derived from the sense of touch with those derived from the sense of sight*.

* A person born blind and suddenly restored to sight, is the case supposed by Berkley and other writers, and so happily exemplified by Cheselden. Such a person, it is clear, would gain nothing by the aid of sight, until the connection

The association of ideas, derived as they are from the external senses, operates imperceptibly to an extent that we have no means of ascertaining, because the original and absolute negation of each sense in succession, so that each should be in turn insulated, is an impossible condition, notwithstanding the seemingly possible independence, in a state of society at least, of the animal and vital functions. Touch, in the extended sense of physical feeling, is the basis of all; sight, hearing, smell, and taste, like the sense of touch itself in its strict and limited import, are but modifications of it. That either

Intercourse of the senses necessary to their development.

between touch and sight grew up and established itself in his mind.

“ L’objet propre et immédiat de la vûë n’est autre chose que la lumière colorée : tout le reste, nous ne le sentons qu’à la longue et par expérience. Nous apprenons à voir précisément comme nous apprenons à parler et à lire.”—*Voltaire. Physique Newtonienne, Chap. 7.*

Our Shakspeare who ‘needed not the spectacles of books to read nature, but looked inwards and found her there,’ puts this distinction with admirable force and shrewdness, in the dialogue between Gloster and the fellow who feigned to be cured of his native blindness at St. Alban’s shrine.

GLOSTER.

Saunder, sit there; the lying’st knave in Christendom.
 If thou hadst been born blind,
 Thou might’st as well know all our names, as thus
 To name the several colours we do wear.
 Sight may distinguish colours :
 But *suddenly* to nominate them all,
 It is *impossible*.

2d Part of KING HENRY VI. Act 2.

or all of these therefore should be wanting, is not incompatible with their constitution; but the sense of contact is so essentially and indivisibly incorporate with the organic nervous system, that its negation would be paramount to acephalous monstrosity. Hence its influence as a substitute and corrector in relation to the rest, when wanting or imperfect, can never be fully appreciated, because it cannot, like them, be subjected to analytical test. But from what we see of the effects of privation of one or more of the external senses, and of their reciprocity in general towards each other in cases of malformation and disease, is it not in the highest degree probable, that their natural intercourse and cooperation are essential to the developement of each respectively? To illustrate my meaning—If it be possible to suppose a case in which the eye was the only external organ of sense, would the unfortunate possessor have any distinct idea of visible objects; or, *mutatis mutandis*, the ear of sounds? Certainly not. Dumbness is in most cases only a consequence of the absence of hearing; the organs of speech are perfect: so the loss of visual perception, (not of light more than of unharmonized articulation) would result in the case supposed, from the absence of the associated sensations and ideas thence derived.

Single
vision.

How it happens that impressions made upon our two eyes at one and the same time are represented single to the sensorium, we know as little

as why we hear one sound with two ears, and smell one scent with two nostrils. The mind is incapable of receiving two distinct impressions at the same instant. The interval is too small to be measurable, but the simple experiment of Haller affords unexceptionable evidence of the fact, that we employ our eyes severally, and not at the same instant, in distinct vision*.

But we know that if the direction of the two eyes is in conformity, each with the other, objects appear as they are, singly; and that when a certain divergence or derangement of the visual axes exists, objects appear double. If the image, for example, is thrown upon a point of the retina of one eye, not in correspondence with the spot impressed in the other, this effect is produced. The double image of a candle is seen when gentle pressure is made on the globe of one eye; and it is either on the horizontal or vertical direction, according as the finger is applied to the side of the cornea, or below it. It is observed that a more considerable inclination of the optical axis is required to produce a double image in the transverse than in the vertical plane.

We are not, however, to conclude, that a double image is formed only, when the obliquity

Double vision.

Double vision with one eye.

* Elem. Phys. Vol. V. Sec. IV. 9.

of the optic axis is such, as to throw the image beyond the area of the points of correspondence in the retina. It may happen when but one eye is employed, from a partial compression of the retina, optic nerve, or cerebrum, or some peculiarity of figure, or opaque streaks in the humors intercepting the radiant pencils, so as to produce a double refraction.

Double vision from strabismus.

Neither is double vision a common result of strabismus where the distortion of one eye is obvious and permanent; for in squinting, whether congenital or acquired, the distorted eye is weak in comparison with its fellow, and in the majority of cases the loss of association is the consequence of its weakness. It is, in fact, wholly unemployd in intent vision, which it would only tend to confuse. Where double vision occurs, it is seldom if ever a permanent symptom, although the squint becomes confirmed, or even increases. The disappearance of this symptom might be accounted for by the very probable accommodation of the deranged eyes, and the substitution of new points of correspondence in the distorted eye under the influence of habit; but in every instance of deviation, I believe it will be found that the averted eye is unfit, in respect of power, and therefore ceases to associate with its fellow. Even in the cast or leer the affected eye is unemployd in vision. The focal distance of the

two eyes is in such cases so much at variance, that confusion would necessarily result from their simultaneous employment, if that were possible. This question is not affected by the arguments which go to prove, that for the purpose of intent vision, one eye only is or can be employed at the same time. The points of correspondence are essential to preserve the unity of vision, because an indistinct or confused perception, or a double image, would be produced in the state of indolent vision, when it is admitted that both are employed. The defective eye, it is true, extends the field of sight; but if the sound eye be closed, the person discovers that he is indebted to it for little more; and therefore, if it correspond in direction with its fellow, he finds an advantage in closing it for the purpose of accurate vision; if it is permanently averted, it is as much unemployed, as if it were closed. Cases have occurred in which the exclusive employment of the averted eye has at length restored its tone and direction. The squinting eye recovers its position when the sound eye is closed, but relapses when the latter is again opened, because its employment ceases. Cases of squint arising from mechanical causes are of course excepted in this observation, being incapable of even temporary rectification; but in these the turned eye is idle.

It must be evident to all persons who con-

Adjustment
of the eye

to objects
at different
distances.

sider the subject, that the rays of light which issue from an object at some distance from the eye, and those issuing from a much nearer object, cannot be collected into foci at the same given distance behind the crystalline lens, unless the eye have a power of altering its focal distance. It must do for itself what a convex glass does for those, who by reason of a certain configuration cannot see near objects distinctly, or a concave glass for those who have no distinct sight of objects beyond a moderate distance. In the first, owing to a defective refracting power, the rays cannot be brought to a focus soon enough; in the second, owing to too great a refractive power, they are brought into a focus too soon. The picture in the one, without the aid of the glass, would be formed behind the retina, and in the other anterior to it. The point of perfect indolent vision, or the extreme focal distance of the eye, and the range or space through which it has the power of preserving distinct vision nearer to the eye, varies in different individuals, and very often as before stated, in the eyes of the same individual.

Various hy-
potheses.

I shall content myself with a very brief mention of the principal hypotheses to explain the adjusting mechanism. To enumerate all with barely intelligible conciseness, would occupy a large portion of this volume; such is the interest which this subject has excited. It has been ascribed to a change of figure in the cornea, to

the variations in the diameter of the pupil, to a change of figure of the globe by the action of its muscles, to a change of figure of the lens by an action proper to itself, to a change of place of the lens by the contraction of the ciliary processes, and the compression of the vitreous humor at its circumference.

The first supposes a close aponeurotic expansion derived from the tendons of the recti muscles, bracing the anterior segment of the globe; the second assumes the muscularity of the iris, or the extension of its texture, by the sudden injection of its vessels, and *vice versâ*, its abridgment by their contraction; the third, a power in the muscles of the globe either to shorten or elongate its axis; the fourth attributes muscularity to the crystalline; and the fifth a similar structure to the ciliary processes.

I shall not enter into a discussion of the merits of these hypotheses, because no one, I believe, disputes the force of the objections to which they are more or less exposed.

A healthy state of the retina, of the crystalline lens, and of the iris and ciliary apparatus, are conditions indispensable to the perfection of this mechanism. It is impaired in proportion to the debility of the retina in the various forms of amaurosis; it is suspended during the per-

Conditions
requisite.

manent contraction or dilatation of the pupil, and it is lost after the removal of the crystalline under the most favourable circumstances; but the failure of any one of these conditions, exclusively, is destructive to it; as for example, though the retina and crystalline be healthy, if the iris be motionless, or though the retina be sound and the iris active, if the crystalline be absorbed. I know that very different statements have been given to the public, so different indeed as to be almost the converse of these. I am ready to admit that the results are subject to modifications, as the cases vary, and no two are exactly similar; but these are the general results of my experience. I have already said that the iris by regulating the quantity of light assists in the office of adjustment to distance, and that these functions are in a degree consentaneous. I am disposed to consider adjustment as the result of a change of figure in the lens, such as we may coarsely imitate by gentle pressure of the crystalline of the horse or ox, held in a vertical position between the thumb and fore finger. Its form and lamellated texture render it peculiarly susceptible of such a change, and the absence of a connecting medium between its plates, indeed of any vascular organization, prevents the possibility of a nebulous obscurity resulting from pressure so applied. A very slight increase of its curvature, we have been informed on competent authority,

would be sufficient to explain the phenomenon of adjustment, assuming its quiescent state, which its elasticity tends incessantly to restore while subjected to compression, as that fitted for perfect indolent vision.

Notwithstanding the absence of anatomical proof, I cannot but regard the motions of the iris as muscular motions, and the pupillary portion an orbicular sphincter, such as environs the several outlets or apertures of the body. To this structure I attribute its uniformity under varying magnitudes—its incapacity of contraction, when having a fixed point, as happens in some malformations; when confined by adhesion at any point of the circle to the capsule of the lens, or when its texture has been the subject of adhesive inflammation—its recovery of a prolapse through a section of the cornea, and resuming its circular figure when overstretched, as in extraction, by a gentle friction of the eyelid—the extreme velocity of its contraction, and the comparative slowness of its relaxation—its ordinary preservation of a mean or middle state between the spasmodic contraction induced by acute inflammation and the dilatation we must from ascertained phenomena presume to be induced by absolute darkness long continued—its inferior power of contraction in children, and the increase of its power by exercise, as in artisans incessantly employed upon minute objects, in whom it is

Iris in part
muscular,

apt to acquire a rigidity which scarcely admits of dilatation—its obedience, in all respects, to the laws which regulate the muscular system—its contractility in proportion to the strength and perfection of the nerve of sense with which it is associated—its incapacity of perfect contraction when tremulous, and its spastic contraction, even to the resistance of the influence of belladonna, in tetanus—its relaxation when the sphincters are relaxed, as in syncope, asphyxia, apoplexy, or compression of the brain, and after the use of alcohol in excess—its complete dilatation when under the influence of the sedative poisons, as opium, hyoscyamus, belladonna, &c. to which its proper nerves are in a peculiar manner irritable.

and partly
elastic.

The ciliary portion of the iris I regard as an elastic structure. It is by virtue of its elasticity that the extraordinary dilatation of the pupil, such as we see under the use of belladonna, is produced. Here, as in other parts, elasticity is opposed to muscular motion; hence when the latter is paralysed or from any cause diminished, the former strikingly predominates; when the nervous supply is intercepted, the pupil gapes widely, the action of elasticity being independent of the sensorium.

Pupils of
animals.

All animals which have a moveable iris, have the pupil circular, oblong or elliptical,

forms favourable to the arrangement of marginal fibres*. In fish the iris is evidently a prolongation of the choroid without interruption of continuity; it is therefore motionless. I concentrated the sun's rays in the focus of a pocket lens, and threw them upon the pupil of a perch, at the moment of drawing it from the water; it underwent no change. In other animals it contracted to a line vertical (cat) or horizontal (adder, toad,) according to the figure of the pupil, or to a small pin's head aperture, where it was of a circular form, as in the common snake.

If we look through the vitreous humor exposed for a small space on its posterior side, we observe the plicæ advancing upon its anterior surface beyond the margin of the lens, like a circular fan or skreen; if the lens is pressed evenly backward, the plicæ separate and extend the sacculated circle of Petit, to which their edges are affixed. On remission of the pressure, the lens springs forward, and the leaves of the fan are closed. The circumferential compression of the globe increases the closeness of their application. In the dead body, only the most coarse and remote analogies can be obtained to the functions of the living. But I cannot believe so obvious and yet so exquisite

Theory of
the author.

* It is worthy of notice, that fish, in whom the iris is without motion, furnish the remarkable exceptions; viz. the dolphin, the skate, the cuttle, &c.

a contrivance for changing the site and figure of the apparatus, as this view affords, can be without necessity or occasion. Looking then at the posterior origin of the processes from the choroid, and their attachment externally to the ciliary ring; their insertion into the vitreous capsule to the edge of the fossula, their encroachment upon the anterior segment of the crystalline, and their termination by distinct prolongations in the substance of the iris at its great circumference; assuming the choroid and annulus as fixed points, and the iris and processes as the moveable parts of the apparatus, it follows that the plicæ will be unbraced and partially open in the state of mean dilatation of the pupil belonging to passive or atonic vision, and in the state of extreme dilatation of the pupil accompanied with blindness to near objects, totally relaxed and floating. On the contrary, by the steadily contracted state of the pupil suited to the nearest extremity of the focal range, they will be closed and braced together; and bearing upon the circumference of the crystalline at every point, will necessarily elongate the axis of the lens. These being the extreme states, so, in proportion, the intermediate degrees of adaptation will be accounted for. Hence the actions of the pupil, however excited, will extend their influence to the lens, and by this catenation of motions the general conformity of adjustment to light and adaptation

to distance to be explained. And this forms no objection to the hypothesis; because it is only in the voluntary and steadily preserved contraction of the pupil that the latter object is or can be required; for blindness would as surely ensue from gazing on the sun, as death from suspending the actions of the respiratory muscles, were it in our power to do either; and therefore the involuntary has the ascendancy over the voluntary action in both these cases, as it has in all cases of mixed muscles.

Radiated fibres are described by Zinn and Haller as raised on the posterior face of the iris, and advancing even to the margin of the pupil. They are distinct from those seen upon its anterior surface, and regarded as continuations of the ciliary processes. In man no such fibres are distinguishable by the naked eye, but if the observation, however obtained, be correct, it affords a strong presumption in favour of the power of the iris to change the figure of the lens by the instrumentality of the plicæ. The capsule, it is true, is fixed by the processes, but this opposes no impediment to the change supposed; for the membrane of Petit, to which alone the processes are affixed, is relaxed when they are closed, and extended when they are separated, and thus permits the capsule to yield only in the degree required for the change of figure of the lens, or, in other words, pre-

Uveal prolongations of the ciliary processes.

serves its exact adaptation to the face of the lens in its opposite and varying states. This I take to be the use of the membranous circle of Petit, that it gives the processes the complete command of the continuous capsule.

Some cases of dilated pupil are accompanied by a bulging of the lens. This is not the effect but the cause of the dilatation, for it never follows the application of belladonna, provided the capsule be entire; but if from any cause the lens be protruded so as to bear down the natural resistance of the processes, the pupil becomes dilated by its pressure.

Faculty of adaptation, how far enjoyed by animals.

It would require a more intimate acquaintance than we possess, with the economy of the various classes of animals, to determine the several degrees in which they enjoy or require the power of adaptation to distances; but although many unquestionably have a great reach of sight, it is highly improbable that any animal approaches to man in minuteness or accuracy of near vision. The curvatures of the cornea and lens, which are inverse to each other, and the corresponding variations in the quantity of the aqueous humor, are obviously appropriated to the different densities of the media in which they habitually dwell.

The crystalline of man, compared with ani-

mals, is of the softest consistence, and occupies the smallest portion of the volume of the eye-ball. The firmness of the crystalline is always in proportion to its convexity.

The absence of the processes in fish; their very slight indication, (being close and delicate striæ instead of folds,) in birds, and such reptiles as possess them; the absence in all of the membrane and circle of Petit, and the insertion of the processes into the capsule of the lens in the latter classes, offer a marked contrast to the appearances observed in man and quadrupeds, in whom they are full and strongly marked, and especially at the salient angle opposite to the crystalline, where they are unadhering and free to move. In fish as we have said, the pupil is without motion; in birds and reptiles, as in man and quadrupeds, its motions are vivacious; in some we are told, voluntary, which, whether it be so or not, must be stated on pure conjecture. The adjusting power in fish and birds has been attributed to other mechanism, on account of certain peculiarities of structure, which seemed, *primâ facie*, to be adapted to that purpose, as the choroid gland in fish, and the pecten in birds; or of such deviations from the human structure as rendered the several hypotheses inapplicable.

I believe that the motions of the iris in animals are single and obedient solely to the stimulus

of light, and that they have no controul of the pupil by volition ; a property which pertains exclusively to the adjusting power, and which is exerted independently of the variations of light. It is probable that they possess it in so far only as it results from the adaptation to light.

The iris is a mixed muscle ; its motions are regulated in part by the stimulus of light upon the retina, and in part by an effort of the will.

Involun-
tary,

That the motions of the iris which take place upon the sudden changes of light are involuntary, there can be no doubt, for they are observed even in sleep, when the will cannot be exerted, and in the earliest infancy. There is another proof that these motions are involuntary, viz. that they occur in some forms of perfect amaurosis. I have seen the pupil act briskly, where the person has been totally devoid of the perception of light from bright sunshine, or the flame of a candle held before the eye.

The sympathy of the iris with the retina must be ascribable to a communication between the retina and the ciliary nerves which supply the iris. The small lenticular ganglion from which these nerves are derived, lies upon the optic nerve, and is probably the medium of communication.

On the other hand, every one may satisfy himself of a power which the will is capable of exercising over the iris, in viewing alternately near and distant objects; the state of relaxation or moderately dilated pupil being suited to the remote, and its tonic or relatively contracted state to the near object. It is seldom that this change is sufficient to be obvious to a bystander where the light remains unchanged, because the faculty is seldom exercised in these circumstances, and still more rare for the state of accommodation to be preserved in defiance of the changes of light, because it is an unnatural effort. I have several times observed, in persons whose eyes were steadily fixed upon an object at some yards' distance, that the approach of a candle towards the eye did not stimulate the pupil to contraction, until it was so placed as that its image should fall upon the most sensible part of the retina, when the pupil instantly contracted. So that the voluntary is in subordination to the involuntary power, where they are opposed; that is, when the stimulus of light opposes the adaptation of the eye to distance. But by continued application, the mind is capable of acquiring over the motions of the iris an extraordinary power, as is well known to be the case with other muscles subjected in any degree to volition. Of this I have seen two or three remarkable instances, but none so striking as that of my ingenious and learned friend Dr. P. M.

and voluntary motion of iris.

Roget, in whom, I may be permitted to say, profound scientific knowledge is accompanied by a characteristic aversion to ostentatious display. It affords me much pleasure to lay before my reader the peculiarity to which I have alluded in the person of Dr. R. as described by himself, at my request.

*Bernard Street, Russell Square,
Feb. 21, 1820.*

MY DEAR SIR,

“ I am much pleased with the view you design to take, in your intended work, of the subser-
viency of the motions of the iris to the changes which accompany distinct vision at different distances, and of these motions being subordinate to the effect of light on the retina; and the more so as they accord with a circumstance relative to my own eyes which I have often made the subject of experiment, and which you will probably recollect my shewing to you some years ago.

“ When I have stated that I possessed the power of dilating and contracting at pleasure the iris, the fibres of which are usually considered as no more under the dominion of the will than the heart or bloodvessels, my assertion has, in general, excited much astonishment. Such, however, is strictly the fact. I can easily satisfy any person who witnesses the movements

I can produce in them, that this power is totally independent of the influence of light; since I can effectually exert it, although the position of my eye with regard to the window or candle, as well as the direction of the optic axis, continue unchanged. However singular this power may appear, it admits, I conceive, of a very natural explanation. The effort of which I am conscious, when performing the voluntary contraction of the pupil, is the same as that which accompanies the adaptation of the eye to the vision of near objects, and is of course productive of an increase of its refractive power. This very same power of moving the iris is in fact possessed in a greater or less degree, by every person who enjoys the faculty of distinct vision at different distances. It is accordingly well known, that if a person after looking at a distant object, transfers his attention to a near object, the pupil always contracts. But this change, it is supposed, can never be effected, unless some real object or image, from which light radiates, be present to direct the sight. I have never, indeed, met with any person besides myself, who, while steadily directing his eye to a distant object, and while no other object intervened, could, by a mere effort of volition exerted on the eye, augment its refractive power so as to adapt it to the vision of near objects. That I have acquired such a power I can ascribe to no other cause, than to my hav-

ing from my childhood, been much in the habit of observing optical phenomena, and of practising various experiments relating to vision, a subject which I early took great delight in cultivating.

“ It is still more easy for me, while an object is placed near my eye and distinctly seen, immediately to relax the organ so as to fit it for the distinct vision of the most distant objects : and these changes I can effect in succession with considerable rapidity, each change being accompanied with a corresponding enlargement or diminution of the pupil. The increasing the refractive power of the eye, is always the change that constitutes the effort ; the state of vision adapted to parallel rays being that of complete relaxation. The effort which attends this voluntary contraction of the pupil, when there is no object before the eye to call for such a change, is followed by a sense of fatigue ; and if often repeated or too long continued, it becomes painful, and continues so for some time afterwards. The fatigue is felt almost exclusively in the eye to which my attention had been directed during the experiment, although the same change in the refractive power takes place, and I believe to the same extent, in the other eye. It is also remarkable, that when there exists a real object of sight which is looked at, and which requires an equal change

in the eye for distinct vision, as in the former case, no sense of fatigue, or hardly any, is experienced.

“ I need scarcely add, that while I thus alter the refractive power of my eye from that which adapts it to the distance of the objects I look at, those objects appear indistinct, from their images either forming before the rays reach the retina, or tending to form beyond it.

I am,

DEAR SIR,

very faithfully yours,

P. M. ROGET.”

B. TRAVERS, ESQ.



In addition to the nerves derived from the lenticular ganglion, the iris receives two or more branches from the nasal nerve, (5th pair,) and its actions may possibly be subjected to the will by virtue of the influence which these nerves convey, for from the same source is derived the nerve which supplies the levator palpebræ, which is purely a voluntary muscle.

Ciliary
nerves from
the nasal.

The limited motion which the pupil has, when the retina is for the most part insensible, may be considered as an involuntary or automatic motion, similar to that which in a healthy eye affords protection to the retina; and if as sometimes happens, the iris contracts in a state of blindness, this likewise must be regarded as its involuntary action, for volition cannot precede sensation. It is probable that those motions of the iris, which are in conformity to the impressions of light upon the retina, are purely involuntary; and that those which are in conformity to the situation of objects, and are therefore directly subservient to vision, are under the influence of the will. Hence the dependence of the adjusting faculty upon the perfection of the retina.

Lenticular
ganglion.

The ganglia have been conjectured by an ingenious author, to be bars or stops upon volition, and this case of the iris, which he assumed to be purely involuntary, was incorrectly cited in support of the hypothesis. By others, ganglia have been supposed to be small sensories or cerebral receptacles, capable of rendering a supply of nervous energy to their filaments, by which they are in a measure independent of the brain and its appendages. The theory, which I have ventured to suggest, attributes the voluntary motions of the iris to nerves unconnected with ganglia, the involun-

tary to those derived from the lenticular ganglion, which I regard as a direct medium of communication between these nerves and the retina.

The phenomena of ocular spectra, or images of luminous objects remaining upon the retina after the external impression is withdrawn, are highly interesting and curious. Luminous sparks and flashes, halos or variously colored rings, it is well known, are produced at will by friction or pressure of the closed eyelids, and the first are an instant effect of concussions of the brain. The red is that color called up by the rudest artificial pressure; the violet by the slightest; and the gentlest impulse is the natural one, in which the light suffers no decomposition. Are these appearances really retinal impressions, or illusory mental phantasms founded on the feeble and obscure analogy subsisting between mechanical pressure and the impression of light? Although blind persons see such appearances, I doubt if they ever present themselves in cases where the retina is disorganized, or after the extirpation of the eyeball, as the mutilated feel their fingers and toes. They seem to me therefore to establish the essential connection between the retina and the faculty of perception, or the connection between the corporeal and mental impressions; and this is confirmed by what we observe of morbid spectra, which are

Ocular
spectra.

symptoms of various disordered states of the retina, of which I shall speak hereafter.

I have said that the duration of an impression is in proportion to its intensity. The experiment of the revolving fire-stick demonstrates that the impressions upon single points of the retina, although successive, become blended or confused by vividness and consequent proportionate duration; for if it were not luminous, the appearance of a continuous circle would scarcely be produced. Spectra are direct or reverse. The first is the impression of a luminous object, the shadow of that upon which the eye has for some time dwelt, although with no peculiar degree of intentness, and presenting the outline of the object in color. This either vanishes at once, or it presents a circle of the primary colors, variously associated or successively exhibited, in the order of their relation. The latter is especially the case after looking at the sun or a very bright light. This is the simple effect of a temporary over-excitement of the retina, analogous to the echo of a noise in our ears, by which the auditory nerve has been over-excited. The reverse spectrum is produced, when a color, occupying a certain space, has been so intensely impressed, (as when for example we make the experiment,) as to exhaust the irritability of the retina, and

Direct.

Reverse.

render it inexcitable by any and every combination of the rays of light, in which that color is a constituent. Hence the color of the spectrum is that which results from the abstraction of the offensive ray from white light, or the reverse of that of the object. The stimulus most remote from that which has excited the distress, is the only one to which the retina is alive, and in this it finds the relief of contrast.

In another case the reverse spectrum seems to depend on the excess of susceptibility in the retina, as when the eye has been fixed on a black ground; here the spectrum is white. Hence it is that the ash grey wall, presented to the eye on arriving at the mouth of a cavern, has a silvery brightness. The contrast of white light is alone capable of exciting the retina which has been altogether deprived of its natural stimulus.

Thus we have two states or degrees of nervous excitement; the first, simple over-excitement to the extent of continued or renovated impression. The second, excitement to exhaustion, leaving only a negative sensibility. A third state is that of non-excitement, and consequently accumulated excitability. The two last are directly opposed, being minus and plus states of sensibility, and thus the con-

Explanation of these phenomena.

templation of a white surface gives a black spectrum, as the black gives a white one.

As they are presented to the healthy eye, spectra need no further explanation. They are to be referred to the preternatural duration or intensity, or to the privation of the natural stimulus. They are accordingly produced artificially and at will in all persons. The organ is passive. The hypothesis of spasmodic action in the retina is altogether gratuitous.



In the "ANATOMICAL DESCRIPTION," I have unavoidably embodied the chief of what it is needful to say on the economy of the appendages. A few additional circumstances, however, come properly to be noticed under this head.

The actions
of palpebral
muscles.

The levator palpebræ being purely a voluntary muscle, the simple suspension of its action effects the closure of the lids, as its contraction opens them in the act of waking. Hence the disposition in the upper lid to fall announces the approach of sleep. In febrile and exhausted states of the system, its impaired energy occasions the drooping expressed by the term

'heavy-eyed,' one of the most characteristic symptoms in the physiognomy of disease. A similar state belongs to some morbid affections of vision, of which I shall have occasion to speak hereafter. A voluntary closure of the eyelids, as when the eye is from any cause irritable to light, is performed by the orbicularis palpebrarum, which in some casualties and morbid states contracts spasmodically, and the relaxation of this muscle assists the opening of the closed lids. In going to sleep and awaking from it, the lower lid is therefore passive; in a voluntary shutting and opening of the eye it participates, although inconsiderably, in both actions. Winking is an alternation of the actions of the levator and orbicularis, and therefore a seasonable relief to the former, and a means of preserving the moist and clear condition of the cornea. It is performed by a very slight contraction of the palpebral portion of the orbicularis. The combination of the action of the corrugator and orbicularis is seen in the strained closure of the lids to resist their separation by external force, knitting and depressing the eyebrows, and throwing the nose and forehead into folds; and the equipoise of the actions of the orbicularis and levator is evinced in the approximation or screwing of the eyelids, and peering, as is customary in short-sighted persons. When they

are both in full action, the corrugator acts as a moderator to the levator; the orbicularis is the antagonist of the latter.

Actions of
the mus-
cles of the
globe.

The actions of the straight muscles in various combinations, and in succession, explain the several intermediate motions to those which they singly perform, and the revolving motions of the ball round its socket. The rotation on its axis inward is performed by the superior oblique, that in the opposite direction by the inferior. The combined actions of the whole preserve the relative position of the eye to the object, independent equally of the motions of the object and the head. The motions of the eyes are in perfect correspondence, and the will cannot place them in opposition.

Superciliary arch
and muscles.

The prominence of the superciliary ridge, as well as the fulness of the brow, is subject to great variety, and is sometimes an impediment to the facility of operations. On the physiognomy I need not say its influence is most marked. The elevation of the eyebrow performed by the occipito-frontalis co-operating with the levator, in staring, and its depression and approximation to the nose by the orbicularis and corrugator in frowning, are habitually employed to a manifest advantage in the opposite states of deficient or feeble, and of superabundant or daz-

zling light. The eye's 'mute eloquence which passes speech,' belongs chiefly to its appendages. An opera dancer would be as effective with a divided tendo achillis, as a tragic actor who had lost the moveable apparel of the orbits.

The closed eyelids are penetrated by a full light, so as in ordinary circumstances to occasion waking, and distress to persons whose eyes are inflamed. The superior tarsus, when drawn up, slides under the arch of the orbit, but retains its apposition to the globe, owing to the laxity of its attachment with the integument of the palpebra.

Tarsi penetrable to light.

The origin of some fibres of the orbicularis from the ligamentous expansion which supports and protects the lacrymal sac, gives it a power of compressing the sac in its contraction, and thus assists in the excretion of the tears. This is in part proved by the epiphora which accompanies a fixed state of the lower palpebra from injuries, and the paralysis of the orbicularis, which states also prevent the due apposition of the puncta. Hence too, people wink often and forcibly, whose eyes are disposed to water, and after shedding tears.

Muscular compression of lacrymal sac.

The conjunctiva has been supposed to secrete a lubricating fluid, which serves the purpose of

Conjunctiva a non-secreting surface.

keeping the cornea clear, and facilitating the motions of the lids. This forms, according to that opinion, the habitual lacrymal discharge, and the secretion of the lacrymal gland is but an occasional one, as when from mental emotion or irritation of the conjunctiva the profuse and palpable discharge which we call 'tears' is poured out. I believe the notion rests solely upon the supposed relation of the conjunctiva to the class of mucous membranes. But this need be no fetter upon our conception of the matter, for not only do we see from the varieties of its surface that its economy is not throughout the same, but anatomists describe its continuity with the cutis as much as with the membrana narium. Again, the capillaries of mucous membranes carry red blood, which is not the case in the conjunctiva of the globe in health. But there is no evidence of such a secretion; upon the cornea it is not assumed to exist, yet the difference between the corneal and sclerotic portion is only in the strictness of its adhesion. The follicles and caruncula are specifically provided for preventing the effects of friction, and the incessant although insensible escape of the tears from the lacrymal ducts, unavoidable under the act of winking, in which the upper lid sweeps over and preserves the polish of the cornea, renders such a provision superfluous and therefore improbable. In disease, the sclerotic conjunctiva secretes a mucus which is immediately obvious (the

corneal surface is excepted because its vessels do not admit red blood) and this is in conformity with what we see of the mucous membrane properly so called, as of the urethra and intestinal canal, which continually shew that the secretion can be set up by disease upon a whole surface, while in the healthy state this function is confined to its follicles and lacunæ.

A young woman who had never shed tears, and was incapable of doing so, had a shrivelled, opake, and cuticular conjunctiva.

The puncta lacrymalia absorb the tears, not by any capillary attraction, but by a vital action as absorbent mouths. They are often spasmodically contracted, and afford a resistance to the introduction of Anel's probe, but yield to the point of a pin, so as afterwards readily to admit a probe of much larger dimensions. When over-dilated, they lose for a time their absorbing power, and the epiphora is increased. When they are morbidly patulous and atonic, as sometimes happens in age, the epiphora is permanent; and their function is frequently arrested by inflammation of the sac, for we often find the epiphora altogether independent of obstruction.

Excretion
of tears.

The direction of the superior duct varies a little in relation to the sac, according to the de-

gree of elevation of the upper lid. By drawing the lid upwards and towards the nose, it is brought nearly into a line with the axis of the sac.

The area of the sac and natal portion of the duct, exceeding that of their orifices, facilitates the passage of the tears ; the slight elevations of the lining membrane and the narrowness and obliquity of the nasal opening probably retard the excretion, which would be inconvenient if constantly taking place.

PART II.

PATHOLOGY

OF THE

MEMBRANES.

CHAPTER I.

SECTION I.

CONJUNCTIVA.

THE vessels of the conjunctiva of the globe are derived from two sources:—1. The palpebral arteries and veins; 2. The ophthalmic muscular branches, and accompanying veins. The first, creeping upon the sclerotic conjunctiva in the sinus palpebrales, and at the angles of the palpebræ, have a reticular distribution upon the loose portion of the conjunctiva. The second, after penetrating the tendons of the straight muscles, advance in four distinct fasciculi. These spreading, as they advance

Blood vessels of the conjunctiva.

upon the opposite sides of the globe, form numerous lateral anastomoses with each other, so as to present a faint *circulus arteriosus* upon the sclerotic coat *. In a state of congestion a free communication is conspicuous between these two orders of vessels, and their distinctive character is preserved under very high degrees of inflammation. In a complete section of the conjunctiva at a short distance from the cornea, both sets may be divided without injury to the sclerotic. It is by infinitely frequent and minute subdivisions of these vessels, that the tissue which unites the conjunctiva to the sclerotic is supplied; and hence in inflammation, the areolar distribution of these vessels is most conspicuously demonstrated where this texture is most abundant. At the verge of the cornea both orders of vessels are rectilinear, and never present the rectangular arrangement; for the looseness of the conjunctiva upon the sclerotic gradually diminishes from the point of its reflection to the verge of the cornea, and its adhesion to the cornea is so strict, as to render an artificial separation impracticable. This remarkable difference in strictness of adhesion subsisting between the conjunctiva and subjacent textures, suited to their difference of economy, explains some varieties in the morbid affections of the conjunctiva covering these parts respectively.

* See Plate I. fig. 1.

Independent of the accompanying veins of the muscular arterial fasciculi, long and tortuous branches are seen to proceed from the meshes of the conjunctiva, distinguished from the arteries by their purple hue, their isolated course, and more superficial seat. Their sharp spiral curves are larger as they descend towards the base of the visible hemisphere of the globe, where their attachment to the sclerotic is least strict. These are the palpebral veins of the conjunctiva.

Although in the tonic and tranquil state of the eye, little, if any, red blood is admitted into the superficial vessels, yet under a very temporary excitement, colored blood has a ready admission into the vessels of the sclerotic conjunctiva. Such, however, is the condensation of the connecting texture upon the cornea, as to prevent the admission of red blood into its vessels under a very high degree of inflammation, as even where the white ground of the sclerotic is extinguished*. The susceptibility of parts permeable to red blood to increased vascularity under excitement, is in proportion to the quantity of cellular texture entering into their composition, or connecting them with subjacent parts. Compare, in this view, the membrane of the fauces and the trachea — pleura

Character-
istic differ-
ence of
conjunct-
iva of
sclerotic
and cornea,
under in-
flammation.

* I believe further, that it is inadmissible, except a morbid change has previously taken possession of this texture. But of this hereafter.

pulmonalis and costalis—periosteum and perichondrium—lining membrane of veins and arteries.

Since the easy admission of red blood into the vessels of the sclerotic conjunctiva discovers a distribution of vessels, not otherwise known, it affords opportunities of observing the accession and progress of inflammation; and this portion of the membrane presents, when inflamed, appearances different from those of the inflamed corneal conjunctiva. But although the colorless circulation of the latter shews the rise and progress of inflammation obscurely, its perfect transparency in health makes the results of it more conspicuous.

Cornea obscured by inflammation.

The first effect of inflammation upon the cornea, is haze or dimness, which depends upon the loaded state of its (serous) vessels. The dimness is immediately removed by the recovery of the circulation, as after the removal of an irritant; for example, a foreign particle on the cornea; or after a free evacuation where the cause is less obvious. Hence transient dimness is merely a condition of congestion. This state, however, continued, produces a deeper and more permanent opacity; *viz.* effusion into the connecting texture, and thickening of the conjunctiva upon the cornea. This is the progress of simple ophthalmia in the generic sense of the term. Contrast the epidermis in the state of

blush (congestion) and of incipient vesication (effusion). The peritoneal coat of the liver, the arachnoid and synovial membranes doubtless exhibit, in the distinct stages of congestion and effusion, the transient and permanent opacity.

The conjunctiva is to the cornea, what the periosteum is to the bone. It nourishes the superficial lamellæ; wherever it is completely detached, the exposed surface of the cornea ulcerates, and its vessels repair the breach. To pursue the analogy, the interlamellar texture of the cornea may represent the medullary membrane; gangrene therefore does not ensue but from a permanent destruction of both textures, as by blows and explosions, which mechanically disorganize; by the action of lime, gunpowder, strong acids, and other chemically destructive agents; or by the strangulation of the vessels of both textures, as in the excessive chemosis, which destroys on the same principle as the paraphymosis, or the strangulated hernia.

Relation of
conjunctiva
to cornea.

The forms of inflammation of the conjunctiva which I shall now proceed to refer to, I consider as specific variations from the simple acute inflammation*, of which the ordinary signs are familiar to every practitioner, originating in a healthy subject from an obvious occasional or accidental cause, as an extraneous particle, or a blow not injuring the texture, or a blast of cold

* See Plate I. fig. 2.

air. An inflammation purely local, uninfluenced by constitution, both from the nature of its origin, its recent existence, and the health of the subject in whom it occurs. Such is the simplest example we can suggest of the morbid disposition natural to this organ, or to any organ; it is frequent, for all are liable to it, if all are not equally exposed: it is in fact an instance of what may be termed, without a misnomer, the inflammation of health.

Inflamma-
tion of con-
junctiva,
modified
by scrofula.

The inflammation of the conjunctiva, termed ‘strumous,’ where it has not proceeded to a change of texture, is not marked by any prominent local character. The vascularity is inconsiderable. This inflammation sometimes accompanies pustule of the sclerotic conjunctiva, in which case the vascularity is diffused instead of being partial, as in pure pustular inflammation, and the intolerance of light characteristic of the strumous inflammation is present in a greater or less degree. It accompanies also the morbid secretion of the lids when the eyeball becomes affected by the acuteness and duration of that disease, and the pustule on the cornea, especially the variolous pustule. In its simplest form it is almost peculiar to young children, stationary, marked by a very slight redness of the sclerotic conjunctiva, and the greatest possible degree of intolerance. I have known it in more than one instance of such severity and duration as to occasion a distortion of the spine from

the habitual depression of the head, and the obstinate maintenance of an awkward and unnatural posture of the body to screen the eyes from light.

The disproportionate degree of inflammation makes it difficult to account for this excessive morbid sensibility. It is purely a disorder of function; for although it far exceeds that which accompanies the acutest inflammation to which the organ is liable, it never in my experience impairs the faculty of vision. I attribute it to a morbid sympathy of the retina with the secreting surfaces of the primæ viæ and the skin, for neither of these organs perform their healthy functions during its existence. The tongue, the index of the former, shews by various signs gastric irritation or disordered digestion, and the cutaneous surface is remarkably dry and harsh. Accordingly it is cured by diaphoretics, as tartar emetic to nausea, James's powder, or calomel combined with opium in small doses; by the warm bath; and materially corrected, if not removed, by a preternatural secretion in the vicinity, as by an open blister on the nape of the neck. I have often seen an aggravated intolerance removed in twelve hours by the application of a blister.

This state of intolerance bears an analogy to cases of depraved, or rather of painfully acute sensibility in other organs of sense. The

senses of hearing and of smell are in some rare cases rendered morbidly acute, independent of the slightest organic affection, so that the ordinarily agreeable stimuli of these organs in a state of health, *viz.* an acute sound and a pungent odor, become causes of distress. An amateur of music, when labouring under an occasional disorder of the auditory passages, compared his sensations during a fine performance of instrumental music to those of Hogarth's enraged musician; all was jar and discord. Every snuff-taker knows the effect of a catarrh to spoil his enjoyment.

The nebula and the pustule of the corneal conjunctiva are the terminations of this inflammation when it affects the texture of the organ, to which may be added the small herpetic ulcers, reddish brown points, giving to the cornea a scabrous appearance. The healing action is always remarkably languid and protracted, as if the state of excessive irritability checked its progress, and prevented its completion.

Aphthous
or pustular
inflammation of conjunctiva.

The conjunctiva of the sclerotic is disposed to form aphthæ or pustules at the verge of the cornea, or near to it. In the former situation, where the more lax adhesion becomes abruptly strict, the pustule is elevated or cone-like, and is the termination of a distinct pencil of vessels; which arrangement sometimes precedes and announces the disposition to pus-

tule. When it is situated at a distance of a line or two from the corneal margin, it is broad and flattened. It is a small speck or patch of lymph, and seldom advances to suppuration. It is common to see one on either side of the cornea, in the transverse axis of the globe*. Sometimes they appear in detached clusters, or a zone of pustules environs the cornea. This resembles the aphtha of the mouth and fauces and intestinal canal.

The pustules of the corneal conjunctiva which are less frequent, except in children, are generally situated near to the margin of the cornea, where one or more pustules of the sclerotic portion appear. Like the aphtha of the glans penis and the stricter parts of fine cutaneous texture, the pustule on the cornea usually forms an ulcer.

The ophthalmia with puriform discharge is a disease of the palpebræ. The secretion is supplied by the meibomian follicles and the conjunctiva bordering them, and likewise by the caruncula lacrymalis.

Inflam-
mation of the
follicles
with puri-
form dis-
charge.

A puriform discharge is furnished by the cryptæ of the tonsils, the lacunæ of the urethra, and the mucous glands of the nares, fauces, rectum and vagina, in mild inflammation of these parts. But in the vehement acute form of inflammation, the

* See Plate I. fig. 6.

matter of suppuration is furnished by the tumid and villous surfaces of these membranes.

Acute suppurative inflammation of the conjunctiva.

The sclerotic conjunctiva in acute suppurative ophthalmia presents the following states: 1st. Serous effusion (œdema) which is common to other inflammations, and especially those of a less vigorous kind. 2d. Effusion of lymph (chemosis) peculiar to this form of inflammation, by which it acquires a solid augmentation of bulk. 3d. Villosity, or a subsequent prolongation of the extreme vessels in the form of villi, which secrete pus. The strict adhesion of the conjunctiva to the cornea prevents these changes from taking place upon that membrane. Upon the tarsi the conjunctiva thus affected becomes preternaturally vascular, thickened, and scabrous, or forms fleshy eminences. That the vascular villi of the conjunctiva secrete pus, may be ascertained by the aid of a lens. The pus, when formed, collects in the interstices of the villous texture. We have no evidence, as before observed, that the conjunctiva is a secreting surface in the healthy state.

Mild acute suppurative inflammation of the conjunctiva.

A form of disease intermediate to these in extent and severity, a modification of the suppurative ophthalmia, is the villosity and puriform secretion of the conjunctiva palpebralis, as seen upon eversion of the lids, while the membrane upon the globe is simply intu-

mescent giving it a more rounded figure, and moderately vascular. This is the mild acute suppurative ophthalmia, which seldom injures the cornea, but frequently leaves after it the same fungous or granulated state of the conjunctiva palpebralis which so often follows the most acute form.

The difference then between the inflammation of the meibomian follicles and caruncula, (the disease which if neglected terminates in lippitudo,) and the suppurative inflammation of the conjunctiva, whether of the palpebræ or the globe, is a difference in kind as well as in seat; the one is the conversion of a transparent and bland secretion proper to the organ (meibomian) into a viscid and irritating mucus, puriform in appearance; the other is the *de novo* production of a true suppurative surface by inflammation.

The highly contagious nature of the suppurative ophthalmia, whether in the mild or vehement acute form, is sufficiently proved. For one person affected with this disease above three months old, I should think at least twenty are subject to it under that age. The mother is the subject of fluor albus or gonorrhœa, and the discharge is usually perceived about the third day. In new born infants the disease begins in the conjunctiva palpebralis, and is often confined to that portion of the membrane. Where by neglect or improper treatment, it extends to

Suppurative ophthalmia communicated by contact.

the conjunctiva of the globe, it often destroys the cornea. I have repeatedly seen the most virulent form of the disease produced by accidental translation of the matter of gonorrhœa from its source in the same subject, and from one to another, as from the husband to his wife. I have also known it set up by the fluid injected into the eye of a patient, spirting into the eye of the medical attendant, and by the use of a sponge which had been recently employed to cleanse the eyes of an infant affected with the disease. The mild as well as the acute form of the disease, it is well known, runs through armies, schools, and families. There is much reason to believe it epidemic as well as contagious, but the former is a point less easy of decision.

Chemosis.

The chemosis, as must appear by the description above given, is an affection widely differing from ecchymosis, with which it has been by some writers confounded. It is after the existence of this morbid condition which is characteristic of the suppurative ophthalmia, that the conjunctiva forms fungous excrescences, pendulous flaps, or hard callous rolls protruding between the palpebræ and globe, and everting the former, (ectropeon) or if not protruding, causing the turning of the lid over against the globe, (entropeon.) The tarsal portion takes on from the same cause the hard granulated surface, which keeps up incessant irritation of

the sclerotic conjunctiva, and at length renders the cornea opaque. These eminences, sometimes cone-like and sometimes flattened, are not granulations in reality, *i. e.* adventitious glands secreting pus. Granulations, I believe, are never formed without breach of texture.

Preternatural elongations and excrescences of the conjunctiva, concealed in the hollows of the palpebræ, are a sequel of the protracted mild suppurative ophthalmia, where the palpebral conjunctiva has been the principal seat of disease. They are similar to those of the membrane lining the rectum, and the fine skin at the verge of the anus after inflamed piles, and the pudendum muliebre in acute gonorrhœa. All such membranous growths are, I believe, referrible to irritation of inflamed parts by the decreased and confined secretion, as the warts in external gonorrhœa.

Elongations
and excres-
cences.

A firm fleshy fungus, which sometimes attains considerable bulk, so as to project from between the eyelids and globe in an orbicular figure, even to the circumference of the orbit, I have extirpated. Such fungi are exclusively formed of the conjunctiva, and usually originate from injury.

Fungous
conjunc-
tiva.

There is a malignant fungus of the conjunctiva, for like the mucous membrane of other parts, this is sometimes the seat of car-

Carcinoma-
tous fungus
of conjunc-
tiva.

cinoma; and excepting the lacrymal gland, I believe no other texture related to the organ of vision is ever primarily so affected. I have removed the contents of the orbit for a painful tubercular fungus, with ulcerated depressions containing an ichorous discharge. The coats and humors of the eye were for the most part absorbed, the lacrymal gland schirrhous. The disease afterwards returned upon the palpebræ and destroyed the patient. I have at this time a similar case under my observation. The fleshy tubercles grow from the conjunctiva, both on the cornea and sclerotic, and the inferior palpebra is extensively ulcerated*. It is accompanied by lancinating pains in the supra-orbitar region, and an unhealthy discharge.

Pannus.

The Pannus is a chronic thickening and opacity of the conjunctiva of the sclerotic, generally unaccompanied by inflammation. By relaxation of the connecting tissue the membrane becomes redundant in extent, and forms folds or duplicatures, on one, or on all sides of the cornea, which encroach upon it considerably in the motions of the globe. The elongated uvula is the only analogy that occurs to my mind. This is often unpreceded by inflammation, and the extension is purely membranous.

Pterygium,

The membranous pterygium is a true nebula

* See Plate II. fig. 1.

of the sclerotic conjunctiva; the fleshy is an membranous and fleshy. adipose or sarcomatous growth beneath the sclerotic conjunctiva. It extends from either canthus or sinus palpebralis, most commonly from behind the caruncula lacrymalis; and by its increase forcibly detaches the conjunctiva from the cornea. In its progress it occasions a permanent and indelible opacity by the thickening of the conjunctiva, and the deposition of lymph in the interspace of these membranes, in the form of a little tongue-shaped process. The wedge-like figure of the fleshy pteryx, and its gradual extension upon the cornea, afford the best pathological demonstration of the continuity of the conjunctiva; and the spread fan-like figure of the membranous, its semi-transparency as well as its termination in simple nebula of the corneal conjunctiva, shews the difference in the nature of the two diseases. Both this and the disease last mentioned, like other morbid growths of the cellular texture or beneath it, are most prevalent in warm climates.

Adipose, steatomatous, and even cartilaginous tumors form in the cellular tissue of the conjunctiva sclerotic, and produce the same Conjunctival tumors on the sclerotic, change when situated in the vicinity of the cornea as the disease last mentioned, *viz.* a marginal interstitial deposition.

Circumscribed tumors of a dense and firm and cornea.

texture are sometimes formed upon the surface of the cornea, and attain a considerable magnitude; but such cases are rare. I excised the anterior hemisphere of the eyeball in an elderly lady, in whom the cornea was concealed by a tumor, of a dark purple color, protruding to such an extent between the eyelids, as to occasion great inconvenience and deformity. It had the appearance of being disposed in lobes, somewhat resembling a bunch of currants of unequal size. On dissection, the cornea and sclerotic proved to be entire, and the morbid growth, lying upon and adhering to the corneal and a small portion of the sclerotic surface, had acquired the lobulated appearance, as if by degeneration of the covering conjunctiva, for delicate white bands, the only vestiges of this membrane, were seen intersecting the lobules at irregular distances, in the form of septa. The substance, on section, was firm, of a dark color, here and there mottled with white, and measured a quarter of an inch in thickness from the external surface of the cornea*.

Encanthis. The Encanthis is a morbid enlargement of the lacrymal caruncle, in the form of a granular tumor, involving the valvula semilunaris. Sometimes the short down growing upon this gland takes on a morbid growth and harshness. The disease is extremely irritating, and occasions epiphora by a forcible diversion of the lacrymal

* Plate II. fig. 2. and fig. 4.

puncta from each other, and from the surface of the globe. I have never known it assume the malignant character ascribed to it by some writers.

The elongated *valvula semilunaris* retains its crescentic figure even to the margin of the cornea, where it has a loose and thin edge. By this and other parts of the conjunctiva, fringes or clusters of soft red caruncles are sometimes produced, resembling those occasionally seen in the site of the *carunculæ myrtiformes*, and about the *os externum vaginæ*.

Elongated
valvula se-
milunaris.

The *frena* or *frenula* connecting the conjunctiva palpebrarum and conjunctiva sclerotic, a troublesome, and often irremediable deformity, follows burns and wounds of the conjunctiva tarsi, and the excision of tumors connected with this portion of the membrane. They are membranous bands formed by adhesive inflammation of the opposed and contiguous surface. (*pleura costalis* and *pulmonalis*—peritoneum of the intestines and parietes.) It is not necessary that both surfaces should be wounded, if the position be by a mistake of treatment preserved, as by the application of a bandage. “The opposite uninflamed surface,” as Mr. Hunter observes, “accepts of the union.” I have seen these *frena* produced by a slit eyelid from a fall, and trifling as the inconvenience might seem, it so restricted the motions of the globe,

Frena.

and the disease was so materially aggravated by operations to relieve it, *i. e.* by the multiplication of frenula, that the patient became disturbed in his intellects, from an exaggerated sense of his misfortune.

Co-ad-
hering tarsi.

The co-adhesion or concretion of the tarsi by organized adhesion of the conjunctiva tarsorum is rare. I saw a remarkable case of it in a full grown boy, whose eye was found perfect after the division, though he had been thus blind from his infancy. It is similar to the co-adhesion of the nymphæ or labia pudendi, and the closed anus in new born infants.

Indisposi-
tion of con-
junctiva to
ulcerative
inflamma-
tion.

The conjunctiva is not prone to ulcerate, whilst the substance of the cornea readily assumes that action; hence the frequency of ulcers not opening externally, and of ulcers penetrating into the anterior chamber. Its readiness to assume the adhesive inflammation is evinced by the rapid formation of a superficial speck where it has been scratched or abraded, and the assistance it affords in healing open ulcers of the cornea. There is a marked disposition in these cicatrices to ulcerate in subsequent attacks of inflammation, which are in the same degree as in other parts slower to heal than the original texture. The synovial membrane is as much less disposed to ulceration than the cartilage, as the conjunctiva is than the cornea, or

the periosteum than the bone, or the peritoneum than the mucous coat of the bowel. All these external close membranes accord in their disposition to adhesive inflammation.

The conjunctiva, viewing its compound pathological character, bears its respective relations to the sclerotic and the cornea, and affinity to the two distinct classes of membranes: *viz.* the mucous upon the sclerotic, and the serous upon the cornea; hence the frequency of pustule and the tendency to suppurative inflammation of the sclerotic portion, and the indisposition to ulcerate and proneness to adhesive inflammation of the corneal.

Pathological relations of conjunctiva,

SECTION II.

CORNEA.

Ulcers of
the cornea,

THE cornea is disposed to adhesive inflammation, ulceration, and sloughing. It rarely suppurates. The ulcer of the cornea begins, not in abscess, but in a circumscribed deposit of lymph, or in pure ulcerative absorption without pus. In most instances, when of spontaneous origin, it begins in the interlamellar texture. When the conjunctiva has been detached, and the cornea deeply injured, as by a large spiculum, or by an ulcerated pustule of the corneal conjunctiva, the ulcer is filled by an inspissated mucus, or a little dirty white slough which may be picked or washed out, leaving a clear but rough fovea. The ulcerative process is unaccompanied by any appearance of colored vessels, and the adhesive process is, in many instances, conducted by colorless vessels. That the proper vessels of the cornea are capable of secreting adhesive matter, is proved by indelible opacities both with and without breach of its texture, and the healing of interstitial ulcers, without any appearance of a colored vessel.

and their
modes of
healing.

The organizing process is, however, in some

instances, performed by colored vessels.— Where interstitial ulcers open externally, or pustules of the conjunctiva terminate in ulcers of the cornea, a narrow pencil of vessels is produced from the sclerotic conjunctiva to the breach, which organizes the lymph deposited by the proper vessels of the corneal texture. I have sometimes observed, that the fasciculus of red vessels produced to complete the healing of an ulcer, opening externally, instead of coming from the nearest point of the sclerotic, crosses the greater diameter of the cornea. I have never seen such a production of vessels without a narrow and very delicate substratum of recent lymph in their track; nor have I observed this peculiar deposit distinct from the production of vessels, prior to their appearance, but the vestige of it is discernible for a short time after the vessels have disappeared. In superficial lesions of the cornea, as from the insinuation of a foreign particle, the part is at once restored by adhesion, and marked by a superficial speck; it is only where the ulcerative process has supervened and the conjunctiva is at the same time destroyed at the mouth of the fovea that nature adopts the mode of healing by colored vessels. Their office is, I think, limited to the organization of lymph deposited by the transparent vessels of the interlamellar texture; because when the ulcerative process is checked, the ulcer presents the signs of the adhesive action, *viz.* the marginal

halo of lymph and the contraction and filling up of the fovea, before the vessels of the sclerotic conjunctiva are produced. In this state there is often a pause in the restorative process, when the stimulus of a single injection is followed by the appearance of the red vessels, the effect of which is speedily manifested by a reddish brown tint communicated to the deposit, which soon becomes distinctly vascular. In other words, the adhesive process is already commenced before this phenomenon is observed. I have never seen the conjunctival fasciculus running to a transparent fovea. When the conjunctiva is entire, as in the interstitial ulcer, no red vessel appears, nor can be made to appear by stimulant injections, although they certainly quicken the adhesive process in such cases.

From analogy we are led to conclude that the vessels which secrete are distinct from those which organize the deposit, in open breaches of all textures. An insulated pellicle formed upon the bed of an ulcer never becomes skin, but if it be connected by never so narrow an isthmus with the circumference, its organization is perfected. After the ligature of an artery, the barrier of lymph is deposited from the vessels opening upon the divided cellular membrane, as is evident from its origination within the fissure, but injections shew that it is organized by the vessels of the lining membrane. The same

fact is still more clearly demonstrated after the division of the sclerotic conjunctiva, for we may observe a distinct interval to transpire between the deposition of new matter in the breach, and its vascularization by ramuli from the divided trunks. This is in opposition to the opinion of Mr. Hunter, who cites the same example to prove the reunion of divided trunks, or inosculation, an hypothesis which has been totally abandoned, since it has been ascertained that the permanent obliteration of arteries is the invariable consequence of a solution of their continuity, whether occasioned by wound or ulceration. I believe that in all parts the capillaries terminating upon the newly exposed surface furnish the deposit, and that this becomes the matrix of new vessels opened from its ramifications, under the extraordinary impulse consequent upon the obstruction of the trunk.

The appearance of colored vessels upon the conjunctiva of the cornea is to be referred to one or other of the following states, and may be classed accordingly:—1st, To the presence of adhesive inflammation excited by a pustular ulcer of the cornea *, as in the instance last described, and in that of acute interstitial ulcer opening externally, described at page 114.—2d, To the duration of acute strumous ophthalmia, in which the serous vessels of the cornea are opened to red

Colored
vessels
upon the
cornea.

* See Plate I, fig. 3.

blood upon its entire circumference, in the form of radii converging to a centre, to an equal extent of from one to two lines *. In this case the cornea is more or less obscured.—3rd, To a state of chronic inflammation, in which straggling solitary vessels, having a varicose appearance, run to one or more specks, or proceeding from opposite sides of the sclerotic conjunctiva, course over the opaque cornea and freely anastomose upon it †. This state is a common sequel of the suppurative ophthalmia, whether accompanied or not with the granular conjunctiva tarsi, and which I have been accustomed to designate “chronic inflammation with vascular cornea.” It is commonly seen in cases of disorganized globe and spoiled cornea, from whatever cause.

The first of these conditions I consider adventitious to the adhesive inflammation excited by the open ulcer of the cornea. It is proved to be so by a temporary deposition of a narrow layer of lymph; the direct course of vessels along it to the breach; their passage not always by the nearest route, *i. e.* from the nearest point of the sclerotic; the entire freedom of the cornea from blood-vessels in other parts; and the spontaneous disappearance of the vessels and the lymph track after the healing of the ulcer. It is the most striking and beautiful instance we have of the handicraft of nature, of the produc-

* See Plate I. fig. 4. † See Plate I. fig. 5.

tion of vessels in inflammation for a specific purpose, and their gradual contraction to obliteration; the determination ceasing when that purpose is accomplished.

The second and third description of appearances I consider to be produced by the continued *vis a tergo* overcoming the resistance opposed by the enfeebled tone of the vessels. The second is combined with recent and diffused nebula of the cornea, capable of removal by absorption. The third is as often present with ulcerated specks as with simple opacities, which, whether partial or complete, are seated in the corneal texture, and have usually existed prior to the appearance of the red vessels, and neither the vessels nor the opacities spontaneously disappear. After repeated circular sections of the conjunctiva near the cornea, these vessels undergo contraction, especially under the use of styptic applications, as the liq. plumb. acetatis, and solutions of copper, alum, &c.; that portion of the opaque matter which has been recently deposited, is at the same time absorbed. This operation seems to act beneficially in two ways; *viz.* by throwing up a barrier of lymph to impede the direct course of the vessels, and by diverting them to the purpose of its organization.

When I speak of the 'production' of vessels, Production of vessels.

I am not unaware of the ambiguity or impreciseness, at least, of the term, which is so different in a mathematical and a general sense. It would be wandering widely from the subject of this treatise, to enter into a discussion of the question, whether the phenomenon of organization is to be referred to an elongation of vessels by virtue of a force operating upon their elasticity, or an occasional formation of ramusculi from contiguous branches. To divided vessels, the former supposition cannot apply, as their orifices, as before observed, become permanently closed. I may observe also, that elongation of vessels implies a looseness of cohesion in the textures in which they appear, which does not belong to the corneal conjunctiva in its healthy state; and the example which I have given in illustration of the formation of vessels, is strikingly opposed, in this respect, to the instance adduced of original vessels acquiring increased capacity, and being rendered, by the color of their contents, conspicuous. In the first, the corneal surface is otherwise healthy; in both the second and third, it is raised, thickened, and more or less disorganized.

We are led by analogy to conclude that the effect of vascular congestion from altered or interrupted texture is only less in degree than that from complete obstruction in larger vessels; *viz.* the

extension and enlargement of collateral branches. Observe the vessels of the sclerotic conjunctiva in organic amaurosis ; of the skin covering indurated tumors ; and lastly, the communicating branches after the ligature of the trunk in aneurism. Mr. Hunter thought that the vessels might be formed in a patch of lymph independent of the circulation. “ I think,” says he, “ I have been able to inject what I suspected to be the beginning of a vascular formation in a coagulum, when it could not derive any vessels from the surrounding parts. By injecting the crural artery of a stump above the knee where there was a small pyramidal coagulum, I have filled this coagulum with my injection as if it had been cellular, but there was no regular structure of vessels.” Then, likening extravasation under inflammation, and the vascularization of the membranes of the chick to this appearance of a self-organized coagulum, he adds, “ I conceive that these parts have a power of forming vessels within themselves.”—“ But where this coagulum can form an immediate union with the surrounding parts, it either receives vessels at this surface, or forms vessels first at this union, which communicate with those of the surrounding surface*.”

The infinitely more probable theory of the derivation of vessels from parent branches for

* Hunter on the Blood, p. 92 et seq.

the organization of deposits, is supported by daily observation, and satisfactorily explains the phenomena.

That vessels are capable of producing their kind is as certain as their reproduction of bone, tendon, and other elementary textures. The dependence of one order of vessels upon another is shewn by the existence of *vasa vasorum*; and it seems to me most probable that the vessels first seen in a patch of lymph are fabricated by the *vasa vasorum*, bloodvessels and absorbents, of the terminal vessels of the wounded surface.

Acute interstitial ulcer of cornea.

The acute interstitial ulcer sometimes opens externally, by absorption of the conjunctiva, as well as of that portion of the lamellæ superjacent to it. Its figure and extent are determined by the deposit of adhesive matter. This is frequently crescentic, and traverses a part or the whole diameter of the cornea. It is most frequently situated near the upper or lower margin of the cornea, but occasionally crosses the centre. Upon close examination, the conjunctiva will be found to be absorbed at the part opposite to the ulcer, and the exposed scabrous surface of the cornea renders the motions of the upper lid acutely painful. The deposition of the adhesive track precedes the appearance of red vessels, which are derived to it in one or more fasciculi from the sclerotic conjunctiva, and by

which its healing is perfected, as in the ulcer opening from the surface, before described.

The terms *onyx* and *unguis* have been indiscriminately applied to extensive collections of lymph and pus between the layers of the cornea, and to similar collections situated in the anterior chamber. They are applicable only to the crescentic interlamellar depositions above described. The acute interstitial ulcer in debilitated habits of body or when it is produced by considerable violence done to the cornea, instead of opening upon either of its surfaces, spreads between its lamellæ, and in this case a considerable quantity of puriform matter is secreted. If it occupy a large and central portion of the cornea, it usually terminates by slough of the entire membrane.

Onyx and unguis.

When, as more frequently happens, the interstitial ulcer opens into the anterior chamber, it produces the *hypopion*, which is a mixed secretion of lymph and pus; the former flaky and inorganizable, and situated exterior to the fluid. The soft lymph pendulous from the mouth of the ulcer is often observed connecting the *hypopion* with it. I never recollect to have seen the puriform *hypopion* unaccompanied with ulcer penetrating the interior lamella of the cornea. In these cases, the integrity of the chamber is preserved, and the iris has no share in the restoration.

Hypopion.

Procidencia
iridis.

When the external ulcer opens into the anterior chamber, so that the cornea is perforated, the iris falls into the breach and becomes united to it by adhesion. When the opening is small, as from simple ulceration, the iris presents a small black point; if large, as from sloughing, the opposed portion of the iris is protruded in the form of a little sac; and when this happens, the adhesive process is sometimes set up at once, by its pressure on the margin of the aperture in the cornea, and by the ready disposition of the iris to take on a corresponding action. But the adhesive process is not so promptly set up in this case as in the procidencia following wound, and the prolapsus often increases in size until a stimulant is employed. The healing action is marked by a dusky white line at the verge of the opening. The contraction of the chamber and the disfiguration of the pupil are proportioned to the extent of the prolapsus.

Procidencia
corneæ.

In the progress of an external ulcer to the interior of the cornea, and before it penetrates into the chamber, a remarkable appearance is occasionally presented, viz. a transparent vesicle, which fills the aperture, and is supposed to be the membrane of the aqueous humor. I have never seen this state maintained; the prolapsus iridis follows in a few hours, notwithstanding the use of the lunar caustic and other stimulants. This has led me to question its being a distinct texture, and its appearance corresponds accurately to

that of the innermost lamella of the cornea, which after losing its support yields to the pressure of the humor, and assumes the vesicular form. The falling-in or cup-like depression of the continuous surface of the cornea, where the circumscribed interstitial ulcer opens into the anterior chamber, serves to confirm this conjecture. I have never seen the appearance which I have heard others describe as demonstrating the adhesive inflammation of this tunic, viz. colored vessels arborescent upon a deposit of lymph coating the interior of the cornea. If the observation be accurate, the case is very rare.

Chronic interstitial ulcers from pure ulcerative absorption, succeed to acute inflammation, in which large quantities of blood have been lost, and occur frequently in children imperfectly nourished, or adults much debilitated from various causes. The cornea is perfectly transparent, but indented like a bonce when struck upon a marble hearth, or pitted, according as the ulcers are diffused or circumscribed; the vision very slightly affected. Under nutritive diet, effective tonics, and moderate topical stimuli (vin. opii. sulph. zinci) they become hazy; and this denotes the commencement of the adhesive action.

Chronic
interstitial
ulcer of
cornea.

Opacities are of three kinds :

Opacities ;
their kinds.

1. Thickening of the conjunctiva and effusion

of adhesive matter between it and the cornea, or between the lamellæ of the latter. This is commonly the product of acute strumous ophthalmia. The corneal surface loses its smoothness and polish, as well as its transparency, when the conjunctiva is affected; when the opacity is in the cornea this is not the case. This is that form of opacity which, while recent, admits of removal by excitement of the absorbents more or less completely, and especially by that which mercury produces, the corneal texture being sound. It is what I have been accustomed to call nebula, and though presenting great varieties of shade, it has a soft, diffused, semitransparent character.

2. A slow change of texture without breach, similar to that by which the pleura, or choroid, or capsule of the lens is converted into bone. The yellow pearly opacity, resembling the inside of an oyster-shell, is of this kind. It is the result of continued, or frequently relapsing (strumous) rather than violent inflammation, and is deep-seated. In this case the layers of the cornea become opaque, indurated, and condensed, so as not to admit of separation by the knife or maceration; and if such opacities are in any degree relieved, it is by an absorption of the interlamellar deposit in their vicinity.

3. New matter, supplying an absolute loss of substance of the cornea, from ulceration or gangrene. This differs from the second chiefly in

its figure being more abruptly circumscribed, and bearing more resemblance to a cicatrix. In point of density the second often exceeds it, as when the cicatrix does not penetrate the cornea. Both these species of opacity are white in the recent state, and in general the more conspicuously their color is contrasted with this appearance, as yellow or brown, the less is the probability of reducing them.

The peculiar hue and loss of tension, as well as lustre, of the *dead* cornea in acute suppurative ophthalmia, has been aptly pictured by Mr. Saunders, by the terms ‘cindery, ragged, flocculent.’ It is important, because I have satisfied myself that the first change of the cornea in this disease is purely nebulous, produced by the deposition of adhesive matter; and if the inflammation be arrested even on the verge of gangrene, the cornea is susceptible of restoration by absorption. This fact I had lately an opportunity of establishing, in the case of a lady who was rendered blind by acute suppurative inflammation of the conjunctiva: so inevitable to all appearance was the destruction of the cornea, which had sloughed in a deep sulcus at its junction with the sclerotic above, that the most experienced practitioner of my acquaintance in this branch of surgery pronounced the case hopeless and irremediable, and took his leave. The highest tonic regimen, bark, wine, and opium, followed

Gangrene preceded by adhesive deposition in acute suppurative ophthalmia.

close upon a very active and bold depletion, and the anterior chamber was fortunately and unexpectedly preserved. No sooner was a sign of the arrest of sloughing ulceration obtained, than I commenced a mercurial course; in three days the system was affected; the recovery of the figure and transparency of the cornea was rapid and complete beyond all expectation, and an equally perfect state of vision was restored and established.

The gangrenous opacities of the cornea produced by lime or other substances destroying its texture, are sometimes superficial and defined in extent, and a process resembling exfoliation ensues. More frequently this disorganization is integral and complete. The cornea, disorganized by acids, is rendered instantly opaque, shrivelled, and of a yellow color, almost resembling a piece of wash leather.

In general, opacities which have a recent diffused semi-transparent character (nebulous) admit of absorption; not so those in which the interstitial deposition has been abundant and of long standing, and the lamellæ are compacted, owing to the entire obliteration of the cellular texture; or in which a new portion of cornea is formed.

Cuticular
conjunctiva
of the
cornea.

I have seen several cases of the conversion of the conjunctiva into a skin, rugous and opaque, knitting the lids close to the globe, so

as to obliterate the sinus palpebrales. I have called it cuticular conjunctiva. In these cases there is no secretion of tears. I have had occasion to observe the accession and progress of this disease in early and advanced life, among the sequelæ of chronic inflammation of the conjunctiva, and am disposed to consider it depending on an obliteration of the ducts of the lacrymal gland.

All stimulant substances, not escharotic, applied to remove opacities of the cornea, act in the same manner as rubefacients upon the skin; they excite a temporary vascular action, which is followed by a corresponding excitement of the absorbents. I have often seen an opaque portion of the cornea cleared by a puncture with the couching needle. If the point of salutary excitement is exceeded, the increased vascularity is permanent, and occasions increased deposition. Injections applied to ulcers do not excite the absorbent action in the same ratio, but occasion a permanent increase of the vascular action, which is here below the ordinary standard. This instance of the adaptation of the same means to different ends, according to the state of the part, is perhaps the best practical illustration of Mr. Hunter's quaint but expressive phrase, "stimulus of necessity."

Action of
topical
stimuli on
opacities.

Opaque specks, even cicatrices are obliterated during the period of growth, and as is

Absorption
during
growth.

observed of cicatrices in other parts of the body, change their relative position remarkably in the years of growth. Thus a conspicuous speck, encroaching upon the pupil in the infant, becomes a small and scarce discernible speck in the grown child, situated near the verge of the cornea. In other instances, if originally small, it has disappeared altogether. Like cicatrices of other parts they are always considerably smaller than the ulcers of which they are the vestiges.

Staphylo-
ma; its
kinds.

The staphyloma is of two kinds, viz. from dilatation and from breach. In the first case the corneal lamellæ have not completely given way, but are only bulged, the membrane having been so far weakened by ulceration as to have lost its due resistance, and the staphyloma consequently affects the whole diameter of the cornea (spheroidal). In the second the staphyloma is circumscribed, the recent lymph, corresponding to the breach, yielding at one or more points to the pressure of the humor (conoidal).

In the spheroidal staphyloma the effect of pressure is to thicken the remaining lamellæ by a deposition of adhesive matter, as in the aneurismal and herniary sac; so that the transverse section of it greatly exceeds in diameter that of the healthy cornea. In the conoidal staphyloma the recently deposited matter yields to the

pressure *a tergo* before its organization is complete. Sometimes the two forms are combined, and one or more conoidal protrusions are formed upon a spheroidal staphyloma. When, as in the first case, the corneal texture has not actually given way, the anterior chamber is in most instances preserved, and the iris is free. In the other case the iris is usually complicated with the staphyloma. The remedialness of the deformity occasioned by the disease, by means of an operation, depends upon a sufficient portion of the iris being left. The iris is kindly disposed to granulate, as we see in sloughs of the entire cornea from suppurative ophthalmia*.

Three or four days after the operation for staphyloma, the iris is seen coalescing with the conjunctiva and throwing up fleshy pullulations, which contracting into a little button-like eminence, seal up and permanently secure the crystalline and vitreous humors; thus the spherical figure of the globe is preserved to support the lids. But if the section be posterior to the plane of the iris, the vitreous humor escapes and the globe collapses and sinks in the socket.

* I have seen in such cases a permanent staphyloma of the iris, the pupil closed, and the exposed iris retaining its character, occupying the situation and presenting the figure of the cornea. The case is not common, as the cicatrization of the pupil precedes the fall of the cornea.

Conical
cornea.

The cornea is occasionally subject to a process of thinning, or an absorption of its interlamellar texture, and in consequence, loses its natural tonic resistance to the pressure of the contents of the globe. It usually assumes a conoidal figure, but this is not always the case; the projection of the cornea is sometimes uniform, describing the segment of a larger sphere. The apex of the cone corresponding to the centre of the cornea, when this figure is assumed, exhibits a degree of tenuity and brilliancy which gives it the appearance of a pellucid fluid, like a dew-drop suspended. The patient's vision becomes so inconveniently short as to render objects confused at a very moderate distance; the change is sometimes slow, occupying months, and even years; and on the contrary, I have seen it produced in its greatest extent in the short space of eight weeks: both eyes are generally affected, though not always in the same degree. The disease is unpreceded by inflammation, or any obvious assignable cause; it is more frequent in women than in men, and in my experience affects middle life. I have never seen it commencing in childhood or old age. It is as much the disease of the robust as of the weakly constitution and frame of body. If inflammation is excited by stimulants, the apex of the cornea turns opaque; if left to itself, the cornea does not give way, but remains in the condition described. No

remedy yet proposed has been followed by a beneficial result ; but a pupillar aperture set in a black ring frame, about a quarter of an inch or more in depth, greatly assists the patient by lessening the confusedness of his vision.

It seems that the presence of adhesive inflammation is the chief distinction between the staphyloma from dilatation and the conical cornea : the absorption is therefore in the one case the ulcerative and in the other the interstitial.

The last stage of healing in external ulcers of the cornea exhibits beautifully the third kind of absorption, viz. the modelling, as described by Mr. Hunter. We see it in the lowering, rounding, and smoothing of the jagged edges of the cup of the ulcer, a compromise in some sort with the full and complete finishing of the adhesive process, viz. indelible opacity ; and in some cases this state of imperfect restoration is perpetuated to a manifest advantage, for a transparent indentation occasions little, if any impediment to vision.

Finishing
process in
ulcers.

SECTION III.

SCLEROTICA.

Vessels of
sclerotic.

BRANCHES from the straight vessels of the conjunctiva penetrate the sclerotic obliquely towards the margin of the cornea, and the long ciliary vessels pass in sulci of this membrane to the plexus ciliaris at the root of the iris. At the interior border of the sclerotic, where the annulus ciliaris is adhering closely to this tunic, the ciliary communicate with the muscular branches, and being in deep-seated inflammation fully injected with red blood, the condensation of color gives the well known and remarkable appearance of a vascular zone at the margin of the cornea. Injections do not demonstrate this anastomosis; for the communicating vessels, like those which are continued upon the cornea, are too delicate to admit of artificial injection, and only admit red blood after a strong and steadily supported inflammatory action*. When once they have received red blood they very slowly recover their healthy

* A very successful injection of an eye in the state of acute iritis could alone demonstrate this fact to the entire satisfaction of anatomists.

calibre, as is proved by the faint appearance of the zone long after the inflammation has ceased, and the almost instantaneous reproduction of the state of congestion on forcibly separating the lids. When an inflammation at first affecting only the conjunctiva is allowed to progress, the ciliary vessels partake of the action, and this sign of the extension of it to the interior tunics makes its appearance. But the sclerotic from its situation and texture serves as a shield to the finer tunics, from external inflammation as well as from external violence. By the interposition of the sclerotic the vascular communication of the choroid and conjunctiva is rendered extremely minute and anastomotic; and for this reason inflammation of the conjunctiva may and often does reach to a considerable height, without any indication of its extending to the parts beneath the sclerotic. An acute and obstinate inflammation of the conjunctiva, not threatening injury to the cornea, as the pustular, and that with puriform discharge, does not in any degree affect the choroid and iris. On the other hand, when inflammation has extended to these tunics the vision is affected in a much greater degree than appearances would often lead us to expect. I only mean to remark that if the transmission of blood to the deeper seated tunics had followed readily to that of the conjunctiva, the conse-

Situation
and tex-
ture, their
effect.

quences of every severe superficial ophthalmia would have been mischievous.

Ordinary
inflammation of sclerotic, secondary.

When the sclerotic partakes of the inflammation of the conjunctiva, for it is only as intermediate to the conjunctiva and the other tunics that it is usually affected, the vessels which pursue a straight course to the margin of the cornea are strongly distinguished. They have a somewhat brighter hue than the areolar vessels upon the loose portion of the conjunctiva. I have exhibited this difference of arrangement of the vessels in the sclerotic and conjunctival inflammation, as seen in a singular case of inflammation accompanied with pustules*. This appearance is always observed, as sclerotic inflammation is always present, during the morbid changes upon the cornea, viz. interlamellar deposits of lymph and ulcerations.

Sclerotitis;

I have occasionally observed in a recent ophthalmia this turgescence of the straight vessels, unaccompanied by any affection of the cornea or iris, and with so slight a vascularity of the loose conjunctiva, as to give reason to consider it a primary sclerotitis. The inflammation is more obstinate than acute; the motions of the ball are painful. By continuance the cornea becomes

* See Plate I. fig. 6.

nebulous, and the surface roughened, from effusion beneath the conjunctiva.

The inflammation of the sclerotic sometimes accompanies, and is sometimes vicarious with rheumatic inflammation. This is not surprising, as its texture is of the same class with the ligaments of the joints. The rheumatic ophthalmia presents the zonular arrangement of the vessels, more or less cloudiness of the aqueous humor, and a pupil displaced or drawn a little to one side. It is often seen in company with, or following gonorrhœa, eruptions, or sore throat of a pseudo-syphilitic character; and the pains to which, in my experience, it is generally allied, are those which succeed to the exhibition of mercury*.

and rheu-
matic oph-
thalmia.

The sclerotic, although a firm texture, possesses in certain persons such a degree of tenuity and consequent transparency, as to convey an obscure tint of the subjacent choroid in the vicinity of the cornea. This is most observable in those of light-colored hair and iris, and in persons of lax and weakly habits. It is relatively thinner in such persons. It is evidently slenderer in its texture adjoining the cornea, than elsewhere. A morbid discoloration of the sclerotic is usually combined with an organic amaurosis, whether congenital or induced by inflammation or its consequences. The sclerotic sometimes yields in the spheroidal staphyloma, a disease

Staphy-
loma of the
sclerotic.

* See note A.

proper to the cornea, so much as greatly to increase the conspicuousness and deformity of the disease. This happens in hydropic and other degenerations of the humors. It also frequently becomes extenuated or bulged near its junction with the cornea, in the amaurosis which follows inflammation of the choroid. This protrusion, larger or smaller, is sometimes circumscribed, and in other instances diffused over a large portion of the ball *. It is often seen encircling the cornea, and presenting a sacculated or pouch-like appearance. It has a bluish grey tint, and the globe is of course misshapen in proportion to its size. An increase in size of the whole globe, or hydrophos oculi, is often joined with it.

Persons who are not aware that it is the result of a chronic process, viz. an interstitial absorption of the sclerotic, sometimes mistake it from some faint resemblance to the black fungoid tumor, for a malignant disease. I have heard it pronounced a fungus hæmatodes, and the extirpation of the organ advised. I think it may not improperly be designated *staphyloma scleroticæ*.

Staphyloma of the choroid.

I have met with one or two instances of the actual protrusion of the choroid at the margin of the cornea, which had the appearance of resulting from the separation of the sclerotic; like the staphyloma iridis from the fall of the cornea, described page 123.

* See Plate I. fig. 7.

SECTION IV.

CHOROID AND IRIS.

THE appearance of the vascular zone at the margin of the cornea, which, taken by itself, is a sign of the inflammation having extended to the sclerotic, if accompanied with dulness of the humors, a spastic contraction, or a very sluggish and limited motion of the pupil, an impatience of light, and a considerable dimness of vision, demonstrates that the choroid and iris participate in the inflammation. We ought to consider, that the local and vascular relations of the choroid and iris, distinct as they certainly are both in texture and properties, are such as to make it exceedingly improbable that the one should not, in all cases, participate more or less in the inflammation of the other. We are permitted to see the primary changes induced by disease in the living organ, upon the iris only, and we have not as yet any precise marks by which we can ascertain the commencement of inflammation in the one or the other texture. It is probable, however, that as the iritis presents considerable varieties in its form, its access and progress, relatively to the superficial inflammation, and the kind and degree of pain and dim-

Choroiditis.

ness which accompany it, that the choroid is the seat of the primary inflammation in those cases in which the changes upon the iris take place later than the other signs of internal inflammation, viz. the arrangement of the vessels, the pain, and the obscurity of vision. I have often seen cases of this description which I have felt disposed to denominate "Choroiditis."

Iritis.

The indications above mentioned, are still further confirmed by the presence of an habitual aching pain affecting the globe of the eye, forehead, and region of the orbit, and by certain appearances of inflammation upon the iris, as hair-like red vessels and specks of extravasated blood in its substance. Adhesive inflammation takes place between the fibres of this muscle; the pupil loses its thin flowing edge, and becomes thick, stunted, and gibbous. Iritis of moderate acuteness is often unaccompanied by any other appearance of inflammation; there is no distinct deposit of lymph, and it is rather inferred from the fixedness or slight change of figure of the pupil, than demonstrated. I believe the adhesive matter, in this case, is deposited on the posterior surface, formerly called uvea, for in the course of a few days, the opacity of the capsule of the crystalline, and the co-adhesion with it of the pupillary margin, becomes evident, provided the inflammation be unchecked. In this form of inflammation the

pain is often augmented in the evening, or at an early hour of the morning, to such intensity as to compel the patient to rise, and even totally to deprive him of rest. Sometimes the pain affects the whole corresponding side of the head. In other instances, it is confined to the eyeball and its immediate vicinity, as the forehead and temple, and bones of the cheek. The sensation is sometimes that of pulsatile pain, marking every injection of the ophthalmic artery, as of the radial artery in a whitloe. A sense of continued pressure or constriction, as from extreme distension of the vessels, is the more common character of the patient's sufferings. In the vehement acute iritis, lymph is variously deposited upon the face of the membrane, in small tufts here and there, or larger tubercular masses. The pupil, in this case, is usually much misshapen, being rendered angular at those points of the circle at which the deposit has taken place, or is most abundant. Its aperture is sometimes partially covered, and sometimes completely blocked by a deposit of lymph. The pain, in this state, is not always augmented in proportion. It affects more the head than the organ. The vision is nearly if not quite extinguished. The appearance of a stratum of lymph, coating the face of the iris, with a turbid state of the aqueous humor, belongs to chronic inflammation, which tends to opacity of the capsule of the lens, and constriction of the pupil.

Primary.

A primary inflammation of the iris, as for example, from syphilis, or from mercury, is distinguished from the secondary, or that by extension from the conjunctiva, by the more sparing vascularity of the conjunctiva, and consequently more distinct and conspicuous appearance of the vascular zone *. The attack is more sudden, the pain in the region of the orbit and head, commences with the inflammation, and is more severe; the vision is more quickly and completely bedimmed. The effusion of lymph is *en masse*, and the disfiguration of the pupil greater.

Secondary.

In the inflammation of the iris by continuity, the conjunctival vascularity is more conspicuous and diffused, and the cornea is so much clouded, as partially to obscure the view of the iris; the albuminous deposit is wanting, or if any has taken place, it is small in quantity, white, flocculent, and partially diffused in the aqueous humor, or is deposited at the ciliary margin of the iris, forming a lymphatic hypopion; the pupil is little, if at all misshapen. The pain in the secondary iritis is usually confined to the ball, and is comparatively inconsiderable. Although the vision is much bedimmed, there is greater susceptibility to the painful impression of light. This state I have heard others describe as the adhesive inflammation of the anterior chamber.

* See note B.

The terminations of iritis, if unsubdued, are, Terminations of iritis.
 1st, constricted or closed pupil, with opaque capsule; 2d, co-adhesion of the iris and cornea, partial or entire, the former assuming the convexity of the latter; 3d, organic amaurosis, followed by disfiguration of the globe, and often by protrusions of the choroid and sclerotic.

Iritis, as I have formerly observed, is very Mercurial iritis.
 frequently in company with, or succeeding to syphilis, and the symptoms called mercurial, as peculiar eruptions, sore throat, and pains of a rheumatic character. Primary iritis is rarely seen unaccompanied or unpreceded by such symptoms. I have never said or thought that it could not exist independently of these symptoms, and their supposed causes, having seen such instances. But I have since had additional opportunities of confirming the facts before advanced, that where mercury had been used in various ways before the iris was affected, and before the other symptoms appeared which were referred to its use;—where the primary affection was either altogether questionable, or at most a gonorrhœa, or a superficial sore, which healed by a simple topical application—the iritis has yielded to the steadily supported influence of mercury upon the system, in a manner the most satisfactory; and that no other remedy with which I am acquainted, was competent to this effect*.

* I think it right to state, that the salutary effect of mer-

Morbid
changes of
iris.

The iris undergoes a change of color as well as texture, by a continuance of inflammation. This is owing to the loss of its transparency, and the interruption given to its proper secretion by the lymph deposited upon its posterior surface. The healthy iris is transparent, as may be seen in the albino, white rabbit, and ferret; hence the use of the pigmentum nigrum.

It suffers a loss of mobility from the agglutination of its fibres, and ultimately of its posterior surface to the tunic hyaloidea, by which the posterior chamber is annihilated. It is from this morbid condition extending to the plicæ ciliares, that the loss of figure of the globe, or the staphyloma of the sclerotic and choroid results. A notable thickening and rigidity, a leather-like toughness of the iris, and a varicose state of its vessels, are changes accompanying

cury in iritis, unassociated with any specific action, was an observation made at the same time by Dr. Farre and myself, at the 'London Infirmary for Diseases of the Eye.' It was first given to the public in the second edition of Mr. Saunders's work, then in the press. I am quite satisfied that the observation was original, notwithstanding all the attempts of the German scholars to convince us, that at Vienna, and elsewhere, it was a matter, "*Lippis et tonsoribus notum.*"

I shall further add, that I am unacquainted with any fact in Medical Surgery which ranks with this in point of importance; whether we consider the urgency and frequency of the occasion, or the indispensable necessity, and almost unerring efficacy of the remedy.

the state of chronic closed pupil, after reiterated attacks of inflammation.

A morbid change sometimes, but rarely witnessed, is the conversion of a choroid into a shell of osseous matter.

I shall have occasion to speak of others under another head.

SECTION V.

RETINA:

Inflamma-
tion of
retina.

THE retina is sometimes, though rarely, the seat of inflammation; but it is an error to suppose that intolerance of light is a sign of this affection, as is clearly proved in the strumous ophthalmia, in which, although the intolerance is in excess, the retina is uninjured: and, secondly, because the effect of inflammation upon a nerve of sense is to produce direct palsy, not increased excitability. Inflammation of the passages and auxiliary textures of the organs of sense may render the impression of their natural stimuli painful, but here, as in the case before referred to, and probably in all cases, the increased acuteness of the sense is sympathetic. The organic sensibility, we may conclude, is increased in the sentient, as in other organs, by inflammation. This is probable from the first and predominant symptom of inflamed retina, viz. a sudden attack of vehement dashing pain of the most distracting kind, which is described to extend from the bottom of the eyeball to the occiput, or in the reverse direction, and the supervention, within a few hours, of total blindness, with occasional sparks and flashes of vivid

light. The pupil, upon inspection, is gaping and motionless, as in confirmed amaurosis, and the humors are thick and muddy. The external signs of inflammation are in the commencement disproportionate, and quite insufficient to account for the symptoms.

In some cases, however, the signs of choroid inflammation are present with the attack of pain and the loss of sight. The pupil is not thrown open, but it is without motion. In addition to diffused vascularity of the conjunctiva, the straight ciliary vessels are remarkably loaded, so as to give a livid red hue to the sclerotic around the cornea. The pupil becomes in a few days plugged with lymph, or the whole iris bulges forward, changes color, and the crystalline turns opaque; or instead of this, the same splendid tapetum-like appearance presents itself which is observed in the commencement of the medullary fungus, upon looking obliquely through the pupil. The pain in this attack is accompanied with a sense of confusion so alarming, that the patient apprehends the loss of his intellects. I once saw the disease marked throughout with so much disturbance of the nervous system, *e. g.* vigilance, temporary wanderings, catches of the muscles of the face, startings and frightful dreams, in the short intervals of repose from exhaustion,—coupled with a sense of heat, constriction, and tenderness of the whole scalp,—that I was disposed to consider the oph-

Accompanied with inflammation of the other tunics.

thralmia as secondary, and subordinate to inflammation of the brain or its membranes. When the internal signs of inflammation are less obvious, and the humors and internal tunics undergo a slow but complete disorganization in the progress of the disease, meteoric flashes are frequent, even after the inflammation has run its course; and I have known patients gratified with this *ignis fatuus*, although conscious that it was no more. I have seldom seen an example of this inflammation, which seemed to afford time for the beneficial operation of a remedy. I have in more than one instance given a full trial to the lancet, and the immediate operation of mercury; but though both were carried as far as could be permitted with safety, the vision was lost. In others the external inflammation has been subdued, and the vision has been recovered so far as to enable the person to distinguish surrounding objects with tolerable precision; but the gaping and motionless pupil, the discolored humors, and the superficial congestion, which remained, afforded little hope of its continuance. One lamentable instance occurred under my observation, of its destroying both eyes in a middle-aged lady within the short interval of a fortnight. She expressed, in the agony of her suffering, a conviction that she must either lose her sight or her senses.

Amaurosis,
organic and
functional.

Amaurotic affections, as is well known, differ infinitely in degree, but they differ also in kind; and this affords a more scientific basis of classi-

fication. I divide them into two classes, the organic and the functional. The first comprehends alterations, however induced, in the texture or position of the retina, optic nerve, or thalamus. The second includes suspension or loss of function of the retina and optic organ, depending upon a change either in the action of the vessels, or in the tone of the sentient apparatus.

As causes of the first, we may enumerate,

1. Læsion, extravasation of blood, inflammatory deposition upon either of its surfaces, and loss of transparency of the retina.

2. Morbid growths within the eyeball, dropsy, atrophy, and all such disorganizations as directly oppress or derange the texture of the retina.

3. The state of apoplexy, hydrocephalus, tumors or abscesses in the brain, in or upon the optic nerve, or its sheath, and thickening, extenuation, absorption, or ossification of the latter.

As causes of the second,

1. Temporary determination; vascular congestion, or vacuity, as from visceral and cerebral irritation; suppressed or deranged, or excessive secretions, as of the liver, kidneys, ute-

rus, mammæ and testes; various forms of injury and disease; and sudden translations of remote morbid actions.

2. Paralysis idiopathica, suspension or exhaustion of sensorial power from various constitutional and local causes; from undue excitement or exertion of the visual faculty; and from the deleterious action of poisons on the nervous system, as lead, mercury, &c.

From this description it will be understood, that organic, and many forms of functional amaurosis are incurable; and the functional, by continuance, lapses into the organic disease. Even under the continued suspension of function, much more the duration of a state of excitement, the power of the retina, as of other parts, gradually fades, and is at length exhausted. Thus the removal of a cataract from the eye of a person who had been the subject of the disease for thirty years, was unsuccessful in restoring useful vision. This was a sensorial defect, for the eye had every appearance of health, both before and after the operation.

I am aware of the objections to which this, like most other attempts at a scientific arrangement of such subjects, consistent with practical views, is exposed. Thus the comprehending under the same heads the states of temporary

and permanent congestion of the vessels of the retina and brain, and the disordered actions of the vascular and proper texture of the retina, may, *primâ facie*, appear to be examples of incongruity. But for the purpose of descriptive arrangement, a line of division must be somewhere drawn; and opposed to the gradual and often imperceptible transition from functional to organic disease, this division must appear more or less forced and artificial. I conclude that the difference between the disposition to apoplexy and the state of apoplexy, may be acknowledged in the eye as well as in the brain, and that the purely functional irregularities of the former organ as a whole, may be classed with as much propriety as those of the heart or the stomach.

In treating of the disorders of any sense or function, I deem it an essential character of a scientific arrangement, to include in one view the entire organ, philosophically speaking, subservient to that sense or function: hence, the brain and retina should not be considered separately, but in conjunction. Secondly, to regard the locality and demonstrableness of diseased states, as affording the best ground of division; because the presence or absence of certain external characters affords a stronger distinction between functional and organic disorders, than we could hope to obtain from any

analysis of the symptoms characterising the varieties of disordered function, in the present state of our knowledge.

History,
and con-
current dis-
eases.

The history and concomitant appearances or morbid states associated with amaurosis, usually indicate to which class it belongs : as for example, diseased changes in the situation or texture of the eyeball, or in the brain, a hemiplegia, or partial paralysis, with other signs of apoplectic or hydrocephalic pressure, whether resulting from an injury of the head or otherwise ; or an acute deep-seated inflammation, whether accompanied by a visible opacity or not, point out the organic nature of the affection. I have seen such an amaurosis produced by abscess in the cerebral substance, and by the medullary fungus of the cerebrum. On the other hand, I have known the following distinct sources of irritation operating to produce functional amaurosis, viz. wound of the scalp *, caries of the skull, abscess and caries of the antrum maxillare, with excessive œdema of the integuments of the lids and cheek, a large abscess under the masseter and muscles of the cheek, and an abscess at the extremity of a molar tooth, while the crown of the tooth was sound. In all these cases it is to be under-

* A læsion of the frontal nerve is mentioned among the occasional causes of an amaurosis from Hippocrates downwards. A striking example is reported by Sabatier. *Traité d'Anatomie*, Tom. 3. p. 228.

stood that the eye was sound, and the orbit was untouched by the disease of the parts in the vicinity, to which the amaurosis was clearly attributable. In like manner an excessive use or rather abuse of the visual faculty, the disordered functions of the stomach, liver, uterus, &c. ; sudden and alarming depletion, excessive or obstinately suppressed secretions, difficult dentition, the presence of worms in the intestinal canal, and the deleterious effects of noxious agents upon the organ or the system, are sufficiently obvious causes of the functional amaurosis.

The professions, circumstances, and habits of patients throw much light on the origin and nature of amaurotic affections. Such as have a direct influence are, sedentary occupations disposing to torpid liver and bowels, combined with the continued exercise of the eye in a depending position of the head upon minute objects* ; in too strong or insufficient light ; upon polished reflecting surfaces † ; habitual exposure of the organ to a high degree of heat ‡ ; to acrid

* Needle-workers, writers, draughtsmen.

† Inspectors of linen and scarlet cloths, and of new bank-notes ; money-counters. It is a curious fact, that several persons so employed at the Bank, at the issue of a new coinage of silver, were affected with symptoms of amaurosis. Colour-manufacturers, burnishers, landscape-painters.

‡ Smiths, stokers in iron furnaces and glass-houses, tavern cooks, &c.

fumes and vapours* ; and the customary employment of optical glasses†. Immoderate grief, excessive indulgence in venery, protracted suckling, continued diarrhœa, repeated hæmorrhages, profuse salivation ; and, on the other hand, obstinate amenorrhœa, or constipation of bowels, with determination of blood to the head in a full habit, are ordinary predisposing or constitutional causes of this disease, as I have had abundant opportunities of learning‡.

* A wholesale manufacturer of blacking became the subject of gutta serena. He had been a constant superintendant of the process upon a large scale. The mixture of sulphuric acid, with the several ingredients, disengages a pungent and offensive vapor, by which the eyes are very painfully affected.

† Watch-makers and engravers, philosophical instrument-makers, sea officers.

‡ There are strong shades of difference in the cases of these unfortunate persons, as regards the intensity of their feelings under the hopeless privation of sight. The man of pure life has the support of the best philosophy. The literary man has not enjoyed his '*Noctes Atticæ*' in vain ; they have provided him with resources. Even the aged voluptuary rises with some degree of complacency as a '*conviva satur*' from the banquet of nature ; and contemplating the various evils of the common lot in the circle of his friends, meets his calamity with somewhat of martyr fortitude. The most pitiable is the amaurosis of early life, from excess of sexual indulgence, and especially of solitary vice. The following are strong examples :—A country lad, of robust constitution, became the alternately favoured paramour of two females, his fellow-servants, under the same roof. He was the subject of gutta serena in less than a twelvemonth. Another at an early period of puberty, suddenly fell into des-

Amaurosis, of whichever class, is either perfect or imperfect. The first is marked by total insensibility to light; the second, by defect of vision, infinitely varied in kind and degree. I need scarcely remark, that not only the appearances and symptoms vary, but the essential character of the disease varies in its stages. Thus, an affection, purely functional in its origin, by duration becomes an organic disease.

ORGANIC AMAUROSIS.

When the eyeball is the seat of organic amaurosis, it commonly presents some, or all of the following appearances :

Signs of organic change in the eyeball.

1. A pupil fully or preternaturally dilated, contracting feebly, in the first case, on the sudden admission of light, and absolutely motionless in the second. This appearance is not peculiar but common to both classes, though by no means invariable in either.

2. A congestion of the superficial vessels, especially of the long fasciculi of conjunctival veins.

pondency, and shunned society. He never left his chamber but when the shade of night concealed him from observation, and then selected an unfrequented path. It was not discovered until too late, that in addition to other signs of nervous exhaustion, a palsy of the retina was the consequence of habitual masturbation.

3. A peculiar bluish grey tint of the sclerotic coat ; sometimes a degree of bulging or protrusion on one or more sides of the globe ; or simply a loss of sphericity, its sides appearing flattened.

4. A diffused turbidity or milkiess, apparently of the vitreous humor, strikingly observable when contrasted with the jetty brightness of a healthy eye. It is little more than the healthy appearance of the humors in the eye of the horse. This state, which the antients termed glaucoma, is very often mistaken for incipient cataract ; and I have known it called a black cataract, and the operation of extracting the transparent lens performed. It appears deep-seated, diffused, and of uniform density ; and in examining some such cases at long intervals, I have not found the appearance vary. The lens remains transparent. There are, however, some cases of a deep-seated opacity so closely resembling that of incipient cataract, that it becomes next to impossible to decide the actual state of the lens. I have seen the latter, upon an experimental extraction in such a case, semi-transparent, and of a bright yellowish tint throughout, and the sight of the patient has been considerably improved. The vision is in general defective in a much greater degree than the visible opacity explains ; and this, combined with the depth of the opacity, a dilated and sluggish

pupil, and some other symptoms of amaurosis, makes for the opinion that it belongs to the latter class. But where other signs of impaired retina are wanting, and the states of dimness and opacity correspond, the operation would be warrantable, although the site of the opacity should be disputable, if it were the express desire of a patient properly in possession of the circumstances.

5. Another yet more common appearance is that of a white or greenish yellow spot, apparently in the fundus of the eye, a little to one side of the visual axis; sometimes it has a disc of such breadth and splendor, as to look like the tapetum of sheep, or the colored choroid of fish; but more commonly it occupies a circumscribed annular space, and is seen only in a strong light, and in particular directions of it. Although this appearance is commonly associated with impaired vision, I have now and then seen it in persons who made little, if any complaint of their sight. This appearance has been referred to a circumscribed opacity of the retina, and the central spot supposed to correspond to the porus opticus, or axis of the optic nerve. It has also been conjectured to be the macula lutea of Soemmering*. It is probably with more

* A point of opacity within the reflecting mirror of the eye must, of necessity, create so much delusion, that we can scarcely venture, by inspection, to determine its precise seat.

propriety to be attributed to a deficient secretion of the choroid pigment, a preternatural adhesion betwixt the choroid and retina, and a discoloration or resplendent appearance of the retina from that cause. I have been led to this opinion from observing it combined with that form of amaurosis in which the vision is confused to dimness in the broad light of day, and is tolerably clear and agreeable after sunset; and also with that which is disturbed by the partial illumination of objects.

I have also been enabled to make the following observations regarding this appearance. It is neither suddenly induced nor preceded by any signs of inflammation; there is often a degree of blindness joined with it greater than its extent could account for; and a recovery of vision, to which I have been witness under such circumstances, is not accompanied by any perceptible change in the appearance. I am therefore disposed to regard its connection with amaurosis, whatever it may be, as a casual coincidence, a change incidental to age, like the arcus senilis of the cornea; for it is by no means

Even the opacities of the cornea and crystalline capsule are liable, in some instances to be confounded. It is highly doubtful whether anatomy would determine the point in question; except by a nice comparison with the sound organ at a very early period after death, the morbid opacity of the retina would certainly pass undetected.

a constant appearance in that disease, nor is it incompatible with useful vision.

I have more than once seen a condensed and palpable opacity at the fundus of the eye succeeding to inflammation of the choroid, which had destroyed vision; and this I have considered to be produced by a change in the texture of the retina. What adds to the probability is, that the crystalline in this case afterwards, as if progressively, becomes opaque; a common sequel of amaurosis induced by inflammation.

Opacity of
the retina.

In the amaurosis from inflammation of the choroid or retina, where the diseased action has entirely subsided, the veins of the conjunctiva are varicose, the iris is discolored, thick, tough, inelastic, and preternaturally vascular; the substance of the crystalline is more or less absorbed, or converted into a fluid and discoloured; the vitreous humor is opaque and of a deep yellow color. The retina, like the other transparent textures, becomes opaque under inflammation, and it is probable that under these circumstances, adhesive matter is effused upon the interior of the choroid; this supposition I have never had an opportunity of verifying by dissection, in cases of which the history was known.

Amaurosis
from deep-
seated in-
flamma-
tion.

From absorption of the vitreous humor and collapse of the retina.

I some time ago dissected the eyes of a man who had cataracts with amaurosis. The cataracts had been formed ten years prior to his death; one of them fell down behind the pupil, and he was spontaneously restored to sight, as by a natural couching. Gradually he lost his sight, the eye still remaining plump, and the pupil clear of any opaque substance. The change which had taken place was an interstitial absorption of the vitreous humor, which was proved by the immediate discharge of an unusual quantity of watery humor, on opening the tunics, and the appearance of the vitreous capsule collapsed into a little opaque bag, and adhering to the ciliary body at the inferior margin of the iris. A remnant of the crystalline was involved in it, not exceeding in size a large pin's head. The remains of the retina were a mere film or string extending from its attachment, at the back of the globe, to this bag or net of the vitreous capsule. The pupil of the other eye, in which the cataract had retained its place, was closed, and the lens adhered firmly to the iris by its capsule, which was involved with the collapsed tunic of the vitreous lying behind it; for the humor was as completely absorbed in this as in the eye first examined, and the texture of the retina as nearly obliterated. Thus the amaurosis resulted from collapse of the retina, owing to absorption of

the vitreous humor. The fall of the lens in one eye resulted from the absorption of the vitreous humor, and would have occurred from the same cause in the other eye, but for the adhesion previously existing betwixt its capsule and the iris. The eyes preserved their figure by the increased secretion of the aqueous humor, which is always in proportion to the default of the vitreous; and could the retina have retained its position, the vision, which was for a time recovered, would probably have been retained.

A young gentleman, the subject of amaurosis in his left eye, was affected with symptoms of a diseased action in the brain; as, deep-seated pain in the fore part of the head on the same side, disposition to sleep, and inability to employ his mind as heretofore. He was repeatedly blooded and blistered without relief. The digestive functions were much disordered, and he was put upon a course of alterative medicine. The disease, however, advanced; the eyelid became paralytic, and a slight degree of strabismus was accompanied with occasional double vision. The lethargy and the derangement of the secreting organs, and consequent emaciation and debility, increased, and his death soon followed. The eye had no unhealthy appearance; the pupil was regular, and moderately active. On examination, a firm lardaceous tumor, of the size of a garden bean, was found compressing the

From cerebral tumor.

optic ganglion and nerve at its origin thence, of the same side.

Amaurosis
from con-
cussion.

I have seen several cases of amaurosis from concussion, as by a blow on the temple, or the eye. Of these some were attended with signs of disorganization—some were superficially inflamed—and others presented no external appearance of injury. One was the case of a captain of artillery, who was struck by what is called the *wind of a ball*, on the right side of the head. He received no wound, but lost, instantly and irrecoverably, the sight of his right eye.

In another case, a young gentlemen received a blow on the eye, by which it was inflamed; the inflammation was superficial and easily subdued, but the vision was so much impaired, that a surgeon was consulted, who observed the pupil to be dilated and without motion. The iris recovered its activity by depletion, but useful vision was lost. It is not always the eye on the same side of the head which has received the blow that is affected. One remarkable case I shall take the liberty to mention.

A man who had good vision of the right eye, and was nearly dark from a cataract in the left, received a violent blow on the left temple. From that time he lost totally the sight of his right (or well) eye, which has now the faded appearance

of an incurable organic amaurosis, and owing to the rupture of the lens, which was at the time undergoing absorption, recovered sight with his left eye, which he still enjoys. Frequently the amaurosis from concussion is purely functional, and is cured by a full blood-letting, blisters, and purgatives.

I have observed several forms of congenital organic amaurosis: one, in which the organ is preternaturally small and soft, and even flaccid to the touch, as if from deficiency of the vitreous humor; the iris tremulous, and not influenced by the belladonna; the globe affected with an incessant tremor, and not subject to the control of the will. I have often seen this motion of the globe uncombined with the tremulous iris in cases where there was little more than a natural feebleness of the retina.

Congenital
organic
amaurosis.

A second depends on a deficiency of the pigmentum nigrum; here the tremulous motion of the globe is present; strong light produces uneasiness, and vision is dazzled and confused; the vessels of the choroid give the interior of the eye a deep red tinge, but not the bright scarlet of the albino, or the white rabbit. I have seen several of the children of two families thus affected; they are considerably aided by cylindrical shades, such as are used by connoisseurs in pictures; goggles; glasses covered with

black gauze, and every other contrivance to absorb light; even a coat of black varnish besmeared around the eye. I may observe in general, that an amaurotic disposition, greater or less, exists in all persons whose hair and eyebrows approach to white*.

A third form of congenital amaurosis is that in which the sclerotica so encroaches upon the cornea, that the latter scarcely exceeds the diameter of the pupil, while the volume of the globe appears somewhat greater than natural. Various malformations of the pupil, an extreme diminutiveness, and even a total deficiency of the iris, are not in my experience ordinarily associated with an imperfectly organized retina.

A fourth kind of congenital amaurosis is unaccompanied by any appearance of organic derangement. The eyes move in concert as if attracted by a faint perception of light, in an oblique direction; but the infant is too certainly blind. A diseased state of the thalami or optic nerve would, I apprehend, be discovered by inspection of these cases after death. It is proba-

* Professor Beer states, that dark colored eyes are more inclined to become amaurotic than those of lighter color. This observation is not at variance with my own, since the above remark refers only to white-haired persons, the characteristic of whose amaurosis is photophobia, or intolerance of light, and in whom the disposition depends on a defective pigment.

ble that the opaque retina is sometimes congenital as well as the opaque cornea : of the latter I have seen instances ; others are related by the late Mr. Ware.

FUNCTIONAL AMAUROSIS.

The functional amaurosis admits of the following subdivision.

1st. *The symptomatic*, or that which is only a symptom of some general disease or disorder of the system, as for example, general plethora, general debility, &c.

2nd. *The metastatic*, or that produced by the sudden transference of the morbid action from another organ of the body ; as for example, from the skin, the testicle, &c.

3rd. *The proper*, or that which immediately depends upon a peculiar condition of the retina ; as for example, the visus nebulosus, muscæ volitantes, &c.

I proceed to treat of them in succession.

1. *Symptomatic.*

Like nervous deafness, amaurosis sometimes follows typhus and scarlet fever, and the various forms of acute constitutional disease. This I

Amaurosis from constitutional disease and general debility.

have several times met with as a result of infantile fevers. It is also sometimes a consequence of chronic wasting diseases, in which organic changes interrupt the nutrition of the system. I have seen a rapid and severe salivation instituted for a remote affection, and where no disease had previously affected the eyes, terminate in gutta serena of both. The same has been observed of the sense of hearing. The state of the circulation has a marked influence upon imperfect amaurosis*. I know patients

* The effect of fever upon a nervous deafness, was strongly evinced in the case of a lady whom I knew. She had been incurably deaf many years, when, during the existence of a puerperal fever, it was remarked, that she had recovered distinct and even acute hearing, which again left her, after the febrile action had subsided.

I was once consulted by a gentleman who was the subject of this species of deafness to a painful degree. He informed me that he was in possession of a remedy for the disease, but unfortunately it was available only while in actual use, and too severe to be employed incessantly. His object was to ascertain if a less objectionable one was known. It consisted in occasional drastic purging, abstemious diet, and the hard daily exercise of a man training to walk against time, or fight, or ride a race. Under this alterative plan, he had so excited the action of the extreme vessels as to restore the sentient tone of the nerve. By adopting it, he had more than once recovered a perfect state of hearing, which remained while he had resolution to pursue it. But he thought, as would most others, *'le jeu ne vaut pas la chandelle.'*

While upon this subject, I shall take the liberty of still further extending this digression by adding a much more remarkable proof of the influence of vascular action upon the brain

whose vision it benefited in a high degree, and others in whom it is as much deteriorated by the quickened circulation of a full meal and a few glasses of wine. The former are persons of spare and meagre habits ; the latter plethoric.

The influence of mental emotion in producing this disease is most frequently seen in the instance of grief. Young widows are peculiarly liable to amaurotic affections ; and cases are re-

and its more immediate functions, and leave the reader to form his own conclusions.

“ A young woman, who was employed as a domestic servant by the father of the relator when he was a boy, became insane, and at length sunk into a state of perfect idiocy. In this condition she remained for many years, when she was attacked by a typhus fever; and my friend having then practised some time, attended her. He was surprised to observe as the fever advanced, a developement of the mental powers. During that period of the fever, when others were delirious, this patient was entirely rational. She recognized in the face of her medical attendant, the son of her old master, whom she had known so many years before, and she related many circumstances respecting his family and others, which had happened to herself in her earlier days. But alas! it was only the gleam of reason. As the fever abated, clouds again enveloped the mind ; she sunk into her former deplorable state, and remained in it until her death, which happened a few years afterwards.”

Take's Description of the Retreat for Insane Persons of the Society of Friends, p. 137.

A man labouring under recent concussion of the brain, and from this cause comatose, was freely let blood, and afterwards took a full dose of emetic tartar. After vomiting, he became immediately sensible.

lated, in which what the poet calls 'a short madness' has been productive of the same unhappy consequence.

What might be called the " amaurosis lacticantium," in which the infant preys upon its mother, and that in which the impaired energy of the whole nervous system, occasioned by various states of physical disorder, shews itself especially in this organ, may be taken as familiar instances of the amaurosis from constitutional debility.

Amaurosis
from ple-
thoric con-
gestion.

Amaurosis depending on vascular congestion is marked by some or all of the following symptoms, viz. dilated and sluggish or immoveable pupil, ptosis, or strabismus, and oblique or double vision of the affected eye ; a preternatural action of the carotids, flushed face, sense of weight, pain, or stricture of the scalp, lethargy, occasional tinnitus aurium, with greatly disordered and irritable stomach. The patient frequently complains, particularly in straining, stooping, or on first lying down, of seeing luminous sparks or flashes*, and a reflection of one or more of the choroidal vessels, the visible pul-

* Persons labouring under dyspepsia are often troubled with this symptom on first closing the eye to sleep ; and in the progress of amaurosis from nervous exhaustion, it is sometimes accompanied with the sensation of a crackling or snapping noise.

sation of which is a cause of much distress to him. A person thus affected accurately described to me the zona minor iridis, as distinctly presented to his view.

A loss of balance in the sanguiferous system, occasioning an undue determination of blood to the head, often exists, distinct from general plethora, and is aggravated by loss of blood. The following case is an example :

From determination of blood to the head.

A young medical man came to me one morning from the country in extreme anxiety, with an earnest solicitation that I would instantly apply a ligature to his carotid artery. This gentleman, aged 25, was of short stature, and constitutionally healthy. His pupils were large, and his countenance was suffused and bore the appearance of preternatural determination of blood to the head. He had been the subject of two attacks of inflammation ; one in April, the other in October of the same year ; during which he lost upwards of an hundred ounces of blood. He had now a constant heavy pain in the head chiefly over the coronal suture, and in the direction of the sinuses, with tinnitus of the left ear. After stooping the giddiness was extreme, and a golden colored spot, edged with black, appeared floating before the eye. He had been troubled with muscæ in excess, for a year and a half past ; he had now fire sparks flashing before

the sight, and saw a pulse in the choroid synchronous with that of the wrist*. When looking at near objects he was not troubled with muscæ, but they were always numerous, in proportion as the object was remote. He did not complain of much dimness. His complaints were not relieved by topical blood-letting. He recovered gradually but perfectly, under a regulated diet, and a course of the blue pill with saline aperients.

Amaurosis
from inanition.

The amaurosis, from depletion, is sometimes mistaken for its opposite, viz. that from plethoric congestion; this is owing to the coincidence of a dilated and immoveable pupil, muscæ, and a deep-seated pain in the head, with occasional vertigo; and its occurrence often in a corpulent habit. It succeeds somewhat abruptly to uterine floodings, and large and sudden depletion for acute diseases. The pain is not confined to the region of the orbit, though it affects chiefly, if not exclusively, the same side of the head; it is that peculiar nervous pain to which women are subject after uterine hæmorrhage, attended with a sense of defined pressure, as of an iron finger on the brain; and sometimes a

* The subjects of chronic iritis, and in whom the pupil is fixed, and the capsule of the lens more or less opaque, are often distressed with this or other signs of undue determination of blood to the head, which is not in any degree relieved by drawing blood.

distressing jarring noise like that of a mill or threshing-floor, or the rattling of the shingles as a heavy wave of the sea recedes. It is perhaps connected with an imperfect injection of the medullary substance. By a cautious use of tonics it is relieved; by whatever lowers or stimulates, whether diet or medicine, it is decidedly aggravated. The vision in this form of amaurosis is further enfeebled by the loss of as much blood as flows from two or three leech-bites. This is not imaginary; I have seen distinctly marked cases of it, in which large and copious venesection was still urged as the only resource of art. This I consider to be a fatal mistake.

As the causes of amaurosis, to whichever class it belongs, present infinite gradations, so do the imperfections of vision. An unhealthy secretion of the meibomian follicles and caruncula lacrymalis, a very inconsiderable obstruction in the excretories of the tears, or a preternatural excitability of the conjunctival surface from any cause, will give occasion to such a degree of weakness and dimness, as greatly to interfere with, if not to interrupt, the transaction of business. The improvement of the vision in strength and clearness, during the use of astringent lotions and stimulant ointments, is continually observed. Persons affected with an irritable state of the conjunctiva from any cause, frequently complain, not that their sight

Amaurosis
sympathe-
tic with ir-
ritable con-
junctiva.

is indistinct, but weak ; by which nevertheless they mean, that they cannot maintain distinct vision for any considerable time together. The retina appears to be sympathetically affected in these cases. They are often accompanied with muscæ, and remarkably benefited by blisters, as well as by applications, which improve the condition of the conjunctiva and eyelids*.

FUNCTIONAL AMAUROSIS.

2. *Metastatic.*

Amaurosis
by metastasis
from the
chest.

Amaurosis by metastasis is not unfrequent. I have seen it from the state threatening effusion into the chest, from gout in the foot, and swelled testicle; in all which cases the oppressed organs were suddenly relieved, and the eye as suddenly affected. Thus a person goes to bed with good vision and rises blind.

A lady, above the middle age, who had long been subject to occasional attacks of pulmonary congestion, after one of unusual severity, threatening hydrothorax, was suddenly affected with paralysis of the upper eyelid of the left eye ; the sight was slightly, if at all, impaired. On the following day however she had totally lost the sight of that eye, the pupil of which was dilated and motionless. On the morning of the third day, the upper eye-

* See note C.

lid of the right eye was paralysed, and the vision of that eye was also much impaired. On the fourth day the ptosis on the left side had disappeared, and the eyelid on the right side resumed its position. She was now in a state nearly approaching to complete blindness; both pupils dilated, although the left most so, and nearly, if not quite inactive. The attack was accompanied by a marked simultaneus relief from the threatening symptoms of the original complaint, and occasional fugitive pains across the front and top of the head. Upon inspecting the eyes opposite the light, the appearance described 5, page 149, was conspicuous in both eyes, and led her physicians, who were of the first eminence, to apprehend an incipient opacity in some interior texture. Under the frequent administration of calomel and rhubarb, in moderate doses, and the alternate repeated application of blisters behind the ear, and to the nape of the neck, with abstemious diet, the vision of both eyes was gradually restored.

A man, the subject of hernia humoralis, lost an unusual quantity of blood by the bites of leeches applied to the part. The testes were suddenly and greatly reduced, and he complained of uneasy sensations in his head; to use his own phrase, a pain like opening and shutting*. Without any other visible sign of

From the
testis.

* I once saw an attack of hemiplegia originate under simi-

amaurosis than a dilated and sluggish state of the pupils, he described a dark screen seeming to rise gradually from below upward, and at length totally obscuring the sight. He lost blood from the head repeatedly, and underwent a full course of mercury without benefit. A state of perfect amaurosis ensued.

The gout attacks the eye through the medium of the stomach. Vomiting occurs with pain in that organ, on the subsidence of an inflammation in the extremities, and is succeeded by violent pain in the head. The loss of sight is sudden and permanent.

From the
foot.

A gentleman, after an attack of gouty inflammation in the foot which suddenly ceased, was attacked with pain in the stomach and vomiting; this in the course of the day subsided, and in the night, a violent pain in the head was succeeded by an almost total loss of sight, which was never afterwards in any degree restored, although, by steeping the feet in a hot infusion of mustard, the great toe inflamed so much as entirely to relieve the head and stomach.

lar circumstances, viz. a sudden reduction of enormously enlarged testes by leeches and cold lotions; and since the first edition of this work was published, I have known a case of fatal apoplexy succeed to a gangrenous inflammation of the scrotum, from extravasation of the fluid injected for the cure of hydrocele, within three days from the operation.

To this class belong the cases of amaurosis consequent upon the sudden suspension of the catamenia, and of habitual hemorrhoidal discharges; the rapid healing of large ulcers of long standing, and the sudden retrocession of cutaneous eruptions*.

FUNCTIONAL AMAUROSIS.

3. *Proper.*

A short case or two will best explain what I would call a temporary palsy of the retina from over excitement.

Amaurosis
from over
excite-
ment.

The following account is that of a young gentleman who was ardently engaged in the study of the profession when thus interrupted.

“ Having habituated myself for the preceding twelve months to intense study, reading and writing to a very late hour, which had been only interrupted for a few days by a slight inflammation of my right eye, I quitted London to recruit my health in the pure air of ———. This daily improved, but I found a growing imperfection in the vision of my left eye, which advanced unaccompanied by inflammation, pain, or any other external symptom of disease. It seemed at first a film before the sight, but at length amounted to a total loss of vision. On

* See note D.

examination, I found the pupil greatly dilated, and learned that the iris had little or no action. By the advice of Mr. T. whom I now consulted, I applied a blister, extending from the centre of the forehead round the eye to the root of the nose. This drew well, and I continued it open for ten days, closing the eye from light during that period. I took at the same time a calomel and opium pill thrice a-day. In the space of a few days my mouth became sore; the pupil acted, though unequally, and I experienced a gradual recovery of vision. In the course of six weeks, I was enabled to resume my studies, and could perceive no defect of vision. I had gradually reduced the dose of calomel, and now discontinued it, drinking the decoction of sarsaparilla. At the distance of four months from this occurrence, the pupil is regular and active, and the sight unimpaired."

One of our most eminent and indefatigable artists in landscape was the subject of a superficial irritable ophthalmia, accompanied with much dimness and confusion of vision. This continued after the inflammation had subsided under the ordinary treatment. He became seriously alarmed to find, upon attempting to renew his occupations, that he was unable to discriminate the shades of color from each other, and that in fact he had lost the visual tact, if I might so express myself, essential to

his pursuit. He submitted, by my advice, to a gentle course of mercury, and has since enjoyed his former accuracy of vision.

Examples of this species of amaurosis frequently occur among sea officers and others, suddenly, and without any preceding inflammation. I have repeatedly seen it of sudden accession with no other external sign than an inactive pupil.

A captain in the navy had made much use of his right eye for many years in observations with telescopes and sextants. About a week before he applied to me, he observed a mist before this eye, which increased until it was so dense, that he could neither distinguish the features of his friends, nor the large letters of a title page. The eye was free from inflammation, the pupil large and sluggish; he had no pain either in the eye or the head. He was bled copiously from the arm and temple, and briskly purged with calomel and jalap at short intervals. Blisters were applied to the temples. He then rubbed in a drachm of the strong mercurial ointment for several nights in succession; this produced a copious flow of saliva and violent diarrhœa, so that no benefit was obtained. By the calomel and opium pill taken night and morning his gums were immediately made sore. In three days the mist began to clear, and he was de-

lighted to find that he could tell the hour by his watch. He continued improving so rapidly that, at the expiration of ten days, he could read an ordinary print with perfect facility. The pupil had recovered its natural magnitude and activity.

In one instance this form of the disease followed a long exposure to the heat of the sun with such suddenness as to lead the patient to attribute it to a '*coup de soleil*;' and in another it was referred to the habit of reading by fire-light. It is seldom that both eyes are affected, and probable in some cases that the discovery of the amaurosis, and not the disease itself, is of recent occurrence. This point, however, can generally be ascertained.

Symptoms
of amauro-
sis.

I now proceed to mention the leading symptoms of amaurosis. A great source of difficulty in the arrangement of this extensive and complicated subject is the circumstance of many symptoms being common to both classes. I shall appropriate them, as far as I am able, in my description. Pain affecting the forehead and temples is a precursory symptom of amaurosis, diminishing in proportion as the dimness increases; when the amaurosis is perfect, it usually ceases altogether if the disease has its seat in the eyeball. We must judge by its situation

Pain.

and extent, but especially by its association with other symptoms, if the pain be characteristic of organic amaurosis. Pain affecting the parts before-mentioned, occasionally inconsiderable, and declining as the dimness increases, is common in some forms of functional amaurosis. If it be severe, remitting imperfectly, immediately increased by exercise, whether diffused over the entire side of the head, or circumscribed to a small space of the anterior cerebral lobes, it is usually connected with an organic cerebral change; but in this case, derangement and torpor of the primæ viæ, loss of strength and flesh, disposition to stupor, occasional confusion of intellect, inaptitude to exertion, and paralysis of one or more muscles, will be concomitant symptoms.

I have met with cases of amaurosis clearly depending on cerebral disease or irritation, in which the scalp was universally tender even to soreness.

There is an intermittent spasmodic pain accompanying some cases of amaurosis, shooting through the orbit into the head, of the most acute and distressing severity; it makes a periodic attack at or about the same hour, every night, or every second night, and continues for several hours; it is accompanied with convulsive quivering of the muscles of the eye and eye-

Spasmodic
pain.

lids, and profuse lacrymation ; there is nothing in the appearance of the organ to explain its nature and origin. What has been described as an intermittent ophthalmia, is I think improperly so termed—the pain, not the inflammation, is intermitting. The pain of tooth-ache and ear-ache, according to the state of the vascular system, is subject to intermissions more or less complete, but the periodic pain to which I refer, is independent of any visible sign of inflammation. I believe it is a *tic douloureux* affecting one or more of the orbitar branches of the fifth pair. I have cured it in two cases by arsenic, where opium failed to prevent the paroxysm. I have known one instance of a similar affection, without any defect of vision.

Paralysis.

Paralysis of the levator palpebræ is a sign of cerebral pressure, and always accompanied with some degree of imperfect vision ; this, however, varies considerably. Paralysis of the orbicularis palpebrarum is less frequent. It is generally connected with a paralysis of the muscles on the same side of the face. A palsy of either of these muscles is sometimes attended by a degree of vertigo so considerable

Vertigo.

as to make the patient in danger of falling, if the eye be uncovered. In these cases near objects appear remote, and much diminished in size, as if seen through an inverted opera-glass.

The vertigo seems to be excited by this illusion, as it happens to most persons in looking from such an eminence as renders objects dwarfish, for it ceases as soon as the affected eye is closed. This symptom is usually removed by depletion.

In other cases of fallen eyelid the affection Ptosis. of vision is so slight as scarcely to occasion inconvenience, so that a person may read or write while he supports the lid ; but the pupil is invariably over dilated, and I have observed that the pupil does not recover its activity proportionably with the recovery of vision ; on the other hand, I have seen both palpebræ affected with paralysis in succession, each for a day or thereabouts, and in this case the blindness supervened upon the removal of the ptosis.

Ptosis follows injuries of the head and top of the spine : I have known a permanent ptosis and dilated pupil follow an injury of the cervical vertebræ after an interval of some months, without any other symptom of palsy. It is remarkable that there was no paralytic affection below the seat of injury. But paralysis from irritation may happen in any direction. In this case vision was in great measure restored by a course of mercury. The use of strong lead washes will produce a ptosis. I lately saw a temporary paralysis of the muscles on one side

of the face, from frequently touching an ulcer of the fauces with the oxymel æruginis.

Loss of association and direction.

In proportion as vision fails, the eye affected with amaurosis loses its fellowship with the sound eye, and this loss of correspondence becomes a conspicuous character of the disease. It is owing to this loss of correspondence that persons, affected with an imperfect amaurosis of one eye, often mistake the relative position and distance of objects, and frequently see them reflected.

In perfect amaurosis, or gutta serena, as it is absurdly called, the peculiar inexpressiveness or vacancy of countenance, depending on the non-convergence of the optic axes, is too remarkable to escape an ordinary observer, especially if both organs are affected. The patient has either a fixed unmeaning stare, or a constant rolling motion of his eyes. The loss of association in strabismus results from a relative debility of one of the straight muscles, and if both eyes are employed, is generally accompanied with double vision; but that which I have just described is in no degree depending upon loss of muscular energy, partial or general, direct or indirect; but on the total failure of sensation, by which the actions of all muscles subject to the will are directed.

Strabismus.

Strabismus is either congenital, or from the

debility of scrofula, like the paralysis of the lower limbs in children; or from a morbid association accidentally contracted and impressed by habit in childhood; or from a wound of the frontal nerve; or a speck upon the cornea rendering the vision oblique; or from violence done to the affected straight muscle. I have seen a complete internal strabismus, the effect of a blow on the temple, which a school-boy received in fighting. From its suddenness, and the ecchymosis of the conjunctiva on the temporal side, I concluded the abductor was lacerated or palsied; and so it proved; for in a few weeks the distortion was entirely removed*. It is also a symptom of irritation arising from difficult dentition, worms, &c.; or of pressure at the origin or in the course of the nerve proper to the affected muscle.

There is a complaint of cross sight occasionally made by persons who have no perceptible strabismus. It happens in looking downwards as in ordinary reading. In looking at objects on the same horizontal plane with the eyes, it is not perceived. It is a relaxation of one of the inferior straight muscles.

* Mr. Cheselden relates the case of a gentleman who had strabismus, with double vision, produced by a blow on the head. By degrees, the most familiar objects came to appear single again, and in time all objects did so, without any amendment of the distortion.

Hemiopsia
or partial
impairment
of the re-
tina.

The retina is often partially affected in organic amaurosis. Thus some persons describe a horizontal, others a vertical screen, eclipsing one half of the object viewed, or even of the field of vision. In order to see a given object entire, which is upon a level with the eye, they are compelled to move the eye or the head, in the direction which the obliquity of their vision requires. Again, cases now and then occur in which persons have lost their lateral vision, while they see objects in the direct line of the axis of vision. In the greater number of cases, however, the vision of amaurotics is oblique, and in perfect amaurosis, the perception of light, if any, is also oblique. The gradual return of vision is generally first perceived in this direction. The sensibility of the retina, whether more or less, seems to be greatest at the part farthest removed from the axis of vision, or rather from the entrance of the nerve, for it is more frequently observed on the temporal than on the nasal side. I am unable to offer a satisfactory conjecture in explanation of this fact.

A gentleman, who died of apoplexy in his 36th year, and who lost eight pounds of blood in the three days preceding his death, had consulted me for depraved sight of one eye, six months before that event. The pupil was permanently dilated. He had double vision whilst looking

directly forward; if he looked obliquely to either side, his vision was single. A slight strabismus was perceptible. Many cases analogous to this have fallen under my notice, in which no opportunity was afforded of ascertaining the cause of disease*. The vision is sometimes perfect or nearly so with the eye, which, by loss of correspondence with its fellow, occasions the duplicity of objects viewed with both. I have known it equal in power to that of the other eye when employed singly. The double vision and giddiness cease, when either eye is employed alone, or is closed. The paralysis affects the *nervi motores oculorum* directly in such cases, and the optic nerve suffers by sympathy. Where the vision of the affected eye is materially bedimmed, the ptosis or strabismus are more marked, and the symptoms of double vision and vertigo in proportion.

A distorted relative position of objects is also not an uncommon symptom of organic amaurosis. Thus, the lines of a printed page seem zig-zag, and the two eyes of a face appear in different planes, whether one or both eyes are affected. If one object is seen in its proper place, the situation of a contiguous object is erroneous, both as to distance and parallel. If only one eye is affected, the employment of the sound eye exclusively corrects the error.

Distorted
position of
objects.

* See note E.

In the case of simple non-correspondence, it is corrected by either eye indifferently. This is the reverse of what happens when the eyes are perfect, in which case the delusions, arising from the use of one eye only, are corrected by employing both. Both this and the preceding are for the most part, not always, symptoms of an organic affection. I have been led to this conclusion from observing the morbid appearances and the inefficacy of remedies, where such signs of the disease were established. But I have known instances of their removal.

Muscæ,
fixed and
floating.

Muscæ are either fixed, when they are usually allied to spectra, and belong to organic amaurosis; or floating, when they are I believe characteristic of functional amaurosis, sympathetic or proper. I have known the fixed musca, permanent, without variation for years, darkening a certain defined portion of the field of vision. In some rare instances, it precedes acute choroid inflammation; more frequently it is unconnected with any particular morbid state. Around the opaque spot persons have sufficiently distinct vision. The spot varies in density in different individuals, and under a long but gentle mercurial course, I have known it become considerably less dense, so as not to intercept bright light. Its circumference sometimes reflects a tinge of color or a luminous halo. The fixed musca seldom presents

the fantastic shapes of the floating*, but it is not uncommon for the two forms to co-exist.

The *musca volitans* is sometimes solitary, following the eye at a fixed angle as it passes along a line; sometimes two, three, or more are presented; more frequently an immense assemblage, descending in a cloud as the eye is raised, and ascending as it is depressed. They are obvious to so many analogies, and apprehension of impending blindness makes patients so minute in their observation and description of them, that it is scarcely possible to do justice to our experience in attempting to describe them. Sometimes they are represented as globular, sometimes annular and flat like a piece of money. Portions of flue, of soot, insects' wings, transparent vesicles, or minute globules of quicksilver, connected like the links of a chain, or short hairs with their bulbs attached to them, are ordinary resemblances. They occupy the air with some persons, and are seen upon looking at the sky, or upon a white sheet of paper, and especially in shifting the eye from one object to another; to some they appear in the fire or candle only, and with others they seem to cover the ground, so that

* To this remark there are exceptions. A gentleman, who a short time ago consulted me, compared the spectrum constantly before each eye to a large dragon fly, darkening the field of sight.

they walk in them knee-deep. Almost every person has, at some time or other, seen these appearances, but especially those subject to dyspepsia, and disordered function of the stomach and liver. At the moment of approaching deliquium, they appear in one vast cloud, and they are harbingers of the intense bilious headache. At the instant of their appearance, the sentient extremities upon the fingers and tongue are so benumbed, that objects of touch and taste convey a very indistinct impression, as if some muffle were interposed. These sensations I am describing *ad vivum*, for I was formerly often the subject of this attack, which was followed by a certain degree of confusion of intellect, and temporary suspension of memory, so as greatly to embarrass, if not to take away the power of intelligible expression. I mention these opposite and transitory states of emptiness and plethora concomitant with the floating muscæ, to shew the purely functional origin of the affection. The one (deliquium) is an uninjected, the other (sick headache) an over-injected or congested state of the nervous texture; or suspension from vacuity, and suspension from plethora. An analogy is plainly to be perceived between the corresponding states of the sentient and visual extremities, described in the last affection, to that of a temporary incomplete paralysis.

The fixed musca is generally an organic affection, probably a deposit or extravasation between the choroid and retina, compressing to a certain space, the papillæ of the retina, to which the musca corresponds in figure. In other instances, it is independent of deranged structure, and may be presumed to be only an insensible point on the retina. The single muscæ sometimes coalesce, and form a larger spot. The floating muscæ are altogether a functional affection, not interfering with useful vision, and sometimes, though not often, removed. To some persons they disappear upon looking through glasses, and others see them only upon remote objects. Their magnitude diminishes as the distance is increased, to those who see them at all distances. They are simply a disordered circulation in the vessels of the retina *, and occur oftener in nervous and spare than in plethoric and robust persons; they are generally induced by overstraining the organ, almost always accompanied with a weak and irregular digestion, and varying with, if not depending upon, the condition of the stomach.

Colored spectra, or luminous impressions of objects remaining upon the retina, are usually preceded by the fixed muscæ, and may then be regarded as a more advanced stage of the com-

Morbid
spectra.

* In some cases they have been supposed to depend on floating particles in the humors or minute scabrous points in the cornea.

plaint. This is not always the case, I have known them to be symptoms of functional derangement, and to disappear as the vision recovered. In this affection, a halo of light encircles the opaque spot during the exercise of vision; and if a bright luminous object be contemplated, a colored image or the reflexion of it is presented to the mind for a time, greater or less, after the eye is withdrawn or closed. Of the same species are the various morbid refractions of luminous bodies, presenting the object double to one eye, or curiously divided and distorted, as in looking through a crinkled pane of glass*; and the appearance of prismatic colors in the forms of circles, rainbows, cones, &c. Sometimes ordinary objects are imperfectly represented, or even dark, so that they would not be known but from their outline being illuminated. Thus a man, a tree, or a house, appears fringed with a glory; and on the other hand, it is not uncommon for the outline of objects to be lost in shade, while the centre is clearly discerned.

I might illustrate these observations by a multitude of cases in my possession, which I omit for the sake of conciseness, and in conformity to the plan of this work. On this subject, however, I shall take the liberty of introducing the

* I have known cases in which interrupted vision was produced by several apertures made with the needle in a capsular cataract, so that the moon appeared as if cut in pieces.

case of an intelligent young gentleman, very accurately drawn up by himself, for the purpose of shewing the gradations of this disease in its progress, as well as its origin.

“ About a year and a half ago the first symptoms appeared, which gave me any uneasiness with respect to my sight. For several months I read incessantly, not only throughout the day, but also for five or six hours each night by candle-light; and I now perceived numerous circular motes, which combining, formed clouds of irregular figures before my eyes. These motes always appear when I look at the sky or any light-colored object in a strong light; they move with the eye, retaining for some time the same position with relation to each other and to the centre of vision: each consists of a slightly opaque circumference and a central spot, the diameter being, as well as I can judge, about four or five minutes of the circle of vision. Sometimes films appear curved or twisted like hairs, and of the same degree of opacity as the motes. There is a collection of these films always before the right eye, but at such a distance from the centre of vision as not to disturb sight. The number of the motes seems increased by violent exercise as well as by close reading, or a disordered state of stomach. Sometimes for a moment a small circular black spot appears near the centre of vision, and some-

Case of
muscae and
spectra.

times, though not so frequently, one faintly luminous.

“The candle next appeared surrounded with a faint halo, which became more vivid as I continued this severe exertion of my sight. When my eyes are unusually weak, or a light is presented to them after I have been some time in darkness, instead of the halo a globular appearance of a muddy yellow color surrounds the flame.

“About six months ago, I began to be annoyed by the retina retaining impressions made upon it. After looking at any white or bright metallic object, on turning away my eyes I distinctly perceive its outline in a darker shade, on any surface to which I may direct my view; the impression lasting from two or three seconds to half a minute, according to the strength of light, the brightness of the object, and the length of time for which I have viewed it. The flame of a candle leaves its image impressed on the retina frequently for a couple of minutes; the sun for a still longer time; the image in both instances being of a muddy yellow color.

“A kind of penumbra surrounds light-colored objects in a strong light, and prevents me from accurately distinguishing their outline. When the object is under a sufficiently small angle to be seen entire without moving the eye, it

seems double, one image being such as would appear to a healthy eye, the other much fainter; thus is the moon seen, a piece of money, or the gilt letters over shop windows. These appearances take place indifferently, whether I use either eye or both.

“ In a few instances, a very severe exertion of my eyes produced the appearance of innumerable black particles dancing before them.

“ When I read for any considerable time, I have a disagreeable sense of heat in my eyes, with pain in the eyeballs, extending to the lower part of the forehead. I am not constantly subject to headaches, though occasionally afflicted by them, especially if I delay breakfasting for any length of time after rising. My tongue is frequently foul for weeks together, my digestion seems weak, and I seldom enjoy a good appetite.

“ I ought to observe, that most of the above-mentioned symptoms seem to have been mitigated since I came to London. Since the application of the blisters, the halo round the flame of the candle has nearly disappeared.”

A very frequent and characteristic symptom of functional amaurosis is a thin mist, fog, smoke, or gauze, or as I have heard some pa-

Amblyopia: nebulous or misty vision.

tients represent it, an indefinable something, as if vision required a peculiar atmosphere, intervening between the eye and the object, which takes off the '*acies oculorum acer claraque*,' the sharp edge of clear vision. Letters of a book run together, and the outline of all minute objects is indistinct. In some cases this indistinctness is constant and unvarying; in others it is the result of exercise of the organ, for a period, varying in different persons from ten minutes, or even less, to half an hour. Repose of the organ, whether obtained by closing the lids, or looking vacantly on distant objects, or gentle friction of the lids, or a slightly stimulant application, enables the person to resume for a short time; but the hindrance returns, and if the employment be persisted in, the dimness becomes little short of blindness, and sometimes occasions pain, always a painful sense of weakness. This affection is unaccompanied with irritable conjunctiva; there is no tendency to suffusion. It is seldom relieved by glasses, and never permanently. It is sometimes combined with *muscæ*, but more frequently distinct. The iris appears irritable and unsteady; it contracts often quickly, but vacillates between contraction and dilatation without a change of the light.

Oscillatory
vision.

Another functional affection is an oscillation or wavering of objects, so that the want of steadiness occasions a dazzling and confused per-

ception. This may be the result of simple congestion; but I have known it unaccompanied by any sign of this state, and in persons of a frame and temperament distinctly opposed to it. With this is often combined a delusion of something waving or flapping in an oblique relation to the eye, as towards the temple, or pendulous from the eyelash, or brow, unaccompanied by any distinct perception of figure.

An occasional symptom of functional amaurosis is a loss of the faculty of distinct vision at different distances. A gradual abridgment of the focal range at its near extremity, occurring in advanced life, and requiring the aid of convex glasses, has been supposed to depend upon a permanent change in the figure of the globe; I should rather refer it to a loss of power of the retina incidental to age, and a consequent imperfection of function in those parts, which execute the office of adjustment. It is a change similar to this, taking place in early or middle life, and with more abruptness, (the indistinctness sometimes pervading near objects exclusively, and in other cases, remote ones,) which I consider to be a symptom of amaurosis. It cannot be admitted, that the distinct vision of an object, at a permanent focal distance, proves the power of the retina to be unimpaired. If the organ is originally perfect as an optical instrument, so that the rays of light flowing from near, as well as from remote objects, form images upon

Loss of the
adjusting
power.

the retina sufficiently perfect for distinct vision; and if the range of distinct vision be, whether suddenly or gradually, so abridged, that the eye is incapable of relieving itself by a change of focus, the feebleness of the retina is invariably demonstrated by other signs, for the imperfection of adjustment seems in all cases to be in proportion to the loss of vigor of the retina. Ordinary observation proves that the effect of wear and tear is to allow of good distant vision, in which the parallelism of the rays of light supersedes the necessity of adjustment, while the near sight, which requires the active or tonic state of the adjusting faculty, is impaired or lost. But if, as sometimes happens, the vision of near objects remains good, while the distant is obscured, the evidence of the faultiness of the retina is direct. The correction of a defective adjustment by the use of glasses, in either case, proves no more than that the retina is not organically affected, while the failure of this corrective, which is frequent in the cases referred to, demonstrates the functional debility of the retina. In most of these cases the use of glasses is of temporary benefit, but if continued, it is followed by uneasiness or pain in the eyeball.

Many phenomena of impaired adjustment correspond to the degree of mobility of the iris; for in some persons it is quick to contract, but unable to preserve its contraction, and falls open or fluctuates in the same quantity of light, and

I have observed that the point of clear vision shifts accordingly; in others it contracts slowly and imperfectly; in others again it is permanently contracted or dilated, and this, independent of any other defect of sight than an abridgment of the original range of distinct vision, at one or other extremity*.

I have met with different reports, as to the time of day, in which persons affected with imperfect amaurosis, enjoy the best sight. Some see clearest on first waking in the morning, whereas others are particularly dim for an hour or two after rising. In these cases, the state of the stomach has an obvious influence. Emptiness will produce muscæ, and a temporary blindness. Some see only in a full light, others in a weak one, as after sunset. Candle-light, though generally least favorable to such persons, is not invariably so. In a considerable proportion of cases, amaurotic patients see clearest in the evening, and their vision seems to gain strength by exercise. They see better for example on retiring to rest, than they have seen at any period of the day.

Influence of
light on
amaurotics,

These differences are, in most cases, referri-

according
to the state
of the re-
tina,

* See note F.

determining the requisite degree of illumination of objects for vision, and the adaptation of the pupil to that purpose. But in other instances, as I have before hinted, a reflection takes place within the eye, owing to some change in the quality or quantity of the pigment, which renders a screen or colored glasses, or a dark day or twilight, in their several degrees, favorable or even essential to vision. This partakes of the nature of an organic disease.

and of the
pupil.

I have known persons absolutely blind for two or three minutes, upon going into a darkened room, owing to the imperfect sensibility of the retina, and consequent slow dilatation of the pupil; and they made no complaint, as persons usually do, of dimness from the opposite transition. Such persons, indeed, require a full strong light to see at all. But that such a defect is not directly or exclusively depending on the state of the pupil, is proved by the occasional coincidence of good vision with a permanently contracted pupil. I have met with cases of remarkably small and habitually contracted pupil, in which the glare of light was even painful, and where the inconvenience was at once removed by moderating the light, without any perceptible alteration in the diameter of the pupil. A lady of quality, in whom I made this observation, told me that it had equally attracted the notice of Mr. Hunter, whom she had formerly

consulted. The cases of day and night blindness present the opposite extremes of variation in susceptibility of the retina, and these must be regarded as cases of proper functional amaurosis. The remarkable efficacy of blisters upon the temples in these cases confirms this fact.

I had abundant opportunities formerly of observing the influence of trades, in aggravating as well as producing amaurotic affections: it was a common remark with tailors and shoemakers, that they never saw so well as upon Monday morning, which they justly attributed to the repose of the organ during Sunday.

The activity of the iris, evinced in the motions of the pupil, is, generally speaking, the surest indication of the health of the retina. The contraction is slow, or it is incomplete, or both, upon the sudden admission of light to the eye, where the retina is defective in sensibility. The mean state of the pupil is that of dilatation where an amaurotic affection exists, and this will sometimes discover to an attentive observer, which of the two eyes is affected. When the perception of light fails altogether, the pupil is generally fully dilated, and absolutely motionless. It is in other cases not perfectly a circle.

Action of the iris an index of the state of the retina.

The activity of the iris requires the free and uncompressed state of the retina, iris, and ci-

Phenomenon of active iris in

perfect
amaurosis.

liary nerves. In the various forms of amaurosis, its activity is proportioned to the degree of integrity which these several parts retain, and the intensity of the stimulus. If the retina be opaque, compressed, or unsupported, the iris mechanically disordered, or the ciliary nerves palsied, the pupil is inactive, independently of the state of vision. In the first of these cases, it is evident the vision will be lost; but we continually see useful vision combined with the second and third, as after operations in which the iris has been half destroyed, or has become permanently adherent, or in malformations where it is half wanting; and in paralysis of the ciliary nerves accompanying the state of ptosis. But how shall we explain the activity of the iris in a state of absolute blindness? a case by no means uncommon. We can only explain it by concluding the organ to be sound, and the cause of the amaurosis remote, or at least external to it. Its motions in such a case are purely involuntary; the mental perception being suspended or annihilated. All that is required to excite them is the impingement of the ordinary stimulus upon the unchanged retina, the white sheet upon which the images of objects are impressed, the instrument, not the organ of perception. The iris, in such a case, acts by a sympathy independent of the brain.

Thus in a case of circumscribed tumor com-

pressing the left optic nerve, immediately behind the ganglion opticum, although the blindness was complete, the iris was active. In two young ladies, in whom the eyes, as in the former case, were perfect, and the blindness complete, the iris was even vivacious; and there was the strongest presumptive evidence, from the symptoms, that the amaurosis was in the cerebral portion of the nerve*.

If this theory be correct, the activity of the pupil in complete blindness proves, that the retina and orbitar portion of the optic nerve are unaltered, and that the disease has its seat in the cerebrum, or cerebral portion of the nerve; while, at the same time, the ciliary nerves are unaffected by it in their origin and course. On the contrary, the fully dilated and motionless pupil shews, that these nerves are paralysed—the disease may be cerebral or orbital, or both. We see this exemplified in hydrocephalus, and in orbitar tumors compressing the nerve and globe. In cases of perfect amaurosis, in which the pupil, of its ordinary size, is absolutely without motion, a case by no means uncommon, the retina has most probably undergone a change of texture. The ciliary nerves are uncompressed, as may be inferred from the

* Janin relates two cases of lively pupil in a state of total blindness.—*Mem. et Observ. sur l'Œil*, p. 426.

undilated state of the pupil, but the source of their excitement, sympathy with the retina, is destroyed. The symptoms of the disease, in its early stage, will point out its seat, where its locality is definable*.

Blindness,
with di-
lated pupil,
from frac-
tured basis.

A man was trepanned for a fracture with depression of the right frontal and parietal bones. After the operation he became sensible, but it was discovered that he was totally blind, being unable to perceive a lighted candle held close before his eyes. The pupils were fully dilated and insensible to light. On the fifth day he died of inflammation of the membranes of the brain, having continued until his death in total darkness. On dissection, a fracture of the frontal and parietal bones was discovered on the left side, corresponding to that on the right, but without depression; and these two fractures were connected by a transverse fracture, extending across the basis of the cranium, *i. e.* through the orbitar plates of the frontal bone anterior to the junction of the optic nerves. This transverse fracture extended into the bones of the face, so as to separate them from those of the cranium, and there was displacement of the bones

* It is to be regretted that in the many excellent observations of Morgagni and others, of diseased states of the optic nerve, the opportunity of learning the signs of the disease during life was so seldom enjoyed.

sufficient to occasion a considerable pressure upon the optic nerves.

In this interesting observation, given to me by my able and excellent friend Mr. Brodie, it is evident that all the nerves entering the orbit must have been compressed. Hence the paralysis of the iris concomitant with that of the retina.

In hydrocephalus, the pupils are invariably fully dilated and motionless. In apoplexy generally, but with exceptions; sometimes contracted, but still immovable; which Dr. Cooke, in his late Treatise on that subject, considers a fatal prognostic. In injuries of the head, with symptoms of depression, the pupils are generally dilated and motionless, but sometimes inconsiderably enlarged, and slightly moveable; in other instances contracted; and very frequently one is permanently dilated, and the other contracted. These varieties depend on the situation in which pressure is applied, and the extent which it occupies, and in some degree on the nature of the compressing cause, whether bone driven in or fluid effused; in hydrocephalus the result is uniform. But it is not the loss of the sight which occasions the dilatation of the pupil, in injuries where these circumstances coin-

cide, but compression of the ciliary nerves, or of those from which they are derived; the loss of motion in the iris is a gradual and not a sudden effect of the loss of sight, and it seldom happens that the vision is lost in those casualties, in which the pupil is permanently dilated.

Among the morbid changes of the retina, ossification has been rarely met with*.

It is remarkable that in the thickened, attenuated, softened, ossified, or otherwise morbid states of the optic nerve or its sheath, the diseased appearance has seldom extended beyond the ganglion opticum. The eyeball has frequently been free from disease. The blindness has probably in as many instances proved a cause, as an effect, of the degenerations of the nerve. Cases indeed are related, of a considerable and very obvious change in the structure of the nerve, where the sight of the corresponding eye has been unaffected.

Case of
Milton.

It has occurred to me, in concluding the subject of amaurosis, that the case of our great Epic Poet, drawn up by himself for the purpose of its being submitted to Thevenot,

* Vide Morgagni, Lett. 52, Art. 30.

a celebrated French oculist, may not be uninteresting to my readers. I subjoin it as the best account that I know of the symptoms of amaurosis, in its progress from the state of functional debility, to the confirmed, perhaps organic, gutta serena. I have preserved his own words for the sake of accuracy.

“ Decennium, opinor, plus minus est, ex quo debilitari atque hebescere visum sensi, eodemque tempore lienem, visceraque omnia gravari, flatibusque vexari ; et mane quidem, si quid pro more legere cœpisssem, oculi statim penitus dolere, lectionemque refugere, post mediocrem deinde corporis exercitationem recreari : quam aspexissem lucernam, Iris quædam visa est redimere : haud ita multo post sinistrâ in parte oculi sinistri (is enim oculus aliquot annis prius altera nubilavit) caligo oborta, quæ ad latus illud sita erant, omnia eripiebat. Anteriora quoque, si dexterum forte oculum clausissem, minora visa sunt. Deficiente per hoc fere triennium sensim atque paulatim altero quoque lumine, aliquot ante mensibus quam visus omnis aboleretur, quæ immotus ipse cernerem, visa sunt omnia nunc dextrorsum, nunc sinistrorsum natate ; frontem totam atque tempora inveterati quidem vapores videntur insedissee ; qui somnolentâ quâdam gravitate oculos, a cibo præsertim usque ad vesperam, plerumque urgent atque deprimunt ;

ut mihi haud raro veniat in mentem Salmydessii
vatis Phinei in Argonauticis :

———— κάρος δέ μιν ἀμφεκάλυψεν
Πορφύρεος, γαῖαν δὲ περίξ ἐδόκησε φέρεσθαι
Νειόθεν, ἀβληχρῶ δ' ἐπὶ κόματι κέκλιτ' ἀναυδος*.

Sed neque illud omiserim, dum adhuc visûs aliquantulum supererat, ut primum in lecto decubuissem, meque in alterutrum latus reclinassem, consuevisse copiosum lumen clausis oculis emicare ; deinde, imminuto indies visu, colores perinde obscuriores cum impetu et fragore quodam intimo exilire ; nunc autem, quasi extincto lucido, merus nigror, aut cineraceo distinctus, et quasi intextus solet se affundere : caligo tamen quæ perpetuo observatur, tam noctu, quam interdiu, albenti semper quam nigricanti propior videtur ; et volvente se oculo aliquantulum lucis quasi per rimulam admittit.”

LEONARDO PHILARÆ, ATHENIENSI :

Septemb. 28, 1654.

Miltoni Opera, Amstelodami, 1698. p. 330.

* ———— Vertigo vero ipsum circumdedit
Atra, et terram opinatus est circumagi
Ab imo, in languidum vero soporem delapsus est elinguis.
BECK'S APPOLLONIUS RHODIUS. Lib. 2. v. 203.

PATHOLOGY
OF THE
HUMORS.

CHAPTER II.

SECTION I.

AQUEOUS HUMOR.

THE simple redundancy of the aqueous humor is a sequel of chronic inflammation, affecting the internal texture of the globe. Its figure is preserved, but the distended sclerotic has a dark blue tinge; the cornea is extended and prominent, the pupil dilated and inactive, and the vision is inconsiderable, if not extinct. In other instances, the state of hydrophthalmia is accompanied with loss of figure of the globe, and staphylomatous enlargement of the cornea, which is specked or exulcerated, and frequently presents fasciculi of red vessels on its surface. This state is the result of a disorganizing inflammation.

Hydroph-
thalmia.

The bulged and transparent cornea, whether spheroidal or conical, gives the appearance or the idea of a redundant aqueous humor; but this is only the consequence of the increased capacity of the chamber. The distinction is important; for the treatment of the hydrophthalmia and the conical cornea proceeds, as it seems to me, on opposite principles.

Rapid re-
production.

The aqueous humor is always rendered turbid by inflammation of the choroid and iris, but resumes its transparency when the inflammation is subdued. When discharged by accident or operation, it is reproduced in a period of from eight to twelve hours. It is regenerated in all states of the organ, in which the anterior chamber is even in part preserved, in quantity sufficient to give plumpness and figure to the globe, and to refract the light with accuracy enough for the distinct vision of large objects.

Effusions of lymph, from inflammation of the iris, of puriform matter from internal ulcer of the cornea and abscess of the eyeball, and of blood from concussions and wounds of the organ, are frequently observed in the chamber of the aqueous humor.

Solvent
power in-
consider-
able.

The solvent action of the aqueous humor over the exposed fragments of the crystalline lens is not, in my belief, superior to that of water,

which I have found by experiment to be exceedingly slow. A knife or needle, too highly tempered, has occasionally been broken in the operation for cataract, and the point has been left in the anterior chamber. This accident once happened in my own hands. The rusted appearance of the aqueous humor, and the gradual disappearance of the fragment have led to a conclusion, that it underwent a chemical solution. The rapid removal of the fluid and flocculent cataract, when dissipated in the chamber, has been explained in the same way. I believe that the aqueous humor has no greater solvent property than common water, and that this would be quite insufficient to explain the very quick restoration of its clearness, which we often witness, where it has been loaded with opaque matter. The fragments of the lens have no more power of resisting absorption than an extraneous substance, and the process improperly termed solution, is essentially referrible to the operation of the absorbents. The secreting function of the chamber is evidently a powerful one, from the reproduction of the humor in the course of a single night. That the absorbent function is nearly equal to it, is proved by the facts above-mentioned, but still more strikingly, by the rapid diminution and removal of the matter effused under inflammation, when quickened by the excitement of mercury.

SECTION II.

VITREOUS HUMOR.

THE absorption of the vitreous humor is evident in cases of floating cataract, and in some forms of organic amaurosis, marked by preternatural flaccidity, even without a diminution of volume; also in cases of absorbed crystalline and membranous cataract, with adhesions to the iris.

Diseased
eyes of
horses.

I examined the decayed eyes of horses, and found in a considerable number the opaque lens sunk in the vitreous chamber, and this humor almost entirely absorbed. The eye was filled by a morbid accumulation of aqueous humor, so that on a single puncture the whole fluid contents of the globe, which was larger and more tense than usual, escaped uninterruptedly. The sclerotic and choroid in these cases, although often thickened, and even the opposite sides coadhering, were entire. The retina was usually drawn into folds, and partially absorbed. In some cases the globe was greatly enlarged and flaccid, resembling an undistended dropsical cyst; the crystalline opaque, of its

natural size and firm, and sometimes its capsule thickened and scabrous, bearing marks of inflammation, but in place of the healthy vitreous humor, a gelatinous fluid, of a deep yellow or amber color, filled the globe. In other cases, where the tunics were disorganized, and thickened from injuries, the space occupied by the humors was either exceedingly reduced, or obliterated altogether, by the coadhesion of the opposite sides of the globe. In most cases where the lens was cataractous, and not impacted in the anterior chamber, nor fastened by adhesions of its capsule to the iris, the substance of the vitreous humor was shrunk as before described; and the crystalline, partially absorbed, had receded and sunk in proportion. The globe was supported in its figure by a morbid collection of aqueous humor.

The tremulous iris is, I believe, always connected with a relative disproportion in volume of the vitreous humor, whether congenital or the result of operations and injuries. Tremulous iris. Couching and the operation by absorption, if roughly performed, break down a portion of the vitreous cells, which become obliterated; hence the frequency of floating cataract and tremulous iris after these operations. The loss of a very considerable proportion of the vitreous humor may take place without permanently impairing the vision, except of minute objects, as is proved

by the successful issue of some cases of extraction, in which this accident has happened.

I have suspected a diseased state of the vitreous humor in some cases of cataract in elderly people, accompanied by a preternatural convexity of the globe, in which a slightly glairy fluid has distilled in quantity from the eye during the operation, of a consistency between that of the vitreous and aqueous humors.

Discolored
vitreous
humor.

A diseased state of this humor, frequent in organic amaurosis, with or without cataract, and especially accompanying diseased changes of the iris, is that in which it assumes a deep yellow or a chocolate brown color. From its rapid and uninterrupted egress, in this and the former case, even to a partial collapse of the globe, there is reason to infer that the cellular texture is broken down; for although the cells of the healthy humor communicate, a gush only of the fluid ensues from wound or rupture of the capsule; the support afforded by the closed lids prevents its further escape, and the obliteration, by inflammation of the ruptured cells, speedily follows.

Hemor-
rhage into
vitreous
cells.

I have known blood effused into the cells of the vitreous humor within twelve hours after the operation of extraction, in consequence of straining upon the night-chair, which was in-

stantly followed by severe pain darting towards the occiput. The coagulum was visible both to the patient and to the surgeon; the former described it as a central circular spot, intercepting the light which was strongly reflected from its circumference; in the sunshine it had a bright scarlet hue, and was liver-colored in the shade; it was in the course of time absorbed, so that the patient gradually recovered tolerable vision.

Another case was one of active and continued hemorrhage; it was not occasioned, as far as could be ascertained, by any improper exertion. It produced an excessive distention of the globe, and was attended with exquisite pain. These symptoms commenced in the evening of the day of operation, and, on the day following, the humor, loaded with an enormous coagulum of blood, protruded at the section.

I have met with other cases, in which hemorrhage into the vitreous cells occurred in consequence of a blow. Inflammation and swelling of the globe ensued, and the cornea, yielding to the pressure, sloughed, when the humor protruded gradually in the form of a large spongy mass, loaded with coagula of blood, so as forcibly to separate and distend the lids, and occupy the entire circle of the orbit. In these cases a severe pain is felt in the head two or

three inches above the orbit, and in the temple. The occasional hemorrhage is profuse. The pain is relieved by opiates, and the eyeball ultimately sinks with a total loss of figure.

I have reason to believe that this disease, which at one period assumes much of the aspect and character of a fungus, has sometimes been mistaken for one of a malignant character; a mistake not very unlikely to occur, judging from first appearances, where disorganization is complete.

Change of
substance
of the
vitreous
humor.

The vitreous humor is subject to a complete change of consistence and a total loss of transparency, the texture of its cells and its volume and figure remaining; the secretion is converted from a transparent albumen into an opaque substance resembling curd. In one case it was like ground rice boiled. Although the opacity is visible, the appearance differs widely from that of cataract. While the crystalline remains transparent, the same bright-colored appearance is seen at the bottom or sides of the eye, which is supposed to announce the incipient medullary fungus. In the progress of the disease also, as in the malignant disease, the lens appears to become opaque, and is protruded so as forcibly to dilate the pupil; this becomes fixed, its edge

roughened by detached pigment, and the iris convex, so as to give a conoidal figure to the globe.

Several years ago I extirpated the eye of a fine infant, eight months old, in whom this disease was concluded from the appearances described, to be the malignant fungus in its nascent state. The child has since grown to be a fine healthy boy; the other eye has remained sound. Upon section of the eye, the vitreous humor presented the appearance which I have described; the tunics were all entire*. As the loss of vision had been but recently discovered, and the appearances had in the interval sensibly changed, so as to denote the progress of the disease, this case could not be considered as a congenital mal-organization.

I have since seen several cases of a convex and permanently dilated pupil, with a deep-seated opacity of a splendid yellow tint in children, and doubting, from the preceding history and the child's freedom from indisposition, that such appearances indicated a malignant disease, I have abstained from operating. To my surprise, the appearances have continued stationary for years, unaccompanied with any disorder of the health. One, a child of four years old, I have very recently examined, having seen it

* See Plate III. fig. 4.

at intervals during that period, since the first notice of the disease at the age of three months. I can discover no difference in the appearance of the eye at this time, from that which it then assumed. The bright yellow tint occupies the temporal hemisphere of the globe, supposing it were bisected in a vertical direction ; the figure of the globe is slightly conoidal, the pupil much dilated as if from pressure, not perfectly circular, and its edge apparently everted, forming a narrow white line, while small detached flakes of the pigment lie behind it next the lens. The pupil of the other eye is constricted, and closed by an opaque capsule. The child is well grown and in perfect health.

I therefore regard these cases as a simple and uniform conversion of the substance of the vitreous humor, by an altered action of the secreting vessels, wholly independent of a malignant character. Unfortunately we have no accurate signs by which to distinguish, in their incipient state, the malignant fungus and the disease above described ; nor do we know that the disease may not sooner or later take on an active and malignant character, as is certainly now and then occurring in the testicle, female breast, and other textures.

The peculiar tint and splendor of the opaque substance, (a mother described it to me as

resembling, when first perceived, the scale of a tench,) is not to be depended upon as a sign of malignity. It evidently depends upon an opaque reflecting surface at the fundus of the globe; and the appearance is produced equally by an opaque retina, as by a morbid growth, except that in the latter it is somewhat more lustrous, from its greater density and projection; the convexity of the iris, the immobility of the pupil, and the apparent opacity of the crystalline, are secondary signs, and common to both. There are, however, two marks of distinction sufficiently strong, between the malignant fungus and this disease of the vitreous humor; viz. the progressive or stationary condition of the disease, denoted by the state of the tunics and the eyeball generally, and secondly, the presence or absence of pain and constitutional irritation. To these I might add, especially as regards children, the affection of one or both organs, as affording a strong presumption that the disease is harmless in the first case; in the second, a conclusion that it is malignant.

It is remarkable, that both the fungus hæmatodes, or malignant fungus of the eyeball, and the disease which I have just described, are of most frequent occurrence in infancy; I am not aware of having seen the latter in the adult. I have now under my observation a very re-

markable case of *congenital* malignant fungus. The child is eight months old. At its birth the eyeball was of the size of a walnut, it is now of the proportional size represented by Fig. 2. Plate V.

SECTION III.

CRYSTALLINE HUMOR.

I AM not aware of having witnessed any other result of inflammation of the crystalline and its capsule, than opacity, with the exception of one case. This was that of a lad, who, after a severe blow on the globe of the eye, which produced acute inflammation, had a suppuration within the crystalline capsule, which projected through the pupil in a globular form, and was filled with pus. There was no deposit upon the iris. Under the action of mercury the pus and lens were absorbed together. The continued application of belladonna did not prevent the gradual constriction of the pupil, and the case terminated in a capsular opacity, with constricted and mis-shapen pupil, and co-adhesion of the iris and cornea.

Abscess of
the cap-
sule.

The capsule readily unites by adhesion, when simply incised. This is of course prevented by the intervention of any portion of lens. The capsule, when adhering to the iris, receives delicate red vessels, which run in small brown peduncles or foot stalks of lymph, produced from the interior border of the pupil; small flaky

Capsular
opacities.

portions of the pigment are also frequently detached, and conspicuous upon the margin of the capsule. This is an appearance commonly seen in the constricted pupil with partially transparent capsule, after chronic iritis. It is often the result of repeated attacks of inflammation at short intervals, to which a constricted state of the pupil certainly predisposes. The iris is much thickened by repeated depositions of lymph, until its texture becomes quite altered. There is a very imperfect and deranged state of vision, according to the degree and extent of opacity of the capsule, which admits of no improvement by the direction of the light; and sometimes a marked and painful determination of blood to the head. Except in this case, and in punctured wounds, the capsule is seldom partially opaque, but though its opacity is diffused, it is often not of uniform density, so that it has a dotted or mottled appearance. When calcareous matter is deposited, it is in small flakes or scales, which have a brighter tint than the opaque membranous portion. The opacity of the capsule, as of the cornea, varies in degree, from the slightest nebula to the opacity from change or conversion of texture. The incipient nebulosity is often, as before observed, difficult of discernment. Where the capsule is completely opaque, the lens undergoes a slow absorption; the capsule, however, remains transparent in most cases of senile cataract, not pre-

ceded by inflammation. The capsule, like all other textures of the body, undergoes absorption when detached.

The cataract, from opacity of the humor Morgagni, is in my belief purely hypothetical. There is an appearance of semi-opacity and yellowness in the lens, in some cases of defective vision, insufficient to account for the degree of dimness. I believe that this is not the cause of it, and that the disease is amaurosis. This I judge from the appearance being stationary, and the symptoms being those of the latter disease. I have known it to be confidently pronounced an incipient cataract, and the patient to remain in anxious expectation of an operation for years, without any sensible change of its density, although in the interim the person had lost his vision. On the contrary I may remark, that the degree of opacity of some soft caseous cataracts, when held up to the light immediately after extraction, appears quite insufficient to explain the degree of blindness, although the sight has been restored by the operation.

Amaurosis
mistaken
for cata-
ract.

The fluid, flocculent, caseous, and hard cataract, are the four principal and easily distinguished degrees of density, of the opaque crystalline. The caseous admits of division into soft and hard, as it approaches nearer in consistence to the second or fourth species. The

Species of
lenticular
cataract.

nucleated and mixed cataract—the first an opacity confined to the centre, the circumference and superficies transparent, the second a soft caseous or fluid superficies upon a firm centre—are well marked varieties. I refer the reader to my Papers on this subject in the fourth and fifth volumes of the Medico-Chirurgical Transactions*. The opacity of the posterior capsule, *i. e.* the tunica hyaloidea, is very rare, which it would not be if the lens were invested, as most persons suppose, in a capsula propria, especially after the operation of extraction, in which the anterior capsule only is lacerated, and the lens alone escapes. Where it is met with, the lens and anterior capsule are usually transparent, and when this is not the case, and the cataract escapes with a posterior fold of opaque capsule, it is always in my experience accompanied with a considerable discharge of vitreous humor, for it is owing to a detachment of the tunica hyaloidea, beyond the angle of union with the crystalline membrane, or a separation, beyond the margin of the lens, of the opaque from the transparent portion of that tunic†.

* Vol. IV. p. 278., and Vol. V. p. 391.

† Until the perfect capsule of the crystalline lens can be exhibited detached from the eye, and the vitreous capsule and Petitian canal at the same time demonstrated entire, and capable of complete inflation, I shall continue to believe, through evil and good report, that the appearances actually and uniformly presented, and supported by all the phenomena of the pathology of these parts, warrant the opinion which I have

What has been called 'black cataract,' when this term is used as applied to the lens, and not synonymously for amaurosis, is a modification of the fourth or hard species. A yellowish brown is the ordinary tint, but I have seen it occasionally of a blackish brown color.

Some peculiar circumstances relative to the formation of cataract deserve to be briefly noticed *.

Formation
of cataract.

Although the period of its completion from its first appearance is very variable, and can never with any certainty be predicted, it is usually slow; and sometimes a clouded or semi-opaque state or a distinct nucleated opacity remains stationary for years, or even for life; yet it occasionally forms with rapidity although no inflammation is present.

The rapid formation of cataract is generally attended by inflammation, or preceded by diseases of other textures. This result of iritis has been already explained. I have seen a yellow-colored opacity posterior to the lens preceding the rapid formation of cataract. The eye became the subject of a superficial but

elsewhere given, that the lens is incased betwixt the strong membranous production, commonly called the anterior capsule, and the proper capsule of the vitreous humor.

* See note G.

violent inflammation, from sympathy with its fellow which was acutely inflamed. The cataract was completely formed in two days. The pain was of the most acute kind, affecting the eyeball, temple, and cheek. In the former state some useful vision remained, which was now completely extinguished. The previous opacity was a morbid state, I believe, of the vitreous humor, and the lens transparent, until the attack of inflammation.

Partial displacement.

The residence of a perfect cataract in the eye is injurious, or at least attended with much risk of destructive inflammation. The vitreous humor undergoes a partial absorption, and the lens, losing to the same extent its support, bulges forward and presses upon its capsule and the iris. What operators call a narrow anterior chamber, arises more or less from this cause. Where the capsule yields from a blow or by absorption, and the pupil is dilated by the protruding lens, a violent inflammation, attended with very acute pain, is the invariable consequence. I have known this happen suddenly and independent of external injury, where the formation of the cataract has been gradual, and unattended with pain; and the spontaneous occurrence, though not so frequent, is precisely similar in its effects to that produced by the too free laceration of the capsule with the needle.

I have heard of the complete spontaneous absorption of the congenital cataract at an early age, and although the eyes had a constant tremulous motion, the person was in after-life enabled to follow useful occupations. I have never seen such a case, but I refer to an instance which is well authenticated. The tremulous motion of the globe is not incompatible with a perfect state of vision.

Spontaneous absorption.

The absorption of the matter of the opaque lens is quick in proportion to the looseness of its texture, and its complete exposure, by breaking up and detaching its fragments, to the operation of the aqueous humor; and also to the plentiful secretion of healthy aqueous humor*. In confirmation of the latter statement I have observed, that in all cases of narrowed anterior chamber, by the partial co-adhesion of the iris and cornea, consequent upon the injury which produced the cataract, or inflammation from any other cause, it is slow; and that absorption does not take place during the existence of inflammation, in which state, the aqueous humor is in a morbid condition, and

Progress of absorption.

* I do not consider this fact as militating against the opinion given at page 200. The turbid state of the humor indicates the arrest of its secretion; and its copiousness and transparency the unabridged extent and health of the secreting surface.

if the inflammation be deep-seated and protracted, the vitreous humor partakes of it.

I have seen a case of dislocated lens occupying the anterior chamber, and producing inflammation of the iris; from which membrane it has derived an adventitious capsule of lymph, organized by colored vessels.

SECTION IV.

DISEASES AFFECTING THE EYEBALL.

UNDER this head might properly be classed Effects of injuries. the morbid changes which result from the various forms of injury, to which, as all parts are exposed, all are liable in common. These, however, it is impossible to enumerate, and indeed would be, for any practical purpose, unnecessary, after describing the peculiar morbid disposition of each texture, and the characters of inflammatory action which they severally exhibit. The mode and extent of the injury, and the instrument with which it is inflicted, will determine its importance, as regards the preservation of the organ and its functions. Concussion and extravasation of blood are, both of them, frequent causes of a sudden loss of vision, which is, in many instances, gradually restored. The lesions of the internal tunics are to be seriously apprehended, from the probability of the retina being included in the mischief—the case of foreign bodies penetrating deeply into the globe, from the probable disorganization and dissolution of the vitreous humor, and the consequent suppuration, or state of atrophy, of the

globe. Sometimes the organ is at once destroyed by rupture of the nerve and muscles, and a partial evulsion of the globe from its socket; or by so free a lacerated wound, as to occasion large staphylomatous protrusions of the choroid, or the escape of the humors *in toto*, and instant collapse. More frequently, however, the cornea, or lens, or iris, are so far severally or exclusively affected, as to leave the figure of the ball uninjured, and to make the secondary changes which may be expected to supervene, an object worthy of the most interesting and anxious attention; and, I may add, to afford considerable scope for the salutary exercise of art.

Suppuration of the eyeball.

From a long continued and exasperated inflammation of the interior tunics, but more frequently from injury, the eyeball suppurates, and its texture is totally destroyed. The globe becomes rapidly enlarged, greatly protruded, and exceedingly tense. The conjunctiva, highly tumid and vascular, is rolled out upon the cheek, so as completely to evert the lower eyelid. The pain is very acute, lancinating through the eyeball and head, and continues day and night without intermission. The patient's health is greatly disturbed, and the symptomatic or irritative fever, as in the thecal abscess, or acute paronychia, is considerable. The anterior chamber is at first filled by soft white lymph, then pus

collects in quantity; the clouded cornea turns opaque and slowly yields by ulceration, or dies and sloughs off, when the contents of the globe are more or less discharged, and the pain and symptoms of irritation gradually subside. The eyeball afterwards shrinks up, and the cornea is obliterated. The hypopion or purulent secretion filling the anterior chamber, originating from internal ulcer of the cornea, is not accompanied by the enlargement, or the acute pain and high irritative fever which mark the abscess of the globe; these are referrible to the extreme distention and corresponding resistance of an unyielding texture like the sclerotic, as in the abscesses of tendinous sacs and thecæ. The termination is the same in both; *viz.* the perishing of the cornea.

I had formerly been led to suppose, that the malignant disease termed cancer, affected the bulb or globe of the eye. Such is the doctrine of most writers on the subject. I have, however, satisfied myself that, as regards the eye, this disease is peculiar to the lacrymal gland, conjunctiva, and eyelids; and I have classed it accordingly. On the contrary, I had believed that the disease termed soft cancer, medullary fungus, or fungus hæmatodes—for these latter terms are descriptive of the appearances of the same disease in its several varieties—had its origin in some individual and peculiar texture; some

Malignant
diseases.

writers giving it to the retina and medullary substance, some to the vascular tissue of the choroid, and others to the fibrous texture of the sclerotic. I am, upon the evidence of many cases and dissections, assured, that this is not the fact as regards the eye; that, on the contrary, each and every texture, if we except the crystalline and cornea, is capable of generating it, and is occasionally its proper nidus. The disease, therefore, comes properly to be noticed in this section.

Malignant
fungus.

The early appearances of this formidable disease, of which it has fallen to my lot to see numerous instances, have been accurately described by Mr. Saunders and Mr. Wardrop. The disease, in my experience, has proved speedily destructive, when arrived at that stage in which the visible enlargement and loss of figure of the ball, the consequent livid blue tint of the sclerotic, and the distended vessels of the conjunctiva and eyelids present themselves. The character of the disease is by these decided; they are proofs of its rapid and destructive progress, and taken together with the primary appearances, must be regarded as fatal prognostics. The staphylomatous protrusions of the sclerotic and choroid coats, may, without the exercise of a careful discrimination, be confounded with this disease. I speak from a distinct remembrance of two cases in particular, in which the existence of the malignant fungus was a matter of dispute

between very competent persons, prior to the extirpation of the organ, by which its existence was instantly demonstrated ; and from the recollection of several in which the proposal of an operation was overruled, and as the event proved, judiciously, the patients having remained well, and the organ tranquil. Abscess of the globe, chronic enlargement and disfiguration of it from choroidal inflammation, proptosis from enlargement of the appendages, and tumors within the orbit, hydrops oculi, &c. are, on the contrary, sufficiently easy of distinction from the malignant disease, by the absence of the characteristic signs of the latter. Nevertheless I have known some of these mistaken for it. I have before noted a case, *viz.* protrusion of the vitreous humor from the eyeball, with which the fungus protruding through the slough of the cornea might, *primâ facie*, be confounded by a person unacquainted with the history of the case. But it rarely happens that the origin of the disease has not been accurately noted by the patient or his friends, or that the germ of the disease, in the infant at least, is not apparent upon inspection of the other eye. The complexion, as the disease proceeds, acquires the leaden paleness of cancer, and the rest is broken by deep and lancinating pain. If a child is the subject of the disease, it is heavy-headed and lethargic, as one affected by hydrocephalus ; disturbed by occasional convulsive starts ; the stomach often re-

jects food, the frame emaciates rapidly, and the highest possible degree of irritability and fretfulness is present. The child usually expires in convulsions. The adult suffers from spasmodic shoots of pain through the ball and head, and simultaneous startings in going to rest; but the constitutional disturbance is inconsiderable previous to the protrusion of the fungus; and hæmorrhage, which usually comes on at this period, is exceedingly distressing.

The metallic appearance at the fundus of the eye, sometimes presents colored blood-vessels, branches of the arteria centralis, which penetrate the vitreous humor; the opacity seems to advance towards the pupil, and might be mistaken for a protruding soft cataract, an appearance which, as Mr. Saunders has remarked, is altogether delusive. In a case in which Mr. Hunter was consulted, the operation for cataract was actually undertaken, and the lens being found transparent, the eye was immediately extirpated, from a conclusion that the disease was malignant.

A dissection of the eye, after the destruction of the cornea, furnishes a very indistinct clue to the original seat of this disease; it is in this state a firm semi-organized mass of lymph intermixed with and surmounted by coagula of blood*; all

* It is seldom that the blood-colored fungus acquires that enormous size, and protrudes to such a deforming extent as

the textures of the eye are broken up, but here and there the vestiges of one or more may be traced. If examined at an earlier period, that is, before it fungates, the section presents the real character of the disease, the medullary or soft brain-like substance, which we see in other organs of the body, commonly arranged in small lobes or *moleculæ*. Sometimes one, and sometimes another of the proper textures, appears to be the matrix of the disease. The fungus, in one instance, adheres intimately to the sclerotic, and detaching the choroid and retina, throws these and the vitreous humor to the opposite side of the globe. Frequently it splits the sclerotic into two lamellæ, distinctly originating in the interstitial substance of that coat. Its progress, by absorption of a part of the sclerotic, gives occasion to a rapid growth of the diseased texture, external to it, within the orbit; but more frequently the diseased growth is luxuriant upon the outer surface of the sclerotic, to which it is as firmly attached as on the inner, while that tunic retains its integrity and forms a perfect septum between the diseased masses. Hence, fibrous membrane has been supposed to give origin to it. But in other cases, the disease unquestionably begins in the choroid, and, that

is seen in Saunders, Pl. III. It is to be regretted that an examination was refused in that case, although there can be little doubt that he would have confirmed this description of the ultimate state of the disease.

tunic gradually degenerates into the diseased mass which, occupying a large portion of the globe, is throughout deeply tinged with the black pigment. Sometimes the sclerotic has a morbid growth externally, and the choroid on the interior. Again, these tunics seem to be often only secondarily affected, and are removed by partial absorption in the progress of the disease; the septiform productions, extended, displaced, and broken down, of the tunica hyaloidea, inclose the fungus, and although no vestige of the vitreous humor remain, it is plain that it has formed the nidus of the diseased growth. The iris and corpus ciliare evidently degenerate in the same manner as the choroid. Again, the disease has seemed to originate at the point of entrance of the optic nerve into the globe, pushing the humors before it; and the nerve itself has upon section been found diseased, both contiguous to the sclerotic, and at the distance of three quarters of an inch from that tunic, where the intermediate portion has preserved its healthy aspect. Nay, the optic ganglion, tractus opticus, and thalamus, have been repeatedly found, one or other or all diseased, and the surrounding adipose substance in the orbit has exhibited the disease in its genuine character, and to a considerable extent, where it had no direct communication with the diseased contents of the globe*.

* I have a colored drawing which accurately exhibits this state, taken at the moment of inspection.

So also, the lymphatic glands, at the angle of the jaw, frequently take on the same character of diseased structure. It appears to me, therefore, that this is not a disease of this or of that texture, as writers would insinuate, but of all the textures, the crystalline and cornea excepted, which yield to its progress, but never exhibit a specific change of texture. The process of suppuration, ulceration, and sloughing, have no share in the diseased action, and are only seen in the cornea. The other tunics and humors yield by progressive absorption, without pus. Its appearance, in comparing the sections before fungating, is evidently modified by its situation, as for example, in the sclerotic and choroid, adipose substance, and vitreous humor; the phenomena of color, of hemorrhage, &c. depend much upon situation, also the preservation of figure, degree of enlargement, and the rapidity of growth, according as it is confined to the interior, or originally affects the exterior of the globe, or communicates with the orbit. We see these modifications of appearance, upon comparing it in the different viscera, and in the cellular membrane, tendinous aponeuroses, and the nerves. The deep blue and black tubera characterise the choroid fungus; the medullary, the substantia alba of the optic nerve or brain; a more dense fibrous brown tuber, clear of stain, is the production of the sclerotic. These several parts are found to be directly and peculiarly involved, upon dissection.

I have a preparation exhibiting a genuine example of the disease affecting the anterior right lobe of the cerebrum, and protruding the eye from its socket, while the eye itself was perfectly free from disease. This shews the progress of the disease by absorption, and not by contiguity, conformable to our opinion of its nature.

I must refer the reader to Plates 3, 4, 5, and 6, and the accompanying descriptions, for further details on this subject.

PATHOLOGY
OF THE
APPENDAGES.

CHAPTER III.

SECTION I.

ORBITAR APPENDAGES.

ABSCESS sometimes forms within the orbit, Abscess. and previous to its discharge occasions an equal protrusion of the globe, with eversion of the palpebra, dilated pupil, and suspended vision. Its situation and effect upon the eye give much pain and apprehension to the patient, as well as considerable disturbance to the system at large. The sight is sometimes permanently extinguished. In other cases it returns after the discharge of the abscess, and consequent removal of pressure.

Adipose and steatomatous tumors are occasionally formed in the cellular and fatty tex- Adipose and encysted tumors.

ture cushioning the globe. They occupy the interspace of the recti muscles, and in their progress emerge between the globe and the orbitar circumference. They have therefore an oblong figure. The globe of the eye is turned and fixed in an opposite direction, and so compressed as to be rendered dim. I have removed them when projecting over the top or on one side of the globe, in several instances. When the conjunctiva is freely divided, the fatty tumor is easily hooked forward, and dissected out by a few touches of the narrow bistoury. The cyst containing a fluid, which is usually transparent, it is not so easy to remove entire, owing to its tenuity and the instant escape of its contents if it be accidentally torn or wounded. In the empty or collapsed state it is scarce possible to extirpate it completely, and even though the integrity of the cyst be preserved, its extent backwards within the orbit renders this in some instances a matter of much difficulty. If the cyst be cut in half, although the lips of the wound heal kindly, it suppurates periodically and discharges many times at the cicatrix, which closes in the intervals. The encysted tumor, although it extend to the bottom of the orbit, seldom occasions the distortion of the globe. A disagreeable sense of numbness and coldness affects the integument of the glabella and forehead, after the division of the frontal and supratrochlear nerves; these therefore should be avoided in the operation. The tumor

sometimes projects exterior to the tarsus, so as to rise upon the palpebra, but more commonly it is beneath the tarsus and contiguous to the globe. In the former case the cyst lies upon the periosteum of the orbit and is adherent to it; in the latter it is adherent to the globe.

In the last annual report of the London Infirmary for diseases of the eye, is the notice of a singular case of hydatid cyst protruding the globe, with the following remark: "One of these cases was a protrusion of the eye from the orbit, by a cyst containing hydatids deeply seated in the cavity. The hydatids were evacuated by a puncture in the cyst; the eye returned into its natural situation, and the patient was completely cured. This is the only instance of such an affection that has occurred since the opening of the Infirmary."

Hydatid
tumor.

The looseness of the connecting texture in the orbit, and the number and tortuosity of the vessels, seem to predispose to that disease of the arterial and venal extremities, which gives origin to those peculiar vasculo-cellular tumors, the precise nature of which is not yet satisfactorily ascertained; which add to a structure most resembling that of *nævus maternus*, the formidable character of aneurism. See my case of aneurism by anastomosis in the orbit, in the *Medico-Chirurgical Transactions*, Vol. II. Art. I.

Aneurismal
tumor.

and another by Mr. Dalrymple, the able and ingenious surgeon to the Norfolk and Norwich hospital, Vol. VI. Art. 7.

Sarcoma-
tous and
cartilagi-
nous tu-
mor.

Tumors sometimes form beneath the periosteum of the orbit, giving to the touch a firm resistance. I have seen several cases of this description where the tumor appeared to extend the depth of the orbit, and was presenting on the nasal side. Their anterior edge is thin, being bound down to the orbital circumference, but when they protrude and compress the globe to blindness, as is sometimes the case, it is to be inferred that they have attained considerable bulk posterior to the globe. I once removed one on the abductor side of the globe by scraping it clean away from the bone; it was of the hardness of cartilage and of great extent. I am unable to say whether the disease returned, having soon afterwards lost sight of the patient. The impression I had of the case was unfavorable, from the character, as well as the extent and connections of the tumor.

Exostoses.

Exostoses of the orbit are not common. I have never seen them in the living subject of a size to create deformity or material inconvenience.

Polypi.

Polypi of the frontal, sphenoid, and ethmoid sinuses in their progress burst through the eth-

moid and lacrymal bones, and sometimes extrude the eyes, so as to occasion the most horrible deformity. If when they first appear at the inner canthus, having an elastic feel, we puncture them, a thick glairy fluid is discharged, but from the extent of the disease when it has advanced thus far, the swelling does not subside. I know of no disease which presents so truly formidable an appearance as the polypus of these parts, when it has arrived at such an extent as to break up the bony structure of the nose or antrum, and shew itself in the orbits.

The lacrymal gland is subject to simple interstitial enlargement, to suppuration, and to scirrhus, like other glands of similar structure ; its enlargement is known by the lobulated appearance of the tumor, on further stretching the skin of the projected eyelid. It often suppurates in children, and occasions an excessive swelling above the upper lid, depressing the tarsus upon the globe so as completely to conceal it. The abscess may be conveniently opened and discharged beneath the lid, with a narrow curved bistoury. I removed the lacrymal gland greatly enlarged and in a state of true scirrhus, from the orbit of a middle-aged man, a merchant's clerk in this city*. The vision of that eye had suffered considerably during the growth of the

Diseases of
lacrymal
gland.

* Represented by fig. 6. plate II.

tumor; in other respects he continued quite well when I last saw him, after an interval of some years. There was no other deformity than a slight drooping of the lid at the outer angle. All these operations should be performed beneath the eyelid when the circumstances admit of it.

SECTION II.

FACIAL APPENDAGES.

PALPEBRÆ. The little abscess called a styè, *Hordeolum*, situated on either edge of the palpebra, commonly has its origin in an obstruction of one or more of the meibomian follicles, like the mammary abscess, which is an obstruction of one or more of the lactiferous tubes. Obstruction is followed by inflammation of the follicle and surrounding cellular membrane, and it terminates in a little painful abscess. Another description of styè is an abscess forming around the bulbs of the eye-lashes from inflammation of the ciliary foveolæ, which sometimes has its origin in a disease of the hair-bulb. After the discharge of the abscess and before the falling off or evulsion of the hair, the foveola appears exulcerated within and at its mouth, and continues for a long time to discharge a thin ichor by which the edges of the tarsi are denuded of conjunctiva, or this membrane is kept in a state of exulceration; the discharge forms a scab, by which the lids are firmly agglutinated during sleep, but it is detached, and the diseased secretion renewed by their separation. By the recovery of the foveola

the healthy growth of the cilia is restored. Sometimes the affected foveolæ become obliterated by the adhesive action, when the hairs of course are not reproduced. An habitual production of diseased cilia as well as nails is not uncommon, and for this state plucking in either case is only a palliative remedy. The disease is in the glandular structure which forms them, and its obliteration or removal, by a natural or artificial process, is in most cases the only method by which it can be cured. Independent of the abscess of the meibomian follicle and ciliary foveola, the conjunctiva upon the margins of the tarsi, and the continuous cutis, are liable to furuncular inflammation. The term styè is I believe indiscriminately applied to all. The disposition to form styè is generally a mark of scrofula, and from one or other of these causes is continually recurring as the system is affected.

Warts and vesicles.

Transparent vesicles and skin warts are not uncommon upon the margins of the tarsi. The former occur upon the meibomian border more especially, the latter upon the ciliary.

Lippitudo.

The first stage of lippitudo is a simple excoriation; the second, an ulceration of the borders of the palpebræ. It is the result of inflammation of the palpebral conjunctiva, aggravated by the acrimonious quality of the vitiated meibomian

secretion. In the chronic form of the disease in strumous subjects, the conjunctiva is greatly thickened, indurated, and altered in its texture; the ciliary glands are destroyed, together with the fine cuticle of the lid, to some extent beyond the ciliary margin; and a partial eversion of the lids, owing to the tumefied state of the conjunctiva, increases the deformity. The mouths of the meibomian glands are obliterated, and the ducts plugged by their inspissated secretion; sometimes the conjunctiva fungates so as to render the eversion complete, and a process of cicatrization makes it permanent. Thus the ectropeon may result from a neglected lippitudo.

The eyelashes are subject to become morbidly dry, harsh, and variously distorted, instead of having an equal curve, and their natural softness and pliancy. The inversion of one or more cilia upon the conjunctiva produces, by continued irritation, a painful degree of intolerance with an undue secretion of mucus and tears, and an opacity of the conjunctiva of the cornea with the prolongation of the colored vessels upon this membrane. In this way the marginal opacity extends over the surface of the cornea and occasions blindness. This state frequently exists independent of entropion. The disordered state of the cilia, above described, is owing to a disease of the glands which

Diseased
cilia.

secrete and nourish the cilia, as mentioned in speaking of the hordeolum.

Tinea ciliaris.

The tinea ciliaris is a disease of the ciliary foveola, and hence is commonly combined with lippitudo. In the slightest form a branny crust surrounds the roots of the cilia, the skin of the lid being very partially, if at all abraded; in the more advanced stage, a mucus is secreted by the inflamed and excoriated ciliary border, and the thinner part of it evaporating leaves a scab. In the most inveterate form, the disease is the same with the lippitudo which has advanced to ulceration; the cilia fall off, and either diseased cilia are produced, so that the pore and the hair mutually react and keep up the disease, or the hair gland is permanently destroyed and the foveola obliterated. The porrigo or crusta lactea overspreading the eyelids and cheeks, with chaps and exulcerations behind the ears, and within the meatus auditorius, are concomitant affections, especially in children.

Trichiasis or entropion.

The trichiasis is a morbid incurvation of the tarsus, affecting either a part or the whole of it, from the cicatrization and consequent contraction of wounds, burns, and lippitudinous ulcers upon its meibomian edge, or the palpebral fold of the conjunctiva. Whether the entire cartilaginous border or only a part is in-

verted, depends upon the situation and extent of the disease which has produced it. But it very frequently arises, especially in aged persons, from a simple loss of elasticity in the cartilage, or a redundancy of the integument of the lid and cheek, or these causes combined. There is a case less frequent, in which trichiasis depends on a thickened and callous roll of palpebral conjunctiva, over which the lid turns. From whatever cause the disease originates, the eye becomes irritable, the motion of the lids occasions pain and watering, and from the incessant friction of the tarsus upon the globe, results the inveterate chronic inflammation with opacities, fed by vessels overshooting the cornea. It is very rare, with the exception of the case of protruded conjunctiva last mentioned, that the excision of an elliptical fold of skin at the basis of the lid, is not an efficient remedy. In that case, the roll of conjunctiva must be excised. The excision of the entire cartilage I think superfluous, and a remedy far more severe than the disease.

The ectropeon is the result of injury to the eyelid, as wound, burn, herpetic ulcer, or the sequela of chronic lippitudo. The tarsus of the lower palpebra sometimes falls outward from an apparent loss of elasticity, or the unequal action of the orbicularis muscle. The lid receding from the globe suffers the tears to collect in

Ectropeon.

a pool between them. An unhealthy state of the conjunctiva is, if not the cause, as when villous and redundant, a certain consequence of its eversion and exposure. The case is much aggravated when coadhesion, after burns or neglected wounds, ulceration from any cause, or long enduring eversion, takes place between the skin of the eyelid and cheek. This case admits of palliation, but not of cure. I have much improved several cases by first detaching the fastened lid and forcing it to heal by granulation, and afterwards, removing a triangular portion of the cartilage, according to the proposal of a modern author, for the correction of the eversion, which is the best remedy for such eversions as do not depend upon the protruded conjunctiva *. In this, which is the simplest case of ectropeon, the excision of the diseased conjunctiva is sufficient. Where the everted lid is adherent to the bone, there is a deficiency of cellular substance to produce granulations, and the case is, generally speaking, slightly if at all benefited by operation.

* This remedy results from considering the relative condition of the tarsus and skin at the base of the eyelid, in the two diseases, entropeon and ectropeon. In the first the integument is elongated, in the second the tarsus. As in the first case by removing a portion of the redundant skin, we turn out the inverted tarsus, so in the latter by removing a portion of the elongated tarsus, we turn in the everted. It will be understood, that it is only relatively that we speak of the elongation of the tarsus. It is everted, and strictured in the state of eversion by the skin.

Tumors of the eyelids are encysted, varying in size, and containing a thin yellow fluid, or a fluid of the consistence of honey, or a white and dense caseous substance; or like the common steatom. They are adhering to the tarsi or moveable. In the first case, they give a diffused elevation to the skin of the lid, are circumscribed, and tense to the touch. Upon examination on the interior of the tarsus, a white hollow spot is discerned, surrounded by a blush, which corresponds to the point of their intimate adhesion to and partial absorption of the cartilage. Upon a free incision through the cartilage at this point, the entire cyst is easily expressed through the section. A thickening of the membrane covering the cartilage, will give the sensation of a tumor which does not exist. The adhesion of these cysts to the tarsus is sometimes so intimate, that if their removal were attempted by dissection externally, it would be scarcely possible to detach them, without removing a portion of the cartilage. They are often two or three in number, and their fluid contents are not often absorbed.

Tumors of
the palpe-
bræ.

The steatomatous tumors form in the cellular substance beneath the cutis, and are freely moveable, and easily turned out through a free incision of the skin. The atheromatous and lardaceous tumors form on or near the edges of the tarsi, and are very common in weakly children,

in whom they acquire a considerable bulk. If left, the skin ulcerates, and a scab forms upon the top, when they may be readily expressed entire between the nails of the thumbs. They resemble the sebaceous tumors behind the ears, and on other follicular parts of the skin, arising from obstruction of the follicles, which, being dilated and their sides condensed by inflammation with the surrounding texture, form these cysts.

Abscess of
the upper
lid.

Suppuration of the upper eyelid occurs from slight causes of irritation. The matter should be early discharged, for the cellular membrane, owing to its laxity and abundance, is subject to so rapid and excessive a distention, that if unrelieved, it sloughs out, and an ugly puckering or even a permanent eversion of the tarsus ensues, from deficiency of substance for granulations. I have known this deformity produced in an aggravated degree, by the suppuration going on insidiously and unsuspectedly, under the mask of œdema. The origin of it was snipping off a small skin wart upon the palpebra with a pair of scissors, and the subsequent irritation of the wound by the application of court plaster.

Constricted
and closed
puncta.

LACRYMAL PASSAGES. The puncta are sometimes much constricted, sometimes obliterated by preceding chronic inflammation; hence epiphora from imperfect or non-absorption of the

tears, proportionate suffusion from excitement, and dimness. The constricted or closed punctum is always best opened with the point of a middle-sized pin; it afterwards readily admits the dilating probe; but if no vestige of the punctum remains, it is useless to attempt to form an artificial canal. I have seen a congenital deficiency of the puncta, but the case is very rare; obliteration is much less so.

The over dilated or patulous puncta occur in old people, with more or less separation of the lower lid from the globe. They are so large as apparently to have lost their contractile as well as absorbing power; the conjunctiva of the palpebra is tumid and slightly villous, and the meibomian secretion is morbidly increased.

Patulous puncta.

The lacrymal conduits are subject to be wounded or divided, hence incurable fistulæ. I have met with several such cases, and have tried in vain to heal them. Small abscesses occur in or adjoining the lacrymal conduits which are broken and discharged by the passage of the probe. In more than one instance, I have turned out a considerable quantity of calcareous matter wedged in these ducts, like the calculi of the salivary ducts.

Wounds of lacrymal ducts.

With the constricted punctum a stricture of the lacrymal conduit, at the entrance of the sac-

Stricture at the mouth of the sac.

culus lacrymalis, is often combined. This stricture is readily ascertained, and easily yields to the dilating probe. The tears regurgitate, and cause suffusion, but there is no evidence of any affection of the sac. The most frequent situation of stricture is at the point of termination of the sacculus lacrymalis in the ductus nasalis. The tumid state of the lining membrane during acute inflammation of the palpebral conjunctiva, occasions a temporary obstruction, and this will continue for a time after the subsidence of the inflammation, but in a less degree. The canal in this state is exquisitely sensible, and the use of probes is improper. The obstruction is gradually removed under the treatment adapted to the inflamed palpebral conjunctiva, with which the lining membrane is continuous.

Acute.

Chronic.

A more considerable and permanent obstruction arises from continued vascularity and slow thickening of the lining membrane, the sac becomes slightly elevated from habitual distention, and a little mucus on pressure is returned upon the eye. Yet there is no discoloration of the skin, or sign of inflammation of the sac, and the epiphora is partial, that is, the tears are only impeded, and the epiphora only occurs when the eye is employed or in any way excited, and the secretion quickened.

Obstruction partial,

In the state of incomplete obstruction, if the

tarsi are unaffected, no mucus is discharged on pressure, nor is the sac perceptibly enlarged, nevertheless the suffusion upon reading, writing, working, or exposure to cold air, is exceedingly troublesome. Water injected by the puncta will find its way into the nostril, but slowly and only in part; so it is with the tears. When from long continuance of this state the obstruction is confirmed, the epiphora is incessant, the sac becomes sensibly dilated into a tumor, and upon pressure a very considerable discharge of purulent mucus takes place, so as to flood the eye. The sac, when once habituated to a state of over distension and a secretion of purulent mucus, will not contract upon its contents. Thus a very moderate degree of obstruction, or no obstruction at all may co-exist with this state; it may continue, even though the bony part of the canal should be destroyed, and the matter on pressure flow readily into the nostril.

or complete.

The lacrymal sac is liable to acute inflammation and abscess, a very troublesome, painful, and disfiguring disease, the signs and progress of which are well known. The surrounding cellular membrane becomes œdematous, and the cheek and side of the face are enormously swollen, so as to obliterate the orbital fossa and fold of the lower eyelid. When the abscess is chro-

Abscess of sac.

nic, the sac having been previously distended owing to obstruction, the contiguous cellular membrane passes into the state of adhesive inflammation, so that the swelling is not dropsical, but firm and hard. This occasions considerable embarrassment to the young surgeon, from the obliteration of the points, the infra-orbital edge especially, by which the operator directs his incision, and the depth of the sac from the surface. If the disease be left to pursue its course, the skin discolors, the sac ulcerates, and its contents are diffused in the cellular substance; or as more commonly happens where a previous obstruction has existed, the skin and sac, being condensed by the adhesive inflammation, yield together, and the discharge is external.

Fistula. Hence the fistula lacrymalis, properly so called, a term incorrectly applied to all stages of the disease, of which it is but the last. It must not be supposed, however, that abscess of the lacrymal sac is always preceded by obstruction to the tears, any more than that abscess of the prostate is always preceded by obstruction to the passage of urine. It is frequently a sudden and rapid disease, unpreceded by epiphora. In other cases it is slow and obviously progressive from the state of imperfect obstruction and retention of mucus and tears. The termination of acute abscess is more speedy and favourable for this reason, than of the chronic.

In the former case, upon introducing a common sized probe after opening the sac, it passes readily into the nose.

The lining membrane of the lacrymal sac is liable to take on a morbid action. It forms a hard and dense tumor, which slowly ulcerates and destroys the skin to the extent of the sac. An irritable button-like fungus, of a malignant aspect, is then protruded. A fungus of a looser texture sometimes follows the abscess of the sac, or, in other words, the sac laid open by ulceration, throws up luxuriant granulations.

Fungus of
sac.

The sac is also subject to dropsy, in which state it acquires the size of a pigeon's egg, projecting the lower lid next the nose; the tumor is perfectly transparent, containing a fluid like that of hydrocele. Its natural openings are closed, for it is incapable of evacuation by pressure; it is very considerably extended within the orbit on the nasal side. This has been termed the hydatid tumor of the lacrymal sac.

Dropsy of
the sac.

Injuries, as blows flattening the nose in early life, or occasioning exostosis of the ossa nasi or unguis, produce incurable disease, or permanent destruction of these passages. To these may be added polypi and fungous tumors so situated, or of such magnitude as to compress the sac or nasal extremity of the canal, or occasion absorp-

Diseases of
the canal
and sur-
rounding
parts.

tion of its bony parietes; and caries of the spongy, lacrymal, æthmoid, or maxillary bones. The ulcerative absorption or exfoliation of the bones renders the opening into the nose preternaturally large. But in obstinate chronic fistulæ, accompanied with erysipelatous or herpetic inflammation, or ulceration of the surrounding integument, it is not uncommon to find the bones denuded of their periosteum on the orbital side, still preserved by the pituitary membrane which remains attached to the nasal. In such cases the proper canal is usually obliterated.

There is a sponge-like fungoid growth, sometimes affecting the interior chambers of the face, which speedily fills and obliterates the nasal duct; it is hard and brittle, much disposed to profuse bleeding, and very quickly regenerated when broken down in attempts to remove it entire. It occasions considerable deformity by forcibly expanding the nasal cartilages. I have long had a case of this description under my care, in a middle-aged woman. Many severe operations have been only available to keep it in check. The fungus is of five years' growth.

I have often found the canal completely obliterated by ossific inflammation at its upper orifice in skulls; and I know cases of enlargement of the ossa nasi, and of periosteal inflammation and thickening, marked by habitual overflowing

of the tears and occasional erysipelatous inflammation of the surface, in which the canal is evidently destroyed. Malignant herpetic ulcers of the lupous class, not unfrequently occurring at this part, expose and destroy the whole lacrymal apparatus.

PART III.

TREATMENT

OF THE

DISEASES OF THE EYE.

CHAPTER I.

IT will be necessary in this department of my work to refer to the states of disease described in the Pathology, but I shall endeavour to avoid repetition, and to seize upon the principles of treatment, to the exclusion of over-minute practical details. The leading object of my undertaking I have already accomplished, however imperfectly; namely, the description of the principal phenomena of disease in the several textures of which the organ is composed. For the purpose of illustration I have unavoidably anticipated, in some instances, the subject of treatment, and the remarks which I have yet to offer will lie in a small compass; for it would be idle to suppose that general principles of treat-

ment require to be enforced, after the nature of a disease is clearly pointed out. The maxims and modes of successful practice, so far as they are hitherto known, are accessible to all inquirers of ordinary capacity; and that man is unworthy of his profession who seeks to mystify them, for the purpose of being esteemed wiser than his neighbours. The innumerable modifications and varieties of disease render it impossible to lay down rules that admit of universal application, and the general intelligence of the profession in the present day, forbids such an attempt, if it were in the contemplation of any individual to make it.

SECTION I.

SIMPLE INFLAMMATION.

Causes. THE causes of ophthalmia, like those which lead up to inflammation in other organs, refer first, to the state of the system; secondly, to the direct operation of external agents upon the organ. A person whose general health is disordered, or who is recently convalescent from some other malady, frequently becomes the subject of ophthalmia. The extreme states and sudden changes of temperature; the prevalence of easterly winds, of fog and damp, and peculiar conditions of atmosphere; exposure to draughts of cold air; concentrated heat and light; extraneous particles, and other less obvious circumstances, are regarded as occasional causes.

Whatever is the exciting cause of inflammation of the conjunctiva, the first visible phenomenon is a state of congestion, owing to an increased influx of blood into the capillaries: it may pass away, but the continuance and increase of this, with certain other phenomena,

determine that the act of inflammation is set up.

The sensation of a foreign particle within the lids, whether real or delusive, commencing with the state of congestion, gives occasion to a spasmodic contraction of the orbicularis palpebrarum. A pungent pricking pain in the organ creates a copious secretion of tears, which collecting within the palpebræ gush out at intervals, and their discharge affords a temporary relief. The increased temperature, volume, and sensibility of parts under inflammation, explain the following symptoms, viz. the sensation of burning heat and scalding tears, the constriction or girthing of the eyelids, and a sense of weight upon the globe; the involuntary exclusion of air and light, and sympathetic pains in the region of the orbit. Symptoms.

The simple inflammation of the conjunctiva, *i. e.* an inflammation not sympathetic with injury to the organ, nor depending upon any established disorder of the system, nor modified by a scrofulous diathesis, is easily and speedily reduced by the ordinary means adapted to this end. In its acutest form the loss of a few ounces of blood, and some brisk doses of purgative medicine are sufficient to subdue it. Even when it arises from superficial injury to the cornea, if treated in the commencement, it is scarcely less manageable. Treatment
of simple
ophthal-
mia.

Febrile irritation.

It is rarely that any sensible febrile irritation is present in simple acute ophthalmia, but if there be any, and in certain irritable habits the constitution sympathises with the smallest local malady, it yields to the means above mentioned ; repose of the organ, soothing applications, suspension of ordinary employments, a light vegetable diet and diaphoretic diluents.

Blood-letting.

In many inflammations it is unnecessary to draw blood ; the organ recovers speedily on the removal of excitement, the use of soothing applications, and the operation of cathartics. In some, general blood-letting is contra-indicated, both by the character of the inflammation, and the habit of the patient ; while on the other hand, the degree of congestion makes it desirable to assist the recovery of the organ by unloading the vessels in the vicinity. In others, a question may arise as to the mode of proceeding to be adopted, in which the patient's convenience or preference may be consulted, or a disposition habitual to not a few persons, to a troublesome erysipelatous inflammation after leech-bites, may be admitted as an objection * ; but there are cases in which the indication is peremptory, both as to the use of topical and general blood-letting. If it be important to

* The swelling and discoloration which so often follow the application of leeches to the eyelids, especially the lower, make the remedy little less an evil than the disease.

make the system sustain and feel a reduction of power, blood must be taken by the lancet, either from a vein or the temporal artery *. Cupping has a very decided superiority over leeches; both are well adapted to relieve local congestion. But these modes of depletion are obviously too indirect, however extensively employed, to be used with the first-mentioned view, as a substitute for the lancet. Bleeding from the angular vein, and scarification of the conjunctiva are other means adopted for the relief of the turgid vessels. The latter practice is, in most cases, objectionable in the acute stage of inflammation; in the chronic it is highly beneficial, as in the thickened and over-vascular state of the palpebral conjunctiva; and a considerable discharge of blood may be thus obtained if it be briskly performed with a sharp lancet, the lower lid kept everted, and continually fomented with hot water.

On the subject of local applications in acute ophthalmia, there is considerable variety of professional opinion, but little in the evidence of patients. Dr. Johnson, whose opinion in these matters there can be no presumption in criticising, had a saying, “that there is little virtue in a lotion.” In the main, and speaking of them comparatively, if it refers, as I conclude, to medicated lotions, I am much of his opinion; but

Topical applications,

* See note H.

warm and
cold.

warm and cold baths; whether employed for a part or the whole, have very unequivocal and sensible effects. These effects are likewise very different, as might be expected. Although the sensation of cold is most agreeable to an organ under acute inflammation at the moment of its application, it is generally followed by increase of heat and pain; and in familiar instances, the pulsatile action of the vessels leading to an inflamed part, is so increased as to evince its stimulating effect, and the re-action thereby induced. When, however, the acuteness of inflammation has subsided, and the sensibility of the part is in proportion diminished, the effect of cold is only tonic, and has a salutary tendency to restore the balance of circulation. I therefore decidedly prefer, as a general practice, a tepid application in the painfully acute stage of inflammation, and I appeal to general observation in proof of its efficacy in promoting a grateful sense of coolness, and a more permanent relief from pain. It is objected to as being in the common phrase, "relaxing," which term exactly expresses its recommendation at the period of which I speak. We see its relaxing and resolving effect in incipient acute inflammations of the skin, the lymphatic glands, absorbents, &c. Moisture is a condition almost necessary to inflamed organs, and when the application is continued for some hours, as in poultices, it partakes so soon of the temperature of the surface, that this question is

of less importance, but the indication is the same with very few exceptions. To conclude these remarks on what may be regarded as too trifling to excuse prolixity, I prefer tepid water to all applications in the painfully acute stage of inflammation.

It is remarkable that even the weaker forms of medicated lotions irritate, and none more than that which is esteemed of all the most sedative, I mean opium. The relief afforded by anodyne fomentations in general, is very various. I have often known them objected to as painful, and patients to inquire if they might not substitute warm water for the aqueous solution of opium, and infusions of poppy and hemlock. The same observation applies especially to painful herpetic cutaneous affections, and acutely irritable ulcers. Upon these a solution of opium often acts as a stimulant and augments pain, while the lunar caustic solution as often assuages it. I do not deny that there are occasional exceptions to this remark. I have met with cases in which no other application than the aqueous solution of opium could be borne. I have also known the vapor of laudanum afford the most marked relief to the characteristic symptom of the strumous ophthalmia, viz. irritability to light.

Anodyne
lotions.

Although during the state of morbidly elevated

sensibility accompanying the outset of acute inflammation, warm applications are most soothing, and therefore most eligible; the continuance of them beyond their necessity is a loss of time, if not injurious. When the extreme vascular congestion and excessive sensibility are reduced, and the inflammation tends to become chronic, the use of cold lotions of a slightly tonic quality is substituted with great advantage for ablutions of warm water. The sulphates of alum and zinc are best. The smearing of the tarsal edges with cetaceous ointment or cold cream at bed-time is useful in the acute stage, and as it subsides, the tutty or lead, or very dilute citrine ointment may be advantageously substituted.

Œdematous
ophthalmia.

The œdematous elevation of the conjunctiva is significant of a feeble action, and is by some regarded as erysipelatous. A more than ordinary fulness of the sclerotic conjunctiva is often combined with the nausea, foul tongue, and præcordial oppression, which manifest disorder of the stomach and liver in cutaneous erysipelas; and the solution of emetic tartar given at short intervals, operates very beneficially in reducing it.

Atonic
ophthalmia.

There are inflammations which assume a chronic character in their commencement, evidently depending on a state of atony, of very partial extent, void of pain, and scarcely possessing any

sign of inflammation, except the congestion of vessels, or if any, so feebly marked as to encourage us to disregard them in treatment. In such cases a single stimulus will often restore the healthy action at once. The vinous tincture of opium has acquired a nostrum-like importance, from its restorative operation in such cases; a virtue I believe not proper to it. A drop or two of the zinc or the lunar caustic solution, of water impregnated with calomel, or a minute portion of the citrine ointment, or any other stimulant introduced within the palpebræ would do as much. Some old women use their urine with admirable effect in these cases. It is the character of the morbid action, not the application, that explains this sudden recovery. The re-excited or increased momentum of the arterial action clears the stagnant capillaries, and the unloaded vessels recover their tone. Such cases are frequently relapsing, unless means similar to those of cure are continued as prophylactics.

In certain habits, or states of the system, whether the ophthalmia arises from constitutional disorder or local injury, bleeding, purging, and blistering, the ordinary means of arresting inflammation, are employed without apparent benefit, or at least with a very disproportionate degree of advantage; and if the plan is persevered in, it soon becomes injurious; the irritability by which it is marked, increasing as the

Irritable
ophthalmia.

strength fails. These are cases in which opium, if we so combine it as to countervail its tendency to check the natural secretions, has an admirable effect, viz. with calomel, antimony, or ipecacuanha.

Inflamma-
tion threat-
ening the
cornea.

In the treatment of simple acute ophthalmia, the object to be kept in view is the soundness of the cornea; the organ is in no danger of deeper injury. The main indication for an activity of treatment beyond that successfully adopted in ordinary cases, is furnished by the state of this membrane. Where the sclerotic conjunctiva is much raised, and the surface of the cornea has in any degree lost its polish, and still more when lymph is effused in or upon the cornea, so as to obscure vision, the anti-inflammatory measures must be as vigorous and decided as the integrity of the organ is important. Blood-letting and blisters, calomel, antimony, and the neutral salts comprise all the requisite means.

Chronic
simple in-
flamma-
tion.

It is seldom that the simple inflammation becomes chronic. Blisters, and issues or setons, the zinc and acetous acid washes, and tonics, especially pure air and exercise, are the most efficacious remedies; but the red and thickened state of the conjunctiva at the margins of the lids, is an occasional and not unfrequent termination of it. Here scarification and the diluted mercurial ointments are employed with obvious

advantage; but with some persons all greasy applications inflame so much as to aggravate the complaint, and in such instances moderately stimulant washes, of which a portion is to be admitted within the lids, may be substituted.

SECTION II.

INFLAMMATION MODIFIED BY STRUMA.

THE apthous inflammation, the inflammation of the follicles, and that characterized by intolerance of light in excess, and commonly denominated strumous ophthalmia, are almost always of an atonic character ; and although obstinate when to a certain degree established, are easily subdued in the early stage, or at least prevented from arriving at such a height as to do permanent mischief to the cornea. They are, with very few exceptions, constitutional diseases ; and the same remark applies to many instances of the mild acute suppurative ophthalmia. This is proved by the disorder prevailing in the system of nutrition, by the general debility of the habit, and by the concurrence of local affections in other parts referable to the same source. The habit, age, and sex of the patient frequently contribute to the predisposition. The sphere and mode of life have also a decided influence in the production of these diseases. Children are most frequently affected by them, and those es-

pecially, subject from infancy to glandular enlargements, chilblains, cutaneous eruptions and chaps, psoriasis, tinea, and porrigo. Imperfect nutriment, whether from the nature or deficient quantity of their food or defect in their powers of assimilation and absorption, contributes to them. To this may be added an impure atmosphere and want of cleanliness. The tendency to such diseases is demonstrated before they exist, and to prevent their recurrence is often more difficult than to remove them. It is common for a parent to say, "I know what will remove the complaint, but I cannot prevent its return." This however arises from neglecting to follow up the cure to its completion, and properly to employ the interval of the attacks.

A gentleman determined to relinquish animal food, and lived wholly upon vegetables and water. From the enjoyment of good ordinary health, he was in the course of six months reduced to a lamentable state of disease. The whole mucous surface became affected successively after a severe and obstinate attack of mild acute suppurative ophthalmia. His system was so alarmingly debilitated by the protraction of his disease, owing to the prostration of his restorative powers rather than to the violence of the morbid action, that a residence in the south of Europe became necessary for the final re-establishment of his health. The disposition

of such a class of diseases to fasten on the organ when once seated, in other words, to become chronic, is as characteristic as their tendency to re-appear when for the time removed. They come slowly, and so depart. Violent means fail to cure them. They are, to the surprise of persons who mistake their character, unaffected by them; and if such means be long persisted in, they are changed for the worse. If the remedies employed increase the debility of the system at large, it must follow that the part suffers, if this account of their constitutional origin be correct. Hence it is not uncommon for those who treat all inflammations alike, to express their surprise at the obstinacy of these affections, after going through and through again the routine of an active antiphlogistic treatment.

When the inflammation is of a sthenic character, as is more frequent where rapid changes are taking place upon the cornea, as a diffused opacity, or the formation of pustule and its passing into ulcer on that membrane, especially where the deeper-seated tunics are partaking by continuance of the inflammation, the necessity of a more active practice is sufficiently demonstrated. But as a general observation, blood-letting is not salutary in these inflammations. They are rarely attended with any very acute pain. Rough and depressing purgatives,

either from quantity or quality, are injurious. Warm applications are of no advantage, if not injurious. Blisters on the nape of the neck and behind the ears, are for the most part of very great utility, where the severity or permanency of the inflammation calls for them. When the corneal surface is affected, and the sensibility is from this cause painfully augmented, this is especially the case. They should in such cases, if required, be kept open as long as they do not irritate the system. Where the morbid appearances upon the cornea are notwithstanding stationary, or slowly progressive, issues and setons are of great avail.

The principle of treatment indicated in such cases is to lessen the irritability without materially depressing the power of the system. The selection of medicine and applications, the regulation of diet, the degree of relief proper for the organ from its natural stimulus, when painful, must of course be determined by the circumstances of the case under consideration. The arrangement of the vessels at the verge of the cornea, and the condition of that membrane, are the special points for observation.

If the cornea be opaque, calomel, or the blue pill, or the oxymuriate of mercury should be exhibited in combination with opium, slightly to affect the system. The efficacy of the

mercurial mainly depends on its combination with opium; it irritates too much if administered alone in quantity sufficient for the purpose.

The following may serve as a synoptical sketch of the treatment for each form.

1. *Strumous inflammation without change of texture, vascularity more or less, intolerance excessive.*

Calomel and opium, or hydr. c. cretâ and Dover's powder at night; emetic tartar to nausea; gentle alvine evacuants; diaphoretic drinks; large open blister on the nape of the neck; leeches; tepid bath; tepid or cold water washes, as most agreeable; vapor of opium; large bonnet shade; no bandages*; spacious airy apartments and light bed clothing.

2. *With recent diffused opacity of corneal conjunctiva, and vessels raised upon and over-shooting the corneal margin.*

Calomel and antimony, or opium, or any other more appropriate exhibition of mercury, to ptyalism; occasional purgatives; leeches; blisters

* Close bandages I would observe are always prejudicial. They create a morbid sensibility where it had not before existed, and greatly add to it when present.

alternated behind the ears and on the nape of the neck and temples.

3. *With herpetic ulcers of the cornea.*

The same ; blisters on the temples ; as the inflammation yields, sol. argent. nitrat. : vin. opii : sol. cup. sulph. : dilute zinc lotion.

4. *With pustules.*

If partial, weak zinc or alum lotion ; ung. hydr. nitr. ; occasional brisk purgatives ; infusion of roses with additional acid ; tonic bitters ; calumba, gentian, &c. ; blisters behind the ears, repeated if necessary. If the vascularity is diffused by the multiplication of pustules or the duration of inflammation with irritability to light ; treatment as in strumous inflammation without breach. Ung. zinci. et sub-acet. plumbi.

5. *With inflammation of the follicles and puriform discharge.*

Active measures at first, but not long continued. Blisters, when becoming chronic, with thickened lids, scarifications ; zinc, alum, or copper wash, dilute ; ung. hydr. nitr. : hydr. nitr. oxid. : sub-acet. cupri ; tonics and sedatives. If obstinate, issue or seton.

6. *Convalescent state.*

Infusion of roses ; cascarilla ; calumba ; decoction of bark, with dilute sulphuric or nitric acid ; steel : rhubarb and soda, or magnesia, as aperients. Tonic collyria and gently stimulant ointments ; nutritive diet ; country air ; shower or sea bath in the warm months.

SECTION III.

ACUTE SUPPURATIVE INFLAMMATION OF THE CONJUNCTIVA.

THE suppurative inflammation is of all the most dangerous to the organ ; and its sequelæ, even under a favorable termination, lingering, and sometimes difficult of removal. It is in its nature acute, but this acuteness is either mild or vehement. The former has been confounded with the inflammation of the follicles with puriform discharge, known also by the name of psorophthalmia, ophthalmia tarsi, mucosa, &c. I believe, as I have before explained *, that the diseases are in their seat and nature distinct, and that the discharge is the only symptom common to both. From the occasional presence of diffused vascularity of the conjunctiva with the inflammation of the palpebra, the misconception has probably arisen. The flakes of mucus lying in the palpebral sinuses are not indicative of the suppurative inflammation, for these are often seen in the inflammation of the follicles, where the pal-

* See page 97.

pebral conjunctiva is very slightly affected, and the secretion is not that of suppurative inflammation, but of an irritated mucous surface. (Fluor albus and gonorrhœa.) The intumescence and elevation of the palpebral conjunctiva, (chemosis palpebrarum,) its villosity, and the fluid and truly puriform nature of the secretion, are characteristic of the mild acute form of suppurative ophthalmia, in which the conjunctiva of the globe is also tumid and vascular; but I do not deny that under aggravation, the inflammation of the meibomian border and follicles may be followed up by the mild suppurative inflammation of the conjunctiva.

In the mild form of the complaint the cornea is not endangered, unless the disease be neglected or exasperated by stimulants. A very slight haze of the cornea is the worst direct result of it. There is not that excessive swelling of the lids, that intense pain, nor that profuse secretion, which characterises the vehement acute form of the disease; but these symptoms exist in a degree sufficient to require immediate and active treatment, and to this the acuteness of the inflammation speedily yields. The alum solution should be early substituted for the emollient fomentations, which, during the acute period, should be freely used; and this should be directed in a gentle stream over the conjunc-

tival surface, from a syringe furnished with an ivory pipe, introduced at the temporal angle of the lids, without forcibly separating them. Simple purging and abstinence are generally sufficient to allay the febrile irritation, which is moderate. Topical bleedings and a suppurating surface opened by blistering the back of the neck, are of great efficacy. When the pain and irritability to light subside, and the discharge becomes gleet, the conjunctiva pale and flaccid, tonics, especially the extract of bark and the acids, do great good. As an application, the liquor plumbi acetatis may now be advantageously employed. While we are permitted to see the cornea, and to see it clear and bright, for this is the index by which we are guided, we need be under no apprehension. The vehement acute suppurative inflammation is sudden in its attack, accompanied with most severe darting pains; the upper lid is in a few hours prolonged upon the cheek, owing to the infiltration and enormous swelling of the tissue connecting the conjunctiva to the tarsus. The cornea is nearly concealed by the fold of conjunctiva which overlaps it all around, and the corneal surface is dusky. The system sympathises, chilliness is succeeded by a hot and dry skin, and the pulse is frequent and hard. The instant relief of a large venesection is indiscribable. The pain is mitigated, if not removed; the pulse softened, and the patient sinks into a sound sleep, and

perspires freely. Upon inspection we observe the high scarlet hue and bulk of the chemosis sensibly reduced, and the cornea has a brighter aspect.

But it is rarely that a single blow suffices to vanquish the disease, especially where it arises, as is most frequently the case, from the contact of morbid matter. The most violent cases in my experience have been those produced by the matter of gonorrhœa applied to the eyes, of which I have seen several unequivocal examples. With large blood-lettings repeated, subject to the discretion of the practitioner, until the inflammation yields, a brisk catharsis should be combined, and this followed by a tea-spoonful of a solution of emetic tartar every hour, so as to keep up a state of nausea, perspiration, and faintness. The discharge, at first ropy, viscid, and sparing in quantity, becomes thin, gleetly, and more abundant; as the swollen lid subsides, the conjunctiva sinks and becomes pale and flabby; and if at this period, the pain and febrile irritation being past, the cornea retains its tone and brightness, all is well; the disease has given way, and a careful but prompt exhibition of tonics, with the use of cooling astringent lotions, will prevent its lapsing into a chronic form. But if, when the lowering practice has been pushed to the extent of arresting acute inflammation, the patient being at the same time sunk and exhausted, the cornea

shews a lacklustre and raggedness of its whole surface, as if shrunk by immersion in an acid, or a grey patch in the centre, or a line encircling or half encircling its base, assuming a similar appearance, the portion so marked out will infallibly be detached by a rapid slough, unless by a successful rally of the patient's powers we can set up the adhesive action so as to preserve in situ that which may remain transparent.

To know how far to go and not outstep the boundary; to know when to venture upon a short and sudden reverse of treatment, is the great difficulty of this highly important case. It is a fatal mistake to consider the first change, which is a true adhesive nebula, as the sign of gangrene or death, and thus to temporise, or even under this delusion to support the diseased action *. Another, is to treat the discharge as the disease, which is in fact but an inconsiderable sign of it as regards its importance, and to stimulate by strong astringent injections in its commencement. But the pathology which attributed the destruction of the cornea to the corroding quality of the matter secreted, was so lamentably erroneous, that we cannot be surprised at any effects, however mischievous, which resulted from the treatment thence deduced.

* See page 119.

In closing my observations on the treatment of inflammation of this organ, I shall take the liberty of making one or two general remarks. When inflammations in their nature destructive are arrested by the vigor of the means employed, the system stands in great need of the power thus lost for its recovery ; to restore parts partially injured, and to supply the place of those which are destroyed. We see this fact exemplified in many instances both of disease and injury. A patient labouring under pneumonia is relieved, by excessive bleedings, of his attack, and dies a month afterwards of dropsy. A person threatened with apoplexy, who by the advice of his physicians is cupped once a month, soon falls a victim to erysipelas.

If much blood is lost in severe injuries, especially of aged people, the healing powers are prostrate, and gangrene ensues. I mention this as a caution against that inconsiderate detraction of blood (and it applies as forcibly to the abuse of mercury) which proceeds without proportioning the quantity to the absolute necessity of the case, and, secondly, without balancing the effect upon the system at large against the importance of the organ. When I hear, as I often have heard, of sixty and seventy ounces of blood taken at one time for an ophthalmia, and this followed by repeated smaller bleedings, I must protest against the necessity

of such a practice, and say with Falstaff, "the better part of valor is discretion."

One of the great errors, it appears to me, in the treatment of inflammations of the eye, though of late years much corrected, has been the irritation of the inflamed organ by stimulant drops and ointments. The advantage of them is fully admitted at a proper season; but during the presence of active inflammation their use is as revolting to common sense as it is injurious*. I am satisfied many eyes have been thus destroyed. An anomalous species of ophthalmia, or a pseudo ophthalmia is produced by it, which differs as much from the real character of the disease in either of its forms, and may be as readily distinguished from it, as an artificial from a natural flower. Thus, to mention one of many cases, I have seen the star-like arrangement of the vessels

* I have mentioned certain cases in which stimulants act beneficially. Even mustard has been applied to inflamed eyes, with some real or supposed benefit. The temporary relief which follows pungent applications is to be attributed to the copious secretion and flow of tears which they occasion, which is nature's own mode of relieving the distension of the vessels, quickened by additional excitement. The pain of every inflamed organ is augmented by the retention of its secretion, and in proportion relieved by its discharge. But the means employed to promote this end should not be such as are likely to support and increase the morbid action. Pain is only an effect of this morbid action, and to assuage it by measures calculated to perpetuate the cause, is, to say the least, a most unscientific method of proceeding.

around the margin of the cornea, the cornea and remaining portion of the conjunctiva clear, and the choroid and iris perfectly free from inflammation, the sequel of an inflammation of the follicles which had been incessantly stimulated; and I know cases of permanent and excessive congestion, or rather varices of all the veins of the conjunctiva with an actual discoloration of the sclerotic, such as would lead to the belief that the person laboured under confirmed organic amaurosis, where however the sight is perfect. Here the plan of irritative applications had been unremittingly pursued by several practitioners in succession. The anomaly consists in the existence of such appearances unallied with the states of which, by their habitual association, we consider them characteristic. An apprehension suggests itself to my mind, when I see such cases, that the external character may be the prototype of internal disease, or, at least, that the confirmed existence of the one may predispose to the production of the other.

SECTION IV.

SECONDARY DISEASES OF THE CONJUNCTIVA.

THE granular state of the tarsal conjunctiva is a very common result of the mild suppurative ophthalmia. It is characterised by a gleety discharge, irritability to light, drooping of the upper lid, a pricking sensation as of sand in the eye, and a preternaturally irritable and vascular state of the sclerotic conjunctiva; with these are frequently combined, opacities of the cornea. The lid should be everted, and the projecting granules shaved off from the surface and orbital edges of the tarsus, with a keen-edged lancet, or, if peduncular and prominent, they will be more conveniently snipped off with the flat scissors. In doing this, care should be taken to avoid injuring the continuous membrane.

Granular
conjunc-
tiva.

When in addition to the state above described, vessels are ramifying over the cornea, opacity of its covering conjunctiva being a contemporaneous result of the inflammation, or a consequence of the irritation excited by the granulations, a section of the membrane should be made at one

With vas-
cular cor-
nea.

line's distance from the margin of the cornea. For this purpose, the globe should be thrown forward, and fixed in a state of tension by depressing the edges of the palpebræ with the fingers. The membrane yields instantly to a light hand, and its edges gape asunder; in aggravated cases, the operation, which is painful, requires to be repeated, and some adroitness in exposing and fixing the globe is requisite to its complete performance. After the excision of the granulations and the division of the conjunctiva, a solution of the sulphate of copper, or some astringent, is very advantageously employed in the way of injection. A few drops of the liq. plumb. acetatis, or the tinct. opii vinos. are often highly effective. It should be observed that the two states above described often exist apart, but the treatment adapted to them respectively is equally essential. The application of the blue stone, or of the lunar caustic, is often useful in preventing the regeneration of the granulations after their excision*.

Fungous
conjunc-
tiva, elon-
gations, ex-
crescences,
pannus, &c.

Another consequence of the disease above described, are folds and flap-like elongations of the conjunctiva filling the palpebral sinuses, and occasioning such a fulness of the lids as to prevent the patient from more than half opening the eye. Upon eversion of the lids they roll out upon the cornea. Another state ensuing

* See note I.

upon the excessive chemosis, is a fungoid protrusion of the conjunctiva in a thickened and indurated state. The conjunctiva also, at the point of its reflection from the lid upon the globe, occasionally forms a tumor of considerable magnitude. I have seen it projecting from beneath the upper lid equal in bulk to a middle-sized walnut, producing great distortion and inconvenience, and rapidly increasing so as completely to cover the eye. Such states more frequently result from injuries, as falls and blows. The treatment of all these cases consists simply in the excision of the tumors, which is most conveniently done with a lancet shaped knife, cutting on both sides. The same may be said of the disease which I have denominated pannus*, the elongated valvula semilunaris, and the caruncular excrescences which sometimes form in clusters between the tarsus and the globe. In the first named disease, a circular excision of the redundant opaque membrane should be made with the curved scissars at a short distance from the margin of the cornea, and the scissars will be found most convenient in the removal of elongations and excrescences, while such parts are raised by a pair of small forceps. The broad

* This term is differently appropriated. In the disease to which I have applied it, the conjunctiva clothes and covers the cornea from that side to which the eye is directed, but it has no affinity to the membranous pterygium, or any form of nebulous opacity of that membrane.

or ring-ended forceps are often convenient on these occasions.

Pterygium
and encan-
this,

The fleshy pterygium is sometimes a chronic and even a stationary condition of disease producing no inconvenience, nor threatening to interfere with vision. Whenever this is the case, I am decidedly of opinion that it should be let alone. When, by its progress, it is encroaching upon the sight, it should be raised by dissection as close as possible to the margin of the cornea, and the relaxed portion of the membrane removed by an incision mid-way between the base of the pterygium and the cornea, and concentric to that membrane. I have experienced the inconvenience pointed out by Professor Scarpa, of carrying the excision to the caruncula, viz. the deposit of lymph in the site of the cicatrix becoming united with the caruncula, and forming a hard frenum or cord which prevents the abduction of the eye. I am also satisfied that the disease is permanently arrested when the connection with the cornea is severed. In this operation I prefer the cornea knife to the scissors. It is inadmissible to interfere with any portion of the pterygium that may have encroached upon the cornea. It may be necessary to repress the tendency to reproduction by the application of the caustic pencil to the section of the tumor; but the frequent or diffused application of escharotics is objection-

able, as a morbidly thickened and tubercular state of the membrane is the consequence of the irritation thus excited. The treatment of the membranous pterygium consists in nipping up a crescentic portion of the opaque membrane as near as convenient to the cornea, and freely excising it with a pair of curved scissars. The extremities of the line of excision both in this and the former species should extend beyond the diseased part.

The encanthis, when it attains any considerable bulk, becomes condensed with the *valvula semilunaris*, and presents appendices corresponding to the *cornua* of this fold. The treatment consists in simple excision.

The membranous bands connecting the lid Frena, to the globe should be divided, with the precaution to avoid wounding the palpebral conjunctiva. No bandage should be employed, and during the day the patient should not be suffered to keep the eyelids closed. In my experience, escharotics only exasperate the evil.

Tumors upon the globe, unconnected with Tumors, the palpebra, should be dissected from the sclerotic; and this is the more important, in proportion as they are seated near to the cornea. Where the tumor is tied by angular folds to the eyelid, considerable attention is necessary to

prevent the adhesion of the conjunctival surfaces during the stage of healing, as in the case of frena. The best mode of preventing the approximation of the opposed surfaces, is to produce a partial eversion of the lower lid, by a strip of plaster carried from its margin in an oblique direction across the cheek, and frequently renewed.

TREATMENT
OF THE
DISEASES OF THE EYE.

CHAPTER II.

SECTION I.

DISEASES OF THE CORNEA.

THE term, inflammation of the cornea, must be understood as applied to the compound texture so denominated, and not to the lamellæ of horny substance which has no vessels proper to itself, but derives them from the covering and connecting cellular tissue. These vessels nourish and preserve it in the condition essential to its economy. The crystalline humor is a simpler texture, being wholly dependant on its capsule—as the nails, like the horse's hoof, are sustained by the lamellæ of the cutis in which they are implanted—or the hair, by the bulb alone to which it is attached. It is rarely that red vessels are seen in the interlamellar texture of the cornea. Deposits of adhesive matter and

of pus are frequent; the former most so; those of blood are rare, being only a result of severe injury, superadded to a state of inflammation. The cornea is rendered turbid by a congestion in the vessels of its covering or connecting texture; and in this, and the case of interstitial inflammatory secretions, may, if in any, be said to be inflamed. But its subserviency in these processes to the conjunctiva and sclerotic, make the strict propriety of the term questionable as applied to the corneal lamella. It would be as incorrect to speak of an inflamed crystalline, hair, or nail.

Nebula and
onyx.

It is only necessary to observe, that the practice employed to reduce inflammation, is then most strongly indicated when the cornea is rendered opaque, or presents an onyx of adhesive matter.

Superficial
external
ulcer.

The superficial ulcer is commonly attended with much inflammation of the conjunctiva, and, by continuance, of the sclerotic. The eye is very irritable to light, and the sensation of a foreign particle in the motions of the lids acutely painful. The pain is often spasmodic, and relieved by profuse lacrymation at intervals. Opium should be so combined as to operate on the skin, and the bowels must be kept freely open.

Touching the ulcer with the solution of the

argentum nitratum is the best local treatment, much superior, as an anodyne, to sedative lotions. Warm fomentations afford temporary relief. It will be found advantageous, if not indispensable to prevent relapse, to affect the system with mercury where the inflammation of the sclerotic is intense. The cicatrix being confined to the superficial lamellæ is of very inconsiderable density, so as in time to be scarcely perceptible, and in children to wear quite away.

The indolent and the deep sloughing ulcer may be touched once, or oftener, with the caustic pencil, or washed once a day, or oftener, with the solution. The cleansing of the ulcer, and the opaque adhesive circle is the sign for a less frequent use of it, and the deposition of new matter, undergoing a vascular organization, renders its further use hazardous. The occasional use of leeches is often a necessary accompaniment to this treatment. The administration of tonics and sedatives is at the same time essential.

Indolent
and deep
sloughing
ulcer.

The acute interstitial ulcer cannot be treated distinctly from the adhesive inflammation; it is a sign only of the inflammation which constitutes the disease. In proportion as this is reduced, its disposition to extend is checked, or we are enabled to employ auxiliaries to that end. But in favourable circumstances of constitution they are not wanted. Healing is a spontaneous

Acute in-
terstitial
ulcer.

action, vicarious with destruction, and commences on the arrest of inflammation.

Abscess. A large collection of matter in the cornea, whether the puriform onyx, or central abscess, requires, at the same time, a supporting constitutional treatment, mild cathartics, and the application of blisters; calomel should be avoided, as in most instances where ulceration is present. The puncture of the cornea is seldom practised with advantage. By the means above-named, I have seen large effusions absorbed, and no trace left of their existence.

Hypopion. When the hypopion is so large as to rise towards the pupil, and the ulceration of the cornea is extending, I think its discharge by section near its margin advisable. If not too long delayed, the ulcerative process is checked by it, which would otherwise run into sloughing; and the cornea recovers with only partial opacity and disfigurement.

Procidencia iridis. The prolapsus iridis from ulcer should, if small, be touched with the caustic pencil, ground to a fine point. If large and extending, it should be snipped off with a pair of curved scissors, and the caustic pencil immediately applied to the cut surface and margin of the ulcer. In this way I have seen many cases recover with good though abridged vision. This circumstance depends on

thes ite of the ulcer and the relation of the prolapsed portion of the iris to the pupil. The same treatment is best adapted to prolapsus from wound, as after extraction. The inflammation accompanying these states requires the occasional application of leeches, gentle purgatives, sedatives, light tonics, and mild nutritive diet.

The chronic interstitial ulcer requires only stimulant and astringent injections; blisters in the neighbourhood of the eye, bark and opium, pure air and good diet, with a due attention to the secretions. Rhubarb and aloe are the best aperients.

Chronic interstitial ulcer.

The opacities, in their nature removable, are the nebulous, which depend on a loss of transparency from recent inflammation, or recent interstitial deposition without breach of texture. Cicatrices are only so far benefited as the surrounding deposit is of this description, and susceptible of absorption. The actually changed texture of the entire cornea depending on an obliteration of the interstitial texture, like the cicatrix itself, undergoes no change from the use of stimulant applications. The most effective injections are the lunar caustic and the oxy-muriate of mercury, one or two grains to one ounce of water; the former may be used in the decline of the inflammation; the latter, not until after its disappearance. Levigated glass, calomel,

Opacities.

loaf-sugar, are by some coarse practitioners blown into the eye for this purpose. The principle of their operation is the same. In the use of applications to remove opacities, the points of importance to be determined are the time and the frequency of their use. They are mischievous when inflammation is excited or increased by them; their effects as excitants should be temporary. The mercurial ointments are less effective, in my experience, than the injections. Where the internal use of mercury is indicated by the character and duration of the inflammation which has given rise to opacity, its effect upon the latter is more marked than that of any local remedy.

Strumous
nebula of
the cornea.

Under the head of strumous nebula with vessels overshooting the cornea, I have advised ptyalism, upon the strength of several decided proofs of its efficacy; but no form of recent opacity is so intractable; and I should be uncandid not to state that I have seen it increased from day to day under the mercurial action. The vessels which shoot in radii upon the cornea and at length meet in the centre of the membrane, if the disease is unchecked, are situated beneath the conjunctiva and belong to the sclerotic, as may be easily ascertained by close inspection; and the uncontrollable nature of sclerotic inflammation, of which I shall speak presently, is well known to those who have seen much of

it. The deposition is interstitial. The hydr. \bar{c} cretâ or the oxymuriate, in small but frequent doses, will sometimes succeed better in this case than the other forms of mercury; and the combination of blue pill or calomel with antimony, better than that with opium.

In constitutions which discover an insusceptibility to be affected by the mercurial pill; or in which its exhibition in sufficient doses is attended with griping pain and diarrhœa, friction should be employed; and indeed in all cases in which the saving of time and strength is peculiarly an object, this is the more certain and efficacious proceeding. I know that the prejudice often existing against the use of the remedy in any shape, is most strongly opposed to this, its best form. But among persons otherwise intelligent, such a prejudice soon gives way to the more rational feeling of confidence in the practitioner. It is necessary, however, that he should support this feeling by a proper confidence in himself—by a steady perseverance in his design: having, therefore, upon mature deliberation decided, that the mercurial action should be set up, nothing but the clearest demonstration of the patient's inability to support it should interfere with the full and fair execution of the plan. A character notoriously abused by indiscriminate excess, is in much danger of being further injured by half mea-

tures. This, I think, has been the case of mercury. It is not the most delicate frame which is most ready to admit, or least able to support it; and it is not the quantity consumed, but the quantity absorbed, which is to be taken into account by the practitioner. The progress of disease during its exhibition is no argument against its continued employment; in this view, unless the system be fairly under its influence, all that has been given goes for nothing; nay, I have had occasion to see many cases in which, after all the signs of absorption were manifest, its operation upon the disease was for a time unobserved, or was null, and was yet ultimately all that could be wished. I venture upon these remarks from having myself felt "afraid to go forward lest I should go wrong," in some very obstinate cases of strumous nebula in young and very delicate subjects, the issue of which gave me no reason to regret that my confidence had triumphed over my fears. And therefore the stationary condition, nay, the natural progress of a disease during the period occupied by the introduction of mercury, or even after its introduction, for a time to be limited, would not deter me from prosecuting it in a case wherein I placed my dependence upon its power; but an alarming degree of arterial excitement, or certain morbid appearances of the organ, not looked for in the natural and ordinary course of the disease, would, as a matter

of course, determine me to withhold it. These remarks are not confined to the case under notice; they are of general application.

I shall take this opportunity of briefly adverting to another point of the ordinary treatment of this case, of some importance. The division of the conjunctival vessels on the decline of the inflammation is injurious during the acute stage of the disease, and at any period its effect upon the vessels, by which the nebula is secreted and maintained, is from their situation indirect; so that it stands upon the same ground as scarification, and no other.

The staphyloma, if purely corneal, and of such size as to occasion deformity, and expose the organ to farther injury, or if producing habitual irritation and inflammation of the tarsal borders, should be excised; the ligature passed through and including two-thirds of the diseased cornea, by means of a curved needle, assists the operator, by steadying the globe. If the staphyloma is from dilatation, the iris will be left; if from breach, it is compacted, and removed with the cornea. This circumstance makes no material difference in the healing, unless the section be made much posterior to the ciliary ring, when the globe collapses from the escape of the vitreous humor; which is not the case when the section is at the base of the cornea, although

Staphy-
loma.

the iris should be included in it, for the vitreous humor is in a considerable degree sunk by absorption in the staphyloma, and the aqueous as much superabundant. A flat double-edged knife is the most convenient instrument for a circum-cision of two-thirds of the staphyloma, which is executed in its passage across the globe; the remaining portion may be finished by one stroke of the scissars. A compress of soft linen should be laid upon the closed lids, and retained by a roller. Where the staphyloma is partial and conical, the section is corneal, and its edges should be touched with the *argentum nitratum* to prevent a corneal fistula. But when, as in many cases, the protrusion is not such as to prevent the easy motion of the lids, or occasion inconvenience, it should be left, screened or not, at the option of the patient. No benefit results from tapping the globe of the aqueous humor, either in this case or in the *hydrops oculi*.

Fungous tumors of the cornea must be treated as the staphyloma. They are of very rare occurrence.

Conical
cornea.

The discharge of the aqueous humor is equally useless in this case, and so are all applications to arrest the disease. I have found repeated blisters, and the more powerful tonics, as steel or arsenic, decidedly serviceable. To these may be added,

cold bathing, and the practice of often opening the eyes in cold spring water. I am unable to say, whether a section of the cornea, as in extraction, would be productive of benefit. It has occurred to me as not improbable. The disease, however, is constitutional, and must be so treated. The tubular spectacle frame with a pupillar aperture, I have found to afford more aid in correcting the vision, than any form of lens.

SECTION II.

SCLEROTITIS, CHOROIDITIS, AND IRITIS.

THE signs of inflammation extending to the sclerotic have been described. It is seldom, if ever, the cornea being the seat of diseased actions, that the sclerotic does not participate. Inflammation cannot pass from the surface of the eye to the interior tunics, without involving this membrane, and the impediment which is happily opposed to its progress, the slowness with which it is in consequence propagated, is accounted for by the texture and properties of the sclerotic, and the minuteness of the vascular communication through its medium between the conjunctiva and the choroid. The structure and properties of the sclerotic also explain why the primary scleratitis is a rare disease. In the commencement of this disease, the cornea is slightly, if at all clouded, and the activity of the iris but little impaired. An obtuse pain in the eyeball is materially relieved by blood-letting, and by antimony and ipecacuanha with opiates. It is by no means so decidedly influenced by mercury as the iritis, and its obstinacy and disposition to relapse, render the case

often difficult of treatment. The subject of it is usually reduced and irritable in a high degree, from suffering with rheumatic inflammation in the elbow, knee, or ankle-joints *. I have generally observed that the previous use of mercury has more or less contributed to this state. I have also noticed the frequent accompaniment of gonorrhœal inflammation with this disease, or its existence a short time previous. Though it is necessary to use mercury with more reserve than in other forms of inflammation, to suspend its operation at intervals, and allow the system to recover from its immediate effects, yet its exhibition will be found, in the majority of cases, indispensable. The rude and profuse employment of it hurries on the disease, and the extension of the inflammation to the interior tunics ultimately destroys the organ. The nitric acid may often be exhibited with marked benefit, in the intervals of the mercurial action.

The Plummer's pill, the oxymuriate in doses of one-twelfth to one-eighth of a grain, or in feeble subjects, the hydr. cum cretâ, five grains to ten, twice or thrice a day, are most available and beneficial forms of the remedy in these cases. As auxiliaries, soothing and allaying irritation, I should mention the Dover's powder, hemlock, and hyoscyamus, and the extract of sarsaparilla, either dissolved in the

* See note K.

decoction, or taken freely in the solid form. I have seen an obstinate chronic inflammation yield before these latter remedies, in which mercury had been productive of no benefit. In the motley diseases now known by the cant term of pseudo-syphilis, their efficacy is admitted by the most competent authorities.

On the treatment of deep-seated inflammation, whether affecting the choroid or iris, I shall not now dwell, having in an Essay on this subject, published three years ago, pretty fully stated my opinion; and when treating of the signs of these diseases in the present volume, having repeated my conviction of the remarkable efficacy of mercury, and of the comparative insignificance of every other remedy. One full blood-letting or more should be premised in the acute stage of the disease; and topical blood-lettings during the exhibition of it, are generally required at short intervals. I have now and then found that the incipient inflammation, where it has extended from the conjunctiva, yields to a copious venesection, and two or three brisk doses of calomel and rhubarb, followed up by the infusion of senna; but, generally speaking, the system must be made to feel the influence of mercury before the disease is permanently subdued. The inflammation which has proceeded to the effusion of adhesive matter, never, in my experience, yields either to the lancet, continued nausea, or full purging; and it is remarkable

that the cases presenting this termination of inflammation are always most sensibly and immediately benefited by the remedy in question, whether the cornea or the iris be affected, or any other texture of the body.

That in many instances, however, the deposition takes place notwithstanding, or immediately succeeding to the action of mercury, and is most prone to do so, (I do not say from that cause,) I am as sure as that it seldom fails to yield to its continuance or renewal. But when the mercury arrests inflammation previous to this event of it, there is reason to infer that it prevents such termination, and its less rapid and decided influence under these circumstances, is not a reason why, if the inflammation resists the ordinary antiphlogistic measures, it should not be employed. I believe that the mode of action of the remedy varies according to the degree of its influence, which again varies according to the habit of the patient, the form or stage of the disease, and the quantity of the remedy which is received into the system. But if any two facts are well established in modern medicine, I apprehend they are these:—first, the power of mercury to arrest acute membranous inflammation, both prior to and after the effusion of adhesive matter; and second, its power rapidly to remove, by an excitement of the absorbing system peculiar to itself, the newly effused ad-

hesive matter. If these facts are admitted, then the propriety of its use is indicated in iritis, as in carditis, pleuritis, peritonitis, and the only practical question that can arise respecting it is, how far the patient's strength is equal to support the remedy. There are, I admit, states of the organ as well as of the constitution, in which it cannot be borne, and no sooner is its influence felt, than the inflammation threatens disorganization, and if the plan is persevered in, quickly runs on to it. The globe becomes enlarged or misshapen, the sclerotic assumes a livid hue, and the veins a state of varicose congestion; sometimes the eyeball suppurates, and the little remaining vision is completely extinguished. In cases where age, or the existence of other diseases, or the already excessive use of mercury, has greatly enfeebled the powers of the system, it must be used, if ventured upon at all, very sparingly, or with intermissions, and the system must be supported by every admissible means, both of nourishment and medicine, during its employment.

SECTION III.

AMAUROSIS.

THE term amaurosis comprehends all those imperfections of vision which depend upon a morbid condition, whether affecting structure or function, of the sentient apparatus proper to this organ. That the term is not so defined according to its etymological import is well known, but it is thus employed by pathologists, if I have rightly understood its meaning.

The diseases of the other coats and humors of the eye which are present in a considerable number of these cases, are effects of an inflammation which has destroyed the retina. Such are especially, discoloration and absorption of the vitreous humor, or a bright yellow opacity of the crystalline lens, which is indurated—its capsule condensed with it, and firmly adhering to the constricted and perhaps irregular pupil, with peduncles of lymph or detached flakes of the black pigment projecting from its posterior border—or a capsule containing calcareous concretions with an absorbed lens, and a concave and tremulous iris, or an obliterated pupil, or a staphyloma of the sclerotic or choroid.

Organic
amaurosis
from in-
flammation.

From a change of texture independent of inflammation.

But there are cases in which a change in the structure of the retina is to be inferred, of a description less conspicuous indeed, but not less fatal to vision. This is the result of a slow and insidious morbid action, and although sometimes accompanied with superficial inflammation, is more frequently altogether independent of inflammation. The congestion of the superficial vessels, the extenuation and consequent blue tint of the sclerotic, the appearances supposed to indicate a caligo of the vitreous humor, or an opacity of the retina, or a deficiency of the pigmentum, seen upon looking towards the fundus of the eye, are signs of this change.

Functional amaurosis.

When the eyeball has the appearance of health, and the loss of vivacity in the motions of the pupil, is the only sign of an amaurosis obtained from inspection of the organ, we are scarcely warranted to suppose any disease of structure. I have called such cases functional, and my object in doing so is to discriminate them from the organic, in the belief that much practical advantage may be gained from the distinction. Diagnosis is a study interesting in a scientific view, but it is awfully important as it affects practice and character. An amaurosis depending on a change of structure in the brain or eyeball, is an irremediable case. The same may too often be said of that which presents no evidence of structural disease, of which

I shall presently mention examples. It is creditable to a practitioner to know such cases; and if his ingenuousness is equal to his knowledge, he will be a gainer in reputation in every way.

Functional amaurosis I have arranged under three heads: the symptomatic, the metastatic, and the proper. The first includes a class of diseases so large and diversified, that to consider them and the rationale of their treatment in detail, would occupy a volume. Suffice it therefore to say, that the amaurosis being subservient to the disease which affects the system at large, or some one important organ, the latter is the proper object of medical treatment. I may instance the morbid states and actions of the vascular system, the disorder of the digestive organs in its several degrees from impaired appetite to confirmed hypochondriasis, the interruption to the healthy functions of the uterus, the excess, or deficiency, or accumulation of the wonted secretions and excretions, the presence of local irritation, as wounds and abscesses, caries, worms, &c., and the influence of strong mental emotion producing a morbid irritability. These co-existing with an amaurosis must be regarded as the original and substantive disease, the removal of which is the aim and end of treatment. It must be obvious that it is rather the degree, than the nature and origin of the

functional disease, that should in most cases influence our prognosis, yet the latter circumstances, it is equally clear, afford more or less encouragement, in proportion as the pre-existing states of diseases ordinarily admit of relief or otherwise. Thus, for the sake of illustration, I may observe, that the amaurosis from gastric diseases, from plethora, from irritation, are all of them relievable, and, if treated at an early period, remediable. Whereas paralysis, the sequel of fever or of epilepsy*, or severe constitutional diseases, whether acute or chronic, or depending upon habitual cerebral congestion combined with organic visceral disease, or induced by the operation of noxious agents on the system, is a hopeless form of the malady. It resembles in appearance and character the ordinary gutta serena, or idiopathic palsy of the retina, which occurs in early as often as in advanced life, in which, excepting the gaping and motionless pupil, and the absence of physionomical expression, no defect appears; on the contrary, the fine, large, well-opened, and singularly brilliant eye, often excites admiration of its beauty as an organ, though unillumined by the mind.

* I know a family of several well-formed children, three of whom have dark hair and eyes, the others light hair and blue eyes. Towards puberty, all the dark haired children have become epileptics, and gradually lost their sight; the eyes, except in the expansion and immobility of the pupils, retaining every appearance of health.

The metastatic amaurosis is rare but well defined. The restoration of the original malady, if it be practicable without involving the patient's safety, or the substitution of an artificial excitement or discharge, which may serve as an equivalent, appears to be the natural indication, and such a practice has been attended with success*. But the prognosis is necessarily one of great uncertainty.

The proper functional amaurosis presents great variety; but if treated at an early period is very often cured. The extreme states of light and temperature, and the over-exertion of the organ, are the chief causes of it. The remission or removal of these hurtful circumstances even of itself does much towards the cure. The continuance of them frustrates the end of treatment, and the amaurosis becomes confirmed, and ultimately passes into the organic form. The emeralopi[†], and many other cases not assum-

* See a remarkable case of "Amaurosis from suppressed purulent discharge," successfully treated by Professor Beer, in the "Analecta" of the "Quarterly Journal of Foreign Medicine and Surgery, No. IV."

Although the metastasis of gout, of which I have known two marked instances, has been fatal to vision; yet in three cases, in which I extracted the cataract from gouty subjects, and a smart attack of the disease followed the operation, the eyes were unaffected and the sight was well recovered.

† See an excellent paper on this disease as it affects seamen in tropical climates, by Mr. R. W. Bampfield, Surgeon of the Royal Navy, in the 5th Vol. of the *Medico-Chirurgical Transactions*.

ing this precise character, are essentially depending on the injurious influence of the extremes of temperature, and light, and intense colors. I call to mind several cases distinctly referable to each of the above-named causes. During the correction of this sheet I have been consulted for an amaurosis immediately succeeding to exposure, during several hours, to cold and incessant rain; and which I have the pleasure to say is advancing towards recovery. I have exemplified the treatment of these cases in the pathology*; if active measures are taken without delay they generally warrant a favourable prognosis, but only on this condition.

The functional amaurosis varies in its rate of progress as well as in its ultimate extent. Some are sudden in their accession and perfect, as many instances of the metastatic and the proper; others advance steadily but sensibly to a point little short of blindness, at which they begin to assume an organic character; and of others again the actual progress is scarcely perceptible for months in succession, fluctuating from day to day between better and worse. I should say that the slow and the steadily progressive amaurosis are more to be apprehended in the result, that is, are less tractable than either the sudden or the rapidly advancing disease, supposing all to be alike free from the unequivocal signs of organic change.

* Page 168 & seq.

The removal of an irritating or oppressing cause will often effect a sudden and marked relief, as by clearing the intestinal canal of vitiated secretions therein accumulated, by restoring the digestive functions labouring under manifest derangement, or by taking away blood where the necessity is indicated. I have seen an incipient amaurosis distinctly arrested by the extraction of a diseased tooth, when the delay of a similar operation had occasioned gutta serena on the opposite side two years before.

The floating muscæ, when the disease is once established, are seldom if ever removed, yet patients retain good sight who have been troubled with them during half their lives. When the mind becomes indifferent about them, they are no longer observed, except in states of anxiety, irritation, or bodily weakness; and the subjects of them are usually aware of this fact.

It appears then upon this representation that certain cases purely functional, whether the affection originates in the organ, or in a remote part of the system, are, in their character, so nearly approaching to the organic class, as at once to convey the impression of their irremediable nature. In common with these they have many symptoms, hence the difficulty of diagnosis; and some of them quickly tend to altered structure, although the external signs of

this change are faintly indicated. On the other hand, cases are of frequent occurrence, more frequent than has been generally supposed, which admit of material and decided improvement, and even of complete recovery; and I would repeat, with the exception of those above adverted to, that it is rather the degree than the nature and origin of the functional disease that should influence our prognosis.

External
remedies.

The treatment of amaurosis is almost exclusively constitutional. To the various forms of external remedies, such as stimulant vapors, drops, and ointments; spirituous, ethereal, and aromatic embrocations; sternutatories, &c. &c. my experience leads me to attach no value. The faith yielded to such applications is a relic of the not very remote superstition, which ascribed miraculous powers to the hand of a living king, or a dead culprit. Ophthalmic surgery has been more degraded by manual officiousness, and the confidence placed in externals has been more injurious to its improvement, than to that of any other branch of the profession. It is fortunately not now-a-days necessary to do something when nothing can avail. I am quite aware that the transient effect of stimuli is in many of these cases grateful, and seems partially to remove the obscurity of vision, but the patient soon discovers that this is but a fillip. When, indeed, a disordered state of the

conjunctiva and eyelids exists in conjunction with an imperfect amaurosis, a more permanent benefit is often obtained by the rectification of this state, sufficient not only to afford encouragement in the use of topical remedies, but to induce a belief that the affection of the retina is, in a degree at least, sympathetic with that of the surface*. I should make a reserve of cupping, issues, or setons, in certain cases which it is unnecessary to specify, and of blisters in almost all. These, if managed as the case directs, Blisters. are a remedy of great value. In some, as temporary irritants only; in others, as irritants and drains. With the former view either the vesicle should be preserved by simply puncturing it, or the cuticle should be removed on dressing the blister, and the simple ointment applied. The process should be frequently repeated, and alternately over the superciliary ridge, upon the temple, upon the mastoid process, or the nape of the neck, as most eligible. Or if a more extended surface of irritation is desired in the immediate vicinity of the eye, the blister should take the shape of a chemist's retort, reaching from the zygoma to the glabella. It should be borne in mind, that the operation of blisters is very different in different individuals, as regards their susceptibility. The irritation and discharge

* See page 163.

of an efficient blister, as big as a crown, will sink the powers of a delicate female for days, and this effect will be especially felt in a weak retina. I have often known the obscurity of vision decidedly increased for a time by the application. Such cases are yet more affected by the direct loss of blood, even in the smallest quantity, and the permanent blister would be injurious. How is it that a blister is as useful in a proper nervous or paralytic amaurosis, as in one depending upon the congestion of the blood-vessels? I have been asked this question by intelligent persons. The fact is unquestionable, and the answer obvious, that the simple and temporary irritation is the object in one case, and a permanent irritation and derivation of blood in the other; and the blister is to be managed accordingly. Hence in a very susceptible subject, or a very irritable skin, a mustard plaster applied for ten minutes, and repeated now and then, may answer the first purpose more conveniently. It is in this particular view that the moxa is used in this and other diseases with so much advantage on the Continent. The eschar, if left to itself and not converted into an issue, is superficial, but the irritation is of the severest kind.

Electricity.

I have heard and read of the effects of electricity and galvanism in amaurosis. Some nar-

rators of their occasional efficacy are undoubtedly entitled to credit. I have had recourse to them in many cases, some of a very favorable description, but have never witnessed a single instance of benefit arising from the application of these powers.

The degree of constitutional power which enters into the disease forms the first and most important question in the general treatment. Extremes, it is said, meet, and it is certain that a strong and delusive similarity often prevails between the signs of diseases, which result from conditions diametrically opposite. The treatment in cases of general plethora and of cerebral compression I need not point out. But I have mentioned cases of undue determination of blood to the organ, which are especially common after deep-seated chronic inflammation, or distress from over-excitement, by which its vessels have lost their tone; an effect decidedly increased by depletion. Such cases are not difficult of discrimination from the former, if a due attention is given to the history.

General
treatment.

All the cases of direct debility and proper paralysis of the retina are aggravated by loss of blood, and the great prevailing mistake in the treatment of amaurosis is the indiscriminate deduction of blood. The same observation, it appears to me, applies to the treatment of cases of

general palsy. The practical idea of compression derived from the demonstrated instance of apoplexy, prevails over and puts aside the theoretic idea, derived from the admitted condition of nervous debility or exhaustion.

I have never known any real benefit derived from what are called antispasmodic and anti-nervous medicines, camphor, assafoetida, valerian, &c. Neither do I recollect an instance of decided benefit from the emetic practice, although in respect to its high authority, I have tried it fairly in many instances. The cases of gastric disorder to which it is especially applicable are most benefited by a long continued course of the blue pill, with gentle saline purgatives and tonic bitters.

In most of these cases we must depend, first, on the regulation of the visceral functions; and secondly, on the employment of such restoratives as the system requires and can bear. The blue pill, with colocynth, rhubarb, or aloes, and the combination of soda with rhubarb and calumba or gentian, are best adapted to the former purpose. The exhibition of general tonics is often strongly indicated, and I have seen much benefit derived from the mineral acids, bark, steel, when admissible, and arsenic, after a due regulation of the digestive functions. I know of no article of the class of stimulants that has any direct

claim to notice, or any approach to a specific virtue, such as has been ascribed to the *arnica montana*, *aconite*, &c.*

When the amaurosis is recent and sudden, Mercury. and either the signs of an obscure inflammation are present, or only the amplitude and inactivity of the pupil correspond to the patient's history, the indication is less simple; mercury should be introduced with all convenient rapidity into the system, I mean so as to ruffle it in the least possible degree. No advantage is obtained by salivation; on the contrary, I think it hurtful; when mercury is beneficial, its efficacy is perceived as soon as the mouth is sore †. I have seen it tried, and have myself tried it in many cases of perfect amaurosis, without the smallest advantage; but in cases of recent occurrence, imperfect, but rapidly progressive from bad to worse, I have been witness to its power in suddenly arresting the disease in too many instances not to entertain a far higher opinion of it than of any other article of the *materia medica*. I shall not again discuss the knotty question of its *modus operandi*; "*causa latet: vis est notissima.*" The form of its administration must be regulated by the circumstances of the case.

* Some oculists still adhere to the practice of the archangel, and

————— "purge with *euphrasy* and *ruc*

The visual nerve."

† See note L.

Dietetic.

Superadded to the entire repose of the organ, the natural tonics, viz. a pure, dry atmosphere, the cold bath, horse exercise, nutritious diet, early and sufficient rest, agreeable society, and a mind as much as possible diverted from the object upon which it is unfortunately and pertinaciously prone to dwell—these are of greater avail than drugs: and some lighter forms of sympathetic amaurosis are as effectually cured by them as by the blue pill and rhubarb, and upon the self-same principle.

SECTION IV.

DISEASES AFFECTING THE EYEBALL.

THE treatment of those injuries to which the organ is subject from external violence, is comprehended in the directions given for the treatment of inflammation and its consequences. In the suppuration of the ball when the patient's suffering is acute and the constitutional irritation severe, and the part notwithstanding its great tension affords no immediate prospect of relief by a natural opening, the cornea, iris, ciliary ring, and some extent of the sclerotic should be so divided by a deep transverse incision, as to evacuate the globe of its contents. In this manner about a tea-spoonful of pus, more or less, is discharged. The section of the cornea alone, effects this object so imperfectly as to afford little if any relief. The eye should afterwards be lightly covered with a soft poultice confined in a cambric bag.

Suppuration of the ball.

The extirpation of the eye, when that operation is determined upon, is most conveniently performed with a straight double-edged knife,

Extirpation of the ball.

which is to be employed for the purpose of freely dividing the septum of the conjunctiva and oblique muscles, so as to separate the globe and lacrymal gland from the palpebræ and base of the orbit. When this is done, the globe admits of being drawn gently forward by a ligature previously passed through its anterior segment. A double-edged knife, curved breadthwise, should then be introduced at the temporal commissure of the lids, for the purpose of dividing the muscles, vessels, and nerves, by which the globe remains attached, with greater convenience and dispatch. The hemorrhage is repressed by means of a small portion of fine sponge introduced into the orbit, and a light compress of linen should then be laid upon the lid supported by a roller. The sponge should not be suffered to remain longer than the following day, when a soft poultice in a muslin bag may be substituted for the compress. An opiate should be given at bed-time.

The practice of cramming the orbit with lint or charpie, and leaving it to be discharged by suppuration, is objectionable. I knew one case in which this measure was followed by a most extensive suppuration within the cavity, and by abscesses in the neighbouring integument of the lids and forehead; and another has been communicated to me, in which its ill effects were evident.

I once lost a patient, a middle-aged countryman, otherwise in health, within a fortnight after this operation, owing to a suppuration of the dura mater, on the same side of the head. The attack of inflammation was sudden and rapid, commencing about a week after the operation, and ushered in by a severe rigor after exposure to cold, in the square of the Hospital; an imprudence quite unauthorized. There was no continuity of inflamed surface to account for this, although the morbid appearances were confined to the membranes of the corresponding hemisphere. I have performed the operation many times without any serious after-symptom.

The propriety of this measure, from its severity and the uncertainty of its preserving life, should be always matter of very deliberate consultation. I will only observe, that if but one eye is affected with the disease, and the patient free from any material disorder of health, we should be slow to reject the operation on account of glandular enlargements in the vicinity of the orbit, or of tubercles of a suspicious character in other parts of the body. Such affections, supposed to be of the same morbid character, have disappeared in more than one case of malignant fungus, after the removal of the diseased part.

Glandular enlargements and tubercles.

A gentleman, whose case, a fungoid tumor involving the knee-joint, was considered desperate, and was absolutely abandoned as hopeless by the ablest surgeons in this town, on account of many tubercular swellings on other parts of his body, in addition to extreme weakness and emaciation, put himself under the care of an older practitioner, who considered the objections theoretical; the limb was amputated by this gentleman, and the patient recovered; all the tumors subsiding as he regained his health.

In another case which I recently witnessed, an enormous swelling of the thigh had its origin in the centre of the great sciatic nerve, and the subcutaneous cellular membrane, both of the trunk and limbs, was studded with medullary tubercles of various sizes; on this account amputation was considered to be contra-indicated, and it was only resorted to when a sudden hemorrhage from the ulceration of a vein in the diseased mass, threatened immediate dissolution. The operation was now held out as a last resource, and was dexterously performed just below the small trochanter, by my highly valued friend Mr. George Young, while I compressed the iliac artery at the groin. The stump healed slowly, and the man survived three months. The advanced stage of hectic to which he had

been reduced by the duration of the disease, was apparently protracted by the removal of the limb. From the history of the case, there was some reason to believe that this man's life might have been saved by the earlier performance of the operation; for the disease was entirely adventitious, and although the pleura was loaded with tubercles, they had not in any degree injured the substance of the lungs. The right sac of the pleura was lined by a thick pellicle of lymph recently effused, and a large quantity of pus was also contained in this cavity; the other viscera were sound and healthy. Admitting therefore the malignant character of such a disease, if the symptoms do not indicate the affection of vital organs, it is possible that the removal of the principal source of irritation may admit of a change in favour of the constitution, and put a stop to its progress. We know not how far the multiplied production of these tubercles may be a result of sympathetic irritation, and when doubts of this description arise, cases like those which I have mentioned should be borne in mind, that the patient's chance of recovery may not be forfeited by indecision.

TREATMENT
OF THE
DISEASES OF THE EYE.

CHAPTER III.

SECTION I.

ON THE OPERATIONS FOR THE
CATARACT.

BEFORE speaking of the operations, I shall offer a few preliminary considerations.

The extent and importance of the subjects of this and the following chapter, the deep professional interest which they have of late years excited, and the copiousness of the historical details connected with them, render it impossible for me to go minutely into them, consistently with the plan of the present work. Such an undertaking, if it were not superfluous, would of itself furnish materials for a volume of ordinary size ; but so much has been ably

written upon the subject, that the inquiring student can be at no loss for all requisite elementary information. This premised, I shall take the liberty of confining myself to those general results of my personal observation, which appear to me worthy of communication.

It has been a custom with oculists where a person has a full formed cataract in one eye, and retains the vision of the other, to advise the postponement of the operation until that also is dark—this advice I think erroneous. I am satisfied that the cataractous eye, if it becomes the subject of an accidental inflammation, is strongly disposed to go into amaurosis; and further, that the retina loses its vigor by the permanent exclusion of light. I speak from repeated observation of the fact. The objection to the operation on the ground of inconvenience arising from the difference of focus of the two eyes, when one only is the subject of the disease, is trivial, and a consideration altogether subordinate; such a defect may always be remedied by glasses properly adjusted. In several cases of amaurosis ensuing upon cataract, I have been disposed to regard the change in consistence and volume of the lens, as productive of a destroying inflammation, in others of a partial absorption of the vitreous humor.

The cataractous eye is not unfrequently with amaurosis;

amaurotic ; nor is it always possible to determine the presence of amaurosis, when the opaque lens is so dense as to account for complete darkness.

It often happens that a patient has a full formed cataract in one eye which presents the signs of amaurosis, and an incipient cataract, or one as much advanced, in the other, which is at present free from these symptoms. In this case the cataract of the latter should be removed without delay.

with ab-
sorbed lens.

In cases of congenital or infantile cataract, which become the subject of operation at an adult age, the lens is found to have undergone absorption, and the capsule alone remains. This absorption does not take place, except in cases of injury, in the cataract formed during adult life. When the lens has early undergone a natural absorption, and the cataract is simply capsular, the organ is always imperfect ; the operation therefore seldom increases the distinctness of vision, although it may enlarge the field of sight. The fluid cataract of the adult is always joined to a weak, often an insensible retina.

Degree of
vision.

It would be incorrect to say that the operation was unadvisable in all cases of cataract in which the patient has no sense of light, for it is possible that the density of the lens may be

such as absolutely to exclude the light, and that the motions of the iris may be therefore suspended, or from some degree of pressure of the lens, or adhesion of the uvea to the capsule, that the pupil may be undilated, and the circumference of the lens permanently covered. But undoubtedly a case of this description is unpromising. A strong sense of light by which at least to know the direction in which it enters the apartment—to be sensible of its falling on the eye, and of a shade, as the hand for example, intercepting it, with a corresponding freedom of motion in the pupil, is the most favourable state for the operation. There is in this case perception enough to determine the sensibility of the retina, and not enough to occasion the unsteadiness of the globe. If a patient has vision, the eye is irritable to light, and involuntarily rolls as far as possible towards the nose on the introduction of the instrument, one of the greatest perplexities in the operation. Another reason why an operator may naturally prefer an eye in which vision is interrupted, is this: patients are practical and not speculative philosophers, and estimate operations by the amount of the good conferred, not by the magnitude of the evil averted. A blind person restored to sight, is thus gratified in a much greater degree than one whose partially obscured vision is rendered clear. These however are not reasons for deferring the operation

beyond the period at which useful vision ceases, nor do I think any reason can be given for delay, tantamount to the risque of injury from incidental inflammation, or impotence from a continued suspension of the function of the organ.

Local circumstances.

There are several circumstances in the structure and condition of the organ which have an important influence on the facility and success of operations*. These are shortly, the degree of projection of the orbit, or the relative volume of the eyeball and its socket ; the absolute size, prominence, and tension of the ball ; the dimensions of the anterior chamber ; the clear and healthy, or thickened and partially opaque state of the cornea ; the absence or presence and encroachment of the arcus senilis ; the proportional diameter of the cornea to the globe, and its actual diameter ; the healthy state and proportion of the aqueous and vitreous humors ; the free and active, or adhering and constricted state of the pupil. A small cornea, a narrow or partially obliterated chamber, and a contracted pupil, are circumstances decidedly unfavorable to any and all operations.

Couching.

The operations have been so repeatedly and

* To these might be added circumstances of temperament, viz. a calm and steady, or an irritable and very moveable eye.

minutely described, that I shall not fatigue my reader with a prolix detail of them. They are three in number. Couching or depression, extraction, and absorption. The first and most antient is now seldom performed in this country. The cases to which it is alone applicable are those cataracts of firm consistence, the circumstances of which offer a serious impediment to the much more eligible method of extraction. These circumstances may be inferred from the enumeration above given. The needle employed by Scarpa is best adapted to the purpose. The couching-needle may be passed through the sclerotic at a line's breadth from the cornea, and a little below the horizontal diameter, so as to avoid the long ciliary artery; or through the inferior part of the cornea and pupil; and the lens may be depressed vertically or horizontally. The term 'reclination' has been applied to the latter method. In both cases the lens must be hitched into a breach of the vitreous humor below the border of the pupil. Its anterior capsule, and the capsule of the vitreous humor, must be divided or torn through, to render the operation effective. The lens corresponds in diameter to the iris, and there is therefore no natural space into which it can be depressed. The posterior capsule, identical with that of the vitreous humor, must be lacerated to admit of its dislocation backwards and downwards; and if its anterior capsule was

left entire, it would become a secondary capsular cataract, and require a subsequent operation.

Kerato-
nyxis.

The operation of couching through the cornea has of late years been warmly advocated, as being unattended by the injurious consequences ascribed to the perforation of the sclerotic and choroid. It is reasonable to prefer that operation which inflicts the smallest injury, and to conclude that it is least liable to be followed by severe inflammation. But the subtelties of theory have little weight in the scale against experience, and no one who has seen much of these operations considers the puncture of the tunics to form a material objection, if it is executed with a proper instrument, and agreeably to the directions which are furnished by a knowledge of the organ. I have so often seen the eye perfect in its aspect and function, after several such penetrations of the larger tunics, and the inflammation immediately resulting from each operation so slight and transitory, as to be convinced that the objection is either hypothetical, or is drawn from unskilful and rash procedures.

The real objection to couching is the ultimate step of the operation, viz. the breaking up of the fine texture that fills the globe by the forcible depression of the lens. Whether it be depressed edgeways or breadthways, makes no difference in the result; it must still occupy a

breach in the cells of the vitreous humor, and must derange and disorder that delicate texture and those connected with it. A slow insidious inflammation marked by a gradual development of the symptoms of disorganization, viz. congestion of vessels, turbid humors, flaccid tunics, and palsied iris, is too often the consequence. The sight, instead of improving when the immediate effects of the injury are passed away, remains habitually weak and dim, or declines and fades altogether. The advocates for reclamation seem to forget that the principle, which is the same in both operations, is the real ground of objection. As to the position of the lens, I suspect less mischief is done by the old method of depression, as less force is required to break a space for the vertical than the horizontal lens, provided the depression be carried to no greater extent than is necessary to clear the inferior border of the pupil. After all, the argument is mere trifling about the position of the lens, absolute or relative; it can occupy no place but that made for it without serious injury to the organ. It is not fair to bring against any operation objections that apply only to the unskilful performance of it; and this it is easy to see is the secret of the frightful catalogue of disasters which the spirit of controversy promulgates, and which those who practise these operations declare to be totally unauthorized in their experience. For example,

what has the wound of the retina, of the ciliary body and processes, of the iris, &c. to do with the operation of couching properly performed? Yet all these are marshalled in formidable array as objections, for the obvious purpose of demonstrating the superior advantages of couching through the cornea.

Absorption.

If the operation just described is attempted upon a flocculent cataract, the lens, instead of descending solidly, breaks into pieces, which undergo a gradual absorption. This is the operation by absorption; the perfection of which however consists in making the free central aperture by laceration of the anterior capsule, the preliminary step. The needle is introduced either through the cornea or the sclerotic. In most instances the anterior operation is to be preferred, as I have elsewhere stated. The more minutely the lens is broken up and divided in its texture, and the more its fragments are dissipated in the anterior chamber, the quicker the progress of absorption; and the softer the texture of the lens, the more readily and safely is this object accomplished. If the substance of the lens is dense and compact, this division is not accomplished without considerable force, and the inflammation which follows is hazardous; if the fragments are bulky, and press upon the iris, such a result is still more to be apprehended. If therefore this operation is resorted to in a case of firm cataract,

it must of necessity be several times repeated if we would preserve the organ uninjured, and this forms an insuperable objection to it in all such cases*. I would add, that even the utmost caution is inadequate to prevent an internal inflammation from the bulging of the lens after its capsule is freely rent, or its separation, during the absorbing process, into fragments of such a size as to oppress the iris. On this account an amaurosis is not unfrequently the result of this operation, although the slower and milder method is decidedly attended with the least risque. These objections are not applicable to the soft caseous and flocculent cataract, but even in this case the cure is often lingering, and subject to be interrupted by inflammation. It is especially to the cataract of infancy that the operation of absorption is applicable. Here indeed there is no alternative, it is fluid, or flocculent; often so far absorbed, that only a thin scale or flake remains of lenticular substance betwixt the capsules, so that its consistence does not allow of depression, and the eye is too unsteady to admit of extraction with

* I pass over the description of an operation which consists in the introduction of a knife, whether through the cornea or sclerotic, for the purpose of cutting up the hard crystalline *in situ*, and throwing the slices into the anterior chamber; and I mention it only by way of caution, if caution be necessary against a measure so desperate and ill advised. It levels with the proposal to extract through the sclerotic.

safety, if this operation was otherwise as eligible, which in fact it is not. It is impossible to conceive a more simple, sufficient, or gratifying operation than that of Mr. Saunders, if the intention is perfectly executed. I have now enjoyed extensive opportunities of ascertaining its value; having operated, during a period of ten years, upon children of all ages, from four months upwards, and I do not hesitate to affirm that it ranks in my estimation as one of the finest discoveries of modern science.

Cataract
with adhe-
sion to the
iris.

The primary cataract adhering to the iris is for the most part capsular; but whether it be so or not, the needle is best adapted to it. Its toughness and the firmness of its attachment, and the difficulty of couching it, when detached, are circumstances which often render the operation imperfect. The aperture by laceration of the capsule in the centre, and its extension as much as possible by the varied movements of the needle, should be the object of the surgeon, rather than the detachment of the membrane entire. In this, and in all cases in which the needle is used, the employment of the extract of Belladonna, softened by the addition of a little water, is a point of the first importance, both prior and subsequent to the operation. The skin above and below the eyebrow should be thickly painted with the solution once or oftener in the twenty-four hours, and this

varnish should be preserved moist for a period of half an hour, in order to admit of its absorption. The frequency of the application must be determined by its effect upon the pupil. The preternatural dilatation should not be incessantly maintained; for if it be, the pupil will, in all probability, be misshapen when the application is suspended, and the iris recovers its power.

The operation of extraction is by far the most Extraction. perfect ever devised for the cure of cataract; but it is one of considerable difficulty, and the several modifications which have been at various times suggested, owe their origin to the disappointments and defeats which operators meet with in learning to execute it with success. The preference entertained for couching rests on no better ground than its greater facility, and therefore less risque. No operation in surgery, I am well satisfied, requires an equal degree of temper and experience for its accurate and successful performance.

The Baron de Wenzel is reported to have said that he had 'spoiled a hat-full of eyes' before he had learned to extract. This was doubtless a figure of speech, but it serves to shew the appreciation of its difficulty by a great master of the art. Excellent directions for the operation have been given by Wenzel in his treatise, translated by the late Mr. Ware; and the essay

of the latter gentleman, who was in no respect inferior to the Baron as an operator, upon the impediments to the success of the operation, is a work of much merit, and should be diligently studied by all who undertake it. It is objected to this operation, that it is one of which the result is a matter of hazard. I reply, not more so, in the hands of qualified persons, than hernia, lithotomy, aneurism, and other important operations. Secondly, if it fails, it fails beyond recovery. This I contend is rarely the case in the hands of competent persons. That it sometimes is the case I do not deny, nor would I believe that man on his oath who ventured for himself to deny it; but I may be allowed to ask, is not this exception to the general issue of the operation, a condition of every human work? What operation I should be glad to learn, is not impugnable by such an argument? Thirdly, it is followed by a higher degree of inflammation, and one of a less manageable kind. This again, as the former and all the objections in detail admit of this general answer. They apply to the performance, not to the principle of the operation. Thus, if the corneal section be clean, and situated midway between the pupillar edge and the margin of the cornea, or a little nearer to the latter, if it be of such extent as to allow of the perfectly easy escape of the lens, if the sclerotic conjunctiva, sclerotic, and especially the iris be untouched, and

the capsule freely lacerated, without lesion of the vitreous capsule, then the operation is perfect. But although all these points should be imperfectly, that is, not strictly fulfilled, yet the result of the operation is ordinarily successful with a due attention on the part of the surgeon. There is not one of them that I have not repeatedly seen reversed, and yet the patient has recovered excellent vision. So that the failure of the operation is by no means a necessary consequence of the casualties that may attend it, even although they should be such as to excite a considerable degree of alarm in the mind of the operator. The deviation of the section from the course intended, the wound, or removal, or prolapsus of a portion of the iris, the escape of a part of the vitreous humor, these, I grant, are derogations from the perfection of the operation. But if the lens be extracted with tolerable facility, such accidents are seldom, with the aid of care and time, permanently injurious to vision. Nevertheless, they are such departures from the fair procedure of the operation, as ought in common candor to clear it of all imputation from an imperfect result.

The main impediment to the success of this very valuable operation is, as I have elsewhere stated, a section of insufficient magnitude. The easy extraction of a cataract, like the easy extraction of a stone, almost invariably does well,

Inadequate
section.

and the difficult and forcible removal of either as certainly augurs unfavorably. The enlargement of the section, if too short, is difficult, and always dangerous to the iris in the collapsed state of the cornea; it is attended moreover with imminent risque of a laceration from the want of due support, of the vitreous capsule, the loss of a portion of this humor, and the consequent sinking of the lens behind the iris. Thus one difficulty leads on another.

Again, the protrusion of the iris before the lens in its exit, which only happens from a too narrow section, is almost always followed by the falling of that membrane into the wound, a protracted healing of the wound, and a loss of figure of the cornea.

Escape of
vitreous
humor.

The free escape of the vitreous humor, owing to an imperfect section, undue pressure, &c., occasions the sinking of the lens in the globe. Such a circumstance may embarrass an operator, and induce him to leave the cataract, in the hope of its absorption, or of removing it at a future time, rather than risque the further loss of vitreous humor. This should never be done. For as soon as the wound closes, the cataract is raised by the renewal of the aqueous humor, and pressed forward upon the iris. I have seen an inflammation supervene in such a case which speedily went on to suppuration, and destroyed

the eye. If upon making the section, an inordinate quantity of aqueous humor escapes, and the lens sinks from this cause, the case is different; here the vitreous humor is already partially absorbed, and the lens is supported by the aqueous. The same ill consequences will not follow in this case, if the surgeon prefers to relinquish the operation. The cornea heals kindly, and he may afterwards operate with the needle. However, in most instances, the lens may be supported by gentle pressure on the inferior part of the globe, and extracted or rather turned out with the hook or spoon end of the curette; and I should always pursue this method under such circumstances, as long as the globe retained its figure.

It is a point of considerable importance that the section should be purely corneal. I mean that it should not be carried so low as to verge upon the sclerotic, and thus to leave the corneal margin of an insufficient breadth for union *. Two ill consequences arise from this :

Section
verging on
sclerotic.

* I have stated elsewhere an additional reason for making the section not too distant from the pupil, viz. the easier escape of the lens. See "Observations on the Cataract." Med. Chir. Trans. Vol. V. I prefer it midway between the pupil and margin of the cornea. If it be higher than this, the lower margin of the pupil insinuates itself into the section, and the cicatrix not only disfigures the cornea in the greatest degree, but encroaches very disadvantageously upon the pupil.

first, the iris, unsupported at its base, commonly falls into, and prolapses at the wound, even though the section be ample in extent, and the escape of the lens perfectly easy; and secondly, from the defect or narrowness of the corneal margin and the non opposition of homogeneous parts, the healing is always remarkably slow, even though no prolapsus should take place. An oozing of humor is continually occurring, and I have sometimes seen a portion of the capsule, now turned opaque, protrude, and subsequently slough out at the section. When a prolapsus, of whatever kind, prevents the healing of the wound, it should be completely snipped off with a pair of iris scissars, and the surface and edges of the wound touched with the caustic pencil. This practice I have repeatedly adopted with the best effect, in prolapsus from wound as well as from ulcer.

Extraction
of soft ca-
taract.

Soft and semi-transparent and unadhering capsular cataracts may all be conveniently extracted. They pass through a smaller section. The capsule is easily laid hold of with a hook or forceps. The semi-transparent, by which I mean the cataract with an opaque nucleus and transparent circumference and capsule, forms in most cases a secondary cataract; that is, a portion of the transparent lamellæ and capsule become opaque, and occupy the pupil or a part of it. It is rent and detached with the greatest ease by a

touch of the needle passed through the cornea, after the healing of the section.

The construction of instruments employed in operations is a point which every man must decide for himself. The knife of the eminent Professor Beer of Vienna is that which I am in the habit of using, thinking it on the whole better adapted than either Richter's or Wenzel's, to make a safe and expeditious section.

Instru-
ments.

The more or less inflammation which follows the operation is of course depending in great measure upon the habit of body. The patient should be well purged, and live abstemiously for a short time previous to it. If disposed to fullness in the vessels of the head, cupping may be premised the day before the operation. It is a matter of some importance to examine the section, and adjust it accurately before finally closing the eye. I think it useful to let the patient rest for a few minutes with his eye closed, and then to direct him to open it two or three times successively; a slight friction of the lids assists the pupil to recover its figure, and dissipates any small floating particles of lens. The sitting posture in an easy chair is most favourable after the operation, until the patient feels fatigued and desires to go to bed. Confinement to bed produces great restlessness, and is of no advantage to persons not constitu-

Preparative
and after
treatment.

tionally ill. If the patient complains of pain on the evening of the day of operation, a full blood-letting removes it, and should not be omitted*. I never give opiates. A light bandage passed round the night-cap and fastened to it is a sufficient covering for the eyes. Compresses on the eye-lids are generally better omitted; the bandage may in most cases be laid aside on the second or third day, and a deep black shade substituted for it. During the night, however, the bandage should be applied for the first week to prevent the accident of rubbing the eyes in sleep.

I know of no peculiarities requiring a distinct notice in the treatment of inflammation after extraction. Topical blood-letting and blisters are sometimes necessary, and a strict antiphlogistic regimen should always be enforced. There is often an irritability to light, and aversion to open the eye, which is removed by two or three brisk doses of calomel. When the section protrudes only in a small degree, it soon levels down so as to restore the figure of the membrane. When the protrusion is more considerable, the patient is afterwards subject to repeated irritable ophthalmia, and a troublesome exulceration of the cicatrix sometimes occurs. I have

* It is the custom of M. Roux, of Paris, a dexterous and successful operator, to apply a blister to the nape of the neck after the operation.

in one case seen small transparent vesicles form on the line of the cicatrix at intervals, which occasioned much intolerance and distress to the patient for a long time subsequent to the healing of the section.

The inflammation of the iris, the interstitial ulceration and opacity of the cornea, the separation of the edges of the section by the intervention of another texture, the redundant deposit of lymph in the section, or the ulceration of its edges, are the mischiefs which occur after unfavorable extractions. Blood shed by a wound of the iris in the anterior chamber is quickly absorbed. Where it has even filled the entire chamber, I have found the aqueous humor clear on the succeeding day.

Unfavorable results of the operation.

The coalition of the iris and cornea adjoining the section, occasioning a disfigured pupil, is the result of a prolapsus or a lesion of the iris. Although the process of healing is painfully retarded, and the corneal cicatrix is ever after conspicuous from its breadth and prominence, excellent vision is often obtained under these circumstances. The iritis may, however, be vehement, and proceed to amaurosis, or it may terminate favorably in constricted pupil. This state is seldom uncombined with a secondary cataract, *i. e.* a portion of continuous capsule, which having become opaque, knits up the pupil by adhe-

sion to its margin. The dimness of the cornea, if any, is slight and transient, except an interstitial herpetic ulcerative action, connected with a bad condition of the edges of the section, be present, when the cornea takes on an opacity of a very intractable kind. The sclerotic is in this case inflamed, and very minute depressions appear on the surface of the cornea, which undergoes a total loss of brilliancy, although it remains obscurely transparent. The restoration of smoothness to the surface does not diminish the lacklustre appearance of the membrane. The patient has a perception of light, but no vision of objects. In fact, the cornea precisely resembles that of the dead subject. Mercury is of uncertain efficacy in this case, which fortunately is very rare. Time and tonics do most for it.

I have now adverted to the principal miscarriages of the operation, both during and consequent upon its performance, which I have met with, or witnessed in the practice of others. When the operation is perfect, its pre-eminence is too conspicuous to admit of illustration. It exacts the homage of admiration beyond any effort of the art.

The adjustment of the light, its exclusion from the other eye by the compress and bandage,

the regulation of the seats of the patient and the surgeon, the light and firm support of the upper lid, the calm and easy penetration, and the quick and steady passage of the knife across the chamber, and without a pause, through the opposite border of the membrane, so as to anticipate the escape of the humor, and preserve the iris *in situ*, the deliberate completion of the section, all pressure being removed, either by the progress of the knife, or by a clean back stroke, or by the aid of the finger-nail dividing the cornea upon its edge, as may be most expedient, are, in brief, the material points of the operation. I will only add the capsule should be freely lacerated in the centre, not incised concentrically to the lower border of the pupil.

It would scarcely be credited by a by-stander who saw the operation happily executed upon a steady and well-formed eye, that it presented any difficulty; a conclusion applied to every thing well done, whether warranted or not. But the incidental embarrassments are too frequent and numerous to admit of being always anticipated, and the only security against them is the constant habit of practising the operation, and the confidence thence acquired, tempered with a due sense of responsibility.

Habit will make any man ambi-dexter; and the rest for the elbow, so much insisted upon, if

once laid aside, will prove a hindrance rather than a help to an operator. After once thoroughly understanding the minutiae of the operation, habit will also render it unnecessary for him to rehearse the several steps and stages of the performance before advancing to it. The memory of a successful operator is altogether technical, and his mementos are carried, to use a homely figure, *sur le bout du doigt*.

SECTION II.

OF THE OPERATIONS FOR ARTIFICIAL PUPIL.

FROM morbid alterations of the cornea, or iris, or both, result those several states of the organ which suggest the formation of an artificial pupil. The disease may be simple, that is, affecting exclusively the cornea or the iris, or it may be complicated, and involve both textures.

Simple states:

1. An indelible central opacity of the cornea, more or less eclipsing the healthy pupil.

2. A closed or obliterated pupil; the crystalline capsule opaque, and adhering to the iris; and probably the lens also opaque, unless the disease is consequent upon the operation of couching or extraction.

The first supposes a healthy state of the iris and anterior chamber, the second a transparent cornea.

Complicated states:

1. A closed pupil, with or without concealed cataract, combined with a partially opaque cornea.
2. A central opacity of the cornea combined with a constricted pupil and cataract.
3. In addition to the closed pupil, a partial adhesion of the iris to the opposite surface of the opaque cornea.
4. A permanent prolapse of the iris through an ancient breach or section of the cornea, involving more or less of the pupillary margin.

In both the latter cases, the anterior chamber is reduced in dimensions in proportion to the extent of the adhesion or prolapse.

These are the chief circumstances—it would be endless and useless to detail all their possible modifications,—which have given rise to the proposal of an operation, having for its principle, the formation of a permanent aperture in the iris opposed to a transparent portion of cornea.

Many very ingenious methods of accomplishing this object have been devised both by foreign and British surgeons and oculists. The

tracts of the late Mr. Gibson of Manchester, and of my friend Mr. Guthrie, surgeon to the Westminster Eye Infirmary, are well entitled to the diligent perusal of students investigating this subject. A remark, which I had early occasion to make in reference to the treatment of cataract, is pointedly applicable to this subject, to wit, that no one method of operating commands an exclusive preference, and that the eligibility of either can only be determined by the peculiar character and bearing of the case before us. It follows, therefore, that a particular description of the various modes of operating, without reference to the precise conditions to which they are applicable, although interesting as an *exposé* of professional ingenuity, can have no other tendency than to embarrass by a multiplicity of materials, and that it is quite impossible to arrive at a fair estimate of the respective merits of each operation by such a mode of proceeding. Infinitely varied as are the states which call for the operation, a sufficient fertility of invention has been exhibited to admit of an unhesitating preference of some one or other method well suited to every case that can occur, and so far as regards this point, the judgment of the young surgeon requires only to be assisted in its decision by the experience of those who have enjoyed repeated opportunities of putting the merits, general and comparative, of each manœuvre to the test.

In the hope of simplifying a subject which has been in some degree complicated by useless amplification and over refinement, I shall content myself with setting down the operative method which I regard as best adapted to each particular state described.

Simple states :

1. *A central opacity eclipsing the pupil.* A section is to be made, with the cornea knife, in the transparent portion of the cornea, from two to three lines in length. This being done, by a gentle pressure upon the opposite side of the eyeball, the iris protrudes in the form of a little sack or bag at the wound, which is to be snipped off with a fine pair of scissars. The iris then recedes, and presents a permanent aperture more or less circular. The corneal section may be made on either side of the pupil as required. The merit of this highly ingenious operation is due to the late Mr. Gibson. It is applicable only to the above state, for if the pupil is closed and in adhesion with the capsule, or if adhesions exist between the iris and cornea, no protrusion will take place. In making the section, it is very important that the direction of the knife should be perpendicular to the cornea, for if its passage is oblique, the cicatrix will be so much extended as to obscure the new pupil. On this account, the practice of Professor Beer

to draw out with forceps and excise the pupillary margin, more completely answers the intention.

There is another operation which I have performed successfully in this case. A narrow bladed and finely pointed knife, cutting on one edge, such as was used by Mr. Cheselden for dividing the iris, is introduced through the sclerotic coat and ciliary margin of the iris into the anterior chamber, with its cutting edge opposed to the face of the iris ; that membrane is then to be completely divided on the temporal side, including the border of the pupil, by repeated gentle nicks. The iris being sound, and consequently elastic, the section immediately assumes the figure of an equilateral triangle. The superiority of the operations before-mentioned consists in their less liability to be followed by cataract. If cataract ensues, as is pretty uniformly the case in the simple division, it must be broken up for absorption in a subsequent operation with the needle, provided that measure should ultimately be necessary.

2. *A closed pupil, the crystalline capsule opaque and adhering, and probably the lens also opaque, if not previously extracted or depressed.* It should be observed, that in the majority of instances the capsule and lens have undergone the change here presumed ; but this is a matter not

always possible to be ascertained, and one which affords no ground for varying the plan of operation. It is therefore best to provide for it. The section should be made precisely as in extraction. The centre of the iris should then be raised under the flap of the cornea with the forceps, and as large a piece of the membrane as can be embraced by the convex scissars, should be clipped off. Through such an opening there will be no impediment to the passage of the lens. I have repeatedly performed this operation with perfect success.

Wenzel, finding the mere division of the closed fibres then only useful when they are on the stretch, included a central portion of the iris in the section of the cornea, and removed the triangular flap thus formed, with a stroke of the scissars; a method perfectly efficacious in the state of closed pupil, whether the cataract remains or not. It is only necessary to bear in mind, that a sufficient portion of the iris must be excised to allow of the easy escape of the lens, a point to which Wenzel's directions do not extend, since his operation supposed the previous depression or removal of the cataract.

In the seventh volume of the *Medico-Chirurgical Transactions* is an interesting paper by Professor Maunoir, of Geneva, relating three

successful operations for artificial pupil performed with his scissars in the manner recommended by him. In two of these cases the pupil was constricted upon an opaque capsule and lens. To this paper is appended a letter from Scarpa, justly complimenting M. Maunoir on his skill and success, and adding his opinion that an operation compounded of Wenzel's and Maunoir's, is the most appropriate to the case of constricted or closed pupil with opaque lens.

Complicated states :

1. *Closed pupil, combined with a partially opaque cornea.* To this state either of the operations last described may be applicable; this must however depend upon the extent of the opacity. A section of the opaque part of the cornea is unadvisable, as it is strongly disposed to ulcerate instead of healing kindly. I should therefore avoid it, if a portion of the cornea remained sound, sufficient to allow of the unavoidable encroachment of the cicatrix. But in all cases of closed pupil, the iris retaining its position, I hold it to be expedient, if possible, to remove a portion of that membrane; and to this end the section of the cornea is indispensable. The mere division of the fibres of the iris is ineffective, by reason of the loss of its elasticity. An opacity of the cornea however may be of such extent as to leave no choice of operation, as the cicatrix of

the section of that membrane would obscure the small portion which remains transparent. In such a case, the separation of the ciliary margin of the iris, after the manner of Scarpa or Schmidt, is the only practicable proceeding.

2. *Central opacity of the cornea, combined with constricted pupil and cataract.* In this case we need only deviate from the usual method of extracting, by dipping the point of the knife behind the pupillary margin on the nasal side, so as to include a sufficient portion of the iris. If after the removal of the lens, the incised portion should not be completely detached, the flap may be easily snipped off with the iris scissors. It may be useful to remark, that pressure should, as much as possible, be avoided during the extraction of the lens. Other modes of procedure in this case are as follow :

1. An opening is to be made in the cornea, distant about three lines from the point at which the new pupil is to be formed. Through this aperture the ciliary margin of the iris, detached by the double hook of the ingenious M. Reisinger of Augsburg, is to be drawn out and excised. If the cataract should impede vision, it must be treated in a subsequent operation.

2. Dividing the iris horizontally on the nasal

side, and couching or breaking up the cataract before withdrawing the needle, which must be adapted to that purpose.

I do not hesitate to prefer to either of these modes, the extraction of the lens by excising a portion of the iris, a thing so easy to be done that it is often difficult to avoid it. The distinct performance of the operation for artificial pupil, and the treatment of the lens by the absorbing process, after the lapse of an interval, is for obvious reasons objectionable, when it is possible to do otherwise.

3. *Closed pupil and partial adhesion of the iris to the opaque cornea.* The separation of the cornea and iris when in adhesion, is an attempt altogether unadvisable. It is only at that part of the transparent cornea, which is free from adhesion to the iris, that the attempt to make an artificial pupil can be of any avail. The removal of a portion of the fixed iris, by hooking it through a limited section of the cornea, for the purpose of strangulation or excision, is an operation of much delicacy. It is however in high repute with the German surgeons. If the iris is at any part rendered tense by adhesion to the cornea, an extensive vertical or oblique division of its fibres with the iris knife, or Maunoir's scissars, is best adapted to this case. The simple incision of the iris is enough, if it either retain its natural and healthy texture, or

be placed upon the stretch ; and if not, it is inefficient, as before observed, owing to its inelasticity. But in this, as in all cases, if the opacity of the cornea is of such extent as not to allow of incision, the operation of Scarpa must be resorted to.

4. *Permanent prolapse of the iris through a breach of the cornea, involving more or less of the pupillary margin.* This is the state for which the operation was first devised and practised, and when it is consequent upon the removal of the lens, is the most favorable condition for the artificial pupil. The appropriate procedure is that of Mr. Cheselden, viz. the transverse division of the stretched fibres of the iris ; and which, if the section be made in front of the membrane, *i. e.* from before backwards, admits of no improvement. The edges of the section instantly recede, and form an excellent pupil. If the lens has been previously extracted, the intention is completed at once ; otherwise the lens must be couched or broken up, and in the latter case may require a subsequent operation. Sharp, Woolhouse, and others, who followed Cheselden's plan indiscriminately, naturally complained of their want of success. Wenzel discovered the cause, and demonstrated the necessity and the mode of removing a portion of the membrane. This was a very important step in advance, and is the principle of the most successful operation since performed for the artificial pupil.

It may happen that a partial adhesion of the pupillary margin to the cornea may be combined with a healthy lens. In this case, the removal of the free border of the pupil, drawn by a pair of forceps through an incision of the cornea, will be preferable on account of preserving the transparency of the lens.

I am fully aware, not only that other states than those which I have mentioned, may frequently occur; but that even in these, circumstances may possibly arise, to render other modes of operation more expedient than those which I have recommended. In fine, I consider it quite impossible to reduce a subject in its nature so purely circumstantial, and therefore discretionary, to the rule and line. The *rationale* of such operations is simple and intelligible, and it may safely be left to the genius of the surgeon to meet the exigencies of each individual case, in this as in many other instances. Manual adroitness is, in an especial degree, required in these operations, not only because the space within which the instrument is to move is so confined as to endanger contiguous parts, but because the division of textures in a morbid state is opposed—especially of the iris, on account of its inelasticity and over-vascularity—by a greater degree of resistance and a larger effusion of blood, than the division of the same parts in health. Hence the operation must be

executed as quickly as is consistent with gentleness. For another reason this is important; the organ upon which we are operating is an unsound one, and having been recently and perhaps repeatedly the subject of inflammation, is in too irritable and delicate a state to admit of violent or long continued manual efforts. For the latter reason, it is also highly desirable to finish the operation at one sitting, and I therefore decidedly disapprove of coupling with the formation of an artificial pupil, the displacement and breaking up of the lens to undergo the tedious process of absorption, whenever it is possible to extract or even to couch it. The organ has already suffered too much, and the operator should either not interfere with the transparent lens, or should remove that which is already opaque; and as the latter may almost always be presumed, while it remains *in situ* behind a closed pupil, that operation is preferable, which provides for its removal.

So much for the mechanism of the operation; it now only remains for me to add a remark or two on the more important question of its practical application and value, and the circumstances which should influence our prognosis and determine our practice. There are two main questions for consideration when these cases present themselves to our notice, both of which should be determined as far as we are

able to decide them, before the operation is undertaken. The first in importance as in order is, whether the retina retains its sensibility, and the vitreous humor its texture and transparency. The second, whether the manipulation required is so far practicable as to afford a fair prospect of success. The circumstances under which vision has been suspended are more or less favorable, according to the seat, extent, duration, and character of the inflammation. If the disease is confined to the cornea, the case affords the best encouragement. In the prolapsus iridis from ulceration of the cornea, the iris is only passively concerned, and here it seldom happens that the retina has suffered. If the closure of the pupil has supervened upon wound or injury, as the operation of couching or extraction, it is in general more favorable than when it results from idiopathic inflammation of the choroid and iris of long standing, or of repeated attacks of inflammation. In the latter cases, the organ usually presents certain signs of an organic change in its altered volume and figure, in the yielding and crumpling of the flaccid sclerotic under the impression of the finger, the permanent congestion of the sclerotic and choroideal vessels, the great convexity and discoloration of the iris, and the yellowness of the opaque lens, if any part of it is visible, the partial detachment of the pigmentum nigrum, &c. An extensive adhesion of the iris to the

cornea denotes the greatest degree of organic derangement, and constitutes the most unfavorable state for operation.

In a great proportion of cases in which the operation might, in a manual view, be executed with perfect success, no advantage would result from it; just as in cataract, complicated with amaurosis, the extraction proves to be of no avail.

Difficult as the execution may be and often is, it is the state of the eye by reason of the disorganizing inflammation which has preceded it, that forms the most frequent impediment to its success. When the signs of organic change in the eyeball are present, the operation should never be attempted; without some healthy perception of light, I should think it afforded a very small chance of success*. In the most favorable circumstances, the patient should be led to entertain a moderate degree of expectation; and as persons in a state of blindness are invariably over-solicitous to submit to any experiment for the recovery of vision, the surgeon, for his credit's sake, should be careful not to limit his inquiry to the mere practicability of an

* I say, healthy, because the morbid perception, as of gleams and flashes of blue or variegated light, stars, and sparks, so common in these cases, is decisive of the disorganization of the retina.

operation ; nor, when taking a larger and more deliberate view, to be drawn into it against his judgment. If this is undecided, let him so state the circumstances as to make himself responsible only for the mechanical process. Let it, for example, be expressly understood that without it the case is hopeless, and that if unhappily nothing should be gained, nothing will be lost by the operation. It is seldom, if ever, wise to do the operation upon one eye, the other remaining sound.

The ensuing inflammation is in general moderate, particularly so, if the lens has been previously removed. The success of the operation, however, is sometimes foiled by the train of morbid actions which ensues from the thoroughly diseased condition of the cornea and iris, where the instant result had inspired a hope of better fortune.

TREATMENT
OF THE
DISEASES OF THE EYE.

CHAPTER IV.

DISEASES OF THE APPENDAGES.

OF the treatment of diseases of the orbital cavity and appendages much cannot be said. I have spoken of the excision of adipose tumors and cysts. Such cases are sufficiently within the observation of the general surgeon to render a fuller discussion of them unnecessary in a work, the more particular object of which is to communicate information upon a department of pathology, which, unfortunately for mankind, he has too much neglected to cultivate.

SECTION I.

DISEASES OF THE EYELIDS.

STYES, if large and painful from inflaming the Hordeolum. eyelids, should be discharged with the point of a lancet, and poulticed, or bathed with a slightly astringent wash, according to circumstances. When phlegmonous, indurated, and slow to suppurate, occasional friction will often promote absorption of these little swellings, as we may conjecture was known of old, from the reputed specific effects of a wedding-ring, or the tail of a black cat.

The disposition to stye is not only very troublesome, but very injurious to beauty. The permanently conspicuous redness of the borders of the tarsi, a slight degree of thickening and elevation of the conjunctiva, and small cuticular denudations, are the results of their frequent formation, and the loss or scantiness of the cilia greatly increases the deformity. The nitrated, or red or white precipitate ointment of mercury, diluted so as to give a momentary smart upon closing the lids, should be used daily or thrice a week at bed-time, till the part acquires a healthy aspect; and the lids should be occasionally smeared with any soft and unirritating

salve at intervening periods. Alum and zinc washes assist this object. The chronic indurated styte, if not dispersed by the stimulant ointment, should be excised. An appropriate attention to the habit of patients is essential, for this is always faulty.

Lippitudo. The acute lippitudo generally yields to a single stimulant application. Some exceptions however occur. The lead and zinc ointment, or one combined with opium, will often agree with those slight, but very irritable lippitudoes sometimes met with* ; but there are persons to whose sensations even cetaceous ointment is painful, and who derive no benefit whatever from unctuous applications. In this case hot water affords most relief, and it is a remarkable fact, that it is soothing and refreshing to the eye, at a temperature which is not endurable to the hand.

The chronic lippitudo is a very deforming disease, and often very intractable. It is accompanied with much intolerance. The vessels of the palpebral conjunctiva are turgid, and at length varicose, the membrane a little overlaps the thickened tarsal border ; this is partially if not quite denuded of cilia, and small surfaces of the adjoining cutis are excoriated. The follicles are plugged, and here and there is one so

* The addition of ten or fifteen drops of the liq. plumbi acet. to two drachms of the ung. zinci, I have found to answer completely in such cases.

much distended by inspissated mucus, as to occasion acute inflammation. These should be opened with the point of the lancet, and the white consolidated secretion removed, the conjunctiva should be occasionally scarified, and the meibomian borders stimulated by one of the ointments above-named. The tarsal edges should also be frequently bathed with an astringent lotion. In the aggravated and obstinate cases of lippitudo, where the conjunctiva is altered in its texture, the sulphate of copper lightly carried over the thickened conjunctiva and ulcerated border of the tarsus, is highly useful; and stimulant solutions of copper, zinc, lunar caustic, or sublimate, applied by a camel-hair brush to the tarsal edges before smearing them with the ointment, are likewise advantageous.

The degree of strength in which the ointment should be used, the quantity to be used, and the mode of applying it, are points of no small importance in the treatment of these diseases. Unless it excites a pretty smart irritation and provokes a copious flow of tears, it does little if any good; but the irritability of the conjunctiva varies so much according to the stage of the disease, the time of making the application, and even the general habit, that it is impossible to fix a standard of strength. As to the manner, patients should be instructed in the intention; and for the strength and quantity, in the desired effect of the remedy. The degree of irrita-

tion should be such as to prevent the patient from keeping his eyes open for some succeeding minutes; but no increased congestion should be apparent on the following day. The patient therefore should feel his way, and measure the irritability of the conjunctiva, by advancing gradually from a lower to a higher stimulus. In acute lippitudo a little cold cream or spermaceti will occasion a severe smarting and profuse flow of tears, whereas in the chronic form, the strong mercurial ointment is often necessary to produce this effect*.

* The 'golden ointment,' as it is called, is an excellent remedy. I shall be accused of heterodoxy; but I must in justice assert, that the inventor of this arcanum deserves well of his country, for if his patriotism be equivocal, the virtue of his nostrum is at least certain, when judiciously prescribed. If it did not unfortunately aspire to be a panacea, its beneficial operation would be without exception; and indeed the greatest evil of quack, as of regular medicines, is their abuse. Few things capable of doing much good, are not also capable of doing mischief. An old lady of Paris, whose husband had become famous for an eye-water, had the misfortune to lose her spouse and his secret together. In this dilemma harassed by applications for the nostrum, she had recourse to the water of the Seine, and was not more gratified than surprised to find that the collyrium had lost nothing of its virtue.—After having enriched herself by a successful traffic, it so chanced that she fell sick, and conscience-stricken at the prospect of death, she applied to an eminent professor of surgery, instead of a priest, to relieve herself of the burthen of sin with which her soul was encumbered. "Soyez tranquille, mon amie," said the professor, "de tous les Medecins vous êtes le plus innocent: vos remedes n'ont fait du mal à personne!"

The correction of the diseased states and secretions of the ciliary apparatus proceeds upon the same principle as the cure of lippitudo, with which, in a greater or less degree, they are very generally combined. The re-establishment of a healthy conjunctival surface and a healthy meibomian secretion, is the object to be attempted. In general the mercurial ointments are the best remedies for this disease.

Tinea ciliaris.

Cleanliness is a point of the first importance, and it is the more necessary to mention it, because the disease is often set up, and is always aggravated, by neglect of it. The margins of the lids, and the roots of the cilia should be thoroughly cleansed from loose scabs and branny incrustations before anointing them; the ointment, liquefied by a gentle heat, should be applied upon both edges of the cartilage with a camel-hair brush; keeping them through the day slightly besmeared with a mild ointment, as the tutty, prevents the formation of fresh crusts. It is needless to say, that more depends upon the patient than the surgeon in the cure of these complaints, and that the incurable states, those which admit only of palliation, are invariably the consequence of neglect, and might, therefore, have been prevented.

When cilia are inverted from a diseased growth, they must be kept plucked until by the improved

Trichiasis.

condition of the hair gland, under the means used, the disease is removed. If a case occurs in which the vitiated site or incurvation of one or more cilia does not admit of correction, the corresponding follicle should be obliterated by repeatedly touching it with a fine caustic pencil. When the incurvation is depending on a disease of the tarsus, the case must be treated as entropion.

Entropion.

The treatment of the inverted eyelid, upon the plan recommended by Scarpa, will, according to my experience, be effective in nine cases out of ten; that is, by the removal of a fold of skin with a pair of scissars from the surface of the eyelid. The relaxation of the integument operating as a cause of the disease, is more frèquent upon the lower than the upper lid, but the operation is applicable to cases originating from other causes. The surgeon should be careful to adapt the position and extent of the wound to the site and degree of the inversion. I have now and then met with a case in which the inversion was clearly depending upon a callous roll of conjunctiva at the orbitar edge of the tarsus, in which case the disease was removed by the excision of this roll; of itself a disease requiring such a remedy, as before noticed. In cases of a circumscribed inversion produced by cicatrix from burn or wound, I have found an operation similar to that of Dr. Crampton, an effective

remedy; sometimes the complete division of the conjunctiva and tarsal cartilage, including the inverted portion, and parallel to its border, with the aid of sticking-plaister, has proved sufficient. I should see no objection to the entire removal of that portion of the tarsal edge which was incorrigibly inverted from such a cause, especially when combined with distichiasis, by which is meant a preternatural growth of cilia from the meibomian border of the tarsus; but the removal of the entire cartilage, which I have twice performed in aggravated cases of this disease, although by no means difficult of execution, is an operation of great and needless severity, and one which, in my experience, is not warranted by the degree of relief which it affords; to say nothing of the permanent deformity which it occasions.

The ordinary ectropeon is cured by the excision of a portion of the thickened or redundant conjunctiva which occasions it. The perpendicular division, or the removal, as the circumstances require, of a triangular portion of the tarsal border by a double incision, as mentioned p. 240, is the operation best adapted to the long-established and aggravated forms of the disease; an adhesion of the everted eyelid to the cheek, adds much to the difficulty of the case, and renders all modes of treatment merely

Ectropeon.

palliations of the deformity. I have, however, succeeded in greatly lessening the deformity in some such cases.

Palpebral
tumors.

Concerning tumors of the eye-lids I have little to add to what will be found in the pathology. Often the encysted tumor is seated superficially, and loosely connected to the tarsus, in which case it must be removed on the outside of the eyelid, by just separating and turning to either side the fibres of the orbicularis muscle. It is only when an intimate adhesion subsists, (the cyst is often formed betwixt the cartilage and the ligamentary membrane which covers it,) and the appearance of a white circumscribed indentation is seen upon everting the tarsus, that the excision is to be made from the interior by division of the cartilage; in which case it is always executed with perfect facility. If the cyst be not extirpated, but merely incised and its contents expressed, the tumor speedily re-appears. If its adhesion to the tarsus be such as to prevent the entire removal of it, the remnant of the cyst should be touched with the caustic pencil.

Lagoph-
thalmus,

For the permanently drooping lid, if an operation be ever desirable,—which, as an unclosed state of the lids, is a pretty certain fore-runner of diseased conjunctiva, amounts with me to a

question—a fold of integument may be removed by the knife, or by pencilling out a portion of it with the strong nitric acid. It is unnecessary to describe an operation for dividing the cohering tarsi. When complicated with adhesion to the globe, the case is incurable.

and cohe-
ring tarsi.

SECTION II.

OBSTRUCTION OF THE LACRYMAL PASSAGES.

Stricture of
the lacry-
mal and
nasal ducts.

THE treatment of the disease improperly termed "fistula lacrymalis," has occupied a large share of the labor and talent of the profession *; yet, notwithstanding this advantage, the practice is to this day unsettled and unsatisfactory †.

* See the numerous papers in the *Memoirs of the French Academy*, and the works of *Sharpe*, *Pott*, *Desault*, and other eminent writers.

† In proof of this remark, I may observe that nearly all the schemes hitherto suggested have been executed within my knowledge, by different surgeons, viz. the small probe and injecting syringe of *Anel*, the sound and syringe for the nasal duct, the seton of silk or catgut, the bougie or nail-headed style, the metallic tube, &c. In *Paris*, *M. Dubois* employs the silk seton of *Mejan*, *M. Dupuytren* the permanent tube of *Wathen*, *M. Roux* the mesh seton, introduced by means of a watch-spring from the sac. *M. Beer*, of *Vienna*, uses, for a seton, a coil of catgut, such as is used for fiddle-strings. Among the surgeons of this town, *Mr. Ware's* style is chiefly in use, although the practice is evidently losing credit.

Mr. Pott was in error when he concluded in his criticism of Anel's practice, that the stricture of the lacrymal ducts was very rare, because the mucus of the sac was habitually, or upon pressure, discharged at their orifices; the stricture of the ducts is, on the contrary, frequent; and although this morbid secretion of the sac is often present with a free state of the lacrymal ducts, the cases of obstruction on the nasal side are very frequent, in which no such symptom exists.

The absorption of the meibomian mucus by the puncta lacrymalia, and its regurgitation on pressure, as described and considered by Scarpa to constitute the first stage of the disease, independent of a permanent stricture, is, I think, hypothetical; for, if founded in fact, this symptom would be present in every severe lippitudo or ophthalmia with puriform discharge, which every body knows is not the case. Besides, if the duct were open, there is no reason why the fluid, once admitted, should be arrested or regurgitate instead of passing into the nose, but the office of the puncta is the absorption of the lacrymal fluid, as that of the lacteals is the absorption of chyle, and absorbent mouths are distinguished from capillary tubes by the selection of their proper fluid. It by no means follows because a purulent secretion is discharged from these orifices that they have derived it

Mucous
discharge.
Professor
Scarpa's
hypothesis.

from the eye. Further, there is every reason to believe that the fluid so discharged is the proper secretion of the sac, and cases are frequent in which it is retained and cannot be expressed, owing to strictures both of the lacrymal and nasal ducts. As to the proof of the meibomian border of the lid of the affected eye being more vascular than the other, I need only remark that the irritation of an obstructed sac naturally produces this appearance upon a continuous and highly sensible membrane; if the redness proves any thing, it proves the presence of irritation, and stricture is as probable a source of it as any. But it is demonstrable that the "flusso palpebrale" is as seldom present with the symptoms of obstruction in a degree sufficient to support the hypothesis of obstruction from that cause, as the actual obstruction is rare in those cases of its excess which are of ordinary occurrence.

Origin of
stricture.

The effect of a severe cold in the head to produce a coryza and troublesome watering of the eye, may enable us to form a pretty accurate idea of the cause of a permanent stillicidium; for although an over-excitability state of the conjunctival surface may occasion a more plentiful secretion of the lacrymal fluid, yet it cannot be questioned that the same temporary condition may prevail in the membrane lining the sac and duct, as in the other parts to which it is distribut-

ed; I mean a state of vascular congestion and intumescence. This continued, would lead to a permanent thickening of this membrane, and from that cause a diminution of the calibre of the canal. An adhesive process, whether primary or consecutive to the states of suppuration and ulceration, finally closes the duct, so as to render it absolutely impervious. The actual obliteration of the canal by the degeneration of the membrane into a texture resembling cartilage, is a secondary morbid change, and only the result of long continued obstruction.

I have had occasion before to observe that the inflammation and abscess of the sac, although frequently preceded, and in great measure produced by obstruction of the nasal duct, is by no means always referable to that cause; a considerable degree of obstruction endures for years without a tendency to excite inflammation of the sac; and on the other hand, the inflammation and abscess of the sac in its acutest form, as from exposure to cold and other exciting causes, and sometimes from injury, often exists without any degree of obstruction. In proof of this I may remark that the incipient inflammation of the sac often admits of resolution by the use of leeches, &c., without further inconvenience to the patient; and the whole treatment required for the abscess in many

Abscess independent of stricture.

cases, is simply the discharge of the matter, or in other words, the treatment applicable to a common abscess.

A free opening of the sac for the purpose of discharging its contents, shortens the sufferings of the patient, and saves the skin; but unless the previous existence of symptoms demonstrates the presence of a stricture, an abscess of the lacrymal sac is by no means a sufficient proof of it, to warrant the employment of any further measures. The existence of an abscess is of itself a cause of temporary obstruction, and the stage immediately preceding the formation of abscess may have been the cause of a temporary stricture, of which the abscess and its discharge are the termination. Of this I am well satisfied: that the supposed invariable connection of an abscess of the lacrymal sac with a stricture of the duct, enforced in the writings of the French Academicians, Mr. Pott, M. Desault, and others, have led to an officious and often injurious treatment of this painful and sufficiently distressing malady; and at all events, the first indication is simply that of giving issue to the matter, by a free incision of the sac, and applying a soft poultice in a bag to the inner angle of the orbit.

Treatment
of abscess.

Supposing, therefore, the case of abscess so far advanced, instead of introducing a style into the ductus nasalis, after opening such abscess, I

recommend simply the examination of the duct with a fine probe ; if the probe passes without resistance into the nose, the case requires no further operative treatment, the integument recovers its healthy condition under an emollient application, the discharge gradually diminishes, and the wound heals. If, on the other hand, upon examination with the probe introduced through the wound into the sac, resistance is offered to its passage into the nose, no more favorable opportunity will be presented for overcoming such resistance. This therefore should be accomplished, but to this the operative process should be limited, and the wound should be suffered to heal without further disturbance.

An erysipelatous inflammation of the integuments of the face in the vicinity of the lacrymal sac, in which the peculiar characters of that inflammation seem to indicate that the cutis is primarily affected, however this may be in fact the case, requires to be narrowly watched, especially if it extend to suppuration ; for then there will be reason to apprehend a sloughing ulceration of the cellular texture, and probably, the destruction of a portion of the sac from this cause ; so that a lacrymal fistula will be the termination of the disease. But a more immediate cause for apprehension exists, if inflammation has been preceded by any sign of obstruc-

Erysipelatous inflammation.

tion to the passage of the tears, and this, I believe, will be found to be most frequently the case. The inflammation symptomatic of deep-seated suppuration is erysipelalous, as is well known to every practical surgeon, and this is more especially the case where any fascial or ligamentous texture intervenes, like that which covers and supports the sacculus lacrymalis. Therefore, although the incision of the sac is manifestly improper and unadvisable, unless it is distinctly ascertained to be the seat of suppuration, the erysipelalous nature of the inflammation must not be considered to indicate the confinement of the disease to the integument, and the previous healthiness of the sac. I do not hesitate to say that the evil of an uncalled-for incision of the sac is, in every point of view, less than the opening formed by a process of disease under the circumstances supposed, for in the latter case it will be difficult to prevent a permanent fistula.

Moist or
watery eye.

The tear falling over the cheek is a sign of complete obstruction, except under strong excitement, when indeed it happens even though the duct is free; but the moist or watery eye indicating the retardation, not the arrest of the tear, is by much the more frequent case. This depends upon an imperfect obstruction of the nasal duct. This state often exists without any other external symptom of disease, and it is a

source of considerable inconvenience from the continual suffusion which it occasions, and the necessity it imposes of incessantly wiping the eye.

The epiphora, or, more properly, the stillidium lacrymarum, resulting from the constricted puncta, or obstructed lacrymal ducts, is relieved by the introduction of a small silver probe into the sac once, or oftener, as may be required. Frequently the obstruction is confined to the saccular extremity of the duct. The case is common, the inconvenience considerable, and the relief complete. The obliterated punctum or canal is a case which admits of no remedy.

Constricted puncta and obstructed ducts.

The patulous puncta are usually combined with a swollen and atonic state of the canals and sac; there is no contraction of the orifice on contact with the probe, no obstruction to its passage into the nose, nor any excretion of mucus upon the eye or from the nostril; the situation and figure of the sac are conspicuous from its prominence. Such a state, most frequent in elderly persons, may in part depend upon a feebleness or paralysis of the orbicularis muscle, and a redundant fulness of the skin producing a partial eversion, or an enlargement of the semilunar fold of the conjunctiva, dis-

Patulous puncta and atony of sac.

placing the puncta or disturbing their relative position. It results also from long continued distension of the sac, owing to a morbid increase and retention of its secretion ; and under such circumstances, it may be partially relieved by astringent washes, but it is not, in my experience, curable.

Stricture
symptoma-
tic of con-
junctival
inflamma-
tion.

The stricture which is occasioned by the extension of conjunctival inflammation to the lacrymal excretories, should be treated only as a sign of that disease. When under the influence of a treatment purely antiphlogistic and soothing applications, the inflammation subsides, the temporary interruption to the function of these organs ceases ; or if it should not cease altogether, the use of a gentle stimulant collyrium will put an end to it. When, however, the state of distended sac, the regurgitation of mucus upon the eye, and the gathering of the tears in the lacus lacrymalis are altogether chronic, there can be little doubt of the existence of a stricture, partial or complete ; and I am unacquainted with any other mode of treating this disease than such as is adapted to the removal of the stricture, and the restoration of the canal. I am satisfied that the practice of introducing stimulant liquids into the hollow of the inner canthus, in the supine position of the head, and of injecting the sac with astringent lotions, has no

other effect than that of aggravating the symptoms of the complaint; how indeed can any other result be rationally expected?

When from the duration of this state the overflow of tears becomes continual, the distension of the sac and the discharge of mucus excessive—the conjunctiva towards the inner angle has a preternatural vascularity, the outline of the sac assumes a circumscribed phlegmonous hardness, and a blush begins to appear upon the skin covering it—when the eminences of the puncta lacrymalia are shrunk and absorbed in the swelling, and in short, the mucous is about to pass into the purulent secretion—even at this period I have repeatedly averted the formation of abscess by re-opening the nasal duct. But when the disease has advanced another stage, and the pointing of the tumor and sense of fluctuation are perceptible, no advantage could be expected from the introduction of the probe through the lacrymal canal, if it were possible; we have now a disease requiring a distinct treatment, and to prevent a complicated fistula—such as results from the yielding of the sac, the diffusion of its contents into the cellular substance, and sinuses spreading in various directions beneath the integument,—the free incision of the sac should be made without delay, and the treatment of the original disease postponed.

Permanent
distension
threatening
suppura-
tion.

Fluctua-
tion.

The nail-
headed
style.

When the integrity of the parts is restored, it will be necessary in this case to have recourse to the same mode of proceeding which is adapted to the other stages of the disease, and which appears to me to be the only method of treatment applicable to it upon a rational principle; for I confess myself at a loss to understand how relief can be afforded by the practice of introducing a style to remain in the duct, and I am strongly disposed to doubt whether any permanent benefit was ever derived from such a practice. I am quite aware that the mere opening of the sac affords an immediate and considerable degree of relief; and if a stricture has existed in the nasal duct, which is at the same time overcome by the introduction of the probe, the relief will be still more complete; but the style which occupies the sac and duct can have no conceivable beneficial influence until it is withdrawn. The disease is transferred from the eye to the cheek, and the oozing of the tears through a small fistulous aperture in the sac, is substituted for their overflow of the natural channel. The state is, upon the whole, less irksome to patients, and in so far the practice must be considered as palliative; but I may fairly say that I have scarcely seen one instance in which this practice had been adopted, and the style was still retained, whether at the expiration of three weeks, or three months, or three

years, or double the latter period, in which the disease did not exist in undiminished force, under the modifications which I have just described, that is, as an established lacrymal fistula. Patients are reluctant to part with the style, because, as is natural, they ascribe the degree of relief they have obtained from the opening of the sac, and the diversion of the excretion, to what appears to them to be an essential part of the process.

I have recommended the introduction of a probe into the nose, when such an opportunity is presented, from unwillingness to lose one so favorable for the restoration of the canal; and the only case in which the permanent dilatation is required, is when the passage of the instrument in the direction of the duct is so firmly resisted, as to compel the forcible renovation of the canal. In this case it is obvious that some means must be used to preserve it, and for this purpose two modes of practice are employed. Some surgeons having introduced a dilator into the duct, so far as the obstruction permits, fasten it there, and from day to day renewing the attempt to overcome the obstruction gain upon it by little and little, until at length the instrument enters the nostril; here it is left for some days, when either an instrument of larger dimensions or a seton is substituted for it, which is not finally withdrawn until the object is accomplished.—Others forcibly overcome the obstruction at once,

Dilatation
gradual or
immediate.

and afterwards place a style or tube in the newly formed passage. I am not now speaking of the penetration of the os unguis or the breaking through of the bony parietes, but of the re-opening of the original passage; which being obliterated by a morbid structure of the lining membrane, of such firmness as to require the employment of force, and to occasion a free hemorrhage from the nostril, is, in fact, the same thing as an artificial channel. Of the two practices, I decidedly prefer the latter; the former is drivelling, tedious, and painful to a degree.

Averse to any and every permanent tent, I formerly introduced a probe into the nose for many days in succession, but the daily increasing facility with which it passed was not a compensation for the pain it inflicted, and the ulceration of the wound by the repeated interruption of the cicatrizing process.

The au-
thor's prac-
tice.

The practice which I have long employed, and which I adopted as the most successful, after a trial of the several methods of which I have made mention, the tube only excepted, is too obvious to have the merit of novelty. In a large proportion of cases, it has proved successful in curing the disease, both in slight and aggravated forms, in early and advanced stages, without entailing the inconvenience and deformity inseparable from the various contrivances for permanent

dilatation, and avoiding altogether a fistulous aperture. Contented with accomplishing the passage of a moderate sized probe into the nose, after the incision of the sac, my attention is exclusively directed to the reduction of the inflammation, and the restoration of the soft parts, with which, be it expressly understood, I never interfere, except in the case of abscess discoloring the skin, and threatening fistula. Thus, with this single exception of abscess, the treatment of the obstruction is one and the same, so far as the point of obstruction is concerned; and it is a point always important to be ascertained; the more so, as it is by no means of uniform occurrence.

It can hardly be required that I should occupy the time of the reader in shewing that the practice of opening a passage partially closed, or even an artificial passage, as nearly as possible in the same direction, when the former is obliterated, commands a decided superiority over the practice of making an artificial opening. This applies to the treatment of the urethra, as well as of the ductus nasalis, and it is only in case of abscess, in which the distended and inflamed integument threatens to give way by ulceration, that in either case I think it necessary to deviate from it.

A set of silver probes, of about five inches

Lacrymal
probes.

long, varying in size, flattened at one end, and slightly bulbous at the point, are the instruments I use for the purpose of restoring the passage. The probe is introduced with perfect facility by one who is familiarly acquainted with the anatomy of the part, from either of the puncta lacrymalia, into the corresponding nostril, when no obstruction is offered to its passage. If the punctum be constricted, it is readily entered and dilated by a common pin; and upon withdrawing it, by one of the smaller probes; the direction and relative situation of the lacrymal ducts, the sac, and the nasal canal, point out the proper course of the instrument. It is confirmed by its advance without the employment of force, and the sensation conveyed by the free and unencumbered motion of its point; until the point is fairly within the sac, it is necessary to keep the eyelid gently stretched and slightly everted; the upper lid being drawn a little upward toward the brow, the lower as much downward toward the zygoma. The point carried home to the sac and touching lightly its nasal side, the lids may be left at liberty, while a half circular motion is performed by the instrument; the surgeon neither suffering the point to recede, or, on the other hand, allowing it to become entangled in the membrane.

The probe now rests in a perpendicular di-

rection upon the eyebrow towards its inner angle, and in this direction it is to be gently depressed until it strikes upon the floor of the nostril, where its presence is readily ascertained by a common probe, passed beneath the inferior turbinated bone. The probe of smallest dimensions is of sufficient firmness to preserve its figure in its passage through the healthy duct, but it is too flexible to oppose any considerable obstruction, without danger of a change of figure : for the stricture of the lacrymal ducts it is of sufficient strength.

Very many cases of recent origin, and in which the stricture has no great degree of firmness, are completely cured by three or four introductions of the probe into the nostril, at intervals of one or two days.

I have seldom met with a stricture so firm as not to yield to the full-sized probe. I am fully aware of the objection that immediately presents itself, viz. that a passage so obtained is not permanent ; by several repetitions of the operation it is often rendered so ; but if the resistance is not altogether removed, after a trial of the experiment for some days in succession, I introduce a style having a small flat head, a little sloped, through the punctum lacrymale into the nose, and leave it for a period of twenty-four hours in the duct.

Lacrymal
styles.

If worn longer, as for two days, it ulcerates the orifice ; but I have never seen it injure the punctum in the smallest degree, when worn for the full period first named. A day or two should be suffered to elapse before the style is again introduced, and it should then be passed through the other lacrymal duct. The injection of tepid water should be made on the intervening days with Anel's syringe. The plan requires perseverance, as may be said of all plans by which so difficult an object is sought to be effected. In many cases the resistance, in the first instance opposed, is inconsiderable, yet it is sufficient to maintain the disease. The probe passes daily with increasing facility, and after a very few repetitions, with as much ease as through the healthy canal ; yet the stillicidium, and even the mucous discharge do not immediately subside, because, although the obstruction is removed by which these symptoms were originally set up, the parts have not yet recovered the loss of tone which the state of habitual obstruction and inaction has induced ; and here the use of the probe is unavailing, if not injurious, as in all cases in which the full-sized probe passes without impediment. It is important that operators should consider this, and not lose sight of the vital function of the parts, in treating the morbid alterations of structure which have interrupted and deranged them. For this mitigated, but not recovered state, time alone, with attention

to prevent distension by occasional gentle pressure of the sac if accompanied with mucous discharge, is often sufficient ; but the injection of a solution of alum, or even of cold spring water, and the use of astringent washes, will assist. Sniffing a stimulant vapor, as of vinegar, or diluted nitric acid, into the nostril, I have also found useful. It is of course unnecessary to pass a probe, when the fluid injected by the punctum drips in a stream through the nostril or into the throat, as the head of the patient is inclined forwards or backwards ; but this test of the freedom of the passage should be had, before the use of the probe is laid aside.

If it be objected to this operation, that it is always painful, and often tedious, I can only reply, that there is too much truth in the objection. I shall be happy to be instructed in one equally effective, and free from these objections. I am far from assuming that all the other measures employed might not be crowned with success in favorable cases ; this, like other complaints, sometimes recovers, not so much in consequence, as in despite of treatment.

Of all the other modes, the seton of Mejan ^{Seton.} alone appears to me to be a rational practice ; it too is tedious, and, during its use, deforming. The tube seems, on the other hand, ^{Tube.} to be of all the most objectionable. I have seen

cases of its employment, in which it very speedily became plugged with mucus, the sac habitually loaded, the nostril dry, and the stillicidium permanent. But how a metallic tube can be expected to form a substitute for the natural duct, an inorganic to serve in lieu of an organized part in perpetuity, the functions of the puncta and sac to be restored, and as it were in consent with it, I confess myself at a loss to conceive. I have more than once heard patients sorely regret that they had submitted to its introduction, having received no degree of permanent benefit from the operation, and I have been called upon to remove it, which is not easily done, in one case from the disease which it had set up in the contiguous soft parts, and in others from an exasperation of the symptoms of the complaint. I am now speaking from what has incidentally passed under my notice of the practice of others; but I ought in candor to add, that some very intelligent surgeons, both English and Foreign, have lately assured me of the general success of the practice in the able hands of M. Dupuytren, at Paris*.

In the use of the lacrymal probes, caution is requisite; they must be passed with great gentleness, and if the extremity becomes confined, a little withdrawn, so as to prevent their hitching

* See Note M.

in the membrane, and passing beneath it; the size should never be such as to distend the lacrymal canal, lest it should injure the texture and destroy the tone of the part; and no considerable degree of pressure should be made with one so slight as to be in danger of becoming curved. A probe of sufficient dimensions and firmness to preserve its straightness, is quite within the measure of the lacrymal orifices and ducts, and has strength enough to overcome an ordinary stricture. Injections should be frequently employed to ascertain the progress of the case towards recovery. They are of great use in almost all stages of the disease.

There are undoubtedly many cases of slight epiphora not depending upon mechanical obstruction of the lacrymal excretories*. The zinc and the lunar caustic solutions, the thebaic tincture, the mercurial ointments introduced between the lids will remove such forms of the complaint, if the patient is so far inconvenienced as to apply to his surgeon for relief, which is not always the case. Again, the gleet discharge of the sac, as it is not always present with stricture, is sometimes, though not often, present without it. Stimulant collyria, cold water, and alum injections, and constitutional tonics, must be employed to cure it. The chronic, thickened, and hardened state

Epiphora
independ-
ent of ob-
struction.

* See note N.

of the sac after abscess, and in the state of fistula, is removed by leeches, cold poultices, and saturnine lotions; and if the skin be free from inflammation, it is reduced by the mercurial ointment. A small fistulous aperture, where the disease has been left to nature, is a common and troublesome case. The aperture should be freely dilated, the open state of the canal ascertained by the pocket probe, and the part afterwards treated as above directed.

Abscess
with caries.

No peculiar treatment is required in the abscess with caries of the bones; a case much less frequent than would be imagined from its description as a stage of the disease. In this case, as in that where the sac has yielded to ulceration before the integument, the skin should be freely divided, that is, beyond the confines of the sac. I never met with a case requiring the use of a trocar, nor do I believe the perforation of the os unguis is ever really required.

Relaxed
sac.

I am not practically acquainted with the effect of pressure upon the relaxed or hernial lacrymal sac. It is an old, and, I believe for a far better reason, an obsolete practice, viz. the difficulty of its application, and the feebleness of its effect.

Dropsy of
sac.

For the opportunity of seeing and treating an interesting case of dropsy of the sac, (the dis-

ease described at page 247,) I am indebted to the kindness of Mr. Alexander, to whose extensive observation of this class of diseases it was new, as it was to mine. I exposed the distended and transparent sac by dissection, and removed by the scissars the two anterior thirds of it. A process of suppuration which ensued was for some time troublesome, but the wound at length healed soundly, and the complaint was cured by this treatment.

With the disease in which the sac is said to Mucocele. acquire the size of a pigeon's egg from an accumulation of inspissated, or rather indurated secretion, having a cartilaginous hardness, and a livid color, I am entirely unacquainted.

The first of these is the fact that the United States is a young nation, and that its history is a history of growth and expansion. The second is the fact that the United States is a nation of immigrants, and that its history is a history of the struggle for a common identity. The third is the fact that the United States is a nation of diverse peoples, and that its history is a history of the struggle for equality and justice.

It is the history of a people who have built a great nation out of a wilderness, and who have done so in a short time. It is the history of a people who have fought for freedom and independence, and who have won. It is the history of a people who have built a great nation out of a wilderness, and who have done so in a short time.

APPENDIX.

DR. CHRISTIAN SALAMON, of the Medical and Chirurgical Academy of St. Petersburg, one of ten gentlemen deputed three years ago, by his Majesty the Emperor Alexander, to visit foreign schools for the purpose of acquainting themselves with the state of medical science, an appointment equally honorable to both parties, has politely favored me with the following anatomical sketch, which is the result of some very delicate and laborious dissections. Some of these I have derived much instruction and pleasure from being permitted to witness, and although I do not feel satisfied in all points of the accuracy of Dr. Salamon's conclusions, I have nevertheless seen enough of his general professional intelligence, his talent for minute investigation, and his method of conducting it, to feel assured that the following brief memoir, in his own words, will make no inconsiderable addition to the interest of this work. I have the pleasure, at the same time, to announce, that those who take an interest in these researches, will shortly be gratified by the appearance of an anatomico-physiological dissertation on this subject, upon which Dr. Salamon is at present employed.

OBSERVATIONS
ON
SOME POINTS
OF THE
ANATOMY OF THE EYE.

SCLEROTIC, before reaching the cornea, increases in thickness, and divides into two layers; the outer advances beyond the inner, and is connected with the exterior layers of the cornea; the inner corresponds to the interior layers of the cornea. On the inside of the inner layer of the sclerotic, near its termination, is an annular groove in the whole circumference, which receives a tendinous ring (annulus tendinosus *); this ring is situated without the choroid, and firmly adherent to the sclerotic coat; on its inside it is connected with the origin of the venous layer of the choroid coat.

Cornea consists of layers which are more firmly united at its centre than at the circumference. The inner surface of it is covered with a serous membrane, (*membrana humoris aquei*, *Wrisbergi*,) the existence of which is easiest shewn in eyes of aged persons; this membrane can be separated from the innermost layer of the cornea, and differs from it in its greater tenacity and transparency. The latter quality it preserves in spirit; the greater firmness and more express character of a serous membrane distinguish it from the layers of the cornea; it is not so liable as these to ulceration, or to be destroyed by an ulcerative process, and, therefore, sometimes protrudes and forms the disease called by Professor Beer, 'Keratokele.'

* *Doellingeri descriptio oculi humani. Wurceburgi.*

Iris. Having subjected the iris to maceration, as I knew that by such a process the choroid coat may easily be divided into two layers, I succeeded in doing the same with this membrane. To such a division of the iris into two layers, I was led by the observation of some writers on the anatomy of the eyeball, that the membrane of the aqueous humor is continued over the iris into the posterior chamber; but with them it has been a mere supposition, and not proved by dissection. If there is such a continuation over the iris, this membrane must be divided into two layers; in ascertaining this I succeeded, and shall now endeavour to give a description of my dissection. I performed the division more easily from the pupillar margin of the iris, where this membrane is thicker, and at this place I could evidently distinguish the turn which is formed by the anterior layer of the iris continued into the uvea; betwixt these two membranes I saw distinctly the nerves and vessels distributed in a tortuous manner. Both membranes appeared somewhat transparent. The anterior layer, constituting the fore part of the iris, secretes on its inside and between the two layers a pigmentum, which exhibited itself to me in dark eyes, darker than in light ones. From the remarkable difference of this pigmentum in its color, I am inclined to think, that the different color of the iris particularly depends upon it, which then only can appear evident, when the uvea secretes its pigmentum. The anterior layer is afterwards continued to the tendinous ring, where it unites with a serous membrane, which I consider the origin of the venous layer of the choroid coat, under an acute angle. The posterior layer or uvea secretes on its back part the pigmentum nigrum; when this pigmentum is removed, there appear small white processes going off from the ciliary processes to the uvea, being continued from the ciliary towards the pupillar margin, but not quite reaching the latter; these processes are, like the ciliary processes, more distinctly seen in dark eyes, and differ from them only in their smallness.

Choroidea is easily divided into two layers, after maceration of several days. I. The outer layer, or *choroidea, stricte sic*

dicta, is the thinner serous membrane, in which the ciliary veins are distributed to form the vasa vorticosa; it appears more distinct at its origin on the inside of the tendinous ring, where it unites with the anterior layer of the iris, and exhibits here evidently in its transparency the nature of a serous membrane. I think that this origin of the venous layer of the choroid coat has been described by Duverney as a peculiar serous membrane, covering the choroid coat. This venous layer appears more pallid at its beginning, on account of the ciliary ligament situated under it, and the deficiency of pigment; just behind the ciliary ligament it is perforated by the ciliary nerves and vessels of the iris. 2. The inner layer, or ruyschiana, is firmer, and secretes its pigmentum nigrum in the back part of the eyeball on its outside; as soon as it reaches the origin of the zonula ciliaris, it forms the ciliary body (*corpus ciliare*), which begins with a dentated margin, and secretes here its pigmentum nigrum on the inside; hence the impression of it appears on the zonula ciliaris. Professor Beer distinguishes the posterior part of it as the 'pars non plicata corporis ciliaris,' which is larger on the temporal than on the nasal side of the globe, on account of the retina advancing more forward on the nasal side, as the optic nerve enters more on that side of the globe. This *pars non plicata* is the very part through which the needle is brought into the vitreous humor in operations through the sclerotic coat, and it is the part which is united by cellular tissue with the zonula ciliaris, to which the *processus ciliares* have no adhesion in the human eye. Professor Beer calls the anterior part of this body *pars plicata*, to the formation of which the ciliary processes contribute. The *ruyschiana*, after having formed this body, continues forward, having to its inner surface firmly united the ciliary processes, and to its outer the ciliary ligament, to the back part of the iris into the uvea; so that I consider the *ruyschiana* as the mere continuation of the uvea. This continuity is not disturbed, after having separated the ciliary processes with their origins; and the appearance of both membranes is completely the same, each exhibiting the nature of a thin serous membrane.

Having now described the choroid coat and the iris, and the connection of them anterior to the tendinous ring, I must here remark, that when this tendinous ring is separated from the sclerotic coat, the venous layer of the choroid and the anterior lamina of the iris form one membrane turning towards the cornea for the space of about one line; which appearance makes me believe, that it is the membrane of the aqueous humor, though I could not follow this membrane further by dissection, so as to shew clearly its continuation. Yet it is evident that this membrane divides before the tendinous ring into two, the outer and posterior forming the venous layer; the inner and anterior, forming the iris, continues, uvea and ruyschiana. That it is a division of this membrane in these two different directions, I conclude from the finer structure of each of these two membranes than of that before the tendinous ring. The expressed character of a serous membrane in the latter, and its similarity in structure with that of the aqueous humor, make me believe, that it is really the membrane of the aqueous humor itself; pathological observations prove also such a contiguity to the iris, i. e. the corneitis so quickly followed by iritis, and *vice versâ*; so that the primary inflammation of the cornea is denied by eminent pathologists.

As to the nature of the iris, choroidea, and ruyschiana, I am inclined to think that they are of a serous kind, from the appearance which they exhibit in their natural state, and the more so, from the morbid alterations to which they are subjected during inflammation, which is most evident in the iris, viz. the disposition to throw out coagulable lymph even in the slightest degrees of inflammation, and thus to produce an adhesion of the uvea to the capsule of the lens, or to close the pupil entirely; in other cases to form partial or total adhesions of the iris to the cornea. The tubercles in the syphilitic iritis, which Beer calls condylomata, and appear at the ciliar or pupillar margin of the iris, are of a more or less brownish and red color, which variety of color depends on the smaller or greater organization of the coagulable lymph.

In a higher degree of iritis, though more rarely, there may be formed an abscess, which occupies, as Beer observes, the middle of the iris; in these respects, as to the liability of adhesive inflammation, and rare occurrence of suppuration, in the substance of the iris, it coincides in its nature with that of serous membranes. The same liability to adhesion we may observe in the choroid coat, when a dissection of the eyeball is performed after a deep-seated inflammation, when we shall find not rarely adhesions of the venous membrane to the sclerotic coat, but more frequently of the ruyschiana to the retina; or after the operation for cataract, adhesion of the zonula ciliaris to the ciliary processes. The difference of function in the iris and ruyschiana, though they are the continuation of a serous membrane, I explain from the addition of other parts, as in the iris, of the ciliary nerves and vessels, to which I think the motion of the iris is to be attributed; and in the uvea and ruyschiana, from the other ciliary arteries, which secrete the pigmentum nigrum.

Ligamentum ciliare, is a cellular substance of a conical shape, situated between the choroidea and ruyschiana, just above the corpus ciliare and ciliary processes, its basis turned to the iris, its apex backwards. It is of various colors; in light eyes it is lighter, looser, and larger. As to the use of it, I think it is for defending the vessels and nerves of the iris, which go through it. These vessels and nerves are situated at the back part of the globe without the venous layer of the choroid coat, and as soon as they reach the ligament perforate this membrane.

Processus ciliares, are situated on the inside of the ruyschiana, occupying nearly the anterior half of the ciliary body; they originate by their bases in the angle formed by the uvea, continuing into the ruyschiana; they are situated outwards and backwards; their attenuated termination is where the connection of the zonula ciliaris with the ciliary body begins. They may be separated from the corpus ciliare by the help of a needle, and elevated. There appear some larger and

some smaller processes, and two commonly arise together. The origins of these processes form the boundary of the posterior chamber in its entire circumference. From this description it is evident that the depression of the crystalline lens into the posterior chamber (as described by some oculists), cannot be done without a violent injury to the ruyschiana or iris. From these processes arise smaller ones, continuing to the back part of the uvea. As to these processes, I have still to remark, that they are described by some anatomists as connected with the choroid coat, but I could not find such a connection. That they are formed by the ruyschiana, I can also not admit, because, 1. they may be separated and raised from the corpus ciliare without injuring the continuity of the ruyschiana; 2d. they are different in their structure, endowed with greater firmness and elasticity; 3d. they do not secrete pigmentum nigrum in the human eye. I consider these processes as consisting in themselves of a different structure from that of the membranes of the eyeball; they appear to me very elastic, and of a substance which I might call one betwixt tendon and ligament. These processes are covered with a cellular tissue, which I have seen fully injected; this cellular tissue seems to be the secreting apparatus of the aqueous humor in the posterior chamber.

Retina, covers the corpus hyaloideum, and is connected with it at its back part, after having entered the eyeball, but much firmer in its connection at the anterior part, where the zonula ciliaris originates at the dentated margin of the ciliary body; here it forms the ora serrata, which is considered the end of the retina. Professor Doellinger describes a thinner continuation under the zonula ciliaris as far as the canal of Petit. I repeated these dissections, and found that there exists a substance exhibiting itself as cellular texture, destitute of medullary substance; whether this is mere cellular texture, or a continuation of the inner layer of the retina, is uncertain. As to the membrane described by Jacob in a late number of the Philosophical Transactions, I have seen it in brutes; it appears evidently of a serous nature.

Zonula Ciliaris. An accurate description of this part has been given by Professor Doellinger (über das Strahlen-blättchen), of which I shall mention shortly the anatomical facts. The zonula ciliaris is situated under the corpus ciliare, and the serrated margin of that body denotes its commencement, from which place it goes to the anterior capsule, and unites with it intimately. The ruyschiana is easily separated from the retina until it reaches the zonula ciliaris; it is united with this by firm cellular texture. The zonula Zinnii has about three lines of breadth, has an anterior and posterior margin, an outer and inner surface; the outer one is connected with the corpus ciliare; the inner surface is connected with the attenuated continuation of the retina; the anterior part of the zonula is free. The canalis Petiti is formed by the zonula Zinnii and hyaloid membrane; the hyaloid membrane is connected with the posterior capsule of the lens more backward, and the zonula Zinnii more forwards with the anterior capsule, so as to leave a triangular space. The zonula consists of fascicles, which appear more evident when the canal is filled with air (Zinn); these fascicles are connected with the serrate prominences of the retina.—Since Winslow's time, this zonula is derived from a splitting of the hyaloid membrane; but the following observations are opposed to this opinion: 1. The hyaloid membrane has such a thinness, that it cannot be divided into two layers, as Zinn had already observed. 2d. The zonula has a quite different structure; the hyaloid membrane has nothing fibrous. 3d. The hyaloid membrane is at the posterior convexity of the lens not thinner than in the other regions of the vitreous humor. 4th. Between the corona ciliaris and hyaloid membrane is situated the continuation of the retina under the zonula. I have to mention last, the distribution of vessels in the zonula, which also proves, that it is not a continuation of the hyaloid membrane; the anterior part of the zonula obtains its vessels with the anterior capsule of the lens; the posterior part of the zonula from the arteria centralis after its division upon the posterior capsule of the crystalline lens, and forming here an anastomosis with the other vessels; and finally, the zonula has been

injected with the capsule, but the hyaloid membrane has not shewn the least trace of injection.

Lens crystallina, is included in a proper capsule ; the anterior is firmer than the posterior, which depends on the connection with the zonula ciliaris, and obtains its vessels from the corpus ciliare. In the posterior capsule is distributed the arteria centralis, and it is connected with the hyaloid membrane by loose cellular tissue.

Humor vitreus, consists of cells, filled with a fluid like aqueous humor. It obtains its vessels from the retina, and the central artery going to the capsule gives off the arteria lateralis Albini. When the cells are destroyed, they are not restored, but the space is filled by a fluid, which resembles aqueous humor.

Fig. 2.

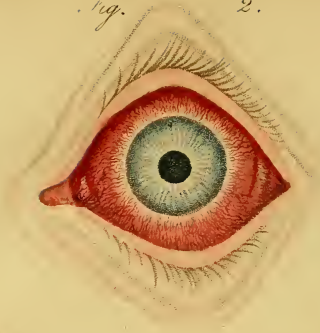


Fig. 3.

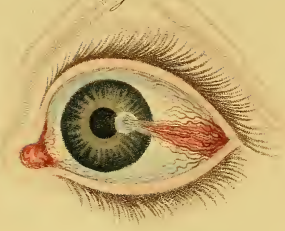

Fig. 4.

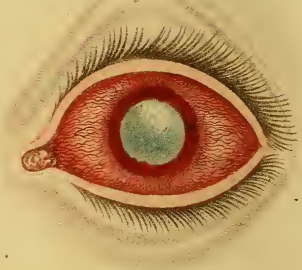


Fig. 1.

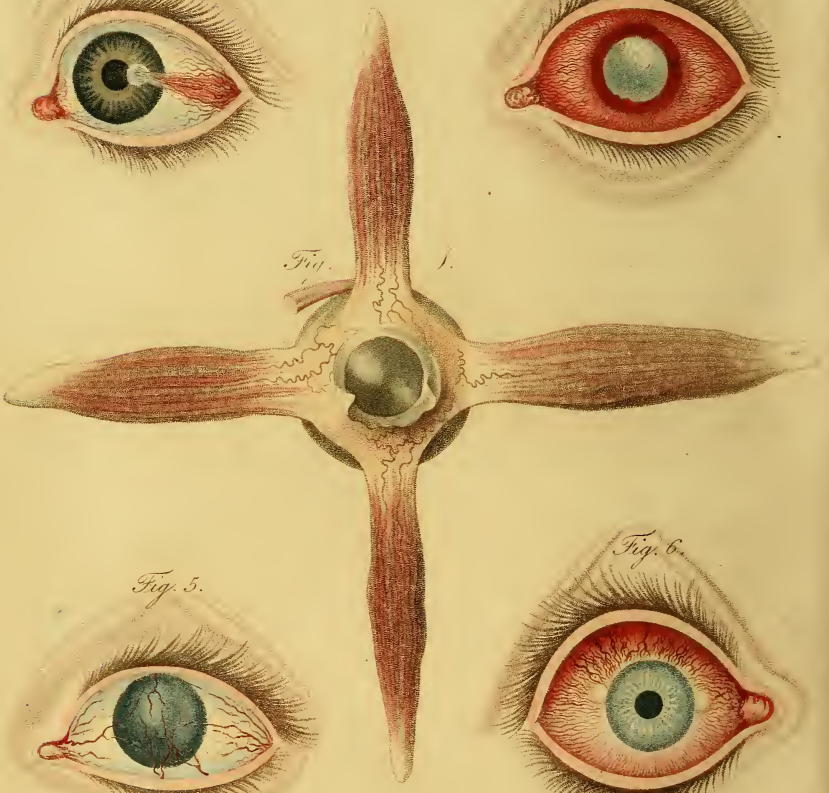

Fig. 5.

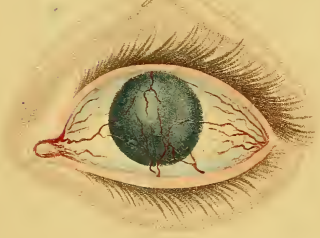

Fig. 6.

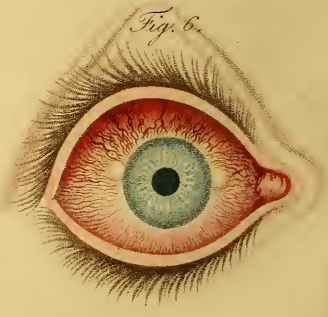
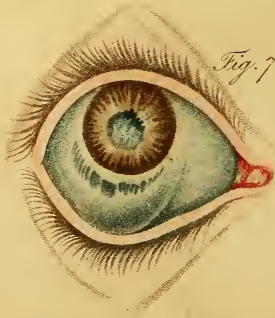


Fig. 7.



Drawn by E. Thomson

Eng^d by J. Stewart.

EXPLANATION OF THE PLATES.

PLATE I.

Fig. 1. A plan of the muscular branches of the ophthalmic artery, from Soemmering. Icon. Ocul. Hum. Tab. 4ta.

Fig. 2. Simple acute inflammation of the conjunctiva. See page 91.

Fig. 3. A plan to shew the cicatrization of an ulcer of the cornea, whether pustular or interstitial, and communicating with the surface, by a fasciculus of vessels carrying red blood. See page 109.

Fig. 4. The state of strumous nebula with vessels in the form of radii overshooting the cornea. These are not continuous with, but distinct from the vessels of the conjunctiva, and beneath it. See page 110.

I have seen cases of the prolongation of these vessels even to the centre of the cornea, organizing the nebulous deposit, affecting both eyes of the same patient, and occasioning total opa-

city and blindness, perfectly restored by continued ptyalism. The first change was the breaking and clearing of the dense deposit of lymph, then the fading away of the rose-colored zone at the verge of the cornea, and lastly, the gradual disappearance of the vessels on the cornea. See page 288 & seq.

Fig. 5. A plan of the anastomosis of colored vessels upon an opaque cornea; 'chronic inflammation with vascular cornea.' See page 110.

Fig. 6. Aphthous or pustular inflammation of the conjunctiva. Two large aphthæ are seen, one on either side of the cornea, situated nearly in the transverse axis of the globe. This figure was selected for the purpose of shewing the peculiarity of two distinct orders of vessels bounded by the pustules. The upper segment of the hemisphere presents the ordinary superficial vessels of the conjunctiva, having the areolar distribution. The lower are the straight vessels penetrating the sclerotic, and appearing through the transparent conjunctiva. This twofold arrangement is seldom so distinctly seen. See pages 95 and 128.

Fig. 7. The blue tumor of the sclerotic, 'staphyloma scleroticæ,' accompanying various disorganized states of the globe. See page 130.

The figures 2, 4, 6, and 7, in this plate, are from nature. The three former have an appearance of unnatural magnitude, from the artificial elevation of the upper and the depression of the lower lid, for the purpose of exhibiting the conjunctival surface around the cornea.

PLATE II.

Fig. 1. Carcinoma of the conjunctiva affecting the globe and eyelids.

This very accurate representation of the disease was taken from the eye of a patient of mine in St. Thomas's Hospital, by Dr. Zuckerbecker, a very intelligent physician now settled at Moscow. See page 100.

Fig. 2. A section of the fungous growth represented in situ, *Fig. 4.*

Fig. 3. The state of central slough of the cornea in the last stage of acute suppurative inflammation.

Fig. 4. A peculiar fungous growth interstitial to the conjunctiva and cornea. See page 102.

This figure represents the appearance of the disease, as it was presented to me in the person of an elderly lady from Somersetshire, and the idea I then formed of it was, that the fungus had originated from the iris, or choroid tunics, consequent to a slough of the cornea. Finding that the sclerotic tunic was sound, I proposed the excision of the tumor by an operation simi-





Fig. 3.

Fig. 4.

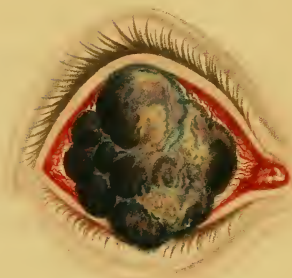
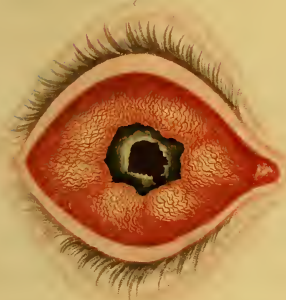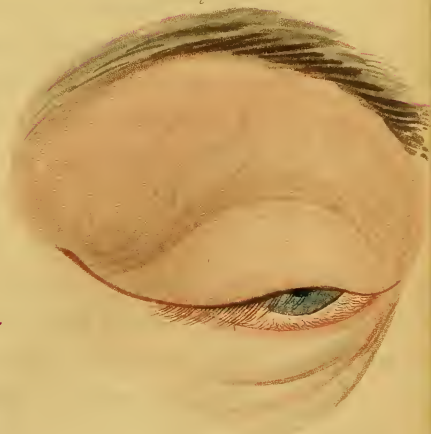

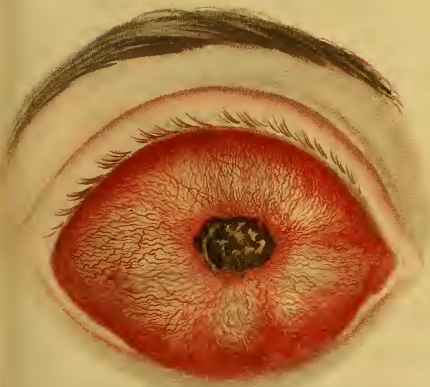
Fig. 5.

Fig. 6.



Drawn by H. Thompson

Engr'd by J. Stewart



lar to that for staphyloma. This was executed with facility, and the patient quickly recovered, the remaining portion of the globe collapsing in the orbit. The surface had the deep blue tint, and the currant or berry-like appearance denoted, likening it to what is termed by the Germans 'Staphyloma racemosum,' but it proved to be totally different in its nature from that disease.

The section *Fig. 2.* is shrunk from immersion in spirit; it is varicolored and of unequal consistence; in some parts pulpy, in others firm; the sclerotic is not altered in its structure; the iris is thickened by inflammation, the pupil closed, and the capsule of the lens, which is shrunk and opaque, adherent to the uvea. The red line is the section of the iris, and the yellow substance beneath and adhering to it represents the shrunk crystalline. These parts were quite free from the disease and changed only by compression. The cornea which is seen at the base of the fungus has lost its lamellated structure, and hence appears firmer; its surface is rough and has a brownish tint, as if beginning to degenerate into the morbid mass which lies above it. This not only covers the cornea, but at one part a little overlaps the sclerotic. The section discovers a subdivision of the larger into lesser lobes, separated by whitish lines intersecting the mass perpendicularly. The lobes differ in structure and

in color, as if originating in cells and distinct from each other. In one part adjoining the surface a whitish spot is conspicuous, of a cartilaginous hardness. The fungus is covered by a membrane easily torn; if this be not the conjunctiva, no trace of that membrane remains; but I am disposed to think from its relation to the tumor, and the continuity of the conjunctiva scleroticæ with this membrane, at that part of the circumference of the cornea where the pulpy mass has encroached upon the sclerotic, that the covering membrane is formed of the conjunctiva in an altered state. The intimate adhesion of the fungus to the covering membrane, the total change in texture of the conjunctiva, and the fuller evolution of the disease next the surface, lead me to suppose that it originates from that membrane; and from its lobular arrangement I conclude, that the morbid growth occupies the cells of the connecting membrane indicated by the white lines intersecting it.

Fig. 5. Abscess of the eyeball terminating in ulceration and death of the cornea and disorganization of the globe. See page 220.

Fig. 6. Scirrhus of the lacrymal gland. See page 233. The deformity was removed by extirpation of the gland.

Fig. 1.

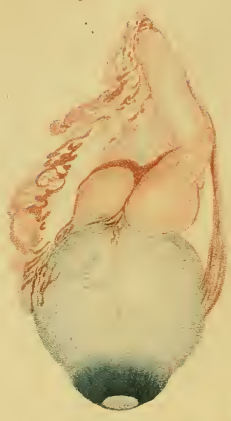


Fig. 2.

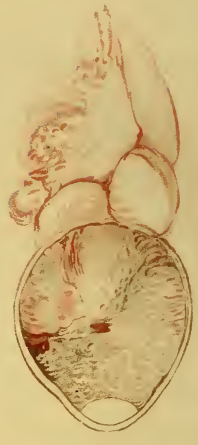


Fig. 3.

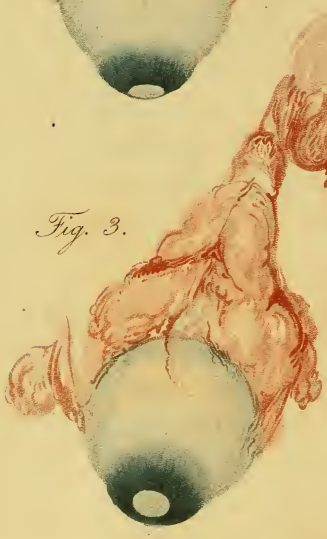


Fig. 5.

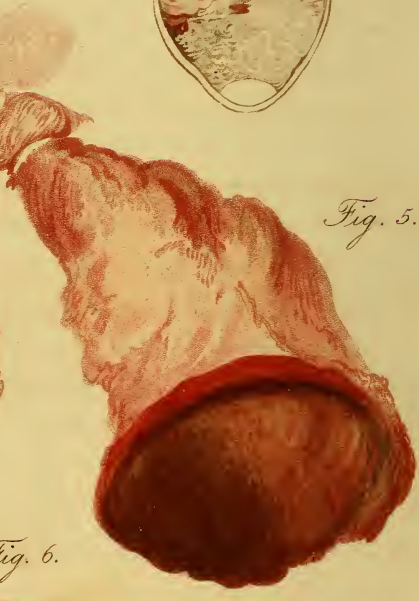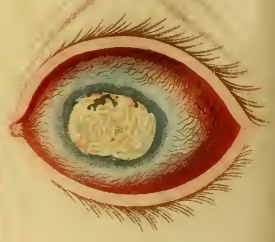


Fig. 6.

Fig. 7.

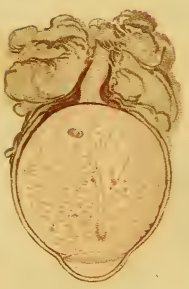

Fig. 4.



Drawn by H. Thomson.

Eng^d by J. Stewart.

PLATE III.

Fig. 1. and *3.* represent in different positions the eye of a child affected with the malignant fungus, prior to the opacity of the cornea; in which are observable the change of figure of the globe and annihilation of the anterior chamber, by the bulging of the opaque lens and iris.

Fig. 2. is a section of the same eye.

These drawings having been made immediately upon the removal of the eyes after death, represent accurately the recent appearances, but by a minute dissection after hardening in spirit, I have been enabled to trace some vestiges of the several textures which the mere sections do not exhibit, in a manner which would have given the representation, if that had been possible, additional interest, as it throws much light on the origin and progress of the diseased growth.

A substance answering the description of the 'sarcoma medullare,' occupies the upper and back part of the eyeball, by which the vitreous humor, which has undergone a similar degeneration, is compressed and pushed forward and downward. The sclerotic is in a perfectly

healthy state, as are also the cornea, iris, and a considerable part of the choroid; the lens absorbed, its capsule firmly adherent to the uvea. The diseased mass is evidently deposited between the venous and arterial layers of the thickened choroid coat; the former adherent to the sclerotic, being situated external to the morbid mass; the latter (which has been described as the tunica ruyschiana), separated and protruded by it, is denoted by a line crossing the section obliquely. Here no pigmentum nigrum is secreted. The corresponding posterior part of the retina is destroyed, the anterior is adherent to the choroid. At the back of the eyeball is a medullary tumor contained in a capsule, formed by the surrounding cellular texture. A similar tumor is formed by the optic nerve at its entrance. The texture of these is somewhat firmer than that within the ball, and between these tubera and the internal diseased mass there is no communication.

Fig. 4. represents the other eye of the same subject, when by the progress of the disease the cornea had perished by ulceration, and the fungus, represented *Fig. 5.*, was just about to protrude. The leaden tint of the extenuated sclerotic is characteristic.

Fig. 5. represents the contents of the orbit on removal after death.

Fig. 6. is a section of the fungous mass.

The optic nerve filled with the morbid deposition has its neurilemma thickened; and a similar substance occupies the cellular texture within the orbit. The white lines bifurcating from the extremity of the nerve, represent the sclerotic thickened. On both sides of the entrance of the optic nerve, a mass is formed on the interior of the sclerotic, resembling that on its outside except that its texture is firmer. Forwards, on the right side of the figure, the sclerotic is distinctly split into two layers by the pulpy substance which has insinuated itself between them. This corresponds to the upper half of the globe.

The plate, which represents only a recent section, does not illustrate the remaining points of the description. They have been since made out by subdivision and careful separation of the several parts of the mass from each other. As they are highly curious I subjoin them.

The interstitial deposit is seen in the whole anterior circumference of the sclerotic, but the layers of this membrane are less widely separated from it at the inferior part of the ball. At the posterior part, where the sclerotic is single, the membrane is much altered, but it has no where given way, so that the diseased masses upon its

opposite surfaces have no direct communication. By the mass formed on its inside, the choroid coat is distinctly seen to be protruded forwards. At the anterior part, the sclerotic is firmly connected with the thickened choroid coat. The entire centre of the cornea has perished by an ulcerative process, but a fragment of corneal lamella remains to denote its place, and behind it is a portion of membrane adhering, and resembling the iris much altered in its structure. The softest part of the fungus is connected with this membrane, and between it and the choroid no trace appears of the humors or retina. This anterior mass is distinguished from the posterior growth of the sclerotic, from which it is separated by the choroid, by its softer texture and darker color. Hence it appears that the morbid substance within the ball consists of two different formations; first, of the sclerotic degenerated on its exterior and interior surfaces, and likewise in its substance; secondly, of the choroid degenerated on its interior surface.

Fig. 7. This figure represents the section of the eye of a child, aged eight months, which I extirpated several years ago. The subject of the operation has since enjoyed perfect health. See page 207, where *Fig. 4.* is referred to by a misprint.

The cells of the vitreous humor are filled

with an opaque lardaceous substance, by which the lens was slightly protruded, and the iris rendered convex. The eyeball was but little increased in size or altered in figure. The sclerotic was in some parts thinner than usual, and had a bluish hue from the preternaturally firm adhesion of the choroid coat. The retina was for the most part absorbed, the other tunics perfect, and the optic nerve free from disease.

There is no evidence to prove this change of structure malignant, although the external appearances closely resembled those of *Fig. 3*.

PLATE IV.

Fig. 1. 2. and 4. are from preparations in the Museum at St. Thomas's Hospital.

Fig. 1. Is the section of an eye extirpated by the late Mr. Ware. The morbid growth fills the thickened sheath of the nerve, and tubera are seen on both sides of the globe formed in the substance of the sclerotic. The mass, distinguished by a greyish tint and occupying the posterior third of the globe, protrudes the choroid tunic. The crescentic line of division is formed by the choroid. The anterior mass, which is darker, and closer in texture, corresponds to the vitreous humor. The choroid and iris are anteriorly compacted with the sclerotic and cornea; the retina has disappeared.

Fig. 2. Section of an eye in which the disease spreads from the sheath and substance of the nerve through one side of the sclerotic tunic almost as far as the cornea. It forms a broad and compact mass of a yellow color. On the opposite side this tunic is unaltered. The choroid adjoining the tumor of the sclerotic has undergone a similar change, being of a deep claret color, equally dense in structure, and about half the breadth of the diseased sclerotic with

Fig. 1.

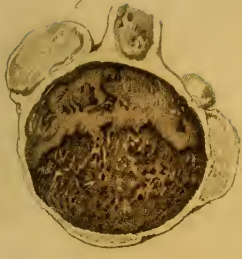

Fig. 2.

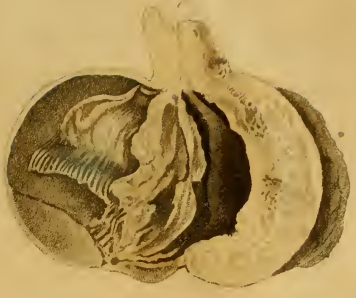


Fig. 3.

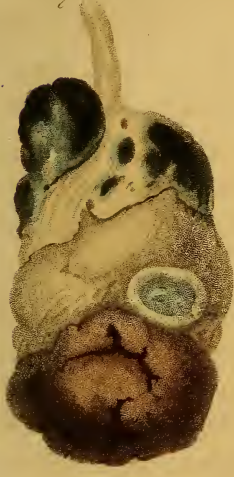

Fig. 4.

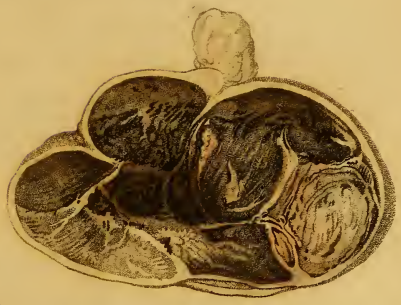

Fig. 5.

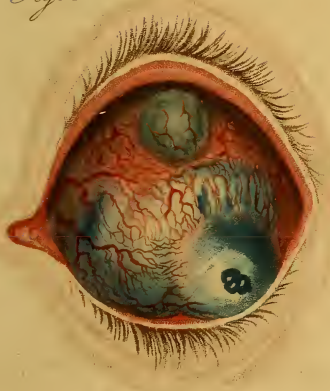

Fig. 6.



Drawn by H. Thomson.

Engraved by J. Mitchell.

which it is compacted. The shrivelled retina is seen proceeding from the extremity of the nerve encompassed by the choroid tunic, which, on the side opposite to the morbid growth, retains much of its color and texture.

Fig. 3. is a representation of a fine specimen of this disease in its more acute form. See page 315. The man from whose eye this drawing was taken, was a farmer's servant, of temperate habits, who had always enjoyed good health.

The following brief particulars of the case are extracted from my clinical register.

Five months before his admission into St. Thomas's Hospital, October 1817, he first perceived a dimness in the vision of this eye, and after this had continued about a week, he was attacked with an ophthalmia, accompanied by severe pain across the forehead and orbits. The pain was much exasperated by stooping, which excited a sensation of the eyes being extruded from their sockets. After a period of three weeks the inflammation subsided, and he afterwards felt only occasional pains darting through the temples. About eight weeks since, he discovered that he had totally lost the vision of his right eye, and about a month ago the fungus seen beneath the cornea first made its appearance. On his admission into the hospital, the

fungus had the size of a filberd, of a reddish brown color and irregular figure, protruding from the under part of the ball, driving up and shrivelling the cornea with which it was unconnected, and covering the lower lid. He now suffered little, if any pain; and was free from glandular enlargements. His digestive functions were unimpaired, his general health good, and the opposite eye healthy in appearance. Towards the end of the month the fungus had much increased in size, and was disposed to frequent and free hemorrhage. On the 7th of November, I performed the operation of extirpation. Some pieces of soft lint were afterwards placed within the orbit, and the lids supported by a compress. The patient continued in a perfectly favorable state until the 10th, when he had a slight chilliness followed by perspiration. He complained of pain darting towards the back of the head; his pulse was 72, and hard. A free suppuration having commenced, the lint was removed from the cavity of the orbit. Sixteen ounces of blood were drawn from his arm. His bowels had been freely open since the operation. From this day until the 15th he continued free from fever and from pain; a healthy and copious suppuration was established; he had a soft and natural pulse, except that it was sometimes a little irregular. On the 16th he left his ward, and remained for some time in the square of the hospital, thinking

the air would be of use to him. Soon after coming in he was attacked with a very severe rigor, followed by heat and profuse sweating. On the 17th he had considerable fever. The scalp above the external angle of the orbit was considerably puffed and tender to the touch, and a free incision was made to the bone, when a collection of matter was discharged from beneath the periosteum. On the 18th, his febrile symptoms having yielded to the exhibition of antimonials, the skin clammy, occasional intermission of the pulse, and great lowness, he was put upon a nourishing diet, and ordered to take bark, and an opiate at night. 19th. He had slept well, but his looks were much altered for the worse; he was partially comatose, and his answers were lingering and not always coherent. The pulse was slow and feeble, and the intermissions more frequent and longer; his tongue when protruded was tremulous and drawn a little to the left side. On the 20th he was attacked with convulsions, which continued until an early hour of the morning of the 21st, when he expired.

On examination, thirty-five hours after death, a large quantity of purulent matter escaped from beneath the dura mater. Upon raising that membrane, a purulent deposition extended over the whole of the right hemisphere, to which it

was confined. The dura mater retained its attachment to the cranium ; no communication could be traced between the morbid appearance of this membrane and the orbit ; the optic foramen being completely closed and the nerve in a perfect state. The substance of the brain had a natural appearance, allowing for some congestion occasioned by pressure.

I cannot avoid remarking the importance of this history, setting aside the consideration of the malignant disease, with which in fact the sequel had no connection. 1st. To shew the tendency of an extraneous substance to provoke a more copious suppuration from the orbital cavity than otherwise follows the operation. 2ndly. To demonstrate the tendency of membranous inflammation to spread, both by continuity (pericranium) and by contiguous sympathy (interior membranes of the brain). 3dly. To prove the ill-effects of exposure to cold during a free suppurative process in the vicinity of the visceral cavities, of which I have seen several well marked examples ; two, for instance, of the extension of the suppurative action from the parietes of the chest to the pleura, under circumstances very similar.

Dissection of the Eye.

The whole cavity of the eyeball is filled with

a dark friable fungous mass, and no trace of the textures within the choroid can be distinguished. The sclerotic, much extended and thinner than in health, is in various parts of a purple hue, from the intimate adhesion of the choroid, which is thickened and filled with blood-vessels. Anteriorly this coat could be separated from the sclerotic; but backwards it had completely degenerated into the morbid substance. On the outside of the optic nerve, in the situation of the foramen centrale, the sclerotic had given way, and the morbid mass projected in the form of a tumor of the size of a large pea. The iris and lens were completely destroyed, the cornea in its middle part ulcerated, and the tumor beginning to protrude through it; the optic nerve was free from disease.

Fig. 4. is the section of a diseased eye, the history of which is not known. The sclerotic, it will be observed, is in parts morbidly thickened, the cavity appears to be divided into chambers, which are filled by a dark-colored substance, compacted with the sclerotic, and interspersed with specks and patches of white, giving it a marbled appearance. The light-colored mass on the lower and right side of the drawing, corresponds to the vitreous body; and a remnant of lens, inclosed in its capsule, retains its relative situation to that

body, but is so displaced by the extension of the morbid growth adherent to the cornea, as to be situated almost at right angles with that membrane. The sheath of the nerve is thickened. The disease seems to be a degeneration of the choroid and iris.

Fig. 5. is a very exact representation of an eye which I extirpated at the commencement of the year 1820.

The subject of this disease was a respectable tradesman, forty-two years of age. He had enjoyed good health until two years before, when he experienced a sensation of heaviness in the upper eyelid, as if unable to raise it, though no ptosis appeared. Pain commenced in the same side of the head, extending from the forehead to the occiput, and was subject to frequent exasperation, depriving him of rest. By slow degrees the sight of the eye, at first only misty, totally failed. The cornea became glazed and dead in appearance. Three months prior to the operation, the eyeball became also the seat of pain, for that in the head was not diminished by day or night, and the ball at the same time began to enlarge. The vessels assumed the varicose appearance represented, and the sclerotic protruded in several points, which had a deep blue color, and seemed threatening to burst. About this time he was three or four

times seized with a dazzling of vision, giddiness, and momentary confusion, like slight shocks of apoplexy. Lastly, the principal protrusions gave way, and a continual hemorrhagic oozing took place. In this state the operation was done. It was followed by scarce any indisposition; in a fortnight he resumed his employment, and has continued to this time free from uneasiness and in the enjoyment of perfect health.

Fig. 6. is a section of the same eye. The disease is here in its most advanced stage; the eyeball is double its natural size; the sclerotic of a deep blue color, being in some parts so much extenuated as to seem on the point of bursting; the veins of the conjunctiva varicose and turgid with blood. The mass contained in the eyeball, wherein are no traces of the internal parts, has a greater vascularity than in *Fig. 3.* At the upper part of the cornea, the sclerotic has yielded to the disease, and a large tumor projects. The cornea is not altered in structure, otherwise than by compression and collapse. By the side of the optic nerve, and beneath it, a distinct tuber presents itself, the section of which corresponds in appearance to that of the mass which occupies the globe. The nerve is not affected with the disease.

PLATE V.

Fig. 1. represents the eye of a girl, a patient of Mr. Astley Cooper, in Guy's Hospital. The disease was accompanied with glandular enlargements, and of several months standing.

Fig. 2. is the eye of an infant, aged eight months, likewise a patient of Mr. Cooper, in Guy's Hospital, in whom the disease was congenital. See page 210.

From the central position of the cornea, and the enormous protrusion and equal figure of the ball, the disease was supposed to be seated in the orbitar appendages. It is remarkable that the child was well nourished and apparently suffered little constitutional disturbance. The right eye was sound.

This child, I have since learned, died very shortly after leaving the Hospital*.

* SECOND EDITION.—I regret that the part was not examined. But from a careful dissection recently made of the disease in a child of three years, which (except that it was more advanced, having fungated) resembled it in size and figure, and from the analogy it bore to other specimens in their earlier stage, I entertain no doubt that the entire contents of the orbit would ultimately have been converted, if they were not already, into the medullary or white pappy substance, and that a luxuriant bleeding fungus would have

Fig. 1.

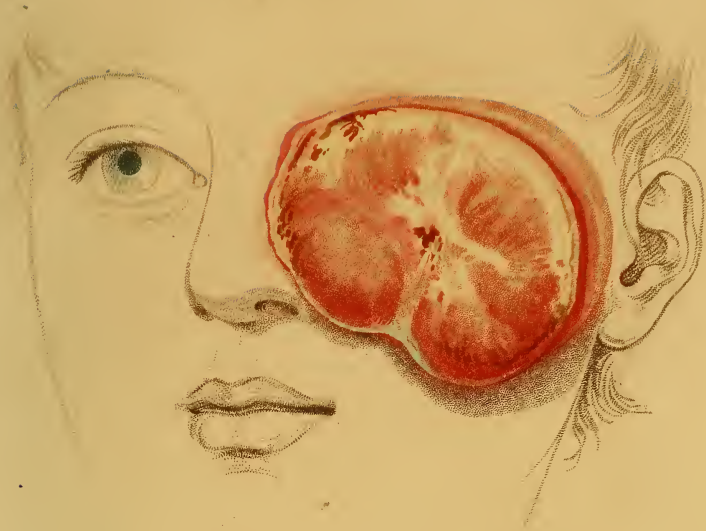
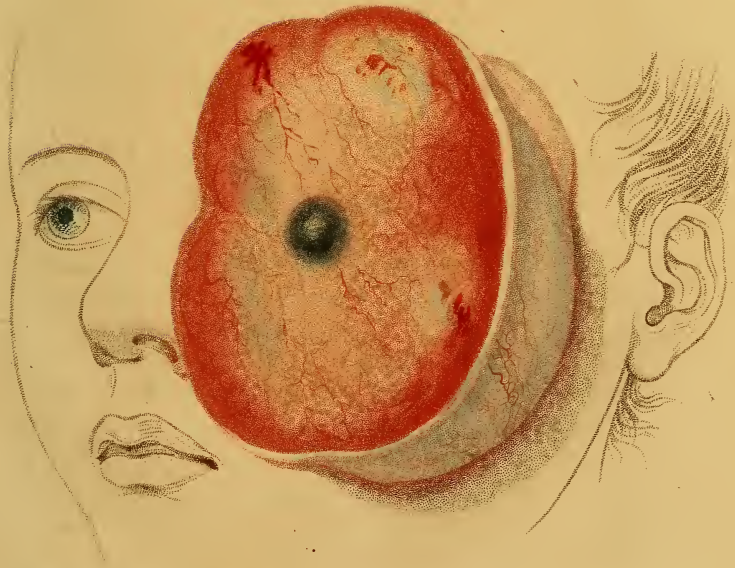
Fig. 2.



Drawn by H. Thomson.

Eng^d by J. Mitchell.

This engraving was reduced from a drawing of the size of life, upon a scale of 25 to 36.

A proptosis or protrusion of the ball conveys a delusive idea of the increased magnitude of the organ. I have occasionally met with cases of proptosis to such an extent as to occasion a morbid change upon the cornea, with a varicose state of the vessels of the conjunctiva; and with others, in which, although the cornea remained clear, the vision was materially deranged, where the cause of the protrusion was altogether obscure, and the progress of the disease had been so slow as to occupy a period of several years.

In these cases both eyes are equally affected; they are attended with a distressing degree of deformity, obtuse pain in the forehead, and other

been thrown up on the sloughing of the cornea. In the case just referred to, this hæmatoid fungus was of the size of a small orange, and the morbid growth, a true medullary sarcoma, filled up, and corresponded in shape to the pyramidal form of the orbit. The nerve was imbedded in the centre of the sarcoma, and the periosteum of the orbit, thickened and detached from the bone, invested it closely as a sheath, while the fibrous section of the sclerotic, the only texture distinguishable, plainly shewed the disease springing from both its surfaces. On the os frontis were situated two medullary tubera, one adhered to the external surface of the periosteum, the other to the internal; and the latter had absorbed the outer table, being seated in, and adherent to, the diploe of the bone.

occasional signs of determination of blood to the head. It is probably a morbid increase of the adeps contained in the orbit, obstructing its circulation, as well as protruding the eyeball. The disease, when acute, is of a different and more formidable nature. The following short history is an example:—

Highland, a lighterman, stout and healthy, aged twenty-nine, after frequent bleedings from the right nostril, with an obstructed and snuffling respiration, for which he was unable to account, was attacked with a severe pain over the whole front of the head, with a sense of weight in that part, and extreme lethargy. Although naturally of an active cheerful disposition, he became morose, indolent, and fond of solitude; at intervals he was attacked with tremors, cold perspirations, and syncope. These symptoms had become established, when the right eye began to protrude from its socket; his pain was at this time more severe, and a copious glairy discharge was set up from the nostril. As the disease advanced, his manner to his relations became strange, his intellect confused, and his gait unsteady. The protrusion steadily increased for several weeks without abatement of his pain, except for a few hours after occasional blood-letting. Convulsions at length ensued, and terminated his existence about three months after the commencement of

the proptosis. It is remarkable that he retained the vision of the affected eye up to the period of its protrusion; and before that was obvious to his friends, he described the sensation of something pushing the eye out of its socket. It is also remarkable, that through the whole period of his disease, although his bowels were extremely torpid, he had a good appetite, and little, if any, febrile irritation. These particulars I learned from his surgeon and relatives, having myself seen him only a few days before his death. Upon dissection I found the following appearances:—behind the cavity of the right orbit lay a tumor, which had the appearance of an oblong polypous cyst, and anterior to this was a blood-colored fungus filling the orbit and extruding the globe. The cyst lay anterior to the dura mater, adhering to its surface, and so situated as to make the right hemisphere of the cerebrum appear truncated of its anterior lobe. The æthmoid bone, frontal sinus, and orbitar plate of the os frontis on the same side were in a state of caries, so that the finger passed readily from the orbit into the cavity of the cranium and posterior nares. A large quantity of yellow viscid matter occupied the frontal sinus, such as had been discharged during life by the nostril. The os frontis in front of the sinus and above the orbit was denuded, and presented numerous worm-hole ulcerations. The anterior lobe of the brain was discolored and softened; there was an extra quantity of water

in the left ventricle, and some fluid blood in the right. On a transverse section of the right hemisphere of the brain, it was found broken down in its texture, and the dura mater partially absorbed at its basis, the tumor having opened into the ventricle. The right thalamus was much diminished in bulk, though entire. The hæmatoid fungus in the orbit was mingled with spicula of bone, and distinct from the tumor. The dura mater to which the cyst adhered was continuous behind the cyst, except at the lower part, where it was destroyed. The disease appeared, therefore, to be connected with the external surface of the dura mater, and by its increase to have occasioned absorption of the bones and displacement of the eye, (which was sound, as were also the optic nerve and muscles of the globe,) and ultimately to have ulcerated through the dura mater and anterior cerebral lobe, and discharged itself into the right ventricle. All the nerves were sound except the olfactory; this had disappeared, together with the æthmoid bone, on the right side.

SECOND EDITION.—I have two cases at present under my observation, of malignant proptosis, from some such formidable and inaccessible disease as that above detailed. In one, a polypous tumor plugs and distends the nostril on the same side; in the other, the temporal wall of the orbit has given way, and the disease is extending to the integuments.

Fig. 1.

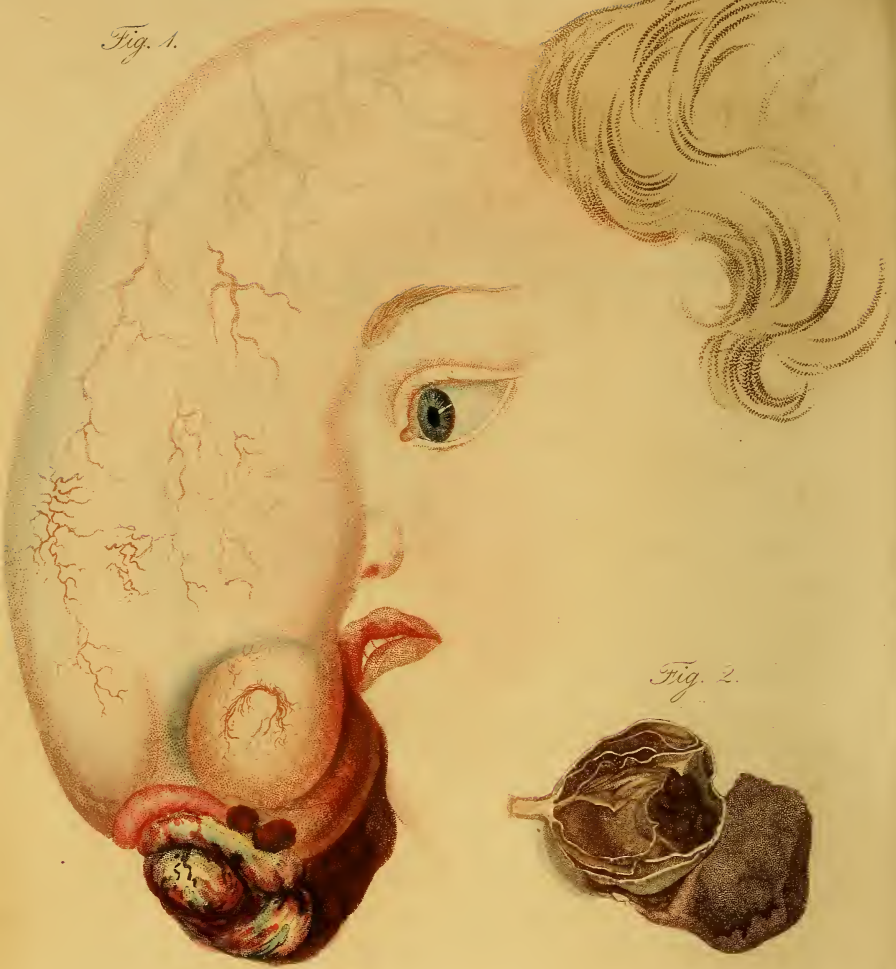

Fig. 2.

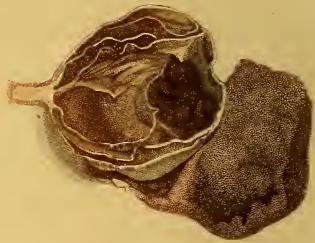


Fig. 3.

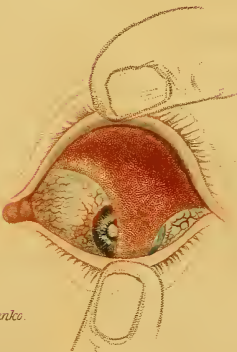
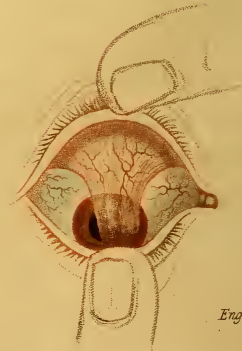


Fig. 4.



Drawn by F. Savenko

Eng^d by J. Mitchell.

PLATE VI.

The drawings in this plate are from the portfolio of Dr. Savenko, a gentleman whose accurate knowledge of anatomy adds greatly to the value of his elegant talent for delineation.

Fig. 1. represents a malignant tumor of the eyeball in a boy aged four years. This dreadful disorganization had attained a magnitude nearly equal to that of half the head. The eyelids were enormously extended and swollen, with varicose veins running over the surface, many times larger than their natural size. The tumor was of a reddish color, elastic, and very painful to the touch. Betwixt the margins of the lids grew a fungus, having an unequal surface, which, during the progress of the disease, assumed various colors from red to black, secreting a bad smelling ichor intermingled with blood. At the most prominent part of this fungus, the cornea could be distinguished. The continual flowing of the blood and ichor into the mouth increased the hideous appearance of the face. The tumor, from the excessive elongation of the upper lid, hung over the cheek and covered one side of the mouth.

The origin of the tumor could not be distinctly ascertained, and the case was dismissed

from the hospital as incurable : its termination is not known.

Fig. 2. is a section of the eye of a woman, aged 46, which was extirpated by Mr. Astley Cooper, at Guy's Hospital, in August 1820.

Two years before that time, the cornea of her left eye became opaque from chronic inflammation.

In this state, after a severe attack of fever, the surface of the eye began to throw up a vascular fungoid tumor. On her admission it was of the diameter of a shilling, covering the cornea and a part of the sclerotic, and protruding between the eyelids. It was slightly lobulated, of a dark purple color mingled with red ; it sometimes bled, but was never painful. She was the mother of nine children, and her health had been generally good. She recovered speedily from the operation.

Dissection of the Eye.

The tumor is situated without the globe ; it appears pulpy, vascular, and of an unequal dark color. It is of a square figure, formed of various lobes separated by delicate fibrous bands, and adheres to the sclerotic and the margin of the cornea. These two mem-

branes could be traced entire beneath the tumor. The globe being divided, the vitreous humor escaped in a liquid state and of a yellow color. The lens had disappeared. Within the globe and opposite to the outer tumor, is another and smaller morbid growth which has no communication with the former, and is of a softer and very vascular substance. It occupies the lower and anterior part of the globe, raises and compresses the retina, and is distinctly situated between the layers of the choroid coat; the venous layer on the outside is thickened; it can be traced backwards, and is firmly adherent to the sclerotic coat, from which it is separated with the help of a needle. The arterial (ruyschiana) is thickened, but much less so than the venous layer; it forms a tumor within and behind the morbid mass, which thus produces a complete separation between the two layers of the choroid coat. The retina, though displaced, is entire and adhering to the ciliary body, the whole of which is beginning to change into a similar morbid mass, covered with pigmentum nigrum. The processes are only in some places slightly distinguishable. The uvea is also changed. The iris preserves its color, though imperfectly; it is adherent at its centre to the cornea. The optic nerve is not diseased, but thinner than in health. All the points of situation and figure are distinctly and faithfully exhibited in the engraving.

I beg leave to offer a few additional observations on the several specimens of fungoid disease exhibited in *Plate II. Figures 2. and 4: Plates III. IV. V. and Plate VI. Figures 1. and 2.* The first of this series is unique in my experience. In the explanation, I have stated my opinion that the seat of the disease is the cellular texture connecting the conjunctiva to the cornea. I find no other texture degenerated, nor otherwise affected than the contiguity and extent of the disease explains. It was not characterized by any symptom of malignity; neither pain in the ball or in the head worthy of notice, nor any affection of the constitution. The deformity and the fear of its increase were the inducements to the operation, which was performed in the year 1819. This was attended by no untoward symptom, and up to this time the subject of the disease has continued well.

In its fresh section the tumor nearly resembled that described in *Plate VI. Figure 2.*; in its situation it is not very dissimilar; the cornea supports the former, the sclerotic the latter; but in the latter the covering membrane is not traceable; and I have little doubt that the conjunctiva gave origin to the fungus in both instances. The internal tumor, however, gives a more complicated and formidable character to the disease depicted in the last plate.

Plate III. with the exception of *Figure 7.* exhibits the various appearances of the medullary sarcoma in its several stages, in the eyes of a child who was under my observation from the commencement of it to the termination. In one eye (*Figure 2.*) the disease seems to have begun in the interstitial texture of the choroid; the sclerotic is also affected on its outer surface, and both the nerve and the vitreous humor have undergone a kindred change. In the other (*Figure 6.*), which had advanced to an ultimate state of disorganization, both surfaces of the sclerotic, the interstitial texture of that membrane, and the adipose membrane of the orbit, are loaded with the diseased growth; and by after-dissection the choroid too was distinctly ascertained to have partaken of the same action, as is seen in the preparation in my possession. In *Plate IV. Figures 1. and 2.* shew the disease affecting the integral texture of the sclerotic and choroid coats, and optic nerve. In *Figure 1.* the vitreous humor is evidently the basis of the disease. In *Figure 2.* the retina retains its character, and what remained of the vitreous humor was, it is presumable, fluid. In *Figure 4.* the vitreous and crystalline humor are still marked, notwithstanding the displacement, reduced bulk, and total deterioration of the former. The sclerotic is not specifically affected; the irregularities of its figure are owing to the several protrusions

of the morbid mass, deeply stained in parts, as in *Figure 1.* with the pigment of the choroid, by which tunic it is formed. *Figures 3. 5. and 6.* have a common character; they are specimens of the genuine fungus hæmatodes in its acute form. This, in my belief, is not the character of either of the preceding, or of the figures in *Plate V.*; but as the last-mentioned were not subjected to dissection, I cannot speak of them decidedly.

Figure 1. of Plate VI. is a rare disease:—a child was lately brought to the hospital with a large and rapidly increasing tumor upon the forehead, just above the orbit, and depressing the upper eyelid. The eye was free from disease. The swelling had a firm but elastic feel, and was immoveable. The child was irritable, and of an unhealthy aspect. The disease was concluded to be a medullary osseous fungus. I am disposed to think that this disease had a similar origin, and that the bony parietes of the orbit have been absorbed, and by its increase the eyeball protruded and disorganized in the manner represented.

Figure 2. shews conclusively the proper interstitial origin of the disease in the choroid; it is separated by the outer layer of this membrane and the healthy sclerotic, from the similar fungoid degeneration of the conjunctiva.

If the reader will compare with these the specimens delineated and described in Mr. Saunders's Treatise, *Plate II.* and Mr. Wardrop's Essay on the Fungus Hæmatodes, *Plates II. and III.* a striking analogy will be obvious to him in the seat and texture of these diseases. They appear to me to substantiate the observations at page 227, that the disease is not peculiar to any individual texture, but in turn affects nearly all of which the organ is composed.

1. The cerebrum, optic nerve, in its medullary and neurilemmatous texture; the sclerotica, choroides, and its appendages; the iris, retina, tunica hyaloidea, and vitreous humor; the muscles, cellular and adipose substance, and the tunica conjunctiva, are all susceptible of it.

2. The cornea and crystalline lens are alone insusceptible. These structures are least vascular, being naturally impermeable to red blood.

3. The choroid is the most strongly disposed to assume it, the retina least so. In Mr. Saunders's *Plate II. Figure 4.* this tunic intimately involves, and is indeed assimilated in texture with the morbid secretion occupying the vitreous humor.

4. Some of these diseases appear to be chronic; those, for example, which have a dense,

firm, and semi-organic character. The pulpy or brain-like are also slow by comparison with the highly organized or hematoid species. The latter is sometimes engrafted on the medullary, but it is as often primary. They frequently co-exist in distinct parts of the same structure.

5. The comparative firmness and rapidity of growth seem to depend on the texture from which the growth proceeds. Speaking generally, the sclerotic and sheath of the nerve degenerate into the dense and firm sarcoma, sparingly organized; the cerebral substance and the medullary part of the nerve into the pulpy or curd-like matter, which is the secretion also of the vitreous cells; the hæmatoid fungus is, I believe, the production of the choroid and its appendages. While the disease is confined to the sclerotic, or to the vitreous cells, it is slow; when the choroid partakes of it, it is luxuriant, increases rapidly, and bursts up the containing textures.

6. So also the color distinguishes the share which the choroid takes by the profuse morbid secretion of pigment. In the rich collection of specimens at St. Thomas's Hospital, to which I have been much indebted, is one in which, except the shell of the sclerotic, no traceable part of the organ remains but an immense flocculent mass, a sort of tomentum of black pigment.

It was extirpated some years ago by my lamented colleague, Mr. Henry Cline. The patient left the Hospital well, and has not since been heard of. It is probable then that the texture, color, and rate of progress of the disease, vary according to the texture which is affected; and probably a similar observation applies to other organs according as they are more or less vascular.

7. Cellular structure seems to form the common *nidus* of the morbid deposit, whether the *membrana adiposa*, or the common connecting tissue, or that proper to an organ, as the vitreous humor. Hence it is as often interstitial as superficial to the several tunics; and often both in combination, as in some of the instances described.

As regards the pathological history and relations of these truly formidable and hitherto obscure diseases, much interesting information may be obtained by the perusal of Mr. Langstaff's valuable cases and observations in the VIIIth and IXth Volumes of the Medico-Chirurgical Transactions.

Unfortunately, in a practical view, our knowledge of them does not enable us to say when they are, or are not (if ever not) constitutional; when to anticipate success from an operation,

or the contrary, with sufficient certainty to afford us encouragement to be active, or a pretext for doing nothing. I have said that certain morbid appearances in other parts should not always preclude the consideration of relief—much less the most advanced state of the malignant disease confined to one organ ; yet it has not unfrequently destroyed the patient when so confined ; and after the operation, it often re-appears in a remote part. Mr. Cooper removed some years ago a fungoid tumor from the shoulder of a gentleman, who soon afterwards died of the disease in the eyeball. In another case he removed the fungous eyeball, and the patient died of the disease in the kidney. Unfortunately such instances are not rare. But on the other hand, there are not wanting cases to shew that the malignant disease in some of its forms, or in certain textures, may be strictly circumscribed to a part and almost stationary during a period of years ; and, secondly, parts to all appearance so affected have been removed without any return of the disease, during a similar period of observation ; and these facts warrant the operation whenever the fungus is so placed, and the constitution so supported as to admit of it.

Fig. 3. A fleshy pterygium. The subject of it was a female about 21 years of age and of a

scrophulous habit. She had experienced repeated attacks of the scrophulous ophthalmia, in one of which the cornea gave way, and the iris prolapsed at the ciliary margin. A pterygium was then formed originating from beneath the whole base of the upper eyelid ; it was of a triangular form, extending to the lower margin of the cornea ; of a sarcomatous density, about one line thick, and forming a fold when the eye was directed upwards. It was completely cured by the operation of dividing and detaching it at its basis. The patient recovered her sight, and ultimately no vestige of the disease remained.

Fig. 4. A membranous pterygium. The subject of it was a girl sixteen years of age ; it supervened upon chronic ophthalmia, and resembled the former in size and shape, but was transparent, so that the cornea and pupil appeared through it. This was likewise successfully removed.

NOTES.

NOTE A.

THE relations of structure in every organ are such as to render it impossible that any texture can long be singly affected. But it seems reasonable to consider that texture as the proper seat of the morbid action which presents the earliest, or strongest, or exclusive signs of it. I do not therefore adopt the term "Ophthalmitis Scleroticæ," as applied to all the deeper seated inflammations; nor do I consider the corneal and iritic inflammations merely symptomatic, and as having their proper seat and base in the sclerotic, (although in rare instances it may be so,) because from the affinity and vascular connection of the parts, that membrane presents the ordinary appearances of inflammation during their existence. However inflammation may deviate from the ordinary course and the order of local relation, and, however complicated its results may be, it is to be referred to the texture primarily and principally affected, and is thence properly denominated; as in the instances of scleratitis to which this note refers.

Intolerance of light is considered by some respectable authors to be diagnostic of sclerotic inflammation. This is not my opinion, having in numberless instances witnessed that symptom in the most aggravated degree in the absence of every external sign of inflammation. But on the other hand I am willing to admit, on the ground above stated, that sclerotic inflammation is often present in such instances.

The sympathy of the sclerotic and the ligamentous capsules with the urethra in gonorrhœa, is as unquestionable as that which has been more generally observed, because more

frequently occurring, between the latter and the synovial membrane. I have seen cases so nearly resembling that described by Dr. Vetch in his late valuable treatise*, under the head of 'gonorrhœal ophthalmia,' (page 243,) that I can vouch for the accuracy of the description. This phenomenon it is not so easy to explain as the coincidence of the suppurative inflammation of the conjunctiva with acute gonorrhœa, which, notwithstanding the apparent contradiction of some experiments, I am convinced originates from contact, as is indeed proved by the history of the ophthalmia of infants, and by the fatal effects which have unfortunately fallen more than once under my observation, of an accidental application of morbid matter to the sound organ.

The disposition between remote parts to be reciprocally affected admits of two modes of explanation. First, by a partial sympathy depending on identity of structure (serous, synovial, mucous surfaces). Second, by a mode of the universal sympathy which prevails throughout the system, independent of the alliances of structure and organization, which disposes parts different in properties to be affected reciprocally by the same forms of diseased action; (joints of the hand and foot, stomach and retina, in gout; muscular fibre and ligamentous capsules in rheumatism; skin, mucous membrane, and iris, in syphilis). To the numerous, extensive, and complicated sympathies of the latter class belong many cases of metastasis, in which the secondary often differ from the primary forms of diseased action. Inflammation in one organ occasions in another congestion, and *vice versâ*; and the cessation of an habitual secretion in one, whether natural or morbid, gives occasion to inflammation in another. Preternatural irritability, swelling, pain, spasm, are thus excited by this reciprocal sympathy, in remote organs; or a metastasis, a change of place, strictly speaking, occurs; the morbid action abruptly quitting one part before it appears in the other. But not only does the

* See "A Practical Treatise on the Diseases of the Eye," by John Vetch, M.D. F.R.S.E. London, 1821.

reflected action often differ in its nature from the original, but this, in many instances, continues in undiminished activity, so that the metastasis is only an incidental feature of the association. Now if the sclerotic and the ligamentous capsule are liable to be reciprocally affected, we may refer it to the first stated sympathy of kindred textures, as in the case of hernia humoralis and gonorrhœa, whether simply propagated or metastatic; and of rheumatic or scrofulous inflammation passing from joint to joint. But if the above mentioned parts are, as I believe, subject to be consensually affected during gonorrhœal inflammation*, I should explain it by reference to the second and more diffused sympathy which connects all organs and textures through the medium of the common sensory, with various degrees of affinity, according to their vital powers and properties.

NOTE B.

IN the history of the idiopathic iritis, by Dr. Schmidt of Vienna, a yellowish red tubercle is described as forming upon the surface of the membrane; which enlarges, and at length bursts and discharges its contents into the chamber. This he denominates an abscess, of which the cyst remains visible for some time afterwards. But for the general accuracy of this author's descriptions, I should decide against the correctness of this observation. I have never been able to discover any thing resembling an abscess in the iris, though perfectly familiar with the appearance of a tubercle like that described; and it is highly improbable that lymph should be effused in tubercles, which in some parts become rapidly organized and absorbed, and in other parts form cysts of abscesses, upon the same texture, at one and the same time. Such abscesses would degenerate into ulcers,


* I speak here of true sclerotic inflammation independent of any mixture of puriform conjunctival ophthalmia.

an appearance never witnessed. Pus, as I believe, is never formed in pure iritis.

A species of iritis is described by the same author which he names the arthritic, an inflammation either primary or secondary in a gouty habit to a common ophthalmia. It is attended with excruciating pain. Its diagnostic signs are the appearance of a narrow white ring at the verge of the cornea, and a varicose disposition of the vessels of the conjunctiva. In spare and irritable individuals the pupil becomes contracted as in the idiopathic iritis, the blood vessels of the iris are varicose, and the disease terminates in a diminution of volume of the eye-ball. In persons of full habit and relaxed fibre, the pupil, on the contrary, becomes remarkably contracted, but not uniformly, being transversely oval. No lymph is effused, but a greenish yellow appearance of the humors is observed, and the lens bulges forward, of a sea-green color. This pain which is periodical, and announced by a burning sensation around the organ and a profuse flow of tears, is of the most severe description. The vessels of the choroid assume the same varicose state as those of the conjunctiva, and the transparent sclerotic presents a dark ring in the situation of the corpus ciliare. Total blindness accompanies this state, and atrophy of the globe ensues.

In this country we have not been accustomed to distinguish gouty inflammations in this organ. If an inflammation, characterised as above, is peculiar to the arthritic diathesis, the distinction is borne out; if not, the division is frivolous. I am unable to decide upon the value of the diagnostic sign first mentioned; not that it has altogether escaped my observation, as being in some instances of deep seated inflammation more strongly marked than in others; but that no evidence has been conclusive to my mind of the existence of a distinct species of iritis affecting gouty subjects. A varicose state of the vessels is the ordinary result of continued inflammation, whatever be the texture affected. The same may be said of the ultimate state of atrophy of the entire organ from interstitial absorption. But to speak my opinion candidly,

the two states which are here described as varieties of iritis, according to the different habits of body in which it appears, are essentially different forms of disease. The fully dilated and transversely oval pupil, the collapsed and disorganised iris, the varicose vessels of the choroid and conjunctiva, the attenuation of the sclerotic and bulging of the ciliary ring, all indicate not an existing inflammation, but a disease gone by; they are slow after changes which ensue upon acute destructive inflammation of the choroid and retina; and the agonizing attacks of pain which I have often witnessed in this precise condition, are the result of an universal congestion of the vessels and consequent distension of the eyeball, for every loss of blood gives temporary relief, and when the loss of volume is observed to commence, these attacks cease and return no more. That the angularities of the pupil are in one form of the iritis (syphilitic) observed to be upward and downward, and in another (arthritic) from side to side; that the sclerotic vessels, in one case, advance boldly to the cornea; and, in another, are separated by a line which is only visible through a magnifier, are circumstances too much of a contingent and casual nature to be admitted, as affording a ground for invariable and specific distinctions; and to look at them as types of corresponding constitutional states, is almost ludicrous.



NOTE C.

THIS head and that of amblyopsia, page 185, include a very considerable proportion of the cases of functional amaurosis. The amblyopsia may be regarded as the advanced stage of the symptomatic amaurosis, and borders upon paralysis. The disorder of the conjunctival surface, in many instances of pure weakness of sight, unattended by any degree of dimness, is so slight, as either to induce a belief that it has no share in the disease, or that it stands in the relation of an indirect effect, rather than of an exciting cause of the complaint. We must therefore con-

sider it in such cases as a primary nervous affection ; or as originating from sympathy with some other organ, or some peculiar state of the system. The existence of such causes, in many instances, is too obvious to escape notice : in others, I have looked for it in vain. Neither has the organ been over-exerted nor oppressed ; nor have the functions of the stomach, liver, uterus, &c., varied from a state of health. Excepting the absolute suspension of all such employments as demand the exercise of what may be called active vision, to speak honestly, I know of no remedy for the disease. It is more frequent in early and middle, than in advanced life ; and in females than in males. There is no unusual intolerance of light, nothing amounting to actual pain, no defect of vision ; in short, the sum and substance of the complaint is the sensation of an effort to see, and the want of power to continue it. The removal of the exciting cause, the first and most important step in the treatment of all diseases, although so negative as almost to amount in the patient's estimation to an abandonment of the case, is in this more efficient than active measures, as abstinence may on some occasions be advantageously substituted for cathartics. Accordingly I have known the complaint materially mitigated by perseverance in this system for six or twelve months, with a scrupulous attention to regimen ; and perhaps by extension of the principle, a state of protracted sleep, if it were possible, might be the readiest mode of cure.

A young gentleman who consulted me three years ago for muscæ, a weakness of sight, and inability to exercise his sight in any way requiring continued attention, a painful sensation from looking at pointed objects, as pins, needles, or the corner of a chimney piece*, I have lately seen. There is not now, nor ever has been,

* This is the only example I have met with of this very expressive symptom of a tender, or highly irritable retina. It seems to me to resemble those disagreeable but natural sensations, viz. the teeth on edge, or the *cutis anserina*, when amounting, as in some individuals, to a morbid excess, and excited by impressions of which they alone are susceptible.

the slightest deviation from a healthy appearance of the eyes; the pupils contract freely, and there is no intolerance of light, nor does his uneasiness, though it compels him to desist from employment, ever amount to pain. He has a frame rather spare than plethoric, a healthy complexion, good appetite, animated disposition, and spirits corresponding to his health, if some apprehension about his sight did not occasionally depress him. His education has been from this cause interrupted, and he is unable to indulge his inclination in the choice of a profession.

Before I saw him he had been subjected to different plans of treatment. First, undue determination of blood without any sufficient reason was presumed; for this hypothesis he suffered leeching, cupping, and blistering. Secondly, it was regarded as a nervous affection; evacuations of blood were countermanded, and a particular attention to the bowels, sea-bathing, exercise, and various tonics substituted. I gave my opinion in writing three years ago, that the disorder was purely functional, that the systematic regulation of the bowels, attention to diet and exercise, with as much indulgence of the organ as was possible, comprised all the means of treatment which my experience suggested. That depletion on the one hand and the higher tonics on the other, would not amend, if they did not aggravate the complaint. At the same time, I recommended a trial to be given to the blue pill, the bitter infusion, and blisters. The disease is as nearly as possible the same at this moment, as when I was first consulted. His own observation is, that his sight is evidently more affected by the state of his stomach than any other circumstance, that the more observant he has been of the plans laid down for the regulation of diet, &c. the more tranquil and comfortable has been the state of his eyes. Reading a few pages of a book is infinitely more distressing than the glare of a theatre or a ball room; and the sense of debility is greater during the morning than at any other time. But even though the bowels are perfectly regular, and the digestion strong, the same feeling prevails; and on the other hand, when these functions have been very irregular, it

has often happened, that the state of vision has been as good as at the best.

~~~~~

#### NOTE D.

PROFESSOR Beer refers to many cases of this description, as from suppression of febrile diseases of the skin, scarlatina, variola, &c. in the first period of the eruptions. The pupil in these cases is much contracted and immoveable; the prognosis favorable, if treated early. He has also seen the disease after suppressed chronic diseases of the skin, as psora; after the amputation of the plica polonica, and very many in consequence of an abrupt healing of old leg ulcers. The prognosis in these cases is unfavorable. In that arising from suppressed catarrhus narium, in which the pupil is angular and drawn toward the outer canthus, he considers the prognosis encouraging. He mentions as rare and unfavorable forms of the metastatic amaurosis, those arising from suppressed secretion of milk in lying-in women, and from suppressed passions of the mind.

~~~~~

NOTE E.

AN elderly gentleman, the subject of confirmed organic amaurosis, whom I had seen at intervals, died lately, and his friends kindly afforded me an opportunity of examining his head after death. In the year 1816 he first complained of dimness—was unable to mend his pen as usual, changed his spectacles repeatedly—and from writing a small neat hand wrote large and straggling. In walking he imagined that he saw objects on the ground which intercepted his path, and endeavoured to avoid them by taking long and high steps. The flames of the candle at night appeared multiplied and undefined. There was little if any difference between the two eyes. About the time that his sight grew dim, he complained of uneasiness and oppression in the head. He

often described the horrible sensation of passing under an archway, with the fear of being crushed by its falling*. His habit was plethoric, and he was apparently in the full vigor of health. As these symptoms, together with much lethargy, was considered to threaten apoplexy, he was freely and repeatedly bled, and in other respects treated accordingly. He became totally blind and soon afterwards dark. His eyes were perfect in appearance. They had the unmeaning roll characteristic of the disease in its last stage. Pupils a good deal dilated and motionless. A full course of mercury and electricity were employed without any effect. The latter was persisted in for six months.

In the progress of the case he was attacked with fits of a mixed kind, partly apoplectic, with temporary hemiplegia, and in part epileptic; his mind and speech failed him. Great torpor of bowels and indigestion, scantiness of urine and pain in voiding it, coldness and œdematous swelling of the lower extremities, with frequent and severe convulsions of his whole frame, were the symptoms most remarkable towards the close of his life.

On inspection of the head, the ventricles of the brain were found greatly surcharged with serous fluid, and the optic nerves to and from the ganglion opticum shrunk, or rather absorbed; so that they appeared flat instead of cylindrical, and of a straw color instead of a silvery whiteness. In slitting, and cutting them across, it was evident that only the sheath of the nerve remained, the medullary substance had entirely disappeared. The eyes nevertheless were in all respects sound, and had the plumpness and clearness of health. There was no vestige of an apoplectic effusion.

The following case exemplifies the exclusive paralysis of the *nervi motores* referred to in the paragraph to which this note belongs.

* Another morbid horror, somewhat resembling this, I have heard described, viz. the approximation of the walls of the apartment, so as to give the patient the impression of being in a closet just large enough to contain his person. I scarcely need observe that all such delusions have their origin in the sensorium.

Mrs. W. a healthy woman, aged 28, suckling an infant of five months, was attacked, in June 1820, with severe pain in the head on first rising in the morning, which in an hour or two subsided, but after some time it continued during the whole day, affecting chiefly the left side. She, of her own accord, applied leeches to her temples and a blister behind each ear, but without relief. In August following finding the pain almost insupportable, her family surgeon was consulted. The bowels, he informed me, were so obstinately costive as to be with difficulty acted upon by powerful cathartics. Being still unrelieved after brisk and effective purgative medicine, she concluded it to be rheumatism, and wrapped her head in flannel. In crossing the road on the 8th of November following, she felt a sudden smart shock between the orbitar processes, like a pea striking her forehead. From this moment the pain in the head ceased; but she found the vision imperfect—that is, she saw objects in unnatural positions, and although she could see distinctly with either eye, she could not with both, and therefore tied up one, the left, which was rather the weakest, when engaged in business. Both eyes appeared perfectly healthy, and the pupils were equally active. On the third of December following she first saw objects double, and the strabismus was so marked as very sensibly to disfigure a pretty and pleasing countenance. Both eyes were turned towards the nose, the left most so. Both pupils nevertheless acted freely. She had suffered no return of pain since the 18th ultimo. She was now cupped to twenty ounces from the nape of the neck and temples. Her bowels had been kept in action by the pil. hydrarg. and an occasional purgative draught. Since the double vision began, these were directed to be continued. A large blister was applied to the occiput after the bleeding, and three days afterwards no improvement appearing, each temple was bled with six leeches, and these parts were also blistered. The dose of blue pill was gradually raised to ten grains twice a day, and in a fortnight the mercurial action was established.

Previous to this event, it was noticed that her vision had

been less confused. She was cupped twice in this period to six ounces, and blisters applied behind the ears were kept open for some days. Her mouth continued sore about a month, during which time she gradually recovered single and perfect vision, and the strabismus was corrected. During her recovery she saw but one object on looking stedfastly in a straight direction; but upon turning her eyes to either side, or upwards, she still saw objects double; and even now that her vision in all directions is ordinarily single, whilst in a supine posture, and especially whenever her mind recurs to the subject, her vision is occasionally double.

During her treatment, she was seldom free from a sense of heaviness about the forehead and occiput, and vertigo. The pulse was quick and feeble, countenance pale and haggard, mind irritable and anxious; and she laboured evidently under great debility, both muscular and nervous. The recovery of the eyes was very gradual; no sensible acceleration of the rate of progress was observed during the mercurial influence. She did not however lose what had been gained in sight, though she lost strength. Even since the recovery of the sight, and in a great measure of her flesh and strength by country air, the continuance of weight and uneasy sensations in the head, led me to recommend a seton in the nape of the neck, which she adopted with advantage.

This young woman, I should observe, the mother of several children, acted as her husband's book-keeper, and, whilst pursuing this sedentary and anxious occupation, had been accustomed to drink freely of potent home brewed beer.

This case is contradistinguished to that in which the affection of the retina precedes the strabismus. Here, it is the symptom—there, the cause of the strabismus. The sympathetic affection of the retina in the case just related, is the slightest possible. In the majority of such cases, it is more marked, so that the vision of one eye is much stronger and clearer than that of the other, and *one* eye may be said to

be in fault. When strabismus ensues upon amaurosis, this difference is still more conspicuous. But the prognosis is not least serious when the retina is least affected; a squint from blindness adds little to the case but confirmation that the retina is insensible; but strabismus coming first connects the origin of the disease with the cerebrum, and what alarm we feel in one case for the sense of vision, we feel in the other for life, or, what is of yet more value, for intellect.

I must beg my reader's excuse for still farther lengthening this note. A few days ago I was desired to visit a gentleman between thirty and forty years of age, who had just arrived from the West Indies, on account of a large and hard tumor seated in the abdomen, about the nature of which his medical attendants were in doubt, from its external character, its apparent insulation, and frequent change of place, being sometimes in the epigastrium or beneath the umbilicus, and at other times distinctly felt in the right iliac region, in the position of the caput coli. Sometimes it was concealed and could not be felt any where. The disease was of seven months standing, attended with marked symptoms of stricture in some part of the intestinal canal: a very imperfect and disturbed state of the alimentary functions, frequent hiccough, sharp pains in the belly, and great emaciation.

On the day of my seeing him, he was suddenly seized with a new symptom; viz. convulsions and total blindness; and in the interval of the fits, which were protracted and severe, he complained of pain across the top and front of the head. His pulse was regular, but compressed; his skin was covered with a cold perspiration; except during the convulsive paroxysm, his mind was perfect, but his manner was changed from anxiety to apathy. The pupils were dilated to the utmost, as in hydrocephalus; he had no sense of light, no perception of its interruption. I directed his head to be immediately shaved, and twelve ounces of blood to be taken by cupping from the temples, and above each mastoid process. Afterwards a blister to be applied in the direction of the coronal and sagittal sutures, sinapisms to his feet, and a pill to

be taken, composed of five grains of calomel and half a grain of opium. Two hours afterwards, the convulsions recurring, and his skin being still cold and clammy, he was ordered a cordial draught and a small quantity of brandy in gruel occasionally. At the same time a turpentine glyster was administered; this was soon followed by a very plentiful discharge from the bowels, a warm and copious perspiration, and a sound sleep of several hours. The next morning he awoke free from pain, and his vision was as perfect as ever. He had no return of convulsion or cerebral disorder of any kind. No material change occurred in the symptoms of the original malady during this short but truly alarming attack.

This amaurosis, there can be no doubt, was an example of sympathetic irritation and congestion. The cupping was a precautionary measure indicated by the amaurosis; there was pain, a firm pulse, and this unequivocal symptom of compression; effusion was instantly threatened; a stimulus at this moment appeared hazardous. We expected to see him expire in each fit. The pill, followed by the stimulant glyster, was remedial, and for the time saved him.

P. S. Since the above was written, this gentleman is deceased. On inspection, a firm, very irregular, fungoid tumor, of the size of a man's double fist, knobulated, fissured, and of a truly malignant aspect, was found occupying the head of the colon; and by its origin from an extensive surface of the mucous membrane, partially inverting and concealing the termination of the ileon and the cæcum, of which only the appendix vermiformis was seen. He had no other organic disease.

NOTE F.

THE different forms of amblyopsia amaurotica enumerated by Professor Beer are as follow:—

Visus interruptus—the person in reading sees only single words or letters.

- Visus dimidiatus—S. hemiopsia.
 Visus muscorum—S. myodesopsia.
 Visus reticulatus—a higher degree of the former.
 Visus lucidus—Photopsia. Marmaryge. (*Hipp.*) Sparks and flashes of lightning perceived by the patient.
 Photophobia—light painful.
 Oxiopsia—a state of vision which enables the patient to see with perfect accuracy the smallest point when deprived of light.
 Visus nebulosus.
 Visus duplicatus—S. Diplopia, Luscitas, et Strabismus.
 Visus coloratus—S. Crupsia, all objects seem colored, green, blue, yellow, &c.
 Visus defiguratus—S. Metamorphosia.
 Myopia and Presbyopia.
 Nyctalopia and Emeralopia.
 Amblyopia vaga—periodica—intermittens.

NOTE G.

PROFESSOR WALTHER, in an essay on this subject, has stated some very original and curious notions. He thinks that cataract is the primitive and natural state of the lens, and that congenital cataract is therefore not an altered but an unaltered condition, in consequence of a check given to the developement of the embryon. Like other malformations, it is not owing to the influence of any active or formative cause, but having been originally present in every embryon at certain periods of its existence, does not disappear in its progress to a more perfect state, as it does where this progress is unchecked. The three months' fetus has a hare lip, and but one cavity for the mouth and nostrils. The iris is imperforate, and so are all the apertures of the perfect body. The eyelids are fastened together over the naked eye, and

the cavity of the umbilical cord being one with the abdomen, exomphalos is the natural and original state.

Walther considers cataract to be always the result of inflammation of the capsule, acute or chronic. By a powerful magnifier he has discovered a wreath of vessels about a quarter of a line distant from the pupillary edge of the iris, forming a concentric circle with the pupil. To this vascular wreath vessels pass in radii from the circumference of the capsule, and into the posterior surface of the iris. Nay, a network of more delicate vessels is described to have been seen deeper seated in the lens itself, "the larger trunks of which are not always derived from the circumference of that body, but evidently come from its posterior surface directly forwards, and then divide into branches*." This is an appearance entirely morbid, the same authority deciding that there is no organized connection between the lens and its capsule in health, and that the lens is nourished by imbibition or absorption of the humor Morgagnii, secreted by the vessels of the capsule, into which it again deposits its waste, being merely furnished with absorbent and exhalent vessels. Hence inflammation of the lens is always secondary to that of the capsule, in the same manner as inflammation of the capsule is secondary to that of the iris. Spots seen in the capsule, whether grey or brown, are, we are told, deposits of lymph, in which the prolonged vessels are seen terminating.

The inflammation of the capsule and of the lens are described as diseases marked by certain signs and appearances. The latter is always chronic like that of the bones, cartilages, and fibrous textures. When the disease is established, the blood vessels of the lens and capsule become varicose. The firm cataract is the termination of inflammation in induration. The milky exemplifies suppuration. The dry siliquous or shrunk cataract is a dry gangrene. The hard cataract when occurring without inflammation is a scirrhus, and the purulent may sometimes be the effect of ulceration

* I quote the words of the Analysis in the Quarterly Journal of Foreign Medicine and Surgery.

of the lens. Other cataracts are considered to be sarcomatous!

The first part of these observations, namely, that referring to the appearances exhibited in inflammation of the capsule, from its consistency and analogy with the phenomena that are open to observation, has been anticipated in the way of hypothesis, and may be admitted with proper allowance for the chances of optical delusion in the employment of a sextuple magnifier. But unfortunately the enthusiastic devotion to system which the author betrays in his pathological notions, (which are to my seeming pure nonsense,) gives an air of marvel to the whole story.

Professor Beer divides cataracts into true and spurious. The true is within the capsule; the spurious is placed between it and the iris. The principal kinds are,

True. 1. Lenticular. 2. Anterior capsular. 3. Posterior capsular. 4. Morgagnian. 5. Capsulo-lenticular. 6. Cystic. 7. Siliquous. 8. Cataract with a cyst or sac containing pus. 9. Trabecular.

Spurious. 10. Lymphatic. 11. Purulent. 12. Sanguineous. 13. Pigmentous.

The distinction and dignity of a name given to each variety, is the only novelty of this list. The cystic is the floating cataract, the capsule opaque and thickened, and the lens more or less absorbed. The siliquous is the capsular cataract, the lens being absorbed, as after wound or rupture of the capsule*. The cyst containing pus is rare. The trabecular is probably the radiated. As to the four last, they are results of iritic inflammation, not cataracts; nor are they in this country confounded with them. They are seldom if ever met with but after blows, wounds, and operations.

* Do the travelled pedants, who deal such heavy blows among their ignorant and besotted countrymen, suppose that these every day forms have escaped our notice? In England, as in Germany, the same things are seen, but their importance is differently estimated; they are differently explained, arranged, and reasoned upon. I am content it should be so.

NOTE H.

THE often mooted questions—first, in what cases topical blood-letting commands an advantage, if in any, over phlebotomy, as usually practised at the arm;—second, whether drawing blood from an artery is of greater efficacy than from a vein, the quantity being the same—may be answered, I think, in a few words. To the first I should reply—if the system is inflamed, i. e. if the pulse indicates that the action of the heart is excited by the state of the organ, or if the activity or rapid progress of the inflammation, however local, threatens the safety of the organ, we ought not to trust to topical blood-letting. In such cases it may be employed subserviently with great advantage, but not principally. If on the other hand no such sympathy is evinced, and the inflammation, though acute, is in its nature weak and slow of progress, the local blood-letting may commonly suffice. But is it in such cases to be preferred? Generally I think it is, because the inflamed vessels are relieved from the state of congestion and tension, and are enabled to recover their contractile tone, at a smaller expense to the system. To pale the inflamed conjunctiva by opening a vein in the arm, supposing there is no disposition to syncope, will require a loss of from twelve to sixteen ounces of blood; whereas this effect will often be produced by a loss of one third of that quantity drawn as quickly from the immediate neighbourhood of the inflamed organ. Syncope from dread of the lancet will produce the best effect of a topical bleeding, and may stand in its stead. It will be no substitute for general bleeding where that is indicated, for the same reason that topical bleeding is no adequate substitute for general. Thus, though a general bleeding will answer the main purpose of a local one, it is least economical when neither the character of the inflammation, nor the danger of its duration calls for it; and therefore in strumous and other weakly habits, in atonic and sluggish inflammations, it is least eligible.

Nevertheless when the inflammation and the part affected are such as to require general blood-letting, and the patient owes his safety to its employment, topical is continually had recourse to with remarkable advantage, and the latter is more eligible as an auxiliary in such cases, than the former as a substitute in those of an opposite description. The difference of the inflammatory action according to the texture of the organ affected, is comprehended in the above general statement.

Leeches are the least effectual mode of topical blood-letting. In many instances the blood derived by them is not sufficient to counterbalance the irritation caused by the wound, and they act as irritants, augmenting the vascularity, swelling, and pain.

To the second question my observation leads me to reply in the negative. The effect upon the heart's action will be determined by the quantity lost, and by that alone—taking the distance from the heart and the size of the current—in any artery which it is usual or would be discreet to bleed from.

NOTE I.

THE gratitude of the public, the highest, if not the only reward for public benefit to which an honorable mind aspires, is unquestionably due to Dr. Vetch, for the successful treatment of this formidable disease, especially in its first and most formidable stage. He reprobates the excision of the granulations and the division of the conjunctiva. Although I have seen cases of the absorption of large and even pendulous granulations, and believe that such absorption almost invariably takes place where the disease is left to run its course, abundant experience has convinced me that the employment of the scissars is highly important to the favorable issue of the case, since the preservation of the cornea depends chiefly upon the restoration of the lining membrane of the lids, which this practice essentially promotes. Yet

so highly do I appreciate the importance of caustic and astringent applications judiciously employed, that if the joint use of these remedies were in any case proscribed, I should prefer, as a single measure, the use of the lunar caustic or the blue vitriol, to the employment of the knife.

Dr. Vetch objects to the use of these substances in solution as too stimulant, and contends that when lightly applied in the solid form they act most beneficially. There is much truth in this observation. The fact is, that in this, as in all chronic morbid changes, the treatment rests not upon one, but on a variety or perhaps a combination of measures; not upon this or that form or mode of application, but upon a form and mode suited to the existing circumstances. A topical application made with advantage to-day would probably be hurtful to-morrow. To watch the caprices of the case, the moment of excitement and of relaxation, to subdue, to soothe, or to support promptly, and thus to break the force of each successive relapse, varying the means as the circumstances permit, are points indispensable to conduct the case to a favorable termination, and are those which distinguish the man of science from the empiric. But the local treatment is by no means the only material part of the 'Therapeia' of these cases.

NOTE K.

WHERE these circumstances are not present, the subjects of this inflammation are, in my experience, weakly and of a scrofulous habit; the tame, indolent, shifting character of the disease, while it retains its primitive character, viz. the pink colored zone at the verge of the cornea, vivid one day, and scarcely perceptible the next, render it more difficult to subdue than a fixed and vigorous action; and the practitioner is insensibly betrayed into irresolution by the seeming inertness of the disease and the obvious delicacy of the patient. But diseases, like other dangers, are formidable in proportion as they are disguised, and it would often prevent mischief, if a bolder practice were instituted in the outset than circumstances appear to the inexperienced to warrant.



NOTE L.

THIS statement requires some qualification. What I mean is this; where the mercurial action being fairly established is productive of no sensible improvement, its continued and freer use is attended with no advantage, and is, therefore, constitutionally injurious; but I do not mean to say that the full advantage will always be obtained by a short and gentle course; on the contrary, where in the commencement of the mercurial action the improvement is only sufficient to give encouragement to persevere, a course of three or even four months is often necessary to accomplish the end in view.

In amaurosis supervening on inflammation, especially recent inflammation, the remedy promises most; but even here, if the inflammation has induced perfect amaurosis, it will often restore the iris to its color and activity without materially benefitting vision; for mercury is not a remedy

for paralysis. If however from inflammation—whether the result of injury or spontaneous, whether from the operation of a direct or a remote cause, the state of congestion or atony, the state of serous or lymphatic, perhaps of partial sanguineous effusion—the sensorial function be interrupted, our first hope is topical blood-letting and counter irritation—the second, the action of mercury.

At the distance of four years from a fall on the occiput, followed by severe symptoms of cerebral injury, I have known sight restored to the eye which had ever since been deprived of it, by a full mercurial course. Again and again I have seen the same effect produced by the same agent, where neither injury nor any other cause nor symptom of inflammation had ever existed, and where only a slow moving pupil corresponded to the patient's complaint of dimness, to such an extent as to render indistinguishable the features of a person standing before him: and on the other hand I have never known it to be of any efficacy in cases, ushered in by severe frontal pains, in which blindness was already complete, and the pupil largely and permanently dilated, where the greenish cast of the humors was strongly marked, and the visus lucidus was complained of.

NOTE M.

I CONFESS that I have seen no reason to alter the opinion here expressed, in several trials of this plan of treatment with the tube of M. Dupuytren, since the publication of this work. Through a learned member of the university of Paris, a patient of mine, and also of M. Dupuytren, I requested the professor to favor me with a case that might serve as a report in detail of the treatment which he had adopted. Upon this gentleman the tube operation, though performed by the Baron, was unsuccessful; but as he had previously worn for two or three years a nail-headed style with as little advantage,

the case certainly did not afford a fair chance of success, and the failure was attributed to this circumstance. M. Dupuytren, with the liberal and courteous spirit of a true friend to science, immediately transmitted to me the subjoined report of an interesting case which had very recently occurred; and I have great satisfaction in presenting it to my readers.

“Madame Daive, âgée de quarante deux ans, demeurant à Sarre-Louis, vint à Paris dans le mois de Mai 1821, pour consulter Mons. le Professeur Dupuytren pour une tumeur lacrymale d’un côté, et une fistule de l’autre côté.

“Il y a six ans que la malade s’aperçut pour la première fois, que l’œil du côté gauche étoit larmoyant, qu’il se fermoit souvent à son grand angle une petite tumeur qui se vidoit par la pression, et qui ne tarδοit pas à se reproduire. Cette dame avoit un écoulement involontaire de larmes sur la joue; l’œil de ce côté étoit toujours chassieux, larmoyant, la narine toujours sèche. Cette petite tumeur augmenta bientôt de volume, la peau qui la recouvroit, s’enflamma, s’amincit; les paupières se tuméfièrent. Ces accidens la firent recourir aux soins d’un chirurgien, qui ouvrit de suite cette tumeur: du pus, des larmes, du mucus, et du sang s’écoulèrent; la malade fût soulagée, l’inflammation tomba; mais à la tumeur succéda une fistule qu’il falloit guérir, et voici les moyens qui furent employés.

“On fit d’abord des injections. Quoique continuées pendant un temps assez long, elles n’eurent aucun résultat heureux. Ce premier moyen ayant échoué, on en essaya un second; c’est-à-dire, qu’on tenta de faire passer dans les fosses nasales un ressort de montre. On fit des essais pendant plusieurs jours, leur inutilité fit adopter le moyen suivant, dans l’intention de désobstruer par cautérisation les voies lacrymales. Un stilet rougi au feu fut introduit entre les lèvres de la fistule, et les cautérisa: du gonflement survint; au bout de quelques jours il diminua; bientôt les escarres formées se détachèrent; des bourgeons charnus s’élevèrent; mais le chirurgien s’appliqua chaque jour à introduire, pendant quelques instans, un cylindre de nitrate d’argent poudré. Cette manière d’agir eut pour résultat l’aggrandissement de

la fistule, l'adhérence de ses bords aux os ; les bords prirent une organisation cutanée : enfin on introduisit pendant longtemps une espèce de broche en plomb—Tous ces moyens loin de guérir la maladie, l'avoient rendue presque incurable. Désirant trouver un remède à son infirmité, Madame Daive se présenta chez M. le Baron Dupuytren ; elle se trouvoit alors dans l'état suivant.

“ Au grand angle de l'œil gauche existoit une ouverture de trois lignes de diamètre ; les bords tapissés par la peau amincie, avoient pris l'organisation cutanée dont s'emparent toujours les ouvertures fistuleuses, qui donnent passage à des corps étrangers. Par là s'écouloient sans cesse des larmes qui venoient irriter l'œil, enflammer et excorier la peau de la joue.

“ Au grand angle de l'autre œil existoit depuis quatre ans une petite tumeur, plus grosse pendant le temps humide, plus aussi le matin que le soir. Cette tumeur pouvoit être facilement vidée par la pression ; alors il s'écouloit par les points lacrymaux une matière purulente, muqueuse, mêlée à l'humeur des larmes ; la narine de l'un et l'autre côté étoit sèche.

“ La guérison de la tumeur lacrymale étoit certaine, celle de la fistule pouvoit être douteuse ; la malade en fut prévenue, et l'opération pratiquée le 4 Mai 1821, de la manière suivante.

“ La malade étoit assise sur une chaise placée vis-à-vis d'une fenêtre, la tête appuyée sur la poitrine d'une aide : Monsieur Dupuytren tend alors avec le *medium* et le doigt indicateur de la main gauche, la peau des paupières de l'œil droit, en la portant un peu en dehors, tandis qu'avec la main droite armée d'un bistouri à lame étroite, il fait à la peau qui recouvre la tumeur, une incision perpendiculaire, qui la divise, ainsi que le sac lacrymal. On vit bien que l'instrument n'avoit pas dévié, par la profondeur à laquelle il pénétra sans difficulté, et à la sortie de mucosité purulente. Changeant alors de main, M. Dupuytren saisit avec la droite le bistouri, et avec la gauche le mandrin, revêtu de sa canule en or*. Le bistouri est un peu retiré pour permettre à

* Voyez la description à la fin de l'observation.

l'extrémité du mandrin qui est glissé sur sa lame, d'être introduite à mesure qu'on fait entrer le mandrin ; enfin lorsqu'on est entré à la hauteur du canal nasal, il ne reste plus qu'à l'enfoncer. On est averti qu'il a pénétré assez avant, par la résistance qu'on éprouve à l'enfoncer davantage ; ce qui provient du contact de la canule sur le rebord de la gouttière lacrymale. Voulant s'assurer que la communication existoit entre le sac lacrymal et le fossé nasal, Monsieur Dupuytren ferma l'ouverture antérieure des fosses nasales, et ordonna à la malade de faire des efforts comme pour se moucher, aussitôt on vit de l'air mêlé à du pus et à des mucosités sanguinolentes s'échapper par la petite ouverture ; on y présenta la flamme d'une bougie, elle fut éteinte.

“ De l'autre côté l'ouverture fistuleuse permit l'introduction de la canule ; elle fut facile, et chose étonnante, mais qui arrive toujours, c'est que la malade ne sentant nullement la canule, avoit peine à croire qu'on l'eût introduite.

“ Restoit à savoir l'issue qu'auroient ces deux opérations. Au bout de vingt quatre heures la petite plaie du côté droit fut cicatrisée, la tumeur n'existoit plus, le cours des larmes étoit parfaitement rétabli, et la narine de ce côté avoit repris son humidité naturelle.

“ Plusieurs jours après l'opération, l'ouverture fistuleuse du côté gauche parut un peu rétrécie ; cependant la malade éprouvoit de ce côté la même incommodité.

“ Que pouvoit-on faire pour cicatriser cette ouverture ? Devoit-on détruire les adhérences de la peau, enlever les bords de la fistule ? Mais en agissant ainsi, on pouvoit craindre de ne pas réussir, et d'aggraver au contraire l'état de la malade ; aussi ce parti ne fut-il pas adopté.

“ Les succès brillans que Monsieur le Professeur Dupuytren venoit d'obtenir dans la guérison de fistules recto-vesicales, uretro-vaginales, par le cautère, lui suggérèrent l'idée d'employer ce moyen. En effet quinze jours après l'opération, l'ouverture fistuleuse n'ayant fait aucun progrès vers la cicatrisation, Monsieur Dupuytren la toucha avec un petit pinceau de charpie trempée dans du nitrate de mercure, avec excès d'acide nitrique ; par-dessus il mit encore de la charpie

hachée, également imprégnée de ce caustique. Du gonflement, de la douleur survinrent ; ils furent calmés par quelques lavemens, des pédiluves (bains de pieds) synapisés, du petit lait, &c.

“ Au bout de quatre jours l’escarre tomba, et Monsieur Dupuytren vit avec plaisir que la plaie s’étoit un peu rétrécie. Enhardi par ce premier succès, il fit une seconde, troisième, quatrième, et jusqu’à une septième cautérisation ; toutes furent pratiquées à quatre ou cinq jours d’intervalle, chaque fois on trouva l’ouverture rétrécie. Enfin le 3 Juillet, deux mois depuis l’opération pratiquée, cette ouverture fistuleuse à parois cutanées, organisée depuis plusieurs années, et que plusieurs médecins avoient jugé incurable, étoit parfaitement cicatrisée, le cours des larmes rétabli ; en un mot, il étoit difficile de pouvoir assurer que cette malade avoit eu une tumeur lacrymale d’un côté, et une fistule de l’autre, tant elle étoit bien guérie. On ne pouvoit voir à l’œil que la malade avoit dans le nez deux canules en or, et leur présence se faisoit si peu sentir, que la malade avoit peine à croire qu’on les lui eut laissées. Enfin elle quitta Paris parfaitement guérie, et heureuse d’avoir été délivrée d’une infirmité qu’on avoit jugé incurable.”

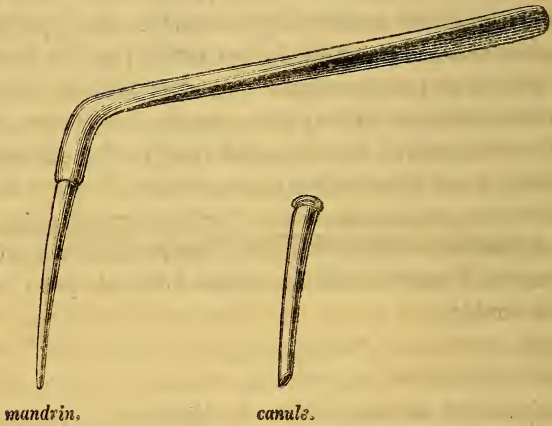
Description de la canule d’or de Monsieur le Professeur Dupuytren.

“ Cette canule doit être aussi longue que le conduit nasal ; par conséquent elle est de 10 à 14 lignes, sur une, ou une et demie de diamètre, cependant sa partie supérieure est un peu plus large ; elle offre une légère courbure pour s’accommoder à celle du canal. Un rebord renflé, en forme de bourrelet saillant en dehors, fait le contour de l’ouverture, qui doit aboutir au sac lacrymal ; il est destiné à s’opposer à la chute de la canule dans le nez, chute qui permettroit à la maladie de se reproduire ; l’autre extrémité de la canule est taillée en bec de flûte, afin qu’un de ses côtés moins long, ne dépasse point le côté interne du canal nasal qui finit avant l’externe. La canule est portée sur son mandrin formé de deux parties, qui se

réunissent à angle un peu obtus ; l'une d'elles, plus longue, aplatie, est celle que saisit la main de l'opérateur ; l'autre se cache dans la canule qu'un renflement subit l'empêche de dépasser.

“ Par ordre de M. le Baron Dupuytren,

“ MARX.”



NOTE N.

THOUGH their general complexion is little serious, very embarrassing and distressing cases of this description are sometimes met with. The conjunctival surface is highly irritable, and a profuse gush of scalding tears overruns the cheek, at the moment that the eye is opened and exposed to the light. The skin of the lower lid and cheek is excoriated, and the cuticle becomes rough and scaly from the quantity and quality of the lacrymal discharge. The patient's only relief consists in keeping the eyelids closed. The repeated passage of the probe, if some slight obstruction should have existed, and the flowing of water injected by the puncta in a stream from the nostril, afford sufficient proof of the freedom of the canal, but no relief to the epiphora. A preternatural sensibility of the membrane may be inferred from the excessive pain and dread of the operation. I have seen such a case in a delicate young female of many months' duration; in which neither soothing nor astringent applications, neither antiphlogistic nor alterative, tonic nor sedative medicine, produced the smallest benefit. The congestion of the superficial vessels is inconsiderable: no morbid appearance is seen on everting the upper lid; the orifices of the canaliculi lacrymales are natural; there is no fullness nor uneasiness felt on pressure in the region of the lacrymal gland. What is this disease? Is it an affection of the lacrymal gland? and if so, does it result from any undue excitement, or any morbid irritability, like a 'tic sensitif' of the lacrymal branch of the fifth pair? Is it sympathetic with the surface or the retina? Does it depend on a deficiency of the mucus which dilutes and sheaths the tears, or a chemical change in the quality of the lacrymal secretion, or a spasmodic affection of the orbicularis palpebrarum? Of these suggestions some may be negatived by the absence of

such a symptom during the palpable existence of such conditions; the infrequency of this case, and the frequency of the cases proposed; others are altogether hypothetical, and I will not add to the '*obscurum per obscurius.*'

THE END.

By the same Author,

AN INQUIRY

INTO THE

PROCESS OF NATURE

IN REPAIRING

INJURIES OF THE INTESTINES;

ILLUSTRATING THE

TREATMENT OF PENETRATING WOUNDS,

AND

STRANGULATED HERNIA.

